



This is a digital copy of a book that was preserved for generations on library shelves before it was carefully scanned by Google as part of a project to make the world's books discoverable online.

It has survived long enough for the copyright to expire and the book to enter the public domain. A public domain book is one that was never subject to copyright or whose legal copyright term has expired. Whether a book is in the public domain may vary country to country. Public domain books are our gateways to the past, representing a wealth of history, culture and knowledge that's often difficult to discover.

Marks, notations and other marginalia present in the original volume will appear in this file - a reminder of this book's long journey from the publisher to a library and finally to you.

Usage guidelines

Google is proud to partner with libraries to digitize public domain materials and make them widely accessible. Public domain books belong to the public and we are merely their custodians. Nevertheless, this work is expensive, so in order to keep providing this resource, we have taken steps to prevent abuse by commercial parties, including placing technical restrictions on automated querying.

We also ask that you:

- + *Make non-commercial use of the files* We designed Google Book Search for use by individuals, and we request that you use these files for personal, non-commercial purposes.
- + *Refrain from automated querying* Do not send automated queries of any sort to Google's system: If you are conducting research on machine translation, optical character recognition or other areas where access to a large amount of text is helpful, please contact us. We encourage the use of public domain materials for these purposes and may be able to help.
- + *Maintain attribution* The Google "watermark" you see on each file is essential for informing people about this project and helping them find additional materials through Google Book Search. Please do not remove it.
- + *Keep it legal* Whatever your use, remember that you are responsible for ensuring that what you are doing is legal. Do not assume that just because we believe a book is in the public domain for users in the United States, that the work is also in the public domain for users in other countries. Whether a book is still in copyright varies from country to country, and we can't offer guidance on whether any specific use of any specific book is allowed. Please do not assume that a book's appearance in Google Book Search means it can be used in any manner anywhere in the world. Copyright infringement liability can be quite severe.

About Google Book Search

Google's mission is to organize the world's information and to make it universally accessible and useful. Google Book Search helps readers discover the world's books while helping authors and publishers reach new audiences. You can search through the full text of this book on the web at <http://books.google.com/>





ANATOMY



MANUAL
OF
PRACTICAL ANATOMY

BY

THE LATE D. J. CUNNINGHAM
M.D. (EDIN. ET DUBL.), D.SC., LL.D. (ST. AND. ET GLAS.), D.C.L. (OXON.), F.R.S.,
LATE PROFESSOR OF ANATOMY IN THE UNIVERSITY OF EDINBURGH


FIFTH EDITION

EDITED BY ARTHUR ROBINSON
PROFESSOR OF ANATOMY IN THE UNIVERSITY OF EDINBURGH

VOLUME SECOND
THORAX; HEAD AND NECK

WITH 236 ILLUSTRATIONS

NEW YORK
WILLIAM WOOD AND COMPANY
MDCCCCXII



PREFACE TO FIFTH EDITION

The main object of this preface is to thank those who have kindly assisted me in the production of the book. At the same time, it may be pointed out that the reasons for the adoption of the Basle nomenclature were fully stated in vol. i., and that the alterations which have been made in the plans of dissection in vol. ii. are not less numerous than those made in vol. i. The alterations include changes in the method of dissecting the face, the posterior triangle, and the deeper parts of the neck. Two plans of dissection to display the middle ear and its surroundings are described. They can be carried out on opposite sides of the head, and the steps of the second method are those followed by the surgeon operating for the relief of mastoid and middle ear disease. The dissection of the thorax has been very largely re-arranged with the object of giving the dissector an opportunity of studying the relative positions of the organs in the mediastinum whilst they are practically undisturbed.

The various plans of dissection described were decided on, after many trials, as those best adapted to give the student a clear idea of the relative positions of important structures; and I am greatly indebted to my first and second assistants, Dr. E. B. Jamieson and Mr. T. B. Johnston, and Professor R. B. Thomson of Cape Town, for the trouble they have taken and the help they have given in devising, modifying, and testing new plans of work.

I am indebted also to Dr. Jamieson for dissections of the brain and heart; to Mr. Johnston for the dissections of the parotid gland; to Mr. W. W. Carlow for the dissection of the diaphragm; and to Messrs. M. B. and J. Rogers,

and F. M. Halley for other dissections upon which they have expended time and skill, and which have been used in the preparation of the new illustrations.

I wish also to thank Professor Arthur Thomson for permission to use the illustrations of his beautiful dissections of the eye ; Professor A. M. Paterson for permission to use two diagrams illustrating the connections of some of the cranial nerves ; and Dr. Logan Turner for the loan of the specimens from which the illustrations of the dissection of the mastoid region and middle ear were made.

All the new illustrations are from drawings made by Mr. J. T. Murray. They are characteristic of his excellent work, and I am indebted to him for the care and skill he has expended on their production.

The new indices and the glossary are the work of Mr. J. Keogh Murphy, F.R.C.S. I believe they will prove to be of great service ; and I desire to thank him not only for the time and trouble he has spent upon them, but also for many useful suggestions which he has made during the progress of the work.

ARTHUR ROBINSON.

EDINBURGH, *July* 1912.

CONTENTS



THORAX.

	Page
INTRODUCTORY,	1
THORACIC WALL,	5
THORACIC CAVITY,	10
THORACIC JOINTS,	112

HEAD AND NECK.

FACE AND FRONTAL REGION OF HEAD,	117
SIDE OF THE NECK,	142
POSTERIOR TRIANGLE,	142
THE SCALP AND THE SUPERFICIAL STRUCTURES OF THE TEMPORAL REGION,	152
THE DISSECTION OF THE BACK,	161
REMOVAL OF THE BRAIN,	200
THE ANTERIOR PART OF THE NECK,	222
TEMPORAL AND INFRATEMPORAL REGIONS,	265
SUBMAXILLARY REGION,	279
OTIC GANGLION AND TENSOR PALATI,	292
THE GREAT VESSELS AND NERVES OF THE NECK,	294
THE LATERAL PART OF THE MIDDLE CRANIAL FOSSA,	325
DISSECTION OF THE ORBIT,	333
PREVERTEBRAL REGION,	350
THE JOINTS OF THE NECK,	356
MOUTH AND PHARYNX,	364
CAROTID CANAL,	385
NERVUS MAXILLARIS,	386
NASAL CAVITIES,	389

	PAGE
SPHENO-PALATINE GANGLION AND INTERNAL MAXILLARY	
ARTERY,	402
THE LARYNX,	406
THE TONGUE,	429
ENCEPHALON—THE BRAIN.	
MEMBRANES AND BLOOD VESSELS OF THE BRAIN,	439
BASE OF BRAIN,	452
THE CEREBRUM,	459
THE MESENCEPHALON,	506
BASAL GANGLIA OF THE CEREBRAL HEMISPHERES,	512
THE PARTS OF THE BRAIN WHICH LIE IN THE POSTERIOR	
CRANIAL FOSSA,	520
THE AUDITORY APPARATUS.	
EXTERNAL MEATUS,	547
MEMBRANA TYMPANI,	549
TYMPANIC CAVITY OR MIDDLE EAR,	550
AUDITORY OSSICLES,	555
AUDITORY TUBE,	559
INTRAPETROUS PART OF THE FACIAL NERVE AND THE ACUSTIC	
NERVE,	562
VESTIBULUM,	566
CANALES SEMICIRCULARES OSSEI,	567
THE COCHLEA,	567
BULBUS OCULI.	
GENERAL STRUCTURE OF THE EYEBALL,	571
THE SCLERA,	572
THE CORNEA,	573
TUNICA VASCULOSA OCULI,	574
THE RETINA,	579
THE VITREOUS BODY,	581
LENS CRYSTALLINA,	583
CHAMBERS OF THE EYEBALL,	584
DEX,	585

A GLOSSARY

OF THE

INTERNATIONAL (B.N.A.)

ANATOMICAL TERMINOLOGY



GENERAL TERMS.

TERMS INDICATING SITUATION AND DIRECTION.

Longitudinalis	Longitudinal	} Referring to the long axis of the body.
Verticalis	Vertical	
Anterior	Anterior	} Referring to the position of the long axis of the body in the erect posture.
Posterior	Posterior	
Ventral	Ventral	} Referring to the front and back of the body or the limbs.
Dorsal	Dorsal	} Referring to the anterior and posterior aspects, respectively, of the body, and to the flexor and extensor aspects of the limbs, respectively.
Cranial	Cranial	
		} Referring to position nearer the head or the tail end of the long axis.
Caudal	Caudal	} Used only in reference to parts of the head, neck, or body.
Superior	Superior	
		} Used in reference to the head, neck, and body. Equivalent to cranial and caudal respectively.
Inferior	Inferior	
Proximalis	Proximal	} Used only in reference to the limbs.
		} Proximal nearer the attached end.
Distalis	Distal	} Distal nearer the free end.
		} Used in reference to planes parallel with the sagittal suture of the skull, <i>i.e.</i> vertical antero-posterior planes.
Sagittalis	Sagittal	
		} Used in reference to planes parallel with the coronal suture of the skull, <i>i.e.</i> transverse vertical planes.
Frontalis	Frontal	

Horizontalis	Horizontal	} Used in reference to planes at right angles to vertical planes.
Medianus	Median	
Medialis	Medial	} Referring to the median vertical antero-posterior plane of the body.
Lateralis	Lateral	
Intermedius	Intermediate	} Referring to structures relatively nearer to or further away from the median plane.
Superficialis	Superficial	
Profundus	Deep	} Referring to structures situated between more medial and more lateral structures.
Externus	External	
Internus	Internal	} Referring to structures nearer to and further away from the surface.
Ulnaris	Ulnar	
Radialis	Radial	} Referring, with few exceptions, to the walls of cavities and hollow organs. <i>Not</i> to be used as synonymous with medial and lateral.
Tibial	Tibial	
Fibular	Fibular	} Used in reference to the medial and lateral borders of the forearm, respectively.
		} Used in reference to the medial and lateral borders of the leg, respectively.

THE BONES.

B.N.A. TERMINOLOGY.

Vertebræ

Fovea costalis superior

Fovea costalis inferior

Fovea costalis transversalis

Radix arcus vertebræ

Atlas

Fovea dentis

Epistropheus

Dens

Sternum

Corpus sterni

Processus xiphoideus

Incisura jugularis

Planum sternale

Ossa Cranii.**Os frontale**

Spina frontalis

Processus zygomaticus

Facies cerebralis

Facies frontalis

OLD TERMINOLOGY.

Vertebræ

Incomplete facet for head of rib, upper

Incomplete facet for head of rib, lower

Facet for tubercle of the rib

Pedicel

Atlas

Facet for odontoid process

Axis

Odontoid process

Sternum

Gladiolus

Ensiform process

Supra-sternal notch

Anterior surface

Bones of Skull.**Frontal**

Nasal spine

External angular process

Internal surface

Frontal surface

GLOSSARY

xi

B. N. A. TERMINOLOGY.

Os parietale

Lineæ temporales
Sulcus transversus
Sulcus sagittalis

Os occipitale

Canalis hypoglossi
Foramen occipitale magnum
Canalis condyloideus
Sulcus transversus
Sulcus sagittalis
Clivus

Linea nuchæ suprema
Linea nuchæ superior
Linea nuchæ inferior

Os sphenoidale

Crista infratemporalis
Sulcus chiasmatis
Crista sphenoidalis
Spina angularis
Lamina medialis processus pterygoidei
Lamina lateralis processus pterygoidei
Canalis pterygoideus [Vidii]
Fossa hypophyseos
Sulcus caroticus
Conchæ sphenoidales
Hamulus pterygoideus
Canalis pharyngeus
Tuberculum sellæ
Fissura orbitalis superior

Os temporale

Canalis facialis [Fallopium]
Hiatus canalis facialis
Vagina processus styloidei
Incisura mastoidea
Impressio trigemini
Eminentia arcuata

Sulcus sigmoideus
Fissura petrotympanica
Fossa mandibularis
Semicanalis tubæ auditivæ

Os ethmoidale

Labyrinthus ethmoidalis
Lamina papyracea
Processus uncinatus

OLD TERMINOLOGY.

Parietal

Temporal ridges
Groove for lateral sinus
Groove for sup. long. sinus

Occipital

Anterior condyloid foramen
Foramen magnum
Posterior condyloid foramen
Groove for lateral sinus
Groove for sup. long. sinus
Median part of upper surface of basi occipital
Highest curved line
Superior curved line
Inferior curved line

Sphenoid

Pterygoid ridge
Optic groove
Ethmoidal crest
Spinous process
Internal pterygoid plate
External pterygoid plate

Vidian canal
Pituitary fossa
Cavernous groove
Sphenoidal turbinal bones
Hamular process
Pterygo-palatine canal
Olivary eminence
Sphenoidal fissure

Temporal Bone

Aqueduct of Fallopium
Hiatus Fallopium
Vaginal process of tympanic bone
Digastric fossa
Impression for Gasserian ganglion
Eminence for sup. semicircular canal
Fossa sigmoidea
Glaserian fissure
Glenoid cavity
Eustachian tube

Ethmoid

Lateral mass
Os planum
Unciform process

B. N. A. TERMINOLOGY.

Os lacrimale

Hamulus lacrimalis
Crista lacrimalis posterior

Os nasale

Sulcus ethmoidalis

Maxilla

Facies anterior
Facies infra-temporalis
Sinus maxillaris
Processus frontalis
Processus zygomaticus
Canales alveolares
Canalis naso-lacrimalis
Os incisivum
Foramen incisivum

Os palatinum

Pars perpendicularis
Crista conchalis
Crista ethmoidalis
Pars horizontalis

Os zygomaticum

Processus temporalis
Processus fronto-sphenoidalis
Foramen zygomatico-orbitale
Foramen zygomatico-faciale

Mandibula

Spina mentalis
Linea obliqua
Linea mylohyoidea
Incisura mandibulæ
Foramen mandibulare
Canalis mandibulæ
Protuberantia mentalis

OLD TERMINOLOGY.

Lachrymal Bone

Hamular process
Lachrymal crest

Nasal Bone

Groove for nasal nerve

Superior Maxillary Bone

Facial or external surface
Zygomatic surface
Antrum of Highmore
Nasal process
Malar process
Posterior dental canals
Lacrimal groove
Premaxilla
Anterior palatine foramen

Palate Bone

Vertical plate
Inferior turbinate crest
Superior turbinate crest
Horizontal plate

Malar Bone

Zygomatic process
Frontal process
Tempora-malar canal
Malar foramen

Inferior Maxillary Bone

Genial tubercle or spine
External oblique line
Internal oblique line
Sigmoid notch
Inferior dental foramen
Inferior dental canal
Mental process

The Skull as a Whole.

Ossa suturarum
Foveolæ granulares (Pacchioni)
Fossa pterygo-palatina
Canalis pterygo-palatinus
Foramen lacerum
Choanæ
Fissura orbitalis superior
Fissura orbitalis inferior

Wormian bones
Pacchionian depressions
Spheno-maxillary fossa
Posterior palatine canal
Foramen lacerum medium
Posterior nares
Sphenoidal fissure
Spheno-maxillary fissure

Upper Extremity.**B. N. A. TERMINOLOGY.****Clavicula**

Tuberositas coracoidea
Tuberositas costalis

Scapula

Incisura scapularis
Angulus lateralis
Angulus medialis

Humerus

Sulcus intertubercularis
Crista tuberculi majoris
Crista tuberculi minoris
Facies anterior medialis
Facies anterior lateralis
Margo medialis
Margo lateralis
Sulcus nervi radialis
Capitulum
Epicondylus medialis
Epicondylus lateralis

Ulna

Incisura semilunaris
Incisura radialis
Crista interossea
Facies dorsalis
Facies volaris
Facies medialis
Margo dorsalis
Margo volaris

Radius

Tuberositas radii
Incisura ulnaris
Crista interossea
Facies dorsalis
Facies volaris
Facies lateralis
Margo dorsalis
Margo volaris

Carpus

Os naviculare
Os lunatum
Os triquetrum
Os multangulum majus
Os multangulum minus
Os capitatum
Os hamatum

OLD TERMINOLOGY.**Clavicle**

Impression for conoid ligament
Impression for rhomboid ligament

Scapula

Supra-scapular notch
Anterior or lateral angle
Superior angle

Humerus

Bicipital groove
External lip
Internal lip
Internal surface
External surface
Internal border
External border
Musculo-spiral groove
Capitellum
Internal condyle
External condyle

Ulna

Greater sigmoid cavity
Lesser sigmoid cavity
External or interosseous border
Posterior surface
Anterior surface
Internal surface
Posterior border
Anterior border

Radius

Bicipital tuberosity
Sigmoid cavity
Internal or interosseous border
Posterior surface
Anterior surface
External surface
Posterior border
Anterior border

Carpus

Scaphoid
Semilunar
Cuneiform
Trapezium
Trapezoid
Os magnum
Unciform

Lower Extremity.

B.N.A. TERMINOLOGY.

Os coxæ

Linea glutæa anterior
 Linea glutæa posterior
 Linea terminalis
 Spina ischiadica
 Incisura ischiadica major
 Incisura ischiadica minor
 Tuberculum pubicum
 Ramus inferior oss. pubis
 Ramus superior oss. pubis
 Ramus superior ossis ischii
 Ramus inferior oss. ischii
 Pecten ossis pubis
 Facies symphyseos

Pelvis

Pelvis major
 Pelvis minor
 Apertura pelvis minoris superior
 Apertura pelvis minoris inferior

Femur

Fossa trochanterica
 Linea intertrochanterica
 Crista intertrochanterica
 Condylus medialis
 Condylus lateralis
 Epicondylus medialis
 Epicondylus lateralis

Tibia

Condylus medialis
 Condylus lateralis
 Eminentia intercondyloidea
 Tuberositas tibiæ
 Malleolus medialis

Fibula

Malleolus lateralis

OLD TERMINOLOGY.

Innominate Bone

Middle curved line
 Superior curved line
 Margin of inlet of true pelvis
 Spine of the ischium
 Great sacro-sciatic notch
 Lesser sacro-sciatic notch
 Spine of pubis
 Descending ramus of pubis
 Ascending ramus of pubis
 Body of ischium
 Ramus of ischium
 Pubic part of ilio-pectineal line
 Symphysis pubis

Pelvis

False pelvis
 True pelvis
 Pelvic inlet
 Pelvic outlet

Femur

Digital fossa
 Spiral line
 Post. intertrochanteric line
 Inner condyle
 Outer condyle
 Inner tuberosity
 Outer tuberosity

Tibia

Internal tuberosity
 External tuberosity
 Spine
 Tubercle
 Internal malleolus

Fibula

External malleolus

Bones of the Foot.**Talus****Calcaneus**

Tuber calcanei
 Processus medialis tuberis calcanei
 Processus lateralis tuberis calcanei

Os cuneiforme primum**Os cuneiforme secundum****Os cuneiforme tertium****Astragalus****Os calcis**

Tuberosity of
 Inner
 Outer

Inner cuneiform**Middle cuneiform****Outer cuneiform**

THE LIGAMENTS.

Ligaments of the Spine.

B.N.A. TERMINOLOGY.	OLD TERMINOLOGY.
Lig. longitudinale anterius	Anterior common ligament
Lig. longitudinale posterius	Posterior common ligament
Lig. flava	Ligamenta subflava
Membrana tectoria	Posterior occipito-axial ligament
Articulatio atlanto-epistrophica	Joint between the atlas and the axis
Lig. alaria	Odontoid or check ligaments
Lig. apicis dentis	Suspensory ligament

The Ribs.

Lig. capituli costæ radiatum	Anterior costo-vertebral or stellate ligament
Lig. sterno-costale interarticulare	Interarticular chondro-sternal ligament
Lig. sterno-costalia radiata	Anterior and posterior chondro-sternal ligament
Lig. costoxiphoidæ	Chondro-xiphoid ligaments

The Jaw.

Lig. temporo-mandibulare	External lateral ligament of the jaw
Lig. spheno-mandibulare	Internal lateral ligament of the jaw
Lig. stylo-mandibulare	Stylo-maxillary ligament

Upper Extremity.

Lig. costo-claviculare	Rhomboid ligament
Labrum glenoidale	Glenoid ligament
Articulatio radio-ulnaris proximalis	Superior radio-ulnar joint
Lig. collaterale ulnare	Internal lateral ligament of elbow-joint
Lig. collaterale radiale	External lateral ligament
Lig. annulare radii	Orbicular ligament
Chorda obliqua	Oblique ligament of ulna
Articulatio radio-ulnaris distalis	Inferior radio-ulnar joint
Discus articularis	Triangular fibro-cartilage
Recessus sacciformis	Membrana sacciformis
Lig. radio-carpeum volare	Anterior ligament of the radio-carpal joint
Lig. radio-carpeum dorsale	Posterior ligament of the radio-carpal joint
Lig. collaterale carpi ulnare	Internal lateral ligament of the wrist joint

B.N.A. TERMINOLOGY.

Lig. collaterale carpi radiale
 Articulationes intercarpæ
 Lig. accessoria volaria
 Lig. capitulorum (oss. metacar-
 palium) transversa
 Lig. collateralia

OLD TERMINOLOGY.

External lateral ligament of the
 wrist joint
 Carpal joints
 Palmar ligaments of the metacarpo-
 phalangeal joints
 Transverse metacarpal ligament
 Lateral phalangeal ligaments

The Lower Extremity.

Lig. arcuatum
 Lig. sacro-tuberosum
 Processus falciformis
 Lig. sacro-spinosum
 Labrum glenoidale
 Zona orbicularis
 Ligamentum iliofemorale
 Lig. ischio-capsulare
 Lig. pubo-capsulare
 Lig. popliteum obliquum
 Lig. collaterale fibulare
 Lig. collaterale tibiale
 Lig. popliteum arcuatum
 Meniscus lateralis
 Meniscus medialis
 Plica synovialis patellaris
 Plicæ alares
 Articulatio tibio-fibularis
 Lig. capituli fibulæ
 Syndesmosis tibio-fibularis
 Lig. deltoideum
 Lig. talo-fibulare anterius
 Lig. talo-fibulare posterius
 Lig. calcaneo-fibulare
 Lig. talo-calcaneum laterale
 Lig. talo-calcaneum mediale
 Lig. calcaneo-naviculare plantare
 Lig. talo-naviculare
 Pars calcaneo-navicularis } lig.
 Pars calcaneo-cuboidea } bifur-
 catum

Subpubic ligament
 Great sacro-sciatic ligament
 Falciform process
 Small sacro-sciatic ligament
 Cotyloid ligament
 Zonular band
 Y-shaped ligament
 Ischio-capsular band
 Pubo-femoral ligament
 Ligament of Winslow
 Long external lateral ligament
 Internal lateral ligament
 Arcuate popliteal ligament
 External semilunar cartilage
 Internal semilunar cartilage
 Lig. mucosum
 Ligamenta alaria
 Superior tibio-fibular articulation
 Anterior and posterior superior
 tibio-fibular ligaments
 Inferior tibio-fibular articulation
 Internal lateral ligament of ankle
 Anterior fasciculus of external
 lateral ligament
 Posterior fasciculus of external
 lateral ligament
 Middle fasciculus of external lateral
 ligament
 External calcaneo-astragaloid liga-
 ment
 Internal calcaneo-astragaloid liga-
 ment
 Inferior calcaneo-navicular ligament
 Astragalo-scaphoid ligament
 Superior calcaneo-scaphoid liga-
 ment
 Internal calcaneo-cuboid ligament

THE MUSCLES.

Muscles of the Back.**Superficial.**

B.N.A. TERMINOLOGY.

OLD TERMINOLOGY.

Levator scapulae

Levator anguli scapulae

Muscles of the Chest.

Serratus anterior

Serratus magnus

Muscles of Upper Extremity.

Biceps brachii

Lacertus fibrosus

Brachialis

Triceps brachii

Caput mediale

Caput laterale

Pronator teres

Caput ulnare

Brachio-radialis

Supinator

Extensor carpi radialis longus

Extensor carpi radialis brevis

Extensor indicis proprius

Extensor digiti quinti proprius

Abductor pollicis longus

Abductor pollicis brevis

Extensor pollicis brevis

Extensor pollicis longus

Lig. carpi transversum

Lig. carpi dorsale

Biceps

Bicipital fascia

Brachialis anticus

Triceps

Inner head

Outer head

Pronator radii teres

Coronoid head

Supinator longus

Supinator brevis

Extensor carpi radialis longior

Extensor carpi radialis brevior

Extensor indicis

Extensor minimi digiti

Extensor ossis metacarpi pollicis

Abductor pollicis

Extensor primi internodii pollicis

Extensor secundi internodii pollicis

Anterior annular ligament

Posterior annular ligament

Muscles of Lower Extremity.

Tensor fasciæ latae

Canalis adductorius (Hunteri)

Trigonum femorale (fossa Scarpa
major)

Canalis femoralis

Annulus femoralis

M. quadriceps femoris—

Rectus femoris

Vastus lateralis

Vastus intermedius

Vastus medialis

M. articularis genu

Tibialis anterior

Tensor fasciæ femoris

Hunter's canal

Scarpa's triangle

Crural canal

Crural ring

Quadriceps—

Rectus femoris

Vastus externus

Crureus

Vastus internus

Subcrureus

Tibialis anticus

B.N.A. TERMINOLOGY.

Tendo calcaneus
 Tibialis posterior
 Quadratus plantæ
 Lig. transversum cruris
 Lig. cruciatum cruris
 Lig. laciniatum
 Retinaculum musculorum peroneorum superiorum }
 Retinaculum musculorum peroneorum inferiorum }

OLD TERMINOLOGY.

Tendo Achillis
 Tibialis posticus
 Accessorius
 Upper anterior annular ligament
 Lower anterior annular ligament
 Internal annular ligament

External annular ligament

Axial Muscles.**Muscles of the Back.**

Serratus posterior superior
 Serratus posterior inferior
 Splenius cervicis
 Sacro-spinalis

Ilio-costalis—

Lumborum
 Dorsi
 Cervicis

Longissimus—

Dorsi
 Cervicis
 Capitis

Spinalis—

Dorsi
 Cervicis
 Capitis

Semispinalis—

Dorsi
 Cervicis
 Capitis

Multifidus

Serratus posticus superior
 Serratus posticus inferior
 Splenius colli
 Erector spinæ

Ilio-costalis—

Sacro-lumbalis
 Accessorius
 Cervicalis ascendens

Longissimus—

Dorsi
 Transversalis cervicis
 Trachelo-mastoid

Spinalis—

Dorsi
 Colli
 Capitis

Semispinalis—

Dorsi
 Colli
 Complexus
 Multifidus spinæ

Muscles of Head and Neck.

Epicranius
 Galea aponeurotica
 Procerus
 Pars transversa (nasalis)
 Pars alaris (nasalis)
 Auricularis anterior
 Auricularis posterior
 Auricularis superior
 Orbicularis oculi
 Pars lacrimalis

Occipito-frontalis
 Epicranial aponeurosis
 Pyramidalis nasi
 Compressor naris
 Dilatores naris
 Attrahens aurem
 Retrahens aurem
 Attollens aurem
 Orbicularis palpebrarum
 Tensor tarsi

B. N. A. TERMINOLOGY.

Triangularis
 Quadratus labii superioris—
 Caput zygomaticum
 Caput infraorbitale
 Caput angulare
 Zygomaticus
 Caninus
 Quadratus labii inferioris
 Mentalis
 Platysma
 Sterno-thyreoid
 Thyreo-hyoid

OLD TERMINOLOGY.

Depressor anguli oris
 Zygomaticus minor
 Levator labii superioris
 Levator labii superioris alæque nasi
 Zygomaticus major
 Levator anguli oris
 Depressor labii inferioris
 Levator menti
 Platysma myoides
 Sterno-thyroid
 Thyro-hyoid

Muscles and Fascia of the Orbit.

Fascia bulbi	Capsule of Tenon
Septum orbitale	Palpebral ligaments
Rectus lateralis	Rectus externus
Rectus medialis	Rectus internus

Muscles of the Tongue.

Genio-glossus	Genio-hyo-glossus
Longitudinalis superior	Superior lingualis
Longitudinalis inferior	Inferior lingualis
Transversus linguæ	Transverse fibres
Verticalis linguæ	Vertical fibres

Muscles of the Pharynx.

Pharyngo-palatinus	Palato-pharyngeus
M. uvulæ	Azygos uvulæ
Levator veli palatini	Levator palati
Tensor veli palatini	Tensor palati
Glosso-palatinus	Palato-glossus

Deep Lateral Muscles of Neck.

Scalenus anterior	Scalenus anticus
Scalenus posterior	Scalenus posticus
Longus capitis	Rectus capitis anticus major
Rectus capitis anterior	Rectus capitis anticus minor

Muscles of Thorax.

Transversus thoracis	Triangularis sterni
Diaphragma pars lumbalis	Diaphragm, lumbar part—
Crus mediale	Crura and origins from arcuate ligaments
Crus intermedium	
Crus laterale	
Arcus lumbo - costalis medialis (Halleri)	Ligamentum arcuatum internum
Arcus lumbo - costalis lateralis (Halleri)	Ligamentum arcuatum externum

Muscles of the Abdomen.

B. N. A. TERMINOLOGY.	OLD TERMINOLOGY.
Ligamentum inguinale (Pouparti)	Poupart's ligament
Ligamentum lacunare (Gimbernati)	Gimbernati's ligament
Fibræ intercrurales	Intercolumnar fibres
Ligamentum inguinale reflexum (Collesi)	Triangular fascia
Annulus inguinalis subcutaneus	External abdominal ring
Crus superius	Internal pillar
Crus inferius	External pillar
Falx aponeurotica inguinalis	Conjoined tendon
M. transversus abdominis	Transversalis muscle
Linea semicircularis (Douglasi)	Fold of Douglas
Annulus inguinalis abdominalis	Internal abdominal ring

Perineum and Pelvis.

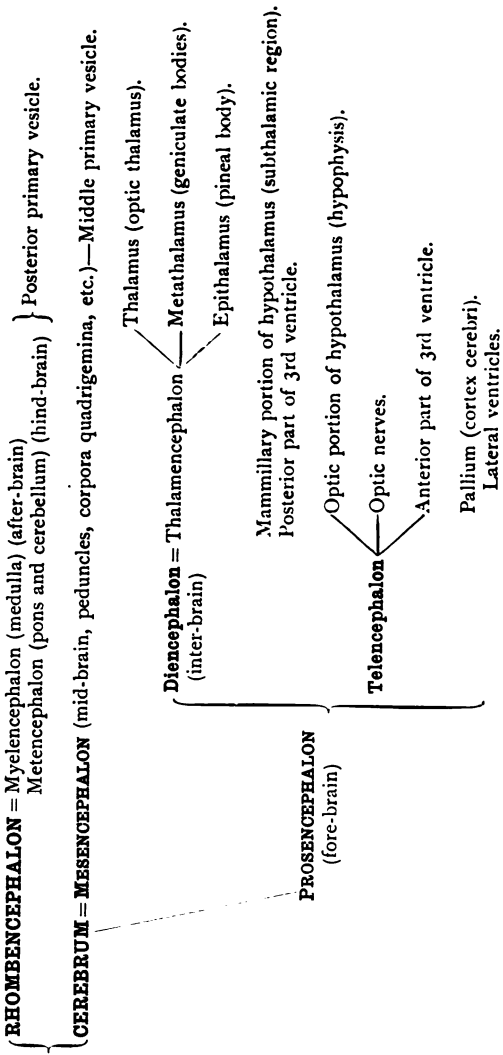
Transversus perinei superficialis	Transversus perinei
M. sphincter urethræ membranaceæ	Compressor urethræ
Diaphragma urogenitale	Deep transverse muscle and sphincter urethræ
Fascia diaphragmatis urogenitalis superior	Deep layer of triangular ligament
Fascia diaphragmatis urogenitalis inferior	Superficial layer of the triangular ligament
Arcus tendineus fasciæ pelvis	White line of pelvis
Ligamenta puboprostatica	Anterior and lateral true ligaments of bladder
Fascia diaphragmatis pelvis superior	Visceral layer of pelvic fascia
Fascia diaphragmatis pelvis inferior	Anal fascia

THE NERVOUS SYSTEM.**Spinal Cord.**

Fasciculus anterior proprius (Flechsig)	Anterior ground or basis bundle
Fasciculus lateralis proprius	Lateral ground bundle
Nucleus dorsalis	Clarke's column
Pars thoracalis	Dorsal part of spinal cord
Sulcus intermedius posterior	Paramedian furrow
Columnæ anteriores, etc.	Anterior grey column
Fasciculus cerebro-spinalis anterior	Direct pyramidal tract
Fasciculus cerebro-spinalis lateralis (pyramidalis)	Crossed pyramidal tract
Fasciculus cerebello-spinalis	Direct cerebellar tract
Fasciculus antero-lateralis superficialis	Gowers' tract

GLOSSARY

The Brain or Encephalon is divided into parts as follows :—



Brain.

B.N.A. TERMINOLOGY.

OLD TERMINOLOGY.

Rhombencephalon

Eminentia medialis
 Ala cinerea
 Ala acustica
 Nucleus nervi abducentis
 Nuclei n. acustici
 Fasciculus longitudinalis medialis
 Corpus trapezoideum
 Incisura cerebelli anterior
 Incisura cerebelli posterior
 Sulcus horizontalis cerebelli
 Lobulus centralis
 Folium vermis
 Tuber vermis
 Lobulus quadrangularis
 Brachium conjunctivum cerebelli
 Lobulus semilunaris superior
 Lobulus semilunaris inferior

Cerebrum

Pedunculus cerebri
 Colliculus superior
 Colliculus inferior
 Aqueductus cerebri

 Foramen interventriculare
 Hypothalamus
 Sulcus hypothalamicus
 Massa intermedia
 Fasciculus thalamo-mammillaris
 Pars opercularis
 Thalamus
 Pallium
 Gyri transitive
 Fissura cerebri lateralis
 Gyrus temporalis superior
 Gyrus temporalis medius
 Gyrus temporalis inferior
 Sulcus centralis (Rolandi)
 Sulcus temporalis superior
 Sulcus temporalis medius
 Sulcus circularis
 Sulcus temporalis inferior
 Gyrus fusiformis
 Sulcus interparietalis
 Sulcus corporis callosi
 Sulcus cinguli
 Fissura hippocampi
 Gyrus cinguli

Eminentia teres
 Trigonum vagi
 Trigonum acusticum
 Nucleus of 6th nerve
 Auditory nucleus
 Posterior longitudinal bundle
 Corpus trapezoides
 Semilunar notch (of cerebellum)
 Marsupial notch
 Great horizontal fissure
 Lobus centralis
 Folium cacuminis
 Tuber valvulæ
 Quadrate lobule
 Superior cerebellar peduncle
 Postero-superior lobule
 Postero-inferior lobule

Crus cerebri
 Anterior corpus quadrigeminum
 Posterior corpus quadrigeminum
 Iter e tertio ad quartum ventriculum, or aqued. of Sylvius
 Foramen of Monro
 Subthalamic region
 Sulcus of Monro
 Middle commissure
 Bundle of Vicq d'Azyr
 Pars basilaris
 Optic thalamus
 Cortex cerebri
 Annectant gyri
 Fissure of Sylvius
 First temporal gyrus
 Second temporal gyrus
 Third temporal gyrus
 Fissure of Rolando
 Parallel sulcus
 Second temporal sulcus
 Limiting sulcus of Reil
 Occipito-temporal sulcus
 Occipito-temporal convolution
 Intraparietal sulcus
 Callosal sulcus
 Calloso-marginal fissure
 Dentate fissure
 Callosal convolution

B.N.A. TERMINOLOGY.

Stria terminalis
 Trigonum collaterale
 Hippocampus
 Digitationes hippocampi
 Fascia dentata hippocampi
 Columna fornicis
 Septum pellucidum
 Inferior cornu
 Commissura hippocampi
 Nucleus lentiformis
 Pars frontalis capsulæ internæ
 Pars occipitalis capsulæ internæ
 Radiatio occipito-thalamica
 Radiatio corporis callosi
 Pars frontalis
 Pars occipitalis

OLD TERMINOLOGY.

Tænia semicircularis
 Trigonum ventriculi
 Hippocampus major
 Pes hippocampi
 Gyrus dentatus
 Anterior pillar of fornix
 Septum lucidum
 Descending horn of lateral ventricle
 Lyra
 Lenticular nucleus
 Anterior limb (of internal capsule)
 Posterior limb (of internal capsule)
 Optic radiation
 Radiation of corpus callosum
 Forceps minor
 Forceps major

Membranes of Brain.

Cisterna cerebello-medullaris	Cisterna magna
Cisterna interpeduncularis	Cisterna basalis
Granulationes arachnoideales	Pacchionian bodies
Tela chorioidea ventriculi tertii	Velum interpositum
Tela chorioidea ventriculi quarti	Tela chorioidea inferior

Cerebral Nerves.

N. oculomotorius	Third nerve
N. trochlearis	Fourth nerve
N. trigeminus	Fifth nerve
Ganglion semilunare (Gasseri)	Gasserian ganglion
N. naso-ciliaris	Nasal nerve
N. maxillaris	Superior maxillary nerve
N. meningeus (medius)	Recurrent meningeal nerve
N. zygomaticus	Temporo-malar nerve
Rami alveolares superiores posteriores	Posterior superior dental
Rami alveolares superiores medii	Middle superior dental
Rami alveolares superiores anteriores	Anterior superior dental
Ganglion spheno-palatinum	Meckel's ganglion
N. palatinus medius	External palatine nerve
N. mandibularis	Inferior maxillary nerve
Nervus spinosus	Recurrent nerve
N. alveolaris inferior	Inferior dental
N. abducens	Sixth nerve
N. facialis	Seventh nerve
N. intermedius	Pars intermedia of Wrisberg
N. acusticus	Eighth or auditory nerve

B. N. A. TERMINOLOGY.

Ganglion superius
 N. recurrens
 Ganglion jugulare
 Ganglion nodosum
 Plexus œsophageus anterior }
 Plexus œsophageus posterior }
 Nervus accessorius
 Ramus internus

 Ramus externus

OLD TERMINOLOGY.

Jugular ganglion of 9th nerve
 Recurrent laryngeal nerve
 Ganglion of root } of vagus
 Ganglion of trunk }
 Plexus gulæ
 Spinal accessory
 Accessory portion of spinal
 accessory nerve
 Spinal portion

Spinal Nerves.

Rami posteriores	Posterior primary divisions
Rami anteriores	Anterior primary divisions
N. cutaneus colli	Superficial cervical nerve
Nn. supraclaviculares anteriores	Suprasternal nerves
Nn. supraclaviculares medii	Supraclavicular nerves
Nn. supraclaviculares posteriores	Supra-acromial nerves
N. dorsalis scapulæ	Nerve to the rhomboids
Nn. intercosto-brachiales	Intercosto-humeral nerve
N. thoracalis longus	Nerve of Bell
N. thoraco-dorsalis	Long subscapular nerve
N. cutaneus brachii medialis	Lesser internal cutaneous nerve
N. cutaneus brachii lateralis	Cutaneous branch of circumflex nerve
Fasciculus lateralis	Outer cord (of plexus)
Fasciculus medialis	Inner cord
N. cutaneus antibrachii lateralis	Cutaneous branch of musculo-cutaneous nerve
N. cutaneus antibrachii medialis	Internal cutaneous nerve
Ramus volaris	Anterior branch
Ramus ulnaris	Posterior branch
N. cutaneus antibrachii dorsalis	External cutaneous branch of musculo-spiral
N. axillaris	Circumflex nerve
N. interosseus volaris	Anterior interosseous
Ramus palmaris N. mediani	Palmar cutaneous branch of the median nerve
Nn. digitales volares proprii	Collateral palmar digital branches of median nerve
Ramus dorsalis manus	Dorsal cutaneous branch of ulnar nerve
Ramus cutaneus palmaris	Palmar cutaneous branch of ulnar nerve
N. radialis	Musculo-spiral nerve
N. cutaneus brachii posterior	Internal cutaneous branch of musculo-spiral nerve
N. cutaneus antibrachii dorsalis	External cutaneous branches of musculo-spiral nerve

B.N.A. TERMINOLOGY.

Ramus superficialis
 N. interosseus dorsalis
 Nn. digitales dorsales
 N. ilio-hypogastricus
 Ramus cutaneus lateralis

 Ramus cutaneus anterior

 N. genito-femoralis
 N. lumbo-inguinalis

 N. spermaticus externus

 N. cutaneus femoris lateralis
 N. femoralis
 N. saphenus
 Ramus infrapatellaris

 N. ischiadicus
 N. peronæus communis
 Ramus anastomoticus peronæus
 N. peronæus superficialis
 N. peronæus profundus
 N. tibialis
 N. cutaneus suræ medialis
 N. suralis
 N. plantaris medialis
 N. plantaris lateralis
 N. pudendus

OLD TERMINOLOGY.

Radial nerve
 Posterior interosseous nerve
 Dorsal digital nerves
 Ilio-hypogastric nerve
 Iliac branch of ilio-hypogastric nerve
 Hypogastric branch of ilio-hypogastric nerve
 Genito-crural nerve
 Crural branch of genito-crural nerve
 Genital branch of genito-crural nerve
 External cutaneous nerve
 Anterior crural nerve
 Long saphenous nerve
 Patellar branch of long saphenous nerve
 Great sciatic nerve
 External popliteal nerve
 Nervus communicans fibularis

 Musculo-cutaneous nerve
 Anterior tibial nerve
 Internal popliteal nerve
 Nervus communicans tibialis
 Short saphenous nerve
 Internal plantar
 External plantar
 Pudic nerve

THE HEART AND BLOOD-VESSELS.

Heart.

Atrium	Auricle
Auricula cordis	Auricular appendix
Incisura cordis	Notch at apex of heart
Trabeculæ carneæ	Columnæ carneæ
Tuberculum intervenosum	Intervenous tubercle of Lower
Sulcus longitudinalis anterior	Anterior interventricular groove
Sulcus coronarius	Auriculo-ventricular groove
Limbus fossæ ovalis	Annulus ovalis
Valvula venæ cavæ	Eustachian valve
Valvula sinus coronarii	Valve of Thebesius

Arteries.**B.N.A. TERMINOLOGY.**

Sinus aortæ
 A. profunda linguæ
 A. maxillaris externa
 A. alveolaris inferior
 Ramus meningeus accessorius
 A. buccinatoria
 A. alveolaris superior posterior
 Aa. alveolares superiores anteriores
 Ramus carotico-tympanicus
 A. chorioidea
 A. auditiva interna
 Rami ad pontem

A. pericardio-phrenica
 Rami intercostales
 Truncus thyreo-cervicalis
 A. transversa scapulæ
 A. intercostalis suprema
 A. transversa colli
 A. thoracalis suprema
 A. thoraco-acromialis
 A. thoracalis lateralis
 A. circumflexa scapulæ
 A. profunda brachii
 A. collateralis radialis

A. collateralis ulnaris superior
 A. collateralis ulnaris inferior
 Ramus carpeus volaris
 Ramus carpeus dorsalis
 Aa. metacarpeæ dorsales
 A. volaris indicis radialis
 Arcus volaris superficialis
 Arcus volaris profundus
 A. interossea dorsalis
 A. interossea recurrens

A. interossea volaris
 Ramus carpeus dorsalis
 Ramus carpeus volaris
 Aa. digitales volares communes
 Aa. digitales volares propriæ
 Arteriæ intestinales

A. suprarenalis media
 A. hypogastrica
 A. umbilicalis
 A. pudenda interna
 A. epigastrica inferior

OLD TERMINOLOGY.

Sinuses of Valsalva
 Ranine artery
 Facial artery
 Inferior dental artery
 Small meningeal artery
 Buccal artery
 Posterior dental artery
 Anterior superior dental arteries
 Tympanic branch of int. carotid
 Anterior choroidal artery
 Auditory artery
 Transverse arteries (branches of Basilar artery)
 Arteria comes nervi phrenici
 Anterior intercostal arteries
 Thyroid axis
 Suprascapular artery
 Superior intercostal
 Transversalis colli
 Superior thoracic artery
 Acromio-thoracic artery
 Long thoracic artery
 Dorsalis scapulæ
 Superior profunda
 Anterior branch of superior profunda
 Inferior profunda
 Anastomotica magna
 Anterior radial carpal
 Posterior radial carpal
 Dorsal interosseous arteries
 Radialis indicis
 Superficial palmar arch
 Deep palmar arch
 Posterior interosseous artery
 Posterior interosseous recurrent artery
 Anterior interosseous artery
 Posterior ulnar carpal
 Anterior ulnar carpal
 Palmar digital arteries
 Collateral digital arteries
 Intestinal branches of sup. mesenteric
 Middle capsular artery
 Internal iliac artery
 Obliterated hypogastric
 Internal pudic artery
 Deep epigastric artery

GLOSSARY

xxvii

B.N.A. TERMINOLOGY.

A. spermatica externa
 Aa. pudendæ externæ

A. circumflexa femoris medialis
 A. circumflexa femoris lateralis
 A. genu suprema
 A. genu superior lateralis
 A. genu superior medialis
 A. genu media
 A. genu inferior lateralis
 A. genu inferior medialis
 A. malleolaris anterior lateralis
 A. malleolaris anterior medialis
 A. peronæa
 Ramus perforans
 A. malleolaris posterior lateralis
 A. malleolaris posterior medialis
 Rami calcanei laterales
 Rami calcanei mediales
 A. plantaris medialis
 A. plantaris lateralis
 Aa. metatarsæ plantares
 Aa. digitales plantares

OLD TERMINOLOGY.

Cremasteric artery
Superficial and deep external pudic arteries
Internal circumflex artery
External circumflex artery
Anastomotica magna
Superior external articular artery
Superior internal articular artery
Azygos articular artery
Inferior external articular artery
Inferior internal articular artery
External malleolar artery
Internal malleolar artery
Peroneal artery
 Anterior peroneal artery
 Posterior peroneal artery
Internal malleolar artery
External calcanean artery
Internal calcanean artery
Internal plantar artery
External plantar artery
Digital branches
Collateral digital branches

Veins.

V. cordis magna
 V. obliqua atrii sinistri
 Lig. venæ cavæ sinistræ
 Vv. cordis minimæ
 Sinus transversus
 Confluens sinuum
 Plexus basilaris
 Sinus sagittalis superior
 Sinus sagittalis inferior
 Spheno-parietal sinus
 V. cerebri internæ
 V. cerebri magna
 V. terminalis
 V. basalis
 V. transversa scapulæ
 V. thoraco-acromialis
 Vv. transversæ colli
 V. thoracalis lateralis
 V. azygos
 V. hemiazygos
 V. hemiazygos accessoria
 V. hypogastrica
 V. epigastrica inferior
 V. saphena magna
 V. saphena parva

Great cardiac vein
 Oblique vein of Marshall
 Vestigial fold of Marshall
 Veins of Thebesius
 Lateral sinus
 Torcular Herophili
 Basilar sinus
 Superior longitudinal sinus
 Inferior longitudinal sinus
 Sinus alæ parvæ
 Veins of Galen
 Vena magna Galeni
 Vein of the corpus striatum
 Basilar vein
 Suprascapular vein
 Acromio-thoracic vein
 Transversalis colli veins
 Long thoracic vein
 Vena azygos major
 Vena azygos minor inferior
 Vena azygos minor superior
 Internal iliac vein
 Deep epigastric vein
 Internal saphenous vein
 External saphenous vein

Lymphatics.

B.N.A. TERMINOLOGY.
Cisterna chyli

OLD TERMINOLOGY.
Receptaculum chyli

THE VISCERA.**Digestive Apparatus.**

Arcus glosso-palatinus	Anterior pillar of fauces
Arcus pharyngo-palatinus	Posterior pillar of fauces
Gl. lingualis anterior	Gland of Nuhn
Ductus submaxillaris	Wharton's duct
Gl. parotis accessoria	Socia parotidis
Ductus parotideus (Stenonis)	Stenson's duct
Dentes præmolares	Bicuspid teeth
Dens serotinus	Wisdom tooth
Papillæ vallatæ	Circumvallate papillæ
Recessus pharyngeus	Lateral recess of pharynx
Tela submucosa	Pharyngeal aponeurosis
Plicæ circulares	Valvulæ conniventes
Gl. intestinales	Crypts of Lieberkuhn
Valvula coli	Ileo-cæcal valve
Columnæ rectales	Columns of Morgagni
Plicæ transversales recti	Valves of Houston
Valvula spiralis	Valves of Heister
Noduli lymphatici aggregati (Peyeri)	Peyer's patches
Intestinum jejunum	Jejunum
Intestinum ileum	Ileum
Noduli lymphatici lienales (Malpighii)	Malpighian corpuscles

Respiratory Apparatus.**Larynx**

Prominentia laryngea	Adam's apple
Incisura thyreoidea superior	Superior thyroid notch
M. ary-epiglotticus	Aryteno-epiglottidean muscle
M. vocalis	Internal thyro-arytenoid muscle
M. thyreo-epiglotticus	Thyro-epiglottidean muscle
Appendix ventriculi laryngis	Laryngeal sac
Plica vocalis	True vocal cord
Plica ventricularis	False vocal cord
Ligamentum ventriculare	Superior thyro-arytenoid ligament
Ligamentum vocale	Inferior thyro-arytenoid ligament
Glottis	Glottis vera
Rima vestibuli	Glottis spuria
Cartilago thyreoidea	Thyroid cartilage

GLOSSARY

xxix

B.N.A. TERMINOLOGY.

Membrana hyo-thyreoidea
 Cartilago corniculata (Santorini)
 Tuberculum epiglotticum
 Pars intermembranacea (rimæ
 glottidis)
 Pars intercartilaginea (rimæ
 glottidis)
 Conus elasticus (membranæ
 elasticæ larynges)
 Glandula thyreoidea
 Glomus caroticum

Nose

Concha nasalis suprema (Santorini)
 Concha nasalis superior
 Concha nasalis media
 Concha nasalis inferior

OLD TERMINOLOGY.

Thyro-hyoid membrane
 Cartilage of Santorini
 Cushion of epiglottis
 Glottis vocalis
 Glottis respiratoria
 Crico-thyroid membrane
 Thyroid gland
 Intercarotid gland or body
 Highest turbinate bone
 Superior turbinate bone
 Middle turbinate bone
 Inferior turbinate bone

Urogenital Apparatus.

Corpuscula renis
 Paradidymis
 Appendix testis
 Ductus deferens
 Gl. urethrales
 Glandula bulbo-urethralis (Cowperi)
 Folliculi oophori vesiculosi
 Cumulus oophorus
 Tuba uterina
 Epoophoron
 Appendices vesiculosi
 Ductus epoophori longitudinalis
 Orificium internum uteri
 Orificium externum
 Processus vaginalis
 Glandula magna vestibuli

Malpighian corpuscles
 Organ of Giralde's
 Hydatid of Morgagni (male)
 Vas deferens
 Glands of Littre
 Cowper's gland
 Graafian follicles
 Discus proligerus
 Fallopian tube
 Parovarium
 Hydatids of Morgagni (female)
 Gärtner's duct
 Internal os (of uterus)
 External os
 Canal of Nuck
 Bartholin's gland

Peritoneum.

Bursa omentalis
 Foramen epiploicum
 Lig. phrenico-colicum
 Excavatio recto-uterina (cavum
 Douglasi)
 Lig. gastro-lienale

Lesser peritoneal sac
 Foramen of Winslow
 Costo-colic ligament
 Pouch of Douglas
 Gastro-splenic omentum

SENSE ORGANS.

The Eye.

Sclera
 Lamina elastica anterior (Bowmani)

Sclerotic coat
 Bowman's membrane

B.N.A. TERMINOLOGY.	OLD TERMINOLOGY.
Lamina elastica posterior (Descemeti)	Descemet's membrane
Spatia anguli iridis	Spaces of Fontana
Angulus iridis	Irido-corneal junction
Zonula ciliaris	Zonule of Zinn
Septum orbitale	Palpebral ligament
Fascia bulbi	Capsule of Tenon
Commissura palpebrarum lateralis	External canthus
Commissura palpebrarum medialis	Internal canthus
Tarsus superior	Superior tarsal plate
Tarsus inferior	Inferior tarsal plate
Lig. palpebrale mediale	Internal tarsal ligament
Raphe palpebralis lateralis	External tarsal ligament
Tarsal glands	Meibomian glands

The Ear.

Canalis semicircularis lateralis	External semicircular canal
Ductus reuniens	Canalis reuniens
Ductus cochlearis	Membranous cochlea
Recessus sphericus	Fovea hemispherica
Recessus ellipticus	Fovea hemi-elliptica
Paries jugularis	Floor of tympanum
Paries labyrinthica	Inner wall
Fenestra vestibuli	Fenestra ovalis
Fenestra cochleæ	Fenestra rotunda
Paries mastoidea	Posterior wall
Antrum tympanicum	Mastoid antrum
Paries carotica	Anterior wall
Processus lateralis	Processus brevis (of malleus)
Processus anterior	Processus gracilis

MANUAL

OF

PRACTICAL ANATOMY.

THORAX.

THE dissection of the thorax is commenced on the *thirteenth* day¹ after the subject has been placed in the dissecting-room. By that time the upper limbs have been detached from the trunk.

In form, the thorax resembles a truncated cone. Anteriorly and posteriorly it is flattened; laterally it is full and rounded. During life the movements of the thoracic walls produce alterations in the capacity of the chest cavity, and play an essential part in the function of respiration; these movements the student should study upon himself and his friends.

The thoracic cavity is bounded *anteriorly* by the sternum and costal cartilages; it is bounded *posteriorly* by the twelve thoracic vertebræ and the intervening fibro-cartilages, together with the portions of the ribs which extend laterally from the vertebral column as far as the angles; the lateral boundaries are formed by the bodies of the ribs, from their angles posteriorly to their anterior extremities anteriorly. These parts constitute the framework of the thorax, and can be studied on the skeleton as well as upon the *part* before the dissection is commenced.

The anterior wall of the thorax is shorter than the posterior wall and, during expiration, the upper margin of the sternum

¹ Saturdays and Sundays are not counted.

THORAX

lies opposite the fibro-cartilage between the second and third thoracic vertebræ, whilst the lower end of the body of the sternum corresponds in level with the middle of the body of the ninth thoracic vertebra. The bodies of the thoracic vertebræ project anteriorly into the cavity of the thorax, and greatly diminish its antero-posterior diameter in the median plane; but the backward sweep of the posterior portions of the ribs produces a deep hollow on either side of the vertebral column, for the reception of the most massive part of the lung.

The superior aperture, *inlet of the thorax*, is a narrow opening which is bounded by the first thoracic vertebra, the

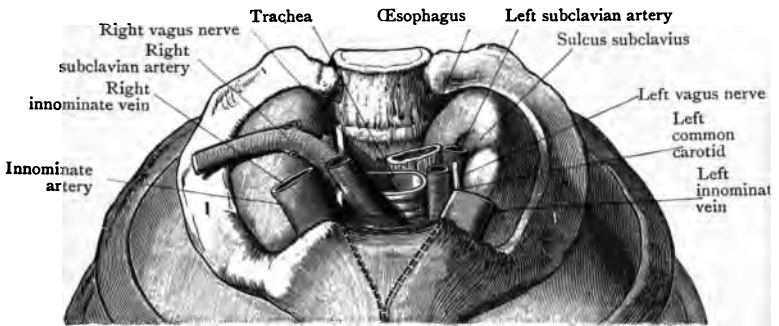


FIG. 1.—Cervical Domes of the Pleural Sacs, and parts in relation to them.

first pair of costal arches, and the manubrium sterni. The plane of this opening is very oblique; it slopes from the first thoracic vertebra anteriorly and downwards. Through the inlet of the thorax the apices of the lungs project upwards into the root of the neck, and, between them, the following structures pass through it:—the windpipe, the gullet, the vagi, the phrenic nerves, the left recurrent nerve, the ganglionated sympathetic trunks, the thoracic duct, and the great arteries and veins which carry blood to and from the head and neck and the upper limbs.

The base or inferior end of the thorax is very wide, and is sometimes called the *outlet*. Anteriorly it is bounded by the xiphoid process, and posteriorly by the twelfth thoracic vertebra. Between these points the lower margin of the thorax presents a curved outline. Starting from the sternum, it passes downwards, laterally, and posteriorly, as far as the tip of the eleventh costal cartilage; thence it proceeds up-

wards, posteriorly, and medially to the vertebral column. In the first part of its extent it is formed by the cartilages of the seventh, eighth, ninth, tenth and eleventh ribs, and in the second part by the lower border of the twelfth rib.

The lower margin of the thorax gives attachment to the diaphragm, a highly vaulted or dome-shaped musculo-tendinous partition, which intervenes between the cavity of the thorax above and that of the abdomen below. It forms a convex floor for the thorax, and a concave roof for the abdomen. By its upward projection it greatly diminishes the general vertical depth of the thoracic cavity.

But the diaphragm does not form an unbroken partition. It presents three large openings, by means of which structures pass to and from the thorax, viz.—(1) for the aorta, thoracic duct, and vena azygos; (2) for the œsophagus and vagi nerves; (3) for the inferior vena cava. Besides these there are other smaller apertures which will be mentioned later.

THORACIC WALL.

Two days at least should be devoted to the dissection of the thoracic wall.

In addition to the osseous and cartilaginous framework, the walls of the chest are built up partly by muscles, and partly by membranes, and in connection with these there are numerous nerves and blood-vessels.

Muscles, . . .	{	External intercostals.
	{	Internal intercostals.
	{	Transversi thoracis.
	{	Subcostals.
Membranes, . . .	{	Anterior intercostal membranes.
	{	Posterior intercostal membranes.
	{	Pleural membrane (parietal part).
Nerves and Arteries,	{	Intercostal nerves.
	{	Aortic intercostal arteries.
	{	Superior intercostal arteries.
	{	Internal mammary arteries.

Dissection.—Portions of certain of the muscles of the upper limb and of the abdominal wall are still attached to the thoracic wall on each side. Antero-posteriorly the dissector will meet with the *pectoralis major*, the *pectoralis minor*, and the *serratus anterior*, whilst towards the lower margin of the chest he will recognise the *rectus abdominis anterior*^{lv.} and the *obliquus externus* and *latissimus dorsi* upon its lateral aspect. The rounded tendon of the *subclavius* may also be seen taking origin from the first costal arch. These remnants must be removed so as to bare the costal arches and the intercostal muscles. In detaching

serratus anterior and external oblique be careful not to injure the *lateral cutaneous nerves* which make their appearance in the intervals between their digitations. The *anterior cutaneous nerves* and *perforating branches* of the internal mammary artery must also be preserved; they pierce the origin of the pectoralis major in the intervals between the costal cartilages, close to the margin of the sternum.

Intercostal Muscles and Membranes.—These muscles and membranes occupy the eleven intercostal spaces on each side. In each space there are two strata of muscular fibres—a superficial and a deep. The superficial layer of muscular fibres is called the *external intercostal muscle*, and the deep layer the *internal intercostal muscle*.

The *external intercostal muscles* are already exposed, and very little cleaning is necessary to bring out their connections. Note that entering into their constitution there is a large admixture of tendinous fibres, and that these, as well as the muscular fibres, are directed obliquely downwards and anteriorly from the lower border of the rib above to the upper border of the rib below. They do not extend farther anteriorly, in the various spaces, than the region of union of the bony with the cartilaginous parts of the costal arches. In many cases, especially in the upper spaces, they do not reach so far. When the muscular fibres stop, the tendinous fibres are prolonged onwards to the sternum in the form of a membrane, which is called the *anterior intercostal membrane*. The external intercostal muscles of the two lower spaces are exceptions to this rule. They extend anteriorly to the extremities of the spaces. Posteriorly the muscles extend as far as the tubercles of the ribs, but this is a point which can be satisfactorily demonstrated only after the thorax has been opened.

Dissection.—To bring the *internal intercostal muscles* into view it is necessary to reflect the external intercostal muscles, and also the anterior intercostal membranes. Divide them along the lower border of each space, and throw them upwards. In effecting this dissection, care must be taken of the intercostal vessels, which lie between the two muscular strata, and of the lateral branches of the intercostal nerves.

The *internal intercostal muscles*, thus laid bare, will be seen to be similar in their constitution to the external muscles. The fibres, however, run in the opposite direction—viz., from above, obliquely downwards and posteriorly. Superiorly, each is attached to the inner surface of the upper rib, immediately above the costal groove; inferiorly, it is attached upon the

inner surface of the lower rib, close to the upper margin. The internal intercostal muscles are prolonged anteriorly to the sternum. Posteriorly they extend to the angles of the ribs. The *posterior intercostal membranes* extend from the spine to posterior borders of the internal intercostals where they become continuous with the fascial layer between the external and internal intercostal muscles. They will be seen when the thorax is opened.

If the internal oblique muscle of the abdomen has not been removed, the dissector should note that the anterior fibres of the lowest two internal intercostal muscles become continuous with the fibres of that muscle.

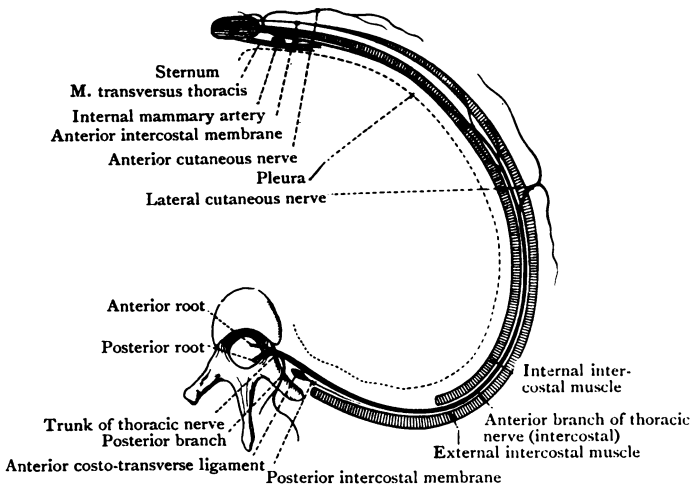


FIG. 2.—Diagram of one of the Upper Intercostal Nerves.

Intercostal Nerves.—The intercostal nerves are altogether out of sight in the present stage of the dissection. They are hidden by the lower borders of the ribs which bound the intercostal spaces superiorly. By gently pulling upon their lateral cutaneous branches they can be drawn downwards, and they are then seen to lie between the two muscular strata as far anteriorly as a point midway between the vertebral column and sternum. There they sink into the substance of the internal intercostal muscles, amidst the fibres of which they may be traced to the anterior extremities of the bony parts of the ribs, where they reach the deep surface of inter

intercostal muscles and are carried medially, first anterior to the pleura, and then anterior to the transversus thoracis muscle. Lastly, they cross anterior to the internal mammary artery and turn anteriorly, at the side of the sternum, as the *anterior cutaneous nerves* of the pectoral region. Each nerve, before it reaches the surface, pierces—(a) the internal intercostal muscle; (b) the anterior intercostal membrane; (c) the origin of the pectoralis major; and (d) the deep fascia (Fig. 2).

This description holds good for the upper five intercostal nerves only. The lower six nerves leave the anterior ends of the intercostal spaces and run into the abdominal wall. As they leave the thoracic wall the upper four of the six pass posterior to the upturned costal cartilages, and all six pass between the interdigitating slips of the diaphragm and the transversus abdominis muscles.

The intercostal nerves are the anterior branches of the upper eleven thoracic nerves. As they traverse the thoracic wall they give off—(a) the lateral cutaneous branches, (b) twigs to the intercostal, subcostal, and transversus thoracis muscles. The terminal extremities of the upper five become the anterior cutaneous nerves of the thorax. (For the abdominal distribution of the lower six see Vol. I., p. 394.)

The lateral cutaneous branches arise midway between the vertebral column and the sternum. They pierce the external intercostal muscles, and pass between the digitations of the serratus anterior.

The first intercostal nerve does not give a lateral branch, and it does not become cutaneous anteriorly. The lateral cutaneous branch of the second intercostal nerve is the so-called intercosto-brachial nerve.

It is not necessary to make a dissection of the intercostal nerves in more than two or three of the spaces.

Intercostal Vessels.—The intercostal arteries should be dissected in spaces in which the nerves have not been traced, and in which, therefore, the internal intercostal muscles are still entire. It is only in a well-injected subject that a satisfactory view of these vessels can be obtained. In each intercostal space *one* artery is found passing *dorso-ventrally*; and in each of the upper nine intercostal spaces, *two* anterior intercostal arteries run *ventro-dorsally*.

In the upper two spaces the vessels which run dorso-ventrally are derived from the *superior intercostal* division of the costo-cervical branch of the subclavian artery; in the lower nine spaces they spring directly from the aorta, and are called the *aortic intercostal arteries*.

The *anterior intercostal arteries* of the upper six spaces proceed directly from the internal mammary, whilst those of seventh, eighth, and ninth spaces arise from the musculo-phrenic artery.

The intercostal vessels are distributed for the most part between the two muscular strata. From the angles of the ribs onwards to a point midway between the vertebral column and sternum, the *aortic intercostal arteries* lie under shelter of the lower margins of the ribs which bound the spaces superiorly, and at a higher level than the corresponding nerves. Then each divides into two branches, which pass ventrally in relation to the upper and lower margins of the intercostal space. They give off small branches which accompany the lateral cutaneous nerves. The lower two aortic intercostal arteries are carried onwards into the abdominal wall. The branches of the *superior intercostal artery* are disposed in a manner similar to the aortic intercostal vessels.

The *anterior intercostal arteries* are two in number for each space, except the last two. At their origins they lie under cover of the internal intercostal muscles, and they run laterally in relation to the upper and lower margins of the ribs bounding the spaces. After a short course they pierce the internal intercostal muscles, and end by anastomosing with the aortic and superior intercostal arteries.

Dissection.—The dissector should next proceed to remove the intercostal muscles. This dissection must be done with great care, for immediately subjacent to the internal intercostals and the ribs is the delicate pleural membrane which lines the inner surface of the chest wall. The membrane must not be injured or detached from the deep surfaces of the ribs during this stage of the dissection. As the internal intercostal muscles are removed, the anterior perforating branches of the internal mammary and musculo-phrenic arteries, and the anterior cutaneous nerves must be preserved.

When the muscles are removed the internal mammary artery with its two accompanying veins will be seen behind the costal cartilages, about half an inch from the side of the sternum. Clean these arteries in the intervals between the cartilages and note the small lymph glands which lie beside them. Each internal mammary artery ends by dividing into superior epigastric and musculo-phrenic terminal branches in the interval between the sixth and seventh rib cartilages. Most likely this space will be so narrow that a view of the bifurcation cannot be obtained. If this is the case, pare away the edges of the cartilages over the artery, or,

if necessary, remove the medial part of the sixth cartilage completely. The muscle posterior to the internal mammary artery is the transversus thoracis (O.T. triangularis sterni). Endeavour to define its slips in the intervals between the costal cartilages.

The dissector should note, as an important practical point, that towards the lower margin of the thorax the pleural sac is not prolonged downwards to the lowest limit of the recess between the diaphragm and the costal arches. Indeed, in the axillary line, it will be found to fall considerably

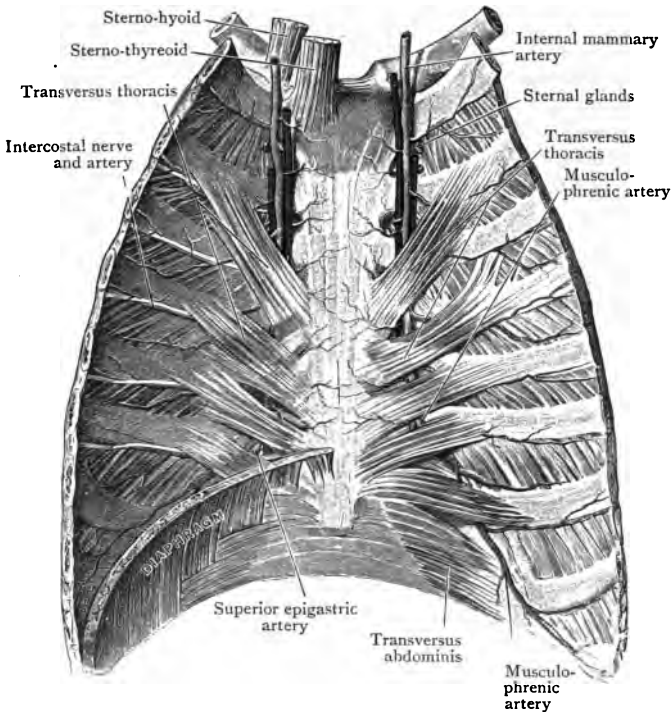


FIG. 3.—Dissection of the posterior surface of the Anterior Wall of the Thorax.

short of this. Consequently the dissector will come down directly upon the diaphragm, when the internal intercostal muscles are removed from this portion of the chest wall. The fibres of the diaphragm correspond somewhat in their direction with those of the internal intercostal muscles, and it is no uncommon occurrence for the student to remove them, and thus expose the peritoneum, under the impression that he has simply laid bare the pleura. When the dissection is properly executed a strong fascia will be seen. It passes from the surface of the diaphragm to the surface of the costal pleura and holds the latter in position. Preserve this membrane for further examination.

Arteria Mammaria Interna.—This vessel arises, in the root of the neck, from the first part of the subclavian. It enters the thorax by passing downwards, posterior to the sternal end of the clavicle and the cartilage of the first rib, and it descends to the interval between the sixth and seventh costal cartilages, where it ends by dividing into the *superior epigastric* and the *musculo-phrenic branches*.

Placed anterior to the internal mammary artery are the upper six costal cartilages, with the intervening internal intercostal muscles and anterior intercostal membranes. The intercostal nerves cross anterior to it before they turn forwards to gain the surface. Posterior to the upper part of the artery is the pleura; and the transversus thoracis intervenes between the lower part of the artery and the pleural sac.

In addition to its two terminal branches, a large number of small collateral twigs proceed from the internal mammary—

- | | |
|------------------------------------|---|
| 1. The anterior intercostal, . . . | } to the thoracic parietes. |
| 2. The perforating, . . . | |
| 3. The pericardio-phrenic, . . . | } to parts in the interior of the thorax. |
| 4. Mediastinal and thymic, . . . | |
| 5. Superior epigastric, . . . | } the terminal branches. |
| 6. Musculo-phrenic, . . . | |

The *anterior intercostal arteries* are supplied to the upper six intercostal intervals, and have been dissected already (p. 6). Two are given to each space: frequently these arise by a common trunk.

The *perforating arteries* accompany the anterior cutaneous nerves, and reach the surface by piercing the internal intercostal muscles, the anterior intercostal membranes, and the pectoralis major muscle. One, or perhaps two, are given off in each intercostal space. In the female those of the second, third, and fourth spaces attain a special importance, inasmuch as they constitute the principal arteries of supply to the mammary gland.

The *superior epigastric artery* passes between the sternal and costal origins of the diaphragm and enters the sheath of the rectus muscle of the abdominal wall.

The *musculo-phrenic artery* turns laterally and downwards, along the costal origin of the diaphragm and behind the rib-cartilages. Opposite the eighth costal cartilage it pierces the diaphragm and terminates on its abdominal surface. It gives off the *anterior intercostal arteries* to the seventh, eighth, and ninth intercostal spaces (p. 7).

Musculus Transversus Thoracis (O.T. Triangularis Sterni).

—This is a thin muscular layer placed on the deep surface of the sternum and costal cartilages. It is continuous below with the transversus abdominis, and arises from the posterior surface of the xiphoid process, the lower part of the body of the sternum, and from the medial ends of the fifth, sixth, and seventh costal cartilages. Its fibres radiate in an upward and lateral direction, in the form of five slips, which are inserted into the deep surfaces and lower borders of the second, third, fourth, fifth, and sixth costal cartilages, close to their junction with the ribs (Fig. 3).

In many cases the muscle is feebly developed, and does not show such wide connections. Upon its anterior aspect are placed the internal mammary artery and some of the intercostal nerves.

It is only a partial view of the muscle which is obtained in the present dissection, but it is not advisable to remove the costal cartilages to expose it further, as this would materially interfere with the subsequent display of other more important structures in their proper relations.

THORACIC CAVITY.

Before the dissection of the interior of the thorax is commenced it is necessary that the dissectors should have some general knowledge of the cavity and its contents. The shape and the boundaries have been studied already (p. 1), and it must now be understood that the cavity is divided into two lateral parts by a median septum called *the mediastinum*, which extends from the sternum anteriorly to the vertebral column posteriorly, and from the upper aperture of the thorax above to the diaphragm below.

The mediastinum is formed by the heart, enveloped in a fibro-serous sac called the pericardium; the great vessels passing to and from the heart, *i.e.* the pulmonary artery and veins, the aorta, and the vena cava superior; the œsophagus; the trachea and the commencements of the bronchi; the thoracic duct; the azygos, hemiazygos and accessory hemiazygos veins; the vagi and phrenic nerves; numerous lymph glands; and the areolar tissue in which these structures are embedded and by which they are bound together. For convenience of description the mediastinum is divided into a *superior* and an *inferior portion*, by an imaginary plane which passes from the lower border of the manubrium sterni anteriorly, to the lower border of the fourth thoracic vertebra

posteriorly; and the inferior mediastinum is subdivided into anterior, middle, and posterior portions. The *anterior mediastinum* is the part anterior to the pericardium, the *posterior mediastinum* the part posterior to the pericardium, whilst the pericardium and the heart with the great vessels and the phrenic nerves with their accompanying vessels form the *middle mediastinum*. It is customary, however, to speak of the mediastinum as if it were a space, and to say that the various viscera, vessels, etc., lie in the mediastina (Fig. 19, p. 44).

The lateral portions of the thoracic cavity are known as

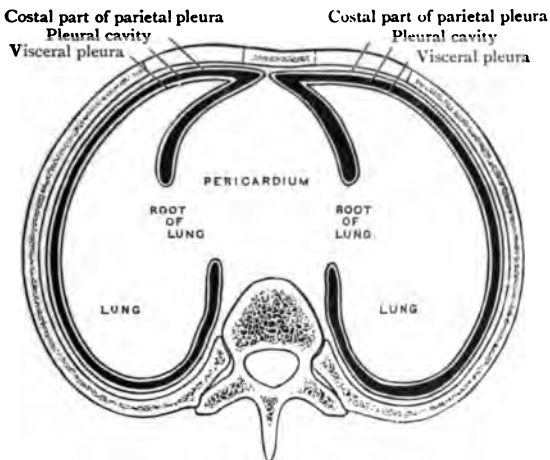


FIG. 4.—Diagrammatic representation of a cross section through the Thorax.

the pleural spaces; each contains the corresponding lung surrounded by an invaginated serous membrane called the pleural sac. There are therefore two pleural sacs, and each is so disposed that it not only lines the chamber in which the lung lies, but is also reflected over the surface of the lung, so as to give it an external covering which is intimately connected with the pulmonary substance. Consequently, the wall of each pleural sac is separable into two portions, an investing or visceral part which covers the surface of the lung, and a lining or parietal part which clothes the inner surfaces of the boundary of each lateral part of the thoracic cavity. It must be clearly understood, however, that the two terms are merely applied to indicate different portions of a continuous membrane.

Each lung lies free in the pleural space except along its medial surface, where it is attached to the heart by the pulmonary vessels, to the corresponding bronchial tube, and by a fold of pleura to the side of the pericardium.

The dissection which has already been made shows the pleura lining the deep surfaces of the costal arches and the internal intercostal muscles. This part is called the *costal pleura*, and it is part of the *parietal pleura*, but before it can be more fully investigated and before the remaining parts of the pleuræ and the lungs can be examined, further dissection is necessary.

Dissection.—The pleural membrane previously exposed by the removal of the contents of the intercostal spaces must now be carefully separated from the inner surfaces of the ribs by the gentle pressure of the fingers. The separation should be carried anteriorly to the junction of the ribs with their cartilages and posteriorly as far as possible. When this has been done the ribs, from the second to the sixth inclusive, must be divided, with bone forceps, at their junctions with their cartilages, and at the same time any fibres of the transversus thoracis which may be attached to them must be cut. *The first and the seventh and those below the seventh must not be interfered with.* Afterwards the ribs must be divided as far dorsally as possible and the separated portions removed. After the separated parts of the ribs are detached, remove any sharp spicules of bone from the cut ends of the remaining portions.

The outer surface of the costal part of the parietal pleura will be exposed in the area from which the ribs have been removed, and the dissector should notice that it has the appearance of a fibrous membrane with a rough surface, the roughness being due to fragments of the connective tissue (endothoracic fascia) which connect it with the adjacent parts.

After he has examined the outer surface of the pleura, the dissector should divide it by a vertical incision about midway between the anterior and posterior borders of the area exposed. At each end of the vertical incision a transverse incision must be made. One of the two flaps so formed must be thrown anteriorly, and the other posteriorly. The pleural sac is now opened and the lateral surface of the lung, covered with the visceral portion of the pleura, is exposed.

The cavity of the sac and its relations to the mediastinal septum, the diaphragm, and the root of the neck can be explored with the fingers; and the borders, surfaces, and the root of the lung can be examined.

The Pleural Sacs are two in number, a right and a left. They are serous sacs, and are therefore closed. After opening into the interior, the dissector should notice the difference between the rough outer surface of the wall of the sac and its smooth and glistening inner surface, and in order that he may thoroughly understand the relationship of the wall of the sac to the lung, the mediastinum and the wall of the thoracic cavity, he should follow the wall of the sac, with his fingers, at three different levels—(1) at the level of the

manubrium sterni; (2) at the level of the third intercostal space; and (3) at the level of the fifth costal cartilage. He must trace the wall of the sac in the vertical plane also.

Commencing at the level of the third intercostal space, he should place his fingers on the surface of the lung and follow it anteriorly and medially until, behind the sternum, he reaches the sharp anterior border, which should be pulled laterally; then, turning from the lung to the parietal pleura, he should place his fingers on the inner surface of the anterior flap and follow it medially. He will find, at a certain point posterior to the sternum, and to the left of the median plane, that his fingers cease to pass towards the opposite side but are carried posteriorly, along the lateral boundary of the mediastinum, until they come to the big blood vessels and the air tube of the lung which collectively form its root. Along the front of the vessels his fingers will now pass laterally, following the reflection of the pleura on the front of the vessels, to the medial surface of the lung, and then anteriorly to its anterior border. Round the anterior border they will arrive at the lateral surface of the lung; along this they will pass to the posterior border and thence anteriorly along the posterior part of the medial surface to the posterior surface of the root, where they will feel, distinctly, the hard outline of the bronchus. Following the posterior surface of the root medially, they will reach the posterior part of the lateral boundary of the mediastinum, along which they will pass posteriorly to the vertebral column, and thence laterally along the posterior parts of the ribs, and finally anteriorly along the inner surface of the posterior flap to its anterior margin.

If the dissector has followed the above instructions he cannot fail to have recognised that the pleural sac is invaginated by the lung, which in its growth laterally from the mediastinal septum has invaginated and expanded a part of the medial wall of the sac. The dissector should now examine a transverse section of a hardened thorax, or if that is not available, the diagram on p. 11. The study of either will convince him that the lung carrying the invaginated part of the wall of the pleural sac on its surface has expanded until it has practically obliterated the cavity of the sac, and he will find that the invaginated pleura on the surface of the lung, which is called the *visceral pleura*, everywhere in close apposition with the non-invaginated

portion which is termed the *parietal pleura*; all that intervenes between the two portions being a thin stratum of fluid, sufficient to lubricate the surfaces and prevent friction during the movements of the lung and the chest wall.

After he has grasped the facts noted above the dissector should follow the inner surface of the pleura in the transverse plane at the level of the ^{5th} fifth costal cartilage, that is, below the level of the root of the lung. At that level he will find that the parietal pleura covering the lateral surface of the mediastinal septum is connected with the visceral pleura on the medial surface of the lung by a thin fold, the pulmonary ligament (O.T. ligamentum latum pulmonis). This consists of an anterior and a posterior layer, which correspond, respectively, with the layers on the front and the back of the root of the lung, but are in contact with each other at the level of the fifth rib, on account of the absence of the great blood vessels and air tube of the lung. The pulmonary ligament extends laterally from the mediastinum to the medial surface of the lung, and from the root of the lung above, to within a short distance from the diaphragm below. Its medial, lateral, and upper borders are attached respectively to the mediastinal septum, the lung, and the lower border of the lung root, and are continuous with the pleura covering each, but its lower border is free. When he has satisfied himself regarding the nature and the attachments of the pulmonary ligament, the dissector should trace the pleura in the horizontal plane at the level of the manubrium sterni, that is, above the level of the root of the lung. There he will find that the medial wall of the sac is not reflected on to the lung, but that it passes posteriorly along the lateral surface of the mediastinal septum from the sternum anteriorly to the vertebral column posteriorly, and thence laterally and anteriorly to the sternum in an unbroken circle. In the same way he will be able to trace the visceral pleura in a similar but smaller unbroken circle around the upper part of the lung.

Having traced the pleura in three horizontal planes the dissector must next trace it in the vertical plane, first around the lung, and then around the wall of the thorax. Commencing with the lung, the fingers should be passed along the anterior border to the apex, thence, down the thick posterior border, to the base, and anteriorly, across the concave base, to the anterior border. By doing this he will again demonstrate to himself

the fact that the lung is ensheathed in visceral pleura. Next, placing his fingers on the inner surface of the parietal pleura behind the costal cartilages, he should carry them upwards towards the head, and he will find that they pass upwards into the root of the neck for a distance of from one to two inches above the level of the anterior part of the first rib, but, on account of the oblique position of the rib, only to the level of its neck posteriorly. The apex of the sac, therefore, lies in

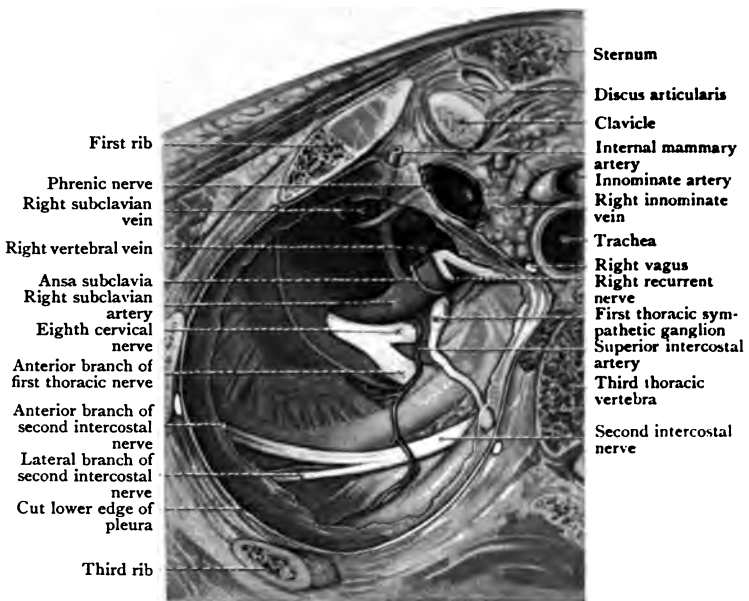


FIG. 5.—Structures in relation with the apex of the pleural sac, seen from below.

the root of the neck, and by carefully palpating its inner surface, the dissector will be able to distinguish the subclavian artery which passes across its anterior surface below the highest point, and, possibly, he may be able to locate the internal mammary and costo-cervical arteries (O.T. superior intercostal). The first descends from the subclavian trunk anterior to the apex of the sac, and the second passes first upwards to the apex and then posteriorly above it. After the dissector has examined the position and relations

apex of the sac he should follow its posterior wall downwards, just lateral to the line of the vertebral column, and, if he is dealing with a subject in good condition, he will find that he can pass his fingers downwards to the lower border of the twelfth rib, where they will be carried anteriorly on to the diaphragm and over its surface to the anterior wall of the thorax. If the dissector carries out the examination of the pleural sac in a thorough manner, and if he has appreciated the significance of the arrangements found at different levels, he will have repeatedly convinced himself that the lung, carrying the blood vessels and air tube with it, has invaginated a portion of the lower part of the medial wall of the pleural sac, and has then expanded anteriorly, posteriorly, upwards and, to a certain extent, downwards beyond the margins of the aperture of invagination, whose position is indicated by the root of the lung and the line of attachment of the pulmonary ligament. The portion of the wall of the pleura which is invaginated by the lung is represented by (1) the visceral pleura, (2) the layers covering the root of the lung, and (3) the pulmonary ligament.

Before each lung is removed the dissectors should note that its anterior margin does not extend so far anteriorly, and the inferior margin does not extend so far downwards, as the corresponding part of the pleura. The portions of the pleura unoccupied by the lung are called the pleural sinuses. The sinus along the anterior margin of the pleura is the *costo-mediastinal sinus*, and that along the lower margin, the *phrenico-costal sinus*. The walls of the sinuses are separated by a capillary space filled with pleural fluid, and the margins of the lungs enter into the sinuses and recede from them during inspiration and expiration, respectively.

In the event of the lungs not having been hardened in situ by formalin injection the dissectors may, with the consent of the dissectors of the head and neck, introduce the nozzle of the bellows into the cervical part of the trachea and inflate the lungs with air. A truer conception of these organs will thus be obtained, and a demonstration will be afforded of their high elasticity, and of their connection with the wind-pipe.

After the dissector has completed the general examination of the walls of the pleural sac, he should pull the anterior margin of the lung laterally to expose its medial surface, the front of the root and the front of the pulmonary ligament; then he should divide the root and the pulmonary ligament, from above downwards, close to the medial surface of the

lung. The lung, thus set free, is to be removed from the thorax, wrapped in a cloth damped with preservative solution, and placed aside for future study.

When the lung has been removed the margins of the pleural sac must be examined, and their positions relative to the chest wall noted. This cannot be done to the best advantage until both lungs have been removed. When this has been done the dis-

sector should introduce one hand into each pleura, and placing an index finger in each apex, he should note that the apex is situated about one inch above the junction of the lateral two-thirds with the medial third of the clavicle, a fact which he can demonstrate with the aid of his partner on the opposite side, who should hold two macerated clavicles in their proper positions. The apices of opposite sides, therefore, are some distance apart, and are separated from each other by the structures occupying the median part of the neck; *i.e.* the

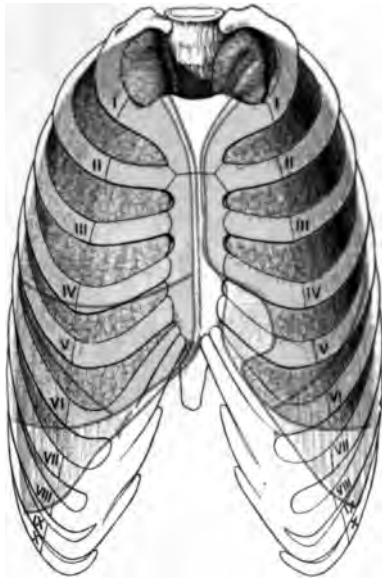


FIG. 6.—Diagram to show the relation of the lungs and the pleural sacs to the anterior thoracic wall. The lungs are depicted in red, and the pleural sacs in blue.

air tube, the gullet, and the great arteries passing upwards to the head. As the anterior margins of the pleuræ are traced downwards from the apices they will be found to converge, passing behind the sterno-clavicular joints and coming into apposition at the lower border of the manubrium sterni, immediately to the left of the median plane. Traced further downwards the anterior margins remain in apposition, the right frequently overlapping the left and both inclining slightly to the left, to the level of the fourth costal cartilages. From the fourth cartilage

the anterior margin of the right sac continues to descend, still with a slight inclination to the left, till it reaches the xiphoid process, where it becomes continuous with the inferior margin. This turns laterally, passing behind the xiphoid process and the cartilage of the seventh rib ; it then crosses the junction

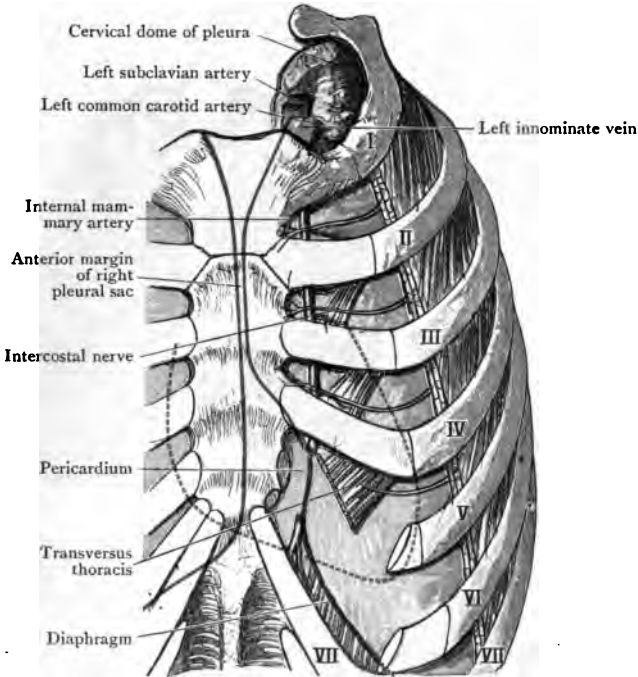


FIG. 7.—Diagram to show the parts which lie anterior to the pericardium and heart. The outline of the heart is indicated in red by a dotted line, and the anterior margins of the pleural sacs are represented by blue lines.

of the bone and cartilage of the eighth rib and reaches the level of the tenth rib in the mid-axillary line ; turning posteriorly, it crosses the eleventh and twelfth ribs, and just below the middle of the latter it becomes continuous with the posterior margin, which ascends along the line of the angle of the ribs to the apex. On the left side, at the level of the fourth costal cartilages, the anterior margin of the left pleura turns away from the median plane, for a variable distance,

passing behind the fifth costal cartilage at the margin of the sternum, or even an inch more laterally; it then descends to the lower border of the sixth cartilage, where it becomes

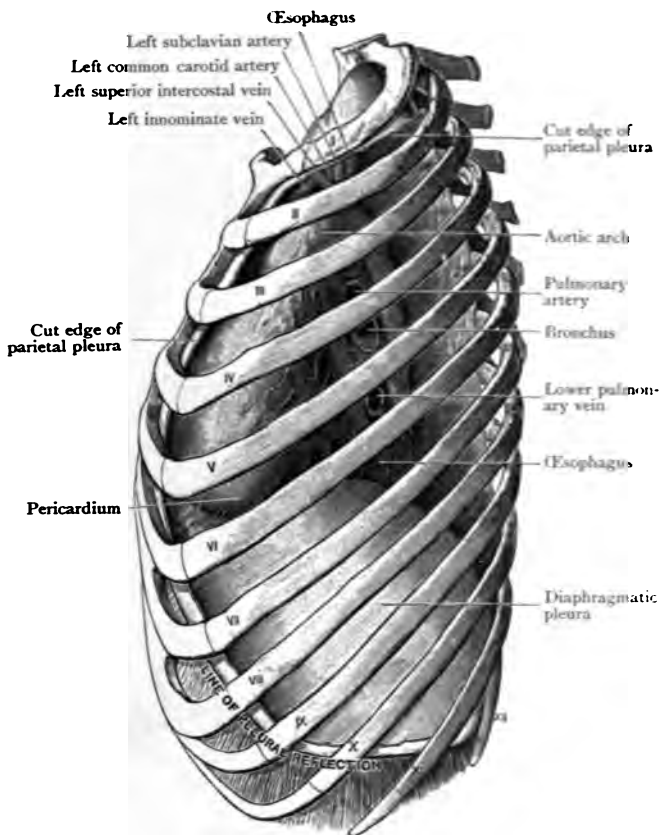


FIG. 8.—Left Pleural Sac, of a subject hardened by formalin injection, opened into by the removal of the costal pleura. The left lung also has been removed so as to display the mediastinal pleura. The line along which the pleura is reflected from the diaphragm on to the thoracic wall is exhibited.

continuous with the lower margin of the pleura, which passes laterally and posteriorly along the lower border of the sixth cartilage, across the medial end of the sixth space, and across the seventh cartilage to the junction of the cartilage and

bone of the eighth rib. The remainder of its course and the position of its posterior margin are the same as on the right side.

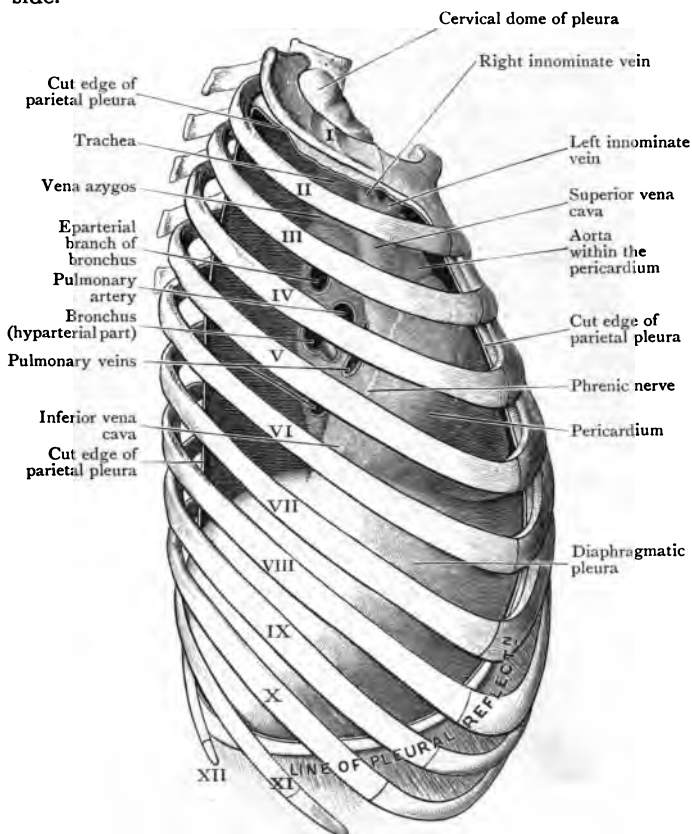


FIG. 9.—The Right Pleural Sac, in a subject hardened by formalin injection, opened into by the removal of the costal part of the parietal pleura. The right lung also has been removed to display the right mediastinal pleura. Note the line of diaphragmatic reflection of the pleura.

The student should mark out the margins of the pleural sacs on the living body, using himself and his friends for the purpose, until he can indicate them correctly, judging from the contour of the body alone and without feeling for the skeletal points.

After the dissector has made himself thoroughly conversant

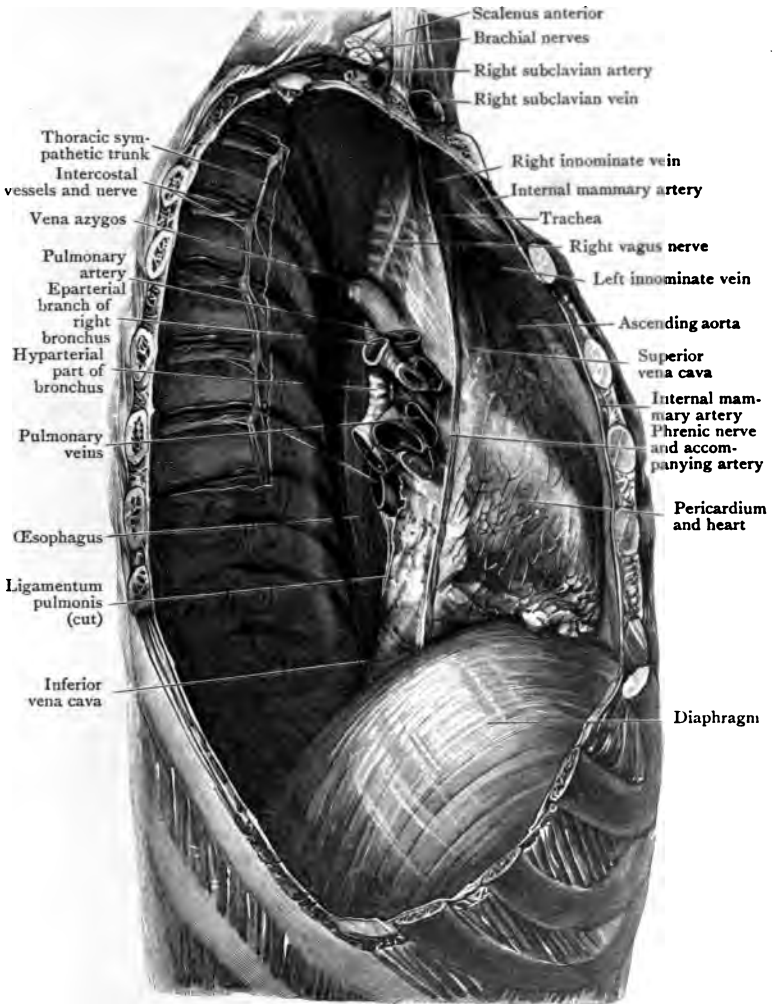


FIG. 10.—The Right Pleural Chamber opened up by the removal of its lateral wall. The lung has been taken away so as to expose the mediastinal wall of the pleural chamber. Several of the structures in the mediastinal septum are seen shining through the mediastinal pleura.

11-2b

with the limits of the pleural sacs, he should examine the cut section of the root of the lung, and should endeavour to recognise, through the mediastinal part of the parietal pleura, the positions of the main constituent parts of the mediastinum. As these vary on the opposite sides, each side must be considered separately, and each dissector must make himself well acquainted with the conditions on both sides.

On the right side, in the posterior part of the face of the section of the lung root, at least two parts of the bronchial tube will be seen; an upper, which is the so-called eparterial bronchus, and a lower, the main stem of the right bronchus. Anterior to and between the two bronchi is the pulmonary artery, and more anteriorly, and at a slightly lower level, the upper pulmonary vein. The lower pulmonary vein lies in the lowest part of the root, below and slightly posterior to the main bronchus. If the specimen is well injected, branches of the right bronchial artery may be distinguished on the posterior faces of the air tubes; and anterior to and between the great blood vessels, and between them and the bronchi, are a number of bronchial glands, which are easily distinguished by the black pigment deposited within them.

In the posterior part of the root of the lung, *on the left side*, the dissectors will see the cut section of the left bronchus, and, in many cases, a section of its first ventral branch also. The left pulmonary artery is above the bronchus, and its anterior wall is on a slightly anterior plane. The upper left pulmonary vein is anterior to the bronchus, and the lower left pulmonary vein is below the bronchus. In a well injected specimen the two left bronchial arteries may be seen on the posterior wall of the bronchus, and a number of bronchial glands will be found between and around the large blood vessels and the bronchus.

Turning next to the mediastinal pleura *on the right side*, the dissectors will note, anterior to and below the root of the lung, a large bulging, due to the heart and pericardium, which lie in the middle mediastinal area. Continuous with the upper and lower ends of the posterior part of this bulging they will see two longitudinal elevations. The upper, from the level of the third costal cartilage to the lower margin of the first rib, is due to the superior vena cava and above that level, to the right innominate vein. The lower elevation is very short, and is caused by the upper part of the inferior

vena cava. A secondary ridge, formed by the phrenic nerve and the accompanying blood vessels, descends along the elevation caused by the superior vena cava, crosses anterior to the root of the lung, runs down along the posterior part of the bulging due to the heart, and the anterior border of the inferior caval elevation. Arching over the root of the lung is a curved ridge, due to the upper part of the vena azygos, as it passes anteriorly to join the superior cava. Above the vena azygos and posterior to the superior cava, the right lateral surface of the trachea, or main air tube, may be seen or felt in the superior mediastinal region, and, descending obliquely across it, from above downwards and posteriorly, the right vagus nerve can be palpated or seen. Posterior to the root of the lung and to the bulging due to the heart, the œsophagus may be recognised in the posterior mediastinal area, either by touch or sight, or both. Somewhat posterior to the œsophagus the margin of the ascending portion of the vena azygos may be noted, and still further posteriorly are the bodies of the vertebræ and the posterior parts of the ribs. Crossing the bodies of the vertebræ transversely the right intercostal vessels may be visible or they may be felt, and, descending along the line of the heads of the ribs, the ganglionated trunk of the sympathetic can be recognised by touch, if not by sight.

The dissectors should examine next the mediastinum and the posterior wall of the thorax on the left side (see Figs. 8, 11, and 13).

By inspection and palpation they will easily recognise the positions of the larger and more important structures. Below and anterior to the root of the lung the mediastinal pleura is bulged much more laterally on the left than on the right side by the heart covered by the pericardium. Arching posteriorly and to the left, over the root of the lung, in the superior mediastinal area, is the arch of the aorta, and from its posterior end the descending aorta runs downwards, in the posterior mediastinal area, first posterior to the root of the lung, and then posterior to the heart but separated, in part, from the latter by the œsophagus, which diverges towards the left side in the lower part of the thorax. Above the arch of the aorta the left common carotid and subclavian arteries and the œsophagus can be distinguished in the above order antero-posteriorly. A long slender secondary ridge, p

bone of the eighth rib. The remainder of its course and the position of its posterior margin are the same as on the right side.

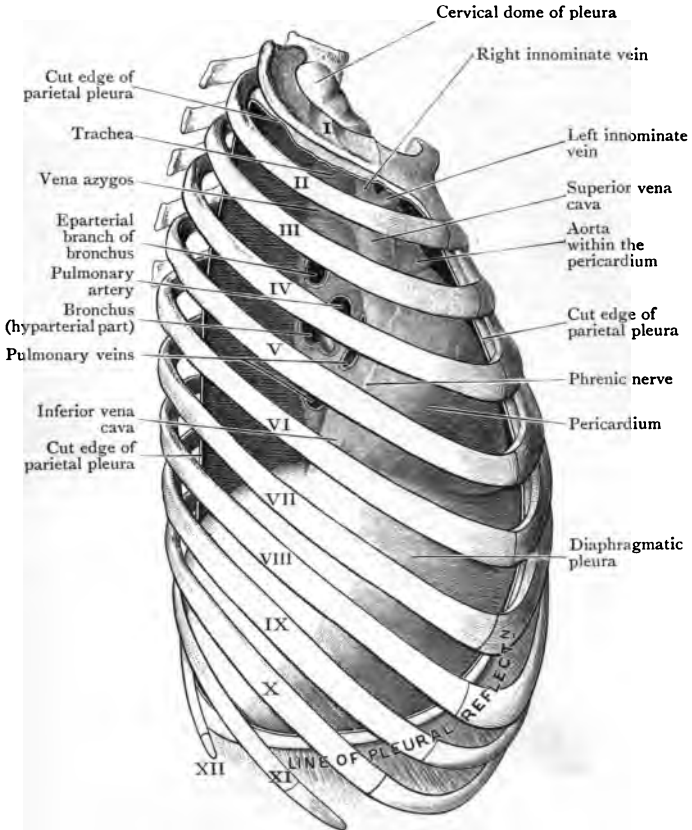


FIG. 9.—The Right Pleural Sac, in a subject hardened by formalin injection, opened into by the removal of the costal part of the parietal pleura. The right lung also has been removed to display the right mediastinal pleura. Note the line of diaphragmatic reflection of the pleura.

The student should mark out the margins of the pleural sacs on the living body, using himself and his friends for the purpose, until he can indicate them correctly, judging from the contour of the body alone and without feeling for the skeletal points.

After the dissector has made himself thoroughly conversant

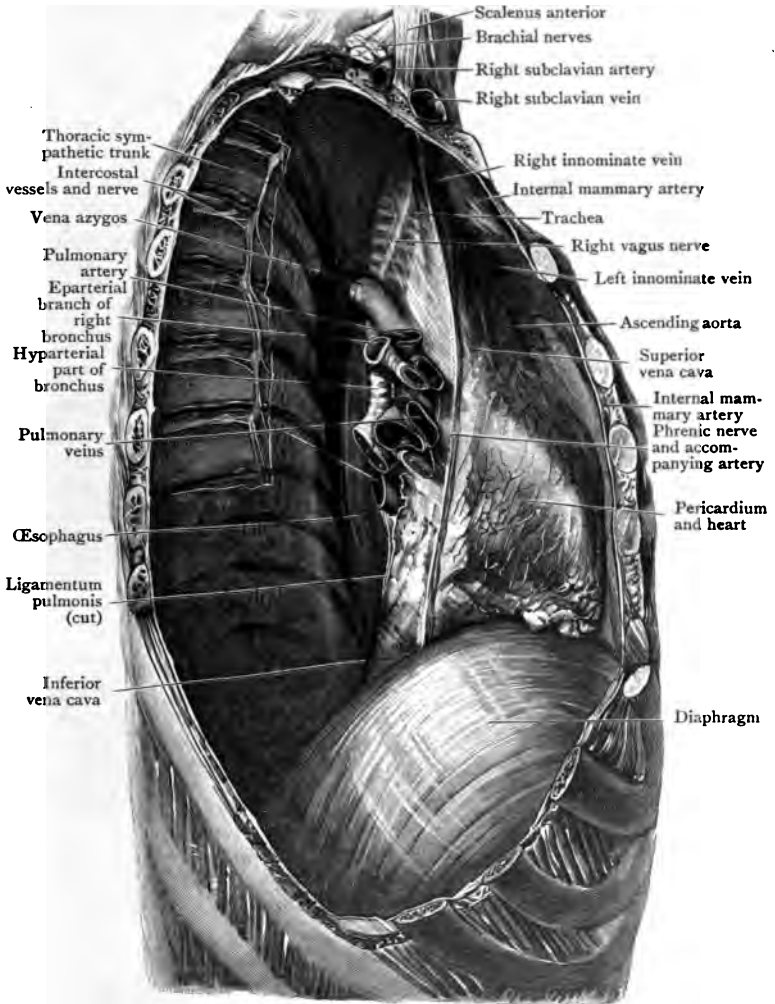


FIG. 10.—The Right Pleural Chamber opened up by the removal of its lateral wall. The lung has been taken away so as to expose the mediastinal wall of the pleural chamber. Several of the structures in the mediastinal septum are seen shining through the mediastinal pleura.

11—2 b

bone of the eighth rib. The remainder of its course and the position of its posterior margin are the same as on the right side.

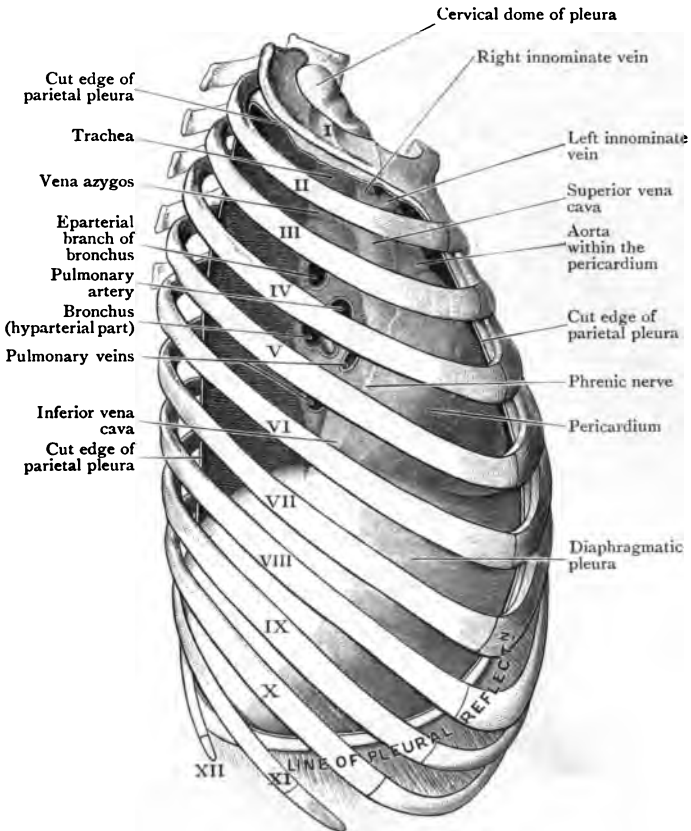


FIG. 9.—The Right Pleural Sac, in a subject hardened by formalin injection, opened into by the removal of the costal part of the parietal pleura. The right lung also has been removed to display the right mediastinal pleura. Note the line of diaphragmatic reflection of the pleura.

The student should mark out the margins of the pleural sacs on the living body, using himself and his friends for the purpose, until he can indicate them correctly, judging from the contour of the body alone and without feeling for the skeletal points.

After the dissector has made himself thoroughly conversant

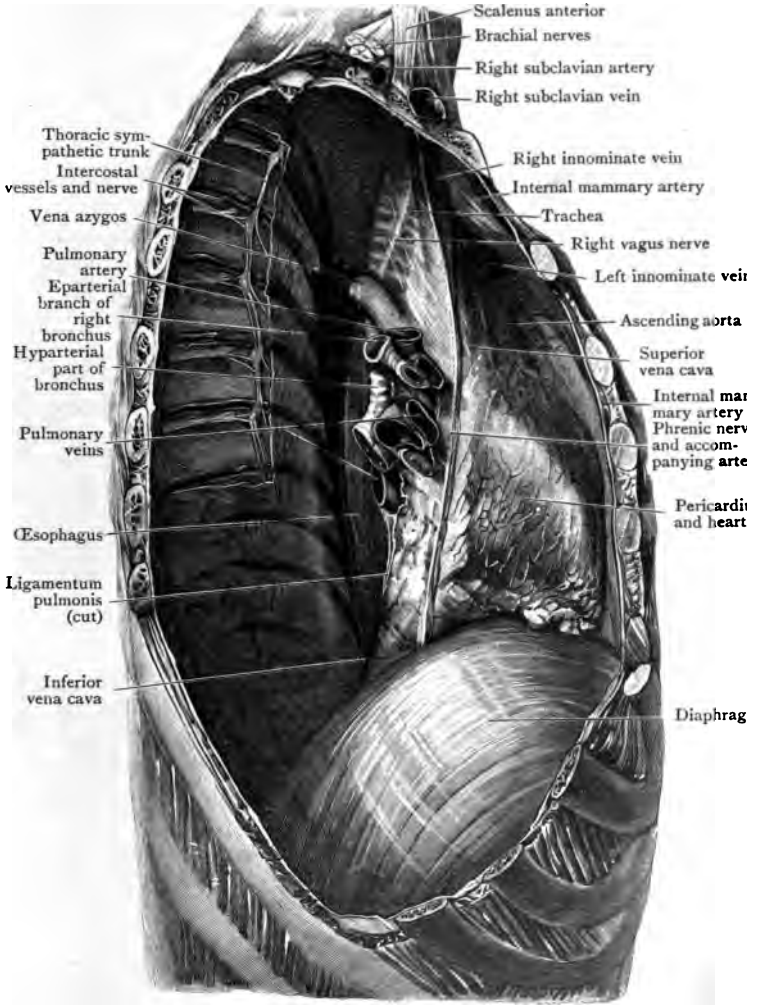


FIG. 10.—The Right Pleural Chamber opened up by the removal of its lateral wall. The lung has been taken away so as to expose the mediastinal wall of the pleural chamber. Several of the structures in the mediastinal septum are seen shining through the mediastinal pleura.

11—2 b

bone of the eighth rib. The remainder of its course and the position of its posterior margin are the same as on the right side.

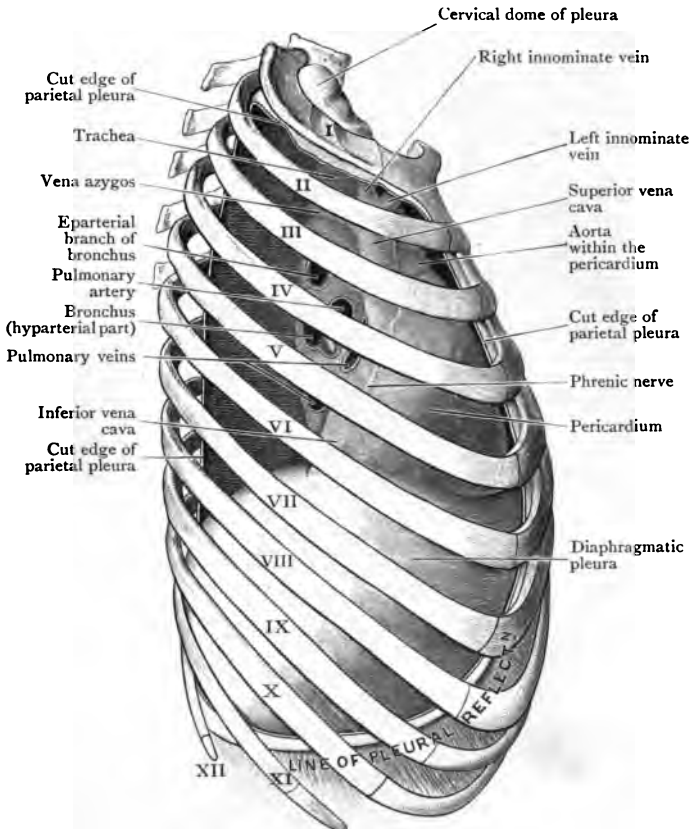


FIG. 9.—The Right Pleural Sac, in a subject hardened by formalin injection, opened into by the removal of the costal part of the parietal pleura. The right lung also has been removed to display the right mediastinal pleura. Note the line of diaphragmatic reflection of the pleura.

The student should mark out the margins of the pleural sacs on the living body, using himself and his friends for the purpose, until he can indicate them correctly, judging from the contour of the body alone and without feeling for the skeletal points.

After the dissector has made himself thoroughly conversant

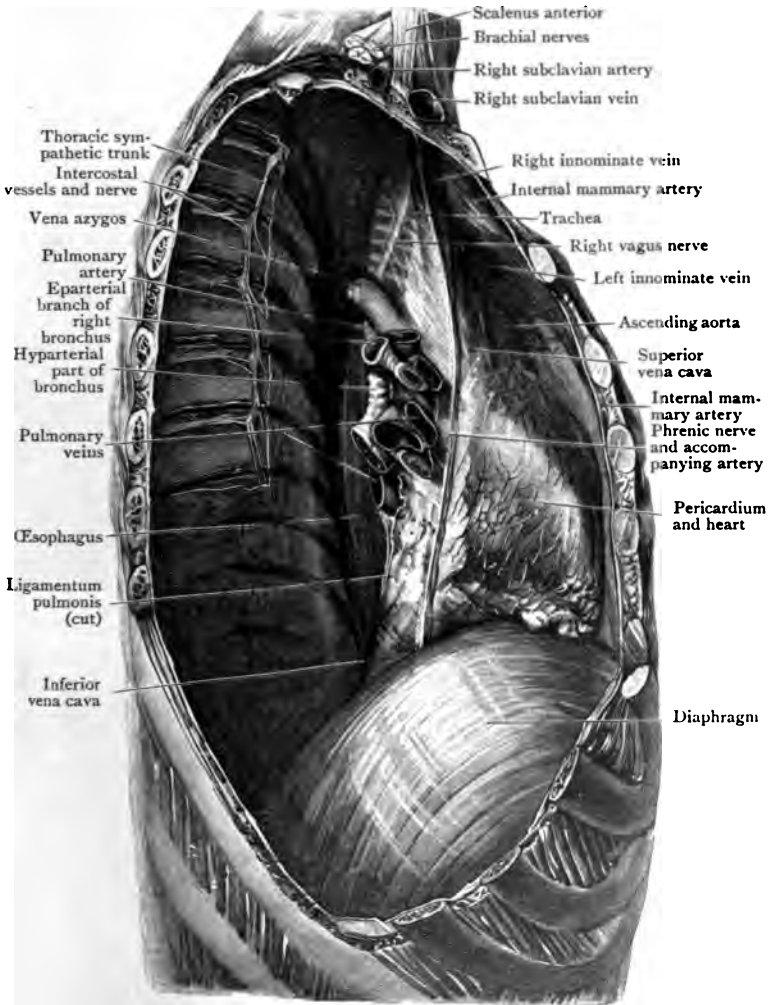


FIG. 10.—The Right Pleural Chamber opened up by the removal of its lateral wall. The lung has been taken away so as to expose the mediastinal wall of the pleural chamber. Several of the structures in the mediastinal septum are seen shining through the mediastinal pleura.

11-2 b

at the level of the second costal cartilage (see Fig. 12). As it turns anteriorly the vein lies immediately to the right side of the œsophagus, trachea and vagus nerve.

The tributaries of the vena azygos are: (1) The right superior intercostal vein which drains blood from the greater part of the second and third intercostal spaces. (2) The eight lower intercostal veins and the subcostal vein of the right side. (3) The vena hemiazygos, and frequently (4) the vena hemiazygos accessoria. Both the latter enter it from the left. In many cases the accessory azygos vein joins the hemiazygos vein. (5) Two or more bronchial veins from the right lung. (6) Some veins from the œsophagus. (7) Some minute pericardial veins.

The vena azygos commences in the abdomen where it anastomoses either with one of the upper lumbar veins or directly with the inferior vena cava. Thus it forms a more or less direct anastomosis between the two venæ cavæ.

The intercostal veins and the accompanying arteries and nerves, on both sides, and the hemiazygos and accessory azygos veins will be studied at a later period of the dissection (see p. 108).

Contents of the Mediastinum and the Structures of the Posterior Part of the Left Half of the Thorax seen from the Left Side.—After the removal of the four pleural flaps described on p. 25 the following structures are visible on the left side of the thorax (see Fig. 13). Below and anterior to the root of the lung is the pericardium, covering the left ventricle, the left atrium, the conus arteriosus of the right ventricle and the pulmonary artery. Above the root of the lung is the arch of the aorta. The arch of the aorta terminates posteriorly in the descending aorta, which passes downwards posterior to the root of the lung and the pericardium, but it is separated from the lower part of the posterior wall of the pericardium by the œsophagus, which, at this level, is passing towards the left side. On the left and anterior aspect of the aortic arch, from behind forwards, lie the left vagus nerve, the superior cervical cardiac branch of the left sympathetic trunk, the inferior cervical cardiac branch of the left vagus, and the left phrenic nerve with its accompanying vessels. Crossing the arch obliquely, from behind forwards and upwards, is the left superior intercostal vein, which passes lateral to the vagus and medial to the phrenic nerve. Above

the arch of the aorta are the lower parts of the left common

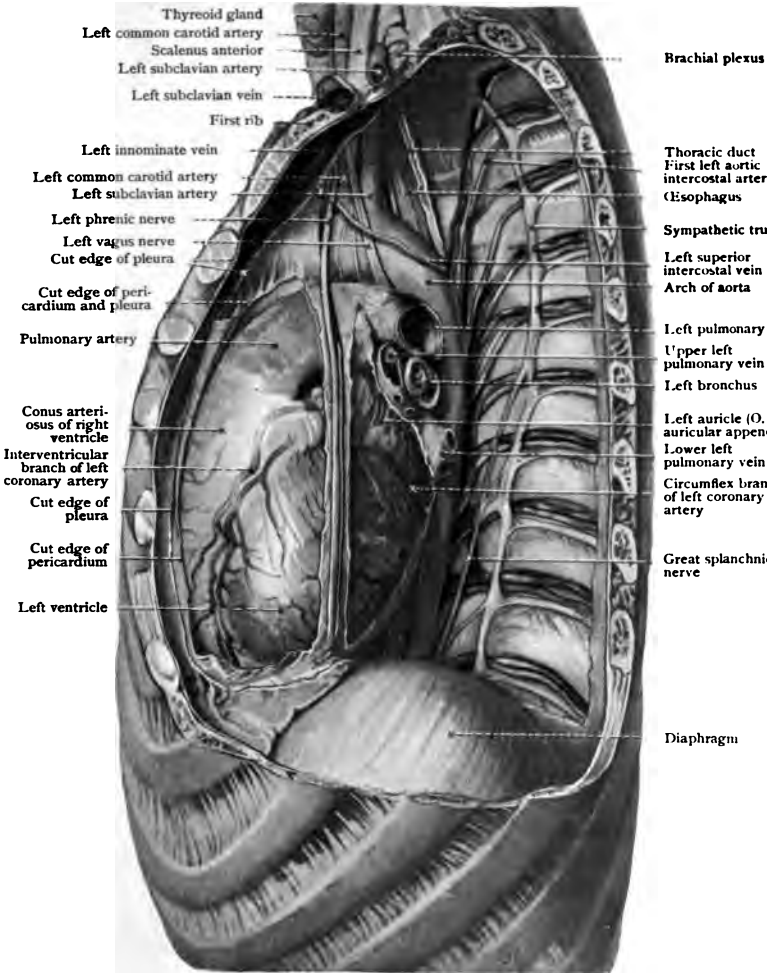


FIG. 13.—Dissection of Thorax from left side showing the constituent parts of the superior, middle, and posterior mediastina.

carotid and left subclavian arteries, and posterior to the latter lies the oesophagus, with the thoracic duct running along its left lateral border.

Posterior to the descending aorta are the left aortic intercostal arteries, the accompanying veins, and the splanchnic nerves; and still more posteriorly and laterally lie the sympathetic trunk of the left side and the left intercostal spaces and their contents.

Dissection.—After the structures exposed by the removal of the left pleura have been located, the dissectors should direct their attention to the sympathetic trunk and its branches and communications. The arrangement of these is exactly similar to that already described on the right side (see p. 26). When the dissectors have confirmed this statement they should turn to the left subclavian artery, which is the most posterior of the three great branches which spring from the arch of the aorta. Clean this vessel without disturbing the vagus nerve, which descends along its anterior border. Afterwards clean the part of the aortic arch which lies posterior to the vagus nerve, and the descending aorta. Whilst cleaning the arch avoid injuring the left superior intercostal vein, and, as the descending aorta is being cleaned, endeavour to preserve any of the aortic branches of the sympathetic which may have been found previously during the examination of the sympathetic trunk.

As the aorta is cleaned the left border of the lower part of the œsophagus will be brought more clearly into view, but the dissector must not attempt to clean the œsophagus at this stage.

After the descending portion of the aorta is cleaned, the left aortic intercostal arteries should be examined. They are nine in number; they emerge from the posterior aspect of the aorta, and they all pass medial to the sympathetic trunk as they approach the intercostal spaces. The upper arteries ascend very obliquely to gain their proper spaces. Accompanying the arteries are the corresponding veins. The lower veins pass, posterior to the aorta, to their terminations in the hemiazygos and accessory hemiazygos veins, and will be more fully studied at a later stage; but the veins from the second and third spaces unite into a trunk called the left superior intercostal vein.

The Left Superior Intercostal Vein.—This vein is formed by the intercostal veins from the second and third intercostal spaces of the left side, and it not uncommonly receives a communication from the first and fourth spaces. It descends along the medial border of the first left aortic intercostal artery to the posterior end of the aortic arch, there it turns anteriorly, along the left side of the aortic arch, and, passing at the same time obliquely upwards, it crosses lateral to the left vagus and medial to the left phrenic nerve. At a later period of the dissection it will be traced to its termination in the left innominate vein.

Dissection.—After the left superior intercostal vein has been secured and studied, the dissectors should clean the region posterior to the left subclavian artery, and expose thoroughly the left border of the œsophagus, as that tube lies in the superior mediastinum, and the upper part of the thoracic portion of the thoracic duct, which runs along the border of the œsophagus.

After this stage of the dissection is completed, the dissectors should examine the triangular interval between the left phrenic and left vagus nerves in the upper part of the thorax. Commencing above, they should follow the vagus nerve downwards; just before it reaches the lower border of the aortic arch, it gives off a very distinct branch which turns round the lower border of the arch. This is the important *recurrent nerve* which supplies the majority of the intrinsic muscles of the larynx of the same side. Immediately anterior and medial to the point where the recurrent nerve turns beneath the arch, a very distinct fibrous cord must be defined. It connects the arch with the upper border of the left pulmonary artery close to its origin. This is the *ligamentum arteriosum*, and it is the remains of the ductus arteriosus, through which blood passed from the pulmonary artery to the aorta during foetal life. When this has been secured the areolar tissue between the phrenic and vagus nerves must be carefully removed. In this tissue two small nerves will be found which run downwards, parallel with the vagus, across the arch of the aorta. The one next the vagus is the superior cervical cardiac branch of the left sympathetic, and the one next the phrenic is the inferior cervical cardiac branch of the left vagus. When these nerves are followed downwards they will be found to end in the superficial cardiac plexus, which lies in the areolar tissue below the aortic arch and to the right of the ligamentum arteriosum.

Dissection.—After the pericardium has been cleaned, incisions should be made through it on each side, and the flaps formed should be turned aside so that the dissectors may make themselves familiar with the relationships of the heart to the mediastinal portions of the pleural sacs. Two longitudinal incisions must be made on each side, one anterior and one posterior to the longitudinal strip of pleura left on the lateral surface of the phrenic nerve (see Figs. 12 and 13). On the right side the incisions should commence at the level of the upper pulmonary vein. On the left side the anterior incision should begin at the lower border of the aortic arch and the posterior at the level of the left pulmonary artery (see Fig. 13). On both sides the longitudinal incisions must descend to the lower border of the pericardium. On both sides incisions should be carried anteriorly from the upper and lower ends of the anterior longitudinal incision to the line along which the mediastinal pleura was left attached to the anterior surface of the pericardium (see Figs. 12 and 13). From the upper end of the posterior longitudinal incision on the right side a cut should be made downwards and posteriorly along the anterior aspect of the root of the lung to the upper end of the inferior vena cava (see Fig. 12).

From the upper end of the posterior longitudinal incision on the left side an oblique cut must be made downwards and posteriorly, along the line of

the anterior surface of the root of the left lung. When the incisions have been made, the anterior flaps can be turned anteriorly and the posterior flaps downwards. None of the flaps must be removed, for it will be necessary to replace them in position at a later stage of the dissection.

When the flaps marked out by these incisions are turned aside the dissectors will find that, on the right side, they have exposed the greater part of the right atrium (see Fig. 12). They should note that the area of the atrium which is exposed is separated into two parts by a vertical sulcus, the *sulcus terminalis*, which runs from the anterior face of the cardiac end of the superior vena cava to the anterior aspect of the terminal part of the inferior vena cava. This sulcus divides the atrium into a posterior part, the sinus venosus, and an anterior part, the atrium proper, whose upper and anterior part is prolonged medially to the anterior surface of the heart. On the left side the greater part of the heart exposed by the reflection of the pericardial flaps is the left ventricle, but in the upper part of the area the auricle (O.T. auricular appendage) of the left atrium is seen. Anterior to it lie the stem of the pulmonary artery and the upper part of the anterior portion of the right ventricle. A line of fat, in which lie the interventricular branch of the left coronary artery and the accompanying vein, indicates the position of the septum between the left and right ventricles (Fig. 13).

After the dissection is completed and the dissectors have carefully noted the relative positions of the various structures which have been exposed, they should proceed to study the phrenic nerves, which have been retained in position by the strips of pleura on their lateral surfaces (see Figs. 12 and 13).

Nervi Phrenici.—Each phrenic nerve arises in the neck from the cervical plexus, receiving fibres from the third, fourth, and fifth cervical nerves. It descends on the scalenus anterior muscle and, at the root of the neck, passes anterior to the subclavian artery and posterior to the corresponding vein, but on the left side, as it leaves the scalenus anterior, it lies anterior to the subclavian artery and posterior to the commencement of the innominate vein. As it enters the upper aperture of the thorax it crosses the internal mammary artery, passing from its lateral to its medial side, then it descends along the lateral border of the mediastinum, anterior to the root of the lung, to the diaphragm where it breaks up into branches. The majority of the branches pass between the muscular fibres of the diaphragm and, after communicating with the abdominal sympathetic nerve fibres which form the diaphragmatic plexus, they are distributed to the muscle from its lower surface. The relations of the phrenic nerves in the thorax are different on the two sides, and the left phrenic nerve, as a whole, is on a plane somewhat anterior to the right.

The *right phrenic nerve* descends along the lateral borders of the right innominate vein and the superior vena cava to the point where the latter enters the pericardium, then along

the side of the pericardium, which separates it from the venous sinus of the right atrium (see Fig. 12).

The Left Phrenic Nerve.—In the upper part of the thorax the left phrenic nerve runs downwards between the left common carotid and the left subclavian arteries and, whilst lying between them, it crosses anterior to the left vagus and posterior to the left innominate vein. In the lower part of the superior mediastinum it passes lateral to the arch of the aorta and the left superior intercostal vein, then, descending into the middle mediastinum, it lies at first anterior to the root of the left lung, and afterwards it runs downwards along the side of the pericardium, which separates it from the anterior part of the left atrium and from the lateral part of the left ventricle of the heart.

The left phrenic nerve is longer than its fellow of the right side, partly on account of the lower position of the diaphragm, and partly on account of the greater projection of the heart on the left side.

Branches of the Phrenic Nerves.—The main distribution of the phrenic nerves is to the diaphragm, but some minute sensory twigs are given off by each nerve to the pericardium and to the pleura. The student should note the great importance of the phrenic nerves. They are the nerves of supply to the diaphragm, which is the chief muscle of respiration.

Pulmones.—Before proceeding to the further dissection of the constituent parts of the mediastinum, the dissectors should study the lungs which they previously removed. The lungs are two soft, comparatively light, spongy organs placed one on either side of the mediastinum. The weight of the right lung, when it is filled with an average amount of blood, is 22 oz. and that of the left 20 oz. When the thorax is opened the lungs collapse to about one-third of their original bulk (unless they have been hardened *in situ*), and it is difficult for the student to realise their proper size and shape until they are distended to their original dimensions with the aid of the bellows (see p. 16).

When healthy and sound, the lungs lie free within the cavity of the chest, and are attached only by their roots and by their pulmonary ligaments. It is rare, however, that a healthy lung is seen in the dissecting-room, for adhesions between the visceral and parietal portions of the pleura, due to pleurisy, are generally present. Each lung is accurately adapted to the space in which it lies, and, when hardened

in situ, it bears on its surface impressions and elevations which are an exact counterpart of the inequalities of the structures with which its surfaces are in contact at the moment of fixation.

In the natural condition each lung resembles half a cone, and it presents for examination an *apex*, a *base*, a *costal surface*, a *medial surface*. An *anterior* and a *posterior border* separate the medial from the lateral surface; and an *inferior* or *basal border* separates the base from the medial and lateral

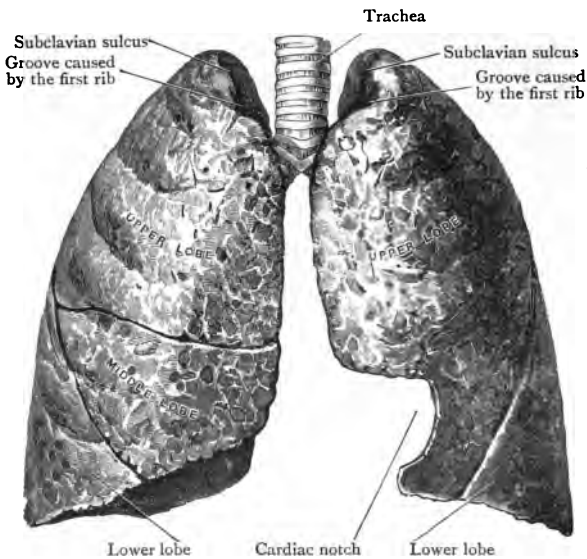


FIG. 14.—The Trachea, Bronchi, and Lungs of a Child, hardened by formalin injection.

surfaces. The apex rises into the root of the neck for one and a half inches above the level of the anterior part of the first rib, and it is crossed by the subclavian artery, which makes a groove upon the anterior border, a short distance below the summit, although the artery is separated from the lung by the membranous cervical diaphragm (Sibson's fascia), and by the pleura.

The base of each lung has a semilunar outline and is adapted to the upper surface of the diaphragm. Consequently it is deeply hollowed out, and, as the right cupola of the

diaphragm ascends higher than the left, the basal concavity of the right lung is deeper than that of the left lung. The lateral and posterior parts of the basal margin of the lung are thin and sharp and extend downwards into the phrenico-costal sinus of the pleura, which intervenes between the diaphragm and the wall of the thorax. This margin reaches a much lower position posteriorly and laterally than anteriorly, but in all situations it falls considerably short of the bottom of the sinus. The mediastinal part of the basal margin, which lies along the lower border of the pericardium, is more rounded.

The diaphragm separates the base of the right lung from

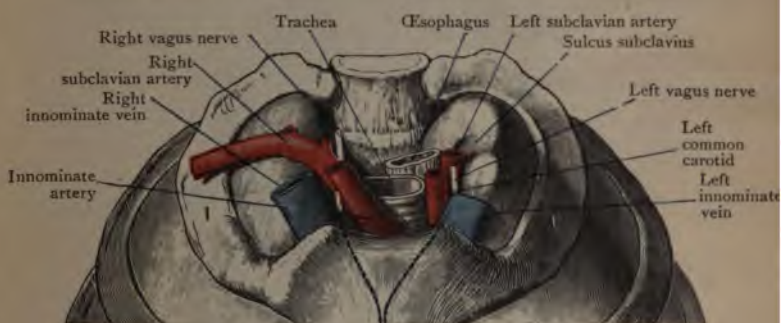


FIG. 15.—Cervical Domes of the Pleural Sacs, and parts in relation to them.

the upper surface of the right lobe of the liver, and the base of the left lung from the left lobe of the liver, the stomach, the spleen, and, in some cases, from the left extremity of the transverse colon.

The *costal surface* of the lung is very extensive and convex. It lies in relation with the costal pleura, which separates it from the ribs and intercostal muscles, the transversus thoracis and the sternum, and it bears the impressions of the costal arches.

The medial surface is separable into an anterior or *mediastinal portion* and a posterior or *vertebral portion*. The vertebral portion lies against the sides of the bodies of the vertebræ. The mediastinal part is applied against the mediastinal partition and presents markings which are the exact counterparts of the inequalities of the corresponding lateral surface

of the mediastinum. Thus, it is deeply hollowed out in adaptation to the pericardium upon which it fits. The pericardial concavity occupies the greater part of the mediastinal surface, and, owing to the greater projection of the heart to the left side, it is much more extensive in the left lung than in the right lung.

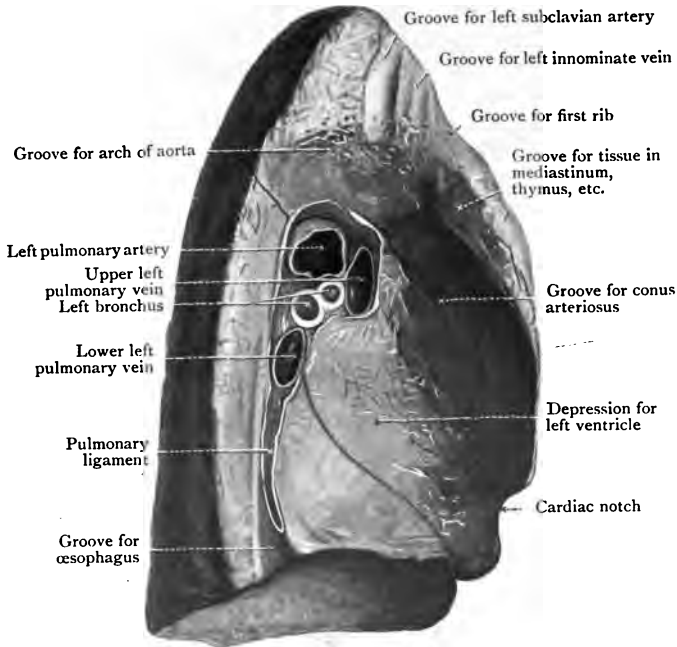


FIG. 16.—Medial of a Left Lung hardened *in situ*.

At the upper and posterior part of the pericardial area is the hilus of the lung. This is a wedge-shaped depressed area through which the bronchus and the pulmonary artery enter and the pulmonary veins and lymphatics leave the lung. It is surrounded by the pleura which is reflected from its margin on to the root of the lung, and the layer of reflected pleura round the hilus is continuous, below, with the pulmonary ligament. The portion of the pericardial area anterior to the upper part of the hilus of the left lung corresponds with the

position of the conus arteriosus and the stem of the pulmonary artery, and the same portion of the pericardial area on the right side corresponds with the position of the lower part of the superior vena cava posteriorly and with the ascending aorta anteriorly (Fig. 17). Below and posterior to the lower

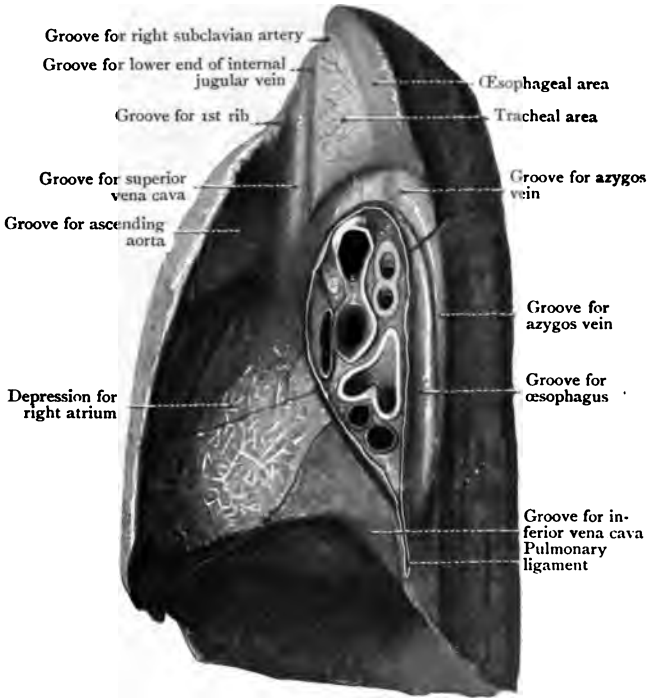


FIG. 17.—The Medial Surface of a Right Lung hardened *in situ*.

and posterior part of the pericardial area on the right lung is a secondary depression due to the upper part of the inferior vena cava. Posterior to the pericardial area and the hilus there is a narrow strip of the mediastinal surface of the lung which is in relation with the lateral wall of the posterior mediastinum. On the right lung this portion of the surface presents a longitudinal depression which corresponds with the right border of the oesophagus, and more posteriorly at the upper part there may be a groove caused by the vena

azygos. The left lung in the corresponding situation is marked by a deep longitudinal groove which is produced by the contact of the lung with the descending thoracic aorta; and, close to the base, a small triangular area, anterior to the aortic groove, lies in relation with the left border of the lowest part of the thoracic portion of the œsophagus.

The portion of the mediastinal surface which lies above the hilus and pericardial hollow is applied to the lateral aspect of the superior mediastinum and the markings upon it are different on the two sides. On the left side a broad deep groove, caused by the aortic arch, curves over the hilus and becomes continuous posteriorly with the aortic groove on the posterior mediastinal area. From this arched groove a sharply cut sulcus, caused by the left subclavian artery, ascends on the medial side of the apex and, turning laterally above, it crosses the anterior border of the apex a short distance below the summit. Immediately anterior to the subclavian sulcus the medial surface of the apex is occasionally marked by a shallow sulcus caused by the lateral margin of the left innominate vein, and more inferiorly its anterior margin is depressed by the first rib. That portion of the surface which lies posterior to the subclavian sulcus is separated by areolar tissue from the œsophagus.

On the right lung also a curved sulcus arches over the hilus. It is caused by the vena azygos, as it passes anteriorly to join the superior vena cava. This groove is much narrower and less distinct than the sulcus on the left lung due to the aortic arch. From the anterior end of the sulcus for the azygos vein a broad shallow sulcus passes upwards to the lower and anterior part of the apex. This is produced by the superior vena cava and the innominate vein, and in some cases it is prolonged to the upper part of the apex by a slight longitudinal depression due to the pressure of the internal jugular vein. Arching laterally, across the upper part of the anterior aspect of the apex, there is a shallow groove produced by the right subclavian artery. Posterior to the sulcus for the innominate vein, the medial surface of the apex lies in relation with the right side of the trachea, and still further posteriorly it is either in relation with the right lateral border of the superior mediastinal part of the œsophagus, or it is separated from it by a mass of areolar tissue.

The anterior and posterior borders of the lung are in

marked contrast with each other. The anterior is comparatively short and thin and it extends medially into the costo-mediastinal sinus of the pleura, which lies posterior to the sternum and the costal cartilages. It commences at the apex, curves downwards, anteriorly and medially, posterior to the sterno-clavicular articulation, to the lower border of the manubrium sterni, and then it descends vertically to the base. Immediately below the highest point of the apex it is grooved by the subclavian artery on each side, and on the left side it presents a cardiac notch at the level of the fifth costal cartilage. The posterior border is rounded and indistinct. It descends from the apex to the base, along the line of the articulations of the heads of the ribs with the bodies of the vertebræ, and it is much longer than the anterior border.

Lobes of the Lungs.—The *left lung* is divided into two lobes by a long, deep *oblique fissure* which penetrates its substance to within a short distance of the hilus. This fissure begins above at the posterior border, about two and a half inches below the apex, at the level of the vertebral end of the third rib, which corresponds with the medial end of the spine of the scapula. It is continued on the lateral surface, in a somewhat spiral direction, downwards and anteriorly till it cuts the inferior margin opposite the lateral part of the costal cartilage. The *upper lobe* of the lung lies above and anterior to this cleft. It is conical in form, with an oblique base. The apex and the whole of the anterior border belong to it. The *lower lobe*, somewhat quadrangular, is more bulky than the upper, and lies below and posterior to the fissure; it comprises the entire base and the greater part of the thick posterior border.

In the *right lung* there are two fissures subdividing it into three lobes. The *oblique fissure* is very similar in its position and relations to the fissure in the left lung, but it is more vertical in direction. It separates the lower lobe from the upper and middle lobes. The second cleft, the *horizontal fissure*, begins at the anterior border of the lung at the level of the fourth costal cartilage and extends horizontally till it joins the oblique fissure. The middle or intermediate lobe, thus cut off, is wedge-shaped in outline. It lies between the oblique and horizontal fissures.

Differences between the two Lungs.—The dissectors should particularly note the following differences between the two

lungs :—(1) The right lung is slightly larger than the left, in the proportion of 11 to 10. (2) The right lung is shorter and wider than the left lung. This difference is due to the great bulk of the right lobe of the liver, which elevates the right cupola of the diaphragm to a higher level than the left cupola, and also to the heart and pericardium, which project more to the left than the right, and thus diminish the width of the left lung. (3) The anterior sharp margin of the right lung is more or less straight; the corresponding margin of the left lung presents, in its lower part, a marked angular deficiency (*incisura cardiaca*) for the

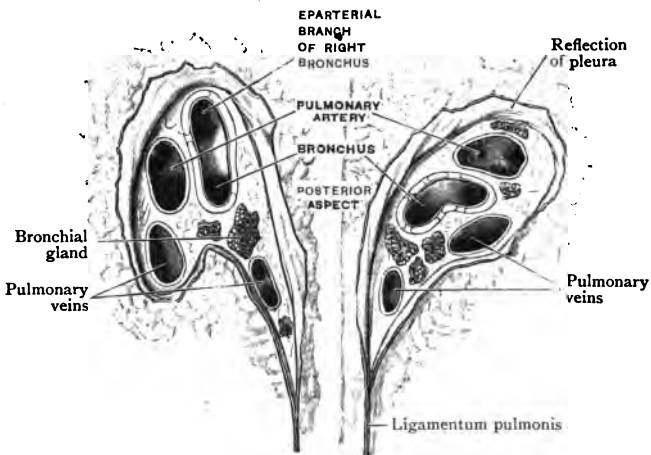


FIG. 18.—The two Pulmonary Roots transversely divided close to the hilus of each lung.

reception of the heart and the pericardium. (4) The right lung is subdivided into three lobes, and the left lung into two.

Radix Pulmonis.—The root of the lung is formed by a number of structures which enter the lung at the hilus or slit on its mediastinal surface. The structures which form the root are held together by an investment of pleura, and they constitute a pedicle which attaches the lung to the contents of the mediastinum. The pleura has already been removed from around them, and now a more detailed examination of the constituent parts of the root and of its relations must be made. The portion of the root still

attached to the mediastinum should be used for this purpose.

Dissection.—Commence with the vagus nerve and follow it downwards from a point just above the vena azygos on the right side, and from the arch of the aorta on the left, looking carefully for small branches which spring from its anterior border and pass to the anterior surface of the root, where they communicate with the twigs from the sympathetic ganglia, and from the deep cardiac plexus, to form the *anterior pulmonary plexus*, from which branches are distributed to the walls of the air tube and the blood vessels. On the left side a few twigs may be found passing from the superficial cardiac plexus to the anterior pulmonary plexus. After the branches of the vagus to the anterior pulmonary plexus have been identified, the trunk of the vagus, on each side, must be followed down to the posterior surface of the root of the lung, where it breaks up into branches which unite with twigs from the corresponding sympathetic trunk to form the posterior pulmonary plexus (see p. 28). The posterior pulmonary plexuses of opposite sides are connected together by strong branches, which pass both anterior and posterior to the œsophagus, and each gives branches to the walls of the bronchial tube and the blood vessels of the root of its own side. These various branches must be found and identified. After the posterior pulmonary plexuses are satisfactorily displayed the bronchial blood vessels should be found and cleaned.

Arteriæ Bronchiales.—As a rule, two bronchial arteries are distributed to the left lung and one to the right lung. The two left bronchial arteries spring from the descending aorta. The right bronchial artery is a branch either of the first right aortic intercostal artery or of the upper left bronchial artery. The bronchial arteries and their branches run along the posterior surfaces of the bronchi and their branches, and are the proper nutrient vessels of the lungs. Part of the blood which they convey to the lungs is returned by the pulmonary veins to the left atrium of the heart, but the remainder is returned by bronchial veins, which open on the right side into the vena azygos, and on the left side into the vena hemiazygos accessoria, or into the left superior intercostal vein.

Dissection.—After the bronchial vessels have been traced, the dissector should separate the great vessels and the air tube from each other. Whilst attempting this, he will find that his work is greatly impeded by the hardened and pigmented bronchial glands. The relative positions of the constituent parts of the roots of the lung have been noted already (p. 22).

The Relations of the Roots of the Lungs.—Anterior to the root of each lung are the phrenic nerve, with its accompanying vessels, and the anterior pulmonary plexus; behind it, the posterior pulmonary plexus, and below it, the ligamentum pulmonis. In addition, in front of the root of the right lu

is the superior vena cava, and above and behind it, the vena azygos. Whilst above the root of the left lung is the aortic arch, and behind it, the descending aorta (Figs. 12 and 13).

Bronchi.—There are two primary bronchial tubes, one for each lung. They spring from the termination of the trachea, and each passes downwards and laterally, in the root of the corresponding lung, to the hilus, through which it enters the lung. After passing through the hilus it descends, in the substance of the lung, to the base, lying nearer the posterior than the anterior border. In the root of the lung the bronchus is crossed anteriorly by the pulmonary artery,

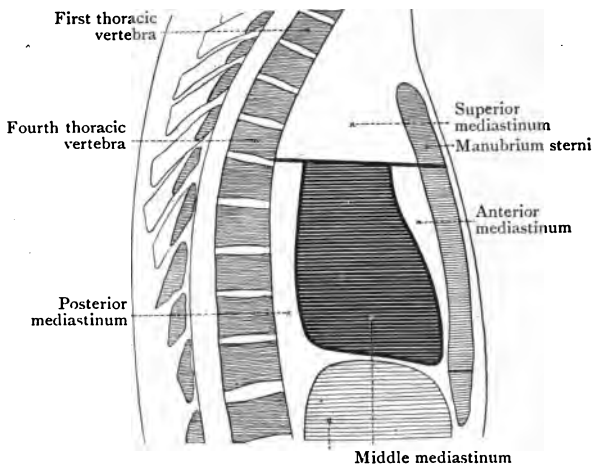


FIG. 19.—Diagram of the Mediastina.

which afterwards descends on the postero-lateral aspect of the intra-pulmonary part of the bronchial tube.

The relations of the bronchi are considered later (p. 96).

The Mediastinum and its Contents.—It has been pointed out already that the mediastinum is the interval which extends from the sternum to the vertebral column between the two pleural sacs; that it is occupied by some of the most important viscera, vessels and nerves in the body, *i.e.* the heart enclosed in the pericardium; the aorta and its great branches; the great vessels which carry the blood to and from the heart; the œsophagus and trachea; the vagi and phrenic nerves; and the thoracic duct. It was

noted further that the mediastinum is separated, for descriptive purposes, into two main parts, the *superior* and the *inferior mediastinum*, by an imaginary plane which passes from the lower border of the manubrium anteriorly to the

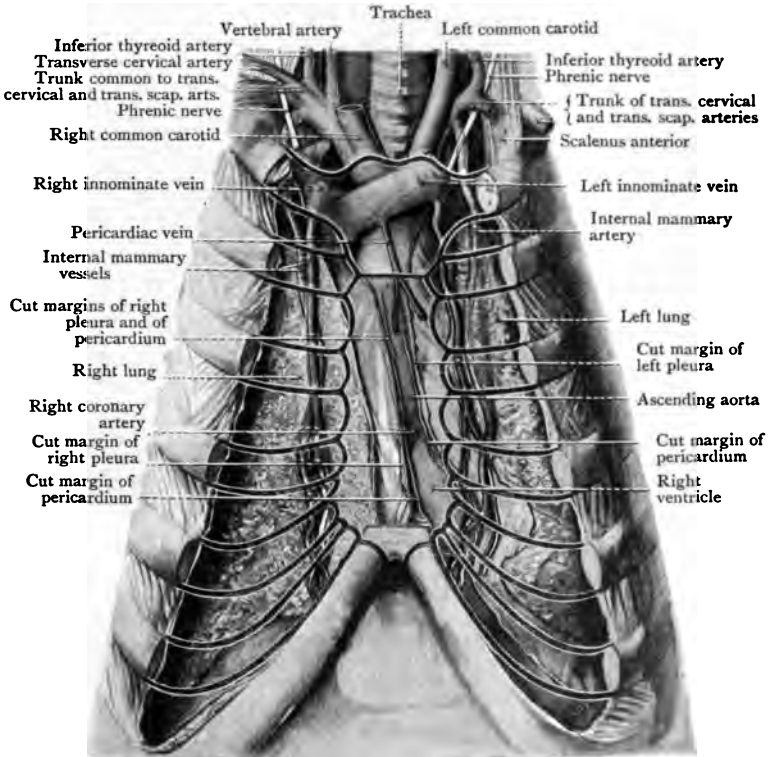


FIG. 20.—Dissection of the Anterior Part of the Thorax. The sternum and costal cartilages were replaced in position after the dissection had been made. The right scalenus anterior is cut away from its insertion up to the level of the upper border of the subclavian artery.

lower border of the fourth thoracic vertebra posteriorly ; it has been noted also that the inferior mediastinum is separable into three parts: (1) the *anterior mediastinum*, anterior to the pericardium, (2) the *posterior mediastinum*, posterior to the pericardium, and (3) the *middle mediastinum* occupied by the pericardium, the heart, the great vessels immediately adjacent

to the heart, and the phrenic nerves with their accompanying vessels. These sections of the mediastinum and their contents must now be examined in detail.

Dissection.—The remains of the anterior part of the mediastinal pleura must be divided longitudinally immediately posterior to the sternum, from the lower end of the thorax to the apices of the pleural sacs. The sternal extremities of the first ribs must be then cut through, close to the manubrium sterni, and, at the same time, the sternal heads of the sterno-mastoid muscles must be separated from the manubrium, if that has not already been done by the dissector of the head and neck. After the sterno-mastoid muscles and the first ribs are divided, the sterno-hyoid and sterno-thyroid muscles must be cut through transversely, as close to the upper margin of the manubrium as possible. Next, the body of the sternum must be separated from the xiphoid process and the tips of the seventh costal cartilages. The sternum with the attached costal cartilages may then be removed and placed aside, but it must be carefully preserved for future use.

When the sternum is removed the mediastinum is exposed from the front. As seen from the front, the superior mediastinum, which lies posterior to the manubrium, is a relatively wide triangular area, with its apex below. The anterior mediastinum, on the other hand, is merely a narrow cleft between the adjacent anterior margins of the pleural sacs, except opposite the anterior end of the left fifth costal cartilage where the left pleural sac deviates slightly to the left and the anterior mediastinum becomes slightly wider (Fig. 20).

The anterior parts of both the superior and the anterior mediastina are occupied by areolar tissue in which, as far down as the third or fourth costal cartilages, remains of the thymus gland may be found.

Thymus.—The thymus gland is a bilobed organ, developed from the third visceral clefts. It is well developed in the fœtus and in the child until the end of the second year. Then it frequently undergoes atrophy, but it may persist even until old age.

Dissection.—All the remains of the mediastinal pleura and the thymus gland should now be taken away, and the anterior surface of the pericardium and the contents of the superior mediastinum should be thoroughly cleaned. When this has been done the right and left innominate veins and their tributaries will be exposed. The innominate veins should be traced to their union with the superior vena cava. To the left of the superior vena cava and below the left innominate vein lie the upper part of the ascending portion of the aorta, and the anterior part of the aortic arch. When these contents of the upper part of the mediastinum have been thoroughly cleaned, the various structures found in the mediastinum must be studied in detail.

Venæ Anonymæ.—The innominate vein of each side is formed posterior to the sternal end of the corresponding clavicle by the union of the internal jugular and subclavian veins of the same side, and it ends, at the lower border of the right first costal cartilage, by uniting with its fellow of the opposite side to form the superior vena cava.

The *right innominate vein* is short and its course is

almost vertical. It is accompanied on its medial side by the innominate artery, on its lateral side by the right phrenic nerve, and posteriorly by the right vagus nerve. Antero-laterally it is in relation with the anterior margin of the right pleura.

The *left innominate vein* is much longer than the right.

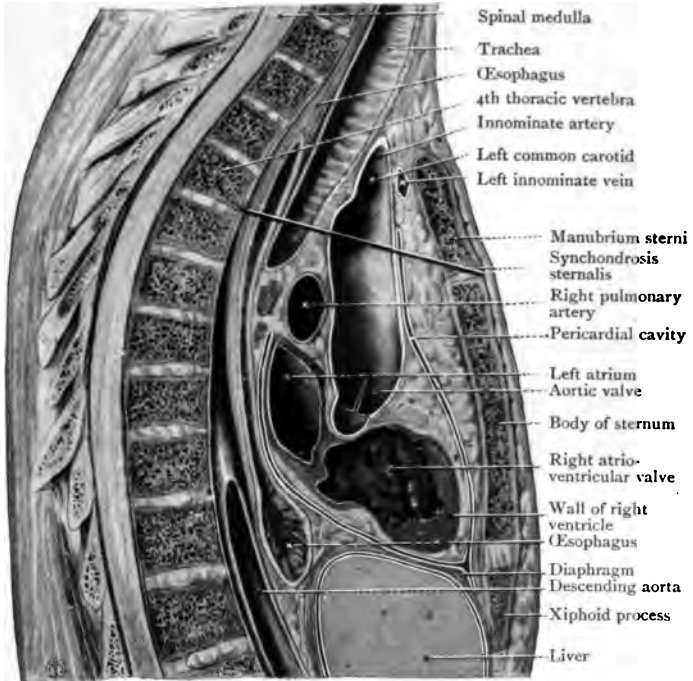


FIG. 21.—Sagittal section of the Thorax of an old man. The upper border of the manubrium sterni and the bifurcation of the trachea are lower than in the average adult.

It passes obliquely to the right and downwards, posterior to the upper half of the manubrium sterni ; it lies posterior to the remains of the thymus gland and the lower ends of the sterno-hyoid and thyreoid muscles, and anterior to the three great branches of the aortic arch and the left phrenic and vagus nerves.

Tributaries.—These are (1) the internal jugular vein, (2) the subclavian vein, (3) the vertebral vein, (4) the internal mammary vein, and frequently (5) the inferior thyreoid vein

of the same side. In addition, the right innominate vein receives the right lymph duct, or lymph vessels from the head and neck, the upper extremity and the right half of the thorax of the same side; and the left innominate vein receives (*a*) the left superior intercostal vein, (*b*) some pericardiac and thymic veins, and (*c*) the thoracic duct.

Dissection.—After the innominate veins and their tributaries have been studied the left vein may be pushed aside, or, if necessary, it may be cut in order to display the three great branches of the arch of the aorta.

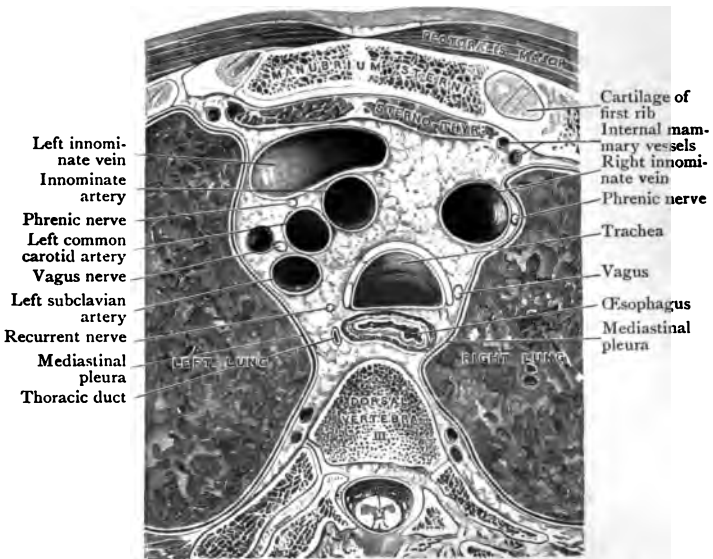


FIG. 22.—Transverse section through the Superior Mediastinum at level of the third thoracic vertebra.

Arteria Anonyma.—The innominate artery is the largest of the three great branches of the aortic arch. It commences, from the upper border of the arch, posterior to the centre of the manubrium, passes upwards and to the right, and terminates, posterior to the upper border of the right sternoclavicular articulation, by dividing into the right common carotid and the right subclavian arteries. Anterior to it are the manubrium sterni, with the attachments of the sternohyoid and thyreoid muscles, the right sternoclavicular joint, the remains of the thymus gland, and the left innominate vein.

Posterior to its lower part is the trachea, but as the artery passes upwards and to the right it gains the side of the trachea and has the upper part of the lung and pleura posterior to it. To its left, at its commencement, is the left common carotid artery, and at a higher level the trachea. On its right side is the right innominate vein, which separates it from the right phrenic nerve and the pleura. As a rule it gives off its terminal branches only, but occasionally a small artery, called the *thyreoidea ima*, springs from it.

The Thyreoidea Ima.—This artery is frequently absent. When it is present it springs from the innominate artery, or from the arch of the aorta, and runs upwards, anterior to the trachea, to the thyroid gland.

Arteria Carotis Communis Sinistra.—The left common carotid artery springs from the arch of the aorta immediately to the left of, and slightly posterior to, the innominate artery. It passes upwards, through the superior mediastinum and posterior to the left sterno-clavicular joint, into the neck. Its *anterior relations* in the thorax are similar to those of the innominate artery. *Posterior to it*, from below upwards, are the trachea, the left recurrent nerve, the œsophagus and the thoracic duct, and, on a plane somewhat more to the left, the left phrenic and vagus nerves, and the subclavian artery. *To its right* lie first the innominate artery, and then the trachea; and *to its left* is the left pleura. It gives off no branches in the thorax.

Arteria Subclavia Sinistra.—The left subclavian artery springs from the posterior part of the aortic arch, posterior to the left common carotid. It passes vertically upwards, through the superior mediastinum and posterior to the sternal end of the clavicle, into the root of the neck. *Anterior to it* are the left phrenic and vagus nerves, which separate it from the left common carotid artery. *Posterior*, and to its left side, it is in relation with the left mediastinal pleura and the lung. *To its right* side are the trachea and the left recurrent nerve, and, at a higher level, the œsophagus and the thoracic duct. It gives off no branches in the thoracic part of its course.

Dissection.—The lateral walls of the pericardium have already been exposed and opened (see p. 33); the flaps then made should be replaced and fixed in position. When this has been done, the outline of the sac will be fully displayed, and the dissectors can then study its relations to adjacent organs.

The Pericardium.—This is a fibro-serous sac which occupies the middle mediastinum. It surrounds the heart and the roots of the great vessels which enter and leave the heart.

The Fibrous Pericardium.—The fibrous or outer part of the pericardium is conical in form. *Its base* rests upon the diaphragm, principally on the central tendon but also upon the muscular portion, particularly upon the left side. Near the median plane it is blended with the central tendon, and can be separated from it only by the aid of the edge of the scalpel; more laterally the areolar tissue which connects the pericardium and the diaphragm is easily broken down by the handle of the knife. The diaphragm separates the pericardium mainly from the upper surface of the liver, but also, towards the left and anteriorly, from the fundus of the stomach. *The apex* of the fibrous sac blends with the outer coats of the aorta, the pulmonary arteries and the superior vena cava. The *anterior surface* lies behind the body of the sternum and the cartilages of the ribs from the second to the sixth inclusive, but it is separated from them by the lungs and pleuræ, except (1) in the median plane of the anterior mediastinum, where condensations of the areolar tissue of the mediastinum, called the superior and inferior *sterno-pericardiac ligaments*, connect the anterior surface of the fibrous sac to the upper and lower ends of the body of the sternum respectively, and (2) in the region of the sternal extremity of the left fifth costal cartilage, where the left pleura retreats somewhat towards the left side, and the pericardium comes into direct relation with the sternum and the left transversus thoracis muscle. This portion of the pericardium is the so-called *bare area*. It is usually of small extent, and frequently it does not extend beyond the margin of the sternum, but it is of importance because through it the surgeon attempts to tap the pericardium when the sac is distended with fluid.

The *lateral walls* of the pericardium are in relation with the mediastinal pleura, the phrenic nerve and the pericardiophrenic vessels intervening (O.T. comes nervi phrenici). The *posterior surface* lies anterior to the descending aorta and the œsophagus medially, whilst laterally it is supported posteriorly by the lungs and pleuræ. At the junction of the upper parts of the lateral and posterior surfaces, on each side, two pulmonary veins enter the pericardium and receive sheaths from its fibrous wall.

Dissection.—When the relations and prolongations of the fibrous pericardium have been studied, the two anterior flaps already made in the lateral walls of the sac (see p. 33) should be connected together and converted into one large anterior flap. This can be done by a transverse cut, passing across the median plane just above the diaphragm. The large triangular flap thus formed should be thrown upwards towards the apex of the pericardium.

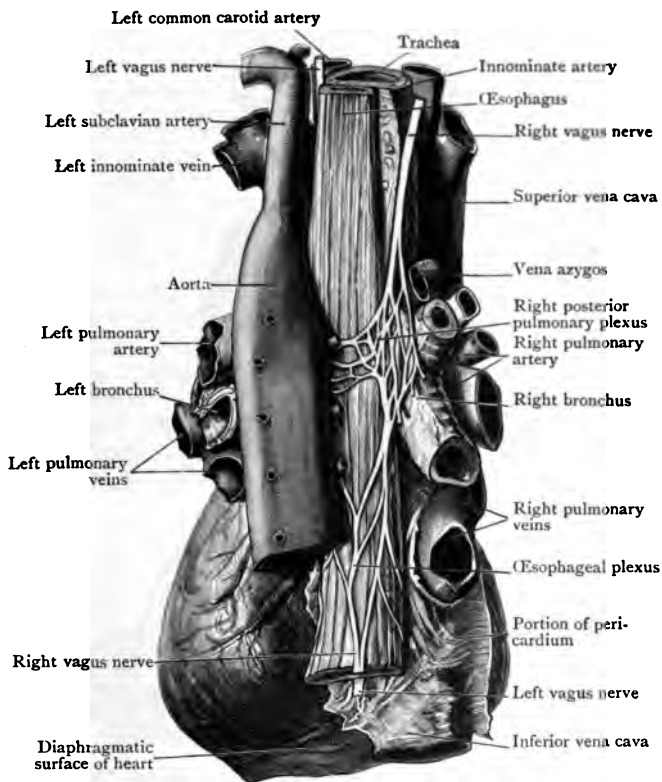


FIG. 23.—Posterior Aspect of the Heart with the Descending Aorta, the Trachea and Bronchi, and the Esophagus.

The Serous Pericardium.—The serous pericardium is a closed and invaginated sac which lines the inner surface of the fibrous sac and envelops the heart and the roots of the great vessels passing to and from the heart.

The uninvaginated portion of the wall of the serous sac,

which lines the inner surface of the fibrous sac, is called the *parietal layer*, and the invaginated portion, which envelops the heart, is the *visceral portion*. The inner surface of the sac is lined by a flat endothelium, and, during health, is smooth and

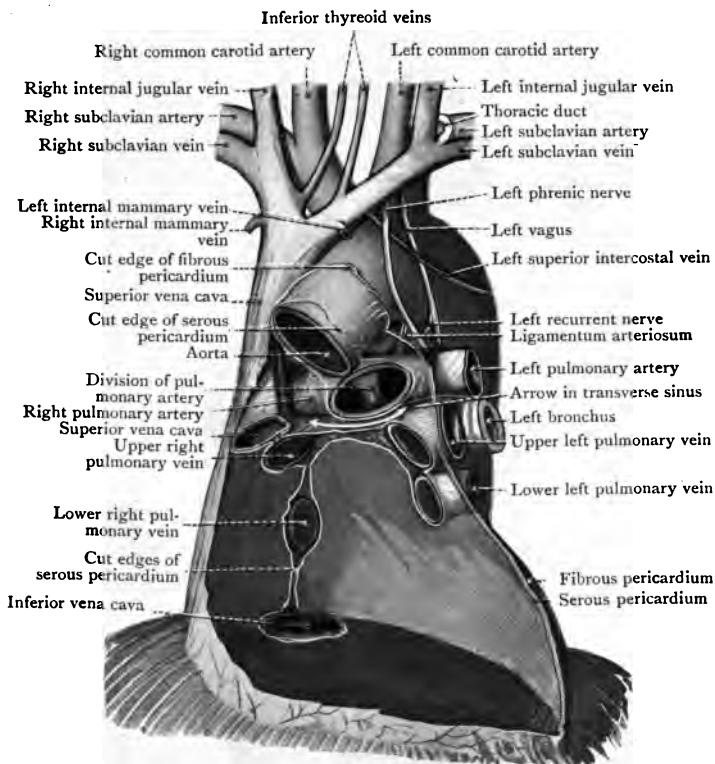


FIG. 24.—The Pericardium and Great Vessels of the Heart. The thoracic organs were hardened *in situ* by formalin injection. The pericardium having been opened by the removal of its anterior wall, the great vessels were divided and the heart removed.

glistening. The parietal and visceral layers are separated, during health, merely by a thin layer of serous fluid, which prevents friction between the two surfaces as they move over each other during the contractions and expansions of the heart.

The Sterno-costal Surface of the Heart.—Before the dissectors disturb the heart, which has been exposed by the reflection of the anterior wall of the pericardium, they should note carefully not only the parts of the heart which are visible, but also their relations to the anterior wall of the thorax. The latter they can easily do by replacing the sternum and costal cartilages in position from time to time.

They will find that the sterno-costal surface is divided into an upper, right, or atrial portion and a lower, left, or ventricular portion by an oblique sulcus, *the coronary sulcus* (O.T. *auriculo-ventricular*), which is quite distinct below and on the right, but is masked above and to the left by the roots of the pulmonary artery and the aorta. The position of this sulcus can be indicated on the surface by a line extending obliquely downwards and to the right, from the sternal end of the third left to the sternal end of the sixth right costal cartilage. Below and to the left of the sulcus is the ventricular part of the sterno-costal surface, terminating on the left and below in the *apex* of the heart, which lies posterior to the fifth left intercostal space, three and a half inches from the median plane. The ventricular area of the sterno-costal surface is divided by the anterior longitudinal sulcus (O.T. anterior interventricular sulcus) into a right two-thirds, formed by the right ventricle, and a left third, formed by the left ventricle. The anterior longitudinal sulcus terminates on the lower border of the sterno-costal surface, to the right of the apex, in a slight notch, the *incisura cordis*. The apex, therefore, is formed entirely by the left ventricle. The lower margin of the sterno-costal surface lies on the diaphragm. It is formed chiefly by the lower border of the right ventricle, and only to a small extent by the apical part of the left ventricle.

The upper and right portion of the sterno-costal surface is formed by the atria, which are to a large extent concealed by the pulmonary artery and the ascending part of the aorta. Above and to the right is the right atrium, continuous above with the superior vena cava and below with the inferior vena cava, whilst its auricular portion (O.T. auricular appendage) curves upwards and to the left, along the line of the coronary sulcus, to the root of the pulmonary artery.

Crossing the front of the right atrium, immediately below the lower end of the superior vena cava, is a sulcus, the s

terminalis. If the heart is pulled a little over to the left this sulcus can be traced downwards, along the lateral aspect of the right atrium, to the anterior aspect of the upper end of the inferior vena cava. It indicates the separation between

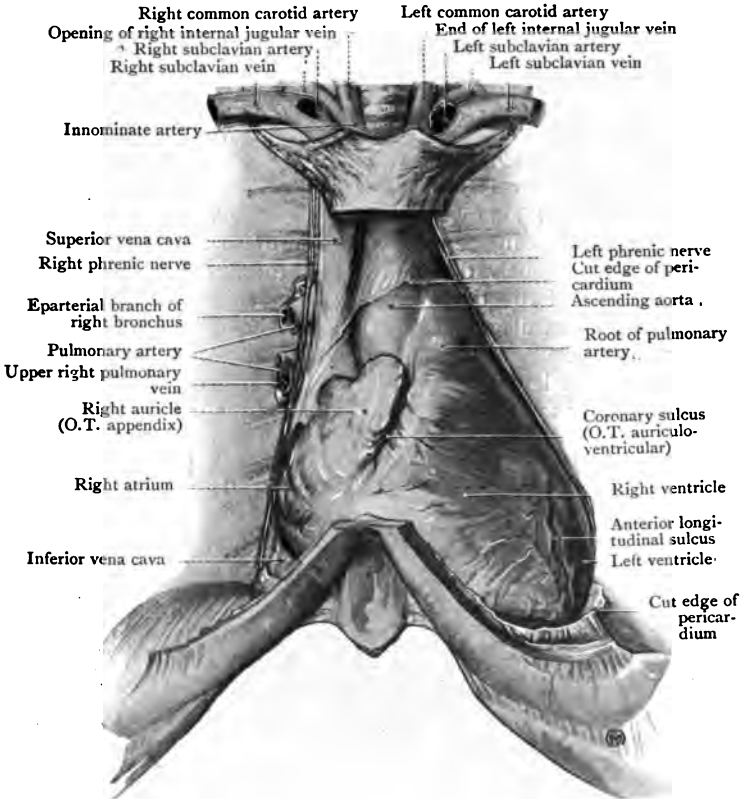


FIG. 25.—Dissection of the Middle and Superior Parts of the Mediastinum from the anterior aspect.

the venous sinus of the atrium, into which the great veins open, and the cavity of the atrium proper.

The whole of the right border of the heart is formed by the right atrium. Its position can be indicated on the surface by a line, convex to the right, which commences at the level of the third right costal cartilage, half an inch from the

sternum, and terminates opposite the sixth right cartilage at the same distance from the right margin of the sternum. At the upper and left corner of the atrial area is the apex of the left auricle (O.T. auricular appendage), and between the two auricles are the roots of the pulmonary artery and the aorta, the former anterior to the latter. The rounded portion of the upper part of the right ventricle, immediately below the pulmonary artery, is the *conus arteriosus*.

If a finger is introduced into the cleft between the aorta anteriorly and the superior vena cava posteriorly, it can be passed across, from the right to the left side of the pericardial cavity, through a passage, called the *transverse sinus of the pericardium* (Figs. 24 and 27). This sinus lies anterior to the superior vena cava and the atria, and posterior to the ascending aorta and the stem of the pulmonary artery. The upper border of a finger placed in the sinus will indicate the position of the upper border of the heart. This border is formed to a slight extent by the upper border of the right atrium, but mainly by the upper border of the left atrium. Its position can be indicated, on the anterior surface of the body, by a line commencing half an inch from the side of the sternum at the lower border of the second left costal cartilage, and ending at the same distance from the sternum on the upper border of the third right cartilage. Whilst a finger is kept in the transverse sinus a pointer should be introduced into the right pulmonary artery through its cut end in the root of the right lung. The dissector will note, as the pointer traverses the right pulmonary artery, that it passes first posterior to the superior vena cava and then along the upper border of the transverse sinus, that is along the upper border of the heart where that border is formed by the left atrium; therefore the position of the right pulmonary artery may be indicated, on the anterior surface of the body, by the right two-thirds of the line which marks the position of the upper border of the heart.

The left border of the anterior surface of the heart is formed, to a slight extent, by the left atrium, but mainly by the left ventricle. It is convex to the left and its position is marked, on the surface of the body, by a line which commences above at the lower border of the left second costal cartilage, half an inch from the sternum, and terminates below at the apical point in the fifth left intercostal space.

Before proceeding further the dissector should s

the information he has gained regarding the relationship of the apex of the heart and the borders of the sterno-costal surface of the heart to the anterior wall of the thorax. The *upper border* is formed by the atria, and as the heart lies *in situ* it is concealed to a great extent by the aorta and the

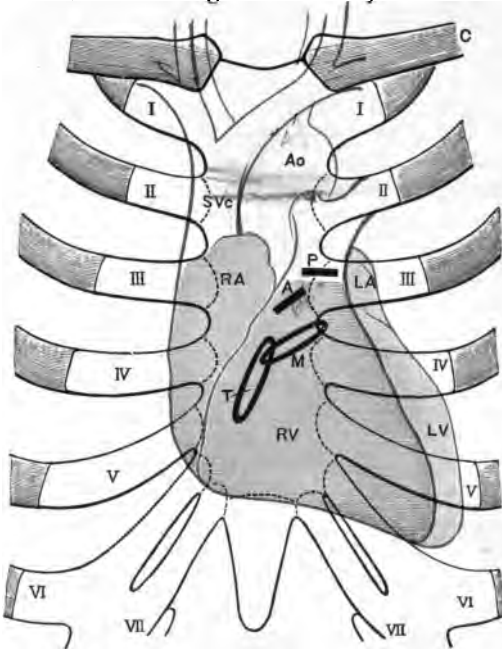


FIG. 26.—The relations of the Heart and of its Orifices to the Anterior Thoracic Wall. (Young and Robinson.)

I to VII. Costal cartilages.
 A. Aorta.
 Ao. Aortic orifice.
 C. Clavicle.
 LA. Left atrium.
 LV. Left ventricle.

M. Mitral orifice.
 P. Pulmonary orifice.
 RA. Right atrium.
 RV. Right ventricle.
 Svc. Superior vena cava.
 T. Tricuspid orifice.

pulmonary artery. Its position is marked on the surface by a line extending from the lower border of the second left to the upper border of the third right costal cartilage, commencing and terminating about half an inch from the border of the sternum. The *right border* is formed entirely by the right atrium, and its position is indicated on the sur-

face by a line, convex to the right, commencing above at the lower border of the right second costal cartilage, half an inch from the side of the sternum, and terminating below at the sixth right cartilage half an inch from its junction with the sternum. More than two-thirds of the *lower border* are formed by the right ventricle, and the remainder by the apical portion of the left ventricle, and the two parts may be separated by a distinct notch, the *incisura cordis*. This border is slightly concave downwards, in correspondence with the upward convexity of the diaphragm on which it rests, and it has a slight inclination downwards and to the left. It is marked, on the surface of the body, by a line extending from the sixth right costal cartilage, near the sternum, to the apical point, which lies in the left fifth intercostal space from $3\frac{1}{4}$ to $3\frac{1}{2}$ inches from the median plane. The left border, which is formed mainly by the left ventricle and only to a slight extent by the left atrium, extends from the apex to a point on the lower border of the left second costal cartilage half an inch from the margin of the sternum.

The coronary sulcus, which indicates the plane of union of the atria and ventricles and, therefore, the plane of the atrio-ventricular and aortic and pulmonary orifices of the heart, can be indicated, on the surface, by a line extending from the sternal end of the third left costal cartilage to the sternal end of the sixth right cartilage. Posterior to the left extremity of this line, at the level of the upper part of the third left costal cartilage, is the orifice of the pulmonary artery. The aortic orifice is a little lower and slightly to the right, posterior to the sternum at the level of the lower border of the third left cartilage. Immediately below the aortic orifice, posterior to the left margin of the sternum, at the level of the upper part of the fourth left cartilage, lies the mitral orifice; and the tricuspid orifice is situated posterior to the middle of the sternum, opposite the fourth intercostal spaces. The positions of the great orifices cannot be confirmed at this stage of the dissection, and they will be noted again at a later period when the heart is opened.

After the sterno-costal aspect of the heart, the boundaries of the transverse sinus, and the general position of the heart have been studied, the dissectors should turn the apex of the heart upwards and to the right, and examine the internal and posterior surfaces whilst the heart is still *in situ*.

the information he has gained regarding the relationship of the apex of the heart and the borders of the sterno-costal surface of the heart to the anterior wall of the thorax. The *upper border* is formed by the atria, and as the heart lies *in situ* it is concealed to a great extent by the aorta and the

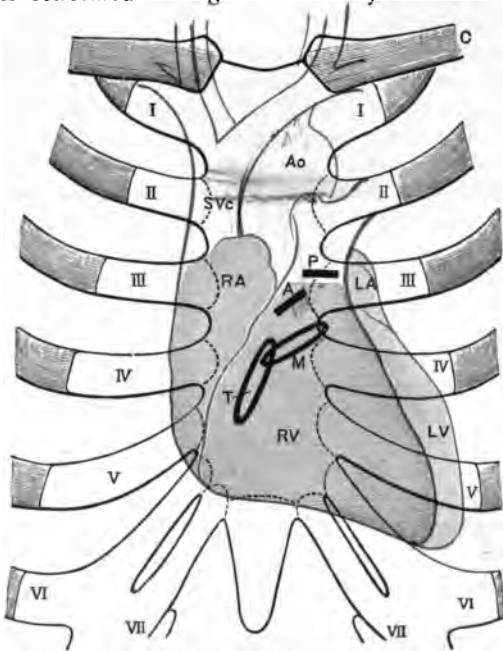


FIG. 26.—The relations of the Heart and of its Orifices to the Anterior Thoracic Wall. (Young and Robinson.)

I to VII. Costal cartilages.
 A. Aorta.
 Ao. Aortic orifice.
 C. Clavicle.
 L.A. Left atrium.
 LV. Left ventricle.

M. Mitral orifice.
 P. Pulmonary orifice.
 RA. Right atrium.
 RV. Right ventricle.
 SVC. Superior vena cava.
 T. Tricuspid orifice.

pulmonary artery. Its position is marked on the surface by a line extending from the lower border of the second left to the upper border of the third right costal cartilage, commencing and terminating about half an inch from the border of the sternum. The *right border* is formed entirely by the right atrium, and its position is indicated on the sur-

face by a line, convex to the right, commencing above at the lower border of the right second costal cartilage, half an inch from the side of the sternum, and terminating below at the sixth right cartilage half an inch from its junction with the sternum. More than two-thirds of the *lower border* are formed by the right ventricle, and the remainder by the apical portion of the left ventricle, and the two parts may be separated by a distinct notch, the *incisura cordis*. This border is slightly concave downwards, in correspondence with the upward convexity of the diaphragm on which it rests, and it has a slight inclination downwards and to the left. It is marked, on the surface of the body, by a line extending from the sixth right costal cartilage, near the sternum, to the apical point, which lies in the left fifth intercostal space from $3\frac{1}{4}$ to $3\frac{1}{2}$ inches from the median plane. The left border, which is formed mainly by the left ventricle and only to a slight extent by the left atrium, extends from the apex to a point on the lower border of the left second costal cartilage half an inch from the margin of the sternum.

The coronary sulcus, which indicates the plane of union of the atria and ventricles and, therefore, the plane of the atrio-ventricular and aortic and pulmonary orifices of the heart, can be indicated, on the surface, by a line extending from the sternal end of the third left costal cartilage to the sternal end of the sixth right cartilage. Posterior to the left extremity of this line, at the level of the upper part of the third left costal cartilage, is the orifice of the pulmonary artery. The aortic orifice is a little lower and slightly to the right, posterior to the sternum at the level of the lower border of the third left cartilage. Immediately below the aortic orifice, posterior to the left margin of the sternum, at the level of the upper part of the fourth left cartilage, lies the mitral orifice; and the tricuspid orifice is situated posterior to the middle of the sternum, opposite the fourth intercostal spaces. The positions of the great orifices cannot be confirmed at this stage of the dissection, and they will be noted again at a later period when the heart is opened.

After the sterno-costal aspect of the heart, the boundaries of the transverse sinus, and the general position of the heart have been studied, the dissectors should turn the apex of heart upwards and to the right, and examine the and posterior surfaces whilst the heart is still *in situ*

examination of the venæ cavæ will show that the lower inch of the superior vena cava lies within the fibrous pericardium and that it is ensheathed, except along its postero-medial border, by a covering of the serous layer, whilst the inferior vena cava can scarcely be said to have any intra-pericardial course, for it joins the lower and posterior part of the right atrium immediately after piercing the fibrous layer, but the margin of the orifice by which it enters is surrounded by the serous layer except along a narrow line posteriorly. The left pulmonary veins are covered by the serous layer on their superior, anterior, and inferior aspects, but not posteriorly; and the right pulmonary veins, which enter the left auricle as soon as they have pierced the fibrous pericardium, are in relation with the serous layer merely along the medial and lateral borders of the orifices in the fibrous layer through which they enter.

Dissection.—After the examination of the reflections of the serous layer of the pericardium is completed, the dissectors should study the vessels and nerves which supply the walls of the heart. They are the coronary arteries and the cardiac veins and nerves, and they lie in the coronary and longitudinal sulci of the heart, which have been noted already. To display them the visceral pericardium superficial to them must be cut and turned aside, the fat which lies in the sulci around the vessels must be removed, then the main vessels can be traced to their origins and terminations, and an endeavour should be made to preserve the fine nerves which accompany the vessels.

Arteriæ Coronariæ.—The coronary arteries are the nutrient vessels of the heart. They spring from dilatations of the commencement of the aorta which are called the *sinus aortæ* (Valsalva). There are three sinuses of the aorta, an anterior and two posterior, and only two coronary arteries, a right and a left; the right artery springs from the anterior sinus, and the left from the left posterior sinus.

The *right coronary artery* passes anteriorly from the anterior aortic sinus, between the pulmonary artery and the right auricle; turns downwards and to the right, in the coronary sulcus, to the lower part of the right margin of the heart, round which it curves. Then it proceeds to the left, in the posterior part of the coronary sulcus, till it reaches the posterior end of the inferior (posterior) longitudinal sulcus, where it divides into a small transverse and a large interventricular branch. The *transverse branch* continues to the left till it anastomoses with the circumflex branch of the left coronary artery. The *interventricular* (descending) *branch* runs anteriorly in the

inferior longitudinal sulcus on the diaphragmatic surface of the heart, and it anastomoses with the interventricular or descending branch of the left coronary artery at the cardiac notch on the lower margin of the heart. In addition to its terminal branches, the right coronary artery supplies branches to the roots of the pulmonary artery and the aorta, and to

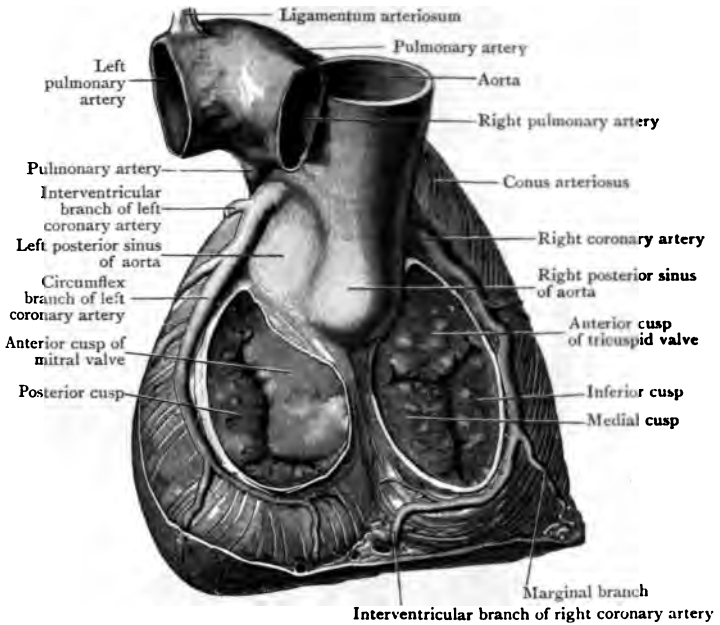


FIG. 28.—The Base of the Ventricular Part of the Heart from which the Atria have been removed. The detached atria are depicted in Fig. 31. The specimen was hardened *in situ*.

the walls of the right atrium and the right ventricle, the larger and more numerous branches being given to the ventricle. One of the latter, the *marginal branch*, passes along the lower margin of the heart towards the apex of the ventricle (see Fig. 29).

The *left coronary artery*, as it springs from the left posterior aortic sinus (Fig. 28), lies posterior to the pulmonary artery. For a short distance it runs to the left, then it turns anteriorly, between the pulmonary artery and the left auricle,

and divides into a descending or interventricular, and a circumflex branch. The *interventricular branch* passes down the sterno-costal surface of the heart, in the anterior longitudinal sulcus (Fig. 29), and turning round the lower border, in the cardiac notch, it anastomoses with the interventricular branch

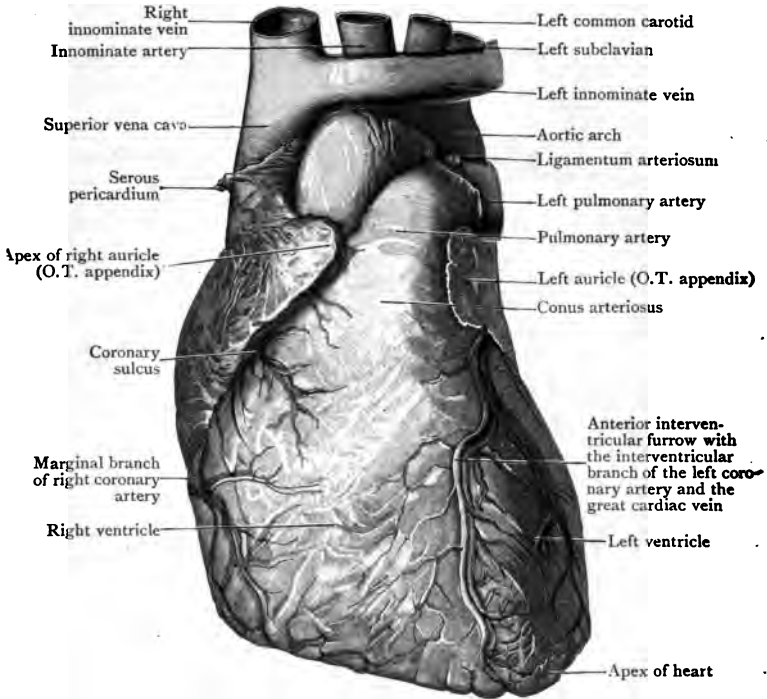


FIG. 29.—Sterno-costal Surface of the Heart.

of the right coronary artery. The *circumflex branch* runs to the left, in the coronary sulcus, turns round the left border of the heart (Fig. 28) and anastomoses, on the posterior surface, with the transverse terminal branch of the right coronary. From the stem of the artery twigs are given to the roots of the pulmonary artery and the aorta, and its terminal branches supply the walls of both ventricles and the walls of the left atrium.

Venæ Cordis.—The cardiac veins are: (1) the coronary.

sinus; (2) the great cardiac vein; (3) the inferior (posterior) ventricular vein; (4) the middle cardiac vein; (5) the oblique vein; (6) the small cardiac vein; (7) the anterior cardiac veins; and (8) the *venæ minimæ cordis*.

The *coronary sinus* lies at the base of the heart, in the posterior part of the coronary sulcus, between the left atrium and the left ventricle. It can be displayed when the apex of the heart is turned upwards and to the right. Its right extremity opens into the right atrium, immediately below and to the left of the orifice of the inferior vena cava. At its left

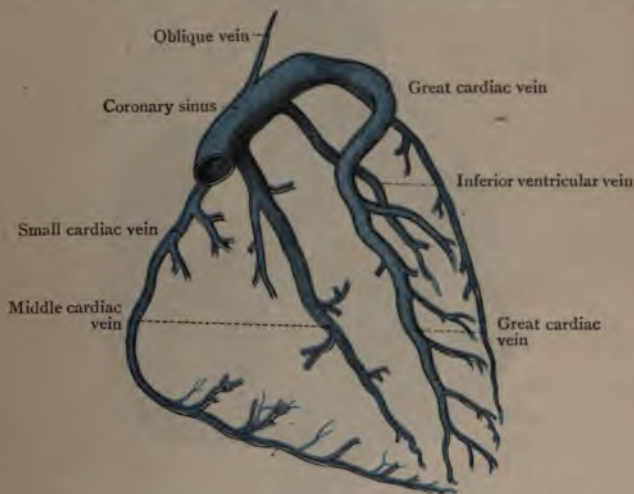


FIG. 30.—The Coronary System of Veins on the Surface of the Heart. (Diagram.)

extremity it receives the great cardiac vein. The *great cardiac vein* ascends along the anterior longitudinal sulcus (Fig. 29), where it lies in relation with the interventricular branch of the left coronary artery. At the upper end of the interventricular sulcus it turns round the left border of the heart, with the circumflex branch of the left coronary artery, and it ends in the left extremity of the coronary sinus. The *inferior* (posterior) *ventricular vein* or veins, from the diaphragmatic surface of the left ventricle, and the *middle cardiac vein*, which runs posteriorly in the inferior longitudinal sulcus, end in the lower border of the coronary sinus. The *oblique vein* descends

on the posterior wall of the left atrium and ends in the upper border of the sinus; and the *small cardiac vein* (O.T. *right coronary*) runs along the lower margin of the heart with the marginal branch of the right coronary artery, curves round the right border of the heart, in the coronary sulcus, ends in the right extremity of the coronary sinus. The *anterior cardiac*

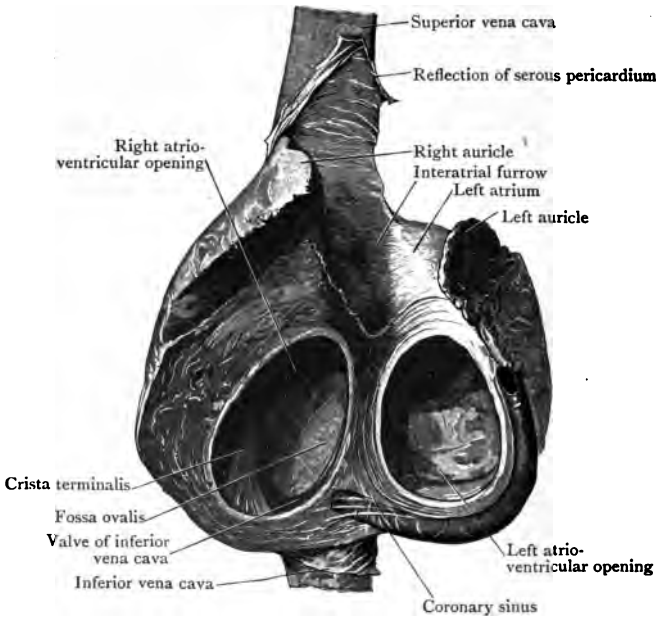


FIG. 31.—The Anterior Aspect of the Atrial Part of the Heart. The atria have been removed from the ventricles. The ventricular portion of the same heart is depicted in Fig. 28. The specimen was hardened *in situ*.

veins are small vessels which ascend along the anterior surface of the right ventricle and terminate directly in the lower and anterior part of the right atrium. The *venæ cordis minimæ* are small veins which pass from the substance of the heart, and more particularly from the walls of the right atrium and ventricle, and open, by small orifices, into the cavity of the right atrium. The orifice through which the great cardiac vein opens into the coronary sinus is usually provided with a valve; the orifice of the small cardiac vein may be provided

Cardiac Nerves

The cardiac nerves are branches of the sympathetic trunk. They are distributed to the heart and its vessels. The cardiac nerves are divided into the cardiac plexus and the coronary plexus. The cardiac plexus is situated in the upper part of the thorax, and is formed by the union of the vagus and sympathetic nerves. The coronary plexus is situated in the lower part of the thorax, and is formed by the union of the sympathetic nerves. The cardiac nerves are distributed to the heart and its vessels. They are distributed in the substance of the heart. Here they are developed in connection with them.

Dissection.—The chambers of the heart will be examined with their external walls removed. The heart is still in situ. The sternum and its costal cartilages are removed. The atrium and the ventricle are then opened. The coronary artery, and afterwards the left ventricle and the aorta, which springs from it. The examination of the terminations of the pulmonary veins, and the removal of the heart and the pericardium have been removed. (See p. 59.)

Atrium Dextrum (O.T. Right Auricle). Open the *atrium* by means of the following incision. Enter the knife at the apex of the auricle (O.T. auricular appendix) and run it posteriorly, close to the upper border of the auricle, to the sulcus terminalis and through the lateral wall of the atrium to the posterior border of the lower end of the superior vena cava; then downwards, posterior to the sulcus terminalis to the inferior vena cava; and finally anteriorly, across the lower end of the sulcus terminalis and above the anterior aspect of the lower end of the inferior vena cava, to the coronary sinus. Throw the flap thus formed anteriorly, and clean the interior of the cavity with a sponge.

As the flap is turned anteriorly a vertical muscular bundle will be noted on its inner surface. This is the *crista terminalis*, which corresponds in position with the sulcus terminalis on the outer surface. It marks the boundary between the anterior part, the atrium, and the posterior part, which is known as the venous sinus because the great veins of

the body and heart open into it. These two parts of the cavity differ, however, not only in position and their relations to the great veins, but also in the characters of their walls. The whole of the interior of the atrium presents a polished glossy appearance, due to the endocardial lining; but whilst the wall of the venous sinus is smooth, the rest of the wall of the atrium is rendered rugose by a large number of muscular ridges

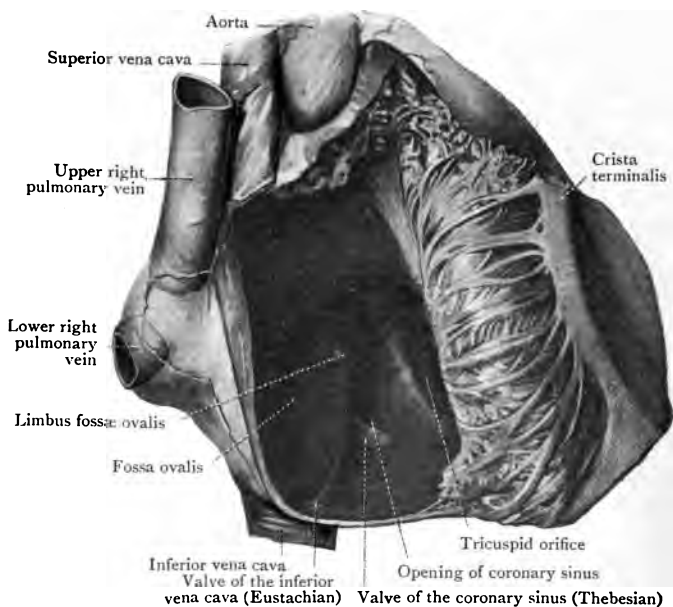


FIG. 32.—The Right Atrium. Part of the posterior wall and the whole of the right lateral and anterior walls have been thrown anteriorly.

which commence at the crista terminalis and run anteriorly to the right margin of the atrium. These bundles, on account of their somewhat parallel arrangement, are called the *musculi pectinati*.

The veins which open into the right atrium are the (1) superior vena cava, (2) inferior vena cava, (3) coronary sinus, (4) anterior cardiac veins, and (5) venæ cordis minimæ. The aperture by which the blood leaves it is the tricuspid orifice.

The *orifice of the superior vena cava* is in the upper and posterior part of the atrium, at the level of the third right costal

cartilage. It is entirely devoid of any valvular arrangement. Immediately below it on the posterior wall of the atrium, in a well-fixed heart, will be found a rounded prominence, *the intervenous tubercle* (Lower), which tends to throw the

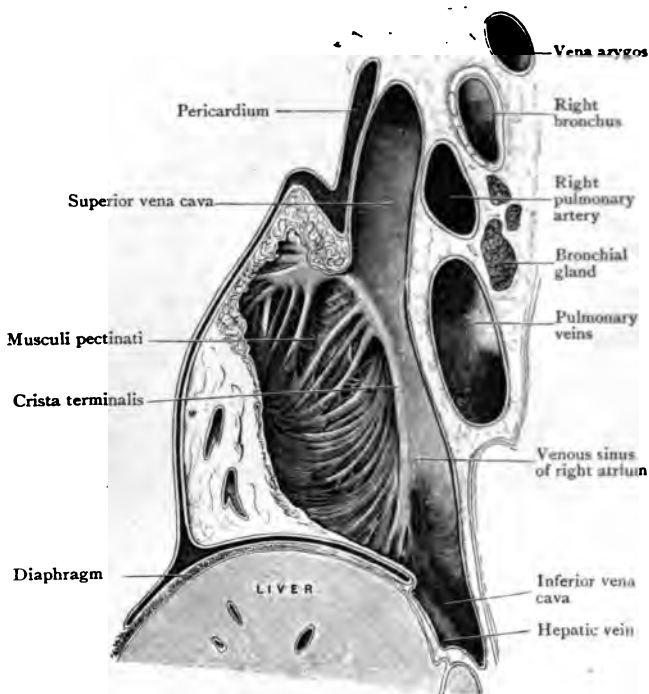


FIG. 33.—Sagittal section through the Right Atrium of the Heart and the Root of the Right Lung.

stream of blood entering the atrium by the superior vena cava downwards and anteriorly into the atrio-ventricular orifice.

The *orifice of the inferior vena cava* is in the lower and posterior part of the atrium, at the level of the sixth right costal cartilage and the lower border of the eighth thoracic vertebra. Running along its anterior margin, and intervening between it and the atrio-ventricular opening, is the remnant of a valve, *the valve of the vena cava* (Eustachian). It terminates, to the left, in the lower end of a muscular ridge, *limbus fossæ ovalis*

(O.T. *annulus ovalis*), which lies on the inter-atrial septum and forms the anterior and upper boundary of a shallow fossa, the *fossa ovalis*. At the upper end of this fossa there was, during foetal life, a foramen, the *foramen ovale*, through

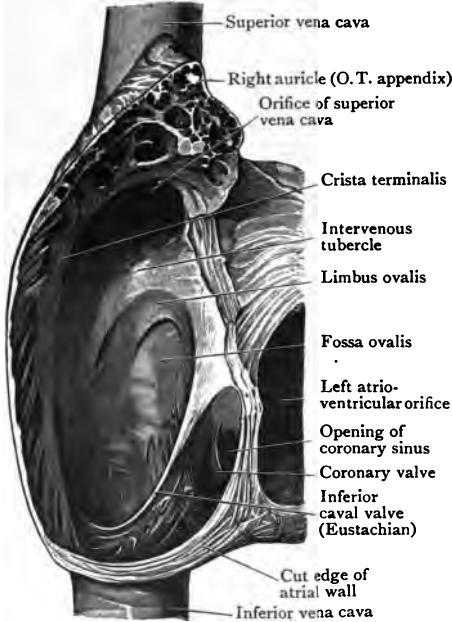


FIG. 34.—Interior of Right Atrium as seen by the removal of the anterior wall, or that wall opposed to the base of the Ventricles. This is a part of the same specimen that is depicted in Fig. 31.

which the two atria communicated with each other. The object of the valve of the vena cava, which in foetal life was much more perfect, was to direct the oxygenated inferior caval blood through the foramen ovale into the left atrium, whence it was passed into the left ventricle, and was then distributed, by the aorta, throughout the whole system.

During foetal life it would have been useless to pass the blood through the lungs, which were inactive and devoid of air. At the same time, had the oxygenated blood been passed through the right atrium into the right ventricle, it would have failed to reach

the head and the upper extremities, for, leaving the right ventricle by the pulmonary artery, it would have entered the aorta through the ductus arteriosus beyond the origin of the left subclavian artery and, therefore, beyond the innominate and left common carotid arteries.

In many cases a small part of the foramen ovale persists in the adult. If it is present it will be found on the left of the upper curved end of the limbus ovalis.

The *opening of the coronary sinus* lies to the left of the lower end of the limbus ovalis and directly posterior to the tricuspid orifice. On its right margin lies a valvular fold, *the valve of*

the *coronary sinus* (O.T. Thebesian), which turns the blood, flowing from left to right in the sinus, anteriorly into the atrio-ventricular orifice. The *venæ minimæ cordis* and the anterior cardiac veins open directly into the atrium by small orifices scattered irregularly over the walls.

The *tricuspid orifice* is in the lower and anterior part of the atrium. It opens anteriorly into the lower and posterior part of the cavity of the right ventricle, and is sufficiently large to admit the tips of three fingers. It is bounded by a fibrous ring to which the cusps of the right atrio-ventricular valve are attached. These cusps will be examined when the right ventricle is opened.

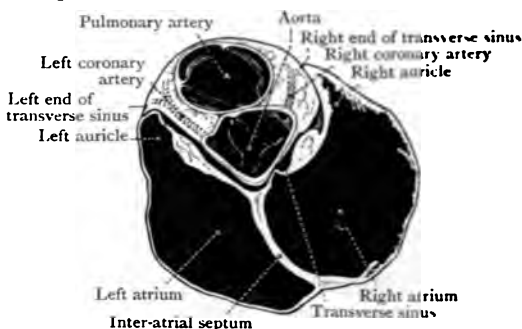


FIG. 35.—Transverse section through the Upper Part of the Heart.

The Septum Atriorum and the Fossa Ovalis.—The inter-atrial septum is a fibro-muscular partition which intervenes between the right and left atria. In the *fœtus* it is pierced by an obliquely directed foramen, the foramen ovale, already referred to; and in the adult it is marked on the lower and posterior part of its right side by a shallow depression, the *fossa ovalis*, which is bounded anteriorly and above by a muscular ridge, the *limbus ovalis*, whilst below and posteriorly it fades away into the orifice of the inferior vena cava.

The floor of the fossa ovalis is very thin; it marks the situation of the lower part of the foramen ovale of the *fœtus*, and is formed by a portion of the inter-atrial wall which, during *fœtal* life, acted as a flap valve and prevented regurgitation of blood from the left to the right atrium.

The Vena Cava Superior.—The superior vena cava returns to the right atrium the blood from the head and neck, the

upper extremities, the wall of the thorax, and the upper parts of the walls of the abdomen. It commences, by the union of the right and left innominate veins, at the level of the lower border of the sternal end of the right first costal cartilage; and it terminates, in the upper and posterior part of the right atrium, at the level of the right third costal cartilage, about half an inch from the right border of the sternum. It lies partly in the superior and partly in the middle mediastinum, and its lower half is within the fibrous pericardium and is partly ensheathed by the serous pericardium.

Tributaries.—The tributaries of the superior vena cava are the two innominate veins, by whose junction it is formed, and the vena azygos, which enters it immediately before it pierces the fibrous pericardium, at the level of the second right costal cartilage.

Relations.—The superior vena cava lies to the right of, and somewhat posterior to, the ascending aorta. *Posterior to* its upper part are the right pleura and lung on the right, and the right vagus and the vena azygos on the left, and, at a lower level, the right bronchus, the right pulmonary artery, and the upper right pulmonary vein. *Anteriorly* and on the left it is overlapped by the ascending aorta, and on the right by the right pleura and lung. *On its left side* above is the lower end of the innominate artery, and below is the ascending aorta; and *on the right side* is the right pleura, with the right phrenic nerve and the accompanying vessels intervening.

The Thoracic Part of the Inferior Vena Cava.—Only a small portion, about three-quarters of an inch, of the inferior vena cava is found in the thorax. It ascends from the diaphragm along the mediastinal surface of the right pleura and lung, pierces the pericardium anterior to the lower border of the right ligamentum pulmonis, and immediately ends in the lower and posterior angle of the right atrium.

Relations.—*Anterior to it* is the diaphragm; *posterior to it* the vena azygos, the splanchnic nerves and the thoracic duct; and *to its right* the phrenic nerve with its accompanying vessels and the right pleura and lung (see Fig. 12).

Ventriculus Dexter.—The cavity of the right ventricle should be opened by three incisions. The first should be made transversely across the upper end of the conus arteriosus, immediately below the commencement of the pulmonary artery. It should begin a little to the right of the upper

end of the anterior longitudinal sulcus and terminate a little to the left of the coronary sulcus. The second must commence at the right end of the first and pass obliquely downwards and to the right, along the left margin of the coronary sulcus, to the lower border of the heart. The third commences at the left end of the first, follows the line of the anterior inter-ventricular sulcus, lying a little to its right side,

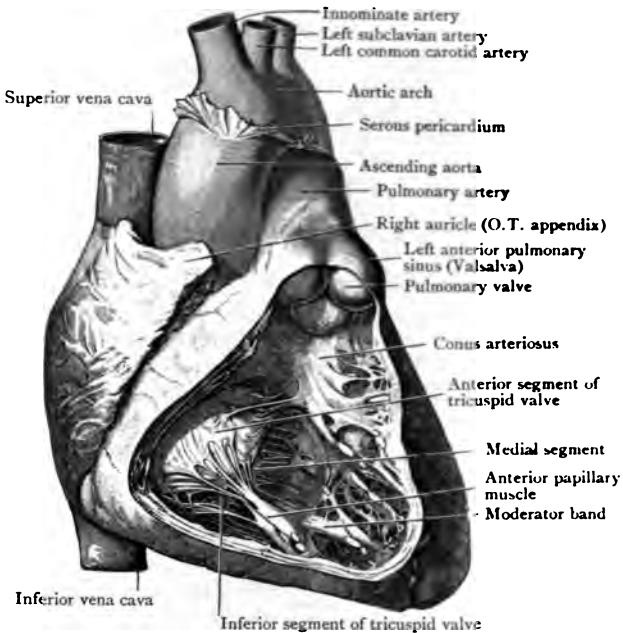


FIG. 36.—The Interior of the Right Ventricle.

and also terminates at the lower margin of the heart. After the triangular flap thus formed is turned downwards and to the right, the cavity of the ventricle should be cleaned with the aid of sponge and forceps. If the *moderator band* of muscle fibres, which connects the anterior wall of the ventricle with the inter-ventricular septum, interferes with the necessary displacement of the flap, it must be divided.

The cavity of the right ventricle has a triangular outline. The atrio-ventricular orifice opens into the lower and posterior angle, the pulmonary artery springs from the upper and

anterior angle, and between the two orifices is a strong and rounded muscular ridge, the *supra-ventricular ridge*. This projects into the cavity converting it into a U-shaped tube which commences posterior to and below the supra-ventricular ridge, runs anteriorly and to the left, towards the apex, and turns upwards and anteriorly, along the anterior part of the inter-ventricular septum and anterior to the supra-ventricular ridge, to the orifice of the pulmonary artery.

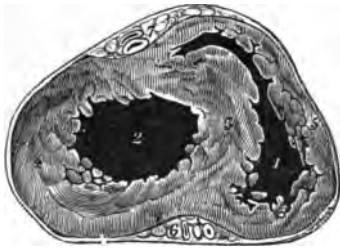

FIG. 37.—Transverse section through the Ventricular Part of the Heart seen from above. (From Luschka.)

1. Cavity of right ventricle.
2. Cavity of left ventricle.
3. Ventricular septum.
4. Thick wall of left ventricle.
5. Thinner wall of right ventricle.
6. Inferior longitudinal (inter-ventricular) sulcus with middle cardiac vein and inferior branch of right coronary artery.
7. Anterior longitudinal (inter-ventricular) sulcus with great cardiac vein and anterior branch of left coronary artery.

On transverse section the cavity of the right ventricle is semilunar in outline, in consequence of the thick inter-ventricular septum, which forms the left and posterior wall, bulging into the cavity (Fig. 37). Its walls are much thicker than the walls of the right atrium, but much thinner than the walls of the left ventricle (Fig. 41). The reason for these differences is obvious: the auricle has merely to force the blood through the wide atrio-ventricular orifice into the right ventricle, and the right ventricle has only to send the blood through the lungs to the left atrium; but the left ventricle has to force the blood through the whole

of the body, the head and neck, and the limbs; and the muscular strength of the walls of the cavities of the heart is proportional to the work they have to do.

The portion of the right ventricle which ascends to the orifice of the pulmonary artery is the *conus arteriosus*. Its walls are smooth and devoid of projecting muscular bundles, but the inner surface of the walls of the remaining part of the ventricle is rendered extremely irregular by the projection of a lace-work of fleshy ridges called *trabeculæ carneæ*. Some of the trabeculæ are merely ridges raised in relief upon the

surface; others are attached to the wall at each extremity, but are free in the rest of their extent. The cavity of the ventricle is invaded, however, not only by the *trabeculæ carneæ*, but also by a number of conical muscular projections, the *musculi papillares*. These are attached by their bases to the wall of the ventricle, whilst their apices are connected, by a number of tendinous strands, to the margins and the ventricular surfaces of the cusps of the atrio-ventricular valve. As a rule there is one large anterior papillary muscle attached to the anterior wall, a large inferior papillary muscle attached to the inferior wall, and a number of smaller papillary muscles attached to the septal wall. Occasionally the anterior and inferior muscles are represented by a number of smaller projections. It must be noted that the *chordæ tendineæ* from each papillary muscle, or group of papillary muscles, gain insertion into the margins and ventricular surfaces of two adjacent cusps of the valve. The result of this arrangement is, as the papillary muscles contract simultaneously with the contraction of the general wall of the ventricle, that the *chordæ tendineæ* hold the margins of the cusps together and prevent them being driven backwards into the atrium.

One of the *trabeculæ carneæ*, which is usually strong and well marked, passes across the cavity from the septum to the base of the anterior papillary muscle. This is the *moderator band*. It tends to prevent over-distension of the cavity of the ventricle, by fixing the more yielding anterior wall of the ventricle to the more solid septum.

There is one opening of entrance into the right ventricle, the atrio-ventricular, and one opening of exit, the pulmonary orifice. Each is guarded by a valve.

The right *atrio-ventricular orifice* lies at the lower and posterior part of the right ventricle, its centre being behind the middle of the sternum at the level of the fourth intercostal space. It is about one inch in diameter, and is surrounded by a fibrous ring. It admits the tips of three fingers, and it is guarded by a valve possessing three cusps, an anterior, a medial, and an inferior. The anterior cusp intervenes between the atrio-ventricular orifice and the conus arteriosus. The medial cusp lies in relation with the septal wall; and the inferior cusp with the inferior wall of the ventricle.

The bases of the cusps are attached to the fibrous ring

round the margin of the orifice. Their apices, margins, and ventricular surfaces are attached to the chordæ tendineæ. Their auricular surfaces, over which blood flows as it enters the ventricle, are smooth, and their ventricular surfaces are more or less roughened by the attachment of the chordæ tendineæ, but the roughening is less marked on the ventricular surface of the anterior cusp over which the blood flows as it passes through the conus arteriosus to the pulmonary orifice.

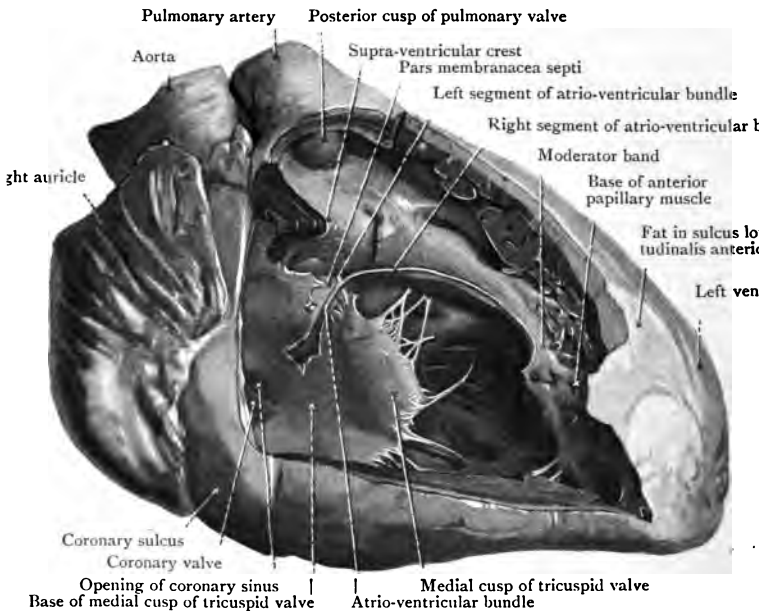


FIG. 38.—Dissection of the Right Ventricle showing the Atrio-ventricular Bundle.

The Atrio-ventricular Bundle.—The atrio-ventricular bundle is a small bundle of peculiar muscle fibres, of pale colour, which forms the only direct muscular connection between the walls of the atria and the ventricles (see p. 92). To expose this bundle, the anterior part of the medial cusp of the tricuspid valve must be detached from the fibrous atrio-ventricular ring. When this has been done, the pars membranacea, or upper fibrous part of the inter-ventricular septum will be exposed, and the atrio-ventricular bundle will be found running along its posterior and lower border to the upper end of the muscular part of the septum, where it divides into right and left branches. The right branch runs along the right side of the septum to the moderator band, along which it passes to the anterior papillary muscle. The left branch passes between the pars membranacea

and the upper end of the muscular part of the septum, and then descends along the left side of the septum. Both branches send off numerous ramifications which are distributed to the various parts of the walls of the ventricles.

The *pulmonary orifice* lies at the upper, anterior, and left part of the ventricle, at the apex of the conus arteriosus. Its centre is behind the third left costal cartilage immediately to the left of the left border of the sternum, and its margin is surrounded by a thin fibrous ring to which the bases of the three semilunar cusps of the pulmonary valve are attached.

Dissection.—Note that immediately above its commencement the wall of the pulmonary artery shows three distinct bulgings; these are the pulmonary sinuses (Valsalva) of which two are anterior, and the third is situated posteriorly. Make a transverse incision across the wall of the pulmonary artery immediately above the dilatations, and from each end of the transverse incision make a vertical incision upwards towards the arch of the aorta; raise the flap so formed and examine the cusps of the valve from above.

The Pulmonary Valve.—Each cusp of the valve is of semilunar form. Its upper or arterial surface is concave, its lower or ventricular surface is convex; and it consists of a layer of fibrous tissue covered, on each surface, by a layer of endothelium. The fibrous basis of the cusp is not equally thick in all parts. A stronger band runs round both the free and the attached margin. The centre of the free margin is thickened to form a small rounded mass—the *nodulus of the valve*—and the small thin semilunar regions on each side of the nodule are called the *lunule of the valve*. When the ventricular contraction ceases, and the elastic reaction of the wall of the pulmonary artery forces the blood backwards towards the ventricle, the cusps of the valve are forced into apposition; the nodules meet in the centre of the lumen; the ventricular surfaces of the lunulæ of adjacent cusps are compressed against each other, and their free margins project upwards into the cavity of the artery, in the form of three vertical ridges which radiate from the nodules to the wall of the artery. Regurgitation of blood into the ventricle is thus effectually prevented.

The dissector may readily demonstrate the general appearance of the cusps and their relationship to each other by packing the concavity of each cusp with cotton wool.

Arteria Pulmonalis.—The pulmonary artery lies within the fibrous pericardium, and is enclosed, with the ascendi

part of the aorta, in a common sheath of the serous pericardium. It commences at the upper end of the conus arteriosus, posterior to the sternal extremity of the third left costal cartilage. It is about two inches long, and it runs upwards and posteriorly into the concavity of the aortic arch, where it bifurcates into two branches. The bifurcation takes place posterior to the sternal end of the left second costal cartilage.

Relations.—At its commencement it is placed anterior to the lower end of the ascending aorta, but as it runs upwards and posteriorly it passes to the left side of the latter vessel, and lies anterior to the upper part of the anterior wall of the left atrium, from which it is separated by the transverse sinus of the pericardium. Anterior to it is the upper part of the anterior wall of the pericardium, which separates it from the anterior part of the mediastinal surface of the left pleura and lung. To its right side, below, are the right coronary artery and the apex of the right auricle, and above is the ascending aorta. To its left side lie the left coronary artery and the anterior end of the left auricle.

Dissection.—Cut away the anterior wall of the pulmonary artery up to the level of its bifurcation and pass probes into its right and left branches. Note that the right branch runs transversely to the right, and that the left branch runs posteriorly and to the left.

The *right pulmonary artery* commences at the bifurcation of the pulmonary stem, below the arch of the aorta. As it runs to the right, towards the hilus of the right lung, along the upper border of the left atrium and the transverse sinus (Figs. 21 and 27), it passes posterior to the ascending aorta and the superior vena cava, and anterior to the œsophagus and the stem of the right bronchus. It enters the hilus of the lung below the eparterial branch of the bronchus, above and posterior to the upper right pulmonary vein, and it descends, in the substance of the lung, on the postero-lateral side of the stem bronchus, and between its ventral and its dorsal branches, where it will be dissected at a later period (p. 98).

Branches.—As it enters the hilus of the lung it gives off a branch which accompanies the eparterial bronchus, and as it descends in the substance of the lung it gives off branches which correspond with the branches of the stem bronchus (see p. 98).

The *left pulmonary artery* runs posteriorly and to the

left, across the anterior aspect of the descending aorta and the left bronchus, to the hilus of the left lung. It is covered anteriorly and on the left by the anterior part of the mediastinal surface of the left pleural sac. As it descends in the substance of the lung it lies along the postero-lateral aspect of the stem bronchus and between its ventral and dorsal branches (p. 98).

Branches.—Except that it has no branch corresponding with that which accompanies the eparterial bronchus on the

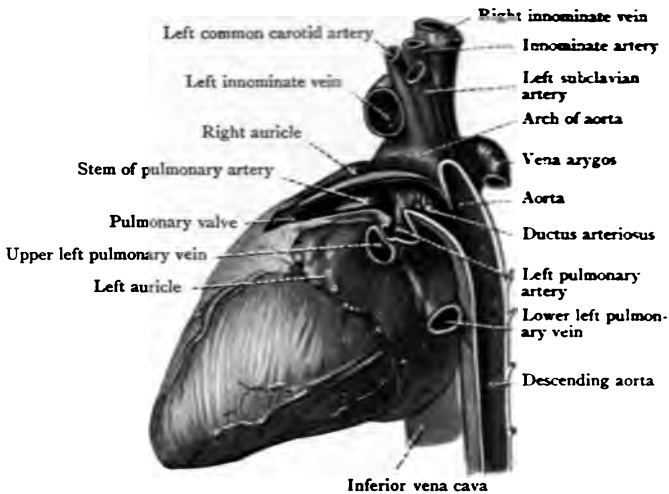


FIG. 39.—Dissection of the Heart and Great Vessels of a Fœtus, showing the angular junction of the Ductus Arteriosus with the Aorta.

right side, the branches of the left pulmonary artery are similar to those given off by the right pulmonary artery.

Ligamentum Arteriosum.—The ligamentum arteriosum is a strong fibrous band which connects the commencement of the left pulmonary artery with the lower surface of the arch of the aorta. It is the remains of the walls of a wide channel, the *ductus arteriosus*, which united the left pulmonary artery with the aorta throughout the whole period of pre-natal life.

During fetal life the lungs had no ærating function; therefore the right pulmonary artery and the part of the left pulmonary artery beyond the origin of the ductus arteriosus were small, for they had merely to convey sufficient blood to maintain the life and growth of the non-functional lungs. At this period, therefore, the blood which had entered the right ventricle

through the superior vena cava and the right auricle (see p. 68), was ejected, by the ventricle, into the pulmonary artery and the greater part of it passed through the ductus arteriosus into the aorta, which it entered beyond the origin of the left subclavian artery, and there mingled with the more oxygenated blood from the placenta, the lower part of the body, and the lower limbs, which passed from the inferior vena cava through the right atrium and the foramen ovale to the left atrium, and thence to the left ventricle by which it was pumped into the aorta.

It is obvious that the passage of blood from the pulmonary artery into the aorta could take place only so long as the pressure in the pulmonary artery was greater than the pressure in the aorta. At birth, when the blood rushed through the rapidly enlarged right and left pulmonary arteries into the lungs, as they expanded with the first respiratory efforts, the pressure in the pulmonary artery and the ductus arteriosus was reduced below that in the aorta, and the blood in the aorta would have flowed into the ductus arteriosus had it not been that the angle of union between the ductus arteriosus and the aorta had become more and more acute during the latter part of foetal life, with the result that the upper and right margin of the orifice of communication attained a position overhanging the lower and left margin (Fig. 39); and as soon as the blood pressure in the aorta exceeded that in the ductus arteriosus, this margin, acting as a flap valve, was driven against the left and lower margin, closing the orifice effectually. After this occurred the utility of the ductus arteriosus terminated, and it was converted into a fibrous cord—the ligamentum arteriosum.

Note that the left recurrent nerve curves round the lower surface of the aortic arch on the left side of the upper end of the ligamentum arteriosum, and that the superficial cardiac plexus lies below the aortic arch immediately to the right of the ligament.

In a few cases the ductus arteriosus remains patent for several years of life after birth, and occasionally it is patent throughout the whole of life.

Dissection.—Cut through the remains of the upper part of the conus arteriosus immediately below the bases of the cusps of the pulmonary valve, and carefully dissect the upper part of the conus and the lower part of the pulmonary artery away from the front of the commencement of the ascending aorta. When this has been done, turn the lower end of the pulmonary artery upwards and pin it to the arch of the aorta (see Fig. 40). The upper part of the anterior wall of the left ventricle and the commencement of the aorta are now exposed, and the dissector should note three bulgings at the commencement of the aorta—the three aortic sinuses. One of the three sinuses lies anteriorly, and the right coronary artery springs from it. The other two, a right and a left, lie posteriorly, and the left coronary artery springs from the left sinus.

Make a transverse incision across the upper end of the left ventricle, a short distance below the base of the anterior aortic sinus. On the right side extend the incision into the upper part of the inter-ventricular septum and carry it downwards and anteriorly in the septum to the apex of the heart. From the left extremity of the upper transverse incision carry an incision downwards and anteriorly through the left lateral border of the anterior surface of the left ventricle, parallel with the incision already made in the septum, towards the apex. As this incision is made pull the anterior

wall of the left ventricle forwards till the base of a large papillary muscle which springs from its internal surface is exposed; carry the incision anterior to this and then onwards to the apex, and remove the anterior wall of the left ventricle and the anterior part of the inter-ventricular septum. The cavity of the left ventricle and the mitral valve, which guards the left atrio-ventricular orifice, are now exposed (Fig. 40).

Ventriculus Sinister.—The cavity of the left ventricle is longer and narrower than that of the right ventricle. It reaches to the apex, and when exposed from the front it appears to be of conical shape. In cross section it has a circular or broadly oval outline, and its walls are very much thicker than those of the right ventricle (Fig. 37). When the interior has been cleaned with the aid of a sponge and forceps, the dissector will note that its walls are covered with a dense mesh-work of trabeculæ carneæ, which are finer but much more numerous than those met with in the right ventricle. The network is especially complicated at the apex and on the inferior wall of the ventricle, whilst the surface of the septum and the upper part of the anterior wall are, comparatively speaking, smooth. But whilst the trabeculæ carneæ in the left ventricle are slighter and more numerous than those in the right, the muscoli papillares, on the other hand, are less numerous and much stronger; indeed, as a general rule there are only two papillary muscles in the left ventricle, an anterior and an inferior, the former attached to the anterior wall and the latter to the inferior wall of the cavity. The chordæ tendineæ from the papillary muscles pass to the margins and to the ventricular surfaces of the two cusps of the mitral valve, which guards the left atrio-ventricular orifice, the chordæ tendineæ from each papillary muscle gaining attachment to the adjacent margins of both cusps.

Dissection.—Detach the anterior papillary muscle from the anterior wall of the ventricle and note that its chordæ tendineæ go to the anterior and left margins of the cusps of the mitral valve. Introduce the blade of a scalpel between the anterior margins of the cusps and carry it downwards between the groups of chordæ going to the apex of the papillary muscle; then split the papillary muscle from its apex to its base leaving each half connected with a corresponding group of chordæ tendineæ. The cusps of the mitral can now be separated from each other, and the atrio-ventricular orifice and the cavity of the ventricle can be more completely examined.

The Orifices of the Left Ventricle.—There are two orifices of the left ventricle—one of entrance, the left atrio-ventricular orifice, and one of exit, the aortic orifice.

The Left Atrio-ventricular Orifice.—The left atrio-

ventricular orifice lies in the lower and posterior part of the ventricle posterior to the left margin of the sternum at the level of the fourth left costal cartilage. It is somewhat smaller than the right atrio-ventricular orifice and admits the tips of two fingers only, a fact which will be better appreciated when the orifice is examined from the left atrium at a later period. It is guarded by a bicuspid valve, called the mitral valve, which prevents regurgitation of blood from the left ventricle into the left atrium.

The Mitral Valve.—The mitral or left atrio-ventricular valve consists of two cusps, a large anterior and a small posterior. Occasionally, however, as on the right side, small additional cusps are interposed between the bases of the main cusps. The bases of the cusps are attached to a fibrous ring which surrounds the atrio-ventricular orifice and their apices project into the cavity of the ventricle. To their apices, margins, and ventricular surfaces are attached the chordæ tendineæ from the papillary muscles, which hold the margins of the cusps together and prevent the valve being driven backwards into the atrium during the contraction of the ventricle. The dissector should note, however, that the chordæ tendineæ spread less over the ventricular surface of the anterior than over that of the posterior cusp, and he should associate this fact with the circumstance that blood flows over both surfaces of the large anterior cusp, which intervenes between the atrio-ventricular and the aortic orifices. By means of this large anterior cusp of the mitral valve the cavity of the ventricle, which has, on the whole, a somewhat conical form, is converted into a bent U-shaped tube, one limb of the tube lying below and to the left, and the other anteriorly and to the right. The blood enters the ventricle below and posteriorly through the atrio-ventricular orifice. It runs anteriorly towards the apex of the cavity along the inferior surface of the anterior cusp of the mitral valve, then, as the ventricle contracts, it is driven upwards, anteriorly, and to the right, to the aortic orifice, along the anterior surface of the large anterior cusp of the mitral valve. The portion of the cavity of the left ventricle which lies directly below the aortic orifice is known as the *aortic vestibule* (Fig. 40). Its walls consist mainly of fibrous tissue; therefore they remain quiescent during the contraction of the ventricle and, as a result, the rapid closure of the aortic valve is not interfered with when

the ventricular contraction ceases and the elastic reaction of the walls of the aorta tends to force blood back into the ventricle.

The *aortic orifice* lies at the upper, right, and anterior part of the cavity, posterior to the left margin of the sternum at

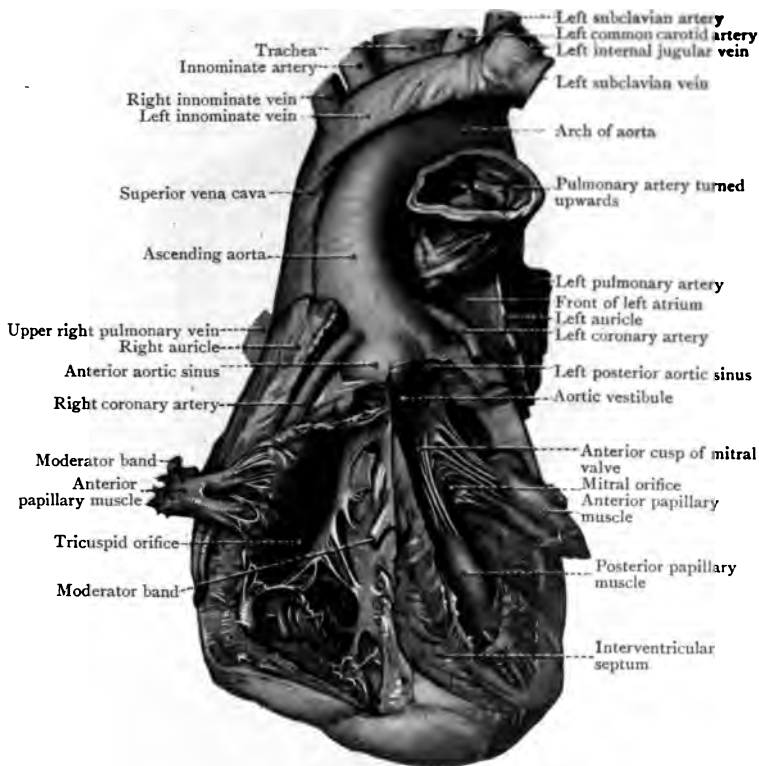


FIG. 40.—Dissection of the Heart from the anterior aspect.

the level of the third intercostal space. Its left and inferior margin is separated from the atrio-ventricular orifice by the anterior cusp of the mitral valve. It is guarded by a valve, *the aortic valve*, which prevents regurgitation from the aorta into the ventricle. This valve, like the pulmonary valve, consists of three semilunar cusps, but in contradistinction to

the pulmonary valve, one of the cusps is placed anteriorly and the other two posteriorly. The cusps of the aortic valve are stronger than the cusps of the pulmonary valve described on p. 75, but correspond with them in all details of structure.

Before terminating his examination of the left ventricle the dissector should note that the muscular wall of the cavity is thickest a short distance from the atrio-ventricular

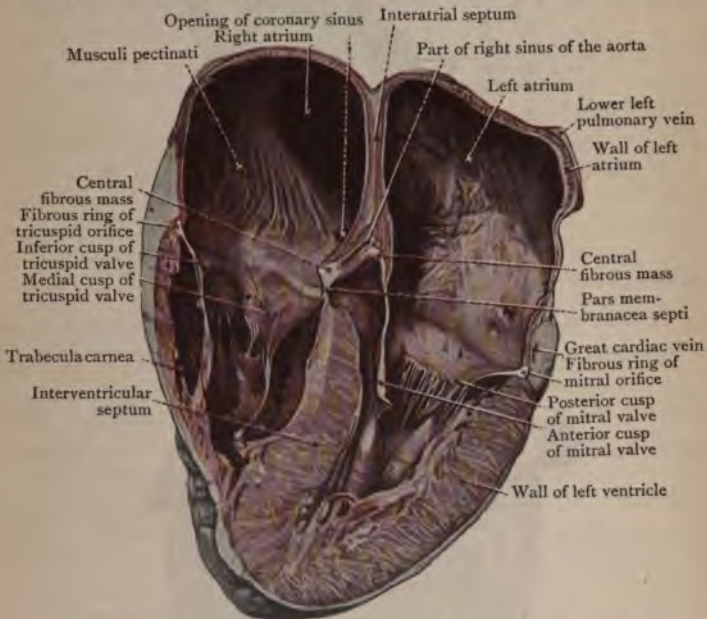


FIG. 41.—Section of the Heart showing the Interventricular and Interatrial Septa and the Fibrous Rings round the Orifices.

orifice and thinnest at the apex, and he should examine the inter-ventricular septum.

The Inter-ventricular Septum.—The inter-ventricular septum is a musculo-membranous partition which separates the left ventricle not only from the right ventricle, but also from the lower part of the right auricle. In the greater part of its extent the septum is thick and muscular, and is thickest below and anteriorly, where it springs from the lower border of the heart immediately to the right of the apex and opposite the

cardiac notch. The muscular part becomes gradually thinner as it passes upwards and posteriorly and, a short distance from the atrio-ventricular orifices, it terminates in a fibrous membrane, the *pars membranacea septi*, which connects the muscular part of the septum with the fibrous rings which surround the atrio-ventricular orifices and the orifices of the pulmonary artery and the aorta. The *pars membranacea* is the thinnest part of the septum. Occasionally it is deficient in whole or in part, and in such cases a communication exists between the two ventricles, and, in some rare cases, between the left ventricle and the right auricle.

The *pars membranacea* was exposed from the right side when the anterior part of the medial cusp of the tricuspid valve was removed during the dissection of the atrio-ventricular bundle (see p. 74).

Finally the dissector should note that the inter-ventricular septum is placed obliquely, so that its anterior border lies to the left and its inferior border to the right; and that its right lateral surface, which looks anteriorly and to the right, bulges towards the cavity of the right ventricle (Fig. 37).

The Aorta.—The aorta is the great arterial trunk of the body. It commences from the upper, anterior and right portion of the left ventricle, at the level of the third intercostal spaces and posterior to the left margin of the sternum. It terminates at the level of the lower border of the fourth lumbar vertebra, to the left of the median plane, where it divides into the right and left common iliac arteries. It is described as consisting of three main parts: (1) the ascending part, (2) the arch, and (3) the descending part. The descending part is divided into (a) thoracic and (b) abdominal portions. The first two parts and the thoracic portion of the third part are met with in the dissection of the thorax.

The Ascending Part of the Aorta.—The ascending aorta commences at the aortic orifice of the left ventricle and runs upwards to the right and slightly anteriorly, posterior to the first piece of the body of the sternum, to the level of the sternal end of the right second costal cartilage, where it becomes the arch of the aorta. It lies in the middle mediastinum, is enclosed in the fibrous sac of the pericardium, and is ensheathed by a covering of the serous sac which is common to it and the stem of the pulmonary artery. The lumen of this portion of the aorta is not of uniform diameter; on the

contrary it presents four dilatations, three at the commencement, the *aortic sinuses* (Valsalva), and one along the right border, the *great sinus of the aorta*. The latter is merely an indefinite bulging along the right border of the vessel.

Relations.—The lower part of the ascending aorta lies posterior to the upper part of the conus arteriosus and the lower

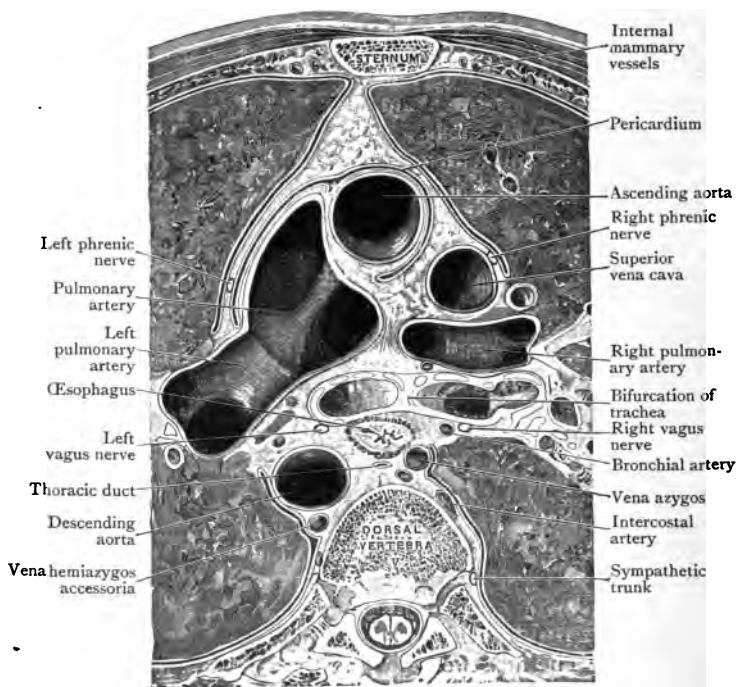


FIG. 42.—Transverse section through the Mediastinal Space at the level of the fifth dorsal vertebra.

part of the stem of the pulmonary artery ; but the upper part is in direct relation with the anterior wall of the pericardium, which separates it from the anterior part of the mediastinal surface of the right pleura and lung. Posterior to the ascending aorta, from below upwards, are the left atrium, the right pulmonary artery and the right bronchus. To the right are the right auricle below and the superior vena cava above ; and

to the left lie the left auricle below, and the upper part of the stem of the pulmonary artery above.

Branches.—Only two branches are given off from the ascending part of the aorta; they are the right and left coronary arteries. The right springs from the anterior aortic sinus and the left from the left posterior sinus. Their distribution has been described already (p. 60).

The Superficial Cardiac Plexus.—Before the arch of the aorta is studied, the position, connections and relations of the superficial cardiac plexus should be defined. It lies below the arch of the aorta, above the bifurcation of the stem of the pulmonary artery, and between the ascending aorta on the right and anteriorly, and the ligamentum arteriosum to the left and posteriorly. The positions of the superior cervical cardiac branch of the left sympathetic trunk, and the inferior cervical cardiac branch of the left vagus, on the left side of the arch of the aorta, have been defined already (p. 33). Trace these nerves to the plexus, clear away the areolar tissue from around the plexus, and trace branches posteriorly and upwards from it towards the deep cardiac plexus, which lies posterior to the arch of the aorta. Other branches which spring from the superficial part of the cardiac plexus descend along the pulmonary artery and form the right coronary plexus, which is distributed with the right coronary artery.

The Arch of the Aorta.—The aortic arch commences at the termination of the ascending part of the aorta, at the level of the second costal cartilage, and posterior to the right margin of the sternum, from which it is separated by the anterior part of the mediastinal portion of the right pleura and lung, or by the remains of the thymus gland (see Fig. 43). It runs posteriorly, to the left, and slightly upwards, through the middle mediastinum and round the left margins of the trachea and œsophagus (see Figs. 13 and 43), to the level of the lower border of the left side of the fourth thoracic vertebra, where it becomes continuous with the descending part of the aorta. It is curved in both the vertical and the horizontal planes, and as it passes posteriorly and to the left it forms a convexity upwards, and also a convexity which is directed anteriorly and to the left. Its lower border is connected with the left pulmonary artery by the ligamentum arteriosum, and from its upper border arise the three great vessels which supply the head, neck, and upper extremities.

Relations.—*Above*, the left innominate vein runs along its upper border immediately anterior to the origins of the innominate artery, the left common carotid artery and the left subclavian artery, which spring from its upper border; the first arises from the apex of the convexity, posterior to the centre

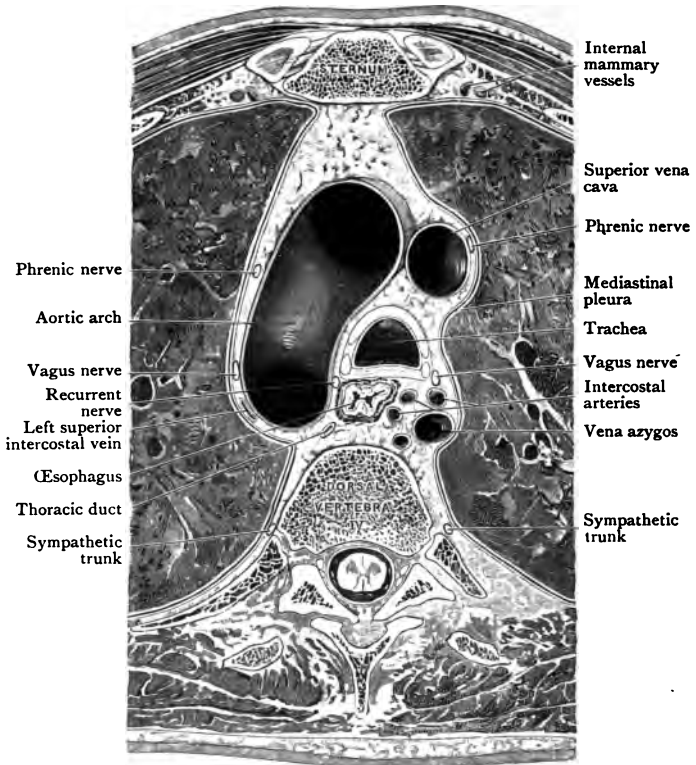


FIG. 43.—Transverse section through the Superior Mediastinum at the level of the fourth dorsal vertebra.

of the manubrium sterni; the second arises close to, and sometimes in common with the first, whilst the origin of the subclavian is a little more posterior and to the left, separated by a distinct interval from the left common carotid (Figs. 20 and 24). *Below* the arch lie (1) the bifurcation of the pulmonary artery and portions of its right and left branches; (2) the liga-

mentum arteriosum, which connects the left pulmonary artery with the arch; (3) the superficial part of the cardiac plexus immediately to the right of the ligamentum arteriosum; (4) the left recurrent nerve on the left side of the ligament; and (5) still further to the left, the left bronchus passes beneath the arch on its way to the hilus of the left lung. *To the right* of the arch are the trachea, the œsophagus, the left recurrent nerve, and the thoracic duct. The nerve lies in the angle between the œsophagus and the trachea, and the thoracic duct is posterior to and to the left of the œsophagus (Fig. 43). The left side of the arch is overlapped by the posterior part of the mediastinal surface of the left pleura and lung, but intervening between the pleura and the arch are (1) the left phrenic nerve, (2) the inferior cervical cardiac branch of the left vagus, (3) the superior cervical cardiac branch of the left sympathetic, (4) the left vagus, and (5) the left superior intercostal vein. The vein passes upwards and anteriorly, lying to the left of the vagus and the cardiac nerves, and to the right of the phrenic nerve (Fig. 13).

Dissection.—Divide the right coronary artery close to its origin. Cut through the anterior wall of the ascending part of the aorta on each side of the anterior aortic sinus; extend the incisions upwards to the commencement of the aortic arch, and examine the aortic valve. Note that it is formed by three semilunar cusps which are much stronger than the semilunar cusps of the pulmonary valve (p. 75), but are exactly similar in structure and attachments. Note further that one cusp lies anteriorly, and the other two posteriorly. Examine the aortic sinuses and note that the right coronary artery springs from the anterior sinus, and the left coronary from the left posterior sinus. Note further that the orifices of the coronary arteries, as a rule, lie immediately above the level of the upper margins of the semilunar cusps. Replace the stem of the pulmonary artery in position, and note the relative positions of the pulmonary, aortic, and atrio-ventricular orifices.

Topography of the Great Orifices of the Heart.—Replace the sternum in position and note the relations of the cardiac orifices to that bone. The pulmonary orifice is highest. It lies to the left of the margin of the sternum at the level of the third costal cartilage. The aortic orifice is a little lower, and more to the right, posterior to the left margin of the sternum, at the level of the third left intercostal space. Below the aortic orifice is the left atrio-ventricular orifice, posterior to the left margin of the sternum at the level of the left fourth costal cartilage. Still lower and more to the right is the right atrio-ventricular orifice, posterior to the centre of the sternum at the level of the fourth intercostal spaces (Fig. 44).

Dissection.—Divide the phrenic nerves immediately above the diaphragm; then, with the handle and the edge of the scalpel, detach the lower part of the pericardium from the diaphragm. The attachment of the pericardium to the muscular part of the diaphragm is not close, and can easily be broken down. The attachment to the central tendon is much more firm and, as the median plane is approached, the aid of the edge of the knife will probably be necessary before a separation can be effected.

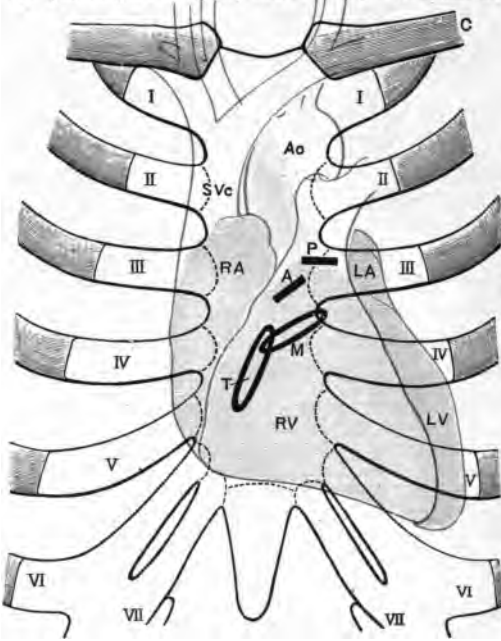


FIG. 44.—The relations of the Heart and of its Orifices to the Anterior Thoracic Wall. (Young and Robinson.)

I to VII. Costal cartilages.
 A. Aorta.
 Ao. Aortic orifice.
 C. Clavicle.
 LA. Left atrium.
 LV. Left ventricle.

M. Mitral orifice.
 P. Pulmonary orifice.
 RA. Right atrium.
 RV. Right ventricle.
 SVC. Superior vena cava.
 T. Tricuspid orifice.

Divide the right innominate vein and the right phrenic nerve, immediately above the upper end of the superior vena cava, and as the division is made take care not to injure the right vagus posterior to the vein. Then divide the vena azygos just posterior to its entrance into the superior vena cava. Cut the inferior thyreoid veins, the innominate artery, and the left common carotid artery, immediately above the upper border of the left innominate vein, and then divide the left innominate vein, in the interval between the left common carotid and the left subclavian arteries. Cut the left phrenic

nerve, the superior cardiac branch of the left sympathetic, and the inferior cervical cardiac branch of the left vagus, immediately above the upper border of the aortic arch. Next divide the aortic arch. Enter the knife at the upper border of the arch, between the left common carotid and left subclavian arteries and anterior to the left vagus and the left recurrent nerve, and cut from above downwards, completing the division of the arch at the lower border, immediately to the left of the upper end of the ligamentum arteriosum. The left superior intercostal vein will be divided at the same time, but care must be taken not to injure the left recurrent nerve, which is curving round the arch from the front to the back. When the incisions are completed, pull the anterior part of the aortic arch, with the superior vena cava and the lower parts of the innominate veins, anteriorly, and separate them from the lower part of the trachea and from the bronchi. As the separation proceeds, keep the edge of the knife turned towards the aortic arch, to avoid injury to the deep part of the cardiac plexus, which lies anterior to the bifurcation of the trachea. When the lower border of the arch is reached, the twigs which connect the superficial with the right half of the deep part of the cardiac plexus will be exposed, and must be divided. When this has been done detach the posterior surface of the pericardium from the front of the œsophagus and the descending aorta, taking care to avoid injury to the plexus formed by the vagi nerves on the anterior aspect of the œsophagus. As soon as the separation is completed, the heart, with the remains of the pericardium and the lower parts of the phrenic nerves, can be removed from the thorax, and the investigation of the left atrium and the structure of the heart can be proceeded with; but, before this is done, the dissector should note that the posterior wall of the pericardium intervenes between the posterior wall of the left atrium and the anterior surfaces of the œsophagus and the descending part of the aorta, as the latter structures lie anterior to the middle four thoracic vertebræ (Fig. 21).

After the heart and the roots of the great vessels have been removed from the thorax, fasten the left vagus and the recurrent nerve to the part of the arch left *in situ* by one or two points of suture; then cut away the remains of the pericardium from the heart, leaving only those portions of it which mark the lines of reflection of the parietal to the visceral portions of the serous sac. Note, as the posterior wall of the pericardium is removed, that it forms the posterior boundary of the oblique sinus (p. 21).

The Left Atrium.—The left atrium, like the right, is separable into two parts—a larger main portion, the atrium proper or body; and a long narrow prolongation, the auricle (O.T. auricular appendage), which runs from the left margin of the body anteriorly and to the right. The four pulmonary veins, two on each side, open into the left atrium. They enter close to the upper ends of the lateral borders of the posterior surface, and not uncommonly the right or the left pair may fuse into a common trunk at the point of entrance.

It has been noted previously that the left atrium forms the greater part of the base of the heart, a small part of anterior or sterno-costal surface, and a still smaller part of the left border. The only part which can be seen from front, when the heart is *in situ*, is the apical portion

auricle (appendage), for the portion which enters into the formation of the sterno-costal surface is hidden by the roots of the aorta and the pulmonary artery (Fig. 35).

The posterior wall of the left atrium is of quadrangular outline. Along its superior border lie the pulmonary arteries. It is bounded inferiorly by the posterior part of the coronary

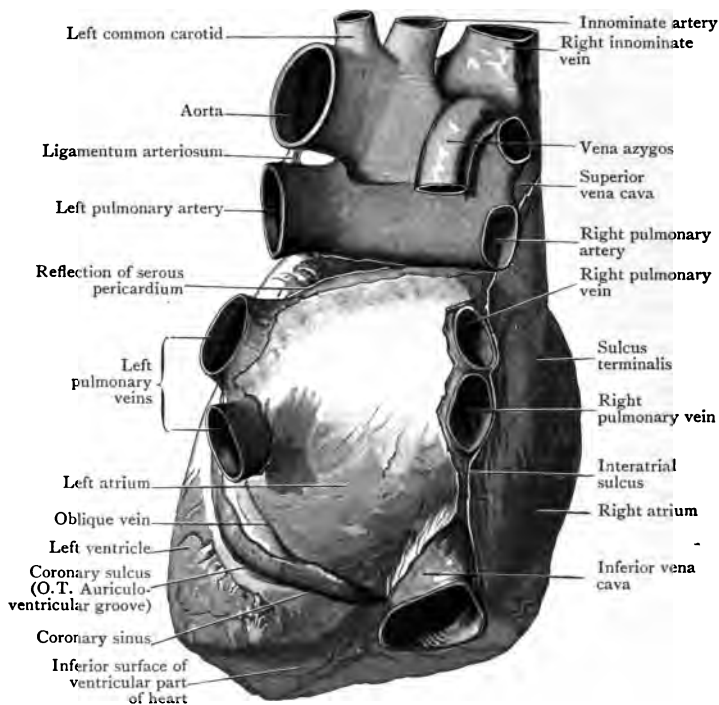


FIG. 45.—Posterior or Basal Aspect of a Heart hardened *in situ* by formalin injection.

sulcus, in which lies the coronary sinus, and on the right by an indistinct inter-atrial sulcus, which indicates the position of the posterior border of the inter-atrial septum. Descending obliquely across the posterior wall of the left atrium, from the lower border of the left inferior pulmonary vein, downwards and to the right to the coronary sinus, is the oblique vein (Marshall), which is the remains of the left duct of

Cuvier of the foetus. Occasionally it becomes the lower end of a left superior vena cava.

Dissection.—Open the left atrium by three incisions—one horizontal and two vertical. The horizontal incision must run from side to side along the lower border of the atrium, immediately above the coronary sulcus; and the vertical incisions must ascend from the extremities of the horizontal to the upper border of the posterior surface, each passing to the medial side of the terminations of the corresponding pulmonary veins. When the incisions have been made the posterior wall of the atrium must be turned upwards whilst the cavity is being examined.

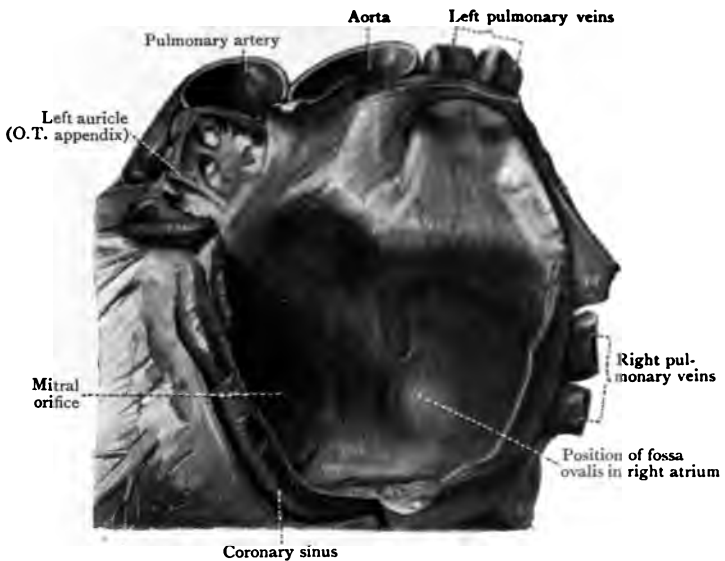


FIG. 46.—The Left Atrium opened from behind. The greater part of the posterior wall has been thrown upwards.

The inner surface of the wall of the left atrium is smooth and generally devoid of muscular bundles, but the inner surface of the wall of its auricle (O.T. auricular appendage) is covered with muscoli pectinati, a fact which can be demonstrated by carrying an incision anteriorly into it. As this incision is made, the dissectors should note that, in a formalin hardened heart, a strong muscular ridge descends along the left border of the cavity anterior to the orifices of the left pulmonary veins, entirely concealing them from view when the cavity is examined from the front.

On the right or septal wall of the left atrium the

of the valve of the foramen ovale is marked by one or more small semilunar depressions situated between slender muscular ridges. The portion of the septal wall which lies below and posterior to these depressions forms the floor of the fossa ovalis, and is the remains of the valve of the foramen ovale of the fœtus.

The Orifices of the Left Atrium.—The orifices of the left atrium are the openings of the *four pulmonary veins*, which convey to it the oxygenated blood from the lungs; a number of minute openings which are the mouths of the *venæ cordis minimæ*; and the *left atrio-ventricular orifice* through which blood passes from the left atrium to the left ventricle.

The openings of the pulmonary veins are situated in the posterior wall, nearer the upper than the lower part, and close to the lateral borders, two on each side. They are entirely devoid of valves. The orifices of the *venæ cordis minimæ*, which are scattered irregularly, are also valveless; but the left atrio-ventricular orifice, which lies in the lower part of the anterior wall of the atrium, is guarded by a bicuspid valve, *the mitral valve*, which has been described already (p. 79). This orifice is smaller than the corresponding orifice on the right side, and admits the tips of two fingers only.

The Structure of the Walls of the Heart.—The last step in the dissection of the heart consists in the examination of the structure of its walls. On the outside the walls are covered with the *epicardium*, which is the visceral part of the serous pericardium; and on the inside they are lined with the smooth and glistening *endocardium*, which plays a large part in the formation of the flaps of the valves, and is continuous, through the orifices, with the inner coats of the arteries and veins. Between the epicardium and the endocardium lies the muscular tissue of the heart, which is termed the *myocardium*. The muscular fibres of the myocardium are disposed in layers, in each of which the fibres take a special direction.

The arrangement of the various layers of the myocardium cannot be displayed in an ordinary dissecting-room heart, in which the continuity of the fibres has been destroyed by the incisions made to display the cavities, but the arrangement of the layers is practically the same in the hearts of all mammals. Therefore, for the purpose of studying the layers, the dissector should obtain a sheep's heart. This should be filled with a paste made of flour and water; then it should be boiled for a quarter of an hour. The boiling expands the paste, softens the connective tissue, and hardens the muscular fibres. After the boiling is finished the heart should be placed for a time in cold water. After it has cooled, first the epicardium and then the muscular fibres should be gradually torn off.

The atrial fibres are difficult to dissect. They consist of three groups: (1) A superficial group running more or less transversely and common to both atria. They are best marked near the coronary sulcus. (2) A deep group special to each auricle. The extremities of these fibres are connected

with the fibrous atrio-ventricular rings, and they pass over the auricles from front to back. (3) The third group consists of sets of annular fibres surrounding the orifices of the veins which open into the atria.

The fibres of the ventricles are more easily dissected. They consist, for the main part, of two groups—the superficial and the deep. The fibres of each set are common to both ventricles, and the dissectors should note the remarkable spiral or whorled arrangement of the superficial fibres which occurs at the apex, where they pass into the deeper parts of the wall.

The superficial fibres spring mainly from the fibrous atrio-ventricular rings. Those which are attached to the right ring turn inwards at the apex and become continuous with the papillary muscles of the left ventricle, whilst the fibres which spring from the left ring pass in the same way to the papillary muscles of the right ventricle. The deeper fibres form an ∞ -shaped layer, one loop of the ∞ surrounding the right and the other the left ventricle.

The fibrous rings of the atrio-ventricular orifices intervene between the atrial and the ventricular muscle fibres, but the two groups are brought into association with each other by the atrio-ventricular bundle described on p. 74. It has been assumed that the impulses which regulated the movements of the ventricles were conveyed to them from the atria by the fibres of this bundle, but it has been shown recently that numerous nerve fibrils are intimately intermingled with the fibres of the atrio-ventricular bundle. It is possible, therefore, that the connection between the atria and the ventricles is neuro-muscular.

The Action of the Heart.—The differences between the various parts of the heart, *i.e.* the thinness of the walls of the atria as contrasted with the thickness of the walls of the ventricles, and the greater thickness of the walls of the left as contrasted with those of the right ventricle, are associated with the functions of the various chambers, and with the action which the heart plays in the maintenance of the circulation of the blood. The heart is a muscular pump, provided with receiving and ejecting chambers. It has three phases of action: (1) a period of atrial contraction; (2) a period of ventricular contraction, which immediately succeeds the atrial contraction; (3) a period of diastole or rest.

During the period of diastole or rest the chambers, previously contracted, dilate, as the muscular fibres of the heart relax. The dilatation is aided by the respiratory movements of the thorax. As the dilatation progresses blood flows into the right atrium from the superior vena cava, the inferior vena cava, and the coronary sinus; and into the left atrium through the four pulmonary veins. The atrial contraction commences with the contraction of the circular fibres which surround the mouths of the veins entering the atria, and thus the blood is prevented from passing back into the veins. As the contraction extends to the general fibres of the atria the blood is forced onwards into the ventricles, which become distended. Then the ventricular contraction commences, the atrio-ventricular valves close, and, as the contraction proceeds, the blood is driven out of the ventricles through the arterial orifices, that in the right ventricle being ejected into the pulmonary artery, and that in the left ventricle into the aorta.

When the ventricular contraction is completed the period of diastole commences; and, as long as the heart remains alive, the cycle is repeated.

The work of the atria is merely to force the blood through the widely open atrio-ventricular orifices into the ventricles and to expand the dilating walls of the ventricles. For this purpose no great force is required, therefore the walls of the atria are thin. The work of the ventricles is much more severe, therefore their walls are thicker, but the right ventricle only to exert sufficient force to drive the blood through the lungs to the

auricle, that is, through a comparatively short distance and against a comparatively small resistance; therefore its walls are thin as compared with the walls of the left ventricle, which has to be sufficiently strong to force the blood through the whole of the trunk, the head and neck, and the upper and lower limbs.

The Topography of the Heart.—Before proceeding to the study of the trachea, the dissectors should replace the heart in position and revise their knowledge of its relations to the surface. Its position can be indicated on the anterior wall of the thorax by the following four lines:—(1) A line commencing at the lower border of the second left costal cartilage, half an inch from the left border of the sternum, and ending at the upper border of the third right costal cartilage, half an inch from the right border of the sternum. This line indicates the position of the upper border of the heart, which is formed by the atria. (2) A line from the upper border of the third right costal cartilage to the sixth right costal cartilage. This line should commence and end half an inch from the border of the sternum, and should be slightly convex to the right. It indicates the right border of the heart, which is formed by the right atrium alone. (3) A line from the sixth right costal cartilage to the apex, which lies behind the fifth left intercostal space three and a half inches from the median plane. This line marks the position of the lower border of the sterno-costal surface, which is formed, in the greater part of its extent, by the right ventricle, the left ventricle entering into its constitution only in the region of the apex. (4) A line from the apex to the lower border of the second left costal cartilage. This line should be convex upwards and to the left; the point of greatest convexity should coincide with the lower border of the fourth left costal arch, and the upper extremity should be situated half an inch from the left margin of the sternum. It marks the position of the left border of the heart, which is formed in four-fifths of its length by the left ventricle and in the remaining fifth by the left atrium.

A line from the upper border of the sternal end of the third left costal cartilage to the lower border of the sternal end of the sixth right cartilage indicates the anterior part of the coronary sulcus. The points indicating the positions of the arterial and atrio-ventricular orifices must be placed below and to the left of the line of the coronary sulcus in the following order from above downwards; *pulmonary orifice,*

aortic orifice, mitral orifice, tricuspid orifice. The centre of the pulmonary orifice is posterior to the third left costal cartilage at the margin of the sternum. The aortic orifice lies posterior to the left half of the sternum opposite the third inter-

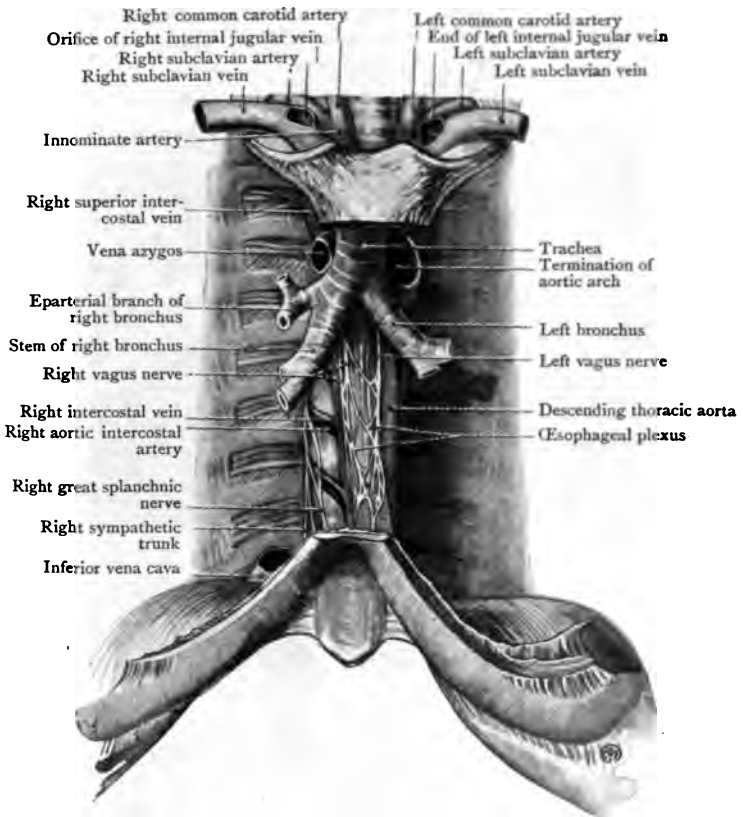


FIG. 47.—Dissection of the Posterior Mediastinum and the posterior part of the Superior Mediastinum from the anterior aspect.

costal spaces. The mitral orifice is posterior to the left border of the sternum at the level of the fourth left costal cartilage ; and the centre of the tricuspid orifice is posterior to the middle of the sternum at the level of the fourth intercostal spaces.

The Thoracic Portion of the Trachea.—The thoracic portion of the trachea, like the cervical portion, is a wide

tube kept constantly patent by a series of cartilaginous rings embedded in its walls. Posteriorly the rings are deficient and in consequence the tube is flattened behind (Fig. 43). It enters the thorax at the upper aperture, posterior to the upper border of the manubrium, and it terminates, at the level of the lower border of the manubrium and the upper border of the fifth thoracic vertebra, by dividing into a right and a left bronchus. It lies, therefore, in the superior mediastinum,

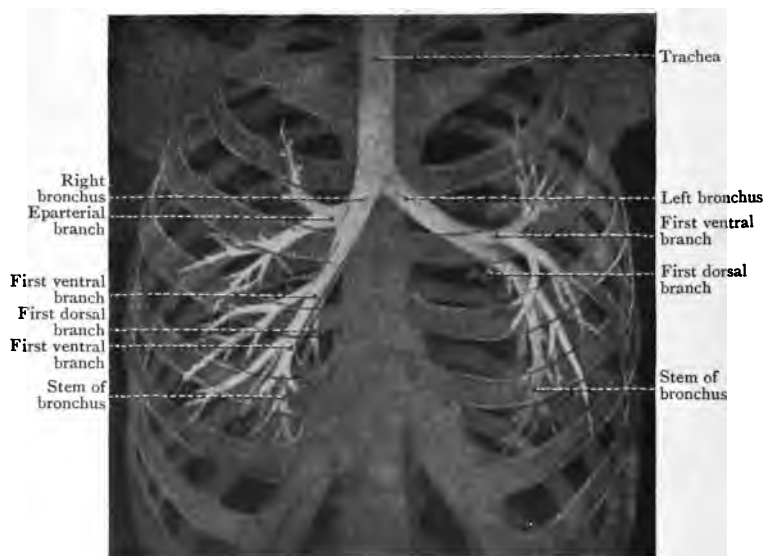

FIG. 48.—Drawing of a Stereoscopic Skiagraph of the Trachea and Bronchi injected with starch and red lead.

and its median axis is in the median plane, except at the lower end where it deviates slightly to the right.

Relations.—*Posteriorly*, it is in contact with the œsophagus, which separates it from the vertebral column; and in the angle between its left border and the anterior surface of the œsophagus is the left recurrent nerve (Fig. 43).

Anteriorly, it is in relation below with the arch of the aorta, the deep part of the cardiac plexus intervening; and at a higher level with the innominate and left common carotid arteries, the left innominate vein and the inferior thyreoid veins. More superficially lie the remains of the

thymus, and still more superficially the manubrium sterni with the origins of the attached muscles.

On the right, it is in relation with the upper part of the mediastinal surface of the right pleura and lung (Fig. 43), the right vagus nerve, and the arch of the azygos vein (Fig. 12). It is also in relation, on its right side, near its lower end and more anteriorly, with the superior vena cava, and at a higher level with the innominate artery.

Its left lateral relations are the arch of the aorta below and the left subclavian and left common carotid arteries above.

The Bronchi.—Each bronchus passes downwards and laterally first to the hilus of the corresponding lung and thence downwards in the substance of the lung to its lower end. It can, therefore, be divided into an extra-pulmonary and an intra-pulmonary portion. The extra-pulmonary part, like the trachea, is kept permanently open by the presence of cartilaginous rings in its walls; and as the rings are deficient posteriorly, the extra-pulmonary part of each bronchus presents a flattened posterior surface similar to that of the trachea. The lumina of the intra-pulmonary parts of the bronchi are kept patent by cartilaginous plates which are irregularly distributed in the substance of the walls.

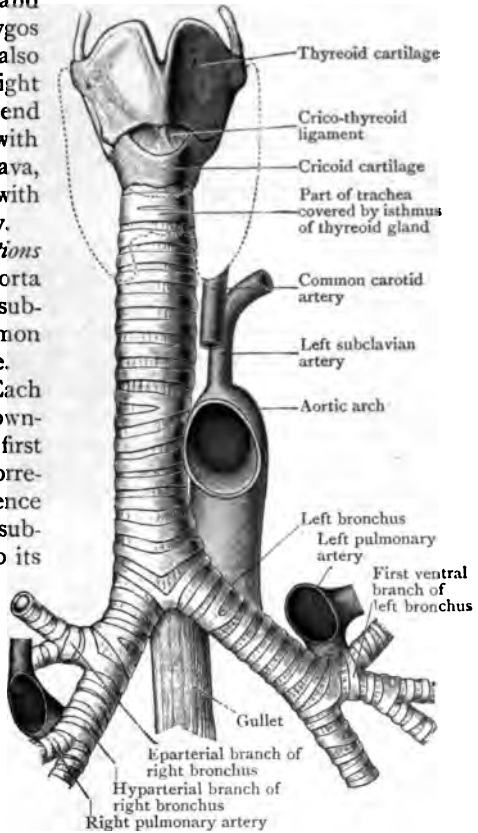


FIG. 49.—The Trachea and Bronchi. The dotted line gives the outline of the thyroid gland.

Relations of the Extra-pulmonary Part of the Right Bronchus.—The right bronchus is much more vertical than the left (Fig. 48), and, as the ridge which separates the orifices of the two bronchi at their origins, lies to the left of the median line of the trachea, the right bronchus is the direct continuation of the trachea, and foreign bodies, which have entered the windpipe, pass more frequently into it than into the left bronchus. It passes downwards and laterally from the upper border of the fifth thoracic vertebra to the level of the upper part of the sixth thoracic vertebra, where it enters the hilus. *Anterior to* the extra-pulmonary part of the right bronchus are the ascending part of the aorta, the lower part of the superior vena cava, and the right pulmonary artery. *Above it* is the arch of the azygos vein; and *posterior to it* are the azygos vein, the posterior pulmonary plexus, and the right bronchial artery. This part of the right bronchus gives off one branch, which arises close to the hilus and is called the eparterial bronchus, because it originates immediately above the point where the right pulmonary artery crosses anterior to the stem bronchus.

Relations of the Extra-pulmonary Part of the Left Bronchus.—The extra-pulmonary part of the left bronchus commences and ends at the same level as the corresponding part of the right bronchus, but it has further to go, because the hilus of the left lung is further from the median plane than the hilus of the right lung; therefore it is longer and less vertical than the right bronchus. It gives off no branches.

Anterior to it are the left pulmonary artery, and the upper and left part of the pericardial sac which separates the bronchus from the left auricle. *Above it* is the arch of the aorta, and *posterior to it* are the descending aorta, the posterior pulmonary plexus, the left bronchial arteries, and the œsophagus.

Dissection.—The intra-pulmonary parts of the bronchi and the intra-pulmonary parts of the pulmonary arteries and veins should now be dissected. The dissectors must commence at the hilus of the lung and follow the bronchus and the vessels into the interior of the lung, cutting away the lung substance, but avoiding injury to the main branches of the bronchus and of the artery, and the main tributaries of the veins.

Relations of the Intra-pulmonary Parts of the Bronchi, the Pulmonary Arteries and the Pulmonary Veins.—After passing through the hilus each bronchus descends, in the substance of the lung, to the lower end of the lung, lying nearer the medial than the lateral surface, and nearer the posterior than the anterior border. As it descends it gives off two sets of

branches: (1) *ventral*, which run towards the anterior border of the lung, and (2) *dorsal*, which pass posteriorly to the thick posterior border. As these branches are given off below the point where the pulmonary artery crosses anterior to the bronchus they are called *hyparterial branches*. The hyparterial branches arise alternately, first a ventral and then a dorsal branch, and, in addition, a number of small accessory branches are given off from the stem bronchus in some of the intervals between the dorsal and ventral branches. *On the right side*, the eparterial bronchus, which is given off from the extra-pulmonary part of the right stem bronchus, supplies the upper lobe of the right lung. The first ventral hyparterial branch supplies the middle lobe, and all the remaining branches are distributed to the lower lobe. *On the left side*, the first ventral branch goes to the upper lobe of the left lung, and all the other branches go to the lower lobe.

The intra-pulmonary part of each pulmonary artery descends along the postero-lateral aspect of the intra-pulmonary part of the stem bronchus, between the ventral branches anteriorly and the dorsal branches posteriorly, and it gives off branches which correspond with the branches of the main bronchus.

The vein from the upper lobe, on the right side, runs along the antero-medial aspect of the eparterial bronchus to the hilus, where it joins the vein of the middle lobe, which lies along the antero-medial border of the first ventral hyparterial bronchus, to form the upper right pulmonary vein. The vein from the lower lobe ascends along the antero-medial border of the intra-pulmonary part of the stem bronchus. On the left side, the upper left pulmonary vein accompanies the first ventral bronchus, and the lower accompanies the intra-pulmonary part of the stem bronchus; each vein lies along the ventro-medial aspect of the bronchus which it accompanies.

The Thoracic Portions of the Vagi Nerves.—The thoracic parts of the vagi nerves, which are still in position, should now be examined. Both vagi enter the thorax at the upper aperture. The *right vagus* descends, through the superior mediastinum, posterior to the right innominate vein and the superior vena cava, passing obliquely downwards and posteriorly (Fig. 12) along the side of the trachea, and between the trachea medially, and the right pleura laterally, to the arch of the azygos vein. Next it passes between the trachea medially, and the arch of the azygos vein laterally, and reaches the posterior aspect of the root of the right lung, where it breaks up into a number of branches which unite with branches of the sympathetic trunk to form the posterior pulmonary plexus. It emerges from the plexus as a single trunk which runs downwards and medially, in the posterior mediastinum, to the front of the œsophagus. On the œsophagus it breaks up into branches which unite with branches of the left vagus to form the *œsophageal plexus* (Fig. 47). At the lower end of the thorax the right vagus again becomes distinct; it passes to the posterior aspect of the œsophagus and enters the abdomen through the œsophageal orifice of the diaphragm.

Thoracic Branches of the Right Vagus.—Whilst the right vagus is in the superior mediastinum it gives off a thoracic cardiac branch, which goes to the right half of the deep cardiac plexus, and some anterior pulmonary branches to the front of the root of the right lung, where they join with branches of the cardiac plexus to form the anterior pulmonary plexus. As it passes posterior to the root of the lung it gives branches to the bronchi and the lung; and in the posterior mediastinum it gives branches to the œsophagus, and to the posterior part of the pericardium and pleura.

The Left Vagus.—As the left vagus descends through the superior mediastinum it lies at first between the left common carotid artery and the left phrenic nerve anteriorly, and the left subclavian artery posteriorly, and then on the left side of the arch of the aorta. In the latter situation it is crossed laterally by the left superior intercostal vein. Below the lower border of the aortic arch it passes posterior to the root of the left lung, where it breaks up into branches which enter into the formation of the posterior pulmonary plexus. At the lower border of the root of the left lung it emerges from the plexus as two trunks, which descend, into the posterior mediastinum, to the œsophagus, where they unite with branches of the right vagus to form the œsophageal plexus. At the lower end of the thorax the left vagus again becomes a single trunk which passes through the œsophageal orifice of the diaphragm on the anterior aspect of the œsophagus.

Thoracic Branches of the Left Vagus.—In the superior mediastinum, whilst it lies against the left side of the aortic arch, it gives off the left recurrent branch, branches to the upper and anterior part of the pericardium, and branches to the left anterior pulmonary plexus. Posterior to the root of the left lung, it supplies branches to the left bronchus and the left lung; and during its course through the posterior mediastinum, as it takes part in the œsophageal plexus, it gives branches to the œsophagus, to the posterior part of the pericardium, and to the left pleura.

The Thoracic Part of the Left Recurrent Nerve.—The left recurrent nerve springs from the trunk of the left vagus near the lower border of the left side of the aortic arch. It curves round the lower border of the arch, posterior and to the left of the ligamentum arteriosum, and passes upwards, posterior and to the right of the arch,

through the superior mediastinum, in the angle between the left border of the trachea and the œsophagus, and posterior to the left common carotid artery. As it turns round the arch it gives branches to the deep cardiac plexus, and, as it ascends along the left border of the trachea, it gives offsets to the trachea and to the œsophagus.

The Deep Cardiac Plexus.—The deep cardiac plexus lies between the arch of the aorta and the bifurcation of the trachea. It is more or less distinctly separable into right and left parts, and the right part is connected with the superficial cardiac plexus. The right part of the plexus receives (1) three cardiac branches from the cervical part of the right sympathetic trunk; (2) the two cervical cardiac branches of the right vagus; (3) the cardiac branch of the right recurrent nerve; (4) the thoracic cardiac branch of the right vagus. It is connected with the superficial cardiac plexus and gives branches to (1) the right anterior pulmonary plexus; (2) the right atrium; (3) the right coronary plexus. The left part of the deep cardiac plexus receives (1) the middle and lower cervical cardiac branches of the left sympathetic trunk; (2) the upper cervical cardiac branch of the left vagus; (3) the cardiac branches of the left recurrent nerve. It gives branches to (1) the left anterior pulmonary plexus; (2) the left atrium; (3) the left coronary plexus.

Dissection.—Cu: through the right and left bronchi, close to their origins from the trachea; then divide the trachea at the upper aperture of the thorax and remove its thoracic portion, but avoid injury to the vagi and the left recurrent nerves. The extra-pulmonary parts of the bronchi will be retained in position by the bronchial arteries and the branches of the pulmonary plexuses; and the thoracic part of the œsophagus will be fully exposed.

The Thoracic Part of the Œsophagus.—The thoracic part of the œsophagus enters the thorax at the upper aperture, passes downwards, through the superior and posterior mediastina, and leaves, at the level of the tenth thoracic vertebra, by passing through the œsophageal orifice of the diaphragm into the epigastric region of the abdomen. As it enters the superior mediastinum it lies somewhat to the left of the median plane, but as it descends it passes medially, gains the median plane at the level of the fifth thoracic vertebra, and continues downwards in that plane to the level of the seventh thoracic vertebra. There it passes forwards

and to the left, across the anterior aspect of the descending aorta and posterior to the pericardium (Figs. 12 and 21).

Posterior Relations.—*In the superior mediastinum* it is anterior to the left longus colli muscle and the vertebral column. In the upper part of the *posterior mediastinum* it is separated from the vertebral column by (1) the posterior part of the œsophageal plexus, (2) the upper six right aortic intercostal arteries, (3) the thoracic duct, (4) the vena azygos, (5) the vena hemiazygos and the accessory hemiazygos vein; and in the lower part by (6) the œsophageal plexus and (7) the descending aorta.

Anterior Relations.—Anterior to it, *in the superior mediastinum*, lie the trachea, the left recurrent nerve, the upper part of the left common carotid artery, the left subclavian artery, the arch of the aorta, and the structures which lie anterior to those already mentioned. *As it passes from the superior to the posterior mediastinum* its anterior relations are first the commencement of the left bronchus and then the right pulmonary artery.¹ *In the posterior mediastinum*, the œsophageal plexus is on its anterior surface, intervening between it and the posterior wall of the pericardium, which separates both the plexus and the œsophagus from the posterior wall of the left atrium; and at a lower level the œsophagus lies posterior to the diaphragm (Fig. 21).

Right Lateral Relations.—*In the superior mediastinum*, it is in relation with the right pleura and lung and with the arch of the vena azygos (Figs. 12 and 22), and *in the posterior mediastinum* with the œsophageal plexus and right pleura and lung, until it passes anteriorly and to the left, anterior to the descending aorta.

Left Lateral Relations.—*In the superior mediastinum*, it is in relation on the left side with the thoracic duct, the left subclavian artery, the left pleura and lung, and the termination of the arch of the aorta. *From the fifth to the seventh thoracic vertebra* its left lateral relations are the œsophageal plexus and the descending aorta; and *at its lower end*, as it lies anterior to the descending aorta, it comes again into relation with the left pleura and lung.

The dissector should note (1) that, after death, the œsophagus is somewhat compressed antero-posteriorly by the structures between which it lies. It probably has a similar form during life when empty and flaccid, but becomes

¹ Verify this statement by replacing the heart *in situ*.

more circular when solids or fluids are passing along it; and (2) that it is somewhat constricted at the level of the left bronchus.

An inch or more of the upper part of the posterior mediastinal portion of the tube should be removed and dissected under water in a cork-lined tray. It will be found to possess from without inwards the following coats: (1) an external fibrous sheath; (2) a muscular coat; (3) a submucous coat; and (4) a mucous internal lining. The submucous coat forms a loose connection between the muscular and mucous coats; consequently, when the muscular

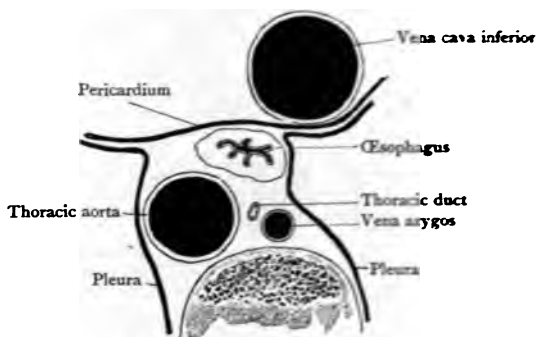


FIG. 50.—Tracing of section through the Posterior Mediastinum at the level of the eighth thoracic vertebra.

coat is contracted the mucous lining is thrown into longitudinal folds. The muscular coat consists of an external layer of longitudinal fibres and an internal layer of circular fibres.

Aorta Descendens.—The descending aorta commences at the termination of the aortic arch, at the lower border of the left side of the fourth thoracic vertebra. It passes downwards, through the posterior mediastinum, and it leaves the thorax by passing through the aortic aperture of the diaphragm, opposite the lower border of the twelfth thoracic vertebra. Its length is about seven inches. In the upper part of its extent it lies to the left of the vertebral column; but in the lower part it lies anterior to the column, in the median plane.

Branches.—Branches spring from both the anterior and the posterior aspects of the descending aorta. Those from the anterior aspect are the two left bronchial arteries, four

oesophageal branches, and some small and irregular mediastinal and pericardial branches. The posterior branches are nine pairs of aortic intercostal arteries and one pair of subcostal arteries.

Relations.—*Anterior* to the thoracic part of the descending aorta, from above downwards, are the root of the left lung; the upper part of the posterior wall of the pericardium, separating the aorta from the left atrium; the oesophagus, separating the aorta from the lower part of the posterior wall of the pericardium; and the crura of the diaphragm, which separate the lower portion of the thoracic aorta from the

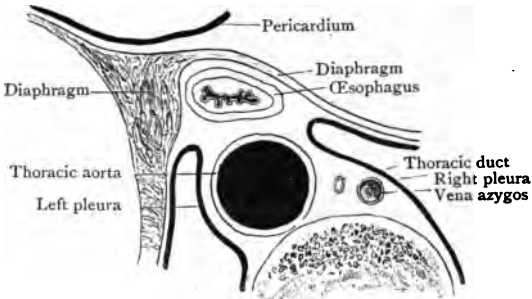
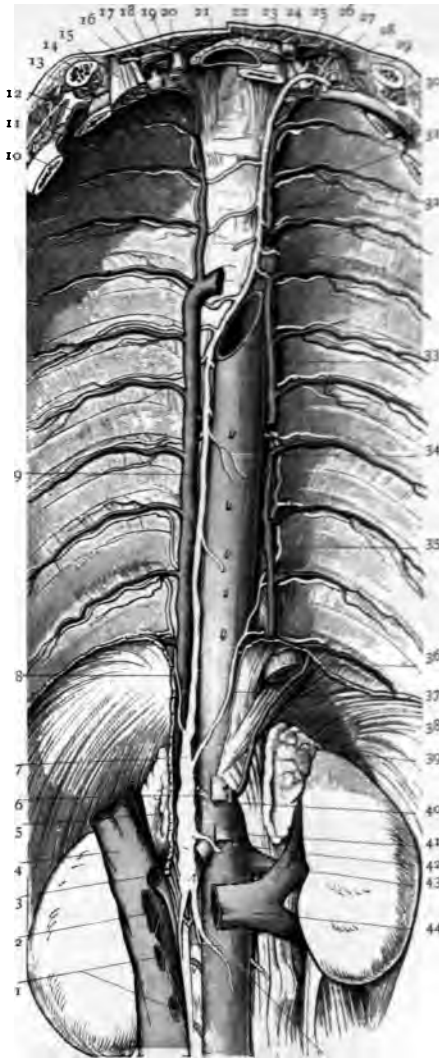


FIG. 51.—Tracing of a section through the lower part of the Posterior Mediastinum, where its anterior wall is formed by the diaphragm.

omental bursa of the peritoneum and from the posterior surface of the caudate lobe (O.T. Spigelian) of the liver. *Posteriorly* are the vertebral column, its own intercostal and subcostal branches, the hemiazygos and accessory hemiazygos veins; and it is overlapped posteriorly in the upper part of its extent by the left pleura and lung. *Along its right side*, in its whole length, are the thoracic duct and the vena azygos, and anterior to them, from the fifth to the lower part of the seventh thoracic vertebra, lies the oesophagus. At a lower level a mass of areolar tissue separates the aorta from the right pleura and lung. *On its left side* it is in relation with the left pleura and lung.

Dissection.—Turn the remains of the lower part of the oesophagus downwards towards the diaphragm. Clean the thoracic duct, the right aortic intercostal arteries, and the hemiazygos and accessory hemiazygos veins, which lie posterior to the oesophagus. Then trace the thoracic duct in the



45

FIG. 52.—The Thoracic Duct and its Tributaries.

whole of the thoracic portion of its course, and arrange with the dissector of the head and neck to display the cervical portion of its course.

The Thoracic Duct.—The thoracic duct is a vessel of small calibre but of great importance, for it conveys, to the left innominate vein, the whole of the lymph from the lower extremities, the abdomen (except that from part of the upper surface of the liver), the left side of the thorax, including the left lung and pleura and the left side of the heart, the left upper extremity, and the left side of the head and neck. It is the upward prolongation of a dilated sac, the *cisterna chyli*, which lies between the right crus of the diaphragm and the bodies of the first and second lumbar vertebræ. It enters the thorax through the aortic orifice of the diaphragm, lying between the aorta on the left and the *vena azygos* on the right. It continues upwards through the posterior mediastinum, lying between the descending aorta and the *vena azygos*, anterior to the right aortic intercostal arteries and the *hemiazygos* and accessory *hemiazygos* veins, and posterior to the right pleura below and the *œsophagus* above. At the level of the fifth thoracic vertebra it crosses to the left of the vertebral column, and then ascends, through the superior mediastinum, along the left border of the *œsophagus*, in contact, on the left, with the left pleural sac, and separated posteriorly from the left longus colli muscle by the mass of areolar tissue. Anterior to the thoracic duct, in the superior mediastinum, are the termination of the aortic arch, the left subclavian, and the left common carotid arteries, in that order from below upwards. At the upper end of the thorax the thoracic duct enters the root of the neck, and, at the level of the seventh cervical vertebra, it turns laterally, posterior to the left common carotid artery, the left vagus nerve, and the left internal jugular vein, and anterior to the vertebral artery and veins, the thyreo-cervical trunk or inferior thyreoid artery, and the phrenic nerve. Then, turning downwards, anteriorly and medially, on the anterior aspect of the *scalenus anterior*, it crosses anterior to the *transversa colli* and *transversa scapulæ* arteries, and terminates in the upper end of the innominate vein, in the angle of junction of its internal jugular and subclavian tributaries. Immediately before its termination it receives the left common jugular and subclavian lymphatic trunks, unless they end separately in one or other of the three large veins. When the thoracic duct is distended it

has a beaded or nodulated appearance on account of the numerous valves which lie in its interior. The terminal valve is usually situated a short distance from the point of entrance of the duct into the left innominate vein.

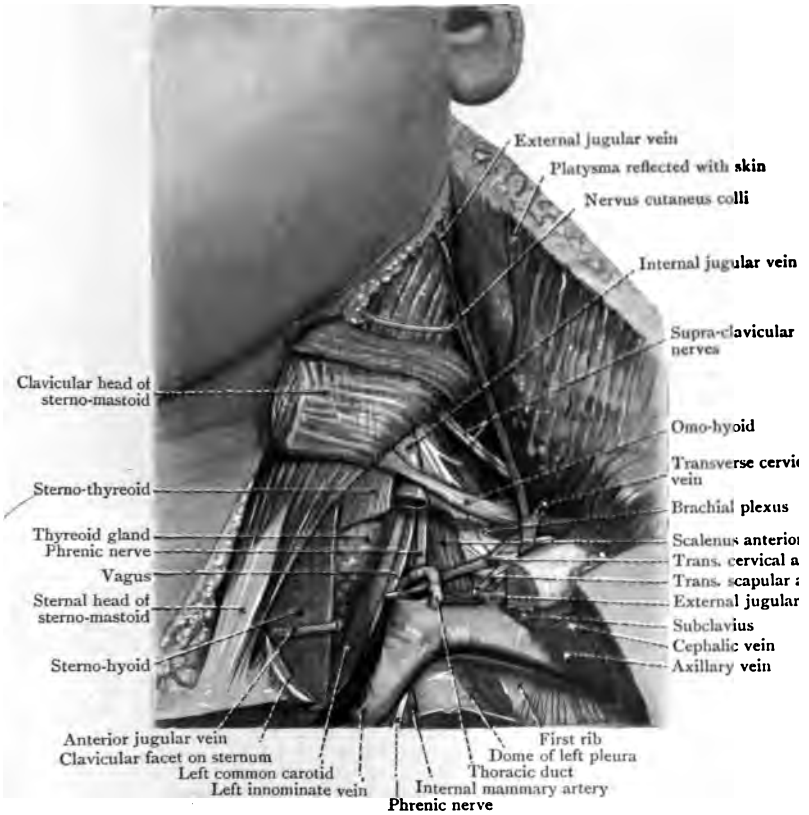


FIG. 53.—Dissection of the Root of the Neck showing the termination of the Thoracic Duct.

The Right Lymphatic Duct.—From the point where the thoracic duct turns from the front to the left of the vertebral column a small lymphatic vessel, which frequently communicates with the thoracic duct, may be traced upward along the front of the column to the root of the neck,

where it ends in the commencement of the right innominate vein. This is the *right lymphatic duct*. Immediately before its termination it may be joined by the right common jugular and right subclavian lymphatic trunks, but, as a rule, the two latter vessels open separately into the subclavian, the internal jugular, or the innominate veins (Parsons). The right lymphatic duct conveys lymph from the upper part of the right lobe of the liver, the right side of the thorax, including the right pleura and lung and the right half of the heart, and, if it is joined by the jugular and subclavian trunks, the lymph from the right upper extremity and the right side of the head and neck also.

Lymphoglandulæ Thoracales.—During the dissection of the thorax the dissector will have noted certain groups of lymph glands. These are of considerable importance, for their enlargement in disease is not infrequently the cause of serious thoracic trouble; but whilst some, such as the bronchial glands, are quite obvious, others are frequently so small that they escape notice. The following are the chief groups:—(1) Two chains of minute glands which are placed in relation to the anterior thoracic wall and follow the course of the internal mammary vessels. They are termed *sternal lymph glands*, and are joined by lymphatic vessels from the anterior thoracic wall, the mammary glands, the anterior part of the diaphragm, and the upper part of the anterior wall of the abdomen. (2) Two chains of glands on the posterior thoracic wall—one on either side of the vertebral column in relation to the vertebral extremities of the ribs. These are very minute; afferents to them accompany the intercostal vessels; therefore they are called the *intercostal lymph glands*, and they receive the lymphatics of the posterior thoracic wall. (3) *Anterior mediastinal lymph glands*, two or three in number, which receive lymphatics from the diaphragm and upper surface of the liver. They occupy the lower open part of the anterior mediastinum. (4) *Posterior mediastinal lymph glands*, which follow the course of the thoracic aorta, and are joined by lymphatics from the diaphragm, pericardium, and oesophagus. (5) *Superior mediastinal lymph glands*, an important group, eight to ten in number, and placed in relation to the aortic arch and the bifurcation of the trachea. The lymphatics of the heart, pericardium, and thymus enter these. (6) *Bronchial lymph glands*, continuous above with the preceding, and massed chiefly in the interval between the two bronchi. They are also prolonged into the roots of the lungs. The lymphatic vessels of the lungs pour their contents into them. In the adult, they are generally dark in colour, and sometimes quite black.

Dissection.—Cut through the descending aorta immediately above the diaphragm. Detach its upper end from the left vagus and the left recurrent nerve which were previously fastened to it, then draw it forwards and divide the intercostal and subcostal arteries, which arise from its posterior surface, close to their origins and remove it.

Arteriæ Intercostales.—There are eleven pairs of intercostal arteries. The upper two pairs are derived indirectly

from the subclavian arteries; the remaining nine pairs are branches of the thoracic part of the descending aorta.

The Aortic Intercostal Arteries.—The nine pairs of aortic intercostal arteries spring from the posterior surface of the descending aorta, either separately or by a series of common trunks, one for each pair. The right arteries are longer than the left because the aorta lies to the left of the median plane; and, since the descending aorta commences only at the level of the lower border of the fourth thoracic vertebra, the four or five highest pairs have to ascend to gain the level of the spaces to which they are distributed.

The *right aortic intercostal arteries* run across the anterior aspects of the bodies of the vertebræ, lying posterior to the thoracic duct and the vena azygos; then they turn posteriorly, between the sides of the bodies of the vertebræ and the parietal pleura; and, finally, immediately before they enter the intercostal spaces, they pass between the sides of the bodies of the vertebræ medially and the sympathetic trunk laterally. The shorter left aortic intercostal arteries run posteriorly, first between the left pleura and the bodies of the vertebræ, and then between the sympathetic trunk and the vertebral bodies. As each artery enters the space to which it belongs it gives off a *dorsal branch*, which passes posteriorly, between the vertebral column medially and the anterior costo-transverse ligament laterally; it gives off a spinal twig, which enters the vertebral canal through the corresponding intervertebral foramen; then it divides into a medial and a lateral branch which accompany the medial and lateral divisions of the posterior branch of the corresponding thoracic nerve. After giving off the dorsal branch, the trunk of the artery runs laterally, along the upper border of the space to which it belongs, at first anterior to the posterior intercostal membrane, and then between the internal and external intercostal muscles. Its further course has been described already (p. 6). As it passes along the upper border of the intercostal space, in the shelter of the subcostal groove of the rib, it is situated between the intercostal vein above and the anterior branch of the thoracic nerve below.

The Subcostal Arteries.—The subcostal arteries are the last pair of branches which spring from the posterior aspect of the thoracic part of the descending aorta. They enter the abdomen, by passing beneath the lateral lumbo-costal

arches, and they run, in company with the last thoracic nerves, along the lower borders of the last pair of ribs.

Arteriæ Intercostales Supremæ.—The superior intercostal arteries, which supply the upper two intercostal spaces on each side, are derived from the costo-cervical branches of the subclavian arteries (Fig. 5). Each superior intercostal artery commences at the level of the upper border of the neck of the first rib. It descends anterior to the neck of the rib, posterior to the parietal pleura and between the first thoracic ganglion of the sympathetic trunk medially and the first thoracic nerve; which is passing upwards to the brachial plexus, laterally (Fig. 5). At the lower border of the neck of the first rib it gives off the posterior intercostal artery to the first intercostal space; then it crosses anterior to the neck of the second rib, and, turning laterally, it becomes the posterior intercostal artery of the second space.

Nervi Intercostales.—The intercostal nerves are the anterior branches of the thoracic nerves. They pass laterally in company with the arteries. The twigs which connect them with the sympathetic ganglia have been noted already (p. 26). Each nerve lies at a lower level than the corresponding artery, and is at first placed between the posterior intercostal membrane and the pleura, and then between the two muscular strata. The further course of the nerves is described on p. 5.

The *first thoracic nerve* runs upwards, anterior to the neck of the first rib, to join the brachial plexus. It gives a small branch to the first intercostal space, but this nerve, although it is disposed after the manner of an intercostal nerve, does not furnish, as a rule, a lateral cutaneous or an anterior branch. The *second intercostal nerve*, as a rule, sends a branch upwards, anterior to the neck of the second rib, to join that portion of the first thoracic nerve which enters the brachial plexus. This communicating twig is usually minute and insignificant, but sometimes it is a large nerve; when this is the case, the intercosto-brachial nerve (O.T. intercosto-humeral), or lateral cutaneous branch of the second intercostal nerve, is very small or altogether absent.

Venæ Intercostales.—The *intercostal veins* differ in their arrangement upon the two sides of the body. On the *right side* they terminate in three different ways:—

1. The intercostal vein of the first or highest space joins the *right innominate vein* (sometimes the *vertebral vein*).
2. The intercostal veins of the second and third spaces (and sometimes that of the fourth space) unite into a common trunk, termed the *right superior intercostal vein*, which joins the upper part of the *vena azygos*.
3. The intercostal veins of the lower eight spaces join the *vena azygos*.

On the *left side* of the body *four* modes of termination may be recognised :—

1. The intercostal vein of the first space joins the *left innominate vein* (sometimes the *vertebral vein*).
2. The intercostal veins of the second and third spaces (and sometimes that of the fourth space) converge and by their union form a single trunk, termed the *left superior intercostal vein*, which crosses the arch of the aorta and joins the *left innominate vein* independently of the first intercostal vein. The union with the left innominate vein may be absent, and then the trunk formed by the veins of the second and third spaces joins the accessory hemiazygos vein.
3. The intercostal veins of the fourth, fifth, sixth, seventh, and eighth spaces terminate in the *accessory hemiazygos vein* (O.T. *vena azygos minor superior*), which crosses posterior to the aorta and joins the hemiazygos vein, or it ends directly in the *vena azygos*.
4. The intercostal veins of the ninth, tenth, and eleventh spaces join the *hemiazygos vein* (O.T. *vena azygos minor inferior*).

Vena Azygos (O.T. **Vena Azygos Major**).—This has already been studied, but should now be revised (p. 29), and then the dissector should examine the hemiazygos and accessory hemiazygos veins.

Vena Hemiazygos Accessoria.—The accessory hemiazygos vein is formed, on the left side of the body, by the union of the intercostal veins of the fourth, fifth, sixth, seventh, and eighth spaces. It communicates above with the left superior intercostal vein, which carries the blood from the second and third intercostal spaces to the left innominate vein; and it receives the left bronchial veins. At the level of the seventh thoracic vertebra it crosses to the right, posterior to the aorta and thoracic duct, and ends by joining either the hemiazygos vein or the *vena azygos*. In addition to the intercostal veins it receives the left bronchial veins.

Vena Hemiazygos (O.T. **Vena Azygos Minor Inferior**).—This vein takes origin within the abdomen as the *left ascending lumbar vein*. It enters the thorax by piercing the left crus of the diaphragm, and is continued upwards, upon the vertebral column, as far as the eighth or seventh thoracic vertebra. At this point it turns to the right, and,

arches, and they run, in company with the last thoracic nerves, along the lower borders of the last pair of ribs.

Arteriæ Intercostales Supremæ.—The superior intercostal arteries, which supply the upper two intercostal spaces on each side, are derived from the costo-cervical branches of the subclavian arteries (Fig. 5). Each superior intercostal artery commences at the level of the upper border of the neck of the first rib. It descends anterior to the neck of the rib, posterior to the parietal pleura and between the first thoracic ganglion of the sympathetic trunk medially and the first thoracic nerve; which is passing upwards to the brachial plexus, laterally (Fig. 5). At the lower border of the neck of the first rib it gives off the posterior intercostal artery to the first intercostal space; then it crosses anterior to the neck of the second rib, and, turning laterally, it becomes the posterior intercostal artery of the second space.

Nervi Intercostales.—The intercostal nerves are the anterior branches of the thoracic nerves. They pass laterally in company with the arteries. The twigs which connect them with the sympathetic ganglia have been noted already (p. 26). Each nerve lies at a lower level than the corresponding artery, and is at first placed between the posterior intercostal membrane and the pleura, and then between the two muscular strata. The further course of the nerves is described on p. 5.

The *first thoracic nerve* runs upwards, anterior to the neck of the first rib, to join the brachial plexus. It gives a small branch to the first intercostal space, but this nerve, although it is disposed after the manner of an intercostal nerve, does not furnish, as a rule, a lateral cutaneous or an anterior branch. The *second intercostal nerve*, as a rule, sends a branch upwards, anterior to the neck of the second rib, to join that portion of the first thoracic nerve which enters the brachial plexus. This communicating twig is usually minute and insignificant, but sometimes it is a large nerve; when this is the case, the intercosto-brachial nerve (O.T. intercosto-humeral), or lateral cutaneous branch of the second intercostal nerve, is very small or altogether absent.

Venæ Intercostales.—The *intercostal veins* differ in their arrangement upon the two sides of the body. On the *right side* they terminate in three different ways:—

1. The intercostal vein of the first or highest space joins the *right innominate vein* (sometimes the *vertebral vein*).
2. The intercostal veins of the second and third spaces (and sometimes that of the fourth space) unite into a common trunk, termed the *right superior intercostal vein*, which joins the upper part of the *vena azygos*.
3. The intercostal veins of the lower eight spaces join the *vena azygos*.

On the *left side* of the body *four* modes of termination may be recognised:—

1. The intercostal vein of the first space joins the *left innominate vein* (sometimes the *vertebral vein*).
2. The intercostal veins of the second and third spaces (and sometimes that of the fourth space) converge and by their union form a single trunk, termed the *left superior intercostal vein*, which crosses the arch of the aorta and joins the *left innominate vein* independently of the first intercostal vein. The union with the left innominate vein may be absent, and then the trunk formed by the veins of the second and third spaces joins the accessory hemiazygos vein.
3. The intercostal veins of the fourth, fifth, sixth, seventh, and eighth spaces terminate in the *accessory hemiazygos vein* (O.T. *vena azygos minor superior*), which crosses posterior to the aorta and joins the hemiazygos vein, or it ends directly in the *vena azygos*.
4. The intercostal veins of the ninth, tenth, and eleventh spaces join the *hemiazygos vein* (O.T. *vena azygos minor inferior*).

Vena Azygos (O.T. **Vena Azygos Major**).—This has already been studied, but should now be revised (p. 29), and then the dissector should examine the hemiazygos and accessory hemiazygos veins.

Vena Hemiazygos Accessoria.—The accessory hemiazygos vein is formed, on the left side of the body, by the union of the intercostal veins of the fourth, fifth, sixth, seventh, and eighth spaces. It communicates above with the left superior intercostal vein, which carries the blood from the second and third intercostal spaces to the left innominate vein; and it receives the left bronchial veins. At the level of the seventh thoracic vertebra it crosses to the right, posterior to the aorta and thoracic duct, and ends by joining either the hemiazygos vein or the *vena azygos*. In addition to the intercostal veins it receives the left bronchial veins.

Vena Hemiazygos (O.T. **Vena Azygos Minor Inferior**).—This vein takes origin within the abdomen as the *left ascending lumbar vein*. It enters the thorax by piercing the left crus of the diaphragm, and is continued upwards, upon the vertebral column, as far as the eighth or seventh thoracic vertebra. At this point it turns to the right, and,

arches, and they run, in company with the last thoracic nerves, along the lower borders of the last pair of ribs.

Arteriæ Intercostales Supremæ.—The superior intercostal arteries, which supply the upper two intercostal spaces on each side, are derived from the costo-cervical branches of the subclavian arteries (Fig. 5). Each superior intercostal artery commences at the level of the upper border of the neck of the first rib. It descends anterior to the neck of the rib, posterior to the parietal pleura and between the first thoracic ganglion of the sympathetic trunk medially and the first thoracic nerve; which is passing upwards to the brachial plexus, laterally (Fig. 5). At the lower border of the neck of the first rib it gives off the posterior intercostal artery to the first intercostal space; then it crosses anterior to the neck of the second rib, and, turning laterally, it becomes the posterior intercostal artery of the second space.

Nervi Intercostales.—The intercostal nerves are the anterior branches of the thoracic nerves. They pass laterally in company with the arteries. The twigs which connect them with the sympathetic ganglia have been noted already (p. 26). Each nerve lies at a lower level than the corresponding artery, and is at first placed between the posterior intercostal membrane and the pleura, and then between the two muscular strata. The further course of the nerves is described on p. 5.

The *first thoracic nerve* runs upwards, anterior to the neck of the first rib, to join the brachial plexus. It gives a small branch to the first intercostal space, but this nerve, although it is disposed after the manner of an intercostal nerve, does not furnish, as a rule, a lateral cutaneous or an anterior branch. The *second intercostal nerve*, as a rule, sends a branch upwards, anterior to the neck of the second rib, to join that portion of the first thoracic nerve which enters the brachial plexus. This communicating twig is usually minute and insignificant, but sometimes it is a large nerve; when this is the case, the intercosto-brachial nerve (O.T. intercosto-humeral), or lateral cutaneous branch of the second intercostal nerve, is very small or altogether absent.

Venæ Intercostales.—The *intercostal veins* differ in their arrangement upon the two sides of the body. On the *right side* they terminate in three different ways:—

1. The intercostal vein of the first or highest space joins the *right innominate vein* (sometimes the *vertebral vein*).
2. The intercostal veins of the second and third spaces (and sometimes that of the fourth space) unite into a common trunk, termed the *right superior intercostal vein*, which joins the upper part of the *vena azygos*.
3. The intercostal veins of the lower eight spaces join the *vena azygos*.

On the *left side* of the body *four* modes of termination may be recognised:—

1. The intercostal vein of the first space joins the *left innominate vein* (sometimes the *vertebral vein*).
2. The intercostal veins of the second and third spaces (and sometimes that of the fourth space) converge and by their union form a single trunk, termed the *left superior intercostal vein*, which crosses the arch of the aorta and joins the *left innominate vein* independently of the first intercostal vein. The union with the left innominate vein may be absent, and then the trunk formed by the veins of the second and third spaces joins the accessory hemiazygos vein.
3. The intercostal veins of the fourth, fifth, sixth, seventh, and eighth spaces terminate in the *accessory hemiazygos vein* (O. T. *vena azygos minor superior*), which crosses posterior to the aorta and joins the hemiazygos vein, or it ends directly in the *vena azygos*.
4. The intercostal veins of the ninth, tenth, and eleventh spaces join the *hemiazygos vein* (O. T. *vena azygos minor inferior*).

Vena Azygos (O. T. **Vena Azygos Major**).—This has already been studied, but should now be revised (p. 29), and then the dissector should examine the hemiazygos and accessory hemiazygos veins.

Vena Hemiazygos Accessoria.—The accessory hemiazygos vein is formed, on the left side of the body, by the union of the intercostal veins of the fourth, fifth, sixth, seventh, and eighth spaces. It communicates above with the left superior intercostal vein, which carries the blood from the second and third intercostal spaces to the left innominate vein; and it receives the left bronchial veins. At the level of the seventh thoracic vertebra it crosses to the right, posterior to the aorta and thoracic duct, and ends by joining either the hemiazygos vein or the *vena azygos*. In addition to the intercostal veins it receives the left bronchial veins.

Vena Hemiazygos (O. T. **Vena Azygos Minor Inferior**).—This vein takes origin within the abdomen as the *left ascending lumbar vein*. It enters the thorax by piercing the left crus of the diaphragm, and is continued upwards, upon the vertebral column, as far as the eighth or seventh thoracic vertebra. At this point it turns to the right, and,

crossing posterior to the aorta and the thoracic duct, it joins the vena azygos. Before it terminates it may receive the accessory hemiazygos vein.

The thoracic tributaries of this vein are the intercostal veins of the lower three spaces of the left side and the left subcostal vein. In the abdomen it receives the upper two left lumbar veins.

The Anterior Intercostal Veins.—The blood is drained from the anterior part of the thoracic wall by veins which accompany the intercostal branches of the internal mammary arteries. They terminate in the internal mammary veins.

The veins of the thoracic parietes are extremely variable, and the description given above must be looked upon as representing merely their more usual arrangement.

THORACIC JOINTS.

The dissector should now complete the dissection of the thorax by an examination of the various thoracic joints.

Dissection.—When the portion of the sternum with the cartilages of the ribs, which was laid aside, is studied, the following joints will be noted: inter-sternal, costo-sternal, and inter-chondral. Very little dissection is necessary. After the ligaments have been defined, the dissector should remove a thin slice from the anterior aspect of each articulation, in order that the interior of the joint may be displayed.

Synchondrosis Sternalis.—The joint between the manubrium and the body of the sternum is a synchondrosis. The opposing surfaces of bone are covered with a layer of hyaline cartilage, and are united by intermediate fibro-cartilage. The joint is supported by some anterior and posterior longitudinal fibres which are developed in connection with the strong and thick periosteum. The posterior ligament is the stronger of the two. The joint between the body of the sternum and the xiphoid process is also a synchondrosis till middle life, at which period the two parts become ossified together.

Sterno-chondral Articulations.—Seven ribs articulate with each side of the sternum by means of their cartilages.

The articulations of the first and the sixth are peculiar, inasmuch as they articulate with single pieces of the sternum, viz. with the manubrium and the lowest piece of the body, respectively; whereas each of the cartilages of the other true ribs articulates with two segments of the sternum. The cartilage of the first rib is implanted upon the side of the manubrium

without any synovial membrane, or other material, intervening. The second costal cartilage is usually separated from the sternum by two synovial cavities, between which an interarticular ligament is developed. In the case of the other joints it is more common to find a single synovial cavity and no interarticular ligament. There is, however, considerable variety in these articulations, and a synovial membrane is very frequently wanting altogether in the sterno-chondral joint of the seventh costal cartilage.

With the exception of the first, which is a synchondrosis, the sterno-chondral joints belong to the diarthrodial variety. They are provided with anterior and posterior ligaments, and also, in those cases where the joint presents a double synovial cavity, with an interarticular ligament.

Anterior and posterior sterno-costal radiate ligaments. These are strong, flattened bands of fibres which radiate from the extremities of the rib-cartilages and blend with the periosteum on the anterior and posterior surfaces of the sternum. The *interarticular ligaments* are feeble bands which pass from the tips of the rib-cartilages to the sternum, and divide the articulations in which they exist into an upper and a lower compartment, each of which is lined with a synovial stratum.

Inter-chondral Articulations.—Interchondral joints are formed between the adjacent margins of the ribs from the sixth to the tenth. The joint cavities are surrounded by ordinary capsular ligaments, each of which is lined internally with a synovial stratum; they are, therefore, diarthrodial joints.

Costo-vertebral Articulations.—The costo-vertebral joints are separable into two groups, capitular and costo-transverse.

The *capitular articulations* are the joints between the heads of the ribs and the bodies of the vertebræ and the intervertebral fibro-cartilages; they are diarthrodial joints. With the exceptions of the first and the last three ribs, the head of every rib articulates with the bodies of two adjacent vertebræ and the intervening intervertebral fibro-cartilage, and it is connected with them by an articular capsule and an interarticular ligament. The interarticular ligament connects the intervertebral fibro-cartilage with the ridge which separates the two facets on the head of the rib. It is united, anteriorly and posteriorly, with the capsule, and separates the joint cavity into an upper and a lower compartment. The anterior part of the capsule is specialised into three radiating bands which form the *radiate ligament*. The upper and lower bands

to the corresponding vertebræ, whilst the intermediate band is attached to the intervertebral fibro-cartilage. The capitular joints of the first, and the tenth, eleventh, and twelfth ribs are each formed between the head of the rib and the corresponding vertebra. The interarticular ligament is absent; therefore each joint possesses only one cavity. The anterior parts of the capsules of these joints are not, as a rule, specialised into radiate bands.

The Costo-transverse Articulations are the joints formed

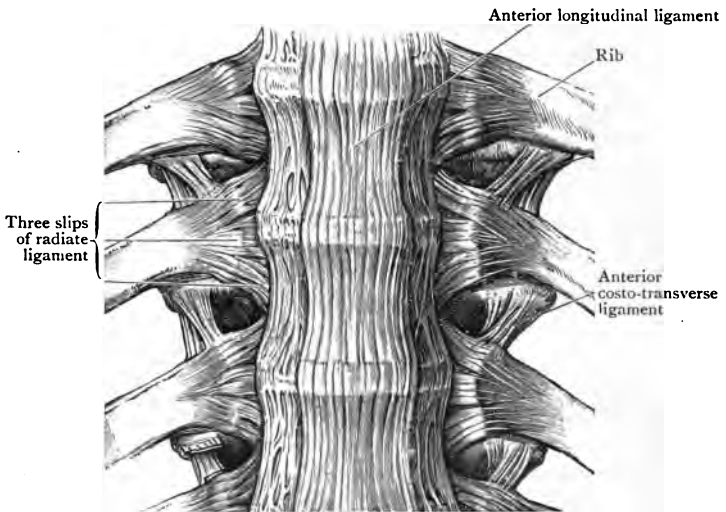


FIG. 54.—Anterior aspect of the Costo-vertebral Joints; also Anterior Longitudinal Ligament of Vertebral Column.

between the necks and the tubercles of the ribs and the transverse processes of the vertebræ.

The tubercle of each rib, with the exception of the eleventh and twelfth, articulates with the tip of the transverse process of the vertebra of the same number, by a circular articular facet which is surrounded by an articular capsule lined with a stratum synoviale. The joint is, therefore, a diarthrodial joint and the upper and posterior part of the capsule is greatly thickened, and is called the *ligament of the tubercle* (O.T. *posterior costo-transverse ligament*). In addition to the capsule and its posterior thickening there are three accessory

costo-transverse bands, the anterior and posterior costo-transverse ligaments and the ligament of the neck of the rib. The *anterior costo-transverse ligament* ascends from the anterior margin of the upper border of the neck of the rib to the lower border of the transverse process above. The *posterior costo-transverse ligament* passes upwards from the posterior part of the upper border of the neck of the rib to the junction of the lamina and the transverse process of the vertebra above; and the *ligament of the neck of the rib* (O.T. *middle costo-transverse ligament*) connects the posterior aspect of the neck of the rib with the anterior aspect of the transverse process of the vertebra of the same number.

In the case of the eleventh rib the costo-transverse ligaments are rudimentary or absent, and in the case of the twelfth rib they are usually entirely absent.

Intervertebral Articulations.—The *bodies* of the vertebræ are held together by a series of synchondrodial joints, supported anteriorly by an anterior longitudinal ligament, and posteriorly by a posterior longitudinal ligament. The *vertebral arches*, by means of the articular processes, form a series of diarthrodial joints surrounded by capsular ligaments, each capsule being lined with a synovial stratum. Certain ligaments pass between different portions of the vertebral arches and their processes, viz., the ligamenta flava between adjacent laminae, the inter-transverse, the inter-spinous, and the supra-spinous ligaments.

The laminae and the spinous processes of the vertebræ have been removed by the dissector of the head and neck in opening up the vertebral canal to display the spinal medulla. Consequently, the ligamenta flava, the inter-spinous and supra-spinous ligaments, cannot be seen at present.

The *anterior longitudinal ligament* (O.T. *anterior common ligament*) is situated anterior to the bodies of the vertebræ, and extends from the atlas vertebra above to the first piece of the sacrum below. It consists of stout glistening fibrous bands, which are firmly attached to the margins of the vertebral bodies and to the intervertebral fibro-cartilages. The most superficial fibres are the longest, and extend from a given vertebra to the fourth or fifth below it. The deeper fibres have a shorter course, and pass between the borders of two, three, or four adjacent vertebræ. The dissector cannot fail to notice that the origin of the longus colli muscle is inseparably connected with this ligament.

The *posterior longitudinal ligament* (O.T. *posterior common ligament*) is placed on the posterior aspects of the vertebral bodies, and therefore within the vertebral canal. It is firmly connected to the margins of the vertebral bodies and to the intervertebral fibro-cartilages, but is separated from the central parts of the bodies by some loose connective tissue and by a plexus of veins. It is constricted where it covers this venous plexus, but widens out opposite the fibro-cartilages. It therefore presents a scalloped or denticulated appearance.

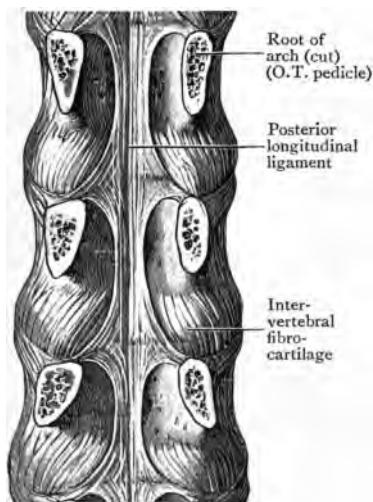


FIG. 55.—Posterior Longitudinal Ligament of the Vertebral Column. The vertebral arches have been removed from the vertebræ.

The *intervertebral fibro-cartilages* are a series of discs of white fibro-cartilage, thicker anteriorly than posteriorly, which are interposed between the bodies of adjacent vertebræ. The peripheral part of each disc, *annulus fibrosus*, is tough and fibrous; the central portion, *nucleus pulposus*, is soft and pulpy. The discs increase the elasticity of the spine, and tend to restore it to its natural curvature after it has been deflected by muscular action.

The intervertebral fibro-cartilages constitute the main bond of union between the bodies of the vertebræ, but, except in old people, they are not directly attached to the bone. A thin layer of encrusting hyaline cartilage coats the opposing vertebral surfaces.

Vertical and horizontal sections must be made through two or more of the fibro-cartilages, in order that their structure may be displayed.

The *intertransverse ligaments* are feeble bands which pass between the tips of the transverse processes. In the lower part of the thoracic region they are intimately blended with the intertransverse muscles: in the middle and upper parts of the thoracic region they entirely replace the muscles.

HEAD AND NECK.

THE dissectors of the Head and Neck begin work as soon as the subject is brought into the room. During the first three days, whilst the body is in the lithotomy posture, they dissect the face, the anterior part of the eyelids, the superficial part of the nose, and the anterior part of the scalp. During the following five days, when the body is lying on its back, they dissect the posterior triangle, and complete the dissection of the scalp.

It is only by dissecting the face at this period, whilst the parts are in good condition, that the dissector can gain any satisfactory idea of its component parts; and it is essential that the contents of the posterior triangle, which is such an important surgical region, should be displayed before the dissector of the arm has disturbed its posterior boundary.

The first day should be devoted to the examination of the anterior part of the frontal region of the head and the face, the study of the surface anatomy of the ocular appendages, the reflection of the skin, and the cleaning of the superficial muscles of the face and anterior part of the scalp. On the second day the dissectors should display the superficial surface of the parotid gland; they should also find and clean the superficial vessels and nerves, and trace them to their terminations. On the third day the superficial muscles must be reflected, and the deeper vessels and nerves must be exposed and cleaned, and the auricle should be examined and dissected. On the fourth day, when the body has been placed upon its back, the dissectors should commence the dissection of the posterior triangle of the neck, and should complete that part of the dissection in three days. On the seventh day they should complete the examination of the scalp. The eighth day should be devoted to a final study of the brachial plexus in association with the dissectors of the upper extremity.

FACE AND FRONTAL REGION OF HEAD.

The dissectors should commence the study of the face and frontal region by an examination of the bony prominences and ridges in the area to be dissected.

In the centre of the facial area is the prominent outer portion of the nose, consisting of a lower mobile part formed mainly by skin and cartilage, and an upper rigid portion formed by the nasal bones and the frontal processes

the maxillæ. On either side of the nose are the sockets for the eyeballs, each of which is bounded above by the supra-orbital margin of the frontal bone and below by the orbital margins of the maxilla and the zygomatic bone (O.T. malar). The supra- and infra-orbital margins meet laterally in the region of the cheek bone (zygomatic). From the posterior part of the zygomatic bone, the zygomatic arch, formed partly by the zygomatic and partly by the temporal bone, extends posteriorly to the ear. Above the zygomatic arch is the region of the temporal fossa, which is bounded superiorly by the temporal line. The line terminates anteriorly in the lateral part of the supra-orbital margin. Above the medial part of the supra-orbital margin the superciliary arch can be felt, and at a higher level, above the lateral part of the supra-orbital margin, lies the frontal tuber. The region above the nose and between the medial ends of the superciliary arches is the *glabella*.

Below the zygomatic arch lies the ramus of the mandible covered by the masseter muscle; and extending anteriorly from the lower end of the ramus is the body of the mandible. A line dropped vertically through the junction of the medial third with the lateral two-thirds of the supra-orbital margin, will cut through the supra-orbital notch of the frontal bone, the infra-orbital foramen of the maxilla, and the mental foramen of the mandible, all three of which may be felt if firm pressure is made in the proper situations. The first, which lies in the supra-orbital margin, transmits the supra-orbital vessels and nerve. The second is placed about half an inch below the infra-orbital margin. It transmits the infra-orbital vessels and nerve. The third lies midway between the second premolar tooth of the mandible and the lower border of the mandible; it transmits the mental branches of the inferior alveolar vessels and nerve.

After the bony points of the region have been studied, the surface anatomy of the ocular appendages should be examined. Under this head are included (1) the eyebrows; (2) the eyelids; (3) the conjunctiva.

The *eyebrows* are two curved tegumentary projections placed over the supra-orbital arch of the frontal bone; they intervene between the forehead above and the ocular regions below. The short stiff hairs which spring from the eyebrows have a lateral inclination.

FACE AND FRONTAL REGION OF HEAD 119

The *eyelids* (*palpebræ*) are the semilunar curtains provided for the protection of each eyeball. The upper lid is the longer and much the more movable of the two. When the eye is open, the margins of the two lids are slightly concave and the interval between them, *rima palpebrarum*, is elliptical in outline. When the eye is closed, and the margins of the lids are in apposition, the *rima palpebrarum* is reduced to a

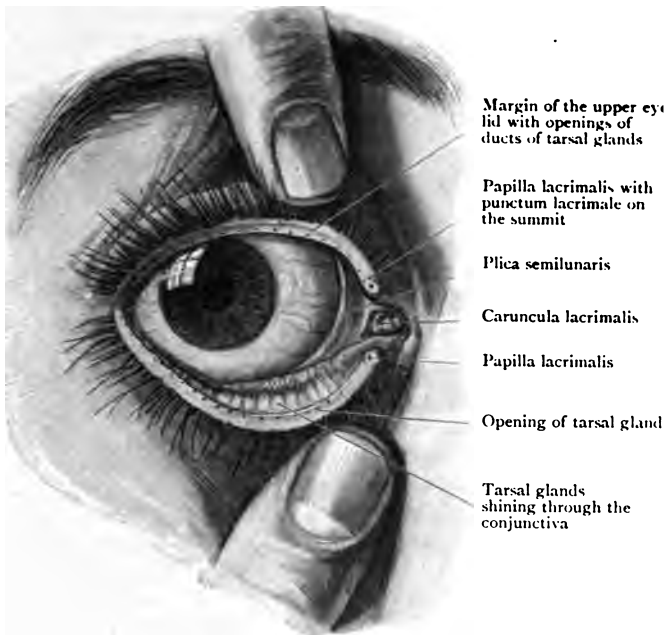


FIG. 56.—Eyelid slightly everted to show the Conjunctiva (enlarged).

nearly horizontal line. Owing to the greater length and mobility of the upper lid, the *rima*, in this condition, is placed below the level of the cornea or clear part of the eyeball.

At the extremities of the *rima palpebrarum* the eyelids meet and form the *palpebral commissures*, and immediately lateral to the medial commissure the *rima* expands into a small triangular space called the *lacus lacrimalis*. If the dissector now examines the free margins of the lids he will note that to the lateral side of the *lacus lacrimalis* they

are flat, and that in each case the eyelashes project from the anterior border, whilst the tarsal glands open along the posterior border, a distinct interval intervening between the cilia and the mouths of the glands. On the other hand, the small portion of the margin of each eyelid which bounds the lacus lacrimalis is more horizontal in direction, somewhat rounded, and destitute both of eyelashes and of tarsal glands. At the very point where the eyelashes in each eyelid cease, and the palpebral margin becomes rounded, a minute eminence with a central perforation will be seen. The eminence is the *papilla lacrimalis*, whilst the perforation, called the *punctum lacrimale*, is the mouth of the *lacrimal duct*, which conveys away the tears. Endeavour to pass a bristle into each of the orifices. The upper duct at first ascends, whilst the lower one descends, and then both run horizontally to the lacrimal sac.

The *conjunctiva* is the membrane which lines the deep surfaces of the lids, and is reflected from them on to the anterior aspect of the eyeball. At the margins of the lids it is continuous with the skin, whilst, through the puncta lacrimalia and the lacrimal ducts, it becomes continuous with the lining membrane of the lacrimal sac. The line of reflection of the conjunctiva from the lids on to the eyeball is termed the *fornix conjunctivæ*. Owing to the greater depth of the upper lid, the conjunctival recess between the upper lid and the eyeball is of greater extent than that of the lower lid. The conjunctiva is loosely connected with the eyelids on the one hand, and with the sclera of the eyeball on the other. Over the cornea the membrane becomes thinned down to a mere epithelial covering, which is closely adherent.

In connection with the conjunctiva, the *plica semilunaris* and the *caruncula lacrimalis* must be examined. The caruncula is the reddish fleshy-looking elevation which occupies the centre of the lacus lacrimalis. From its surface a few minute hairs project. The plica semilunaris is of interest because in the human eye it is the rudimentary representative of the membrana nictitans, or third eyelid, found in many animals. It is a small vertical fold of conjunctiva, which is placed immediately to the lateral side of the caruncula, and it slightly overlaps the eyeball at this point.

Dissection.—Distend the eyelids slightly by placing a little tow or cotton wool steeped in preservative solution in the conjunctival sac; then stitch

the margins of the lids together. Distend the cheeks and lips slightly by placing tow or cotton wool steeped in preservative solution in the vestibule of the mouth—that is, between the cheeks and lips externally and the teeth and gums internally; then stitch the red margins of the lips together.

Reflect the skin by means of three incisions, a median longitudinal and two transverse. Commence the median incision midway between the root of the nose and the external occipital protuberance, carry it anteriorly to the forehead and then downwards along the median line of the forehead, the nose and the lips, to the tip of the chin. Commence the upper horizontal incision at the level of the rima palpebrarum; carry it laterally from the longitudinal incision to the medial commissure, then round the margins of the rima to the lateral commissure, and, finally, posteriorly to the ear. The lower horizontal incision should run from the angle of the mouth to the posterior border of the ramus of the mandible. Reflect the upper and middle flaps and leave them attached posteriorly. Reflect the lower flap downwards to the lower border of the mandible. Note, whilst reflecting the skin, that many of the superficial fibres of the facial muscles are implanted into its deep surface. It is these fibres which tend to displace the margins of wounds of the face, and necessitate the application of numerous and firmly tied sutures in order to secure quick and accurate union. Whilst reflecting the skin the dissector must be careful to keep his knife playing against its deep surface; otherwise he is certain to injure the sphincter muscle of the eyelids, and the superficial extrinsic muscles of the ear which lie in the temporal region.

After the skin is reflected the superficial muscles must be cleaned. That which will first attract attention is the orbicularis oculi around the orbit. Above the orbicularis oculi is the frontalis belly of the epicranial muscle. To the medial side of the orbicularis oculi lie the muscles of the nose, and below it the muscles of the upper lip pass downwards to the orbicularis oris. Passing anteriorly and upwards, over the posterior part of the lower border of the mandible, are the upper and posterior fibres of the platysma, and more medially are the muscles of the lower lip.

Commence with the **Orbicularis Oculi** (O.T. **Orbicularis Palpebrarum**).—Pull the eyelids laterally and note a prominent cord-like band which extends from the frontal process of the maxilla to the medial commissure, where it becomes continuous with both eyelids; this is the medial palpebral ligament (O.T. internal tarsal ligament). A somewhat similar band, the lateral palpebral raphe (O.T. external tarsal ligament), extends from the lateral commissure to the zygomatic bone. After the medial palpebral ligament has been recognised, clean first the thicker *orbital part* of the orbicularis oculi, which covers the superficial bony boundaries of the orbit, and then the thinner *palpebral portion*, which lies in the eyelids. The palpebral part is not only thin but also pale, and its fibre

each eyelid, sweep in gentle curves from the medial palpebral ligament to the lateral palpebral raphe, gaining attachment to both. They form a continuous layer of uniform thickness in each eyelid, except near the free margins, where, close to the bases of the eyelashes, there is a more pronounced fasciculus termed the *ciliary bundle*.

The *orbital portion* of the muscle passes upwards to the forehead, laterally to the temporal region and downwards into the cheek. Its fibres are relatively dark and coarse. They all take origin medially from the medial part of the palpebral ligament, the medial angular process of the frontal bone, and the frontal process of the maxilla, and they sweep laterally round the margin of the orbit in the form of a series of concentric loops. The *pars lacrimalis* of the orbicularis oculi (O.T. tensor tarsi) will be described when the eyelids are dissected (p. 140).

Musculus Epicranius (O.T. **Occipito-Frontalis**).—The epicranium is a quadricipital muscle possessing two occipital heads, the occipitales muscles, and two frontal heads, the frontales muscles; they are all inserted into an intermediate aponeurosis, the *galea aponeurotica* (O.T. *epicranial aponeurosis*), which extends from the frontal to the occipital region (p. 158). The lower part of each frontal head blends with the orbicularis oculi, and from its medial border a small muscular bundle, known as the *musculus procerus* (O.T. *pyramidalis nasi*), descends to the dorsum of the nose. At present only the frontalis and the procerus are to be displayed.

The **Frontalis** becomes apparent immediately above the upper border of the orbicularis oculi. As it is cleaned care should be taken to avoid injury to the branches of the supra-orbital nerve which pierce it. It has little or no attachment to bone. Below, its fibres either blend with the fibres of the orbicularis oculi or they are attached to the skin of the eyebrows. Above, they terminate in the galea aponeurotica in the region of the coronal suture. The lateral border is attached to the temporal ridge by aponeurotic fibres, and the medial border blends with its fellow of the opposite side for a short distance above the root of the nose. Above the union the medial fibres of opposite sides diverge, and below it they pass downwards over the nasal bones as the proceral muscles.

Musculus Procerus (O.T. **Pyramidalis Nasi**).—The proceral muscles are often absent; when present, each springs from

the lower and medial part of the corresponding frontalis. It descends over the nasal bone and ends on the dorsum of the nose, where some of its fibres blend with the transverse part of the nasalis and others are inserted into the skin.

Along the lower and medial border of the orbicularis oculi will be found the muscles of the nose and the upper lip.

The proper muscles of the nose are the musculus nasalis and the musculus depressor septi, but the procerus may also be looked upon as partly a nasal muscle, and the angular head of the quadratus labii superioris has a nasal attachment.

Musculus Nasalis.—The musculus nasalis consists of two parts, the *pars transversa* (O.T. *compressor naris*), and the *pars alaris* (O.T. *dilator naris*). The *pars transversa* springs from the root of the frontal process of the maxilla, passes across the cartilaginous part of the nose, above the ala, and ends in an aponeurosis which connects it with its fellow of the opposite side. The *pars alaris* springs from the maxilla, at the side of the lower part of the anterior nasal aperture, and it terminates in the posterior part of the ala and the mobile part of the septum of the nose. The nasalis is partly concealed by the medial fibres of the quadratus labii superioris.

Musculus Depressor Septi Nasi.—This small muscle is frequently difficult to display. It springs from the superficial fibres of the upper part of the orbicularis oris, and is inserted into the anterior part of the septum of the nose. It depresses the septum and reduces the antero-posterior diameter of the anterior nasal aperture.

After the muscles of the nose have been examined clean the superficial muscles of the mouth and cheek.

The Muscles of the Mouth and Cheeks.—The muscles of this group form two layers, a superficial and a deep. Those of the superficial group are the orbicularis oris, quadratus labii superioris, zygomaticus, triangularis, risorius, quadratus labii inferioris; those of the deeper group are the buccinator, caninus, incisivi and mentalis. All, with the exception of the orbicularis oris, are bilateral. The members of the superficial group must be examined first; the deeper muscles will be displayed after the superficial vessels and nerves have been dissected.

Orbicularis Oris.—The orbicularis oris is the sphincter muscle of the oral aperture. It lies in the substance of the lips, and consists of a deeper layer of fibres which are arrange^d

in concentric ellipsoidal rings, and a series of superficial fibres into which all the other muscles of the lips and cheeks converge. The details of its formation cannot be understood until the attachments of the other muscles have been studied.

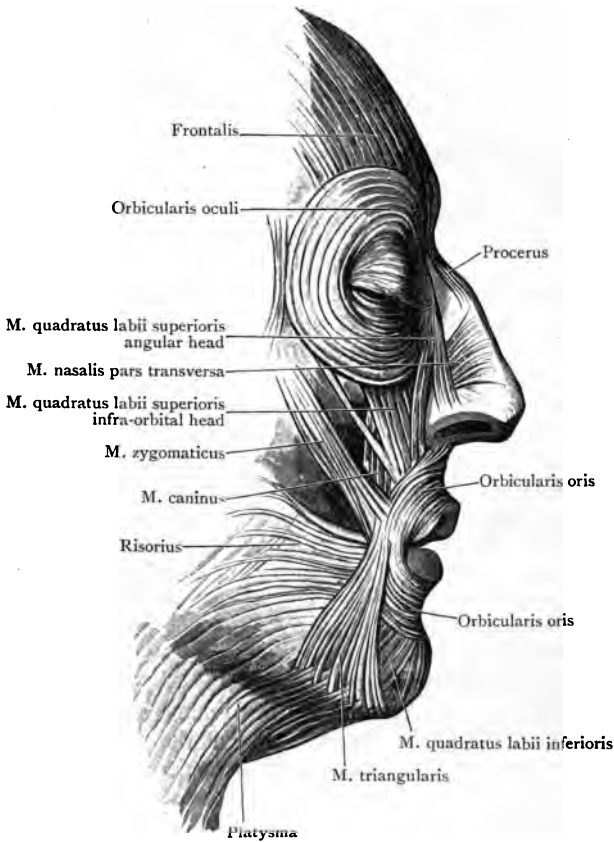


FIG. 57.—The Facial Muscles.

Musculus Quadratus Labii Superioris.—The quadratus labii superioris possesses three heads—a zygomatic, an infra-orbital, and an angular. As the muscle is cleaned the dissector should secure the upper part of the anterior facial vein, which crosses its superficial surface.

The *zygomatic head* (O.T. *zygomaticus minor*) springs from the anterior part of the facial surface of the zygomatic bone, under cover of the lower lateral part of the orbicularis oculi. It runs downwards and anteriorly, and is inserted into the lateral part of the upper portion of the orbicularis oris and into the adjacent part of the skin of the upper lip.

The Infra-orbital Head (O.T. *Levator Labii Superioris Proprius*).—This head springs from the whole length of the infra-orbital border, under cover of the orbicularis oculi. It is inserted into the upper lateral part of the orbicularis oris and the skin of the upper lip.

The *angular head* (O.T. *levator labii superioris alaeque nasi*) springs from the frontal process of the maxilla. It broadens as it descends, and it is inserted into the ala of the nose and into the upper part of the orbicularis oris.

Musculus Zygomaticus.—The zygomaticus (O.T. *zygomaticus major*) is a comparatively long, slender muscular band which springs from the facial surface of the zygomatic bone, under cover of the lower lateral fibres of the orbicularis oculi and to the lateral side of the zygomatic head of the quadratus labii superioris. Its fibres pass downwards and medially to the angle of the mouth, where some blend with the orbicularis oris and others are inserted into the skin.

The Risorius.—This muscle, when well developed, consists partly of some of the uppermost fibres of the platysma muscle of the neck, which bend anteriorly to the angle of the mouth, and partly of additional fibres which spring from the fascia over the masseter muscle and the parotid gland. Both groups of fibres blend with the fibres of the orbicularis oris at the angle of the mouth.

Musculus Triangularis.—The triangularis (O.T. *depressor anguli oris*) springs from the oblique line on the lateral surface of the body of the mandible. Its fibres converge as they pass anteriorly and upwards, and, at the angle of the mouth, they blend with the orbicularis oris, in which some of them curve past the angle and terminate in the substance of the upper lip (Figs. 57, 58).

Musculus Quadratus Labii Inferioris (O.T. *Depressor Labii Inferioris*).—This muscle springs from the lower part of the superficial surface of the mandible, between the mental tubercle and the mental foramen, its posterior border being overlapped by the triangularis. The fibres pass

and medially, some to blend with the orbicularis oris and others to gain attachment to the skin of the lower lip.

Platysma.—Only the upper part of the broad, flat, quadrangular subcutaneous muscle of the neck is at present visible. The posterior fibres ascend over the lower border of the ramus and the posterior part of the lower border of the body of the mandible, and they have already been seen taking part in the formation of the risorius. The anterior fibres gain direct insertion into the anterior part of the lower

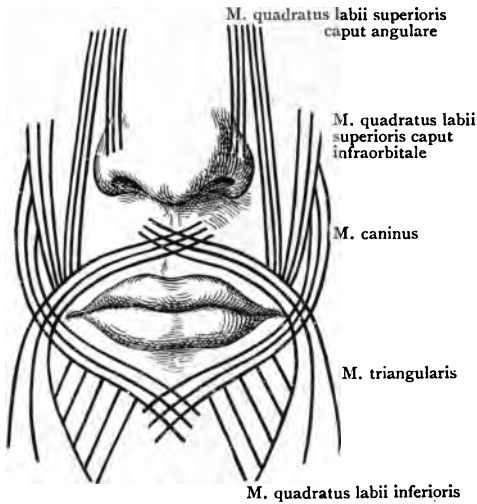


FIG. 58.—Diagram of the Orbicularis Oris Muscle.
The fibres which enter it from the buccinator are not represented.

border of the body of the mandible. The latter attachment is the only bony attachment which the muscle possesses, all its other attachments being either to fascia or to skin.

Dissection.—Cut through the posterior half of the platysma along the lower border of the mandible; detach the risorius from the fascia on the masseter; then turn the risorius and the detached part of the platysma towards the angle of the mouth. Whilst doing this be careful to avoid injuring the branches of the vessels and nerves of the face.

As soon as the platysma and the risorius are reflected search below the level of the ear for branches of the great auricular nerve which ascend over the lower part of the parotid gland. Some of them pierce the parotid and terminate in its substance, others end in the skin of the masseteric region.

Find the anterior facial vein and the external maxillary artery at the

lower and anterior angle of the masseter as they cross the lower border of the mandible. Clean them at this point, but do not trace them towards their terminations at present.

At the posterior border of the mandible note the fascia over the superficial surface of the parotid gland. It ascends from the fascia of the neck, and is attached above to the zygomatic arch. Note also that at the anterior border of the parotid this fascia blends with the fascia on the superficial surface of the masseter muscle. Cut through the fascia covering the parotid gland immediately anterior to the ear, extending the incision from the zygoma above to the angle of the mandible below; then raise the fascia from the gland, dissecting carefully anteriorly, upwards, and downwards. As the extremities and the anterior border of the gland are approached, look carefully for nerves and vessels which emerge from beneath them, and also for the duct of the gland, which appears from under cover of the anterior border about a finger's breadth below the zygoma. The duct has thick walls, is of considerable size, and is easily recognised. It runs anteriorly across the masseter and turns round the anterior border of the muscle, bending at right angles to its original course. It pierces, in turn, the fascia covering the buccinator muscle, the buccinator muscle itself and the mucous membrane of the mouth; and it opens into the vestibule of the mouth, on a small papilla opposite the second molar tooth of the maxilla. Above the duct and below the zygomatic arch find (1) the accessory parotid, a small detached part of the parotid which lies a short distance anterior to the anterior border of the main mass of the gland; (2) the transverse facial vessels; and (3) the zygomatic branches of the facial nerve. Below the duct find the buccal and the mandibular branches of the facial nerve. At the upper end of the parotid seek for the superficial temporal vessels. Posterior to them lies the auriculo-temporal branch of the third division of the trigeminal nerve, and anterior to them, the temporal branches of the facial nerve. From, or from beneath, the lower extremity of the gland emerge (1) the cervical branch of the facial nerve, (2) the posterior facial vein (O.T. anterior division of the temporo-maxillary vein), and (3) the external jugular vein.

The Terminal Branches of the Facial Nerve.—The dissector should note that there are five terminal branches, or groups of branches, of the facial nerve: (1) temporal; (2) zygomatic; (3) buccal; (4) mandibular; (5) cervical. They all emerge from under cover of the parotid gland, the temporal branches at its upper end, the cervical at its lower end, and the remaining three groups of branches at its anterior border. The temporal branches will be followed when the temporal region and the scalp are being dissected, and the cervical branch when the anterior triangle of the neck is displayed; but the remaining three groups of branches should now be followed to their terminations.

The upper filaments of the *zygomatic branch or branches* run anteriorly, across the zygomatic bone, and terminate, in both the upper and the lower eyelid, in the fibres of the orbicularis oculi. If the branches are carefully traced, one of them will be found to communicate with the zygomatico-

facial branch of the second or maxillary division of the fifth nerve. This small nerve pierces the zygomatic bone a short distance below the lateral border of the orbit.

The lower filaments are larger. They run anteriorly along the lower border of the zygomatic arch, under cover of the musculus zygomaticus and the infra-orbital part of the

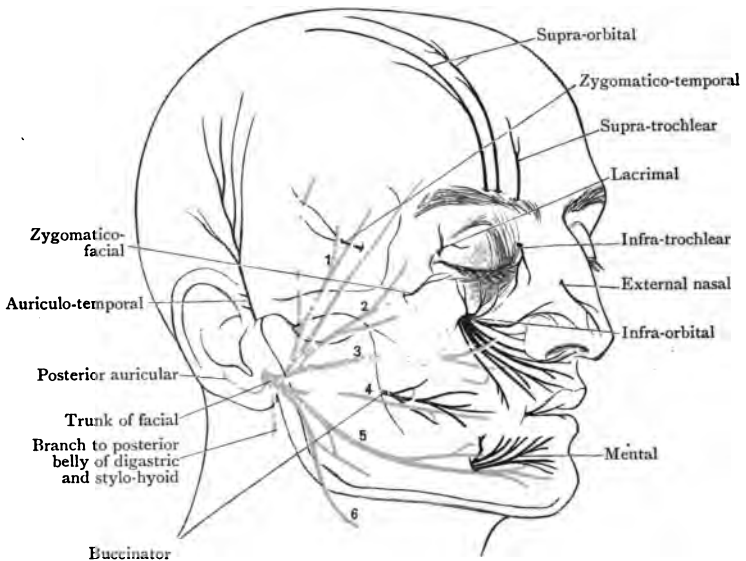


FIG. 59.—Nerves of the Face. The facial nerve is depicted in yellow, the sensory branches of the trigeminal in black.

- | | |
|------------------------------|-----------------------|
| 1. Temporal branches. | 4. Buccal branch. |
| 2 and 3. Zygomatic branches. | 5. Mandibular branch. |
| | 6. Cervical branch. |

quadratus labii superioris, and deep to the latter they communicate with the infra-orbital branch of the maxillary division of the fifth nerve, forming with it the *infra-orbital plexus*.

The *buccal branch or branches* run towards the angle of the mouth. At the anterior border of the masseter they communicate, around the anterior facial vein, with the buccinator branch (O.T. long buccal) of the third division of the fifth, and they supply the buccinator and the orbicularis oris.

Dissection.—In order to trace the branches to their terminations and to display fully the infra-orbital plexus, cut through the musculus zygomaticus

and the quadratus labii superioris immediately below their origins, and turn them downwards towards the upper lip. When this has been done, clear away the fatty tissue which lies on the deep aspect of the quadratus labii superioris and secure the infra-orbital vessels and nerve, as they emerge from the infra-orbital foramen. The infra-orbital plexus lies deep to the quadratus labii superioris, and on the superficial aspect of the musculus caninus. From the plexus three groups of branches are distributed: (1) palpebral, which pass upwards to the lower eyelid; (2) nasal, which run medially to the nose; and (3) labial, which descend to the upper lip. Either by means of these branches, or more directly, the lower zygomatic twigs of the facial nerve are distributed to the musculus zygomaticus, the muscles of the lower eyelid, muscles of the nose, and the muscles of the upper lip.

The *mandibular branch or branches* run anteriorly along the mandible to be distributed to the muscles of the lower lip. As they pass anteriorly they lie deep to the triangularis, and they communicate, under cover of it, with the mental branch of the inferior alveolar (O.T. dental) nerve. To display this communication the triangularis must be reflected, and the mental vessels and nerves must be found as they emerge from the mental foramen.

Arteria Maxillaris Externa (O.T. Facial).—The external maxillary artery is a tortuous vessel which enters the face at the lower and anterior angle of the masseter, after turning round the lower border of the mandible and piercing the deep fascia of the neck. From that point it runs anteriorly and upwards to the angle of the mouth and then, assuming a more vertical direction, it is prolonged upwards, as the angular artery, to the medial commissure of the eyelids, in the substance of the angular head of the quadratus labii superioris. Immediately after its entrance into the face it is comparatively superficial, being covered by skin, superficial fascia, and platysma, and it is easily compressed against the bone. More anteriorly it lies between the zygomaticus superficially and the buccinator deeply, then between the quadratus labii superioris and the caninus, and, as already stated, its terminal part is usually embedded in the substance of the quadratus labii superioris.

Branches.—The branches of the external maxillary artery form two groups, a posterior and an anterior. The branches of the posterior group pass posteriorly and are of small size. They are distributed to the masseteric, buccal, and malar regions where they anastomose with the transverse facial, the buccinator, and the infra-orbital arteries.

The branches of the anterior group run anteriorly

ceive special names: they are the inferior labial, the superior labial, the lateral nasal, and the angular continuation.

The *inferior labial* (O.T. *inferior coronary*) arises below the level of the angle of the mouth and passes towards the

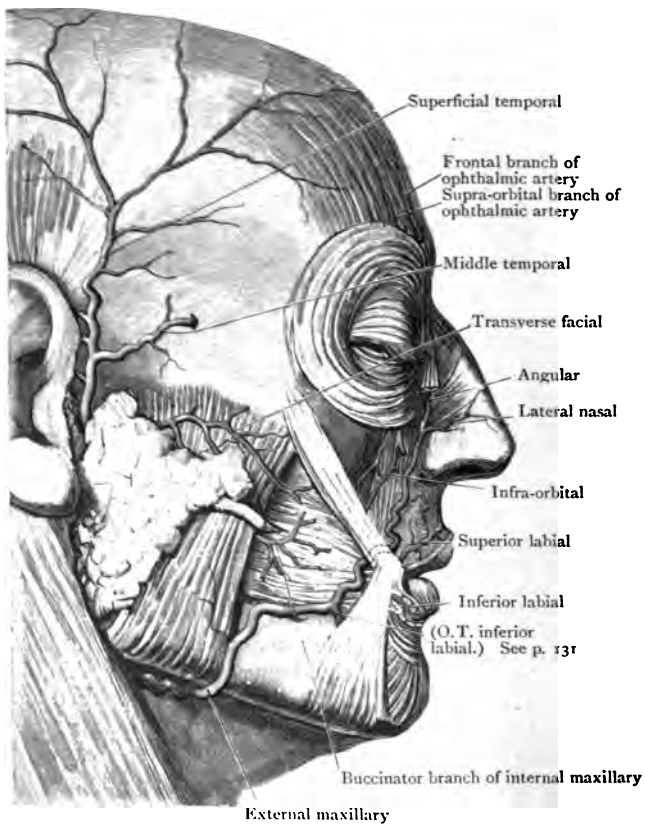


FIG. 60.—Arteries of the Face.

median plane, under cover of the *triangularis*, the *quadratus labii inferioris*, and the *orbicularis oris*. In the substance of the lip it lies immediately adjacent to the mucous membrane, and it anastomoses in the median plane with its fellow of the opposite side.

The *superior labial* arises about the level of the angle

of the mouth and runs medially in the upper lip, between the orbicularis oris and the mucous membrane. Before it anastomoses with its fellow of the opposite side, it gives off a branch, *the septal artery of the nose*, which passes upwards and ramifies on the lower and anterior part of the nasal septum, where it anastomoses with the septal branch of the sphenopalatine artery.

The Angular Artery.—This is the continuation of the external maxillary beyond the point of origin of the lateral nasal branch. It runs upwards in the substance of the angular head of the quadratus labii superioris, and it terminates at the medial commissure of the eye by anastomosing with the nasal branch of the ophthalmic. The *lateral nasal branch* springs from the external maxillary at the point where it becomes the angular. It ramifies on the side of the nose and anastomoses in the median plane with its fellow of the opposite side.

In addition to the branches already noted, a very definite branch is usually given off from the anterior aspect of the external maxillary artery immediately after it crosses the lower border of the mandible. This branch (O.T. inferior labial) runs towards the median plane under cover of the triangularis and the depressor labii inferioris, and it anastomoses not only with the inferior labial (O.T. inferior coronary) above, and its fellow of the opposite side in the median plane, but also with the mental branch of the inferior alveolar artery.

Vena Facialis Anterior (O.T. Facial).—The anterior facial vein is a less tortuous vessel than the external maxillary artery to which it corresponds, and it lies posterior, and on a slightly more superficial plane. It commences as the *angular vein*, which is formed at the medial commissure of the eyelids, by the union of the frontal and supra-orbital veins, which descend from the forehead. It passes downwards and posteriorly, in a comparatively straight line, to the anterior inferior angle of the masseter, which it crosses immediately behind the external maxillary artery; then it pierces the deep fascia of the neck, and enters the submaxillary triangle. In the upper part of the face it lies on the quadratus labii superioris; then it is situated between the zygomaticus and the risorius superficially and the buccinator deeply; and as it crosses the anterior angle of the masseter it is covered with the skin, superficial fascia, and the platysma.

Tributaries.—In addition to the frontal and supra-orbital veins, it receives external nasal, palpebral, superior labial, inferior labial, masseteric and superficial parotid tributaries. As it crosses the buccinator muscle it is joined by the deep facial vein, which connects it with the pterygoid plexus of veins in the infra-temporal region.

Dissection.—After the branches of the facial nerve, the external maxillary artery and the anterior facial vein have been studied, the dissection of the deeper muscles and the deeper vessels and nerves must be proceeded with; but the supra-orbital and supra-trochlear nerves, the supra-orbital vessels, and the corrugator supercilii muscle may be left till the scalp is dissected (p. 156).

Musculus Caninus (O.T. Levator Anguli Oris).—The caninus is concealed by the lower part of the orbicularis oculi, the quadratus labii superioris, and the zygomaticus, and it is crossed superficially, near the angle of the mouth, by the external maxillary artery. When the structures superficial to it are turned aside, the muscle will be found springing from the canine fossa below the infra-orbital foramen. It passes downwards to the angle of the mouth, where it blends with the orbicularis oris, some of its fibres passing into the lower lip (Fig. 57). It is an elevator of the angle of the mouth.

The Buccinator.—This muscle occupies the interval between the upper and the lower jaws and forms a most important part of the substance of the cheek. Above, it springs from the alveolar border of the maxilla, in the region of the molar teeth. Below, it arises from the alveolar border of the mandible, also in the region of the molar teeth, and, posteriorly, it is attached to the pterygo-mandibular raphe, which forms a bond of union between the buccinator and the superior constrictor of the pharynx. This attachment will be seen to better advantage when the wall of the pharynx is studied (p. 373). Anteriorly, its fibres converge towards the angle of the mouth, where they blend with the orbicularis oris, of which they form a large part. The manner in which the fibres enter the orbicularis must be carefully noted. The upper and lower fibres pass directly to the corresponding lips; the middle fibres, on the other hand, decussate at the angle of the mouth, so that the lower fibres of the series enter the upper lip, whilst the higher fasciculi reach the lower lip (Fig. 61).

The Molar Glands.—The buccinator is covered posteriorly

by a pad of fat, the *suctorial pad*, and by a strong layer of fascia which must be carefully removed. As this is being done the dissector will find, both superficial and deep to the fascia, a number of small glands, the *molar salivary glands*. The ducts of these glands pierce the buccinator and open into the vestibule of the mouth. One or two *buccal lymph glands* also are sometimes found resting on the superficial surface of the buccinator.

Dissection.—After the dissection of the buccinator and the molar glands is completed, remove the stitches from the lips; evert the lips and dissect the mucous membrane from the deep surfaces, in order to expose the muscular slips which attach the orbicularis oris to the alveolar margins of the upper and the lower jaws, and to display the mentalis muscle. As the lips are everted the dissector should note that a fold of mucous membrane, the *frenulum labii*, passes from each lip to the gum of the corresponding jaw in



FIG. 61.—Arrangement of the Fibres of the Buccinator Muscle at the Angles of the Mouth.

the median plane; and as the mucous membrane is removed a number of small *labial salivary glands*, which lie in the submucous tissue, will be seen. They are readily felt in the living subject by pressing the tip of the tongue against the inner surfaces of the lips.

Musculi Incisivi Labii Superioris et Inferioris.—These are four small muscular bundles, two upper and two lower, which attach the deeper part of the orbicularis oris to the alveolar margins of the jaws in the regions of the upper and lower lateral incisor teeth.

Musculus Mentalis.—When the incisive muscles of the lower jaw are detached from the bone and the lower lip is further everted, a distinct muscular bundle will be found on each side, springing from the outer surface of the socket of the canine tooth, under cover of the quadratus labii inferioris. The two bundles converge and blend together, between the medial borders of the muscoli quadrati labii inferioris, to form a single bundle which is inserted into the skin of the chin. It is an elevator of the skin of the chin.

Nervus Buccinatorius (O.T. Long Buccal).—This nerve is a branch of the third division of the trigeminal nerve. It passes anteriorly into the cheek from under cover of the ramus of the mandible. It is a sensory nerve, and it supplies branches to the skin on the outer surface and the mucous membrane on the inner surface of the buccinator muscle. In order to display it at the present stage it may be necessary to make an antero-posterior incision through the middle of the anterior border of the masseter.

Eyelids.—The following strata will be exposed in each eyelid as the dissection is carried from the surface towards the conjunctiva.

UPPER LID.	LOWER LID.
1. Integument.	1. Integument.
2. Palpebral part of the orbicularis oculi.	2. Palpebral part of the orbicularis oculi.
3. The tarsus, the palpebral fascia, and the expanded tendon of the levator palpebræ superioris.	3. The tarsus and the palpebral fascia.
4. Conjunctiva.	4. Conjunctiva.

In addition to these structures, two ligamentous bands, named the medial palpebral ligament (O.T. internal tarsal ligament) and the lateral palpebral raphe (O.T. external tarsal ligament), will be noticed. They attach the tarsi to the medial and lateral margins of the orbit.

Integument and Orbicularis Oculi.—These strata have been examined already, and the skin has been reflected.

Dissection.—Separate the palpebral part of the orbicularis oculi from the remainder by a circular incision; turn the palpebral part towards the rima palpebrarum, and take care, whilst raising the muscle fibres, to preserve the palpebral vessels and nerves, and at the same time to avoid injury to the palpebral fascia. As the dissection is completed the origin of the muscle from the medial palpebral ligament (p. 121) will be displayed.

Tarsi.—The removal of the palpebral part of the orbicularis oculi brings into view the palpebral fascia and the tarsi. These lie in the same morphological plane, and they constitute the ground-work of the eyelids.

The *tarsi* are two thin plates of condensed fibrous tissue, placed one in each eyelid so as to occupy an area immediately

adjoining its free margin. They differ very materially from each other. The *superior tarsal plate* is much the larger of the two, and presents the figure of a half oval. Its deep surface is intimately connected with the subjacent conjunctiva, whilst its superficial surface is clothed by the orbicularis muscle, and is in relation to the roots of the eyelashes. Its superior border is thin, convex, and continuous with a tendinous expansion of the levator palpebræ superioris. The inferior border of the tarsal plate is thickened and straight, and the integument adheres firmly to it.

The *inferior tarsal plate* is a narrow strip which is similarly placed in the lower lid.

Glandulæ Tarsales (O.T. Meibomian Follicles).—At this stage the student should examine the tarsal glands, which he will display by everting the eyelids. They are placed on the deep surfaces of the tarsi. To the naked eye they appear as closely placed, parallel, yellow granular-looking streaks, which run at right angles to the free margins of the lids. They are more numerous and of greater length in the upper lid, and, being lodged in furrows on the deep surface of the tarsal plates, they are distinctly visible upon both aspects of these, even while the conjunctiva is in position. Their ducts open upon the free margin of each lid posterior to the eyelashes.

The Palpebral Fascia.—The palpebral fascia is a sheet of fibrous membrane which occupies the interval between the tarsi and the margins of the orbit, forming, with the tarsi, a septum between the orbit and the exterior. Its peripheral border is attached to the orbital margin, except at the medial angle of the orbit, where it occupies a more posterior plane, and is attached to the crista lacrimalis, posterior to the medial palpebral ligament and the lacrimal sac. Its central border in the lower lid is connected with the lower border of the lower tarsus. In the upper lid it blends with the expanded tendon of the levator palpebræ superioris, and is attached with it to the anterior surface of the upper tarsus. It is pierced by the supra-orbital, supra-trochlear, and lacrimal branches of the first division of the trigeminal nerve, and by the terminal branches of the ophthalmic artery.

Raphe Palpebralis Lateralis.—The lateral palpebral raphe (O.T. external tarsal ligament) is merely a thickening of the palpebral fascia, between the lateral commissure and the

medial border of the fronto-sphenoidal process of the zygomatic bone (O.T. malar), to which it connects both the tarsi.

Ligamentum Palpebrale Mediale (O.T. *Internal Tarsal Ligament*).—The medial palpebral ligament is a strong fibrous band which connects the medial ends of both tarsi to the frontal process of the maxilla. It lies between the skin anteriorly, and the lacrimal sac posteriorly. By its upper and lower borders it gives attachment to fibres of the orbicularis

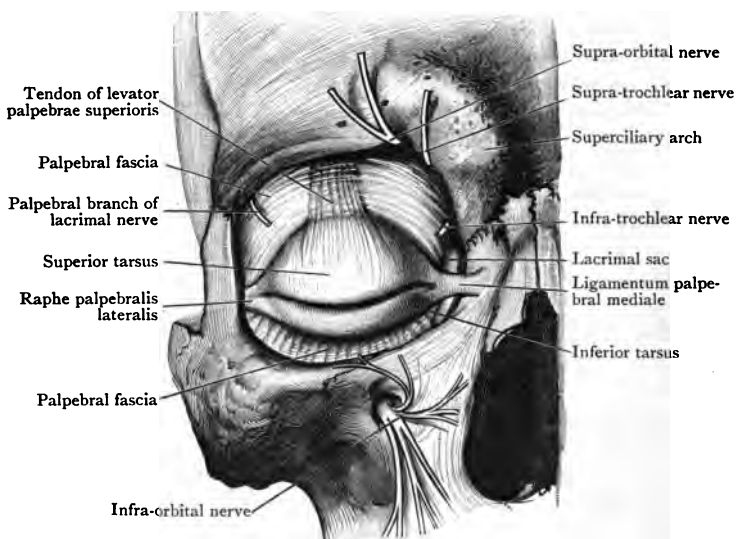


FIG. 62.—Dissection of the Right Eyelid. The orbicularis palpebrarum has been completely removed.

oculi, and by the lateral part of its posterior surface, to the pars lacrimalis of the orbicularis oculi (O.T. tensor tarsi).

Levator Palpebrae Superioris.—Only the anterior expanded tendon of this muscle can be seen at the present stage of the dissection, and that, as a rule, in only a partially satisfactory manner. The muscle arises within the orbital cavity, extends forwards to the upper eyelid, and ends in an expanded tendon which splits into three lamellæ; a superior lamella, which blends with the upper part of the palpebral fascia and is attached with it to the anterior surface of the upper tarsus; an intermediate lamella, which is connected with the upper

border of the upper tarsus; and an inferior lamella, which gains insertion into the upper fornix of the conjunctiva. It raises the upper eyelid by pulling on the upper tarsus, and at the same time elevates the upper fornix of the conjunctiva.

Vessels and Nerves of the Eyelids.—At the medial commissure two arteries, the *palpebral branches* of the ophthalmic, pierce the palpebral fascia and run laterally, one in the upper and one in the lower lid. At the lateral margin of the orbit, one or more branches of the lacrimal division of the ophthalmic pierce the palpebral fascia and anastomose with

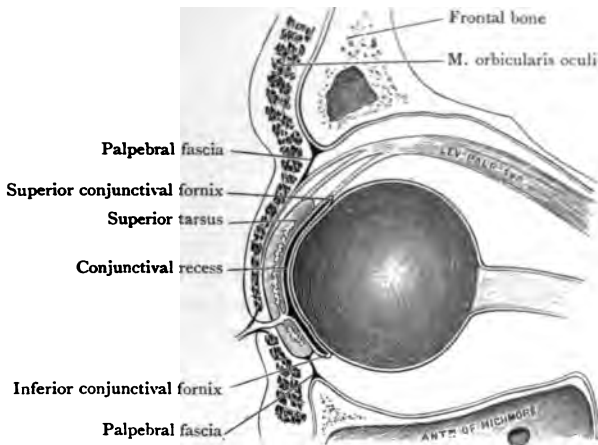


FIG. 63.—Diagram of the Structure of the Eyelids.

the palpebral arteries. An arterial arch, *arcus tarseus*, is thus formed close to the margin of each eyelid, between the orbicularis muscle and the tarsus.

The veins run medially towards the root of the nose and open into the frontal and angular veins.

The nerves are more numerous and come from a number of different sources. The motor filaments for the various parts of the orbicularis oculi are derived from the temporal, and zygomatic branches of the facial nerve. They enter from the lateral margins. The sensory twigs for the upper lid come from the lacrimal, supra-orbital, supra-trochlear, and infra-trochlear branches of the first or ophthalmic division of the trigeminal nerve; and the lower lid is supplied by t¹

infra-orbital branch of the second or maxillary division of the fifth nerve. The lacrimal nerve will be found piercing the palpebral fascia near the lateral part of the upper border of the orbit; the supra-orbital lies in the supra-orbital notch at the junction of the lateral two-thirds with the medial third of the upper border; and the supra- and infra-trochlear pierce the palpebral fascia at the medial end of the upper border. The branches of the infra-orbital nerve pass to the lower lid in the palpebral branches of the infra-orbital plexus (p. 128).

Apparatus Lacrimalis.—The following structures are included under this head: (1) the lacrimal gland and its ducts; (2) the conjunctival sac; (3) the puncta lacrimalia; (4) the lacrimal ducts; (5) the lacrimal sac; (6) the naso-lacrimal duct; (7) the lacrimal part of the orbicularis oculi.

Glandula Lacrimalis.—This lies in the upper and lateral part of the orbital cavity under cover of the zygomatic process (O.T. external angular) of the frontal bone. It can be exposed by cutting through the palpebral fascia at the upper and lateral angle of the orbit, and it will be found that the anterior part of the gland projects slightly beyond the orbital margin and rests upon the conjunctiva as the latter is reflected from the lateral part of the upper lid on to the eyeball. If the anterior border of the gland is raised and the point of the knife carried carefully up and down in the fascia under it, several exceedingly fine ducts will be found passing from the gland into the lateral part of the upper fornix of the conjunctiva. The ducts vary in number, and the secretion which they convey, which constitutes the tears, is carried, by the involuntary movements of the upper eyelid, over the exposed surface of the eyeball and is directed towards the medial commissure; there it passes through the puncta lacrimalia into the lacrimal ducts, and is carried by them to the lacrimal sac, whence it passes by the naso-lacrimal duct into the inferior meatus of the nose. Under ordinary circumstances, the amount of lacrimal secretion is merely sufficient for lubrication, and practically the whole of it is evaporated from the surface of the eyeball; consequently, when the lacrimal ducts and the lacrimal sac are extirpated, a proceeding which is necessary under certain circumstances, the patient suffers little or no inconvenience from the overflow of tears, so long as the secretion is not excessive. If the amount of secretion is greater than can be removed by evaporation, the excess,

under ordinary circumstances, passes through the puncta into the ducts and thence through the lacrimal sac and naso-lacrimal duct to the nose; and if the secretion becomes so abundant that it cannot be removed by evaporation and drainage, part flows through the rima as tears.

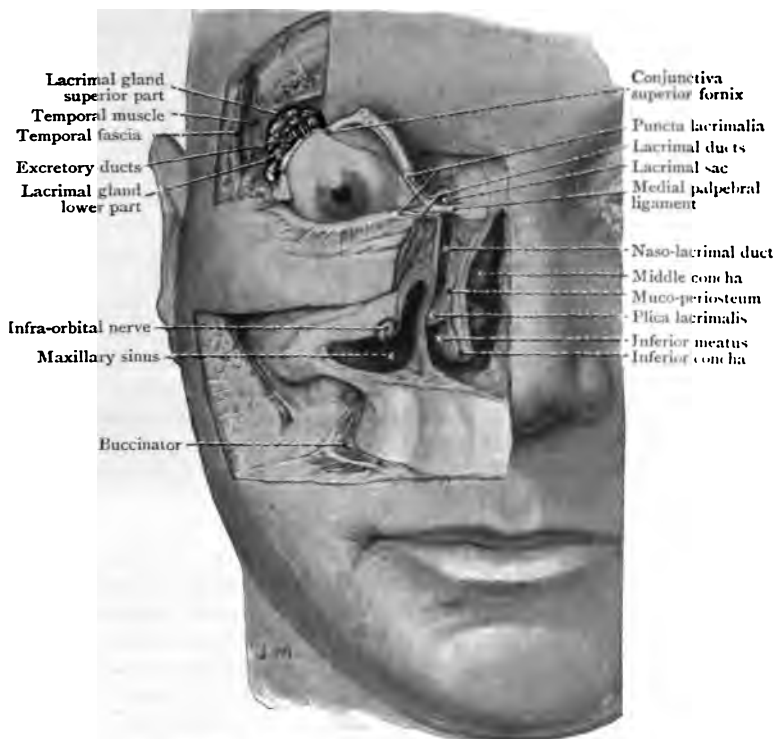


FIG. 64.—Dissection of Lacrimal Apparatus.

The Conjunctival Sac.—The conjunctival sac is the potential space between the eyelids and the eyeball. It opens externally through the rima and communicates with the lacrimal sac through the puncta and the lacrimal ducts.

The Puncta Lacrimalia.—It has been noted already that the punctum lacrimale of each lid lies at the lateral margin of the lacus lacrimalis (p. 120). Small probes should not

passed through the puncta into the lacrimal ducts and along the ducts into the lacrimal sac (Fig. 64).

Saccus Lacrimalis.—The lacrimal sac is the blind upper end of a canal which extends from the orbit to the inferior meatus of the nose. It is lodged in the fossa lacrimalis in the anterior part of the medial wall of the orbit. It lies posterior to the medial palpebral ligament, from which it receives a fibrous expansion, and it is covered on its lateral aspect, and on the lateral part of its posterior aspect, by the pars lacrimalis of the orbicularis oculi. The lacrimal ducts open into its antero-lateral aspect, under cover of the medial palpebral ligament; and it is continuous below with the naso-lacrimal duct. The anterior wall of the sac should be incised and a probe passed down the naso-lacrimal duct into the nose. Note that as the probe passes along the duct it inclines downwards, laterally and slightly posteriorly.

Pars Lacrimalis Orbicularis Oculi (O.T. Tensor Tarsi).—This small special portion of the orbicularis oculi springs from the posterior aspect of the lateral part of the medial palpebral ligament and passes posteriorly and medially, round the lateral part of the lacrimal sac, to the crista lacrimalis of the lacrimal bone, to which it is attached. When it contracts it compresses the lacrimal sac, and so tends to facilitate the flow of the lacrimal secretion into the nose.

Ductus Naso-Lacrimalis.—This duct will be seen at a later period of the dissection. It is a bony canal, lined with muco-periosteum, which runs, in the lateral wall of the nose, from the lacrimal sac to the upper and anterior part of the inferior meatus. It is about half an inch long. At the medial side of its lower end is a fold of mucous membrane, the *plica lacrimalis*, which serves as a flap valve (Fig. 64).

The dissection of the face should be completed by an examination of the nasal cartilages and the external nasal branch of the ophthalmic division of the trigeminal nerve. The nerve will be found emerging between the lower border of the nasal bone and the lateral cartilage. After its emergence it descends to the tip of the nose supplying filaments to the skin.

Dissection.—The cartilaginous part of the nose should now be examined by stripping off the nasalis muscle and the remains of the integument.

Nasal Cartilages.—In addition to the septal cartilage,

which will be more appropriately studied in the dissection of the nasal cavities, two cartilaginous plates will be found upon each side. These are :—

1. The lateral cartilage.
2. The cartilage of the ala.

The *lateral cartilage* is a triangular plate which, by its posterior margin, is attached to the lower border of the nasal bone and the upper part of the sharp margin of the nasal notch of the maxilla. In the median plane this cartilage

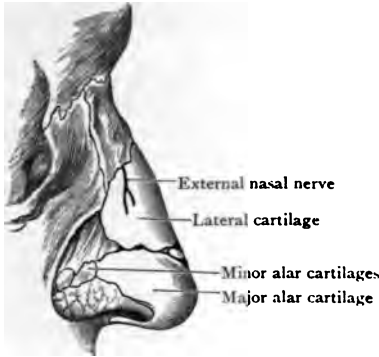


FIG. 65.—Cartilages of the Nose.

becomes continuous with its fellow of the opposite side, and also with the subjacent anterior border of the septal cartilage of the nose. Below, there is a slight interval between the two lateral cartilages, in which is seen the margin of the nasal septal cartilage. The inferior border of the lateral cartilage is connected with the lateral part of the alar cartilage by some dense fibrous tissue.

The *alar cartilage* is bent upon itself and folded round the orifice of the nostril anteriorly and laterally. Posteriorly it is deficient. The *lateral part* is oval, and does not reach down to the margin of the nostril, nor posteriorly as far as the nasal notch of the maxilla. The interval between it and the bone is filled in by fibrous tissue in which one or two small islands of cartilage (*cartilagine minores vel sesamoideæ*) appear. *Anteriorly*, the bent part of cartilage comes into contact with its neighbour and forms the point of

nose. *Medially*, the medial part of the cartilage is in the form of a narrow strip which lies upon the lower part of the septal cartilage, and projects slightly below it so as to support the margin of the nostril upon this side. Its extremity is turned slightly laterally.

SIDE OF THE NECK.

On the fourth day after the body is brought into the room it is placed upon its back, and the dissectors of the head and neck should examine the side of the neck and commence the dissection of the posterior triangle.

The side of the neck is bounded below by the clavicle, above by the lower border of the mandible, the mastoid portion of the temporal bone, and the superior nuchal line of the occipital bone. Anteriorly it extends to the median plane, and posteriorly to the anterior border of the trapezius muscle. It is divided into anterior and posterior parts, the *anterior* and *posterior triangles*, by the sterno-mastoid muscle. If the head is pulled over towards the opposite side, the sterno-mastoid muscle will be seen descending from the mastoid portion of the temporal bone and the superior nuchal line of the occipital bone, to the upper border of the sternal third of the clavicle and the anterior surface of the manubrium sterni.

In the lower part of the posterior region, posterior to the sterno-mastoid and above the convex middle third of the clavicle, there is a depression called the *fossa supraclavicularis major*, to distinguish it from the *fossa supraclavicularis minor* which lies above the sternal end of the clavicle between the sternal and clavicular heads of the sterno-mastoid. The brachial plexus, the third part of the subclavian artery, and the supra-clavicular lymph glands lie in the region of the fossa supra-clavicularis major, and the fossa supra-clavicularis minor indicates the position of the internal jugular vein near its lower end.

POSTERIOR TRIANGLE.

Dissection.—To expose the boundaries and contents of the posterior triangle make the following three incisions through the skin. (1) From the back of the auricle along the upper border of the mastoid part of the

temporal bone and the superior nuchal line to the external occipital protuberance. (2) From the sternal to the acromial end of the clavicle, following the line of that bone. (3) Join the anterior extremities of 1 and 2 by a vertical incision passing along the back of the external acoustic meatus and then down the middle of the sterno-mastoid muscle. Reflect the flap, thus marked out, from before backwards, and note that the skin is thicker over the upper and posterior part of the triangle than over the lower and anterior part.

When the skin is reflected the superficial fascia and the lower part of the platysma muscle will be exposed.

The *superficial fascia* in the region of the posterior triangle is comparatively thin, and embedded in its lower and anterior part is the lower and posterior part of the platysma.

The Platysma.—The platysma is a thin sheet of muscle which commences in the superficial fascia of the infra-clavicular region, whence it ascends across the clavicle and through the superficial fascia of the side of the neck, to the face where its upper border has been examined already (p. 126). It covers the lower and anterior part of the posterior triangle, and the upper and posterior part of the anterior triangle; and it is supplied by the cervical branch of the facial nerve, which emerges from the lower end of the parotid gland.

Dissection.—Make an incision through the lower part of the platysma along the line of the clavicle, and turn the part above the incision upwards and anteriorly. Whilst making the incision and whilst reflecting the muscle, be careful not to injure the supraclavicular cutaneous nerves and the external jugular vein, which lie directly subjacent to it.

After the platysma is reflected, clean the external jugular vein, which emerges from the lower end of the parotid and passes downwards, inclining posteriorly, to the lower and anterior angle of the posterior triangle, where it pierces the deep fascia. Whilst cleaning the vein, avoid injury to the nervus cutaneus colli, which sometimes crosses superficial to the vein about the middle of its length. Secure and clean the posterior auricular vein, which descends behind the auricle and joins the external jugular a little below the level of the angle of the mandible. Next, find and clean the superficial branches of the cervical plexus as they pierce the deep fascia. They are (1) *descending branches*, the anterior, middle, and posterior supra-clavicular nerves. (2) A *transverse branch*, the nervus cutaneus colli (O.T. transverse cervical). (3) *Ascending branches*, the great auricular and the small occipital.

The *anterior* and *middle supra-clavicular nerves* will be found piercing the deep fascia immediately above the clavicle, the anterior at the posterior border of the sterno-mastoid and the middle above the convexity of the clavicle. They descend into the pectoral region as far as the lower border of the second rib and their lower portions will be displayed by the dissector of the arm. The *posterior supra-clavicular nerves* pierce the deep fascia at a somewhat higher level. They descend across the lower and anterior part of the trapezius to the acromial region, and to the skin of the arm over the upper part of the deltoid, where they will be exposed by the dissector of the arm.

The *Deep Fascia*.—The deep fascia forms the superficial boundary or roof of the posterior triangle. It is attached below to the upper border of the middle third of the clavicle ;

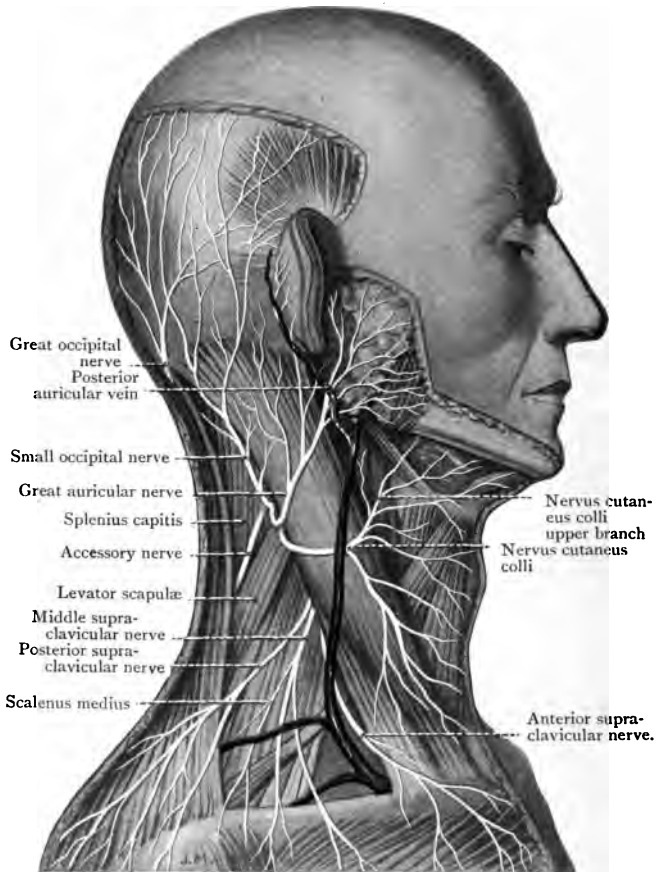


FIG. 66.—The superficial branches of the cervical plexus.

above, to the superior nuchal line of the occipital bone ; anteriorly it is continuous with the fascia of the sterno-mastoid and posteriorly with the fascia of the trapezius. It is pierced by (1) the supra-clavicular branches of the cervical plexus, (2) the external jugular vein, (3) small cutaneous branches of the

transverse cervical, transverse scapular (O.T. suprascapular), and occipital arteries, and, occasionally, by the occipital artery itself. It is not a very strong layer, and it is frequently difficult to display it as a continuous sheet. Over the upper part of the triangle it forms a single layer, but below, it splits into two lamellæ, a superficial and a deep. The superficial layer which is already displayed, is attached to the upper border of the clavicle from the sterno-mastoid anteriorly to the trapezius posteriorly. It is pierced by the external jugular vein and the supraclavicular nerves.

Dissection.—Trace the supraclavicular nerves upwards through the deep fascia to the posterior border of the sterno-mastoid; then, pulling them aside, cut through the superficial layer of the deep fascia immediately above the clavicle and along the posterior border of the sterno-mastoid, and turn it upwards. Introduce the handle of the scalpel behind the clavicle and note that it can be passed downwards as far as the posterior border of the lower surface of the bone. Its further progress is barred by the attachment of the second layer of the deep fascia to this border, where it blends with the posterior lamella of the costo-coracoid membrane. Pass the handle of the knife forwards behind the sterno-mastoid and note that, without using any great force, it can be pushed medially until it crosses the median plane; therefore, the space between the two layers of deep fascia in the lower part of the posterior triangle is continuous anteriorly with the space which lies above and posterior to the manubrium sterni, between the first and the second layers of the deep fascia of the anterior part of the neck. Laterally, this space extends as far as the coracoid process, and upwards to a short distance above the posterior belly of the omo-hyoid muscle. Clear away the areolar tissue which lies between the two layers of the deep fascia, and expose a further part of the external jugular vein, and the terminal parts of the transverse cervical and the transverse scapular (suprascapular) veins, as they join the posterior border of the external jugular. Pull the lower part of the external jugular vein posteriorly and expose the termination of the anterior jugular vein in its anterior border. Dissect carefully behind the clavicle and find the transverse scapular (suprascapular) artery. Trace the second layer of the deep fascia upwards and note that it is continuous with the fascia which surrounds the posterior belly of the omo-hyoid muscle; indeed it is the tension of this portion of the deep fascia which holds the posterior belly of the muscle down in its position.

Remove the remaining parts of the deep fascia, first from the upper, and then from the lower part of the triangle, and expose the floor and the remaining contents of the triangle.

Commence above, in the region of the junction of the upper third and the lower two-thirds of the posterior border of the sterno-mastoid, and secure the great auricular, the small occipital, the accessory nerve, and the nervus cutaneus colli. The great auricular is most easily found. It turns round the posterior border of the sterno-mastoid, in the region indicated, and runs upwards and anteriorly, parallel with and slightly above and posterior to the external jugular vein. The small occipital will be found hooking round the lower border of the accessory nerve a little above the great auricular; and the nervus cutaneus colli lies a little below the great auricular.

Follow the small occipital and the great auricular nerves to their

terminations, but the *nervus cutaneus colli* must be traced only to the point where it crosses either superficial or deep to the external jugular vein. It eventually divides into upper and lower terminal branches, which will be seen when the anterior triangle is dissected.

Nervus Occipitalis Minor.—The small occipital is a sensory branch of the second cervical nerve. It emerges from under cover of the sterno-mastoid, and ascends for a short distance along its posterior border, then it passes to the superficial surface of the muscle, pierces the deep fascia, and divides into occipital, mastoid, and auricular branches. The occipital and mastoid branches supply the skin in the regions indicated by their names. The auricular is distributed to the skin of the upper third of the cranial surface of the auricle.

Nervus Auricularis Magnus.—This consists of cutaneous filaments derived from the second and third cervical nerves. After turning round the posterior border of the sterno-mastoid it runs upwards and anteriorly, towards the angle of the mandible, in the deep fascia on the superficial surface of the sterno-mastoid, and breaks up into three sets of terminal branches, mastoid, auricular, and facial. The *mastoid branches* go to the skin of the mastoid region. The *auricular branches* supply the skin of the lower two-thirds of the cranial surface and the lower third of the lateral surface of the auricle. The *facial branches*, which have already been seen, ramify in the posterior part of the face, in the parotid and masseteric regions. Some of the filaments enter the substance of the parotid.

Dissection.—The accessory nerve, previously found at the junction of the upper third with the lower two-thirds of the posterior border of the sterno-mastoid, must now be traced downwards and posteriorly, through the triangle, to the point where it disappears under cover of the trapezius, at the junction of the upper two-thirds with the lower third of the anterior border of that muscle. As the nerve is cleaned, attempt to secure twigs from the third and fourth cervical nerves which communicate with it in the posterior triangle.

Turn next to the posterior belly of the omo-hyoid muscle, which crosses the lower part of the triangle. Note that it divides the triangle into a large upper or occipital portion, and a small lower or subclavian portion. Cut through the fascia on the surface of the muscle, parallel with the muscle fibres, and turn it upwards and downwards; then turn the upper border of the muscle laterally and find the nerve from the *ansa hypoglossi*, which emerges from under cover of the sterno-mastoid and enters the deep surface of the omo-hyoid to supply it.

Take away the remains of the superficial layer of deep fascia, and the areolar tissue beneath it from the upper part of the triangle. Whilst removing the latter note a number of lymph glands which lie embedded in it along the posterior border of the sterno-mastoid, superficial to the stems and branches of the cervical nerves. At the apex of the triangle look for the occipital artery, which either emerges between the adjacent

borders of the trapezius and the sterno-mastoid, or pierces the trapezius a little further posteriorly.

Between the accessory nerve above and the posterior belly of the omohyoid below find (1) the upper part of the brachial plexus; (2) its branch to the subclavius; (3) its suprascapular branch; (4) its dorsalis scapulae branch; (5) its long thoracic branch; (6) branches from the third and fourth cervical nerves to the levator scapulae; (7) branches from the third and fourth cervical nerves to the trapezius, and others which communicate with the accessory nerve in the posterior triangle; and (8) the upper and posterior part of the transverse cervical artery. Find the transverse cervical artery as it appears from under cover of the upper border of the omohyoid. It runs upwards and posteriorly. Next secure the nerve to the subclavius, which lies under cover of the deep fascia above the omohyoid and a short distance behind the sterno-mastoid. Trace it upwards to its origin from the trunk formed by the union of the fifth and sixth cervical nerves. Clean the latter nerves and the upper part of the seventh cervical nerve, which lies immediately below them. Then find the suprascapular nerve, which springs from the lateral border of the trunk formed by the fifth and sixth nerves. It lies immediately above the anterior part of the posterior belly of the omohyoid, and disappears under cover of the posterior part. Turn the trunk formed by the fifth and sixth cervical nerves anteriorly and find, posterior to it, the upper roots of the long thoracic nerve, which spring from the fifth and sixth nerves, and are emerging through the fibres of the scalenus medius muscle. The nervus dorsalis scapulae (O.T. nerve to the rhomboids) lies at a slightly higher level than the suprascapular nerve. It springs from the fifth cervical nerve, runs downwards and posteriorly, and disappears, through the floor of the triangle, between the adjacent borders of the levator scapulae above and the scalenus medius below. Above the dorsal scapular nerve are the branches from the third and fourth cervical nerves to the trapezius and the communications to the accessory nerve.

When the structures mentioned above have been found and cleaned, proceed to the dissection of the subclavian portion of the triangle. Find the transverse scapular artery (O.T. suprascapular), which lies behind the clavicle, and therefore, strictly speaking, outside the limits of the triangle. Then remove the second layer of deep cervical fascia which binds the posterior belly of the omohyoid to the posterior border of the clavicle, and find behind it (1) a further part of the external jugular vein; (2) a further part of the transverse cervical artery; (3) the lower part of the nerve to the subclavius; (4) the upper portion of the third part of the subclavian artery; (5) the lowest root and the lower parts of the trunks of the brachial plexus; (6) a part of the long thoracic nerve; (7) supraclavicular lymph glands.

First clean the lower end of the external jugular vein and follow it behind the clavicle to its termination in the subclavian vein. Note the valves near its lower end. Next clean the transverse cervical artery and the nerve to the subclavius. Follow the nerve to the subclavius across the front of the third part of the subclavian artery; and afterwards clean the lower part of the subclavian artery and the adjacent part of the brachial plexus, which lies behind and above the artery. Note that the artery and the plexus are covered by a layer of deep cervical fascia, the backward prolongation of the prevertebral layer of fascia, which passes on to them from the lateral border of the scalenus anterior, and is prolonged along them to become continuous with the sheath of the axillary artery.

As the areolar tissue is cleared from the subclavian portion of the triangle a number of supraclavicular lymph glands may be noted. They receive lymph from the axillary glands, and they transmit it to the large lymph vessels at the root of the neck.

After the contents of the lower part of the triangle are thoroughly cleaned, remove the remains of the fascia covering the muscles which form the floor of the triangle. Note that this fascia is continuous anteriorly, round the tips of the transverse processes of the cervical vertebræ with the prevertebral fascia. Posteriorly it blends with the sheaths of the deeper

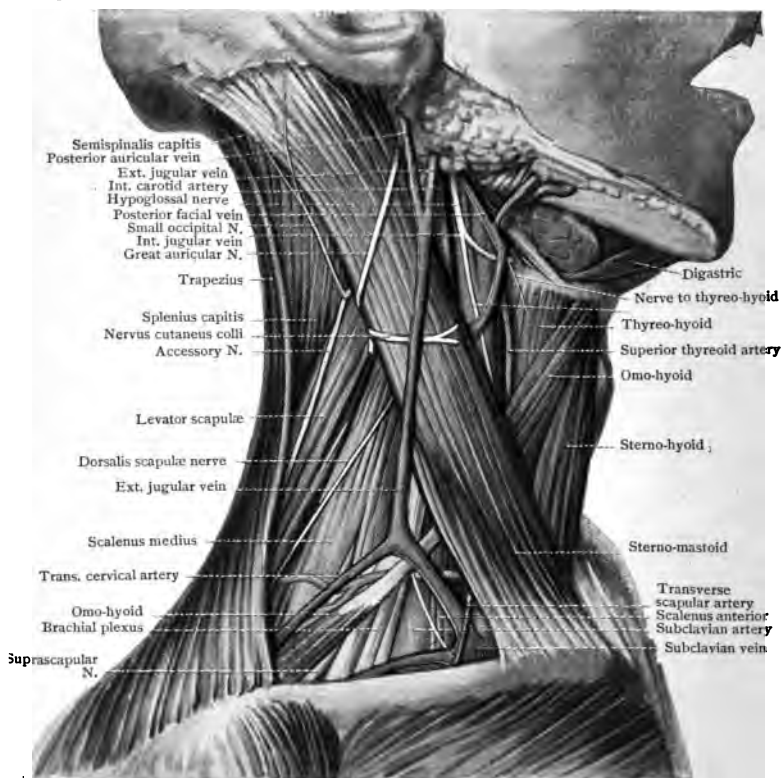


FIG. 67.—The Triangles of the Neck seen from the side. The clavicular head of the sterno-mastoid muscle was small, and therefore a considerable part of the scalenus anterior muscle is seen.

muscles at the back of the neck; above it is attached to the superior nuchal line; and below, as already stated, it is prolonged into the axilla along the axillary vessels and nerves.

Boundaries and Contents of the Posterior Triangle.—The dissection of the triangle should be completed in two days. On the third day the dissector should revise his knowledge of the boundaries and the relative positions of the contents.

The triangle is bounded *anteriorly* by the posterior border of the sterno-mastoid ; *posteriorly* by the anterior border of the trapezius ; *below* by the upper border of the middle third of the clavicle ; and *above* by the superior nuchal line of the occipital bone, or by the meeting of the upper ends of the sterno-mastoid and the trapezius. The *roof* is formed by the deep cervical fascia, which is covered by superficial fascia and skin, and in its lower and anterior part by the platysma, which is embedded in the superficial fascia. It is pierced by (1) the external jugular vein at the lower and anterior angle ; (2) the supraclavicular nerves, a short distance above the clavicle ; (3) small cutaneous branches of the transverse scapular, transverse cervical, and occipital arteries ; (4) lymphatic vessels passing from the superficial structures to the glands in the triangle. It is frequently stated that the small occipital, the great auricular, and the cervical cutaneous nerves also pierce the roof. As a general rule they turn round the posterior border of the sterno-mastoid under cover of the fascia, and pierce the fascia as it lies on the muscle.

The *floor* is formed by the splenius capitis, the levator scapulæ, the scalenus medius, and the scalenus posterior muscles, with the addition, occasionally, of a small part of the semispinalis capitis (O.T. complexus) above, and the upper serration of the serratus anterior below ; the latter appears in the area of the triangle only when the clavicle is very fully depressed. The muscles of the floor are covered with a layer of fascia which is the backward continuation of the prevertebral fascia of the anterior cervical region.

The contents of the posterior triangle are :—

1. Fatty areolar tissue.
2. The posterior belly of the omo-hyoid muscle.
3. Lymph Glands, { Post sterno-mastoid.
 { Supraclavicular.
4. Arteries,¹ { Third part of subclavian.
 { Transverse cervical and its terminal branches.
 { Occipital (sometimes).
5. Veins,² { External jugular.
 { Transverse cervical.
 { Transverse scapular (O.T. suprascapular).
 { Termination of anterior jugular.

¹ The transverse scapular artery (O.T. suprascapular) lies *posterior* to the clavicle and is not, strictly speaking, in the triangle.

² The subclavian vein is *posterior* to the clavicle and therefore is not contained within the triangle.

6. Nerves,	}	Accessory.	}	Branches of cervical plexus.
		Small occipital.		
		Great auricular.		
		Nervus cutaneus colli.		
		To levator scapulæ.		
		„ trapezius.		
		„ scalenus medius.		
		„ „ posterior.		
		Supraclavicular.		
		To posterior belly of omo-hyoid from ansa hypoglossi.		
		Trunks of brachial plexus.		
		The nervus dorsalis scapulæ.	}	Branches of the brachial plexus.
		„ long thoracic.		
		„ suprascapular.		
		„ nerve to the subclavius.		

Some of the contents of the triangle which are now displayed require further consideration.

The Posterior Belly of the Omo-hyoid Muscle.—The posterior belly of the omo-hyoid muscle springs from the upper border of the scapula and upper transverse scapular ligament. It enters the posterior triangle, at its lower and posterior angle, and runs upwards and anteriorly, at a variable distance from the clavicle, to the posterior border of the sterno-mastoid. Either immediately behind or under cover of the posterior border of the sterno-mastoid it joins the intermediate tendon which connects it with the anterior belly. Its nerve has already been seen entering its deep surface (p. 146) it divides the posterior triangle into a lower or subclavian portion and an upper or occipital portion.

The Accessory Nerve (O.T. Spinal Accessory).—The portion of the accessory nerve which appears in the posterior triangle consists of fibres which arise from the cervical part of the spinal medulla and with them are incorporated some filaments derived from the second cervical nerve. Before appearing in their present situation the spinal fibres entered the cranium through the foramen magnum and left it by passing through the jugular foramen; then they passed downwards and posteriorly, through the deeper fibres of sterno-mastoid, where they received the communication from the second cervical nerve. As already pointed out, the nerve usually enters the posterior triangle at the level of the union of the upper third with the lower two-thirds of the posterior border of the sterno-mastoid. It runs downwards and posteriorly through the triangle, along the line of the levator scapulæ, and disappears

under the trapezius at the junction of the upper two-thirds with the lower third of its anterior border. As it enters the triangle the small occipital nerve turns round its lower border, and, as it crosses the triangle, it is joined by twigs from the third and fourth cervical nerves.

The Branches of the Cervical Plexus.—The dissector should note that whilst many of the branches of the cervical plexus lie within the area of the posterior triangle, the plexus itself is under cover of the upper part of the sternomastoid, where it will be exposed and studied when the sternomastoid is reflected. The branches which appear in the triangle are the *superficial branches*—the small occipital, the great auricular, the nervus cutaneus colli, and the supraclavicular nerves; and the *deep posterior branches*, that is, the nerves to the scalenus medius and posterior, the nerve to the levator scapulae, the branches to the trapezius and the communication to the accessory nerve.

The Third Part of the Subclavian Artery.—Only a portion of this part of the subclavian artery is in the triangle; the lower and lateral part is behind the clavicle. The part in the triangle is situated deeply in the anterior inferior angle and below the omo-hyoid muscle. It is *covered with* the skin, superficial fascia, the platysma, deep fascia, the external jugular vein, the ends of the transverse scapular, and transverse cervical veins, and the nerve to the subclavius muscle. *Behind* it is the lowest trunk of the brachial plexus, which separates it from the insertion of the scalenus medius. *Below*, it rests upon the first rib, against which it can be compressed, and, more medially, on the cervical pleura.

The Brachial Plexus and its Supraclavicular Branches.—Only the upper portion of the brachial plexus lies in the region of the posterior triangle, *i.e.* the roots, the trunks, and some of the branches; the remainder lies either posterior to the clavicle or in the axilla. The cervical portion lies in the lower and anterior part of the posterior triangle partly in the occipital and partly in the supraclavicular areas. The detailed study of the plexus should be left till the fifth day after the body has been placed upon its back, when the dissector of the head and neck will assist the dissector of the upper extremity to disarticulate the clavicle and to lay bare the whole of the plexus (p. 160).

The fourth day after the body has been placed upon its

back should be devoted to the study of the temporal region and the anterior part of the scalp.

THE SCALP AND THE SUPERFICIAL STRUCTURES OF THE TEMPORAL REGION.

Under the term "scalp" are included the soft structures which cover the vault of the cranium above the temporal ridges and anterior to the superior nuchal line. Its constituent parts are arranged in five layers: (1) skin; (2) superficial fascia; (3) the epicranium, consisting of four muscular

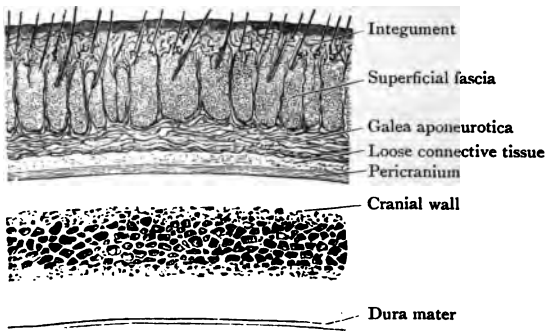


FIG. 68.—Section through the Scalp and Cranial Wall.

bellies, the two occipitales and the two frontales muscles, and the aponeurosis called the galea aponeurotica, which connects them together; (4) a layer of loose areolar tissue; (5) the periosteum, which is here called the pericranium. In the temporal region the wall of the cranium is much more thickly covered than in the scalp area, and it is possible to distinguish eight layers of soft tissues between the surface and the bone: (1) skin; (2) superficial fascia; (3) extrinsic muscles of the ear; (4) the thin lateral extensions of the galea aponeurotica; (5) a thin layer of fascia descending from the temporal ridge to the auricle; (6) the strong temporal fascia; (7) the temporal muscle; (8) periosteum.

The Scalp.—The scalp and the superficial temporal region are richly supplied with blood vessels and nerves, which all

enter from the periphery, passing into the superficial fascia after piercing the deep fascia of adjacent regions. As a consequence of this arrangement large flaps of the scalp may be torn from the centre towards the margin, but, so long as they remain attached at the periphery, their sources of vitality are not seriously interfered with, and if they are cleaned and replaced healing occurs rapidly and satisfactorily.

Dissection.—The skin has already been removed from the anterior parts of the scalp and the temporal region. A median longitudinal incision must now be made through the skin of the posterior part of the scalp as far as the external occipital protuberance, and the flap on either side of the incision must be turned downwards and posteriorly to the superior nuchal line. When this has been done the dissector should examine the auricle of the external ear, and familiarise himself with its various parts before he commences the dissection of its extrinsic muscles.

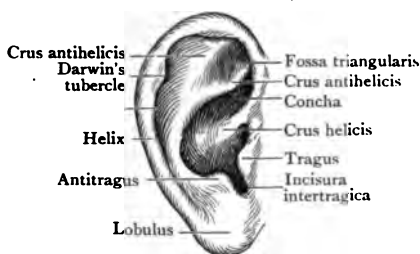

FIG. 69.—The Auricle.

Auricle or Pinna.—The auricle consists of a thin plate of yellow fibro-cartilage, covered with integument. It is fixed in position by certain ligaments, and possesses two sets of feeble muscles—viz., one group termed the *extrinsic muscles*, passing to the cartilage from the aponeurosis of the epicranium and the mastoid process, and a second group in connection with the cartilage alone, and therefore called the *intrinsic muscles*.

The *concha* is the wide and deep fossa which leads into the external meatus; the *antihelix* is the curved prominence which bounds this posteriorly; the *helix* is the folded or in-curved margin of the auricle; and the *lobule* is its soft dependent part. The concha is partially subdivided into an upper and a lower part by the commencement of the helix, which curves upwards and forwards on its floor to become continuous with the anterior border of the auricle. This portion of the helix is called the *crus helicis*. A small pro-

minence anterior to the meatus, and projecting posteriorly so as to overshadow it, is termed the *tragus*, whilst a similar eminence posterior to and below the meatus receives the name of the *antitragus*. The notch between these two prominences is termed the *incisura intertragica*. But it will be noted that the upper end of the antihelix bifurcates, and in this way two fossæ are marked off from each other; one—the *fossa of the helix*, or *scaphoid fossa*—is placed between the helix and the antihelix, and the other—the *fossa of the antihelix*, or *triangular fossa*—is situated between the two diverging crura of the antihelix.

Ligaments,	}	Anterior. Superior. Posterior.
Extrinsic muscles, {	{	Auricularis anterior. Auricularis superior. Auricularis posterior.
Intrinsic muscles, {	{	Musculus helicis major. Musculus helicis minor. Musculus tragicus. Musculus antitragicus. Musculus transversus. Musculus obliquus.
	}	Upon the lateral face of the cartilage.
	}	Upon the cranial face of the cartilage.

Dissection.—When the dissector has noted the various parts of the auricle he should endeavour to display its extrinsic muscles; they are the *auriculares anterior* (O.T. *atrahens*), *superior* (O.T. *attollens*), and *posterior* (O.T. *retrahens*). The two former spring from a lateral prolongation of the galea aponeurotica into the temporal region. The anterior is inserted into the front of the helix, and the superior into the cranial surface of the auricle. To display them pull the auricle downwards and posteriorly, and carefully remove the superficial fascia and, at the same time, avoid injury to the auriculo-temporal nerve, the temporal branches of the facial nerve, and the branches of the superficial temporal artery which are ascending through the superficial fascia of the temporal region to the scalp. The auricularis posterior arises from the outer surface of the mastoid part of the temporal bone and passes anteriorly to its insertion into the cranial aspect of the concha. To display it pull the auricle anteriorly and remove the fascia from the surface of the muscle, at the same time secure the posterior auricular artery and nerve as these ascend posterior to the external meatus. As this is being done one or more mastoid lymph glands may be seen, and care must be taken to avoid injuring the branch of the posterior auricular nerve to the occipitalis muscle, which passes posteriorly along the lower border of the auricularis posterior or on its deep surface.

The auriculares muscles are supplied by the facial nerve; the anterior and the anterior part of the superior by its temporal branches, and the posterior and the posterior part of the superior by the posterior auricular branch. After the auriculares muscles have been defined remove the skin from the entire extent of the auricle to display the cartilage, the ligaments, and the intrinsic muscles.¹ Great care is required to make a successful dissection.

¹ In most cases it will be advisable to defer this part of the dissection till the body is turned on its back for the second time (p. 200).

The **auricular cartilage** extends throughout the entire auricle, with the exception of the lobule and the portion between the tragus and the helix. These portions are composed merely of integument, fatty tissue, and condensed connective tissue. The shape of the cartilage corresponds with that of the auricle itself. It shows the same elevations and depressions, and by its elasticity it serves to maintain the form of the auricle. But it also enters into the formation of the cartilaginous or lateral portion of the external acoustic meatus. By its medial margin this part of the cartilage is firmly fixed by fibrous tissue to the rough outer edge of the auditory process of the temporal bone, but it does not form a complete tube. It is deficient above and anteriorly, and here the tube of the meatus is completed by tough fibrous membrane, which stretches between the tragus and the commencement of the helix.

In a successful dissection of the cartilage of the auricle, two other points will attract the attention of the student. The first is a deep slit, which passes upwards so as to separate the lower part of the cartilage of the helix, termed the *processus heliis caudatus*, from the cartilage of the antitragus; the second is a sharp spur of cartilage which projects anteriorly from the helix, at the level of the upper margin of the zygoma. This is termed the *spina heliis*.

The Ligaments of the Auricle.—The ligaments are three bands of fascia. The anterior passes from the spine of the helix to the root of the zygoma. The superior and posterior are both attached to the cartilage in the region of the concha; the former blends above with the temporal fascia, and the latter is attached to the mastoid portion of the temporal bone.

The Intrinsic Muscles of the Auricle.—The two muscles of the helix, the tragus and the antitragus, are placed upon the lateral face of the cartilage. The transversus and the obliquus lie upon the cranial surface of the auricle.

The *musculus antitragicus* is the best-marked member of the lateral group. It lies upon the lateral surface of the antitragus, and its fibres pass obliquely upwards and posteriorly. Some fasciculi can be traced to the *processus heliis caudatus*.

The *musculus tragicus* is a minute bundle of short vertical fibres situated upon the lateral surface of the tragus. When well developed a slender fasciculus may sometimes be observed to pass upwards from it to the anterior part of the helix, where it is inserted into the spine of the helix.

The *musculus heliis major* is a well-marked band, which springs from the *spina heliis*, and extends upwards upon the anterior part of the helix, to be inserted into the skin which covers it.

The *musculus heliis minor* is a minute bundle of fleshy fibres which is placed upon the *crus heliis* as it crosses the bottom of the concha.

The *musculus transversus auriculæ* is found upon the cranial aspect of the auricle. It is generally the most strongly developed muscle of the series, and its fibres bridge across the hollow which, on this aspect of the auricle, corresponds to the antihelix.

The *musculus obliquus auriculæ* is composed of some vertical fasciculi bridging across the depression which corresponds to the eminence of the lower limb of the antihelix.

After the auricular muscles and the auricle have been dissected, trace the temporal branches of the facial nerve, the branches of the superficial temporal vessels, and the auriculo-temporal nerve upwards, from the point where they emerge from under cover of the upper end of the parotid through the superficial fascia of the temporal region to their terminations in the superficial fascia of the scalp (about half an inch behind the zygomatic process of the frontal bone angular process) find

the zygomatico-temporal branch of the maxillary nerve. Next pull the auricle anteriorly and trace the posterior auricular nerve to its termination in the occipitalis muscle, and in the intrinsic and extrinsic muscles of the auricle, and the posterior auricular artery to its anastomoses with the occipital and superficial temporal arteries. After this part of the dissection is completed, turn to the anterior part of the scalp and find the medial and lateral branches of the supra-orbital nerve. The medial branch pierces the fibres of the frontalis and the lateral branch pierces the galea aponeurotica a little further posteriorly. Trace both branches backwards through the superficial fascia as far as possible; they extend to the level of the lambdoid suture. Then secure the supra-trochlear nerve, which pierces the frontalis above the medial margin of the orbit, and trace it upwards to its termination. With the branches of the supra-orbital nerve are branches of the supra-orbital artery, and the supra-trochlear nerve is accompanied by the frontal branch of the ophthalmic artery.

When the nerves and vessels in the anterior region have been cleaned, the head should be turned well over to the opposite side, and the branches of the occipital artery and the great occipital nerve should be sought for in the posterior region; they radiate upwards and anteriorly from the upper extremity of the trapezius. After they have been secured, the occipitalis muscle must be cleaned. It springs from the lateral part of the superior nuchal line, and after a short course upwards and anteriorly it terminates in the galea aponeurotica. The remains of the superficial fascia should now be removed from the surface of the galea aponeurotica (O.T. epicranial aponeurosis), and then the dissector should make a survey of the vessels and nerves which are met with in the scalp and the superficial fascia of the temporal region.

Nerves and Vessels of the Scalp and the Superficial Temporal Region.—Branches of ten nerves are found, on each side, in the superficial fascia of the region which lies above the supra-orbital margin, the zygomatic arch and the superior nuchal line. Of these, five lie mainly anterior to the auricle and five posterior to it; and of each group four are sensory and one is motor. The four sensory nerves anterior to the auricle are all branches of the trigeminal nerve. They are the *supra-trochlear* and *supra-orbital* branches of the *first* or *ophthalmic division*; the *zygomatico-temporal branch* of the *maxillary* or *second division*; and the *auriculo-temporal branch* of the *mandibular* or *third division*. The motor nerve is the *temporal branch* of the *facial nerve*.

The four sensory nerves, distributed mainly to the scalp area behind the auricle, are the *great auricular* and the *small occipital* branches of the cervical plexus; the *great occipital*, which is the medial division of the posterior branch of the second cervical nerve; and the *smallest occipital*, not yet seen, but which will be displayed when the body is turned on its face. It lies medial to the great occipital, and is the medial division of the posterior branch of the third cervical nerve.

The motor nerve distributed posterior to the auricle is the *posterior auricular branch* of the facial nerve.

The *arteries* distributed to the scalp are five in number on each side; they anastomose freely, and are derived, either indirectly or directly, from the internal and external carotid arteries. Three are distributed mainly anterior to, and two posterior to the region of the auricle. The three anterior to the auricle are the *frontal* and *supra-orbital branches* of the ophthalmic branch of the internal carotid, which accompany the supra-trochlear and supra-orbital nerves, and the *superficial temporal branch* of the external carotid. This branch divides into two main branches, an anterior, which accompanies the temporal branches of the facial nerve, and is usually a very tortuous vessel, and a posterior branch, which accompanies the auriculo-temporal nerve, as it ascends anterior to the auricle towards the vertex of the cranium. The two arteries posterior to the auricle are both branches of the external carotid. They are the *posterior auricular*, which accompanies the posterior auricular branch of the facial nerve to the mastoid region and the posterior part of the parietal region, and the *occipital*, which is distributed to the occipital area and posterior part of the parietal area.

The *terminations of the veins* which drain the blood from the scalp are as follows. The *frontal* and *supra-orbital veins* unite, at the medial border of the orbit, to form the *angular vein*, which is the commencement of the anterior facial vein already dissected (p. 131). The blood it conveys passes eventually to the internal jugular vein. The *superficial temporal vein* accompanies the corresponding artery. It unites, immediately above the posterior root of the zygoma, with the middle temporal vein, which pierces the temporal fascia at that point. The trunk formed by the union of the superficial and middle temporal veins is the *posterior facial vein*, which descends through the parotid gland, emerges from under cover of its lower end and terminates immediately below the angle of the mandible by joining with the anterior facial vein to form the common facial vein. Whilst in the gland, it gives off the commencement of the external jugular vein. The *posterior auricular vein* descends posterior to the external meatus and terminates in the external jugular vein. The *occipital vein* accompanies the *occipital artery* into the sub-occipital region, and ends in the *occipital venous plexus*.

In addition to the arteries and veins there are numerous *lymph vessels* in the scalp, but they cannot be displayed by ordinary dissecting methods. Nevertheless, it is important that the student should remember their usual terminations. The lymph vessels of the anterior area end in small lymph glands which are embedded in the superficial surface of the parotid gland. Those of the posterior area terminate either in lymph glands which lie superficial to the mastoid part of the temporal bone, or in occipital lymph glands, which lie in the neighbourhood of the superior nuchal line.

Dissection.—After the vessels and nerves of the scalp have been traced, the dissector should cut through the fibres of the orbicularis oculi and the frontalis over the medial part of the supra-orbital eminence and display the **corrugator supercillii muscle**. It springs from the medial end of the supra-orbital ridge of the frontal bone and passes anteriorly and laterally, through the fibres of the orbicularis oculi, to its insertion into the skin of the eyebrow. It is supplied by the temporal branch of the facial nerve.

Galea Aponeurotica (O.T. Epicranial Aponeurosis).—The galea aponeurotica is fully exposed as soon as the superficial fascia of the scalp is completely removed. It is a strong layer of aponeurosis connected anteriorly with the frontal bellies of the epicranium, posteriorly with the occipital bellies, and between the occipital bellies, with the external occipital protuberance and the medial parts of the superior nuchal lines, or with the supreme nuchal lines when they are present. Laterally it becomes thinner, descends over the upper part of the temporal fascia, and gives origin to the anterior and superior auriculares muscles. It is so closely connected with the superjacent skin, by the dense superficial fascia, that the two cannot be separated, except with the aid of the cutting edge of the scalpel; but above the supra-orbital ridges, the temporal ridges, and the superior nuchal lines it is only loosely connected to the pericranium by the layer of loose areolar tissue; therefore the three closely connected superficial layers, the skin, superficial fascia, and the galea aponeurotica, can easily be torn from the pericranium, a circumstance taken advantage of by the Indians who scalped their defeated foes. The looseness of the areolar tissue beneath the galea aponeurotica permits the latter to be drawn forwards and backwards by the alternate contractions of the occipitalis and frontalis muscles, and, as it moves, it carries with it the skin and superficial fascia with which it is so closely blended.

Dissection.—The dissector, after studying the attachments of the galea aponeurotica, and after he has made himself thoroughly conversant with the nerve and vascular supply of the scalp, and has appreciated the fact that every part of its area is supplied by more than one nerve and that the blood vessels anastomose very freely together, should next convince himself of the greater looseness of the areolar layer beneath the galea in the medial area and its greater denseness and closer attachment to the various parts of the superjacent epicranium, and the subjacent pericranium at the margins of the scalp area. He may do this by introducing the handle of a scalpel through a median incision in the galea, and passing it anteriorly and posteriorly and from side to side.

The Layer of Loose Areolar Tissue.—This is the fourth layer of the scalp. It is but slightly vascular and is of loose texture, but is not equally loose over the whole area of the scalp; on the contrary in the regions of the temporal and supra-orbital ridges it becomes much denser, and, at the same time, much more closely connected with the galea aponeurotica and the frontalis muscles, whilst posteriorly it disappears where the occipitalis muscles and the galea become attached to the superior nuchal lines. It is on account of these peculiarities that effusions of blood or inflammatory exudations in the areolar layer easily raise the greater part of the scalp from the bone, but such effusions do not readily pass from beneath the scalp into either the facial, temporal, or occipital regions.

On the fifth day after the body has been placed upon its back, the eighth after it was brought into the room, the dissector of the head and neck must assist the dissector of the upper extremity to display the whole extent of the brachial plexus and the origins of the branches which spring from it; and he should take the opportunity to revise his own knowledge of the plexus. Detach the clavicular head of the sterno-mastoid from the clavicle, and displace the sternal head towards the median plane. When this has been done the anterior and upper parts of the sterno-clavicular joint capsule will be fully exposed, for the pectoralis major, which covered the lower part of the anterior surface, has already been reflected by the dissector of the upper extremity.

Dissection.—The sterno-clavicular joint is described on p. 28 of Vol. I. After the dissectors have noted that the fibres of the capsule run medially and downwards from the clavicle to the sternum, the anterior, superior, and posterior portions must be divided close to the sternum, care being taken to avoid injury to the anterior jugular vein, which passes laterally close to the upper and back part of the joint. When the division is completed, elevate the sternal end of the clavicle by depressing the

acromial end, introduce the knife into the cavity of the joint, close to the sternum, and carry it laterally below the clavicle, to detach the lower part of the interarticular cartilage from the sternum and the cartilage of the first rib, and to divide the lower part of the capsule and the costo-clavicular ligament, which lies immediately lateral to it. If the subclavius muscle has not already been detached, it also must be divided, and then the clavicle can be displaced laterally, and the whole extent of the plexus will be exposed.

The Brachial Plexus.—The brachial plexus is fully described on p. 28, Vol. I., and only a brief resume of the main facts regarding it is given here. The plexus is formed by the last four cervical nerves and the larger part of the first thoracic nerve; it also receives a communication from the fourth cervical nerve and not uncommonly a small twig from the second thoracic nerve. These various nerves constitute the *roots of the plexus*. The roots of the plexus emerge from between the scalenus medius and the scalenus anterior, and unite to form *three trunks*, upper, middle, and lower, which lie superficial to the scalenus medius, the lowest of the three being wedged in between that muscle posteriorly and the third part of the subclavian artery anteriorly. The *upper trunk* is formed by the fifth and sixth nerves and the communication from the fourth. The seventh nerve alone forms the *middle trunk*; and the *lowest trunk* is formed by the eighth cervical and first thoracic nerves and the communication from the second thoracic. Almost immediately after their formation the trunks divide into anterior and posterior divisions, and the divisions reunite to form *three cords*, lateral, medial, and posterior. The *lateral cord* is formed by the anterior divisions of the upper and middle trunks, the *medial cord* by the anterior division of the lowest trunk, and all three posterior divisions unite to form the *posterior cord*. The cords descend behind the clavicle and subclavius muscle, through the cervico-axillary canal, to the level of the coracoid process of the scapula where the plexus terminates and each cord divides into two *terminal branches*. The terminal branches of the lateral cord are the lateral head of the median nerve and the musculo-cutaneous nerve. Those of the medial cord are the medial head of the median and the ulnar nerve, and the posterior cord divides into the axillary (O.T. circumflex) nerve and the radial (O.T. musculo-spiral). In addition to the terminal branches, *collateral branches* are given off from the roots, the trunks and the cords; and the roots are connected with the middle and lower ganglia of the cervical part of the sympathetic trunk by grey rami communicantes. The branches given off from the roots are twigs of supply to the longus colli, the scalenus anterior, the scalenus medius, and the scalenus posterior, the roots of origin of the long thoracic nerve, which supplies the serratus anterior (O.T. magnus) and the dorsal scapular nerve (O.T. nerve to the rhomboids). The roots of the long thoracic nerve spring from the fifth, sixth, and seventh nerves; the upper two pierce the scalenus medius and the lowest passes anterior to that muscle. The three unite, behind the trunks of the plexus, to form the stem of the nerve, which descends behind the cords of the plexus into the axilla. The dorsalis scapulæ nerve arises from the lateral border of the fifth nerve; it disappears under cover of the levator scapulæ and supplies the two rhomboid muscles, and, sometimes, the levator scapulæ.

The branches from the trunks of the plexus are the suprascapular nerve and the nerve to the subclavius. They both spring from the upper trunk. The collateral branches of the three cords of the plexus, are (1) from the outer cord: the lateral anterior thoracic nerve; (2) from the posterior cord: the upper and lower subscapular nerves and the thoraco-dorsal nerve (O.T. long subscapular); and (3) from the medial cord: the medial anterior thoracic, the medial cutaneous nerve of the arm (O.T. lesser internal

us) and the medial cutaneous nerve of the forearm (O.T. internal

Position of the Brachial Plexus.—The plexus lies in the lower and part of the posterior triangle of the neck, partly above and partly the posterior belly of the omo-hyoid; posterior to the clavicle; and the middle of the supraclavicular fossa. *Above the clavicle* it is covered by the skin, the superficial fascia, the platysma, branches of the supraclavicular nerves, the first deep fascia, the external jugular vein, and the terminal parts of the deep cervical and transverse (supra) scapular veins; the second deep cervical fascia, the transverse cervical artery, the posterior belly of the omo-hyoid, the nerve to the subclavius, and the third part of the axillary artery. *Behind the clavicle* it is crossed superficially by the transverse scapular artery (O.T. suprascapular). *Below the clavicle* it is covered by the skin and superficial fascia, the platysma, the middle supraclavicular nerves, the deep fascia, the pectoralis major, the pectoralis minor, the cephalic vein, the branches of the thoraco-acromial artery, the acromioclavicular ligament, and the axillary artery and vein.

Anterior relations in the neck are the scalenus medius and the long thoracic nerve. *In the axilla* the serratus anterior, the fat in the interval between the serratus anterior and the subscapularis, and finally the subscapularis itself.

When the brachial plexus has been examined, the clavicle must be returned to its position and the skin flap, reflected from the posterior triangle, replaced and fixed in position by a few sutures.

On the ninth day after the body is brought into the room, and on the sixth day after it has been placed on its back, the body may be turned upon its face, with the thorax and the pelvis supported by blocks. The body will remain upon its face for several days, and during that period the dissectors of the head and neck must complete the dissection of the posterior part of the scalp; dissect the muscles, vessels and nerves of the occipital and the suboccipital region; and remove and examine the spinal medulla.

THE DISSECTION OF THE BACK.

Dissection.—Make a median longitudinal incision from the external occipital protuberance to the seventh cervical spine, and a second laterally from the seventh cervical spine to the acromion, and throw the flap laterally. If this has been done the posterior triangle will be exposed from behind, and the dissector should take the opportunity of noting the positions of the muscles and the constituent parts of the floor from this aspect. Afterwards the dissector should look for the superficial nerves in the superficial fascia over the posterior part of the trapezius. If the great occipital nerve was not found in the dissection of the scalp secure it at once, as it pierces the deep fascia covering the upper end of the trapezius, about midway between the external occipital protuberance and the posterior border of the mastoid process of the temporal bone; trace it upwards through the dense superficial fascia of the scalp and clean the branches of the occipital artery which are situated in the same region. The smallest occipital nerve will be found

in the superficial fascia between the great occipital and the median plane. It is the medial division of the posterior branch of the third cervical nerve, and it supplies the skin of the medial and lower part of the posterior portion of the scalp and the adjacent part of the skin of the back of the neck. Trace it upwards to its termination and downwards to the point where it pierces the deep fascia covering the trapezius. At a still lower level look for the medial divisions of the posterior branches of the other cervical nerves. They are variable in number and position, but those which are present will be found piercing the deep fascia over the trapezius, at a short distance from the median plane, and running downwards and laterally towards the posterior triangle.

After the cutaneous nerves have been found remove the remains of the superficial fascia and the deep fascia from the surface of the trapezius.

The Terminal Part of the Great Occipital Nerve.—The great occipital nerve is the large medial division of the posterior branch of the second cervical nerve. It enters the posterior part of the scalp, after piercing the upper part of the trapezius and the deep fascia of the back of the neck, and ramifies in the superficial fascia of the scalp over the occipital bone and the posterior part of the parietal bone, accompanying the branches of the occipital artery, and communicating with the great auricular and small occipital nerves.

Arteria Occipitalis.—After emerging from between the trapezius and the sterno-mastoid, at the apex of the posterior triangle, or piercing the upper part of the trapezius, the terminal part of the occipital artery passes through the deep fascia of the back of the neck and enters the superficial fascia of the posterior part of the scalp. It anastomoses with its fellow of the opposite side, and with the posterior auricular and the superficial temporal arteries. As a rule, it breaks up into two main branches, a lateral and a medial. The medial branch gives off cutaneous twigs and a meningeal branch, which passes through the parietal foramen and anastomoses with a branch of the middle meningeal artery. Through the same foramen, passes an emissary vein which connects the occipital veins with the superior sagittal (longitudinal) sinus.

Musculus Trapezius.—The trapezius and latissimus dorsi constitute the first layer of the muscles of the back. Only that part of the trapezius which lies above the level of the seventh cervical spine belongs to the dissector of the head and neck; the lower part and the latissimus must be cleaned by the dissector of the arm, but the dissector of the head should take the opportunity to revise his knowledge of the whole origin and insertion of the muscle. It arises from the medial third of the superior nuchal line of the occipital bone,

the external occipital protuberance, the whole length of the ligamentum nuchæ, the seventh cervical spine, the tips of all the thoracic spines and the corresponding supraspinous ligaments.

In the region of the seventh cervical spine the origin is more aponeurotic than elsewhere, and the fine tendinous fibres of the muscles of the two sides form an ovoid aponeurotic area some two inches in length.

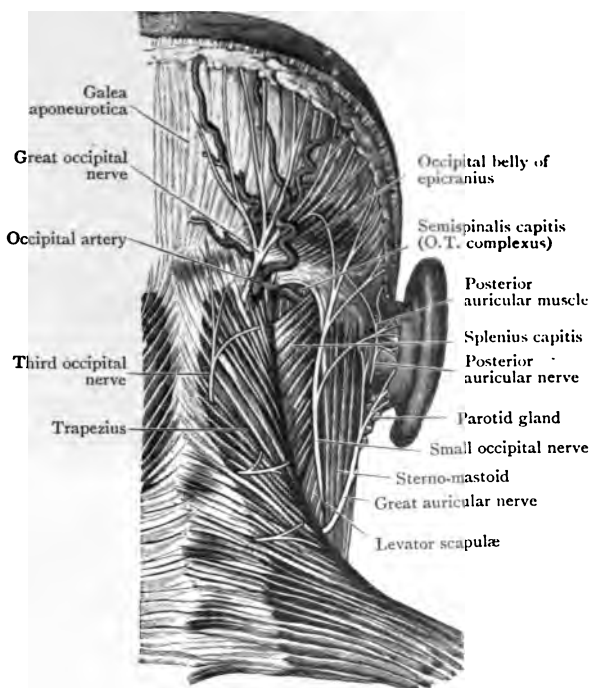


FIG. 70.—Superficial dissection of the Back of the Neck.

The upper fibres of the muscle descend in oblique curves and are inserted into the lateral third of the posterior border and the adjacent part of the superior surface of the clavicle; the intermediate fibres run horizontally, towards the shoulder, and are inserted into the medial border of the acromion and the upper lip of the posterior border of the spine of the scapula. The lower fibres ascend and terminate in a small

triangular tendon which plays over the smooth triangle at the root of the scapular spine and is inserted partly into the lower and partly into the upper lip of the spine. The muscle is supplied by the accessory and the third and fourth cervical nerves. It draws the scapula medially and braces the shoulder backwards, raises the tip of the shoulder, or depresses the scapula and turns the glenoid fossa upwards according to whether the intermediate, the upper, or the lower fibres are mainly in action.

Dissection.—On the second day after the subject has been placed on its face, the trapezius may be reflected. This must be done in conjunction with the dissector of the arm. First separate the muscle from the occipital bone, and then divide it about half an inch from the spines of the vertebræ. The muscle can now be raised and thrown laterally towards its insertion. On its deep surface the accessory nerve, the twigs of supply from the third and fourth cervical nerves and the superficial cervical artery will be noticed. It is the duty of the dissector of the upper limb to dissect these, but the dissector of the head and neck should trace the superficial cervical artery to its origin from the transversa colli.

The attachments of the levator scapulæ also must be defined. Two twigs from the third and fourth cervical nerves, which lie on its surface and finally enter its substance, have already been secured. Further, passing downwards under cover of this muscle, the dorsal scapular nerve (O. T. nerve to the rhomboids) and the descending branch (O. T. posterior scapular) of the transversa colli artery will be found. Almost invariably the dorsal scapular nerve gives one or two twigs to the levator scapulæ.

The levator scapulæ, the rhomboids, the posterior serrati and the splenius are classed as muscles of the second layer. The rhomboids and the lower part of the levator belong to the dissector of the arm; the remaining muscles are the property of the dissector of the head and neck.

Musculus Levator Scapulæ.—This muscle arises by four slips from the posterior parts of the transverse processes of the upper four cervical vertebræ. These unite to form an elongated muscle which extends downwards and posteriorly to be inserted into that portion of the vertebral border of the scapula which is placed above the root of the spine. Its nerve-supply comes from the third and fourth cervical nerves, and also from the dorsal scapular nerve.

The origin of the posterior belly of the omo-hyoid muscle may now be examined. It is attached to the upper transverse ligament of the scapula and the adjacent part of the superior border of the bone. The transverse scapular artery (O. T. suprascapular) will be noticed passing over the upper transverse ligament whilst the suprascapular nerve traverses the notch below it.

The *second day's* work is now completed, and on the *same day* the

dissector of the upper limb must finish his share of the dissection of the back, so as to allow the dissector of the head and neck to begin the examination of the deeper structures on the dorsal aspect of the trunk.

Three days are allowed for this dissection, and these may be disposed of in the following manner:—On the *first day*, all the muscles, fasciæ, nerves, and blood vessels of the back, with the exception of those in connection with the sub-occipital triangle, should be studied; on the *second day*, the sub-occipital triangle must be examined; and on the third day the medulla spinalis (O.T. spinal cord) must be displayed.

Musculi Serrati Posteriores.—These are two thin sheets of fleshy fibres, which are placed upon the posterior aspect

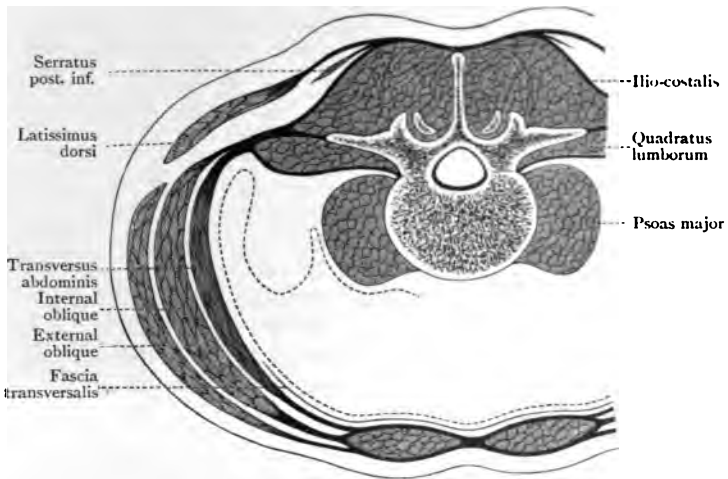


FIG. 71.—Diagram to show the Connections of the Lumbo-dorsal Fascia.

of the thoracic wall. The *serratus posterior superior* is much the smaller of the two; it arises by a thin aponeurotic tendon from the lower part of the ligamentum nuchæ; from the spinous process of the seventh cervical vertebra; and from the spinous processes of the upper two or three thoracic vertebræ. It passes obliquely downwards and laterally, and is inserted into the outer surfaces of the second, third, fourth, and fifth ribs, a short distance anterior to their angles.

The *serratus posterior inferior* will be brought into view by raising and throwing medially that portion of the latissimus dorsi which the dissector of the upper limb has left attached to the lumbo-dorsal fascia. It takes origin from the spinous processes of the last two thoracic and upper two lumbar

vertebræ, and the supraspinous ligaments between them. The dissector will note, however, that this is not an independent and distinct attachment, but that it is effected through the medium of the lumbo-dorsal fascia, with which the aponeurotic tendon of the muscle blends. The muscle passes upwards and laterally and is inserted into the outer surfaces of the lower four ribs.

Fascia Lumbo-dorsalis.—On the third day after the body is placed upon its face the dissector of the head and neck should associate himself with the dissector of the abdomen in the examination of the lumbo-dorsal fascia. It is an aponeurotic layer, thin in the thoracic portion of its extent, but thick and strong in the lumbar and sacral regions; and in all these regions it binds down the muscles of the back to the sides of the spinous processes and to the transverse processes of the vertebræ.

The Dorsal Part of the Lumbo-dorsal Fascia (O.T. Vertebra Aponeurosis).—This part of the lumbo-dorsal fascia is a thin transparent lamina which extends from the tips of the spines and the supraspinous ligaments to the angles of the ribs. At the upper end of the thoracic region it dips beneath the serratus posterior superior into the neck, and at the lower end it blends with the aponeurosis of origin of the serratus posterior inferior, and through that becomes continuous with the posterior layer of the lumbar portion.

Dissection.—To display the lumbar part of the lumbo-dorsal fascia clear away the remains of the origin of the latissimus dorsi, which springs from its posterior surface, and then reflect the serratus posterior inferior by cutting through it at right angles to its fibres and turning it medially and laterally towards its origin and insertion. As the lateral part is turned aside secure its nerves of supply, which are derived from the lower intercostal nerves, and enter its deep surface. Next remove the remains of the origin of the serratus posterior inferior, and then the posterior layer of the lumbar part of the lumbo-dorsal fascia will be completely exposed.

The Lumbar Part of the Lumbo-dorsal Fascia.—This portion of the lumbo-dorsal fascia is separable into three lamellæ, a posterior, a middle, and an anterior. All three fuse together laterally, where they become connected with the internal oblique and the transversus abdominis muscles. The *posterior layer*, which is the strongest of the three, is a dense tendinous aponeurosis. It is continuous *above* with the thoracic part. *Below*, it is attached to the posterior part of the lateral lip of the iliac crest, and to the dorsum of the sacrum and the coccyx.

Medially, it is attached to the tips of the spines of the lumbar vertebræ and the sacrum; and *laterally* it blends with the posterior surface of the middle lamella (Fig. 71). The aponeurosis of origin of the latissimus dorsi and the serratus posterior inferior arise from its posterior surface.

Dissection.—Make a longitudinal incision through the posterior layer of the lumbar part of the lumbo-dorsal fascia, midway between its medial and its lateral borders. At each end of the longitudinal incision make a transverse incision extending from the spine medially to the lateral border of the rounded mass of spinal muscles lying under cover of the fascia. Turn the medial part of the divided fascia towards the median plane, and verify its attachment to the vertebral spines and the supraspinous ligaments. Pull the lateral part aside, and at the lateral border of the mass of posterior spinal muscles it will be found to blend with a deeper layer, the middle lamella. Push the mass of posterior spinal muscles towards the median plane, and follow the middle lamella of the fascia to its attachment.

The *middle lamella* is attached medially to the tips of the transverse processes of the lumbar vertebræ; below to the iliac crest, and above to the last rib. Laterally it blends with the posterior and anterior lamellæ, and immediately lateral to its line of union with the posterior lamella the internal oblique arises from its posterior surface. To expose it thoroughly the mass of posterior spinal muscles must be pushed medially.

Dissection.—After the middle lamella has been examined divide it longitudinally, close to its attachment to the tips of the transverse processes, and transversely along the line of the iliac crest, and turn it laterally. A considerable part of the posterior surface of the quadratus lumborum muscle will then be exposed. Displace the lateral border of the quadratus lumborum towards the median plane, and the anterior lamella of the lumbar part of the lumbo-dorsal fascia will be brought into view.

The *anterior lamella* of the lumbar part of the lumbo-dorsal fascia is attached medially to the anterior surfaces of the roots of the transverse processes of the lumbar vertebræ; laterally it blends with the fused middle and posterior lamellæ to form the common aponeurosis of origin of the transversus abdominis muscle, and it is by means of the three lamellæ of the lumbar fascia that the latter muscle arises from the tips of the spines, and the tips and the roots of the transverse processes of the lumbar vertebræ. The upper border of the anterior lamella becomes thickened, and extends anterior to the quadratus lumborum from the last rib to the transverse process of the first lumbar vertebra as the *arcus lumbo-costalis lateralis* (O.T. external arcuate ligament); the

lower border blends with the ilio-lumbar ligament. The dissector should verify these various attachments by passing his fingers over the posterior surface of the lamella from its lateral to its medial border, and from its upper to its lower end.

Dissection.—After satisfying himself regarding the lamellæ of the lumbar part of the lumbo-dorsal fascia and their relations to the posterior spinal muscles, to the quadratus lumborum, and to the internal oblique and the transversus abdominis muscles, the dissector should make a longitudinal incision through the anterior lamella, and the peri-renal fascia anterior to it; and, introducing his finger through the opening into the extra-peritoneal fatty tissue, he should scrape away the latter until he exposes the kidney, below the level of the last rib, and the adjacent part of the colon, which lies along the lower and lateral part of the kidney. After this has been done he should reflect the serratus posterior superior and secure its nerves of supply which spring from the upper intercostal nerves and enter its deep surface; then he should remove the thoracic part of the lumbo-dorsal fascia and commence the study of the posterior spinal muscles, beginning with the splenius.

Musculus Splenius.—The splenius has a continuous origin from the lower half of the ligamentum nuchæ, and from the spines of the seventh cervical and upper six thoracic vertebræ. Its fibres pass obliquely upwards and laterally, forming a thick flat muscle, which soon divides into a cervical and a cranial portion, termed respectively the splenius cervicis and the splenius capitis.

The *splenius cervicis* turns anteriorly and is inserted by tendinous slips into the tubercles of the transverse processes of the upper two or three cervical vertebræ, medial to the levator scapulæ.

The *splenius capitis* passes under cover of the upper part of the sterno-mastoid muscle, and gains insertion into the lower part of the mastoid portion of the temporal bone and into the lateral portion of the superior nuchal line of the occipital bone. To see this insertion, the sterno-mastoid muscle may be divided along the superior nuchal line, but it must not be detached from the temporal bone.

Dissection.—The deeper spinal muscles must now be dissected. Begin by reflecting the splenius muscle. Detach it from its origin and throw it laterally and upwards towards its insertion. Whilst doing this, preserve the cutaneous branches of the cervical nerves which pierce it.

When the splenius capitis is fully reflected, a small triangular space will be noticed close to the superior nuchal line of the occipital bone. Anteriorly, it is bounded by the longissimus capitis (O.T. trachelo-mastoid); posteriorly, by the lateral border of the semispinalis capitis (O.T. complexus); and above, by the superior nuchal line of the occipital bone. The floor of this little space is formed by the superior oblique muscle of

the head, and it is traversed by the occipital artery, which in this part of its course gives off its descending branch (O.T. *arteria princeps cervicis*), and its meningeal branch.

The Third Layer of Muscles.—Under this head are included a series of muscular strands which stretch with a greater or less degree of continuity along the entire length of the dorsal aspect of the vertebral column. In the lumbar region they constitute a bulky fleshy mass which may be considered the main starting-point. This mass is the *musculus sacro-spinalis* which has the following origins:—(1) from the spines of all the lumbar vertebrae; (2) from the supraspinous ligaments which bind the lumbar spines together; (3) from the dorsum of the sacrum and from the posterior sacro-iliac ligament; (4) from the posterior fifth of the iliac crest; (5) from the deep surface of the posterior layer of the lumbo-dorsal fascia. In great part the superficial surface of this muscular mass is covered by and is adherent to the posterior layer of the lumbo-dorsal fascia.

Superiorly the sacro-lumbalis divides into three columns. The lateral column first separates from the general mass, and to it the name of *ilio-costalis* is given; the middle column is termed the *longissimus*, and the medial column, which becomes quite distinct only as the upper part of the dorsal region is approached, is called the *spinalis*. The semispinalis muscle is also included in the third layer.

The *Ilio-costalis* is a column of muscular bundles which extends from the lumbar to the cervical region. It is separable into three segments known, from below upwards, as the *ilio-costalis lumborum*, the *ilio-costalis dorsi*, and the *ilio-costalis cervicis*.

Ilio-costalis Lumborum.—This muscle and the *longissimus dorsi* become distinct at the level of the last rib, and the interval between them is marked by the exits of the lateral divisions of the posterior branches of lower thoracic nerves.

The muscle ends above in a series of six or seven slender tendons, which are inserted into the angles or the corresponding parts of the lower six or seven ribs.

The *Ilio-costalis Dorsi* (O.T. *Musculus Accessorius*) arises by six or seven slender tendons from the angles of the lower ribs, on the medial sides of the tendons of insertion of the *ilio-costalis lumborum*, and it is inserted by a series of similar tendons into the angles of the upper six ribs and to the transverse process of the seventh cervical vertebra.

The *Ilio-costalis Cervicis* (O.T. *Cervicalis Ascendens*).—This highest segment of the *ilio-costalis* arises, on the medial side of the *ilio-costalis dorsi*, by four slips which spring from the third, fourth, fifth, and sixth ribs; it is inserted into the transverse processes of the fourth, fifth, and sixth cervical vertebrae.

To display the *ilio-costalis* properly, the dissector should first evert the lowest segment, and then in turn the middle and upper segments, but whilst doing this he must take care to preserve the lateral divisions of the posterior branches of the spinal nerves.

The *Longissimus* is the middle and largest of the three muscle columns. It extends upwards, through the thoracic and cervical regions, to the head, and it also is separable into three segments: *longissimus dorsi*, *longissimus cervicis*, and *longissimus capitis*. The interval between the *longissimus* and the *spinalis* is frequently difficult to define, but if the fascia is carefully cleaned from the lateral to the medial border of the *longissimus* in the upper thoracic region, the separation will become apparent, and after it has been found the attachments of the *longissimus* must be defined.

Longissimus Dorsi.—The dorsal part of the *longissimus* possesses two rows of slips of insertion: a medial row of tendinous slips which are

attached to the tips of the transverse processes of the thoracic and the accessory processes of the lumbar vertebræ, and a lateral row of muscular slips which are inserted into the lower ten ribs, on the lateral sides of their tubercles, and to the transverse processes of the lumbar vertebræ, and to the posterior surface of the middle lamella of the lumbar fascia.

Longissimus Cervicis (O.T. *Transversalis Cervicis*).—This portion of the longissimus springs from the transverse processes of the upper four thoracic vertebræ, and is inserted into the posterior tubercles of the transverse processes of the cervical vertebræ from the second to the sixth inclusive.

Longissimus Capitis (O.T. *Trachelo-mastoid*).—The longissimus capitis lies in the neck under cover of the splenius. It arises in common with the longissimus cervicis from the transverse processes of three or four of the upper thoracic vertebræ, and, in addition, from the articular processes of a like number of the lower cervical vertebræ. The narrow fleshy band which results is inserted into the posterior part of the mastoid portion of the temporal bone, under cover of the splenius capitis and sterno-mastoid muscles.

The Spinalis.—This is the most medial, shortest, and weakest of the three columns, and the most difficult to define. Below, it is intimately blended with the longissimus dorsi, but it may be regarded as taking origin by four tendons from the spines of the upper two lumbar and lower two thoracic vertebræ. These end in a small muscular belly, which is inserted by a series of slips into a very variable number of the upper thoracic spines. It is closely connected with the subjacent semispinalis dorsi.

Spinalis Cervicis.—This upward prolongation of the spinalis is not always easy to define. It springs from the spines of the lower four cervical vertebræ and is inserted into the spines of the second, third, and fourth cervical vertebræ.

Dissection.—The occipital artery has already been seen crossing the apex of the posterior triangle (p. 149), and its terminal branches have been dissected as they ramify in the scalp (p. 157). The second part of the vessel, which extends from under shelter of the mastoid process, along the superior nuchal line of the occipital bone, to the point where it pierces the trapezius to become superficial, can now be exposed fully. To effect this, the longissimus capitis (O.T. *trachelo-mastoid*) must be divided a short distance below its insertion, and, along with the splenius capitis, thrown upwards as far as possible.

Arteria Occipitalis.—The second part of the occipital artery is now displayed. In the region of the mastoid process it is very deeply placed; indeed, no less than five structures lie superficial to it. These are (enumerating them in order from the vessel to the surface)—(1) the origin of the posterior belly of the digastric muscle; (2) the mastoid process; (3) the longissimus cervicis; (4) the splenius capitis; and (5) the sterno-mastoid.¹ As the artery runs posteriorly, it very soon emerges from under cover of the first three of these structures, and a little farther on it leaves the shelter of the splenius, and is then covered by the sterno-mastoid alone. Issuing from under cover of the posterior border of that muscle,

¹ It is not uncommon to find the artery at this point of its course between the splenius and the longissimus capitis.

the artery crosses the apex of the posterior triangle, and disappears under the trapezius, which it finally pierces near the external occipital protuberance, to reach the scalp. Two muscles constitute its deep relations—viz., the insertions of the superior oblique and the semispinalis capitis (O.T. complexus).

The following *branches* may be traced from this portion of the occipital artery : (1) descending (O.T. *arteria princeps cervicis*); (2) meningeal; (3) muscular.

The *ramus descendens* (O.T. *arteria princeps cervicis*) is a twig of some size, which passes medially to the lateral border of the semispinalis capitis (O.T. complexus); there it divides into a superficial and a deep branch. The former ramifies on the surface of the semispinalis capitis, whilst the latter sinks under that muscle, where it will be followed to its anastomosis with the deep cervical artery at a later stage in the dissection.

The small *meningeal branch* enters the posterior cranial fossa through the mastoid foramen, and supplies the dura mater and cranial wall in this region.

The *muscular twigs* go to the neighbouring muscles.

The *veins* corresponding to the occipital artery are two, or perhaps three, in number. They drain the blood from the occipital portion of the scalp, and open into the sub-occipital plexus, which is drained by the vertebral and deep cervical veins. The most lateral of the occipital veins frequently communicates with the transverse sinus (O.T. lateral) through the mastoid foramen.

Dissection.—The semispinalis capitis, which has been exposed by the reflection of the splenius and the turning aside of the longissimus cervicis and longissimus capitis, must now be cleaned, and whilst this is being done and its attachments are being defined, care must be taken of the medial divisions of the posterior branches of the second, third, fourth, and fifth cervical nerves. The first of these—or, in other words, the great occipital—from its great size, runs little risk of injury, but the others are liable to be overlooked. They all emerge from the substance of the muscle close to the median plane.

Semispinalis Capitis (O.T. *Complexus*).—The semispinalis capitis is the uppermost part of a muscular column consisting of three segments, which are spoken of collectively as the semispinalis, and individually as the semispinalis dorsi, the semispinalis cervicis, and the semispinalis capitis. It belongs to the third layer of muscles, of which the greater number have been dissected already. The two lower segments will be dissected subsequently, but it is convenient to examine the semispinalis capitis at once. It is a thick fleshy mass which springs by tendinous slips from the transverse processes of the upper six thoracic vertebræ and the articular processes of the fourth, fifth, and sixth cervical vertebræ. Its massive upper extremity

is inserted into a somewhat oval area on the occipital bone, between the superior and inferior nuchal lines close to the external occipital crest. It is separated from its fellow muscle of the opposite side by the *ligamentum nuchæ*; and its most medial part, which is to a certain extent distinct from the general mass, is divided into two bellies by an intermediate tendon and is frequently spoken of as the *biventer cervicis*. Occasionally the remainder of the muscle is also intersected by a tendinous septum.

Dissection.—The *semispinalis capitis* must now be reflected by detaching it from the occiput and throwing it laterally. This dissection requires

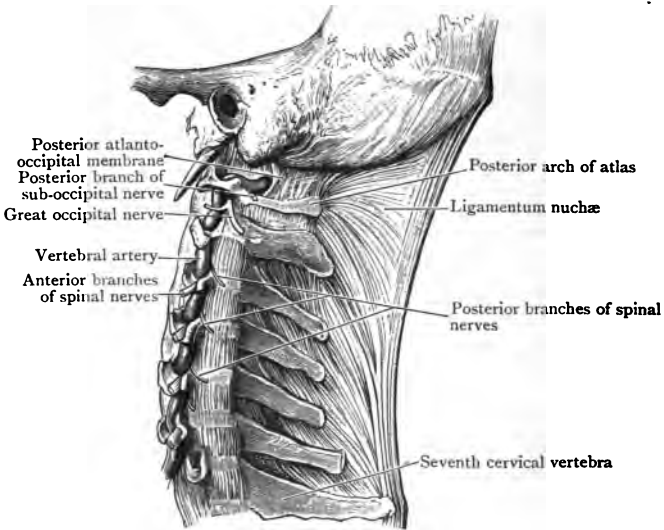


FIG. 72.—Dissection of the Ligamentum Nuchæ and of the Vertebral Artery in the Neck.

care, not only on account of the nerves which have been seen to perforate the muscle to reach the surface, but also on account of the structures which it covers. In its upper part it lies over the sub-occipital triangle and the muscles bounding it, whilst below it covers the *semispinalis cervicis*. A thick dense fascia is placed over these subjacent parts, and in this lie certain of the cervical nerves and the anastomosis between the descending branch of the occipital artery and the *arteria profunda cervicis*. The dissector must specially look for a small twig from the posterior branch of the sub-occipital nerve which enters the deep surface of the upper part of the *semispinalis capitis*, and for a larger branch to the same muscle from the great occipital nerve.

Ligamentum Nuchæ (Fig. 72).—This is a strong fibrous partition placed in the median plane between the muscles on

each side of the back of the neck. It represents a powerful elastic structure in quadrupeds, which helps to sustain the weight of the dependent head. In man, however, there is not much elastic tissue developed in connection with it, and it appears to be a continuation upwards of the supraspinous ligament from the spine of the seventh cervical vertebra to the external occipital protuberance. In shape it is somewhat triangular. By its base it is attached to the external occipital crest; by its anterior border it is fixed by a series of slips to the posterior tubercle of the atlas, and to the bifid spines of the cervical vertebræ, in the intervals between their tubercles. Its apex is attached to the spine of the seventh cervical vertebra, whilst its posterior border is, in a measure, free, and gives origin to the trapezius, rhomboid, serratus posterior superior, and splenius muscles.

Arteria Profunda Cervicis.—The *deep cervical artery* springs from the costo-cervical branch of the subclavian, and reaches the dorsum by passing posteriorly between the transverse process of the last cervical vertebra and the neck of the first rib. At the present stage of the dissection it is seen ascending upon the semispinalis cervicis muscle and anastomosing with the descending branch of the occipital. Both vessels anastomose with twigs from the vertebral artery.

The *arteria profunda cervicis* is accompanied by a large vein—the *vena profunda cervicis*. This vessel begins in the sub-occipital plexus, and it ends in the vertebral vein close to its termination. It reaches this point by turning forwards under the transverse process of the last cervical vertebra.

Posterior Branches of the Spinal Nerves.—The nerves of the back must now be examined. They are the posterior branches of the spinal nerves. With *four* exceptions (*viz.*, the first cervical, fourth and fifth sacral, and the coccygeal nerves), each posterior division will be found to divide into a *lateral* and a *medial division*.

Examine these nerves successively in the cervical, dorsal, and lumbar regions. It is well, however, to defer the dissection of the sacral and coccygeal nerves until the multifidus muscle has been studied.

Cervical Region.—In this region the posterior branches of the spinal nerves are eight in number. The posterior branch of the *sub-occipital* or *first nerve* fails to divide into a medial and a lateral division. It lies deeply in the sub-

occipital triangle, and will be examined when this space is dissected.

The posterior branch of the *second cervical nerve* is very large. It appears between the vertebral arches of the atlas and epistropheus vertebræ. The posterior branches of the succeeding *six cervical nerves* arise from the corresponding spinal nerve-trunks in the intervertebral foramina. They turn dorsally on the medial sides of the posterior intertransverse muscles, and appear in the intervals between the transverse processes.

The *lateral divisions* are of small size, and are entirely devoted to the supply of adjacent muscles.

The *medial divisions* are not all distributed alike, nor indeed do they present the same relations. Those from the *second, third, fourth, and fifth nerves* run medially towards the spinous processes, superficial to the semispinalis cervicis muscle, and under cover of the semispinalis capitis. When close to the median plane they turn posteriorly, pierce the semispinalis capitis, splenius, and trapezius muscles, and become superficial. In their course to the surface they give numerous twigs to the neighbouring muscles.

The medial division of the second nerve is remarkable for its large size. It receives the special name of *great occipital*. It will be noticed turning round the lower border of the inferior oblique muscle, to which it supplies some twigs. In passing to the surface it pierces the semispinalis capitis (O.T. complexus) and trapezius. To the former it gives several twigs. The distribution of this nerve on the occiput has been noticed already (p. 156).

The medial division of the third nerve also sends an offset to the occipital portion of the scalp (p. 156).

The medial divisions of the *lower three* posterior branches of the cervical nerves resemble the preceding, in so far that they take a course medially towards the spinous processes. They differ from them, however, in running deep to the semispinalis cervicis, and in being, as a rule, entirely expended in the supply of muscles.

Dorsal Region.—The posterior branches of the thoracic nerves make their appearance in the intervals between the transverse processes. The *lateral divisions* proceed laterally, under cover of the longissimus muscle, and appear in the interval between the longissimus dorsi on the one hand and

the ilio-costalis on the other. The *upper six or seven* of these nerves are exhausted in the supply of the middle and lateral columns of the sacrospinalis; the *lower five or six*, however, are considerably larger, and contain both motor and sensory fibres. After giving up their motor fibres to the muscles, they become superficial, by piercing the serratus posterior inferior and the latissimus dorsi, in a line with the angles of the ribs. The cutaneous distribution of these nerves has already been examined by the dissector of the upper limb.

The *medial divisions* also are distributed differently in the upper and lower portions of the dorsal region. The *lower five or six* are very small, and end in the multifidus muscle. The *upper six or seven* pass medially between the multifidus and semispinalis, and after supplying the muscles between which they are situated, they become superficial. In passing towards the surface they pierce the splenius, rhomboids, and trapezius muscles, and thus gain the superficial fascia, where they have been dissected already.

Lumbar Region.—The *medial divisions* of the posterior branches of the five lumbar nerves are small, and, like the corresponding twigs in the lower dorsal region, they have a purely muscular distribution. They end in the multifidus.

The *lateral divisions* sink into the substance of the sacrospinalis, and are concerned in the supply of that muscle, and also of the lumbar intertransverse muscles. The *upper three* of these nerves are of large size, and become cutaneous by piercing the superficial lamella of the lumbo-dorsal fascia. They have already been traced by the dissector of the lower limb to the skin of the gluteal region. The lowest lateral division communicates with the corresponding branch of the first sacral nerve.

Blood Vessels of the Back.—In the *cervical region* the dissector has already noticed the arteria profunda cervicis, and the descending branch of the second part of the occipital artery. Deep in the sub-occipital region he will subsequently meet with a small portion of the vertebral artery. In addition to these, however, minute twigs may be discovered, in a well-injected subject, passing posteriorly from the vertebral artery in the intervals between the transverse processes, and also in the sub-occipital space. These supply the muscles, and anastomose with the other arteries in this region.

In the *dorsal region* the *posterior branches* of the aortic inter-

costal arteries make their appearance between the transverse processes. Each of these vessels reaches this point by passing dorsally in the interval between the body of a vertebra and the anterior costo-transverse ligament. It is associated with the corresponding posterior branch of a spinal nerve, and is distributed with it to the muscles and integument of the back.

In the *lumbar region* similar branches are derived from the lumbar arteries. They are distributed in the same manner.

In both dorsal and lumbar regions these vessels, before reaching the back, furnish small *spinal branches* which enter the vertebral canal through the intervertebral foramina. These will be traced at a later period.

The *veins* accompanying the dorsal branches of the lumbar and intercostal arteries pour their blood into the lumbar and intercostal veins. They are of large size, being joined by tributaries from the posterior vertebral venous plexus, and also by others from within the vertebral canal.

Dissection.—The remains of the third layer of spinal muscles must now be dissected. They are the semispinalis dorsi and semispinalis cervicis.

The semispinalis cervicis is already exposed; but to display the semispinalis dorsi it is necessary to remove the spinalis dorsi muscle.

The *semispinalis dorsi* is composed of a series of muscular slips, with long tendons at either end, which arise from the transverse processes of the sixth to the tenth thoracic vertebrae. It is inserted into the spines of the upper four thoracic and lower two cervical vertebrae. The *semispinalis cervicis* lies under cover of the semispinalis capitis. It springs from the transverse processes of the upper five thoracic vertebrae, and is inserted into the spines of the second to the fifth cervical vertebrae. The slips composing the semispinalis muscles stretch over five or more vertebrae.

Dissection.—The fourth layer of muscles must now be examined. It includes the multifidus, the rotatores, the interspinales, the intertransversales, and the recti and oblique muscles of the sub-occipital region. The latter have already been exposed by the reflection of the semispinalis capitis (complexus). To display the other members of the group the semispinalis dorsi and cervicis must be detached from the spines and drawn aside, and the sacrospinalis must be separated from the lumbar and sacral spines and turned laterally, if this has not already been done in tracing the nerves.

Musculus Multifidus.—In the *lumbar* and *sacral regions* the multifidus will be seen to constitute a thick fleshy mass, which clings closely to the vertebral spines. In this situation it has a very extensive origin—viz., (1) from the deep surface of the aponeurotic origin of the sacrospinalis; (2) from the posterior surface of the sacrum as low as the fourth aperture; (3) from the posterior sacro-iliac ligament; (4) from the posterior superior spine of the ilium; and (5) from the mammillary processes of the lumbar vertebrae. In the *thoracic region* it takes origin from the transverse processes of the vertebrae, and in the *cervical region* from the articular processes of at least four of the lower cervical vertebrae. The bundles which compose the

multifidus pass over two, three, or four vertebræ, and are inserted into the whole length of the various spinous processes of the movable vertebræ as high up as the epistropheus (O. T. axis).

Musculi Rotatores.—These are a series of small muscles which may be exposed by raising the multifidus. In the dorsal region each muscle springs from the root of a transverse process, and is inserted into the lamina of the vertebra immediately above, close to the root of the spinous process. Somewhat similar muscles have been described in the cervical and lumbar regions, and also a series of longer and more superficial slips which connect alternate vertebræ with each other.

Musculi Interspinales and Intertransversarii. The *interspinal muscles* can hardly be said to exist in the dorsal region, except in its upper and lower parts, where they are present in a rudimentary condition. In the neck they are arranged in pairs, occupying each interspinous interval, with the exception of that between the epistropheus and atlas. In the lumbar region also they are well marked and in pairs: here they are attached to the whole length of the spinous processes. The *intertransverse muscles* are strongly developed in the lumbar region, and occupy the entire length of the intertransverse intervals. Additional rounded fasciculi may be observed passing between the accessory processes. These are termed the *interaccessorii*. In the *dorsal region* intertransverse muscles, poorly developed—are found only in the lower three or four spaces. In the *cervical region* they are present in pairs and will be examined subsequently.

Levatores Costarum.—These constitute a series of twelve fan-shaped muscles, which are classified as muscles of the thorax, but they are exposed when the longissimus and ilio-costalis are removed, and therefore should be examined now. They pass from the transverse processes to the ribs. The first muscle of the series springs from the tip of the transverse process of the last cervical vertebra, and, expanding as it proceeds downwards and laterally, it is inserted into the outer border of the first rib, immediately beyond the tubercle. Each of the succeeding muscles takes origin from the tip of a thoracic transverse process, and is inserted into the outer surface of the rib immediately below, along a line extending from the tubercle to the angle.

Posterior Branches of the Sacral Nerves.—These are very small. The *upper four* will be found emerging from the posterior sacral foramina; the *fifth* appears at the lower end of the sacral canal.

To expose the *upper three* the multifidus covering the upper three sacral apertures must be carefully removed. Each of these three nerves will be found to divide in the usual manner into a medial and lateral division.

The *medial divisions* are very fine, and end in the multifidus.

The *lateral divisions* are somewhat larger, and join

together so as to form a looped plexus upon the dorsum of the sacrum. This communicates above with the lateral division of the last lumbar nerve and below with the posterior branch of the fourth sacral nerve. Branches proceed from the loops to the surface of the sacro-tuberous ligament (O.T. great sacro-sciatic). Finally they become superficial by piercing the glutæus maximus muscle, and they supply a limited area of skin over the glutæal region. They have already been examined by the dissector of the lower limb.

The *lowest two* posterior branches of the sacral nerves do not separate into medial and lateral divisions. They are very small, and, after communicating with each other, and also with the *coccygeal nerve*, they distribute filaments to the parts on the posterior aspect of the lower portion of the sacrum and on the dorsal aspect of the coccyx.

Twigs from the lateral sacral artery accompany the sacral nerves and anastomose with twigs from the glutæal arteries.

Posterior Branch of the Coccygeal Nerve.—This is a slender twig which emerges from the inferior opening of the sacral canal, and, after being joined by a filament from the last sacral nerve, is distributed on the dorsum of the coccyx.

Posterior Vertebral Venous Plexus.—A plexus of veins is situated upon the superficial aspect of the vertebral arches subjacent to the multifidus muscle. This plexus collects blood from the integument and muscles of the back, and in the thoracic and lumbar regions pours it into the posterior tributaries of the intercostal and lumbar veins. In the neck it is especially well marked, and its blood is emptied into the vertebral veins. Not many of these venous channels will be seen in an ordinary dissection. They are, however, a source of serious trouble during operations upon the vertebræ.

Dissection.—The fourth day after the body is placed upon its face must be devoted to the dissection of the sub-occipital triangle, and the fifth day to the display of the medulla spinalis (O.T. spinal cord), its membranes, nerve-roots, and blood vessels.

If the dissector is pushed for time, it is better that he should proceed at once to expose the spinal medulla, and defer the dissection of the sub-occipital region until the head and neck have been removed from the body.

Sub-Occipital Space.—The sub-occipital space is a small triangular area, exposed by the reflection of the semi-spinalis capitis (O.T. complexus) and the splenius muscle. It is *bounded* by three muscles—(1) the rectus capitis

posterior major forms its upper and medial boundary ; (2) the obliquus inferior limits it below ; and (3) the obliquus superior bounds it above and to the lateral side. Its floor consists of two structures—viz. the posterior arch of the atlas and the thin posterior atlanto-occipital membrane.

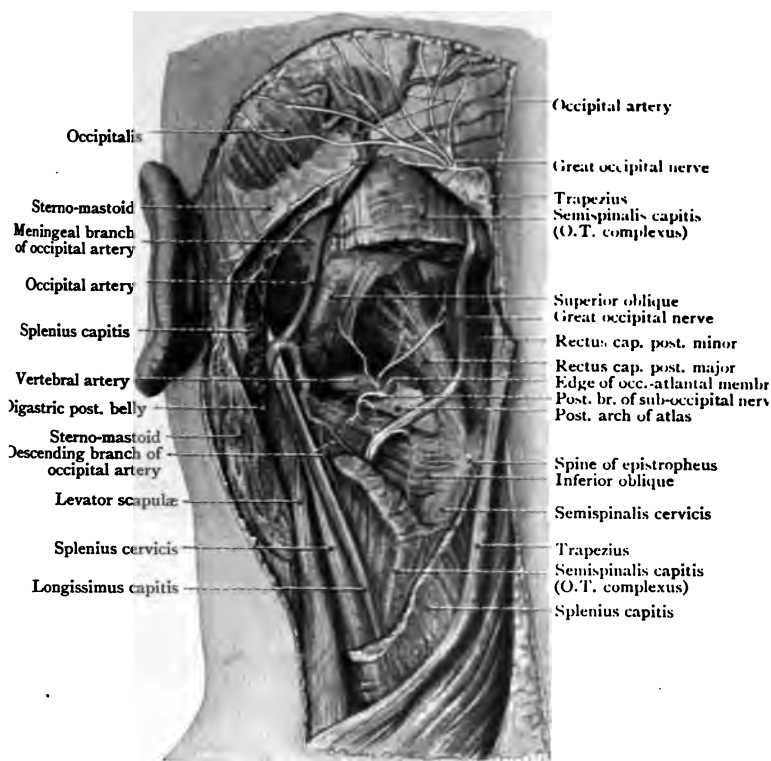


FIG. 73.—Dissection of the Sub-occipital Region. Note that in this specimen the occipital artery is superficial to the longissimus capitis muscle.

It contains a portion of the vertebral artery and the posterior branch of the sub-occipital or first cervical nerve.

Dissection.—Before cleaning the muscles bounding the triangle, the posterior branch of the sub-occipital nerve must be secured. This can best be done by tracing into the space the minute twig which it has been seen to give to the deep surface of the semispinalis capitis, or, if this has

not been retained, by endeavouring to find the twig which it gives to the rectus capitis posterior major. The tissue in which the nerve lies is very dense, and the dissection is in consequence somewhat difficult.

Rectus Capitis Posterior Major.—This muscle springs by a pointed origin from the spine of the epistropheus (O.T. axis), and, expanding as it passes upwards and laterally, it is inserted into the occipital bone along the lateral portion of the inferior nuchal line and the surface immediately below.

Rectus Capitis Posterior Minor.—This is a small fan-shaped muscle, placed to the medial side of, and overlapped by, the preceding muscle. It takes origin from the tubercle on the posterior arch of the atlas, and is inserted into the medial part of the inferior nuchal line of the occipital bone and the surface between this and the foramen magnum.

Obliquus Capitis Inferior.—This muscle extends from the extremity of the spine of the epistropheus to the posterior border of the transverse process of the atlas. The great occipital nerve will be seen hooking round its lower border.

Obliquus Capitis Superior.—This muscle springs from the transverse process of the atlas, and is inserted into the occipital bone in the interval between the nuchal lines, below and to the lateral side of the semispinalis capitis.

Posterior Branch of the Sub-Occipital Nerve.—The posterior branch of the sub-occipital nerve does not divide into medial and lateral divisions. It enters the sub-occipital triangle by passing dorsally, between the posterior arch of the atlas and the vertebral artery, and at once breaks up into branches which go to supply five muscles—viz. the two posterior recti, the two oblique muscles, and the semispinalis capitis. In addition to these muscular twigs it gives a *communicating*, and sometimes a *cutaneous filament*.

The *communicating branch* generally proceeds from the nerve to the obliquus capitis inferior, and joins the great occipital nerve. The *cutaneous branch*, when present, accompanies the occipital artery to the integument over the occiput.

Arteria Vertebralis.—Only the third portion of this vessel lies in the sub-occipital triangle. Emerging from the foramen in the transverse process of the atlas, it runs posteriorly and medially in the groove upon the posterior arch of the same bone. In this course it lies immediately posterior to the lateral mass of the atlas and above the sub-occipital nerve. It leaves the space by passing anterior to the thickened lateral ex-

tension of the posterior atlanto-occipital membrane, which runs from the posterior arch of the atlas to the posterior lip of its articular process and is called the oblique ligament of the atlas; then it pierces the dura mater and enters the vertebral canal.

Small branches proceed from the vertebral artery in this situation to supply the parts in its immediate neighbourhood, and to anastomose with the descending branch of the occipital artery and the arteria profunda cervicis.

Dissection to open the Vertebral Canal.—The first step consists in thoroughly cleaning the laminae and spinous processes upon both sides. The multifidus must be completely removed from the dorsum of the sacrum. At the same time the posterior branches of the nerves must be retained, so that their continuity with the various spinal nerve-trunks may be afterwards established. The posterior wall of the vertebral canal should now be removed *in one piece* by sawing through the laminae on either side, and dividing the ligamenta flava, from the third cervical vertebra down to the lower opening of the canal on the back of the sacrum.

In making this dissection the student must attend to the following points:—(1) the cut should be directed through the laminae close to the medial sides of the articular processes; (2) the saw must be used in an oblique plane, so that the cut through the laminae slants slightly medialwards; (3) in cutting through the cervical laminae the head and neck should hang over the end of the table, and be flexed as much as possible, whilst the saw is worked from below upwards; (4) in the case of the lumbar region, where, indeed, most difficulty will be met, a high block must be placed under the abdomen of the subject, whilst the blocks supporting the chest and pelvis are removed. It will probably be necessary at this point to have recourse to the hammer and chisel.

The laminae and spinous processes which are thus removed are connected with each other by the ligamenta flava and the supraspinous and interspinous ligaments. They should be laid aside for the present. A description of these ligaments will be found on p. 358. When the specimen is fresh, however, the dissector should test the high elasticity of the ligamenta flava by stretching the specimen.

Between the dura mater and the walls of the canal, the dissector will notice a quantity of loose areolar tissue and soft fat. The latter is especially plentiful in the sacral region, where it somewhat resembles the marrow in the medullary cavity of a long bone. Great numbers of large veins and minute arteries ramify in this areolo-fatty material.

Arteriæ Spinales.—In a well-injected subject a minute spinal artery will be seen entering the vertebral canal through each intervertebral foramen. These arteries are derived from different sources in the different regions of the spine. In the cervical region they come from the vertebral artery, and in the thoracic region from the posterior branches of the intercostal arteries; in the lumbar region from the dorsal branches of the lumbar arteries. They supply the spinal medulla and its

meninges, the bones, the periosteum, and the ligaments ; and their arrangement is very much the same in each of the three regions.

Each spinal artery may be looked upon as giving off *three main twigs*: of these, one, termed the *pre-laminar branch*, a very small twig, ramifies upon the deep surface of the vertebral arches and ligamenta flava ; another, the *neural branch*, can be followed to the dura mater, which it pierces immediately above the point of exit of the corresponding spinal nerve ; whilst the third, the *post-central branch*, is carried medially, anterior to the dura mater, towards the posterior surface of the vertebral bodies, and divides into an ascending and a descending twig. These anastomose with the corresponding twigs above and below, and in this manner a continuous series of minute arterial arcades is formed, from which branches pass medially to form a series of cross anastomoses with the corresponding vessels of the opposite side.

In the *cervical region* small branches from the ascending cervical artery also find their way into the vertebral canal ; whilst in the *sacral portion* of the canal the dissector will find branches from the lateral sacral arteries.

Internal Vertebral Venous Plexus.—This plexus extends along the whole length of the vertebral canal, and consists essentially of four subsidiary longitudinal plexuses, two anterior and two posterior, which anastomose freely with each other.

The *posterior plexuses* are united by many cross branches, which run along the deep aspect of the vertebral arches and ligamenta flava. Above, they communicate with the occipital sinus, whilst all the way down they are connected with the *posterior vertebral venous plexus* by wide channels which pierce the ligamenta flava. Laterally they send branches through the intervertebral foramina to join the posterior branches of the intercostal and lumbar veins.

The *anterior plexuses* cannot be dissected whilst the medulla spinalis (O.T. spinal cord) and its membranes are *in situ*, but it is convenient to describe them at this stage. Indeed, the dissection is one of considerable difficulty, even under the most advantageous circumstances. They form two main longitudinal venous channels placed one upon either side of the posterior longitudinal ligament of the vertebral bodies, and they are joined by transverse branches which cross the median

plane anterior to that ligament opposite each vertebral body. Each transverse vein receives large tributaries from the interior of the vertebra. Superiorly, each of the main longitudinal channels communicates with the occipital sinus or the basilar plexus within the cranium; and each of the posterior channels gives off a branch which emerges above the posterior arch of the atlas to join the commencement of the vertebral vein. Opposite the various intervertebral fibro-cartilages the anterior plexus sends off branches which run towards the intervertebral foramina, where they join with corresponding branches of the posterior plexus, to form the intervertebral veins which accompany the corresponding spinal nerves.

Meninges of the Medulla Spinalis (Fig. 74).—The medulla spinalis, like the brain, with which it is continuous, is enveloped by three membranes termed *meninges*. The most external investment is a strong fibrous membrane called the *dura mater*; the second, in order from without inwards, is a non-vascular tunic termed the *arachnoid*; whilst the third and most internal is the *pia mater*. These membranes are directly continuous with the corresponding investments of the brain.

Dissection.—The outer surface of the dura mater must now be cleaned. This is effected by removing the loose areolar tissue, soft fat, and posterior intraspinal veins from the vertebral canal. It is necessary, also, to define carefully the numerous lateral prolongations which the membrane gives to the spinal nerves.

Dura Mater Spinalis (Fig. 74).—In the vertebral canal the dura mater constitutes an exceedingly dense and tough fibrous tube, which extends from the foramen magnum above, to the level of the second or third piece of the sacrum below. It is separated from the walls of the vertebral canal and its lining periosteum by an interval, which is filled by loose fat and areolar tissue, and the internal vertebral venous plexus. Even before the membranous tube is laid open, the dissector can readily satisfy himself that it forms a very loose sheath around the spinal medulla and the nerve-roots which form the cauda equina; in other words, it is very capacious in comparison with the volume of its contents. Its calibre, moreover, is by no means uniform; in the cervical and lumbar regions it is considerably wider than in the thoracic region, whilst in the sacral canal it rapidly contracts and finally ends by blending with the *filum terminale*, a fibrous thread which is prolonged

downwards through the sacral canal from the extremity of the medulla spinalis (O.T. spinal cord).

The cylindrical tube of spinal dura mater does not lie free within the vertebral canal, although its attachments are of such a nature that they do not in any way interfere with the free movement of the vertebral column. *Above*, the dura mater is firmly attached to the second and third cervical

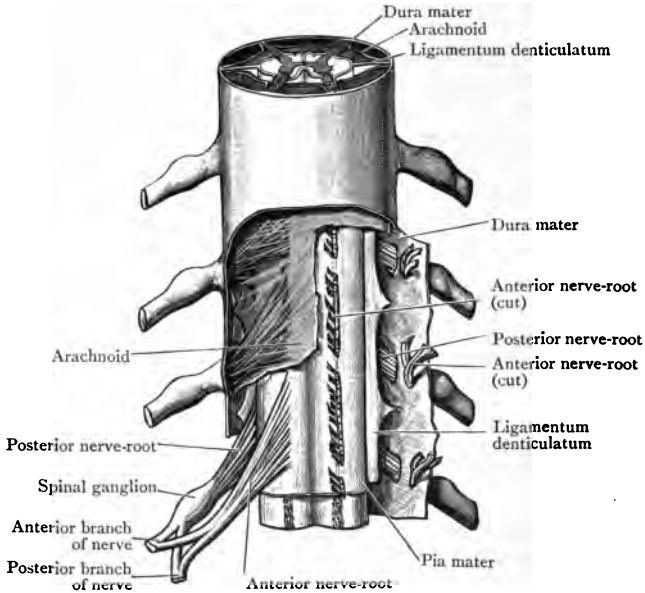


FIG. 74.—Membranes of the Medulla Spinalis (O.T. Spinal Cord), and the mode of origin of the Spinal Nerves.

vertebræ, and around the margin of the foramen magnum; *below*, the filum terminale, on which it terminates, can be traced as far as the dorsal aspect of the coccyx, where it is lost by blending with the periosteum. On either side the spinal nerve-roots, as they pierce the dura mater, carry with them into the intervertebral foramina tubular sheaths of the membrane, which are attached to the margins of the foramina, whilst, anteriorly, loose fibrous prolongations—more numerous above and below than in the dorsal region—connect the tube of dura mater to the posterior longitudinal ligament of the

vertebral column. No connection of any kind exists between the dura mater and the vertebral arches or ligamenta flava.

Dissection.—The tube of dura mater may now be opened with the scissors. The incision should be carried through the membrane in the median plane. Care, however, must be taken not to injure the delicate arachnoid, which is subjacent.

Cavum Subdurale.—The subdural cave (O.T. space) is the capillary interval between the dura mater and the arachnoid (Fig. 74). The deep surface of the dura, which is turned towards this space, is smooth, moist, and polished. The dissector will notice, upon either side, the series of apertures of exit for the roots of the spinal nerves. These are ranged in pairs opposite each intervertebral foramen. The subdural space is prolonged laterally, for a short distance, upon each of the nerve-roots, and has a free communication with the lymph paths present in the nerves.

Viewed from the inside of the tube of dura mater, each of the two nerve-roots belonging to a spinal nerve is seen to carry with it a special and distinct sheath. When examined, however, on the outside of the tube of dura mater, they appear to be enveloped in one sheath, because the two sheaths are closely held together on the outside by intervening connective tissue, which can be removed with a little careful dissection. When this is done, the two tubular sheaths will be seen to remain distinct as far as the ganglion on the posterior root of the nerve. At that point they blend with each other.

Arachnoidea Spinalis (Fig. 74).—The arachnoid resembles the dura mater in forming a loose, wide investment for the spinal medulla. Unlike the dura, however, it is remarkable for its great delicacy and transparency. The sac which it forms is most capacious, and can be demonstrated most easily towards its lower part, where it envelops the extremity of the spinal medulla and the collection of long nerve-roots which constitute the *cauda equina*. Make an incision into it, and insert the handle of the scalpel, or, better still, inflate the sac with air by means of a blowpipe. Above, the arachnoid becomes continuous, at the level of the foramen magnum, with the arachnoid membrane of the brain, whilst, laterally, it is prolonged upon the various nerve-roots, thus contributing to each a tubular sheath. It terminates blindly below at the level of the second or third sacral vertebra.

Cavum Subarachnoideale (Fig. 74).—This term is applied to the wide space between the arachnoid and pia mater. It is occupied by a variable amount of cerebro-spinal fluid, and

is directly continuous with the cranial sub-arachnoid space. Three incomplete septa partially subdivide the spinal sub-arachnoid space into compartments. One of these septa is a median partition called the *septum subarachnoideale*, which connects the pia mater covering the posterior aspect of the spinal medulla with the arachnoid. In the upper part of the cervical region the subarachnoid septum is represented merely by a number of strands passing between the two membranes; in the lower part of the cervical region and in the thoracic region it is almost complete. The two other septa are formed by the *ligamenta denticulata*. These spread outwards from each side of the medulla spinalis, and will be studied with the pia mater.

Dissection.—Take away the arachnoid mater from a portion of the spinal medulla, and proceed to the study of the pia mater.

Pia Mater Spinalis.—This is a firm vascular membrane, closely adherent to the surface of the medulla spinalis (O.T. spinal cord). It is thicker and denser than the pia mater of the brain, largely owing to the addition of an outer layer of fibres which run chiefly in a longitudinal direction. The pia mater sends a fold into the antero-median fissure of the medulla spinalis, and the septum which occupies the posterior median fissure of the medulla spinalis is firmly attached to its deep surface. Anteriorly, in the median plane, the pia mater is thickened to form a longitudinal glistening band, which receives the name of the *linea splendens*. Of course, this can be seen only after the medulla spinalis (O.T. spinal cord) has been removed from the vertebral canal. The blood vessels of the medulla spinalis lie between the two layers of the pia mater before they enter the substance of the spinal medulla, and the various spinal nerves receive from it closely fitting sheaths which blend with their connective-tissue sheaths.

Ligamentum Denticulatum (Figs. 74 and 75).—This is a remarkable band, which stretches laterally from either side of the medulla spinalis, and connects it with the dura mater. Its *pial* or *medial attachment* extends in a continuous line, between the anterior and posterior nerve-roots, from the level of foramen magnum above to the level of the body of the first lumbar vertebra below. Its lateral *margin* is widely serrated or denticulated. From twenty to twenty-two denticulations may be recognised, and the highest is attached to the margin of the foramen magnum. They occur in the intervals between the

spinal nerves, and, pushing the arachnoid before them, they are attached by their pointed extremities to the inner surface of the dura mater.

The ligamenta denticulata maintain the medulla spinalis (O.T. spinal cord) in the middle of the tube of dura mater and partially subdivide the sub-arachnoid space into an anterior and a posterior compartment. In the anterior compartment the anterior nerve-roots pass laterally; the posterior compartment contains the posterior nerve-roots, and is imperfectly subdivided into two lateral subdivisions by the septum posticum.

Medulla Spinalis (O.T. Spinal Cord).

—The spinal medulla itself may now be studied *in situ*. It is a cylindrical structure, slightly flattened anteriorly and posteriorly, which extends from the foramen magnum, where it is continuous with the medulla oblongata of the brain, to the lower border of the body of the first or the upper border of the body of the second lumbar vertebra.

Its lower end rapidly tapers to a point, and is termed the *conus medullaris*. From the extremity of this, a slender filament, termed the *filum terminale*, is prolonged downwards to the dorsal surface of the coccyx.

In the female the average length of the medulla spinalis is 43 cm. ; in the male it is 45 cm.

Throughout the greater part of the thoracic region of the spine the medulla spinalis presents a uniform girth, but in the cervical and lower thoracic regions it shows marked swellings, termed respectively the *intumescentia cervicalis* and *intumescentia lumbalis*. From these enlargements proceed the nerves which supply the upper and lower limbs. The *cervical swelling* is the more evident of the two. It begins at the upper end of the medulla spinalis (O.T. spinal cord) and attains its greatest

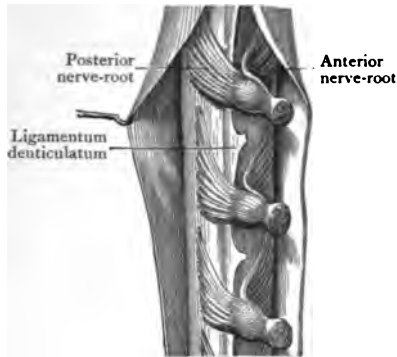

FIG. 75.—Lateral view of the Medulla Spinalis, Dura Mater, and Ligamentum Denticulatum. (Hirschfeld and Leveillé.)

breadth (13 to 14 mm.) opposite the fifth or sixth cervical vertebra. Below, it subsides opposite the second thoracic vertebra. The *lumbar swelling* begins at the level of the tenth thoracic vertebra, and attains its maximum transverse diameter (11 to 13 mm.) opposite the last thoracic vertebra. Below, it rapidly tapers into the *conus medullaris*.

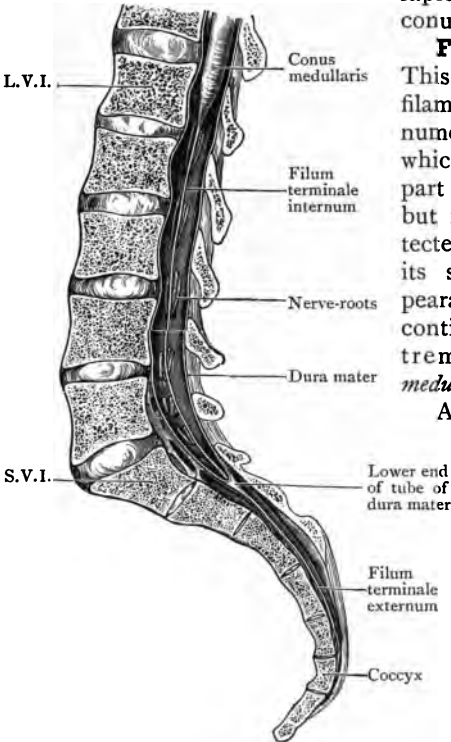


FIG. 76.—Sagittal section through the lower part of the Vertebral Canal.

Filum Terminale.— This delicate thread-like filament lies amidst the numerous long nerve-roots which occupy the lower part of the vertebral canal, but it can readily be detected from these (1) by its silvery glistening appearance, and (2) by its continuity with the extremity of the *conus medullaris*.

Although the central canal of the medulla spinalis is prolonged down in its interior for nearly half its length, and nervous elements can be traced in its substance for a like distance, the *filum terminale* is chiefly composed of pia mater. The *linea splendens* and the lower ends of the

ligamenta denticulata may also be considered to be continued into it. At the level of the second or third sacral vertebra it pierces the tapered end of the tube of dura mater, and receives an investment from it; and, finally, reaching the lower end of the sacral canal, it terminates by blending with the periosteum on the dorsal surface of the coccyx or the last piece of the sacrum.

In length it measures about six inches. The part within the tube of dura is termed the *filum terminale internum*, the portion outside is the *filum terminale externum*.

Spinal Nerves.—Thirty-one spinal nerves take origin from each side of the medulla spinalis (O.T. spinal cord). These are classified into five groups, according to the vertebræ with which they are associated. The thoracic, lumbar, and sacral nerves correspond in number with the vertebræ in each of those regions—thus, there are twelve thoracic, five lumbar, and five sacral nerves, each of which issues from the vertebral canal below the vertebra with which it numerically corresponds. In the cervical region, however, there are eight nerves, the first of which comes out between the occiput and the atlas, and is therefore distinguished by the special name of the *sub-occipital nerve*. There is only one coccygeal nerve on each side.

Spinal Nerve-Roots (Figs. 75 and 77).—Each spinal nerve springs from the side of the spinal medulla by *two roots*—an *anterior* and a *posterior*. Except in the case of the sub-occipital nerve (where the posterior root is sometimes absent), the posterior nerve-root is the larger of the two. In addition, the posterior root is distinguished by possessing an oval ganglion, termed the *spinal ganglion*. There is, also, a wide physiological difference between the two roots—the posterior root is composed of afferent fibres, the anterior root consists of efferent fibres. Immediately beyond the ganglion the two roots unite to form the *spinal nerve-trunk*, which contains a mixture of both efferent and afferent nerve-fibres.

The *mode of attachment* of the two nerve-roots to the side of the medulla spinalis is somewhat different in the two cases. In each instance they are attached by several separate *fila radicularia*, which spread out from each other as they approach their attachments. In the case of the posterior root the fila enter the spinal medulla consecutively along a continuous straight line and at the bottom of a slight furrow. The fila of the anterior root, on the other hand, are not so regularly placed. They emerge from the medulla spinalis over an area of some breadth. The portion of the medulla spinalis which stands in connection with a pair of nerves receives the name of a “neural segment.”

It will be noted that the *size* of the nerve-roots differs greatly. The lower lumbar and upper sacral nerve-roots are much

the larger, whilst the lower sacral and the coccygeal roots are the smaller. In the cervical region the roots increase in size from above downwards, but more rapidly in the lower members of the group; in the thoracic region the roots of the first nerve are large, but those which succeed it are small and of uniform size.

In *relative length*, and in the *direction* which they follow in the vertebral canal, the nerve-roots also show great differences. This is due to the medulla spinalis being so much shorter than the canal in which it lies. In the upper part of the cervical region the nerve-roots are short, and proceed laterally in a more or less horizontal direction. Below the upper cervical

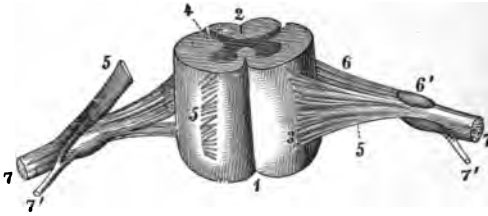


FIG. 77.—A segment of the medulla spinalis; anterior aspect.
(Schwalbe, after Allen Thomson.)

- | | |
|--|--------------------------|
| 1. Anterior median fissure. | 6. Posterior nerve-root. |
| 2. Posterior median sulcus. | 6'. Spinal ganglion. |
| 3 and 5. Filia of anterior nerve-root. | 7. Anterior branch. |
| 4. Posterior lateral groove. | 7'. Posterior branch. |

region the nerve-roots become more oblique, and the lower the origin of the nerve the longer is its course in the canal. The arrangement of the lower thoracic, the lumbar, sacral, and coccygeal nerve-roots is particularly characteristic. They are exceedingly long, and descend vertically from the lower portion of the medulla spinalis, forming a bundle which is called the *cauda equina*.

Mode of Exit of Spinal Nerves from Vertebral Canal.—

The lower six cervical nerves, the thoracic nerves, and the lumbar nerves make their exit through the intervertebral foramina; whilst each of the two branches of the upper four sacral nerves finds its way out by a sacral foramen. The upper two cervical nerves, the fifth sacral nerve, and the coccygeal nerve, however, follow a different course. The sub-occipital emerges by passing over the posterior arch of

the atlas, and the second cervical nerve by passing over the vertebral arch of the epistropheus (O.T. axis). The fifth sacral and the coccygeal nerve leave the sacral canal through its lower aperture (Fig. 78).

Dissection.—The nerve-roots of one or two spinal nerves in each region should be followed into the corresponding intervertebral foramina.

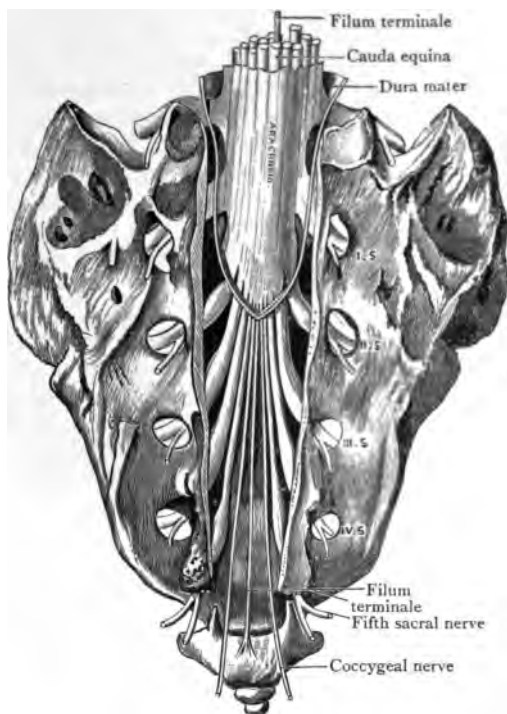


FIG. 78.—The Sacral Nerve-roots (lower part of Cauda Equina) and the Membranes in relation to them. (After Testut.) The posterior wall of Sacral Canal is removed.

This can be easily done by snipping away the articular processes with the bone-forceps. The position of the ganglion on the posterior root, the connections of the sheath of dura mater, the union of the two roots to form the spinal nerve-trunk, and the division of the latter into the anterior and posterior branches can thus be studied. An attempt should also be made at the same time to discover the minute *ramus meningeus*. This is a fine twig which is formed by the union of a small filament from the spinal nerve-trunk with a minute branch from the sympathetic trunk.

It takes a recurrent course through the intervertebral foramen to end in the bones and periosteum of the vertebral canal.

Ganglia Spinalia.—These ganglia are oval swellings developed upon the posterior nerve-roots, just before they unite with the anterior roots to form the spinal nerve-trunks. They are found upon the posterior roots of all the nerves, except, occasionally, upon those of the sub-occipital and the coccygeal nerves.

The spinal ganglia are formed upon the posterior nerve-roots as they lie in the intervertebral foramina, except in the cases of the first two cervical and the sacral and coccygeal nerves. The ganglia of the first two cervical nerves lie upon the posterior arch of the first and the vertebral arch of the second cervical vertebræ respectively; the ganglia of the sacral nerves are placed within the sacral canal, but outside the tube of dura mater. The ganglion on the posterior root of the coccygeal nerve is inside the tube of dura mater.

Spinal Nerve-Trunks.—These are formed by the union of the anterior and posterior nerve-roots immediately beyond the spinal ganglia. This union takes place in the case of the coccygeal and sacral nerves in the sacral canal; in the lumbar, thoracic, and lower six cervical nerves, in the intervertebral foramina; and in the case of the first two cervical nerves, on the arches of the atlas and epistropheus.

The nerve-trunk is exceedingly short; indeed, it divides almost immediately into its *anterior* and *posterior branches*. In the case of the sacral and coccygeal nerves, this subdivision takes place in the sacral canal, and the spinal nerve-trunks of these nerves are distinctly longer than in the case of the nerves which occupy a higher level.

The distribution of the posterior branches has already been examined (p. 173).

Dissection.—At this stage the dissector may adopt one of two methods in the further treatment of the medulla spinalis and the nerves which spring from it. If the medulla spinalis is fresh and in such a condition that it may be successfully hardened, it is best to transfer it at once to the preservative fluid. If, on the other hand, it is soft and not fit for proper preservation, it should be removed with all its membranes and nerve-roots, and placed in a cork-lined tray filled with water. There is no method by which the arachnoid, the pia mater, the ligamenta denticulata, and the nerve-roots can be so well studied as this.

In removing the medulla spinalis, the spinal nerves should be divided as they lie in the intervertebral foramina, and in such a manner that as long a piece as possible of each nerve remains attached to the dura

mater and the spinal medulla. Wherever it is possible the ganglia should be taken with the nerves. The same rule applies to the sacral nerves also. The medulla spinalis and its membranes should then be cut across at the highest limit of the vertebral dissection. By pulling upon the dura mater the whole specimen may now be lifted from the vertebral canal and transferred to the water-bath. The dura mater should then be slit down the median plane, and the edges of the incision must be turned aside. By fixing the dura mater with pins to the cork at the bottom of the tray, the further dissection can be conducted with great advantage.

Arteries of the Medulla Spinalis (O.T. Spinal Cord).—It is only when the arterial injection is particularly good that the spinal arteries can be made out satisfactorily.

A large number of small arteries are supplied to the medulla spinalis. These are the *anterior* and *posterior spinal arteries* which spring from the vertebral in the cranium, and a series of *lateral spinal arteries* which reach the side of the medulla spinalis and are derived from different sources in each region. *In the neck* they come from the vertebral, ascending cervical, and deep cervical arteries; and *in the thoracic and lumbar regions* from the posterior branches of the intercostal and lumbar arteries. By the anastomoses of these arterial twigs, five longitudinal trunks are formed upon the surface of the medulla spinalis. One of these lies in the median plane anteriorly, and may be termed the *antero-median artery*. The other four are placed in relation to the sulci along which the posterior nerve-roots enter the medulla spinalis. One runs downwards anterior to the line of entrance of these roots, and the other posterior to it on each side of the medulla spinalis. These slender arterial trunks may therefore be termed the *postero-lateral longitudinal vessels*.

The *antero-median vessel* is formed above by the union of the two anterior spinal branches of the vertebral arteries. One of these is larger than the other, and takes a much greater share in the formation of the median trunk. Below the level of the fifth pair of cervical nerves the continuity of the median vessel depends upon the reinforcements which it obtains from the lateral spinal vessels. The number of lateral spinal arteries which join the median vessel is very variable. The majority of these arteries end on the nerve-roots; only five to ten reach the median vessel. The *antero-median artery* runs downwards, under cover of the *linea splendens* of the pia mater. Its calibre is uniform throughout, and where the medulla spinalis ends it proceeds onwards for some distance upon the *filum terminale*.

The *postero-lateral arteries* on each side of the medulla spinalis are formed in the upper part of the cervical region by the bifurcation of the corresponding posterior spinal branch of the vertebral artery. Lower down their continuity is maintained by twigs which reach them on the posterior roots of the spinal nerves from the lateral spinal arteries. It may be

regarded as a rule, that where a lateral spinal artery gives a branch to one of the postero-lateral arterial trunks, it does not furnish another to the antero-median arterial trunk. In this way different lateral spinal arteries are in connection with the longitudinal trunks on the anterior and posterior aspects of the medulla spinalis. The postero-lateral vessels end at the lower extremity of the medulla spinalis.

From the five main arterial channels which thus extend along the spinal medulla numerous anastomosing twigs ramify in the pia mater.

Veins of the Medulla Spinalis.—These veins are small and numerous, and their disposition cannot be said to correspond with that of the arteries. They are very tortuous, and form a plexus with elongated meshes. Six more or less perfect longitudinal venous trunks may be noticed on the surface of the medulla spinalis in connection with this plexus; two of these are median, and are placed respectively on the anterior and posterior aspects. The anterior trunk runs upwards under cover of the antero-median spinal artery. The other four are lateral, and are situated two on either side, in relation, respectively, to the anterior and posterior nerve-roots.

Upon each side, the veins of the medulla spinalis effect communications with the veins in the vertebral canal by means of small twigs which run laterally on the nerve-roots.

How to distinguish the anterior from the posterior surface of the medulla spinalis.

ANTERIOR SURFACE.	POSTERIOR SURFACE.
<ol style="list-style-type: none"> 1. Linea splendens. 2. Single anterior spinal artery in median plane. 3. Anterior nerve-roots smaller than posterior, and springing by fila which emerge from the medulla spinalis, not in a continuous straight line, but irregularly over an area of some width. 	<ol style="list-style-type: none"> 1. The postero-lateral arteries in relation to the posterior nerve-roots. 2. Fila of origin of posterior nerve-roots entering the medulla spinalis along a straight and continuous line, and at the bottom of a distinct sulcus. 3. Posterior nerve-roots larger than the anterior, and provided with ganglia.

Preservation of the Medulla Spinalis.—If the medulla spinalis is in a fit state for preservation, it should be immersed for a few weeks in methylated spirit, to which a small amount (4 per cent) of formalin has been added. When sufficiently firm, the dissector should endeavour to learn something of its internal structure by making transverse sections across it at different levels, and inspecting the cut surface closely with the naked eye, or with the aid of a magnifying glass.

Internal Structure of the Medulla Spinalis.—A good deal can be learned by a naked-eye inspection of cross sections of

the medulla spinalis made in different regions and at different levels.

In such sections the *antero-median fissure* and the *postero-median septum and sulcus*, which partially divide it along the whole of its length into right and left halves, become obvious.

The antero-median fissure is much shorter than the postero-median septum. It dips dorsally to a commissure of white matter, *anterior white commissure*, which connects the two halves of the medulla spinalis; and it contains a fold of pia mater and branches of the anterior spinal vessels. The postero-median sulcus is a shallow furrow which runs along

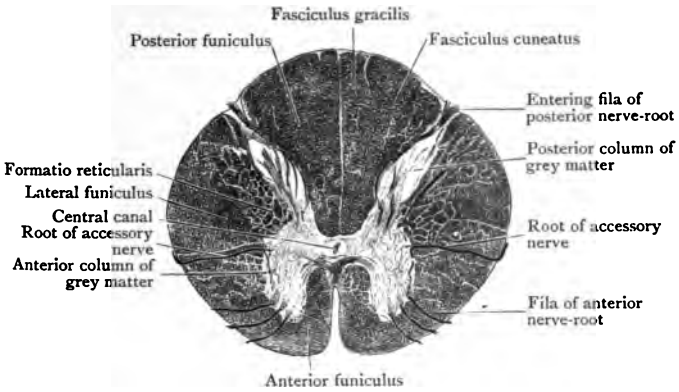


FIG. 79.—Transverse section through the upper part of the Cervical Region of the Medulla Spinalis.

the posterior surface of the medulla spinalis in the median plane, and the postero-median septum extends from the bottom of the sulcus to a transverse grey commissure called the *posterior commissure*.

The two halves of the medulla spinalis, thus marked off from each other, are to all intents and purposes symmetrical, and they are joined by a more or less broad band or commissure which intervenes between the anterior fissure and the posterior septum.

An inspection of the surface of each lateral half of the medulla spinalis brings into view a groove or furrow at some little distance from the postero-median sulcus; it is called the *postero-lateral sulcus*. Along the bottom of this groove

the fila of the posterior nerve-roots enter the medulla spinalis (O.T. spinal cord) in accurate linear order. There is no corresponding furrow on the anterior part of each lateral half of the medulla spinalis in connection with the emergence of the fila of the anterior nerve-roots; and it should be noted that these fila emerge over a broad area, which corresponds in its width to the thickness of the subjacent anterior column of grey matter.

The medulla spinalis is composed of an inside core of grey matter which is surrounded on all sides by an external coating of white matter.

Grey Matter of the Medulla Spinalis.—The grey matter in the interior of the medulla spinalis has the form of a fluted column. When seen in transverse section, it presents the shape of the letter H. In each lateral half of the medulla spinalis there is a comma-shaped mass of grey matter, the concavity of which is directed laterally. The crescents of opposite sides are connected across the median plane by a transverse band, which is called the *grey commissure*. The postero-median septum passes from the surface of the medulla spinalis to the grey commissure. The bottom of the antero-median fissure is separated from it by an intervening strip of white matter which is termed the *anterior white commissure*. In the grey commissure may be seen the central canal of the spinal medulla. It is just visible to the naked eye as a minute speck. This canal tunnels the entire length of the spinal medulla, and opens above (after having traversed the lower half of the medulla oblongata) into the fourth ventricle of the brain. The portion of the grey commissure which lies posterior to the central canal is called the *posterior commissure*, the portion anterior to it receives the name of *anterior grey commissure*.

In each crescentic mass of grey matter certain well-defined parts may be recognised. The projecting portions which extend posterior and anterior to the connecting transverse grey commissure are termed the *posterior* and the *anterior grey columns*. They can be distinguished from each other at a glance.

The *anterior grey column* is short, thick, and very blunt at its extremity. Further, its extremity is separated from the surface by a tolerably thick coating of white matter, through which the fila of the anterior nerve-roots pass on their way to the

surface. The thickened end of the anterior column is termed the *caput columnæ anterioris*, and the constricted part close to the grey commissure is called the *cervix columnæ anterioris*. The *posterior grey column* in most localities is elongated and narrow. Further, it is drawn out to a fine point, which almost reaches the bottom of the postero-lateral sulcus. This pointed extremity receives the name of the *apex columnæ posterioris*; the slightly swollen part which succeeds it is the *caput columnæ posterioris*; whilst the slightly constricted part adjoining the grey commissure goes under the name of the *cervix columnæ posterioris*.

Covering the tip of the posterior column there is a substance which differs in its composition from the general mass of grey matter, and presents a translucent appearance. It is termed the *substantia gelatinosa (Rolandi)*.

The grey matter is not present in equal quantity throughout the entire length of the medulla spinalis. Therefore it is necessary that it should be considered in different regions, and it must be understood, when the terms cervical, lumbar, sacral, etc., are applied to different portions of the spinal medulla, that these terms apply to the regions to which the nerves of the same name are attached.

Wherever there is an increase in the size of the nerves attached to a particular part of the medulla spinalis, there a corresponding increase of the grey matter may be noticed. It follows from this that the districts in which the grey matter bulks most largely are the lumbar and cervical swellings. The great nerves which go to form the limb plexuses enter and pass out from those portions of the medulla spinalis. In the intermediate thoracic region there is a reduction in the quantity of grey matter, in correspondence with the smaller size of the thoracic nerves.

The shape of the crescentic masses of grey matter is not the same in all regions. In the thoracic region both columns are narrow, although the distinction between the anterior grey column and the more attenuated posterior grey column is still sufficiently manifest. In the cervical region the contrast between the grey columns is most marked; the anterior grey column is very thick in comparison with the posterior grey column. In the lumbar region, on the other hand, the difference in the thickness of the two grey columns is not nearly so apparent, owing to a broadening out of the

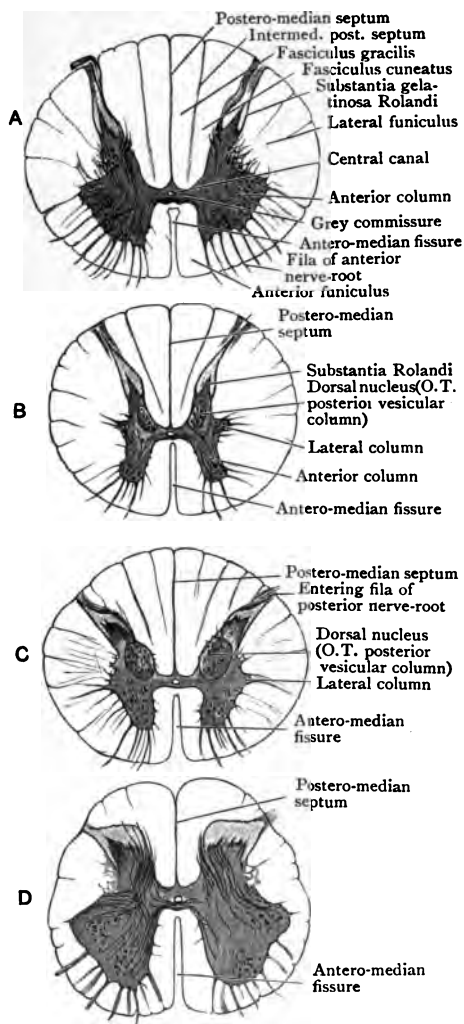


FIG. 80.—Transverse sections through the Medulla Spinalis in different regions. A. Cervical Region; B. Mid-thoracic Region; C. Lower Thoracic Region; D. Lumbar Region.

posterior grey column. A section taken from the centre of each region can very readily be recognised by the features mentioned.

In the thoracic region of the spinal medulla, more especially in the upper part, there is another character which is very distinctive. A pointed and prominent triangular projection juts out from the lateral aspect of the crescentic mass of grey matter nearly opposite the grey commissure. This is called the *lateral grey column* (Fig. 80, B and C). It disappears in the cervical and lumbar swellings, but again becomes evident both in the upper cervical and in the lower sacral regions.

Below the thoracic region the postero-medial septum dimin-

ishes and the antero-medial fissure increases in depth, until,

in the sacral region, they are almost equal in depth and the central canal occupies the centre of the medulla spinalis.

White Matter of the Medulla Spinalis.—The white matter forms a thick coating on the outside of the fluted column of grey matter. It is marked off into three funiculi. The *posterior funiculus* is wedge-shaped in transverse section, and lies between the postero-median septum and the posterior grey column. The *lateral funiculus* occupies the concavity of the grey crescent. Posteriorly it is bounded by the posterior grey column and the postero-lateral sulcus, whilst anteriorly it extends as far as the most lateral fila of the anterior nerve-roots. The *anterior funiculus* includes the white matter

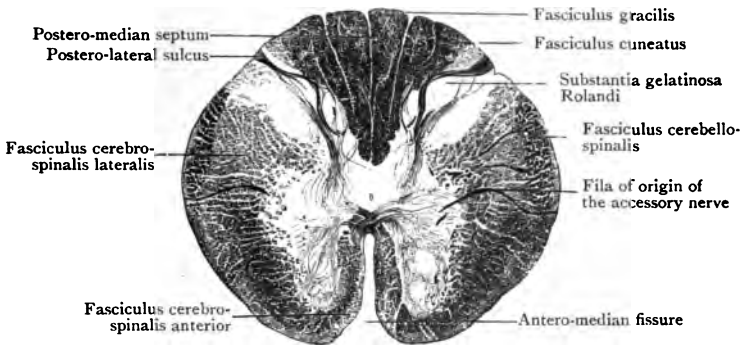


FIG. 81.—Transverse section through the upper cervical part of the Medulla Spinalis of a full-time Fœtus, treated by the Pal-Weigert process.

between the antero-median fissure and the anterior column of grey matter, and also the white matter which separates the thick extremity of the anterior grey column from the surface of the spinal medulla and is traversed by the emerging fila of the anterior nerve-roots.

In the cervical region a faint longitudinal groove runs downwards on the surface of the posterior funiculus of the medulla spinalis. This indicates the position of a septum which passes into the funiculus from the deep surface of the pia mater and divides it incompletely into two unequal strands. The groove is termed the *intermediate posterior sulcus*. The strand on its medial side is the *fasciculus gracilis* (Goll's), whilst the lateral and larger strand receives the name of the *fasciculus cuneatus* (Burdach's).

The white matter of the medulla spinalis increases steadily in quantity from below upwards.

The fasciculi gracilis and cuneatus, which form the posterior funiculus of the medulla spinalis, are composed of fibres which enter the spinal medulla as the fila of the posterior nerve-roots. In the lower portion of the medulla spinalis the two fasciculi are not marked off from each other.

In the lateral and anterior funiculi of the adult spinal medulla it is not possible with the naked eye to distinguish the different strands of fibres of which they consist, but the student should remember that such strands or tracts are present. The three best-defined tracts in the antero-lateral part of the spinal medulla are, (1) the fasciculus cerebello-spinalis (O.T. direct cerebellar tract); (2) the fasciculus cerebro-spinalis lateralis (O.T. crossed pyramidal tract); (3) the fasciculus cerebro-spinalis anterior (O.T. direct pyramidal tract).

The *fasciculus cerebello-spinalis* ascends to the cerebellum, but, traced in the opposite direction, it is found to disappear in the lower thoracic region of the medulla spinalis. The *fasciculus cerebro-spinalis lateralis* occupies a larger district of the medulla spinalis. It is placed in the lateral funiculus anterior to the posterior column of grey matter and immediately medial to the fasciculus cerebello-spinalis. As the fasciculus cerebello-spinalis disappears in the lower part of the medulla spinalis the fasciculus cerebro-spinalis lateralis comes to the surface, and it can be traced as low as the fourth sacral nerve. The *fasciculus cerebro-spinalis anterior* forms the narrow strip of the anterior funiculus, which lies immediately adjacent to the antero-median fissure. It reaches down to about the middle of the thoracic region of the medulla spinalis and then disappears.

After the body has been five days on its face it will be replaced upon its back with the thorax and pelvis supported by blocks, and the dissectors of the head and neck should at once proceed to clean the temporal fascia, and afterwards to remove the brain and study the interior of the cranium.

Dissection.—Take away the anterior and superior auricular muscles and remove the thin layer of fascia subjacent to them which descends from the lower border of the galea aponeurotica to the zygomatic arch. When this has been done the strong temporal fascia will be exposed. Note that it is attached above to the temporal ridge and below to the upper border of the zygomatic arch. The details of its connections will be studied at a later period.

REMOVAL OF THE BRAIN.

After the superficial attachments of the temporal fascia have been noted the dissectors of the head and neck should proceed to remove the brain.

Dissection.—The head being supported upon a block, extend the median incision, already made in the galea aponeurotica, to the nasion anteriorly and

to the external occipital protuberance posteriorly, and cut through the loose areolar tissue and the pericranium in the same line down to the bone. With the handle of the scalpel, or with a chisel, detach the pericranium from the bone on each side and turn it posteriorly and downwards to the temporal ridges, leaving the bone perfectly bare. Note that although the pericranium is loosely attached over the surface of the various bones of the vault, it is firmly attached along the lines of the cranial sutures by processes that dip in between the bones and separate their edges. Detach the galea aponeurotica and the temporal fascia from the temporal ridge on each side with the edge of the knife; then carrying the edge of the knife anteriorly and posteriorly between the temporal muscle and the bone detach the upper part of the muscle from the skull. When this has been done, each half of the scalp can be turned down over the ear.

The dissectors should next obtain a saw, a chisel, and a mallet, and

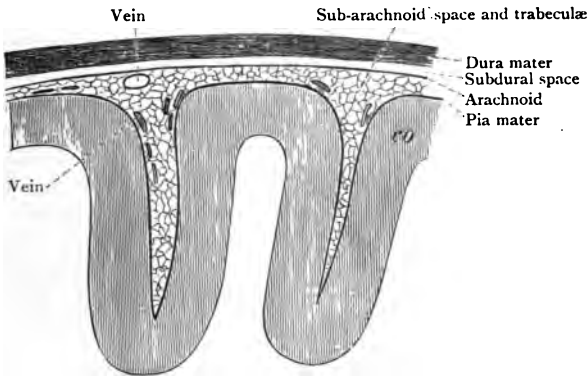


Fig. 82.—Diagrammatic section through the Meninges of the Brain. (Schwalbe.)

co. Grey matter of cerebral gyri.

proceed to remove the calvaria. The line along which the saw is to be used may be marked out on the skull by encircling it with a piece of string, and then marking the cranium with a pencil along the line of the string. Anteriorly, the cut should be made fully three-quarters of an inch above the margins of the orbits; posteriorly, it should be carried round at the level of a point midway between the lambda¹ and the external occipital protuberance. The saw should be used to divide the outer table of the skull only. When the diploe is reached, the sawdust will become red and moist, and the saw should then be abandoned. The hammer and chisel are now brought into requisition, and by short sharp strokes with these the inner table can readily be split along the line in which the outer table of the cranium is divided. When this has been done, insinuate the hook at the end of the cross-bar of the chisel into the fissure in front, and wrench off the skull-cap.

Dura Mater Encephali.—The brain is clothed by three distinct membranes, which are termed the *meninges*. These

¹ The term "lambda" signifies the apex of the occipital bone, or the point at which the sagittal and lambdoidal sutures

are from without inwards—(1) the dura mater; (2) the arachnoid; and (3) the pia mater.

When the skull-cap is detached, the outer surface of the dura mater, as it covers the upper surface of the cerebral hemispheres, is exposed. It is rough, and dotted over with bleeding points. If a portion is placed in water, its roughness becomes still more manifest, and is seen to be due to a multitude of fine fibrous and vascular processes by which it is connected with the deep surface of the bones. These have necessarily been torn asunder in the removal of the skull-cap. The bleeding points are most numerous along the median line, or, in other words, along the line of the superior sagittal sinus (O.T. longitudinal); and if the handle of the knife is run from before backwards, so as to make pressure along this line, a considerable quantity of blood will ooze out. This shows that a number of small veins from the cranial bones have been ruptured. The degree of adhesion between the dura mater and the inner surface of the cranial bones varies in different subjects and in different localities. In all cases it is strongly adherent along the lines of the sutures, like the pericranium externally; and, further, it is much more firmly attached to the base than to the vault of the cranium. In the child—indeed, as long as the bones of the cranium are growing—it is more adherent than in the adult; and it is more firmly bound to the bone again in old age.

The dissectors should now clean the outer surface of the dura mater with a sponge. They will then recognise the *middle meningeal artery* upon each side, ascending in the substance of the membrane, and sending off its branches in a widely arborescent manner. It stands out in bold relief from the membrane. If the skull-cap is examined, its inner surface will be observed to be deeply grooved by the branches of the artery and the veins which accompany and lie external to them (Wood Jones). The meningeal arteries are not intended for the supply of the membrane alone, as the name might lead one to imagine. They are also the nutrient vessels of the inner table and diploe of the cranial bones.

Granulationes Arachnoideales (O.T. Pacchionian Bodies).
—These granulations are almost invariably present, and, as a rule, are best marked in old subjects. They are small granular bodies, ranged in clusters on either side of the superior sagittal (O.T. longitudinal) sinus, into which many of them

protrude (Fig. 83). As a general rule, they are most evident towards the posterior part of the parietal region. At first sight they appear to be protrusions from the dura mater, but this is not the case. They spring from the arachnoid and the subarachnoid tissue, and are enlargements of the normal villi of the membrane (Fig. 84).

Two Layers of the Dura Mater.—Having noted these preliminary details from an examination of the outer surface of the dura mater, the student is in a position to understand that this membrane does not belong entirely to the brain. It performs a double function: (1) it acts as an internal periosteum to the bones forming the cranial cavity; and (2)

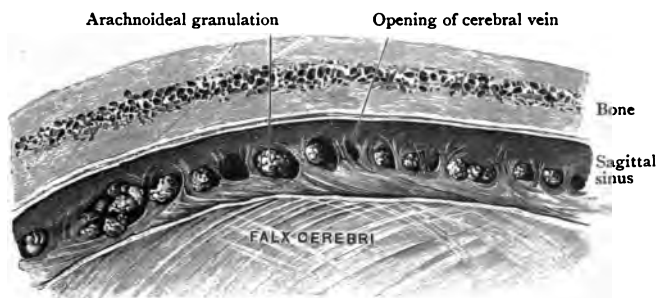


FIG. 83.—Median section through the Frontal Bone and corresponding part of the Superior Sagittal Blood Sinus. The arachnoideal granulations are seen protruding into the sinus. (Enlarged.)

it gives support to the different parts of the brain. Consequently, it consists of two strata, which, in most localities, are firmly adherent, but they can usually be easily demonstrated in the dissecting-room. These strata may very appropriately be termed the *endocranial* and the *supporting layers*. Along certain lines these two layers separate from each other. In some cases they separate so as to form blood channels, termed *sinus durae matris*, for the conveyance of venous blood; in other cases they separate in order that the inner supporting layer may form strong folds or partitions, which pass in between certain parts of the brain; and by these partitions the cranial cavity is divided into compartments communicating freely with one another, and each holding a definite subdivision of the brain (Fig. 87).

Dissection.—These points must now be verified. Begin †

head forwards. Support it in this position, and make two incisions through the dura mater in an antero-posterior direction—one on each side of the superior sagittal sinus, and along its whole length. From the mid-point of each of these incisions another cut must be made through each lateral portion of the dura mater downwards to the cut margin of the skull immediately above the ear (Fig. 85). The dura mater covering the upper aspect of the brain is thus divided into a central strip containing the superior sagittal sinus, and four triangular flaps. The flaps should now be turned downwards over the cut margin of the skull, and in this position they preserve the brain, during its removal, from laceration by the sharp bony edge.

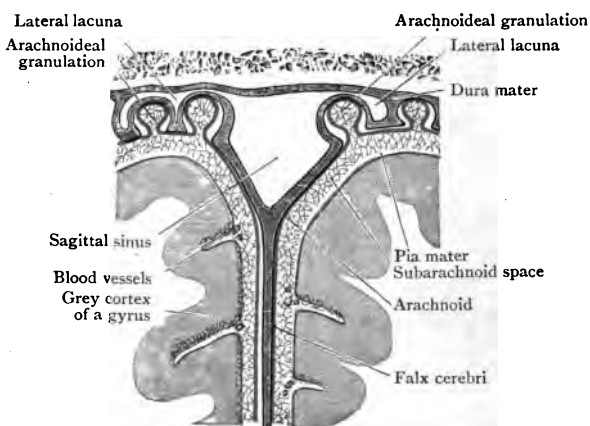


FIG. 84.—Diagram of a frontal section through the middle portion of the cranial vault and subjacent brain to show the membranes of the brain and the arachnoideal granulations.

Cavum Subdurale.—The subdural space is the term applied to the interval between the dura mater and the arachnoid—Figs. 83 and 84. It contains a very small quantity of serous fluid, which moistens the opposed surfaces of the membranes. A striking contrast between the two surfaces of the dura mater will be noted. The external surface is rough and flocculent; the internal surface is smooth and glistening.

Venæ Cerebri.—The cerebral veins which return the blood from the surface of the cerebral hemispheres will be seen shining through the arachnoid. They are lodged for the most part in the sulci between the gyri, and run upwards to the median plane. When they reach the superior sagittal sinus they turn anteriorly, and lie against the wall of the sinus, for some distance, before they open into it.

Sinus Sagittalis Superior (O.T. Superior Longitudinal).—Open into this venous channel by running the knife through its upper wall from behind forwards (Figs. 85 and 86). It begins anteriorly at the crista galli of the ethmoid bone, where it not infrequently communicates with the veins in the nasal cavity through the foramen cæcum. It extends

Frontal air sinus

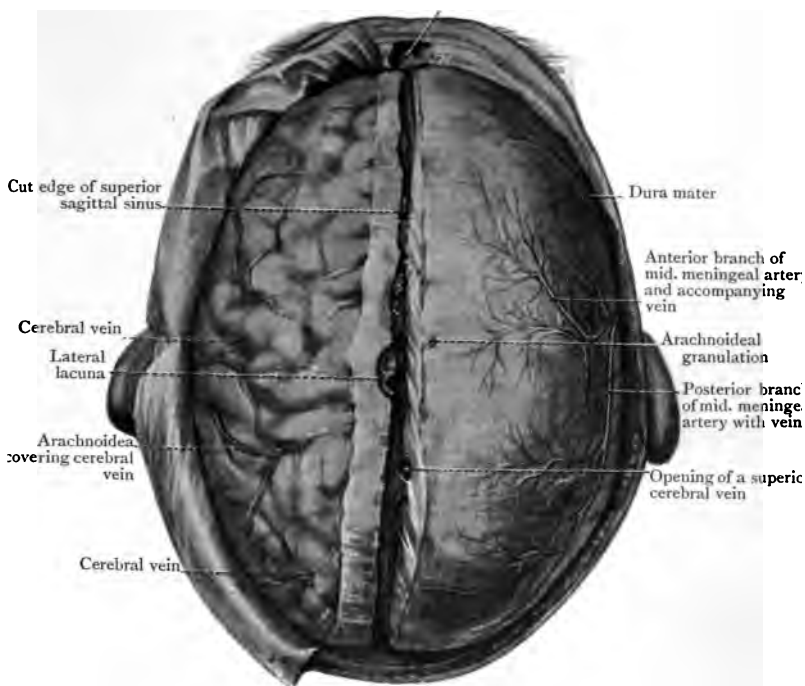


FIG. 85.—Superior Sagittal Sinus; Dura Mater; Middle Meningeal Artery and Veins; Arachnoidea and Superior Cerebral Veins.

posteriorly, grooving the cranial vault in the median plane, to the internal occipital protuberance, on the right aspect of which it becomes continuous with the right transverse sinus (O.T. lateral). Its lumen, which is triangular in cross-section, is very small anteriorly, but expands greatly posteriorly. On either side of the sinus, and opening into it, are a number of clefts between the two layers of the dura mater; th

the *lateral lacunæ*. The inferior angle of the channel is crossed by a number of minute bands, named *chorde Willisii*; and arachnoideal granulations bulge into it. The mouths of the superior cerebral veins open into the sinus, or into the lateral lacunæ, pouring their blood into the sinus in a direction contrary to that in which the blood flows within the

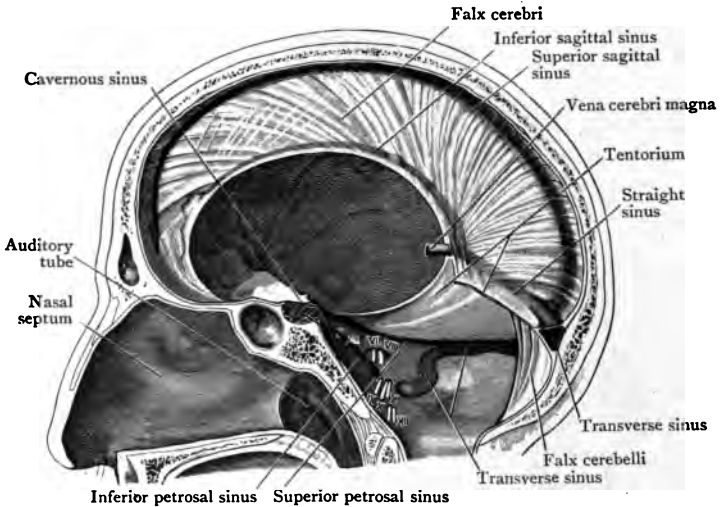


FIG. 86.—Sagittal section through the Skull a little to the left of the median plane to show the processes of Dura Mater.

- | | | |
|-----------------------|--|-----------------------------|
| V. Trigeminal nerve. | | IX. Glossopharyngeal nerve. |
| VII. Facial nerve. | | X. Vagus nerve. |
| VIII. Acoustic nerve. | | XI. Accessory nerve. |
| | | XII. Hypoglossal nerve. |

channel—that is, the terminal portions of the veins are directed anteriorly, whilst the blood in the sinus flows posteriorly.

The Relation of the Arachnoideal Granulations to the Superior Sagittal Sinus and the Lateral Lacunæ.—When the granulations push themselves into the sinus or the lateral lacunæ they push before them a thin continuous covering of the floor of the space, and when they project still further and encroach upon the bones of the skull they are covered also by a thin expansion of the roof of the space.

Falx Cerebri (Figs. 86, 87).—This is a sickle-shaped reduplication of the inner layer of the dura mater, which descends in the median plane, between the two cerebral hemispheres.

In order to expose it, the cerebral veins must be divided as they open into the superior sagittal sinus, and the hemisphere gently pulled laterally. Anteriorly, the falx cerebri is narrow, and attached to the crista galli of the ethmoid bone. It increases in breadth as it passes backwards, and posteriorly it is attached in the median plane to the upper surface of the tentorium cerebelli. The anterior part of the falx is frequently cribriform, and is sometimes perforated by apertures to such an extent that it almost resembles lace-work. Along

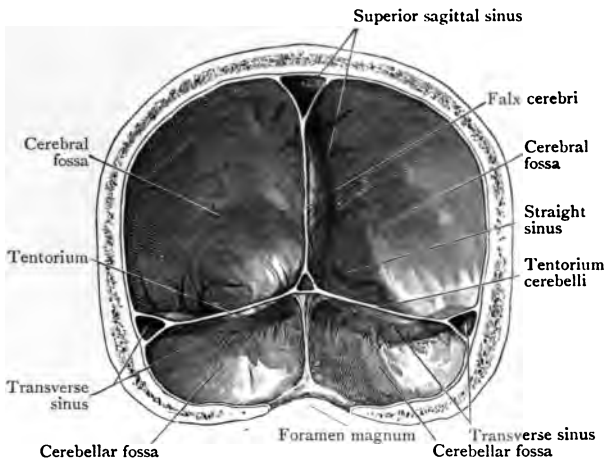


FIG. 87.—Frontal section through the Cranial Cavity in a plane which passes through the posterior part of the foramen magnum. The posterior part of the cranial cavity, from which the brain has been removed, is depicted.

each border its two layers separate to enclose a blood-sinus. Along its upper convex margin runs the *superior sagittal sinus*; along its concave free border courses the much smaller *inferior sagittal sinus*; whilst along its attachment to the tentorium is enclosed the *straight sinus*. Its inferior concave margin overhangs the corpus callosum, with which, however, it is not in contact, except to a very slight extent, posteriorly.

Removal of the Brain.—The dissectors should now proceed to remove the brain. Having divided the attachment of the falx cerebri to the crista galli, pull it posteriorly. Next, removing the block upon which the head rests, and supporting the occiput and posterior lobes of the brain with the left hand, let the head drop well downwards. In all probability the frontal lobes will fall away by their own weight from the anter-

of the base of the cranium, and perhaps carry with them the olfactory bulbs. Should they remain in position, however, gently raise them with the fingers, and at the same time separate the olfactory bulbs from the cribriform plate of the ethmoid with the handle of the knife. As the olfactory bulbs are raised the minute *olfactory nerves* which spring from them and perforate the cribriform plate of the ethmoid bone are torn across. The large round and white *optic nerves* (second pair of cerebral nerves) now come into view, as they leave the cranial cavity through the optic foramina. When these are divided, the *internal carotid arteries* will be exposed, and more posteriorly, in the median plane, the infundibulum will be seen; it is a hollow conical process which extends from the tuber cinereum at the base of the brain to the hypophysis (O.T. pituitary body), which lies in the fossa hypophyseos (O.T. pituitary fossa). Divide the carotid arteries and the infundibulum. Posterior to the infundibulum is the upper border of the dorsum sellæ, terminating on each side in the rounded posterior clinoid process. Passing anteriorly on each side of the dorsum sellæ is the corresponding third cerebral nerve, which must not be touched at present. A little more laterally, and on a slightly lower plane, is the medial or free border of the tentorium cerebelli, a fold of the inner layer of the dura mater which lies above the cerebellum and forms the roof of the posterior fossa of the cranium.

Carefully displace the temporal pole of the brain from under cover of the posterior border of the small wing of the sphenoid, which lies to the lateral side of the optic nerve and the cut end of the internal carotid artery; then raise the temporal lobe from the floor of the middle fossa, and from the upper surface of the tentorium cerebelli. Pass the knife posterior to the dorsum sellæ, immediately above the level of the third cerebral nerve, and cut through the midbrain, as it ascends from the posterior fossa, from its lateral surface inwards to the median plane. Repeat the operation in the same way on the opposite side, and remove the cerebrum and upper part of the midbrain from the cranium.¹

Place the removed cerebrum in the vault of the cranium and lay it aside. Then note the relative positions of the parts exposed. Anteriorly lies the floor of the anterior fossa of the cranium; behind it, on a more depressed plane, the middle fossa, and still more posteriorly the sloping tentorium cerebelli.

In the median plane anteriorly is the projecting crista galli, partially dividing the anterior fossa into lateral halves. On either side of the crista galli is the depression from which the olfactory bulb was dislodged, and still more laterally are the portions of the floor of the anterior fossa which form the roofs of the orbits; they bulge upwards as well-marked convexities. Each lateral part of the floor of the anterior fossa terminates posteriorly in a sharp margin, formed by the posterior border of the small wing of the sphenoid. This margin overhangs the anterior part of the middle fossa. It is covered with a thickening of dura mater in which runs the sphenoparietal blood sinus, and it terminates medially in a projecting process, the *anterior clinoid process*. On the medial side of each anterior clinoid process lie the corresponding optic nerve and internal carotid artery, and springing from the upper surface of the artery is its ophthalmic branch, which runs anteriorly under cover of the optic nerve. Posterior to the divided ends of the internal carotid arteries, and in the median plane, is the infundibulum descending into the hypophyseal fossa, and more posteriorly, on either side, are the projecting posterior clinoid processes. The area between the four clinoid processes is covered by a fold of the inner layer

¹ For alternative method see p. 217.

of the dura mater, termed the *diaphragma selle*. In its centre is an aperture through which the infundibulum passes to join the hypophysis (O.T. pituitary body); and it binds down the hypophysis in the fossa. In its anterior and posterior margins, respectively, are lodged the sinus intercavernosus anterior and the sinus intercavernosus posterior (O.T. circular sinus).

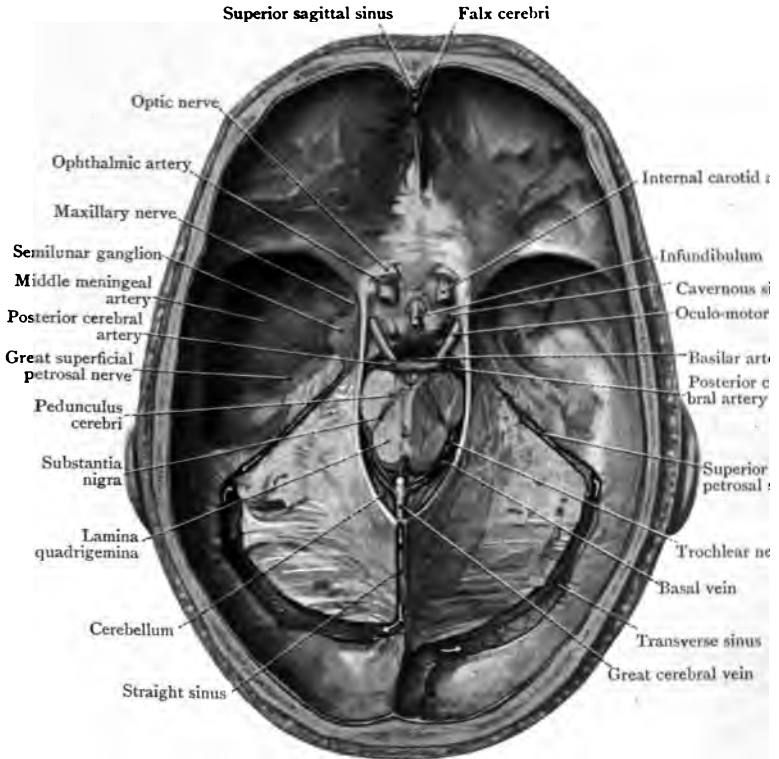


FIG. 88.—Interior of the Cranium after the removal of the cerebrum. The transverse, straight, and superior petrosal sinuses have been opened, and the dura mater has been removed from the floor of the middle fossa.

In the dura mater, on each side of the hypophyseal (pituitary) fossa, lies the corresponding cavernous sinus, which will be dissected later, and still more laterally are the depressed lateral portions of the middle cranial fossa, lined with dura mater, in which the trunk and some of the branches of

the middle meningeal artery are visible. Posterior to the middle fossa lies the tentorium cerebelli covering the cerebellum. The peripheral margin of the tentorium is attached, on each side, to the posterior clinoid process, the upper margin of the petrous part of the temporal bone, the posterior inferior angle of the parietal bone, and to the transverse ridge on the inner surface of the occipital bone. The central or free margin crosses the attached margin behind the posterior clinoid process on each side, and is attached anteriorly to the apex of the anterior clinoid process. It bounds an oval opening, the door of the tent, through which pass the midbrain surrounded by the arachnoid and the pia mater, and the posterior cerebral arteries. Piercing the midbrain nearer its posterior than its anterior border is the aquæductus cerebri (O.T. aqueduct of Sylvius). Posterior to the aqueduct is the lamina quadrigemina of the midbrain and anterior to it the pedunculi (O.T. crura) cerebri. Each peduncle consists of an anterior part, *the basis pedunculi* (O.T. *crusta*), and a posterior part, *the tegmentum*, the two being separated by a lamina of dark coloured tissue, *the substantia nigra*. The bases pedunculi are entirely free from each other, but the tegmental portions are united together anterior to the aqueduct.

Running anteriorly and laterally from the medial side of each peduncle to the angle between the anterior ends of the free and the attached borders of the tentorium, is the third cerebral nerve. Close to the midbrain the nerve passes between the posterior cerebral artery above and the superior cerebellar artery below; and between the free and attached borders of the tentorium it pierces the dura mater, in the middle fossa, and enters the wall of the cavernous sinus. Between the posterior ends of the third nerves lies the upper end of the basilar artery, dividing into the two posterior cerebral branches; and the dissectors should note that the arteries lie in an enlargement of the subarachnoid space which is known as the *cisterna interpeduncularis*. In the median plane posterior to the midbrain is the divided *vena cerebri magna* (O.T. *great vein of Galen*). It passes posteriorly and upwards, and pierces the apex of the tentorium to enter the straight sinus, which lies in the angle of union between the falx cerebri and the tentorium cerebelli.

Curving posteriorly around the midbrain and ending posteriorly in the great cerebral vein on each side is the *vena*

basalis, and immediately above it, running anteriorly, is the slender fourth cerebral nerve. If the free border of the tentorium is turned laterally, at the point where it is crossing the attached border, the fourth nerve will be seen perforating the inner layer of the dura mater to enter the wall of the cavernous sinus.

When the dissectors have verified the facts noted above, they should examine the lower free border of the falx cerebri, in which they will find the small *inferior sagittal sinus*, which terminates posteriorly, at the apex of the tentorium, in the straight sinus. The straight sinus must now be opened by carrying the knife posteriorly through the falx cerebri along its line of union with the tentorium. Then the falx cerebri must be cut away from the occipital bone, and as this is done the posterior part of the superior sagittal sinus will be opened up. After the falx has been removed the right and left transverse and the right and left superior petrosal sinuses must be opened by incisions carried along the attached border of the tentorium (Fig. 88). The dissectors will probably find that the superior sagittal sinus turns to the right and becomes continuous with the right transverse sinus, whilst the posterior end of the straight sinus turns to the left and joins the left transverse sinus. In a certain number of cases this arrangement is reversed, and not uncommonly, as in the specimen shown in Fig. 88, there is a communication between the right and left transverse sinuses across the front of the internal occipital protuberance. Occasionally the superior sagittal, the two transverse sinuses, the straight sinus, and the occipital sinus unite anterior to the internal occipital protuberance in a common dilatation, the *confluens sinuum* (O.T. torcular Herophili). The transverse sinus, on each side, runs from the internal occipital protuberance to the lateral end of the superior border of the petrous part of the temporal bone, where it dips downwards into the posterior fossa, and at the same point it is joined by the superior petrosal sinus, which runs postero-laterally along the superior border of the petrous part of the temporal bone from the cavernous sinus to the transverse sinus, connecting the two together.

Dissection.—With the point of the scalpel open the sphenoparietal sinus, which runs along the posterior border of the small wing of the sphenoid, and trace it medially to the cavernous sinus, but do not open the latter. Then remove the dura mater from the lateral part of the middle fossa on one side to expose the semilur (ian) ganglion of the

fifth nerve, the middle meningeal artery and its two terminal branches, the accessory meningeal artery, if it is present, and the great superficial petrosal nerve. Commence immediately to the lateral side of the anterior part of the free border of the tentorium, where a cut through the inner layer of the dura will open into a space (O.T. Meckel's cave) between the two layers of the dura, in which lies the *semilunar ganglion*. From the postero-medial border of the ganglion the *posterior branch* or *sensory root* passes backwards into the posterior fossa to enter the pons; and from its anterior-lateral border the *ophthalmic branch* passes upwards and anteriorly in the lateral wall of the cavernous sinus, the *maxillary branch* runs anteriorly to the foramen rotundum, and the *mandibular branch* passes downwards into the foramen ovale. By the side of the mandibular nerve the accessory meningeal artery may be found entering the cranium; and a little further posteriorly the *middle meningeal artery* will be seen passing into the middle fossa through the foramen spinosum. After entering the cranium the middle meningeal artery runs anteriorly and laterally, across the floor of the middle fossa, towards the lateral wall and divides into an anterior and a posterior branch; the former ascends on the anterior part of the lateral wall to the anterior inferior angle of the parietal bone, and the latter runs posteriorly and laterally, and then ascends on the inner surface of the squamous part of the temporal bone. The *great superficial petrosal nerve* appears on the anterior surface of the petrous part of the temporal bone through the *hiatus nervi facialis*, which lies to the medial side of the *eminentia arcuata*. It runs anteriorly and medially and disappears beneath the semilunar ganglion.

After the structures mentioned above have been found and cleaned, the dissectors must remove the tentorium cerebelli. Cut through the free border immediately posterior to the point where it crosses the attached border; the fourth nerve also will be divided by this incision. Repeat the incision on the opposite side, and then cut through the membrane close to its attached border, but to the medial sides of the superior petrosal and transverse sinuses; next divide the *venæ basales* at their points of junction with the *vena cerebri magna* (O.T. vein of Galen); then raise the anterior part of the tentorium and, passing the knife beneath it, separate it from the falx cerebelli, which is attached to its lower surface in the median plane. The tentorium may now be lifted out and the arachnoid covering the upper surface of the cerebellum will be exposed.

After the upper surface of the cerebellum has been cleaned, cut through the third cerebral nerves, and then press backwards the pedunculi cerebri and the pons (Varolii), which lies immediately below them, to expose the fifth and the sixth nerves. Cut the fifth nerves as they cross the upper borders of the petrous parts of the temporal bones, and then divide the small sixth nerves, which lie more medially and at a slightly deeper level. Press the pons and cerebellum still

further back and divide the seventh and eighth nerves as they enter the internal acoustic meatus. Below the eighth nerves lie the ninth, tenth, and eleventh nerves. These also

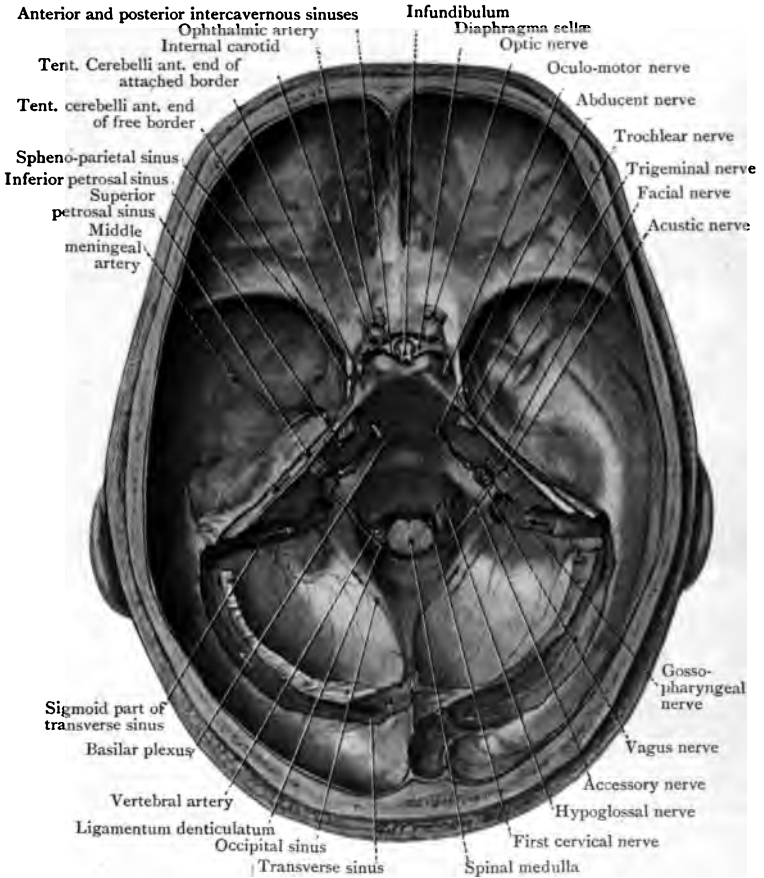


FIG. 89.—Dissection of the Interior of the Cranium after the removal of the Brain and the Tentorium Cerebelli.

must be cut; and the roots of the twelfth nerves, which lie deeper and more medially, must be identified and divided. The pons can then be displaced still further and the front of the medulla oblongata will be exposed into

view. Pass the knife downwards, anterior to the medulla oblongata, into the vertebral canal, and, cutting firmly backwards and laterally, on each side, divide the medulla spinalis and the vertebral arteries. Withdraw the knife, pass two fingers downwards anterior to the medulla oblongata and lift it and the pons and the cerebellum out of the posterior fossa. Place these lower parts of the brain, which collectively constitute the hind brain, with the hemispheres previously

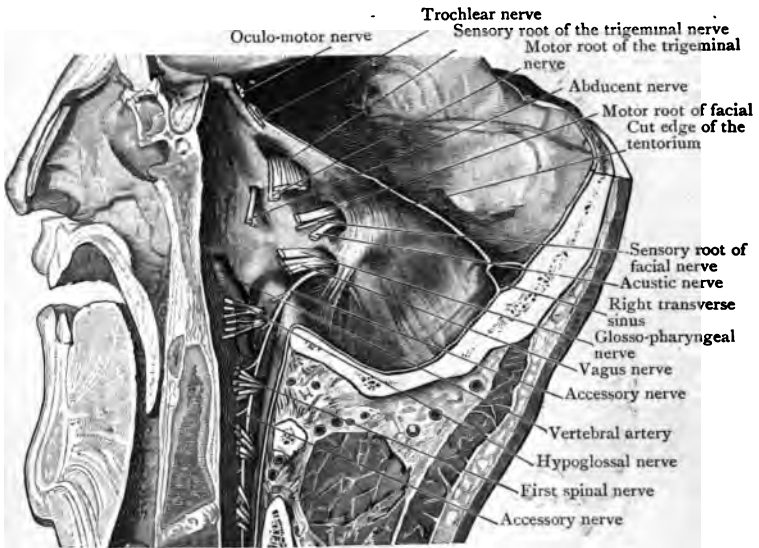


FIG. 90.—Section through the Head a little to the right of the Median Plane. It shows the posterior cranial fossa and the upper part of the vertebral canal after the removal of the brain and the medulla spinalis.

removed, and then examine the cut ends of the cerebral nerves and the blood sinuses which lie in the region of the posterior fossa.

In the upper end of the vertebral canal lies the upper extremity of the severed medulla spinalis, attached on either side to the margin of the foramen magnum by the uppermost dentation of the ligamentum denticulatum. Anterior to the ligamentum denticulatum, on each side, is the vertebral artery, and still more anteriorly, on a slightly deeper plane, the fila of the anterior root of the first cervical

nerve may be distinguished. At a higher level on each side the two rootlets of the hypoglossal nerve pierce the dura, as they pass into the hypoglossal canal (O.T. anterior condyloid foramen). The spinal root of the accessory nerve passes through the foramen magnum into the cranium, posterior to the ligamentum denticulatum, and, turning laterally over the margin of the foramen magnum, it joins the cerebral fibres of the accessory and the tenth nerve, with which it passes through an aperture in the dura opposite the jugular foramen. Immediately above the eleventh and tenth nerves the smaller trunk of the ninth nerve pierces the dura. Above the ninth nerve the eighth nerve and the motor and sensory roots of the seventh nerve pass into the internal acoustic meatus, accompanied by the small auditory branch of the basilar artery and the auditory vein. The two roots of the seventh nerve lie in a groove on the upper and anterior aspect of the eighth, the small sensory root (O.T. *pars intermedia*) being situated between the motor root and the eighth nerve. The small motor and the large sensory root of the fifth nerve pass through an opening in the dura which lies above and medial to the internal acoustic meatus; and the sixth nerve pierces the dura mater below and to the medial side of the opening for the fifth nerve, opposite the side of the base of the *dorsum sellæ*. The small fourth nerve pierces the under surface of the free border of the tentorium at the point where it is crossing the attached border.

After the dissectors have familiarised themselves with the positions of the cerebral nerves as they pierce the dura mater, they should examine the *falx cerebelli* and complete the display of the cranial blood sinuses.

The **Falx Cerebelli** is a small sagittal fold of the inner layer of the dura mater which projects anteriorly, between the lateral lobes of the cerebellum, from the internal occipital crest (Figs. 87, 89).

Sinus Transversus (O.T. Lateral).—The horizontal part of the transverse sinus has already been traced from the internal occipital protuberance to the superior border of the petrous part of the temporal bone, where it turns downwards to the jugular foramen. At first the descending portion runs downwards, on the inner surface of the mastoid part of the temporal bone, and then anteriorly and again downwards across the upper and anterior surfaces of the ju

of the occipital bone. On account of the sinuosity of its course this part is called the *sigmoid portion of the transverse sinus*. Open this part of the sinus and find the mouth of the mastoid emissary vein in its posterior border about half-way down.

The dissectors should now obtain the basal part of a macerated skull and should note the relation of the transverse sinus to the outer surface. They will find that the position of the sinus can be indicated on the external surface, by a line which commences at the external occipital protuberance, passes forwards, with a slight upward convexity, along the superior nuchal line to the upper part of the mastoid part of the temporal bone and then descends to the level of the lower margin of the external meatus.

Sinus Occipitalis.—The occipital sinus is not uncommonly absent. When it is present it commences in the right or left transverse sinus or the confluens sinuum, and descends for a short distance in the posterior border of the falx cerebelli. It terminates below in two lateral branches, which leave the falx cerebelli and run along the borders of the foramen magnum between the layers of the dura mater, to terminate anteriorly in the lower ends of the transverse sinuses.

Sinus Petrosus Inferior.—The inferior petrosal sinus lies along the posterior angle of the petrous part of the temporal bone extending from a point lateral to the opening for the sixth nerve to the medial side of the opening in the dura for the ninth nerve of the same side. Lay the sinus open. It opens anteriorly into the cavernous sinus, from which it receives blood, and it passes posteriorly through the jugular foramen to join the upper end of the internal jugular vein.

Plexus Basilaris.—The two inferior petrosal sinuses are connected together across the upper surface of the basilar part of the occipital bone by a plexus of small venous channels, to which the term basilar plexus is applied. Unless these channels happen to be distended with blood the dissectors will probably be unable to display this plexus.

The dissectors should note that the dura mater is much more firmly attached to the bones of the base than it was to the bones of the vertex, a fact which should have attracted their attention as they removed the membrane from the floor of the middle fossa. They should note also that it gives sheaths to the nerves which pierce it, and that at the margins

of the various foramina its outer layer becomes continuous with the periosteum on the outer surface of the cranium, whilst at the margin of the foramen magnum the inner layer becomes continuous with the single layer of dura mater which surrounds the medulla spinalis; and that at the same level the arachnoid and pia mater of the brain become continuous with the arachnoid and pia mater of the spinal medulla (O.T. spinal cord). Before terminating the survey of the interior of the cranium the dissectors should revise their knowledge of the blood vessels, and their relations to the dura mater; and they should remove the hypophysis (O.T. pituitary body) and investigate its naked-eye structure.

Sinus Durae Matris.—*Four blood sinuses lie in the median plane:* (1) the superior sagittal sinus in the upper or attached border of the falx cerebri; (2) the inferior sagittal sinus in the free part of the lower border of the falx cerebri; (3) the straight sinus along the line of attachment of the falx cerebri with the tentorium cerebelli; (4) the occipital sinus in the upper part of the attached border of the falx cerebelli.

Two sinuses lie in a higher horizontal plane: these are the sphenoparietal sinuses, which run along the posterior borders of the small wings of the sphenoid bone.

Six sinuses lie in a lower horizontal plane: (1) the two cavernous sinuses at the sides of the body of the sphenoid; (2) the two superior petrosal sinuses along the upper angles of the petrous parts of the temporal bones, in the anterior parts of the attached border of the tentorium cerebelli; (3) the horizontal parts of the transverse sinuses in the posterior parts of the attached border of the tentorium. The terminal parts of the transverse sinuses descend along the anterior parts of the lateral walls of the posterior fossa.

Two sinuses run obliquely downwards, posteriorly, and laterally: these are the two inferior petrosal sinuses.

Three sinuses run transversely connecting paired sinuses of opposite sides: (1) the anterior intercavernous sinus in the anterior border of the diaphragma sellæ; (2) the posterior intercavernous sinus in the posterior border of the diaphragma sellæ; and (3) the basilar plexus which connects together the inferior petrosal sinuses across the upper surface of the basilar part of the occipital bone.

ALTERNATIVE METHOD OF REMOVING THE BRAIN.—If it is thought desirable to remove the brain entire by the more rapid but less

method usually adopted in the post-mortem room, then the following steps should be taken after the falx cerebri has been detached from the crista galli and the dura mater lining the vault of the cranium has been thrown aside (see p. 204).

Remove the block upon which the head has been resting, and, supporting the occiput and the posterior part of the brain with the left hand, let the head drop well downwards and in all probability the weight of the frontal lobes will draw them away from the floor of the anterior fossa of the skull, and possibly the *olfactory lobes* may be carried with them. If the olfactory bulbs remain in position on the cribriform plates of the ethmoid at the sides of the crista galli, gently raise them with the handle of the scalpel and press them backwards on to the under surfaces of the frontal lobes. As the olfactory bulbs are raised the *olfactory nerve filaments* which pass from their lower surfaces through the cribriform plates are torn. As the frontal lobes are pressed backwards the large round and white *optic nerves* come into view as they are leaving the cranial cavity through the optic foramina. When these are divided the *internal carotid arteries* will be exposed, and more posteriorly in the median plane lies the *infundibulum*, a hollow conical process which connects the *hypophysis cerebri* (O.T. *pituitary body*) with the *tuber cinereum* at the base of the brain, and more laterally are the *oculo-motor nerves*. Sever each of these structures in turn. On the lateral side of each third nerve lies the medial or free border of the tentorium cerebelli passing anteriorly to be attached to the anterior clinoid process. Turn this margin aside with the point of the knife, and the minute *trochlear nerve* (fourth cerebral nerve) will be brought into view. It lies under shelter of the free border of the tentorium, and should be divided at this stage. The head must in the next place be turned forcibly round, so that the face is directed over the left shoulder. Raise the posterior part of the right cerebral hemisphere with the fingers, and note that it rests upon the tentorium cerebelli—a broad horizontal process of dura mater which intervenes between it and the cerebellum. Divide the tentorium along its attached border, and take care whilst doing this not to injure the subjacent cerebellum. Now turn the head so as to bring its left side uppermost, and treat the tentorium on that side in the same manner. The two parts of the *trigeminal nerve* (fifth cerebral nerve) perforating the dura mater near the apex of the petrous portion of the temporal bone; the *abducent nerve* (sixth cerebral nerve) piercing the dura mater behind the dorsum sellæ of the sphenoid bone; the *facial nerve* and the *acoustic nerve* disappearing into the internal acoustic meatus; the *glossopharyngeal*, the *vagus*, and the *accessory nerves* leaving the skull through the jugular foramen; and the two slips of the *hypoglossal nerve* piercing the dura mater over the hypoglossal canal (O.T. anterior condyloid foramen), will each in turn come into view upon either side, and must be divided in succession. In the case of the three nerves passing out of the cranium through the jugular foramen, the dissector should endeavour to leave the accessory of the right side intact within the cranium, by dividing its roots of origin from the medulla oblongata, whilst on the other side he should remove it with the brain. This nerve is readily recognised because it ascends from the vertebral canal into the cranial cavity through the foramen magnum. Now thrust the knife into the vertebral canal, and divide the medulla spinalis and the vertebral arteries, as they turn anteriorly upon the upper part of the medulla spinalis (O.T. spinal cord); then sever the accessory nerve of the left side, and the roots of the first pair of spinal nerves. When this has been done let the head fall well downwards, gently dislodge the medulla oblongata and cerebellum, and the whole brain can be removed. The *vena cerebri magna* (Galen), as it passes from the

interior of the brain to enter the straight sinus, is ruptured by this proceeding.

Meningeal Veins.—In addition to the named blood sinuses, venous channels accompany the meningeal arteries and more particularly the trunks and branches of the middle meningeal artery. These vessels are of wider calibre than the corresponding arteries, and lie external to them in the grooves on the inner surfaces of the cranial bones. When the arteries are distended they compress the middle parts of the veins and drive the blood into their anterior and posterior margins. When this occurs each artery appears to be accompanied by two veins, a circumstance which is probably responsible for the statement that some of the meningeal arteries have *venæ comites*.

Emissaria.—Emissary veins are blood channels which connect the sinuses of the dura mater with the veins which lie outside the cranium. They are: (1) Emissary veins connected with the superior sagittal sinus—(a) from the anterior extremity of the sinuses an emissary vein passes through the foramen cæcum. This vein divides below and either becomes continuous with the veins of the nasal fossæ, or its branches pass through foramina in the nasal bones and join the angular veins; (b) two parietal emissary veins, which pass through the parietal foramina and connect the superior sagittal sinus with the occipital veins. (2) Emissary veins connected with the transverse sinuses—(a) two mastoid emissary veins, one on each side, pass through the mastoid foramina and connect the sigmoid parts of the transverse sinuses with the posterior auricular veins; (b) two post-condyloid veins, one on each side, pass through the condyloid canals and connect the lower ends of the transverse sinuses with the plexuses of veins in the suboccipital triangles. (3) Emissary veins connected with the cavernous sinuses—(a) a vein which traverses the foramen ovale, or the foramen Vesalii, and connects the cavernous sinus with the plexus of veins around the external pterygoid muscle; (b) a plexus of veins which passes through the temporal bone with the internal carotid artery and connects the cavernous sinus with the pharyngeal venous plexus; (c) in a sense the ophthalmic vein may be considered an emissary vein, for although under ordinary circumstances it is a tributary of the sinus, blood can flow through it in the opposite direction from the sinus into the orbit, and then along the tributaries which connect the ophthalmic vein with the angular vein, and along the canals which connect the ophthalmic vein through the orbital fissure with the veins in the infratemporal region.

The Arteries of the Cranial Cavity.—(1) *The vertebral arteries*; (2) *the internal carotid arteries*; (3) *the meningeal arteries*.

Arteriæ Vertebrales.—The vertebral arteries pierce the spinal dura mater below the foramen magnum, through which they enter the cranium. As each artery passes through the foramen it lies anterior to the highest dentation of the ligamentum denticulatum, and it passes between the hypoglossal and first cervical nerves. It was divided when the hind brain was removed, and its cut extremity lies near its point of entrance into the cranial cavity.

Arteriæ Carotides Internæ.—Each internal carotid artery enters the cranium at the lacerate foramen between the apex of the petrous part of the temporal bone and the body of the sphenoid, where it pierces the outer layer of the dura mater. Then it runs anteriorly in the cavernous sinus to the medial side of the anterior clinoid process, where it turns upwards, pierces the inner layer of the dura mater and the arachnoid, and gives off its ophthalmic branch, which runs anteriorly below the optic nerve to the orbit. The artery was cut immediately behind its ophthalmic branch during the early stages of the removal of the brain.

Meningeal Arteries.—These are the nutrient arteries of the dura mater, and of the inner table and diploe of the cranial bones. They are derived from a great number of different sources, but the only one of any size is the *middle meningeal branch* of the internal maxillary artery. The others are small twigs, and, except in a well-injected subject, will not be easily made out. They are: (1) *anterior meningeal* from the anterior ethmoidal artery; (2) *the accessory meningeal* from the internal maxillary artery; (3) some small branches from the ascending pharyngeal, occipital, and vertebral arteries.

Each *middle meningeal artery* is a branch of the corresponding internal maxillary artery. It enters the cranium through the foramen spinosum of the sphenoid, and divides upon the inner surface of the great wing of that bone into two large terminal branches. Of these, the anterior branch ascends upon the great wing of the sphenoid, and the anterior inferior angle of the parietal bone, grooving both deeply, whilst the posterior branch turns posteriorly upon the squamous portion of the temporal bone. The branches which proceed from these trunks spread out widely and,

with the accompanying venous channels, occupy the arbor-
escent grooves on the inner surface of the cranial vault.

The vein which accompanies the middle meningeal artery passes through the foramen spinosum and ends in the plexus around the external pterygoid muscle.

Each *anterior meningeal artery* proceeds from the anterior ethmoidal artery as it accompanies the anterior ethmoidal nerve across the cribriform plate of the ethmoid bone. It supplies a limited area of dura mater and bone in the anterior fossa of the cranium.

The *accessory meningeal arteries* (O.T. *small meningeal*) are somewhat inconstant; they arise either directly from the

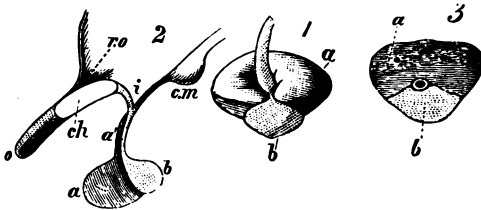


FIG. 91.—1, Hypophysis; 2, in median section; 3, in horizontal section. (Schwalbe.)

a. Anterior lobe.
b. Posterior lobe.
cm. Corpus mamillare.
i. Tuber cinereum.
ch. Optic chiasma in section.

ro. Optic recess of the third ventricle.
o. Optic nerve.
a'. Infundibulum with projection from anterior lobe upwards anterior to it.

internal maxillary or from the middle meningeal. Each enters the cranium through the corresponding foramen ovale, but it should not be looked for at the present stage, as it is best examined along with the semilunar (O.T. Gasserian) ganglion and the three divisions of the trigeminal nerve.

The *meningeal branches from the ascending pharyngeal arteries* are the terminal twigs of those vessels. They enter the cranium through the lacerate and jugular foramina, and through the hypoglossal canal (O.T. anterior condyloid foramen). The branch which passes through the jugular foramen is the largest.

The *meningeal branches of the occipital and vertebral arteries* are small, and are distributed in the posterior cranial fossa. The former enter through the jugular, mastoid, and parietal foramina, the latter through the foramen magnum.

The *meningeal veins* may be regarded as being arranged in two sets: one set consists of small channels which pour their blood into the blood sinuses; the other set is composed of veins which accompany the meningeal arteries and carry their blood to venous trunks on the exterior of the cranium.

Hypophysis Cerebri (O.T. Pituitary Body) (Fig. 91).—The over-hanging margin of the diaphragma sellæ should be cut away and the hypophysis carefully dislodged from the fossa hypophyseos (O.T. pituitary fossa) of the sphenoid bone. It is an oval structure, slightly flattened from above downwards, and with its long axis directed transversely. It consists of a large anterior lobe, and a smaller posterior lobe. The anterior lobe is hollowed out posteriorly so as to form a concavity for the lodgment of the posterior lobe. If a sagittal section is made through the body, the line of separation between the two lobes is seen very distinctly. The infundibulum, which connects the hypophysis with the tubèr cinereum of the brain, is attached to the posterior lobe only (Fig. 91, 1). Thus, even in the adult, there is a clue to the different modes of development of the two lobes. The posterior lobe is derived from the brain, whilst the anterior lobe is an off-shoot from the primitive buccal cavity.

When the inspection of the interior of the cranium is completed the dissectors must fill the cranial cavity with tow steeped in preservative solution; replace the skull-cap in position and retain it by bringing the scalp flaps over it, and stitching them accurately together. The brain must be put in a jar in a 5 per cent solution of formalin and placed aside till the dissection of the remaining parts of the head and neck is finished.

THE ANTERIOR PART OF THE NECK.

After the skull-cap has been replaced and the scalp has been stitched over it let the head hang down over the end of the table, pull the chin as far from the sternum as possible and fix it in position with hooks. Then examine the region of the front of the neck. It is a large triangular area, bounded laterally by the anterior borders of the sterno-mastoid muscles, above by the lower border of the mandible, and below by the middle part of the upper border of the manubrium sterni; and it is divided by the median plane into two smaller subsidiary triangles, *the anterior triangles of the neck*, each of which is bounded above by the mandible, posteriorly by the sterno-

mastoid, and anteriorly by the median plane. Pass the index finger from the chin to the sternum along the median line and locate in sequence the body of the hyoid bone, the angular anterior border of the thyroid cartilage, the rounded arch of the cricoid cartilage and the rings of the trachea. The latter are partly masked by the isthmus of the thyroid gland. Place the thumb and the forefinger on the body of the hyoid bone and carry them posteriorly, one on each side, along its great cornua. Note that the posterior ends of the cornua lie immediately in front of the anterior borders of the sternomastoid muscles. Above the body of the hyoid bone lies the *submental triangle* roofed in by the mylo-hyoid muscles, which form the diaphragm of the mouth; and above each great cornu is the corresponding *submaxillary region*. Between the body of the hyoid bone and the upper margin of the thyroid cartilage is the thyreo-hyoid space, bounded posteriorly by the middle part of the thyreo-hyoid membrane, which lies anterior to the upper part of the pharynx and the middle of the epiglottis (Fig. 159). Trace the upper border of the thyroid cartilage posteriorly and note that it terminates on each side in a pointed projection, the superior cornu, which lies immediately in front of the anterior border of the sternomastoid. Between the lower margin of the thyroid cartilage and the upper border of the cricoid cartilage lies the cricothyroid ligament, forming part of the anterior wall of the lower portion of the larynx.

The dissectors should make themselves thoroughly familiar with the landmarks mentioned above, both on their own necks and on the necks of their friends, and they should note that whilst in the dead subject there may be some difficulty in palpating the isthmus of the thyroid gland, as it crosses anterior to the second, third, and fourth rings of the trachea, they will have no difficulty in locating the small soft cushion-like mass in the living subject.

Dissection.—The skin was cut along the lower border of the mandible at the commencement of the dissection of the face; now, make a median incision through it from the chin to the sternum and turn the triangular flap, thus marked out, posteriorly and laterally, to a short distance beyond the anterior margin of the sternomastoid. When this is done the superficial fascia covering the anterior triangle on each side will be exposed. It is thickest and most laden with fat in the submental region. In part of it lie the fibres of the platysma, running upwards and towards the mandible. The anterior fibres of the muscle to the anterior part of the lower border of the mandible, and .

of the deep fascia is about half-way between the sternum and the thyrocartilage. The attachments of the second layer of deep fascia of the lower part of the neck may be summarised as follows. It is attached below to the posterior surface of the manubrium sterni and to the posterior border of the clavicle, to which it binds the posterior belly of the omo-hyoid (p. 145). Above, it fuses with the more superficial layer, along an oblique line which ascends from the level of the coracoid process to the level of the upper end of the trachea. Above that level it forms, with the superficial layer, a common lamella, which ascends on the infra-hyoid muscles to gain attachment to the body and great cornu of the hyoid bone. The space between the two layers contains, in the region of the anterior triangle, the lower parts of the anterior jugular veins, the anastomosis between them, and the areolar tissue in which they are embedded. In the posterior triangle its contents are the lower end of the external jugular vein, the terminations of the transverse cervical and transverse scapular veins, the transverse scapular artery, and areolar tissue. Note that the anterior jugular vein on each side lies superficial to the deep fascia in the upper part of the neck; then it pierces the first layer of deep fascia and lies between the two layers, where it anastomoses with its fellow of the opposite side; finally it turns laterally deep to the sterno-mastoid, and terminates in the external jugular vein at the anterior boundary of the sub-clavian part of the posterior triangle.

Dissection.—Make two incisions through the deep fascia of the upper part of the anterior triangle, one along the lower border of the mandible from the angle to half an inch from the chin, and a second at right angles to the first, from its middle to the great cornu of the hyoid bone. Whilst making the horizontal incision avoid injuring the external maxillary artery (O.T. facial) and the anterior facial vein, which pierce the deep fascia at the level of the anterior border of the masseter. Reflect the two triangular flaps of fascia marked out by the incisions and expose the lower surface of the submaxillary gland, the submaxillary lymph glands, the anterior and posterior bellies of the digastric muscle, the lower part of the stylo-hyoid muscle, and a further part of the anterior facial vein.

The majority of the submaxillary lymph glands lie the lower border of the mandible on the superficial surface of the submaxillary gland. The anterior facial vein crosses the posterior part of the submaxillary gland superficially. The external maxillary artery dips deeply between the mandible and the submaxillary gland.

and lower part of the submaxillary gland usually overlaps the stylo-hyoid and the posterior belly of the digastric muscles, and not infrequently it overlaps the great cornu of the hyoid bone also. Its anterior border may overlap the anterior belly of the digastric. Raise the lower border of the gland and expose another layer of deep fascia covering the muscles which lie deep to it. Place the handle of the knife on this fascia and push it gently upwards. Note that it passes upwards to the level of the mylo-hyoid line on the inner surface of the mandible, to which the mylo-hyoid muscle is attached. The fascial sheath in which the submaxillary gland is enclosed consists, therefore, of a superficial layer of deep fascia which extends from the great cornu of the hyoid bone to the lower border of the mandible, and a deeper layer which passes from the great cornu of the hyoid to the mylo-hyoid line of the mandible. The two layers blend in front of the anterior belly of the digastric, and posteriorly they unite, behind the posterior belly of the digastric, with the connective tissue in which the carotid vessels are embedded.

Dissection.—Remove the deep fascia in the region of the anterior triangle and expose the divisions and the contents of the triangle.

The Divisions of the Anterior Triangle.—After the deep fascia is removed, the dissector will recognise that each anterior triangle may be divided into three subsidiary areas which are called the digastric, the carotid, and the muscular triangles, by means of the two bellies of the digastric muscle and the anterior belly of the omo-hyoid muscle.

The *digastric triangle* is bounded by the two bellies of the digastric muscle and the lower border of the mandible.

The boundaries of the *carotid triangle* are, above and in front, the posterior belly of the digastric; below and in front, the anterior belly of the omo-hyoid; and, behind, the anterior border of the sterno-mastoid.

The *muscular triangle* is bounded, above and behind, by the anterior belly of the omo-hyoid; below and behind, by the anterior border of the sterno-mastoid; and in front, by the middle line of the neck.

An additional triangle common to the two sides lies between the hyoid bone below, the two anterior bellies of the digastrics laterally, and the mandible above. This is called the *submental triangle*.

The Middle Line of the Neck.—Before commencing the

dissection of the contents of the subsidiary parts of the anterior triangle the dissectors of both sides should, together, study the structures which lie in the middle line of the neck and immediately to either side of it; for this region is of the highest importance to the surgeon. The area is divided by the hyoid bone into supra-hyoid and infra-hyoid portions.

In the *supra-hyoid part* lie structures which are concerned in the construction of the floor of the mouth. The dissector

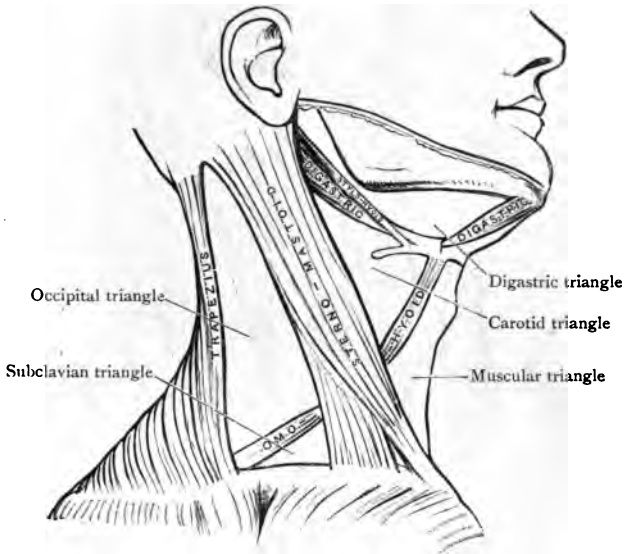


FIG. 92.—Diagram to show the Boundaries of the Triangles of the Neck.

will have noticed already that the fatty superficial fascia is more fully developed here than elsewhere in the neck, and that the anterior margins of the two platysma muscles meet and decussate in the median plane, for about half an inch or so, below the chin. The anterior bellies of the two digastric muscles are attached to the mandible, one on either side of the symphysis. From this they descend towards the hyoid bone, and diverge slightly from each other so as to leave a narrow triangular space, the *submental triangle*, between them (Fig. 93). The floor of this space is formed by the anterior portions of the two mylo-hyoid muscles, whilst

and lower part of the submaxillary gland usually overlaps the stylo-hyoid and the posterior belly of the digastric muscles, and not infrequently it overlaps the great cornu of the hyoid bone also. Its anterior border may overlap the anterior belly of the digastric. Raise the lower border of the gland and expose another layer of deep fascia covering the muscles which lie deep to it. Place the handle of the knife on this fascia and push it gently upwards. Note that it passes upwards to the level of the mylo-hyoid line on the inner surface of the mandible, to which the mylo-hyoid muscle is attached. The fascial sheath in which the submaxillary gland is enclosed consists, therefore, of a superficial layer of deep fascia which extends from the great cornu of the hyoid bone to the lower border of the mandible, and a deeper layer which passes from the great cornu of the hyoid to the mylo-hyoid line of the mandible. The two layers blend in front of the anterior belly of the digastric, and posteriorly they unite, behind the posterior belly of the digastric, with the connective tissue in which the carotid vessels are embedded.

Dissection.—Remove the deep fascia in the region of the anterior triangle and expose the divisions and the contents of the triangle.

The Divisions of the Anterior Triangle.—After the deep fascia is removed, the dissector will recognise that each anterior triangle may be divided into three subsidiary areas which are called the digastric, the carotid, and the muscular triangles, by means of the two bellies of the digastric muscle and the anterior belly of the omo-hyoid muscle.

The *digastric triangle* is bounded by the two bellies of the digastric muscle and the lower border of the mandible.

The boundaries of the *carotid triangle* are, above and in front, the posterior belly of the digastric; below and in front, the anterior belly of the omo-hyoid; and, behind, the anterior border of the sterno-mastoid.

The *muscular triangle* is bounded, above and behind, by the anterior belly of the omo-hyoid; below and behind, by the anterior border of the sterno-mastoid; and in front, by the middle line of the neck.

An additional triangle common to the two sides lies between the hyoid bone below, the two anterior bellies of the digastrics laterally, and the mandible above. This is called *the submental triangle*.

The Middle Line of the Neck.—Before commencing the

dissection of the contents of the subsidiary parts of the anterior triangle the dissectors of both sides should, together, study the structures which lie in the middle line of the neck and immediately to either side of it; for this region is of the highest importance to the surgeon. The area is divided by the hyoid bone into supra-hyoid and infra-hyoid portions.

In the *supra-hyoid part* lie structures which are concerned in the construction of the floor of the mouth. The dissector

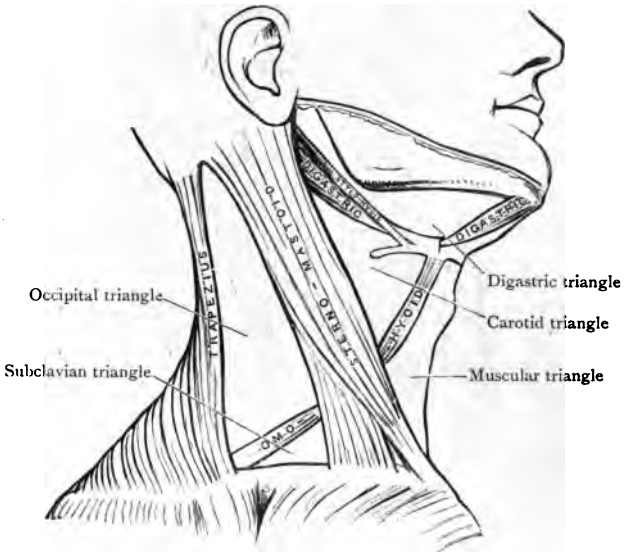


FIG. 92.—Diagram to show the Boundaries of the Triangles of the Neck.

will have noticed already that the fatty superficial fascia is more fully developed here than elsewhere in the neck, and that the anterior margins of the two platysma muscles meet and decussate in the median plane, for about half an inch or so, below the chin. The anterior bellies of the two digastric muscles are attached to the mandible, one on either side of the symphysis. From this they descend towards the hyoid bone, and diverge slightly from each other so as to leave a narrow triangular space, the *submental triangle*, between them (Fig. 93). The floor of this space is formed by the anterior portions of the two mylo-hyoid muscles. whilst

and lower part of the submaxillary gland usually overlaps the stylo-hyoid and the posterior belly of the digastric muscles, and not infrequently it overlaps the great cornu of the hyoid bone also. Its anterior border may overlap the anterior belly of the digastric. Raise the lower border of the gland and expose another layer of deep fascia covering the muscles which lie deep to it. Place the handle of the knife on this fascia and push it gently upwards. Note that it passes upwards to the level of the mylo-hyoid line on the inner surface of the mandible, to which the mylo-hyoid muscle is attached. The fascial sheath in which the submaxillary gland is enclosed consists, therefore, of a superficial layer of deep fascia which extends from the great cornu of the hyoid bone to the lower border of the mandible, and a deeper layer which passes from the great cornu of the hyoid to the mylo-hyoid line of the mandible. The two layers blend in front of the anterior belly of the digastric, and posteriorly they unite, behind the posterior belly of the digastric, with the connective tissue in which the carotid vessels are embedded.

Dissection.—Remove the deep fascia in the region of the anterior triangle and expose the divisions and the contents of the triangle.

The Divisions of the Anterior Triangle.—After the deep fascia is removed, the dissector will recognise that each anterior triangle may be divided into three subsidiary areas which are called the digastric, the carotid, and the muscular triangles, by means of the two bellies of the digastric muscle and the anterior belly of the omo-hyoid muscle.

The *digastric triangle* is bounded by the two bellies of the digastric muscle and the lower border of the mandible.

The boundaries of the *carotid triangle* are, above and in front, the posterior belly of the digastric; below and in front, the anterior belly of the omo-hyoid; and, behind, the anterior border of the sterno-mastoid.

The *muscular triangle* is bounded, above and behind, by the anterior belly of the omo-hyoid; below and behind, by the anterior border of the sterno-mastoid; and in front, by the middle line of the neck.

An additional triangle common to the two sides lies between the hyoid bone below, the two anterior bellies of the digastrics laterally, and the mandible above. This is called *the submental triangle*.

The Middle Line of the Neck.—Before commencing the

dissection of the contents of the subsidiary parts of the anterior triangle the dissectors of both sides should, together, study the structures which lie in the middle line of the neck and immediately to either side of it; for this region is of the highest importance to the surgeon. The area is divided by the hyoid bone into supra-hyoid and infra-hyoid portions.

In the *supra-hyoid part* lie structures which are concerned in the construction of the floor of the mouth. The dissector

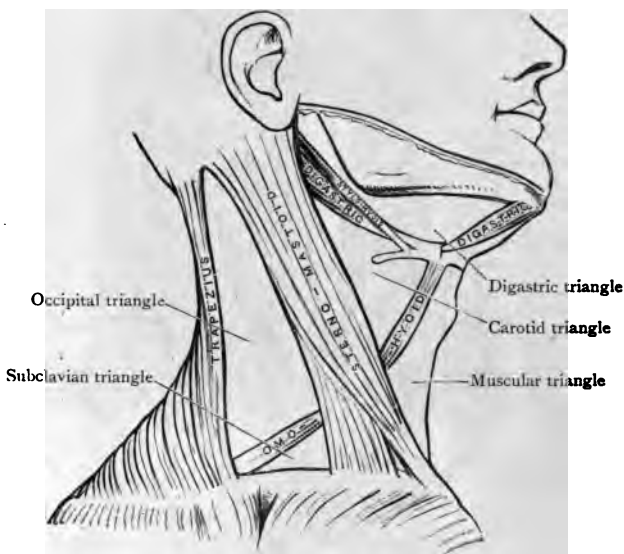


FIG. 92.—Diagram to show the Boundaries of the Triangles of the Neck.

will have noticed already that the fatty superficial fascia is more fully developed here than elsewhere in the neck, and that the anterior margins of the two platysma muscles meet and decussate in the median plane, for about half an inch or so, below the chin. The anterior bellies of the two digastric muscles are attached to the mandible, one on either side of the symphysis. From this they descend towards the hyoid bone, and diverge slightly from each other so as to leave a narrow triangular space, the *submental triangle*, between them (Fig. 93). The floor of this space is formed by the anterior portions of the two mylo-hyoid muscles, whilst

and lower part of the submaxillary gland usually overlaps the stylo-hyoid and the posterior belly of the digastric muscles, and not infrequently it overlaps the great cornu of the hyoid bone also. Its anterior border may overlap the anterior belly of the digastric. Raise the lower border of the gland and expose another layer of deep fascia covering the muscles which lie deep to it. Place the handle of the knife on this fascia and push it gently upwards. Note that it passes upwards to the level of the mylo-hyoid line on the inner surface of the mandible, to which the mylo-hyoid muscle is attached. The fascial sheath in which the submaxillary gland is enclosed consists, therefore, of a superficial layer of deep fascia which extends from the great cornu of the hyoid bone to the lower border of the mandible, and a deeper layer which passes from the great cornu of the hyoid to the mylo-hyoid line of the mandible. The two layers blend in front of the anterior belly of the digastric, and posteriorly they unite, behind the posterior belly of the digastric, with the connective tissue in which the carotid vessels are embedded.

Dissection.—Remove the deep fascia in the region of the anterior triangle and expose the divisions and the contents of the triangle.

The Divisions of the Anterior Triangle.—After the deep fascia is removed, the dissector will recognise that each anterior triangle may be divided into three subsidiary areas which are called the digastric, the carotid, and the muscular triangles, by means of the two bellies of the digastric muscle and the anterior belly of the omo-hyoid muscle.

The *digastric triangle* is bounded by the two bellies of the digastric muscle and the lower border of the mandible.

The boundaries of the *carotid triangle* are, above and in front, the posterior belly of the digastric; below and in front, the anterior belly of the omo-hyoid; and, behind, the anterior border of the sterno-mastoid.

The *muscular triangle* is bounded, above and behind, by the anterior belly of the omo-hyoid; below and behind, by the anterior border of the sterno-mastoid; and in front, by the middle line of the neck.

An additional triangle common to the two sides lies between the hyoid bone below, the two anterior bellies of the digastrics laterally, and the mandible above. This is called *the submental triangle*.

The Middle Line of the Neck.—Before commencing the

dissection of the contents of the subsidiary parts of the anterior triangle the dissectors of both sides should, together, study the structures which lie in the middle line of the neck and immediately to either side of it; for this region is of the highest importance to the surgeon. The area is divided by the hyoid bone into supra-hyoid and infra-hyoid portions.

In the *supra-hyoid part* lie structures which are concerned in the construction of the floor of the mouth. The dissector

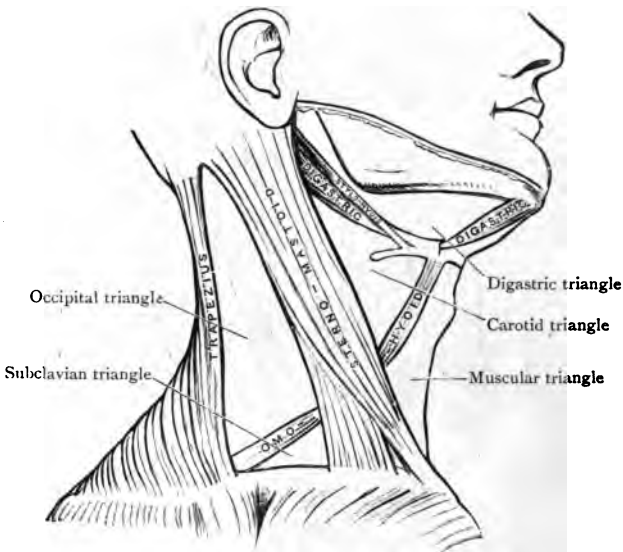


FIG. 92.—Diagram to show the Boundaries of the Triangles of the Neck.

will have noticed already that the fatty superficial fascia is more fully developed here than elsewhere in the neck, and that the anterior margins of the two platysma muscles meet and decussate in the median plane, for about half an inch or so, below the chin. The anterior bellies of the two digastric muscles are attached to the mandible, one on either side of the symphysis. From this they descend towards the hyoid bone, and diverge slightly from each other so as to leave a narrow triangular space, the *submental triangle*, between them (Fig. 93). The floor of this space is formed by the anterior portions of the two mylo-hyoid muscles, whilst

bisecting the floor of the triangle, in the median plane, is the fibrous raphe into which these muscles are inserted. Not infrequently the medial margins of the digastric muscles send decussating fibres across the interval. Within the submental triangle are the *submental glands*, which receive lymph from

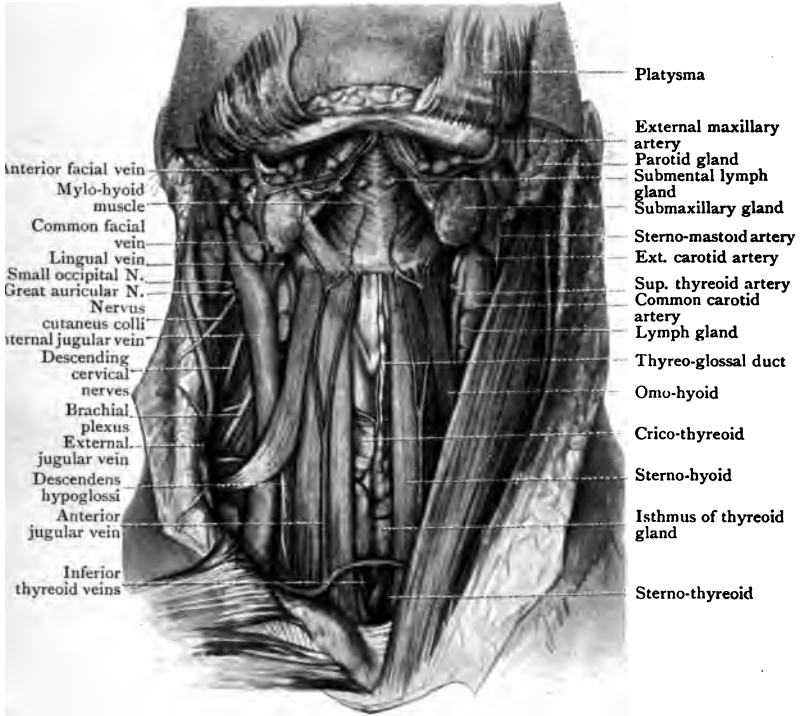


FIG. 93.—Dissection of the Front of the Neck. The Right Sterno-mastoid has been removed.

the median part of the lower lip and chin and the anterior part of the tongue.

In the median area of the *infra-hyoid part* there is a narrow intermuscular interval, bounded on each side, above, by the medial margins of the sterno-hyoid muscles, and to a smaller extent, below, by the medial margins of the sterno-thyreoid muscles (Fig. 93); more laterally lie the anterior bellies

of the omo-hyoid muscles. In this median intermuscular interval the following structures will be found: (1) the median part of the thyreo-hyoid membrane; (2) the anterior border of the thyreoid cartilage with the projecting *prominentia laryngea* (O.T. *pomum adami*) at its upper end; (3) the arch of the cricoid cartilage; (4) the crico-thyreoid ligament with the anastomosis between the crico-thyreoid arteries, and the anterior ends of the crico-thyreoid muscles; (5) the first ring of the trachea with the anastomosis between the medial terminal branches of the superior thyreoid arteries; (6) the isthmus of the thyreoid gland; (7) the inferior thyreoid veins, and (8) the lower cervical rings of the trachea. Occasionally the third or middle lobe of the thyreoid gland and the *levator glandulæ thyreoideæ*, or one or other of them, is found extending upwards from the isthmus of the thyreoid gland. When it is present the middle lobe either terminates above in a pointed extremity or becomes continuous with a fibrous cord, the remains of the thyreo-glossal duct, which disappears posterior to the hyoid bone. The *levator* extends from the isthmus or from the third lobe, and is attached above to the lower border of the hyoid bone.

Dissection.—To display these structures fully the fascia which covers and binds together the infra-hyoid muscles of opposite sides must be removed. When this has been done the anterior part of the thyreoid cartilage will be exposed, and, above it, in the thyreo-hyoid interval, lies some loose areolar tissue. If an incision, directed upwards and posteriorly, is made into this tissue, behind the lower border of the hyoid bone, the infra-hyoid bursa will be opened, and when this and the areolar tissue are removed, the thyreo-hyoid membrane will be exposed. Note that the membrane extends from the upper border of the thyreoid cartilage posterior to the body of the hyoid bone to its upper border. When the areolar tissue in the lower part of the intermuscular interval is removed the inferior thyreoid veins will be displayed; they disappear, below, behind the sternum where they join the innominate veins. Occasionally also a small unpaired artery, the *thyreoidea ima*, will be found ascending, in the median plane, to the isthmus of the thyreoid gland. Behind the inferior thyreoid veins lies another layer of deep cervical fascia, the pretracheal layer. It covers the front of the trachea, envelops the isthmus of the thyreoid gland, and is attached above to the lower border of the thyreoid cartilage. The part which extends from the isthmus of the thyreoid gland to the thyreoid cartilage acts as a suspensory ligament of the isthmus. The dissectors will find that, so long as the attachments of this part of the pretracheal fascia are not interfered with, they cannot displace the isthmus of the thyreoid gland downwards. On the other hand, if they cut through the attachment of the fascia to the thyreoid cartilage, introduce the handle of the knife through the incision, and press downwards, they will be able to displace the isthmus of the thyreoid gland to a lower level and expose the upper rings of the trachea. At the root of the neck the pretracheal fascia descends into the thorax,

along the anterior surface of the trachea, and it blends below with the fibrous pericardium.

Remove the pretracheal fascia from the region of the intermuscular interval, first above and then below the isthmus of the thyroid gland. As the fascia is dissected away the following structures will be displayed. Immediately below the thyroid cartilage is the crico-thyroid ligament, overlapped on each side by the anterior part of the crico-thyroid muscle. Crossing anterior to the ligament, transversely, is the anastomosis between the crico-thyroid branches of the superior thyroid arteries. It lies nearer the lower than the upper border of the ligament. Below the crico-thyroid ligament is the convex anterior part of the cricoid cartilage; then follows the crico-tracheal ligament, uniting the cricoid cartilage to the first ring of the trachea. The isthmus of the thyroid gland lies at a lower level opposite the second, third, and fourth rings of the trachea. Along its upper border is the anastomosis between the medial terminal branches of the superior thyroid arteries, and below it are the lower cervical tracheal rings.

The superficial layers of the deep fascia must now be removed from the whole area of each anterior triangle, and for this purpose and for the satisfactory dissection of the contents of the triangles, it is necessary that the head be turned well over to the opposite side; therefore the dissectors must arrange to work alternately.

Commence with the digastric triangle. Its boundaries are the lower border of the mandible and the two bellies of the digastric muscle.

Its contents are: (1) the lower part of the submaxillary gland; (2) the submaxillary lymph glands; (3) part of the external maxillary artery; (4) part of the anterior facial vein; (5) the mylo-hyoid nerve; (6) the mylo-hyoid artery; (7) a small part of the hypoglossal nerve; (8) a small part of the lingual vein.

Dissection.—Remove the deep fascia which was previously turned aside (p. 225) and clean the submaxillary lymph glands. Most of these glands lie immediately below the mandible in the angle between it and the submaxillary gland, but some may be found on the superficial surface of the gland. Turn the gland upwards and fix it with hooks; then secure the mylo-hyoid nerve and artery as they enter the posterior border of the anterior belly of the digastric about the middle of its length. Define the band of fascia which surrounds the intermediate tendon of the digastric and binds it to the great cornu of the hyoid bone. Note that the tendon is embraced by the cleft lower end of the stylo-hyoid muscle. Clean the posterior belly of the digastric and the stylo-hyoid muscle which descends along its anterior border. Note that the posterior belly of the digastric and the stylo-hyoid disappear, postero-superiorly, under cover of the angle of the mandible. Clean the anterior belly of the digastric, and then examine the floor or medial boundary of the triangle. Immediately behind the anterior belly of the digastric it is formed by the posterior fibres of the mylo-hyoid muscle; and more posteriorly and on a deeper plane it is formed by the hyoglossus.

Clean the portion of the mylo-hyoid which is exposed and, at its posterior border, immediately above the great cornu of the hyoid bone,

secure the hypoglossal nerve and the lingual vein, the vein lying below the nerve. Displace the lingual vein and the hypoglossal nerve upwards; cut through the fibres of the hyoglossus, immediately above and parallel with the great cornu, and display the lingual artery, which in this position lies immediately above the great cornu, parallel with the lingual vein but separated from it by the hyoglossus muscle.

All the structures which have been mentioned above will be met with in the dissection of other regions, when a full account of them will be given.

Turn next to the carotid triangle, so called because it contains parts of the common, internal, and external carotid arteries. It is bounded posteriorly by the anterior border of the sterno-mastoid; above and anteriorly by the posterior belly of the digastric; and below and anteriorly by the anterior belly of the omo-hyoid.

Dissection.—Trace the anterior facial vein from the digastric triangle across the superficial surface of the posterior belly of the digastric to its posterior border, where it unites with the posterior facial vein, which is descending from under cover of the lower end of the parotid gland. The trunk formed by the union of the anterior and posterior facial veins is the common facial vein. Trace the common facial vein downwards and posteriorly to its union with the internal jugular vein, at or under cover of the anterior border of the sterno-mastoid. Remove the deep fascia and the areolar tissue, and the lymph glands which lie in the angle between the posterior belly of the digastric and the anterior border of the sterno-mastoid, below the lower end of the parotid gland; secure the lingual vein, which passes backwards from the tip of the great cornu of the hyoid bone to join the internal jugular vein; and the hypoglossal nerve as it crosses anteriorly at a higher level, superficially to the internal and external carotid arteries. As the nerve turns anteriorly across the large arteries it is itself crossed, superficially, by the sterno-mastoid branch of the occipital artery, and it gives off its descending branch. Trace the descending branch downwards, in the fascia which lies superficial to the lower part of the internal and the upper part of the common carotid arteries, to the point where it disappears under cover of the anterior belly of the omo-hyoid, avoiding injury to the lingual, common facial, and superior thyreoid veins;¹ and secure the communicating branch, from the second and third cervical nerves, which joins its posterior aspect. The latter nerve may cross either superficial or deep to the internal jugular vein. Return to the hypoglossal nerve at the point where it gives off its descending branch, and trace it anteriorly to the upper aspect of the posterior end of the great cornu of the hyoid bone, where it gives off the branch of supply to the thyreo-hyoid muscle. Trace the branch into that muscle below the level of the great cornu, then follow the trunk of the hypoglossal anteriorly to the digastric triangle. Note that as it runs anteriorly it passes deep to the posterior belly of the digastric and the stylo-hyoid muscle, and superficial to the hyoglossus, which ascends to the tongue from

¹ The lingual vein may join the common facial vein, in which case the latter usually enters the internal jugular opposite the interval between the hyoid bone and the thyreoid cartilage, as in the specimen depicted in Fig. 93. The superior thyreoid vein joins the internal jugular or the common facial vein opposite the thyreo-hyoid interval.

the upper border of the great cornu. Remove the fascial sheath from the superficial surfaces of the lower parts of the internal and external carotid arteries, and from the upper part of the common carotid artery. Note that the latter divides into the two former at the level of the upper border of the thyroid cartilage, and that the external carotid is at first medial and anterior to the internal carotid.

Five branches may spring from the external carotid in the carotid triangle, three from its anterior surface: the superior thyroid, the lingual and the external maxillary; one from its medial surface, the ascending pharyngeal; and one from its posterior surface, the occipital; but not uncommonly the occipital and the external maxillary arise beyond the limits of the carotid triangle under cover of the posterior belly of the digastric. The superior thyroid springs from the front of the lower part of the external carotid below the level of the great cornu of the hyoid and runs downwards to the lower angle of the carotid triangle, where it disappears under cover of the anterior belly of the omo-hyoid. The lingual arises immediately above the level of the tip of the great cornu. It runs anteriorly above the level of the cornu, forming a loop, convex upwards, which lies deep to the hypoglossal nerve; and it disappears under cover of the posterior border of the hyoglossus muscle. The ascending pharyngeal branch, which springs from the medial surface of the lower end of the external carotid, ascends on a deeper plane, between the external and internal carotids and the wall of the pharynx, and will be followed at a later stage of the dissection. The external maxillary and the occipital arise immediately below the posterior belly of the digastric and almost at once disappear under cover of the muscle; not uncommonly they arise under cover of its lower border. Before proceeding to clean the branches of the external carotid secure the internal and external laryngeal branches of the superior laryngeal branch of the vagus nerve. The internal branch will be found in the posterior part of the thyreo-hyoid interval below the great cornu of the hyoid bone and behind the posterior border of the thyreo-hyoid muscle, beneath which it disappears. It is accompanied by the laryngeal branch of the superior thyroid artery. The external branch is more difficult to find; but, if the superior thyroid artery and the upper part of the common carotid are displaced posteriorly, the nerve will be found, lying deep to them, in the fascia which covers the anterior part of the inferior constrictor muscle. Remove the fascia from the surface of the internal jugular vein, which overlaps the posterior borders of the common and internal carotid arteries. Dissect in the interval between the vein and the arteries and secure the vagus nerve, which lies deeply. Remove the remains of the fascia from the carotid arteries and the internal jugular vein, but avoid injury to the hypoglossal nerve and its branches; and note the presence of the upper deep cervical lymph glands which lie on the superficial surfaces of the great arteries and the internal jugular vein. The glands are sometimes very large, and the dissectors should remember that they receive lymph from the face, the mouth and tongue, the posterior part of the nose and the upper part of the pharynx. After the large vessels are cleaned, remove the fascia from the branches of the external carotid artery and the twigs they give off, so far as they lie in the region of the carotid triangle. Commence with the superior thyroid. Immediately after its origin it gives off a small infra-hyoid branch, then a laryngeal branch which accompanies the internal laryngeal branch of the superior laryngeal nerve; and, just before it disappears under cover of the anterior belly of the omo-hyoid, a sterno-mastoid branch arises from its posterior border and runs downwards and posteriorly, along the upper border of the omo-hyoid, across the superficial aspect of the common carotid artery and the internal jugular vein.

Next, clean the lingual artery and note its small supra-hyoid branch. The external maxillary artery gives off no branches in the carotid triangle, but a sterno-mastoid branch of the occipital artery will usually be found passing downwards and posteriorly, superficial to the loop of the hypoglossal nerve. Push the lower border of the parotid gland upwards, and immediately under cover of it, at the level of the angle of the mandible, secure the accessory

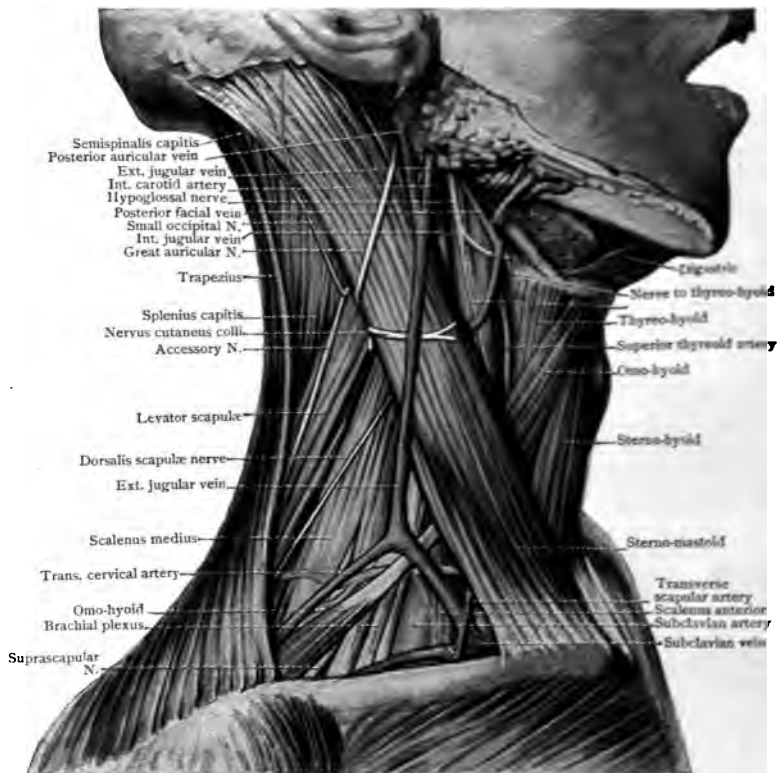


FIG. 94.—The Triangles of the Neck seen from the side. The clavicular head of the sterno-mastoid muscle was small, and therefore a considerable part of the scalenus anterior muscle is seen.

nerve, as it emerges from under cover of the posterior belly of the digastric and crosses superficial to the internal jugular vein. It is sometimes accompanied by an additional branch to the sterno-mastoid from the occipital artery.

The floor or medial boundary of the carotid triangle is formed by the upper part of the thyreo-hyoid muscle, the

posterior part of the hyoglossus and the middle constrictors of the pharynx. The two latter muscles be displaced at present, but the thyreo-hyoid is exposed, the great cornu of the hyoid bone, and part of the cricoid cartilage can be seen in the angle between the great cornu of the hyoid bone and the lower part of the posterior belly of the digastric muscle.

The Muscular Triangle.—When the deep fascia is removed the muscular triangle is removed portions of the floor. Three muscles are brought into view. Posteriorly is the anterior belly of the omo-hyoid, more anteriorly is the same plane is the sterno-hyoid, and below and anteriorly is the latter, but on a deeper plane, is a small part of the thyreo-hyoid.

The muscles mentioned may be considered as forming the floor or medial boundary of the triangle, and if the floor is taken the structures they cover, which lie more deeply, are under cover of the floor. These structures are now to be exposed.

Dissection.—Divide the anterior belly of the omo-hyoid muscle along its anterior border of the sterno-mastoid and turn it upwards and outwards into the hyoid bone. As this is done its twig of supply from the ansa hypoglossi will be cut. Divide the sterno-hyoid as low down as possible and turn it upwards to its insertion into the body of the hyoid bone and cut its supply from the loop which is called the *ansa hypoglossi* by the union of the descending branch of the hypoglossal nerve and a communicating branch from the cervical plexus. Secure the sterno-thyreoid from the ansa hypoglossi; then remove the floor of the lower part of the thyreo-hyoid muscle, the greater part of the thyreo-hyoid and the anterior part of the thyreoid cartilage. The sterno-thyreoid is inserted into an oblique line on the outer surface of the lamina of the thyreoid cartilage and that the thyreo-hyoid muscle is inserted into the same line and is inserted into the great cornu of the hyoid bone. The crico-thyreoid branch of the superior thyreoid artery may be cut and turned downwards and anteriorly along the upper end of the trachea accompanied by the external laryngeal nerve; or the nerve may be cut and turned deep to the upper end of the muscle.

Divide the sterno-thyreoid as low down as possible and turn it upwards to its insertion; remove the fascia under cover of it and expose the lower lobe of the thyreoid gland, and below it a small part of the trachea.

The dissector should note that whilst the sterno-mastoid muscle is removed the posterior part of the lateral lobe of the thyreoid gland and its lower extremity are not exposed, but if the sterno-mastoid muscle is removed posteriorly the whole of the lateral surface of the lobe is brought into view. The dissector should note also that until the sterno-mastoid muscle is removed posteriorly only a small portion of the upper end of the common carotid artery, the lower parts of the internal and external carotid arteries, and indeed, the common carotid may be entirely concealed. On the removal of the anterior border of the internal jugular vein projects

sterno-mastoid in the upper and posterior angle of the carotid triangle ; and it also is not uncommonly hidden when the sterno-mastoid is well developed. During life, however, when the muscle is soft and pliable the structures concealed by it are readily exposed, for the muscle is easily displaced posteriorly after the fascia has been divided along its anterior border. In the dissecting-room it is not possible to obtain a proper view of the course and relations of the common carotid artery and the internal jugular vein, or to appreciate the relations of the first part of the subclavian artery and the relations of the scalenus anterior muscle, until the sterno-mastoid has been reflected. Divide the external jugular vein immediately below the point where it is joined by the posterior auricular tributary and turn it downwards. Divide the great auricular nerve at the level of the angle of the mandible and turn it posteriorly ; and turn posteriorly the *nervus cutaneus colli*, whose two terminal branches have been cut already. The clavicular head of the sterno-mastoid was cut when the clavicle was removed ; now divide the sternal head, turn the muscle upwards towards its insertion. As the muscle is turned upwards, sterno-mastoid branches of the transverse scapular, superior thyreoid, and occipital arteries will be exposed ; and if they interfere with the reflection of the muscle they must be divided. Slightly above the level of the sterno-mastoid branch of the occipital artery the accessory nerve will be found passing through the deeper fibres of the muscle, and care must be taken to avoid injury to it ; but it may be dissected out of the muscle and left in position on the lateral surface of the internal jugular vein.

Deep Cervical Fascia.—When the sterno-mastoid has been reflected a deep fascial plane of the neck is exposed in which lie many lymph glands. Before carrying the dissection further the dissector should reconsider the arrangement of the deep cervical fascia. He has already seen that it forms a complete sheath enclosing the muscles of the neck and the structures which lie between and under cover of them. The general arrangement of the fascia is studied best on transverse sections of the neck made at the level of the isthmus of the thyreoid gland and a short distance above the sternum. At the former level it is possible to recognise (1) a superficial layer ; (2) a pretracheal layer ; (3) a prevertebral layer ; and (4) a fascial sheath which encloses the common carotid arteries, the internal jugular vein and the vagus nerve, as they lie in the angular interval between the sterno-mastoid laterally, the thyreoid gland, the trachea, œsophagus medially, and the prevertebral muscles posteriorly. The *first or superficial layer*, as it is traced posteriorly, splits to enclose the sterno-mastoid muscle. Beyond the sterno-mastoid it passes posteriorly to the anterior border of the trapezius muscle, forming the roof of the posterior triangle, then splits again to enclose the trapezius, along the surfaces of which it is prolonged till it blends with the supraspinous ligaments and the ligamentum

nuchæ. The lamella which covers the deep surface of the sterno-mastoid is blended with the lateral surface of the carotid sheath. The pretracheal layer, which has been dissected already in the median plane, ensheaths the thyroid gland and blends postero-laterally with the medial surface of the carotid sheath. The prevertebral layer covers the anterior surfaces of the prevertebral muscles and, passing laterally, blends with the posterior aspect of the carotid sheath; then,

turning round the tips of the transverse processes of the vertebræ, it passes posteriorly, covering the muscles which form the floor of the posterior triangle; and it becomes continuous with the sheaths of the deep muscles of the posterior part of the neck.

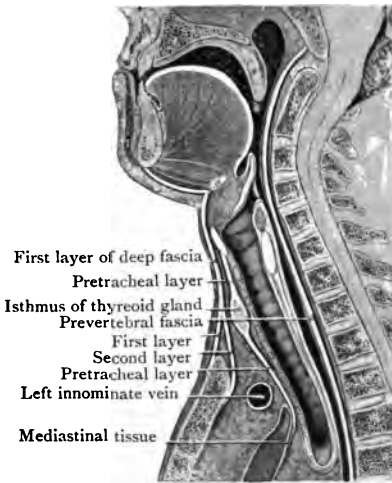


FIG. 95.—Diagram of deep cervical fascia in sagittal section.

Laterally and posteriorly, the superficial layer of the deep fascia passes upwards over the sterno-mastoid and the trapezius to be attached to the superior nuchal lines and the mastoid portions of the temporal bones. In the anterior

cervical region it is attached to the body and the great cornua of the hyoid bone, and then, as it is prolonged further upwards, it splits anteriorly to enclose the submaxillary gland, and posteriorly to enclose the parotid. It has been noted already that the lamella which passes superficial to the submaxillary gland is attached to the lower border of the mandible, and that which passes deep to the gland is connected above to the mylo-hyoid line on the inner surface of the mandible. The layer which passes superficial to the parotid gains attachment to the zygoma and is prolonged forwards to blend with the fascia covering the masseter. The lamella which passes deep to the parotid covers its postero-medial and antero-medial surfaces; the posterior part is attached above to the lower

border of the tympanic plate and the anterior part to the posterior border of the petro-tympanic fissure (O.T. Glaserian). It also gains an intermediate attachment to the styloid process and to the posterior border of the angle of the mandible. This particular portion is relatively thick; it lies in relation with the lower part of the antero-medial surface of the parotid and is known as the *stylo-mandibular ligament*.

When the superficial layer is traced downwards it is found to split, between the cricoid cartilage and the sternum, into two lamellæ. The more superficial of the two lies superficial to the sterno-mastoid and is attached below to the upper border of the sternum and the upper border of the clavicle. In the anterior region the deeper lamella descends upon the anterior surfaces of the infra-hyoid muscles and is attached below to the posterior surface of the manubrium; laterally it passes deep to the sterno-mastoid and is fused with the lateral border of the carotid sheath. In the posterior triangle the deeper lamella ensheaths the posterior belly of the omo-hyoid and binds it down to the posterior border of the clavicle. The space between the two lamellæ has been called the supra-sternal space. Its boundaries and contents have been fully described already (p. 224).

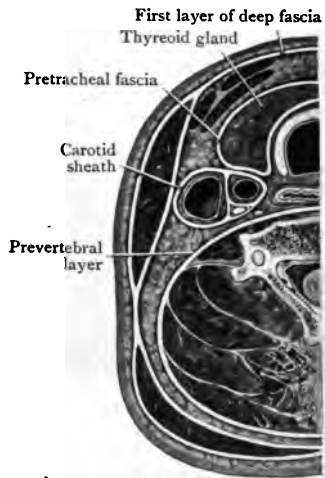


FIG. 96. — Diagram of deep cervical fascia in transverse section at the level of the thyroid gland.

The upper attachment of the *pretracheal layer* is to the cricoid cartilage and to the laminæ of the thyroid cartilage below the insertion of the sterno-thyroid muscle. At its lower end it blends with the fibrous pericardium in the middle mediastinum.

The *prevertebral layer* can be followed upwards to the base of the skull, where it is attached, in the anterior cervical region, to the posterior and medial margins of the jugular foramen and to the basilar part of the occipital bone, anterior

to the insertions of the prevertebral muscles and posterior to the superior constrictor of the pharynx. Below, it blends with the fascia on the anterior aspect of the vertebral column in the posterior mediastinal region.

The Carotid Sheath.—The term carotid sheath is applied to the fascia which surrounds and embeds the carotid arteries, the internal jugular vein, and the vagus nerve. Part of it has been removed already, and the dissector will have noted that it is in no sense a membrane, but merely the fibro-areolar tissue which fills the interval between the transverse processes of the vertebræ posteriorly, the trachea, larynx, pharynx, œsophagus, and the lateral lobe of the thyroid gland medially, and the sterno-mastoid laterally; that it is continuous with the fascial planes in its immediate neighbourhood, and that

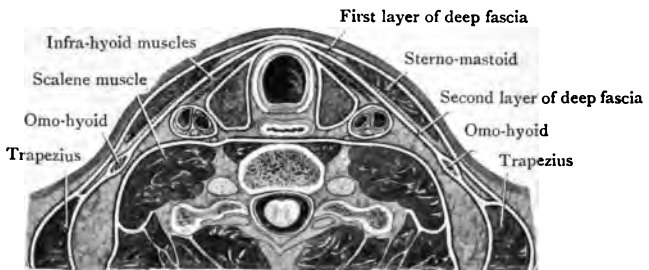


FIG. 97.—Diagram of the deep cervical fascia in a transverse section of the lower part of the neck.

through it run the carotid arteries, the internal jugular vein, and the vagus nerve, each in its own special compartment.

Dissection.—Remove the areolar tissue and the glands which lie under cover of the sterno-mastoid; stitch together the two parts of the divided anterior belly of the omo-hyoid muscle and fix the muscle to the common carotid artery and the internal jugular vein with one or two stitches; then proceed to display the structures which lie under cover of the sterno-mastoid. A glance at the following list will convince the dissector that they are extremely numerous.

Structures beneath the Sterno-Mastoid

Muscles.—The upper part of the splenius capitis; the upper and posterior part of the posterior belly of the digastric; the origins of the levator scapulæ, the scalenus medius, the longus capitis (O.T. rectus capitis anticus major), the rectus capitis lateralis and the scalenus anterior; the intermediate

tendon of the omo-hyoid, and the lower and posterior part of the sterno-hyoid and sterno-thyreoid.

Arteries.—The upper part of the common carotid (the lower part is still concealed by the lower parts of the omo-hyoid and the lower parts of the sterno-hyoid and sterno-thyreoid muscles); the transverse scapular and its sterno-mastoid branch; the transverse cervical; the sterno-mastoid branch of the superior thyreoid; the occipital and its sterno-mastoid branches.

Veins.—The greater part of the internal jugular vein; a part of the lower transverse portion of the anterior jugular vein; and, occasionally, the lower end of the external jugular vein when that vessel dips anteriorly to its termination.

Nerves.—The cervical plexus and its branches, including the phrenic nerve; part of the accessory nerve.

If the lower parts of the divided sterno-hyoid and sterno-thyreoid muscles are displaced downwards, the lower part of the common carotid and the commencement of the first part of the subclavian artery will be exposed. Crossing the front of the latter are the lower portion of the cervical part of the vagus and a strand of sympathetic fibres called the ansa subclavia; on the left side, the subclavian artery and the ansa are concealed by the commencement of the innominate vein. At the same time the middle thyreoid vein will be exposed, and the posterior border of the lateral lobe of the thyreoid gland also.

Dissection.—Commence by cleaning the anterior branches of the cervical nerves from the second to the eighth, as they emerge between the muscles attached to the tubercles of the transverse processes of the cervical vertebræ. The first nerve, which turns downwards anterior to the transverse process of the atlas, will be exposed later. As the upper nerves are cleaned the dissectors will find that the second is connected to the third, and the third to the fourth, by looped strands, convex posteriorly, which constitute the two lower loops of the cervical plexus. The second nerve is connected with the first also by a loop, convex anteriorly, which passes upwards anterior to the transverse process of the atlas and posterior to the upper part of the internal jugular vein. It can be exposed if the vein is pulled anteriorly; and the dissector must at the same time secure the twigs of connection which pass from the medial side of the loop to the hypoglossal nerve and to the superior cervical ganglion of the sympathetic trunk, which lies behind the upper part of the internal carotid artery.

After he has defined the loops of the plexus he should trace the remains of the small occipital, the great auricular, the transverse cutaneous nerve of the neck and the supraclavicular branches, which he displayed in the posterior triangle, to their origins from the roots of the plexus. The communicating branches which pass anteriorly to the descendens hypoglossi from the second, and sometimes also from the third cervical nerve, must be

followed ; they may cross either superficial or deep to the internal jugular vein. Then the phrenic nerve, which springs from the fourth cervical nerve, and receives additional twigs from the third and fifth nerves, must be followed downwards and anteriorly till it disappears under cover of the lower part of the internal jugular vein. It lies upon the surface of the scalenus anterior and passes deep to the omo-hyoid muscle and the transverse cervical and transverse scapular arteries. Running parallel with, and anterior to it, is the ascending cervical branch of the inferior thyreoid artery.

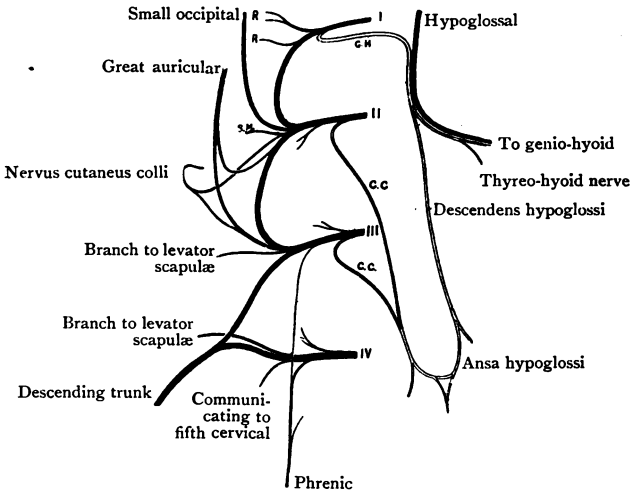


FIG. 98.—Diagram of the Cervical Plexus and the Ansa Hypoglossi.

I, II, III, IV.—Anterior branches of the upper four cervical nerves.

- | | | | |
|------|---------------------------------------|------|--------------------------------------|
| R. | Branches to recti and longus capitis. | C.H. | Communicating branch to hypoglossal. |
| S.M. | Branches to the sterno-mastoid. | | |
| C.C. | Rami communicantes cervicales. | | |

This diagram shows that the descendens hypoglossi, the branch to the thyreo-hyoid, and in all probability the branches to the genio-hyoid, are composed of fibres given to the hypoglossal by the communicating twigs it receives from the first cervical nerve.

Plexus Cervicalis.—This is a looped plexus formed by the first four cervical nerves. It lies in the upper part of the side of the neck under cover of the sterno-mastoid. The upper loop of the plexus, which connects the first and second nerves together, is directed forwards and lies between the internal jugular vein anteriorly, and the transverse process of the atlas posteriorly. The second and third loops, which

unite the second and third and the third and fourth nerves are directed posteriorly; and they lie on the superficial surface of the upper part of the scalenus medius muscle. The first loop is connected with the upper ganglion of the sympathetic trunk and with the hypoglossal nerve; and the roots of the second, third and fourth nerves also are connected, by grey rami, with the upper cervical sympathetic ganglion.

The branches of the plexus are divisible into two main groups, the superficial and the deep. *The deep branches* are separable into two groups: the anterior, which run forwards and the posterior, which run backwards; and the *superficial branches* are classified as ascending, transverse and descending.

The *anterior group of deep branches* includes: (1) the ramus communicans cervicalis, and (2) the phrenic nerve.

The *posterior group of deep branches* is formed by: (1) The communicating branches to the accessory nerve. (2) Branches of supply to (a) the sterno-mastoid from the second nerve; (b) the levator scapulæ from the third and fourth; (c) the trapezius from the third and fourth; (d) the scalenus medius from the second, third, and fourth. (3) Less important muscular branches from the first loop to (a) the rectus capitis lateralis; (b) the rectus capitis anterior (O.T. rectus capitis anticus minor); (c) the longus capitis (O.T. rectus capitis anticus major). (4) Muscular branches from the third and fourth nerves to the longus colli.

The *ascending group of superficial branches* is formed by the small occipital and great auricular nerves. The *transverse branch* is the nervus cutaneus colli, and the *descending branches* are the supraclavicular nerves. All the superficial nerves have already been traced in the earlier stages of the dissection (pp. 145, 146), but the phrenic nerve requires careful consideration.

Nervus Phrenicus.—The importance of the phrenic nerve depends upon the fact that it is the nerve of supply to the chief muscle of respiration, the diaphragm. The majority of its fibres spring from the fourth cervical nerve, but it receives twigs from the third and, not uncommonly, from the fifth nerve also. It descends from the neck through the superior and posterior mediastinal regions of the thorax, and, after piercing the diaphragm, it is distributed on its lower surface. Only the cervical portion of the nerve belongs to the dissector of the neck; the remainder is displayed by the dissector

of the thorax (p. 341). In the neck the nerve runs downwards and anteriorly, on the superficial surface of the scalenus anterior, which forms its deep relation. In this part of its course it is covered by skin, superficial fascia and platysma, deep fascia and sterno-mastoid; and, deep to the sterno-mastoid, it is overlapped by the internal jugular vein, and it is crossed by the omo-hyoid, the anterior jugular vein, and the transverse cervical and transverse scapular arteries on both sides; on the left side by the thoracic duct, and on the right side by the right lymph duct. At the root of the neck it passes from the medial border of the anterior scalene to the anterior surface of the first part of the subclavian artery; and it is covered anteriorly by the clavicle on both sides, by the subclavian vein on the right side, and by the commencement of the innominate vein on the left side, and it crosses either anterior or posterior to the internal mammary artery. It gives off no branches in the neck, but it sometimes receives a communication from the nerve to the subclavius.

After the dissector has completed the examination of the formation, the relations, and the branches of the cervical plexus, he should replace the divided infra-hyoid muscles in position and study their attachments and relations.

The **Infra-hyoid Muscles** are a series of flat, band-like muscles which lie upon the trachea, thyreoid gland, and larynx. They are disposed in two strata—viz., the omo-hyoid and the sterno-hyoid constituting a superficial layer; and the sterno-thyreoid and thyreo-hyoid a deep layer.

Musculus Omohyoideus.—This is a two-bellied muscle. The *posterior belly* springs from the upper border of the scapula and the upper transverse scapular ligament. It crosses the posterior triangle of the neck, dividing it into occipital and subclavian portions, and terminates under cover of the sterno-mastoid muscle in an intermediate tendon; and it is superficial to the phrenic nerve and the scalenus anterior. The tendon is held in position by a strong process of cervical fascia which is firmly attached below to the sternum and the first costal cartilage. The *anterior belly* emerges from under cover of the anterior border of the sterno-mastoid, and takes an almost vertical course through the anterior triangle. It is inserted into the lower border of the body of the hyoid bone, at the lateral side of the sterno-hyoid. In the anterior triangle of the neck it forms the boundary between the

THE ANTERIOR PART OF THE NECK 243

carotid and the muscular subdivisions, and it lies superficial to the internal jugular vein, the common carotid artery, the descendens hypoglossi, the superior thyroid artery, the external laryngeal nerve, the attachments of the sterno-thyreoid and thyreo-hyoid muscles to the lamina of the thyreoid

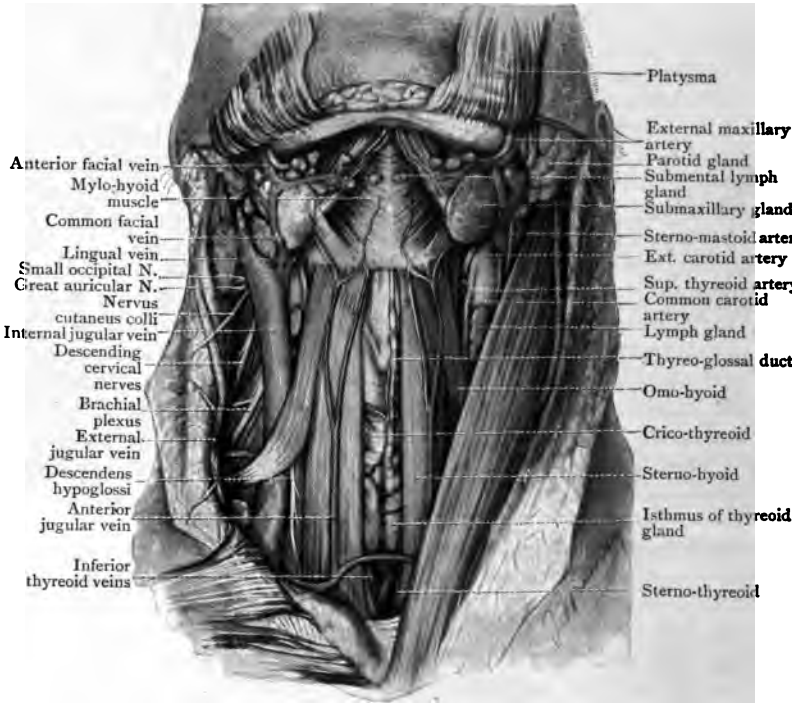


FIG. 99.—Dissection of the Front of the Neck. The Right Sterno-mastoid has been removed.

cartilage; and immediately below its insertion it covers part of the thyreo-hyoid membrane. Both bellies are supplied by branches from the *ansa hypoglossi*.

Musculus Sternohyoideus.—This arises from the posterior aspect of the medial end of the clavicle, the posterior sterno-clavicular ligament, and the posterior surface of the manubrium. It is inserted into the lower border of the body

of the hyoid bone, between the median plane and the insertion of the omo-hyoid. A short distance above the sternum an oblique tendinous intersection frequently divides it into two portions. The lower part of the muscle is covered by the sterno-mastoid, and it is crossed by the anterior jugular vein. Its principal deep relations are the lower part of the common carotid artery and the sterno-thyreoid muscle, which separates it from the lateral lobe of the thyreoid gland. It is supplied by branches from the *ansa hypoglossi*.

Musculus Sternothyroideus.—This muscle lies under cover of the preceding and is both broader and shorter. It springs from the posterior aspect of the manubrium sterni and from the cartilage of the first rib. Diverging slightly from its fellow as it ascends, it is inserted into the oblique line on the lateral face of the lamina of the thyreoid cartilage. An incomplete tendinous intersection may sometimes be noticed interrupting its muscular fibres. The nerve supply is derived from the *ansa hypoglossi*. In the neck it is covered in the greater part of its extent by the sterno-hyoid; but the posterior part of its insertion is covered by the anterior belly of the omo-hyoid; and the lower and anterior part is covered by skin and fascia only. The nerve supply is derived from the *ansa hypoglossi*.

Musculus Thyreohyoideus.—This muscle lies on the same plane as the sterno-thyreoid, and may be regarded as its upward continuation. It takes origin from the oblique line on the outer surface of the lamina of the thyreoid cartilage, and is inserted into the lower border of the great cornu of the hyoid bone under cover of the omo-hyoid muscle. It conceals part of the lamina of the thyreoid cartilage and the lateral part of the thyreo-hyoid membrane, and the aperture in the membrane through which the laryngeal branch of the superior thyreoid artery and the internal laryngeal nerve enter the pharynx. It is supplied by a twig from the *hypoglossal nerve*.

Dissection.—The dissectors of the head and neck should now proceed to study the relations of the common carotid and subclavian arteries, the cervical part of the thoracic duct, and the dome of the pleura, before these are disturbed by the dissectors of the thorax. Whilst this is being done, the omo-hyoid must be retained in position, but the upper and lower portions of the other infra-hyoid muscles may be turned upwards and downwards respectively.

Remove the remains of the fascial sheath from around the common

carotid artery and the adjacent part of the internal jugular vein. Separate the vein from the artery and clean the portion of the vagus nerve which lies between them on a posterior plane. Note that on the right side the nerve crosses the anterior surface of the subclavian artery, and there gives off its recurrent branch; and that on the left side it lies medial to the subclavian artery on an anterior plane.

After the lower parts of the vagi have been cleaned, look for the terminal part of the thoracic duct on the left side and for the right lymphatic duct on the right side. In seeking for the thoracic duct pull the lower end of the left internal jugular vein aside and displace the common carotid artery anteriorly; then look for the duct as it turns laterally from the border of the œsophagus a little below the level of the cricoid cartilage; trace it posterior to the internal jugular vein to its termination in the commencement of the innominate vein. On the right side look for the right lymphatic duct entering the innominate vein in the angle of union of the internal jugular and subclavian veins. Next look for the cervical portion of the sympathetic trunk, which descends posterior to the common carotid. Clean the nerve trunk carefully and clean also the inferior thyreoid artery, which crosses anterior or posterior to it, at the level of the cricoid cartilage. Displace the common carotid laterally, and in the angle between the borders of the trachea and the œsophagus find the recurrent branch of the vagus; trace it upwards to the point where it disappears under cover of the lateral lobe of the thyreoid gland, and downwards to the subclavian artery.

Arteria Carotis Communis.—The common carotid arises differently on the two sides. On the right side it springs from the termination of the innominate artery, behind the sterno-clavicular joint, and on the left side from the aortic arch in the superior mediastinum. The left artery ascends to the back of the left sterno-clavicular articulation. From the sterno-clavicular joint each common carotid artery runs upwards, posteriorly, and slightly laterally to the upper border of the thyreoid cartilage, which lies opposite the disc between the third and fourth cervical vertebræ; and there it ends by dividing into its two terminal branches—the internal and the external carotid arteries.

Superficial Relations.—Above the level of the anterior belly of the omo-hyoid the common carotid artery is covered by the skin, the superficial fascia and the platysma, the deep fascia and the anterior margin of the sterno-mastoid. It is crossed immediately above the omo-hyoid by the sterno-mastoid branch of the superior thyreoid artery and, at a higher level, by the superior thyreoid vein; and it is overlapped by the anterior margin of the internal jugular vein. In the lower part of its extent it lies more deeply: its superficial relations are the skin and superficial fascia, the deep fascia and the sterno-mastoid; the anterior jugular vein, crossing transversely, deep to the sterno-mastoid and above the upper

border of the clavicle ; the omo-hyoid, the sterno-hyoid, and the sterno-thyreoid muscles. Deep to the muscles, the branches of the *ansa hypoglossi* descend in front of its sheath ; and the middle thyreoid vein crosses it to join the internal jugular vein.

Posterior to it lie the transverse processes of the cervical vertebræ and the origins of the longus colli, longus capitis (O.T. rectus capitis anticus major), and the scalenus anterior. The inferior thyreoid artery crosses posterior to it at the level of the cricoid cartilage ; and the vertebral artery lies between it and the transverse process of the seventh cervical vertebra. On the right side, the recurrent branch of the vagus crosses

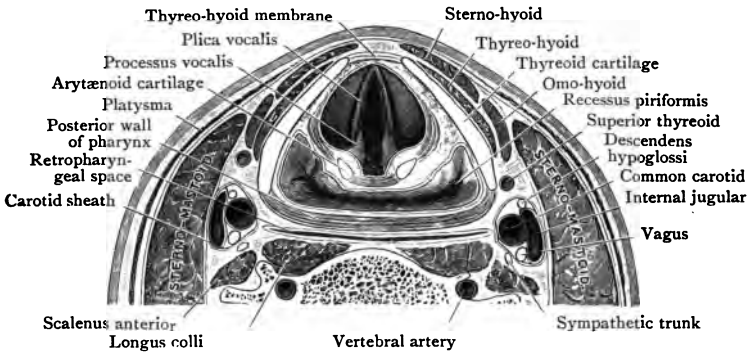


FIG. 100. — Transverse section through the Neck at the level of upper part of Thyreoid Cartilage.

posterior to it, immediately above its origin ; and on the left side the thoracic duct turns laterally behind it, between it and the vertebral artery.

To its medial side, below, lie the trachea and œsophagus, with the recurrent nerve in the angle between their adjacent borders ; and to the medial side of its upper part are the larynx and pharynx. The lateral lobe of the thyreoid gland lies either medial to the artery, separating it from the œsophagus, pharynx, trachea, and larynx, or it forms a direct anterior relation (Figs. 97, 101). Between its upper extremity and the inferior constrictor muscle of the pharynx lies the carotid body. As a rule, the terminal divisions are the only branches of the common carotid, but occasionally the superior thyreoid or the ascending pharyngeal artery arises

from it, instead of from the external carotid. This is more especially the case when the division of the common carotid takes place at a higher level than usual.

Carotid Body.—This is a little oval, reddish-brown body, placed upon the deep aspect of the common carotid artery at the point where it bifurcates. To expose it, therefore, the vessel must be twisted round in such a manner that its posterior surface comes to look forwards. It is closely connected with the sympathetic filaments which twine around the carotid vessels; and in structure it is similar in its nature to the minute coccygeal body, which rests upon the anterior aspect of the coccyx. It is included, therefore, in the group of ductless glands. Entering it are numerous minute arterial twigs, which take origin from the termination of the common carotid and the commencement of the external carotid. The function of this remarkable little body is quite unknown. Most likely it is a vestigial structure.

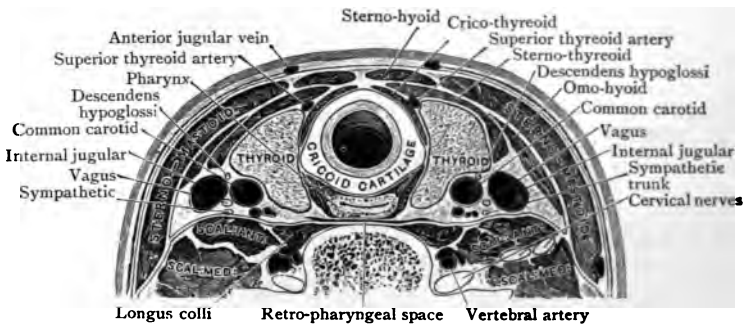


FIG. 101.—Transverse section through the Neck at the level of the Cricoid Cartilage.

Arteria Subclavia.—The relations of the third part of the subclavian artery were examined during the dissection of the posterior triangle (p. 151). Those of the first and second parts must now be studied. On the right side a small portion of the first part is already exposed between the lower ends of the internal jugular vein and the common carotid artery; the remainder can be seen if the internal jugular vein is drawn aside. On the left side the first part of the artery is concealed by the commencement of the innominate vein, which must be pushed aside. On both sides the second part of the artery lies posterior to the scalenus anterior, which must be left in position.

The subclavian artery is the first portion of the great arterial trunk which carries blood for the supply of the upper

extremity. It arises differently on the two sides of the body. On the right side it takes origin behind the sterno-clavicular articulation from the bifurcation of the innominate artery.

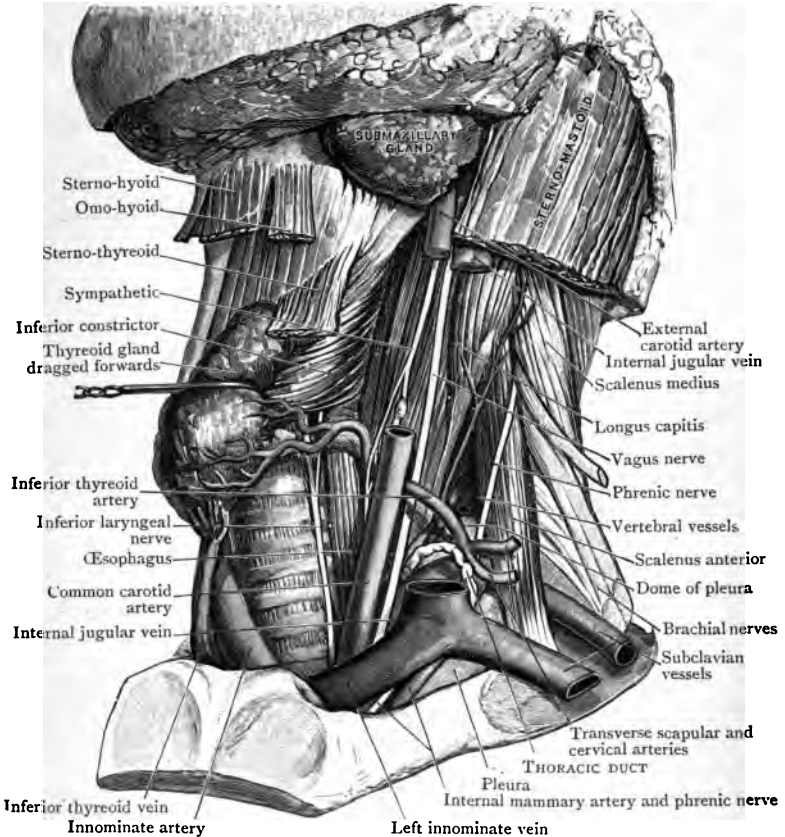


FIG. 102.—Deep Dissection of the Root of the Neck on the Left Side to show the Dome of the Pleura and the relations of the Terminal Part of the Thoracic Duct. The sterno-mastoid and the depressors of the hyoid and larynx have been removed.

On the *left side* it arises from the aortic arch in the superior mediastinum. In both cases it takes an arched course laterally across the root of the neck, posterior to the scalenus anterior and on the anterior surface of the cervical dome of

pleura, a short distance below its summit. At the outer border of the first rib it becomes the axillary artery.

For descriptive purposes the artery is divided into three parts. The *first part* extends from the origin of the vessel

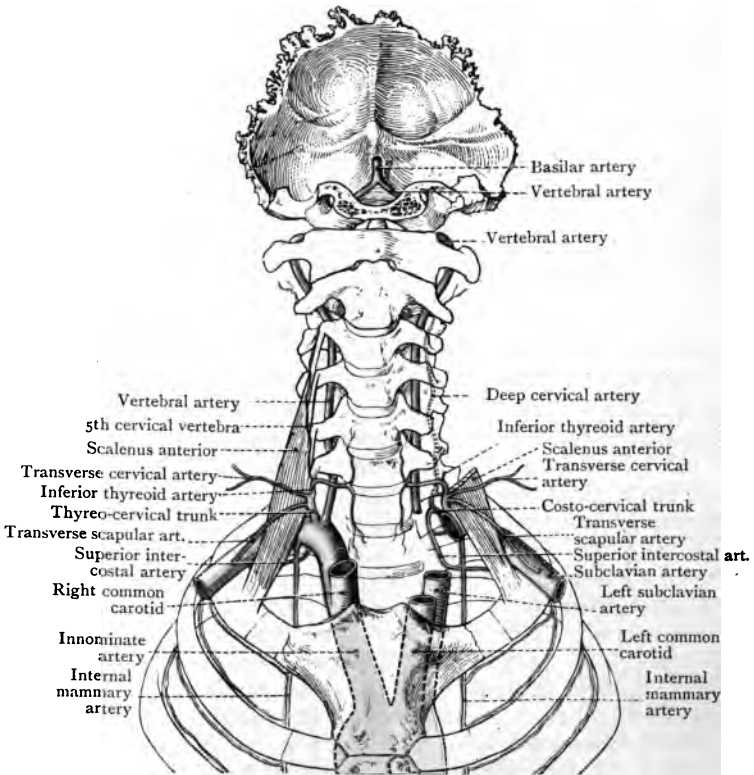


FIG. 103.—Diagram of Subclavian Arteries and their branches.

to the medial margin of the scalenus anterior; the *second portion* lies posterior to that muscle; and the *third part* extends from the lateral border of the scalenus anterior to the outer border of the first rib.

First Part.—Owing to the difference of origin, the relations of the first portion of the subclavian artery are not the same

on the two sides of the body. The first part of the *right subclavian* extends obliquely upwards and laterally, and at its termination at the medial margin of the scalenus anterior it has reached a point above the level of the clavicle. It is placed very deeply. Anteriorly, it is covered by the skin, superficial fascia, platysma, deep fascia, and three muscular strata—viz., the clavicular origin of the sterno-mastoid, the sterno-hyoid, and the sterno-thyreoid. Three veins and some nerves are placed anterior to it. At the medial margin of the scalenus anterior it is crossed by the internal jugular and vertebral veins, whilst the anterior jugular vein, as it passes laterally under cover of the sterno-mastoid, is separated from it by the sterno-hyoid and sterno-thyreoid muscles. The nerves which cross anterior to it are the vagus, a loop from the sympathetic (ansa subclavia), and in some cases cardiac branches of the vagus and sympathetic as they run to the thorax. At the lower margin of the artery the vagus nerve gives off its recurrent branch.

The cervical dome of the pleura is both below and posterior to the artery, and the recurrent branch of the vagus nerve hooks round below and ascends posterior to it.¹

On the *left side*, the first part of the subclavian ascends almost vertically from its origin from the aortic arch, and, reaching the root of the neck, it curves laterally across the dome of the pleura to the medial margin of the scalenus anterior. The relations of the cervical part are somewhat different from those on the right side. The same fascial and muscular layers, and the same nerves and veins, are anterior to it. Owing to its different direction, however, the nerves and veins are placed more or less parallel to it. Three additional relations are established—viz., the phrenic nerve and the left innominate vein lie anterior to it; and the thoracic duct first passes upwards in relation to its medial or right side, and then arches over it to reach the angle of junction between the subclavian and internal jugular veins.

The recurrent nerve on the left side hooks round the arch of the aorta, and lies to the medial side of the subclavian artery.

Second Part.—The second portion of the subclavian artery

¹ If the lung has been removed by the dissector of the thorax the lower and posterior relations should be verified by examination from the thoracic side.

forms the highest part or summit of the arch, and rises from half an inch to an inch above the level of the clavicle.

In this part of its course the vessel is not so deeply placed. *Anteriorly* it is covered by—(1) skin; (2) superficial fascia and platysma; (3) deep fascia; (4) clavicular head of the sterno-mastoid; (5) scalenus anterior. The phrenic nerve on the right side is also an anterior relation, but it is separated from the artery by the medial margin of the scalenus anterior. *Posteriorly and inferiorly*, the vessel is in relation with the pleura, Sibson's fascia intervening. The subclavian vein lies at a lower level than the artery and on an anterior plane, and is separated from it by the scalenus anterior.

The *third part* of the subclavian artery is described on p. 151.

Branches of the Subclavian Artery.—Four branches spring from the subclavian trunk (Fig. 103). Three take origin, as a general rule, from the first part of the artery close to the scalenus anterior, and one from the second part. They are—

From the <i>first part.</i>	{	1. Vertebral.	{	Inferior thyreoid
		2. Thyreo-cervical		Transverse cervical
		3. Internal mammary.		Transverse scapular.
From the <i>second part.</i>	{	Costo-cervical.	{	Superior intercostal.
				Deep cervical.

In a great number of cases a branch of considerable size will be observed springing from the third part of the subclavian artery. This, in all probability, is the descending branch of the transverse cervical, arising directly from the subclavian. It is so common an occurrence that the dissector must always be prepared to meet it.

Arteria Vertebralis.—This is the first branch which is given off by the subclavian. It springs from the upper and posterior aspect of the trunk about a quarter of an inch from the medial margin of the scalenus anterior on the right side, and from the point where the vessel reaches the root of the neck on the left side. Only a small portion of it is seen in the present dissection. It proceeds upwards in the interval between the longus colli and the scalenus anterior muscles, posterior to the common carotid, and disappears into the foramen transversarium of the transverse process of the sixth cervical vertebra. It is placed very deeply, and is covered

anteriorly by its companion vein and the common carotid artery. Numerous large sympathetic twigs accompany it.

The vertebral artery on the *left side* is posterior to the internal jugular vein and the common carotid artery, and it is crossed by the thoracic duct.

The *vertebral vein* issues from the aperture in the transverse process of the sixth cervical vertebra. It passes downwards, antero-lateral to its companion artery, and posterior to the internal jugular vein, to open into the posterior aspect of the commencement of the corresponding innominate vein. Near its termination it crosses the subclavian artery. It receives the *deep cervical* and the *anterior vertebral veins*.

Truncus Thyreocervicalis (O.T. Thyroid Axis).—This is a short wide trunk, which arises from the anterior aspect of the subclavian artery, close to the medial margin of the scalenus anterior, and under cover of the internal jugular vein. It lies between the phrenic and vagus nerves, and almost immediately breaks up into its three terminal branches—viz., the inferior thyreoid, the transverse scapular, and the transverse cervical.

Arteria Thyreoidea Inferior.—This vessel takes a sinuous course to reach the thyreoid gland. At first, it ascends for a short distance along the medial border of the scalenus anterior, and under cover of the internal jugular vein; then, at the level of the cricoid cartilage, it turns suddenly medial-wards and passes posterior to the sympathetic, the vagus, and the common carotid artery, to the posterior border of the thyreoid gland, where it gives off branches to the larynx and then descends along the posterior border of the gland, distributing branches to its substance and to the trachea and the oesophagus.

The following branches will be noticed arising from the inferior thyreoid artery:—

- | | | |
|------------------------|--|-----------------|
| 1. Ascending cervical. | | 5. Oesophageal. |
| 2. Inferior laryngeal. | | 6. Glandular. |
| 3. Tracheal. | | 7. Muscular. |
| 4. Pharyngeal. | | |

Arteria Cervicalis Ascendens.—This small but constant vessel runs upwards in the interval between the scalenus anterior and longus capitis, and gives branches to the muscles in front of the vertebral column. It also gives off *spinal branches*, which enter the vertebral canal upon the spinal nerves, and

anastomose with branches from the vertebral artery. The ultimate distribution of the spinal branches has been noticed already (p. 193).

Arteria Laryngea Inferior.—This small vessel accompanies the inferior laryngeal nerve to the larynx. The *tracheal, œsophageal,* and *pharyngeal branches* supply the trachea, the gullet, and the pharynx. They are of small size, and anastomose with the bronchial and œsophageal branches of the thoracic aorta. The *glandular branches* are usually two in number. One ascends upon the posterior aspect of the lateral lobe of the thyroid gland, whilst the other is given to its base or lower end. They inosculate with the corresponding vessels of the opposite side, and also with the branches of the superior thyroid artery. The *muscular branches* are a series of irregular twigs given to the various muscles in the neighbourhood.

Vena Thyreoidea Inferior.—The inferior thyroid vein does not run in company with the artery of the same name. It is a comparatively large vessel which comes from the lateral lobe and the isthmus of the thyroid gland, and descends upon the trachea under cover of the sterno-thyroid muscle. The veins of both sides enter the thorax, and frequently unite to form a short common stem, which opens into the left innominate trunk. In other cases, however, the right vein will be observed to open separately into the angle of union between the two innominate veins. Both veins, as they proceed downwards, receive tributaries from the larynx, trachea and œsophagus.

The *anterior vertebral vein* accompanies the ascending cervical artery, and opens into the vertebral vein as it issues from the foramen transversarium of the sixth cervical vertebra.

The Transverse Scapular and Transverse Cervical Arteries.—Both of these arteries have already been examined in the greater part of their courses (p. 147). After taking origin from the thyreo-cervical trunk, they both pass laterally across the scalenus anterior muscle and the phrenic nerve under cover of the clavicular head of the sterno-mastoid. The *transverse scapular* crosses the anterior scalene muscle close to its insertion, immediately above the subclavian vein; the *transverse cervical* is placed at a slightly higher level.

The *transverse scapular* and *transverse cervical veins* have already been seen joining the external jugular vein.

Arteria Mammaria Interna.—The internal mammary artery springs from the lower and anterior aspect of the subclavian, directly below the thyreo-cervical trunk. It passes downwards upon the anterior surface of the pleura, posterior to the medial end of the clavicle and the medial end of the subclavian vein, to reach the thorax. As it lies posterior to the subclavian vein the phrenic nerve passes from the lateral to the medial side, either anterior or posterior to it. In the neck the internal mammary artery is not accompanied by a vein.

Truncus Costocervicalis.—This branch takes origin from the posterior aspect of the second portion of the subclavian artery, close to the medial border of the scalenus anterior. On the left side, however, it proceeds, as a rule, from the first part of the parent trunk. To bring it into view the subclavian artery must be dislodged from its position. It is a short trunk which passes upwards and posteriorly over the apex of the pleura to the neck of the first rib, where it divides into the *deep cervical artery* and the *superior intercostal artery*.

If the lung is removed from the thorax the dissector should take the opportunity of examining this artery from the thoracic aspect.

Arteria Cervicalis Profunda.—This branch passes dorsally and disappears from view between the transverse process of the seventh cervical vertebra and the neck of the first rib. It has been already noticed in the dissection of the back of the neck (p. 173).

The *deep cervical vein* is a large vessel. It joins the vertebral vein.

Arteria Intercostalis Suprema.—The superior intercostal artery turns downwards anterior to the neck of the first rib, between the first thoracic nerve and the first thoracic ganglion of the sympathetic. It gives a posterior intercostal branch to the first space and ends as the posterior intercostal artery of the second space (Fig. 5).

Vena Subclavia.—The subclavian vein is the continuation of the axillary vein into the root of the neck. It begins at the outer border of the first rib, and arches medially on the anterior surface of the lower end of the scalenus anterior. At the medial margin of this muscle, and posterior to the sternal end of the clavicle, it joins with the internal jugular to form the innominate vein. In connection with

the subclavian vein note: (1) that the arch which it forms is not so pronounced as the arch of the corresponding artery; (2) that throughout its whole course it lies at a lower level, and upon a plane anterior to the artery; and (3) that it is separated from the artery by the scalenus anterior and the phrenic nerve. In the whole of its course the vein lies posterior to the clavicle.

The sheath of the subclavian vein is attached to the posterior surface of the costo-coracoid membrane. This is a relation of some practical importance; for, on account of it, a forward movement of the clavicle drags upon the vein, and in cases where the vessel is wounded there is always a danger of air being sucked into the vein by such a movement.

The *tributary* of the subclavian vein is the external jugular vein, which joins it at the lateral margin of the scalenus anterior.

Ductus Thoracicus et Ductus Lymphaticus Dexter.—The *thoracic duct* is the vessel by means of which the chyle and the lymph, derived from by far the greater part of the body, are poured into the venous system on the left side (p. 106). Its terminal or cervical portion is displayed in the dissection of the neck. It is a small, thin-walled vessel, frequently mistaken for a vein, which enters the root of the neck at the left margin of the œsophagus. It is there that it should be sought. At the level of the seventh cervical vertebra it arches laterally and anteriorly, and then downwards, above the apex of the pleura, and it enters the innominate vein in the angle of the union of the internal jugular vein with the subclavian. As the thoracic duct courses laterally it lies at a higher level than the subclavian artery, and passes posterior to the common carotid artery, the vagus nerve and the internal jugular vein, and anterior to the vertebral artery and vein and the thyreo-cervical artery or its inferior thyreoid branch; and as it runs downwards to its termination it is separated from the scalenus anterior by the transverse cervical and transverse scapular arteries and the phrenic nerve. Further, as it approaches the point at which it ends, it crosses the first part of the subclavian artery.

A valve composed of two segments guards its entrance into the innominate vein.

Ductus Lymphaticus Dexter.—The right lymph duct is the corresponding vessel on the right side, but it is a comparatively insignificant channel which conveys lymph from a

much more restricted area. It commences in the posterior mediastinum, where it not uncommonly communicates with the thoracic duct; and it ascends to the root of the neck on

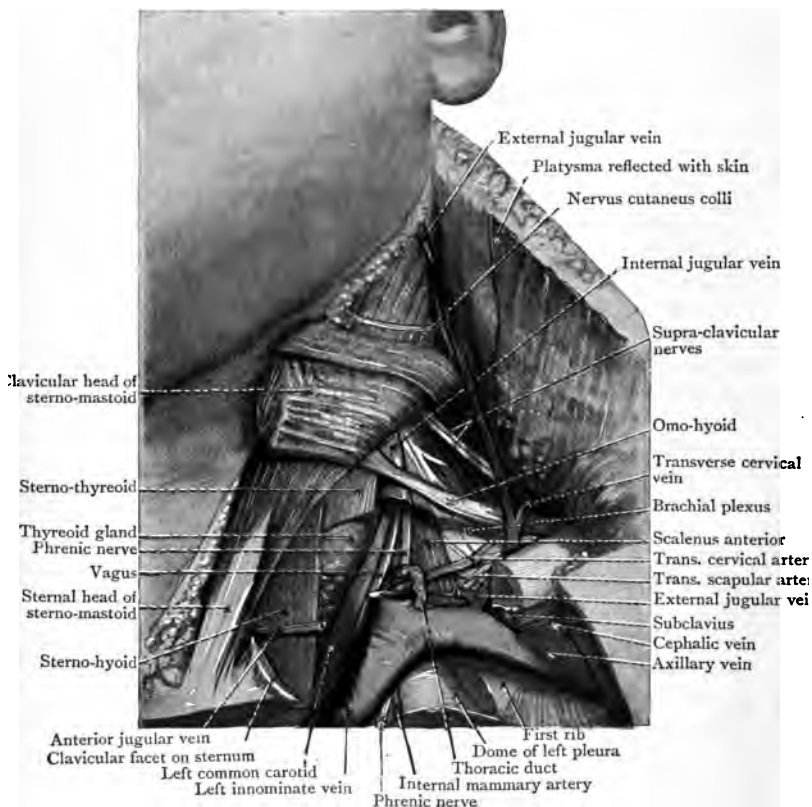


FIG. 104.—Deep Dissection of the Root of the Neck on the Left Side to show the Dome of the Pleura and the relations of the Terminal Part of the Thoracic Duct. The sterno-mastoid and the depressors of the hyoid and larynx have been removed.

the right side, where it terminates in the commencement of the innominate vein by opening into it in the angle of union of the subclavian and internal jugular veins. As in the case of the thoracic duct, its orifice is guarded by a double valve. Lymph passes to it from the intercostal glands which lie in

the upper interspaces of the right side, and from the thoracic visceral glands of the right side. About half an inch from its termination it is sometimes joined by the right subclavian and jugular lymph trunks, which convey lymph from the right upper extremity and the right side of the head and neck, respectively. Under these circumstances it constitutes the main lymph drain for the following districts: (1) right upper limb; (2) right side of the head and neck; (3) upper part of right thoracic wall; (4) right side of diaphragm and upper surface of liver; (5) thoracic viscera on right side of median plane, viz. right side of heart and pericardium and the right lung and pleura. But not uncommonly the right jugular and subclavian lymph trunks open separately into the internal jugular, the subclavian, or the innominate vein.

Cervical Pleura.—The pleural sac of each side, with the apex of the corresponding lung, projects upwards into the root of the neck, and the dissector should now examine the height to which it rises, and the connections which it establishes (see Figs. 1 and 5). Its height with reference to the first pair of costal arches varies in different subjects. In some cases it extends upwards for two inches above the sternal end of the first rib; in others for not more than one inch. These differences depend on the degree of obliquity of the thoracic inlet. Posteriorly, in the majority of cases, the apex of the pleura corresponds in level with the neck of the first rib. It forms a dome-like roof for each side of the thoracic cavity, and is strengthened by a fascial expansion (frequently termed *Sibson's fascia*), which covers it completely, and is attached on the one hand to the transverse process of the seventh cervical vertebra and on the other to the inner margin of the first rib.

Note that it is in relation with: (1) the scalenus anterior; (2) the scalenus medius; (3) the subclavian artery; (4) the vertebral artery; (5) the costo-cervical trunk; (6) the superior intercostal artery; (7) the internal mammary artery; (8) the innominate vein; (9) the vertebral vein; (10) the subclavian vein; (11) the vagus nerve; (12) the phrenic nerve; (13) the recurrent nerve on the right side; (14) the first thoracic nerve; (15) the first thoracic ganglion of the sympathetic; (16) the ansa subclavia (*Vieussenii*).

The scalenus anterior covers the antero-lateral part of the

dome, separating it from the subclavian vein, which ends at the medial border of the muscle. Immediately above the vein the subclavian artery crosses the dome below its apex. The internal mammary artery descends from the subclavian, passes posterior to the subclavian vein, and is crossed, as it lies behind the vein, by the phrenic nerve, which passes in some cases anterior to, and in others posterior to the artery.

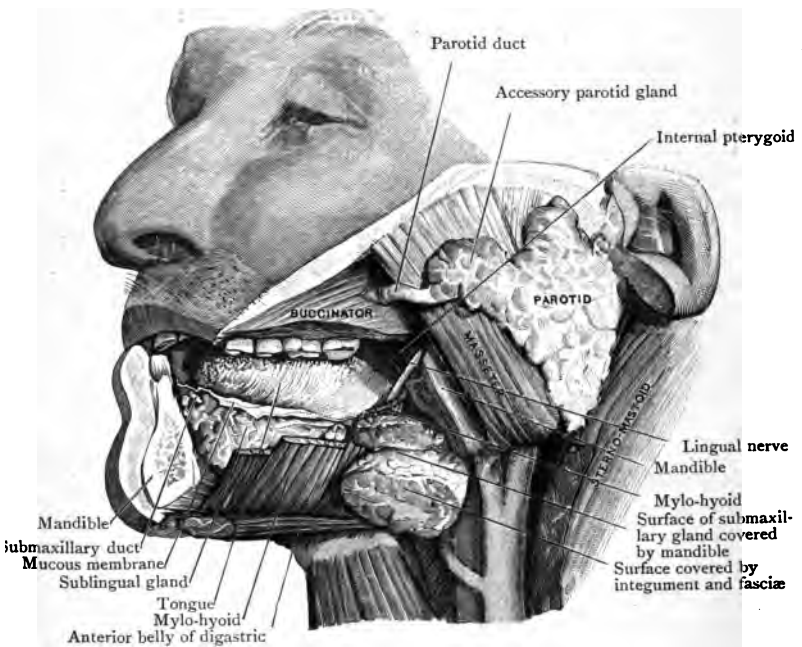


FIG. 105.—Dissection of the Parotid, Submaxillary, and Sublingual Glands.

The costo-cervical artery ascends from the subclavian and crosses the apex of the dome; its superior intercostal branch descends, posterior to the apex, between the first intercostal nerve on the lateral side, and the first thoracic sympathetic ganglion on the medial side. The vagus nerve descends anterior to the medial part of the subclavian artery, and, on the right side, its recurrent branch turns round the lower border of the artery; the ansa subclavia lies to the lateral side of the recurrent nerve.

It is not possible to examine the relations of either the whole of the internal jugular vein or the external carotid artery, or the whole of the cervical portion of the internal carotid, until the parotid gland has been removed, the infra-temporal and submaxillary regions have been dissected, and the posterior belly of the digastric and the styloid process have been detached and displaced anteriorly. It is important, however, that the internal jugular vein should be retained in position whilst these parts of the dissection are being proceeded with: the dissector should therefore stitch the subclavian vein to the anterior surface of the scalenus anterior, and the lower part of the internal jugular vein to the first part of the subclavian artery, before proceeding to the study and removal of the parotid gland.

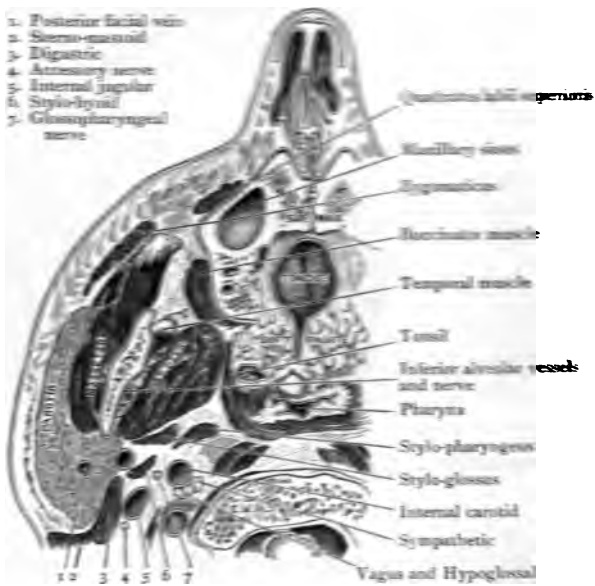


FIG. 106.—Transverse section through the Head at the level of the Hard Palate. It shows the relations of the parotid gland, etc.

Glandula Parotis.—The parotid gland is wedged into a more or less triangular interval, the *parotid space*, which is bounded anteriorly by the posterior borders of the masseter, the ramus of the mandible, and the internal pterygoid, and postero-medially by the anterior border of the sterno-mastoid, the mastoid process, the posterior belly of the digastric, the styloid process, and the stylo-hyoid muscle. The space extends upwards to the external acoustic meatus, and it is prolonged downwards into the *triangle*, into which

the lower extremity of the gland descends for a short distance beyond the angle of the mandible. The gland, however, is more extensive than the space and passes for a varying distance forwards beyond its anterior border over the superficial surface of the masseter.

In accordance with the position which it occupies the gland may be described as possessing three surfaces, two extremities, and four borders. The surfaces are superficial or lateral, postero-medial, and antero-medial; the extremities, upper and lower; the borders, anterior, posterior, medial, and

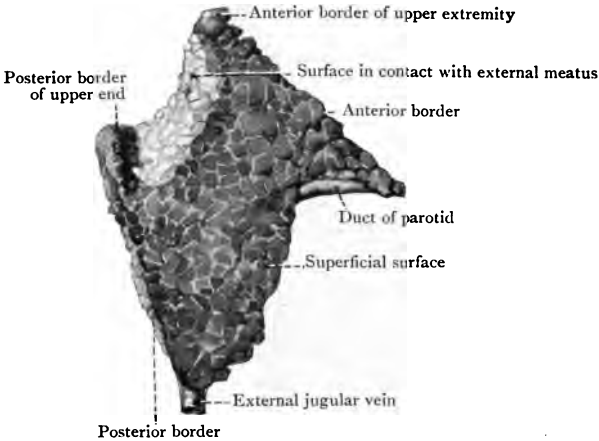


FIG. 107.—Parotid Gland, lateral view.

superior. The medial border separates the antero-medial from the postero-medial surface. The anterior and posterior borders separate the lateral surface from the antero-medial and postero-medial surfaces, respectively. The upper border intervenes between the upper surface and the other three surfaces.

The *superficial surface* is triangular in outline (Fig. 105). It is covered by skin, superficial fascia, platysma and risorius, and deep fascia. Embedded in it are a few superficial parotid lymph glands, which receive lymph from the anterior part of the scalp, the face above the level of the mouth, and from the lateral surface of the auricle. Posteriorly, it is in relation with the mastoid process and the anterior border of

the sterno-mastoid muscle. Above it crosses the posterior part of the lower border of the zygoma and the lower surface of the external meatus.

From beneath the part in contact with the zygoma emerge the auriculo-temporal nerve, the temporal branches of the facial nerve, and the superficial temporal artery, on their way to the scalp; and the posterior facial vein disappears under cover of it. Its lower extremity, which is wedged between the angle of the mandible and the anterior border of the sterno-mastoid, is usually in contact with one of the upper deep cervical glands, whilst the posterior facial vein, the commencement of the external jugular vein, and the cervical branch of the facial nerve emerge from it; the former passing downwards and posteriorly, and the two latter downwards and anteriorly.

From beneath the anterior border, which rests upon the masseter, the duct of the gland (Stensen's), the transverse facial artery, and the zygomatic, buccal, and mandibular branches of the facial nerve pass forwards; and the transverse facial vein disappears under cover of it.

The duct of the parotid gland (Stensen's), after appearing from under cover of the anterior border of the gland, runs anteriorly across the masseter, at the level of a line drawn from the lobule of the auricle to a point situated midway between the red margin of the upper lip and the ala of the nose. At the anterior border of the masseter it turns inwards, at right angles to its former course, and after piercing the sucking pad of fat, the buccinator fascia, the buccinator muscle and the mucous membrane of the vestibule of the mouth, it opens into the vestibule, on the apex of a papilla, opposite the second molar tooth of the maxilla.

Immediately anterior to the anterior border of the gland, below the zygoma and above the duct, lies a small separated portion of the gland substance called the accessory parotid; its duct opens into the main duct.

Dissection.—The gland must be removed piecemeal as the structures which pass through it are dissected out. The facial nerve and its branches are the most superficial structures in the substance of the parotid; therefore they must be dissected first. Trace the terminal branches posteriorly into the gland until they join the main divisions, which are the upper or temporo-facial and the lower or cervico-facial. The temporal and zygomatic branches spring from the temporo-facial division, the buccal, mandibular, and cervical from the cervico-facial division. Follow the divisions posteriorly with the posterior facial vein to their union with the trunk of the nerve, which pierces the postero-medial surface of the gland; then trace the trunk across

the root of the styloid process to the stylo-mastoid foramen and secure the branch which springs from it to supply the posterior belly of the digastric and the stylo-hyoid muscles, and the posterior auricular branch. As the trunk of the nerve is being cleaned the posterior auricular branch of the external carotid artery will probably be exposed, passing upwards and posteriorly along the upper border of the posterior belly of the digastric to the back of the external meatus, and crossing either superficial or deep to the nerve. Next, remove the deeper parts of the gland and expose the posterior facial vein, descending towards the angle of the mandible. It receives the transverse facial and the internal maxillary veins, and it gives off the commencement of the external jugular vein; and then it passes out of the lower end of the gland and unites with the anterior facial vein to form the common facial vein. Deep to the veins will be found the upper end of the external carotid artery dividing into its superficial temporal and internal maxillary branches; and the transverse facial and middle temporal offsets of the superficial temporal will also be displayed.

When the remains of the deeper part of the gland have been removed, the styloid process with the origin of the stylo-hyoid muscle, and the posterior belly of the digastric will be exposed; and the internal jugular vein and the internal and external carotid arteries will be seen disappearing under cover of the digastric. If the occipital artery lies at its lower level, it also will be noted as it runs upwards and posteriorly, along the lower border of the digastric, crossing superficial to the two large vessels, and to the accessory nerve, which emerges from under cover of the digastric and passes downwards and posteriorly across the internal jugular vein.

The dissector should now obtain a gland which has been removed uninjured from the parotid space, or a cast of a gland, and proceed to study the relations of the upper end and the postero-medial and antero-medial surfaces.

The *upper extremity* presents a deep concavity which is usually separable into a larger lateral part which lies in contact with the cartilaginous part of the external meatus, and a smaller medial part which touches the bony wall of the meatus (Fig. 109). The anterior boundary of the upper end forms a sharp ridge, which lies in the narrow interval between the capsule of the temporo-mandibular articulation and the front of the external meatus.

The *postero-medial surface* is marked by a series of depressions which correspond with the structures in the postero-medial boundary of the parotid space. Above is a shallow depression corresponding with the anterior border of the mastoid process, and below the latter a groove caused by the anterior border of the sterno-mastoid. More medially is a shallow depression due to the posterior belly of the digastric and the stylo-hyoid, and, still more medially and at a higher level, a sulcus which corresponds with the position of the styloid process. Below the level of the digastric groove the postero-medial surface covers portions of the internal jugular

PAROTID GLAND

213

vein and the internal and external carotid arteries. The commencement of the external jugular vein, the posterior facial vein, and the cervical branch of the facial nerve emerge from this part of the surface. Immediately above the digastric groove, close to the medial border, the external carotid enters the gland; and directly lateral to the upper end of the groove for the styloid process the facial nerve passes over the gland substance. The dissector should note that the postero-medial surface of the gland is separated from the upper parts of the internal jugular vein and the internal carotid artery, and from

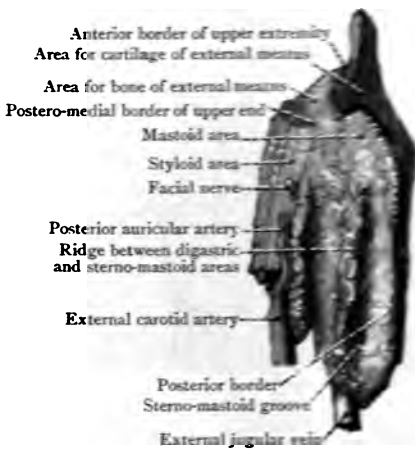

FIG. 108.—Parotid Gland, postero-medial aspect.

the last four cerebral nerves by the posterior belly of the digastric, the styloid process and the muscles attached to it.

The *medial border* of the gland lies in the angle between the postero-medial and the anterior boundaries of the parotid space, where the styloid process, the stylo-hyoid muscle, and the posterior belly of the digastric disappear under cover of the posterior border of the internal pterygoid muscle; and from it a process, the *pterygoid lobe*, usually projects anteriorly, for a short distance, between the internal pterygoid and the inner surface of the ramus of the mandible. Through the base of this process the external carotid passes from the postero-medial to the antero-medial surface of the gland.

The Antero-medial Surface.—The medial part of the

antero-medial surface is directed anteriorly and lies in relation with the lower part of the posterior border of the internal pterygoid, the stylo-mandibular ligament, and the posterior border of the ramus of the mandible. The more lateral part is directed medially and rests against the lateral surface of the masseter. This surface is pierced (1) by the external carotid artery, (2) the posterior facial and the internal maxillary veins, (3) all the terminal branches of the facial nerve except the cervical, and (4) by the duct of the gland.

As the dissector examines the parotid space he will note that as the external carotid disappears under cover of the

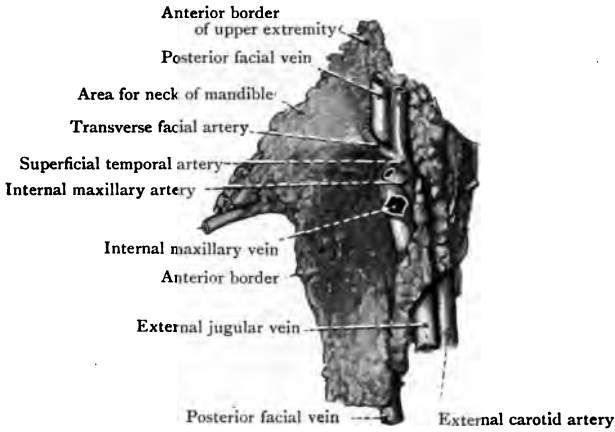


FIG. 109.—Parotid Gland, antero-medial aspect.

posterior belly of the digastric it is placed so far anteriorly that it is also under cover of the posterior border of the mandible; and it does not emerge from under cover of the mandible until it reaches the level of the neck of the bone, where it appears on the antero-medial surface of the gland and divides into its two terminal branches. Further, he will now readily recognise the impossibility of studying the upper end of the cervical part of the internal carotid, the upper part of the internal jugular vein, and the last four cerebral nerves, until he is in a position to reflect the posterior belly of the digastric and the styloid process; and as both of them are, to a certain extent, under cover of the

mandible it is obvious that the mandible must be removed. This will be done during the dissection of the temporal and infratemporal regions, which must now be proceeded with.

TEMPORAL AND INFRATEMPORAL REGIONS.

Fascia Temporalis.—The temporal fascia is a strong glistening membrane which is stretched over the temporal fossa, binding down the temporal muscle. Its upper margin is attached to the upper of the two curved lines which constitute the temporal ridge on the lateral aspect of the skull, and anteriorly to the temporal line of the frontal bone. As it approaches the zygomatic arch, it splits into two laminæ, which are separated from each other by a narrow interval filled with fat. The two laminæ are attached one to the upper border of the zygomatic arch and the posterior border of the zygomatic bone, and the other to the medial surfaces of these two portions of bone. They can readily be demonstrated by dividing the superficial layer close to its attachment, and throwing it upwards; by the handle of the knife the attachment of the deep layer can then be made out. In the upper part of its extent, the temporal fascia is comparatively thin and the fibres of the subjacent muscle may be seen shining through it; below, it is thicker, and owing to the fat which is interposed between its laminæ, it is perfectly opaque. It is pierced immediately above the posterior part of the zygomatic arch by the middle temporal branch of the superficial temporal artery and by the middle temporal vein (p. 157).

Musculus Masseter.—The masseter is a massive quadrate muscle which covers the ramus of the mandible. Its fibres are arranged in two sets—a superficial and a deep. The *superficial part* of the muscle arises from the anterior two-thirds of the lower border of the zygomatic arch, and its fasciculi are directed downwards and posteriorly. The *deep part* springs from the whole length of the medial aspect of the zygomatic arch, and also from the posterior third of its lower border. Its fibres proceed downwards and anteriorly. Only a small piece of the upper and posterior part of this portion appears on the surface. The masseter is inserted into the lateral surface of the ramus of the mandible, over an area

which extends downwards to the angle, and upwards so include the lateral aspect of the coronoid process.

Dissection.—To display the temporal muscle, and at the same time expose the nerve and artery of supply to the masseter, make the following dissection. Divide the deep part of the temporal fascia along the border of the zygomatic arch and remove it. The middle temporal and the zygomatico-temporal nerve, which pierce it, must be dissected from it and preserved. The zygomatic arch, with the attached masseter, must next be thrown down by dividing the bony arch anterior and posterior to the origin of the muscle. First make use of the saw, and then complete the division by means of the bone forceps. The posterior cut should be made immediately anterior to the mandibular (O.T. glenoid) fossa, the head of the lower jaw; the anterior cut must extend obliquely through the zygomatic bone, from the extreme anterior end of the upper margin of the arch, downwards and anteriorly to the point where the lower jaw meets the zygomatic process of the maxilla. When the division is completed, and the nerve and artery to the masseter are divided, the zygomatic arch and the attached masseter may be readily thrown downwards to the angle of the mandible. The fleshy origin of the deep part of the masseter from the medial surface of the zygomatic arch can now be seen. The dissection is frequently complicated by a number of fibres of the temporal muscle joining this part of the masseter. In turning the masseter down, its nerve and artery of supply must first be cleared; they pass laterally through the incisura mandibulæ (O.T. sigmoid notch) posterior to the tendon of the temporal muscle. Leave the masseter attached to the angle of the jaw and clean the temporal muscle.

Musculus Temporalis.—The temporal muscle is fan-shaped. It arises from the whole extent of the temporal fossa, from the lower of the two lines which constitute the temporal ridge, and from the infratemporal crest on the great wing of the sphenoid bone. It receives additional fibres also from the deep surface of the temporal fascia. From this broad origin the fasciculi converge towards the coronoid process of the mandible. The anterior fibres descend vertically, the posterior fibres first pursue a nearly horizontal course, whilst the intermediate fasciculi proceed with varying degrees of obliquity. As the muscle approaches its insertion, a tendon is developed upon its superficial aspect, and this is inserted into the summit of the anterior edge of the coronoid process. The deep part of the muscle remains fleshy, and gains insertion to the medial surface of the same bony prominence by an attachment which reaches as low down as the point where the anterior margin of the ramus merges into the body of the mandible. The insertion cannot be fully examined at present; it will be dealt with later.

Dissection.—Detach the coronoid process from the mandible, and turn it upwards with the attached temporal muscle. A very oblique

TEMPORAL AND INFRATEMPORAL REGIONS

required; it should extend from the centre of the incision above, downwards and anteriorly, to the point where the anterior margin of the masseter meets the body of the mandible. First use the saw, and then complete the division with the bone forceps. The *supra-orbital* (O.T. *supra-orbital*) and its companion artery are in a position of danger during this dissection, and must be carefully guarded. They proceed downwards and backwards under cover of the lower part of the temporal muscle, and are subsequently the nerve traverses its substance. The coronoid process and the coronoid muscle must be thrown well upwards, and the zygomatic fibres separated, by the handle of the knife, from the bone forming the lower part of the temporal fossa. This will bring into view the *deep temporal arteries* as they ascend between the cranial wall and the muscle. This is the time to follow the *middle temporal artery* also. It will be noticed to give branches to the muscle, and it extends upwards upon the zygomatic part of the temporal bone. The *zygomatico-temporal nerve* also should be traced to the point where it emerges from the zygomatic aperture on the temporal surface of the zygomatic bone. At this point it lies under cover of the temporal muscle.

The infratemporal region (O.T. *pterygo-maxillary*) may now be fully opened up by removing a portion of the ramus of the mandible. Two horizontal cuts must be made—one through the neck of the mandible, and the other immediately above the level of the mandibular (O.T. *inferior dental*) foramen. To find the level of the foramen, the handle of the knife should be thrust between the ramus and the subjacent soft parts, and carried downwards. Its progress will soon be arrested by the entrance of the inferior alveolar vessels and nerve into the foramen, and the lower border of the instrument will correspond with the line along which the bone should be cut. Both incisions should be made with the saw, until the lateral table of the bone is cut through, and then the bone forceps may be employed to complete the division.

Parts displayed by the above Dissection.—When the fat and areolar tissue are removed, the pterygoid muscles will come into view. The *external pterygoid* extends horizontally to the neck of the mandible. The *internal pterygoid*, embracing the anterior part of the external pterygoid muscle between its two heads of origin, proceeds downwards and posteriorly upon the deep surface of the ramus of the mandible. It bears very much the same relation to the medial aspect of the ramus that the masseter presents to its lateral surface. The great blood vessel of the space—the *internal maxillary artery*—proceeds anteriorly upon (frequently under cover of) the external pterygoid muscle. The *nerves* of the region also will be found in close relationship to the same muscle. Thus, emerging from between its upper border and the cranial wall, at the level of the infratemporal crest, are the *masseteric* and the two *deep temporal nerves*; appearing from under cover of its lower border are the *inferior alveolar* and the *lingual nerves*; whilst the *auriculo-temporal nerve* is related to its medial surface posteriorly and the *buccinator nerve* anteriorly.

The former appears posterior to the temporo-mandibular joint, and the buccinator nerve either pierces it or emerges from between its two heads of origin. The *spheno-mandibular ligament* also will be seen. It is the thin strip of membrane which lies medial to the inferior alveolar nerve.

Musculus Pterygoideus Externus.—The external pterygoid

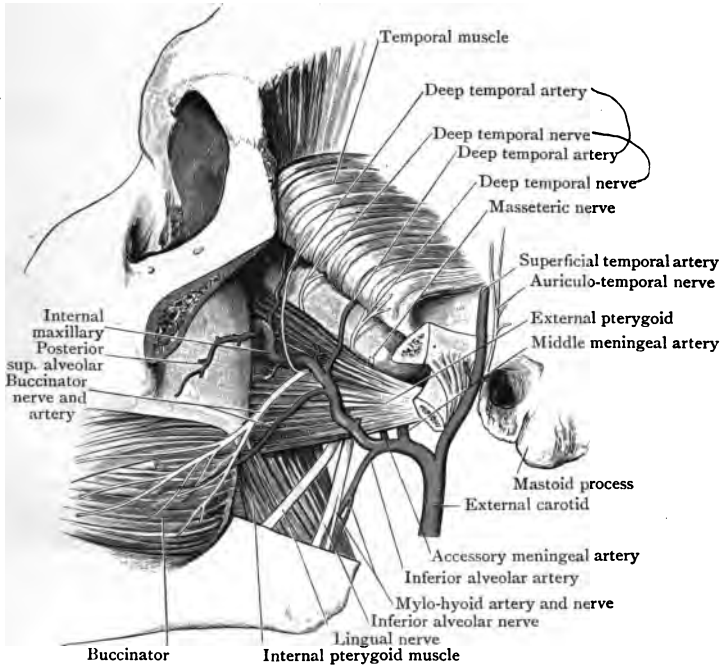


FIG. 110.—Dissection of the Infratemporal Region.

arises in the infratemporal fossa by two heads, an upper and a lower. The *upper head* springs from the infratemporal ridge and surface of the great wing of the sphenoid; the *lower head* takes origin from the lateral surface of the lateral pterygoid lamina (O.T. external pterygoid plate). The muscle diminishes in width as it passes posteriorly, and it is inserted into the fovea pterygoidea on the anterior surface of the neck of the mandible, and also into the anterior margin of the discus articularis of the temporo-mandibular articulation.

TEMPORAL AND INFRATEMPORAL REGION

Musculus Pterygoideus Internus—The internal pterygoid muscle also is bicapital at its origin, and takes its origin from the anterior origin of the lower head of the external pterygoid muscle, the *superficial* and smaller end of the internal pterygoid muscle arising from the lower and posterior part of the lower border of the maxilla, and also from the infra-orbital foramen, the infra-orbital process (O.T. tuberosity) of the palate bone, the infra-orbital fossa hidden by the external pterygoid muscle, the infra-orbital fossa from the medial surface of the infra-orbital foramen, and from the surface of the pyramidal process of the zygomatic bone which appears between the two heads of the muscle. The two heads of the muscle unite at the lower margin of the anterior part of the external pterygoid and the fibres proceed downwards with a posterolateral direction to the lower part of the insertion into the angle of the mandible and to the lower and posterior part of the medial aspect of the ramus as high as the mandibular foramen.

Arteria Maxillaris Interna—This vessel is the artery of the two terminal branches of the external maxillary artery. It takes origin immediately posterior to the lower border of the mandible and proceeds anteriorly to the anterior part of the infratemporal fossa, where it disappears from view by dividing between the two heads of origin of the external pterygoid muscle and entering the pterygo-palatine fossa. It is divided into three parts for convenience of description. The *first part* runs horizontally between the base of the mandible and the spheno-mandibular ligament. It runs along the lower border of the posterior part of the external pterygoid muscle, and usually crosses the inferior alveolar nerve superficially. The *second part* extends obliquely upwards and anteriorly upon the lateral surface of the external pterygoid muscle, under cover of the insertion of the temporal muscle. The *third part* dips between the two heads of the external pterygoid into the pterygo-palatine fossa.

This is the most frequent arrangement, but it is not uncommon to find the *second part* of the artery going in a deeper plane, viz. between the internal and external pterygoid muscles. In that case the vessel makes a bend anteriorly between the heads of the external pterygoid muscle and appears on its surface before entering the pterygo-palatine fossa.

The *branches* of the internal maxillary artery are classified

according to the portion of the vessel from which they spring. Only one branch of the third part, viz. the *posterior superior alveolar artery*, can be studied in this dissection. Those arising from the first and second parts are:—

FROM THE FIRST PART.	FROM THE SECOND PART.
1. Arteria auricularis profunda.	1. Arteria masseterica.
2. Arteria tympanica.	2. Rami pterygoidei.
3. Arteria meningea media.	3. Arteriæ temporales profundæ.
4. Ramus meningeus accessorius.	4. Arteria buccinatoria.
5. Arteria alveolaris inferior.	

The *Deep Auricular Artery*.—This small vessel pierces the anterior wall of the external acoustic meatus to supply the skin which lines it, and also the superficial part of the tympanic membrane.

The *Meningeal and Tympanic Branches* proceed upwards under cover of the external pterygoid muscle, and, therefore, cannot be fully studied until that muscle is reflected.

The *Inferior Alveolar Artery* arises opposite the middle meningeal, and runs downwards, upon the spheno-mandibular ligament, to enter the mandibular foramen. It is generally accompanied by two venæ comites, and it is placed posterior to the inferior alveolar nerve. Just before entering the foramen, the inferior alveolar artery gives off the slender *mylo-hyoid branch*, which is carried downwards and anteriorly, with the corresponding nerve, upon the deep aspect of the mandible, to the digastric triangle of the neck.

The branches from the second part are given off for the supply of the neighbouring muscles. The *Masseteric* passes horizontally, posterior to the temporal muscle, with the nerve of the same name, and has been seen entering the masseter muscle. The *Pterygoid Branches* are irregular twigs to the pterygoid muscles. The *Deep Temporal Branches* are two in number—*anterior* and *posterior*; they pass upwards in the temporal fossa, between the bony wall of the cranium and the temporal muscle. They supply twigs to the temporal muscle, and they anastomose with the middle temporal artery. The *Buccinator Branch* accompanies the buccinator nerve, and is distributed to the buccinator muscle and the mucous

membrane of the cheek. It anastomoses with the external maxillary (O.T. facial) artery.

The *Posterior Superior Alveolar Branch*, from the third part of the internal maxillary artery, descends upon the posterior aspect of the maxilla, and sends branches through the alveolar canals of the maxilla for the supply of the upper molar and præmolar teeth (Fig. 110). Some small twigs go to the gum and others supply the lining membrane of the maxillary sinus.

Pterygoid and Internal Maxillary Veins.—The veins in this region are very numerous, but they cannot be studied satisfactorily in an ordinary dissection. They constitute a dense plexus, termed the *pterygoid plexus*, around the external pterygoid muscle. Tributaries corresponding to the branches of the internal maxillary artery open into this network, whilst the blood is led away from its posterior part by a short wide trunk, called the *internal maxillary vein*. This vessel accompanies the first part of the internal maxillary artery into the parotid gland, and joins the posterior facial vein behind the neck of the mandible.

The pterygoid venous plexus is connected with the cavernous sinus by an emissary vein. It communicates with the inferior ophthalmic vein, through the inferior orbital fissure, and with the anterior facial vein by an anastomosing channel called the *deep facial vein* which descends across the external surface of the buccinator muscle.

Articulatio Mandibularis.—Before the external pterygoid muscle is thrown anteriorly, the temporo-mandibular joint must be examined. It is a diarthrodial joint of the ginglymus type, and its cavity is separated into an upper and a lower part by a discus articularis. In connection with it there are the following ligaments:—

LIGAMENTS PROPER.	ACCESSORY LIGAMENTS.
1. Capsule. 2. <u>Temporo-mandibular</u> .	1. <u>Spheno-mandibular</u> . 2. <u>Stylo-mandibular</u> .
DISCUS ARTICULARIS.	

The *capsule* encloses the joint cavity. Above, it is attached posteriorly, laterally, and me margin of the man-

dibular fossa, and anteriorly to the anterior margin of the articular tubercle. Below, it is attached to the neck of the mandible; and between its upper and lower attachments it is connected with the margins of the discus articularis.

The *temporo-mandibular ligament* (O.T. *external lateral*) is a strong triangular band which is attached above to the lateral surface of the posterior part of the zygoma and to the tubercle at the root of the zygoma. Its fibres run downwards and posteriorly to the neck of the mandible.

The *spheno-mandibular ligament* (O.T. *internal lateral*) is a long membranous band which extends from the spine of the sphenoid to the lingula and to the sharp medial margin of the

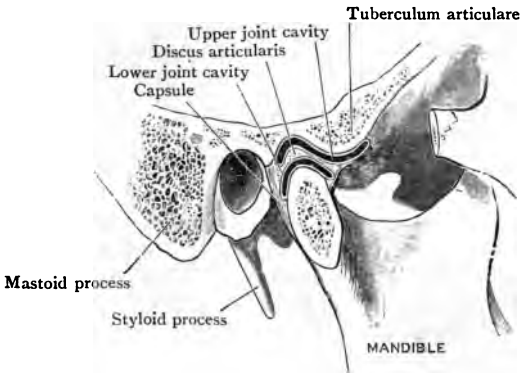


FIG. III.—Section through Temporomandibular Joint.

mandibular foramen. It is not in direct relationship with the joint. Above, it lies medial to the external pterygoid muscle and the auriculo-temporal nerve; lower down, the internal maxillary vessels intervene between it and the neck of the mandible; whilst, still lower, the inferior alveolar vessels and nerve are interposed between it and the ramus of the mandible.

The *stylo-mandibular ligament* has been noticed already. It is a fibrous band, derived from that portion of the deep cervical fascia which forms a part of the capsule of the parotid gland. It is attached above to the styloid process, and below to the angle and posterior border of the ramus of the mandible, between the internal pterygoid and masseter muscles.

An examination of these ligaments will show that very

little is added to the strength of the joint by their presence. The security of the joint depends not so much upon its ligaments as upon the strong muscles of mastication, which keep the head of the mandible in its place.

The *discus articularis* is an oval plate of fibro-cartilage, with its long axis directed transversely. It is interposed between the condyle of the mandible below and the mandibular fossa (O.T. glenoid) and the articular tubercle (O.T. eminentia articularis) above, and it divides the joint cavity into upper and lower parts, each of which is provided with a separate synovial lining. To expose the cartilage, the temporo-mandibular ligament must be removed. The disc will then be seen to be adapted to the two bony surfaces between which it lies. Above, it is concavo-convex in correspondence with the tuberculum articulare and the mandibular fossa of the temporal bone; whilst below, it is concave, and fits upon the upper aspect of the condyle of the mandible. In the centre it is thin, and in some cases it is perforated. Its circumference is thick, more especially posteriorly. It should be noted also that the external pterygoid muscle is partly inserted into its anterior border.

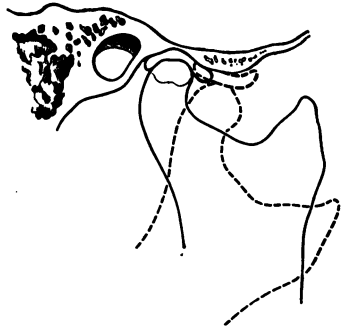

FIG. 112.—Diagram of the different positions occupied by the head of the mandible and the discus articularis as the mouth is opened and closed.

The *synovial stratum* which lines the capsule enclosing the upper cavity of the joint is of greater extent and looser than that of the lower compartment. This is in association with the larger size of the articular surface of the temporal bone as contrasted with the condylar surface.

Movements.—The movements which the mandible can perform at the temporo-mandibular joint are the following:—(1) depression; (2) elevation; (3) protraction; (4) retraction; (5) lateral or chewing movements. When the mandible is depressed the discus articularis and the condyle move anteriorly on the mandibular fossa, and the condyle finally takes up a position on the tuberculum articulare. This forward gliding of the disc and condyle in the upper compartment of the joint is accompanied by another movement in the lower compartment of the joint,

which consists in a rotation of the condyle of the mandible on the lower surface of the articular disc. Elevation of the mandible or closure of the mouth is brought about by a reverse series of changes in both compartments of the joint. Whilst these movements are going on, the mandible rotates around a transverse axis which traverses the bone in the neighbourhood of the mandibular foramen. This is the point, therefore, of least movement, and consequently in opening and shutting the mouth the inferior alveolar vessels and nerves are not unduly stretched. In protraction and retraction the movement is chiefly confined to the upper compartment of the joint, and the condyle of the mandible with the articular disc glides anteriorly and posteriorly upon the temporal articular surface. In the lateral movements of the jaw the mandible is carried alternately from side to side, as in the process of chewing.

The muscles on each side which are chiefly engaged in producing these movements are the following:—(1) *depressors*—the platysma, the mylohyoid, and the anterior belly of the digastric; (2) *elevators*—the masseter, internal pterygoid, temporal; (3) *protractors*—the external pterygoid, and to some extent the internal pterygoid and the superficial fibres of the masseter; (4) *retractor*—the posterior fibres of the temporal and the deep fibres of masseter; (5) *lateral movement* is produced by the muscles of opposite sides acting alternately.

Reflection of External Pterygoid.—The condyle of the mandible must now be disarticulated and thrown anteriorly with the attached external pterygoid muscle. It is well to detach the discus articularis with the head of the bone, in order that it may be more thoroughly examined. Care must be taken not to injure the auriculo-temporal nerve, which lies in close proximity to the medial aspect of the joint. When the disarticulation is complete, the muscle may be displaced anteriorly by gently pushing the condyle under the internal maxillary artery.

The reflection of the external pterygoid muscle brings into view, after a little dissection, the *mandibular division of the trigeminal nerve*, emerging from the foramen ovale, and breaking up into its branches of distribution. The slender *chorda tympani* will be found proceeding downwards and anteriorly to join the lingual nerve; and the *middle meningeal, tympanic, and accessory meningeal arteries* may be traced to the points where they leave the infratemporal region.

Arteriæ Meningea Media et Tympanica and Ramus Meninge Accessorius.—The *middle meningeal artery* has already been seen arising from the first part of the internal maxillary artery. It proceeds upwards, medial to the external pterygoid muscle and lateral to the tensor palati, and disappears from view through the foramen spinosum, by which it enters the cranial cavity (p. 212). It is usually embraced by the two roots of the auriculo-temporal nerve.

The *accessory meningeal artery* and the *tympanic artery* generally arise from the middle meningeal. The *accessory meningeal* inclines anteriorly and upwards, and enters the cranial cavity by passing through the foramen ovale; the *tympanic* runs upwards and posteriorly, and reaches the tympanum by passing through the petro-tympanic fissure (O. T. Glaserian). In the tympanic cavity it anastomoses with the styloid-mastoid branch of the posterior auricular artery.

Nervus Mandibularis.—The mandibular branch of the trigeminal nerve arises within the cranium from the semilunar (O.T. Gasserian) ganglion, and enters the infratemporal region through the foramen ovale. It is composed of *sensory fibres*, but it is accompanied through the foramen by the small *motor root* of the trigeminal nerve; and by the union of the sensory and motor parts, immediately after they gain the exterior of the cranium, a *mixed nerve-trunk*

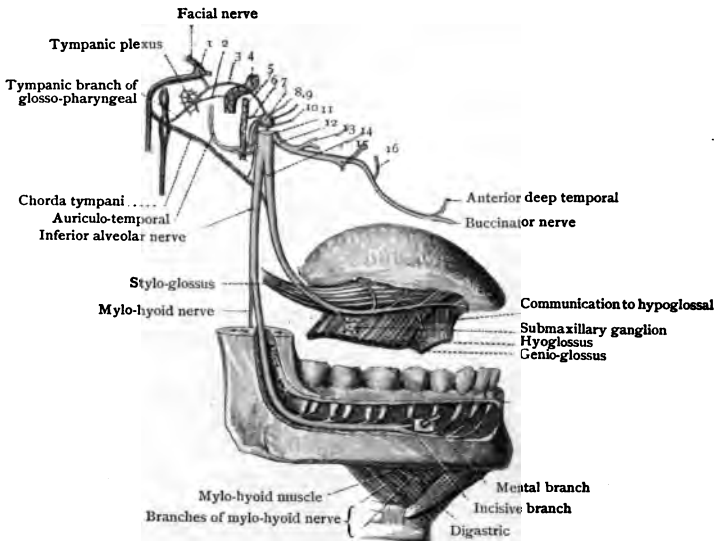


FIG. 113.—Diagram of Mandibular Nerve. By Prof. A. M. Paterson.

- | | | |
|-------------------------------------|---------------------------------|--|
| 1. Ganglion geniculi | 7. Otic ganglion | 13. Masseteric and post. deep temporal |
| 2. Carotico-tympanic nerve | 8. Nerve to tensor tympani | 14. Lingual nerve |
| 3. Small superficial petrosal nerve | 9. Nerve to tensor palati | 15. } Pterygoid branches |
| 4. Internal carotid artery | 10. Nerve to internal pterygoid | 16. } |
| 5. Middle meningeal artery | 11. Mandibular nerve trunk | |
| 6. Symp. root of otic ganglion | 12. Anterior division | |

results. This nerve-trunk lies medial to the external pterygoid muscle and lateral to the tensor palati, and after a very short course (not exceeding 5 mm.) it ends by dividing into two parts, named the *anterior* and *posterior divisions* of the mandibular nerve (Fig. 113).

The trunk of the mandibular nerve gives off two branches before it divides, viz., (1) *nervus spinosus* (O.T. *recurrent nerve*), and (2) the nerve to the internal pterygoid muscle.

The *nervus spinosus* is a very slender twig which enters
11—18 a

the cranium by accompanying the middle meningeal artery through the foramen spinosum. It supplies the dura mater.

The *nerve to the internal pterygoid* will be found passing under cover of the posterior border of the internal pterygoid muscle at its upper end. In close relation to the root of this nerve is the *otic ganglion*.

From the two terminal divisions of the mandibular trunk the chief branches of distribution arise. The anterior division is much the smaller of the two, and is composed almost entirely of motor fibres derived from the motor root of the trigeminal nerve. The only sensory fibres which it contains are those which form the *buccinator nerve*. It gives off the following branches:—

- | | |
|------------------------------|-------------------------------|
| 1. <u>Masseteric.</u> | 3. <u>External pterygoid.</u> |
| 2. <u>Two deep temporal.</u> | 4. <u>Buccinator.</u> |

The large *posterior division* is chiefly sensory. It contains only a very few fibres from the motor root, and these are prolonged into its inferior alveolar branch, and afterwards come off in the form of the *mylo-hyoid nerve*. The branches of the posterior division are: (1) auriculo-temporal; (2) inferior alveolar; (3) lingual.

Nervus Massetericus.—The masseteric nerve runs horizontally above the external pterygoid muscle, and, passing through the incisura mandibulæ (O.T. sigmoid notch) posterior to the temporal muscle, it enters the posterior and upper part of the deep surface of the masseter. Before reaching the masseter it gives one or two twigs to the temporo-mandibular joint.

Nervi Temporales Profundi.—There are usually two deep temporal nerves, *anterior* and *posterior*. The posterior nerve is the smaller of the two; it frequently arises by a common root with the masseteric. Both deep temporal nerves pass laterally above the external pterygoid, and then turn upward on the medial wall of the temporal fossa. They supply the temporal muscle.

Nervus Buccinatorius.—The buccinator nerve (O.T. long buccal) is the largest of the branches arising from the anterior division of the mandibular nerve. It proceeds laterally between the two heads of the external pterygoid muscle, and then runs downwards and anteriorly under cover of the temporal muscle, and under cover of the anterior

border of the masseter also, to reach the outer surface of the buccinator muscle. There it unites with branches of the facial nerve to form the *buccal plexus*, from which branches are distributed to the mucous membrane and skin of the cheek.

The buccinator nerve is a sensory nerve, and all the sensory fibres in the anterior division of the mandibular nerve enter into its composition. A few motor fibres, however, are also prolonged into it; these come off from it in two branches, viz., (1) in the nerve to the external pterygoid, which, as a rule, arises in common with the buccinator nerve; and (2) in a third twig of supply to the temporal muscle. This *temporal branch* springs from the buccinator nerve, after it has reached the lateral surface of the external pterygoid, and proceeds upwards to supply the anterior part of the temporal muscle (Fig. 110). In some cases the buccinator nerve pierces the temporal muscle instead of passing under cover of it.

Nervus Auriculo-Temporalis.—The auriculo-temporal nerve springs by two roots from the posterior division of the mandibular nerve, under cover of the external pterygoid. The two roots are composed of sensory fibres and each receives a communication from the otic ganglion, by means of which it is brought indirectly into association with the glossopharyngeal nerve. The roots embrace the middle meningeal artery, and unite posterior to it to form a stem which runs posteriorly between the neck of the mandible and the spheno-mandibular ligament. At the interval between the ear and mandible it turns upwards, in relation to the deep surface of the parotid gland, crosses the zygoma in company with the superficial temporal artery, and enters the scalp, where it breaks up into terminal branches.

Its branches are: (1) one or two strong branches of communication to the temporo-facial nerve; (2) a few slender filaments which enter the posterior aspect of the temporo-mandibular joint; (3) some twigs to the parotid gland; (4) terminal filaments to the skin over the temporal region and summit of the head; (5) auricular branches.

The *auricular* branches are usually *two* to the skin lining the interior of the external meatus, and *two* to the integument over the upper and anterior part of the auricle. The former gain the interior of the meatus by passing between the osseous and cartilaginous portions of the canal.

Nervus Alveolaris Inferior.—The inferior alveolar nerve

(O.T. inferior dental) is the largest branch of the mandibular nerve. Emerging from under cover of the external pterygoid, at the lower border of the muscle, it passes downwards upon the speno-mandibular ligament and enters the mandibular foramen. The inferior alveolar artery runs downwards posterior to it, whilst the lingual nerve is anterior to it and upon a somewhat deeper plane. The inferior alveolar is a sensory nerve, but a few fibres from the motor root are prolonged downwards within its sheath as far as the mandibular foramen. At this point they come off as the slender mylo-hyoid nerve.

The *mylo-hyoid nerve*, accompanied by the artery of the same name, pierces the speno-mandibular ligament and proceeds downwards and anteriorly in a groove upon the inner surface of the mandible to the digastric triangle. A narrow prolongation of the speno-mandibular ligament bridges over the groove and holds the nerve and vessel in position. In the digastric triangle the mylo-hyoid nerve has been dissected already (p. 230). It breaks up into numerous branches for the supply of two muscles, viz., (1) the mylo-hyoid, and (2) the anterior belly of the digastric.

Nervus Lingualis.—The lingual nerve is entirely sensory. In the first part of its course, like the other branches of the mandibular nerve, it lies medial to the external pterygoid muscle. As it descends it appears at the lower border of the muscle. Then it proceeds downwards and anteriorly, between the internal pterygoid muscle and the mandible, and enters the submaxillary region, where it will afterwards be traced to the tongue. It lies anterior to and on a slightly deeper plane than the inferior alveolar nerve. It gives off no branches in the infratemporal region, but, whilst still under cover of the external pterygoid, it is joined at an acute angle by the *chorda tympani branch* of the facial nerve. Not infrequently, also, a communicating twig passes between it and the inferior alveolar nerve.

Chorda Tympani.—This is a slender nerve which arises from the facial in the canalis nervi facialis (O.T. aqueduct of Fallopius). It gains the infratemporal region by traversing the tympanic cavity and appearing through the medial part of the petro-tympanic fissure (O.T. Glaserian), whence it runs downwards and anteriorly, medial to the speno-mandibular ligament. It is joined by a slender filament from the otic

ganglion, and it unites with the lingual nerve a short distance below the upper end of the latter.

Dissection.—The student should now endeavour, by means of a Hey's saw, a chisel, and the bone forceps, to remove the outer table of the mandible, and thus open up the mandibular canal.

Structures within the Mandibular Canal.—The mandibular canal is traversed by the *inferior alveolar vessels and nerve*, which give off twigs to the roots of the molar and præmolar teeth. Both the artery and the nerve terminate by dividing into a mental and incisor branch.

The *mental artery and nerve* appear on the face through the mental foramen, and have been examined already; the *incisor artery and nerve* pass anteriorly to the symphysis and send up twigs to the canine and incisor teeth. The vessel anastomoses in the bone with the corresponding artery of the opposite side.

SUBMAXILLARY REGION.

The superficial area of the submaxillary region has been dissected already, under the name of the anterior part of the digastric triangle (p. 230). It is now necessary to carry the dissection to a deeper plane, in order to expose a number of parts in connection with the tongue and floor of the mouth. The structures thus displayed are:—

1. Submaxillary gland and its duct.
2. Sublingual gland.
3. Side of the tongue, and the mucous membrane of the mouth.
4. Muscles. {
 - Mylo-hyoid.
 - Digastric.
 - Stylo-hyoid.
 - Hyoglossus.
 - Stylo-glossus.
 - Genio-hyoid.
 - Genio-glossus.
5. Nerves. {
 - Mylo-hyoid.
 - Hypoglossal.
 - Lingual.
 - Glosso-pharyngeal.
6. Submaxillary ganglion.
7. Lingual artery and veins.
8. Part of the external maxillary artery.
9. Stylo-hyoid ligament.

Dissection.—To prepare the part for dissection, it is necessary to throw back the head to its full extent, and turn it slightly to the opposite side.

If the stuffing in the mouth has not been previously removed, it should be taken out now. When this has been done, divide the external maxillary artery and the anterior facial vein at the point where they cross the lower border of the mandible. Next detach the anterior belly of the digastric from its attachment to the anterior part of the medial aspect of the lower border of the mandible; and then, with the saw, cut through the mandible lateral to the median plane.¹ It is essential that the division of the anterior part of the mandible should be slightly lateral to the median plane on each side, in order that the median part of the bone, with the attachments of the genioïd muscles, may be left intact.

After the division of the bone has been completed the lower border of the lateral part of the mandible must be everted, turned slightly upwards, and fixed in position with hooks. When this has been done the boundaries and contents of the submaxillary region can be examined.

Part of the region has already been seen as the digastric portion of the anterior triangle of the neck, but it will now be obvious that the region occupied by the submaxillary gland is much more extensive than the digastric triangle; for, although both are bounded anteriorly and posteriorly by the anterior and posterior bellies of the digastric muscle, the upper boundary of the digastric triangle is the lower border of the mandible, whilst the submaxillary region extends upwards to the level of the mylo-hyoid ridge on the inner surface of the mandible.

After the mandible has been turned upwards the dissector should proceed, in the first place, to examine the relations of the digastric and stylo-hyoid muscles, then the mylo-hyoid muscle, and afterwards he must study the submaxillary and sublingual glands and the deeper structures which are found in the medial boundary of the submaxillary region.

Musculus Digastricus.—This muscle limits the submaxillary region inferiorly and separates it from the carotid and submental triangles.

The *anterior belly* of the digastric springs from the inner surface of the lower border of the mandible close to the symphysis; and the *posterior belly* arises from the mastoid notch of the temporal bone on the medial side of the mastoid process. The two bellies converge upon the upper border of the hyoid bone, where they are united by an intermediate tendon, which is attached to the hyoid bone at the junction of the body with the great cornu, by a strong loop of fibrous tissue developed from the deep cervical fascia. Posterior to the loop, through which it plays, the intermediate tendon passes through the cleft lower end of the stylo-hyoid muscle.

Relations.—The anterior belly is covered by the skin, superficial fascia and the platysma, and the deep fascia. It is overlapped by the anterior border of the submaxillary gland, and its deep surface is in contact with the mylo-hyoid muscle. Its anterior border is the posterior boundary of the submental

¹ If the part is soft and pliable there may be no necessity to make this division of the bone.

triangle, and its posterior border is the anterior boundary of the digastric triangle.

The relations of the posterior belly are more numerous and important. Posteriorly, it is covered by the mastoid process and the attachments of the sterno-mastoid and splenius capitis muscles. Between the mastoid process and the angle of the mandible it forms part of the postero-medial boundary of the parotid space and is covered by the parotid gland; next it is covered by the angle of the mandible and the insertion of the internal pterygoid muscle. As it lies in the anterior triangle it is covered by the skin, the superficial fascia and platysma, and the deep fascia; it is crossed by the anterior facial vein, and is overlapped by the posterior part of the submaxillary gland.

It is superficial to the internal jugular vein, the internal and the external carotid arteries, the external maxillary artery, the middle constrictor of the pharynx, and the lower and posterior part of the hyoglossus muscle. The accessory nerve passes posteriorly and downwards between it and the internal jugular vein, and the occipital artery passes upwards and posteriorly under cover of its lower border, superficial to the accessory nerve. The hypoglossal nerve descends vertically on its deep surface in the angle between the internal jugular vein and the internal carotid artery, and the glosso-pharyngeal nerve passes anteriorly and downwards between it and the internal carotid. The posterior auricular artery runs upwards and posteriorly along the posterior part of its upper border under cover of the postero-medial surface of the parotid, and the stylo-hyoid muscle descends along the same border.

The posterior belly is supplied by the *facial nerve*, and the anterior belly by the *mylo-hyoid branch* of the inferior alveolar nerve.

Musculus Stylohyoideus.—The stylo-hyoid muscle is a small muscular bundle which springs from the posterior border and lateral surface of the middle third of the styloid process and descends along the upper border of the posterior belly of the digastric. It divides below into two slips which embrace the intermediate tendon of the digastric and are then inserted into the hyoid bone, at the junction of the great cornu with the body. Its main relations are practically the same as those of the posterior belly of the digastric, but it is

not under cover of the mastoid process, the sterno-mastoid, and the splenius muscles. It is supplied by the *facial nerve*.

Dissection.—Turn the anterior part of the submaxillary gland posteriorly, and clean the posterior part of the mylo-hyoid muscle, which lies deep to it. Note that a process, the deep part of the gland, springs from the medial surface of the superficial part and passes anteriorly, deep to the mylo-hyoid. Dissect the external maxillary artery out of the deep sulcus in the posterior part of the gland, without injuring its submental branch which runs anteriorly along the lower border of the mandible; then displace the posterior part of the gland anteriorly and expose the hypoglossal nerve immediately above the great cornu of the hyoid bone, and, at a higher level, the lingual nerve. Both nerves lie on the lateral surface of the hyoglossus muscle. Hanging from the lower border of the lingual nerve is the small submaxillary ganglion, from which several branches pass to the gland. Note again the deep part of the gland, springing from the medial surface of the superficial part, and also the duct of the gland emerging from the superficial part of the gland and passing anteriorly, with the deep part, between the mylo-hyoid muscle laterally and the hyo-glossus medially. Then study the position and relations of the superficial portion of the gland. The relations of the deep part will be seen after the mylo-hyoid is reflected.

Glandula Submaxillaris.—The submaxillary salivary gland consists of a superficial larger portion and a deep smaller portion. The superficial portion is lodged in a space which is bounded anteriorly by the anterior belly of the digastric; posteriorly by the posterior belly of the digastric, the stylo-hyoid, and the stylo-mandibular ligament; below by the deep fascia of the neck; and laterally by the inner surface of the body of the mandible and the lower part of the medial surface of the internal pterygoid muscle. The fascial relations of the gland have been described already (p. 226). The dissector should note now that, in accordance with the contour of the space in which it lies, he can recognise that the superficial part of the gland possesses an anterior and a posterior extremity, and three more or less well-defined surfaces, inferior, lateral, and medial. The *posterior extremity* abuts against the stylo-mandibular ligament, which separates it from the parotid, and it overlaps the stylo-hyoid and posterior belly of the digastric. It is cleft by a groove in which lies the external maxillary artery. The *anterior extremity* rests on the anterior belly of the digastric.

The *inferior surface* is covered by the layer of deep cervical fascia which extends upwards from the great cornu of the hyoid bone to the lower border of the mandible; it is crossed posteriorly, under cover of the deep fascia, by the

anterior facial vein. Along its upper border lie the majority of the submaxillary lymph glands; the external maxillary artery turns round between it and the lower border of the mandible at the anterior border of the masseter; and the submental branch of the external maxillary artery runs anteriorly in the angle between it and the bone.

The *lateral surface* is in relation posteriorly with the lower

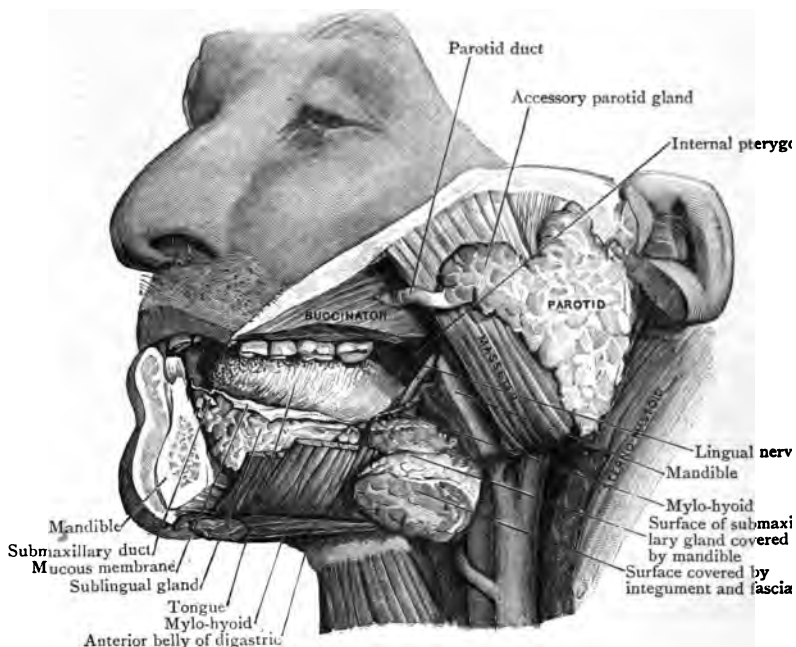


FIG. 114.—Dissection of the Parotid, Submaxillary, and Sublingual Glands.

part of the medial surface of the internal pterygoid, and anteriorly with the inner surface of the body of the mandible below the mylo-hyoid ridge. The external maxillary artery, after it emerges from the groove in the posterior end of the gland, and before it turns round the lower border of the mandible, runs anteriorly and downwards between this surface and the internal pterygoid; and the mylo-hyoid artery and nerve lie between it and the body of the mandible before they pass, more anteriorly to the medial surface of the gland.

The *medial surface* is in relation with the mylo-hyoid and hyoglossus, the lingual nerve and the submaxillary ganglion, and the hypoglossal nerve. It overlaps the stylo-hyoid muscle, both bellies of the digastric, and the great cornu of the hyoid bone; and the deep part of the gland and the duct both spring from this surface before they pass anteriorly between the mylo-hyoid and the hyoglossus muscles.

The nerve supply of the gland is derived from the lingual nerve, the submaxillary ganglion, the sympathetic plexus on the external maxillary artery; and its vascular supply consists of small submaxillary branches from the external maxillary artery.

The relations of the deep part of the gland and the duct will be investigated after the mylo-hyoid has been reflected.

Dissection.—Displace the superficial part of the gland and the submental branch of the external maxillary artery posteriorly; cut the mylo-hyoid vessels and nerve, and turn the anterior belly of the digastric downwards; then clean the mylo-hyoid muscle and examine its attachments.

Musculus Mylohyoideus.—This is a thin sheet of muscular fibres, which arises from the mylo-hyoid ridge upon the inner surface of the body of the mandible, by an origin which extends from the last molar tooth to the symphysis. Its fibres are directed downwards, medially, and anteriorly, and present two different modes of insertion. The posterior fibres are inserted into the body of the hyoid bone; these, however, form a comparatively small part of the muscle. The greater number of the fibres are inserted into a median raphe, which extends between the symphysis of the lower jaw and the body of the hyoid bone. The two mylo-hyoid muscles, therefore, stretch across from one side of the body of the mandible to the other, in front of the hyoid bone, and constitute a floor for the anterior part of the mouth. This floor is frequently termed the *diaphragma oris*. The mylo-hyoid muscle is supplied by the *mylo-hyoid branch* of the *inferior alveolar nerve*.

Dissection.—Cut the mylo-hyoid muscle a little below its origin from the mylo-hyoid ridge and turn it downwards and anteriorly. Whilst doing this be careful not to injure the mucous membrane of the mouth which lies in contact with it above.

Parts exposed by the Reflection of the Mylo-hyoid (Fig. 115).—The side of the tongue is now brought into view, with a number of structures in connection with it. First

note the mucous membrane stretching from the tongue to the gum of the lower jaw ; then identify the various muscles. The *hyoglossus*, a portion of which was previously visible behind the mylo-hyoid, is fully exposed. It is a quadrangular sheet of fleshy fibres which extends from the hyoid bone to the side of the tongue. Mark its position, because all the structures in this region have a more or less intimate relationship to it. Thus, posterior and also superficial to its upper part, the *stylo-glossus muscle* will be recognised, whilst anterior

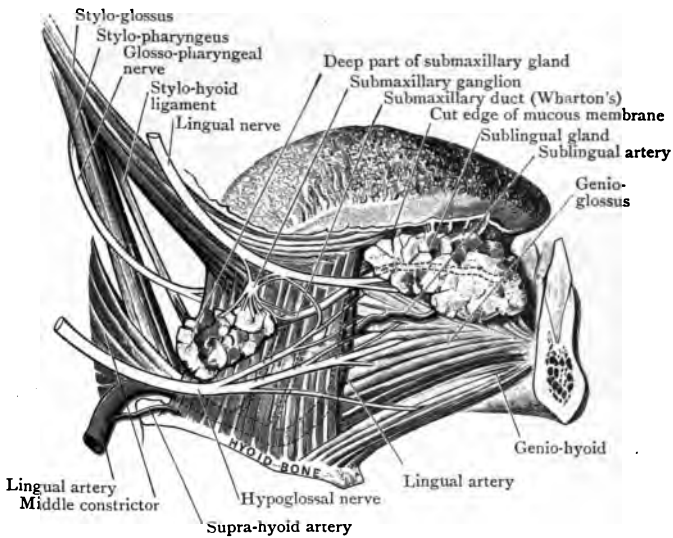


FIG. 115.—Dissection of Submaxillary Region.

to it are the *genio-glossus* and the *genio-hyoid*. The *genio-hyoid* muscle occupies the antero-inferior part of the region, whilst the anterior part of the *genio-glossus* is seen in the interval between it and the *hyoglossus*. Upon the surface of the *hyoglossus*, the *lingual* and *hypoglossal* nerves, the connecting loop between them, the deep portion of the *submaxillary gland* with the *submaxillary duct*, and the *submaxillary ganglion* are to be dissected. The *lingual nerve* occupies the highest level, and passes anteriorly upon the muscle near its insertion into the tongue. The *hypoglossal nerve*, with its *vena comitans*, crosses the *hyoid bone*, whilst the

deep part of the submaxillary gland and the submaxillary duct (Wharton's) occupy an intermediate place. Although the submaxillary ganglion is very minute, its relations are so precise that it is very easily found. By seizing the lingual nerve and dissecting carefully in the interval between it and the deep part of the submaxillary gland, the ganglion will be exposed, and its roots and branches of distribution made out. Upon the genio-glossus, anterior to the

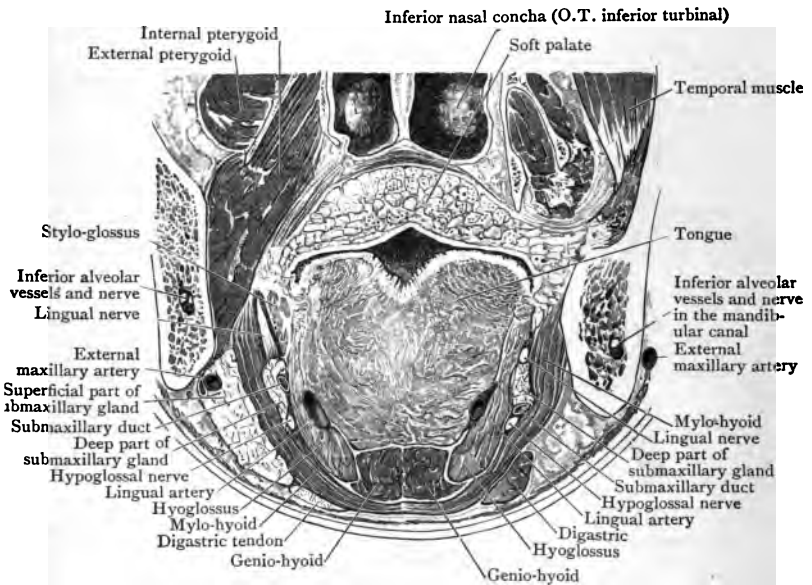


FIG. 116.—Frontal section through the Tongue and Submaxillary Region in a plane posterior to the molar teeth.

hyoglossus, the dissector will note the *sublingual gland* with its artery of supply. If the stylo-hyoid and the posterior belly of the digastric are displaced posteriorly, certain structures will be seen passing under cover of the posterior margin of the hyoglossus muscle. These are:—(1) the glosso-pharyngeal nerve immediately below the stylo-glossus muscle; (2) the stylo-hyoid ligament a little lower down; and (3) the lingual artery close to the hyoid bone.

Musculus Hyoglossus.—This is a quadrate, flat muscle which arises from the whole length of the greater cornu, and also from

the body of the hyoid bone. Its fibres pass upwards to the posterior part of the side of the tongue, medial to the styloglossus. The hyoglossus is supplied by the *hypoglossal nerve*.

Musculus Stylo-glossus.—The stylo-glossus muscle is an elongated fleshy slip which takes origin from the anterior aspect of the styloid process near its tip, and, to a slight extent, from the upper part of the stylo-hyoid ligament also. Passing down-

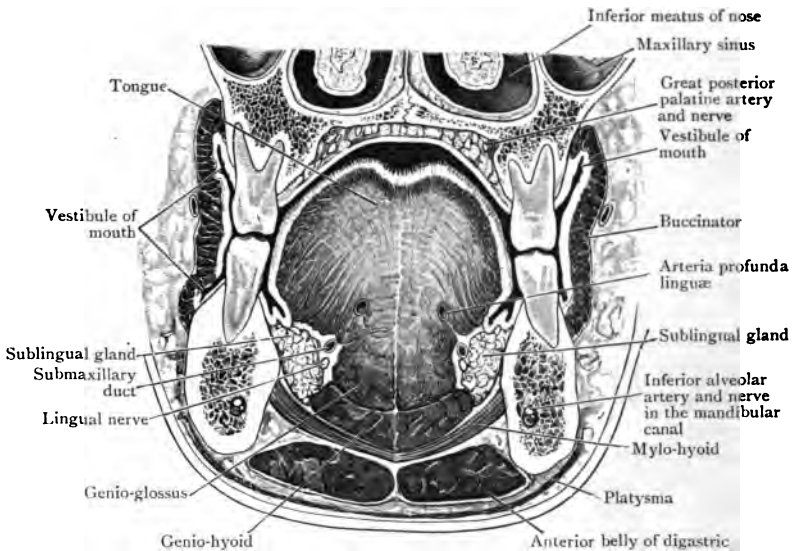


FIG. 117.—Frontal section through the Closed Mouth in the plane of the second molar teeth.

wards and anteriorly its fibres may be traced upon the side of the tongue as far as the tip. Some of them decussate with the fasciculi of the hyoglossus muscle. The nerve of supply to the stylo-glossus comes from the *hypoglossal*.

Musculus Geniohyoideus.—The genio-hyoid muscle is placed close to the median plane, in contact with its fellow of the opposite side. It is a short muscle which arises from the spina mentalis upon the posterior surface of the symphysis of the mandible. It extends downwards and posteriorly to gain insertion into the anterior aspect of the body of the hyoid bone. The *hypoglossal nerve* supplies the genio-hyoid.

The Deep Part of the Submaxillary Gland.—It has been noted already that the small deep part of the submaxillary gland springs from the medial surface of the superficial part at the posterior border of the mylo-hyoid muscle. It will now be obvious that it passes anteriorly and upwards, between the mylo-hyoid laterally and the hyo-glossus and genio-glossus medially, until it comes into contact with the sublingual gland. It is accompanied by the lingual nerve and the submaxillary duct, both of which lie on its medial surface.

Ductus Submaxillaris.—The duct of the submaxillary gland (O.T. Wharton's duct) emerges from the medial surface of the main part of the gland, and proceeds, with the deep part of the gland, anteriorly and upwards upon the hyo-glossus muscle. At first it lies between the lingual nerve above and the hypoglossal nerve below. Reaching the surface of the genio-glossus muscle, it is crossed laterally, and then below and medially, by the lingual nerve. Then it passes to the medial side of the sublingual gland, and gains the floor of the mouth, where it opens by a small orifice placed on the summit of a papilla which lies close to the side of the frenulum linguæ.

The wall of the duct is much thinner than that of the parotid duct. If a small opening be made in it, the dissector will experience little difficulty in passing a fine probe or bristle along it into the mouth.

Glandula Sublingualis.—The sublingual gland lies in the floor of the mouth, and is the smallest of the larger salivary glands. It is almond shaped, about one inch and a half long; and its relations are very definite. Its prominent *upper border* can be seen within the mouth, beneath the anterior part of the tongue, where it is covered by a fold of mucous membrane termed the plica sublingualis (Fig. 146). *Medially* it rests upon the genio-glossus muscle, whilst *laterally* it is lodged in a fossa on the inner aspect of the mandible, immediately lateral to the symphysis and above the mylo-hyoid ridge. *Below*, it is supported by the mylo-hyoid muscle. Its anterior extremity reaches the median plane, above the anterior border of the genio-glossus, and is in contact with its fellow of the opposite side. The duct of the submaxillary gland and the lingual nerve are prolonged anteriorly medial to the sublingual gland.

Numerous small ducts (the number varying from eight

to twenty) proceed from the sublingual gland. These, as a rule, open into the mouth on the summit of the plica sublingualis (Birmingham).

Nervus Lingualis.—In the dissection of the infratemporal region, the lingual nerve was seen passing downwards between the ramus of the mandible and the internal pterygoid muscle. As it descends it inclines anteriorly, and, after passing over the attachment of the superior constrictor muscle of the pharynx to the posterior end of the mylo-hyoid ridge, it lies below and posterior to the last molar tooth between the mucous membrane of the mouth and the body of the mandible. At this point it is in danger of being hurt by the clumsy extraction of one of the lower molars, and here also it may be divided by the surgeon, from the inside of the mouth. In its further course the nerve keeps close to the side of the tongue, crossing the styloglossus and the upper part of the hyoglossus, and, beyond that, the submaxillary duct. Its terminal branches are placed immediately under the mucous membrane of the mouth, and it can be traced as far as the tip of the tongue.

The *branches* which proceed from the lingual nerve in the submaxillary region are of two kinds—(1) twigs of communication; (2) branches of distribution.

Twigs of Communication.	$\left\{ \begin{array}{l} 1. \text{ Two or more to the submaxillary ganglion.} \\ 2. \text{ One or two which descend along the anterior border of the hyoglossus muscle to unite with the hypoglossal nerve.} \end{array} \right.$
Branches of Distribution.	
	$\left\{ \begin{array}{l} 1. \text{ Slender filaments to the mucous membrane of the mouth and gums.} \\ 2. \text{ A few twigs to the sublingual gland.} \\ 3. \text{ Branches to the tongue.} \end{array} \right.$

The *lingual branches* pierce the substance of the tongue, and then incline upwards to supply the mucous membrane with the papillæ over the anterior two-thirds of this organ.

Ganglion Submaxillare.—This is a minute ganglion which lies upon the upper part of the hyoglossus muscle in the interval between the lingual nerve and the deep part of the submaxillary gland. In size, it is not larger than the head of a large pin; and, when freed from the connective tissue surrounding both it and its branches, it will be seen to be suspended from the lingual nerve by two short branches, which enter its upper border, and are separated by a distinct interval. Of these, the posterior connecting twig is frequently in the form of two

or three filaments, which convey to the ganglion its sensory and secretory roots, whilst the anterior connecting branch must be looked upon as a twig given by the ganglion to the lingual nerve.

In common with the other ganglia developed in connection with the branches of the trigeminal nerve, this ganglion has three roots—viz. (1) a *sensory root* from the lingual nerve; (2) a *secretory root* from the chorda tympani; and (3) a *sympathetic root* from the plexus around the external maxillary artery.

From its lower border several minute twigs proceed, and these are distributed—(1) to the submaxillary gland and duct; (2) to the sublingual gland from the branch which it gives to the lingual nerve; and (3) to the mucous membrane of the mouth.

Nervus Hypoglossus.—This nerve has been traced in the dissection of the anterior triangle to the point where it disappears under cover of the mylo-hyoid muscle (p. 231). It is now seen passing anteriorly upon the hyoglossus muscle, above the hyoid bone and below the level of the deep part of the submaxillary gland. At the anterior border of the hyoglossus it gains the surface of the genio-glossus muscle, into the substance of which it sinks; and finally it breaks up into branches which supply the muscular substance of the tongue. Upon the hyoglossus muscle it is accompanied by a vena comitans.

The *branches* which spring from the hypoglossal nerve in this region are very numerous, and are entirely distributed to muscles. It supplies—(1) the stylo-glossus; (2) the hyoglossus; (3) the genio-glossus; (4) the genio-hyoid; and (5) the intrinsic muscles of the tongue.

In addition, it communicates freely with the lingual nerve. The more apparent of these connections take place in the form of one or more loops in relation to the anterior border of the hyoglossus. Other communications with the same nerve are effected in the substance of the tongue.

Reflection of the Hyoglossus.—The hyoglossus should now be carefully detached from the hyoid bone, and thrown upwards towards the tongue. In doing this there is no need to divide the structures which lie upon its surface. By the reflection of this muscle the following structures will be fully displayed—(1) the profunda linguæ artery and the veins which accompany it; (2) the dorsales linguæ arteries and veins; (3) the posterior part of the genio-glossus; (4) the origin of the middle constrictor of the pharynx; and (5) the attachment of the stylo-hyoid ligament.

Musculus Genioglossus.—This is a flat triangular muscle, the medial surface of which is in contact with its fellow of the opposite side in the median plane. It arises by a short pointed tendon from the upper mental spine on the posterior aspect of the symphysis of the mandible, and from this its fleshy fasciculi spread out in a fan-shaped manner. By far the greater part of the muscle is inserted into the tongue by an insertion which extends throughout the whole length of the organ from the tip to the base; below the tongue, a few fibres reach the side of the pharynx. The genio-glossus is supplied by twigs from the *hypoglossal nerve*.

Arteria Lingualis.—As the lingual artery is now fully exposed, it can be conveniently studied at this stage. It springs from the anterior aspect of the external carotid, and is separable into two parts—viz. (1) a part extending from its origin to the posterior border of the hyoglossus muscle; (2) a part lying in relation to the upper border of the hyoid bone and extending to the anterior border of the hyoglossus, where it divides into two terminal branches, the sublingual and the deep artery of the tongue.

The *first part* has been fully examined in a previous dissection. It lies in the carotid triangle of the neck, and is therefore comparatively superficial. It is crossed by the hypoglossal nerve, and lies, medially, against the middle constrictor. The *second part* proceeds anteriorly along the upper border of the great cornu of the hyoid bone, and is covered by the hyoglossus muscle, which intervenes between it and the hypoglossal nerve. The nerve, however, is placed at a slightly higher level. The deep or medial relations of the artery in this stage of its course are the middle constrictor of the pharynx and the genio-glossus.

The *branches* of the lingual artery are:—

1. Suprahyoid from the *first part* (p. 233).
2. Dorsalis linguæ from the *second part*.
3. Sublingual.
4. Profunda.

Rami Dorsales Linguæ.—The dorsalis linguæ is generally represented by two or more well-marked branches, which pass upwards, under cover of the hyoglossus muscle, to end in twigs to the mucous membrane covering the pharyngeal part of the dorsum of the tongue. Some twigs are supplied

also to the muscular substance of the organ, and a few may be traced backwards into the tonsil.

Arteria Sublingualis.—This springs from the termination of the second part and emerges from under cover of the anterior border of the hyoglossus, and then ascends upon the genio-glossus to reach the sublingual gland, which it supplies. It gives branches to the surrounding muscles also; and it anastomoses with its fellow of the opposite side and with the submental branch of the external maxillary artery.

Arteria Profunda Linguae.—The deep artery of the tongue ascends almost vertically upon the genio-glossus, overlapped by the anterior border of the hyoglossus; when it reaches the under surface of the tongue, it runs towards the tip and ends in terminal branches. It can easily be exposed by dividing the mucous membrane along its course, when it will be seen to lie close to the attachment of the frenulum of the tongue, and to be continued forwards in the interval between the genio-glossus and the inferior longitudinal muscle. Its course is tortuous to allow of the protrusion or elongation of the organ, and it gives off numerous branches.

Lingual Veins.—The lingual artery is accompanied by two small venæ comites which lie with it under cover of the hyoglossus; but the main vein of the tongue crosses the lateral surface of the hyoglossus, and another smaller vein, the *vena comitans hypoglossi*, accompanies the hypoglossal nerve. The venæ comites of the artery and the vena comitans hypoglossi unite with the main vein to form the lingual vein, which opens into the common facial vein or into the internal jugular vein.

Stylo-hyoid Ligament.—This is the last structure to be examined in this dissection. It is a fibrous cord which springs from the tip of the styloid process and passes antero-inferiorly to be attached, under cover of the hyoglossus muscle, to the lesser cornu of the hyoid bone. It is not uncommon to find it partially ossified; in other cases it may assume a ruddy hue and contain muscular fibres.

OTIC GANGLION AND TENSOR PALATI.

During the dissection of the submaxillary region the dissector has noted a nerve ganglion, *the submaxillary ganglion*, connected with the lingual branch of the mandibular nerve,

and when he was examining the infratemporal region reference was made to the otic ganglion, which is associated with the trunk of the mandibular nerve and the branch which it supplies to the internal pterygoid muscle. This ganglion and its connections should now be displayed, and afterwards the tensor palati muscle should be cleaned and followed from its origin to the hamulus of the medial pterygoid lamina.

Dissection.—Cut the lingual and inferior alveolar nerves immediately below their origins; evert the upper part of the mandibular nerve and examine the otic ganglion; then divide the internal pterygoid, along the posterior border of the lateral pterygoid lamina, depress the lower part of the muscle and clean the tensor palati, which forms the medial relation of the middle meningeal artery, the otic ganglion and the mandibular nerve, separating them from the lateral surface of the auditory tube (Eustachian).

Ganglion Oticum.—This is a minute oval body about 4 mm. in length. It lies immediately below the foramen ovale, between the mandibular nerve laterally, the tensor veli palatini medially, and the middle meningeal artery posteriorly; and it is intimately associated with the origin of the nerve to the internal pterygoid.

The otic ganglion is usually described as receiving motor, sensory, and sympathetic roots. The *motor root* is supplied by the nerve to the internal pterygoid muscle; the *sympathetic root* comes from the plexus around the middle meningeal artery. In addition to these, the *small superficial petrosal nerve* enters the posterior border of the ganglion, and conveys to it *sensory fibres*.

The following are the *branches* which proceed from the otic ganglion:—

Branches of distribution.	{	A twig which passes downwards and anteriorly to the tensor veli palatini. (Tensor palati.)
	{	A twig which proceeds upwards and posteriorly to supply the tensor tympani.
Connecting branches.	{	One or more fine filaments to one or both of the roots of the auriculo-temporal nerve.
	{	A minute communicating filament to the chorda tympani.

Musculus Tensor Veli Palatini.—This flat and band-like muscle is closely applied to the deep surface of the internal pterygoid muscle. It arises from the scaphoid fossa at the root of the medial pterygoid lamina, from the posterior border of the lower surface of the great wing of the sphenoid, from the spine of the sphenoid, and from the lateral aspect of the auditory tube (O.T. Eustachian). It descends to the lower end of the medial pterygoid lamina and ends in a tendon which turns horizontally under the hamulus into the soft palate, where its attachments will be seen later.

THE GREAT VESSELS AND NERVES
OF THE NECK.

As soon as the dissection of the infratemporal and the submaxillary regions is completed the dissector should turn to the study of the external carotid artery and its relations.

Arteria Carotis Externa.—The external carotid is one of the two terminal branches of the common carotid. It commences therefore at the level of the upper border of the thyroid cartilage, opposite the disc between the third and fourth cervical vertebræ; and, after running upwards and posteriorly to the level of the neck of the mandible, it terminates, between that portion of bone and the upper part of the antero-medial surface of the parotid gland, by dividing into two terminal branches, the superficial temporal and the internal maxillary. At its commencement it lies anterior and medial to the internal carotid; and it is called external not on account of its relation to the internal carotid, but because it is distributed mainly to the parts on the exterior of the skull. It is at first comparatively superficial in the upper part of the carotid triangle; next it passes under cover of the lower part of the postero-medial surface of the parotid and the posterior belly of the digastric and the stylo-hyoid muscles. At the upper border of the stylo-hyoid it enters a groove in the medial border of the parotid, through which it passes to the upper part of the antero-medial surface of the gland, posterior to the neck of the mandible, where it terminates.

Relations.—As it lies in the carotid triangle it is covered by the skin, superficial fascia and platysma, branches of the nervus cutaneus colli and the cervical branch of the facial nerve, and the deep fascia. Beneath the deep fascia it is crossed superficially by the common facial and lingual veins and the hypoglossal nerve; and, at the upper end of the triangle, it is concealed by the lower end of the parotid gland and it is crossed from behind forwards by the posterior facial vein. After it leaves the carotid triangle it is overlapped by the angle of the mandible, and is crossed by the posterior belly of the digastric and the stylo-hyoid. At its termination it is concealed by the upper part of the parotid and is crossed by branches of the facial nerve.

GREAT VESSELS AND NERVES OF NECK 295

To its medial side lies the wall of the pharynx, from which it is separated, in the region of the carotid triangle, by the external and internal laryngeal branches of the superior

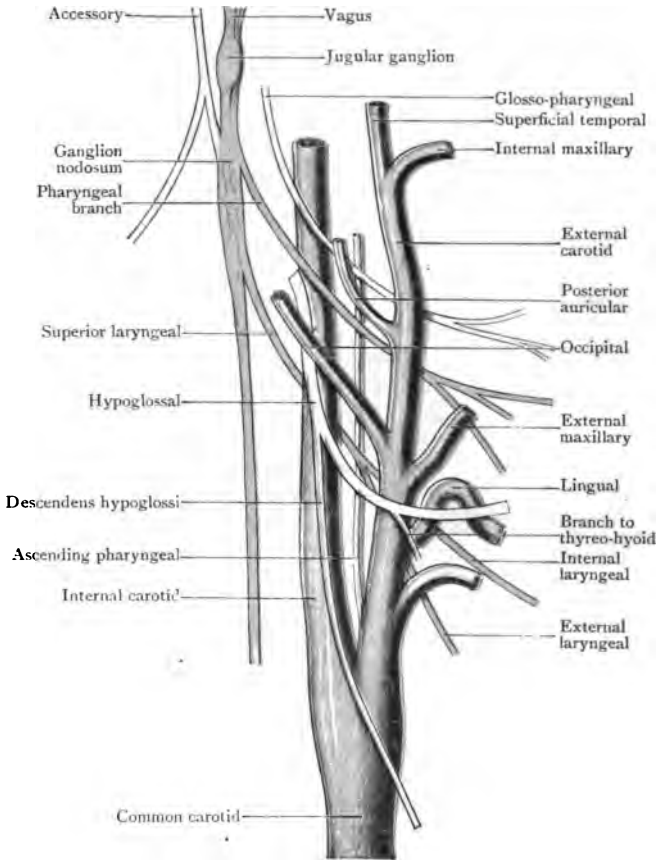


FIG. 118.—Diagram of Carotid System of Vessels in the Neck with the Glosso-pharyngeal, Vagus, Accessory, and Hypoglossal Nerves.

laryngeal nerve. The medial relations at a higher level will be seen to greater advantage at a later stage when the styloid process is detached and displaced. They are the pharyngeal branch of the vagus, the stylo-pharyngeus, the glosso-pharyngeal

nerve, and the styloid process or the stylo-hyoid ligament. These structures lie to its mèdial side after they have passed obliquely between it and the internal carotid, which has gradually attained a plane posterior and medial to that in which the external carotid lies.

In the whole of its extent the external carotid is accompanied by numerous sympathetic nerve fibres, derived from the upper cervical sympathetic ganglion; they constitute the *external carotid plexus*, which distributes offsets along all the branches of the artery.

Branches.—The branches of the external carotid artery are the superior thyreoid, the lingual, and the external maxillary from its anterior aspect; the occipital and the posterior auricular from its posterior aspect; the ascending pharyngeal from its medial side; and the superficial temporal and the internal maxillary are its terminal branches.

Arteria Thyreoidea Superior.—This vessel arises within the carotid triangle, from the anterior aspect of the external carotid close to its origin. It runs downwards and anteriorly, under cover of the omo-hyoid, sterno-hyoid, and sterno-thyreoid muscles, to the apex of the lateral lobe of the thyreoid gland, where it ends by breaking up into three terminal branches.

The following branches proceed from it:—

- | | | |
|------------------------|--|--------------------|
| 1. Hyoid. | | 4. Crico-thyreoid. |
| 2. Superior laryngeal. | | 5. Glandular. |
| 3. Sterno-mastoid. | | |

Ramus Hyoideus.—This is a minute twig, which springs from the superior thyreoid in the carotid triangle. It runs along the lower border of the hyoid bone, under cover of the thyreo-hyoid muscle, and anastomoses with its fellow of the opposite side, and with the hyoid branch of the lingual artery.

Arteria Laryngea Superior.—This is a larger vessel. It springs from the superior thyreoid in the carotid triangle, and, associating itself with the internal laryngeal nerve, it enters the pharynx after piercing the thyreo-hyoid membrane.

Arteria Sternocleidomastoidea.—The sterno-mastoid branch is a small vessel which runs downwards and posteriorly, across the carotid sheath along the upper border of the anterior belly of the omo-hyoid muscle, to reach the deep surface of the sterno-mastoid muscle, into which it sinks. It gives,

in addition, minute twigs to the depressor muscles of the larynx.

Ramus Cricothyroideus.—The crico-thyroid artery runs medially upon the crico-thyroid ligament, and anastomoses with its fellow of the opposite side. It has already been noticed in the dissection of the middle line of the neck (p. 229).

Rami Glandulares.—The glandular rami are the three terminal branches. They spring from the main trunk at the apex of the lateral lobe of the thyroid gland. The largest is distributed on the medial surface of the lateral lobe; the smallest ramifies on its lateral surface; whilst the third runs downwards upon the anterior border of the lateral lobe, and then along the upper border of the isthmus towards its fellow of the opposite side. The anastomosis between the thyroid arteries of the two sides is by no means free.

Venæ Thyroideæ Superiores.—The superior thyroid veins emerge from the gland and form a trunk which receives tributaries corresponding in a great measure with the branches of the artery. It crosses the upper part of the common carotid and joins the internal jugular vein.

Arteria Lingualis.—The lingual artery springs from the external carotid at the level of the great cornu of the hyoid bone in the carotid triangle. It runs along the upper border of the great cornu. As its name indicates it is the artery of supply to the tongue. It has already been dissected in the carotid triangle and the submaxillary region, and the details of its course and relations are given on pp. 233, 291.

Arteria Maxillaris Externa (O.T. Facial Artery).—The external maxillary artery can be studied, at the present stage of the dissection, from its origin up to the point where it mounts upon the mandible to reach the face. This is termed the *cervical part* of the artery. It springs from the anterior aspect of the external carotid, immediately above the lingual, in the upper part of the carotid triangle, and passes vertically upwards, on the lateral surface of the middle constrictor muscle of the pharynx, to the angle of the mandible, where it disappears under cover of the posterior belly of the digastric and the stylo-hyoid muscle. At this point the superior constrictor is medial to it and separates it from the

lateral surface of the tonsil. At the upper border of the stylo-hyoid it enters a deep groove in the posterior end of the submaxillary gland. Emerging from this it turns downwards and anteriorly between the lateral surface of the gland

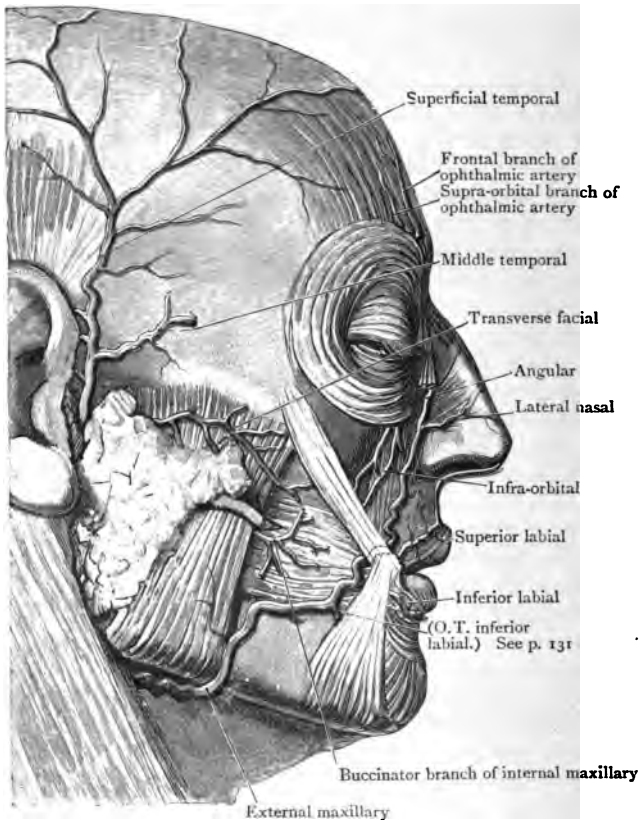


FIG. 119.—Arteries of the Face.

and the internal pterygoid muscle, and turning round the lower border of the mandible at the anterior border of the masseter it enters the face. For details of its facial course see p. 129.

Four named branches spring from the external maxillary artery in the cervical part of its course :—

1. Ascending palatine.
2. The tonsillar.

3. Glandular.
4. The submental.

Arteria Palatina Ascendens.—The ascending palatine branch is given off for the supply of the soft palate, but it distributes branches to the tonsil and auditory (O.T. Eustachian) tube also. It ascends between the stylo-

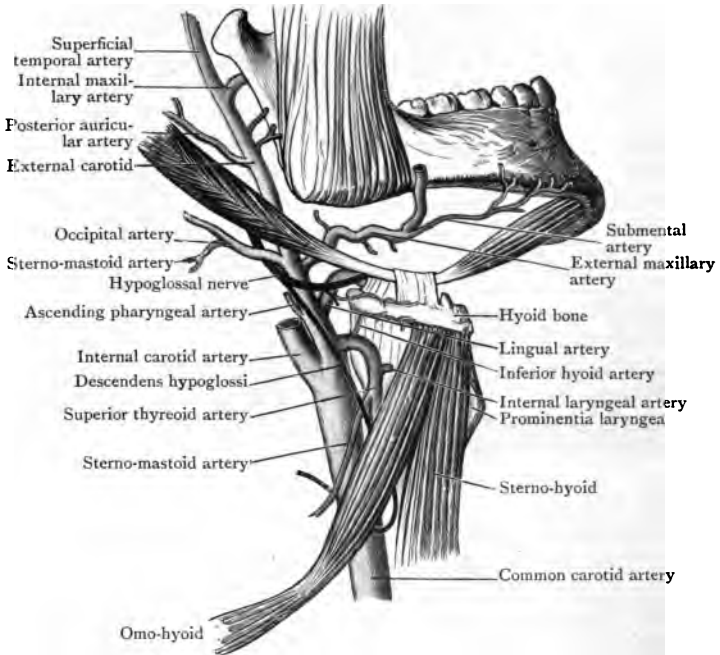


FIG. 120.—Diagram of the External Carotid Artery and its Branches.

pharyngeus and stylo-glossus muscles, and will be seen when the styloid process is reflected.

Ramus Tonsillaris.—The tonsillar branch runs upwards between the internal pterygoid and stylo-glossus muscles, then turns medially, pierces the superior constrictor, and enters the tonsil.

The *glandular branches* are given to the submaxillary gland as the external maxillary artery passes through it.

Arteria Submentalis.—This is a branch of some size. It arises close to the base of the mandible, and runs towards the chin upon the mylo-hyoid muscle. Near the symphysis it changes its direction, and is carried upwards over the border of the mandible, to end in branches for the muscles and integument of the chin and lower lip. In the submaxillary region it gives numerous twigs to the surrounding muscles and glands, and anastomoses with the sublingual artery by branches which pierce the mylo-hyoid muscle. It anastomoses, in the face, with the inferior labial branch of the external maxillary and the mental branch of the inferior alveolar.

Vena Facialis Anterior.—The *cervical portion* of the anterior facial has already been seen (p. 231) passing posteriorly and downwards, superficial to the submaxillary gland. After receiving tributaries corresponding to the branches of the similar part of the external maxillary artery, it joins the posterior facial vein. The short trunk thus formed is termed the *common facial vein*, and it pours its blood into the internal jugular at the level of the hyoid bone.

Arteria Occipitalis.—The occipital artery springs from the posterior aspect of the external carotid at the same level as the external maxillary. It takes the lower border of the posterior belly of the digastric muscle as its guide, and runs upwards and posteriorly, under cover of the sterno-mastoid muscle, and generally under cover of the lower border of the posterior belly of the digastric, to reach the interval between the mastoid portion of the base of the skull and the transverse process of the atlas. Thence onwards it has been studied in the dissection of the scalp and the back of the neck (pp. 162, 170). The first part of the vessel crosses the internal carotid artery, the vagus nerve, the accessory nerve, and the internal jugular vein, whilst the hypoglossal nerve hooks round it.

The only branches which spring from this portion of the occipital are: (1) muscular twigs; and (2) a meningeal branch.

The *muscular twigs* are given to the neighbouring muscles, and one of them, larger than the others and very constant, is termed the *sterno-mastoid branch*, runs parallel with the accessory nerve, and sinks with it into the substance of the sterno-mastoid muscle.

A *meningeal branch* associates itself with the internal jugular vein, and can be followed upwards upon it to the jugular foramen, through which it passes into the cranium.

Arteria Auricularis Posterior.—The posterior auricular artery will be found above the level of the posterior belly of the digastric, and, like the occipital, it takes origin from the posterior aspect of the external carotid artery. In the first part of its course it is placed deeply, and runs upwards and posteriorly between the styloid process of the temporal bone and the postero-medial surface of the parotid gland to reach the interval between the mastoid process and the back of the auricle. Then it joins the posterior auricular nerve. Its further course has been studied in the dissection of the scalp (p. 157).

This portion of the posterior auricular artery gives off (1) muscular twigs; (2) a few branches to the parotid gland; and (3) the stylo-mastoid artery.

Arteria Stylomastoidea.—This is a slender vessel which enters the stylo-mastoid foramen. In the interior of the temporal bone it has an extensive distribution. It supplies twigs to the mastoid cells and to the tympanic cavity and is carried onwards in the canalis facialis (O.T. Fallopiian) to anastomose with the petrosal branch of the middle meningeal.

Arteria Maxillaris Interna.—The commencement of the internal maxillary artery, from the termination of the external carotid, between the neck of the mandible and the antero-medial surface of the parotid gland, has been seen already, and the artery has been traced through the infratemporal region to the pterygo-palatine fossa, where its terminal branches will be dissected at a later period.

Arteria Temporalis Superficialis.—Like the internal maxillary, this artery commences between the neck of the mandible and the antero-medial surface of the parotid gland. It passes upwards and, as it emerges from under cover of the upper end of the parotid, it crosses the posterior end of the zygomatic arch and enters the superficial fascia of the scalp, in which it ascends on the superficial surface of the temporal fascia, and anterior to the auricle it breaks up into two branches, *frontal* and *parietal*. These anastomose with each other and with their fellows of the opposite side. The frontal anastomoses with the supra-orbital and

frontal branches of the ophthalmic also, and the parietal with the posterior auricular and the occipital arteries. Whilst it is still under cover of the parotid it gives branches to the

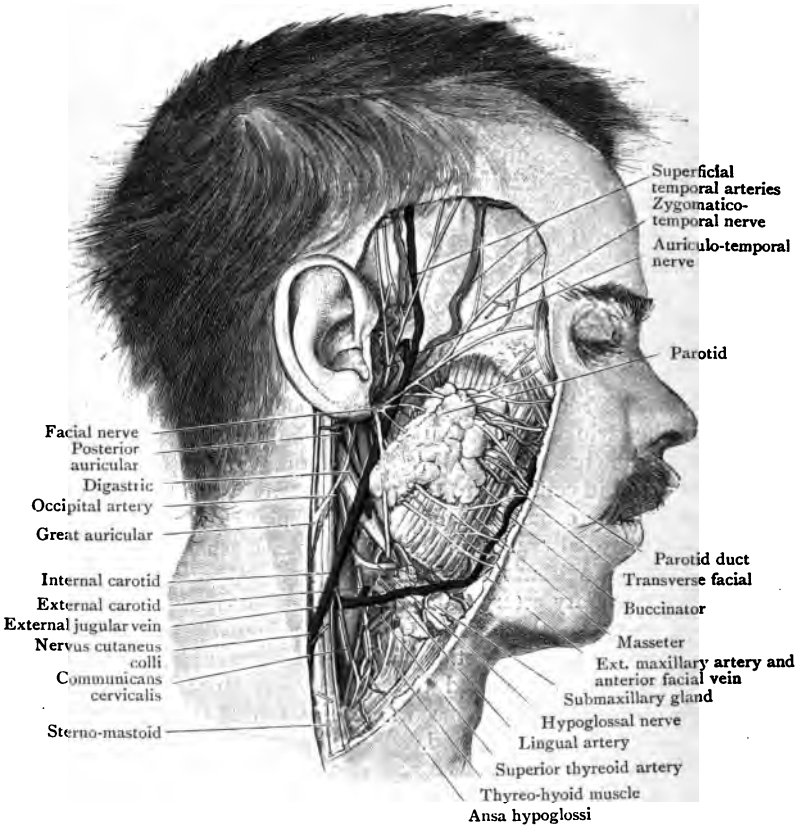


FIG. 121.—Dissection of the Parotid Region and the upper part of the Anterior Triangle of the Neck.

gland ; *anterior auricular branches* to the auricle ; the *transverse facial*, which passes along the lower border of the zygomatic arch across the masseter. As the superficial temporal crosses the zygoma it gives off a *zygomatico-orbital branch*, which runs to the lateral border of the orbit, and a *middle temporal*

branch, which perforates the temporal fascia and anastomoses in the temporal fossa with the deep temporal branches of the internal maxillary. The course of this branch and also the distribution of the terminal branches have been followed in earlier stages of the dissection (pp. 266, 267).

Dissection.—Divide the posterior belly of the digastric immediately below its origin, and turn it downwards and anteriorly towards the hyoid bone; then examine the stylo-pharyngeus muscle. It may be necessary to cut the occipital and posterior auricular arteries in order to gain free access to the deeper parts, but this should not be done unless it is necessary. Care must be taken whilst cleaning the stylo-pharyngeus to avoid injuring the glosso-pharyngeal nerve, which turns round its posterior border and crosses its superficial surface.

Musculus Stylopharyngeus.—This is the longest of the three slender muscles which spring from the styloid process. It arises from its deep or medial surface close to its root, and extends downwards and anteriorly to gain the side of the pharynx, where it disappears under cover of the upper border of the middle constrictor muscle. Whilst under cover of the middle constrictor its fibres blend with those of the palato-pharyngeus, and, with these, are inserted into the posterior border of the corresponding lamina of the thyroid cartilage. Some of the fibres, however, are lost in the wall of the pharynx. If the dissector removes the fascia at the posterior part of the thyreo-hyoid space he will expose the lower fibres of the middle and the upper fibres of the inferior constrictor, and in the interval between them, on a deeper plane, the lateral surface of the lower part of the stylo-pharyngeus.

Dissection.—Snip through the base of the styloid process with the bone forceps, and throw it and the attached muscles downwards and anteriorly. The upper parts of the internal carotid artery and the internal jugular vein are now exposed, and the ascending pharyngeal artery can be followed to the base of the skull.

Arteria Pharyngea Ascendens.—To expose this vessel the dissector must push the external carotid anteriorly and clean the interval between it and the internal carotid. The ascending pharyngeal springs from the medial surface of the external carotid close to its lower end and is its smallest branch. It ascends along the lateral border of the pharynx, lying between the stylo-pharyngeus laterally and the constrictors of the pharynx medially, first in a plane between the external and internal carotid arteries, and then to the medial side of the internal carotid. As it passes upwards it gives

pharyngeal branches to the wall of the pharynx and *prevertebral branches* to the prevertebral muscles. At the base of the skull it gives off *meningeal branches*, which enter the cranial cavity through the hypoglossal canal, the jugular foramen, and the foramen lacerum; and *palatine branches*, which pierce the pharyngeal aponeurosis above the upper border of the superior constrictor and descend, along the levator palati, to the soft palate. Offsets from these branches are given to the auditory tube (O.T. Eustachian) and to the tonsil.

Dissection.—After the ascending pharyngeal artery has been examined, the *internal carotid artery*, the *glosso-pharyngeal*, *vagus*, *accessory*, and *hypoglossal nerves*, and the *superior cervical ganglion*, with their various connections and branches, must be dissected. A dense and tough fascia envelops these structures, and a great amount of patience is required to trace the branches of the nerves through it. One nerve—the *pharyngeal branch of the vagus*—which proceeds downwards and anteriorly upon the superficial or lateral aspect of the internal carotid, is especially liable to injury, and must therefore be borne in mind from the very outset of the dissection. The *internal laryngeal* and the *external laryngeal nerves* have been previously displayed in the anterior triangle of the neck. These, if traced upwards, will lead to the *superior laryngeal branch* of the *vagus*, which lies in relation with the deep aspect of the internal carotid artery. Near the base of the skull all the nerve-trunks will be found making their appearance, close together, in the interval between the internal jugular vein and the internal carotid artery; whilst posterior to the vein the *rectus lateralis muscle* and the *first loop* of the *cervical plexus* will be seen.

Arteria Carotis Interna.—The internal carotid artery is one of the two terminal branches of the common carotid, and it commences at the level of the upper border of the thyroid cartilage. From this point it proceeds upwards in the neck, in a vertical direction, until it reaches the base of the skull; there it disappears from view by entering the carotid canal of the petrous portion of the temporal bone, through which it reaches the interior of the cranium. The internal carotid artery can therefore be very appropriately divided into three parts—viz. (1) a cervical; (2) a petrous; and (3) an intracranial. The cervical part alone comes under the notice of the student in the present dissection.

In the first part of its extent the internal carotid artery lies in the carotid triangle, and is therefore comparatively superficial. It is covered by the integument, platysma, and fascia, and is overlapped by the sterno-mastoid muscle and

the anterior border of the internal jugular vein ; it is crossed by the hypoglossal nerve and the sterno-mastoid branch of the occipital artery, the lingual and common facial veins ; and the

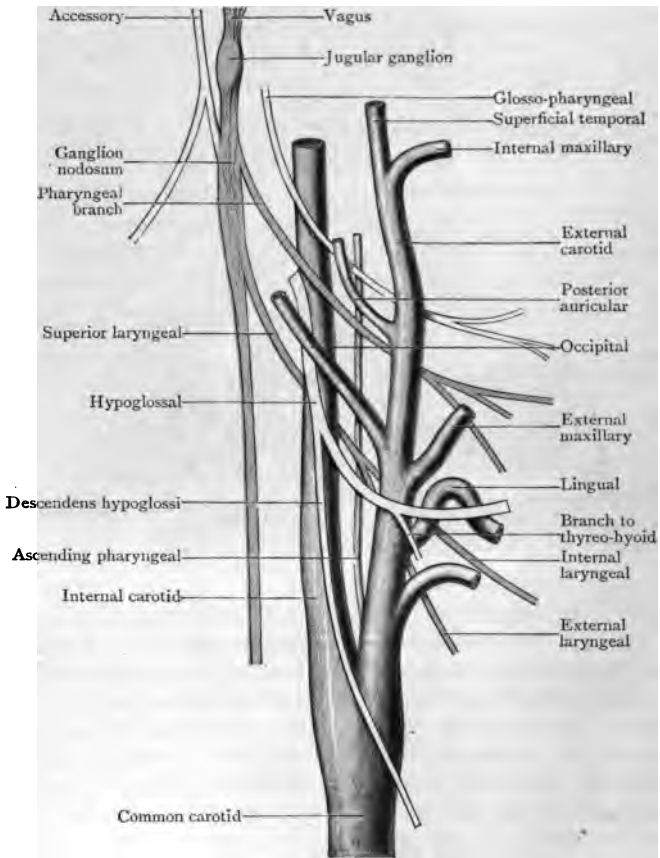


FIG. 122.—Diagram of Carotid System of Vessels in the Neck with the Glosso-pharyngeal, Vagus, Accessory, and Hypoglossal Nerves.

descendens hypoglossi descends on its superficial surface. As it proceeds upwards, it comes to lie under cover of the lower end of the parotid gland, and then at a higher level under cover of the posterior belly of the digastric, the stylo-hyoid,

the stylo-pharyngeus, and the styloid process, which separate it from the postero-medial surface of the parotid gland. It will be noted also that *three nerves* and *two arteries* cross the vessel superficially, viz. :—

- | | |
|--|--|
| <ol style="list-style-type: none"> 1. The hypoglossal nerve. 2. The glosso-pharyngeal nerve. 3. The pharyngeal branch of the vagus nerve. | <ol style="list-style-type: none"> 1. The occipital artery. 2. The posterior auricular artery. |
|--|--|

The hypoglossal, as already noted, crosses it in the carotid triangle; the other nerves cross it under cover of the posterior

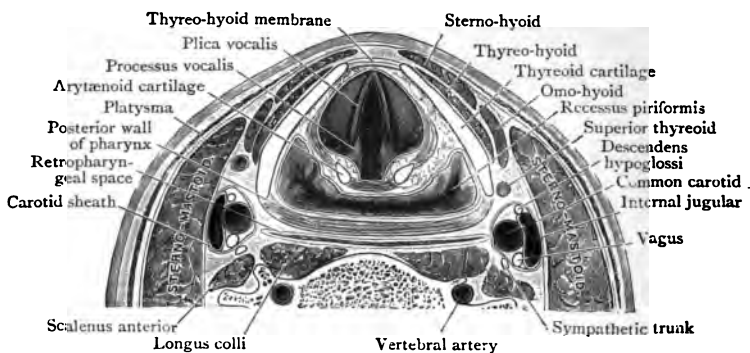


FIG. 123.—Transverse section through the Neck at the level of upper part of Thyroid Cartilage.

belly of the digastric. The occipital artery crosses it at the level of the lower border of the posterior belly of the digastric, and the posterior auricular at the level of its upper border.

The relationship of the external carotid artery to the internal carotid is a varying one. At first the external carotid lies antero-medial to it; but soon, owing to its inclination posteriorly, it comes to lie directly superficial to the internal carotid. The following structures intervene between the two vessels :—

- | | |
|---|--|
| <ol style="list-style-type: none"> 1. Styloid process. 2. Stylo-pharyngeus muscle. 3. Glosso-pharyngeal nerve. | <ol style="list-style-type: none"> 4. Pharyngeal branches of vagus and sympathetic. 5. A portion of the parotid gland. |
|---|--|

Posterior to the internal carotid is the longus capitis (O.T. rectus capitis anticus major) and the sympathetic trunk; postero-laterally are the glosso-pharyngeal, the vagus, the accessory and the hypoglossal nerve; and still more laterally

and posteriorly is the internal jugular vein. On its *medial aspect* the internal carotid is related to the pharynx, the ascending pharyngeal artery and the levator veli palatini.

Before leaving this vessel, note that near the base of the skull four nerves appear in the interval between it and the internal jugular vein; these are the glosso-pharyngeal, the vagus, the accessory, and the hypoglossal.

Vena Jugularis Interna.—The internal jugular vein is the largest venous channel of the neck. It enters the neck through the postero-lateral compartment of the jugular foramen, where it is directly continuous with the transverse sinus of the cranial cavity. From the jugular foramen it proceeds downwards, until it reaches the posterior aspect of the medial end of the clavicle, where it joins the subclavian vein to form the innominate vein. Its commencement in the jugular foramen shows a slight dilatation, termed *the bulb*, the lumen of which remains at all times patent owing to the connection of its walls to the margins of the foramen. The skull cap should be removed and a probe should be passed from the transverse sinus into the internal jugular vein, to demonstrate the continuity of the two channels.

Relations.—At its commencement the internal jugular vein lies postero-lateral to the upper end of the cervical part of the internal carotid artery, from which it is partially separated by the last four cerebral nerves. As it descends it assumes a more directly lateral relationship, first to the internal and then to the common carotid, overlapping each vessel to a slight extent anteriorly; and it is enclosed with them and the vagus nerve in a common sheath of deep cervical fascia, the nerve lying in its own compartment of the sheath between the arteries medially and the vein laterally, and in a posterior plane.

The superficial or lateral relations of the vein in the upper part of its extent are the styloid process, with the stylo-pharyngeus and stylo-hyoid muscles, and the posterior belly of the digastric, which separate it from the upper part of the postero-medial surface of the parotid gland. In this part of its extent it is crossed superficially, along the upper border of the posterior belly of the digastric, by the posterior auricular artery, and at the lower border of the digastric by the accessory nerve, passing downwards and posteriorly, and by the occipital artery passing upwards and posteriorly

superficial to the nerve. At a slightly lower level it is concealed by the lower part of the postero-medial surface of the parotid, and it is crossed by the sterno-mastoid branch of the occipital artery. After it emerges from under cover of the parotid, it lies under cover of the anterior border of the sterno-mastoid, except in the region of the upper part of the carotid triangle, where it may project anteriorly, beyond the anterior border of the muscle, for a short distance. It is separated from the sterno-mastoid by numerous deep cervical lymph glands; and under cover of the muscle it is crossed superficially, at the level of the upper part of the thyroid

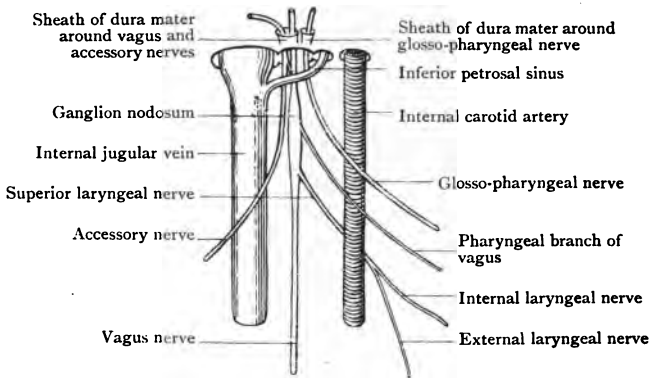


FIG. 124.—Diagram of the relation of parts in the Jugular Foramen.

cartilage, by the communicans cervicalis from the cervical plexus, and, at the level of the cricoid cartilage, by the intermediate tendon of the omo-hyoid, the sterno-mastoid branch of the superior thyroid artery and the nerve to the posterior belly of the omo-hyoid. Below the omo-hyoid it is covered by the posterior border of the sterno-hyoid, and is crossed by the anterior jugular vein; and at its termination it lies posterior to the sternal end of the clavicle.

Posteriorly, it is in relation with the rectus capitis lateralis; the rectus capitis anterior (O.T. anticus minor); and the loop between the first and second cervical nerves. At a lower level its posterior relations are the transverse processes of the cervical vertebræ and the muscles attached to their anterior tubercles, viz., the longus capitis (O.T. rectus capitis anticus

major) and the scalenus anterior. Between its posterior surface and the scalenus anterior are the ascending cervical artery, the phrenic nerve, and, crossing superficial to the latter, the transverse cervical and the transverse scapular arteries. On the left side the terminal part of the thoracic duct also crosses the phrenic nerve posterior to the internal jugular vein. At the medial border of the scalenus anterior the thyreo-cervical artery is posterior to it, and at a lower level, the first part of the subclavian artery and the dome of the pleura.

The right vein is usually the larger of the two; and as they approach the root of the neck both veins incline slightly to the right, with the result that, on the right side, the lower part of the vein is separated from the common carotid artery by a small triangular interval bounded below by the subclavian artery, whilst on the left side the vein overlaps the anterior aspect of the common carotid artery.

Tributaries.—Immediately below its commencement the internal jugular vein is joined by the inferior petrosal sinus, and then, successively, by offsets from the pharyngeal plexus, by the lingual vein, the common facial vein, the superior and middle thyroid veins. In some cases it is joined near its upper end by a *vena comes* which runs with the occipital artery; and, occasionally, near its lower end, it receives the lymph trunks which usually open into the commencement of the innominate vein.

Dissection.—Slit open the lower part of the vein and examine the valve which lies close to its extremity. It consists of two or three semilunar flaps which prevent regurgitation of blood from the innominate vein into the internal jugular.

Nervi Glosso-pharyngeus, Vagus, Accessorius. — After the removal of the brain these nerves were seen leaving the cranial cavity through the middle compartment of the jugular foramen in the interval between the commencement of the internal jugular vein postero-laterally and the inferior petrosal sinus antero-medially (p. 215, and Fig. 125, p. 310). The dissector should again examine the interior of the cranial cavity and refresh his memory as to the manner in which they enter the foramen. The *glosso-pharyngeal* occupies the most anterior position, and it is cut off from the others by a separate tube-like sheath of dura mater. The *accessory* is placed posterior to the *vagus*, and both are included within the same sheath of dura mater. They therefore

traverse the foramen in close contact with each other. Reaching the exterior of the skull, the three become associated with the hypoglossal nerve; and the four nerves lie for a short distance in the interval between the internal jugular vein and the internal carotid artery, but soon they choose different routes. The *accessory* inclines posteriorly, superficial or deep to the internal jugular vein; the *glossopharyngeal* runs anteriorly, superficial to the internal carotid,

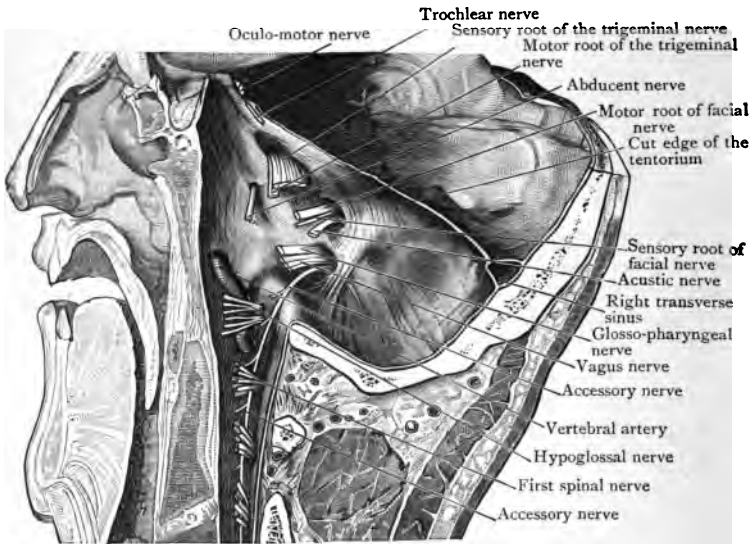


FIG. 125.—Section through the Head a little to the right of the Median Plane. It shows the posterior cranial fossa and the upper part of the vertebral canal after the removal of the brain and the medulla spinalis.

and under cover of the posterior belly of the digastric; at a lower level the hypoglossal turns anteriorly across the external and internal carotid arteries; and the *vagus* proceeds vertically downwards, first between the internal jugular vein and the internal carotid, and then between the vein and the common carotid (Fig. 100).

In an ordinary dissection it is impossible to follow out many of the minute twigs which take origin from these nerves in the region of the basis cranii. To do so it is necessary to possess a perfectly fresh part which has been specially prepared by having the soft parts toughened with spirit and the bone softened by immersion in a weak solution of acid.

Even then the dissection is a difficult one, although it should certainly be undertaken by the advanced student, in the event of his being able to obtain a part for the purpose.

In the following description of these nerves the account of the branches which can in all cases be traced is printed in *ordinary type*, whilst that of those requiring special dissection is printed in *small type*.

Nervus Glosso-pharyngeus.—The glosso-pharyngeal nerve inclines downwards and anteriorly and crosses the internal carotid artery superficially. At first it lies medial to the styloid process and the stylo-pharyngeus muscle, then it hooks round the lower border of the muscle and curves anteriorly upon its superficial surface to gain the base of the tongue. In the dissection of the submaxillary region, its terminal part was seen disappearing under cover of the hyoglossus muscle, where it ends in *lingual branches*.

In the present dissection the following branches should be made out:—

- | | | |
|---|--|-----------------|
| 1. Communicating branch from
the facial. | | 3. Pharyngeal. |
| 2. Nerve to the stylo-pharyngeus. | | 4. Tonsillitic. |
| | | 5. Lingual. |

The *communicating branch from the facial* springs from the nerve to the posterior belly of the digastric, and, as a rule, emerges from midst the fibres of that muscle to join the glosso-pharyngeal close to the lower part of the jugular foramen.

The *stylo-pharyngeal nerve* is a small twig which enters the muscle of the same name. The greater part of its fibres, however, are continued through the muscle to the mucous membrane of the pharynx.

The *pharyngeal branches* consist—(1) of one or two small twigs which perforate the superior constrictor to reach the mucous membrane of the pharynx; and (2) a larger nerve which comes off higher up and passes with the pharyngeal branch of the vagus to the pharyngeal plexus. It frequently divides into two or more branches.

The *tonsillitic branches* proceed from the glosso-pharyngeal near the base of the tongue. They form a plexus over the tonsil, termed the *circulus tonsillaris*, and give twigs to the mucous membrane of the isthmus faucium and the soft palate.

The *terminal* or *lingual branches* will be followed in the dissection of the tongue.

There are still other points in connection with the glosso-pharyngeal nerve which require mention. At the lower part of the jugular foramen two small ganglia are formed upon its trunk, and from the lower of these certain minute branches are given off. The upper ganglion is called the *ganglion superius*; the lower one is termed the *ganglion petrosum*.

The *superior ganglion* is a small ganglionic swelling, which involves only a portion of the fibres of the nerve trunk. It is placed in the upper part of the bony groove in which the nerve lies as it proceeds through the jugular foramen. No branches arise from it.

The *petrous ganglion* is a larger swelling, which involves the entire nerve-trunk, and lies at the opening of the jugular foramen, between the vagus nerve and the inferior petrosal sinus (which intervenes between the inferior petrosal sinus and the anterior border of the foramen). Its length is not more than one or three lines. Three branches of communication enter or proceed from it. These connect it with—(1) the superior cervical sympathetic ganglion; (2) the auricular branch of the vagus; and (3) the jugular ganglion of the vagus.

In addition to these twigs the *tympanic nerve* takes origin from the petrous ganglion.

Tympanic Nerve.—The ultimate destination of this nerve may be regarded as the otic ganglion, but it takes a very circuitous route to reach that structure and it gives off branches on the way. It enters a small foramen on the ridge which separates the jugular fossa from the carotid foramen on the lower surface of the petrous bone, and it is conducted by a narrow canal to the tympanic cavity. It crosses the inner wall of this chamber, grooving the promontory. Having gained the anterior part of the tympanum, it enters the bone a second time, and runs in a minute canal which tunnels the petrous bone below the upper end of the channel in which is lodged the tensor tympani muscle. In this part of its course the tympanic nerve is joined by a branch from the ganglion geniculi of the facial nerve, and, after the junction is effected, it is termed the *small superficial petrosal nerve*.

The canal in which the *small superficial petrosal nerve* is lodged opens into the cranial cavity upon the anterior surface of the petrous bone, immediately lateral to the hiatus canalis facialis (O. T. Fallopii). Through this the nerve emerges, and soon leaves the interior of the cranium by passing downwards in the interval between the great wing of the sphenoid bone and the petrous part of the temporal bone, or through the canaliculus innominatus, or through the foramen ovale. Outside the skull it ends by joining the otic ganglion.

In the tympanic cavity the *tympanic nerve* gives branches of supply—(1) to the mucous membrane of the tympanum; (2) to the lining membrane of the mastoid cells; and (3) to the mucous membrane of the auditory tube (Eustachian). It is connected with the sympathetic plexus on the internal carotid artery by the *superior and inferior carotico-tympanic branches* which pierce the substance of the petrous part of the temporal bone.

Nervus Vagus.—The vagus passes through the middle compartment of the jugular foramen in company with the accessory—both being included within the same sheath of the dura mater. In the neck it pursues a vertical course, lying, at first, between the internal jugular vein and the internal carotid artery, and afterwards between the same

vein and the common carotid artery, enclosed within the sheath which envelops the vessels, but on a plane posterior to them. In posterior relations, therefore, it resembles those of the internal and common carotid arteries. At the root of the neck it enters the thorax, and has different relations on the two sides. On the right side it crosses the first part of the subclavian artery; on the left side, after crossing anterior to the thoracic duct, it proceeds downwards between the common carotid and left subclavian arteries posterior to the left innominate vein. For its thoracic relations see p. 99.

The vagus, like the glossopharyngeal, has two ganglia in connection with its upper part. These are the *ganglion jugulare* and the *ganglion nodosum*.

Ganglion Jugulare (O.T. Ganglion of Boeck).—This is situated within the jugular foramen. It is a rounded swelling which is connected by communicating twigs with several of the nerves in the neighbourhood, and it gives off two branches of communication.

Branches of Communication.—(1) With the facial nerve; (2) with the petrous ganglion of the glossopharyngeal; (3) with the accessory; (4) with the superior ganglion of the sympathetic.

Branches of Distribution.—(1) Meningeal; (2) laryngeal nerves. The *meningeal branch* is a minute twig which runs upwards through the jugular foramen, and, dividing into two branches, a distribution to the dura mater in the posterior cranial fossa.

The *laryngeal nerves* (O.T. Arnold's nerves) receive their communication from the petrous ganglion of the glossopharyngeal, and pass directly upon the lateral surface of the bulb of the larynx, where they enter a minute aperture on the posterior part of the wall of the larynx. A narrow canal then conveys it through the wall of the larynx to the temporal bone, and, on its way, it crosses the stylomastoid foramen at a distance above the stylo-mastoid foramen. It is here that it enters into relation with the facial nerve and is connected by a branch with the external acoustic meatus, whence it communicates with the posterior auricular branch of the facial. It supplies the skin on the posterior surface of the ear, the outer surface of the walls of the meatus, the skin covering the tympanic membrane of the inner surface of the wall of the meatus, and its branches supply the

Ganglion Nodosum.—After emerging from the jugular foramen, the vagus nerve is joined by the cervical sympathetic nerve, and swells out into the *ganglion nodosum* (ganglion of trunk).

The *ganglion nodosum* is an elongated cylindrical structure of about three-quarters of an inch in length, which is opened upon the stem of the vagus trunk.

an artery. It arises from the anterior processes of the third, fourth, and fifth ribs, and, tapering superiorly, passes into the scalene tubercle of the first rib, and also into the space between the two subclavian

arteries. Its surface is concealed by the clavicle. Along its medial border lie the internal jugular vein, the omohyoid; the phrenic nerve; and the transverse subclavian arteries passing posteriorly to the nerve. Between it

and the clavicle, above, with the tip of the coracoclavicular ligament, and below, with the clavicle, the subclavian artery is held. Its lateral border touches the medial border of the sternocleidomastoid muscle, its inferior thy-

roid gland is a more powerful muscle, arising from the posterior surface of the transverse processes (with the scalene muscles), and it is inserted into the upper surface of the sternum, the rib and the gro-

oves of the posterior triangle of the neck. In relation with the brachiocephalic vein, the subclavian artery, the scapula; and the descending branch of the transverse subclavian muscle. The long thoracic muscle, in relation with the apex of the axilla, is of the long thoracic muscle.

The scalenus posterior muscle arises from the transverse process of the sixth cervical vertebra, and springs by two or three heads from the

HEAD AND NECK

of the cranium. Strong branches
between it and the first
and the superior cervical ganglion.
Further, the hypoglossal nerve
to it by fibrous attachment, in the
exchange of nerve filaments takes place.

Distribution of the Cervical Plexus

branches which spring from the
neck are the following: (1) pharyngeal;

(2) laryngeus; (3) recurrent; (4) cardiac.

Laryngeus Superior.—The pharyngeal branch
upper part of the ganglion nodosum
and anteriorly, superficial to the internal
carotid artery, and in the *pharyngeal plexus*. It is

divided into two branches, of which the upper is the
Laryngeus Superior.—This, a much larger branch,
arises from the middle of the ganglion nodosum.

It runs downwards and anteriorly, but differs from the
superior laryngeal nerve in passing deep to the internal carotid artery.
In its distribution it ends by dividing into the *internal*
laryngeal nerves; both of these have been
previously seen in the dissection of the anterior

When it divides, the superior laryngeal effects communication
with the superior cervical ganglion of the sympathetic system.
It receives one or two filaments from the pharyngeal plexus.

The *internal laryngeal nerve* runs to the interval between the hyoid
bone and the thyroid cartilage; there it divides into two branches,
running under cover of the posterior border of the thyrohyoid
muscle, it pierces the membrane of the pharynx, and then descends
into the larynx.

The *external laryngeal nerve* is a very slender branch,
which runs downwards and anteriorly to reach the crico-thyroid
muscle, in which it ends.

It supplies a few filaments to the inferior constrictor of the pharynx,
and communicates with the superior cardiac branch of the sympathetic, which
is a communicating branch from the superior cervical ganglion of the sympathetic.

Nerve Recurrens.—The recurrent nerve arises from the
superior cervical ganglion on both the two sides. On the *right side*, after springing

HEAD AND NECK

tion, and one or more minute ganglia in connection with it. Its terminal twigs are in the tonsils and mucous membrane of the pharynx, and the *(ramus lingualis vagi)* connects the pharyngeal plexus with the hypoglossal nerve.

Hypoglossus.—The hypoglossal nerve makes its exit from the cranium through the canalis hypoglossus (foramen anterior condyloid foramen). It pierces the dura mater in separate parts, which unite into one stem at the exit from the foramen. As it issues from the canal it lies deeply between the internal jugular vein and the internal carotid artery. Immediately afterwards it inclines laterally, and makes a half spiral turn around the ganglion nodosum of the vagus. It then appears between the two vessels, and descends between them to the lower border of the posterior belly of the digastric muscle; where it passes into the carotid triangle. Its close connection with the ganglion nodosum of the vagus has been noted already (p. 314). In the carotid triangle it hooks under the lower end of the occipital artery, below its sternocleidomastoid branch, and, turning anteriorly, it crosses the occipital artery between its internal and external carotid arteries and the loop of the superficial temporal artery superficially. Then it passes on the medial side of the posterior belly of the digastric and the stylo-hyoid muscle, and enters the digastric triangle, where it disappears medial to the mylo-hyoid, and at the anterior border of the hyoglossus muscle enters the base of the tongue.

Branches of Communication.—Near the base of the skull the hypoglossal nerve is brought into connection with—(1) the superior cervical ganglion; (2) the vagus; and (3) the first cervical nerve; as it turns round the occipital artery it receives (4) the *ramus lingualis vagi* from the pharyngeal plexus; and on the surface of the hyoglossus it communicates with (5) the lingual nerve (p. 290).

Branches of Distribution.—(1) The *meningeal branch* arises from the upper part of the canalis hypoglossi, and, regaining the foramen anterior of the cranium, it is distributed to the dura mater and the foramen magnum. (2) *Vascular twigs* are said to be supplied to the deep aspect of the internal jugular vein. (3) The *descendens hypoglossi*, which conveys fibres of the first cervical nerve to the infra-hyoid muscles. (4) The *nerve to the thyreo-hyoid*, which also consists of fibres of the first cervical nerve. (5) The *terminal branches*, which supply the geni-hyoid and all the intrinsic and extrinsic muscles of the tongue, except the palato-glossus.

Nervus Caroticus Internus.—This branch has been noted passing from the upper end of the ganglion into the carotid canal. Its distribution will be considered later.

Nervi Carotici Externi.—Two to six filaments, called external carotid branches, run to the external carotid artery, and form a loose interlacement around it and its branches. From this *external carotid plexus* a branch is given to the carotid body, and prolongations are continued on all the branches of the artery. The part continued upon the external maxillary artery supplies the sympathetic root to the submaxillary ganglion, whilst the subdivision upon the middle meningeal artery furnishes the corresponding root to the otic ganglion, as well as the *external superficial petrosal nerve* which runs to the ganglion geniculi of the facial nerve.

Rami Laryngo-pharyngei.—The laryngo-pharyngeal branches pass between the two carotid arteries to join the pharyngeal plexus, and some join the superior laryngeal nerve.

Nervus Cardiacus Superior.—This is a long slender branch which springs by several roots from the ganglion, and then proceeds downwards, posterior to the carotid artery. At different stages of its course it is joined by other branches of the sympathetic, by a branch from the vagus, and also by filaments from the external laryngeal and recurrent nerves. The *right superior cardiac nerve* is continued into the thorax by passing posterior or anterior to the subclavian artery, and it ends in the deep cardiac plexus. The *left superior cardiac nerve* follows the left common carotid artery in the thorax, and, crossing the left side of the arch of the aorta, ends in the superficial cardiac plexus.

Ganglion Cervicale Medium.—This ganglion is the smallest of the three ganglia of the neck. It is placed opposite the sixth cervical vertebra in close proximity to the inferior thyroid artery, upon which it not infrequently rests. Its branches are: (1) *grey rami communicantes*, which pass between the contiguous margins of the scalenus anterior and longus colli muscles and connect it with the *fifth and sixth cervical nerves*; (2) *thyroid branches*, which run to the thyroid gland, along the inferior thyroid artery, and form connections with the external laryngeal and recurrent nerves; (3) the middle cardiac nerve.

On both sides the *middle cardiac nerve* enters the thorax and is lost in the deep cardiac plexus. On the *right side*

it passes posterior or anterior to the subclavian artery; on the *left side* it is continued downwards between the common carotid and subclavian arteries.

Ganglion Cervicale Inferius.—The inferior cervical ganglion is lodged in the interval between the transverse process of the seventh cervical vertebra and the neck of the first rib. In this position it lies posterior to the vertebral artery. It is by no means uncommon to find it more or less completely fused, over the neck of the first rib, with the first thoracic ganglion. The connection between it and the middle cervical ganglion is generally in the form of two or more slender nerve cords, of which one passes anterior to the subclavian artery. The latter loops round the subclavian artery and is termed the *ansa subclavia* (Viessenii).

The branches of the inferior cervical ganglion are

1. Grey rami communicantes to the seventh and eighth cervical vertebrae.
2. Rami vasculares.
3. Inferior cardiac nerve.

The *rami vasculares* are fine branches which form a plexus around the subclavian artery and its branches. Those around the vertebral artery are remarkable for their large size.

The *nervus cardiacus inferior* on both sides enter the deep cardiac plexus.

After the vessels and nerves of the neck have been studied the dissectors should examine the *thyroid gland*.

Glandula Thyreoides.—The thyroid gland is a highly vascular solid body, which clasps the upper part of the trachea and extends upwards for some distance upon each side of the larynx. It varies greatly in size in different individuals; and in females and children it is always relatively larger than in adult males. It consists of three well-marked subdivisions, viz., two lateral lobes joined across the median plane by the isthmus. Each lateral lobe is somewhat conical in form; its base lies at the level of the fifth or the sixth tracheal ring, whilst its apex rests against the side of the thyreoid cartilage. Its *superficial or lateral surface* is full and rounded, and is clothed by the *pretracheal layer* of fascia, from which it derives a sheath; and it is covered by the *sterno-thyreoid, sterno-hyoid, and omohyoid muscles*. Its *anterior border* of the sterno-mastoid (Figs. 11, 12). Its *deep or medial surface* is adapted to the

lies, viz., to the side of the trachea, the cricoid cartilage, and the thyreoid cartilage. Its *posterior border* is in relation with the lateral margins of the œsophagus and the lateral margin of the pharynx, and in many cases it overlaps the common carotid artery. Its anterior border is connected with

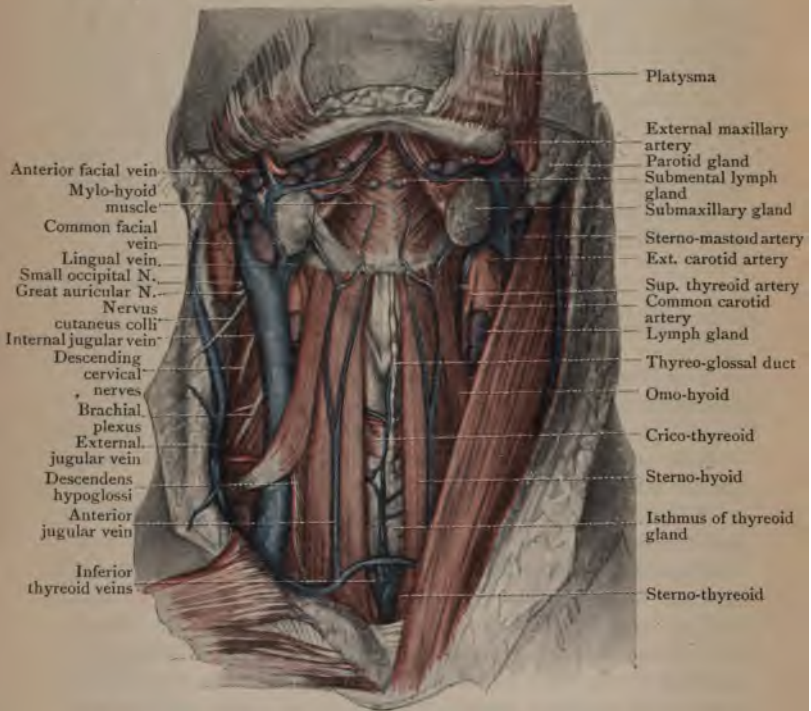


FIG. 126.—Dissection of the Anterior Part of the Neck. The Right Sterno-mastoid has been removed.

the corresponding border of the opposite lateral lobe by the isthmus. Above the isthmus it is in relation with the anterior terminal branch of the superior thyreoid artery, and below the isthmus with the commencement of the inferior thyreoid vein.

The *isthmus* of the thyreoid gland has already been seen in the dissection of the middle line of the neck. It is a band of varying width which lies anterior to the second, third,

and fourth rings of the trachea, and, therefore, nearer the lower than the upper ends of the two lateral lobes.

An additional lobe, the *pyramidal* or *middle lobe*, is frequently present. It is an elongated slender process which springs from the isthmus, on one or other side of the median plane (more usually on the left side), and extends upwards towards the hyoid bone. To this it may be connected by fibrous tissue, or by a narrow slip of muscular fibres called the *levator glandulæ thyreoideæ*. In some cases this little muscle has an attachment to the thyroid gland independently of the pyramidal process. The thyroid gland is firmly connected to the parts upon which it lies, and therefore follows the larynx in all its movements.

The dissector should note the great vascularity of the thyroid gland. Four large arteries, and occasionally a fifth smaller vessel, convey blood to its substance. The two *superior thyroid branches* of the external carotid arteries divide at the apex of each lateral lobe into three branches for its supply; the two *inferior thyroid branches*, from the thyreo-cervical trunks of the subclavian arteries, distribute their terminal branches to the basal portion and deep surface of each lateral lobe. The occasional artery is the *thyreoidea ima*, a branch of the innominate or, more rarely, of the common carotid or the aortic arch. It ascends upon the anterior aspect of the trachea to reach the isthmus of the thyroid gland. These thyroid arteries anastomose with each other.

The veins which drain the blood away from the thyroid gland are still more numerous. They arise in part by tributaries which spring from a venous network on the anterior face of the structure, but chiefly by branches which emerge from its substance. They are *three* in number on each side—viz. the superior thyroid, the middle thyroid, and the inferior thyroid. The *superior and middle thyroid veins* cross the common carotid artery and join the internal jugular; the *inferior thyroid vein* descends on the trachea. At the root of the neck it usually joins its fellow of the opposite side to form a common stem which opens into the left innominate.

Trachea and Œsophagus.—The windpipe and the gullet in the cervical portion of their course may now be studied. Both begin at the level of the cricoid cartilage, anterior to the sixth cervical vertebra. From this point they extend downwards, anterior to the vertebral column, to the thoracic cavity.

The *trachea*, or *windpipe*, is a wide tube which is kept constantly patent by the cartilaginous rings embedded in its walls. These rings do not form complete circles; posteriorly they are deficient, and, in consequence, the posterior surface of the trachea is flattened. Above, it is continuous with the larynx, and, throughout its course in the neck, it is placed in the median plane of the body. The *anterior* relations of the

trachea have already been fully discussed in connection with the description of the parts occupying the middle line of the neck (p. 229). *Posteriorly*, it rests upon the gullet. Upon *either side* is the common carotid artery; whilst closely applied to it in its upper part is the lateral lobe of the thyroid gland. The recurrent nerve ascends, on each side, in the angle between the trachea and œsophagus.

The *œsophagus* or *gullet* is a narrow tube, with thick muscular walls, which extends from the pharynx to the stomach. In the cervical part of its course it lies between the trachea and the longus colli muscles, and as it descends

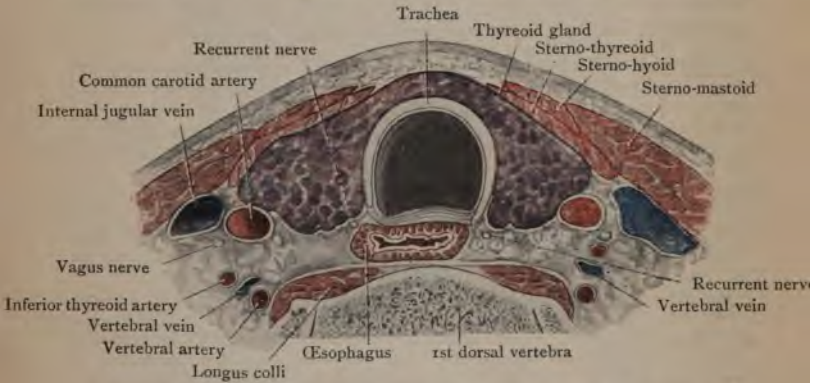


FIG. 127.—Transverse section through the Thyroid Gland, Trachea, and Gullet, at the level of the first Thoracic Vertebra.

it inclines slightly to the left, so that it comes more closely into relation with the lateral lobe of the thyroid gland and the carotid sheath upon the left side than with the same structures on the opposite side.

The dissector may terminate his dissection of the neck by an examination of the scalene muscles, and the rectus capitis lateralis.

Musculi Scaleni.—These muscles constitute the fleshy mass which is seen extending from the transverse processes of the cervical vertebræ to the upper two costal arches. They are three in number, and are named, from their relative positions, *anterior*, *medius*, and *posterior*.

Musculus Scalenus Anterior.—This is a well-defined muscle which is separated from the scalenus medius by the roots of

the brachial plexus and the subclavian artery. It arises from the anterior tubercles of the transverse processes of the third, fourth, fifth, and sixth cervical vertebræ, and, tapering somewhat as it descends, it is inserted into the scalene tubercle on the inner margin of the first rib, and also into the superior surface of the same bone between the two subclavian grooves.

The upper part of its *anterior surface* is concealed by the sterno-mastoid and the lower part by the clavicle. The common carotid artery descends along its medial border. Between it and the sterno-mastoid lie the internal jugular vein; the intermediate tendon of the omo-hyoid; the phrenic nerve, passing downwards and medially; and the transverse cervical and transverse scapular arteries passing posterolaterally, superficial to the phrenic nerve. Between it and the clavicle lies the subclavian vein.

Its *posterior surface* is in relation, above, with the tips of the lower cervical transverse processes, and below, with the apex of the pleura, the second part of the subclavian artery, and its costo-cervical branch. The *lateral border* touches the roots of the brachial plexus, and the *medial border* is in relation with the thyreo-cervical artery, its inferior thyreoid branch, and with the vertebral artery.

Musculus Scalenus Medius.—This is a more powerful muscle than the preceding. It springs from the posterior tubercles of all the cervical transverse processes (with the exception, in some cases, of the first), and it is inserted into a rough oval impression which marks the upper surface of the first rib between the tubercle of the rib and the groove for the subclavian artery.

It forms part of the floor of the posterior triangle of the neck. Its superficial surface is in relation with the brachial plexus and the third part of the subclavian artery. Its posterior border touches the levator scapulæ; and the dorsal scapular nerve and the descending branch of the transverse cervical artery pass between it and that muscle. The lower part of its anterior border is in relation with the apex of the pleura, and the upper two roots of the long thoracic nerve pierce the substance of the muscle.

Musculus Scalenus Posterior.—The scalenus posterior is generally inseparable, at its origin, from the scalenus medius. It is the smallest of the three, and springs by two or three

Nervus Caroticus Internus.—This branch has been noted passing from the upper end of the ganglion into the carotid canal. Its distribution will be considered later.

Nervi Carotici Externi.—Two to six filaments, called external carotid branches, run to the external carotid artery, and form a loose interlacement around it and its branches. From this *external carotid plexus* a branch is given to the carotid body, and prolongations are continued on all the branches of the artery. The part continued upon the external maxillary artery supplies the sympathetic root to the submaxillary ganglion, whilst the subdivision upon the middle meningeal artery furnishes the corresponding root to the otic ganglion, as well as the *external superficial petrosal nerve* which runs to the ganglion geniculi of the facial nerve.

Rami Laryngo-pharyngei.—The laryngo-pharyngeal branches pass between the two carotid arteries to join the pharyngeal plexus, and some join the superior laryngeal nerve.

Nervus Cardiacus Superior.—This is a long slender branch which springs by several roots from the ganglion, and then proceeds downwards, posterior to the carotid artery. At different stages of its course it is joined by other branches of the sympathetic, by a branch from the vagus, and also by filaments from the external laryngeal and recurrent nerves. The *right superior cardiac nerve* is continued into the thorax by passing posterior or anterior to the subclavian artery, and it ends in the deep cardiac plexus. The *left superior cardiac nerve* follows the left common carotid artery in the thorax, and, crossing the left side of the arch of the aorta, ends in the superficial cardiac plexus.

Ganglion Cervicale Medium.—This ganglion is the smallest of the three ganglia of the neck. It is placed opposite the sixth cervical vertebra in close proximity to the inferior thyreoid artery, upon which it not infrequently rests. Its branches are: (1) *grey rami communicantes*, which pass between the contiguous margins of the scalenus anterior and longus colli muscles and connect it with the *fifth and sixth cervical nerves*; (2) *thyreoid branches*, which run to the thyreoid gland, along the inferior thyreoid artery, and form connections with the external laryngeal and recurrent nerves; (3) the middle cardiac nerve.

On both sides the *middle cardiac nerve* enters the thorax and is lost in the deep cardiac plexus. On the *right side*

There are still other points in connection with the glosso-pharyngeal nerve which require mention. At the lower part of the jugular foramen two small ganglia are formed upon its trunk, and from the lower of these certain minute branches are given off. The upper ganglion is called the *ganglion superius*; the lower one is termed the *ganglion petrosum*.

The *superior ganglion* is a small ganglionic swelling, which involves only a portion of the fibres of the nerve trunk. It is placed in the upper part of the bony groove in which the nerve lies as it proceeds through the jugular foramen. No branches arise from it.

The *petrous ganglion* is a larger swelling, which involves the entire nerve-trunk, and lies at the opening of the jugular foramen, between the vagus nerve and the inferior petrosal sinus (which intervenes between it and the anterior border of the foramen). Its length is not more than two or three lines. Three branches of communication enter or proceed from it. These connect it with—(1) the superior cervical sympathetic ganglion; (2) the auricular branch of the vagus; and (3) the jugular ganglion of the vagus.

In addition to these twigs the *tympanic nerve* takes origin from the petrous ganglion.

Tympanic Nerve.—The ultimate destination of this nerve may be regarded as the otic ganglion, but it takes a very circuitous route to gain that structure and it gives off branches on the way. It enters a small foramen on the ridge which separates the jugular fossa from the carotid foramen on the lower surface of the petrous bone, and it is conducted by a narrow canal to the tympanic cavity. It crosses the inner wall of this chamber, grooving the promontory. Having gained the anterior part of the tympanum, it enters the bone a second time, and runs in a minute canal, which tunnels the petrous bone below the upper end of the channel in which is lodged the tensor tympani muscle. In this part of its course the tympanic nerve is joined by a branch from the ganglion geniculi of the facial nerve, and, after the junction is effected, it is termed the *small superficial petrosal nerve*.

The canal in which the *small superficial petrosal nerve* is lodged opens into the cranial cavity upon the anterior surface of the petrous bone, immediately lateral to the hiatus canalis facialis (O.T. Fallopii). Through this the nerve emerges, and soon leaves the interior of the cranium by passing downwards in the interval between the great wing of the sphenoid and the petrous part of the temporal bone, or through the canaliculus innominatus, or through the foramen ovale. Outside the skull it ends by joining the otic ganglion.

In the tympanic cavity the *tympanic nerve* gives branches of supply—(1) to the mucous membrane of the tympanum; (2) to the lining membrane of the mastoid cells; and (3) to the mucous membrane of the auditory tube (Eustachian). It is connected with the sympathetic plexus on the internal carotid artery by the *superior* and *inferior carotico-tympanic branches* which pierce the substance of the petrous part of the temporal bone.

Nervus Vagus.—The vagus passes through the middle compartment of the jugular foramen in company with the accessory—both being included within the same sheath of dura mater. In the neck it pursues a vertical course, lying, at first, between the internal jugular vein and the internal carotid artery, and afterwards between the same

vein and the common carotid artery, enclosed within the sheath which envelops the vessels, but on a plane posterior to them. Its posterior relations, therefore, are similar to those of the internal and common carotid arteries. At the root of the neck it enters the thorax, and has different relations on the two sides. On the *right side* it crosses the first part of the subclavian artery; on the *left side*, after crossing anterior to the thoracic duct, it proceeds downwards between the common carotid and left subclavian arteries, posterior to the left innominate vein. For its thoracic relations see p. 99.

The vagus, like the glosso-pharyngeal, has two ganglia in connection with its upper part. These are the *ganglion jugulare* and the *ganglion nodosum*.

Ganglion Jugulare (O. T. Ganglion of Root).—This is situated within the jugular foramen. It is a rounded swelling which is connected by communicating twigs with several of the nerves in the neighbourhood, and it gives off two branches of distribution.

Branches of Communication.—(1) With the facial nerve; (2) with the petrous ganglion of the glosso-pharyngeal; (3) with the accessory; (4) with the superior ganglion of the sympathetic.

Branches of Distribution.—(1) Meningeal; (2) Auricular nerve.

The *meningeal branch* is a minute twig which runs upwards through the jugular foramen, and, dividing into two branches, is distributed to the dura mater in the posterior cranial fossa.

The *auricular nerve* (O. T. Arnold's nerve) obtains a filament of communication from the petrous ganglion of the glosso-pharyngeal, and passes posteriorly upon the lateral surface of the bulb of the internal jugular vein to enter a minute aperture on the posterior part of the lateral wall of the jugular fossa. A narrow canal then conducts it through the substance of the temporal bone, and, on its way, it crosses the canalis facialis a short distance above the stylo-mastoid foramen. It is thus brought into close relation with the facial nerve and is connected with it by an ascending and a descending branch of communication. Finally, it appears on the surface of the skull, in the interval between the mastoid process and the external acoustic meatus, where it communicates with the posterior auricular branch of the facial. It supplies the skin on the posterior aspect of the outer surface of the walls of the meatus, the skin covering the lower half of the inner surface of the wall of the meatus, and the lower half of the tympanic membrane.

Ganglion Nodosum.—After emerging from the jugular foramen, the vagus nerve is joined by the cerebral *portion* of the *accessory nerve*, and swells out into the ganglion nodosum (O. T. ganglion of trunk).

The *ganglion nodosum* is an elongated reddish-coloured swelling of about three-quarters of an inch in length, which is developed upon the stem of the vagus half an inch

trachea have already been fully discussed in connection with the description of the parts occupying the middle line of the neck (p. 229). *Posteriorly*, it rests upon the gullet. Upon *either side* is the common carotid artery; whilst closely applied to it in its upper part is the lateral lobe of the thyroid gland. The recurrent nerve ascends, on each side, in the angle between the trachea and œsophagus.

The *œsophagus* or *gullet* is a narrow tube, with thick muscular walls, which extends from the pharynx to the stomach. In the cervical part of its course it lies between the trachea and the longus colli muscles, and as it descends

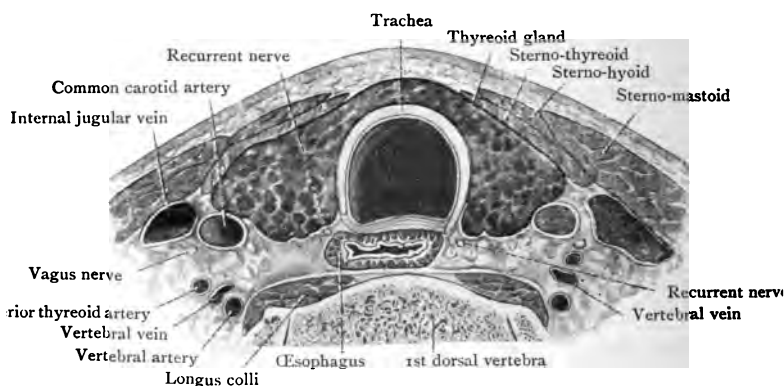


FIG. 127.—Transverse section through the Thyroid Gland, Trachea, and Gullet, at the level of the first Thoracic Vertebra.

it inclines slightly to the left, so that it comes more closely into relation with the lateral lobe of the thyroid gland and the carotid sheath upon the left side than with the same structures on the opposite side.

The dissector may terminate his dissection of the neck by an examination of the scalene muscles, and the rectus capitis lateralis.

Musculi Scaleni.—These muscles constitute the fleshy mass which is seen extending from the transverse processes of the cervical vertebræ to the upper two costal arches. They are three in number, and are named, from their relative positions, *anterior*, *medius*, and *posterior*.

Musculus Scalenus Anterior.—This is a well-defined muscle which is separated from the scalenus medius by the roots of

the brachial plexus and the subclavian artery. It arises from the anterior tubercles of the transverse processes of the third, fourth, fifth, and sixth cervical vertebræ, and, tapering somewhat as it descends, it is inserted into the scalene tubercle on the inner margin of the first rib, and also into the superior surface of the same bone between the two subclavian grooves.

The upper part of its *anterior surface* is concealed by the sterno-mastoid and the lower part by the clavicle. The common carotid artery descends along its medial border. Between it and the sterno-mastoid lie the internal jugular vein; the intermediate tendon of the omo-hyoid; the phrenic nerve, passing downwards and medially; and the transverse cervical and transverse scapular arteries passing posterolaterally, superficial to the phrenic nerve. Between it and the clavicle lies the subclavian vein.

Its *posterior surface* is in relation, above, with the tips of the lower cervical transverse processes, and below, with the apex of the pleura, the second part of the subclavian artery, and its costo-cervical branch. The *lateral border* touches the roots of the brachial plexus, and the *medial border* is in relation with the thyreo-cervical artery, its inferior thyreoid branch, and with the vertebral artery.

Musculus Scalenus Medius.—This is a more powerful muscle than the preceding. It springs from the posterior tubercles of all the cervical transverse processes (with the exception, in some cases, of the first), and it is inserted into a rough oval impression which marks the upper surface of the first rib between the tubercle of the rib and the groove for the subclavian artery.

It forms part of the floor of the posterior triangle of the neck. Its superficial surface is in relation with the brachial plexus and the third part of the subclavian artery. Its posterior border touches the levator scapulæ; and the dorsal scapular nerve and the descending branch of the transverse cervical artery pass between it and that muscle. The lower part of its anterior border is in relation with the apex of the pleura, and the upper two roots of the long thoracic nerve pierce the substance of the muscle.

Musculus Scalenus Posterior.—The scalenus posterior is generally inseparable, at its origin, from the scalenus medius. It is the smallest of the three, and springs by two or three

slips from the transverse processes of a corresponding number of the lower cervical vertebræ in common with the scalenus medius. It is inserted into the upper border of the second rib, immediately anterior to the insertion of the levator costæ.

The scalene muscles are supplied by twigs from the *anterior branches of the cervical nerves, particularly the lower four.*

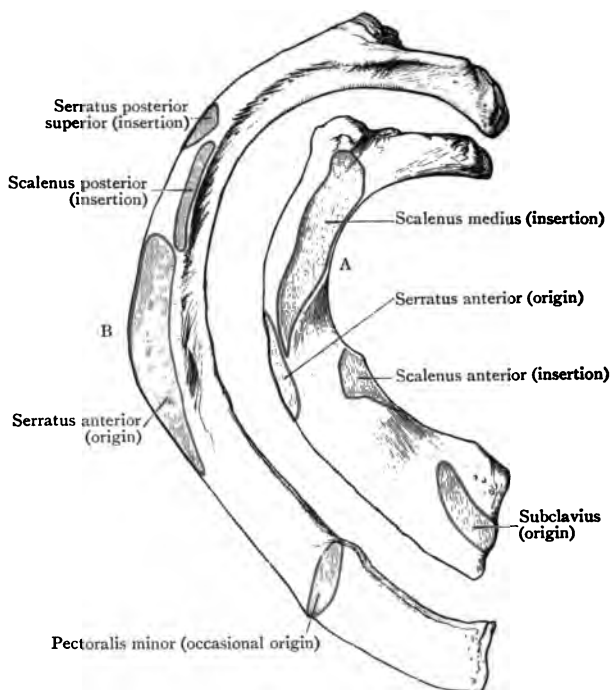


FIG. 128.—Muscle-Attachments to the Superior Surface of the First Rib, and the Outer Surface of the Second Rib.

A, First rib; B, Second rib.

Dissection.—The little muscle termed the rectus capitis lateralis should now be cleaned, and its attachments defined. It lies in the interval between the transverse process of the atlas and the jugular process of the occipital bone, posterior to the commencement of the internal jugular vein. The anterior branch of the first cervical nerve will be seen emerging from under cover of its medial margin.

Rectus Capitis Lateralis.—The rectus lateralis arises from the anterior part of the upper surface of the extremity of the transverse process of the atlas, and is inserted into the under surface of the jugular process of the occipital bone. It is supplied by a twig from the *anterior branch of the first cervical nerve*.

Removal of the Head and Neck from the Trunk.—By the time that the dissectors of the head and neck have arrived at this stage of their work, the dissectors of the thorax have in all probability finished their dissection. If this is the case, the head and neck may be removed from the trunk by cutting through the vertebral column at the level of the intervertebral fibrocartilage between the third and fourth thoracic vertebræ. By this proceeding the upper three thoracic vertebræ, with the attached portions of the first, second, and third pairs of ribs, are removed with the neck. The scalene muscles and the longus colli are therefore preserved intact.

THE LATERAL PART OF THE MIDDLE CRANIAL FOSSA.

The structures contained within the middle cranial fossa may now be examined. In carrying out this dissection, the head should be supported on a block so that the floor of the cranial cavity looks upwards. The following are the structures which must be displayed:—

1. Cavernous venous sinus.
2. Internal carotid artery.
3. Middle meningeal artery.
4. Accessory meningeal artery.
5. The two roots of the Trigeminal nerve, with the Semilunar ganglion and the three main divisions of the trigeminal nerve.
6. Oculo-motor nerve (3rd cerebral).
7. Trochlear nerve (4th cerebral).
8. Abducent nerve (6th cerebral).
9. Internal carotid plexus of the sympathetic.
10. Greater superficial petrosal nerve.
11. Smaller superficial petrosal nerve.

Dissection.—The dura mater has already been removed from one half of the middle cranial fossa, and on that side it is only necessary to differentiate the structures which lie in the cavernous sinus; on the other side the dura mater must be stripped from the medial part of the lateral portion of the middle cranial fossa. Enter the knife at the anterior clinoid process, and carry it posteriorly to the apex of the petrous bone. This incision must go no deeper than is necessary to divide the dura mater, and must be made immediately to the lateral side of the openings in the membrane through which the oculo-motor, the trochlear, and trigeminal nerves pass. It is

very important to preserve these apertures intact, so that the proximal ends of the nerves may be held in position during the dissection. The incision through the dura mater may now be carried postero-laterally along the upper border of the petrous bone in the line of the superior petrosal sinus, and antero-laterally along the posterior margin of the lesser wing of the sphenoid. After the incisions are made raise the dura mater with great care, for it is intimately connected with the nerves which lie subjacent to it. Thus, where it forms the lateral wall of the cavernous sinus, it is closely applied to the oculo-motor and trochlear nerves, and firmly attached to the ophthalmic division of the trigeminal nerve, whilst over the petrous bone it is united to the surface of the semilunar ganglion. The edge of the knife, therefore, must be kept close to the membrane, and a small portion of the membrane may be left upon the nerves. This can be removed afterwards as the nerves are defined.

Sinus Cavernosus.—The cavernous sinus has been opened

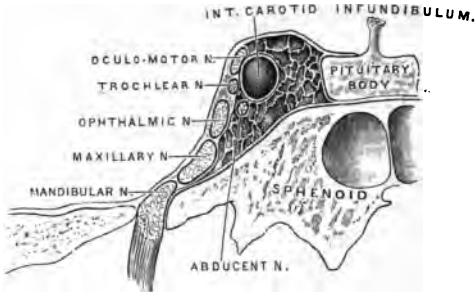


FIG. 129.—Section through the Cavernous Sinus. (After Merkel, somewhat modified.)

by the above dissection. It is a short, wide venous channel, which extends along the side of the body of the sphenoid bone, from the lower and medial end of the superior orbital fissure (O.T. sphenoidal fissure) to the apex of the petrous portion of the temporal bone. Anteriorly, blood is conducted into it by the ophthalmic veins and the spheno-parietal sinus; whilst posteriorly the blood is drained away by the superior and inferior petrosal sinuses. But it has still other connections. Thus, it receives blood from the lower part of the lateral surface of the brain by the superficial middle cerebral vein and some small inferior cerebral veins. It is united with the corresponding sinus of the opposite side by means of the anterior and posterior intercavernous sinuses (p. 217). Lastly, one or more emissary veins leave its lower aspect; one passes out of the cranium by the foramen ovale, or it may be

the brachial plexus and the subclavian artery. It arises from the anterior tubercles of the transverse processes of the third, fourth, fifth, and sixth cervical vertebræ, and, tapering somewhat as it descends, it is inserted into the scalene tubercle on the inner margin of the first rib, and also into the superior surface of the same bone between the two subclavian grooves.

The upper part of its *anterior surface* is concealed by the sterno-mastoid and the lower part by the clavicle. The common carotid artery descends along its medial border. Between it and the sterno-mastoid lie the internal jugular vein; the intermediate tendon of the omo-hyoid; the phrenic nerve, passing downwards and medially; and the transverse cervical and transverse scapular arteries passing posterolaterally, superficial to the phrenic nerve. Between it and the clavicle lies the subclavian vein.

Its *posterior surface* is in relation, above, with the tips of the lower cervical transverse processes, and below, with the apex of the pleura, the second part of the subclavian artery, and its costo-cervical branch. The *lateral border* touches the roots of the brachial plexus, and the *medial border* is in relation with the thyreo-cervical artery, its inferior thyreoid branch, and with the vertebral artery.

Musculus Scalenus Medius.—This is a more powerful muscle than the preceding. It springs from the posterior tubercles of all the cervical transverse processes (with the exception, in some cases, of the first), and it is inserted into a rough oval impression which marks the upper surface of the first rib between the tubercle of the rib and the groove for the subclavian artery.

It forms part of the floor of the posterior triangle of the neck. Its superficial surface is in relation with the brachial plexus and the third part of the subclavian artery. Its posterior border touches the levator scapulæ; and the dorsal scapular nerve and the descending branch of the transverse cervical artery pass between it and that muscle. The lower part of its anterior border is in relation with the apex of the pleura, and the upper two roots of the long thoracic nerve pierce the substance of the muscle.

Musculus Scalenus Posterior.—The scalenus posterior is generally inseparable, at its origin, from the scalenus medius. It is the smallest of the three, and springs by two or three

Nervus Trigeminus.—The two roots of this nerve have already been seen piercing the dura mater at the apex of the petrous portion of the temporal bone under the anterior margin of the tentorium. Now that the dura mater has been raised from the lateral part of the middle cranial fossa, the further relations of these nerve-roots within the cranium may be studied. It will be noticed that the loosely connected

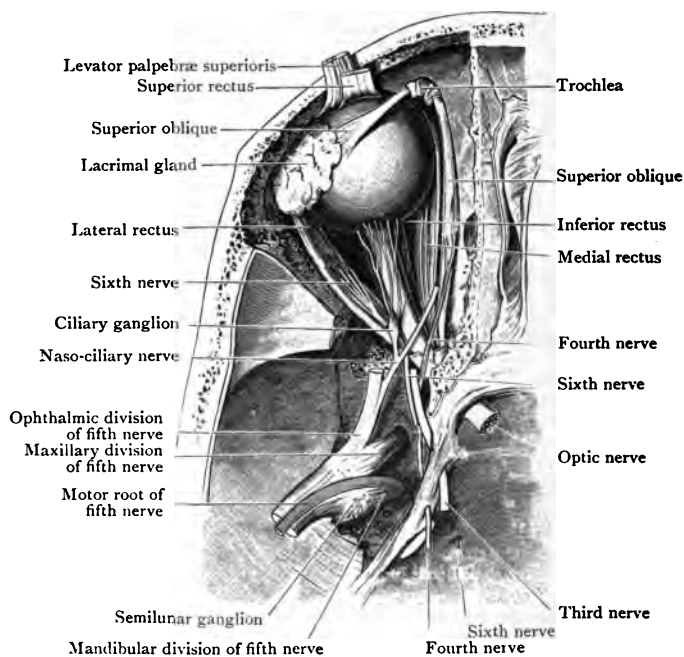


FIG. 131.—Dissection of the Orbit and the Middle Cranial Fossa. Both roots of the fifth nerve with the semilunar ganglion are turned laterally.

and parallel funiculi of the *portio major*, or sensory root, at once begin to divide and join with each other so as to form a dense plexiform arrangement, whilst, at the same time, the nerve-root increases somewhat in breadth. The interlacement, thus brought about, occupies the smooth depression which marks the anterior aspect of the apex of the petrous portion of the temporal bone, and it sinks into the semilunar ganglion (O.T. Gasserian).

The *Ganglion Semilunare* (O.T. Gasserian) is somewhat crescentic in form. It lies upon the sutural junction between the apex of the petrous bone and the great wing of the sphenoid bone, where it is enclosed within a recess or space, called the *cavum Meckelii*, formed by a separation of the two layers of the dura mater. The concavity of the ganglion is directed postero-medially, and it is upon this aspect that it receives the interlacing fibres of the sensory root of the trigeminal nerve; the convexity of the ganglion is directed antero-laterally and from it emerge the three main divisions of the trigeminal nerve. These are—(1) the first, or ophthalmic division; (2) the second, or maxillary division; and (3) the third, or mandibular division. The medial border of the ganglion is connected with the internal carotid sympathetic plexus by filaments of communication.

The *portio minor* or motor root of the fifth nerve should now be followed. Before the nerve pierces the dura mater the motor root lies along the medial side of the large sensory root, but it soon changes its position and comes to lie beneath the sensory part. To display this relationship, draw the cut ends of the two roots through the aperture in the dura mater which leads into the *cavum Meckelii*, and, gently dislodging the semilunar ganglion from its place, turn it antero-laterally so as to expose its deep surface. The small and firm motor root can readily be recognised lying in a groove upon the deep surface of the ganglion; and if it is displaced from this, it will be seen to have no connection with the ganglion, but to be continued onwards towards the foramen ovale. It ultimately joins the mandibular division of the trigeminal nerve. This junction may take place within the cranium, in the foramen ovale, or immediately outside the skull.

The three principal divisions of the trigeminal nerve may next be examined. Begin with the *mandibular division*, which is the largest. This proceeds directly downwards, and almost immediately leaves the cranial cavity through the foramen ovale.

•• Whilst isolating this large nerve-trunk and defining the bony aperture through which it makes its exit, look carefully for the accessory meningeal artery, which enters the cranium through the same foramen. If the injection has been forced into this vessel it can easily be detected. An emissary vein which connects the cavernous sinus with the pterygoid venous plexus also passes through the foramen ovale.

The *maxillary division* is composed entirely of sensory fibres. It runs anteriorly in relation to the lower and lateral part of the cavernous sinus, and, after a short course within the cranium, makes its exit through the foramen rotundum. Near its origin it gives off a fine *meningeal branch* to the dura mater of the middle fossa of the cranium.

The *ophthalmic division* is the smallest of the three branches of the trigeminal nerve, and, like the maxillary, it is composed entirely of sensory fibres. It passes anteriorly in the lateral wall of the cavernous sinus, and ends, close to the superior orbital fissure, by dividing into three terminal branches. As it traverses the sinus it is accompanied by the oculo-motor and trochlear nerves, both of which occupy a higher level. Like the other two divisions of the trigeminal nerve, the ophthalmic nerve gives off a *meningeal branch*. This small twig passes into the tentorium cerebelli.

The terminal branches of the ophthalmic division of the trigeminal nerve are the naso-ciliary, the lacrimal, and the frontal. The *naso-ciliary*, as a rule, takes origin first; the *lacrimal* is given off soon after; and then the stem of the nerve is continued onwards as the *frontal*. These three nerves enter the orbit through the superior orbital fissure.

Nervus Oculomotorius (Third), Nervus Trochlearis (Fourth), and Nervus Abducens (Sixth).—It has been noted already that the *oculo-motor* nerve pierces the dura mater within the small triangular area, in the middle cranial fossa, which lies immediately anterior to the crossing of the attached and free margins of the tentorium (p. 210). It has been noted also that the trochlear (fourth) nerve pierces the dura mater in the posterior fossa under the free margin of the tentorium. Both now proceed anteriorly in the lateral wall of the cavernous sinus. The oculo-motor nerve occupies the highest level, then comes the trochlear nerve, and immediately below that the ophthalmic division of the trigeminal nerve. They therefore present a numerical order from above downwards. The *abducent nerve*, which pierces the dura mater in the posterior fossa, at the lower and lateral part of the dorsum sellæ, curves round the lateral side of the internal carotid artery, and then passes anteriorly more directly within the cavernous sinus than the others (Fig. 130).

The oculo-motor, trochlear, and abducent nerves during their course in the cavernous sinus receive communica-

LATERAL PART OF MIDDLE CRANIAL FOSSA 331

tions from the carotid plexus and from the ophthalmic nerve; and they all enter the orbit by passing through the superior orbital fissure. Before doing so, the oculo-motor nerve divides into an upper and a lower division. As they pass through the superior orbital fissure the various

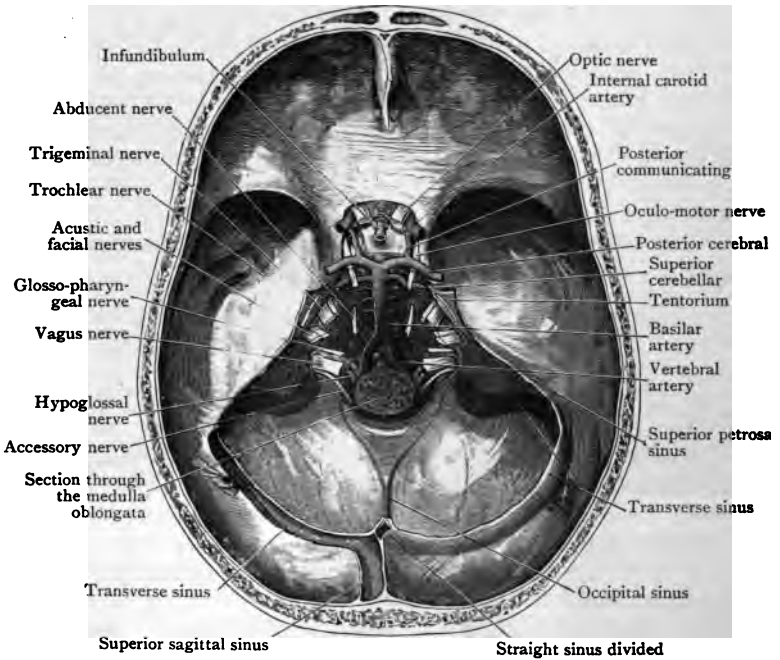


FIG. 132.—Floor of the Cranium after the removal of the Brain and the Tentorium Cerebelli. The blood-vessels forming the circulus arteriosus have been left in place.

nerves undergo a change in their relative positions. This, however, will be studied in the dissection of the orbit.

Arteria Carotis Interna.—The intracranial portion of the internal carotid artery may now be examined. It lies upon the lateral aspect of the body of the sphenoid, and, for the greater part of its course, it traverses the cavernous sinus. It emerges from the carotid canal into the foramen lacerum at the apex of the petrous bone; then it passes through the upper part of the foramen lacerum, pierces the outer layer

of dura mater, and enters the middle cranial fossa at the root of the posterior clinoid process ; there it bends at right angles, and passes anteriorly to the lower root of the small wing of the sphenoid, where it turns abruptly upwards and pierces the inner layer of the dura mater, immediately posterior to the entrance of the optic nerve into the optic foramen, and on the medial side of the anterior clinoid process. It was severed at this point during the removal of the brain ; but it will be afterwards seen to end on the basal aspect of the brain, at the commencement of the fissura lateralis (O.T. Sylvian fissure), by dividing into the anterior and middle cerebral arteries. Throughout its whole course it is surrounded by sympathetic filaments, and soon after its entrance into the cranium the abducent nerve crosses its lateral side.

The intracranial portion of the internal carotid artery gives off the following branches :—

- | | | |
|--|---|--|
| 1. Branches to the hypophysis, | } | These are minute twigs
which arise in the
cavernous sinus. |
| 2. Branches to the semilunar ganglion, | | |
| 3. Branches to the dura mater, | | |
| 4. Ophthalmic, | } | These will be studied at a later
stage. |
| 5. Posterior communicating, | | |
| 6. Anterior cerebral, } terminal | | |
| 7. Middle cerebral, } branches. | | |
| 8. Choroidal. | | |

Plexus Caroticus Internus.—The sympathetic filaments which form this plexus can be satisfactorily dissected only in a subject which has not been injected ; and even then, the dissection is an exceedingly difficult one. The *internal carotid plexus* is placed in the cavernous sinus and is chiefly massed upon the lower and medial aspect of the internal carotid artery, at the point where it makes its bend upwards. It supplies filaments to the hypophysis, to the third and fourth nerves, and to the ophthalmic division of the trigeminal nerve, and gives the sympathetic root to the ciliary ganglion (O.T. lenticular ganglion).

Nervus Petrosus Superficialis Major.—This small nerve, along with a small arterial twig from the middle meningeal artery, can readily be exposed in the groove on the anterior face of the petrous bone which leads from the hiatus canalis facialis to the foramen lacerum. It is placed under the semilunar ganglion, which must therefore be turned antero-laterally. In the canalis facialis it joins the ganglion geniculi of the facial nerve. When traced in the opposite direction, it will

be found to enter the foramen lacerum, where it joins the *nervus petrosus profundus* from the carotid plexus. The trunk formed by the union of these two filaments is the *nervus canalis pterygoidei* (O.T. *Vidian nerve*).

Nervus Petrosus Superficialis Minor appears upon the anterior face of the petrous bone, through an aperture which is placed immediately lateral to the hiatus canalis facialis. It leaves the cranial cavity by passing downwards between the great wing of the sphenoid and the petrous part of the temporal bone, or through the canaliculus innominatus or through the foramen ovale, to reach the otic ganglion. This minute nerve, as has been mentioned already (p. 312), is formed by the union of the tympanic branch of the glosso-pharyngeal with a branch from the ganglion geniculi of the facial.

External Superficial Petrosal Nerve.—It is convenient at this stage to take note of a fourth petrosal nerve—the *external superficial petrosal*. It takes origin from the sympathetic plexus which accompanies the middle meningeal artery, and, entering the petrous bone, is conducted to the ganglion geniculi of the facial nerve.

Middle and Accessory Meningeal Arteries.—The entrance of the *middle meningeal artery* through the foramen spinosum should now be examined. It gives minute twigs to the semilunar ganglion, and one—the *petrosal artery*—which accompanies the great superficial petrosal nerve into the hiatus canalis facialis. The further course of the middle meningeal artery has been described already (pp. 220). The nervus spinosus of the mandibular nerve also enters the cranium through the foramen spinosum (p. 275).

The *accessory meningeal artery* enters the cranium through the foramen ovale, and is distributed chiefly to the semilunar ganglion.

DISSECTION OF THE ORBIT.

Within the orbital cavity the following structures are grouped around the eyeball and the optic nerve:—

Muscles, . . .	}	Rectus superior.
		Rectus inferior.
		Rectus lateralis.
		Rectus medialis.
		Obliquus superior.
		Obliquus inferior.
Vessels, . . .	}	Levator palpebræ superioris.
		Ophthalmic artery and its branches.
		Ophthalmic veins (superior and inferior) with their tributaries.

Nerves, . . . {

- Oculo-motor (3rd cerebral).
- Trochlear (4th cerebral).
- Abducent (6th cerebral).
- Frontal, } from ophthalmic division of the trigeminal
- Lacrimal, } or fifth cerebral nerve.
- Naso-ciliary, }
- Zygomatic branch of the maxillary division of the tri-
- geminal nerve.
- Ciliary ganglion.
- Lacrimal gland.
- Fascia Bulbi.

Dissection.—The roof of the orbit must be removed with the aid of the saw, the chisel, and the bone forceps. Begin by removing the thick cranial wall above the orbital opening, leaving only a thin portion corresponding to the superior orbital arch. Whilst this is being done, care should be taken to preserve the soft parts of the forehead and the upper eyelid. It is of great advantage to retain, throughout the whole examination of the orbital cavity, the bony ring which constitutes its opening on the face. The thin roof of the orbit may next be removed with the chisel and bone forceps. The lesser wing of the sphenoid, where it forms the upper boundary of the superior orbital fissure, should be taken away by the bone forceps, but the dissector should carefully preserve intact the ring of bone around the optic foramen. The superior orbital fissure is now fully opened up, and the various nerves, as they enter the orbit from the cavernous sinus, may be followed out. Lastly, the anterior clinoid process may be taken away with advantage.

Periosteum.—If the dissection has been successfully carried out, the periosteum clothing the under surface of the orbital roof will be exposed uninjured. The periosteum of the orbit forms a funnel-shaped sheath, which encloses all the contents of the cavity except the zygomatic nerve, and is but loosely attached to its bony walls. Posteriorly it is directly continuous, through the superior orbital fissure, with the dura mater. Expanding with the cavity, it becomes continuous anteriorly, around the orbital opening, with the periosteum which clothes the exterior of the skull. Here also it presents important connections with the palpebral fascia.

Reflection of the Periosteum and the subsequent Dissection.—The periosteum should be divided along the middle line of the orbit, and then transversely close to the orbital opening. It can now be thrown medially and laterally. When this is done, the lacrimal gland will be exposed in the antero-lateral part of the cavity. Further, the large frontal nerve, lying upon the upper surface of the levator palpebræ superioris, will be seen in the middle line of the orbit; as it approaches the anterior part of the cavity it is joined by the supra-orbital artery. The other superficial structures are usually more or less obscured by the soft pliable fat, which everywhere fills up the interstices between the different orbital contents. On carefully separating this, along the medial wall of the orbit, the superior oblique muscle will be more fully displayed, and lying upon and entering

the posterior part of this muscle the small trochlear or fourth cerebral nerve will be discovered. The dissector often fails to find this nerve, because as a general rule he looks for it too far forwards. Lastly, the lacrimal nerve and artery will be found, running along the lateral wall of the orbit, above the level of the upper margin of the lateral rectus muscle.

These structures must be thoroughly cleaned and isolated by the removal of the fat from around them. As the superior oblique muscle is followed anteriorly it will be found to end in a slender tendon, which passes through a ring-like pulley attached to the medial angular process of

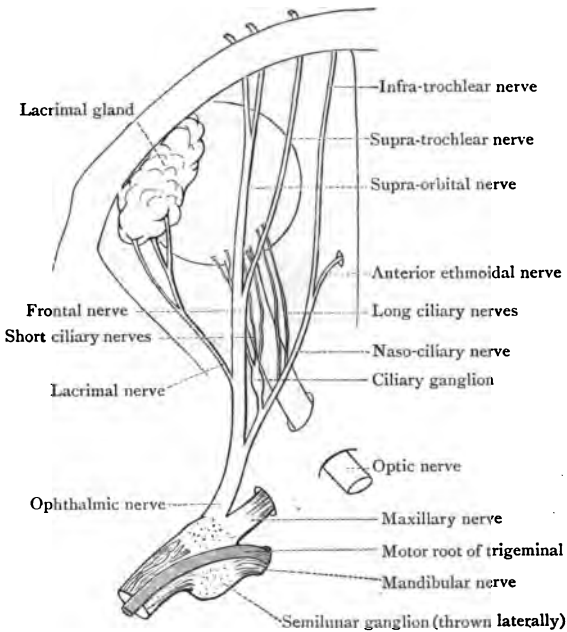


FIG. 133.—The Ophthalmic Nerve of the Left Side. The semilunar ganglion and the nerves have been everted and turned over to show the motor root.

the frontal bone. This pulley must be defined, and the tendon of the muscle followed laterally from it to its insertion into the eyeball. Note that the levator palpebræ superioris lies upon the upper surface of the superior rectus, and, if it is raised, a nerve twig will be noticed emerging from the substance of the rectus superior for the supply of the levator palpebræ muscle. This is a branch of the superior division of the third nerve.

The dissection of the above parts will be facilitated by grasping the anterior part of the eyeball with the forceps and drawing it forwards. It may be retained in this position by running a fine needle and thread through the ocular conjunctiva and stitching it to the nose. In doing this, however, take care that the needle does not penetrate the cornea, because this might render the subsequent inflation of the eyeball impossible.

Nervus Frontalis.—The frontal nerve is the continuation of the stem of the ophthalmic division of the trigeminal nerve, after it has given off its lacrimal and naso-ciliary branches. It enters the orbit through the superior orbital fissure, above the muscles, and runs anteriorly upon the upper surface of the levator palpebræ superioris, immediately subjacent to the periosteal lining of the orbital cavity. It ends at a variable distance from the orbital opening by dividing into the supra-orbital and supra-trochlear branches.

The *supra-trochlear nerve* is the medial and smaller of the two terminal branches of the frontal. It runs towards the trochlea of the superior oblique muscle, above which it pierces the palpebral fascia, leaves the orbit, and turns round the orbital arch to reach the forehead. Its further course has been described already (p. 156). In the orbit it gives off one small twig close to the pulley of the superior oblique muscle. This passes downwards to join the infra-trochlear branch of the naso-ciliary nerve.

The *supra-orbital nerve* is continued onwards, in the line of the parent stem, and, passing through the supra-orbital notch or foramen, it turns upwards on the forehead (p. 156). In the dissection of the scalp this nerve has been seen to divide into a lateral and a medial division. Sometimes the separation takes place within the orbit, and in that case the larger *lateral* part occupies the supra-orbital notch.

Nervus Lacrimalis.—This is the smallest of the terminal branches of the ophthalmic division of the fifth. It enters the orbit through the superior orbital fissure, above the level of the muscles, and runs anteriorly, along the lateral wall of the cavity, above the upper margin of the lateral rectus muscle. At the anterior part of the orbit it continues its course, under cover of the lacrimal gland, until it reaches the lateral part of the upper eyelid, in which it ends (p. 137). Within the orbital cavity it gives numerous twigs to the deep surface of the lacrimal gland, and sends downwards a filament which connects it with the zygomatic branch of the maxillary nerve.

Nervus Trochlearis.—The small fourth nerve is destined entirely for the supply of the superior oblique muscle. Having entered the orbit through the superior orbital fissure, above the muscles, it passes antero-medially, under the periosteum, and

finally sinks into the upper or orbital surface of the superior oblique muscle not far from its origin.

Glandula Lacrimalis.—The lacrimal gland is a small, flattened and distinctly lobular structure of oval form, which is placed transversely in the antero-lateral part of the orbit. It consists of two parts or groups of lobules—a superior and an inferior—imperfectly separated from each other. The *glandula lacrimalis superior*, which constitutes the main mass of the gland, lies in the orbital cavity. Its lateral convex surface is lodged in a hollow upon the medial aspect of the zygomatic process of the frontal bone, and it is bound to the lateral part of the orbital arch by short fibrous bands which proceed from the periosteum. The deep or medial surface is slightly concave, and rests upon the levator palpebræ superioris and lateral rectus, which intervene between it and the eyeball. The *glandula lacrimalis inferior* lies below and anterior to the superior part, from which it is partially separated by the expanded tendon of the levator palpebræ superioris. It projects into the base of the upper eyelid, and rests upon the conjunctiva which lines the under aspect of the lid. This portion of the gland has been already examined in the dissection of the eyelids (p. 138). Even in the undissected subject it can be seen through the conjunctiva when the upper eyelid is fully everted.

The lacrimal gland secretes the tears, and its ducts (three to five from the superior part and three to nine from the inferior part) open upon the under surface of the upper eyelid in the neighbourhood of the fornix (Fig. 64).

Musculus Levator Palpebræ Superioris.—This muscle rests upon the upper surface of the rectus superior. Posteriorly, it is narrow and pointed, but it expands as it passes above the eyeball to reach the upper eyelid. It arises from the under surface of the roof of the orbit immediately anterior to the optic foramen, and in the anterior part of the orbital cavity it widens out into a broad membranous expansion, the connections of which have been described already (p. 136). The lateral and medial margins of this expansion are fixed to the rim of the orbital opening, in close proximity to the ligamentum palpebrale mediale and the raphe palpebralis lateralis. By these attachments excessive action of the muscle upon the upper eyelid is in a measure checked.

Dissection.—Divide f

¹ throw the ends anteriorly and

posteriorly. The levator palpebræ superioris also may be cut midway between its origin and insertion. On raising the posterior portion a minute nerve twig will be seen entering its deep or ocular surface. This comes from the superior division of the third or oculo-motor nerve.

The eyeball should now be inflated. This may be done from the front or from behind. If the latter method is selected, gently separate the fat under cover of the superior rectus muscle, and push the ciliary vessels and nerves away from the optic nerve. Next make a small incision through the sheath of the nerve. Pass a ligature round the nerve anterior to the opening, and then pass a blowpipe, provided with a styilet, through the incision and along the nerve into the interior of the eyeball. When the globe of the eye is fully inflated, the ligature may be tightened as the blowpipe is withdrawn. A very much better plan, however, is to inflate the

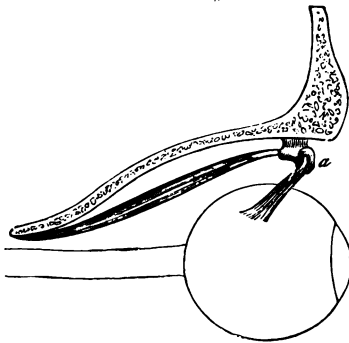


FIG. 134. — Diagram of the Superior Oblique Muscle. (From Hermann Meyer.)

a. Trochlea and synovial sheath.

eyeball from the front. For this purpose make an oblique valvular aperture in the sclero-corneal junction, with the point of a sharp narrow-bladed knife. Through this the blow-pipe may be introduced, and on its withdrawal after the inflation of the eyeball the valvular character of the opening is sufficient to prevent the escape of the air.

Posterior to the eyeball the dissector will notice a quantity of loose bursal-like tissue. This is the *fascia bulbi* (O.T. *capsule of Tenon*). Seize the upper part of this with the forceps, and remove a small portion with a pair of scissors. An aperture is thus made into the fascia, and the handle of the knife can be introduced into the space between it and the eyeball. In favourable

cases the extent of the fascia can be gauged, and perhaps even the prolongations or sheaths which it gives to the tendons of the ocular muscles may be made out. The description of the fascia bulbi is given on p. 347.

Musculus Rectus Superior.—The rectus superior, which lies under cover of the levator palpebræ superioris, is now fully exposed. It arises from the upper margin of the optic foramen, passes anteriorly above the optic nerve, and ends upon the upper aspect of the eyeball in a thin, delicate tendon, which expands somewhat to be inserted into the sclera about three or four lines posterior to the sclero-corneal junction. It is supplied by a branch from the superior division of the oculo-motor nerve.

Musculus Obliquus Superior.—This muscle arises from the roof of the orbit immediately anterior to the upper and medial part of the optic foramen. It passes anteriorly, along

the medial wall of the cavity above the medial rectus. At the anterior part of the orbit it ends in a slender tendon, which enters the *trochlea* and at once changes its direction, proceeding postero-laterally, upon the upper surface of the eyeball, under cover of the superior rectus. Beyond the lateral edge of the superior rectus the tendon expands somewhat, and is inserted into the sclera midway between the entrance of the optic nerve and the cornea.

The *trochlea* or *pulley* through which the tendon passes is a small fibro-cartilaginous ring, which is attached by fibrous tissue to the trochlear fossa—a depression in the frontal bone close to the medial angular process. The pulley is lined with a synovial sheath which facilitates the movement of the tendon, and from its lateral margin it gives a fibrous investment to the tendon.

Dissection.—Divide the superior rectus midway between its origin and its insertion, and reflect the cut ends. On raising the posterior part of the muscle the superior division of the oculo-motor nerve is brought into view, as it sinks into the deep or ocular surface of the muscle. It sends a twig to the levator palpebræ superioris. The removal of some fat will bring the optic nerve more fully into view. At the posterior part of the orbit three structures will be seen crossing the optic nerve—viz., (1) the naso-ciliary nerve; (2) the ophthalmic artery; and (3) the superior ophthalmic vein. These should be carefully cleaned and their branches followed out. From the naso-ciliary nerve one or two delicate thread-like branches—the *long ciliary nerves*—will be found passing along the optic nerve to reach the eyeball. The *short ciliary nerves*, much more numerous, accompany the long ciliary branches, and can readily be disengaged from the fat which surrounds the optic nerve. A strong member of this group should be selected and followed posteriorly; it will lead the dissector to the *ciliary ganglion*. This is a minute body which is situated upon the lateral side of the optic nerve in the posterior part of the orbit. With a little patience and care the roots which the naso-ciliary nerve and inferior division of the oculo-motor nerve give to this ganglion can be isolated, and perhaps even the sympathetic root from the internal carotid plexus will be found.

Nervus Opticus.—The optic nerve enters the orbit through the optic foramen. It carries with it a strong loose sheath of dura mater, and also more delicate investments from the arachnoid and pia mater. The ophthalmic artery, which accompanies it, lies on its infero-lateral aspect. Within the orbit the nerve inclines antero-laterally, and at the same time somewhat downwards, to the back of the eyeball, where it pierces the sclera a short distance to the medial side of its centre. The dissector has noted already that the ophthalmic artery and vein and the naso-ciliary nerve cross

above the optic nerve, and that it is closely accompanied by the delicate ciliary nerves and vessels. The optic nerve is slightly longer than the distance which it has to run from the optic foramen to the globe of the eye, so that the movements of the eyeball may not be interfered with. Within the eyeball the optic nerve spreads out in the retina.

Nervus Naso-ciliaris.—The naso-ciliary nerve (O.T. nasal) arises from the ophthalmic division of the trigeminal in the anterior part of the cavernous sinus. It passes through the superior orbital fissure and enters the orbital cavity, between the two heads of the lateral rectus muscle and between the two divisions of the third nerve. It then inclines antero-medially, and, crossing the optic nerve obliquely, it runs between the medial rectus and superior oblique muscles to the medial wall of the orbit, where it divides into two terminal branches—viz., the infra-trochlear and the anterior ethmoidal nerves. In addition to these it gives off in the orbit the following branches: (1) long root to the ciliary ganglion: (2) long ciliary nerves: (3) posterior ethmoidal nerve.

Radix Longa Ganglii Ciliaris.—This is a very slender filament which springs from the naso-ciliary as it enters the orbit between the heads of the lateral rectus. It runs along the lateral side of the optic nerve, and enters the upper and posterior part of the ciliary ganglion.

Nervi Ciliares Longi.—The two long ciliary branches spring from the naso-ciliary as it crosses the optic nerve. They pass anteriorly, upon the medial side of the optic nerve, to reach the globe of the eye where they pierce the sclera. One of the long ciliary nerves very constantly unites with one of the short ciliary filaments.

Nervus Ethmoidalis Posterior passes through the posterior ethmoidal foramen to the ethmoidal cells and the sphenoidal air sinus.

Nervus Infra-trochlearis.—The infra-trochlear branch runs along the medial wall of the orbit below the superior oblique muscle. After passing under the trochlea of that muscle it emerges from the orbit and appears upon the face, where it has been dissected already (p. 128). Near the pulley it receives a communicating twig from the supra-trochlear nerve.

Nervus Ethmoidalis Anterior.—This is the larger of the two terminal branches of the naso-ciliary nerve. It leaves

the orbit by the anterior ethmoidal canal, and is conducted to the interior of the cranium, in which it appears at the lateral margin of the cribriform plate of the ethmoid. The canal in which it runs can readily be opened up with the bone-forceps to expose the nerve. Upon the cribriform plate it turns anteriorly, under the dura mater, and almost immediately disappears, through a slit-like aperture at the side of the crista galli, into the nasal cavity. There it gives *internal nasal branches* to the mucous membrane, and is continued downwards upon the posterior aspect of the nasal bone. Finally, it emerges upon the face, as the *external nasal nerve*, by passing between the lower margin of the nasal bone and the lateral cartilage of the nose. Its terminal filaments have been described already (p. 140).

Ganglion Ciliare (Fig. 138).—The ciliary ganglion is a small quadrangular body, not much larger than the head of a large pin. It is placed in the posterior part of the orbit, between the optic nerve and the lateral rectus muscle, and very commonly on the lateral side of the ophthalmic artery. At its posterior border it receives its three roots; whilst from its anterior border the short ciliary nerves are given off.

The *sensory root* comes from the naso-ciliary, and is called the *long root*. The *short* or *motor root* is a short, stout trunk; it comes from the branch of the oculo-motor nerve which goes to the inferior oblique muscle. The *sympathetic root* comes from the internal carotid plexus, it joins the ganglion, close to the entrance of the long root from the naso-ciliary nerve. In some cases it joins the long root before it reaches the ganglion.

Nervi Ciliares Breves.—The short ciliary nerves are from four to six in number. They come off in two groups, superior and inferior. The lower nerves are generally more numerous than the upper. As these fine nerves pass along the optic nerve they divide and thus increase in number; at the back of the eyeball from twelve to eighteen may be counted. Finally they pierce the sclera by a series of apertures which are placed around the entrance of the optic nerve.

Arteria Ophthalmica.—The ophthalmic artery is a branch of the internal carotid. It accompanies the optic nerve into the orbit through the optic foramen. At first it lies below the optic nerve, but soon winds round its lateral side, and, crossing above it, passes anteriorly along the medial

above the optic nerve, and that it is closely accompanied by the delicate ciliary nerves and vessels. The optic nerve is slightly longer than the distance which it has to run from the optic foramen to the globe of the eye, so that the movements of the eyeball may not be interfered with. Within the eyeball the optic nerve spreads out in the retina.

Nervus Naso-ciliaris.—The naso-ciliary nerve (O.T. nasal) arises from the ophthalmic division of the trigeminal in the anterior part of the cavernous sinus. It passes through the superior orbital fissure and enters the orbital cavity, between the two heads of the lateral rectus muscle and between the two divisions of the third nerve. It then inclines antero-medially, and, crossing the optic nerve obliquely, it runs between the medial rectus and superior oblique muscles to the medial wall of the orbit, where it divides into two terminal branches—viz., the infra-trochlear and the anterior ethmoidal nerves. In addition to these it gives off in the orbit the following branches: (1) long root to the ciliary ganglion; (2) long ciliary nerves; (3) posterior ethmoidal nerve.

Radix Longa Ganglii Ciliaris.—This is a very slender filament which springs from the naso-ciliary as it enters the orbit between the heads of the lateral rectus. It runs along the lateral side of the optic nerve, and enters the upper and posterior part of the ciliary ganglion.

Nervi Ciliares Longi.—The two long ciliary branches spring from the naso-ciliary as it crosses the optic nerve. They pass anteriorly, upon the medial side of the optic nerve, to reach the globe of the eye where they pierce the sclera. One of the long ciliary nerves very constantly unites with one of the short ciliary filaments.

Nervus Ethmoidalis Posterior passes through the posterior ethmoidal foramen to the ethmoidal cells and the sphenoidal air sinus.

Nervus Infratrochlearis.—The infra-trochlear branch runs along the medial wall of the orbit below the superior oblique muscle. After passing under the trochlea of that muscle it emerges from the orbit and appears upon the face, where it has been dissected already (p. 128). Near the pulley it receives a communicating twig from the supra-trochlear nerve.

Nervus Ethmoidalis Anterior.—This is the larger of the two terminal branches of the naso-ciliary nerve. It leaves

the orbit by the anterior ethmoidal canal, and is conducted to the interior of the cranium, in which it appears at the lateral margin of the cribriform plate of the ethmoid. The canal in which it runs can readily be opened up with the bone-forceps to expose the nerve. Upon the cribriform plate it turns anteriorly, under the dura mater, and almost immediately disappears, through a slit-like aperture at the side of the crista galli, into the nasal cavity. There it gives *internal nasal branches* to the mucous membrane, and is continued downwards upon the posterior aspect of the nasal bone. Finally, it emerges upon the face, as the *external nasal nerve*, by passing between the lower margin of the nasal bone and the lateral cartilage of the nose. Its terminal filaments have been described already (p. 140).

Ganglion Ciliare (Fig. 138).—The ciliary ganglion is a small quadrangular body, not much larger than the head of a large pin. It is placed in the posterior part of the orbit, between the optic nerve and the lateral rectus muscle, and very commonly on the lateral side of the ophthalmic artery. At its posterior border it receives its three roots; whilst from its anterior border the short ciliary nerves are given off.

The *sensory root* comes from the naso-ciliary, and is called the *long root*. The *short* or *motor root* is a short, stout trunk; it comes from the branch of the oculo-motor nerve which goes to the inferior oblique muscle. The *sympathetic root* comes from the internal carotid plexus, it joins the ganglion, close to the entrance of the long root from the naso-ciliary nerve. In some cases it joins the long root before it reaches the ganglion.

Nervi Ciliares Breves.—The short ciliary nerves are from four to six in number. They come off in two groups, superior and inferior. The lower nerves are generally more numerous than the upper. As these fine nerves pass along the optic nerve they divide and thus increase in number; at the back of the eyeball from twelve to eighteen may be counted. Finally they pierce the sclera by a series of apertures which are placed around the entrance of the optic nerve.

Arteria Ophthalmica.—The ophthalmic artery is a branch of the internal carotid. It accompanies the optic nerve into the orbit through the optic foramen. At first it lies below the optic nerve, but soon winds round its lateral side, and, crossing above it, passes anteriorly along the medial

wall of the orbit, below the superior oblique muscle. At the medial side of the orbit it ends by dividing into two terminal branches—viz., the frontal and the dorsal nasal (Fig. 136).

The *branches* of the ophthalmic artery are very numerous, and they can seldom be satisfactorily displayed, unless a special injection has been made. They are:—

- | | | |
|-------------------------------|-------------------|------------------|
| 1. Lacrimal. | 4. Ciliary. | 7. Palpebral. |
| 2. Muscular. | 5. Supra-orbital. | 8. Dorsal nasal. |
| 3. Arteria centralis retinae. | 6. Ethmoidal. | 9. Frontal. |

Arteria Lacrimalis.—The lacrimal branch accompanies the lacrimal nerve, and supplies the gland of that name and

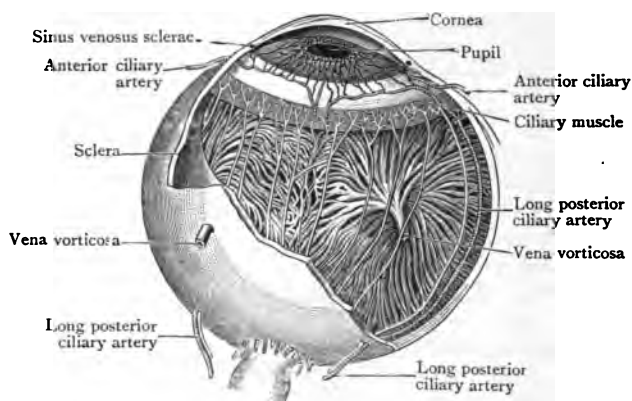


FIG. 135.—Dissection of the Eyeball showing the Arrangement of the Ciliary Nerves and Vessels.

the conjunctiva. In each eyelid an arterial arch, the *arcus tarseus*, is formed by the anastomoses of the two lateral palpebral branches of the lacrimal with the two medial palpebral branches of the ophthalmic.

Rami Musculares come off at variable points, not only from the main artery, but also from certain of its branches. They supply the muscles contained in the orbital cavity.

The *Arteria Centralis Retinae* is a minute but important artery. It pierces the infero-medial surface of the optic nerve, about half an inch posterior to the eyeball, and passes, in its substance, to the interior of the globe of the eye.

Arteriae Ciliares are very numerous. Two groups are

recognised—viz., a posterior and an anterior. The *posterior ciliary arteries* run with the ciliary nerves. They arise as two trunks which spring from the ophthalmic whilst it lies below the optic nerve. These divide into several slender branches, which pierce the sclera around the entrance of the optic nerve. Two members of this group of vessels enter the eyeball on either side of the optic nerve, somewhat

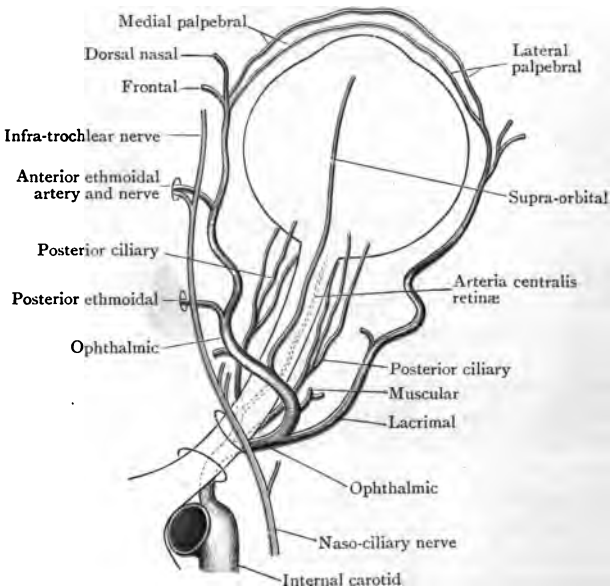


FIG. 136.—Diagram of the Ophthalmic Artery and its Branches. (After Quain and Meyer, modified.)

apart from the others. They are termed *arteriæ ciliares posteriores longæ* (Fig. 135). The *arteriæ ciliares anteriores* come off, in the anterior part of the orbit, from the lacrimal and muscular branches. They vary in number from six to eight, and run to the anterior part of the eyeball, where they form an arterial circle under the conjunctiva. Finally, they pierce the sclera immediately posterior to the cornea.

Arteria Supraorbitalis.—This accompanies the supra-orbital nerve to the forehead, where it was dissected at a previous stage (p. 157).

Arteriæ Ethmoidales.—There are two ethmoidal branches, an anterior and a posterior; they pass through the anterior and posterior ethmoidal foramina on the medial wall of the orbit. The *arteria ethmoidalis posterior* supplies the mucous lining of the posterior ethmoidal cells, and sends twigs to the upper part of the nose. The *arteria ethmoidalis anterior* is a larger branch. It runs in company with the anterior ethmoidal nerve, and gives off minute twigs at each stage of its course. Thus in the anterior ethmoidal foramen it gives branches to the mucous lining of the anterior ethmoidal cells and the frontal sinus; during its short sojourn in the cranial cavity it gives off a small *arteria meningea anterior*; in the nasal cavity it gives twigs to the mucous membrane. Its terminal branch appears on the face and supplies the side of the nose.

Arteria Dorsalis Nasi.—The dorsal artery of the nose is distributed at the root of the nose, and anastomoses with the angular branch of the external maxillary artery.

Arteria Frontalis.—This accompanies the supra-trochlear nerve to the forehead, where it has been dissected already (p. 157).

Venæ Ophthalmicæ.—As a general rule there are two ophthalmic veins, superior and inferior. The *superior ophthalmic vein* is the larger of the two and it accompanies the artery. It takes origin at the root of the nose, where it communicates with the angular vein. The *inferior ophthalmic vein* lies below the level of the optic nerve, and it is brought into communication with the pterygoid venous plexus by an offset which passes through the inferior orbital fissure. The two ophthalmic veins receive numerous tributaries during their course through the orbit; finally they pass between the two heads of the lateral rectus muscle, and through the superior orbital fissure to open into the cavernous sinus, either separately or by a common trunk.

Musculi Recti Oculi.—The four straight muscles of the eyeball diverge from the apex of the orbit. They form the sides of a four-sided or pyramidal space in which are enclosed the optic nerve and the greater part of the globe of the eye. The *rectus superior*, which has been reflected, has been studied already. The *rectus medialis* springs from the medial side of the optic foramen, and the *rectus inferior* takes origin from a fibrous band which bounds the medial end of the

superior orbital fissure. The *rectus lateralis* is distinguished from the others by arising from a fibrous arch, the extremities of which are termed its two heads of origin. The *lower head* arises in common with the rectus inferior from the body of the sphenoid, where this bounds the medial end of the superior orbital fissure; the *upper head* is attached above the superior orbital fissure upon the lateral side of the optic foramen, where its origin becomes continuous with the superior rectus. Through the archway which intervenes between the two heads of the lateral rectus pass the two

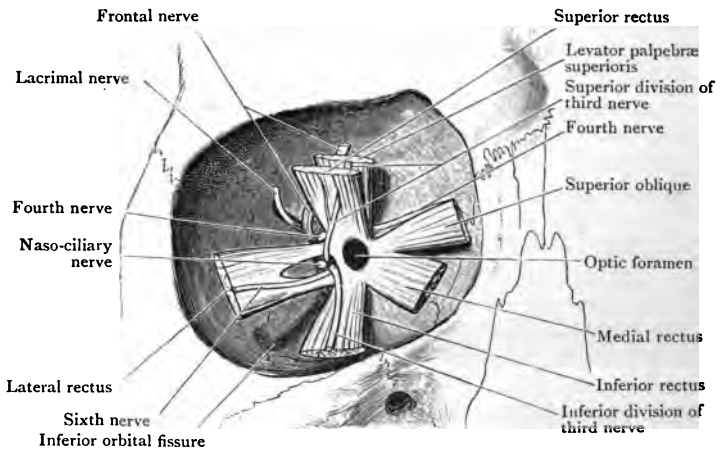


FIG. 137.—Diagram of the Orbital Cavity, and of the origin of the ocular muscles in relation to the optic foramen and the superior orbital fissure, and the nerves that traverse the latter.

divisions of the oculo-motor nerve, the naso-ciliary nerve, the abducent nerve, and the ophthalmic veins (Fig. 137).

A better view of these attachments may be obtained by dividing the optic nerve close to the optic foramen and turning the eyeball anteriorly.

The manner in which the recti muscles are inserted into the eyeball should next be studied. Each ends in a delicate membranous tendon, which is inserted into the sclera, about a quarter of an inch posterior to the sclero-corneal junction.

Nervus Oculomotorius.—The two divisions of this nerve enter the orbit through the superior orbital fissure, between the two heads of the lateral rectus. The *superior division* has

been traced to the rectus superior and the levator palpebræ superioris. The *inferior division* is larger. It almost immediately divides into three branches for the supply of the rectus medialis, the rectus inferior, and the obliquus inferior. The nerves to the two recti enter the ocular surfaces of the muscles; the nerve to the inferior oblique is prolonged anteriorly, in the interval between the rectus inferior and rectus lateralis, and enters the posterior border of the inferior oblique muscle. Soon after its origin this branch gives the *short motor root* to the ciliary ganglion.

Nervus Abducens.—The sixth nerve will be found closely applied to the ocular surface of the lateral rectus. It enters the orbit through the narrow interval between the heads of lateral rectus muscle and it supplies this muscle only.

Arrangement of the Nerves in the Superior Orbital Fissure.—When the orbit is dissected, and the various nerves met with in the dissection of the cavernous sinus are traced into the cavity, the dissector will note that the arrangement of the nerves in the superior orbital fissure is somewhat different from that in the sinus.

The lacrimal, frontal, and trochlear nerves enter the orbit above the muscles on very much the same plane (Fig. 137). The other nerves enter between the heads of the lateral rectus. Of these the superior division of the oculo-motor nerve is the highest, next comes the naso-ciliary nerve, then the inferior division of the oculo-motor nerve, and the abducent nerve occupies the lowest level.

Dissection.—The inferior oblique muscle is placed very differently from the other muscles of the orbit. It is situated below the eyeball, running below its inferior surface to gain its lateral surface. It must be dissected from the front. It is necessary, therefore, to restore the eyeball to its natural place. Next, evert the lower eyelid and remove the conjunctiva from its deep surface as it is reflected on to the globe of the eye. A little dissection in the floor of the anterior part of the orbit and the removal of some fat will reveal the inferior oblique muscle.

Musculus Obliquus Inferior.—This muscle arises from a small depression on the orbital surface of the maxilla, immediately lateral to the opening of the naso-lacrimal duct. It passes laterally, below the inferior rectus muscle, and, inclining slightly posteriorly, ends in a thin membranous tendon, which gains insertion into the lateral aspect of the sclera of the eyeball under cover of the rectus lateralis. The insertion is not far from that of the superior oblique, but

is placed more posteriorly. It is supplied by the *inferior division* of the *third nerve*.

Fascia Bulbi (O.T. Capsule of Tenon).—The connections of the fibrous sheath of the eyeball are somewhat complicated, and they cannot be satisfactorily displayed, in every detail, in an ordinary dissection. The fascia may be studied

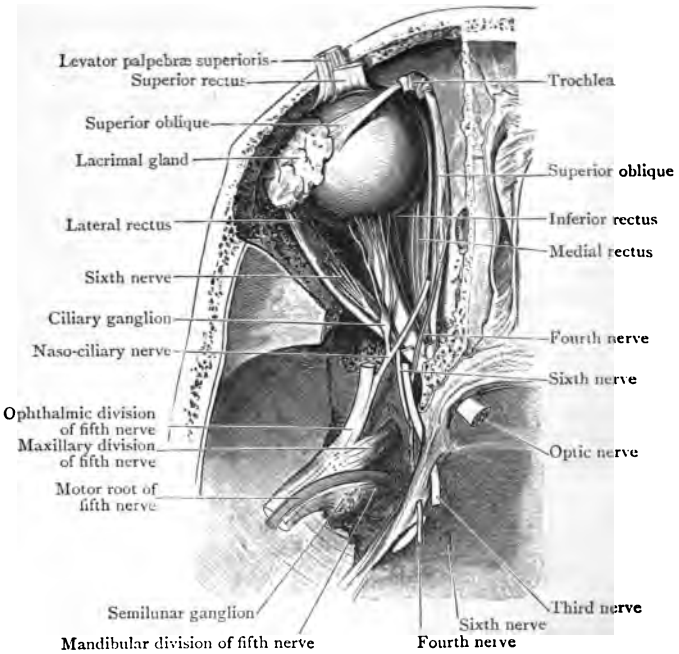


FIG. 138.—Dissection of the Orbit and the Middle Cranial Fossa. Both roots of the fifth nerve with the semilunar ganglion are turned laterally.

from a threefold point of view—(1) in its connection with the eyeball; (2) in its connections with the muscles inserted into the globe of the eye; and (3) in its connections with the walls of the orbit.

The relation which the fascia bulbi bears to the eyeball is very simple. The membrane is spread over the posterior five-sixths of the globe—the cornea alone being free from it. *Anteriorly*, it lies in relation with the ocular conjunctiva, with which it is in connection, and it ends by blending

with the conjunctiva close to the margin of the cornea. *Posteriorly*, it fuses with the sheath of the optic nerve where the nerve pierces the sclera. The internal surface of the membrane (*i.e.* the surface towards the globe of the eye) is smooth, and is connected to the eyeball by some soft yielding and humid areolar tissue, the interval between them constituting, in fact, an extensive lymph space called the *spatium interfasciale*. Its external surface is in contact posteriorly with the orbital fat, to which it is loosely adherent; and it is firmly attached to the ocular conjunctiva more anteriorly. It obviously, therefore, forms a membranous socket in which the eyeball can glide with the greatest freedom.

The tendons of the various ocular muscles are inserted into the eyeball within this fascia, and they gain its interior by piercing the membrane opposite the equator of the globe (Fig. 139). The lips of the openings through which the four recti muscles pass are prolonged posteriorly upon the muscles, in the form of sheaths, very much in the same manner that the infundibuliform fascia is prolonged upon the spermatic cord from the abdominal inguinal ring. These sheaths gradually become more and more attenuated, until at last they blend with the perimysium of the muscular bellies. In the case of the superior oblique muscle the corresponding prolongation is related only to its reflected portion; when it reaches the pulley it ends, by becoming attached to its margins. The sheath of the inferior oblique may be traced upon the muscle as far as the floor of the orbit. The medial or ocular edge of each of the four apertures through which the recti muscles pass is strengthened by a slip of fibrous tissue (Lockwood), and as the fascia bulbi is firmly bound to the bony wall of the orbit at various points these slips act as pulleys, and protect the globe of the eye from pressure during contraction of the muscles. The aperture for the superior oblique is not furnished with such a slip, and it is doubtful if the opening for the inferior oblique muscle possesses one.

Dissection.—An admirable view of the relations which the fascia bulbi presents to the eyeball and the tendons of the ocular muscles can be obtained by the following dissection:—Divide the lateral commissure of the eyelid to the margin of the orbital opening. Pull the eyelids widely apart, so as to expose as much as possible of the anterior face of the eyeball. Next divide the conjunctiva by a circular incision just beyond the cornea. At this point the fascia bulbi is so intimately connected with the conjunctiva that it is divided at the same time. Now raise care-

fully both conjunctiva and fascia bulbi from the surface of the eyeball, and spread them out round the orbital opening, as is depicted in Fig. 139. The openings in the fascia bulbi for the tendons of the ocular muscles and the thickened margins of these apertures are well seen. Note also the sheaths which are given to the muscles.

Check and Suspensory Ligaments.—The connections of the fascia bulbi to the walls of the orbital cavity are somewhat complicated. The *suspensory ligament* (Lockwood) plays an important part in this respect. It stretches across the anterior part of the orbit, after the fashion of a hammock, and gives support to the eyeball. Its two extremities are

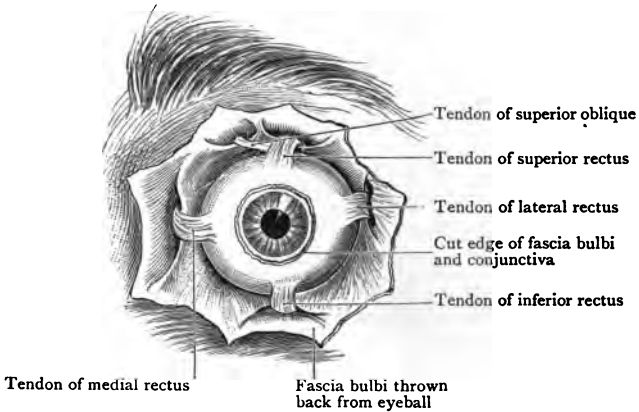


FIG. 139.—Dissection of the Fascia Bulbi from the front.

narrow, and are attached respectively to the zygomatic and lacrimal bones. Below the eyeball it widens out and blends with the fascia bulbi. The *lateral* and *medial check ligaments* also constitute bonds of union between the fascia bulbi and the orbital wall. They are strong bands which pass from the sheaths around the lateral and medial recti muscles to obtain attachment to the zygomatic and lacrimal bones respectively, where they are brought into association with the extremities of the suspensory ligament. The function of the check ligaments is to limit the contraction of the medial and lateral recti muscles, and thus prevent excessive rotation of the eyeball in a lateral or medial direction. There is a similar but less direct provision by means of which the action of the superior and inferior recti muscles is limited.

The action of the former muscle is checked through an intimate connection with the levator palpebræ superioris in the anterior part of the orbit; the action of the inferior rectus is checked through a connection with the suspensory ligament.

Dissection.—In order that the zygomatic branch of the maxillary division of the trigeminal nerve may be displayed in its course through the orbit, the orbital contents must be removed. The nerve will then be found in the midst of a little soft fat in the angle between the floor and lateral wall of the orbit.

Nervus Zygomaticus (O.T. Temporo-Malar).—This small nerve arises, in the infra-temporal fossa, from the maxillary division of the trigeminal nerve. It enters the orbit by passing through the inferior orbital fissure and almost immediately divides into two terminal branches—the zygomatico-temporal and the zygomatico-facial.

Ramus Zygomaticotemporalis.—This branch runs antero-superiorly upon the lateral wall of the orbit, under cover of the periosteum, and, after receiving a communicating twig from the lacrimal nerve, it enters the zygomatico-orbital canal of the zygomatic bone. This conducts it to the anterior part of the temporal region, where it has been examined already (pp. 155 and 156).

Ramus Zygomaticofacialis.—The zygomatico-facial branch also enters a zygomatico-orbital canal, and is finally conducted to the face by the zygomatico-facial canal which traverses the zygomatic bone (p. 127).

PREVERTEBRAL REGION.

The following are the structures to be displayed in this dissection:—

Prevertebral muscles.	Vertebral vein.
Intertransverse muscles.	Vertebral and cranio-vertebral
Cervical nerves.	articularions.
Vertebral artery.	

Dissection.—To separate the anterior part of the head with the pharynx from the posterior part and the vertebral column a somewhat complicated dissection is necessary. Place the head upside down, so that the cut margin of the skull rests upon the table; divide the common carotid artery, the internal jugular vein, the vagus nerve, and the sympathetic trunk, on each side, at the level of the neck of the first rib; pull the trachea and œsophagus, together with the great blood vessels and nerves, away from the anterior surface of the vertebral column. The separation must

be effected right up to the base of the skull. At this point great caution must be observed, otherwise the pharyngeal wall or the insertions of the prevertebral muscles will be damaged. The base of the skull having been reached, the point of the knife should be carried across the basilar portion of the occipital bone, between the pharynx and the prevertebral muscles, to divide the thick investing periosteum.

The basilar portion of the occipital bone must now be divided by means of a chisel. Still retaining the part upside down, place the skull so that its floor rests upon the end of a wooden block. Then apply the edge of the chisel to the under surface of the basilar portion of the occipital bone, adjust it accurately in the interval between the pharyngeal wall and the prevertebral muscles, and with a wooden mallet drive it through the base of the skull, inclining it, at the same time, slightly posteriorly.

The next step in the dissection consists in making two saw-cuts through the cranial wall. The head having been placed upon its side, the saw must be applied to the lateral aspect of the skull, half an inch posterior to the mastoid process, and be carried obliquely antero-medially to reach a point immediately posterior to the jugular foramen. A similar saw-cut must be made upon the opposite side of the head.

To complete the dissection the dissector must again have recourse to the chisel. Placing the preparation so that the floor of the cranium looks upwards, divide the base of the skull, on each side, in the interval between the petrous portion of the temporal bone and the basilar portion of the occipital bone. Anteriorly, this cut should reach the lateral extremity of the incision already made through the basilar portion; whilst posteriorly, it should be carried to the medial side of the jugular foramen to reach the medial end of the saw-cut. When this has been done upon both sides of the basilar portion, the anterior part of the skull carrying the pharynx and the great blood-vessels and nerves can be separated from the posterior part of the skull and cervical portion of the vertebral column. The only large nerve which will be divided is the hypoglossal, but, as it is cut close to the basis cranii, and above its connection with the ganglion nodosum of the vagus, it retains its position.

The pharynx and anterior portion of the skull should now be covered with a piece of cloth soaked in preservative solution, and the whole enveloped in an oil-cloth wrapper. It can then be laid aside until the dissection of the prevertebral region and the ligaments of the cervical vertebræ and the occiput have been completed.

Returning to the posterior part of the skull and the cervical portion of the vertebral column, the dissector should proceed to define the attachments of the muscles which lie anterior to the transverse processes and the bodies of the vertebræ. These are three in number on each side, viz. :—

1. The longus colli.
2. The longus capitis (O.T. rectus capitis anticus major).
3. The rectus capitis anterior (O.T. anticus minor).

Musculus Longus Colli.—This is the most powerful of the prevertebral muscles, and it lies nearest to the median plane. Its connections are somewhat intricate, but when it has been thoroughly cleaned it will be seen to consist of three portions—viz., upper and lower oblique parts, and an intermediate vertical part.

The *lower oblique* division arises from the lateral aspect of the bodies of

the upper two or three thoracic vertebrae. It extends upwards, and slightly laterally, and ends in two tendinous slips which are inserted into the anterior tubercles of the transverse processes of the fifth and sixth cervical vertebrae. In the interval between this portion of the longus colli and the *scolenus anterior*, the vertebral artery will be seen. The upper *oblique* part arises by

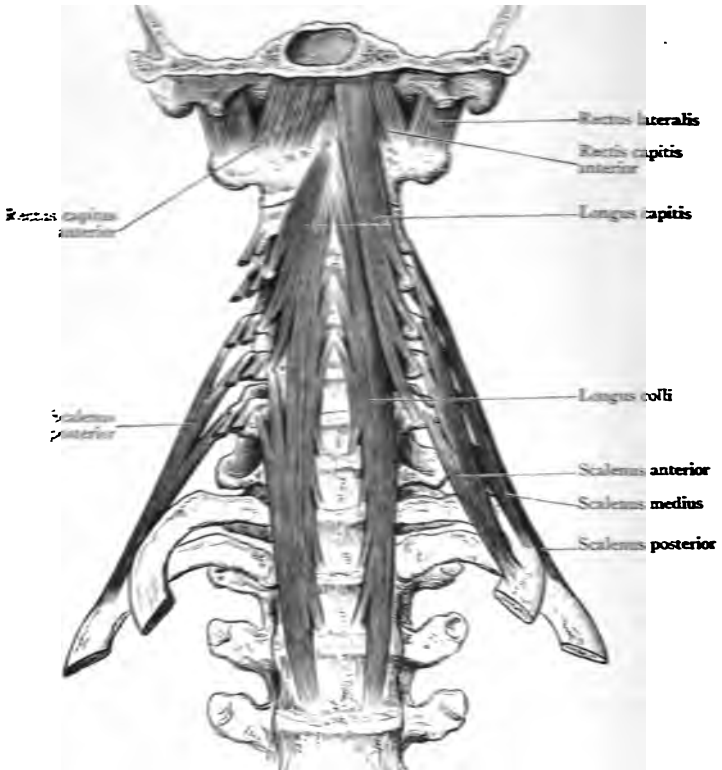


FIG. 140. — Prevertebral Muscles of the Neck. On the right side the longus capitis has been removed. (Paterson.)

three tendinous slips from the anterior tubercles of the transverse processes of the third, fourth, and fifth cervical vertebrae; it tapers somewhat as it proceeds upwards and medially to obtain a pointed and tendinous insertion into the anterior tubercle of the atlas. The *vertical part* of the muscle is much the largest of the three divisions. It lies along the medial side of the *oblique portions*, and is intimately connected with both of them. It arises in common with the inferior oblique part by two or three slips from the sides of the bodies of the upper two or three thoracic vertebrae; above

this it derives additional slips of origin from the bodies of the lower cervical vertebrae: lastly, its lateral border is reinforced by slips from the transverse processes of the lower three or four cervical vertebrae. It stretches vertically upwards, and is inserted upon the medial side of the upper oblique part of the muscle by three tendinous processes, which obtain attachment to the bodies of the second, third, and fourth cervical vertebrae.

Longus Capitis (L. **Rectus Capitis Anticus Major**).—The long capitis is an elongated muscle which arises by four tendinous slips from the anterior tubercles of the transverse processes of the third, fourth, fifth, and sixth cervical vertebrae. It is inserted anteriorly to the lesser occipital, upon the under aspect of the oblique part of the upper oblique part. To reach this insertion the muscle inclines slightly medially and downwards upon the anterior aspect of the posterior arch of the atlas, and then runs upwards from the first part of the occipital condyle.

Rectus Capitis Anterior—**Anticus Minor**.—This is a small muscle. It is partly situated on the under aspect of the lesser occipital, and partly should be considered part of the lesser occipital. It arises from the anterior tubercle of the transverse process of the sixth cervical vertebra, and is inserted into the under aspect of the lesser occipital. It is a long muscle, and is situated in the neck.

Before proceeding further to the study of the muscles of the neck, the attachment of the greater occipital must be noted.

Greater Occipital.—This is a long muscle which arises from the greater occipital foramen of the sixth cervical vertebra, and is inserted into the under aspect of the greater occipital. It is a long muscle, and is situated in the neck.

Spinal Accessory.—This is a long muscle which arises from the transverse process of the sixth cervical vertebra, and is inserted into the under aspect of the greater occipital. It is a long muscle, and is situated in the neck.

The spinal accessory nerve runs over the greater occipital, and is situated in the neck.

Sternocleidomastoid.—This is a long muscle which arises from the sternum and clavicle, and is inserted into the mastoid process of the temporal bone.

the inferior oblique, and the superior oblique. The anterior tubercles and the costal portions of the transverse processes of the third, fourth, fifth, and sixth cervical vertebræ should then be snipped off with the bone forceps.

Arteria Vertebralis.—This is an artery of great importance, for, together with its fellow of the opposite side and the basilar artery, which is formed by their union, it supplies the hind-brain, the mid-brain, and the posterior parts of the cerebral hemispheres, and it helps to supply the spinal medulla. It

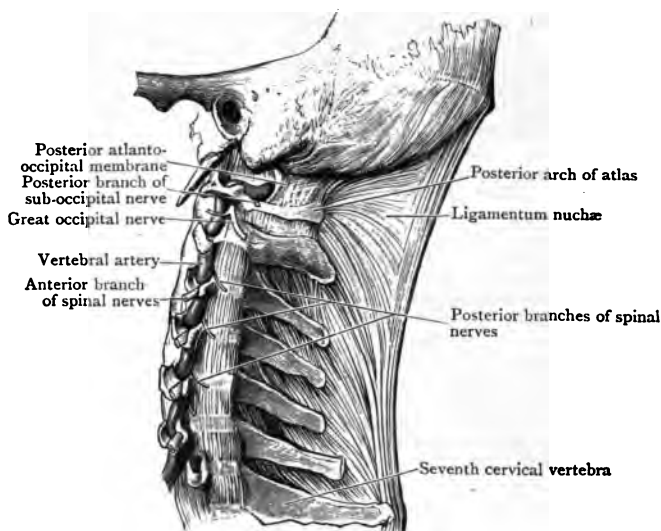


FIG. 141.—Dissection of the Ligamentum Nuchæ and of the Vertebral Artery in the Neck.

commences at the root of the neck, as a branch of the first part of the subclavian artery, and it runs upwards, through the transverse processes of the cervical vertebræ, to the base of the skull. It enters the skull through the foramen magnum and unites in the posterior fossa of the cranium, at the lower border of the pons, with its fellow of the opposite side to form the basilar artery. On account of its varying relations it is divided into four parts. The first part, which extends from the subclavian artery to the transverse process of the sixth cervical vertebra, has been seen already (p. 251). It lies between the longus colli medially, the scalenus anterior

laterally, the transverse process of the seventh cervical vertebra and the inferior cervical ganglion of the sympathetic posteriorly, and the vertebral vein and the common carotid artery anteriorly.

The second part, now exposed, commences where the artery enters the transverse process of the sixth cervical vertebra. It passes vertically upwards, through the series of foramina transversaria, till it reaches the foramen in the transverse process of the epistropheus. In that it runs laterally as well as upwards to gain the foramen in the more laterally placed transverse process of the atlas; and, as it emerges upon the upper aspect of the atlas, the third part commences and curves round the lateral and posterior aspects of the upper articular process of that bone, in a groove upon the upper surface of the posterior arch. As soon as it has passed under cover of the lateral margin of the posterior atlanto-occipital membrane it becomes the fourth part. The fourth part turns upwards, pierces the dura mater and passes into the skull through the foramen magnum, anterior to the uppermost digitation of the ligamentum denticulatum; then, turning antero-medially, between the hypoglossal nerve above and the first cervical nerve below, it passes to the anterior surface of the medulla oblongata, and, as already stated, joins its fellow of the opposite side at the lower border of the pons.

Relations.—The relations of the first part have already been sufficiently considered. The second part lies in and between the transverse processes of the cervical vertebræ, medial to the intertransverse muscles, lateral to the bodies of the vertebræ, and anterior to the anterior branches of the cervical nerves as they pass laterally. It is surrounded not only by the sympathetic nerve plexus derived from the inferior cervical ganglion, which accompanies all parts of the artery, but also by a venous plexus which terminates below in the vertebral vein or veins. The third part of the artery lies on the posterior arch of the atlas in the anterior boundary of the sub-occipital triangle. As it turns posteriorly from the foramen in the transverse process of the atlas the anterior branch of the first cervical nerve lies to its medial side, between it and the lateral mass of that bone; and, as it turns medially, posterior to the upper articular facet, the trunk of the first cervical nerve lies below it on the posterior arch, and

the posterior branch enters the triangle from beneath its lower border. For the relations of the fourth part see above and p. 443.

Branches.—No branch of importance is given off from the first part. The second part gives off lateral spinal (p. 193) and muscular branches. The branches from the third part are muscular twigs, and branches to anastomose with twigs from the occipital and the deep cervical arteries. The fourth part gives off a meningeal branch before it perforates the dura mater and, afterwards, a series of branches to the central nervous system (see pp. 443, 444).

Vena Vertebralis.—Only the first part of the vertebral artery is accompanied by a definite vertebral vein. There are no accompanying veins with the fourth part of the artery, but a plexus is formed round the commencement of the third part, by the union of tributaries from the venous plexus in the vertebral canal and from the plexus of veins in the sub-occipital triangle. This plexus accompanies the second part of the artery through the transverse processes of the cervical vertebræ; it anastomoses with the venous plexuses in the vertebral canal; and it terminates below in one or two vertebral veins; these accompany the first part of the artery and end in the posterior aspect of the commencement of the innominate vein.

Dissection.—The muscles must now be completely removed, in order that the vertebral and cranio-vertebral joints, and the ligaments in connection with the cervical portion of the vertebral column may be examined.

THE JOINTS OF THE NECK.

The epistropheus, atlas, and occipital bone present a series of articulations in which the uniting apparatus is very different from that of the vertebræ below.

Articulations of the Lower Five Cervical Vertebræ.—The lower five cervical vertebræ are united together very much upon the same plan as the vertebræ in other regions of the vertebral column. Both the bodies and the vertebral arches are connected by distinct articulations and special ligaments.

Three separate joints may be said to exist between the opposed surfaces of the *bodies* of two adjacent cervical vertebræ—viz., a central synchondrosis and two small lateral diarthrodial joints.

The *synchondrosis* occupies by far the greatest part of the interval between the vertebral bodies, and it presents the usual characters of such an articulation. The opposed bony surfaces are coated with a thin layer of hyaline or encrusting cartilage, and are brought into direct union by an interposed disc of fibro-cartilage. The intervertebral fibro-cartilages are distinctly deeper anteriorly than posteriorly, and upon this circumstance the cervical curvature of the column in great measure depends.

The two *diarthrodial joints* are placed one on each side where the disc of fibro-cartilage is absent. They are of small extent, and are confined entirely to the intervals between the projecting lateral lips of the upper surface of the body

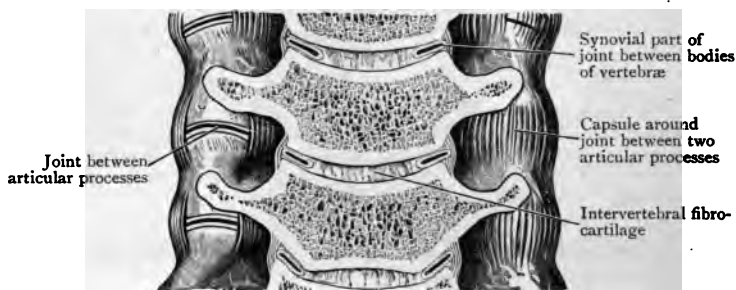


FIG. 142.—Frontal section through bodies of certain of the Cervical Vertebrae.

and the bevelled-off lateral margins of the lower surface of the vertebral body immediately above. The bony surfaces are coated with encrusting cartilage, and are separated by a synovial cavity protected by a feeble capsular ligament.

The *ligaments* which bind the bodies of the lower five cervical vertebrae together are the direct continuation upwards of the anterior and the posterior longitudinal ligaments of the vertebrae. When the medulla spinalis was removed, the laminæ of the vertebrae, below the epistropheus, were taken away so that very little dissection will be required to make out the connections of both of these ligaments. The *anterior longitudinal ligament* is a strong band placed on the anterior faces of the vertebral bodies. It is more firmly fixed to the intervening intervertebral fibro-cartilages than to the bones. The *posterior longitudinal ligament*, which lies on

the posterior aspects of the vertebral bodies, constitutes the anterior boundary of the vertebral canal. In the cervical region it completely covers the bodies and does not present the denticulated appearance which is so characteristic lower down. It is attached chiefly to the fibro-cartilages and the adjacent margins of the bones.

The *vertebral arches* of the lower five cervical vertebræ are bound together by (*a*) the articulations between the articular processes; (*b*) ligamenta flava; (*c*) interspinous ligaments; and (*d*) intertransverse ligaments; (*e*) ligamentum nuchæ.

The *joints* between the opposing articular processes are of the diarthrodial variety. The surfaces of bone are coated with cartilage; there is a joint cavity surrounded by a distinct capsular ligament lined with a stratum synoviale. This ligament is more laxly arranged in the neck than in the lower regions of the vertebral column.

The *ligamenta flava* may be examined on the laminæ which were removed for the display of the spinal medulla, and which the dissector was directed to retain. They fill up the gaps between the laminæ of the vertebræ, and can be best seen when the anterior aspect of the specimen is viewed.

Ligamenta Flava.—These ligaments are composed of yellow elastic tissue. Each is attached superiorly to the anterior surface and inferior margin of the lamina of the vertebra above, whilst inferiorly it is fixed to the posterior surface and superior margin of the lamina of the vertebra next below. In this way they form with the laminæ a smooth, even, posterior wall for the vertebral canal. Each ligament extends from the posterior part of the articular processes to the median plane, where its free thickened median border is in contact with its fellow of the opposite side. The median slit between them, in the space between each pair of vertebral arches, is filled with some lax connective tissue, which allows the egress from the vertebral canal of some small veins. The width of the ligaments in the different regions of the vertebral column depends upon the size of the vertebral canal. Therefore they are widest in the neck and in the lumbar part of the column. The ligamenta flava, by virtue of their great strength and elasticity, are powerful agents in maintaining the curvatures of the vertebral column; they also give valuable aid to the muscles in restoring the

vertebral column to its original position after it has been bent in a ventral direction.

The *interspinous ligaments* are most strongly developed in the lumbar region, where they fill up the intervals between the adjacent margins of contiguous spinous processes. In the thoracic region, and more so in the neck, they are very weak.

The *supraspinous ligaments* are thickened bands which connect the summits of the spinous processes. In the neck they are replaced by the ligamentum nuchæ (p. 172).

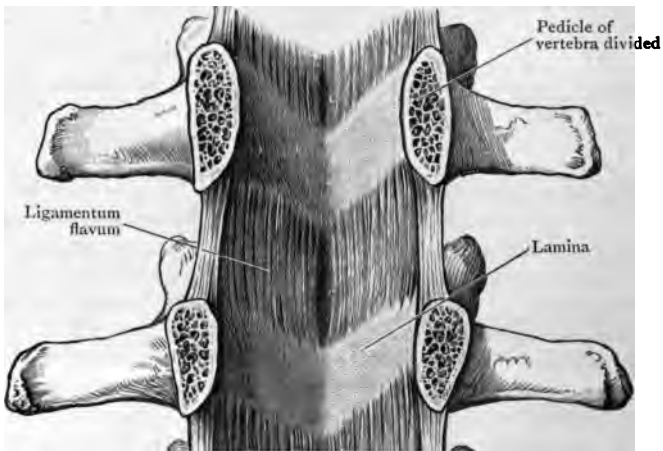


FIG. 143.—The Ligamenta Flava in the Lumbar Region of the Spine.

The *intertransverse ligaments* are feebly marked in the cervical region and extend chiefly between the anterior bars of the transverse processes.

Articulations of the Epistropheus, Atlas, and Occipital Bone.—The articulations which exist between these three bones all belong to the diarthrodial class. Between the atlas and epistropheus (O.T. axis) there are three such joints—viz., a pair between the opposed articular processes, and a third between the anterior face of the dens and the posterior face of the anterior arch of the atlas. Between the atlas and occipital bone there is a pair of joints—viz., between the occipital condyles and the elliptical cavities upon the upper aspects of the lateral masses of the atlas.

The ligaments connecting these three bones together may be divided into three main groups, as follows:—

Ligaments connecting atlas with epistropheus, . . .	{	Anterior longitudinal. Ligamenta flava. Capsular. Transverse portion of cruciate ligament with inferior crus. Accessory ligaments of the atlanto-epistropheal joints.
Ligaments connecting occipital bone with atlas, . . .	{	Anterior longitudinal ligament. Anterior occipito-atlantal membrane. Posterior occipito-atlantal membrane. Transverse part of cruciate ligament with superior crus.
Ligaments connecting occipital bone with epistropheus,	{	Capsular. Membrana tectoria. Superior and inferior crura of the cruciate ligament. Alar. Apical.

Anterior Longitudinal Ligament (Fig. 144).—This is a continuation upwards of the common anterior longitudinal ligament. Below, it is attached to the anterior aspect of the body of the epistropheus, whilst above, it is fixed to the anterior arch of the atlas. It is thick and strong in the middle, but thins off towards the sides.

Ligamenta Flava.—These fill the interval between the laminae of the epistropheus and the posterior arch of the atlas, to the contiguous margins of which they are attached. They are broader and more membranous than the ligamenta flava at lower levels.

Capsulae Articulares.—These are somewhat lax, and are attached to the margins of the articular processes.

Membrana Atlanto-Occipitalis Anterior (Fig. 144).—This membrane extends from the upper border of the anterior arch of the atlas to the under surface of the basilar portion of the occipital bone, anterior to the foramen magnum. On each side of the median plane it is thin and membranous, and stretches laterally so as to abut against the atlanto-occipital capsular ligament. In the median plane it is strengthened by the upper part of the anterior longitudinal ligament.

Membrana Atlanto-Occipitalis Posterior.—This is a thin and weak membrane which occupies the gap between the posterior arch of the atlas and the posterior border of the foramen magnum, to both of which it is attached. It is very firmly

connected with the dura mater, and on each side it reaches the atlanto-occipital capsular ligament. Each of its lateral borders forms an arch over the groove, posterior to the upper articular facet of the atlas, in which the vertebral artery and the first cervical nerve are lodged. It is not uncommon to find these fibrous arches ossified.

Atlanto-Occipital Capsular Ligaments.—These connect the occipital condyles with the lateral masses of the atlas.

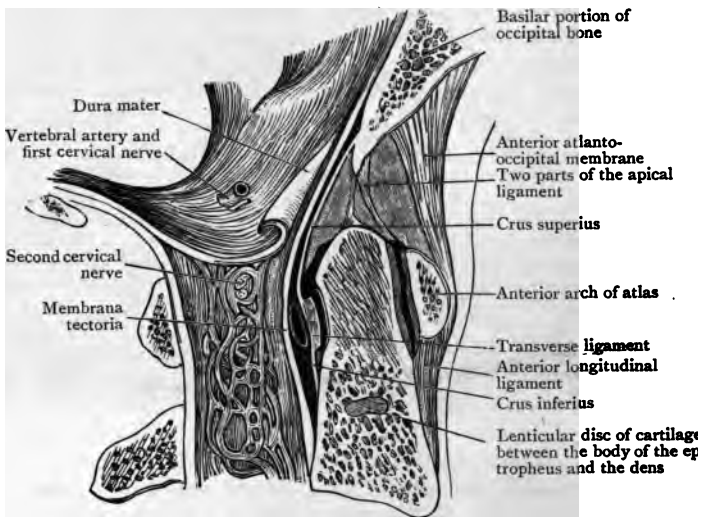


FIG. 144.—Median section through the Basilar Portion of Occipital Bone, the Atlas, and the Epistropheus. (From Luschka, slightly modified.)

Between the membrana tectoria and the transverse ligament a small synovial bursa may be seen.

They completely surround the joints, and are connected anteriorly with the anterior atlanto-occipital membrane, and posteriorly with the posterior atlanto-occipital membrane.

The occipital bone, therefore, around the foramen magnum is attached by special ligaments to each of the four portions of the atlas—viz., to the anterior arch, to the two lateral masses, and to the posterior arch.

Dissection.—The remaining ligaments are placed within the vertebral canal in connection with its anterior wall. For their proper display it

is necessary therefore to remove, with the bone forceps, the laminae of the epistropheus and the posterior arch of the atlas. The squamous part of the occipital bone also must be taken away by sawing it through, on each side, immediately posterior to the jugular process and the condyle, carrying the saw cut into the foramen magnum. The upper part of the tube of dura mater, which still remains in the vertebral canal, must next be carefully detached. A broad membranous band stretching upwards over the posterior aspect of the body and dens of the epistropheus is displayed. This is the membrana tectoria.

The Membrana Tectoria (O.T. Posterior Occipito-axial Ligament).—This is a broad ligamentous sheet which is attached below to the posterior aspect of the body of the epistropheus, where it is continuous with the posterior longitudinal ligament of the vertebræ. It extends upwards, covering the dens and the anterior margin of the foramen magnum, and is attached above to the superior grooved surface of the basilar portion of the occipital bone.

Dissection.—Detach this membrane from the epistropheus and throw it upwards upon the basilar portion of the occipital bone. By this proceeding the accessory ligaments of the atlanto-epistropheal joints and the cruciate ligament are brought into view, and very little further dissection is required to define them.

Accessory Atlanto-epistropheal Ligaments (Fig. 145).—These are two strong bands which take origin from the posterior aspect of the body of the epistropheus close to the base of the dens. Each band passes upwards and laterally, and is attached to the medial and posterior part of the lateral mass of the atlas. To a certain extent they assist the alar ligaments in limiting the rotary movements of the atlas upon the epistropheus.

Ligamentum Cruciatum (Fig. 145).—The cruciate ligament is composed of a transverse and a vertical part. The *ligamentum transversum atlantis* is by far the most important constituent of this apparatus. It is a strong band which stretches from the tubercle on the medial aspect of the lateral mass of the atlas on one side to the corresponding tubercle on the opposite side. With the anterior arch of the atlas it forms a ring which encloses the dens—the pivot around which the atlas bearing the head turns. It is separated from the posterior aspect of the dens by a loose synovial membrane which extends anteriorly on each side until it almost reaches the synovial membrane in connection with the median joint between the dens and the anterior arch of the atlas. Indeed,

in some cases a communication exists between the two synovial cavities.

The *vertical part* of the cruciate ligament consists of an upper and a lower limb, which are termed the crura. Both are attached to the dorsal surface of the transverse ligament. The *crus superius* is the longer and flatter of the two, and extends upwards on the posterior aspect of the dens to be attached to the upper aspect of the basilar part of the occipital bone immediately beyond the anterior margin of

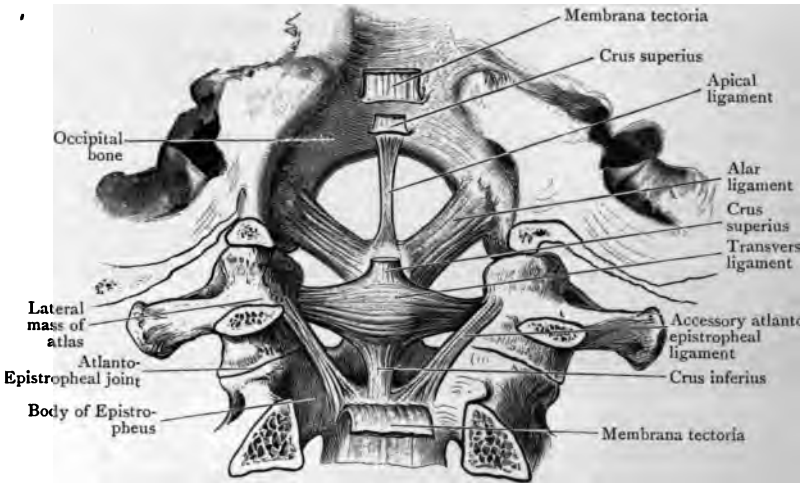


FIG. 145.—Dissection showing the posterior aspects of the Ligaments connecting the Occipital Bone, the Atlas, and the Epistropheus with each other.

the foramen magnum. The *crus inferius*, much shorter, extends downwards, and is fixed to the posterior aspect of the body of the epistropheus.

Dissection.—Detach the superior crus from the occipital bone, and throw it downwards. The apical ligament is thus displayed, and a better view of the alar ligaments is obtained.

Ligamentum Apicis Dentis.—The apical ligament of the dens consists of two parts—an anterior and a posterior. The *posterior part* is a rounded cord-like ligament which is attached below to the summit of the dens, and above to the anterior margin of the foramen magnum. This ligament, inasmuch

as it is developed around the continuation of the chorda dorsalis from the dens to the basis cranii, is a structure of considerable morphological interest. The *anterior part* of the apical ligament is a flat and weak band which is attached above to the anterior margin of the foramen magnum at the same point as the posterior portion. Below, the two portions are separated by an interval filled with cellular tissue, and the anterior part is attached to the dens immediately above its articular facet for the anterior arch of the atlas.

Ligamenta Alaria (Fig. 145).—These are very powerful bands which spring, one from each side of the summit of the dens. They pass laterally and slightly upwards to be attached to the medial aspect of the condyloid eminences of the occipital bone. They limit rotation of the head, and in this they are aided by the accessory atlanto-epistropheal ligaments.

Movements.—Nodding movements of the head are permitted at the atlanto-occipital articulations. Rotatory movements of the head and atlas around the dens, which acts as a pivot, take place at the atlanto-epistropheal joints. Excessive rotation is checked by the alar ligaments.

MOUTH AND PHARYNX.

The dissectors must now return to the anterior part of the skull, which had been laid aside while the dissection of the prevertebral region was being carried on. The mouth and pharynx should engage their attention in the first instance.

Mouth.—The mouth is the expanded upper part of the alimentary canal which is placed in the lower part of the face, below the nasal chambers. Its cavity is controlled by muscles which are under the influence of the will, and it is separable into two parts: a smaller external part, termed *the vestibule*, which is bounded externally by the lips and cheeks, and internally by the teeth and gums; and a large part, the *mouth proper*, which is placed within the teeth.

The mucous lining of the mouth should be thoroughly cleansed, and the two subdivisions of the cavity examined through the *oral fissure*.

Vestibulum Oris.—The *vestibule* of the mouth, which passes round the teeth and gums, is a mere fissure-like space, except when the cheeks are inflated with air. It is into this part of the mouth that the parotid ducts open (p. 261).

Above and below, it is bounded by the reflection of the mucous membrane from the lips and cheeks on to the alveolar margins of the maxilla and mandible. *Anteriorly*, it opens upon the face by means of the oral fissure; whilst *posteriorly*, it communicates, on each side, with the cavity of the mouth proper through the interval between the last molar tooth and the anterior border of the ramus of the mandible. The existence of this communication is of importance in cases of spasmodic closure of the jaws when all the teeth are in place, because through it fluids may be introduced into the posterior part of the mouth proper.

In paralysis of the facial muscles the lips and cheeks fall away from the dental arches and food is apt to lodge in the vestibule.

Cavum Oris Proprium.—The *mouth proper* is bounded anteriorly and laterally by the gums and teeth, whilst posteriorly it communicates by means of the isthmus faucium with the pharynx. The *floor* is formed by the tongue and the mucous membrane which connects it with the inner aspect of the mandible; the roof is vaulted, and is formed by the hard and the soft palates. Into this part of the buccal cavity the ducts of the submaxillary glands and the ducts of the sublingual glands open (p. 288). When the mouth is closed the dorsum of the tongue is usually applied more or less closely to the palate and the cavity is almost completely obliterated.

The various parts which bound the oral cavity may now be examined in turn.

Labia Oris.—The structure of the lips has in a great measure been examined already in the dissection of the face (p. 133). Each lip is composed of four layers: (1) Cutaneous; (2) muscular; (3) glandular; and (4) mucous. The *skin* and *mucous membrane* become continuous with each other at the free margin of the lip. From the inner aspect of the upper lip the mucous membrane is reflected to the alveolar margin of the maxilla and from the inner aspect of the lower lip to the mandible. In each case it is raised in the median plane in the form of a free fold termed the *frenulum*. The *muscular layer* constitutes the chief bulk of the lips. It is formed by the orbicularis oris and the various muscles which converge upon the oral fissure. Numerous *labial glands* lie in the submucous tissue which intervenes between

the mucous membrane and the muscular fibres. The ducts of these glands pierce the mucous membrane and open into the vestibule. In each lip there is an arterial arch formed by the corresponding labial arteries (p. 130).

The lymph vessels of both lips join the submaxillary lymph glands, but some of the lymph vessels of the upper lip pass to the superficial parotid glands.

Buccæ.—Six layers enter into the construction of the cheeks, all of which have been examined in the dissection

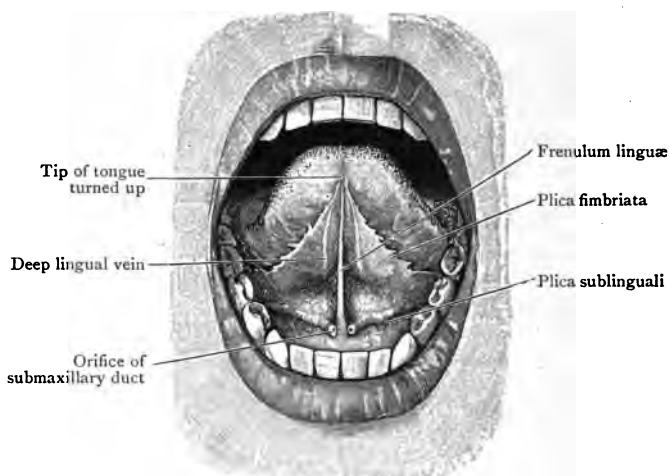


FIG. 146.—The Sublingual Region in the Interior of the Mouth.

of the face—(1) Skin; (2) a fatty layer traversed by some of the facial muscles and the external maxillary artery; (3) the bucco-pharyngeal aponeurosis; (4) the buccinator muscle; (5) numerous *buccal glands*, similar in character to the labial glands, lie in the submucous tissue between the mucous membrane and the buccinator muscle; (6) the mucous membrane. Four or five mucous glands of larger size, termed the *molar glands*, occupy a more superficial position. They lie either external or internal to the bucco-pharyngeal aponeurosis, close to the point where this is pierced by the parotid duct, and their ducts open into the vestibule of the mouth. The *bucco-pharyngeal aponeurosis* is a dense fascia which covers the buccinator muscle. Above and below, it is attached to

the alveolar portions of the maxilla and mandible, whilst posteriorly it is continued over the pharynx. The muscles which traverse the *fatty layer* are chiefly the zygomaticus, the risorius, and the posterior fibres of the platysma. The parotid duct pierces the inner three layers of the cheek, and opens into the vestibule of the mouth opposite the second molar tooth of the maxilla.

Gingivæ et Dentés.—The mucous membrane of the gums is smooth, vascular, and firmly bound down to the subjacent

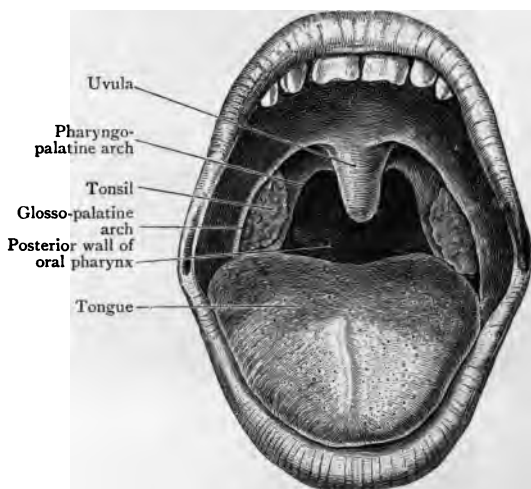


FIG. 147.—Isthmus of the Fauces as seen through the widely opened Mouth. The tonsils in the subject from which this drawing was made were somewhat enlarged.

periosteum of the alveolar portions of the jaws by a stratum of dense connective tissue. It is continuous on the one hand with the mucous membrane of the lips and cheeks, and on the other with the mucous membrane of the mouth proper. The gums closely embrace the necks of the teeth.

In the adult the teeth in each jaw number sixteen. From the median line posteriorly, on each side, they are the two incisors, the canine, the two præmolars, the three molars.

Floor of the Mouth.—The mucous membrane is reflected from the inner aspect of the mandible to the side of the tongue, but in the anterior part of the mouth the tongue lies

is to be made from the normal position and there the mucous membrane of the side of the floor from one side of the hard palate to the other. On the other side in this region the mucous membrane of the sublingual gland, the *plica sublingualis*, and the sublingual folds. Portions of the tongue is pulled up with a retractor. The mucous membrane will be seen to connect to either side of the floor. This is the *frenulum linguae*. On the side of the tongue the dissector must note the openings of the sublingual ducts. Each terminates in a small papilla close to the side of the frenulum. The space between the side of the tongue and the ducts is the summit of the plica sublingualis, or the opening of the sublingual ducts.

Roof of the Mouth.—The hard and the soft palates form the roof of the mouth and vaulted roof of the mouth (Fig. 146). The arch from the middle of the posterior free margin of the soft palate and resting upon the dorsum of the tongue, the uvula will be seen (Fig. 147). Running along the median line of both the hard and the soft palates is a raphe which terminates anteriorly opposite the incisive foramen, in a slight elevation or papilla termed the incisive papilla. In the anterior part of the hard palate the mucous membrane, on each side of the raphe, is thrown into three or four transverse hard corrugations or ridges; more posteriorly it is comparatively smooth. By carefully palpating the postero-lateral angles of the palate the dissector will be able to feel the hamuli of the medial pterygoid laminae.

Isthmus Faucium.—This name is given to the communication between the mouth proper and the pharynx (Fig. 147). To obtain a good view of it the mouth must be well opened and the tongue depressed. The isthmus faucium and the parts which bound it can be examined best in the living subject (Fig. 147). It is bounded above by the soft palate, below by the dorsum of the tongue, and on each side by two curved folds of mucous membrane, termed respectively the arcus glossopalatinus (O.T. anterior pillars of the fauces) and the arcus pharyngopalatinus (O.T. posterior pillars of the fauces).

The arcus palatini spring from the base of the uvula, and arch laterally and then downwards. The arcus glossopalatinus inclines anteriorly as it descends; it ends upon the side of the posterior part of the tongue, and it encloses the glosso-

palatinus muscle. The *arcus pharyngopalatinus*, more strongly marked, inclines posteriorly, and is lost upon the side of the pharynx; it encloses the pharyngo-palatinus muscle.

In the triangular interval which is formed by the divergence of these two folds lies the *tonsil*.

Strictly speaking, the term *isthmus faucium* should be confined to the interval between the two glosso-palatine arches, as the tonsil and the pharyngo-palatine arches belong to the lateral wall of the pharynx.

Pharynx.—The pharynx is a wide musculo-aponeurotic canal, about 5 inches long, which extends from the base of the cranium to the level of the body of the sixth cervical vertebra. There, at the lower border of the cricoid cartilage, it becomes continuous with the œsophagus. Placed posterior to the nasal cavities, the mouth and the larynx, it serves as the passage which conducts air to and from the larynx, as well as the food from the mouth to the œsophagus.

Under ordinary conditions it is expanded from side to side and compressed antero-posteriorly, so that it possesses anterior and posterior walls and two lateral borders. Above the level of the orifice of the larynx there is always sufficient space for the passage of air to the lungs, but below the orifice of the larynx the anterior and posterior walls are in contact, except when separated by the passage of food.

It is widest above, at the base of the cranium, posterior to the orifices of the auditory tubes (O.T. Eustachian). Thence it narrows to the level of the hyoid bone. It widens again at the level of the upper part of the larynx and then rapidly narrows to its termination.

To obtain a proper idea of the connections of the pharynx, the dissector should distend its walls moderately by stuffing it with tow. This may be introduced either from above, through the mouth, or from below, through the œsophagus.

The pharynx will now present a somewhat ovoid form. *Posteriorly*, its wall is complete, and, when in position, it lies anterior to the upper six cervical vertebræ, the prevertebral muscles, and the prevertebral fascia. To these it is bound by some lax connective tissue which offers no impediment to the movements of the canal during the process of deglutition. *Laterally*, the pharynx is related to the great vessels and nerves of the neck, as well as to the styloid process and the muscles which take origin from it. Upon this aspect of

the pharynx also is placed the pharyngeal plexus of nerves, which supplies its walls with motor and sensory twigs. *Anteriorly*, the pharyngeal wall is interrupted by the openings of the nasal cavities, mouth, and larynx; and it is from the structures which lie in proximity to these apertures that it derives its principal attachments. Thus from above downwards it is attached on each side—(a) to the medial pterygoid lamina; (b) to the pterygo-mandibular raphe; (c) to the side of the tongue; (d) to the inner aspect of the mandible; (e) to the hyoid bone; (f) to the thyreoid cartilage; (g) to the cricoid cartilage. *Above*, it is attached to the basis cranii. These various attachments will be studied more fully when the constituent parts of its walls are dissected.

It should be noted that an altogether false idea of the natural form of the pharynx is obtained when it is examined in its present stuffed condition, and removed from the vertebral column. When seen in transverse sections of the frozen body it will be noted that, with the exception of its upper or nasal part, which remains patent under all conditions, the anterior wall is more or less nearly approximated to the posterior wall, and below the opening of the larynx it presents the appearance of a simple transverse slit.

Pharyngeal Wall.—The wall of the pharynx consists of four well-marked strata. These are from without inwards: (1) bucco-pharyngeal fascia; (2) pharyngeal muscles; (3) pharyngeal aponeurosis; (4) mucous membrane. The muscular layer, which is composed of the three constrictor muscles, with the stylo-pharyngeus and pharyngo-palatinus on each side, must now be dissected.

For this purpose place the preparation so that the chin rests upon a block and the pharynx hangs downwards with its posterior surface towards the dissector. The constrictor muscles should now be carefully cleaned, in the direction of the muscular fibres, by removing the bucco-pharyngeal fascia, which covers them.

Bucco-pharyngeal Fascia.—This is a coating of fibrous tissue which ensheaths both the buccinator and the pharyngeal muscles.

Venæ Pharyngææ.—Upon the posterior wall and lateral borders of the pharynx the dissector should notice numerous veins joined together in a plexiform manner. These constitute the *pharyngeal venous plexus*, which collects blood from the pharynx, soft palate, and prevertebral region. It communicates with the pterygoid plexus and the cavernous sinus. Two or more channels lead the blood from it to the

internal jugular vein. This venous plexus, together with the pharyngeal plexus of nerves, will require to be removed in order to display the muscles properly.

Constrictor Muscles.—The constrictor muscles are three curved sheets of muscular fibres which are so arranged that they overlap each other from below upwards; thus, the

- a. Buccinator.
- b. Tensor veli palatini.
- c. Levator veli palatini.
- d. Superior constrictor.
- e. Middle constrictor.
- f. Inferior constrictor.
- g. Thyreo-hyoid.
- h. Hyoglossus.
- k. Stylo-hyoid.
- l. Mylo-hyoid.
- m. Crico-thyreoid.
- n. Stylo-pharyngeus.
- o. Stylo-glossus.
- p. Stylo-hyoid ligament.
- q. Pterygo-mandibular raphe.
- 1. Glosso-pharyngeal nerve.
- 2. Superior laryngeal artery.
- 3. Superior laryngeal nerve.
- 4. External laryngeal nerve.
- 5. Inferior laryngeal nerve and artery.

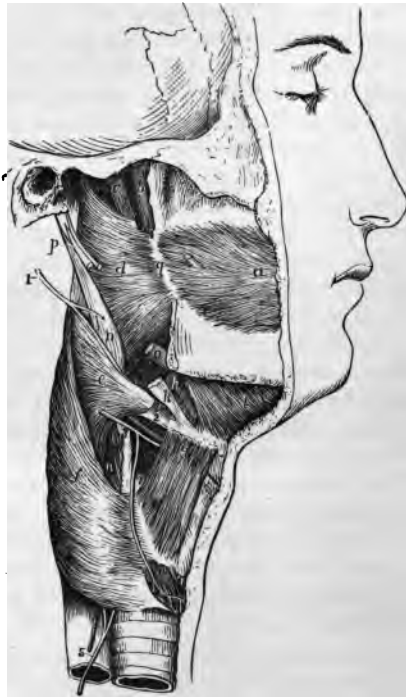


FIG. 148.—Profile view of the Pharynx to show the Constrictor Muscles. (From Turner.)

inferior constrictor overlaps the lower part of the middle constrictor, whilst the middle constrictor, in turn, overlaps the lower part of the superior constrictor. The three muscles are inserted, in the median plane, into the median raphe which descends from the basilar portion of the occipital bone along the posterior aspect of the pharynx.

Musculus Constrictor Pharyngis Inferior (Fig. 148, f).—

The inferior constrictor muscle is relatively short anteriorly at its origin, and relatively long posteriorly, where it blends with the fellow of the opposite side in the median raphe of the posterior wall of the pharynx. It arises from the posterior part of the side of the cricoid cartilage, and from the inferior cornu, the oblique line, and the upper border of the thyreoid cartilage. The muscle curves posteriorly and medially around the pharyngeal wall to meet its fellow of the opposite side in the median raphe. The lower fibres take a horizontal direction, but the remainder ascend, with increasing degrees of obliquity, until the highest fibres reach the raphe at a point a short distance below the basis cranii. The lower margin of the inferior constrictor overlaps the commencement of the œsophagus, and the inferior laryngeal nerve and the laryngeal branch of the inferior thyreoid artery pass upwards, under cover of it, to reach the larynx.

Musculus Constrictor Pharyngis Medius.—This is a fan-shaped muscle (Fig. 148, *e*). It arises from the great and small cornua of the hyoid bone and from the lower part of the stylo-hyoid ligament. From this origin its fibres pass round the pharyngeal wall, to be inserted with the corresponding fibres of the opposite side into the median raphe. As they pass postero-medially, the lowest fibres descend, the highest ascend, and the intermediate fibres run horizontally. The lower portion of this muscle is overlapped by the inferior constrictor, and in the interval which separates the margins of the muscles anteriorly, opposite the thyreo-hyoid interval, the internal laryngeal nerve and the laryngeal branch of the superior thyreoid artery will be seen piercing the thyreo-hyoid membrane to gain the interior of the pharynx.

Dissection.—The superior constrictor possesses a somewhat complicated origin, and to bring this fully into view it will be necessary to cut through the internal pterygoid muscle about its middle, if this has not already been done (p. 293), and turn the upper and lower portions aside.

Musculus Constrictor Pharyngis Superior (Fig. 148, *d*).—The superior constrictor has a weak but continuous line of origin from the following parts: (*a*) the lower third of the posterior border of the medial pterygoid lamina and its hamulus; (*b*) the pterygo-mandibular raphe, which is common to it and the buccinator muscle; (*c*) the posterior end of the mylo-hyoid ridge on the inner aspect of the mandible; (*d*) the mucous membrane of the mouth and side of the tongue.

From this somewhat extensive origin, the fibres curve postero-medially to reach the median raphe, whilst, as a rule, some of the highest gain a distinct insertion into the pharyngeal tubercle on the under surface of the basi-occipital bone.

The lower part of the superior constrictor is overlapped by the middle constrictor, and the stylo-pharyngeus passes into the interval between the two as it descends to its insertion (Fig. 148, *n*). The upper border of the muscle, which is free and crescentic, falls short of the basis cranii.

Raphe Pterygo-mandibularis (Fig. 148, *q*).—This is a strong, narrow, tendinous band, which extends from the hamulus of the medial pterygoid lamina to the posterior part of the mylo-hyoid ridge of the mandible. It acts as a tendinous bond of union between the buccinator and superior constrictor muscles, and its connections can be appreciated best by introducing the finger into the mouth and pressing laterally along the course of the raphe.

Sinus of Morgagni.—This name is applied to the semi-lunar space which intervenes between the upper crescentic margin of the superior constrictor and the basis cranii. The deficiency in the muscular wall of the pharynx in this region is compensated for by the increased strength of the pharyngeal aponeurosis, which, in this situation, is called the *pharyngo-basilar fascia*. In contact with the outer surface of the aponeurosis are two muscles belonging to the soft palate—viz. the *levator veli palatini* and the *tensor veli palatini* (Fig. 148, *c* and *b*). The levator, which is rounded and fleshy, lies posterior to the tensor, which is flat and more tendinous. The tensor can readily be recognised from its position in relation to the deep surface of the internal pterygoid muscle and from its tendon turning medially under the hamulus of the medial pterygoid lamina. In the upper part of the space, close to the basis cranii and between the origin of the two muscles, will be seen the *auditory tube* (O.T. *Eustachian tube*).

Pharyngeal Aponeurosis.—The upper part of the pharyngeal aponeurosis, the *pharyngo-basilar fascia*, is strong, and it maintains the integrity of the wall of the pharynx where the muscular fibres are absent. As it is traced downwards it gradually becomes weaker, until it is ultimately lost as a distinct layer. It lies between the muscles and mucous membrane and comes to the surface only where the muscles are absent. It is the principal means by which the pharynx is

attached to the base of the skull, and it is united also to the auditory tubes and the bony margins of the *choanae*.

Dissection.—The pharynx should now be opened by a vertical median incision through the entire length of its posterior wall. At the upper

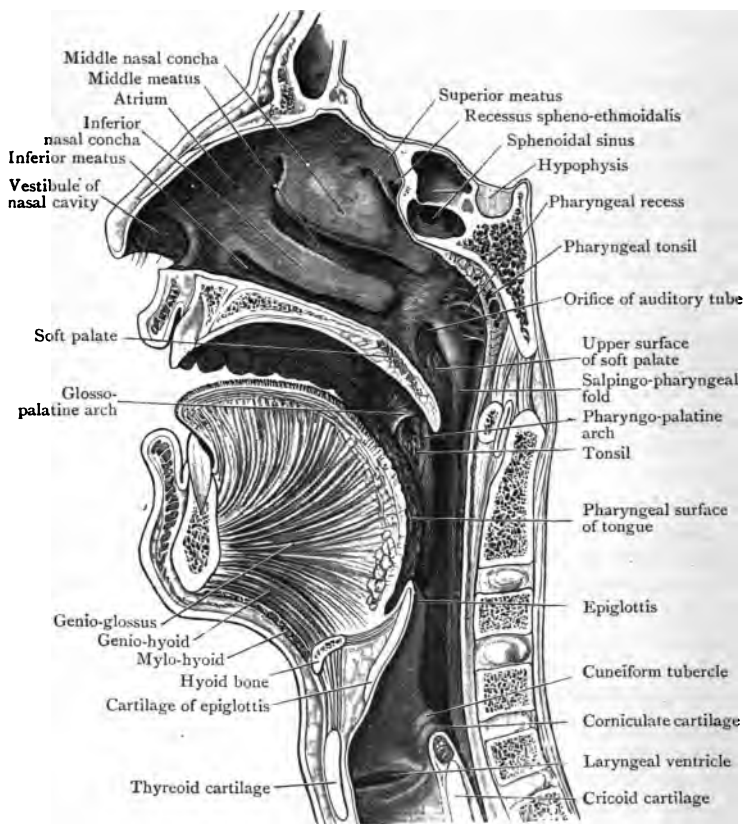


FIG. 149.—Sagittal section, a little to the right of the median plane, through the Nasal Cavity, the Mouth, Larynx, and Pharynx.

extremity of this cut, the knife should be carried transversely, close to the basis cranii. The stuffing should be removed and the mucous surface of the pharynx cleansed.

Interior of the Pharynx.—The *mucous membrane* is now exposed, and it should be noted that it is continuous,

through the various apertures which open into the pharynx, with the mucous membrane of the *nasal cavities*, the *auditory tubes* and *tympanic cavities*, the *mouth proper*, the *larynx*, and the *œsophagus*.

Racemose glands, which lie immediately subjacent to the mucous membrane and secrete mucus, are present in great numbers. There are also numerous *lymph follicles*, and in certain localities these are aggregated together into large masses (the tonsils and the pharyngeal tonsil). These will be studied with the regions of the pharynx in which they are placed.

The soft palate projects into the pharynx, posterior to the isthmus faucium, and divides the cavity of the pharynx into an upper and a lower part. The *upper part*, called the *naso-pharynx*, communicates with the nasal cavities and the tympanic cavities by four apertures, viz. the two choanæ (O.T. posterior nares) and the two auditory tubes (O.T. Eustachian tubes).

The *lower portion* of the pharynx may be regarded as consisting of an *oral part*, which lies posterior to the mouth and tongue, and a *laryngeal part*, placed posterior to the larynx. Below the soft palate there are three openings into the pharynx, viz. the *opening of the mouth* or *isthmus faucium*, the *opening of the larynx*, and the *opening of the œsophagus*.

Pars Nasalis.—The naso-pharynx is situated immediately posterior to the nasal cavities and below the body of the sphenoid and the basilar part of the occipital bone. It is the widest part of the pharynx. Its walls, except the soft palate, are not capable of movement, and, consequently, its cavity always remains patent, and presents under all conditions very much the same form.

In its *anterior boundary* are the choanæ, through which it opens into the nasal cavities. The *choanæ* are two oblong orifices which slope from the base of the cranium downwards and anteriorly to the posterior border of the hard palate. Each is an inch long and half an inch wide, and it is separated from its fellow by the posterior part of the septum nasi, which in this region is formed by the vomer. By looking through the choanæ a partial view of the lower two meatuses of the nose and of the posterior ends of the middle and inferior conchæ may be obtained.

On the *lateral wall* of the naso-pharynx, on each side, is seen the orifice of the auditory tube, and posterior to it the pharyngeal recess. The *ostium pharyngeum* of the auditory tube lies immediately posterior to the lower part of the corresponding choana, at a level which corresponds closely with the posterior end of the inferior concha. It is bounded above and posteriorly by a prominent and rounded margin termed the *torus tubarius*, which is altogether deficient below and anteriorly. A fold of mucous membrane, termed the *salpingo-pharyngeal fold*, descends upon the lateral wall of the pharynx from the posterior lip of the orifice of the auditory tube. As this is traced downwards it gradually disappears.

The dissector should pass a Eustachian catheter through the nose into the auditory tube. Hold the catheter with the point downwards. Pass it posteriorly through the right nasal cavity, along the septum of the nose, to the posterior wall of the pharynx. Pull it towards the palate till the bent end of the catheter catches against the back of the hard palate. Turn the point through a quarter of a circle to the right side of the head and it will enter the right auditory tube. If it is desired to catheterise the left auditory tube pass the catheter through the left nasal cavity, and in the final stage turn the point to the left side.

In the natural condition of parts there is a deep recess on the lateral wall of the naso-pharynx immediately posterior to the prominent posterior lip of the orifice of the auditory tube. This is termed the *lateral recess* of the pharynx.

The *roof* and *posterior wall* of the naso-pharynx are not marked off from each other. They form together a continuous curved surface. The upper portion of this surface looks downwards and may be regarded as the roof; the lower portion, which looks anteriorly, constitutes the posterior wall. The *roof* is formed by the basilar part of the occipital bone, and also by a small part of the under surface of the basi-sphenoid, covered with a dense periosteum and a thick coating of mucous membrane. The *posterior wall* is supported *posteriorly* by the anterior arch of the atlas and the anterior surface of the epistropheus. In that part of the roof which lies between the two lateral recesses of the naso-pharynx there is a marked collection of lymphoid tissue, the *pharyngeal tonsil*. Over its surface the mucous membrane is thickened and wrinkled, and in its lower part a small median pit, termed the *pharyngeal bursa*, may usually be found; it is just large enough to admit the point of a fine probe.

The *floor* of the naso-pharynx is formed by the curved,

sloping upper surface of the soft palate. Between the posterior border of the soft palate and the posterior wall of the pharynx there is an interval, termed the *pharyngeal isthmus*, through which the naso-pharynx communicates with the oral pharynx.

It is important to note that the posterior wall and roof of the naso-pharynx can be explored by the finger introduced through the mouth and the pharyngeal isthmus.

When the naso-pharynx is illuminated, by light reflected from a mirror

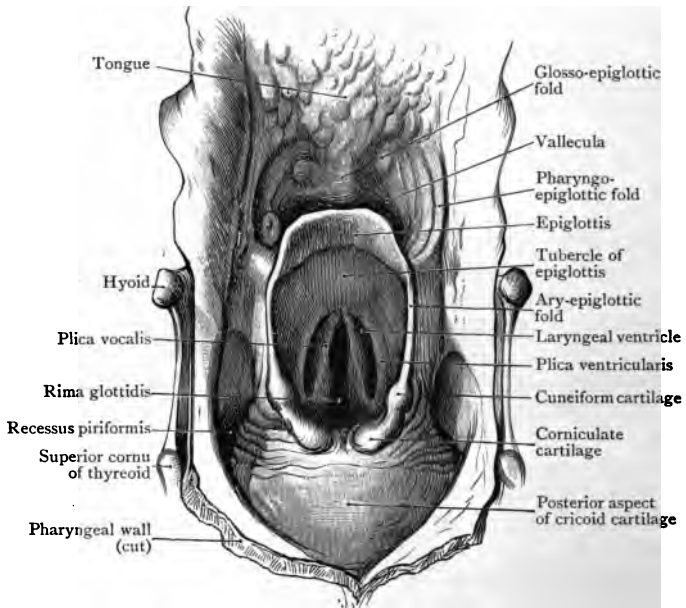


FIG. 150.—Superior Aperture of Larynx exposed by cutting through the posterior wall of the pharynx.

introduced through the mouth, a view of the four orifices which open into this part of the pharynx may be obtained. Owing to the mirror being placed obliquely, and below the level of the hard palate, only the posterior parts of the inferior conchæ are visible through the choanæ, and the inferior meatuses of the nose are altogether out of sight. The middle and superior meatuses of the nose and the middle and superior conchæ, however, can be brought into view and their condition ascertained. The lateral walls of the naso-pharynx and the orifices of the auditory tubes can also be fully inspected.

Pars Oralis.—The oral pharynx lies posterior to the mouth and tongue. The pharyngeal part of the tongue, which looks

more or less directly posteriorly, forms its *anterior wall* in its lower part. Above this is the isthmus of the fauces, or the opening into the mouth, limited on either side by the glosso-palatine arch. These arches may be regarded, therefore, as the lateral boundary lines between the mouth and the pharynx. On the *lateral wall* of the oral pharynx the pharyngo-palatine arch forms a prominent fold which is gradually lost as it is traced downwards. Within this fold is the pharyngo-palatine muscle. This is an important relation, because the posterior palatine arches form the lateral boundaries of the pharyngeal isthmus, and by the contraction of the pharyngo-palatine muscles the two posterior arches can be approximated until the opening of the isthmus is obliterated; the passage of food and fluids from the oral pharynx into the naso-pharynx is thus prevented.

The arcus glosso-palatinus and the arcus pharyngo-palatinus form, on each lateral wall of the oral pharynx, the anterior and posterior limits of a triangular interval in which is lodged the tonsil. The upper part of this area, above the level of the tonsil, presents a small depression termed the *supra-tonsillar fossa*.

In the child, and not uncommonly in the adult, a triangular fold of mucous membrane, the *plica triangularis*, extends posteriorly from the lower part of the glosso-palatine arch and the base of the tongue across the surface of the tonsil. The upper border of the fold may be free or it may become attached to a greater or less extent to the surface of the tonsil.

Pars Laryngea.—The laryngeal portion of the pharyngeal cavity diminishes rapidly in width to the level at which it becomes continuous with the œsophagus. In its anterior wall, from above downwards, may be seen: (1) the epiglottis; (2) the superior aperture of the larynx with the recessus piriformis on either side; and (3) the posterior surfaces of the ary-tænoid and cricoid cartilages, covered with muscles and mucous membrane.

Aditus Laryngis.—The *superior aperture of the larynx*, situated below the pharyngeal part of the tongue, is a large, obliquely placed opening which slopes rapidly from above downwards and posteriorly. It is somewhat triangular in outline, and the basal part of the opening, placed above and anteriorly, is formed by the free border of the epiglottis.

Posteriorly, the opening rapidly narrows, and finally ends in the interval between the two ary-tænoid cartilages. The sides of the aperture are formed by two sharp and prominent folds of mucous membrane, termed the *ary-epiglottic folds*, which connect the lateral margins of the epiglottis with the ary-tænoid cartilages. Two small nodules of cartilage, in the posterior part of each ary-epiglottic fold, give rise to two rounded eminences, of which the anterior is the *cuneiform tubercle*, and the posterior the *corniculate tubercle*.

On either side of the lower part of the laryngeal opening there is a small three-sided or pyramidal depression, called the *recessus piriformis*. On the lateral side it is

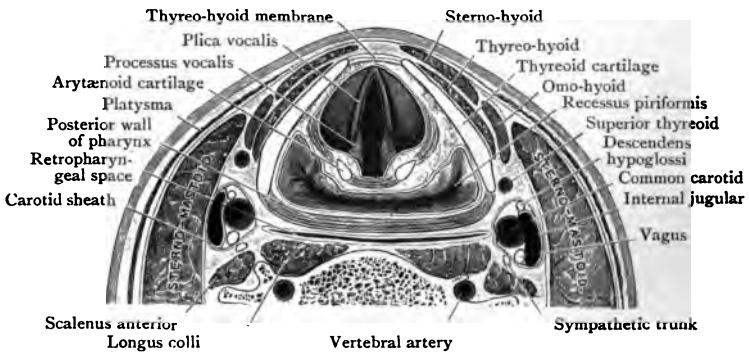


FIG. 151.—Transverse section through the Neck at the level of upper part of the Thyroid Cartilage.

bounded by the posterior part of the lamina of the thyroid cartilage and the thyreo-hyoid membrane; on the medial side by the ary-tænoid cartilage and the ary-epiglottic fold; whilst its posterior wall is formed by the posterior wall of the pharynx, when this is in place. The recessus piriformis presents a wide entrance, which looks upwards; but it rapidly narrows towards the bottom (Figs. 150 and 151); and it is important to the surgeon because in this little pocket foreign bodies introduced into the pharynx are liable to be caught.

Below the opening of the larynx, the anterior and posterior walls of the pharynx are always closely applied to each other, except during the passage of food.

The *œsophageal opening* is placed opposite the lower border

of the cricoid cartilage. This is the narrowest part of the pharynx.

Velum Palatinum.—The soft palate is a movable curtain, which projects downwards and posteriorly into the pharynx. During deglutition it is raised, and helps to shut off the nasal part of the pharynx from the portion below. *Anteriorly*, it is attached to the posterior margin of the hard palate; *on each side* it is connected with the lateral wall of the pharynx; whilst *posteriorly* it presents a free border. From the centre of this free margin the conical process, termed the *uvula*, projects; whilst the sharp concave part of the border, on either side of the uvula, becomes continuous with the pharyngo-palatine arch, which descends on the side wall of the pharynx. The *upper surface* of the soft palate is convex and continuous with the floor of the nasal cavities; the *inferior surface* is concave and forms part of the vaulted roof of the mouth. From the posterior part of this surface on each side a glosso-palatine arch curves downwards; and along its median plane may be seen a slightly marked median ridge or raphe.

The soft palate is composed of a fold of mucous membrane, between the two layers of which are interposed muscular, aponeurotic, and glandular structures, together with blood vessels and nerves.

Palatal muscles,	{	The two levatores veli palatini.	
		The two tensores veli palatini.	
		The two glosso-palatini.	
		The two pharyngo-palatini.	
		The musculus uvulæ.	
Palatal aponeurosis.			
Palatal glands.			
Arteries,	{	Ascending palatine from external maxillary.	
		Palatine branch from ascending pharyngeal.	
		Twigs from the descending palatine branch of the internal maxillary.	
Nerves,	{	Middle palatine,	} from the spheno-palatine ganglion.
		Posterior palatine,	
		Branches from pharyngeal plexus,	

The *racemose mucous glands* in the soft palate form a very thick layer, immediately subjacent to the mucous membrane which clothes its inferior surface. Close to the posterior border of the hard palate the soft palate contains very few muscular fibres; there it is composed chiefly of the two layers of mucous membrane enclosing the glands, and the palatal aponeurosis.

Dissection.—The dissection of the soft palate is difficult, and it is only in a fresh part that the precise relations of the different muscular layers can be made out. Begin by rendering it tense by means of a hook, and then remove carefully the mucous membrane from its upper and lower surfaces, and also from the glosso- and pharyngo-palatine arches. The latter proceeding will expose the glosso-palatine and the pharyngo-palatine muscles on each side.

Musculus Glosso-palatinus.—The glosso-palatinus is a delicate muscular slip, which arises from the side of the posterior part of the tongue and curves upwards and medially to reach the under surface of the soft palate, above the glandular layer. There its fibres spread out and become continuous with the corresponding fasciculi of the opposite side. It forms the lowest muscular stratum of the soft palate.

Musculus Pharyngo-palatinus.—The pharyngo-palatinus forms two muscular strata in the soft palate which enclose, between them, the musculus uvulæ and the levatores palati muscles. The *upper layer* is very weak and confined to the posterior part of the velum. It constitutes the most superficial muscular stratum on the upper aspect of the soft palate, and becomes continuous with the corresponding portion of the muscle of the opposite side. The *deeper layer* takes origin from the posterior margin of the palate bone and from the palatal aponeurosis, and some of its fibres mingle with those of the corresponding muscle of the opposite side. Lateral to the soft palate the two strata come together, and are joined by one or two delicate muscular slips which spring from the lower border of the cartilage of the auditory tube. These slips are sometimes described as the *salpingo-pharyngeus muscle*. The pharyngo-palatinus, thus formed, arches downwards and posteriorly in the posterior arch of the fauces, and spreads out into a thin sheet of fibres in the wall of the pharynx. Blending to some extent with the stylo-pharyngeus, it is inserted into the posterior border of the thyreoid cartilage. Some of its fibres, however, incline posteriorly and are inserted into the pharyngeal aponeurosis.

Musculus Uvulæ.—This delicate muscle is placed on the upper aspect of the soft palate, and, posteriorly, it is covered by the superficial fibres of the pharyngo-palatinus. These must be removed to expose it fully. It consists of two minute slips which, as a rule, arise from the posterior nasal spine of the hard palate, and lie one on either side of the

median plane. As they pass posteriorly into the uvula they unite into a single rounded muscular bundle.

Dissection.—The levator palati muscle has been seen already on the outer aspect of the pharynx in the sinus of Morgagni. To display it from the inside it is necessary to remove the wall of the pharynx between the auditory tube above and the upper border of the superior constrictor below, and then follow its fibres into the soft palate. In a well-injected subject the dissector will observe the ascending palatine artery in relation to this muscle.

Musculus Levator Veli Palatini.—The levator palati is a rounded fleshy muscle which arises from the lower and medial border of the cartilage of the auditory tube, and from the rough surface on the under aspect of the apex of the petrous part of the temporal bone. It passes downwards and anteriorly, crosses the upper border of the superior constrictor, pierces the pharyngeal aponeurosis, passes below the orifice of the auditory tube and enters the soft palate. There its fibres spread out below the uvular muscle and above the anterior or deep portion of the pharyngo-palatinus. Anteriorly, some of the fibres are inserted into the palatal aponeurosis; but more posteriorly, the majority of the fibres become continuous with the corresponding fasciculi of the opposite side.

Musculus Tensor Veli Palatini.—The origin of the tensor veli palatini and the relations of its muscular belly were noted on p. 293. The muscle descends from the base of the skull along the lateral surface of the medial pterygoid lamina, and ends in a tendon which turns horizontally towards the median plane, below the hamulus, where a bursa mucosa facilitates the play of the tendon on the bone. In the soft palate the tendon expands below the lower layer of the pharyngo-palatinus, and some of its fibres blend with the palatal aponeurosis whilst others gain attachment to the horizontal part of the palate bone.

Palatal Aponeurosis.—The palatal aponeurosis extends posteriorly from the posterior margin of the hard palate to give strength and support to the soft palate. At first it is strongly marked, but it weakens rapidly as it passes posteriorly. The small portion of the soft palate which it supports contains few muscular fibres, and remains always more or less horizontal in position. The much more extensive posterior muscular part of the soft palate constitutes the movable sloping portion. The tensor palati operates upon the anterior aponeurotic portion of the soft palate.

Vessels and Nerves of the Soft Palate.—The *ascending palatine branch* of the external maxillary artery is, as a rule, the principal artery of supply to the soft palate. It has already been traced on the wall of the pharynx (p. 299), where it lies in the sinus of Morgagni, in relation to the levator palati muscle, which it accompanies into the soft palate. The *palatine branch* of the ascending pharyngeal artery may also be traced into the soft palate. In cases where the preceding artery is small, this twig will be found enlarged so as to take its place (p. 304). The *descending palatine branch* of the internal maxillary artery also sends small twigs to the soft palate and tonsil.

Two nerves enter the soft palate from the spheno-palatine ganglion—viz. the *posterior palatine* and the *middle palatine nerve*. It would appear, however, that they do not supply the muscles, but are distributed to the mucous membrane. The levator palati, the musculus uvulæ, the glosso-palatinus, and the pharyngo-palatinus are supplied by twigs from the pharyngeal branches of the vagus, which convey to them fibres which are originally derived from the cerebral part of the accessory nerve (*v. p. 315*) (W. Aldren Turner). The tensor palati is probably supplied by the branch which it receives from the otic ganglion, which conveys to it fibres originally derived from the motor part of the trigeminal nerve.

Tonsillæ Palatinæ.—The palatine tonsils are two prominent masses of lymphoid tissue, placed one on each lateral wall of the pharynx, in the triangular interval between the two palatine arches and immediately above the pharyngeal part of the tongue. The pharyngeal or internal surface of the tonsil is covered with mucous membrane and presents a number of orifices which lead into crypts or recesses in its substance. The deep or external surface is embedded in the pharyngeal wall and is supported by the superior constrictor muscle of the pharynx (see p. 298). It is covered by a layer of fibrous tissue which forms an incomplete capsule for the organ. It is important to note that between the tonsil and the superior constrictor there is some lax connective tissue, so that the organ can be pulled forwards by the volsellum without dragging the wall of the pharynx with it.

The tonsils have a rich *blood-supply*. They derive arterial twigs from the tonsillar and ascending palatine branches of the external maxillary, the descending palatine branch of the internal maxillary, the ascending pharyngeal, and the dorsalis linguæ.

Tuba Auditiva (O.T. Eustachian Tube).—This is the

canal which conveys air from the pharynx to the tympanic cavity. It is divided into two portions, according to the parts which enter into the construction of its wall. Thus, in the *lateral part* of its course, as it nears the tympanic cavity, its wall is bony, and it runs in the interval between the tympanic and petrous portions of the temporal bone. The *medial part* consists mainly of cartilage. It is placed on the base of the skull, and is lodged in the gutter or groove between the petrous part of the temporal bone and the great wing of the sphenoid. This is the subdivision of the tube which comes under the notice of the dissector at the present stage, and he should first note its direction and then study its relations and the construction of its wall.

The direction of the canal can be readily ascertained by passing a probe into it through its pharyngeal orifice. It runs postero-laterally with a slight inclination upwards and passes first above and then to the lateral side of the levator palati, and along the medial side of the upper part of the tensor palati. It lies, therefore, in a considerable part of its extent between the two muscles.

Before removing the mucous membrane from the pharyngeal part of the tube the dissector should note that at the lower margin of the orifice there is a prominent rounded eminence, the *levator cushion*, due to the subjacent levator veli palatini. The removal of the mucous membrane will reveal the fact that the wall of the tube is formed, in great part, by a triangular plate of cartilage, which is folded upon itself so as to protect the tube on its upper and medial aspects. The cartilage is deficient below and laterally, its place being taken by dense fibrous tissue, which connects the margins of the cartilage and completes the wall of the canal. The projecting free base of the cartilage gives rise to the torus tubarius already examined on the lateral wall of the nasopharynx (p. 376). A muscular slip, which descends from the lateral margin of the cartilage, in relation to the outer unprotected side of the tube, has been termed the *dilatator tube* (Rudinger). It joins the tensor palati. The interior of the tube is lined with mucous membrane continuous with that of the pharynx and the tympanic cavity; and its calibre varies considerably in different parts of its course. It is narrowest at a point termed the *isthmus*, situated at the junction of the osseous and cartilaginous parts. As the tube is traced

thence to the pharynx it gradually increases in calibre and it attains its greatest width at its opening into the NASOPHARYNX.

CAROTID CANAL

The carotid canal, which traverses the interior of the petrous part of the temporal bone, contains the internal carotid artery, the internal carotid continuation of the cervical sympathetic and a plexus of veins.

Dissection.—The carotid canal may be opened up by removing its inferior wall with the bone forceps. In doing this, it is not necessary to interfere with the auditory tube, which lies in close proximity. The dissection must be made on one side only.

Arteria Carotis Interna.—The internal carotid artery in this part of its course is about three-quarters of an inch long. At first it ascends vertically; then, bending suddenly, it runs horizontally antero-medially. It emerges from the canal at the apex of the petrous bone and enters the foramen lacerum, where it turns upwards, pierces the external layer of the dura mater, and enters the middle fossa of the skull. From this point onwards the internal carotid artery has been examined already (p. 331). Whilst within the carotid canal it lies below and anterior to the cochlea and the tympanic cavity. The great superficial petrosal nerve and the semilunar ganglion are placed above it, but are separated from it by a thin plate of bone, which is, however, sometimes absent.

Nervus Caroticus Internus.—The dissector has already noted this large branch proceeding from the upper end of the superior cervical ganglion and entering the carotid canal with the internal carotid artery. It divides almost immediately into two parts, which are placed on either side of the artery. Each of these soon divides into a number of branches which communicate together around the internal carotid artery forming the *internal carotid plexus*. The further dissection of these branches is a matter of some difficulty, and can be satisfactorily effected only under specially favourable circumstances.

At the posterior end of the cavernous sinus a ganglion is sometimes found in the plexus, and where the sixth nerve crosses the internal carotid artery the plexus is very dense. This part is known as the *cavernous plexus*. At the anterior end of the cavernous sinus the carotid plexus

breaks up into branches which accompany the anterior and middle cerebral arteries.

The internal carotid plexus communicates with the tympanic plexus by means of superior and inferior carotico-tympanic branches given off in the carotid canal, and with the spheno-palatine ganglion by the great deep petrosal branch, which unites with the great superficial petrosal of the facial nerve to form the nerve of the pterygoid canal (O.T. Vidian). It gives branches also to the semilunar ganglion, the third, fourth, sixth and the ophthalmic branch of the fifth nerve, and a branch which accompanies the naso-ciliary nerve into the orbit and joins the ciliary ganglion.

NERVUS MAXILLARIS.

As the maxillary nerve passes anteriorly, from the semilunar ganglion to the face, it traverses the foramen rotundum, the upper part of the pterygo-palatine fossa, the pterygo-maxillary fissure, the inferior orbital fissure and the infra-orbital canal. The dissector should therefore proceed to expose the nerve in these localities.

Dissection.—Remove the temporal muscle and the upper head of the external pterygoid muscle, and, placing the saw upon the cut margin of the skull at a point immediately above the external meatus, carry it obliquely downwards and anteriorly through the squamous part of the temporal bone and the great wing of the sphenoid, towards the medial end of the superior orbital fissure. This saw-cut should enter the superior orbital fissure immediately to the lateral side of the foramen rotundum. A second saw-cut should then be made from the cut margin of the cranial wall, immediately above the anterior margin of the great wing of the sphenoid bone, downwards into the superior orbital fissure to meet the first saw-cut. The wedge-shaped piece of bone included between these cuts can now be removed. Additional space may be obtained, and the pterygo-palatine fossa may be more fully opened up, by removing what remains of the great wing of the sphenoid upon the lateral side of the foramen rotundum, but the circumference of this aperture must be carefully preserved. Proceed, in the next place, to open up the infra-orbital canal. In its posterior part its upper wall is usually so thin that it can easily be removed by a pair of dissecting forceps, but anteriorly it sinks deeply under the lower part of the rim of the orbital opening, and here the chisel must be employed. The maxillary nerve can now be defined and its branches displayed. The infra-orbital artery and vein, which accompany the nerve in the infra-orbital canal, will be exposed at the same time.

Nervus Maxillaris.—The maxillary nerve springs from the semilunar ganglion within the cranial cavity (p. 330). It is composed entirely of sensory fibres, and passes anteriorly, outside the dura mater and in relation to the lower part of the cavernous sinus, to the foramen rotundum through which it enters the pterygo-palatine fossa. It crosses the upper part of this fossa, curves laterally through the pterygo-maxillary

fissure into the infra-temporal fossa, and, near the middle of the inferior orbital fissure, enters the infra-orbital canal, where it receives the name of *infra-orbital*. The infra-orbital canal traverses the floor of the orbit, which, it should be remembered, forms the roof of the maxillary sinus also. Finally, the nerve emerges upon the face through the infra-orbital foramen, and breaks up, under cover of the quadratus labii superioris, into numerous branches which form a dense plexus with twigs from the facial nerve. Its

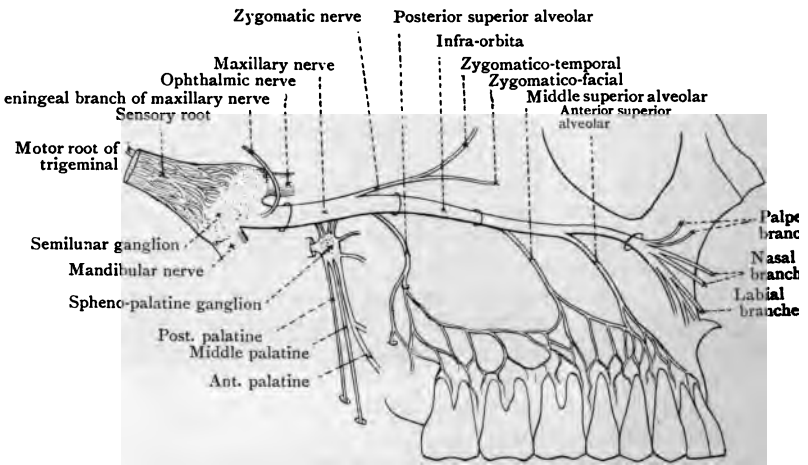


FIG. 152.—Diagram of the Maxillary Nerve.

terminal filaments are distributed to the lower eyelid, the nose, and the upper lip. The course of the maxillary nerve may be separated into five stages, in each of which branches are given off. These are:—

- | | |
|-----------------------------------|----------------------------------|
| 1. Within the cranium, | { Meningeal (p. 330). |
| 2. In the pterygo-palatine fossa, | { Spheno-palatine. |
| 3. In the infra-temporal fossa, | { Zygomatic (already described). |
| | { Posterior superior alveolar. |
| 4. In the infra-orbital canal, | { Middle superior alveolar. |
| | { Anterior superior alveolar. |
| 5. In the face, | { Palpebral, |
| | { Nasal, |
| | { Labial, |
| | } already described. |

The *zygomatic nerve*, which has already been dissected in the orbit, can now be traced to its origin from the maxillary nerve in the infra-temporal fossa. The *spheno-palatine branches* are two stout twigs which arise from the under aspect of the maxillary nerve, and proceed vertically downwards, in the pterygo-palatine fossa, to the spheno-palatine ganglion, of which they constitute the *sensory roots*.

Nervi Alveolares Superiores.—These are usually three in number, and are distinguished as posterior, middle, and anterior. The middle superior alveolar nerve is sometimes absent as a separate trunk, in which case it arises in common with the anterior superior alveolar branch.

The *posterior superior alveolar nerve* takes origin in the infra-temporal fossa, and almost immediately divides into two branches, which proceed downwards upon the posterior aspect of the body of the maxilla. They contribute a few fine filaments to the mucous membrane of the cheek and to the gum, and then disappear into the minute posterior dental foramina to supply the three molar teeth and the lining membrane of the maxillary sinus.

The *middle superior alveolar nerve* supplies the two premolar teeth. It arises from the infra-orbital nerve, and can be easily detected (when present) by gently raising the parent trunk from the floor of the infra-orbital canal. It descends in a minute canal which traverses the lateral wall of the maxillary sinus.

The *anterior superior alveolar nerve*, much the largest of the three alveolar branches, springs from the infra-orbital as it approaches the anterior part of the canal. It can be brought into view by raising the parent trunk from the floor of the canal, and it will then be seen to enter a special bony tunnel which traverses the maxilla in the anterior wall of the maxillary sinus. The dissector should endeavour to open up this canal with the chisel. After supplying a branch to the mucous membrane of the lower and anterior part of the nasal cavity, the anterior superior alveolar nerve divides into branches for the incisor and the canine teeth.

While traversing the maxilla, the three superior alveolar branches communicate with each other, and form two nerve-loops (Fig. 152). Numerous twigs proceed from these, and join in a fine plexus. It is from this plexus that the terminal filaments to the teeth and gum take origin.

Arteria Infra-orbitalis.—The infra-orbital artery is a

branch of the internal maxillary. It arises in the pterygo-palatine fossa and accompanies the infra-orbital nerve. In the face its terminal twigs anastomose with branches of the external maxillary, transverse facial, and buccinator arteries; in the infra-orbital canal it gives some fine branches to the contents of the orbital cavity, and also the *anterior superior alveolar artery* which accompanies the nerve of that name, and supplies the incisor and canine teeth, and the lining membrane of the maxillary sinus.

The *infra-orbital vein* joins the pterygoid plexus.

NASAL CAVITIES.

Dissection.—The portion of the mandible which still remains, together with the tongue and larynx, must now be removed from the upper part of the skull. From the angle of the mouth on each side carry the knife posteriorly, through the buccinator and the mucous membrane of the cheek, the pterygo-mandibular raphe, and the lateral wall of the pharynx. The internal pterygoid muscle has been divided already, but it will be necessary to cut the internal carotid artery, the smaller vessels which are still undivided and the nerves which still connect the pharynx with the skull. The larynx and tongue must be laid aside for future dissection.

The anterior part of the skull should next be divided into two lateral parts by sawing through it in the sagittal direction close to one side of the nasal septum. As a general rule the nasal septum is not vertical, but deviates more or less to one or other side of the median plane. This deviation is more frequently directed to the right than to the left side. Endeavour to determine the direction which it takes in the skull under observation, by passing a probe into the nasal cavity through the choanæ. The section through the skull should be made close to the concave side of the septum. Begin anteriorly by introducing a knife into the nostril of that side, and carry it upwards through the cartilaginous part of the nose to the nasal bone. Then place the specimen so that the face rests upon the table, and divide the soft palate in the median plane. The section may now be completed by sawing through the hard palate and bony roof of the nasal cavity to the side of the median plane. The dissector should make every effort to preserve the septum of the nose intact. As a general rule the upper concha is partially injured. This is not a very serious matter, as the lateral aspect of the nasal cavity can be studied upon the opposite side when the septum of the nose has been removed.

Septum Nasi.—The nasal septum divides the cavity of the nose into two narrow chambers—the right and left nasal cavities. It is not placed accurately in the median plane, but almost invariably shows a bulging or deviation to one or other side (more frequently to the right side). Immediately above the orifice of the nostril or anterior aperture of the nasal cavity, the septum shows a slight depression,

which corresponds to the *vestibule* of the nose, and forms the medial wall of this subdivision of the nasal cavity. The vestibular part of the partition is clothed with skin, continuous with the external integument; from this a number of stiff hairs, termed *vibrissæ*, project. Over the rest of its extent the septum nasi is covered with mucous membrane, which is closely adherent to the subjacent periosteum forming with it a muco-periosteum; and it is

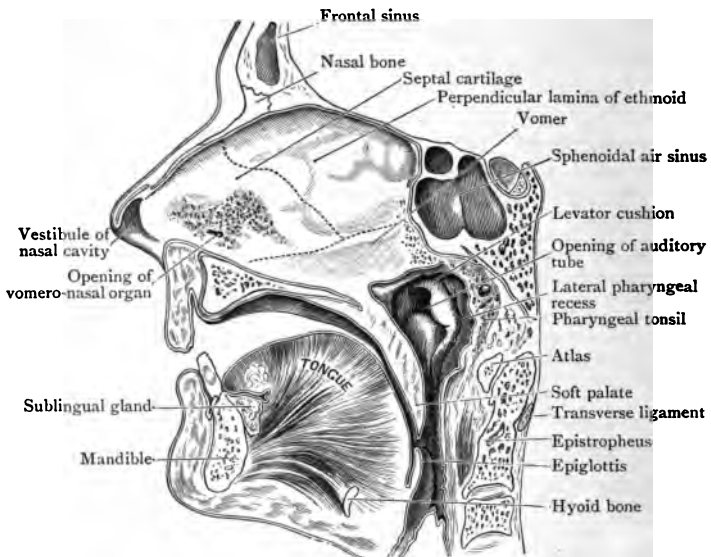


FIG. 153.—Antero-posterior section through the Nose, Mouth, and Pharynx, a little to the left of the median plane.

separable into two districts, viz., a lower or *respiratory area*, and a much smaller upper or *olfactory area*, comprising not more than the upper third of the septum, in which branches of the olfactory nerve spread out. The respiratory mucous membrane is very thick and spongy. It is highly vascular and contains numerous mucous glands. The minute orifices of the gland ducts can be detected by the naked eye. Over the olfactory district of the septum the mucous membrane is softer and more delicate, and not so thick. In the fresh state it presents a yellowish colour, and the glands are smaller.

In favourable cases a minute orifice may be detected in the mucous membrane, on the lower and anterior part of the nasal septum, immediately posterior to the vestibular area. It is placed above the anterior end of a well-marked elongated projection which passes obliquely posteriorly and upwards, and corresponds to the thickened lower margin of the septal cartilage. This aperture varies in diameter from $\frac{1}{2}$ mm. to $1\frac{1}{2}$ mm. (Schwalbe). It leads into a narrow canal, which passes posteriorly for a short distance, and then ends blindly. It is of interest because it represents in the human subject the rudiment of the *vomero-nasal organ* (O.T. *organ of Jacobson*), a tubular structure which is highly developed in some of the lower animals.

Construction of the Nasal Septum.—Strip the muco-periosteum from the exposed surface of the septum nasi and the parts forming the septum will be rendered visible. The bulk of the partition is composed of the perpendicular lamina of the ethmoid and the vomer posteriorly, and of the septal cartilage anteriorly. Small portions of other bones take a minor part in its construction. Thus, above and posteriorly there are the crest and rostrum of the sphenoid; above and anteriorly is the nasal spine of the frontal bone; whilst below there is the crest of bone formed by the apposition of the palatal processes of the palate and maxillary bones of opposite sides.

Cartilago Septi Nasi.—The septal cartilage fills up the wide angular gap which intervenes between the perpendicular lamina of the ethmoid and the vomer, and it projects anteriorly towards the point of the nose. It is a broad irregularly quadrilateral plate. Its *upper and posterior border* is in apposition with the anterior border of the perpendicular lamina of the ethmoid; its *lower and posterior border*, much thickened, is received into the groove in the anterior border of the vomer and the nasal crest of the maxillæ. The angle between these two borders is prolonged posteriorly, for a varying distance, in the form of a tongue-shaped cartilaginous process, which occupies the interval between the two plates of the vomer. The *upper and anterior border* of the septal cartilage is in contact above with the suture between the two nasal bones; below this it is related to the two lateral cartilages of the nose, whilst still lower down it is seen in the interval between the two larger alar cartilages.

Its connection with the lateral cartilage on each side is a very intimate one; indeed, below the nasal bones, the three cartilages are directly continuous, but lower down they are separated by a fissure which runs upwards for some distance on each side. The *lower and anterior border* is very short; it is free, and extends posteriorly to the anterior nasal spine.

The anterior angle of the septal cartilage is blunt and rounded, and does not reach to the point of the nose, which is formed by the alar cartilages.

The deviation of the septum nasi from the median plane will now (in all probability) be seen to be due to a bulging to one side of the vomer and perpendicular lamina of the ethmoid along their line of union. It is not developed until after the seventh year.

Dissection.—The septal cartilage and thin bony part of the septum must now be removed piecemeal. This must be done very carefully, as it is necessary to preserve intact the muco-periosteum which clothes the opposite side of the septum. It is in this muco-periosteum that the nerves and blood vessels must be examined.

Vessels and Nerves of the Septum Nasi.—The following is a list of the nerves:—

Nerves of Smell, . . .	Olfactory.
Nerves of Common sensation, . . .	<ol style="list-style-type: none"> 1. Naso-palatine. 2. <u>Medial nasal branch of the anterior ethmoidal nerve.</u> 3. <u>Nasal branches from spheno-palatine ganglion and from the nerve of the pterygoid canal (O.T. Vidian).</u>

The Medial Group of Olfactory Nerves.—These nerves are distributed in the muco-periosteum of the upper part of the nasal septum and are barely distinguishable, except in a fresh part; further, they are so soft that it is hardly possible to isolate them. They enter the nasal cavity through the medial series of apertures in the cribriform plate of the ethmoid, and proceed downwards in grooves on the surface of the perpendicular lamina of the same bone.

Nervus Naso-palatinus.—The naso-palatine nerve is a long slender twig which can easily be detected upon the deep surface of the muco-periosteum of the septum. It springs from spheno-palatine ganglion, and enters the nasal cavity through the spheno-palatine foramen. In the first part of its course it runs medially upon the inferior surface of the body of the sphenoid. Having gained the nasal septum, it changes its direction and passes downwards and anteriorly, in a shallow groove on the surface of the vomer under cover of the muco-periosteum. Finally it enters the foramen of Scarpa, and, where the two foramina of Scarpa open into the common incisive foramen, the nerves of opposite sides unite in a plexus from which branches are given to the mucous membrane covering the anterior part of the hard palate. The naso-palatine nerve is accompanied by the posterior nasal septal artery; and, as it lies on the surface of the vomer, it supplies some small twigs to the muco-periosteum of the septum nasi.

A few nasal branches from the spheno-palatine ganglion, and also from the nerve of the pterygoid canal, reach the muco-periosteum over the superior and posterior part of the septum. They are very minute, and it is questionable if the dissector will be able to discover any trace of them in an ordinary part.

The medial nasal branches of the anterior ethmoidal nerve will be found descending over the anterior part of the nasal septum. They may be traced as far as the vestibule.

The arteries which convey blood to the septum nasi are: (1) the posterior nasal septal, which accompanies the naso-palatine nerve; (2) a branch of the anterior ethmoidal accompanying the medial branches of the anterior ethmoidal nerve; (3) some minute twigs to the upper part of the septum from the posterior ethmoidal artery; (4) the septal branch of the superior labial artery, which is distributed upon the columna nasi.

Dissection.—The muco-periosteum of the septum may now be divided, by the scissors, along the roof of the nasal cavity. Before doing this, disengage from its surface the naso-palatine nerve and the medial branches of the anterior ethmoidal nerve, in order that they may be afterwards traced to their origins. When the layer of muco-periosteum, thus detached from the roof of the nose, is thrown down the nasal cavity is exposed.

Cava Nasi.—The nasal cavities are two chambers placed one on each side of the septum nasi. They are narrow, but the vertical depth and antero-posterior length of each cavity is very considerable. The width increases somewhat from above downwards; thus, in the upper part, the superior concha is separated from the septum by an interval of only 2 mm., whilst lower down a space of 4 or 5 mm. intervenes between the inferior concha and the septum. Each nasal cavity presents a medial wall formed by the septum, a lateral wall, a roof, a floor, and an anterior and a posterior aperture.

The anterior apertures of the nasal cavities, or nostrils, are two oval orifices which open upon the face and look downwards. The posterior apertures, or choanae, open into the nasopharynx and look posteriorly and downwards.

The narrow roof of the nasal cavity consists of an intermediate horizontal portion formed by the cribriform plate of the ethmoid bone, and of an anterior and a posterior sloping part. The anterior part is formed by the narrow grooved nasal surface of the frontal spine of the frontal bone, the nasal bone, and the angle between the lateral cartilage and

the septal cartilage. The posterior part of the roof is composed of the anterior and under surfaces of the body of the sphenoid, and also of the ala of the vomer, the sphenoidal process of the palate bone, and the vaginal process of the medial pterygoid lamina, all of which are applied to the under surface of the sphenoidal body.

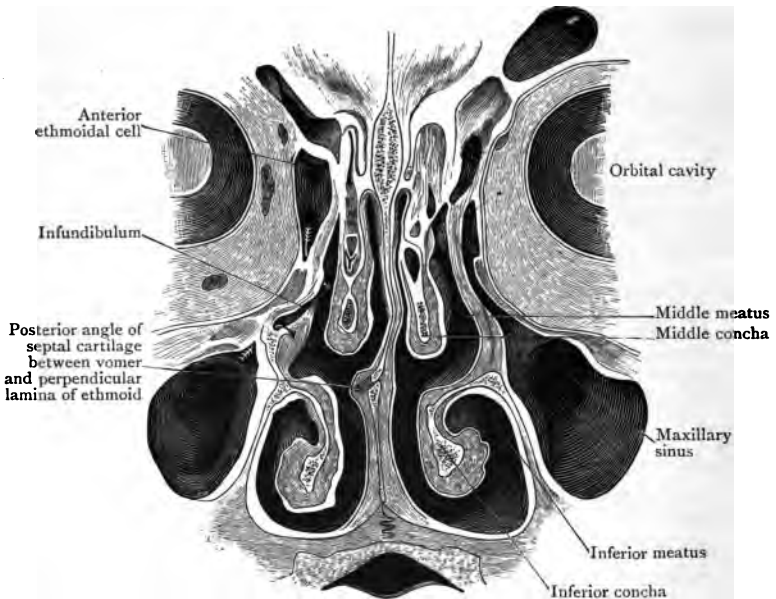


FIG. 154.—Posterior aspect of Frontal section through the Nasal Cavities opposite the Crista Galli of the Ethmoid Bone.

The upper arrow shows the opening of an anterior ethmoidal cell into the hiatus semilunaris. The lower arrow passes from the maxillary sinus into the hiatus semilunaris.

The floor of the nasal cavity is of considerable width. It is formed by the palatal processes of the maxilla and the palate bones, and is concave from side to side. Further, it presents a gentle antero-posterior slope, being slightly higher anteriorly than posteriorly. On the anterior part of the floor, and close to the septum nasi, the dissector may see a minute funnel-shaped depression of the muco-periosteum into the incisive foramen. This is of interest from a developmental point of view; for it is a vestige of the extensive communication which

existed in the embryo between the cavities of the nose and the mouth.

Lateral Wall of the Nasal Cavity.—The lateral wall of the nasal cavity is rendered uneven and complicated by the projection of the three conchæ (O.T. turbinal bones).

The part which the different bones take in the formation of the lateral wall of the cavity of the nose must in the first place be studied in a sagittal section through the macerated skull, and the dissector should constantly refer to such a preparation during the dissection. Anteriorly, it is formed by the lateral cartilage, the alar cartilage, the nasal bone, and the frontal process of the maxilla. More posteriorly the lacrimal, the ethmoid, and the inferior concha, with a small portion of the body of the maxilla, enter into its construction; whilst still more posteriorly are the perpendicular part of the palate bone and the medial pterygoid lamina of the sphenoid. Placed in relation to the lateral aspect of this wall are the ethmoidal air-cells, which intervene between the upper part of the nasal cavity and the orbit, whilst, at a lower level, the great air sinus of the maxilla, the *maxillary sinus*, is situated immediately to the lateral side of the nasal cavity (Fig. 154).

Turning now to the dissection, the dissector will see that the lateral wall is separable into three areas or districts. These are—(1) the vestibule; (2) the atrium meatus medii; (3) the region of the conchæ and the intervening meatuses.

Vestibulum Nasi.—The vestibular part (Fig. 155, 6, 6') of the lateral wall is a depression of a somewhat oval form placed immediately above the aperture of the nostril. It is partially divided into an upper and lower portion by a short ridge, which projects anteriorly from its posterior boundary; and it is clothed throughout with integument continuous with the skin. From this a number of stout, stiff hairs, termed *vibrissæ*, project (Fig. 155, 5). The *vibrissæ* which spring from the anterior part of the region incline posteriorly, whilst those which are implanted into the posterior part are directed anteriorly; in this manner a sieve-like arrangement is provided at the anterior aperture of the nose. The vestibular part of the lateral wall is placed opposite the corresponding area on the septum nasi, and the two together constitute an ampullated entrance to the nasal cavity. The capacity and shape of this section of the cavity is influenced to a certain extent by the contraction of the nasal muscles.

Atrium Meatus Medii.—This part of the lateral wall of the nasal cavity (Fig. 155, 8) is placed above, and slightly posterior to the vestibular district, and it receives its name from the fact that it lies immediately anterior to the middle meatus.

It is slightly hollowed out and concave, and at its upper part, near the nasal bone, a feeble elevation termed the *agger nasi* may be noticed; this begins close to the anterior part of the attached margin of the middle concha, and runs obliquely

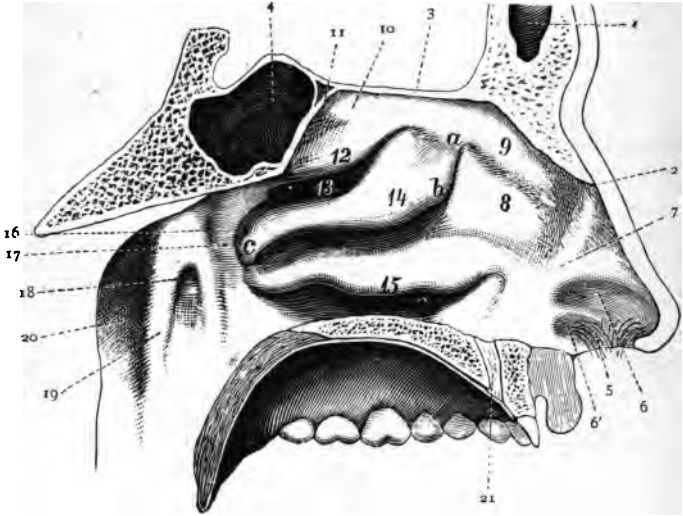


FIG. 155.—Lateral Wall of the Left Nasal Cavity. (From Schwalbe.)

- | | |
|--|--|
| 1. Frontal air sinus. | 11. Recessus sphenoidalis. |
| 2. Free border of the nasal bone. | 12. Superior concha. |
| 3. Cribriform plate of ethmoid. | 13. Superior meatus. |
| 4. Sphenoidal air sinus. | 14. Middle concha. |
| 5. Vibrissæ. | 15. Inferior concha. |
| 6', 6. The two parts of the vestibular area. | 16. Plica naso-pharyngea. |
| 7. Elevation intervening between the vestibular district and the atrium. | 17. Meatus naso-pharyngeus. |
| 8. Atrium meatus medii. | 18. Orifice of auditory tube. |
| 9. Agger nasi, or rudiment of an anterior concha. | 19. Posterior lip of auditory tube. |
| 10. Concha suprema. | 20. Lateral recess of pharynx. |
| | 21. Incisive foramen. |
| | a, b, c. Free border of the middle concha. |

downwards and anteriorly. It represents an additional concha which is present in some mammals. A slight depression above the agger nasi, which leads posteriorly to the olfactory district of the lateral wall of the nasal cavity, is the sulcus olfactorius.

Conchæ (O.T. turbinal bones).—Posterior to the vestibule
 = shell.

and the atrium are the conchæ with the intervening meatuses. The *superior concha* (Fig. 155, 12), which projects from the labyrinth of the ethmoid bone, is very short, and is placed on the upper and posterior part of the lateral wall of the cavity. Its free border begins a short distance below the centre of the cribriform plate, and passes obliquely downwards and posteriorly to a point immediately below the body of the sphenoid, where it ends. The *middle concha* (Fig. 155, 14) also is a part of the ethmoid. Its free border begins a short distance below the anterior end of the cribriform plate, and at first takes a vertical course downwards; then, bending suddenly, it passes posteriorly, and it ends midway between the body of the sphenoid and the posterior border of the hard palate. The *inferior concha* (Fig. 155, 15) is an independent bone; it extends posteriorly upon the lateral wall of the nasal cavity, midway between the middle concha and the floor of the nose. Its lower free margin is somewhat convex downwards.

Meatus Nasi.—The *superior meatus* (Fig. 155, 13) is a short narrow fissure between the superior and middle conchæ. The posterior ethmoidal cells open into its upper and anterior part by one, or, in some cases, by several apertures.

To bring these orifices into view, the superior concha should be turned aside by introducing the blade of a pair of forceps under its entire length, and forcing it upwards. Care should be taken not to injure the mucous membrane more than is necessary.

The *middle meatus* is a much more roomy passage which extends posteriorly from the atrium, between the middle and inferior conchæ.

The middle concha should be forcibly tilted upwards and posteriorly.

The upper and anterior part of the middle meatus leads into a funnel-shaped passage which runs upwards into the corresponding frontal sinus. This passage, the *infundibulum*, constitutes the channel of communication between the frontal sinus and the nasal cavity.

Upon the lateral wall of the middle meatus a deep curved groove or gutter, which commences at the *infundibulum* and runs from above downwards and posteriorly, will be seen. In this groove, which is termed the *hiatus semilunaris* (Fig. 156), are the openings of the anterior ethmoidal cells and

the maxillary sinus. The upper boundary of the hiatus semilunaris is prominent and bulging. It is termed the *bul**la ethmoidalis*. On or above the bulla is the aperture of the middle ethmoidal cells (Fig. 156). The slit-like opening of the maxillary sinus lies in the posterior part of the hiatus semilunaris.

The dissector should now open up the maxillary sinus by removing its lateral wall. This may be done by sawing upwards through the root of the zygomatic process of the maxilla.

The orifice by means of which this great air sinus com-

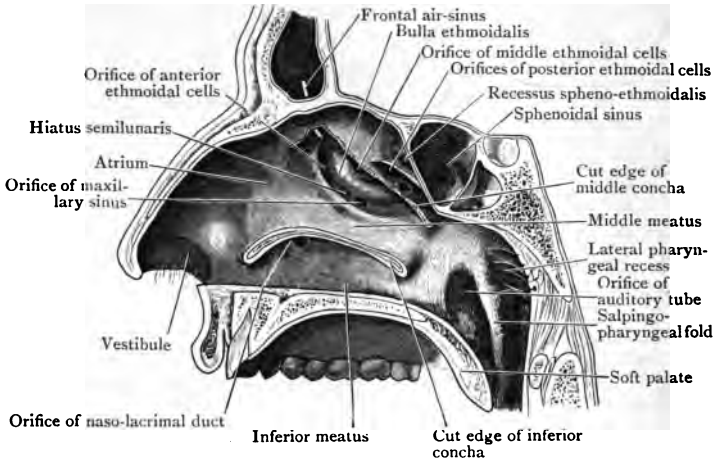


FIG. 156.—Lateral wall of Nasal Cavity and Naso-pharynx. The three conchæ have been removed.

municates with the middle meatus lies in the medial wall of the cavity much nearer the roof than the floor—a position highly unfavourable for the escape of fluids which may collect in it. Sometimes, however, a second orifice, circular in outline, will be found. This is situated lower down; when it is present it opens into the middle meatus, immediately above the middle point of the attached margin of the inferior concha.

The dissector should note that, on account of the relationship of the infundibulum to the hiatus semilunaris and of the latter to the opening of the maxillary sinus, there is a tendency, in some cases, for the secretion of the frontal sinuses to flow into the maxillary sinus.

The *inferior meatus* is the horizontal passage which lies between the inferior concha and the floor and lateral wall of the nasal cavity. It is placed posterior to the vestibule, and the free border of the inferior concha turns downwards and limits it anteriorly (Fig. 156). On this account, and because its floor slopes downwards and posteriorly, the inferior meatus is more accessible to the current of expired air than to the current of inspired air. In the anterior part of this meatus will be found the opening of the naso-lacrimal duct which conveys the tears to the nasal cavity (Fig. 156).

To bring the aperture of the naso-lacrimal canal into view, remove a small portion of the anterior part of the inferior concha with the scissors.

The orifice of the naso-lacrimal duct varies in form, according to the manner in which the mucous membrane is arranged around it. Sometimes it is wide, patent, and circular; at other times the mucous membrane is prolonged over the opening, reducing its size and acting as a flap valve to the orifice. In some cases, indeed, the orifice may be so minute that it is difficult to find. Its continuity with the lacrimal sac should in all cases be established by passing a probe from above downwards through the naso-lacrimal canal (Fig. 64).

A *fourth* meatus is generally present on the lateral wall of the nasal cavity. This is due to the partial subdivision of the superior concha into an upper and lower part by a short groove which proceeds anteriorly from the anterior aspect of the body of the sphenoid. This additional meatus is termed the *recessus sphenoidalis*, and in its posterior part is the aperture of the sphenoidal air sinus (Fig. 156). This orifice may be circular or slit-like, according to the manner in which the mucous membrane is disposed around it.¹ The upper portion of the superior concha which is placed above this additional meatus is called the *concha suprema* (Fig. 155, 10).

To the narrow cleft-like portion of the nasal cavity which extends from the roof to the floor between the septum medially and the conchæ laterally the term *meatus communis* is applied; and the part of the cavity which lies posterior

¹ When the recessus sphenoidalis is absent, the sphenoidal air sinus opens into the interval between the roof of the nasal cavity and the superior concha.

to the conchal region, and between it and the choanæ, is the naso-lacrimal duct (Fig. 155. -1)

Muco-periosteum of the Lateral Wall of the Cavum Nasi.

—It has been noted that the vestibule is lined with integument. The remainder of the lateral wall, as well as the roof and floor of the nasal fossa, is lined with mucous membrane which is so closely blended with the subjacent periosteum that the two are inseparable and form a muco-periosteum. This is continuous through the naso-lacrimal duct with the ocular conjunctiva, through the various apertures with the delicate lining membrane of the air-cells which open into the nasal cavity, and through the choanæ with the pharyngeal mucous membrane. On the lateral wall, as on the septum, the muco-periosteum is mapped out into an upper olfactory and a lower respiratory portion. This subdivision cannot be appreciated by the naked eye, for the one district passes into the other without any sharp line of demarcation. The *olfactory region* comprises merely the upper concha; the *respiratory region* includes the middle and inferior conchæ, the middle meatus, the lower meatus, and the atrium. In the lower part of the lateral wall the muco-periosteum is thick and spongy. This is particularly noticeable over the lower borders and posterior extremities of the middle and inferior conchæ, where the membrane presents an irregular surface and forms soft bulging cushions. This condition is largely due to the presence of a rich venous plexus, the vessels of which run for the most part in an antero-posterior direction. In the case of the lower concha, the veins are so numerous that the muco-periosteum assumes the character of cavernous tissue, and is sometimes spoken of as the “erectile body.” When ^{swollen} turgid with blood it swells out and obliterates the interval between the concha and the septum. The muco-periosteum of the floor, meatuses, and the atrium, is smoother than, and not so thick as, that over the conchæ. Everywhere numerous mucous glands are embedded in it, and the minute punctiform orifices of the ducts are visible to the naked eye. In the olfactory region the lining membrane of the nose, in the fresh state, is of a yellowish colour, and it is softer and more delicate than in the respiratory part.

The great vascularity of the mucous membrane of the nose is doubtless for the purpose of moistening and raising the temperature of the inspired air.

Nerves and Vessels on the Lateral Wall of the Nasal Cavity :—

- | | |
|--------------------------------------|--|
| Nerves of Smell, . | Olfactory nerves. |
| Nerves of Common
Sensation, . . . | 1. Lateral nasal branches of anterior ethmoidal. (17th) |
| | 2. Nasal branch of anterior superior alveolar. (18th) |
| | 3. Posterior superior nasal branches from sphenopalatine ganglion and from the nerve of the pterygoid canal. |
| | 4. Two posterior inferior nasal branches from the anterior palatine nerve. |

The *olfactory nerves* are from twelve to twenty fine filaments which spring from the lower surface and the extremity of the olfactory bulb, and, passing through the apertures in the cribriform plate of the ethmoid into the nasal cavity, they separate into a lateral and a medial group. To each nerve an investment from the cerebral membranes is given. The *medial or septal nerves* were described on p. 392. The *lateral nerves* descend in the muco-periosteum on the lateral wall of the nasal cavity. At first lodged in shallow grooves or minute bony canals, they soon divide into bunches of branches which spread out over the upper concha and the region immediately below. The dissection of these nerves is exceedingly difficult, but in a well-preserved part they can generally be partially displayed.

The *posterior superior nasal nerves*, which come from the sphenopalatine ganglion and from the nerve of the pterygoid canal, are minute filaments, but the dissector should nevertheless endeavour to trace them to their distribution upon the lateral wall. They enter the nose through the sphenopalatine foramen, which is situated at the posterior end of the superior meatus.

The best plan to adopt for their display is to trace the largest of the group, the naso-palatine nerve, which has already been exposed on the nasal septum, laterally across the roof of the nasal cavity. This will lead the dissector to the foramen, and by carefully dissecting the muco-periosteum in its neighbourhood the other nerves of the group may be detected as they enter the nasal cavity.

They are distributed to the muco-periosteum over the upper and middle conchæ, and the posterior part of the septum.

The *inferior nasal nerves* are two in number; they both arise from the anterior palatine nerve.

Make a vertical incision, through the muco-periosteum over the posterior part of the medial pterygoid lamina, and carefully raise the membrane from the posterior part of the lateral wall of the nasal cavity.

The *upper* of the two inferior nasal nerves will be found emerging through a small aperture in the perpendicular part

of the palate bone, at a point between the posterior extremities of the middle and inferior conchæ. It divides into an ascending and descending branch. Both run anteriorly; the former on the middle concha, the latter on the inferior concha. The *lower* of the two inferior nasal nerves appears through a foramen in the perpendicular part of the palate bone, immediately posterior to the inferior concha, upon which it is distributed.

The *anterior ethmoidal nerve* (O.T. *nasal*) should be exposed as it descends in the groove upon the deep surface of the nasal bone (p. 393). It gives medial branches to the septum, and lateral branches to the muco-periosteum over the anterior part of the lateral wall, and to the anterior parts of the middle and inferior conchæ.

The main *artery* of supply to the nasal muco-periosteum is the *spheno-palatine*, a branch of the internal maxillary. It gains entrance to the nasal cavity through the spheno-palatine foramen, in company with the posterior superior nasal nerves. The septal branch of this vessel accompanies the naso-palatine nerve, whilst others are distributed upon the lateral wall of the cavity. Several twigs are given also by the *descending palatine branch* of the internal maxillary and the *two ethmoidal arteries*, but these are small and will be seen only in cases where the injection of the subject has been unusually successful.

SPHENO-PALATINE GANGLION AND INTERNAL MAXILLARY ARTERY.

The spheno-palatine ganglion is situated in the pterygo-palatine fossa on the lateral side of the spheno-palatine foramen; and at this stage it can be exposed best by dissecting from the medial or nasal side.

Dissection.—The muco-periosteum has already been removed from the posterior part of the lateral wall of the nasal cavity, and the inferior nasal branches of the anterior palatine nerve have been found piercing the perpendicular part of the palate bone. The dissector cannot fail to notice the course taken by the trunk from which these filaments arise. The lamina of bone which forms the medial wall of the pterygo-palatine canal is so thin that the nerve can be distinctly seen through it. By carefully opening up this canal with a chisel, and following the anterior palatine nerve upwards, the dissector will be led to the ganglion in the pterygo-palatine fossa. The naso-palatine nerve should at the same time be traced to its origin. The ganglion is so hemmed in by the bony walls of the fossa that it is very difficult to display it thoroughly; but by removing the orbital process of the

palate bone, and a portion of the body of the sphenoid, with the bone forceps, it may be more or less satisfactorily exposed. In the same restricted space will be found the terminal portion of the internal maxillary artery, from which numerous branches are given off.

Ganglion Spheno-palatinum.—This is a small, triangular flattened body, which is lodged in the pterygo-palatine fossa. It is embedded in soft fat, and is surrounded by the terminal branches of the internal maxillary artery. Two stout spheno-palatine branches descend from the maxillary nerve and join it from above, but only certain of their fibres are involved in the ganglion; the remainder are continued directly into the nasal and palatine nerves which proceed from the ganglion. The spheno-palatine branches may be regarded as constituting the *sensory roots* of the ganglion.

From the spheno-palatine ganglion branches are given off which radiate in four directions—viz., medially to the nose; downwards to the palate; posteriorly to establish connections with the facial nerve and carotid plexus, as well as to supply the mucous membrane of the pharynx; and anteriorly to the orbit.

Medial branches,	. Posterior superior nasal nerves.
Descending branches,	{ Anterior palatine.
	{ Middle palatine.
	{ Posterior palatine.
Posterior branches,	{ Nerve of pterygoid canal.
	{ Some lateral posterior superior nasal branches.
Anterior branches,	. Orbital.

From the internal maxillary artery twigs are given off which accompany these nerves.

Posterior Superior Nasal Nerves.—There are two groups of the posterior superior nasal nerves, a medial and a lateral. The medial branches pass through the spheno-palatine foramen and across the roof of the nasal cavity to the posterior part of the septum. The largest of them, the naso-palatine nerve, runs downwards and anteriorly in a groove on the surface of the vomer (p. 392). Some of the branches of the lateral posterior group also pass through the spheno-palatine foramen and are distributed to the superior meatus, to the superior and middle conchæ, and to the posterior ethmoidal air cells. Other branches of the lateral group pass posteriorly, some in the muco-periosteum of the upper and posterior part of the nasal cavity, and one in the pharyngeal canal (O.T.

pterygo-palatine or pharyngeal nerve). They are distributed to the muco-periosteum of the posterior part of the roof of the nasal cavity, to the adjacent parts of the wall of the pharynx, to the sphenoidal air sinus, and to the pharyngeal part of the auditory tube.

The *descending branches* are the palatine nerves, and with them are incorporated the posterior inferior nasal nerves. The palatine nerves are three in number, anterior (O.T. great or posterior palatine), middle, and posterior. As a rule these spring by a common trunk from the lower aspect of the ganglion. The trunk descends in the pterygo-palatine canal, which has been opened up already, but to expose the nerves a dense fibrous investment must also be removed. The nerve-trunk will then be seen breaking up into its constituent parts.

Dissection.—Trace, in the first instance, the two smaller nerves—viz., the middle and posterior palatine branches. These leave the main canal and enter the small palatine canals, which conduct them through the pyramidal process of the palate bone. Before opening these up it is well to secure the nerves as they emerge from the lower openings of the canals. This can very readily be done, by dissecting posterior to the hamulus of the medial pterygoid lamina and gently separating the soft parts from the under aspect of the pyramid of the palate bone. As the dissection is being made from the inside, the *middle palatine nerve* will be first encountered, and it will be seen to pass posteriorly into the soft palate, under cover of the tendinous expansion of the tensor veli palatini.¹ This must be divided, in order that the nerve may be followed to its distribution. The *posterior palatine nerve* will be found issuing from its canal a short distance to the lateral side of the preceding nerve. It is distributed to the soft palate in the neighbourhood of the tonsil. It is smaller than the middle palatine nerve, and is sometimes absent. The large *anterior palatine nerve* should now be followed onwards to the hard palate. To do this the lower part of the palatine canal must be opened up by removing a small portion of the posterior and lateral part of the horizontal plate of the palate bone.

The *anterior palatine nerve* is the largest branch of the spheno-palatine ganglion. It descends through the pterygo-palatine canal, accompanied by the great palatine branch of the internal maxillary artery; it enters the palate through the great palatine foramen and runs anteriorly, in a groove on the lower aspect of the hard palate, towards the incisive foramen. It supplies the gum, the mucous membrane, and the glands of the vault of the mouth; and, in the neighbourhood of the incisive foramen, it communicates with the naso-palatine

¹ The present is a good opportunity to observe the corrugated or wrinkled appearance of the tendon of the tensor palati, as it passes under the hamulus.

nerve. As it passes down the pterygo-palatine canal the posterior inferior nasal branches, which were enclosed in its sheath, leave it and enter the nasal cavity (p. 401).

In tracing the anterior palatine nerve in the palate, the dissector should note the numerous glands which are placed under the mucous membrane of the vault of the mouth, and the manner in which these indent the bone.¹

Dissection.—Considerable difficulty will be experienced in exposing the nerves in the *pharyngeal* and *pterygoid canals*, which are very inaccessible.

To open up the pharyngeal canal the sphenoidal process of the palate bone must be cautiously removed with the bone forceps, and then the dissector should proceed to open up the pterygoid canal (O.T. Vidian), which traverses the root of the pterygoid process. As the bone is very hard and brittle at this point, the dissection must be effected very carefully.

The *nerve of the pharyngeal canal* belongs to the posterior superior nasal group (p. 403).

Nervous Canalis Pterygoidei (O.T. Vidian).—The nerve of the pterygoid canal is formed by a junction between the *great superficial petrosal branch* of the facial and the *great deep petrosal branch* of the carotid plexus. It traverses the pterygoid canal, and joins the posterior aspect of the sphenopalatine ganglion, of which it may be considered to represent both the *motor* and *sympathetic root*. In the canal it is invested by a strong fibrous envelope, and when this is removed it may sometimes be noticed to break up into a fine plexus which surrounds the accompanying artery. It has already been seen to give some fine filaments to the muco-periosteum of the nose.

The Rami Orbitales.—The orbital branches of the ganglion are exceedingly minute; they pass anteriorly through the inferior orbital fissure to supply the periosteum of the orbit.

Termination of Internal Maxillary Artery.—The internal maxillary artery breaks up into its terminal branches in the pterygo-palatine fossa. They are—

1. Posterior superior alveolar (p. 271).
2. The infra-orbital (p. 388).
3. The descending palatine.
4. The sphenopalatine.

The Descending Palatine Artery.—The descending palatine

¹ An equally good method of tracing the anterior palatine nerve is to remove the palatal processes of the palate and maxilla with the bone forceps, and then to display the nerve and artery on the upper surfaces of the mucous membrane and glands.

artery is a terminal branch of the internal maxillary artery. As it descends in the pterygo-palatine fossa it gives off, usually, the artery of the pterygoid canal, and as it enters the pterygo-palatine canal several small palatine arteries spring from it; then it becomes the *great palatine artery*. The great palatine artery descends through the great palatine foramen into the hard palate; there it runs anteriorly to reach the incisive foramen, through which it passes into the nasal cavity to anastomose with the posterior artery of the septum, which is an offset of the spheno-palatine artery.

The *small palatine arteries*, which spring from the descending palatine, immediately before it becomes the great palatine artery, in the upper part of the pterygo-palatine canal; they descend through the small palatine canals, and are distributed to the soft palate, the palatine arches, and to the tonsil.

The Spheno-palatine Artery.—The spheno-palatine artery enters the nasal cavity through the spheno-palatine foramen. It gives off (1) a branch to the sphenoidal air sinus, (2) a branch which passes posteriorly to the upper part of the pharynx through the pharyngeal canal (O.T. pterygo-palatine artery) to be distributed to the roof of the posterior part of the nasal cavity and to the roof of the pharynx; this branch anastomoses with the ascending pharyngeal artery. Then the spheno-palatine artery divides into lateral and septal posterior nasal branches. The lateral branches are distributed to the lateral wall of the nasal cavity, where they anastomose with the branches of the posterior and anterior ethmoidal arteries, and with the lateral nasal branch of the external maxillary. They supply not only the muco-periosteum of the lateral wall of the nasal cavity, but also the muco-periosteum of the air sinuses which open into the cavity. The posterior septal branch of the spheno-palatine artery accompanies the posterior nasal septal nerve along the surface of the vomer; it anastomoses with the great palatine artery, and with the septal branch of the superior labial artery.

THE LARYNX.

The lateral portions of the mandible, which are still attached by mucous membrane to the sides of the tongue, should be removed, and the dissection of the larynx commenced.

General Construction and Position.—The larynx constitutes the upper expanded portion of the air-passage which is specially modified for the production of the voice. Its walls are composed of cartilages, muscles, ligaments, and an internal lining of mucous membrane. Before proceeding with the dissection the student should study the form and connections of the nine laryngeal cartilages in a permanent specimen (*v. p. 422*).

The larynx is placed in the upper and anterior part of the neck, where it forms a marked projection. It lies below the hyoid bone and tongue, and is directly continuous with the trachea inferiorly. Anteriorly it is covered by the integument and fasciæ, and, on either side of the median plane, by two thin strata of muscles—viz., the sterno-hyoid and omo-hyoid; the sterno-thyreoid and the thyreo-hyoid. As a general rule a narrow process of the thyreoid gland, termed the *pyramidal lobe*, is also continued upwards on its anterior surface. On *each side* the lateral lobe of the thyreoid gland is prolonged upwards upon it; and it is related to the great vessels of the neck. *Posteriorly* it is in relation to the pharynx, which separates it from the prevertebral muscles. If the tip of the epiglottis is taken as its upper limit, the larynx in the adult may be regarded as being placed anterior to that portion of the vertebral column which extends from the lower border of the second to the lower border of the sixth cervical vertebra; but its position alters somewhat with the movements of the head and also during deglutition.

Interior of the Larynx.—The cavity of the larynx is smaller than might be expected from an inspection of its exterior. On looking into its interior from above it will be seen to be subdivided into three portions by two elevated folds of mucous membrane which extend antero-posteriorly, and project inwards from each side of the cavity.—The upper folds are termed the *plicæ ventriculares* (O.T. *false vocal cords*); the lower pair receive the name of the *plicæ vocales* (O.T. *true vocal cords*). The latter are the chief agents in the production of the voice, and the larynx is so constructed that changes in their relative position and in their degree of tension are brought about by the action of the muscles and the recoil of the elastic ligaments.

Vestibulum Laryngis.—The vestibule is the upper subdivision of the laryngeal cavity (Fig. 150); it extends from the

superior aperture (*aditus laryngis*) of the larynx down to the plicæ ventriculares. In its lower part it exhibits a marked lateral compression. Its width, therefore, diminishes from above downwards, whilst owing to the obliquity of the aditus the anterior wall is longer than the posterior. *Anteriorly* it is bounded by the posterior surface of the epiglottis and the thyreo-epiglottic ligament, both covered with mucous mem-

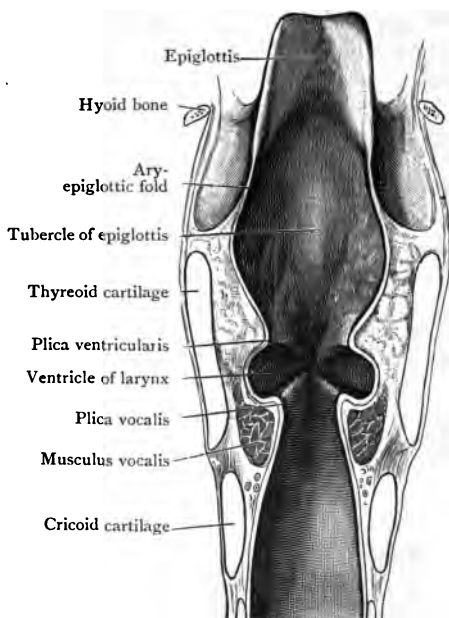


FIG. 157.—Frontal section through the Larynx to show the Compartments.

brane. This wall descends obliquely from above downwards and anteriorly, and becomes narrower as it approaches the anterior ends of the plicæ ventriculares. Each *lateral wall* of the vestibule is formed by the medial surface of the ary-epiglottic fold. For the most part it is smooth and slightly concave, but in its posterior part the mucous membrane bulges medially in the form of two elongated vertical elevations placed one posterior to the other. The

anterior elevation is formed by the cuneiform cartilage and a mass of glands associated with it, enclosed within the ary-epiglottic fold; the posterior elevation is due to the anterior margin of the arytaenoid cartilage and the corniculate cartilage. A shallow groove descends between these rounded elevations and terminates below by running into the interval between the ventricular and the vocal folds. The *posterior wall* of the vestibule is narrow, and corresponds to the interval between the upper parts of the two arytaenoid cartilages.

The *aditus laryngis* has already been examined in the dissection of the pharynx (p. 378). The parts which bound it should again be carefully studied.

The *epiglottis* projects upwards posterior to the root of the tongue. Its lingual or anterior surface is free in the upper part of its extent only, and is attached to the pharyngeal part of the tongue by a prominent median fold of mucous membrane, termed the *glosso-epiglottic fold*. Two lateral folds are also present; they connect its margins with the lateral walls of the pharynx at the side of the tongue and are called the *pharyngo-epiglottic folds*. Between the two layers of mucous membrane which constitute each of these three folds, there is a small amount of elastic tissue. The depression on each side between the tongue and the epiglottis which is bounded by the glosso-epiglottic and the pharyngo-epiglottic folds is termed the *vallecula* (Fig. 150). The posterior free surface of the epiglottis forms the greater part of the anterior boundary of the vestibule of the larynx. The upper part of this surface is convex, owing to the manner in which the upper margin is curved towards the tongue; below this convexity there is a slight concavity, and still lower a marked bulging over the upper part of the thyreo-epiglottic ligament. This last projection is called the *tubercle of the epiglottis*; it forms a conspicuous object in laryngoscopic examinations of the larynx.

The *ary-epiglottic folds* of mucous membrane enclose between their two layers some connective tissue, the ary-epiglottic muscles, and, posteriorly, the cuneiform and the corniculate cartilages, which surmount the arytaenoid cartilages. As already mentioned, these small nodules of cartilage raise the posterior part of the ary-epiglottic fold in the form of two rounded eminences or tubercles which are easily seen when the larynx is examined by the laryngoscope.

The **Middle Subdivision of the Laryngeal Cavity** (Fig. 157) is the smallest of the three. Above it is bounded by the ventricular folds, below by the vocal folds; it communicates with the vestibule above and the inferior compartment of the larynx below.

Plicae Ventriculares (O.T. *false vocal cords*).—The ventricular folds are two prominent mucous folds which extend antero-posteriorly on the lateral walls of the laryngeal cavity. They are soft and somewhat flaccid, and their free borders are

slightly arched, with the concavities looking downwards. Within each fold are contained—(1) a ligamentum ventriculare; (2) numerous glands which are chiefly aggregated in its middle part; and (3) a few muscle fibres. The interval between the ventricular folds is termed the *rima vestibuli*; it is considerably wider than that between the vocal folds. It follows, therefore, that the four folds are distinctively visible when the cavity of the larynx is examined from above, but when examined from below, the vocal folds alone can be seen.

Plicæ Vocales (O.T. *True vocal cords*).—The vocal folds are placed below the ventricular folds, and extend from the angle between the laminæ of the thyreoid cartilage, anteriorly, to the

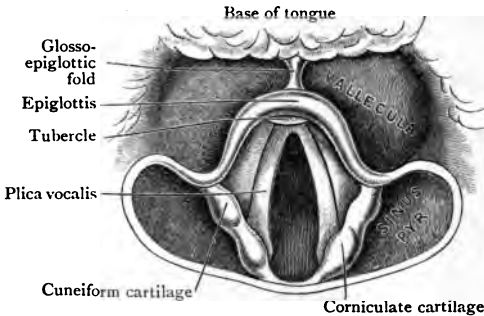


FIG. 158.—The Larynx as seen in the living person by means of the Laryngoscope.

vocal processes of the arytaenoid cartilages posteriorly. Each vocal fold is sharp and prominent, and its mucous membrane is thin and is firmly bound down to the subjacent vocal ligament. In colour it is pale, almost pearly white, whilst posteriorly the point of the vocal process of the arytaenoid cartilage, which stands out in relief, presents a yellowish tinge. In frontal section each vocal fold is somewhat prismatic in form, and the free border looks upwards and medially (Fig. 157).

The vocal folds are the agents by means of which the voice is produced. The ventricular folds are of little importance in this respect; indeed, they can in great part be destroyed without any appreciable difference in the voice resulting.

The *rima glottidis* is the elongated fissure by means of which the middle compartment of the larynx communicates with the lower subdivision. It is placed somewhat below

the middle of the laryngeal cavity, of which it constitutes the narrowest part. Anteriorly it corresponds to the interval between the vocal folds; posteriorly it corresponds to the interval between the bases and vocal processes of the ary-tænoid cartilages (Fig. 160). It is composed, therefore, of two very distinct parts—(1) a narrow anterior portion, between the vocal folds, involving less than two-thirds of its length, and called

the *pars intermembranacea*; (2) a broader, shorter portion, between the ary-tænoid cartilages, termed the *pars intercartilaginea*. The form of the rima glottidis undergoes frequent alterations in the living person. During ordinary quiet respiration it is lanceolate in outline, and the intermembranous part has the form of an elongated triangle with the base directed posteriorly. When the glottis is widely opened the broadest part of the fissure lies between the ex-

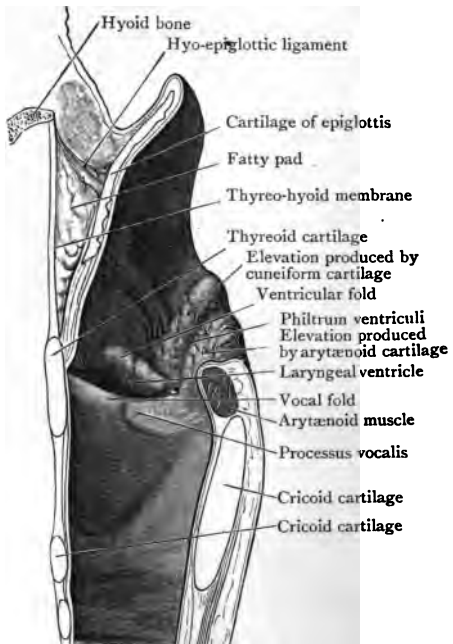


FIG. 159.—Median section through the Larynx to show the Lateral Wall of its Right Half.

processes of the ary-tænoid cartilages, and there each side of the rima presents a marked angle. The two vocal folds, on the other hand, may be approximated so closely to each other, as in singing a high note, that the intermembranous part is reduced to a linear chink. The length of the entire fissure differs considerably in the two sexes. In the male its average length is 23 mm.; in the female, 17 mm.

The lateral wall of the larynx, in the interval between the ventricular and the vocal folds, shows a pocket-like depression

or recess, termed the *ventriculus laryngis* (O.T. *laryngeal sinus*). The dissector should endeavour to gauge the extent of this, by means of a probe bent at the extremity. The recess passes upwards, undermining the ventricular fold, and its mouth or orifice is narrower than its cavity. Under cover of the anterior part of the ventricular fold a slit-like aperture will be detected. This leads into the *appendix ventriculi* (O.T. *laryngeal saccule*), a small diverticulum, which ascends between the ventricular fold and the lamina of

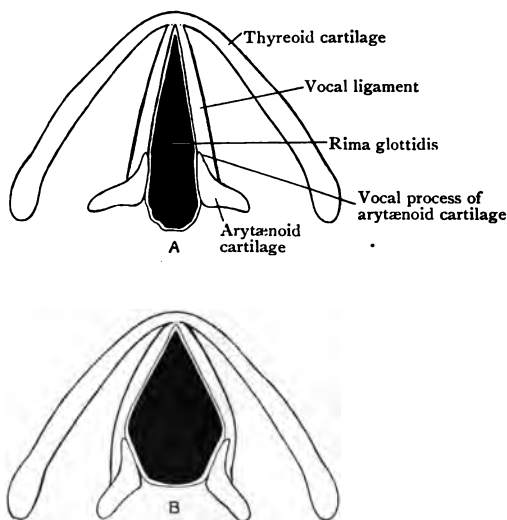


FIG. 160.—Diagram of the rima glottidis.

A. During ordinary easy breathing.

B. Widely open.

the thyroid cartilage. This sac is of variable extent, but as a rule it ends blindly at the level of the upper border of the thyroid cartilage.

Distend the ventricle, and, if possible, the appendix, with cotton wadding. This will greatly facilitate the subsequent dissection.

The **Lowest Subdivision of the Laryngeal Cavity** (Fig. 157) leads directly downwards into the trachea. Above, it is narrow and laterally compressed, but it gradually widens out until in its lowest part it is circular. It is bounded by the sloping inner surface of the conus elasticus, and by the inner

aspect of the cricoid cartilage. It is through the anterior wall of this compartment that the opening is made in the operation of laryngotomy.

Mucous Membrane of the Larynx.—This is continuous above with that lining the pharynx, and below with the mucous lining of the trachea. Over the laryngeal or posterior surface of the epiglottis it is closely adherent, but elsewhere, above the level of the vocal folds, it is loosely attached by submucous tissue. As it passes over the vocal folds it is very thin and tightly bound down, and in inflammatory conditions of the larynx, attended by œdema, this attachment usually prevents the infiltration of the submucous tissue from extending downwards below the rima glottidis.

The mucous membrane of the larynx has a plentiful supply of racemose glands which secrete mucus. Over the surface of the vocal folds these are completely absent.

Dissection.—Place the larynx upon a block so that its anterior surface looks upwards, and fix it in that position with pins. The branches which the external laryngeal nerve gives to the crico-thyroid muscle should in the first place be followed out; and, carefully preserving the superior and inferior laryngeal vessels and the internal and inferior laryngeal nerves, the dissector should in the next place proceed to remove the thyroid gland, and the omo-hyoid, sterno-hyoid, sterno-thyroid, and thyreo-hyoid muscles. The fibres of origin of the inferior constrictor muscle also should be cleared away from the thyroid and cricoid cartilages. The broad thyreo-hyoid membrane, the crico-thyroid ligament, and the crico-thyroid muscles are now exposed, and their attachments may be defined.

Membrana Hyo-thyreoidea.—This is a broad membranous sheet, which occupies the interval between the hyoid bone and the thyroid cartilage. It is not equally strong throughout, but shows a central thick portion, the *median thyreo-hyoid ligament*, largely composed of elastic fibres, and cord-like right and left margins, the *lateral thyreo-hyoid ligaments*, whilst in the intervals between the central part and the lateral margins it is thin and weak. The median ligament is attached above to the posterior aspect of the upper margin of the body of the hyoid bone; below, it is fixed to the sides of the deep median notch which interrupts the superior border of the thyroid cartilage. The upper part of its anterior surface is, therefore, placed posterior to the posterior hollowed-out surface of the body of the hyoid bone; a mucous bursa is interposed between them, and in certain movements of the head and larynx the upper border of the thyroid cartilage is allowed to slip upwards posterior to the hyoid bone. On each side of

the strong central part the thyreo-hyoid membrane is attached below to the upper margin of the lamina of the thyroid cartilage, and above to the deep aspect of the great cornu of the hyoid bone. It is pierced by the internal laryngeal nerve and superior laryngeal vessels. The lateral thyreo-hyoid ligament, which forms the posterior border of the membrane, on each side, is rounded and cord-like, and is composed chiefly of elastic fibres. It extends from the tip of the great cornu of the hyoid bone to the extremity of superior cornu of the thyroid cartilage. In this ligament there is usually developed

a small oval cartilaginous or bony nodule, which is termed the *cartilago triticea*.

Musculus Cricothyroideus.—The cricothyroid muscle is placed on the side of the cricoid cartilage, and bridges over the lateral portion of the crico-thyroid interval. Taking origin from the lower border and outer surface of the arch of the cricoid cartilage, its fibres spread out in an upward and posterior direction, and are inserted into the inner aspect of the lower margin of the

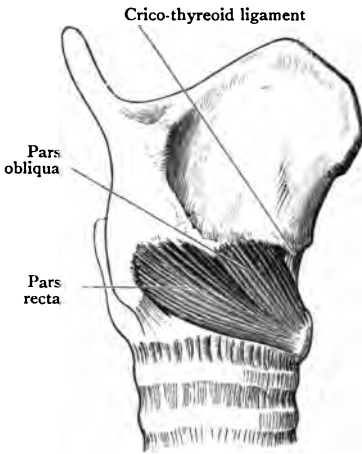


FIG. 161.—The Crico-thyroid Muscle.

thyroid lamina, and also into the anterior border of its inferior cornu. As a general rule, it is divided into two parts. The *anterior* or *oblique part* is composed of those fibres which are attached to the lamina of the thyroid cartilage; the *posterior* or *straight part* is formed of those fibres which are inserted into the inferior cornu of the thyroid cartilage. It is closely associated with the inferior constrictor muscle. The cricothyroid muscle is supplied by the *external laryngeal branch* of the superior laryngeal nerve.

Conus Elasticus.—Extending upwards, from the upper border of the anterior and lateral parts of the cricoid cartilage to the thyroid and arytaenoid cartilages, is a strong elastic membrane, the *conus elasticus*, which is separable into a

median and two lateral parts. The median part is the *crico-thyreoid ligament* which extends from the upper border of the anterior part of the cricoid arch to the lower border of the thyreoid cartilage. Each lateral part (O.T. lateral part of crico-thyreoid membrane) runs upwards and medially and terminates in a free thickened border, the *ligamentum vocale*, which lies in the substance of the plica vocalis and is attached posteriorly to the vocal process of arytenoid, and anteriorly to the angle of union of the two laminae of the thyreoid cartilage. The inner surface of the conus elasticus is covered with the mucous membrane of the lowest section of the cavity of the larynx, and the outer surface is in relation with the lateral crico-arytenoid and the vocalis muscles.

Dissection.—The position of the larynx must now be reversed. Fix it upon the block in such a manner that its posterior aspect is directed upwards. The œsophagus should then be slit open by a median incision through its posterior wall. Next remove the mucous membrane which covers the posterior aspect of the cricoid and arytenoid cartilages. In doing this, bear in mind that the inferior laryngeal artery and the inferior laryngeal nerve pass upwards, between the thyreoid and cricoid cartilages, and must be preserved.

Upon the posterior aspect of the broad lamina of the cricoid cartilage the dissector will now note the two posterior crico-arytenoid muscles, and the attachment of the tendinous band through which the longitudinal fibres of the œsophagus are fixed to the cricoid cartilage. The band takes origin from the prominent median ridge on the posterior aspect of the cricoid cartilage. On the posterior surface of the arytenoid cartilages, and bridging across the interval between them, are the transverse and oblique parts of the arytenoid muscle. Especial care must be taken in cleaning this muscle in order that the connections of the superficial decussating fibres may be ascertained fully.

The lateral layer of the right ary-epiglottic fold of mucous membrane should now be cautiously removed. This will expose the ary-epiglottic muscle, the cuneiform cartilage, and the corniculate cartilage of that side. This is perhaps the most difficult part of the dissection, because the dissector has to establish the continuity of the sparse fibres, which compose the pale ary-epiglottic muscle, with the decussating fibres of the arytenoid muscle.

Musculus Crico-Arytenoideus Posterior.—The posterior crico-arytenoid muscle is somewhat fan-shaped (Fig. 162). It springs by a broad origin from the depression which marks the posterior surface of the cricoid cartilage, on each side of the median ridge, and its fibres converge to be inserted into the posterior surface of the *muscular process* or projecting lateral angle of the base of the arytenoid cartilage.

In pursuing this upward and lateral course, the fibres run with different degrees of obliquity. The uppermost fibres are short and nearly horizontal ;

the intermediate fibres are the longest, and are very oblique; whilst the lowest fibres are almost vertical in their direction.

Musculus Arytænoideus.—The arytænoïd muscle consists of two portions—a superficial part, termed the *arytænoideus obliquus*, and a deeper layer, called the *arytænoideus transversus*.

The *arytænoideus obliquus* is composed of two bundles of muscular fibres, each of which springs from the posterior aspect of the muscular process of the corresponding arytænoïd

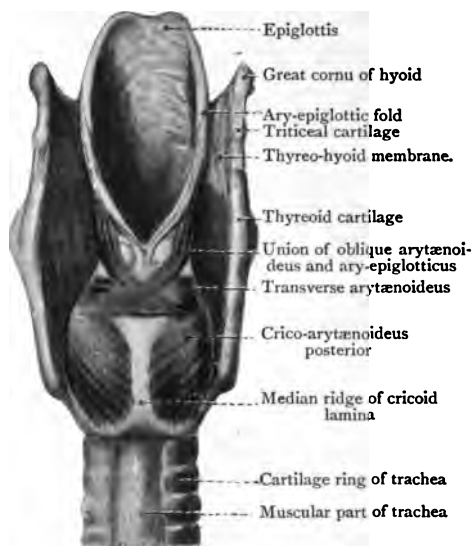


FIG. 162.—Muscles of the Posterior Aspect of the Larynx.

cartilage (Fig. 162). From these points the two fleshy slips proceed upwards and medially, and cross each other in the median plane like the limbs of the letter X. Reaching the summit of the arytænoïd cartilage of the opposite side, some of the fibres are inserted into it, but the greater proportion are prolonged, round the base of the corniculate cartilage, into the aryepiglottic fold. There they receive the name of the *aryepiglotticus muscle*, and as they approach the epiglottis they are joined by the fibres of the thyroepiglotticus muscle. The oblique arytænoïd muscles may be considered as constituting a sphincter muscle

for the superior aperture of the larynx. Each bundle starting from the base of one of the arytaenoid cartilages is prolonged into the ary-epiglottic fold of the opposite side, and along this to the margin of the epiglottis.

The *arytaenoideus transversus* is an unpaired muscle. It is composed of transverse fibres which bridge across the interval between the two arytaenoid cartilages, and are attached to the posterior aspect of the lateral border of each arytaenoid cartilage. Many of the fibres turn round the arytaenoid

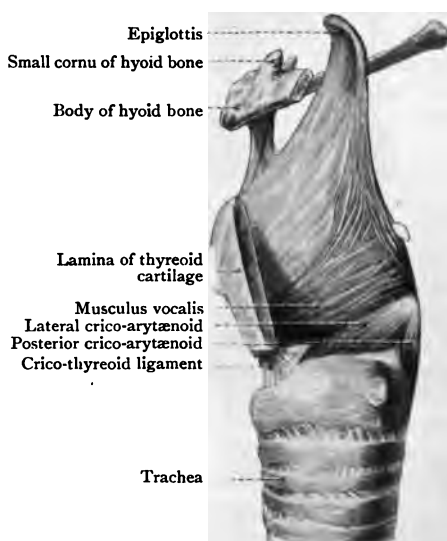


FIG. 163.—Lateral view of the Muscles of the Larynx. The fibres passing postero-superiorly from the upper border of the musculus vocalis are the fibres of the thyreo-epiglotticus. They blend above with the ary-epiglotticus.

cartilage and become continuous, on each side, with the fibres of the thyreo-arytaenoid muscle.

Dissection.—The further dissection of the laryngeal muscles should be confined to the right side of the larynx. The left side should be reserved for the study of the nerves and vessels. Place the larynx on its left side, and, having fixed it in this position, remove the right crico-thyroid muscle. The right lateral part of the thyreo-hyoid membrane should next be divided, and the right inferior cornu of the thyroid cartilage disarticulated from its facet on the side of the cricoid cartilage. An incision should now be made through the right lamina of the thyroid cartilage, a short distance to the

right side of the median plane, and the detached piece must be carefully removed. Three muscles are now exposed, and must be cleaned. They are named from below upwards:—

1. The lateral crico-arytænoid.
2. The thyreo-arytænoid.
3. The thyreo-epiglotticus.

Musculus Cricoarytænoides Lateralis.—The lateral crico-arytænoid muscle is triangular in form, and smaller than the posterior crico-arytænoid (Fig. 163). It springs from the upper border of the lateral part of the cricoid cartilage, extending to the facet on the lamina which supports the base of the arytænoid cartilage; a few of its fibres take origin from the conus elasticus also. From this attachment its fibres run posteriorly and upwards, and converge to be inserted into the anterior surface of the processus muscularis of the arytænoid cartilage. The superficial or lateral surface of this muscle is covered by the lamina of the thyreoid cartilage and the upper part of the crico-thyreoid muscle; its deep surface is applied to the conus elasticus.

Musculus Vocalis.—The musculus vocalis is a sheet of muscular fibres which springs, anteriorly, from the angle of union of the two laminae of the thyreoid cartilage. It runs posteriorly, along the ligamentum vocale and the upper part of the conus elasticus, and is inserted into the lateral surface of the body and the anterior surface of the muscular process of the arytænoid cartilage. Its lower fibres blend with the upper margin of the lateral crico-arytænoid muscle and the medial fibres, which run along and to a certain extent are attached to the ligamentum vocale,¹ form a bundle, triangular in frontal section, to which the term internal thyro-arytænoid muscle was formerly applied. The vocalis muscle protracts the arytænoid cartilage, and adducts and relaxes the vocal ligaments.

Musculus Thyreoepiglotticus.—The thyreo-epiglottic muscle springs from the thyreoid cartilage, immediately above the musculus vocalis, with the upper border of which it is more or less blended. Its fibres run posteriorly and upwards, into the ary-epiglottic fold, where they blend with the ary-epiglotticus, and they are inserted into the lateral border of the lower half of the epiglottis.

¹ The fibres which are attached to the ligamentum vocale are called collectively the *ary-vocalis muscle*.

Musculus Thyreoarytænoideus (O.T. Thyro-arytenoideus Externus).—This muscle also springs from the angle of union of the two laminæ of the thyreoid cartilage, in close association with the vocalis. Its fibres pass posteriorly, and are inserted into the lateral surface of the arytenoid cartilage. It protracts the arytenoid cartilage, and adducts and relaxes the vocal fold.

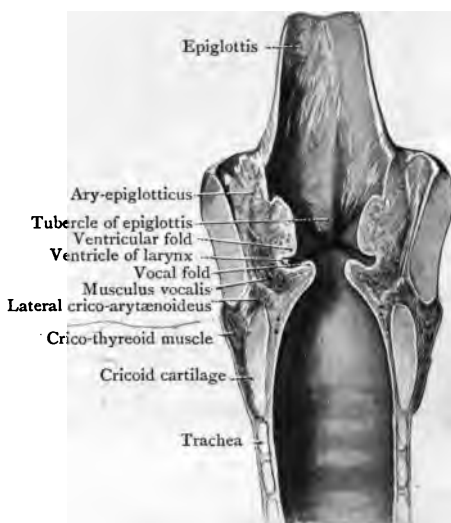



FIG. 164.—Frontal section of Larynx showing Muscles.

Dissection.—The lateral crico-arytenoid muscle should now be carefully removed, and at the same time the dissector should endeavour to disengage the fibres of the thyro-arytenoid from the deeper musculus vocalis, in order that the relation of the latter to the vocal ligament may be studied. Finally remove the musculus vocalis. This will display the outer surface of the conus elasticus, the vocal ligament, and the wall of the laryngeal ventricle. By carefully dissecting between the two layers of mucous membrane which form the ventricular fold, the weak ventricular ligament, which gives it support, may be discovered, as well as a number of racemose glands which lie in relation to it.

Ligamentum Vocale.—This ligament is the thickened free border of the lateral part of the conus elasticus, and it constitutes the support of the vocal fold. It is attached, anteriorly, close to its fellow of the opposite side, to the middle of the angular depression between the two laminæ of

of the thyroid gland. There are a numerous processes to be seen on the surface of the gland. One of the processes is the arytenoid process. It is a small, conical process of the arytenoid cartilage. It is situated on the lateral surface of the thyroid gland. It is situated on the lateral surface of the thyroid gland. It is situated on the lateral surface of the thyroid gland.



of the thyroid gland. There are a numerous processes to be seen on the surface of the gland. One of the processes is the arytenoid process. It is a small, conical process of the arytenoid cartilage. It is situated on the lateral surface of the thyroid gland. It is situated on the lateral surface of the thyroid gland. It is situated on the lateral surface of the thyroid gland.

Ligamentum Thyroideum.—The first cord supports the arytenoid cartilage. It is a small, conical process, but somewhat flattened. It is situated on the lateral surface of the thyroid gland. It is situated on the lateral surface of the thyroid gland. It is situated on the lateral surface of the thyroid gland. It is situated on the lateral surface of the thyroid gland. It is situated on the lateral surface of the thyroid gland.

Dissection.—Remove the remains of the ary-epiglottic fold, the ventricular and the vocal folds, and the lateral part of the conus elasticus on the right side of the larynx, but be careful not to injure the ary-tænoid cartilage or the corniculate cartilage. Should the cuneiform cartilage be present in the ary-epiglottic fold it should be detached and preserved. By this dissection a closer view of the side wall of the laryngeal cavity can be obtained. The undissected vocal fold of the left side should be examined again, the laryngeal ventricle and appendix explored, and their precise connections and extent determined. When the dissector has satisfied himself upon these points he can proceed to display the vessels and nerves of the larynx. The superior laryngeal artery and the internal laryngeal nerve reach the pharynx by piercing the lateral thin part of the thyreo-hyoid membrane, and they descend along the lateral wall of the recessus piriformis to the larynx. By applying traction to the nerve, and at the same time dividing the mucous membrane upon the medial surface of the thyreo-hyoid membrane, they can easily be discovered. In following the branches into which they divide, the mucous membrane must be gradually removed from the wall of the larynx. The inferior laryngeal artery and nerve enter from below and proceed upwards, under cover of the lamina of the thyreoid cartilage. They can be satisfactorily displayed only by the removal of this piece of cartilage, but the dissector is not recommended to adopt this method unless another larynx is available for the examination of the cartilages and joints. By drawing the thyreoid cartilage laterally the more important branches can be studied.

Ramus Internus of the Nervus Laryngeus Superior.—

In the dissection of the neck the internal laryngeal nerve was seen springing from the superior laryngeal branch of the vagus. It is a sensory nerve, and its branches are distributed chiefly to the mucous membrane of the larynx. After piercing the lateral part of the thyreo-hyoid membrane, it divides into three branches. The *uppermost* of these sends filaments to the ary-epiglottic fold, to the mucous membrane which covers the epiglottis, and to the three folds anterior to it. The twigs which go to the epiglottis ramify on its posterior surface, but many of them pierce the cartilage to reach the mucous membrane on its anterior surface. The *intermediate branch* of the internal laryngeal nerve breaks up into filaments, which are given to the mucous membrane lining the side wall of the larynx. The *lowest branch* descends and gives filaments to the mucous membrane which covers the lateral and posterior aspects of the ary-tænoid and cricoid cartilages. A fairly large twig, which proceeds from this branch, runs downwards upon the posterior aspect of the cricoid cartilage to join the laryngeal branch of the recurrent nerve.

Nervus Recurrens.—The recurrent nerve has previously been seen arising from the vagus, and it has been traced, in the neck, up to the point where it disappears under cover of

the lower border of the inferior constrictor muscle and becomes the *inferior laryngeal nerve*, which ascends upon the lateral aspect of the cricoid cartilage, immediately posterior to the crico-thyreoid joint. There it is joined by the communicating twig from the internal laryngeal nerve, and almost immediately afterwards it divides into two branches. The *larger* of the two proceeds upwards, under cover of the lamina of the thyreoid cartilage, and breaks up into filaments which supply the lateral crico-arytænoid, the thyreo-arytænoid, the vocalis and the thyreo-epiglottic muscles; the *smaller* or *posterior branch* inclines upwards and posteriorly, upon the posterior aspect of the cricoid cartilage, and under cover of the posterior crico-arytænoid muscle. It supplies twigs to that muscle, and is then continued onwards to end in the arytænoid muscles.

The inferior laryngeal nerve is, therefore, the motor nerve of the larynx. It supplies all the muscles with the exception of the crico-thyreoid, which obtains its nerve-supply from the external laryngeal. The inferior laryngeal nerve, however, contains a few sensory fibres also. These it gives to the mucous membrane of the larynx below the rima glottidis.

Laryngeal Arteries.—The *superior laryngeal artery*, a branch of the superior thyreoid, accompanies the internal laryngeal nerve; the *inferior laryngeal artery*, which springs from the inferior thyreoid, accompanies the inferior laryngeal nerve. These two vessels ramify in the laryngeal wall and supply the mucous membrane, glands, and muscles.

Laryngeal Cartilages and Joints.—The cartilages which constitute the skeleton of the larynx and give support to its wall are the following:—

- | | | | | | |
|------------------------------------|---|---------|-----------------|---|---------|
| 1. Thyreoid, | } | single. | 4. Arytænoid, | } | paired. |
| 2. Cricoid, | | | 5. Corniculate, | | |
| 3. Cartilage of the
epiglottis, | | | 6. Cuneiform, | | |

They are connected by certain ligaments.

Dissection.—The mucous membrane and muscles must be carefully removed from the cartilages, and the ligaments must be defined. Great caution must be exercised in cleaning the arytænoid cartilages and the corniculate cartilages, in order that the latter may not be injured.

Cartilago Epiglottica.—The epiglottic cartilage is a thin, leaf-like lamina of yellow fibro-cartilage which is placed posterior to the tongue and the body of the hyoid bone, anterior to the upper aperture of the larynx. When divested of the

mucous membrane which covers it posteriorly and also, to some extent, anteriorly, the epiglottic cartilage has the form of an obovate leaf and is indented by pits and pierced by numerous perforations. In the pits glands are lodged, and through the foramina vessels and, in some cases, nerves pass. The broad end of the cartilage is directed upwards and is free; its margins are to a large extent enclosed within the ary-epiglottic folds. The anterior surface is free only in its upper part. This part is covered with mucous membrane and looks towards the base of the tongue. The posterior surface is covered throughout its whole extent with the mucous membrane of the larynx. The pointed lower end of the cartilage, the *petiolus*, is connected by a stout fibrous band, termed the thyreo-epiglottic ligament, to the angle between the laminae of the thyreoid cartilage.

Epiglottic Ligaments. — The epiglottis is bound by ligaments to the base of the tongue, to the side wall of the pharynx, to the hyoid bone, and to the thyreoid cartilage. The *glosso-epiglottic fold* and the two *pharyngo-epiglottic folds* have been studied already. In each there is a small quantity of elastic tissue. The *hyo-epiglottic ligament* is a short, broad elastic band which connects the anterior face of the epiglottis to the upper border of the body of the hyoid bone. The *thyreo-epiglottic ligament* is strong, elastic, and thick. It proceeds downwards, from the lower pointed extremity of the epiglottis, and is attached to the angular depression between the two laminae of the thyreoid cartilage, below the median notch.

The triangular interval which is left between the lower part of the cartilage of the epiglottis and the median part of the thyreo-hyoid membrane contains a pad of soft fat, and is imperfectly closed above by the hyo-epiglottic ligament.

Cartilago Thyreoidea. — This is the largest of the laryngeal cartilages. It is composed of two broad and somewhat quadrilateral plates, termed the *laminae*, which meet anteriorly at an angle, and become fused along the median plane. Posteriorly, the laminae diverge from each other and enclose a wide angular space. The *anterior borders* of the laminae are fused only in their lower parts. Above they are separated by a deep, narrow V-shaped notch called the *incisura thyreoidea superior*. In the adult male the angle formed by the meeting of the anterior borders of the two laminae, especially in the upper part, is very projecting; and, with the margins of the

superior thyreoid notch, which lies above, it constitutes a marked subcutaneous prominence in the neck, which receives the name of the *laryngeal prominence* (O.T. *pomum Adami*). The *posterior border* of each lamina is thick and rounded, and is prolonged beyond the superior and inferior borders of the lamina in the form of two slender cylindrical processes, termed the cornua. The *superior cornu*, longer than the

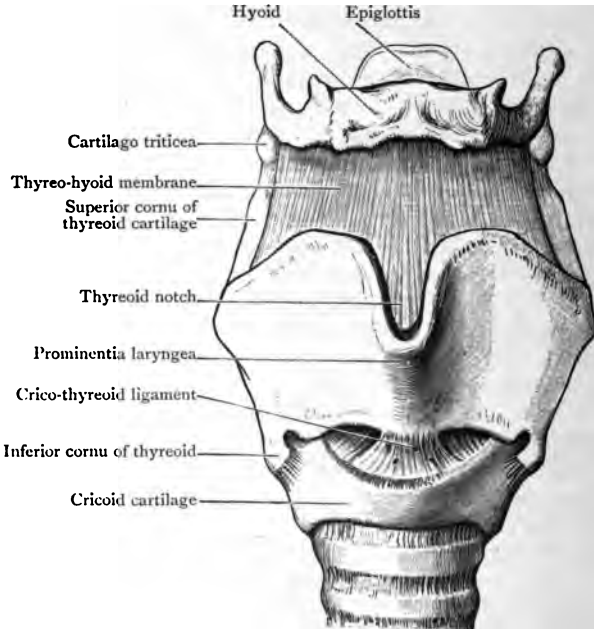


FIG. 166.—Anterior aspect of the Cartilages and Ligaments of Larynx.

inferior cornu, gives attachment to the lateral thyro-hyoid ligament. The shorter, stronger *inferior cornu* curves slightly medially. On the medial aspect of its tip there is a facet which articulates with the side of the cricoid cartilage. The *superior border* of the lamina is for the most part slightly convex, and anteriorly it dips down to become continuous with the margin of the superior thyreoid notch. The *inferior border* is to all intents and purposes horizontal, but it is divided by a projection, termed the *inferior tubercle*, into

a short posterior part and a longer anterior part. The *outer surface* of the lamina is relatively flat. Immediately below the posterior part of the upper border, and anterior to the root of the superior cornu, there is a distinct prominence called the *superior tubercle*. From this an oblique ridge descends towards the inferior tubercle on the lower border of the lamina. This ridge gives attachment to the sterno-thyreoid, thyreo-hyoid and the inferior constrictor muscles, and divides the outer surface of the lamina into an anterior and a posterior part. To the latter, which is much the smaller of the two, is attached the inferior constrictor muscle of the pharynx. The *inner surface* of the lamina is smooth and slightly concave. To the angular depression between the two laminae are attached the thyreo-epiglottic ligament, the ventricular and the vocal ligaments.

Crico-thyreoid

Joints.—The articulation, on each side,

between the tip of the inferior cornu of the thyreoid cartilage and the side of the cricoid cartilage, belongs to the diarthrodial variety. The opposed surfaces are surrounded by a capsular ligament which is lined with a synovial stratum. The movements which take place at these joints are of a twofold character—viz., (1) gliding; (2) rotatory. In the first case the cricoid facets glide upon the thyreoid surfaces in different directions. The rotatory movement is one in which the cricoid cartilage rotates around a transverse axis which

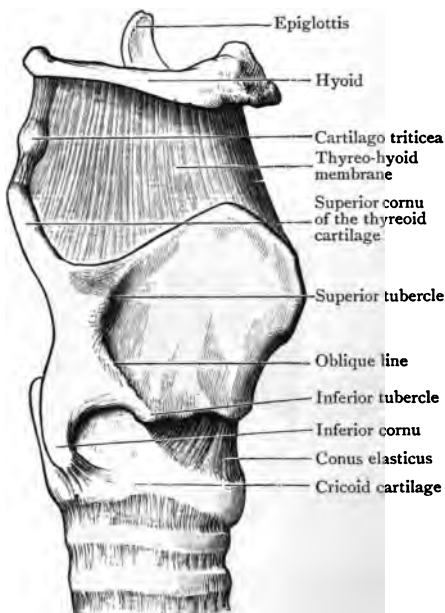


FIG. 167.—Profile view of Cartilages and Ligaments of Larynx.

passes through the centre of the two joints. Each capsular ligament is strengthened by stout bands on the posterior aspect of the joint.

The thyreoid cartilage should now be removed by dividing the ligaments which surround the crico-thyreoid joint.

Cartilago Cricoidea.—This is shaped like a signet ring.

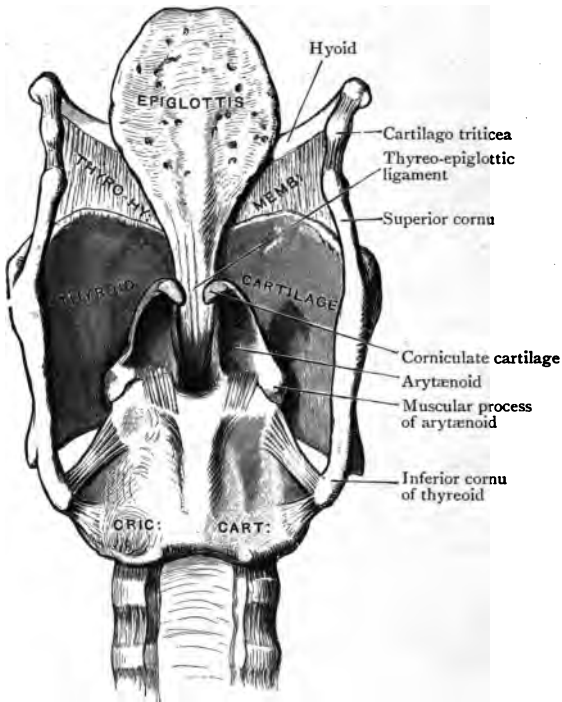


FIG. 168.—Posterior aspect of Cartilages and Ligaments of Larynx.

The broad posterior part, *the lamina*, is somewhat quadrilateral in form. Its superior border presents a faintly marked median notch, and on each side of this there is an oval convex facet which articulates with the base of the arytenoid cartilage. The posterior surface of the lamina is divided, by an elevated median ridge, into two slightly hollowed-out areas which give attachment to the posterior crico-arytenoid muscles. The median ridge itself gives origin to a tendinous

band which proceeds upwards from the longitudinal fibres of the œsophagus. The anterior part of the cricoid cartilage is the *arch*. The lower border of this is horizontal, and is connected to the first tracheal ring by membrane, the *cricotracheal ligament*. The arch is narrow anteriorly, and is attached to the lower border of the thyroid cartilage by the crico-thyroid ligament. Posteriorly, the upper border rapidly ascends. Upon the posterior part of the lateral surface of the cricoid cartilage there is a circular, slightly elevated, convex facet, which looks laterally and upwards, for articulation with the inferior cornu of the thyroid cartilage. Internally the cricoid cartilage is lined with mucous membrane, and its lumen is circular below, but elliptical above.

The narrow band-like part of the anterior arch of the cricoid cartilage lies below the lower border of the thyroid cartilage, whilst the lamina is received into the interval between the posterior portions of the laminæ of the thyroid cartilage.

Cartilaginee Corniculatæ.—Before proceeding to the study of the arytænoid cartilages the dissector should examine the corniculate cartilages and the manner in which they are held in position. They are two minute pyramidal nodules of yellow elastic cartilage which are placed on the summits of the arytænoid cartilages, and are directed posteriorly and medially. Each corniculate cartilage is enclosed within the corresponding ary-epiglottic fold of mucous membrane, and is joined to the apex of the arytænoid cartilage by a synchondrodial joint.

Cartilaginee Arytænoideæ.—In dealing with the arytænoid cartilages it is well to remove one in order that its external form may be studied; the other should be retained in position, for the purpose of examining the crico-arytænoid joint and the movements which can be performed at that articulation.

The *arytænoid cartilages* are pyramidal in form, and surmount the upper border of the lamina of the cricoid cartilage. The *apex* of each is directed upwards, and is curved postero-medially. It supports the corniculate cartilage. Of the three surfaces, one looks medially, towards the corresponding surface of the opposite cartilage, from which it is separated by a narrow interval; another looks posteriorly; whilst the third is directed antero-laterally. The *medial*

surface is narrow, vertical, and even, and is clothed with mucous membrane. The *posterior surface* is concave; it lodges and gives attachment to the arytænoideus transversus muscle. The *antero-lateral surface* is the most extensive of the three, and is uneven for muscular and ligamentous attachments. Upon this aspect of the arytænoid cartilage the musculus vocalis and the thyreo-arytænoid muscles are inserted. The surfaces of the arytænoid cartilage are separated by three borders, viz., an anterior, a posterior, and a lateral. The *lateral border* is the longest, and, at the base of the cartilage, it is prolonged postero-laterally in the form of a stout prominent angle or process, termed the *processus muscularis*. It gives attachment anteriorly to the crico-arytænoideus lateralis muscle; and posteriorly to the crico-arytænoideus posterior. The *anterior border* of the arytænoid cartilage is prolonged into the projecting anterior angle of the base. This is called the *processus vocalis*. It is sharp and pointed, and gives attachment to the vocal ligament (O.T. true vocal cord). The *base* of the arytænoid cartilage presents an elongated concave facet, on its under aspect, for articulation with the upper border of the lamina of the cricoid cartilage.

Crico-arytænoid Joints.—These articulations are of the diarthrodial variety. There is a distinct joint cavity surrounded by a capsular ligament, which is lined with a synovial stratum. The cricoid articular surface is convex, that of the arytænoid concave; both are elongated in form, but they are placed in relation to each other so that the long axis of the one intersects or crosses that of the other, and in no position of the joint do the two surfaces accurately coincide. The movements allowed at this joint, as the dissector can readily determine, are of a twofold kind—(1) *gliding*, by which the arytænoid is carried medially or laterally, or, in other words, a movement by which the arytænoid advances towards or retreats from its fellow; (2) *rotatory*, by which the arytænoid cartilage revolves round a vertical axis. By this movement the vocal process is swung laterally or medially, so as to open or close the rima glottidis.

The dissector should note that the capsule of this joint is strengthened posteriorly by a strong band which plays a most important part in the mechanism of the articulation. It restricts movement of the arytænoid cartilage.

Cartilagine Cuneiformes.—These are two little rod-shaped

nodules of yellow elastic cartilage, which are placed one in each ary-epiglottic fold near its posterior end. They are not always present.

Action of the Laryngeal Muscles.—The dissector should now consider the manner in which the muscles of the larynx operate upon the vocal ligaments in the production of the voice. *Tension of the vocal cords is produced by the contraction of the crico-thyroid muscles.* The oblique parts of the muscles pull the upper border of the cricoid cartilage upwards, whilst the straight portions, through their insertions into the inferior cornua, draw the cricoid cartilage posteriorly, thereby increasing the distance between the angle of the thyreoid cartilage and the vocal processes of the arytenoid cartilages. When the crico-thyroid muscles cease to contract, the relaxation of the cords is brought about by the elasticity of the ligaments. The vocalis and the thyreo-arytenoideus must be regarded as antagonistic to the crico-thyroid muscles. When they contract they approximate the angle of the thyreoid cartilage to the arytenoid cartilages, and still further relax the cords, and when they cease to act, the elastic ligaments of the larynx again bring about a state of equilibrium.

The *width of the rima glottidis* is regulated by the arytenoideus muscle, which draws together the arytenoid cartilages. The lateral and posterior crico-arytenoid muscles also modify the width of the rima glottidis. When they act together they assist the arytenoid muscle in closing the glottis, but when they act independently they are antagonistic muscles. Thus the *crico-arytenoidei posteriores*, by drawing the muscular processes of the arytenoid cartilages postero-laterally, swing the processus vocales and the vocal folds laterally, and thus open the rima. The *crico-arytenoidei laterales* act in exactly the opposite manner. By drawing the muscular processes in an opposite direction they close the rima.

But the muscles of the larynx have another function to perform besides that of vocalisation. It was formerly thought that the superior aperture of the larynx was closed, during deglutition, by the folding back of the epiglottis; that in fact the epiglottis, during the passage of the bolus of food, was applied like a lid over the entrance to the vestibule of the larynx. The investigations of Prof. Anderson Stuart have shown that the superior aperture of the larynx is closed during swallowing by the close apposition and the forward projection of the two arytenoid cartilages, which are forced against the tubercle of the epiglottis. The muscles chiefly concerned in this movement are the thyreo-arytenoid muscles and the transverse arytenoid muscle. These muscles form a true sphincter vestibuli. The ary-epiglotticus muscle also assists in the closure.

THE TONGUE.

The tongue is a muscular organ placed on the floor of the mouth. It has important duties to perform in connection with the functions of mastication, deglutition, and articulation. Moreover, the mucous membrane which covers it is specially modified, in certain localities, in connection with the peripheral terminations of the nerves of taste. The root of the tongue is attached to the hyoid bone; the pointed anterior extremity

is free ; the upper border of the base forms the lower boundary of the isthmus faucium.

Mucous Membrane.—The lingual mucous membrane is a part of the general mucous lining of the buccal cavity. The *dorsum of the tongue*, when the mouth is closed and the organ is at rest, is strongly arched antero-posteriorly, and, for the most part, is moulded into the vaulted roof of the mouth. The tongue consists of two developmentally distinct parts, termed oral and pharyngeal. These are marked off from each other, even in the adult, by a V-shaped groove called the *sulcus terminalis*. The apex of this sulcus points posteriorly, and coincides with a median blind pit which receives the name of the *foramen cæcum*. From this the two limbs of the sulcus diverge antero-laterally, and they reach the margins of the tongue at the attachments of the glosso-palatine arches.

The *oral part* of the tongue, by its upper or dorsal surface, stands in relation to the hard palate, and to some extent to the anterior part of the soft palate also. The *pharyngeal part* of the tongue looks posteriorly, and forms the anterior wall of the oral portion of the pharynx. In its upper part it is related to the soft palate, whilst below it is intimately related to the epiglottis. On the lateral wall of the pharynx, immediately above this portion of the tongue, is the tonsil.

The mucous membrane which envelops the tongue presents very different appearances in different localities. That portion which is spread over the pharyngeal part of the tongue, and is prolonged upwards over the surface of the tonsil, is smooth and somewhat glossy and presents no visible papillæ. It is from this district that the glosso-epiglottic fold takes origin, and every here and there the surface is studded with low projections, which are produced by lymph follicles placed subjacent to the mucous membrane. Each of these small elevated areas, as a rule, presents in the centre a minute pit, visible to the naked eye.

Anterior to the foramen cæcum and sulcus terminalis the mucous membrane which covers the dorsum, sides, and tip of the oral part of the tongue is beset with papillæ of different kinds. As these are individually visible to the naked eye the mucous membrane presents a very characteristic appearance. Further, a median groove or sulcus extends

posteriorly from the tip of the tongue to the foramen cæcum, and divides the anterior two-thirds of the dorsum into two halves.

On the under surface of the tongue the mucous membrane is smooth and comparatively thin. In the median plane it forms the *frenulum linguæ*, which has been studied at an earlier stage. On either side of the median line the deep lingual vein may be noticed, in the living subject, extending anteriorly towards the tip. To the lateral side of this,

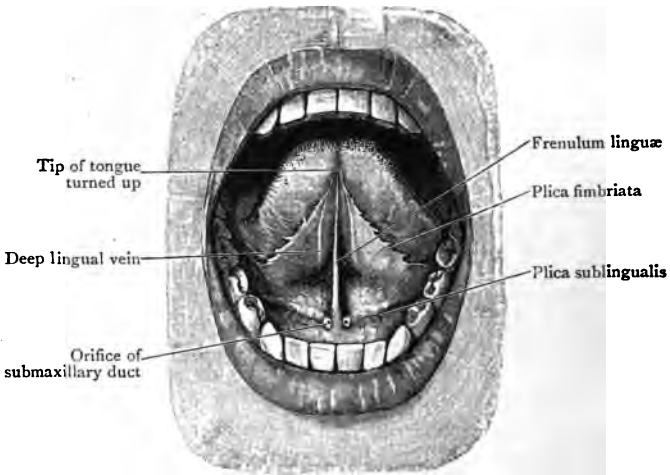


FIG. 169.—The Sublingual Region in the interior of the mouth.

and, therefore, somewhat nearer the border of the tongue, is a delicate and feebly marked fold of mucous membrane, from the free border of which a row of fringe-like processes or fimbriæ project. It is termed the *plica fimbriata*; as it extends anteriorly, towards the tip of the tongue, it inclines towards the median plane. On the side of the tongue, immediately anterior to the lingual attachment of the glosso-palatine arches, five short vertical fissures in the mucous membrane, separated by intervening folds, may be noticed. These are the *papillæ foliatæ*. They are the representatives of leaf-like folds of the mucous membrane, which are much more highly developed in certain of the lower animals (hare and rabbit),

and which are specially concerned in receiving the impressions of taste.

Papillæ Linguales.—These are of four kinds, and differ in size, shape, and in the position they occupy on the surface of the tongue. They are termed the vallate, the fungiform, the conical, and the filiform.

Papillæ Vallatæ.—The vallate papillæ (O.T. circumvallate), seven to twelve in number, are the largest, and are placed immediately anterior to the sulcus terminalis, in two rows which diverge from each other in an antero-lateral direction, like the two limbs of the letter V. The foramen cæcum lies immediately posterior to the median vallate papilla, which forms the apex of the V. In form, a vallate papilla is broad and somewhat cylindrical, slightly narrower at its attached than at its free extremity, and it is sunk in a pit. It is thus surrounded by a deep trench, the outer wall of which, termed the *vallum*, is slightly raised beyond the general surface of the mucous membrane, and forms an annular elevation which encircles the free extremity or summit of the papilla.

Papillæ Fungiformes.—The fungiform papillæ are much smaller, but are present in much greater numbers. They are found chiefly on the tip and sides of the tongue, but they are scattered at irregular intervals over the dorsum also. Each papilla presents a large, full, rounded, knob-like extremity, while it is greatly constricted at the point where it springs from the mucous surface. In the living tongue the fungiform papillæ are distinguished by their bright red colour.

Papillæ Conicæ.—The conical papillæ are present in very large numbers. They are smaller than the fungiform variety, and although they are quite visible to the naked eye they can be more conveniently studied by the aid of an ordinary pocket lens. They are minute conical projections which taper towards their free extremities, and they occupy the dorsum and sides of the tongue anterior to the sulcus terminalis. They are arranged in parallel rows which are placed close together, and in the posterior part of the dorsum these diverge from the median sulcus in an antero-lateral direction. Towards the tip of the tongue the rows of conical papillæ become more or less transverse in direction, and on the sides of the tongue they are arranged perpendicularly.

Papillæ Filiformes.—The filiform papillæ are similar in

general characters to the conical papillæ, but the epithelial cap at the apex of the cone is broken up into thread-like processes.

Muscles of the Tongue.—The tongue is composed almost entirely of muscular fibres, with some adipose tissue intermixed. It is divided into two lateral halves by a median septum, and the muscles in connection with each of these

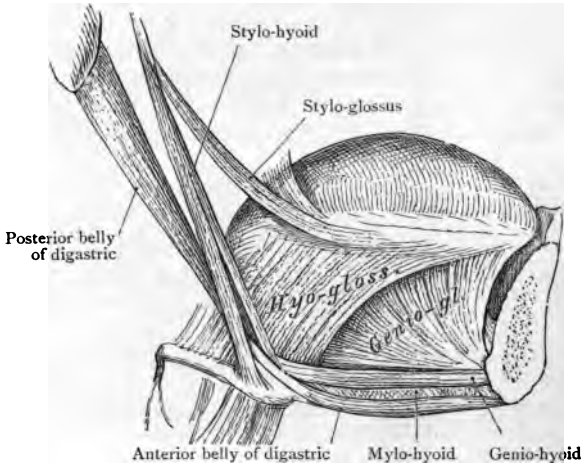


FIG. 170.—Muscles of the Tongue. (From Gegenbaur.)

consist of an intrinsic and an extrinsic group. They are as follows :—

- | | | |
|--------------------|---|--|
| Extrinsic Muscles, | { | <ol style="list-style-type: none"> 1. Genio-glossus. 2. Hyo-glossus. 3. Chondro-glossus. 4. Stylo-glossus. 5. Palato-glossus. |
| Intrinsic Muscles, | { | <ol style="list-style-type: none"> 1. Superior longitudinal. 2. Inferior longitudinal. 3. Vertical. 4. Transverse. |

The *extrinsic muscles* take origin from parts outside the tongue, and thus are capable not only of giving rise to changes in the form of the organ, but also of producing changes in its position. The *intrinsic muscles*, which are placed entirely within the substance of the tongue, are, for the most part, capable of giving rise to alterations in its form only.

With the exception of the chondro-glossus, the extrinsic muscles have been studied already, but the dissector should take this opportunity of examining more fully their insertions, and the manner in which their fibres are related to one another and to those of the intrinsic muscles. For this purpose carefully reflect the mucous membrane from the right half of the tongue, and follow the muscles into that side of the organ. At the same time the lingual nerve and the profunda linguæ artery should be preserved. On the under surface of the tongue, near the tip, the removal of the mucous membrane will expose a group of glands, aggregated together so as to form a small oval mass on each side of the median plane. This is known as the *apical gland* or the *gland of Nuhn*.

The *stylo-glossus* will be seen running along the side of the tongue to the tip, where the muscles of opposite sides become to a certain extent continuous. The *hyo-glossus* extends upwards to the side of the tongue, and its fibres pass,

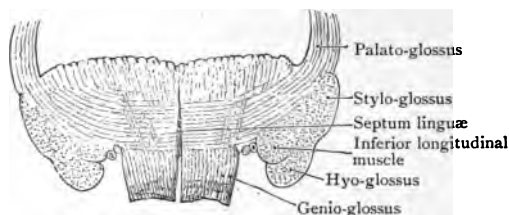


FIG. 171.—Transverse section through the posterior part of the Tongue. (From Gegenbaur.)

for the most part, under cover of those of the *stylo-glossus* to reach the dorsum, over the posterior part of which they spread out, beneath the mucous membrane. The *genio-glossus* sends its fibres vertically upwards into the tongue on each side of the median septum, and its insertion stretches from the tip to the base. The fibres of the *palato-glossus* become continuous with those which form the stratum transversum.

The *chondro-glossus* is not always present. It is separated from the deep surface of the *hyo-glossus* by the lingual vessels, and by the pharyngeal slip of the *genio-glossus*. It is a slender muscular band which takes origin from the medial aspect of the root of the smaller cornu, and the adjoining part of the body of the hyoid bone. Its fibres ascend, to enter the tongue and finally spread out on the dorsum under cover of the superior longitudinal muscle.

Musculus Longitudinalis Superior.—This is a continuous layer of longitudinal fibres which covers the entire dorsum linguæ, from the root to the tip, immediately beneath the mucous membrane. Towards the base of the tongue it is

thinner than in front, and there it is overlapped by the transverse fibres of the *hyo-glossus*, and is intermixed with the fibres of the *chondro-glossus*.

Musculi Longitudinales Inferiores.—The inferior longitudinal muscles are two rounded fleshy bundles placed upon the inferior aspect of the tongue, one on each side. Posteriorly, each inferior longitudinal muscle lies in the interval between the *hyo-glossus* and the *genio-glossus*, and is attached to the *hyoid bone*; anteriorly, it is prolonged to the apex of the tongue between the medial border of the *stylo-glossus* and the *genio-glossus*; with the former it is more or less blended.

Musculus Transversus Linguae.—The fibres of this muscle

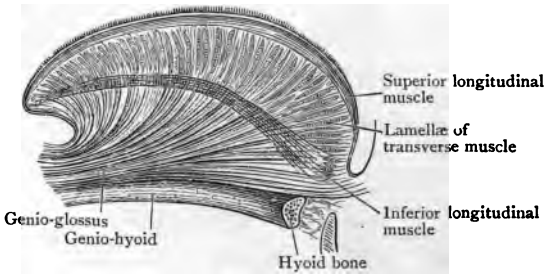


FIG. 172.—Longitudinal section through the Tongue.
(From Aeby.)

lie under the superior longitudinal fibres, and constitute a thick layer which extends laterally from the lateral face of the *septum linguae*, to the side of the tongue. The fibres of the *genio-glossus* ascend through this transverse stratum and break it up into numerous lamellæ (Fig. 172). It is joined by the fibres of the *palato-glossus* (Henle) (Fig. 171).

Musculus Verticalis Linguae.—The vertical fibres extend in a curved direction from the dorsum to the under aspect of the tongue, and decussate with the fibres of the transverse muscle.

Nerves and Vessels of the Tongue.—The nerves of the tongue are—(1) the *glosso-pharyngeal*; (2) the *lingual*; (3) the *hypoglossal*; and (4) a few twigs from the *internal laryngeal*. These should be traced on the left side of the tongue, where the *mucous membrane* is still in position.

The *glosso-pharyngeal nerve* has been traced up to the point

where it disappears under cover of the **hyo-glossus muscle**. There it divides into two branches. The *smaller* of these extends anteriorly, upon the side of the tongue, and may be traced as far as a point midway between the root and the tip. The *larger* branch turns upwards, and is distributed to the mucous membrane which invests the posterior third of the *dorsum linguæ*. It gives twigs to the vallate papillæ, and some fine filaments may be followed to the anterior surface of the epiglottis. The **glosso-pharyngeal nerve** is a nerve of taste and of common sensibility.

The *lingual* and *hypoglossal nerves* are described on pages 289 and 316, and their terminal branches should now be traced as far as is possible.

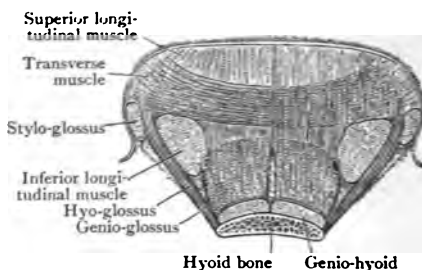


FIG. 173.—Transverse section through the Tongue. (From Aeby.)

The *internal laryngeal nerve* gives a few delicate filaments to the glosso-epiglottic and pharyngo-epiglottic folds and the mucous membrane of the root of the tongue.

The *arteria profunda linguæ* should be followed to the tip of the tongue, where it forms a small loop of anastomosis with its fellow of the opposite side.

Septum Linguæ.—The septum of the tongue can be seen best by making a transverse section through the organ. This will display, in a measure, the transverse and vertical muscular fibres also. The septum is a median fibrous partition. It is strongest posteriorly, where it is attached to the **hyoid bone**. It does not reach the dorsum of the tongue, being separated from it by the superior longitudinal muscle.

ENCEPHALON—THE BRAIN.

Directions.—If the brain was divided into two parts, when it was removed, they should be fixed together with large pins passed through the cerebellum into the cerebral hemispheres; the brain should then be placed on a dissecting-room platter, with its superior surface uppermost. It is necessary to keep it moist, during the whole dissection, by means of a cloth dipped in water. Unless this is done the membranes are apt to become dry, and then they are exceedingly difficult to remove.

General Appearance of the Brain.—When viewed from above, the brain presents an ovoid figure, with the broad end directed posteriorly. Its greatest transverse diameter is in the neighbourhood of the part which lies between the two parietal tubers of the cranium. The only portions which are visible when the brain is in this position are the two convoluted hemispheres of the cerebrum. These are separated from each other by a deep median cleft, called the *longitudinal fissure*, which extends from the anterior to the posterior end of the brain.

The position of the brain should now be reversed. Turn it so that it rests on its superior surface.

The inferior aspect of the brain is usually termed the “base.” It presents an uneven and irregular surface, which is more or less accurately adapted to the inequalities on the floor of the cranium. On this surface the main subdivisions of the organ may be recognised. Thus, posteriorly is seen the short cylindrical portion, called the *medulla oblongata*, through which, at the foramen magnum, the brain becomes continuous with the spinal medulla. The medulla oblongata rests on the under surface of the cerebellum, being received into the vallecule or hollow which intervenes between the two cerebellar hemispheres. The *cerebellum* is a mass of considerable size which lies under the posterior parts of the cerebral hemispheres. It can be easily recognised on account of the closely set, curved and parallel fissures which traverse its surface. Above the medulla oblongata, and in direct connection with it, is a prominent white elevation called the *pons*. The basilar artery extends upwards in a median groove on its surface. Immediately anterior to the pons there is a deep hollow or recess. This is bounded posteriorly by the

pons, on either side by the projecting temporal lobes of the cerebrum, and anteriorly by the orbital portions of the frontal lobes of the cerebrum. At the present stage of the

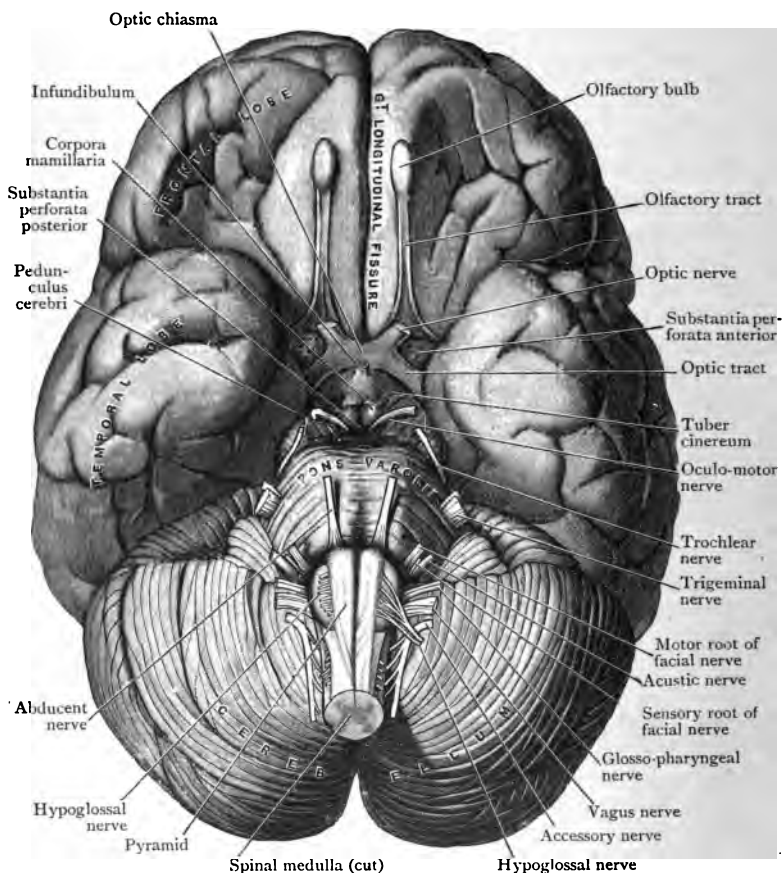


FIG. 174.—The Base of the Brain with the Cerebral Nerves attached.

examination of the brain, the bottom of this hollow is hidden from view by the arachnoid, which stretches over it like a veil; but the *hypophysis* will be seen within its limits if it has been removed with the brain. Passing laterally from either side of the anterior part of this recess will be seen the deep

fissura lateralis (O.T. Sylvian fissure), which intervenes between the pointed and projecting extremity of the temporal lobe and the frontal lobe of the cerebrum ; whilst in the median plane, anteriorly, the longitudinal fissure will be seen between the frontal portions of the cerebral hemispheres. On either side of the longitudinal fissure, and separated from it by a narrow gyrus, the *olfactory tract* and *bulb* may be recognised.

MEMBRANES AND BLOOD VESSELS OF THE BRAIN.

Arachnoidea Encephali.—The arachnoid forms the intermediate covering of the brain. It is placed between the dura mater and the pia mater, and is directly continuous with the arachnoid of the spinal medulla. It is an exceedingly thin and delicate membrane, which can be seen best on the base of the brain, as in that locality it is not so closely applied to the pia mater as elsewhere. Unlike the pia mater it does not (except in the case of the longitudinal and the lateral fissures) dip into the sulci or fissures on the surface of the cerebrum and cerebellum. It bridges over the inequalities on the surface of the brain and it is spread out in the form of a very distinct sheet over the medulla oblongata, the pons, and the hollow on the base of the brain which lies anterior to the pons. The cut ends of several of the cerebral nerves will be seen passing through this sheet ; whilst, anteriorly, immediately to the lateral side of the optic nerve, the internal carotid artery will be noticed piercing it.

Cavum Subarachnoideale.—The interval between the arachnoid and the pia mater receives the name of the subarachnoid space. It contains the subarachnoid fluid, and is broken up by a meshwork of fine filaments and trabeculæ, which connects the two bounding membranes (viz., the arachnoid and the pia mater) in the most intimate manner, and form a delicate sponge-like interlacement between them. Where the arachnoid passes over the summit of a cerebral gyrus, and is consequently closely applied to the subjacent pia mater, the meshwork is so close and the trabeculæ so short that the two membranes cannot be separated from each other. To the dissector they appear to form a single lamina. In the intervals between the rounded margins of adjacent gyri distinct

angular spaces exist between the arachnoid and the pia mater. In these the subarachnoid tissue can be studied, and it will be seen that these intervals on the surface of the cerebrum serve as communicating channels for the free passage of the subarachnoid fluid from one part of the brain to another. The larger branches of the arteries and veins of the brain traverse the subarachnoid space; their walls are directly connected with the subarachnoid trabeculæ and are bathed by the subarachnoid fluid.

Cisternæ Subarachnoideales.—In certain situations the arachnoid is separated from the pia mater by intervals of

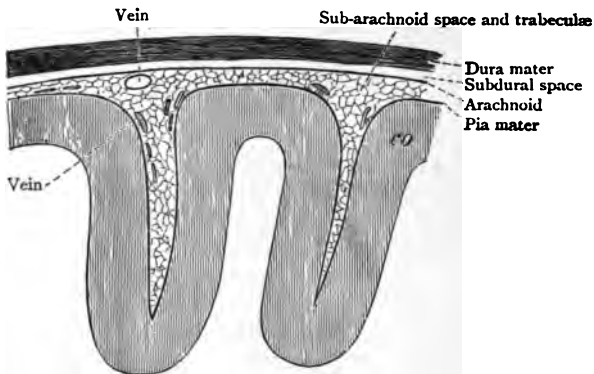


FIG. 175.—Diagrammatic section through the Meninges of the Brain. (Schwalbe.)

co. Grey matter of cerebral gyri.

considerable depth and extent. These expansions of the subarachnoid space are termed cisternæ subarachnoideales. In them the subarachnoid tissue is relatively reduced. There is no longer a close meshwork; the trabeculæ connecting the two bounding membranes take the form of long filamentous intersecting threads which traverse the spaces. A beautiful demonstration of these may be obtained by dividing in the median plane, with the scissors, the sheet of arachnoid which is spread over the medulla oblongata and pons, and turning the two pieces gently aside.

Certain of the cisternæ require special mention. The largest and most conspicuous is called the *cisterna cerebello-medullaris* (O.T. *magna*). It is a direct upward continuation of the posterior part of the subarachnoid space

of the spinal meninges into the posterior part of the cranium. It is formed by the arachnoid membrane bridging over the wide interval between the posterior part of the under surface of the cerebellum and the medulla oblongata.

The *cisterna pontis* is the name given to another of these recesses. It is the continuation upwards, on the floor of the cranium, of the anterior part of the subarachnoid space of the spinal meninges. In the region of the medulla oblongata it is continuous on either side with the cerebello-medullary cistern, so that this subdivision of the brain is completely surrounded by a wide subarachnoid space. Within the *cisterna pontis* are the vertebral and basilar arteries.

Anterior to the pons the arachnoid membrane crosses between the pro-

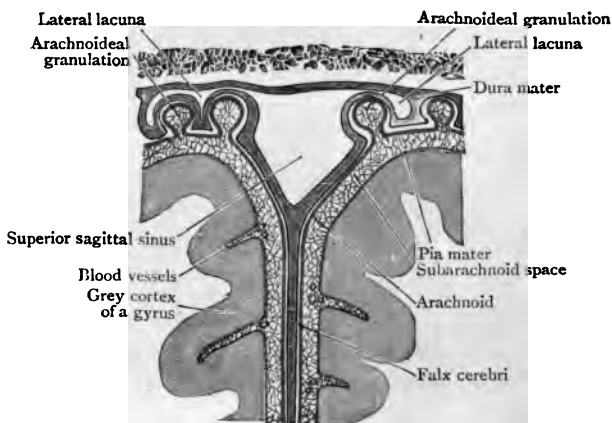


FIG. 176.—Diagram of a frontal section through the middle portion of the cranial vault and subjacent brain to show the membranes of the brain and the arachnoid granulations.

jecting temporal lobes, and covers in the deep hollow in this region of the base of the brain. This space is called the *cisterna interpeduncularis*, and within it are placed the large arteries which take part in the formation of *circulus arteriosus*. It is continuous anteriorly with the *cisterna chiasmatis*, which lies anterior to the optic chiasma and lodges the anterior cerebral arteries.

All the subarachnoid cisterns communicate in the freest manner with one another, and also with the narrow intervals on the surface of the cerebrum. The subarachnoid space does not communicate in any way with the subdural space. In certain localities, however, it communicates with the ventricular system of the brain. Three such apertures are described in connection with the fourth ventricle, whilst another slit, on each side, is said to lead from the *cisterna interpeduncularis* into the lower end of the corresponding inferior horn of the lateral ventricle.

Extending laterally from the *cisterna interpeduncularis*, on each side, is the *cisterna fossæ lateralis cerebri*, which extends along the stem of the lateral fissure into the lateral fossa, around the middle cerebral artery. Anteriorly the *cisterna chiasmatis* is continuous with a prolongation which

extends into the longitudinal fissure with the anterior cerebral arteries. A dilatation of the subarachnoid space over the dorsum of the mid-brain round the great cerebral vein (O.T. vena magna Galeni) is called the *cisterna venae magne cerebri*.

Granulationes Arachnoideales (O.T. Pacchionian Bodies).

—The connection of the arachnoideal granulations with the arachnoid has been referred to already (p. 202).

Pia Mater Encephali.—The pia mater forms the immediate investment of the brain. It is finer and more delicate than the corresponding membrane of the spinal medulla, and it follows closely all the inequalities on the surface of the brain. Thus, in the case of the cerebrum, it lines both sides of every sulcus and forms a fold within it. On the cerebellum the relation is not so intimate; it is only the larger fissures of the cerebellum which contain folds of pia mater.

It has been noted that the larger blood vessels of the brain run in the subarachnoid space; the finer twigs enter the pia mater and ramify in it before passing into the substance of the brain. As they enter they carry with them sheaths derived from the pia mater. Consequently, if the dissector raises a portion of this membrane from the surface of the cerebrum, a number of fine processes will be seen to be withdrawn from the cerebral substance. These are the blood-vessels, and they give the deep surface of the membrane a rough and flocculent appearance.

The pia mater is not confined to the exterior of the brain. A fold is carried into its interior. This will be exposed in the dissection of the brain, and will be described under the name of the tela chorioidea (O.T. velum interpositum) of the third ventricle.

Dissection.—The blood vessels of the brain should now be followed out as far as it is possible to do so without laceration of the brain substance. Begin by stripping the arachnoid from the base of the brain. This will bring into view the main trunks. As the vessels of the brain are described, many parts which have not yet come under the notice of the dissector must be mentioned.

Arteries which supply Blood to the Brain.—Four main arterial trunks carry blood into the cranium for the supply of the brain—viz., the two internal carotid arteries and the two vertebral arteries. The vertebral arteries enter through the foramen magnum, whilst the internal carotid arteries gain admittance through the lacerate foramina after traversing the carotid canals. These vessels have been divided in the

removal of the brain. The cut ends of the internal carotids will be seen, on the base of the brain, immediately to the lateral sides of the optic nerves; the vertebral arteries lie on the sides of the medulla oblongata. A very remarkable and complete anastomosis takes place at the base of the brain by the inosculation of branches which spring from the internal carotid and vertebral arterial systems. This is termed the *circulus arteriosus* (Willis), and the branches which take part in its formation lie in the *cisterna interpeduncularis* and the *cisterna chiasmatis*.

Two systems of branches, both going to the cerebrum but differing greatly in their mode of distribution, proceed from the vessels forming the arterial circle. One system consists of very numerous slender twigs, which, as a rule, come off in groups in certain localities, and at once pierce the substance of the cerebrum so as to gain its interior. These are the *central* or *basal branches*. The other system is composed of branches which ramify over the surface of the cerebrum, and is termed the system of *cortical branches*. The central parts of the brain, including the basal ganglia, receive their blood-supply from the basal system, and the vessels which constitute this group do not anastomose with each other. The cortical vessels supply the cerebral cortex and the finer branches, which ramify in the pia mater, anastomose with one another; therefore, the neighbouring vascular districts of the cerebral cortex are not sharply cut off from each other.

Arteria Vertebralis.—The vertebral artery enters the sub-arachnoid space in the upper part of the vertebral canal by piercing the dura mater and the arachnoid. Gaining the interior of the cranium, through the foramen magnum, it is continued upwards on the side of the medulla oblongata. Soon it inclines to the anterior aspect of the medulla oblongata, and, meeting its fellow of the opposite side in the median plane, it unites with it, at the lower border of the pons, to form the basilar artery.

During this part of its course the vertebral artery gives off the following branches:—

- | | | |
|-----------------------------------|--|---------------------|
| 1. Posterior spinal. | | 3. Anterior spinal. |
| 2. Posterior inferior cerebellar. | | 4. Bulbar. |

Arteria Spinalis Posterior.—This is the first branch that is given off after the vertebral artery pierces the dura mater.

It passes downwards on the spinal medulla along the line of the posterior nerve-roots (p. 193).

Arteria Cerebelli Inferior Posterior.—The posterior inferior cerebellar artery is the largest branch of the vertebral artery. It takes origin immediately above the posterior spinal artery,

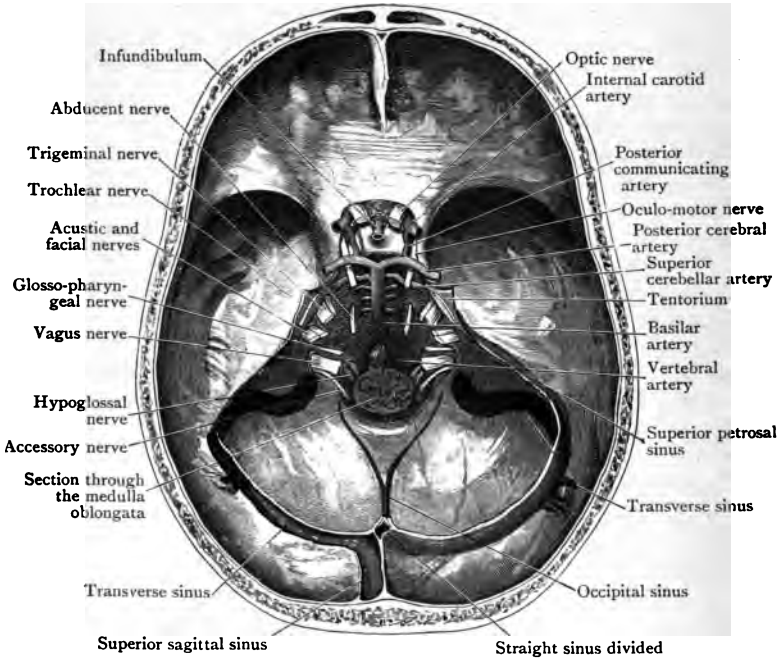


FIG. 177.—Floor of the cranium after the removal of the brain and the Tentorium Cerebelli. The blood vessels forming the Circulus Arteriosus have been left in place.

and pursues a tortuous course posteriorly, on the side of the upper part of the medulla oblongata, among the fila of the hypoglossal nerve, and then among the fila of the vagus. Finally, turning round the restiform body, it gains the vallecula of the cerebellum, where it ends by dividing into two terminal branches. Of these, one turns posteriorly, in the vallecula, between the inferior vermis and the lateral hemisphere of the cerebellum, whilst the other ramifies on the posterior

part of the inferior surface of the corresponding cerebellar hemisphere.

Arteria Spinalis Anterior.—The anterior spinal artery arises near the lower border of the pons, and it is rare to find the vessels of the two sides of equal size. They converge on the anterior surface of the medulla oblongata and unite, forming the commencement of the median vessel which extends downwards on the ventral face of the spinal medulla.

The *bulbar arteries* are minute vessels which enter the substance of the medulla oblongata ; they spring both from the vertebral artery itself and also from its branches.

Arteria Basilaris.—The basilar artery, which is formed by the union of the two vertebral arteries, is a short trunk. It extends, in the median plane, from the lower to the upper border of the pons. At the latter point it ends by dividing into the two posterior cerebral arteries. The basilar artery lies in the middle part of the cisterna pontis and occupies the median groove on the ventral or anterior surface of the pons. Anteriorly it is supported by the basilar portion of the occipital bone and the dorsum sellæ of the sphenoid.

The branches which spring from the basilar artery proceed laterally for the most part from either side of the vessel. They are :—

- | | | |
|----------------------------------|--|-------------------------|
| 1. Pontine. | | 4. Superior cerebellar. |
| 2. Internal auditory. | | 5. Posterior cerebral. |
| 3. Anterior inferior cerebellar. | | |

Rami ad Pontem.—The pontine branches are numerous slender twigs which run laterally on the surface of the pons and enter its substance.

Arteria Auditiva Interna.—The internal auditory artery will be seen amongst the pontine branches. It accompanies the acoustic nerve into the internal acoustic meatus, and is distributed to the internal ear.

Arteria Cerebelli Inferior Anterior.—This artery inclines postero-laterally to reach the anterior part of the inferior surface of the cerebellum.

Arteria Cerebelli Superior.—The superior cerebellar artery is a large vessel which springs from the basilar close to its termination. It winds laterally and posteriorly, along the upper border of the pons, to reach the upper surface of the cerebellum, upon which it spreads out in a number of large branches.

Arteria Cerebri Posterior.—Immediately beyond the origin of the two superior cerebellar arteries the basilar trunk bifurcates into the two posterior cerebral arteries. These diverge from each other, and, curving laterally and posteriorly, encircle the mesencephalon. Then they run posteriorly towards the under surface of the splenium of the corpus callosum. In this course each posterior cerebral artery lies deeply in the interval between the corresponding pedunculus cerebri and the hippocampal gyrus, and, finally, passing on to the tentorial surface of the cerebral hemisphere it disappears

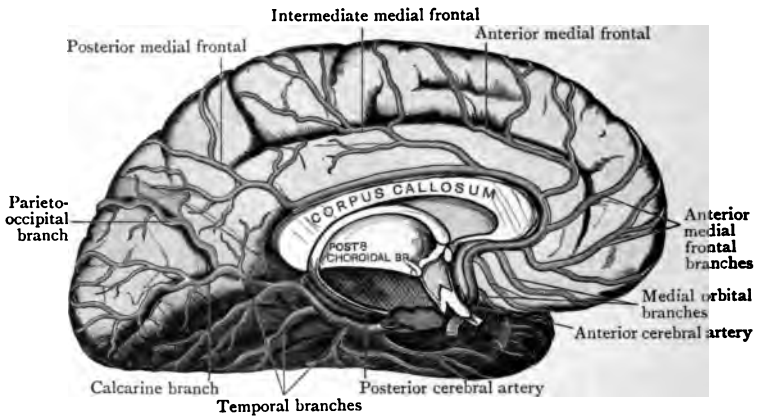


FIG. 178.—Medial and Tentorial Surfaces of the left Cerebral Hemisphere. The district supplied by the anterior cerebral artery is tinted *purple*; by the middle cerebral artery, *blue*; and by the posterior cerebral artery, *red*. (Semi-diagrammatic.)

from view, by sinking into the anterior extremity of the calcarine fissure. In this fissure the artery ends by dividing into two terminal branches, viz., the calcarine and the parieto-occipital (Figs. 178 and 180).

The oculo-motor nerve passes anteriorly in the interval between the posterior cerebral and the superior cerebellar arteries, close to the place where they arise from the basilar; and the small trochlear nerve winds round the pedunculus cerebri below the posterior cerebral artery.

The following branches spring from the posterior cerebral artery:—

Central or basal	<table border="0"> <tr> <td rowspan="3" style="font-size: 2em; vertical-align: middle;">{</td> <td>Postero-median.</td> </tr> <tr> <td>Postero-lateral.</td> </tr> <tr> <td>Posterior chorioidal.</td> </tr> </table>	{	Postero-median.	Postero-lateral.	Posterior chorioidal.	Cortical	<table border="0"> <tr> <td rowspan="3" style="font-size: 2em; vertical-align: middle;">{</td> <td>Temporal.</td> </tr> <tr> <td>Calcarine.</td> </tr> <tr> <td>Parieto-occipital.</td> </tr> </table>	{	Temporal.	Calcarine.	Parieto-occipital.
{	Postero-median.										
	Postero-lateral.										
	Posterior chorioidal.										
{	Temporal.										
	Calcarine.										
	Parieto-occipital.										

The *postero-median central arteries* arise close to the origin of the parent trunk. They proceed upwards, in the interval between the pedunculi cerebri, and, piercing the substantia perforata posterior (O.T. posterior perforated space), they supply the thalami and the medial parts of the pedunculi cerebri.

The *postero-lateral central arteries* are a group of small slender twigs which arise on the lateral surface of the pedunculus cerebri, and go to the corpora quadrigemina and the thalamus.

The *posterior chorioideal artery*, somewhat larger, goes to the tela chorioidea of the third ventricle and the chorioid plexus of the lateral ventricle (Figs. 178 and 179).

The *temporal branches*, two or three in number, turn laterally, over the hippocampal gyrus, and ramify on the under surface of the temporal lobe of the cerebrum (Figs. 178 and 180).

The *calcarine branch* follows the calcarine fissure to the occipital pole of the cerebral hemisphere, round which it turns to reach the lateral surface of the occipital lobe. It is the chief artery of supply to the cuneus and the lingual gyrus, and is therefore specially concerned in the nutrition of the visual centres of the cerebral cortex (Fig. 178).

The *parieto-occipital artery* is the smaller of the two terminal branches of the posterior cerebral. It runs upwards in the parieto-occipital fissure, and reaching the upper margin of the cerebrum it turns round it to reach the lateral surface of the occipital lobe. It supplies branches to the cuneus and præcuneus (Figs. 178, 180).

Arteria Carotis Interna.—The cut extremity of this great vessel lies on the lateral side of the optic chiasma, in the angle between the optic nerve and the optic tract. At the substantia perforata anterior, close to the commencement of the lateral fissure, it ends by dividing into the anterior and middle cerebral arteries (Fig. 179). The *middle cerebral artery* is the larger of the two terminal branches, and, as it enters the lateral (O.T. Sylvian) fissure, it appears to be the continuation of the parent trunk. The *anterior cerebral artery*, on the other hand, proceeds medially from the internal carotid at almost a right angle. This explains how it is that emboli pass more frequently into the middle cerebral than into the anterior cerebral artery. From the internal carotid artery, after it has emerged from the cavernous sinus (p. 331), the following branches arise:—

- | | |
|---|-----------------------|
| 1. Ophthalmic (already studied,
p. 341). | 3. Chorioideal. |
| 2. Posterior communicating. | 4. Middle cerebral. |
| | 5. Anterior cerebral. |

Arteria Communicans Posterior.—This, as a rule, is a slender branch which passes posteriorly to join the posterior cerebral between its postero-median and postero-lateral groups of basal twigs (Fig. 181).

Arteria Chorioidea.—The chorioideal artery enters the

inferior cornu of the lateral ventricle, and passes into the chorioid plexus in that cavity (Fig. 179).

Arteria Cerebri Anterior.—The anterior cerebral runs first horizontally, above the optic chiasma, towards the median plane (Figs. 178, 179). Then, bending sharply upon itself, it turns upwards in the anterior part of the longitudinal fissure, anterior

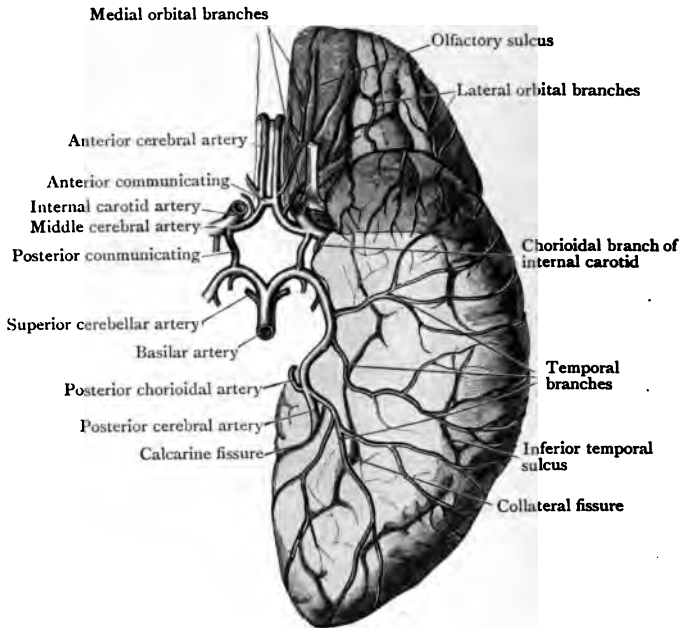


FIG. 179.—Inferior Surface of the Cerebral Hemisphere. The districts supplied by the three cerebral arteries are tinted differently: posterior cerebral artery, *red*; middle cerebral artery, *blue*; anterior cerebral artery, *purple*.

to the lamina terminalis, and along the rostrum to the genu of the corpus callosum, round which it bends; then it passes posteriorly along the medial face of the hemisphere, on the upper surface of the corpus callosum, to the parieto-occipital fissure (Fig. 178). As it lies anterior to the lamina terminalis it is connected with the opposite anterior cerebral artery by the *anterior communicating artery*, and as it passes along the longitudinal fissure, between the hemispheres, it lies close to its fellow of the opposite side.

Numerous branches proceed from the anterior cerebral artery :—

- | | | |
|------------------|---|------------------------------|
| Basal or central | { | Antero-median. |
| Cortical | { | Medial orbital. |
| | { | Anterior medial frontal. |
| | { | Intermediate medial frontal. |
| | { | Posterior medial frontal. |

The *antero-median arteries* pierce the base of the brain anterior to the optic chiasma. They supply the rostrum of the corpus callosum, the lamina terminalis, and the septum pellucidum.

The *medial orbital branches* are two or three in number. They turn round the margin of the longitudinal fissure to reach the medial part of the

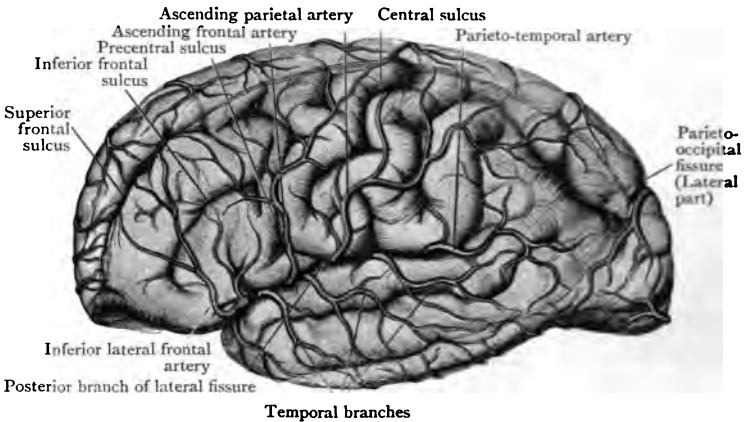


FIG. 180.—Lateral Surface of the Cerebral Hemisphere. The districts supplied by the three cerebral arteries are tinted differently: anterior cerebral, purple; middle cerebral, blue; posterior cerebral, red. (Semi-diagrammatic.)

orbital surface of the frontal lobe. They supply the gyrus rectus, the olfactory tract and bulb, and the medial orbital gyrus (Figs. 178 and 179).

The *anterior medial frontal artery* ramifies upon the anterior part of the medial surface of the frontal lobe, and its terminal twigs turn round the upper margin of the cerebral hemisphere, and supply the upper part of the lateral surface of the frontal lobe (Fig. 178).

The *intermediate medial frontal artery* ramifies on the medial surface of the frontal lobe posterior to the preceding branch. Its terminal part passes over the paracentral lobule, and reaches the adjacent portion of the lateral surface of the cerebral hemisphere (Fig. 178).

The *posterior medial frontal artery* ramifies on the medial surface of the præcuneus, and its terminal twigs turn round the upper margin of the cerebral hemisphere to gain the lateral surface.

Arteria Cerebri Media.—At first the middle cerebral artery passes laterally and then upwards in the lateral fissure. It

wood breaks up into a number of large terminal branches, which spread out on the surface of the insula. Before the posterior ramus of the lateral fissure is opened up, to expose the insula, these branches may be seen emerging from between its two lips (Fig. 130). Then they diverge and supply a wide area of cortex on the lateral surface of the hemisphere.

The branches which spring from the middle cerebral artery may be classified as follows:—

General or basal branches.	}	Antero-lateral.				
Cortical branches.		Frontal.	<table border="0"> <tr><td> Lateral orbital.</td></tr> <tr><td> Inferior lateral frontal.</td></tr> <tr><td> Ascending frontal.</td></tr> </table>	Lateral orbital.	Inferior lateral frontal.	Ascending frontal.
		Lateral orbital.				
	Inferior lateral frontal.					
	Ascending frontal.					
Parietal.	Ascending parietal.					
Parieto-temporal.						
		Temporal.				

The arteries of the *antero-lateral basal group* are very numerous. They pierce the *substantia perforata anterior* and supply the lentiform nucleus, the internal and the external capsule, the caudate nucleus, and a portion of the thalamus.

The *frontal and parietal branches* turn round the upper lip of the posterior ramus of the lateral fissure and ascend on the lateral surface of the hemisphere. The *frontal branches* are: 1) *lateral orbital* to the lateral part of the orbital surface of the frontal lobe; 2) *inferior lateral frontal* to the inferior and middle frontal gyri; 3) *ascending frontal*, which runs upwards in relation to the anterior central gyrus.

The *ascending parietal branch* extends in an upward and posterior direction in relation to the postcentral gyrus, and its terminal twigs supply the greater part of the cortex of the superior parietal lobule.

The *parieto-temporal branch* is a very large artery which issues from the posterior part of the posterior branch of the lateral fissure: it sends branches upwards to the inferior parietal lobule, and others which incline downwards over the posterior part of the temporal lobe. Its twigs, as a rule, do not encroach upon the lateral surface of the occipital lobe.

The *temporal branches*, two or three in number, issue from the posterior ramus of the lateral fissure, and, turning downwards and posteriorly, over its lower lip (*i.e.* the superior temporal gyrus), they ramify upon the lateral surface of the temporal lobe.

Circulus Arteriosus (O.T. Circle of Willis).—This remarkable anastomosis is placed beneath the base of the brain in the deep hollow anterior to the pons. It takes the form of a heptagonal or hexagonal figure, and the vessels which compose it lie in the cisterna interpeduncularis and the cisterna chiasmatis. Anteriorly it is closed by the anterior communicating artery which links together the two anterior cerebral arteries. On either side is the posterior communicating artery connecting the internal carotid (from which the anterior

cerebral springs) with the posterior cerebral. The arterial ring is completed posteriorly by the bifurcation of the basilar artery into the two posterior cerebral vessels (Fig. 181). As a rule the circulus arteriosus is not symmetrical. One posterior communicating artery is almost invariably larger than its fellow of the opposite side.

Dissection.—The brain being placed with its base uppermost, the dissector should proceed to remove the blood vessels and membranes from

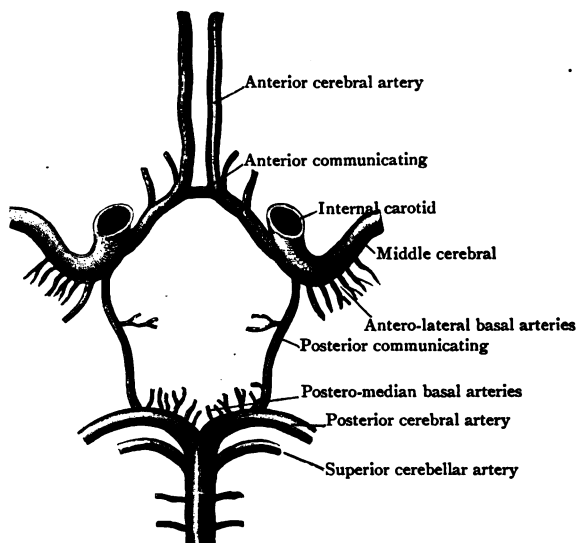


FIG. 181.—Diagram of the Circulus Arteriosus.

its surface. This must be done with the forceps and a pair of scissors. It is a dissection which requires very delicate manipulation, because the cerebral nerves, at their points of attachment to the brain, are so intimately connected with the pia mater that any undue traction applied to the membranes will tear the nerves away. Indeed, in the case of the medulla oblongata, the dissector is advised to leave the pia mater in position until the nerve roots have been studied. The relation of the pia mater to the fourth ventricle also renders this desirable.

In removing the arachnoid and pia mater from the lateral surface of the cerebrum, it is well to raise it first from the margins of the hemisphere, and then to work towards the lateral fissure (Sylvian). By this method, the membranes and vessels within this great fissure and in relation to the insula can be withdrawn without damage to the brain substance. Of course, at the present stage, the membranes cannot be removed from every part of the brain; but as the dissection proceeds, opportunities for completing the process will arise.

BASE OF BRAIN.

Fossa Interpeduncularis.—When the membranes are removed from the base of the brain, the *pedunculi cerebri* (O.T. *crura*), two large rope-like strands, will be seen issuing from the upper aspect of the pons. Placed close together as they emerge from the pons, they diverge as they proceed upwards and anteriorly, and, finally, each peduncle disappears into the corresponding half of the cerebrum. Turning round the lateral aspect of each peduncle, where it passes into the cerebrum, will be seen a flattened band, called the *optic tract*. These bands converge as they pass anteriorly, and are finally joined together by a short transverse commissural portion, termed the *optic chiasma*. This chiasma is placed below the posterior end of that portion of the longitudinal fissure which intervenes between the inferior surfaces of the frontal lobes of the cerebrum. The *optic nerves* run antero-laterally from the chiasma.

The cerebral peduncles, the optic tracts, and the optic chiasma enclose a deep rhomboidal or lozenge-shaped interval on the base of the brain, which is termed the *interpeduncular fossa*. Within the limits of this area the following parts may be seen. The *substantia perforata posterior* bounded anteriorly by the *corpora mamillaria*; anterior to the corpora mamillaria is the tuber cinereum, and attached to it is the *infundibulum* of the hypophysis. These structures take part in the formation of the floor of the third ventricle of the brain.

The *oculo-motor nerves* issue from the brain within the interpeduncular fossa. Each nerve emerges from the medial side of the corresponding pedunculus cerebri.

Substantia Perforata Posterior (O.T. **Posterior perforated space**).—At its posterior angle, immediately anterior to the pons, the interpeduncular fossa is very deep, and is roofed by a layer of grey matter in which are numerous small apertures. This is the *substantia perforata posterior*. From the apertures which are dotted over its surface the postero-median basal branches of the posterior cerebral artery have been withdrawn.

Corpora Mamillaria.—These are two small, white, pea-shaped eminences placed, side by side, anterior to the *substantia perforata posterior*. At a later stage of the dissection

their connections with the columns of the fornix will be displayed.

Tuber Cinereum.—This is a slightly raised field of grey matter which occupies the interval between the corpora

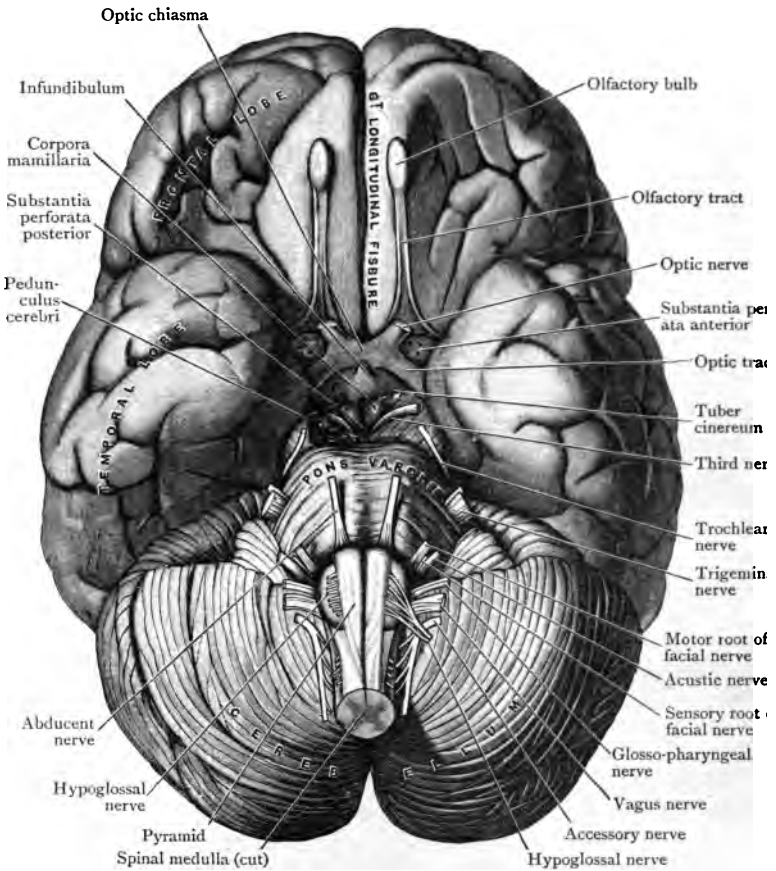


FIG. 182.—The Base of the Brain with the Cerebral Nerves attached.

mamillaria posteriorly, the optic chiasma anteriorly, and the optic tracts laterally. Springing from the anterior part of the tuber cinereum, immediately posterior to the optic chiasma, is the infundibulum or stalk of the hypophysis. In the

A
of
filia
div
erit
the
In
the
an
te



... These are ...
 ... of the ...
 ... the ...
 ... the ...
 ... the ...

Cerebral Nerves — Twelve ...
 ... from the brain on either ...
 ... the olfactory or first; ...
 ... the second or second; ...
 ... the third or third; ...
 ... the fourth or fourth; ...
 ... the fifth or fifth; ...
 ... the sixth or sixth; ...
 ... the seventh or seventh; ...
 ... the eighth or eighth; ...
 ... the ninth or ninth; ...
 ... the tenth or tenth; ...
 ... the eleventh or eleventh; ...
 ... the twelfth or twelfth.

... have a "superficial" and a
 ... "superficial origin" is most
 ... enter or leave the brain surface;
 ... the connections which are
 ... the different nerves with nuclei or
 ... the substance of the brain. These
 ... (1) those in connection with which
 ... nerve fibres end; and (2) those from
 ... nerve fibres arise. It is the
 ... only which come under notice of the
 ... of the present time.

... eight of the cerebral nerves have a superficial
 ... the ventral part of the hind brain which is
 ... by the nucleus oblongata and the pons.

Trigeminal Nerve — Upon the lateral aspect of the
 ... oblongata, in its upper half, is a very conspicuous

oval prominence called the olive. A distinct sulcus or groove, which passes downwards anterior to this body, separates it from an elongated strand, termed the pyramid of the medulla oblongata. From the bottom of this sulcus and its prolongation downwards issue a series of nerve fila which belong to two different nerves. Those which issue from the lower part of the groove, below the level of the olive, belong to the *anterior root* of the *first cervical nerve*; those which emerge from the

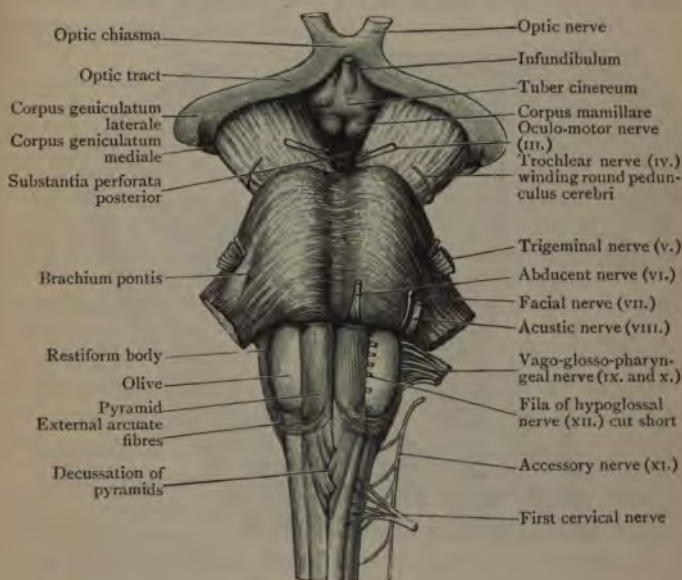


FIG. 183.—Anterior aspect of the Medulla oblongata, Pons, and Mesencephalon of a full-time Fœtus.

upper part of the groove, in the interval between the olive and the pyramid, form the *hypoglossal nerve*.

Glosso-pharyngeal, Vagus, and Accessory Nerves.—Posterior to the olive, in the postero-lateral sulcus of the medulla oblongata, is another continuous row of nerve fila. These extend downwards, beyond the level of the olive, and are attached to the whole length of the medulla oblongata in linear order. They belong to three nerves, but it is impossible at present (seeing that the nerve-trunks which they

removal of the brain its connection with that body was severed.

Substantiæ Perforatæ Anteriores. — These are small triangular districts of grey matter, one on each side. Each is bounded posteriorly by the uncinatè extremity of the hippocampal gyrus; anteriorly by the diverging striæ of the olfactory tract; and medially by the optic tract. Laterally it passes into the roof of the lateral fissure, and is perforated by the antero-lateral basal arteries. The grey matter in this area is continuous above with the grey matter of the lentiform nucleus (O.T. lenticular).

Lamina Terminalis. — If the anterior border of the optic chiasma is displaced posteriorly a thin lamina will be noticed. It passes upwards from the chiasma into the longitudinal fissure, to become connected with the rostrum of the corpus callosum. This is the *lamina terminalis*. It closes the third ventricle anteriorly, and is continuous on either side with the grey matter of the substantia perforata anterior.

Superficial Origins of the Cerebral Nerves. — Twelve cerebral nerves are enumerated arising from the brain on either side of the median plane. They are the olfactory or first; the optic or second; the oculo-motor or third; the trochlear or fourth; the trigeminal or fifth; ~~the abducent~~ or sixth; the facial or seventh; the acoustic or eighth; the glosso-pharyngeal or ninth; the vagus or tenth; the accessory or eleventh; and the hypoglossal or twelfth.

Each of these nerves is said to have a "superficial" and a "deep" origin. By the term "superficial origin" is meant the region where its fibres enter or leave the brain surface; the term "deep origin" indicates the connections which are established by the fibres of the different nerves with nuclei or clusters of nerve-cells within the substance of the brain. These nuclei are of two kinds: (1) those in connection with which the afferent or entering nerve fibres end; and (2) those from which the efferent or emerging nerve fibres arise. It is the superficial attachments only which come under notice of the dissector at the present time.

No fewer than eight of the cerebral nerves have a superficial attachment to the ventral part of the hind brain which is formed by the medulla oblongata and the pons.

Hypoglossal Nerve. — Upon the lateral aspect of the medulla oblongata, in its upper half, is a very conspicuous

oval prominence called the olive. A distinct sulcus or groove, which passes downwards anterior to this body, separates it from an elongated strand, termed the pyramid of the medulla oblongata. From the bottom of this sulcus and its prolongation downwards issue a series of nerve fila which belong to two different nerves. Those which issue from the lower part of the groove, below the level of the olive, belong to the *anterior root* of the *first cervical nerve*; those which emerge from the

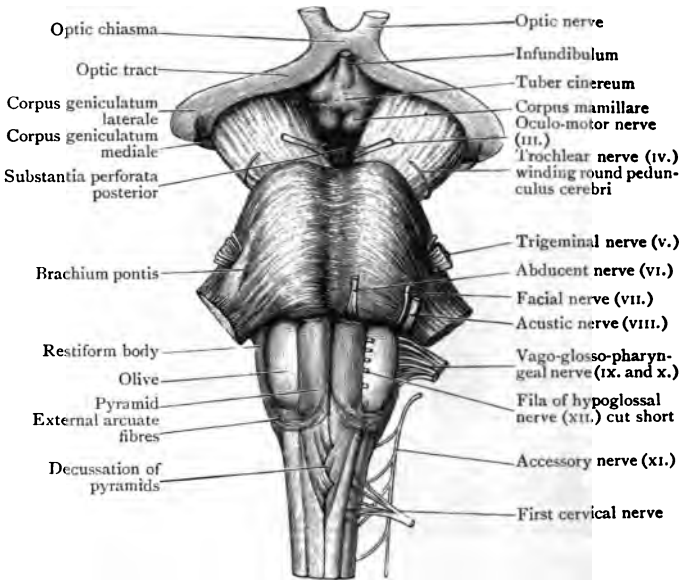


FIG. 183.—Anterior aspect of the Medulla oblongata, Pons, and Mesencephalon of a full-time Foetus.

upper part of the groove, in the interval between the olive and the pyramid, form the *hypoglossal nerve*.

Glosso-pharyngeal, Vagus, and Accessory Nerves.—Posterior to the olive, in the postero-lateral sulcus of the medulla oblongata, is another continuous row of nerve fila. These extend downwards, beyond the level of the olive, and are attached to the whole length of the medulla oblongata in linear order. They belong to three nerves, but it is impossible at present (seeing that the nerve-trunks which they

build up are divided) to determine precisely the number of fila which belong to each. From below upwards the nerves which they form are the *accessory*, the *vagus*, and the *glosso-pharyngeal*. The fila of the *vagus* and the *glosso-pharyngeal* are much more closely crowded together than those of the *accessory*.

The roots of the *accessory*, which spring from the medulla oblongata, constitute only one part of the nerve. The *spinal*

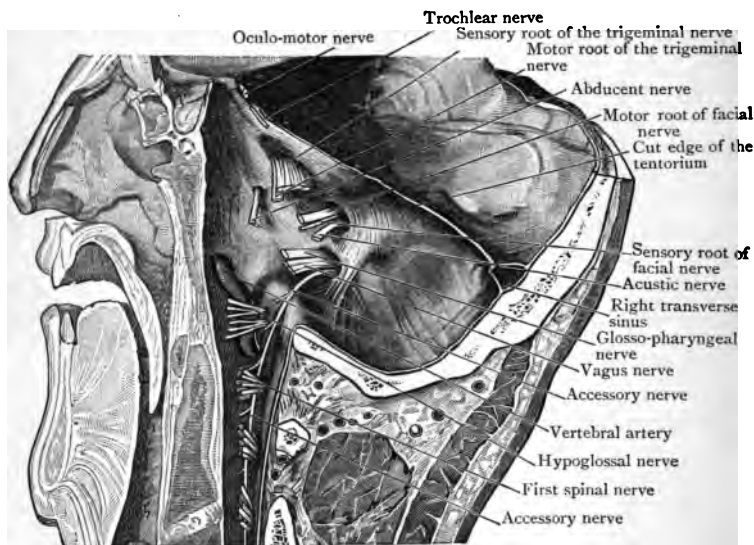


FIG. 184.—Section through the Head a little to the right of the Median Plane. It shows the posterior cranial fossa and the upper part of the vertebral canal after the removal of brain and the spinal medulla.

part springs from the spinal medulla, as low down as the sixth cervical nerve, by a series of roots which issue from the lateral funiculus, posterior to the attachment of the *ligamentum denticulatum*.

Acoustic and Facial Nerves.—These issue close together at the lower border of the pons, and immediately above the restiform body. The *acoustic nerve* is the larger of the two, and it lies on the lateral side of the facial. Its two roots, termed the cochlear and the vestibular, embrace the restiform body.

The *facial nerve* issues from the pons close to its lower border, and just to the medial side of the acoustic nerve, by two roots, a large motor root, and a small sensory root (O.T. pars intermedia). The two roots unite in the internal acoustic meatus.

Abducent Nerve.—This is a small nerve which emerges from the groove between the lower border of the pons and the lateral part of the pyramid.

Trigeminal Nerve.—This is the largest of all the cerebral nerves. It appears at the side of the pons, nearer its upper

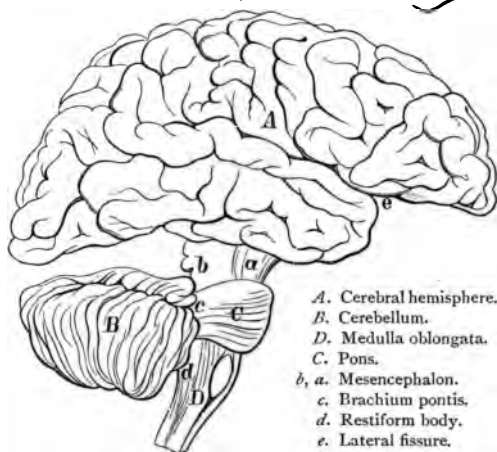


FIG. 185.—Diagrammatic view of the manner in which the several parts of the Brain are connected with one another. (From Schwalbe.)

than its lower border and in a line with the facial and acoustic nerves. It consists of two roots—a large sensory root, *portio major*, composed of a great number of fila loosely held together, and a small, more compact motor root, *portio minor*, which emerges antero-medial to the point at which the sensory root enters the pons.

Trochlear Nerve.—The superficial origin of the trochlear or fourth nerve cannot be seen at present. It emerges from the anterior medullary velum, on the dorsal aspect of the brain-stem. It is a delicate little nerve which has a long intracranial course. It winds round the lateral side of the pedunculus cerebri, between the cerebrum and cerebellum.

Oculo-motor Nerve.—This may be seen within the interpeduncular fossa. It issues by several fila from the sulcus oculomotorius on the medial face of the cerebral peduncle.

Optic Nerve.—This is a large round nerve which passes antero-laterally from the optic chiasma.

Olfactory Nerves.—These arise from the olfactory bulb and enter the nasal cavity through the foramina in the cribriform plate of the ethmoid bone.

General Connections of the Several Parts of the Brain.—Before proceeding to the more particular study of the different parts of the brain the student should acquire a general conception of the manner in which these are connected with each other. In the posterior cranial fossa, below the tentorium, are placed the medulla oblongata, the pons, and the cerebellum, which constitute collectively the *Rhombencephalon* or *hind-brain*. They surround a cavity which is called the fourth ventricle of the brain, and all stand in intimate connection with one another. The upper end of the medulla oblongata terminates chiefly in the pons, but two large strands on its posterior or dorsal aspect, termed the restiform bodies, pass posteriorly into the cerebellum (Fig. 185, *d*). The transverse fibres of the pons are gathered together on either side in the form of a large rope-like strand, the *brachium pontis*. This disappears into the corresponding hemisphere of the cerebellum (Fig. 185, *c*).

The great mass of the brain is termed the cerebrum. This occupies the anterior and middle cranial fossæ, and extends posteriorly into the occipital region above the tentorium cerebelli. The greater part of the cerebrum is formed by the cerebral hemispheres, which are separated from each other, in the median plane, by the longitudinal fissure. At the bottom of this fissure may be seen the *corpus callosum*, a broad commissural band which connects the two cerebral hemispheres with each other. Each hemisphere is hollow—the cavity in its interior being termed the *lateral ventricle* of the brain. Between and below the cerebral hemispheres, and almost completely concealed by them, is the *thalamencephalon*. The principal parts forming this portion of the brain are the two thalami, between which is the *third ventricle* of the brain—a deep, narrow cavity occupying the median plane. The third ventricle communicates with the

lateral ventricles through the *foramen interventriculare* (O.T. *foramen of Monro*).

The cerebrum is connected with the parts in the posterior cranial cavity (pons, cerebellum, and medulla oblongata) by a narrow stalk called the *mid-brain*, or *mesencephalon*. The mid-brain is built up of a ventral portion, the pedunculi cerebri, passing between the pons and the cerebrum (Fig. 185, *a*), and a dorsal portion, the lamina quadrigemina. It is tunnelled by a narrow passage—the *aquæductus cerebri* (O.T. *aqueduct of Sylvius*)—which connects the fourth and the third ventricles.

THE CEREBRUM.

Cerebral Hemispheres.—Each cerebral hemisphere presents a lateral, a medial, and an inferior surface, which are separated from one another by more or less distinctly marked borders. The *lateral surface* is convex, and is adapted to the concavity of the cranial vault. The *medial surface* is flat and perpendicular, and is more or less completely separated from the corresponding surface of the opposite hemisphere by the falx cerebri, which occupies the longitudinal fissure. The *inferior surface* is irregular, and is adapted to the anterior and middle cranial fossæ, and also to the upper surface of the tentorium cerebelli. Traversing this surface, in a transverse direction, nearer the anterior than the posterior end of the hemisphere, is the stem of the lateral fissure (O.T. Sylvian) (Fig. 182). This deep cleft divides the inferior surface into an anterior or *orbital area*, which rests upon the orbital plate of the frontal bone and is, consequently, concave from side to side, and a more extensive posterior or *tentorial area*, which lies on the floor of the lateral part of the middle cranial fossa and the upper surface of the tentorium cerebelli. The tentorial portion of the inferior surface is arched antero-posteriorly, and looks medially as well as downwards.

The borders which separate the surfaces from each other are the supero-medial, the superciliary, the infero-lateral, the medial occipital, and the medial orbital. The *supero-medial border*, convex antero-posteriorly, intervenes between the medial and lateral surfaces. The *superciliary border* is highly arched, it separates the orbital surface

from the lateral surface. The *infero-lateral border* marks off the tentorial part of the inferior surface from the lateral surface. The *medial occipital border* is not very distinct, except in cases where the brain has been hardened *in situ*. It extends from the posterior extremity of the hemisphere to the posterior end of the corpus callosum, and intervenes between the medial surface and the tentorial part of the inferior surface. The *medial orbital margin* extends from the frontal pole to the lamina terminalis and separates the orbital from the medial surface.

The most projecting part of the anterior end of the cerebral hemisphere is called the *frontal pole*, whilst the most projecting part of the posterior end is termed the *occipital pole*. On the under surface of the hemisphere, the prominent rounded portion of cerebral substance which extends anteriorly below the lateral fissure receives the name of the *temporal pole*. In a well-hardened brain a broad groove is usually present on the medial aspect of the occipital pole of the right hemisphere. This corresponds to the termination superior sagittal venous sinus.

Longitudinal Fissure.—This great median cleft is occupied by the fold of dura mater termed the falx cerebri. Anteriorly and posteriorly, it completely separates the cerebral hemispheres from each other, but the intermediate part is floored by the corpus callosum—the commissural band which passes between the hemispheres and connects them together. The upper surface of the corpus callosum can be displayed by gently drawing asunder the two sides of the longitudinal fissure.

Dissection.—If two brains are available, the dissector is advised, at this stage, to separate the cerebrum from the cerebellum, pons and medulla oblongata in one of them, by cutting transversely through the mid brain if this has not been done already. The cerebrum may then be split in the median plane by placing a long knife in the longitudinal fissure and dividing, with one sweep, the various parts which connect the two sides to each other. By this proceeding, the three surfaces of each cerebral hemisphere are exposed, and the gyri and sulci can be studied fully and satisfactorily. If only one brain is at the disposal of the student, he should not, at this stage, separate the cerebral hemispheres from each other, but should endeavour to follow out the gyri and sulci with the various parts of the brain in position. No doubt he studies the hemisphere in this way at a disadvantage, but as the dissection proceeds, opportunities will occur which will enable him to examine those districts of the surface which he can see only imperfectly at present.

Cerebral Gyri and Sulci.—The surfaces of the cerebral

hemispheres are rendered highly irregular by the presence of gyri, separated from one another by intervening furrows, termed sulci and fissures. The surface pattern which is presented by these gyri and sulci is, in its general features, the same in all human brains; but when the comparison is pushed into more detail many differences become manifest, not only in the brains of different individuals but also in the two cerebral hemispheres of one individual.

Of the furrows two varieties must be recognised, viz., complete and incomplete. The *complete fissures* are few in number and they consist of inwardly directed folds which involve the whole thickness of the cerebral wall. They consequently show in the interior of the cerebral cavity or lateral ventricle in the form of elevations on its walls. In this category are included (1) the hippocampal fissure; (2) the anterior portion of the calcarine fissure; and (3) a portion of the collateral fissure. The *incomplete fissures and the sulci* are merely furrows of varying depth which do not produce any effect on the surface of the ventricular walls.

General Structure of the Cerebral Hemispheres.—Each cerebral hemisphere is composed of an outside coating of grey matter, spread in a continuous and uninterrupted layer over its surface, and an internal core of white matter. The grey coating is termed the *cerebral cortex*, whilst the white internal part is called the *medullary centre*. Each gyrus shows a corresponding structure. It has an external covering of grey matter supported upon a core of white medullary matter. But, in addition to the grey matter on the outside, there are certain large deposits of grey matter embedded in the substance of each hemisphere in its basal part. These constitute the basal nuclei, and although to a certain extent they are isolated from the grey matter on the surface, nevertheless, at certain points, they are directly continuous with it.

By means of the gyri and sulci the grey matter on the surface of the hemisphere is increased, and its close association with the vascular pia-mater is maintained without any unnecessary increase of the bulk of the organ. The vascular pia-mater dips into every fissure and sulcus, and opportunity is therefore afforded for the cortical vessels to break up into twigs of exceeding fineness before they enter the substance of the hemisphere. The distribution

of the blood to the grey cortex is in this way rendered uniform.

Cerebral Lobes and Interlobar Fissures.—Certain of the fissures which traverse the surface of the cerebrum are arbitrarily chosen for the purpose of subdividing the surface into districts, termed lobes. These fissures, which receive the name of *interlobar*, are the following—(1) the lateral fissure (O.T. Sylvian); (2) the central (O.T. fissure of Rolando); (3) the parieto-occipital; (4) the collateral; and (5) the circular sulcus (O.T. limiting sulcus of Reil).

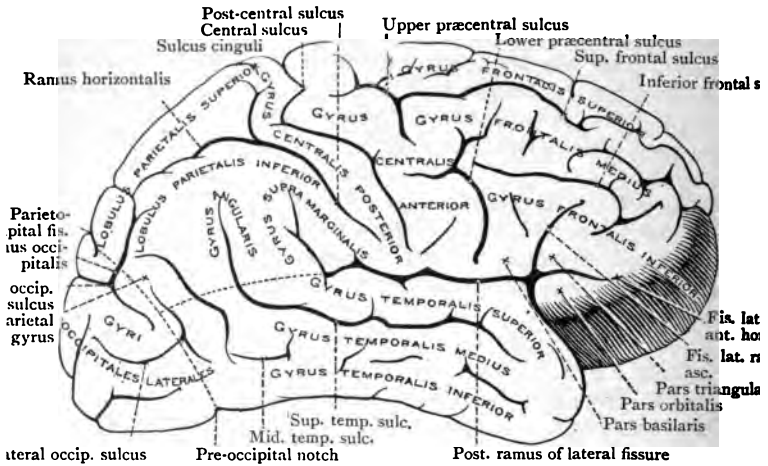


FIG. 186.—Gyri and Sulci on the Lateral Surface of the Cerebral Hemisphere.

The lobes which are mapped out by these fissures are—(1) the frontal; (2) the parietal; (3) the occipital; (4) the temporal; (5) the insula. To these may be added a sixth lobe, in no way related to the interlobar fissures, viz., the olfactory lobe.

Lateral Fissure (O.T. Sylvian).—This is the most conspicuous fissure on the surface of the cerebrum. It is composed of a short main stem, from the lateral extremity of which three branches radiate. The *stem* is placed on the inferior surface of the cerebrum (Fig. 182). It begins at the substantia perforata anterior. Thence it passes laterally, forming a deep cleft between the temporal pole and the orbital surface of the frontal lobe. Appearing on the lateral

the insula to meet the temporal operculum. Its margin forms the upper lip of the posterior branch of the lateral fissure.

The *frontal operculum* (Fig. 186) is the small triangular piece of cerebral cortex between the anterior ascending and horizontal branches of the lateral fissure. It is sometimes termed the *pars triangularis*.

The *orbital operculum* (Fig. 186) is for the most part on the under surface of the hemisphere. It lies below the anterior horizontal limb of the lateral fissure, and passes posteriorly from the orbital aspect of the frontal lobe over the anterior part of the insula.

Sulcus Centralis (O.T. Fissure of Rolando).—The central sulcus takes an oblique course across the lateral surface of the cerebral hemisphere (Fig. 186). Its upper end in many cases cuts the supero-medial border of the hemisphere a short distance posterior to the mid-point between the frontal and occipital poles, whilst its lower end terminates above the middle of the posterior branch of the lateral fissure. When its superior extremity turns round the supero-medial border of the hemisphere it is continued posteriorly, for a short distance, on the medial surface (Fig. 187). Although in its general direction the sulcus centralis is oblique, it is far from being straight. Nearer to its upper than to its lower end it is bent posteriorly so as to form a bay, within which is accommodated a portion of the cerebral cortex which represents the motor area of the opposite upper limb. The upper and lower limits of this bay are termed the *upper* and *lower genua* of the fissure.

Fissura Parieto-occipitalis.—The greater part of this fissure is situated on the medial surface of the cerebral hemisphere (Fig. 187); only a very small part appears on the lateral face (Fig. 186).

The *lateral part of the parieto-occipital fissure* (O.T. *external parieto-occipital*) cuts the supero-medial border of the hemisphere, in a transverse direction, from one and a half to two inches anterior to the occipital pole. It is usually not more than half an inch in length, and it is brought to an abrupt termination by an arching convolution which winds round its extremity, and receives the convenient name of *arcus parieto-occipitalis* (Fig. 186).

The *medial part of the parieto-occipital fissure* (Fig. 187)

runs downwards, in a nearly vertical direction, on the medial surface of the hemisphere, as a conspicuous and deep sulcus, at its lower end, forms the calcarine fissure.

Fissura Collateralis (Fig. 187). The collateral fissure is a deeply marked fissure on the tentorial part of the inferior surface of the cerebral hemisphere. It begins near the orbital pole, and extends anteriorly towards the temporal pole. Posteriorly it lies below and parallel to the calcarine

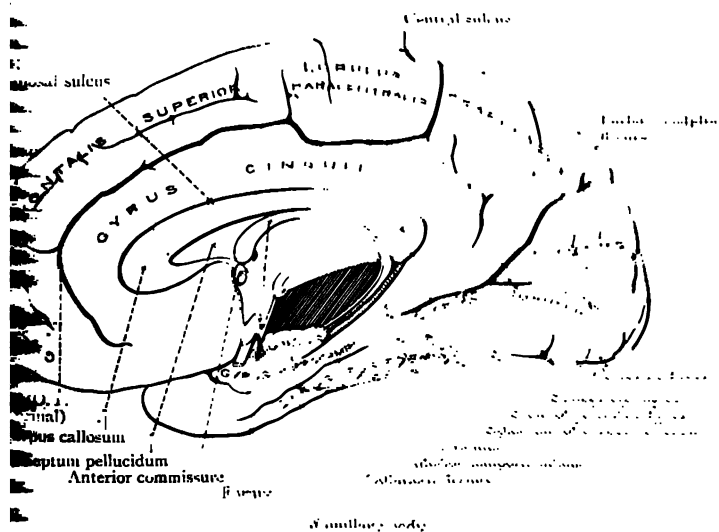


FIG. 187.—The Gyri and Sulci on the lateral and ventral aspects of the cerebral hemisphere.

whilst anteriorly it is separated from the upper margin of the hippocampal gyrus which is its highest and medial convolution on the external part of the inferior surface of the hemisphere (Fig. 187).

Anterior to the collateral fissure, a shallow sulcus, which is the anterior end of the temporal sulcus and intervenes between the temporal pole and the anterior end of the body of the hippocampal gyrus, is the ecto-rhinal or ecto-rhinal fissure (Fig. 188).

Gyrus Cinguli (O.T. *Gyrus Cinguli*) (Fig. 187).

This is a stout gyrus forming the anterior part of the corpus callosum.

the medial surface of the hemisphere. It commences on the lower portion of the anterior part of the medial surface, curves first upwards and then posteriorly. Finally, turning upwards, it cuts the supero-medial border of the hemisphere a short distance behind the upper end of the sulcus centralis, and terminates on the lateral surface of the parietal lobe. It separates the anterior portion of the medial surface into a marginal and a central area. The central part is the *gyrus cinguli* (O.T. *callosal gyrus*). The marginal part is separated into two portions by a branch of the sulcus cinguli, which projects upwards above the middle of the corpus callosum. The anterior part is the medial area of the superior frontal gyrus; the posterior part is the *paracentral lobule*.

Boundaries of the Frontal Lobe.—The frontal is the largest of the cerebral lobes. On the lateral surface of the hemisphere it is bounded posteriorly by the central sulcus, and below by the posterior branch of the lateral fissure. On the medial surface it is limited by the sulcus cinguli; whilst on the inferior surface of the hemisphere the stem of the lateral fissure forms its posterior boundary.

Lateral Surface of the Frontal Lobe.—On the lateral surface of the frontal lobe the following sulci and gyri may be recognised:—

Sulci	{	Sulcus præcentralis inferior.		Gyri	{	Gyrus centralis anterior.
		Sulcus præcentralis superior.				Gyrus front- alis superior { Pars superior.
		Sulcus paramedialis.				Pars inferior.
		Sulcus frontalis superior.				Gyrus front- alis medius { Pars superior.
		Sulcus frontalis medius.				Pars inferior.
		Sulcus frontalis inferior.				Gyrus front- alis inferior. { Pars basilaris.
		Sulcus diagonalis.				Pars triangularis.
		Sulcus fronto-marginalis.				Pars orbitalis.

Sulcus Præcentralis Inferior (Fig. 186).—The inferior præcentral sulcus consists of a vertical and a horizontal part, and, when present in a well-marked form, it presents a figure like the letter T or F. The *vertical portion* lies anterior to the lower part of the central sulcus (O.T. fissure of Rolando), and the *horizontal portion* extends antero-superiorly into the middle frontal gyrus.

Sulcus Præcentralis Superior (Fig. 186).—This is a short vertical sulcus which lies anterior to the upper part of the

central sulcus. It is almost invariably connected with the posterior end of the superior frontal sulcus.

Gyrus Centralis Anterior.—The anterior central gyrus is a long continuous gyrus which is limited anteriorly by the two præcentral sulci, and posteriorly by the central sulcus. It extends obliquely across the hemisphere, from the supero-medial margin above to the posterior branch of the lateral fissure below (Fig. 186).

Sulcus Frontalis Superior (Fig. 186).—The superior frontal sulcus extends anteriorly from the sulcus præcentralis superior.

Gyrus Frontalis Superior (Figs. 186, 187).—The superior frontal gyrus lies above the superior frontal sulcus and passes round the supero-medial border on to the medial surface of the hemisphere. It terminates anteriorly in the frontal pole.

Sulcus Frontalis Inferior (Fig. 186).—This lies at a lower level than the superior sulcus of the same name. The posterior end of the inferior frontal sulcus is placed in the angle between the vertical and horizontal parts of the inferior præcentral sulcus, and is not infrequently confluent with one or other of these. It passes anteriorly towards the superciliary margin of the hemisphere, and ends a short distance from it in a terminal bifurcation.

Gyrus Frontalis Medius (Fig. 186).—The middle frontal gyrus is the broad convolution which lies between the superior and inferior frontal sulci.

Gyrus Frontalis Inferior (Fig. 186).—The inferior frontal gyrus is that portion of the lateral surface of the frontal lobe which is placed anterior to the inferior præcentral sulcus and below the inferior frontal sulcus.

The *sulcus paramedialis* is the term applied to a series of short irregular furrows arranged longitudinally, close to the supero-medial border of the hemisphere. These rudimentary sulci partially subdivide the superior frontal gyrus into an upper and lower division, and are of interest in so far that they are best marked in high types of brain.

The *middle frontal sulcus* (Fig. 186) lies horizontally in the anterior part of the middle frontal gyrus, and divides it into an upper and a lower part (Fig. 186). As it approaches the superciliary margin of the hemisphere it bifurcates, and its terminal branches spread out widely from each other, and together constitute a transverse furrow called the *sulcus fronto-marginalis*.

Owing to the subdivision of the superior and middle frontal gyri in the manner indicated, the gyri in the anterior part of the lateral surface of the frontal lobe are arranged in five horizontal tiers.

Gyrus Frontalis Inferior.—The inferior frontal gyrus possesses a special interest and importance, on account of the supposed localisation within it, on the left side, of the

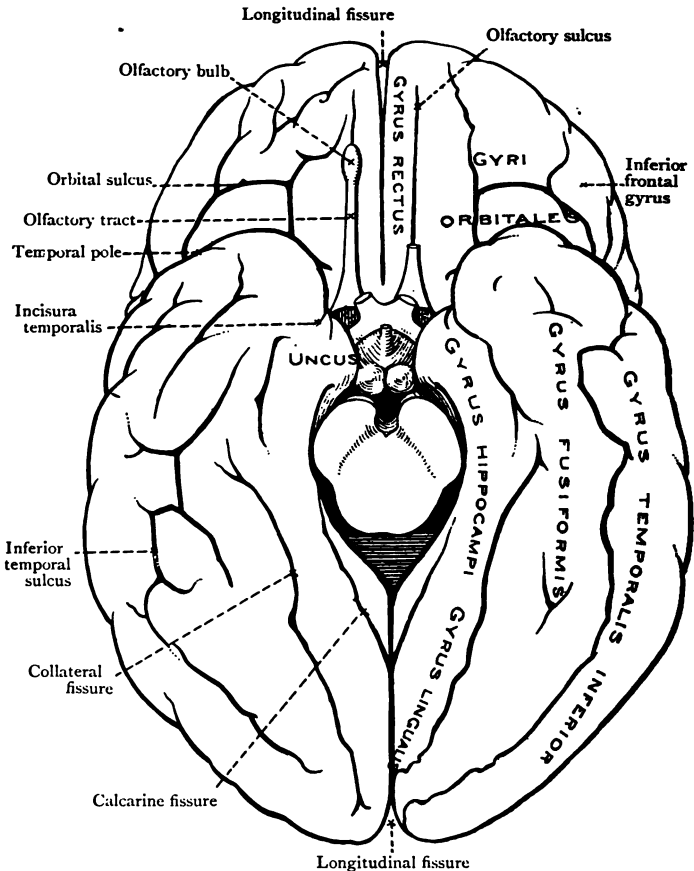


FIG. 188.—Gyri and Sulci on the Tentorial and Orbital Surfaces of the Cerebral Hemispheres.

speech-centre. It consists of an *upper non-opercular* and a *lower opercular portion*. The latter is cut up into three parts by the two anterior branches of the lateral fissure. These

are termed the *pars basilaris*, the *pars triangularis*, and the *pars orbitalis*.

The *pars basilaris* (Fig. 186) is that part which lies between the vertical limb of the inferior præcentral sulcus and the anterior ascending ramus of the lateral fissure. It forms the anterior portion of the fronto-parietal operculum, and it is traversed in an oblique direction by a shallow furrow, termed the *sulcus diagonalis*.

The *pars triangularis* (Fig. 186) is simply another name for the frontal operculum. It is triangular in form, and lies between the anterior ascending and anterior horizontal rami of the lateral fissure.

The *pars orbitalis* (Fig. 186) is placed below the anterior horizontal ramus of the lateral fissure.

Medial Surface of the Frontal Lobe.—On this aspect of the frontal lobe is the elongated, more or less continuous, medial part of the superior frontal gyrus (O.T. marginal gyrus). It lies between the supero-medial border of the hemisphere and the sulcus cinguli (Fig. 187).

In the anterior part of this gyrus one or two curved sulci are usually present. These are termed the *sulci rostrales*.

The posterior end of the medial surface of the superior frontal gyrus is more or less completely cut off from the anterior part. It forms part of the *paracentral lobule*, and lies anterior to the upper end of the central sulcus (Fig. 187).

Orbital Surface of the Frontal Lobe.—On this aspect of the frontal lobe there are two sulci—viz. the olfactory and the orbital.

Sulcus Olfactorius.—The olfactory sulcus (Fig. 188) is a straight furrow which runs parallel to the medial orbital border of the hemisphere. It is occupied by the olfactory tract and bulb, and it cuts off a narrow strip of the orbital surface close to the medial border which receives the name of *gyrus rectus* (Fig. 188).

The *orbital sulcus* is a compound furrow which assumes many different forms. Most frequently it takes the shape of the letter H, of which the three component parts are a lateral limb, a medial limb, and a transverse limb.

The *lateral limb* curves round the orbital part of the inferior frontal gyrus, and limits it medially. The *medial limb* marks off a convolution between itself and the olfactory

parieto-occipitalis, it bifurcates into two widely spread-out branches. These form a short transverse fissure in the occipital lobe, termed the *sulcus occipitalis transversus* (Ecker) (Fig. 186).

The upturned ends of the posterior branch of the lateral fissure, of the superior temporal sulcus and of the middle temporal sulcus (Fig. 186) extend for a short distance, one posterior to the other, into the inferior parietal lobule.

Gyri on the Lateral Surface of the Parietal Lobe.—The interparietal sulcus maps out three districts or areas on the lateral surface of the parietal lobe. These are the posterior central gyrus and the superior and inferior parietal lobules.

The *gyrus centralis posterior* (Fig. 186) is a long gyrus which extends obliquely across the hemisphere from the supero-medial border above to the posterior branch of the lateral fissure below. Anteriorly, it is bounded by the central sulcus, and posteriorly, by the superior and inferior postcentral sulci.

The *superior parietal lobule* is the area of cerebral cortex which lies between the ramus horizontalis below and the supero-medial border of the hemisphere above. It is bounded anteriorly by the superior postcentral sulcus; and posteriorly, it is connected with the occipital lobe by the arcus parieto-occipitalis. It is continuous around the supero-medial border of the hemisphere with the præcuneus.

The *inferior parietal lobule* lies below the ramus horizontalis and the ramus occipitalis, and posterior to the inferior postcentral sulcus. It is more or less directly continuous with the occipital lobe posteriorly and with the temporal lobe below. It presents three arching gyri, viz. the supra-marginal anteriorly, the post-parietal posteriorly, and the angular between them.

The *supra-marginal gyrus* (Fig. 186) is folded round the upturned end of the posterior branch of the lateral fissure and is continuous with the superior temporal gyrus. The *angular gyrus* (Fig. 186) arches over the upturned end of the superior temporal sulcus, and is continuous with the middle temporal gyrus. The *post-parietal gyrus* (Fig. 186) winds round the upturned end of the middle temporal sulcus, and runs into the inferior temporal gyrus.

Boundaries of the Occipital Lobe.—The occipital lobe forms the posterior pyramidal part of the cerebral hemi-

sphere, and it encloses the posterior horn of the lateral ventricle. On the surface it is very imperfectly mapped off from the parietal and temporal lobes, which lie anterior to it. It presents three surfaces and an apex or occipital pole. On the medial aspect of the hemisphere it is separated from the parietal lobe (*i.e.* the præcuneus) by the parieto-occipital fissure. On the tentorial part of the inferior surface it is not separated either from the temporal lobe or from the gyrus hippocampi, which lie anterior to it. It is necessary, therefore, on this aspect, to employ an arbitrary line of demarcation, which extends from the præ-occipital notch, on the infero-lateral border of the hemisphere, to the isthmus of the gyrus fornicatus, which lies below the posterior end of the corpus callosum. On the lateral surface the parieto-occipital fissure, and an arbitrary line from that fissure to the præ-occipital notch, may be regarded as separating the occipital from the parietal and temporal lobes.

Medial Aspect of the Occipital Lobe.—On the medial surface are (1) the calcarine fissure; (2) the cuneus; and (3) part of the gyrus lingualis.

The *calcarine fissure* commences below the isthmus of the gyrus fornicatus and takes a curved course towards the occipital pole where it bifurcates into short branches. At a point somewhat nearer its anterior than its posterior extremity it is joined by the parieto-occipital fissure and the two fissures together form a >-shaped figure.

When calcarine and parieto-occipital fissures are fully opened up, so as to expose the bottom in each case, two well-marked deep or submerged gyri will be displayed (Fig. 189). One of these, the *gyrus cunei*, marks off the parieto-occipital fissure from the calcarine fissure; the other interrupts the calcarine fissure immediately posterior to its junction with the parieto-occipital. It is called the *anterior cuneo-lingual deep gyrus*, and it divides the calcarine fissure into an anterior and a posterior part. The *anterior* part of the *calcarine fissure* corresponds very nearly to the stem of the >-shaped fissural arrangement. It is very deep and, being a complete fissure, it gives rise to an elevation, called the *calcar avis*, on the medial wall of the posterior horn of the lateral ventricle. The *posterior* part of the *calcarine fissure* is much shallower.

The *cuneus* (Fig. 187) is the wedge-shaped or triangular district on the medial aspect of the occipital lobe between the parieto-occipital and calcarine fissures.

The *gyrus lingualis* (Figs. 187, 188) is a well-marked gyrus situated between the calcarine fissure above and the pos-

parieto-occipitalis, it bifurcates into two widely spread-out branches. These form a short transverse fissure in the occipital lobe, termed the *sulcus occipitalis transversus* (Ecker) (Fig. 186).

The upturned ends of the posterior branch of the lateral fissure, of the superior temporal sulcus and of the middle temporal sulcus (Fig. 186) extend for a short distance, one posterior to the other, into the inferior parietal lobule.

Gyri on the Lateral Surface of the Parietal Lobe.—The interparietal sulcus maps out three districts or areas on the lateral surface of the parietal lobe. These are the posterior central gyrus and the superior and inferior parietal lobules.

The *gyrus centralis posterior* (Fig. 186) is a long gyrus which extends obliquely across the hemisphere from the supero-medial border above to the posterior branch of the lateral fissure below. Anteriorly, it is bounded by the central sulcus, and posteriorly, by the superior and inferior postcentral sulci.

The *superior parietal lobule* is the area of cerebral cortex which lies between the ramus horizontalis below and the supero-medial border of the hemisphere above. It is bounded anteriorly by the superior postcentral sulcus; and posteriorly, it is connected with the occipital lobe by the arcus parieto-occipitalis. It is continuous around the supero-medial border of the hemisphere with the præcuneus.

The *inferior parietal lobule* lies below the ramus horizontalis and the ramus occipitalis, and posterior to the inferior postcentral sulcus. It is more or less directly continuous with the occipital lobe posteriorly and with the temporal lobe below. It presents three arching gyri, viz. the supra-marginal anteriorly, the post-parietal posteriorly, and the angular between them.

The *supra-marginal gyrus* (Fig. 186) is folded round the upturned end of the posterior branch of the lateral fissure and is continuous with the superior temporal gyrus. The *angular gyrus* (Fig. 186) arches over the upturned end of the superior temporal sulcus, and is continuous with the middle temporal gyrus. The *post-parietal gyrus* (Fig. 186) winds round the upturned end of the middle temporal sulcus, and runs into the inferior temporal gyrus.

Boundaries of the Occipital Lobe.—The occipital lobe forms the posterior pyramidal part of the cerebral hemi-

sphere, and it encloses the posterior horn of the lateral ventricle. On the surface it is very imperfectly mapped off from the parietal and temporal lobes, which lie anterior to it. It presents three surfaces and an apex or occipital pole. On the medial aspect of the hemisphere it is separated from the parietal lobe (*i.e.* the præcuneus) by the parieto-occipital fissure. On the tentorial part of the inferior surface it is not separated either from the temporal lobe or from the gyrus hippocampi, which lie anterior to it. It is necessary, therefore, on this aspect, to employ an arbitrary line of demarcation, which extends from the præ-occipital notch, on the infero-lateral border of the hemisphere, to the isthmus of the gyrus fornicatus, which lies below the posterior end of the corpus callosum. On the lateral surface the parieto-occipital fissure, and an arbitrary line from that fissure to the præ-occipital notch, may be regarded as separating the occipital from the parietal and temporal lobes.

Medial Aspect of the Occipital Lobe.—On the medial surface are (1) the calcarine fissure; (2) the cuneus; and (3) part of the gyrus lingualis.

The *calcarine fissure* commences below the isthmus of the gyrus fornicatus and takes a curved course towards the occipital pole where it bifurcates into short branches. At a point somewhat nearer its anterior than its posterior extremity it is joined by the parieto-occipital fissure and the two fissures together form a >-shaped figure.

When calcarine and parieto-occipital fissures are fully opened up, so as to expose the bottom in each case, two well-marked deep or submerged gyri will be displayed (Fig. 189). One of these, the *gyrus cunei*, marks off the parieto-occipital fissure from the calcarine fissure; the other interrupts the calcarine fissure immediately posterior to its junction with the parieto-occipital. It is called the *anterior cuneo-lingual deep gyrus*, and it divides the calcarine fissure into an anterior and a posterior part. The *anterior* part of the *calcarine fissure* corresponds very nearly to the stem of the >-shaped fissural arrangement. It is very deep and, being a complete fissure, it gives rise to an elevation, called the *calcar avis*, on the medial wall of the posterior horn of the lateral ventricle. The *posterior* part of the *calcarine fissure* is much shallower.

The *cuneus* (Fig. 187) is the wedge-shaped or triangular district on the medial aspect of the occipital lobe between the parieto-occipital and calcarine fissures.

The *gyrus lingualis* (Figs. 187, 188) is a well-marked gyrus situated between the calcarine fissure above and the pos-

terior part of the collateral fissure below. It commences at the occipital pole and narrows, as it passes anteriorly, to its union with the hippocampal gyrus. It lies partly on the medial surface and partly on the tentorial surface of the occipital lobe.

Tentorial Surface of the Occipital Lobe.—On this aspect lie part of the gyrus lingualis and the posterior part of the fusiform gyrus. They are separated by the posterior part of the collateral fissure. The gyrus fusiformis takes part, anteriorly, in the formation of the temporal lobe, and it is separated from the inferior temporal gyrus by the inferior temporal sulcus.

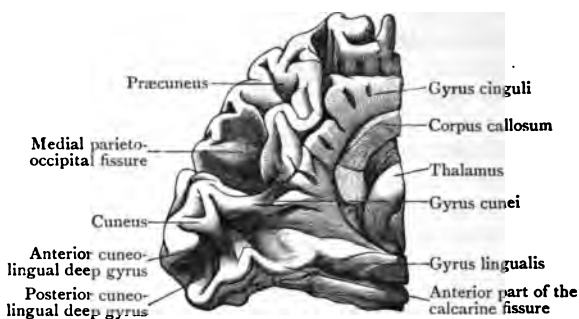


FIG. 189.—Posterior part of medial surface of the Left Hemisphere. The calcarine and the parieto-occipital fissures are widely opened up to show the deep gyri within them.

Lateral Surface of the Occipital Lobe.—There are two well-marked sulci on this surface of the occipital lobe—viz. the sulcus occipitalis transversus and the sulcus occipitalis lateralis or sulcus lunatus of Elliot Smith.

The *sulcus occipitalis transversus* (Fig. 186) extends transversely across the upper part of the lobe posterior to the arcus parieto-occipitalis. It has already been described as the terminal bifurcation of the ramus occipitalis of the interparietal sulcus.

The *sulcus occipitalis lateralis* (Fig. 186) is a short horizontal furrow which divides the lateral surface of the lobe into an upper and a lower area of very nearly equal extent. These areas are connected by means of superficial annectant gyri with the parietal and temporal lobes.

Boundaries of the Temporal Lobe.—The temporal lobe lies posterior to the stem of the lateral fissure and below its posterior branch. It presents an upper, a lateral, and a tentorial surface, with a free apex or pole which projects anteriorly. Above, it is bounded by the posterior branch of the lateral fissure together with the artificial line drawn posteriorly from that fissure. On the tentorial surface it is separated from the hippocampal gyrus by the collateral fissure; whilst posteriorly, it is marked off from the occipital lobe by the arbitrary lines described on p. 470. The apex or temporal pole projects anteriorly on the under surface of the brain. It should be noticed that the recurved extremity of the hippocampal gyrus, which lies to the medial side of the hemisphere, does not reach the temporal pole, but is separated from it by the *incisura temporalis* or *ectorhinal fissure*.

Upper or Opercular Surface of the Temporal Lobe.—This is the surface of the temporal operculum which is opposed to the insula and the fronto-parietal operculum. The lateral fissure must therefore be widely opened up to expose it. For the most part the surface is smooth, but towards its posterior part there are a few shallow furrows, called the *sulci of Heschl*, whilst anteriorly, also on the deep aspect of the temporal pole, two or three furrows are evident.

Lateral Surface of the Temporal Lobe.—On this aspect of the lobe there are two horizontal sulci, called the superior and middle temporal sulci.

The *superior temporal sulcus* (Fig. 186) is a long, continuous and deep cleft which begins near the temporal pole and proceeds posteriorly, below the posterior branch of the lateral fissure. Its posterior end turns upwards, into the parietal lobe, and is surrounded by the angular gyrus.

The *middle temporal sulcus* is placed midway between the superior temporal sulcus and the infero-lateral border of the hemisphere. It is very rare to find it in the form of a continuous cleft. Usually it is broken up into several isolated pieces, placed one posterior to the other. Its posterior part turns upwards into the parietal lobe (Fig. 186), where it is surrounded by the post-parietal gyrus, and lies close to the artificial line of demarcation between the occipital and parietal lobes.

By these two temporal sulci the lateral surface of the

temporal lobe is mapped out into three tiers of horizontal gyri, which are termed the *superior*, *inferior*, and *middle temporal gyri* (Fig. 186).

Tentorial Surface of the Temporal Lobe.—On this surface there is one fissure, termed the inferior temporal sulcus.

The *inferior temporal sulcus* (Fig. 188) lies below and lateral

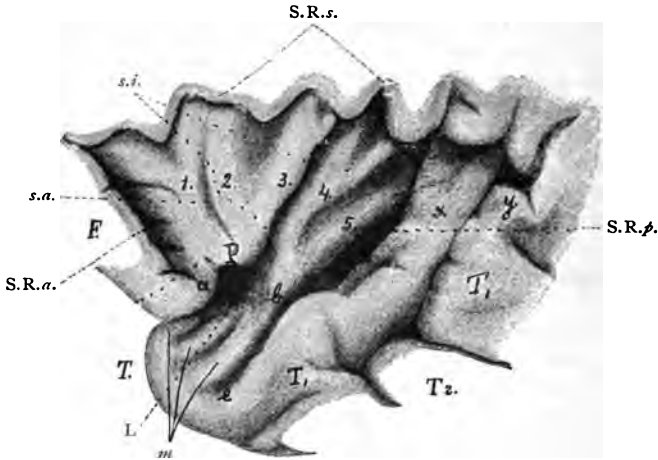


FIG. 190.—Fissures and Gyri on the Surface of the Insula. (Eberstaller.)

1, 2, and 3. Three short gyri on the frontal part of the insula.
4 and 5. Two long gyri on parietal part.
S.R.a. Anterior part of limiting sulcus.
S.R.s. Superior part of limiting sulcus.
S.R.φ. Inferior part of limiting sulcus.
L. Limen insulæ.
P. Pole of the insula.

F. Orbital operculum (for the most part removed).
T. Temporal pole.
T1. Superior temporal gyrus.
T2. Middle temporal gyrus.
x, y. Gyri of Heschl.
s.i. Sulcus centralis insulæ.
s.a. Sulcus præcentralis insulæ.
m. Gyri on deep surface of temporal pole.

to the collateral fissure, and close to the infero-lateral border of the hemisphere. It runs in an antero-posterior direction and is not always confined to the temporal lobe, but may extend posteriorly towards the occipital pole. It is usually broken up into two or more separate pieces.

The *fusiform gyrus* (Fig. 188) is situated between the collateral fissure and the inferior temporal sulcus. It extends from the occipital pole to the temporal pole.

The narrow strip of surface below and lateral to the

inferior temporal sulcus is continuous, round the infero-lateral margin of the hemisphere, with the inferior temporal gyrus on the lateral surface of the cerebrum, and is reckoned as a part of it.

The three temporal gyri and the fusiform gyrus run into one another at the temporal pole.

Insula (O.T. Island of Reil).—The insula is a triangular field of cerebral cortex which lies on a deeper plane than the general surface of the hemisphere, and is hidden from view by the four opercula which overlap it (p. 463). It is bounded by a distinct limiting sulcus, *sulcus circularis* (Reil), which has been described already; and its dependent apical part or pole, which looks downwards, is in close relation to the stem of the lateral fissure, and to the *substantia perforata anterior* on the base of the brain.

The insula is divided into several diverging gyri by a series of radiating sulci. Of the latter, one, which presents the same direction and lies in the same plane as the central sulcus, receives the name of the *sulcus centralis insulae*. It divides the insula into an anterior *frontal* part and a posterior *parietal* portion.

Olfactory Lobe.—The olfactory lobe is small and rudimentary in the human brain. It comprises (1) the olfactory bulb and tract with the three *striae*, and (2) the *trigonum olfactorium*.

The *olfactory tract* is a narrow white prismatic band, which expands anteriorly into a swollen bulbous extremity termed the *olfactory bulb*. Both the tract and the bulb lie in the olfactory sulcus on the orbital surface of the frontal lobe, whilst the inferior surface of the bulb, when the brain is in position, rests on the cribriform plate of the ethmoid bone and receives the numerous olfactory nerves which reach it through the foramina in that part of the cranial floor.

Posteriorly, the olfactory tract divides into two or three diverging *striae*. The *medial stria* (O.T. *mesial root*), curves abruptly medialwards, and may be followed into the extremity of the gyrus cinguli and the subcallosal gyrus. The *lateral stria* (O.T. *lateral root*) runs postero-laterally over the lateral part of the *substantia perforata anterior*, and gradually disappears from view. In animals, in which the olfactory apparatus is better developed than in man, it may be traced into the uncinatè extremity of the hippocampal

gyrus. The intermediate stria, which is not always present, runs posteriorly across the trigonum olfactorium.

The *gyrus sub-callosus* is a narrow cortical strip, of some morphological importance, which lies on the medial surface of the hemisphere immediately below the genu of the corpus callosum.

The *trigonum olfactorium* is the little triangular field of grey matter which occupies the interval between the medial and lateral striæ of the olfactory tract at the point where they begin to diverge.

Gyrus Fornicatus.—This gyrus, sometimes called the limbic lobe, is seen on the medial and tentorial surfaces of the hemisphere. It is a ring-like convolution, the extremities of which approach each other closely at the substantia perforata anterior.

The upper and anterior part of the gyrus fornicatus lies in intimate relation to the extremities and upper surface of the corpus callosum, and it is called the *gyrus cinguli*. The lower portion of the gyrus fornicatus is termed the *hippocampal gyrus*, and forms the medial part of the tentorial portion of the lower surface of the hemisphere. The continuity between the hippocampal gyrus and the gyrus cinguli is established, below the posterior end of the corpus callosum, by a narrow portion of the gyrus fornicatus called the *isthmus*. From this point the hippocampal gyrus extends anteriorly towards the temporal pole. Finally, at the side of the pedunculus cerebri, the hippocampal gyrus is folded on itself, and ends in a recurved hook-like extremity, termed the *uncus*. The uncus does not reach the temporal pole.

The *gyrus cinguli* (O.T. *callosal convolution*) begins below the anterior end of the corpus callosum at the substantia perforata anterior, and, winding round the genu of the callosum, it is continued posteriorly on its upper surface to the thickened posterior extremity or splenium. Finally, curving round this, it becomes greatly narrowed through the calcarine fissure cutting into it. This narrow part is termed the *isthmus*, and constitutes the link of connection between the gyrus cinguli and the hippocampal gyrus.

The gyrus cinguli is separated from the superior frontal gyrus and the paracentral lobule by the sulcus cinguli; from the præcuneus by the subparietal sulcus; and from the lingual gyrus by the calcarine fissure. It is separated from the corpus callosum by the *callosal sulcus*.

The *hippocampal gyrus* is bounded below and laterally by the anterior part of the collateral fissure, and anteriorly by the incisura temporalis, which separates its hooked extremity, or uncus, from the temporal pole. Supero-medially it is limited by the hippocampal fissure; whilst posteriorly it is divided into two parts by the anterior extremity of the calcarine fissure. Of these, the upper is the isthmus, which connects it with the gyrus cinguli, whilst the lower portion is continuous with the gyrus lingualis.

If the hippocampal fissure, which lies above the hippocampal gyrus, is opened up, in a soft brain, the *fascia dentata* and the *fimbria* lying side by side will be brought into view. In a hardened brain the examination of this region should be deferred (p. 492).

THE CORPUS CALLOSUM.

A dissection should now be made with the view of exposing the upper surface of the corpus callosum, which is the commissural band connecting the cerebral hemispheres at the bottom of the longitudinal fissure.

Dissection.—With a long knife slice off the top of the right hemisphere at the level of the sulcus cinguli. The white medullary centre of the cerebral hemisphere, enclosed on all hands by the grey cortex, is brought into view, and the appearance receives the name of *centrum semi-ovale*. From the central white mass medullary prolongations proceed into all the gyri.

A transverse incision may next be made through the middle of the gyrus cinguli; then the anterior and posterior parts of the gyrus cinguli should be torn away from the hemisphere in a lateral direction. If this is done successfully the manner in which the fibres of the corpus callosum enter the hemisphere will be seen. In cases where the student is dissecting the brain for the second time the knife should not be used at all in carrying out this dissection. The top of the hemisphere down to the level of the sulcus cinguli should, in the first instance, be torn off, and then the gyrus cinguli may be treated in the same way. By this expedient the fibres of the corpus callosum may be traced into the gyri.

Cingulum.—If the deep surface of the gyrus cinguli, which has been torn away, is examined, a large bundle of longitudinally directed fibres will be noticed embedded in its substance. This is the cingulum. It can be easily dislodged; a very slight degree of traction is all that is required to lift it out of its bed. It begins anteriorly at the *substantia perforata anterior*, curves round the convexity of the corpus callosum, and then descends, round its posterior end, and terminates in the hippocampal gyrus. The cingulum is a

long association bundle composed of several systems of fibres which run only for short distances within it. It is closely associated with the gyrus fornicatus.

Dissection.—The gyri and sulci on the medial surface of the left hemisphere may now be studied, and then the dissection, which has been carried out with the view of exposing the corpus callosum, may be repeated

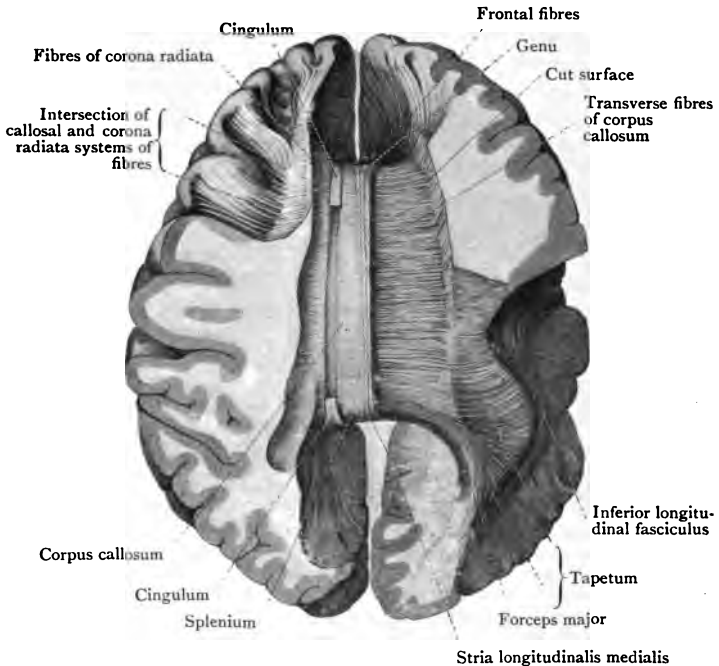


FIG. 191.—The Corpus Callosum exposed from above and the right half dissected to show the course taken by the fibres.

on the left side. In doing this, however, take care not to injure the medial surface of the left hemisphere posterior to the parieto-occipital fissure. Indeed, an effort should be made to preserve that fissure intact, so that it and the cuneus may be studied afterwards, on this side, in connection with the gyri and sulci on the under surface of the hemisphere.

The upper surface of the corpus callosum is now exposed, and it will be seen that it unites into one mass the medullary centres of the two hemispheres. The continuous white field, consisting of the corpus callosum and the medullary centre of each hemisphere, receives the name of *centrum ovale*.

Corpus Callosum.—This is the great transverse commissure

of the cerebrum. It is placed nearer the anterior than the posterior end of the brain, and it unites the medial surfaces of the two cerebral hemispheres throughout very nearly a half of their antero-posterior length.

Its *upper surface* is convex antero-posteriorly and concave from side to side, and it forms the bottom of the longitudinal fissure. On each side of the fissure it is covered by the gyrus cinguli (O.T. callosal gyrus). Only in its posterior part

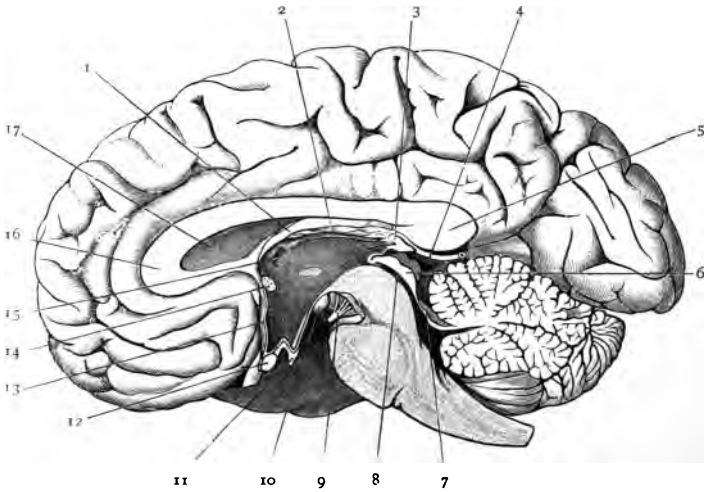


FIG. 192.—Median section through the Brain.

- | | | |
|---------------------------------|--------------------------|--------------------------------|
| 1. Fornix. | 6. Corpora quadrigemina. | 12. Optic chiasma. |
| 2. Tela chorioidea. | 7. Ant. medullary velum. | 13. Lamina terminalis. |
| 3. Pineal body. | 8. Aquæductus cerebri. | 14. Anterior commissure. |
| 4. Vena magna cerebri. | 9. Oculo-motor nerve. | 15. Foramen interventriculare. |
| 5. Splenium of corpus callosum. | 10. Corpus mamillare. | 16. Genu of corpus callosum. |
| | 11. Infundibulum. | 17. Septum pellucidum. |

is it touched by the falx cerebri ; anteriorly, that fold of dura mater falls considerably short of it. The upper surface of the corpus callosum is coated by an exceedingly thin layer of grey matter continuous, at the bottom of the callosal sulcus, with the grey cortex of the hemisphere. In this are embedded, on either side of the median plane, two delicate longitudinal bands of fibres called the *striæ longitudinales medialis* and *lateralis*. The *stria longitudinalis medialis* is the more strongly marked of the two, and it is separated from

its fellow of the opposite side by a faint median furrow. The *stria longitudinalis lateralis* is placed more laterally. So thin is the grey coating of the corpus callosum that the transverse direction of the bundles of callosal fibres can be easily seen through it.

The striæ with the thin layer of grey matter associated with them represent a gyrus called the *gyrus supracallosus*.

The two *extremities* of the corpus callosum (Fig. 192) are

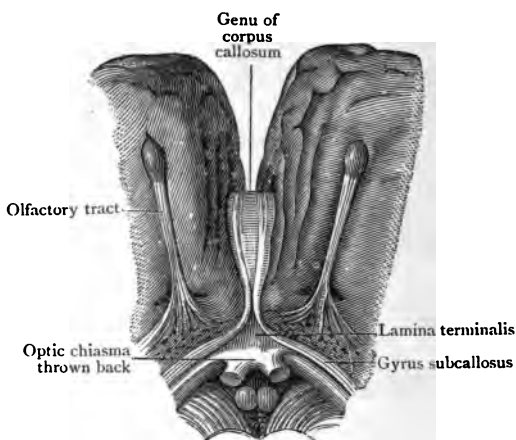


FIG. 193. — Anterior end of the Corpus Callosum and the Subcallosal Gyri as seen from below when the frontal lobes of the hemispheres are slightly separated from each other. (From Cruveilhier.)

greatly thickened, whilst the intermediate part, the *truncus* (O.T. *body*) is considerably thinner. The massive posterior end, which is full and rounded, lies over the mesencephalon, and extends posteriorly as far as the highest point of the cerebellum. It is called the *splenium*. The anterior end, which is not quite so massive, is folded, downwards and posteriorly, upon itself, and is called the *genu*. The recurved lower portion of the corpus callosum rapidly thins as it passes posteriorly, and is termed the *rostrum*. The fine terminal edge of the rostrum, the *lamina rostralis*, is connected with the lamina terminalis (Fig. 192).

Both the lateral and the medial longitudinal striæ, which lie upon the upper surface of the corpus callosum, turn

downwards, round the splenium, and end in the *fasciola cinerea*. The *fasciola cinerea*, which is situated immediately beneath the splenium, is a narrow strip of grey matter, continuous posteriorly with the medial and lateral striæ of the same side and anteriorly with the fascia dentata hippocampi. Anteriorly, the striæ pass round the genu, and then along the under surface of the rostrum until they terminate in the corresponding *gyrus subcallosus*. The *gyrus subcallosus* is a ridge which descends from the rostrum of the corpus callosum and passes to the surface of the substantia perforata anterior. There the fibres of the striæ contained in the *gyrus* emerge from its substance, and pass posterolaterally along the posterior limit of the substantia perforata anterior towards the anterior extremity of the temporal lobe.

Fibres of the Corpus Callosum.—The transverse fibres of the corpus callosum, as they enter the white medullary centre of the cerebral hemisphere, radiate from each other towards various parts of the cerebral cortex. This radiation is called the *radiatio corporis callosi*. The more anterior of the fibres which compose the genu of the corpus callosum sweep anteriorly in a series of curves towards the frontal pole of the hemisphere. They form the *forceps minor*. A large part of the splenium, forming a solid bundle termed the *forceps major*, bends suddenly and abruptly posteriorly into the occipital lobe. Fibres from the trunk of the corpus callosum and also from the splenium curve round the lateral ventricle and form a very definite stratum called the *tapetum*. This is a thin layer in the medullary centre of the hemisphere which forms the roof and lateral wall of the posterior horn and the lateral wall of the posterior part of the inferior horn of the lateral ventricle.

VENTRICULUS LATERALIS.

The lateral ventricle, in the interior of the cerebral hemisphere, should now be opened up on each side. The corpus callosum, which forms the roof of the central part (O.T. body) and anterior horn of this cavity, must, therefore, be partially removed.

Dissection.—Make a longitudinal incision, through the corpus callosum, about a quarter of an inch from the median plane on each side. The central portion of the corpus callosum which lies between these incisions is to be kept in position. The lateral portions must be turned laterally and detached completely. As this is being done, it will become evident that the lower part of the splenium which is prolonged into the *forceps major* is in reality a portion folded anteriorly in close apposition with the under surface of the posterior end of the corpus callosum. Be careful to leave the *forceps major* in its place.

The central part and the anterior horn of the ventricle are now exposed; but the cavity of the ventricle runs posteriorly into the occipital lobe in

the form of a posterior horn, and downwards and anteriorly into the temporal lobe as the inferior horn. The posterior horn can, at present, be opened on the right side only. Carry the knife posteriorly through the medullary substance which forms its roof, and remove a sufficient amount of this to

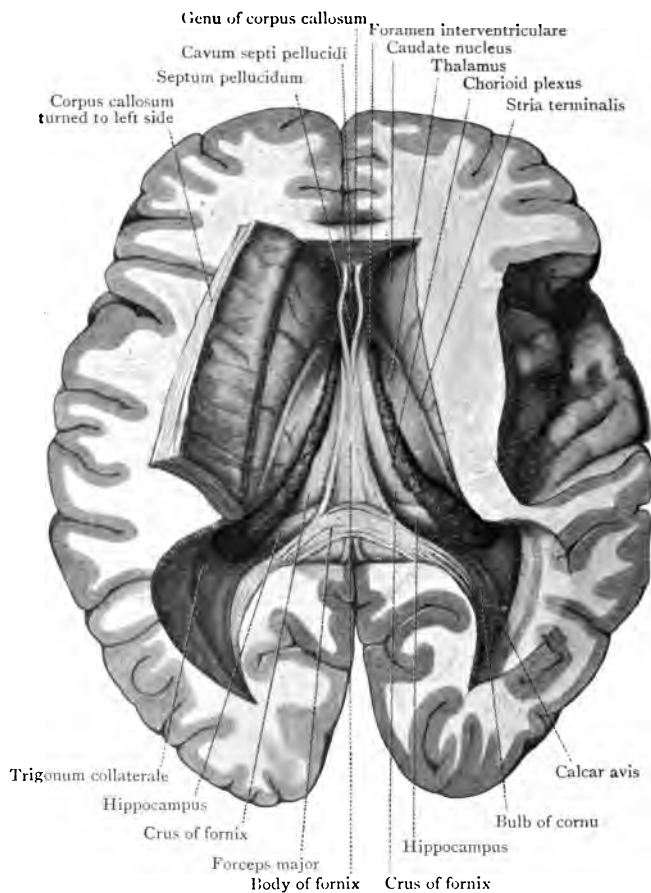

FIG. 194.—Dissection to show the Lateral Ventricles. The trunk of the corpus callosum has been detached from the genu and the splenium and turned over to the left.

give a complete view of the interior of this part of the cavity. Greater difficulty will be experienced in opening up the inferior horn. Place the point of the knife in the upper part of the horn, where it joins the central part of the ventricle, and carry the blade in an antero-inferior direction,

through the lateral part of the temporal lobe, towards the temporal pole, following the course of the cavity. This corresponds very nearly with the course of the superior temporal sulcus. The lateral wall of the inferior horn is thus incised, and a sufficient amount of the lateral part of the temporal lobe must be removed to give a view of the cavity. In doing this, the temporal operculum will be taken away, but the surface of the insula should be preserved from injury.

Lateral Ventricle.—The dissector will now perceive that each cerebral hemisphere is hollow. The cavity in the interior is called the lateral ventricle. It is lined with a thin dark-

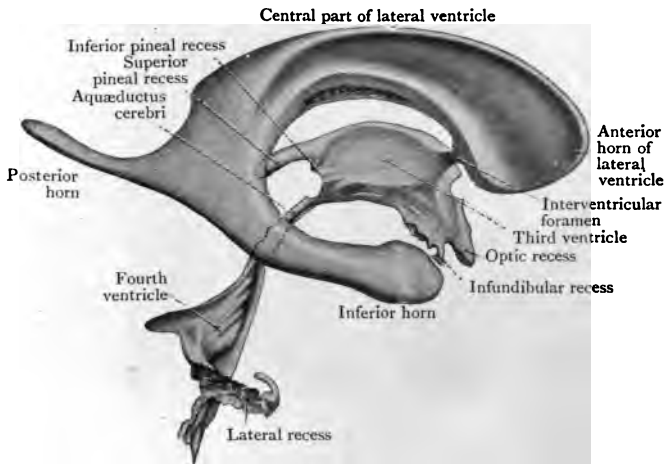


FIG. 195.—Cast of the Ventricles of the Brain (from Retzius).

coloured layer of epithelium, which is termed the *ependyma*. In certain places its walls are in apposition with each other, but in other localities spaces of varying capacity, and containing cerebro-spinal fluid, are left between the bounding walls. The lateral ventricle communicates with the third ventricle of the brain by means of a small foramen, which is termed the *interventricular foramen* (O.T. *foramen of Monro*). This aperture, which is just large enough to admit a crow-quill, lies at the anterior end of the thalamus, and posterior to the column of the fornix (O.T. *anterior pillar*).

The shape of the lateral ventricle is very irregular, and can be best understood by the study of a plaster cast of its interior (Fig. 195). It is composed of a central part (O.T. *body*) and three horns, viz., an anterior, a posterior,

and an inferior horn. The *anterior horn* is that part of the cavity which lies anterior to the interventricular foramen.

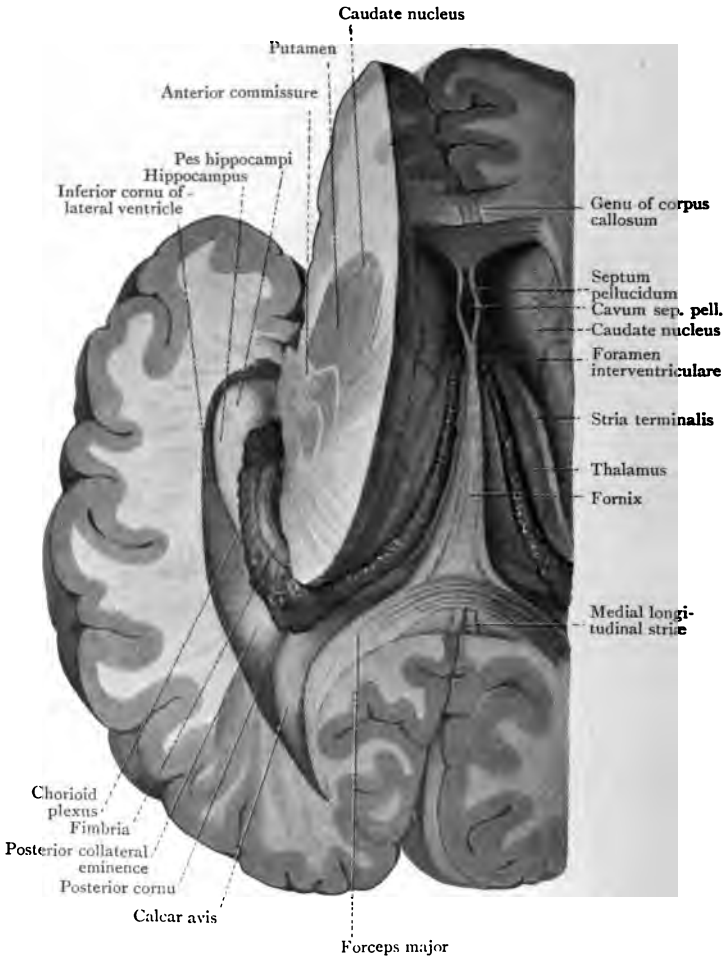


FIG. 196.—Dissection to show the Posterior and Inferior Cornua of the Lateral Ventricle on the left side.

The central part is the portion of the ventricle which extends from the interventricular foramen to the splenium of the corpus callosum. At that point the posterior and inferior

horns diverge from the posterior end of the central part. The *posterior horn* curves posteriorly and medially into the occipital lobe. It is very variable in its length and capacity. The *inferior horn* passes with a bold sweep round the posterior end of the thalamus, and then tunnels, in an antero-inferior direction, through the temporal lobe towards the temporal pole.

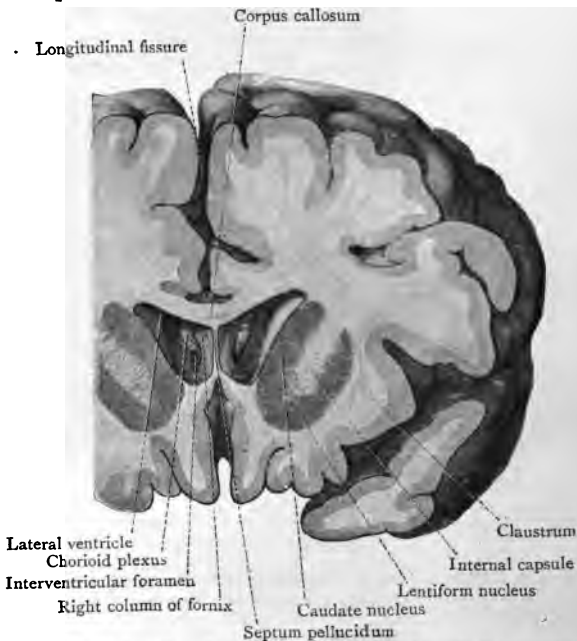


FIG. 197.—Frontal section through the Cerebrum through the anterior part of the lentiform nucleus. Seen from the anterior aspect.

Cornu Anterius Ventriculi Lateralis.—The anterior horn forms the anterior part of the cavity, and extends antero-laterally and downwards in the frontal lobe. When seen in frontal section it presents a triangular outline—the floor sloping upwards and laterally to meet the roof at an acute angle (Fig. 197). It is bounded *anteriorly* by the posterior surface of the genu of the corpus callosum, whilst the *roof* is formed by the anterior part of the trunk of the corpus callosum. The *medial wall*, which is vertical, is formed by

the septum pellucidum—a thin median partition between the lateral ventricles of opposite sides. The sloping *floor* presents a marked elevation or bulging, viz., the smooth rounded and enlarged anterior extremity of the pear-shaped *caudate nucleus*.

Pars Centralis Ventriculi Lateralis.—The central part of the ventricle is *roofed* likewise by the corpus callosum. On the *medial side* it is bounded by the posterior part of the septum pellucidum, and more posteriorly by the attachment of the fornix to the under surface of the corpus callosum.

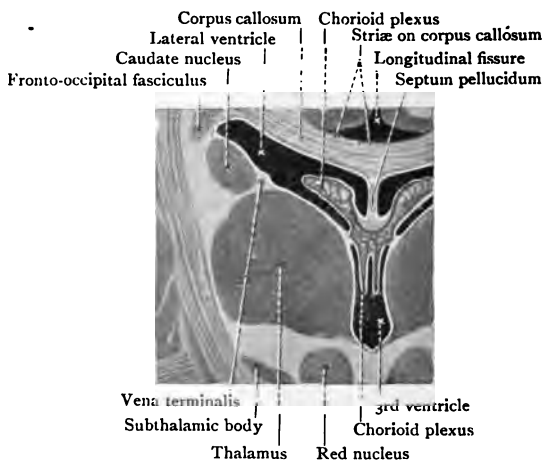


FIG. 198.—Frontal Section showing immediate relations of Lateral and Third Ventricles. (Part of Fig. 217 enlarged.)

On the *lateral side* it is closed, as in the case of the anterior horn, by the meeting of the roof and the floor of the cavity.

On the *floor* a number of important objects may be recognised. Latero-medially, and, at the same time, to some extent antero-posteriorly, these are—(1) the caudate nucleus; (2) a groove extending obliquely, postero-laterally, between the caudate nucleus and the thalamus, in which are placed the terminal vein (O.T. vein of corpus striatum) and a white band called the stria terminalis (O.T. tænia semicircularis); (3) a portion of the upper surface of the thalamus; (4) the chorioid plexus; (5) the thin sharp lateral edge of the fornix.

The *caudate nucleus* as it passes posteriorly, on the lateral part of the floor of the central part of the lateral ventricle, narrows very rapidly.

The *terminal vein* is seen through the ependyma in the groove between the caudate nucleus and the thalamus. It joins the internal cerebral vein (O.T. vein of Galen) at the interventricular foramen. In the same groove is placed the *stria terminalis*—a narrow band of white matter, which bends downwards and disappears from view in the region of the

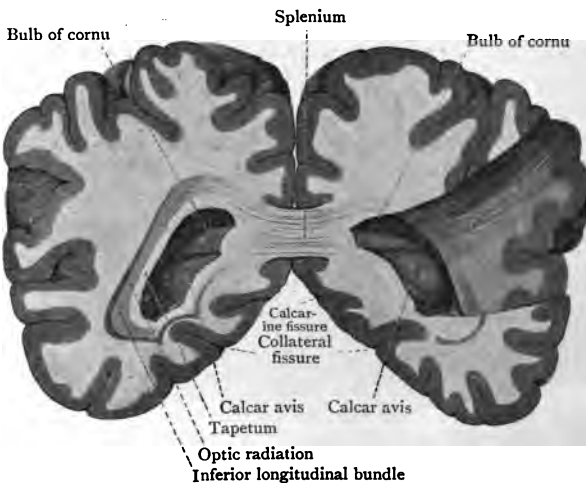


FIG. 199.—Frontal section through the Posterior Horns of the Lateral Ventricles.

interventricular foramen. Its fibres ultimately reach the *substantia perforata anterior*, in which they end.

The portion of the upper surface of the *thalamus*, which appears in the floor of the lateral ventricle is, in great part, covered by the *chorioid plexus* of the lateral ventricle. The plexus is a rich vascular fringe which appears from under cover of the sharp lateral edge of the *fornix*. It is continuous anteriorly, through the interventricular foramen, with the corresponding chorioid plexus of the opposite side; whilst posteriorly, it is carried into the inferior horn of the ventricle. Although the chorioid plexus has all the appearance of lying free within the ventricle it is invested by an epithelial layer

of ependyma, which excludes it from the cavity and is connected on the one hand to the sharp margin of the fornix, and on the other to the upper surface of the thalamus.

Cornu Posterius Ventriculi Lateralis.—The posterior horn is a diverticulum which runs, from the posterior end of the central part of the ventricle, into the occipital lobe. It tapers to a point and describes a gentle curve, the convexity of which is directed laterally. The *roof* and *lateral wall* of this portion of the ventricular cavity is formed by the tapetum of the corpus callosum.

Upon the *medial wall* two elongated curved elevations may be seen. The upper of these, termed the *bulb of the cornu*, is produced by the fibres of the forceps major as they curve posteriorly, from the lower part of the splenium of the corpus callosum, into the occipital lobe. The lower elevation is known as the *calcar avis*. It varies greatly in size, in different brains, and is caused by an infolding of the ventricular wall which corresponds with the anterior part of the calcarine fissure.

Dissection.—The dissector should now insinuate his fingers underneath the fronto-parietal operculum of the insula and tear this portion of the cortex away in an upward direction. The frontal operculum (*pars triangularis*) and the orbital operculum should be dealt with in the same manner. The greater part of the temporal operculum has already been removed in opening up the inferior horn of the ventricle; therefore the insula is now fully exposed to view, and its relation to the parts in the interior of the ventricle can be seen.

Cornu Inferius Ventriculi Lateralis (O.T. Descending Cornu).—The inferior horn must be regarded as the direct continuation of the main ventricular cavity into the temporal lobe. The posterior horn is merely a diverticulum from the main cavity. At first directed postero-laterally, the inferior horn suddenly sinks downwards, posterior to the thalamus, into the temporal lobe, in which it takes a curved course, antero-medially, to a point about an inch posterior to the extremity of the temporal pole. In the angle between the diverging inferior and posterior horns the cavity of the ventricle exhibits a triangular expansion of varying capacity. This is called the *trigonum collaterale*.

The *lateral wall* of the inferior horn is formed, for the most part, by the tapetum of the corpus callosum. At the extremity of the horn the *roof* presents a slight bulging into the ventricular cavity. This is the *amygdaloid tubercle*, and it is

produced by a superjacent collection of grey matter, termed the *amygdaloid nucleus*. The *stria terminalis* and the greatly attenuated and expanded *tail of the caudate nucleus* are both prolonged into the inferior horn, and are carried anteriorly in its roof to the amygdaloid nucleus.

On the *floor* of the inferior horn the dissector will note the following parts: (1) the hippocampus; (2) the chorioid plexus; (3) the fimbria; and (4) the eminentia collateralis.

Hippocampus (O.T. **Hippocampus Major**).—This is overlapped by the chorioid plexus, which must be turned aside.

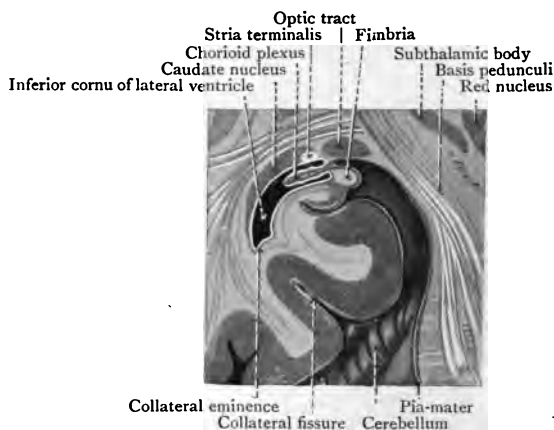


FIG. 200.—Frontal Section to show relations of Inferior Cornu of Lateral Ventricle. (Part of Fig. 217 enlarged.)

It is a prominent elevation on the floor of the inferior horn of the lateral ventricle, and is strongly curved in conformity with the course taken by the horn in which it lies. It presents, therefore, a medial concave margin and a lateral convex margin. Narrow posteriorly, it enlarges as it is traced anteriorly, and it ends, below the amygdaloid tubercle, in a thickened extremity, the *pes hippocampi*. The surface of the *pes hippocampi* is marked by some faint grooves which intervene between a number of ridges called the *hippocampal digitations*. The hippocampus is the internal elevation which corresponds to the hippocampal fissure on the exterior of the wall of the ventricle.

Fimbria (Hippocampi).—The fimbria is a narrow but very

distinct band of white matter which is attached by its lateral margin along the concave medial border of the hippocampus. The white matter composing it is continuous with the thin white layer (alveus) which is spread over the surface of the hippocampus, and it presents two free surfaces and a sharp free medial border. The fimbria has been noted already in connection with the hippocampal fissure and the fascia dentata (p. 479), and the relations which it presents to the crus of the fornix and the uncus are pointed out on p. 494.

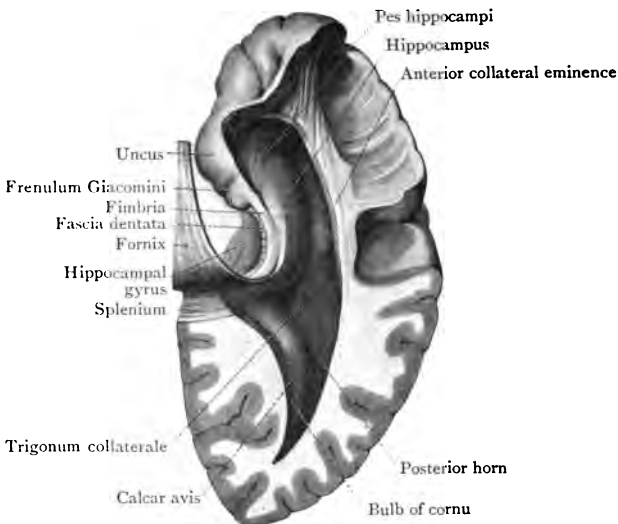


FIG. 201.—Dissection to show the Posterior and Inferior Cornua of the Lateral Ventricle.

Chorioid Fissure of the Cerebrum.—When the pia mater in the region of the hippocampal fissure is removed from the surface of the brain, the chorioid plexus in the interior of the inferior horn of the lateral ventricle is usually withdrawn with it, and a fissure appears between the fimbria and the roof of the ventricular horn. This is termed the *chorioid fissure of the cerebrum*; it is the lower part of the *great transverse fissure*. By the withdrawal of the chorioid plexus it is converted into an artificial gap, which leads directly from the exterior of the brain into the interior of the inferior horn of the lateral ventricle.

Plexus Chorioideus.—The chorioid plexus is a system of convoluted blood-vessels enclosed within a fold of pia mater which is prolonged, into the inferior horn of the

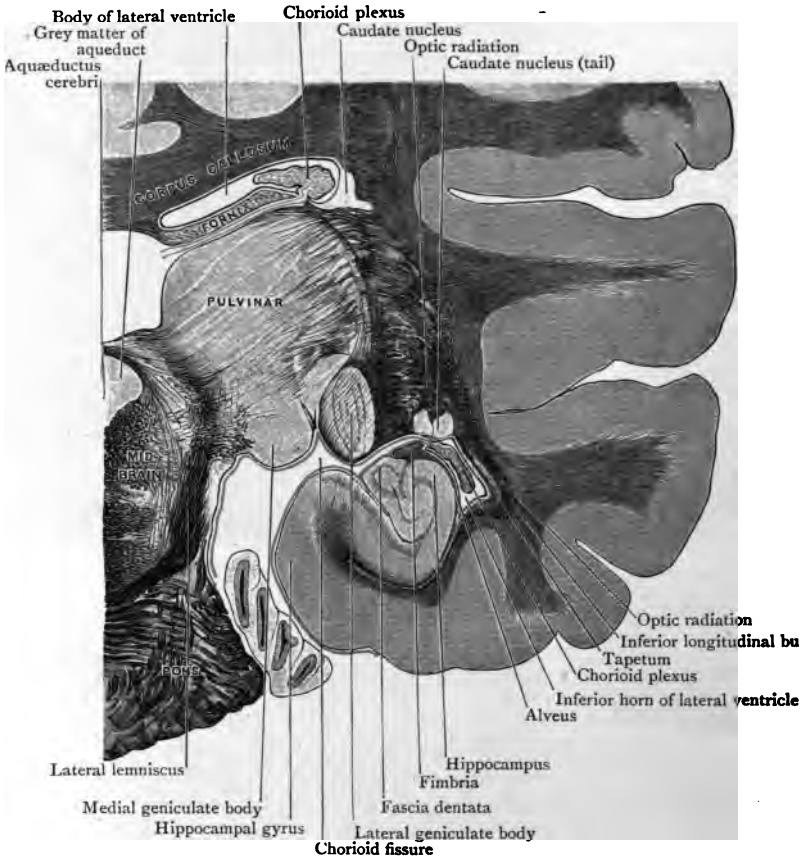


FIG. 202.—Frontal section through the Cerebrum, Mid-brain, and Pons in the plane of the geniculate bodies. It shows the relation of the dentate and chorioid fissures to the inferior horn of the lateral ventricle.

lateral ventricle, through the chorioid fissure of the cerebrum. It lies on the surface of the hippocampus and, at the posterior extremity of the thalamus, it becomes continuous with the chorioid plexus in the central part of the

lateral ventricle (Fig. 200). But it must not be supposed that the chorioid plexus lies free in the ventricular cavity. It is clothed in the most intimate manner by an epithelial ependymal layer, which represents the medial wall of the inferior horn pushed into the cavity by the chorioid plexus. The ventricle, therefore, opens on the surface through the chorioid fissure only after this thin epithelial layer is torn away by the withdrawal of the chorioid plexus.

Eminentia Collateralis.—This eminence may present two distinct forms, which may be distinguished from each other as the eminentia collateralis posterior and the eminentia collateralis anterior.

The *posterior collateral eminence* is a smooth elevation in the floor of the trigonum collaterale, in the interval between the calcar avis and the hippocampus as they diverge from each other. The *anterior collateral eminence* is not always present. It forms an elongated elevation on the floor of the inferior horn of the lateral ventricle, on the lateral side of the hippocampus. Both eminences correspond to the collateral fissure on the tentorial aspect of the cerebral hemisphere.

Dissection.—The remains of the right temporal lobe and of the right occipital lobe should now be detached from the cerebrum by cutting through the forceps major of the splenium of the corpus callosum and through the fimbria where it passes into the crus of the fornix. The knife should then be carried anteriorly from the anterior extremity of the inferior horn, above the level of the uncus, through the temporal pole. The temporal lobe, with the hippocampal gyrus along its medial side, can then be separated from the remainder of the brain, along the line of the chorioid fissure of the cerebrum. In the detached part of the cerebrum (Fig. 201) a good view is obtained of the floor of the inferior horn and of the parts in relation to it. Further, by replacing it in position, the chorioid fissure can be better understood, and by turning the brain upside down a view is obtained of the roof of the inferior horn and the structures in relation to it. In this way the tail of the caudate nucleus and the stria terminalis can be traced into the amygdaloid nucleus.

The cut edge of the central part of the corpus callosum, which is still in position, should now be still further pared away, so as to bring the subjacent septum pellucidum and the fornix more fully into view.

Fimbria (Figs. 200, 201).—This is simply a continuation of the crus (O.T. posterior pillar) of the fornix. It is a conspicuous band of white matter, which presents a prominent free border. Anteriorly, it runs into the recurved extremity of the uncus, whilst, if it is traced posteriorly, it will be seen to curve upwards, posterior to the thalamus, and become

continuous with the crus of the fornix below the posterior part of the corpus callosum (p. 491).

Fascia Dentata Hippocampi.—The fascia dentata is the free edge of grey matter which is placed between the fimbria and the deep part of the upper surface of the hippocampal gyrus. The groove between it and the fimbria is termed the *fimbrio-dentate sulcus*. Its margin is notched, and its surface is scored with numerous closely-placed transverse grooves. It begins posteriorly, in the region of the splenium of the corpus callosum, and it runs anteriorly into the cleft of the uncus, from which it emerges again in the form of a delicate band, called the frenulum of Giacomini, which crosses the recurved part of the uncus in a transverse direction.

Hippocampal Fissure.—This is a complete fissure, and the elevation on the ventricular wall, which corresponds to it, is called the hippocampus (Fig. 217). It begins posterior to the splenium of the corpus callosum, where it is continuous with a shallow part of the callosal sulcus, and it passes anteriorly, between the fascia dentata and the hippocampal gyrus. Its anterior end is embraced by the uncus.

SEPTUM PELLUCIDUM—FORNIX—TELA CHORIOIDEA VENTRICULI TERTII.

Septum Pellucidum.—This is a thin vertical partition which intervenes between the anterior cornua and the anterior parts of the central portions of the two lateral ventricles (Fig. 198). It is triangular in shape, and is prolonged posteriorly in the narrow interval between the trunk of the corpus callosum and the fornix, to each of which it is attached. Anteriorly, it occupies the gap posterior to the genu of the corpus callosum; whilst below, in the narrow interval between the rostrum of the corpus callosum and the fornix, it is prolonged downwards to the base of the brain (Fig. 207).

The septum pellucidum is composed of two thin laminæ which lie one on each side of the median plane. The median cleft between the layers is termed the *cavum septi pellucidi* (O.T. *fifth ventricle*) (Figs. 194 and 196).

Dissection.—The narrow middle strip of the corpus callosum, posterior to the genu, should now be removed. Cut it transversely across, and, gently raising it, separate the upper edge of the septum pellucidum from its lower

surface. Posterior to the septum pellucidum the under surface of the median part of the corpus callosum will be found to lie upon and to be connected with the upper surface of the fornix. Sever this connection also. The left half of the forceps major should be preserved, so that its connection with the occipital lobe may be more fully made out later. By snipping off the upper edge of the septum pellucidum with the scissors, the two laminae, with the interposed cleft, will be exposed.

Cavum Septi Pellucidi (O. T. Fifth Ventricle).—This is the name which is applied to the median cleft between the two laminae of the septum pellucidum. It varies greatly in extent, in different brains, and it contains a little fluid. It is completely

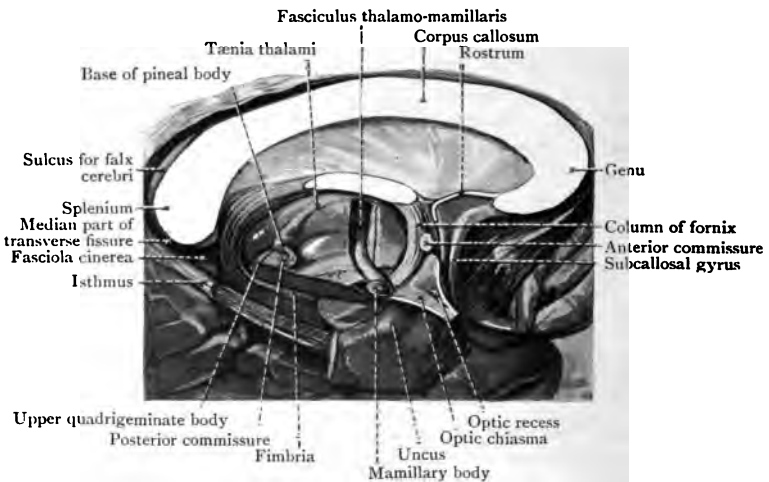


FIG. 203.—Dissection showing the relations of the Fornix.

isolated, having no communication either with the ventricles or with the exterior.

Fornix.—The fornix is an arched structure, composed of longitudinal and transverse fibres. It consists of a central part or body, which ends in two columns anteriorly and two crura posteriorly.

Corpus Fornicis.—The body of the fornix is triangular in shape. Anteriorly, where it is continuous with the columns, it is narrow; posteriorly it broadens out, becomes flattened, and is prolonged into the crura. The upper surface of the body of the fornix is in contact with the under surface of the corpus callosum, and is adherent to it in the median plane

posteriorly. More anteriorly it is attached to the posterior part of the lower edge of the septum pellucidum. Beyond these attachments the upper surface of the body of the fornix forms a part of the floor of the lateral ventricle, on each side, and is clothed with ependyma. It presents a sharp lateral edge, from under which the chorioid plexus projects into the cavity of the lateral ventricle. The lower surface of the body of the fornix rests upon the tela chorioidea of the third ventricle (O.T. *velum interpositum*), a fold of pia mater which separates it from the third ventricle and the two thalami.

Columnæ Fornicis (O.T. *anterior pillars*).—The two columns of the fornix are two rounded strands which emerge from the anterior end of the body of the fornix, and then, diverging slightly, pass downwards anterior to the interventricular foramen. Their lower ends sink into the grey matter on the lateral walls of the third ventricle, and end at the base of the brain in the corpora mamillaria.

Each corpus mamillare has the appearance of being a twisted loop of the corresponding column of the fornix, in which the fibres turn upon themselves, and are then continued upwards and posteriorly into the anterior tubercle of the thalamus. This appearance, however, is deceptive. In the interior of the corpus mamillare there is a nucleus of grey matter. In this the fibres of the column end; while the other fibres, which seem to be continuous with the fornix fibres, take origin within the nucleus. The strand, thus formed, is called the fasciculus thalamo-mamillaris (O.T. bundle of Vicq d'Azyr) (Fig. 203).

The connections which have just been described cannot be made out at present, but at a later period the dissector will experience little difficulty in tracing the column of the fornix to the corpus mamillare, and in displaying the connection of this with the fasciculus thalamo-mamillaris.

Crura Fornicis (O.T. *posterior pillars*).—The crura of the fornix are flattened bands which diverge widely from the body of the fornix. At first they are adherent to the under surface of the corpus callosum, but soon they sweep downwards, round the posterior ends of the thalami, and enter the inferior horns of the lateral ventricles. There each crus comes into relation with the corresponding hippocampus, and a portion of its fibres become spread out on the surface of that prominence, forming the *alveus*, whilst the remainder constitute the fimbria, which has been described already (p. 494, Fig. 203).

The transverse fibres of the fornix cross the lower surface of the body and the anterior part of the interval between the diverging crura. In the latter place they may be adherent to the lower surface of the corpus callosum. On each side

Dissection.—Each vena terminalis should now be divided as it unites with the internal cerebral vein. The apex of the tela chorioidea should then be seized with the forceps and pulled posteriorly, till the whole structure is reversed. The entire upper surface of the thalamus on each side is thus exposed, and, between the thalami, is seen the third ventricle. The epithelial roof of this ventricle, which is invaginated into the cavity by the chorioid plexuses of the third ventricle on the under surface of the tela, is torn away with the tela. The basal part of the tela is intimately connected with the pineal body, which lies on the mesencephalon behind the third ventricle. Care therefore must be taken to extricate this body from the pia mater ; otherwise it is sure to be pulled away.

THE THALAMI AND THE THIRD VENTRICLE.

Thalamus.—The thalamus is a large mass of grey matter which lies obliquely across the path of the pedunculus cerebri as it ascends into the hemisphere. The smaller anterior end

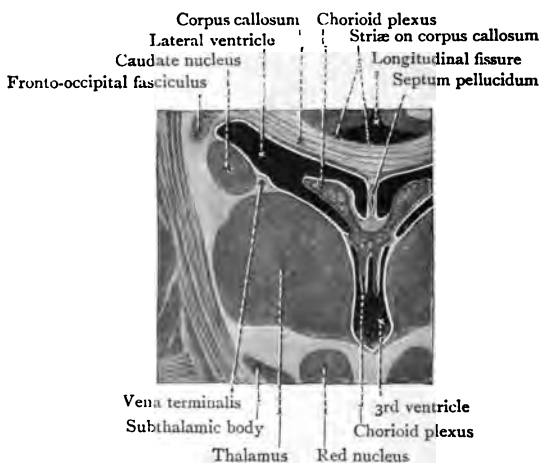


FIG. 205.—Frontal section showing immediate relations of Lateral and Third Ventricles. (Part of Fig. 217 enlarged.)

of the thalamus lies close to the median plane, and is separated from the corresponding part of the opposite side only by a very narrow interval. The enlarged posterior ends of the two thalami are placed more widely apart ; and in the interval between them, the corpora quadrigemina are situated. In their anterior two-thirds, the two thalami lie close together, but are separated by a deep median cleft, the third ventricle

of the brain. Each thalamus presents an anterior and a posterior extremity, and four surfaces. The inferior and lateral surfaces are in apposition and, indeed, directly connected with adjacent parts. The superior and medial surfaces are free.

The *lateral surface* of the thalamus is applied to a mass

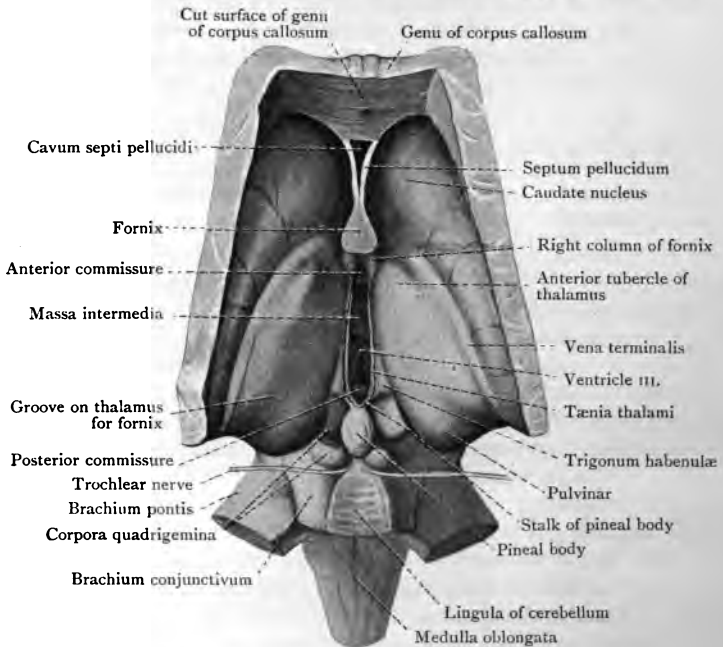


FIG. 206.—The two Thalami and the Third Ventricle as seen from above.

of white matter, termed the *internal capsule*, which is composed largely of fibres from the *basis pedunculi*. The *inferior* or *ventral surface* of the thalamus rests chiefly upon the *subthalamic region*, which is the prolongation upwards of the tegmental part of the pedunculus cerebri. The relation, therefore, which the thalamus presents to the upward continuation of the pedunculus cerebri is very intimate.

The *superior surface* of the thalamus is free. On the lateral side it is bounded by the groove which inter-

venes between the thalamus and the caudate nucleus and contains the vena terminalis and the stria terminalis. On the medial side, the superior surface of the thalamus is separated, in its anterior half, from the medial surface by a sharp edge, or prominent ledge, of the ependyma of the third ventricle. This is called the *tznia thalami*, and the ridge which it forms is accentuated by the fact that subjacent to it there lies a longitudinal strand of fibres called the *stria medullaris*. A short distance anterior to the pineal body the *tentia* lies upon the upper border of a raised white band, the *habenula*.

The *habenula* divides posteriorly into two parts, one of which becomes continuous with the pineal body, whilst the other passes across to the opposite *habenula*, through the *habenular commissure*, which lies anterior to the pineal stalk.

Between the *habenula* medially and the upper quadrigeminal body posteriorly, lies a small triangular depressed area, the *trigonum habenulae*.

The superior surface of the thalamus is slightly convex, and is of a whitish colour owing to the presence of a thin superficial coating of nerve fibres (*stratum zonale*). It is divided into two areas by a faint oblique groove which begins near the anterior extremity of the thalamus, and extends obliquely, laterally and posteriorly. This sulcus corresponds to the free lateral edge of the fornix. The two areas thus mapped out are very differently related to the ventricles of the brain. The *lateral area* includes the anterior extremity of the thalamus, and forms a part of the floor of the lateral ventricle; it is covered with ependyma, and overlapped by the choroid plexus. The *medial area* intervenes between the lateral and third ventricles of the brain, and takes no part in the formation of the walls of either. It is covered with the *tela chorioidea*, above which is the fornix. It includes the posterior extremity of the thalamus.

The *anterior extremity* of the thalamus, called the *anterior tubercle*, is rounded and prominent. It projects into the lateral ventricle, lies postero-lateral to the free portion of the column of the fornix, and bounds the interventricular foramen posteriorly.

The *posterior extremity* of the thalamus is very prominent, and projects posteriorly over the mesencephalon (Fig. 206). This projecting part is called the *pulvinar*. But the posterior

end of the thalamus shows another prominence. This is situated below and to the lateral side of the pulvinar. It is oval in form, and receives the name of the *corpus geniculatum laterale*.

The *medial surfaces* of the two thalami are placed very close together, and are covered not only with the lining ependyma of the third ventricle, but also with a moderately thick layer of grey matter continuous with the grey matter which surrounds the aquæductus cerebri (Sylvius). A band of grey matter, termed the *massa intermedia*, crosses the third ventricle and joins the two thalami together.

Corpus Pineale.—This is a small body of a darkish colour, and about the size of a cherry-stone, which is placed between the posterior extremities of the two thalami on the dorsal aspect of the mesencephalon (Fig. 206). It occupies the depression between the two superior quadrigeminal bodies, and is shaped like a fir-cone. Its base, which is directed anteriorly, is attached by means of a hollow stalk or peduncle. This stalk is separated into a dorsal and a ventral part by a continuation into it of a pointed recess of the cavity of the third ventricle. The dorsal part of the stalk becomes continuous on each thalamus with the *tænia thalami*; the ventral part is folded round a narrow but conspicuous cord-like band of white fibres (*posterior commissure*) which crosses the median plane immediately below the base of the pineal body.

Commissura Anterior Cerebri.—In the anterior part of the cleft between the two thalami, and immediately anterior to the columns of the fornix, a round bundle of white fibres will be seen crossing the median plane. This is the *anterior commissure*. It is very much larger than the posterior commissure, and will be afterwards followed towards the temporal lobe, in which the greater part of it ends.

Ventriculus Tertius.—This name is given to the deep narrow cleft between the two thalami. It is deeper anteriorly than posteriorly, and extends from the pineal body posteriorly to the anterior commissure and lamina terminalis anteriorly. Its *floor* is formed by the parts already studied within the interpeduncular fossa on the base of the brain, viz., the tuber cinereum, the corpora mamillaria, and the grey matter of the substantia perforata posterior, and also, more posteriorly, by the tegmenta of the cerebral peduncles. *Anteriorly*, it is bounded by the lamina terminalis and the anterior commissure; whilst

its *lateral walls* are formed by the medial surfaces of the two thalami. A little anterior to the middle of the ventricle the cavity is crossed by the *massa intermedia*, which connects the thalami with each other, and anterior to this the column of the fornix is seen descending in the lateral wall. At first the column is distinct and prominent, but as it approaches the corresponding corpus mamillare it gradually becomes

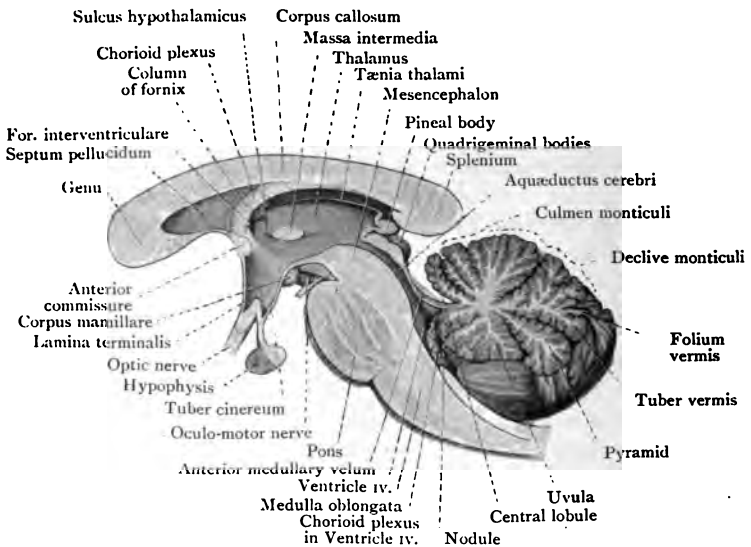


FIG. 207.—Median section through the Corpus Callosum, Third Ventricle, Mesencephalon, Pons, Cerebellum, and Medulla Oblongata.

more and more sunk in the grey matter on the side of the ventricle.

The *roof* of the third ventricle is formed by a thin epithelial layer which stretches across the median plane, from the one tænia thalami to the other, and is continuous with the remainder of the epithelial lining of the cavity. It is applied to the under surface of the tela chorioidea, which overlies the ventricle, and is invaginated into the cavity by the chorioid plexuses which hang down from the under surface of that fold of pia mater. In the removal of the tela chorioidea the thin epithelial roof was torn away.

The third ventricle communicates freely with the lateral

ventricles, and also with the fourth ventricle. The *aquæductus cerebri* (*Sylvius*), a narrow channel which tunnels the mesencephalon, brings it into communication with the fourth ventricle. The opening of this canal will be seen at the posterior part of the floor of the ventricle, immediately below the posterior commissure. The *interventricular foramen*, which puts it into communication with the two lateral ventricles, is a Y-shaped aperture which lies at the anterior part of the ventricle, and its two diverging limbs pass laterally and slightly upwards, between the most prominent parts of the columns of the fornix and the anterior tubercles of the thalami. They are usually large enough to admit a crow-quill, and through them the epithelial lining of the three ventricles becomes continuous.

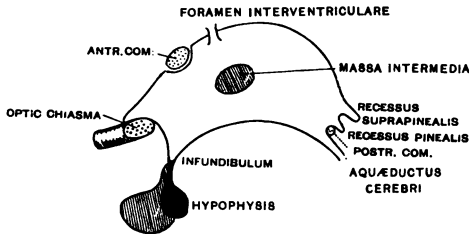


FIG. 208.—Diagrammatic outline of the Third Ventricle as viewed from the side.

From each lateral part of the interventricular foramen a distinct groove passes posteriorly, on the lateral wall of the ventricle, to the mouth of the aquæductus cerebri. It is termed the *sulcus hypothalamicus*.

The outline of the third ventricle is seen to be very irregular when it is viewed from the side in a median section through the brain (Fig. 207), or as it is exhibited in a plaster cast of the ventricular system of the brain. It presents several diverticula or recesses. Thus, in the anterior part of the floor there is a deep funnel-shaped recess, *recessus infundibuli*, leading down, through the tuber cinereum, into the infundibulum of the hypophysis. Another recess, *recessus opticus*, lies above the optic chiasma. Posteriorly, two additional recesses are present. One, the *recessus pinealis*, passes posteriorly, above the posterior commissure and the entrance of the aquæductus cerebri, for a short distance into the stalk of the pineal body. The second is placed above this, and is carried posteriorly for a greater distance. Its walls are epithelial, and therefore it cannot be seen in an ordinary dissection. It is termed the *recessus suprapinealis*.

Dissection.—The further study of the cerebral hemispheres should be postponed until after the examination of the mid-brain or mesencephalon. The membranes should be removed from the upper surface of the cerebellum, and the prominent anterior part of that organ may then be

pulled posteriorly to expose, as far as possible, the *corpora quadrigemina*, *i.e.* the four rounded eminences on the dorsal aspect of the mesencephalon. In doing this, care should be taken to secure and preserve the slender trochlear nerve which issues from a lamina, called the anterior medullary velum, immediately below the inferior pair of quadrigeminal bodies, and winds round the lateral side of the pedunculus cerebri.

THE MESENCEPHALON.

The mesencephalon is the stalk which occupies the aperture of the tentorium cerebelli, and connects the cerebral hemispheres with the parts in the posterior cranial fossa.¹ It is about three-quarters of an inch long, and it consists of a dorsal part, the *lamina quadrigemina*, and a much larger ventral part, which is formed by the two large *pedunculi cerebri*. In the undissected brain the lamina quadrigemina is completely hidden from view by the splenium of the corpus callosum, which projects posteriorly over it, and also by the superimposed cerebral hemispheres. The pedunculi cerebri, however, can be seen, to some extent, at the base of the brain, where they bound the posterior part of the interpeduncular fossa. The mesencephalon is tunnelled from below upwards by a narrow passage called the aquæductus cerebri (Sylvius). This channel lies much nearer the dorsal than the ventral surface.

Lamina Quadrigemina.—The dorsal surface of the lamina quadrigemina is raised into four eminences or *colliculi*, two superior and two inferior, which are called the *corpora quadrigemina*. Each colliculus is composed, for the most part, of grey matter, although each has a superficial coating of white fibres. The *superior pair* are larger and broader than the *inferior pair*, but they are not so well defined nor yet so prominent.

A longitudinal and a transverse groove separate the quadrigeminal bodies from each other. The *longitudinal groove* occupies the median plane, and extends upwards as far as the posterior commissure. From its lower end a short but well-defined narrow band of white fibres, the *frenulum veli*, passes to the anterior medullary velum, a lamina placed immediately below the inferior pair of quadrigeminal prominences. The

¹ If the mesencephalon was divided, when the brain was removed, the divided parts must be fixed together with pins while the superficial characters are being studied.

upper part of the longitudinal groove is occupied by the pineal body. The *transverse groove* curves round posterior to each of the superior pair of quadrigeminal bodies and separates them from the inferior pair.

Brachia of the Corpora Quadrigemina.—The corpora quadrigemina are not marked off from the side of the mesencephalon, for each body has in connection with it, on that aspect, a prominent white strand, which is prolonged upwards and anteriorly under the projecting pulvinar. The strands are called the *brachia* of the corpora quadrigemina, and they are separated from each other by a continuation, on the side of the mesencephalon, of the transverse groove which intervenes between the two pairs of bodies.

Corpus Geniculatum Mediale.—Closely connected with the brachium of the inferior quadrigeminate body will be seen the corpus geniculatum mediale.

It is a little oval eminence, very sharply defined, which lies on the side of the upper part of the mesencephalon under shelter of the pulvinar of the thalamus.

Connections of the Brachia and the Origin of the Optic Tract.—It will now be seen that the brachia are intimately connected with the optic tract.

The *inferior brachium* proceeding upwards from the lower quadrigeminal body advances towards the corpus geniculatum mediale, and disappears from view under cover of that prominence. Upon the opposite side of the same geniculate body, the *medial root* of origin of the *optic tract* arises, and the appearance is such that the dissector might very naturally conclude that the inferior brachium and the root of the optic tract are continuous. That, however, is not the case. The *superior brachium* is carried upwards and anteriorly between the overhanging pulvinar and the corpus geniculatum mediale. It partly enters the corpus geniculatum laterale, but a portion of it is directly continuous with the *lateral root* of the optic tract.

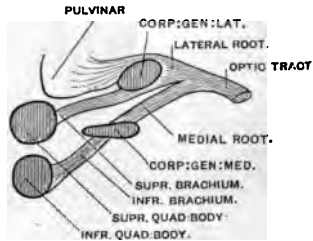


FIG. 209.—Diagram of the Roots of the Optic Tract.

The optic tract divides at its posterior end into a medial and a lateral root. The *medial root* enters the corpus geniculatum mediale. The

lateral root is partly continuous with the superior brachium, and partly with the corpus geniculatum laterale and the pulvinar. The superior quadrigeminal body, the corpus geniculatum laterale, and the pulvinar constitute the *lower visual centres*.

Pedunculi Cerebri (O.T. *crura cerebri*).—The pedunculi cerebri constitute the chief bulk of the mesencephalon. When viewed from below, they appear as two large rope-like strands, which emerge, close together, from the upper aspect of the pons, and diverge as they proceed upwards to enter the cerebral hemisphere. At the point where each

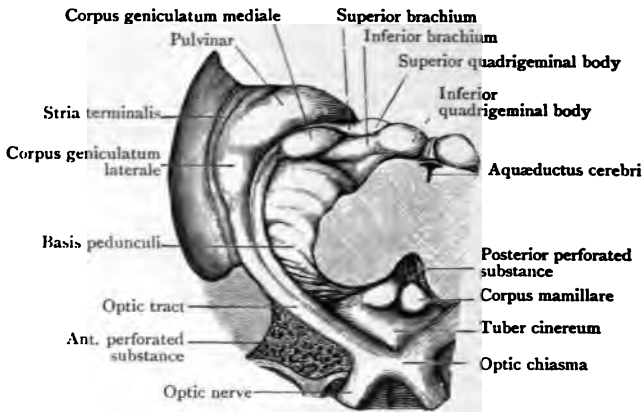


FIG. 210.—The Origin and Relations of the Optic Tract.
(Professor Thane, from *Quain's Anatomy*.)

peduncle disappears into the corresponding hemisphere, it is embraced, on its lateral side, by the optic tract and the gyrus hippocampi.

The pedunculus cerebri of each side consists of two parts, viz., a dorsal *tegmentum*, which is prolonged upwards to the region below the thalamus; and a ventral *basis* (O.T. *crusta*), which is carried upwards into the internal capsule on the lateral side of the thalamus. When the base of the brain is examined it is the basis pedunculi which is seen. It is white in colour and streaked in the longitudinal direction. On the exterior of the mesencephalon, the separation between the two parts of the pedunculus cerebri (*i.e.* the tegmentum and the basis pedunculi) is indicated by a medial and a lateral groove or sulcus. The medial sulcus is the deeper

and more distinct. It looks into the interpeduncular fossa, and from it emerge the fila of the oculo-motor nerve. It consequently receives the name of the *sulcus oculomotorius*. The lateral sulcus is termed the *sulcus lateralis*.

Cut Surface of the Mesencephalon.—Much nearer the dorsal than the ventral surface of the mesencephalon the transversely divided *aquæductus cerebri* may be seen. This narrow passage leads from the fourth ventricle below to the third ventricle above. It is surrounded by a thick layer of grey matter, called the *central grey matter of the aqueduct*. In a fresh brain this is always very conspicuous, and in its midst are situated the nuclei of the oculo-motor and trochlear nerves, and the upper motor nucleus of the trigeminal nerve, although of course these cannot, except in very favourable circumstances, be detected by the naked eye. Below, the grey matter of the aqueduct is continuous with the grey matter spread out on the anterior wall of the fourth ventricle; whilst above, it is continuous with the grey matter on the floor and sides of the third ventricle.

The division between the tegmentum and the basis pedunculi, on each side, is rendered very evident by a conspicuous lamina of dark pigmented matter which intervenes between them. This is termed the *substantia nigra*.

Substantia Nigra.—As seen in transverse section, the substantia nigra presents a somewhat crescentic outline. It is a thick band interposed between the basal and tegmental parts of the pedunculi cerebri, and it consists of a mass of grey matter in the midst of which are large numbers of pigmented nerve cells. It begins below, at the upper border of the pons, and it extends upwards into the subthalamic region. Its margins come to the surface at the oculo-motor and lateral sulci, and its medial part is traversed by the emerging fibres of the oculo-motor nerve. The surface turned towards the tegmentum is concave and uniform; the opposite surface is convex, and is rendered highly irregular by the presence of numerous slender prolongations of its substance into the basis pedunculi.

Basis Pedunculi (O.T. *crusta*).—The basis pedunculi is somewhat crescentic when seen in section, and stands quite apart from its fellow of the opposite side. It is composed of a compact mass of longitudinally directed nerve fibres which

are carried upwards into the internal capsule. The intermediate third or more of each basis pedunculi is composed of the important *cerebro-spinal fasciculus* (O.T. *pyramidal tract*) as it descends from the motor area of the cerebral cortex, but this is quite indistinguishable from the portions of the crusta which lie on either side of it.

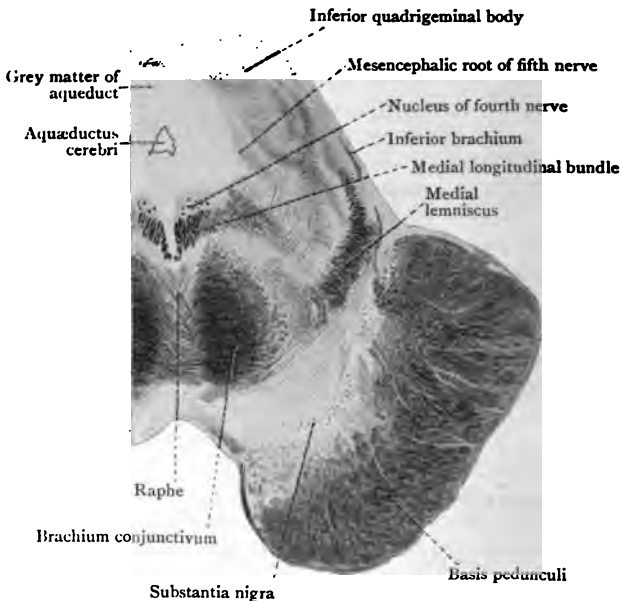


FIG. 211.—Transverse section through the Mesencephalon at the level of the inferior quadrigeminal body: the right side only is reproduced. The drawing is taken from a Weigert-Pal specimen, and therefore the grey matter is pale and the strands of white matter are dark. The dark colour of the substantia nigra is not evident owing to the thinness of the section.

Tegmentum.—Unlike the basis pedunculi, the tegmentum is undivided, a faint line in the median plane, termed the *median raphe*, alone indicating its bilateral character. Towards the dorsum of the mesencephalon it is fused with the bases of the corpora quadrigemina, and its lateral surfaces only are free.

The tegmentum is composed of an admixture of grey and white matter, constituting what is termed a *formatio reticularis*. The white matter is composed of fibres running both transversely and longitudinally. Certain

of the longitudinal fibres are grouped together and form well-marked tracts, which, in a section through the mesencephalon of a fresh brain, can be detected by the naked eye. These tracts are: (1) the medial longitudinal bundles; (2) the brachia conjunctiva; (3) the lemniscus.

The *medial longitudinal bundle* (Figs. 211 and 212) is a small compact fasciculus which is placed upon the lateral aspect of the lower portion of the aqueduct.

The *brachia conjunctiva* (O.T. *superior cerebellar peduncles*) are two

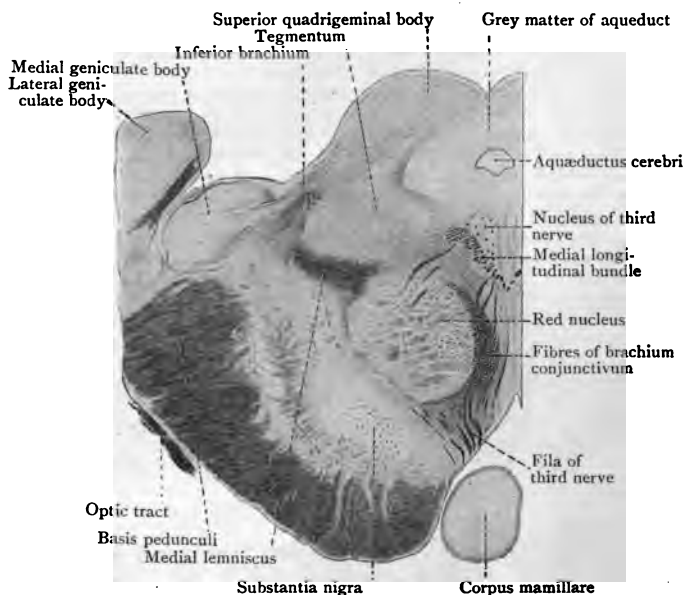


FIG. 212.—Section through upper part of Mesencephalon at level of superior quadrigeminal body. The drawing is taken from a Weigert-Pal specimen. The dark colour of the substantia nigra is not evident owing to the thinness of the section.

large strands which are continued upwards from the cerebellum into the mesencephalon. By pulling away the margin of the cerebellum, where it overlaps the lower quadrigeminal bodies, these brachia will be seen on the surface as they converge in an upward direction. Stretching across the interval between them, and bringing them into continuity with each other, is a thin lamina called the anterior medullary velum. When the brachia conjunctiva reach the bases of the inferior quadrigeminal bodies, they sink into the substance of the mesencephalon, and, in a transverse section through the lower part of this portion of the brain, they may be seen as two white strands, semilunar in outline and placed one on either side of the grey matter of the aqueduct. As they ascend, they gradually assume a deeper (*i.e.* a more ventral) position in the tegmental part of the mesen-

cephalon, and they decussate with each other across the median plane and proceed upwards to the red nuclei.

The term *lemniscus* (L.T. *fillet*) is given to two tracts presenting very different connections. The *medial lemniscus* (Figs. 211 and 212) is a sensory tract passing upwards to the thalamus. The *lateral lemniscus* belongs to the auditory apparatus, and is a part of a chain through which the cochlear nuclei establish connection with the inferior quadrigeminal body and the medial geniculate body. The lateral lemniscus can be readily detected as it emerges from the upper part of the lateral sulcus of the mid-brain, and passes, postero-superiorly, to the lower border of the inferior quadrigeminat body and inferior brachium. It has the form of a raised triangular band which encircles the lateral surface of the upper end of the brachium conjunctivum (Fig. 221).

Within the upper part of the tegmentum there is a collection of nuclear matter which is termed the *nucleus ruber*, from its ruddy appearance when seen in section. It is rod-like in form, and extends upwards into the tegmental region below the thalamus. In transverse section it presents a circular outline, and it is closely associated with the upward prolongation of the fibres of the brachia conjunctiva cerebelli. The brachium conjunctivum cerebelli is an efferent tract from the nucleus dentatus of the lateral hemisphere of the cerebellum, and its fibres end in the red nucleus and the pulvinar of the thalamus of the opposite side. The tegmentum of the pedunculus cerebri may be considered to consist of two parts: viz., a *lower part*, which is subjacent to the inferior quadrigeminal bodies, and is largely occupied by the decussation of the brachia conjunctiva cerebelli; and an *upper part*, subjacent to the superior quadrigeminal bodies, which is traversed by the emerging bundles of the third nerve, and contains the nucleus ruber.

BASAL GANGLIA OF THE CEREBRAL HEMISPHERES.

The basal ganglia of the cerebral hemispheres must now be examined. They are the caudate and lentiform nuclei, which together form the corpus striatum; the claustrum; and the amygdaloid nucleus. With these it is necessary to study also the composition of the thalamus and the external and internal capsules.

Dissection.—The right and left portions of what remains of the cerebrum should be separated from each other by a median incision. On the left portion the sulci and gyri on the lower surface of the hemisphere may be examined, if this has not been done already on another specimen.

A series of sections should, in the next place, be made through both the right and left portions of the cerebrum, with the view of displaying the basal ganglia. On the *right side* remove a succession of thin slices by carrying a long knife in a horizontal direction through the parts which form and lie below the floor of the central part of the lateral ventricle. It is not advisable to proceed farther down than the level of the anterior commissure.

On the *left side* of the brain a series of vertical-transverse or frontal sections should be made through the remaining portion of the cerebrum.

Begin by cutting off the portion anterior to the head of the caudate nucleus, and then proceed posteriorly until the posterior part of the thalamus is reached. One of the sections should be planned to pass through the anterior commissure.

Nucleus Caudatus.—This nucleus has already been partly examined in connection with the lateral ventricle, into the

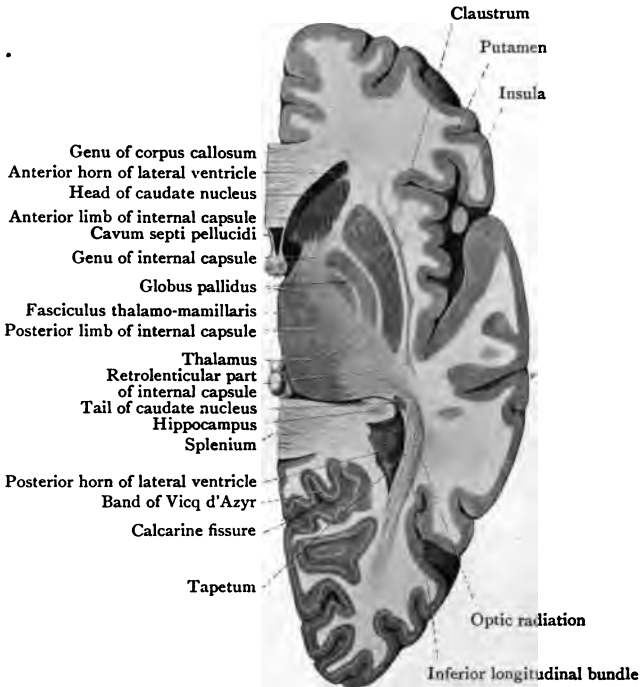


FIG. 213.—Horizontal section through the Right Cerebral Hemisphere at the level of the widest part of the lentiform nucleus.

cavity of which it bulges. It is a piriform highly arched mass of grey matter, which presents a thick swollen head or anterior extremity, and a long attenuated tail. The head projects into the anterior horn of the lateral ventricle, whilst its narrower part is prolonged laterally and posteriorly on the floor of the central part of the ventricle, where it is separated from the thalamus by the stria terminalis. Finally, its tail turns downwards and then anteriorly into the inferior horn

of the lateral ventricle, on the roof of which it is prolonged until it finally joins the amygdaloid nucleus. The caudate nucleus, therefore, presents a free ventricular surface covered with ependyma, and a deep surface embedded in the substance of the hemisphere, and for the most part related to the internal capsule.

Owing to its arched form, it follows that in horizontal sections, below a particular level, it is cut at two points, and both the head and the tail must be looked for in the field of

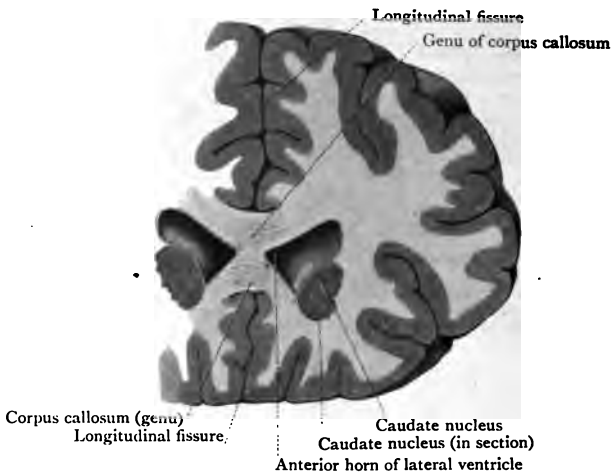


FIG. 214.—Frontal section through the Frontal Lobes of the Cerebrum. The posterior surface of the anterior part of the cerebrum is depicted so that the reader is looking into the anterior horns of the lateral ventricles from behind.

section (Fig. 213). In frontal sections posterior to the amygdaloid nucleus it is also divided at two places.

Nucleus Lentiformis.—This mass of grey matter lies on the lateral side of the caudate nucleus and the thalamus, and is, for the most part, completely embedded within the medullary substance of the cerebral hemisphere. It does not occupy so large an area as the nucleus caudatus. Indeed, it presents a very close correspondence in point of extent with the insula on the surface.

When seen in horizontal section (Fig. 213) it presents a shape similar to that of a biconvex lens. Its medial surface

bulges more than the lateral surface, and its point of highest convexity is placed opposite the stria terminalis or the interval between the caudate nucleus and the anterior end of the thalamus.

When seen in frontal section, the appearance presented by the lentiform nucleus differs very much in the different planes of section. Figure 215 represents a section through

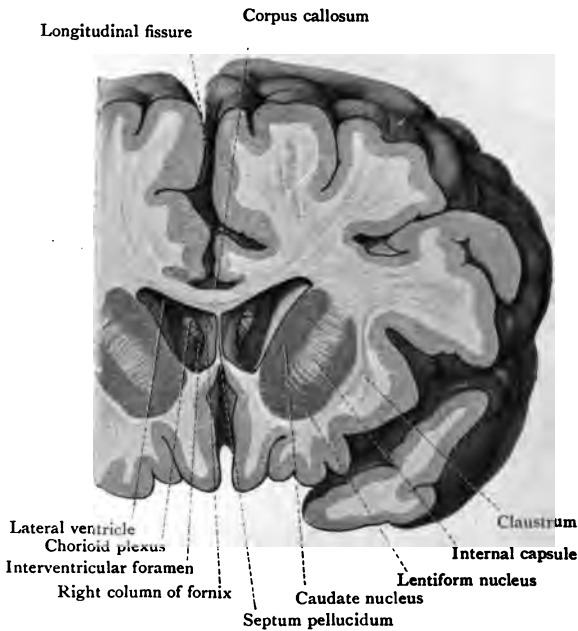


FIG. 215.—Frontal section through the Cerebral Hemisphere cutting through the anterior part of the lentiform nucleus. Seen from the anterior end.

its anterior portion. Here it is semilunar or crescentic in outline. Further, it is intimately connected with the head of the caudate nucleus by bands of grey matter which pass between the two nuclei and break up the anterior part of the internal capsule. It is due to the ribbed or barred appearance which is presented by such a section as this that the term *corpus striatum* is given to the two nuclei.

When the section is made in a more posterior plane, the divided lentiform nucleus assumes an altogether different shape, and is seen to be completely cut off from the caudate

it thickens considerably, and at the base of the brain it comes to the surface, at the substantia perforata anterior, and becomes continuous with the grey matter of the cerebral cortex. Its extent corresponds very nearly with the area occupied by the insula, and its lateral surface shows ridges and depressions corresponding to the insular gyri and sulci.

Capsula Interna.—This term is applied to the broad band of white matter which intervenes between the lentiform nucleus laterally, and the thalamus, stria terminalis, and caudate nucleus on the medial side. Anteriorly it is much

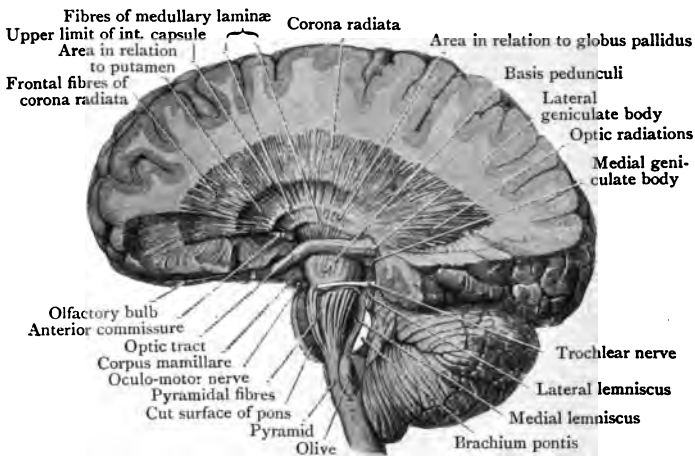


FIG. 218.—Dissection of Internal Capsule and Pyramidal Fibres.

broken up, by the connecting bands of grey matter which pass between the head of the caudate nucleus and the anterior part of the putamen of the lentiform nucleus (Fig. 215), but more posteriorly it forms a solid white mass of nerve fibres. When seen in horizontal section, the internal capsule is bent upon itself opposite the interval between the caudate nucleus and the thalamus (Fig. 216). This bend, which points medially, is called the *genu*. About one-third of the internal capsule lies anterior to the genu, and this part is called the *anterior limb*; the remaining two-thirds, which lie posterior to the genu, constitute the *posterior limb*.

Connections of the Internal Capsule.—The internal capsule is directly continuous below with the basis of the cerebral

peduncle. The dissector can easily satisfy himself in the specimens before him of this continuity; it is apparent in the more posterior of the frontal sections which he has made through the left portion of the cerebrum.

It has been mentioned already that the fibres which occupy the middle third or more of the basis of the cerebral peduncle belong to the motor cerebro-spinal fasciculus. In the internal capsule these fibres occupy the anterior two-thirds of the posterior limb, being thus placed immediately posterior to the genu. The fibres which constitute the medial third of the basis pedunculi come from the anterior limb of the internal capsule; whilst the fibres which form the lateral third of the basis pedunculi are situated in the posterior limb.

When the fibres of the internal capsule are traced upwards, they are found to spread out in a radiating manner so as to reach the various gyri of the cerebral hemispheres. This arrangement is termed the *corona radiata*. As the fibres of the corona radiata are liberated from the internal capsule, and spread out to reach their destinations, they are intersected by fibres of the corpus callosum, which also radiate in every direction to gain the cortex of the cerebrum, and they are intersected also by bundles of association fibres.

Nuclei of the Thalamus.—When a horizontal section is made through the thalamus in a fresh brain, or in one which has been preserved by means of formalin or a chromic salt, the grey matter composing it is seen to be broken up into a lateral, a medial, and an anterior nucleus by thin white medullary laminae.

Capsula Externa.—This term is applied to the thin stratum of white matter which intervenes between the lentiform nucleus and the claustrum (Figs. 213 and 216).

Dissection.—The fasciculus thalamo-mamillaris and the anterior commissure should now be followed, as far as this is possible, in what remains of the right half of the cerebrum. The dissection is not difficult.

By the removal of the remains of the lentiform nucleus the anterior commissure will be exposed in its course towards the temporal lobe. In the first instance, it passes transversely, then postero-laterally below the putamen. Next it bends suddenly in a posterior direction above the inferior horn of the lateral ventricle to reach the medullary centre of the temporal lobe. If the dissection be successfully accomplished, the anterior commissure will be seen to present a twisted or rope-like appearance.

The fasciculus thalamo-mamillaris may be traced from the corpus mamillare upwards into the anterior nucleus of the optic thalamus by scraping away the grey matter on the side of the third ventricle. The continuity between the column of the fornix and the corpus mamillare should at the same time be established. Within the corpus mamillare there is a nucleus of grey matter.

The dissectors have now examined all those portions of the brain which lie in the anterior and middle cranial fossae, and certain terms, not hitherto mentioned in connection with the various structures which have been studied, now require consideration. It has been noted already that the

part of the brain which connects the lower segment in the posterior fossa with the upper segment in the middle and anterior fossa is called the **mesencephalon**. The parts above the mesencephalon form collectively the **prosencephalon**, and the mesencephalon and prosencephalon together constitute the **cerebrum**.

The prosencephalon itself is separable into two main parts, the **telen-cephalon** (end brain), and the **diencephalon**. The telencephalon includes the cerebral hemispheres with their grey nuclei, the olfactory bulbs and tracts and the associated parts, and the *pars optica hypothalami*; under the latter term are included the tuber cinereum, the infundibulum, the hypophysis, the optic tracts, the optic chiasma, and the lamina terminalis.

The diencephalon includes two closely associated segments, the *pars mamillaris hypothalami* and the *thalamencephalon*.

The *pars mamillaris hypothalami* is formed by the mamillary bodies and those portions of the walls of the third ventricle which lie below the sulcus hypothalamicus. The thalamencephalon is separated into the *thalamus* (O.T. *optic thalamus*), the *metathalamus*, formed by the two geniculate bodies, and the *epithalamus*, which consists of the pineal body, the habenula, the habenular commissure, and the trigonum habenulae.

THE PARTS OF THE BRAIN WHICH LIE IN THE POSTERIOR CRANIAL FOSSA.

The parts which lie below the tentorium cerebelli in the posterior cranial fossa are the *medulla oblongata*, the *pons*, and the *cerebellum*. These are grouped around the *fourth ventricle* of the brain—a cavity which communicates with the central canal of the medulla spinalis below and with the aquæductus cerebri above; and they constitute the rhombencephalon or hind brain.

Medulla Oblongata.—This is the continuation of the spinal medulla into the brain. It is not more than one inch in length, and may be reckoned as beginning at the level of the foramen magnum. Thence it proceeds upwards, in a very nearly vertical direction, and ends at the lower border of the pons. At first its girth is similar to that of the spinal medulla, but it rapidly expands as it approaches the pons, and consequently it presents a more or less conical appearance. Its anterior surface lies in the groove on the basilar portion of the occipital bone, whilst its posterior aspect is sunk into the vallecula of the cerebellum.

The medulla oblongata is a bilateral structure, and this is evident even on an inspection of its exterior. The antero-median and postero-median sulci on the surface of the spinal

medulla are prolonged upwards on the anterior and posterior surfaces of the medulla oblongata.

The *antero-median groove*, as it passes from the spinal medulla on to the medulla oblongata, is interrupted, at the level of the foramen magnum, by several strands of fibres which cross the median plane from one side to the other. This intercrossing is termed the *decussation of the pyramids*. Above this level the furrow is carried upwards to the lower

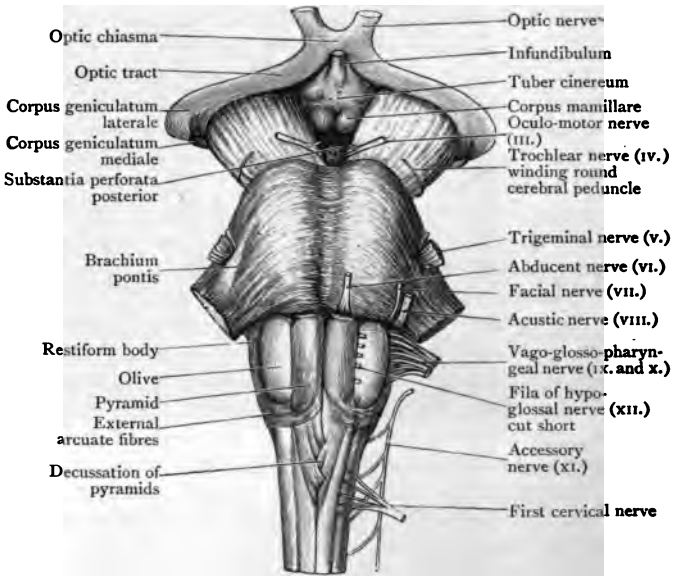


FIG. 219.—Anterior aspect of the Medulla Oblongata, Pons, and Mesencephalon of a full-time Fœtus.

border of the pons. There it expands slightly, and ends in a blind pit, termed the *foramen cæcum*.

The *postero-median fissure* is carried up for only half the length of the medulla oblongata. Then the central canal of the medulla spinalis becomes the fourth ventricle of the brain, and as it expands dorsally it pushes aside the lateral lips of the posterior median sulcus till the epithelium of its posterior wall appears on the surface, in the triangular interval between the diverging posterior columns of the medulla oblongata,

where it forms the posterior wall or roof of the lower part of the fourth ventricle.

The surface of each lateral half of the medulla oblongata should now be studied. It is well, however, to defer the examination of the medullary part of the floor of the fourth ventricle till a later period. The dissector has already noticed two linear rows of nerve fila issuing from and entering the medulla oblongata on each side. The *anterior row* consists of the roots of the hypoglossal and the uppermost part of the anterior root of the first cervical nerve. They continue upwards on the medulla oblongata in the line of the anterior nerve roots of the spinal medulla, and they emerge along the bottom of a more or less distinct groove. The *posterior row* is formed of the nerve fila of the accessory, vagus, and glosso-pharyngeal nerves, and they lie in series with the posterior roots of the spinal nerves.

By these two rows of nerve fila, each side of the medulla oblongata is divided into three districts, viz., an anterior, a lateral, and a posterior, similar to the surface areas of the three funiculi on the side of the medulla spinalis. At first sight, indeed, they appear to be direct continuations upwards of those portions of the spinal medulla; it is easily demonstrated, however, that that is not the case, and that the fibres in the three funiculi of the medulla spinalis undergo a rearrangement as they are traced into the medulla oblongata.

Anterior Area of the Medulla Oblongata—Pyramis.—The district between the antero-median furrow and the row of hypoglossal nerve fila issuing from the medulla receives the name of the pyramid. An inspection of the surface is almost sufficient to show that this is formed by a compact mass of longitudinally directed fibres. It expands somewhat, and assumes a more prominent appearance as it passes upwards, and, finally, reaching the lower border of the pons, it becomes slightly constricted and disappears from view by plunging into that structure. The pyramids are the great motor strands of the medulla oblongata.

Although the pyramid, at first sight, appears to be the continuation upwards of the anterior funiculus of the spinal medulla, it contains within itself only a very small proportion of fibres which occupy that funiculus. This will be at once manifest if the *decussation of the pyramids* is examined. For this purpose introduce the back of the knife-blade into the

antero-median furrow below the decussation, and on one side push in a lateral direction the anterior funiculus of the medulla spinalis. The pyramid will then be seen to divide into two portions, viz., a small strand termed the *fasciculus cerebrospinalis anterior* (O.T. *direct pyramidal tract*), which proceeds downwards into the anterior funiculus of the spinal medulla

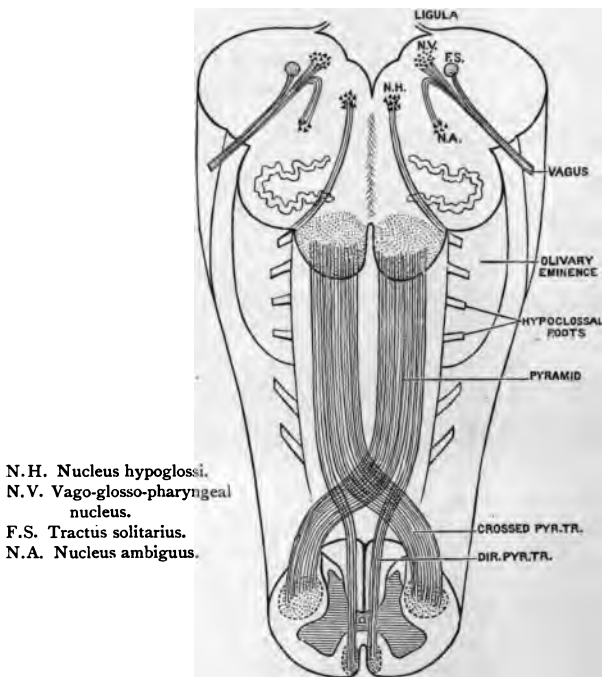


FIG. 220.—Diagram of the Decussation of the Pyramids.
(Modified from Van Gehuchten.)

close to the antero-median furrow, and a much larger strand called the *fasciculus cerebrospinalis lateralis* (O.T. *crossed pyramidal tract*), which, at this level, is broken up into three or more coarse bundles which sink posteriorly and, at the same time, cross the median plane to take up a position in the opposite lateral funiculus of the spinal medulla, close to the posterior column of grey matter. It is the intercrossing of the corresponding bundles of the fasciculi cerebro-

spinales laterales of opposite sides which produces this characteristic decussation.

But if the fasciculus cerebrospinalis anterior of the anterior funiculus of the spinal medulla is alone represented in the corresponding district of the medulla oblongata, it may be asked : What becomes of the larger lateral part of the anterior funiculus of the spinal medulla in the medulla oblongata? It is thrust aside by the decussating bundles of the fasciculus cerebrospinalis lateralis, and thus comes to occupy a deep position in the medulla oblongata.

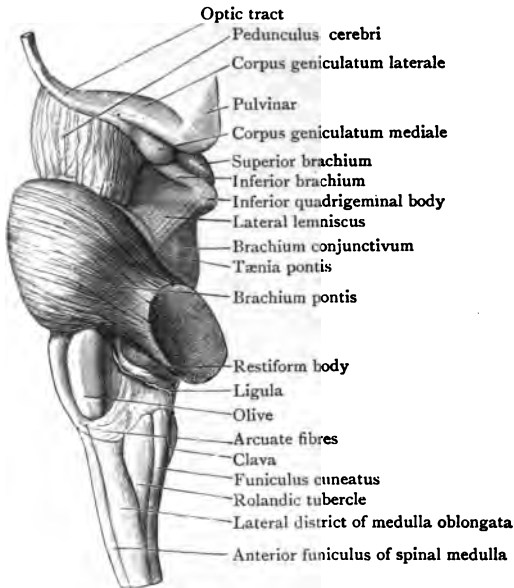


FIG. 221.—Lateral view of the Medulla Oblongata, Pons, and Mesencephalon of a full-time Foetus.

Lateral Area of the Medulla Oblongata.—This is the district on the surface of the medulla oblongata which is included between the two rows of nerve fila, viz., the hypoglossal fila anteriorly, and the fila of the accessory, vagus, and glosso-pharyngeal posteriorly. It presents a very different appearance in its upper and lower parts. In its lower portion it appears to the eye as a continuation upwards of the lateral funiculus of the spinal medulla; in its upper part is seen the striking oval prominence named the *olive*.

The lower part of this district, however, is very far from

being an exact counterpart of the lateral funiculus of the spinal medulla. It has been noted already that the large fasciculus cerebros spinalis lateralis, which in the spinal medulla lies in the lateral funiculus, is not present in that district of the medulla oblongata; above the decussation of the pyramids it forms the chief part of the pyramid of the opposite side. Another small strand of fibres, the *fasciculus cerebellospinalis* (O.T. *direct cerebellar tract*), prolonged upwards in the lateral

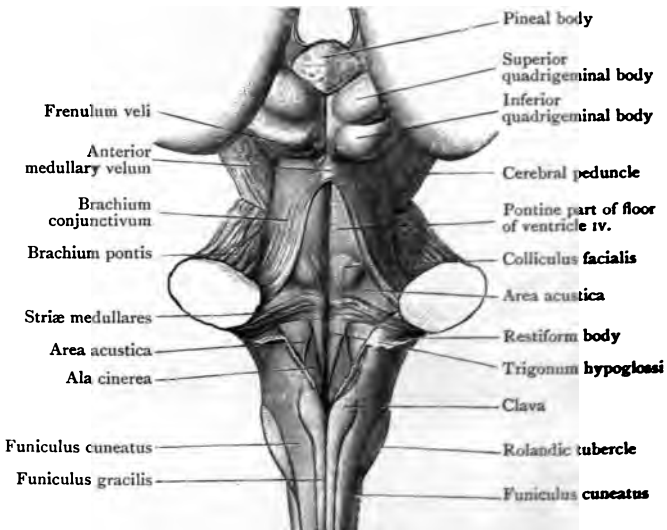


FIG. 222.—Posterior view of the Medulla Oblongata, Pons, and Mesencephalon of a full-time Fœtus. The greater part of the roof of the fourth ventricle is removed.

funiculus of the spinal medulla, gradually leaves this portion of the medulla oblongata. This tract of fibres lies on the surface, and it is often visible to the naked eye as a white streak inclining obliquely into the posterior district of the medulla oblongata to join its upper part, *i.e.*, the restiform body. The great majority of the remainder of the fibres which are prolonged upwards from the lateral funiculus of the spinal medulla disappear from the surface at the lower border of the olive, by dipping into the substance of the medulla oblongata under cover of that projection. A narrow band, however, is carried upwards to the pons, in the interval

between the posterior border of the olive and the fila of the vagus and glosso-pharyngeal nerves.

The *olive* is a smooth oval projection, which occupies the upper part of the lateral area of the medulla oblongata. Its long axis, which is vertical, is about half an inch long, and its upper end is separated from the lower border of the pons by an interval or groove.

Posterior Area of the Medulla Oblongata.—In its lower half this region is formed by the cuneate and gracile funiculi ; and in its upper half it is formed, medially, by the ependymal roof of the fourth ventricle and, laterally, by the diverging funiculi.¹ It is separated from the lateral area on each side by the row of fila belonging to the accessory, vagus, and glosso-pharyngeal nerves.

The lower part of the posterior area corresponds more or less closely with the posterior funiculi of the spinal medulla. It will be remembered that in the cervical part of the spinal medulla the posterior areas on each side is divided by a distinct septum of pia mater into a postero-median strand and a postero-lateral strand. These are prolonged upwards into the medulla oblongata, and in the lower part of the posterior area they stand out distinctly, and are separated from each other by a continuation upwards from the medulla spinalis of the postero-intermediate sulcus. In the medulla oblongata these strands receive different names. The medial one is called the *funiculus gracilis*, whilst the lateral one is designated the *funiculus cuneatus*. Each of these strands, when it reaches the lower part of the fourth ventricle, ends in a slightly expanded prominence. The swollen extremity of the funiculus gracilis is called the *clava* ; it is thrust aside from its fellow of the opposite side by the opening up of the central canal to form the fourth ventricle. The thickened end of the cuneate funiculus receives the name of the *tuberculum cinereum*, but it is in the young brain only that it is well marked.

In sections through this region of the medulla oblongata, it is seen that the prominences produced by the two strands and their enlarged extremities are in a great measure due to the

¹ The dissector should note that the lower part of the cavity of the hind-brain, *i.e.* the fourth ventricle, is not behind but *in* the upper part of the medulla, which it separates into dorsal and ventral parts ; the dorsal part forms a portion of the roof of the ventricle, whilst the ventral part forms a portion of the floor.

presence of two elongated nuclei, which lie subjacent to them and gradually increase as they are traced upwards. These are termed the *gracile* and the *cuneate nuclei*, and it can easily be shown that as the grey matter increases in quantity the fibres of the two corresponding strands diminish in number. Indeed, it is doubtful if any of their fibres are prolonged upwards beyond the level of the nuclei.

But a third longitudinal elevation also is apparent in the lower part of the posterior area of the medulla oblongata. This is placed on the lateral side of the funiculus cuneatus—between it and the posterior row of nerve fila—and it has no counterpart in the posterior funiculus of the spinal medulla. It is called the *funiculus of Rolando*, because it is produced by the substantia gelatinosa Rolandi approaching the surface. Extremely narrow below, the funiculus of Rolando widens somewhat as it is traced upwards, and it, finally, ends in an expanded extremity called the *tubercle of Rolando*. The thin layer of fibres which appear on the surface of the tubercle and funiculus of Rolando and cover the substantia gelatinosa Rolandi in this position belong to the tractus spinalis (O.T. spinal root) of the trigeminal nerve.

The *restiform body* forms the upper part of the posterior area on each side. It lies between the lower part of the floor of the fourth ventricle and the fila of the vagus and glosso-pharyngeal nerves, and is thrust laterally by the enlargement of the fourth ventricle. It is a large rope-like strand, which inclines upwards and laterally, and then finally takes a turn posteriorly, and enters the cerebellum, of which it constitutes the *inferior peduncle*. The restiform body, therefore, is to be regarded as the main connection between the cerebellum, above, and the medulla oblongata and medulla spinalis below. At the same time, it must be understood that it is not formed of fibres which are prolonged into it from the funiculus gracilis and funiculus cuneatus of its own side. It is true that a surface inspection of the medulla oblongata might lead very naturally to this supposition, because there is no sharp line marking it off from the tubercles of these strands.

The fibres which build up the restiform bodies come from several different sources. It will be sufficient to indicate the more important of these—(1) from the lateral funiculus of the spinal medulla through the *fasciculus cerebellospinalis*; (2) from the cerebellum as the *cerebello-olivary fibres*

which go to the opposite inferior olivary nucleus: 3 from the cuneate and gracile nuclei of both sides in the form of the *arcuate fibres*.

Fibræ Arcuatae Externæ.—On the surface of the medulla oblongata, more particularly in the neighbourhood of the lower border of the olive a number of curved bundles of fibres, termed the *external arcuate fibres*, may be noticed. They vary greatly in number and in distinctness, and are sometimes so numerous as to cover the olive almost entirely. An attentive examination will show that they come to the surface in the antero-median fissure between the pyramids, in the groove between the pyramid and the olive, and sometimes also through the substance of the pyramids. But at whatever point they reach the surface, the majority have one destination, viz., the restiform body—a considerable part of which they form. They are derived from the cuneate and gracile nuclei of the opposite side.

Dissection. The pyramid of one side should now be carefully raised. When detached from its bed it should be gently pulled upwards towards the pons. In this way its entrance into the pons is brought very clearly into view. Further, numerous arcuate fibres will be seen running anteriorly upon the medial aspect of the opposite pyramid to reach the surface, and the ventral edge of the medial lemniscus will be exposed also.

Pons. The pons is the marked prominence on the base of the brain which is interposed between the medulla oblongata and the pedunculi cerebri, and lies anterior to the cerebellum. It is convex from side to side, as well as antero-posteriorly, and the transverse streaks on its surface show that, superficially, it is composed of transverse bundles of nerve fibres. On either side these transverse fibres collect themselves together to form a large compact strand which sinks postero-laterally into the corresponding hemisphere of the cerebellum. This strand is termed the *brachium pontis* (O.T. *middle cerebellar peduncle*).

The ventral surface of the pons is in relation to the basilar portion of the occipital bone and the dorsum sellæ of the sphenoid bone. It presents a median groove which gradually widens as it is traced upwards (Fig. 219). The groove lodges the basilar artery, but is not caused by that vessel; it is due to the prominence produced, on either side, by the passage downwards through the pons of the bundles of fibres which form the pyramids of the medulla oblongata.

Where the pons becomes the brachium pontis the large trigeminal nerve will be seen entering its ventral surface, nearer its upper than its lower border.

With the exception of the restiform bodies, the whole of the medulla oblongata enters the lower aspect of the pons, and its constituent parts are carried upwards within it. The pedunculi cerebri emerge from its upper aspect. The *dorsal surface* of the pons cannot be studied at present. It is turned towards the cerebellum, which hides it from view, and it forms the upper part of the anterior boundary or floor of the fourth ventricle.

Cerebellum.—The cerebellum is distinguished by the numerous parallel and more or less curved sulci which traverse its surface and give it a foliated appearance. As in the case of the cerebral hemispheres, the grey matter is spread over the entire surface, whilst the white matter forms a central core in the interior.

The cerebellum consists of a median portion, the *vermis*, and two *lateral hemispheres*. The distinction between these main subdivisions of the organ is not very evident on its superior surface. Anteriorly and posteriorly there is a marked deficiency or notch in the median plane (Fig. 223). The *posterior notch* is smaller and narrower than the anterior notch. It is bounded laterally by the posterior parts of the cerebellar hemispheres, and anteriorly by the vermis, and it is occupied by the falx cerebelli. The *anterior notch* is much wider and, when viewed from above, it is seen to be occupied by the inferior pair of quadrigeminal bodies and the brachia conjunctiva cerebelli. Its sides are formed by the lateral hemispheres, and the posterior end is bounded by the vermis.

On the *superior surface* of the cerebellum there is little distinction to be noted between the vermis and the upper surface of each lateral hemisphere. The upper surface of the vermis forms a median elevation, from which the surface slopes gradually downwards, on each side, to the margin of the hemisphere. On the upper surface of the vermis four regions are recognised. Anteriorly, at the posterior end of the anterior notch, lies the *central lobe*, and prolonged upwards from it on the dorsal surface of the anterior medullary velum, between the brachia conjunctiva, are a few folia which constitute the *lingula*. Posterior to the central lobe is the *monticulus*, separable into two parts—an anterior elevated end,

to the *vermis* and a posterior sloping ridge, the *Latinus*. Posterior to the latter is the anterior boundary of the posterior notch, and a slightly elevated part, the *floccus cerebelli*.

On the *inferior surface* of the cerebellum, the distinction between the three constituent parts of the organ is much more marked. On that aspect the hemispheres are full prominent and convex, and they are separated by a deep *median sulcus* which is continued forwards from the posterior notch. This sulcus was termed the *vallecula cerebelli*, and in its anterior part the medulla oblongata is lodged. If the medulla is forced away from the cerebellum, and the lateral hemispheres are pulled apart, so as to expose the upper boundary of the vallecula, it will be seen that this is formed by the inferior surface of the *vermis*, and further, that the vermis is separated, on each side, from the corresponding lateral hemisphere by a distinct fissure, termed the *sulcus valliculae*.¹

If the margin of the vermis, where it forms the posterior boundary of the anterior notch on the superior aspect of the cerebellum, is gently raised, and at the same time the *metencephalon* is pulled anteriorly, two strands lying upon the dorsal aspect of the pons will be seen. These are the *brachia conjunctiva cerebelli* (O.T. *superior peduncles*). They emerge from the white matter of the cerebellum, converge as they proceed upwards, and, finally, they disappear under the inferior quadrigeminal bodies. The thin lamina which is stretched across between them is the *anterior medullary velum*. It is continuous below with the white core of the vermis, and it helps to form the roof of the upper part of the fourth ventricle. From its dorsal surface, close to the inferior quadrigeminal body, the small trochlear nerves emerge.

Certain of the sulci which traverse the surface of the cerebellum, deeper and longer than the others, map out districts which are termed lobes. The most conspicuous of all these clefts is the *great horizontal sulcus*.

Great Horizontal Sulcus of the Cerebellum.—The great horizontal sulcus begins anteriorly, and passes round the circumference of the cerebellum, cutting deeply into its lateral and posterior margins. Anteriorly, its lips diverge from each

¹ A further dissection of the epithelial roof of the fourth ventricle and its covering of pia mater will be torn away, and the lower part of the floor or anterior boundary of the fourth ventricle will be displayed.

other so as to embrace the large brachia pontis (O.T. middle peduncles), where they pass into the interior of the cerebellum. The great horizontal sulcus divides the cerebellum into an upper and a lower part, which may be studied separately.

Lobes on the Upper Surface of the Cerebellum.—It has been noted already that the upper surface of the vermis superior is subdivided. The divisions commencing from the anterior end are:—(1) the lingula; (2) the central lobule; (3) the culmen monticuli; (4) the declive monticuli; (5) the folium vermis. With the exception of the lingula, each of these is continuous

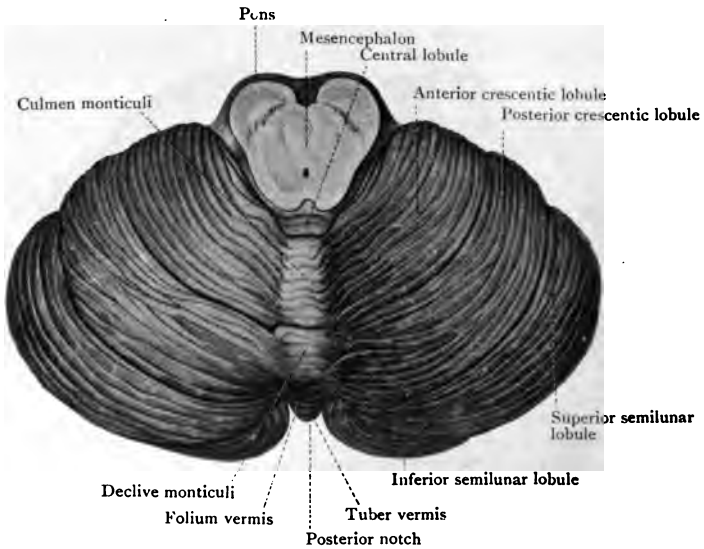


FIG. 223.—Upper Surface of the Cerebellum.

on either side with a corresponding district on the upper surface of the hemisphere, and forms with these districts a cerebellar lobe. Thus, the central lobule is prolonged laterally on each side in an expansion called the *ala*; the culmen constitutes a median connecting piece between the two *anterior crescentic lobules* of the hemispheres; the declive stands in the same relation to the *posterior crescentic lobules*; and the folium vermis is the connecting band between the *superior semilunar lobules* of the hemispheres.

Lingula.—The lingula can be seen only when the posterior boundary of the anterior notch is pushed posteriorly. It consists of four or five small folia, continuous with the grey matter of the vermis, prolonged anteriorly on the surface of the anterior medullary velum, in the interval between the brachia conjunctiva.

Lobus Centralis with its Alæ.—The central lobule lies at the posterior

THE BRAIN

of the anterior notch, and is largely hidden by the culmen. It is a leaf-like lamina which is prolonged laterally for a short distance round the posterior notch in the form of two expansions, termed the *ala*.

Lobus Culminis.—The *culmen monticuli* constitutes the summit or highest part of the monticulus of the vermis. It is prolonged laterally on either side into the corresponding hemisphere as the *anterior crescentic lobule*. This is the most anterior subdivision on the upper surface of the hemisphere. The two anterior crescentic lobules, with the culmen and *ala*, form the *lobus culminis cerebelli*.

Lobus Clivi.—The *folium monticuli* lies posterior to the culmen, from

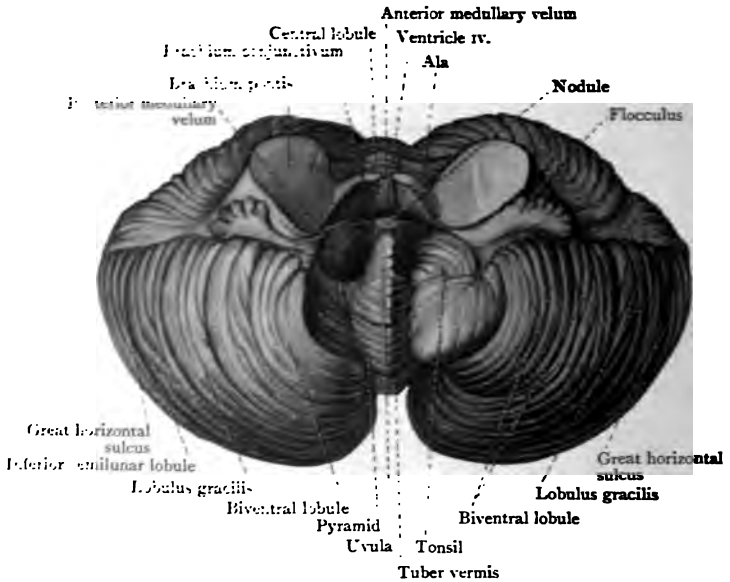


FIG. 224.—Lower Surface of the Cerebellum. The tonsil on the right side has been removed so as to display the posterior medullary velum and the furrowed band.

which it is separated by a distinct fissure, and it forms the sloping part or descent of the monticulus of the vermis. On each side it is continuous with the *posterior crescentic lobule* of the lateral hemisphere, and the three parts are included under the one name of *lobus clivi*.

The two crescentic lobules on the upper surface of the hemisphere are frequently described together as the *quadrate lobule*.

Lobus Semilunaris Superior (O.T. *lobus cacuminis*).—The *folium vermis* forms the most posterior part of the superior portion of the vermis, and it bounds the great horizontal fissure, superiorly, at the posterior notch. It is a single folium, the surface of which may be smooth or beset with rudimentary secondary folia, and it is the connecting link between the two *superior semilunar lobules* of the hemispheres—

the three parts constituting the *lobus semilunaris superior*. As the folium vermis is traced laterally into the semilunar lobule of the hemisphere, it is found to expand greatly. The result of this is that the lobus semilunaris superior on each side forms an extensive foliated district bounding the posterior part of the great horizontal sulcus superiorly.

Lobes on the under surface of the Cerebellum.—The connection between the several portions of the inferior part of the vermis, and the corresponding districts on the under surface of the two hemispheres is not nearly so distinct as in the case of the superior part of the vermis and the lobules on the upper surface of the hemispheres.

Proceeding postero-anteriorly the following subdivisions of the inferior part of the vermis are recognised—(1) the tuber vermis, (2) the pyramid, (3) the uvula, and (4) the nodule.

On the under surface of the hemisphere there are five lobules mapped out by intervening sulci. These are—(1) the *flocculus*, a little lobule lying on the brachium pontis; (2) the *biventral lobule*, which lies immediately

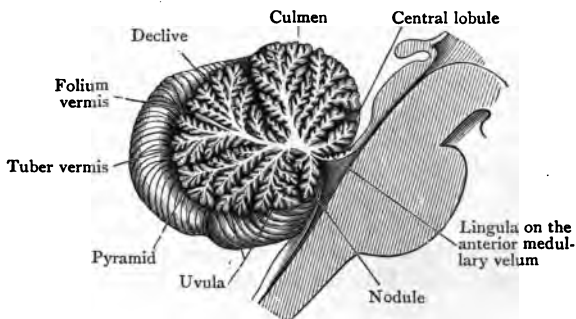


FIG. 225.—Median section through the Vermis of the Cerebellum.
(From Gegenbaur.)

posterior to the flocculus, and is partially divided into two parts by a fissure which traverses its surface; (3) the *tonsil*, a rounded lobule, which bounds the vallicula on the medial side of the biventral lobule; (4) the *inferior semilunar lobule*, placed posterior to the biventral lobule, and bounding the great horizontal sulcus inferiorly.

These lobules of the hemispheres, with the corresponding portions of the inferior part of the vermis, constitute the lobes on the under aspect of the cerebellum.

Lobus Noduli.—The lobus noduli comprises the nodule and the flocculus of either side with an exceedingly delicate connecting lamina of white matter, termed the *posterior medullary velum*.

The velum cannot be properly seen at present, but it will be exposed at a later stage of the dissection.

Lobus Uvulæ.—The uvula is a triangular elevation placed between the two tonsils. It is connected across the sulcus valliculæ with each tonsil by a low-lying ridge of grey matter which is scored by a few shallow furrows, and in consequence termed the *furrowed band*. The two tonsils and the uvula form the *lobus uvulæ*.

To see the furrowed band it will be necessary to remove the tonsil on one side, when the posterior medullary velum also will be exposed.

Lobus Pyramidis.—The pyramid is connected with the biventral lobule on each side by a faint ridge which crosses the sulcus valliculæ. The term *lobus pyramidis* is given to the three lobules which are thus associated with each other.

Lobus Tuberis.—The *tuber vermis*, which forms the most posterior part of the vermis, is composed of several folia, which run directly into the inferior semilunar lobule on each side. The three parts of the *lobus tuberis* are thus linked together. The inferior semilunar lobule is traversed by two, or it may be three, curved fissuræ. The most anterior of these cuts off a narrow, curved strip of cerebellar surface called the *lobulus gracilis*.

Dissection.—A median section should now be made through the vermis of the cerebellum and the two medullary vela into the cavity of the fourth ventricle. When the two parts of the cerebellum are drawn slightly asunder, a view of the fourth ventricle is obtained; further, the connections of the two medullary vela and the arrangement of the peduncles of the cerebellum can be more clearly understood.

Arbor Vitæ Cerebelli.—The cut surface of the cerebellum presents a very characteristic appearance. The grey matter on the surface stands out distinctly from the white matter in the interior. Further, the complete manner in which the surface is cut up by the sulci into secondary and tertiary folia is seen. The central mass of white matter in the vermis is termed the *corpus medullare*. From this, prolongations pass into the various lobules, and these give off branches to supply each folium with a central white stem or core. The term *arbor vitæ* is applied to the appearance which consequently results when a section is made through the cerebellum.

Cerebellar Peduncles.—The cerebellar peduncles are the structures which connect the cerebellum with the medulla oblongata, the pons and the mid-brain. They are three in number on each side—viz., the middle, the superior, and the inferior. They are all directly connected with the white medullary centre of the cerebellum, and are composed of fibres which emerge from or enter the white central substance of the organ.

The *middle peduncle* is the brachium pontis, and is much the largest of the three. It is formed by the transverse fibres of the pons, and it enters the cerebellar hemisphere on the lateral side of the other two. The lips of the anterior part of the great horizontal sulcus are separated widely from each other to give it admission.

The *inferior peduncle* is simply the restiform body of the medulla oblongata. Leaving the dorsum of the medulla oblongata it turns sharply posteriorly and enters the cerebellum between the other two peduncles.

The *superior peduncles* are the brachia conjunctiva of the cerebellum. They are composed of fibres which come, for the most part, from the nucleus dentatus of the cerebellar hemisphere. As they issue from the cerebellum, the peduncle lies close to the medial sides of the corresponding middle peduncles. They then proceed upwards towards the inferior pair of quadrigeminal bodies. At first they form the lateral boundaries of the upper part of the fourth ventricle, but they converge, as they ascend on the dorsal aspect of the pons, so that ultimately they overhang the fourth ventricle and enter into the formation of its roof. They disappear under cover of the quadrigeminal bodies, and their course in the mesencephalon has been described already (p. 511).

Medullary Vela.—The medullary vela are closely associated with the peduncles. They consist of two thin laminæ of white matter which are projected out from the white central core of the cerebellum. The *anterior medullary velum* stretches across the interval between the two brachia conjunctiva (superior peduncles), with the medial margins of which it is directly continuous. It is triangular in form, and is continuous below with the white matter of the cerebellum. Spread out on its dorsal surface is the tongue-shaped prolongation of grey matter from the cortex of the cerebellum which is termed the *lingula*, and issuing from its substance, close to the inferior quadrigeminal bodies, are the two trochlear nerves.

The *posterior medullary velum* is somewhat more complicated in its connections. It presents the same relation to the nodule that the anterior velum presents to the lingula. It is a wide thin lamina of white matter—so thin that it is translucent—which is prolonged out from the white centre of the cerebellum above the nodule. From the nodule it stretches laterally to the flocculus, thereby bringing these two small portions of the cerebellum into association with each other. Where it issues from the white matter of the cerebellum it might almost be said to be in contact with the anterior medullary velum, but as the two laminæ are traced anteriorly they diverge from each other: the anterior velum is carried upwards between the brachia conjunctiva of the cerebellum, whilst the posterior medullary velum turns downwards, round the nodule, and ends in a slightly thickened free crescentic edge. The cavity of the fourth ventricle is carried

posteriorly between the two vela, which form a tent-like roof for it.

Isthmus Rhombencephali.—If the dissectors examine the rhombencephalon from the side they will recognise that there is a region below the lamina quadrigemina and above the cerebellum which is bounded dorsally by the anterior medullary velum, laterally by the brachia conjunctiva, and ventrally by the upper part of the pons; it is to this region that the term *isthmus rhombencephali* is applied. It contains the upper part of the fourth ventricle.

Ventriculus Quartus.—This cavity is somewhat rhomboidal in form. Below, it tapers to a point and becomes continuous with the central canal of the lower part of the medulla oblongata; above, it narrows in a similar manner and is continued into the aquæductus cerebri of the mid-brain. The anterior wall is termed the *floor*, and is formed by the dorsal surface of the ventral part of the upper portion of the medulla oblongata and by the dorsal surface of the pons. The posterior wall is called the *roof*. On either side a narrow pointed prolongation of the ventricular cavity is carried laterally, from its widest part, round the upper part of the corresponding restiform body. This is termed the *lateral recess* (Fig. 222, p. 525). It is seen to the greatest advantage when the cerebellum is divided in the median plane and the halves are turned aside.

The lateral boundary of the fourth ventricle, on each side, is formed, from below upwards, by the clava, the upper part of the funiculus cuneatus, the restiform body or inferior peduncle of the cerebellum, the brachium pontis or middle peduncle of the cerebellum, and the brachium conjunctivum or superior peduncle of cerebellum.

Dissection.—On one side cut through the brachium conjunctivum, the brachium pontis and the restiform body, and so separate one lateral half of the cerebellum, which must be laid aside for the present but must be preserved for future use.

When the dissection is completed the dissectors will be able to recognise that the anterior part of the cavity of the fourth ventricle is rhomboidal in form. It constitutes the so-called *rhomboidal fossa*, which is surrounded by the lateral boundaries of the ventricle and closed anteriorly by the pons and the posterior surface of the ventral part of the upper portion of the medulla oblongata. Only the *lower part* of the

rhomboidal fossa lies in the medulla oblongata: the *intermediate part* is in the metencephalon, that is, it lies anterior to the cerebellum and posterior to the lower part of the pons; and the *upper part* is in the isthmus rhombencephali.

The *lower part of the rhomboidal fossa* is triangular in outline, and its inferior angle is continuous with the central canal of the lower part of the medulla oblongata. The anterior boundary or floor of this part of the fossa is marked by a number of converging sulci, and is called the *calamus scriptorius*. Along the lateral margins of the lower part of the fossa will be seen the remains of the torn epithelial roof of the lower part of the fourth ventricle. These torn margins are the *tæniæ of the fourth ventricle*. The *intermediate part of the rhomboidal fossa* is separable into a lower wider part, which is prolonged laterally, on each side, below and posterior to the restiform body, as the *lateral recess of the fourth ventricle*. The upper section of the intermediate part of the fossa is bounded laterally by the brachia pontis and is much narrower than the lower part. The *upper part of the rhomboidal fossa* lies posterior to the pons and between the brachia conjunctiva. At its upper end it becomes continuous with the aquæductus cerebri of the mid-brain.

The *floor, or anterior boundary, of the fossa rhomboidalis* is the floor, or anterior boundary, of the fourth ventricle. In the upper part of its extent it is formed by the posterior surface of the pons, and in the lower part by the posterior surface of the ventral part of the upper portion of the medulla oblongata. It is divided into lateral portions by a *median sulcus* which is deeper below, in the region of the calamus scriptorius, and shallower above. On each side of the median sulcus is the eminentia medialis. In the upper part of the fossa the eminentia medialis occupies practically the whole of each lateral half of the floor; in the upper part of the intermediate portion of the fossa a nodular eminence, the *colliculus facialis*, appears on its surface; below the colliculus it narrows rapidly, and it terminates, below, in a pointed triangular process called the *trigonum hypoglossi*. The medial eminence is bounded laterally by a sulcus, the *sulcus limitans*. In the upper region, along the lateral border of the sulcus limitans, is a narrow bluish tinted area called the *locus cæruleus*; the colour of this area is due to a subjacent collection of pigmented cells which constitute the *substantia*

ferruginea. Opposite the colliculus facialis the sulcus limitans expands into a shallow fossa, the *superior fovea*. The lower end of the sulcus limitans terminates, in the upper part of the inferior section of the rhomboidal fossa, in a definite depression, the *inferior fovea*. To the lateral side of the superior and inferior foveæ and the intermediate part of the sulcus limitans is the *area acustica*, which is prolonged laterally into the lateral recess where, in rare cases, a projection, the *tuberculum acusticum*, appears on its surface. Below the inferior fovea, between the trigonum hypoglossi medially and the area acustica laterally, lies a depressed, grey-coloured, triangular area called the *ala cinerea*, which is separated from the lower part of the floor, the *area postrema*, by a raised bundle, the *funiculus separans*. Immediately above the inferior fovea a number of ridges, the *medullary striæ* (O.T. *striæ acusticæ*), cross the floor of the fossa. Laterally they cross the restiform body, at the lateral border of the fossa, and become continuous with the cochlear root of the acoustic nerve; and medially they disappear into the median sulcus.

The *roof of the fourth ventricle* is formed, in the upper area, by the medial parts of the brachia conjunctiva and the intervening anterior medullary velum. Descending upon the latter, from above, is the frenulum veli; and issuing from it, in the same region, are the rootlets of the trochlear nerves. The lower part of the upper portion of the roof is covered by the lingula of the cerebellum. The roof of the intermediate section of the ventricle is the white matter of the vermis of the cerebellum, and the roof of the lower part is epithelial ependyma and the obex.

The *tela chorioidea of the fourth ventricle* is the layer of pia mater which covers and strengthens the epithelial roof of the lower part of the cavity. Between it and the epithelium at the lower end of the roof, is a thin layer of grey matter, called the *obex*. Above, at the posterior medullary velum, the tela becomes continuous with the pia mater on the lower surface of the vermis of the cerebellum. Laterally the tela is prolonged, on each side, posterior to the restiform body, over the lateral recess, and it forms the stronger part of the wall of that expansion. Between the medial part of the tela chorioidea of the fourth ventricle and the pia mater on the lower surface of the vermis of the cerebellum lies the cisterna cerebello-medullaris (O.T. cisterna magna).

Apertures in the Tela Chorioidea of the Fourth Ventricle.—In the early stages of development the tela chorioidea and ependyma form an unbroken layer, but at a later period they are perforated by three apertures. One of the apertures, the *apertura medialis ventriculi quarti* (O.T. *foramen of Magendie*), lies immediately above the obex, at the lower angle of the ventricle, and through it the cavity of the fourth ventricle communicates with the cerebello-medullary portion of the subarachnoid space. The other two apertures lie at the apices of the lateral recesses, immediately posterior to the fila of the glossopharyngeal nerves.

Chorioid Plexuses of the Fourth Ventricle.—The chorioid plexuses are vascular invaginations of the ependyma beneath the tela chorioidea. In the lower part of the ventricle they form two parallel bands, one on each side of the median plane, and their lower ends project through the medial aperture. At the upper part of the tela chorioidea they communicate together, and then each passes laterally into the corresponding lateral recess and their lateral extremities project through the lateral apertures.

Dissection.—The dissector should now introduce his fingers into the great horizontal sulcus of that half of the cerebellum which is still connected with the medulla oblongata and the pons, and tear the upper part of this side of the organ away from the lower part. By this proceeding in the manner in which the peduncles enter the white medullary centre, and also to some extent the general distribution of their fibres, will be seen.

When these have been demonstrated this half of the cerebellum should also be separated by cutting through the peduncles at the points where they enter the central white matter. A horizontal section may then be made through the other half of the organ, rather nearer its upper surface than its lower surface. This will reveal the nucleus dentatus.

Nucleus Dentatus of the Cerebellum.—This is a collection of grey matter, embedded in the white medullary centre of the lateral hemisphere of the cerebellum. It presents an appearance very similar to a nucleus which lies in the olive of the medulla oblongata. It is a thin lamina of grey matter, which appears on section as a wavy line folded upon itself, so as to form a crumpled grey capsule with a mouth open towards the median plane. The greater number of the fibres which build up the brachium conjunctivum issue from its mouth.

There are other smaller isolated nuclei of grey matter in the white medullary centre of the cerebellum, but these cannot, as a rule, be

demonstrated in a specimen obtained in the dissecting-room. They lie nearer the median plane.

Dissection.—A series of transverse sections should now be made through the pons and the medulla oblongata, in order that something of their internal structure may be learned.

As a matter of fact little of the structure of the medulla oblongata can be learnt from specimens obtained in the dissecting-room; but in sections properly prepared and stained a number of important points can be seen.

Structure of the Medulla Oblongata.—When transverse sections are made through the medulla oblongata at different levels, a faint line, called the median raphe and occupying the median plane, is seen to divide it

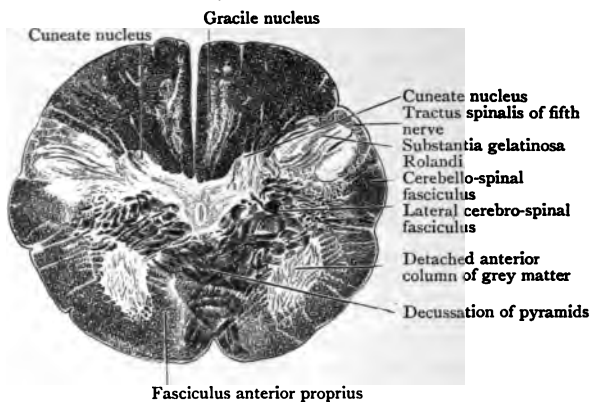


FIG. 226.—Section through the lower part of the Medulla Oblongata of the Orang.

into two exactly similar lateral portions. The raphe is formed by the close intersection of fibres running in different directions.

Each half of the medulla oblongata is composed of (*a*) strands of white matter; (*b*) grey matter, which is present both in the form of direct continuations into the medulla oblongata of portions of the grey matter of the spinal medulla, and in the form of isolated clumps, which are not represented in the spinal medulla; and (*c*) the formatio reticularis, a substance which is composed of grey matter coarsely broken up by fibres which traverse it in different directions. The white matter, as in the spinal medulla, is disposed for the most part on the surface and the grey matter in the interior, but in the open part of the medulla oblongata the grey matter comes to the surface on its dorsal aspect, and forms the obex (p. 538).

When the grey matter of the spinal medulla is traced up into the medulla oblongata, many striking changes in its arrangement become apparent. Owing to the increase in size of the large wedge-shaped gracile and cuneate funiculi, the posterior columns of grey matter become pressed laterally, so that they soon assume a position at right angles to the median plane, and lie very nearly in the same transverse line. At the same time, the cuneate

STRUCTURE OF MEDULLA OBLONGATA 541

and gracile nuclear columns of grey matter which grow out from the basal portion of the posterior column and underlie the strands of the same name,

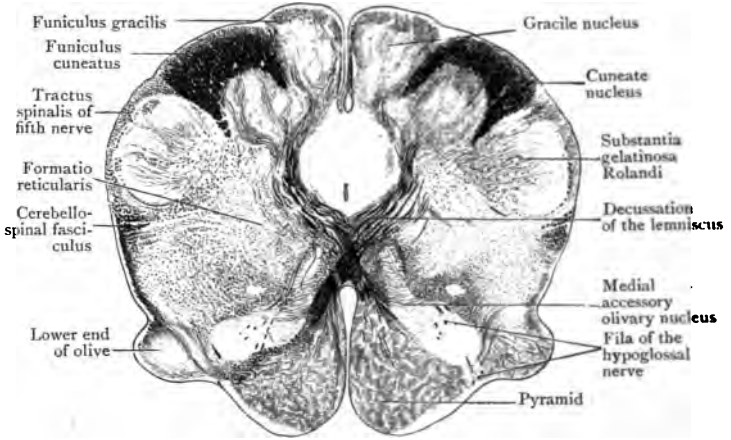


FIG. 227.—Transverse section through the lower part of the Medulla Oblongata of a full-time Fœtus above the Decussation of the Pyramids, treated by the Weigert-Pal method. The grey matter is white, and the medullated strands of nerve fibres are black.

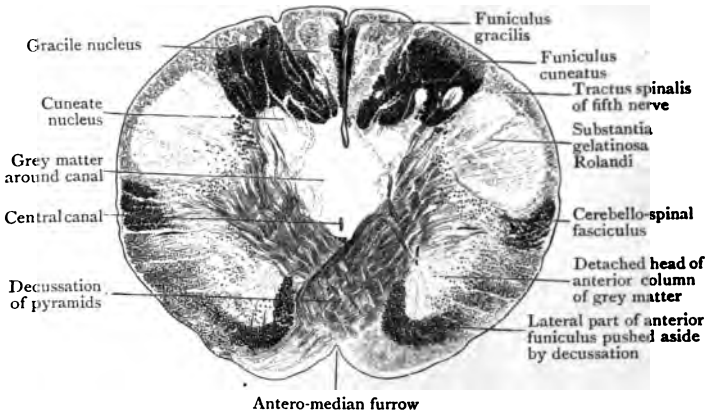


FIG. 228.—Transverse section through lower end of the Medulla Oblongata of a full-time Fœtus, treated by the Weigert-Pal method. The grey matter is therefore bleached white; whilst the medullated tracts are black.

begin to make their appearance. From the deep aspect of these nuclei, fibres, which take origin within them, stream antero-medially through the

neck of the posterior column, so as to reach the raphe. The caput columnæ is in this way cut off from the basal portion. The basal portion remains in close relation to the central canal, whilst the caput and substantia gelatinosa (Rolando) is placed close to the surface, enlarges as it is traced upwards, and forms the prominence on the surface which has been described already as the funiculus and tubercle of Rolando. The fibres which have thus broken up the neck of the posterior column, and which come from the cuneate and gracile nuclei, are termed the *internal arcuate fibres*. They reach the raphe on the deep or dorsal aspect of the pyramids, and, in the median plane, they form a very complete decussation with the corresponding fibres of the opposite side. This decussation is termed the *decussation of the lemniscus* or the *sensory decussation*. As soon as they reach the opposite side of the medulla oblongata, the *internal arcuate*

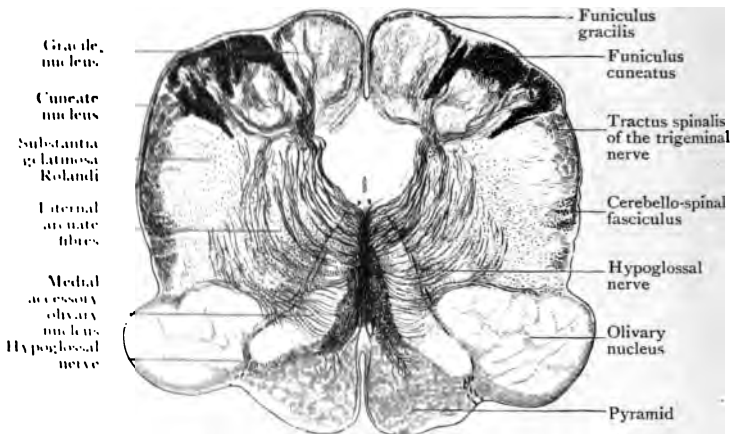


FIG. 550. Transverse section through the Medulla Oblongata of new-born Child at the level of the lower part of the olive, stained by the Weigert-Pal method.

fibres turn upwards and form a longitudinal tract called the *lemniscus*. It is placed close to the raphe and on the dorsal aspect of the corresponding pyramid.

The anterior column of grey matter shares a like fate in the medulla oblongata, but at a lower level, at the hands of the fasciculus cerebro-spinalis lateralis (O.T. crossed pyramidal tract). This great bundle, in passing from the pyramid into the lateral funiculus of the opposite side of the spinal medulla, traverses the anterior column, completely breaks up its intermediate part and separates its head from its basal portion. The further history of the detached head need not be traced, but it is well to note that the basal part of the anterior column of grey matter remains in position on the ventral and lateral aspect of the central canal.

At a higher level the central canal, surrounded by the basal portions of the two columns of grey matter, gradually inclines towards the dorsal aspect, until it reaches the surface. The grey matter which surrounds it is now spread out on the floor of the fourth ventricle, and in such a manner that

STRUCTURE OF MEDULLA OBLONGATA 543

the portion which corresponds to the basal part of the anterior column of the spinal medulla is situated close to the median plane, whilst the part which represents the base of the posterior column occupies a more lateral position. Therefore the nucleus of origin of the hypoglossal nerve is placed in the median part of the floor, whilst the nucleus of termination of the vagus and glosso-pharyngeal nerves lies in the lateral part of the floor.

The most conspicuous of the isolated clumps of grey matter in the medulla are the olivary nucleus and the two accessory olivary nuclei. The *olivary nucleus* lies subjacent to the olivary eminence, and is a very conspicuous object in transverse sections through this region. In such sections, it presents the appearance of a thick wavy or undulating line of grey matter, folded upon itself so as to enclose a space filled with white matter and open

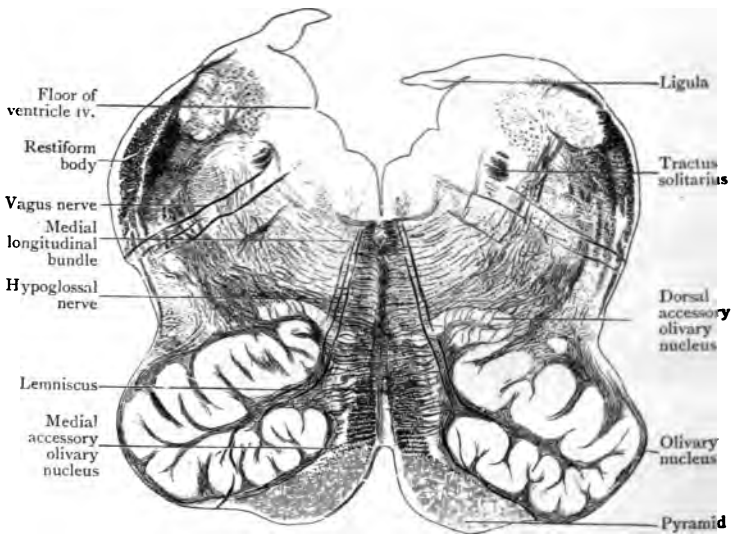


FIG. 230.—Transverse section through the Medulla Oblongata at the level of the mid-point of the olive (Weigert-Pal stain).

towards the median plane. It is in reality a lamina arranged in a purse-like manner with its open mouth directed towards the raphe.

The *accessory olivary nuclei* are two band-like laminae of grey matter, which are placed one on the dorsal and one on the medial aspects of the main nucleus.

Posterior to, or deeper than, the olive and pyramid is the *formatio reticularis* of the medulla oblongata. It is divided into a lateral and a medial field by the fila of the hypoglossal nerve as they traverse the substance of the medulla oblongata to reach the surface. In the lateral portion, which lies posterior to the olive, there is a considerable quantity of grey matter, continuous with that of the spinal medulla; it is therefore called the *formatio grisea*. In the medial part, however, which lies posterior to the pyramid, the grey matter is extremely scanty, and the reticular matter here is termed the *formatio alba*.

The nerve fibres which traverse the *formatio reticularis* run both in the transverse and in the longitudinal direction. The *transverse fibres* are the *internal arcuate fibres*. The *longitudinal fibres* are derived from different sources in the two fields. In the lateral part of the formation they represent the fibres of the lateral funiculus (after the removal of the cerebello-spinal and the lateral cerebro-spinal fasciculi), which are continued up under cover of the olive. In the medial part, or *formatio alba*, two longitudinal strands take origin, viz., the *lemniscus* and the *median longitudinal fasciculus*. Both lie close to the raphe. The *lemniscus* is placed immediately posterior to the pyramid, and is formed by the internal arcuate fibres after their decussation. The *median longitudinal fasciculus* takes form in the upper part of the medulla oblongata, immediately subjacent to the grey matter

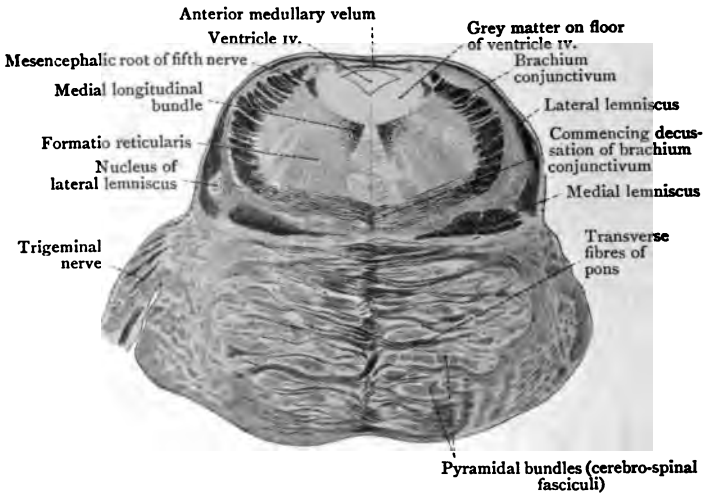


FIG. 231.—Transverse section through the upper part of the Pons of the Orang.

of the floor of the fourth ventricle. It is formed by longitudinal fibres of the *formatio alba* which come from the *fasciculus anterior proprius* of the spinal medulla.

Internal Structure of the Pons.—When transverse sections are made through the pons, it is seen to consist of two well-defined parts, viz., a ventral and a dorsal. Broadly speaking, the *ventral part*, *pars basalis*, corresponds to the pyramidal parts of the medulla, and the basal parts of the *pedunculi cerebri*; whilst the *dorsal part* corresponds to the *formatio reticularis* of the medulla oblongata and the tegmental parts of the *pedunculi cerebri*.

The *basal part of the pons* is the larger of the two subdivisions. It is composed of a large number of transverse bundles of fibres, through the midst of which coarse longitudinal bundles of fibres proceed downwards from the bases of the *pedunculi cerebri* to form, in the medulla oblongata, the two pyramids. Scattered amongst these transverse and longitudinal bundles of fibres, and filling up the interstices between them,

there is a large amount of grey matter which forms the *nuclei pontis*. Of the transverse fibres two distinct sets may be recognised, viz., the superficial transverse fibres, through the midst of which the bundles of cerebro-spinal fibres are prolonged, and a deeper set termed the *corpus trapezoidum*. The *superficial transverse fibres* traverse the entire thickness of the ventral part of the pons, and on each side, pass into the corresponding brachium pontis. The *trapezoid fibres* lie posterior to the cerebro-spinal bundles in the boundary area between the dorsal and ventral parts of the pons, but encroaching considerably into the ground of the former. They are seen only in the lower part of the pons, and they pass into the lateral lemniscus. They take origin in the terminal nucleus of the cochlear division of the acoustic nerve.

The *dorsal or tegmental part of the pons* is, for the most part, formed of a prolongation upwards of the formatio reticularis of the medulla. Superiorly it is carried into the tegmental parts of the pedunculi cerebri. It is divided into two lateral parts by a median raphe, which is continuous below with the raphe of the medulla oblongata and above with the raphe of the tegmental part of the mesencephalon, whilst over its dorsal surface is spread a thick layer of grey matter which belongs to the upper part of the floor of the fourth ventricle. In transverse sections through the pons a dark spot in the lateral part of the floor indicates the position of a small mass of pigmented cells called the *substantia ferruginea*. It underlies the locus cœruleus.

Four strands of longitudinal fibres are seen on each side in transverse sections through the dorsal part of the pons. These are (1) the medial lemniscus, (2) the lateral lemniscus, (3) the medial longitudinal bundle, and (4) the brachium conjunctivum.

The *medial lemniscus* assumes in the pons a ribbon-shaped form. It is placed between the ventral part of the pons and the formatio reticularis of the dorsal part.

The *lateral lemniscus*, largely composed of fibres derived directly or indirectly from the corpus trapezoidum, is seen in the upper part of the pons. It sweeps round the lateral side of the brachium conjunctivum to gain the surface.

The *medial longitudinal bundle* is much more distinct than it is lower down in the medulla oblongata. It has separated itself more completely from the longitudinal fibres of the formatio reticularis, and it is now seen, close to the median plane, immediately subjacent to the grey matter of the floor of the fourth ventricle.

The *brachium conjunctivum*, in transverse sections, presents a semi-lunar outline. It occupies a lateral position in the dorsal part of the pons, and gradually sinks deeply into its substance, although it does not become completely submerged until it reaches the mesencephalon.

The *superior olive* is a small isolated clump of grey matter which is embedded in the dorsal part of the pons in the path of the corpus trapezoidum.

THE AUDITORY APPARATUS.

THE organ of hearing admits of a very natural subdivision into three parts, viz., the external, the middle, and the internal ear. The *external ear* consists of the auricle and the external acoustic meatus. The auricle collects the waves of sound, and is, comparatively speaking, of subsidiary importance in man, although it is highly developed and of considerable service in some of the lower animals. The external acoustic meatus is a passage leading inwards from the bottom of the concha to the membrana tympani, which separates the external from the middle ear. The *middle ear* is a narrow chamber termed the *tympanic cavity*. It is interposed between the external acoustic passage and the internal ear or labyrinth, and the main part of its lateral wall is formed by the membrana tympani. Stretching across the cavity of the tympanum, from its lateral to its medial wall, there is a chain of three small bones, called the auditory ossicles. The *internal ear* or labyrinth is a most essential part of the organ. It consists of a complicated system of cavities situated in the densest part of the petrous portion of the temporal bone. These cavities contain fluid called perilymph, and also a membranous counterpart of the bony chambers, called the membranous labyrinth. Within the latter there is fluid termed endolymph.

Dissection.—The dissection of the ear should be conducted differently on opposite sides.

On one side remove the lateral pterygoid lamina and the remains of the external and internal pterygoid muscles, if that has not been done already. Then clear away the tensor palati muscle and expose the lateral surface of the auditory tube. Dissect on the postero-medial aspect of the tube and expose the levator palati muscle from the lateral side. Follow the muscle downwards and medially, below the lower orifice of the tube, into the soft palate. Then detach the auditory tube from the posterior border of the medial pterygoid lamina; cut the levator palati, at the point where it enters the soft palate, and separate the cartilaginous part of the auditory tube from any parts of the wall of the pharynx which may still be connected with it. When this has been done turn to the temporal bone; place the saw at right angles to the external surface of the squamous part and saw through the bone, along the line of the petro-tympanic fissure, to the posterior border of the spine of the sphenoid. Turn next to the medial surface and saw through the body of the sphenoid at the level of the anterior boundary of the foramen lacerum; then, with the aid of the chisel and bone forceps, detach the posterior border of the great wing of the sphenoid from

the anterior angle of the petrous part of the temporal bone. When the dissection is properly done the greater part of the temporal bone is removed from the remainder of the skull, with the cartilaginous part of the auditory tube attached to the anterior angle of its petrous portion, and a small part of the body of the sphenoid bone attached to its apex. The anterior wall of the mandibular fossa was separated by the first saw cut, and the posterior wall is exposed, with the cartilaginous part of the auditory tube attached to its medial end and the cartilaginous part of the external acoustic meatus to its lateral border. The dissector should now cut away the tragus of the auricle, to expose the orifice of the external meatus which lies at the bottom of the concha; then, with knife or scissors, he must remove the anterior

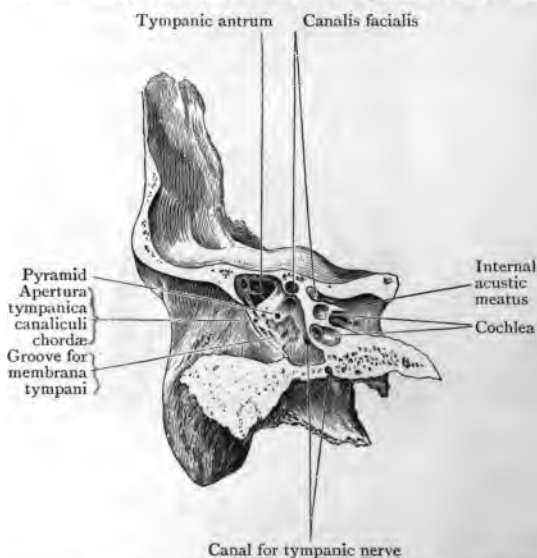


FIG. 232.—Frontal section of the Right Temporal Bone passing through the external and the internal acoustic meatuses.

wall of the cartilaginous part of the external meatus. Next pass a probe into the bony part of the meatus to gauge its length, and, whilst the probe is kept in position as a guide, cut away the anterior wall of the bony part of the meatus, taking care not to injure the tympanic membrane which closes the medial end of the meatus. When the dissection is completed the boundaries of the meatus and the outer surface of the tympanic membrane should be examined.

Meatus Acusticus Externus.—The external acoustic meatus runs anteriorly and medially from its lateral orifice to its medial boundary, and, during its course, it forms a slight curve with the convexity upwards. Its total length, measured from the bottom of the concha to the tympanic membrane, is about

2.4 mm., of which 8 mm. corresponds with the cartilaginous, and 16 mm., with the bony part of the canal; but, as the membrana tympani is placed obliquely, the anterior wall and the floor are longer than the posterior wall and the roof, respectively. Moreover, the diameter of the canal is not uniform. It is narrowest at the isthmus, which lies about 5 mm. from the tympanic membrane; and its vertical diameter is greatest at the lateral end, whilst its antero-posterior diameter is greatest at its medial end. These facts must be borne in mind during the removal of foreign bodies which have made their way into the canal. As the tube passes from

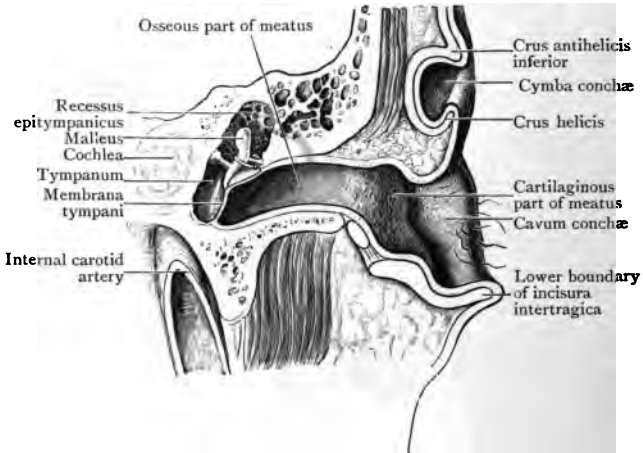


FIG. 233.—Vertical transverse section through the Right Ear : anterior half of section viewed from behind. (Howden.)

the surface medially it describes a gentle sigmoid curve, but its general direction is towards the median plane with a slight inclination anteriorly. The skin lining the cartilaginous portion is abundantly furnished with ceruminous glands and is provided also with laterally directed hairs, which tend to prevent the entrance of dust. The cutaneous lining of the osseous part, which is thin and tightly adherent to the subjacent periosteum, is destitute of hairs, and glands are for the most part absent. The cutaneous lining of the meatus is continued in the form of an exceedingly delicate layer over the outer surface of the membrana tympani.

When the direction, the length, and the diameters of the external meatus have been noted, the dissectors should examine the lateral surface of the tympanic membrane.

Membrana Tympani.—The slope of the tympanic membrane has already been referred to. It slopes very obliquely downwards, anteriorly and medially, and it is deeply concave externally. The deepest point of the concavity is the *umbo*, which corresponds with the lower end of a bar of bone, *the handle of the malleus*, which is embedded in the membrane and can be seen through the thin layer of tissue covering it. The handle of the malleus extends upwards, and slightly posteriorly, from the umbo towards the roof of the meatus; and a short distance from the upper margin of the membrane it becomes continuous with a small laterally directed process, *the lateral process of the malleus*, which bulges the membrane towards the meatus. Above the lateral process of the malleus is a portion of the membrane which is less tense than the remainder. This is the *membrana flaccida* (Shrapnell's membrane). It is bounded anteriorly and posteriorly by relatively thickened folds, the *anterior* and *posterior tympano-malleolar folds*. The whole of the peripheral margin of the membrane, except that which corresponds with the *membrana flaccida*, is lodged in a ring-like sulcus of bone, the *annulus tympanicus*, which is formed by the tympanic element of the temporal bone.

Dissection.—After the examination of the external meatus is completed the dissector must secure the tensor tympani muscle, which springs from the anterior aspect of the petrous part of the temporal bone, close to the apex and above the level of the cartilaginous part of the auditory tube. Having secured it, he must trace it laterally, above the auditory tube, to the point where it passes into the bony canal through which it enters the tympanum. Then he must cut away the antero-lateral wall of the cartilaginous part of the auditory tube, from the pharyngeal orifice to the upper extremity, and pass a probe through the bony part of the tube into the tympanum. He should next turn to the anterior surface of the petrous part of the temporal bone and, with chisel and bone forceps, carefully remove the tegmen tympani and expose the tympanic cavity from above. The dissection must be carried anteriorly into the auditory tube and posteriorly into the tympanic antrum. As the dissection is carried anteriorly a narrow margin of bone must be left along the anterior border of the tympanic membrane, and care must be taken to avoid injury to the tendon of the tensor tympani, which emerges from the extremity of its bony canal, near the medial wall of the tympanum, and crosses the cavity to be inserted into the malleus. The chorda tympani nerve, which passes anteriorly, close to the tympanic membrane and above the tendon of the tensor tympani, must also be preserved if possible.

Tympanic Cavity or Middle Ear.—The tympanic cavity is a small chamber, filled with air, which is placed between the bottom of the meatus externus and the internal ear or labyrinth. Posteriorly it communicates, by a relatively large orifice, with the tympanic antrum and mastoid air-cells; whilst anteriorly the auditory tube opens into it and puts it into connection with the cavity of the pharynx. It contains the chain of auditory ossicles which crosses from its lateral to its medial wall, and it is lined with delicate mucous membrane.

The vertical depth and the antero-posterior length of the tympanic cavity are each about half an inch (12.5 mm.).

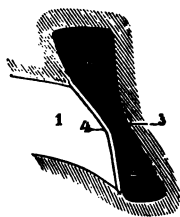


FIG. 234.—Schematic vertical section through the Tympanum. (From Testut.)

1. External meatus.
2. Tympanic cavity (the upper "2" is in the recessus epitympanicus).
3. Promontory on medial wall.
4. Membrana tympani.

Its width, from side to side, is about a sixth of an inch (4.5 mm.); and, as both its lateral and medial walls bulge into the cavity, its width in the centre is still further reduced.

The tympanic cavity consists of (1) an upper part, which extends upwards beyond the level of the membrana tympani, and to which the term *recessus epitympanicus* is applied; and (2) the *tympanum proper*, which lies immediately to the inner side of the membrana tympani.

The tympanic cavity presents for examination a roof and a floor, with four walls, viz., anterior, posterior, lateral, and medial.

The *roof* is composed of a thin plate of bone termed the *tegmen tympani*. This separates it from the middle fossa of the cranium. In chronic inflammatory conditions of the middle ear, an extension of the inflammatory process to the meninges of the brain is always to be feared.

The *floor* or *jugular wall* is narrow, and is also formed by a thin osseous lamina, which is interposed between the tympanum and the jugular fossa. It separates the tympanum from the bulb of the internal jugular vein, and an extension of an inflammatory condition of the middle ear, through the bone to the vein, may lead to thrombosis.

The *posterior* or *mastoid wall* presents, in its upper part, the opening or *aditus* which leads from the recessus epi-

tympanicus into the tympanic antrum, and below this, close to the medial wall, is a small hollow conical projection termed *the pyramid*. This is perforated, on its summit, and the aperture leads into a canal which curves posteriorly and then downwards until it opens into the lower part of the last stage of the canalis facialis. The curved canal of the pyramid lodges the stapedius muscle, the delicate tendon of which enters the tympanic cavity through the aperture on the summit of the pyramid. Lateral to the pyramid is the aper-

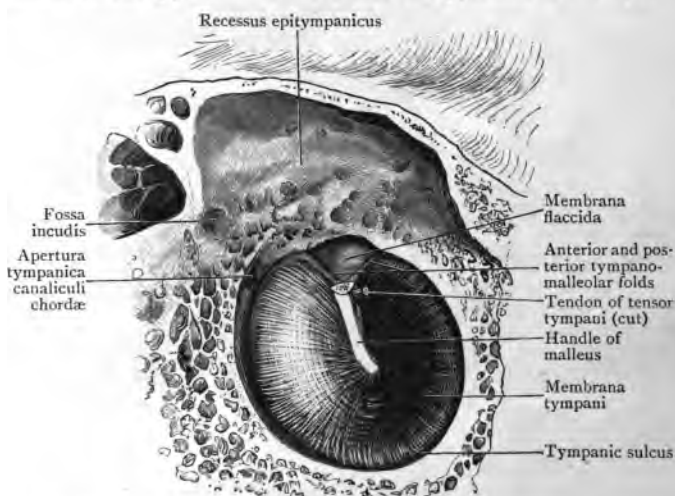


FIG. 235.—Left Membrana Tympani and Recessus Epitympanicus viewed from within. The neck and head of the malleus have been removed to show the membrana flaccida. (Howden.)

ture on the posterior wall called the *apertura tympanica canaliculi chordae* through which the chorda tympani nerve enters the tympanum.

The *anterior wall* is narrow, because the medial and lateral walls converge anteriorly. The upper part of this wall is occupied by the opening of the tensor tympani canal; the intermediate part by the tympanic orifice of the auditory tube; and the lowest part is a lamina of bone which separates the tympanic cavity from the carotid canal. The tympanic end of the septum between the auditory tube and the tensor tympani canal, the *processus cochleariformis*, serves as a pulley

round which the tendon of the muscle turns abruptly, in a lateral direction, towards the malleus.

The *medial wall*, which intervenes between the tympanum and the labyrinth, presents certain important points for study. The greater part of this wall bulges laterally, into the cavity, in the form of a very evident elevation termed the *promontory*. Above the posterior part of the promontory there is an oval foramen, the *fenestra vestibuli*. Its long axis is directed antero-posteriorly, and it opens into the vestibular part of

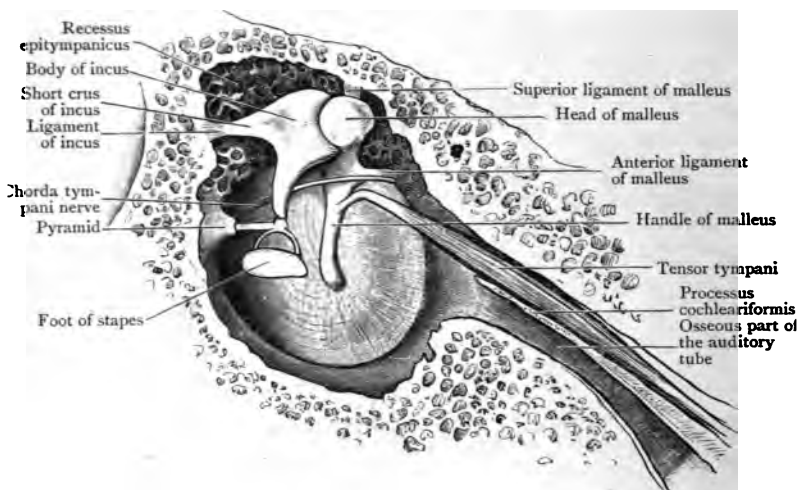


FIG. 236.—Left Membrana Tympani and Chain of Tympanic Ossicles seen from the inner aspect. (Howden.)

the labyrinth in the macerated bone, but is closed in the recent state by the footpiece of the stapes, the most medial of the auditory ossicles. The pyramid, on the posterior wall, is immediately posterior to the fenestra vestibuli. Above the fenestra vestibuli, in the angle formed by the meeting of the roof and medial wall of the tympanum, and therefore in the recessus epitympanicus, is an antero-posterior ridge. This is produced by the canalis facialis bulging into the tympanum. The wall of the canal is very thin, and allows the white colour of the facial nerve, which is contained within the canal, to be readily seen. The posterior end of the promontory is the aperture

which, in the macerated bone, leads into the cavity of the cochlea, but, in the recent state, it is closed by a membrane which is stretched across it, and receives the name of the secondary membrane of the tympanum.

The lateral wall of the tympanic cavity is formed by the membrana tympani and the squamous part of the temporal bone.

Membrana Tympani.—The membrana tympani is an elliptical disc of membrane which is stretched across the medial end of the meatus acusticus externus, and it forms the greater part of the lateral wall of the tympanum. It is placed very obliquely; its lower and its anterior borders both inclining medially.



FIG. 237.—Left Tympanic Membrane as viewed from the external meatus during an otoscopic examination. The dotted lines indicate the manner in which the tympanic membrane is subdivided arbitrarily into four areas or quadrants. (Howden.)

Its mode of attachment deserves some attention. At the medial end of the meatus a ring-like ridge of bone, very distinctly grooved, forms, as it were, a frame in which the membrane is set. But this ridge is deficient above, where the extremities of the bony ridge are separated by a deep notch (the notch of Rivinus). This notch is occupied by a portion of the membrane which is not so dense in its texture (seeing that the fibrous layer is absent), and not so tightly stretched as the remainder; consequently it receives the name of the membrana flaccida (Shrapnell's membrane). The edge of that part of the membrane which is fixed in the circular bony groove, sulcus tympanicus, is thickened, and at the notch of Rivinus it is carried down, anterior and posterior to the

membrana flaccida, in the form of two bands, called respectively the *anterior* and *posterior tympano-malleolar folds*.

The membrana tympani is composed of three layers—viz., an external cuticular layer, an intermediate fibrous lamina, and an internal mucous layer. The handle of the malleus is intimately connected with the fibrous layer, and is covered medially by the mucous layer. It draws the membrane towards the tympanic cavity, and is the cause of the concavity on the outer surface. The deepest point of this concavity

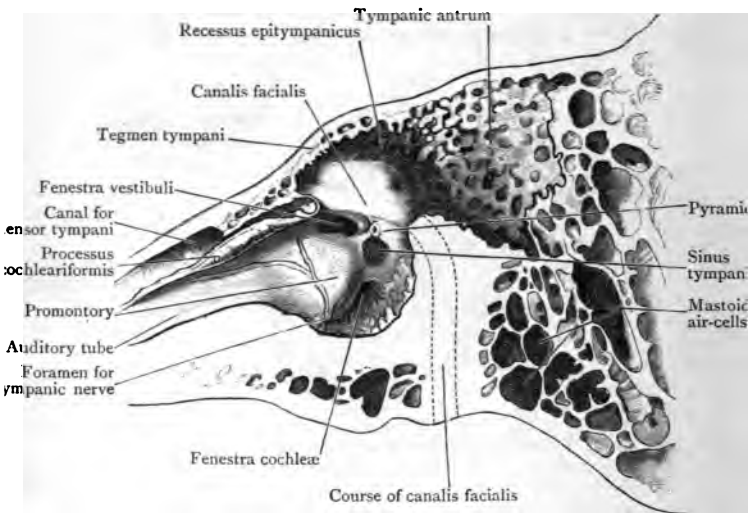


FIG. 238.—Vertical section through the Left Ear : postero-medial half of section viewed from the front. (Howden.)

corresponds with the flattened extremity of the handle of the malleus, and is termed the *umbo*.

In examining the living ear, with a speculum, the surface of the membrana appears highly polished, and a cone of light extends downwards and forwards from the tip of the handle of the malleus. A pair of *striæ* (Prussak's *striæ*), which correspond to the anterior and posterior tympano-malleolar folds, extend from the processus lateralis of the malleus to the margins of the notch of Rivinus, and thus map out the membrana flaccida. The long crus of the incus can be faintly seen through the membrana tympani, parallel with and posterior to the handle of the malleus.

Antrum Tympanicum.—The *antrum* is a recess or air-chamber, in the petrous parietal bone, with a

diameter of about one-third of an inch. It is placed posterior to the tympanum, and communicates by a relatively large opening, *the aditus*, with the upper part of that cavity. It lies at a depth of about half an inch from the surface of the skull in the adult, but in the child it is placed much more superficially. It is lined with mucous membrane, which is continuous with the lining membrane of the tympanum. The mastoid portion of the temporal bone also is occupied by air-spaces, *the air-cells*, which may extend downwards into the mastoid process. They are continuous with one another and with the tympanic antrum, and are lined by a continuation of the same mucous membrane.

Tympanic Mucous Membrane.

—The tympanum is lined throughout with a thin mucous membrane which is continuous with the mucous membrane of the pharynx. As already mentioned, it forms the innermost layer of the *membrana tympani*, and it is prolonged posteriorly into the tympanic antrum and mastoid air-cells. It covers the ossicles also, and it invests the tendons of the stapedius and tensor tympani muscles.

Ossicula Auditus.—The auditory ossicles are the malleus, the incus, and the stapes.

The *malleus* presents a head, a neck, a manubrium, and two processes termed the *processus lateralis* and the *processus anterior*. The *head* is large and rounded. It is directed upwards, and lies above the level of the *membrana tympani*, in the *recessus epitympanicus*, close to the roof of the tympanum. On its posterior aspect there is a notch-like articular surface, for articulation with the body of the incus. The *manubrium* is attached to the fibrous layer of the *membrana tympani*. The *processus lateralis* (*O.T. brevis*) is a stunted projection which springs from the root of the manubrium. It is directed laterally, and abuts against the

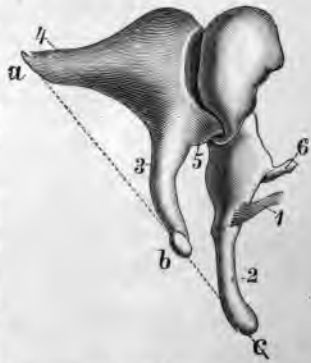


FIG. 239.—Left Malleus and Incus.
(After Helmholtz.)

1. Tendon of tensor tympani.
2. Handle of the malleus.
3. Long crus of the incus.
4. Short crus of the incus.
5. Anterior process of the malleus. The straight line *abc* connects the extremities of the two crura of the incus with the extremity of the manubrium of the malleus.
- 6.

membrana tympani immediately below the membrana flaccida. The *processus anterior* (O.T. *gracilis*) is a slender spicule of bone which passes anteriorly into the petro-tympanic fissure. It almost invariably breaks in detaching the malleus from the

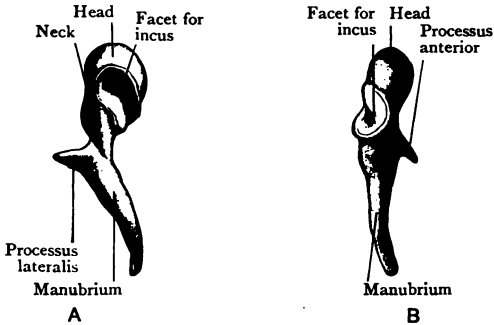


FIG. 240.—The Left Malleus. (Howden.)

A. Posterior aspect.

B. Medial aspect.

adult skull, but it can be easily preserved in the skull of an infant.

The *incus* is shaped somewhat like a præmolar tooth in

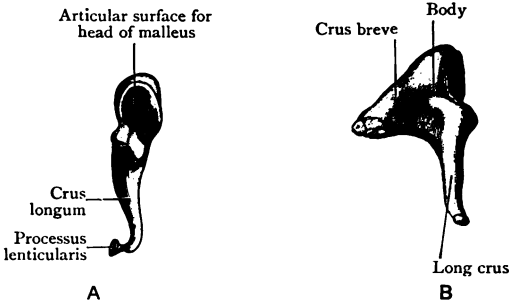


FIG. 241.—The Left Incus. (Howden.)

A. Anterior aspect.

B. Medial aspect.

which the roots are very divergent. It presents a body and a long and a short crus. The *body* with an articular surface, which looks anteric the head of the malleus. The *short cr* lateres with anteriorly,

and its extremity is attached, by ligaments, to the posterior wall of the tympanum, near the opening into the tympanic antrum. The *long crus* proceeds downwards and medially, in a direction nearly parallel to that of the manubrium of the malleus, but more medial, and on a plane posterior to that process. On its inferior extremity, which is bent medially, there is a small knob of bone called the *processus lenticularis*. This articulates with the head of the stapes.

The malleus and incus move together on an axis which is formed by the processus anterior of the malleus and the crus breve of the incus. The articular surfaces of the two bones are provided with peculiar catch-teeth which interlock when the bones are performing their ordinary movements. When, however, force is applied to the inner surface of the membrana tympani, as, for instance, when the tympanum is inflated through the auditory tube, the incudo-malleolar joint gaps and the malleus moves by itself. Traction upon the attachments of the stapes, through the incus, is thus avoided.

The *stapes* is shaped like a stirrup, and presents a head or lateral extremity separated by a slightly constricted *neck* from two crura which join a medial plate, the basis stapedis. The *head* is excavated by an articular cup for the processus lenticularis of the incus. The *crura* are grooved longitudinally on their concave sides (*sulcus stapedis*). The posterior crus is more sharply curved than the anterior crus. The *base* fits into the fenestra vestibuli and corresponds in its outline with that aperture. Its lower border is straight, whilst its upper border is curved.

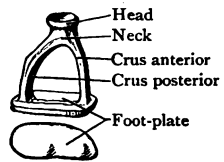


FIG. 242.—Left Stapes.
(Howden.)

Ligaments of the Auditory Ossicles.—In addition to the delicate capsular ligaments, which surround the joints between the auditory ossicles, there are certain bands which connect the bones to the walls of the tympanum and serve to restrain their movements.

In connection with the malleus there are (1) an *anterior ligament* which passes from its anterior part, at the root of the processus anterior, to the anterior wall of the tympanum in the neighbourhood of the petro-tympanic fissure; (2) a *lateral ligament* which extends from its lateral process to the margin of the notch of Rivinus; and (3) a *superior ligament* which connects the head with the roof of the tympanum.

The *ligament of the incus* binds the extremity of its short crus to the posterior wall of the tympanum, whilst the *annular ligament of the stapes* connects the margin of its base to the circumference of the fenestra vestibuli.

Tympanic Muscles.—These are two in number, viz., the stapedius and the tensor tympani.

The *stapedius* occupies the interior of the pyramid and the canal which curves downwards from it. The delicate tendon of the stapedius enters the tympanum, through the aperture on the summit of the pyramid, and is inserted into the posterior aspect of the neck of the stapes. It is supplied by a branch from the *facial nerve*.

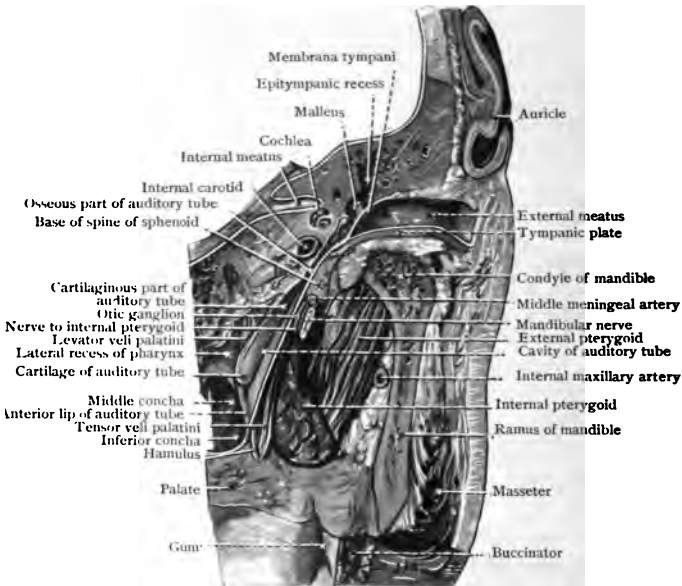


FIG. 243.—Oblique section of a part of the Head showing the relation of the Auditory Tube.

The *tensor tympani* arises from the upper part of the cartilage of the auditory tube and from the contiguous parts of the great wing of the sphenoid and the petrous part of the temporal bone. From its origin it passes postero-laterally, upon the processus cochleariformis and above the osseous part of the auditory tube. In the tympanic cavity the tendon turns at right angles, round the extremity of the processus cochleariformis, and passes towards the lateral wall of the tympanum, to its insertion into the upper

part of the medial surface of the manubrium of the malleus. The tensor tympani receives its nerve of supply from the *otic ganglion*.

Chorda Tympani Nerve.—The chorda tympani, which traverses the tympanic cavity in close relation to the upper part of the membrana tympani, is described on p. 546.

Tympanic Plexus.—This has been described previously on p. 312.

Tuba Auditiva (O.T. Eustachian).—The auditory tube is the passage which places the tympanic cavity in communication with the pharynx. Through it air reaches the tympanic

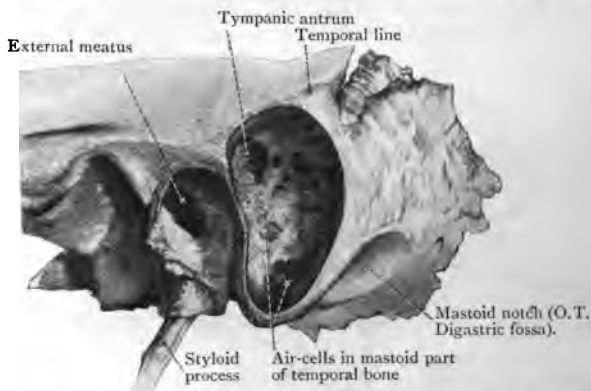


FIG. 244.—Dissection of the Tympanic Antrum and the mastoid part of the temporal bone from the outer side.

cavity and antrum and the mastoid cells. It consists of an osseous and a cartilaginous portion. The *osseous portion* is about half an inch in length. It is widest at its entrance into the tympanum, and narrowest at its other end. The *cartilaginous portion* is about an inch in length, and has been already described on p. 383.

Dissection: Second Method.—On the opposite side the bony part of the external meatus, the tympanic antrum, and the tympanic cavity should be approached from the postero-lateral aspect. The dissection of the bone should be carried out after the manner adopted by the surgeon when operating for the cure of extensive mastoid and middle ear disease, but, to facilitate the dissection, and to gain better access to the bone, the auricle may be removed by cutting through the cartilaginous part of the external meatus.

After the auricle has been cut away clear all the soft parts, including

the periosteum, from the outer surface of the mastoid part of the temporal bone, and identify (1) the supra-meatal triangle and the supra-meatal spine, which lie at the junction of the superior with the posterior border of the bony part of the external meatus, and (2) the temporal line which passes, posteriorly and upwards, above the supra-meatal triangle. The objects of the first stage of the dissection are (1) the removal of the outer compact layer; (2) the opening up of the cancellous tissue of the mastoid part of the temporal bone, and the exposure of the mastoid air-cells and the cavity of the tympanic antrum, whilst, at the same time, injury to the posterior wall of the bony part of the external meatus and to the sigmoid part of the transverse sinus, which lies in a groove on the inner aspect of the posterior part of the mastoid portion of the temporal bone, is avoided. The tympanic antrum lies at the level of the supra-meatal triangle, that is above and posterior to the external meatus, and

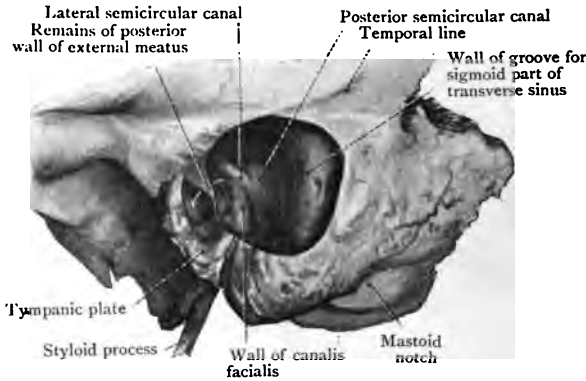


FIG. 245.—Dissection of the Tympanic Antrum and the petro-mastoid part of the temporal bone from the outer side. The arrow is passing through the aditus from the tympanic antrum into the tympanic cavity.

about half an inch from the superficial surface of the temporal bone. The dissection should be commenced above, below the temporal line, and should be carried, anteriorly and medially, into the bone, parallel with the posterior wall of the external meatus, until the tympanic antrum is opened into. After the tympanic antrum has been identified, the cancellous tissue of the anterior part of the mastoid area must be gradually removed till the more medially situated and more compact bone is exposed. When this stage of the dissection is completed, the dissector should note the following points:—(1) In the anterior boundary of the exposed area is the compact posterior wall of the bony part of the external meatus. (2) Posteriorly is a broad projecting ridge indicating the position of the groove which lodges the sigmoid part of the transverse sinus. (3) At the upper and deeper part of the area are the medial wall of the tympanic antrum and the aditus leading into the tympanic cavity. (4) The intermediate area is occupied by the remains of the mastoid air-cells, which may extend down to the tip of the mastoid process. They are continuous above the tip of the the tympanic

antrum. (5) On the medial wall of the aditus and the anterior part of the medial wall of the tympanic antrum is a horizontal ridge which indicates the position of the lateral semicircular canal of the labyrinth, and, below it, on the medial wall of the mouth of the aditus, is a vertical ridge indicating the position of the canalis facialis, which lodges the important facial nerve.

The next stage of the dissection consists in the removal of the posterior wall of the external meatus, and the exposure of the outer surface of the tympanic membrane (p. 549). After the tympanic membrane has been examined, a seeker should be passed through the aditus into the tympanic cavity, and its handle should be allowed to rest on the lower part of the exposed area; then, whilst the seeker remains in position, the remainder of the posterior wall and the upper boundary of the external meatus, from the level of the seeker to the level of the roof of the tympanic antrum, can

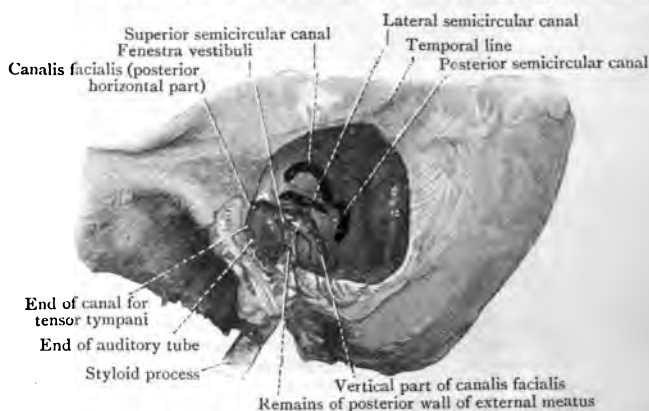


FIG. 246.—Dissection of the Tympanic Cavity and the semicircular canals from the outer side.

be cut away without fear of injury to any important structure. The dissection should be completed by the removal of the tympanic membrane and ossicles, and when this has been done a very complete view will be obtained of the medial walls of the tympanic cavity, the aditus, and the tympanic antrum. Anteriorly, on the medial wall of the tympanic cavity, is the promontory, which marks the position of the first turn of the cochlea. Above and posterior to the promontory is the fenestra vestibuli. The fenestra cochleæ lies at the lower and posterior part of the promontory, in the anterior part of a recess called the fossula fenestræ cochleæ. Above the fenestra vestibuli is a ridge caused by the posterior horizontal part of the canalis facialis; this becomes continuous, on the medial wall of the aditus, with the vertical ridge which indicates the position of the vertical part of the canal. Above the latter is the horizontal ridge due to the lateral semicircular canal. The dissector should open the canalis facialis to expose the facial nerve; then he should open the lateral semicircular canal, and afterwards remove the bone above and posterior to it to expose the walls of the superior and posterior vertical semicircular canals (Figs. 245, 246).

INTRAPETROUS PART OF THE FACIAL NERVE AND THE ACUSTIC NERVE.

The facial and acustic nerves have already been traced into the internal acustic meatus (p. 215). The dissector should now open up this meatus and follow the facial nerve in its course through the petrous portion of the temporal bone. The canal which it occupies is termed the *canalis facialis* (O.T. *aqueduct of Fallopius*). It begins at the bottom of the internal acustic meatus, and opens on the exterior of the skull at the stylo-mastoid foramen. Between its commencement and termination it pursues a complicated course, and this, combined with the density of the bone, renders the dissection very difficult.

Dissection.—On the side on which the middle ear has been opened from the lateral aspect and the canalis facialis has already been partially opened up, the dissector should complete the dissection of the intrapetrous part of the facial nerve and should examine the acustic nerve.

Separate the temporal bone from the other cranial bones which still adhere to it, and fix it in the natural position (in a vice if possible). Remove the squamous portion by a horizontal saw cut at the level of the upper surface of the petrous portion. Make a second horizontal saw cut, immediately above the roof of the internal acustic meatus, and carry it laterally into the tympanum, in which it should emerge immediately above the already opened canalis facialis where the latter lies above the fenestra vestibuli. Then, with the bone forceps or chisel, remove the remains of the roof of the internal meatus and follow the facial nerve along the canalis facialis to the hiatus canalis facialis, and so expose the ganglion geniculi. Secure the branches which arise from the ganglion and then follow the nerve posteriorly above the fenestra vestibuli. The greater part of the vertical portion of the canal has already been opened from the lateral aspect; the remainder can now be displayed by means of two saw cuts—(1) a frontal section (vertical transverse) carried medially from the lateral surface of the bone to the posterior border of the stylo-mastoid foramen; (2) a sagittal cut (vertical antero-posterior) carried from the posterior surface of the bone to meet cut (1). The portion of bone between the two cuts must then be removed, and the dissection must be completed with bone forceps. Three branches are given off in this part of the canal.

Intrapetrous Portion of the Facial Nerve.—As the facial nerve traverses the petrous bone, it may be divided into four stages, which differ from one another in the relations they present and in the direction which they take. They are:—

1. A part within the internal acustic m
 2. A very short part which extends
- of the internal
acustic meatus to the ganglion {

3. A part which occupies that portion of the canalis facialis which runs along the medial wall of the tympanic cavity.
4. A part which extends vertically downwards to the stylo-mastoid foramen.

First Stage.—In the internal acoustic meatus, the facial nerve runs almost directly laterally in company with the acoustic nerve. In this stage of its course it lies in relation to the upper and anterior part of the acoustic nerve, and its motor and sensory roots join. At the bottom of the acoustic meatus it enters the canalis facialis.

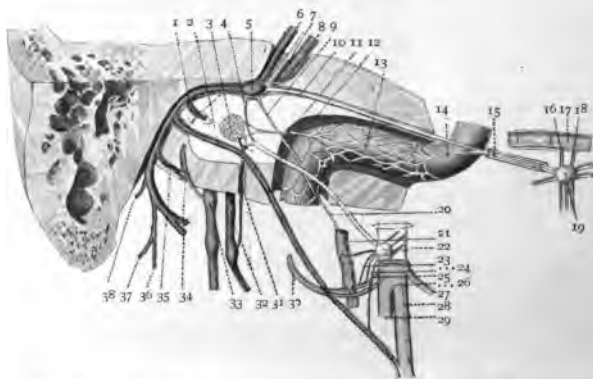


FIG. 247.—Diagram of Intrapetrous part of facial nerve and its connections.
(Prof. A. M. Paterson.)

1. Nerve to stapedius. 2. Chorda tympani. 3. Tympanic plexus. 4. Communication to small superficial petrosal nerve. 5. Ganglion geniculi. 6. Motor part of facial nerve. 7. Sensory part of facial nerve. 8. Acoustic nerve. 9. External petrosal nerve. 10. Great superficial petrosal nerve. 11. Carotid canal. 12. Carotico-tympanic branch. 13. Carotid plexus. 14. Great deep petrosal. 15. Nerve of pterygoid canal. 16 and 18. Spheno-palatine branches. 17. Maxillary nerve. 19. Spheno-palatine ganglion. 20. External petrosal. 21. Middle meningeal artery. 22. Otic ganglion. 23 and 24. Branches to auriculo-temporal nerve. 25. Communication to chorda tympani. 26. Posterior division of mandibular nerve. 27. Anterior division of mandibular nerve. 28. Lingual nerve. 29. Inferior alveolar nerve. 30. Auriculo-temporal nerve. 31. Tympanic branch of glossopharyngeal. 32. Glossopharyngeal nerve. 33. Vagus. 34. Auricular branch of vagus. 35. Communication from facial to auricular branch of vagus. 36. Nerve to digastric (post. belly). 37. Nerve to stylo-hyoid muscle. 38. Posterior auricular nerve.

Second Stage.—The second part of the facial nerve is very short. It runs laterally, with a slight inclination anteriorly, between the vestibule and cochlea, and very soon ends in the swelling termed the *ganglion geniculi*.

Third Stage.—At the ganglion geniculi, the facial nerve bends suddenly and proceeds posteriorly and slightly

downwards in that portion of the canal which runs along the upper part of the medial wall of the tympanic cavity, immediately above the fenestra vestibuli (O.T. ovalis).

The first three portions of the facial nerve are nearly horizontal, and pursue a somewhat V-shaped course. The apex of the V is directed anteriorly, and corresponds to the ganglion geniculi.

The *fourth stage* is vertical, and arches downwards, posterior to the pyramid, to gain the stylo-mastoid foramen.

The *branches* which spring from or join the facial nerve during its passage through the temporal bone are:—

- | | | |
|---|---|-------------------------|
| <ol style="list-style-type: none"> 1. The greater superficial petrosal nerve, 2. Communicating twig to the smaller superficial petrosal, 3. External superficial petrosal nerve, 4. Nerve to stapedius. 5. Chorda tympani. 6. Communicating twigs to the auricular branch of vagus. | } | from ganglion geniculi. |
|---|---|-------------------------|

The *great superficial petrosal nerve* has been examined already (p. 212). Its origin from the ganglion geniculi of the facial can now be seen.

The *communicating branch* to the small superficial petrosal arises from the ganglion geniculi, and unites with the fibres of the tympanic nerve which issue from the tympanic plexus.

The *external petrosal nerve* is not always present. It joins the sympathetic plexus which accompanies the middle meningeal artery.

The *nerve to the stapedius muscle* arises from the facial as it arches downwards posterior to the pyramid. It enters the base of the pyramid and thus reaches the stapedius muscle.

The *communicating twigs to the auricular branch* of the vagus arise a short distance above the stylo-mastoid foramen.

Chorda Tympani.—The chorda tympani represents to a large extent the sensory fibres set free from the trunk of the facial nerve. It is the largest branch given off by the facial during its passage through the *canalis facialis*. It takes origin a short distance above the stylo-mastoid foramen, and arching upwards and anteriorly, in a narrow canal in the petrous portion of the temporal bone (the canaliculus chordæ tympani), it appears in the tympanum by passing through the tympanic aperture of the canaliculus chordæ below the base of the pyramid, and close to the inner margin of

membrana tympani. The bony tunnel which it occupies can easily be opened up in a decalcified bone, but is somewhat difficult to expose in the hard bone. After entering the tympanum the chorda tympani runs anteriorly upon the upper part of the membrana tympani under cover of the mucous layer. It crosses the handle of the malleus on the medial aspect near its root. Finally, reaching the anterior end of the tympanic cavity it crosses the anterior process (O.T. gracilis) of the malleus, passes above the tensor tympani, and traverses the medial end of the petro-tympanic fissure, which conducts it to the exterior of the skull. From this point to its junction with the lingual nerve the chorda tympani has already been traced (p. 278).

Acoustic Nerve.—In the internal acoustic meatus the acoustic nerve lies at a lower level than the facial, and at the bottom of the passage it splits into two parts, termed the *cochlear* and *vestibular divisions*. These trunks again subdivide and supply the different parts of the labyrinth of the ear through the foramina of the lamina cribrosa.

After the examination of the intrapetrous part of the facial nerve and the acoustic nerve is completed the dissector should display the labyrinth of the internal ear by means of two saw cuts—(1) an antero-posterior vertical cut carried from the upper surface of the bone downwards to the floor of the tympanum along the junction of its medial and posterior boundaries; (2) a horizontal cut. This cut should be commenced at the apex of the petrous part of the temporal bone and should be carried laterally till it joins the vertical cut posteriorly, and enters the tympanic cavity anteriorly at the level of the mid-height of the promontory. When the upper part of the petrous portion of the temporal bone, separated by the two cuts, is removed, the vestibular and cochlear parts of the labyrinth and portions of the semicircular canals will be displayed. The dissector should demonstrate the positions and curves of the semicircular canals and the canalis facialis by passing bristles through them.

Auris Interna.—The internal ear or labyrinth consists of an intricate system of cavities in the petrous part of the temporal bone, the *osseous labyrinth*, and a series of hollow membranous structures, connected with the filaments of the acoustic nerve, which lie in the osseous labyrinth and constitute the *membranous labyrinth*.

The *osseous labyrinth* is composed of an intermediate chamber termed the vestibule, posterior to which are placed the three semicircular canals, whilst anteriorly is the cochlea. All these cavities communicate with one another. The corresponding membranous parts do not completely occupy the

osseous chambers, and the intervening space is filled with a fluid termed the *perilymph*. The *membranous labyrinth* also contains a fluid which receives the name of *endolymph*.

Vestibulum.—The vestibule is a small ovoid bony chamber, possessing an antero-posterior diameter of about one-sixth of an inch. It is situated between the medial wall of the tympanum and the bottom of the internal acoustic meatus.

Into the posterior part of the vestibule the three semi-circular canals open by *five round apertures*; whilst in its lower and anterior part is the opening of the *scala vestibuli* of the cochlea.

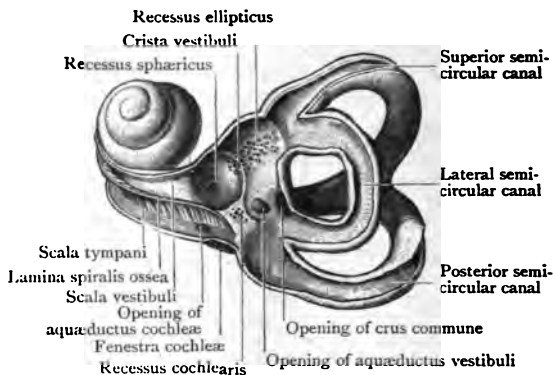


FIG. 248.—Interior of the Left Bony Labyrinth viewed from the lateral aspect. (Howden.)

On the *lateral wall* is the fenestra vestibuli, which is closed, in the recent state, by the delicate periosteal lining of the chamber and the base of the stapes. When these parts are removed, the vestibule communicates directly with the tympanum. On the anterior part of the *medial wall* of the vestibule there is a circular depression, termed the *recessus sphaericus*, which is bounded posteriorly by a vertical ridge, called the *crista vestibuli*. The bottom of the recessus sphaericus is perforated by some minute holes which give admission to filaments from the acoustic nerve. On the *roof* of the vestibule is another depression, named the *recessus ellipticus*. It is placed posterior to the crista vestibuli.

A small aperture placed on the posterior part of the medial wall also deserves mention. It is the mouth of the *aqueductus vestibuli*—a small canal which opens posteriorly to

the posterior surface of the petrous part of the temporal bone, where it opens under the dura mater.

Canales Semicirculares Ossei.—These are three bony canals or tubes placed posterior to the vestibule. They are bent upon themselves, so that each forms considerably more than half a circle, and they occupy planes at right angles to each other like three faces of a cube. They are termed superior, posterior, and lateral, and they open into the posterior part of the vestibule by five round orifices, the number of openings being thus reduced through the adjoining extremities of the superior and posterior canals becoming fused together so as to present a common canal, the *crus commune*, with a single

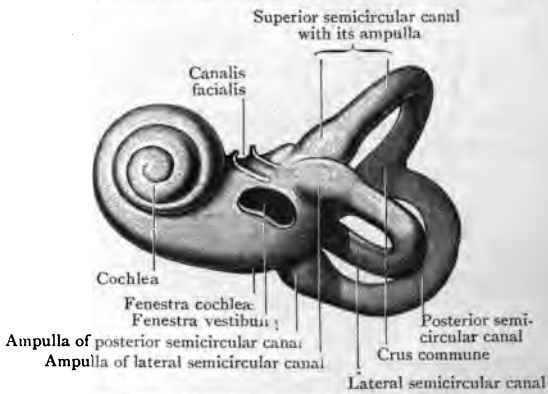


FIG. 249.—Left Bony Labyrinth viewed from lateral side. (Howden.)

orifice. One extremity of each canal where it joins the vestibule becomes expanded into what is termed its *ampulla*. There are thus three ampullated ends.

The *superior semicircular canal* forms the highest part of the labyrinth, and gives rise to a smooth elevation on the anterior surface of the petrous part of the temporal bone, immediately anterior to its superior angle. It is vertical, and placed almost transversely to the long axis of the petrous part of the temporal bone. The *posterior semicircular canal*, which is the longest of the three tubes, is also vertical, and lies in a plane parallel to the posterior surface of the petrous part of the temporal bone. The *lateral semicircular canal* is the shortest of the tubes, and it lies in a horizontal plane.

Cochlea.—The cochlea is a tapering tube which is coiled

spirally for two turns and a half around a central pillar, termed the *modiolus*. The appearance produced is somewhat similar to that of a spiral shell. The cochlea lies anterior to the vestibule, with its base directed towards the bottom of the internal acoustic meatus; whilst its apex is directed antero-laterally, and lies in close relation with the canal for the tensor tympani muscle.

The cochlear tube rapidly diminishes in diameter as it is traced towards the apex of the cochlea, and its closed extremity is termed the *cupola*. The first turn which it takes around the modiolus produces the bulging on the medial wall of the tympanum, which has been described under the name of the promontory.

The *modiolus* is thick at the base, but rapidly tapers towards the apex. Its base abuts against the bottom of the internal acoustic meatus. It forms the inner wall of the cochlear tube, and winding spirally round it, like the thread of a screw, is a thin lamina of bone, termed the *lamina spiralis*, which partially subdivides the tube into two passages.

Numerous minute canals traverse the modiolus, and one more conspicuous than the others, the *longitudinal canal of the modiolus*, extends along its centre. The spiral lamina also is tunnelled by small canals in communication with those in the modiolus, whilst one, the *spiral canal of the modiolus*, winds spirally around the central pillar in the attached margin of the spiral lamina. All these channels convey filaments from the cochlear division of the acoustic nerve to the membranous cochlea, whilst the spiral canal lodges the *ganglion spirale cochleæ*, which is the peripheral ganglion of the cochlear part of the acoustic nerve.

The *membranous cochlear tube* or *ductus cochlearis* is placed between the free margin of the spiral lamina and the opposite side of the wall of the cochlear tube, and completes the subdivision of the bony cochlea into two compartments, which are termed the scala tympani and the scala vestibuli. The *scala tympani* is the larger of the two. It begins at the fenestra cochleæ, where the secondary membrane of the tympanum shuts it off from the tympanic cavity. At the apex of the cochlea it communicates with the scala vestibuli by means of an aperture, termed the *helicotrema*. At the base of the cochlea the *scala vestibuli* communicates with the lower and anterior part of the vestibule. The perilymph therefore, in the semicircular canals and vestibule, is directly continuous with that in the scala vestibuli and scala tympani.

It can now be understood how vibrations of the *membrana tympani* are communicated to the perilymph within the osseous labyrinth. The chain of auditory ossicles through the base of the stapes affects the perilymph in the vestibule. The vibrations of the perilymph passing along the *scala vestibuli* into the *scala tympani* in turn affect the secondary membrane of the tympanum which is stretched across the *fenestra cochleæ*. With every inward movement of the *membrana tympani* and of the base of the stapes, there is an outward movement of the membrane of the *fenestra cochleæ*, and *vice versa*. The vibrations of the perilymph affect the endolymph in the membranous labyrinth, and thus excite the terminations of the acoustic nerve.

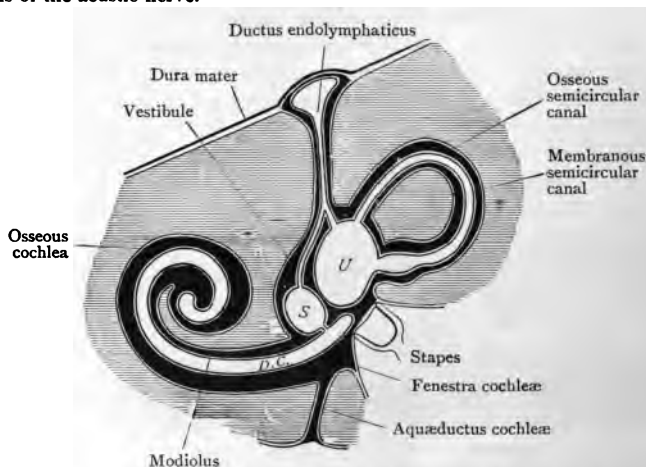


FIG. 250.—Diagram of the Osseous and Membranous Labyrinth.
(Modified from Testut.)

U. Utricle. S. Saccule. D.C. Ductus cochlearis.

Membranous Labyrinth.—In the vestibule there are two membranous sacs, termed the utricle and the saccule. The *utricle* occupies the recessus ellipticus on the wall of the vestibule, and lies above and posterior to the saccule. Into it open the *membranous semicircular canals*.

The *saccule* is smaller, and occupies the recessus sphaericus on the anterior part of the medial wall of the vestibule. It communicates by means of a short narrow tube, termed the *canalis reuniens*, with the ductus cochlearis or membranous cochlear tube.

The saccule and the utricle are only indirectly brought into communication with each other; a slender tube termed the *ductus endolymphaticus* occupies the aquæductus vestibuli, and divides into two branches which pass respectively into the saccule and the utricle (Fig. 250).

The *ductus cochlearis*, or *scala media*, lies between the two *scalæ* of the cochlear tube. It ends blindly at each extremity, but close to its basal end it is brought into communication with the saccule by the *canalis reuniens*.

BULBUS OCULI.

The bulbus oculi or eyeball is not perfectly spherical: it may be said to be composed of the segments of two spheres. The anterior or corneal segment, forming only about one-sixth of the entire eyeball, possesses a shorter radius than the posterior or scleral segment. The anterior clear corneal part of the eyeball forms, therefore, a dome-like bulging or prominence on the front of the globe of the eye. The terms *anterior* and *posterior pole* are respectively applied to the central points of the anterior and posterior segments of the eyeball. The imaginary line which joins these poles receives the name of the *sagittal axis*, whilst another line drawn in a coronal direction around the globe of the eye midway between the two poles so as to divide the eyeball into two hemispheres is termed the *equator*. Imaginary *meridional lines* also are drawn between the two poles so as to cut the equatorial line at right angles.

Dissection of the Eyeball. A satisfactory dissection of the globe of the eye can be made only when the eyeball is fresh, or after it has been hardened for several days in a 10% solution of formol. In the dissecting-room it is often impossible to obtain suitable specimens; but it is always easy to procure eyeballs of the pig, sheep, or ox, and these suit the purpose admirably. It is advisable, however, that the dissector should complete his study of the organ by the examination of a fresh human eyeball obtained from the *post mortem* room. In point of size, and also in other particulars, the eyeball of the pig more closely resembles the human eyeball, but it is perhaps better that the student should begin with the eyeball of the ox, seeing that in it the dissection can be more easily carried out.

When the dissector has provided himself with six eyeballs obtained from oxen, he should remove from them the conjunctiva, fascia bulbi, ocular muscles, and fat, which adhere to them. Pinching up, with the forceps, the conjunctiva and the fascia bulbi close to the corneal margin, he should slip through these layers with the scissors and divide them round the whole edge of the cornea. He can then easily strip all the soft parts from the surface of the sclera, working steadily posteriorly towards the entrance of the optic nerve. A little posterior to the equator of the eyeball the *vene vorticosae* will be noticed issuing from the sclera at wide intervals from each other, and on approaching the posterior aspect of the eyeball the posterior ciliary arteries and the ciliary nerves will be seen piercing the sclera around the entrance of the optic nerve.

Before beginning the actual dissection of the eyeball, it is important that the student should obtain a general conception of the parts which compose it. This can be done by sections through three hardened specimens in three different planes. One specimen may be divided at the equator into an anterior and a posterior portion. Another may be divided

in an antero-posterior direction into a medial and a lateral half. A third should be divided horizontally and a portion of the vitreous body should be removed (Fig. 251). When the sections are made, they should be placed under water in a cork-lined tray, and preserved for reference as the study of the eyeball is proceeded with.

General Structure of the Eyeball.—The eyeball consists of three concentrically arranged coats enclosing a cavity in which three refracting media are placed.

The tunics are: (1) an external fibrous envelope composed of a posterior opaque part, called the *sclera*, and an

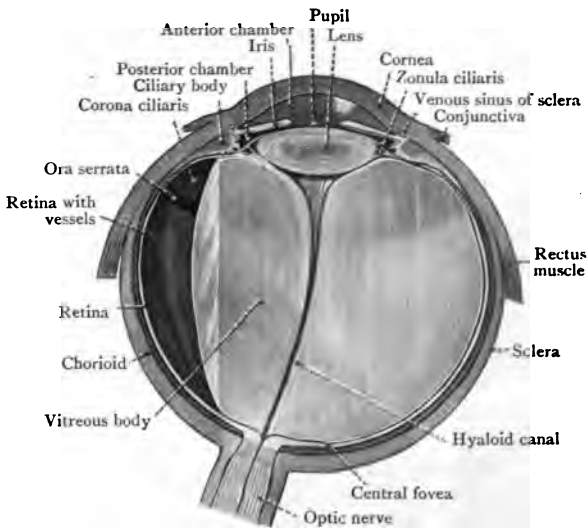


FIG. 251.—Diagrammatic section of Eyeball.

anterior clear transparent portion called the *cornea*; (2) an intermediate vascular envelope known as the *uveal tract*, in which three subdivisions are recognised, viz., a posterior part called the *chorioid*, an anterior portion termed the *iris*, which lies posterior to the cornea, and an intermediate *ciliary body*; (3) the nervous internal tunic or *retina*, in which the fibres of the optic nerve spread out.

The refracting media are: (1) posterior to the cornea a watery fluid, called the *aqueous humour*, contained in a space partially subdivided by the iris into the *two chambers of the eye*; (2) the *crystalline lens* posterior to the posterior

chamber; and (3) the *vitreous body*, occupying the posterior part of the interior of the eyeball.

Dissection.—The superficial surface of the sclera and the cornea should now be examined; but to complete the study of the external tunic a further dissection is required. Selecting an eyeball for this purpose, an incision should be made, with a sharp knife, through the sclera at the equator. This must be done carefully, and the moment that the subjacent black chorioid coat appears the knife should be laid aside. The cut edge of the sclera should now be seized with the forceps, and the incision carried completely round the eyeball, with the scissors, along the line of the equator. The outer fibrous tunic is thus divided into an anterior and a posterior portion. These must now be raised from the subjacent parts. As the anterior portion is turned anteriorly, some resistance will be met close to the margin of the cornea from the attachment of the ciliary muscle to the deep surface of the sclera. This can easily be broken through with the blunt point of the closed forceps; as soon as this is done the aqueous humour escapes. In the case of the posterior part of the sclera, its complete separation can be effected by dividing the fibres of the optic nerve close to the point where they appear through the sclera.

When the above dissection is successfully carried out, the outer fibrous tunic is isolated in two portions, whilst a continuous view of the intermediate vascular coat is obtained. The eyeball, denuded of its external tunic, should now be placed in a shallow vessel filled with water.

Sclera.—The sclera is what is commonly known as the white of the eye. It is a dense, resistant tunic, opaque-white in colour, which envelops the posterior five-sixths of the globe of the eye. It is thickest posteriorly, and becomes thinner as it is traced anteriorly. Near the cornea, however, it again becomes thicker, owing to the accession of fibres which it receives from the tendons of the ocular muscles. Except at the optic entrance and close to the margin of the cornea, where it adheres to the surface of the subjacent ciliary muscle, the deep surface of the sclera is very loosely attached to the chorioid coat. Some pigmented flocculent connective tissue, the lamina fusca, passes between the two coats and traverses what is in reality an extensive lymph space, termed the perichorioid space.

The point at which the optic nerve pierces the sclera does not correspond with the posterior pole of the eyeball. The optic entrance, as it is termed, is situated about 3 mm. to the medial or nasal side of the posterior pole and 1 mm. below it. There the outer fibrous sheath of the optic nerve, which is derived from the dura mater, blends with the sclera, and the bundles of nerve fibres pass through a series of small apertures. This perforated portion of the sclera is called the lamina cribrosa.

The sclera is pierced also by numerous blood-vessels and nerves. The long and short posterior ciliary arteries with the ciliary nerves perforate the sclera around the optic entrance; four or five *venæ vorticosæ* issue from the interior of the eyeball by piercing the sclera a short distance posterior to the equator, at wide intervals from each other; whilst the anterior ciliary arteries pierce it near the corneal margin.

Anteriorly the sclera is not only contiguous to, but is directly and structurally continuous with, the cornea. This is termed the *corneo-scleral junction*, and the faint groove on the surface, which corresponds with it, receives the name of the *scleral sulcus*. At this junction the scleral tissue slightly overlaps the corneal tissue, and the line of union, when

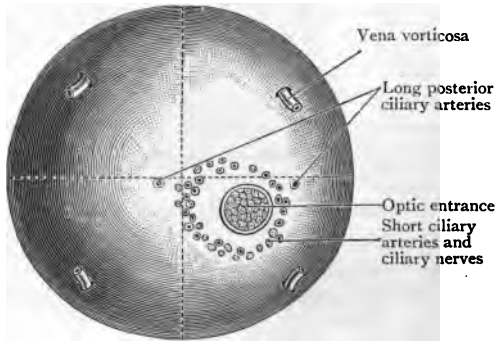


FIG. 252.—Diagram of the posterior aspect of the Left Eyeball. The excentric position of the optic entrance is somewhat exaggerated. (After Testut, modified.)

seen in section, is oblique. Close to this a minute canal in the substance of the sclera, termed the *sinus venosus scleræ* (O.T. canal of Schlemm), encircles the margin of the cornea.

Cornea.—The cornea forms the anterior sixth of the outer tunic of the eye. It is transparent and glass-like, and it forms the window through which the rays of light gain admittance into the eyeball. The curvature of the cornea is more accentuated than that of the sclera, and thus it constitutes the segment of a smaller sphere. When viewed from the posterior aspect it appears circular, but when looked at from the front it is seen to be slightly wider in the transverse direction. This is due to the fact that the sclera overlaps it to a greater extent above and below than it does at the sides. The posterior concave surface of the cornea forms the anterior

boundary of the anterior chamber of the eyeball, and is separated by the aqueous humour from the anterior surface of the iris.

The anterior convex surface of the cornea is clothed with the conjunctiva, reduced to a transparent epithelial layer. On its posterior aspect there is an elastic glassy stratum, termed the *posterior elastic lamina*. When the cornea is relaxed this membrane becomes wrinkled, and it can be torn away in shreds from the proper corneal tissue.

Ligamentum Pectinatum Iridis.—At the margin of the cornea the posterior elastic lamina is fibrillar, and some of its fibres are continued into the iris, forming the *ligamentum pectinatum iridis*, whilst others are prolonged posteriorly into the chorioid and the sclera. The ligamentum pectinatum iridis bridges across the angle between the cornea and the iris, and the bundles of fibres into which the posterior elastic lamina breaks up in this region constitute an annular meshwork or sponge-like series of minute spaces termed the *spatia anguli iridis* (O.T. *spaces of Fontana*). These communicate with the anterior chamber of the eyeball, and are filled with aqueous humour.

Tunica Vasculosa Oculi.—The intermediate or vascular tunic, frequently spoken of as the uveal tract, is exposed, in its entire extent, in the eyeball from which the sclera and the cornea have been removed. It is separable into three parts—(1) a posterior portion, the chorioidea; (2) an intermediate part, the corpus ciliare; and (3) an anterior segment, the iris.

Chorioidea.—The chorioid is the largest part of the vascular tunic. It lines the posterior segment of the eyeball, between the sclera externally and the retina internally. It is thickest posteriorly, where it is pierced by the optic nerve, and becomes thinner anteriorly, as it approaches its union with the ciliary body. Its superficial surface is connected with the deep surface of the sclera by some lax connective tissue, and also by blood-vessels and nerves which pass from the one into the other. The deep surface of the chorioid is moulded upon the retina and connected with a layer of deeply-pigmented cells which usually adheres to the chorioid when that tunic is removed, although in reality it is a portion of the retina.

In the eyes of many mammals, but not in man, the posterior part of the

chorioid, when viewed from the front, presents an extensive brightly-coloured area, which exhibits a metallic lustre. This appearance is due to the presence of an additional layer in the chorioid termed the *tapetum*. In the horse, elephant, and ox, the *tapetum* is composed of fibres (*tapetum fibrosum*); in carnivora, it is formed of cells (*tapetum cellulosum*). In the ox, it is a brilliant green colour with a golden lustre; in the dog, it is white with a bluish border; in the horse, it is blue with a silvery lustre.

The chief bulk of the chorioid coat is composed of blood-vessels. These are arranged in two well-marked layers, viz., a deep, closely-meshed capillary layer called the *lamina chorio-capillaris*, and a more superficial venous layer composed of

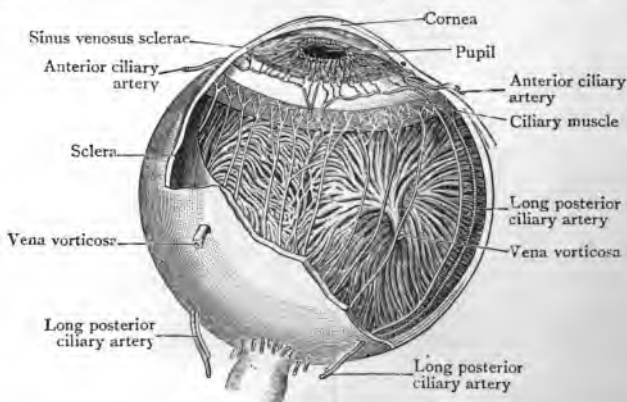


FIG. 253.—Dissection of the Eyeball showing the Vascular Tunic and the Arrangement of the Ciliary Nerves and Vessels.

the *vasa vorticosæ*. The short posterior ciliary arteries pass anteriorly between these vascular layers.

The eyeball in which the outer surface of the chorioid is exposed should be immersed in water and the pigment washed out of it by means of a camel-hair brush. The *vasa vorticosæ* will then appear as white curved lines converging towards four or five points, from which the *venæ vorticosæ* take origin (Fig. 253).

Corpus Ciliare.—The ciliary body is separable into an antero-external part, the *orbiculus ciliaris*, and a postero-internal part, the *corona ciliaris*.

The *orbiculus ciliaris* consists of the ciliary muscle, the ganglionated ciliary nerve plexus, and plexuses of arteries and veins associated with the iris and ciliary body. It is

continuous with the iris internally, the sclera anteriorly, and the corona ciliaris and the chorioid posteriorly.

Ciliary Muscle.—This is composed of involuntary muscular tissue, but the arrangement of its fibres can be seen only when thin sections of the eyeball are examined under the microscope. It is then obvious that the fibres are disposed in two groups, viz., a radiating and a circular.

The *radiating fibres* arise from the deep aspect of the sclera close to the margin of the cornea. From this they radiate posteriorly, in a meridional direction, and gain insertion into the chorioid coat in the region of the ciliary processes. The *circular fibres* consist of two or three bundles

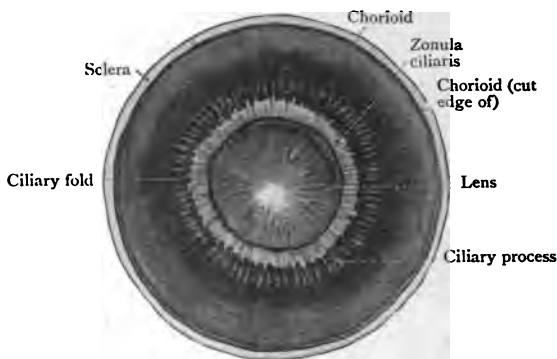

FIG. 254.—Posterior view of Lens and Zonula Ciliaris.
(Professor Arthur Thomson.)

placed upon the deep aspect of the radiating portion of the muscle. They form a muscular ring around the outer circumference of the iris.

Dissection.—To obtain a view of the ciliary processes, a frontal section should be made through an eyeball a short distance anterior to the equator. The portion of the vitreous body which occupies the posterior segment of the eyeball should be carefully removed. When this is done, the deep aspect of the corona ciliaris will be seen. It is covered with ciliary processes which radiate posteriorly from the circumference of the crystalline lens. By washing out the pigment from this part of the vascular tunic, the arrangement of the processes will be displayed more fully.

A second dissection may be made in another eyeball with the object of exposing the ciliary processes from the front. In this case remove the cornea with the scissors by cutting round the corneo-scleral junction. The iris is now brought conspicuously into view, and may, with advantage, be studied at this stage. Several cuts in the meridional direction, and at

equal intervals from each other, should, in the next place, be made through the anterior part of the sclera. The strips of sclera should then be separated from the ciliary muscle, and pinned outwards in a cork-lined tray filled with water. The last step in the dissection consists in the removal of the iris.

The *corona ciliaris* lies on the posterior aspect of the orbiculus ciliaris and is continuous anteriorly with the iris and posteriorly with the chorioid. It consists of a number of larger folds, the *processus ciliares*, 70 to 72 in number, which are intermingled with a number of smaller folds, the *plicae*

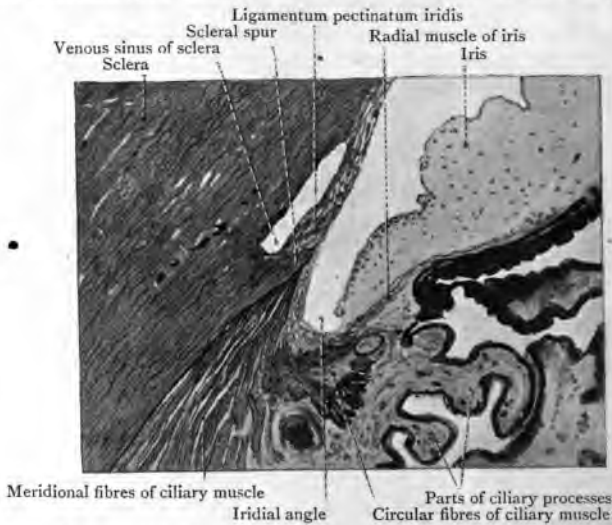


FIG. 255.—Section of Iridial Angle. (Prof. Arthur Thomson.)

ciliares. The ciliary processes extend from the anterior margin of the chorioid to the anterior margin of the corona ciliaris, where they end in bulbous extremities. The bulbous ends occupy the space between the peripheral margin of the iris and the margin of the anterior surface of the crystalline lens, and they form the peripheral boundary of the posterior chamber of the eyeball. The *plicae ciliares* are much less prominent than the ciliary process, and both the processes and the folds are in relation posteriorly with the hyaloid membrane, which separates them from the vitreous body, and with the peripheral part of the zonula ciliaris to which they are attached.

Iris. The iris lies anterior to the crystalline lens, and it is separated from the cornea by the anterior chamber filled with aqueous humour. By its circumference it is continuous with the ciliary body, and it is connected by the ligamentum pectinatum iridis with the margin of the cornea.

The iris is circular in form, and has a central perforation termed the *pupil*. Its anterior surface is faintly striated in a radial direction. It is coloured differently in different individuals. Its posterior surface is deeply pigmented. The pupil presents a very nearly circular outline,¹ and during life it constantly varies in its dimensions so as to control the amount of light which is admitted into the interior of the eyeball. These changes in the size of the pupil are produced by the two groups of involuntary muscular fibres which are present in the substance of the iris. One group is composed of muscular fibres arranged circularly around the pupil in the form of a *sphincter*; the second group consists of fibres which have a radial direction, and pass from the sphincter towards the circumference of the iris, so as to constitute a *dilatator muscle*. By some anatomists these radial fibres are considered to be *elastic* and not *muscular*.

Ciliary Nerves.—The ciliary nerves arise from the ciliary ganglion and the naso-ciliary nerve. They pierce the sclera around the optic entrance, and extend anteriorly, between the sclera and the chorioid, in the perichorioid lymph space. They will be seen, in the specimen in which the sclera has been turned aside in separate flaps, in the form of delicate white filaments (Fig. 253). In the posterior part of the eyeball they occupy grooves on the deep surface of the sclera, and can be separated from it only with difficulty. Reaching the ciliary zone the ciliary nerves break into branches, which join in a plexiform manner and send twigs to the ciliary muscle, the iris, and the cornea.

Ciliary Arteries.—There are three groups of ciliary arteries: (1) the short posterior ciliary arteries; (2) the long posterior ciliary arteries; and (3) the anterior ciliary arteries.

The *short posterior ciliary arteries*, branches of the ophthalmic, pierce the sclera around the optic entrance,

¹ It may be as well to mention here that the pupil in the ox and the sheep is greatly elongated in the transverse direction. In the pig, however, it is approximately circular.

and are distributed in the chorioid coat between the vasa vorticosa and the membrana chorio-capillaris.

The *long posterior ciliary arteries*, also branches of the ophthalmic, are only two in number. They perforate the sclera on either side of the optic nerve (Fig. 252), a short distance beyond the short ciliary arteries, and then pass anteriorly between the sclera and the chorioid. When they gain the ciliary zone each artery divides into an ascending and a descending branch, and these, with the anterior ciliary arteries, form an arterial ring termed the *circulus iridis major*. Branches are given off from this circle to the ciliary muscle, the ciliary processes, and the iris.

The *circulus iridis minor* is the name applied to a second arterial ring in the iris at the outer border of the sphincter pupillæ.

The *anterior ciliary arteries* are very small twigs, which arise from the branches of supply to the recti muscles. They pierce the sclera close to the margin of the cornea, take part in the formation of the *circulus iridis major*, and send twigs to the ciliary processes.

Venæ Vorticosa.—From each venous vortex in the chorioid a large vein arises, which makes its exit from the eyeball by piercing the sclera, obliquely, a short distance posterior to the equator. They are four or five in number.

Dissection.—The vitreous body and retina, in the posterior part of the eyeball which was cut into two for the purpose of exposing the ciliary processes from the posterior aspect, should now be dislodged. By raising the chorioid coat from the deep surface of the sclera, under a flow of water from the tap, the venæ vorticosa entering the deep surface of the sclera will be brought into view. When these are divided, and the separation of the two coats is carried posteriorly towards the optic entrance, the posterior short ciliary arteries, as they emerge from the sclera and enter the posterior part of the chorioid, will be seen.

In the eyeball from which the sclera and cornea have been removed, the iris, ciliary processes, and the chorioid should be carefully stripped off piecemeal under water. This will expose the retina.

Retina.—The retina is composed of two strata—viz., a thin *pigmentary layer*, which adheres to the deep surface of the chorioid coat, and has been removed with it, and a delicate *nervous layer*, which is moulded on the surface of the vitreous body, but presents no attachment to it except at the optic entrance. The retina extends anteriorly, beyond the equator of the eyeball, and, a short distance from the ciliary zone, it appears to end in a well-defined wavy or

festooned border termed the *ora serrata*. This appearance, however, is somewhat deceptive. The nerve elements, it is true, come to an end along this line, but a lamina in continuity with the retina is in reality prolonged antero-medially as far as the margin of the pupil. The part in relation to the ciliary processes is exceedingly thin, and cannot be detected by the naked eye. It is termed the *pars illaris retinae*. The portion on the deep surface of the iris is called the *stratum pigmenti iridis*.

During life the *retina proper* is transparent, but after death it soon assumes a dull greyish tint and becomes opaque. Posteriorly it is tied down at the optic entrance. When viewed from the anterior aspect this appears as a conspicuous circular disc termed the *papilla nervi optici*, upon which is a depression, the *excavatio papillae*. From this spot the optic nerve fibres radiate out so as to form the deep or anterior layer of the retina. The optic disc, in correspondence with the entrance of the optic nerve, lies to the medial or nasal side of the antero-posterior axis of the eyeball. Exactly in the centre of the human retina, and therefore in the axis of the globe of the eye, there is a small yellowish spot termed the *macula lutea*.¹ It is somewhat oval in outline, and a depression in its centre is called the *fovea centralis*.

Retinal Arteries and Veins.—In a fresh eyeball the *arteria centralis retinae* will be seen entering the retina at the optic disc. It immediately divides into a superior and an inferior branch, and each of these breaks up into a large lateral or temporal division, and a smaller medial or nasal division. These ramify in the retina as far as the *ora serrata*; but the resultant branches do not anastomose with each other, nor with any of the other arteries in the eyeball.

The *retinal veins* converge upon the optic disc, and disappear into the substance of the optic nerve in the form of two small trunks which soon unite.

The retinal vessels, the optic disc, and the macula can all be examined in the living eye by means of the ophthalmoscope. The red reflex obtained from the fundus of the eyeball is produced by the blood in the lamina chorio-capillaris.

¹ There is no macula lutea in the eyeball

of sheep.

Dissection.—For the study of the vitreous body and the crystalline lens, which together may be termed the “eye-kernel,” it is better to take an eyeball which is not perfectly fresh (Anderson Stuart). The eyeball selected for this purpose should be allowed to stand untouched from one to three days, according to the season. The coats of the eye should then be divided round the equator, and on gently separating the cut edges, and turning the coats anteriorly and posteriorly, the “eye-kernel” will slip out. It should be allowed to drop into a vessel filled with clean water. The examination of the parts forming the “eye-kernel” will be greatly facilitated by placing it *en masse* in strong picro-carmine solution for a few minutes. When removed from the staining fluid, it should be well washed in water. In this way the hyaloid membrane enclosing the vitreous body, the capsule of the lens, and the zonula ciliaris, are stained red, and their connections become very apparent (Anderson Stuart).

Vitreous Body.—This is a soft, yielding, transparent, jelly-like body, which occupies the posterior four-fifths of the interior of the eyeball. The retina is spread over its surface as far forwards as the ora serrata, but is in no way attached to it, except at the optic disc. Anterior to the ora serrata, the ciliary processes are applied to the vitreous body and indent its surface. More anteriorly, the vitreous body presents a deep concavity, the *fossa hyaloidea*, for the reception of the posterior convex surface of the crystalline lens.

The substance of the vitreous body is enclosed within a delicate transparent membrane, which completely envelops it, and receives the name of the *hyaloid membrane*. Extending anteriorly through the midst of the vitreous mass, from the region of the optic disc to the crystalline lens, is a minute canal, lined with a tube-like prolongation of the hyaloid membrane, and containing a watery fluid. This is termed the *hyaloid canal*; it represents the path taken by a branch of the arteria centralis retinae, which, in the foetus, extends to and supplies the capsule of the lens, but afterwards disappears.

The hyaloid canal, as a rule, cannot be seen in an ordinary dissection of the eyeball; but if the “eye-kernel” be shaken up in the picro-carmine solution as recommended by Anderson Stuart, it may sometimes be rendered evident through the staining fluid entering it. It is represented diagrammatically in Fig. 251.

Zonula Ciliaris (O.T. Zonula of Zinn). Between the corona ciliaris externally and the margin of the lens internally lies a fibrous membrane called the zonula ciliaris. Its external margin is attached to the posterior surfaces of the ciliary processes and the hyaloid membrane, and its internal margin is connected with the lens. As it approaches the margin of the crystalline lens, it splits into two parts, viz., an

exceedingly delicate deep lamina, which lines the fossa hyaloidea, and a more superficial stronger part, which becomes attached to the capsule of the crystalline lens.

The zonula ciliaris lies subjacent to the ciliary processes, and is radially plaited or wrinkled in correspondence with these. Thus the elevations or wrinkles of the zonula extend into the intervals between the ciliary processes, whilst the ciliary processes in their turn lie in the depressions between the wrinkles of the zonula. When the eye is fresh, these opposing parts are closely adherent.

The zonula ciliaris is strengthened by radially directed elastic fibres, and after the delicate membrane which lines

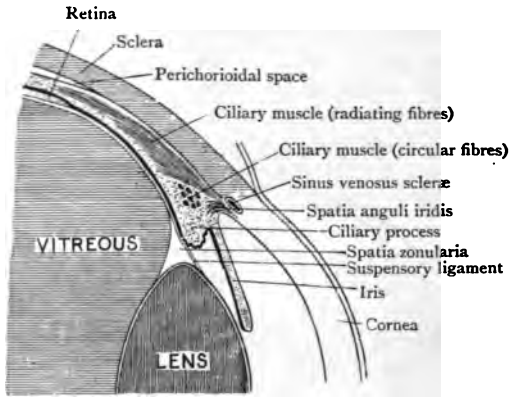


FIG. 256.—Diagrammatic representation of the Ciliary Region, as seen in vertical section.

the fossa hyaloidea is given off from its deep surface, it extends inwards as a distinct layer, and is attached to the anterior surface of the capsule of the lens a short distance beyond the margin of that body. In this manner the *suspensory ligament of the lens* is formed. But this is not the only attachment of the suspensory ligament. Some scattered fibres are attached to the circumference or equator of the lens (equatorial fibres), whilst others are fixed to its posterior surface close to its margin (post-equatorial fibres).

In this way the crystalline lens is firmly fixed in the fossa hyaloidea. Further, the degree of its curvature is influenced by the place of its attachment to the cornea.

the ciliary muscle, which by their contraction pull upon the ciliary processes, and produce relaxation of the zonula ciliaris.

Spatia Zonularia (O.T. canal of Petit).—In reality the spatia zonularia constitute a more or less continuous circular lymph space, which surrounds the circumference of the lens. It lies between the anterior and posterior layers of the suspensory ligament and is filled with a watery fluid.

By introducing the point of a fine blow-pipe into the spatia zonularis through the suspensory ligament, it can be partially, or, perhaps, completely, inflated with air. It then presents a sacculated appearance.

Dissection.—The crystalline lens may be removed by snipping through the suspensory ligament with scissors.

Lens Crystallina.—The crystalline lens is a biconvex, solid, and transparent structure which lies between the iris and the vitreous body. It is enclosed within a glassy, elastic capsule, to which the different parts of the zonula ciliaris are firmly cemented, and it presents for study an anterior surface; a posterior surface, and a circumference or equator.

The *anterior surface* is not so highly curved as the posterior surface. Its central part, which corresponds with the pupillary aperture of the iris, looks into the anterior chamber of the eye. Around this part the margin of the pupillary orifice of the iris is in contact with the lens, whilst nearer the equator the anterior surface of the lens is separated from the iris by the fluid in the posterior chamber of the eyeball. The *posterior surface* of the lens presents a higher degree of curvature than the anterior surface, and is received into the fossa hyaloidea of the vitreous body. The *equator* or *circumference* is rounded. It forms one of the boundaries of the spatia zonularia, and the manner in which the zonula ciliaris is attached to the capsule in this vicinity has been described already.

Faint radiating lines may be seen on both surfaces of the lens. These give a clue to the structure of the lens. They indicate the planes along which the extremities of the lens-fibres come into apposition with each other.

The *capsule* of the lens is a resistant glassy membrane, which is considerably thicker anteriorly than posteriorly.

The anterior wall of the capsule may now be divided with a sharp knife. A little pressure will cause the body of the lens to escape through the opening. The stained capsule can be very advantageously studied whilst floating in water.

If the lens body is compressed between the finger and thumb, it will be noted that the outer portion or *cortical part* is soft, whilst the central part or *nuclear* is distinctly firmer. When the lens is hardened in alcohol it can easily be proved that it is composed of numerous concentrically arranged laminae.

Chambers of the Eyeball.—The *anterior chamber* of the eyeball is the space between the cornea anteriorly, and the iris and central part of the lens posteriorly. At the irido-corneal angle it is bounded by the ligamentum pectinatum iridis, and there the aqueous humour which fills this chamber finds access to the spatia anguli iridis.

The *posterior chamber* is a circular space or interval which is bounded anteriorly by the posterior surface of the iris, and posteriorly by the circumferential part of the anterior face of the lens. Externally, this space is closed by the thick anterior projecting ends of the ciliary processes. It also is filled with aqueous humour.

INDEX.

- Accessory parotid, 126, 127, 261
 Aditus laryngis, 378, 408, 409
 Agger nasi, 396
 Alae of thyreoid cartilage, 414, 415,
 421, 423
 Alveus, 497
 Ampullæ of semicircular canals,
 567
 Amygdaloid nucleus, 491, 494, 512,
 514
 Annular ligament of Stapes, 557
 Ansa hypoglossi, 146, 234, 243,
 244, 246
 subclavia, Vieussenii, 239, 250,
 257, 258, 319
 Antihelix, 153
 Antitragus, 154
Aorta, 10, 83
 arch, 23, 30, 32, 44, 78, 85, 89, 96,
 98, 100, 102, 103, 106, 247
 position of, 85
 ascending, 39, 55, 83, 98
 position of, 83
 descending thoracic, 31, 44, 50,
 58, 77, 89, 98, 102, 104, 106,
 109, 111
 Aortic groove on left lung, 40
 cusp, 87
 great sinus of, 84
 orifice, 74, 83
 sinus of (Valsalva), 78, 80, 84, 87
 valve, 87
 Apertura medialis ventriculi quarti,
 539
 tympanica caniculi chordæ, 551,
 564
 Apex columni anterioris, 197
 Apical gland, 434
 Apices of the auricles, 55, 65, 76,
 84, 89, 98
- Aponeurosis**, 366
 bucco-pharyngeal, 366
 of palate, 382
 pharyngeal, 373
 vertebral, 235, 236, 237
Appendix ventriculi, 412, 421
Aquæductus cerebri, 503, 505, 506,
 509, 511
 vestibuli, 566
Aqueous humour, 571, 584
Arachnoidea encephali, 438, 439
 spinalis, 185
Arachnoideal granulations, 202,
 206, 442
Arch lateral lumbo-costal, 109, 167
 glosso-palatine, 430, 431
Arcus glosso-palatinus, 368, 378,
 380, 381, 382, 430, 431
 parieto-occipitalis, 464, 471, 472,
 474
 pharyngo-palatinus, 368, 369,
 378, 380, 381, 382
 tarseus, 137, 342
Area acustica, 525
Artery or Arteries, alveolar, an-
 terior superior, 386, 389
 alveolar inferior, 270, 272, 278,
 279
 alveolar posterior superior, 270,
 271
 angular, 128, 131
 of external maxillary, 344
 anonyma. *See* Innominate
 anterior cerebral, 450, 447, 448
 branches of—
 anterior medial frontal, 449
 antero-median, 449
 intermediate medial frontal, 449
 medial orbital, 449
 posterior medial frontal, 449

Artery or Arteries—

- maxillary, internal, 242, 262, 267, 269, 272, 274, 294, 296, 301, 402, 403, 405, 406
- mediastinal, 104
 - of the medulla spinalis, 193
- meningeal, anterior, 220, 221, 344
 - accessory, 212, 220, 221, 270, 274, 333
 - of ascending pharyngeal, 220, 221, 304
 - of internal maxillary, 220, 221
 - middle, 202, 210, 212, 220, 270, 274, 277, 293, 333
 - of occipital, 220, 221, 301
 - of vertebral, 220, 221, 356
- mental, 279, 300
- musculo-phrenic, 7, 9
- mylo-hyoid, 270, 278, 283
- nasal branches of anterior ethmoidal, 393
 - of posterior ethmoidal, 393, 406
 - posterior (of sphenopalatine), 406
 - posterior of the septum, 392
- nutrient of skull and diploe, 202
- occipital, 145, 149, 156, 157, 162, 169, 170, 232, 239, 262, 296, 300, 302, 303, 306
 - descending branch, 169, 171, 172
 - meningeal branch, 169, 171
 - sterno-mastoid branch, 316
- oesophageal, 103, 104, 253, 307
- ophthalmic, 220, 339, 341
- palatine, ascending, 383
 - of ascending pharyngeal, 304, 383
 - descending, 383, 405, 406
 - of dorsalis linguæ, 383
 - of lacrimal, 342
 - of ophthalmic, 342
 - small, 406
- palpebral, 137, 342
- parieto-occipital (of posterior cerebral), 447
- perforating, of internal mammary, 4, 9
- pericardial, 104
- pericardio-phrenic, 50
- petrosal of middle meningeal, 301, 333
- pharyngeal, 253
 - ascending, 232, 246, 296, 303, 307, 406
 - branches, 304
 - canal, artery of, 485

Artery or Arteries—

- pontine, 445
- posterior auricular, 302
- cerebral, 457
 - communicating, 480
 - occipital, 303
 - of septum, 406
- prevertebral branches of ascending pharyngeal, 304
- profunda cervicis, 172, 173, 175
 - linguæ, 290, 291
- pterygoid, 270
 - canal, artery of, 405
- pulmonary, 10, 22, 30, 34, 38, 44, 55, 70, 75, 78, 84, 85, 90, 99
 - right, 76, 84, 86, 98, 101
 - left, 76, 86, 99
 - fœtal condition of, 77
 - relations of extra-pulmonary part, 99
 - orifice of, 83
 - relations of, 76
 - topography of, 76
- ranine, 434
- retinal, 581
- septal of the nose, 131
- short posterior ciliary, 574
- sphenopalatine, 402, 405, 406
- spinal, 109, 176, 181, 182, 193, 252
 - neural branches of, 182
 - pre-laminar branches of, 182
 - post-central branches of, 182
 - anterior, 445
 - posterior, 443
- sterno-mastoid, of occipital, 231, 233, 235, 239, 300, 308
 - of superior thyreoid, 232, 235, 239, 245, 296, 308
 - of transverse scapular, 235, 239
- stylo-mastoid, 147, 151, 161, 274, 307
- subclavian, 23, 25, 31, 32, 34, 35, 235, 239, 246, 247, 254, 257, 258, 309, 315, 323
 - branches of, 251
 - left, 86, 88, 89, 100, 102, 106, 250, 255
 - right, 250
- subcostal, 104, 109
- sublingual, 291, 292, 300
- submental, 282, 283, 284, 292, 300
- superior epigastric, 7, 9
 - intercostal, 7, 109, 110

Artery or Arteries—

- superior labial, 130, 393
 - septal branch of, 393
- supra-hyoid of lingual, 232, 291
- supra-orbital, 156, 157
- temporal of posterior cerebral, 447
 - deep, 267, 270, 303
 - middle, 262, 265, 266, 267, 270, 302
 - superficial, 127, 157, 261, 262, 277, 294, 296, 301
- thoraco-acromial, 161
- thyreo-cervical, 106, 251, 252, 253, 254, 309, 323
 - ascending cervical branch of, 240
 - inferior, 106, 235, 245, 246, 251, 252, 255, 315, 321, 323
 - superior, 229, 230, 232, 234, 243, 246, 253, 296, 308, 321
- thyroidea ima, 49, 229, 320, 321
- tonsillar, 299
- tracheal, 253
- transversa colli, 106, 145, 147, 149, 161, 164, 239, 242, 251, 252, 253, 255, 309, 323
- transverse facial, 127
 - scapular, 106, 145, 147, 149, 161, 164, 225, 242, 251, 252, 253, 255, 309, 323
- tympanic, 270, 274
- vertebral, 106, 175, 179, 180, 214, 220, 246, 251, 252, 253, 255, 257, 323, 353, 354, 355, 442, 443
- zygomatico-orbital, 302

Articulations. *See* Joints

- Ary-epiglottic folds, 329, 408, 409, 415, 418, 420, 421, 427

- Arytenoid cartilages, 379, 420

Atria of heart, 34, 65, 68. *See* Heart

- Atrio-ventricular apertures, 69, 71, 73, 79, 83, 92
 - bundle, 74, 83, 93
 - fibrous rings, 93

Atrium medii nasi, 395**Auditory apparatus**, 546

- Auditory tube**, 293, 299, 312, 375, 376, 381, 382, 383, 384, 559

- bony position, 559
- cartilage of, 384
- cartilaginous portion, 539
- levator cushion of, 384
- ossicles, movements of, 557
- parts of, 384

Auditory tube—

- pharyngeal orifice of, 384
- Auricle**, 153, 546
- cartilage of, 270

Back, 161

- blood-vessels, 170, 175
 - nerves, 162, 173, 177
- Basal ganglia**, 512
- Basilar sinus**, 183, 216
- Basis pedunculi**, 508, 509, 510
- Biventral lobule**, 533

- Brachia conjunctiva**, 511, 545 cerebelli, 529, 530

Brachial plexus, 151

- Brachium pontis cerebri**, 458, 531 conjunctiva cerebelli, 512

Brain. *Also* vol. i. p. 28

- basal ganglia, 437, 512
- base, 437
- blood-vessels, 442
- cerebellum, 437
- cerebral hemispheres, 459
- cerebrum, 459
- corpus callosum, 479
- fornix, 496
- fourth ventricle, 458, 520
- general appearance, 437
- general connexion of several parts, 458
- general structure, 461
- lateral ventricles, 458
- lobule paracentral, 466
- lobe frontal, 466-470
 - lateral surface of, 466
 - medial surface of, 469
 - orbital surface of, 469
- limbic, 477-479
- occipital, 472-474
 - lateral surface of, 474
 - medial surface of, 474
 - tentorial surface of, 474
- olfactory, 477-478
- parietal, 470-472
 - lateral surface of, 471
 - medial surface of, 470
- temporal, 475-477
 - lateral surface of, 475
 - opercular surface of, 475
 - tentorial surface of, 476
- medulla oblongata, 437
- meninges, 439
- mesencephalon, 506
- origin of nerves, 454
- parts in posterior cranial fossa, 452

- Brain**—
 peduncles of, 506, 508
 pons Varolii, 437
 posterior horn of ventricle, 473
 preservation of, 437
 removal from cranium, 211, 217
 septum pellucidum, 495
 thalami, 500
 third ventricle, 503
 velum interpositum, 498
- Bronchi**, 10, 22, 38, 44, 70, 77, 97
 eparterial, 22, 76, 98
 hyperarterial, 10, 38, 44, 70
 left, 87, 98, 103
 relations of intrapulmonary part,
 98
 right, 84, 98, 101
- Buccal aponeurosis**, 366
 glands, 366
 plexus, 277
- Bucco-pharyngeal fascia**, 366, 370
- Bulb**,
 of cornu, 490
 of jugular vein, 307, 350
 olfactory, 208
- Bulla ethmoidalis of nose**, 398
- Bundle, atrio-ventricular**, 74
- Bursa, pharyngeal**, 376
- Calamus scriptorius**, 537
- Calcar avis**, 473, 490
- Calcarine fissure**, 446, 465, 473.
 478, 490
- Canal carotid**, 385
 central, of spinal medulla, 181
 of modiolus, 568
 facial, 552, 561, 562, 563, 564,
 565
 for tensor tympani, 551
 hyaloid, 581
 lacrimal, 138, 140
 membranous, 569
 pharyngeal, 405
 pterygoid, 405
 semicircular, 561, 565
 lateral, 567
 posterior, 567
 superior, 567
 spiral, of modiolus, 568
- Canalis reuniens**, 569
- Canalis facialis**, 552, 561-565
- Canthi**, 120
- Capitular articulations**, 112
- Capsule, external**, 450, 512, 519
 internal, 450, 512, 514, 518
 of lens, 583
- Caput columnar anterioris**, 197
- Cardinal notch**, 53
- Plexus, deep**, 65, 85, 89, 96, 99.
 100
 superficial, 33, 43, 65, 78, 85,
 87
 revolution, 93
- Carotid body**, 247
 canal, 385
 gland, 294
 plexus, 318
 sheath, 235
 triangle, 226, 232, 233
- Cartilago arytenoid**, 379, 408, 410,
 411, 414, 415, 416, 417, 418,
 419, 420, 421, 427
 corniculate, 408, 415, 416, 421,
 427
 cricoid, 230, 414, 415, 426
 cuneiform, 408, 415, 421, 426
 of epiglottis, 422
 lateral of nose, 141
 alar of nose, 141
 minor or sesamoid of nose, 141
 nasal, 140
 of pinna, 155
 sesamoid of larynx, 420
 triticea, 414
 thyreoid, 229, 230, 414, 415, 421,
 423
- Cartilaginee corniculatae**, 422, 427
- Caruncula lacrimalis**, 120
- Cauda equina**, 190
- Caudate nucleus**, 444, 488, 489, 491,
 518
- Cavernous plexus**, 285, 331, 332, 386
 sinus, 209, 210
- Cavity of thorax**, 1, 10
- Cavum Meckelii**, 212, 329
 oris, 365
 septi pellucidi, 495, 496
 subarachnoideale, 185, 439
 subdurale, 185, 204
- Central canal of spinal medulla**, 196
 of medulla, 521
 of modiolus, 568
 grey matter of aqueduct, 505
- Central lobe**, 462
 lobule, 531
- Centre, lower visual**, 508
- Centrum ovale**, 480
- Cerebellar peduncles**, 534
 superior, 535
- Cerebello-olivary tract**, 525
 -spinal tract, 525
- Cerebellum**, 437, 529

Cerebellum—

- arbor vitæ, 534
- brachia conjunctiva, 535
- corpus medullare, 534
- fissures, 529, 531
- hemispheres, 529
- lingula of, 538
- lobes, 529, 531, 532, 533, 534
- lobules, 531, 533
 - central, 529, 531
 - linguli, 538
- lobus noduli, 533
 - Pyramidis, 534
 - tuberis, 534
 - uvulæ, 533
- monticulus, 529
- notches, 529
- peduncles, superior, 532
 - brachia pontis, 529
 - inferior, 527
- surface of, inferior, 530
 - superior, 535
- vallecula, 530
- vermis, 529

Cerebral cortex, 461

- hemispheres, 461
 - basal ganglia, 512
 - borders, 459, 460
 - corona radiata, 519
 - cortex, 461
 - fissures, 462-479
 - general structure, 458
 - grey matter, 461
 - gyri, 461, 462, 479
 - internal capsule, 518
 - island of Reil, 477
 - lobes, 462, 466, 470, 472, 475, 477
 - medullary centre, 461
 - orbital area, 459
 - poles, 465
 - sulci, 461
 - tentorial area, 459
 - ventricles, 483, 492, 496, 503-506

Cerebrum, 459, 520

- anterior commissure, 503, 519
- borders of, 459
- corpus callosum, 446, 497
- fornix, 488, 496, 499
- frontal pole of, 460
- hemispheres, 459
- inferior surface, 459
- lateral surface, 459
 - ventricles, 483-492
- longitudinal fissure, 439, 449
- massa intermedia, 504

Cerebrum—

- medial surface, 459
- occipital pole of, 460
- orbital area, 459
- pedunculi, 210, 212
- posterior commissure, 503, 505
- septum pellucidum, 449, 488
- temporal pole of, 460
- tentorial area, 459
- thalamus, 447-450
- third ventricle, 503-506
- transverse fissure, 499
- tela chorioidea, 442
- Ceruminous glands, 548
- Cervical fascia, 235**
 - ganglion, inferior, 319
 - middle, 318
 - superior, 317, 318
- pleura, 248, 250, 257
- plexus, 151, 239, 240
 - communicating branches of, 241
 - muscular branches, 241
 - sympathetic, 245, 247, 252
- Cervix columnæ,**
 - anterioris, 197
 - posterioris, 197
- Chambers of eyeball, 571, 584
- Cheeks, 366
- Chest. *See* Thorax
- Chiasma, optic, 441
- Choanæ, 374, 375, 377, 389
- Chondroglossus, 434
- Chorda tympani, 564
- Chordæ tendineæ, 73, 74, 79, 80
 - Willisii, 206
- Choroid, 571, 574
 - coat, 574
 - lamina corporis capillaris, 575
 - plexuses, 497
 - vasa vorticosa, 575
- Choroidal fissure, 492, 493, 494
- Chyle, 105
- Ciliary body, 571, 574
 - circular fibres of, 576
 - folds, 577
 - ganglion, 338
 - muscle, 576
 - orbicularis ciliaris, 576
 - processes, 577
 - radiating fibres, 576
 - zone, 579, 583
- Cingulum, 479
- Circular sinus, 209, 217
 - sulcus, 462, 463
- Circulus arteriosus, 441, 443, 450
 - iris major, 579

- Circulus iridis minor, 579
 tonsillaris, 311
Cisterna cerebello-medullaris, 440,
 538
 chiasmatis, 441, 443, 450
 chyli, 105
 interpeduncularis, 210, 441, 443,
 450
 pontis, 441
 subarachnoidales, 440
 venæ magnæ cerebri, 442
Clastrum, 512, 516, 517
Clava, 526
Clivus, 532
Cochlea, 565, 567
 canal of, medial longitudinal,
 568
 cupola, 568
 duct of the, 569
 ganglion spirale, 568
 lamina spiralis, 568
 membranous cochlear tube, 568
 modiolus of, 568
 canal, medial spiral of, 568
 scala vestibuli, 566
Collateral fissure, 461, 462, 465
Colliculus facialis, 537
Colliculi (of lamina quadrigemina),
 506
Column of Burdach, 199
 of Goll, 199
Columns of grey matter of cord, 197
 lateral grey, 198
Commissures, anterior, of brain, 503,
 519
 posterior, 503, 505
Commissures of cord, 195, 196
 palpebral, 119
Conchae of ear, 153
 of nose, 376, 377, 389, 395, 396,
 397, 399, 400, 401, 402, 403
Conical papillæ, 432
Conjunctiva, 120, 139
 fornix conjunctivæ, 120
 plica semilunaris, 120
 caruncula lacrimalis, 120
Conus arteriosus, 30, 39, 54, 70,
 72, 74, 78, 84
 elasticus, 414, 415, 418, 419, 421
 medullaris, 187, 188
Convolution. *See* Gyrus
Cord, gangliated, of sympathetic,
 2, 23, 25, 108, 109
 spinal. *See* Spinal medulla
 vocal, 579, 581
Cords of brachial plexus, 151
Cornea, 572, 573, 574, 579
Corneo-scleral junction, 573
Cornu Ammonis, 491, 492, 493, 497
Cornua of lateral ventricles, 497,
 490, 491, 492
 of thyroid cartilage, 424
Corona ciliaris, 577
 radiata, 519, 575, 596
 radiator, 519
Coronary plexus, 65, 65
 sinus, 89
 sulcus, 68
 valve, 81
Corpora mamillaria, 452, 453, 497,
 503, 504
 quadrigemina, 210, 447, 500, 506,
 507, 511, 512, 529
 superior, 503, 506, 507
 brachia of, 507
 geniculatum, 512
Corpus callosum, 446, 458, 473,
 478, 479, 480, 481, 488, 490,
 495, 496, 497, 498, 499
 central part, 494
 fibres, 481, 483
 genu, 448, 478, 482, 483, 487,
 495
 lamina rostralis, of, 482
 rostrum, 448, 449, 482, 483
 radiation, 483
 truncus of, 482, 487
 splenium, 446, 478, 482, 483,
 486, 494, 495, 499
Corpus geniculatum external, 503
 internal, 507
 laterale, 507, 508
 mediale, 506, 507
Corpus mamillare, 519
 striatum, 512, 515
 trapezoidum, 545
Costo-mediastinal sinus, 12, 16, 25
 -transverse joint-, 113
 ligaments of the vertebrae, 113
 -vertebral articulations, 112
Cranial fossa, middle, 325, 333
Crescentic lobule, 531, 532
Cricoid cartilage, 230, 414, 415, 426
Crico-thyroid membrane, 297, 415
Crista vestibuli, 566
Crura of crucial ligament, 363
Crura of stapes, 557
Crus heliæ, 153
Crus laterale of malleus, 555
 of incus, 555
Crystalline lens, 571, 578, 581, 582
Culmen monticuli, 530, 531

- Cuneate funiculus, 540, 541
 nucleus, 541
 tubercle, 379
- Cuneiform cartilage, 408, 415, 421
 tubercle, 379
- Cuneus, 447, 473
- Cupola modioli, 568
- Decussation** of the lemniscus, 542
 motor, 542
 of pyramids, 542
 sensory, 542
- Declive Monticuli, 531
- Dentate fascia, 479, 483, 492, 495
 fissure, 479, 495
 nucleus of cerebellum, 539
- Diaphragm**, 3, 35, 50, 70, 88, 99, 100, 102, 103, 105, 241
 central tendon of, 88
 crura of, 104, 105, 111
 membranous cervical, 36
- Diaphragma oris, 284
 sellæ, 209
- Diaphragmatic line of pleural reflection, 14, 17, 18, 19
 pleura, 16
- Digastric triangle, 226
- Dilatator pupillæ, 578
- Diencephalon, 520
- Disc, intervertebral, 357
 optic, 580, 581
- Discus articularis of jaw-joint, 268, 271, 272, 273, 274
- Dissections—Thorax—**
 thoracic wall, 3, 4, 7
 thoracic cavity, 12, 25, 29, 32, 33, 43, 46, 48
 pericardium and heart, 49, 51, 60, 65, 76, 78, 79, 87, 88, 89, 91
 deep of the thorax, 98, 101, 104, 109
 thoracic joints, 112
- Head and Neck—**
 face, 117, 120, 126, 128, 132, 133, 134, 140
 posterior triangle of neck, 142, 143, 145, 146
 scalp, 153, 154, 158, 159
 sterno-clavicular joint, 159
 back, 161, 162, 164, 166, 167, 168, 171, 172, 176, 178, 179, 181, 185, 191, 192, 200
 removal of the brain, 200, 203, 207, 211, 217, 222

- Dissections—Head and Neck—**
 anterior part of neck, 223, 225, 229, 230, 231, 234, 238, 239, 244, 261, 262, 303, 304, 309, 310, 317, 324, 325
 temporal and infratemporal regions, 266, 274, 279, 293
 submaxillary region, 279, 282, 284
 great vessels and nerves of neck, 303, 304, 309, 324
 lateral part of middle cranial fossa, 325, 329
 orbit, 334, 335, 339, 346, 348, 350
 prevertebral region, 350, 353, 356
 joints of neck, 358, 361, 362, 363
 maxillary nerve, 386
 pharynx, 369, 370, 372, 374, 376, 381, 382
 nasal cavities, 389, 393, 397, 398, 399
 sphenopalatine ganglion, 402, 405
 larynx, 413, 415, 417, 419, 421, 422
 brain, 457, 460, 479, 480, 483, 484, 485, 490, 494, 495, 496, 498, 500, 505, 512, 519, 528, 536, 539, 540
 auditory apparatus, 546, 549, 559
 intrapetrous portion of facial nerve, 562, 565
 eyeball, 570, 572, 575, 576, 579, 581, 583
- Duct**, lymphatic, right, 48, 242, 245, 255
 naso-lacrimal, 120, 140, 346, 399
 of Cuvier (foetal), 91
 parotid, 126
 sublingual, 289
 sub-maxillary, 288
- thoracic**, 2, 18, 31, 32, 48, 49, 70, 87, 102, 104, 106, 108, 111, 242, 245, 255
- Ductus arteriosus**, 33, 77, 78
 cochlearis, 569
 endolymphaticus, 569
- Dura mater** encephali, 201
 layers of, 202, 203
 partitions, 203
 sinuses, 162, 202, 205, 207, 211, 217
 spinalis, 183

- Ear, 547**
 annulus tympanicus, 549
 concha of, 546, 547
 external, 546
 internal or labyrinth, 546, 565
 mastoid ear cells, 550
 meatus - external acustic, 546,
 547, 548, 549, 550, 559,
 560, 561
 membrana tympani, 547, 548,
 549, 553, 554, 555, 561
 middle ear, 546, 550
 tragus of, 547
 tympanic cavity, 546, 550
 tympanic antrum, 550, 551, 554,
 555, 559, 560, 561
 tympanic membrane, umbo of,
 549
 Ecto-rhinal fissure, 465, 475
 Elastic lamina of cornea, 574
 Eminence, olivary, 524, 525, 526
 Eminentia collateralis, anterior, 494
 posterior, 494
 Endocardium, 92
 Endolymph, 546, 566
 Eparterial bronchus, 22, 76, 98
 Ependyma, 485, 526
 Epicardium, 92
 Epicranial aponeurosis, 122, 123,
 154, 156, 158
Epiglottis, 379, 408, 409, 423
 action of, 422
 cartilage, 422
 frenum, 409
 petiolus of, 423
 tubercle of, 409
 Ethmoidal cells, 395
 Eustachian orifice, 293, 299, 312,
 375, 376, 381, 382, 383, 384
 tube, 293
 Excavatio papillæ, 580
 Eyeball, 570
 bulbus oculi, 570
 chambers, 571, 584
 anterior, 585
 posterior, 585
 equator, 570, 572
 general structure of, 571
 meridional lines, 570
 poles, 570
 refracting media, 571
 sagittal axis, 570
 tunics, 571
 Eyebrows, 118
 "Eye-kernel," 581
 Eyelids, 119, 134
 Eyelids, conjunctiva, 119
 glands, 132
 ligaments, 121
 tarsi, 134
 vessels and nerves, 137
Face, 117
 arteries, 128
 muscles, 120
 nerves, 126
 surface anatomy, 117
 Falciform lobe, 465, 481
 Falx cerebelli, 212, 215, 529
 Fascia, axillary, 147
 buccinator, 261
 bucco-pharyngeal, 366, 370
 bulbi, 347-350
 carotid sheath, 235, 236, 238
 cerebri, 206, 459
 cervical, 145, 224, 225, 235
 deep cervical, 235
 deep of posterior triangle, 144
 dentate, 479, 483, 492, 495
 intra-thoracic, 12
 lumbo-dorsal, 166, 167
 palpebral, 135
 parotid, 126
 peri-renal, 168
 pharyngo-basilar, 373
 pretracheal, 229, 230, 235, 236,
 237
 prevertebral, 235, 236, 237
 of Sibson, 36
 submaxillary, 226
 superficial cervical, 235
 temporal, 265, 266
 Fasciculus cerebro-spinalis, 510,
 519, 527
 cerebello-spinalis, 200
 anterior, 200
 lateralis, 200, 542
 Fasciculus cuneatus, 199, 200
 gracilis, 199, 200
 thalamo-mamillaris, 447
 Fasciola cinerea, 483
 Fauces, isthmus of, 365, 368
 pillars, 368
 Fenestra cochleæ, 552, 561, 568
 vestibuli, 552, 557, 561, 562, 564,
 566
 Fibræ arcuatæ, 528
 Filum terminale, 183, 187, 188
 Fimbria, 479, 491, 492, 494
Fissure or Fissures, calcarine, 446,
 461, 465, 473, 478, 490
 central, 462, 464

- Fissure or Fissures**—
of cerebellum, 529, 531
of cerebrum, 462, 479
chorioid, 492, 493, 494
collateral, 461, 462, 465, 474, 475,
476, 479, 499
dentate, 479
ecto-rhinal, 465, 475
great horizontal, 530
longitudinal, 439, 449, 460
transverse of brain, 492
hippocampal, 461, 465, 495
lateral of brain, 451, 459, 462,
463, 466, 476
anterior ascending limb, 463
anterior horizontal limb, 463
posterior ramus, 463
longitudinal of brain, 437, 439,
449, 460
of lung, 41
of medulla, 195
oral, 365
palpebral, 119
parieto-occipital, 448, 462, 464
lateral, 464, 470, 473, 480
medial, 464
of spinal medulla, 195
transverse of brain, 499
Fœtal circulation, 68, 69, 77
Fold, ary-epiglottic, 379, 408, 409,
415, 418, 420, 421, 427
glosso-epiglottic, 409, 423, 430
pharyngo-epiglottic, 409, 423
salpingo-pharyngeal, 376
tympano-malleolar, 549
anterior, 549, 554
posterior, 549, 554
ventricular. *See* Plicæ
vestigial, 91
vocal. *See* Plicæ
Folium vermis, 530
Fontana, spaces of, 574
Foramen cæcum of medulla oblon-
gata, 521
cæcum of tongue, 430
interventriculare, 459, 486, 489,
502, 505
of Magendie, 539
ovale, 68, 78, 92
Foramina venæ minimæ cordis,
92
Forceps major, 483, 490, 494,
496
minor, 483
Formatio alba, 543
grisea, 543
Formatio reticularis, 510, 543, 545
Fornix, 488, 492, 495, 496, 499
body, 496, 497, 498, 499
columns of, 485, 497
of conjunctiva, 119
crura of, 496, 497, 498
transverse fibres of, 497
Fossa of antihelix, 154
cranial, middle, 325, 333
of helix, 154
hyaloidea, 581, 582, 583
interpeduncularis, 452, 503
nasal, 393
ovalis, 68, 69, 92
pterygo-palatine, 386, 388
recessus, 379
rhomboidalis, 536, 537
scaphoid of ear, 154
supraclavicularis, major, 142
minor, 142
supra-sternal, 178
supra-tonsillar, 378
triangular of ear, 154
Fourth ventricle, 536
ala cinerea, 538
area acustica, 538
area postrema, 538
colliculus facialis, 538
eminentia medialis, 537
floor, 536
fovea superior, 538
funiculus separans, 538
lateral recesses, 536
medullary striæ, 538
plexus chorioid, 539
roof of, 536, 538
substantia ferruginea, 538
tuberculum acusticum, 538
Fovea centralis retinæ, 580
inferior, 538
recessus ellipticus, 566
recessus sphaericus, 566
superior, 538
Frenulum of Giacomini, 495
of lips, 133, 365
veli, 506
Frenum of epiglottis, 409
linguæ, 288, 292, 368
Frontal lobe, 449, 462
operculum, 463
pole, 465
region of head, 117
sinus, 396, 397
Fronto-parietal operculum, 463, 475
Fungiform papillæ, 432
Funiculus anterior, 199, 200

Funiculus—

gracilis, 540, 541
 lateral, 199, 200
 posterior, 199, 200
 Furrowed band, 533

Galea aponeurotica, 122, 123, 154, 156, 158

Gangliated cord of sympathetic, 2, 23, 26, 108, 109

Ganglion, basal, 512
 cervical, inferior, 355
 middle, 318
 superius of glosso-pharyngeal, 312

ciliary, 332, 339, 341, 386, 578
 long root of, 340
 short roots of, 34

cœliac, 28
 communications of, 313
 first thoracic sympathetic, 110, 254

geniculi of facial, 312, 332, 333, 562, 563, 564

jugulare of vagus, 312, 313

nasal branches of, 393

nodosum of vagus, 313, 314, 315, 316, 317

orbital branches of, 405

otic, 276, 277, 279, 293, 383, 559

petrosom of glosso-pharyngeal, 312, 313, 317

semilunar, 211, 212, 275, 326, 328, 329, 332, 333, 385, 386

spheno-palatine, 386, 388, 392, 393, 402, 403, 404, 405

spinal, 189

spirale, 568

splanchnic, 28

submaxillary, 282, 284, 285, 318
 inferior cervical sympathetic, 317, 319
 middle cervical sympathetic, 318, 319
 superior cervical sympathetic, 312, 314, 317, 385
 superius of glosso-pharyngeal, 312
 of vagus, 313, 315

Genu of corpus callosum, 448, 478
 of internal capsule, 518

Giacomini, frenulum of, 495

Glabella, 118

Gland, buccal, 366
 carotid, 305, 306
 labial, 365
 lacrimal, 138, 334, 336, 337

Gland, lacrimal inferior, 337
 superior, 337
 molar, 366
 mucous of soft palate, 380
 sublingual, 368
 ducts of, 368
 submaxillary, 225, 226, 368
 thyreoid, 407
 lateral lobe, 407
 pyramidal lobe, 407

Globus pallidus, 516

Glosso-epiglottic folds, 409, 423, 430

Glottis, true, 410
 pars intercartilaginea, 411
 pars intermembranacea, 411
 vocalis, 407, 410

Goll, column of, 199

Gracile funiculus, 540, 541
 lobule, 534
 nucleus, 541

Granulationes Arachnoideales, 202, 206

Grey commissure, 195, 196
 matter of the medulla spinalis, 196

Groove, aortic on left lung, 40
 coronary, 53, 57, 71, 89, 91
 interventricular, 53, 63, 71

Gullet, 2, 10, 17, 23, 26, 29, 30, 31, 32, 39, 40, 49, 50, 58, 85, 87, 89, 96, 99, 100, 101, 103, 106

Gums, 367

Gyrus or Gyri, 461, 462, 479
 angular, 472, 475
 callosal, 479
 central anterior, 450, 467
 inferior, 467, 468
 middle, 467
 superior, 467

cinguli, 466, 471, 478, 479, 481
 posterior, 472

cunei, 447, 473

cuneo-lingual, anterior deep, 473

dentatus, 479, 483, 491, 495

fornicatus, 473, 478, 480

of frontal lobe, 450

frontal, 450
 inferior, 469
 middle, 466
 superior, 466, 469

fusiformis, 474, 476

hippocampal, 446, 447, 465, 474, 475, 478, 479, 494, 495, 508

opercula, 469
 anterior, 470

Gyrus or Gyn

- gyrus cinguli, 471
- gyrus frontalis, 471
- gyrus hippocampi, 471, 472
- gyrus isthmus, 472
- gyrus lingualis, 472
- gyrus marginalis, 472
- gyrus olivaris, 472, 473
- gyrus opercularis, 472, 473
- gyrus orbitalis, 472, 473
- gyrus paracentralis, 472, 473
- gyrus postcentralis, 472, 473
- gyrus precentralis, 472, 473
- gyrus prefrontalis, 472
- gyrus prehypocampi, 472, 473, 474, 475, 477
- gyrus supramarginalis, 472
- gyrus subcallosus, 472, 473, 474, 475, 477
- gyrus subcallosus, 472
- gyrus subcallosus, 472, 473, 474, 475

Heart, 93

- action, 93
- position, 93

Head and Neck, 117

- secondary apparatus, 546
- secondary apparatus, 452
- base, 299
- encephalon, 437
- carotid canal, 385
- cranial cavity, 299
- eyeball, 579
- face, 117
- frontal region of head, 117
- intrapetrous part of the facial nerve, 546
- infra-temporal region, 265
- joint, 356
- larynx, 406, 416
- lateral part of middle cranial fossa, 325
- structure in, 325
- maxillary nerve, 386
- mouth and pharynx, 364
- movements, 364
- nasal fossa, 393
- cavities, 389
- neck, 142, 222
- orbit, 333
- content of, 333, 334
- prevertebral region, 359
- structure in, 359
- calp, 152
- submaxillary region, 279
- structures contained in, 279
- temporal region, 152, 265

Heart, 93

- action, 93

Heart—

- anterior longitudinal sulcus, 53-63, 71
- aortic orifice, 79, 81
- position of, 81, 87
- valve, 81
- cusps of, 81
- apex, 53, 55, 56
- atrio-ventricular orifices, 69, 71, 73, 79, 83, 92
- bundles, 74, 83, 93
- position of, 87
- rings, 93
- atrium, 30, 34, 53, 54, 65, 68, 74, 76, 89
- antrum*, 65, 66, 68, 74
- sinistrum*, 68, 76, 84, 89, 102, 104
- position, 89
- orifices of, 92
- atrio-ventricular fibrous rings, 93
- fibres of atria, 92
- auricles, 55, 65, 76, 84, 89, 98
- base, 59
- bicuspid valve (mitral), 80
- border, left, 55
- right, 55
- chordæ tendinæ, 73, 74, 79, 80
- conus arteriosus, 30, 39, 54, 70, 72, 74, 78, 84
- coronary sinus, 68
- sulcus, 53, 57, 71, 89, 91
- valve of, 69
- crista terminalis, 65, 66
- endocardium, 92
- epicardium, 92
- external form, 53
- foramen ovale, 68
- foramina venæ minimæ cordis, 64, 69, 92
- fossa ovalis, 68, 69
- general relations, 50
- great sinus of aorta, 84
- incisura cordis, 53, 57
- inferior longitudinal surface, 58
- interatrial sulcus, 89
- limbus fosse ovalis, 67, 69
- mitral valve, 80, 92
- moderator band, 71, 74
- musculi papillares, 73, 79, 80
- pectinati, 66, 91
- myocardium, 92
- nerves, 33, 43, 65, 78, 85, 87, 89, 96, 99, 100
- orifices, topography of great, 87
- pars membranacea septi, 74, 83

Heart—

- pulmonary orifice**, 71, 72
 cusps of valve, 75
 lunulæ of the valve, 75
 nodules of the valve, 75
 sinus, 75
 topography of, 75, 87
 valve, 75, 78
 semilunar valves, 73, 78, 81
 septum atriorum, 69
 ventriculorum, 71, 72, 78, 82
 sinus venosus, 34, 54, 66
 sulcus anterior inter-ventricular, 71
 terminalis, 34, 54, 63
 supra-ventricular ridge, 72
 surfaces, 53, 56, 58
 diaphragmatic, 58
 sternocostal, 53, 56
 topography, 57, 75, 94
 trabeculæ carneæ, 72, 79
 tricuspid valve, 66, 73, 83
 cusps of, 73
 tubercle, intervenous (Lower), 67
 valve of the coronary sinus, 69
 valve of the vena cava (Eustachian), 67
ventricle, left, 79
 cavity, 79
 fibres of the ventricles, 93
ventricle, right, 70, 74
 atrio-ventricular orifice, 71
 cavity, 72
 conus arteriosus, 72
 ventricles, 34, 53, 55, 70, 74, 79
 vessels, 63, 64, 76, 78, 85, 87
 wall, 92
 Helicotrema, 568
 Helix, 158
 crus, 153
 fossa, 154
 processus caudatus, 155
 spine, 155
Hemisphere, cerebellar, 529
 cerebral. *See* Cerebral hemispheres
 Heschl, sulci of, 475
 Hiatus semilunaris of nose, 397, 398
Hippocampus, 491, 492, 493, 497
 digitations, 491
 minor, 494
 pes, 491
 tænia, 442, 447
 Horner, muscle of, 121
 Hyaloid canal, 581
 membrane, 581
 Hyparterial bronchi, 10, 38, 44, 70

Hypophysis cerebri, 208, 209, 218,
 222, 439

- Incisive bundle, 123, 133
 pad, 133
Incisura cardiaca, 53
 intertragica, 154
 temporalis, 465, 475
 thyroidea, 423
Incus, 556, 557
 body, 556
 crus, long, 536
 short, 557
 processus articularis, 557
 Inferior corpus quadrigeminum, 530
 Infra-orbital plexus, 128, 129, 389
 Infundibulum of brain, 208, 218,
 453
 of hypophysis, 505
 of nose, 397
Insula, 450, 475, 476, 477, 490,
 578
 opercula of, 477
 Interarticular meniscus, 113
 Interatrial sulcus, 89
 Intercavernous sinuses, 326
 Inter-chondral articulations, 113
 Intercostal membranes, 4, 108, 109
Internal acoustic meatus, 566
 capsule, 501, 515, 516, 518
 anterior limb, 518
 connections of, 518, 519
 genu, 518
 posterior limb, 518
 ear, 546, 565
 Interpeduncular fossa, 452
 Intervertebral fibro-cartilages, 112
 Intumescencia cervicalis, 187
 lumbalis, 187
 Iris, 571, 574, 576, 577, 578, 579
 Island of Reil, 477
Isthmus of auditory meatus, 548
 of auditory tube, 384
 of fauces, 368, 369, 378
 of gyrus cinguli, 478, 479
 fornicatus, 478
 of limbic lobe, 478
 of pharynx, 376, 377
 of thyroid gland, 229, 320
 of rhombencephalon, 536
 Jacobson's nerve, 312, 563
Joints, atlanto-epistropheal, 362
 atlanto-occipital, 361
 capitular, 113
 costo-transverse, 113

Juxta—

- arteria, 335, 337
- ductus, 335, 337
- foramen, 335, 337
- ganglion, 335, 337
- musculus, 335, 337
- nerve, 335, 337
- plexus, 335, 337
- septum, 335, 337
- sterno-clavicular, 335, 337
- sternum, 335, 337
- trachea, 335, 337
- vertebra, 335, 337
- vertebrae, 335, 337
- vertebrae, 335, 337
- vertebrae, 335, 337
- vertebrae, 335, 337

- lingual ganglion, 335, 337
- lingual gland, 335, 337
- lingual nerve, 335, 337, 338, 339, 340, 341, 342, 343
- lingual artery, 335, 337, 338, 339
- lingual vein, 335, 337, 338, 339
- lingual muscle, 335, 337
- lingual duct, 335, 337
- lingual gland, 335, 337
- lingual nerve, 335, 337
- lingual artery, 335, 337
- lingual vein, 335, 337
- lingual muscle, 335, 337

- Lamina laterales, 200
- Lamina laterales, 110, 130
- Lamina terminalis, 218, 220, 254, 255
- chorda, 218, 220, 254, 255
- chorda, 218, 220, 254, 255
- chorda, 218, 220, 254, 255
- chorda, 218, 220, 254, 255
- chorda, 218, 220, 254, 255
- chorda, 218, 220, 254, 255
- chorda, 218, 220, 254, 255
- chorda, 218, 220, 254, 255
- chorda, 218, 220, 254, 255

- Laminae, 570
- Larynx, 436, 410
- musculus laryngis, 378, 408, 400
- cartilages, 422, 423, 426, 427
- general construction, 407
- glottis, 410
- inferior, 407
- mucous membrane, 413
- position, 407
- superior aperture, 408
- ventricles of, 412
- ventricle, 407
- vocal cords, 410

- Lateral Recesses of fourth ventricle, 530
- of pharynx, 376

- Lateral sulcus of mesencephalon, 526

- Lateral Ventricles, 485, 502
 - anterior horns of, 485, 487
 - central part of, 485, 487
 - cornua, 487, 490
 - ependyma of, 485
 - inferior horns of, 483, 484, 485, 487, 490, 491
 - posterior horns of, 483, 484, 485, 486, 487, 490
 - pars centralis, 488

- Lemniscus, 512, 545
 - internal, 544
 - lateral, 512, 545
 - medial, 512, 528, 545

- Lena, 583
 - capsule of, 582, 583
 - central part of, 584
 - nucleus of, 584
 - suspensory ligament, 582, 583

- Lenticular ganglion, 332
- Lenticular nucleus, 514, 515, 517, 518

- Levator palati, 547

- Ligaments, accessory atlanto-epistropheal, 362
 - alar epistropheal, 364
 - alar, 364
 - anterior costo-transverse, 109, 115
 - anterior longitudinal, 115, 357, 360
 - apical dens, 363
 - atlanto-epistropheal, 362, 363
 - atlanto-occipital capsular, 361
 - of auditory ossicles, 557
 - auricular, 154
 - capitular, 112
 - connecting atlas, epistropheus, and occipital bone, 360
 - cruciatum transversum atlantis, 362
 - crico-thyroid, 229, 230, 297
 - crico-tracheal, 427
 - cruciatum, 362, 363
 - crus superius of, 363
 - inferius, 363, 413, 415
 - epiglottidean, 423
 - of epiglottis, 423
 - flava, 181, 358, 360
 - hyo-epiglottic, 423
 - ilio-lumbar, 168
 - of incus, 557
 - interspinous, 359
 - intertransverse, 116, 359

Ligaments—

- intervertebral, 116
 fibro-cartilage, 116
 annulus fibrosus, 116
 nucleus pulposus, 116
 of malleus, anterior, 557
 of incus, 557
 lateral, 557
 superior, 557
 medial palpebral, 121, 134, 136,
 140, 337
 of neck of rib, 114
 oblique of atlas, 181
 occipito-atlantal, 362, 363
 of pinna, 153
 pterygo-mandibular, 463
 pulmonary, 14, 16, 35, 43, 70
 posterior costo-transverse, 115
 posterior longitudinal, 116, 182,
 357
 of stapes, 557
 radiate, 113
 sacro-tuberosus, 178
 spheno-mandibular, 268, 269,
 270, 271, 272, 277, 278
 sterno-chondral, 113
 sterno-clavicular, 243
 sterno-costal radiate, 113
 sterno-pericardiac, 50
 stylo-hyoid, 286, 287, 290, 292, 296
 stylo-mandibular, 237, 263, 271,
 272, 282
 supraspinous, 166, 173, 181, 359
 suspensory, of axis, 363
 of lens, 583
 of orbit, 349
 of Lockwood, 349
 of eyelids, palpebral, 121
 temporo-mandibular, 271, 272,
 273
 thyreo-epiglottic, 408, 420, 423
 thyreo-hyoid, median, 413
 lateral, 413, 414
 of the neck of the rib, 115
 transverse, of atlas, 362
 of the tubercles, 114
 upper transverse of scapula, 164,
 242
 vocale, 415, 418, 419, 420, 428
- Ligamentum arteriosum**, 33, 77,
 78, 85, 87, 89, 100
 denticulatum, 186, 188, 214, 215,
 220, 355
 pulmonis, 14, 16, 35, 43
 nuchæ, 172
 pectinatum iridis, 574, 584
- Ligamentum ventriculare**, 410,
 420
Ligamenta flava, 181, 358, 360
Ligula, 531
 limbic lobe, 478
Limbus fossæ ovalis, 67
Linea splendens, 186, 188
Lines of pleural reflection, 14, 17,
 18, 19
Lingual glands, 283, 434
Lingula, 529, 535
Lips, 365, 366
Liver, caudate lobe of, 104
Lobe or Lobes, of cerebellum under
 surface, 533
 central, of cerebellum, 531
 of cerebrum, 462
 alæ of, 532
 cerebellar, 531
 cerebral, 462
 culmen monticuli, 532
 culminis, 532
 of clivus, 532
 of culmen, 532
 frontal, 449, 462
 insular, 462
 limbic, 478
Lobus tuberis, 534
 culminis cerebelli, 532
 clivi, 532
 declive monticuli, 532
 posterior crescentic lobule, 532
 folium vermis, 532
 gracilis, 534
 semilunaris superior, 532
Lobe or Lobes, of lung, 41
 of nodulus, 533
 occipital, 450, 462
 olfactory, 462
 parietal, 450, 462
 of pyramid, 534
 pyramidal, of thyreoid gland, 321
 substantia perforata anterior, 462
 semilunar superior, 532
 temporal, 450, 462
 of tuber, 534
 of uvula, 534
Lobule or Lobules, biventral,
 533
 central, of cerebellum, 531
 crescentic, anterior, 531, 532
 posterior, 531, 532
 of ear, 153
 gracile, 534
 paracentral, 449
 parietal, 450

Lobule or Lobules—

- parietal inferior, 471, 472
- superior, 471, 472
- posterior superior, 531
- quadrate, 532
- Locus ceruleus**, 537, 545
- Longitudinal bundle**, medial, 511
- sagittal, inferior, 217
- superior, 207
- Lumbo-dorsal fascia**, 166, 167, 168
- Lung**, 17, 35
 - aortic groove, 40
 - apex, 17, 36
 - azygos groove, 40
 - base, 36, 37
 - borders, 36
 - bronchi, 22
 - differences between right and left, 41
 - fissures, 41
 - hilus, 38, 40, 44
 - incisura cardiaca, 42
 - innominate groove, 40
 - ligamentum pulmonis, 35
 - lobes, 41
 - pedicle, 14, 42, 43
 - root, 42, 43
 - subclavian groove, 36, 40
 - surfaces, 36, 37
 - sulci, 40, 42
 - weight, 35
- Lunule**, 75
- Lymph duct, right**, 48, 107
- Lymph glands**, apical of tongue, 434
 - bronchial, 22, 43, 108
 - buccal, 133
 - cervical, 146
 - upper deep, 232, 261, 308
 - intercostal, 108, 256
 - mastoid, 154, 158
 - mediastinal, 10, 89
 - anterior, 7, 108
 - posterior, 108
 - superior, 108
 - occipital, 158
 - parotid, 158, 260, 366
 - space, perichorioidal, 578
 - sternal, 107, 108
 - submaxillary, 225, 230, 283, 366
 - submental, 228
 - supraclavicular, 147
 - of thorax, 10, 108, 257
 - thoracic visceral, 257
- Lymph vessels of lips**, 366
- vessels, pulmonary, 38

- Lymph trunks**, left common jugular, 106
 - left subclavian, 106
 - right jugular, 108, 257
 - right subclavian, 108, 257

Lyra, 498

- Macula lutea**, 580
- Magendie**, foramen of, 539
- Malleus**, 552, 554, 555, 556, 557, 565
 - handle of, 549, 565
 - head, 555
 - lateral process of, 549
 - processus lateralis, 554, 555
 - anterior, 555, 556, 565
- Mammillary bodies**, 452, 453, 497, 503, 504
- Manubrium**, 549, 554, 555, 557
- Marshall**, oblique vein of, 90
 - vestigial fold of, 90
- Mastoid antrum**, 565
 - air cells, 555, 559, 560
- Meatus**, external, acoustic, 259
 - internal acoustic, 562, 563, 565, 568
 - nasi, 397
 - inferior, 399
 - middle, 397
 - superior, 297
 - naso-pharyngeal, 400
- Mediastinal lymph glands**, 10, 89
 - pleura, 14, 23, 25, 33, 46, 49, 50, 70, 76, 77, 84, 85, 87
 - space, 14
- Mediastinum**, 10, 44
 - anterior, 11, 45, 46
 - inferior, 10, 45
 - middle, 11, 45
 - posterior, 1, 11, 26, 30, 45
 - superior, 10, 45, 46
- Medulla oblongata**, 520
 - antero-median groove of, 521
 - anterior area of, 522
 - central canal, 521
 - closed part, 520
 - decussation of pyramids, 520, 522
 - external arcuate fibres, 438, 528
 - floor of fourth ventricle, 526-528
 - formatio reticularis, 510, 543, 545
 - foramen cæcum, 521
 - fossa rhomboidalis, 536, 537
 - funiculus cuneatus, 525, 526
 - gracilis, 526

- Medulla oblongata**—
 funiculus lateralis, 525
 of Rolando, 526
 furrows, 521
 grey matter, 540
 internal structure, 540
 lateral area of, 524
 lemniscus et tractus cerebello-
 spinalis, 512, 525, 545
 nuclei, 522
 olivary eminence, 525, 526, 528
 open part, 536-539
 origin of nerves, 522
 posterior area of, 526
 median fissure of, 521
 pyramidal tract, 522
 pyramids, 522, 528
 raphe, 540, 542
 restiform body, 525
 structure of, 540, 541, 542, 543
 tubercle of Rolando, 527, 531
 white matter, 540
- Medulla spinalis**, 186, 187, 194
 differences in surfaces, 194
 internal structure, 194
 grey matter of, 196
 white matter of, 199
- Medullary centre**, 461
 external, 576
 internal, 576
 laminae, 516
 vela, 535
- Meibomian follicles.** *See* Tarsal
 glands
- Membrana chorio-capillaris**, 579
 flaccida, 556
 tympani, 556
- Membrane**, crico-thyroid, 297, 415
 anterior, 360, 361
 costo-coracoid, 161
 flaccida, 553, 554
 hyaloid, 581
 intercostal, anterior, 4
 posterior, 5, 29, 109, 110
 nictitans, 120
 of Shrapnell, 556
 posterior atlanto-occipital, 179,
 181, 355, 360, 361
 tectoria, 362
 thyreo-hyoid, 229, 243, 296, 413
 417
 tympanic, 270
- Meninges of brain**, 201, 414
 of spinal medulla, 183
- Mesencephalon**, 459, 506, 520
 Middle ear, 546, 550
- Mitral valve, 80, 92
 Moderator band, 71, 74
 Modiolus, 568
 Molar salivary glands, 133
 Monticulus of cerebellum, 529
 Morgagni, sinus of, 372, 382, 383
 Motor decussation, 542
- Mouth**, 364
 floor, 367
 roof, 368
 tongue, 431
 vestibule, 364, 366
- Muco-periosteum of nose, 400
 olfactory region, 400
 respiratory region, 400
- Muscle or Muscles**—
 angular head of quadrate muscle,
 124
 antitragicus, 155
 ary-epiglotticus, 415, 416, 429
 arytaenoideus, 429
 obliquus, 415, 416
 transversus, 415, 416, 417, 420,
 429
 ary-vocalis, 418
 auricularis anterior, 154
 posterior, 154
 superior, 154
 buccinator, 123, 127, 132, 261,
 270, 277, 372, 373
 caninus, 123, 128
 chondro-glossus, 435
 ciliary, 572, 578, 583
 of eyelid, 376
 constrictor, middle of pharynx,
 234, 281, 290, 291, 297, 303,
 315, 371, 372, 373
 inferior of pharynx, 234, 246,
 303, 314, 315, 371, 372, 413,
 414
 superior of pharynx, 132, 289,
 297, 299, 304, 311, 371, 372,
 373, 382, 383
 crico-arytaenoideus lateralis, 415,
 418, 419, 422, 429
 posterior, 415, 418, 422, 429
 crico-thyroid, 230, 314, 413, 414,
 417, 429
 depressor septi nasi, 123
 digastric, 230, 238, 259, 262, 264,
 274, 278, 280, 281, 282, 286,
 294, 297, 300, 303, 305, 306,
 307, 316
 dilatator pupillae, 578
 tubae, 384
 of ear, extrinsic, 154

Muscle or Muscles—

- of ear, intrinsic, 155
- operans, 122
- of eye, lateral rectus, 335, 342, 344, 344, 345, 346
- oblique, 335, 337, 338, 339, 344, 349
- obliquus superior of eye, 336, 337, 338, 349, 342, 346, 348
- medial rectus, 340, 344, 346
- obliquus inferior of eye, 341, 345, 346, 348
- of face, 120
- frontalis, 122
- genio-glossus, 285, 286, 287, 288, 290, 291, 292, 434, 435
- genio-hyoid, 285, 287, 290
- glossopalatinus, 381, 383
- gluticus maximus, 178
- helic. major, 155
- minor, 155
- hyoglossus, 230, 231, 234, 281, 282, 284, 285, 286, 287, 288, 289, 290, 291, 292, 310, 311, 316, 434, 435
- intercostalis, 169
 - cervicis, 169
 - dorsi, 169, 175
 - lumborum, 169
- mentalis, 133, 133
- mylo-hyoid, 240, 242, 243, 244
- infra-orbital head of quadrate muscle, 124
- infra-orbitary, 177
- intercostal, 1, 169
- interquadrates, 176, 177
- intermaxillares, 176, 177, 353, 354
- of jaw movements, 274
- of laryngeal movements, 420
- faciales, 121
- laryngeus dors., 3, 102
- levator palati, 304
 - glandulae thyroideae, 220, 321
 - palpinae superiores, 138, 139, 331, 338, 339, 337, 338, 339, 340
 - scapulae, 149, 180, 162, 238, 241, 323
 - vel palatum, 307, 373, 382, 383, 384
- levator costarum, 177
- linguales, 200, 202
- longissimus, 169
 - capitis, 168, 170, 306, 351

Muscle or Muscles—

- longissimus, cervicis, 170
- Gorsii, 169, 174
- longitudinal of tongue, inferior, 292, 435
- superior, 434, 435, 436
- obliquus capitis superior, 168, 171, 179, 180
 - externus abdominis, 3
 - capitis inferior, 174, 179, 180
 - of orbit, 346
 - internus abdominis, 167
- occipitalis, 156
 - superior, of neck, 180
 - of orbit, 338
- longus capitis, 246, 308, 351
- colli, 102, 106, 241, 246, 251, 322, 351, 354
- masseter, 126, 127, 259, 261, 265, 266, 270, 274, 276, 277, 283, 298, 302
- mentalis, 123, 133
 - levator costarum, 177
- of mouth, 123, 132
- multifidus, 176, 177
- mylo-hyoid, 230, 270, 274, 278, 280, 282, 284, 285, 288, 290, 300, 316
- nasalis, 123
 - pars transversa, 123
 - pars alaris, 123
- naso-ciliary, 336
- of nose, 122
- oblique superior of head, 354
 - inferior of head, 354
- obliquus auriculae, 155
- omo-hyoid, 146, 150, 161, 164, 234, 238, 242, 244, 246, 290, 413
- orbicularis oris, 121, 122, 123, 132, 136
 - oculi, 121, 134
 - orbital part, 121
 - palpebral portion, 121, 134
 - pars lacrimalis, 122, 136
- palato-glossus, 434, 435
- pharyngo-palatinus, 303, 369, 378, 381, 382, 383
- pectorales, 3
- platysma, 120, 126, 127, 143, 161, 260, 274
- prevertebral, 351
- pterygoid, external, 267, 268, 269, 270, 271, 273, 274, 275, 276, 277, 278, 546

Muscle or Muscles—

pterygoid, internal, 259, 263, 267,
 269, 274, 275, 276, 278, 281,
 282, 283, 289, 293, 298, 299,
 373, 546
 procerus, 122, 123
 quadratus labii inferioris, 123, 125
 lumborum, 167
 labii superioris, 123, 124, 129,
 387
 angular head, 125, 128
 infra-orbital head, 125, 128
 zygomatic head, 125
 rectus abdominis, 3
 capitis anterior, 238, 241, 308,
 351
 capitis lateralis, 238, 241, 308,
 353
 inferior, 344
 lateralis, 304
 lateralis of neck, 345
 medialis, 344
 posterior major, 179, 180
 posterior minor, 180
 superior, 324, 325
 rhomboideus major, 164
 minor, 164
 risorius, 123, 125, 126, 260
 rotatores spinæ, 176, 177
 sacro-spinalis, 169
 salpingo-pharyngeus, 381
 scalenus anterior, 34, 106, 235,
 238, 242, 246, 247, 248, 249,
 251, 252, 255, 257, 259, 309,
 322, 323, 354
 medius, 149, 161, 238, 241, 257,
 323
 posterior, 149, 323
 semispinalis capitis, 149, 168,
 170, 171, 172, 174, 178
 cervicis, 171, 172, 174, 176
 dorsi, 171, 176
 serratus anterior, 3, 149, 161
 posterior, inferior, 164, 165,
 166, 167
 posterior, superior, 164, 165, 168
 sphincter pupillæ, 578
 spinalis, 169, 170
 cervicis, 170
 dorsi, 170
 splenius capitis, 149, 164, 168,
 178, 238, 281
 cervicis, 168
 stapedius, 551, 554, 555, 558
 sterno-hyoid, 46, 47, 48, 239, 242,
 243, 246, 250, 296, 316, 434

Muscle or Muscles—

sterno-mastoid, 241, 242, 244,
 245, 250, 251, 259, 261, 281,
 296, 300, 304, 315, 323
 sterno-mastoid structures, beneath
 the, 238
 sterno-thyreoid, 46, 47, 48, 239,
 243, 244, 246, 250, 434
 stylo-glossus, 285, 286, 287, 289,
 290, 299, 413, 434, 435
 stylo-hyoid, 230, 259, 262, 263,
 280, 281, 282, 284, 286, 297,
 298, 305, 307, 413
 stylo-pharyngeus, 294, 295, 299,
 303, 373, 381
 subcostalis, 29, 306
 subclavius, 3
 subscapularis, 16
 supra-trochlear, 336
 supra-orbital, 336
 temporal, 265, 266, 267, 269, 270,
 274, 276, 277
 tensor veli palatini, 274, 275, 293
 tarsi, 121, 373, 382, 383, 384, 404
 tympani, 293, 312, 549
 thyreo-arytænoideus, 417, 419,
 422, 429
 thyreo-epiglotticus, 418, 422
 thyreo-hyoid, 231, 234, 243, 244,
 296, 314, 413
 tragicus, 155
 transversus abdominis, 167
 auriculæ, 155
 of tongue, 435
 thoracis, 6, 8, 9, 12, 50
 trapezius, 162, 241, 315
 triangularis, 123, 125, 128, 129
 of tympanic cavity, 558
 uvulæ, 381, 383
 vertical, of tongue, 435
 vocales, 415, 418, 419, 422, 429
 zygomaticus, 123, 125, 128, 129
 Muscular triangle of neck, 222, 226,
 232, 233, 259
 Myocardium, 92
 Nares, posterior, 374, 375, 377, 389
 Nasal cartilages, 140
 cavities, 393
 anterior apertures of, 393
 part, 393
 conchæ, 395
 floor, 394
 lateral wall, 395
 posterior apertures of, 393, 394
 roof of, 393

- Nasal fossa, 393**
 atrium, 395
 conchæ, 396, 397
 inferior meatus, 399
 infundibulum, 397
 lateral wall, 395
 middle meatus, 397
 olfactory part, 400
 recessus sphenoidalis,
 399
 respiratory part, 400
 superior meatus, 397
 vestibule, 395
- Nasal septum, 391**
 cartilage of, 391
 construction of, 391
 olfactory area of, 390
 respiratory area of, 390
 vessels and nerves of, 392
- Nasal vestibulum, 395**
- Naso-lacrimal duct, 140**
- Naso-pharynx, 375**
- Neck, 141**
 anterior triangle, 226
 deep dissection, 294
 digastric triangle, 226
 carotid triangle, 226
 fasciæ, 224
 infra-hyoid region, 227
 joints, 356
 mid-line, 226
 muscular triangle, 226
 occipital triangle, 168
 posterior triangle, 142
 side of, 142
 submaxillary triangle, 226
 submental triangle, 226, 227
 supraclavicular region, 224
 suprahyoid region, 227
 surface anatomy, 224
- Nerve or Nerves, abducent, 212,**
 215, 218, 327, 330, 345, 346,
 386, 457
 accessory, 145, 146, 150, 162,
 213, 218, 232, 235, 239, 262,
 281, 300, 304, 307, 309, 310,
 312, 313, 315, 455, 456
 acromial, 182, 228
 acoustic, 213, 215, 218, 456,
 562, 563, 565
 cochlear division, 565
 vestibular division, 565
 anterior cutaneous, 4, 110
 anterior thoracic, 160
 alveolar inferior, 267, 268, 276,
 277, 278, 279, 293
- Nerve or Nerves—**
 alveolar superior, 388
 anterior, 388
 middle, 388
 posterior, 388
 aortic, 100
 auricular of auriculo-temporal,
 277
 great, 126, 143, 145, 146, 151,
 156, 235, 239, 241
 of great occipital, 156
 posterior, 154, 156, 157
 of small occipital, 239, 241
 of vagus, 312, 313
 auriculo-temporal, 127, 156, 261,
 267, 274, 276, 277, 293
 branches of, 277
 axillary, 160
 to azygos uvulæ, 383
 brachial, 109, 147, 157, 160,
 323
 buccinator, 128, 134, 267, 268,
 276, 277
 of facial, 126, 128
 of sympathetic, 314
 cardiac, 30, 33, 65, 87, 89, 250
 inferior, 319
 middle, 318
 of vagus, 30, 33, 87, 89, 99,
 100, 250, 314, 315
 superior, 317, 318
 carotic external, 317, 318
 internal, 317, 318, 385
 carotico-tympanic, 312, 386
 cerebral superficial origins, 454
 cervical, 353
 cervical, first, 353, 522
 anterior branches, 324, 325
 loop between first two, 353
 posterior divisions, 162, 173,
 174
 chorda tympani, 549, 551, 552,
 565
 ciliary, 141, 149, 161, 578
 long, 339, 340
 short, 341
 clavicular, 274, 278, 290, 293
 coccygeal, 178
 cochlear, 565
 communicans hypoglossi, 308, 316
 communicating of 9th to 7th,
 311
 communication of hypoglossal,
 316
 cords of brachial plexus, 160
 cranial, 123, 456

Nerve or Nerves—

- cranial, superficial origin of, 454, 455, 456, 457, 458, 459
- cutaneous colli, 143, 145, 151, 224, 235, 239, 241
- descendens hypoglossi, 239, 243, 305
- descending of cervical plexus, 143
- to digastric, 267, 268, 276, 277, 278, 279, 293
- dorsal, posterior divisions of, 174
- scapular, 147, 160, 164, 323
- ethmoidal, 344
 - anterior, 340, 402
 - medial nasal, 393
 - posterior, 340
- long thoracic, 323
- of face, 126
- facial, 213, 215, 218, 263, 281, 282, 313, 338, 456, 457, 557, 558, 561, 562, 563, 564
 - buccal branches, 127, 128, 261
 - cervical branches, 127, 261, 294
 - division, 184, 198, 262
 - cervico-facial division, 261
 - communicating branches of, 564
- facial, communicating with auriculo-temporal, 277
- of great auricular, 126, 146, 241
- intrapetrous part, 562, 563, 564
- mandibular branches, 127, 128, 129, 261
- muscular to stylohyoid and digastric, 262, 281
- posterior auricular, 262, 301
- sensory root, 215
- superficial origin, 458
- temporal branches, 127, 128, 137, 156, 261
- temporo-facial division, 261
- zygomatic branches, 127, 128, 137, 261
- frontal, 330, 334, 336, 346
- glosso-pharyngeal, 213, 215, 218, 277, 281, 286, 304, 306, 307, 309, 310, 311, 435, 436, 455
- ganglion, superius of, 312
- lingual branches, 311
- petrous ganglion, 312
- superficial origin, 458, 522
- tympanic branch, 312, 563
- of heart, 33, 43, 65, 78, 85, 87, 89, 96-99, 100

Nerve or Nerves—

- hypoglossal, 213, 215, 218, 220, 231, 232, 233, 244, 281, 282, 284, 285, 287, 288, 290, 291, 292, 294, 300, 304, 305, 306, 307, 309, 310, 314, 316, 317, 351, 355, 435, 436, 455, 522
- superficial origin, 457, 522
- incisor, 279
- infra-mandibular, 264
- infra-orbital, 128, 129, 138, 387
- nasal branches, 128
- orbital branches, 128
- palpebral branches, 128
- plexus, 128
- infra-trochlear, 137, 138, 340
- intercostal, 28, 110
 - second, 110
- intercosto-brachial, 110
- of Jacobson, 312, 563
- labial, 129
- lacrimal, 137, 138, 330, 335, 336, 346
- laryngeal, external, 232, 234, 243, 295, 314
 - inferior, 315, 372, 413, 421, 422
 - internal, 232, 295, 304, 314, 372, 413, 421, 422, 435, 436
- laryngeal, recurrent, 2, 33, 49, 78, 87, 89, 96, 100, 108, 245, 246, 250, 257, 258, 314, 315, 421
- superior, 232, 295, 304, 314, 318
- internal branch of, 421
- laryngo-pharyngeal, 317, 318
- lateral cutaneous, 4, 6, 110
- nasal of internal ethmoidal, 481
- to levator palati, 380
- scapulæ, 151
- lingual, 267, 274, 276, 278, 279, 282, 284, 285, 286, 288, 289, 290, 292, 293, 434, 435, 436, 565
 - branches of, 289
 - of ninth, 314
 - of vagus, 316
- long thoracic, 160
- lumbar, 150, 166
 - posterior divisions of, 175
- malar, 261, 263, 265, 347
- mandibular, 212, 274, 275-278, 293
- masseteric, 267, 276
- mastoid, 110, 136
- maxillary, 212, 403
- medial cutaneous, of arm, 160
 - of forearm, 161
- median, of arm, 160

Nerve or Nerves—

- meningeal branch of trigeminal, 327, 330, 385
- of vagus, 313
- of hypoglossal, 316
- mental, 128, 129, 279
- mylo-hyoid, 230, 276, 278, 281, 284
- musculo-cutaneous, of arm, 160
- nasal of anterior superior alveolar, 401
 - external, 341
 - internal, 341
 - of infra-orbital, 129
 - posterior inferior, 405
 - superior, 401, 402, 403
- naso-ciliary, 140, 330, 339, 340, 341, 345, 346, 386
- palatine, 392, 401, 402, 403
- occipital, great, 156, 161, 162, 174
- small, 143, 145, 146, 151, 156, 239, 241
- smallest, 156, 161
- oculo-motor, 210, 212, 218, 326, 327, 330, 331, 332, 335, 338, 345, 346, 347, 386, 446, 458
- nucleus of, 509
- oesophageal, 99, 109
- olfactory, 208, 218, 392, 401, 458
- omohyoid, 146, 150
- ophthalmic, 212, 386
- optic, 208, 218, 339, 341, 458, 572
 - superficial origin, 458
- to palate, 380, 383
- palatine, anterior, 402, 403, 404, 405
 - great, 380
 - middle, 383, 404
 - posterior, 383, 404
 - small, 380
- palpebral, 129, 138
- parotid, 277
- pericardiac, 34, 99
- petrosal, external superficial, 318, 333, 386, 564
 - great deep, 333, 386, 405, 564
 - great superficial, 212, 332, 385, 405
 - small superficial, 333
- pharyngeal, 311
 - of pharyngeal canal, 405
 - of glosso-pharyngeal, 295, 315
 - of sympathetic, 315
 - of vagus, 295, 304, 306, 314, 315, 383

Nerve or Nerves—

- phrenic, 2, 10, 23, 25, 30, 33, 34, 43, 49, 50, 70, 87, 88, 89, 239, 240, 241, 250, 251, 253, 254, 255, 257, 258, 309, 323
- pneumogastric. *See* Nerve, Vagus
- long thoracic, 147
- pterygoid, 293, 333
- of pterygoid canal, 386, 393, 405
- pulmonary, 43, 99, 100, 101
- radial, 160
- roots of accessory, 522, 526
 - glosso-pharyngeal, 522, 526
 - vagus, 522, 526
- sacral, 177
 - posterior branches of, 177
- to scalenus medius, 151
 - posterior, 151
- of scalp, 156
- spheno-palatine, 388, 403
- spinal, 5, 189, 192
 - anterior primary divisions, 109, 192
 - classification, 189
 - exits from vertebral canal, 190
 - ganglia, 185, 189, 192
 - origin from cord, 189
 - posterior primary divisions, 173, 174, 178, 192
 - roots, 185, 189
- spinal accessory. *See* Accessory accessory part, 215
- spinal part, 215
- spinosus, 275, 333
 - to external pterygoid, 277
 - to internal pterygoid, 275, 276
- splanchnic, 26, 28, 32, 70
 - great, 28
 - lowest, 28
- to stapedius, 564
- sternal, 145
- stylo-hyoid, 230, 285
- to stylo-pharyngeus, 311
- to subclavius, 147, 161
- sub-occipital, 172, 173, 179, 180, 190
- subscapular, 160
- supraclavicular, of brachial plexus, 145, 149, 161
 - of cervical plexus, 143, 151, 161, 239, 241
- supra-orbital, 121, 137, 138, 156
- supra-scapular, 147
- supra-trochlear, 137, 138, 156, 340, 344

Nerve or Nerves—

- sympathetic. *See* Sympathetic
temporal, of auriculo-temporal,
277
of buccinator, 277
deep, 267, 276
of facial, 137, 156, 261
of orbital, 334, 350, 388
to tensor palati, 293
tympani, 293
thoracic first, 109, 254, 257
thyreoid, 318
thyreo-hyoid, 316
tonsillitic, 311
to trapezius, 151
trigeminal, 212, 218, 329, 330,
457, 529
mandibular division, 329
maxillary division, 329, 330
motor root, 215, 329
ophthalmic division of, 326,
327, 329, 330, 336
roots of, 328
semilunar ganglion, 211, 212
sensory root, 212, 215, 328
tractus spinalis of, 527
for temporo-mandibular joint, 277
thoraco-dorsal, 160
trochlear, 211, 212, 215, 218, 326,
327, 330, 332, 335, 336, 346,
386, 446, 457, 506, 530
roots of, 538
superficial origin, 457
tympanic, 312
ulnar, 160
vagus, 2, 10, 23, 25, 30, 32, 33,
35, 49, 89, 100, 106, 108,
213, 215, 218, 232, 239, 245,
252, 257, 258, 300, 304, 307,
309, 310, 312, 313, 315, 435,
456
ganglion jugulare, 313
nodosum, 313
left, 30, 99
right, 23, 99
superficial origin, 455
thoracic branches of, 99
vascular of hypoglossal, 316
vestibular division of acoustic, 565
zygomatic, 334, 350, 388
zygomatico-temporal, 156, 266,
267, 350
-facial, 350
Nictitating membrane, 120
Nodule of cerebellum, 533
Nose, cartilages of, 140, 391

Nose—

- conchæ of, 401
fossæ. *See* Nasal fossæ
septum, 390, 401, 402
vestibule, 390
Nostril, 390
Notch, preoccipital, 470, 473
of Rivinus, 553, 554
Nucleus, amygdaloid, 491, 494,
512, 514
auditory, 538
caudate, 488, 489, 491, 494, 502,
512, 513, 514, 515, 518, 538
cochlear, 512
cuneatus, 527
dentatus of cerebellum, 450, 454,
512, 514, 515, 517, 518, 539
glosso-pharyngeal, 538
gracilis, 527, 541
hypoglossal, 537
of lens, 584
lentiform, 514, 515, 517, 518
oculo-motor, 509
olivary, 543
accessory, 541
of optic thalamus, 519
pontis, 545
pulposus, 115
ruber, 512
trigeminal, 509
trochlear, 509
vagus, 538
Nühn, gland of, 434
Obex, 538
Oblique sinus of pericardium, 58,
59, 89
Obliterated ductus arteriosus, 33,
77, 78
Occipital lobe, 450, 462
pole, 465
sinus, 183, 216, 217
triangle, 163
Esophageal plexus, 99-102
Esophagus, 2, 10, 17, 23, 26, 29,
30, 31, 32, 39, 40, 49, 50,
58, 85, 87, 89, 96, 99, 100,
101, 104, 106
Olfactory bulb, 322, 439, 469, 477
lobe, 418
strix, 477, 478
tract, 439, 469, 477
trigone, 478
Olivary eminence, 524, 525, 526
nucleus, 543
Olive, 524, 525, 526

- Olive, superior, 545
 Omental bursa, 104
 Opercula insulæ, 463
 frontal, 464, 490
 fronto-parietal, 463, 475, 490
 orbital, 464, 490
 temporal, 463, 475, 490
Optic chiasma, 452, 505
 disc, 580, 581
 entrance, 572, 578, 579
 thalamus, 417, 450, 487
 tract, 452, 507, 508
Optic nucleus—
 lateral root, 507, 508
 medial root, 507, 508
 Ora serrata, 580, 581
 Oral fissure, 365
 Orbit, 333
 Orbital operculum, 464, 490
 periosteum, 334
 Ossicles, auditory, 546, 550, 554,
 555, 556
 Ostium pharyngeum, 376
 Otic ganglion, 276, 277, 279, 293,
 383

Palate, hard, 373
 soft, 375, 380, 382
 Palatal aponeurosis, 382
 Palpebræ, 119, 134
Palpebral commissures, 119
 conjunctiva, 119
 fascia, 135
 fissure, 119
 lateral palpebral raphe, 121
 medial palpebral ligament, 121
 Papillæ foliatæ, 432
 incisive, 368
 lacrimalis, 120
 Papillæ vallatæ, 432
 conical, 432
 filiform, 432
 foliatæ, 431
 fungiform, 432
 Papilla nervi optici, 580
 Paracentral lobule, 449
 Paramedian sulcus of spinal medulla,
 195
 Parietal lobe, 450
 lobule, 450
 Parieto-occipital fissure, 462
 Parotid, accessory, 261
 duct, 127, 261
 fascia, 126
 gland, 126, 127, 233, 259, 281
 lymph glands, 257

 Parotid, pterygoid lobe of, 263
 space, 259, 262, 281
 surfaces of, 260, 262
 Pars basilaris of inferior frontal
 gyrus, 469
 Pars ciliaris retinae, 580
 mamillaris hypothalami, 520
 membranacea septi, 74, 83
 orbitalis of inferior frontal gyrus,
 469
 triangularis of inferior frontal
 gyrus, 464
 Peduncle of brain, 446, 447
Peduncles of cerebrum, 210, 212,
 452, 500, 501
 basis pedunculi, 210
 tegmentum, 210, 503, 508, 509,
 510, 512
Pericardium, 10, 25, 26, 30, 33,
 38, 50, 98, 104
 bare area of, 50
 fibrous, 50, 70, 75, 83
 oblique sinus, 58, 59, 89
 parietal, 52, 89
 serous, 51, 59, 70, 75
 transverse sinus, 54, 59, 76
 vestigial fold, 92
 visceral, 52, 89
 Perilymph, 546, 566
 vibrations of, 569
 Pes anserinus hippocampi, 491, 492,
 493, 497
 Petrosal sinus, inferior, 312
 superior, 326
 Petrous ganglion, 312, 313, 317
Pharyngeal aponeurosis, 370
 bursa, 373, 376
 plexus, 309, 311, 314
 tonsil, 376
Pharynx, 369
 bucco-pharyngeal fascia, 370
 constrictor muscles, 370, 371
 glands, 375
 interior of, 374
 isthmus, 384
 laryngeal part, 378
 lateral recesses, 376
 lymphoid follicles, 376
 muscles, 371
 naso-pharynx, 375
 oesophageal opening, 379
 openings, 370, 375, 376
 oral part, 377
 recess of, 376
 relations of, 369
 roof, 376

Pharynx—

- tonsil, 376
- veins, 370
- walls, 370
- Phrenico-costal sinus, 16
- Pia mater encephali, 442
 - spinalis, 186
- Pillars** of fauces, 368
- Pineal body, 500, 503, 505
- Pinna, 153
 - extrinsic muscles of, 153
 - intrinsic muscles of, 153
- Piriform recess, 379
- Pleura**, 7, 11, 12, 33
 - apex of, 15, 257
 - base of, 16
 - cervical, 15, 248, 250, 257
 - costal, 12, 25
 - diaphragmatic, 16
 - dome of, 309
 - lines of reflection, 14, 17, 18, 19
 - mediastinal, 14, 23, 25, 33, 46, 49, 50, 70, 76, 77, 84, 85, 87
 - parietal, 12, 14
 - pulmonary ligament, 14
 - relations, 76
 - visceral, 11, 14, 104, 105
- Pleural cavities, 12
 - sac, 12
- Plexus**, basilar, venous, 183, 216, 217
 - brachial, 109, 147, 151, 160, 323.
 - See also vol. i. p. 28
 - buccal, 277
 - cardiac, deep, 65, 85, 89, 96, 100, 101, 315
 - superficial, 33, 43, 65, 78, 85, 87, 315
 - carotid, 247, 296, 341, 386
 - external, 318
 - internal (nervous), 385
 - cavernous, 331, 332, 385, 386
 - cervical, 151, 239, 240
 - communicating branches, 241
 - deep posterior branches, 151, 241
 - muscular branches, 241
 - superficial branches, 143, 151, 241
 - chorioid, 488, 489, 492, 493, 494, 499, 502
 - coronary of heart, left, 65, 101
 - right, 65, 85, 101
 - diaphragmatic, 34
 - hypoglossal, 316
 - infra-orbital, 128, 129, 387
 - branches of, 129
 - internal vertebral (venous), 182

Plexus—

- intraspinal (venous), 182
- oesophageal, 99, 100, 102, 104
- pharyngeal, 309, 311, 314, 315
 - nervous, 370
 - position of, 16
 - posterior sacral, 178
 - posterior vertebral (venous), 176, 178
- pterygoid (venous), 132, 271, 370, 389
- pulmonary, anterior, 43, 99, 100, 101
 - posterior, 43, 98, 100, 101
- renal, 28
- spinal (venous), 182
- suboccipital (venous), 157, 173
- submaxillary sympathetic, 284
- tympanic, 386
- vertebral (venous), 355, 356
 - sympathetic, 355
- Plica sublingualis, 288, 289
 - fimbriata, 368
 - of tongue, 431
 - lacrimalis, 140
 - semilunaris, 119, 120
 - triangularis, 378
- Plicæ ventriculares, 407, 408, 409, 411, 419, 421
 - vocales, 407, 409, 410, 411, 419, 421
- Poles of cerebrum, 465
 - of eyeball, 570
 - occipital, 465, 473, 474, 476
 - temporal, 465, 475, 479, 485, 487, 494
- Pons** Varolii, 212, 437, 528
 - brachium pontis, 528
 - bundle, medial longitudinal of, 545
 - corpus trapezoidum, 545
 - fibres, superficial transverse of, 545
 - longitudinal of, 545
 - trapezoid of, 545
 - floor of fourth ventricle, 536
 - internal structure, 544
 - lemniscus, 542, 545
 - nuclei, 545
 - pyramidal tract, 544
 - raphe, 540, 544
 - reticular formation, 543
 - substantia ferruginea, 545
 - tegmental part, 545
 - transverse fibres, 545
- Posterior longitudinal bundle, 544

- Præcuneus**, 449, 470, 472, 473, 477, 478
Præoccipital notch, 473, 490
Pretracheal fascia, 229, 230, 235
Prevertebral fascia, 235, 236, 237
Process, anterior of malleus, 556
 ciliary, 577, 579, 581, 582, 583, 584
 cochleariformis, 551, 558
 helicis caudatus, 155
 lenticularis of incus, 557
 muscular, of arytenoid, 428
 vocalis of arytenoid, 428
Promontory of tympanum, 552, 568
Prosencephalon, 520
Prussak, stric of, 554
Pterygoid lobe of parotid gland, 263
 plexus, venous, 132, 271, 370, 387
Pterygo-maxillary region, 152, 263
Pulley of superior oblique, 335, 339
Pulvinar of thalamus, 507
Puncta lacrimalia, 120, 139
Pupil, 578
 sphincter and dilatator muscles of, 578
Putamen of thalamus, 516
Pyramid of cerebellum, 533
 decussation of, 533, 534
 of medulla, 523
 of tympanum, 551, 552, 558, 564
Pyramidal lobe of thyroid, 321
 tract, 544
 crossed, 544
 direct, 544
Quadrangle lobule of cerebellum, 532
Quadrigeminal bodies, 506, 507
 brachia of, 506, 507
Radiate ligament, 113
Radiatio corporis callosi, 483
Rami communicantes, grey, 28
 white, 26
Raphe, lateral palpebral, 121, 134, 135, 337
 of medulla, 540, 542
 of palate, 382
 of pharynx, 373
 pterygo-mandibular, 132, 373, 389
 of tongue, 436
Recesses, lateral, of fourth ventricle, 536
 of pharynx, 376
Recessus epitympanicus, 550, 552, 555
 ellipticus, 566
 infundibuli, 505
 pinealis, 505
 piriformis, 379
 spheno-ethmoidalis, 399
 sphericus, 566
 suprapinealis, 505
 triangularis, 505
Red nucleus, 512
Reil, island of, 477
Restiform body, 527, 528, 529
Retina, 571, 579, 580
Rhombencephalon, 458, 520
Rima glottidis, 410
 vestibulæ, 410
 palpebrarum, 119
Rivinus, ducts of,
 notch of, 553, 554
Rolando, central fissure of, 462, 464
 funiculus of, 199, 200
 substantia gelatinosa of, 542
Root-ganglia, 189, 191
Root of lung, 22
Roots of olfactory tract, 482
 of spinal nerves, 189, 191
Rostrum of corpus callosum, 458
Saccule, 569
Sac lacrimal, 136
Salivary glands, molar, 133
 labial, 133
Salpingo-pharyngeal fold, 376
Scala media, 569
 tympani, 568, 569
 vestibuli, 568, 569
Scalene tubercle, 313
Scalp, 132
 blood-vessels, 157
 epicranial-aponeurosis, 158
 fascia, 158, 159
 loose areolar tissue, layer of, 159
 nerves, 156
 strata, 152, 159
 temporal region of, 152
 surgical anatomy, 153, 159
Sclera, 571, 572, 573, 574, 579, 578
Scleral coat, 572
 sulcus, 573
Semicircular canals, lateral, 561, 567
Semilunar valves, 75, 78, 81
Sensory decussation, 542
Septal cartilage of nose, 391
Septum atriorum, 69
 nasal, 389

- Septum of tongue, 436
 pellucidum, 449, 488, 494, 495,
 497
 posterius of arachnoid, 186
 ventriculorum, 71, 72, 78, 82
- Sheath, carotid, 235
- Sibson's fascia, 36, 251, 257
- Sinus**, aortic, 60, 80
 basilar, 183, 216
 bulb of, 307
 cavernous, 209, 210, 217, 271,
 325, 326, 327, 329, 330, 331,
 332, 334, 346
 confluens sinuum, 217
 coronary, 89
 costo-mediastinal, 16, 370
 frontal, 396, 397
 inferior sagittal, 207, 211, 217
 petrosal, 309
 intercavernous, 326
 anterior, 209, 217
 posterior, 209, 217
 maxillary, 395, 398
 oblique, of pericardium, 58, 59,
 89
 occipital, 183, 216, 217
 of Morgagni, 373, 382, 383
 petrosal, inferior, 216, 217, 312,
 326
 superior, 211, 217, 326
 petro-squamous, 217
 pharyngeal venous, 327
 phrenico-costal, 16, 37
 pterygoid venous, 327
 pulmonary (Valsalva), 60, 75
 sigmoid part, 560
 sigmoid portion of, 216
 sphenoidal, 397, 399
 spheno-parietal, 211, 217, 326
 straight, 207, 210, 211, 217,
 499
 superior sagittal, 162, 202, 205,
 206, 207, 217
 transverse, 171, 205, 211, 215,
 217, 307, 560
 of pericardium, 54, 59, 76
- Space** interpeduncular, 452
 mediastinal, 10
 parotid, 259
 perichoroidal, 572
 subarachnoid, 439
 subdural, 204
 suboccipital, 204
- Spaces of Fontana, 574
- Spatia anguli iridis, 574, 584
 zonularia, 583
- Spatium interfasciale (of eye), 348
- Spheno-ethmoidal recess, 399
 sinus, 397, 399
- Spheno-palatine ganglion, 386, 388,
 392
- Sphincter pupillæ, 578
- Spina helices, 158
- Spinal medulla, 28
 anterior surface, 194
 arteries, 193
 caput of columns, 197
 central canal, 196
 cervical enlargement, 187
 columns, 196, 197, 199
 commissures, 196
 conus medullaris, 188
 direct cerebellar tract, 200
 fasciculus cerebro-spinalis later-
 alis, 200
 anterior, 200
 cuneatus, 200
 gracilis, 200
 filum terminale, 188
 fissures, 195
 grey matter, 196
 internal structure, 194
 lumbar enlargement, 188
 meninges, 183
 origin of nerves, 189
 posterior surface, 187
 regions, 198
 substantia gelatinosa, 197
 sulci, 195
 surfaces, 187
 veins, 194
 white matter, 199
 nerve-roots, 189
 nerve-trunks, 189, 192
 root-ganglia, 189
 venous plexuses. *See* Plexus.
- Spiral canal of modiolus, 568
- Splanchnic ganglion, 28
- Splenium of corpus callosum, 446
- Stapes, 552, 557, 566
 base, 557
 crura, 557
 head, 557
 neck, 557
- Stensen, duct of, 261
- Sternal line of pleural reflection, 18,
 19
 lymph glands, 107
- Sterno-chondral articulations, 112
- Sterno-costal radiate ligament, 111
 interarticular ligaments, 111
- Straight sinus, 54, 59, 76

- Stratum pigmenti iridis, 580
 Stria longitudinalis medialis, 481,
 482, 500
 lateralis, 482, 483
 medullaris, 502
 terminalis, 488, 489, 491, 502,
 513, 514, 578
 olfactory, 477, 478
 Striae medullares, 538
 longitudinales, 482
 of Prussak, 554
 Subarachnoid cisternæ, 439
 space, 439
 Subclavian groove, 40
 triangle, 249
 Subdural space, 204
 Sublingual gland, 280, 286, 288,
 289, 290, 292
 Submaxillary duct, 282, 285, 286,
 288, 289
 ganglion, 282, 284, 285, 318
 gland, 225, 280, 281, 282, 283,
 284, 285, 286, 288, 289,
 290
 nerve supply, 284, 298
 region, 279
 triangle, 279, 280
 Submental triangle, 223, 226, 227
 Suboccipital space, 178
 Substantia ferruginea, 545
 gelatinosa, Rolandi, 197, 527
 nigra, 210, 510
 perforata anterior, 447, 450, 454,
 478, 479, 483, 517, 518
 posterior, 447, 452, 503
 Subthalamic region, 501
 Sucking pad of fat, 133, 266
Sulcus or Sulci, of brain, 461
 callosal, 478
 centralis insulæ, 464, 466, 467,
 469, 470, 471, 472, 477
 cinguli, 465, 466, 469, 479
 circular, 477
 coronary, 68
 diagonal, 469
 fimbrio-dentate, 495
 frontal, inferior, 467
 middle, 467
 superior, 467
 fronto-marginal, 467
 of Heschl, 475
 of spinal medulla, 195
 intermediate posterior of spinal
 medulla, 199
 great horizontal, 530, 531
 hypo-thalamic, 505
Sulcus or Sulci—
 intraparietal, 471, 472
 horizontal ramus of, 471
 occipital ramus of, 471, 474
 lateralis mesencephali, 506
 limitans (of 4th ventricle), 537,
 538
 lunatus, 474
 of lungs, 41
 occipitalis transversus, 472, 474
 lateralis, 474
 olfactorius, 396, 469
 olfactory, 477
 orbital, 469
 lateral, 469
 medial, 469
 transverse, 470
 paramedial, of cerebrum, 467
 post-central, inferior, 471, 472
 superior, 471, 472
 postero-lateral of cord, 195
 precentral, 467
 inferior, 466, 469
 superior, 466
 rostrales, 469
 scleral, 573
 sub-parietal, 471, 478
 temporal operculum, 485
 inferior, 476, 477
 middle, 472, 475
 superior, 472, 475, 485
 terminalis of heart, 34
 of tongue, 430
 tympanicus, 553
 vallecule, 530
 venosus scleræ, 573
 Surface anatomy of neck, 223
 Suprasternal fossa, space, 224
 Supratonsillar fossa, 378
 superior, 317, 318
 inferior, 319
 middle, 318
Sympathetic, cervical, 245, 247, 252
 abdominal, 34
 branches of, 27, 28, 32, 254
 dorsal branch, 108
 first thoracic ganglion, 110, 257,
 258
 gangliated cord, 2, 23, 25, 27
 thoracic, 2, 23, 26, 109, 110,
 254
 Synchondrosis sternalis, 112
Tænia of 4th ventricle, 537
 Tapetum, 483, 490, 574
 of choiroid, 575

- Tarsal glands, 120
 Tarsi, 134
 inferior, 135
 superior, 135
 Tegmentum, 210, 503, 508, 509, 510, 512
 Tegmen tympani, 550
 Tela chorioidea, 442, 447, 497, 498, 499, 500, 502, 504, 538
 that which is in, 539
 Telencephalon, 520
Temporal fascia, 265, 266
 lobe, 462
 notch, 470, 473
 operculum, 463
 pole, 465
 region, 152, 265
 Tensor tympani, 565
 palati, 547
 Tentorium cerebelli, 208, 212, 218, 459
 Thalamencephalon, 458, 520
Thalamo-mamillary region, 519
 anterior tubercle, 502
 lateral area, 502
 massa intermedia, 503, 504
 medial area, 502
 surface, 503
 posterior extremity, 502
 pulvinar, 502
Thalamus, 447, 450, 487, 488, 489, 497, 499, 512, 513, 514, 518, 520
 epi-thalamus, 520
 meta-thalamus, 520
 Third ventricle of brain, 498, 499, 500, 502, 503, 504, 505
 tænia thalami, 500, 501, 502, 503, 504, 505, 508
 Thoracic duct, 2, 10, 31, 32, 48, 246, 250, 313
 ganglia, 312, 314, 317
Thorax, 1
 cavity, 1, 10
 inlet, 2
 joints, 111
 lymph glands, 107
 outlet, 2
 viscera, 10
 walls, 3, 109
 Thymus gland, 46, 47, 48, 85
 Thyreo-hyoid membrane, 229, 243, 296, 413, 417
Thyroid gland, 229, 234, 244, 246, 252, 253, 297, 319, 320, 321, 322, 407
 Thyroid, cartilage, 229, 234, 244, 423
 isthmus, 229, 320, 321
 incisura, 423
 laryngeal prominence, 424
 lateral lobe, 407
 paramedial lobe, 407
 prominentia laryngea, 229
 pyramidal lobe of, 321
Tongue, 429
 dorsum, 430
 frenulum, 288, 431
 glands, 283, 434
 lateral lobes of, 319
 mucous membrane, 430
 muscles, 285, 433, 434
 nerves, 289, 435
 oral part, 430
 papillæ, 432
 pharyngeal part, 430
 relations of, 319
 septum, 436
 vessels, 321, 435
Tonsil, 299, 369, 383
 cerebellar, 533
 pharyngeal, 378
 vessels of, 383
 Topography of heart, 94
 confluens sinuum, 211
 Torus tubarius, 376
 Trabeculæ carneæ, 72, 79
 Trachea, 2, 10, 17, 23, 49, 85, 87, 89, 95, 99, 101, 321
 Tragus, 158
 Transverse fissure, 499
 sinus of pericardium, 54, 59, 76
 venous sinus, 171, 205
Triangle, anterior, of neck, 222, 226
 carotid, 226, 232, 233, 259
 contents of, 231
 digastric, 226
 contents of, 230
 muscular, of neck, 226, 234
 occipital, 168
 posterior, of neck, 148
 contents of, 149
 subclavian, 249
 submaxillary, 223
 submental, 223, 226, 227
 suboccipital, 168, 172
 supraclavicular, 149
 suprameatal, 560
 Triangular fossa, 154
 Tricuspid valve, 69

- Trigonum** s. laterale, 400
 lat. anter., 502
 hypogloss., 557
- Trifidus, f. superior obliquus, 330
- Trunk, dorsal aspect, 161
- Trunk-ganglion, f. vagus, 313
- Trunks, f. radial plexus, 151
- Tube, auditory**, 203, 304, 340, 347, 349, 551, 558, 559
 osseus, part, 550
 cartilaginous, part, 550
- Tuber cinereum**, 453, 503, 505, 520
 nodale, 533
 pyramide, 533
 uvula, 533
 vermis, 533
- Tubercle, amygdaloid**, 400, 493
 anterior of thalamus, 503
 corniculata, 379
 coniform, 370
 intervenus, 67
 of K. lambr., 527
 of hyr. of cartilage, 424, 425
 scalena, 313
 of vermis, 533
- Tympan** ovalicular folds, 554
- Tympanum**, 312, 557, 558, 559
 alius of, 555, 561
 medial wall of, 561
 anterior wall, 551
 antrum, 557
 cavity, 505
 cavity, promontory of, 561
 floor, 550
 jugular wall, 550
 lateral wall, 553
 mastoid wall, 550
 medial wall, 552
 membrane of, 553
 mucous membrane, 555
 muscles, 558
 ossicles, 555
 posterior wall, 550
 promontory of, 552, 568
 pyramidal of, 551, 552, 558, 564
 roof, 550
 secondary membrane of, 553
 stapes, 558
 tegmen tympani, 550
- Umbo of tympanic membrane, 554
- Uncus**, 191
- Uncus of hippocampal gyrus**, 478, 479, 492
- Utricle, 369
- Uveal tract, 571
- Uvula**, 368, 380
 of cerebellum, 533
 palate, 380
- Vallate papillae, 432
- Vallecula cerebelli**, 520, 530
 larynx, 409
- Valsalva**, sinuses of, 60
- Valve, aortic**, 87
 bicuspid, 80, 92
 coronary, 68
 mitral, 80, 92
 pulmonary, 75, 78
 of coronary sinus, 89
 of the vena cava (Eustachian), 67
 semilunar, 75, 78, 81
 tricuspid, 69
- Vene vorticosae**, 573
 alveolar inferior, 267, 270
 anterior, 262, 280, 281
- Vein or Veins angular**, 131, 137, 157, 344
 anonyma. See Innominate
 ascending lumbar, 111
 auditory, 215
 auricular, posterior, 143, 157
 azygos, 10, 23, 26, 29, 40, 44, 70, 88, 98, 99, 102, 104, 106, 109, 111
 hemiazygos, 10, 30, 102, 104, 106, 111
 accessory hemiazygos, 10, 30, 102, 104, 106, 111
 basalis, 211, 212
 brain, internal of, 499
 bronchial, 30, 111
 cardiac, 60, 63
 cephalic, 161
 cerebral, 204, 206
 inferior, 326
 internal, 489
 superficial middle, 326
 cervical deep, 254
 coronary sinus, 63
 comitans nervi hypoglossi, 290, 292
 of occipital artery, 309
 of the medulla spinalis, 194
 parietal emissary, 219
 posterior auricular, 235
 emissary, 162, 172, 216, 219, 326
 anterior, 171
 facial, 192

Vein or Veins—


- facial, common, 231, 263, 300, 305, 309
- deep, 132, 271
- posterior, 127, 157, 231, 261, 262, 263, 271, 294
- transverse, 262
- frontal, 132, 137, 157
- great central, 499
- hemiazgygos, 10, 101
- accessory, 111
- inferior labial, 132
- infraorbital, 242, 245, 247, 250, 252, 253, 254, 255, 256, 257, 389
- innominate, 22, 26, 32, 34, 35, 46, 47, 48, 49, 50, 85, 88, 89, 96, 99, 106, 111, 239, 313
- intercostal, 30, 32, 110
 - anterior, 112
 - superior, 30, 32, 35, 48
- intercostal-right superior, 111
- intraspinal, 178
- jugular, anterior, 224, 225, 239, 242, 245, 250, 308
 - external, 127, 145, 147, 149, 161, 225, 235, 239, 255, 261, 262, 263
 - internal, 40, 47, 106, 234, 235, 239, 242, 243, 245, 246, 247, 250, 252, 255, 256, 257, 259, 262, 264, 281, 300, 303, 305, 307, 309, 310, 312, 313, 315, 316, 323
- lingual, 231, 292, 294, 305, 309
- lumbar, 176
- magna cerebri, 210, 212, 218, 442
- mammary, internal, 112
- masseteric, 132
- mastoid, 216, 219
- maxillary, internal, 262, 263, 271
- mediastinal, 46
- meningeal, 219, 222, 300
- minimæ cordis, 69
- nasal, 205
- oblique of Marshall, 90
- occipital, 157, 162, 172
- oesophageal, 30
- ophthalmic, 219, 271, 326, 344, 345
 - inferior, 344
 - superior, 339, 344
- palpebral, 132
- pericardial, 30, 48

Vein or Veins—

- pharyngeal, 370
- post-condyloid, 219
- profunda cervicis, 173
- pterygoid, 132, 271
- pulmonary, 10, 22, 33, 38, 50, 58, 60, 70, 89, 92
 - relations of intra-pulmonary parts, 99
- ranine, 231, 292, 294, 305
- retinal, 580
- spinal, 194
 - cardiac veins, anterior, 64
 - great cardiac vein, 63
 - middle, 63
 - small, 64
 - facial vein, posterior, 126
 - oblique vein, 63
 - subcostal, 30
 - superior intercostal, 30, 32, 35, 87, 89, 100, 111
 - temporal superficial, 157
 - venæ minimæ, cordis, 64, 92
 - ventricular vein, inferior, 63
- subclavian, 40, 47, 106, 108, 250, 254, 256, 257, 258, 259, 323
- superficial parotid, 132
- superior labial, 132
- supra-orbital, 132, 157
- temporal middle, 265
- terminalis, 488, 499, 500, 502
- of thoracic wall, 110
- thyreoid, inferior, 47, 88, 96, 229, 253, 320, 321
 - middle, 239, 247, 309, 321
 - superior, 231, 245, 297, 309, 321
- thymic, 48
- transverse scapular, 161, 225, 253
- transversa colli, 161, 225, 253
- vertebral, 47, 111, 183, 250, 252, 254, 257
 - anterior, 253
 - anterior medullary, 506, 511, 535
 - posterior medullary, 533, 535
- Vela medullary, 535
- Velum palatinum, 380
 - muscles of, 380
 - medullary, inferior, 535
 - anterior, 506, 530
 - superior, 506, 530
- Vena cava inferior, 23, 26, 33, 34, 39, 54, 58, 65, 67, 70

... .. 116
 117
 118
 119
 120
 121
 122
 123
 124
 125
 126
 127
 128
 129
 130
 131
 132
 133
 134
 135
 136
 137
 138
 139
 140
 141
 142
 143
 144
 145
 146
 147
 148
 149
 150
 151
 152
 153
 154
 155
 156
 157
 158
 159
 160
 161
 162
 163
 164
 165
 166
 167
 168
 169
 170
 171
 172
 173
 174
 175
 176
 177
 178
 179
 180
 181
 182
 183
 184
 185
 186
 187
 188
 189
 190
 191
 192
 193
 194
 195
 196
 197
 198
 199
 200

... .. 116
 117
 118
 119
 120
 121
 122
 123
 124
 125
 126
 127
 128
 129
 130
 131
 132
 133
 134
 135
 136
 137
 138
 139
 140
 141
 142
 143
 144
 145
 146
 147
 148
 149
 150
 151
 152
 153
 154
 155
 156
 157
 158
 159
 160
 161
 162
 163
 164
 165
 166
 167
 168
 169
 170
 171
 172
 173
 174
 175
 176
 177
 178
 179
 180
 181
 182
 183
 184
 185
 186
 187
 188
 189
 190
 191
 192
 193
 194
 195
 196
 197
 198
 199
 200



INDEX

ium collaterale, 490
mulæ, 502
oglossi, 537
lea of superior oblique, 339
 , dorsal aspect, 161
ganglion of vagus, 313
s of brachial plexus, 351
auditory, 293, 304, 546, 548,
 549, 551, 558, 559
 seus part, 559
 artilaginous part, 559
 cinereum, 453, 503, 505,
 526
 le, 533
 mid, 533
 a, 533
 is, 533
le, amygdaloid, 490, 493
rior of thalamus, 503
iculate, 379
iform, 379
venous, 67
olando, 527
pyreoid cartilage, 424, 425
ne, 313
rrmis, 533
ino-malleolar folds, 554
num, 312, 557, 558, 559
 is of, 555, 561
 edial wall of, 561
 rior wall, 551
 am, 557
 y, 565
 y, promontory of, 561
 , 550
 lar wall, 550
 al wall, 553
 oid wall, 550
 ial wall, 552
 ibrane of, 553
 ous membrane, 555
 cles, 558
 les, 555
 erior wall, 550
 ontory of, 552, 568
 mid of, 551, 552, 558,
 564
 , 550
 ndary membrane of, 553
 es, 558
 ten tympani, 550

 of tympanic membrane, 554
 , 494
 of hippocampal gyrus, 478,
 479, 492



