

S F

911

P38

MEDIAN NEUROTOMY

IN THE TREATMENT OF

CHRONIC TENDINITIS AND PERIOSTOSIS OF THE FETLOCK

BY

C. PELLERIN,

LATE REPETITOR OF CLINIC AND SURGERY TO THE
ALFORT VETERINARY SCHOOL.

TRANSLATED, WITH ADDITIONAL FACTS RELATING TO IT.

BY

PROF. A. LIAUTARD, M. D., V. M.



NEW YORK :

WILLIAM R. JENKINS,

VETERINARY PUBLISHER AND BOOKSELLER,

851-853 SIXTH AVENUE,

1896.

LIBRARY OF CONGRESS.

Chap. _____ Copyright No. _____

Shelf SF 911
P 38

UNITED STATES OF AMERICA.





MEDIAN NEUROTOMY

IN THE TREATMENT OF

CHRONIC TENDINITIS AND PERIOSTOSIS OF THE FETLOCK

BY

C. PELLERIN,

LATE REPETITOR OF CLINIC AND SURGERY TO THE
ALFORT VETERINARY SCHOOL.

TRANSLATED, WITH ADDITIONAL FACTS RELATING TO IT,

BY

PROF. A. LIAUTARD, M. D., V. M.



NEW YORK:
WILLIAM R. JENKINS,
VETERINARY PUBLISHER AND BOOKSELLER,
851-853 SIXTH AVENUE.
1896.

SF911
P 38

Copyright, 1896, By WILLIAM R. JENKINS.

All Rights Reserved.



PRINTED BY THE
PRESS OF WILLIAM R. JENKINS,
NEW YORK.

INTRODUCTION.

On the 25th of June, 1892, when I was adjunct to the Chair of Clinic and Surgery in the Alfort Veterinary School, I successfully performed upon a mare suffering with chronic tendinitis, the section of the median or cubito-plantar nerve.

This special neurotomy had already been performed in Germany and in Belgium, but this was the first time in France.

I have used it a great number of times since, and have always obtained good results against that disease. It can also be advantageously applied in periostosis of the fetlock.

To actual cauterization, recommended for those affections, with which the surgeon was almost entirely powerless, and at best giving only a temporary relief, median neurotomy is called to render enormous services.

When one thinks of the great number of animals which, otherwise doomed to destruction, through it will almost at once become of much greater value than before, and useful for several years longer, one is astonished at the advantages that the operation will bring to all trades and industries employing the horse as a motor.

Agriculture, so much neglected of late, but which, notwithstanding, has remained one of the principal sources of wealth for the country, will also be benefited in a double way. First, this operation will benefit it through the general

gains already mentioned; but, again, it will be possible, at little expense, to obtain, in the large cities, horses which, free from lameness, could be advantageously disposed of in spite of their blemishes. These animals in the fields will render as good service as others of a higher price, while the latter, for the benefit of the cultivator, will take the place of the former.

As there are no little savings through economies, either commercial, industrial, and especially rural, this operation must be welcome.

I have already presented two communications concerning it to the Société Centrale de Médecine Vétérinaire. To-day, I believe it is sufficiently known to make of it a general study.

This, therefore, I submit to the judgment of the veterinary world, and shall be most happy if it prove useful.

The work is divided into two parts: The first covers the study of median neurotomy itself; the second, the exact relations of the facts as I have observed them.

C. PELLERIN.

Paris, 10th January, 1895.

PART FIRST.

MEDIAN NEUROTOMY, OR MESONEURECTOMY

Definition.—Median neurotomy is an operation which consists in dividing the median or cubito-plantar nerve and in excising two or three centimetres of the peripheral end.

Denomination.—Foreign authors, who before me have studied the section of the median, having given no name to that operation, I myself have filled the omission.

I have called it “Median Neurotomy” because it is performed on that nerve. This name is simple, besides it is short, and gives an exact idea of the surgical action, as it contains the name of the operation and that of the organ upon which it is performed; these three essential qualities made me adopt it. It is preferable to that of *radial neurotomy*, which indicates immediately that it is performed in the radial region; but this could induce error, as there is a radial nerve upon which the operation is not performed.

Cubito-plantar neurotomy would have been a rather long name, and *anti-brachial neurotomy* does not indicate upon what nerve the resection is made.

It is also possible to designate median neurotomy by a compound word. The term *medianotomy* (*medianus*, middle, *τομή*, section), used somewhat carelessly by Ries, should not be kept in use, as it is formed of a Latin and a Greek root, and does not indicate that it means a neurotomy. *Mesoneuro-*

to my (*μέσοζ* middle, *νεῦρον* nerve, *τομή* section), might be used, or else *mesoneurotomy*, which has the same roots but is more regular. Again, it is better to use *meso-neurectomy* (*μέσοζ* middle, *νεῦρον* nerve, *ἐχτομή* excision), or, still better, *mesoneurectomy*, which has the same roots and is more regular. These two last names indicate that excision is meant.

Generally, one ought to say *nevrectomy*, and not *neurotomy*, which, if it were not for the habit of the use of the term, would indicate a section, and not a partial excision.

I have selected the word *mesoneurectomy*, but placed it only in second line, as I am afraid it will be accepted with difficulty in general practice; however, I will often use it in the course of this subject.

History.—The history of median neurotomy is short. Peters (1), instructor in the Berlin Veterinary School, is, as far as I know, the first who performed it. On the 2d of December, 1885, he presented to the Society of the Veterinary Practitioners of Berlin a long and interesting paper upon "Neurotomy in Cases of Chronic Lameness of the Horse's Legs." After severely criticizing, in the first part, plantar neurotomies, and specially the high operation, he gave, in the second part, the relations of several neurotomies performed upon the median, naming the diseases against which he had employed it, and giving the *modus operandi* he used, with the results he had obtained.

Ries (2), professor at Ettelbruck (Luxemburg), in an article entitled, "A Veterinary Excursion in Belgium," says: "Upon a young saddle horse, I was able to see the very serious accidents resulting from this fancy neurotomy which is performed upon the median beyond the Rhine. Consecutively to

(1) J. Peters: "Wochenschrift für Thierheilkunde und Wchzucht von Adam." 1886. pp. 190 and 201.

(2) Ries: "Recueil de Méd. Vét." 15th May, 1890. p. 312.

the operation performed against navicular disease (or sub-acute podotrochilitis), appeared a laminitis, which assumed the chronic form and was followed by perforation of the dropped sole. Everything justifies me in believing that medianotomy has had its day at Cureghem. It is proper at this time to ask the following question: Is gangrene, as an accident subsequent to neurotomy, the termination of a more or less severe laminitis, or is chronic laminitis a special complication of the section of the median nerve?"

Hendrickx (1), adjunct of surgery in the Cureghem School, says, at the end of an article upon "The Late Accidents Following Plantar Neurotomy": "Lately a German author has recommended the section of the median nerve in the anti-brachial region; he claimed that the ordinary accidents did not appear after the operation. We acknowledge not to understand the effect that the section of the median nerve could have to prevent serious complications. The application which has been made of this process in the clinic of the Cureghem school is not of a nature to give me great confidence in the efficacy of this operation. Here two horses were operated upon, and on one of them we saw, after five or six weeks, serious troubles of the foot and tendons, which rapidly assumed such a character that the animal had to be killed."

I have taken care in reproducing literally these two authors, who evidently speak of the same horse, banishing as they do in an absolute manner mesoneurectomy.

Ellenberger (2) quotes a work of Goldmann, published in the "*Zeitschrift für Veterinärkunde mit besonderer Berücksichtigung der Hygiene, Organ für Rosstärzte der Armee,*" 3d year, p. 249), upon the "Neurotomy of the Median Nerve." I was

(1) Hendrickx: "Annales de Méd. Vét." Nov., 1890. p. 586.

(2) Ellenberger: "Jahresbericht über die Leistungen auf dem Gebiete der Veterinär-Medicin," year 1891, p. 145.

unable to obtain this journal, and therefore could not consult the article of Goldmann. However, the analysis made of it by Ellenberger contains very interesting data upon the *modus operandi* and the results obtained.

On the 8th of December, 1892, at a meeting of the Société Centrale de Médecine Vétérinaire, Moussu, professor at Alfort, presented in my name (1) a paper relating to a case upon "Nevrotomy performed upon the median nerve or the cubito plantar," and also another one on the study of "Median Nevrectomy or Mesoneurectomy." In the latter I considered all the questions relating to the operation, indications, anatomy of region, *modus operandi*, results, etc.

At the beginning of the year 1894, Angelo Baldoni (2), of the Milan school, published a pamphlet upon "The Median Nevrectomy of the Horse," which he kindly sent me, and in which I have the honor of being quoted several times.

I saw in that pamphlet that Kull (3), a German veterinarian, had in 1893 performed with good results the section of the median upon a horse that suffered with ringbones (*formes*) and a disease of the foot not named.

The work of Baldoni contains new and even original ideas, but too theoretical and almost imaginary, upon the indications, the effects of the operation, and the place to perform it.

In April, 1894, at the Société Centrale, Moussu again presented in my name (4) another article, entitled "De la névrotomie médiane ou mésoneurectomie employée contre la nerf-férule" (Median neurotomy or mesoneurectomy em-

(1) Pellerin: "Névrotomie pratiquée sur le nerf médian ou cubito-plantaire.—De la névrotomie médiane ou mésoneurectomie." (Bul. Soc. Cent. Méd. Vét. 1892. p. 746.)

(2) Angelo Baldoni: "La nevrectomia del mediano nel cavallo." Milan, 1894.

(3) Kull: "Zeitschrift für Veterinärkunde," 1893, p. 14.

(4) Pellerin: "De la névrotomie médiane ou mésoneurectomie employée contre la nerf-férule." (Bull. Soc. cent. 1895, p. 268.)

ployed against chronic tendinitis), in which I related new cases that I had observed.

Bossi, of Pisa (1), in October, 1894, published a small pamphlet, which he sent me: "Recherches sur la névrectomie du nerf médian chez le cheval" (Researches upon the nevrectomy of the median nerve in the horse).

This author used the operation therapeutically only once. The object of his work was to specially make researches experimentally upon the new ideas advanced by Baldoni, which I had criticized in my second communication, and see if they were correct.

This is all I know of the history of median neurotomy. Perhaps other facts have been published by foreign veterinarians; but the difficulty inherent in bibliographical researches in foreign languages have prevented me from finding them, and will be sufficient excuse for possible but involuntary omissions.

One may have remarked that in this historical *resumé*, except for Ries and Hendrickx, whose very short notices I have quoted *in extenso*, I have only mentioned the authors without discussing them; this is because I believe it more rational to comment on them in the course of the description of the operation.

Indications.—Peters has used the section of the median with good results against navicular disease, ringbones and chronic tendinitis; but he has not stated whether he operated above or below the branch that this nerve sends posteriorly, on a level with the articulation of the elbow, to the internal flexor of the metacarpus and to the flexors of the phalanges. (Fig. 2, 3, 4 and 5, N' N'')

As seen by his own indications, he concludes to substitute

(1) Bossi: "Ricerche sulla nevrectomie del mediano degli equini." Pisa, 1894.

median for plantar neurotomies. The advantages which he finds in the first are that it does not destroy the sensibility in the lower parts of the leg as the section of the digital nerve does, and that, on the contrary, it seems to preserve it in the skin; and also because for affections seated below the fetlock there is but one operation to perform, and thus the horse needs not to be turned over or thrown down again; and again because defective cicatrices of the fetlock and phalanges are avoided. All these reasons are evidently very correct; but, as will be seen further on, they are insufficient to ignore or leave aside plantar neurotomies.

Goldman has employed the section of the median to relieve lameness, following the data of Peters; but he has performed it only against navicular disease and ringbones.

Baldoni divides the indications as follows:—1st, “In sectioning a part of the nerve well above the humero-radial joint, before it furnishes the branch of the flexors, we suppress the sensibility, not only in the sphere of the flexors, but in all the half of the leg below the antibrachial, and hence to the foot.”

He then indicates to perform the operation at that height when there are lesions of the tendons and of the lower regions of the fetlock.

The partial excision of the median above the point where the branch of the flexors is given off is irrational, as the insensibility of the tendons is sufficient with the section of the nerve below said branch. I will bring to the support of this affirmation most conclusive facts. Besides, the internal flexor of the metacarpus and the flexors of the phalanxes are unnecessarily deprived of important motor threads. Indeed, though this operation does not give rise to immediate paralysis of these muscles, as I convinced myself in performing it, on the 27th of November, 1892, upon a horse for experiment, and which presented, until the day after, when he was destroyed, a normal flexion of the lower part of the leg, I fear

later on an atrophy of the muscles, they being unnerved by the posterior branch of the median, and specially of the internal flexor of the metacarpus, which receives no nervous influence from any other source.

The author does not say in his notes if, clinically, he performed the operation to the height given.

2d. "In sectioning," continues Baldoni, "a part of the branch which connects with the flexors, sensibility is removed from them."

This author has never used this excision therapeutically, as he never had opportunity to; but he claims that it would give good results in cases of chronic tendinitis only. I am satisfied, on the contrary, that the operation will produce but little, if any, loss of sensibility of the tendons; this being specially due to branches given off from a lower point (see anatomy). Finally, as in the section of the median nerve above the branch of the flexors, there would consecutively appear possible muscular atrophies.

3d. In continuing, Baldoni says again: "In sectioning a part of the median nerve below the humero radial articulation, after it has furnished the branch of the flexors, the sensibility is entirely cut off in the lower half of the leg below the anti-brachial (the foot included), and the sensibility of the flexor muscles remains intact."

This is the only practical median neurotomy; I never used any other. It cuts off the sensibility of the extremity of the leg in part only; but, far from leaving that of the flexors, as the author says, it takes enough of it off to remove the lameness due to chronic tendinitis.

Baldoni recommends it only to take the place of plantar neurotomies—that is, against navicular diseases and ringbones.

Then, again, he recommends it against shoulder lameness. He says that plantar neurotomy has given good results in similar cases, and that if cubito plantar neurotomy has given

better results, it is because of its being nearer to the seat of the disease. These facts are peculiar to the clinics of the Milan School; the author gives no explanation of them, but promises an early discussion of the same.

I shall not comment upon them, but will only say that they cannot be explained except by an error of diagnosis.

Bossi has based the indications upon experiments made with the object of finding out what parts would lose their sensibility through the section of the cubito plantar at the different heights mentioned by Baldoni.

Peters has also already experimented with the same object, for he says in his paper that one may be convinced by pricks that the section of the median cuts off the sensibility of the flexors tendons, but that this feeling remains in the skin.

In order to explore the sensibility of the tendons, Bossi has exposed them; he has pricked them with heated cautery-needles, and then has introduced at various depths a lanceolated needle.

The sensibility of the fetlock and coronet was determined simply by pricking these regions.

In making the section of the median above the branch of the flexors, he has found a diminution and sometimes a complete loss of the sensibility of the tendons and of the internal side of the fetlock and coronet. The external side of these regions had, on the contrary, preserved almost a normal sensibility.

In performing the neurotomy of the flexors branch, a diminution in the sensibility of the tendons has been observed.

And again, in performing the median neurotomy above the flexors branch, in place of the plantar, Bossi has found the internal side of the foot free from sensibility, while the external side, as well as the anterior face, remained as sensitive as in the normal condition.

Unfortunately,—and what seems to me more interesting—Bossi has not attempted to find out in this last neurotomy what became of the sensibility of the tendons, probably because he thought, as he writes in his pamphlet—and no doubt from an incorrect translation—that I performed mesoneurectomy above the branch of the flexors.

He concludes by saying that neurotomy above the branch of the flexors is the only one to perform, and only in cases of tendinitis which have remained rebel to all ordinary treatments; that neurotomy of the branch of the flexors and that above it would not be sufficient to cut off the sensibility of the tendons; and that the last operation is in no way superior to plantar neurotomy.

On this last point, I am entirely of his opinion.

And now that the general ideas of those authors are known, I will expose mine, which are for the most part based upon the observation of clinical facts, having only in view neurotomy of the median *below the branch of the flexors*.

As far as using it against navicular disease, sidebones and ringbones is concerned, I have some reservations to make.

1st. *Navicular Disease*.—I have not used the section of the cubito plantar against that disease alone, as I consider that there is no advantage to put aside the lower and double plantar neurotomy, which is efficacious and is so very seldom followed by complications. Mesoneurectomy evidently gives some results, as observed by several surgeons; anyhow, reasoning indicates it; but, in my opinion, these results must be less perfect than those obtained with the lower and double neurotomy, because the organs contained in the hoof are still sensitive on the external side through the influence of the cutano-cutaneous. For the same reasons, it would probably be less dangerous for the foot, but, on the other hand, it would partially and without advantage unnerve the regions situated between the upper part of the fore-arm and the coronet.

In pathology, perturbations must not be uselessly produced; a good treatment, whatever it may be, and which has shown its results, must not be thrown aside for another, until this one has proved itself positively superior to the other. Such is not the case to-day, and I shall continue to use low and double neurotomy against navicular disease.

2d. *Sidebones and ringbones.* — When these blemishes exist only on one side, it is better to have recourse to plantar neurotomy, high and unilateral, which is very efficacious and generally free from subsequent complications.

When one has to treat cartilaginous or phalangeal bony deposits, existing on each side or all round the fetlock and coronet, I thought in my former communications, as it has been proved that median neurotomy is absolutely harmless, that it could be employed with better advantage than high and double neurotomy, which is somewhat dangerous. In accordance with these ideas, I performed it, on the 17th of July, 1894, upon a horse which was very lame in the near fore-leg from a large periostosis of the coronet, resulting itself from an incomplete fracture of the *os coronoe*. (Observation XII.) Immediately after the operation the animal was much improved, and less lame, probably from the shock upon the nerves, as the next day the lameness was greater, the following day still more marked, and after a few days it had returned to the same degree as previous to the operation. It lasted after the cicatrization of the wound. The result was consequently *negative*, and three weeks after I had to perform the high and double operation. I could have operated then only on the outside, as the inside was already rendered insensitive by the mesoneurectomy; but I was desirous of having the opportunity to test the sensibility of the two plantar nerves.

Here is what I observed:

During the various manipulations performed on the internal side: viz., incision of the skin and perinervous cellular

tissue raising and section of the nerve, sutures of the skin, the animal exhibited no reaction, the sensibility was entirely gone. On the outside, on the contrary, the struggles were as violent as they generally are in all neurotomy, varying as they do according to the excitability of the subject.

Immediately after this second operation the animal was free from lameness, even in trotting, and the claudication did not return at least for a month, or about during which time I was able to observe him. After complete cicatrization of the last wounds he was sold.

This case, or rather experiment, for it was really one, shows that median neurotomy is insufficient for exostosis located around the coronet; that it can only give a moderate relief; and that it can produce a radical cure only in a case when there is no pain on the external side. It is therefore useless against lesions existing only on that side. This failure of the operation against all affections having their seat below the fetlock, is due to the fact that the sensibility is partly kept up by the external plantar nerve.

At any rate, every time I have had recourse to mesoneurectomy against chronic tendinitis complicated with periostosis of the external side of the coronet or pain in the foot on the same side, I have only obtained improvement. (Observations III, VII, VIII, XIV, and XV.)

Therefore, for double ringbones and sidebones, I shall continue to perform high and double neurotomy. Unfortunately, it is somewhat dangerous and ought not to be performed except with care. For instance, it is not rare, when a leg has double sidebones, to see that the lameness is caused only by one of the two; in this case it is prudent to unnerve only first on the side which seems to produce the lameness (oftener it is the most recent instead of the largest), and, if unsuccessful, to operate then on the other side.

At times the periostosis is only on the anterior face of the

coronet. In this peculiar case, Baldoni says he obtained good results with the section of the median. This is possible; but I will consider it later.

3d. *Chronic Tendinitis*.—In general, anterior chronic tendinitis, whether it involves the carpal reinforcing band, the proforans, perforatus, the suspensor ligament or several of these organs together, is the morbidness against which mesoneurectomy is specially indicated, against which it is always successfully employed. I can make this statement, having performed it myself a number of times and oftener alone than any of the authors who have written on the subject. (Observations I., II., IV., and V., VI., IX. and X., XI., XIII., XIX. and XX.)

Every practitioner knows how the sprains of the ligaments and of the tendons that posteriorly support the fetlock are frequent in horses used on the pavements of large cities, and especially those of Paris. Every one also knows what serious affections these tendinites constitute. Blisters, actual cauterizations applied several times, most ordinarily give only temporary relief, or only allow a slight service afterwards, but very seldom and almost never bring on complete recoveries.

Ordinarily the lameness continues, at times less severe, at others more marked, no matter what mode of treatment is used. To this affection is frequently added, after more or less time, the no less serious complication of knuckling, against which we are powerless, as tenotomy only gives temporary relief. And then the animal affected with tendinitis becomes, in the majority of cases, unable to perform remunerative work. After a long time, sometimes after years of treatment, during which he has done but little work, he has to be killed.

In these conditions one is in presence of a serious accident, against which there was so far no good mode of treatment. One presents itself, "*median neurotomy*," which is bound to be accepted by veterinarians without fear of throwing useless

perturbations in pathology, as it is, beyond any doubt, superior to all treatments precedently tested.

Mesoneurectomy is to be used with judgment against chronic tendinitis. Thus it would certainly be dangerous to employ it at the beginning of the affection when softening and a complete giving way of the tendons might take place. And again, as the known treatments might in some cases prove sufficiently successful to allow the animal to be used at slow work, it is prudent not to be hasty. I estimate that about four weeks after the beginning of the lameness one may operate without fear of the rapid accidents on the tendons, as after that time one may be certain as to the efficacy of the means previously employed. One must, however, be careful not to put off too long, as knuckling sometimes appears rapidly, and if median neurotomy does not remove this difficulty I am certain that its manifestation can be prevented, the operation having for result to produce the free resting of the extremity on the ground.

The excision of the median has given me immediate and better results when the tendinitis existed in the upper part of the tendons.

Mesoneurectomy will also give good results in cases of tendinitis existing in concordance with a ringbone situated on the inside of the coronet.

4th. *Periostosis of the Fetlock*.—Upon a horse for experiment suffering with periostosis of the fetlock (probably after a sprain of that joint), against which cauterization in lines had been applied, and which periostosis had given rise to severe lameness, median neurotomy, performed December 4th, 1892, failed to give immediate results. It is true, however, that the lameness might have disappeared later on.

Of course the experiment was not encouraging, but notwithstanding, on the 9th August, 1894, with Congis, veterinarian, at Crépy-en-Valois, I performed in this locality the section

of the median nerve against an enormous periostosis of the fetlock, due to an arthritis following a prick of a pitchfork received in 1891 (Observ. XVI). The lameness remained after the operation as it was before, viz., very severe.

At the beginning of November, 1894, Congis informed me that the lameness had diminished very much and that the animal had resumed the work which he was obliged to quit before my intervention. In the meantime, the same veterinarian informed me that on the 9th of September, 1894 (Observ. XVII), he had operated with complete success on a mare belonging to him, against a periostosis of the fetlock of several years' standing, overcoming severe lameness.

And again, the 3d of November, 1894 (Observation XVIII), I myself operated with advantage against a similar case.

These facts prove that the section of the median can give good results against the periostosis of the fetlock, and suggest the use of it in cases of lameness resulting from it when all other means of treatment have failed.

The wonderful effects of mesoneurectomy against chronic tendinitis of the fetlock may surprise, as anatomical knowledge (see anatomy below) teaches us that the cubito-cutaneous co-operates for a small part in the innervation of the tendons and of the fetlock.

Clinical facts, however, must be respected.

They can nevertheless be explained by the admission that with the section of the median nerve a sufficient diminution of the sensibility is obtained to remove the lameness due to the tendinitis and to the periostosis of the fetlock, but that the innervation of the tendons and of the metacarpo-phalangeal joint has not been completely destroyed. This is fortunate, and explanatory of the rarity of accidents following median neurotomy.

5th. *Periostosis of the Knee*.—Mesoneurectomy, it seems to me, ought to act advantageously against periostosis of the

carpal joint. Upon a horse for experiment, one of whose knees was surrounded with exostosis, producing much lameness, this was as marked after as before the operation, which was performed the 4th of December, 1892; of course the lameness might have subsided later on. Perhaps, as said Moussu, this failure was due to the fact that the majority of the pericarpal nervous threads (divisions connecting with the synovial, the ligaments and all the subcutaneous tissues) are furnished specially by the radial and musculo-cutaneous nerves.

Nevertheless, as soon as I have the opportunity I will renew clinically this experiment.

Surgical Anatomy of the Region.—Before describing the operation let us glance at the anatomy of the region.

Peters and Goldmann have failed to give us any. In my first communication, I have, from many dissections, described surgically the region where the section of the median is made. Baldoni and Bossi have given the descriptive anatomy of the two principal nerves (median or cubito-plantar and cubital or cubito-cutaneous) of the fore-leg.

Surgical anatomy being the only one really useful, I reproduce it as I formerly gave it, insisting, however, somewhat more minutely on that of the nerves.

The region upon which median neurotomy is performed, situated at the internal and upper part of the fore-arm, may be limited; above by the axilla, below by the union of the upper with the middle third of the fore-arm, in front, by the skin which covers the internal border of the radius; behind by that which lies on the internal border of the internal flexor of the metacarpus.

It can be divided into three superposed layers: 1st, the outer; 2d, the middle; 3d, the inner.

I. Outer Layer (Figs. 6 and 1).—It includes, 1st, the skin

(P); 2d, the inferior and posterior part of the sterno-aponeuroticus (S. A.) and its aponeurosis (A. s. a.)

1st. *Skin*.—It is thin and mobile, becomes thicker downwards and forwards; up, it forms wrinkles or folds more or less numerous according to the subjects; the hair is generally not abundant, but long and fine.

2d. *Inferior and Posterior part of the Sterno-Aponeuroticus*.—Under the skin, to which it is united by dense and close cellular tissue, is the lower part of that muscle which shows itself under the aspect of light red fibres, parallel to each other and running in the direction of the leg. This muscle, thick above, becomes thin downwards, to end 6 or 10 centimeters below the upper extremity of the radius in a very thin aponeurosis which continues its lower part. Hence, the immediate indication not to operate too high, so as to have only a thin part of the muscle to divide.

II. Middle Layer (Fig. 1).—Is formed by the antibrachial aponeurosis (Ab).

Antibrachial Aponeurosis.—Very strong and resisting, and of a nacreous, white color, it surrounds the fore-arm in forming a sheath to the muscle. It is attached on the internal border of the radius. Its external face is united to the internal face of the sterno-aponeuroticus by conjunctive tissue very dense and divided into several layers. As soon as the fleshy portion of the sterno-aponeuroticus is continued in its lower part by its fascia, the connective tissue disappears almost entirely, becomes very rare, and the two aponeuroses are then intimately united together.

III. Inner Layer (Fig. 2, 3, 4 and 5).—It is made up of 1st, (in front) the upper portion of the internal border of the radius (R) with the internal lateral ligament of the humero-radial joint; 2d, (behind) the superior part of the internal

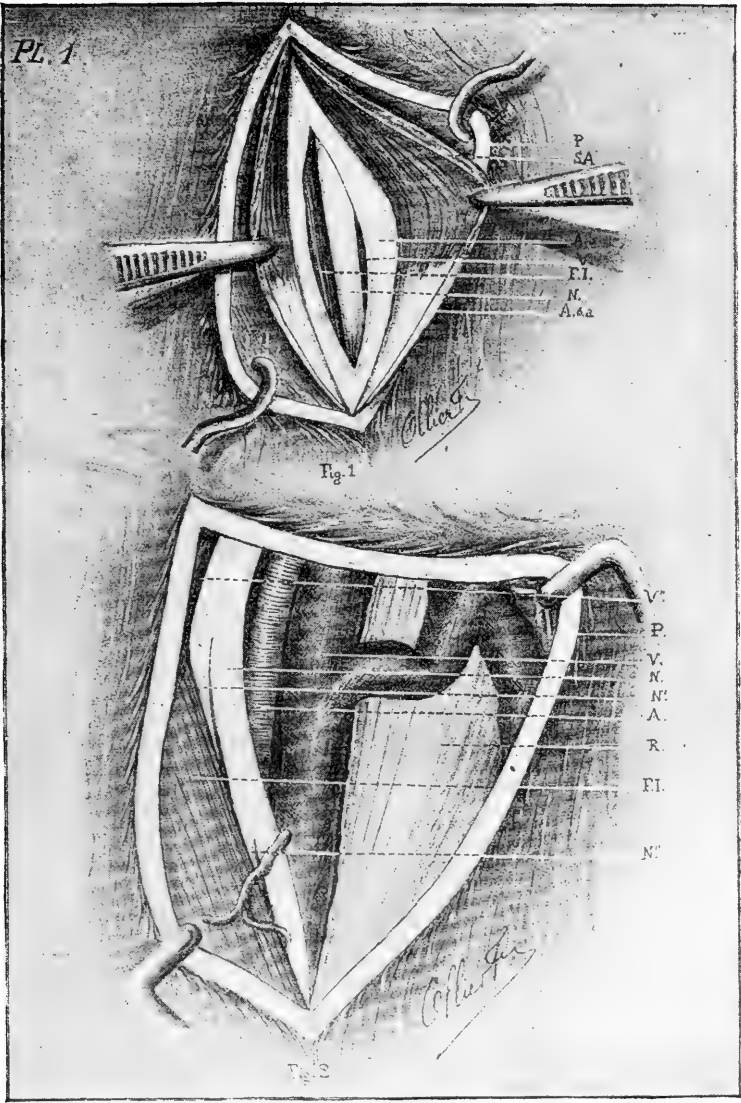


PLATE I.

- Fig. 1.—*Superficial and Middle Layers.*—Ab, antibrachial aponeurosis ; Asa, terminal aponeurosis of the sterno-aponeurotic ; FI, internal flexor of the metacarpus ; N, median nerve ; P, skin ; S A, sterno-aponeurotic muscle ; V, posterior radial vein.
- Fig. 2.—*Deep Layer.*—A, posterior radial artery ; FI, internal flexor of the metacarpus ; N, median nerve ; N' N'' posterior nervous branches ; P, skin ; R, radius ; V, V'', posterior radial veins.

border of the internal flexor of the metacarpus (Fi.); in the middle, 3d, the median nerve (N.); 4th, the posterior radial artery (A.); 5th, the posterior radial veins (V. V. V' V'').

1st. *Radius and Internal Lateral Ligaments of the Humero-Radio-Cubital Joint.*—To the internal part of the superior extremity of the radius is found, in front, the bicipital tuberosity to which the biceps (*coraco-radialis*) is inserted; behind this tuberosity and at the same height, there are rough impressions for the attachment of the internal lateral ligament of the joint. These impressions are very important, as they serve to determinate the selective spot for the operation.

Lower down the internal border of the bone, thick and rounded, is in immediate contact with the skin.

The internal lateral ligament of the elbow articulation, which extends from the humerus to the radius, is interesting, because it is covered by the median nerve, the posterior radial artery and veins.

2d. *Internal Flexor of the Metacarpus.*—This muscle, situated against the posterior face of the radius, is elongated from above below and wider in its middle. It flexes the cannon. When exposed, it appears of a dark, red color, its fibres running vertically.

3d. *Median or Cubito-Plantar Nerve.*—Leaving the posterior part of the mass of the brachial plexus, it is the satellite nerve of the humeral artery and one of its terminal divisions, the posterior radial.

In company with this artery, the nerve passes on the internal face of the articulation of the elbow, then of the upper and internal tuberosities of the radius. When it reaches 5 or 6 centimeters below the articular edge of this bone, it penetrates between the posterior face and anterior border of the internal flexor of the metacarpus, to which it closely adheres. Therefore, it becomes necessary to perform the operation

sufficiently high to reach the nerve before it penetrates between the bone and the muscle.

A little above the carpus, the median bifurcates to form the metacarpal nerves, viz., the whole internal one, while the external is constituted by the union of one of those bifurcations with the end of the cubito-cutaneous.

Below the articulation of the elbow, one and rarely two branches of the cubito-plantar (two in fig. 2, N.' N."') are given off and run outwards and backwards into the internal flexor of the metacarpus and in the flexors of the phalanges. This branch (the highest when there are two) must, as we have shown in the indications, be respected by making the sections sufficiently low.

Further down, several nervous divisions rise from the median to ramify in the muscles of the posterior antibrachial region, and the metacarpal nerves also stretch out their branches as far as the knee, the tendons of the flexors of the phalanges and the fetlock. The internal, towards the middle of the cannon, sends to the external a sub-cutaneous anastomosis.

On the level with the fetlock the metacarpal nerves become plantar and give several anterior and posterior branches which ramify in the various parts of the phalangeal region.

4th. *Posterior Radial Artery* -- One of the terminal branches of the humeral artery whose direction continues, it is always situated a little deeper than the nerve which accompanies it.

5th. *Posterior Radial Veins*.—They are the continuation of the metacarpal veins. Three or four in number, often anastomosed together, they run upwards on the posterior face of the radius, accompanying the posterior radial artery, and sometimes the median nerve, and surrounding it with a venous fasciculus.

PL. 2.

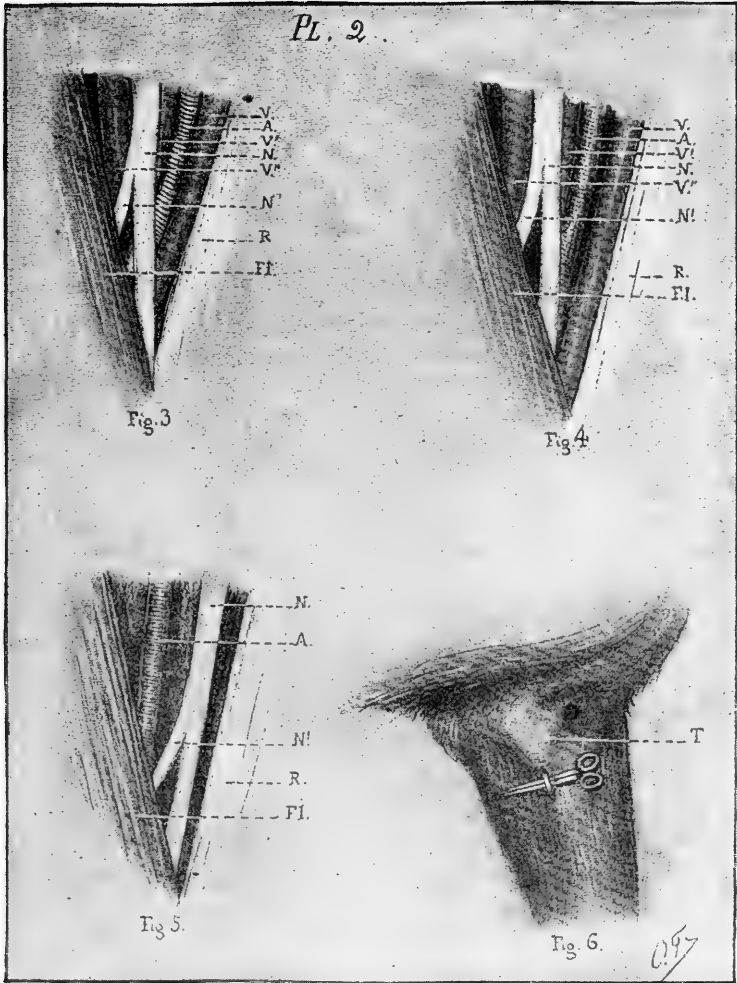


PLATE II.

Figs. 3, 4 and 5.—*Deep Layer (abnormalities)*.—(The veins are not represented in fig. 5.) A, posterior radial artery; FI, internal flexor of the metacarpus; N, median nerve; N'', posterior nervous branch; R, radius; V, V', V'', posterior radial veins.

Fig. 6.—*Third Step of the Operation*.—T, præmînce formed by the internal and superior tuberosity of the radius.

Relations between the Nerve, Artery and Veins.—On a level with the internal lateral ligament of the elbow joint, one finds, going from forward backwards, a posterior radial vein, the posterior radial artery, the median nerve and a second posterior radial vein (fig. 2). Going downwards, a few centimeters below this point, all these organs disappear between the radius and the internal flexor of the metacarpus. It is first the vein behind the nerve which penetrates under the muscle, then the artery which, in order to do this, passes under the nerve. The vein in front of the nerve, and which has also to pass under it, comes afterwards. Last comes the cubito-plantar itself, which, lower down generally, remains superficial in a greater length, a most favorable condition, as there is less risk to injure the blood-vessels.

At the point where the neurotomy is to be performed—that is, where the nerve disappears—it is first intimately related to the posterior and then to the superior or face of the vein situated in front of it; the artery is covered by both.

Further down, between the bone and the muscle, from the outer to the inner parts, the nerves, vein and artery are found; (this is not illustrated in our plates).

These dispositions are not always constant: for instance, in fig. 2, the vein situated in front, runs down as low as the nerve; in figs. 3 and 4, there are three veins; one in front of the artery, one between it and the nerve, and one between the nerve and the internal flexor of the metacarpus; besides, in fig. 4, the front vein disappears the last under the muscle. In passing downwards, it had remained superficial to the nerve, which would have rendered the operation difficult. In fig. 5, the relations are still more abnormal, as the artery is entirely back of the nerve.

The operator must not be deterred by these abnormal conditions; a little skill and attention will isolate the median without injury to the vessels accompanying it.

OPERATION.

I have already performed this operation a great many times, either for experiment or with a therapeutic object. I will therefore describe it, the *modus operandi* that I have followed, mentioning the modes used and employed by others when they present special peculiarities.

To begin with, a first question presents itself: When a horse is affected on both anterior extremities, with diseases which necessitate the use of mesoneurectomy, can he be operated on both the same day? I can, without hesitation, answer in the affirmative, as in three occasions (Observ. IX and X, XIV and XV, XIX and XX) I have, without any trouble, made the section of the two medians at one sitting.

Instruments and Dressing.—The instruments that are necessary are: curved scissors, two bistouries, one convex and one straight, a grooved probe, bull-dog forceps, artery forceps, a blunt tenaculum, a blunt curved tenotome, two-pointed tenacula, all very clean and kept on a tray. To apply the dressing, if one is judged necessary, use suture needle, strong thread, or better, carbolized or sublimated silk and iodoformed gauze. As a dressing proper, carbolized cotton, solution of van Swieten, or any other antiseptic liquid ought to be ready in sufficient quantity.

Preparation and Securing of the Animal.—The day before the operation, the foot of the lame leg is carefully examined, and if an acute disease is found, neurotomy is postponed until complete recovery.

Baldoni, before throwing the horse down, produces artificial ischemia. The leg is enveloped from the coronet to the elbow with an elastic band, and at that point an India rubber

tube is tightly applied when the band is removed, the tube being kept in position by being secured to the withers with a string. This, however, Baldoni does not consider as indispensable. I am not only of his opinion, but consider it useless.

The subject, without having been previously fed, is thrown on the side of the leg to be operated on.

Goldmann recommends chloroformization. I have never used it; it is not indispensable, and therefore should be discarded.

To expose the internal and superior face of the fore-arm, all that there is to do is to remove the outer fore-leg from its hobble and secure it on the corresponding hind ones above the hock. This mode is used by Goldmann. I have used it also, but have discarded it, as it does not permit sufficient access to the region, and then one is exposed to operate too low down. Peters, besides, carries the leg to operate forward with a flat leather strap and prevents its free motion forwards by tying it with a rope to the corresponding hind leg. In some cases this process must hardly be sufficient.

I prefer to carry the leg to be operated forward with the bar-hobbles; one of the hobbles is fixed on the fetlock of the fore leg and the other on the cannon of the hind leg on the same side. At the same time, while the outer leg is secured as above stated, the lower one is kept extended by pulling on a rope attached on its fetlock.

Some German operators, to obtain the same result, use a pole which passes under the neck at its base, and is fixed on the cannon or fetlock, and held forward by assistants. I have obtained good results by this process, though with powerful animals the restraint would certainly be inadequate.

Preparation of Region.—The hair must be clipped upon the supero-internal part of the fore arm. The parts must be

soaped, washed, cleaned with the solution of van Swieten, and thoroughly dried with a clean cloth.

Bossi recommends local anesthesia with cocaine injections in the part to be operated, of 8 cubic centimeters of 4 per 100 solution. This injection is followed by a little massage to facilitate its introduction deeper, and its effects upon a broader surface. Before beginning the dissection of the nerve, he also recommends to drop a little of the solution in the wound. These, he says, render great assistance in relieving the sensibility of the median.

I am of his opinion, though it appears that cocaine interferes with the healing of the wound. This anesthesia had already been recommended in plantar neurotomy (De Jouy, 1889).

Elective Place.—I will not mention those named by Baldoni, they are useless; I will simply say that outside of the three places that he speaks of, to divide the cubito-plantar, he recommends a fourth one lower, a little above the middle of the internal face of the fore-arm. It is there, he says, that the greatest difficulty exists, because the nerve is situated so deeply.

I agree with him, this place must be discarded.

The place of election must be measured in height and from forward backward.

1st. *In Height.*—As I have shown in the anatomy of the region, the operation must be done, in my opinion, sufficiently low to avoid a greater thickness of the sterno-aponeuroticus as well as the incision of the nervous branch of the flexors, and sufficiently high, however, to reach the median, previous to its entrance between the bone and the muscle. Consequently the nerve must be excised at the point where it is about to disappear.

This point is immediately under the round eminence

formed superiorly by the articulation of the elbow and inferiorly by the bicipital tuberosity and the rough impressions which prolong it backward (fig. 6). The incision shall then begin immediately below the termination of this eminence and extend downward. In large horses, it shall be about the width of a finger higher up.

2d. *From Forward Backward*.—This is easier to indicate; when the first point is found, all that is required is to feel for the posterior border of the radius; the incision is made immediately behind and in the direction of this border. I recommend to make the incision a little back of the bone, so as to avoid the cutting of the vein, which is always in front of the nerve there.

The pulsations of the posterior radial artery in fine horses will also facilitate the research of this place of election. Then the incision will be made on the point, where the artery is felt the lowest down.

Peters and Goldmann give as datum the place where the radial pulse is felt. This is not sufficiently precise, as, among most horses, the pulse can be felt upon a length measuring from 8 to 10 centimeters. It is where the pulse is felt the lowest down that the true place of selection is situated.

Modus Operandi.—To facilitate the description, I shall divide in three parts :

- 1st. Incision of the skin and of the sterno-aponeuroticus.
- 2d. Incision of the antibrachial aponeurosis.
- 3d. Dissection and excision of the nerve.

1st. *Incision of the Skin and Sterno-aponeuroticus*.—The surgeon places himself in front of the leg to operate on. The skin being stretched at the point of selection, an incision is made with the convex bistouri, beginning at the point above-named and extending downwards from three to four centimeters in the direction of the leg.

The sterno-aponeuroticus is then well exposed and is divided in a similar way. This muscle differs in thickness, as it extends downward more or less in the various animals. Ordinarily it is quite thin, and the incision, beginning upon the muscular part itself, ends at the point where it is continued by the aponeurosis. In other cases the incision does not reach downwards to the extremity of the muscular fibres; and again at others, it goes beyond them.

While this is being done, there is a small hemorrhage, which soon stops of itself.

When the incision is made, the edges of the wound are spread open with the tenacula held by assistants.

Peters, instead of these, keeps the wound open by passing a piece of cotton tape through the edges thus kept apart by opposite traction on them, one forward, one backward and a little downward, to stop the hemorrhage.

Baldoni uses special forceps or tenacula whose jaws, divided in several teeth, are curved and pointed.

I think these are practical and might be used.

The connective tissue covering the antibrachial aponeurosis is carefully dissected and divided so as to expose it, when it will appear with its handsome, white nacreous color.

2d. *Incision of the Antibrachial Aponeurosis.*—An incision, similar to the preceding, is made in that aponeurosis when the hemorrhage has stopped.

This part of the operation is quite difficult, as in doing it one must be careful to avoid injuring the posterior radial veins, which would render the balance of the operation very difficult. To this effect the incision is carried a little backwards, and by raising the aponeurosis with bull-dog forceps, it can be safely divided with a bistouri, or, as Peters indicates, with scissors.

Here Goldmann operates in the following manner: At the lower end of the first incision, he makes into the antibrachial aponeurosis a puncture large enough to introduce a

curved, blunt tenotome, with which, the sharp edge turned upwards, he divides the aponeurosis, in length equal to that of the cutaneous incision.

Though not indispensable, I have found this measure advantageous in the cases in which I have employed it.

When this is done the dark coloration of the internal flexor of the metacarpus is seen, indicating that the nerve may be looked for. Until this muscle is in full sight, it is useless to attempt searching for the nerve.

3d. *Dissection and Excision of the Nerve.*—At the same moment that the muscle is discovered, often in front, the nerve is often seen in front. It is recognized by its whitish color, its flattened form, filamentous structure and its sensibility. Ordinarily, one also observes a large, dark vein in front of the median, which rests on its posterior face and lower down over it, on the superior one.

The artery remains most always concealed by the nerve and the vein; however, in some instances, it is readily discovered. The connective tissue which covers the cubito-plantar is carefully divided with a straight bistoury, the veins being carefully avoided. The grooved tenaculum may be used to isolate the nerve.

When the dissection of the nerve is sufficient, it is raised gently, and the curved scissors introduced under it from forward backwards (fig. 6). Instead of the scissors, a blunt, curved, grooved tenaculum can be used to raise and hold the nerve. In fact this instrument is preferable, and of late I have used it entirely, as with it the nerve can be secured easily, more readily, and without danger for the surrounding blood vessels.

When the scissors are used, holding them flatwise, they are turned half way so as to allow the introduction, under the isolated part of the nerve, of the straight bistoury, or better, the curved, blunt tenotome with the sharp edge turned towards the sternum, when the nerve is divided by one stroke of the

instrument. If the nerve has been raised in using the blunt curved tenaculum, the introduction and division of the nerve is made with the sharp instrument introduced also under the nerve, elevated by the tenaculum.

The lower stump of the nerve, which has retreated into the wound, is taken hold of with the forceps, and excised in a length of about two centimeters.

German and Italian operators secure and raise the nerve with a silk thread passed underneath it; the section of the nerve being made above and below the ligature.

On account of the violent struggles of the animal it is difficult to take hold and divide the nerve with forceps only, as is sometimes done in plantar neurotomy.

In some instances the incision is a little too low down, and only the internal flexor is seen; in such cases remember that the cubito-plantar is then intimately related to the anterior border of the muscle, and that in the dissection one must not mistake the vein for the muscle, as the section of the first would be most serious.

At any rate, in following these rules, it is impossible to mistake the vein for the nerve.

The difference between the artery and the nerve is seen in the round shape and the light, rosy color of the first. These peculiarities will be readily observed when the vessel looked at is at the bottom of the wound; when it is pulled out of it with the scissors, these peculiarities will disappear and a mistake might be made. Moreover, the want of sensibility of the artery and the presence of the pulse will suffice to distinguish between the two. The diagnosis between the nerve and the artery ought to be made with the blood vessel at the bottom of the wound.

Dressing.—The wound is carefully washed with liquor of van Swieten. In the beginning I used to dress the wound somewhat. I introduced a little iodoformed gauze in the

wound, and held it in place with two or three stitches of the skin. It certainly would be possible to apply sutures on the skin only, covering the parts with iodoform collodion and thus have all the requirements of a severe antiseptis sufficient to obtain a cicatrization by first intention. This is often obtained in plantar-neurotomies and specially in the external high and low operations. For the internal, the manipulations of restraint, the hobbles, &c., are more than sufficient to prevent immediate reunion, specially in cases of the low operation. Goldmann has obtained two cicatrizations *per primam* in having a continual disinfection of the parts before and during the operation, and in closing the wound with a pin suture and glueing it with collodion. Now I use no longer dressing or suture; after the washing of the wound, I cover it with iodoform, and the cicatrization is more rapid. Goldmann had already done the same—it is simpler and better.

Peters applies a little sub-cutaneous wadding dressing.

Baldoni, after washing the wound, puts a drain tube in it, holding it in place with stitches. This drain tube is useless and disturbs the cicatrization.

Bossi makes a cat-gut continued suture of the sterno-aponeuroticus, and one interrupted or twisted on the skin. He uses no drain tube dressing, but now applies a flat dressing held into place by several turns of dextrined gauze, which is changed every three or four days. This last measure is certainly useless.

Immediate Effects.—1st. *In action.*—Almost always, even in trotting, immediately after the operation, a great diminution and often a complete removal of the lameness is observed. In all the horses that I have operated for chronic tendinitis, this immediate result proved absent but once (Obs. XIII), and notwithstanding, the lameness disappeared later on. This fact is not uncommon in other neurotomies and therefore is not surprising.

In periostosis of the fetlock, in three operations made for therapeutics, there was complete disappearance of the lameness in two; in the third it became less severe, but only a few days later disappeared entirely.

2d. *At Rest*.—Returned to his stall, the animal stands almost constantly on the operated leg, which is no longer carried forward, and often resting and relieved from supporting its share of the body. I have never seen this condition missing. When the subject has chronic tendinitis of both fore legs, and that the most diseased one is operated first the effects are still more striking. Before the operation, it was naturally the less affected leg that would carry the most weight of the body, but as soon as the median nerve is cut, the contrary is observed; the operated leg is almost always carrying weight while the other is at rest and carried forward.

This phenomenon proved most remarkable after the second, fourth and fifth neurotomies. It even showed itself later on after the operation, when the inflammation of the repairing process was present.

After Cares.—If, as I recommended at first a small dressing, of idoformed gauze has been made, the next day it is removed after cutting the stitches and the wound is exposed. Every day this is well washed with Van Swieten solution or any other antiseptic solution, then covered with iodoform and carbolized vaseline until completely healed. Weather permitting, douches can be made on the forearm, specially if there is swelling.

If no dressing is used, the same cares of the wound are indicated.

Goldmann, in the cases when, to obtain immediate cicatrization, he had applied a pin suture, has sometimes seen after three days a raising of the stitches caused by the formation of pus, and on that account has modified the treatment and adopted that of the wounds uncovered. If, with the same object, a simple cutaneous suture was used, one would have to

watch for the possibility of this suppuration and then remove the threads, as soon as it would show itself.

Except Goldmann, who recommends to exercise the horses after fourteen days, foreign authors say nothing as to the considerations to be taken to return the operated to their work. After several hesitations, I have accepted the following indications: fifteen days of complete rest, eight days of slow walking, during which walking the horse should always be led, eight days of light work, eight days of moderate work, then return to the steady ordinary service.

Only about four weeks of rest are necessary, and this cannot be termed too long an illness.

During the three months following the operation, the foot is shod with care and in such a manner as to stop from the start the morbid manifestations which might occur.

After Effects.—The day following the operation, there is a small swelling round the incised structure; the following days it subsides, running down to the knee, and after a short time it disappears. The wound cicatrizes rapidly; in a fortnight it is all closed.

In some animals, there is the next day some difficulty in moving the operated leg, which is carried slowly and a little forward, while yet the toe drags on the ground. Still the rest in the stable is free and plumb. This stiffness disappears after a few days; it is due to the inflammation following the neurotomy and also principally to the incision of the sterno-aponeuroticus. I have observed that the higher the muscle is divided the greater the stiffness.

After the time required, the animals when returned to their work do not go lame, even in trotting.

The after effects are complete only after about two months.

It means that until that time, the operated animals, while able to work without lameness, become more and more free in their movements.

Goldmann says he has observed in all the sections of the median that there is a great increase in the growth of the hoof.

Is it not a preconceived idea, as if, on one side Brauell (1857) claims that "*the hoof grows so much more rapidly as the foot is more neurotomized;*" on the other, Chauveau (1853), after a section in the upper part of the forearm of all the nerves, ramifying in the lowest part of the leg, only remarks that "*such neurotomy, as complete as possible, has not interfered at all with the nutritive and secretory actions of the dermis.*" Comeny (in 1887), after a series of experiments with high neurotomy, comes to the same conclusion; and we may add that French practitioners have never spoken of this increase in the growth of the hoof after the same operation.

And again, after mesoneurectomy, I have never seen any change in the growth of the hoof, and I have had several animals under observation for more than two years.

This peculiarity, however, has no importance and deserves no longer discussion.

Accidents.—Ries and Hendrickx have observed, after the neurotomy of the median made at Cureghem, an accident, that, according to the former, assumed the form of chronic laminitis, but which, according to the latter involved the foot and its tendons. Whatever they may have been, these accidents were very serious, as the animal had to be destroyed.

Was not there perhaps another startling cause? Notwithstanding, it can be said that the Belgian operator was unfortunate, as in sixty-one cases of neurotomy on the median that I know, this is the only one I find on record. The two accidents mentioned in my original communication were made through mistake.

At the beginning, I was afraid of the softening of the tendons and of the ligaments, sloughing of the hoof, rebel cicatrization of the wounds, but at present I am entirely reas-

sured as, with the exception of the above mentioned case, none of these accidents have been seen.

And again, in supposing that some lacerations of tendons should have occurred, it would not be an evidence that mesoneurectomy had been the cause; as it is a known fact that if a horse suffering with chronic tendinitis is kept for a long time, an elongation of the tendons may take place. Delperier told me of a remarkable case; a horse which its owner cared very much for, was affected with tendinitis of both fore legs and was entirely disabled; for years he had not worked; one day, to have a consultation of the great master, Henry Bouley, then Professor at Alfort, the horse was started to go to the school, but at a short distance from it he stopped and fell; the tendons of both fore legs were ruptured.

In fact, tendinous ruptures have been known without previous chronic tendinitis.

In my first communication I had assimilated median neurotomy to that of the sciatic nerve, performed by Rousseau and reported by Benjamin, who spoke of a softening of the tendons after the operation of Rousseau and expressed the fear that it might also occur after mesoneurectomy. I wish to insist in remarking that accidents must be less common after sciatic than after median neurotomy, as with the first the actions of both metatarsal nerves and therefore the two plantar (digital) which continue them, is entirely destroyed, while in the second the external metacarpal nerve is left with a certain action, formed, as it is, partly by the cubito-cutaneous.

Out of 17 cases of median neurotomy, Goldmann has seen once, in an animal with weak feet, a well-marked dropping of the sole. Was it due to the operation?

Weber has told of a horse, which, neurotomized for chronic tendinitis, had later on generalized periostosis of the cannon and of the coronet.

Congis (Observation XIII.) observed, four months after the operation, some induration in the fold of the coronet.

It is not proved that these two morbid manifestations, somewhat similar to each other, were due to median neurotomy, as I am informed that it could not be said whether they had not started previous to the operation. And even if they had started after, it would not be evidence that the operation was the cause of them; examples are very numerous of their appearance without section of the median; the horse of the eighth observation proves it.

It will be only later, if it is found that these indurations occur frequently after the operation, that median neurotomy can be accused of being the cause.

At any rate, these hypertrophies are not serious; in the case recorded by Weber, the animal that had been mesoneurotized on both legs, was able to work for two years after with those pericostoses, and was killed afterwards, not on account of them, but because he was completely worn out. As to the case of Congi, he was not either disturbed by the induration of the fold of the coronet, the author himself reporting him as *perfectly cured*.

Until the present time, no painful neuromas has been mentioned as following mesoneurectomy, a complication which is so common in plantar-neurotomy, even after cicatrization of the skin. I must remark that as far as the coming on of neuromas goes, there is certainly a predisposition to them, as I have seen a horse who had four neuromas after four high neurotomies.

Accidents due to the section of the median are therefore generally very rare and not serious, which is explained by the fact, as already stated, that the innervation is yet partially preserved in the lower parts of the leg through the cubito-cutaneous.

Results.—In the following table are given all the operations published to this date with the results obtained:

Table of Results of Median Neurotomy.

DISEASES	PETERS	Results	GOLDMANN	Results	HENDRICKX	Results	PELLERIN	Results	BALDONI	Results	KULL	Results	BOSSI	Results
Chronic Tendinitis.	1	Recovery	1	1	1	1	11 (6 on 3 horses)	Recoveries	1	1	1	1	1	Recovery
Chronic tendinitis and lesions of the tendons.....	1	Recovery	1	1	1	1	5 (2 on the same horse)	Improved	2	1 recovery 1 failure	1	1	1	1
Perforation of the fetlock.....	1	Recovery	1	1	1	1	3 (1 operation by Congis)	2 recoveries 1 improved	1	1 recovery 1 failure	1	1	1	1
Side Bones.....	1	1	1 (Internal side)	1	1	1	1	1	6	3 recoveries 2 impmt 1 failure	1	1	1	1
Ring Bones.....	1 (Kind un-mentioned)	Recovery	1	1	1	1	1	Failure	4	3 recoveries 1 failure	1	1	1	1
Narvicular disease..	2	Recovery	14	Recovery { in 13. In 1 return of lameness after four months	2	1 fatal accident. No report on the other case	1	1	1	1	1	1	1	1
Chronic lameness after a punctured wound of the foot	1	1	1	1	1	1	1	1	1	1	1	1	1	1
Shoulder lameness	1	1	1	1	1	1	1	1	3	2 recoveries 1 failure	1	1	1	1

By this table it is shown that the operations performed in 61 cases by different surgeons, have given 13 recoveries in 13 cases of chronic tendinitis; 2 recoveries, 5 improvements and 1 failure in 8 cases of chronic tendinitis with lesions at the coronet; 2 recoveries and 1 improvement in 3 cases of periostosis of the fetlock; 4 recoveries, 2 improvements, 1 failure in 7 cases of cartilaginous calcification (side bones); 6 discoveries, 2 failures in 8 cases of phalangeal exostosis (ringbones); (it is to be regretted that in this last disease, the authors, and Baldoni specially, have not mentioned whether the lesion existed on the outer or the inner side, as, unless one is satisfied with improvement only, recovery is possible only when it is on the external side); 15 recoveries, 1 return of the lameness after 4 months, one failure followed by accident, 1 case without after information out of 18 cases of navicular disease; 1 recovery in 1 case of old lameness after an operation for deep punctured wound of the foot; and to finish, 2 recoveries (?) and one failure in 3 cases of shoulder lameness.

Median neurotomy is then really efficacious against chronic tendinitis and can render good services in periostosis of the fetlock; for the other affections I have not experimented sufficiently to present conclusions, and my opinion on this subject I have already given.

I wish, however, to remark that the section of the median is compatible with a severe service. Observ. IV and V speak of a horse from which I removed part of both cubito-plantar, and which, notwithstanding, performed an exceptional service for eighteen months afterwards.

Conclusions.—From the preceding facts and arguments, I believe I have the right to place median neurotomy among the practical operations and to advise its use without hesitation in decided cases of chronic tendinitis or of periostosis of the fetlock, when the ordinary forms of treatment have failed.

In such instances the veterinarian will have the satisfaction of making an animal, then only fit to be destroyed, able to perform good and long services.

PART SECOND.

OBSERVATIONS UPON MEDIAN NEUROTOMY OBTAINED BY THE AUTHOR.

OBSERVATION I.—On the 25th of June, 1892, was brought to the clinic of Alfort a small mare, used for light draught, sherry bay color, seven years old, measuring 1 meter 55 in height, the property of Mr. G.

She had been bought of the *Compagnie Générale des Petites Voitures*, for one hundred and some francs.

In trotting and even walking, she was very lame on the off fore leg, which was the seat of a severe chronic tendinitis with knuckling of the fetlock to the second degree. The swollen tendons showed evidences of a cauterization in points.

The owner states that in those conditions the mare is useless and wishes that anything be done, dangerous or not, to relieve her of her lameness.

I knew that in Germany neurotomy of the median had been performed at the upper part of the radius; thinking this was a case in which to try it, it was proposed and accepted.

Immediately the animal was thrown down, secured properly and operated.

As soon as allowed to get up, the animal, which was very lame before, even in walking, showed no lameness, even when trotted.

The next day, there was swelling of the right fore-arm and the animal dragged her leg somewhat with difficulty. These two conditions disappeared rapidly, the wound properly treated

was cicatrized in less than a month, and at that date the knuckling only remained.

Through peculiar circumstances, the animal was kept at rest two months and a half. When then the owner came for her, she was in the same condition, free from lameness. Desirous to follow her and to know what would be the result after she had been put to work, I inquired about her, and on the 28th of November, 1892, I was told that "*the operation had been a perfect success; the mare did not go lame at her full work in trotting, but had remained a club-foot.*"

The result was there as perfect as it could be expected, as long as the knuckling could not be removed.

Since, I have learned that the mare had been sold in March, 1893, and had brought a good price, after having worked six months, four of which in the winter, without lameness or any accident.

This fact is a *recovery*.

OBSERVATION II.—Norman mare, 11 years, used for rapid heavy work, owned by Mr. A.

She was bought to the Alfort Clinic, the 24th of November, 1892; for months she had tendinitis of both fore-legs, upon which blistering applications had been without results. Both of her legs were stiff, but the off one, which was the most diseased, was lamer.

In the stable, she rested alternatively upon one leg, then on the other; the near one more frequently carrying the weight, as it was the less affected.

Median neurotomy was performed on the right leg, the 26th of November, 1892.

After a few days of rest, the lameness had diminished, and the immediate effect in action, though quite evident, was not much marked. On the other hand, it was most shown when in the stable, as then it was the off leg, the most diseased,

which, contrary to what existed before, was able to carry the weight of the body oftener.

The after results of the operation were very simple, and the wound cicatrized in fifteen or twenty days.

I tried to find out afterwards what had become of the mare, and on the 26th of September, 1893, the owner wrote :

“The mare did not go lame on the operated leg; for a month and a half she had done hard work in snowy weather, on the pavement of Paris, without showing the least trouble; but as she was also affected on the left leg, which caused her to go lame now and then, and again, as, even before becoming disabled, she proved too light for her work, she was not considered worth the expense of a second operation and was disposed of, to be sold for the butchery.”

My colleague and friend, Mr. Motreff, who had watched her, wrote in the same sense :

“She performed quite a hard service for a month, free from lameness on the operated leg. There was no softening of the tendons, an accident which you mentioned as possible, and that notwithstanding the severity of her work : proof of which is, that she ruptured her tendons in the violent efforts she made to move very heavy loads. However, the lameness of the *non-operated leg* laid her up again, and rather than incur further expenses, my client disposed of her. To-day the mare is dead. But I can assure you that the operation was a success, and that if in my practice a valuable animal becomes disabled with tendinitis, I shall have no hesitation to have him operated.”

Here again is a *recovery*.

It may be objected that the mare was sold to the butcher. This sale is sufficiently explained by these letters. As to her death at the butcher slaughter house, it must be remembered that for the public, and especially for dealers, chronic tendinitis is considered as an affection absolutely incurable, especially

when both legs are affected. Those ideas, correct for so long a time, cannot be eradicated from one day to the other.

OBSERVATION III.—The 8th of December 1892, at Alfort, I performed mesoneurectomy upon a bay gelding, for quick heavy draught, the property of Mr. G., of Paris.

For several months back, the horse had been affected on the left fore leg with periostosis of the coronet, complicated with very serious tendinitis and knuckling which gave rise to excessive lameness; the animal was walking on three legs.

Firing applied on the tendons remained without result.

Immediately after the operation, the animal being exercised trotting, showed but little lameness; when he was trotted a second time it was more marked; at a third test, about same condition, though less marked than before the operation. The wound made on the sterno-aponeuroticus was probably the cause of the reappearance of the lameness.

In the stable, the animal puts his operated leg freely on the ground.

In from 15 to 20 days the cicatrization of the wound was complete.

The 1st of January, 1893, when I left the school, the animal was very little lame.

I learned since, that towards the end of January, the lameness was scarcely visible, but that upon the advice of a veterinarian, the horse had been sold without having been returned to his work.

I was unable to follow him afterwards. The immediate sale, upon veterinary advice, did not surprise me very much, as it will take time before my colleagues will accustom themselves to appreciate that in mesoneurectomy they have an efficacious mode of treatment against chronic tendinitis.

Though this animal was not returned to his work, this case may be considered as an incomplete recovery or *improvement*.

OBSERVATIONS IV. and V.—A black heavy draught stallion, 7 years old, belonging to Mr. L., from La Plaine, St. Denis.

He was bought in the month of August, 1892, for one thousand francs; after one or two months of work as a shaft-horse, he became lame on both fore legs with tendinitis. He worked very little, but yet the lameness increased in severity. The 13th of March, 1893, he was sent to a farmer to be used on the farm. Notwithstanding the change and the great reduction of work, the tendinitis became so painful that the farmer, towards the end of May, 1893, notified the owner that it was impossible to keep him any longer, as he had become entirely unable to do the lightest work. At the same time, the veterinarian who had taken care of him while at the farmer's, informed the owner also that the inflammation of the tendons was so marked that it was useless to expect anything from firing, and he advised median neurotomy as the only means to give him relief.

Returned to his owner the 5th of June, 1893, I examined him. He was much reduced in flesh, suffered excessively from both fore-legs, the seat of two tendinites, which, though not the seat of great tumefaction, are very painful; they are scarcely touched than by a sudden motion of his legs he indicates the great pain he has felt. In the stable, he alternatively rests upon one leg and then the other, more frequently, however, on the right, which is less diseased. The owner, on seeing the condition of his animal, did not believe in any interference to cure him, and had decided to send him to the butchery. On my insisting, and more to be agreeable to me than with hope of a favorable result, he consented to have him operated.

On the 10th of June, 1893, I performed mesoneurectomy upon the left leg, the most diseased. When left to rise, in walking, as it was impossible to make him trot, the lameness had disappeared from the operated leg. In the stall, it is on that leg that most of the weight of the body is carried. The

wound healed up rapidly; it was closed in fifteen days, and then in trotting the lameness had entirely disappeared from the left operated leg. Suffering only on one side, the condition of the animal improved; he had regained flesh.

On the 30th of June, 1893, the operation was performed on the right leg, and was followed by an immediate and complete removal of the lameness. The cicatrization lasted again fifteen days, during which the animal was kept at rest; he then began to take walking exercise, and by degrees improved more and more in condition.

Towards July 23d, 1893, he did light work; from the 30th, he did half duty. Every morning, as draught-horse, he went to Paris and returned, having made, without fatigue, a distance of 6 or 7 kilometers, pulling a heavy load of refuse from the city.

Fifteen days later, August 15th, his work became harder; he went in the country in the afternoon, carrying the dirt from city streets, and traveled an average of 20 kilometers a day. The first trips he returned a little tired; douches, camphorated alcoholic frictions and one day of rest straightened him once again. At the end of August, he resumed his ordinary work, the morning in the city, the afternoon in the country. Since he worked regularly, the leader in a team of four, I did not allow him to return to the shaft. His driver was most satisfied with his work, and would not change him for any other of the stable, where there are 60 other good animals.

I must say that in August, 1894, one year after resuming work, some swelling occurred on the left tendon, with a slight soreness and lameness. Was this due to a blow or a relapse of the tendinitis? I was unable to decide. It became, however, necessary to blister the parts, which treatment, with a rest of 10 or 15 days, relieved the lameness and allowed the animal to resume his work, which has not been interrupted since.

I was desirous to notice this peculiarity, as it proves that in case of any inflammation starting on the tendons of a leg which has been mesoneurectomized, it is possible to blister that region and thus to relieve the inflammatory process and also the lameness accompanying it.

The two tendinites, even the left, seem to have diminished, but yet, as is observed in all operated individuals, they are a little painful to the touch, a condition due probably in great part to the sensibility of the skin, which has not been destroyed by the operation.

These two operations, which constitute *two recoveries*, are as complete as possible; I have indeed followed the animal in question for eighteen months of very hard work, and will still follow him, as he is yet with the same owner. And again, the result is yet more perfect, as it shows an animal which was going to be killed as useless, and which, after having its two medians divided, performs without lameness an exceptional work.

The subject of this observation was presented to the Société Centrale on the 26th of April, 1894, where its condition and working abilities could be seen.

It is a remarkable, a marvelous recovery; it is more than that, it is a resurrection, which by itself is sufficient to give median neurotomy a great practical value and to have it immediately adopted.

OBSERVATION VI.—Very light gray mare, a trotter, 11 years old, owned by Mr. H., Paris. Since January, 1893, this animal suffers very much with a tendinitis of the right fore leg; the services that she renders are insignificant, she is too lame. Blistering, points firing, gave no result whatever.

Several veterinarians have seen her, and considering her incurable, advised to have her destroyed. I saw her in the beginning of January, 1894. The lameness was excessive, even

in walking, and mesoneurectomy alone could give her relief. She was operated on the 13th of that month.

When up from the bed, the mare goes scarcely lame, even in trotting. In three weeks the wound is healed, and 25 days after the operation she does light work, easier than before, entirely free from lameness in walking, imperceptibly so in trotting.

Afterwards, and up to the beginning of April, she works quite hard, and what little lameness remained is gradually passing away. Notwithstanding this result, as she is blemished by the swelling of her tendons, her owner disposed of her to a horse dealer, who himself sold her to a farmer.

Having inquired about her, I was written in November, 1894, that she is entirely well, and does an excellent service.

The result is excellent. This case a *recovery*.

OBSERVATION VII.—Heavy draught grey stallion, 8 years old, owned by MM. G. de K. and G. de L., of Paris.

Bought in March, 1893, this animal has on the external face of the anterior coronet, an exostosis which has grown and lames him. The lameness not being very severe, he is kept at work until the end of the year; but at that time, tendinitis and knuckling complicate the case on the same leg, and he becomes very lame, even in walking, thus becoming unable to perform a remunerative work. Consulted in the beginning of February, 1894, I advised mesoneurectomy, predicting at least an improvement; that is, the disappearance of the pain due to the tendinitis, doubting the result on account of the external periostosis of the coronet.

The operation is done on the 17th of February, 1894. In getting up, the lameness has almost entirely disappeared, even in trotting. The wound heals rapidly. I prescribe 15 days of complete rest, 8 of walking exercise, 8 of light work, and 8 of half work. The patient resumes his work afterwards, which

he does without fatigue, and which consists in pulling every day, in Paris, 2,000 kilograms. A slight lameness, scarcely noticeable in trotting, remains; but the horse, entirely useless before the operation, has now worked without interruption for the last ten months.

The small lameness, which has not disappeared, is evidently due to the phalangeal periostosis, existing on the outside of the coronet, which receives its sensibility through the cubito cutaneous.

There has then been only *improvement*. The subject was exhibited before the Société Centrale, the 26th of April, 1894.

OBSERVATION VIII.—The 22d of March, 1894, I had occasion to operate at Mr. G.'s, of Paris, a brown bay gelding.

The subject has a very serious chronic tendinitis on the near fore leg, and besides has the fold of the coronet filled with a hard, thickening tendon; upon all these lesions are to be seen lines of firing, which has been applied without result. The animal walks much on his heels, and is very lame even in walking.

Immediately after the section of the median, the lameness has almost entirely disappeared.

Three weeks after, Mr. G. sold him for 250 francs, whereas previous to the operation he could not obtain 60 for the butchery. I have learned that since he does a good light work in the City.

He was sold because the administration to which he belonged could no longer use him on account of the blemishes of his left fore leg.

The result was therefore very good, and, without fear of exaggeration, can at least be considered as an *improvement*.

As Mr. G. gave me this information upon this subject, he told me that he had just operated upon a horse suffering with tendinitis, and that immediately after the operation, the

animal was entirely free from lameness. He was sold shortly after, and having lost sight of him, I am unable to say what were the results. I did not count him in my observations.

OBSERVATIONS IX and X.—A grey heavy draught stallion, 8 years old, property of M. M., from the Plaine St. Denis, is for the last 18 months suffering with tendinitis of both fore-legs.

I had often recommended median neurotomy, but the owner would not consent to it. In May, 1894, the animal being unable to perform any duty, I was allowed to operate. At that time, the tendinites are enormous, very painful and complicated, with slight knuckling of the left leg, but knuckling to the 3rd degree on the right. The patient moves only with great difficulty.

The operation is performed the 19th of May, 1894, on both legs at one time.

When up, after the operation, the walking is very easy; there is, so to speak, no more lameness; but the movements of the right leg, which is knuckled very much, remain irregular.

In the stable, the anterior biped is even and steady.

The horse has not at all suffered from this double operation, and the cicatrization of the two wounds has taken place very fast.

Here I must mention a little incident. There was no vacant stall for him in the stable, and immediately after the operation, he was tied up in a coach house where there was no manger, nor hay-rack. He was obliged to take his food from the floor; and as a consequence of this, the knucklings, and principally that of the right leg, had a tendency to become more marked.

Fortunately, I observed this condition and was able to bring it to an end, by changing the mode of his feeding.

The animal has been walked and exercised as recom-

mended in all these cases. He returned to his work. In spite of the knuckling of the right leg, which had but improved, while that of the left had disappeared, the horse was able to do his duty, free from lameness, while, previous to the operation, he could not be utilized.

He thus worked for three months, and on account of his blemish, the knuckling, he was sold to a farmer, who works him with satisfaction.

Here the results were as complete as they could be, as there was no hope to remove the blemish of the right leg; and I register these two observations as *two recoveries*.

OBSERVATION XI.—Very large, grey stallion, 10 years old, owned by M. D., of Vincy-Manœuvre.

For three years, he has been suffering with tendinitis of the right fore-leg, which has given rise to quite a bad lameness. Mr. Delamarre, veterinarian, has fired him twice in points, but without success. After hearing of the reports I had made before the Société Centrale, he asked me to come and operate the lame patient.

The operation was done June the 18th, 1894; immediately after, there was great diminution in the lameness, and a better standing in the stable.

Since that time, I have received letters from both the owner and the veterinarian, by which I am informed that the healing of the wound was very rapid, that the animal is lame no longer, that after three weeks he had resumed his work as wheeler of a heavy truck team, that with the exception of a few days, because of a mild attack of distemper, he has not stopped working.

In brief, the owner and his veterinarian were very well satisfied, and state that I am justified in considering this case as one followed by *radical and remarkable recovery*.

OBSERVATION XII.—Heavy draught bay stallion, 7 years, owned by Mr. G., of Paris.

During June, 1894, he became very lame on the near fore-leg, which I diagnosed to be caused by an incompleated fracture of the *os coroneæ*. Notwithstanding a proper treatment, the lameness remains very severe on three legs, and periostosis makes its appearance.

To test the value of mesoneurectomy in similar cases, I performed it on the 17th of July. When up, the lameness is considerably reduced: this evident improvement was probably the result of nervous shock; a few days after the lameness reappears and remains as severe as before the operation.

The *failure* is complete.

The 8th of August, 1894, I performed the double high neurotomy, which was followed by complete success—proving the correctness of the diagnosis. During that operation I was able to control interesting facts, mentioned in the indications for the operation, and which showed that if the internal plantar nerve was entirely insensible, the external had, on the contrary, kept almost its normal sensibility.

OBSERVATION XIII.—Very light grey horse, enormous in size, having cost 1,800 francs, when five years old; is now 12, and belongs to Mr. de C., of Crépy-en-Valois.

Since the month of March, 1893, this animal, working on a farm, has a sprain of the tendons of the off fore leg, which lames him. The 31st of August, 1893, Veterinarian Congis is consulted; it is he who afterwards asked me to operate on the horse, and furnished me with all the information of the case. On the 2d of September, 1893, he fires the tendinous region. The lameness subsides some and the animal returns to his work, which has to be suspended at repeated intervals by half day's rest. In July, 1894, the lameness is excessive, and the leg at rest is carried forward of the plumb line to be relieved.

Consulted again, the veterinarian recommends median neurotomy, which I perform the 22d of July, 1894. Once up, the lameness is as severe as before. On the 25th, there is great improvement; he walks easily, trots very slightly lame, and much better than before the operation.

The 6th of August shows him without any irregularity of action. He receives walking exercise for a week, and is then put to work in the field.

Since that time, the recovery has remained permanent; as a wheeler of a heavy truck team, he has carried heavy loads of beets, a weight (wagon and load) of 5,000 kilograms, and during this hard work has been used every day, and notwithstanding the rapidity of the gait he had sometimes to assume, compelled as he was to follow his younger and more vigorous leaders.

Mr. Congis, who saw him in November, says that he noticed nothing wrong about him, except a little induration in the fold of the coronet; he considers the case a *handsome success*.

It is a recovery.

OBSERVATIONS XIV AND XV.—Sorrel mare, 14 years old, that I bought August 1st, 1894.

She walks with difficulty on the anterior biped, the toes of both fore feet come first on the ground, while the heels scarcely reach it.

The tendons, without being tumefied, are a little sensitive to pressure, indicating a slight tendinitis. There is contraction of the heels, very painful ascending corns, especially on the outside. I suspect navicular disease.

She is a worn-out animal, upon which I desire to experiment with mesoneurectomy.

The operation is performed on both legs the 2d of August 1894. Immediately after, the walking is much freer and the

resting on the ground firmer. Exploration of the feet shows that the corns are sensitive only on the outside.

The wounds heal rapidly, and the animal shows no fatigue from the operation.

Three weeks after, I harnessed her to a light wagon, and she made about 10 kilometers quite comfortably.

In the first days of September she was sold, and since does a light service in Paris, a service that she could not have done before the neurotomy was performed.

I am quite certain that she would do excellent work in the country.

There is, then, in this case, only *two improvements*.

Altogether, the soreness of the tendinitis has disappeared, but that of the outside corns, and perhaps also of the navicular disease, remained partly.

OBSERVATION XVI.—Light draught bay horse, property of M. M., of Crepy-en-Valois.

An enormous periostosis of the right fore fetlock, due to aumatic arthritis, following a wound made by a pitchfork, has given rise to a very marked lameness.

Mr. Congis had fired the diseased part with penetrating points, on the 25th of February, 1892, and on the 30th of September a temporary improvement had followed, and the horse was able to do a light picking up service.

In August, 1894, the lameness is very severe; the animal walks on three legs and the owner thinks of having him killed, when Mr. Congis calls me to perform median neurotomy.

It is done August 9th, 1894. When up, the lameness is as marked as before.

Later on, a comparative improvement takes place.

I am informed on the 8th of November that the lameness,

though not entirely removed, has considerably diminished, and the horse can be utilized again about the farmhouse.

There is only *an improvement*.

OBSERVATION XVII.—Sorrel mare, Anglo-Norman, trotter, belonging to Mr. Congis, veterinarian, at Crépy-en-Valois.

It was he who neurotomized her, and in November, 1894, sent me the following information.

“I bought this mare having an old periostosis of the left fore fetlock. She could make 5 leagues and a half an hour without whip, and trotted beautifully. On several occasions, I treated her, and, with a great deal of care, I had succeeded in making her travel every day over a more or less long distance, when in July, 1894, she became quite lame. She was fired with deep points, producing good effects, but this did not remove the lameness. On the 9th of September, 1894, I, with my assistant, mesoneurectomized her. The immediate result was excellent. Exercised walking and trotting, immediately after the operation, she went perfectly sound. It is important to state that the periostosis of the fetlock had become very large, and that it had produced a marked deviation of the phalangeal lever.

“These two experimental tests (Observation XVI) prove that mesoneurectomy is an operation not to be ignored in cases of periostosis of the fetlock, and that it must be preferred to firing.

“My mare was put in harness in the first days of October, and could trot nearly as fast as before her lameness. No lameness now, even at this fast gait; one of our colleagues has witnessed this.

“I sold the mare on account of the size of the ugly periostosis.”

This observation can be considered as a *recovery*.

OBSERVATION XVIII.—Dark bay mare, 13 years old, belongs to a cab company in Paris.

For several years back, she suffered with a periostosis of the right fore fetlock, for which she was fired several times. Now and then, she is laid up for a few days.

In October, 1894, she became lame, but the lameness now is persistent, and she had been laid up so long that on the 3rd of November, at all risks, I performed median neurotomy.

When up from the bed of operation, the lameness had entirely disappeared, even in trotting. I was quite surprised at the result, being then ignorant of those of the two preceding observations, and having to help me in my prognosis of a similar case, only the negative result of the horse for experiment (see the indications above mentioned), with the immediate effects, also negative, of Observation XVI.

The wound healed rapidly, and what soreness resulted from the inflammation following the operation, had subsided toward the 18th of November.

On the 25th of that month, she was put in harness and does a short call, free from lameness.

After all of the indicated necessary after cares had been taken, she was put back to her service on the 5th of December, and has worked ever since without going lame.

This fact is a *recovery*.

OBSERVATIONS XIX and XX.—Bay mare, aged 8 years, belongs to a cab company of Paris.

On the 16th of December, 1894, I performed median neurotomy on the two legs at one time, which were affected with chronic tendinitis. The mare, which was for a long time unable to work, was stiff in the anterior biped, but principally lame in the right leg.

Immediately after the operation, she trotted with much more freedom, and there was no more lameness.

Towards the first of January, 1895, she began to return to harness; since she has made several short calls, walking or trotting.

In the latter end of the month, I am sure she will be able to resume her ordinary work; consequently, I count here again two *recoveries*.

In consulting these 20 observations, one will see that mesoneurectomy employed against chronic tendinitis, has given me 11 recoveries in 11 cases; against tendinitis with diseases of the fetlock, 5 improvements out of 5 cases; against periostosis of the fetlock, 2 recoveries and one improvement out of 3 cases; and against ring bones, one failure out of one case.

These facts confirm plainly my opinions upon median neurotomy, as well as the conclusion closing the first part of this article.

My colleague and associate, M. Nigon, in whose presence and with whose assistance I performed some of these operations, the good results of which he has been able to observe, thinks as I do, that mesoneurectomy, opposed to chronic tendinitis and periostosis of the fetlock, constitute a real surgical progress.

APPENDIX

In the *Revue Vétérinaire* for November, 1895, published at the Veterinary school of Toulouse, Mr. J. Sendrail, adjunct to the Chair of Clinical Surgery, writes:—

“Though it is ten years since Peters, of Berlin, made this operation known, and notwithstanding the writings, already numerous, of Goldmann, Moller, Baldoni, Pellerin, Blanchard and others, it is not yet generally known. It deserves, however, to enter on the domain of our surgery, where it is called to render great services.

“When, some months ago, I presented to the readers of the *Revue Vétérinaire* the pamphlet of Mr. Pellerin upon this question, I abstained from any remarks as to the operation itself, as the number of observations I possessed was too small to justify me in giving an opinion. Since then I have taken advantage of every opportunity that presented itself to perform median neurotomy, and I consider it my duty to mention the results obtained. I also believe it to be useful to my readers to give a *resumé* of the principal data necessary to know how to perform the operation and to describe the modes of operation I have adopted.

“*Indications.*—Median neurotomy, according to some authors, has so many indications that it is a true panacea against all causes of chronic lameness of the anterior extremities. But exaggerations of too enthusiastic authors must always be carefully put aside in all new discoveries.

“This operation cannot possess such general effects, and among the cases against which it has been recommended, some are absurd, inefficacious and useless.

“Absurd, as in cases of shoulder lameness. This needs no discussion, and the results claimed by those who give this indication cannot be explained except by an error of diagnosis.

“Unefficacious, when the articulations are mechanically stiffened by ankylosis or extensive periostosis.

“Useless, in cases where plantar neurotomy is sufficient, such as navicular disease, side and ring bones. In these cases, I believe it is better to have recourse to plantar neurotomy, as, harmless as mesoneurectomy is, it is better not to remove the sensibility in such extensive regions without necessity.

“If, then, it is true that the operation can render service in the treatment of various chronic affections of the lower regions of the fore-legs, it is only really advantageous in a small number of them. But if we consider the serious nature of those affections and the inefficacy of the other modes of treatment used against them, the importance granted to median neurotomy and the praises given to it are well justified.

“The principal indication of this operation is indeed chronic tendinitis. And, knowing how many horses are disabled by this alteration of the tendons, or one of its complications, most unavoidable, knuckling, and also how we are almost powerless in their presence—actual cauterization, tenotomy, etc., giving, at least generally, only temporary and illusory results—it is evident that mesoneurectomy very happily comes to complete the resources of surgical therapeutics.

“There is also another indication to which I desire to call attention: it is the persistency or the recurrency of lameness of navicular disease after plantar neurotomy. This operation is and must remain still the treatment of predilection against that disease; but it may be insufficient, the section of one of

the branches of the nerves may not remove entirely the sensibility of the foot, and the lameness remains. In this case, neurotomy above the fetlock not being entirely free from danger, one way remains, upon the efficacy of which one can depend: that is, the neurotomy of the median.

“This operation can also be very useful in cases, comparatively frequent, in which, several months or even years after plantar neurotomy, the lameness of navicular disease returns. In such occurrence, all that we could do was to try to remove the nervous cicatrices, extirpate the neuromata; but, besides the fact that this was always a more or less difficult thing to do, the return of the lameness may have several other causes, escaping this surgical intervention.

“Thus we have two serious affections, chronic tendinitis of the suspensory apparatus of the fetlock and rebel navicular disease, against which we were completely powerless, and against which mesoneurectomy becomes at last a defensive process. These two affections may exist on the same leg. It is known, in fact, that painful diseases of the feet and those of long standing are often complicated with tendinitis and knuckling. Median neurotomy then becomes truly precious, permitting as it does to remedy at the same time the primitive and casual lesion, and also the secondary consecutive, no less serious.”

Place of Election.—Operation.—These are not different from those laid down in the first part of this work, the same general rules being followed by both writers.

Results.—Speaking of these, Mr. Sendrail continues:—

“Immediately after the operation, the animal carries weight on his operated leg as well as the sound one, he points no longer; and if the lameness still continues for a few days it ordinarily disappears with the swelling consecutive to the traumatism. All my operated patients have returned to light work fifteen days or three weeks after the operation; but

for some time to come they use their diseased leg with less facility, and are more apt to stumble.

“Applied rationally, mesoneurectomy gives results more constant, and generally sufficiently complete to render to the operated ones all their value as working animals.

“From my own observations, median neurotomy applied against chronic tendinitis has always been followed by removal of the lameness.

“Altogether, that is the essential result, the one looked for most commonly, as it allows the utilization of a disabled animal. But I have obtained more of this operation, as I have seen, with horses seriously knuckled, the fetlock was partly straightened and even resumed its proper position.

“This result is explained by the loss of sensibility of organs, insensible in their normal condition, that had accidentally become sensitive from the inflammation.

“So as not to apply upon these organs painful strains, the animal bends its fetlock forward. As mesoneurectomy suppresses this pathological sensibility, the horse presses freely upon his tendons and the fetlock returns in its backward position, as much as it is allowed to do so by the length still preserved by its suspensory supports. Count must, indeed, be taken of the definitive shortening that those may have undergone in serious tendinitis, shortening which fixes, without remedy, the fetlock in its abnormal position.

“Recovery or only improvement of knuckling, should not be considered as a constant effect of median neurotomy; but, as it has been observed, it must be mentioned. In two cases, principally, the fetlock became straightened in a much appreciable measure; in a third, the knuckling had altogether disappeared.

“This last observation is worth reporting. It was a large Breton horse, 11 years old, used to heavy work, dragging railroad cars, which necessitates violent efforts. When I saw

him, the 21st of last March, he had been lame for five months with a severe tenositis of the reinforcing band of the perforans (localization not uncommon in heavy draught horses); this was on the right fore leg. He was very lame and unable to do any work. At rest, the diseased leg is always carried forward. Pressure on the tendon is very painful. There is knuckling at the second degree. Blistering applications and lines cauterization have failed to give any results.

“Mesoneurectomized the 22d of March, he leaves the hospital the 4th of April, free from lameness and the fetlock much straightened. A few days after, he resumes his hard work and fulfils it to his owner's satisfaction. Two months after the operation, the deviation of the fetlock has entirely disappeared, and the diseased leg does not differ from the other, except by the large size of the tendon.

“Against navicular disease, old and rebel, median neurotomy has also given me good results; as example, I present the following case:

“A Tarbian mare, 10 years old, had, two years ago, low plantar-neurotomy performed on the left anterior leg. She continued to go tender, but yet has been able to do her work. For three months back, her lameness has increased. Median neurotomy is done on the 23d of June, and ten days after, she has recuperated all her previous gait.

“I have spoken on the indications for mesoneurectomy of cases where navicular disease was complicated with tendinitis. Here is a typical subject:

“An aged mare has had, four years ago, low plantar-neurotomy performed on both fore legs for navicular disease. The lameness disappeared, but returned again some four or five months ago, much more severe, and as a consequence, very serious tendinites developed themselves on both legs.

“The entire region of the tendons is considerably swollen

and very painful to the touch. The animal walks with difficulty, and can scarcely stand on her fore legs.

“The 31st of May, I performed mesoneurectomy on the left leg. Immediately after the operation, the operated leg is alone able to carry the weight of the body, the right is still carried forward. Twelve days later, the owner takes her away and refuses to consent to the expenses of the second operation. To-day she is still very lame on the right fore leg.

“These examples are sufficient to show the importance of the services that median neurotomy can render. This operation must then be considered as classical, and as one that all practitioners shall often have opportunity to perform with profit and honor.”

WILLIAM R. JENKINS'

CATALOGUE

1896

Any of these Books will be sent, Post Paid, on receipt
of Price.

(*) *Single asterisk designates New Books.*

(**) *Double asterisk designates Recent Publications.*

- ANDERSON.** "Vice in the Horse" and other papers
on Horses and Riding. By E. L. Anderson. Demy,
8vo, cloth.....2 00
- ANDERSON.** "How to Ride and School a Horse."
With a System of Horse Gymnastics. By Edward
L. Anderson. Cr. 8vo.....1 00
- (**) **BACH.** "How to Judge a Horse." A concise treatise
as to its Qualities and Soundness; Including Bits and
Biting—Saddles and Saddling, Stable Drainage, Driv-
ing One Horse, a Pair, Four-in-hand, or Tandem, etc.
By Captain F. W. Bach. 12mo, cloth, fully illustrated
\$1 00; paper.....50
- BANHAM.** "Tables of Veterinary Posology and
Therapeutics," with weights, measures, etc. By
George A. Banham, F.R.C.V.S. 12mo, cloth.....75
- BAUCHER.** "Method of Horsemanship." Including
the Breaking and Training of Horses.....1 00

BELL. "The Veterinarians Call Book (Perpetual)."

By Roscoe R. Bell, D V.S., Profssor of Materia Medica, Therapeutics and Hygiene in the American Veterinary College, New York; President of the Long Island Veterinary Society; late U. S. Government Veterinary Inspector, etc.

A visiting list, that can be commenced at any time and used until full, containing much useful information for the student and the busy practitioner. Among contents are items concerning: Veterinary Drugs; Poisons; Solubility of Drugs; Composition of Milk, Bile, Blood, Gastric Juice, Urine, Saliva; Respiration; Dentition; Temperature, etc., etc. Bound in leather 1 25

(*) **BRADLEY.** "Outlines of Veterinary Anatomy."

PART I.: *The Anterior and Posterior Limbs.* By O. Charnock Bradley, Member of the Royal College of Veterinary Surgeons; Professor of Anatomy in the New Veterinary College, Edinburgh. (Ready in June.) 12mo, cloth, 189 pages.....

CLEMENT. "Veterinary Post Mortem Examinations."

By A. W. Clement, V.S. Records of autopsies, to be of any value, should accurately represent the appearances of the tissues and organs so that a diagnosis might be made by the reader were not the examiners conclusions stated. To make the pathological conditions clear to the reader, some definite system of dissection is necessary. The absence in the English language, of any guide in making autopsies upon the lower animals, induced Dr. Clement to write this book, trusting that it would prove of practical value to the profession. 12mo, cloth, illustrated 75

- (**) **CADIOT.** "Roaring in Horses." Its Pathology and Treatment. This work represents the latest development in operative methods for the alleviation of roaring. Each step is most clearly defined by excellent full-page illustrations. By P. J. Cadiot, Professor at the Veterinary School, Alfort. Trans. Thos. J. Watt Dollar, M.R.C.V.S., etc. Cloth.....75
- CHAUVEAU.** "The Comparative Anatomy of the Domesticated Animals." By A. Chauveau. New edition, translated, enlarged and entirely revised by George Fleming, F.R.C.V.S. 8vo. cloth with 585 Illustrations 5 75
- CLARKE.** "Horses' Teeth." A Treatise on their Anatomy, Pathology, Dentistry, etc. Revised and enlarged. By W. H. Clarke. 12mo, cloth..... 2 50
- CLARKE.** "Chart of the Feet and Teeth of Fossil Horses." 25
- CLEAVELAND.** "Pronouncing Medical Lexicon." Pocket edition. Cloth.....75
- COURTNEY.** "Manual of Veterinary Medicine and Surgery." By Edward Courtney, V. S. Crown, 8vo, cloth.....2 75
- (**) **COX.** "Horses: In Accident and Disease." The sketches introduced embrace various attitudes which have been observed, such as in choking; the disorders and accidents occurring to the stomach and intestines; affection of the brain; and some special forms of lameness, etc. By J. Roalfe Cox, F.R.C.V.S. 8vo, cloth, fully illustrated.....1 50

CURTIS. "Horses, Cattle, Sheep and Swine." The origin, history improvement, description, characteristics, merits, objections, etc. By Geo. W. Curtis, M.S.A. Superbly illustrated. Cloth, \$2 00; half sheep, \$2.75; half morocco.....3 50

DALZIEL. "British Dogs." Describing the History Characteristics, Points, and Club Standards, etc., etc. With numerous colored plates and wood engravings. By Hugh Dalziel. Vol. I., \$1 00. Vol. II., 8vo.4 00

DALZIEL. "The Fox Terrier." Illustrated. (Monographs on British Dogs).....1 00

DALZIEL. "Fox Terrier Stud Book." Edited by Hugh Dalziel.

Vol. I. Containing Pedigrees of over 1,400 of the best-known Dogs, traced to their most remote known ancestors1 00

Vol. II. Pedigrees of 1,544 Dogs, Show Record, &c.1 00

Vol. III. Pedigrees of 1,214 Dogs, Show Record, &c.1 00

Vol. IV. Pedigrees of 1,168 Dogs, Show Record, &c.1 00

Vol. V. Pedigrees of 1,662 Dogs, Show Record, &c.1 00

DALZIEL. "The St. Bernard." Illustrated....1 00

DALZIEL. "St. Bernard Stud Book." Edited by Hugh Dalziel.

Vol. I. Pedigrees of 1,278 of the best-known Dogs, traced to their most remote known ancestors, Show Record, &c.....1 00

Vol. II. Pedigrees of 504 Dogs, Show Record, &c.,1 00

- DALZIEL.** "The Diseases of Dogs." Their Pathology, Diagnosis and Treatment, with a dictionary of Canine Materia-Medica. By Hugh Dalziel 12mo, paper, 60c.; cloth.....80
- DALZIEL.** "Diseases of Horses." 12mo, cloth..1 00
- DALZIEL.** "Breaking and Training Dogs." Being concise directions for the proper education of dogs, both for the field and for companions. Second edition, revised and enlarged. Part I, by Pathfinder; Part II, by Hugh Dalziel. 12mo, cloth, illus2.60
- DALZIEL.** "The Collie." Its History, Points, and Breeding. By Hugh Dalziel. Illustrated, 8vo, paper, 50c., cloth.....1 00
- DALZIEL.** "The Greyhound." 8vo, cloth, illus..1 00
- DANCE.** "Veterinary Tablet." Folded in cloth case. The tablet of A. A. Dance is a synopsis of the diseases of horses, cattle and dogs with the causes, symptoms and cures.....75
- DANA.** "Tables in Comparative Physiology." By Prof. C. L. Dana, M.D.....25
- DAY.** "The Race-horse in Training." By Wm. Day, 8vo3 50
- (**) **DUN.** "Veterinary Medicines, Their Actions and Uses." By Finlay Dun, V.S. Revised edition (almost entirely re-written) 8vo, cloth.....3 50
- DWYER.** "Seats and Saddles." Bits and Biting, Draught and Harness and the Prevention and Cure of Restiveness in Horses, By Francis Dwyer. Illustrated, 1 vol., 12mo, cloth, gilt.....1 50

FLEMING. "A Treatise on Practical Horseshoeing."
By George Fleming, M.R.C.V.S. Cloth..... 75

(*) **FLEMING.** "Veterinary Obstetrics." Including the
Accidents and Diseases incident to Pregnancy, Parturi-
tion, and the early Age in Domesticated Animals.
By Geo. Fleming, F.R.C.V.S. With 212 illustrations.
New edition revised, 226 illustrations, 758 pages... 6 25
773 pages, 8vo, cloth (old edition)..... 3 50

FLEMING. "Rabies and Hydrophobia." History.
Natural Causes, Symptoms and Prevention. By Geo.
Fleming, M. R.C.V.S., 8vo, cloth..... 3 75

FLEMING. "Propagation of Tuberculosis." Stating
Injurious Effects from the consumption of the Flesh
and Milk of Tuberculous Animals. By Geo. Fleming,
M.D., M.R.C.V.S., and others. 8vo, cloth..... 1 50

FLEMING. "Tuberculosis." From a Sanitary and
Pathological Point of View..... 25

FLEMING. "The Contagious Diseases of Animals."
Their influence on the wealth and health of nations.
12mo, paper..... 25

FLEMING. "Operative Veterinary Surgery." Part
I, by Dr. Geo. Fleming, M.R.C.V.S. This valuable
work, the most practical treatise yet issued on the
subject in the English language, is devoted to the
common operations of Veterinary Surgery; and the
concise descriptions and directions of the text are illus-
trated with numerous wood engravings: 8vo, cloth, 2 75

**Orders are now received for the second volume, which
is expected by December.**

FLEMING. "Human and Animal Variolæ." A Study in Comparative Pathology. Paper25

FLEMING. "Animal Plagues." Their History, Nature, and Prevention. By George Fleming, F.R.C. V.S., etc. First Series. 8vo, cloth, \$6.00; Second Series. 8vo, cloth.....3 00

FLEMING. "Roaring in Horses." By Dr. George Fleming, F.R.C.V.S. A treatise on this peculiar disorder of the Horse, indicating its method of treatment and curability. 8vo, cloth, with col. plates.1 50

(**)**FLEMING-NEUMANN.** "Parasites and Parasitic Diseases of the Domesticated Animals." A work which the students of human or veterinary medicine, the sanitarian, agriculturist or breeder or rearer of animals, may refer for full information regarding the external and internal Parasites—vegetable and animal—which attack various species of Domestic Animals. A Treatise by L. G. Neumann, Professor at the National Veterinary School of Toulouse. Translated and edited by George Fleming, C. B., L.L.D., F.R.C.V.S. 873 pages, 365 illustrations, cloth.7 50

(**)**FRIEDBERGER-FROHNER.** "Pathology and Therapeutics of the Domesticated Animals." By Dr. Friedberger. Translated by Prof. W. L. Zuill, M.D., D.V.S. 2 vol.....12 00

GRESSWELL. "The Diseases and Disorders of the Ox." By George Gresswell, B.A. With Notes by James B. Gresswell. Crown, 8vo, cloth, illus....3 50

GRESSWELL. "Diseases and Disorders of the Horse." By Albert, James B., and George Gresswell. Crown, 8vo, illustrated, cloth1 75

GRESSWELL. Manual of "The Theory and Practice of Equine Medicine." By J. B. Gresswell, F.R.C.V.S., and Albert Gresswell, M.R.C.V.S., second edition, enlarged, 8vo, cloth.....2 75

GRESSWELL. "Veterinary Pharmacology and Therapeutics." By James B. Gresswell, F.R.C.V.S. 16mo, cloth.....1 50

GRESSWELL. "The Bovine Prescriber." For the use of Veterinarians and Veterinary Students. By James B. and Albert Gresswell, M.R.C.V.S. Cloth.75

GRESSWELL. "The Equine Hospital Prescriber." drawn up for the use of Veterinary Practitioners and Students. By Drs. James B. and Albert Gresswell, M.R.C.V.S. Cloth.....75

GRESSWELL. "Veterinary Pharmacopœia, Materia Medica and Therapeutics." By George and Charles Gresswell, with descriptions and physiological actions of medicines. By Albert Gresswell. Crown,8vo,cl. 2 75

(**)**GOTTHEIL.** "A Manual of General Histology." By Wm. S. Gottheil, M.D., Professor of Pathology in the American Veterinary College, New York; etc., etc.

Histology is the basis of the physician's art, as Anatomy is the foundation of the surgeon's science. Only by knowing the processes of life can we understand the changes of disease and the action of remedies; as the architect must know his building materials, so must the practitioner of medicine know the intimate structure of the body. To present this knowledge in an accessible and simple form has been the author's task. 8vo., cloth, 148 pages, fully illustrated.,. 1 00

(*)**HASSLOCH.** "A Compend of Veterinary Materia Medica and Therapeutics." By Dr. A. C. Hassloch, V.S., Lecturer on Materia Medica and Therapeutics, and Professor of Veterinary Dentistry at the New York College of Veterinary Surgeons and School of Comparative Medicine, N. Y. 12mo, cloth, pages..

HAYES. "Veterinary Notes for Horse-Owners." An every day Horse Book. Illustrated. By M. H. Hayes. 12mo, cloth.....5 00

HAYES. "Riding." On the Flat and Across Country. A Guide to Practical Horsemanship. By Captain M. H. Hayes. Second edition, 16mo, cloth.....4 25

HAYES. "Illustrated Horse Breaking." By Captain M. H. Hayes. 12mo, cloth, illustrated.....8 40

HAYES. "The Horsewoman." By Captain M. H. Hayes and Mrs. Hayes. 12mo, cloth, illustrated.4 25

HEATLEY. "The Horse Owner's Safeguard." A handy Medical Guide for every Horse Owner. 12mo, cloth1 50

HEATLEY. "Practical Veterinary Remedies." 12mo, cloth.....1 00

(**)**HEATLEY.** "The Stock Owner's Guide." A handy Medical Treatise for every man who owns an ox or cow. By George S. Heatley, M.R.C.V. 12mo, cloth1 25

HILL. "The Principles and Practice of Bovine Medicine and Surgery." By J. Woodroffe Hill, F.R.C.V.S. Cloth. (Temporarily out of print).

HILL. "The Management and Diseases of the Dog." Containing full instructions for Breeding, Rearing and Kenneling Dogs. Their Different Diseases. How to detect and how to cure them. Their Medicines, and the doses in which they can be safely administered. By J. Woodroffe Hill, F.R.C.V.S. 12mo, cloth, extra fully illustrated.....2 00

HINEBAUCH. "Veterinary Dental Surgery." For the use of Students, Practitioners and Stockmen. 12mo, cloth, illustrated.....2 00
 Sheep..... 2 75

(**) **HOARE.** "A Manual of Veterinary Therapeutics and Pharmacology." By E. Wallis Hoare, F.R.C.V.S. 12mo, cloth, 560 pages.....2 75

"Deserves a good place in the libraries of all veterinarians. * * * Cannot help but be of the greatest assistance to the young veterinarian and the every day busy practitioner."—*American Veterinary Review.*

(*) **KOBERT.** "Practical Toxicology for Physicians and Students." By Prof. Dr. Rudolph Kobert, Director of the Pharmacological Institute, Dorpat, Russia. Translated and edited by L. H. Friedburg, Ph.D., of Dept. of Chemistry, College of City of New York, Prof. of Chemistry and Toxicology at the American Veterinary College, New York, and New York Homœopathic Medical College and Hospital. Authorized edition. (*In Press.*)

KOCH. "Etiology of Tuberculosis." By Dr. R. Koch. Translated by T. Saure. 8vo, cloth1 00

KEATING. "A New Unabridged Pronouncing Dictionary of Medicine." By John M. Keating, M.D., LL.D., Henry Hamilton and others. A voluminous and exhaustive hand-book of Medical and scientific terminology with Phonetic Pronunciation, Accentuation, Etymology, etc. With an appendix containing important tables of Bacilli, Microcci Leucomaines, Ptomaines; Drugs and Materials used in Antiseptic Surgery; Poisons and their antidotes; Weights and Measures; Thermometer Scales; New Official and Unofficial Drugs, etc., etc. 8 vo, 818 pages.....5 00

LAMBERT. "The Germ Theory of Disease." Bearing upon the health and welfare of man and the domesticated animals. By James Lambert, F.R.C.V.S. 8vo. paper.....25

LAW. "Farmers' Veterinary Adviser." A Guide to the Prevention and Treatment of Disease in Domestic Animals. By Professor James Law. Illustrated. 8vo, cloth.....3 00

LIAUTARD. "Animal Castration." A concise and practical Treatise on the Castration of the Domestic Animals. The only work on the subject in the English language. Illustrated with forty-four cuts. 12mo, cloth.....2 00

(*)**LIAUTARD.** "Median Neurotomy." 8vo, cloth.....1 00

LIAUTARD. "Vade Mecum of Equine Anatomy." By A. Liautard, M.D.V.S. Dean of the American Veterinary College. 12mo, cloth.....2 00

LIAUTARD. "Translation of Zundel on the Horse's Foot." Cloth.....2 00

LIAUTARD. "How to Tell the Age of the Domestic Animal." By Dr. A. Liautard, M.D., V.S. Profusely illustrated. 12mo, cloth.....50

LIAUTARD. "On the Lameness of Horses." By A. Liautard, M.D., V.S.....2 50

(**)**LIAUTARD.** "Manual of Operative Veterinary Surgery." By A. Liautard, M.D., V.M., Principal and Professor of Anatomy, Surgery, Sanitary Medicine and Jurisprudence in the American Veterinary College; Chevalier du Merite Agricole de France, Honorary Fellow of the Royal College of Veterinary Surgeons (London), etc., etc. 8vo, cloth, 786 pages and nearly 600 illustrations.....6 00

LONG. "Book of the Pig." Its selection, Breeding, Feeding and Management. 8vo, cloth4 25

(**)**LUPTON.** "Horses : Sound and Unsound," with Law relating to Sales and Warranty. By J. Irvine Lupton, F.R.C.V.S. 8vo, cloth, illustrated.....1 25

LUPTON. "The Horse." As he Was, as he Is, and as he Ought to Be. By J. I. Lupton, F.R.C.V.S. Illustrated. Crown, 8vo1 40

MAGNER. "Facts for Horse Owners." By D. Magner. Upwards of 1,000 pages, illustrated with 900 engravings. 8vo, cloth, \$5.00; sheep, \$6.00; full morocco.7 50

MAGNER. "Veterinary Diagrams." (1) The Structure of Horses Feet (in colors). The Structure of Horses Feet (Effects of Bad Treatment of the Feet). Mounted and Varnished.....2 00
(2) The Shoeing of the Horse. The Education of the Horse. Mounted and Varnished.....2 00

MAYHEW. "The Illustrated Horse Doctor." An accurate and detailed account of the Various Diseases to which the Equine Race is subject; together with the latest mode of Treatment, and all the Requisite Prescriptions written in plain English. By E. Edward Mayhew, M.R.C.V.S. Illustrated. Entirely new edition, 8vo, cloth.....2 75

McBRIDE. "Anatomical Outlines of the Horse." 12mo, cloth.....2 50

McCOMBIE. "Cattle and Cattle Breeders." Cloth.1 00

M'FADYEAN. "Anatomy of the Horse." A Dissection Guide. By J. M. M'Fadyean, M.R.C.V.S. This book is intended for Veterinary students, and offers to them in its 48 full-page colored plates numerous other engravings and excellent text, the most valuable and practical aid in the study of Veterinary Anatomy, especially in the dissecting room. 8vo, cloth5 50

M'FADYEAN. "Comparative Anatomy of the Domesticated Animals." By J. M'Fadyean. Profusely illustrated, and to be issued in two parts. Part I—Osteology, ready. Paper, \$2 50; cloth.....2 75

(Part II. in preparation.)

MILLS. "How to Keep a Dog in the City." By Wesley Mills, M.D., V.S. It tells how to choose manage, house, feed, educate the pup, how to keep him clean and teach him cleanliness. Paper.....25

(*)**MOLLER.** "Operative Veterinary Surgery." By Professor Dr. H. Moller, Berlin. Translated and edited from the 2d edition, enlarged and improved, by John A. W. Dollar, M.R.C.S.

Prof. Moller's work presents the most recent and complete exposition of the Principles and Practice of Veterinary Surgery, and is *the standard text-book on the subject throughout Germany.*

Many subjects ignored in previous treatises on Veterinary Surgery here receive full consideration, while the better known are presented under new and suggestive aspects.

As Prof. Moller's work represents not only his own opinions and practice, but those of the best Veterinary Surgeons of various countries, the translation cannot fail to be of signal service to American and British Veterinarians and to Students of Veterinary and Comparative Surgery.

1 vol., 8vo. 722 pages, 142 illustrations5 25

MORETON. "On Horse-breaking." 12mo, cl...50

MOSSELMAN-LIENAU. "Veterinary Microbiology." By Professors Mosselman and Liénaux, National Veterinary College, Cureghem, Belgium. Translated and edited by R. R. Dinwiddie, Professor of Veterinary Science, College of Agriculture, Arkansas State University. 12mo, cloth, 342 pages.....2 50

(*) **NOCARD.** "The Animal Tuberculoses, and their Relation to Human Tuberculosis." By Ed. Nocard, Professor of the Alfort Veterinary College. Translated by H. Scurfield; M.D. Ed., Ph. Camb.

Perhaps the chief interest to doctors of human medicine in Professor Nocard's book lies in the demonstration of the small part played by heredity, and the great part played by contagion in the propagation of bovine tuberculosis. It seems not unreasonable to suppose that the same is the case for human tuberculosis, and that, if the children of tuberculosis parents were protected from infection by cohabitation or ingestion, the importance of heredity as a cause of the disease, or even of the predisposition to it, would dwindle away into insignificance. 12mo, cloth. 143 pages.....1 00

PEGLER. "The Book of the Goat." 12mo, cloth. 1 75

PELLERIN. "Median Neurotomy in the Treatment of Chronic Tendinitis and Periostosis of the Fetlock." By C. Pellerin, late repetitor of Clinic and Surgery to the Alfort Veterinary School. Translated, with Additional Facts Relating to It, by Prof. A. Liautard, M.D., V.M. 8vo, boards, illustrated.....1 00

PROCTOR. "The Management and Treatment of the Horse" in the Stable, Field and on the Road. By William Proctor. 8vo.....2 40

PETERS. "A Tuberculous Herd—Test with Tuberculin." By Austin Peters, M. R. C. V. S., Chief Inspector of Cattle for the New York State Board of Health during the winter of 1892-93. Pamphlet, ...25

REYNOLD. "Breeding and Management of Draught Horses." 8vo, cloth.....1 40

ROBERTSON. "The Practice of Equine Medicine."

A text-book especially adapted for the use of Veterinary students and Veterinarians. By W. Robertson, Principal and Professor of Hippopathology in the Royal Veterinary College, London. 8vo. cloth, 806 pages, revised edition.....6 25

(**)**ROBERGE.** "The Foot of the Horse," or Lameness and all Diseases of the Feet traced to an Unbalanced Foot Bone, prevented or cured by balancing the foot. By David Roberge. 8vo, cloth5 00

(*)**SMITH.** "A Manual of Veterinary Physiology."

By Veterinary Captain F. Smith, M.R.C.V.S. Author of "A Manual of Veterinary Hygiene."

Throughout this manual the object has been to condense the information as much as possible. The broad facts of the sciences are stated so as to render them of use to the student and practitioner. In this second edition—rewritten—the whole of the Nervous System has been revised, a new chapter dealing with the Development of the Ovum has been added together with many additional facts and illustrations. About one hundred additional pages are given. *Second edition*, revised and enlarged, with additional illustrations3 75

(**)**SMITH.** "Manual of Veterinary Hygiene." 2nd edition, revised. Crown, 8vo, cloth3 25

STORMMOUTH. "Manual of Scientific Terms."
Especially referring to those in Botany, Natural
History, Medical and Veterinary Science. By Rev.
James Stormmouth.....3 00

(**) **STRANGWAY.** "Veterinary Anatomy." New
edition, revised and edited by I. Vaughn, F.L.S.,
M.R.C.V.S., with several hundred illustrations. 8vo,
cloth5 00

(*) **SUSSDORF.** Colored Plates specially for Lectures.
Size 40x27. By Professor Sussdorf, M.D. Translated
by Prof. W. Owen Williams, of the New Veterinary
College, Edinburgh. Plate 1.—Diagram of the Horse
(left or near side view). Plate 2.—Diagram of the
Mare (right side view). Showing the position of the
viscera in the large cavities of the body.

Price, unmounted.....1 75 each
" mounted on linen, with roller...1 75 extra "

"Anatomy of the Cow" (in preparation).

VETERINARY DIAGRAMS in Tabular Form.
Size, 28½ in. x 22 inches. Price per set of five... 4 75

No. 1. "The External Form and Elementary Ana-
tomy of the Horse." Eight coloured illustrations—
1. External regions; 2. Skeleton; 3. Muscles (Superior
Layer); 4. Muscles (Deep Layer); 5. Respiratory Ap-
paratus; 6. Digestive Apparatus; 7. Circulatory Ap-
paratus; 8. Nerve Apparatus; with letter-press descrip-
tion1 25

No. 2. "The Age of Domestic Animals." Forty-two
figures illustrating the structure of the teeth, indicat-
ing the Age of the Horse, Ox, Sheep, and Dog, with
full description75

No. 3. "The Unsoundness and Defects of the Horse."
 Fifty figures illustrating—1. The Defects of Conformation; 2. Defects of Position; 3. Infirmities or Signs of Disease; 4. Unsoundnesses; 5. Defects of the Foot; with full description..... 75

No. 4. "The Shoeing of the Horse, Mule and Ox."
 Fifty figures descriptive of the Anatomy and Physiology of the Foot and of Horse-shoeing.....75

No. 5. "The Elementary Anatomy, Points, and Butcher's Joints of the Ox." Ten coloured illustrations—1. Skeleton; 2. Nervous System; 3. Digestive System (Right Side); 4. Respiratory System; 5. Points of a Fat Ox; 6. Muscular System; 7. Vascular System; 8. Digestive System (Left Side); 9. Butcher's Sections of a Calf; 10. Butcher's Sections of an Ox; with full description1 25

WALLEY. "Hints on the Breeding and Rearing of Farm Animals." 12mo, cloth.....80

WALLEY. "Four Bovine Scourges." (Pleuro-Pneumonia, Foot and Mouth Disease, Cattle Plague and Tubercle.) With an Appendix on the Inspection of Live Animals and Meat. Illustrated, 4to, cloth..6 40

WALLEY. "The Horse, Cow and Dog." By Dr. Thomas Walley. A poetical account of the "Troublous Life of the Horse"; "The Life of a Dairy Cow," and "The Life of a Dog"; with an article on Animal Characteristics. 12mo, cloth,80

- (*) **WALLEY.** "A Practical Guide to Meat Inspection." By Thomas Walley, M.R.C.V.S., formerly principal of the Edinburgh Royal (Dick) Veterinary College; Professor of Veterinary Medicine and Surgery, etc. *Third Edition*, thoroughly revised, with forty-five coloured illustrations, 12mo, cloth.....3 00


An experience of over 30 years in his profession and a long official connection (some sixteen years) with Edinburgh Abattoirs have enabled the author to gather a large store of information on the subject, which he has embodied in his book. Dr. Walley's opinions are regarded as the highest authority on Meat Inspection.

- (**) **WILLIAMS.** "Principles and Practice of Veterinary Medicine." New author's edition, entirely revised and illustrated with numerous plain and colored plates. By W. Williams, M.R.C.V.S. 8vo., cl..6 00

- (**) **WILLIAMS.** "Principles and Practice of Veterinary Surgery." New author's edition, entirely revised and illustrated with numerous plain and colored plates. By W. Williams, M.R.C.V.S. 8vo, cloth.....6 00

- ZUNDEL.** "The Horse's Foot and Its Diseases." By A. Zundel, Principal Veterinarian of Alsace Lorraine. Translated by Dr. A. Liautard, V.S. 12mo, cloth illustrated.....2 00

- ZUILL.** "Typhoid Fever; or Contagious Influenza in the Horse." By Prof. W. L. Zuill, M.D., D.V.S. Pamphlet.....25









LIBRARY OF CONGRESS



0 002 863 883 8