

















THE  
MEDICAL AND SURGICAL HISTORY

OF THE  
WAR OF THE REBELLION.

PART II.  
VOLUME II.

LIBRARY  
UNIVERSITY OF  
CALIFORNIA.

SURGICAL HISTORY.

Prepared, under the direction of JOSEPH K. BARNES, Surgeon General United States Army.

By GEORGE A. OTIS, ASSISTANT SURGEON UNITED STATES ARMY.

FIRST ISSUE.

WASHINGTON:  
GOVERNMENT PRINTING OFFICE.

1876.



RD302

12

1972

BIOLOGY LIBRARY

12059

Gift of U.S. Government to U.S. 1972

## MEMORANDUM.

A few words may be necessary to explain the relation of this volume to the large work, The Medical and Surgical History of the War of the Rebellion, of which it is a component part.

In October, 1865, the Surgeon General published, under the title of *Circular No. 6*, "Reports on the Extent and Nature of the Materials available for the preparation of a Medical and Surgical History of the Rebellion," that had been accumulated in his Office. The circular comprised a report on the materials relating to military medicine, prepared by Assistant Surgeon J. J. WOODWARD, U. S. A., and one on the surgical materials, prepared by the writer of this volume. Such elaboration was given to these preliminary reports, that, while subserving the purpose of the Surgeon General of calling the attention of Congress to the value of the data in his possession, the inconvenience arose that, in many quarters, they were regarded as an attempted digest of these materials, and were very frequently quoted as in fact the completed official medico-military report of the War. The recommendation of the Surgeon General, sustained by the Secretary of War, was so far complied with, that, in the "*Act making Appropriations for Sundry Civil Expenses, etc.*" approved July 28, 1866, an item was inserted making provision for the preparation of plates and illustrations for a first part of a Medical and Surgical History; but it was not until March 3, 1869, that, by Public Resolution, No. 15, the Government Printing Office was authorized to print "five thousand copies of the First Part of the Medical and Surgical History of the Rebellion," to "be disposed of as Congress may hereafter direct." As the labor of designing the illustrations and digesting and arranging the data had long been prosecuted, the work was rapidly pushed toward completion, and, in the winter of 1870, the First Part appeared, divided into a Medical Volume, a Surgical Volume, and an Appendix, the whole comprising eighteen hundred quarto pages, prefixed by a concise but comprehensive chapter by Surgeon General BARNES on the inception, progress, and scope of the work, and the probable requirements for its completion. The latter, it was thought, would demand two more parts of equal magnitude, each subdivided into medical and surgical volumes. On June 8, 1872, was approved "*An Act for the Completion and Publication of the Medical and Surgical History of the War*" in two Parts of eighteen hundred pages each, in addition to the first Part already compiled. With the limited clerical force at the disposition of the Surgeon General, it was found utterly impracticable to complete this undertaking within the fiscal period of two years wherein the appropriation for the purpose was available, and accordingly, in the *Act making Appropriations for Sundry Civil Expenses, etc.*, approved June 23, 1875, the unexpended balance of the appropriation of June 8, 1872, was continued, and, moreover, an additional appropriation was made for a second edition of the six volumes of the entire work.

In the Surgical Volume of the First Part, after the Prefatory paper of the Surgeon General, the Introduction of the editor, and a Chronological Summary of Losses in Battles and Engagements, an exposition of the statistics and detailed reports of Special Wounds and Injuries of the Several Regions was commenced and continued through five Chapters, treating respectively of the Injuries of the Head, Face, Neck, Spine, and Chest. The nature and results of forty-nine thousand and sixteen cases of injury by war-weapons were set forth. It was aimed to give concise details of as large a number as possible of individual facts bearing on the practice of military surgery. The space occupied by the detailed reports was so great, that discussion and comment on the material was to a great extent reserved for a later portion of the work.

In the present, or Surgical Volume of the Second Part of the Medical and Surgical History, the presentation of the facts regarding the Special Wounds and Injuries is continued, according to regional classification, through four Chapters. In Chapter VI, eighty-five hundred and thirty-eight cases of Wounds of the Abdomen are tabulated, and detailed abstracts of six hundred and ten of them recorded. In Chapter VII, thirty-one hundred cases of Wounds of the Pelvis are enumerated, six hundred and ten being detailed. In Chapter VIII, twelve thousand six hundred and eighty-one cases of shot Flesh Wounds of the Back are tabulated, with abstracts of two examples. In Chapter IX, eighty-eight thousand seven hundred and forty-one cases of Wounds of the Upper Extremities are considered—fifty-five thousand and eighty-six injuries of the soft parts, and thirty-three thousand six hundred and fifty-five cases of shot fractures. Detailed abstracts are given of eight hundred and seventeen cases; the principal facts concerning thirty-seven hundred and twelve excisions and eighty-two hundred and forty-five amputations are concisely recorded in tabular form; the remainder of the cases are adverted to in numerical statements.

The Record of the yet more numerous Injuries of the Lower Extremities constitute the subject-matter of Chapter X, with which the Surgical Volume of the Third Part of the History will begin. A chapter will succeed on Fractures and Luxations from other causes than gunshot injury reported during the War, to be followed by one on the reported instances of Burns, Scalds, and Frostbites. This will conclude the review of Special Wounds and Injuries, and will be followed by a chapter of generalities on shot wounds, their nature, frequency, and fatality, and principal complications, as pyæmia, secondary hæmorrhage, gangrene, and tetanus. Generalities on amputations, excisions, and ligations will also be presented. Chapters on the Use of Anæsthetics in field and hospital, with details of the alleged deaths from chloroform, on the *Materia Chirurgica*, including Artificial Limbs and Prosthetic Apparatus, and on the Transportation of the Wounded by Land and Water, will follow, and a copious Analytical Index of the three surgical Parts will conclude the Volume.

GEORGE A. OTIS.





TABLE OF CONTENTS  
OF  
VOLUME II OF PART II  
OF THE  
MEDICAL AND SURGICAL HISTORY OF THE REBELLION,  
BEING THE  
SECOND SURGICAL VOLUME.

MEMORANDUM . . . . . p. III.

CHAPTER VI. INJURIES OF THE ABDOMEN.

	Page.		Page.
<b>SECTION I. Contusions and Wounds of the Abdominal Parietes.</b>	31	<b>SECTION III. PENETRATING WOUNDS OF ABDOMEN—(Continued.)</b>	
<b>Punctured and Incised wounds</b> . . . . .	3	<b>Wounds of the Small Intestines</b> . . . . .	60
Sabre and Bayonet wounds . . . . .	3	Punctured and Incised wounds . . . . .	61
Others Punctured and Incised wounds . . . . .	4	Gunshot wounds . . . . .	64
<b>Lacerated and Contused wounds</b> . . . . .	4	Wounds of the Duodenum . . . . .	67
<b>Rupture of Muscles</b> . . . . .	5	Wounds of the Jejunum . . . . .	68
<b>Gunshot Flesh wounds</b> . . . . .	6	Wounds of the Ileum . . . . .	70
TABLE I. Partial numerical statement of shot wounds of the Abdomen . . . . .	6	PLATE II. Enterorraphy of Ileum, facing . . . . .	72
TABLE II. Cases of injuries of the Abdominal Walls re- turned during the War . . . . .	8	<b>Wounds of the Large Intestines</b> . . . . .	75
<b>Complications of Parietal wounds</b> . . . . .	8	Punctured and Incised wounds . . . . .	76
Hæmorrhage . . . . .	8	Gunshot wounds . . . . .	76
Foreign bodies . . . . .	11	PLATE IV. Fæcal Fistula of Colon, facing . . . . .	77
Gangrene . . . . .	12	Abstracts of fifty-nine cases of recovery . . . . .	77
Hernia . . . . .	13	PLATE V. Shot perforation of Abdomen, facing . . . . .	81
Nervous disorders . . . . .	13	Balls voided at stool . . . . .	98
Tetanus . . . . .	14	Fatal cases . . . . .	102
<b>SECTION II. Visceral Injuries without External Wounds.</b>	15	<b>Abnormal Anus</b> . . . . .	109
<b>Ruptures of the Liver</b> . . . . .	16	Suture . . . . .	111
<b>Ruptures of the Spleen</b> . . . . .	18	Anaplasty . . . . .	111
<b>Ruptures of the Kidney</b> . . . . .	20	Enterorraphy . . . . .	112
<b>Ruptures of the Stomach</b> . . . . .	22	PLATE III. Suture of Ileum, facing . . . . .	113
<b>Ruptures of the Intestines</b> . . . . .	22	Palfyn's method . . . . .	114
PLATE I. Rupture of Jejunum, facing . . . . .	23	Reybard's method . . . . .	115
<b>Ruptures of the Omentum and Mesentery</b> . . . . .	23	Le Dran's method . . . . .	115
<b>Ruptures of the Blood-vessels</b> . . . . .	24	Method of the Four Masters and Duverger . . . . .	116
<b>Ruptures of the Diaphragm</b> . . . . .	25	Method of Denans . . . . .	116
TABLE III. Numerical statement of Visceral Injuries without external wound . . . . .	26	Method of Ramdohr . . . . .	117
<b>SECTION III. Penetrating Wounds of the Abdomen.</b>	29	Jobert's method . . . . .	118
<b>Simple Penetrations and Perforations</b>		Lembert's method . . . . .	119
<b>without Visceral injury</b> . . . . .	31	Géty's method . . . . .	119
Abstracts of Punctured and Incised wounds . . . . .	31	Views of Gross and Reybard . . . . .	123
Abstracts of cases of Gunshot wounds . . . . .	34	Enterorraphy in Shot wounds . . . . .	125
<b>Wounds of the Stomach</b> . . . . .	41	<b>Wounds of the Liver</b> . . . . .	129
Punctured and Incised wounds . . . . .	41	Punctured and Incised wounds . . . . .	129
Gunshot wounds . . . . .	44	Gunshot wounds . . . . .	131
Abstracts of cases of recovery . . . . .	45	Memoranda of fifty nine uncomplicated cases . . . . .	131
Fatal complicated cases . . . . .	48	Memoranda of one hundred and fourteen compli- cated cases . . . . .	132
Gastric fistula . . . . .	52	PLATE VI. Metastatic Fæcal, facing . . . . .	133
		Recoveries, abstracts of cases . . . . .	139

TABLE OF CONTENTS.

CHAPTER VI. INJURIES OF THE ABDOMEN—CONTINUED.

SECTION III. WOUNDS OF ABDOMEN—[Continued.]	Page.	SECTION III. ABDOMINAL EFFUSIONS—[Continued.]	Page.
<b>Wounds of the Spleen</b> .....	149	Paracentesis .....	191
Punctured and incised wounds .....	149	Bile .....	192
Gunshot wounds .....	150	Urine .....	193
Tabular statement of the recorded operations of Spleno- tomy .....	152	Feces, etc. ....	194
<b>Wounds of the Pancreas</b> .....	158	Pus .....	197
<b>Wounds of the Kidney</b> .....	162	Air or gases .....	198
Gunshot wounds .....	163	Traumatic peritonitis .....	199
Memoranda of twenty-six alleged cases of re- covery .....	163	<b>Frequency of Wounds of the Abdomen</b> .....	201
Abstracts of fatal cases .....	167	<b>Mortality of Wounds and Injuries of the Abdomen</b> .....	202
<b>Wounds of the Suprarenal Capsules</b> .....	173	TABLE IV. Statement of the cases of Penetrating wounds of the Abdomen returned during the War .....	202
<b>Wounds of the Omentum, Mesentery, and Blood-vessels</b> .....	174	TABLE V. Number of Penetrating shot wounds of the Abdomen in other wars, with ratio of mortality. ....	203
<b>Complications</b> .....	176	Deadliness of shot wounds of Abdomen .....	204
Hæmorrhage .....	176	Observations by Surg. J. J. B. Wright .....	204
Foreign bodies .....	179	Examples of Impalement .....	204
Visceral protrusions .....	180	PLATE XI. Rupture of Ilium, facing .....	205
PLATE X. Hernia of Jejunum, facing .....	184	<b>Concluding observations</b> .....	205
Hernia .....	184	Laparotomy for traumatism .....	206
Herniotomy, abstracts of twelve cases .....	186	Diagnosis .....	206
Abdominal effusions .....	188	Treatment .....	207
Blood, abstracts of four cases .....	189	Bibliography .....	208

CHAPTER VII. INJURIES OF THE PELVIS.

SECTION I. Shot Fractures of the Pelvic Bones	Page.	SECTION II. FOREIGN BODIES IN THE BLADDER—[Continued.]	Page.
<b>Shot fractures of the Ilium</b> .....	212	Lithotomy for ordinary vesical calculi .....	282
PLATE XXXVI. Shot fracture of Ilium, facing .....	212	Extraneous bodies escaping by the Urethra .....	283
Penetrations without visceral injury .....	213	<b>Shot wounds of Bladder, other examples</b> .....	283
Abstracts of cases .....	214	Recovery, abstracts of twenty-eight cases .....	286
Abstracts of fractures of both Ili- a .....	215	Fatal shot wounds .....	290
Illustrated shot fractures .....	218	Urinary infiltration .....	296
TABLE VI. Indicating the relative liability of the right and left Ili- a to shot injury .....	221	Remarks on shot wounds of the Bladder .....	297
PLATE XXXIV. Curious shot fracture of Ilium, facing .....	221	<b>Wounds of the Prostate</b> .....	303
PLATE XXXV. Fracture of Os Iliopubicum, facing .....	225	<b>Wounds of the Rectum</b> .....	305
Caries and Necrosis .....	225	Stercoral fistule after shot wounds of the Rectum .....	308
PLATE XXXVII. Shot perforation of Ilium, facing .....	225	Recovery after shot wounds of the Rectum .....	310
Pyæmia and Septicæmia .....	229	Fatal shot wounds of the Rectum .....	315
Excisions of portions of the Ilium .....	230	Anal fistule .....	321
<b>Shot fractures of the Pubis</b> .....	237	Anal fissure .....	321
<b>Shot fractures of the Ischium</b> .....	240	Hæmorrhoids .....	322
Excisions of portions of the Ischium and extraction of foreign bodies .....	245	Foreign bodies .....	322
<b>Shot fractures of the Sacrum</b> .....	246	<b>Wounds of the Blood-vessels and Nerves</b> .....	323
Excisions of portions of the Sacrum .....	250	Punctured and incised wounds .....	323
<b>Shot fractures of the Coccyx</b> .....	252	Gunshot wounds .....	324
<b>Shot fractures of the Pelvic Bones in gen- eral</b> .....	251	Wounds of the Internal Pubic artery .....	324
TABLE VII. Numerical return of fourteen hundred and ninety cases of shot fracture of the Pelvis .....	255	Wounds and ligations of the Sciatic artery .....	326
Excisions of portions of the Pelvic bones .....	255	Wounds of the Ilio-lumbar artery .....	327
PLATE XLII. Instruments for resection, facing .....	256	Wounds and ligations of the Gluteal artery .....	327
<b>Injuries of the Pelvic Ligaments</b> .....	256	Wounds and ligations of the Internal Iliac or Hypogastric artery .....	330
<b>SECTION II. Injuries of the parts contained in the Pelvis</b> .....	257	Wounds and ligations of the Common Iliac artery .....	333
<b>Shot penetrations or perforations without Visceral injury</b> .....	257	Wounds and ligations of the Spermatic artery .....	337
<b>Injuries of the Bladder</b> .....	262	Wounds of the Veins .....	338
Ruptures of the Bladder .....	263	Wounds of the Nerves .....	339
Punctured, Incised, and Lacerated wounds .....	263	<b>SECTION III. On Injuries of the Genital Organs</b> .....	343
Concussions of the Bladder .....	264	<b>Wounds of the Penis</b> .....	343
<b>Shot wounds of the Bladder</b> .....	264	Incised wounds .....	343
<b>Foreign bodies in the Bladder</b> .....	268	Gunshot wounds .....	345
Vesical calculi formed about projectiles .....	269	<b>Wounds of the Urethra</b> .....	349
PLATE VII. Vesical calculi, facing .....	272	Gunshot wounds .....	350
Calculi having nuclei of bone or of encrusted bone splinters .....	276	Recovery after gunshot wounds of the Urethra .....	351
Calculi consequent on shot wounds of Bladder .....	279	Traumatic strictures .....	351
PLATE VIII. Vesical calculi removed after shot wounds, facing .....	280	Urethral fistules .....	360
TABLE VIII. Descriptive numerical statement of twenty-one cases of lithotomy .....	282	Deep Urethral fistules .....	364
		Urethro-rectal fistules .....	369
		Fatal shot wounds of the Urethra .....	372
		Urinary infiltration and free incision .....	373
		Injuries not caused by shot .....	374
		Foreign bodies .....	375
		Treatment of wounds of the Urethra and of traumatic strictures and fistules .....	380

TABLE OF CONTENTS.

CHAPTER VII. INJURIES OF THE PELVIS—[CONTINUED.]

	Page.		Page.
SECTION III. WOUNDS OF THE URETHRA—[Continued.]		SECTION III. INJURIES, ETC., OF THE TESTIS—[Continued.]	
Organic Strictures (three abstracts).....	386	Excisions of both Testes (three abstracts).....	414
Dilatation and Divulsion.....	388	Atrophy of the Testes.....	415
Urethrotomy.....	392	Injuries of the Spermatic Cord (five abstracts).....	417
Internal Urethrotomy.....	392	Contusions of the Testis (three abstracts).....	418
PLATE XII. Urethral instruments, facing.....	395	Sarcocoele (one abstract).....	418
External perineal Urethrotomy (seven abstracts).....	396	<b>Wounds of the Scrotum</b> .....	419
Urethrophony and Urethroplasty (four abstracts).....	401	Hydrocoele.....	420
<b>Injuries and diseases of the Testis</b> .....	405	Operations for Hydrocoele.....	421
Shot injuries of the Testis.....	405	Varicocele.....	422
Shot lacerations of the Testis (twenty abstracts).....	406	<b>Concluding observations</b> .....	423
Excisions of the Testis for shot injury.....	409	TABLE IX. Statement of thirty-one hundred and seventy-four cases of injury to the Pelvis.....	423
Abstracts of thirty two cases of recovery.....	409		
Fatal cases (seven abstracts).....	413		

CHAPTER VIII. FLESH WOUNDS OF THE BACK.

	Page.		Page.
Relative frequency of Shot wounds of the Back unattended by Fracture.....	427	<b>Punctured and Incised wounds of Back</b> .....	429
TABLE X. Statement of Wounds of the Back and Hips in the field or primary hospitals.....	428	<b>Gunshot wounds of the Back</b> (abstracts of two cases).....	429
TABLE XI. Statement of twelve thousand six hundred and eighty-one Gunshot Flesh wounds of the Back.....	428	PLATE IX. Laceration of the Buttocks, facing.....	430
		<b>Skin Grafting</b> .....	431
		Fatality of Shot wounds of Back.....	432

CHAPTER IX. WOUNDS AND INJURIES OF THE UPPER EXTREMITIES.

	Page.		Page.
Prolegomena.....	433	SECTION I. FLESH WOUNDS—[Continued.]	
TABLE XII. Collated return indicating the relative frequency of shot wounds of the upper extremity.....	434	Amputations of the Forearm.....	471
SECTION I. <b>Flesh Wounds of the Upper Extremity</b> .....	435	TABLE XVI. Summary of fourteen cases.....	471
<b>Punctured and Incised Wounds</b> .....	435	<b>General observations on Flesh-wounds of the Upper Extremity</b> .....	471
Ligation of the Brachial artery.....	436	SECTION II. <b>Fractures of the Clavicle and Scapula</b> .....	473
Ligation of the Ulnar artery.....	436	<b>Sabre and Bayonet wounds</b> .....	473
Ligation of the Radial artery.....	436	<b>Shot fractures of the Clavicle and Scapula</b> .....	474
Wounds of the Palmar arches.....	437	TABLE XVII. Statement of twenty-two hundred and eighty shot fractures of the Clavicle and Scapula.....	474
<b>Gunshot Wounds</b> .....	438	<b>Shot fractures of the Clavicle</b> .....	475
False Anchylosis.....	438	Excisions of the Clavicle.....	476
Atrophy and Deformity after sloughing.....	439	TABLE XVIII. Summary of twenty-two cases.....	480
Pyæmia.....	440	<b>Shot fractures of the Scapula</b> .....	481
Lesion of the large Blood-vessels.....	440	PLATE XLV. Shot fracture of Left Scapula, facing.....	488
Ligations of the Axillary artery.....	442	Excisions of portions of the Scapula.....	492
Abstracts of fifteen cases.....	442	TABLE XIX. Summary of forty examples.....	495
Ligations of the Brachial artery.....	446	Partial excisions of Clavicle and Scapula.....	497
TABLE XIII. Summary of seventy-six cases.....	448	TABLE XXI. Summary of nine cases.....	497
Ligations of Ulnar artery.....	451	SECTION III. <b>Wounds of the Shoulder Joint</b> .....	501
Ligations of Radial artery.....	452	<b>Wounds treated on the Experiment plan</b> .....	502
Ligation of Interosseous, Superficial Palmar Arch, and other arteries.....	454	Wounds unattended by Fracture.....	502
Flesh wounds involving large Blood-vessels treated without operation.....	454	Wounds attended by Fracture of the bones composing the Shoulder Joint.....	503
Blood-vessels primarily involved, abstracts of nine cases.....	454	Abstracts of thirteen cases of recovery.....	505
Sloughing involving the larger Blood-vessels.....	456	Abstracts of nine fatal cases.....	510
Hæmorrhage from the Subclavian or its branches.....	456	<b>Excisions at the Shoulder</b> .....	519
Hæmorrhage from the Axillary or its branches.....	456	TABLE XXI. Statement of eight hundred and eighty-five cases of excisions at the Shoulder.....	520
Hæmorrhage from the Brachial or its branches.....	457	Excisions of the Head of the Humerus with portions of the Clavicle and Scapula.....	520
Hæmorrhage from the Ulnar or its branches.....	458	PLATE XIII. Results of excisions of the Head of the Humerus, facing.....	520
Hæmorrhage from the Radial or its branches.....	458	TABLE XXII. Tabular summary of forty-two cases.....	524
Hæmorrhage from the Interosseous artery.....	458	Partial excisions of the Head of the Humerus.....	526
Flesh wounds involving the larger nerves.....	461	TABLE XXIII. Tabular summary of fourteen cases.....	528
Injuries of the Brachial plexus.....	463	<b>Decapitations of the Humerus</b> .....	529
Injuries of the Circumflex, Musculo-cutaneous, and Musculo-spiral nerves.....	463	Primary decapitations of the Head of the Humerus.....	529
Injuries of the Median nerve.....	464	Successful operations, abstracts of six cases.....	529
Neurotomy.....	465	PLATE XIV. Results of excisions of the Head of the Humerus, facing.....	529
Injuries of the Ulnar nerve.....	466	TABLE XXIV. Summary of one hundred and nineteen cases.....	531
Injuries of the Radial nerve.....	467	Unsuccessful operations.....	532
Amputations consequent on Flesh wounds.....	468		
Amputations at the Shoulder Joint.....	468		
TABLE XIV. Summary of fourteen cases.....	468		
Amputations of the Upper Arm.....	469		
TABLE XV. Summary of fifty four cases.....	469		



TABLE OF CONTENTS.

CHAPTER IX. WOUNDS AND INJURIES OF THE UPPER EXTREMITIES (CONTINUED).

SECTION III. DECAPITATIONS OF THE HUMERUS—(Continued).	Page.	SECTION III. AMPUTATIONS AT THE SHOULDER—(Continued).	Page.
PLATE XVII. Results of excisions of the Head of the Humerus, facing.....	536	TABLE XLIII. Tabular summary of three hundred and sixty eight cases.....	620
TABLE XXV. Tabular summary of fifty-six cases.....	536	Unsuccessful operations (two abstracts).....	630
Intermediary decapitations of the Humerus.....	537	TABLE XLIV. Tabular summary of one hundred and seventeen cases.....	631
Successful cases (two abstracts).....	537	Operations with unknown results.....	636
TABLE XXVI. Tabular summary of twenty-one cases.....	539	TABLE XLV. Tabular summary of fourteen cases.....	636
Unsuccessful cases (two abstracts).....	540	Intermediary amputations at the Shoulder Joint.....	636
TABLE XXVII. Tabular summary of thirty-four cases.....	541	Successful operations (abstracts of three cases).....	637
Secondary decapitations of the Humerus.....	542	TABLE XLVI. Tabular summary of eighty-five cases.....	638
Successful cases (three abstracts).....	543	PLATE XLVI. Shot comminutions of the Humerus, facing.....	640
TABLE XXVIII. Tabular summary of thirteen cases.....	543	Unsuccessful cases (abstracts of three cases).....	641
PLATE XVII. Results of excisions of the Head of the Humerus, facing.....	544	TABLE XLVII. Tabular summary of seventy two fatal cases.....	642
Unsuccessful cases (two abstracts).....	545	Secondary amputations at the Shoulder Joint.....	645
TABLE XIX. Tabular summary of thirteen cases.....	545	Successful operations (three abstracts).....	645
Decapitations of the Humerus of uncertain date (two abstracts).....	547	TABLE XLVIII. Tabular summary of forty-seven cases.....	647
TABLE XXX. Tabular statement of seventeen cases.....	547	Unsuccessful operations (abstract of one case).....	649
<b>Excisions of the Head and portions of the Shaft of the Humerus</b> .....	548	TABLE XLIX. Tabular summary of nineteen cases.....	650
Primary excisions of the upper extremity of the Humerus.....	548	Period unknown, amputations at the Shoulder Joint.....	651
Successful operations (abstracts of twenty-nine cases).....	548	Successful operations.....	651
TABLE XXXI. Tabular summary of two hundred and thirteen cases.....	554	TABLE L. Condensed summary of ninety-one cases.....	651
Unsuccessful operations (abstracts of nine cases).....	559	Unsuccessful operations.....	653
TABLE XXXII. Tabular summary of eighty fatal cases.....	570	TABLE LI. Condensed summary of twenty-eight cases.....	653
Intermediary excisions of the upper extremity of the Humerus.....	573	Results of operation unknown.....	654
Successful operations (abstracts of fourteen cases).....	573	TABLE LII. Condensed summary of eleven cases.....	654
TABLE XXXIII. Tabular summary of ninety one cases.....	576	Recapitulation.....	655
Unsuccessful operations (abstracts of seven cases).....	584	<b>Concluding observations on shot injuries of the Shoulder</b> .....	656
TABLE XXXIV. Tabular summary of sixty-four cases.....	585	Treatment.....	657
Secondary excisions of the upper extremity of the Humerus.....	589	Excision, Expectation, etc.....	659
Successful operations (abstracts of eight cases).....	589	TABLE LIII. Mode of treatment and results of injuries of the Shoulder Joint in other wars.....	661
TABLE XXXV. Tabular summary of thirty-eight cases.....	591	TABLE LIV. Statement of one hundred and fifty invalid pensioners treated either by expectation, excision, or amputation.....	662
Unsuccessful operations (abstracts of two cases).....	595	<b>SECTION IV. Injuries of the Shaft of the Humerus.</b>	
TABLE XXXVI. Tabular summary of twelve cases.....	596	<b>Expectant conservative measures</b> .....	666
Excisions of the upper extremity of the Humerus of uncertain date.....	597	Shot contusions and partial fractures treated by expectation (abstract of one case).....	667
TABLE XXXVII. Tabular summary of nineteen cases.....	597	Partial shot fractures (abstracts of two cases).....	668
<b>Excisions of the Shoulder, parts not definitely determined</b> .....	597	Complete shot fractures (abstracts of eleven cases).....	669
TABLE XXXVIII. Tabular summary of thirty-nine cases.....	598	Pseudarthrosis (abstracts of three cases).....	673
<b>Concluding observations on Excisions at the Shoulder after shot injury</b> .....	599	<b>Excision in the continuity of the Humerus for shot fracture</b> .....	675
TABLE XXXIX. Numerical summary of the eight hundred and eighty-five excisions at the Shoulder.....	599	Primary excisions of the shaft of the Humerus.....	675
TABLE XL. Tabular summary of two hundred and one cases practised in Confederate army.....	601	Successful cases (abstracts of four cases).....	675
TABLE XLI. Number of excisions of upper extremity of the Humerus in other wars, with ratio of mortality.....	607	TABLE LVI. Condensed summary of three hundred and twenty-six cases.....	676
<b>Amputations at the Shoulder</b> .....	613	Fatal cases (abstracts of three cases).....	682
Scapulo-humeral amputations after shot fracture.....	613	TABLE LVII. Condensed summary of one hundred and forty-five cases.....	686
TABLE XLII. Numerical statement of eight hundred and fifty two amputations at the Shoulder Joint after fracture.....	614	Result not ascertained.....	686
Primary amputations at the Shoulder Joint.....	614	TABLE LVIII. Condensed summary of sixteen cases.....	686
Successful operations (abstracts of thirteen cases).....	615	Intermediary excisions of the shaft of the Humerus.....	686
		Successful cases (one abstract).....	686
		TABLE LX. Condensed summary of sixty-four cases.....	687
		Fatal cases (one abstract).....	688
		TABLE LXI. Condensed summary of twenty-nine cases.....	688
		Secondary excisions of the shaft of the Humerus.....	690
		Successful cases (abstracts of four cases).....	690
		TABLE LXI. Condensed summary of thirty-six cases.....	690

TABLE OF CONTENTS.

CHAPTER IX. WOUNDS AND INJURIES OF THE UPPER EXTREMITIES—CONTINUED.

SECTION IV. EXCISIONS IN THE HUMERUS—(Continued.)	Page.	SECTION IV. AMPUTATIONS OF THE ARM—(Continued.)	Page.
Fatal cases (abstract of one case).....	693	Intermediary amputations in the middle third of the Arm	761
TABLE LXII. Condensed summary of five cases.....	693	Successful cases (abstracts of six cases).....	761
Period unknown.....	693	TABLE LXXVIII. Summary of two hundred and fifty-five cases of recovery after intermediary amputations in the middle third of the shaft of the Humerus.....	763
Successful cases.....	693	Fatal cases (abstracts of two cases).....	766
TABLE LXIII. Condensed summary of fifty-one cases.....	694	TABLE LXXIX. Summary of ninety-three unsuccessful cases of intermediary amputations in the middle third of the shaft of the Humerus.....	768
Fatal cases.....	695	Intermediary amputations at the lower third of the Arm	769
TABLE LXIV. Condensed summary of twelve cases.....	695	Successful cases (four abstracts).....	769
Results unknown.....	695	TABLE LXXX. Summary of ninety-four cases of recovery after intermediary amputations in the lower third of the shaft of the Humerus.....	771
TABLE LXV. Condensed summary of twelve cases.....	695	Fatal cases (two abstracts).....	772
Concluding observations on excisions in the continuity of the shaft of the Humerus for shot injuries.....	695	TABLE LXXXI. Summary of sixty-seven unsuccessful cases of intermediary amputations in the lower third of the shaft of the Humerus.....	773
TABLE LXVI. Numerical, of six hundred and ninety-six cases of excisions in the shaft of the Humerus for shot injury.....	696	Intermediary amputations of the Arm without indication of the seat of incision.....	774
<b>Amputations of the Arm for shot injury</b> .....	697	Successful cases.....	774
TABLE LXVII. Summary of five thousand four hundred and fifty-six amputations of the Arm for shot injury.....	697	TABLE LXXXII. Summary of twelve cases of recovery after intermediary amputations of the Arm, the point of ablation unspecified..	774
Primary amputations in the Continuity.....	697	Fatal cases.....	774
Primary amputations in the upper third of the Arm.....	698	TABLE LXXXIII. Summary of thirty-four unsuccessful cases of intermediary amputations of the Arm, the point of ablation unspecified	774
Successful cases (abstracts of ten cases).....	698	Secondary amputations in the Continuity.....	775
TABLE LXVIII. Summary of eleven hundred and fifty-five cases of recovery after primary amputations in the upper third of the shaft of the Humerus.....	700	Secondary amputations in the upper third of the Arm	775
Fatal cases (abstracts of three cases).....	717	Successful cases (two abstracts).....	775
TABLE LXIX. Summary of one hundred and eighty-three unsuccessful cases of primary amputations in the upper third of Humerus.....	718	TABLE LXXXIV. Summary of one hundred and twenty-seven cases of recovery after secondary amputations in the upper third of the Humerus.....	777
Primary amputations in the middle third of the Arm.....	721	Fatal cases (five abstracts).....	779
Successful cases (four abstracts).....	721	TABLE LXXXV. Summary of forty-six unsuccessful cases of secondary amputations in the upper third of the Humerus.....	781
TABLE LXX. Summary of one thousand and nineteen cases of recovery after primary amputations in the middle third of the shaft of the Humerus.....	721	Secondary amputations at the middle third of the Arm	782
Fatal cases (two abstracts).....	736	Successful cases (five abstracts).....	782
TABLE LXXI. Summary of one hundred and forty-three unsuccessful cases of primary amputations in the middle third of the shaft of the Humerus.....	737	TABLE LXXXVI. Summary of one hundred and twenty-seven cases of recovery after secondary amputations in the middle third of the shaft of the Humerus.....	784
Primary amputations in the lower third of the Arm.....	739	Fatal cases (three abstracts).....	786
Successful cases (abstracts of six cases).....	739	TABLE LXXXVII. Summary of thirty-five unsuccessful cases of secondary amputations in the middle third of the Arm.....	787
TABLE LXXII. Summary of four hundred and six cases of recovery after primary amputations in the lower third of the shaft of the Humerus.....	741	Secondary amputations of the Arm at the lower third.	788
Fatal cases (abstracts of two cases).....	746	Successful cases (three abstracts).....	788
TABLE LXXIII. Summary of one hundred and six unsuccessful cases of primary amputations in the lower third of the shaft of the Humerus.....	747	TABLE LXXXVIII. Summary of thirty-seven cases of recovery after secondary amputations in the lower third of the Arm.....	789
Primary amputations of the Arm without indication of the seat of incision.....	748	Fatal cases (two abstracts).....	790
Successful cases.....	749	TABLE LXXXIX. Summary of twenty-four unsuccessful cases of secondary amputations in the lower third of the Arm.....	791
TABLE LXXIV. Summary of seventy-seven cases of recovery after primary amputations of the Arm, the point of ablation unspecified..	749	Secondary amputations of the Arm without indication of the seat of incision (one abstract).....	791
Fatal cases.....	750	TABLE XC. Summary of fifteen cases of secondary amputations of the Arm, the period of ablation unspecified.....	792
TABLE LXXV. Summary of one hundred and seventy fatal primary amputations of the Arm, the point of ablation unspecified.....	750	Amputations in the continuity of the Arm of uncertain date.....	792
Intermediary amputations in the Continuity.....	752	Amputations in the upper third of the Arm of uncertain date.....	792
Intermediary amputations in the upper third of the Arm	753	Successful cases.....	793
Successful cases (abstracts of four cases).....	753	TABLE XCI. Summary of sixty-one successful cases of amputations in the upper third of the Humerus of uncertain date.....	793
TABLE LXXVI. Summary of two hundred and thirty-nine cases of recovery after intermediary amputations in the upper third of the shaft of the Humerus.....	755	Fatal cases.....	793
Fatal cases (abstracts of two cases).....	758		
TABLE LXXVII. Summary of one hundred and eight fatal cases of intermediary amputations in the upper third of the shaft of the Humerus.....	759		

TABLE OF CONTENTS.

CHAPTER IX. WOUNDS AND INJURIES OF THE UPPER EXTREMITIES—(CONTINUED.)

	Page.		Page.
<b>SECTION IV. AMPUTATIONS OF THE ARM—(Continued.)</b>		<b>SECTION V. WOUNDS OF THE ELBOW JOINT—(Continued.)</b>	
<b>TABLE XCII.</b> Summary of twenty-one fatal cases of amputations at the upper third of the Humerus of uncertain date.....	794	Fatal cases (eleven abstracts).....	811
Undetermined cases.....	794	<b>PLATE XIX.</b> Necrosis of the Humerus after shot injury, facing.....	842
<b>TABLE XCIII.</b> Summary of twelve cases of amputations at the upper third of the Humerus of uncertain date and undetermined result..	794	<b>Excisions at the Elbow Joint for shot injury.</b>	845
<b>Amputations in the middle third of the Arm of uncertain date.....</b>	794	<b>TABLE CVI.</b> Numerical statement of six hundred and twenty-six cases of complete or partial excisions of the bones of the Elbow Joint for shot injury.....	815
Successful cases.....	794	Primary excisions at the Elbow.....	845
<b>TABLE XCIV.</b> Summary of forty-five cases of recovery after amputations in the middle third of the shaft of the Humerus of uncertain date.....	795	Recoveries after primary excisions at the Elbow (twelve abstracts).....	846
Fatal cases.....	795	<b>PLATE LIII.</b> Results of excisions of the Elbow for shot injury, facing.....	850
<b>TABLE XCV.</b> Summary of thirteen cases of unsuccessful amputations in the middle third of the shaft of the Humerus of uncertain date.....	795	<b>TABLE CVII.</b> Summary of two hundred and fifty cases of recovery after primary excisions at the Elbow Joint for shot injury.....	851
Undetermined cases.....	796	Fatal cases of primary excisions at the Elbow (four abstracts).....	861
<b>TABLE XCVI.</b> Summary of nine cases of amputations in the middle third of the shaft of the Humerus of uncertain date and uncertain result.....	796	<b>TABLE CVIII.</b> Summary of sixty-eight fatal cases after primary excisions of the Elbow Joint for shot injury.....	863
<b>Amputations in the lower third of the Arm of uncertain date.....</b>	796	<b>TABLE CIX.</b> Summary of four cases of primary excisions of the bones of the Elbow Joint with undetermined result.....	864
<b>TABLE XCVII.</b> Summary of twenty-four cases of amputations in the lower third of the shaft of the Humerus of uncertain date.....	796	Intermediary excisions at the Elbow.....	865
<b>Amputations in the continuity of the Arm of uncertain date, without indication of the seat of incision.....</b>	797	Recoveries after intermediary excisions at the Elbow (fourteen abstracts).....	865
Successful cases.....	797	<b>PLATE LI.</b> Bones of Elbow excised for shot injury, facing..	872
<b>TABLE XCVIII.</b> Summary of three hundred and forty-five cases of recovery after amputations in the Arm of uncertain date, without indication of the seat of incision.....	797	<b>TABLE CX.</b> Summary of one hundred and twenty-seven cases of recovery after intermediary excisions of the bones at the Elbow for shot injury.....	874
Fatal cases.....	801	Fatal cases of intermediary excisions at the Elbow (seven abstracts).....	879
<b>TABLE XCIX.</b> Summary of one hundred and ninety-four fatal cases of amputations in the Arm of uncertain date and seat.....	801	<b>TABLE CXI.</b> Summary of sixty-nine unsuccessful cases of intermediary excisions of the Elbow Joint for shot injury.....	881
Undetermined cases.....	803	Excision with undetermined result (one abstract).....	884
<b>TABLE C.</b> Summary of one hundred and sixty cases of amputations in the Arm in which the precise seat of operation and the result are unknown.....	803	Secondary excisions at the Elbow.....	884
<b>Recapitulation.....</b>	805	Recoveries after secondary excisions at the Elbow (eleven abstracts).....	884
<b>TABLE CI.</b> Statement of the ages of three thousand and sixty-eight patients who submitted to amputation of the Arm for shot injury.....	806	<b>TABLE CXII.</b> Summary of forty-nine cases of recovery after secondary excisions of the bones of the elbow for shot injury.....	889
<b>Concluding observations on shot injuries of the Upper Arm.....</b>	807	Fatal secondary excisions at the Elbow (two abstracts).....	890
Simple shot fractures.....	815	<b>TABLE CXIII.</b> Summary of five fatal cases of secondary excisions at the Elbow for shot injury.....	891
Shot contusions of the Humerus (sixteen abstracts).....	817	Excisions at the Elbow of uncertain date (one abstract).....	892
Excisions in the Continuity.....	819	<b>TABLE CXIV.</b> Summary of fifty-three cases of excisions at the Elbow Joint, of uncertain date, for shot injury.....	892
Amputations in the Continuity.....	822	<b>Recapitulation.....</b>	894
<b>TABLE CII.</b> Statement showing the percentages of mortality of the various subdivisions of the fifty-four hundred and fifty-six amputations of the Arm for shot injury.....	824	<b>TABLE CXV.</b> Statement of parts excised in six hundred and twenty-six instances of excisions at the Elbow for shot injury.....	894
<b>TABLE CIII.</b> Relative percentage of mortality of amputations in the upper, middle, and lower thirds of the Upper Arm for shot injury.....	824	<b>TABLE CXVI.</b> Period of the war at which the excisions at the Elbow were practised, with the results.....	891
<b>TABLE CIV.</b> Mode of treatment and results of shot fractures involving the shaft of the Humerus on the occasions named and from the authorities quoted....	826	<b>TABLE CXVII.</b> Results of five hundred and seventy-three excisions at the Elbow according to the season at which the operations were practised.....	895
<b>SECTION V. Wounds and Injuries of the Elbow Joint...</b>	827	<b>TABLE CXVIII.</b> Statement of the result of four hundred and ninety-five excisions at the elbow for shot injury, according to the ages of the patients.....	895
Punctured and Incised wounds.....	827	Excisions at the Elbow in the Confederate service (abstracts of seven cases).....	896
Bayonet wounds of the Elbow (three abstracts).....	827	<b>TABLE CXIX.</b> Summary of one hundred and thirty-eight cases of excisions at the Elbow after shot injury, practised in the Confederate army.....	898
Sabre wounds of the Elbow (six abstracts).....	828	<b>TABLE CXX.</b> Dates and results of one hundred and thirty-eight Confederate cases of excisions at the Elbow for shot injury.....	900
Shot wounds.....	829		
<b>TABLE CV.</b> Tabular statement of two thousand six hundred and seventy-eight shot fractures of the bones of the Elbow Joint.....	829		
Shot wounds of the Elbow treated on the expectant plan.....	830		
Cases of recovery (twenty five abstracts).....	830		



TABLE OF CONTENTS.

CHAPTER IX. WOUNDS AND INJURIES OF THE UPPER EXTREMITIES—[CONTINUED.]

	Page.		Page.
<b>SECTION V. EXCISIONS AT THE ELBOW—[Continued.]</b>		<b>SECTION VI. EXCISIONS IN THE FOREARM—[Continued.]</b>	
Excisions at the Elbow in other campaigns.....	901	Fatal cases after primary excisions in the Forearm (five abstracts).....	950
TABLE CXXI. Results of cases of shot fracture of the Elbow treated by excision on the occasions named and from the authorities quoted.....	901	TABLE CXXVII. Condensed summary of seventy-one fatal primary excisions of the bones of the Forearm.....	951
<b>Concluding observations on Excisions at the Elbow</b> .....	904	Primary excisions in the bones of the Forearm with undetermined results (five abstracts).....	953
PLATE LIV. Results of resections at the Elbow for shot injury, facing.....	908	Intermediary excisions in the bones of the Forearm.....	953
<b>Amputations at the Elbow Joint</b> .....	909	Recoveries after intermediary excisions (eight abstracts).....	953
Primary disarticulations (abstracts of four cases).....	910	TABLE CXXVIII. Summary of one hundred and twenty cases of recovery after intermediary excisions in the bones of the Forearm for shot injury.....	957
Intermediary disarticulations (abstract of one case).....	912	Fatal intermediary excisions in the Forearm (seven abstracts).....	959
Secondary disarticulations (abstract of one case).....	913	TABLE CXXIX. Summary of twenty-nine fatal cases after intermediary excisions in the bones of the Forearm.....	961
Disarticulations of uncertain date.....	913	Secondary excisions in the bones of the Forearm.....	961
TABLE CXXII. Summary of forty cases of Amputations at the Elbow Joint for shot injury.....	913	Recoveries after secondary excisions (two abstracts).....	961
<b>Concluding observations on Injuries of the Elbow</b> .....	916	Fatal secondary excisions (one abstract).....	962
<b>SECTION VI. Wounds and Operations in the Forearm</b> .....	917	TABLE CXXX. Condensed summary of forty secondary excisions of the bones of the Forearm.....	963
TABLE CXXIII. Partial numerical statement of gunshot wounds of the Forearm in the field or primary hospitals in various campaigns during the last year of the Rebellion, 1864-65.....	917	Excisions in the Forearm of uncertain date.....	963
<b>Punctured and Incised wounds</b> .....	918	TABLE CXXXI. Summary of one hundred and thirty-two cases of excisions in the Forearm, the time between the injury and operation being unknown.....	964
Sabre wounds (abstracts of five cases).....	918	<b>Concluding observations on Excisions in the Shafts of the Bones of the Forearm</b> .....	966
<b>Shot wounds</b> .....	919	<b>Amputations in the Continuity of the Forearm for shot injury</b> .....	967
Contusions and partial fractures.....	919	TABLE CXXXII. Numerical statement of seventeen hundred and forty-seven cases of amputations in the Forearm for shot injury.....	967
Shot contusions of the Radius and Ulna (abstracts of eight cases).....	919	Primary amputations in the Forearm for shot injury.....	967
Partial shot fractures of the bones of the Forearm (abstracts of five cases).....	921	Recoveries after primary amputations in the Forearm (one abstract).....	967
<b>Shot Fractures of the Forearm</b> .....	921	TABLE CXXXIII. Summary of nine hundred and ten cases of recovery after primary amputations in the Forearm for shot injury.....	968
TABLE CXXIV. Numerical statement of the nature and treatment of five thousand one hundred and ninety-four shot fractures of the bones of the Forearm.....	922	Fatal primary amputations in the Forearm (one abstract).....	978
<b>Shot Fractures of the Forearm treated by Expectation</b> .....	922	TABLE CXXXIV. Condensed summary of ninety-seven fatal cases of primary amputations in the Forearm.....	978
Fractures involving both bones of the Forearm.....	922	Intermediary amputations in the Forearm for shot injury.....	980
Recoveries under expectant treatment after fractures of both bones of the Forearm (abstracts of four cases).....	922	Recoveries after intermediary amputations in the Forearm (one abstract).....	980
Fatal cases of shot fractures of the Ulna and Radius (one abstract).....	924	TABLE CXXXV. Condensed summary of three hundred and forty-four successful intermediary amputations in the Forearm for shot injury.....	981
Fractures of the Ulna treated by expectation.....	925	Fatal intermediary amputations in the Forearm (one abstract).....	985
Successful cases (five abstracts).....	925	TABLE CXXXVI. Condensed summary of one hundred and six fatal intermediary amputations in the Forearm for shot injury.....	986
Fatal cases (two abstracts).....	927	Secondary amputations in the Forearm for shot injury.....	987
Shot fractures of the Radius treated by expectation.....	927	Recoveries after secondary amputations in the Forearm (one abstract).....	987
Successful cases (eight abstracts).....	927	TABLE CXXXVII. Summary of one hundred and fifty-five successful secondary amputations in the Forearm for shot injury.....	988
PLATE XVI. Hospital Gangrene, facing.....	928	Fatal secondary amputations in the Forearm (one abstract).....	990
Fatal cases of shot fractures of the Radius (four abstracts).....	930	TABLE CXXXVIII. Summary of twenty-nine fatal secondary amputations in the Forearm for shot injury.....	990
Complications.....	932	Amputations in the Forearm of uncertain date.....	991
Treatment.....	932	TABLE CXXXIX. Tabular statement of one hundred and six cases of amputations in the Forearm of uncertain date.....	991
<b>Excisions in the Continuity of the bones of the Forearm for shot injury</b> .....	933		
TABLE CXXV. Numerical statement of nine hundred and eighty-six cases of excisions in the Forearm for shot injury.....	933		
Primary excisions in the shaft of the Ulna, of the Radius, or of both bones.....	933		
Recoveries after primary excisions in the Forearm.....	933		
Recoveries after excisions in the shafts of both bones (two abstracts).....	934		
Recoveries after excisions in the shaft of the Ulna (seven abstracts).....	934		
Recoveries after excisions in the shaft of the Radius (four abstracts).....	937		
TABLE CXXVI. Summary of five hundred and eighty-nine cases of recovery after primary excisions of bones of the Forearm for shot injury.....	939		

TABLE OF CONTENTS.

CHAPTER IX. WOUNDS AND INJURIES OF THE UPPER EXTREMITIES—[CONTINUED.]

	Page.		Page.
SECTION VI. WOUNDS IN THE FOREARM—[Continued.]		SECTION VII. EXCISIONS AT THE WRIST—[Continued.]	
<b>Concluding observations on Shot Wounds of the Forearm</b> .....	991	<b>Concluding observations on Excisions at the Wrist for shot injury</b> .....	1013
TABLE CXL. Mode of treatment and results of shot fractures involving the bones of the forearm on the occasions named and from the authorities quoted .....	993	<b>Amputations at the Wrist for shot injury</b> .....	1017
SECTION VII. Wounds and Operations at the Wrist.....	995	TABLE CXLIII. Summary of sixty-eight amputations at the Wrist Joint for shot injury. ....	1017
TABLE CXL. Numerical statement of the treatment of fourteen hundred and ninety-six shot fractures of the bones of the Wrist .....	995	SECTION VIII. Wounds and Operations in the Hand.....	1019
<b>Shot fractures at the Wrist treated by Expectation</b> .....	996	TABLE CXLIV. Numerical statement of eleven thousand three hundred and sixty-nine fractures of the bones of the Hand for shot injury .....	1019
Abstracts of five cases of shot fractures at the Wrist treated by expectation.....	997	Shot wounds of the Hand treated by expectation.....	1020
<b>Excisions at the Wrist for shot injury</b> .....	999	Abstracts of two cases.....	1020
TABLE CXLII. Numerical statement of the nature and results of ninety-six cases of excisions at the Wrist for shot injury .....	999	PLATE LI. Effects of division of Ulnar Nerve and of shot perforation of the Hand, facing .....	1020
Abstracts of ninety-six cases of excisions at the Wrist .....	1000	Shot wounds of the Hand treated by excision.....	1021
<b>Excisions at the Wrist in the Confederate service</b> .....	1012	Shot wounds of the Hand treated by amputation.....	1021
Abstracts of thirteen cases.....	1012	Shot wounds of the Palmer Arch.....	1023
		<b>List of Reporters and Operators</b> .....	1
		List of Plates.....	XVII
		Corrigenda .....	XIX



THE  
MEDICAL AND SURGICAL HISTORY

OF THE  
WAR OF THE REBELLION (1861-65).

PART II, VOLUME II.

BEING THE SECOND SURGICAL VOLUME.

ON SPECIAL WOUNDS AND INJURIES—CONTINUED.

CHAPTER VI.

INJURIES OF THE ABDOMEN.

LIBRARY  
UNIVERSITY OF  
CALIFORNIA

Though the abdominal and pelvic cavities are contiguous and constitute, in reality, but one, yet their injuries will be described separately, and an arbitrary boundary must be established. The abdominal cavity properly so called, will then be limited, below, by a plane corresponding with the ileo-pectineal line or superior strait of the pelvis; above, by the diaphragm; posteriorly, by the lumbar spine; laterally and anteriorly, by muscles.

Injuries of the spine have been discussed in the third chapter of the preceding volume. Wounds of the soft parts in the dorsal and lumbar regions will be enumerated with *Wounds of the Back*, except those which penetrate the abdominal cavity, which will be discussed in the third section of this chapter.

The chapter will contain a brief notice of the contusions and simple wounds of the anterior abdominal walls, that were reported during the war; a fuller account of the injuries of the abdominal viscera proper, unattended by external wounds; and an extended description of the penetrating wounds of the abdomen, within the limits above defined. Attention will be chiefly invited to the gunshot wounds of the stomach, small and large intestines, and of the liver, spleen, pancreas, and kidneys.

John Bell devoted the third and fourth of his admirable discourses<sup>1</sup> to "*wounds of the belly*," and commenced the former with the following observations: "Every wound is a disease, and every disease is different according to the constitution of the parts affected, and according to the offices which the parts are destined to fulfil. In the abdomen, we find the principles which explain its diseases very simple and plain: we find the chief cause of danger to be the tendency of the peritoneum to inflame; we find every wound apt to excite this inflammation, and every inflammation, however slight, apt to spread, to extend itself over all the viscera, and terminate in gangrene and death. Upon these grounds, we cannot but pronounce a wound of the belly to be a mortal wound." The illustrious John Hunter<sup>2</sup> said: "All wounds that enter the belly, which have injured some viscus, are to be treated according to the nature of the wounded part, with its complications; which will be many, because the belly contains more parts of very dissimilar uses than any other cavity in the body; each of which will produce symptoms peculiar to itself, and the nature of the wound." The broad principles thus enunciated by these great writers,—that the main danger to be dreaded in wounds of the abdomen was inflammation of the peritoneum, and that the lesions of the several viscera should be revealed by distinctive disorders in their respective functions,—still guide us in dealing with this difficult subject.

At the beginning of the war, the medical men who were summoned from their accustomed avocations to become military surgeons, possessed the general knowledge derived from their clinical experience in civil practice, and from the teachings of modern text-books, based mainly, as regards injuries of the abdomen, upon the teachings of Callisen, Richter, Morgagni, Scarpa, Litre, Portal, Hevin, Cooper, Travers, and Gross,<sup>3</sup> and were especially instructed in the application of this information to the treatment of the injuries, incident to war, by Guthrie's precepts,<sup>4</sup> which were earnestly advocated by Dr. Tripler, the medical director of the first large organized army, who epitomized them in a chapter of his excellent manual,<sup>5</sup> and illustrated them by instances derived from his own extended experience, and from the writings of Dr. Macleod and others, on the surgery of the Crimean War. As the war progressed, however, and surgeons earned the right to rely upon their own observations, it was found expedient to modify the rules laid down by these eminent authorities, in some essential particulars, as will appear in the subsequent pages of this chapter.

That the prognosis of wounds of the abdomen is very unfavorable, the diagnosis very obscure, and the results of treatment discouraging, are stubborn facts, that remain unchanged by the experience of the war. Yet it may be hoped that the observations accumulated will be found to afford a basis for more precise notions respecting the mortality, for some clues for the differential diagnosis and hints, at least, as to what to do and leave undone, in the treatment of this class of injuries. For, to speak more definitely, we are placed in

<sup>1</sup> BELL, J., *Discourses on the Nature and Cure of Wounds*, Edinburgh, 1795, Part II, p. 56.

<sup>2</sup> HUNTER, *A Treatise on the Blood, Inflammation, and Gunshot Wounds*, London, 4to, 1794, p. 544.

<sup>3</sup> CALLISEN, *Principia Synt. matris Chirurgiæ Hodiernæ*, Hafniae, 1788, Vol. I, p. 597; RICHTER, *Anfangsgründe der Wundarzneikunst*, Göttingen, 1801, B. V. S. 3; MORGAGNI, *De Vultu ribus et Ictibus Ventris*, in *Epist.* LIV, of the treatise *De Sedibus et Causis Morborum*, Op. Omnia, Patavii, 1765, Liber III, p. 176; SCARPA, *Memorie Anatomico-chirurgiche sull'Ernia*, sec. ed., Pavia, 1819; LITRE, *Observations sur des Plaies de Ventre*, in *Mém. de l'Acad. des Sciences*, 1795, p. 32; MARDOLIN, *Article Plaies de l'Abdomen*, in the *Dict. de Med.* en XXX, T. I, p. 152; COOPER, *The Anatomy and Surgical Treatment of Unguinal and Congenital Hernia*, folio, London, 1804 and 1807; TRAVERS, *An Inquiry into the Process of Nature in Repairing Injuries of the Intestines*, London, 1812; GROSS, *An Experimental and Critical Inquiry into the Nature and Treatment of Wounds of the Intestines*, Louisville, 1843; HEVIN, *Mém. de l'Académie de Chirurgie*.

<sup>4</sup> GUTHRIE, *On Wounds and Injuries of the Abdomen and Pelvis*, London, 1847, p. 7, and *Commentaries*, 6th ed., London, 1853, p. 535.

<sup>5</sup> TRIPPLER, *Handbook for the Military Surgeon*, Cincinnati, 1861, p. 88.

possession of statistical data on the relative frequency and death-rate of these injuries; we have clinical abstracts and *post-mortem* descriptions of the effects of lesions of the several viscera, which, if they do not elucidate more fully the distinctive phenomena of such injuries, fail to do so because of the imperfection of our knowledge in regard to the normal functions of many of the organs involved; and, finally, we have a great mass of cases of traumatic peritonitis treated without venesection, and mainly by opium, with rest and starvation, and a certain number of cases in which the problem of the justifiable limits of operative interference is presented. After recording a series of instances of each of the three groups of abdominal lesions, these inquiries will be examined in detail.

## SECTION I.

### CONTUSIONS AND WOUNDS OF THE ABDOMINAL PARIETES.

The superficial wounds of the abdomen implicating the walls only may be considered in two groups. First, the punctured, incised, and lacerated wounds and contusions inflicted by cutting weapons or miscellaneous causes; secondly, those produced by shot.

**PUNCTURED AND INCISED WOUNDS.**—Those that were narrow and oblique were frequently of difficult diagnosis, but extended cuts readily disclosed whether they were penetrating or otherwise. Simple punctured wounds were treated by the application of a dossil of moist lint, rest, and position to relax the muscles; incised wounds required, in addition, adhesive plasters, retentive bandages, and sutures.

*Sabre and Bayonet Wounds.*—Sword wounds in this region were infrequent. The few reported were inflicted by thrusts rather than cuts. Bayonet wounds were more common. But the more important wounds of this class were those penetrating the cavity, and will be noted in the third section. Among the few sword wounds of the parietes was one followed by extensive ventral hernia:

**CASE 1.**—Corporal Simeon A. Holden, Co. D, 1st Maine Cavalry. Wounded at the cavalry affair at Upperville, June 21, 1863, by a sabre cut in the lumbar region, extending nearly to the umbilicus. He recovered, and was discharged on November 25, 1864, and was a pensioner in 1872. Examining Surgeon P. H. Harding reported that, at the cicatrix, there was "a rupture and protrusion of intestines," and that the disability was three-fourths and permanent.<sup>1</sup>

Such protrusions require to be restrained by the application of a truss with a broad, somewhat concave, pad. They almost invariably follow extensive divisions of the muscular walls of the abdomen, unless the utmost pains is taken, in the primary dressings, to secure close coaptation. Few particulars of interest are recorded in connection with the other sabre and bayonet wounds of this region:

**CASE 2.**—Private C. D. Wheat, Co. B, 21st New York Cavalry, aged 18 years. New Market, May 16, 1864. Sabre wound of the abdomen. Treated in Harrisburg and New York hospitals. Furloughed, and, not returning, reported a deserter on December 30, 1864.

**CASE 3.**—Private John Wilkinson, Co. E, 11th New Jersey, aged 18 years. Bayonet flesh wound, right side of abdomen. Camp near Beverley Ford, August 19, 1863. Sent to Fairfax Seminary Hospital. Furloughed on September 2d; readmitted on October 3d; sent to duty on January 12th, 1864. Reported by Surgeon D. P. Smith, U. S. V.

**CASES 4-18.**—On the occasions named, the thirteen following cases of bayonet flesh wounds occurred, without very grave consequences, and these men were ultimately returned to duty: Pt. W. B. Ensign, K, 130th New York, White House Landing, June 26, 1863; Pt. W. Foster, H, 37th Kentucky, Glasgow, April, 1864; Corp. J. McCabe, E, 210th Pennsylvania, September 19,

<sup>1</sup> A subsequent report relates this case as a penetrating wound of the liver.



1864, duty November 23, 1864; Pt. F. Pierson, B, 115th New York, Malvern Hill, August 14, 1864; Pt. T. Toomy, G, 52d Kentucky, September 19, 1864, duty September 16, 1864; Pt. M. Riley, A, 26th Ohio, July, 1864, duty August 7, 1864; Pt. A. Berrish, L, 4th New York Cavalry, October 19, 1864; Pt. W. H. Campbell, K, 31st Maine, Petersburg, April 2, 1865, duty June 10th; Pt. S. G. Swain, A, 30th Iowa, duty June 11, 1863; Pt. J. G. Norton, B, 17th New York, duty October 14, 1863; Pt. J. H. Garban, I, 63d Ohio, Pocatigo, January 21, 1865; Pt. S. Luddy, V. R. C., December 9, 1863, duty January 11, 1864; Pt. T. Evans, 144th New York, June 9, 1864.

The following received somewhat graver bayonet wounds of the walls of the belly: Serg't. W. H. Simpson, K, 102d U. S. C. T., March 27, 1864, at Detroit, a long seton wound in left umbilico-inguinal region, resulting in ventral hernia; discharged for disability, rated at three-fourths. Pt. M. Jennings, F, 7th Missouri, Vicksburg, December, 1863, extensive bayonet wound of abdominal walls; united by interrupted sutures, and healed by first intention; duty January 7, 1864.

*Other Punctured and Incised Wounds.*—The reports specify twelve serious cases of punctured or incised wounds of the abdominal walls by knives or dirks, which eventually recovered, without complications of note, all of the patients being returned to duty:

CASES 19-30.—Pt. J. Laughberry, C, 18th United States Infantry, October 9, 1864, duty November 24, 1864; Pt. Z. Wood, G, 37th Illinois, October 21, 1864, duty November 26, 1864; Pt. T. E. Grogan, M, 13th New York Heavy Artillery, August 6, 1864; Pt. J. Reehart, I, 5th Missouri Cavalry, December, 1863, duty January 2, 1864; Pt. G. W. Adams, F, 64th Ohio, May 9, 1864; Corp. R. L. Gallatin, B, 8th Iowa, February 9, 1865, duty April 20, 1865; Pt. W. Jarvis, K, 2d United States Infantry, March, 1865, duty March 8, 1865; Pt. J. F. Barrow, F, 7th Vermont, January 11, 1865, duty January 31, 1865; Corp. J. Benoit, A, 7th Vermont, January 11, 1865, duty January 31, 1865; Pt. J. Wicker, A, 97th Illinois, November 25, 1864; Pt. S. Williams, 20th New York Battery, May 9, 1865, duty May 17, 1865; Pt. D. Cushman, E, 2d Vermont, March 1864, duty April 5, 1864.

Guthrie and Tripler taught that it was worse than useless to pass sutures through the muscular structures of the abdomen, and that incised wounds should be united by stitches including the integument only. It is unnecessary to review their familiar arguments, or the theories adduced on the other side.<sup>1</sup> Later experience attests the utility of deep sutures, and it was generally observed during the war that ventral protrusions were only to be prevented, after extended division of the abdominal walls, by exact coaptation of the divided muscular tissues.

Interrupted and twisted sutures were sometimes employed; but the quilled suture answered the best purpose, reducing the extensible cellulo-fibrous cicatrix to the narrowest dimensions. Twice, by this means, I secured firm cicatrices without protrusion, in extensive incised wounds in the bellies of horses, where the difficulty of exact reunion is great. The drawings (Figs. 1 and 2) will refresh the reader's recollection of this form of suture, which recent improvements in plastic surgery and the treatment of ruptured perinæum have proved to be so useful. It is well to tie the threads in a bow-knot, or to

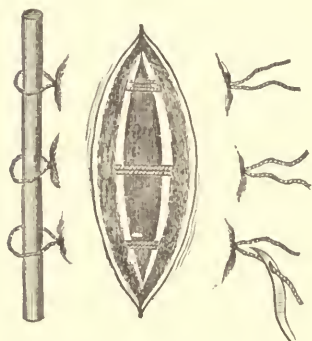


FIG. 1.—Application of the quilled suture to an incised wound.

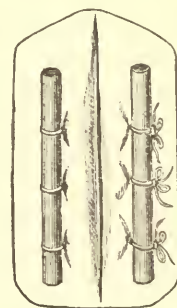


FIG. 2.—Quilled suture completed.

leave the ends long if wire is used, in order to loosen the stitches, when inflammatory swelling requires it. The sutures should be allowed to remain until the fourth or fifth day, and the loop of each double thread then being cut, the pieces should be withdrawn simultaneously in opposite directions.

*LACERATED AND CONTUSED WOUNDS.*—Sixty-eight examples of non-penetrating injuries of this group were specified. It is unnecessary to enumerate them, as the cases

<sup>1</sup>The results of experience, however, may be referred to: MATTHEW (*loc. cit.*, p. 324) in discussing the flesh wounds of the abdomen in the Crimean War, says: "The uselessness and even the injurious tendency of sutures, when inserted into the substance of muscle, has been much insisted on, but it would appear needlessly so." LEGOUËST (*op. cit.*, p. 370) remarks: "Tous les auteurs conseillent de rendre la coaptation des bords de la plaie plus parfaite à l'aide de bandelettes agglutinatives; mais tous les chirurgiens savent aussi que ce moyen n'est qu'illusoire; \* \* \* si les muscles ont été profondément divisés, nous pensons qu'il faut avoir recours à la suture enchevillée. \* \* \* Cette suture ne doit pas se borner à la peau, mais elle doit comprendre les muscles eux-mêmes, et les anses du fil doivent aller jusqu'au fond de la plaie."

presented no features of especial interest, and this class is sufficiently illustrated by shot wounds. All of the sixty-eight patients recovered, save one (Sergeant H. Brandenburg, I, 39th New York), who died of intercurrent typhoid fever. In these, as in all wounds of the abdomen, the necessity of absolute rest was conspicuously illustrated, and the importance of maintaining muscular relaxation by elevating the head and shoulders and flexing the lower limbs. Fomentations and cataplasms were generally and advantageously used. In several lacerations with large flaps, sutures were employed with benefit.<sup>1</sup> It was noticed that lacerations above the umbilicus healed less readily than those lower down; probably because of the greater mobility of the upper part of the abdominal parietes during respiration, and the strain of the arches of the lower ribs. There were sixteen graver lacerated and contused wounds from miscellaneous causes, complicated with internal mischief, differing from the visceral injuries, in the second section, by the existence of external lesions, and from the penetrating wounds, in the third section, in the absence of any primary opening of the cavity. Seven of the cases of this group were fatal.

*Rupture of Muscles.*—Though enumerated among the physical lesions external to the peritoneum, yet, as Mr. Pollock observes, in his able account of Injuries of the Abdomen,<sup>2</sup> ruptures of the abdominal muscles as a result of external violence are not often detected unless the accident prove fatal, and then they are usually associated with some visceral complication. Such ruptures may occur during tetanic spasms, or violent gymnastic efforts, or *in coitu*; but I find only one case on the records, of rupture of the rectus from violence:

CASE 31.—Private John Merkel, Co. A, 4th Pennsylvania Cavalry, aged 30 years, entered Satterlee Hospital, December 13, 1862. He had been thrown from his horse in September, and in falling came in contact with the stump of a tree, apparently producing laceration of the rectus muscle of the right side, and considerable protrusion of the umbilicus, according to his statement, about the size of a hen's egg. He was rendered insensible and remained in that condition for three hours. Peritonitis followed, and, two days after the accident, a small quantity of blood was passed from the bowels. After the subsidence of the inflammation the abdomen was bandaged, a pad was applied over the umbilicus, and rest and quiet were enjoined. On admission to hospital he complained of no pain, except when the bowels were opened or he was shaken in any way. The umbilicus protruded to about the size of a plumb, was quite mobile, and could be handled without giving pain—slight pressure reduced it a great deal. For about two inches above and below the umbilicus there was a tenderness of rectus of right side, with slight dulness on percussion, and a feeling of hardness. On January 11th, he had a cough for which the compound licorice mixture was ordered, and his bowels being constipated, he was directed to take two compound cathartic pills and a draught of solution of citrate of potassa. A slight attack of ague followed, which was arrested by quinia. On February 7th, 1863, Merkel was discharged from service. The case is reported by Dr. J. M. DaCosta.<sup>3</sup>

It is difficult to draw the line between such cases as this and those belonging to the next section, as attended by serious visceral injury. The bloody stools and peritonitis on the second day indicate internal mischief, though, fortunately, of a mild character. There is no abrupt line of separation between the superficial injuries and those associated with grave internal trouble, and only the results determine how they shall be classed. Every abdominal injury must be treated as if it were serious, until time develops its true nature. Hospital records are usefully suggestive of the probabilities of prognosis. Thus, at Guy's Hospital,<sup>4</sup> in eight years, of seventy-one cases of abdominal injuries admitted consecutively, forty-four, or three-fifths, recovered without other definite symptoms than passing collapse and local tenderness; in ten cases, symptoms of peritonitis set in, yielding to treatment in seven, but terminating fatally in three; while in seventeen cases, or one-fourth, rupture of the viscera took place. This affords an idea of the average risks in such accidents.

<sup>1</sup> NEUDÖRFER (*Handbuch der Kriegschirurgie*, Leipzig, 1867, H. II, S. 706) dwells upon the utility of sutures in lacerations (Risswunden) of the abdomen, in his experience in the Italian and Mexican wars.

<sup>2</sup> POLLOCK, G., *Injuries of the Abdomen*, in HOLMES'S *System of Surgery*, 2d ed., 1870, Vol. II, p. 621; LARREY, *Clin. Chir.*, T. II, p. 488.

<sup>3</sup> M. LEGOUËST prints a similar case in the *Gazette des Hôpitaux*, 1860, No. 76, and refers to it in his *Chirurgie d'Armée*, p. 372. Mr. Pollock (*op. cit.*) p. 630, quotes it. VIDAL, *Path. Exl.*, T. IV, p. 128, describes a rupture *in coitu*. A similar case occurred, during the war, at New Berne.

<sup>4</sup> BRYANT, *A Practice of Surgery*, London, 1872, p. 290.



GUNSHOT FLESH WOUNDS.—Of cases coming under surgical treatment of shot wounds of the head and chest, it has been seen<sup>1</sup> that those involving the external soft parts predominate numerically. The proportion between the numbers of penetrating and non-penetrating shot wounds of the abdomen treated more nearly approaches an equality. This fact, which did not escape the authors of the Confederate *Manual*,<sup>2</sup> is illustrated by the numerical casualty returns of the Union army for the last year of the war (TABLE I):

TABLE I.

*Partial Numerical Statement of Shot Wounds of the Abdomen, in the Field or Primary Hospitals in various Campaigns, during the last Year of the Rebellion, 1864-65.*

BATTLE, ACTION, OR SERIES OF ENGAGEMENTS.  Names or Dates.	WOUNDS OF ABDOMINAL PARIETES.		PENETRATING WOUNDS OF THE ABDOMEN.		MISSILE.		TOTAL WOUNDED.	PERCENTAGE OF ABDOMEN WOUNDS.
	Cases.	Deaths.	Cases.	Deaths.	Large projectiles, cannon shot, shell, and bombs (fragments, grapeshot, and canister.	Small projectiles, musket-carbine, rifle-pistol balls, and small missiles from shrapnel and canister.		
Army of the Potomac from May 4 to August 31, 1864.....	762	4	634	257	102	1,285	38,944	3.58
Armies of the Cumberland, Tennessee, and Ohio during the Campaign to Atlanta, from May 4 to September 8, 1864....	446	14	771	488	96	1,074	23,308	5.23
Armies of the Cumberland, Tennessee, and Ohio, and Cavalry, General Hood's invasion of Tennessee, from October 25 to December 31, 1864.....	70	.....	73	20	14	129	3,610	3.96
General Sherman's Campaign in 1865 through the Carolinas....	39	1	58	42	3	94	1,533	6.32
Armies of the James and Ohio, etc., from Fort Fisher to Goldsboro', N. C., 1865.....	7	2	35	7	3	38	1,075	3.90
Army of the West Mississippi during the siege of Mobile, from March 26 to April 9, 1865.....	26	3	27	14	8	45	2,111	2.50
Army of the James during General Grant's Campaign against Petersburg, from May 4, 1864, to April 9, 1865.....	221	2	438	103	48	591	16,120	4.08
Engagements in the Shenandoah Valley, May 4 to Aug. 30, 1864	43	.....	74	27	4	98	2,196	5.32
Campaign in the Shenandoah Valley, Aug. 21 to Dec. 30, 1865.	165	.....	174	51	39	221	7,542	4.49
Army of the Potomac, from Sept. 1, 1864, to April 9, 1865.....	217	3	294	136	27	483	10,407	4.91
Aggregate.....	1,996	29	2,581	1,145	314	4,058	106,846	4.28

Of the forty-five hundred and seventy-seven shot wounds included in this return, twenty-five hundred and eighty-one, or more than half, are recorded as penetrating wounds of the abdomen.<sup>3</sup> The field returns include among penetrating wounds of the abdomen those in which the entrance is through the dorsal region, or diaphragm or pelvis, whereas only lesions limited to the anterior and lateral walls are commonly reported among the flesh wounds of the abdominal parietes. Therefore, to estimate aright the relative

<sup>1</sup> *First Surgical Volume*, pages 308 and 599.

<sup>2</sup> "It is in the regional cavity of the abdomen that the proportion of penetrating wounds is the greatest. The cranium, from its form, structure, and coverings, serves as a strong defence even against gunshot. The osseous, yet elastic and moveable ribs, the sternum, and muscular parietes greatly protect the contents of the cavity which they enclose; but the extensively exposed surface of the abdomen, anteriorly and laterally, has no power of resistance to offer against a projectile directly impinging it; and when the important cavity is once penetrated by these means, death is the almost inevitable result. Even the chances of a favorable termination which may exist in wounds from other causes are generally wanting; and much of their treatment, such as the use of sutures, and other means to insure the apposition of cut edges, is inapplicable—from the parts to a certain distance being almost necessarily deprived of their vitality—to injuries from gunshot wounds."—*A Manual of Military Surgery, prepared for the use of the Confederate States Army*, Richmond, 1863, p. 61.

<sup>3</sup> "It is a commentary on the remark of Sir Charles Bell: "although wounds of the belly are common enough immediately after a battle, bearing a fair relative proportion to other wounds, yet a few days suffice to remove them, so that by the end of the first week there is scarcely one to be seen."—that this number, derived from the returns of the Union army for one year, nearly equals the aggregate of penetrating wounds of the abdomen collected from the reports of the general hospitals and other sources, from both armies, throughout the war.

frequency of the several groups of injuries, it is necessary to analyze the gross aggregates, and to determine, for example, how many of the cases reported as "flesh wounds of the back," "side," or "hip," should be numbered with wounds of the abdominal parietes,—and how many of the penetrating wounds should be separated as interesting the pelvic viscera. Many of the shot wounds have their entrance in one region and exit in another; many are at first regarded as superficial, and are subsequently found to have implicated or penetrated the peritoneum. The absence of standard rules of classification and inevitable imperfection of diagnosis are thus the two principal causes of the discrepancies in returns in which a certain uniformity should appear; for, undoubtedly, an exact regularity obtains, and becomes more discernible as the observations are weighed as well as counted.

Of cases of shot wounds believed to involve the abdominal walls only, and situated in the epigastric, hypochondriac, umbilical, iliac, and hypogastric regions,<sup>1</sup> four thousand four hundred and sixty-nine were reported by name. Nearly one-fourth of these are unaccounted for,—a larger proportion of undetermined cases than usual, that might have been diminished by careful search, had it been practicable to find time for that labor. Of the three thousand one hundred and thirty-four determined cases, two hundred and fifty-three terminated fatally, or a little over eight per cent.<sup>2</sup> This is a large mortality rate when compared with that following gunshot scalp wounds or that resulting from gunshot flesh wounds of the thorax. The explanation is undoubtedly furnished by the frequency with which peritonitis complicates these non-penetrating wounds, and the facility with which the abdominal viscera may be injured without an opening being made in the peritoneal cavity.

Gunshot flesh wounds of the abdomen varied greatly in their form and extent, according to the size, shape, velocity, and direction of the projectiles that inflicted them. Small missiles sometimes lodged, sometimes pocketed the clothing and were withdrawn with it from the cul-de-sac thus formed,—often produced long furrowed wounds and often seton

<sup>1</sup> Flesh wounds of the dorsal and gluteal regions and some of those of the lumbar region will be discussed in the eighth chapter, and some of those of the lumbar, inguinal, and perineal regions, in the seventh chapter.

<sup>2</sup> This, though a larger proportion than that given in the preliminary report, in *Circular No. 6, S. G. O., 1865*, p. 24 (2,164 flesh wounds of the abdomen, 114 deaths, or a mortality rate of 5.2), does not compare, as Professor Longmore has pointed out (*On the Classification and Tabulation of Injuries and Surgical Operations in Time of War*, *Med. Chir. Trans.*, Vol. LIV, p. 238), with the fatality of the corresponding series of cases in the British and French Crimean returns. It is not probable that the mortality rate of the American returns would be materially modified if the terminations of the 1,335 unfinished cases were ascertained. The 3,134 determined cases afford a fair average of the death rate. This rate is slightly augmented by the addition of the fatal visceral shot injuries without external wounds, recorded in the next section. In these two groups all of the cases of non-penetrating gunshot injuries reported by name are included. The cases in which the abdominal viscera were injured or supposed to be injured, although the cavity was not opened, are not excluded, and "the indiscriminate mixing together of these latter cases with the penetrating wounds," to which Dr. Longmore courteously objects, has been sedulously avoided. It seems more probable that the lack of discrimination may be found in the British and French Crimean returns, in which the mortality rates of gunshot flesh wounds of the abdomen are inordinate and the aggregates too small to afford fair averages. The British returns give, as Dr. Longmore correctly observes, "115 gunshot injuries of the abdomen in which the peritoneal cavity was not penetrated;" but not "22 deaths," as incorrectly stated by M. Chenu and by Dr. Longmore; but 17 deaths. (See MATTHEW, *op. cit.*, Vol. II, p. 327.) Mistaken probably by the entry of five invalided officers, M. Chenu (*op. cit.*, p. 197) and Dr. Longmore (*l. c.*, p. 237) record the mortality rate of the British cases as 19.1 per cent, instead of 14.7 per cent, as recorded by the official annalist. Dr. Longmore proceeds to say that in the French statistics of the Crimean War "the percentage of mortality of these non-penetrating wounds is shown to be nearly the same" as in the English statistics. The French historian, M. Chenu, gives 148 cases in the Crimea of non-penetrating gunshot wounds of the abdomen, with 28 deaths, or a mortality rate of 18.91. I shall have further occasion to examine the validity of Professor Longmore's criticisms, reluctantly descending to details, which the unjust animadversions upon the American returns compel me to notice. It will be admitted that Professor Longmore's illustration of the difficulty of comparing the American with the French and British returns is, in this instance, at least, sufficiently unfortunate. But this is a minor consideration. A more important object is to arrive at some approximation to the ordinary fatality of this group of wounds. This is probably presented by the American returns. It has been noted that the British and French Crimean statistics are too limited to afford fair averages. In M. Chenu's *Surgical History of the Italian War* (T. II, p. 493) he gives 380 cases of contused gunshot wounds of the abdomen without penetration, with 11 deaths, or a mortality rate of 2.89, a difference, as compared with his Crimean return, of 16.02. In the British returns from the New Zealand War (*Stat. San. and Med. Rep.*, 1865, Vol. VII, p. 474) the cases of gunshot wounds of the muscles and parietes of the abdomen were only eight in number, and all recovered. Six cases are noted in the account of the wounded in the Indian Mutiny (WILLIAMSON, *Med. Surg.*, p. 102), none of them proving fatal. GUTHRIE and HESSEN refer to a number of cases of gunshot wounds of the parietes of the abdomen; but adduce no fatal cases, except such as were complicated by visceral injuries. LAUREY, BAUDENS, and SCRIVE are silent on the subject. So far as the British and French authorities adduce information they do not corroborate the high rate of mortality Professor LONGMORE ascribes to this group of injuries. DEMME (*Studien*, B. II, S. 121) cites 185 cases with 15 deaths, a percentage of 8.1. Dr. STROMEYER (*Erf. über Schussw.*, 1866, S. 6) gives 13 cases with no deaths. Generalarzt BECK (*Chir. der Schussw.*, S. 519—Werder's Corps at Metz) gives 33 cases, of which only one, a shell contusion with visceral rupture, was fatal. Dr. H. FISCHER (*Kriegschir. Erf.*, Vor Metz, S. 128) gives 18 cases with no deaths.

wounds. Instances were common in which such missiles wounded the hands or forearms on striking or emerging from the abdominal walls. The larger projectiles produced extended lacerations and contusions. A good illustration of a cicatrix after a laceration of the abdominal walls by a shell fragment, is furnished by PLATE V, opposite page 162, in the *First Surgical Volume*. Contusions from spent grape and canister shot were numerous. There is a series of two hundred and thirty-eight such cases, of which five had a fatal result, in consequence of peritonitis being lighted up. In a few instances belonging to this group, the ecchymosēs resulted in superficial abscesses or in peculiar indolent ulcers, with a sanious discharge, the vitality of the tissues being lessened, but not absolutely destroyed. These ulcers were benefited by camphorated lotions or other mildly stimulating dressings, while saturnine lotions, or emollients, on the one hand, and terebinthinate, or strongly stimulating topical applications, on the other, were disadvantageous. The seton wounds were sometimes quite long. It is an error to suppose that the cylindrical musket balls are rarely deflected. They often pursue long subcutaneous or intermuscular tracks, and occasionally make nearly the circuit of the trunk.<sup>1</sup> Illustrations of these different forms of injury will be cited in describing the complications. The complications observed in a few cases of this group of injuries were: hæmorrhage, foreign bodies, gangrene, hernia, nervous disorders, tetanus. As many of these are common to the miscellaneous and shot wounds, it will be best, to avoid repetitions, to tabulate all the cases belonging to this section, and to consider their complications together:

TABLE II.

*Numerical Statement of the Cases of Injuries of the Abdominal Parietes returned during the War.*

NATURE OF INJURY.	Cases.	Died.	Discharged.	Duty.	Unknown.
Sabre and Bayonet Wounds.....	18	.....	3	15	.....
Other Punctured and Incised Wounds.....	12	.....	.....	12	.....
Lacerated and Contused Wounds (slight).....	65	1	8	59	.....
Lacerated and Contused Wounds (severe).....	16	7	9	.....	.....
Gunshot Flesh Wounds.....	4,469	253	532	2,349	1,335
Gunshot Contusions.....	233	5	22	98	113
Aggregate.....	4,821	266	574	2,533	1,448

COMPLICATIONS OF PARIETAL WOUNDS.—It will be unnecessary to cite more than a few instances, inasmuch as the subject must be reverted to in the third section, where it will be desirable to adduce numerous illustrative cases.

*Hæmorrhage.*—Punctured and lacerated wounds are commonly followed by only a few drops of blood, and incised, contused, and shot wounds are rarely attended by serious hæmorrhage; but, occasionally, the epigastric, internal mammary, and circumflex iliac may be wounded, and require torsion, or compression, on the ligature. Sometimes these vessels when divided retract in the muscles, and it is requisite to enlarge the wound in order to tie them. This happens particularly when the epigastric is divided near where it enters the

<sup>1</sup> Similar observations have been made, in the Franco-German war, regarding the action of the *chassepôt* missile in striking the abdominal walls. Dr. B. BECK (*Chirurgie der Schussverletzungen*, Freiburg, i. B., 1872, S. 522) mentions having noticed seton wounds of the abdominal walls "seven and eleven inches in length; but the healing process progressed without serious inconvenience." He regards furrowed and seton wounds as comparatively unimportant unless they pass deeply, in proximity with the peritoneum, when they may be very serious.



rectus. M. Legouest<sup>1</sup> has twice had occasion to use the ligature in profuse bleeding from superficial wounds of the abdomen. Sometimes, from punctured wounds, the bleeding is interstitial, the blood escaping in the cellular tissue and forming a tumor, or else dissecting up the aponeurotic planes. It may be absorbed, or may give rise to a sanguineous abscess, which ought to be evacuated by a timely incision, lest there should be inflammatory trouble lighted up in the contiguous peritoneum, or infiltration of the muscular bundles. It must be confessed that the histories of the examples of hæmorrhage, in wounds of the abdominal walls, that appear upon the reports, do not impress the investigator with a favorable estimate of the manner in which this complication appears to have been dealt with by our army surgeons. Here, as in the management of bleeding from the wounded internal mammary and intercostal arteries, timid, inefficient, temporizing treatment appears to have been followed by lamentable loss of life. The instances to be cited teach emphatically that wounds of the epigastric, circumflex, mammary, and lumbar arteries are not to be regarded as trivial, but demand the rigorous application of the rules for the management of wounded arteries, the exposure of the bleeding point, and a proximal and a distal ligature.<sup>2</sup> Schindler and Hesselbach have invented compressors for the epigastric artery, and the practitioner will find propositions in the books for compression by bougies introduced in the wound, or by raising a fold of the soft parts, and recommendations of the ever ready styptics; but all such means should be rejected by those who would practice sound surgery. The rule of Chelius in regard to astringent styptics ("their use, therefore, is confined to bleeding from small vessels, from mucous membranes, and to so-called parenchymatous bleedings") must be strictly observed, and the arteries under consideration must not be regarded as *small vessels*, in the sense in which the term is here employed. In two cases compression was resorted to with impunity:

CASE 32.—Corporal W. D. Ashford, Co. C, 11th Iowa, aged 24 years, was wounded at Yazoo City, March 5, 1864, by a conoidal ball, which entered in the groin and emerged at the epigastric region. Secondary hæmorrhage occurred, eight days afterward, from the epigastric artery. The hæmorrhage was controlled by a plaster of Paris compress. Tincture of myrrh was given internally, and egg-nog and porter. He recovered, and was returned to duty on November 16, 1864.

CASE 33.—Private A. Marske, Co. I, 7th Illinois, aged 30 years, was wounded at Fort Blakeley, April 9, 1865, by a conoidal ball, which entered a little to the right of and above the umbilicus and emerged from the right lumbar region. On April 13th, he entered Sedgwick Hospital at New Orleans. On the 17th, hæmorrhage, to the amount of twenty-five ounces, occurred, from the anastomosing branches of the internal mammary and deep epigastric arteries. The bleeding was arrested and controlled by styptics, aided by compression. Hæmorrhage did not recur. The patient recovered, and returned to duty on July 1, 1865. Assistant Surgeon A. Hartsuff, U. S. A., reports the case.

But in a larger number of instances, a reliance on compression and styptics resulted lamentably:

<sup>1</sup> LEGOUEST, *Chirurgie d'Armée*, 2<sup>d</sup>me éd., p. 371. Once on the epigastric, and once on the circumflex iliac.

<sup>2</sup> Professor CHISOLM (*A Manual of Military Surgery, for the Use of Surgeons of the Confederate States Army*, 3d ed., Columbia, 1861, p. 337) dismisses non-penetrating wounds of the abdomen with the remark: "When the abdominal walls are not perforated, but the entire track of the ball lies in the thickness of the muscles, the wound is simply a flesh wound of a comparatively trivial character, and should be treated accordingly." Professor F. H. HAMILTON (*A Treatise on Military Surgery and Hygiene*, pp. 318, 373) is silent in regard to hæmorrhage as a complication of punctured, incised, and gunshot superficial wounds of the abdomen, but treats of it under "wounds penetrating the abdominal parietes" (p. 374). A comment suggested by his practice is therefore reserved for the third section, when it will be necessary to revert to this subject. Professor GUOSS (*A System of Surgery*, 5th ed., Vol. II, p. 658) dwells with emphasis on the occasional profuseness and obstinacy of bleeding from the epigastric, mammary, circumflex, and lumbar arteries, on the accumulation of blood beneath the muscles, and adds: "However the bleeding may be induced, or from whatever source it may emanate, the only way to arrest it is to ligate the affected vessel, unless, as may occasionally happen, it is situated favorably for neupressure. BOYER (*Traité des Maladies Chirurgicales*, 5<sup>ème</sup> éd., T. VI, p. 8) speaks forcibly on the importance of the ligature, and gives details of an interesting fatal case of wound of the epigastric, in which this measure was neglected. But Mr. POLLOCK (*HOLMES'S System of Surgery*, 2d ed., Vol. II, p. 658) has, perhaps with greater earnestness than any other author, insisted on the danger of trifling with hæmorrhage in this region: "Perhaps we shall be excused," he says, "if we trespass out of our province on this one occasion, and speak an extra word or two of caution to the practitioner who may have to deal with hæmorrhage in a wound of the abdomen. If there be severe hæmorrhage, and the wound not sufficient to allow the bleeding mouth of the vessel to be seen, no hesitation need be felt regarding treatment. The wound should be enlarged—enlarged until the wounded vessel can be seen, and can be secured. We need not fear hæmorrhage so long as such a wound is open and we can place a finger on the bleeding point. When the surgeon trusts to external pressure and closes the wound without securing the wounded artery, then there is abundant cause for anxiety. If these principles be of importance in hæmorrhage of ordinary character, they are tenfold important when applied to the treatment of wounds in the region of the groin, or the neighbourhood of the crest of the ilium."

CASE 34.—Private A. Newman, Co. A, 49th New York, aged 38 years, received a lacerated wound of the abdominal walls in the hypogastric and left iliac regions, from a fragment of shell, at Spottsylvania, May 18, 1864. He was treated at the field hospital and at Washington till May 27th. He was then transferred to the Summit House Hospital at Philadelphia. A few days after admission, recurring hæmorrhages from the wound took place, and were treated by cold applications, styptics, and compresses confined by a bandage. The patient finally sank from loss of blood, and died on June 23, 1864.

CASE 35.—Private P. McNabb, Co. E, 16th Missouri, was wounded while on picket, May 24, 1862. A conoidal ball, after producing a flesh wound of the right forearm, entered the right inguinal region, passed inward toward the median line, and lodged somewhere without wounding any of the viscera. No peritonitis or other indication of penetration of the cavity ensued. From the regimental hospital the patient was transferred, on June 4th, to the general hospital at Monterey. A few days after admission hæmorrhage came on, but was readily checked by compression and styptics. It recurred, however, more copiously, and apparently proceeded from the epigastric artery. Compression was again resorted to, with temporary success. The patient sank, and died on June 15, 1862. The notes of the case are derived from the reports of the regimental surgeon, G. S. Walker, and that of Surgeon N. R. Derby, U. S. V.

CASE 36.—Corporal W. Blair, Co. F, 65d Pennsylvania, aged 26 years, received a flesh wound of the parietes of the right inguinal region, from a conoidal ball, at Spottsylvania, May 12, 1864. The wound presented no serious complication, and the patient was soon conveyed to Washington and placed in Lincoln Hospital, and was allowed full diet and a supporting treatment. The wound became inflamed and irritable, and hæmorrhage supervened. This was arrested by compression, but recurred, when applications of the solution of persulphate of iron were used in addition to pressure. Repeated bleedings took place, with a fatal result. The patient sank, in spite of free stimulation, and died on June 30, 1864.

CASE 37.—Sergeant W. Blunt, Co. D, 3d Massachusetts, aged 25 years, received, at Gettysburg, July 3, 1863, a gunshot flesh wound in the left groin, and was sent to the Twelfth Corps Hospital. Gangrene supervened. On July 18th, intermediary hæmorrhage occurred, and thirty ounces of blood were lost from the epigastric artery. The vessel was not tied, and the patient died on July 18, 1863.

CASE 38.—Private J. Lowe, Co. B, 29th U. S. Colored Troops, received a furrowed wound through the muscles of the left side of the hypogastric region, from a conoidal ball, at Petersburg, July 30, 1864. He was carried to the field hospital of the Ninth Corps, where water dressings were applied. On August 18th, he was transferred to the Summit House Hospital, Philadelphia. A few days after hæmorrhage took place, and was controlled by compression. Repeated bleedings recurred, however, and the patient died on August 27, 1864, from secondary hæmorrhage of the epigastric artery.

Yet a sixth case proved fatal, after the extreme measure of ligating the external iliac artery had been resorted to, thus converting the lesion into a penetrating wound:

CASE 39.—Lieutenant John Ridge, Co. G, 13th Iowa, aged 30 years, was wounded, July 20, 1864, at Anta, by a musket ball, which passed through the abdominal parietes, making a seton wound from a little above the pubes to the point of emergence in the left iliac region. Brief details are given in five different reports from the field, Nashville and Louisville hospitals, by the regimental surgeon, Dr. W. M. Thomas, and by Surgeons Herbst and McDermont, U. S. V. There had been no serious primary bleeding, and the patient's condition was encouraging when he entered the Officers' Hospital at Louisville, on August 6th. He was ordered light, nourishing diet, with tonics and simple dressings. On the 8th, there was bleeding from the lower orifice of the wound, which was checked by the application of solution of persulphate of iron. The hæmorrhage recurred profusely on the 9th, and less copiously on the 10th and 11th, and was treated by styptics and pressure. On the 12th, there was free, healthy suppuration. On the 26th, a slight hæmorrhage occurred, and Monsel's salt and pressure were again resorted to, and again on the 27th, 28th, and 29th. On the 29th, the blood lost was estimated at thirty-two ounces. On the 30th, on the ninth recurrence of the hæmorrhage, Surgeon C. McDermont, U. S. V., tied the external iliac artery. The patient rested well that night, and the bleeding did not recur. On the following day, he was ordered a draught, thrice daily, of sulphate of quinia with the tincture of the sesquichloride of iron. The date of separation of the ligature is not recorded. On September 10th, there was a severe chill. Quinine was then prescribed in full doses. This treatment was pursued until September 30th, without benefit. A more generous diet was then ordered, with milk punch, and "as much wine as could be borne." Death "from pyæmia" is recorded on October 4, 1864. No autopsy.

There were a number of other instances of ligations of arteries; but they were in cases of penetrating wounds. It is probable that if the detailed histories could be had, it would be learned that in the cases cited the compression entailed extravasation in the deeper tissues, followed, perhaps, by suppuration or sloughing,—while the application of Monsel's salt rendered the relations of parts indistinguishable, and attempts at ligation difficult and uninviting. This series affords an impressive lesson of the necessity of adhering to standard surgical rules even in what may be regarded as minor accidents.<sup>1</sup>

<sup>1</sup> DEPUYREX (*Leçons Orales de Clinique Chirurgicale*, 2<sup>ème</sup> éd. par PAILLARD et MARX, 1839, T. VI, p. 407) says: "Le repos, la diète, les réfrigérans et la compression suffisent presque toujours pour arrêter cette hémorrhagie." The master has here fallen into a common error of didactic authors in generalizing, without facts on which to base an average. A few lines above, he has stated that copious hæmorrhage from wounds of the abdominal walls is very rare. The statistics of the War of the Rebellion indicate its rarity as less than one per cent. Therefore a military surgeon of large experience may never meet a case. It is highly improbable that he should encounter a series, and be enabled to test the advantages of different modes of treatment. He should, therefore, act promptly, in accordance with general principles and the lessons derived from the experience of others. Enough facts have been presented to demonstrate the danger of neglecting to secure the artery in all serious bleedings from wounds of the abdominal walls, and to indicate the culpability of hereafter omitting this simple precaution.



*Foreign Bodies.*—Instances of the lodgement of balls and other foreign bodies, such as portions of clothing and equipments, coins, fragments of various articles carried in the pockets, were common in this region. The following is a curious example:

CASE 40.—Private R. B. Seybert, Co. H, 11th Pennsylvania Volunteers, Second Bull Run, August 30, 1862, converted his tin-cup into a pail by putting a hoop of sixteenth of an inch iron wire to it and slinging it to the right side of his belt. A conoidal musket ball struck the wire, twisting it, and entered the abdominal walls two inches in front of the right anterior superior process. The short end of the wire protruded an inch to the left and a little below the umbilicus. With some difficulty, and a slight enlargement of the wound, the foreign body (FIG. 3) was extracted. The man recovered without the occurrence of peritoneal inflammation, and was returned to duty January, 1863, from Fairfax Seminary Hospital. Surgeon H. W. Ducahet, U. S. V., contributed the specimen and notes. August 16, 1871, the Pension Examining Board, at Philadelphia, reports this pensioner as complaining of pain and loss of rest from muscular contraction, and expresses the opinion that the tenth rib was fractured at the entrance cicatrix. There was no aggravation of the disability, which was last rated at three-fourths. His age is given as 26 years, and weight 125½ pounds avoirdupois. He was last paid on March 2, 1872.

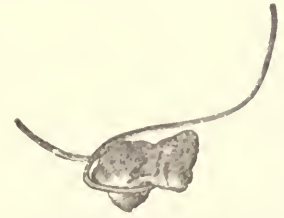

FIG. 3.—Bullet and wire extracted from abdominal walls. Spec. 4417. (Reduced to one third.)

A fragment of shell, which entered the thoracic parietes, lodged, and was cut out from the abdominal wall near the umbilicus, is figured in the *First Surgical Volume*, page 590 (case of Private Julius Wilt). The following is an instance of a musket ball making a partial superficial circuit, a circumstance more common than Guthrie<sup>1</sup> admitted:

CASE 41.—Private Theodore Lozar, Co. H, 15th New Jersey, shot, at the battle of Chancellorsville, May 3, 1863. A conoidal musket ball entered at the cartilage opposite the left external rib and lodged. The man was conveyed to Washington, and entered Douglas Hospital on May 7th. On May 11th, Assistant Surgeon W. Thomson, U. S. A., discovered the projectile (FIG. 4) in the right transverse muscle, opposite the wound of entrance, and removed it through a counter incision. The patient contracted variola, and was transferred to Kalorama Hospital on June 7, 1863, where he died July 19, 1863, with pyæmic complications.




FIG. 4.—Conoidal musket ball removed from the abdominal walls. Spec. 4622.

There were forty-nine other cases of extraction of balls or other foreign bodies from the abdominal parietes. In twenty-two cases, the patients returned to duty; in twenty-two, they recovered and were discharged, and five died:

CASES 42-90.—The following recovered and were returned to duty; Pt. J. L. Hays, 17th Connecticut, Gettysburg, July, 1863; Corp. P. Kelly, 53d Illinois, duty January 26, 1864; Pt. B. Hayes, 90th Pennsylvania, July 1, 1863, duty February 15, 1864; Pt. J. B. Edgar, 36th Illinois, December 31, 1864; Brig. Gen. Barlow, Second Corps, September 17, 1862, duty November, 1862; Serg't F. Lorens, 2d New York Cavalry, duty October 29, 1863; Corp. G. W. Smith, 51st Indiana, April 29, 1863; Capt. Daniel, May 27, 1862, healed by first intention; Pt. T. A. Shelton, 57th Virginia, July 1863, duty September 25, 1863; Pt. C. Daily, 8th New Jersey Cavalry, April, 1865; Pt. R. Mulberger, 7th New York, April 5, 1865; Pt. J. Gavin, 38th Illinois, February 15, 1863, duty November 25, 1864; Pt. W. B. Donkersly, 2d New York, May 2, 1863, duty September 21, 1863; Pt. C. J. Mahoney, 48th New York, February 20th, 1864, duty June 20, 1864; Corp. N. J. Wheeler, 12th Massachusetts, May 6, 1864, duty May 12, 1864; Pt. J. McNulty, 137th Illinois, July 14, 1864, duty; Pt. W. Graham, 12th New York, July 18, 1861, duty; Serg't M. Mullins, 2d New York Cavalry, transferred October 31, 1863, duty; Pt. W. Evans, 80th Ohio, May 14, 1863, duty; Pt. C. Scott, 58th Pennsylvania, Gettysburg, July 3, 1863, duty December 8, 1863; Pt. J. Meanes, 31st New Jersey, May 3, 1864; Pt. J. Stick, 4th Connecticut, June 15, 1864.

In the case of Private Scott, the projectile, represented in the adjacent wood-cut (FIG. 5), is preserved in the Museum. It entered above the crest of the right ilium, and was extracted, a fortnight after the reception of the injury, by Acting Assistant Surgeon W. G. Smull, from beneath the integument near the median line.

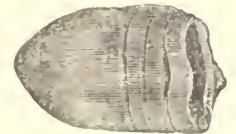


FIG. 5.—Laterally compressed conoidal ball, removed from the abdominal walls. Spec. 2669.

The following recovered and were discharged the service: Pt. J. Carter, 57th New York, December 13, 1862, discharged July 16, 1863; Pt. J. O'Brady, 6th New York Artillery, September 17, 1862; Pt. J. W. Meyers, 13th Illinois, Vicksburg, May, 1863, discharged March 25, 1864; Pt. T. Gleason, 47th New York, February 29, 1864, discharged August 25, 1864; Pt. W. W. Newton, 86th Illinois, August 7, 1864; discharged June 14, 1865; Pt. P. West, 25th Illinois, September 29, 1863; discharged July 3, 1864; Pt. J. Wilson, 1st U. S. Colored Troops, October 27, 1861, discharged March 13, 1865; Pt. J. Lopeman, 127th U. S. Colored Troops, April 2, 1865, discharged September 8, 1865; Pt. R. Stevenson, 198th Pennsylvania, March 29, 1865, discharged June 16, 1865; Pt. W. Rich, 61th New York, March 25, 1865, discharged September 6, 1865; Pt. M. D. Cavanaugh,

<sup>1</sup> GUTHRIE, *Commentaries*, London, 1855, p. 537.

10th Vermont, April 2, 1865, discharged September 9, 1865; Pt. J. Southwick, 88th Pennsylvania, September 17, 1862, discharged September 27, 1863; Capt. J. W. Hague, 134th Pennsylvania, December 13, 1852, discharged May 26, 1863; Corp. G. Hatch, 1st New York Sharpshooters, March 31, 1865, discharged May 31, 1865; Serg't R. Anderson, 51st New York, September 16, 1862; discharged June 30, 1866; Pt. P. W. Waggoner, 89th Indiana, May 18, 1864, discharged September 16, 1864; Pt. Charles O'Bryan, 88th New York, September 4, 1863, discharged; Pt. G. W. Canfield, 80th Indiana, May 14, 1864; Pt. C. Granger, 2d New York M. R., March 31, 1865; Pt. B. Jones, 141st Pennsylvania, May 3, 1863; Pt. A. Hunsecker, 29th Ohio, May 1, 1863; Pt. W. Cubbon, E, 5th Michigan, May 31, 1862, discharged January 13, 1863.

The following cases terminated in death: Pt. S. B. Plummer, 10th Kansas, April 9, 1865, died, May 4, 1865, from pyæmia; Pt. W. L. McMichael, 13th Tennessee Cavalry, April 12, 1864, died June 27, 1864; Pt. J. J. Smoot, 1st Kentucky Cavalry, died, October 9, 1863, from peritonitis; Lient. J. D. Priest, 56th Massachusetts, June 22, 1864; Pt. T. Fenton, 69th New York, December 13, 1862.

The fatal cases were instances in which the extraction of the foreign body was delayed, and its irritation induced abscesses, or extended sloughing or peritonitis. Guthrie's suggestion, that when a ball is deeply situated in the walls of the abdomen "it is often better left alone unless it prove troublesome" (*Comm.*, p. 535), is unsound.<sup>1</sup> There are no other exceptions to the general rule of extracting foreign bodies than the instances in which they are so situated in vital organs that their extraction may immediately jeopardize life. It is especially important to extract them from the abdominal walls; for they rarely become encysted there; the action of the muscles and disposition of the sheaths facilitating their movement; the liability to abscess-formation in propinquity to the peritoneum presenting a constant source of danger while they remain. The course of balls, making a long track, was indicated by a red or reddish-blue line, when they passed beneath the skin or first layer of muscles. It was sometimes necessary to make an incision for the evacuation of pus and sloughs at the middle of the track; but it was considered injudicious to lay open the canal, the seton wounds healing sooner, as a general rule, than the furrowed wounds.

*Gangrene.*—Sloughing was an infrequent but dangerous complication, supervening oftenest in shot lacerations, produced either by shell fragments, or by elongated balls striking sideways. These sloughing wounds, by leading to secondary hæmorrhages, septicæmia, exhaustive suppuration, and consecutive peritonitis, contributed largely to the mortality list of gunshot flesh wounds of the abdomen, though many of the fatal cases are returned under headings representing what was regarded as the immediate cause of death. It is not impossible that a few cases properly referable to this category may be included in the third section, having been returned as penetrating wounds, although the involvement of the peritoneal cavity was secondary and through extension by contiguity. However, it has been sought, in revising the registers, to amend the diagnoses, and to transfer the cases to their proper positions, as far as the reported details warranted, and thus a number of examples, in which the injuries primarily affected only the parietes, have been restored to the group of flesh wounds:

CASE 91.—Private Adolph Voshage, Co. L, 9th New York State Militia, aged 29 years, was wounded at Fredericksburg, December 13, 1862, admitted to Harewood Hospital December 23, 1862. A musket ball had entered near the left anterior superior spinous process, and emerged near Poupart's ligament. On January 14, 1864, sloughing appeared, and was treated by free cauterization with nitric acid. Pus had burrowed deeply, and the sinuses were laid open, and tents were introduced. There was recurrent gangrene on the 27th, and great destruction of tissue. Frequent hæmorrhages took place, which were arrested by tampons. In the middle of March, the immense sore was granulating kindly, but pus continued to burrow in the muscular interstices. By May 1st, the wound had cicatrized. The destruction of tissue was so great that the thigh was flexed on the abdomen, and the patient moved about by resting alternately on the nates and palms of his hands. He was discharged July 7, 1863, "for spurious ankylosis of left hip joint." The limb remained contracted and useless, unfitting him for manual labor, according to the Pension Board, April, 1870. He died, July 23, 1871, "of uræmia," according to the report of the attending physician, M. H. Schuler, M. D.

<sup>1</sup> BECK (*Chir. der Schussverl.*, S. 523) advises delay in extracting deep-seated balls, until the danger of peritonitis is passed. Consult also DEMME, *Studien*, B. II, p. 127; NEUDÖRFER, *Handb. der Kriegschir.*, II. II, S. 710; LEGOUÉST, *Chir. d'Armée*, p. 373.

*Hernia.*—Ventral rupture was, of course, a frequent result<sup>1</sup> of incised, lacerated, and shot wounds of the abdominal walls, and an occasional consequence of contusions followed by muscular atrophy. The production of true inguinal hernia was also often ascribed to these causes, as in the following cases:

CASES 92-94.—1. Reported from DeCamp Hospital,—Pt. C. Stark, Co. K, 87th Pennsylvania, aged 25 years, shell wound of left side of abdominal walls, left inguinal hernia; discharged. 2. Reported from Finley Hospital,—Corp. H. Crandall, Co. H, 112th New York, aged 41 years; shell wound of abdominal parietes, "causing inguinal hernia." 3. Reported from Davenport Hospital,—Pt. G. F. Marion, Co. K, 29th Iowa, aged 32 years, Spoonville, Arkansas, April 2, 1864, "shot wound of abdominal walls, resulting in inguinal hernia." The list might be largely augmented. Eleven other instances are noted, in which the production of inguinal, femoral, or umbilical ruptures is ascribed to shot wounds.

An examination of the details of these cases fails to discover any other relation than coincidence between the shot wounds and inguinal, crural, and umbilical ruptures. Great liability of men of the military age and stature to hernia is observed, even in classes of recruits selected after the most rigorous physical examination;<sup>2</sup> naturally the proportion of ruptured men was greatly augmented, when, during the war, the recruiting regulations were either relaxed or systematically disregarded. And soldiers, laboring under this infirmity, rarely failed to recall some blow or muscular strain which connected their infirmity with the incidents of service, and a wound of the abdominal walls was adduced by a ruptured applicant for discharge as an unquestionable cause of, perhaps, a scrotal hernia. On the other hand, direct ventral hernia was an almost uniform and necessary consequence of extensive injury of the muscular walls. Much ingenuity was demanded, in some cases, in the adjustment of suitable retentive bandages or apparatus.<sup>3</sup> This important subject will be reverted to in the third section.

CASE 95.—Private B. W. Hall, Co. H, 92d New York, received a lacerated wound of the abdomen, by a fragment of shell, at Fair Oaks, May 31, 1862. The wound was dressed at the field hospital. On June 7th, the patient was transferred to Knight Hospital, New Haven, whence he was discharged from service on April 29, 1863, on account of "hernia from wound." Pension Examiner S. C. Wait, in a report dated February, 1868, states: "the missile struck the abdomen just inside of Poupart's ligament, at the upper or inner inguinal ring, causing the loss of a portion of the muscular and ligamentous covering of the abdomen, letting the bowels out, and producing traumatic hernia. The tumor under the skin is very large. He wears a truss and a wide strap around him all the time to keep the bowels, etc., in. While walking, he rotates the left thigh inwardly and has to keep the left leg forward of the other. Locomotion is very difficult and embarrassing. His disability is greater than the loss of a leg, and is permanent in its present degree."

*Nervous Disorders.*—Profound shock was the occasional consequence of simple contusions of the parietes, and also of shot contusions and flesh wounds; but it was not common in the absence of visceral lesion. There were cases, too, of tympanitis and constipation following contusions and wounds of the parietes, in which the temporary paralysis of the muscular coat of the bowel was ascribed to concussion of the nerve centres. Persistency of collapse appears to have been indicative of internal lesion; but the intensity of the symptoms was not a standard by which the nature of the case could be determined. At the military hospital for nervous affections, at Christian street, Philadelphia, Dr. Mitchell and his associates, Drs. Morehouse and Keene, had opportunities of observing few, if any, cases of abdominal wounds. Otherwise the records would probably have been

<sup>1</sup> There are on the rolls of the Pension Office not less than five thousand seven hundred and thirty-five pensioners for "wounds and injuries of the abdomen," of whom (See *Report of the Commissioner of Pensions to the Secretary of the Interior for the year ended June 30, 1871*, p. 7, and APPENDIX, Table A, p. 20) three thousand two hundred and eighty-three are reported as having hernia (2,740 single, 543 double). To determine in what proportion the hernial protrusions in these thirty-two hundred and eighty-three cases were really due to external lesions or to the incidents of military service, would be an inquiry worthy of the attention of the supervising officers of the Pension Bureau.

<sup>2</sup> For estimates of the proportion of adult males in the population subject to rupture, according to age and stature and avocation, consult a lecture by MALGAIGNE, in the *Gazette*, and *Moniteur des Hôpitaux*, and *L'Union Médicale* for 1854. I printed an English version of it in the *Virginia Medical and Surgical Journal*, Vol. III, p. 229.

<sup>3</sup> Consult, in regard to trusses for ventral hernia, GAUJOT, *Arsenal de la Chirurgie Contemporaine*, Paris, 1872, T. II, p. 613; BIGG, *Orthopædy: The Mechanical Treatment of Deformities, Debilities, and Deficiencies of the Human Frame*, London, 1865, p. 370; EMMERT, *Praktische Verbandlehre*, Bern, 1871, S. 316; and, in regard to abdominal bandages, GOFFRES, *Trécis Iconographique de Bandages, Pansements et Appareils*, Paris, 1866, p. 114.



enriched by careful studies of the obscure nervous affections sometimes consequent upon them. Twenty cases appear on the reports, in which partial paralysis in one or both of the lower extremities was attributed to shot wounds of the parietes:

CASES 96-99.—1. Pt. J. T. Reese, Co. C, 184th Pennsylvania, shot flesh wound in right inguinal region, "partial paralysis of lower extremities," Cold Harbor, June 3, 1864; discharged February 15, 1865. 2. Corp. H. B. Smith, Co. K, 5th Vermont, aged 40 years, wound of right inguinal region by conoidal ball, Winchester, September 19, 1864, "numbness of right thigh;" discharged January 13, 1865. 3. Pt. J. Murphy, Co. B, 63d New York, shot wound of left inguinal region, Antietam, September 17, 1862, "paraplegia;" discharged. 4. Pt. W. G. Thornton, Co. H, 141st Pennsylvania, aged 24 years, flesh wound of abdomen, Chancellorsville, May 3, 1863, "paralysis of left leg;" discharged March 11, 1864. There were sixteen other cases of this nature.

An examination of the imperfect details of these cases from the hospital and pension reports indicates that the loss of motor power was due, in most instances, to contracted cicatrices, or to muscular atrophy, and that only those in which some injury to the spine might be suspected were examples of true paralysis. Among the punctured wounds, there were no instances of that local irritation of the nerve filaments to which Boyer has especially called attention.<sup>1</sup>

*Tetanus.*—No instances are recorded of the apparition of tetanus in the punctured and miscellaneous wounds of the abdominal walls; but eleven cases are recorded among the gunshot flesh wounds of this region. Ten well-developed cases terminated fatally. The eleventh, which is described as an example of "slight trismus, with tetanic symptoms," had a favorable issue. When these cases are added to those in which tetanus complicated penetrating wounds of the abdomen, and superficial and deep wounds of the pelvis, the greater frequency of this complication in injuries of the abdomen as compared with injuries of the chest, adverted to on page 635 of the *First Surgical Volume*, will become apparent.

CASE 100.—Private E. Gorman, 11th Connecticut, was wounded at New Berne, March 14, 1862, by a large shell fragment. A rectangular portion of the integument and subjacent connective and adipose tissue, six by eight inches, was torn from the anterior part of the abdomen, from the xiphoid appendage above to the umbilicus below, and three or four inches on either side of the median line. The huge wound resembled, at the first glance, the exposed raw surface made by a blister plaster, such was its regularity; but on closer examination, save some slight laceration at the edges, its appearance was as if cleanly dissected by a cutting instrument, the fibres of the external oblique and rectus being as neatly exposed as could have been done by a careful anatomist. The large wound was covered by a cerate cloth. There was not much pain; but an unnatural vivacity and nervous exaltation, which awakened solicitude. The patient was treated at the field station on the right wing. The apparent absence of the usual symptoms of grave shock was remarked. On the 19th, the patient was removed to Academy Green Hospital, at New Berne. The nervous irritability that had excited alarm became aggravated on transportation, the distance being five or six miles. Anodynes were administered, but on the following day well-pronounced symptoms of tetanus appeared, and, rapidly augmenting in intensity, ended fatally in less than thirty-six hours. Chloroform and opium were the remedial agents unavailingly employed. [The name and dates appear on the report of Surgeon G. Derby, 23d Massachusetts, and I have described the case from recollection, and a memorandum in the *Boston Medical and Surgical Journal*, Vol. LXVI, p. 240.]

The ten other cases will be tabulated in the special chapter on tetanus.

The survey of this large group of cases of injuries of the abdominal walls indicates the proportion of instances in which troublesome complications arise; the necessity of enlarging wounds to control hæmorrhage, to remove foreign bodies, or to prevent the confinement of pus;<sup>2</sup> the necessity of promoting cicatrization by position, bandaging, and sometimes by sutures; and of averting peritonitis by quietude and the use of opium.

<sup>1</sup> BOYER, *Traité des Maladies Chirurgicales et des Opérations qui leur conviennent*. Cinquième éd. publiée par le baron Philippe Boyer, Paris, 1849, T. VI, p. 4. BOYER states that this local nervous irritation can be best relieved by introducing a caustic troche into the wound.

<sup>2</sup> Dr. G. B. MACLEOD (*Notes on the Surgery of the War in the Crimea*, London, 1858, p. 263) indulges in an uncalled for denunciation of *débridement* in wounds of the abdomen; but does not reiterate his strictures in his recent articles on "Wounds," which replaces the sound teachings of the original compiler, in the eighth edition of COOPER'S *Dictionary of Practical Surgery*, London, 1872, p. 1019. HUNTER'S rebuke (*On the Blood, Inflammation, and Gunshot Wounds*, p. 532) of the abuse of *débridement* by the continental surgeons, of his day was opportune, salutary, and effective; but the parrot-like iteration of his censures by modern British writers, when the practice that evoked them has long been obsolete, is superfluous and tiresome, and especially ill-timed in treating of wounds of the abdomen, where the importance of enlarging wounds to tie bleeding vessels or to remove foreign bodies, and of early intervention in threatened suppuration, is almost universally conceded.

## SECTION II.

## VISCERAL INJURIES WITHOUT EXTERNAL WOUNDS.

The effect of contusions of the abdomen is often not limited to the walls; but extends sometimes to the whole visceral mass, but more commonly to the large solid and fixed viscera, the liver, spleen, and kidneys; and, less frequently, to the hollow viscera, the stomach, intestines, and gall-bladder. Probably all the organs contained in the abdomen, even the blood-vessels,<sup>1</sup> may be torn or ruptured, without the existence of external wounds.<sup>2</sup> These injuries are classified on the registers according to the causes producing them; those due to blows, falls, kicks from men and horses, the buffer accidents on railways, the contusions inflicted by the wheels of wagons, cannon, and caissons, being placed in one group, and those caused by the impact of nearly-spent large projectiles being placed in a second group. But it will be more convenient to consider them here, according to the part injured. It is an open question, whether a blow on the abdomen may produce sudden death without any organic lesion. The affirmative and popular opinion has been handed down among surgeons, and appears to rest on Sir Astley Cooper's authority<sup>3</sup> and upon very little evidence, and Mr. Pollock and Mr. Bryant are justified in their skepticism regarding it. It need not be further discussed here; for no instance in which a fatal result was ascribed to such a cause was reported during the war. There were cases, however, in which very severe symptoms were induced by comparatively trifling blows, or by injuries attended with slight apparent physical lesions. The diagnosis of visceral complications without external sign of injury is very difficult; for, as will be fully illustrated in the next section, the distinctive signs of direct wounds of the several organs contained in the abdomen are by no means clear or constant. Little dependence is to be placed on pain or shock as signs of visceral lesion; for, as has been seen in the section on parietal wounds and contusions, these effects accompany injuries limited to the walls. When the pain is persistent, and radiating from one spot, it may be significant of internal trouble; and if the collapse returns a few days after the injury, it is supposed to mean internal hæmorrhage or extravasation. The collapse from bleeding, however, resembles syncope as distinguished from shock. The nature and position of the injury afford some clue. Vomiting, tympanitis, blood in the stools or urine, jaundice, and glucosuria, pain in the shoulder, and general itching, may be so conjoined with other circumstances as to become characteristic. The differential diagnosis has been well discussed by Mr. LeGros Clark.<sup>4</sup>

<sup>1</sup>M. LEGUEST (*Chirurgie d'Armée* 2ème éd., p. 372) saw a case of transverse laceration of the left side of the aorta, one quarter of an inch in length, three fingers-breadth above the promontory of the sacrum, in a farrier, who received, at the line of the umbilicus, a kick from a horse. The hæmorrhage was rapidly fatal.

<sup>2</sup>Though I have not met with any recorded instances of such lacerations of the supra-renal capsules, and but one of the pancreas.

<sup>3</sup>POLAND, in his MS. Prize Essay, *On Wounds and Injuries of the Abdomen*, quoted by Mr. POLLOCK (*Holmes's System*, Vol. II. p. 625) and by Mr. BRYANT (*The Practice of Surgery*, 1872, p. 239), cites three cases in support of the popular view. BRANBY COOPER (*Lectures on the Principles and Practice of Surgery*, Am. ed., Phila., 1852, p. 564) says that "it is authentically recorded that a slight blow upon the epigastrium has caused immediate death, without any apparent cause being discovered on *post-mortem* examinations," but gives no instances. TAYLOR (*Medical Jurisprudence*, 1858, p. 299) gives a supposed case from M. Wood (*Med. Gaz.*, Vol. XLIV, p. 213).

<sup>4</sup>CLARK, *Lectures on the Principles of Surgical Diagnosis*. London, 1870, Lectures X and XI.



It is only when resulting from contusions by spent projectiles, that injuries of this class are especially incident to warfare;<sup>1</sup> the majority of the cases are due to the same causes that are observed to produce such lesions in civil practice. Assistant Surgeon J. S. Melcher, 5th Missouri Volunteers, states<sup>2</sup> that he saw two men killed at the engagement at Wilson's Creek "by spent solid shot striking the abdomen. One was in great agony, with excessive tumefaction, for five hours. The other lived twenty hours, in great pain. There was no abrasion of the skin in these cases." Ruptured viscera would probably have been discovered had autopsies been made. Sudden tympanitis, *ballonnement subit*, is pronounced by Jobert to be the most characteristic sign of rupture of the intestines. The cases cannot be identified in the battle-field reports.

*Ruptures of the Liver.*—Five cases were reported. Four were due to a buffer accident, the passage of carriage-wheels, and a blow from the tongue of a wagon, and proved speedily fatal from hæmorrhage or peritonitis:

CASES 101-104.—The Museum contains no illustrations of this form of injury. Few details are given of the cases reported: 1. Reported by Surgeon F. Mechem, U. S. V.: Private G. P. Leipard, Co. I, 2d Ohio Heavy Artillery. Contusion in right hypochondrium by collision of cars, January 29, 1865; rupture of liver; death in a few hours. 2. Reported by Surgeon D. W. Bliss, U. S. V.: Private H. H. Thayer, Co. H, 4th New York Heavy Artillery. Contusion, without external injury, of right side of abdomen, by the tongue of a wagon. Admitted into Army Square Hospital January 5, 1864. Liver injured. Died, in three days, from peritonitis. 3. Reported by Assistant Surgeon V. H. B. Lung, 49th Ohio: Pt. D. Mezmer, Co. C, 49th Ohio, Murfreesboro', December 31, 1862. Contusion of abdomen; death the same day. 4. Reported by Assistant Surgeon J. H. Frantz, U. S. A.: Jackson Miller, Portsmouth, Va., May 1, 1865, crushed by cart-wheel, liver ruptured. Death from internal hæmorrhage the same day.

The fifth is more interesting, the patient having survived for forty-eight days:

CASE 105.—Private W. Howard, Co. G, 30th U. S. Colored Troops, was struck in the right side, July 30, 1864, at Petersburg, by a large spent fragment of shell, and was conveyed to the hospital for colored troops. There was extensive ecchymosis on the outer side of the right hypochondrium, but no abrasion of the skin. The patient was faint, and there was pain and great tenderness in the injured region, with moderate collapse, unattended by indications of internal hæmorrhage. Rest in bed and warm fomentations constituted the treatment. The patient was sent, after a few days, on a hospital transport steamer to Philadelphia, and entered Satterlee Hospital; but was soon after transferred to Summit House Hospital, under charge of Surgeon J. H. Taylor, U. S. V., who reports the case. Except the pain in the hepatic region, there were no symptoms of injury of the liver; no jaundice, nor deficiency of bile in the stools, nor gastric irritability. Active counter-irritation by epispastics was employed unavailingly to remove the local pain. The general treatment was supporting, tonics and stimulants being prescribed. The patient steadily lost ground, and died September 16, 1864. At the autopsy, old pleuritic adhesions were found in the left pleura. In the abdominal cavity there were slight traces of peritonitis. But "the superior posterior portion of the right lobe of the liver was very much lacerated, the substance of this portion of the organ being reduced to a pulp, breaking down under pressure, and showing a complete line of demarcation between the injured and healthy parts."

Pain, collapse, hæmorrhage, dulness on percussion, bilious vomitings, followed by peritonitis, white stools, jaundice, and saccharine diabetes, are the symptoms usually ascribed to ruptures of the liver. Only the three latter are characteristic. There is no question that patients may recover from this form of injury, when the rent in the liver is not so great as to cause hæmorrhage to a hopeless extent.<sup>3</sup> This organ is more readily lacerated when diseased. It is most commonly fissured on its convex surface.<sup>4</sup> Sometimes, the

<sup>1</sup> In the British Army in the Crimea: "Four fatal cases occurred from rupture of viscera, without external wound. Two of these were rupture of the liver, one of the spleen, and one of the intestines." MATTHEW, *Surgical History of the British Army, which served in Turkey and the Crimea during the War against Russia, in the years 1854-55-56*, London, 1858, Vol. II, p. 332. BECK, *Chirurgie der Schusserverletzungen*, Freiburg, i. B. 1872, Zweite Hälfte, S. 520, remarks: "At the sieges of Malghara and Venice, and lately before Strasbourg and Belfort, I have seen wounded, with no outward sign of injury, who suffered from contusion and rupture of the intestines, rupture of the stomach, the liver, the spleen; rarely of the kidney and large blood-vessels; in a few cases the patients reached the hospital, but died shortly afterward. At Kehl, we had a fatal case of this kind. Captain v. F—, an artillery officer, who lived only a very short time after the reception of the injury."

<sup>2</sup> MELCHER, *Appendix to Part I. Med. and Surg. Hist. of the Rebellion*, p. 18.

<sup>3</sup> Mr. ERICHSEN (*The Science and Art of Surgery*, 1869, Vol. I, p. 444) gives a case of rupture of the liver, fatal on the sixteenth day, in which the laceration was beginning to cicatrize and a well marked case of recovery. In Guy's Hospital Museum there are several preparations illustrating the repair of these injuries. See Prep. 1918-1951-5, in *Pathological Catalogue of the Museum of Guy's Hospital*, London, 1857, Vol. II, p. 102. For a remarkable instance of recovery, see PRYER, *Medico-Chirurgical Transactions*, 1813, Vol. IV, p. 330.

<sup>4</sup> Mr. CLARK says (*Lectures, etc.*, p. 293): "in superficial lacerations I have found, almost invariably, that it is the under surface of the liver that is torn." My observations accord rather with those of Mr. BRVANT (*The Practice of Surgery*, 1872, p. 301), who says: "fissures of the liver are usually met with on its upper surface." This opinion is corroborated by the specimens preserved at Netley (see *Specs.* 1504, 1506, *Catalogue of the Preparations*

capsule of Glisson remains intact, while the gland substance is crushed, and such cases are likely to result in abscesses, and eventually in recovery.<sup>1</sup> In the majority of cases, death occurs within a few hours, in some within a few days. In a series of nine cases noted by Mr. Bryant (*Op. cit.*, p. 300), "five died rapidly, three survived three, seven, and nine days, respectively."<sup>2</sup> It is believed that a sudden action of the abdominal muscles may produce this lesion.<sup>3</sup> Unless the laceration extends far backward and involves the vena cava the amount of extravasated blood is commonly not considerable. It is generally found partly coagulated and partly fluid.<sup>4</sup> General peritonitis is not an inevitable nor even a general consequence of rupture of the liver. The differential diagnosis is not easy. The attendant collapse and vomiting and modification of percussion sounds are not peculiar; the seat, direction, and persistence of the pain may, or may not be significant; icterus is not uniformly present; glucosuria, though demonstrated experimentally in lower animals, has rarely been observed clinically. A perceptible depression at the fissure has, according to Emmert (*Lehrbuch der Chir.*, B. III, S. 244), been observed by Steffens. This, which could only be readily detected in lacerations of the under surface, and traumatic diabetes, would be conclusive, while the other signs in conjunction, would be strong presumptive evidence.

In the minor lacerations of the liver in which alone there is the prospect of the formation of adhesions and the question of treatment arises, *absolute rest*, the patient not being allowed to raise himself or be raised in bed, is the accepted essential condition. Opium must be given, and, after the danger of bleeding is past, hot fomentations and poultices afford great comfort. The remaining treatment must be guided by symptoms.

contained in the *Museum of the Army Medical Department*, edited by GEORGE WILLIAMSON, M. D., Assistant Surgeon to the Forces, London, 1845, p. 199; *Spec.* 1400 in *Descriptive Catalogue of the Pathological Museum of the Pennsylvania Hospital*, by WILLIAM PEPPER, Philadelphia, 1869, p. 72; the case detailed by Mr. ATHOL JOHNSON (*Med. Chir. Trans.*, 1851, Vol. XXXIV, p. 55), and quoted in Holmes's *System*, Vol. II, p. 648, and by many others. For other illustrations of ruptures of the liver, see *Spec.* 2368 (plaster cast), in *A Descriptive Catalogue of the Warren Anatomical Museum*, by J. B. S. JACKSON, M. D., Boston, 1870, p. 478; *Spec.* 545 (plaster cast), in *A Descriptive Catalogue of the Boston Society for Medical Improvement*, Boston, 1847, p. 162; *Specs.* 1815, 1816 (Class V, Div. II, in *Catalogue of the Museum of the Royal College of Surgeons of Edinburgh*, 1836, p. 225; *Spec.* 1, Series XVIII, in *A Descriptive Catalogue of the Anatomical Museum of St. Bartholomew's Hospital* (Mr. PAGET'S revision of STANLEY'S CATALOGUE), London, 1846, Vol. I, p. 338; GROSS, *System*, 5th ed. Vol. II, p. 682; KIRKBRIDE, *Clinical Reports*, Case XII, in *Am. Jour. Med. Sci.*, 1834, Vol. XV, p. 329; GREEN, *Cases of Fracture of the Liver*, *Am. Jour. Med. Sci.*, 1830, Vol. VI, p. 539; *Bulletin de la Société Anatomique*, T. XXIII, p. 193, T. XXVI, p. 100, T. XXVIII, p. 260; MOHRENHEIM, *Wienerische Beiträge*, B. I; THEDEN, *Med. Chir. Nachrichten*, Jahrg. III, St. 43, S. 341; RUST'S *Magazin*, B. XXII, Hft. 1, S. 195; HUNTER, *Rupture of Liver*, death on the tenth day, from hæmorrhage, in *Proceedings of the Pathological Society of Philadelphia*, *Am. Jour. Med. Sci.*, N. S., 1870, Vol. LIX, p. 405.

<sup>1</sup> I find that DUPUYTREN (*Leçons Orales de Clinique Chirurgicale*, T. VI, p. 443) had observed this cause of abscesses of the liver. RICHERAND'S experiment of precipitating a cadaver from a gallery to the floor of his lecturing amphitheatre, and thus producing ruptures of the liver, will also be remembered. He sought thus to explain the association of hepatic abscesses with cranial fractures, the etiology of what we now term metastatic foci in the liver. Consult LOUIS, *Mémoire sur les Abscès du Foie*, in *Recherches Anat. Path.*, Paris, 1826. RICHERAND, *Nosograph. Chir.*, T. V, p. 244. Dr. LIPELL, in his excellent article on rupture of the abdominal viscera (*Am. Jour. Med. Sci.*, N. S., Vol. LIII, p. 340), gives the case of extensive hepatic laceration with unbroken peritoneum, and quotes another from Mr. POLLOCK (HOLMES'S *System*, Vol. II, p. 416). For an interesting case of recovery from hepatic abscess, due to a fall from a horse, see Dr. HARLEY'S paper, read before the Clinical Society of London (*Lancet*, 1870, Vol. II, p. 569). Compare, also, cases by HEATON, *Brit. Med. Jour.*, 1869, Vol. II, p. 8, and MOORE, *Ibid.*, 1870, Vol. II, p. 693.

<sup>2</sup> Preparation 1391, of the HUNTERIAN MUSEUM, shows a laceration of the liver extending through the whole thickness of the organ. The patient, who was crushed, survived two days. *Descriptive Cat. of the Path. Specimens contained in the Museum of the Royal College of Surgeons of England*, Vol. III, p. 152. Assistant Surgeon C. F. GUNN, U. S. A., has reported (*Circular* 3, S. G. O., 1871) a fatal case of rupture of the liver by the passing wheel of a carriage. The diagnosis was verified after death. An attendant laceration of the spleen was not detected until the autopsy. For a case, in which death was almost immediate, see PEARSON, *Transactions of the College of Physicians*, London, Vol. III. For an interesting case in which a laceration was found nearly cicatrized and a large effusion of blood partially absorbed, when the patient died from a cause foreign to the accident, see PELLETAN, *Clinique Chirurgicale*, Paris, 1840, T. II, p. 112; VELPEAU, *Traité Complet d'Anatomie Chirurgicale*, T. II, p. 159, among other instances, cites two unpublished cases by M. FORGET. In the discussion on Mr. ATHOL JOHNSON'S paper above cited, LLOYD and SOLLY (*Lancet*, 1851, Vol. I, p. 94) called in question the cicatrization of lacerations of the liver; but COPELAND considered the fact demonstrated.

<sup>3</sup> TAYLOR, *Medical Jurisprudence*, Am. ed. of Griffith, 1845, p. 320. For a case in which this accident happened to an individual attempting to avoid a fall from his horse, see MALE'S *Épître de Juridical or Forensic Medicine*, London, 1816, p. 119.

<sup>4</sup> DEVERGIE, *Médecine légale, théorique et pratique*, 2ème éd., 1810, T. II, p. 45. From several of the following dissertations de *hepatite vel de Jecinoris inflammatione*, particulars of cases of traumatic hepatitis and of the *post-mortem* appearances after rupture, may be gleaned: GERBIARD, C. A., Halae, 1721; BIANCHI, Genevæ, 1725; HOEPFNER, J. C., Halae, 1726; SMITH (MARK), Edinburgh, 1766; WILLAN, Edinburgh, 1780; ROSSUM, Louvain, 1782; YPEREN, Leyden, 1782; MACAY, Edinburgh, 1785; CAUSLAND, Edinburgh, 1787; MACLEAN, Edinburgh, 1790; MILLER, Edinburgh, 1795; ACREL, Upsala, 1797; HORNE, J., Edinburgh, 1799; AINSLIE, Edinburgh, 1801; BEECH, FYFE, MAXWELL, Edinburgh, 1801; STOKK, KEATINGE, Edinburgh, 1802; BROADFOOT, O'BEIRN, Edinburgh, 1803; MELLVILLE, Edinburgh, 1806; WHITE, Baltimore, 1808; HUGGINS, Edinburgh, 1801; ZIMMERMANN, Leyden, 1815; ROWAN, Baltimore, 1815; PACÉE, Leyden, 1816; RAGUENET, Strasbourg, 1820.



*Ruptures of the Spleen.*—Notwithstanding the looseness of its attachments, and its consequent mobility, the delicacy and friability of the texture of the spleen exposes it to injury from external violence. Next to the liver, this viscus is probably the most frequently

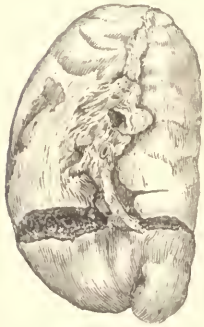

FIG. 6.—Spleen torn completely through by a blow from the fist. Spec. 5600. [Reduced to one-fourth.]

lacerated of the abdominal organs.<sup>1</sup> Its extended rupture commonly gives rise to fatal hæmorrhage.<sup>2</sup> Yet, that recoveries occur in such cases, is indicated by observation and demonstrated by *post-mortem* investigations.<sup>3</sup> Very extended lacerations are followed by profuse internal hæmorrhage, and the consequent symptoms and result. The patient, from whom the preparation represented in the wood-cut (FIG. 6) was taken, survived a rupture of the spleen from a blow with the fist less than fifteen minutes. The case is related by Surgeon J. F. Weeds, U. S. A., in *Circular No. 3*, S. G. O., 1871, page 107. Fissures and lacerations of the spleen are generally most conspicuous on the convex surface, though often extending through the entire substance of the organ,<sup>4</sup> as in Dr. Weeds's case. Another instance, a laceration by a

railroad accident, is recorded on page 38 of the *First Surgical Volume*. Two other cases are reported, both represented by preparations in the Museum, and it is not improbable that among the fatal cases that will be referred to hereafter, returned as deaths from contusions of the abdomen, or among the cases of recovery after grave contusions in the left hypochondrium, there may have been examples of rupture of the spleen. Professor Gunther<sup>5</sup> relates a case of recovery in which he regarded the signs of rupture of the spleen and intra-abdominal extravasation as indisputable.

CASE 106.—Private Charles G——, Co. B, 26th Illinois Volunteers, was struck in the left side of the abdomen, November 23, 1863, at the battle of Mission Ridge, by a spent cannon ball, or, more strictly, by an unexploded shell, which rolled against his side, as he was lying down, and was stopped by the impact. The blow produced great distress in the abdomen, and nausea, yet there was no visible ecchymosis or other injury of the integument, and, after taking a restorative draught, the wounded man felt able to walk several miles to Chattanooga, where he was received in one of the hospitals. He was confined to his bed until December 20, 1863, when he was transferred to the general field hospital, under the care of Acting Assistant Surgeon E. A. Ball.

<sup>1</sup> The literature of ruptures of the spleen is copious. MORGAGNI (*De Sedibus et Causis Morb.*, Patavii, 1765, Vol. II, p. 279, Ep. LIV, 15) adduces many cases from the old authors: Thus three examples, caused by blows from canes, are recorded by TULPIUS (*Obs. Med.*, Amstelodami, 1641, Lib. II, Obs. 29); FONTEYN (*Epitome*, VESALI ad HORSTII, p. 22); CRASSIUS (*Miscellaneorum Curiosorum*, Dec. III, Ann. II). Other examples, the results of kicks from horses, of blows from the fist, of falls and other forms of violence, are noted by BOHS (*De Remanitione Vulnerum*, Lipsiæ, 1689). ALBRECHT (Lien a forti percussione ruptus, in the *Acta Eruditorum*, Venet., 1740, An. X, Dec. III, Obs. 6) and others, enumerated by HEISTER, in his *Institutiones Chirurgicæ*, Amstelodami, 1739. EYSEL, *De Ruptura Lienis*, Erford 1696; SCHMID, *Historia Lienum Ruptorum*, Argent., 1725; HUNAU, *Mém. de l'Acad. de St. Petersburg*, 1726, Vol. I; HAUTESIERK, *Recueil d'Observat. de Méd. des Hôpitaux Mil.*, Paris, 1773; BIETT and AUSSANDON are quoted by BRESCHET, *Dict. des Sci. Méd.*, T. VIII, p. 149. Among the American cases recorded are those of BUST, *Rupture of the Spleen from a Fall*, *Am. Jour. Med. Sci.*, N. S., Vol. LX, p. 573, and WARING, *Three cases of Ruptured Spleen*, *Am. Jour. Med. Sci.*, N. S., 1856, Vol. XXXII, p. 354. INGALLS, *Boston Med. and Surg. Journal*, 1829, Vol. I, p. 296; LOPEZ, *N. Am. Med. Chir. Rev.*, Vol. IV, p. 286; ADAMS, *Dublin Med. Press*, March 21, 1860.

<sup>2</sup> As in HENNEN'S Case, LXXVI (*Princ. of Mil. Surg.*, 3d ed., p. 445). GUTHRIE (*Comm.*, 5th ed. p. 530, and *Lectures*, p. 56) adverts to ruptures of this organ, "which I have several times seen occur in consequence of falls, or from blows from cannon-shot, which have not opened into the cavity," fatal "from hæmorrhage filling the general cavity of the abdomen." C. J. LANGENBECK (*Nosologie und Therapie der Chirurgischen Krankheiten*, Göttingen, 1830, S. 554) records a case fatal in fourteen hours, and cites several others. "Yet, copious bleeding is not a necessary consequence of this lesion; for, in a patient recently under my care, who sustained this and other injuries and survived for some hours, there was not more than two ounces of blood in the abdomen, though there was an extensive rent in the spleen. In one of my cases, a deep linear cicatrix on the convex surface of the spleen seemed to indicate the position of a former wound, but the patient died of a more recent injury."—CLARK, *Op. cit.*, p. 268.

<sup>3</sup> Preparation 2018<sup>60</sup>, of Guy's Museum, illustrates the repair of the spleen after injury (*Path. Cat.*, Vol. II, Addenda, p. 65). Mr. CLARK (*Lectures on Surg. Diagnosis*, p. 293) does not think that the spleen can be placed in the same category with the liver and kidney, as to frequency of recovery, because of its peculiar texture and vascularity. The subject will be more fully discussed under the head of penetrating wounds.

<sup>4</sup> For other illustrations, see Spec. 37, Series X, *Catalogue of the Pathological Museum of St. George's Hospital*, by Dr. OGLE and Mr. HOLMES, London, 1856, p. 520; JACKSON, J. B. S., *Boston Soc. Cat.*, I. c. Spec. 567; PORTAL, *Cours d'Anatomie Médicte*, T. V, p. 345; *St. Bartholomew Hosp. Cat.*, Series V, Prep. 22, p. 352; *Netley Collection Cat.*, Prep. 1586, p. 208; *Edinburgh Cat.*, R. C. S., Spec. 1909, XXXI, D; ASSOLANT, *Recherches sur la Rate*, pp. 101, 102; PIGNÉ, *Bull. de la Soc. Anat.*, 1837, p. 125.

<sup>5</sup> MOEBIUS, *Deutsche Klinik*, No. 20, May 18, 1850, B. II, S. 222. The case was that of a man of 27 years, who fell from a height of thirty feet, the left side striking a carpenter's trestle. An audible *souffle jugulaire* attended the effusion of blood. For descriptions of ruptured spleens, consult FOURNIER, in LIEUTAUD'S *Historia Anatomico-medica*, L. I, *Lesiones abdominis*, Obs. 977, 978, Paris, 1767; DURET, *Jour. Gén. de Méd. Chir. et Phar.*, T. XCIX, p. 136; MONTALCÓN, *Historia Méd. de Murcia*, p. 305; ZOPF, *Eph. Acad. Nat. Cur.*, Norimberg, 1740, Obs. 125, "mors subita ex rupto liene;" DUNCAN, *Med. Chir. Rec.*, 1830, Vol. XVII, p. 227; ANSELL, *London Lancet*, 1839, Vol. II, p. 894; NECKEL, in *Med. Zeit.*, May, 1839, quoted in *Arch. Gén. de Méd.*, S. III, T. VI, p. 97; COOPER, *Lancet*, 1840, Vol. I, p. 486. Thesis in *Arch. Gén. de Méd.*, 1851, 5ème série, T. IV, p. 85; BARTH, *Ibid.*, 1855, T. V, p. 285; CHARCOT, *Gaz. des Hôp.*, 1858; LOVE, *Lancet*, 1859, Vol. I, p. 329; ERICHSEN, *Lancet*, 1859, Vol. II, p. 9; HEDDLE, *Med. Chir. Rev.*, 1839, p. 391.

who took notes of the case, and contributed the specimen represented in the wood-cut (Fig. 7). At this date the patient was emaciated, his pulse frequent and feeble; he had slight cough without expectoration; the abdomen was tympanitic and slightly painful on pressure; anorexia, micturition, and defecation regular; legs oedematous; complained of excessive lassitude and weakness. The swelling of the abdomen subsided considerably until ten days before his death; but the pain and soreness persisted. He was able to walk about the tent every day before his death, which took place on January 8, 1861, a month and thirteen days from the reception of the injury. At the autopsy, a discoloration of the integument in the left hypochondriac region was noted, a sugillation resembling incipient *post-mortem* decomposition. On opening the thoracic and abdominal cavities, the lungs were found to be normal; the pleura of the base of the left lung was adherent to the diaphragm. From the under surface of the diaphragm, in this region, extended a large abscess as far down as the left and right iliac regions. Its boundaries were noticed in detail by the reporter; but it may be said to have occupied the entire lesser peritoneal cavity. Its walls were lined by an abundant dark gray, shaggy exudation, and it contained fetid, cheesy pus. It communicated with the left pleural cavity through an opening in the diaphragm, and the lung in its immediate vicinity, though crepitant and well filled with air, was brown-colored and more friable than elsewhere. The spleen was ruptured, and divided along the hilus into two portions; the larger weighed three and one-half ounces, the smaller, two ounces. The proper substance of the spleen is much broken down. On microscopical examination of the specimen at the Museum, it is found, in a transverse section in glycerine, that the polygonal arrangement of the trabeculae enclosing the proper substance of the spleen has everywhere disappeared. The capillaries are much shrunken, which may be due to long immersion in alcohol without previous injection. No Malpighian corpuscles are visible. There are melanotic or pigment deposits infiltrated at frequent intervals throughout the tissue. The peritoneal investment is thickened and coated with lymph in some places.

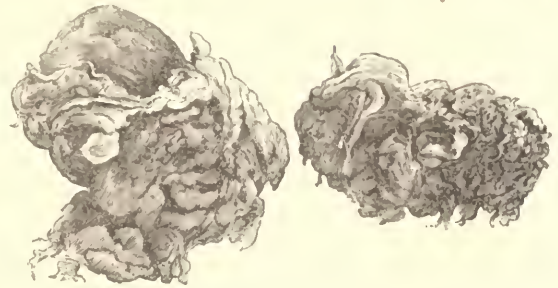


FIG. 7.—Fragments of spleen ruptured by the contusion of an unexploded shell, and broken down by suppuration. *Spec.* 2113. (Reduced to one-fourth.)

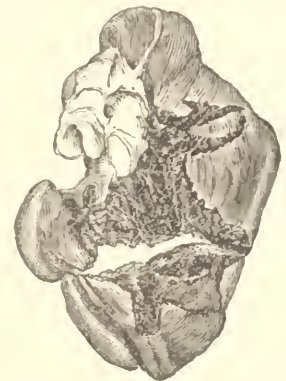

FIG. 8.—Enlarged spleen, ruptured by a fall. *Spec.* 5948. [Reduced to one-fourth.]

CASE 107.—John S.—, aged 45 years, weighing about 170 pounds, an epileptic, fell from a stable-loft during the night of October 24th, and his body was found lifeless on the pavement in the morning. There was a slight cut on the scalp, but no other external evidence of injury. At the autopsy, six hours after death, the brain and its membranes were found to be much congested; but there was no intracranial effusion of blood or serum. There were old pleuritic adhesions on the left side; but the lungs were normal. The heart was flabby, and contained no coagula. The liver was cicatrized; the stomach and intestines showed no abnormal alteration. The spleen was much enlarged, weighing twenty and one-half ounces avoirdupois, and was ruptured, radiating fissures extending completely through its substance. Profuse hemorrhage into the peritoneal cavity had resulted from this laceration. The specimen, represented in the accompanying wood-cut (Fig. 8), and the memorandum of the case, were contributed to the Army Medical Museum by Dr. J. F. Hartigan. A thin microscopical section in the vicinity of the rupture exhibits increased vascularity and abnormal enlargement of the Malpighian corpuscles, and numerous small deposits of pigment cells.

The first of these cases is very interesting on account of the protracted duration of life after the accident. If there was any primary laceration and extravasation, the former must have been slight, and the latter circumscribed. The case should be described, perhaps, as an example of traumatic splenitis terminating in abscess. M. Vigla<sup>1</sup> and M. Collin<sup>2</sup> have published exhaustive papers on ruptures of the spleen, occurring in diseased subjects, from muscular contraction or very slight external violence. The former believes in the possibility of recovery, though all the cases he has collected proved fatal. Peritonitis did not occur in any case, and on the absence of its signs M. Vigla finds a distinction between the symptoms of splenic rupture and those of rupture of the intestinal tube, which they closely resemble. M. Collin adds a number of cases observed in Africa.

<sup>1</sup> VIGLA, *Recherches sur la Rupture Spontanée de la Rate*, in Arch. Gen. de Méd. 4<sup>e</sup> Série T. III, p. 377, 1843, T. IV, 17, 1844. The author analyzes seventeen cases, all of which were fatal—fourteen within forty-eight hours, one on the sixth day, two early, but date not specified. The exact diagnosis was made out in very few instances. Diaphragmatic pleurisy, internal bleeding from rupture of an aneurism or large vessel, were among the lesions suspected. M. Vigla holds that the absence of the signs of peritonitis distinguishes these cases from rupture of the intestinal tube. Absolute rest, opium, and hæmostatics constituted the treatment.

<sup>2</sup> COLLIN, *Des Ruptures Spontanées de la Rate*, in Mémoires de Chirurgie de Médecine et de Pharmacie Militaires, 2<sup>e</sup> Série, T. XV, p. 1, 1855. The author regards splenic ruptures in subjects with malarial cachexy as more common than has heretofore been admitted. He describes capsular ruptures unattended by hemorrhage. In examining and palpating cachectics with enlarged spleens, practitioners should exercise great caution, and such patients should be warned to be always on their guard. The diagnosis was equivocal in all the cases collected by Mr. Collin. No pathognomonic sign can be suggested.



He inclines to the opinion that the prognosis is uniformly unfavorable, although he demonstrates in several instances the existence of cicatrization. He mentions three examples of generalized peritonitis following the accident.

*Ruptures of the Kidney.*—Notwithstanding its protected position in the loins, well padded with adipose tissue, rupture of the kidney is not an infrequent accident. But few fatal cases, however, appear on the reports during the war. An interesting case, fatal from hæmorrhage, a complete longitudinal laceration of the right kidney, caused by the passage of a wagon-wheel, is recorded by Assistant Surgeon Gunn, U. S. A., in *Circular No. 3, S. G. O., 1871*, page 106. The morbid specimen was not preserved, and the Museum is still without a preparation illustrating this form of injury.<sup>1</sup> One fatal case, in the war, was from a buffer accident, another from a shell contusion:

CASE 108.—Private Gerald Tiffany, 27th New York Battery, aged 44 years, falling between the platforms of two railway cars, February 6, 1864, was caught and squeezed between the buffers. The compression was antero-posterior and over a space to the left of the umbilicus in front, and between the crest of the ilium and the ribs behind. There was ecchymosis in the lumbar region, but the integuments were intact. The patient was conveyed to Kalorama Hospital. There was profound collapse, from which he slowly rallied. The abdomen was tender and swollen, the urine bloody. Emollient fomentations were applied and opiates were administered, and diluents and a light diet were prescribed. There were symptoms of peritonitis during the first week, but not of an aggravated character. The hæmaturia persisted for three weeks, clots being passed occasionally molded of the form of the ureter. There was dulness of percussion over the left flank. The symptoms seemed to indicate rupture of the left kidney, with limited and probably extra-peritoneal urinary extravasation. Balsamic remedies were employed, and the bloody appearance of the urine at last disappeared: an albuminous condition of the secretion persisting. Œdema of the lower extremities supervened. With occasional amendments, the evidence of uremic infection became more confirmed. The patient had several severe attacks of diarrhoea, and sank and died from the effects of his injuries on April 6, 1864. No autopsy.

CASE 109.—Private Nathaniel J. Loveland, Co. D, 19th Massachusetts, received, June 25, 1862, a severe contusion of the left side of the abdomen, from a fragment of shell, at Oak Grove, in the advanced trenches near Richmond, of General Dana's brigade of the First Corps. The shock was great and of long continuance; there was a bruise in the left flank, and excessive tenderness, anuria, and pain and retraction of the left testicle. Surgeon J. Franklin Dyer, 19th Massachusetts, notes, at the regimental hospital, "serious danger apprehended." The patient was placed on a hospital car and sent to Savage's Station, and thence to Yorktown, where he died on June 27, 1862.

Very probably other instances may be included among the fatal abdominal contusions reported without distinct specification of the symptoms. There were also a number of cases of recovery in which there was reason to suspect the existence of laceration of the kidney, or at least of severe contusion of its substance. Unfortunately they are not reported with fulness or precision of detail. That recoveries take place<sup>2</sup> after very considerable laceration of the kidney, with extravasation of both blood and urine, has long since been demonstrated by clinical observation and the investigations of pathologists:

CASE 110.—Private J. H. Dulepohn, Co. K, 142d Pennsylvania, aged 20 years, was struck in the left lumbar region, July 2, 1863, at Gettysburg, by a large fragment of shell, which caused a grave contusion with ecchymosis, but without abrasion of the skin. There was shock, and much pain and tenderness at the injured part, and the urine was scanty and bloody. The

<sup>1</sup> "When not very severe, and uncomplicated with other injuries, such cases usually do well. It is generally known by an attack of hæmaturia following a blow in the lumbar region, local pain as a rule co-existing. This hæmaturia may be only passing, and cease after the lapse of two or three days, when it is probable that only a contusion of the kidney had taken place; for in severer injuries the bleeding lasts fifteen days or more. At times clots will be passed, assuming the shape of the ureter. I have before me the notes of some half a dozen cases in which these symptoms were present, and from which recovery took place."—BRYANT, *The Practice of Surgery*, London, 1872, p. 304.

<sup>2</sup> Preparation 1728, Class VI, Division II, Section IX, of the Museum of the British Army Medical Department, represents a rupture of the right kidney (*Catalogue*, p. 235). At the Museum of St. George's Hospital, London, specimens 1, 2, 3, and 4 of Series XI illustrate ruptures of the kidney. The first is the right kidney of a boy of fifteen years, run over by a cart. There was extensive hæmorrhage into the sub-peritoneal cellular tissue; the kidney was the only organ injured. The patient did not rally from collapse. Prep. 2 shows rupture of the left kidney of a man of sixty-seven years. Prep. 3 shows a rupture of the left kidney from a fall; there was copious hæmorrhage into the peritoneal cavity. Prep. 4, of two granular kidneys, shows a cicatrix in the right, from a rupture that occurred eighteen months before death.—(*Catalogue*, p. 530.) At St. Bartholomew's Museum, Prep. 11, of Series XXVI, is the specimen from a case of rupture of the ureter described by STANLEY in the *Medico-Chirurgical Transactions*, Vol. XXVII, p. 8. The kidney itself appears healthy. In the Pathological Cabinet of the New York Hospital, Sect. VII, Prep. 747 is a kidney ruptured by violence; 748 shows the repair of a rupture that almost completely divided the organ horizontally near the centre; "lymph is copiously effused between the separated surfaces and upon the exterior."—(RAY'S *Cat.* 297.) Prep. 2063, of Guy's Hospital Museum, is a "kidney showing slight laceration on its surface, produced by injury."—(WILKS'S *Cat.*, 1859, Vol. II, Pt. 2, p. 30.) Prep. 2451, of the Warren Anatomical Museum, is a kidney with a horizontal laceration, one-eighth to one-third of an inch in depth; there was a large effusion of blood about it, but none in the bladder. The patient, who jumped from a railroad car in motion, survived the accident forty-eight hours.—*Bull. de la Soc. Anat.*, T. XVIII, p. 186, T. XV, p. 106, T. XXVII, p. 112.

pain extended along the course of the ureter, and there was retraction of the testicle and smarting at the orifice of the urethra. There was much difficulty in micturition, and occasionally tubular clots of blood were passed, after which the urine flowed in a stream, with great relief. The patient was suffering with diarrhoea. He was treated with hot fomentations to the injured part, and with chalk mixture and spirits of nitric ether, until the 11th, when he had sufficiently rallied to be transferred to the Satterlee Hospital, at Philadelphia, under the care of Surgeon I. E. Hayes, U. S. V., who reports the case. He was ordered infusion of buchu, and counter-irritation over the loins, and, as soon as the irritability of the bowels permitted, he was placed on nourishing diet, with ferruginous medicines and bitter tonics. The hæmaturia disappeared after the third week from the reception of the injury, and the patient gradually convalesced, and was transferred to the Invalid Corps, December 31, 1863.

CASE 111.—Lieutenant H. T. Burrows, Co. C, 7th Maryland, was struck, May 5, 1864, by a fragment of shell, in the left lumbar region. He was treated by Surgeon C. S. Nordquist, 83d New York Volunteers, at the 2d division hospital of the Fifth Corps. Severe pain and difficult micturition, with hæmaturia, led to the belief that a laceration of the kidney had been induced. On May 12th, this officer was sent to Washington and was treated in quarters by Surgeon Antisell, U. S. V. He recovered, and on June 8, 1864, was placed on Court-Martial duty.

No instances are specified in the reports of ruptures of the gall-bladder,<sup>1</sup> or of the hepatic or common duct,<sup>2</sup> or ureter,<sup>3</sup> nor are instances given of rupture of the pancreas,<sup>4</sup> or supra-renal capsules, yet a number of fatal cases were recorded in which visceral ruptures were diagnosticated, when opportunity to ascertain the extent and nature of the lesion were either not afforded or not improved. Some of these, of which it is mentioned that "all the viscera were pulpified," might have included illustrations of some of the rarer forms of abdominal lesions; but the descriptions are too vague to be instructive. Thus, Assistant Surgeon V. H. B. Lang, 49th Ohio, reports two instances of men killed, by contusions from spent shells, at the battle of Murfreesboro':

CASES 112-113.—Pt. John Bolles, Co. A, 49th Ohio, shell contusion of abdomen, December 31, 1862, death on the same day; Pt. Joseph Stanch, C, 49th Ohio, rupture of abdominal viscera by shell contusion, Murfreesboro', December 31, 1862.

In other cases, the fatal result was delayed:

CASE 114.—Captain D. M. Myers, Co. G, 14th New York, was struck in the abdomen, at the engagement at Honey Hill, South Carolina, November 30, 1861, by a spent cannon ball. There was no external injury; but collapse, followed by nausea and vomiting, tenderness and tension of the abdomen, and bloody stools, indicated serious internal mischief. This officer was conveyed to the hospital at Hilton Head. Symptoms of traumatic peritonitis were combated by opium and emollient fomentations. He died on December 17, 1861. No autopsy.

CASE 115.—Private J. Robbins, Co. G, 119th Pennsylvania, received, at the Wilderness, May 14, 1864, a severe contusion of the abdomen from a fragment of shell. Extreme depression followed, from which he slowly rallied. Opiates were administered. There was extreme tenderness in the region of the liver, and jaundice. The patient was treated on a hospital transport steamer and conveyed to Alexandria, where he died on May 28, 1864.

CASE 116.—Private J. Crooks, Co. I, 2d Massachusetts Artillery, aged 46 years, was struck, March 8, 1865, at Kinston, North Carolina, on the right side of the abdomen, by a large fragment of an exploded shell. There was intense nervous depression, followed by symptoms of traumatic peritonitis, and indications of injury of the liver or spleen. The patient survived to be transported to the Dale Hospital, in Massachusetts, where he died on April 25, 1865.

<sup>1</sup>BRESCHET, in his excellent article *Déclairement* (*Diet. des Sci. Méd.*, T. VIII, p. 148), cites cases of rupture of the gall-bladder from Bonetus, Salmuthius, Bertinus, Hoffman, Portal, and the contributors to the *Ephemerides Cur. Nat.* SALMUTH (*Obs. med. posth.*, Brunsvic, cent. 1, obs. 3, 1648) relates the case of a boy of twelve years, who survived four days the rupture of the gall-bladder by a blow.—BERTINUS (*Medicina absoluta*, Basl., 1587) records an early instance. FERGUS (*Med. Chir. Trans.*, Vol. XXXI, 1842, p. 47) reports a case in a boy of seventeen years, crushed by a cart-wheel; he died on the ninth day, after appearing to be fairly convalescent. LESTER (*Sur les ruptures et les perforations de la vésicule biliaire*, Paris, 1821) records a case, fatal in four days. HÖRING (*Diss. sistens experim. de mutationibus quas materic in cavum peritonei ingesta subeunt*, Tubingæ, 1817) proves, experimentally, that extravasation of bile in the peritoneal cavity is not necessarily fatal in the lower animals. I have met with no instances of recovery in the human subject. At St. Bartholomew's Museum, Prep. 14, of Series XIX, shows a rupture of the gall-bladder, three-fourths of an inch long. The specimen is from a man 50 years old, who was kicked near the region of the liver while stooping. He died in fifteen hours.

<sup>2</sup>POLAND (*MS. Fothergillian Prize Essay*) reports a case, quoted by Mr. Pollock, in *Holmes's System*, Vol. II, p. 649, of rupture of the common choledoch duct in a boy of seventeen years, from a blow on the abdomen, followed by great pain and speedy death. Mr. BRYANT (*The Pract. of Surgery* p. 305) relates another case from Dr. Sutton's practice, in which a man survived a rupture of the hepatic duct thirty-eight days. CAMPAIGNAC (*Gazette Hebdomadaire*, 1823, T. II, p. 204) gives yet another example, a rupture of the left branch of the hepatic duct, near the lobule of Spiegelius, from the passage of a cart-wheel. The patient died from peritonitis on the eighteenth day. Another case is quoted in the *Lancet*, 1829, Vol. II, p. 452, from *Grafe and Walther's Journal*. CLARK (*Op. cit.*, p. 295) gives a complicated case. ELLIS (*Boston Med. and Surg. Jour.*, 1860, Vol. LXII, p. 22) reports a fatal case of rupture of the common duct, in a woman of 22 years, crushed by a sleigh. T. M. DRYSDALE (*Am. Jour. of Med. Sci.*, N. S., Vol. XLI, 1861, p. 399) records a case of rupture of the common duct of the liver, in a boy of 13 years; death on the fifty-third day.

<sup>3</sup>STANLEY (*Med. Chir. Trans.*, Vol. XXVII, p. 1) relates two cases; and POLAND (*Guy's Hosp. Rep.* for 1869) a third case. In all, the ureter was ruptured by stretching, and near the renal end. MORAGANI (*De Sed. et Causis*, Ep. LIV), VATER (in HALLER'S *Disp. Chir.*, T. IV, p. 5, *Diss. de Generat. Calc.*), HEUERMANN (*Abhandl. der vœrnehmst. Chirurg. Operationen*, Kopenhagen, 1778), and DESAULT have also recorded cases.

<sup>4</sup>COOPER (*London Lancet*, Dec. 31, 1839, Vol. I, p. 486) reports the case of J. C., aged 33 years, run over by a light cart moving with great speed. No marks of external injury were visible; but the lower left ribs were fractured, and "the pancreas was literally smashed, and embedded in semi-coagulated blood." The spleen and left kidney were also ruptured. He died a few hours after the accident. CLARK (*Op. cit.*, p. 298) says: "I have on record but one instance of laceration of the pancreas, which occurred in a lad, who was the subject of other severe injuries, that speedily proved fatal." DEVERGIE (*Méd. Légale*, 2ème éd., T. II, p. 94) cites a case, an unknown woman, crushed by a carriage on a road in Flanders.

*Ruptures of the Stomach.*—Some of the fatal cases of contusions by spent cannon shot, when the injury is stated to have been in the epigastric region and attended by vomiting of blood, were probably examples of rupture of the stomach; but no details of these cases were recorded.<sup>1</sup> Commonly, the shock or profound collapse that attends rupture of this organ is speedily fatal. If life is prolonged, there is pain radiating from the seat of injury, of indescribable acuteness and intensity. Hæmatemesis is a constant symptom. The extent of laceration and the degree of repletion of the organ at the time of rupture influence the result. It is believed, but not demonstrated, that a small laceration of an empty stomach may be followed by recovery.

*Ruptures of the Intestines.*—Five cases were reported; four were accompanied by the usual symptoms in such cases. These symptoms are described in Poland's paper<sup>2</sup> with his accustomed graphic accuracy and precision. In the third case the agonizing pain that commonly attends such injuries was absent, probably because of the absence of fecal extravasation. The lesion of the bowel is depicted in the print opposite page 23 (PLATE I), a photographic print by the Woodbury process. The perforation of the gut, and the infiltration of blood into its coats, are represented as perfectly as in the wet preparation, in the Museum.<sup>3</sup>

Sudden and excessive meteorism, produced by the escape of intestinal flatus into the peritoneal cavity, is, as has been remarked, regarded by Jobert<sup>4</sup> as the most characteristic sign of rupture of the intestines, and he gives, in support of his opinion, a case remarkable not only for the accuracy of the diagnosis, but as an illustration of the reparative efforts of nature in such accidents. The significance of sudden tympanitis is probably not exaggerated by Jobert; yet it is a sign by no means uniformly present in intestinal rupture.

CASE 117.—Private F. Landenslager, Co. H, 22d Veteran Reserve Corps, aged 23 years, received a kick in the abdomen, in an affray, on the night of September 30, 1864, at Albany, New York. There was no external ecchymosis; but the blow was followed by faintness, nervous depression, and, soon after, by excruciating abdominal pain and tenderness, with tympanitis, and vomiting. He died on October 2, 1864, from acute traumatic peritonitis with fecal extravasation. At the autopsy, two small perforations were found near the middle of the ileum, through which a part of the contents of the bowel had passed out into the cavity of the peritoneum. Assistant Surgeon M. F. Cogswell, U. S. V., reports the case.

CASE 118.—Teamster W. H. Wood was kicked in the umbilical region, by a mule, at Cape Girardeau, Missouri, September 22, 1864. He was conveyed to hospital, suffering intense pain, with collapse and vomiting. The abdomen was distended and exquisitely tender on pressure. Opiates and hot fomentations afforded but slight mitigation of the distressing symptoms, which terminated fatally, in about forty-eight hours, September 24, 1864. At the autopsy, the jejunum was found to be ruptured, and blood and fecal matter effused in the peritoneal cavity. The case is reported by Acting Assistant Surgeon W. A. Wilcox.

<sup>1</sup> Examples of rupture of the stomach have been collected by MORGAGNI (*Op. cit.*, Ep. LIV., Art. 15), BRESCHET (*Dict. des Sci. Méd.*, T. VIII, p. 150), and VELPEAU (*Dict. de Méd.*, T. I, p. 177). The cases of LIEFTAND, ANDRY, FORTAL, SANDEFORT, BOSQUES, and DUPUTREN have been often cited. HENRICI (*Ueber die Wunden des Magens*, Leipzig, 1864, S. 11, 68, 69) enumerates twenty-two ruptures of the stomach from various causes. STROMEYER (*Maximen u. s. w.*, S. 633) cites a case of abdominal contusion, at Idstedt, in which hæmatemesis recurred on the fourteenth day. At the autopsy a rupture of the stomach was found.

<sup>2</sup> POLAND, *A Collection of Several Cases of Contusions of the Abdomen, accompanied with Injury to the Stomach and Intestines*, in Guy's Hospital Reports, 1858, Third Series, Vol. IV, p. 123. He gives abstracts of sixty-four cases of ruptured stomach and bowels. Of fifty-six, in which the time of death is stated, ten were fatal in the first five hours; eighteen, in from five to twenty-four hours; nineteen, in from twenty-four to forty-eight hours; nine between the third and sixteenth days, during the period of reparative attempts.

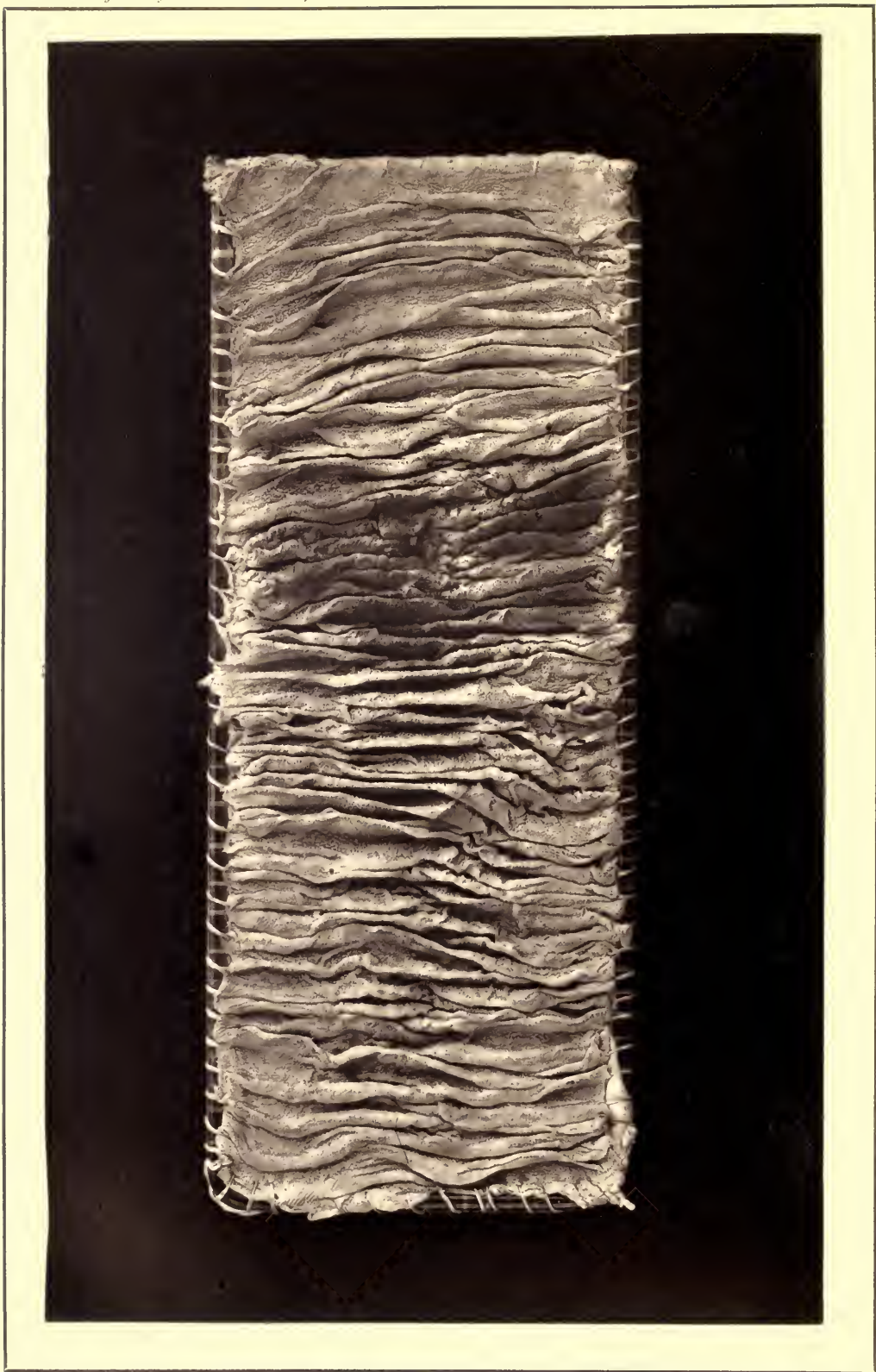
<sup>3</sup> The rupture was in the jejunum, which, from its fixed position, is more frequently torn than any other portion of the intestinal canal, especially by crushing weights. In fourteen examples adduced by POLAND, in half the laceration was at the upper part of the jejunum. All of these perished from collapse and peritonitis. For other instances, consult DRAKE (*Western Med. and Phys. Journal*, Vol. 1, p. 550); HART (*Dob. Hosp. Rep.*, Vol. V, p. 257); BARADUC (*Bull. de la Soc. Anat.*, T. XIII, p. 309). See TAYLOR (*Med. Jour.*, p. 321), WATSON (*On Homicide*, p. 159), and HENKE (*Zeitsch. der S. A.*, 1836, XXI) for interesting medico-legal cases. For pathological specimens compare Prep. 404 (*N. F. Hosp.*), 351 (*Pennsylvania Hosp.*), 485 (*Boston Soc. Med. Improv.*); Preps. 93, 110, 111, 112, at *St. George's Hosp.*, London; Prep. 1164, at Netley. The ileum is also frequently ruptured: FIDELL (*Am. Jour. Med. Sci.*, N. S., Vol. LIII, p. 351) records a fatal instance, in a man of 50 years, kicked by a woman with her bare foot; ANSAN (*Ibid.*, O. S., Vol. XXI, p. 530) gives a case fatal in sixteen hours, from the kick of a horse. For specimens, see Prep. 105, at *St. George's*, and 1165, 1166, at Netley. HEGGERS, according to MORGAGNI, recorded a case of rupture of the duodenum. COLLIER (*London Med. Gaz.*, 1858, Vol. XII, p. 766) records another example in a boy of 13 years, struck by a churn handle. The pathological specimen of a third case is Prep. 108 at *St. George's Hosp.* (*Cal.*, p. 431), from a man of 40 years, run over by a cab. SPEER (*Dob. Hosp. Rep.*, Vol. IV, p. 359) records a case of rupture of the cæcum. MOURINEAU (*Gaz. Méd.*, 1852, p. 788) gives an instance of rupture of the ascending colon. Pathological specimens of these lesions are desiderata.

<sup>4</sup> JOBERT (de Lamballe) *Traité théorique et pratique des Maladies chirurgicales du canal intestinal*, Paris, 1829, T. II.



LIBRARY  
UNIVERSITY OF  
CALIFORNIA.





*Am. Photo-Relief Printing Co.*

*1002 Arch St., Philadelphia.*

PLATE I. RUPTURE OF THE JEJUNUM BY THE KICK OF A HORSE.

No. 6188. SURGICAL SECTION.

CASE 119.—Frank R——, aged 11 years, a servant of Mr. Smoot, Ordnance Corps, was kicked by a horse in the lower umbilical region, while assisting a child to mount. On receiving the blow, he ran to the house and examined the injured part, and then walked a short distance to his mother's quarters, crying. He was put to bed, and was presently attended by Dr. J. S. Kennedy, who found him, half an hour after the reception of the injury, vomiting blood, complaining of great nausea, and great tenderness over the umbilical region, but of no acute pain. The pulse was accelerated and the heat of surface augmented. There was no abrasion or visible contusion of the surface. An anodyne was prescribed, and absolute rest in the easiest posture. At the Doctor's second visit, in the evening, the stomach was less irritable, but the abdominal tenderness was extreme, and extended to the hepatic region, and was attended with much pain, referred chiefly to the right hypochondrium. During the night, the febrile disturbance augmented; there was excessive restlessness and anxiety, with occasional retching. In the morning, Dr. Kennedy found the little patient almost moribund; a clammy sweat covered the surface; the pulse was rapid and thready; the patient was conscious and free from pain. He never rallied from this condition, and expired twenty-four hours after the reception of the injury. The remains were sent to Washington, where a *post-mortem* examination was made by Dr. J. F. Hartigan. Careful inspection could not reveal the slightest contusion or ecchymosis externally, nor extravasation in the abdominal muscles. About half a pint of clear serum was contained in the cavity of the abdomen; the peritoneum was agglutinated in various parts, and bands of lymph covered the intestines. About the middle of the jejunum there was found a small rupture of about half an inch, irregular in shape, surrounded with coagula. The other organs were healthy. The notes of the cases, and the specimen, No. 6188, represented in PLATE I, were contributed to the Museum by Dr. J. F. Hartigan.

CASE 120.—Private I. Bishop, 50th New York Engineers, was struck in the abdomen on June 4, 1864, at the battle of Cold Harbor, by a large fragment of shell. Collapse was immediate and intense, and reaction was slowly brought about by the administration of diffusible stimulants, the application of external warmth, with friction of the surface of the extremities. Surgeon C. N. Hewitt, 50th New York, reports that there was excessive tenderness, with meteorism, as soon as reaction was established. Opium was freely administered, and warm cataplasms were applied over the abdomen. The patient, suffering acutely, lingered for nearly forty-eight hours, and died on June 6, 1864. A large rent, with gangrenous edges, appeared in the jejunum. Fæces and a small amount of semi-fluid blood were found in the peritoneal cavity.

CASE 121.—Private J. Bence, Co. B, 98th Pennsylvania, was struck in the belly, at Hatcher's Run, March 25, 1865 by a spent cannon shot. There was no ecchymosis in the umbilical region where the missile struck; but the patient was prostrated, and there was much pain and anxiety. When admitted to the 2d division hospital of the Sixth Corps, Surgeon S. F. Chapin inferred, from the tension and tenderness of the abdomen, and bloody stools, that the small intestines were greatly contused or ruptured. Symptoms of traumatic peritonitis were more aggravated. Opiates did not control the pain or nausea. Symptoms of internal gangrene supervened, and the case terminated fatally on April 2, 1865. There is no record of an autopsy.

Ruptures of the membranous viscera are more fatal than wounds of the same part, or than wounds or ruptures of the solid organs. Larrey,<sup>1</sup> in his Memoir on the Austrian Campaign, describes several cases of abdominal contusion by shot, in which many of the viscera were injured, though, perhaps, none actually lacerated. Among the cases reported during the war, in which the character of the lesion cannot be precisely determined, were the following:

CASES 122-124.—1. Pt. T. Brown, Co. I, 5th Massachusetts, aged 44 years, contusion in hypogastrium, with injury of small intestines; Petersburg, March, 1865; died on April 24, 1865. 2. Pt. J. Rand, Co. C, 79th Ohio; shell contusion of the bowels; Kenesaw, June 26, 1864; died on August 21, 1864. 3. Pt. W. Bowditch, Co. B, 15th New York, aged 30 years; shell contusion of abdomen, with injury of viscera; Chupin's Farm, September 29, 1864; died on October 13, 1864.

Assistant Surgeon E. Bentley,<sup>2</sup> U. S. A., has reported, since the war, two cases of rupture of the intestines, with judicious remarks on their medico-legal relations.<sup>3</sup>

*Ruptures of the Omentum and Mesentery.*—In proof that such lacerations, unaccompanied by any outward marks of injury, sometimes cause death, Professor Gross (*System*, Vol. II, p. 679) adduces a case reported by Dr. Derner, of a huzzar, in whom a violent leap of his horse caused a rent in the omentum an inch and a half long, which led to the extravasation of five ounces of blood in the peritoneal cavity, and death the next morning. No parallel instance was reported during the war. But an interesting example of rupture

<sup>1</sup> LARREY, D. J., *Memoires de Chirurgie Militaire et Campagnes*, T. III, p. 334.

<sup>2</sup> BENTLEY, *Path. Deductions from Conditions found in the Study of Morbid Anatomy*, in Pacific Med. and Surg. Jour., 1872, Vol. VI, p. 127.

<sup>3</sup> Mr. THOMAS BRYANT (*A Practice of Surgery, a Manual*, London, 1872, p. 392) gives the following list of the preparations illustrating ruptures of the intestines, in the museum of Guy's Hospital: "In Guy's Museum there is a specimen (Prep. 1851<sup>85</sup>) of perforation of the small intestines of a man who had received a kick from a horse; he died thirteen days after the accident, with extensive peritonitis following fecal effusion. Prep. 1851<sup>86</sup> consists of a portion of jejunum, taken from a man who had been kicked in the abdomen; the injury was quickly followed by symptoms of extravasation, and death in forty-eight hours. Prep. 1850<sup>88</sup> was taken from a case of perforation of small intestine from the kick of a horse, terminating in death in twenty-four hours. No. 1851<sup>89</sup> is a portion of jejunum presenting two openings, in which the mucous membrane is inverted, following the blow from a kick in the abdomen. No. 1851<sup>90</sup> is an example of laceration of the jejunum; the bowel is seen to be completely divided; this was taken from a man æt. 37, who was run over by a cart, and lived twenty-four hours; and lastly, the specimen marked 1851<sup>91</sup> is from a case that occurred in the practice of my father, the late Mr. T. E. Bryant, of Kensington; it is a portion of ileum having a small perforation, produced by a blow in running against a post; a state of collapse came on, the patient did not rally, but died on the third day."



of the mesentery was communicated, which was followed by the intrusion and strangulation of the intestines in the abnormal aperture. The preparation from this case is No. 505 of the Medical Section of the Museum.<sup>1</sup> The following, if not a rupture, must have been a contusion of the mesentery, followed by abscess and, possibly, by fecal fistula:

CASE 125.—Private William Williams, Co. K, 9th Pennsylvania, received a shell contusion of the abdomen, three inches below the umbilicus, at Fredericksburg, December 13, 1862. He was carried to the field hospital, whence he was transferred, on the 23d, to Washington and admitted to Lincoln Hospital. Two days after admission, an abscess, which had formed at the point of injury, opened and discharged pus which was apparently mixed with fecal matter; this discharge continued from day to day, and the abdominal walls sloughed about the opening until it was three inches long by two inches wide. No inflammation of the bowels or peritoneum, except this abscess, appeared until January 11, 1863; nor was there swelling or meteorism, nor any prostration or disturbance of the system. The patient appeared to be free from the influence of shock; he suffered no pain, ate well what was allowed him, chiefly bread and milk, without nausea, and was able to get out of bed without assistance; pulse normal, bowels regular. On January 11th, he began to be restless, had some fever, much thirst, and considerable nausea; the bowels became swollen, inflamed, and painful. Fomentations and poultices were applied, and calomel and Dover's powders given without relief. The nausea increased, fecal matter apparently being constantly thrown up. The pulse was rapid, small, and easily compressed. He died on January 16, 1863. The autopsy was made nineteen hours after death. The lungs exhibited intense hypostatic congestion. On the left side posteriorly was a circumscribed pleuritis with a thick deposit of fibrinous lymph. Throughout the lung substance were numerous black spots averaging one line in diameter. The lungs weighed thirty-five and one-half ounces. The auricles of the heart were distended with black clots; a white fibrinous clot appeared in the right ventricle, attached by its base to the tricuspid valve. The left ventricle was empty and firmly contracted. The heart weighed nine and one-half ounces. The liver weighed fifty-seven ounces. Fibrinous lymph was found upon the peritoneal coating; it was irregularly mottled—blue and dark; its substance was decidedly hard. One fluid ounce of pale, yellow serum was found in the cavity of the pericardium. The spleen weighed five ounces, and was of a pale reddish color. Pus, in considerable quantity, was found in the peritoneal sac. The kidneys weighed five ounces. Upon opening the abdomen and raising the injured portion of its wall, dark yellow pus came through an opening opposite to the injury; there was thickening and injection of the intestinal walls, especially those of the large intestine. The lower part of the ileum had apparently lost both its mucous and muscular coats, and was contracted so as to resemble a cord. The mesentery was enormously thickened, its glands inflamed, and large collections of black fetid pus were found in it, which communicated with the sac of the peritoneum nearly opposite the opening through the mesentery and abdominal walls. Abscesses were found on the outside of the peritoneum in the left iliac region, which communicated with abscesses in the course of the lymphatic glands following the course of the great vessels. Peritonitis was found connecting the omentum by adhesions to the anterior wall of the abdomen. The subject was five feet eight inches high, and emaciated.

There are cases of intestinal obstruction following contusions of the abdomen, that are ascribed to injury covering the affected portion of the bowel,<sup>2</sup> as in the following instance, reported by Assistant Surgeon Warren Webster, U. S. A.:

CASE 126.—Private J. O. Wilson, Co. F, 1st Ohio Artillery, aged 30 years, was admitted into Douglas Hospital, having received on January 22, 1862, a kick from a horse in the right hypochondriac region. There was no abrasion of the skin, and but a slight redness of the part struck, with extreme tenderness, especially in the region of the liver. The patient was dull, listless, and at times unconscious; pulse full and slow, tongue furred, eyes suffused, skin hot and dry. Diaphoretics and purgatives were given. He remained in the same condition two days. No evacuation of the bowels having occurred, the purgative was repeated, which produced copious evacuations, and an amelioration of all the symptoms. He slowly improved, recovered, and returned to duty on August 20, 1862.

The safety of a resort to purgatives in such cases admits of question. It is more prudent to trust to rest and emollients.

*Ruptures of the Blood-vessels.*—If examples of lesions of the larger arteries or veins, without the parenchyma of viscera, were included among the fatal cases of abdominal contusions without external wounds, they were not specified with sufficient precision to be recognized. A few such examples are found in the annals of surgery. M. Legouest's observation of a rupture of the aorta has been noted (p. 15). Velpeau<sup>3</sup> refers to three cases of rupture of the ascending cava. Professor Gross<sup>4</sup> cites a fatal instance of laceration of the splenic vein, recorded by Dr. Miling.

<sup>1</sup> WOODWARD, *Catalogue of the Medical Section of the United States Army Medical Museum*, 4to, Washington, 1867, p. 50.

<sup>2</sup> ASHURST, *The Principles and Practice of Surgery*, Philadelphia, 1871, p. 366.

<sup>3</sup> VELPEAU, *Dict. de Méd.*, T. 1; one by GRUAF, in *Eph. Nat. Cur.*, Dec. III, An. 2, p. 86; another by BRESCHET, (*Dict. des Sci. Méd.*, T. VIII, p. 137); a third by RICHERAND (*Nosographie et Thérap. Chir.*, T. IV). VELPEAU makes one of his rare errors in stating that ruptures of the blood-vessels are observed only in cases of crushing and not as the result of blows. BOURGUIGNON cites another case of rupture of the vena cava (*Bull. de la Soc. Anat.*, T. XIII, p. 507). A specimen of rupture of the vena cava by a blow is preserved in Guy's Hospital Museum, No. 152173, *Catalogue* l. p. 91.

<sup>4</sup> GROSS, *A System of Surgery*, 5th ed., Vol. II, p. 687.

There is an interesting preparation in the Museum of an aneurism of the superior mesenteric artery,<sup>1</sup> in which the lesion of the inner and middle coats of the vessel may have been due to violence, as there is no visible atheromatous alteration. The tumor represented in the wood-cut (FIG. 9) is of the size of a small orange. It was recognized by its position and pulsation during the life of the patient, who died of another disease; but the antecedent history is, unfortunately, unrecorded.

*Ruptures of the Diaphragm.*—No well-defined example of this lesion was reported, though, from the descriptions of some of the cases of crushing of the upper part of the abdomen by carriages, the probability of its existence might be surmised. There were also imperfect accounts of anomalous spasmodic affections following blows on the epigastrium, and referred to the diaphragm, that seemed analogous to the phenomena described by Generalarzt Stromeyer, on page 629 of his *Maximen*. Wounds of the diaphragm, as will be seen in the next section, were not uncommon. A preparation of strangulated phrenic hernia, in which the stomach and part of the great omentum have intruded into the thoracic cavity through the œsophageal opening, is preserved in the Museum.<sup>2</sup>

It must be regretted that the facts concerning the majority of the instances of this small and obscure group of injuries of the abdominal organs without external wounds, were so imperfectly recorded. It is one of the disadvantages of collecting data on official forms, that the particulars of rare and anomalous cases are often omitted, while the details of familiar injuries and operations are related with laudable, yet fatiguing minuteness. Lists are appended of the severe and sometimes fatal shot contusions of the abdomen that were barely noted on the reports during the war, and these, with the brief memoranda on the preceding pages, may revive the recollections of surgeons in regard to some of these doubtful cases, and enable them to contribute toward perfecting the history of injuries of this group.

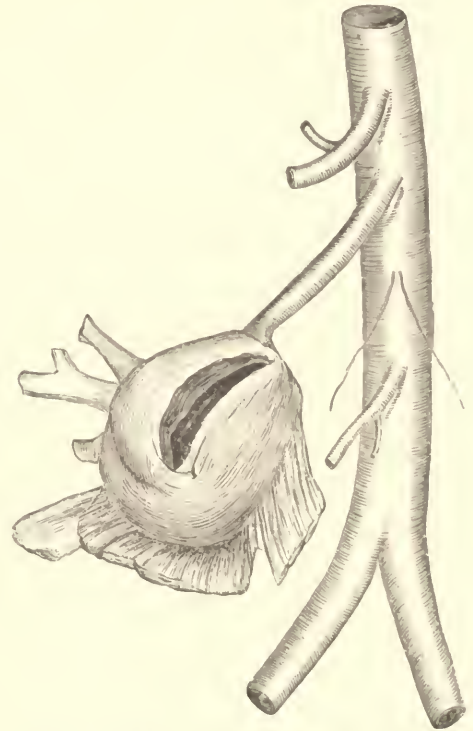


FIG. 9.—Aneurism of the superior mesenteric artery. *Sp. c.* 503, Sect. II. A. M. M.

CASES 127-138.—The following were returned as examples of "shell contusions of the abdomen, with internal injury." They recovered from symptoms of more or less gravity, and were sent to duty at periods varying from a few weeks to several months. Their names do not appear on the Pension List: 1. Pt. D. Conklin, Co. G, 29th Connecticut, aged 21 years; Chapin's Bluff, September 29, 1864; duty, December 2, 1864. 2. Pt. J. N. Burk, Co. G, 14th New York Heavy Artillery; Petersburg, July 30, 1864; duty, January 23, 1865. 3. Pt. J. Bolls, Co. D, 19th Illinois, Murfreesboro', December 29, 1862, "contusion of bowels from piece of shell; hæmorrhage from bowels; peritonitis;" duty, March 15, 1863. 4. Pt. J. C. Reamer, Co. F, 7th Wisconsin, aged 24 years, "shot contusion of abdomen, injuring stomach; much inflammation;" Gettysburg, July 3, 1863; duty, August 3, 1863. 5. Pt. J. Miller, Co. C, 1st Maryland, aged 22 years; Petersburg, June 18, 1864; duty, October 25, 1864. 6. Assistant Surgeon J. Gardner, 21th Kentucky, "shot contusion over spleen;" Atlanta, August 6; duty, September 6, 1864. 7. Pt. J. Thompson, Co. G, 148th Pennsylvania, aged 19 years; Gettysburg, July 3; duty, August 11, 1863. 8. Capt. J. H. Lyons, Co.

<sup>1</sup> *Catalogue of the Medical Section*, Chap. II, Sec. 2, No. 503, p. 22. The specimen was contributed by Surgeon M. Goldsmith, U. S. V. No. 2, of the *Muscle Dupuytren*, is an aneurism of the inferior mesenteric (BISCH, *Des Anévrismes et de leur Traitement*, Paris, 1856, p. 44); and Mr. CRISP (*A Treatise on the Structure, Diseases, and Injuries of the Blood-vessels*, 1857, p. 113) found two aneurisms of the mesentery, whether superior or inferior is not stated, among three hundred and sixty-four preparations of aneurism in the London Museum. From the catalogues I find that Preparations 114 and 219, at St. George's, and 1304<sup>2</sup> at Guy's, are specimens of aneurisms of the superior mesenteric artery, from disease.

<sup>2</sup> *Catalogue of the Medical Section*, Chap. IV, Sec. 3, No. 522, p. 50. Case of Sergeant L. McB., 11th Veteran Reserves.



A, 57th Pennsylvania, aged 36 years; Spottsylvania, May 12; duty, May 24, 1864. 9. Pt. J. Wood, Co. D, 5th U. S. Colored Troops, aged 22 years; Chapin's Farm, September 30, 1864; duty November 2, 1864. 10. Surgeon J. M. Rice, 25th Massachusetts, aged 34 years; Roanoke Island, February 7, 1862; duty, February 21, 1862. 11. Pt. T. Tull, Co. A, 15th West Virginia, aged 41 years; Snicker's Gap, July 18, 1861; contusion ascribed to "wind of shell in epigastrium, grave symptoms of internal injury;" reported by Surgeon Jernyngham Boone, 1st Maryland P H B.; duty September 8, 1864. 12. Pt. H. Kimball, Co. H, 6th Pennsylvania; Fredericksburg, December 13, 1862; duty December 24, 1862.

CASES 139-145.—The following, reported as injured by shot contusions of the abdomen "with injury of the internal organs," recovered, with various degrees of disability, for which they were discharged from service: 1. Pt. B. Shoop, Co. I, 1st Michigan, "contusion of liver;" Fredericksburg, December 13th; discharged December 23, 1862; not a pensioner. 2. Corp. W. F. Smith, Co. H, 26th Illinois, "contusion in epigastrium by solid spent cannon shot;" Farmington, Mississippi, May 9, 1862; discharged October 2, 1862. 3. Corp. E. Ivers, Co. E, 81st Pennsylvania, aged 36 years; Petersburg, March 31, 1865; discharged July 10, 1865. 4. Pt. T. Riley, Co. H, 143d Pennsylvania, aged 23 years; Spottsylvania, May 10th; discharged October 4, 1864. 5. Sergeant D. Payborne, Co. C, 77th New York; Wilderness, May 6th; discharged November 30, 1864. 6. Pt. A. Hendrickson, Co. D, 29th Ohio; Chancellorsville, May 3d; discharged September 16, 1863. 7. Pt. H. Thomas, Co. K, 6th Connecticut, aged 34 years; North Anna River, May 25, 1864; discharged September 23, 1864.

The following were among the instances of fatal contusions of the abdomen, reported without precise specification of the nature of the internal lesions:

CASES 146-149.—1. Reported by Surgeon S. Marks, 10th Wisconsin; Sergeant H. E. Price, Co. D, 104th Illinois, Peach Tree Creek, July 20, 1864; contusion of abdomen by cannon ball; death the same day. 2. Reported by Surgeon H. B. Fowler, 12th New Hampshire; Pt. J. E. Reese, Co. C, 10th New York Artillery, Petersburg, April 2, 1865; shell contusion of right side of abdomen; died April 3, 1865. 3. Reported by Surgeon W. O. Macdonald, U. S. V.; Pt. A. D. Snook, F, 205th Pennsylvania, Petersburg, April 2, 1865; shell contusion in flank, tympanitis; terrible shock; died April 3, 1865. 4. Reported by Surgeon M. M. Manly, 2d U. S. Colored Cavalry; Pt. G. Nixon, Co. H, 2d U. S. Colored Cavalry, Petersburg, July 5, 1864; shell contusion on right umbilical region, great tension and pain in abdomen; great shock; died the same day. There are many other fatal cases reported as "shell contusions of the abdomen," in which the absence of external lesions is not especially noted.

TABLE III.

*Return of Visceral Injuries without External Wounds, reported during the War.*

RUPTURES	Cases.						RESULT.	
		Liver.	Spleen.	Kidney.	Intestines.	Viscera undetermined.	Recovery.	Fatal.
From shot.....	41	1	1	3	5	31	21	20
From other violence .....	11	4	2	1	4	.....	1	10
Total.....	52	5	3	4	9	31	22	30

The most careful records of the attendant circumstances would probably not have afforded elements for the solution of the problems presented in this group of cases. It would still be difficult to trace the relations between the symptoms and the apparent alterations of texture, with any uniformity. The cases that have been adduced sufficiently exemplify the complexity of the lesions and the ambiguity of the symptoms to be considered in framing a diagnosis in injuries of this group. There may be profound and persistent shock, unattended by organic injury; acute local pain or general tenderness are not conclusive proof of the existence or otherwise of visceral lesion; tympanitis and constipation cannot be accepted as evidence of textural alteration, for they may depend on concussion of the ganglionic centres; vomiting and retention of urine are common in abdominal contusions without reference to the parts struck; hæmorrhage rarely occurs except from a ruptured viscus, yet, when intra-peritoneal, the syncope it induces is with difficulty distinguished from shock in the early stage, and, when discharged from the digestive or urinary canals, it is not necessarily indicative of fatal injury.

But if the diagnosis and prognosis are doubtful, the treatment of these cases is comparatively plain. Absolute rest, the patient not being moved or allowed to move

himself, caution in the employment of restoratives and stimulants, warmth to the surface, evacuation of the bladder with a catheter if requisite, and the administration of opium, if there be much pain, are the safe expectant measures that constitute the early treatment applicable to nearly all cases. The complications must be met as they arise. Tight bandages, ice poultices,<sup>1</sup> with internal hæmostatic remedies, or general and local depletion during the hæmorrhagic period, have been employed. The utility of leeches over the seat of pain, and of subsequent counter-irritation by blisters, has been strongly advocated. In ruptures of the stomach,<sup>2</sup> as the rule prohibiting food or drink or medication by the mouth is absolute, opium has commonly been administered by enema. Assistant Surgeon E. Bentley, U. S. A., has called attention to the utility and convenience of the hypodermic introduction of morphia, under such circumstances. In ruptures of any portion of the digestive tube, the premature administration of food or drink, or purgative medicine, is extremely hazardous. For several days the patient must be literally, and, for a fortnight, nearly starved. Only toward the close of this period is it safe to venture upon aperients, and then only in the shape of the mildest laxative enemata. After the first few days, as much of iced milk by the mouth, and of beef-tea enemata, as may be requisite to sustain life, may be cautiously administered. A review of the records of the treatment of this class of cases suggests this repetition (which may appear superfluous to most readers) of well-known rules. Watchfulness of the state of the bladder, is another golden rule applicable to all of these cases. Some operative expedients, recommended for promoting the elimination of effusions of bile, urine, fæces, blood, and pus, or in the treatment of fistulous outlets resulting from such extravasations, will be more conveniently considered in connection with wounds of the several viscera.

But little information has been acquired relative to the morbid alterations of texture that result from contusions producing visceral injury short of actual laceration. Preparation 363, of the Medical Series of the Museum, exhibits a portion of the "greater curvature of stomach, thickened with conspicuous rugæ, and coated with pseudo-membrane," from an artilleryman, who received, at Beaufort, an injury from the limber of a gun, in

<sup>1</sup> The value of this therapeutical resource is, perhaps, inadequately appreciated. VIDAL (*Traité de Path. Ext.*, T. V, p. 83) regards it as, with the exception of phlebotomy, almost the sole available effective means at our disposition, in the parenchymatous bleedings from ruptures of the abdominal viscera. Professor GROSS (*System. l. c.*, Vol. II, p. 661) emphatically commends the application of ice under such circumstances. Mr. BRYANT (*Præctice*, already cited, p. 403, *note*) adds his favorable estimate of the utility of ice poultices, and gives the following directions for making them: "Ice poultices, as suggested by Maisonneuve, appear excellent things for the local application of cold; they are made as follows: Take of linsed meal a sufficient quantity to form a layer from three-quarters to an inch thick, spread on a cloth of proper size; upon this, at intervals of an inch or more, place lumps of ice of convenient size—of a big marble—then sprinkle them over lightly with the meal, cover with another cloth, folding in the edges to prevent the escape of the mass, and apply the thick side to the surface or wound. The exclusion of air retards the melting of the ice, and the thick layer intervening between it and the surface prevents painful or injurious contact; for injuries to the abdomen this expedient seems very applicable."

<sup>2</sup> After the remarks on ruptures of the stomach on page 22, I inadvertently omitted the following reference to recent American cases, and to the rarity of pathological preparations of this lesion, a memorandum which may be of interest to pathologists. The following cases are reported in American periodicals: WEIR, *American Medical Times*, 1860, Vol. I, p. 45; Rupture of stomach, in a boy of 14 years, by striking a clothes-line in falling from a housetop, death in eleven hours; no other viscera injured. COLLINS, *Boston Medical and Surgical Journal*, 866, Vol. LXXIII, p. 202; rupture of the stomach, by a fall from a tree, in a lad of 13 years; death in less than nine hours. BUST, *Amer. Journal of Medical Sciences*, 1870, Vol. LX, N. S., p. 575; rupture of the stomach from a fall; I know of no specimen of rupture of the stomach, preserved as a pathological preparation, except No. 1817<sup>26</sup> at Guy's Hospital Museum (*Cat.*, Vol. II, p. 27). In the *Medico-Chirurgical Transactions*, Vol. V, p. 93, Vol. V, p. 574, Vol. VIII, p. 228, Vol. XIII, p. 226, Vol. XIV, p. 247, and Vol. XXI, p. 11, will be found some very interesting papers by MURCHISON, CRAMPTON, CHEVALIER, WHEELWRIGHT, TRAVERS, ELLIOTSON, and WEEKES, on ruptures of the stomach, with many references to analogous cases. In the proceedings of the Pathological Society of London, reported in the *British Medical Journal*, December 3, 1870, Vol. II, p. 617, "Mr. Davy exhibited the Ruptured Stomach of a Dog, which had been run over in the streets. There was no external injury, yet the stomach was traversed by a large rent. Mr. Arnott had no idea that these cases were rare or he would have brought some before the Society. In one case, a little boy fell from a ladder; there was no external mark, yet there was a large rupture of the stomach. At University College Hospital, a man came complaining of colicky pains. He had already been supplied with diarrhoea medicine; while there he was taken very ill and speedily died. The day before he had had a fall and hurt his side, but he walked home and partook of a meal as well as of the physic. There was a large rent in the wall of his stomach, and its contents were lying in the peritoneal cavity. Dr. Murchison had seen as many as three in one day, the result of a railway accident, the passengers' stomachs being full. Mr. Hulke had seen a case where the stomach formed part of the contents of an umbilical hernia, and in forcible attempts at reduction, a rent four or five inches long, was made in its wall. Dr. Moxon had seen the stomach of a boy, run over by a carriage, where the vertebral column seemed to have cut the stomach like a knife."

the autumn of 1863, and suffered afterward from pain in the epigastric region, and nausea and vomiting, and died from chronic diarrhœa in the summer of 1864. Larrey, in his *Memoirs and Clinique*, gives a number of detached observations of adhesions, indurations, and various exudations, consequent upon visceral contusions. Dr C. Handfield Jones (*Med. Chir. Trans.*, Second Ser., 1855, Vol XXXVIII, p. 213) adds to the scanty data respecting the morbid anatomy of the pancreas injured by violence, an instance of wasting of this viscus, in a man of twenty-four years, who survived, for three and a half days, a fall of forty feet.

It has been stated, at the beginning of this section, that no case was reported of sudden death ascribed to a blow upon the abdomen, without attendant organic lesion. Current opinion is adverse to this statement, and opposite assertions have been made.<sup>1</sup> On reviewing the evidence, I find no facts to justify a modification of the statement.

There have not been wanting reports of alleged traumatic effects from the wind of balls.<sup>2</sup> But since experience, fully in accord with theory, has shown that the air displaced by large projectiles undergoes no chemical or physical modification, and that its displacement cannot exert any deleterious effect upon the tissues, and this has been latterly demonstrated experimentally,<sup>3</sup> such reports<sup>4</sup> do not appear to merit serious consideration.<sup>5</sup>

<sup>1</sup> Dr. F. H. HAMILTON (*A Treatise on Military Surgery*, 1865, p. 322) asserts that "A large shot, whose momentum is nearly expended, may cause instant death as it falls, or obliquely impinges upon, or rolls over the surface of the belly. We have already mentioned, in our general remarks, an example of this kind which came under our observation. In such cases death is the result of the shock, and it is not necessarily accompanied with any lesion of the viscera." Turning to the general remarks referred to, on p. 192 of the work cited, there is found, first, a purely hypothetical case; next, the case of Private Booth, of whom it is stated "Precisely where he was hit we had no means of knowing;" and next, two cases of injury of the head. Surely neither one of these is "an example of the kind" under consideration. Yet the author reiterates his allegation in his *Principles and Practice of Surgery*, 1872, p. 101.

<sup>2</sup> Surgeon B. RHETT, of the Marine Hospital at Charleston, regards (*Cases of Injury to the Nervous System by the Explosion of Shell*, in *Am. Jour. Med. Sci.*, N. S., 1873, Vol. LXV, p. 92) "the capability of compressed air or wind from a missile to bruise or inflict visible injury" is still a "mooted point." He adduces the case of a Confederate soldier, on St. John's Island, "with a purple, yellow, and green bruise extending from the mamma to the ilium of right side, and from the umbilicus to the dorsum," who was "standing, with his rifle held by the barrel at arm's length and the butt resting on the ground, when a large shot or shell passed between himself and his rifle without touching either or moving him from his position. Immediately after he observed the discoloration he was sent to the hospital for fear of internal injury." Dr. Rhett adds, justly: "The case rests upon my evidence of the injury and upon the soldier's account of the cause!"

<sup>3</sup> By Professor PELIKAN's experiments, detailed in the *Comptes rendus des Séances de l'Académie des Sciences*. Compare LEGOUËZ, *op. cit.*, p. 110.

<sup>4</sup> Surgeon GEORGE BERR, U. S. V., has published (*The New York Medical Journal*, 1865, Vol. I, p. 428) observations on *Cases of Injuries of the Nervous Centres from Explosion of Shells, without Wound or Contusion*, "under the impression that they will constitute an additional variety in the list of injuries to the nervous system." He narrates, apparently without any ironical intention, phenomena which almost every military surgeon has had occasion to observe in persons who, during a cannonade, though unhurt, were badly frightened.

<sup>5</sup> In addition to the references to sources of information respecting ruptures of the several abdominal viscera, that have been given, the reader may advantageously consult the chapter on ruptures or wounds of internal organs, in *A Manual of Medical Jurisprudence for India*, by NORMAN CHEEVERS, M. D., Calcutta, 1870. In a country where malarial poison is almost universally prevalent, ruptures of the liver and spleen from comparatively slight violence are not uncommon, and numerous instances are here recorded. Seventeen new examples of ruptures of abdominal viscera are collected in an original article in the *Brit. and For. Med. Chir. Rev.* for 1867, Vol. XXXIX, p. 186, by Dr. F. OGSTON, of Aberdeen University. Case 16 of this series, describes a rupture of the cystic duct. Dr. LIDELL's important dissertation on rupture of the abdominal and pelvic viscera (*Am. Jour. Med. Sci.*, N. S., Vol. LIII, p. 340) will again claim attention in connection with injuries of the bladder. Dr. J. Q. A. HUBSON, in a paper on *Injuries and Wounds of the Abdomen*, read before the Meigs and Mason Academy of Medicine, November, 1871, analyzes recent observations on the subject, without adding to them. Dr. F. D. LEXIE records (*New York Jour. of Med.*, 1850, N. S., Vol. V, p. 27) a rupture of the jejunum, with some interesting features. Assistant Surgeon SEWARD (*Trans. Med. and Phys. Soc. of Bombay*, 1857-8) reports a careful autopsy in a case of rupture of the jejunum by a blow. Mr. RIVINGTON (*Lancet*, 1872, Vol. II, p. 848) relates a case of ruptured jejunum, in a brewer falling into a vat, remarkable for the absence of early severe symptoms. Dr. BURNET, of Newark (*Phila. Med. and Surg. Reporter*, 1869, Vol. XXI, p. 289), relates a case of rupture of the liver and kidney from a blow; no jaundice, no hæmaturia, no marks of violence; collapse, with syncope, and great pain in the right hypochondrium, the only marked symptoms; death in twenty-seven hours, when it was found that there had been profuse bleeding into the peritoneal cavity. Dr. FINSELL, in the reports of the New York Pathological Society (*Phila. Med. and Surg. Jour.*, 1856, Vol. IX, pp. 420-587), records two cases of rupture of the ileum. Dr. HESTER (*New Orleans Med. and Surg. Jour.*, 1852, Vol. IV, p. 278) describes the autopsy in a case of rupture of the spleen, remarkable as resulting in an abscess, which discharged through a perforation of the stomach. A fatal case of laceration of the gall-bladder, by a fall, is noted by JOHN BELL, in his *Discourses*, and also in his *Principles of Surgery*, new ed., 1826, Vol. I, p. 520. In the *Lancet*, *Medical Gazette*, and *Med. Times and Gazette*, the following instances of visceral ruptures, without external wounds, may be found: Of the liver, from falls, four cases, in *Lancet*, 1828-9, Vol. II, p. 725; *Med. Gaz.*, 1829, Vol. III, p. 191; *Ibid.*, 1844, Vol. II, p. 115; *Med. T. and Gaz.*, 1866, Vol. I, p. 522. From passage of carriage-wheels, eight cases: *Med. Gaz.*, 1830, Vol. V, p. 127; *Ibid.*, 1845, Vol. XXXV, p. 879; *Med. T. and Gaz.*, 1851, N. S., Vol. III, p. 234; *Ibid.*, 1852, Vol. IV, p. 120; *Ibid.*, 1853, Vol. X, p. 19; *Ibid.*, 1857, Vol. XV, p. 254; *Ibid.*, 1864, Vol. II, p. 553; *Ibid.*, 1866, Vol. II, p. 253. From blows, four cases: *Lancet*, 1833-4, Vol. II, p. 562; *Ibid.*, 1844, Vol. II, p. 115; *Med. T. and Gaz.*, 1866, Vol. I, p. 8; *Ibid.*, 1868, Vol. I, p. 393. Of ruptures of the spleen, eleven cases: *Med. Gaz.*, 1829, Vol. III, p. 591; *Med. T. and Gaz.*, 1861, Vol. II, p. 435; *Ibid.*, 1862, Vol. I, p. 31; *Ibid.*, 1865, Vol. II, p. 35; *Ibid.*, 1866, Vol. I, p. 350; *Ibid.*, 1866, Vol. II, p. 253; *Ibid.*, 1867, Vol. I, p. 722; *Lancet*, 1826-7, Vol. I, p. 581; *Ibid.*, 1857, Vol. II, p. 456; *Ibid.*, 1861, Vol. I, p. 287; and a case of recovery, recorded by Dr. HYDE SALTER, *Ibid.*, 1857, Vol. II, p. 413. See also cases by Drs. WILSON and PLAYFAIR, *Edin. Med. Jour.*, 1857, Vol. II, pp. 851, 858, and 958. Of ruptures of the kidney, eleven cases, including two recoveries: *Med. Gaz.*, 1831, Vol. VII, p. 828; *Med. T. and Gaz.*, 1858, N. S., Vol. XVI, p. 63; *Ibid.*, 1860, Vol. I, p. 76; *Ibid.*, 1866, Vol. II, p. 253; *Ibid.*, 1867, Vol. I, p. 722; *Lancet*, 1866-7, Vol. I, p. 588; *Ibid.*, 1845, Vol. II, p. 685; *Ibid.*, 1851, Vol. I, p. 600; and two recoveries, *Lancet*, 1845, Vol. II, p. 684; *Ibid.*, 1848, Vol. I, p. 685.



## SECTION III.

## PENETRATING WOUNDS OF THE ABDOMEN.

In examining the injuries of the head and chest that came under surgical treatment, the lesions of the soft parts were found to largely predominate numerically over the penetrating wounds; the cranial cavity being protected by its bony case, and the thoracic cavity, partially protected by its bony and cartilaginous walls, being further defended by the upper extremities, the breastplate, belts, buttons, shoulder-scales, often by the musket, and occasionally by books, watches, or other articles carried in the breast pocket. In injuries of the abdomen, however, the number of penetrating wounds that came under treatment equalled, if it did not exceed, the number of wounds involving the walls only: for the abdominal cavity, though protected by the vertebral column behind, and partially by the lower ribs, and the broad wings of the innominata, is covered only by the soft parts on its anterior and lateral aspects. The belly is less defended than the chest by the upper extremities; yet, in some positions, the course of weapons or projectiles directed toward the abdomen is arrested or deflected by the forearms or hands, or by what may be held in them. The belly is also less protected than the upper part of the trunk by the accoutrements: the waist-belt and belt-plate, the cartridge-box and canteen, leaving a comparatively large surface exposed. Of the relative frequency of wounds of this region, some statistical information will be offered at the close of this chapter, together with estimates of the resulting mortality. In treating of wounds of the chest, facts were adduced to prove that their gravity was commonly appreciated inadequately. Such an argument will be unnecessary in regard to wounds of the belly, for the deplorable fatality of this class of injuries commonly furnishes the subject for the first comment made on them by systematic authors. It is said that Mr. Abernethy used quaintly to remark, that Nature would have nothing to do with these cases; but stood by and shook her head, and left the patient to his hopeless fate. But the true lovers of Nature, among whom, it is to be hoped, all good surgeons are numbered, cannot permit any aspersion of their mistress, and will point to many beautiful exemplifications of her almost divine power, even in wounds of the abdomen, in the prevention of extravasation and in the repair of injuries, by the effusion of lymph, in eliminating foreign bodies by artificial outlets, and in the process of hæmostasis. It is but too true, however, that these examples are the rare exceptions,<sup>1</sup> and that, in imitating them or in aiding them, art can do but little.<sup>2</sup> Apparently a large

<sup>1</sup> JOHN BELL (*The Principles of Surgery*, London, 1826, Charles Bell's ed., Vol. 1, p. 480) observes: "Thence it comes to pass, that in one short sentence we announce the general principles of such wounds,—in one short and general prognostic we declare them to be fatal; we thus bestow but a few moments on their general character, while we spend hours in marking their lesser varieties, and in recording all the accidents and chance cures, collecting evidence about hair-breadth escapes, till we almost lose sight of the general principle which proves such wounds to be mortal. This confusion must be peculiarly felt by a diligent student, who, the more he reads, the more he wonders, finds amuses at the groin, and miraculous recoveries in every book, and runs of cures, till he forgets that there are dangers."

<sup>2</sup> Notwithstanding the most diligent and intelligent endeavors; for the operations devised by PHYSICK, DU PUYTREN, and Professor GROSS for the relief of artificial anus, and the investigations concerning enterography by TRAVERS JOBERT, and Dr. GROSS, if not of frequent successful applicability are at least conceived in the true philosophic spirit of the inductive method: "Non est fingendum, nec excogitandum, sed invenendum quid Nature faciat aut ferat."—BACON, *De dignitate et augmentis Scientiarum*.



number of recoveries are recorded in this section; yet, relatively, the number is small, even in comparison with the fatal cases that appear on the hospital records, and insignificant, when this category is augmented by the multitude of deaths on the field.<sup>1</sup> Many of the recoveries will be found, too, to be cases in which the peritoneal cavity was not, in reality, implicated, for there are considerable portions of the liver, spleen, kidneys, and colon, over which the serous investment is wanting.

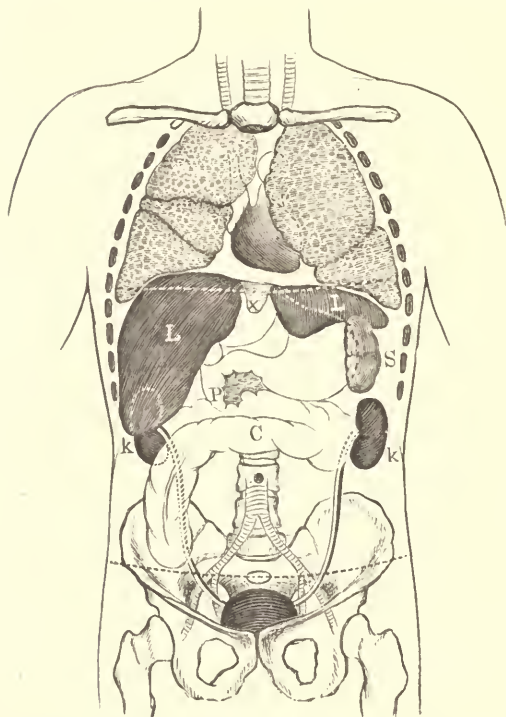


FIG. 10.—Diagram of some of the relations of the abdominal viscera. *L L*—Space occupied by liver in different positions and movements of diaphragm. *X*—Xiphoid Cartilage. *C*—Colon. *K K*—Kidneys. *P*—Pancreas. *S*—Spleen. [After Bryant.]

Of the obscurities of diagnosis, there will be abundant illustration in treating of special wounds. The surgeon, in estimating the probabilities, mentally recalls the position of the several viscera. A diagram (FIG. 10) may refresh the memory on these points.<sup>2</sup> Since the war, outline figures have been furnished to medical officers, on which to map out areas of dulness on percussion, or to indicate entrance and exit wounds, and have proved advantageous in securing precision and in economizing description.

Wounds penetrating the abdominal cavity are separated, as elsewhere, into the groups of punctured, incised, lacerated, and contused wounds, and these varieties are further divided, by classical writers, into four subdivisions, viz: 1. Simple penetration of the peritoneal cavity, without injury or protrusion of the viscera. 2. Those with protrusion of the uninjured viscera. 3. Those with injury of the viscera without protrusion. 4. Those with protrusion of the wounded viscera. A large proportion of the shot wounds, with which we are mainly concerned, are comprised in

the third subdivision. The few examples of cases belonging to the first two groups may be considered together; those comprised in the two latter, will be arranged under the heads of the different viscera that may be involved, and, when several viscera are implicated, will be grouped with that viscus of which the wounds are either the rarest or the most dangerous.

Some recent observations<sup>3</sup> indicate that, in the shock attendant on wounds of the belly that are soon to terminate fatally, there is a great and constant diminution in the animal temperature, as considerable as that which, when occurring in the course of some internal diseases, uniformly presages dissolution. Should these observations be corroborated and confirmed, the thermometric test will afford a more accurate basis for prognosis than any we now possess.

<sup>1</sup> Of the mortality of shot wounds of the abdomen as observed in the British Army in the Crimea. Dr. MATTHEW remarked: "where penetration of the abdominal cavity by gunshot injury was considered to be beyond doubt, death was the rule—recovery the rare exception, only nine patients (including both men and officers) having survived, out of one hundred and twenty, where this was believed to have taken place, and even of this small number some of the cases were not quite unequivocal."—*Op. cit.*, Vol. II, p. 328.

<sup>2</sup> The obvious inaccuracies in the diagram, which is altered from one given by Mr. THOMAS BRYANT (*Practice*, already cited, p. 308), are due to my failure to convey to the draughtsman a clear understanding of the alterations designed, and the want of time to prepare another cut.

<sup>3</sup> Consult DEMARQUAY'S paper *de la Chaleur animale dans les Maladies chirurgicales*, in the *Nouveau Dictionnaire de Médecine et de Chirurgie pratiques*, 1867, T. VI, p. 822, and Mr. CLARK'S comments thereon in his *Lectures (l. c., p. 288)*. The latter author has a chapter on the subject in his *Outlines of Surgery and Surgical Pathology*, London, Churchill, 1872, which I have not yet seen.

*Simple Penetrations and Perforations without Injury of the Viscera.*—Malgaigne<sup>1</sup> denied the existence of this group of injuries, maintaining that the repletion of the abdominal cavity by the contained organs precluded the possibility of the intrusion of a foreign body without the infliction of some visceral lesion. This theoretical objection suggests the belief that such injuries are at least less frequent than is asserted by some writers. The cases of recovery, after penetrating wounds of the cavity, are not conclusive evidence of the absence of visceral lesions; for it is demonstrable that many punctures of the epiploon or of the intestines are followed by recovery. But autopsies and experiments on the cadaver establish, beyond doubt, the possibility of deep penetration, or even of transfixion of the abdominal cavity without visceral lesion, the foreign body gliding between the smooth and movable organs.

Guthrie justly observes<sup>2</sup> that it is easy to conceive of a blunt instrument, like the small end of a ramrod, being passed between the loose viscera of the abdomen without wounding any of them, but more difficult to understand how pointed weapons or ball should do so. Yet such exceptional cases are occasionally observed. Surgeon B. A. Clements, U. S. A., has recorded<sup>3</sup> a case of bayonet wound through the abdomen in which the viscera apparently escaped injury, though frequent micturition and highly colored urine caused anxiety lest there might be lesion of the kidney. After a slight peritonitis, the man rapidly recovered. Surgeon B. J. D. Irwin, U. S. A., has related<sup>4</sup> a still more remarkable example of a bayonet transfixion through the abdomen, without serious symptoms or results.

Nine instances of bayonet wounds penetrating the peritoneal cavity without lesion of the viscera appear in the reports of the war. All but two were attended by traumatic peritonitis; but six had a favorable termination. If the diagnoses were exact in all of these cases, the proportion of recoveries would be less surprising than the number of deaths. If the wounds were really simple, unattended by visceral lesion, they should heal almost as readily as the punctures by a trocar in ascites.<sup>5</sup>

CASE 150.—Private E. Flynn, Co. F, 61st Illinois, was admitted into the Post Hospital at St. Louis, October 18, 1864, from quarters, with a bayonet stab penetrating into the abdominal cavity. The wound was situated to the right of the linea alba, about two inches below the navel. Cold-water dressings were applied and stimulants and anodynes were given. He recovered, and was returned to duty on March 14, 1865. Surgeon J. K. Rogers, U. S. V., reported the case.

CASE 151.—Private J. F. Morehead, Co. F, 130th Indiana, aged 33 years, was admitted into Clay Hospital, Louisville, January 21, 1865, with a bayonet wound penetrating the abdominal cavity, received at Louisville on the same day. On February 14th, the patient was transferred to the hospital at Indianapolis, whence he was returned to duty on March 28, 1865. Surgeon Francis Greene, U. S. V., reported the case.

CASE 152.—Sergeant J. O'Donovan, Co. F, 20th Massachusetts, aged 27 years, was admitted into Douglas Hospital, Washington, July 18, 1865, from the "Soldiers' Rest," with a bayonet stab in the epigastric region, received the day previously while endeavoring to quell a mutiny. The wound penetrated the peritoneal cavity and was followed by acute peritonitis, which

<sup>1</sup> MALGAIGNE, *Traité d'Anatomie Chirurgicale*, 2<sup>me</sup> éd., 1857, T. II, p. 325.

<sup>2</sup> GUTHRIE, *Commentaries on the Surgery of the War in Portugal, Spain, France, and the Netherlands, from the Battle of Roliça, in 1808, to that of Waterloo, in 1815*, sixth edition, revised to 1855, p. 546. Examples of the form of injury referred to may be found in PARE, *Œuvres Complètes*, éd. Malgaigne, T. II, p. 106; WISEMAN, *Severall Chirurgicall Treatises*, London, 1676, p. 373; RAVATON, *Chirurgie d'Armée*, Paris, 1748, p. 237; LA MOTTE, *Traité Complet de Chirurgie*, Paris, 1732, T. III, p. 125; MUYSS, *Praxis Medico-chirurgica Rationalis*, Leiden, 1682.

<sup>3</sup> CLEMENTS, *Notes on Surgical Cases*. In *Am. Jour. of Med. Sci.*, N. S., 1861, Vol. XLII, p. 37; Musician, Co. E, 7th Infantry, aged 32 years. Bayonet entered at extremity of left twelfth rib, and emerged through the right hypochondrium, two and one-half inches from the linea alba.

<sup>4</sup> IRWIN, *A Case of Severe Punctured Wound—Body transfixed by a Bayonet—Recovery*, in *Am. Med. Times*, 1862, Vol. IV., p. 273. An athletic Apache Indian, 25 years old, a hostage, attempting to escape from a guard of United States troops, in a pass of the Chiricahui mountains, in February, 1861, was knocked down by a sentinel, and "held pinned to the earth by a bayonet, which transfixed his body. The weapon entered the abdomen in the anter or upper angle of the left hypochondriac region, passed directly backward and downward, and made its exit a little below the posterior corresponding space, about two inches from the vertebral column. The victim was held in that position for some moments. \* \* \* Momentary weakness was all that appeared preternatural in him. The amount of hæmorrhage was very slight. He was tied and placed on his back; kept strictly quiet, and the cold-water dressing applied. \* \* \* Not a bad symptom appeared, and, on the fourth day, the wounds were perfectly healed by adhesive inflammation. \* \* \* On the ninth day he walked to the place of execution," where the body was allowed to remain suspended, *in terrorem*, so that an opportunity for *post-mortem* inspection was not afforded.

<sup>5</sup> FOLLIN, *Plaies de l'Abdomen*, in *Dictionnaire Encyclopédique des Sciences Médicales*, Paris, 1869, p. 142.

was treated by opiates and other remedies. He recovered, and was discharged from service. The examining board for pensions at Boston reported, on February 21, 1870, that there was a small triangular-shaped cicatrix on the linea alba, five inches above the umbilicus. The applicant had recently an attack of apoplexy, and was still hemiplegic. The disability was total, yet due to other causes than the wound. The applicant's claim for pension was rejected.

CASE 153.—Private J. O'Brien, Co. B, 46th Pennsylvania, aged 23 years, accidentally received a bayonet thrust in the abdomen, penetrating the peritoneal cavity, at Chattanooga, March 1, 1865. He was treated in hospitals at Chattanooga, Nashville, and Louisville, and ultimately recovered, and was returned to duty on May 19, 1865. Surgeon J. H. Phillips, U. S. V., reports the case.

CASE 154.—Reported by Surgeon H. Z. Gill, U. S. V.: Pt. Thomas Neil, Co. B, 17th New York; "Bayonet stab in abdomen, penetrating the peritoneal cavity, but not injuring the intestines;" Lovejoy Station, Georgia, September 2, 1864. Recovered, and does not appear on Pension Roll.<sup>1</sup>

The sixth is probably the case referred to by Assistant Surgeon B. Howard,<sup>2</sup> U. S. A., as the first instance in which he successfully employed the occlusive dressing he described as a method, to be termed "hermetically sealing:"

CASE 155.—Private — Camp, 18th United States Infantry, received a penetrating bayonet wound of the abdomen in November, 1862. The edges of the wound were approximated by metallic sutures, the surface was then dried and covered with a few shreds of charpie arranged crosswise, after the manner of warp and woof, and, upon this, a few drops of collodion were poured. The dressing remained intact until the wound was entirely healed, a period of a few days only. The patient recovered without symptoms of peritonitis.

The three following cases terminated fatally from peritonitis, or from hæmorrhage with shock:

CASE 156.—Private C. Hunt, Co. D, 1st Kentucky, aged 18 years, was admitted to Hospital No. 8, Nashville, June 1, 1864, with a bayonet wound of the abdominal cavity, inflicted by a sentinel on the previous evening. Simple dressings were applied. He died, probably from the effects of hæmorrhage and shock, on June 10, 1864. No important vessel or viscus was implicated. Surgeon R. R. Taylor, U. S. V., reported the case.

CASE 157.—Private R. Dow, Co. D, 78th U. S. Colored Troops, was admitted to the Corps d'Afrique Hospital, New Orleans, April 27, 1864, with a penetrating bayonet wound of the abdomen, received at the storming of the works at Port Hudson. Simple dressings were applied, and the symptoms of acute peritonitis that had supervened were controlled by opiates, emollient fomentations, restricted diet, etc. The patient died on May 23, 1864. Surgeon F. E. Piquette, 86th U. S. Colored Troops, reports that the results of traumatic inflammation were the only internal lesions to be observed.

CASE 158.—Private J. Holderman, Co. E, 96th Pennsylvania, aged 36 years, was admitted to Stone Hospital, Washington, August 20, 1864, from Forrester Hall Prison, Georgetown, where he had been confined on account of desertion. In an affray with the guards he had received bayonet wounds of the head, arms, and abdomen; he was probably laboring under *delirium tremens* when injured. The intestines protruded; being uninjured they were reduced, and the wound was closed with sutures and adhesive straps, and opiates were given in full and frequent doses. Death ensued August 24, 1864, from acute peritonitis. Assistant Surgeon P. Gleman, U. S. V., reported the case.

The following example of a sword thrust, penetrating the abdominal cavity, and followed by protrusion; but not wounding the viscera, was recorded:<sup>3</sup>

CASE 159.—Private Scott, 31st New York, was stabbed with a small sword, November 15, 1861. The point of the weapon entered to the right of the umbilicus. The wound was closed with adhesive plaster and a compress and bandage, and the patient was placed on his back, with his body flexed. During the night a knuckle of intestine protruded, and became strangulated. Surgeon F. H. Hamilton enlarged the wound, returned the gut, which was dark brown, and secured the wound with sutures. Quiet was enjoined, and, under the influence of opium, the pain and vomiting gradually ceased. Died November 19, 1861. The autopsy revealed no lesion of the intestines, nor internal hæmorrhage.

In most of the foregoing examples, there was no visceral protrusion. The next two cases were accompanied by protrusion of the omentum, and exemplify the treatment of this complication by ligature and by excision:

CASE 160.—Private J. H. Westfall, Co. F, 11th Illinois Cavalry, aged 19 years, received an incised wound of the abdomen, in a brawl at Vicksburg, December 1, 1864. On the 6th he was admitted into Hospital No. 2, Vicksburg; the omentum was protruding from the wound. A ligature was placed around the protrusion, the wound was poulticed, and one-third of a

<sup>1</sup>In the report in Circular 3, S. G. O., 1871, pp. 101-2, Acting Assistant Surgeons J. T. KING and C. W. YOUNG record (Cases 347, 358) instances of punctured wounds of the peritoneal cavity without visceral injury, promptly followed by recovery; and Assistant Surgeon J. W. WILLIAMS describes (Case 339) an instance of bayonet-stab in the left hypochondrium, in which the profuse bleeding suggested the probability of a lesion of the spleen; but the patient rapidly recovered without suffering from peritonitis, or from ill consequences from the considerable extravasation of blood within the cavity.

<sup>2</sup>HOWARD, *American Medical Times*, Vol. VII, p. 157. In this article, and in his letter in the *First Surgical Volume*, p. 497, Dr. Howard refers to the case of a private of the 18th Infantry, and gives the date 1861. In a special report (File A, 145, Div. S. R., S. G. O.) he gives the date November, 1862, as stated in the abstract, and the man's name. No other information appears on the medical records of the 18th Infantry for 1861-62, nor is the man pensioned.

<sup>3</sup>HAMILTON, *A Treatise on Military Surgery and Hygiene*, 1865, p. 377.



grain of morphia was given. Poultices of linseed meal were continued until the 13th, when adhesive plaster dressings were substituted. The protrusion sloughed off, and the wound healed under simple dressings. The man was returned to duty January 13, 1865. Surgeon Robert F. Stratton, 11th Illinois Cavalry, reported the case. Westfall is not a pensioner.

CASE 161.—Squire McAvin, a freedman, aged 17 years, received a punctured wound of the abdomen with a knife, in an affray at Vicksburg, April 17, 1865. He was admitted on the same day to the hospital for freedmen. The wound was about three inches to the left of the umbilicus, and parallel with it, the epiploon protruding about three inches; the bowels were not injured. The protrusion was cut off and simple dressings applied. The patient recovered, and was returned to duty May 5th, 1865. Surgeon T. J. Wright, 64th U. S. Colored Troops, reports the case.

Another case, that of Private Blaney, 21st Pennsylvania, a recovery after protrusion of the unwounded omentum, was fully reported, with instructive comments, by Dr. Walter F. Atlee,<sup>1</sup> who follows Robert and M. H. Larrey in advising that protruded omentum should be let alone, instead of the rule laid down by Boyer and advocated by the majority of surgeons, that when healthy and intact it should be returned. This interesting question of the proper management of protrusions of the omentum and intestines may be deferred until examples of hernia of wounded viscera shall have been adduced.

An instance in which the peritoneal cavity would appear to have been transfixied by an arrow, is recorded by Surgeon C. E. Goddard,<sup>2</sup> U. S. A. The barbed, iron-headed arrow, twenty-six inches in length, entered three inches to the right of the spine of the fifth lumbar vertebra and emerged two inches to the right of the ensiform cartilage. Slight internal hæmorrhage and circumscribed peritonitis ensued; but the patient recovered without other ill consequences. The arrow was sent to the Museum, and is represented in the wood-cut (Fig. 11). One case is reported in which a ramrod<sup>3</sup> is supposed to have transfixied the abdominal cavity without injury to the viscera:<sup>4</sup>

CASE 162.—Private Henry Manypenny, Co. D, 70th New York, was wounded at Wapping, July 23, 1863, and admitted to the 2d division hospital of the Third Corps. Surgeon C. K. Irvin, 72d New York Volunteers, reports that a ramrod perforated the abdomen through the left groin. The symptoms were not extremely grave, and the patient was sent to Mount Pleasant Hospital on July 30th. The wound of emergence was in the left lumbar region. The diagnosis is recorded with brevity rather than elegance: "ramrod driven plumb through the guts." There was no serious peritonitis or other evidence of visceral lesion, and the man was returned to duty, cured, on September 23, 1863, as reported by Assistant Surgeon C. A. McCall, U. S. A., and does not appear on the Pension Roll.

Many of the alleged examples of transfixion or impalement are found on critical examination to be wonderful only in name, the intruding body gliding upon aponeuroses or dissecting up loose connective tissue, without injuring the peritoneal cavity. Thus, Dr. Maury<sup>5</sup> gives a figure to show that a case described under



FIG. 11.—Kiowa arrow, the shaft divided in order to withdraw the barbed and feathered extremities from a man's body. *Spec. 5843*. One fourth size of nature.

<sup>1</sup> ATLEE (W. F). *Case of Wound of the Abdominal Walls, with protruded Omentum*. In *Am. Jour. Med. Sci.*, N. S., Vol. XLIII, p. 89, 8. In Circular 3, S. G. O., 1871. Assistant Surgeon E. A. KOEPER records (Case 316, p. 95) a case of an incised wound, with protrusion of unwounded intestines and of omentum. The viscera were replaced, the wound sewed up, opium administered, and ice-poultices applied to the abdomen. Assistant Surgeon J. P. CLEARY relates (*Ibid.*, Case 317) a similar successful case. Acting Assistant Surgeon F. BARKES describes (*Ibid.*, Case 318) a recovery after replacement of an immense protrusion of nearly the entire intestinal canal.

<sup>2</sup> GODDARD, In Circular No. 3, S. G. O., 1871, p. 153, Case 473.

<sup>3</sup> HENNEN (*op. cit.*, 2d ed., p. 402) records the recovery of a soldier shot through the abdomen by a ramrod at Badajoz, in 1812. GUTHRIE, *Commentaries*, 6th ed., p. 545, gives the oft-quoted details. Case of Private Carpenter, 43d regiment.

<sup>4</sup> BESSEMS (*Annal. de la Soc. de Méd. d'Anvers*, Janv. 1845) records the case of a person transfixied by an iron spindle, which entered through the left flank and emerged to the right of the naval, without injuring the viscera or causing peculiar symptoms. Complete recovery followed in twenty days. Dr. F. H. HAMILTON, of New York, *Buffalo Med. Jour.*, January, 1859, and *Treat. on Mil. Surg.*, p. 233, has reported, from the practice of Dr. Throop, of Luzerne, Pennsylvania, an account of a perforation of the belly by an iron rod half an inch in breadth, which entered the right inguinal region, and emerged two inches from the spine of the last dorsal vertebra, and was supposed to have traversed the abdominal cavity. But a few drops of blood were lost, only a slight stinging sensation followed the withdrawal of the rod, and the patient, a harness-maker, æt. 25 years, was sitting up and playing the violin on the eighth day. Dr. C. BELL, of Concord, relates (*Boston Med. and Surg. Jour.*, 1856, Vol. LIII, p. 509) an unequivocal instance of penetration of the abdomen by the sharp point of a joist, on which a man of 17 years fell from a scaffolding in a barn, a height of fifteen feet. After slight localized peritonitis, the patient recovered.

<sup>5</sup> TOWNSEND, *Hospital Reports, Clinic of V. F. MAURY*, M. D., in *Philad. Med. and Surg. Reporter*, 1870, Vol. XXII, p. 273.

the formidable title of "a tamping iron driven through the side," was, in reality, only a superficial flesh wound of the left hypochondrium.<sup>1</sup>

Protrusion of uninjured omentum or loops of small intestine occurred in punctured wounds of the abdomen, and were not infrequent in incised wounds. These injuries, rarely received in battle, were, unhappily, not very uncommon in brawls and affrays, and therefore were oftener inflicted by knives and dirks than by more soldierly weapons. The steel offensive weapons generally used in the armies during the war are represented in the wood-cuts (FIGS. 12, 13, 14, 15) on a scale of one-tenth. Of penetrations or perforations of the abdomen by shot, without injury of the viscera, many alleged examples were reported, not less than nineteen being specially recorded under this head. Some of these were, undoubtedly, extra-peritoneal perforations in the iliac fossa; others might be suspected to be simply flesh wounds in the flank. No case occurred that resembled Hennen's famous Case LXIV, of recovery from a wound from a grape-shot passing through the abdomen; but there were incontestible instances of recoveries after musket balls had either perforated or fairly lodged within the peritoneal cavity. Of the perforations through the iliac fossa, with unequivocal penetration of the peritoneal cavity, the case of Major Power affords a good example, being attended by that rare complication of shot wounds, a protrusion of the intestines:

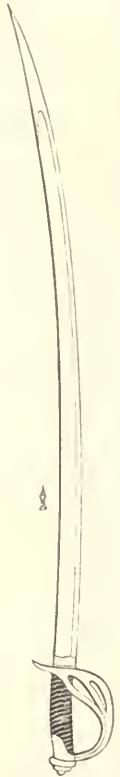

FIG. 12.—U. S. Cavalry sabre.



FIG. 14.—Bayonet of the Springfield rifle-musket.

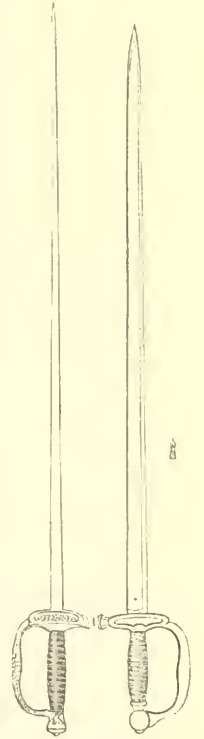


FIG. 13.—Swords of U. S. staff and non-commissioned officers.

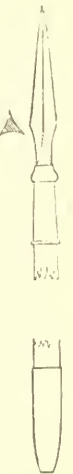

FIG. 15.—Lance.

CASE 163.—Lieutenant John Power, adjutant 16th U. S. Infantry, was struck, at the battle of Murfreesboro', January 1, 1863, by a conoidal musket ball, which entered a little in front of the anterior superior spinous process of the left ilium, and, passing downward and forward toward the symphysis pubis, laying open the abdominal cavity, making an oblique canal, two inches long, through the muscular walls. Surgeon John M. Todd, 65th Ohio, who records the case, could learn little of the immediate symptoms produced by the wound. He states that the officer, who was a large, muscular man, was brought from the field about twelve hours after the reception of the wound, and that through the long ragged wound a knuckle of the ileum, about two and one-half inches long, protruded. The bowel was apparently uninjured, and, being properly cleansed with tepid water, it was readily reduced. The external wound was then closed by two points of interrupted suture, which were supported by adhesive strips, over which a compress moistened with cold water was laid; strict quietude was enjoined in the recumbent position. After twenty-four hours, violent inflammatory action, of which the wound and its immediate surroundings were the focus, set in. The succeeding twenty-four hours witnessed the inflammatory action in its acme. It then involved the anterior and lateral surfaces of both thighs, and the body as high up as the umbilicus. The integument and subjacent connective tissue of the genitals participated in the inflammation and were enormously swollen. Thus matters continued for five days. [The report is silent as to the measures employed to combat the local inflammation, which appears to have been of an erysipelatous nature.] At the expiration of this time, however, hectic supervened, with rapid emaciation, and every indication foreboded evil. Supporting remedies, such as quinia, with beef tea and wine, were now liberally employed. On the evening of the seventh day from the inception of the inflammation, an abscess of the scrotum and adjacent parts, pointing at the upper posterior part of the scrotum, opened spontaneously and discharged copiously a very offensive sanies. After this there was considerable sloughing of the loose cellular tissue. In the midst of the purulent and sloughed matter, the instrument of all the mischief, a conical leaden bullet, was discharged. After this the discharge gradually subsided, the entrance wound closed kindly by granulation, the sinus in the scrotum closed by the same process, with slight apparent loss of tissue. Appetite returned and the patient rapidly recuperated, and in fifteen days from the date of his admission to the field hospital he was sufficiently convalescent to undertake a long journey to Nashville in an ambulance wagon, with every prospect of a speedy and entire recovery. There was no functional disturbance of the digestive tube or urinary organs. Lieutenant Power regained his

<sup>1</sup>BOYER (*Traité des Mal. Chir.*, 5ème éd., T. VI, p. 10) justly observes: "Une épée peut traverser de part en part l'abdomen, sans intéresser le péritoine, quoiqu'en ne considérant que la position des deux orifices, la pénétration paraisse évidente."

accustomed vigorous health and returned to his regiment for duty. He was brevetted major for gallantry; but received his lineal promotion as captain in 1865 only. He resigned from the army in September, 1869. He has not applied for a pension.

In some cases, the diagnosis appears to have been based upon the apparent direction of the ball and the negative character of the subsequent symptoms, no positive evidence being adduced in support of the assertion that penetration existed, as in the following:

CASE 164.—Private G. B. Phelps, Co. F, 16th Connecticut, aged 26 years, Antietam, September 17, 1862. Treated at hospitals at Locust Springs, Frederick, and New Haven, where the injury is described as a gunshot wound of the left side or left hypochondrium; but, at the general hospital at Brattleboro', whither the patient was transferred as late as May 7, 1863, Surgeon E. E. Phelps, U. S. V., returns the diagnosis: "musket ball perforating the abdominal cavity, with lesion of the peritoneum only." This soldier was sent to modified duty in the Veteran Reserve Corps, February 17, 1864. As he was employed as a nurse at Locust Springs, and as he is not a pensioner, the Brattleboro' diagnosis if true, lacks verisimilitude.

CASE 165.—Captain C. H. Reddick, Co. C, 13th Virginia Cavalry, aged 35 years, Front Royal, August 16, 1864. Missile entered the right flank, passed through the abdomen, and emerged at the side of the spine, without wounding the intestines. Treated in Confederate hospital at Petersburg. There was paralysis of the right lower extremity; but Surgeon W. L. Baylor, P. A. C. S., who reports the case, states that this gradually disappeared, and that the officer entirely recovered.

CASE 166.—Corporal J. A. Michael, Co. E, 1st West Virginia Cavalry, aged 22 years, Gainesville, October 28, 1863. Pistol ball entered abdominal cavity at the left iliac region, and passed directly through, without injuring the intestines, lodging beneath the integument over the crest of the ilium. He was treated at the hospital of the 3d division, Cavalry Corps. Acting Assistant Surgeon J. Walsh, who reports the case, states that there was no evidence of injury to any viscera. The patient recovered, and returned to duty December 15, 1863.

There were instances in which the absence of lesion of the viscera was verified by autopsy, as in the following case, recorded by Surgeon O. A. Judson, U. S. V.:<sup>1</sup>

CASE 167.—Private W. Whipple, Co. I, 3d Vermont, was struck in the left hypochondriac region, at the Wilderness, May 6, 1864, by a conical musket ball, which penetrated the peritoneal cavity. No account of the symptoms or treatment appear on the field records. The patient was brought to Washington and placed in Carver Hospital, where he died on May 16, 1864. The diagnosis of "penetration of the peritoneal cavity without injury of the viscera," in the monthly report, attracting attention, a special inquiry was made as to the cause of death, and the reply was: "peritonitis." It is to be regretted that the situation of the missile and the appearances of the viscera were not recorded.

At the autopsy of a case reported by Surgeon Edwin Bentley, U. S. V., on page 443 of the *First Surgical Volume*, the track of a round musket ball was traced from the left ninth intercostal space, where it entered the chest, through the lung and diaphragm, thence, grazing the walls of the stomach and colon and coils of the jejunum, the missile passed to its point of lodgement in the second lumbar vertebra (FIG. 16). The patient survived three weeks. There were no symptoms of peritonitis; the signs attendant on the pulmonary lesions, at first, and ultimately the hectic fever, which declared itself when a psoas abscess developed, being the prominent features. An analogous case, of a ball passing obliquely across the abdominal cavity, through the convolutions of the jejunum and ileum, without apparent injury to any portion of the digestive tube, will be adduced among the cases of wounds of the liver.

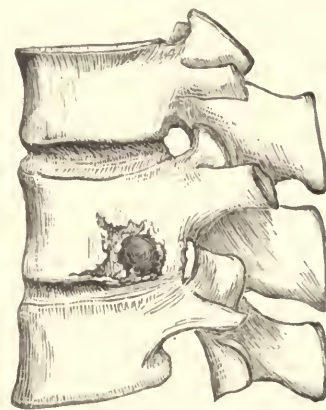


FIG. 16.—Round musket ball that traversed the abdominal cavity without injuring the viscera, and lodged in the second lumbar vertebra. Spec. 3349.

The observations of Hunter<sup>2</sup> on shot wounds through the body, implicating the

<sup>1</sup> PARRISH, in a report on Surgery (*Summary of the Transactions of the College of Physicians of Philadelphia*, 1846, Vol. I, p. 254, and *Am. Jour. Med. Sci.*, N. S., Vol. X, p., 148), records the case of Joseph Cox, shot through the abdomen, in the Southwark riots. The patient lived fifteen days, and a pistol ball was found lying loose in the pelvis, having inflicted no injury upon the viscera and gravitated to its position along the planes of connective tissue.

<sup>2</sup> HUNTER (*A Treatise on the Blood, Inflammation, and Gunshot Wounds*, p. 513) observes: "Wounds of the parietes of the abdomen, not immediately inflicted on such a viscus as has the power of containing other matter, will in general do well, let the instrument that made the wound be what it will.\* There will be a great difference, however, should that instrument be a ball passing with great velocity, for in this case a slough will be produced. But if it should pass with little velocity, then there will be less sloughing, and the parts will in some degree heal by the first intention, similar to those made by a cutting instrument: but although the ball has passed with such velocity as to produce a slough, yet that wound shall do well, for the adhesive inflammation will take place on the peritoneum all round the wound, which will exclude the general cavity from taking part in the inflammation, although the ball has not only penetrated, but has wounded, parts which are not immediately essential to life, such as the spleen, mesen-

\* "What I mean by a containing viscus, is a viscus that contains some foreign matter, as the stomach, bladder, uterus, gall bladder, &c. to which I may add blood vessels."



omentum and mesentery, but avoiding the hollow viscera, are very properly cited by writers on this subject as worthy of meditation by all military surgeons. There were a few instances in which the viscera appear to have primarily escaped injury, yet finally, by ulcerative absorption—either the products of inflammation, or the missile, or some foreign substance carried in—gained admission to the digestive canal and passed away by the natural passages.

CASE 168.—Sergeant H. T. Angel, aged 23 years, was wounded at Petersburg, October 28, 1864, by a conoidal musket ball, which entered about three inches to the left of and a little above the umbilicus. On November 2d, he was admitted into the 2d division hospital, Alexandria. A small mass, supposed to consist of omentum, protruded from the wound. The patient complained of no pain and seemed quite comfortable, except some slight oppression. His tongue was coated. Anodynes were given with a milk diet, and stimulants and tonics were employed to some extent. On November 7th, a hæmorrhage took place from the rectum, amounting to about two pints, and again, on the 9th, the same quantity of blood was lost. Opium and acetate of lead seemed to check the bleeding, although he passed small quantities of blood once or twice afterward, with his feces. On the 7th, one of his feet became swollen and so remained. Pulse feeble, and ranging from 93 to 120. By November 12th, his appetite had returned, and there seemed to be an improvement in all his symptoms. He continued to improve until the 21st, when he had a chill; from this time he had one or two chills daily, with intense febrile reaction. On the 23d, he complained of loss of appetite, and weakness; but he was not troubled with pain until the afternoon of the 25th, when his breathing became quite short and more difficult, and there was pain, increased on pressure, in the abdomen. This condition continued until death, which occurred on the morning of November 25, 1864. At the autopsy, the great omentum was found to be inflamed, thickened, and contracted in surface; there was no fluid in the peritoneal cavity. The surface of the parietal peritoneum was dark and inflamed, and the small intestines were adherent to it by numerous threads of organized fibrin. The missile had penetrated the abdominal cavity, passed through the mesentery, and between the intestines without perforating any of them, and had fractured and lodged in the body of the fourth lumbar vertebra, on the left of the aorta. A portion of the ileum, about two feet from the ileo-cæcal valve, had become adherent to the peritoneum around the wound in the vertebra, and the intestine, at that spot, had ulcerated through so that the discharges from the wound were poured into the intestine and thus carried off. The bleeding from the rectum must have entered the intestine through this ulceration, its source being very likely a lumbar artery. The small intestines were adherent to each other, and the tissue of their coats softened so that they tore in several places when handled. Acting Assistant Surgeon Thomas Bowen reported the case.

An abstract is given, on page 584 of the *First Surgical Volume*, of the case of Private Thomas B. B——, who was wounded at Petersburg, March 25, 1865, by a ball, which lodged over the transverse colon. He suffered from traumatic peritonitis of moderate intensity; but there was no indication of penetration of the bowel until April 29th, when, after an attack of tormina with tenesmus, the ball (FIG. 17) was passed during defecation. In this case, it is quite possible that there was no primary lesion of the gut, and that the missile made its way into the intestinal canal by ulcerative absorption. The printed history closed with the patient's recovery, and discharge from the service on September 22, 1865. Since then it has been learned that, in December, 1872, B—— was pensioned. His application for pension was accompanied by his photograph, in which the cicatrix of his wound was well shown. The photograph is carefully copied in the accompanying wood-cut (FIG. 18).



FIG. 17.—Conoidal musket ball voided at stool. Spec. 1559.

Medical Inspector F. H. Hamilton, U. S. A., has recorded<sup>1</sup> a somewhat analogous case, with a less fortunate result, the missile being eliminated through an abscess into the

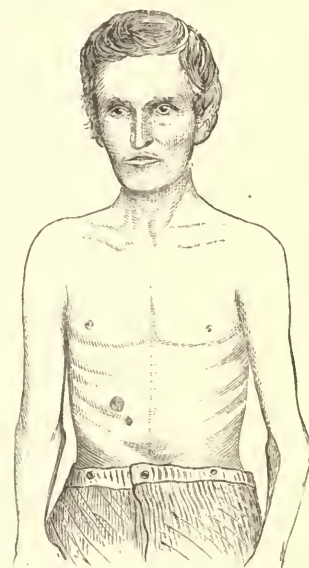


FIG. 18.—Cicatrix from a wound made by a ball (FIG. 17) which lodged against the transverse colon. (From a photograph taken seven years after the injury.)

tery, etc. and perhaps gone quite through the body; yet it is to be observed, that wherever there is a wound, and whatever solid viscus may be penetrated, the surfaces in contact, surrounding every orifice, will unite by the adhesive inflammation, so as to exclude entirely the general cavity, by which means there is one continued canal wherever the ball or instrument has passed; or if any extraneous body should have been carried in, such as clothes, etc. they will also be included in these adhesions, and both these and the slough will be conducted to the external surface by either orifice."

<sup>1</sup> HAMILTON, (F. H.), *A Treatise on Military Surgery and Hygiene*, p. 276. "He seemed in a fair way of recovery: but died on July 28, 1863.

sigmoid flexure or the rectum, and escaping by the anus on the fortieth day; after which suppuration continued, and the patient died, hectic, at the close of the seventh month:

CASE 169.—Corporal John J. English, 5th Indiana Battery, was wounded at Murfreesboro', December 31, 1862, by a musket ball, which entered the left inguinal region. He was taken to the field hospital of the 2d division, Fourteenth Corps. The situation of the ball could not be determined, but, from the absence of grave symptoms, Surgeon J. L. Toed, 3d Illinois, hoped that the missile had not penetrated the peritoneal cavity, and, on January 5, 1863, the patient was sent to Nashville. Here Surgeon Charles Schnessler, 6th Indiana, recorded the wound of the left groin as severe and probably penetrating. Still there were no very grave symptoms, and, on the 18th, the patient was transferred to Louisville, to Hospital No. 8. Acting Assistant Surgeon Oetzelong describes the wound as severe and situated in the left inguinal region; but gives no particulars of the progress or incidents of the case, which terminated fatally, July 28, 1863, no notes of an autopsy being preserved. Medical Inspector Hamilton, however, states (*Am. Med. Times*, Vol. VII, p. 186) that "the ball escaped from the rectum on the fortieth day," that it was "a conical ball, which entered just below and in front of the anterior superior spinous process of the ilium, on the left side," and that "when I saw Corporal English he was in bed, the wound in front had closed, but matter continued to discharge by the rectum. His bowels were regular; but he was obliged to urinate often, and urination was attended with some pain. His health was steadily improving, and there was but little reason to doubt his final and complete recovery. The ball, which he showed me, was a little battered."

It cannot be doubted that such cases, with intestinal lesion of a secondary nature, should be distinguished from those in which a missile gains admission to the intestinal canal at an early period after shot penetration of the abdomen, as in the instances cited by Surgeons Thomaine, Ducachet, and Rulison,<sup>1</sup> and others that will be adduced, in which the colon was directly perforated. Some other examples might be given in which balls probably entered the intestinal canal by ulcerative absorption; yet it is not possible to assert, in regard to any of these cases, that there was absolutely no primary visceral lesion, while in some of them there was unquestionably complete or partial perforation of the walls of the intestine. It will, therefore, be better to group them farther on. I will cite here,<sup>2</sup>

<sup>1</sup> THOMAINÉ (R.), Case of Captain R. Stolpe, *First Surgical Volume*, p. 515. DUCACHET, *Gunshot Wounds of Abdomen*, in *Am. Med. Times*, 1868, Vol. VII, p. 134. RULISON, *The Escape of Balls by the Rectum*, in *Am. Med. Times*, Vol. VII, p. 242.

<sup>2</sup> Dr. W. J. RUNDLE (*The Med. Times and Gazette*, 1866, Vol. I, p. 305) gives the following particulars of this case, with a drawing of the pathological preparation, by Dr. Coussens, which is copied in the wood-cut (Fig. 19): "A. B., aged 40 years, an officer in the Royal Artillery, received a severe gunshot wound of the abdomen during the Indian mutiny, seven years and a half before his death. On April 2, 1858, when commanding a company of Artillery at an attack upon some forts of the Island of Beyt, in the Gulf of Cutch, he was struck by a bullet just above the sword belt, which passed down between the cloth and lining of the tunic for a short distance, and then obliquely entered the abdomen two inches above and one inch to the right of the umbilicus. He was immediately carried off the field, placed on board ship, and then taken to Bombay. The medical officers who attended him had at first very little hope of his recovery, and he was mentioned in the dispatch of the commanding officer as being 'very dangerously wounded in the abdomen.' The history of this part of the case is very deficient, and little is known respecting the progress of the wound beyond the fact that it healed in the course of four or five weeks, and that he rapidly regained his health and strength. \* \* He continued in his usual health up to Monday, October 15, 1865, when, about midday, he began to complain of sickness and abdominal pain. During the evening I visited him, and prescribed a draught and full enema. In a few hours, however, he rapidly changed, and, at five the next morning, I found him in a state of collapse, vomiting frequently a fetid and dark-coloured fluid, with a cold skin and almost imperceptible pulse. He gradually sank, and died at 7 A.M. *Post-mortem Examination Forty-eight Hours after Death.*—The body presented, externally, a cicatrix about the size of a sixpence; it was situated two inches above the umbilicus and one to the right of the median line, and was continuous, with a fibro-cellular cord, which extended obliquely downward and inward through the abdominal walls for two inches, and then became lost in the surrounding structures. On opening the abdomen, the parietal peritoneum was free from adhesions, and everywhere healthy; and no scar or puckering could be seen on its surface marking the spot at which the bullet penetrated the cavity. The superficial intestines were pale and much distended with flatus; but on turning them aside, a few coils, deeply congested, were found lying in the right iliac region. In this situation the alimentary canal was bound together by several old and firm adhesions, and around one of them—a short and narrow band attached to two adjacent pieces of intestine—another portion of the gut had become completely twisted. At the seat of the twist the intestine was stretched into the semblance of a cord, and perfectly occluded, and about three inches below it the bullet was discovered lying loose in the canal. The peritoneal cavity was quite free from any kind of effusion, and there were no flakes of lymph or other traces of recent inflammation. The mesentery was likewise healthy, and contained a moderate amount of fat; and neither in this organ nor in the coats of the intestines could any thickening or cavity be found to indicate the part where the missile had remained encysted for so many years. All the other organs were healthy. The bullet is about the size of a small nut, flattened at one extremity and irregularly conical at the other. It weighs 372 grains, and appears to have been rudely manufactured from a rod of lead, according to the custom of the Asiatics."

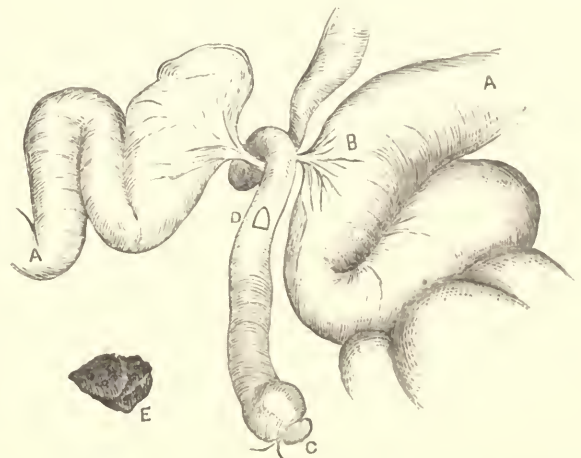


FIG. 19.—Sketch of a strangulation of the ileum, caused by an adventitious fibrous band, due to the irritation produced by a bullet. A, B—Coils of intestine united by the fibrous band, B, around which the gut, C, was entangled. D—Bullet lying loose in the canal. E—Size and shape of bullet. (After COULSSON.)

however, an instance of a ball traversing the abdominal cavity without injuring the viscera, and remaining, for seven years, encysted in the mesentery probably, and then, becoming displaced, causing the formation of a fibrous band, which became the cause of strangulation, the missile, meanwhile, entering the intestinal tube by ulceration. This very remarkable case is recorded by Dr. William John Rundle, of Portsmouth, England.

There is an interesting group of penetrating shot wounds of the abdomen, in which the missile, entering anteriorly or laterally, lodges in the iliac or psoas muscles. Nothing can be better than John Bell's description of these wounds.<sup>1</sup> Most of them result, eventually, in paralysis or in hectic. When it is practicable to discover the track of the ball, it is generally found to have traversed the great intestine or the extra-peritoneal soft tissues in the iliac fossa; in rare instances, it may pass harmlessly between the coils of the small intestines. Possibly this was the course of the ball, in the following case, which is interesting though defective in many important details. The removal of a ball from its lodgement in front of the transverse process of a dorsal vertebra is a very difficult surgical achievement, and it is a pity that the reporter has not given a more circumstantial account of the steps by which he accomplished it:

CASE 170.—Private Jacob White, Co. G, 13th New Jersey, aged 54 years, was wounded at Chancellorsville, May 3, 1863. The wound was dressed at the field hospital, and, on the 7th, the patient was transferred to Washington and admitted to Carver Hospital. Assistant Surgeon E. F. Bates, U. S. V., who reports the case, states that "a minié ball entered two and a half inches above the anterior superior spinous process of the left ilium, passed through the cavity of the abdomen, and imbedded itself in the psoas muscle to the left side of the last dorsal vertebra. The wound of entrance was of more than ordinarily large size, so that no difficulty was experienced in introducing the finger directly into the cavity of the abdomen, nor was inordinate pain suffered from the attempt." [Here the reporter fails to specify the results of this exploration, and leaves us in ignorance whether the finger came in contact with the small or large intestines or with any viscus, an unfortunate omission. He continues as follows:] "During the ensuing two months, pains of a dull character were constantly experienced through the whole lumbar region. It was not, however, until July 11, 1863, that the locality of the ball was approximately diagnosed. At that time, a slight swelling appeared opposite the last dorsal vertebra. The patient was unable to sleep soundly at night, as before, and suffered uneasiness from the fact of being constantly bathed in perspiration. On July 20th, he was placed upon the table, and I extracted the ball from its position before the transverse process of the vertebra. Great relief was at once experienced; in the course of an hour the patient walked well and easily. He was allowed full diet, with beef-steak, custard, and a half-pint or pint of sherry wine daily. On August 17th, he was examined and recommended for sixty-days' furlough; the opening by which the ball was extracted had entirely closed, there being a slight discharge from the wound of entrance. It is probable that the transverse process of the vertebra was slightly injured; very minute osseous particles had, from time to time, escaped with the pus." He was readmitted from furlough on October 19th, and, on November 12th, transferred to hospital at Newark, New Jersey, whence he was returned to duty February 24, 1864, and, on January 2, 1865, he was discharged from service and pensioned. Though "unable to bear severe labor," he was on the list in September, 1872.

Ravaton pretended to believe that it was possible to discriminate simple penetrating wounds of the abdomen by the rational symptoms alone,<sup>2</sup> and gravely formulated the signs of shot wounds interesting only the epiploon

In treating of visceral protrusions in abdominal wounds, and of the treatment of escaped omentum and intestine, there will be occasion to exemplify, by numerous instances, that the gravity of simple divisions of the parietal peritoneum, and the danger from contact of the air with parts of the viscera, were formerly exaggerated. Evidence does not justify.

<sup>1</sup> BELL (*Discourses on Wounds, etc.*, Part II, p. 63) says: "Here also the patient is peculiarly exposed to wasting suppurations, and to still greater dangers. The ball, if it have entered near the navel, or upon the middle line of the belly, will stick in the lumbar vertebra, and will cause paralysis of the bladder and lower extremities, soon followed by death. If it have passed obliquely through the abdomen, or to one side of the middle line, it will lodge in the thick flesh of the Iliac or Psoas muscle; and the patient, after having passed through the first dangers, feels little more than a weight and weariness of the loins; but when he raises himself to sit up in the bed, the weariness is converted into pain. Sometimes the ball makes a bed for itself, and lies harmless in the loins;—sometimes also, if the shot has entered near the pubis, by passing over the thigh, and has gone obliquely upward, there is a frequent draining of matter, and a small fistulous sore; but most frequently of all, the outward wound closes, the patient is never relieved from a dull and heavy pain, never recovers the free use of his limbs, nor is able to support his body erect, but wastes under a slow hectic fever; and when he dies, there is found a great abscess in the loins."

<sup>2</sup> RAVATON (*Chirurgie d'Armée* 1768, p. 228) observes: "Les coups de feu qui intéressent l'épiploon, sont annoncés par une douleur vague, tiraillément d'estomac, quelquefois qui occupe tout l'abdomen, envies de vomir plus ou moins fréquentes, et qui augmentent à proportion de l'étendue de la plaie et de sa proximité de l'estomac, le plus ou moins précipité."



however, a modification of the old opinions regarding the fatality of deep wounds. It is true, that a certain number of bayonet and sword thrusts through the body, and of instances of transfixion and of impalement, have been recorded in this section, and that it is necessary to admit the possibility of the passage of balls or blunt weapons through the abdominal cavity without injury of the solid viscera or intestinal canal, since this has been demonstrated by dissection.<sup>1</sup> Yet such exceptions are really very rare. Professor Gross formulates the rule justly in saying<sup>2</sup> "the viscera seldom entirely escape in any case." Guthrie<sup>3</sup> and M. Legouest<sup>4</sup> remark on the difficulty of conceiving of the passage of sharp-pointed instruments among the viscera, without lesion, however smooth and polished the investments may be. This drawing of Vesalius (FIG. 20) will remind the reader of some of the obstacles to such a transit. The "numerous instances" of sword thrusts, bayonet stabs, and shot wounds through the abdomen that authors enumerate, when sifted, appear rather as much-reiterated instances,<sup>5</sup> while many of them, when critically examined, and shown incontestably to be examples of deep penetration or perforation, lack evidence of being unattended by visceral lesion, and prove only that slight lesions of this nature are not necessarily fatal. In his long career, Larrey observed only a single instance<sup>6</sup> in which a ball penetrated the abdominal cavity without producing any immediately serious results. Even in this case, a lesion, however trivial, existed; for, as M. Legouest remarks, there was a contusion of the intestine. It is remarkable that these alleged cases are more frequent in civil than in military experience, an anomaly not satisfactorily explicable by the imperfection of observations in time of war. Allowing

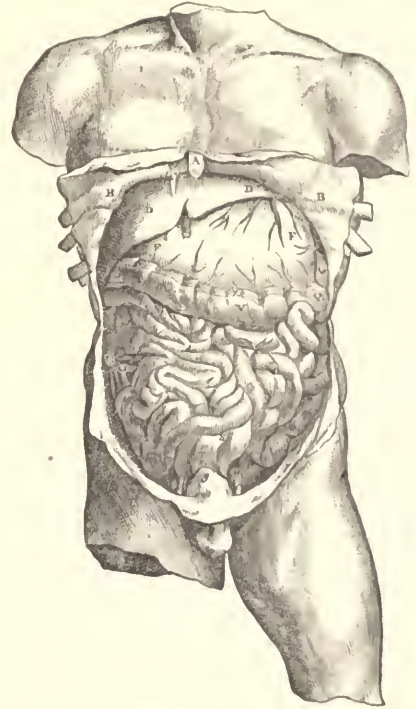


FIG. 20.—A—Eusiform cartilage. BB—Peritoneum and broken ribs reflected. C—Suspensory ligament. DD—Liver. E—Round ligament. FF—Stomach (*viscus hujus ventriculus cibus admodum erat turgidus*). G—Spleen. N—Commencement of the large intestine. O—Vermiform appendage. P, Q, R—Transverse colon. R—Sigmoid flexure. g—Bladder. (After VESALIUS, Lib. V. *Sexta figura*.)

<sup>1</sup> Hence, notwithstanding MALGAIGNE'S resolute denial (*Traité d'Anat. Chir.*, T. II, p. 325), the majority of modern classical authors, BOYER (*Traité des mal. chir.*, T. VI, p. 11), DUPUYTREN (*Leçons orales de clin. chir.*, T. VI, p. 428), and NÉLATON (*Élém. de path. chir.*, T. VI, p. 112) teach that stabbing and cutting weapons and balls, after traversing the abdominal walls, may glide upon the smooth surfaces of the viscera without wounding them. JOHN BELL (*op. cit.*, p. 60) admitted this: "In judging of wounds of the lower belly," he said, "much must be taken into account, before we form our opinion. We are often likely to be deceived: we see the patient lying quiet and easy, while we know that he is on the very brink of danger; and there is often great confusion and alarm, when the patient is absolutely safe; for balls sometimes turn so, that a shot shall pass through among all the bowels without wounding one; though it must be acknowledged, that the belly is so full of parts essential to life that there can hardly be a wound of the abdomen, in which one or other of the bowels is not concerned."

<sup>2</sup> GROSS, *A System of Surgery*, 5th ed., Vol. II, p. 659.

<sup>3</sup> GUTHRIE, *Commentaries*, 6th ed., p. 546.

<sup>4</sup> LEGOUEST, *Chirurgie d'Armée*, 2ème éd., p. 375: "Mais si l'on considère comme très-problématique la possibilité d'une plaie pénétrante de l'abdomen par armes piquantes ou par coups de feu, on est obligé d'admettre celle des plaies simples du péritoine par instruments tranchants, puisqu'on a vu quelquefois les intestins parfaitement intacts sortir à travers les solutions de continuité des parois abdominales."

<sup>5</sup> I will quote JOHN BELL'S explanation of WISEMAN'S case, and will not impugn that of the venerable LA MOTTE, but may make my estimate of GARENGEOT and his cases appreciated, by comparing him, among contemporaneous authors with Dr. DEMME. As BELL says: "One man is known by one quality or failing, another by another manner. HEISTER is remarked for sober systematic writing after the right German fashion; PETIT for good sense, and sound and careful observation, and GARENGEOT for tales like that about the soldier's nose." "Our good old surgeon Wiseman," Bell notes elsewhere, "has said with great simplicity, as a great many have said after him, 'Thus it frequently happeneth that a sword passeth through the body without wounding any considerable part;' he means that a rapier or ball often passes quite across the belly, in at the navel, and out at the back, and that (without one bad sign) the patient recovers and (as has very often happened) walks abroad in good health, in eight days; which speedy cure has been supposed to imply a simple wound, in which all the bowels have escaped. But we see now how this is to be explained; for we know, that in a thrust across the abdomen, six turns of intestine may be wounded,—each wound may adhere; adhesion, we know, is begun in a few hours, and is perfected in a few days; and when it is perfect all danger of inflammation is over; and when the danger of inflammation is over, the patient may walk abroad; so that we may do just as old Wiseman did in this case here alluded to: 'Bleed him and advise him to keep his bed and be quiet. In short, a man thus wounded, if he be kept low, has his chance of escaping by an adhesion of the internal wounds.'

<sup>6</sup> LARREY, *Clinique Chirurgicale*, T. I, p. 50.

due weight to this consideration, the Parisian "three days," of 1830, 1848, and 1851, should not furnish more of these exceptional cases than the wars of Napoleon, or the Irish-American riots than all the battles of the Rebellion.<sup>1</sup>

A man of the 80th British regiment was shot through the belly, from the navel to the back, in India, and recovered without serious symptoms; but when he died of cholera six years subsequently, it was found that the jejunum had been either contused or divided in three places.<sup>2</sup> I can learn of no shot perforations of the abdomen without visceral lesions, in the Crimean or Italian wars; but have collected a few scattered illustrations in the foot-note, and must, in fairness, not forget to state that in the Franco-German war, so careful an observer as Dr. Bernhard Beck professes to have observed seven such instances.<sup>3</sup> The diagnosis was verified by an autopsy in one only of the two fatal cases. The others would be more conclusive had not, in one of the recoveries, fœcal fistula occurred. Of the other four recoveries it is ascertained only that ventral hernia supervened in one, and diaphragmatic hernia in another. Until the real tracks of the projectiles can be traced, these observations can have no great weight.

It must be concluded, then, that really *simple penetrating wounds* of the abdominal cavity, that is penetrations or perforations without visceral lesion, are very rarely inflicted, either by sharp or blunt weapons, or by shot; and that most of the apparent exceptions are explicable by one or the other of two conditions: either that the true course of the

<sup>1</sup> I have already cited the alleged case occurring in the Southwark riots (p. 35, note). Dr. SANBORN (*Boston Med. and Surg. Jour.*, 1849, Vol. XLII, p. 200) relates another: The case of Kelley, a lad of 14, wounded in the riots at Lowell, by a ball entering in the centre of the epigastrium, and passing out four inches from the spine, fracturing the tenth rib. Vomiting, abdominal tension, and other signs of peritonitis were combated by venesection, opium, cold lotions, absolute rest, and abstinence. On the twelfth day portions of clothing were discharged from the posterior wound, which then healed. The reporter is satisfied that the missile made a direct and not a circuitous course. PAILLARD (Note in DUPUYTREN'S *Léçons orales*, T. VI, p. 46) relates two instances, observed at Hôtel-Dieu and Beaujon, in July, 1830, of men shot through the body from the epigastrium to the side of the vertebral column, without visceral lesion, and a third case (*Relation chirurgicale du siège de la citadelle d'Anvers*, 1833, p. 74) under his care at Antwerp, all of which recovered without serious symptoms. But while he would have these cases credited, he adds: "Il ne faut pas s'abuser cependant sur le mode d'action de ces coups prétendus heureux," and admits that such cases are commonly attended by visceral lesion. In 1848, two similar cases (*Gazette Médicale de Paris*, 1848, and a paper by Dr. GIBB in the *British American Journal of Medical and Physical Sciences*, October, 1848, reprinted in *New York Jour. of Med.*, 1849, N. S., Vol. III, p. 82) were observed at La Charité and at Val de Grâce. In one of these cases it was not doubted, even by Velpeau, that the ball, which entered the right umbilical region and passed out to the left of the vertebral column, had traversed the abdomen. The patient succumbed to a suppurative phlebitis following a precautionary venesection, and the autopsy revealed that the ball had made a circuit on the aponurotic planes! Among the wounded at the barricades, after the *Coup-d'État* of December, 1851, I had the opportunity of seeing two cases of supposed shot penetrations of the abdomen without visceral injury, one in M. ROUX'S ward at Hôtel-Dieu, the other in the service of M. MICHON, at La Pitié. One of these cases terminated fatally, and the diagnosis was disproved at the autopsy, lesions of the intestines, without extravasation, being discovered. Dr. B. BECK (*Die Schusswunden*, Heidelberg, 1850, S. 207) states: "I have observed two cases where musket balls entered and made their exit, without immediate opening of the intestines; one recovered completely in fourteen, the other in twenty-two days." BILGIER (*Chirurgische Wundlehren*, Berlin, 1763, S. 271) cites a case observed by Dr. CÖLER at the battle of Loboschitz, in the year 1756, which is analogous to HENNE'S case. A soldier was shot through the abdomen by a large shrapnel ball, which entered on the right and emerged on the left side. The wounds were large, about five inches apart, leaving the uninjured intestines open to view. The only notable symptom was a large abscess in the pubic region, which discharged a piece of cloth of the man's uniform. Recovery was complete in three months. RAVATON (*Chirurgie d'Armée*, p. 236, *et seq.*, Obs. L and LI) relates two supposed instances of shot penetrations of the abdomen without visceral injury. Dr. DEMME (*Studien*, B. II, S. 129) finds it difficult to understand how French and British authors can call in question shot perforations of the abdomen without visceral injury, as he had satisfied himself in repeated instances (*mehrere Fälle*), that even grape shot might traverse the peritoneal cavity without lesion of the contents. This assertion elicits from Dr. BECK the criticism, unhappily not unmerited, that he regards Dr. DEMME'S work "as a romance containing much that is interesting, and as a pleasing and complacent compilation of innumerable untruths (unwahrheiten) and unfounded and fictitious statements."

<sup>2</sup> Private Paul Massey, 80th British regiment, was shot in the abdomen at the battle of Ferozeshah, December 22, 1845. The symptoms consequent on the injury were so inconsiderable that Surgeon MACDONALD thought the ball had coursed around the abdomen. The patient, however, stated that he had passed blood by stool. Recovery followed slowly; but appeared to be perfect. The man died May 13, 1851, of "blue spasmodic cholera." Surgeon J. H. TAYLOR reported the autopsy, and with Dr. WILLIAMSON, who figures the pathological preparation (*Military Surgery*, 1863, Plate V, opp. p. 111, No. 1271 of the Netley Collection), believed that the appearances indicated a perforation of the jejunum, in three places, by the ball. Professor LONGMORE (Article *Gunshot Wounds*, in HCLMES'S *System*, 2d ed., Vol. II, p. 207) thinks it more likely that the gut was contused than perforated.

<sup>3</sup> BECK (*Chirurgie der Schussverletzungen*, Freiburg, i. B. 1872, S. 526) cites seven cases of penetrating shot wounds of the abdomen (*einfach penetrirende Wunden*), with five recoveries and two deaths, observed in the hospitals of General Werder's corps after the engagements, in 1870, about Metz. In one of the fatal cases, a man of the 112th Baden Infantry, wounded in the left hypochondrium by a chassépot ball, which fractured the twelfth rib, had traumatic peritonitis with icterus, and died in seven days. At the autopsy the ball was found resting in the vertebral column, having wounded none of the viscera. The other fatal case (W——, 21st Baden Dragoons) was from a large mitrailleur ball, passing from the lower right hypochondrium, on the axillary line, to the left of the navel. There was protrusion of unwounded intestines at the exit orifice. The patient died the day of the injury and no necropsy was made. Of the five survivors: in the case of Private M——, 114th Baden, a ball entered the right hypochondrium and lodged; there was secondary lesion at least of the transverse colon, for fœcal fistula ensued. L——, 108th Baden, recovered after the supposed lodgement of a ball in the abdominal cavity. T——, 95th Baden, also recovered after the lodgement of a ball entering the right hypochondrium. A French prisoner survived a perforating wound; but had diaphragmatic hernia. K——, 111th Baden, recovered, with ventral hernia, after a shot wound, with alleged penetration without consequent peritonitis.



weapon or projectile evades the cavity it apparently enters; or else, traversing the cavity, is really associated with injuries of the viscera, with lesions usually unattended by extravasation, and susceptible of repair.

**WOUNDS OF THE STOMACH.**—The position of the wound, its depth and direction, the escape of food or drink, vomiting of blood, pain and faintness, are the principal signs of a wound of this organ. Associated with them, there may be thirst, singultus, tympanitis, small and frequent pulse with pallor, cold extremities, and other symptoms common to many forms of injuries of the belly, occurring even in some examples of non-penetrating wounds. The danger of extravasation is absent when the organ is empty, and the risk of hæmorrhage is less as the lesion is distant from the curvatures. Wounds near the pylorus endanger the hepatic artery, and those at the cardiac extremity, the left coronary. With some such description, systematic writers commonly preface accounts of wounds of this organ. But without dwelling on the semeiology and diagnosis, I will venture to say that apart from ocular evidence, or that derived from the introduction of the educated finger, extravasation of the contents of the stomach is the only pathognomonic sign of the division of its walls; and will hasten to the more instructive task of collating individual facts to exemplify that the complexity of the conditions under which the lesions are observed is such as to preclude much uniformity in the attendant phenomena, and that although bloody vomiting, coming on immediately after a stab or shot wound in the vicinity of the stomach, may afford a strong presumption of a lesion of that organ, it is an uncertain sign, that may be absent when the stomach is wounded, or present when the injury is simply a contusion of the stomach, or a wound of the liver or intestines. Dr. J. J. Chisolm<sup>1</sup> entertains the most hopeful prognosis of any of the Confederate or Union writers who have adverted to wounds of the stomach, and endeavors to justify his teaching by the argument that soldiers most frequently go into battle with empty stomachs; but he specifies no instances of recovery. Dr. E. Warren<sup>2</sup> omits wounds of the abdomen in his epitome. The compilers of the Confederate *Manual*,<sup>3</sup> in a judicious analysis of the differential diagnosis of penetrating wounds of the belly, refer briefly to the significance of hæmatemesis. The *Confederate States Medical and Surgical Journal*, and the southern medical journals

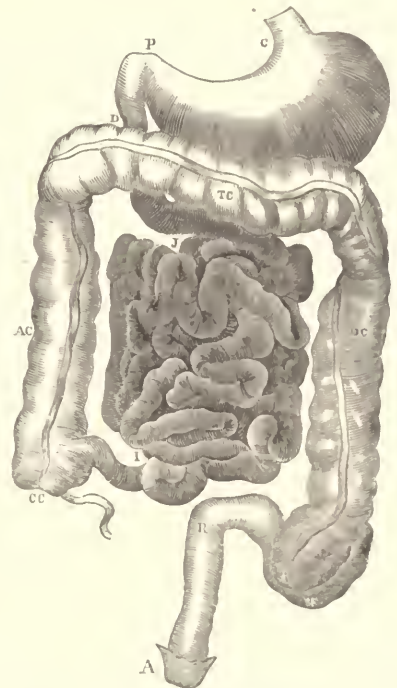


FIG. 21.—Stomach and Intestinal Canal of the adult human subject. (After BUNTON, in *Cyclopaedia of Anatomy and Physiology*, Vol. V, Supplement, p. 307.) C P—stomach. C—cardiac. P—pyloric orifice. J I—small intestine. J—jejunum. I—ileum. C C to A—large intestine, viz: C C—caecum. A C—ascending colon. T C—transverse colon. D C—descending colon. S F—sigmoid flexure or sigmoid colon. R—rectum. A—anus.

<sup>1</sup> CHISOLM, *A Manual of Military Surgery*, Columbia, 3d ed., 1864, p. 349: "In gunshot wounds of the stomach the contents escape externally, and also into the peritoneal cavity, where, as extraneous substances, they light up general and, usually, fatal peritonitis. As soldiers most frequently go into battle without previously having had a meal, the flaccid condition of the stomach, without contents to escape from this organ, is a great safeguard in case of wounds, and hence perforating wounds of this viscus more frequently recover under these circumstances than when gunshot injuries are received under other conditions. The location of the wound is often, in the army, the only basis for diagnosis, as the escape of contents and vomiting of blood are not constant symptoms, and shock, which is usually present, is common to all wounds of the abdominal viscera."

<sup>2</sup> WARREN (E.), *An Epitome of Practical Surgery, for Field and Hospital*, Richmond, 1863, pp. 402.

<sup>3</sup> *A Manual of Military Surgery, prepared for the Use of the Confederate States Army by Order of the Surgeon General*, Richmond, 1863, p. 62:

"If the stomach has been penetrated there will probably be vomiting of blood from the first."



published since the war, contain no observations on the subject. Dr. D. C. Peters<sup>1</sup> has printed a case of recovery from a supposed shot perforation of the stomach, and this case has been repeated with some references to the literature of the subject, by Dr. J. A. Lidell<sup>2</sup> and Dr. F. H. Hamilton.<sup>3</sup> It is possible to adduce a half-dozen alleged recoveries that must be discredited as erroneous returns; a number of recoveries in which the gastric lesions are authenticated by the same evidence as was produced in the case recorded by Dr. Peters, to wit: the unsupported testimony of the patient; and some instructive fatal cases, of undoubted authenticity, attended with gastric fistulæ or other complications.

*Punctured and Incised Wounds.*—A few fatal examples, unattended by any unusual features, were reported.<sup>4</sup> Recoveries from stabs, with complete solution of the walls of the stomach, are far less frequent than a superficial examination of the annals of surgery would lead the reader to infer.<sup>5</sup>

CASE 171.—Corporal P. Whittaker, Co. C, 1st Mississippi Mounted Infantry, was admitted into Hospital No. 2, at Vicksburg, June 26, 1864, from the transport *Diana*, with a punctured wound in the epigastric region. He had vomited blood and was suffering from excessive nausea, intense thirst, with great anxiety and languor. The surface was clammy and the extremities were cold. He died on June 27, 1864. No autopsy. The case is recorded by Surgeon Harmon Benson, 14th Wisconsin.

CASE 172.—Private J. W. —, Co. B, 5th New York Artillery, was admitted into the Jarvis Hospital, Baltimore, March 15, 1864, with a punctured wound in the left hypochondriac region. He had been stabbed by a bayonet, the point entering seven and one-half inches below the left nipple, and six inches from the ensiform cartilage, at a point corresponding with the chondro-costal extremity of the ninth rib. He was drunk, and his bladder was paralyzed. The bladder was evacuated by a catheter, and simple dressings were applied to the wound. There was very little bleeding, and but little vomiting. On the 16th, he was comparatively comfortable. On the morning of the 17th, there was excruciating pain, vomiting, tympanitis, and all the symptoms of traumatic peritonitis, with bloody vomiting, and blood in the stools. Death followed, on March 18, 1864. At the autopsy it was found that the bayonet had transfixed the jejunum and the stomach, and that blood, feces, and an ascaris lumbricoides had been extravasated into the peritoneal cavity. The preparation of the stomach, presented with the foregoing notes by Acting Assistant Surgeon B. B. Miles, is figured in the wood-cut (FIG. 22). The preparation of the jejunum is represented further on.

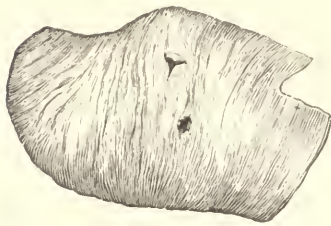


FIG. 22.—Section of inverted stomach punctured by a bayonet near the cardiac extremity. *Spec.* 2258.

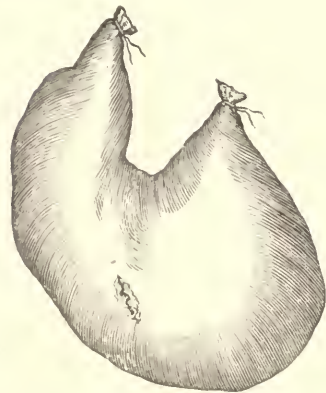


FIG. 23.—Stomach with the middle of the anterior wall punctured by a bayonet. *Spec.* 4-67. [Reduced to one-fourth.]

CASE 173.—Private E. Owens, Co. K, 4th United States Cavalry, aged 32 years, was admitted to Hospital No. 1, Nashville, March 27, 1864, with an incised wound of the stomach, received at Nashville on the preceding day. He died on April 4, 1864. The case is reported by Surgeon R. L. Stanford, U. S. V.

CASE 174.—Private Robert Frazer, Co. C, 4th Illinois Cavalry, aged 20 years, was admitted into Gayoso Hospital, Memphis, from his regiment, April 17, 1865, with an incised wound of the stomach. He died on the same day. Surgeon Daniel Stahl, U. S. V., reports the case.

The preparation represented in the adjacent wood-cut (FIG. 23) was removed from a patient who survived a bayonet stab in the stomach for thirty-six hours. A branch of the right gastro-epiploic artery was ligated. Hypodermic injections of morphia allayed the excruciating pain in this case, and cold milk, held in the mouth or against the fauces, relieved the excessive thirst better than ice. Assistant Surgeon E. Bentley,

<sup>1</sup> PETERS, *Cases in Military Surgery*, in *Am. Med. Times*, 1863, Vol. VI, p. 160. The case is also recorded in Circular No. 6, S. G. O., 1865, p. 25. The patient's name on the muster-roll is George Bowes, and appears variously as G. M. or G. H. Bowes or Bowers on the hospital registers.

<sup>2</sup> LIDELL, *Injuries of the Abdominal Viscera occasioned by Fire-arms*, in *Am. Jour. Med. Sci.*, 1867, N. S., Vol. LIII, p. 350. Dr. LIDELL gives Hennen's summary of the literature, and notices the case of St. Martin.

<sup>3</sup> HAMILTON (F. H.), *A Treatise on Military Surgery and Hygiene*, 1865, p. 358, and *Principles and Practice of Surgery*, 1872, p. 115. St. Martin and Bowes are the examples adduced.

<sup>4</sup> Surgeon CLEMENTS has recorded (*Circular No. 3, S. G. O.*, 1871, p. 91) a case of recovery from an incised wound, which was believed to involve the pyloric extremity of the stomach. Acting Assistant Surgeon HOGG (*Ibid.*, p. 101) cites a recovery from a punctured wound, supposed to have penetrated the anterior wall of the stomach. In both cases there was hæmatemesis; but no extravasation. In the same report, page 100, Assistant Surgeon BENTLEY relates a case, in which he unavailingly practiced gastrorhaphy.

<sup>5</sup> The number of examples of recovery from unequivocal penetrating, punctured, or incised wounds of the stomach is not large. The often-quoted case by TRAVERS (*Edinb. Jour. Med. Sci.*, 1826, Vol. I, p. 81) is accompanied by very valuable observations on wounds of the stomach. Dr.

U. S. A., gives a full account of the case, in the report in Circular 3, S. G. O., 1871, page 100. The stomach was in a state of repletion when the injury was received, and the

PHYSICK (GIBSON'S *Institutes and Practice of Surgery*, 7th ed., 1865, Vol. I, p. 121) was accustomed to relate in his lectures, that Dr. ARCHER, of Hartford county, Maryland, in a case of incised wound of the stomach obtained a successful issue by stitching the coats of the stomach to the wall of the abdomen. Dr. CHARLES WM. ASHBY (*The Stethoscope and Virginia Medical Gazette*, 1851, Vol. I, p. 660) relates a case of recovery after protrusion of nearly the whole stomach, in a negro lad of six years, the contents escaping through an aperture in the anterior wall three-fourths of an inch in length. The boy had fallen on the points of a pair of sheep-shears, which had entered obliquely, grazing the left edge of the sternum and the costal cartilages. A single fine-silk stitch was placed in the middle of the wound, which was brought near the external one, which was sewed up. Dr. C. HAPFOLDT (*Charleston Medical Journal and Review*, 1855, Vol. X, p. 341) relates, at length, a recovery from a wound of the stomach by a bowie-knife. I cannot regard the evidence of complete penetration of the stomach in this case as conclusive. A report of an alleged recovery from an incised wound, three inches long, of the anterior wall of the stomach, closed by the interrupted suture, in Dr. O. BLANCHARD (*Oregon Physio-Medical Journal*, 1868, Vol. II, p. 124), does not inspire confidence. Dr. BURRITT (*Notes of Practice, in Phila. Med. and Surg. Reporter*, 1871, Vol. XXV) records, as a recovery from an incised wound of the stomach, a case in which the evidence does not at all warrant the admission of any serious lesion of that organ. Dr. D. C. PETERS (*Am. Med. Times*, 1868, Vol. VI, p. 161) alludes to a Mexican, stabbed in the epigastrium by a cheese-knife, who "had hæmatemesis and other symptoms which caused me to believe that the stomach had been wounded." Dr. F. H. HAMILTON (*A Treatise on Mil. Surg.*, p. 361) cites this as a recovery from "a punctured wound of the stomach," though Dr. PETERS explicitly states that "introducing my finger into the wound I could not discover any wound of the stomach." ARCHER'S case, already noted, is detailed in the *Medical Repository*, 1812, Third Hexade, Vol. III, p. 215, *et seq.*, in a paper entitled "A Case of extraordinary recovery from wounded stomach, which occurred in the practice of the late Hon. John Archer, M. D., in a letter from his son, John Archer, M. D., of Maryland, to Joseph Glover, M. D., of Charleston, South Carolina." It is the more remarkable because food escaped into the peritoneal cavity, and half-digested matter, in which portions of cabbage were recognized, was evacuated through an abscess in the groin. PHYSICK or GIBSON reported the case erroneously; the external wound only was sewed up, by an old soldier. ARCHER saw the patient on the third day and "thought it best to cut all the stitches \* \* \* \*"; they were merely in the cutis and would have broken loose in two days more." The incision in the stomach was two inches long, and was made just after the ingestion of a full meal of bacon and cabbage and cider. Other American cases will be referred to under the head of *gastrotony*. Of those here cited, only the two recorded by ARCHER and ASHBY are incontestable instances of recovery from wounds of the stomach, the observations of Drs. CLEMENTS, HOGG, HAPFOLDT, BLANCHARD, BURRITT, and PETERS being open to criticism. In the *Annals of British Surgery*, besides the case of TRAVERS, already noted, is the remarkable case recorded by SCOTT (*Medical Communications*, 1784, Vol. II, p. 78), of a sailor, aged 25, stabbed in the stomach by a small sword; there was no protrusion, and sutures were not employed. The patient recovered under the use of opiate and nutritive enemata. FOUSTH'S case (*Medical Times*, 1850, Vol. I, p. 494) of a constable stabbing himself with a bayonet, though endorsed by the editor (who blunders again in addressing WISEMAN'S raper transfusion in the "right hypochondrium," *Chirurg. Treatises*, p. 173, as a wound of the stomach), was plainly not a lesion of the stomach, the patient drinking and retaining "amazing quantities" of seidlitz draughts and cold water soon after the infliction of the injury. In Mr. MAUNDER'S case (*Clinical Lectures and Reports of the London Hospital*, 1864, Vol. I, p. 120) the evidence of any direct lesion of the stomach is equally defective. The two cases reported by the Reverend JAMES FIELD, of Antegoa (in the *Philosophical Transactions*, No. 371, p. 78, or Vol. VII, p. 506, of the abridgment by EAMES and MARTYN, 1734), of the negro father and son who inflicted vast gashes in each other's stomachs, which were stitched up by Mr. FORDERST, surgeon, so that in a month's time they were both perfectly cured, derive their only claim to authenticity from the place in which they are published. In the works of continental European surgeons, we find recorded in HEVIN'S erudite paper (*Mém. de l'Acad. royale de Chir.*, T. I, p. 391) the case of sword stab in the stomach successfully treated by COGILLAN, a surgeon of Belle-Isle, which furnishes BOYER (*op. cit.*, T. VI) with his argument for the utility of album in hæmatemesis; and in the same exhaustive, but never exhausted, dissertation, the memorable cases of LESSERÉ (*l. c.*, p. 592) and CARTERAT (*l. c.*, p. 594). In the *Bulletin de la Faculté de Médecine de Paris*, T. V, 1817, pp. 386, 391, *et seq.*, are printed the much-cited observations of RINSTRAT, PERCY, and LAROCHE, of Antwerp, all three of which are in point, save that RINSTRAT had to deal with a lacerated rather than an incised wound. In two of these cases a modification of LEBRAN'S looped suture was advantageously employed. Of more recent cases, that reported after Waterloo, by JOHN THOMSON, and mentioned by HENNEN (*op. cit.*, p. 143), of a pike stab in the stomach, the fact of complete ultimate recovery is not positively stated. But LARREY (*Mém. et Camp.*, 1812, T. III, p. 91) records an unequivocal instance of recovery from a penetrating sword wound of the stomach: "J'ai la preuve que les plaies de l'estomac se guérissent très-bien, et même sans suture. Je rapporterai succinctement, à l'appui de cette assertion, l'observation d'une assez large blessure reçue par un soldat de la garde vers la grosse extrémité de ce viscère, et produite par la pointe très-acérée d'un sabre, qui pénétra d'abord dans la poitrine entre la septième et la huitième côte, lésa une petite portion du poulmon, coupa le diaphragme, et perfora l'estomac dans la portion correspondante de sa grosse extrémité. La douleur locale, les vomissemens sauguins, l'issue par la plaie des liquides que le blessé avalait; enfin, la direction elle-même de la plaie, ainsi que sa profondeur, ne laissent point de doute sur l'ouverture de l'estomac. Les premiers jours furent très-orageux, et le malade se trouva plusieurs fois aux portes du tombeau; cependant, à l'aide des rafraichissans, des saignées locales et générales, de la diète prolongée, des lavemens emolliens, et de la position du blessé que je faisais tenir constamment sur le côté droit, la plaie se cicatrisa, et ce militaire sortit de l'hôpital pour entrer dans les vétérans de la garde. Il a conservé une hernie du poulmon, qui se manifeste sous la cicatrice, et qu'il contient, avec quelque peine, au moyen d'un bandage fait exprès." In the old collection of cases, a certain number of instances of recoveries from punctured and incised wounds of the stomach may be found; but care is requisite to discriminate original observations and to verify the authenticity of citations. ALBICASIS (*De Chirurgia*, Arabicæ et Latine, cura JOHANNIS CHANNING, Oxon., 1778, 4to, Lib. II, Sect. 85, p. 379) states that he once cured a knife wound of the stomach by the suture. DIEMERBROECK (*Opera Omnia Anatomica*, Utrechti, 1685, p. 22) refers to cases collected by CORNAX and SCHENCKIUS, and gives a circumstantial account of a recovery he witnessed himself, in 1641, in a Batavian country boy, stabbed with a knife in the cardiac extremity of the stomach. I have not access to the great collection of JOHN SCHENCKIUS, printed in seven volumes, at Freiburg, about 1580, but it is said to contain a paper by OETHEI'S (*De vulneribus ventriculi sanatis*) describing the case of a soldier at Marpach, in Fulda, who recovered from a stab in the stomach. The viscus was drawn out and stitched with sutures which were attached to the abdominal wall. HAMEL, in the *Zodiacus Medicæ Gallicæ*, October, 1680, *Obs.* II, p. 206, records the case of "a young man named Crotte," of Lexovium (Lisieux), who fully recovered from a sword wound of the upper part of the stomach. STALPART VAN DER WIFEL'S successful gastrostomy is recorded in ETMÜLLER (HALLER'S *Disputationes*, T. V, p. 670). Other unquestioned recoveries are recorded by FOCKLER (*De vulnere ventriculi duplicato*, Erford, 1716), by DÜRR (*De vulnere ventriculi ægryie curato*, Leipsig, 1730), by LOUBET (*Traité des Plaies*, Paris, 1783, p. 211), by RICHTER (*Chirurgische Bibliothek*, 1790, B. X, S. 203), by TEN HAAF (*Verhandeling over de voor-naamste Kuetzuren*, n. s. w., Rotterdam, 1781). The last five appear to have been recoveries without the use of the suture. PURMANS (*Lehrbeerkranz oder Wundartzney*, Franckfurth, 1692, S. 410) records two cases of gastrostomy, which he successfully practiced in the persons of Krespen and Müller, soldiers of Colonel Cannon's regiment, and describes how he drew out the edges of the wounded stomach with a small hook and inserted one or two stitches. He adds that he never observed inflammation in such cases. He does not state whether they were punctured, incised, or shot wounds. Probably they did not belong to the latter class; for there is no allusion to paring of the bruised edges. SCHLICHTING, in his *Traumatologia Nov. Antiqua* (4to, Amsterdam, 1718, p. 79), refers to a case he successfully treated by the looped suture, "after the precepts of BOHNIUS." A similar case, which I have been unable to verify, is said by HENNEN, to be recorded by KLYFFKENS, in the "*Annales de la Littérature*." As much must be admitted of the cases ascribed to MATHEI'S (*Diff. Med. Quæst.*), to MENZEL (*Mis. Nat. Cur.*, Dec. 11, Ann. I, Obs. 1), and to GAYANI, by ETMÜLLER. There seems to be no reason to discredit the three cases which FLAJANI (*Collezione di osservazioni e riflessioni di chirurgia*, Roma, 1803, Vol. I, p. 7) records. Brogini, Parichini, and the subject of the ninth observation, appear to have recovered from incised wounds of the stomach. In the case of Parichini, gastrostomy was practiced. Of the recoveries with fistula, and of the cases of the Prussian, Bohemian, and French cultivators, mention will be made elsewhere. Of cases recently reported, that of HYEEL (*Handb. der Topog. Anat.*, Wien, 1865, S. 674) is well authenticated, and two, published by Professor BOBSERI, of Bologna (*Bulletino delle Scienze Mediche*, Nov. 1871), and a third recorded by Dr. PEYRANI (*Lo Sperimentale*, Jan. 1871), border on the marvellous in their coincidence and in the rapidity of their uncomplicated progress toward recovery. Dr. WIGAND (*Memorab.* VII, 12, 1862) gives an authentic case,



symptoms usually ascribed to wounds of this organ were well defined. The stomach was drawn out, and the incision in its walls was closed by the interrupted suture; the viscus was then replaced, and the external wound was united in the same manner.

There is still diversity of opinion as to the proper rules of practice in punctured and incised wounds of the stomach, even where the viscus protrudes or presents at the external wound. If the puncture is small, it is advised that the lips of the opening should be pinched up with a pair of forceps and a thread tied around it (FIG. 24), as practiced by Sir Astley Cooper,<sup>1</sup> for a wound of the intestine, and, with signal success, by Travers,<sup>2</sup> for a wound of the stomach by a razor, in the well-known case reported by him, with very valuable observations on wounds of the stomach from various causes. If the wound is a trifle



FIG. 24.—Ligature around a punctured membrane.

larger, it is recommended that it should be closed by one or more points of interrupted suture (FIG. 25), placed by means of a delicate needle with fine thread, or else by some one of the ingenious stitches that will be described in treating of wounds of the intestines.<sup>3</sup> In more extensive

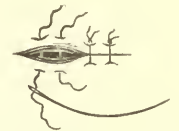


FIG. 25.—Interrupted suture.

solutions of continuity, the continued suture (FIG. 26) or one of its numerous modifications may be required. Whether the sutures should be cut close to the knots and the organ returned unattached into the cavity, or whether the ligatures should be suffered to hang loosely from the external wound, or whether the lips of the wound in the viscus should be stitched to the abdominal walls, are points on which opinions are divergent, and which must come again under consideration in connection with the subject of suture of the intestines.

**Gunshot Wounds.**—Not less than nineteen cases of recovery from alleged shot wounds of the stomach were reported. The evidence, in each instance, has been examined, and the inferences are that, in some cases, the diagnoses had no foundation, and the erroneous returns were due to culpable carelessness or ignorance, the term stomach being sometimes employed by simpletons apparently as an euphuism for belly; that in other cases, hospital surgeons or pension examiners have related and endorsed the narratives of patients, and described as facts events which, if they ever occurred, transpired long before

<sup>1</sup> COOPER, A., *The Lectures of, on the Principles and Practice of Surgery, with additional Notes and Cases.* By FREDERICK TYRRELL, London, 1827, Vol. III, p. 232.

<sup>2</sup> TRAVERS, *A Case of Wound, with protrusion of the Stomach.* In *Edin. Jour. of Med. Sci.*, 1826, Vol. I, p. 81.

<sup>3</sup> In wounds of the stomach, LE DRAN advised the looped suture, or suture *à anse*, that bears his name (*The Operations in Surgery of M. LE DRAN.*



FIG. 27.—Looped suture; suture *à anse*; Le Dran's suture.

Translated by Mr. GATAKER, surgeon, 4th ed., London, 1768, p. 60), and which has been much advocated, apparently from theoretical considerations. It is simply the interrupted suture with the threads untied, but left long enough to twist the ends together into a cord (FIG. 27), to be brought out of the external wound, with a view of untwisting and separately withdrawing the threads. It is mentioned by all of the classical authors, and Professor GROSS (*Wounds of the Intestines*, p. 99) gives a figure of it, but expresses a doubt whether the inventor ever employed it upon the human subject. The *basting* or *darning* stitch (FIG. 28), the suture *à points passés* of French writers, devised by BERTRANDI (*Traité des Opérations de Chirurgie*, traduit de l'Italien par Sollier, Paris, 1784, Chap. II, p. 15), was highly praised by such respectable authorities as SABATIER, DESAULT, and BOYER, though Dr. GROSS does not find that they have adduced any facts in illustration of its efficiency. To obviate the danger of separating adhesions by the traction necessary to withdraw the thread in this form of suture, BÉCLARD used two threads of different colors, and, when they were to be withdrawn, made traction upon an end of one thread and the opposite end of the other, so that the wound, subjected to equal simultaneous tractions in opposite directions, was not disturbed, an expedient which LARREY and others have employed in various sutures. The form of suture employed is not specified in many of the comparatively small lists of successful examples of gastrorraphy, but BÉRAUD asserts (*Dict. de Méd.*, T. XII, p. 302) that LAROCHE and PERCY, in their famous cases, employed the looped suture. CARTERAT (*Mém. de l'Acad. de Chir.*, I, p. 594) succeeded with the glover's stitch. STALPART VAN DER WIEL (*Obs. Méd.*, Cent. I, No. 39) and FIELD (*Philosoph. Trans.*, No. 371, p. 78) sewed the wall of the stomach to the muscles of the abdominal parietes.

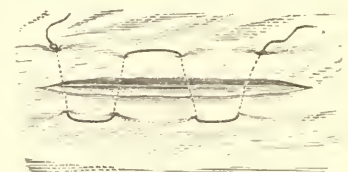


FIG. 28.—Suture *à points passés*, or basting stitch. Sutura transgressiva of PETIT, BERTRANDI, and SABATIER.



the patients came under their observation, and are destitute of corroborative evidence; that, in a few instances, recovery followed injuries which careful and competent observers pronounced to be shot wounds of the stomach; finally, that, even in the latter small category, not more than one incontestable example of recovery was recorded.

Careful investigation of the recorded symptoms and progress of the six following cases has failed to elicit any evidence in corroboration of the diagnoses of "severe gunshot wound of the stomach," with which they were reported. None of the names appear on the Pension List:

CASES 175-180.—1. Reported by Assistant Surgeon C. W. Cadden, Purnell Legion: Pt. J. Noch, Co. B, 95th Pennsylvania, Gaines's Mills, June 27, 1862; made prisoner; exchanged July 21; treated at Camden Street and West's Building hospitals, Baltimore; discharged October 9, 1862. 2. Reported by Surgeon P. N. Woods, 39th Iowa: Capt. J. M. Brown, Co. F, 39th Iowa; Parker's Cross Roads, Tennessee, December 30, 1862; resigned July 13, 1863. 3. Reported by Surgeon W. Threlkeld, U. S. V.: Pt. S. Leslin, Co. K, 6th Veteran Reserve Corps, aged 45 years; Sandusky, Ohio, May 18, 1865; treated at the Johnson's Island Hospital and Camp Dennison; discharged July 17, 1865. 4. Reported by Assistant Surgeon Dallas Bache, U. S. A.: Capt. Riley A. Read, Co. F, 9th Kentucky; Murfreesboro', January 3, 1863; treated at field and Nashville hospitals; mustered out December 15, 1864. 5. Reported by Surgeon J. C. McKee, U. S. A.: Pt. J. E. Yates, Co. B, 1st Virginia Artillery, aged 30 years; Sailor's Creek, April 6, 1865; treated at Second Corps and Washington hospitals; released June 14, 1865. 6. Reported by Surgeon John Neill, U. S. V.: Corp. A. Atkins, 5th New York; Gaines's Mills, June 27, 1862; treated at Fort Monroe, Washington, and Philadelphia hospitals; discharged October 4, 1862.

The evidence that the stomach was really wounded in the following case is equally unsatisfactory. The man is pensioned on account of the "impaired power of arm:"

CASE 181.—Reported by Acting Assistant Surgeon J. B. Smith: Corp. T. Raley, Co. I, 73d Ohio; Gettysburg, July 3, 1863; gunshot wound of stomach and of right hand; treated at field and Cincinnati hospitals; discharged October 27, 1863.

Of the many medical officers who observed the following case, Surgeon G. Derby, U. S. V., alone accepted the patient's statement—that there had been a gastric fistula:

CASE 182.—Corporal G. A. Shay, Co. L, 1st Maine Cavalry, aged 29 years, received a shot wound of the left side, in an engagement on the Boydton Plank Road, October 27, 1864. He was taken to the field hospital of the Cavalry Corps, where simple dressings were applied. Both openings had closed by December 16, 1864, and he was sent to Washington and placed in Lincoln Hospital. During the journey to Washington one of the wounds reopened, but cicatrized again a few days after his arrival at the hospital. He was furloughed February 20, 1865, and returned to duty March 27th; but, on May 3d, was admitted to the Cavalry Corps Hospital on account of an "old gunshot wound." On May 7th, he was transferred to Carver Hospital, and, on the 27th, to Cong Hospital, Augusta, whence he was discharged from service on July 10, 1865. In a letter dated June 12, 1865, Surgeon George Derby, U. S. V., says: "The ball entered at the edge of the last rib of left side, and came out within two inches of the spinal column, left side, passing through the stomach. Food passed out of both openings, at different times, during six weeks." Examiner James B. Bell reports, August 21, 1865, "the ball passed through the lower part of the left chest. The chest is weak and the wound imperfectly healed."

In the following case the patient did not disclose to the hospital surgeons that there had been gastric fistula, reserving that information for the second pension examiner:

CASE 183.—Private John Maxwell, Co. K, 21st New Jersey, aged 20 years, was wounded at Fredericksburg, May 3, 1863. On the 17th he was admitted into the 1st division hospital at Annapolis, from the steamer State of Maine, and placed under the care of Acting Assistant Surgeon L. Smith, who has entered on the medical descriptive list that "the ball entered the posterior and superior portion of the ilium, passed under the muscles, making its exit about an inch below the xiphoid cartilage, producing a suppurating wound." Simple dressings were applied to the wound; the patient improved rapidly, and was returned to duty June 15th, and mustered out with his regiment June 19, 1863. Pension Examiner S. L. Cordist reports, under date of July 17, 1863: "Conoidal ball entered left hip posteriorly, six and one-half inches from the anterior superior spinous process of the ilium and just at the edge of the crest of the same, and emerged in the linea alba, four and one-half inches above the umbilicus and just at the lower edge of the epigastrium. The wounds have entirely healed, and there is no disability apparent; but the applicant declares himself incapable of walking any distance, and that violent cramp ensues from any active exercise, causing a loss of all power over the left limb, and that a hearty meal will produce the same effect." Maxwell was examined in September, 1865, and May, 1866, by Examining Surgeon Charles Cook, of Jersey City.

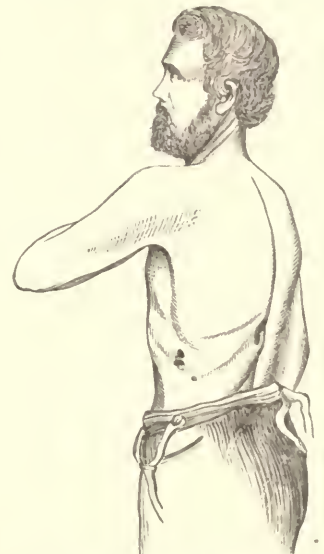

FIG. 29.—(Fistulae in a case of recovery from an alleged wound of the stomach. [From a photograph.]

who states, in a communication to this office, that "the ball entered one and a half inches to the right of the spinal column, below the last or lower asternal costa, passed upward and forward, perforating the stomach, and out one and a half inches below the sternum. Fluids swallowed continued to flow through the orifice below the sternum for about ten days. Was taken from the field at Chancellorsville, after being wounded twenty-four hours, and carried to Libby Prison at Richmond. Rebel surgeons gave him no attention whatever for six days, considering his case hopeless. Complains that his food distresses him; of constant weakness at epigastrium, and of general debility." [This pensioner died February 25, 1870; but no *post-mortem* observations have been reported.]

The patient whose history is next related, like many others, was incapable of appreciating the kindness which dictated an expectant treatment:

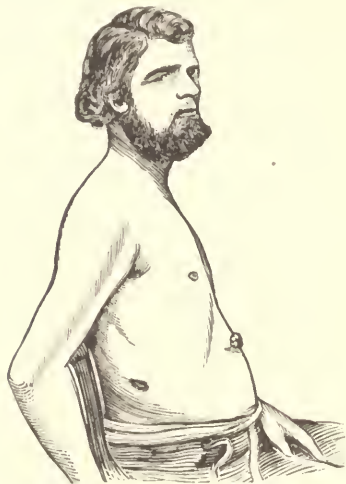

FIG. 30.—Scars of entrance and exit in a case of alleged wound of the stomach. [From a photograph.]

CASE 184.—Private P. H. Chick, Co. I, 3d Maine, aged 24 years, received a penetrating wound of the abdomen, by a conoidal ball, at the Wilderness, May 6, 1864. He was taken prisoner and remained in the hands of the enemy until the wounds had healed, receiving little or no attention, his case being at first considered hopeless. He was finally paroled, and, on March 9, 1865, was admitted into Cony Hospital, Augusta, Maine. The ball had entered two inches below the ensiform cartilage, in the median line, passed through the diaphragm, and came out through the base of the right lung and tenth rib. The patient stated that air passed freely in and out of the wound of exit with a whistling sound, and that coffee and other fluids which he swallowed ran out of the wound of entrance for many days. Confederate Surgeons told him that bile came from the wound of entrance. He was discharged from service April 21, 1865, at which time Surgeon George Derby, U. S. V., reports that he was well and strong, and his digestion was perfectly good. There was a ventral hernia through the rectus muscle—a tumor as large as a hen's egg—projecting at any expulsive effort. The right side of the body was a little sensitive in walking, so that he moves with the toes averted, bringing the foot down square instead of heel and toe. Examining Surgeon Edmund Russell reports, August 4, 1865: "Musket ball entered near the pit of the stomach and came out near the spine, fracturing two ribs. His bowels swell, and he suffers pain if he does any thing hard; is very weak." Examining Surgeon C. W. Snow reports, September 2, 1867: "Gimshot wound of right lung. The stomach was wounded by the same ball, I judge, from his statement of symptoms and from the course of the ball." This pensioner's condition was reported unchanged when he was last paid, Dec. 4, 1872.

An unusual proportion of alleged recoveries from shot wounds of the stomach were thus observed at Cony Hospital.

The following case, reported by Assistant Surgeon D. C. Peters, U. S. A., has been adduced as an irrefragable instance of recovery from a shot perforation of the stomach.<sup>1</sup> It will be observed that there is no other evidence of the gastric extravasation and of the hæmatemesis than the patient's statement. It is noticeable that Assistant Surgeons DuBois and MacKenzie, who successively had the patient in charge, made no note of these remarkable features:

CASE 185.—Private George H. Bowes, 8th Illinois Cavalry, in a skirmish, September 13, 1862, was shot in the abdomen. Captain J. D. Ludlam, 8th Illinois Cavalry, certifies that this man "was shot in a cavalry skirmish, by the enemy, near Middletown, Maryland, and left on the field. I afterward sent an ambulance and brought him in. I did not think he would live through the night. I saw him when shot, and I was commanding the squadron." Surgeon C. Hard, 8th Illinois Cavalry, does not refer to the case on his monthly report. As most of the wounded of the battles of South Mountain and Antietam were taken to Frederick the search for the patient was directed there, and it was found that Assistant Surgeon H. A. DuBois, in charge of Hospital No. 4, records, that Bowes entered that hospital on September 19th, with a shot wound believed to involve the intestines. The particulars of the progress and treatment of the case are not recorded. On January 5, 1863, the patient was transferred to the hospital at Camp B, Frederick, where Assistant Surgeon T. G. MacKenzie recorded the case without any details. On March 9th, the patient was transferred to Jarvis Hospital, Baltimore, and came under the charge of Assistant Surgeon D. C. Peters, in whose language a more detailed history may be given: "George H. Bowes, aged 19, a private in the 8th Illinois Cavalry, was transferred from Frederick, Maryland, to this hospital, March 7, 1863. The patient states that the day previous to the battle of South Mountain his regiment was in the advance, skirmishing with the enemy, when he became engaged in a hand to hand encounter with a rebel horseman. The man fired several shots at him with his revolver, one of which took effect in his abdomen. The ball entered the abdomen about two inches above the umbilicus and one inch to the left of the linea alba, traversed backward and slightly upward, and made its exit just beneath the tenth rib, at a point that is about two and one-half inches from the spinous process of its vertebra. The wound immediately placed him *hors de combat*, and he commenced to

<sup>1</sup> An abstract of the case was printed in Circular 6, S. G. O., 1865, p. 25. Assistant Surgeon PETERS published a copy of his official report, in a paper entitled *Cases in Military Surgery*, in the *Am. Med. Times*, 1863, Vol. VI, p. 160. The case is the only example of recovery from a shot wound of the stomach, during the war, mentioned by Dr. HAMILTON, *Treatise on Military Surgery*, 1865, p. 300, and *Principles and Practice of Surgery*, 1872, p. 115.

vonfit blood, and it at the same time poured from his nostrils. The free hæmorrhage caused syncope, which temporarily arrested it, but, at spells for the following seven days, he had a series of these hæmorrhages. He further states that after receiving the wound he had bloody passages from his bowels, which gave him intense pain, and continued for about the same length of time. There was but a small amount of blood that escaped from the wounds. The surgeon who examined him on the field informed him that the ball had passed through his body. The injury was followed by acute inflammation, as he complains of having suffered much pain and tenderness in the whole abdomen, and says he had fever. He was confined to his bed, undergoing active treatment, for several weeks. Whenever he received fluids or solids into his stomach, he states that, for a period of two months, a part of the half-digested material would escape from the anterior wound and soil the dressings. From his system not receiving proper nutrition, he became very weak and emaciated; but finally the wounds closed, and since then he has regained his health rapidly. The healthy action of the prime viæ is again fully established, but, owing to contractions formed in the healing of the track of the wound, he is bent forward, and cannot by any force straighten himself. The treatment at present is directed toward overcoming these contractions. Remarks: Cases of recovery from gunshot wounds of the abdomen are by no means uncommon; but recovery from wounds of the stomach (and there is every probability this comes under that category) and other abdominal viscera are exceptional to the general rule." Private Bowes was discharged from hospital and from the military service April 2, 1863. His pension claim was admitted November 21, 1863, on his captain's certificate, already quoted, and a certificate of disability by Dr. Peters, which was substantially an extract from the foregoing report. The disability was rated as total. No further particulars are given by any pension examining surgeon. The pensioner was last paid in September, 1872, his condition being described as unchanged.

The opinion of the attending surgeon, in the following case, inspires less confidence than that of the pension examiner:

CASE 186.—Private George Hart, Co. G, 1st West Virginia Artillery, was wounded, during General Averill's raid, at Rocky Gap, August 26, 1863. Surgeon William D. Stewart, U. S. V., noted the case as "gunshot wound of the stomach." The patient was taken prisoner and remained in the hands of the enemy until November 25, 1863, when he was paroled, and admitted into the post hospital at New Creek, West Virginia. He was discharged from service June 22, 1864. Pension Examiner George McCook reports, under date of July 11, 1864: "The ball struck the fifth rib, left side, near its sternal attachment, was diverted, passed downward and lodged, inflicting an extensive injury on the rectus muscle. The ball was extracted. Suppuration followed. An abdominal hernia, embracing a circumference of six inches, has resulted. The abdominal parietes are weakened. A broad truss is required to control the rupture; the ability to bend his body is diminished. Disability total and permanent."

The next observation is important, because the symptoms immediately following the injury were observed and recorded. Unfortunately, the reporter suffered an interval of four years to elapse before placing the case on record. It may be ungracious to deny the exactness of his diagnosis; which, indeed, furnishes the most plausible explanation of the phenomena; yet none of the symptoms related are inconsistent with the hypotheses that the visceral lesions might have been limited to the left lobe of the liver or to the duodenum.

CASE 187.—Private Patrick Sweeney, 7th New York Cavalry, aged 21 years, was shot, in a quarrel at a brothel in Washington, about midnight, January 4, 1862. In a special report, February 2, 1866, Surgeon C. L. Hubbell, 7th New York Cavalry, states: "He stood with his side rather toward the man firing, and about ten feet distant. The pistol was a Colt's revolver, second size. The ball entered about an inch below the last rib, directly underneath the cardiac region, and, passing through the stomach and liver, lodged just beneath the skin, at a point about four inches back of the crest of the ilium, near the outer border of the latissimus dorsi muscle. It was readily removed by a small incision. In about half an hour after the injury the man was brought to my regimental hospital, near where the Campbell Hospital was afterward located. He was vomiting blood profusely, and was almost pulseless. The first indication was to check the hæmorrhage; this, and the vomiting, also, was arrested entirely at the expiration of twenty-four hours, by the constant application of cloths, wet in ice-water, to the hypogastric region. No drink whatever and no nourishment were allowed, except a little cold crust-water, in quantities of a teaspoonful only about once in an hour, although the thirst was urgent. As it seemed to me that, in order to secure the union of the wound in the stomach, the organ must contract to its smallest possible size, and must rest, allowing only so much nutriment and drink as would sustain life and be easily absorbed. The dejections from the bowels were black and tar-like for several days, as in melæna. On the second day, peritonitis with great tenderness and considerable tympanitis supervened, but, by the exhibition of large doses of morphia and the continued application of cold cloths, it was entirely subdued, and at the end of one week it was evident that all danger in the case had passed. No solid food was allowed until about the tenth day, but beef tea and other nutritious drinks were given in small quantities at a time. At the end of the sixth week, he was able to walk about the hospital with a cane, and, at the time the regiment was disbanded, in March, appeared quite well and was able to eat and digest the army rations. I shall always attribute the recovery in this case to the faithful use of cold wet cloths, producing contraction of the stomach and arresting the hæmorrhage. I afterward saw, on different battle fields, several gunshot wounds of the abdomen, all of which resulted fatally in a few hours. In none of them was the stomach perforated."

Assistant Surgeon H. Culbertson's diagnosis, in the following case, is in disaccord with the conclusions of several other observers:

CASE 188.—Sergeant F. A. Barnard, Co. A, 37th Wisconsin, aged 25 years, was shot through the body by a conoidal musket ball, at Petersburg, June 18, 1864, the missile entering the right hypochondrium and emerging at the left. He was



taken to the Ninth Corps Hospital, and treated by restoratives and simple dressings. Surgeon M. K. Hogan, U. S. V., reports the case simply as a "gunshot wound of the abdomen." On July 24th, the sergeant was transferred to the Fairfax Seminary Hospital, where Surgeon D. P. Smith, U. S. V., reports the injury as a wound of the left lobe of the liver. The patient was furloughed December 3d, and on January 6, 1865, transferred to Harvey Hospital, Madison, where Surgeon H. Culbertson, U. S. V., reported the case as a "gunshot perforation of the abdomen, with wound of the stomach." The wound healed, and the patient was discharged March 8, 1865, and pensioned. Examining Surgeon D. D. T. Hamlin, M. D., of Elk Horn, Wisconsin, reports, November 22, 1865, the wound as "causing painful respiration, with some contraction of lower part of chest on both sides. Disability one-half and permanent."

The five remaining cases of the group of nineteen recoveries from alleged shot wounds of the stomach cannot be accepted as such:

CASES 189-193.—1. Case of Sergeant Terwilliger (p. 577, *First Surgical Volume*): Pension Examiner R. Loughran, of Ulster County, New York, reports, October 16, 1871, that the ball passed "through the stomach, upper lobe of liver and lower lobe of right lung," which statement conflicts with those of numerous hospital surgeons who observed the recent wound. 2. Private Christy, Co. F, 102d Ohio, Cold Harbor, June 4, 1864, reported by Surgeon R. Barr, 67th Pennsylvania, as receiving a "gunshot wound of the abdomen, penetrating stomach," which conflicts with other reports, and is unsustained by any probable testimony. 3. Corporal T. Chapin, Co. F, 2d Michigan, Knoxville, Tennessee, November 24, 1863, died September 6, 1868; reported by Surgeon A. M. Wilder, U. S. V., as a recovery from "gunshot wound of left side and stomach, an opinion not corroborated by Pension Examiner David Clark, of Flint, Michigan, or by the subsequent history. 4. Sergeant J. H. White, Co. D, 53d North Carolina, Gettysburg, July 3, 1863, reported by Surgeon H. James, U. S. V., as recovery from a "gunshot wound of the stomach and liver," was paroled September 25, 1863. 5. Private J. C. Reamer, Co. F, 7th Wisconsin (ante p. 25, Case 130), reported by Surgeon I. I. Hayes, U. S. V. The visceral injury appears to have been unattended by external wound.

I presume that no writer on medical jurisprudence would contend that, in any one of this group, the evidence of recovery from a shot wound of the stomach was unimpeachable. In the four instances in which the contents of the stomach are alleged to have escaped by the wound, that fact is attested only by the patient's statement.<sup>1</sup> In three instances, there are positive and uncontradicted statements by surgeons, unsustained by precise descriptions of symptoms; and, in twelve cases, the evidence is hopelessly conflicting or utterly inadequate.

*Fatal Complicated Shot Wounds.*—Shot wounds of the stomach are seldom uncomplicated. In reviewing the wounds of other abdominal viscera, many will be found associated with lesions of the stomach. Some cases that have furnished specimens for the Museum, or that presented features of especial interest, may be cited here. One is an example of a shot wound of the stomach complicated with wounds of the diaphragm and colon, and with fracture of the spine:

CASE 194—Private John B——, Co. I, 9th Minnesota, aged 28 years, was wounded, in front of Nashville, December 16, 1864, by a conoidal musket ball, which penetrated the left chest at the cartilaginous junction of the eighth and ninth ribs, three inches below the nipple. On the night of the same day he was admitted to Hospital No. 8, Nashville. The shock of injury was very great, and he suffered intensely from sharp pain in the chest and abdomen. There was, also, paralysis of motion and of sensation in the left lower extremity. Expectant treatment was used, but the patient soon fell into a collapse, and died at 8.30 o'clock, P. M., on December 17, 1864. At an autopsy, twenty-two hours after death, pleuritic adhesions were

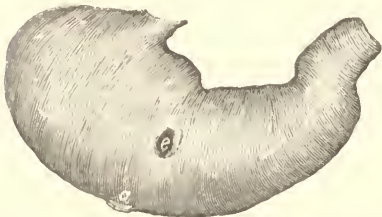


FIG. 31.—Posterior view of a stomach perforated by a musket ball; *a*, entrance; *e*, exit. *Spec.* 3749. [Reduced to one-fourth.]

found; the capacity of the left pleural cavity was much diminished; the abdominal cavity showed evidences of intense peritonitis, and the viscera were softened and of a dark green color. The missile had passed downward, inward, and backward, and piercing the diaphragm near its anterior border, had left an opening two inches in length, through which a portion of omentum had escaped into the pleural cavity. It then entered the great curvature of the stomach about midway and passed out at the middle of the posterior surface (FIG. 31), leaving an interval of three inches between the openings. Thence it passed through the transverse colon, and fecal matter, with a large amount of escaped blood, were found in the abdominal cavity; it then struck the left anterior side of the body of the fourth lumbar vertebra, grooving deeply its left border, passed against the left surface of the spinal cord, fractured the left horizontal and spinous processes of the third

<sup>1</sup>The grains of allowance, with which the statements of patients are to be received, are well exemplified in the following incident, in a debate in the New York Pathological Society, November 27, 1867 (*The Medical Record*, 1867-68, Vol. II, p. 498): "Dr. HOWARD stated that he had met with several flesh wounds produced by pistol bullets at short range, and had invariably found that they healed by first intention. He did not think it improbable that a wound might be made in the stomach and yet close with equal rapidity, leaving hardly a vestige of its course afterward. Dr. SAYRE stated that he had only seen one case of *bona fide* gunshot wound of the stomach, and that was in the person of Beverley Cole, of California. In that instance there was vomiting and purging of blood, and a discharge of the contents of the stomach through the wound. It was three years since he had

lumbar vertebra, and was found immediately to the right of the spine of the second lumbar vertebra, underlying the integument and fascia of that region, very much changed from its original shape. The specimen of the vertebra (No. 3748) is represented in the fifth volume of *Photographs of Surgical Cases and Specimens*, A. M. M., p. 18. The notes of the case and the specimens were contributed by Acting Assistant Surgeon H. C. May.

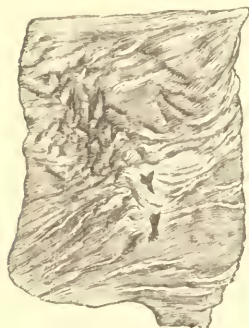

FIG. 32.—Inner surface of a portion of the great extremity of the stomach perforated through a fold by a pistol ball at close range. *Spec.* 1332. [Reduced to one-fourth the size of nature.]

Another example of a shot wound of the stomach, associated with perforation of the vertebral column, has been related in the *First Surgical Volume*, and was remarkable for the characteristic symptoms of the gastric lesion; which, on reference to the abstract of the case, on page 445, will be found to correspond closely with the descriptions of systematic writers. The case furnished to the Museum two pathological preparations, which are represented by the accompanying wood-cuts (FIGS. 32 and 33).<sup>1</sup>

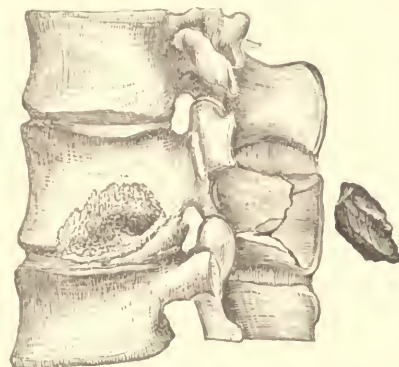


FIG. 33.—First three lumbar vertebrae, the body of the second perforated by a pistol ball, which traversed the canal obliquely and escaped through the right lamina. *Spec.* 1331. [Reduced one-half.]

In a case that will be detailed in treating of wounds of the pancreas, Acting Assistant Surgeon T. L. Leavitt<sup>2</sup> asserts that there was a shot perforation of the inferior curvature of the stomach "large enough readily to admit two fingers," the patient surviving fifteen days, without the slightest functional gastric disorder. Obviously, this statement is simply incredible. In the interpretation of the next case, I cannot subscribe to the views of the experienced and competent reporter, Acting Assistant Surgeon B. B. Miles, although they are sustained by the officer in charge of the hospital, Dr. D. C. Peters. I think the faecal fistula was in the transverse colon, and that, in the very complicated pathological processes that took place during the hundred and eleven days the patient survived his injury, whatever gastric disturbance existed was of a secondary and comparatively unimportant nature:

CASE 195.—Corporal R. C. T—, Co. G, 5th Wisconsin, aged 21 years, was wounded, at the engagement at Hatcher's Run, February 7, 1865, and was at once carried to the field hospital of the 1st division, Sixth Corps, in charge of Surgeon Redfern Sharpe, 15th New Jersey. The injury is entered on the register as a "gunshot wound of the side," and, while details of the early symptoms are wanting, collateral evidence indicates that the wound was supposed to be unattended by visceral complications. The patient was conveyed, in an ambulance wagon and by rail, over twenty miles, to the base hospital at City Point. Thence he was transported on a steamer to Baltimore and admitted to Jarvis Hospital, where the diagnosis—"gunshot wound of left side, perforation of stomach"—was recorded on the monthly report by Assistant Surgeon D. C. Peters, U. S. A. The patient was placed in charge of Acting Assistant Surgeon B. B. Miles, in whose language the further history of the case may be related: "Admitted February 11, 1865, with gunshot wound of left side, through the stomach, entering anteriorly, about two inches below the xiphoid cartilage, making its exit between the ninth and tenth ribs, about four inches from the junction of the costal cartilages with the ribs. Wound received at Hatcher's Run, February 6, 1865. On admission, this man's feces, instead of passing out the natural channel, were discharged through the wound for a considerable time; but, finally, the discharge ceased, and the feces passed out the natural channel. He continued to improve, and was so much better that he was able to see the case, and the patient was now doing well. Dr. HEWITT remarked that the case referred to by Dr. SAYRE had been under his immediate care, being assisted by Dr. VALENTINE MOTT, jr., and Dr. C. S. TRIPLER, and that the symptoms were as Dr. SAYRE had related them, *except that there was no discharge of the contents of the stomach through the wound.* Dr. SAYRE stated that he had *merely reported the symptoms as they were detailed to him by the patient, some time after the accident.*"

<sup>1</sup> All of the preparations exemplifying lesions of the stomach, by pointed or cutting weapons or by shot, that the Army Medical Museum possesses, have been figured in the text. The surgical reports show that many opportunities of supplying deficiencies, in this direction, have been lost. Medical officers shall not be suffered to forget that the compiler is also the curator of the surgical section of the Museum, always ready to remind them of their obligation to perfect the series of that rich collection. At the museum of the Pennsylvania Hospital, Preparations 1305 and 1306 illustrate, respectively, incised and shot wounds of the stomach; but are without histories, (*Cat.*, p. 61.) At the New York Hospital, Preparations 377 and 378 exemplify stabs, and 379 a pistol ball perforation of the stomach; the patients survived these injuries forty-eight hours, two days, and three days, respectively, and all are reported to have died from peritonitis, (*Cat.*, pp. 178, 179.) In the museum of St. George's Hospital, Specimen 196, Series IX, shows a large circular hole in the anterior wall of the stomach, caused by a charge of small shot, (*Cat.*, p. 419.) In the Fort Pitt collection, Specimen 1035 is the stomach of a man with a shot perforation near the greater curvature; the patient survived eight hours, (*Cat.*, p. 142.) This is probably identical with 1125, Netley. These eleven are all the modern pathological preparations of such lesions that I can find recorded.

<sup>2</sup> LEAVITT. *The Tenacity of Human Life*, in *The Med. and Surg. Reporter*, 1865, Vol. XII, p. 105.



walk about his ward; but, owing to some imprudence or over-exertion, he took a relapse and rapidly grew worse, so that he died May 28, 1865. Autopsy, twenty-four hours after death: On examination, both lungs were found adherent to the pleuræ, but more especially the left. It was also so strongly adherent to the diaphragm that the diaphragm was ruptured in detaching the lower lobe of the lung. This lung was also covered with strong bands of lymph, and its substance was carnified. The spleen was adherent to the ribs and to the stomach, and also the diaphragm, and was covered with bands of lymph, and its substance was very hard. The left kidney was also adherent, somewhat contracted, and hard. There was extensive peritonitis, and both greater and lesser omentum were very black, as were also the small intestines, colon, and rectum. An examination of the stomach revealed a large cicatrix where it had been perforated by the ball. The stomach was forwarded to the Army Medical Museum, Washington, D. C., by B. B. Miles, Acting Assistant Surgeon, U. S. A." [The records of the Museum show that the pathological specimen was received at the Museum July 22, 1865, and numbered 664 on the preparer's book; but the evidence of the lesion of the walls of the stomach was regarded as so unsatisfactory that the preparation was not admitted to the catalogue.]

The following is an interesting instance of the lodgement of a ball in the stomach.<sup>1</sup>

CASE 196.—Private James White, Co. A, 90th New York, was wounded at the battle of Cedar Creek, October 19, 1864. The regimental medical officer, Assistant Surgeon N. Stub, gives no particulars of the case. The patient was sent to the field hospital of the 1st division of the Nineteenth Corps. Assistant Surgeon John Homans, U. S. A., reports that he had a "severe gunshot wound of the abdomen," and that he was transferred to Martinsburg on October 20th, but no further details. He was sent by rail to Baltimore, and entered Patterson Park Hospital on October 23d. Acting Assistant Surgeon A. McLetchie reports the further progress and result of the case as follows: "On admission, he was able to walk up a flight of stairs without much inconvenience. On examination, I found that a minie ball had penetrated the epigastric region. Slight redness and swelling encircled the opening; the edges of the wound were everted. No discharge escaped from the wound. The patient complained of excruciating pain in the lumbar region. I had a flaxseed poultice applied to the wound, and recommended absolute rest, and a low diet of animal broths, with a little sherry wine. On October 24th, the patient reported a very restless night, with occasional vomiting of a glairy fluid. The pulse was small, at 91, the tongue clean, the urine free and clear. He was ordered to continue treatment, and to take a pill of one grain of camphor and two grains of extract of henbane every three or four hours. In the afternoon, he had a healthy dejection. He had intense lumbar pain. He complained also of a sensation as of a globe in the throat. He takes his chicken broth sparingly. He is ordered a belladonna plaster (four by two inches) over the loins. October 25th, patient and nurse state there was a normal stool this morning. Occasional hicough. October 27th, great prostration; difficulty of swallowing; frequent vomiting; pulse quick and small; skin clammy and cold. He died at half past five o'clock A. M. At the autopsy, it was found that the ball, having penetrated the abdominal wall one inch above the umbilicus, had passed through the right lobe of the liver, then through the lesser curvature of the stomach, partially severing the duodenum from the stomach, and was found lying loose in the stomach."

A patient survived a perforation of the stomach and of the spleen by a round pistol ball for ten days:<sup>2</sup>

CASE 197.—Surgeon T. F. Perley, U. S. V., reports that Sergeant Cyrus E. Bussey, Co. K, 11th Maine, was admitted to the post hospital at Camp Berry, Portland, Maine, November 18, 1864, having been shot in the left hypochondrium by the accidental discharge of a pistol charged with a round ball. The missile passed between the cartilages of the fifth and sixth ribs, the attachments of the diaphragm, the cardiac extremity of the stomach, the spleen, and lodged in the long muscles of the back to the left of the spine. There was copious hæmorrhage, and the contents of the stomach escaped by the wound. The fatal event did not take place until November 28, 1864.

<sup>1</sup> DUPUYTREN, *Lectures Orales*, T. VI, p. 464, says: "If a ball, after perforating the stomach, remains in that viscus, no attempt to extract it should be made. Sooner or later it will probably be voided at stool."

<sup>2</sup> I can learn of no unequivocal examples of recovery from a shot wound of the stomach prior to the last decade of the eighteenth century. There is a case ascribed to FALLOPIUS by ROMBERG and other writers; but I cannot find in the section *de ventriculi vulnere* of the Modenese professor (T. II, p. 395, of the *Opera græcina omnia*, Venetiis, 1605) any specific case of shot wound. FALLOPIUS says (T. II, p. 256) "*De ventriculo vero sanavi ego aliquando entans, per quod egrediebatur cibus*;" but does not assert, nor does the context indicate, that this was a shot wound. There is also an account in the *Ephemerides Naturæ Curiosæ*, Dec. II, Ann. 1, *Obs.* 26, of a peasant who recovered, after a shot wound of the stomach, having voided a ball at stool a month after the reception of the injury. Probably the missile entered the transverse colon by ulcerative absorption. Possibly PUCHMANN'S two successful cases of gastrotomy (*Lorbeer-Krantz*, n. s. w., 8, 410) were instances of shot wounds; but he does not so state. The first plausible recorded example is that related in GERSON'S *Magazin* (B. IX, S. 200), of a French officer wounded at the battle of Kaiserslautern, in 1794. The wound remained open fifty days, during which period food often escaped. Then the wound closed permanently. GERSON saw this officer in 1807, with a deep cicatrix in the epigastric region. This case is probably identical with that observed by PÉRY (*Jour. de Méd. de Leroux, Boyer, et Carrisart*, 1802, T. III, p. 510) and commonly referred to by writers on gastric fistula (see GÉRARD, *Perf. spont. de l'estomac*, 1803, p. 70). The next recorded case is that referred to by Dr. THOMSON (*l. c.*, p. 103) in 1815, after Waterloo, a doubtful instance, the ultimate result being unknown. The case recorded by BRITON (*Trans. Med. and Phys. Soc. of Calcutta*, 1825, Vol. I, p. 59), of a trooper attempting suicide, in 1819, by discharging a pistol at the epigastrium, is destitute of the slightest evidence that the wound implicated the stomach, and writers must have repeated it without examination. BEAUMON'S famous case of St. Martin, wounded June 6, 1822, is next in date. An authentic case, that occurred in Algeria, is recorded by BAUDENS (*Clinique des plaies d'armes à feu*, 1836, p. 122): L—, a grenadier of the 67th, was shot through the stomach, October 4, 1833. There was hæmatemesis, and liquids escaped by the wound for thirty days, when the fistula permanently closed. All that is really known of a case misquoted by BALLINGALL (*op. cit.*, p. 351) is contained in the following sentence of ALCOCK'S summary of penetrating shot wounds of the abdomen: "One case of recovery occurred in an officer, in which there was lesion of the stomach." (*Notes on the Medical History and Statistics of the British Legion in Spain*, 1838, p. 50.) BECK (*Die Schusswunden*, 1850, S. 212) cites a case related to him by an Austrian colleague, where there was every indication of a wound of the stomach, and the ball was voided at stool. Nothing indicates that the Austrian may not have read of this case in the *Ephemerides*. In his excellent memoir on shot wounds of the stomach, TRITLER (*Peninsular Jour. of Med.*, 1856, Vol. IV, p. 2) records the case of Dr. R. B. Cole, who accidentally shot himself, at San Francisco, June 3, 1851. With the utmost deference for my old friend and chief, I cannot concede that the evidence he has adduced conclusively proves the existence of a penetrating wound of the stomach in this case. There was no escape of the contents of the stomach by the wound; liquids were soon swallowed and retained; the hicough and hæmatemesis are explicable without any lesion of the stomach;



The next case is one of several instances of associated lesions of the stomach and colon:

CASE 198.—Acting Assistant Surgeon J. B. Potter reports that "Private James Cochran, Co. G, 16th Veteran Reserves, was wounded by the accidental discharge of a pistol, at Phillipsburg Barracks, February 5, 1865. The ball entered the left lumbar region, striking the transverse process of one of the vertebra, perforated the descending colon and some part of the stomach. The injury was immediately followed by incessant vomiting, and by bloody discharges from the bowels. As soon as notified, I had the man removed to the hospital. I found the ball lodged in the abdominal wall, and extracted it. I made two visits subsequently, and left the patient quite comfortable for the night, having given the necessary instructions to the steward. In the morning, I learned that the second lieutenant of his company had assumed the authority of calling a resident physician, without my knowledge or consent, who had changed the treatment, though the patient was then comparatively easy. At the morning visit, February 6th, the patient was worse, and he continued to fail thenceforward. Indeed, I had never entertained any hopes of his recovery from the first time I examined his wound. I remained with him that night. The next morning he died, February 7, 1865." Acting Assistant Surgeon Potter concludes by demanding a court of inquiry into the conduct of the line officer who intruded in the case.

As frequently as any other complication, lesions of the lung and diaphragm were associated with shot wounds of the stomach. The following instance will further exemplify that shot wounds of the stomach may interest the outer tunics only:

CASE 199.—Surgeon A. Chappel, U. S. V., reports that: Orderly Sergeant *Eugene W. Field*, 2d Maryland rebel cavalry, while attempting to haul down the national colors from a flagstaff, in Hanford County, Maryland, was shot by a patriot, 73 years of age (in accordance with the spirit of the celebrated order of General Dix). The wounded man was sent to Baltimore, and entered West's Buildings Hospital, on the 14th, two days after the reception of his injury. There were numerous wounds distributed over the right hypochondrium and epigastrum. The patient was suffering from the symptoms of traumatic pneumonia conjoined with peritonitis. There was great tenderness on pressure at the epigastrum, and constant vomiting. Death ensued July 15, 1864. Acting Assistant Surgeon A. Kessler reports the autopsy: "Upon laying the *cavum thoracis* open, a large quantity of dark, partly coagulated fluid escaped; the *cavum mediastinum* was filled with a similar fluid. The right lung was found hepatized with the exception of the superior posterior lobe, that was comparatively healthy; the left lung was found entirely sound. The anterior and lateral portion of the right lung exhibited numerous marks of duckshot, some of which penetrated to a considerable extent. The heart was struck by a shot, which lodged in the outer wall; otherwise it was sound. The stomach was also struck by several shot, none of which, however, penetrated into the cavity, which was filled with a yellow fluid. The cardiac orifice was considerably inflamed, and a deep congestion extended over the largest portion of the lesser curvature; this accounts for the extreme tenderness of the stomach and the constant vomiting of the deceased. The liver was gray, ash-colored, and somewhat enlarged; numerous marks of shot were visible all along the right and left lobe, and also upon the peritoneum. The intestines appeared to be in a normal condition and showed no signs of being wounded."

In other cases of this group, the patients escaped the immediate dangers of traumatic peritonitis, and succumbed from inanition, or exhaustive suppuration, or complex causes of constitutional irritation. Thus, the same reporter, Surgeon A. Chappell, U. S. V., records the case of Corporal *McIntosh*, Co. D, 1st North Carolina, aged 31, wounded at Cedar Creek by a round musket ball, which perforated the left lung, diaphragm, and stomach; the patient perished from exhaustion twelve days afterward, November 1, 1864. 2. Acting Assistant Surgeon W. B. Crain returns the case of Private J. Humbolt, 1st Illinois

the subjective symptoms ("He tells me that, after a full meal, he feels the stomach dragging upon the ribs, and is sure it is adherent to their inner surface," *l. c.*, p. 7) are quite fallible. Dr. H. CULBERTSON (*Ohio Med. and Surg. Jour.*, 1859, Vol. XI, p. 301) reports the case of N. Speed, aged 19—penetration of the anterior wall of the stomach by an accidental discharge of small shot, February 6, 1859, being demonstrated by the presence, in the coagula vomited, of "the rough and flattened shot." In transmitting a copy of this article to this office, December 25, 1871, Assistant Surgeon H. CULBERTSON, U. S. A. (retired), adds: "Six months ago, I learned this young man was living and well." Dr. SCHOLTZ (*Wiener Med. Wochenschr.*, 1861, XIV, 3, 4) reports the recovery of a student who attempted suicide by firing a pistol at the pit of the stomach. The ball passed through the stomach, midriff, and left lung. There was persistent vomiting of clots mixed with fluid blood, extreme thirst, and difficult breathing. Convalescence, retarded by the mental condition, was fairly established in eighty-one days. Dr. SCHOLTZ ascribes the successful issue to the absence of food in the stomach, and of bone splinters or other foreign bodies in the wound. Dr. K. FISCHER (*Militärärztliche Skizzen aus Süddeutschland und Böhmen*, Aarau, 1867, S. 63) records, without particulars, a recovery from a "shot wound perforating the stomach from right to left, the entrance and exit orifices being five to six inches apart." This is probably identical with a case reported by Mr. F. H. LOVELL (*Cases of Gunshot Wounds occurring during the late War in Germany*, in the *Lancet*, 1866, Vol. II, p. 622); J. K——, 4th Austrian Infantry, Trautenuau, June 27, 1856, aged 25; shot wound of entrance in seventh left intercostal space in a line vertically below the nipple, exit wound in sixth right intercostal space, five inches from the first, and nearer the sternum. He had not taken food or drink for fourteen hours. He did not faint or vomit. On the 28th he vomited, but could not say that there was blood in the matter ejected. When the wound was dressed, a dark fluid, with gas, bubbled out. He was not sick on that day, and complained of little pain then or afterward. Subsequently there were more copious discharges of gas by the wound, especially after the ingestion of effervescent mixtures. This was believed to demonstrate the existence of a gastric fistula. On the 26th of August, he was able to sit up, and was reported convalescent. It is less probable, but not impossible, that this case is again referred to by Generalarzt BECK, who reports (*Chirurgie der Schusswunden*, Freiburg, i. B., 1872, S. 528) that during the Austro-Prussian War of 1866, he successfully treated a soldier, in whose case there was no escape from the diagnosis of shot wound of the stomach. The same author (*loc. cit.*, S. 529) records two cases of recovery from shot wounds of the stomach in the French-Prussian War, 1870-71, but remarks, that probably "the missiles, grazing the walls of the stomach only, did not cause an extensive separation." SOGIN (*Kriegschirurgische Erfahrungen*, Leipzig, 1872, S. 92) gives the case of Hoffmann, wounded at Gorze, August 16, 1870. Persistent vomiting for two days, with diarrhoea, the latter lasting ten days; epigastrum distended and exceedingly painful. Complete recovery in fifty-five days. But the author adds: "Whether in this case the stomach was perforated, or the anterior wall only grazed, cannot be definitely ascertained."

Artillery, aged 27 years, wounded at New Creek, November 28, 1864, by a conical musket ball, which perforated the left lung, diaphragm, stomach, and colon. The fatal result was forty days later, January 7, 1865. Some complicated cases, remarkable for the length of time the patients survived, were reported without such details of the symptoms, progress, and *post-mortem* appearances as would lend interest to detailed abstracts. Surgeon T. Crosby, U. S. V., reports one, received at the Columbian Hospital from Spottsylvania, with a shot perforation of the stomach and two folds of intestine. The man lived nine days from the date of injury. The ball entered the left hypochondrium and lodged in the muscles of the back. A similar case, resulting fatally in seven days, is reported by Surgeon J. Trenor, jr., from Beaufort, South Carolina. Surgeon W. S. Love, P. A. C. S., records the case of Private *C. J. Presnell*, 6th North Carolina, aged 28 years, who died with symptoms of profound collapse, at the field hospital for prisoners, September 28, 1864, nine days after being wounded at the battle of Opequan.

*Gastric Fistule.*—Besides the cases that have been adduced, upon evidence quite open to criticism, at least three examples occurred of stomacal fistule<sup>1</sup> resulting from shot wounds; but, unfortunately, only very imperfect records of the circumstances preceding the fatal termination have been preserved. Though the personal esteem enjoyed by one of the three who succumbed to this rare lesion, made this gallant officer an object of peculiar interest, he shared in the removals necessitated by the harsh exigencies of war, and it has been necessary to glean a narrative of his case from the records of different hospitals and the reports of the several surgeons who successively attended him:

CASE 200.—Lieutenant-Colonel John G. C.—23d Massachusetts Volunteers, aged 37 years, was wounded, near Fort Darling, on May 16, 1864, by a musket ball, which entered the fifth intercostal space anteriorly, about four inches to the left of the median line. The missile shattered his watch before entering the walls of the thorax, and, as appeared in the sequel, some parts of the machinery of the watch were driven in with the projectile. This regiment, forming the extreme right of the Army of the James, and being overwhelmed by the turning movement of the enemy, successfully executed on that disastrous day, the wounded officer was, with great difficulty, hastily carried from the field, and, after halting a short time in the rear where the ground was comparatively sheltered, the stretcher-bearers conveyed him to the landing at Bermuda Hundred, where his friend and comrade, Surgeon G. Derby, U. S. V., placed him, on the evening of the day of battle, on one of the hospital transports for Fort Monroe. Surgeon J. A. Emmerton, 23d Massachusetts, gives no particulars of the symptoms immediately after the injury; but it is inferred from his silence, and from the report of Surgeon G. Derby, that, apart from grave collapse, there was no symptom indicative of direct lesion of the stomach. Dr. Rush, 101st Pennsylvania, states: "my recollections are distinct that a wound of the stomach was not suspected at first, nor for a considerable time after he entered the hospital; the case was regarded as a

<sup>1</sup> In Dr. MURCHISON'S excellent paper on gastro-cutaneous fistule (*Med. Chir. Trans.*, 1858, Vol. XLI, p. 11) twenty-five instances are tabulated chronologically. In nineteen of the twenty-five cases, the fistule were consequent upon simple or cancerous ulceration. Among these are the celebrated Dorpat case, on which BIDDER and SCHMIDT (*Jahrbücher*, 1854, B. LXXXIV, S. 3) experimented, and GRÜNEWALDT wrote his dissertation "*svæi gastrici humani indoles physica et chemica, et vis digestiva*," the case figured by Dr. W. ROBERTSON (*Edin. Jour. Med. Sci.*, 1851, Vol. XII, p. 1) and that recorded by Dr. J. H. COOK (*Western Jour. of Med. and Phys. Sci.*, 1834, Vol. VII, p. 353). Six cases resulted from external violence, three being referred, more or less doubtfully, to punctured, incised, or lacerated wounds, and one to a blow without external wound. Two (the case of St. Martin, and that of Lieutenant Maillot, referred to in the note on recoveries from shot wounds of the stomach, on page 50, as the case "observed by PERCY") were caused by shot wounds. Of BÉRARD'S assertion (*Dict. de Med.*, T. XII, p. 306): "La science possède d'autres observations de fistule de l'estomac ayant succédé à des plaies: c'est là, en effet, la cause la plus fréquente de ces fistules," only the first part is true, and the erroneous second clause infelicitously introduces an unmerited criticism of the scholarly SAMUEL COOPER. By following JOUBDAN'S careless summary (*Fistule de l'estomac*, in *Dict. des Sci. Med.*, T. XV, 578) BÉRARD is led to ascribe a traumatic origin to the two cases noticed by LÉTTAUD (*Hist. Anat. Med.*, 1777, Obs. 114, Vol. II, p. 327), whereas one was DULAC'S case of cancerous ulceration in a girl of 17 (see GÉRARD, *Perf. spont. de l'estomac*, 1803, p. 71), and the other the case of Marguerite of Nordlingen.—WENCKER'S case (*Virginis per 27 annos ventriculorum perforatum aletis historia et sectio*, Strasburg, 1743), of which BÉRARD remarks: "La fistule décrite par WENCKER n'était pas traumatique." The cases of traumatic origin collated by Dr. MURCHISON are those recorded by CORNAX (quoted by JOHANNES SCHENCKIUS, *Obs. Med. Bar.*, Lugduni, 1644, Lib. III, p. 332) of a Bohemian peasant of Puggelbrot, stabbed by a broad hunting-spear, in 1580, who lived many years; the doubtful case of an adult, cited by GOOCH (*Chirurgical Works*, 1792, Vol. I, p. 398), and already mentioned (p. 43) as adduced by MENZELIUS; the case of LESSÈRE, in HEVIN'S memoir, already cited; ETTMULLER'S case, already cited; and Maillot and St. Martin. To them may be added the case recorded by BURROWES (*Med. Facts and Obs.*, 1794, Vol. V, No. 17), resulting from a punctured wound; the case communicated by SIEBERTHAL (*Philosoph. Trans.*, 1719, No. 365, p. 79), a woman stabbed in the left hypochondrium; and the case recently recorded by Dr. LESCHICK, of Großswalde (*Berlin. Klin. Wochenschr.*, 1871, B. VIII, S. 6), of a recovery from an incised wound of the stomach. On the day of the capitulation of Metz, N——, the subject of this observation, is reported to have drunk, in rapid succession, ten glasses of beer, which caused some uneasiness, until he removed the wax tampon he habitually wore, and relieved the repletion. The fistula which MIDDELDOORFF (*de Fistula ventriculi externis et chirurgica curam suavitone, accidente historia fistule arte chirurgorum plastica prospere curati*, Vratislavia, 1859) successfully closed by a plastic operation, though not caused by a wound, was consequent upon an abscess caused by a blow. Professor GÜNTHER (*Lehre von den blutigen Operationen*, Leipzig, 1860, B. IV, Sect. XV, S. 29) reproduces the plates accompanying this dissertation. Dr. MIDDELDOORFF, adding to Dr. MURCHISON'S table, enumerates forty-six cases, twenty-one men, twenty-three women, and two of undetermined sex, and remarks that while, among males, these fistule are more commonly due to external violence, in woman the proportion of non-traumatic fistules largely preponderates.

chest wound, the ball first striking and demolishing his watch, and, entering the chest below the left nipple, passing downward and backward, emerging nearly midway between the sternum and spine." And, elsewhere, Dr. Rush says: "there was not, to the best of my recollection, any very great gastric disturbance." Dr. Derby remarks: "the ball entered the left chest, in front, and so low as to make it doubtful whether above or below or penetrating the diaphragm," and says nothing of the constitutional condition; from which it may be inferred that there was no hæmorrhage or gastric disturbance when Dr. Derby saw the case, twelve hours after the reception of the injury, and that the graver symptoms of the shock had passed off. Here it may be observed that Colonel C—— was a man of small stature, thin and slender, active and resolute, but with greater strength of will than vigor of body. On a previous occasion, at Quaker Bridge, North Carolina, July 6, 1863, I was with him when he received a shell wound over the left clavicle, and, although he was not severely hurt, the immediate nervous depression was very marked. Arriving at Fort Monroe, Colonel C—— entered the Chesapeake Hospital on May 18th, and was placed under the special charge of Assistant Surgeon E. McClellan, U. S. A., who prepared a circumstantial report of the case, and forwarded it from Hampton, although, unfortunately, no record of it, or of its reception at this office, can be found. Dr. McClellan's surgical register, however, supplies some of the facts of the case: "On June 9th, the probable position of the ball, between the seventh and eighth ribs, was determined, and the patient was anesthetized by inhaling the vapor of a mixture of two parts of ether and one of chloroform; and Assistant Surgeon E. McClellan, U. S. A., proceeded to extract the ball. The patient was in excellent condition for the operation, all of the bodily functions being normal, and the mind cheerful and hopeful, with bright anticipations of recovery revived by the discovery of the ball." The next entry is on June 30th: "A fistulous opening exists, connecting the inferior orifice with the cavity of the stomach, which discharges partially-digested food. Condition of parts healthy. Orifice of entrance completely cicatrized." Death resulted July 15, 1864, from exhaustion. Since the foregoing compilation was placed in the printer's hands, the following report of the case, which Dr. E. McClellan had the kindness to prepare, on learning of the miscarriage of the report previously forwarded, has been received: "Lieutenant-Colonel John G. C——, 23d Massachusetts Volunteers, was admitted to the officers' division (Chesapeake) of the United States General Hospital, Fort Monroe, Virginia, May 18, 1864, suffering from a gunshot wound of the left chest, which had been received in action two days previously at or near Bermuda Hundred, Virginia. When Colonel C——, who was then in command of his regiment, went into action, he had in the left breast pocket of his coat a large watch and an iron comb. His coat was buttoned tightly, for the attack of the enemy which he was resisting was made at an early hour. When he was removed from the field, it was found that the ball by which he was wounded had struck upon and destroyed the watch and had broken to many pieces the iron comb. The ball being deflected, the wound of entrance was found to involve the fifth and sixth ribs, a little to the back of the centres of the shafts, the direction being downward and backward; the bones were comminuted. It was supposed that the fragments of watch and comb had been lost when his coat was first opened. An examination made by the ward surgeon failed to determine the presence of any foreign body in the chest; all detached pieces of bone were removed. The hospital being at the time overcrowded with wounded, my attention was not called especially to the case until June 9th. Suppuration was profuse, and, upon examination, the probe impinged upon a metallic body. The wound was enlarged, several pieces of bone were removed, and immediately behind them was found a conical ball, much flattened, and a brass wheel from the watch. The cavity was carefully explored and a hard substance was found partly imbedded in the tissue of the lung. This being removed, proved to be portions of the missing parts of the watch. Prolonged search, assisted by careful washing out of the cavity, obtained the remainder of the works and many portions of the iron comb. When satisfied that all foreign bodies had been removed, the wound was closed. The suppuration diminished, the patient rapidly gained strength, the wound closed to nearly its whole extent, and a favorable termination was anticipated; but, early in July, symptoms of gastric irritation supervened, attended with hectic, and rapidly increased in severity. Emaciation was rapid, but the discharge from the wound was inconsiderable. A few days before his death, being present as he swallowed some brandy, he exclaimed: 'Doctor! it smarts my wound;' and, upon examination, the odor of brandy was found upon the dressing. Constant watching determined the fact that of all fluids taken into the stomach, a small portion was immediately present at the wound. The exhaustion became more profound, the emaciation was wonderfully rapid and extreme, and, on July 15th, he died calmly, of exhaustion, as brave and gallant a gentleman as ever drew sword. The autopsy determined the fact that a prong of the iron comb had escaped detection at the time of operation; that its sharp point had become imbedded in the bottom of the cavity, and that by its means a gastric fistula was established."

Another patient survived his injury seven weeks, the gastric fistula appearing at the close of the third week:

CASE 201.—Corporal Roswell E. M——, Co. K, 1st Massachusetts Heavy Artillery, aged 23 years, was wounded at Spottsylvania, May 19, 1861, by a musket ball, which perforated the left chest from before backward, fracturing the ninth rib. He was taken to the field hospital of the 1st division of the Fifth Corps, and Surgeon W. R. DeWitt, U. S. V., recorded the case in accordance with the foregoing facts. An expectant treatment, with simple dressings, was instituted, and the patient was placed in an ambulance train to be sent to the base hospital. On May 25th, the patient was admitted to Fairfax Seminary Hospital, under the care of Acting Assistant Surgeon York, who records that, on admission, the patient suffered from great dyspnoea, with pneumothorax and tromatopnoea, the air rushing in and out of the wound with the respiratory movements. The left lung was collapsed. On June 2d, there was a profuse and offensive discharge from the wounds, which continued until about June 9th, when there appeared in the discharges a portion of the fluids taken into the stomach, mingled with particles of solid food. There was no cough nor expectoration." No further account of the case is given for the ensuing month, when Assistant Surgeon H. Allen, U. S. A., records: "I saw this patient the first time in the afternoon of July 8th; he was greatly emaciated, though strong enough to sit up on a chair to be examined. The ball had entered about one inch to the left of the xiphoid cartilage, passed backward and slightly downward, making its exit on a level with the eleventh rib, about midway between its most convex portion and dorsal. Respiration was difficult, and each effort accompanied by a loud blowing, whizzing sound through wound of exit. Typical amphoric respiration was heard over the affected region posteriorly. Patient said that no



dyspnoea came on immediately after the reception of the injury, but it was a symptom of a few weeks' duration. The lung sounds were clear (fremitus being present) down to the lower third of the dorsum of the chest, thence to seat of wound it was tympanitic with entire absence of fremitus. Imperfectly digested food occasionally escaped through the posterior opening intermixed with gastric juice. Patient was cheerful, complained of little pain, and was looking forward to an early transfer to his home. He died rather suddenly the following day. The foregoing note of Dr. York was all I could gather concerning the history of this interesting case." Dr. Allen appends the notes of the autopsy: "Lungs: bronchial secretion large in quantity. Color of lungs light pink; in posterior part dark red. Near apex of left lung a tubercle, of the size of a hazel nut, was found. Pleura of lower part of left lung strongly adherent to parietes of chest. Heart normal. Pericardium contained rather a large quantity of light straw-colored fluid. Liver apparently healthy. Spleen about four inches by three, of very dark color and firm consistence. Patient had received a gunshot wound of left side of chest, ball fracturing seventh rib made its exit through the eleventh rib. An abscess, the size of a large orange, was found extending from an inch to the left of the median line to the wound in the middle of the eleventh rib; the abscess did not open into the pleural cavity. It contained about one ounce of pus mixed with dark fluid. The walls, which were of a greenish-black color, were partly covered with thick pus. A fistulous opening from the larger curvature of the stomach into the abscess was found. The fistula was more than half an inch in diameter, and, in appearance, resembled the anus of a chicken. Specimen was preserved and sent to S. G. O., August 1, 1864." [The Museum reception book shows that two specimens were received from Fairfax Seminary Hospital on August 2d, a sternum and a humerus, which were mounted and numbered 2914 and 2915 of the Surgical Series. There is no minute of the reception and rejection of any other specimen from Fairfax Seminary at or about that date. The absence of such a memorandum is conclusive evidence that the specimen was never in the preparer's hands, and affords a strong presumption that it was not received at the Museum. It is true, that among the vast number of specimens arriving at the Museum during that month, some were buried after a superficial examination, on account of being in an advanced state of decomposition; but it is believed that not much of value was lost in this way. The loss of the rare specimen in question, however it occurred, is much to be lamented.]

A third patient lived eighty days from the date at which the stomacal fistula was first observed, one week after the reception of the injury:

CASE 202.—Private Robert B. E——, Co. I, 207th Pennsylvania, aged 21 years, was wounded in the general assault on the lines before Petersburg, April 2, 1865. Admitted to the field hospital of the 1st division of the Ninth Corps. Surgeon A. F. Whelan, 1st Michigan Sharpshooters, recorded the case as a severe penetrating shot wound of the abdomen, complicated by a serious flesh wound of the forearm. An expectant treatment with simple dressings was ordered, and, on April 5th, the patient was placed on the hospital transport State of Maine, to be sent to Alexandria. Acting Assistant Surgeon W. H. Finn records the case on the register of the floating hospital as, from its direction, probably implicating the spleen. The patient was placed, on April 6th, in the third division of the General Hospital at Alexandria, where the ward surgeon registered the diagnosis as "gunshot wound of the abdomen, with perforation of the stomach," and the prognosis as "unfavorable." None of the foregoing records advert to the symptoms. The condition, on admission at the Alexandria Hospital, is thus recorded in an unsigned case-book: "A conoidal ball entered the abdomen on the left side between the eighth and ninth ribs, and passed completely through, perforating the stomach, and making its exit two inches below and a little without the right nipple. There is also a flesh wound of the right forearm, the same ball having passed through it. There was but little prostration of the system. The pulse was normal and the appetite good, and his food seemed to digest well. He suffered no pain; says his wounds are only a little sore. There were no symptoms of peritonitis. Prognosis unfavorable. April 7th, still cheerful and comfortable; pulse strong and normal; wounds were dressed with adhesive plaster and compress, with a bandage tight around the body. Appetite good; diet light and nutritious. April 9th, still comfortable; on removing the dressing this day, after his breakfast, a large quantity of half-digested food streamed out of the wound. This occurrence was witnessed by Drs. Bentley, MacKenzie, and others, and afforded satisfactory evidence of the character of the wound. There were no specially untoward attendant symptoms. April 11th, no change; pulse still good; eats and sleeps well; appears cheerful and contented; there is some irritation of the cuticle about the lower wound, caused by the escape of the contents of the stomach. April 13th, last night patient had an attack of colic from flatulence; was relieved by aromatic water; he seems as well as usual this morning. April 22d, a little depressed in mind; wounds look well; he takes tincture of sesquichloride of iron as a tonic; no food has escaped for two days. On April 24th, the patient was transferred to Sickles Barracks." Sickles Barracks was the designation of another division of the General Hospital. The motive for the transfer is not indicated. It was probably to make room for fresh arrivals of wounded. Here the ward-surgeon registers the case as a "perforating wound of the chest, with injury to the lung," and states that the patient "died June 29, 1865, from exhaustion." There is no indication on Surgeon E. Bentley's reports that an autopsy was held; but he gives the cause of death as "gunshot wound of stomach." The absence of the pathological preparation is not alone to be regretted. There is no account of the later progress of the case. An occasional entry by Acting Assistant Surgeon E. Neal, on the prescription-book of ward O, of Dover's powder with tannic acid, or of camphor mixture with bitter infusion, constitutes the only record of the patient that can be traced, during the two months following his transfer to Sickles Barracks.

In the three cases, the fistules were secondary, and, of course, incomplete at first. In Case 200, the communication between the cavity of the stomach and the exterior was not established until the seventh week from the infliction of the injury; in the second case, the fistula was complete at the end of three weeks; in the third, at the beginning of the second week. One lived only a week after the fistula became complete; the second, four weeks; the third, nearly twelve weeks.

Any discussion of gastric fistules resulting from shot injuries would be incomplete without an allusion to the famous case of St. Martin, first investigated and made known through the medical department of the Army. That the celebrated Alexis is still (March, 1873)<sup>1</sup> living, at St. Elizabeth, Berthier County, Canada East, in the enjoyment of tolerable health, at the age of nearly seventy years, having survived his injury almost half a century,<sup>2</sup> is proof that his abnormal condition is compatible with a reasonable longevity. The external appearance of the fistula (FIG. 34), which I have copied from an original drawing, printed by Beaumont in 1833, has undergone comparatively little modification since that time. The posterior wall of the stomach falls against the opening as a valve, and sometimes protrudes; but no other retentive dressing is found necessary than a loosely folded silk handkerchief. The annexed diagram (FIG. 35) represents the relative position of the fistulous opening and the direction of movement impressed on ingesta by peristalsis, as observed by Beaumont.<sup>3</sup> The only other recovery, with gastric fistula, from a shot wound of the stomach, definitely recorded in surgical annals, is that of Maillot, wounded in Möllendorf's repulse of the French at Kaiserslautern, in May, 1794. In this little known, but authentic case, recorded by Baron Percy, the fistula gradually contracted, and ultimately closed.

Reverting to the lesions of the stomach observed during the war of the Rebellion, it is possible to append to the history of the case of Bowes a very important addition, which has been communicated since the abstract, on page 46, passed through the press. Dr. A. Hard, of Aurora, Illinois, formerly regimental surgeon of the 8th Illinois Cavalry, has written the following statement,

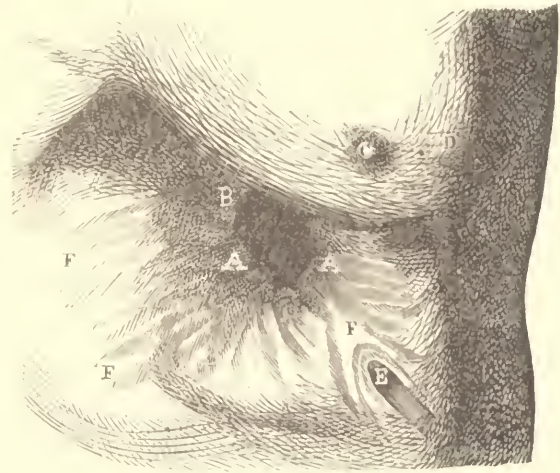

FIG. 34.—Gastric fistula of Alexis St. Martin: "The engraving represents the ordinary appearance of the left breast and side, the aperture filled with the valve, the subject in an erect position. *AA*—the circumference and edge of the aperture, within which is seen the valve. *B*—the attachment of the valvular portion of the stomach to the superior part of the aperture. *C*—the nipple. *D*—the anterior portion of the breast. *E*—the scar where the opening was made with the scalpel, and the cartilages taken out. *FFF*—cartilages of the original wound, around the aperture." [After BEAUMONT, *op. cit.*, p. 25.]

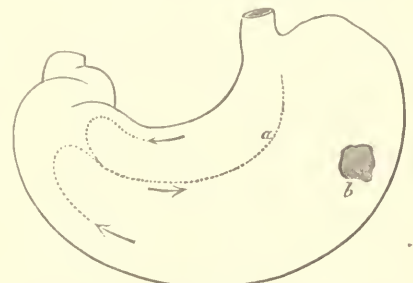


FIG. 35.—Diagram to show the situation of the abdominal opening in St. Martin's case, and the general direction of movement impressed on the semi-fluid food in the digesting stomach. [After Dr. W. BUNTON, in TODD'S *Cyclop. of Anat. and Phys.*, Vol. V, p. 314.]

<sup>1</sup> Dr. F. H. HAMILTON (*A Treatise on Military Surgery and Hygiene*, 1855, p. 360) concludes his account of the case with the characteristic observation: "We are not informed as to the precise period of his death or of its cause," and thus misleads NEUDÖRFER (*Handbuch der Kriegschirurgie*, Leipzig, 1867, S. 707) and his numerous readers. St. Martin has already survived this solecism seven years.

<sup>2</sup> BEAUMONT (*Experiments and Observations on the Gastric Juice, and the Physiology of Digestion*, Plattsburgh, 1833, p. 10) states that St. Martin, a Canadian, of French descent, was about eighteen years of age when wounded, June 6, 1822, at Michillimackinac, where Dr. BEAUMONT was then stationed as surgeon of the post, now designated Fort Mackinaw.

<sup>3</sup> For a full description of the early history of this case the reader is referred to BEAUMONT'S work already cited. Another edition was published in Boston, in 1834. A nearly textual copy of BEAUMONT'S narrative was printed in the *American Medical Recorder* for 1825, Vol. VIII, p. 14, under the title of: *A Case of Wounded Stomach*. By JOSEPH LOVELL, Surgeon General, U. S. A. Very strangely the editor omitted to alter the pronouns or otherwise modify the history communicated by Dr. LOVELL, and the reader is liable to be deceived, as was Professor ROMBERG (*Über Tödlichkeit der Magenwunden in Schmidt's Jahrbücher*, B. 46, S. 230) (and as I was, for a long time), into the belief that Dr. LOVELL is relating his own personal observations. That Dr. LOVELL was not responsible for this error, those familiar with his spotless reputation felt sure; but the editor, Dr. Calhoun, has deferred his vindication for twelve months, printing in the December number of the *Recorder* (Vol. VIII, p. 840,—the article was printed in the January number) an obscure paragraph, with a brief allusion to the "mistake"! Soon afterward DUNGLISON described the case, with remarks on its physiological relations, in his *Elements of Hygiene*, Philadelphia, 1835, p. 216. Interesting accounts of St. Martin's condition in May, 1856, during a visit to New York, may be found in the *Medical and Surgical Reporter*, Vol. IX, p. 306, and the *Boston Medical and Surgical Journal*, 1856, Vol. LIV, p. 266. An account of his visit to Cincinnati, in the same year, is published in the *Cincinnati Medical Observer*, 1856, Vol. I, p. 325. Dr. FRANCIS G. SMITH'S papers on this case, entitled *Experiments on Digestion*, are published in the *Medical Examiner*, 1856, N. S., Vol. XII, pp. 375-513.

which sets at rest the doubts I there ventured to express regarding that case, and establishes it, beyond question, as an authentic instance of recovery from a shot perforation of the stomach. Dr. Hard writes, March 18, 1873:

\* \* \* "I recollect the case of Private Bowes very well. He was shot, with a minié ball, in the stomach, the day before the battle of South Mountain, near Middletown, Maryland [September 14, 1862], and came under my care immediately. The ball penetrated the stomach, as was proved by liquids which he drank escaping through the wound. I was unable to find the ball. At first he suffered severely, and he vomited blood. He could not bear the recumbent posture; but had his shoulders raised, lying in a semi-recumbent posture. I gave him opium freely, to allay pain. The next day, as I was obliged to go forward with my regiment, the patient passed into another surgeon's hands. Since his discharge, Bowes has fully recovered: has married, and has children, and now resides at Crete, Cook County, Illinois." [See CASE 185, p. 46, *ante*.]

The following is an extract from a letter from Mr. Bowes, dated 130 Walsh street, Chicago, March 26, 1873:

"DEAR SIR: Your letter of the 6th instant has just come to hand. As I do not reside in Crete, it has been some time in reaching me. It was about three months after I was wounded that the vomiting of blood stopped entirely. During the latter part of that time, it occurred only when I was moved from bed to bed. The escape of food stopped previous to that, I think about nine or ten weeks after I was wounded. I was not wounded on March 6, 1863, or afterwards." [A. G. Report of Illinois, 1867, Vol. VIII, p. 175, gives this erroneous date.]

Then the observations of the war on this subject may be summed up as embracing four fatal punctured or incised wounds, one incontestable recovery from a shot perforation, a few recoveries from shot wounds in the gastric region, in which the diagnoses were not determined unequivocally, and nearly sixty fatal cases of more or less complicated shot

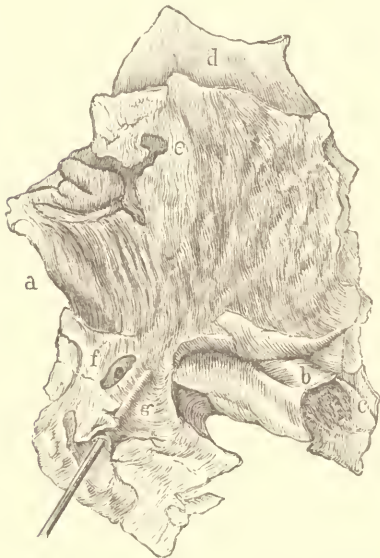


FIG. 36.—Stomach laid open along the greater curvature to show a cicatrized shot track; a, cardia; b, pylorus; c, duodenum; d, omentum major; e, entrance and healed track; f, exit wound, with fistule; g, submucous shot-track. [After KLEBS, *Path. Anat. der Schusswund.*, Taf. VII.]

wounds of the stomach. Deeply regretting the series of unfortunate incidents<sup>1</sup> that impaired the value of some of these observations, in suppressing the light they might have thrown upon the morbid anatomy of these lesions, I have borrowed from Dr. Klebs the representation (FIG. 36) of the process of repair in a partial recovery from a shot wound of the stomach. The preparation was taken from a patient, Helsber, 88th Regiment (Baden), wounded August 6, 1871, at Würth, by a chassépot ball, which passed through the spleen, stomach, liver, diaphragm, left lung, right pleural cavity, and right humerus. He lived until August 24th, eighteen days: "Following the shot channel to the left, two shot openings were found in the stomach, one of which had united with the left shot opening in the liver, forming a funnel-shaped cavity, from the bottom of which a very narrow channel led to the liver shot channel. Opposite the first opening, at the fundus, was a circular opening in the wall of the stomach, one centimetre in diameter, with sharp edges, covered with mucous membrane, the basis of which was formed of closely attached reticulated tissue."<sup>2</sup>

The promptness with which incised wounds of the stomach may cicatrize, is exemplified by the case recorded by Dorsey,<sup>3</sup> of a "man whose stomach was wounded after drinking

<sup>1</sup> The loss of the pathological preparation in CASES 195 and 201, respectively, is a source of much chagrin. The specimen in the latter case would appear not to have reached the Museum. The disappearance of the other specimen I cannot explain. I recall a dried preparation of a stomach submitted to me, with a deposit of lymph an inch long toward the cardiac end of the great curvature, with the inquiry whether it could be regarded as a shot cicatrix; but can find nothing to connect this circumstance with the specimen in question. Habitually, at the Museum, when a specimen is rejected or discarded, a memorandum is attached to the history, stating the reason. In the absence of any such record, the fate of this preparation is left a matter of conjecture.

<sup>2</sup> See, for a further clinical history of the case of Helsber, SOGIN, *Kriegschirurgische Erfahrungen*, Leipzig, 1872, S. 93.

<sup>3</sup> DORSEY, *Elements of Surgery*, 1878, p. 94.



porter. The wound of the stomach was found, on dissection, completely healed; the patient died on the fourth day, of peritoneal inflammation." In several of the early fatal cases it was noticed that there was neither escape outwardly, nor extravasation within the peritoneal cavity, of the undigested food which partially filled the wounded viscus.<sup>1</sup> But extravasation was the rule; and, as was indicated in referring to ruptures of the stomach (p. 22, and *note* 2, p. 27), the fatal issue was more prompt when the injury was received while the organ was in a state of repletion.<sup>2</sup> Hæmatemesis generally occurred very soon after the infliction of the injury; but it was not an absolutely constant symptom.<sup>3</sup> There was commonly intense pain at the seat of injury. The pain was apparently in relation with the extent and acidity of the intra-peritoneal extravasation. Instances are adduced, unattended by extreme pain, in which blood was freely effused in the peritoneal sac; but, where the pain is described as excruciating, it commonly appears that irritating, undigested food had escaped into the cavity of the belly. Blood flowing into the stomacal cavity induced vomiting, followed by persistent hiccough. The external hæmorrhage was seldom considerable. In most of the cases intensity of thirst was noted. Nearly all were attended by constipation, and many by dysuria. Thus, in several particulars, the facts observed were conformable to the deductions of theory. But there were many unexplained exceptions.

The group of cases is so large, comparatively; that, added to the evidence existing in surgical annals, it should afford us a better approximative estimate of the frequency and fatality of wounds of the stomach than has heretofore been entertained.<sup>4</sup> Contemporary authors still cite Percy's estimate that in punctured or incised wounds of the stomach four or five in twenty may survive.<sup>5</sup> But if, from the time of Albucasis to the present day, a score of authentic recoveries from lesions of this class may possibly be gleaned, it would not be difficult to adduce many times that number of fatal cases, and a mortality rate of 99 would be nearer the truth than Percy's estimate of 75 per cent. The unequivocal recoveries from shot wounds of the stomach, with or without fistula, number only six or

<sup>1</sup> Good accounts of autopsies in two such cases are recorded: one by Dr. R. K. SMITH (*Case of Wound of the Stomach*, in the *Medical Examiner*, 1851, N. S., Vol. VII, p. 162), in a case where there was no extravasation or vomiting, though the stomach was filled to repletion, and the patient survived for twenty-six hours an incised wound an inch long near the cardiac extremity of the stomach. Another, by Dr. RAFAEL (*Western Jour. of Med. and Surg.*, 1849, Vol. IV, p. 113), where there was no extravasation, though the stomach was "half full of ingesta."

<sup>2</sup> TRIPLER and Dr. CHESLUM (*ante* p. 41, *note* 1) are at variance as to the probable average condition of the soldier's stomach in action. It does not appear to be a question to be determined *a priori*. TRIPLER (*Peninsular Jour. of Med.*, 1856, Vol. IV, p. 1) says: "In the aggregate number of wounds received in battle, it is fair to presume that no inconsiderable proportion will involve the stomach. When a General can choose his time for engaging the enemy, he will be careful to secure to his men a good meal beforehand. Men, generally, go into action with the stomach well filled. Occupying, as it does under these circumstances, so large and so central a space in the body, it can hardly escape in the indiscriminate lesions consequent upon a well-directed fire. And yet, few military surgeons have seen many cases. Hennen says he never treated one. \* \* There can be but one reason for all this—that is, that this lesion is almost invariably and speedily fatal. The stomach is so important an organ in its functions, in its relations, and its nervous connections, that it will rarely bear so severe an injury as that of a gunshot wound. Hennen remarks: 'Baron Percy calculates that out of twenty cases, four or five only have escaped; this, however, is a most favorable average.' Sir G. Ballingall thinks Percy has abundant reason to be satisfied with his success, and that the experience of others will hardly warrant us to expect a like result. A just prognosis as to the issue of gunshot wounds of the stomach cannot be deduced from the result of penetrating wounds from other causes, whether accidental, or due to operations for the extraction of foreign bodies. The circumstances are altogether different, and, in the latter case, time, place, and other accidents can all be commanded. The gunshot wound, on the other hand, partakes of the nature of a violent blow upon the stomach, a circumstance of itself frequently fatal; its extent is greater than most other penetrating wounds, its shape irregular, its situation as likely to be the most unfavorable as any other, and, in general, the time of its infliction will be when the stomach is distended with food. So that it appears to me, that even when the sufferer reaches the hospital alive, the most unfavorable prognosis is the only prudent one in every case."

<sup>3</sup> For an interesting case by Dr. REED, with a discussion on the occasional absence of this symptom, by Drs. GROSS, WOODWARD, and HARRIS, refer to the *Proceedings of the Pathological Society of Philadelphia*, in the *Am. Jour. Med. Sci.*, 1860, N. S., Vol. XI, p. 121 *et seq.*

<sup>4</sup> According to MAISON (Vol. II, p. 122) wounds of the stomach were pronounced *mortal*, by the faculty of Giessen; *absolutely mortal*, by that of Frankfort; *lethal*, at Leipsig; *not necessarily lethal*, at Hehnstadt. BOHN and TEICHMEYER held that all complete divisions of the walls of the stomach are fatal, and that escapes are miraculous, while ALBERTI, BERHAAVE, and VALENTINI, in his *Pandects*, considered only those wounds mortal that implicated the great curvature, the cardia, or the pylorus.

<sup>5</sup> PERCY, *Bulletin de la Faculté de Médecine de Paris*, 1818, T. V, p. 330. There could not be a better exemplification of the tenacity of error. PERCY was generally a very accurate writer, and would have been the first to explain that he was merely hazarding a rough guess. But this sentence has been accepted as a record of the vast experience of the best-informed military surgeon of his day, and has been repeated, without examination, by almost every writer on the subject. It is often ascribed to LARREY. As late as 1869, Mr. BLENKINS (*Additions to POUCHER'S Dictionary*, p. 84) tells us that wounds of the stomach "Are very fatal. Baron LARREY calculates (1) that four or five only, out of twenty, survive."

seven.<sup>1</sup> A large proportion of the injuries of this group must be sought in the returns of those killed in action. Of shot wounds of the stomach that come under treatment, the percentage of recovery is small. The sixty-four cases of the War of the Rebellion that came under surgical observation, presented a single instance of undoubted recovery, after a shot penetration of the walls of the stomach. Of shot injuries without penetration of the viscus, three were followed by secondary gastric fistula, and eventually terminated fatally. In the single example of lodgement of a ball in the cavity of the stomach, there was no question of gastrotoomy,<sup>2</sup> an operation unlikely to be called for in military surgery.

<sup>1</sup> The five cases of Maillet (1639), St. Martin (1822), the grenadier reported by BAUDENS (1839), the case of Speed (1859), and that of Bowes (1864), can alone be regarded as well-attested recoveries from shot perforations of the stomach. In the cases recorded by BECK, SCHOLTZ, FISCHER and LOVELL, TRIPLER, THOMSON, BRETON, there is doubt either in regard to the extent of the injury or the value of the evidence. Dr. E. TRENOR (*Western Lancet*, 1872, p. 68) admits that the evidence of penetration of the stomach in a recovery reported by him is not conclusive. M. SÉDILLOT (*l. c.*, p. 467) gives credit to a case of traumatic fistula of the stomach resulting from a gun-shot wound, which is reported by THOMASSEN (*Obs. intra-chirurgiques de J. Covillard*, and notes, Strasbourg, 1791). COVILLARD, a surgeon of Montelimart, wrote in 1633-40. From Thomassin's citation, it would appear that he describes from hearsay this gastric fistula, in a soldier wounded in the battles of the Prince of Harcourt against the Spaniards (about 1629). M. SÉDILLOT says that "FALLOPIUS relates that he had cured a man and a woman of wounds of the stomach, from which food escaped. The woman had been perforated (traversée de part en part) by a leaden ball, and God, he says, saved her, because she had resumed chaste and holy habits after having been a strumpet," and refers to the commentary *de vulneribus capitis*, cap. XII. M. SÉDILLOT translates, almost textually, from SCHENKLIUS (*Obs. Med. Rar.*, Leyden, 1654, Lib. III, p. 332), who quotes FALLOPIUS as follows: "Nam suavi mulierem, et hominem a quibus egeredebatur chylus, et cibus. Sanaui mulierem, glande percussam plumbea ab anteriori et posteriori parte. Et hanc Deus sanavit: quia meretrix quondam fuit, jam casta et sancte vivit." *Fallopian de vulneribus capitis*, cap. XII." The reference is to the commentaries of FALLOPIUS on HIPPOCRATES, *de vulneribus capitis*. Other writers refer to the marvellous case of the reformed harlot as in the twentieth chapter of FALLOPIUS, *de vulneribus particularibus*; but neither here, nor in the commentaries, is this passage to be found, either in the Venice edition of 1606, of the genuine works of FALLOPIUS, or in the Frankfort edition of 1600. In the text, I have allowed for one or two instances of evisceration of wounds of the stomach, with death from complications. Those with an appetite for the marvellous can consult Dr. GRANT'S *Case of Gunshot Wound of the Heart and Stomach*, in the *Charleston Med. Jour. and Rev.*, 1857, Vol. XII, p. 303, in which the patient is said to have survived for twenty-six days a shot perforation of the stomach and right ventricle of the heart.

<sup>2</sup> In treating of wounds of the stomach, HENSEN (*op. cit.*, 3d. ed., p. 433) remarks: "The histories of the Bohemian, Prussian, and English cultrivores, in some of whom the knives have been cut out, and in others discharged spontaneously through the coats of the stomach and parietes of the abdomen, as well as many other instances on record, are very encouraging in cases of injuries of this organ. \* \* \* The industrious Poncequet has exceeded all other authors for the vast number of cases he has amassed." When the repetitions are eliminated, the number is anything but vast. Mr. BRYANT (*A Practice of Surgery*, 1872, p. 311) states the number of successful operations for gastrotoomy as seven. Mr. DURHAM (HOLMES'S *System*, 2d ed., Vol. II, p. 549) professes to enumerate seven, inadvertently duplicating the first by the fourth, and really naming six cases. Since the revival of this operation, in 1849, by M. SÉDILLOT, the old chronicles have been again ransacked for illustrations. LARREY (*Mém. de Chir. Mil.*, T. III, p. 90) remarking that "ces faits sont extrêmement rares," tells us that he was shown at Königsberg a small knife that "a cultrivore named Andréas Grünheide swallowed in 1613. The grave symptoms that supervened led Dr. Gruger, a Polish surgeon, to do the operation of gastrotoomy; it was done May 29th of that year, and the peasant lived ten years afterwards." The good baron is evidently citing from memory. The peasant's name is not very incorrectly given, but there is an error of twenty-two years in the date. The knife was swallowed May 29, 1635. Gastrotoomy was practiced July 2, 1635, by Dr. Daniel Schwabe, of Königsberg, in the presence of the faculty. HEVIN, in his encyclopedic memoir, already cited (*Sur les corps étrangers arrêtés dans l'osophage*, *Mém. de l'Acad. royale de Chir.*, 4to, T. I, p. 595), informs us that the case of this Prussian peasant is recorded by several writers, of whom he specifies CLYVELIUS (not Gruger), in the second volume of his history of Prussia (*Epitom. Histor.*, Lib. II, Cap. II), and BECKER (in the appendix to the *Ephemerides*, Dec. II, ann. 5 and 8, Obs. 167). In fact, BECKER prints a portrait of the patient in his paper, dated 1643. MENZEL also refers to him (*Mis. Nat. Cur.*, Dec. II, ann. I, Obs. 1). SOUTH (*Notes to Chelius*, Am. ed., Vol. III, p. 166) correctly refers to this case as quoted from BECKER of Dantzig, by BARNES (*Edinb. Philosoph. Jour.*, 1821, Vol. XI, p. 323), who gives the name of the peasant as Andrew Grünheide, but wrongly names the operator "Shoval." This misprint is copied by FROBER; and GÜNTHER (*Die Blut. Op.*, B. IV, Ab. XV, S. 26), remarking on the identity of the case, wonders where FROBER found the name of the operator as "Shoval," the correct name being plainly Schwabe, that of a well-known Rhodomat. OLIVER (*Philosoph. Trans.*, Jones's ed., 5th Vol.) tells us that he saw the knife at Königsberg, in 1685. It was kept in a velvet bag in the library of the king of Prussia. It was six and one-half inches (English) in length. Mr. DURHAM (HOLMES'S *System*, 2d ed., Vol. II, pp. 549-550) tabulates this case twice. Thus the Prussian cultrivore, Grünheide, on whom SCHWABE practiced gastrotoomy in 1635, has played many parts, figuring as Schwabe's case, Gruger's, Shoval's, Becker's, and Menzel's, and referred to by the careless even as HEVIN'S or LARREY'S case, the case or cases in the *Philosophical Transactions*, in the *Ephemerides*, and cited in an incredible number of collections. There was a second Prussian cultrivore, a woman, from whom HENRICH BERNARD HÜBNER, of Rastenburg, felicitously excised a knife, in 1720 (*Relation von der ermländischen Messer-schluckerin*, Königsberg, 1720). This case is cited by HEVIN, HALLER, and a multitude of others. Mr. DURHAM incorrectly dates it "about 1742." The Bohemian knife-swallower played protean parts also, excusably, perhaps, as he was a juggler, Matthews by name, who lived in the suburbs of Prague, in 1602. The erudite HEVIN (*l. c.*, p. 596) also relates this case, from CROLLIUS (in *Pract. Chym. regal. Basil. Ephemerides*, Dec. 2, ann. 10, Obs. 1). Gastrotoomy was successfully practiced by FLORIAN MATHIS, surgeon to the Emperor Leopold. There were two (so called) English cultrivores; though one, John Cummings, was an American sailor, whose case, yet remembered by old people in Boston, is related by MARCET (*Med. Chir. Trans.*, 1823, Vol. XII, p. 52). The history of the other, William Dempster, of Carlisle, is related by BARNES (*Edinb. Philosoph. Jour.*, 1824, Vol. XI, p. 319). Gastrotoomy was not practiced in either case. There is no question regarding the successful gastrotoomy by CAYROCHE (*Bull. de la Faculté de Med.*, 1819, T. VI, p. 447) in the case of Madame S——, aged 24, who swallowed a silver fork, in 1819; nor of the successful excision of a silver spoon from the stomach of a soldier in 1823, by Dr. L——, endorsed by SÉDILLOT (*Contributions à la Chirurgie*, 1808, T. II, p. 456); nor concerning the successful gastrotoomy for the removal of a bar of lead from the stomach of a man named Bates, aged 27 years, by Dr. JOHN BELL, of Wapello, Iowa (*Boston Med. and Surg. Jour.*, 1860, Vol. LXI, p. 489; reported also by Dr. T. B. NEAL, in *The Med. Examiner*, N. S., 1855, Vol. XI, p. 193). Two cases of alleged successful gastrotoomy, reported by Dr. CHARLES B. NEW, of Rodney, Mississippi (*Western Jour. of Med. and Phys. Sci.*, 1838, Vol. XI, p. 551), and by Dr. A. EWING, of Bayou Sara (*New Orleans Med. and Surg. Jour.*, 1853, Vol. IX, p. 764), are not usually included in the summaries of this operation. The editor of the *American Journal* (Vol. XXIV, 1839, p. 261) remarks of the first, that it is "nothing short of miraculous." The treatment to which "the negro man—the property of John E. Hummons, Esq., of Carroll County, Mississippi," was subjected, in the second case, appears to be regarded as equally outside the domain of surgery. The story of the stick, ten inches long, removed from the stomach of Mateo Sanchez, in 1830, by FRANCISCO GARCIA GARCIA (*El Porvenir Medico*, 1854), translated for the *Medical Examiner*, 1853, Vol. XI, p. 91, by Dr. W. S. W. RICHENBERGER, is akin to this group. Baron LARREY'S recollection (*Mémoires*, T. III, p. 90) of seeing, as a student, Professor Trizac, of Toulouse, remove a knife from the stomach of a canal porter, through an epigastric incision, uniting the wound in the stomach by two stitches, and the wound in the walls by the quilled suture, though explicitly recorded, appears to have been overlooked; and the case of the young man described by M. BOUSSON

Neither was gastroraphy employed in any case. This resource merits more consideration than it receives; for the majority of recoveries from wounds of the stomach have been instances of the successful use of sutures.<sup>1</sup> The complexity of shot wounds, and the attendant lesions of neighboring organs, commonly forbid recourse to this expedient. But in accessible shot wounds of the anterior wall, this means of arresting fatal extravasation should not be neglected. I regard the refreshing of the bruised edges in gastroraphy and enteroraphy as unnecessary. In the modern methods of applying sutures to the alimentary

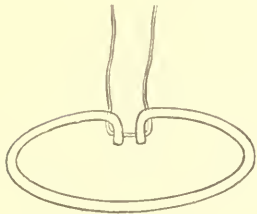


FIG. 37.—Jobert's suture.

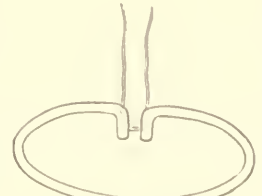


FIG. 38.—Lembert's suture.

canal, inversion and approximation of the serous surfaces is universally sought. (See FIGURES 37 and 38.) Now in all shot wounds of the digestive tube that I have examined, the loss of substance is mainly confined to the muscular, connective, and mucous tissues, the serous membrane remaining sufficiently organized to hold stitches. It will be sufficient to unite these surfaces (*adosser les séreuses*), and what sloughing of the inner tunics there may be, can discharge into the digestive cavity.<sup>2</sup>

(SÉDILLOT, *l. c.*, p. 463), who showed the cicatrix, through which a fork had been removed from his stomach, to Professor Caizergues and other members of the faculty of Montpellier, is also omitted from the later enumerations of successful examples of gastrotomy for the removal of foreign bodies. Many unsuccessful operations have been done for the alleviation of the condition of patients with stricture of the œsophagus. MR. DURHAM records nine: two by M. SÉDILLOT (*l. c.*, pp. 484 and 494), in 1849 and 1853; one by PÉNGER, of Copenhagen, in 1854 (*Arch. für Path. Anat. and Phys.*, B. VI, S. 350); two by Mr. C. FORSTER, in 1858 and 1859 (*Guy's Hosp. Rep.*, 3d Ser., Vols. IV, p. 13, Vol. V, p. 1); two by Mr. S. JONES, in 1860 and 1866 (*Trans. Path. Soc. of London*, Vol. XI, p. 101, and *Lancet*, 1866, Vol. II, p. 465); one by Mr. T. B. CURLING, in 1866 (*Lond. Hosp. R. p.*, 1866, Vol. III, p. 218), one by Mr. A. DURHAM, in 1868 (*Guy's Hosp. Rep.*, 3d Ser., Vol. XIV, p. 195). To these may be added a fatal case recorded by Mr. THOMAS BRYANT (*The Practice of Surgery*, 1872, p. 316); one by Dr. F. F. MAURY (*Am. Jour. Med. Sci.*, 1870, N. S., Vol. CXXVII, p. 265); and one by Dr. LOWE (*Lancet*, 1871, Vol. II, p. 419); one by Mr. THOMAS SMITH (*Trans. Clin. Soc.*, London, 1872, Vol. V, p. 236); two by Mr. WM. MACCORMAC (*Idem*, p. 212), one in his own, and the other in the practice of Mr. LE GROS CLARK; and one by Dr. F. TROUP (*Edinb. Med. Jour.*, 1872, Vol. XVIII, p. 26). Thus, there are six authentic instances of successful gastrotomy for the removal of foreign bodies, viz: MATHIS's, in 1602; SCHWABE's, in 1635; HÜBNER's, in 1720; CAUROCHE's, in 1819; Dr. L.—'s, in 1833 (attested by M. SÉDILLOT), and Dr. BELL's in 1833. There are also the five less credited successes, of PRISAC (about 1790); the Montpellier case, related to M. SÉDILLOT by M. BOUSSON (about 1828); of GARCIA, in 1830; and those of Drs. NEW (1837) and EWING (1852). I find one unsuccessful gastrotomy for the extraction of foreign bodies recorded, but cannot verify the reference. GÜNTHER (*l. c.*, S. 27) ascribes to GIECK, in America, in 1856, an unsuccessful gastrotomy for the removal of a laryngeal probe accidentally introduced into the stomach. On the other hand, when performed for obstruction of the œsophagus, gastrotomy has resulted fatally in sixteen instances, at least. Dr. ASHURST (*Am. Jour. Med. Sci.*, N. S., 1873, Vol. LXX, p. 487) refers to another fatal case reported by Mr. MASON. M. SÉDILLOT (*Contributions à la Chirurgie*, T. II, p. 405) gives "the name *gastro-stomie* (*γαστρία*, stomach; *στόμα*, mouth) to the operation of establishing a permanent opening in the walls of the stomach," and Dr. ASHURST (*Am. Jour. Med. Sci.*, 1873, N. S., Vol. LXX, p. 487) adopts *Gastrostomy* as a more accurate name. But as, in the sixteen or seventeen attempts upon the human subject, an incision into the stomach has, and a permanent opening into its walls has *not*, been accomplished, it appears to me more accurate, as well as more in conformity with surgical idiom, to retain the name gastrotomy, and to restrict its application.

1 There is no recorded example of successful gastroraphy for shot injury unless one of PURMANN's cases may have been of that category; but of the rare recoveries from incised and lacerated wounds of the stomach, many, and those the best attested, were treated by suture. Since compiling the note on page 42, I have compared the chapters of SCHENCKIUS (*Obs. Med. Rar.*, Leyden, 1644, p. 332) and of STALPART VANDER-VIEL (*Observat. Rar.*, Leyden, 1687) on this subject, and am the more convinced of the rarity of authentic instances of this group, and of the correctness of PURMANN's conclusion that a fatal result can rarely be avoided except by gastroraphy. The student must not confound, as many have done, the accounts of successful gastroraphy by GALEN (*Med. Med.*, VI, 4), CÆLSEUS (*De re med.*, VII, 16), ALBUCAZIS (*De chirurgia*, II, 379), HALLY ABRAS (*Pract.*, IX, 43), RHAZES (*Cont.*, XXVIII), PARÉ (*Œuv. comp.*, 6d. Malg., II, 108), VAN SWIETEN (*Comment.*, 311), FABRICIUS AB AQUAPENDENTE (*Œuv. chir.*, II, 79), and SPRENGEL (*Hist. de la Med.*, XVIII, 21). They are all treating of sutures of the abdominal parietes under the name of gastroraphy. But PURMANN's two cases; SCHLICTING's; the Marquise soldier operated on by JOHN SCHENCKELIUS (identified with the case reported by CÆLSEUS, HILDESIUS, and SCHENCKIUS), RICHSTRAT's case, identical with that recorded by KLUYSKEM (*An. de Litt. mèd. et chir.*, Ghent, T. III, 38-9); LAROCHE's case; CARTERAT's, PERCY's, TRAVERS's, and ASHBY's case, were all examples of the successful application of the suture to the walls of the stomach. I do not include the successful gastroraphy ascribed to STALPART VANDER-VIEL; for he only states (*l. c.*, 156) that such an operation was related to him by a Belgian surgeon named GODEFRIDUS. The originality of the cases related by VEGA (*Comment. in Hippoc.*, 1576, Lib. VI, p. 809) and WOLFF's (*Obs. Chir. Med.*, 1701, p. 83; *vulnus ventriculi sanatum*) is equally open to doubt. The case ascribed by SÉDILLOT to SCULTEPUS (*Armament. chir.*, Francofurti, 1666, p. 85, obs. 58) was assuredly not a wound of the stomach. When the cases of gastrotomy and gastric fistula are also abstracted, there remain only the cases of LOUBET, LARREY, and a very few others, of recovery from wounds of the stomach without the use of the suture.

2 Extended bibliographical references on the anatomy, physiology, and medical pathology of the stomach have been compiled by various authors, very fully as regards older authors, by PLOUQUET (*Repertorium*, T. III, Article *Ventriculus*), and later by COPLAND (*Dictionary of Pract. Med.*, Am. ed., 1859, Vol. III, p. 1017), and RAIGE-DELOIRME (at the conclusion of the article *Estomac*, in the *Diet. de Med.*, T. XII, p. 283); but I have met with no comprehensive surgical bibliography. The much-cited dissertation of ETMULLER (*De Vulnere ventriculi per grammat.*, Lipsiæ, 1730, No. 143, Vol. V, p. 167) of HALLEI's *Disputationes*, Lausanna, 1756) sums up, in four pages, the dicta of the ancients respecting wounds of the stomach; but contains an account of only one case, related to ETMULLER by a surgeon of Paris. WENKER's narrative has been already cited. BÉRIARD (*Diet. de Med.*, T. XII, p. 306) criticizes the accurate SAMUEL COOPER with unmerited severity, alleging that "le chirurgien anglais, qui souvent cite à faux, n'été plus malheureux ou plus inexact que jamais dans le passage que je viens de transcrire," *i. e.*, in adducing JUNGEN's as an authority on wounds of the stomach, "La dissertation de JUNGEN, que j'ai lue, ne renferme aucune observation de fistule de l'estomac." COOPER does not allege that it does; but simply that "further information connected with this subject"—of wounds of the stomach—may be found in it, which is true. Curiously, both compilers



WOUNDS OF THE SMALL INTESTINES.—Of the complications of penetrating wounds of the abdomen, lesions of the small intestines are the most frequent, and contribute the largest contingent to the general mortality. The

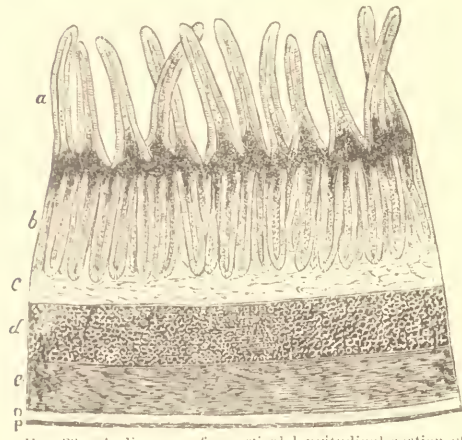


FIG. 39.—A diagram of a vertical longitudinal section of the jejunum as seen under a low power (about 50 diameters): *a*, villi; *b*, follicles of Lieberkühn; *c*, submucous connective tissue; *d*, circular muscular fibres; *e*, longitudinal muscular fibres; *f*, subperitoneal connective tissue; *p*, peritoneum.

great length of this viscus and its position (Figs. 20 and 21) account for this liability to injury. Wounds of the small intestines are often multiple,<sup>1</sup> because of their convolutions. Of the three divisions of the gut, the ileum is the most exposed, next the jejunum, while wounds of the duodenum less frequently come under treatment.<sup>2</sup> The minute anatomy of the intestine explains some of the peculiarities in the appearance of solutions of its continuity. In punctured wounds, the opening is contracted by the circular and longitudinal fibres, and closed by the eversion of the mucous lining.<sup>3</sup> In transverse wounds there is slight gaping from the contraction of the longitudinal fibres; but the calibre

of the intestine is diminished by the contraction of the circular muscular layer and the pouting of the mucous membrane, and the escape of contained matter is impeded. In complete transverse sections of the gut, the divided extremities are separated and puckered, so that it is commonly impracticable to distinguish the upper from the lower portion except by the escape of faecal matter. In large longitudinal wounds,<sup>4</sup> the contraction of the circular muscular fibres (Fig. 39, *d*) produces wide gaping of the edges, and readily permits the

BÉRARD and COOPER, blunder in confounding the dissertation of FABRICIUS, a professor at Helmstadt (*de lethaliitate vulnorum ventriculi*, Helmst., 1751, in SCHLEGEL'S collection, II, S. 199), with that of JÜNCKER, of Halle (whose name they misspell "Jungen"). JÜNCKER, in his paper *de viscerum lisionibus rite dijudicandis et congrue tractandis*, Halle, 1745, and also in his *Conspectus chirurgiæ medicæ*, Halle, 1720, claims to have observed several instances of recovery from wounds of the stomach. The dissertations of J. B. ROBERT (*De ventriculi vulneribus*, Leyden, 1770) and of DÜRR (*De ventriculi vulnere egregie curato*, Lipsiæ, 1790) I have been unable to obtain; nor can I find the paper of HORN (*De ventriculi rupturâ*, s. v. v. Berol., 1817), cited by COOPER and others, though in MURSSINA'S *Journal für Chirurgie*, u. s. w., 1808, B. I. S. 3, there is an interesting report by Generalarzt HORN of a recovery after a stab wound of the stomach. RICHTER'S remarks on this subject (*Chirurgische Bibliothek*, Göttingen, 1790, B. III. S. 552, B. X. S. 203), DESAULT'S case (*Journal de Chirurgie*, Paris, 1792, p. 48), and MORAND'S three cases (*Opuscules de Chirurgie*, Paris, 1768, T. II, pp. 147, 148), and HEYFELDER'S paper *Die Verletzungen des Magens rücksichtlich ihrer Tödtlichkeit* in HECKER'S *Lit. Annot.*, 1828, S. 3), may be profitably consulted, and ROMBERG'S exhaustive medico-legal dissertation (*Über Tödtlichkeit der Magenwunden in gerichtlich-medizinischer Hinsicht*, Schmidt's Jahrb., B. 16 1845, S. 230) is worthy of attentive study. M. FOLLIN presents a good exposition of the subject in the article *Plaies de l'estomac* in the *Dictionnaire Encyclopédique des Sciences Médicales*, 1863, T. I. p. 159. The bibliography of ruptures of the stomach has been referred to in notes on pp. 22 and 27 *ante*. In two recent inaugural dissertations, Dr. HENBICI (*Über die Wunden des Magens*, 75 S., Leipzig, 1861) and Dr. HERMANN (*Über die Schuss- und Stichwunden des Magens*, 16 S.) have industriously collected many examples of wounds, ruptures, fistulæ, and operations for gastrostomy. Neither author appears to have verified his references by consulting the original publications, and Dr. HENBICI is misled into the frequent repetition of identical cases. Some cases are adduced by BIRKHOLZ, *Diss. de gastrotonia*, Lips., 1805, and by MARCUS, *De fistula ventriculi*, Berolini, 1845; but altogether the bulk of ancient and modern information on the subject is to be found collected in the articles cited from SCHENCKIUS, HEVIN, and SÉPILLOT.

<sup>1</sup> TRAVERS, *An Inquiry into the Process of Nature in repairing Injuries of the Intestines*. London, 1812.

<sup>2</sup> JOBERT, *Traité théorique et pratique des maladies chirurgicales du canal intestinal*. Paris, 1829.

<sup>3</sup> This eversion, which is almost constant, depends mainly upon the relaxed condition of the mucous lining on contraction of the circular and longitudinal muscular fibres. It is possibly favored by the contraction of the minute muscular layer between the follicles and connective tissue described by Professor ERNEST BRÜCKE (*Über ein in der Darmschleimhaut aufgefundenes Muskelsystem*, in den *Berichten der Wiener Academie*, Feb. 1851), but this is so minute that its influence must be very small.

<sup>4</sup> GROSS, *An Experimental and Critical Inquiry into the Nature and Treatment of the Wounds of the Intestines*. Louisville, 1843. At page 10, Professor GROSS relates the following experiments: "1. A longitudinal incision, two lines and a half in length, immediately contracted to one line and three-quarters, with a sufficient amount of eversion of the mucous lining to close the resultant orifice. 2. A similar wound, four lines long, diminished in a few seconds to three lines, by one line and a half in width; it assumed an oval shape, and the internal membrane protruded on a level with the peritoneal covering, leaving no perceptible aperture. 3. An oblique cut, seven lines in length, contracted to five, by two and a half in width, with marked eversion of the mucous lining. 4. A transverse wound, two lines and a half long, was reduced almost instantaneously to two lines in diameter; it was of a rounded form, and the two extremities of the gut retracted so as to expose the mucous membrane. 5. In another experiment, in which the incision, likewise transverse, was half an inch in extent, the orifice assumed a rounded, oval shape, and was reduced to four lines, by two and a half in width, the internal coat exhibiting, as in the other cases, a pouting, or everted arrangement. These observations are interesting chiefly as showing the efforts which nature institutes to close a breach of this kind the very moment almost it is inflicted. It is doubtless by a process of this description that the effusion of stereoraceous matter into the peritoneal sac is so generally prevented in those cases in which the solution of continuity is of small extent, not exceeding, for example, a few lines in diameter, and where, consequently, it amounts rather to a puncture than a wound. The eversion of the lining membrane forms a striking and constant feature in injuries of this character, and may be compared, in its effects, to the contraction and retraction observed in the extremities of a divided artery."

escape of the contents of the bowel. With a few conditional reservations, wounds of this portion of the alimentary canal are justly regarded as almost necessarily fatal; not because the visceral lesion is in itself destructive, for it is susceptible of prompt repair,<sup>1</sup> but because the conditions that will secure the peritoneum from the ingress of foreign matter are so rarely fulfilled. In the few instances of recovery that will be adduced, the fortunate issue was due to the agglutination of the injured wall to neighboring parts through plastic exudation and the escape of the intestinal contents externally. Even in these exceptional cases, there is room for doubt whether the lesions really existed in the small intestine, whether in fact the fecal discharge did not proceed from an opening in the colon. Ruptures of the small intestines without external injuries have been noticed on page 22, and reference is there made to the obscurity of the symptoms of that lesion. In wounds, the demonstrative evidence by sight or touch may be superadded. The escape of the intestinal contents, or their appearance upon the vulnerating instrument alone, afford certain proof of penetration of the intestinal canal. Of about six hundred and fifty cases of penetrating wounds of the abdomen returned during the war as mainly implicating the intestinal canal, only about fifty are distinguished as lesions of the small intestines exclusively; eighty-nine were set down as wounds of the large intestines; and over five hundred as cases in which the portion of the canal injured was not discriminated, or as instances in which both portions were interested.

*Punctured and Incised Wounds.*—As the facts adduced on pages 31 and 32 would indicate, lesions of this description were uncommon, and most of the examples were the results of stabs inflicted in private brawls.<sup>2</sup> Very few sword or bayonet wounds involving the intestinal canal came under treatment, though a number of examples of such injuries were observed on the bodies of those slain in battle.<sup>3</sup> In the case of Private J. W——, cited on page 42, a bayonet stab in the left hypochondrium, the jejunum, as well as the stomach, was perforated. The preparation of the inverted intestine is shown in the adjacent wood-cut (FIG. 40). The characteristic triangular form of the puncture is noticeable. Four or five other cases were reported. Fecal extravasation, promptly followed by fatal traumatic peritonitis, appears to have attended them all. The absence of protrusion of the wounded viscera, in this series, was remarkable, and explains why sutures were so little employed. Since the war, this means has been twice resorted to successfully.

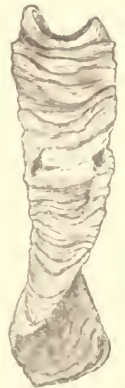

FIG. 40.—Bayonet perforation of the jejunum. *Spec.*, 2254.

CASE 203.—Private W. TILAN, Co. H, 1st Virginia Artillery, aged 19 years, was stabbed while in camp at New Creek, Virginia, November 13, 1864. The weapon, a knife, penetrated the abdominal cavity and wounded the small intestines. The patient was taken immediately to the post hospital. There was no protrusion of the viscera. Simple dressings were applied, and opiates were administered. Acute peritonitis set in, and the patient died on the following day, November 14, 1864. The case is reported by Acting Assistant Surgeon W. B. CRAIG.

CASE 204.—Private D. F. CHAPPEL, Co. L, 1st New York, a stretcher bearer of Battery D, 7th U. S. Artillery, received a sabre thrust in the abdomen, at Petersburg, June 18, 1864. He was admitted to the hospital of the 15th Corps on the same day. He was suffering from severe shock. The wound had been dressed at the front, the walls being united by sutures and

<sup>1</sup> HIPPOCRATES (*Aphor.* VI, 24) declares: "Ἐπίτορον ἢ διάκοπή του λεπτοῦν τε, οὐ ζῆσθαι τεί": *si quid leve sit, intestinum perforatum se, non coalescit.* FERNELIUS (*Civica medicina*, Geneva, 1679, Lib. VII, cap. 8, *De eorum visceribus affectibus*, p. 633, *de ulcere intestinalium*) comments on this aphorism. WEBER (*De cranialis intestinum vulneribus*, Berlin, 1830) gives a list of commentaries on it.

<sup>2</sup> Mr. LE GROS CLARK (*Lectures on the Principles of Surgical Diagnosis*, 1850, p. 209) justly observes: "Recorded instances of recovery, after a penetrating wound of the abdomen with a sharp instrument, are rare; and such fatal result, as the general consequence of wound of intestine, when in communication with the peritoneal cavity, is in accordance with the issue of experiments which have, from time to time, been performed on the lower animals, and especially recorded by Mr. TRAVERS, and more recently by Dr. GROSS, of Philadelphia. For the conditions suppose the escape of some portion of the intestinal contents, whereby acute peritonitis is established; and from this cause, as in similar lesions of other susceptible organs, fatal collapse follows."

<sup>3</sup> See reports of Surgeon J. R. SMITH, U. S. A., and of Assistant Surgeon H. E. BROWN, 7th New York (1864), the surgical report of *Circular* No. 6, S. G. O., 1865, p. 40.

supported by adhesive straps and bandages. It was not deemed proper to disturb the dressings. There was already a good deal of tympanitis and considerable pain. The depression was so great that it was necessary to give brandy. Morphia was also freely administered. The patient was transferred to general hospital at City Point, June 19th, and died on June 20, 1864. The case is reported by Surgeon W. S. Thompson, U. S. V. The particulars of the autopsy are not recorded; but, from the seat and direction of the wound, it was inferred that it penetrated the small intestines.

CASE 205.—Private J. Gossett, Co. D, 12th East Tennessee Cavalry, entered Hospital No. 19, Nashville, January 2, 1864, having been "stabbed in the belly by a sword." There was no visceral protrusion; but extreme pain and tension indicated the probability of lesion of the intestine. The intense peritonitis was not controlled by the free administration of opium. The case, reported by Surgeon John W. Foye, U. S. V., terminated fatally, January 8, 1864.

The following case, though not belonging to the war series, may be noted here, as having furnished a pathological preparation to the Museum. It was recorded in 1867, by Surgeon J. T. Ghiselin, and the specimen was transmitted in 1870, by Surgeon J. H. Bill. It will be observed that the appearances, as accurately represented in the wood-cut (FIG. 41), of punctured stab wounds of the intestine, are not dissimilar to those sometimes observed in small shot wounds (see FIG. 47, on page 70). In preparations preserved in alcohol these lesions are not readily distinguished:

CASE.—Bugler Dennis W.—1st U. S. Cavalry Band, in a quarrel on July 2, 1867, at Fort Vancouver, received a stab, from a butcher knife, in the right groin, a half inch above Poupart's ligament. He died on July 8, 1867, of traumatic peritonitis.

In the next case it was necessary to apply ligatures to several branches of the mesenteric artery, and enteroraphy<sup>1</sup> was very properly though unsuccessfully practiced:<sup>2</sup>

CASE 206.—D. Brazeo, a freedman, aged 25 years, received a punctured wound of the abdomen, from a knife, in a fight on the steamer Cook, at Vicksburg, June 5, 1865. He was conveyed to the hospital for freedmen. The wound was two inches in length, and was situated one inch to the right of the left anterior superior spinous process of the ilium. Knuckles of the jejunum and ileum protruded. The intestines were cut in three places, and several branches of the mesenteric artery were divided. Surgeon T. J. Wright, 6th U. S. Colored Troops, closed the wounds of the intestines by sutures, ligated the wounded branches of the mesenteric artery, and enlarged the opening and returned the intestines. The wound of the parietes was then closed by sutures, and simple dressings were applied. Death resulted on the next day. Extravasated blood and feces were found in the cavity. Acting Assistant Surgeon C. A. Costar reported the case.

<sup>1</sup>Consult, in Circular No. 3, S. G. O., 1871, pp. 93 and 94, an interesting account by Acting Assistant Surgeon W. H. DOUGHY, of a case of visceral protrusion with an incised wound of the ileum, where enteroraphy was successfully practiced, and the utility of ice-poultices in moderating the subsequent inflammatory process was manifest.—*Ibidem*, p. 96, for Acting Assistant Surgeon S. W. BLACKWOOD'S less fortunate case of enteroraphy, in a case in which the ileum and jejunum were wounded in five places.—*Ibidem*, p. 153, for Acting Assistant Surgeon H. S. KILBOURNE'S case of unsuccessful suture of four wounds in a loop of the jejunum, transfixed by a Kiowa arrow. A very interesting report of a case of successful enteroraphy in the person of Private H. Jacobs, Co. I, 3d Cavalry, stabbed in the left of the hypogastric region, at Little Rock, February 20, 1866, a wound three-fourths of an inch in length in the protruding ileum being united by two interrupted sutures, is printed by Acting Assistant Surgeon B. G. JENNINGS, in the *Chicago Medical Journal*, 1866, Vol. XXIII, p. 243, and the *Boston Medical and Surgical Journal*, 1869, N. S., Vol. III, p. 377. Assistant Surgeon E. V. DEWELL forwarded a report and photograph of the case, which would have appeared in Circular 3 had not its publication been anticipated by Dr. JENNINGS.

<sup>2</sup>In American medical journals the following instances of recovery with enteroraphy from punctured and incised wound of the small intestines have been recorded by the following writers: 1. S. WHITE (*The Medical Repository*, 1807, Second Hexade, Vol. IV, p. 367), glovers' suture of the ileum after enterotomy for the removal of a silver spoon; rapid convalescence. 2. J. D. McBRAYER (*West. Jour. of Med. and Surg.*, 1843, Vol. VII, pp. 1, 81, 161), protrusion of two feet of small bowel transversely punctured by a knife; single interrupted suture; convalescent in twenty days. 3. Dr. A. R. KILPATRICK (*West. Jour. of Med. and Surg.*, 1844, No. VIII, p. 100), division of ileum of eight lines by an axe; one point of interrupted suture; ends left, and bowel kept in contact with the abdominal wall; temporary fecal fistula; attained complete recovery. 4. Dr. W. H. VAN BUREN (*New York Jour. of Med.*, 1847, Vol. VIII, p. 170), longitudinal wound of small intestine closed by two interrupted sutures; knots cut close; wounds in parietes enlarged and gut reduced; prompt convalescence. 5. Dr. F. D. LENTE (*New York Jour. of Med.*, 1850, Vol. V, p. 23), two wounds of ileum; ligature of the mesenteric vessels; two interrupted stitches in one and one in the smaller wound of the gut; reduction; rapid convalescence. 6. D. B. HILLIARD (*Med. Examiner*, N. S., 1850, Vol. VI, p. 147), incision in ileum closed by continued suture; end of thread cut close to knot and protruding bowel returned; slight peritonitis; bowels moved by enema on the ninth day. 7. Dr. I. A. COONS (*Ohio Med. and Surg. Jour.*, 1852, Vol. IV, p. 386), protruding wounded ileum treated by the glovers' suture; end cut short; bowels replaced; recovery in six weeks. 8. Dr. L. A. DUGAS (*Southern Med. and Surg. Jour.*, 1852, Vol. VIII, p. 475), two wounds of small intestine, one nearly severing the gut; closed by cut-gut sutures; rapid convalescence. 9. Dr. J. J. CHURCH (*Charleston Med. Jour. and Rev.*, 1853, Vol. VIII, p. 615), stab in left hypogaster; protrusion of ileum; wound half an inch long closed by two interrupted stitches; replacement. 10. Dr. J. C. McTEE (*New Orleans Med. and Surg. Jour.*, 1854, Vol. XI, p. 23), ileum wounded longitudinally in two places; four stitches in the larger and one in the smaller wound; recovery without a bad symptom. 11. Dr. ROBARDS (*Memphis Medical Recorder*, 1856, Vol. V, p. 412), large dirk wound of intestine closed by glovers' suture; wound in abdominal wall enlarged and bowel replaced; wound in parietes closed by interrupted stitches; patient resumed his ordinary avocations in three weeks. 12. Dr. W. CORSON (*Phila. Med. and Surg. Jour.*, 1856, Vol. IV, p. 225), puncture of small intestine by a broken glass bottle; circular ligature; replacement of protruded gut; recovery. 13. J. J. McELRATH (*New Orleans Med. and Surg. Jour.*, 1858, Vol. XV, p. 182), two punctures in ileum closed by circular ligatures; transverse cut an inch long in jejunum, through which several lumbricoid worms escaped; closed by five points of Lembert's suture; recovery prompt and complete. 14. Dr. A. LOPEZ (*North Am. Med. Chir. Rev.*, 1858, Vol. II, p. 1070), wound in the jejunum secured to the wound in the abdominal wall; recovery after a fistula, which gradually closed. 15. Dr. H. L. BYRD (*Ogden Med. and Surg. Jour.*, 1859, Vol. II, p. 227), coil of ileum transfixed by knife; each wound in its

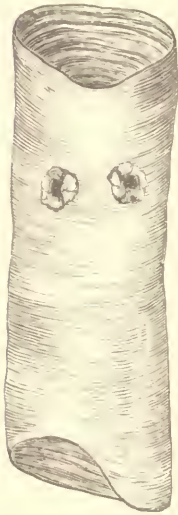

FIG. 41.—Section of ileum showing everted mucous membrane at the two orifices of a stab-wound. *Spec.* 5689.



This series, and the army cases observed since the war, together exemplify the principal varieties of punctured and incised wounds of the small intestine. While minute punctures are not very dangerous,<sup>1</sup> solutions of continuity exceeding four lines are generally fatal, unless art comes to the aid of nature and assists in closing them.<sup>2</sup> Besides the nature and dimension of the wound, the state of plenitude or vacuity of the bowel, the extent of plastic exudation, the separation or opportune contact of contiguous viscera or of the parietal peritoneum, are elements that modify the progress and result of these injuries.

wall closed by two interrupted sutures; gut replaced; recovery. 16. Dr. H. C. MARSH (*Am. Jour. Med. Sci.*, 1866, N. S. Vol. 52, p. 577), two incisions in protruded ileum; four points in one and five in the other of continued suture; replacement; opiates and rigid abstinence; after acute peritonitis with stercoraceous vomiting, prompt recovery, complete in fourteen days. 17. Dr. WANZER (*Chicago Med. Jour.*, and *Phila. Med. and Surg. Reporter*, 1866, Vol. XV, p. 382), laceration, an inch long, of a coil of the ileum from a fall on an iron picket fence; protrusion; continued suture; knots cut close and gut replaced; bowels kept quiet for fifteen days by opium; convalescence in twenty days. 18. Dr. J. L. ORB (*California Med. Gaz.*, and *Boston Med. and Surg. Jour.*, N. S., 1868, Vol. II, p. 368), transverse cuts of small intestine in two places; sewed up by continued suture; prompt convalescence; patient died of phthisis a year afterward; no autopsy. 19. Dr. KPSKLER (*Pacific Med. and Surg. Jour.*, N. S., 1868, Vol. II, p. 6), three Lambert stitches in a wounded protruded jejunum, from which faecal matter was oozing; speedy recovery. 20. Dr. GELCICH (*Pacific Med. and Surg. Jour.*, N. S., 1868, Vol. II, p. 65), wound of ileum closed by continued suture; protruding gut replaced; patient discharged convalescent in fifteen days. 21. Dr. ZINA PITCHER, U. S. A. (*Am. Jour. Med. Sci.*, 1852, p. 42), relates a recovery after complete division of the ileum, united by the method of Ramdohr. 22. Dr. CHISOLM (*Manual of Mil. Surg.*, p. 313) relates that Dr. GASTON performed the same operation successfully in the case of a lunatic, who had cut off two feet of his small intestine! 23. Dr. AQUILA TOLAND records (*West. Jour. Med. and Phys. Sci.*, Second Hexade, 1837, Vol. IV, p. 481) a successful case of enterorraphy in an incised wound of the small intestine. There are not many references to cases of sutures of the small intestine for punctured or incised wounds terminating fatally; but a few surgeons have loyally recorded their reverses; 1. Dr. F. H. HAMILTON (*Treat. on Mil. Surgery*, p. 282) relates a case of wound of the small intestine, half an inch long, made by a dirk, closed by three interrupted stitches, the knots cut close; the protruding gut replaced; the external wound united by suture; venesection and opium; death in forty-two hours. 2. Dr. A. FLEMING (*Am. Jour. Med. Sci.*, 1857, N. S., Vol. XXXIII, p. 312) describes a transverse stab wound of the small intestine, three-fourths of an inch in length, closed by the glover's suture; death in forty-four hours. The return of the gut was impeded by a band, the remains of the umbilical vessels; the epigastric artery had been severed, and blood had escaped into the peritoneal cavity. 3. Dr. HARTSHORN (*The Med. Examiner*, 1854, N. S., Vol. X, p. 645) relates an interesting case of enterorraphy of the small intestines, by Jobert's method, which terminated fatally in six days, on account of adventitious internal strangulation. 4. Dr. FINNELL (*The Med. Record*, 1869, Vol. IV, p. 374) exhibited, at the meeting of the New York Pathological Society, September 8, 1870, a portion of ileum that had been the seat of a stab wound, unsuccessfully closed by sutures. Dr. SAYRE stated that the ends of the suture "had been left to dangle in the peritoneal cavity," an expression which apparently passed unrebuked. The unsuccessful case mentioned in the text, the two successful and two unsuccessful cases mentioned in note 1, p. 62, added to these here enumerated, make an aggregate of thirty-two American instances of enterorraphy of the small intestine, of which twenty-five were successful. The results of foreign experience will be noted further on.

So that Professor GROSS (*System*, Vol. II, p. 676) advocates, and has practiced, the therapeutic measure of puncture of the intestine by a capillary trocar, in excessive gaseous distention from obstruction. Compare, on this point, the paper of M. FOSSAGRIVES, and the discussion which followed in the Paris Academy of Medicine (*Séance du 11 juillet*, 1871), showing that many French and German surgeons had successfully practiced this operation in intestinal pneumatoses. Consult also Dr. FRIEDRICH (*Die Paracentese des Cateriths bei Darmperforation*, Berlin, 1867), and M. DEPAUL (*L'Union Médicale de Paris*, 27 juillet, 1871). Cases of eclectricity in the small intestine, from punctures made inadvertently in tapping in ascites or ovarian disease, have been observed. One is reported by Dr. H. O. HITCHCOCK (*Boston Med. and Sur. Jour.*, 1857, Vol. LV, p. 318). I have mislaid a memorandum of other instances.

I shall revert to the subject in treating of enterorraphy in general; but note here data pertaining specially to wounds of the small intestine. Dr. W. MANSDEN (*On Intestinal Injuries*, in *Montreal Med. Chron.*, 1856, Vol. III, pp. 401-418) describes a recovery from a stab, five sixteenths of an inch in length, in a protruding knuckle of the ileum, through which faecal matter oozed. The gut was reduced after enlarging the parietal wound, and returned into the abdomen without suture. The abdomen was covered with pounded ice, and calomel and opium, with eff-reviving draughts, administered. There appears to have been no serious peritonitis. Dr. D. BEIGIN, of Canada (*Montreal Med. Chronique*, 1851, Vol. I, p. 8), cites a recovery from an injury of the small intestine by a bar of iron, the gut sloughing in the inguinal region, and the faecal fistula healing without interference. A case of recovery, with faecal fistula, from a stab wound in the left umbilico-iliac region, supposed to interest the ileum, is recorded in the *New Orleans Med. and Surg. Jour.*, 1852, Vol. VIII, p. 677. In the files of modern European journals, I find no instances of recovery from incised wounds of the small intestine without the employment of the suture. Very few examples are recorded in ancient authors. In the work of the Spanish surgeon ARCAELAS, translated by JOHN REED (*A most excellent and compendious Method of curing Wounds, etc.*, London, 1588, p. 213), we are told: "But if besides the wound of the bellie, it shall happen any of the bowells to be broken, and the same of the smaller sorte, which are on the right side above the navill, all those things which soever they be, are in judgement of all authors deadly, and so for the most parte we must beleve, of the which sorte it happened mee to have one onely hitherto in cure, whose small guttes were broken, but he dyed the fourth daye." SCHENCKIUS (*Obs. Med. Ritr.*, Lugduni, 1614, Lib. III, Obs. 8, p. 368) quotes a case of recovery from a sword wound, implicating the small and large intestines, from HOLLERIUS (Obs. 17, *proprio libello*), which is not in the *Opera omnia practica*, Genevae, 1621, of that author; but must have appeared in some detached paper, as PLOCCQUET refers to it as *Obs. 17, Ad consilia curandi*, of HOLLERIUS. SEIDELIUS (*De vicia, intestinorum sanatis*), in SCHENCKIUS (*l. c.*, p. 368), gives an instance, which he regards as conclusive, of recovery from an incised wound of the small intestine. PETER RUSSE (*Circa vulnera intestinorum*, in *Zool. Med. Gall.*, Junius, 1680, Obs. IV, p. 123), records a recovery, after faecal fistula, from a stab wound of the small intestine. The case of the maniac, who recovered from eighteen self-inflicted stabs in the abdomen, one of which implicated the small intestine, related by LATRE (*M. m. de l'Acad.*, Feb., 1705), is quoted by JOHN BELL, GUTHRIE, and others. VOGEL, in his important paper (*De gemino coli vulnere non letali*, in SANDIFORT'S *Thesaurus*, Rotterdam, 1769, Vol. II, p. 117), quotes MAICHANQUEZ (*Eph. Acad. Nat. Cur.*, Dec. I, Ann. 3, Obs. 176, p. 332) for a recovery after a stab wound of the ileum. M. LOTIS (*Mém. de l'Acad. Roy. de Chir.*, Paris, 1757, T. III, p. 195) reports a case of sword wound of ileum and colon; wounds healed in less than two months. The man was about to be sent to his regiment, when he ate some green pears; vomiting; death in thirty-six hours. In the marvellous case, related by AMASIAH BRIGHAM (*Am. Jour. Med. Sci.*, N. S., 1845, Vol. IX, p. 355), of the recovery of a lunatic after removal of seventeen inches of the small intestine by a pair of scissors, the same writer (*Ibid.*, 1846, Vol. XI, p. 45) found, six months afterward, when the patient died, that the colon was the portion of the intestine removed. Such looseness of description does not inspire confidence. The extreme rarity of observations of inequivalent recovery from wounds of the small intestines without the use of the suture is evidence of the soundness of GUTHRIE'S declaration (*Wounds and Injuries of the Abdomen*, p. 36) that the "do-nothing system is generally followed by death." In cases where the wounded gut protrudes, practical surgeons generally agree that it is wise to close the wound by enterorraphy; but when the lesion is concealed in the abdominal cavity, many advise that the cure should be left to nature, and limit themselves to what they call general treatment, arrogating the honors of success, if the patient survives, and, if he perishes, pronouncing the injury beyond the resources of art. I cordially subscribe to the rule laid down by LEGOUËST (*Chirurgie d'Armée*, p. 185) on this subject: "In lesions of the intestine by cutting weapons, attended by extravasation of the solid or liquid contents, and in shot wounds, it is then proper to enlarge the external wound with the bistoury, to draw the gut outward, and to close the solution of continuity it has undergone by the suture."

*Gunshot Wounds.*—Large projectiles generally cause hopeless eviscerations; musket balls commonly partially or completely divide the calibre of the small intestines; pistol or carbine balls often make single or twin perforations. The number of cases of lesions of this group, that came under treatment, was not large, and it may be still considered doubtful if an incontestable instance of recovery was observed. Cases, however, that the reporters regarded as such, will be collected here, and the reader can judge if the evidence is conclusive that the small, and not the large, intestine was injured:<sup>1</sup>

CASE 207.—Private John Barr, Co. E, 76th New York, aged 45 years, received a shot wound of the left side of the abdomen, at Spotsylvania, May 9 1861. He was conveyed to the hospital of the 1st division, Fifth Corps, under the care of Surgeon W. R. DeWitt, jr., U. S. V. The field record affords no information regarding the extent or symptoms of the injury. He was sent by an ambulance train through Fredericksburg to one of the hospital transports, and reached Washington on the 18th, and was admitted to Douglas Hospital. Acting Assistant Surgeon Henry Gibbons, jr., compiled the following abstract of the case: "A conoidal musket ball had entered at the junction of the left twelfth rib with its cartilage, and, passing downward, backward, and outward through the ilium, lodged in the gluteal muscles, whence it was removed by incision. On admission, the wound copiously discharged a thin translucent fluid, resembling diluted bile, which evidently came from the small intestine, for, among other reasons, it had no fecal odor. Were further proof of the origin of the discharge required, it would be furnished by the fact that three ascarides lumbricoides escaped from the wound during the second and third weeks of the treatment. The discharge, for nine days prior to admission, was, according to the patient, similar to that above noted. The patient was kept perfectly quiet in a recumbent posture. The discharge from the wound was facilitated by large masses of charpie being used to absorb it. For several weeks the patient was nourished solely by milk, milk-punch, and beef-tee.<sup>2</sup> His appetite was poor, his sleep much disturbed by cough. But there was no abdominal pain or tenderness, and at no time, throughout the treatment, was there any symptom of peritoneal inflammation. On May 22d, a soap and water enema was administered without result.

Nothing more was attempted in this direction, as the patient was doing well, and nature seemed competent to meet every indication. On June 3d, the discharge had entirely ceased, and the patient was much improved. On June 6th, he had a large alvine evacuation, the first since May 9th. On June 11th, with the aid of an enema, he had another large dejection. From this time he improved rapidly. On August 16th, a fragment of necrosed bone, that could be recognized as a portion of the ilium, was removed from the wound in the gluteal region. About the same period bits of necrosed cartilage were taken from the fistulous orifices opening near the wound of entrance. The bowels were disposed to costiveness, and flatulence was troublesome. Early in October there was an attack of dysentery, which lasted one week. On May 5, 1865, a needle-shaped bit of bone escaped from the wound of entrance. On May 8th, both wounds were entirely healed.<sup>3</sup> On July 16th, the patient was photographed at the Army Medical Museum. He was then in good health. A reduced copy of the photograph (the original is at page 15, Vol. II, of the *Surgical Photographic Series*) is represented in the adjacent wood-cut (FIG. 42). Assistant Surgeon W. F. Norris, U. S. A., in reporting this case, states that the patient was discharged from service September 23, 1865, on account of a shot wound of the intestines, with injury to the ribs. The disability is rated at three-fourths, and the man is unfit for the Veteran Reserve Corps. It does not appear that this man has ever made application for pension, and no further information regarding him can be found at the offices of the Adjutants General of the Army and of New York.

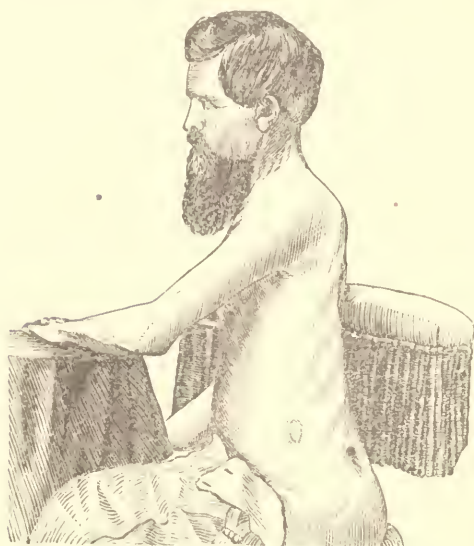

FIG. 42.—Centrics of a shot wound involving the intestinal canal.

Though no precise microscopical or chemical analysis is recorded in this case, the absence of fecal odor, and other characters of the discharge from the intestinal fistula, are significant, and appear to have been considered by the well-informed surgical staff of Douglas Hospital as almost conclusive proof that the discharge came from the small intestine. The escape of lumbricoid worms, of course, has no significance as regards the part of the alimentary canal interested, these entozoa being found in every part.

<sup>1</sup> Dr. LUDF. *Am. Jour. Med. Sci.*, 1867, N. S., Vol. LIII, p. 354) admits the occasional cure of shot wound of the small intestines by the efforts of nature, and explains its mechanism: "Gunshot wounds of the intestinal canal are less fatal than simple rupture of that tube, because, in the first place, the wound in the abdominal parietes prevents the gases which may escape from the injured intestine from becoming confined in the peritoneal cavity; and, in the second place, the commotion in the coats of the intestine, produced by the passage of the bullet, paralyzes the muscular coat for a time, and thus arrests the vermicular movement of the wounded part of the intestine, and prevents extravasation of faeces into the abdominal cavity until adhesion has occurred at the place of injury between the visceral and the parietal peritoneum, and then the fecal matter may be discharged externally."

<sup>2</sup> See Circular 6, S. G. O., 1865, p. 25.

The following interesting case, of which abstracts were forwarded by Surgeon Hewit, from Hospital No. 5, at Frederick, and by Assistant Surgeon Weir, from Hospital No. 1, was regarded by those surgeons, as well as by Dr. J. M. Green, of Aberdeen, Mississippi, and Acting Assistant Surgeons Cherbonnier and Nicolassen, as an unequivocal example of recovery from a shot wound of the small intestine. Dr. Nicolassen describes the earlier history of the case:

CASE 208.—Private *Sterling Sanders*, Co. K, 21st Mississippi, was wounded, at the battle of Antietam, September 17, 1862, by a minié ball, which, "entering the right lumbar region near the crest of the ilium, pierced the small intestine, and made its exit at the umbilicus. From the field he was taken to a barn in the neighborhood, which had been converted into a hospital by Dr. Green, 17th Mississippi, C. S. A. For the first twenty-four hours nothing but a sip of cold water was given to him. Then he took about two tablespoonfuls of beef soup twice a day, but which would make its appearance at the wounds, which were not more than two inches apart, 'almost as soon as swallowed,' as he expresses it. The discharges from the wounds were black and tar-like. In the course of a week, he began to eat a little hard cracker softened in milk. The evacuations from the wounds continued for twenty-one days. No unpleasant symptoms had arisen except occasional colic and chill; no irritability of stomach, no symptom of peritonitis whatever. The treatment had been low diet, lint to absorb the discharge, and scrupulous cleanliness about the wounds. On October 8th, he had the first natural passage, and the wounds began to granulate. On October 17th, he was removed to Sharpsburg and placed under the care of Dr. Young. He began to take light solid food now, such as bread, crackers, small pieces of beef, chicken, or turkey, once a day. During his stay in Sharpsburg, the wounds closed up entirely; but his removal to this hospital, on November 25th, caused them to open again, and, for twenty-nine days, again fecal matter was discharged through them, though he had two natural passages every day. The same scrupulous cleanliness has been observed. December 26th; nothing but wind has escaped from the wounds since December 24th. He has two natural passages daily. His appetite and general health are very good, and have been, ever since he was wounded. He walks about a little. December 28th, continues to do well; wounds apparently closed." On December 29th, the patient was transferred to General Hospital No. 1, Frederick, and placed under the care of Assistant Surgeon R. F. Weir, U. S. A., who continues the record of the case as follows: "January 22, 1863. Doing well; general health good. February 4th. Going about the ward and continues to do well; wounds do not occasion any inconvenience, and are nearly healed; ordered compress and bandage over them. February 10th. Patient having entirely recovered, is, to-day, sent to the South."

In the next two cases, the fact that recognizable ingesta repeatedly appeared, at the orifice of the wound, within a half-hour after being received into the stomach, was regarded as conclusive evidence that the solution of continuity was in the upper part of the digestive tube. It will be seen, hereafter, that the same phenomenon was observed in cases in which the lesion was, beyond question, in the wall of the colon:

CASE 209.—Private *James D. Bishop*, Co. D, 16th Mississippi, aged 22 years, received a gunshot wound of the right side of the abdomen, at Antietam, September 17, 1862. He was removed to a field hospital, where he remained until October 6th, when he was transferred to the hospital at Camp A, Frederick, in charge of Assistant Surgeon William M. Notson, U. S. A., who records that "the ball, which had not been removed or discharged, entered about three-fourths of an inch to the right of, and on a level with, the umbilicus, producing a wound of the small intestines. On admission, fecal discharges were occurring from the wound, and none whatever from the anus. The patient, who was in a very weak and enfeebled condition, was supported by the use of tonics and stimulants. His general health slowly improved; the wounds in the flesh gradually healed, and the discharge of pus, which, at first, was profuse, continually diminished; and, on the 4th of November, all discharge from the wound ceased. On the 6th, he complained of pain, with some distension of the abdomen; one ounce of castor oil with twenty drops of tincture of opium was administered. On the next morning a copious defecation took place by the natural channel, the first since the patient was wounded. There was still some slight discharge of pus from the wound, but this ceased in the course of a day or two. The bowels were not moved again until November 10th, when griping pains again occurred. Oil and laudanum again administered; free evacuation by the rectum again ensued. After this time, there was no discharge from the wound, which soon completely healed. The patient, at the end of April, 1863, was able to walk about, with every prospect of a speedy convalescence." On March 14, 1863, Bishop was transferred to Baltimore, and was admitted to the National Hospital. Acting Assistant Surgeon E. G. Waters forwarded the following details of the progress of the case: "A round musket ball entered the abdominal walls in a line with, and two inches to the right of, the navel, passed backward and outward, opening one of the intestines, and lodged. The patient stated that much of the liquid food and drink he took after the injury continued, for six weeks or more, to appear at the orifice of the wound and escaped therefrom. This was constant after each meal, and generally occurred about half an hour from the time of swallowing his food. The wound still discharging when he was admitted, satisfied me that the missile, or some foreign body, was lodged in the walls of the belly or in its cavity. Accordingly, on March 21st, examination with the probe detected a hard irregular substance exterior to the abdominal cavity, and about six inches from the orifice of the wound. April 1st, conducting a catheter along the canal, at the extremity of which the foreign body could be detected, an assistant depressed the staff and thus elevated the integuments upon its point. An incision of suitable length was then made perpendicular to the walls of the belly, and about an inch internal to the crest of the ilium; when the bullet was seen and removed. It appeared to have encountered the patient's belt-buckle or some similar hard body, was flattened and expanded into two alæ. It presented very much the appearance of a saddle with its flaps spread apart, and it was easy to see how the intestinal coats could have been slit by the passage of this sharp-edged mass in their vicinity. 1



could not gather from his account that he had suffered from peritonitis, although the peritoneum must have been divided to a sensible extent. On May 26, 1863, the man was convalescent, and was discharged from the hospital and sent South, his wound improving, though still fistulous. He had not been, at any time since his admission, able to hold himself erect, though in this particular his attitude was much improved at the time of his discharge." There is no reason to doubt the ulterior complete recovery of this man, though no further precise information has been obtained concerning him.

CASE 210.—Private Daniel C. Moyer, Co. H, 5th Pennsylvania, aged 21 years, was wounded at Gaines's Mill, June 27, 1862. He was taken prisoner, and remained in the hands of the enemy until July 20th, when he was paroled, placed on board the steamer *Louisiana*, and conveyed to Baltimore. He was admitted into Camden Street Hospital, under care of Acting Assistant Surgeon E. G. Waters, who makes the following report of the case: "Moyer was wounded while lying down, the ball entering the left side of the abdomen, two inches above and three and one-half inches exterior to the umbilicus, and one and one-fourth inches below the margin of the ribs; the projectile then passed downward, backward, and outward, emerging, posteriorly, about one inch from the crest of the ilium, and three inches from the spinal column. He was carried first to a neighboring house, and thence to Savage's Station, remaining there some two weeks; thence to Richmond, where he remained at the railway station three days, and thence, by cars through Petersburg, to City Point; thence by steamer to Baltimore. He was indescribably wan, haggard, and emaciated on his admission, and when I first saw him, having no knowledge of the particulars of his case, I took occasion to reprove him for having enlisted, thinking he was at least seventy years old. He told me that no dejection, in the usual manner, had taken place for four days subsequent to the injury; but that the contents of the bowels had escaped through the posterior orifice of the wound. His aliment had also been extruded frequently in the same way, and he had remarked this particularly on the discharge of the seeds of some blackberries a lady in Richmond had given him. This fruit appeared in the discharges from the posterior wound a few minutes after being swallowed. For some days after admission, his attendants spoke of a discharge possessing a fecal odor and appearance, issuing occasionally from the wound in his back. He was much distressed with bedsores on different parts of his body, especially by a large one, following an abscess, which formed superficially around the right elbow joint, produced, doubtless, by pressure on that point, in his efforts to avoid resting his weight on the bedsores. His bowels were kept soluble, and he was inclined on his face and belly. August 20th, the wound posteriorly, after remaining healed for eight or ten days, reopened suddenly and gave exit to unequivocal ordure. This discharge continued three days, and was repeatedly witnessed by the writer. The patient was again kept in a horizontal posture, inclined forward to bring the discharging orifice uppermost, when this disagreeable condition was speedily checked. The orifice closed again, and, in a few days, the patient was permitted to move about the ward, then down to his meals, and, finally, he was sent to Camp Parole, Annapolis, September 19, 1862, cured. At this time he had regained his flesh and strength, and exercised daily without inconvenience or fatigue." He was subsequently transferred to Broad and Cherry streets Hospital, Philadelphia, where Surgeon John Neill, U. S. V., reports him to have been discharged April 30, 1863, on account of "phthisis pulmonalis." Under date of October 1, 1872, Pension Examiner Edward Allister, of Goshen, Indiana, writes that the pensioner "suffers constantly from pain and weakness through the back and loins, and is unable to perform manual labor. He also suffers from a hernial protrusion at the seat of wound of exit. The bowel makes its exit at cicatrix of wound, and extends to the left of the point of exit. At this date, it was about three inches in length and half as wide. The pensioner represents it as being, at times, much larger, and quite hard; which I have no reason to doubt. Disability total, of the third grade. Weight, 160 pounds; age, 30 years; respiration, 19; pulse, 80." Last paid December 4, 1872.

In the next case, there was no other evidence of lesion of the small intestine than the rational signs, and these were not recorded with precision:

CASE 211.—Private Joseph Irwin, Co. B, 29th Pennsylvania, aged 33 years, received a shot wound of the abdomen at Gettysburg, July 2, 1863. He was admitted on the same day to the field hospital of the Twelfth Corps, and a wound of the abdomen, with injury of the intestines, was diagnosed. No mention is made of the symptoms or treatment. On July 23d, the patient was transferred to the Camp Letterman Hospital, and admitted into ward B, under the charge of Acting Assistant Surgeon Charles S. Gamett, who entered on the medical descriptive list, that a minié ball had entered the abdomen at a point three inches above the umbilicus, and made its exit four inches to the right of the fourth lumbar vertebra. Simple dressings to the wound and full diet constituted the treatment. The patient's condition improved, and, on October 12th, he was transferred to Satterlee Hospital, Philadelphia. The ward surgeon gives the following details of the case: "A conical ball entered the back, in the lumbar region, about two inches to the right of the spine, and lodged under the skin in the median line two inches above the umbilicus, whence it was cut out July 4, 1863. The wound in the front has healed; that in the back is nearly well. He has had considerable swelling and pain in the bowels, and vomiting, and difficulty in passing water. About two weeks after the reception of the injury, he was affected with rheumatic pains in the shoulder, followed, at the end of the third week, by intermittent fever, from which he recovered in a fortnight. On admission, he still complained of the rheumatic pain in the back and in the knees. The treatment consisted of tonics, sedatives, laxatives, and liniments. On the 22d, it is noted that several loose, very light dejections occurred; patient complained of chills at night. He had mercury with chalk, and then treatment was addressed to the rheumatic complications, the alkaline method being pursued for some weeks; then iodide of potassium was resorted to, with scarified cups near the most painful parts." On January 26, 1864, the ward surgeon repeats the diagnosis of "lesion of the small intestines, and peritoneum;" but does not advert to tympanitis, bloody stools, or other signs that might have furnished the basis of such a diagnosis. The patient remained in hospital, but no treatment is noted after February, 1864. In March, Irwin was made ward-master. In April, 1865, he was still on duty in this capacity, but recommended for the second battalion of the Veteran Reserves. This recommendation appears to have been unfavorably considered, and the man was discharged from service May 15, 1865. His name is not upon the Pension List.

The five foregoing cases are the only instances of recovery from shot wounds of the abdomen, reported during the war, in which there was any plausible ground for

suspecting that the small intestine was the seat of lesion. Of the many fatal cases recorded, necroscopic details are generally wanting; but, in a small proportion of them, the exact seat of injury is noted, and, in a few, the pathological preparations are preserved.

*Wounds of the Duodenum.*—Opportunities of observing the symptoms attending shot wounds of this portion of the digestive canal were very infrequent. Commonly, shot injuries of this portion of the intestinal canal are accompanied with mortal lesions of adjacent parts. As the descending and middle portions have no proper peritoneal coat, but are only loosely fixed between the laminae of the meso-colon,<sup>1</sup> it is possible for the gut to be wounded without extravasation of its contents into the great peritoneal cavity. In a case related on page 50 (CASE 197), in which the stomach and liver were also implicated, and the duodenum nearly severed, the patient survived the injury eight days. In a case which furnished the illustration of shot perforation of the duodenum represented in the wood-cut (FIG. 43), the ball also penetrated the liver and right kidney, and death, from hæmorrhage, ensued in a few hours. It is deeply to be regretted that in the following case, in which life was prolonged for twenty-four days after the reception of the injury, no precise record of the symptoms has been preserved:<sup>2</sup>



FIG. 43.—Shot perforation of the duodenum. *Spec.* 1772.

CASE 212.—Private James M——, Co. F, 14th New Jersey, aged 27 years, received a penetrating wound of the abdomen, at Winchester, September 19, 1864. The missile, a conoidal ball, entered at the right side of the epigastrium, at the edge of the ribs, and emerged through the right buttock. He was admitted, on the same day, to the hospital of the Sixth Corps. He was an emaciated subject. [The case book contains no further information respecting the general condition of the patient after receiving the wound. The degree of collapse, the presence or absence of hæmatemesis, the precise nature of the feculent discharges from the upper orifice and its probable origin, the extent to which the symptoms of peritonitis were present, cannot be determined.] Water-dressings were applied to the wound, and ferruginous preparations and opiates were administered, with milk punch. A farinaceous and milk diet was allowed. Fæces escaped freely from the wound of exit, and also from the wound of entrance, for a few days. After this, frequent and continued alvine ejections took place through the natural channels. Death resulted on October 12, 1864. At the autopsy, it was found that the ball, entering the right side of the epigastric region, had carried away about half of the calibre of the duodenum, near the orifice of the cystic duct (FIG. 44). It had then passed obliquely downward and backward, through the cæcum (FIG. 45), above the ileo-cæcal valve. It then struck the right ilium, notching its crest about midway. It then traversed the gluteal muscles and emerged through the right buttock, the line of its direction being nearly straight. The exit wound of the cæcum adhered firmly to the fascia of the internal iliac muscle. There was a considerable quantity of blood and pus along the ascending colon. Inflammation and traces of gangrene of the epiploon were noted. The specimens and notes of the case were contributed by Acting Assistant Surgeon W. Leon Hammond.



FIG. 44.—Portion of duodenum lacerated by a musket ball. *Spec.* 3378.

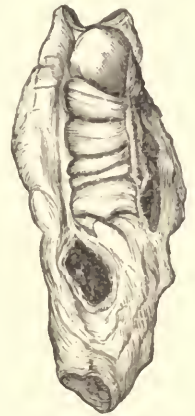


FIG. 45.—Portion of cæcum perforated by a musket ball. *Spec.* 3379.

In two other cases,<sup>3</sup> this portion of the intestinal canal was the principal seat of injury; but few particulars were noted:

CASE 213.—Private J. Stewart, Co. B, 7th New Jersey, on picket duty, November 28, 1864, received a musket ball wound in the epigastrium, implicating the duodenum. Surgeon C. Sehlbach, 7th New Jersey, reports that he lingered for two days, in a very weak state, at the field hospital of the Second Corps, and died November 30, 1864.

CASE 214.—Corporal R. Bessey, Co. A, 17th Vermont, aged 19 years, was wounded at Hanover Court House, May 31, 1864, by a musket ball, which entered the right hypochondrium, and emerged to the right of the tenth dorsal vertebra, implicating the duodenum and probably the liver. There was hæmatemesis and extreme epigastric tenderness and pain, followed by bloody stools. Surgeon James Harris, 7th Rhode Island, enjoined absolute rest, with abstinence and opiates. The

<sup>1</sup> HORNER, *Special Anatomy and Histology*, Sixth ed., 1843, Vol. II, p. 40.

<sup>2</sup> DUPUYTREN (*Leçons Orales*, T. VI, p. 464) remarks of shot wounds of the duodenum: "La Nature a seule des ressources contre cette lésion: le chirurgien n'y peut rien faire."

<sup>3</sup> Surgeon C. H. ALDEN, U. S. A., has recorded (CASE CXXVII, Circular 3, S. G. O., 1871, p. 43) a case of wound of the duodenum by a pistol ball, speedily fatal from attendant lesions of branches of the superior mesenteric artery. LABREY (*Mém. de chir. mil.*, T. III, p. 456) has detailed a very remarkable recovery from a sabre wound of the duodenum.



patient was, however, sent to Washington, and Acting Assistant Surgeon E. B. Harris, at Emory Hospital, reports that there was much tension and tenderness of the abdomen, with nausea, and dejections tinged with blood. The case terminated fatally, June 18, 1864.

*Wounds of the Jejunum.*—The upper two-fifths of the remainder of the small intestine includes a portion of the canal but slightly protected by bone or by parts of the equipment, and is very liable to perforation by shot. These wounds are often complicated by lesions of the adjacent viscera, or of the mesenteric arteries, and are not infrequent in the bodies of those who have perished on the field from hæmorrhage from the great blood-vessels of the abdomen. In the condition its name implies, in wounds of this gut, the danger of immediate extravasation is commonly postponed. But this condition depends upon the period of the digestive process at which the wound may have been inflicted. Even if received during fasting, the patient is not secured from the intrusion of entozoa into the peritoneal cavity, as exemplified by the following case:<sup>1</sup>

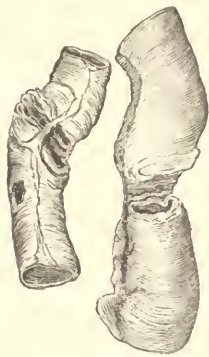

FIG. 46.—Sections of two portions of ileum, each traversed and nearly divided by a conoidal carbine ball. *Spce.* 1204.

CASE 215.—Private *John W.*—, Co. II, 4th Virginia Cavalry, Colonel Mosby's command, was wounded, at Warrenton Junction, May 2, 1863, by a carbine ball, which entered the left side of the abdomen just above the iliac crest, and passed out the opposite side. He was admitted to the 1st division hospital, at Alexandria, on the same day. He suffered intense pain, which was but slightly relieved by anodynes, and died, in great agony, on the 5th. At the autopsy, it was observed that considerable inflammatory action had taken place; the bowels were agglutinated together, and there was a thick deposit of yellowish lymph. The small intestine was perforated in two places (FIG. 45), and from the openings, which were large and ragged, a number of lumbricoid worms had crawled into the cavity of the abdomen. Fæcal matter, also, had been extravasated. The preparation and the notes of the case were contributed by Surgeon Charles Page, U. S. A.

Another result of a shot wound dividing the greater portion of the circumference of the jejunum, about ten feet below its origin, was the formation of a huge stercoral abscess, communicating with the exterior by the entrance and exit channels. The patient survived the injury four weeks, marked scorbutic symptoms appearing toward the close:

CASE 216.—Acting Assistant Surgeon Albert Newman reports that "Private Samuel G. Matkins, Co. D, 14th Missouri Cavalry, was admitted into the post hospital at Lawrence, Kansas, June 23, 1865, about three o'clock, P. M., having received a wound about an hour before by the accidental discharge of a Remington revolver. The ball entered to the right of the lower lumbar vertebra, and lodged under the skin about an inch above the internal abdominal ring, from which place it had been removed by incision before admission. When admitted, the wounded man was suffering great pain, and there was much tenderness of the abdomen. He had constant and intense desire with inability to micturate, and begged to have his urine withdrawn by the catheter. He was ordered two fluid drachms of laudanum, to be repeated in two hours. At nine in the evening, he was sleeping quietly. He had voided his urine, which was perfectly clear. Ordered two grains of powdered opium every four hours, and tepid water dressing. On June 24th, the patient was comfortable, sleeping most of the time; pulse, 130; treatment continued. On June 25th, the patient had rested well; fecal matter was discharging freely from the wound in front; no tympanitis; ordered beef tea; other treatment continued. On June 26th, the patient said he had no pain; he was slightly wandering; he had vomited; pulse, 118; treatment continued. June 27th, had rested well; said he had a little occasional pain, but not much; treatment continued. June 28th, was restless yesterday afternoon, and turned upon the right side; pulse rose to 120; said he had pain this morning, but was now quiet; pulse, 100; treatment continued. June 29th, free from pain; pulse, 100; skin, cool; ordered, every four hours, a powder containing two grains each of opium and sulphate of quinia; beef tea with rice. June 30th, no pain; skin below the natural temperature; pulse, 96; treatment continued. July 1st, comfortable; pulse, 104; treatment continued. July 2d, easy; pulse, 100; treatment continued. July 3d, tranquil; pulse, 96; ordered the powders to be continued at the same intervals, but to contain but one grain of opium with two grains of quinine; beef tea, with rice continued. July 4th, easy; fecal matter discharging from the lumbar wound; a dark slough protruding from the original wound; pulse, 96; treatment continued. July 5th, had much pain in the night; had four alvine dejections, which, the nurse says, were natural in appearance; fecal matter discharging from both wounds; pulse, 96; treatment continued. July 6th, says he had extreme pain in his bowels during the night; sloughs have separated from the wounds, of which the edges are irritated by the discharge. There is considerable, but not excessive, tenderness over the entire abdomen, which is much shrunken; pulse, 88; ordered powdered opium and sulphate of quinia, two grains each, every four hours; beef tea and rice continued. July 7th, had rested well; craved more food; the fecal discharge from the wound in the back had ceased; pulse, 88; chicken and toast allowed, other treatment continued. July 8th, pulse, 84; complained last night of great pain in the bowels and difficulty in passing urine. An additional two-grain dose of opium procured repose. July 9th, pulse, 84; fecal discharge from the lumbar

<sup>1</sup>JACOTUS (*Comment. in Hippoc. coeca præstigia*, Lib. I. Aph. 17, as quoted in SANDIFORT'S *Thesaurus*, Vol. II, p. 118) discusses in detail on wounds of the jejunum, and records an instance of recovery from an incised wound.



wound has recurred; treatment continued. July 10th, comfortable; pulse, 84; treatment continued; extreme attention to cleanliness enjoined. July 11th, pulse, 84; complains of pain in the left side, in the region of the spleen; fecal discharge from the wound in the back again ceased; fecal discharge from the inguinal wound recurred at more or less regular intervals of from two to four hours, instead of oozing away continuously as heretofore; treatment continued. July 12th, pulse, 84; still complains of pain in the left side. July 13th, pulse, 84; rested well. July 14th, pulse 84; had slept but little; had pain in the left side; the back and sides of the trunk are covered with small, irregular purple spots and lines, which do not disappear on pressure; a patch of similar spots an inch in diameter, so thickly crowded as to be almost continuous, at the left and near the lower end of the sternum, to which point he refers his worst pain; says he feels very weak; skin cool; some lividness of hands and feet; ordered a tablespoonful of wine every two hours. July 15th, says he has rested well; pulse, 88; several new spots upon the chest and upper part of the arms; lividness of hands and feet less; treatment continued. July 16th, pulse, 84; some new spots lower down upon the abdomen; lividness of hands and feet increased; continued treatment. July 17th, pulse, 84; spots extend down upon the left forearm; one spot upon the left thigh. July 18th, pulse, 84; spots extend down upon the hips behind; temperature and color of skin unchanged. July 19th, pulse, 84; has had two dejections by the rectum; some fecal discharge from the lumbar wound was nearly filled with granulations. July 20th, pulse, 88; restless. July 21st, pulse, 104; lividness increased; purple spots over both legs. The next morning the pulse was at 112, very small. Died at noon, July 22, 1865, four weeks from the date of the reception of the wound. The autopsy was made three hours after death. Rigor was well marked; great emaciation; abdomen much contracted; intestines bound together by strong adhesions; upon separating these adhesions, numerous small collections of clear pus were disclosed, none of them exceeding in quantity a teaspoonful; the small intestine was found completely divided about ten feet below the duodenum; the portion of small intestine below the division was contracted almost to the size of a goose quill; this portion of the gut communicated with the wound in the groin, and also with that in the loin. Surrounding the right psoas muscle was a cavity of sufficient size to hold a quart, separated by adhesions from the remainder of the abdominal cavity. The upper portion of the small intestine opened into the cavity, which was half full of fecal matter.<sup>1</sup>

The instances in which a ball, traversing the abdomen, wounds more than one convolution of the intestines, are, unfortunately, numerous.<sup>1</sup> This circumstance has such an important relation to the question of enteroraphy in shot wounds that it is well to accumulate evidence concerning it.<sup>2</sup>

CASE 217.—Noted by Assistant Surgeon W. S. Woods, U. S. V.: Private J. Benton, Co. B, 3d Cavalry, aged 30 years, was shot through the body, May 16, 1864, by a conoidal musket ball at short range, while resisting arrest, and was immediately admitted into the post hospital at Benton Barracks, St. Louis. He sank rapidly from the effects of hæmorrhage, the treatment consisting of cold applications to the abdomen and the employment of styptics. He died May 17, 1864. The ball had divided the jejunum five and one-half feet from the pylorus, and again eight and one-half feet below the stomach; finally the ball traversed the colon eighteen inches above the anus. There was much extravasated fecal matter.

CASE 218.—Private R. M. Wells, Co. F, 8th New Hampshire, aged 23 years, was wounded in the abdomen by the accidental discharge of a musket while on picket duty at Natchez, October 29, 1864. He was at once admitted to the Officers' Hospital at Natchez, under the charge of Assistant Surgeon A. E. Canthers, U. S. V., who states that "Wells and a comrade were practicing with their bayonets, when his comrade's gun was accidentally discharged; the ball entered the belly about one and a half inches to the left of the median line, midway between the umbilicus and ensiform cartilage, passed across and backward, and made its exit through the posterior third of the crest of the right ilium. There was incessant vomiting and hicough, and the man suffered terribly until he died, eighteen hours after the casualty. An autopsy, made twenty hours after death, showed that the ball had passed between the lower curvatures of the stomach and the transverse colon, behind the colon, dividing a large branch of the colica media artery, across the abdomen, cutting the upper end of the jejunum entirely across in four places, and emerged from the abdominal cavity just in front of the attachment of the cæcum, extensively fracturing the crest of the ilium in its exit." It then entered the skull of a comrade, causing his death in twelve hours.

CASE 219.—Corporal W. J. Wells, Co. B, 144th New York, aged 19 years, was wounded in the abdomen at Honey Hill, November 30, 1864. He was taken to the regimental hospital, where Surgeon John R. Leal, 144th New York, records the case as a "gunshot wound of the bowels; mortal." On the same day, the patient was transferred to the hospital at Hilton Head, where Assistant Surgeon John F. Huber, U. S. V., notes the injury as a "lesion of the small intestines from a fragment of shell." Death resulted December 2, 1864. A knuckle of the jejunum was divided, and the contents of the bowel had passed into the peritoneal cavity.

Other examples will be given under the head of wounds of the ileum.

<sup>1</sup> LEGOUËST, *Chirurgie d'Armée*, 2ème éd., p. 385: "Les lésions des intestines par les coups de feu sont presque toujours multiples." See, also, BAUDENS, *Clinique des plaies d'armes à feu*, p. 326.

<sup>2</sup> Pathological preparations of shot wounds of the small intestines are not common. I have found none in this country, except in the Army Medical Museum. The following are noted in the catalogues of foreign museums: In the collection at Fort Pitt are two specimens—No. 1162, presented by Surgeon Roe, 28th Regiment, shows a fistula at the point of entrance of the ball through the eleventh left rib, through which the feces were voided; the gut was impervious below the wound. No. 1163, donated by Assistant Surgeon Tighe, shows the small intestine wounded by a ball in three places, and the mesentery in one (*Cat.*, l. c., p. 157). This is probably identical with specimen 1272, at Netley (WILLIAMSON, l. c., p. 113). In the Hunterian Museum, specimens 1178 and 1179 of Series XXIII are portions of jejunum with shot wounds, with everted edges and copious lymph deposits. They are from the same subject, the officer who fought a duel in Hyde Park, September 4, 1783, and was attended by Hunter, who addresses these facts in proof of the rapidity of the formation of adhesions about shot wounds of the intestine (*Cat.*, l. c., Vol. III, p. 68, and HUNTER, *On the Blood, Inflammation, and Gunshot Wounds*, 1791, p. 546). In the Netley Collection, No. 1271 is a portion of jejunum, believed to have been perforated in three places by a musket ball. A memorandum of the case is printed in Note 2, on page 40.

Dr. T. S. Hoynes<sup>1</sup> has sought to determine, by experiments on the cadaver, the number of wounds of the intestine likely to be inflicted by a ball traversing the abdominal cavity. The conditions of his experiments deprive the results of value. Less questionable data are afforded by field experience. In a case observed by Alexander, in the Crimea,<sup>2</sup> a musket ball, entering near the umbilicus and passing out close to the sacrum, was found to have wounded the small intestines not less than sixteen times in its passage. If such were an ordinary effect of shot perforations of the abdomen, there would obviously be no room for surgical intervention. But it is not very common for more than two convolutions to be wounded, or the wall of the small intestines to be perforated in more than four places,<sup>3</sup> in the cases that reach the hospital, as is proved by an examination of the pathological records.



FIG. 47.—Portion of jejunum perforated at one point by a round pistol ball. The mucous membrane is much everted at the orifice. *Spec. 841.* [Half size.]

Musket balls commonly divide a considerable portion of the calibre of a small intestine; carbine or pistol balls sometimes make two perforations of its walls; and, occasionally, a small projectile may perforate the intestinal wall at a single point, and lodge within the gut, as in the case which furnished the specimen represented in the wood-cut (FIG. 47). In such cases, the usual eversion of the mucous tunic ensues, and the appearances are not to be distinguished from those resulting in a true punctured wound, inflicted by a sharp-pointed instrument, as is exemplified by a comparison with the specimen delineated on page 62 (FIG. 41). The following is a minute of the case:

CASE 220.—Assistant Surgeon W. D. Wolverton, U. S. A., reports that Private Joseph M——, Co. H, 11th Infantry, was admitted to post hospital, Camp Grant, September 10, 1866, with a gunshot wound in the abdomen, received in an affray with a negro. The ordinary treatment of absolute rest, with opiates, was enforced. Faecal extravasation, immediately followed by intense peritonitis, with great depression from shock, led to a fatal termination on the following day, September 11, 1866. Acting Assistant Surgeon R. Thomain forwarded the specimen to the Museum. Assistant Surgeon A. A. Woodhull observes (*Cat.*, p. 491): “The solitary follicles and villi are enlarged, as if the subject were suffering under intestinal disease when wounded.” It is difficult to suppose that the application of a circular ligature, or in the closure of the orifice in the gut by a point of interrupted suture, would have accelerated the fatal event in this instance.

In the instances in which balls are voided at stool, very soon after the reception of a shot wound in the abdomen, it may fairly be presumed that the missile has penetrated the intestinal wall at one point only. It is probable, however, that in most of these cases, the projectile has gained admission to the canal through some portion of the wall of the large intestine.

<sup>1</sup> HOYNE. *On the Nature and Treatment of Gunshot Wounds of the Intestines, with Experiments on the Cadaver, in the New York Med. Jour.*, 1865, Vol. I, p. 106. This writer fired eighteen pistol shots at the bellies of dissecting-room subjects, and inflicted ninety lesions of the intestines, or an average of five with each ball, and concluded that “in view of the experiments above recorded, it is apparent, we think, that the method of procedure recommended by LEGUEST must prove eminently dangerous.” This complacent estimate of the value of these experiments is accompanied by the admission that in one of the injected bodies “the organs were slightly displaced.” Properly controlled laboratory experiments are of utility in elucidating many points relating to the effect of projectiles upon the tissues; but correct conclusions are not attained by converting a mutilated dissecting-room subject into a target, with a view of demolishing an hypothesis the experimenter disapproves.

<sup>2</sup> See Deputy Inspector ALEXANDER'S letter to Mr. GUTHRIE (*Commentaries*, 6th ed., p. 576). The man was slooping in the act of defecation when wounded.

<sup>3</sup> In eight of twenty shot injuries of the small intestines noted in Circular 3, S. G. O., 1871, the number of intestinal lesions were noted. Counting lesions without division of the wall, the largest number of distinct wounds of the gut in any case was eight. In two instances, only one portion of the gut was wounded. The aggregate of distinct intestinal lesions, in the eight cases, was thirty. In twenty cases noted in this subsection, the aggregate of the distinct intestinal lesions was fifty-nine; in two cases noted in the *First Surgical Volume* (pp. 445-449), of shot perforations of the abdomen, the small intestines were wounded at two points, in each instance. In thirty-three cases of shot wounds of the small intestines, in which the lesions were recorded with exactness, collated from the works of LAMOTTE, RAVATON, BORDENAVE, PERCY, LARREY, GUTHRIE, BAUDENS, and Professor BILLROTH, and from papers in various journals, including the observation of Director General Alexander, above cited, the aggregate of distinct intestinal lesions was seventy-three. Grouping the sixty-three cases, the aggregate of distinct intestinal lesions is found to be one hundred and sixty-six, or 2.63 intestinal wounds for each shot. In this estimate, what VOGEL (SANDIFORD'S *Thesaurus*, Vol. II, p. 110) terms “twin wounds,” that is, perforations of the opposite sides of the gut on the same level, are counted as distinct lesions.



*Wounds of the Ileum.*—Very many fatal shot perforations are found in the coils of the lower three-fifths of the small intestine. Somewhat protected posteriorly and laterally by the vertebral column and the wings of the innominate, it is fully exposed in the umbilical, hypogastric, and right iliac regions:

CASE 221.—Private Charles B——, Co. L, 8th New York Cavalry, aged 23 years, was wounded at Beverly Ford, June 9, 1863. He was conveyed to Washington on the next day, but died in the ambulance on the way to Lincoln Hospital. An autopsy was made by Assistant Surgeon H. Allen, U. S. A. The wound was in the median line, five inches above the pubis;



FIG. 48.—Carbine-ball, size of nature, removed from the abdominal cavity after death. *Spec. 1231b.*

the stomach was distended with gas; the intestines were natural in position, not abnormally distended, but greatly discolored by hemorrhage. A moderately sized venous clot was found on the inferior surface of the omentum. The cellular tissue about the mesentery was emphysematous. The posterior part of the abdomen was filled with a large black clot, in the midst of which was an ascaris lumbricoides. The missile, a conical carbine ball (FIG. 48), was found in the pubis on the right side of the bladder, lying on the peritoneum. The lining of the oesophagus was unusually

pale; the epiglottis presented a peculiar appearance, its mucous lining being of a purple color, with several dark grayish spots upon its laryngeal surface. The liver weighed thirty-four and one-fourth ounces, and was of an intense green color; the kidneys were extremely flabby and anæmic, and the cellular tissue surrounding them, emphysematous. The right kidney weighed five and one-half ounces, and measured five by two and one-half inches; the left weighed six and one-half ounces, and measured five by two and one-half inches. The spleen weighed four ounces, and measured four and one-half by three inches. Two sections of the small intestine, showing perforations by the missile, are figured in the wood-cut (FIG. 49). The specimens were contributed to the Museum by Surgeon G. S. Palmer, U. S. V.

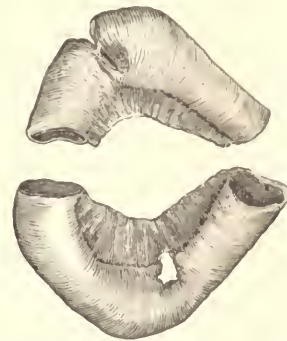

FIG. 49.—Two loops of ileum, with shot perforations. *Spec. 1231a.* [Reduced one-half.]

CASE 222.—Private William Schneider, Co. L, 5th Cavalry, Missouri State Militia, is reported by Surgeon H. Culbertson, U. S. V., to have been admitted into the hospital at Rolla, Missouri, September 17, 1863, with a penetrating wound of the abdomen by a minie ball, received accidentally. Death resulted, from shock, eight hours subsequently to the infliction of the wound. The necropsy showed that the ball passed through the left iliac region, wounding and dividing the ileum, crossed backward to the outer side of the crural nerve, through the iliacus internus, the ilium, and came out about one inch to the left of the lumbo-sacral articulation, and to the left of the ileo-sacral articulation.

CASE 223.—Surgeon William G. David, 6th Regiment, Corps d'Afrique, reports that Private Terrence Boreau was wounded by the accidental discharge of a pistol, in quarters at Port Hudson, Louisiana, March 23, 1864. The ball entered the left iliac region and lodged, causing death in thirteen hours. The necropsy revealed the following lesions: The missile had passed through a knuckle of the small intestines, as also a knuckle of the sigmoid flexure of the colon; perforated the diaphragm, and lodged in the lower lobe of the left lung, causing extensive engorgement of the lung.

CASE 224.—Private J. T. McDowell, Co. H, 21st New Jersey, aged 25 years, was wounded in the abdomen at Chancellorsville, May 3, 1863. He was taken to the field hospital of the 2d division of the Sixth Corps, and was subsequently conveyed by ambulance to Washington, and admitted, on the 8th, into Douglas Hospital. Acting Assistant Surgeon H. L. M. Burritt, who had charge of the case, states that the "patient was shot through the sacrum, which was much comminuted; the ball came out about an inch above the pubes. Fæces escaped freely externally; no natural action of the bowels took place. Two grains of morphia were given daily and extra diet ordered. The patient was failing when he was admitted, but lingered a few days, and gradually sank, with symptoms of peritonitis. A *post-mortem* examination was made six hours after death: The bullet entered at the left ala of the sacrum and emerged in the hypogastric region, one inch above the pubes. The peritoneum was deeply injected, and the peritoneal sac contained a dark greenish and sanguinous mixture of fecal and serous effusion. A fold of the small intestine was twice perforated by the ball, but the bladder was uninjured. Gas and feces passed from behind into the gluteal muscles."

CASE 225.—Edward Mooror, a colored teamster, employed in the quartermaster's department, was shot in the abdomen in a brawl at a grogshop in Georgetown, October 12, 1862. He was taken to the Union Hotel Hospital, under the charge of Assistant Surgeon A. M. Clark, U. S. V., who reports that a "pistol ball had entered the left side about two and one-half inches from the spinal column, grazing the crest of the ilium, and emerged in front, two inches above and a little inside the anterior superior spinous process. Death occurred about forty-two hours after the reception of the injury. The autopsy showed three perforations of the intestines—one through the descending colon, and two through the ileum. The abdomen was distended with clotted blood, which had proceeded from one of the mesenteric veins. No extravasation of fecal matter could be determined. All the other organs were normal."

CASE 226.—Private David P. Taylor, Co. I, 5th Michigan Cavalry, was wounded in the abdomen on the morning of March 24, 1863, at Washington, by the accidental discharge of a Colt's revolver. He was at once removed to Lincoln Hospital. There was some vomiting, small pulse, and extreme restlessness. No movement of the bowels occurred; the patient passed a little urine. He died March 26, 1863, at 3.50 o'clock A. M., nineteen hours after the reception of the injury. A *post-mortem* examination was made nine hours after death: "Subject firm, and very well developed muscles. Height, six feet and one-half inch. No *post-mortem* rigidity present. The brain weighed fifty-four ounces. Small amount of reddish fluid in the lateral ventricle. Choroid plexuses pale. The abdomen when opened was found to contain a considerable quantity of gas. The cellular tissue



about the umbilicus was found distended with blood. The intestines were inflated with gas, and were intensely congested. The intestine was bound to the peritoneum, in very many places, by fleshy exuded lymph. Dark, red colored effusion, with blackish clots, was found at the posterior part, amounting to two and one-half quarts. Effusion to the amount of twelve ounces was found in the pleural sacs. The ball entered the median line of the abdomen three inches above the pubis, passed obliquely backward, keeping to the left side of the vertebral column, fracturing the transverse process of the left side of the third lumbar vertebra at its base, and was cut out, by the attending surgeon, from beneath the fascia. The small intestine was perforated in two places by the missile. There were adhesions on the right side, generally of a recent character. A portion of the small intestine, perforated by the ball, was saved to be sent to the Surgeon General's Office." The specimen was not received at the Museum.

CASE 227.—Assistant Surgeon J. B. Bellangee reports that Private *John Glandell*, Co. K, Mosby's troop, aged 39 years, was wounded in a cavalry fight at Warrenton Junction, May 2, 1863. The missile entered the abdomen at about the centre of the left iliac region, passed obliquely downward, and lodged somewhere in the upper part of the left thigh. This patient was a strong man, and lingered in continual agony until May 5th, when he died. The autopsy revealed the marked results of inflammatory action. The lower part of the ileum was perforated and extensively laid open.

The general subject of the applications of sutures in wounds of the digestive tube will be considered hereafter; but the following facts regarding enteroraphy in cases of shot wounds of the ileum, with protrusion, may properly be placed here. In the first case, three wounds in the protruded ileum were secured by the continued suture. The autopsy revealed two other wounds in the intestinal canal—one in the jejunum, the other in the ascending colon. There was no fecal extravasation, however, fatal gangrene of the small bowel rapidly supervening. The very instructive pathological preparations from this case are preserved in the Museum, and are represented in PLATES II and III. The nearly complete transverse division of the circumference of the gut shown in PLATE II well exemplifies the less extent of injury to the serous than to the mucous and muscular tunics that I have insisted upon as characteristic of shot lesions of the intestines:

CASE 228.—W. W——, colored, was, on May, 23d, 1865, at 12.30 o'clock P. M., admitted to the L'Ouverture Hospital, Alexandria, with a gunshot penetrating wound of the abdomen. An unsigned abstract of the case, believed to be in the handwriting of Acting Assistant Surgeon Thomas Bowen, was sent, with the pathological specimens, to the Army Medical Museum.

Surgeon Edwin Bentley, U. S. V., is understood to have operated in the case; but there is no positive record on the subject. "The missile had perforated the right ilium just below the crest, about five inches back of the anterior spinous process, and in its course upward had wounded the ileum, emerging near the umbilicus. On admission, nearly three feet of the intestines protruded. Three wounds were found in the protruding bowel—two were small, and the third nearly divided the intestine to the mesentery. All three were sewed up by the glover's stitch. The patient's pulse was quick but full, and the breathing short. He died at noon, on May 24, 1865. The autopsy, twelve hours later, revealed a clean-cut round wound, the size of a cherry-stone, just below the crest of the right ilium, and a ragged wound the size of a peach-stone to the right of the umbilicus. The lungs were in a healthy condition; pericardium and heart, normal; liver, rather pale; spleen, remarkably free from blood, looking as though soaked in water, on section; kidneys, fatty. Some coagula of blood, and fluid blood and serum in the abdominal cavity. A small bunch of omentum lying in the anterior wound; this and all parts of the omentum pretty fully injected; ileum throughout irregularly injected in tracks of a pink color, but now and then almost black. A penetrating wound with everted edges, size of a cherry, about eight or ten feet from the end of the jejunum. About eighteen inches from this was a wound almost completely severing the intestine (FIG. 50) to the mesentery, but sewed up, and beyond this were two smaller ones (FIG. 51), also sewed up. No wounds were observed beyond this in the ileum. The external anterior surface of the ascending colon, opposite to and just above the perforation in the innominate bone, was torn open. A little outside of the colon was an opening through the peritoneum. The iliacus internus muscle and the circular hole in the ilium were lined



FIG. 50.—Section of ileum, slit open to show the interior of the gut, with sutures closing a shot wound. *Spec.* 4369.

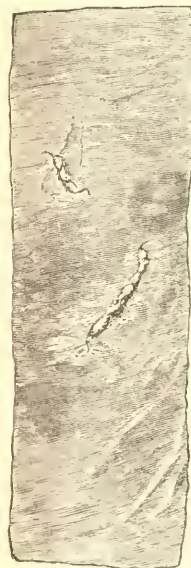
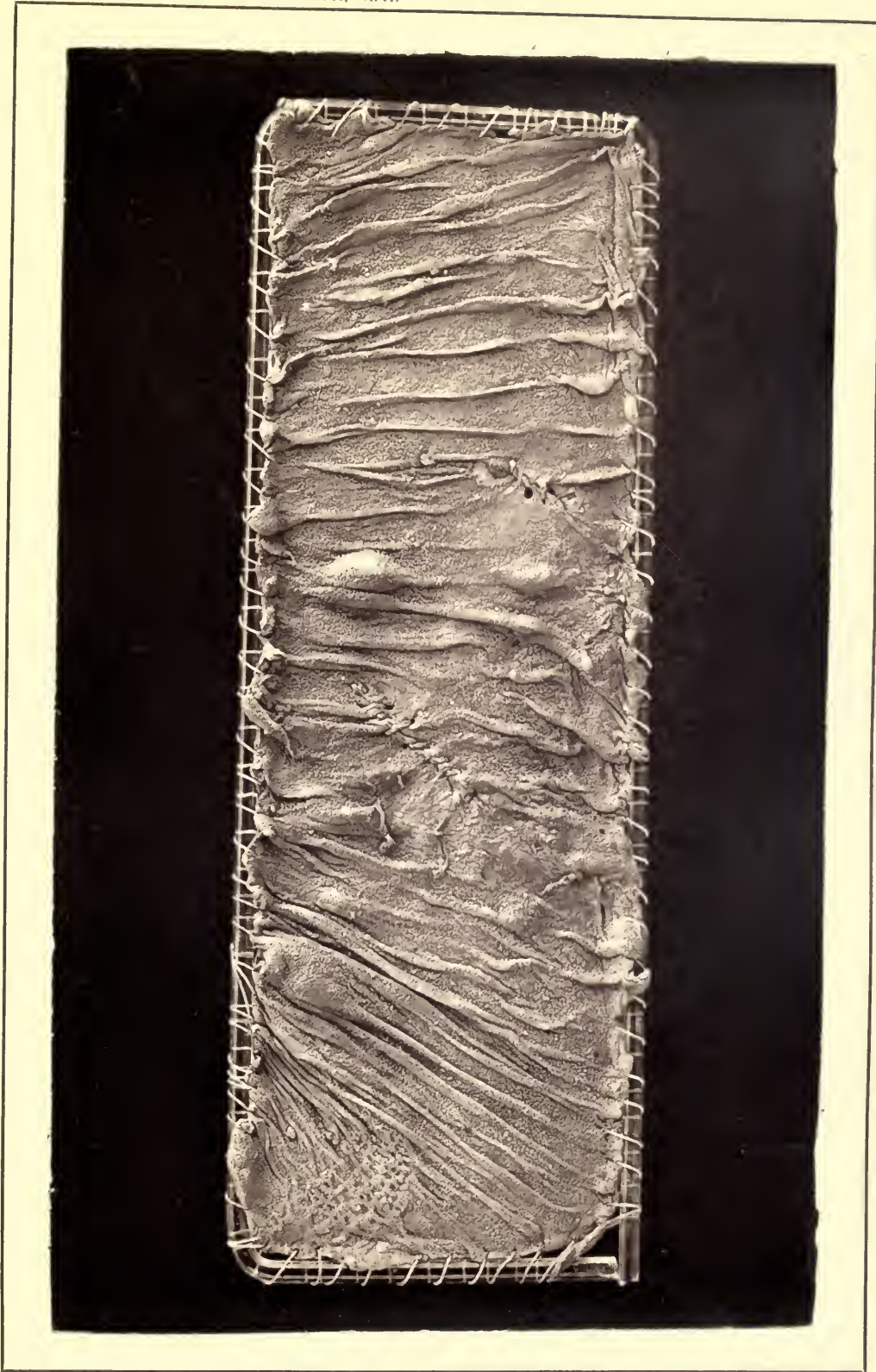
FIG. 51.—Another portion of the same ileum, with shot perforations sewn up. *Spec.* 4370. [Both preparations are reduced to one-fourth.]

with fragments of bone pointing forward. No fragments of bone were felt externally behind this perforation in the haunch bone; and the opening into the bone from the outside was cleanly cut and with smooth edges."

There had been no plastic exudation, either at the breaches of continuity that were united by suture, or at those in the jejunum, colon, and parietal peritoneum. There were circumscribed infiltrations of blood in the submucous connective tissue in the vicinity of



Ward phot.

Am. Photo-Relief Printing Co., Philada.

PLATE II. ENTERORAPHY FOR A SHOT WOUND OF THE ILEUM.

No. 4390. SURGICAL SECTION.





each of the five rents in the intestine. The continued sutures had not satisfactorily inverted and approximated the serous membrane, and some of the punctures were patulous, as though made by a needle unnecessarily large. This was mostly noticeable in the two small oblique divisions, of which an exterior view is given in FIGURE 51, and an interior view in PLATE II, opposite. The nearly complete division illustrated by FIGURE 50, and, of the size of nature, in PLATE III, placed further on, was securely closed, but not with that careful apposition of the serous surfaces that is essential.

Another instance of enteroraphy, in a frightful case of shell wound of the abdomen, with fracture of the pelvis, and protrusion of the intestines, is recorded by Brigade Surgeon Oliver A. Judson, U. S. V., in a letter to Medical Director Tripler:

CASE 229.—“On the afternoon of April 17, 1862, a shell, thrown from a battery about the centre of the enemy's works at Yorktown, exploded near a group of men of the 1st brigade of General Hooker's division, belonging to a reconnoitering party. Five men were injured. Private Jerry Luther, Co. G, 2d Rhode Island, had his left forearm shattered, by a fragment of the shell, to such an extent that it hung merely by shreds of skin. A large piece of the same projectile entered the abdominal cavity, to the left of the linea alba, fracturing the anterior superior spinous process of the ilium, and causing the hernia, perhaps four or five feet in length, of the small intestine, with a portion of the descending colon, and of the omentum. There was also a small wound from a third fragment, in the left thigh. The small intestine having been wounded transversely through half the circumference of the gut, Surgeon Judson applied five stitches by Joberi's method, and the wound was apparently closed sufficiently to prevent the escape of feces. The external wound was then dilated sufficiently to permit the return of the protruded intestine, and it was not deemed advisable to molest the patient further on that occasion. His arm was supported on a splint; a full anodyne dose was administered, and stimulants were freely given. On the morning of April 18th, Surgeon J. W. Mintzer, 26th Pennsylvania, removed the forearm. Luther continued to sink until six in the evening, April 18, 1862, when he died.”

These cases are the only two exceptions that have been found, after careful search, to the too absolute statement on page 26, of the preliminary report in Circular No. 6, S. G. O., 1865, and, so far, the annals of military surgery appear to be barren of instances of successful suture of the small intestine after shot injuries, though recovery has ensued, with temporary fæcal fistula, where sutures were employed.<sup>1</sup> In shot wounds of the large intestines, as will be seen, more fortunate results have been achieved by enteroraphy.

In reviewing the shot wounds of the small intestine, I find no imitation of the excellent practice of Larrey,<sup>2</sup> who, in a case of complete division of the ileum by a ball, approximated the ends of the gut to the external wound. From the special pleading of those who denounce the employment of sutures in shot wounds of the small intestines, it might be inferred that recovery through the unaided efforts of nature was not infrequent, and it would be supposed that some plausible proof that patients under such circumstances would have a better chance of life without surgical interference<sup>3</sup> was readily accessible. But those who advocate this view present no facts in support of their dogmatic assertions. I have sought to collect, at the beginning of this article, the clinical evidence

<sup>1</sup> Mr. I. S. GISSING records (*British Med. Jour.*, 1858, quoted in *Charleston Med. Jour. and Rev.*, 1858, Vol. XIII, p. 677) a case of enteroraphy in the case of John Jeffries, aged 17 years, wounded by the bursting of an iron cannon. Through a lacerated wound in the right flank, a mass of intestines and omentum protruded. One of the protruded convolutions of the bowel (probably a portion of jejunum) was burst through to the extent of a quarter of an inch, from which came fluid feces and pure bile. Mr. GISSING placed three fine interrupted sutures through the wound in the intestine, cut the ends close to the knots, replaced the bowel, and closed the external wound with adhesive strips, and opium was administered in full doses. Sloughing ensued, and fæcal fistula; but by the ninth day, feces passed by the rectum; the wound closed and the patient regained excellent health.

<sup>2</sup> LARREY (*Mém. de Chir. mil. et Camp.*, T. II, p. 160) says: “M. N\*\*\* reçut, à l'assaut du Caïre, un Vili (1799), un coup de balle au bas-ventre, qui lui ouvrit les parois musculaires de cette cavité du côté droit, et une portion de l'intestin iléon. Comme je me trouvais sur le champ de bataille, je lui administrai les premiers secours; les deux bouts de l'intestin étaient sortis, éloignés l'un de l'autre et boursoufflés; le bout supérieur était renversé sur lui-même, de manière que son rebord rétréci, comme le prépuce dans le paraphymosis, étranglait le tube intestinal; le cours des matières en était intercepté, et elles s'accumulaient au-dessus du rétrécissement.” \* \* \* “Je coupai d'abord, par quatre petites incisions faites avec les ciseaux évidés, le collet de l'intestin étranglé, que je remis dans son état ordinaire. Je passai une anse de fil dans la portion du mésentère, correspondant aux deux bouts de l'intestin; je les fis rentrer jusqu'au bord de l'ouverture, que j'avais en soin de débrider, et, le pansement fait, j'attendis les événements. Les premiers jours furent orageux; ensuite les accidents se dissipèrent; ceux qui dépendaient de la perte des matières alimentaires s'apaisèrent successivement; et, après deux mois de soins et de traitement, les deux bouts de l'iléon étaient en rapport et prêts à contracter adhérence. Je secondai le travail de la nature, et fis panser le malade avec l'ingénieux moyen de M. Desault, c'est-à-dire le tampon, qui fut employé pendant deux mois à différentes reprises. Ce militaire est sorti de l'hôpital, parfaitement guéri.”

<sup>3</sup> Dr. F. H. HAMILTON (*A Treatise on Mil. Surg. and Hygiene*, 1865, p. 344) says: “Be assured the patient will have a better chance for life, if we let him entirely alone; and it surprises us that any good surgeon would think otherwise.”

favorable to this view.<sup>1</sup> It must be conceded to be far from conclusive. The evidence in the same direction, afforded by pathological anatomy, is limited, I believe, to a single observation. Mr. Williamson regards the preparation from the case of Paul Massey, which is preserved at Netley, and is figured in the wood-cut (FIG. 52), as "unique." This man survived a penetrating shot wound of the abdomen five and a half years. The symptoms consequent upon the injury were so inconsiderable that it was the opinion of the regimental surgeon, Dr. MacDonald, that the ball had coursed around the abdomen without penetrating it. The patient stated, however, that he had passed blood by stool, soon after the reception of the injury. He became subject to bowel complaint, and for the last twelve months of his life was nearly constantly under treatment for scorbutic dysentery. Surgeon J. H. Taylor, who made the autopsy, and Dr. Williamson, regarded the constrictions as the results of shot perforations. Yet there were no adhesions of the intestines at any point; and Professor Longmore argues, very plausibly, that it seems more likely that the gut was contused than perforated, and that the constrictions gradually supervened. Guthrie (*Inj. of Abd.*, p. 35) regarded the proper management of shot

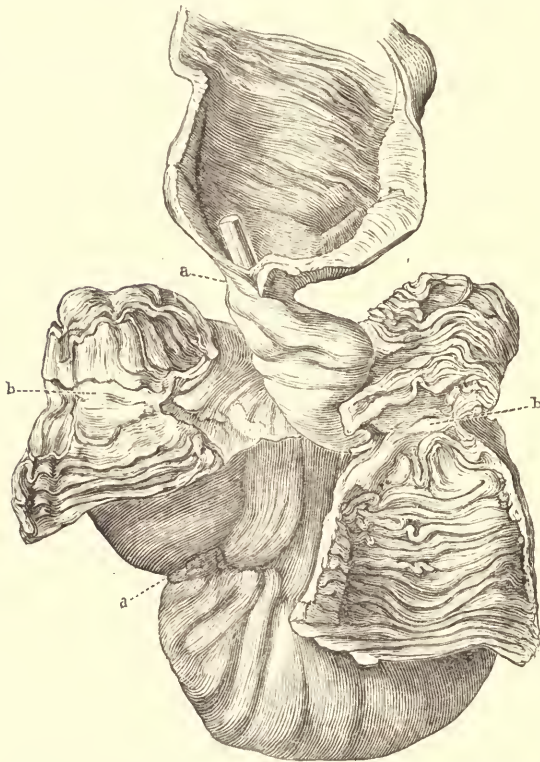


FIG. 52.—Two pieces of the jejunum, showing four contractions following shot injury: *a a*, contractions; *b b*, contractions laid open. *Spec.* 1271, Netley (after WILLIAMSON, Pl. V).

wounds of the intestines as an important point undetermined by his contemporaries, to which the best attention of their successors should be drawn. The observations made in later European wars have not greatly augmented our knowledge of the subject, and it is therefore the more desirable that the experience of the American war, on this point, should be exhaustively discussed. In the majority of the cases sufficiently well defined to be classified in this group, the subdivision of the small intestine implicated was not indicated. Many, perhaps the larger proportion, appear to have been complicated by other

<sup>1</sup> See CASES 207-211 inclusive. GUTHRIE'S CASE 46 (*Wounds and Inj. of the Abd.*, p. 35) is one of the very few recoveries from a musket-ball wound supposed to interest the small intestine. The missile, entering in the right iliac, came out a little below the umbilicus on the opposite side. "A fecal bilious discharge, evidently from the small intestines," took place. The soldier was sent to England from Waterloo, well but weak. JOHN THOMPSON (*Report after Waterloo*, already cited, p. 105) notices this case and one other: "We saw another patient, also considerably advanced in recovery, who had received a wound by a ball which had entered about three inches above the posterior spinous process of the ilium, on the left side, and had passed out of the right hypochondriac region, near to its middle. A part of the food which he took was said to have come, for fifteen days, by the posterior orifice, through which two lumbrici were also discharged. This man never had any vomiting." From the old authors, I can recall only one example of recovery from a shot wound of the small intestines; that related by BORDENAVE (*Mém. de l'Acad. Roy. de Chir.*, T. II, p. 519, Obs. XIV): A Dutch soldier, shot through the right iliac region at Racoux, was treated by M. Poneyés. There was protrusion of a wounded loop of the ileum. The patient recovered with a stercoral fistula, which ultimately closed. Modern wars have furnished few instances. The single case observed by LARREY has been cited on the preceding page. The case of MASSEY was the solitary instance observed in India. None were reported from the Crimea. From the Italian War of 1859, the unreliable DEMME (*Militär-Chirurgische Studien*, Würzburg, 1861, B. II, S. 145) describes the recovery of an Austrian infantry soldier struck, at Solferino, by a musket ball, which was voided at stool, the direction of the wound indicating a lesion of the small intestines (Dünndarms); but he notes that the fecal exodus was very copious; and, if the facts are correctly reported, the most probable inference is that the fecal fistula followed sloughing of the wall of the cæcum. In the Bohemian War, Professor RICHARD VOLKMANN, of Halle (*Einige Fälle von geheiltten penetrirenden Schusswunden des Abdomens aus dem Feldzuge von 1866 in Deutsche Klinik*, 1868, B. II), observed two cases of recovery from penetrating shot wounds, in which he believed that the small intestines were interested. In a carefully reported case of a recovery after fecal fistula from a wound of the abdomen by bird-shot, Dr. MICHAËLIS, an Austrian regimental surgeon (*Wiener Medizinische Presse*, 1868, B. IX, S. 320), concludes that the alimentary canal was wounded in two places, one of the lesions being in the small intestine: "Nach dem Mitgetheilten ist es ausser Frage, dass mindestens zwei verschiedene Darmtheile durch die Schrotkörner zerrissen wurden, und zwar dass eines davon dem Dünndarm, ein anderes dem Dickdarm entspricht."



visceral lesions, of which examples will be adduced hereafter. There are but few good accounts of autopsies. In the following instance, explanation of the obscure attendant phenomena is left to conjecture:

CASE 230.—Private Jacob Krausa, Co. I, 9th New Hampshire, aged 36 years, received a wound of the abdomen and of the left wrist at Petersburg, June 20, 1864. He was taken to the field hospital of the 2d division, Ninth Corps, where simple dressings were applied to the wounds. He was conveyed by hospital transport to Washington, and, on the 24th, admitted into Emory Hospital, and committed to the care of Acting Assistant Surgeon E. W. Thompson, who notes on the medical descriptive list: "Gunshot wound of the abdomen, penetrating the small intestines just below the umbilicus; wound of left wrist, superficial." At the time of admission the wound of the abdomen was highly inflamed and sloughing; fecal matter, mixed with considerable pus, was discharged from the wound. The patient was unable to retain his urine. Stimulants were administered and low diet ordered. Dressings of cold water and kerosene oil were applied to the wound of the abdomen; that of the wrist was dressed simply. On the 29th, the right leg began to swell and become œdematous. Cold-water applications were made to the leg, which reduced the inflammation. On July 2d, Dr. Thompson notes that "mortification has commenced on the leg; the wound is becoming gangrenous;" a wash of dilute nitric acid and water was employed. On the 7th, the patient bled about one ounce from the wound. Death resulted July 8, 1864. Diarrhœa was present throughout the whole time. If an autopsy was made the record was not forwarded to this office.

Protrusion of the unwounded or wounded bowel is well known to be rare in shot wounds. The following instance has been reported by Surgeon W. O'Meagher, 37th New York:

CASE 231.—Private J. McLellan, Co. H, 1st New Jersey Cavalry, was wounded, February 24, 1862, near Pohick, by a musket ball, which entered the right lumbar region and emerged half an inch below the naval, severing the small intestine, the wounded gut being protruded and the extent of the injury revealed. There was profuse bleeding from the divided mesenteric arteries, vomiting, and rapid collapse. The patient sank and died, nine hours after the reception of the wound, February 24, 1862.

The complications and treatment of wounds of the small intestines will be more conveniently considered at the close of the next subsection.

WOUNDS OF THE LARGE INTESTINES.—It has long been known that injuries of this group were less fatal than wounds of the small intestines.<sup>1</sup> The position and structure of the colon account for the less liability in wounds of this portion of the intestinal canal to extravasation of the fecal contents into the peritoneal cavity. The disposition of the muscular coat, and the firm attachments by which the gut is secured, tend to preserve that parallelism between the wounds in the parietes and in the bowel, and that apposition of the intestinal and parietal surfaces that are such important safeguards; and further favorable conditions are found in the facts that the colon is only partially invested by the peritoneum, and that injuries of its ascending and descending portions, especially, do not necessarily jeopardize other organs. In the preliminary report in Circular 6, S. G. O., 1865, p. 26, I stated that "recoveries after wounds of the large intestines have been much more numerous than after wounds of the ileum or jejunum." A closer study of the facts, justifies the assertion that the difference in fatality, in injuries of these two groups, is very great; the lesser mortality of wounds of the large intestine having been abundantly exemplified. Adverting briefly to the miscellaneous injuries of the large intestines, I will adduce a long series of remarkable recoveries from shot wounds, many of which have been kept under observation for several years.

<sup>1</sup> BENJAMIN BELL (*A System of Surgery*, 2d ed., Edinb., 1785, Vol. V, p. 289) is one of the few authors who deny that wounds of the large are less dangerous than those of the small intestines. He says that he has not observed that this is confirmed by experience, though the proofs experience affords are abundant. It has been seen, in the notes to page 63, how few authentic recoveries from wounds of the small intestines were known to the ancients; of wounds of the large intestines, they adduced a considerable number. In the translation of ALBUCAZIS (*De Chirurgia*, Oxonii, 1778, Lib. II, Sect. 85, p. 393) is recorded a recovery from a lance wound of the great intestine. VIDUS VIDIVS (*Comment in lib. HIPPOCRATIS, de vuln. cap.*, 1544) records a recovery from a punctured wound of the large intestine. PARE (*Traité des playes d'arquebutes*, 1552, fol. 79) records the recovery of the silversmith of the ambassador of Portugal from a sword thrust in the colon. MURGELIUS (in SCHEENCKIUS, *l. c.*, p. 368) relates a recovery from a punctured wound of the colon. A. DE HARTWISS (*Eph. Nat. Cur.*, Cent. 1, Francofurti, 1712, Obs. VI, p. 43) relates a case in which a portion of the colon had been cut off by a knife, and a preternatural anus had formed, with ultimate recovery. TUPLIUS (*Obs. medicæ*, Lugduni Bat., 1716, Lib. III, Cap. XX, p. 208) notes a stab wound of the large intestine, with recovery. TIEFFENBACH (*Vulnere in intestinis lethalitas*, Wittenberg, 1720, in HALLER'S *Disp. chir.*, Lausannæ, 1756, Vol. V, p. 63) records a recovery from a bayonet wound in the left hypochondriac region, with injury of the colon. NOURSE, C. (*Philosoph. Trans.*, 1776, p. 427), relates a recovery from a stab wound of the colon. RONALDSON (*Medical Comment.*, 1780, Vol. VII, p. 372) notes a stab wound of the colon; completely cured in five weeks. TUDECIUS (*De intestino colo vulnerato cum hypogastrico vulnerato coalescente*, in *Eph. Med. Phys. Cur.*, Norimbergæ, 1693, Ann. IX, Obs. CXXI, p. 293) cites a case of sword wound of the colon; fatal in sixteen days. At the autopsy the edges of the wound of the colon were found united with those of the abdominal wall.



*Punctured and Incised Wounds.*—Comparatively few examples of these lesions were reported. Surgeon S. W. Gross, U. S. V., has printed<sup>1</sup> an interesting case of recovery, from a sabre wound of the descending colon. Pension Examiner J. R. Bailey, in March 1866, reported the same case with some additional details:<sup>2</sup>

CASE 232.—Private C. A. McCulloch, 3d Kentucky Cavalry, aged 19 years, was shot through the chest, in the skirmish at Sacramento on December 28, 1862, a pistol ball perforating the right lung. In retreating he received also a sword thrust in the left flank, penetrating the abdomen. He rode about a mile after this, and then was too faint to sit upon his horse, and was left at a farm-house. Here he was attended by a practitioner of the neighborhood, who administered purgatives. There could be no doubt that the sabre penetrated the bowels, for there was a very copious discharge of fecal matter by the wound for several days. He was seen, however, occasionally, by Union surgeons, when they could visit the farm-house, which was situated between the lines. After protracted suffering, he recovered and performed some little service. Surgeon Singleton was in charge of the regimental hospital at that time. He reported that McCulloch was discharged in October, 1862, and then enjoyed better health than could be expected. [McCulloch's name is not upon the Pension Roll.]

In the next case, the diaphragm, and the thoracic as well as the abdominal cavity, were implicated; but the fatal termination resulted immediately from the fecal extravasation, due to the wound in the colon:

CASE 233.—Private Stephen Moel, Co. K, 10th Tennessee Cavalry, was admitted to general hospital at Natchez, Mississippi, a half hour after midnight, April 8, 1865, having received, at seven o'clock the previous morning, a punctured wound, from a pocket-knife, in the seventh intercostal space, posteriorly. His pulse was small and rapid, countenance anxious, respiration short and hurried, tongue furred, and abdomen greatly distended. He complained of very severe pain in the diaphragmatic region. A mass, having much the appearance of highly congested adipose tissue, protruded one and a half inches through the external opening. Assistant Surgeon A. E. Carothers, U. S. V., excised the protruding mass, and endeavored to induce hæmorrhage externally by placing the patient on the affected side, but little bleeding occurred. The patient became comatose, and died on April 8, 1865, thirty-eight and one-half hours after the reception of the injury. At the autopsy, a large quantity of bloody serum was found. The diaphragm had been punctured, and the omentum forced upward through the wound in the diaphragm and out of the external wound. There was intense and general inflammation throughout the peritoneum and the pleura of the injured side. The lungs and liver were normal. The colon was found punctured at the left end of the transverse portion, and had permitted the abundant escape of feces into the abdominal cavity. The whole intestinal canal was highly congested. The case is reported by the operator.

In a case of incised wound of the descending colon, without protrusion, enteroraphy was unsuccessfully practiced:<sup>3</sup>

CASE 234.—Corporal M. Moran, Co. H, 111th Pennsylvania, aged 22 years, was stabbed July 26, 1865, in an affray in camp, near Washington, and was taken to the regimental hospital. It was ascertained that a dirk knife had penetrated the abdominal cavity, in the left iliac region. The following day the patient was taken to Lincoln Hospital. The wound in the abdomen was inflamed, the lips red and swollen. A general inflammatory reaction had set in, the patient having been in perfect health at the time of receiving the wound. Chloroform was administered, and Acting Assistant Surgeon W. E. Roberts enlarged the wound in the parietes by an incision one and a half inches long. This fully exposed an oblique wound of the walls of the descending colon. The intestine was drawn down, and the division of its tunics was closed by six points of interrupted suture. Symptoms of peritonitis were combated by a small bleeding from the arm, and by full doses of opium, with cold applications and poultices to the abdomen. The progress of the case was not favorably modified, and death resulted, July 19, 1865, thirteen days from the reception of the wound.

*Gunshot Wounds.*—While few instances were observed of recovery from shot wounds of the transverse colon, many were seen of survival after perforations of the cæcum and ascending portion of the bowel, and a still larger proportion of recoveries was observed in wounds of the sigmoid flexure and other parts of the descending colon. Not a few of

<sup>1</sup>GROSS, S. W. (*Am. Med. Times*, March 19, 1864, Vol. VII, p. 136), and HAMILTON (*A Treatise on Mil. Surg.*, p. 384). Dr. Gross gives the youth's name as William Lowry, and states that he last saw him on February 18, 1862, eight weeks after the reception of the injury.

<sup>2</sup>The American medical periodicals record but few recoveries from stabs in the large intestines treated on the expectant plan: Dr. C. H. RAWSON (*Am. Med. Times*, 1864, Vol. VIII, p. 16) records a case of recovery after fecal fistula, following a stab wound of the descending colon. He infers that the serous and muscular tunics only were divided by the knife, and that the cellular and mucous coats gave way on the ninth day. Dr. W. N. FORBES (*The College [Cincinnati] Jour. Med. Sci.*, 1859, Vol. IV, p. 441) describes a recovery from a stab in the left iliac region, bloody stools indicating that the descending colon was injured; there was no fecal extravasation, and, under an opiate treatment, the patient was well in three weeks.

<sup>3</sup>1. Dr. A. POST has, in the reports of the New York Hospital (*The Annalist*, 1846, Vol. I, p. 26), a case of a stab wound with protrusion of the descending colon, in which a longitudinal incision an inch long was successfully united by two sutures, and the bowel returned. A prophylactic blister was applied, a practice originating, according to Dr. POST, with the late Dr. BORROWE, to which the happiest effects were ascribed. 2. Drs. MASON and WHITNEY, of Prairie du Chien, describe (*Chicago Med. Exam.*, 1867, Vol. VIII, p. 21) a dirk wound of the transverse colon, with protrusion, and division of a large branch of the colica media. Two ligatures were placed on the divided artery, and the intestinal wound was united by the glovers' suture, the serous surfaces being carefully approximated. Complete recovery in four weeks. 3. Dr. J. P. CHESNEY (*Cincinnati Med. Repertory*, 1869, Vol. II, p. 335) records a successful case of enteroraphy in a stab in the descending colon, with protrusion; the intestinal wound, an inch long, was closed by the glovers' suture.



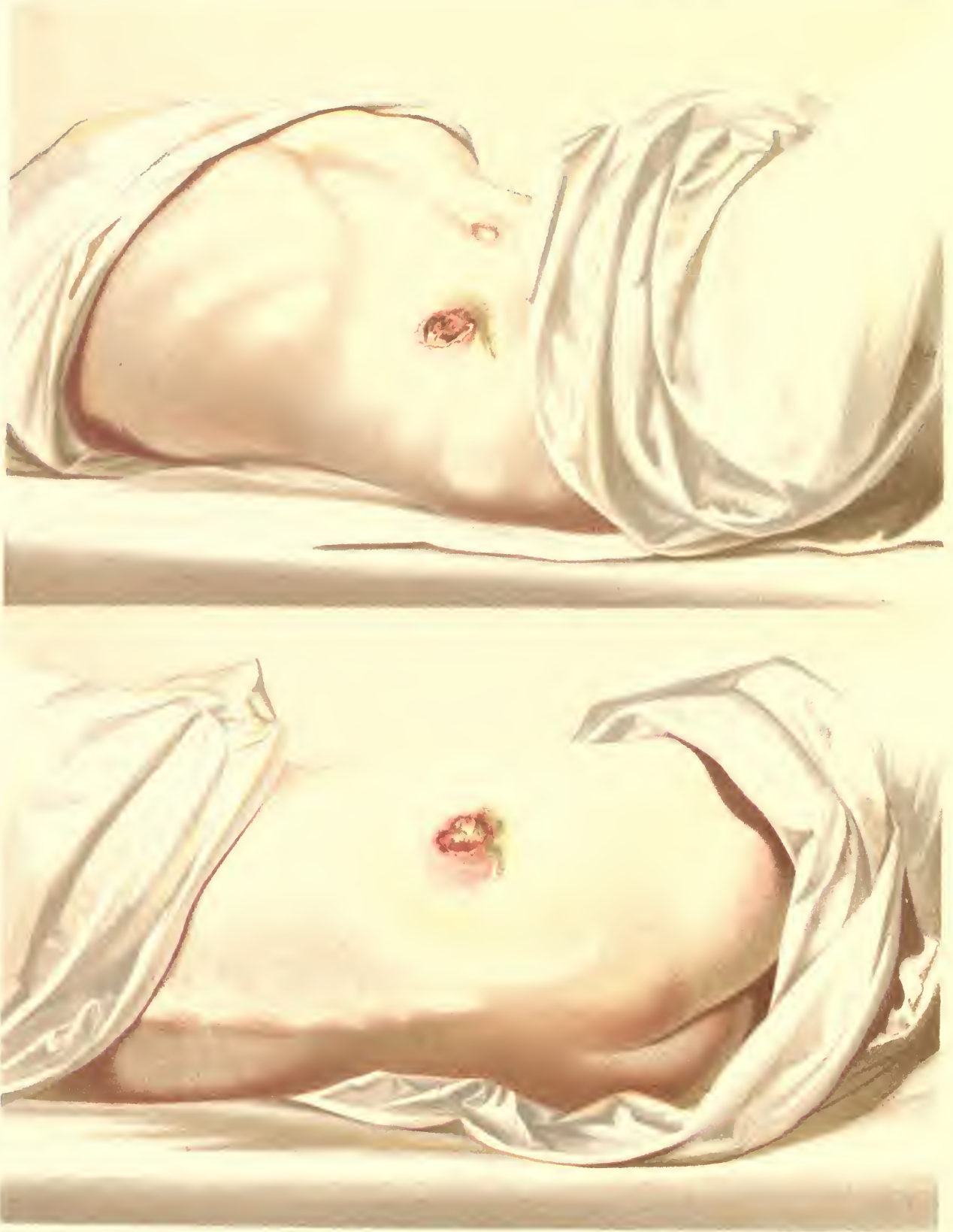


PLATE IV. FAECAL FISTULAE AFTER SHOT PERFORATION OF THE ASCENDING COLON



these fortunate cases were complicated by groovings or perforations of the wings of the innominata. Nearly all were attended by stercoral fistulæ, which commonly closed after a time, without operative interference, reopening at intervals, and then healing permanently. One of the few exceptions to this rule is exemplified in the picture opposite (PLATE IV). After detailing the cases of this important series, the instances of fatal shot wounds of the large intestines will be considered:

CASE 235.—Private Franklin Harsh, Co. G, 7th Ohio, was wounded at Chancellorsville, May 3, 1863, and was taken to the hospital of the Twelfth Corps, where Surgeon H. E. Goodman, 28th Pennsylvania, recorded the injury as a "gunshot penetrating wound of the abdomen and hip." The field record gives no details of the symptoms of treatment. The patient was sent to Aquia Creek by rail, and thence, on a hospital transport, to Washington, and was admitted into Armory Square Hospital. There he remained for a long time, with fecal fistula; but no report of the particulars of the case was made. The case arresting the attention of Surgeon J. H. Brinton, U. S. V., he directed Hospital Steward Stauch to make the colored drawings from which the chromolithograph opposite (PLATE IV) is copied. The drawing appears to have been finished September 13, 1863, at which date, in a letter to Dr. Brinton, Surgeon D. W. Bliss reports that "a minié ball passed through the right hypochondriac region, making its exit through the ilium, near the posterior fourth of the crest. The posterior opening permits the passage of small quantities of fecal matter and of gas. The patient is improving daily, the opening into the gut contracting steadily, and the case promises a favorable termination." On April 28, 1864, the register of Armory Square Hospital shows a certificate from Dr. Bliss that Harsh was "discharged for artificial anus from gunshot wound, incidental to the service,—disability total." On March 15, 1867, Examining Surgeon J. Holloway, Wabash, Indiana, reports of this pensioner: "His wound is on the right side, the ball having passed through the bowel above and to the right of the crest of the ilium. The contents of the bowels, when fluid, frequently pass out of both orifices made by the ball. He is entirely incapacitated for manual labor, his disability total." On June 6, 1866, Harsh's pension was increased to fifteen dollars monthly, and from June 8, 1872, to eighteen dollars monthly. It cannot be learned that any operative interference, with a view of closing the fistulæ, has been attempted.

CASE 236.—Lieutenant G. P. Deichler, Co. I, 69th Pennsylvania, aged 22 years, was wounded by a conoidal musket ball, at Hatcher's Run, Virginia, March 25, 1865. The ball entered the right iliac region, and, passing through the ascending colon, made its exit a little to the left of the last dorsal vertebra. The patient was taken to the field hospital of the 2d division, Second Corps, in charge of Acting Staff Surgeon John Aiken, and from thence to Armory Square Hospital, at Washington, where he was admitted on April 1st, in an exhausted condition, with grave symptoms of peritonitis. There was a copious fecal discharge from both wounds. Appropriate dressings were applied; a fourth of a grain of sulphate of morphia was ordered to be given every second hour, and stimulants were directed. On April 7th, sloughs separated from both wounds, and left a clean granulating surface. A large piece of splacelated omentum was removed from the anterior wound. The opiate treatment was continued till April 27th, when there was a fecal evacuation by the anus, for the first time since the injury. On June 12th, the discharge from the wounds was very slight. Acting Assistant Surgeon C. A. Leale, who reported the foregoing facts, states further, that the edges of the wounds were now refreshed and approximated by adhesive strips. On August 10th, the anterior wound was firmly healed. There was a small fistulous sinus at the posterior wound, discharging pus scantily. On this day, a photograph, from which the cut adjacent (FIG. 53) is copied, was taken at the Army Medical Museum, and the patient left the hospital for his home, at Lancaster, Pennsylvania, in excellent general health. The fistula soon healed. This officer was pensioned, and, in April, 1867, Pension Examiner J. Severgood was able to make a satisfactory report of his condition. Again in December, 1872, the Pension Office received information of the continued good health of this officer, though the effects of his terrible wound, as well as his antecedents, naturally "disqualified him from manual labor."

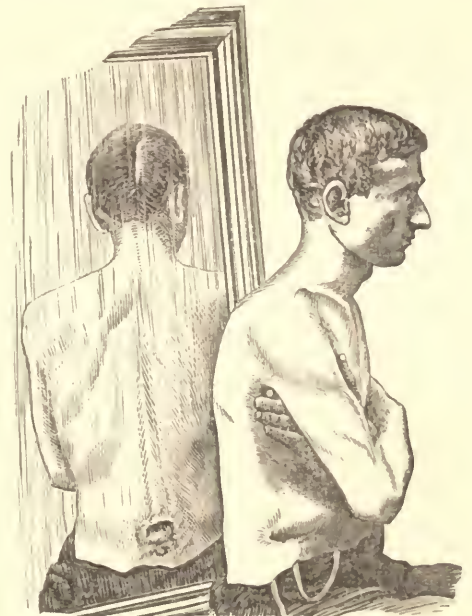


FIG. 53.—Centricæ in a case of shot perforation of the ascending colon. [From a photograph made five months after the reception of the injury.]

CASE 237.—Private Oliver E. Trowbridge, Co. B, 23d Connecticut, aged 23 years, received a shot wound of the abdomen at Lafourche Crossing, Louisiana, June 21, 1863. He was treated in the regimental hospital until August 7th, when he was admitted to the St. Louis Hospital, New Orleans, and registered as "gunshot wound of left thigh." On August 29th, he was sent northward, and discharged the service August 31, 1863. Surgeon W. H. Trowbridge, 23d Connecticut, states, April, 1865, that the records were destroyed by the burning of the plantation house at Lafourche Crossing, used as a regimental hospital, and furnishes the following history of the case: "Wounded by a minié ball in the abdomen, one inch above the anterior superior spinous process of the ilium, right side, from before backward, in such direction as to pass through the ascending colon, etc., and escape through the spinous process of a lumbar vertebra. Patient examined three hours after injury; found him much depressed; pulse feeble; extremities cold; abdominal viscera appeared paralyzed; placed him on his back on a hard bed covered with gutta-percha cloth, with a depression corresponding to the posterior wound, and a channel leading from it to the front of

the bed; gave stimulants and opiates; in a short time fecal matter escaped from the wound freely; gave enema to cleanse the rectum; ordered simple, nutritious diet, and the wound to be cleansed frequently. As the skin became excoriated from discharges, I applied adhesive plasters of sufficient size to cover all excoriations, and perforated at the seat of the wound with an opening corresponding to it so as to allow the free escape of all matters. This appliance worked nicely; in a few days the bowels began their regular movements per anus, the wound also discharging in a gradually diminished degree for twenty days; the anterior wound also, at one time, discharged intestinal gases and fetid pus; it soon, however, healed with a healthy cicatrix. On the twentieth day, I turned the patient face downward and dressed the posterior wound with approximating strips of adhesive plaster, and the wound healed kindly, so that in a few days the patient was walking about the wards of the hospital, and gradually grew erect, comfortable, and happy. At this date, the patient is living in Danbury, Connecticut, complaining only of slight lameness upon over-exertion; he has married since his injury, and enjoys fine health and the comforts of life. He has been seen and examined by Drs. James R. Wood, Frank Hamilton, A. Post, C. Riley, and others, at a meeting of the so-called Surgical Section, holden at the house of Dr. Wood about the month of November, 1863, and pronounced by them the only perfect recovery after gunshot wound of the colon, coming under their notice." Pension Examiner W. H. Trowbridge, of Stamford, Connecticut, reports, December 27, 1868, as follows: "Wounded in abdomen, the ball passing through the ascending colon, and, although he presents the rare case of recovery without artificial anus, he is decidedly debilitated, suffers much distress and inconvenience, and is, in my judgment, entitled to full pension. His case I understand well, he falling under my charge at the time of injury, and I have also kept well advised in relation to his case since his partial recovery. Disability total."

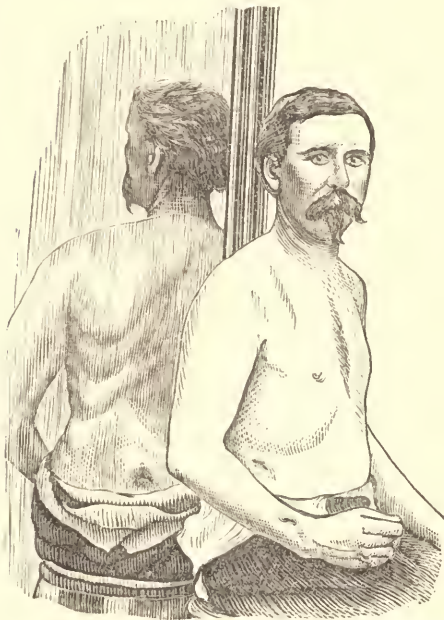


FIG. 54.—Scars from a shot perforation of the ascending colon, and of the forearm.

CASE 238.—Colonel Edward W. H——, 19th Massachusetts, aged 36 years, was wounded at the battle of Antietam, about noon of September 17, 1862, by a musket ball, which shattered the right radius, and entered the abdomen on a level with the umbilicus, three inches above the middle of the crest of the right ilium, and, having traversed the ascending colon, emerged a little to the right of the lumbar vertebra. He lay upon the field until about noon of the following day, when he was removed to a vacant house, and thence to a field hospital, where he was attended by Surgeon J. Franklin Dyer, 19th Massachusetts. On September 21st, fecal matter began to escape from the wound of exit. On the 26th, there were grave symptoms of peritonitis, which were treated by entire rest, morphia, and cold-water dressings. Impacted feces in the lower part of the descending colon were removed mechanically. On October 12th, the patient was removed to a Baltimore hospital, and placed under the care of Brigade Surgeon C. W. Jones, U. S. V. Here he remained four weeks, and then was removed to Boston, and was there attended by Dr. G. H. Gay. In a few weeks the dejections resumed their natural channel, and the fistulous orifices healed soundly. A photograph was made by Whipple to show the cicatrices in the side and forearm. It is numbered 166 of the *Photographs of Surgical Cases*, and is copied in the wood-cut (FIG. 54). Colonel H. was commissioned Lieutenant Colonel, 40th Infantry, and Brevet Brigadier General, on the reorganization of the Army, in 1866, and placed upon the retired list, for wounds received in action, December 15, 1870.

CASE 239.—Private H. D. C. Mills, Co. E, 8th Ohio, aged 20 years, was wounded at Antietam, September 18, 1862, by a musket ball. He was at once conveyed to the field hospital of the 3d division, Second Corps, where he remained under treatment for several days. Assistant Surgeon S. Sexton, 8th Ohio Volunteers, in a communication dated May 17, 1868, makes the following report of the case: "Was wounded by a musket ball, which entered the abdomen in front, at the left lumbar region, a little below the floating ribs; its exit was one half inch to the left of the spine, and nearly on a line with the point of entrance; the descending colon was wounded. Young Mills was of a buoyant, undespairing disposition, and when first seen, soon after he fell, I was impressed by the absence of shock and consequent depression usually manifest in these cases; he remained under my charge on the field for five days, during which time his treatment consisted of quieting doses of morphia and such fluid alimentation as could be procured. On the fourth day, the discharge from the wound of entrance was fecal, and shortly afterward also that of the wound of exit. No symptoms of peritoneal inflammation were observed while the patient remained under my care, and in fact he seemed to suffer but little. On the fifth day, his friends were permitted to remove him to a private house on the Sharpsburg road, near Boonesboro'; where he remained for several weeks under the care of Dr. Otho I. Smith, of Boonesboro', who, it appears, watched the case with great care. For three weeks, patient had constant diarrhoea and nausea; during this time he was nursed by his mother, whose intelligent interest never relaxed day or night, during the whole time; to her I am indebted for an account of the case subsequent to my personal attendance. His diet consisted of a gill of skimmed milk and three draclms of brandy, administered by his mother; the dressings were changed every five minutes for the first two weeks. On the eleventh day, a honey bee, supposed to have been swallowed with the water drank shortly after the receipt of injury, was discharged from the wound of entrance. He had no passage from the bowels by the anus until the latter part of November, although injections were used daily for several weeks. During the closing of the abdominal wounds (the wound of exit healed first) he had convulsive attacks, caused by the accumulation of gas in the intestines; these symptoms persisted for several days, and were relieved by the constant use of chloroform by inhalation. His recovery was considered doubtful for several weeks. When he was taken to his home in Sandusky, Ohio, about the middle of December, the wound of entrance was the size of a shilling; it did not close entirely until the lapse of six months. Owing to the loss of nervous power in the left leg, he was



compelled to use crutches for a long time. The whole left side likewise partook of this loss of power. His health is now, May, 1865, good, but he is compelled to carefully reject unsuitable articles of food, owing to a disposition to the accumulation of gas in the bowels." In a report of the case by Surgeon T. Woodbridge, U. S. V., of the depot for prisoners of war near Sandusky, Ohio, it is stated: "When he came here he was improving, but the contents of his bowels still passed by the anterior wound, but in diminished quantity, and soon ceased altogether, since which time he has rapidly improved and is now in the enjoyment of perfect health." He was discharged the service December 20, 1852. Pension Examiner A. H. Agaril, of Sandusky, reports, on papers received at Pension Office, December 28, 1863, "a rifle ball entered the left iliac region, opened the ascending colon, and passed out at the back. He has had an artificial anus resulting from the wound until quite recently, and now, 1863, suffers from every motion of the bowels. Appearances now are that he may get a more or less complete recovery in the future. Disability total, perhaps temporary." No later report on file in the Pension Office, save that this pensioner was paid to September 4, 1872.

CASE 240.—Corporal George O. Hannaford, Co. I, 1st Maine Cavalry, aged 23 years, was wounded at Deep Bottom, August 16, 1864. He was taken to the field hospital of the Cavalry Corps, where Surgeon S. B. W. Mitchell, 8th Pennsylvania Cavalry, and Assistant Surgeon E. J. Marsh, U. S. A., record the case as a penetrating wound of the abdomen by a conoidal musket ball, but give no particulars of the symptoms or treatment. On the 17th, the wounded man was sent on a hospital transport to Philadelphia, and was admitted on August 20th, into ward C, at Satterlee Hospital, under the care of Acting Assistant Surgeon James Hutchinson. On the 20th, the injury is recorded on the case-book as confined to the muscular walls. On the following day, Dr. Hutchinson makes the entry: "The wound is more serious than I at first supposed, as the ascending colon is opened. The patient has passed pieces of peach-skin, as well as fecal matter, through the wound. The general symptoms continue favorable." On September 5th, the record continues: "The external wound is in a healthy condition; the constitution of the patient is good and temperament cheerful and calm. The stercoraceous discharge is so copious that it is determined to close the anterior orifice by a plastic operation. The lower bowel being emptied by enemata, the edges of the anterior preternatural orifice were pared and approximated by twisted sutures. Opium was given to control the peristaltic action of the intestine. September 6th, condition satisfactory; feces still escaping through the posterior wound. No constitutional symptoms on the 7th. On the 9th, no escape of feces from the orifice in the flank, which was purposely left open. As the hare-lip pins were not causing much irritation they were left in place." When the sutures were removed is not stated. On "September 20th, a little fecal matter escaped. On September 22d, a severe attack of colic occurred. On the 23d, feces escaped freely from both openings." \* \* \* October 17th, wounds discharging laudable pus; improving very fast, appetite good, dysuria. October 18th, hematuria. October 21st to November 19th, when the patient was removed to ward B, the entry "improving" recurs uninterruptedly. The patient was furloughed January 26, 1865, and returned to the hospital May 4, 1865. On May 18, 1865, he was transferred to Coney Hospital, Augusta, Maine, under charge of Surgeon George Derby, U. S. V., who forwarded the photograph from which the wood-cut (FIG. 55) is copied, and states, June 12, 1865, that the "ball entered one inch below umbilicus and came out one inch and a half above the anterior superior spinous process of the right ilium. There has been fecal discharge from both openings at different times. The opening below the umbilicus was closed by an operation at the Satterlee Hospital. A drawing was made, he tells me, by the surgeon in charge. The other opening healed spontaneously. It is evident that the colon was opened by the ball, and probably in two places. This man is now well; the covering of the wound below the umbilicus is very thin and the passage of the contents of the intestine can be distinctly felt by the finger placed over it." Pension Examiner J. P. A. Smith reports, August 18, 1865, "the ball entered one inch below and to the right of the umbilicus, passing through the intestines, coming out just over and through the ileo-caecal valve. The wound causes such a weakness of the bowels and lungs that the pensioner is not able to do anything that requires activity. Disability total and permanent." In September, 1872, his condition was reported to be unchanged.

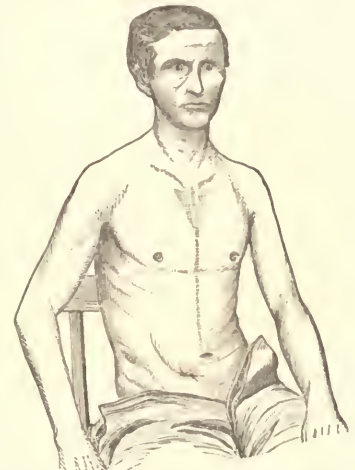

FIG. 55.—Cicatrices in a case of recovery from a shot wound interesting the transverse colon. [From a photograph.]

CASE 241.—Private Patrick Powers, Co. K, 12th Connecticut, aged 30 years, received a wound of the left side of the abdomen at Winchester, September 19, 1864. He was conveyed to the hospital of the 1st division, Nineteenth Corps, under the charge of Assistant Surgeon John Homans, jr., U. S. A., who recorded the injury as a "gunshot wound of the left side, severe." On the 23d, he was transferred to the depot field hospital of the Nineteenth Corps, where Surgeon L. P. Wagner, 11th New York, in charge, registered the case as a "gunshot wound of the left lung." Simple dressings to the wound, and anodynes and stimulants internally, constituted the treatment. On September 30th, he was transferred to the Sheridan Hospital, on December 29th to the Base Hospital, and on January 2, 1865, to the hospital at Frederick, under the charge of Assistant Surgeon R. F. Weir, U. S. A. The register of this hospital furnishes the following memorandum history: "Gunshot penetrating wound of the abdomen, involving the large intestine. January 2, 1865, wounds closed. The patient states that for three or four days after being wounded he vomited fecal matter; peritonitis set in, which lasted until one week prior to admission. February 6th, the wounds are healed, but the patient still suffers from some pain at the seat of the wound and over the course of the sciatic nerve. February 25th, walks on crutches; general health good." On the latter date he was transferred to New Haven, and, on March 1st, admitted into Knight Hospital. Surgeon P. A. Jewett, U. S. V., reports that Powers was discharged from service June 20, 1865, on account of a wound of the right side of the abdomen, perforating the intestine. Pension Examiner H. L. W. Burritt, of Bridgeport, Connecticut, reports, March 12, 1866: "The ball entered the bowels two inches to the left of the umbilicus, passed through the ilium, and came out two inches behind the crest of the ilium. The bowels were evidently injured, and bad adhesions still exist. Motion is painful; capacity for labor not one-fourth of a day. Disability, three-fourths, for life." He was last paid to include December 4, 1872.



CASE 242.—Captain J. F. Charlesworth, Co. A, 25th Ohio, was wounded at Cross Keys, Virginia, June 8, 1862. Pension Examining Surgeon A. H. Hewetson, St. Clairsville, Ohio, reports, April 19, 1866, as follows: "The ball entered a little over two inches to the left of the umbilicus, passing through his sword belt, his clothing, and entirely through his abdomen, making its exit a short distance to left of the spine, a little below the brim of the pelvis, and fell down between his blouse and vest. The missile fractured the ilium, without, at that time, displacing any portion of it. The wounded officer's sensations were described as resembling those on the reception of an electric shock. In a few moments, he experienced severe cramp in his bowels, which continued for some hours. He very soon became insensible, and in this condition was carried off the field. The next day the army retreated, and the captain was carried on a stretcher back to Mount Jackson, a distance of about thirty miles. After a few



FIG. 56.—Cicatrices after a shot perforation of the colon. [From a photograph.]

days' rest, he was taken to Winchester in an ambulance. During all this period, no treatment was instituted by any of the surgeons, except to give opium. When he arrived at Winchester, his condition must have been almost desperate. He was nearly pulseless, his feet and limbs cold, and a clammy sweat covering his body. These symptoms, together with the true hippocratic countenance, led all who saw him to suppose death would soon put an end to his sufferings. Such was the opinion of all the surgeons seeing him at that time. After a few days' rest, he was removed to Wheeling, and from there to his home in St. Clairsville. For twelve days after receiving his wound, he had no nourishment, excepting milk, and could take but very small quantities of that. In an hour or two after the reception of the injury, the contents of the bowels began to discharge through both wounds. After this, fecal matter continued to discharge from the wound of exit until it was almost healed. There was no fecal discharge from the wound of entrance after the first few days; but frequently gas would be forced from it with such force as to make an audible noise. The fractured ilium, as soon as suppuration had fairly begun, made itself known by the fractured portions becoming loosened. Before this occurred, none of the surgeons were aware of the presence of this lesion. During the healing process, quite a large number of spiculae of bone were discharged—about fifteen in all. One of these measured one and one-half inches in length and three-eighths of an inch in width. They were rough and uneven, and caused a considerable amount of trouble in passing from the wound, or in being removed, as some of the largest had to be. I have not the dates showing the exact time occupied in getting over the injury, but it was several months before the patient could get about. He was discharged from service May 13, 1863. The recovery even yet is not

perfect. This officer is still subject to pain, and a weak feeling continues to exist about the abdomen. If careful of himself in every way, avoiding all manual labor, he can get along pretty well; but the least imprudence and overexertion causes him great suffering. The constitutional symptoms were at no time severe. There was slight tenderness over the bowels, no thirst, and but slight fever." He was last paid to include December 4, 1872. The scars are represented in the wood-cut (FIG. 56).

CASE 243.—Sergeant Louis Morell, Co. D, 119th New York, aged 19 years, on the afternoon of July 1, 1863, in the assault on the lines of the Eleventh Corps, received two wounds, and, falling, and remaining on the field between two fires, a third wound. The first wound was from a small ball, which lodged in the globe of the left eye; the second was inflicted an instant afterward by a musket-ball, which entered four inches to the right of the umbilicus, passed directly through the body, and emerged near the right sacro-iliac synchondrosis, having grooved the crest of the innominatum. The sergeant was then in the act of reloading, the right arm elevated to use the ramrod. He recollected seeing his cartridge-box torn by the missile, and the next instant fell unconscious. He dimly recalls a temporary return of consciousness, on being struck soon afterward in the left thigh, by a musket-ball, which passed through the quadriceps extensor, a little above the patella. He remained on the field until the morning of July 4th, without suffering from hunger or thirst. He had an indistinct impression that some one had given him water and had washed the wounds on his head and thigh; the wound in the flank appeared to have escaped notice. On July 4th, he was placed in an ambulance wagon and carried to a neighboring farm house, suffering great torture in the long ride. Arrived at the farm house, his wounds were dressed by a Confederate surgeon on duty there, and he drank a little gruel, portions of which escaped by the posterior wound almost as fast as it was swallowed. The sergeant is positive that, on this and subsequent occasions, an interval of not more than half an hour elapsed between the ingestion of liquids and their escape by the posterior wound. The appearance of the clothing indicated that there had been copious hæmorrhage. Beyond this, the sergeant says, his recollections are very confused and indefinite. Probably he was under the influence of opiates. On July 8th, he was taken to the Eleventh Corps field hospital, suffering again acutely in moving. No record appears here. On August 6th, the patient was again moved to the Camp Letterman Hospital, and was under the immediate charge of Acting Assistant Surgeon James A. Newcombe, in the division in charge of Acting Assistant Surgeon A. B. Stonelake. The case is here registered as "a penetrating shot wound of the abdomen, loss of left eye, knee contracted." There had been a fecal discharge from the posterior wound, but it ceased about July 12th. Getting drenched with rain one night at the field hospital, the wound near the left knee became very painful, and the limb was semi-flexed and could not be again extended. At Camp Letterman, the discharges from the abdominal wounds were purulent. On October 30th, Dr. Stonelake enlarged the posterior wound and removed a considerable fragment of wing of the ilium, perforated by the ball. On October 31st, the wounded man was sent, under care of Acting Assistant Surgeon Newcombe, to New York, and entered Ladies' Home Hospital. At that time he had no fever and suffered very little pain; his bowels were uniformly regular and his health quite good. The anterior wound had healed, but the posterior wound was still open. After the journey to New York there were slight discharges of fecal matter, at long intervals, by the posterior wound. In February, 1864, the patient began to leave his bed, and then the stercoral discharge from the

LIBRARY  
UNIVERSITY OF  
CALIFORNIA.





Ward phot.

H. Mitchell  
THE SINGER & SON, N.Y.

PLATE V. CICATRICES AFTER SHOT PERFORATIONS OF THE ABDOMEN

Fig. 1. Hospital Steward L. Morrell

Fig. 2. Hospital Steward G. Corson.



fistulous opening became more copious. In May, Morell moved about on crutches. The flesh wound in the thigh had nearly healed; but a succession of abscesses had formed, and there was much contraction about the joint. In December, 1864, the hamstring tendons were divided by Surgeon A. B. Mott, U. S. V., and the limb was extended and placed in a useful position. While the patient was confined to his bed, after this operation, the stercoral fistula closed. May 30, 1855, the patient, on the closure of Ladies' Home Hospital, was sent to MacDougal Hospital, at Fort Schnyder. The fecal fistula reopened in June, but soon closed again. On August 18th, Morell was discharged from service and pensioned.<sup>1</sup> Assistant Surgeon Samuel H. Orton, U. S. A., signed the certificate of disability, referring to the shot wounds through the abdomen and left thigh, and the loss of the left eye. July 28, 1866, Pension Examiner A. L. Lowell reports that the exit wound was still open and discharging, and that exfoliations from the ilium still continued. The fistula again closed, and, on May 11, 1867, Morell re-entered the service as a hospital steward, and was assigned to clerical duty in the Division of Surgical Records, of the Surgeon General's Office, where he is still employed. A photograph, showing the cicatrices of entrance and exit, was made at the Museum in March, 1873, and is accurately copied in the left hand or sitting figure in PLATE V.

CASE 244.—Private *J. G. Martin*, Co. K, 19th Virginia Regiment, aged 22 years, was admitted to general hospital, Frederick, September 22, 1862. Acting Assistant Surgeon A. R. Gray makes the following report of the case: "He was wounded at South Mountain, September 14, 1862, by a conical rifle ball, which entered the right natis four inches posterior to, and three inches above, the great trochanter, perforated the ilium, passed upward and inward, emerging through the wall of abdomen one and a half inches above the superior spinous process of the ilium. Upon admission, fecal matter was discharging from wound of exit, and other signs plainly indicated that the lower portion of the ascending colon was injured. Symptoms of peritonitis developed soon after admission, and were combated by large doses of opium; simple dressings were applied to the wounds. For four weeks after the reception of the injury the external wound of exit discharged fecal matter. At this time, the wound of exit had greatly contracted, and the evacuations took place partly through the regular channels. The constitutional and local symptoms of hospital gangrene began to appear, at this time, at the wound of entrance—the edges were indurated and everted, and the surrounding skin was undermined. The patient was then removed to the gangrene tent, and the wound was cauterized with nitric acid. Nevertheless the ulcer increased rapidly in size for several days, and fears were entertained, at one time, that sloughing would involve the intestine; but by repeated and persevering applications of nitric acid, and careful cleaning of the wound several times daily, together with tonic treatment and generous diet, the morbid action was arrested, three weeks after its first appearance. During this time, however, the copious discharge of fecal matter through the wound of exit returned. Attempts were made to close the opening by means of adhesive plasters, with only partial success. After the arrest of the hospital gangrene, both wounds cicatrized kindly; from the lower one fragments of bone, probably portions of the laminated structure of the ilium, were removed. Suppuration was very free and the pus very offensive. Early in the month of February, both wounds again assumed an unhealthy character; the soft parts in immediate connection with the wound of exit became sloughy, discharging fetid, grumous matter, mingled with the discharge from the bowel; the bowel could be plainly seen and felt in the wound, presenting a healthy appearance. On October 12th, hæmorrhage occurred from the upper wound, the patient losing, at the time, about twelve ounces of blood. A free incision of the soft parts was made through the entire abdominal wall, into which cold water was injected and a large fusiform clot of blood removed. At the bottom of the cavity thus exposed no bleeding vessel could be seen or felt, and the source of the hæmorrhage could not be found. The wound was exposed freely to the air, syringed frequently with cold water, and left open for the night. At six o'clock the next morning the cavity of the wound was filled with fecal matter, but the hæmorrhage had not returned. The wound was cleansed and filled with oakum saturated with solution of chlorinated soda, one ounce to one pint of water. Tonic remedies, with generous diet and stimulants, principally porter and ale, constituted the course of treatment pursued; both wounds again assumed a healthy granulating appearance; a plug of lint was kept constantly inserted in the upper one, and hopes were entertained that it might granulate from the bottom, thus preventing the discharge of fecal matter; his general condition improved gradually, and he was able to walk about the ward; the lower wound had nearly healed. All attempts at curing the artificial anus by ordinary means proved futile, and the patient, at his own urgent request, was transferred to Baltimore early in September, 1863, for exchange." On September 25th, the patient was transferred to City Point for exchange, and, on September 28th, was sent to Chimborazo Hospital, Richmond. The case-book of that hospital contains the following information respecting this case: "Fæcal matter escaped from both wounds; did well, and, in five weeks, able to walk about. November 15, 1862, sloughing of exit wound quickly arrested, and, by December 1st, wound nearly healed, when erysipelas supervened. During January, 1863, slight improvement; confined to bed with troublesome cough. In February, 1863, slight hæmorrhage from anterior wound. In March, severe attack of pleuro-pneumonia; during April, general health improved; wounds healthy; fecal matter only escapes from anterior wound, and this with intermissions of sometimes two or three weeks. September 28th, 1863, fecal matter still escapes from anterior wound; injection by posterior wound escapes by anterior wound; constipation." On October 6, 1863, he was furloughed for sixty days. No further information has been obtained.

CASE 245.—Lieutenant *J. P. Breedlove*, Co. B, 4th Alabama, aged 23 years, was wounded in the right iliac region, at Gettysburg, July 3, 1863. He was removed to the Seminary Hospital, and, on the 10th, to the 1st division hospital at Camp Letterman. Dr. T. A. Means, a Confederate surgeon, attending prisoners at Camp Letterman, makes the following minute on the medical descriptive list: "A minie ball entered two inches above Poupart's ligament, ranged downward and backward, and made its exit on the right side, posteriorly, near the crest of the ilium, causing an artificial anus. I saw the patient for the first time August 21st, and found the discharge from the external opening fetid and intimately mixed with fecal matter. The ingesta passed through the natural channel every four days without artificial agencies. Simple dressings were applied to the wound and low diet ordered. August 29th: There is a noticeable lessening of the aperture; the discharge from the anus is more frequent—that from the external wound is gradually diminishing. September 1st to 14th: Full diet ordered; patient doing well. October 13th: The patient was up and exercising to-day for the first time. 14th: Gradual improvement, and closure

<sup>1</sup> Notes of this case have been printed in the *American Medical Times*, 1861, Vol. VIII, pp. 13, 301, and by Dr. F. H. HAMILTON (*Treatise on Military Surg.*, p. 350).

of the external opening. 21st: The discharge of feces still continues from the anterior wound; patient's general health excellent." On November 9th, he was transferred to West's Buildings Hospital, Baltimore, at which time the stercoraceous discharge from the anterior opening had nearly ceased. The records of the latter hospital do not furnish any additional particulars of the case, further than that the patient was transferred to Fort McHenry, March 2, 1864, for exchange or parole.

CASE 246.—Private W. Wease, Co. H, 10th West Virginia, aged 20 years, was wounded by a musket ball in the abdomen, at Droop Mountain, Pocahontas County, November 6, 1863. Surgeon G. C. Gaus, 10th West Virginia, reports that six of the wounded were left at the field hospital in a section of country held by the enemy. On December 17th, these and other wounded men were brought to the post hospital at Beverly, by Surgeon C. E. Denig, 28th Ohio, who reports the case of Wease as a "wound of the large intestine, with fecal fistula." He states that the ball did not lodge. In an appended memorandum, he refers to the progress of the case to April 16, 1864, remarking that the fistulous opening had then healed, and that the patient walked slowly about, and had nearly recovered. August 19, 1864, Surgeon M. J. Borland, 8th Ohio Cavalry, relieving Surgeon A. H. Thayer, 6th West Virginia Cavalry, reports that he found no hospital records on file there. January 11, 1865, the post of Beverly was captured by General Rosser, and all official records there were reported to have been destroyed. Hence it has been impossible to glean any fuller details of the case of Wease. The explicit and careful statement of Surgeon C. E. Denig supplies the essential facts. Examining Surgeon Thomas Kennedy, of Grafton, West Virginia, reports, January 9, 1872, that the "ball entered the right side of the abdomen, between the umbilicus and upper crest of the ilium, four inches from the umbilicus, and came out between the ilium and the spine, four inches from the spine, passing through the large intestine and upper part of the ilium. The contents of the bowels passed out of the posterior wound for some months, and portions of bone were also eliminated. The cicatrices of entrance and exit were depressed and about an inch in diameter. The abdominal muscles around the anterior cicatrix were contracted. Locomotion was difficult, and the physical disability total and temporary. Weight, 135 pounds; age, 30 years; pulse, 63; respiration, 18." In short, this pensioner appears to enjoy tolerable health.

CASE 247.—Private Frank Saville, Co. I, 2d Delaware, aged 21 years, was wounded at Gettysburg, July 2, 1863, by a conical ball. He was admitted to Seminary Hospital from the field, and subsequently transferred to Wilmington, where he entered the Tilton Hospital, July 10th; he was furloughed on April 25, 1864, and returned May 5th, and, on the 10th, was transferred to Summit House Hospital, Philadelphia. On August 18th, he was transferred to Satterlee Hospital, and Surgeon Isaac J. Hayes, U. S. V., in charge, reports: "Ball entered one inch from umbilicus, left side, and passed out near crest of ilium; feces passed from wound of exit for about three months; when admitted here, both wounds were entirely closed and the general health of the patient good." On August 20th, he was detailed as nurse in the ward, and on November 1st was transferred to Wilmington, where he was admitted to Tilton Hospital. The wounds were healed at the time of his admission, and, on November 7th, he was furloughed, and was discharged the service December 19, 1864, on account of "gunshot wound of abdomen injuring intestines and causing artificial anus." Pension Examiner William Corson, of Norristown, reported, November 27, 1869: "Ball entered abdomen four inches from umbilicus, right side, passed out at crest of ilium, posteriorly—wound of colon—fecal matter passed from wounds for two months—tending to diarrhoea without control. Fatigue and pain from exertion or standing. Disability three-fourths, mainly permanent."

CASE 248.—Private J. Labar, Co. E, 28th Pennsylvania, was accidentally wounded by the discharge of the musket of a falling comrade, at Leesburg, March 12, 1862. He was taken to the regimental hospital on the same day, and, on May 22d, was transferred to hospital No. 1, Frederick; thence, on June 3d, to Harrisburg, to hospital at Camp Curtin, where the injury is recorded as a "gunshot wound of the right side, the ball passing through the liver." There is no further hospital record of the case, save that the patient was discharged from service September 29, 1862, and pensioned. Pension Examining Surgeon E. Swift, of Easton, Pennsylvania, reports, August 24, 1866: "Ball entered the right side, six inches from the spine, and three inches above the spine of the ilium, and passed out one and a half inches to the right of the linea alba, and two inches below the end of the sternum. The ball passed through a portion of the liver, lung, and intestine—colon, probably. The anterior orifice is closed; fecal matter was discharged from the wound, which discharge still continues in diminished quantity. His general health has improved, and he can now walk out, or even ride a few miles; still he is very feeble, and utterly unable to do any kind of work, and with little prospect of ever being much better; disability total and permanent." In June, 1866, his pension was increased from eight to twenty dollars a month. He died June 12, 1867. There is no record of an autopsy.

CASE 249.—Private Michael Hickey, 1st Maine Battery, aged 18 years, was wounded at Cedar Creek, October 19, 1864, by a conoidal ball. He was received into the division field hospital on the same day, and on October 21st was admitted to the Nineteenth Corps hospital, at Winchester, where the case was diagnosed as "gunshot wound of the back." He remained in this hospital until December 5th, but the records furnish no evidence of the symptoms or treatment at that time. He was next transferred to Frederick, doing well. The case is thus described: "Gunshot perforating wound of the intestines on the right side, ball entering over fourth lumbar vertebra, passed through the abdominal cavity, wounding the intestines, and emerging one and a half inches above the crest of the right ilium." Assistant Surgeon R. F. Weir, U. S. A., in charge, says: "Patient states that the contents of the bowels came out through the wound in the back for two days, and through that in the side for twenty-five days, after the injury." On March 22, 1865, the patient was transferred to Augusta, and, on the 25th, to Coney Hospital, and was discharged the service June 22, 1865. Pension Examiner Josiah F. Day reported, September 12, 1867: "For about three weeks he had fecal discharges from the wounds of entrance and exit. In six months the wound was entirely healed. About three months ago, at the point of exit, there was discharged a small quantity of pus for three or four days; since that time it has remained well; general health good; he works in a cotton-mill and attends four looms, and has done so for eight months, during which time he has lost one-half of the time. Disability three-fourths."

CASE 250.—Private J. L. McLane, Co. B, 76th New York, aged 24 years, was wounded at Gettysburg, July 2, 1863, by a conoidal ball. He was admitted to the Seminary Hospital on the following day with "gunshot wounds of hip and bowels," and, on July 28th, was admitted to Camp Letterman Hospital, where Acting Assistant Surgeon H. Seaman reported as follows: "Wounded by a minie ball, entering the right groin and making its exit through the buttocks, four inches behind and a little above the level of the trochanter major. He suffered from the passage of feces through the wound of exit for fifteen days; since



that he has not had any unpleasant symptoms. When I took the case, August 15th, the wounds were nearly healed; the general health excellent; at present, August 20th, the wounds are closed. August 21st, furloughed for twenty days." He was discharged the service October 11, 1864. Pension Examiner G. W. Avery, of Norwich, New York, reported, March 9, 1839: "A musket ball entered the left buttock, passing through its centre, lacerating the gluteus maximus; also, a buckshot entered the left groin, where it still remains; disability probably permanent." Pension last paid February, 1873.

CASE 251.—Corporal Simon J. Fought, Co. D, 46th Ohio, aged 25 years, was admitted to the General Hospital at Mound City on July 25th, from Haynes's Bluff, and Surgeon H. Gardner, U. S. V., reports as follows on the hospital case-book: "Was wounded in a skirmish at Black River, Mississippi, on July 5, 1863, by a rifle ball striking the anterior wall of the abdomen, in a line between the anterior superior processes of the ilii, and about half an inch from the angle of the right ilium, and emerging about one and a half inches from the angle of the left ilium; the wound was dressed with simple dressings, cold water, poultices, etc. About two weeks after the wound was received, the contents of the bowels commenced passing out at the point of the entrance of the ball; this continued for some ten days, when it entirely ceased; wound discharging freely, and the discharge very healthy in color and consistence; patient's spirits good; appetite good; general health excellent. August 10th, wound discharging more than for some days; discharge not healthy, having the odor of feces; patient attributes the change to sitting up too long; wound discharges more while the patient is eating than at other times; general health good. August 13th, wound doing well; some feces passed out this morning; since then the discharge has been healthy. August 14th, patient feeling well; wounds doing well; the wound at point of entrance discharging more than at point of exit; granulation going on finely; appetite good. August 15th, wounds granulating finely; in every way a steady and visible improvement. August 16th, patient feels well; the discharge this morning was mixed with the food he ate for supper last evening almost unchanged (he ate mush); the wound granulating around the borders finely. August 17th, the patient has been sitting up for a while to-day; is in the best of spirits; appetite good. August 18th, patient says his bowels have been costive to-day, and that some feces passed through the wound; otherwise, same as yesterday. 19th, wound looks well, discharge clear; bowels loose; appetite good; his bowels have to be kept lax in order to allow them to act without irritating the wound; it having been noticed that whenever he becomes costive a portion of the fecal matter passes out through the wounds. 20th, wounds doing well, patient able to sit up; discharge light; health good; granulation going on finely. 21st, patient walked a little more than usual to-day; discharge a little mixed with fecal matter. 22d, wound doing well; still walking around; discharge perfectly healthy. 23d, he is walking around more and more every day; wounds rapidly healing; discharge healthy, and the patient in the finest spirits. 24th, doing well; discharge not so great, and unmixed; able to sit up most of the day. 25th, discharge this morning healthy, but at noon was thin, watery, and mixed with a small portion of fluid feces; health good; treatment, cerate dressings. 27th, some unhealthy granulations; when the patient eats heartily it is found that the discharge from the wound is mixed with fecal matter; treatment, cerate dressings; caustic to unhealthy granulation, and patient forbidden to indulge his appetite to excess. 29th, doing well; wounds healthy; discharge at noon almost always mixed with feces. August 30th and 31st, much the same. September 11th, doing tolerably well; some fecal matter comes out at the wound of entrance; discharge light, thin, and watery; health good; appetite good; wound of exit almost healed. For the next four days he was much the same. 16th, wound discharging considerably, discharge thin and mixed; had diarrhoea yesterday, but has had no passage to-day. 19th, discharge mixed with a small quantity of fecal matter. 20th, patient affected with diarrhoea. 22d, some fecal discharge. October 1st and 2d, wound looking tolerably well, discharging some in the afternoon, but none in the forenoon. 3d and 4th, wound still looking well, but discharging some fecal matter; discharge of pus small; treatment, cerate and adhesive strips. 5th, patient affected with diarrhoea, which caused more fecal matter to pass through the wound. 9th, wound of exit entirely closed; that of entrance discharging considerably; no fecal matter as long as patient lies quietly. On the 17th, the wound was still contracting; the patient was affected with violent headache and fever, and, on the 21st, the wound of exit again opened, and from this time until October 29th, the wound had gradually healed and was then again closed. November 4th, discharge thin and watery and colored by fecal discharge; general health good; treatment, cerate and plasters. November 7th, much the same as at last report; discharged from service to-day, and started for his home in Columbus, Ohio." At the time of discharge his general health was good, but the wound of right side had not healed. On September 21, 1867, Pension Examiner E. B. Fullerton, of Columbus, reports: "Evident adhesions of bowel to abdominal walls, the sense of weakness being so great that sleep is only obtained by lying on the back or face; has great difficulty in digesting; at times, accumulations just above wound, amounting to partial obstruction of bowels; in walking, and during digestion, he keeps his hand constantly on the wound as a support; he is liable to have the trouble renewed by any fall or sudden movement; disability permanent, and equivalent to the loss of a limb." On July 3, 1868, Pension Examiner A. L. Lovell, of Columbus, reports: "Ball entered abdominal parietes in right inguinal region, and at that point opened the peritoneum and ascending colon, causing a fecal fistula; it then traversed the muscles of the hypogastric region and emerged from the left inguinal region. The fistula is now entirely and permanently healed; the muscles divided by the ball have become partially restored in efficiency, and a healthy cicatrix, extending across the abdominal walls, shows that permanent reparation has taken place; he is a strong, healthy man, and physical signs demonstrate no grave intra-abdominal lesion." An Examining Board of Surgeons, Drs. S. Smith and E. Fullerton, of Columbus, reported, March 1, 1871: "Ball struck the abdomen on the right lower side, just above the groin, passing across through the abdominal cavity, and out on left side; passed fecal matter through the openings for five or six months; both now closed, but evidences of contraction of the gut and adhesions to the abdominal walls and of partial obstruction remain, and mechanical means are necessary sometimes to press forward the contents of the bowels. The great danger in this case is from the permanent obstruction of the bowels and the laceration of the walls. If dependent on manual labor, he would, in our opinion, be in constant danger of fatal injury." Fought was last paid to include December 4, 1872.

CASE 252.—Private H. P. Dugan, Co. I, 121st Pennsylvania, aged 26 years, was wounded at Gettysburg, July 3, 1863, by a conoidal ball, which entered one inch below the crest of the right ilium. He was taken to the field hospital, where the missile was removed through a counter-opening two inches posterior to the point of entrance; simple dressings were applied to the wound. On July 22d, he was transferred to the Chesnut Street Hospital, Harrisburg. Here the fracture of the right ilium



was noted by the ward surgeon, who also states that "since the day he was wounded some fecal matter has escaped with the discharge of pus through the wound. Water dressings and nourishing diet. August 12th, general health improving; fecal discharge much less. August 20th, general health good. Small pieces of necrosed bone have been removed through the opening; there is still a very slight discharge of fecal matter." On September 16th, he was transferred to South Street Hospital, Philadelphia, and placed in Ward I, under the charge of Acting Assistant Surgeon Know, who states that "since his admission the wound has been dressed simply. The external opening communicates with the colon, and wind and feces make their exit through the fistulous opening. On September 20th, he complained of great pain in the lower right side of the pelvis, which was relieved by enemata and the application of warm cloths externally. This trouble occurred again on the 23d, but disappeared under the same treatment." On July 7, 1864, he was transferred to Beverly, New Jersey, at which time the fistulous opening still remained. At Beverly he was reported as "convalescent," and was returned to duty February 21, 1865; but, on the 27th, was admitted into the 2d division hospital at Alexandria, was transferred on May 21st to McClellan Hospital, Philadelphia, and was discharged from service July 8, 1865. Pension Examiner John Neill reports, July 16, 1868, that "the entrance wound is depressed and discharging, with evidence of necrosed bone. The ilium was comminuted, and numerous small pieces of bone have escaped. There is probably more to be discharged. The man is ruddy and in perfect health, and can pursue his trade except when a fresh suppuration takes place. He has entire use of all of his limbs." The Pension Examining Board at Philadelphia reports, March 23, 1870, that the inconvenience and disgusting nature of the disability has not improved, and debars him from obtaining employment, and recommends him for an increase of pension, which was granted. He was last paid on December 4, 1872.

CASE 253.—Corporal C. F. Ballou, Co. I, 44th New York, aged 23 years, was wounded at Gettysburg, July 2, 1863, by a conoidal ball. He was admitted to the Seminary Hospital on the 4th, and, on the 17th, was transferred to the Cotton Factory Hospital, at Harrisburg. Acting Assistant Surgeon L. Post, who had charge of the case, made the following report: "Ball entered the right thigh two inches below Poupart's ligament, and a fragment of ball was taken out near the crest of the ilium. A fragment of the same is supposed to have entered the bowels from the same source. For several days there has been a fistulous opening, and from it gas and thin excrement has passed; there is some soreness in the right side. The discharge of pus from the wound has been excessive; pus has also been discharged from the bowels. To-day, August 15th, the wound appears better. A light, generous diet is allowed; appetite good; pulse soft and natural; the wound has been dressed twice each day, and the symptoms are evidently much improved. August 24th, continues to improve; fistulous opening gradually closing. September 16th: patient is considered to be doing well, and is able to walk out." On December 25, 1863, he was discharged the service. The records of the Pension Office show the following report of the case by W. L. Wood, Acting Assistant Surgeon in charge of hospital at Harrisburg: "Ball entering the pelvis, producing vesical fistula." Pension Examiner C. S. Hurlbut, of Orlean, New York, reported, November 12, 1866: "Ball entered the left leg or thigh, near the hip, passing along the ala of left hip and emerging near the dorsal vertebrae; disability three-fourths." Paid to December 4, 1872.

CASE 254.—Private *Alex. Day*, Lee Battery, Braxton's Artillery, aged 23 years, was wounded at Winchester, September 19, 1864, by a conoidal ball. He was admitted to the depot field hospital for prisoners of war at Winchester on the same day, and Surgeon L. P. Wagner, 114th New York, reported as follows: "Gunshot wound of abdomen, penetrating the large intestine; feces passed through both orifices during four weeks from date of wound." The treatment consisted of applications of simple dressings, and the administration of anodynes. December 10th, the patient was transferred, convalescent, to West's Buildings Hospital, Baltimore, and the case reported as "gunshot wound of right side of abdomen, striking the ilium." On January 5, 1865, he was transferred to Fort McHenry for exchange.

CASE 255.—Private Robert Brierly, Co. A, 1st Delaware, aged 22 years, was wounded, at the battle of Antietam, by a conoidal musket ball, which entered a little to the left of the umbilicus, and lodged under the muscles near the anterior superior spinous process of the right ilium. There was great prostration, with nausea and vomiting, which were treated at the field hospital by the administration of opiates. Three weeks subsequently, the patient was transferred to Frederick, Maryland, under the care of Acting Assistant Surgeon A. V. Cherbonnier, who has furnished a detailed clinical history of the case (*Bd. MSS., Div. Surg. Rec., S. G. O., 33*): "On October 25th, feces escaped through the lower wound, which had been for several days in a sloughing state. The artificial anus continued open until November 15th. On November 25th and December 11th, there were attacks of colic, followed by reopening of the fecal fistula. By the end of December, the wounds appeared sound and permanently healed, and the patient was transferred to Baltimore, and was discharged the service December 31, 1862." His name does not appear on the Pension Roll. [See Circular 6, S. G. O., 1865, p. 26.]

CASE 256.—Surgeon Edward Batwell, 14th Michigan, reports that "Sergeant William Vannalta, Co. K, 14th Michigan, was shot through the bowels, at Lavergne, Tennessee, October 7, 1862. The ball entered at a point about equidistant from the anterior superior spinous process of the ilium, the umbilicus, and the symphysis pubis. I did not attempt to trace its course. When first seen, he lay upon his back, his legs drawn up, his countenance anxious and pale; a cold clammy perspiration covered his face and limbs; pulse 90, small and weak. Stimulants were carefully administered, and, toward evening, reaction had set in to a considerable extent, accompanied by some pain and tenderness over the right side of the abdomen. A grain each of calomel and opium were ordered every third hour, and tepid-water dressings were applied to the wound. October 8th, on removing the dressings, the wounded intestine was seen lying at the bottom of the wound, and a discharge of feces occurred on the slightest movement. The idea of an artificial anus suggested itself as affording the best or only chance of saving his life, and, with this object in view, the intestine was seized and held to the abdominal parietes with four serres-fines. Two grains of opium were administered every third hour, and cold-water applications made. In the evening, the abdominal tenderness had lessened; about two pints of straw-colored urine were drawn off with the catheter. October 9th, the wound looked healthy, and, toward evening, a warm-water enema was given for the removal of any accumulated feces in the lower bowels; the opium was still continued to semi-narcotism. The abdominal tenderness decreased, although some tympanitis was present. Pulse 75 to 80, and rather hard. October 10th, stercoraceous matter escaped freely from the wound; the surfaces were cleansed thoroughly,

and, in the evening, the serres-fines were removed. The formation of an artificial anus was then abandoned for the more desirable objects of endeavoring to close the intestinal aperture (which was now firmly adherent to the surrounding edges of the wound), and to make the bowel permeable. October 11th, the edges of the wound were drawn together with adhesive straps; the dose of opium was increased to three grains every fourth hour; the patient felt very comfortable. On October 15th, the dressings were removed; there was no appearance of fecal discharge, and the tympanitis had entirely disappeared. On the 17th, a large dose of castor oil was given, which operated thoroughly four times without pain or trouble to the patient. On October 21st, he was able to go out of doors, but the pain caused by walking was very great, and was referred to the promontory of the sacrum. This gradually lessened, and toward the end of December he felt very comfortable." On January 5, 1863, he was discharged from service and pensioned. Pension Examiner William F. Breakey reported, June 27, 1866, that "the bullet entered the right side of the abdomen, two inches from the median line and four inches below the umbilicus, and lodged, and has not been extracted. He suffers constant pain in the region of the wound and in the hip and back, which is greatly aggravated by labor or exposure; great general disability." [See Michigan A. G. R., 1863, p. 319.]

CASE 257.—Private Philip Hill, Co. C, 46th Pennsylvania, was wounded at Cedar Mountain, August 9, 1862. He was admitted to Mansion House Hospital, Alexandria, August 15th, and, on August 30th, was transferred to York, Pennsylvania. Surgeon H. Palmer, U. S. V., reported that the ball entered the right natis and passed into the abdominal cavity, wounding the great intestines. Fecal matter escaped from the wound for several days. Hill was discharged the service, November 14, 1862, for total physical disability. His name is not upon the Pension List.

CASE 258.—Private G. W. Smith, Co. K, 8th Alabama, aged 18 years, was wounded in the abdomen at Gettysburg, July 2, 1863. There is no record of the case prior to his admission to hospital at Camp Letterman, August 7, 1863. Assistant Surgeon W. F. Richardson, C. S. A., reports: "Wounded by a minié ball entering the median line one inch below the ensiform cartilage, and passing obliquely downward and outward emerged from the right hip, after passing through the ilium. The patient passed feces through the opening made by the exit of the ball for three weeks. August 7th, the discharge of feces through the wound of exit has ceased; wound suppurating and discharging healthy pus; several spiculae have been removed from the wound. September 20th, general health good; the anterior wound is healed; wound of exit still discharging. October 6th, transferred convalescent." He was admitted to West's Buildings Hospital on the same day, and, on November 12th, was transferred to City Point for exchange. Surgeon George Rex, U. S. V., stated that he was "improving, and probably would recover."

CASE 259.—Private G. W. Crabtree, Co. C, 11th Illinois, was wounded at Pittsburg Landing, April 7, 1862, by a musket ball. He was admitted to Mound City Hospital, from the field, on April 11th, and the following history of the case is given by Surgeon E. C. Franklin, U. S. V.: "Ball entered left side of the abdomen, three inches to the left of the umbilicus, passing through the body, and made its exit one inch from the spine, on the same side. Three days after the injury was received, there was a discharge of fecal matter from both wounds, which continued, at intervals, until May 2d, when the bowels were inclined to be constipated, the discharges through the wounds became profuse, and the patient much distressed; but when the lower bowels were relaxed by mild cathartics, the discharge became slight and the patient comfortable. By May 10th, he was able to sit up and walk about, there having been no discharge of fecal matter since May 3d, the dejections taking place regularly, by the rectum, and the wounds rapidly healing. June 3d, patient entirely convalescent; both wounds healed; quite free from pain; appetite good; bowels regular. When the above case was admitted, the wound was considered fatal; the treatment consisted in keeping the body in an upright position, employing cold-water dressings, and keeping the bowels soluble with saline cathartics. On June 11, 1862, he was returned to duty, perfectly cured." He was discharged the service November 20, 1862. Pension Examiner J. Ravold, of Greenville, Illinois, reported, March 29, 1870: "Gunshot wound of left abdomen; ball taking effect about six inches to the left of navel, passing inward and backward, and issued about two inches higher from a line of the point of entrance, near the spine. From the constant drawing pain in the wounded parts, I am led to believe that there must be some intestinal adhesions to the walls of the abdomen. The pain and cramp-like drawing has of late increased, so as to entirely forbid manual labor. When the weather changes, the pain is accompanied by bloating and fever, which renders his condition very painful. Disability total." This pensioner was last paid to December 4, 1872.<sup>1</sup>

CASE 260.—Private Robert Smith, Co. D, 1st Indiana Cavalry, aged 20 years, was wounded at Helena, Arkansas, July 4, 1863, by a conoidal ball. He was admitted to the regimental hospital on the same day, and, on the next, transferred, on the hospital steamer R. C. Wood, to Memphis. He entered Gayoso Hospital on the 7th, under the charge of Surgeon D. W. Hartshorn, U. S. V., who furnishes the following notes: "This man was struck by a minié ball about two inches above the crest of the ilium; it penetrated the abdomen, passing backward and outward, and lodged near the spine, in the right loin, from which place it was cut out. July 7th, rest and water dressings. July 16th, a grain pill of opium at bedtime. July 19th, wound upon back becoming gangrenous; nitric acid is applied; afterword, resin cerate on lint was applied, and covered by poultices of yeast, flaxseed, and charcoal. A mixture of brandy, sulphate of quinine, and dilute sulphuric acid was ordered; also, one grain of opium at bedtime. July 20th and 22d, same prescription. July 25th, a large slough came off, leaving a healthy ulcerating surface. July 26th, same dressings continued; healthy granulations continue to appear; more or less fecal matter, mixed with pus, has been discharged from the wound near the crest of the ilium, since admission. July 30th, no fecal matter has been discharged from the wound for the last four days, although the pus has still a bad odor. August 8th, no odor in pus. August 22d, both sores doing well, but discharging pus. August 23d, furloughed for thirty days." On October 15, 1863, he was admitted to hospital No. 2, Evansville, Indiana; the wound was still suppurating. The patient was discharged the service March 29, 1863. A transcript from the Pension Office records reports as follows: "Gunshot wound received at Helena, Arkansas, July 4, 1863; ball passing through the left ilium and lodging on the right side of the lumbar vertebrae, in its course wounding intestines, and resulting in artificial anus at the wound of entrance of ball." Examining surgeon's certificate, July 13, 1866, states: "Ball passed through the superior portion of the left hip-bone and came out about two inches to the right of

<sup>1</sup> A history of this case, by E. ANDREWS, M. D., taken from the records of the Mound City Hospital, was published in the *Chicago Medical Examiner*, Vol. V, 1864, p. 551. It is stated in this account that the descending colon was wounded.



the spinal column. It penetrated the bowels in its passage, causing a discharge of fecal matter from the wound for months. So complete a recovery as he has attained is almost without a precedent. The bowels adhere to the cicatrix, which is still sometimes painful, and a slight cause, at any time, might totally disable him. His chief disability now consists in the difficulty of bending forward, because of the wounding of the spinal muscles." Examining surgeon's certificate, August 29, 1867, states: " \* \* \* causing discharge of fecal matter through wound of exit. An artificial anus is thus formed, which emits wind and occasionally fecal matter at this time, \* \* \* ." Examining surgeon's certificate, November 1, 1871, states: " Height, 5 feet 11 inches; weight, 160 pounds; dark complexion; aged 28 years; respiration 18; pulse 69. Ball evidently passed through the descending colon and out near the last lumbar vertebra, just to the right of spinal column. There is evidently adhesion and stricture of the intestinal canal, the bowels being either costive or troubled with diarrhœa. Complains of constant pain and weakness through the lumbar region."

CASE 261.—Lieutenant O. W. Williams, Co. C, 25th Ohio, aged 32 years, was wounded at Devaux Neck, S. C., December 6, 1864. He was admitted to the officers' hospital at Beaufort, on December 8th, from the field, and Surgeon A. P. Dalrymple, U. S. V., in charge, thus reported the case: " Gunshot wound of right side of abdomen, ball entering about one inch from the superior anterior angle of the ilium and penetrating the intestines; ball not extracted; wound severe. He was returned to duty February 8, 1865, and on April 26, 1865, he was discharged the service." Pension Examiner Wm. Laughridge, of Mansfield, Ohio, reported, November 28, 1865: " Musket ball struck and entered the right side of the abdomen, two inches inside and a little below the anterior superior spinous process of the ilium. The bowel was penetrated; the wound is still open and discharging pus—sometimes fecal matter and sometimes flatus; the ball is still lodged somewhere in the body. The right lower limb is almost completely paralyzed; disability total, and permanent." On November 19, 1865, he reports: " There is still an opening, through which gas occasionally passes. As soon as he became conscious after receiving the injury, he felt a severe pain in the back, in the region of the sacro-iliac junction, and has suffered from it ever since. Three years after receiving the injury, he suffered from the formation of an abscess on the back of the sacrum, in the region where he complains of the pain. Soon after he received the injury he experienced loss of power in the lower right limb, which has continued more or less ever since; and about two months afterward a small piece of bone, composed almost literally of cancellated structure, passed from the opening in the abdomen. From its appearance, I am inclined to the opinion that there has been caries of the promontory of the sacrum, or perhaps of the posterior superior spinous process of the ilium; from the appearance of wound and history of case, I believe that the ball passed directly through the abdomen and lodged near the sacro-iliac junction. The opening in the front part of abdomen is now nearly closed, and the paralysis is almost entirely gone. He occasionally experiences some little loss of power during inclement weather, but, according to his own statement, is decidedly improved, and his general health is good, but is still feeble in general strength; ball still lodged in his person." Height, 5 feet 7½ inches; weight, 115 pounds; respiration 18; pulse 80. No increase. He was last paid to December 4, 1872.

CASE 262.—Corporal J. Clemence, Co. F, 14th United States Infantry, aged 21 years, was wounded in the abdomen at Gettysburg, July 2, 1863, by a conoidal ball. He was admitted to Seminary Hospital on the following day, and remained until July 31st, when he was transferred to Camp Letterman Hospital. Acting Assistant Surgeon W. L. Hays, who had charge of the case, reports: " Wounded by a minié ball entering the right lumbar region, midway between the crest of the ilium and the fourth lumbar vertebra, and passing obliquely upward. The missile was removed, on July 10th, from the anterior wall of the belly, two inches above and to the right of the anterior superior spinous process of the ilium. Fœcal matter discharged from the wound of entrance up to August 17th. On September 28th, this man was discharged, cured." He was admitted to the Filbert Street Hospital on the same day, and transferred to Broad and Cherry Streets Hospital December 7, 1863. He was admitted to Fairfax Seminary Hospital April 21, 1864, and registered as a " flesh wound of abdominal parietes," and was transferred, June 21st, to Ward Hospital, at Newark. He was discharged the service December 23, 1864. Examining Surgeon Geo. W. Cook, of Syracuse, reported, March 20, 1866: " Ball entered the back, near the sacrum, and passed out just above the anterior spinous process of the ilium of the right side—a track of about eight inches. The disability is from pain upon change of position, walking, lifting, etc. Disability three-fourths, and of indefinite duration." Last paid to December 4, 1872.

CASE 263.—Private G. B. Burt, Co. F, 7th Maine, received a gunshot wound of the abdomen at Chancellorsville, May 3, 1863. He was admitted to the field hospital of the Sixth Corps, at Potomac Creek, on the following day, with " gunshot wound of the left iliac region, involving intestines," and sent, on June 14th, to Point Lookout. Here the wound was ascertained to interest the caput coli; the treatment consisted of strict attention to cleanliness, with simple dressings. On October 26th, the patient was furloughed; he was readmitted, and registered as a deserter March 31, 1864. He, however, rejoined, and was mustered out with his regiment on June 27, 1864. Pension Examiner H. B. Hubbard, of Taunton, Massachusetts, reports, July 20, 1864: " Entrance of ball lower part of abdomen, left side; exit through the ilium of same side; intestine perforated; liquid fœces still discharged from anterior opening. Disability total, probably permanent." Examining Board of Surgeons J. B. Treadwell, Horace Chase, and John W. Foye, of Boston, reported, November 2, 1870: " Ball entered about two and a half inches above right anterior superior spinous process of ilium, passed backward, and emerged four inches from median line of back and on a level with top of sacrum. States that wounds discharged fœcal matter for twenty months. Wounds are now soundly healed. Complains of dragging sensation and pain in region of anterior wound. There can be very little disability in the case, as he states that he works constantly and carries a magnificent pile of flesh. Disability rated, nevertheless, at five-eighths; height, five feet eight and one-half inches; weight, 192 pounds; aged 30 years; respiration 18; pulse 70.

CASE 264.—Sergeant Thomas Murphy, Co. A, 63d New York, aged 18 years, was wounded at Gettysburg, July 3, 1863, by a conoidal ball, which entered the left iliac region, passed directly through the abdominal cavity, and emerged above the crest of the right ilium, about three inches from the spinal column. Surgeon C. S. Wood, U. S. V., reports<sup>1</sup> that he " saw him twenty-four hours after receiving the injury and found him very prostrate, with feeble pulse, cold clammy skin, vomiting, etc. Fœcal matter was escaping from both orifices. He was placed in a comfortable position and cold water applied to the openings.

<sup>1</sup> WOOD (C. S.), *Three cases of Gunshot Wounds*, in *Am. Med. Times*, 1864, Vol. VIII, p. 172.



and opiates and stimulants administered freely, as it was supposed the case would prove fatal in a few hours. The next morning he was more comfortable, and the stimulants were discontinued, as some reaction had taken place. Beef-tea and full nourishment were ordered, and two grains of opium given every hour. Opium was the only remedy administered during a period of ten days, the quantity being reduced after the fourth day. The bowels were not moved until after the tenth day, when an enema of oil and turpentine was given, after which he continued to improve, and at the end of three weeks the anterior opening had closed by granulation. The posterior orifice closed shortly afterward. He has been walking about for the last week; his bowels are regular, and there is every indication of a complete recovery." On August 4th, he was transferred to the Camp Letterman Hospital and admitted to Ward D, under the care of Acting Assistant Surgeon D. R. Good, who states that "the ball wounded the liver in its course. The patient says that 'a yellow fluid-like bile' was discharged from the wound for some time. August 5th, the wounds are healing nicely and the discharge is healthy. His appetite is good and bowels regular. August 13th, he is walking about the tent and feeling well. September 5th, wounds entirely closed." On September 6th, he was transferred to Mower Hospital, Philadelphia, and was returned to duty February 9, 1864. It does not appear that he has ever applied for a pension.

CASE 265.—Private W. A. Liebe, Co. K, 2d New Jersey, aged 18 years, was wounded by a rifle ball at Crampton's Pass, September 14, 1862. He was admitted to field hospital at Burketsville on the same day, and Assistant Surgeon H. A. Du Bois, U. S. A., made the following report of the case: "The missile entered one inch below and to the right of the umbilicus, and passed out an inch and a half to the left of the spine, below the ribs. Perfect rest was enjoined, cold-water dressings ordered, and the most simple diet and opiates were prescribed. Stercoraceous matter passed from the anterior wound September 15th, and, for the first time, from the posterior wound, on September 25th. The first opening closed by granulation about the 10th of October; the second about the 20th. Patient is now sitting up; bowels regular; flesh and general health good. November 3d, no doubt of a perfect recovery, with no false passage." L. W. Oakley, Surgeon General of New Jersey, March 2, 1866, states: "The ball entered the abdomen through the costal cartilage of the eighth and ninth ribs of the right side, and, passing backward and a little downward and inward, made its exit on the same side, within half an inch of the spine of the last lumbar vertebra. The patient suffered but little from shock, and reaction was fully set up within twelve hours; hæmorrhage but slight. The lad was unusually quiet and tractable, this assisting not a little in his ultimate recovery. At the end of the third day, slight symptoms of peritonitis made their appearance, which, however, were relieved by the free use of morphia; diet confined to essence of beef; wounds dressed with cold water. At the end of the first week the rectum was unloaded by injection, both the wounds discharging stercoraceous matter. This state of things continued until the fourth week, when the anterior wound healed; the posterior remained open until December 1st, when it also closed; the discharges from the rectum, in the meantime, being at regular intervals. Patient was discharged from Camp Convalescent May 27, 1863, and has been perfectly well ever since." Liebe's name is not upon the Pension List.

CASE 266.—Corporal Henry J. Clow, Co. B, 108th New York, aged 19 years, was wounded in the right hypochondriac region at Morton's Ford, February 6, 1865. He was admitted, on the next day, into the field hospital of the 3d division of the Second Corps, under the charge of Assistant Surgeon Samuel T. Miller, 12th New Jersey, who furnished the following details of the case in a letter to Surgeon J. H. Brinton, U. S. V.: "Upon examination, I found that a conical ball had entered the right side at the external edge of the rectus muscle, about four inches from the umbilicus, and a little above; its exit was in the back, about three inches from the spine, and two inches above the crest of the right innominatum. In its course, the missile wounded the ascending colon to a fearful extent—so much so, that for twenty-one days his whole contents of his bowels passed through the anterior and posterior openings. On the twenty-second day he had a natural evacuation through the regular channel, and from this time has had scarcely an unfavorable symptom. March 22d, both the anterior and posterior wounds have healed up; his stools are natural, and there is a fair prospect of a speedy recovery. What is most singular about this is, that he never had any peritoneal inflammation, and, except the escape of the feces, no unfavorable symptoms at all. His treatment consisted simply in a liquid diet and whiskey." On March 24th, Clow was transferred to Alexandria and admitted to the Prince Street hospital, where Surgeon T. Rush Spencer, U. S. V., records the case as "gunshot wound of the right side," but does not indicate that any treatment was necessary. On June 29th, he was transferred to Mower Hospital, Philadelphia, and was returned to duty on July 11th. Assistant Surgeon George M. McGill, U. S. A., in a report to Medical Director McParlin of an inspection of the Fifth and Second Corps hospitals, dated September 7, 1864, refers to this case as follows: "The wound finally closed May 9th; a fecal discharge was maintained thirty-one days. At the present date, when he works he feels weak. Walking causes lancinating pains in the side, in the vicinity of the wound, and in the small of his back. When he coughs the cicatrices introvert; he describes a constant abnormal feeling as that of a tight plaster drawing in his side." It would appear that the man was not fit for field service, as he is spoken of by Dr. McGill as being "an attendant" at the Second Corps hospital, and, on October 26th, he is registered as being admitted on account of an "old wound." On November 26, 1864, he was transferred to Lincoln Hospital, Washington, and was discharged from service January 30, 1865, for physical disability, Assistant Surgeon J. C. McKee, U. S. A., noting on the monthly report that there was "lameness of the right leg." Pension Examiner H. F. Montgomery examined the man on March 1, 1865, and states that "the ball entered at the anterior end of the right lower rib, passed through the abdomen, wounding the colon, and emerged on a line with the top of the ilium and three inches to the right of the spine. Fæcal matter passed out of the wound for thirty-one days. The wounds are healed; but adhesions along the track of the ball render motions of the body painful. In time these adhesions will be elongated. Disability total; will probably diminish." Pension Examiner DeWitt C. Wade, of Oakland County, Michigan, reports, March 9, 1870: "Gunshot wound through both thighs, with fracture of left femur. Several pieces of bone have been removed. Gunshot wound through abdomen, antero-posteriorly, on right side, wounding the ascending colon, and for a time causing a fistulous opening; wounds now all healed. The left limb is much weakened. The abdominal muscles and viscera are debilitated in their action, and he is obliged to wear a wide belt to sustain those organs. The action of the wounded psoas magnus is imperfect, and hence constrained action of right thigh. Rate total and permanent; he should have received the same since his discharge. No vicious habits." The fracture of the femur is not recorded in any of the army reports.

The ascending colon was thought to be solely or principally interested in the thirty-two foregoing cases; in the next case, the transverse colon was believed to be the seat of injury:

CASE 267.—Private Warren Post, Co. G, 84th Pennsylvania, aged 18 years, received a penetrating wound of the abdomen at Fort Republic, June 9, 1862. The ball entered on the left side, at the junction of the tenth rib with its costal cartilage, passed backward and slightly downward through the abdomen, and came out behind and a little to the left of the second lumbar vertebra, and was supposed to have perforated the transverse colon. He was taken prisoner and detained for three months at a field hospital, when he was paroled and sent to Fort Delaware. He remained in the hospital at the latter place for six weeks, and, on October 24th, was admitted into Broad and Cherry Streets Hospital, at Philadelphia. He stated that immediately after the injury his wounds bled freely, and that he also passed blood by the mouth and anus; small pieces of paper and cloth, which had evidently been driven into the wound by the ball, were also discharged; this escape of blood and foreign matter continued, at intervals, for three weeks. On the fifth day after the injury, the lower extremities became paralyzed, and remained so for seven weeks, after which the powers of nature were restored. For a considerable period, on attempting to evacuate the bowels, feces and wind passed from both wounds, especially by that of exit. The seeds of fruit he had eaten were also discharged from both wounds. During the treatment of the case a small spicula of bone was removed from each orifice. On November 20, 1862, he was discharged from service on account of intercostal hernia, at which time Acting Assistant Surgeon John Neill, who reports the case, states that he was enjoying good health. He is not a pensioner.

In the following cases, the descending colon was regarded as the seat of injury:

CASE 268.—Private T. W. Clohosy, Co. B, 72d Pennsylvania, aged 28 years, was wounded at Gettysburg, July 3, 1863, by a conoidal ball, which entered the abdomen about three inches to the left of the umbilicus, and made its exit one inch to the left of the first lumbar vertebra. He states that he soon recovered from the shock, and walked a considerable distance to the field hospital. There was no hemorrhage, but the contents of the intestines passed freely through the posterior wound for about fifteen days and then gradually ceased. The appearance of the discharge bore a great resemblance to condensed milk, and became gradually thinner until it finally ceased. The bowels were moved regularly every day. On August 7th, he was transferred to the Camp Letterman Hospital. When admitted he was quite convalescent. August 11th, health good; wounds closed. August 31st, since the last date the patient has enjoyed good health, and has suffered little or no inconvenience from the wound. [The above information appears upon an unsigned medical descriptive list from Camp Letterman Hospital.] On September 4th, he was transferred to the Convalescent Hospital, Philadelphia. He remained in the hospitals of that city until May, 1864, when he was transferred to the Veteran Reserve Corps and sent to Washington. He was finally discharged from service December 5, 1864, and pensioned. Pension Examiner John Neill, of Philadelphia, reports, April 21, 1869: "The ball entered the abdomen four inches to the left of the umbilicus, and escaped one-half inch from the spine and one-and-one-half inches above the superior posterior spine of the ilium. Since his discharge the wounds have both reopened, and feces has been discharged from the posterior orifice. The pensioner now suffers from hemorrhoids and phthisis. He will not live long." Under date of January 10, 1870, Pensioner Examiner J. H. Cantrell, of Philadelphia, states: "I attended Thomas Clohosy from September 10, 1868, until October 21, 1869, when he died in the city of Philadelphia. The immediate and sole cause of his death was from a gunshot wound, which struck over the stomach but did not penetrate that organ, but did penetrate the descending colon, and came out about one inch from the spine."

CASE 269.—Corporal C. H. Smith, Co. K, 76th, New York, aged 20 years, was wounded at Gettysburg, July 1, 1863, by a conoidal ball. He was admitted to the Seminary Hospital from the field, where he had been treated in a private house, and was afterward transferred to the Citizens' Volunteer Hospital at Philadelphia, where he was admitted on October 3d. He was transferred to Germantown March 14th, and admitted to Cuyler Hospital on the same day, with "gunshot wound of abdomen, perforating cavity and injuring intestines." He was returned to duty October 14, 1864, and discharged the service October 24, 1864. Pension Examiner Horace Lathrop, of Otsego, New York, reported, August 30, 1866: "Ball entered left side just above the crest of the ilium, two inches above the anterior superior spinous process, passed downward and backward through the wing of the ilium, and out near the last lumbar vertebra. There is now an opening in both localities, and the anterior one discharges fecal matter. The colon is probably wounded. He requires constant assistance from another person; his other wounds are healed; disability total." Pension Examiner S. H. Case, of Oneonta, reported, September, 24, 1865: "Has received several gunshot wounds in the vicinity of the pelvis; but the principal, if not the only, disability at present of much account is owing to a wound in the left side. He alleges that feces, wind, and food escaped from the wound through both openings made by the ball, at first, and occasionally now from the wound of entrance. The injury evidently caused an abscess in the loins between said wounds, which opened by ulceration, and from which a large offensive and ill-conditioned discharge now constantly escapes, and at present disables him more than the loss of a hand or foot."

CASE 270.—Private Charles L. Odell, Co. B, 86th New York, aged 22 years, was wounded at Spottsylvania, May 10, 1864, by a conoidal ball. He was taken prisoner, and, on August 24th, was brought, by steamer New York, to Annapolis, and admitted to No. 1 hospital, where the injury was recorded as a "gunshot wound through the abdomen." On August 24th, he was transferred to Camp Parole, whence he was returned to duty, September 30, 1864. On March 19, 1865, he was discharged the service. Pension Examiner Ira W. Bellows, Knoxville, Pennsylvania, reports, May 7, 1866: "Ball entered the left side, over the descending colon, came out through the posterior superior spinous process of the left ilium; fecal matter is now discharging from the wound in the back; general emaciation; is unable to leave his room. Disability total; will probably prove fatal." H. A. Phillips, M. D., of Knoxville, reported that the pensioner died April 19, 1869, at Westfield, Pennsylvania, and states: "I attended Charles L. Odell for about a month prior to his death; when I first saw him, I found him suffering from a fistulous opening, communicating with the bowels, with profuse discharge of fecal and purulent matter, resulting from a wound received in the United States service, from which injury he died, very much emaciated, April 19, 1869."



CASE 271.—Sergeant Lewis E. Morley, Co. F, 61st New York, was wounded at Gettysburg, July 1, 1863, by a conoidal musket ball, which entered a little below the umbilicus and to the left of the linea alba, and passed obliquely through the body, penetrating the sigmoid flexure of the colon and the wing of the left ilium in its passage. When brought to the field hospital he was in a state of collapse. Fæces escaped from the wound. There was excessive tenderness and pain. Opiates were freely administered, and the symptoms of peritonitis gradually abated. On July 10th, the patient was in a condition to be removed to Baltimore. The discharge of fæces from the wounds continued until September 28th, when there was an evacuation by the rectum. The wounds soon afterward closed, and, on October 27th, the patient was sent home on furlough. On November 15, 1863, he returned, and remained an inmate of Jarvis Hospital until October 11, 1864, when he was discharged from service for total disability resulting from his wounds, and sent to his home in Hinsdale, Illinois. He was pensioned, and, on March 18, 1865, Pension Examiner J. C. W. Keenon reported that "the ball entered an inch and a half below the umbilicus, a little to the left of the median line, and passed out through the ilium, leaving an adhesion of the bowels, probably, to the abdominal wall." Morley was in tolerable health when his pension was last paid, December, 1872.

CASE 272.—Private John Haun, Co. I, 20th Indiana, aged 30 years, was shot through the body in an engagement at Oak Grove, June 25, 1862,<sup>1</sup> by a musket ball passing from the right lumbar to the left hypochondriac region. No record of the early symptoms or progress of the case can be found, for the patient was made a prisoner and remained in Richmond until July 25th, when he was paroled and sent to the hospital at Fort Monroe, and thence on the hospital transport State of Maine to Philadelphia, where he was admitted to Broad and Cherry Streets Hospital on July 29, 1862. Surgeon John Neill, U. S. V., reports that "a minie ball penetrated the lumbar region about three inches to the right of the spinal column, and one inch above the iliac bone, and, passing obliquely across in front of the vertebra and slightly upward, made its exit in the left side, immediately below the last rib. Considerable hemorrhage followed from the wound of exit, and four days after the injury fæces and wind passed from the same opening. At the time of admission, his health was very much broken down, and he suffered from a severe cough and from pain in the left chest, resulting from pleurisy contracted before the wound was received. The wound of entrance had healed; that of exit was still open and discharging a small amount of pus, occasionally mixed with fecal matter and fætid gas. The descending colon was supposed to be the part involved, and appeared to be adherent to the abdominal walls at the opening. The wound was dressed with a flaxseed cataplasm; the patient was ordered a good diet, with milk-punch and beef-tea, and stimulating expectorants, with opium at night. Under this treatment his health improved rapidly; the wound granulated slowly, and by October 25th had entirely closed. For four weeks previous to that date, no fæces or wind had passed by the wound, and the patient was convalescent without any bad results." A subsequent report says: "John Haun, reported as cured in January, 1863, had a relapse, the wound again opening and discharging fæces for a few days, and a small piece of flannel shirt. The fecal fistula then again closed." Haun was discharged from service on April 4, 1863. Pension Examiner G. W. Mears, of Indianapolis, furnishes a certificate, dated April 14, 1863, rehearsing the above facts, but stating that the anterior wound was still open. In December, 1863, Haun drew his pension, since which date the Pension Office has received no communication from him or his heirs. Postmaster Hoback, of Francesville, Indiana, informs the editor, April 19, 1873, that Mr. Haun died, from a wound of his abdomen, some six or eight years ago.

CASE 273.—Dr. J. T. Taylor records<sup>2</sup> that Captain W——, U. S. A., was wounded near Mansfield, Louisiana, April 8, 1861, by a minie ball, that entered midway between the umbilicus and the anterior superior spinous process of the left ilium, and passing backward emerged near the sacral articulation of that bone. For eight days he lay among those regarded as fatally wounded, taking morphia and such stimulants and nourishment as he desired. The abdomen was tympanitic and tender. There was a constant discharge of thin fecal matter from the wound of exit. He was now instructed to lie toward the wounded side. The diet was restricted to animal broth, the medicine to three grains of opium daily, and the wounds were scrupulously cleansed, and covered by cold cataplasms of slippery elm, which were made to extend over the abdomen. Portions of clothing and sloughs of cellular tissue were removed from the entrance wound, which soon afterward healed. Pressure was applied to the preternatural anus, and dejections by the rectum were facilitated by enemata. The officer was discharged from hospital in a fair way of recovery.

CASE 274.—Lieutenant J. H. Cook, Co. E, 57th Massachusetts, aged 23 years, was wounded at Petersburg, July 21, 1864, by a conoidal ball. He was admitted to the field hospital of the 1st division, Ninth Corps, on the same day, and the case reported as "gunshot penetrating wound of the left hypochondriac region." He was furloughed on July 25th, and, on October 31st, was admitted to hospital at Readville, Massachusetts, with "gunshot wound of side." He was discharged the service December 27, 1864. Pension Examiner S. L. Sprague, of Boston, May 2, 1866, stated that he examined Lieutenant Cook on February 2, 1865, and that "a minie ball, entering the left side beneath the twelfth rib, was cut out from over the spine of the lowest lumbar vertebra. The ball passed through the abdomen, wounding the intestine. Fæcal discharge is now constant at the wound. There is numbness of the hip and thigh at the right side; he can walk one-half a mile with a cane; he is debilitated, and has constant pain in the hip." Pension Examiner W. H. Page, of Boston, reported, January 26, 1866: "Ball entered at edge of left lower rib, centre of left side, about four inches above the superior process of ilium, and came out on right side of spine, about one inch to right and on a level with the top of crest of ilium. He alleges that there were fecal discharges from the posterior wound for about four weeks; when it healed, but has broken out twice since—the last time being last July; it is now entirely healed; has trouble in passing urine when he gets cold; the urine is very offensive, and he has more or less pain in the kidneys; cannot lift any heavy thing, nor walk any great distance, without having very severe pain in the back. The left leg is also enfeebled by the cutting off of some of the nerves; disability three-fourths, and permanent." Pension last paid to December 4, 1872.

<sup>1</sup> One report says: "Fair Oaks, May 31, which date is given in Circular 6, S. G. O., 1865, p. 25; but the 20th Indiana did not join the Army of the Potomac until June 8, 1862; on June 25th, it was heavily engaged, in Kearney's Division of the Third Corps, at the 'Orchards' or Oak Grove, losing 120 in men and officers." See *Report of General George B. McClellan, Ex. Doc., 38th Congress, 1st Session, p. 120, and Report of the Adjutant General of Indiana, 1865, Vol. II, p. 191.*

<sup>2</sup> TAYLOR (J. THOMAS). *Surgical Observations, in the Southern Jour. Med. Sci., 1867, Vol. II, p. 18.*



CASE 275.—Lieutenant J. E. Mallet, Adjutant 81st New York, aged 21 years, was wounded at the battle of Cold Harbor, June 3, 1864, by a musket ball, which entered three inches to the left of the umbilicus and made its exit a little to the right of the spinal column. The direction of the ball is indicated in the accompanying wood-cut (FIG. 57), engraved from a photograph on the wood block made at the Museum several years ago. This officer, who still survives and holds an important civil office under the Government, has kindly prepared an account of his case, which is peculiarly valuable because of the rarity with which reliable information of the immediate symptoms produced by severe wounds can be obtained. The authenticity of the facts is unquestionable, and, independently of the officer's own statement, is affirmed by the testimony of the medical attendants: "I was wounded," says this brave officer, "at the battle of Cold Harbor, while serving as adjutant of the 81st New York Infantry, or 2d Oswego Regiment, then with the Army of the Potomac, and attached to the first (Marston's) brigade, first (Brooks's) division, Eighteenth (Smith's) Army Corps. It was at about five o'clock in the morning, and in the assault on the enemy's entrenched lines, I was struck. I fell at the distance of about fifteen paces from the works which our men were charging with uncapped pieces. The missile entered my left side. I distinctly remember the sensations experienced upon being hit. I imagined that a cannon-ball had struck me on the left hip-bone, that it took a downward course, tearing the intestines in its course, and lodged against the marrow of the right thigh-bone. I fancied I saw sparks of fire, and curtains of cobwebs wet with dew, sparkling in the sun. I heard a monotonous roar as of distant cataracts. I felt my teeth chatter, a rush of blood to my eyes, ears, nose, and to the ends of my fingers and toes. These sensations crowded themselves in the instants in which I struggled to stand, and actually fell forward on my face. As I fell, I experienced another sensation as of a sudden and violent blow on the nape of the neck, and then became completely insensible. I was awakened to consciousness by cheering, and fearing to be trampled by the advancing lines, I made a desperate effort to regain my feet; and, doubled up as one with a broken back, with my sword strapped to my right wrist, and the scabbard in the other hand, I dragged myself about forty paces to the right and rear, and entered the skirt of a wood, where I saw men hiding behind trees, which angered me, and I again fell insensible. Later, I remember being put on a stretcher by some men of a Massachusetts regiment, and carried some distance to an ambulance. During the day, some one had given me a piece of sponge cake dipped in wine; but it was at once rejected. It rained during the day, and some one covered me with a rubber blanket, which a passer-by presently carried off, and I had the will but not the power to protest. The pain in the wound in the back was intense. I do not recollect distinctly my arrival at the corps hospital; but I recall the visit of Surgeon W. H. Rice, and his exploration of my wound, and his instructions to a friend to take my watch and valuables, and my inference that he considered my case hopeless, and that these mementoes were to be sent home.

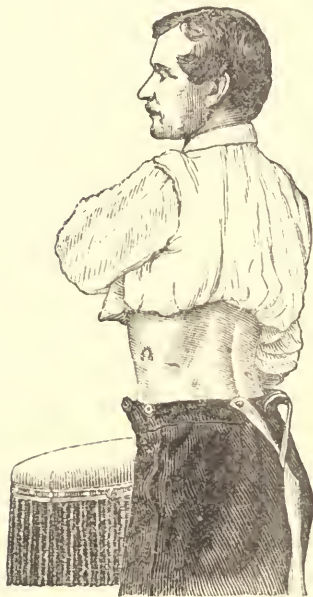


FIG. 57.—Cleavages in a case of shot perforation of the descending colon. [From a photograph.]

On the afternoon of June 3d, I was put in an ambulance wagon with Lieutenant McKinney, and taken as far as Bethesda Church, where we stopped over night. We proceeded on our journey next morning, over very rugged ground. I remember the wounded who could walk, often put their shoulders to the wagon to keep it from upsetting. We arrived at White House Landing, on the York River, late on the afternoon of June 4th. I had suffered much pain from shortness of breath, but was relieved by draughts of water. I was put on a hospital transport, and was laid by the side of the deck, where the breeze could reach me; but it seemed to take away my breath instead of restoring it. I was very faint, and Captain Tyler, of my regiment, and others, have since told me that I was regarded as a dead man. I remember nothing further until we reached Alexandria, and finally Washington, where I asked to be taken to Douglas Hospital; but nearly all the wounded were carried off in ambulance wagons, and I thought I was deserted; but finally they brought a stretcher and carried me to Armory Square, which was nearer the steamboat wharf. I was placed in Ward 1 about midnight. On the morning of June 6th, Medical Inspector Coolidge examined me. From memoranda, made soon afterward, I find that I was frequently unconscious during the next week; but that, on June 12th, I could read the leaded headings of newspapers. On June 15th, I had a distressing pain in the bowels. Gradually my vision improved, and, on June 22d, I began to keep my diary. Acting Assistant Surgeon Bowen was attending me. On June 27th, I ate some blackberries, which made me sick, and for the next two days I was feverish and drowsy. On July 1st, I had severe colic. On July 3d, Surgeon Bliss examined me. On the 5th, I was better, and asked to be sent home. On July 6th, I sat up in an arm-chair. On the 12th, some blackberry seeds were found in the lint removed from the wound in the side. On July 17th, I drank a glass of soda-water, which, in about fifteen minutes, began to bubble out at the orifice in the side, forcing off the adhesive plaster and compresses, and soiling my clothing with a copious foetid discharge of a yellowish color. On July 27th, I was taken on a stretcher to the cars, and rode to New York, and thence on a

steamer to Albany, and thence by rail to Oswego, where I arrived on the 29th, and was attended by Dr. C. P. P. Clark, of Fort Ontario. My hospital diet nearly starved me, and I suffered greatly during the dressings. Pieces of shirt and trowsers and braces were extracted from the wounds at different times. There was a swelling below the wound, which was very sensitive. Some of the surgeons thought it contained the ball; others that a fragment of the eleventh rib was lodged there. On August 11th, I walked for the first time. On August 26th, there was so much pain in the swelling referred to that a surgical consultation was held, and, on the 28th, Dr. Clark incised the swelling and removed a large button that had been driven in by the ball. On October 1st, I reported at the hospital at Annapolis, and on October 31, 1864, was honorably discharged for wounds received in action, on the recommendation of the board of which General Graham was president. In 1865 my health improved, so that I was able to do clerical duty, and from that time to this (1873) my health has been comparatively good. I am nevertheless subject to pain in the spine at damp seasons. My left side and arm are weak, and, in walking a considerable distance, my left leg becomes lame. It may be proper to add that at the time of receiving the wound I had been fasting for

nearly forty-eight hours." The principal facts above recited in a connected form, appear, separately, in the reports of Surgeons W. H. Rice, 81st New York, H. P. Porter, 10th Connecticut, Acting Assistant Surgeon C. H. Bowen, and Surgeon B. A. Vanderkief, U. S. V. Dr. Bowen remarks that the evidence of extensive destruction of the wall of the descending colon was conclusive, and that a spinous process of a vertebra was probably fractured. The evidence of the intestinal lesion consisted in a copious fecal discharge from the wound, which persisted for several weeks, while the patient was at Armory Square. Mr. Mallet received the brevet of Major of United States Volunteers for gallantry.

CASE 276.—Private Allen J. Marker, Co. I, 4th Maine, aged 18 years, was wounded near Centreville, at the battle of Chantilly, September 1, 1862,<sup>1</sup> and was taken to the regimental hospital, where Surgeon G. W. Martin, 4th Maine, recorded his injury as a "gunshot wound of the side and arm." The wounded man was conveyed to Washington, and entered Epiplany Hospital on September 2d. Dr. N. P. Monroe states, without describing the wound of the arm, that "the ball passed through the left side between the ninth and tenth ribs, fracturing the latter, and lodged between the transverse processes of the third and fourth lumbar vertebrae, whence it was extracted, as I was informed, on the previous day." Surgeon J. H. Brinton, U. S. V., saw the patient, and notes the entrance wound as in the eight left intercostal space, and the lodgement as between the apophyses of the second and third lumbar vertebrae, and the ninth rib as fractured. The missile was placed in the Museum by Dr.

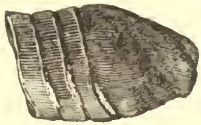

FIG. 58.—Conoidal ball, battered by contact with the ninth rib and the transverse processes of the lumbar vertebrae. *Spec. 6248.*

Brinton, and is represented in the wood-cut (FIG. 58). The missile is said to have lain subcutaneously, and as soon as a counter-incision was made for its extraction, fecal matter was discharged by this wound. From the anterior opening a number of bone splinters were extracted. A slight escape of fecal matter from this opening lasted for fourteen days. From the preternatural anus in the loin a free discharge of feces persisted for nearly seven months. On September 5th, a portion of sphacelated colon presented at the posterior orifice, and was removed with scissors by the ward surgeon. On September 10th, a piece of omentum, "twelve inches long and two inches wide" (*sic*), is said to have been removed. Notwithstanding the free suppuration from the wound in the arm and hypochondrium, the general condition of the patient was encouraging. He was sustained by a nourishing diet, with porter and tonic medicines. Late in October, Hospital Steward Stauch prepared, under Dr. Brinton's

supervision, an excellent water-color drawing of the subject. This is preserved in the *Surgical Series of Drawings*, A. M. M., as No. 15. A reduced copy of the drawing is presented in the accompanying wood-cut (FIG. 59). On November 1st, it is noted that the boy had a steady, hearty appetite, and maintained tolerable health, and that the dejections had taken place by the natural channel, on that day, for the first time since the reception of the injury. The lad was preparing to go to his home. On November 21st, though stercoraceous matter still escaped from the lumbar wound, the patient, at his own desire, was discharged from service by Surgeon James Bryan, U. S. V. The fecal fistula persisted until May, 1863, when the discharge from the wounds became sero-purulent. A month afterward, both wounds healed up soundly, and the patient went to his home at Belfast, Maine. He was pensioned. On September 15, 1864, his condition was so satisfactory that his pension was reduced. He applied for an increase, and, on August 27, 1870, Pension Examiner Charles N. Germain, of Rockland, Maine, made the following report in the case: "A musket ball penetrated the lower third of the left arm, fracturing the humerus, as indicated by cicatrices and by irregularity of the surface of the bone. Arm weakened thereby, so that it is with difficulty he can raise more than thirty pounds. The natural dexterity of the arm is injured, and the hand weakened in its power of grasping. Disability one-half. Secondly, there exists a large depressed cicatrix on his left side, between the ninth and tenth ribs, where a musket ball entered; another large (two by four inches) callused cicatrix, between the third and fourth lumbar vertebrae, where a ball was cut out. In the wound of his side, a false passage existed for three or four months after receiving the wound, from which the excrements of his body escaped. The seat of the wound is now subject to periodical attacks of soreness and pain. By reason of injury to the spine, his back is weak, and his side is slightly paralyzed. If he attempts to perform manual labor his back becomes so weak and lame that he cannot stand erect; his side also becomes weak and painful, producing general exhaustion. If he inclines forward his back becomes painful and weak; his bowels are constipated, requiring the constant use of purgatives; he is reduced in general strength; loss of weight, twenty-five pounds. For this disability, I rate him one-half; for both disabilities, total."

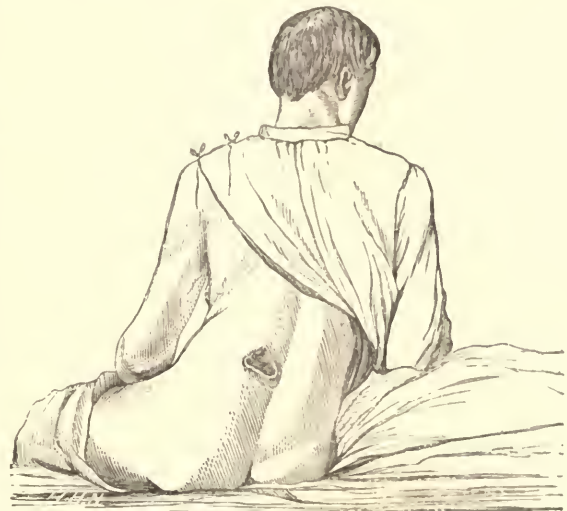

FIG. 59.—Preternatural anus in the lumbar region, from a shot perforation of the colon. *Surg. Drawings*, A. M. M., No. 15.

depressed cicatrix on his left side, between the ninth and tenth ribs, where a musket ball entered; another large (two by four inches) callused cicatrix, between the third and fourth lumbar vertebrae, where a ball was cut out. In the wound of his side, a false passage existed for three or four months after receiving the wound, from which the excrements of his body escaped. The seat of the wound is now subject to periodical attacks of soreness and pain. By reason of injury to the spine, his back is weak, and his side is slightly paralyzed. If he attempts to perform manual labor his back becomes so weak and lame that he cannot stand erect; his side also becomes weak and painful, producing general exhaustion. If he inclines forward his back becomes painful and weak; his bowels are constipated, requiring the constant use of purgatives; he is reduced in general strength; loss of weight, twenty-five pounds. For this disability, I rate him one-half; for both disabilities, total."

CASE 277.—Sergeant Daniel B. Deyo, Co. C, 156th New York, aged 32 years, was wounded in the bowels at Winchester, September 19, 1864. His admission to the regimental hospital, and transfer to the Nineteenth Corps hospital, is noted by Surgeon George C. Smith, 156th New York; but no details are recorded until December 14th, when the patient was sent to Frederick. Here, Acting Assistant Surgeon F. A. Grover states that "the ball entered midway between the spinous process of the ilium and the last rib of the left side, and emerged near the last dorsal vertebra, wounding the descending colon. The patient states that

<sup>1</sup> See *Annual Report of the Adjutant General of the State of Maine for the year 1862*, p. 51, for particulars of the part the regiment bore in this engagement.



he had fecal discharge from both anterior and posterior wounds for three weeks, and also had profuse hemorrhage, from the same source, during that time. The stercooral discharge from the wounds then ceased, and the feces resumed their natural channel. The appetite was good, but the patient suffered occasional slight attacks of diarrhœa, which were controlled by opium. The wounds still discharged small quantities of pus, and, occasionally, air escaped from the anterior opening; a compress and bandage were applied." On January 19, 1865, Deyo was transferred to McDougall Hospital, in charge of Surgeon Samuel H. Orton, U. S. A., who notes a fracture of the last rib. The patient was discharged from service on February 27, 1865, and pensioned, and was last paid to December 4, 1872.

CASE 278.—Private Warren Miller, Co. B, 73d Ohio, aged 19 years, was wounded at Gettysburg, July 2, 1863. He was admitted to Seminary Hospital on the same day, with "gunshot compound fracture of right shoulder, wound of left arm and of left side," and was transferred to Camp Letterman Hospital on July 25th, where the following report of the case is made by Acting Assistant Surgeon E. A. Koerper: "Wounded July 2d, by a minié ball, entering near the crest of the left ilium, six inches to the left of the last lumbar vertebra, and lodging; the ball cannot be found. August 9th, the wound was discharging considerable pus mixed with fecal matter. August 10th to 20th, general health good; his bowels move regularly. September 10th, fecal passages still continue from wound. October 20th to November 8th, health good; still discharging fecal matter from wound." On November 17th, he was transferred to Camp Chase, where he was admitted on the 19th, and the wound reported as "gunshot wound of the left hypochondriac region, perforating the colon, resulting in an artificial anus." He was discharged the service on January 5, 1864; disability, three-fourths. Pension Examiner O. J. Phelps, Pickton, Ohio, under date of February 23, 1864, states: "One wound was in the left forearm, taking out a section of the ulna; another in the left side; ball entered just above the ilium; ball probably remaining in. The third wound was in the flesh on the top of the right shoulder. Disability, total; in part permanent."

CASE 279.—Private M. Meyer, Co. G, 145th Pennsylvania, aged 32 years, was wounded at Spottsylvania, May 10, 1864, by a conoidal ball. He was received into the field hospital of the Second Corps on May 12th, and, on the 13th, he was admitted to the 3d division hospital at Alexandria. Surgeon E. Bentley, U. S. V., reports the case as follows: "Ball entered near the terminal extremity of the eleventh rib, passing backward and slightly upward, and one and one-fourth inches to the left of the spinal column. On admission, fecal matter was passing from both entrance and exit wounds; the bowels were constipated, and there was considerable pain in the regions of injury; anodynes were administered; the appetite was poor; liquid diet was prescribed, and detergent dressings were applied to the wound. On May 19th, an enema of warm water and oil was given, and the bowels moved several times; anodynes were continued, with liquid diet; dressings the same. No further movement of the bowels occurred till May 23d; bowels then quite relaxed; lead and opium pill given May 24th; bowels checked, and no more movement until May 27th; an enema was administered, and the bowels moved freely; anodynes were continued, with liquid diet; bowels then moved nearly every day. May 28th, several small pieces of bone came out at the posterior opening of the wound. June 1st, no discharge of fecal matter from wound. June 3d, bowels relaxed; lead and opium pills given, one every four hours, until the diarrhœa was checked. June 5th, bowels regular; patient suffering less pain; appetite quite good. June 10th, a little gas escaped from the bowels through the external wound; same treatment continued. June 15th, a very little fecal matter came out at the wound; anodynes and liquid diet continued; bowels regular. July 1st, up to this time no more fecal matter or gas had escaped from the bowels; patient feeling pretty well, and appetite good, requiring little opiate medicine. July 11th, a piece of bone made its appearance at the anterior opening, and was taken out, one-half inch in length, one-fourth in breadth, and of the thickness of the rib. July 20th, the patient was doing well, appetite good, and some solid food was allowed; bowels regular; slight suppuration from wound. The patient was able to go about the house and yard. September 1st, continued to improve." September 9th, furloughed for thirty days, and, not returning, was recorded as a deserter October 20, 1864. He is not a pensioner.

CASE 280.—Private E. Proctor, 6th Maine Battery, aged 24 years, was wounded at Gettysburg, July 2, 1863. He was admitted into the field hospital, where the injury was registered as "a gunshot wound of hip." On July 23d, he was transferred to Camp Letterman Hospital, where the following report was made by Acting Assistant Surgeon Charles S. Gauntt: "Wounded by a minié ball entering the back, three inches to the left of the first lumbar vertebra, and making its exit one inch above the anterior superior spinous process of the left ilium. Transferred September 15th, cured." On the next day, he was admitted to Mower Hospital, and Assistant Surgeon C. Wagner, U. S. A., reports as follows: "September 16th, admitted with gunshot wound in left side; wound healing; simple cerate applied. September 28th, wound inclined to slough; dressed with nitric acid and yeast poultice. Same treatment continued, and patient improving until November 13th, when the wound was nearly healed. November 30th, a small piece of bone was removed to-day, which had been keeping up a discharge; it will now probably heal up. December 6th, he complains of pain in hip; wound discharging; cold-water dressings continued; patient asthenic. May 1st, wound still discharges fecal matter occasionally. Up to June 1, 1864, there was no improvement in the wound. July 1st, wound remains about the same, discharging gas and pus occasionally. July 10th to 20th, wound still discharging, and no change in appearance; health otherwise good. July 30th, made an incision down to the bone to remove any loose fragments of bone, but found the orifice perfectly free from necrosis, and introduced a tent to make the wound heal from the bottom. At the same time, gave an anodyne to lock up the bowels. August 7th, the patient again passed feces through the wound. August 28th, has not passed any fecal matter for ten days; has had several natural passages by the rectum, and the track has closed up. September 5th, doing very well; some prospect of a cure. October 15th, wound in abdomen healed; wound of hip still open. He was finally discharged the service June 16, 1865." Examining Surgeon J. B. Walker, of Union, Maine, reported, April 17, 1867: "Wounded by a ball, which entered his back near the posterior part of the crest of left ilium, passed forward and upward, cutting through the bowels, and came out in front of the abdomen, two inches internal from the anterior superior spinous process of the left ilium, leaving a permanent opening from the bowels to the surface on the back, through which gas and fecal matter are constantly oozing without control. Disability total, and permanent." April 21, 1873, application for increased pension was pending.



CASE 281.—Private Franz Escher, Co K, 3d New Jersey Cavalry, aged 41 years, received a wound of the left side of the abdomen at Winchester, August 19, 1864. Diligent search failed to obtain the history of the case previous to his admission, on November 29th, into the field hospital at Winchester, under the charge of Assistant Surgeon H. B. Noble, 2d Ohio Cavalry. Here the injury is recorded as "a gunshot wound of the left ilium." On December 11th, he was transferred to the Filbert Street Hospital, Philadelphia, where Surgeon Thomas B. Reed, U. S. V., notes "gunshot wound of crest of ilium and intestine; the entrance wound was a little anterior to the posterior superior spine of the ilium; that of exit was just behind the anterior superior spine. There was artificial anus and loss of bone. Simple dressings." On May 11, 1865, he was transferred to Satterlee Hospital. Here the ward surgeon makes the following minute upon the prescription book: "Gunshot wound; ball passing through about two inches above the superior border of the ilium, near the anterior superior spinous process of the same, fracturing the hip-bone, and, doubtless, making an opening into the descending colon near its junction with the transverse colon. Occasionally his feces pass out in large quantities through the opening, especially when the bandage is loose, though a small quantity continually remains at the opening. The patient is doing well and the openings are clean and healthy." Bandaging of the abdomen was the only treatment resorted to. On July 25th, he was transferred to the Ward Hospital, Newark, and on September 14th, to DeCamp Hospital, New York, whence he was discharged from service on June 22, 1866, on account of "gunshot wound of the intestine above the crest of the left ilium, resulting in a permanent artificial anus." Pension Examiner J. Henry Clark, of Newark, New Jersey, reports, December 16, 1868: "The pensioner has an artificial anus in the left side of the abdomen, above the sacrum, from which considerable bone has been discharged. He has not defecated, I believe, for two years by the anus, and requires constant attendance. Disability total and undoubtedly permanent." Escher applied for an increase of pension, and, on November 6, 1872, appeared before the Examining Board of Surgeons at Newark, who report as follows: "Wound of sacrum, spine, and abdomen, leaving an artificial anus, which still exists. As permanent in degree, and not caused by vicious habits. We do not find any cause for increasing the rating. Disability total, second grade. Weight, 160; height, five feet eight inches; age, 50; respiration 18; pulse 70." Report signed by Drs. J. D. Orton and A. W. Woodhull.

CASE 282.—Corporal John N. Payne, 5th Vermont, aged 34 years, in the general assault on Petersburg, April 2, 1865, near Fort Welch, received a shot wound of the abdomen, and was taken to the 2d division hospital of the Sixth Corps, under charge of Surgeon S. F. Chapin, 13th Pennsylvania, when the injury was registered as a "gunshot flesh wound of the abdomen."

On April 11th, the patient was transferred to the depot field hospital of the Sixth Corps, under Assistant Surgeon J. S. Ely, U. S. V., who recorded the injury as a "gunshot flesh wound of the left side." On April 12th, the wounded man was sent to Washington and placed in Harewood Hospital. Surgeon R. B. Bontecou, U. S. V., reports that "a musket ball entered over the left hypochondriac region, passed obliquely downward and backward, and emerged near the spine, injuring, in its course, the descending colon; feces passed artificially at the exit of the ball. Simple dressings." A photograph of the patient was made under Dr. Bontecou's direction (*Phot. Surg. Cases*, S. G. O., Vol. I, p. 22). A reduced copy of this picture is presented in the accompanying wood-cut (FIG. 60). In a few weeks the wound healed entirely, and the patient was transferred to Vermont, May 26th, and admitted into Baxter Hospital, Burlington, on the 3rd. On June 29th, he was transferred to Sloan Hospital, Montpelier, where Surgeon Henry James, U. S. V., reviewing the history of the case, remarks: "The ball entered four inches from the median line, between the tenth and eleventh ribs on the left side, passed backward and downward and emerged behind, one inch above the crest of the ilium and two inches from the spine. The patient states that the shock was not great, and that he walked, without assistance, a half mile to the ambulance, which conveyed him about two and one-half miles to the field hospital. On the next day, he was taken about seventeen miles to the base hospital at City Point, where he remained seven days. While there, a considerable quantity of foreign substance, mostly shreds of clothing, was removed from the posterior wound. On April 10th, he was transferred to Harewood Hospital, Washington. On April 13th, after taking cathartic pills, other fragments of clothing were removed from the posterior wound. April 14th, there was a stercoraceous discharge from the posterior wound. For the succeeding three weeks he was kept under the influence of opium. The fecal discharge then ceased, but intestinal gases escaped for several days longer. He had some colicky pains; but not much tenderness, and no vomiting. His appetite was pretty fair most of the time. On May 25th, he was transferred to Burlington. The posterior wound closed early in June; the anterior opening healed a month later. On June 29th, he was transferred to Sloan Hospital, Montpelier, since which time he has had a variable appetite and constipation; otherwise he is in fair health. July 25th, he complains of some lameness along the course of the spine; passages from the bowels regular, appetite good, and patient gaining daily." These particulars are recorded on the back of a photograph made at Sloan Hospital (*Cord Phot. Ser.*, S. G. O., Vol. I, p. 12). Payne was discharged from service September 8, 1865, and was pensioned. June 18, 1867, Pension Examiner Marcus O. Porter, of Middlebury, New York, reports: "A rifle ball entered just below the left nipple, between the tenth and eleventh ribs, passed backward and downward, and emerged three inches lower than the point of entrance. The intestines were penetrated and fecal matter passed out of the wound for three or four weeks. An adhesion of the intestines appears to have been formed to the abdominal wall at the point of exit of the ball. He is entirely unable to perform manual labor on account of weakness of the right side, and the pain and soreness excited by muscular effort." He was last paid to December 1, 1872.

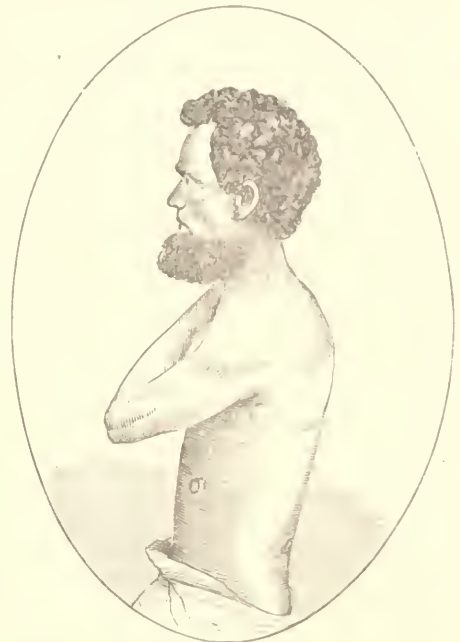

FIG. 60.—Cicatrices after a shot perforation of the descending colon.

CASE 283.—Private W. H. Blodgett, Co. B, 5th Minnesota, aged 18 years, of good habits and strong constitution, was shot by Sioux Indians early in the afternoon of August 18, 1862. After the reception of the wound he walked a distance of twelve miles, to Fort Ridgely, arriving about two o'clock A. M., and was admitted into the post hospital. The ball had entered between the first and second floating ribs, eight and one-fourth inches from the linea alba and two inches perpendicularly above the anterior superior spinous process of the left ilium, making an antero-posterior passage through the body six inches long, and escaping near the inferior articular process of the first lumbar vertebra on the same side; the missile had evidently lacerated the descending colon, near the sigmoid flexure, both in entering and escaping from the body. During the first two days some fetid gas escaped from the bowels; but after the slough had separated the discharges of fecal matter from both orifices became continuous and very copious, so much so, that the patient had to be put in a separate room and his bedding changed. On the fifth day, a very large number of small living worms (*trichocephalus dispar*) appeared on each of the wounds from inside the lacerated bowels. These entozoa disappeared after a few fomentations with a dilute solution of chloride of zinc. The treatment consisted in a strictly liquid and mucilaginous diet, cleanliness, the wearing of a large flannel bandage around the body, an occasional mild cathartic, if needed, and, once, an opiate to stop a slight diarrhoea. The inflammatory symptoms from the bowels were light, and lasted but a short time. The wounds were dressed with lint and simple cerate, the edges being occasionally touched with lunar caustic. As the wounds closed the discharge of fecal matter ceased, and, in four weeks, consisted only of a little mucous matter. By October 1st, the posterior wound had entirely, the anterior nearly, healed; the abnormal fecal discharge had entirely ceased. The soldier was able to eat the usual food without any inconvenience, and had regained his strength. Stooping and raising up quickly produced a sensation of heaviness in the abdomen. He was discharged from service October 24, 1862. Acting Assistant Surgeon Alfred Muller reports the case. A communication from Pension Examiner E. J. Kingsbury, dated June 22, 1867, states that the wound has produced a stricture of the bowels to a certain extent; also chronic gastro-enteritis and chronic constipation. He is totally disabled from obtaining his subsistence by manual labor. Blodgett was last paid December 4, 1872, his condition remaining unchanged.

CASE 284.—Lieutenant W. E. Carter, Co. G, 4th Vermont, aged 33 years, was wounded at the Wilderness, May 5, 1864. He was admitted to Armory Square Hospital, Washington, on May 25th, when the injury was recorded as a "gunshot wound of the abdominal walls." On June 13th, he was furloughed, and on August 6th, was readmitted and subsequently transferred to Volunteer Officers' Hospital, where he was admitted on August 10th, and from which he was returned to duty on August 12, 1864. Dr. George F. Stevens, late Surgeon 77th New York, in a communication received at this office in June, 1868, gives the following account of the case: "Within half an hour he received three wounds: first, through the abdomen, from left to right, cutting the intestine; second, a bullet wound through the hand, at the articulation of the upper phalanx of the thumb with the trapezium; third, a bullet wound of the left thigh, near the knee, the ball penetrating to the bone. The wound of the abdomen was made by some rough missile, either a bullet much battered, or a fragment of shell, or, as the lieutenant supposed, by an explosive bullet. It had entered at a point near the outer extremity of a line between the left inguinal and lumbar regions, and had made its exit at a corresponding point on the right side. In its course, the missile had wounded the intestine, and had torn the abdominal walls so as to allow the bowel to protrude from both the left and right wounds. He was taken to the hospital of the 2d division, Sixth Corps, when I returned the protruded bowels, and brought the wounds together by sutures. On the evening of May 6th, Lieutenant Carter, with the rest of the wounded of the Sixth Corps, was removed to Chancellorsville. On the evening of the 7th, as the army was to fall back, and as there was insufficient transportation for all the wounded, it was determined to leave those who seemed least able to bear moving. The surgeons, whose duty it was to designate those to be left, selected Lieutenant Carter, among many others, declaring that any attempt to move him would be absolutely fatal. After the rear guard had passed, in the retreat, Lieutenant Carter's brother and a wagoner placed him on a stretcher and carried him until they overtook the Vermont Brigade, three miles to the rear, when the commander of his regiment detailed men to carry him. After some time an ambulance was procured, in which he was carried until evening, when he was transferred to another ambulance, in which he rode all night, reaching Fredericksburg at daylight on the morning of the 9th, and finally obtained comfortable quarters. I found him, on the 10th, suffering considerably from his wounds, and with a high inflammatory fever. Water dressings were applied to the wounds, with ice to those of the abdomen, and opium was freely administered. Like most other wounded men, he became very anxious to have a movement of the bowels, and begged for cathartics, which were refused. On the 12th, an officious agent of the Sanitary Commission, hearing of his distress for physic, procured and administered to him a large dose of castor oil. Cathartic action soon commenced, and matter was discharged freely from both orifices made by the missile. Immediately upon discovery of the mischief, I administered a very large dose of opium, and he was kept fully under the influence of that drug for several days. The severe inflammatory symptoms gradually subsided, though fecal matter continued at times to escape from the wounds. May 24th, he was sent to Washington, to Armory Square Hospital, this being the twelfth time he was moved after receiving his wounds. Recovery progressed steadily; fecal matter frequently passing from the wounds until healing took place, which was early in July, when both orifices were closed, the intestine adhering to the abdominal wall. He returned to his regiment in August, but, finding the duties of the command of his company too severe for him, he resigned. In a letter to me, dated May 31, 1868, he says: "The extent of disability remaining is two ruptures, a useless thumb-joint, and a good deal of pain in my left leg." Previous to rejoining his regiment he had been promoted to a captaincy, which he resigned September 14, 1864, and was discharged the service. Examining Surgeon C. P. Frost, of Brattleboro', Vermont, reported April 18, 1868: "Ball entered left inguinal region of abdomen, just above and external to the left internal abdominal ring, and came out nearly at the corresponding point on the opposite side. The intestinal coats were perforated, as was made certain by a fecal discharge from the wound for nearly a month after it was received. There is a hernial protrusion at the point of entrance of the ball, which compels him to wear a truss. At the point of exit the abdominal walls are weak, and much more pain is felt there than when he was originally pensioned, still further incapacitating him from labor than it did at that time. He was also wounded by a musket ball, which passed through the metacarpo-phalangeal articulation of right thumb, producing ankylosis of that joint. A musket ball was also lodged in the popliteal region of the left leg, and was extracted. Disability seven-eighths." Last paid to March 4, 1873.



CASE 285.—Private R. E. Davis, Co. H, 4th New Hampshire, aged 25 years, was wounded at Jacksonville, March 25, 1862. There is no record of this case prior to his admission to hospital at Beaufort, September 15, 1862, with "gunshot wound." He was discharged October 19, 1862. J. H. Streeter, M. D., of Roxbury, Massachusetts, late surgeon of the Enrollment Board, third district of Massachusetts, forwards the following copy from the record of admissions to the Veteran Reserve Corps. "Gunshot wound of left iliac region, wounding intestines. Examined June 21, 1864; wound perfectly healed; had not fully recovered his strength." He adds: "There is no doubt in my mind of the nature of the injury received, as the man was intelligent and gave an accurate description of the inevitable effects of such a wound, especially the discharge from the wound for several months of stercoraceous matter." Pension Examiner B. S. Warren, of Concord, New Hampshire, reported, August 27, 1863: "Appears to have been struck by a ball upon the anterior aspect of the abdomen, one and a half inches above the anterior superior spinous process of the left ilium, a little toward the median line; apparently passed directly through the body, grazing in its exit the crest of the left ilium, nearly three inches from the sacro-iliac symphysis. There are also several buckshot in the upper third of left thigh, which can be felt through the skin. Disability one-half, and permanent." Pensioned at \$4 per month from October 19, 1862, but never paid.

CASE 286.—Sergeant J. E. Fletcher, Co. D, 8th Connecticut, aged 20 years, was struck at the battle of Antietam, September 17, 1862, by a musket ball, which entered six inches to the left of the umbilicus, and, passing somewhat downward, emerged an inch and a half to the left of the spine. The ball opened the descending colon, and when the patient was examined by Surgeon T. H. Squire, 89th New York, there was a profuse fecal discharge from the wound of exit. The ensuing peritonitis was circumscribed, and the patient was transferred to Frederick, a few weeks subsequently, in a satisfactory condition. The fecal fistula finally closed and the patient recovered, and was discharged from service January 9, 1863, and pensioned. Having applied for an increase of pension, he was examined by Pension Examiner R. Farnsworth, of Norwich, who reports, October 1, 1872, that "the sigmoid flexure of the colon was wounded. The pensioner states that a portion of bone was discharged from the exit orifice several weeks after the infliction of the wound. The injury renders defecation difficult, owing probably to the contraction of the colon. The injury to the parts at the junction of the ilium with the sacrum is what causes the most suffering, and unfits him for much manual labor. The inability to labor has increased. He suffers at intervals from severe cramp in the side, preventing him from making any effort for a considerable time." His application for increase of pension was allowed. He was paid September 4, 1872.

CASE 287.—Assistant Surgeon E. F. Hendrick, 15th Connecticut, reports that "A soldier of the 16th New York, aged about 30 years (the name I do not remember), was wounded at Suffolk, Virginia, May 3, 1863, by a conoidal musket ball, which entered three inches to the left of the umbilicus, and escaped from the left lumbar region two inches from the spine; the descending colon was probably perforated. Fæcal matter escaped both at the anterior and posterior openings. He was placed on his back, and the discharges from the intestines allowed to escape through the posterior wound. The case progressed favorably, and in seven weeks the anterior opening had closed. Soon after, the patient was placed upon his abdomen and kept in this position for several weeks. Enemata were administered to facilitate the discharge of fecal matter through the rectum, which had not occurred since the first or second day after the reception of the injury. The discharges soon passed through the natural channel, and, by September 1st, the posterior wound had closed; about a month later the patient was transferred to the Veteran Reserve Corps, and soon after went North, on a furlough, to visit his friends. He at this time was rapidly regaining his health and strength."

CASE 288.—Private W. D. Wikel, Co. D, 20th Pennsylvania Cavalry, aged 18 years, was wounded in the left side of the abdomen, at Piedmont, June 5, 1864. He was left upon the field, and was subsequently removed to Staunton, where he came under the observation of Assistant Surgeon William Grunbein, 20th Pennsylvania Cavalry, who had been sent through the enemy's lines to attend the Union wounded. He remarks that "the ball passed through the sigmoid flexure of the colon, and emerged from the left iliac region; the wound was pronounced mortal. Fæcal matter escaped through both openings; the suppuration was very profuse, especially from the anterior opening. The wound gradually closed, and two months after the receipt of the injury the patient was about well." On September 1st, he was paroled and placed on board the flag-of-truce steamer New York, and conveyed to Annapolis, where he was admitted into the 2d division hospital. On the 22d, he was transferred to Camp Parole, and, on October 14th, to Mower Hospital, Philadelphia, whence he was discharged from service May 26, 1865. Pension Examiner W. M. Guilford, of Lebanon, Pennsylvania, reports that he examined Wikel, on his application for increase of pension, February 26, 1870: "the ball had entered the left groin, a little below the anterior superior spinous process, and escaped through the ilium, a little below its crest, posteriorly. Both orifices are discharging slightly at this time; the wounds are retracted and corrugated. The pensioner alleges that at times the wounds discharge much more freely. The limb of the corresponding side is somewhat atrophied. Disability total, third grade, and probably permanent." In April, 1873, the application for increase was still unadjudicated.

CASE 289.—Private John B. Adams, Co. C, 19th Maine, aged 28 years, was wounded at Gettysburg, July 2, 1863. He was treated in field hospital until August 5th, when he was admitted to Camp Letterman Hospital. Assistant Surgeon H. C. May, U. S. V., makes the following report of the case: "Wounded by a minie ball entering three inches above the anterior superior spinous process of the left ilium, and emerging three inches to the right of the fourth lumbar vertebra. November 2d, the anterior wound is nearly healed; has, ever since injury, and still continues to have, fecal evacuations through the posterior wound. Also wounded in the right leg by a minie ball entering over the internal malleolus, passing upward and backward, and lodging under the integuments over the belly of the gastrocnemius, whence it was removed; wounds healed. Also, wounded in left leg by a minie ball entering the outer aspect of the gastrocnemius, and emerging near the popliteal space; wounds healed. The patient received the last two wounds while crawling off the field on his hands and knees." On November 7th, he was transferred to Baltimore, and, on the 8th, was admitted to Newton University Hospital. On May 24, 1864, he was transferred to New York, and admitted to DeCamp Hospital, and, on June 2d, was sent to Augusta, Maine, where he was received into Cony Hospital on the following day. June 23, 1865, he was discharged from the service. Pension Examiner J. B. Bell, of Augusta, reports, July 23,



1865: "Wound of spine, left kidney, and descending colon, causing an artificial anus, which has now closed; but the bowels do not act properly." For the lame back the disability is rated at two-thirds; and for lameness, caused by wounds of both legs, is rated at one-third. Disability total, and permanent. Pension Examiner C. W. Snow, of Skowhegan, reports, May 8, 1872: "Ball entered just above crest of ilium, on left side, and emerged over spine, fracturing one or more processes of vertebrae. Faecal matter passed through opening in back for several months. Gunshot wound of both legs. Wound of abdomen causes great trouble, the side being weak and painful; solid and hearty food causes great distress; diet is chiefly bread and milk. Disability total, third grade." Weight, 150 pounds; age, 36 years; respiration free; pulse regular. Latest certificate on file, May 8, 1872. Pension, \$18 monthly.

CASE 290.—Captain Henry B. Barnard, Co. L, 2d New York Mounted Rifles, aged 27 years, was wounded at Petersburg, July 30, 1864, by a conoidal ball, which entered the anterior aspect of the upper third of the left thigh and came out at the right gluteal region; in its passage, it wounded the sigmoid flexure of the colon. He was taken to the field hospital, and, on August 3d, was transferred to Washington and admitted into Armory Square Hospital, under the charge of Surgeon D. W. Bliss, U. S. V. Faecal matter and urine escaped from the wounds. Tonics and good diet were ordered. The patient did well, and, on September 8th, was furloughed, at which time the wound was still open. About two months afterward, he returned to the hospital on his way to his regiment, and was "perfectly well." He is reported by the Adjutant General of the State of New York as having been discharged from service January 20, 1865. Pension Examiner H. F. Montgomery reports, March 22, 1865: "There is now, on the inside of the left thigh, one inch from the groin, an ulcer with a hard inflamed base and a fistulous track upward and downward, possibly connecting with the urethra or rectum." Pension Examiners B. L. Hovey and H. F. Montgomery, of Rochester, reported, November 24, 1871, that "the left thigh measures, in circumference, one-half less than the right at a corresponding point. He complains of pain in the back, and lameness after protracted labor." He was last paid December 4, 1872.

CASE 291.—Private Thomas H. Graham, Co. G, 1st Michigan, aged 18 years, was shot through the abdomen, at Bull Run, August 30, 1862, and was placed in an ambulance and sent to Washington, and admitted to Judiciary Square Hospital on the following day. There was but slight hæmorrhage, and the shock and depression were less intense than is commonly observed in penetrating shot wounds of the abdomen. Surgeon John H. Brinton, U. S. V., saw the patient, and took much interest in the case, making notes of its principal features, and a diagram. Pension Examiner R. C. Hutton, also, has made several extended reports of this case, which Dr. A. L. Lowell, of the Pension Bureau, has politely transcribed and transmitted to this office. Dr. Brinton described the wound as inflicted "by a conoidal musket ball, which entered near the lower boundary of the left lumbar region, at a point about six inches to the left of the mesial line of the abdomen, and, passing backward and a little obliquely downward, made its exit about two and a half inches to the left of the spinal column, injuring the crest of the ilium in its course." Dr. Brinton further states that, "after a few days, a faecal discharge occurred from both the openings, and continued until October 25th, when it ceased. The colon only was wounded. October 31st, nearly well; slight discharge of pus from the entrance wound, but no faecal matter; exit wound closed." The hospital records show that Graham was discharged from service June 6, 1863, and pensioned. Several reports from pension examiners are on file, but the latest, by Dr. R. C. Hutton, of Howell, Michigan, covers the whole ground. After rehearsing the facts above related, Dr. Hutton continues: "The crest of the ilium was fractured, and probably considerably shattered, as the subsequent involvement of a considerable portion of the ilium, in a carious condition, indicates. The original wounds are indicated, on the diagram hereto attached, by the numerals 1, 2, both of which remain open ulcers. Subsequently ulcers became established in the order designated by the letters *a*, *b*, and *c*, on the diagram. The points of interest are that a probe may be passed through the original sinus, from 1 to 2, or from 1 to *a*, there being but a slight septum intervening between the two last-designated openings. A second probe, introduced at *b* or *c*, will readily intersect the first any where along its middle third. There is but a slight septum interposing between the openings *b* and *c*. From each of these sinuses there is constantly escaping an unhealthy sanious discharge, together with the faecal contents of the bowels. Occasionally kernels of corn, apple seeds, and other indigestible articles have passed through the stomach and been ejected through these several sinuses. He is of healthy stock, and is a broad-shouldered, deep-chested, capacious stomacher, powerful looking organization, and, before he was thus wounded, ordinarily weighed 185 pounds. Now he bears a sallow, sickly countenance, cannot stand erect, his left side being shortest. The left hip joint has become

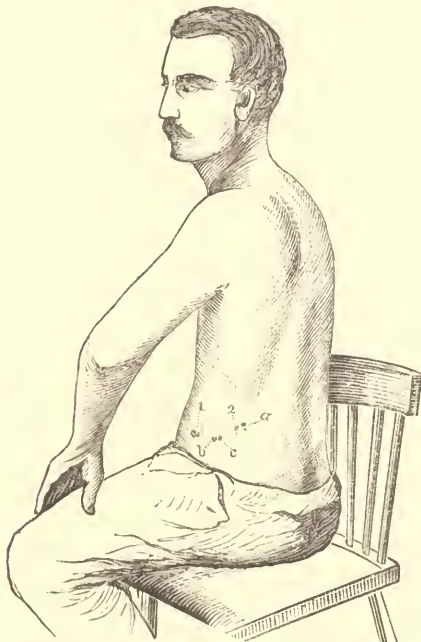

FIG. 61.—Diagram of fistulous sinuses following a shot perforation of the colon and fracture of the crest of the ilium.

partially ankylosed, lateral motion of left leg being entirely destroyed. He can elevate the knee but three or four inches, and is, consequently, quite lame, and frequently unable to move about. The discharges from these wounds make him extremely offensive to society, under the most favorable appliances at his command. He would have died long ago from utter detestation of his condition, were it not for his indomitable pluck and patriotism. I have been intimately acquainted with him before and since his return from the war, and know that the condition of his disability has been constantly growing worse, and that for the past four or five years he has generally needed the attendance and aid of some person to assist him in dressing his wounds daily. I regard his case as utterly hopeless of relief." This report is dated March 6, 1872.

The counter-indications, in this case, to an operation for the removal of necrosed portions of the ilium, and the closure of the preternatural opening in the colon, are not stated. Without other data than the descriptions afford, it would appear possible to resort to such a proceeding, even without interesting the peritoneal cavity. But Dr. Hutton probably reserves good reasons for rejecting such interference, and pronouncing the case "utterly hopeless of relief." Both Drs. Brinton and Hutton illustrate the positions of the lesions in this case by diagrams, one of which has been copied on the opposite page. In the others (FIG. 62), the abdomen is subdivided by transverse and perpendicular lines, as described by Quain and Wilson,<sup>1</sup> and the point of entrance of the ball is marked by Dr. Brinton as near the inner angle of the left lumbar region, and by Dr. Hutton somewhat lower and further to the left. The regions into which the abdomen proper is subdivided by modern anatomists are probably well selected for convenience of description. But the designation of the anterior lateral regions, or flanks, as *lumbar* regions, is at variance with common parlance. In a surgical point of view, it is questionable if it would not be more convenient to make the arbitrary division into four zones anteriorly, with reference to the topographical importance of the anterior superior spinous processes of the ilia, and the incompleteness of peritoneal covering of the colon in the upper iliac regions.<sup>2</sup> Penetrating wounds in the supra-iliac, iliac, and inguinal regions are commonly less grave than those in other parts of the abdomen.

It is inferred that the lesions in the two following cases were in the descending colon, though precise information on the subject is wanting:

CASE 292.—Private *Houston Quinn*, Co. C, 11th Mississippi, aged 22 years, was wounded at the second battle of Bull Run, August 30, 1862. The Confederate records give the following account of the case: "He was admitted to hospital No. 12, Richmond, on September 28, 1862, with gunshot wound through the hip, injuring the colon, the ball lodging. There was an artificial anus, and the wound was doing well, and was dressed with cerate. The soldier was discharged October 5, 1862, the ball being still retained."

CASE 293.—Corporal *W. B. Brown*, Co. F, 24th Alabama, wounded at Chickamauga, September 19, 1863, by a conoidal ball, which passed through the abdomen. Faecal matter passed from both orifices for fifteen days; finally both fistulae healed, and the faeces passed naturally. There were no peritoneal symptoms, and he was sent to the rear in safe condition, October 31, 1863.<sup>3</sup>

It is known that forty-one of the subjects of the foregoing fifty-nine abstracts of cases of partial or complete recovery after shot wounds of the large intestine still survive, and their present condition has been ascertained from the pension returns. Four pensioners (CASES 248, 268, 270, 272) are known to have died, at periods of from four to six and a

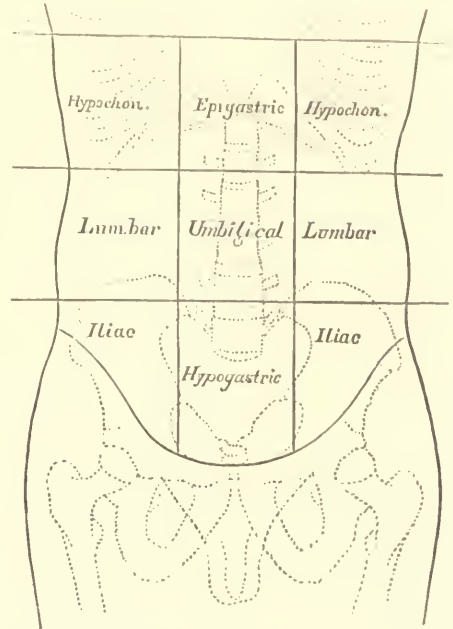


FIG. 62.—Diagram of the subdivisions of the abdominal regions.

<sup>1</sup>QUAIN, *Elements of Anatomy*, Seventh ed., London, 1867, Vol. II, p. 824, Fig. 577. WILSON, *The Anatomist's Vade Mecum*, Am. ed., 1859, p. 516, Fig. 327.

<sup>2</sup>Three transverse lines—the upper connecting the prominent points of the lower costal cartilages, the second, a little above the highest points of the crests of the ilia, the third at the anterior superior spinous processes of the ilia—intersected by two vertical lines from the eighth costal cartilages to the middle of the ligaments of Poupart, would subdivide the front of the abdomen into twelve spaces, those in the upper zone named epigastric, right and left hypochondriac; those in the second zone, upper umbilical, right and left lateral or supra-iliac; those in the third, lower umbilical, right and left iliac; those in the lowest, hypogastric, and right and left inguinal.

<sup>3</sup>This case is reported by CARLYLE TERRY, Chief Surgeon of Hindman's Division, in the *Confederate States Medical and Surgical Journal*, 1864, Vol. 1, p. 77, CASE 49.

half years subsequent to the dates the injuries were sustained. Of seven Confederates and seven Union soldiers, whose ulterior histories have not been traced, the probabilities are that they still live; since cases in which recovery was rapid and complete are, for the most part, included in this group, and none of the names appear on any of the various mortuary records that are accessible for reference in this office. In the four fatal cases adverted to, the stercoral fistulæ remained pervious; and in five of the forty-one cases still under observation, the preternatural openings are yet unclosed; the wounds had fairly healed, in the fourteen remaining cases, before they passed from observation. Therefore, in fifty-nine cases, the stercoral fistulæ persisted in nine; and in fifty closed—within a month, in seventeen cases; within a year, in twenty-eight; in five, at periods extending from one to four years. The intestinal wounds were complicated by fractures of the ilium in eighteen cases; with fractures of the transverse processes of the vertebræ, in two cases at least; with fractures of the humerus or bones of the forearm, in three cases; with fracture of the ribs, in one case.

*Balls voided at Stool.*—It is probable that, in nearly all instances in which balls are voided at stool, the projectile enters the digestive canal through some portion of the colon. When discharged at an early period after the reception of the injury, it may be inferred that the missile primarily and directly penetrated to the cavity of the gut, and that the edges of the orifice through which it entered, having contracted adhesions to the parietes or to the adjacent viscera, fæcal escape has been prevented. When the missile is discharged at a later period, it is reasonable to suppose that it has lodged in parts contiguous to the great intestines and gained admission to the cavity of the bowel by ulcerative absorption, or by the irritation of its presence producing an abscess that seeks an outlet in the nearest hollow viscus. Pathological anatomy teaches us that foreign bodies, sacculated in the abdomen, tend to be eliminated through the colon. The experience of the war furnishes examples of both varieties of cases of this group, of which some instances<sup>1</sup> have been already adduced. In one of these, the case of Captain Stolpe, it was supposed that the projectile, which appeared in the alvine discharges five days after the reception of the wound, had penetrated the stomach. But this appears highly improbable, for there were no acute symptoms of gastric disorder; and it will be recollected that in CASE 196, in which a musket ball unquestionably entered the stomach, it remained there unmoved for eight days. Dupuytren (*Leçons orales*, T. VI, p. 464) thought that if a ball lodged in the stomach, it would be propelled through the pylorus; but the facts observed in CASE 196 indicate that a wound of that organ, interrupting the normal peristaltic movement, may arrest the propulsion of the foreign body.<sup>2</sup> That a ball may pass promptly through the entire alimentary canal, without inducing grave disturbance, is attested by the instances in which captured couriers are alleged to have safely swallowed dispatches concealed in leaden balls, and by the following remarkable instance, communicated by Dr. S. C. Ayres, of Cincinnati:

CASE 294.—Captain Rowland E. Hackett, Co. A, 26th Kentucky, aged 38 years, was wounded at the battle of Nashville, December 15, 1864, and admitted to Cumberland Hospital, under the care of Assistant Surgeon S. C. Ayres, U. S. V., who writes: "My recollection of the case is as follows: I had charge of Wards 11 and 12 at that time, and Captain Hackett was

<sup>1</sup> See cases of STOLPE (*First Surgical Volume*, pp. 515, 538), and BELT (*ibidem*, p. 584, and *Second Surgical Volume*, ante, p. 36), and ENGLISH (*ibidem*, p. 37).

<sup>2</sup> That a ball may penetrate the stomach, without causing any symptom of derangement of the alimentary canal (!), and be propelled onward and voided by the anus on the sixth day, is established, if credit be given to the report published in the *Repertorio Medico-Farmacéutico de la Sociedad de Emulacion de Barcelona*, by Dr. COX, of a lad of fifteen, who survived a shot wound of the lung and stomach twelve days. This marvellous observation is translated in *L'Expérience*, and in the *New York Journal of Medicine*, 1845, Vol. IV, p. 117 and is cited by GUTHRIE (*Inj. of Abdomen, Lecture III*, p. 38) without criticism.



brought into Ward 12, late at night, after the second day's fight, December 16, 1861. I examined him and found that he had been struck on the dorsum of the tongue, and that three of the incisors of the lower jaw had been knocked out. I introduced my finger into the wound and felt one of the teeth lodged in the base of the tongue and removed it without difficulty. There was no hæmorrhage of any account, and he was not suffering much pain. His voice had a very muffled peculiar sound, as if something was lodged in the throat. At the time of the reception of the wound, he was acting as major of the regiment and was on horseback. He was wounded as our troops were making a charge on the rebel works near the 'Granny White' pike. He was cheering his men at the time he was shot, and naturally had his mouth wide open. This may account for the fact that the teeth of the lower jaw were knocked out and that the ball struck the dorsum of the tongue about midway between the tip and the base, and also for the fact that the lower lip was not injured. When I saw him, I thought there was no indication to interfere, and therefore only instructed him to keep quiet in bed. The next morning he was quite comfortable. There had been no hæmorrhage, and no unfavorable symptoms had appeared. I instructed him to watch his evacuations, thinking that possibly the ball might have passed into the œsophagus and thence into the stomach. The next morning, about thirty-six hours after the wound was received, he passed the ball by the rectum. The wound healed kindly, and, in a short time, his voice assumed its natural tone. My recollection of the ball is that it was not a rifle ball, but one about the calibre of a Colt's revolver." The report from Cumberland Hospital, signed by Surgeon B. Cloak, U. S. V., states that the missile was an "Enfield rifle ball," and that the officer was transferred to Louisville January 2, 1865. The report of the officers' branch of the Clay Hospital, at Louisville, signed by Surgeon F. Greene, U. S. V., returns the case as a "shot wound of the tongue from an Enfield rifle ball," and that this officer was discharged on January 15, 1865, to report to his command after twenty days' leave of absence. The register of volunteer officers records Captain Hackett as promoted to a lieutenant colonel April 1st, and honorably mustered out with his regiment July 10, 1865.

Doubtless, in Captain Stolpe's case, the ball, after traversing the diaphragm, penetrated directly into the transverse colon, which, sustained by the general equal pressure, speedily contracted adhesions, and allowed no extravasations to take place. The cases of Belt and English (CASE 169), on the other hand, were examples of secondary perforation of the intestinal wall. Other examples of both varieties of injury were observed. The case of Dowdy, mentioned in Circular No. 6, is interesting. It is identical with the instance recorded by the late Surgeon W. H. Rulison,<sup>1</sup> U. S. V.:

CASE 295.—A Confederate soldier, registered as Private *James T. Dowdy*, 28th Virginia, aged 23 years, was wounded at Gettysburg, July 3, 1863, by a conoidal musket ball, which entered at the tip of the ensiform cartilage, and remained in the body. He was admitted, on July 3d, to the Seminary Hospital, and was removed, on July 29th, to Camp Letterman Hospital. Here Acting Assistant Surgeon James Newcombe reports: "The ball passed through the ensiform cartilage. No great shock was experienced at the time, and no hæmorrhage whatever took place, either by sputa or stool, and only very little escaped externally. About fourteen hours after the reception of the wound, a copious stool was passed. The patient heard something fall heavily and loudly to the bottom of the vessel. Suspecting it to be the ball, he requested the nurse to look carefully for it. A large minié ball was found." Surgeon Rulison mentions that the ball was considerably battered, "showing that it had struck something before wounding the man." On September 17th, Dowdy was transferred to the West Buildings Hospital, Baltimore, whence he was paroled, September 25, 1863, and sent to City Point. In a visit to Virginia, in July, 1870, the editor learned that this man was still living, in good health, in Bedford County, and desired a rectification of the report of his case in Circular No. 6. He did not wish, he said, to exemplify Lord Byron's definition of glory, by being shot through the body and having his name spelled wrongly in the gazette. He should have been registered *Sergeant Albert Dowdy*, Co. G, 28th Virginia, and was wounded at Chester Station, on June 16, 1863, a fortnight before the battle of Gettysburg."

The late Surgeon H. W. Ducachet,<sup>2</sup> U. S. V., recorded two examples of this group. In both instances the missiles appear to have penetrated the wall of the transverse colon— anteriorly, in the one case; in the other, from behind. Other reports have supplied additional particulars of these cases.

CASE 296.—Lieutenant J. S. Harrold, Co. H, 14th Indiana, aged 22 years, was wounded at Chancellorsville, May 3, 1863, by a conical ball, which entered an inch and a quarter below the umbilicus and a quarter of an inch to the left of the median line. The patient was sent by rail to Aquia Creek, and thence, on the transport steamer *Mary Washington*, to Georgetown, and was admitted to Seminary Hospital on May 6th, where Acting Assistant Surgeon Woodbury reported that "the appearance of the wounded man was good; there was slight pain in the abdomen, and nausea; the bowels moved very frequently; the wound looked well. The appearances indicated that the ball, entering the abdomen midway between the pubes and umbilicus, in the median line, had passed on, channeling the bowel in its course. The patient's statement is, that he has been troubled with giddiness and nausea—had also pain and difficult micturition—and no appetite; took medicine from several surgeons on the boat, but does not know its nature. On the morning of May 8th, he had slight pain in the abdomen, and at four in the afternoon there was a yellow, scanty, alvine defecation, that contained a minié ball. After this the patient was comparatively comfortable, but there was nausea and some diarrhœa, and he was directed to take one-eighth of a grain of sulphate of morphia in mint-water. There was vomiting in the morning, and diarrhœa recurred, but not in a severe form, and he was ordered an injection of starch

<sup>1</sup> RULISON, W. H. *The Escape of Balls by the Rectum*, in the *Am. Med. Times*, 1863, Vol. VII, p. 242.

<sup>2</sup> DUCACHET. *Gunshot Wounds of the Abdomen, Balls being passed by the Rectum*, in the *Am. Med. Times*, 1863, Vol. VII, p. 134.

and laudanum, which was repeated on the 14th, when the patient looked much better, and the wound was in excellent condition. On the 18th, vomiting and epigastric pain recurred, and required the use of fomentations and neutral mixture. The nausea and irritability of the bowels returned, at intervals, until the 10th of June, but there was a gradual improvement in the general condition notwithstanding these drawbacks. On the 13th, the officer went home on leave of absence. On September 19th, he was mustered out, and afterward pensioned. Though recorded as discharged at this date, this officer would appear to have seen much active service subsequently, since the report of Pension Examiner J. T. Belles, March 4, 1867, states that he was "wounded at six different times, and in different parts of the body, of which I will only mention two, as either of them alone is sufficient to entitle him to a full pension. First, he was shot in the left forearm, destroying the shaft of the ulna and causing its removal, and injuring the muscles of the part, thereby causing complete ankylosis of elbow joint, rendering the forearm useless; second, wounded in the abdomen, the ball entering at a point above it, midway of the umbilical region, and passing into the intestine, and subsequently discharged at stool. This caused considerable derangement of the muscles of the abdomen and bowels. There is sufficient irritation to cause the lower part of the bowels to discharge considerable pus. Exercise is very painful." He was still a pensioner in September, 1872.

CASE 297.—Corporal C. B. Lupton, Co. B, 2d New York Cavalry, aged 20 years, was wounded at Upperville, June 21, 1863 [Dr Ducachet stated: "Rockville, July 28th;"] but the man entered hospital on June 28th, by a solid conical pistol ball, which penetrated the lumbar region. He was conveyed in an ambulance to Georgetown, and entered the Seminary Hospital, whence Acting Assistant Surgeon T. W. Miller reports the progress of the case as follows: "The ball entered the lumbar region, passing between the second and third lumbar vertebrae and remaining in the abdominal cavity. On admission, the patient had high fever and great abdominal tenderness. He was ordered to have flaxseed cataplasms over the abdomen, to take calomel and opium, and low diet. This treatment was continued until July 2d, when the calomel was omitted and the opiate continued. On July 4th, the ball was passed by the anus, about 4 A. M., without any inconvenience to the patient." After this, he improved without any adverse symptoms, except, at times, a slight diarrhoea, which yielded to appropriate treatment. On July 28th, he was transferred to Armory Square Hospital, Washington, and was returned to duty October 3, 1863. The name does not appear upon the Pension List.

CASE 298.—Private Cyrus Stanley, Co. C, 39th Indiana, is alleged to have been wounded at Stone River, December 31, 1862. His name does not appear upon the list of casualties, and he is supposed to have been made a prisoner. At all events, he was admitted into Armory Square Hospital, Washington, March 20, 1863; on May 5th, was transferred to Convalescent Hospital at Fort Wood, New York Harbor, and, on May 12th, to DeCamp Hospital. Here Acting Assistant Surgeon James W. Dickie has noted upon the descriptive list that "the ball entered half an inch below the last rib and four inches to the right of the vertebra, penetrated the abdominal cavity, and lodged. The patient voided the ball at stool ten days after the reception of the injury. When admitted, the wound had healed and the general health of the patient was good. He suffered, however, from partial paralysis of the right side, and œdema, and loss of motion in the right foot. Bandages were applied over the wound and counter-irritation made to the abdomen; full diet ordered." Stanley was discharged from service June 3, 1863, and pensioned. Pension Examiner Manuel Reed, of Portland, Indiana, reported, March 28, 1869: "The missile entered the right loin, passed through the upper part of the right kidney, and lodged in the bowels, where it remained for ten days, at the end of which time it (an ounce musket ball) was discharged. From the effects of the said wound he is permanently disabled. There is incomplete paralysis of the right side. He is affected, in laboring, by not having complete control over the leg and arm, and not having power of endurance. The muscles are wasting away, shrunken, and flabby. He also has constant pain in the back of the neck and in the spinal column, often so severely that he is confined to his bed for days. His entire system is very much debilitated. Disability total, of the second grade, and permanent." This pensioner was last paid September 4, 1872.

CASE 299.—Corporal Morris D. Tucker, Co. I, 15th Massachusetts, aged 26 years, was wounded at Spottsylvania, May 12, 1864, being struck in rapid succession by several musket balls. He was taken to the hospital of the 2d division, Second Corps, where Surgeon J. F. Dyer, 19th Massachusetts, recorded the injuries as "gunshot flesh wounds of the left hip and leg." On May 26th, the wounded man was taken to Lincoln Hospital, Washington. The hospital record is very meagre, and makes no reference to a lesion of the intestine. Subsequently, Examining Surgeon A. L. Lowell, of Wilmington, Vermont, April 17, 1871, gave the following detailed report of the case: "Weight 130; age 32; respiration abnormal, and pulse irregular. A musket ball entered the left thigh, just above the knee and external condyle, passing upward and inward through the muscles and tendons of the outer and also the anterior aspect of thigh; it inflicted a severe laceration of the soft parts, and made its exit through the rectus muscle, six inches above the knee, and entered the chest at the seventh rib of left side. The extensive laceration and great loss of muscular tissue, fascia, and integument, leaves the injured limb seriously disabled and inefficient; a deep, broad, irregular cicatrix, adherent to the femoral periosteum and restricting the functions of muscular structures of the thigh and leg, marks the site of the wound. The limb is affected with acute neuralgia, with formation, and impairment of nervo-motor function. Another ball entered the same thigh on its posterior aspect and upper third, passing upward, and injuring the sciatic nerve. It is still encysted near the sciatic foramen, where it evidently impinges upon the nerve and causes severe sciatic neuralgia and pain throughout the entire limb. He alleges that his sleep is much disturbed by these paroxysms of pain. The depressed temperature of the limb, and the evident deficiency of muscular tone, demonstrate that the innervation of the limb is seriously injured. The saphenous vein of the left thigh is affected throughout with varices. These two wounds of the same limb result in a degree of disability which is evidently total. Another, and by far the most serious injury, was inflicted by a musket ball, which penetrated the abdomen and intestines in the left inguinal region. This wound resulted in a fecal fistula, which finally healed after several months' treatment. The contents of the bowels were for several months voided at this traumatic opening. He alleges that the bullet was voided with the stools, four weeks after the injury was inflicted. The wound closed with a very thin and extremely sensitive cicatrix, in which is involved fascia, integument, and peritoneum, and the intestines. The movements of gas and the contents of the intestines are distinctly felt through this cicatrix, and it is alleged that every jolt or strain of the abdominal muscles causes acute pain at this point, and oftentimes nausea. This injury is slowly killing the man. His body is much emaciated. The complexion is sallow, and expression languid. The tongue is constantly



coated. The pulse is irregular and thready, and the assimilative functions are seriously deranged. The nerve action is irregular, and shows functional disturbance and irritability. His standard weight in health was 190 pounds; he now weighs 130 pounds. The hepatic region is tender on pressure, and the abdominal walls are tumid. The prognosis in this case is very unfavorable. It is my opinion that the injury inflicted upon the viscera has resulted in serious derangement of the sympathetic nervous system, and that this disturbance is perpetuated by local chronic peritonitis. I have carefully inquired into the past history of this pensioner, and find that he is held by the best citizens of his town to be a man of sterling integrity and of excellent social standing. He is poor, and has a wife and small children to support. He has, since leaving the hospital, tried to earn something, for the support of his family, at various light occupations, but has been compelled by his physical distress to give up all active employment. Such I find, upon the most respectable authority, to have been this man's history since he returned from the hospital. His condition is growing worse, and I question if he survives a year. His condition commands the real sympathy of the entire community where he resides. It is very evident that he has been hitherto very hastily examined and carelessly rated. He has, I am fully satisfied, been entitled to 'total second grade,' act June 6, 1866, since its passage. I therefore recommend that he be rated at that grade from the passage of the act. Disability total, second grade, and permanent." On November 15, 1871, Pension Examiner Thomas F. Smith, of New York, reports of this pensioner: "The ball entered above Poupart's ligament, on the left side, and was passed through the anus. He has had an artificial anus, and is now suffering from chronic peritonitis. Another ball entered upon the external aspect of the right knee and emerged above the knee. This wound was followed by gangrene, causing a large loss of muscular tissue. Another ball entered just below the right trochanter major, and still remains embedded in the deep muscles. There is considerable atrophy of the limb, also neuralgic pains. Another ball entered the fifth intercostal space. Respiration is difficult." This pensioner is still on the Roll."

Since the war, Assistant Surgeon J. H. Patzki has presented to the Museum a pistol or carbine ball (Fig. 63) that penetrated the abdomen through the ilium, and subsequently was voided at stool. The memorandum accompanying the specimen does not indicate the precise point of entry of the projectile, or the exact date of its elimination. It is highly probable, however, that it entered the sigmoid flexure by ulceration, and was discharged in defecation within thirty days from the date of the injury:

CASE A<sup>2</sup>.—"Private George Armstrong, Co. I, 29th Infantry, was shot by a large-sized revolver ball, August 23, 1868, whilst trespassing upon a fruit garden at night. The ball penetrated through the *os ilii* into the abdominal cavity, beyond reach. The abdominal viscera apparently escaped injury. The wound was drained by means of a perforated rubber tube, and dressed with carbolated oil. The patient bids fair to recover." This entry is on the August sick report of the 29th Infantry, signed by Assistant Surgeon Patzki. On the September report, signed by Acting Assistant Surgeon J. T. Pindell, there is the following entry relative to this case: "Private George Armstrong, Co. I. This case was reported last month, with full particulars. Ball subsequently found, having penetrated by ulceration the abdominal viscera and been discharged by the intestines. Patient is still in the hospital and is rapidly convalescing." As the man was wounded on August 23d, and is reported as "rapidly convalescing" on September 30th, the foreign body was probably expelled some days prior to the latter date. Indeed the regiment changed station on September 27th, moving to Tennessee. There were two cases of shot wounds on the September report, of which one is accounted for as "returned to duty." The remaining case, probably that of Armstrong, is recorded as "returned to duty" on the October report. Assistant Surgeon Patzki, in forwarding the specimen, writes: "The ball penetrated the *os ilium* of Private Armstrong, 29th Infantry,—afterward discharged by the bowel (see monthly reports for August and September, 1868), the latter forwarded in my absence by Dr. Pindell." The missile is represented the size of nature in FIG. 63. It weighs two hundred grains. The apex is flattened by impact on the innominate bone.




FIG. 63.—Carbine or pistol ball voided at stool. *Spec. 5539.*

There is yet another instance that may be grouped in this category, though belonging to a class of injuries that will form the subject of the succeeding chapter. It was reported by Dr. S. Cabot to the Boston Society for Medical Improvement,<sup>1</sup> as follows:

CASE 300.—"A soldier received a wound at the battle of Antietam, September 17, 1862, the ball entering the left buttock on a line parallel with the trochanter major, and about two inches behind it, and lodging in the pelvis. Since the receipt of the wound he suffered some pain in the pelvis, knee-joint, and small of the back. The patient was always convinced, from his own sensations, that the ball was situated in the rectum, some distance from the anus, where, in fact, it was discovered by a surgeon in Philadelphia, who refused, however, to remove it, saying that the attempt would be dangerous. The patient being etherized, a thorough examination of the wound was made with a probe, and with an instrument tipped with porcelain, but the ball could not be detected. The finger was then passed into the rectum, and the ball was felt lying beneath the mucous membrane. The membrane was ruptured with the finger and the ball removed with the forceps. The patient did well."

An alleged instance of penetration of the sigmoid flexure of the colon by a musket ball, in a negro lad, who reported that the missile was voided at stool on the fourth day, is printed in a periodical of Cincinnati.<sup>2</sup>

<sup>1</sup> CABOT (*Boston Med. and Surg. Journal*, 1863, Vol. LXXIII, p. 101). The name of the patient has not been identified.

<sup>2</sup> WRIGHT (T. J.), *Cases in Military Surgery*, in *Am. Eclectic Medical Review*, 1868, Vol. IV, p. 108. Dr. WRIGHT records this as a case observed by him while on duty with the 53d Illinois Volunteers, at Camp Holly Springs, near Fort Pickering, in the spring of 1863. Dr. WRIGHT's name is not found in the list of regimental medical officers.



*Fatal Cases.*—While contributing thus largely to our information concerning the progress and results of shot wounds of the large intestines, the experience of the war added little to our knowledge of the pathological anatomy of this group of injuries. I have already adverted to the rarity of preparations illustrating the results of injuries of the colon.<sup>1</sup> The collection of the Army Medical Museum possesses but few examples. In a preparation presented to the Museum by Assistant Surgeon G. A. Mursick, U. S. V. (FIG. 64), the cæcum was perforated by a musket ball, which, entering in the right hypochondrium, passed downward, inward, and backward, and lodged against the sacrum. Though the missile had also traversed the lower portion of the right kidney, the patient survived his injuries twelve days. The margin of the orifice in the gut was ulcerated and coated with false membrane. The case will be fully reported in the subsection on shot wounds of the kidney. Another preparation of a shot perforation of the cæcum, presented by Dr. W. Leon Hammond, has been figured on page 67 (FIG. 45). A third preparation, presented by Surgeon D. Bache, U. S. V. (FIG. 65), well illustrates the relations between the gut and the exterior surface in shot wounds of the colon resulting in the establishment of a preternatural anus. The following are the particulars of the case :

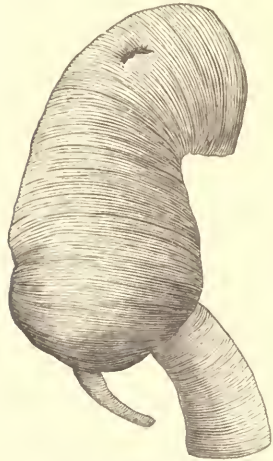

FIG. 64.—Perforation of the colon by a musket ball. *Spec. 1782.* [Half size.]

CASE 301.—Private *John R. M*—, Co. E, 11th Mississippi, was wounded at Gettysburg, July 1, 1863. He was admitted to the General Field Hospital; on July 21st, sent to the hospital at Chester; and, on January 14, 1864, removed to McClellan Hospital, where Acting Assistant Surgeon W. L. Wells gives the following account of the case: "Wounded by a minié ball, which entered in the left iliac region, and passed out below the crest of the ilium after passing through the latter bone. The patient states that there was fecal discharge from the anterior wound for about two weeks after the reception of the injury, and at various intervals since, and that several pieces of bone had been removed from the posterior wound. On January 15th, there was slight fecal discharge from the anterior wound, and on January 26th, the wound in the abdomen was slightly enlarged to remove a piece of bone one half by one inch long. On February 12th, all fecal odor had ceased: the patient was doing well, but complained of tenderness around the wound." On the following day the patient was removed to West's Buildings Hospital, Baltimore, where he died on March 12, 1864. Surgeon T. H. Bache, U. S. V., who forwarded an account of the autopsy, reports the "minié ball entered the left inguinal region, wounded the descending colon, passed through the ilium in its posterior quarter, then lodged subcutaneously back of the pelvis, where it was cut out before the patient came to this hospital. The gut was adherent to the muscular parietes of the pelvis and communicated with an abscess under the iliacus internus and psoas magnus muscles. This cavity communicated with the anterior and posterior apertures. In the cavity of the abscess, and near the posterior exit of the ball from the pelvis, two large fragments of bone were found. The abscess must have been made first by the irritation induced by the bone fragments and by the ball, and increased by the burrowing of pus. The cavity of the descending colon was very small; long coils of feces of small calibre used to pass through the wound of entrance; air

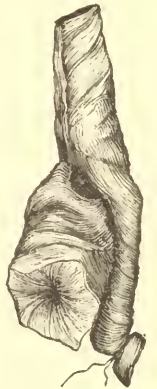

FIG. 65.—A portion of the descending colon and of the anterior parietal wall, showing a preternatural anus. *Spec. 3216.* [One-fourth size.]

<sup>1</sup> But few pathological preparations of the results of injury of the large intestines are found in Museums. In addition to the four specimens 1782, 2218, 3379, 6067, Sect. 1, Army Medical Museum, the following are preserved: 5. Specimen 441, New York Hospital Museum: cæcum, with a laceration in the caput coli, made by a musket ball; from a man of thirty, who died in about twenty-four hours without reaction (*Cat., l. c.*, p. 188). 6. Preparation 104, Series IX, of the Museum of St. George's Hospital, is a small shot laceration of two-thirds of the circumference of the injured flexure of the colon, from a boy of 12 years, who died the day of the injury; there was visceral protrusion in this case (*Cat., l. c.*, p. 430). 7. Preparation 1867<sup>10</sup> of Guy's Hospital Museum is a portion of the descending colon, showing a shot perforation of the wall of the gut nearest the loin; 1867<sup>12</sup> is the flattened rifle bullet passed by the rectum, a few days after the injury; from J. B——, aged 19 years, wounded at Sebastopol, who, afterward, died at Guy's of Bright's disease (*Cat., l. c.*, Vol. II, App. p. 52). 8. Preparation 1877<sup>3</sup>, at Guy's Hospital, is a portion of the descending colon and sigmoid flexure, showing a laceration of the coats without perforation. The following memorandum of preparations, exemplifying injuries of the *small* intestines, should have been inserted on page 62: The preparations figured in the text (2359, 5689) are the only illustrations of punctured or incised wounds of the small intestine the Army Medical Museum possesses. In the Museum of the New York Hospital, specimen 408 is a portion of jejunum removed from a patient who died two years and a half after a stab in the abdomen, involving two-thirds of the calibre of the intestine; the gut is adherent to the parietes by a long slender band; but no trace of a cicatrix can be seen in its tunics (*Cat., l. c.*, p. 180). In the Museum of St. George's Hospital, London, are two such preparations: No. 107 Series IX, is a portion of the ileum, fifteen inches from the ileo-cæcal valve, showing an oval preparation from a knife stab; the patient died from fecal extravasation. The second is 109, a portion of the ileum an inch or two from the ileo-cæcal valve, showing two wounds from the stab of a knife; recent fibrin coats the peritoneal surface about the wound (*Cat., l. c.*, p. 431). The Hunterian Museum has a preparation, presented by Sir W. BLIZARD, Series XXV11, No. 1383, showing a portion of small intestine adherent to the liver and to the abdominal wall, through which, by a preternatural anus, its contents were long emptied.

would be drawn into the cavity and expelled, according as the patient moved and worked the abscess walls as a bellows. During the month the patient remained at West's Buildings Hospital the treatment consisted of opiates, with bark, stimulants, expectorants, and beef-tea, and other concentrated nourishment internally, and detergent dressings, with compresses and bandages over the wound. There was troublesome cough, and the left lung was found much atrophied, after death, with tuberculous deposits throughout, those near the apex in the stage of softening. In the right lung, there were tuberculous deposits at the apex only. The opening

made to extract the ball never healed. Small fragments of bone came out of the wound of entrance from time to time. These fragments, with the ball and detached rings of lead (FIG. 66), were found with the effects of the deceased." Three pathological preparations from the case are preserved at the Museum, and are represented in the accompanying wood-cuts. One shows the relations of the injured intestine to the abdominal parietes (FIG. 65); another the perforation of the ilium (FIG. 67); a third the necrosed fragments of the bone, and the projectile that inflicted the injury (FIG. 66).

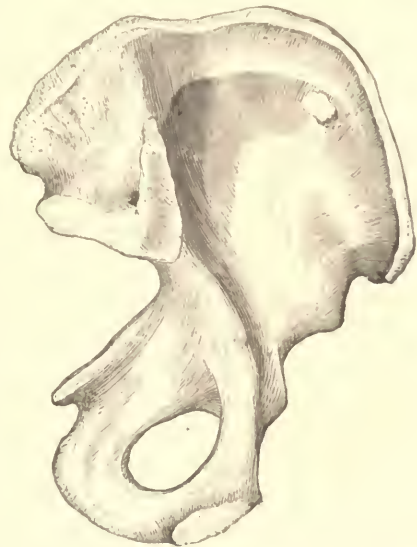

FIG. 67.—Diagram of a slot perforation of the left ilium. A wet preparation of the specimen is numbered 2217, *Surgical Section*. [Reduced one-third]

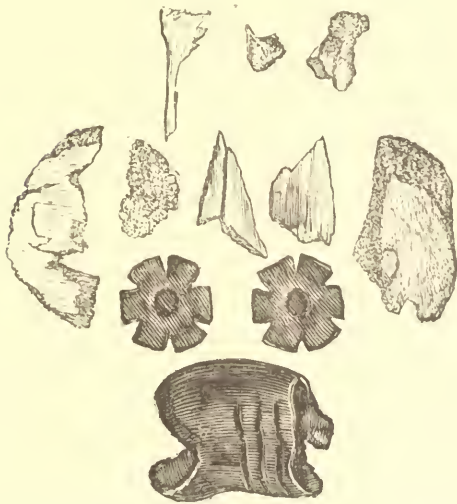


FIG. 66.—Eight necrosed fragments, representing one square inch of the left ilium, a battered ball, and detached rings from the missile. *Spec.* 2214. [Size of nature.]

In addition to cases that have been related, or that will be noticed in connection with injuries of other abdominal viscera, there were eleven instances of fatal shot wounds of the colon in which autopsies were held. But it is to be regretted that, in many of these, the morbid appearances are imperfectly described, and the reader is left in perplexity regarding the conditions actually observed. Yet some of these cases embrace details of interest, and are, to some extent, instructive. In one instance, the patient succumbed from early internal hæmorrhage:

CASE 302.—Private J. T. Hawk, Co. E, 15th New York Cavalry, aged 23 years, wounded at Green Spring Run, November 1, 1864, by conoidal pistol balls in the right arm and abdomen, was admitted to Cumberland Hospital the same day. Acting Assistant Surgeon C. H. Ohr reports that, on admission, the countenance was indicative of great pain, the skin cold and clammy; had vomited; pulse 90 and weak; abdomen full and tender; no bloody stools, but excruciating abdominal pains. Anodynes and stimulants were given. Death at ten o'clock in the evening. Autopsy: The great omentum was very fat; its lower part was infiltrated with coagulated blood; the bowels in the hypogastric region were coated with coagula, and fluid blood was effused in the peritoneal cavity to the extent of six ounces. The ball, entering at the lower edge of the right tenth rib, at the chondriac junction, passed under the lower edge of the liver, thence between the intestinal convolutions, until it reached the transverse colon; it perforated this viscus at its left curvature, and passed on, lodging against the false costal cartilages of the left side, on their outer surface, from which point it was extracted, having passed in nearly a direct line from the right to the left hypochondriac regions.

In other instances the fatal issue was longer deferred, and, in some of them, the late appearance of the symptoms of peritonitis was remarkable:

CASE 303.—Sergeant X. Mehler, Co. E, 74th Pennsylvania, was wounded at Rappahannock, August 22, 1862. He was admitted into Judiciary Square Hospital at Washington on August 24th, where he died. Acting Assistant Surgeon F. H. Brown states: "Gunshot wound; entrance two inches to the left of the median line, on a level with the top of the sacrum; the track of the ball was not marked; it was excised from beneath the integument four inches to the right of the median line, at the level of the umbilicus. On the 26th, there was considerable fever, and peritonitis commenced and increased rapidly, and the patient died, rather suddenly, on the 27th, having had considerable trouble in respiration during the day. At the autopsy, the descending colon was found pierced opposite the wound of exit; there was a considerable quantity of liquid feces in the cavity of the abdomen, and adhesions of the peritoneum and pleura about the seat of injury. In this case, though some tenderness existed, no symptoms at all commensurate with the lesion were present until within thirty-six hours of death, and on the supervention of peritonitis. The presence of the feces in the abdomen did not cause the usual acute pain produced by foreign bodies in the peritoneal cavity."



CASE 304.—Sergeant A. Garron, Co. K, 8th New Jersey, aged 22 years, received a gunshot wound of the abdomen at Chancellorsville, May 3, 1863. He was admitted to the regimental hospital on the same day, and transferred to Washington on May 5th, where he was admitted to Mount Pleasant Hospital on the 9th. Acting Assistant Surgeon Ira Perry gives the following information in the case: "May 9th, ball entered three inches above the pubes and one inch to the left of the median line, and still remains in; slight tympanitis and tenderness; pulse 108; the functions of the bladder normal. Treatment: anodynes to relieve pain and keep the bowels quiet; spirit lotion to the wound; mucilage and essence of beef. May 11th, seven o'clock A. M., for the last hour has been distressed with a hippocatic expression; pale; skin moist and cool; slight hicough; has had a stool, and passed some faeces and offensive decomposed blood. Hoffman's anodyne and tincture of opium were given to relieve the pain. May 12th, has slept well, and, at six o'clock A. M., had a muco-purulent, sanious, and offensive alvine evacuation, with pain, which was relieved by injections of mucilage and opium. May 13th, slept well; no movement of bowels; was comfortable until five o'clock P. M., and then became restless and languid. Hoffman's anodyne, opium, and calomel were administered, with an injection of opium. May 14th, slept well; pulse 108; tongue coated, and appetite poor; abdomen full; wound one and a half inches in diameter and gangrenous; toward evening, became uneasy and vomited up everything; turpentine was applied to the abdomen, and wine or whiskey administered. On the 15th, he was much the same, vomiting everything; pulse 100, and tongue coated yellowish; toward evening, he became restless, and the pulse rose to 132; he vomited everything he swallowed. May 16th, at two o'clock A. M., he was apparently dying, but perfectly sensible; was relieved by anodynes. He died at five o'clock A. M., May 16th. Autopsy, five hours after death: Some fulness, centering at the wound; slight tympanitis. Section showed extensive peritoneal inflammation; abdominal walls and contents agglutinated, except where there was decomposition. One large sinus was filled with pus and decomposed blood; another with gas, mostly in the bowels; and another with a pale gruel-like mixture, as though made from coarse meal. The ball passed in horizontally, perforating the sigmoid flexure of the colon, but was not found; careful search was not made, as there was great stench and decomposition and the friends were waiting for the body."

Surgeon B. B. Breed, U. S. V., records the following example of the formation of a faecal fistula, as a secondary result of the injury inflicted by a musket ball:

CASE 305.—Lieutenant A. Blackburn, Co. F, 1st Arkansas Cavalry, aged 32 years, received a shot wound in the right lumbar region, at Pine Bluff, October 25, 1863. About December 16th, he was admitted to hospital at Little Rock, and was there treated until transferred to the Prison Hospital at St. Louis, February 16, 1864. On admission he was much debilitated; he seemingly improved until March 4th, when he was attacked by erysipelas, and was removed to the erysipelas ward; he was then very feeble, and there was irritability of the stomach, with constant discharge of pus and faecal matter from the wound; he also expectorated large quantities of muco-purulent matter with a faecal odor. The treatment was tonic and stimulant, enemata being given to keep the bowel clear below the preternatural anus, and rigorous attention was paid to the cleanliness of the wound. He gradually grew feebler, and died March 30, 1864, having survived the injury over five months. The autopsy showed that the ball, having entered near the posterior superior spinous process of the right ilium, had passed forward and lodged under the skin about three inches above the anterior superior spinous process of the same bone; an opening was found near the center of the ascending colon, the edges of which were united to those of the external aperture, forming a preternatural anus. This opening in the bowel did not appear until four months and ten days after the reception of the injury, and would seem to have been immediately due to the extension of the inflammatory process consequent on the attack of erysipelas.

CASE 306.—Private M. O'Shea, Co. M, 2d Maryland Cavalry, wounded by a revolver ball at South Bend, December 26, 1864. He was admitted to Cumberland Hospital on the same day; pulse 125, and feeble; skin dry, harsh, and hot; tongue coated, and sordes on teeth; vomiting of bilious matter and constant eructation of gas; hæmorrhage very slight; thin faeces and gas escaped from the wound; little pain. He continued unchanged for several days, and, on January 2d, was able to walk across the room and enjoy his pipe and lemonade. Faeces continued to be discharged from the wound, and, on the 10th, he had a large passage by the rectum. On the 14th, he had a severe chill, followed by profuse perspiration; pulse more feeble; general condition weak, and at times there was delirium. He died January 15, 1865, twenty-one days after the reception of the injury. Autopsy twelve hours after death: "Body much emaciated; abdomen flat; the bullet was found lodged in the psoas magnus muscle of the right side, opposite to the second lumbar vertebra; the descending colon was perforated, and the body of the last lumbar vertebra was fractured; the spleen was enlarged and inflamed; the stomach and liver were normal in appearance; there was extensive inflammation of the bowels and peritoneum, and strong adhesions of the colon to the parietal peritoneum." The case is reported by Acting Assistant Surgeon T. R. Clement.

CASE 307.—Private J. Mallon, Co. G, 37th New York, was wounded at Colchester, January 27, 1862. He was considerably shocked at the time of injury, but was still able to assist in battering in the door of a house occupied by the enemy, after which he sank exhausted. He was then conveyed several miles on horseback to Acetotink; his pulse was small, and his features expressive of profound prostration; he suffered severely, but was quite conscious. Stimulants were administered until reaction took place, which was accompanied by pain, restlessness, hicough, and nausea. Next morning he was conveyed by ambulance to the regimental hospital, about eight miles. On the third day peritonitis supervened; the abdomen was tympanitic but not painful; under palliative treatment he grew somewhat better until the eighth day, some hope being entertained of his recovery; but diarrhoea set in, with profuse and purulent evacuations, and obstinate vomiting and hicough; delirium and collapse followed, and continued until he died, sixteen days after the injury. An autopsy, eight hours after death, showed that the ball had entered at the upper part of the right sacro-iliac symphysis, fracturing the posterior superior spinous process, furrowing the psoas muscle, passing over the promontory of the sacrum, against which it was flattened, into the right iliac fossa, wounding the posterior part of the caecum about an inch from the appendix, furrowing the iliacus muscles, thence directed upward by the right ilium it wounded the transverse colon, anteriorly, in two places, and lodged between the bladder and rectum. The wounds of entrance and exit were three inches apart; the ball weighed nearly one ounce. The intestines were attached, in several places, to one another, to the abdominal parietes, especially of the right side, and to the omentum, which was distinguishable as



a thin membrane, considerably expanded, and in a state of decomposition. Underneath the cæcum was a well of pus, which, together with the other purulent fluids removed from the abdomen, and what was previously passed at stool, would certainly amount to more than a gallon. Fibrinous clots covered the surface of the intestines in thick, soft, and blackish patches, which were then assuming all the appearances of decomposition. Throughout the entire intestinal track this was strikingly evident.<sup>1</sup>

CASE 304.—Private *R. Saults*, Co. E, 51st Georgia, was wounded at Gettysburg, July 3, 1863, by a minie ball. He was admitted to Seminary Hospital on the same day, and, on August 7th, was transferred to Camp Letterman Hospital. There had been more or less excrementitious matter passed daily from the wound since it was received. The patient had rapidly emaciated, and died from exhaustion on August 27th, having survived the injury fifty-six days. An autopsy was made on the same day, and showed that the missile, entering the left lumbar region in a line between the anterior superior spinous process of the ilium and the twelfth rib, penetrating the cavity of the abdomen, and, passing transversely through the descending colon, had made its exit on the left side of the spinal column in close proximity to the third lumbar vertebra: the spleen was pierced by the ball in its passage, and a large abscess was found between the meso-colon and posterior wall of the abdomen, containing a half pint of pus. The case is reported by Acting Assistant Surgeon J. B. Sturdevant.

In four other autopsies, attendant lesions of the solid viscera of the abdomen were observed. In one of these cases, the descending, and in three, the ascending, portions of the colon were interested.

Assistant Surgeon R. M. O'Reilly has contributed, since the war, a very interesting preparation of lesions of the descending colon and of the wing of the left innominatum, with an accompanying history, substantially as follows:

CASE A<sup>2</sup>.—Private John Mollinar, Co. D, 11th United States Infantry, was admitted into the hospital at Fort Laramie, June 27, 1870, with a gunshot wound of the abdomen. The bullet entered about two and a half inches to the right of the left anterior superior spinous process of the left ilium, perforated the descending colon about one inch above the sigmoid flexure, and, after carrying away a portion of the crest of the ilium, made its exit posteriorly at a point nearly opposite the point of entrance. Severe inflammation and intra-pelvic abscesses followed, which were finally subdued. The feces, from the first, were passed by the wound. Two attempts were made to close it, but failed, on account of the sloughing of the parts and the unfavorable condition of the patient's health. Phthisical symptoms developed themselves, and, together with the debility occasioned by the profuse discharges, from which the patient suffered during the first months after his admission, resulted in his death September 25, 1871. An autopsy was made six hours after death. Rigor very slight; body much emaciated; heart and liver healthy. The pleura was closely adherent to the ribs anteriorly and laterally, requiring considerable force to separate them. The lungs were slightly congested, and the lower lobe of the right lung was hepaticized and filled with tubercular deposits. The small intestine was greatly dilated throughout its entire course; the iliac portion was slightly congested. The colon was displaced—the transverse portion was lying across the third lumbar vertebra and was firmly bound down by strong fibrous bands, which required division by the scalpel before the bowel could be released. The large intestine (FIG. 68) was diminished to one-fourth of its natural size, was pale and flabby in appearance, and had a large and ragged opening situated about one inch above the sigmoid flexure, posteriorly, corresponding with the external wound. Immediately inside the wound was a cavity, lined with smooth membrane, occupying nearly the whole space of the internal attachment of the iliacus; it was closed on all sides, except where it communicated with the wound. The sacrum was considerably eroded at its junction with the ilium, which was also necrosed at the point of articulation with the ischium, and on the superior border near the wound. The extensive destruction of the wall of the pelvis in this case is very remarkable. The portions of ilium eliminated must have composed a part equivalent to three inches square, at least. The crest is wanting from a point half an inch behind the tubercle (*tuberculum criste ilii*, of Retzius), and the auricular part of the bone, posterior to a line drawn from this point and then backward along the superior curved line to the sacro-iliac junction, is gone.

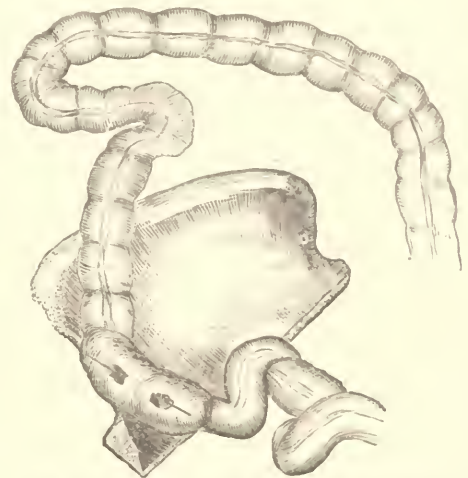


FIG. 68.—Section of a mutilated left ilium, and a portion of atrophied colon, with an abnormal opening near the sigmoid flexure. *Spec. 6667.*

From the aggregate of over six hundred and fifty cases of shot wounds of the intestines that appear on the returns, it would be possible to glean some details of other examples of lesions mainly involving the large intestines; but the eighty-five instances that have been presented sufficiently exemplify, perhaps, the varieties and results of such injuries. Moreover, in examining wounds of other abdominal viscera, cases complicated by intestinal lesions will come under consideration. No hesitation was felt in detailing

<sup>1</sup>An extended account of this case is published by Surgeon W. O. McAGHER, 37th New York, in the *Am. Med. Times*, 1862, Vol. IV, p. 245.

at length a large number of cases closely resembling each other in many features, as it was believed that the value of this cumulative evidence would be appreciated by surgeons.

In the very valuable chapter on gunshot wounds, in the *Surgical Operations* of the late J. Mason Warren,<sup>1</sup> there is an interesting narrative of a case of intestinal fistula in a Massachusetts soldier, shot at Chancellorsville, which I take to be identical with CASE 263 of the foregoing series.

Another recovery from a shot wound of the colon is recorded in the *First Surgical Volume*, p. 7, in the case of Sergeant N. Gilbert, 1st Michigan Cavalry, who received also a sabre-cut on the head. From an account of this case by the late Surgeon W. H. Rulison,<sup>2</sup> U. S. V., the ascending colon appears to have been the portion of the intestine interested. A remarkable case of recovery from a shot wound involving the intestines and bladder, recorded by Assistant Surgeon D. C. Peters,<sup>3</sup> U. S. A., will be noticed with injuries of the latter viscus. Many cases of doubtful authenticity, or described with wide discrepancies, in the field returns and the reports of the pension examiners, have been set aside.<sup>4</sup> Some of these would be interesting if true. For example: Private Hipwell, 15th Illinois, is reported by the regimental assistant surgeon, Dr. J. W. Vanvalzah, as struck in the left hip by a round musket ball, at Shiloh, and discharged October 24, 1862. Pension Examiner H. A. Buck states, April 5, 1863, that the ball entered the right lumbar region, and, according to the patient's statement, was discharged, eight days subsequently, in defecation. Corporal H. C. Grant, also, of Co. C, 52d Illinois, 36 years of age, wounded by a musket ball, at Shiloh, April 6, 1862, appears on the records of the Cincinnati hospitals as a case of uncomplicated shot wound of the belly. At the Chicago hospitals, Acting Assistant Surgeon R. N. Isham states that the injury implicated the intestines; and, in January, 1864, Pension Examiner J. W. Garvin, of Sycamore, Illinois,

<sup>1</sup> WARREN (*Surgical Observations, with Cases and Operations*, Boston, 1867, p. 561. Case CCCXXXVII). DR. WARREN referred the injury to the right iliac region; but in other respects the history corresponds with that of CASE 263. Private Burt was a Massachusetts soldier, and likely to fall under DR. WARREN'S observation. No other case corresponding to the facts detailed by DR. WARREN can be found among the casualties at Chancellorsville.

<sup>2</sup> RULISON. *Am. Med. Times*, 1863, Vol. VII, p. 242.

<sup>3</sup> PETERS. *Interesting Cases of Gunshot Wounds*, in *Am. Med. Times*, 1864, Vol. VIII, p. 3.

<sup>4</sup> After the long list of recoveries from shot wounds of the large intestine that has been furnished in the text, it is hardly necessary to accumulate evidence on this point; but those curious on the subject can refer to the following additional instances: 1. DR. T. F. CLARDY records (*Med. and Surg. Reporter*, 1860, Vol. IV, p. 473) a recovery after a pistol ball perforation of the ascending colon, with fecal fistula for twelve days; the ball was supposed to have lodged in the iliac fossa. 2. DR. DOWELL (*Nashville Med. Record*, 1860, Vol. III, p. 5) records a recovery, after fecal fistula, from a wound of the caecum made by duck-shot. 3. PARÉ, A. (*Opera*, Parisiis, 1582, p. 763), relates a case of wound of the belly; ball passed at stool nine days later; recovery. 4. VALLERIOLA (*Obs. Med.*, Lugduni, 1605, Lib. IV, Obs. 9, p. 290) [see SCIENCKIUS, *Obs. Med. Rar.*, Lugduni, 1644, p. 698]; pistol wound of the intestines; ball voided at stool a few days afterward; recovery. 5. PATINUS (*Tubus intestinale periculosum feliciter curatum*, in *Eph. Acad. Nat. Cur.*, Norimbergae, 1683, Dec. II, Ann. I, Obs. XX, p. 45); shot wound of colon; ball passed at stool on the fifth day; recovered. 6. FRANC, G. (*Tria sclopetoria vulnera notabilia*, in *Eph. Acad. Nat. Cur.*, Norimbergae, 1683, Dec. II, Ann. I, Obs. XX, p. 64); shot wound in the epigastrium; ball passed at stool a month afterward; recovery. This case is also reported by MANGETUS (*Bibl. Chir.*, Geneva, 1721, T. IV, p. 552). The latter author (*ibidem*, T. IV, p. 572) gives another case of shot wound of colon; recovery. 7. PURMANN (*Lothier-Krautz der Wund-Artzney*, Franckfurth, 1692, S. 429); shot wound of colon; ball passed by the anus on the fourth day; recovery in four weeks. 8. FAUDACQ (*Reflexions sur les Playes*, Namur, 1755, p. 562) records the case of a *filie sacré*, shot in the waist; colon injured; linen, cloth, and small shot passed at stool on fourth, fifth, and sixth day; recovery. 9. BILGUER (*Chirurgische Wahrnehmungen*, Berlin, 1763, S. 387, note 8); shot wound of abdomen; ball passed at stool. 10. BUDDEN'S (in BILGUER'S *Chirurgische Wahrnehmungen*, Berlin, 1763, S. 347); shot wound of intestines; fecal matter escaped from wound of exit for six months; recovery. 11. HORN (*ibidem*, S. 362) relates two cases of shot wounds of colon; recovery in three and four months, respectively. 12. CROX (*ibidem*, S. 350); shot wound of intestines and perforation of ilium; fecal fistula; recovery in two months. 13. POHRER (*ibidem*, S. 375); shot wound of intestine; escape of fecal matter; recovery in forty days. 14. RAVATON (*Chirurgie d'Armée*, Paris, 1768, p. 235); shot wound of intestine; slug passed at stool on the sixteenth day; recovery. 15. VOELKER (in SCHMUCKER'S *Vermischte Chirurgische Schriften*, Berlin, 1786, B. II, S. 148); shot wound of descending colon; ball passed at stool; recovery. 16. PERCY (*Manual du Chirurgien d'Armée*, Paris, 1792, p. 238); shot contusion of colon; colon afterward divided; recovery. 17. *Idem*, p. 239, shot perforation of colon; recovery. 18. LABREY (*Mém. de Chir. Mil. et Camp.*, Paris, 1812) states that at the sieges of Acre and Cairo he observed five cases of wounds of the colon; recoveries without stercoral fistula. 19. GUTHRIE (*On Wounds and Injuries of the Abdomen and Pelvis*, London, 1817, p. 36); soldier wounded at Ciudad Rodrigo, in 1812; ball passed by the anus on the fifth day; recovery. 20. *Idem* (*l. c.*, p. 38), relates the case of a sergeant wounded, at Waterloo, about an inch above the umbilicus; ball passed on the sixth day; recovered. 21. BAUFENS (*Cinque des plaies d'armes à feu*, Paris, 1826, p. 341); penetrating shot wound of descending colon; ball removed by incision; fecal fistula; recovery in about two months. 22. LONGMORE (*The Lancet*, 1855, p. 606, Vol. I); gunshot wound of abdomen; ball passed at stool on the third day; probably recovered. 23. BIEFEL (in LANGENBECK'S *Archives*, Berlin, 1869, B. XI, S. 417); shot wound of intestine; escape of fecal matter; recovery. 24. FISCHER, K. (*Militärärztliche Skizzen, aus Süddeutschland und Eibonien*, Aarau, 1867), refers to three cases of recovery from wounds of the ascending colon. 25. MAAS (*Kriegschirurgische Beiträge aus dem Jahre*, 1866, Breslau, 1870, S. 18) cites a case of grenade shot of the large intestine; fecal fistula; recovery in two months. 26. STROMEYER (*Erfahrungen über Schusswunden im Jahre 1866*, Hannover, 1867, S. 43) relates the case of a cavalry officer shot through

reported that "a minie ball entered the abdomen, probably the duodenum, and, at the expiration of twenty-seven days, was passed while at stool. There has been more or less inflammation of a chronic character ever since."<sup>1</sup> But, while they are curious, it is unnecessary to devote much attention to these doubtful cases, in view of the large series of authentic instances by which the various results of injuries of the large intestines have been exemplified. It is obvious that the returns do not furnish the elements for an exact estimate of the mortality resulting from lesions of this group, since even a precise approximation to the aggregate of cases is impracticable. Yet the facts assembled enable us to approach more definite conceptions of the probabilities of recovery in wounds of the large intestines, and of the comparative danger of injuries of the different portions of the alimentary canal.<sup>2</sup> The cases adduced may not appear to substantiate the statement advanced on page 76, implying that wounds of the descending colon are less dangerous than those of the cæcum and ascending portion, since only twenty-seven recoveries were enumerated in the former category, while thirty-two were included in the latter; and, among the fatal cases adduced, after injuries of the transverse colon, those of the descending portion presented the least favorable exhibit. Notwithstanding these facts, a review of all the data bearing on the subject leaves unchanged the impression that wounds of the descending colon are not more dangerous than those of the ascending colon.<sup>3</sup> The reader

the large intestine; fecal fistula for three months; recovery. 27. *Ibid.* (*Maximen der Heilkunst*, Hannover, 1855, 8. 631) records a case of shot wounds of the descending colon, at Idstedt; ball passed at stool on the sixth day. 28. BILLROTH (*Chirurgische Briefe aus den Kriegs-Lazarethen in Weissenburg und Mannheim*, 1870, 8. 188, No. 33); shot wound of intestine; fecal fistula; recovery in about two months. 29. SOEX (*Kriegschirurgische Erfahrungen*, Leipzig, 1872, 8. 94) cites two cases of recovery of penetrating wounds of the colon; fecal fistula; in the second case the liver and gall bladder were probably also injured. 30. H. FISCHER (*Kriegschirurgische Erfahrungen vor Metz*, Erlangen, 1872, 8. 129) relates two cases of shot wounds of colon; escape of fecal matter; recovery in five and two and one-half months, respectively. 31. BECK (*Chirurgie der Schussverletzungen*, Freiburg, 1872, 8. 334 *et seq.*) cites seven cases of recoveries from perforations of the intestines. 32. LENNOX, L. J. (*Canada Lancet*, 1872, Vol. V, p. 112), records the case of a carpenter of Newfoundland, aged 74 years, wounded by a ball from a Smith and Wesson pistol, which passed through the forearm and entered the abdominal wall a little below and to the right of the umbilicus. Probing failed to detect an opening into the peritoneal cavity. There was but little shock or subsequent pyæmia. On August 10th, twelve days after the reception of the wound, the ball was voided at stool. A fortnight afterward, the man was able to be about and to attend to business. 33. HERSTIS, J. W. (*Am. Jour. Med. Sci.*, 1829, Vol. V, p. 399) relates a case of recovery from a fecal fistula of the ascending colon, from a shot wound in the right loin, with fracture of the ilium. 34. TEW, N. S. (*Canada Med. Jour.*, 1865, Vol. I, p. 358), records a recovery, with fecal fistula, from a shot wound of the ascending colon. 35. AMYAND (*Phil. Trans.*, Martyn's Abridg., Vol. IX, p. 157) relates the case of a soldier who appears to have been shot through the descending colon, in Flanders, in 1732; feces escaped by the wounds for several weeks, then gradually assumed the natural channel, and the wounds closed. 36. BESNEY, a Surgeon of the America Revolution (*Mém. of the Am. Acad. of Arts and Sciences*, Vol. I, p. 514), relates the case of David Beveridge, a seaman, who recovered in three weeks from a shot wound of the descending colon, with escape of feces. 37. M. CHEMÉ (*Stat. Méd. Chir. de la Camp. d'Italie*, 1869, T. II, p. 491) records the case of A. Dato, wounded in the rectum at Solferino, June 24, 1859; ball passed at stool eight days after; pensioned August 10, 1861. 38. M. CHEMÉ (*Rapp. Méd. Chir. Camp. d'Orient*, 1865, p. 198) relates the case of Van Heteren, who received, at Sebastopol, February 3, 1855, a shot wound of the ascending colon, with perforation of the inominiate, and stercoral fistula; recovery, and pension, July 1, 1855.

<sup>1</sup> Were these cases accepted—and they are probably not less venacious than many related in the old chronicles—the number of instances, in the text, of bullets voided at stool, would be increased to thirteen. The projectiles entered the alimentary canal by deglutition in one instance, by direct penetration of the intestinal wall in five instances, probably, and by secondary ulceration in seven cases. As nearly as can be ascertained, the foreign bodies appear to have entered some portion of the colon in eleven of the thirteen cases, the ascending portion in two, the transverse in five, the descending colon in four. Fifteen such examples, reported by PARÉ, VALLERIOLA, PATINUS, FRANC, PURMANN, FAUDACQ, BIGGER, RAYATON, VOELKER, GUTHRIE (2), LONGMORE, STROMEYER, LENNOX, and CHEMÉ, are cited in the preceding note, the balls being discharged at intervals of from three to thirty days. HENNES (*op. cit.*, p. 408, Case LXV) describes the case of the Waterloo sergeant, Peter Matthews (CASE 52 of GUTHRIE, and 20 in the preceding note, referred to also by SOUTH in his translation of CHELUS, *Am. ed.*, Vol. I, p. 526), and adds that others have come to his knowledge; but all of those he specifies are included in the foregoing list except that of a seaman wounded at Algiers, reported by DEWAR (*De Vulneribus*, Edinb., 1818). HABERSHON (*Guy's Hosp. R.p.*, 1854, Vol. V, p. 173), MATTHEW (*op. cit.*, Vol. II, p. 350), and HAMILTON (*op. cit.*, p. 357), adduce the case of James Beelan (22 of the preceding note). To these may be added the case of Kelly, reported by DR. NEILL (*Med. Examiner*, 1854, Vol. X, p. 141), in which the passage of a small pebble was the first indication that the intestine had been wounded by a pistol shot in the abdomen; and DR. MERCER (*Proceedings of the Nebraska State Med. Soc.*, 1870, CASE 8, p. 26) records an example of the passage, by stool, of a fragment of the right ilium, after a shot perforation of the ascending colon. BENEDECTUS (in SCHEENCKIUS, *l. c.*, p. 607) gives an instance of an arrow-head that entered the loin being voided at stool after an interval of two years (*post biennium*, not "deux mois," as PERCY quotes). PERCY also cites from FABRICIUS HILDANUS (*Op. om., Obs. Chir.*, Cent. V), a case from DIDIER, of the end of a sword being broken off in the belly and discharged by stool.

<sup>2</sup> DONAU (*Über die Schussverletzungen des Darmkanals*, Leipzig, 1868) makes the following comparative estimate of the fatality of shot wounds implicating the abdominal viscera. The most fatal are those interesting the small intestine; second, those of the stomach; third, those of the large intestine, within the peritoneal sac; fourth, those of the liver; fifth, extraperitoneal wounds of the large intestine. With BARDELEBEN (*Lehrbuch der Chirurgie und Operationslehre*, Berlin, 1865), he places the different parts of the digestive tube, according to their relative liability to injury, in the following order: 1, small intestine; 2, transverse colon; 3, cæcum; 4, ascending colon; 5, descending colon; 6, duodenum.

<sup>3</sup> It would involve a tedious recapitulation of instances to set forth all the facts that justify this conclusion; but it is believed that the student who will consult the facts scattered through the foot-notes will have no doubt of its correctness. In wounds of either the ascending or descending colon, the circumstances of the lesion being extraperitoneal or intraperitoneal will mainly determine the measure of danger. In classifying the fifty-nine recoveries from shot wounds of the large intestine (pp. 77-97), cases regarding which the statements were conflicting were placed in the first group as injuries of the descending colon. It is probable that CASES 239 and 241 properly belong to the third group, or injuries of the descending colon; while



cannot have failed to observe that no instance has been adduced as a recovery from wounds of the large intestine, unless a division of its walls was demonstrated by the escape of fecal matter, or by the intrusion of a foreign body within its cavity. No other evidence of such lesions is absolutely conclusive, though other associated phenomena may warrant strong presumptions. Contusion or partial division of the tunics of the colon may be indicated by bloody stools, and symptoms of traumatic peritonitis, conjoined with circumstances that may suggest the limited nature of the injury, and the portion of the bowel implicated. If the diagnosis of wounds of the bowels in general is difficult, it must be admitted that the differential diagnosis between wounds of the large and small intestines is sometimes unattainable. It has been seen (pp. 65, 80) that the rapidity of the escape of ingesta by the wound affords no criterion. The absence of fecal odor is an important negative sign, the normal closure of the ileo-cæcal valve confining sulphuretted hydrogen below that point. Chemical and microscopical analysis of the discharge from the wound might indicate its situation;<sup>1</sup> but we have no evidence of this nature. The date at which the escape of the intestinal contents was observed, is noted in forty-two of the fifty-nine cases of recovery from wounds of the large intestine, and was within a day or two in thirty-five cases; after the separation of eschars on the twelfth, fourteenth, thirty-fifth, and fortieth days, in seven other instances; while in seventeen cases, this point is left undetermined.<sup>2</sup> There will be occasion hereafter to consider separately the subjects of visceral protrusions and of extravasations attending injuries of the abdomen. The remainder of this subsection will be devoted to the two principal forms of active surgical interference that wounds of the intestine sometimes involve, the operations for the relief of abnormal anus, and the various methods of enterorraphy.

in CASES 247, 251, 259, 260, 263, the testimony as to the part implicated is conflicting. The statistics of amputations, of resections, and of artificial limbs, exemplify how frequently surgeons, who are careful and exact in most of their statements, err in recording the side of the body interested. Photography is a fruitful source of error in this connection. The object may or may not be reversed, and the observer is liable to be deceived, unless he accurately ascertains whether he has before him a positive or negative picture.

<sup>1</sup> As wounds of the colon may be complicated by abnormal openings between the large and the small intestines, as well as accidental communications with the other viscera of the abdomen, of the thorax, and of the pelvis, evidence derived from such precise methods of investigation would have only a conditional value.

<sup>2</sup> These results correspond, as might be anticipated, with those observed elsewhere, as may be found by examining the particulars of the cases enumerated in note 4 on page 106, to which the following instances may be added: MOCAT (*Med. and Surg. Hist. of New Zealand War, in Army Med. Dept. Rep.* for 1865, p. 490) mentions the only recovery in fifteen cases of penetrating shot wounds of the abdomen, as an instance of wound of the cæcum, in an officer, followed by artificial anus, which closed in eighty days, reopened, and closed soundly in one hundred and forty days. HENNEN (*op. cit.*, Cases LXXVI, LXXVII) gives two examples of artificial anus, following shot wounds of the colon, closing spontaneously after a few months; HUNTER (*op. cit.*, p. 550) details a similar case, and others are recorded, in the second volume of the Memoires of the French Academy of Surgery, by REY, GÉRARD, and PONEYÉS. ZIEFF (*Über Unterleibsverletzungen und deren Behandlung, in Deutsche Klinik*, 1851, S. 180) records the recovery, in five weeks, of a youth in whom tempen wads, driven through the loin into the ascending colon, were discharged at stool on the ninth day. Another authentic case of the American War has been discovered since the preceding page was printed: Surgeon T. J. Wright, 6th, Colored Troops, reported that Private Walker Harris, Co. H, 47th U. S. C. T., was wounded at Yazoo City, March 5, 1864, by a musket ball, which entered the left lumbar region. On April 10th, after symptoms of circumscribed peritonitis, the ball was passed in defecation. The patient made a good recovery, and was returned to duty May 23, 1864. WILLIAMSON (*Mil. Surg.*, p. 109) records three cases of recovery, with abnormal anus, from shot wounds of the sigmoid flexure: Hogan, 32d regiment, wounded June 29, 1857, at Lucknow, whose case is related also by Assistant Surgeon F. DECHAUMONT (*Edin. Med. Jour.*, 1858, Vol. IV, p. 491); McCartney, 10th regiment, wounded May 11, 1858, at Chitawarah, fecal fistula persisting, March 15, 1859; Henderson, 15th regiment, wounded at Cabul, October, 1840, fecal fistula remaining at his discharge, August 26, 1844. Besides these three cases, Dr. WILLIAMSON notices that of a sailor, wounded in rowing toward the enemy, who suffered for years with abnormal anus with eversion and protrusion, and furnished specimen 1270, in the Museum of the Army Medical Department, figured in Plate IV of Dr. WILLIAMSON'S work, and expresses his regret that the particulars of the case are unknown. Is not the case identical with that described in DEWAR'S dissertation? Dr. WILLIAMSON also adverts to the case of James Bechan, 19th regiment, described by Drs. LONGMORE, MATTHEW, and HABERSHON, of which Mr. HILTON furnishes the *post-mortem* particulars, the preparation being preserved in Guy's Hospital Museum, numbered 1867<sup>19</sup> (*Appendix of 1863 to Cat.*, p. 52). It will be observed that in the five instances last named, the descending colon was the part injured. Of four shot wounds of the colon recorded in the Surgical Report in Circular 3, S. G. O., 1871, two resulted favorably, in one of which (CASE CLV) there was fecal fistula, following a wound in the descending colon, on the eighth day, and ceasing permanently, on the twelfth. In relation to the date at which fecal discharge is observed, Professor BILLROTH (*Chirurgische Briefe aus den Kriegs-Lazarethen in Weissenburg und Mauthausen*, 1870, S. 204) states the results of his experience in the late Franco-German war, as follows: "I saw fecal fistule in various parts of the anterior wall of the abdomen, where the small intestines are very movable. No other explanation seems possible than that shot wounds of the intestines do not uniformly discharge fecal matter immediately any more than injuries of the larger blood-vessels invariably cause immediate hemorrhage. Probably fecal matter does not always escape immediately. In consequence of the local traumatic peritonitis, the intestine adheres to the abdominal wall, and not until this adherence is accomplished, and the eschar of the intestinal wall separates, does fecal matter escape, emptying directly outward, or else from one wound of an intestine into another. If this hypothesis be correct, the fecal escape, in all such cases, would ensue some days after the reception of the injury. This occurred in cases 33 and 44, and, in Czerny's case, 29, in which fecal matter escaped from the eighth to the fourteenth days."

*Abnormal Anus.*—In about one-fifth of the instances of wounds of the large intestine that have been related,<sup>1</sup> the abnormal communication between the bowel and the exterior of the abdomen remained open, and constituted what is termed an artificial or preternatural anus. In three of the recoveries from wounds supposed to interest the small intestines, there were fecal fistulae, which closed at a comparatively early period. A feature common to all of these cases was the absence, or slight development, of the crescent-shaped septum, commonly formed in cases of preternatural anus following the mortification of the intestine in strangulated hernia. The mechanism of this variety of preternatural anus, illustrated by the familiar drawing of Scarpa (Fig. 69), has been carefully studied. The portion of the intestine by which matters descend from the stomach, and the portion leading to the rectum, meet at the abnormal aperture at a more or less acute angle, and the projection of the mesenteric side of the bowel forms the promontory, or spur, or valve, which causes matters descending to escape externally, instead of passing into the lower portion. This condition, which has been most elaborately discussed,<sup>2</sup> necessarily attends preternatural anus, where the upper and lower bowels of the intestine approach the aperture at an acute angle, as must be the case when a knuckle protrudes and the prolapsed portion is destroyed by mortification. But it is not a necessary or a frequent consequence of the destruction of a limited portion of the intestinal wall by injury. This conclusion, directly at variance with the teaching of Scarpa, is the most important practical lesson deduced from the numerous instances of spontaneous recovery from extensive wounds of the large intestine that have been presented. But when a septum does exist, in traumatic cases, it must be destroyed.

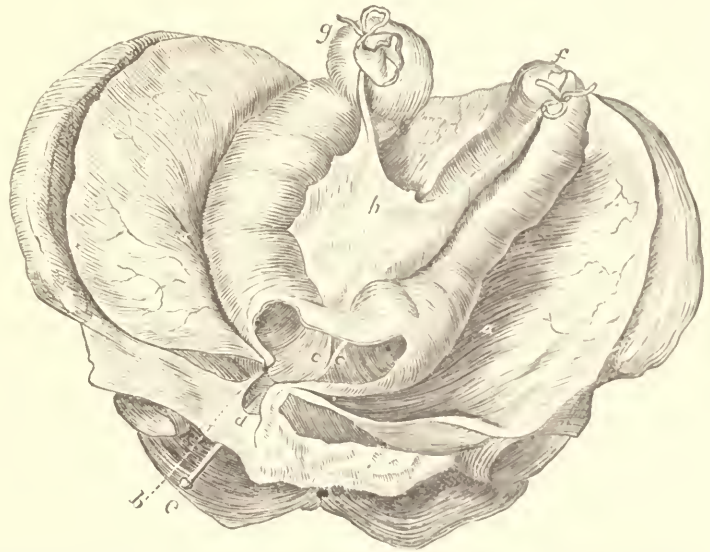


FIG. 69.—Diagram of the relations of a preternatural anus resulting from sloughing of a knuckle of ileum [after SCARPA]: *a*, peritoneum covering the iliac fossa; *b*, the point where the peritoneum forms part of the infundibulum; *c*, the promontory, *Éperon* or spur; *d*, *e*, the fistulous track and outlet of the preternatural anus; *f*, upper part of gut; *g*, lower part of gut; *h*, mesentery.

<sup>1</sup> Abnormal anus has remained pervious in the case of Harsh (235), illustrated by Plate IV, for ten years, and in four others—Dugan (252), Escher (281), Wikol (288), Graham (291)—for periods extending from eight to nearly eleven years, without serious constitutional decay. With the four pensioners who died—cases of Labar (218), of Clohosey (268), of Odell (270), and of Haun (272)—with fecal fistula unclosed after intervals of from four to six years, the local lesions appear to have had only a remote connection with the fatal results. In the fatal cases of M — (301) and of Blackburn (305), the local lesion, complicated by necrosis of the ilium, was a proximate cause of death.

<sup>2</sup> Consult LA PEYRONIE, *Observations avec des réflexions sur la cure des hernies avec gangrene*, in *Mém. de l'Acad. de Chir.*, 1713, T. I, p. 237; LOUIS, *Mém. sur la cure des hernies int. avec gangrene*, *ibid.*, 1757, T. III, p. 145; SABATIER, *Mém. sur les anus contre-nature*, *ibid.*, 1774, T. V, p. 392; DESAULT, *Mém. sur les anus contre-nature*, in *Oeuvres Chir.*, 1813, T. II, p. 352; SCARPA, *Sull' Ernie. Memoria Anatomico-chirurgica*, Milano, 1804; LAWRENCE, *A Treatise on Ruptures*, 5th ed., 1838, p. 379; LALLEMAND, *Rep. Gen. d'anot.*, 1823, T. VII; DELPECH, *ibid.*, T. VII, p. 133; HUBER, *Über den widernatürlichen After und die zu dessen Heilung vorgeschlagenen und ausgeführten Methoden*, Stuttgart, 1817; REYDARD, *Mém. sur le traitement des anus artificiels*, Paris, 1827; LIOUARD, *Sur le traitement de l'anus contre-nature*, Diss., Paris, 1819; JALADE LAFOND, *Considérations sur les hernies abdominales, sur les bandages et les anus contre-nature*, Paris, 1822; COOPER (A.), *The Anatomy and Surgical Treatment of Crural and Umbilical Hernia*, Folio, 1804-7, Part I, p. 34, and Part II, p. 59; JOBERT, *Traité des Maladies Chirurgicales du Canal intestinal*, 1829, T. II, p. 125; LEBLANC, *Sur l'anus contre-nature*, Paris, 1805; PARIS (G. H.), *Traitement des anus contre-nature*, Paris, 1824; AZEMAR, *Considérations sur les anus contre-nature*, Montpellier, 1821; MILLET, *Considérations sur les anus contre-nature*, Paris, 1822; BAUDELOQUE, *Quibusdam methodis ad ano contra-naturam medendum*, Paris, 1827; LAUGIER, *Anus contre-nature*, in *Diet. de Méd.*, 1833, T. III, p. 342; FOUCHER, *De l'anus contre-nature*, Paris, 1857; LAUGIER, *Anus contre-nature*, 1865, *Nouv. diction. de Méd. et de Chir. prat.*, T. II, p. 684; GUYON, *Anus contre-nature*, 1865, in *Diet. encyclopéd. des sci. méd.*, T. V, p. 503; GUÉRIN, *Traitement curatif de l'anus contre-nature accidentel*, 1865.

Though anticipated by Schmalkalden<sup>1</sup> and Physick,<sup>2</sup> Dupuytren<sup>3</sup> has the credit of introducing into practice an effective means of destroying the septum and restoring the continuity of the canal. Instead of division by the gradual tightening of a ligature, as suggested by Schmalkalden, or by the knife, after preliminary transfixion and union of the laminae of the septum, as practiced by Physick, Dupuytren<sup>4</sup> crushed the projecting spur by the serrated blades of a steel forceps, which he denominated an enterotome.<sup>5</sup> This instrument has been

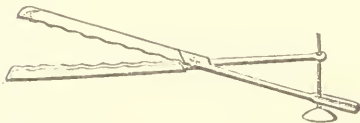


FIG. 70.—Dupuytren's enterotome,  $\frac{1}{2}$  size.

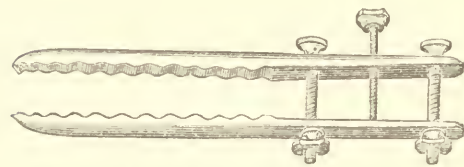


FIG. 71.—Blasius's intestine pincers, or Darmsehre.

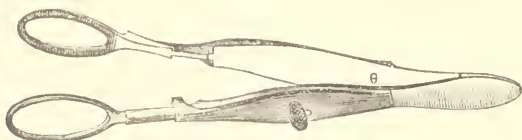


FIG. 72.—Gross's instrument for the operation for the cure of premature anus. [After GROSS.]

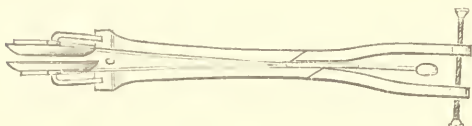

FIG. 73.—Reybard's intestine pincers, or pince entérotome.

successfully employed in more than forty cases. Some objections are offered to it, however, of which the most valid appears to be that the parts nearest the intersection of the blades are divided earlier than the more distant parts. That uniform pressure might be exerted, Günther states that Dupuytren altered the instrument by making the blades parallel, as in the modification known by the name of Blasius (Fig. 71), which Günther<sup>6</sup> regards as satisfactory in all respects.

Delpéch attached much value to a modification of his invention. Other ingenious means of accomplishing the object have been proposed by Professor Gross (Fig. 72), M. Liotard,

Dr. Lotz, M. Reybard (Fig. 73), and Dr. D.

Prince.<sup>7</sup> As the anatomical conditions vary

somewhat, it is convenient to have at command

a variety of instrumental appliances. The de-

struction of the septum by mortification can be

accomplished by either of the clamps repre-

sented, or, the mechanism of the lesions and the obstacle to be removed being clearly

appreciated, the end may be attained by other than mechanical means. In 1841, Vidal

proposed to destroy the septum by caustic, and in

his fifth edition, in 1861, he stated that his plan

had been successfully employed by surgeons in

Paris and in Lyons. Many surgeons discounte-

nance any operation, until a systematic and perse-

<sup>1</sup> SCHMALKALDEN, *Nova methodus intestina uniendo*, Viteb., 1798.

<sup>2</sup> PHYSICK, cited by DORSEY, *Elements of Surgery*, 1818, Vol. II, p. 92; by COATES in the *North Am. Med. and Surg. Jour.*, 1826, Vol. II, p. 269; and by H. H. SMITH, *Princ. and Pract. of Surg.*, 1853, Vol. II, p. 431.

<sup>3</sup> DUPUYTREN, *Mémoire sur une méthode nouvelle pour traiter les anus accidentels*, in the *Mém. de l'Acad. de Méd.*, 1828, T. I, p. 464, reprinted in the *Leçons Orales*, 2<sup>e</sup>me éd., Paris, 1839, T. IV, p. 1, and his elaborate article in the third volume of the *Dictionnaire de Médecine et de Chirurgie Pratique*, p. 117. In 1817, REISINGER, of Augsburg, a friend of DUPUYTREN, published a detailed and authentic account of this operation in a work entitled *Anzeige einer von dem Herren Professor DUPUYTREN zu Paris erfundenen, und mit dem glücklichsten Erfolge ausgeführten Operations-Weise zur Heilung des anus artificialis; wbst Bemerkungen*, an analysis of which appeared in LANGENBECK'S *Neue Chirurg. Bibliothek*, B. I; and later, BRESNET gave a full historical account of the subject in the eighth and ninth numbers of the *Quarterly Journal of Foreign Medicine and Surgery*, in a paper entitled *considérations et observations anatomiques et chirurgicales sur la formation, la disposition, et le traitement des fistules stercorales et des anus contre-nature*.

<sup>4</sup> If the splendid eulogy which LAWRENCE (*Treat. on Rupt.*, 3d ed., p. 413) bestowed on DUPUYTREN'S operation is exaggerated, it more nearly expresses the judgment of the profession, than the small carping that sufers at the brilliant results announced by DUPUYTREN, in forty-one cases operated on by himself, DELPECH, and LALLEMAND, in remarking that "artificial anus must be more common in Paris than in London." The writers, who, from patriotic bias, detract from DUPUYTREN'S credit by citing PHYSICK'S operation on John Axillius, in 1809, are confronted with SCHMALKALDEN'S proposition of 1798, and by the fact that DUPUYTREN was unacquainted with these antecedent essays.

<sup>5</sup> This name is sanctioned by usage; otherwise, as it is proposed to destroy the septum by crushing rather than cutting, *enterotribe*, *enteroclast*, *enteroceraser*, or *gut-clamp*, would be more appropriate.

<sup>6</sup> GÜNTHER, *Lehrer von den blutigen Operationen am Menschlichen Körper*, 1860, B. IV, Ab. XV, S. 175.

<sup>7</sup> DELPECH, *Obs. sur l'anus artificiel*, in *Mém. des Hôpitaux du Midi*, 1830, p. 76; GROSS, *Wounds of Intestines, &c.*, 1843, p. 212, and *System, &c.*, 1872, Vol. II, p. 700, Fig. 491; LIOTARD, *Diss. sur le traitement des anus contre-nature*, Paris, 1819, and in BOERGERY, *Mét. Op.*, T. VII, p. 142, and pl. 43; LOTZ, *Am. Jour. Med. Sci.*, 1836, Vol. XVIII, p. 367, and in SMITH'S *Surgery*, Vol. II, p. 435; REYBARD, *Mém. sur le traitement des anus artificiels, et des plaies des intestins*, 1827; VIDAL, *Path. Ext.*, 5<sup>me</sup> éd., T. IV, p. 262; D. PRINCE, *Am. Jour. Med. Sci.*, 1869, N. S., Vol. LVIII, p. 412, and ASHBURST'S *Surgery*, 1871, p. 372.



vering application of Desault's plan of compression has failed, and the writer cordially subscribes to this view, having obtained unexpected success<sup>1</sup> by this method. Hey, of Leeds, appears to have had good results from this plan of treatment. Over a properly adjusted compress, daily renewed, he placed a metallic weight, gradually adding to its bulk. I think insufficient attention has been paid to Desault's plan. When failing in its curative intent, compression is useful as a palliative measure, as the cases of Cheston, Rezzonico, and others testify.<sup>2</sup> Removal of the septum by excision, as practiced by M. Rayé, or by linear cauterization, as advised by M. Laugier, appears to me less safe than the plan recommended by Reybard, indicated in FIGURE 74.

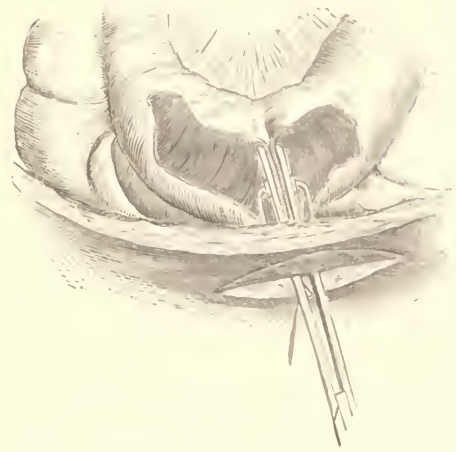


FIG. 74.—Reybard's instrument applied. [After BOURGERY.] (*M. d. op.*, T. VII, pl. 43, Fig. 5).

Suture of the margins of the orifice in the abdominal wall was resorted to by Dr. J. H. Hutchinson, in CASE 210, and by Surgeon Adam Hammer, U. S. V., in the following case of abnormal anus following gangrene of an inguinal hernia:

CASE 309.—Private G. Krug, Co. B, 13th Missouri Cavalry, was admitted to the New House of Refuge Hospital, at St. Louis, May 14, 1863, the case being entered on the register as a "wound of lower part of abdomen." Treatment: horizontal position, simple dressings to wound, and the administration of cathartic enemata daily. On December 9, 1863, he was transferred to the Marine Hospital, where the diagnosis "preternatural anus" was recorded, and the following report of the case was made by the operator, Surgeon A. Hammer, U. S. V., who also had charge of the first named hospital: "Prior to admission, the patient says he had inguinal hernia, and that, after the integuments were cut through, feculent matter issued; time of receiving hernia unknown. June 14th, actual cauterity and wire suture combined for artificial anus. June 30th, same operation. The orifice is about one inch in circumference, feculent matter passing from the orifice freely. In excellent health; horizontal position and simple dressings; doing well." And on the next report: "July 14th, cauterization with nitric acid. July 18th, same operation, and, September 25th, actual cauterity. Faces passing through anus preternaturalis. In good health. Horizontal position, and simple dressing. Good result, and returned to duty July 25, 1865." Krug is not a pensioner. It does not appear that he was wounded in action, and the first hospital entry doubtless refers to a wound made in the operation for strangulated inguinal hernia.

This plan, suggested in 1739 by Lecat, and practiced without advantage by Cruikshank, Bruns, Liotard, and Blandin, appears to have expedited the cure in Judey's case; and MM. Foucher and Patry have lately cited other facts in its favor.<sup>3</sup>

*Anaplasty*, successfully practiced by Collier, in 1820, is said to have been performed by Acting Assistant Surgeon Leale in CASE 236, and there is mention of some form of plastic procedure in CASES 210 and 276. Of this plan and of that of suture, it may be said that when the anatomical conditions admit of the closure of the abnormal anus they are unnecessary, and otherwise, that they are ineffectual.<sup>4</sup>

<sup>1</sup> I have, in an old case book, the memoranda of three cases of abnormal anus, which I have neglected to publish, that resulted favorably under treatment by Desault's method: 1. A wound of the sigmoid flexure, in an Irish servant of Mr. Buckland, of Springfield, Massachusetts; 2. A fecal fistula in the right iliac fossa, from perityphlitis, Mrs. C—, of Belchertown; 3. A mortified right scrotal hernia, in the case of a railway laborer, James Sweeney, aged 42, Ferry street, Springfield, June 26, 1858.

<sup>2</sup> HEY, *Practical Observations in Surgery*, 3d. ed., 1814, p. 224; CHESTON, in COOPER on *Hernia*, loc. cit., Part I, 1801, p. 36; REZZONICO, *Stor. a di un caso di ano preternaturale guarito colla cura palliativa*, in *Ann. univ. di med.*, T. CLXIV, p. 91, 1858; DESAULT, *Œuvres Chir.*, T. II, p. 570; LAWRENCE, *l. c.*, 5th ed., pp. 290 and 422; RAYÉ (C. C.), *Consid. sur la guérison d'un anus anormal par un nouv. proc. opérat.*, in *Ann. de la Soc. M. d. de Gand*, 1838.

<sup>3</sup> CRUIKSHANK, in COOPER on *Hernia*, l. c., Part I, p. 78; BRUNS, *Handb. der Pract. Chir.*; LIOTARD, l. c.; BLANDIN, in *Mém. de l'Acad. de Méd. de Paris*, 1838; CHASSAIGNAC, *Traité oul chirurgical de l'anus contre-nature par la suture directe: considérations pratiques*, in *Arch. gén. de Méd.*, 1855, 5e série, T. V, p. 529. JUDEY's case was communicated January 14, 1823, by RICHERAND (*Arch. gén. de Méd.*, T. I, p. 291); FOUCHER, l. c.; PATRY, in *Bull. de la Soc. de Chir.*

<sup>4</sup> COLLIER (G. F.), *Case of Artificial Anus, cured by an Operation on the Principle of Tagliacozzi*, in *London Med. and Phys. Jour.*, 1820, Vol. 43, p. 466; LAUGIER, *Autoplastie par transformation inodulaire; nouvelle meth. opér. pour achever la guérison des anus contre-nature*, in *Compt. rend. de l'Acad. des Sci.*, 1859, T. XLIX, p. 218; VELPEAU, *Des anus anormaux de pourvus d'épéron*; BRYK, *Ein Beitrag zur Proktoplastik beim Schwelnd. after*, in *Östr. Ztschr. für prakt. Heilkunde*, 1861, B. VII, S. 209.

*Enteroraphy.*—From the evidence presented in the preceding pages, it may fairly be inferred that in all-punctured and incised wounds of the intestinal canal attended with protrusion, the safest practice consists in closing the intestinal wound by suture, and reducing the protruded viscus, unless its structure is irretrievably disorganized and the adoption of the alternative of establishing a preternatural anus is compulsory. It is highly probable that, in the rare instances in which shot lacerations of the intestine are attended by protrusion, a like practice is applicable. In stabs and shot wounds implicating the small intestine, unattended by protrusion, the common practice has been to seek to avert extravasation into the peritoneal cavity by arresting peristaltic action by opium, and by enjoining absolute quiet, and to indulge the hope that adhesions may form through the efforts of nature. Experience teaches that, in the vast majority of instances, such hopes are illusory.<sup>1</sup> Nine times in ten, or oftener, extravasation takes place, and hyperacute peritonitis ensues, and generally proves fatal within forty-eight hours.<sup>2</sup> When the patient rallies from the faintness and depression immediately following the wound, there is almost always tension and tenderness of the belly; then, in John Bell's graphic language, comes on dreadful pain and vomiting, costiveness, hiccough, the torments of the *miserere mei*, and the patient in a great anguish expires. Or else, after the intense pain, there may be an interval of deceitful ease, which is merely a sign of gangrene, and the patient sinks into a low muttering delirium and dies. Guthrie justly declares that "the do-nothing system is generally followed by death."<sup>3</sup> I have shown that in wounds of the small intestines of any magnitude, the pathological evidence of recoveries achieved by the unaided effort of nature, even through the establishment of a preternatural anus, is limited to a very few instances, of which none are absolutely unequivocal.<sup>4</sup> Therefore in wounds of this viscus, unattended by protrusion, when there is danger of extravasation, the external wound should be enlarged, and the wound in the intestine closed by suture.<sup>5</sup>

<sup>1</sup>In 1843, Professor GROSS published the *Experimental and Critical Inquiry into the Nature and Treatment of Wounds of the Intestines*, an invaluable monograph, long since out of print, which placed its author with HEVIN and TRAVERS and SCARPA, as a leading authority on the subject of which it treats. His experimental knowledge augmented by the ripened wisdom evolved in thirty years of observation, in the last edition of his *System*, Volume II, p. 665, Professor GROSS enunciates the practical conclusions at which he has arrived as follows: "From what has been said, it is evident that the great danger in this class of injuries [wounds of the stomach and intestines] is from fecal effusion, so liable to occur even when the wound is comparatively insignificant. The proper treatment, therefore, to be pursued is simply to sew up the wound and to replace the bowel as speedily as possible, watching the case most assiduously afterward, with a view of preventing undue peritoneal inflammation; for, whenever this attains the ascendancy, the patient must necessarily perish. It is folly to think of any other practice; the sheerest nonsense to talk about the irritating nature of intestinal sutures. Enteroraphy is, in itself, one of the most innocent of operations, and it is only surprising that it should ever have been regarded in any other light. What possible harm can result from depositing a little thread in the coats of an intestine, and retaining it there for ten or a dozen days? Some inflammation must, of course, arise; but this is precisely what is needed for the safety of the patient and the cure of the wound. Even if the wound is not more than a line and a half in length, the bowel ought not to be returned without stitching it. Fecal extravasation might occur, and the patient should, therefore, not be subjected to the risk of such a contingency. In several of my experiments death was produced, not by sewing up the bowel, or by the manipulation employed in performing the operation, but by the escape of fecal matter along the large interspaces between the sutures, which thus allowed the wound to gap, and to favor the occurrence in question. Indeed, it may be laid down as an axiom that, whenever the closure of the wound is incomplete, there is danger of intestinal effusion."

<sup>2</sup>The experiments offered by so excellent an authority as TRAVERS (*Inquiry*, &c., p. 136) to prove that fecal extravasation was not a necessary annoyance of punctured and incised wounds of the intestines, have been wrongfully cited by writers, who would have it appear that fecal effusion into the peritoneal cavity is a rare consequence of intestinal wounds (see TEALE'S article in the *Cyclopaedia of Practical Surgery*, Vol. II, p. 136). Mr. ERICSEN, whose treatise is issued to medical officers, goes so far as to affirm that (*Practice and Art of Surg.*, 1869, Vol. I, p. 448) "it is seldom, indeed, that feces are extravasated from gut that is not protruding, unless it be very full at the time of injury, or the wound in it be very extensive," and cites two cases of shot wounds of the intestines within his own observation, in which no extravasation took place. The subject is one of such importance that it will be fully considered hereafter, and I will only remark here that, in my opinion, Mr. ERICSEN'S statement conveys a dangerous fallacy.

<sup>3</sup>M. LEGOUËZ says (*Traité de Chir. d'Armée*, 2<sup>me</sup> éd., p. 281): "Lorsque l'intestin blessé est resté dans la cavité abdominale, la plupart des chirurgiens modernes recommandent d'abandonner la guérison à la nature; il s'en tiennent à ce que l'on appelle les moyens généraux, leur faisant les honneurs du succès si le blessé guérit, et, s'il succombe, considérant la blessure comme au-dessus des ressources de l'art. Quelques observations heureuses excusent cette manière de voir sans la justifier; un grand nombre de cas finissent le embandement."

<sup>4</sup>There are pathological preparations of the small intestine showing small white cicatrices resulting from punctures, as in accidental wounds in paracentesis for ascites or ovarian disease; there are not a few preparations of abnormal anus of the small intestine resulting from the mortification of the protruded bowel in hernia; and there are many clinical histories of cases of abnormal anus resulting from wounds supposed to implicate the small intestine; but *post-mortem* verification of the precise seat of the lesion in these cases is wanting. The preparation figured on page 71 demonstrates a recovery from shot injury of the small intestine, but it is plausibly argued that there was no complete division of the gut in this case.

<sup>5</sup>Though but few authorities have submitted themselves to this view in print, I am fortified in my conviction of its correctness by the concurrence of such surgeons as Drs. H. S. HEWIT, N. S. LINCOLN, H. MCGUIRE, and my colleague, Dr. J. S. BULLING.







Ward phot.

Am. Photo-Kellef Printing Co., Philada.

PLATE III. SHOT WOUND OF THE ILEUM CLOSED BY THE  
CONTINUED SUTURE.

No. 4389. SURGICAL SECTION.

Wounds of the large intestines often do well without interference, and, in these wounds, enteroraphy will seldom be requisite, unless the wounded colon protrudes. Yet there are exceptional cases, in which extending the external wound and sewing up the rent in the gut is the best and only means of preventing extravasation, as is well exemplified by the successful case of enteroraphy, for shot laceration of the colon, recorded by Baudens. Examples of gastroraphy and of enteroraphy have been adduced on pages 44, 62, 72, and 76. Sutures were applied in CASES 206 and 234 to incised wounds of the jejunum and colon; in CASES 228 and 229 to shot wounds of the ileum, with protrusion. One of the pathological preparations is shown in PLATE III, opposite. In addition to the four cases just enumerated, the two following may be regarded as belonging to the war series:

CASE 310.—Surgeon P. H. Flood, 107th New York, reports that Private M. B. Ingram, Co. I, 13th New Jersey, aged 21 years, received a shot wound of the abdomen, on the march through North Carolina, on April 9, 1865, and was treated at the field hospital of the 1st division, Twentieth Corps, on the following day. The ball had lacerated the small intestine. Surgeon H. Z. Gill removed two inches of the lacerated gut, and the opposing ends were then brought together and retained in apposition by sutures. The patient died on April 11, 1865. There is no record of a necropsy.

CASE 311.—The following facts are compiled from a valuable paper by Professor R. A. Kinloch, of the Medical College of South Carolina, in the *American Journal of the Medical Sciences*, for July, 1867: Lieutenant T. G. B—— was wounded, October 22, 1862, near Pocotaligo, by a musket ball, which entered below the anterior superior process of the right ilium, and, passing obliquely upward, emerged three inches to the left of the median line, below the level of the umbilicus. Symptoms of shock were followed by those of traumatic peritonitis. There was vomiting, constipation, excitement, tender abdomen, and a disposition to collapse. On November 2d, the more violent of these symptoms subsided, with discharges of pus and of feces through the orifice of entrance. About November 25th, a dejection by the rectum was induced by an enema. On February 13, 1863, Dr. Kinloch saw the patient with the regular attendant, Dr. Dupont. There were several fecal fistulæ connected with the orifices of entrance and of exit; the patient was feeble and much emaciated. Several sinuses were laid open, and the index was passed into the entrance opening into the gut, which lay very deep. In April, 1863, there was an attack of abdominal pain, with febrile excitement, and jaundice. On May 11th, the patient was placed in the Summerville Hospital. On May 27th, exploratory incisions were made, and it was ascertained that the fistulæ communicated with the upper portion of the bowel; the lower portion could not be found. On June 8th, Dr. Kinloch, in consultation with Surgeon E. E. Jenkins, decided to lay open the peritoneal cavity, with a view of restoring the continuity of the intestinal canal. An incision three and a half inches long was made through the linea alba downward, starting from just below the umbilicus. The lower extremity of this incision was then connected with the external orifice of the abnormal anus, and, numerous adhesions being broken up, a triangular flap was raised. A barrel of intestine was found nearly divided, or so deeply notched as to intercept the continuity of the canal, the upper end adhering to the contour of the abnormal anus, the lower reflected and adherent to the contiguous viscera. The upper end was of increased calibre, the lower contracted, with thickened tunics. Dr. Kinloch excised half an inch of the upper portion of the bowel and two inches of the lower, refraining, as far as possible, from incising the mesentery. One small vessel was ligated. An attempt at invagination of the upper portion within the lower, by Jobert's method, was precluded by the contracted condition of the lower portion of the gut, and Dr. Kinloch was compelled to resort to apposition of the divided extremities, which were united by a number of interrupted silver-wire stitches. Then, by three additional wires, as many points of Lembert's suture were introduced, and the serous surfaces were thus, to some extent, approximated. During the operation, the important precautions of protecting the viscera by towels wrung out of tepid water, and absorbing blood and extravasated matter by soft sponges, were minutely observed. After the operation, which was necessarily protracted, the parietal wound was closed by sutures, and supported by compresses and bandages. The patient, taking morphia and brandy, rallied in the course of an hour from the great depression following the operation. Reaction was slight. On the third day, some of the intestinal sutures gave way, and there was a fecal discharge. On July 4th, there was some abdominal uneasiness, and an enema brought away a copious stool. Thenceforward there were regular alvine evacuations, though the fecal fistula persisted. On July 16th, the patient traveled eighty miles by rail, and, on August 12th, he was able to be about on crutches, daily improving in nutrition. On January 14, 1864, an exploration showed that there was a septum or spur at the orifice of the fistula. On March 28th, Dupuytren's enterotome was applied, and the septum was divided at the end of the fourth day. Subsequently the discharge lessened greatly; yet a small fistula with indurated margins persisted. Repeated cauterization, in April, May, and June, and the twisted suture, failed to close the fistula. But convalescence was fully established, and vigorous general health was fully restored. The reader must be referred to Dr. Kinloch's important paper for fuller details. His concluding remarks are as follows: "I feel confident that surgery is capable of completing the cure in this interesting case. I have been induced to offer the notes for publication with no view of claiming the degree of success aimed at by the several operative procedures instituted, but because the history appeared to me to possess the following points of interest: 1. It adds another instance of recovery after severe gunshot wound of the small intestine. 2. It is an argument against the almost universal practice of abandoning intestinal lesions to nature, rather than risk opening the peritoneal cavity. 3. It is a record of successful conversion of an artificial anus, with its attendant symptoms of falling nutrition, into a fecal fistula, compatible with good nutrition, and a high degree of health and activity. 4. It is illustrative of the readiness with which the function of a large extent of intestine can be resumed after a suspension of over seven months (from October 22, 1862—the day of the reception of the wound—to June 8, 1863, the date of the operation for restoring the continuity of the intestine). 5. It must serve to encourage that hopefulness and boldness so essential to progressive surgery, and at all times preferable to despair."



*Palfyn's Method.*—Systematic writers thus designate the plan of stitching the wounded intestine to the wall of the abdomen, after an eminent surgeon, who lectured in Flanders<sup>1</sup> in the early part of the eighteenth century, and taught that it was useless to sew up the bowel, since the divided parts would not reunite and recovery could only be effected by the formation of adhesions to adjacent parts. Hence he recommended that a single loop of thread be inserted through the lips of the intestinal wound at its centre, and to bring the ends out at the external opening, securing them to the integument by an adhesive strip. This simple expedient has had numerous able advocates, among whom the late John Bell<sup>2</sup> appears to great advantage as a special pleader, and unfavorably as a teacher of sound surgical doctrine. Scarpa, Richter, Zang, Richerand, Lawrence, Larrey, and Hennen,<sup>3</sup> while condemning the employment of intestinal sutures, did not travesty the teachings of those who entertained different views. The plan of Palfyn can hardly be regarded as a method of enteroraphy; but must always hold its place as a valuable resource in some cases of complete divisions of the intestine or of other lesions, in which the establishment of an abnormal anus is accepted as the sole available remedial measure. Thomas Smith, of St. Croix, whose inaugural dissertation<sup>4</sup> has not, it appears to me, received that attention its originality merited, found a great liability to intraperitoneal faecal extravasation in practicing this plan on dogs.

<sup>1</sup> PALFYN (J.). His work, *Van der vornaemste Handwerken de Heelkonst*, Leyden, 1710, was enlarged and republished in German in 1718, and in French, under the title *Anatomic du corps humain, avec des remarques utiles aux chirurgiens*, Paris, 1827. It was also translated into Italian. PALFYN was born at Ghent in 1650, lectured and practiced there, and died in 1730.

<sup>2</sup> JOHN BELL (*Discourses on the Nature and Cure of Wounds*, Part II, p. 120) concludes his denunciation of the treatment of intestinal wounds by suture by a professedly impartial comparison of the method of invagination, recommended by B. BELL, and his own plan, which is identical with that of PALFYN, to whose writings he does not allude. The drawings copied below (FIGS. 75 and 76) were by his own hand. "There remains," he says, "only one thing for me to do, viz., to make sure of my readers having a fair and entire notion of these two doctrines, by putting them down opposite to each other in the form of plans: FIG. I explains the double suture; FIG. II explains the simple stitch: (a) points out the space which must mortify, according to

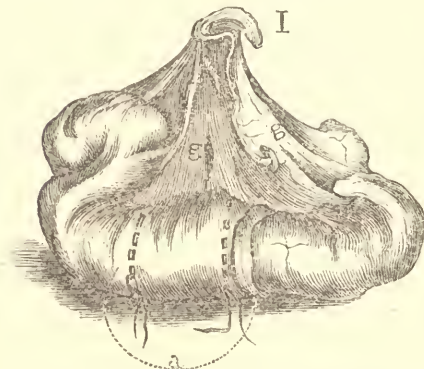


FIG. 75.—Intestinal suture according to John Bell.

to the DOUBLE SEAM METHOD; (b) shows the single stitch by which we hold the two pieces of gut tight with regard to each other, and both close up to the wound; (c) the dotted line, marks the direction in which the gut (e) lies within the gut (f); (g) shows the mesentery; (h) the way in which it keeps the two ends of the divided intestine right; and it cannot be difficult to conceive how the stitch (b) will come easily away with little harm to the intestine, and not till after it has done its business effectually in uniting the inward to the outward wound; so that though the breach which the stitch left were large, still the faeces would be discharged easily, and it would heal gradually along with the outward wound." This unfair statement is treated by Professor GROSS

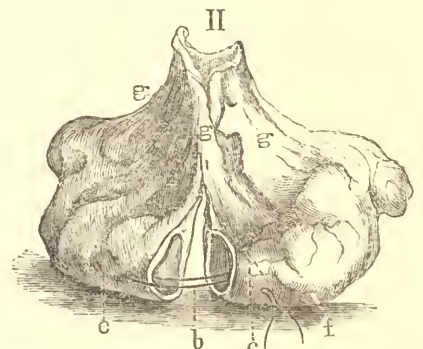


FIG. 76.—Treatment of wounded intestine according to John Bell.

(*Wounds of the Intestines*, *op. cit.*, p. 106) without undue severity: "If there ever was an error committed by any writer more serious, culpable, and mischievous than another, it is most assuredly that of Mr. John Bell, who, while criticizing and condemning, in no measured terms, the advice and practice of others, has himself fallen into a most strange delusion. Had he performed the operation in a single instance upon the human subject, or upon an inferior animal—an experiment from which he affects so much to shrink—he would have become fully sensible of its danger and insufficiency. That the operation, as recommended by this eminent surgeon, might occasionally be attended with success is not improbable, but that it should not be trusted to in the present enlightened state of the healing art must be obvious to all who will be at the trouble to investigate it. Independently of the great risk of faecal effusion into the peritoneal cavity, there are few cases, if any, in which it would not be followed by an artificial anus, an occurrence which never attend enteroraphy when performed in the manner previously pointed out."

<sup>3</sup> SCARPA, *Sull 'Ernia; memorie anatomico-chirurgiche*, Ed. II, Pavia, 1819, Mem. IV, § XXV, p. 131; RICHTER, A. G., *Anfangsgründe der Wundarzneikunst*, Wien, 1798, B. V, S. 40; ZANG, *Darstellung blutiger heilkünstlicher Operat.*, B. III, S. 490; RICHERAND, *Nosographie chir.*, 1821, T. III, p. 319; LAWRENCE, *Treatise on Ruptures*, London, 1810, p. 280; LARREY, D. J., *Recueil de Mém. de Chir.*, 1821, p. 247; HENNEN, *op. cit.*, p. 420.

<sup>4</sup> SMITH (T.), *An Essay on Wounds of the Intestines*, Philadelphia, 1805, p. 28: "April 28. Wishing to give Mr. JOHN BELL'S method of stitching an intestine a fair trial, I made the following experiments [X and XI]: Having obtained two full-grown dogs, a transverse incision was made into the intestines of each of them, which was secured by one stitch and fastened to the wound. No. 10 died in about twenty-four hours. The marks of inflammation were very great and the faeces had been discharged into the abdomen. No. 11 died on the 2d of May. The intestines appeared very much inflamed; faeces, as in the other instances, were found in the abdomen, also water which the animal had drunk. The large intestines appeared gangrenous and tore very easily. Experiments VIII and XII were also unfavorable to this method." [I am indebted for an opportunity of consulting Dr. SMITH'S rare dissertation, to Dr. GEORGE C. HARLAN.—*Editor.*]



Lapeyronie's method<sup>1</sup> differed from that of Palfyn in this only, that, in stitching the bowel to the margin of the external wound, he inserted the thread through the mesenteric attachment, and thus more closely approximated the upper end of the bowel to the external wound. An instance, in which Larrey successfully employed this method in a shot wound of the small intestine, is recorded on page 73.

*Reybard's Method.*—A modern plan, that has attracted much attention in academies, was proposed, in 1827, by M. Reybard.<sup>2</sup> The end chiefly held in view is essentially the same as in the method of Palfyn, the maintenance of the wounded bowel, in strict relation with the abdominal wall; but the inventor sought, in addition, a temporary occlusion of the wound in the gut by means of a disk of ivory or pine, introduced within its cavity. The disk is traversed by a fine thread, each end of which is armed with a needle. The disk being inserted in the gut is fastened by passing the needles through the lips of the wound from within outward, a quarter of an inch from its margin. The fine needles are then removed, the two ends of the thread are twisted together, and passed, by means of a single curved needle, through the abdominal wall near the edge of the external wound, and are then untwisted and tied over a roller or compress. In two days the ligature is to be cut, and it is anticipated that the disk will be expelled by stool. Velpeau and Vidal say that this plan, however successfully it may have proved in experiments on the lower animals, has not been applied on the living human subject.



FIG. 77.—Reybard's disk.

*LeDran's Method.*—If it is doubtful, as suggested by Professor Gross,<sup>3</sup> whether LeDran ever applied his looped suture to intestinal wounds in the human subject, it is unquestionable that it has been successfully employed by others, among whom Bohn, Schlichting, Laroche, and Percy may be specified.<sup>4</sup> Sabatier raised many objections to the *sutura ansata*, and advocated the substitution of the stitch introduced by Bertrandi, and extolled by Garengéot, and practiced, with modifications, by Chopart and Desault and Bécлар.

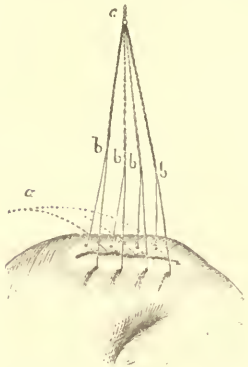


FIG. 78.—Longitudinal wound of the ileum united by the looped suture. The edges *a* are inverted; the four ligatures *b b b b* are twisted separately, and at *c* are twisted together to form a cord, that is secured externally. [After VELPEAU, *Nouv. Él. de Méd. Op.*, p. 14.]

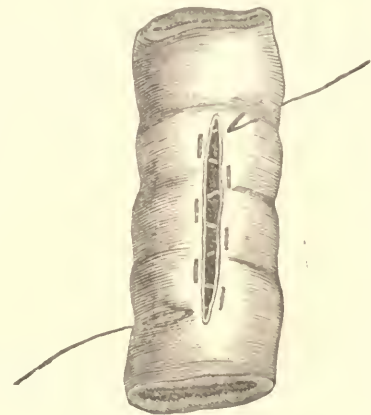


FIG. 79.—Bertrandi's suture.

<sup>1</sup> LAPEYRONIE, *Observations avec des réflexions sur la cure des hernies avec gangrene*, in *Mém. de l'Acad. de Chir.*, 1743, T. 1, p. 337. In the case of the Marpach soldier, treated by DAVID and JOHN SCHENCKELIUS, and described by CETHIUS in SCHENCKIUS (*Obs. med. rar.*, 1644, p. 332), and also by STALPART VANDER WIEL (*Obs. rar.*, 1687, Cent. I, Obs. XXXIX, p. 157), the stitches through the stomach were attached to the abdominal wall; and STALPART relates that he was told by PAULUS GODEFRIDUS, a Belgian surgeon, of a man stabbed in the lower part of the stomach, through which food escaped, which wound was sewed up after the manner of sewing the intestines, and the thread was passed through the muscles of the belly (*ibid.*, Cent. I, p. 156). DR. LOPEZ (*North Am. Med. Chir. Rev.*, 1858, Vol. II, p. 1070) succeeded by this method, after the intervention of an abnormal anus, which gradually closed.

<sup>2</sup> REYBARD, *Mémoires sur le traitement des anus contre nature, des plaies des intestines et des plaies pénétrantes de la poitrine*, Paris, 1827.

<sup>3</sup> GROSS (*Wounds of the Intestines*, &c., p. 99). LE DRAN (*Traité des Opérations de Chirurgie*, Paris, 1742, p. 80) describes his method as follows: "Pour faire la suture en anse, je fais soutenir par un aide chirurgien, l'intestin à l'une des extrémités de la plaie, et je soutiens moi-même l'autre extrémité. J'ai autant d'aiguilles que je dois faire de points, aiguilles rondes, droites et menues, chacune enfilée d'un fil long d'un pied, et non ciré. Je passe à travers de deux lèvres autant de fil qu'il est nécessaire, observant qu'ils soient à trois lignes ou environ de distance l'un de l'autre. Tous les fils étant passés, j'ôte les aiguilles, je noue ensemble tous les bouts des fils d'un des côtés; je noue de même ensemble les bouts de l'autre côté, puis les unissant tous, je fais, en les tortillant deux ou trois tours seulement une espèce de corde. En les tortillant ainsi, je fais francher la portion d'intestin divisée, alors les points qui étoient distans de deux ou trois lignes sont rapprochés l'un de l'autre. C'est ce froicis qui ne permettant pas aux lèvres de s'écarter l'une de l'autre, doit occasionner l'adhérence de l'une à l'autre, sans que l'intestin soit obligé de se coller à quelque autre partie."

<sup>4</sup> SCHLICHTING (*op. cit.*, p. 79) says: "Gelyk Bohnius en meer andere door onderwindinge genogzaam dit bekrachtigen, en ik zelfs veeltyds waargenomen hebbe." BÉCARD (*Plaies de l'intestin*, in *Dict. de Méd.*, T. XVII, p. 64) condemns this suture, after speaking in its favor in the article *Plaies de l'estomac*, in the twelfth volume of the same work.

*Method of the Four Masters and of Duverger.*—The four famous monks who practiced surgery together at Paris, in the middle of the thirteenth century, and many of their contemporaries, attempted to unite wounds of the intestines by direct apposition of the divided surfaces, supporting the intestine by a firm cylinder introduced within its cavity; and great attention appears to have been paid to this subject of enteroraphy by the teachers at the school of Salerno, in accordance, doubtless, with the traditions derived from the Arabians. The Four Masters used to support the bowel by a section of the trachea of an animal; others employed a dried intestine, a canula made of elder-wood, a tallow candle (Scarpa), a gelatine tube (Watson), or a varnished card (Sabatier, Chopart).<sup>1</sup> This plan, also designated as the method of direct reunion or apposition, was revived by Duverger, and an account of his successful operation, about 1745, is given in the celebrated



FIG. 80.—Metallic ferrules employed in the method of Denans.

dissertation of Louis in the third volume of the *Memoirs of the French Academy of Surgery*. It greatly exercised the ingenuity of surgeons of the last and even of the present century, and is the starting point of the various methods now to be passed in review.

*Method of Denans.*—At the period when the researches of Jobert and of Lembert were attracting much attention to the subject of enteroraphy, M. Denans,<sup>2</sup> of Marseilles, proposed a method designed to combine the advantages of approximating the serous surfaces by invagination with the ancient plan of supporting the divided bowel by a hollow cylinder of pewter or silver rings.

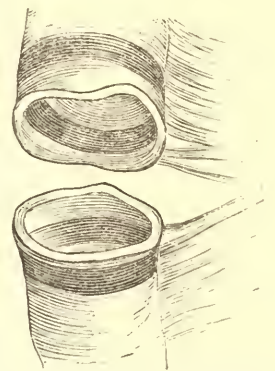


FIG. 81.—Two of the ferrules introduced into the extremities of the divided intestine according to the method of Denans.

<sup>1</sup> WEBER (*Diss. de curandis intestinorum vulneribus*, Berolini, 1830), misquoting, misnames the four masters ("Quatuor magistri, ut PETRUS DE ANGELATA nobis reliquit, atque LOUIS commemoravit, nominantur JAMERIUS, ROGER, THEODORICUS A CERVIA, qui cannulam sambuci nigre adhibebant, atque Guillelmus de Saliceto, qui parte utebatur intestini"), and misleads DIEFFENBACH and EMMERT. PETRUS DE ANGELATA (I cite the *editio princeps* of MORETUS, Venetiis, 1480, folio 23, *de vulnere grossorum intestinorum*) does not so name the four masters; but, after adverting to the practice of JAMERIUS, ROGER OF PARMA, THEOPHORIC OF CERVIA, he continues: "Others, as GUY DE SALICET, insert a piece of intestine," and then: "Alii ut QUATUOR MAGISTRI ponunt tracheam arteriam alicujus animalis, deinde sunt vulnus, et natura postea expellit illas canulas." LOUIS, the learned secretary of the old French Academy of Surgery, carefully investigated this subject, believing that it would be not only curious but instructive to find the original description of this method of supporting the divided intestine by a cylinder of some description. But LOUIS (*Mém. de l'Acad. de Chir.*, 1757, T. III, p. 193) concluded that the original description, with the book and the names of the four masters, was lost irretrievably, unless some better preserved copy of their work than a worm-eaten, illegible fragment, exhibited in 1750, in the library of the College of Navarre, should be discovered. JOBERT, Chancellor of the University of Montpellier, in his translation of GUY DE CHAULIAC, in 1578, speaks of a copy of the work of the FOUR MASTERS, given to him by PHILIP GUILLEIN, a learned physician of Avignon. LOUIS satisfied himself that this work was the first fruits of the nascent Society of Surgeons of Paris, and that "the Four Masters lived toward the end of the thirteenth century, and were known only under this name. Devoted to the practice of surgery among the poor, charity brought them together in the same abode, and they composed in common the work, the loss of which is justly deplored, since it deprives us of much of the information we might derive from the insight and experience of these skilful masters." It is not known that JAMERIUS wrote anything; but the *Chirurgia* of ROGER OF PARMA, who was chancellor at Montpellier, and professor at Salerno, was printed in 1498, and some of his manuscripts are in the Bodleian Library, and in that of Caius College. THEOPHORICUS was a bishop at Cervia, and his *Chirurgia*, in four books, was printed in 1498; but he must have flourished more than two centuries earlier, since his work is much quoted by BRUNUS, who lived at Patavium, in 1552, and whose *Chirurgia magna* was printed in the Venetian Collection of 1499. WILLIAM OF SALICET, a professor at Verona, died about 1277. His *Chirurgia*, in five books, was printed at Venice in 1470, and, in French, at Lyons in 1492, and at Paris in 1506. JEROME OF BRUYNS-WYKE (*The noble experyence of the vertuous handy warke of surgeri*, London, 1525, Cap. L) says: "When the guttes is woundyd ouerthwart, or is in peeces, than it is dedly; yf it be lengthe woundyd, it may be holpen. If that the wounde of the belly is not grete ynough, than shall ye make it greter as I shall shewe you hereafter, than shall you take out propley the guttes, and sow it thereafter as it is nedeful with a skynners nedyll. Jamericus, Theodoricus, Rogerius lay elder pypes in the guttes, under the seme, that the same rotte not. Wilhelmus and some other, lay therein a part of a cryer of a throte goll of a beest, as the IV maysters sayth. But Lanfrancus and Guido they thinke it not be profytable, for that nature is inclyned to outdrawynge straunge thyngys, and thus yt helpe not therefore it was layd, and it is better that the guttes be sowyd, as afore is sayd, and that it be clenzyd of the unclenes."

<sup>2</sup> DENANS, *Recueil de la Soc. de Méd. de Marseille*, 1826; *Bulletin de l'Académie de Médecine de Paris*, 1838, T. II, p. 719; PHILLIPS, in *London Lancet*, 1834-35, Vol. I, p. 202; GROSS, *Wounds of Intest.*, &c., p. 146; VIDAL (l. c., T. IV, p. 139); NÉLATON, *Étém. de Path. Chirurg.*, 1857, T. IV, p. 144. MM. BOURGIER and CLAUDE BERNARD (*Traité complet de l'anat. de l'homme, comprenant l'anat. chir. et la méd. op.*, Folio, Paris, 1866-67, T. VII, p. 110) say of this method: "Nous le répétons, a notre sens on n'a rien imaginé d'aussi ingénieux pour la réunion des plaies de l'intestin en travers, et il nous semble même que les autres chirurgiens qui ont décrit ce procédé, n'en font pas toute l'estime qu'il mérite. A l'expérience, entre les mains de son auteur, il a eu sur deux chiens tout le succès désirable; et depuis, M. P. Guersent en a confirmé les bons résultats en montrant, à la suite d'une opération sur le vivant, les deux bouts d'un intestin parfaitement cicatrisés, sans aucun rétrécissement dans le lieu de la réunion. S'il est un léger reproche, que nous adresserions à ce procédé, ce serait concernant la matière des viroles que l'auteur a employées métalliques, en argent ou en étain. Dans la prévision de la difficulté que pourraient rencontrer à cheminer dans toute la longueur de l'intestin, les trois viroles réunies, et les obstacles qui suivraient leur arrêt dans un point, nous pensons qu'il conviendrait mieux de les fabriquer avec une substance assez solide pour rester en place tout le



The ferrules are secured within the intestine by a stitch, which is very ingenious, but very complicated. A thread, armed with a needle at either end, is inserted at the margin of the ferrules and passed within the broadest, or most concentric, ferrule, and out at the farther margin. FIGURE 82 shows the entrance and exit of the first needle. The thread

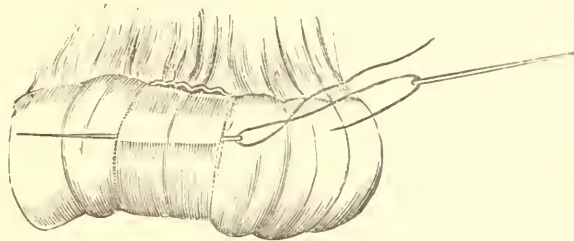


FIG. 82.—Mode of fastening the ferrules by a thread in the method of Denans.

it carries will include the three ferrules, and, if tightened, would strangulate the included segment of the intestine. Therefore, the first needle is reinserted through the puncture of exit, and

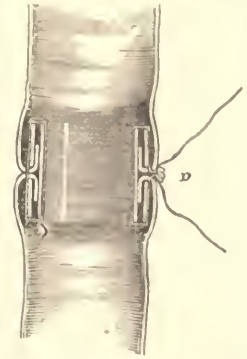


FIG. 83.—Diagram of a section of a divided intestine, with the ferrules in place, and the serous surfaces inverted in apposition, and the apparatus secured by a stitch, according to the method of Denans.

insinuated between the mucous lining of the intestine and the outer ferrule of that side, and brought out at the groove where the inverted serous surfaces are expected to unite. Then the second needle is introduced at the first entrance puncture of the first needle, and brought out at the groove already indicated. Thus, as is illustrated in the diagram (FIG. 83), the ligature, knotted at the point D, is entirely within the intestine, and fastens the ferrules together. The eccentric ferrules are separated from each other by the inverted tunics of the bowel that are expected to cohere by their serous surfaces; between the outer and inner ferrules lie the inverted ends of bowel, subjected to such compression as is relied upon to result in mortification. The ferrules, thus liberated, will be expelled by stool. In his first experiment, Denans states, the ferrules were discharged from the bowels in seventeen days.

*Method of Ramdohr.*—Ramdohr, surgeon to the Duke of Brunswick, in the early part of the last century, is said to have been the first to have successfully united a complete division of the intestine, in the human subject, by the suture. But it is scarcely credible that so many of the surgeons of the thirteenth century should have practiced this operation, and have devised such a variety of plans to facilitate it, unless their labors were sometimes rewarded by success. Ramdohr did not publish an account of his case, but it was related by Moebius, in a scholastic disputation<sup>1</sup> defended at Helmstädt, December 19, 1730, before Heister, and was again described, in 1739, by Heister himself,<sup>2</sup> who, upon the death of the patient from pleurisy, a year after recovery from the operation, had come into possession of the pathological preparation, demonstrating the perfect union of the divided intestine. Richerand, Bérard, and Boyer essayed this method unsuccessfully; Astley Cooper declared the operation impracticable on living animals. Nevertheless Lavielle, Chemery-Halé, and Schmidt are said each to have succeeded on the human subject. Dr. Zina Pitcher succeeded once, though he inyaginated the lower end of the intestine within the upper, and a success is claimed for Dr. Gaston.

temps convenable pour causer les adhérences péritonéales et l'étranglement des bouts de l'intestin, et d'un autre côté, assez altérable et hygrométrique pour se déformer et même se convertir en une pâte que l'intestin expulserait en toute facilité. Des viroles en gélatine, affermies au besoin en les trempant dans les huiles siccatives, nous paraissent réunir toutes les conditions désirables." In 1838 (*Bull. de l'Acad.*, T. II, p. 719) M. Denans proposed to dispense with the suture and to fasten the ferrules together by a spring. Vulcanized rubber rings with automatic catches have also been proposed.

<sup>1</sup> MOEBIUS, in HALLER'S *Disp. anat.*, Göttingue, 1751, Vol. VI, p. 745. His account is inferior to that by HEISTER.

<sup>2</sup> HEISTER (*Institutiones Chirurgicæ*, Amstelodami, 1739) gives the following interesting description of the RAMDOHR method: "Hand joints assimile hinc experimentis illud videtur, quod Serenisissimi Ducis Brunsvicensis Nostri chirurgus aulicus, Ramdohrius, paucos ante annos feliciter



*Jobert's Method.*—In 1822, Jobert proposed a new mode of treating wounds of the intestines involving their entire circumference, and, in 1829, his elaborate treatise on the surgical affections of the alimentary canal appeared.<sup>1</sup> The surgeon, having determined which is the upper end of the gut, dissects away the mesentery a third of an inch from each end, and arrests the bleeding that may ensue. Then, holding the upper extremity by the left hand, with the right he inserts a stitch through it two-thirds of an inch from the divided margin (FIG. 84), and confides the loop to an aid. A second stitch is introduced in like manner at the opposite or mesenteric side of the bowel. Then, with the fingers, or with flat forceps, the lips of the lower portion of the gut are inverted—a difficult procedure. When it is accomplished, the left index is introduced

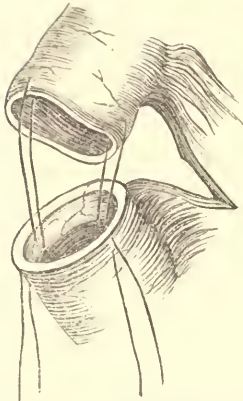


FIG. 84.—The mesentery dissected, and threads placed preparatory to invagination, by Jobert's method.

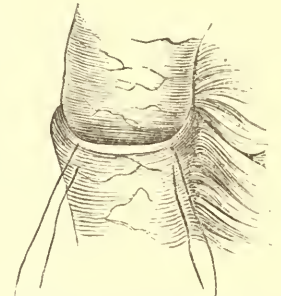


FIG. 85.—The upper extremity of the bowel invaginated within the inverted lips of the lower (Jobert).

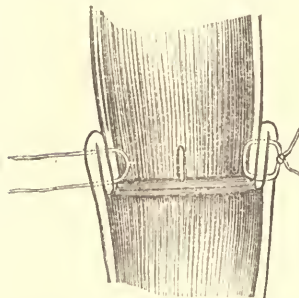


FIG. 86.—Diagram of the relations of the tunics and sutures in enterostomy for complete division of the intestine (Jobert).

into the lower portion of the bowel, and, with the thumb, maintains the inverted hem, and also serves as a guide for the introduction of the inner end of the first loop inserted in the upper portion of the bowel. The inner end of the second loop is inserted in like manner. Then, by gentle tractions upon the two loops, it is sought to invaginate the upper portion within the lower. This being accomplished, the loops may be tightened and knotted, or twisted, or the hem may be traversed by the outer ends of the two loops (FIG. 86), and the stitch then tightened and secured by torsion or by knot. The ends of the ligatures are brought out at the lower angle of the external wound, and the threads are withdrawn on the fourth or fifth day by gentle traction.

admodum in Guelpherbyta femina quadam instituit, dum scilicet, post herniam incarceratam sponte ruptam, propendente et excisa magna intestinorum parte corrupta, binas partes extremas, easdemque sanas, superiori in inferiorem insinuata, leniter per injectum filum conjunxit, in abdomen repositi, filique circumducti ope ad vulnus abdominis atraxit, atque ita non modo effecit, ut cum vulnere confervesceret, et at glutinationem, quod mirum videri poterat, intestinum divisum perveniret, sed feminam quoque velut ex ipsis mortis faucibus retraheret, faecibus postea non per vulnus, sed per anum egredientibus. Mulier illa postea sana vixit, at post annum ex pleuritide obiit atque in inciso cadavere intestina divisa inter se rursus coalita deprehensa sunt; quae ipse mihi una cum parte abdominis, cum qua coalerunt, dono dedit, eaque adhuc in spiritu vini asservo, ut dubitantibus aut discentibus eu semper ostendere possim."

JOBERT (DE LAMBALLE) published the first account of his method in the *Archives g n rales*, Janvier, 1824, T. IV, p. 71 (*Recherches sur l'op ration de l'invagination des intestins*). In his treatise (*Des mal. chirurg. du canal intestinal*, T. I, p. 86) he prefixes to the description of the operation the following statement of his view of the principles involved: "Si l'invagination n'est pas suivie de succ s, cela est donc d  aux nombreux points de suture qui d terminent l'inflammation, et au d faut d'identit  de nature des membranes mises en contact, dont l'une a pour produit une s cr tion folliculaire, et l'autre une exhalation plastique. Ce que j'avance est d'ailleurs prouv  d'une mani re incontestable par les exp riences de MM. Richerand, Thompson d'Edimbourg, Smith de Philadelphie, B clard, J. Cloquet, Emery. Le premier a mis les s reuses en rapport avec les muqueuses, et n'a jamais obtenu de r union. Les autres ont  trangl  l'intestin par une ligature, et ont vu une lympe plastique, exhal e   la surface de la ligature, r unir les deux bouts   mesure qu'ils se divisaient, la ligature tomber dans l'int rieur de l'intestin, et la cicatrisation s'obtenir ainsi par l'adh sion des deux s reuses. J'ai r p t  ces exp riences et j'ai obtenu les m mes effets. J'ai mis aussi une s reuse en contact avec une muqueuse et, pour tout r sultat, j'ai eu un anus contre nature. Il est donc vrai que les muqueuses n'adh rent point avec les s reuses, qui seules, comme le tissu cellulaire, de la nature duquel elles paraissent  tre, forment les cicatrices de ces organes; et c'est   tort, sans doute, que l'on a ni  cette v rit  si importante, surtout lorsqu'il s'agit d'un proc d  op ratoire." JOBERT publishes (*op. cit.*, T. I, p. 80) an account of CLOQUET'S successful operation in the case of N. Lejeune, as an instance of success by this method. It is regarded by LAWRENCE (*l. c.*, p. 306), VELPEAU (*M d. op.*, T. IV, p. 143), and Professor GROSS (*Wounds of Int.*, p. 122), rather as an example of LEMBERT'S method. FLEURY (*M m. sur la suture intestinale*, in *Arch. g n. de M d.*, 2<sup>e</sup> s rie, 1837, T. XIII) records three cases of operations by Jobert's plan. The third was successful. In the *London Lancet* of April 8, 1848, an account is given of an autopsy in a woman, aged 74 years, who had survived, for twelve years, an operation for strangulated crural hernia, by Jobert, in which the intestine was wounded and united by suture: "A white line was discovered running obliquely from the convex to the concave border of the intestine, and ending in a sort of a star, and was easily perceived upon the red ground of the intestine; it presented the usual aspect of a nodulated cicatrix. The coats of the intestine, along the cicatrix, were found neither thinned nor thickened, and, after a careful washing with warm water, the same whitish line was perceived to run on the internal surface as had been noticed on the external. Two valvulae conniventes were observed to have been cut, leaving no doubt that the line was the cicatrix of the intestinal suture applied twelve years before." This account is translated from the Bulletin of the proceedings of the Academy of Medicine of Paris, of March 10, 1848 (*Arch. g n. de M d.*, 4<sup>e</sup> s rie, T. XVI, p. 523). The original account of the operation is in the *Archives*, 2<sup>e</sup> s rie, T. XIII, p. 310.

*Lembert's Method*—In 1826, Lembert proposed his ingenious suture,<sup>1</sup> which is applicable to nearly all varieties of intestinal wounds. Admirably adapted to the purpose of maintaining exact coaptation of the serous surfaces, it is the plan that for nearly half a century has been the most widely approved and practiced. Its application to a longitudinal wound is shown in the wood-cut (FIG. 87). The diagram on page 59 illustrates the mode of inversion and apposition of the serous surfaces accomplished by it. Instead of completely inverting one lip of the division, like Jobert, each lip is inflected at a right angle, and the two are united by stitches carried obliquely, so as to avoid perforating the mucous tunic.

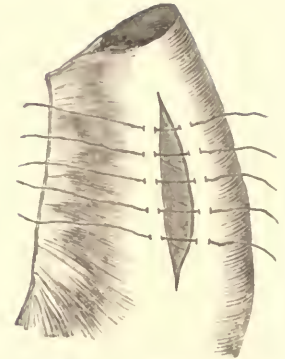
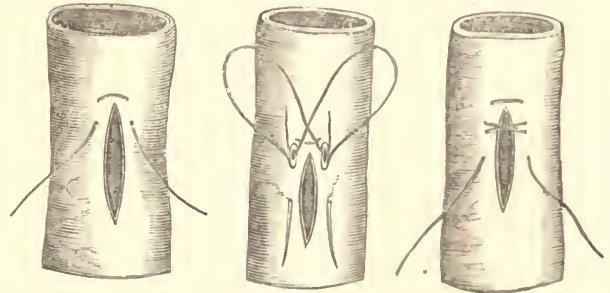


FIG. 87.—Five interrupted sutures of Lembert.

*Gély's Method*—Professor Gross<sup>2</sup> regards this method as “merely a modification of that of Lembert.” The inventor<sup>3</sup> claims

that it affords greater security against faecal extravasation. His opponents allege that it involves the hazard of dangerously coarctating the calibre of the canal. It is termed by the French the suture *en piqué*, and was proposed in 1844. Gély declares (*op. cit.*, p. 29) that it differentiated from the basting stitch (Figs. 28 and 79), and may be considered a complex variety of that obsolete suture.



FIGS. 88, 89, 90.—First, second, and third steps of the application of Gély's modification of the interrupted suture to a longitudinal wound of the small intestine. [After GÉLY.]

A waxed thread is armed at either end with a common small needle. One of these is introduced (FIG. 88) parallel to the wound, without and a little back of one of its angles, at a distance of four or five millimetres, and brought out after traversing the bowel for about the same distance. The same manœuvre is then practiced with the second needle on the opposite lip of the wound. The ends of the threads are then crossed (FIG. 89), the left-hand needle passing to the right, and reciprocally. Each then serves to take another stitch exactly similar to the first, with the precaution of entering the puncture of exit of the thread brought from the opposite side (FIG. 90). This manœuvre is then repeated as often as may be necessary to cover the entire extent of the

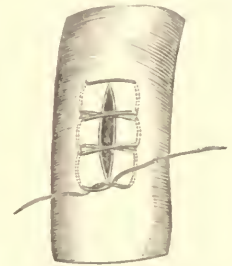


FIG. 91.—Four points of suture placed and ready to be tightened. [After GÉLY.]

<sup>1</sup> *Répertoire générale d'Anatomie et de Physiologie pathologique*, 1827, T. II, p. 101, cited in the *London Lancet*, 1826-27, Vol. I, p. 848; in the *Medico-Chirurgical Review*, 1834, Vol. XXI, p. 229; and VIDAL, *Traité de Pathologie Externe et de Méd. Op.*, T. IV, p. 506. In the communication to the Academy (Séance de 26 Janvier, 1826) the name of the inventor, then an interne of the Paris hospitals, is given as M. LAMBERT, and M. LEGOUËST and others still refer to him by that name. But in the authorized reprint of his paper (*Nouveau procédé d'enterorrhé, in Arch. gén. de méd.*, 1827, T. XIII, p. 234), and in subsequent communications and discussions, the name is spelled LEMBERT. The examples of success by this method are numerous. The first (July 13, 1826), that of N. Lejeune, æt. 41, with wounded strangulated left congenital hernia, treated by CLOQUET, was claimed by JOBERT (*op. cit.*, T. I, p. 80); but LAWRENCE (*l. c.*, p. 306), VELPEAU (*l. c.*, T. IV, p. 143), and Professor GROSS (*l. c.*, p. 122), adjudge it to have been an example of LEMBERT'S method. DIEFFENBACH'S case (*Wochenschr. für die gesammte Heilkunde*, Nov. 26, 1836) of mortified right crural hernia, in a farmer, æt. 50, in which three inches of the intestine was cut off and the ends united by LEMBERT'S method, was practically successful, the patient surviving in good health for several weeks, when, after severe labor in the field, he died from strangulation in a different part of the intestine from the seat of operation. The intestine at the seat of excision was found united though suppurating slightly at two points. It is probable that in many of the cases reported as successes by the interrupted suture, the stitch of Lembert was employed. The case reported by Dr GUMBACHER (*Baderärztliche Mittheilungen*, 1857, B. I, and ZIFF, in *Schmidt's Jahrbücher*, 1864, B. XIII, S. 66) strikingly exemplified its utility, and as much may be said of the examples adduced by GRELLOIS (*Rec. de Méd.*, 1860, 3<sup>e</sup> série, T. III, p. 58), CUVILLIER (*ibid.*, p. 139), MCELKATH (*New Orleans Med. and Surg. Jour.*, Vol. II, p. 1070), and KUNKLER (*Pacific Med. and Surg. Jour.*, Vol. II, p. 6).

<sup>2</sup> GROSS, *System*, l. c., Vol. II, p. 666.

<sup>3</sup> GÉLY, *Recherches sur l'emploi d'un nouveau procédé de suture contre les divisions de l'intestin*, Nantes, 1844, en 8, avec 3 pl.



wound (FIG. 91). The threads are now to be tightened. This is accomplished by taking successively, in a dissecting forceps, each of the transverse points, and even each

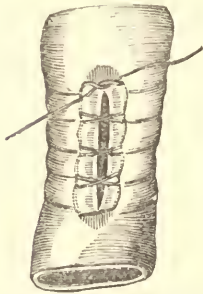


FIG. 92.—Five points of Gély's suture placed to close a longitudinal incision of the ileum, and ready to be tightened. [After GÉLY.]

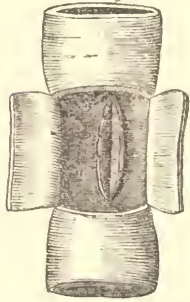


FIG. 94.—Interior of the small intestine, showing the valvular fold produced by the approximated tunics. [After GÉLY.]

one of the two threads of which it consists, and making suitable traction, at the same time depressing the lips of the wound. These presently are approximated with such exactness that no trace appears externally of the threads that have caused the apposition (FIG. 93). It only remains to tie the ends of the opposite threads and to cut them off close to the knot. The knot is as completely concealed between the serous surfaces as are the stitches. If the united interior of an intestine by this method (FIG. 94) is examined, a valvular fold, formed by the approximated tunics, is observed, and on either side the line represented by the loops of thread which completely

close the wound. The inventor claims that the execution of this stitch presents no serious difficulties; that it closes accidental openings with such exactness that primary or consecutive effusion of liquid or gaseous intestinal matters are effectually precluded; that the elimination of the suture through the intestinal cavity is assured; and that the immense advantages of immediate reduction of the wounded bowel and of occlusion of the parietal wound are secured.<sup>1</sup> In support of these claims, M. Gély adduces his successful experiments on dogs and his operation on the woman

Leclerc, aged 45 years, successfully treated by enterorraphy August 25, 1842, for a strangulated mortified left crural hernia. M Blatin has proposed a slight modification of this method,<sup>2</sup> which does not improve it. The theoretical requirements are very well met by M. Gély's plan, which, if successfully applied in a few more instances, will probably become the established mode of practice. By M. Gély's method

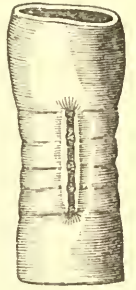

FIG. 93.—Serous surfaces approximated by five stitches, which are tightened, the last tied, and the ends cut off close to knot. [After GÉLY.]

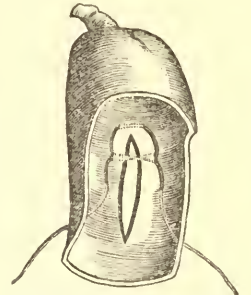


FIG. 95.—View of the mucous surface of the intestine before the completion of Gély's suture. [After GÉLY.]

<sup>1</sup> Dr. GÉLY'S remarks (*op cit.*, p. 17) on M. LEMBERT'S plans are so candid and judicious that it may be well to translate them at length: "M. LEMBERT sought to improve the method of M. JOBERT by relinquishing invagination in complete divisions. Instead of practicing, like the latter, a complete inversion of the coats of the lower end of the bowel, he inflected the margins of each end at a right angle nearly, and maintained them in contact by points of interrupted suture, the threads being carried obliquely through the coats of the bowel, so as not to perforate the mucous membrane. The two extremities of the divided intestine are thus united in the same manner as the lips of an incomplete oblique or longitudinal intestinal wound. The inflection of the lips of the wound, not exceeding a right angle, constitutes a demi-inversion as compared with the complete inversion practiced on the lower end by M. JOBERT. This mode of (*adossement*) applying the serous surfaces back to back, which is likewise effected by the method of M. DENANS, is the simplest and easiest of execution, and as effectual in promoting adhesion as that which M. JOBERT employed. It may be regarded as a radical modification of the method of that surgeon, and is, in our opinion, the fundamental feature of that of M. LEMBERT, the feature that has earned for it general approbation, and caused it to be preferred, by many surgeons, to the method from which it is derived. Every ulterior modification of the methods of enterorraphy must indubitably accept this principle as a starting point. But is the kind of stitch employed by M. LEMBERT really superior to that of M. JOBERT, and does it completely fulfil all the conditions desirable? It appears to us obvious that a negative response may be made to these questions, notwithstanding the praise that has been bestowed on this procedure. M. JOBERT, who employed in his earlier experiments the interrupted suture, speedily discerned its inconveniences, and finally rejected it. He saw that it could only be made effective by multiplying the stitches, and that then it became very dangerous. The procedure of M. LEMBERT may justly be criticised for closing the solution of continuity imperfectly. It is even inferior in this respect to the looped suture. In several of VELPEAU'S experiments union failed to take place in the intervals of the stitches, and fistulous orifices were left there. If, to avoid this trouble, the stitches are multiplied, then the danger they induce as foreign bodies is rapidly augmented. It is important to remark, that the descent of the thread into the intestinal canal is next to impossible where the operator refuses to perforate the mucous tissue. The knots must be absorbed or encysted where they are, and are liable to inflame the peritoneum. DIEFFENBACH'S patient, who died at the end of six weeks, had still two points of suture with suppuration going on around them. These drawbacks are so manifest that no one has yet dared to advocate this method absolutely. This is why some surgeons would have recourse to the rings of M. DENANS, and why M. VELPEAU would substitute a modified continued suture. This plan would undoubtedly avoid the danger of primary extravasation; but one asks what will happen, when this suture has destroyed all the tissues it includes, and if this sort of suture does not hazard secondary perforations more than any other? The spiroid suture appears very dangerous on this ground."

<sup>2</sup> BLATIN (*Gazette des Hôpitaux*, 1844, T. VI, p. 456) proposed to use but one needle, and, successively, threads of different colors. M. Nélaton says that this modification has not been applied on the living human subject. As the suture is expected to fall into the intestinal canal, there can be no advantage in threads of different colors, unless to distinguish the two sets in tightening.



the procedure is the same, whatever may be the direction, extent, or situation of the wound. In all, the approximation of the serous surfaces is accomplished by an equal inflexion of the lips of the wound, never exceeding a right angle or a half-inversion, in

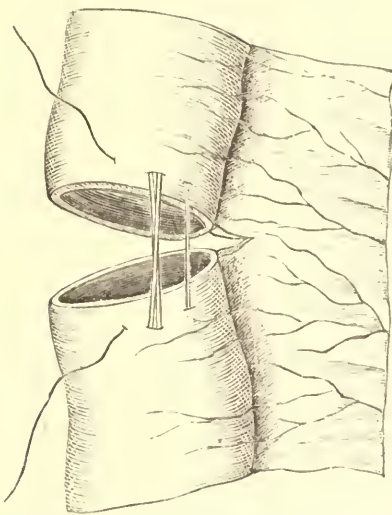


FIG. 96.—Sutures of contiguous wounds, with loss of substance in two knuckles of the bowels. (After GÉLY.)

place of the duplication of one lip proposed in Jobert's original plan. The application of this suture to complete division of the bowel is shown in FIGURE 96. When wounds with loss of substance exist in the contiguous coils of the intestine, it is easy to place the corresponding parts in apposition and to bring about adhesion by the plan indicated in FIGURE 97. Here the inversion of the lips of the solutions of continuity is not requisite.

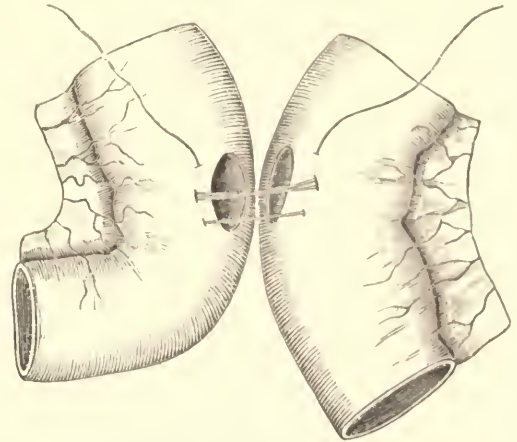


FIG. 97.—Application of Gély's suture to complete divisions of the bowels. (After GÉLY.)

Professor Emmert,<sup>1</sup> of Bern, proposes a plan (FIG. 98) which appears to be a combination of the stitch of Lembert, loop of LeDran, and the darning point of Bertrandi. He claims that it obviates some of the weightier objections to the methods of

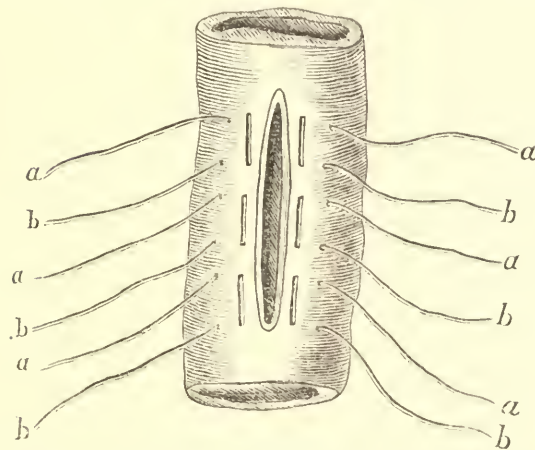


FIG. 98.—Emmert's suture, with threads, each armed with two needles; as many of these loops as the size of the wound may require are placed, and the opposite ends of the ligatures are tied together. (After EMMERT.)

described and figured<sup>2</sup> a grooved director, which he found useful in applying his suture on

<sup>1</sup> EMMERT (C.). *Lehrbuch der Chirurgie*, Stuttgart, 1862, S. 237.  
<sup>2</sup> VÉZIEU. *Bulletin de la Société de Chirurgie*, November 8, 1871.

<sup>3</sup> LEGOUEST. *Traité de Chirurgie d'Armée*, Paris, 1872, 2<sup>m</sup> éd., p. 390.  
<sup>4</sup> It appears to be unwise to sneer at the more complicated methods and modifications of intestinal sutures, that their experiments on animals have suggested to various surgeons, or to denounce them in a mass, as some authors are disposed to do. Some of them have been suggested by difficulties actually encountered in practice. Many of them will be found applicable to particular exigencies. But they should not be attempted on the living subject until the operator has acquired some experience by practicing, as M. Fano used to require his pupils to do, either upon the fingers of a glove, or, better still, upon a recent subject, or on intestines placed in a manikin.

<sup>5</sup> VÉZIEU, *Note sur la suture intestinale*, in *Recueil de Mémoires de Méd. de Chir. et de l'Har. Mil.*, 1871, 3<sup>e</sup> Série, T. XXVI, p. 276.

the cadaver. The plan of M. Bouisson, professor of surgery at Montpellier, which may be regarded as a form of acupressure, and that of M. Béranger-Féraud, proposing reunion by means of pins inserted in cork, have not been sanctioned by experience, and may be esteemed as curious rather than ingenious.<sup>1</sup> While ignorant of the experiments of M. Denans, Baudens succeeded, in some vivisections on dogs, by a similar though less complicated contrivance. He introduced an elastic ring into the upper end of the bowel and inverted the tunics upon it; into the lower end he inserted a single ferrule, slightly concave, and grooved; the lower end was then inserted into the upper, the elastic band slipping into the groove and securing the inverted lip in place.<sup>2</sup> M. Spillmann's project of everting the lips of the divided extremities of the bowel, and compressing them between silver rings, clasped together, with a view of inducing mortification of the approximated mucous surfaces, was a retrograde step.<sup>3</sup> The devices of Amussat, of M. Choisy, of Dr. A. Thomson, for strangulating the ends of the divided intestine on rings, with the expectation that the approximated serous surfaces would cohere, are based on the celebrated experiment of Travers, of encircling the bowel with a ligature.<sup>4</sup> The criticism of Lawrence on the method of Denans may justly be applied to these derivations from it: "A patient who could survive the infliction of such surgery must be endowed with great tenacity of life." M. Moreau-Boutard's plan<sup>5</sup> of excising the everted mucous tissue, and approximating the serous surface with the refreshed connective tissue, cannot be practically executed on the human subject. The earliest form of stitch employed in sewing up the intestines was that known as the continued or glovers' suture. After a time it was denounced and fell into desuetude.<sup>6</sup> By one of those reactions of which the annals of surgery afford so many examples, it is again in favor, and, in some shape, has lately been more generally approved

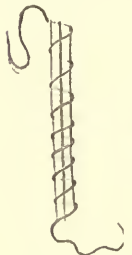


FIG. 100.—The continued suture, *suture à surjet*, spiral or overcast stitch.

in enteroraphy than any other. Though the distinction is rarely made by systematic writers, it is plain that two very different stitches are confounded under this name. One (FIG. 100), in which the thread passes from within outward through one lip of the wound, and from without inward through the other lip, is the true continued suture or stitch of the sempstress; the other (FIG. 101), "executed by introducing the needle first into one lip of the wound from within outward, then into the other in the same way" (S. Cooper), is the glovers' or herring-bone stitch, which gives a puckered line of reunion. The former admits of the inversion of the lips of the intestine, and the approximation of the serous surfaces; the latter does not. The former, under the name of the spiroid suture, rendered good service

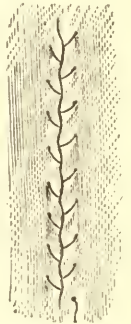


FIG. 101.—The glovers' suture, *sutura pellucida*.

<sup>1</sup> BOUISSON (*Bull. de l'Acad. de Méd.*, 1851, T. XVI, p. 494, and in NÉLATON'S *Éléments de Path. chir.*, T. IV, p. 150). The *suture implantée*, as M. BOUISSON calls it, is made with pins approximated as in the twisted suture. The external wound must be left open, to admit of the withdrawal of the pins. M. BÉRANGER-FÉRAUD (*London Lancet*, 1870, Vol. I, p. 234) employs rows of pins inserted in cork, after the fashion of the teeth of a comb. Neither method has been practiced on the living human subject.

<sup>2</sup> BAUDENS, *Clinique des plaies des armes à feu*, 1836, p. 339. The author says: "J'ai opéré sur des chiens, et j'ai parfaitement réussi; si l'occasion se présentait, je ne craindrais pas d'employer sur l'homme ce procédé dont l'exécution est facile et dont les résultats me semblent devoir être avantageux." He does not state why he prefers to invaginate the lower end within the upper.

<sup>3</sup> SPILLMANN, in DULAC'S thesis *Des divers procédés entérographiques*, Paris, 1845. M. DULAC remarks: "Ce procédé n'a pas besoin de refutation."

<sup>4</sup> PHILLIPS (*London Lancet*, 1834-5, Vol. I, p. 202) gives the fullest account of Amussat's plan and experiments. Consult also, GROSS (*Wounds of the Intestines*, p. 152); TRAVERS (*On the Intestines*, p. 111); LAWRENCE (*op. cit.*, p. 356). CHOISY'S plan is described in RAMPON'S thesis, *Considérations sur quelques points de pathologie*, Paris, 1837, p. 15, and in VIDAL (*op. cit.*, p. 141).

<sup>5</sup> Consult JOBERT'S report, *Mém. de l'Acad. de Méd.*, 1846, T. XII, and *Cyclop. Pract. Surg.*, 1861, Vol. II, p. 731, and VIDAL (*op. cit.*, T. IV, p. 141).

<sup>6</sup> COOPER (S.), *Dictionary of Practical Surgery*, 8th ed., 1872, Vol. II, p. 669, without comment by the editors, is permitted to say: "When we remember, in making this suture, how many stitches are unavoidable; how unevenly, and in what a puckered state, the suture drags the edges of the skin together; and what irritation it must produce; we can no longer be surprised at its now being never practiced on the living subject. It is commonly employed for sewing up dead bodies; a purpose for which it is well fitted; but for the honour of surgery, and the sake of mankind, it is to be hoped that it will never again be adopted in practice."



in enteroraphy in the hands of Nuncianti and of Velpeau,<sup>1</sup> and it has latterly been advocated by Dr. Reybard, of Lyons, to the exclusion of his own and of all other special devices.<sup>2</sup> Professor Gross, than whom no authority is more competent, states that "when judiciously employed, it is capable of affording the most happy results in the treatment of intestinal wounds, no matter what may be their situation, direction, or extent."<sup>3</sup> It is easy to combine with this form of the continued suture the oblique short stitch of Lembert, and this was the plan that Dupuytren ultimately approved, after witnessing the diversified expedients that exercised the ingenuity of his disciples.<sup>4</sup> The methods of enteroraphy<sup>5</sup> have been arranged in three classes, according as direct reunion by the apposition of like tissues, invagination and the approximation of mucous with serous surfaces, or coaptation of two serous surfaces was had in view; and these have been subdivided into fixed sutures, attaching the intestine to the abdominal wall, and free sutures, cut close and returned within the cavity. Divested of pedantic superfluities of description, the various methods show a real progress and better understanding of the difficulties to be overcome. The direct apposition of the cut surfaces, sought by the old masters, is theoretically sound, although the obstacles to its accomplishment appear insurmountable. Possibly, by the use of canule of gelatine or some more appropriate substance they may yet be overcome. Whatever tissues are brought in contact, reunion takes place through plastic exudation, and the stitches that will prevent fecal effusion long enough for adhesions to form will prove the best. Approximating the bowel to the external wound affords the surgeon a certain sense of security, since he may indulge the hope that, if the stitches give way, the patient may recover with an abnormal anus. But the evidence is now overwhelming,

<sup>1</sup> GUTHRIE (*Wounds of Abd.*, p. 26) and JOBERT, in his article on wounds of the intestines, in the British Cyclopaedia of Practical Surgery, quotes the paper of Professor HIPOLITE NUNCIANTI, of Naples, and his three successful cases of enteroraphy: A tailor of 21, with laceration from rude taxis of a strangulated inguinal hernia. A rent, an inch long, was united by the spiral suture, which came by stool on the seventeenth day; recovery was complete on the fortieth. Equal success attended a similar operation for an accidental wound of the intestine inflicted in a lady of 36, with strangulated crural hernia. The suture was discharged by the intestine on the thirteenth day. The third case was of a man with mortified inguinal hernia, lacerated by slight pressure. The rent being sown up, the ligature was discharged internally on the fifteenth, and the man was cured on the fortieth day. VELPEAU (*Nouv. élém. de méd. op.*, T. II, p. 425). "A mon sens, le procédé le plus rationnel est celui de M. LEMBERT, et c'est à lui qu'on fera inévitablement par donner la préférence, si jamais l'observation vient à confirmer les données théoriques qui l'ont fait naître," and afterward, p. 428: "Ce n'en est pas moins cette suture spirale, combinée avec les principes de M. LEMBERT, qui me semble devoir l'emporter."

<sup>2</sup> REYBAR, *Considérations sur le traitement des plaies de l'abdomen avec lésion des intestins, précédés de nouvelles remarques sur le mode de cicatrisation après les sutures*, in *Gazette Hebdomadaire d'Éd. et de Chir.*, 1862, p. 427. *Bulletin de l'Académie royale de médecine*, Paris, 1845, T. X, p. 1036; *Mémoires de l'Acad. roy. de méd.*, Paris, 1846, T. XII, p. 517.

<sup>3</sup> GROSS, *An Experimental and Critical Inquiry into the Nature and Treatment of Wounds of the Intestines*, Louisville, 1843, p. 51. The details of seventeen successful experiments on dogs are related, the continued suture having been employed in intestinal wounds varying in extent and direction.

<sup>4</sup> DUPUYTREN (*Leçons Orales*), T. V, p. 183, and T. VI, p. 455. M. M. PAILLARD and MARX, the editors of DUPUYTREN, warmly maintain the superiority of LEMBERT'S method, and also its claims to priority. M. LEMBERT, they observe, read his memoir before the Academy of Medicine January 26, 1826; it was not until July, 1826, six months subsequently, that JOBERT described an analogous stitch. JOBERT'S priority in proposing invagination is not questioned. LEMBERT, as M. BEAUGRAND informs us (*Diet. encyclopéd. des Sci. Méd.*, Deuxième série, 1868, T. II, p. 146), died in 1851. DUPUYTREN (*Leçons Orales*, T. V, p. 185) says: "Nous croyons encore plus simple et plus efficace pour cette section complète de la circonférence de l'intestin, le procédé que nous avons conseillé dans le cas de plaie longitudinale ou parallèle à l'axe de l'intestin, c'est-à-dire le renversement en dedans des deux bouts de l'intestin, renversement suivi de l'application de la suture du pelletier. Si quelque chose pouvait donner du poids à notre opinion, c'est que M. LEMBERT lui-même ait été conduit à penser comme nous sur ce point, et ait substitué la suture en spirale aux points séparés qui constituaient ses procédés."

<sup>5</sup> CÆLSEUS (*Medicine*, Lib. VII, XVI), regards interference with wounds of the small intestine as futile, taught that the large intestine might be sewed, and would sometimes agglutinate: "Latius intestinum sui potest: non quod certa fiducia sit; sed quod dubia spes, certa desperatione sit potior; interdum enim glutinatur." In note 2, on page 63, an extract is given from REED'S translation of the work of the old Spanish surgeon ARCÆUS (*Method of curing Woundes*, etc., London, 1588), on the fatality of injuries of the small intestines. Continuing, he records four examples of successful enteroraphy of the large intestines: \* \* \* "But of others in whom it happened the greater guts to be perished, we have cured three, being wounded in the gut called colon. And the fourth, the gut longanon (rectum) being hurt. Of these, one had the gut colon broken in three places, yet all of them, by God's help, were restored before the twentieth day. All these bowells we did sowe up, with a needle and thrid, with that kind of stitch which the glovers doe use. I did use also towards them all that kinde of curing which is delivered unto us by John Vigo, which we doe judge best of all others, if a man use it well, and with a pleasant delicate hand. We have therefore followed all his precepts, this onely thing excepted, that we have given no meats, and have used the potion onely sette forth by him; for that we did consider those whome we had in cure to be somewhat strong, and of a more lustie nature, and able enough to abide from meats. For out of Spaine we would not enterprise to use so thinne a dyet." GLANDORP, of Bremen (*Speculum chirurgorum*, 1619, Obs. 31), records a case of recovery from an incised wound of the colon, united by the glovers' suture. Three instances of successful American cases of enteroraphy for stabs of the great intestine, by Drs. POST, MASON, and CHESEBY, are recorded on page 76. Of modern European cases, the following may be cited: JENKINS (GUTHRIE, *Wounds of Abd.*, p. 27, Case 32), in a complete division of the ascending colon by a razor, sewed the two ends together by the continued suture; there was fecal fistula, but ultimate recovery; Mr. N. WARD (*The Medical Times and Gazette*, 1855, N. S., Vol. XI, p. 632) relates a recovery, after enteroraphy for an incised wound of the ascending colon, in a female lunatic, aged 51.



that the risk of fecal extravasation is less when the threads are cut close and the gut returned. Then the beneficent equable pressure may be counted upon to avert effusion and to favor adhesion to the surrounding parts. It then becomes most important that the suture should fall readily within the cavity of the bowel (FIG. 102). It appears to the writer that here the methods of Jobert and of Gély have an incontestable advantage over that of Lembert and all others in which the suture does not perforate the mucous tissue. That enteroraphy is the proper treatment for punctured or incised wounds of the intestines with protrusion, is now questioned by none; that, in similar wounds without protrusion, of the small intestine and of parts of the large intestine covered by the peritoneum, it is proper to enlarge the external wound and find the wounded part, and secure it by enteroraphy, a mass of affirmative evidence has been brought forward. The experience of the war does not enable us to demonstrate the benefits of applying the same

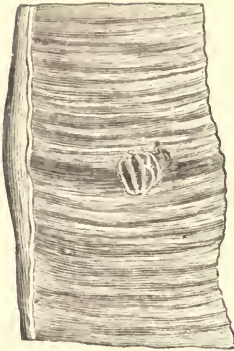


FIG. 102.—Intestinal suture partially detached. [After GROSS, *Wounds of Intest.*, Plate, Fig. 2, and *System*, Fig. 482.]

principles to shot wounds; but contributes some elements toward the determination of this vexed question. Dr F. H. Hamilton, a medical inspector in the army during the war, and a lecturer and writer on military surgery, has opposed, with extreme earnestness, surgical interference with shot wounds of the intestines, and has condemned in emphatic terms the adverse opinions of M. Legouest. It is not to be supposed that any partizan feeling intrudes in his discussion, or that the discovery and enforcement of the wisest practice is not singly held in view, and hence it is a matter of surprise that M. Legouest is represented as alone in his opinions, and that Baudens's teaching<sup>1</sup> and his successful

<sup>1</sup> BAUDENS (*Clinique des plaies d'armes à feu*, 1836, p. 332), treating of shot wounds of the intestines, observes: "When nature, as here [circumscribing the lesion by adhesions], undertakes the cure, the part of the surgeon is restricted to aiding her, combating by appropriate treatment the symptoms of entero-peritonitis. But, unhappily, these sorts of cases are exceedingly rare, and how many disappointments occur from permitting the formation of mortal effusions without opposing them by a surgical intervention, of which the boldness would, at least occasionally, be rewarded by success. It has, indeed, been established as a principle to sew up the intestine, or to establish an artificial anus, when the wound of the abdominal walls is large enough either to permit protrusion of the injured parts, or the ready observation of their lesions without much searching; but I do not know that it has been advised to enlarge shot wounds of the abdomen in order to seek for deeply hidden intestinal lesions. Far from this, I find it everywhere forbidden to probe wounds of this sort, or to make any exploration, for fear of disturbing either a clot occluding the mouth of a small artery, or of destroying adhesions, or, finally, from the puerile apprehension of rupturing a gut already contused or disorganized by the impact of a ball. Ah well! I emphatically declare, and my conviction is based on experience alone, that when a ball traverses the abdomen through the region occupied by the digestive tube, the latter is almost always profoundly disorganized, and nine times in ten, at least, there supervene mortal complications, developed under the influence of an hyper-acute peritonitis, lasting scarcely ever more than twenty-four hours. In these grave conditions, the walls of the belly are perforated, and, as at the outset, the wounded man ordinarily presents no very alarming symptoms, there is a disposition to believe that the ball has glided over the surface of the intestines without injuring them, or else that it has undergone such deviations or reflections as have left these viscera untouched. The wound is dressed simply; the honor of a cure of visceral injury, if it exists, is abandoned to nature, and the surgeon is content to watch over the traumatic phlegmasia. But death presently supervenes. At the autopsy, it is seen that one or many loops of intestine have been perforated; that matters have been extravasated; that an intense inflammation has invaded the peritoneum, and the attendant consoles himself by saying that the mischief was beyond the resources of art. This is erroneous. The surgical domain should not be restricted within so narrow a sphere, and, to extend its limits, I do not fear to place the knife in the perforation made by the projectile in the wall of the abdomen, to enlarge it, to pursue into that cavity itself the examination of the track it has traversed, and to apply to the intestinal lesions a prompt and effective remedy. It is thus, if I had been called to that celebrated publicist, whose recent loss we deplore, I would not have hesitated to extend the entrance wound of the ball for several inches, to remove the extravasated matters, and to apply a suture to the torn intestine. After these preliminaries, having no longer effusion to apprehend, I would have had only to contend with an entero-peritonitis, which perhaps would not have proved mortal. I know that a multitude of considerations foreign to his art intimidate the surgeon who treats his patient at home, and that the fear of being esteemed inhumane or too bold, should his operation be unsuccessful, often stays the hand that alone can preserve the days of the wounded man. But this is not humanity, and I would ever choose for my rule of conduct that well-known aphorism: *melius anceps remedium quam nullum*. But, it will be rejoined, we agree with you that a wound of the abdominal parietes, even of several inches, is not very dangerous, unless complicated by visceral lesions; we conceive that it is of the highest importance to remedy that lesion in order to place the wounded man in the same condition as if he had received a sabre stroke with simple division of the walls of the belly; we agree, also, that nearly all shot perforations of the region of the belly occupied by the intestines are complicated, nine times in ten, by perforations of the latter, perforations which, nineteen times in twenty, are followed by fatal effusions; but by what signs do you ascertain whether there is or is not perforation? The signs are general and local. Among the first are the nervous prostration and signs of extravasation, to be considered hereafter, symptoms that are sometimes characteristic, and may alone suffice to indicate the operation. The local signs are derived from the situation, the direction, the depth of the track pursued by the projectile; the index finger is readily introduced into the belly through a perforation of its wall, and with the pulp of this finger the form of the peritoneal opening is to be studied, and, according as it is direct or oblique, it will be decided in what direction it is necessary to prosecute the search for the wounded parts. It is known that intestinal wounds are nearly always situated directly behind the peritoneal orifice, and this is so generally true, that it is there, ordinarily, that adhesions form between the wounded gut and the wall of the belly, and if a knuckle of intestine protrudes, it is almost invariably the one that has suffered a solution of continuity. Having remarked that the ends of a

enteroraphy in a shot wound of the colon is not placed before the reader. To form a just conception of the state of the question, it is necessary to reflect that the elements for its solution were wanting, at the close of that brilliant epoch in military surgery, when Larrey and Hennen and Guthrie were the guiding lights. After the battle of Waterloo, Thomson might say of "those whom we saw," that "the more that is left to Nature in the process of reunion, and the less her operations are interfered with, the greater will be the chance of ultimate recovery."<sup>1</sup> But Guthrie comprehended that "those whom we saw" formed a lamentably small proportion; that "numbers of others similarly or perhaps more seriously wounded had died. *It will be for those who come after us to decide a point so important, and to which their best attention will be drawn in a manner which, I trust, cannot fail to be of service.*" And then, citing the remark of Thomson, just quoted, Guthrie adds: "The remark is correct provided it be applied to those cases in which no clear indications for interference are present. When they are present, the do-nothing system is commonly followed by death. A well-regulated interference is likely to be more successful." Larrey records but one recovery from a shot wound of the small intestine, and that one was treated by Palfyn's method. In the next quarter of a century the procedures of enteroraphy were greatly perfected. The largest military operations were those of the French in Algiers. Among the leading works published on military surgery was that of Baudens, and this contained accounts of two cases of enteroraphy for shot wounds of the intestine, one of which was completely successful. In the war in the Caucasus, in 1849, the eminent Russian surgeon, Pirogoff, was equally impressed with the vital importance of this question in military surgery. "I regret," he says, "that in the cases that came under my observation, I employed the suture only once, and then in a sort of desperation. I gave up the other wounded as lost; as enteroraphy required time, and many wounded were awaiting my assistance, I did not use the suture. But just this

gut torn by a vulnerating body contracted spasmodically and became of almost cartilaginous hardness, I have often recognized this condition by introducing the finger into the abdomen; and it is then useless to protract the search, seeking to insert the finger into the intestinal wound for there can be no question that the latter exists. With this pathognomonic sign, others not less positive may be conjoined, such as the issue of matters from the perforated canal, matters with which the finger is always more or less impregnated, the odor of which will often indicate the portion of the intestine injured." \* \* \* BAUDENS further on records two cases of shot wounds of the intestine treated by enteroraphy. The first (p. 333) was a soldier of the 13th regiment of the line, wounded, at the Atlas, by a musket ball that entered to the right of the umbilicus and emerged through the quadratus at the right loin. The index introduced into the wound detected two foreign bodies, which were extracted, and proved to be ball-screws, which the soldier had carried in his pouch. The finger also recognized several hard places where the small intestine felt like the trachea. A loop of intestine, including one of the hard spots, was then drawn out at the external wound, and a simple notch in it was united by three Lembert stitches, and BAUDENS was about to reduce the gut, when a larger knuckle was protruded, during a sudden effort, and a nearly complete division of the intestine, distant about eight inches from the first lesion, was revealed. Thinking it safest to treat the two lesions together, BAUDENS included the mesentery that connected them in a strong ligature, and then cut away the intervening eight inches of the bowel, and united the two ends according to LEMBERT'S method, and then reduced the intestine. The soldier, who had not uttered a cry during the operation, which apparently was not very painful, was laid under a shelter-tent, having only the earth for a bed. There were some hopes of him, but he died on the third day. At the autopsy, there was a considerable effusion of organized lymph about the sutures, and adhesions had formed in several directions; in the right iliac fossa there was circumscribed fecal effusion, the ball having perforated the caecum. "Here the peritonéum was red and highly inflamed. Here was evidently the cause of death; and everything led me to believe," says BAUDENS, "that, but for this complication, this soldier would have been saved." The second case is, perhaps, the only instance of completely successful enteroraphy for shot wound on record. One of the Paris volunteers, in 1831, was wounded near the model farm: "L'introduction du doigt à travers la plaie n'ayant fait distinguer d'abord une portion d'intestin durcie par la contraction de sa couche musculaire, ne permit de découvrir bientôt après la solution de continuité dont elle était affectée; et en retirant le doigt, comme il était imprégné de matières stercorées, il me fut aisé de comprendre que le colon transverse avait été lésé. J'agrandis l'ouverture abdominale pour attirer cet intestin vers la plaie, je fis tousser le blessé, et il sortit à l'instant, ainsi que des gaz épanchés dans l'abdomen. L'arc du colon présentait une large échancrure sur l'un de ses bords; je renversai les lèvres de la plaie en dedans, traversai la duplication de l'intestin de manière à fermer la plaie par trois points de suture et à adosser entre elles les séries, selon le précepte de M. LEMBERT; et comme lui encore, je coupai les fils fixés par des noués avant que de réduire les parties. Quelques saignées générales furent faites de bonne heure; plus tard, à notre arrivée à Alger, le ventre fut converti de sangsues, et la guérison s'opéra sans autre complication que s'il n'y avait eu qu'une simple division des parois de l'abdomen." An abstract of this case is printed by Professor GROSS (*Wounds of the Intestines*, Case IV, p. 126).

<sup>1</sup> THOMSON (J.) (*op. cit.*, p. 105) and Dr. P. H. HAMILTON (*Treatise on Military Surgery and Hygiene*, 1835, p. 310) observe: "With the exceptions which we have now stated [the adjustment of fractured transverse vertebral processes, and the removal of fragments of vertebrae or of the innominate] to which may possibly be added a few examples in which fragments of ribs have been slightly driven in, it will be improper to make anything but the most superficial exploration of the wound, either with the finger or the probe. In short it is necessary to declare positively that, whenever the missile has penetrated or perforated fairly the cavity of the abdomen, except in certain cases where the ball has penetrated the liver without impinging upon any portion of its bony parietes, all such deep explorations, for whatever purpose instituted, are positively mischievous, or at all events eminently hazardous. We are not aware that any late surgical writer or teacher, except Legouest, has called in question the soundness of this maxim."



desperate case proved that much is yet to be expected from operative interference.<sup>1</sup> From observations in the Danish war, Dr. Lohmeyer was led to adopt like views, and to express them not less explicitly.<sup>2</sup> In the Crimean war, M. Legouest proclaimed similar doctrines; and in the American war they were carried into execution, as has been seen, by Drs. Bentley, Judson, Gill, and Kinloch, while they were sanctioned, and would have been acted on had suitable occasions offered, by Drs. Hewit, McGuire, Lincoln, and Billings.<sup>3</sup> From the experience of the late Franco-German war, Generalarzt Beck has been led to similar conclusions,<sup>4</sup> which indeed are approved by respectable ancient authorities.<sup>5</sup>

<sup>1</sup>PIROGOFF (N.) (*Grundzüge der Allgemeinen Kriegschirurgie*, Leipzig, 1864, S. 578) relates that in a case of herniotomy he accidentally cut the intestine. He immediately applied four sutures through the serous tunic, cut the ends close to the knots, replaced the intestine, and was agreeably surprised that peritonitis did not ensue.

<sup>2</sup>LOHMEYER (*Die Schusswunden und ihre Behandlung*, Göttingen, 1859, S. 161) remarks: "A closer probing of the wound of the abdomen is indicated only when the escape of the contents of the intestines from a concealed (nicht sichtbar) opening causes peritonitis, that threatens to become fatal should further extravasation be unchecked. Under such circumstances, I would follow the precepts of BAUDENS and of DUPUYTREN, to search for the opening, to sew up the wound in the exposed knuckle, and to return the latter after removing the effused fecal matter; I consider this method more rational than to sew the wound of the intestine to the abdominal wall. \* \* \* Naturally the use of the suture is indicated in complete divisions." After the Italian war of 1859, DEMME wrote (*Militär-Chirurgische Studien*, u. s. w., Würzburg, 1861): "DUPUYTREN, BAUDENS, and others, advise to search immediately for the wound in the intestine. BAUDENS believes it possible to recognize this chiefly by the invariable contraction of the muscular tunic. Both authors would enlarge the wound, expose the injured parts, remove or wash out the fecal matter, apply the suture, and replace the knuckle. BAUDENS, it is true, saw a successful result, by this treatment, in a case of injury of the transverse colon; but most authors condemn the method; I believe that, because of the uncertainty of diagnosis, in the large majority of cases, this method will prove impracticable. Where the conditions are so exceptionally clear that the method of BAUDENS is practicable, it must be regarded as rational. A discussion of principles seems to me here entirely superfluous. As regards the choice of suture, the simplest (e. g. LEMBERT'S) is the best." The passage in DUPUYTREN, to which Drs. LOHMEYER and DEMME allude, is probably that in T. VI, p. 465: "Si une balle avait largement labouré les parois abdominales et ouvert l'intestin \* \* \* il faut aggrandir la plaie extérieure \* \* \* établir un anus artificiel, que l'on guérira plus tard \* \* \* on bien enfin, le chirurgien, après avoir fixé l'intestin au dehors, emploie, pour guérir sa blessure, un des moyens spéciaux imaginés à cet effet, et particulièrement ceux de M. LEMBERT ou de M. JOBERT." I do not think, however, that DUPUYTREN'S authority can be fairly adduced in favor of the practice of searching for shot wounds in the intestine, certainly not to the extent advocated by BAUDENS. It is evident that BAUDENS did not so interpret the lessons of his teacher, else he would gladly have fortified his recommendation by so high an authority.

<sup>3</sup>BILLINGS (J. S.), *MS. note to the editor*, remarks: "In regard to penetrating wounds of the abdomen, where there is reason to suspect intestinal injury, it appears to me to be proper to enlarge the opening, if necessary, to ascertain the nature and amount of injury, to remove foreign bodies and extravasated matter, to employ sutures or ligatures where needed, and to cut these short and return the injured viscera. The results of ovariectomy, of operations for strangulated hernia, etc., demonstrate that the dangers of opening the peritoneal cavity and of handling the viscera have been greatly exaggerated. Success in these operations must depend upon attention to minute details, such as preventing lowering of the temperature, perfect cleanliness, etc. Especial care should be taken to prevent even the smallest particle of fecal matter from escaping into the peritoneal cavity, and to remove such as may escape. Ordinary fecal matter contains immense numbers of microzymes, or minute organisms known as bacteria, monads, microcosms, etc., which if not the direct cause of putrefaction, as seems probable, are at all events closely connected with that process. The great danger in these operations probably arises from the sponges and water used, and the less anything but the perfectly cleansed and disinfected hands of the surgeon comes in contact with the peritoneal surfaces the greater the chance of success." Professor H. MCGUIRE (*Letter to the editor*) expresses his opinion with emphasis: "Penetrating wounds of the belly are nearly all fatal, and we must look for some other means of saving life than we now have." \* \* \* "If the shock, thermometer, etc., indicate wound of the bowel, cut down, and sew it up. You say this is desperate! I answer, the cases justify it. We must do something more than give opium and use ice-poultices." HEWIT, *Appendix to Part I, Med. and Surg. Hist. of the War of the Rebellion*, page 312, observes: "It is next to an impossibility, when a soldier is wounded in the abdomen, with lesion of the intestines, that their contents should not escape into the peritoneal cavity. The necessity of lifting and handling, and the agitation of transportation to a considerable distance, render this result next to an infallible certainty. Some cases might be saved, perhaps, if they could be examined at the moment of reception of the wound, and the edges pared and closed with silver wire. The opportunity to do this has generally passed by the time the patient reaches the hospital. I think it admits of question, whether greater effort should not be made to seek out the wound, to close it by silver wire, and to endeavor to obtain primary union, while peritonitis and constitutional disturbance are treated on general principles?" Professor N. S. LINCOLN (*Letter to the editor*) declares that: "In punctured and incised wounds, when there is adequately strong presumptive evidence of intestinal lesion, though there may be no protrusion, it is the surgeon's duty to enlarge the peritoneal wound, to seek for the wounded intestine and to close the orifice, if it exceeds three lines, by suture. 2d. That in shot wounds of the intestine, unattended by protrusion, unless the perforation may be in the iliac region, with a reasonable likelihood of implicating the part of the large intestine uncovered by peritoneum, and therefore avoiding the risk of intraperitoneal extravasation, it is the safest course to enlarge the track of the ball and to close the intestinal wound by suture. I cannot believe that the necessary enlargement of the peritoneal opening can add, in any considerable degree, to the danger in cases of intestinal extravasation."

<sup>4</sup>BECK (*Char. der Schussverletzungen*, 1872, S. 533). "These various experiments have taught me, that the tendency of wounds of the intestines toward repair is greater than is generally believed; that the wounds close by plastic exudation of the wounded edges without serious disturbance to the functions; that therefore art may interfere more boldly; and that the use of the intestinal suture, as well as the formation of a fistula or artificial anus, would save many wounded."

<sup>5</sup>HEISTER may be cited as an early authority in favor of this practice. In his *Institutiones Chirurgicæ*, Amsterd., 1739, P. I, Lib. I, Cap. VII, p. 110, or *System of Surgery*, 7th ed., 1759, Book I, Chap. VII, 3, p. 75, he writes: "When the intestines are wounded, but not let out of the abdomen, and therefore their wounds are out of reach, the surgeon can do nothing but keep a tent in the external wound, according to the method of dressing laid down at Chap. V, N. XIV, and after this, bleed the patient, if his strength will admit of it, advising him to rest, to live abstemiously, and to lie upon his belly. The rest is to be left to Divine Providence and the strength of his constitution. But the question may be asked here, Whether a surgeon may not very prudently, in this case, enlarge the wound of the abdomen, that he may be able to discover the injured intestine, and treat it in a proper manner? Truly I can see no objection to this practice, especially if we consider that, upon the neglect of it, certain death will follow; and that we are encouraged to make trial of it by the success of others. SCHACHERUS, in *Programmate Publico*, Lipsiæ edit., 1720, mentions a surgeon who performed this operation successfully. So CHESSELDEN, of London, gives us an history where, in the *hernia incurvata*, he laid open the abdomen, returned the intestines, and perfectly cured his patient. See his *Treatise on the High Operation*, page 180, and his *Anatomy*, 3d ed., p. 283." But even FALLOPIUS (*Op. gen.*, Venetiis, 1606, T. II, p. 333) would appear to have favored the plan of enlarging the external wound in order to expose the lesion in the intestine in order to practice enterorrhaphy, which he earnestly advocated for wounds of both the small and large intestines: "Ego tamen dico, quod et crassa, et tenuia sunt consensua," and then, having cited a recovery related by VIDUS VIDUUS, where the latter sewed up the abdominal wall because, as he averred, he could not introduce the hand to sew up the wound in the gut, he emphatically adds: "Quamvis igitur habeamus hoc exemplum,



Dr. Neudörfer condemns any surgical interference with shot wounds of the intestines.<sup>1</sup> Professor Gross, while heartily endorsing the propriety of exploratory incisions and of enteroraphy in cases of ordinary intestinal wounds without protrusion, regards such measures as unlikely to be of benefit in shot wounds of the bowels, because such lesions are commonly multiple.<sup>2</sup> Undoubtedly this consideration is of great weight in prognosis; as to treatment, it may be urged that, in proportion as the danger of fecal extravasation is multiplied, the necessity of employing the only effective remedy becomes more imperative. If Larrey's case be included, there are nine recorded instances of enteroraphy for shot wounds of the intestine,<sup>3</sup> with one complete success, three recoveries with fecal fistula,

tamen dico fuisse (si vera referantur) potius miraculum nature; et ideo dico, quod vulnera intestinorum sunt consuenda." Further on, FALLOPIUS responds successively to the dicta of GALEN in his comments on the aphorism: "si quid gracile intestinum persectum sit, non coalescit."

<sup>1</sup>NEUDÖRFER (*Hambuch der Kriegschirurgie*, Leipzig, 1867, S. 729) remarks: "Was soll also der Arzt mit einem durchgeschossenen Darm machen? Gar nichts!"

<sup>2</sup>GROSS (S. D.), in the last edition of his systematic treatise (*A System of Surgery*, 5th ed., 1872, Vol. II, p. 667), discusses this question as follows: "It is still a mooted question as to what should be done when the wounded bowel does not protrude at the opening in the wall of the abdomen. When we reflect upon the fact that in all lesions of this kind the great danger is from fecal effusion, and that such effusion is almost inevitable even when the opening of the intestine is of very small extent, the duty of the surgeon, I think, plainly, is to enlarge the abdominal orifice, to seek for the wounded tube, and to sew up the cut in the usual manner. Such a procedure, promptly and efficiently executed, while it holds out the only possible chance of safety, would not place the patient in a worse condition than a woman who has undergone the Cæsarean section, or a person whose abdomen has been ripped open by accident; recovery from both of which, as is well known, is by no means infrequent. The truth is, the fatality of penetrating wounds of the abdomen has been greatly exaggerated; and hence a degree of prejudice has arisen against this practice so deeply rooted as to render it almost impossible to surmount it by any course of argument, however well founded. These remarks are more especially applicable to incised wounds. In gunshot wounds no benefit, it seems to me, would be likely to accrue from such a course of treatment, as the bowel is generally pierced in a number of places, and the case, on this account, must, therefore, generally be fatal." A few pages before this, Dr. GROSS (p. 662) remarks: "In 1851, I attended a man, along with Dr. Cummings, in whom a pistol ball, entering a short distance below the navel, a little to the left of the middle line, completely perforated, in its upward and outward passage, the ileum, jejunum, duodenum, and arch of the colon, making thus eight separate orifices." It may be suggested, with deference, that possibly this instance of multiple shot wounds is may have unduly biased the judgment of the eminent professor.

<sup>3</sup>Namely: 1. LARREY, in 1799, shot-wound of ileum, the bowel stitched to the parietes by PALFYN'S, or rather by LAPEYRONIE'S method; fecal fistula, with ultimate recovery. 2. GISSING, in 1858, shot-wound of jejunum, three interrupted sutures, ends cut close and protruded bowel returned; fecal fistula; ultimate complete recovery. These two cases are detailed in notes to page 73, *supra*. 3. BAUDENS, in 1831, shot-wound of the arch of the colon; LEMBERT'S suture; complete success. 4. BAUDENS, about 1830, three shot perforations of the intestine, two treated by enteroraphy, the third escaped notice; death on the third day. These two cases are related in the note to page 125. 5. PROGOFF, in 1819 (*Rep. méd. d'un voyage au Cauc.*, and *Grundzüge*, n. s. w., S. 578), two double shot perforations of the ileum, excision of the wounded portions of the gut, ligation of the mesenteric vessels. PROGOFF lost sight of this patient after the fourth day: "I take it for granted," he says, "that the result was not favorable, and yet I recommend this proceeding as the only possible resource in such injuries." 6. BENTLEY, CASE 228, page 72, *supra*, five shot perforations of jejunum and colon, three sewn up; fatal. 7. JUDSON, CASE 224, page 73, shot laceration of the ileum, suture; death. 8. GILL, CASE 310, page 113, shot perforation of small intestine, enteroraphy; death. 9. KINLOCH, CASE 311, page 113, stercofal fistula following a shot laceration of the small intestine, suture; recovery, with a fistula, tending, at last accounts, to a complete cure. Dr. HAMILTON (*Treat. on Med. Surg. and Hygiene*, p. 312) observes: "It is unfortunately true that in nine cases out of ten, when a ball has penetrated the abdomen, the patient dies within twenty-four or forty-eight hours; and it is equally true that his death is in a great majority of cases caused by extravasation of the contents of the bowels into the peritoneal cavity, and the consequent inflammation. It is indeed not certain that a conical ball ever traverses the region occupied by the small intestines without causing both a rupture of the tube and an extravasation of its contents to a greater or less extent. On the other hand, it is known that a certain number recover after such injuries without any conclusive evidence having been furnished that the intestine was wounded; and that a number still larger recover, with either a permanent, or, as more often happens, with only a temporary, discharge of fecal matter through the wound; and these results have happened under what has been termed the 'general plan of treatment'—that is, without surgical interference." The validity of these objections is not apparent. That a number of patients recover from shot perforations of the abdomen without visceral injury, and that a still larger number recover from shot lesions that may interest the colon where uncovered by peritonæum, may be admitted without affecting the question of operative interference in those shot wounds in which lesions of the small intestine or of the great intestine within the peritoneal cavity are indubitably present. M. LEGOUËST, in the edition of 1872 of his classical *Chirurgie d'Arabe* (a copy of which he has done me the honor to send me), reiterates, after ten years added experience, his conclusions respecting the proper treatment of shot wounds of the intestine, precepts at least not now open to the charge of novelty. The propriety of enteroraphy in the rare instances of shot wounds of the intestines accompanied by protrusion, will not probably be hereafter seriously contested. That incised wounds of the digestive tube concealed within the abdominal cavity should be sought for and secured by suture, is a proposition not universally conceded, but sustained by much favorable evidence. Should it be established as a rule of practice, the only argument for excluding shot wounds from similar treatment, would be that they often involve multiple lesions of the intestines, and that enteroraphy is therefore hopeless. GÜNTHER (*Lehre von den Blutigen Operationen*, 1860, B. IV, Abs. XV, p. 166) cites a series of thirty-five cases of injuries of the stomach or intestines to illustrate the results of operative interference. "In seven cases, the stomach was interested; in four the large, and in twenty-four the small intestine. Of the first two groups, none were fatal; of the third, four. The injured part was replaced, in one successful case, without stitches. In one successful instance, a fold of the mesentery was stitched; but the intestinal wound was not closed. In four recoveries, small wounds of the stomach or intestines were closed by ligatures. In three cases of complete division, invagination was successfully practiced. Twenty-seven times sutures were employed, as follows: in four successful cases the interrupted suture (fastened, in two instances, to the abdominal wound); in five cases, the glovers' suture, one proving fatal; in one, the suture of the four masters; in three, LEMBERT'S suture, one proving fatal; in four, of which two were fatal, JOBEIT'S suture; in one successful case, GÉLY'S; in one instance the injury was occluded by adjoining parts; in nine, the method of suture was not stated. Thirty-one of these patients recovered, and four died. This favorable result certainly cannot be altogether accredited to the suture; doubtless there are unfavorable results unrecorded, patients succumbing either from complications or from insidiously of the suture. But in the four fatal cases the suture was not the cause of the unhappy termination, as at least in three of them there was evidence of advanced reparation. In two cases fistula remained, but soon closed." Most of the cases to which GÜNTHER alludes have been specified in these pages, and many others have been noticed. Besides the instances of suture of the small intestines enumerated in preceding notes, the following may be cited: 1. HUGHAM (*Philosophical Transactions*, 1757, Vol. I, Part I, p. 35) records a stab wound of the ileum, in a sailor, treated by Peter Travers, of Lisbon, by the continued suture the end left hanging out at the angle of the abdominal wound, which was united by interrupted stitches; recovery was complete in thirty-four days. 2. VOGLI (SANDIFORT'S *Thesaurus*, Roterdami, 1769, Vol. II, p. 118, *note*) states that the knife wound of the jejunum described by MACOTIE (mentioned in the note to page 68, *supra*) was united by stitches, and followed by complete recovery in nine weeks. 3. CALTON (*Edinburgh Med. and Surg. Jour.*, 1815,

and five deaths. Already interference contrasts favorably with the do-nothing system.<sup>1</sup> Reflection upon the results of ovariectomy, upon the results of gastrotomy and enterotomy applied to protruded wounded viscera, leads unavoidably, in the writer's opinion, to a conviction of the propriety of incising the abdominal wall when necessary in order to expose and sew up the wounded gut concealed within the cavity,<sup>2</sup> whether divided by a cutting instrument or by shot. The obstacles to success are obvious; but it is a mortal peril which demands an extreme remedy.

Further observations on the complications of intestinal wounds will be presented in later portions of this chapter, and intestinal lesions complicated by wounds of the bladder will be considered in the next chapter.<sup>3</sup>

Vol. XII, p. 27) relates the case of a child whose abdomen was torn open by the tusk of a boar; a complete division of the protruded ileum was united by four points of interrupted suture; recovery in three months. 4. ACUBRIET (*Diss. sur les plaies de l'abdomen*, Paris, 1815) gives a case of enterotomy in an Austrian soldier; a stab in the ileum united by the continued suture; recovery complete in thirty-three days. This is the case in which CHARLIER operated, and it is cited in the Dictionary in sixty volumes by PATESSIER, article on *Wounds*, by PERCY and LAURENT (T. XLIII, p. 48), and by GROSS (*l. c.*, p. 69). 5. CARRÉ (in LARREY, *Clin. Chir.*, T. II, p. 392) narrates the case of Golin, aged 23, a soldier of the 6th regiment of the Guard, with a sabre-wound of the ileum, successfully united by suture, in April, 1820. 6. YANDELL (in GROSS, *Wounds of Int. &c.*, p. 87) relates a case of successful enterotomy in 1830, from incised wound of the protruding small intestine, in the case of Ezekiel, an athletic negro, of 30 years. 7. DAVIDS (*Medico-Chirurgical Review*, 1834, N. S., Am. reprint, Vol. XX, p. 182) records the case of W. Kemble, a butcher, gored by an ox; two perforations of the protruding ileum were closed by interrupted sutures, and the bowel was replaced; recovery was prompt and complete. 8. DIAZ (*Gaceta Médica de Madrid*, Sept. 1853) relates that, in 1838, in the case of a soldier, stabbed in the left iliac region, he applied five points of Lembert's suture, replaced the gut, and closed the external wound with stitches; recovery was complete in one month, and, in six weeks, the soldier resumed regimental duty. 9. BUCK (*New York Jour. of Med. and Surg.*, 1811, Vol. IV, p. 358) relates a case of recovery in five weeks from a stab wound of the protruded small intestine united by four interrupted stitches, in the case of M. Sullivan, aged 26 years. 10. PIROGOFF (*Grundzüge der Allgemeinen Kriegschirurgie*, 1864, S. 578) relates a successful enterotomy for an accidental wound three-fourths of an inch in length in the small intestine, made in herniotomy. 11. ERICHSEN (*The Lancet*, 1851, Vol. II, p. 414) reports a recovery after a stab wound with protrusion of the small intestine, united by the continuous suture, in 1851, in the case of Julia S——, the mother of eleven children. Pus appeared in the stools on the fifteenth day, the date, probably, of the elimination of the suture through the mucous tunie. 12. BUTCH (*Proceedings of Med. Soc. of Algiers*, cited in *The Lancet*, 1865, Vol. I, p. 149) records a recovery from a stab wound in the right flank, with four lesions of the small intestine, all closed by sutures. Of fatal cases, a number are mentioned on page 63. An additional instance is recorded by Mr. CUTLING (*London Med. Gazette*, Vol. XXI, 1837, p. 567): Thomas Hawe, aged 25, two punctured wounds of the ileum, secured by circular ligatures, after Sir Astley Cooper's method; one ligature became displaced; death in twenty-three hours. The records of herniotomy would furnish other instances both of successful and unsuccessful enterotomy; but over one hundred instances have already been adduced, with such a large percentage of recovery, that, with every allowance for the suppression of unfortunate results, the evidence is very encouraging. VELLEAU (*Méd. op.*, T. II, p. 419) remarks that "M. LAVIELLE DE MEMBASTE, MM. CHEMERY-HAVÉ, SCHMIDT, et quelques autres, ont cependant rapporté chacun un exemple de succès n'appuyé du procédé Randharien." The illustrious professor was not a careful proof-reader. It would be vain to attempt to verify the successes of "quelques autres." The case of JOSEPH SCHMID is recorded in a dissertation *de Ileo*, Wien, 1759. "Resecta fuit pars gangrenosa intestini, longa ad sex uncias, sana pars consulto, in hernia inaequareta, conatu felici," says HALLER, *Bibl. Chir.*, 1775, T. II, p. 457. A clue to another of these cases is also found in HALLER (*l. c.*, T. II, p. 577), that of CHEMERY-HAVÉ: "exomphalos gangrenosus intestini, hujus septem uncie siderate resecte, mesenterio sutura unito, procuratus anus praeternaturalis, sponte tamen clausus, et malum integre sublatum." The reference to LAVIELLE may relate to a successful instance of gastrotomy recorded by LÉVELLÉ (*Nouveau doctrine chirurgicale*, Paris, 1812, p. 384).

<sup>1</sup> ANDREWS (E.), in a *Report of the Committee on Surgery to the Illinois State Medical Society*, remarks: "With very few exceptions, bullet wounds into the abdominal cavity are all fatal. It may be a question worthy of serious thought, in view of the hopelessness of our present practice, whether we ought not to cut boldly into the abdominal cavity, wash out the filth, and, bringing the wounded intestines to the surface, endeavor to produce an artificial anus." See *A Record of the Surgery of the Battles fought near Vicksburg*, Chicago, 1863, p. 34. It is not often that the surgeon will be called upon to act in this difficult conjuncture. Very many shot wounds of the intestines are associated with such lesions of the bloodvessels or nerves as involve promptly fatal syncope or collapse; others are complicated by other visceral injuries; in others, again, there is protrusion, and the course of treatment is plain. It is the comparatively small group of intestinal perforations by musket balls or by smaller projectiles, where the finger detects fecal escape, that the necessity of immediate interference may be insisted on. The operation should be done on the field, if practicable. The subsequent removal of the patient, if inevitable, will be less hazardous than transportation with the intestinal wound unclosed.

<sup>2</sup> In addition to the authors already referred to, among whose writings the works of SMITH, TRAVERS, and GROSS, of VOGEL and WEBER, and of JOBERT, GÉLY, and LEMBERT, will be found of especial value, the reader may consult, regarding enterotomy, the comprehensive dissertation of FINGERHUTH, *De vulnere in intestinis sutura*, Bonnæ, 1827; also WESTPHAL, *De vulnere intestini coli feliciter consolidato*, Diss., Gryphisw., 1743; MORAND (S.), *Sur la réunion des deux bouts d'un intestin, une certaine portion du canal étant détruite*, in *Mém. de l'Acad. des Sci.*, 1735, p. 249; SIMON, *De suturarum usu*, Paris, 1761; BELLETETE, *Ergo in plevrique casibus suturæ cruenta sunt inutilis et noxia*, Paris, 1764; BÉGIN, *Mém. sur la réunion immédiate des plaies des intestines*, in *Rec. de mém. de méd.*, Paris, 1827, T. XXII, p. 260; BOYER (Ph.), *Des opérations que réclament les plaies de l'estomac et de l'intestin*, Paris, 1841; MARTINENCQ, *In plagis abdominalis vulnerato intestino pellicionum sutura*, Paris, 1738. PIBRAC, *Mém. sur l'abus des sutures*, in *Mém. de l'Acad. de Chir.*, T. III, p. 408; RITSCHE, *Mém. sur un effet peu connu de l'étranglement dans la hernie intestinale*, in *Mém. de l'Acad. de Chir.*, T. IV, p. 173. HENROZ, *De methodis ad sananda intestina divisa adhibitis, in qua nova sanationis methodus proponitur*, Leodii, 1826; GIBBLE, *An in plagis abdominalis vulnerato intestino pellicionum sutura?* Paris, 1750.

<sup>3</sup> On wounds and injuries of the intestines, many of the more important authorities have been cited in the foregoing pages. The following additional references are accessible in the Surgeon General's Office Library: MALAVAL, *Au tenuum intestinorum vulnus lethale?* Paris, 1734, in HALLER'S *Disputationes*, T. V, p. 77; HILSCHEN, *Diss. de vulnere in intestinis lethaliitate*, Giessen, 1743; BECK (B.), *Versuche über die Heilungsfähigkeit der Darmwunden*, in *Illust. Med. Zeitung*, B. III, S. 142; MARCH, *Penetrating wounds of the abdomen, with punctured wounds of the intestines*, New York, 1851; VILLENEUVE, *Quels sont les phénomènes tant primitifs que consécutifs propres aux plaies des intestins*, Thèse, Paris, 1838; ROCLORÉ, *Quels sont les phénomènes tant consécutifs que primitifs propres aux plaies des intestins*, Thèse, 1841; CROUZET, *Traitement des plaies de l'intestin*, Thèse, 1842; FLEURY, *Plaies de l'intestin produites par des instruments piquants ou tranchants*, Paris, 1851; NEFCOURT, *Quel est le traitement des plaies des intestins*, Thèse, 1844; RAHELLEAU, *Traitement des plaies de l'intestin*, Thèse, 1842; FRIDERICI, *De morbis a situ intestinorum praeternaturali*, Lipsiæ, 1721, in HALLER'S *Disp. Chir.*, T. III, p. 1. This is often cited as SCHACHER'S paper, the dissertation having been defended before that professor. BRUN, *Plaies du bas-ventre par instruments tranchants*, Paris, 1838. CHERINI, *Ferite d'Arma da Fuoco*, Milano, 1866, p. 110.



WOUNDS OF THE LIVER.—Penetrating wounds of the liver are very dangerous, and, indeed, usually prove fatal from primary hæmorrhage; yet the examples of recovery from penetrating shot wounds are more numerous than the remarks of Inspector-General Longmore would indicate;<sup>1</sup> and the rule laid down by Hennen,<sup>2</sup> that “a deep wound of the liver is as fatal as if the heart itself was engaged, the slighter injuries are recoverable,” is too absolute. Hennen refers to two monographs on wounds of the liver, by Kaltschmidt<sup>3</sup> and De Bergen.<sup>4</sup> The first is a scholastic thesis, defended, at Jena, before Kaltschmidt, by Wedekind; the latter an equally theoretical disquisition, which must not be confounded with the tract on diseases of the liver, by Carolus à Bergen. The observations of Meichsner,<sup>5</sup> the dissertations of Reinhart and Suffert, and the more modern dissertations by Dr. L. D. Dargent and by Dr. G. Tornwaldt,<sup>6</sup> are equally deserving of mention. There is a recent treatise by Dr. Ludwig Mayer,<sup>7</sup> devoted exclusively to injuries of the liver; and most writers on military surgery present some observations on the subject.<sup>8</sup> Lacerations of this organ without external breach of surface have been noticed on page 16 of the preceding section. A number of instances of punctured and incised wounds were also reported during the war.

*Punctured and Incised Wounds.*—A recovery, after a bayonet stab implicating the liver, is recorded in the *First Surgical Volume*.<sup>9</sup> The following case, recorded on page 3, of this volume, as a wound of the parietes, was ultimately recognised as a penetrating wound of the liver:

CASE 310.—Corporal S. A. Holden, Co. D, 1st Maine Cavalry, aged 19 years, received, at Upperville, Virginia, June 21, 1863, a stab by a sabre, which entered the right hypochondrium at the side, two inches below the ribs, penetrating the liver. He was taken to a neighboring field hospital in charge of Assistant Surgeon R. A. Dodson, 1st Maryland Cavalry. There was not much bleeding, but great tympanitic distension, which subsided on the tenth day, and was followed by an abscess of the liver. This was incised anteriorly, on July 13th, and a profusion of pus was evacuated. The patient was supported by a sustaining regimen, and, on August 2d, was sufficiently convalescent to bear transportation to the 3d division hospital at Alexandria. The wound had healed, but he was very weak. He improved rapidly, and was returned to duty on October 7, 1863; but, being unfit for active service, he was sent to Armory Square Hospital on March 20, 1864. A ventral hernia had protruded at the site of the cicatrix.

CASE 311.—Assistant Surgeon J. C. G. Happersett, U. S. A., reports that “Private G. Conway, Co. C, 10th Missouri Cavalry, aged 21 years, was admitted into Overton Hospital, Memphis, November 29, 1864, with a penetrating incised wound in the right hypochondrium, inflicted with a knife on the same day. The usual symptoms of profuse intra-abdominal hæmorrhage indicated that the liver was penetrated. The patient died December 1, 1864.”

<sup>1</sup> LONGMORE, *On Gunshot Wounds*, in Holmes's *System of Surgery*, 1870, Vol. II, p. 206. He remarks that about a dozen instances of recovery are recorded by authors. But JOHN THOMSON (*Report after Waterloo*, p. 98) saw after one battle “twelve cases of wounds of the liver, in which considerable progress toward recovery had been made before our return from Belgium.” GUTHRIE (*Lectures*, Part II, Sect. I, Cases 68-77, *Commentaries*, Am. ed., p. 529) refers to some of these, and enumerates five others. DR. L. MAYER (*Die Wunden der Leber*, 1872, S. 124) recapitulates these, and tabulates forty recoveries from shot wounds and twenty-one from stabs of the liver. The annals of the war of the rebellion afford a series almost as numerous of recoveries from injuries of this group.

<sup>2</sup> HENNEN, *Principles of Military Surgery*, 2d ed., 1820, p. 434. He relates two interesting examples of recovery from complicated shot wounds of the liver, Cases LXXIII and LXXIV.

<sup>3</sup> WEDEKIND, *De Valvæ Hepatis Curato, cum Disquisitione in Lethalitate Vulnerum Hepatis*. Preside, C. F. KALTSCHMIDT, Resp., A. J. WEDEKIND, in Haller's *Disputationes Chirurgicæ*, Lausanne, 1756, T. V, p. 83.

<sup>4</sup> DE BERGEN, *De Vulneribus Hepatis*, Francofurti, 1753, and in Sehlegel's *Collection*.

<sup>5</sup> MEICHSNER (ESAIAS), *De vulneræ hepatis sanato*. Cited by JOHN SCHENCK in 1580.

<sup>6</sup> REINHART (F. C.), *De vulnerum hepatis lethalitate*, Glogau, 1758; SUFFERT, (J. E.), *De j. cinoriz vulneribus*, Jenæ, 1812; DARGENT (L. D.), *Des symptômes et du traitement des plaies du foie*, Paris, 1845; TORNWALDT (G.), *De hepatis cystique felle læsionibus*, Halls, 1866.

<sup>7</sup> MAYER (L.), *Die Wunden der Leber und Gallenblase*, München, 1872, Sn 239 mit 5 Tafeln.

<sup>8</sup> SCHENCKIUS (J.), *Obs. med. rar.*, Lugduni, 1644, p. 396; FABRICIUS HILDANUS, *Opera que extant omnia*, Francofurti, 1646, p. 110; PURMANN, *Lorbeer-Kranz*, Franckfurth, 1692, S. 412; LITRE (A.), *Observations sur des plaies du ventre*, in *Mém. de l'Acad. des Sciences de Paris*, 1705, p. 32; MORGAGNI, *De Causis et Sedibus Morborum*, Patavii, 1765, Liber Quartus, LIII. Art. 40, p. 275; LEDRAN, *Traité ou Reflexions tirées de la pratique Clin. Chirurg.*, Paris, 1823, T. II, p. 418; BOYER, *Traité des maladies chirurg.*, 3<sup>e</sup> éd., T. XI, p. 86; LITRE (E.), *Dict. de Méd.*, 1833, T. V, p. 230; BALMGALL, *Outlines of Mil. Surg.*, 5th ed., 1855, p. 316; HENNEN (l. c.); GUTHRIE (l. c.); DR. LONGMORE (l. c.); PROFESSOR PIROGOFF, *Grundzüge der Allgemeinen Kriegschirurgie*, Leipzig, 1864, S. 596; STROMMEYER, *Maximen der Kriegschirurgie*, Hannover, 1855, S. 638; DR. NEIDHÖRTER, *Handbuch der Kriegschirurgie*, Leipzig, 1867, S. 738; DEMME, *Militär-Chirurgische Studien*, Würzburg, 1861, Th. II, S. 134; EMMERT, *Lehrbuch der Chirurgie*, Stuttgart, 1862, S. 244; SOCIN, *Kriegschirurgische Erfahrungen*, Leipzig, 1872, p. 95; FISCHER (H.), *Kriegschirurgische Erfahrungen*, Erlangen, 1872, p. 133; BECK, *Chirurgie der Schussverletzungen*, Freiburg, 1872, S. 533; LEGOUËST, *Chirurgie d'Armée*, Paris, 1872, p. 391; GROSS, *System*, 5th ed., Vol. II, p. 681; CHOLSOL, *A Manual of Mil. Surg.*, 1863, p. 349; HAMILTON, *Treat. on Mil. Surg.*, 1865, p. 363.

<sup>9</sup> Case of Corporal Thomas Powers, Co. G, 2d United States Infantry, *First Surgical Volume*, page 46E.



Punctured and incised wounds of the liver rarely come under the observation of the surgeon. The three cases here referred to are all that have been found in the records of the war. There is room even for questioning the accuracy of the diagnoses in the two instances of recovery. Surgeon John A. Lidell, U. S. V., who has thrown light on many obscure and ill-explored surgical points, has discussed<sup>1</sup> the case detailed in the *First Surgical Volume*, and, after a very careful analysis of the symptoms, failed to find satisfactory evidence of an hepatic lesion. In CASE 310, the inference that the liver was directly injured is derived from the secondary formation of an hepatic abscess. Since the war, one fatal punctured wound of the liver has been recorded by Assistant Surgeon S. M. Horton.<sup>2</sup> The Museum contains no preparation illustrating injuries of this group, and I find none mentioned on the catalogues of other pathological collections. In the annals of surgery there are definite descriptions of about sixty cases of stab wounds of the liver.<sup>3</sup> Dr. Mayer<sup>4</sup> has collected twenty-one instances of recovery from such injuries; but three duplicated cases<sup>5</sup> must be subtracted from the list. Punctured and incised wounds of the liver are to be regarded as less frequent lesions than ruptures of that organ. The treatment does not vary from that indicated for ruptures without external injury; for the parietal wound is comparatively unimportant

<sup>1</sup> LIDELL. *Bayonet Wounds, with Cases*, in *Am. Med. Times*, 1863, Vol. VII, p. 143. Dr. LIDELL gives a more extended account of the case of Corporal Thomas Powers than is at page 468 of the *First Surgical Volume*; but the hemorrhage from the bowels, reported by Dr. F. S. PORTER, had not occurred when the patient was under observation at Stanton Hospital.

<sup>2</sup> HORTON. *Note of a fatal arrow wound of the Liver*, in Circular 3, S. G. O., 1871, p. 153.

<sup>3</sup> I find accounts that appear authentic of twenty-six instances of recovery from punctured or incised wounds of the liver, recorded by the following authors: 1. BERTINUS, G. (*Medicina*, Basil, 1587, Lib. 13, cap. VII); wound of liver; a portion severed and extra-ted; recovery. 2. CABROL, B. (*Alphabet anatomique, avec plusieurs observations particulières*, Genœvæ, 1602); deep wound of liver; recovery. 3. MEISSNER, E. (in SCHEENCKIUS, *Obs. med. rar.*, Lugduni, 1644, Lib. III, Obs. V, p. 397); liver transfixed; recovery. 4. P. HILDANUS (*Op. omni.*, Francofurti, 1646, p. 110); sword wound of liver; portion of liver torn off; recovery. At the autopsy, three years subsequently, it was ascertained that a piece of the liver was lost. 5. SCHIELLHAMMER (*Eph. Nat. Cur.*, Norimbergæ, 1687, Dec. II, Ann. V, Obs. 9, p. 17); knife wound of liver; recovery. 6. LITRE (*Mém. de l'Acad. Roy. des Sci.*, February, 1705); a young man, while deranged, inflicted eighteen wounds; liver injured; recovery. 7. NOLLESON (*Riquil périodique*, etc., 1765, Vol. XXII, p. 258); sword wound in right hypochondrium; base of convex portion of great lobe of liver injured; recovery in five weeks. 8. SÉSSY (*Jour. de Méd. Chir. et Phar.*, 1777, T. 48); punctured wound in the great lobe of liver; recovery. 9. JASSER (in SCHMUCKER'S *Vermischte Chirurg. Schriften*, 1782, B. III, S. 156); three stabs in the abdomen; piece of liver in the wound ligated and cut off; ligature came away on the eighth day. 10. THEDEN (in RICHTER'S *Chirurgische Bibliothek*, Göttingen, 1782, B. VI, S. 288); self-inflicted stab wound of abdomen; escape of small intestines; removal of a piece of diaphragm and of liver (one-half inch by three inches); ileum completely severed. As it was not expected that the man would live, the protruding portions were returned pell-mell, and the wound in the abdominal wall was closed by suture; escape of fecal matter for four weeks, recovered, and lived seven years. 11. LIETAUD (*Hist. Anat.*, 1767); sword cut of liver; copious bleeding; recovery. 12. OPITZ (in RICHTER'S *Chirurgische Bibliothek*, Göttingen, 1791, B. II, S. 476); a peasant girl falling on a bottle, a fragment of glass entered the abdomen; protruding portion of left lobe of liver ligated and cut off; recovery in five weeks. 13. PARISSÉ (*Opuscule de Chirurgie*, 1806); sabre wound of abdominal wall, eight inches in length, wound of liver two inches; recovery in twenty-six days. 14. DRESSEL (*Schmidt's Jahrbücher*, B. I, 1834, S. 60); boy stabbed with a knife; protruding portion of liver came away on the fifth day; recovery in fourteen days. 15. CONSTANTIN (*Jour. heb.*, 1834, No. 14); sailor, aged 26 years, stabbed with bayonet in right hypochondrium; liver injured; slow recovery. 16. FRICKE (*Schmidt's Jahrbücher*, 1836, B. XI, S. 207); knife wound of liver; protruding portion cut off with scissors; recovery. 17. ROUX (*Rapport sur la mém. de M. J. A. ROUX*, in *Bull. de l'Acad. de Méd.*, Paris, 1844, T. X, p. 812); incised wound of liver four fingers wide; copious bleeding; recovery in thirty days. 18. MACPHERSON (*London Med. Gaz.*, January, 1846, p. 112); Hindoo, aged 60 years, received a lance wound; liver protruded; ligated and piece of liver cut off; ligature came away on the ninth day. 19. BECK (*Die Schusswunden*, Heidelberg, 1850, S. 221); puncture of the liver by a foil; recovery. 20. JESTON (*British Med. Jour.*, 1857, p. 697); boy, aged 15 years, cut by being thrown on a plough-share; piece of liver, the size of a shilling, torn out; recovery in six weeks. 21. WALTER (*British Med. Jour.*, 1859); knife wound in abdominal cavity; cut in the left lobe of the liver; copious bleeding, controlled by compression of aorta through abdominal wall; recovery in five weeks. 22. ALLEN, H. (*Med. Reporter*, July, 1855, p. 365); in 1823, a boy, aged about 10 years, fell on a scythe; the false and three of the true ribs of the right side were divided, and the liver wounded about the size of a man's forefinger; recovery in three weeks. 23. SMITH, N. R. (*Cases in Surgery*, in *North Am. Arch. of Med. and Surg. Sci.*, 1835, p. 385); knife wound beneath and a little to the right of the ensiform extremity of the sternum; liver injured; recovery. 24. NEWTON, W. S. (*The Western Lancet*, 1850, Vol. XI, p. 501); W. C., aged 23 years, cut by a saw; a part of the parietes, six by ten inches, and a small portion of the liver, cut; recovery in a few months. 25. PECK, S. W. (*The Western Jour. of Med.*, September, 1867, p. 534); bayonet wound in the upper part of right lumbar region; liver punctured to the depth of four or five inches; intestine, half divided, protruded; interrupted suture to intestine; gut returned after enlarging the external wound; recovery in thirty days. 26. HILL, H. (*Canada Med. Jour.*, 1869, Vol. V, p. 289); W. P., injured by a circular saw; 8th, 9th, 10th, and 11th ribs cut; pleural cavity laid open; diaphragm and liver wounded; cut in liver four inches long and one inch deep; recovery. There are definite descriptions at least of thirty-six fatal cases of this group; but it would, perhaps, be superfluous to enumerate them. BOHN (*Chir. rat.*, Braunschweig, 1727) cites cases from Tulpinus and other old writers. BALBINGTON'S interesting account of a fatal bayonet wound of the liver is in the *Med. Rec. and Researches*, London, 1788, p. 554. Other instances are recorded by SCRIVENS (*Lancet*, 1828), STEIDLE (RICHTER'S *Archiv.*, B. V), and J. MASON WARREN (*Boston Med. and Surg. Jour.*, 1855, Vol. LII, p. 181).

<sup>4</sup> Dr. LUDWIG MAYER indulges in a pleasant literary digression on the liver wounds alluded to by the poets. In HOMER, in the eleventh book of the *Iliad*, Eurypylus strikes Phaulissanon in the liver; in the thirteenth, Deiphobus throws a shining lance, which strikes Byrsenor in the liver; in the seventeenth, Lycomedes wounds, in like manner, Apisnon the son of Hippesus; in the twentieth, Achilles thrusts his sword into the liver of Hector, and the liver protruded. In the Ballad of Chevy Chase, Douglas is killed by an arrow wound of the liver (HERBERG). Finally, the heroic battle-poet, THEODOR KÖRNER, lost his life by a shot wound of the liver, at Giebüsch. (See JOHANNES SCHERR'S *Blücher*.)

<sup>5</sup> CASES 219 = 220; 233 = 249; 258 = 243.

*Gunshot Wounds.*—In this category a great variety of lesions were observed: slight groovings, or divisions of the peritoneal investments only; penetrations with a single outlet; long perforations; extended lacerations; lacerations with protrusion; wounds complicated by the presence of splinters from the ribs, of fragments of clothing, of balls and other foreign bodies. If the patients escaped the early danger of hæmorrhage, they were likely to die of traumatic peritonitis, or from abscess of the hepatic parenchyma. Yet abundant proof was afforded that very serious shot injuries of the liver were not necessarily mortal. This will be fully put in evidence by detailed observations and by tabulated statements, after the principal varieties of lesions observed on necroscopic examination shall have been presented. One hundred and seventy-three cases of shot wounds of the liver appear on the returns as having come under treatment. In fifty-nine, the injury to the liver was the dominant lesion, and the cases in this group may be termed, in a very general sense, uncomplicated cases. In one hundred and fourteen, the hepatic injury was associated with fractures of the ribs or of the vertebral apophyses, or with lesions of the lung, diaphragm, stomach, hepatic ducts, or gall bladder, of the spleen, pancreas, kidneys, or blood-vessels. The military designations of the one hundred and seventy-three patients of this division will be enumerated, that the student, who desires to investigate the subject exhaustively, may refer to the manuscript registers of this office;<sup>1</sup> but details will be given of many instances of recovery, and of those illustrations of the pathological anatomy of lesions of this group of which the Museum affords examples. Of the fifty-nine cases of the first group, twenty-five had a favorable result:

CASES 312-336.—Private T. H. Bradley, Co. K, 39th Massachusetts; Sergeant T. A. Buck, 7th Michigan Cavalry; Corporal Z. Butler, Co. H, 27th Indiana; Private E. Carney, Co. K, 7th Wisconsin; Private S. Case, Co. C, 130th New York; Sergeant W. Clifton, Co. F, 77th U. S. Colored Troops; Private W. M. Crandall, Co. K, 42d Ohio; Sergeant F. Crawley, Co. B, 1st battalion, 12th U. S. Infantry; Private J. Cunningham, Co. D, 26th Michigan; Sergeant P. Fallenstein, Co. F, 98th Pennsylvania; Private E. L. Noyes, Co. F, 142d New York; Sergeant D. Perry, Co. B, 11th New York; Corporal J. M. Roberts, Co. F, 83d Indiana; Private S. Scott, Co. G, 53d U. S. Colored Troops; A. Shively, 12th Kansas; Private G. Smith,<sup>2</sup> Co. C, 126th New York; Corporal J. B. Smith, Co. H, 66th New York; Sergeant W. W. Smith, Co. G, 5th Texas; Sergeant S. K. Suively, Co. M, 13th New York Cavalry; Sergeant G. W. Findall, Co. C, 3th New York Cavalry; Private Y. Vineyard, Co. C, 31st Illinois; Private J. W. Vogus, Co. D, 50th Indiana; Private T. Welsh, Co. F, 18th New York; Private J. Westfall, Co. D, 3d Wisconsin; Corporal L. Whittle, Co. H, 73d New York.

The names of thirty-four patients, in whom comparatively uncomplicated shot wounds of the liver had resulted fatally, were as follows:

CASES 337-370.—Sergeant W. I. Barnes, Co. H, 63th Pennsylvania; Private S. H. Barnum, Co. H, 7th Ohio; Private F. Berst, Co. I, 55th New York; Private G. D. Brown, Co. K, 94th Illinois; Private W. Campbell, Co. B, 2d Pennsylvania; Private A. Cartensen, Co. H, 58th Illinois; Private D. Clauss, Co. E, 44th New York; Private S. Cooney, Co. C, 3d New Hampshire; Sergeant W. F. De Graff, Co. E, 96th Illinois; Private A. Douglass, Co. C, 15th Illinois; Sergeant Win. N. Guthrie, Co. F, 9th New York Heavy Artillery; Private A. Harrington, Co. H, 5th Michigan; Private Job Hirst, Co. H, 48th Pennsylvania; Private L. T. Hunt,<sup>3</sup> Co. G, 2d New York Cavalry; Corporal J. H. Hyney, Co. F, 98th New York; Private R. Johnson, Co. B, 138th Pennsylvania; Private W. Jones, Co. E, 14th Connecticut; Private P. B. Kennedy, Co. I, 9th New York S. M.; F. C. King, Co. K, 13th New Jersey; Private L. Knowlton, 1st Maine Heavy Artillery; Private Th. W. Lear, Co. A, 104th Pennsylvania; Private J. Matthews, Co. C, 11th Pennsylvania; Private S. Mercer, Co. D, 1st Maryland Cavalry; Private E. Morrow, Co. A, 26th Ohio; Private J. M. Mosher, Co. C, 1st Maine Cavalry; Sergeant A. A. N——, Co. D, 2d Massachusetts; Lieutenant S. C. Oakley, Co. F, 162d New York; Private S. Peter, Co. D, 31st Indiana; Private W. H. Sanborn, Co. A, 12th Massachusetts; Private J. Seifert, Co. F, 8th Ohio Cavalry; Private J. Sullivan, Co. E, 32d Ohio; Private E. W. Wallace, Co. F, 25th Connecticut; Private A. J. Walters, Co. A, 140th Pennsylvania; Private A. Whitney, Co. H, 1st Michigan Cavalry. An abstract of Case 361, Private Mosher, is printed in the *First Surgical Volume*, p. 587, with a figure (286) of the ball and coat-button driven through the liver.

<sup>1</sup> Tables giving a synopsis of the leading circumstances of the cases of this series have been prepared; but, with the necessary condensation, they give so little insight into the distinctive features of the individual cases, and yet, in the aggregate occupy so much space, that the method adopted is believed to present a more satisfactory view of the subject.

<sup>2</sup> LIDELL (J. A.), *Gunshot Wound of the Liver*, in *Am. Jour. Med. Sci.*, 1857, N. S., Vol. LIII, pp. 344-5, relates the case of Private G. Smith (CASE 327) as an illustration of the advantages of abstention from venesection and a lowering regimen in such cases; and that of Private Hunt (CASE 350) who was convalescent, when last seen, thirteen days after the injury; but Assistant Surgeon C. A. McCall, U. S. A., reports the fatal termination of the case, five days subsequently, April 24, 1865, at the Cavalry Depot Hospital at City Point.



Thirty-seven patients recovered from shot wounds believed to interest the liver, complicated by various grave injuries either of the abdomen or of other regions:

CASES 371-407.—Lieutenant W. H. Bartholomew, Co. B, 16th U. S. Infantry; Corporal *W. A. C. Biles*,\* 28th North Carolina; Sergeant F. A. Barnard,\* Co. A, 37th Wisconsin; Lieutenant Colonel J. B. Collis, 7th Wisconsin; Corporal D. Cramer, Co. M, 12th Pennsylvania Cavalry; Private M. Duke, 8th Indiana Battery; Private J. O. French, Co. C, 17th Vermont; Corporal W. Freeman, Co. H, 30th Indiana; Private J. Fry, Co. K, 14th Pennsylvania Cavalry; Sergeant J. A. Galloway, Co. H, 8th Pennsylvania Reserves; Private M. Heinig, Co. C, 8th New York; Private H. H. Hardin, Co. D, 18th Kentucky; Private P. Hahn, Co. G, 17th New York; Private S. P. Johnson, Co. A, 12th Missouri Cavalry; Corporal F. A. Jones, Co. H, 6th Indiana; Private J. Kewell, Co. C, 7th Connecticut; Private W. Little, Co. D, 88th Pennsylvania; Private J. Labar, Co. E, 28th Pennsylvania; Sergeant T. Murphy, Co. A, 63d New York; Private X. *McCleary*, 2d Virginia; Private J. F. Matthews, Co. I, 24th New York Cavalry; Sergeant J. Munroe, Co. K, 5th Artillery; Private M. A. Patterson, Co. F, 1st Colorado Cavalry; Private P. C. Pool, Co. B, 20th Wisconsin; Private J. W. Rush, Co. E, 87th Indiana; Private J. A. Rogers, Co. H, 27th Connecticut; Corporal A. A. Sharer, Co. D, 26th Michigan; Private P. Sweeny, Co. G, 7th New York Cavalry; Private F. Siebe, Co. D, 139th New York; Private B. F. Sheridan, Co. A, 9th Massachusetts; Private J. A. Sanner, Co. I, 8th Pennsylvania Cavalry; Private F. Searle, Co. A, 9th New York Heavy Artillery; Orderly Sergeant H. H. Terwilliger, 20th New York State Militia; Lieutenant J. S. Williams, Co. G, 63d Pennsylvania; Sergeant *J. H. White*, Co. D, 53d North Carolina; Lieutenant G. Yomt, Co. I, 3d Missouri; Corporal W. Zimmer, Co. E, 17th Ohio. Abstracts of the cases of Corporal *Biles* (372), of Sergeant Galloway (380), Private F. Siebe (399), and of Private Sheridan (400), are printed in Circular 6, S. G. O., 1865, pp. 24, 26, and 27; the cases of Sergeant Barnard (373), Colonel Collis (374), Private *McCleary* (390), Private Sanner (401), and of Sergeant Terwilliger (403), are published in the *First Surgical Volume*, at pages 47, 584, 244, 570, and 577, respectively; and those of Private Labar (388), Sergeant Murphy (389), and Private Sweeney (390), are printed *supra*, at pages 82, 86, and 47.

Seventy-four cases of this group of complicated wounds terminated fatally:

CASES 408-481.—Sergeant W. G. Alleger, Co. G, 142d Pennsylvania; Private W. A——, Co. F, 114th U. S. Colored Troops; Bugler W. B——, Co. I, 1st U. S. Cavalry; Private M. Bremmm, Co. E, 1st Maryland, E. S.; Private *W. Belcher*, Co. C, 22d Virginia Cavalry; Private R. Bell, Co. K, 15th West Virginia Cavalry; Private N. Binn, Co. I, 3d Kansas; Corporal R. Bailey, Co. E, 45th Pennsylvania; Private G. Brown, Co. I, 15th Connecticut; Corporal H. S. Barse, Co. E, 5th Michigan Cavalry; Private *W. P. Bernard*, Co. A, 44th Georgia; Private H. Byers, Co. G, 8th Ohio Cavalry; Corporal D. Brown, Co. D, 165th New York; Private M. R. Blizzard, Co. I, 81st Ohio; Private F. Cook, Co. K, 6th Michigan; Private W. H. Christian, Co. K, 5th Tennessee Cavalry; Corporal A. Coffin, Co. G, 6th Kansas Cavalry; Private S. O. Crafts, Co. K, 40th Massachusetts; Private S. H. Coyle, Co. D, 97th Ohio; Private A. Delarue, Co. A, 2d Delaware; Private O. H. Dorr, Co. G, 66th Ohio; Corporal *S. B. Davis*, Co. B, 8th Tennessee Cavalry; Private T. Easley, Co. B, 117th Illinois; Corporal J. E——, Co. M, 14th New York Heavy Artillery; Orderly Sergeant *E. W. Field*, 2d Maryland Cavalry; Private G. Fox, Co. C, 101st U. S. Colored Troops; Private L. Glynn, Co. B, 37th New York; Private S. C. Gage, Co. C, 15th New Jersey; Private J. Green, Co. H, 145th Pennsylvania; Private E. Holbrook, Co. F, 16th New York; Corporal F. M. Hogue, Co. D, 14th Indiana; Private G. Horsefall, Co. K, 151st New York; Private L. Hollenbeck, Co. D, 91st New York; Sergeant J. Hart, Co. B, 1st Massachusetts; Private E. N. Haines, Co. A, 19th Wisconsin; Private M. Ireland. ———; 1st Lieutenant *H. L. I——*, Co. B, 7th North Carolina Battery; Private W. James, Co. B, 13th Tennessee Cavalry; 2d Lieutenant F. J. James, 2d U. S. Cavalry; Private J. Kennedy, Co. F, 155th Pennsylvania; Private P. B. Kenney, Co. I, 9th New York State Militia; Private C. G. Kingsbury, Co. D, 39th Massachusetts; Sergeant S. L. Lynn, Co. C, 7th New Jersey; Pt. R. Letson, Co. K, 81st New York; Corporal D. H. M——, Co. H, 6th Pennsylvania Cavalry; Private *A. J. Mustain*, Co. H, 21st Virginia; Seaman *F. McCann*, C. S. Steamer *Isontiga*; Private T. Mullen, Co. B, 1st Iowa Cavalry; Private S. Miller, Co. I, 24th Missouri; Private C. F. M——, Co. E, 19th Veteran Reserve Corps; Corporal J. Menger, Co. C, 151st New York; Private G. B. Parish, Co. B, 7th Wisconsin; Private H. F. Packard, Co. K, 18th Massachusetts; Private W. Roberts, Co. D, 2d New York Artillery; Private *C. Roughton*, Co. A, 32d North Carolina; Private J. W. Royce, Co. G, 3d Indiana Cavalry; Private W. B. Rudd, Co. C, 42d Ohio; Private *A. Stein*, Sibley's Brigade; Private W. Stewart, Co. G, 109th Pennsylvania; Private F. Schlagel, Co. A, 94th Illinois; Private J. Sipes, 6th Tennessee Cavalry; Private A. Stevens, Co. A, 20th Michigan; Corporal J. Sunstine, Co. K, 87th Indiana; Private J. S——, Co. B, 1st District of Columbia Cavalry; Private J. Smith, Co. A, 69th New York; Private W. Tucker, Co. C, 33d North Carolina; Private J. T——, Co. K, 60th New York; Private N. E. Wood, Co. F, 5th New Hampshire; Private C. Whitmore, Co. G, 45th Pennsylvania; Private F. Watkins, Co. D, 117th U. S. Colored Troops; Private J. White, Co. A, 90th New York; Corporal J. L. W——, Co. A, 2d Connecticut Heavy Artillery; Private W. W——, Co. F, 51st Ohio; Private J. Woods, Co. K, 10th New York Cavalry. Abstracts will be found in the *First Surgical Volume* of six of the foregoing cases: CASE 409, Private W. A——, p. 441; CASE 410, Bugler W. B——, p. 446; CASE 431, Corporal J. E——, p. 444; CASE 471, Private James S——, p. 446; CASE 479, Corporal J. L. W——, p. 445; CASE 480, Private W. W——, p. 584.

It has been impracticable to ascertain the termination of the three following cases of shot wounds of the liver and lungs:

CASES 481-483.—Lieutenant *W. G. Wood*, Co. B, 60th Georgia; Corporal *J. Stringfellow*, Co. G, 8th Alabama; Private R. Henry, Co. G, 112th New York.

\* WILLIAMS (P. O.), *Report of a Case of Gunshot Wound of the Liver*, in *Trans. Med. Soc. New York*, 1866, p. 39, describes the wound of Private French, CASE 377, of which an abstract is also printed further on.

\* DUSENBURY (H.), *Cases of Gunshot Wounds of Abdomen involving Viscera*, in *Am. Jour. Med. Sci.*, 1865, Vol. I, p. 399, records the case of Corporal Sharer, CASE 387.

\* SHEETS, *Gunshot Wound of the Abdomen*, in *Med. and Surg. Rep.*, 1865, Vol. XII, p. 445, relates the case of Private Kenney, CASE 447.





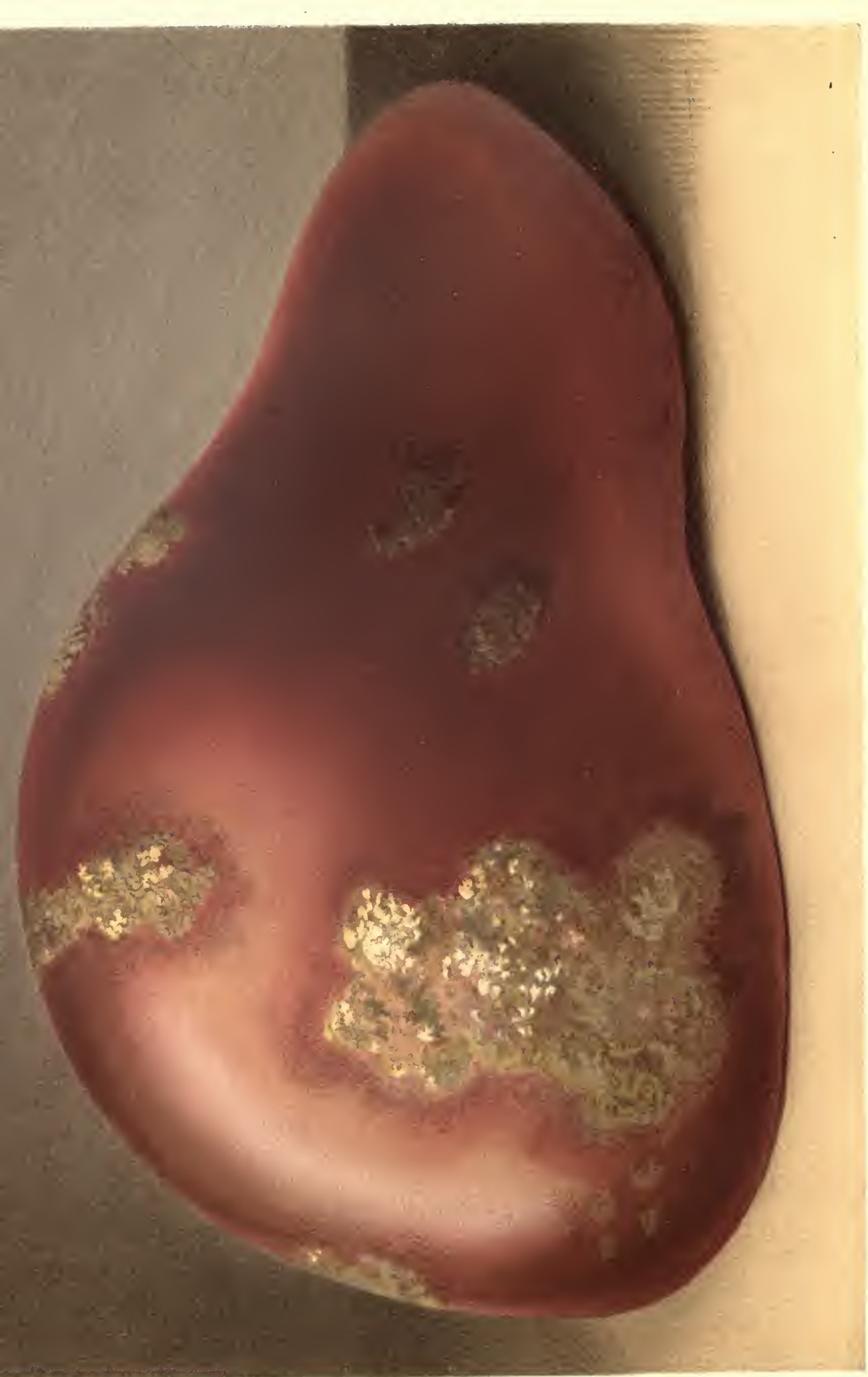


PLATE VI. METASTATIC FOCI IN THE LIVER

N. O. 1240. Surgical Section. V. M. M.

It has been remarked, on page 16, that the Museum possessed no example of rupture of the liver, and it may be added that while the effects of diseases in this organ are fairly illustrated therein, the collection contains no specimens exemplifying the processes in the reparation of its injuries. Of the few pathological preparations preserved, four are examples of metastatic foci. A drawing from one of them, in the recent state, is represented in Plate VI, opposite, and will be described in treating of Pyæmia. The remainder exhibit the direct results of shot injuries.

The velocity of the projectile, apart from its size and direction, is an important element in determining the extent of laceration that it will cause in penetrating the liver. At close range, the missile inflicts great destruction of tissue. At moderate ranges, of from one hundred to five hundred yards, musket balls striking the convex surface of the liver cause an entrance wound that may be described as a stellate fracture. The preparations in the Museum present several examples of this:

CASE 362.—Sergeant Allen A. N——, Co D, 2d Massachusetts, died, in an ambulance carriage, while being conveyed to Lincoln Hospital, Washington, June 10, 1863. He had probably been wounded at Beverly Ford the day previously. An autopsy was made seven hours after the reception of the cadaver. The wound was ten inches above the pubis and three inches to the right of the median line, and was a small opening, depressed and blackened around the edges. The small intestine and omentum were agglutinated together by a thin layer of recent lymph. The cavity of the abdomen contained a large quantity of blackish fluid, mingled with dark clots of venous blood. The mucous lining of the trachea was very pale, and was covered with numerous papillated points, which were readily removed with the finger, and probably consisted of a tenacious mucous secretion. A large, dense, venous clot was present in the right ventricle of the heart, and a much smaller and more fibrous one in the left. One inch to the right of the suspensory ligament of the liver was a stellate opening, and on the inferior surface, to the left of the gall bladder, a large irregular fissure, through which the ball had passed; it went through the body, making its exit two inches to the left of the spine and six inches above the sacrum. The intestines were not injured. The specimen represented in the wood-cut (FIG. 103) was contributed to the Army Medical Museum by Surgeon G. S. Palmer, U. S. V., and the notes of the case by Assistant Surgeon H. Allen, U. S. A., who conducted the *post-mortem* examination.

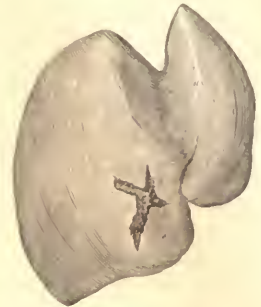

FIG. 103.—Section of liver, showing the entrance of a shot perforation on the anterior surface of the right lobe. *Spec.* 1232. [Reduced to one-twelfth.]

Specimen 1646, figured further on, gives another good illustration of this stellate fissuring caused by a ball entering the liver, with moderate velocity, perpendicularly to its surface. Projectiles moving parallel to the surface of the liver sometimes make long grooves. These, and all shot tracks in the liver, present the same granular appearance, due to the prominence of the acini, that is observed on rupturing a portion of fresh liver:

CASE 440.—Lieutenant Henry L. I——, 7th South Carolina Battery, aged 38 years, was wounded and captured at the Six Mile House, near Petersburg, August 21, 1864. Surgeon L. W. Read, U. S. V., at the 3d division hospital of the Fifth Corps, and Surgeon W. L. Faxon, 32d Massachusetts, at City Point, describe the injury as inflicted by a conoidal musket ball entering the epigastrium and shattering the right elbow joint. The wounded officer was conveyed to Washington and placed in Lincoln Hospital on August 24th, under the care of Acting Assistant Surgeon C. B. Wright, who reported the patient as “anemic from loss of blood, the countenance anxious, the pulse tolerably strong at 95.” There appears to have been no nausea, since the patient took beef-tea and stimulants without inconvenience. There was no jaundice. On the 25th and 26th, the pulse became smaller and more frequent, and the patient complained of loss of sight. Concentrated nourishment and stimulants were retained: but the patient failed rapidly, and died in the afternoon of August 26, 1864, five days after the reception of the injury. Acting Assistant Surgeon H. M. Dean made an autopsy on the following day, and preserved the specimen represented in the wood-cut (FIG. 104), with the following memorandum: “Body well nourished; rigor, well marked; height, 5 feet 11½ inches; œsophagus normal. Lining membranes of larynx and trachea were of a pinkish hue. Posterior portion of lower lobe of each lung was very much congested; otherwise the lungs appeared normal; right weighed 20 ounces; left, 15½ ounces. Pericardium normal. The right side of the heart contained a large black clot; left cavities empty; organ healthy; weight, 9½ ounces. Spleen considerably enlarged and pulpy; weight, 14 ounces. Liver, the ball crossed its superior surface, injuring both the right and left lobe; organ weighed 76½ ounces. Both kidneys were healthy; right weighed 6½ ounces; left, 6½ ounces.”

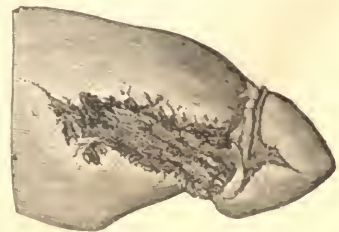

FIG. 104.—Section of convex portions of the left and right lobes of the liver, grooved by a musket ball passing from left to right. *Spec.* 3123. [Reduced to one-fourth.]



It has been noted, on page 16, that by violence, from crushing weights, or the impact of large projectiles at low velocities, the texture of the liver may be either contused or pulpified or widely fissured. The extensive laceration of the liver produced by a discharge, at close range, of a musket loaded with an ounce round ball and three buckshot, is displayed in the adjacent drawing (FIG. 105):



FIG. 105.—Section of right lobe of liver lacerated by a musket ball and buckshot. *Spec.* 2213. [Reduced to one-fourth.]

two inches to the right of the scrobiculum cordis, and emerged from the back about two inches to the right of the vertebral column, passing through the right lobe of the liver and lower lobe of the right lung. A portion of the liver protruded from the wound of entrance. He was at once conveyed to the regimental hospital, where he died in about an hour after the reception of the injury. The necropsy showed extensive laceration of the right lobe of the liver, and fragments of the cartilages of the ribs driven into the parenchyma of that organ. One of the three buckshot that were contained in the cartridge was deflected, and entered the right kidney, carrying away a portion of it. The case is reported by Surgeon F. P. Phelps, 1st Maryland.

The next case exhibits a shot wound of the concave surface of the left lobe of the liver<sup>1</sup> accompanying other injuries:

CASE 452.—Corporal D. H. M——, Co. H, 6th Pennsylvania Cavalry, in a cavalry engagement near Brandy Station, August 1, 1863, was shot through the body, the ball entering the right flank and escaping from the left of the epigastric region. There is no account of the symptoms observed at the field hospital station, which was crowded with wounded. The name, military description, and entry, "gunshot wound of the abdomen, simple dressing," constitute the only field record. On August 24, the corporal was transferred by rail to Washington, a distance of forty miles. He barely survived the transit, and expired in an ambulance wagon on the way to Douglas Hospital. The dressings and clothing were saturated with blood, and there had evidently been very profuse bleeding after he was moved from the car to the wagon. At the autopsy, made by Medical Cadet Edward D. Mitchell, it was inferred, from the size of the wounds of entrance and exit, that they were inflicted by a carbine ball. The notes of the autopsy describe a very erratic course of the projectile; but if the position of the entrance and exit wounds is correctly indicated, it must be inferred that the ball entered the right hypochondrium at the edge of the twelfth rib, scraping off its outer lamina about two and one-half inches from its free extremity, and passed inward and downward, penetrating the right kidney (as represented in *Specimen* 1773, figured further on), and was then deflected by the vertebral column, and passed upward through the duodenum, the posterior and anterior walls of the stomach, the left lobe of the liver near the umbilical fissure (FIG. 106), and emerged two inches to the left and below the end of the ensiform cartilage; or its course may have been the reverse of that described.

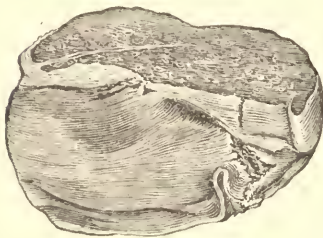


FIG. 106.—Segment of the left lobe of the liver, perforated by a carbine ball. *Spec.* 1645. [Reduced to one-fourth.]

The intestines were inflated. There was a great quantity of blood in the peritoneal cavity. The emulgent vessels had bled with especial freedom. The perforation of the liver is represented in the wood-cut (FIG. 106). The wound of the duodenum is figured on page 67, and there will be a drawing of the perforation of the kidney in the subsection on wounds of that organ.

<sup>1</sup> The following pathological preparations of shot wounds of the liver are preserved in Museums: 1. Specimen 1401, Pennsylvania Hospital Museum, shows the track of a ball, half an inch in diameter, through the anterior portion of the left lobe; the exit wound has a jagged margin and is larger than the orifice of entrance; no history (*Cat.*, p. 73). 2. Specimen 468, New York Hospital Museum, shows a pistol ball perforation of the left lobe, from a man of 31, who died, eight hours after the reception of the wound, from internal hæmorrhage; there is an irregular laceration, an inch in diameter, on the concave surface (*Cat.*, p. 200). 3. Specimen 1506 of the British Army Medical Department at Fort Pitt, shows "an extensive laceration of the convex surface of the right lobe of the liver, from a gunshot wound."

The extraordinary extent and gravity of the complications attending the next case involve its history in an obscurity which the general description and the account of the autopsy fail to remove. The patient appears to have survived a deep perforation of the liver over four months!<sup>1</sup>

CASE 474.—Private John T——, Co. K, 60th New York, aged 25 years, received a gunshot wound of the right side, at Keenesaw Mountain, June 19, 1864. He was taken to the field hospital of the Twentieth Corps. On the 27th, he was transferred to the general field hospital at Chattanooga, and, on July 7th, to the Cumberland Hospital, Nashville, under the charge of Assistant Surgeon S. C. Ayres, U. S. V., who furnished the following details of the case: "The ball struck the sixth rib about the middle of its shaft, fractured it, and passed obliquely backward and downward. The phisicid condition of the patient was bad; he was pale and emaciated, and was suffering from chronic diarrhoea, and from a dry hacking cough. Whenever he coughed there was a protrusion from the wound which very much resembled a hernia, and which receded into the wound when the coughing ceased. A few days after admission, the external wound broke open and discharged a large quantity of blood and pus. No trace of the ball could be found. A tonic and stimulating course of treatment was pursued, and nutritious diet was given. The diarrhoea and cough continued, and although the patient improved a little at first, he afterward failed, became more and more emaciated, and died October 31, 1864. A few weeks before his death the external wound ceased suppurating and healed up. At the autopsy, miliary tubercles, quite profuse, with but little softening, were found in both lungs. The lower lobe of the right lung was partly carinated, and there were numerous pleuritic adhesions. The ball had pierced the diaphragm, passed obliquely downward and backward through the right lobe of the liver, and had carried a spicula of the fractured rib into the substance of the liver. There was a slight indentation on the inner surface of the liver where the ball struck it. The missile was found lodged between the abdominal aorta and vena cava ascendens, and immediately below the right renal vein; it was lying upon the vertebra, and was very firmly encysted. There was no evidence that the bowels had been wounded by the ball in its course from the lower surface of the liver to the place where it lodged. The liver was healthy, and there was no evidence that there had been peritonitis." A preparation of the bloodvessels and ball is represented in the wood-cut (FIG. 107). It is greatly to be regretted that the portion of the liver, including the cicatrized shot track, was not preserved.

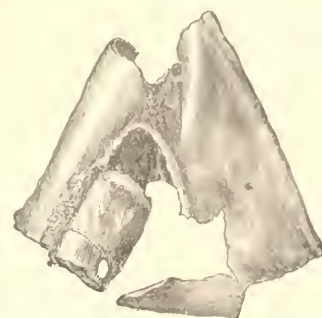


FIG. 107.—A dried preparation of portions of the aorta, vena cava, and renal vein, with a ball, which has injured neither vessel, lodged between the two larger. *Spec.* 910, A. M. M.

CASE 352.—Private Robert Johnson, Co. B, 138th Pennsylvania, aged 20 years, was wounded at Mine Run, November 27, 1863. A conoidal ball entered one inch to the right of the xiphoid appendage, passed downward and forward and lodged at the anterior third of the ninth rib. The patient was treated on the field until December 5, and then transferred to the Third Division Hospital at Alexandria. Stimulants and tonics were given, and cold-water dressings were applied to the wound. The ball was excised on December 14 by Surgeon Edwin Bentley, U. S. V. From the nature of the wound and discharge, it was evident that the ball had passed through the liver. The patient was very courageous, and, not knowing the nature of the wound, was sanguine of recovery. But rigors soon occurred and great constitutional disturbances followed, and the patient gradually sank, and died December 20, 1863. The necropsy revealed empyema of the left pleural cavity. The ball had passed through the left lobe of the liver, which, as well as the spleen, was much disorganized. The intestines were black and softened, as though the tissues were in a state of mortification. The case was reported by Acting Assistant Surgeon A. P. Crafts.

CASE 414.—Private Nicholas Binn, 3d Kansas, was wounded at Camp Hunter, March 20, 1862, by the accidental discharge of a pistol. He was admitted to the Leavenworth City Hospital four hours afterwards. The hæmorrhage was very slight. Surgeon George Rex, U. S. V., who reports the case, found that a probe indicated no trace of the direction of the ball beyond the orifice through the integuments. There was no serious uneasiness or indisposition, with the exception of annoying pain referred to the right subscapular region. All endeavors to discover the course of the ball failed, although the patient was placed in every conceivable position. He seemed to be doing well until the evening of March 23d, when respiration became suddenly embarrassed. With the dyspnoea the pulse became accelerated, beating 120, and the pain shifted from the scapula to the lower extremity of the sternum. The difficulty of breathing soon became so great that respiration could only be carried on in a sitting posture. The pain and orthopnoea alternated. At times the patient breathed freely in the recumbent position; then the diaphragm would be suddenly convulsed, and dyspnoea would immediately ensue. This continued until March 29th, when the patient died. The pulse, when circumstances required, had been easily controlled by a few drops of tincture of veratrum viride, and at times, even during the last few days, there appeared to be some ground for hope of a favorable result. The autopsy showed that the ball had entered the thorax about two inches below the entrance opening in the integument, had passed through the upper margin of the seventh rib about midway between the spine and sternum, and, passing through the diaphragm, the upper or convex portion of the right lobe of the liver, and a second time through the diaphragm, finally lodged in the cellular tissue immediately surrounding the descending aorta, about two inches below the heart. The omentum presented a gangrenous appearance, and the cavities of the chest and abdomen contained large quantities of bloody serum, mixed with pus.

In the five foregoing cases, both the thoracic and abdominal cavities were implicated, and the symptoms and morbid appearances alike presented great complexity

<sup>1</sup> I confess, with mortification, that, though familiar with its details, of which, indeed, a brief abstract was printed at page 481 of the *Catalogue of the Surgical Section of the Army Medical Museum*, this case escaped my memory while compiling the account of cases of traumatic pneumothorax, on page 514 of the *First Surgical Volume*. This, if added to the series there collected, would constitute an eighth example of hernia of the lung, observed during the war.—*Editor*.



It has been already observed that wounds of the liver are often associated with fractures of the lower ribs and spine, and with wounds of the other viscera at the upper part of the abdomen, and of the diaphragm. A number of examples appear in the *First Surgical Volume*. At pages 570 and 584, instances are given of fracture of the ribs with

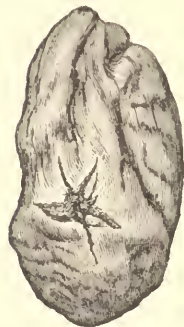

FIG. 108.—Segment of the right lobe of the liver, showing the entrance wound of a pistol ball on the upper anterior surface. *Spec.* 1646. (Reduced to one-fourth.)

hepatic lesions; FIGURES 194 and 196, on pages 441 and 444, represent musket balls lodged in the bodies of vertebræ, after traversing the liver. Instances of wounds of the stomach or intestines attended by lesion of the liver have been noted at pages 48, 82, and 88 of this volume. The entrance wound of a pistol ball, which perforated the eleventh right rib, right lobe of the liver, right kidney, body of the third lumbar vertebra, the spleen, and left kidney, and emerged through the tenth intercostal space, is well shown in the wood-cut (FIG. 103). The specimen was taken from the body of the bugler<sup>1</sup> whose case is related in

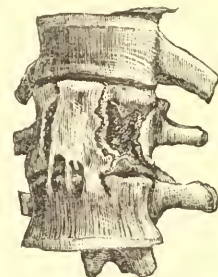


FIG. 109.—The second, third, and fourth lumbar vertebrae, the body of the third perforated from right to left by a pistol ball. *Spec.* 1647. (Reduced to one-fourth.)

the second section of the fourth chapter of the preceding *Surgical Volume*. The perforation of the body of the vertebra is shown in the opposite wood-cut (FIG. 109). The three following are instances of shot perforations of the diaphragm and liver without copious consecutive hæmorrhage:

CASE 427.—Private A. Delarue, Co. A, 2d Delaware, aged 36 years, received a gunshot penetrating wound of the chest and abdomen, at Cold Harbor, June 3, 1864. A conoidal ball passed through the diaphragm and perforated the liver. He was at once conveyed to the field hospital of the First Division, Second Corps, where simple dressings were applied. On June 15th, he was transferred to De Camp Hospital, New York Harbor. Death resulted June 16, 1864. The case is reported by Assistant Surgeon Warren Webster, U. S. A.

CASE 445.—Private W. James, Co. B, 13th Tennessee Cavalry, received three shot wounds at Fort Pillow, Tennessee, April 12, 1864. One ball entered at the anterior border of the right scapula immediately above the inferior angle, passed downward through the liver, and across the abdomen; another entered midway between the acromion process of the scapula and sternal end of the clavicle, passed through the upper lobe of the left lung, and emerged at the posterior border of the deltoid of the right arm; a third ball made a large perforation through the deltoid muscle of the right arm from before backward. On the 14th, the patient was admitted to the hospital at Mound City. The first ball was extracted one inch above the crest of the left ilium. Simple dressings were applied to the wounds. Death resulted April 15, 1864, from exhaustion. The necropsy revealed the course of the missiles as described. The case is reported by Surgeon H. Wardner, U. S. V.

CASE 449.—Private C. G. Kingsbury, Co. D, 39th Massachusetts, aged 28 years, received a penetrating wound of the abdomen at Petersburg, April 1, 1865. He was taken to the field hospital of the Fifth Corps, where simple dressings were applied to the wound. On the 8th, he was transferred on the hospital steamer, State of Maine, to Washington, and admitted to Armory Square Hospital on the 10th. The register and case book at this hospital states that a conoidal ball entered over the second floating rib, left side, midway between the umbilicus and right nipple, and emerged one inch from the spinal column, at the second lumbar vertebra. When admitted, there was pain of an acute character in the region of the wound, with discharge of pus, and a greenish-white secretion exuded from the wound; skin, conjunctiva, and eyes yellow. His pulse was full and rapid, 120 per minute, and respiration greatly impeded; sleepless nights. Death resulted May 29, 1865. At the necropsy, the ball was found to have perforated the liver at its upper lobe; exit at inner border of gall-bladder; it also passed through the lower lobe of the right lung. The thoracic cavity on the right side was filled with pus; pleuritic adhesions very firm, almost impossible to remove them. The abdomen was filled with pus and coagulable lymph. Surgeon D. W. Bliss, U. S. V., reports the case.

The next case exemplifies the hyperacute peritonitis following a shot perforation of the gall-bladder:

CASE 424.—Corp. A. Coffin, Co. G, 6th Kansas Cavalry, received a pistol-shot wound of the abdomen at Fort Scott, Kansas, September 17, 1863. He was immediately admitted to the hospital at Fort Scott. The shock was not great, the pulse being nearly normal, and the pain inconsiderable. The pain became intense in a few hours; abdomen, hard and tumid; pulse, rapid and feeble; and death occurred fifteen hours after the reception of the injury. Autopsy six hours after death: the peritoneal sac was filled with blood, and intense inflammation was established. The ball passed through the cartilage of the ninth rib, the quadrate lobe of the liver, the gall-bladder, and the ascending colon and right kidney, and made its exit near the twelfth dorsal vertebra. The case is reported by Surgeon A. C. Van Dryn, U. S. V.

<sup>1</sup> Part I, Vol. II, Chap. IV, p. 446, case of Bugler William B———. The eleventh rib perforated by a pistol ball. From this case specimen 3291 is figured in the fifth chapter, page 567 (FIG. 267).



A shot wound of the gall-bladder, resulting fatally in twenty-two hours, was erroneously reported in Circular No. 3, 1871, as an instance of recovery.<sup>1</sup> The instance recorded by Paroisse<sup>2</sup> remains an exception to the ordinary termination of such lesions.

CASE 408.—Sergeant W. G. Alleger, Co. G, 142d Pennsylvania, aged 23 years, was wounded at Gettysburg, July 1, 1863. He was treated in the field hospital of the 3d division, First Corps, until the 24th, when he was admitted to Camp Letterman Hospital. Acting Assistant Surgeon W. B. Jones reported that: "A minie ball entered the cavity of the abdomen three inches above and one inch to the right of the umbilicus, passed obliquely to the right and upward, passing through the liver and gall-bladder, and emerged between the sixth and seventh ribs. From the time of injury until decease, large quantities of bile were discharged from the upper wound; his health seemed to remain good until August 1st, when he began to sink; a severe diarrhœa commenced shortly after reception of the injury and continued until he died, being controlled at intervals by the free use of camphor and opium. The treatment consisted of cold-water dressings to wound, and administration of beef-tea, brandy, and opium. He died August 6, 1863."

Death from secondary hæmorrhage, as exemplified in the following case, was an uncommon result of shot wounds of the liver:

CASE 435.—Private S. C. Gage, Co. C, 15th New Jersey, aged 28 years, was admitted to Finley Hospital, Washington, May 8, 1863, with a gunshot penetrating wound of the chest and abdomen, received at Chancellorsville on the 3d. A conoidal musket ball had entered at the right side between the seventh and eighth ribs, nearer to the spine than to the sternum. Its course was inward, upward, and forward; and its exit two and a half inches to the inner side of the right nipple, between the fourth and fifth ribs. The liver was wounded in its passage as well as a portion of the lung. Bile was discharged for several days from the lower or entrance wound. On May 12th, at eleven o'clock at night, uncontrollable hæmorrhage occurred, and death resulted in a short time, May 13, 1863. Assistant Surgeon William A. Bradley, U. S. A., reported the case.

The ordinary result of death from primary hæmorrhage was often caused by perforations by very small projectiles, as in the following instance:

CASE 455.—Private T. Mullen, Co. B, 1st Iowa Cavalry, was wounded at Rolla, May 27, 1863, while attempting to pass the guard, by a pistol ball which inflicted a penetrating wound of the chest and abdomen. He was conveyed to the hospital at Rolla, where cold-water dressings were applied and anodynes administered. Reaction never took place, and death occurred, twenty-four hours from the reception of the injury, from hæmorrhage into the right pleural and abdominal cavities as well as externally. At the necropsy, the ball was found to have entered between the ninth and tenth ribs, about midway between the anterior and posterior median lines, fractured the ninth and tenth ribs, perforated the diaphragm, passed through the right lobe of the liver, leaving a fissure one inch in depth and five inches in length; it again perforated the diaphragm, and, coursing directly onward, emerged to the right of the ensiform cartilage. The case is reported by Surgeon H. Culbertson, U. S. V.

The mode of fatal termination next in frequency, in shot wounds of the liver, was from the consequences of the formation of hepatic abscess:

CASE 456.—Private S. Miller, Co. I, 24th Missouri, aged 18 years, was wounded at Bayou De Glaize, May 18, 1864. A conoidal ball penetrated the upper surface of the right lobe of the liver and the under surface of the right lobe of the lung. He was treated in the hospital of the 3d division, Sixteenth Corps, until June 2d, when he was transferred, on the hospital boat N. W. Thomas, to St. Louis, and admitted to the hospital at Jefferson Barracks. Stimulants and anodynes were there administered. Pyæmia was developed, and death resulted June 8, 1864. At the necropsy, a large abscess was found in the right lobe of the liver, containing about four ounces of pus. Two thirds of the lower lobe of the right lung were solidified. The case is reported by Surgeon John F. Randolph, U. S. A.

An instance of a traumatic hepatic abscess discharging through the bronchial tubes is noted by Acting Assistant Surgeon J. Robertson:

CASE 423.—Private O. H. Dorr, Co. G, 66th Ohio, was wounded at Cedar Mountain, August 9, 1862, by a musket ball, which entered to the right of the ensiform cartilage and emerged near the angle of the ninth rib. He entered Fairfax Street Hospital, at Alexandria, on August 12th. Upon examination, it was thought the pulmonary organs had escaped injury. There was at no time hæmoptysis. The general condition was favorable until August 28th, when there was a chill, followed by severe coughing, the expectoration being purulent and mixed with bilious matter. This form of expectoration continued until the patient's death, September 8, 1862. At the autopsy, it was found that the ball had passed through the lower lobe of the right lung, the diaphragm, and had grooved the convex surface of the liver.

In investigating the complications of wounds of the lung, there was occasion to observe that general pleurisy and pneumonia, so far from being inevitable consequences of

<sup>1</sup> CASE CLIX, of Private Murphy, 6th Cavalry, reported by Assistant Surgeon PATZKI, Circular 3, p. 50. On the publication of this report, Assistant Surgeons PATZKI and W. J. WILSON, and Dr. TURBULL, who made the autopsy in the case, hastened to correct the inaccurate statement that the patient was wounded "November 27, 1870, \* \* \* recovered, and was discharged from service December 27, 1870." He was, in fact, wounded on December 26, and died twenty-two hours subsequently, December 27, 1870. It is due to the clerical assistants at this Office to remark that the mistake was not made here, but at the Post.

<sup>2</sup> PAROISSE, *Opuscules de Chirurgie*, 1806, p. 251, mentions that he had seen in the hands of a surgeon, a ball enclosed in a gall-bladder. The preparation was taken from a military man, who had received a shot wound in the internal lateral part of the right hypochondrium, and two years subsequently died in hospital of a pulmonary trouble. At the autopsy, the ball was found in the gall-bladder, on which no cicatrix could be discovered.

shot wounds of the thoracic cavity, as erroneously taught by routinists, were in reality only exceptional results of such lesions, the pathological alterations being ordinarily limited, in a remarkable degree, to the vicinity of the injured parts. This principle obtains with equal regularity in wounds of the liver. General hepatitis is seldom induced by such lesions. This fact, demonstrated by morbid anatomy, might be inferred from the symptoms. Jaundice, which is known to be a constant sign in general hepatitis,<sup>1</sup> and infrequent in partial hepatitis, is present in only a small proportion of the cases of wounds of the liver.

In considering the liability of the liver to injury in antero-posterior or oblique perforations through the epigastric or hypochondriac regions, the surgeon will reflect upon the general topography of the viscus, its variations in size and position in individuals, its

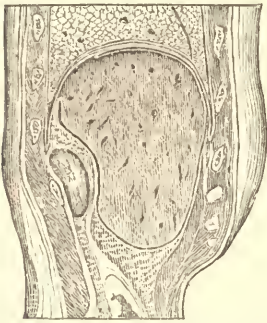


FIG. 110.—View exposed by an antero-posterior section in the right hypochondrium, by a vertical antero-posterior cut connecting the right nipple and hip-joint. [After MAYER.]

variation in position dependent on respiration and upon the conditions of the digestive canal, and its relations to the surrounding viscera in different planes. A ball or sword-thrust directly traversing the right hypochondrium cannot readily avoid the liver (FIG. 110); but a vertical plane through the median line (FIG. 111) of the liver exposes a much more re-

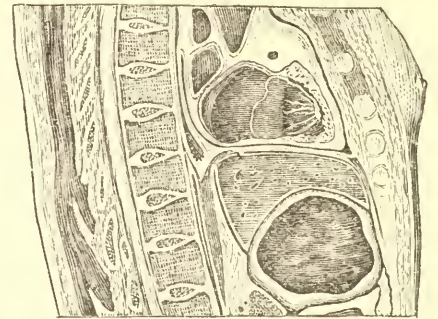


FIG. 111.—View of the lower thoracic and upper abdominal viscera exposed by an antero-posterior section through the median line of the body. [After MAYER.]

stricted surface. The liability of contiguous viscera to injury from balls passing through the liver from side to side transversely or obliquely is illustrated by FIGURE 112. The two following cases exemplify the differences in shot perforations antero-posteriorly and from side to side:

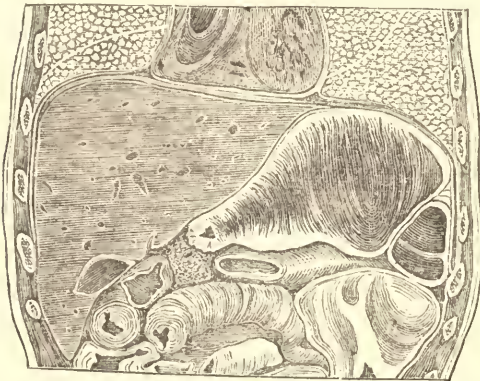

FIG. 112.—Front view of a section made by removing the anterior half of the body, showing the lower portion of the thorax and upper portion of abdomen. [After MAYER.]

CASE 338.—Private S. H. Barnum, Co. H, 7th Ohio, was wounded at Chancellorsville, May 3, 1863, by a conoidal ball. There is no account of this case prior to admission to St. Aloysius Hospital, Washington. On May 7th, Acting Assistant Surgeon J. F. Thompson reported on the Medical Descriptive List: "Wounded by minié ball, which entered three inches from the linea alba, on the right side, passing through the liver, and making its exit an inch or two lower, on the same side, and about four inches from the spine. There was a great discharge of bile from the posterior opening when he was wounded; there was no peritonitis. On the 13th, patient was taken with pleuro-pneumonia of left side, from the effects of which and the wound he died on May 17, 1863. Treatment: At first nothing was done more than applying cold-water dressings to wound, and administration of purgatives. For the pleuro-pneumonia he was cupped, and four drops of tincture of veratrum viride ordered every four

hours; this medicine was suspended after the second dose, as it produced unpleasant head symptoms without reducing the pulse. Small doses of calomel and antimony were then administered."

CASE 434.—Private L. Glynn, Co. B, 37th New York, received his death wound in a skirmish with the enemy near Colechester, Virginia, February 24, 1862. He lived only a few minutes. The ball entered the right side of the thorax, fracturing the ninth rib near the angle, and wounding the lower border of the lung; it then passed through the diaphragm, tearing open the

<sup>1</sup>M. JULES SIMON (*Art. Foie, Nouv. Dict. de Méd. et de Chir. pratique*, 1872, T. XV, p. 96) observes: "L'ictère n'est point un symptôme fréquent dans l'hépatite partielle; loin de là. J. Cruveilhier avait parfaitement remarqué que son apparition tenait à des circonstances spéciales, à un obstacle mécanique au cours de la bile. Haspel, sur un terrain plus vaste, a observé le même fait, qui fut confirmé depuis par Rouis et William McLean. Ordinairement donc, il n'y a pas d'ictère, et, si l'ictère se produit, il est dû à la compression des voies biliaires par l'abcès, ou à d'autres causes d'obstacle mécanique au cours de la bile. Remarquons que l'ictère est, au contraire, constant dans l'hépatite diffuse."



liver, the ascending cava, the stomach posteriorly in two places, at the lesser and greater curvatures, the diaphragm again, the left pleura, fracturing the tenth rib anteriorly, and finally fracturing both bones of the left forearm, near the upper third. The heart was empty, while the cavities of the thorax and abdomen were entirely filled by the resulting hemorrhage. The case is reported by Surgeon W. O'Meagher, 37th New York.<sup>1</sup>

Wounds having tracks approaching parallelism with the long axis of the body are more common in modern than in ancient warfare. Balls not infrequently traverse the liver from above downward, or the reverse. Hence it is important to consider the relations of the organ in the horizontal planes. The cases of Corporal E—— (*First Surgical Volume*, p. 444), of Private Kingsbury (p. 136, *supra*), and some of the complicated cases of wounds of the thorax and abdomen, in which the lung, diaphragm, and perhaps a kidney or coil of intestine were involved, afford examples of these vertical perforations, the frequency of which is doubtless due to the prone position of the soldier receiving the wound. The following is another instance:

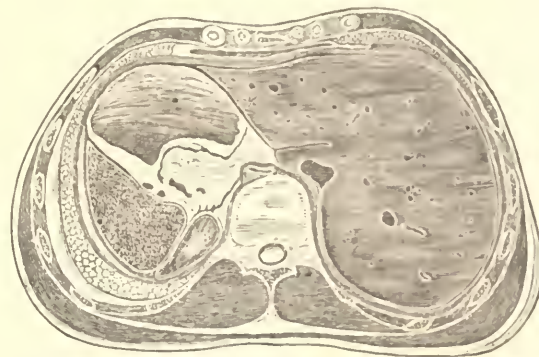

FIG. 113.—View exposed on a transverse section of the trunk between the ninth and tenth dorsal vertebrae, dividing horizontally the lungs, the liver, stomach, pancreas, spleen, and left kidney. [After MAYER.]

CASE 470.—Corporal J. Sumstine, Co. K, 87th Indiana, was wounded at Chickamauga, September 20, 1863; was admitted to hospital at Chattanooga on the same day. A buckshot had passed through the nose and left cheek, and a minié ball, striking to the right of the sternum in a line vertically below the nipple, had passed downward and backward and made its exit close to the crest of the right ilium, involving the lower lobe of the lung and the right lobe of the liver. The patient expectorated blood. Cold-water dressings were applied to the wounds, and a cathartic was given. The next entry is on September 28th, when it is mentioned that the upper orifice discharged blood in the morning; bowels regular; wounds suppurating; moderate febrile reaction; cold-water dressing; whiskey and quinia three daily, with nourishing diet. September 29th, considerable irritative fever; pulse 95; appetite pretty good; bowels regular; respiration slightly hurried; treatment continued. September 30th, pulse 95; extremities cool; tongue dry and slightly cracked; countenance anxious; irritative fever; sanious discharge from wounds. October 10th, restless night, with hacking cough and diarrhœa: continued whiskey and quinine, with beef-tea, Dover's powder, and tannin. October 11th, cough and diarrhœa somewhat better; ordered a mixture of paregoric and spirits of nitric ether, a teaspoonful every four hours, with whiskey, quinine, and good diet. On November 26th, he was admitted to hospital at Bridgeport, Alabama, and, on December 2d, transferred to Murfreesboro, and furloughed on January 12, 1864. Adjutant General's Report of Indiana, Volume VI, p. 470, shows that he died while on furlough, January 14, 1864, one hundred and seventeen days after receiving the injury. The case is reported by Surgeon Jabez Perkins, U. S. V.

In the following instance of a nearly vertical shot perforation of the right lobe of the liver, one of the larger branches of the hepatic duct was divided:

CASE 436.—Private John Green, Co. H, 145th Pennsylvania, was wounded at Gettysburg, July 2, 1863. He was treated in the Seminary Hospital, and subsequently in McKim's Mansion Hospital at Baltimore, where he was admitted July 16th. Acting Assistant Surgeon W. G. Small reported on Medical Descriptive List: "Ball entered three inches from the median line, fracturing the eighth rib near the cartilage, and, passing between the seventh and eighth ribs, perforated the superior portion of the liver to the depth of an inch, and emerged three inches from the point of entrance, on the right side. Treatment: Cold-water dressings, stimulants, and nourishing diet. He suffered much pain and loss of appetite, and bile was discharged at intervals from the wound. He died August 15, 1863, and a *post-mortem* examination showed that the ball had opened a small duct, and that there was much peritoneal inflammation, with adhesions.

*Recoveries from Shot Wounds of the Liver.*—Lists of no less than sixty-two reported instances are printed on pages 131 and 132, thirty-seven cases being complicated by

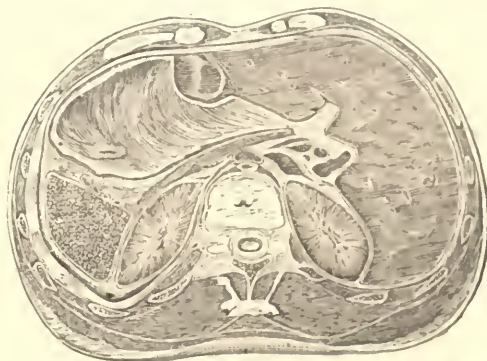

FIG. 114.—View of the abdominal viscera on a horizontal section between the eleventh dorsal and first lumbar vertebrae, dividing the liver, stomach, spleen, and both kidneys. [After MAYER.]

<sup>1</sup> O'MEAGHER, *Cases in Military Surgery*, in *Am. Med. Times*, 1862, Vol. IV, p. 265.



lesions of other organs. In a number of cases the hepatic lesion was demonstrated by the escape, externally, of bile or of a portion of the substance of the liver; but there were many instances in which the diagnoses reposed on evidence far less conclusive.<sup>1</sup>

CASE 312.—Private T. H. Bradley, Co. K, 39th Massachusetts, aged 19 years, was wounded by a pistol ball, at Hatcher's Run, March 30, 1865. He was admitted to the field hospital of the Fifth Corps on the same day, and, on April 3, 1865, was transferred to Washington, Armory Square Hospital, entering on the 5th. Surgeon D. W. Bliss, U. S. V., reported as follows: "Ball entered the right side of back, about the ninth intercostal space, and, passing downward and forward, probably through the liver, emerged from the right side of the abdomen three inches below the line of entrance." The treatment consisted of cold-water dressings and the administration of tonics and stimulants. The patient improved rapidly, and was furloughed on April 26th, and was discharged the service accordingly on May 26, 1865. He is not a pensioner.

CASES 313-315.—Shot wounds in the right hypochondrium were regarded by Acting Assistant Surgeon Butcher, Surgeon G. Grant, U. S. V., and Surgeon E. Bentley, U. S. V., respectively, as undoubtedly attended by injury of the liver. In the case of Private Carney, bile escaped from the wound; this was a perforation; in the two other cases, the ball lodged. Sergeant Buck is not a pensioner. Corporal Butler and Private Carney are pensioned, the examiners' reports not corroborating those of the attending surgeons.

CASE 316.—Surgeon T. H. Squires, 89th New York, reports that "Private S. Case, Co. C, 130th New York, was wounded at Suffolk, April 13, 1863, by a musket ball, which entered the right side of the body three inches above the lower margin of the floating ribs, and came out six inches further back, and on a little lower plane, the wound of exit being three inches from the median line of the back. The wet cloth that was laid on the wounds was stained a greenish-yellow color from the bilious discharge from the posterior orifice, thus showing that the liver, and perhaps the gall-bladder, was perforated." On April 15th, Case was admitted to Hampton Hospital, Fort Monroe; and on October 29, 1863, he was transferred to New York, convalescent. He is not a pensioner.

CASE 317.—Sergeant W. Clifton, 77th U. S. Colored Troops, reported by Surgeon J. B. G. Baxter, U. S. V., as receiving a shot perforation of the convex portion of the liver, February 3, 1865, was returned to duty April 10, 1865, and does not appear on the Pension List.

In the next case a musket ball is supposed to remain lodged in the liver:

CASE 318.—Private W. M. Crandall, Co. K, 42d Ohio, was wounded at Vicksburg, May 22, 1863, by a musket ball, which penetrated the right side of the abdomen. He remained at the field hospital until June 17th, when he was taken on board the hospital steamer R. C. Wood and conveyed to Memphis, entering Gayoso Hospital June 22d. Here the injury was noted as a "gunshot wound of the gastric region." On October 5th, he was sent to the hospital at Camp Dennison, Ohio, whence he was transferred to the Invalid Corps, November 11, 1863. He was discharged from service June 1, 1864, and pensioned. Pensioner Examiner Alexander Steele, of Oberlin, Ohio, reports, December 19, 1866, "the ball entered three and a half inches above, and one inch to the right of, the navel, and is supposed to be in the liver. The wound is open, and has been discharging since September, 1865. There is pain on slight motion, which is increased by labor. Sufficient effort is supposed to have been made to extract the ball, but unsuccessfully. The disability is permanent, and equal to loss of a limb, unless the ball is extracted, which does not seem probable; health otherwise good. Habits, correct." He was last paid December 4, 1872.

<sup>1</sup> The following instances of recovery from alleged shot wounds of the liver are found recorded in the annals of surgery: 1. QUERCETANUS (SCHENCKIUS, *Obs. med. rar.*, 1644, p. 397) relates the case of a nobleman shot in the liver. He was deserted by the surgeons, who considered his case hopeless, but he finally recovered. 2, 3. PUHMANN (*Fünzig sonderbare Schusswunden*, Jena, 1721) cites two cases of shot wounds of the liver, received before Stettin, 1677; recovered in ten and thirteen weeks, respectively. 4. LE ROUX (*Rec. périod. d'obs. de méd.*, T. XIX, 1763); shot fracture of ribs, and wound of liver with loss of substance; recovered in two and a half months. 5. BILGUER (*Chir. Wahrnehmungen*, 1763, S. 388) records a case treated by Feldscherer WALTHER; ball entered below the right short ribs, and was cut out on the opposite side; copious discharge of bile. 6. PIEW (*Med. and Phil. Comm. of Soc. of Edinburgh*, Vol. V, 1777); shot wound of liver, stomach, and lung; recovered in eleven months; purulent matter continued to escape. 7. MICHAELIS (*Nachrichten aus New York*, in RICHTER'S *Chir. Bibl.*, 1782, B. VI, S. 731); shot wound of liver; escape of bile for fourteen days; recovered in three months. 8. DAVID (*Gaz. Méd. de Paris*, T. XIV, p. 957); In 1800, an officer of lancers was shot two inches to the right of the spine, at the twelfth dorsal vertebra, the ball escaping in front; pus tinged with bile for twenty days; recovered in two years; in 1815 the officer was at Paris, entirely well. 9. BLICKE (GUTHRIE, *l. c.*, p. 51); fracture of eighth rib and penetration of liver; for two months purulent bilious matter escaped. 10. RYAN (GUTHRIE, *l. c.*, p. 52); Lieut. H——, shot through upper part of liver; tedious recovery on account of shattered state of constitution from this and a previous dangerous wound. 11. LARREY (*Mém. de Chir. mil.*, 1817, T. IV, p. 272); an officer at the battle of Dresden received a shot fracture of the ninth rib, with lesion of the liver; fragments of bone removed; recovered in seventy days. 12. GUTHRIE (*l. c.*, p. 53); shot wound in right hypochondrium, received in 1814; bilious discharge continued in 1817, and for some years afterward; missile remained in wound. 13. IDEM (*l. c.*, p. 51) cites the case of Sir S. B——; ball struck the cartilages of the false ribs, removing a portion, and injured the liver; escape of bile for several weeks; recovery. 14. BRUCE (GUTHRIE, *l. c.*, p. 52); shot wound of the liver, received at Waterloo; escape of bile; ball remains in wound. 15. GUTHRIE (*l. c.*, p. 53); a soldier of the 48th regiment, shot at Albuhera; copious discharge of blood and bile; recovery. 16, 17. HENNEN (*l. c.*, p. 435) records the case of Lieut. Col. H——; copious bilious discharge; recovered in two and a half months; and also a second case of recovery, complicated by other injuries. 18. BRAUN (RUST'S *Mag. für die gesammte Heilkunde*, B. XVI, S. 241); a tailor, aged 30, in 1816, received a pistol shot in the right epigastrium; copious bleeding, and escape of brown pus with solid brown particles, similar to liver substance; recovery in eight weeks. 19-22. BALDENS (*Clinique des plaies d'armes à feu*, 1836, pp. 220, 304, 353, and 355) records four cases of recoveries from wounds of the liver; in the first case, the lung and diaphragm were also injured, and in the third, the ball was removed from the liver. 23. DUPUYTREN (*Leçons orales de clin. chir.*, 1839, T. VI, p. 478); a citizen, shot in the anterior and upper part of the right hypochondrium; escape of portions of the liver and of bile; fistulous opening for three and a half months; recovery. 24. BECK (*Die Schusswunden*, 1850, S. 178); a soldier, shot through the upper part of the liver, right side, at the battle of Staufen, 1848; recovery. 25, 26. GIBBS (*British Am. Journal*, 1848-49, p. 220) gives a case of shot wound in left lobe of liver; hepatic fistula, with escape of bile and blood; recovery; and (*ibid.*, p. 230) mentions another case of recovery, but gives no particulars. 27. LOHMEYER (*Die Schusswunden*, 1859, S. 165) cites a case from the Danish war, 1850; bile escaped on the sixth day; recovered in about five months. 28. MASSIE (*New Orleans Med. and Surg. Jour.*, Vol. IX, 1853, p. 146); accidental shot wound through anterior margin of right lobe of liver, which protruded and became gangrenous; gangrenous part removed; recovery. 29. WARDNER (*Chicago Med. Examiner*, 1860, Vol. I, p. 33); pistol-shot wound between ninth and tenth ribs; on the sixteenth day pus mixed with bile escaped; recovered in seven weeks. 30. DEMME (*Militär-chir. Studien*,

CASES 319, 320.—There can be no doubt that Sergeant Crawley and Private Cunningham recovered from severe shot wounds of the liver. The former, wounded at Gaines's Mill, June 27, 1862, was attended by Assistant Surgeon Bremerman, and discharged April 24, 1863, by Surgeon John Moore, for "severe wound of the liver." Cunningham, wounded at Petersburg, June 16, 1864, was attended by Assistant Surgeon Forwood; and Pension Examiner Scott, of Ithica, in 1868, confirms the diagnosis, remarking that the ball must "have passed directly through the liver."

CASE 321.—Sergeant P. Fallenstein, Co. F, 98th Pennsylvania, aged 28 years, was wounded at Winchester, September 19, 1864, by a conoidal ball. He was admitted to the field hospital of the Sixth Corps on the same day, and on October 11th was transferred to the Sheridan field hospital at Winchester. Here the injury was diagnosed as "Gunshot wound through liver." On December 4th, he was transferred to Frederick; the wound was here described as a "Gunshot wound of right side of abdomen, without injury of internal organs." On January 4, 1865, he was transferred to Philadelphia, where he was admitted to the Filbert Street Hospital on the 9th, with "severe gunshot wound of parietes of abdomen, with injury to liver." He was returned to duty on January 26th, and mustered out of service June 29, 1865. Pension Examiner J. H. Gallagher, of Philadelphia, reported, June 25, 1866: "Ball entered the abdomen near the linea alba, passed through the right rectus muscle, and was extracted at the back, on nearly a straight line, at the lower border of the chest. The greatest pain is felt at the back, and is of a lancinating character, brought on by stooping and lifting; he also complains of oppression after exercise; he frequently raises clots of blood. Disability one-half, probably permanent." He was last paid to September 4, 1872.

CASE 322.—Private Noyes is a pensioner, who received a shot perforation of the right hypochondrium at Drury's Bluff, May 16, 1864. Assistant Surgeon E. McClellan was positive that the ball passed through the liver.

CASE 323.—Sergeant D. Perry, Co. B, 14th New York, received a gunshot wound at Malvern Hill, July 2, 1862. He was admitted to field hospital on the same day, and, on the 20th, was transferred, by Hospital Steamer Kennebec, to Fort Monroe, where he was admitted to Mill Creek Hospital on the 21st, the injury being reported as "a gunshot wound of the side." He was discharged the service on account of his wound April 23, 1863. Pension Examiner H. B. Day, of Utica, New York, reported, September 12, 1864: "Gunshot wound of right side; the ball passed through the liver; the wound is still open." On March 2, 1870, he reported that "he now is much emaciated; suffers constant pain and soreness of the right side over the region of the liver; pain on top of right shoulder, and weakness and lameness of the right arm, with which he can do but little labor. I do not consider the disability necessarily permanent in the above degree, still he may become worse." He was last paid to March 4, 1873.

CASE 324.—Corporal J. M. Roberts, Co. F, 83d Indiana, received a shot wound of the abdomen at Vicksburg, May 18, 1863. He was admitted to the field hospital of the Fifteenth Corps, and transferred, per steamer R. C. Wood, to Memphis, where he was admitted to Jackson Hospital on June 1st. Surgeon E. M. Powers, 7th Missouri, states: "The missile entered at the scrobiculus cordis, ranging to the right, and lodged between the angles of the tenth and eleventh ribs on the right side. Condition June 2d: Pulse natural; appetite good; spirits good; no fever; wound discharging bilious matter. Treatment: Cold-water dressing. June 10th, ball cut out. There were no bad symptoms, and no treatment required except an occasional opiate at night. The patient was furloughed July 22d, readmitted on September 14th, and on October 11, 1863, was returned to duty." The monthly report of the City Hospital, Indianapolis, for October, 1864, shows this soldier to have been discharged the service, on certificate of disability, on October 26, 1864, the injury being registered "Gunshot wound of the superior portion of the right lobe of the liver." Pension Examiner W. S. Cornett, of Versailles, Indiana, reported, March 24, 1866: "Ball entered a little below the lower end of the sternum, and was extracted from between two of the lower ribs, over the region of the liver; the wound where the ball entered has opened and is discharging, and has been for the last five or six months, so as, in my opinion, to wholly disable him from earning a living at manual labor. Disability total." This pensioner was last paid in December, 1872.

1861, B. II, S. 138); the missile entered between the ninth and tenth ribs, three and one-half inches from the xiphoid process, and escaped between the seventh and eighth ribs near the spine; pus with yellow matter escaped; at the end of the third week a small fistulous opening remained; recovered in eight weeks. 31. PORTA (DEMME, l. c. p. 137); an Austrian, aged 25, shot, at Magenta, in the right hypochondrium; several ribs fractured and fragments carried along; for twelve days pure bile escaped; recovered in seven weeks. 32. *Idem* (DEMME, l. c. p. 137) relates a similar case, where bile escaped for some time without febrile action; recovered in two months. 33. VERGA (DEMME, l. c. p. 138); a French soldier, wounded, at Solferino, below the tenth rib; escape of bilious matter. 34. WILDERS (*Med. Times and Gaz.*, 1862, p. 10); girl, aged 11, shot through wrist and abdomen; vomiting of greenish-colored fluid; recovery in six weeks. 35. HAMILTON (*A Treatise on Mil. Surg.*, 1865, p. 363); a Buffalo polleeman, in July, 1863, was shot in the abdomen one inch to the right of the median line, ball escaping on the same side six inches from point of entrance, between the eleventh and twelfth ribs, striking the convex surface of the liver; recovery in four months. 36. FORMENTO (*Gazette des Hôpitaux*, Sept., 1863, p. 430); soldier, aged 21, wounded at Chancellorsville, May 3, 1863, in the right hypochondriac region; treated at Richmond; lung and liver injured; copious bleeding, and vomiting of green bile; recovered in two months. 37. BROTHERTON (*Edinburgh Med. Jour.*, 1864, p. 826); shot fracture of the eighth and ninth ribs; fragments of bone, driven into the liver, removed; recovered in two and a half months. 38. OCHWADT (*Kriegschir. Erfahrungen während des Krieges gegen Dänemark*, 1864, Berlin, 1865, S. 346); a Dane, wounded April 18, 1864, in the right epigastric region; bile escaped; recovered in four and one-half months. 39-41. STROMEYER (*Erfahrungen über Schusswunden*, 1867, S. 6) mentions three cases of recoveries, from shot wounds of the liver, in 1866, in the hospitals at Langensalza and Kirehheilingen. 42. FISCHER (K.), (*Militärärztliche Skizzen*, 1867, S. 63); recovery from shot wound of liver; discharge of bile. 43-45. VOLKMANN (*Einige Fälle von geheilten penetrirenden Schusswunden des Abdomens und besonders der Leber*, in *Deutsche Klinik*, 1868, No. 1) cites three cases of recoveries from wounds of the liver, with copious escape of bile. 46. BECK (*Kriegschirurgische Erfahrungen*, 1867, S. 238) relates the successful issue of a shot wound of the liver in the Austro-Prussian war of 1866; bile escaped for two months. 47. WHITEHEAD (*The Med. and Surg. Rep.*, 1867, Vol. XVII, p. 311, and *Circular* 3, S. G. O., 1871, p. 49); a sailor, aged 22, was shot from behind; ball removed by incision at a point two and one-half inches from the median line and three and one-half inches below the nipple; wound bled freely and bile continued to discharge for at least a month and a half; recovered. 48-52. BECK (*Chirurgie der Schussverletzungen*, 1872, S. 538) gives five cases of recoveries from shot wounds of the liver, bile having escaped in every instance. 53, 54. FISCHER (H.), (*Kriegschirurgische Erfahrungen*, 1872, S. 130) remarks: "In four instances we diagnosed wounds of the liver. Two had exceedingly happy results. Nevertheless I would like to insist in one instance only on the correctness of the diagnosis." 55. KLEINPAUL (*Schmid's Jahrbücher*, 1871, S. 185) records the case of a French sergeant wounded between the sixth and seventh ribs; escape of bilious matter; recovered in about seven weeks. 56. NICOLSE (*Gaz. de Paris*, 1871) relates a case of recovery in four weeks, with small fistula remaining. 57. VERNEUIL (*L'Union médicale*, 1871, p. 755); a revolver ball passed entirely through the liver in its greatest diameter, ball remaining in the tissues; no suppuration, vomiting, diarrhoea, or fever; recovered. 58. DEBIBS (*Gaz. Méd. de Paris*, 1871); soldier, at Sedan, shot through the right hypochondrium; bilious fistula; recovered. 59, 60. CASES CLVII and CLVIII, of l. c. 3.



CASES 325-328.—Private S. Scott is not a pensioner. He received a shot wound in the right hypochondrium at White River, Mississippi, October 19, 1864. It was thought by Assistant Surgeon D. Scofield, 47th U. S. Colored Troops, to interest the liver. Surgeon B. S. Chase, 53d U. S. Colored Troops, was less positive of the existence of an hepatic lesion. Private Shively is reported, by Acting Assistant Surgeon Joshua Thorne, as shot through the liver, June 20, 1863, and returned to duty September 2, 1863. The name is not on the Pension List. Dr. Lidell has related the case of Private Gilbert Smith, in the *American Journal of the Medical Sciences*, 1867 (misprinted 1857 on p. 131, *supra*), Vol. LIII, p. 344. There is no doubt respecting the severity of the hepatic lesion in this case, and it is interesting to add to Dr. Lidell's report, that G. Smith was reported by the pension examiner in tolerable health in December, 1872, nine years after the reception of the injury. Corporal J. B. Smith furnishes another instance of undoubted recovery from a severe shot perforation of the liver. Wounded at Fredericksburg, December 13, 1862, and attended by Assistant Surgeon C. A. McCall; he was living, in impaired health, December, 1872.

CASE 329.—Sergeant W. W. Smith, Co. G, 5th Texas, aged 25 years, was wounded at Gettysburg, July 2, 1863, by a conoidal ball, which entered the right side of the abdomen. He was taken to the field hospital, where he remained until August 10th, when he was transferred to Camp Letterman. Assistant Surgeon T. J. Vance, C. S. A., who attended the case, states, on a medical descriptive list, that "the ball entered the right hypochondriac region and passed through obliquely, and made its exit some four inches below, and to the right of, the umbilicus. The right lobe of the liver was penetrated by the ball, as was proved by the escape of the secretions, and of a portion of the liver. Cold-water dressings were applied to the wounds, and anodynes given. August 20th: the wounds have healed, though he suffers excruciating pain in the region of the transverse colon. Camphor and opium pills were given, and tincture of iodine applied over the vicinity of the pain. September 1st: patient doing well, though suffering occasionally in the region of the liver and colon. September 20th: health good, pain ceased." On September 25th, he was transferred to West's Buildings Hospital, Baltimore, whence he was paroled on November 12, 1863.

CASE 330.—Sergeant S. K. Snively, Co. M, 13th New York Cavalry, aged 22 years, was wounded at Piedmont, Virginia, October 17, 1864. He was treated in the regimental hospital, and Assistant Surgeon J. F. Bardick, 13th New York Cavalry, gave, April 4, 1866, the following account of the case while in his charge: "Gunshot wound of the right hypochondriac region; a musket ball entered three inches to the right of the umbilicus; the direction was internal and toward the left and downward, injuring the right lobe of the liver; the seat of lodgement of the missile could not be determined, although it still remained in the body. The treatment consisted of the local application of compresses dipped in tincture of opium; morphia internally in large and frequent doses, alternated with tincture of veratrum viride. The patient suffered with nausea and retching, and had painful hæmaturia. A catheter was introduced into the bladder thrice daily." Records on file show that this patient was treated in regimental hospital, at Camp Relief, from March 31, 1865, to May 14, 1865. He was discharged at Alexandria, July 13, 1865, for "gunshot wound between the seventh and eighth ribs, near the sternum, and shell wound of lower third of tibia; disability total." He is a pensioner, and was last paid December 4, 1872.

CASE 331.—Sergeant G. W. Tindall, Co. C, 4th New York Cavalry, aged 19 years, was wounded in the abdomen at Aldie Gap, June 17, 1863, by a rifle ball. He was admitted to a barn hospital, near Aldie, on the same day. Assistant Surgeon R. A. Dodson, 1st Maryland Cavalry, reported: "Missile passed through the lower portion of the liver, and passed out one-half inch from the spine. The treatment consisted in the cautious use of stimulants and of nourishing diet. Constitution impaired; our weeks after the injury, he was still in a critical condition." On August 2d, he was transferred to Alexandria, whence Surgeon E. Bentley, U. S. V., reported: "Ball entered four inches above, and three inches to the right of, the umbilicus, and emerged slightly to the right of the spine of the last dorsal vertebra; the wound was in good condition at the time of his admission." He was furloughed on August 23th for thirty days, and was transferred to the Veteran Reserve Corps on December 10th. On March 27, 1864, he was discharged the service. Surgeons C. Phelps, W. H. Dunning, M. K. Hogan, and T. F. Smith, examining board, New York City, reported, April 3, 1872: "Ball passed through right hypochondrium and emerged before the right border of the lumbar spine, interfering with the movements of back and right upper extremity. Disability one-half, and permanent." He was last paid to September 4, 1872.

CASE 332.—A shot wound of the right hypochondrium, regarded by Surgeon H. Wardner, U. S. V., as a perforation of the liver. Conflicting opinions from Surgeons Wynkoop, Ormsby, Tilton, and Pension Examiner Baker.

CASE 333.—Private J. W. Vogus, Co. D, 59th Indiana, was wounded in the assault on Vicksburg, May 22, 1863, by a minié ball. He was admitted to the McPherson Hospital, at Vicksburg, on June 5th, and Surgeon G. R. Weeks, U. S. V., made the following report of the case: "The ball passed through the right side of the body, entering near the cartilage of the tenth rib, in a line diagonally upward and outward, about three and a quarter inches from the umbilicus, passing out near the twelfth dorsal vertebra. On June 8th, while he was endeavoring to rise in bed, there was a sudden gush of bile from the anterior opening to the extent of half a pint, in the nurse's estimation, after which time, until June 25th, the quantity was about equal each day, and flowed constantly and slowly, after this period, the bile being mixed with an offensive sero-purulent fluid. June 10th, pulse 68; temperature of body, cooler than natural; tongue slightly covered with a whitish fur; stools nearly white in appearance, and very offensive; the urine was unaffected in quantity and quality; appetite poor; no thirst; he craved acids, and had a disgust for meat of all kinds. He was in a state of constant hebetude; he was peevish and very easily annoyed. His digestion was bad when meat or fatty substances were eaten; often they would be ejected or would pass undigested; the articles of a starchy nature were readily digested, and sought after greedily. His countenance was sad and sunken, and he became emaciated very rapidly, being reduced almost to a living skeleton; his mental faculties were blunted, and his appearance was that of a confirmed hypochondriac; I do not remember seeing him laugh once, or even indulge in a smile during the two months he was with us. I had very few facilities for investigating the case, but did the best I could with the material I had to work with. My first observations were made June 10th, in the following manner: I carefully weighed several pieces of dry sponge, and ordered an attendant to apply one until filled with bile; I then substituted another, and accurately weighed the first, subtracting weight of sponge; and in like manner with all the others for twenty-four hours. On the first day I collected 2,832 grains, or nearly six ounces; on the 11th, 2,679 grains; on the 15th, 2,441 grains; and on the 20th, 2,763 grains. The largest



quantity collected was between the hours of three and six in the morning. During this time, his condition was nearly the same, or at least with very slight variation. I found all the specimens tested slightly alkaline, and pursued the following plan in testing: I had him in the sitting posture, and induced him to exert himself so as to force all accumulated bile away; I then wet the slips of test paper in the next product of the liver that passed away, for the reason that physiologists maintain that the bile is rapidly changed on exposure to the atmosphere, or even while in the gall-bladder. Its specific gravity was 1014.7, and was ascertained in the following manner: I accurately tested my weights and found them correct, *i. e.*, I balanced a three and a two grains' weight with a five, and a six and a four with a ten, and, after satisfying myself of their accuracy, I balanced a half-ounce vial with a cap-box filled with dry sand, then filled it with rain-water and weighed it again, thus getting the weight of the water and also of the bottle; I then had it filled with fresh bile and weighed it again; I then divided the weight of bile by the weight of water, taking the quotient for its specific gravity. I also observed, in its behavior with fats, that it produced a soapy compound when mixed in equal quantities, and did not separate by standing three days. During the progress of this case the most marked changes observed were, the rapid emaciation, the impaired digestion of fat, and the impaired condition of his mental faculties, which closely resembled melancholia and hypochondriasis; also the marked disgust for animal diet. His diet was mostly vegetable, except when animal food was ordered to note changes in digestion. I observed that more bile was given off when oily food was taken than when mercurials were administered. My experiments were not carried to that extent desirable, for the reason that he was in a condition that mercury was hurtful, and I did not feel warranted in carrying it to that extent that would decrease his chances of recovery. A constant diarrhoea attended him after June 12th. He was sent to St. Louis on July 29th, convalescent." On August 6th, this patient was admitted to Jefferson Barracks, Missouri, and was discharged the service October 3, 1863. He is not a pensioner.

CASES 334-336.—There is nothing to corroborate the diagnosis of Assistant Surgeon E. J. Marsh in the case of Welsh, wounded at Gaines's Mill, June 27th, and returned to duty September 3, 1862. His name is not on the Pension Roll. In the case of Westfall, the opinion of Surgeon J. Hopkinson, U. S. V., that the ball, perforating the right hypochondrium, wounded the liver, though not contradicted, is not confirmed by Pension Examining Surgeons Crane, of Green Bay, and Hall and Murphy, of Oconto, and this also must be classed with the doubtful cases. L. Whittle (described in Circular 6, S. G. O., 1865, p. 24, as Latimer Whipple) was an unquestioned instance of recovery from a shot wound of the liver. It would appear that this man has fully recovered his health. He received a small pension until September, 1871, when, at the biennial examination, his name was dropped from the roll.

Fourteen of these twenty-five cases can be accepted as indubitable examples of recovery from shot wounds of the liver; in eleven cases, the evidence is inconclusive. The thirty-seven recoveries from complicated injuries in which the liver was involved, remain for examination:

CASE 371.—Surgeon L. D. Waterman, 29th Indiana, reports that "Lieutenant W. H. Bartholomew, Co. B, 16th Infantry was wounded at the battle of Stone River, December 31, 1862, by a musket ball, which entered a little internal to the left anterior superior spinous process of the ilium, seemingly having entered the peritoneal cavity, and then traversing the abdomen, came out in the cæcal region of the right side, a little above, and an inch and a half internal to, the right antero-superior spinous process of the ilium. Some soreness and swelling followed; but, on January 8th, nine days afterward, he journeyed thirty miles in an ambulance wagon, to the hospital. Owing to more important duties, no immediate record was made of the case, beyond the fact that he had taken opium largely. No history of the case came with him. He had no motion of the bowels; pulse slower than natural; tongue furred; aspect heavy; and respiration less than natural. He was able to sit up sometimes, and also to walk up stairs. The exit wound discharged some laudable pus; the track of the ball across the abdomen was discernible only by touch, as a slight groove with elevated edges; there was some loss of flesh, and much restlessness and weariness, from a twelve hours' ride, in a rough ambulance, over bad and muddy roads. I was absent, and no record was kept until January 20, 1863. I learned that, about January 13th, the exit wound sloughed and large quantities of pure bile escaped, occasionally mixed with semi-digested food. He vomited, occasionally, prior to this discharge. The skin, *successively*, around the wound, down the abdomen, down the right thigh, and gradually upward, grew very much jaundiced. Emaciation and loss of appetite followed. From the 10th to the 13th of January, his bowels had been moderately moved regularly every day; the opium was entirely omitted, and milk toast, soup, and tea given daily. After the fistulous discharge of bile began, all disposition to anal evacuations ceased, as I learned from Acting Assistant Surgeon C. Richmond and Surgeon W. Arnold, 37th Ohio, who attended the case. The tongue grew rapidly dry, cracked, and brown; sordes collected on the teeth, crusts on the lips, and the patient was prostrate, very feeble, and disposed to jactitation; the skin around the orifice of exit, and over the lower part of right hypochondriac region, where the discharge flowed, became very much excoriated, and the discharge, by this time of a green, mossy-looking character, mixed with thin, acrid bile, bubbled in small, but almost continuous, quantity from the wound, so as to amount to a gill or two in twenty-four hours. January 24, 1863, I again saw him, and thereafter regularly. I found him in the condition above described. Pulse small, quick, and about one hundred; no appetite; decubitus dorsal slightly inclined to the right side; orifice of entrance healed; track of ball obliterated; emaciation extreme; face pale, thin, with slight hectic-like flush daily; respiration partial, about thirty; voice, faint and infantile; expression, peevishly somnolent; knees drawn up; and typhoid appearance of the mouth. Every twelve hours, injections of warm water were administered (the bowels seeming rather fuller than comported with the emaciation) and the bowels thus moved twice daily until convalescence. Oyster soup and milk were given him regularly three times a day; wound dressed with oiled silk, to protect the skin; the skin, where abraded, was washed with castile soap and covered with isinglass plaster, which was frequently changed. February 1st, healthy bile, with slightly curdled milk, discharged very freely; jaundice disappearing; milk discontinued for a few days; oranges and oyster soup for diet. February 2d, no fecal discharge, and less bile and pus; appetite and countenance improved. February 9th, better every way; able to sit up; voracious appetite; bowels natural, only occasionally slight yellowish discharge (enough

to stain cloth) from the wound, mostly pus; swelling around wound gone; wound healed, except small valvular orifice, large enough to admit a probe. An inch inward from the wound is an irregular, slightly hard, spot, probably the point of attachment of the intestine and peritoneum. About February 11th, went home on furlough to Pottsville, Pennsylvania." Lieutenant Bartholomew returned to his regiment January 4, 1865, and was promoted to a captaincy. In 1872, he was still in the service, and attached to the 16th Infantry.

CASES 372-376.—Some details of three of these cases have been given. Of Corporal *Biles*, it is known that, being paroled, he entered the Pettigrew Hospital, at Raleigh, and was returned to duty December 2, 1864, eighteen months after the reception of his wound at Gettysburg. Corporal D. Cramer (375) appears to have recovered from an antero-posterior perforation of the liver and right lung, with escape of bile and with tromatopnoea, as fully attested by the description of Acting Assistant Surgeon Paulin and Assistant Surgeon Helsby. Private Duke is the subject of seven distinct diagnoses; but all agree that the ball entered two and a half inches to the right of the umbilicus and emerged near the posterior iliac spine. Assistant Surgeon W. C. Daniels, U. S. V., regarded the presence of an hepatic lesion as established beyond doubt. The pension examiners are silent on this point. In March, 1872, this pensioner survived, in impaired health.

CASE 377.—Private Jason O. French, Co. C, 17th Vermont, was wounded at the battle of Cold Harbor, June 3, 1864, and was taken to the Ninth Corps Hospital, where Surgeon J. Harris, 7th Rhode Island, recorded the injury as a shot wound of the thorax. Thence transferred to Washington. French entered Emory Hospital on the 7th, whence Surgeon N. R. Mosely, U. S. V., reports the following particulars: "A minié ball entered the right side, at the lower margin of the eighth rib, near the angle, and emerged half an inch to the right of the spinous process of the first lumbar vertebra. The countenance was pale, the lips livid, the extremities cold; the pulse 110. There was dyspnoea, nausea, and occasional vomiting. The patient was much depressed from loss of blood, which had continued to flow at intervals during the three days succeeding the injury. Brandy and beef-tea were administered, and warm frictions to the extremities were employed, until reaction took place. On June 8th, the pulse was at 100. On this, and on several subsequent days, the bowels were irregular, the stools being sometimes yellow or dark brown, and sometimes clay-colored. On the 9th, the abdomen was tympanitic and tender, the tongue dry, the pulse 110. Acting Assistant Surgeon P. O. Williams directed a saline cathartic with terebinthinate enemata, and warm fomentations, and wine whey, beef-tea, and chicken-broth. On the morning of June 10th, there were two copious alvine discharges. There was still much abdominal tension and tenderness, and there was a jaundical discoloration of the surface. The urine also indicated a bilious discoloration. The pulse was 108, the extremities cold, the countenance cadaveric. Oil of turpentine and Dover's powder were given internally, and hot fomentations and terebinthinate embrocations were applied to the abdomen. On June 11th, the abdominal tenderness was mitigated, the pulse was 100, the tongue and skin moist, the extremities warm. The patient complained of general itching. The treatment was continued, a portion of ipecac being added to the Dover's powders. From June 12th to the 15th, there was gradual improvement. The bowels were regular, the stools clay-colored, the appetite good. A generous milk diet, with Dover's powder and ipecac at bedtime, was directed. On June 20th, there was a profuse discharge of bilious matter from the anterior wound; from the posterior orifice pus, with occasional clots of blood, escaped. On June 25th, large quantities of greenish bile flowed from both wounds. It was inferred that a slough had separated and exposed the right hepatic duct, so copious was the discharge. The general condition was excellent, the patient resting without anodynes. In place of the Dover's powder, tincture of the sesquichloride of iron was ordered. After July 2d, the bilious discharge subsided and the stools regained their natural color. Henceforward the patient's convalescence was uninterrupted. On August 19th, he was transferred to the Smith Hospital, Brattleboro', and was discharged from service July 18, 1865, and pensioned." Examiner D. W. Putnam, of Morrisville, Vermont, reports, January 5, 1872, that the pensioner suffers from dyspnoea, and that he is permanently disabled.

CASE 378.—Corporal Freeman had an antero-posterior shot perforation of the right hypochondrium, and the discharges were believed to be tinged with bile; but no peritonitis ensued. The attending surgeon, I. Moses, and Pension Examiners Mears, Orth, and Beasley, express various opinions as to the extent of the pulmonary and hepatic lesions in this obscure but interesting case. Freeman was still a pensioner, January 1, 1873.

CASE 379.—Private J. Fry, Co. K, 14th Pennsylvania Cavalry, was wounded at Milwood, December 17, 1864, by a conoidal ball. He was admitted to the field hospital at Winchester, the injury being diagnosed as "Gunshot perforation of bowels." December 21st, he was admitted to the National Hospital, Baltimore, and the case thus reported: "Ball entered one inch to the right of the spine, on a line with the tenth vertebra, and emerged on the left side, at the inferior margin of the ribs." On May 23d, he was transferred to Jarvis Hospital, and Assistant Surgeon De Witt C. Peters, U. S. A., reported: "Ball entered to the right of the eighth dorsal spinous process and emerged in front and below the free extremity of the eleventh rib, opening in its course the pleural sac of the right side, and wounding the lung and liver; there was great effusion into the right pleural sac. On May 31, 1865, he was discharged the service. Disability total." Pension Examiner G. R. Lewis reported, October 6, 1865, that "the ball entered to the right of the spinal column, passing through the lungs and liver. His wound affects him in damp weather, but probably unfits him for manual labor at all times." The pensioner was paid to March 4, 1873.

CASE 380.—Sergeant J. A. Galloway, Co. H, 8th Pennsylvania Reserves, was wounded at South Mountain, Maryland, September 14, 1862. The ball entered the right breast between the eighth and ninth ribs, a little anterior to their centre, passed through the lower portion of the right lung, liver, and kidney, and emerged below the twelfth rib, about two inches to the right of the spinal column. He was sent to the hospital at Middletown, thence to Frederick, and on the 26th was transferred to Satterlee Hospital, Philadelphia. The patient stated that on the reception of the injury a bloody discharge occurred through the urethra, and that he spat blood and experienced the most excruciating pain in the right shoulder. When admitted, he was in a critical condition, and suffering from dyspnoea and a severe pain in the right side, extending above the clavicle. The right lung was in a complete state of hepatization. He still passed a considerable quantity of blood from the urethra. He was placed on a mattress, and the shoulders elevated so as to facilitate breathing, and perfect rest enjoined. Anodynes and astringents were

<sup>1</sup>An abstract of this case has been printed by Dr. PETER O. WILLIAMS, of Coxsackie, in the *Transactions of the Medical Society of the State of New York*, 1866, Article VII, p. 39.



freely administered, and he was placed on low diet. This treatment was continued for about two weeks, when tonics, alteratives, and nourishing diet were substituted, with counter-irritation over the liver. December 9th, the upper portion of the right lung was clear upon percussion, but a slight dulness remained in the lower part. The dyspnoea had disappeared, and his general health was good, but he still experienced considerable pain over the region of the liver. He was discharged from service January 16, 1863. The case is reported by Acting Assistant Surgeon N. Hickman. Pension Examining Surgeon J. C. Cotton reported, January 3, 1872: "There is dulness on percussion over the whole right lung; respiratory murmur feeble. Has had hæmoptoe-is twice since the wound was received. Never had any pulmonary trouble before. Has cough and pain all the while. Cannot perform severe labor on account of shortness of breath and weakness." He was last paid on September 4, 1872.

CASE 381.—Private M. Heinig, Co. C, 81st New York, aged 21 years, was wounded at Fair Oaks, May 31, 1862, by a conoidal ball, which entered the right side a little below the lower end of the sternum and emerged on the back about two inches to the right of the spine, having passed through the liver, diaphragm, and lower part of the right lung. He was treated in the field until June 8th, when he was transferred to the Fifth Street Hospital, Philadelphia. He suffered from hæmorrhage and jaundice. He was discharged from service on August 4, 1862. Pension Examiner Edward S. Walker reports, July 10, 1865, that he re-enlisted as sergeant in the 2d New York Artillery, February 8, 1864, and was discharged from service on September 29, 1865, but suffered from pleurisy and was unfit for duty most of the time. He complained of pain in the side, and a feeling of tightness and difficult breathing on making much exertion, or on taking cold. The lower part of the right lung is carnified and adheres to the diaphragm and pleura. He remained a pensioner in March, 1872.

CASE 382.—Private Hardin received, at Richmond, Kentucky, August 29, 1862, a shot perforation from near the xiphoid cartilage to the angle of the eighth rib. Acting Assistant Surgeon R. Peter believed, on grounds apparently adequate, that the diaphragm and convex surface of the liver were interested in the track of the ball. The pension report is not positive. This pensioner was paid December 4, 1872.

CASE 383.—Private P. Hahn, Co. G, 17th New York, aged 19 years, was wounded at Jonesboro', September 1, 1864, by a conoidal ball, which penetrated the eighth intercostal space at the juncture of the posterior and middle thirds, passed obliquely upward and forward, and presented itself between the seventh and eighth left ribs. He was at once conveyed to the hospital of the Fourteenth Corps. Considerable hæmorrhage had taken place, and the dyspnoea was dreadful. Air regurgitated through the wound freely, and emphysema rapidly developed itself. He was made as comfortable as possible, a wide bandage being put on, leaving the wound open so as to prevent an increase of the emphysema, and yet relieve the thoracic breathing. Brandy was administered with morphia, to alleviate, if possible, the fearful distress he experienced. Very little alteration took place for several days, when the urgent dyspnoea gradually subsided and all his most unfavorable symptoms improved. His pulse became more full and strong, and everything promised a successful termination to the case. On the eighth day, a large slough came away from the entrance wound, and was followed by a discharge of pure bile, which continued for several days, affording no little amusement to the patient, as, on a full inspiration, followed by a forcible expiration, he could eject pure yellow bile to a considerable distance. On the thirtieth day, all discharge had ceased, and he was transferred to Hospital No. 3, Nashville. On November 13th, he was transferred to Jefferson Hospital, Indiana, and returned to duty March 20, 1865. Surgeon E. Batwell, 14th Michigan, who reports the case, states that he rejoined his regiment at Savannah, and participated with it in the battle at Bentonville, experiencing no inconvenience or trouble from marching or fighting. He is not a pensioner.<sup>1</sup>

CASE 384.—Private Johnson is reported by Surgeon J. G. Keenon, U. S. V., to have received a shot perforation of the liver and lung in June, 1864, and to have returned to duty July 4, 1864. Private Johnson is not a pensioner.

CASE 385.—Captain Fielder A. Jones, Co. H, 6th Indiana, received a penetrating wound of the abdomen at Cheat River, West Virginia, July 16, 1861. He was treated in private quarters, and was discharged from service August 2, 1861. On August 29, 1861, he was commissioned as lieutenant-colonel of the 8th Indiana Cavalry, with which regiment he served until the termination of the war, and was mustered out July 20, 1865. Examining Surgeon W. J. Wilson, of Macon, reported September 29, 1866: "I have personally known Colonel Jones for the past twelve months and know that he is affected with chronic diarrhoea, which I believe to be the result of a gunshot wound through the right lobe of the liver. The ball entered near the junction of the cartilage with the eleventh rib and emerged between the tenth and eleventh ribs, near their angle. It passed through the right lobe of the liver and fractured the tenth and eleventh ribs. As a result of this wound an abscess yet forms in the liver and is the cause of diarrhoea." In a letter to the editor, dated Fort Seldon, New Mexico, March 13, 1872, Dr. Wilson writes: "For about two weeks after receiving the wound he was confined to his bed under medical treatment, and recovered in that time, and served throughout the remainder of the war as lieutenant-colonel and colonel of the 8th Indiana Cavalry. He was troubled for about twelve months from the time I first knew him (September, 1865) with an occasional dysenteric attack, which I attributed to the effects of his wound—probably a small hepatic abscess. I saw him every day, while I was on leave of absence, during the months of September, October, and November last. He then appeared to have entirely recovered his health, and looked stouter and felt better than I had ever before known him—so much so, that the Mutual Benefit Life Insurance Company of Newark had accepted a large risk upon his life with all the facts before them."

CASES 386-390.—The cases of Kewell and Little were shot perforations of the right hypochondria, the former diagnosed by Surgeon J. Hopkinson, U. S. V., the latter by Acting Assistant Surgeon George Byles, as wounds of the liver. These men are not on the Pension List. The three other cases have been already noted.

CASES 391-395.—Surgeon M. K. Hogan, U. S. V., reports Private Matthews as receiving a shot perforation of the right hypochondrium, at Bethesda, June 2, 1861. At Lincoln Hospital, Assistant Surgeon H. Allen diagnosed a perforation of the liver and probably of the lung. The patient was discharged, and pensioned May 19, 1865. Pension Examiner C. C. P. Clark, of Owego, concurred in the opinion that the ball traversed the liver, and noted that there was an ununited fracture of the tenth rib. This pensioner was on the list in December, 1872. Sergeant Munroe received, in an alteration, October 1, 1863,

<sup>1</sup> BATWELL, E. *Notes of Army Practice, in Med. and Surg. Rep.*, 1865, Vol. XII, p. 251. In this article, Dr. BATWELL includes an interesting abstract of this case.



an antero-posterior pistol-ball perforation of the right lobe of the liver, according to Acting Assistant Surgeon L. Smith. There was slight jaundice. The ball lodged beneath the skin, between the spinous processes of the eighth and ninth dorsal vertebræ, and was removed by Dr. Smith by counter-incision. Acting Assistant Surgeon G. A. Wheeler believed that the ball traversed the thoracic cavity. On admission at Annapolis Junction Hospital there was much pain over the stomach and chest, followed by pain in the hypogaster. In a month the patient amended, and speedily recovered, and returned to duty January 25, 1864. No other facts are furnished to determine whether the ball took a direct or circuitous course. Patterson, recorded by Assistant Surgeon L. C. Tolles, 1st Colorado Cavalry, as wounded at Apache Cañon, March 26, 1862, and discharged January 24, 1863, is reported by Pension Examiner J. S. Redfield, of Bourbon County, Kansas, to have recovered from a shot penetration of the right lobe of the liver, the ball being extracted through a counter-incision near the eleventh dorsal vertebra. This pensioner was last paid December 4, 1872. Dr. Redfield states that there is such hypertrophy of the liver as to interfere with the action of the lower lobe of the right lung, and that there have been repeated attacks of renal hæmorrhage. Private Pool received, at Prairie Grove, an oblique shot perforation, December 7, 1862, the ball entering anteriorly at the ninth rib, four inches to the right of the median line, passing downward and backward and lodging in the dorsal muscles, three inches from the spinous process

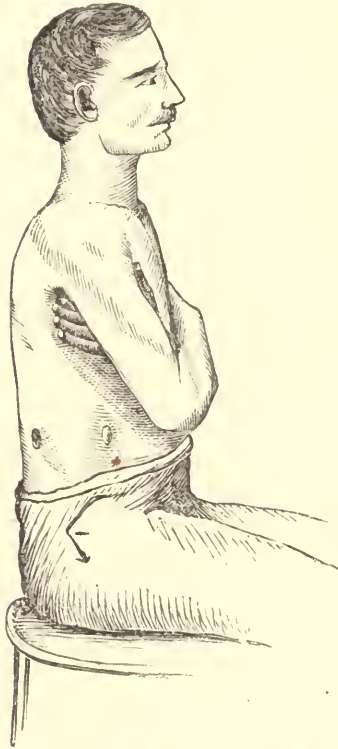


FIG. 115.—Orifices of entrance and exit in a case of shot perforation of the liver.

of the first lumbar vertebra. Surgeon Ira Russell, U. S. V., reports that there was hæmoptysis for twelve days. Assistant Surgeon Short, 26th Indiana, noted, at the Springfield, Missouri, Hospital, the abdominal symptoms as most urgent. Discharged April 30, 1863, and pensioned. Pension Examining Surgeon D. L. Downs, of Richland, Wisconsin, reports that the ball penetrated the diaphragm and liver, producing ventral hernia and chronic phrenitis. Examining Surgeons Bickford and Burnham, of Richland, in 1865, declare that the ball traversed the peritoneal cavity, and that visceral injury and muscular contraction disabled this pensioner, who was still on the roll, October, 1872. Private Rusch recovered from an antero-posterior shot perforation of the right hypochondrium, received at Chicamunga September 20, 1863, was discharged June 10, 1865, and pensioned. Surgeon J. S. Woods, 99th Ohio, Assistant Surgeon J. Perkins, U. S. V., and Acting Assistant Surgeons France and Elrod, and Pension Examiners Justin and Coleman, of Logansport, appear to regard the wound as limited to the thoracic cavity, but Assistant Surgeon W. C. Daniels, U. S. V., was positive that the liver was implicated.

CASE 396.—Private J. A. Rogers, Co. H, 27th Connecticut, was wounded in the abdomen at Fredericksburg, December 13, 1862. He was admitted to the field hospital of the Second Corps on the same day, and transferred to Washington, and admitted to the Stone Hospital on the 20th. The note-book of Surgeon J. H. Brinton, U. S. V., gives the following minutes of the case: "Wounded in the liver, and also in the head, shoulder, and arm; there was constant and profuse discharge from the abdominal wound posteriorly; he sleeps on his back; the color of the discharge is green; this is thin and fluid, and mingled with a thick yellow matter; the attendant thinks there is but one discharge—the yellow is the concrete, the green the fluid portion; the bowels are slightly costive; the appetite poor; the general condition good; after the mixed discharge takes place there is a stream of fine yellow pus. Pulse about eighty all the time. A piece of the overcoat and a portion of rib were removed from the posterior opening. The discharge is not profuse at night; cough will start the flow." A drawing in the note-book, from which the adjacent cut (FIG. 115) is copied, indicates the situation of the wounds of entrance and exit. On February 16, 1863, he was transferred to Mount Pleasant Hospital, whence he was furloughed on February 23d. He was admitted to Knight Hospital, New Haven, on April 23d, and was finally discharged the service on June 9, 1863; disability one-half. He is not a pensioner.

CASES 397-398.—To Dr. Dusenbury's account of the case of Corporal Sharer, in the *American Journal of the Medical Sciences*, 1865, Vol. L, p. 399, may be added the report of Pension Examiner H. S. Scott, of Ithaca, May 5, 1868: "Ball passed through liver and right kidney. There is spinal irritation, with pain, tenderness, and weakness in the small of the back, and an affection of the kidney, the urine being loaded with mucous deposits, abnormally abundant, and passed frequently." This pensioner was on the roll December 4, 1872. The case of Sweeney (398) is identical with case 187, on page 47.

There were no examples of the extraction of balls from the substance of the liver, and but one instance in which an attempt at extraction was unsuccessfully made. Authors who generally forbid explorations of wounds of the abdomen, sanction an extraordinary latitude in incisions for the purpose of removing foreign bodies from the liver, a practical precept apparently derived from Le Dran,<sup>1</sup> which would need qualifications, if there was any real danger of its being blindly obeyed.

<sup>1</sup> LE DRAN (*Traité ou Reflexions tirées de la pratique sur les playes d'armes à feu*, Paris, 1737, p. 190): "Il faut agrandir la playe du péritoine," he says, "comme celle des tégumens communs, parce qu'ici il ne peut se faire de hernie comme il pourroit s'en faire ailleurs; mais il ne faut pas aller plus avant, l'escarre que la balle a fait, étant utile à prévenir l'hémorragie. Si l'incision permet de sentir la balle, quoiqu'elle soit entrée dans la substance du foye, il faut en faire l'extraction." PERCY (*op. cit.*, p. 122) adopts these precepts, but advises "inciser plus largement," to give room for the application of "nos pincettes." NUSSBAUM (in PITHA & BILLROTH'S *Handbuch*, u. s. v., B. III, Abt. II, S. 192) repeats this recommendation, and BAUDENS (*op. cit.*, p. 353) gives a successful instance in which he followed it, and rejects any practice less bold.

When a portion of the lacerated liver substance protrudes at the external wound, it would appear that it may be safely removed by ligature.<sup>1</sup>

CASE 399.—Private F. Siebe, Co. D, 139th New York, aged 23 years, received a wound of the right side of the abdomen at Cold Harbor, June 3, 1864. He was taken to the field hospital of the Eighteenth Corps, and was subsequently sent to Washington, and admitted into Harewood Hospital on the 15th. Surgeon R. B. Bontecou, U. S. V., states, on the medical descriptive list, that "a musket ball entered the right anterior side below the tenth rib, and emerged behind and about one and a half inches from the spine. On admission, the patient was in a very feeble condition; the discharges from the wound consisted of feces, mixed with greenish streaks, from the ascending colon and liver. He complained of pain in the abdomen, which was increased by pressure; the discharge from the rectum was scanty. Cold-water dressings over the abdomen, opium internally, and light, nourishing diet constituted the treatment. July 1st, the pain in the abdomen diminished, but the discharge remained the same. July 15th, the patient complains of occasional colicky pains. The discharge continued the same until August 15th, but from that date the patient began to improve. By September 1st the wound of exit had healed. September 14th, wounds entirely healed. Colicky pain recurred now and then, but the patient was able to be about." He was furloughed October 8, 1864, and was returned to duty, entirely well, November 23, 1864, at which date a photograph, copied in the wood-cut (FIG. 116), was taken at the hospital. Pension Examiner C. Rowland, of Brooklyn, reports, February 23, 1867, that "the ball entered the right side of the sternum, passed through the liver, and made its exit on the right side of the spine, resulting in constant pain in bending his body. He is feeble, and cannot perform manual labor. He alleges that his disability has increased since the granting of his pension, June 2, 1865." He was last paid September 4, 1872.

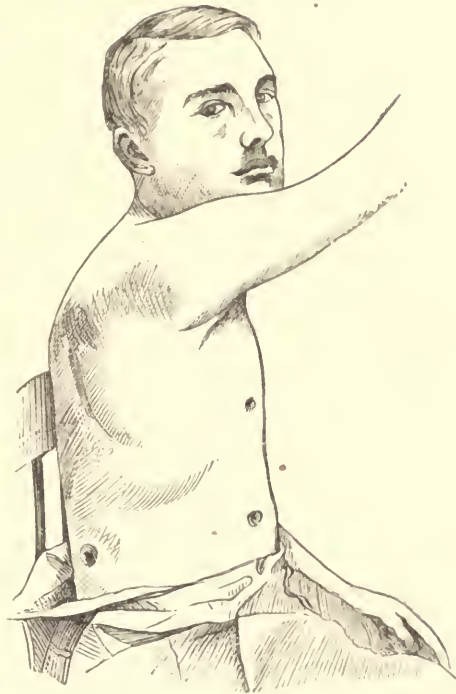


FIG. 116.—Cicatrices after a shot perforation of the liver. [From a photograph.]

CASES 400-401.—The remarkable case of Sheridan, in which there was hernial protrusion of the lung and liver and omentum, is detailed in the *First Surgical Volume*, at page 516. The case of Sanner is briefly noted there, at page 570, among the partial excisions of the ribs. Assistant Surgeon H. Allen states that the ball, "entering between the ensiform cartilage and left seventh rib, perforated the liver, and emerged on the right side, fracturing the tenth and eleventh ribs." Sanner was discharged September 2, 1865, and pensioned. Examiner E. A. Smith, of Philadelphia, remarks on this as a recovery from shot perforation of the liver, bilious matter having escaped from the wound for three weeks. Sanner was still a pensioner December 4, 1872.

CASE 402.—Private F. Searle, Co. A, 9th New York Heavy Artillery, aged 28 years, was admitted into hospital No. 1, at Frederick, July 10, 1864, with a penetrating wound of the abdomen, received the previous day at Monocacy Junction. The injury was noted as a "penetrating wound of the small intestine—duodenum." Tonics, stimulants, and opiates were given, and simple dressings were applied to the wound. He was furloughed September 5, 1864, and remained at his home until March 3, 1865, when he returned to the hospital. Assistant Surgeon T. H. Helsly, U. S. A., reported that Searle was discharged from service June 10, 1865, on account of a "gunshot perforating wound of the lower border of the liver (probably) and penetrating wound of the duodenum, with consequent severe neuralgic pains of the abdomen, dysuria, and inability to endure muscular exertion." Pension Examiner A. F. Sheldon reported, February 7, 1867: "The ball entered four inches from the linea alba (right side), passed through the eighth rib, coursed backward through the body, and made its exit an inch lower than the entrance wound. He is unable to do any hard labor, but can travel about comfortably, and has an agency for the sale of trees. I do not think the disability wholly permanent, as he has improved considerably since I examined him in October last. His general health is now good." Dr. M. F. Sweeting, of South Butler, New York, reported, September 25, 1872: "This man's friends brought him home September 8, 1864, when the case came into my hands for treatment. He brought the following history: 'Struck with a minié ball, which penetrated the liver, capsule of right kidney, and perhaps an intestine.' It seems probable from the discharges that this is the case. I have no doubt that the ball passed through a portion of the liver, causing a leaking of the bile, and, from the bloody discharges with the urine, that the kidney must have been pierced or hit. As to the intestine, I cannot say, but, from some after symptoms, I think it might have been wounded. He was under my treatment until January 25, 1865. I do not think that his health is as good as at the time of his discharge or a year after. I think that adhesions have formed, and are, perhaps, continuing to form, from the constant irritation, which renders him unfit for any manual labor. His general health is very poor. The slightest exertion causes pinching pains through the bowels, followed by a very severe sick headache. He says he never suffered from a headache previous to being wounded. I believe this originates from the liver. I see him often, and do not think he is able to perform any manual labor. I further believe that the wound will cause his death at no very distant day." Searle was still alive in February, 1873.

<sup>1</sup> In CASE 390 (*McCleary*), Assistant Surgeon W. H. GARDNER, U. S. A., removed a portion of the disorganized liver. The case recorded by FABRICIUS HILDANUS (referred by MACPHERSON and others to BLANCARD), the case of DIEFFENBACH (*Zeitschrift, f. d. ges. Heilk.*, 1837), and the cases of JASSER, OPTZ, FRICKE, MACPHERSON, and MASSIE, already noted, appear to demonstrate that this form of *hepatotomy* is not hazardous.



CASES 403-405.—Lieutenant Williams was reported from the regimental hospital as mortally wounded at Chancellorsville, May 3, 1863. At the Officers' Hospital, at Philadelphia, Acting Assistant Surgeon W. Cammack notes that this officer, convalescing from a penetrating shot wound of the abdomen, still had hæmaturia. Pension Examining Surgeon Oliver Everett, of Dixon, Illinois, reported, February 14, 1870, that "the ball, entering the right side between the ninth and tenth ribs, midway between the lower end of sternum and the spine, passed to the left, somewhat downward and slightly backward through the body, wounding the lower lobe of the right lung, the liver, and left kidney, and came out between the spine and the crest of the ilium, on left side. There was also a wound of the thigh from a ball which struck it upon the outer side, about six inches above the knee-joint, passing inward and backward, and came out on the inner posterior face of the thigh. The health of this officer is poor and precarious from the wound of the viscera, and the use of the muscles of the leg is materially impaired." Williams was a pensioner in December, 1872. The cases of White and Terwilliger have been already noted (*supra*, p. 48).

CASE 406.—Lieutenant George Yount, Co. I, 3d Missouri, aged 24 years, was wounded at Vicksburg, May 22, 1863, by a minié ball, which passed through the right arm, about three inches from the waist, carrying away about two inches of the radius. It then entered the chest between the sixth and seventh ribs at the junction of the middle and outer thirds of the left half of the chest, ranged downward and backward, and lodged close to the spine opposite the tenth dorsal vertebra, from which situation it was removed the same evening. On being carried to the rear, he came under the care of Assistant Surgeon F. French, 31st Iowa, who had him laid upon his face and inclined to the right side to facilitate the discharge of blood. There was considerable hæmorrhage, with obstinate vomiting tinged with bile and tasting of fresh blood, although none could be discovered. He was conveyed to the hospital of Steele's Division, where quiet was enjoined. In about a week, the anterior wound commenced discharging bile, which continued to a considerable extent. The posterior wound healed, but in about four weeks inflammation set in; the wound was re-opened, when bile discharged freely—judged to be nearly eight ounces daily. The discharge gradually ceased, and the wound healed, but was again opened July 26th, and a piece of clothing removed. He reached home, August 7th, weighing ninety pounds. The posterior wound soon healed; the anterior wound closed about September 1st. Pension Examiner R. S. Lewis, of Dubuque, Iowa, who furnishes the notes of the case, remarks that the patient has "gradually gained strength. He has suffered from two attacks of acute hepatitis, arising apparently from over-exertion. These attacks yield readily to treatment, but admonish him of the extreme care necessary to prevent a recurrence. The radius was resected six weeks after he was wounded. The wound remained open for a little more than a year, but eventually healed, with very good motion and strength in the wrist." He was discharged from service November 16, 1864, and pensioned. Examining Surgeon W. M. Skinner, of Anamosa, Iowa, reports, March 12, 1869: "The right arm is lessened in size, and weakened. He is subject to paroxysms of pain and cramps in the wounded side, and his general health is a good deal impaired. I regard the disability as equal to the loss of a hand or a foot."

CASE 407.—Private Zimmer received, at Chicamauga, September 20, 1863, a shot perforation of the right side. Surgeon A. T. Watson, U. S. V., believed that the ball grazed the liver in its transit. Zimmer was discharged September 20, 1864, and pensioned. There are several reports from pension examiners dwelling chiefly on the disabilities arising from the thoracic lesion, of which there was no question. Regarding the injury of the diaphragm and liver there was difference of opinion, and the symptoms are not detailed with sufficient exactness to permit a definite conclusion to be drawn.

In eighteen of this series of thirty-seven cases, the existence of hepatic lesions appears to have been indubitable. With the fourteen incontestable recoveries of the first series, the record therefore supplies thirty-two examples not to be excluded, by the most rigorous analysis, from the category of recoveries from shot wounds of the liver. Twenty-three of the thirty-seven cases were complicated by lesions of the diaphragm, and in eighteen of these the lung was injured, and in nine there was fracture of the ribs. Nine were associated with lesions of the stomach or intestines, and six with wounds of the kidney. In two cases it was believed that the gall-bladder was interested. This doubtful point will be more fully examined in treating of abdominal effusions.<sup>1</sup>

An early paper by Dr. George C. Harlan,<sup>2</sup> in the Proceedings of the Pathological Society of Philadelphia, should be consulted, as the most important American contribution to the subject of traumatic affections of the liver.

<sup>1</sup> STROMEYER (*Marimen*, u. s. w., S. 638) says: "I have seen three recoveries of wounds of the liver and one of the gall-bladder. In the case of injury of the gall-bladder there was a great deal of pain during the first few days, which extended over the entire abdomen, but was most severe at the seat of injury." SCHWARTZ, also (*Beiträge zur Lehre von den Schusswunden*, Schleswig, 1854, S. 124), relates the case of a soldier wounded at Kolding, April 23, 1849, by a musket ball, which entered the width of two fingers above the right ilium, and escaped near the navel; peritonitis, severe pain, vomiting, fever; gall escaped immediately from the wound of entrance—opium in large doses. In the latter part of May, the wound of exit closed; the wound of entrance became smaller and fistulous; in July the latter closed, and the man recovered entirely. SOCIN (*Kriegschr. Erf.*, Leipzig, 1872, S. 94) recites the case of F. Rippert, wounded at Wörth, August 6, 1870; ball entered two inches to the right of the first lumbar vertebra, and escaped from the right iliac region; colon, liver, and gall-bladder wounded; continued irregular fever; escape of fecal matter from both wounds; several large incisions in abdominal wall; convalescent in ninety-three days. Consult further: WATON, *Sur une blessure à la vésicule du fiel*, in DE HORNE'S *Jour. de Méd. mil.*, 1788, T. VI, p. 550, and ATTESRIEU, *Diss. de sanandis forsan vesiculae felleæ vulneribus*, Tübingen, 1803.

<sup>2</sup> HARLAN (G. C.), *Four Cases of Wounds of the Liver* (Proceedings Path. Soc. Phila.), in *North Am. Medico-Chir. Review*, 1859, Vol. III, p. 698. The specimens in these cases—one of which resulted from a fall, two from railway accidents, and one from crushing by a cart-wheel—were presented, with the clinical histories, and a summary of the literature of the subject. I regret that, while adverting to ruptures of the liver (p. 16, *supra*), I had not met with this valuable paper, which Dr. MAYER has freely quoted. In KILGOUR'S *Contributions to Pathology*, in *Edinb. Med. and Surg. Jour.*, 1841, Vol. 55, p. 369, there are some valuable observations on wounds of the liver.



WOUNDS OF THE SPLEEN.—The spleen is less subject to wounds than the liver, because of its smaller size and deeper situation. Its liability to rupture, from slight external violence, especially when morbidly hypertrophied, has been exemplified in the preceding section. The older surgeons' were of opinion that wounds of this organ were as deadly as wounds of the heart; but modern instances of its successful extirpation in the lower animals, and partial removal in man, without grave functional disturbances of the economy, have prepared us for the view entertained by later observers,<sup>2</sup> that shot wounds of the spleen, at least, are less fatal than is commonly stated in works on military surgery. The annals of surgery present a number of examples of wounds with protrusion of the lacerated spleen, where considerable portions of the viscus were removed by excision or the ligature. I have tabulated, in a note, the recorded instances of so-called splenotomy; and the reader will not fail to contrast the successful results of the operation in cases of injury, with its fatality when undertaken for the removal of diseased structure. Larrey (*Clinique*, T. II, p. 459) was skeptical regarding the reports of recoveries after hernia of the wounded spleen; but examples have since multiplied, and there is now no question of their authenticity. Protrusion appears to be a favorable complication, the dangers of internal hæmorrhage and of peritonitis being, apparently, notably diminished, in this condition. But protrusion is very rare after shot wounds, although a solitary example will be adduced presently, from the report of Surgeon Hatchitt. Hennen remarked (*op. cit.*, 3d ed., p. 444), of the few wounds of the spleen that he had observed, "some of the slighter recovered, the deep invariably proved fatal." Mr. Erichsen teaches that serious lacerations invariably terminate speedily in death; M. Legouest<sup>3</sup> enunciates the generally accepted view, that, while mortal hæmorrhage or peritonitis sometimes result, in some grave cases complete reparation ensues.

*Punctured and Incised Wounds.*—In his long career, Larrey observed three instances only of wounds of this organ by steel weapons. One of them was received in a duel by a left-handed mounted grenadier, which circumstance leads Larrey to the ingenuous observation that "les personnes qui font des armes de la main gauche sont les plus exposées à la lésion de la rate, parce qu'elles présentent à découvert le flanc de ce côté, où l'arme de l'adversaire se dirige naturellement."—(*Clinique*, T. II, p. 460.) This man recovered, and the two other cases, which were instances of slighter sword-cuts, implicating the spleen, had likewise favorable terminations. Léveillé records<sup>4</sup> an instance of recovery after a severe sabre wound of the spleen, after intense peritonitis and protracted supp-

<sup>1</sup> JOHN BELL (*Discourses on Wounds*, Edinburgh, 1795, Part II, p. 96) says: "A wound of the spleen, liver, or vena cava is as deadly as a wound of the heart, so full are they of blood."

<sup>2</sup> Thus KLEBS, E. (*Beiträge zur pathologischen Anatomie*, Leipzig, 1872, S. 12), gives the case of Heisler, wounded August 25, 1870, as a "healed shot wound through spleen, stomach, liver, both pleurae, with comminuted fracture of the right humerus: death from intra-peritoneal bleeding." At the autopsy, on August 25th (S. 87 and Tafel VII), the spleen large, adherent to neighboring parts, firm, dark red, with large sacculi, presented, in the upper portion, a large retracted cicatrix resulting from a perforation of the spleen from right to left. As there are but few accurate descriptions of this form of injury in the annals of surgery, the reader may be referred also to an interesting history by Professor ALBENESE, of Palermo (*Clinica Chirurgica*, 1871, Vol. 1, p. 22). The patient had four shot wounds. One, with entrance posteriorly in the left eleventh intercostal space, and exit anteriorly through the abdominal walls, had healed completely on the seventeenth day, when the patient died from pyæmic infection due to another of his wounds. "Distaccando le aderenze tra la milza, peritoneo e angolo sinistro del colon, si trova fra essi una raccolta di liquido purulento, color feccia di vino nella quantità di 80 grammi circa. Il colon discendente per l'estensione di 8 centimetri circa è molto più ristretto, e le sue pareti sono ispessite; la milza è quasi il doppio del suo volume normale del peso di grammi 450 e di consistenza ordinaria; sulla sua superficie esterna obliquamente dal suo margine anteriore fino alla sua estremità inferiore si osserva un solco di cicatrice recente lunga circa 7 cm. e larga uno, che interessa fino alla profondità di tre centimetri la sua sostanza.—Pochi grami recenti di sangue nella fossa iliaca sinistra."

<sup>3</sup> LEGOUEST (*Traité de Chirurgie d'Armée*, 2ème éd., p. 402) observes: "Les lésions de la rate ne déterminent pas immédiatement des accidents bien graves; il est même très-présomable qu'un grand nombre guérissent heureusement lorsqu'elles sont peu étendues. Quand elles sont plus considérables, la rate peut être plus ou moins désorganisée, un épanchement de sang rapide et abondant peut se faire dans la cavité du péritoine et entre les feuillets de l'épiploon, et le sujet atteint, au bout de quelques jours, de péritonite, ne tarde pas à succomber. Il est plus que douteux que ces blessures soient toujours accompagnées, ainsi qu'on l'a dit, d'une hémorrhagie mortelle." See also ERICHSEN, *Sci. and Art of Surg.*, 1899, Vol. 1, p. 415.

<sup>4</sup> LEVEILLÉ, *Nouveau doctrine chirurgicale*, Paris, 1812, T. I, p. 490, case of Cheroux, drummer of the 3d Grenadiers, wounded July 6, 1806.

ration. Assistant Surgeon J. W. Williams, U. S. A., has recorded, in Circular No. 3, S. G. O., 1871, page 102, a recovery after a bayonet wound apparently involving the spleen.<sup>1</sup> The experience of the war afforded only a single illustration of this form of injury:

CASE 484.—Assistant Surgeon J. Theodore Calhoun, U. S. A., states, in his "narrative of service": "I saw one interesting bayonet wound of the spleen. The case was thus: A prisoner attempted to escape from the guard-house, and was bayoneted by the sentry on duty, death ensuing in a very few minutes. Some hours after death I made the autopsy. The body was a perfect model of manly symmetry. I regret to say that I took no notes of the case, supposing that bayonet wounds would be seen in profusion on the battle field,—a supposition in which, it is perhaps needless to say, I was most decidedly mistaken. The bayonet had entered the side, several inches below the spleen, passing upward and inward and penetrating the spleen to the depth of an inch or more. In its passage it had cut several arteries, the hæmorrhage from which had been the cause of death,—the only death from primary hæmorrhage that I have witnessed since I entered the service,—popular opinion on the frequency of deaths from hæmorrhage on the field to the contrary notwithstanding. The cavity of the abdomen was filled with clotted blood. The bayonet used was of the old form."

Guthrie, while admitting that such lesions are frequently fatal, remarks that he has "seen, after death, cicatrices in the spleen corresponding to former wounds." The treatment in such cases will be to place the patient on the injured side and to seek to avert the internal effusion of blood and consecutive inflammation by immobility, cold *intus et extra*, and moderate compression. Iced drinks should be of benefit, both by distending the stomach and compressing the spleen, and by directly inducing contraction of the spleen.

*Gunshot Wounds.*—Some thirty imperfect observations made during the war added nothing to the information already in our possession regarding this group of injuries, further than to corroborate the presumptions that the risk of immediate fatal hæmorrhage was formerly exaggerated; that minor lesions are often repaired and sometimes unsuspected; that extended lesions, associated even with very considerable loss of substance of the organ, do not necessarily result fatally, or in any apparent derangement of the function of hæmatisis; and, finally, that there are no distinctive subjective signs of wounds of the spleen.<sup>2</sup> Two instances were recorded of recovery from alleged shot wounds of the spleen, the descriptions leaving much to be desired in sufficiency and exactness of details:

CASE 485.—Captain Michael Murphy, Co. B, 90th Illinois, was wounded at Missionary Ridge, November 25, 1863, by a conoidal ball, and taken thence to a field hospital of the Fifteenth Corps. Surgeon W. W. Bridge, 46th Ohio, described the injury as a "severe gunshot wound of the abdomen, the ball passing through the spleen." The symptoms and progress of the case are not described. It is mentioned that on December 24th, this officer was transferred to Bridgeport, Alabama, thence to Nashville, and thence, on the 27th, attended by Surgeon H. Strong, 90th Illinois, to the Officers' Hospital, at Louisville. On the following day, December 28, 1863, this officer was granted leave of absence by order of General W. T. Sherman, on account of being "shot through the body." He was mustered out of service June 6, 1865. Pension Examiner B. F. Fowler, of Galena, Illinois, reported, September 20, 1865: "Ball entered near the edge of the false ribs, about four inches from the median line and about five inches below the nipple of the left breast, making its exit close to the spine, producing weakness of the back. Disability total, and permanent." Captain Murphy continued to receive his pension December 4, 1872.

Protrusion of the spleen, lacerated by shot, is rare.<sup>3</sup> The following purports to be an example of the successful extirpation of the organ under such conditions:

CASE 486.—On the report of Surgeon James G. Hatchitt, U. S. V., of the sick and wounded at the hospital at Perryville, Kentucky, for December, 1862, the following statement was recorded: "Private W. H. Walden, 9th Tennessee, had his spleen shot out at the battle of Chaplin Hills. The ball entered half an inch to the left of spinous process of the fourth lumbar

<sup>1</sup> Recoveries from punctured and lacerated wounds of the spleen are not common. The cases cited in the text, a score of instances adduced in the table further on, and the cases recorded by PURMANS and PATRY, are the most remarkable. PURMANS (*Lorbeer-Krantz*, u. s. w., 1692, S. 414) states that, in 1672, a soldier at Minden was stabbed in the side, the knife penetrating the spleen; on withdrawing the ragged blade a portion of the spleen, the size of a walnut, was torn out; yet the soldier recovered. M. SAPPÉY (*L'Union méd.*, N. S., 1864, T. XXI, pp. 408, 469) makes an extended report of the extraordinary case observed by Dr. PATRY. A shepherd boy, 11 years old, on June 30, 1850, was gored by an ox; the abdomen was torn open in the left flank; the stomach was very much distended and a mass of intestines protruded. The omentum and spleen were irregularly lacerated, and the mesentery perforated in several places. The parts were cleansed with tepid water; the lacerated portions of the omentum and spleen were removed, and all the viscera were returned except the stomach, which could not be replaced until its contents were expelled by emesis. The boy recovered, and was seen by Dr. PATRY, two years afterward, entirely well. See GUTHRIE, *Lectures*, Part II, p. 57.

<sup>2</sup> So that there has been in this direction no advance since the time of HUNTER (*A Treatise on the Blood, Inflammation, and Gunshot Wounds*, London, 1794, p. 545), who remarks: "A wound of the spleen will produce no symptoms that I know of, excepting, probably, sickness, from its connection with the nerves belonging to the stomach." A quarter of a century later, DUPUYTREN (*Leçons Orales*, T. VI, p. 430) remarks: "Les blessures de la rate n'ont point de signes particuliers, ce qui tient à l'ignorance dans laquelle on est des usages de ce viscère, ignorance qui nous prive du secours que pourrait offrir le trouble de ses fonctions."

<sup>3</sup> GUTHRIE (*Commentaries*, London, 1855, p. 591) remarks: "I have not seen nor heard, during the Peninsular War, of a wound in the abdomen through which the spleen protruded, the patient recovering."



vertebra and came out between the eighth and ninth ribs, midway between the spine and sternum. The spleen was cut off with a ligature, and the patient was up in two weeks, and rapidly recovered." The compiler of the surgical report in Circular No. 6, S. G. O., 1865, not printing this statement, Dr. Hatchitt addressed to the Surgeon General the following letter, dated Frankfort, Kentucky, February 5, 1868: "SIR: In the *Medical and Surgical History of the War* [preliminary report of Circular 6?] you state that there was no authentic report of the extirpation of the spleen. I have frequently thought of calling your attention to the report I made of the successful excision of the spleen, by ligature, at Perryville, Kentucky, while in charge of the wounded of the battle at that place. I am reminded of the case by just reading a report of such a case in the *Medical and Surgical Reporter*, of Philadelphia, page 37 of the present volume. There was no mistaking the diagnosis of the case I reported. Nothing could be plainer; and, were it necessary, it could be substantiated by several medical gentlemen." In response to this letter, a request was made for more definite details respecting the case of Private *Walden*, to which application Dr. Hatchitt replied, February 13, 1868, as follows: "SIR: Yours of the 10th instant, in reference to the case of extirpation of the spleen, is received. I regret that I can now give so few of the details of this case. The subject of this case, Private *Walden*, when first seen by me was under the especial care of Dr. — Alston, a Confederate surgeon from Texas. Dr. Alston had been unable to pay attention to the case. It was several days after the battle. The spleen was much congested and strangulated, the entire body of it protruding from the wound, and too nearly gangrenous to admit of an attempt to reduce it. Dr. Alston applied a ligature, and, in a few days, the spleen fell off. To the astonishment of all, there was not the least functional derangement perceptible following its loss. There was very little peritoneal inflammation following, and the patient kept his bed not exceeding two weeks. Dr. Alston manifested great interest in the case—promised to keep the patient in view, and to keep me informed as to his future health, etc. My recollection is that Dr. Alston kept this private with him until he left Perryville, which was some time in the latter part of February, or first of March following, nearly five months after the reception of the wound. Dr. Alston wrote me from some point on his route for exchange (I think from Cairo, Illinois) that *Walden* had been separated from him, the surgeons being sent to some other point than that to which the soldiers were sent for exchange. I have never been able to hear of Dr. Alston or the private again. I think, had the former afterward heard of this case he would have informed me, knowing my anxiety to learn how he would be affected by the malaria of the South. At the time of the battle of Perryville there was no organization in the medical corps, at least none such as would be effective after such a battle; the whole army moving rapidly on, expecting a more important battle, left us without necessary supplies, etc. There was not even a register, or blank book, or paper to be found, to keep a proper record of the wounded."

A demonstration of the possibility of recovery from a shot lesion of the spleen<sup>1</sup> is afforded by the case of Behan, already noted; who died of Bright's disease at Guy's Hospital, four years after receiving a shot perforation of the colon, at Sebastopol. At the autopsy, a piece of the bullet was found in the spleen.

Of the fatal shot injuries observed, the most interesting, perhaps, is that related on page 19, *supra*, in which traumatic splenitis and abscess followed a contusion by a cannon ball. In another instance, in which multiple abscesses were consequent upon laceration by a shell fragment, the pathological preparation was sent to the Museum, but spoiled on the way:

CASE 487.—Private J. Kearnes, Co. I, 33d Illinois, wounded at Chickamauga, September 19, 1863, taken prisoner, but paroled after the battle; on the 29th, was admitted to hospital at Chattanooga; thence he was transferred, on November 30th, to Tullahoma. Surgeon B. Woodward, 22d Illinois, reported as follows: "Wounded by a piece of shell striking him on the abdomen and making an extensive lacerated wound. When he was brought to the hospital, he was suffering from chronic diarrhœa. About one inch below and two inches to the left of the ensiform cartilage there was a fistulous opening, which communicated with an opening one inch above and two inches posterior to the anterior superior spinous process of the left ilium, discharging pus from both orifices. He died December 9, 1863, having survived the injury eighty-two days. *Sectio cadaveris* revealed a sinuous passage from one orifice to the other, passing through the spleen, the whole of which organ was converted into a semi-cartilaginous mass, full of honeycomb abscesses filled with pus. The stomach had not been perforated, but was so adherent to, and consolidated with, the spleen, that they could not be separated. The under side of the diaphragm was covered with ulcerations; parts of two ribs against which the spleen rested were carious. From the disorganized condition of the spleen, its functions evidently could not have been carried on for weeks." Part of the pathological preparation, comprising the lower ribs, stomach, and spleen, was forwarded to the Army Medical Museum; but it had decomposed to such an extent that the relation of parts could not be made out, and it was discarded, in 1864, and the number (2016, Sect. I) was filled by a specimen of shot fracture of the ulna.

CASES 488-490.—Surgeon J. G. Hatchitt, U. S. V., reported another shot perforation of the spleen, from Perryville: Private S. A. Bullock, Co. I, 31st Tennessee, wounded October 8, died October 29, 1862. Assistant Surgeon I. M. Eastman, U. S. A., recorded the case of Private F. Bardh, Co. B, 8th New York, wounded at Cross Keys, June 8, died June 12, 1862. Surgeon R. Nicols, U. S. V., reported Private M. Hodges, Co. G, 27th Missouri, wounded at Resaca May 15th, died May 19, 1864. The fatal results of these cases are referred to peritonitis consequent on shot lesions of the spleen; but noteworthy details are wanting.

The note occupying the next two pages contains particulars of twenty-six examples of partial or complete removal of the spleen.

<sup>1</sup>In the preliminary report in Circular 6, S. G. O., 1865, p. 27, it is remarked that: "All the cases of gunshot wounds of the spleen that have been reported, were fatal. No symptoms are mentioned that particularly distinguished these from other gunshot injuries involving the abdominal cavity, and it is quite possible that the list of recoveries may include cases in which this viscus was injured, though the diagnosis was not made out."



*Tabular Statement of the recorded Operations of Splenotomy.*

The statements of authors regarding the number and results of operations are somewhat discrepant, differences in enumeration arising from varied interpretations of the authenticity of certain cases, and from accepting or rejecting instances in which only portions of the viscus was removed. Dr. F. H. HAMILTON (*Principles and Practice of Surgery*, 1872, p. 763) says of extirpation of the spleen: "It is reported to have been made seven times, and only three of these patients survived the operation." Dr. S. D. GROSS (*System, etc.*, 5th ed., 1872, Vol. II, p. 687), referring to the case of Zacarelli, as performed in 1544, remarks that the operation was not repeated until 1826, by Quittenbaum, and enumerates the additional cases of K  hler, Wells, Bryant, Penn, and K  berle. RIBES (*Dict. des Sci. Med.*, en L.N., T. XLVII, p. 244), ADELMANN (*Deutsche Klinik*, 1856, B. VIII, S. 175), and DIEFFENBACH (*Die Operative Chirurgie*, Leipzig, 1848, B. II, S. 468, *Die Extirpation der Milz*) mention several operations in the interval between those of Zacarelli and Quittenbaum. Dr. ASHURST (*Principles and Practice of Surgery*, 1871, p. 825) alludes to Magdelain's collection of the operations recorded up to 1868. M. MAGDELAIN'S paper gives abstracts of fifteen operations, nine for injury and six for disease; but it is incomplete, omitting several German, English, and American operations. HAYTL says (*Handbuch der topographischen Anatomie*, Wien, 1867, S. 717) that K  chler (*Extirpation eines Milztumors*, Darmstadt, 1855) has printed a complete list; but being unable to refer to his work, which cannot contain the later cases, I have attempted a tabular statement, verifying the original references except in two instances:

No.	DATE.	PATIENT.	OPERATOR.	OPERATION.	RESULT.	REMARKS AND REFERENCES.
1	April, 1549	A Greek lady, aged 24, wife of an Italian captain.	Zacarelli, a surgeon of Naples, of great repute, assisted by Leonardo Fioravanti, of Bologna.	Hypertrophy of spleen from quartan fever. Loss of extraordinary beauty; leg swelled, and ulcerated. After earnest request an incision was made over the spleen; the vessel secured carefully; entire viscus removed; the wound closed by sutures.	Recovered; cicatrization complete in 24 days. The spleen weighed 32 Italian ounces, or 1340 grammes.	FIORAVANTI, <i>Del Tesoro della vita umana</i> , Venet., 1570, L. II, cap. 8. Fioravanti says that he promised the husband to do the operation, but had leaving done it before, though he did repeat it subsequently, he prevailed on an old Neapolitan surgeon, Zacarelli, to undertake it.
2	1581	A Frenchman of Guyenne, (?).	Surgeon at Gian.	Wound in the left side; spleen removed.	Recovered.	ROESSLER, <i>Pratic nouvelle de Chirurgicalmatische, ou engraînement césarien</i> , Paris, 1590.
3	About 1600	A Parisian.	A barber.	Wound of spleen, with protrusion; protruding portion ligated and cut off.	Recovered.	BALLOUSIUS, <i>Opera unica</i> , T. I, p. 153,3.
4	1673	Wm. Punter, a butcher, at Wexford, England.	A Somersetshire surgeon, assisted by Dr. Turleville.	Stab in the left side; protrusion of epiploon, loops of intestines, and spleen. The patient was three days without sucer, when a surgeon reduced the intestines, excised the spleen and a portion of the epiploon, and closed the wound.	Recovered; emigrated to New England, and reported himself thence in good health.	TIM. CLARKE, in <i>Ephemerides Natur. Curios.</i> , 1673 and 1674, p. 199. Dr. D. TURLEVILLE testified to having aided in the operation. See PLANQUE ( <i>Bibl. de Med.</i> , T. IX, p. 762) and RIBES ( <i>Dict. de Sci. Med.</i> , T. XLVII, p. 244).
5	1678	Melchior Sussen, a farmer, aged 23.	Nicolas Muthias, of Colberg, Pomerania.	Incised wound in left side; partial protrusion of spleen. Patient conveyed to Colberg the same night. The next day the protruding portion of the spleen was ligated, and finally a second ligature was passed around the hilus. Spleen removed by knife on the third day, and bleeding stanchied by styptics.	Recovered in three weeks, and lived six years at least. Became a father, and labored at his accustomed work.	DANIEL CUTGER, <i>Ephem. Med. Physicor. Nat. Cur.</i> , Dec. II, Ann. III, p. 378, Norimb., 1685. Obs. CXCIV. HANNES, <i>Ephem. Nat. Cur.</i> , 1698, Ann. VII, Obs. CL, p. 293, Norimb., 1699. <i>Lion tenu cutleri ablatum evanuit non lethali</i> . Reported also by PLANQUE, <i>Bibl. de Med.</i> , T. IX, p. 762.
6	About 1700	A little girl.	Fantoni, of Turin, and M. Gerbellius.	The spleen torn out while being punished by her mother with a switch. An attempt to return the organ failed. The protruding spleen was then ligated, and on the fourth day removed.	The girl was living in 1703, "ut etiamnum vegetissima vivat."	M. GERBERZUS, <i>Ephem. Mss. Cur.</i> , Descurie III, Ann. IX et X, Obs. CXCIX, p. 370.
7	1711	Pictorie woman with ague, aged 30.	Ferreras.	Enlarged spleen; great marasmus; tumor on left side, with a fistula near the umbilicus and another in the vagina. Extirpation of the spleen.	Recovered, and bore a child; suffered from erysipelas; great pain in abdomen; insomnia; thirst. Died five years after the operation, 1716. No vestige of spleen at the autopsy.	FANTONI, <i>Obs.</i> , <i>Anatomico-Med. Selectiones in Luceni</i> , ed. filio Johanne, Turin, 1699, Ejusd., Genoa, 1738. <i>Extracti splenis de homine histor.</i> , and MORGAGNI, <i>De sed. et caus. morb.</i> , Ejusd., LXV, Art. X, p. 368.
8	Jan. 5, 1734	Thomas Conway.	John Ferguson, a surgeon at Strabane, in Ulster, Ireland.	Wounded with a skane, or great knife, in the left hypochondrium. "I found the spleen out at the wound * * * twenty-four hours after he had received the wound. I made a ligature with a strong waxed thread * * * and cut away 34 ounces of the spleen."	The patient recovered, and was seen by Dr. Ferrius afterward in good health.	FERRERUS, in <i>Philosophical Transactions</i> , Martyn's ed., Vol. IX, 1738, London, 1747, p. 149.
9	June 27, 1743	A British dragoon.	Mr. Wilsen, Surgeon to Sir R. Rich's Dragoons.	Spleen protruded through a wound received at Dettingen. Being inflamed by the cold of the night, it could not be reduced, and was cut off to prevent mortification.		HOME, <i>Medical Facts and Experiments</i> , London, 1759, p. 111; generally cited from Scott's Note, to CIBELIUS'S <i>Handbuch der Chirurgie</i> and Translation, Am. ed., 1847, Vol. I, p. 526.

10	1797	Man 35 years of age.....	Professor Dorsch.....	Knife wound between second and third false ribs; a part of spleen one inch wide and five inches long protruded. Professor Dorsch ligated the protruding portion, and removed more than one-half of the spleen.	Recovered, and lived twenty-three years.
11	1815	Peasant, aged 19.....	Not stated.....	Incised wound of abdomen; protrusion of spleen; gangrene. Protruding portion ligated and cut off.	Recovered; the man was in good health three years later.
12	1816	A Mexican.....	Mr. O'Brien, a naval surgeon, a pupil of Sir Charles Bell.....	Spleen exposed for two days; profuse bleeding. The vessels were secured by ligature, and the spleen completely separated on the twentieth day.	Recovered in 45 days, when the patient remarked that he felt as well as ever.
13	1826	J. F. —, aged 36.....	W. B. Powell, of Kentucky.....	Stabbed in the left side, between tenth and eleventh ribs. Two inches of the spleen protruded. Reduction was unavailingly attempted. The protruding part was then ligated with a tendon.	The wound cicatrized in fourteen days. Dr. Bennett, of Newark, Kentucky, assisted. Nine months after, the patient enjoyed excellent health.
14	1836	German lady, aged 22.....	Dr. Quittenbaum, of Meeklenburg-Schwerin.....	Hypertrophy of the spleen, ascites, oedema of the limbs. Complete extirpation through an incision in the linea alba. Nine pints of serum evacuated. Spleen ten inches long and five inches broad. A vessel ligated.	Death in six hours. The tail of the pancreas was included in the ligature.
15	1836	Man aged 30, gored by an ox.....	Dr. Macdonnell, of Punjab, India.....	Lacerated wound of the abdomen two inches long. The protruding spleen was ligated and afterward excised.	Recovered in two months. The Society at Calcutta has the piece of spleen in its cabinet.
16	1844	Man stabbed in a quarter.....	M. Berthet, of Gray (Haute-Saône).....	Knife wound in the left flank. The spleen protruded, became gangrenous, and was excised eight days after.	Recovered, and lived thirteen years and a half.
17	1855	Man aged 36.....	Dr. Küchler, of Darmstadt.....	Hypertrophy of spleen. Excised. Many vessels tied; wound closed by sutures.	Died in two hours.....
18	Sept. 2, 1855	I. S. —, a farmer, aged 40.....	G. Volney Dorsey, of Piqua, Ohio, assisted by Drs. Brownell and Ledon, of Palestine, Ohio.....	Hypertrophy of spleen from malaria. Incision six inches long in left hypochondrium, and a second four inches long in T. Ligature of one artery. Adhesions of the spleen broken up.	Is reported to have survived, and to look forward confidently to enjoying again good health.
19	1855	A Polish woman, Agrathia Faltiszewska, aged 22.....	Dr. J. Schütz, of Radom, Poland.....	Injury between ninth and tenth ribs; protrusion of spleen. Ligature passed around the hilus and the spleen cut off. Ligature of three small arteries. Part removed weighed two ounces. Gunshot wound in left hypochondrium; protrusion of the spleen; removal.	The wound cicatrized in fourteen days, and the patient recovered entirely.
20	October, 1862	W. H. Walden, 9th Tennessee.....	Dr. Alston, of Texas.....	Gunshot wound in left hypochondrium; protrusion of the spleen; removal.	Survived. Kept his bed only two weeks. Transferred for exchange in March, 1863.
21	Sept. 6, 1864	Adèle Cecily, aged 20.....	M. Pean, of Paris.....	Unilocular cyst of the spleen. Incision from umbilicus to pubes; removal of spleen.	Recovered.....
22	Nov. 20, 1865	Woman, aged 34.....	Mr. T. Spencer Wells, of the Samaritan Hospital, assisted by Drs. Bowen, Kirchie, and Wright.....	Hypertrophy of spleen. Incision 7 inches in length was made, and the spleen removed. The latter weighed 6 lbs. 5 ozs.	Died six days after the operation, from hæmorrhage.
23	June 20, 1866	Charles P. —, aged 30.....	Mr. T. Bryant, of Gray's Hospital, assisted by Mr. Cook.....	Enlargement of the spleen, with leucocythæmia. Excision of the spleen.	Died in two hours. At the autopsy a coagulum, weighing 1½ pounds, was found in the region of the spleen.
24	Sept. 21, 1867	Madame M. —, of Westhofen (Puss-Rhin), aged 32.....	Professor E. Köberle, of Strasbourg.....	Incision in linea alba thirty centimetres in length. Spleen weighing 6750 grammes.	Died during the operation, from uncontrollable bleeding.
25	Nov. 9, 1867	H. F. —, handservant, aged 40.....	Mr. T. Bryant, assisted by Mr. Purnham.....	Spleen adhering to diaphragm. Spleen cut off; four ligatures employed. The removed spleen weighed 10½ pounds.	Died fifteen minutes after the operation, from hæmorrhage.
26	March 5, 1869	Djelloul-ben-Achom, an Arab, aged 35.....	M. Hazille, médecin major.....	Knife wound in hypochondriac region. A portion of spleen, 11½ centimetres long, 9 centimetres wide, 27 centimetres in circumference, protruded. Ligature was applied, and on the fourth day the protruding portion was cut off.	Recovery in twenty days; no ulterior disorder of hæmatisis.

<sup>1</sup> As MARCUS MARIUS (*De dolore nephritico*, Jena, 1672) and SIMON (*Die Exstirpation der Milz am Menschen*, Gießen, 1857) question the authenticity of this case, GÜNTHER (*Die Blut. Op.*, Abs. XV, S. 152) quotes the original version from the copy of ROTSETT in the library of the University of Leipzig. VIARD, a surgeon, and PETTY, a physician, of Ghent, are cited as attesting the felicitous result of this instance of splenotomy by a surgeon of the same locality, and as expressing their wonder what the function of the spleen might be, since its rich vascular supply might be with impunity destroyed.

<sup>2</sup> HESSE and SIMON, regretting that they cannot verify the reference to BAILLON or BACCONIUS, GÜNTHER (l. c., p. 152) cites the case: "Cuidam vulnerato ad notissimas partes splenis apparuit: ignominiosus splenem esse: Innumum valde et vitium contraxit. Alter venit nudicator, qui secuit prius superiorem partem ligatum: convulsiu æger. Estne licitur splen tam necessarius?" MALPIGHI first (Houngery), and afterward RUYSCII, ASSOLLANT, DUCUYTJEN, SEGALAS, and others, extirpated the spleen in dogs. In 1755, there were three dissertations at Halle, *de splene carnisæ excisio*, by FAELIUS, DEISCH, and SCHAFF.



In the twenty-six cases tabulated on the two preceding pages, partial or complete removal of the spleen was undertaken sixteen times on account of traumatic lesions, ten times on account of cystic, hypertrophic, or other pathological alterations. There is the surprising result that the cases of the first group, without exception, terminated favorably.

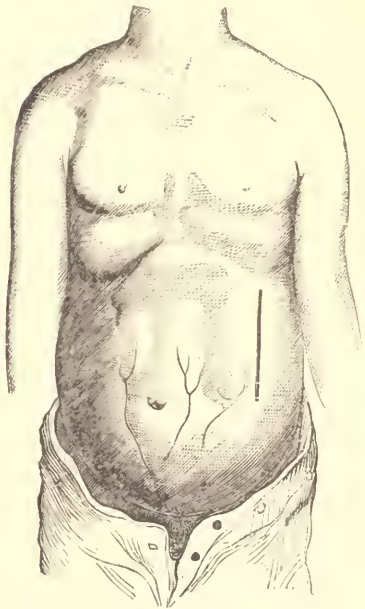


FIG. 117.—Line of incision in a case of splenotomy. [After BRYANT.]

Of the pathological cases, four recovered and six died. The accompanying illustrations (FIGS. 117, 118) are copied from Mr. Bryant's paper,<sup>1</sup> in which the removal of the spleen in certain cases of incurable chronic enlargement is held to be justifiable.<sup>2</sup> The results of the traumatic cases encourage interference for the suppression of dangerous hæmorrhage.

Of shot wounds of the spleen associated with lesions of the stomach or intestines, CASE 197, on page 50, CASE 202, on page 54, CASE 308, on page 105, afford examples. In the *First Surgical Volume*, among wounds of the chest, the cases of Wilcox, on page 445, of B——, on page 446, and the case of P——, on page 589, were complicated by wounds of the spleen. The three following cases have been adverted to as shot wounds of the liver:

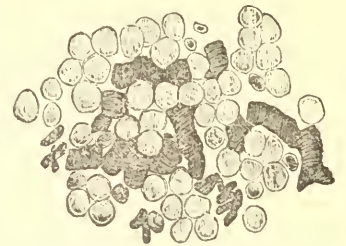


FIG. 118.—Microscopical appearance of the blood in a case of leucocythæmia. [After BRYANT.]

CASE 413.—Private R. Bell, Co. K, 15th West Virginia Cavalry, aged 21 years, was wounded at Ashley's Gap, July 24, 1864, by a conoidal ball, which fractured the tenth rib, penetrated the left lung, perforated the diaphragm, and grooved the anterior borders of the spleen and of the liver. He was treated in the field until the 27th, when he was transferred to the hospital at Frederick. Death resulted August 26, 1864. The case is reported by Assistant Surgeon R. F. Weir, U. S. A.

CASE 425.—Private Samuel O. Crafts, Co. K, 40th Massachusetts, aged 26 years, was wounded at Olustee, Florida, February 20, 1864, and removed to Beaufort on February 23d. Surgeon Charles L. Allen, U. S. V., reported: "Conoidal ball entered below the right nipple, between the fifth and sixth ribs. On February 23d, a linear incision one inch long was made, and the ball was extracted from under the skin on the right side, just anterior to the edge of the scapula. At the time of operation there was great tenderness, but no considerable swelling or inflammation around the wound of entrance; ecchymosis from axilla nearly to crest of ilium. Respiration and circulation were rapid, with dyspnœa; countenance anxious, and expressive of suffering; skin hot and dry; tongue red, with thin white coating; no cough or expectoration. The normal respiratory murmur was heard clearly and distinctly throughout both lungs; no abnormal dulness upon either side. The dyspnœa and rapidity of respiration and circulation gradually increased, also the heat and dryness of the skin; the tongue became more coated, and after a time dry and parched; complete loss of appetite. After a few days, dulness was detected at the base of the left lung, continuing to increase upward, with loss of respiratory sounds in the same region, not replaced by bronchial respiration. Vomiting of impure bile commenced on March 23d, and continued. He died from exhaustion March 26, 1864, having survived the injury thirty-five days. *Post-mortem* appearances: The passage of the ball was traced through the cartilages of the fifth and sixth ribs, near their junction with the ribs; through the left lobe of the liver, behind the œsophagus; through the thickened part of the spleen; through the diaphragm, perforating the left pleural cavity without injuring the lung; and passed out between the tenth and eleventh ribs. About two ounces of clotted blood were found in the left pleural cavity, besides about sixty ounces of sero-purulent fluid. Around the spleen adhesions had taken place, confining eight ounces of dark grumous fluid; only a very small quantity of effusion into the abdominal cavity."

CASE 477.—Private F. Watkins, Co. D, 117th U. S. Colored Troops, aged 22 years, entered the West End Hospital, Cincinnati, August 30, 1864, with two wounds, received in a skirmish at Ghent, Kentucky, on August 29th. Assistant Surgeon R. Bartholow, U. S. A., reported that one ball entered between the seventh and eighth ribs, penetrated the left lung, and passed downward through the stomach, spleen, and liver; another entered the spinal canal. Death, September 1, 1864.<sup>3</sup>

<sup>1</sup> BRYANT (T.), *Case of Excision of the Spleen*, in *Guy's Hospital Reports*, 1866, Vol. XII.

<sup>2</sup> SCHLITZE, *Extirpation de la rate et de ses fonctions*, in *Arch. Gén. de Méd.*, 1<sup>re</sup> série, 1829, T. XX, p. 429; BLUNDELL, *On the Surgery of the Abdomen*, in *The Lancet*, 1828-9, Vol. II, p. 353; QUITTENBAUM, *Comment. de splenis hypertrophici et historia extirpationis hypertrophici cum fortuna adversa in femina riva facta*, Rostock, 1836; SIMON, *Die Extirpation der Milz am Menschen nach dem jetzigen Standpunkte der Wissenschaft*, Giessen, 1857; MARTINI, *Die Extirpation der Milz am Menschen*, in *Deutsche Klinik*, 1859, B. XI, S. 228; SPENCER WELLS, *On Excision of Enlarged Spleen*, in *Med. Times and Gaz.*, 1866, Vol. I, p. 2; PHILIPPEAU X., *Expériences démontrant que la rate extirpée sur de jeunes animaux et replacée dans la cavité abdominale peut s'y greffer, peut continuer à y vivre et à s'y développer*, in *Gaz. hebdom. de méd. et de chir.*, Sept. 21, 1866, p. 601.

<sup>3</sup> BARTHOLOW (R.), *Cincinnati Lancet and Observer*, IV Ser., 1864, Vol. VII, p. 597, for a full report of this case.



In several instances, little more is stated than that the patients perished from internal hæmorrhage, and that there was a great effusion of dark blood.<sup>1</sup>

CASES 491-494.—In the four following cases, the patients perished speedily from internal hæmorrhage: 1. Private J. Myers, Co. G, 5th Illinois Cavalry, wounded April 12th; a musket ball divided the descending colon, spleen, and left kidney, and cartilage of eleventh rib; died April 13, 1865. Reported by Surgeon D. Stahl, U. S. V. 2. Unassigned substitute J. Warren, shot perforation of spleen, March 19, 1865; death in a few hours. Reported by Assistant Surgeon G. M. McGill. 3. B. T. Fairley, Co. B, 4th Pennsylvania Cavalry, aged 26 years, pistol-ball perforation of spleen, December 11, 1864; death the same day. Surgeon James Bryan, U. S. V., notes that the superior mesenteric artery was divided in this case. 4. Corporal A. Mitchell, Co. F, 36th U. S. Colored Troops, aged 36 years, was wounded at New Market, November 29th; a musket ball perforated the spleen and fractured the third lumbar vertebra. Reported by Assistant Surgeon J. H. Frantz, U. S. A.

The proportion of cases of wounds of the spleen, complicated with lesions of the diaphragm and thorax, was considerable:

CASE 495.—Private J. Applegate, Co. A, 13th Indiana, was wounded at Petersburg, July 4, 1864, and was taken to a field hospital, and subsequently removed to the base hospital of the Eighteenth Corps, near Broadway, where he remained under treatment until he died, July 12, 1864. At the autopsy, made by Surgeon C. H. Carpenter, 148th New York, it was found that the ball, fracturing the left tenth rib, had passed through the lower lobe of the lung, the diaphragm, the spleen, and emerged two inches to the left of the spinous process of the lower lumbar vertebra. There was hæmothorax. The abdominal lesions are not described.<sup>2</sup>

CASE 496.—Private Z. Robnult, Co. H, 53d Pennsylvania, was wounded at Fair Oaks, June 1, 1862. He remained at field hospital until the 27th, when he was conveyed by the transport Louisiana to Philadelphia, and entered Wood Street Hospital. Assistant Surgeon C. W. Horner, U. S. V., states that "he lingered until June 19th, with symptoms of inflammation of the pleura and peritoneum; pulse 130; pain intense. The *post-mortem* examination revealed the following pathological conditions: A round ball entered just below the inferior angle of the left scapula, passed in an oblique direction downward between the integument and ribs, fractured the seventh rib, grazed the inferior lobe of the left lung, passed through the diaphragm, traversed the spleen, and lodged in the spinal column. The left pleura was inflamed and thickened, with the lung attached, and, in the lower portion, compressed by the bloody serum which had accumulated to the amount of three quarts. The peritoneum was also inflamed to a limited extent. The missile (Fig. 119) was found impacted in the body of the first lumbar vertebra.



FIG. 119.—Flattened ball. Spec. 4184.

CASE 497.—Surgeon T. H. Squire, 89th New York, reports the following: "William Utter, Co. F, 89th New York, aged 24 years, was wounded, April 19, 1863, while storming fortifications in the Nansmond River, by a musket ball, which made four openings in the body. It first entered the outer aspect of the left forearm five inches above the wrist joint, and, fracturing the radius, came out on the inner aspect, three inches distant from the wound of entrance; then it entered the left chest below the fold of the armpit and three and a half inches from the nipple, and came out on about the same horizontal plane two inches from the spine and eight inches from where it entered the chest, wounding the left lung, and probably breaking one or more ribs. For the first twenty-four hours or more, he had severe pain in the whole of the left chest, with some disposition to cough. For the pain and inflammation, I bled him from the arm. The next day he began to spit blood. On April 25th, there was complete dulness over the whole left chest, with orthopnea, and a constant inclination to cough, which he suppresses as much as possible; but occasionally expectorates, the sputa indicating pneumonia. He has slept but very little, and often has a dark-red cheek; a slough either has come out or is coming out of each of the wounds, and they are discharging; wet dressings, with splint to the arm, and some morphia for the pain and uneasiness, constitute the treatment. May 1, 1863: This case proved fatal last night; he suffered a good deal during the last two days from shortness of breath, and much of the time he kept the sitting posture, either in a chair or in bed. The countenance was pale; lips slightly livid; free, cold perspiration, and tendency to drowse; some cough, but little or no expectoration; pulse most of the time quite small. *Post mortem* revealed the facts that the ball had broken the ninth rib about one and a half inches from its junction with the cartilage; that it entered the abdominal cavity just below the diaphragm, made a deep transverse cut or furrow through the middle of the convex side and substance of the spleen, cutting the organ full half asunder, and cutting the abdominal wall again between the eleventh and twelfth ribs, and coming out of the body at the point indicated in the previous note. Notwithstanding the chief injury was done to the abdominal tissues and organs, the chief pathological results appertained to the chest. The left thorax contained two and a half quarts of wine-colored serum, and when this was nearly all taken out by means of the sponge, I scooped off from the bottom of the cavity a handful of floating substance, which was regarded as semi-organized coagulable lymph. The lung was well compressed in the upper front part of the chest, and recently adherent to a small surface corresponding to the sternal extremity of the clavicle. The pericardium had three ounces of straw-colored serum, and the right pleural cavity eight ounces of the same or similar fluid; some recent adhesion also existed at the front of the right lung, and signs of recent inflammation, circumscribed, at that point. A small portion of the right lobe of the liver adhered to the diaphragm, and adhesive inflammation had apparently prevented the spread of trouble in the peritoneal cavity. Paracentesis of the thorax had been contemplated during his life, but it is quite doubtful if the operation would have saved him."

<sup>1</sup> FALLOPIUS (*Opera genuina omnia*, Venice, 1606, T. II, p. 390) says: "Si vulneratus sit lien, cognoscetis ex sanguine egrediente, qui ater erit, et veluti limus, et vulnus erit sub hypochondrio sinistro: alia non solent succedere ex vulnere lienis, non dolor septi transversæ, non tussicula, nec quicquam aliud." B. BELL (*System of Surg.*, 1787, Vol. V, p. 298) observes of the "deep red color" that "this is a test not to be depended on."

<sup>2</sup> This case is reported, in a memorandum of autopsies, in the *Boston Med. and Surg. Journal*, 1865, Vol. LXXI, p. 112.

CASE 498.—Private John Weston, Co. G, 1st New York Cavalry, aged 18 years, was wounded in a skirmish near Cabletown, March 10, 1864. There is no record of the case prior to his admission to No. 1 hospital at Frederick, from field hospital, on April 6th. Acting Assistant Surgeon A. R. Grey reports, on the Case Book and Medical Descriptive List: "Upon examination, after admission to this hospital, two wounds, one apparently of entrance, the other of exit of ball, were observed on the left side; the wound of entrance situated over the ninth rib, four inches below and in front of the lower angle of the scapula, involving the integument only, through which a probe could be passed two-and-a-half inches under the skin. The wound of exit corresponds to a point midway on a line drawn from the anterior superior spinous process of the ilium and ensiform cartilage, near the junction of the ninth rib with its corresponding cartilage, and passing downward and backward. The discharge from the anterior wound was profuse and fetid, welling up at every motion of patient, and has excoriated the integument for a space of three inches around both wounds. The patient is much emaciated and in a very feeble condition; pulse 120, small, and irritable; ordered one ounce of milk-punch every two hours, and two grains of quinine in pill every four hours, with a good diet; poultices were applied to the wounds, and simple cerate spread over thin cloths to the integument to prevent excoriation. April 8th: general condition somewhat improved; pulse less frequent and fuller; wound less painful upon motion; discharge still profuse and fetid; continue treatment, with two grains of opium at night. April 10th: slight diarrhœa; general condition same as yesterday; appetite better; rests well at night; wound dressed with loose lint and chloride of soda solution; continue quinine and milk-punch. April 12th: little or no appetite; no diarrhœa; pulse more frequent; discharge from anterior wound still profuse; none scarcely from the posterior wound; one ounce of whiskey every two hours. April 14th: strength failing; little or no appetite; dysphagia. April 15th: he died this morning somewhat unexpectedly, as there was no sign of dissolution at midnight, when I saw him. *Post mortem*: Chest: Lower lobe of left lung in contact with the diaphragm hepatized; left pleura costalis very much thickened, and the pleural cavity contained about eleven ounces of sero-purulent fluid; right side not examined. Heart: Normal size and healthy; one ounce of serum in the pericardium. The ninth rib was fractured near its cartilaginous insertion. The anterior and external portion of the spleen, in relation with the under surface of the diaphragm, was deeply grooved, showing the track of the ball, and in a state of ulceration. A small portion of the left lobe of the liver, near the upper border of spleen, was also involved in the ulceration. Costal attachment of diaphragm, and that portion covering the spleen softened, ulcerated, and perforated; the ulceration at that point extending to the pleura and probably causing the empyema. Stomach, peritoneum, and intestines uninjured. Near the point of costal fracture, and a little above it, a wound of the diaphragm is observed, perforating the muscle, and indicating the passage of the ball; no perforation of chest through which the bullet entered or passed out can be found. The posterior wound, which upon admission seemed to indicate the point of entrance, did not present the characteristics of a gunshot wound, and involved integument only. A thorough search for the ball was made in the chest, spleen, and diaphragm, and the thoracic parietes, but it could not be found. Near the lower border of the eighth rib, about one inch from the posterior wound, a portion of cicatrized tissue was felt, corresponding to a faintly marked linear cicatrix, on the inner parietes of chest, indicating, it is conjectured, the point of exit of ball, from which the sinus under the integument had not yet healed."

Shot wounds of the spleen are often associated with wounds of the left kidney, as in the following case:

CASE 499.—Lieutenant Martin K——, Co. A, 69th New York, aged 25 years, was wounded at Spotsylvania, May 12,

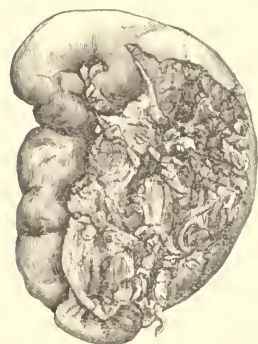

FIG. 120.—Posterior surface of a spleen, showing the lacerated wound of emergence of a musket ball. *Spec.* 3527. [Reduced to one-third.]

1864. He was conveyed by ambulance to Belle Plain, and thence by steamer to Washington, where he arrived thirteen days after the reception of the injury, and was admitted into Douglas Hospital. He died on May 26, 1864. At the autopsy the ball was found to have entered the left side one inch outside of a line falling from the nipple over the eighth rib, to have penetrated the diaphragm in two places, lacerated the spleen (FIG. 120) and left kidney, fractured the ninth and tenth ribs, and lodged in the soft parts beneath the skin, from which place it had been removed on the field. The symptoms previous to death were those due to acute traumatic pleuritis, and two quarts of bloody serum were found in the left thoracic cavity. The pleura was covered thickly with a layer of pink lymph, and the lung was compressed. The occlusion of the two openings in the inferior portion of the cavity and the retention of so large a quantity of fluid is remarkable, and indicates the necessity for ascertaining that free exits exist for such effusions. A quantity of blood was found effused into the abdominal cavity. It is remarkable that life should continue so long with such extensive injuries. Another observation worthy of notice was, that the upper portion of the left thoracic cavity was sonorous on percussion, a condition due to the compressed air in the air vesicles, or to the presence of some air in the thoracic cavity compressed by the increasing effusion. Upon microscopical examination, a transverse section exhibits no modifications of the normal structure except those obviously due to congestion. The Malpighian bodies are natural in number and distribution; the veins and capillaries are enlarged.

In the three following cases, also, the left kidney was implicated:

CASE 500.—Private Henry Sherman, Co. D, 95th New York, aged 17 years, was wounded at Petersburg, March 30, 1865. He was admitted to the field hospital of the 3d division, Fifth Corps, on the following day, and was subsequently transferred to City Point, and afterward to Philadelphia, where he was admitted to the Broad and Cherry Streets Hospital on April 10th. Assistant Surgeon Thomas C. Brainerd, U. S. A., in charge, reported the case as "Wound of the left kidney, spleen, and diaphragm, by conoidal ball; simple dressings. He died, from exhaustion and peritonitis, April 12, 18 5."

CASE 501.—Private John Fink, Co. G, 32d Indiana, was wounded at Liberty Gap, Tennessee, June 24, 1863. He was admitted to No. 1 hospital, Murfreesboro', on the 27th, and the following report of the case is given by Assistant Surgeon William G. McCulloch, 78th Pennsylvania, in charge: "Admitted June 27th, with gunshot flesh wound of the left side and



arm; cold-water dressings; whiskey given every four hours, and an anodyne at night. July 12th, the wound of side discharged four ounces of pus of an unhealthy appearance: patient perspired profusely; prescribed six ounces of whiskey with four drops of aromatic sulphuric acid, one ounce every four hours. July 23d, the patient was given egg-uoog and poached eggs, and continued to improve until the 29th, when he sat up in bed. On the 30th, he had a severe chill, and several on the 31st, followed by fever. On August 1st, patient complained of pain in the bowels; abdomen tympanitic; pulse feeble. He died at eleven o'clock A. M. Autopsy six hours after death: Ball entered the left side; passed through, fracturing the eighth rib; passed between the spleen and kidney, wounding both, and passed out, fracturing the twelfth rib and also the spinous process of the twelfth dorsal vertebra; passed through the latissimus dorsi muscle, and made its exit four inches to the right side of the spine. There was no pus found in the abdomen; there was some burrowing of abscess in the muscles of the back, both above and below the wound.

CASE 502.—Surgeon C. W. McMillan, 1st East Tennessee, reports that Private H. Minnich, Co. B, 45th Pennsylvania, aged 30 years, was wounded at Blue Springs, October 11, 1863, conveyed to Knoxville on October 12th, and died suddenly on the following day, from internal hæmorrhage. The ball had entered on the left eleventh intercostal space three inches from the spine, fracturing the eleventh rib, and was found at the autopsy to have passed downward, wounding the spleen and left kidney; the abdominal cavity was filled with blood.

The routinists who declare that wounds of the lung are always followed by pneumonia and pleurisy, and that hepatitis is an invariable consequence of wounds of the liver, would doubtless maintain that splenitis inevitably resulted from injuries of the spleen. But the facts presented on pages 18 and 19, and in the foregoing abstracts, teach that traumatic lesions of the spleen are not followed by anything of the nature of general parenchymatous inflammation, unless violence is inflicted upon the whole organ. Alterations of texture are limited to the immediate vicinity of the solution of continuity; there is little tendency to abundant pus formation, unless foreign matters are confined; and the bulky exudation products of idiopathic inflammation are absent.<sup>1</sup> The cases observed have not materially affected the questions of diagnosis<sup>2</sup> and treatment.<sup>3</sup>

<sup>1</sup> KLEBS (*Beiträge zur pathologischen Anatomie der Schusswunden*, Leipzig, 1872, S. 100) made the following observation at the hospital at Carlsruhe: "The spleen in CASE 124 gives an instance of normal healing. The channel is closed or rather obstructed by transformed thrombical spleen tissue. The process, after shot injuries of this organ, seems to be: that the powerful muscular contraction closes the opening; if this is not sufficient, coagulated blood fills the rest. In this manner the primary bleeding is soon arrested, and while the thrombosis advances into the injured blood spaces of the spleen, a tissue consisting of spleen tissue and blood thrombi fills the shot channel, and finally forms a deep retracted scar. We see, therefore, in this organ very little inclination toward reproduction of the substance lost by the shot injury." Dr. KLEBS adds: "On the whole, shot wounds of the spleen do not seem as fatal as is generally stated in military surgeries. Observations of cases of recovery have accumulated, and the principal danger of the injury is in consequence of other and subsequent diseases of the organ, that at least may be partly obviated." Among the few recorded cases of recoveries from shot wounds of the spleen is the following, by FIELTIZ (*Richter's Chirurgische Bibliothek*, Göttingen, 1785, B. VIII, S. 532): Shot penetration of spleen: removal of a piece of flannel, with portion of wad, and a small piece of spleen adhering thereto, followed by serious bleeding; recovery. There are other examples in which the patients survived a considerable period, and succumbed to secondary lesions or those unconnected with the injury of the spleen. Thus, LOHMEYER (*Die Schusswunden und ihre Behandlung*, Göttingen, 1859, S. 160) cites the case of an officer who received a perforating wound of the abdomen, the spleen being perforated. The man lived over a month. DEMME also (*Militär-chirurgische Studien*, Würzburg, 1861, B. II, S. 139) relates a case of an Austrian, "shot at Solferino, June 25, 1859, in the left hypochondrium. Repented and profuse bleeding occurred. He recovered sufficiently to be carried to the 'Osped. St. Francesco,' at Milan. \* \* \* On July 13th, twenty days after the receipt of the injury, death occurred, with signs of acute anæmia. At the autopsy the abdominal cavity was found filled with blood, probably from a rupture of the adhesions already formed. The ball, now in my possession, was found in the capsular ligament of the liver, covered with connective tissue. The spleen was injured." And SOGIN (*Kriegschirurgische Erfahrungen*, 1872, S. 93) adduces the case of Leocrépe, who received, at Wörth, an oblique shot perforation, the ball entering the left sixth intercostal space and emerging through the right eighth intercostal space, wounding the spleen, liver, and right kidney, the patient surviving the injury sixteen days.

<sup>2</sup> DUPLYTREN (*Leçons orales de clin. chir.*, Paris, 1833, T. VI, p. 480) remarks: "Quant aux balles qui peuvent atteindre et pénétrer la rate, il n'y a point de signes positifs qui indiquent cette lésion. C'est par des signes négatifs de la blessure des autres viscéres contenus dans l'abdomen que l'on peut établir des présomptions sur celle de la rate. Cet organe, contenant une énorme quantité de vaisseaux volumineux, doit fournir promptement un épanchement considérable dans la cavité abdominale. C'est cette hémorragie intérieure, et l'inflammation qui résulte de la lésion du viscére (splénite) et celle du péritoine, qui doivent attirer l'attention du chirurgien." In like manner, BAUDENS (*Clinique des plaies d'armes à feu*, p. 363) observes: "L'obscurité qui règne encore sur les fonctions de la rate fait qu'il est impossible d'en reconnaître les lésions d'après le trouble qui pourrait en résulter; les signes sont ici négatifs. Ainsi ce sera d'après la direction, la situation et la profondeur du trajet parcouru par le plomb qu'on tirera des inductions plus ou moins vraies. La gravité de solution de continuité de ce viscére provient des épanchements sanguins auxquels celles-ci donnent lieu, épanchements souvent mortels quand la blessure est large et qu'elle a été faite par une arme blanche. Les escarres déterminées par le passage du projectile sont encore ici souvent très salutaires pour prévenir les hémorrhagies; mais quand l'une des grosses artères qui entrent dans cet organe vient à être lésée, il est fort douteux que ce bouchon puisse former la lumière du tube artériel avec assez de force pour empêcher une hémorrhagie foudroyante. Lorsque la plaine n'occupe que la région dorsale et n'a entamé que la face postérieure de la rate, les accidents sont bien moins redoutables que si la perforation siègeait à la face antérieure, parce que, dans le premier cas, l'épanchement sanguin se fait directement au-dehors et peut être arrêté par le tamponnement, tandis que, dans la deuxième hypothèse, le sang s'épanche dans l'abdomen et épuise le blessé."

<sup>3</sup> There is one monograph on wounds of the spleen; POILL, *De lethaliitate vulnerum henis*, Lipsiæ, 1777. The articles of RIBES, *Dict. de Sci. Méd.*, T. 47, p. 222, and of SANSON, *Dict. de Méd. et de Chir. Prat.*, T. 13, p. 271, on wounds of the spleen, contain interesting observations. Mr. GRAY'S prize essay (*On the Structure and Use of the Spleen*, 1854) and Professor KÖLLIKER'S article in the *Cyclopædia of Anatomy and Physiology* present full bibliographical references. Dr. EDWARDS CRISP'S *Treatise on the Structure and Use of the Spleen*, gives the results of much laborious investigation. ASSOLANT'S thesis, *Recherches sur la rate*, 1802, and the numerous dissertations *de Liene*, as those by L'AMUS, Paris, 1577; by SCHNEIDER, Witleb., 1649; by SCHELLHAMMER, Kiel, 1703; by CRAUSE (R. W.), Jenæ, 1705; by ELLER (J. T.), Lugduni, 1716; by QUELMAIZ (S. T.), Lipsiæ, 1748; and by RACHEM, Berlin, 1829, contain some scattered observations on the physical lesions of the spleen.



WOUNDS OF THE PANCREAS.—It is always of advantage, the illustrious Darwin observes, to perceive clearly the measure of our ignorance. In regard to the effects of

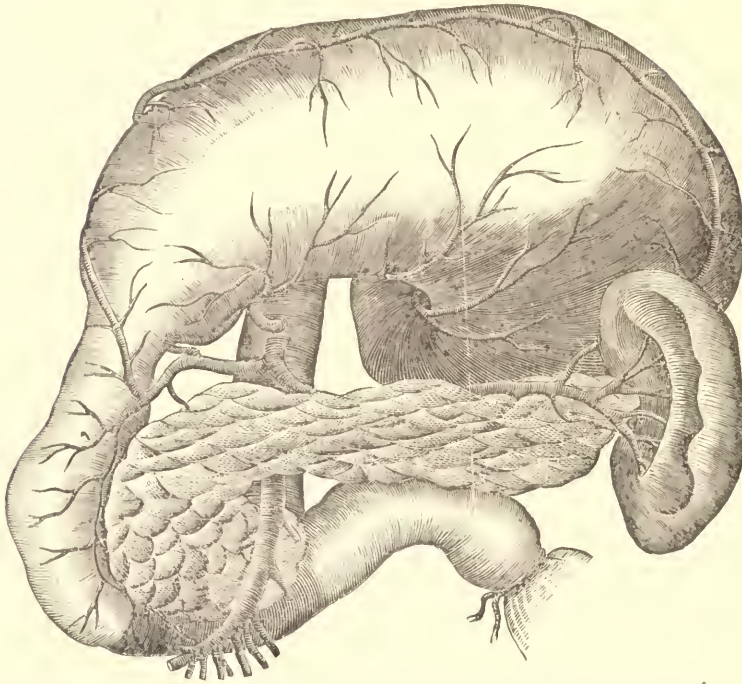


FIG. 121.—Human pancreas, shown in situ by throwing up the stomach. This drawing was taken from a young subject in which the curvature of the head of the pancreas, following that of the duodenum, was particularly well shown. [From Dr. HYDE SALTER'S article *Pancreas*, Vol. V, p. 82, *Cyclop. Anat. and Phys.*]

physical lesions of the pancreas this is readily determined. The instances in which such injuries have been observed are very few,<sup>1</sup> and were either accompanied by mortal lesions of other organs, or were described so imperfectly that the symptoms and results of uncomplicated wounds of the pancreas remained subjects for conjecture or for analogical reasoning. Five cases observed during the war by no means dissipate the interest of obscurity that attaches to this subject. That the pancreas may protrude through a wound in the diaphragm, as indicated by the observations of Caldwell, of Kentucky, and of M. Labor-

derie, is attested by the two following cases, of which the first corroborates also the inferences of the surgeons just mentioned, that a strangulated protruding part of this viscus may be safely excised:<sup>2</sup>

CASE 503.—Surgeon J. G. Thompson, 77th New York, reports the case of "a soldier, name unknown, who was wounded at Cedar Creek, October 19, 1864; the ball entered the right side below the ribs and emerged on the left side. He was removed to the Taylor Hospital at Winchester. While straining at stool, two days subsequently, a hernia of the pancreas occurred of the size of a hen's egg. A silver wire was passed about the pedicle by which it was attached, and twisted tighter each day for about a week, until it became very small and was snipped off with scissors. The treatment consisted of light diet and milk punch, as there was some prostration. No especial unpleasant symptoms supervened, and, by the last of November, the patient was in a fair way for recovery and moving about the hospital. In December he was still doing well." Surgeon Thompson states that the specimen of the excised portion of the pancreas was left with Surgeon S. B. Knox, 49th Pennsylvania, to be forwarded to the Museum. No evidence of its reception or transmission can be found.

CASE 504.—Private William Freshwater, Co. F, 66th Ohio, received wounds of the abdomen, left forearm, and neck, at Port Republic, June 9, 1862. He was conveyed in an army wagon to Front Royal, arriving on the 13th, and on the 14th was sent by rail to Washington, and admitted, on the 15th, to Judiciary Square Hospital. He was placed in a ward under the charge of Acting Assistant Surgeon David W. Cheever, who states that "a ball had entered one and a half inches outside the left nipple, on a level with the seventh rib, and could be felt under the skin near the spinous process of the last dorsal vertebra. Some viscus, thought to be the lower tip of the lung, protruded at the wound. He died in two days (June 17th), with symptoms of peritonitis. *Post mortem*: The ball pierced the diaphragm without touching the lower lobe of the lung; there was no perforation of the intestines, but they were glued together by peritoneal inflammation. The pancreas protruded at the wound."

<sup>1</sup> MONDIÈRE (*Recherches pour servir à l'histoire pathologique du pancréas*, 1836) says: "Nous ne connaissons aucun cas de plaies du pancréas; mais les expériences de BRUNNER (*Ephem. nat. cur.*, Dec., II, Ann. VII, Obs. CXXXII (1688), Norimbergæ, 1716, p. 243) établissent qu'elles ne seraient pas par elles-mêmes très-dangereuses," expressions adopted by RAUGE-DELOIRME, or the compiler of the article *Maladies du Pancréas*, in the *Répertoire générale* (*Dict. de Méd.*, T. XXIII, 1841, p. 68), which, if not absolutely true, justify the epigraph these writers borrow from FERNEL: *Quo minus nota, eo magis exploranda sunt*. JAMAÏN, a very accurate writer, remarks (*Manuel de Pathologie et de Clinique Chirurgicales*, 2ème éd., 1870, T. II, p. 493): "Les lésions traumatiques du pancréas sont excessivement rares; on possède quelques exemples de ruptures de cet organe, dont la cause a été le plus souvent le passage d'une roue de voiture sur l'abdomen."

<sup>2</sup> Attention has been called (*Note 4*, page 21, *supra*) to three cases of rupture of the pancreas without external wounds, viz: 1. S. COOPER'S case (*Lancet*, 1839, Vol. I, p. 486), J. C., aged 33, struck by the wheel of a cart; ribs broken, "pancreas literally smashed," spleen and left kidney also lacerated; death in a few hours. 2. M. LE GROS CLARK'S case (*Lect. on Princ. Surg. Diag.*, 1870, p. 298), a lad, with other internal injuries, which proved speedily fatal. "I am not acquainted with any special sign," says this discriminating and sagacious writer, "by which this organic lesion can be identified." 3. BEVERGEL'S case (*Méd. léq.*, T. II, p. 44), an unknown woman, crushed by a carriage on a road in Flanders; speedy death. To these

The only cases within my knowledge, in which preparations illustrating shot wounds of the pancreas have been preserved, are illustrated by specimens 2430 and 2884 of the surgical series of the Army Medical Museum. These are figured in the next two wood-cuts (Figs. 122 and 123). It is remarkable, though such coincidences are by no means unparalleled, that these and a third case were observed at the same hospital during the same season :

CASE 505.—Private J. Kopriean, Co. B, 51st New York, aged 32 years, was severely wounded at the battle of the Wilderness, May 5, 1864, and was at once taken to the field hospital of the 2d division, Ninth Corps. The records of this hospital contain only the name and military description of the patient, with the entry "gunshot wounds of arm and hip." Searches through the field memoranda, and inquiries among medical officers under whose observation the case was likely to have fallen, have failed to procure any information respecting the early symptoms and progress of the case. As he could not speak English, and his attendants did not understand French, his own statement was not preserved. I can only be inferred that he had to undergo, with the other severely wounded of the Ninth Corps, the trying journey to Washington described in Medical Director McParlin's report, in the Appendix to Part I. Arriving there, he was placed in Lincoln Hospital. Acting Assistant Surgeon E. L. Bliss, the ward surgeon who treated the patient from May 25th, the day of his admission to Lincoln Hospital, three weeks after the reception of the wound, until his death, gives the following information regarding the case, in a report to Assistant Surgeon J. C. McKee, which is here reproduced textually: "DOCTOR: I have the honor to report that Private J. Kōprio, Co. B, 51st New York Regiment, on admission to my ward May 25, 1864, was found to be suffering from a gunshot wound of the back, received on May 5th, the ball having entered about six inches to the left of the spinal column and just below the eighth or ninth rib. Upon examination, it was discovered that the ball had entered the abdominal cavity, but its subsequent course I was unable to determine. Patient's general health was apparently good, and he seemed to suffer but little pain from the injury. Appetite good, bowels regular, urine slightly suppressed and somewhat highly colored. Pulse normally full, but slightly irritable. Ordered nourishing diet, with whiskey and quinine *ter die*. Two moderate doses of *potassæ acetatæ* were administered, which was followed by a relief of the urinal suppression. No noticeable changes appeared for about one week, when a severe hæmorrhage occurred, apparently venous, from the external wound, which was soon suppressed by the use of compresses and styptics. About six hours afterward a quantity of urine was voided which was thickly mixed with blood. These hæmorrhages continued to recur two, three, and four times daily till death, the urinal discharge being very frequent and always bloody. Whiskey or brandy was administered every hour, more or less, as indicated, with an occasional dose of *morphiæ sulphatæ*; always enjoining the most perfect quiet and prescribing the most nutritious liquid diet." Death resulted June 5, 1864. A *post-mortem* examination was made by Acting Assistant Surgeon L. Sehoney, which revealed the course of the ball as follows: "A minie ball entered at the middle portion of the eighth rib, fracturing the same, passed through the centre of the spleen toward the pancreas, penetrating this also in a nearly transverse direction, and (probably a few days before death) sinking toward the splenic artery, tearing it, and lodged at its origin from the cœliac axis; the lung was found emphysematous." The specimen, shown in the wood-cut (FIG. 122), was forwarded to the Museum by Assistant Surgeon J. Cooper McKee, U. S. A., and is a wet preparation, consisting of parts of the descending aorta and cœliac axis, spleen, pancreas, and left kidney. The ball has lodged in a pouch between the sloughing artery and vein.

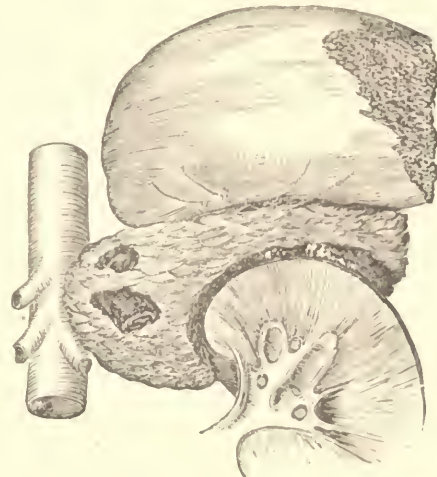


FIG. 122.—A wet preparation of portions of the spleen, pancreas, kidney, aorta, and cœliac axis, showing a musket ball embedded in the pancreas. *Spec.* 2430.

may be added: 4. A case at St. Thomas's Hospital, under TRAVERS (*Lancet*, 1827, Vol. XII, p. 384), an intoxicated woman knocked down by the wheel of a stage coach, which did not pass over her. She lived a few hours. Several ribs were fractured; the pancreas was found completely torn through transversely; the liver was lacerated, and much blood was effused. 5. KLEBERG, of Odessa (*Arch. für Klin. Chir.*, 1868, IX, 2, S. 523), relates a case of a stab in the pancreas in a discharged soldier, Anton Stepanowitch, aged 60, who fell among thieves. The protruding viscus was ligated and excised, and without subsequent fever or peritonitis; the patient left the hospital cured in twenty-one days. 6. LABORDEHE (*Gazette des Hôpitaux*, 1856, No. 2, p. 6) relates the case of a young girl receiving a wound in the epigastrium by falling on a knife. The pancreas is alleged to have protruded through the wound. The protruded portion was ligated and excised. The young girl recovered in three weeks. HYDEL (*Handbuch der topographischen Anat.*, B. I, S. 712) is incredulous as to the relaxation of the pancreas in this case. 7. CALDWELL (D. C.), *Remarkable case of the Protrusion of a body, supposed to be the Pancreas, through a wound between the last true and first false Rib, in the Transylvania Jour. of Med.*, 1828, Vol. I, p. 116. In 1816, a negro man, a slave of Judge Bibb, was stabbed in the left side, and "an oblong body, between three and four inches in length, was observed to be protruded." Drs. ROBERTS, HEARD, and CALDWELL supposed the protruded part might be mesentery, omentum, or lung substance; but, "on a more minute inspection and examination with the fingers, that opinion was changed to the belief that it was the small extremity of the pancreas. \* \* \* The loss of all that portion exterior to the constriction was inevitable, being then in a gangrenous condition. \* \* \* Excision was preferred; \* \* \* the bistoury was selected in preference to the ligature. \* \* \* The patient soon recovered." Eleven years afterward he was living, having "suffered no inconvenience from the loss of the part or its unnatural adhesions." Drs. ROBERTS, HEARD, and CALDWELL, "thinking it almost impossible that the pancreas could escape through a part of the diaphragm and between the ribs," made a critical examination of the part removed, which resulted in their "thorough conviction" that the tissue removed was a portion of the pancreas.

Dr. HYDE SALTER observes (*Cyclop. of Anat. and Phys.*, 1859, Vol. V, p. 108): "The interest that attaches to the deranged anatomy of the pancreas is the interest of obscurity—the interest of diagnosis; I may add, too, the interest of situation; in fact, it is in the situation of the organ that the importance and obscurity of its pathological relations at once result. Close to the stomach, duodenum, liver, spleen, kidney, aorta, cava,



Some negative evidence of interest is presented by the next two cases:<sup>1</sup>

**CASE 506.**—Acting Assistant Surgeon Thaddens L. Leavitt reports that “Corporal Augustus B. Jones, Co. D, 5th Vermont, aged 27 years, was wounded at the battle of the Wilderness, May 10, 1864, laid out on the battle field one day and night, was then removed to field hospital, from there carried by boat to Washington, and jolted over a rough road of two miles to the Lincoln Hospital, which he reached about two o'clock in the morning of the 25th. I mention these facts of transportation to show the immense fatigue and suffering that this patient must have sustained before he reached his destination. Saw him about six o'clock A. M., found him suffering great agony; examined his wound. The ball had entered one line to the left and below the ensiform cartilage, passing through the abdominal cavity, and making its appearance under the skin just above the crest of the left ilium posteriorly, where it was excised at the field hospital. Pulse quick and exceedingly feeble, abdomen distended and tympanitic; took food and stimuli readily, and became much easier under the free use of opium. Patient was much emaciated, and countenance ghastly and indicative of great suffering. About noon saw him again; found him much more comfortable, wounds suppurating nicely and looked well; he expressed himself as expecting soon now to get well. About four o'clock P. M. was conversing with the nurse: apparently in good spirits, without very great pain; swallowed his medicine, etc., and in about five minutes afterward was in articulo moris. The autopsy, which was made some hours after, showed the ball to have perforated the inferior curvature of the stomach, and, strange as it may seem, although an orifice was made directly through the walls of the stomach large enough readily to admit two fingers, no inflammation or even congestion could be detected, except in the immediate locality of the wound, which was beginning to suppurate. Evidently the stomach was also uninjured in its functional capacity, as was witnessed by the reception and digestion of food during life. Some branches of the gastric artery were severed, and about an ounce and a half of dark uncoagulated blood filled the pelvic cavity. The pancreas was perforated at about its middle, but, except in the immediate track of the ball, gave evidence of no departure from its healthy standard; the intestines and colon were pushed aside during the passage of the ball and were uninjured; the omentum was found in a partial state of decomposition and closely adherent to the small intestines. Liver and spleen healthy. General peritonitis had prevailed, and was undoubtedly the cause of death. In this case life was sustained for a period of fifteen days, notwithstanding the serious injury of a vital organ and the being subjected to the most unfavorable circumstances and depressing influences.”

**CASE 418.**—Private *William P. B.*—, Co. A, 44th Georgia, was wounded, near Fort Stevens, in General Early's demonstration on Washington, July 12, 1864, by a cylindro-conical musket ball, which entered below the spine of the left scapula, an inch from the shoulder-joint, and penetrated the chest. He remained a prisoner on the field, and was conveyed to Lincoln Hospital, a few miles distant, being admitted on July 14th. Acting Assistant Surgeon Thaddens L. Leavitt, the ward surgeon, noted that emphysema extended over the entire left chest, that respiration was painful, but not otherwise difficult, and that there was paralysis of motion of the left arm. Simple water dressings to the wound, and a draught with an eighth of a grain of sulphate of morphia in syrup of seneka and wild-cherry bark thrice daily, with extra light diet and a little wine. There was little change in the progress of the case until the 18th, when the pain in the side became great, and was somewhat relieved by sinapisms. There was dulness on percussion, and absence of the respiratory sounds over the posterior left chest.

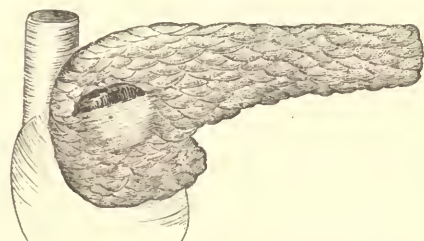


FIG. 123.—Pancreas with a conoidal musket ball embedded in its head. *Spcc.* 2884.

On the 19th, there was extreme dulness in the præcordial region, and the head was forced over to the right side. There was dulness, too, at the base of the right lung, with indistinct respiratory murmur. On the 20th, jaundice was very pronounced, and Dr. Leavitt enters on the register: “Can the liver be injured also?” On the 21st, at 4 o'clock A. M., profuse hæmorrhage from the nose and mouth occurred; bleeding coming apparently from the lung. The local pain was much lessened, the pulse became very weak and thready; the jaundice was extreme; chloride of sodium ordered. On the 22d there was much pain in the left side, dyspnoea, consciousness perfect, pulse failing; death at noon, July 24, 1864. At the autopsy, two hours after death, the wound was traced from the entrance in the scapula through the fractured fifth rib, the track passing downward, inward, and backward, through the lower lobe of the left lung, the diaphragm, the left lobe of the liver to the head of the pancreas, where the ball was found lodged in the head of the viscus, at the angle formed by the cœliac axis with the aorta. The lower lobe of the right lung was hepatized; the left lung was carnified, collapsed, and compressed by a large accumulation of black fluid blood. The pleura was freely lined with partly

mesenteric glands, and cœliac axis, it finds itself in immediate relation with the great vascular, nervous, digestive, and absorbent centres of the abdomen, and may either affect them secondarily, be affected by them, or furnish a source of fallacy and doubt as to whether it be it, or they, or both, that are implicated; and while it is thus placed at the most important point in the whole range of medical anatomy, its situation almost completely precludes it from the advantages of physical diagnosis. The pancreas enjoys an immunity from disease greater than most organs, but I believe this immunity is in part real and in part only apparent; for it cannot be doubted that one reason why the records of its morbid anatomy are so scanty is that, in so large a number of *post mortems*, no examination of the organ is made at all. It is the last to be got at, and, the cause of death having been ascertained, its examination is looked upon as supererogatory; besides, it is often obscured and mutilated in the removal of other organs, and its careful dissection from its situation, which is necessary to examine it satisfactorily, is troublesome and not very easy.”

<sup>1</sup> BELL (B.) (*A System of Surgery*, 1787, Vol. V. p. 298) says: “As the pancreas lies deeply covered with the other viscera, wounds of it can seldom be discovered: But as a division of the duct of this gland will prevent the secretion which it affords from being carried to the bowels, this may, by interrupting or impeding digestion, do much injury to the constitution; and as the liquor will be effused into the cavity of the abdomen, it may thus be productive of collections the removal of which may ultimately require the assistance of surgery.” BOYER (*Traité des Maladies Chirurgicales*, 3me éd., T. VI, p. 15) remarks: “Les plaies qui intéressent le pancréas n'ont pas ordinairement des signes particuliers. Quelques auteurs ont indiqué l'écoulement d'un liquide incolore, par l'orifice extérieur de la plaie, comme le signe caractéristique de cette lésion; mais on n'a peut-être jamais vu cet écoulement de sue pancréatique, et l'on a observé avec raison qu'une simple augmentation dans l'exhalation péritoneale suffirait pour produire un semblable symptôme. Il en est à peu près de même de la blessure du canal thoracique, qui, suivant quelques auteurs, laisse échapper hors du temps de la digestion une lymphé sans couleur, et fournit après le repas un fluide lactiforme qui s'écoulo par la plaie. Mais c'est n'est pas d'après le raisonnement, c'est uniquement sur l'observation qu'il convient de fonder les signes des maladies.”



organized lymph. The heart was normal; its cavities empty, weight nine ounces. The spleen was firm, dark-brown, weight nine and a half ounces. The pancreas was rather large, seven inches long; weight, five ounces (weighed with the ball embedded). There was nothing abnormal in its appearance, except the presence of the foreign body. The specimen was sent to the Museum by Acting Assistant Surgeon H. M. Dean, with a memorandum of the autopsy and the clinical "descriptive list," drawn up by Dr. Leavitt. In the latter, there is no indication of any symptoms calling attention to the pancreas during the eight days the patient was under observation. Indeed it was not until the sixth day from the reception of the injury that the hæmorrhage and jaundice led to the suspicion of the hepatic lesion. Unfortunately, the appearance of the dejections is not noted. On examining the specimen microscopically, no deviation from the normal structure is found in sections made from tissue taken from the left end or tail of the viscus, and from the middle part or body. In close contiguity to the ball is a fine network of fibrillated tissue. As hardened in alcohol, the preparation offers no indication of vascular engorgement having existed. The coats of the great arteries with which the ball was in apposition were uninjured.<sup>1</sup>

The first two of these five observations of shot injuries of the pancreas seem to establish that a portion of this viscus may be separated by violence from the splenic artery and other important attachments, may protrude through an external wound, and may be removed, under such circumstances, without hazardous consequences. The proximate causes of death in the four fatal cases were: in one, shock and peritonitis conjoined; in the other three, secondary hæmorrhage. In four of the five cases, the projectiles penetrated posteriorly in the space between the angle of the left scapula and the angles of the ribs, and passed through the diaphragm and the solar plexus; in one, the ball entered anteriorly, near the tip of the xiphoid cartilage, and was believed to have passed through the stomach.<sup>2</sup>

As, in the three cases which were under treatment for twelve days or more, the lesions of the pancreas were unsuspected, its possible functional derangements were not investigated.<sup>3</sup> The autopsies shed little light on the morbid anatomy of the organ.<sup>4</sup>

<sup>1</sup>HIPPOCRATES nowhere mentions the pancreas. VESALIUS (*De hum. corp. fab.*, L. V, cap. IV, ed. Basileæ, 1542, p. 494) held the opinion of the earlier anatomists, that its office was to underlie the stomach as a pillow, a view refuted by its position in birds and fish, remote from the stomach. A BACCIUS (Rome, 1586) maintained that it served for the transit of the chyle from the intestines to the spleen. After the discovery of the pancreatic duct, in 1642, by WILSON, VESLINGIUS (*Syntagma anat.*, 1674, cap. IV) held that the pancreatic fluid resembled bile, a view supported by ASELLI and RIOLAN. BARTHOLIN regarded the pancreas as the excretory duct of the spleen. A pupil of SYLVIVS, DE GRAAF (*De succo pancreatico*, Lugduni Bat., 1671), extirpated the spleen in dogs to refute this view. A fifth opinion, assigned to LINDENUS (Leyden, 1664), was that the pancreas excreted the effete dregs of the blood. A sixth doctrine taught that it carried off the excretions of the nerves. SYLVIVS (*Thes.* 37) enunciated the true doctrine, that it furnished an important secretion of its own. After many researches by BRUNNER (*Exp. nov. circa Pancreas*, Amsterdam, 1683), PECHLIN (Leyden, 1672), and others, HALLER, after exhausting himself in conjectures, could only say: *Plura possunt esse officia liquoris nondum satis noti*; and MAGENDIE, fifty years later, admitted that the function of the pancreatic fluid was unknown. In 1823, the Academy of Paris made this a prize question, and the analyses of TIEDEMANN and GMELIN, and of LEFRET and LASSAIGNE, received honorable mention, and paved the way for the great discoveries of CLAUDE BERNARD, which, however qualified by the criticisms of FRERICHS and of BIDDER and SCHMID, must stand in the main.

<sup>2</sup>In remarking, on page 49, that the statement of Dr. LEAVITT in regard to the gastric laceration was "simply incredible," it was not designed to imply that the facts were intentionally misrepresented; but that the observation was probably erroneous. Many examples of supposed perforations of the alimentary canal have been sent to the Museum, in which the donors subsequently recognized and admitted that the lacerations were made in the neoprosies. In CASE 506, entered on D. C. Case Book XVI, p. 63, and printed also by Dr. LEAVITT (*Med. and Surg. Rep.*, 1863, Vol. XII, p. 105), it is to be regretted that the pathological preparation was not preserved.

<sup>3</sup>Of the derangements attending the arrest of the emulsifying action of the pancreatic fluid on fatty matters, or the connection between chronic diseases of the pancreas and fatty dejections from the bowels, notwithstanding the masterly researches of Dr. RICHARD BRIGHT (*Med. Chir. Trans.*, 1833, Vol. XVIII, p. 1), doubt still obtains. There are thirty-eight preparations of the diseased pancreas in the Museums of the London Hospitals, and the evidence they present is apparently very conflicting. The possible disorders resulting from derangement of the metamorphic action of the pancreatic fluid or starchy matters are equally involved in obscurity. Consult BÉCOURT (*Récherches sur le pancréas, ses fonctions, et ses altérations organiques*, Strasb., 1830), LLOYD (*Case of Jaundice, with Discharge of Fatty Matter*, in *Med. Chir. Trans.*, 1833, Vol. XVIII, p. 57), and ELLIOTSON (*On the Discharge of Fatty Matters from the Alimentary Canal and Urinary Passage*, in *Med. Chir. Trans.*, 1833, Vol. XVIII, p. 67).

<sup>4</sup>LAWRENCE (*Med. Chir. Trans.*, 1830, Vol. XVI, p. 367) once found the pancreas of "a deep and dull red color," which is supposed to be characteristic of acute pancreatitis. But very little is known of its structural changes. ANDRAL (*Précis d'anat. path.*, T. II, p. 582) says that they "are infinitely rare." BAILLIE (*Morb. Anat.*, Chap. XII) met with an instance of abscess of the pancreas. PORTAL (*Cours d'anat. méd.*, T. V, p. 351) treats of the pathological anatomy of the pancreas from speculation in place of observation, in the same manner that its injuries are described by the surgeons who, with GOOCH (*Chirurgical Works*, 1792, Vol. I, p. 99), declare that "Wounds of the pancreas are to be concluded mortal if its duct or blood-vessels are injured, whence the *succus pancreaticus* or blood may be discharged into the cavity of the abdomen, and there putrefying, cause inevitable death; besides, as the situation of the pancreas is under the stomach, it cannot easily be wounded without the weapon's passing through this organ also." This notion of GOOCH of the pancreatic fluid escaping into the belly is probably derived from the cases given by BONETUS (*Sepulchretum*, Obs. LVII, *et seq.*). These are very unsatisfactory, and the criticism by the great MORGAGNI (Lib. III, Epist. XXX), and, indeed, his entire discussion of this subject, is little better. VIDAL (*Rev. Méd.*, 1824, T. III), and STORCH, in his *Ann. Medici*, record examples of profuse internal hæmorrhage in the pancreas. FEARNSIDE (*Med. Gaz.*, 1850, Vol. XLVI, p. 96) gives a case of hypertrophy. GENDRIN (*Hist. Anat. des inflamm.*, 1826, T. I, p. 292) gives instances of abscesses, including one opening into the jejunum. SEWALL (*Diseases of the Pancreas*, in the *New England Jour. of Med. and Surg.*, 1813, p. 39) collects some cases in his inaugural dissertation; but Professor GROSS (*Elements of Pathological Anatomy*, 2d ed., 1845, Chap. XXIV), with his usual encyclopædic erudition, has collected nearly all the recorded observations on the subject. Consult also HARLES (*Über die Krankheiten des Pankreas*, Nürnberg, 1812), HOFFMANN (*De pancreate ejusque morbis*, Nüremberg, 1807), CRIEVELLIER (*Anat. path.*, 1829-35, Livr. 15 and 19), COPLAND (*Dict. of Pract. Med.*, London, 1859, Part III, p. 4, Article Pancreas), CLARK (*Case of Disease of the Pancreas and Liver*, in *The Lancet*, 1851, Vol. II, p. 152), and KOENIG (*Disquisitio morborum pancreaticis*, Tübingæ, 1829).

WOUNDS OF THE KIDNEY.—Traumatic lesions of the kidneys present many diversities, according as they interest the cortical or tubular structures, the excretory ducts or blood-vessels, or communicate with the peritoneal cavity, or externally in the loins, or

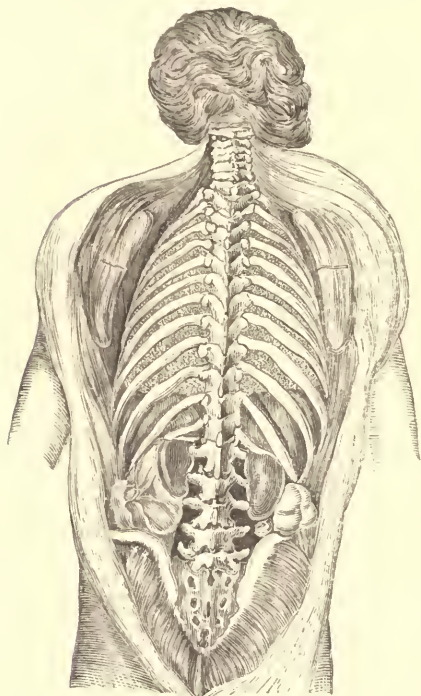


FIG. 124.—A superficial view of the internal organs of the chest and abdomen as seen from behind [Reduced from SIMSON'S *Medical Anatomy*, Pl. XII.]

are complicated with other visceral injuries. The liability of the kidney to rupture, and examples of that form of injury, have been discussed on page 20, *supra*. Punctured and incised wounds of this viscus are uncommon;<sup>1</sup> and no instances were reported during the war.<sup>2</sup> It is well established, however, that, though dangerous, they are not necessarily mortal lesions. Shot wounds of the kidney are not very infrequent. Many alleged instances of recovery, and a yet larger proportion of fatal cases, appear on the returns of the war. The right kidney, lower than the left (FIG. 124), from the position of the liver, is often interested (CASES 380, 411, 452, 457) in shot perforations of the latter. The left kidney, on a higher plane, covered in front by the great end of the stomach, the spleen, and the descending colon, is sometimes implicated (CASES 499, 502, 505) with wounds of those viscera. There was no case of division of the ureter alone. A missile producing this effect would be likely to interest the emulgent vessels also, and such cases rarely reach the hospitals. For the same reason, probably, sympathetic disturbance of branches of the spermatic plexus, from

mechanical derangement of the renal plexus, was comparatively infrequent. The majority of the cases recorded in this group were complicated, and instances in which the symptoms observed were referable solely to renal injuries were very few. Examples of wounds of both kidneys appear only among the fatal cases. The practice which Larrey and Dupuytren enjoined, of freely enlarging the lumbar orifices of wounds of the kidney to prevent the infiltration of urine internally, or into the dorsal muscles, does not appear to have been at all followed. There were but few references to the formation of urinous abscesses, and no examples of persistent urinary fistulæ. Nephrotomy was not practiced

<sup>1</sup> HENSEN remarks (*Princ. Med. Surg.*, 3d ed., p. 425): "The cases on record of recoveries after wounds of the kidney are not numerous. The excellent HALLER gives us one in his *Opuscul. Patholog.*, Obs. 63; and BOURIENNE furnishes another in the *Journal de Médecine*, tome xlii, p. 554. There is also a case of Dr. BORTHWICK in DUNCAN'S "*Annals of Medicine*" for 1793, where a wound was inflicted by a sword, and the patient recovered. Wounds of this part are treated of by almost all the systematic writers. A special dissertation on them was published by GITTLER, at Leipzig, so far back as 1596, the only monograph with the existence of which I am acquainted."

<sup>2</sup> The old writers give some instances of recovery from punctured and incised wounds of the kidney. Thus, FALLOPIUS (*De vuln. cap.*, c. XII) writes: "Vidi renem sinistrum pugione vulneratum sanari: quia parenchyma, scilicet sanguis ille crassus concrevit in carnem." MONTALCÓN (*Art. Reins, Dict. des Sci. Méd.*, 1820, T. XLVII, p. 425) says that VALLEBOIA records a successful case. SCIENCKIUS (*Obs. Med. rar.*, 1644, p. 461) quotes a case from DODONÆUS (*Med. obs. exempla*, Hardewyck, 1621, cap. XXXII), a woman stabbed in the loins; bloody urine; wound in kidney healed, "quem (renem) vulneratum fuisse, particula ejus e vulnere exempta ostendit." LA MOTTE (*Traité complet de Chir.*, 3<sup>me</sup> éd., 1771, T. II, Obs. CCXLVII, p. 129) gives a remarkable recovery from a wound of the kidney. In his notes to BECK (*Elem. of Med. Jurisp.*, 5th ed., 1835, Vol. II, p. 218), DUNLOP refers to a case related by Dr. KNOX, of Edinburgh, of a boy at the Cape of Good Hope, who received a deep wound in the left kidney from a butcher knife, but speedily recovered. In SCHMIDT'S *Jahrbücher* for 1868, B. 140, S. 299, what appears to be the same case is reported by Dr. SCHUSTER (*Oesterreichische Zeitschrift für prakt. Heilkunde*, 1868, B. XIV, S. 12), who cites from Herr Lorinser's division, the instance of a butcher boy, aged 11, who had received a stab wound, three inches deep, on the right side immediately below the twelfth rib, three inches from the spine; considerable hæmorrhage; urine, mixed with blood, passed for three days; on the seventh day, slight icteric coloration of skin; a copious light-brown fluid, which proved to be urine, escaped from the wound; recovery in fifty days. BECK (*Chirurgie der Schussverletzungen*, 1872, S. 543) cites a case related to him by Dr. SCHELLDORF: M. F——, in January, 1868, fell backward upon a scythe, which caused an incision four and a half inches long, through which the right kidney, slightly wounded, protruded. The bloody effusion was removed and the kidney returned, and ice applied; bloody urine passed during eight days; the patient recovered completely. BOURIENNE (*Jour. de Méd. Chir. Phar., etc.*, Juillet-Décembre, 1774, T. XLII) recites a case of



*Gunshot Wounds.*—Shot wounds of the kidney are often associated with wounds of the stomach, liver, spleen, diaphragm, intestines, or spine. Many examples have already been adduced. The case which furnished the preparations of shot lesions of the duodenum and of the liver, represented by FIGURES 43 and 106, of which some details are recorded on page 134 (CASE 452), afforded also an illustration of a shot perforation of the kidney, which is represented in the adjacent wood-cut (FIG. 125). Other examples are enumerated further on. Such cases were usually speedily fatal from shock, or from shock and hæmorrhage conjoined. The least complicated instances are observed when a ball enters in the lumbar region and penetrates the cortical substance. Then it is inferred that the kidney is implicated, by the depth and direction of the wound, bleeding,<sup>1</sup> pain in the renal region (according to most writers, though Hunter says, *Op. cit.*, p. 515: "the sensation will be trifling"), and pain and spasmodic retraction in the testis. If the wound extends to the tubular structure, usually urine mixed with blood escapes by the external wound, and there is hæmaturia. When the peritoneum is also wounded, urine escapes into the cavity of the belly, and fatal peritonitis is almost inevitable. The instances of recovery from shot wounds of the kidney reported during the war, though not infrequent, are generally wanting in such details as would establish them as unequivocal.<sup>2</sup>

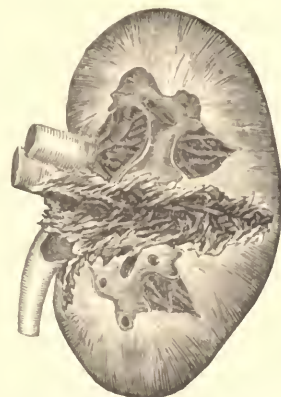


FIG. 125.—Section of a kidney with a shot perforation from before backward. *Spec.* 1773.

CASE 508.—Private Samuel M. Haldeman, Co. K, 4th Pennsylvania, aged 32 years, received a perforating wound of the abdomen at White Oak Swamp, June 30, 1862. He remained in the field hospital until July 25th, when he was transferred to McKin's Mansion Hospital, Baltimore. Surgeon L. Quick, U. S. V., in charge, states that the "ball entered above the crest of the ilium, passed through the left kidney, and out at the lumbar region." On September 19th, he was transferred to West's Buildings Hospital, and was discharged from service December 27, 1862, and pensioned. Pension Examiner Thomas B. Reed, of Philadelphia, reported, May 8, 1867: "The ball passed in about the ninth rib, right side, fractured it, and came out near the spine on the same level. The kidney was wounded, and he had hæmatemesis for several days after the injury. He is unable to stoop or lift a weight, or do any sort of labor for any length of time. His general health is somewhat impaired." The Pension Examining Board at Philadelphia reported, May 19, 1873, that "stooping or lifting still causes pain. He suffers from nervousness, caused by the injury to the spinal nerves, but has no trouble with his kidneys at this time."

CASE 509.—Private W. Norris, Co. E, Davis Legion, was wounded at Aldie, June 21, 1863, and made a prisoner. Assistant Surgeon R. A. Dodson, 1st Maryland Cavalry, states that a pistol ball passed in to the right of the spine and through the kidneys and lodged. The inflammatory symptoms were great; the catheter was used for ten days. There was afterward pain on the passage of the urine, which was mixed with pus corpuscles; the wound was still discharging on July 16th, with less pain on micturition. He was afterward paroled.

bayonet wound in the side, penetrating the kidney; severe pain, vomiting, distension of abdomen, and convulsive retraction of the testicle followed; on the second day blood passed *per urethram*; recovery in twenty-four days. Mr. VERNON (*Saint Bartholomew's Hosp. Rep.*, London, 1865, p. 124) records that W. M——, aged 14, fell from a height of forty feet, and received a wound of the soft parts, immediately above the right iliac crest, through which protruded the lower end of the right kidney; a piece of its substance had been chipped out, leaving a gap, which would admit the finger end; tenderness of abdomen; discharge of small quantities of blood-stained urine by the urethra, and free discharge of urine from wound; recovery in three weeks. Mr. ACKERLEY, of Liverpool (*Observations on Wounds of the Abdomen*, in *London Med. Gaz.*, 1837, Vol. XX, p. 549), relates the case of J. K——, aged 30, wounded in two places by the extended blades of a pair of tailor shears, the one entering the abdomen about two inches above the anterior superior spinous process of the ilium on the left side, and from which about four inches of the omentum were protruding; the other just beneath the last rib on the same side and near the spine. Copious discharge of urine from the latter for two days. Protruding omentum removed with a pair of scissors and the several gastric-epiploic arteries secured by ligature, which was left hanging from the wound; recovery in fourteen days. Dr. PEPPER (*Am. Jour. Med. Sci.*, N. S., 1868, Vol. LV1, p. 150) records the case of R. S——, aged 26, stabbed in the upper part of the left lumbar region; urine bloody and highly albuminous; the amount of blood in the urine steadily diminished; pleurisy of left side, and considerable effusion on the tenth day; death on the twenty-third day. The progressive improvement in the condition of the urine and the *post-mortem* appearances of the kidney lead to the belief that the wound of this organ had almost entirely healed.

<sup>1</sup> JOHN BELL (*Discourses*, already cited, p. 100) says truly: "Bleedings from wounds of the mesentery—kidney—emulgent vein, or any smaller vessel, are often slow and gentle, and are not known by the common signs of inward bleeding."

<sup>2</sup> M. LEGOT EST records an instance of reparation in a shot wound of the kidney (*Chirurgie d'Armée* 2<sup>e</sup> éd., p. 403): "Les coups de feu, outre la blessure constituée par leur trajet, semblent quelquefois faire éclater le rein et déterminer des déchirures étendues. Sur un soldat russe, blessé à Inkermann (*Crimée*, 1855), de deux coups de feu, l'un aux reins, et l'autre au genou gauche, et qui succomba à cette dernière blessure, nous pûmes constater la guérison de la plaie du rein; traversée d'avant en arrière et vers le milieu de sa hauteur, l'organe avait beaucoup diminué de volume et présentait au centre, sur ses deux faces, une cicatrice déprimée, fibreuse et solide à laquelle venaient se joindre, comme les rayons d'une étoile, cinq autres cicatrices irrégulières."



The following history of a recovery from a shot wound of the left kidney was communicated by Assistant Surgeon R. J. Perry, P. A. C. S., to the *Confederate States Medical and Surgical Journal*. It is printed at page 75 of the first volume of that periodical, copies of which are so rare that it is often desirable, instead of citing articles contained in it, to quote them at length :

CASE 510.—“The records of military surgery show that gunshot wounds of the kidney are almost always fatal, and being so considered, the unfortunate victim is too often left to his fate without proper attention. The following case presents several points of unusual novelty and interest, and teaches the important lesson that the surgeon should never abandon, as hopeless, any case of injury, however unpromising it may seem. Patients do occasionally recover from wounds of the kidney as well as from lumbar abscesses caused from renal calculi, and should therefore always be treated with proper care throughout. Lieutenant A——, 2d Tennessee Infantry, in perfect health, of robust constitution and abstemious habits, was wounded in the battle of Shiloh, on April 6, 1862, by a minie ball, entering immediately below the heart, and passing out through the upper portion of the left kidney. There was considerable hæmorrhage, causing excessive prostration. In this condition he was captured by the enemy and removed to Pittsburg Landing, on Tennessee River, several miles distant from the battle-field, where he remained for six days without any attention, not even the removal of his bloody clothing, or dressing of his wounds. He was then placed upon a transport and conveyed to Louisville, Kentucky, and sent to hospital for treatment. During the month of July following, while his wounds were still discharging profusely, he was attacked with typhoid fever, and a large abscess formed in the lower part of abdomen, about one inch to the left of the line alba, which caused great pain. The second or third week in August he was removed from Louisville to Camp Chase, by way of Cincinnati. Several days after his arrival at Camp Chase, very much enervated from the prolonged attack of fever, the abscess above referred to opened outwardly and discharged an immense quantity of dark sanious fluid mixed with urine. This greatly alarmed him, and the extreme mental anxiety, added to his fearful nervous prostration, came near proving too formidable for the unfortunate victim; but all of these difficulties were combatted by a good constitution and the inflexible determination of a veteran soldier to such a degree that, when an exchange of prisoners was effected, he was able to proceed to Vicksburg, Mississippi, where he was released about the first of October. He commenced his journey home-ward (Lynchburg, Virginia), travelling only during the day, resting at night, suffering much from his wounds and abscess, which still continued to discharge an admixture of unhealthy pus and urine. In about two weeks he reached Knoxville, Tennessee, at which place I was then on duty, manifesting symptoms of very great nervous prostration. The second day after his arrival at Knoxville I was called to see him, at the house of his sister, at nine o'clock A. M., and found him with a severe chill, followed by high febrile reaction. On examination, I found the anterior wound entirely healed and cicatrized; the posterior wound and abscess very irritable, manifesting no disposition to heal, and both discharging, though not profusely, a thin sanious fluid, mixed with urine. He complained of severe excruciating pains in lumbar region, passing but little urine through the urethra—secretions generally deranged. I ordered warm stimulating poultices to wound and abscess, and administered one grain of extract of hyoscyamus. I visited him again at four o'clock P. M.; found him restless, looking pale, anxious, and alarmed; pulse irritable and frequent; administered anodyne for the night. I saw him the succeeding morning at nine o'clock; rested rather comfortably during the night, still suffering from pains in lumbar region, but much more composed; pulse regular but frequent; continued warm applications to wound and abscess, and anodynes to relieve pain. For several days subsequent he was annoyed with rigors simulating intermittent fever, but which gradually subsided, leaving him much debilitated and troubled with night-sweats, which were overcome by the use of elixir vitriol, tannin, and sponging with stimulating lotions. I then placed him upon nutritious diet and tonics, such as iron, tincture of bark, and quinine. The discharge of urine and unhealthy pus continued for some sixteen or eighteen days, when the discharge of urine ceased and the pus became more laudable. Simple lint and sweet-oil dressings were then substituted for the warm applications. The second or third week in November the wound was almost entirely healed, with but slight discharge, and about the 15th of December he resumed his journey to Lynchburg, and in a short time was entirely restored, with some little impairment of general health. I met Lieutenant A—— in October, 1863, in perfect health, with the exception that upon too frequent exercise or exposure he was annoyed with some measiness and pain in lumbar region.”

CASE 511.—Private M. Selvoir, Co. E, 5th New Hampshire, aged 27 years, was wounded at Farmsville, April 6, 1865, by a round ball, which entered at the left ninth rib anteriorly, five inches from the median line, passed backward, and emerged half an inch to the left of the spinous process of the twelfth dorsal vertebra. He was conveyed to the field hospital of the Second Corps, thence, on the 19th, by the hospital transport State of Maine, to Washington, entering Finley Hospital. Acting Assistant Surgeon Dusenbury<sup>1</sup> reports that the patient stated that for a number of days after the injury he was confined to bed, and complained of severe pain in the left testicle. There was slow, steady hæmorrhage into the pelvis of the kidney, which found its way out with the urine, partly discolored and partly coagulated. After the subsidence of the hæmorrhage some pus was observed with the urine, which soon disappeared, with other troublesome symptoms, when the wounds healed rapidly, so that by July 1st they were entirely healed, with slight tenderness over the cicatrices. The patient was able to go about without inconvenience, and on August 1st did guard duty about the hospital. August 29th, he was transferred to Concord, and mustered out of service September 6, 1865. He is not a pensioner.

CASE 512.—Private T. A. G. Hunting, Co. H, 34th Massachusetts, aged 47 years, received a shot wound in the left lumbar region at Piedmont, June 5, 1861. He was made a prisoner, and appears at the Confederate prison hospital at Staunton; was afterward paroled, and, on August 24th, sent to hospital at Annapolis, thence, on September 22d, to Camp Parole, thence to Dale Hospital, Worcester, February 7th. He returned to duty March 21, 1865, and was discharged the service on May 23, 1865. A certificate of Assistant Surgeon Charles G. Allen, 34th Massachusetts, states: “Gunshot wound in the back, which fractured

<sup>1</sup> DUSENBURY (H.), *Cases of Gunshot Wounds of the Abdomen involving Viscera*, in *Am. Jour. Med. Sci.*, 1865, N. S., Vol. 1, p. 100

one of the ribs; he has partial paralysis of one leg, besides considerable disturbance of the urinary organs." Examining Surgeon Oramel Martin, of Worcester, reports, November 18, 1865: "Ball passed into left side, just above the ilium, about four inches from the spine, and passed inside of spine and out about the centre of the right side. He says blood passed with his urine about twenty-one days, and that the wound pains him in stooping or exercising; the scar has adhered to the skin and muscles. The motions of the body, I think, are impaired; disability three-fourths and permanent." This pensioner was paid March 4, 1873.

CASE 513.—Private James Ford, Co. G, 10th Infantry, was wounded at Chancellorsville, May 3, 1863. He was treated in the field till May 9th, then was transferred to Finley Hospital; on June 20th, to Christian Street Hospital, Philadelphia; on August 4th, to Turner's Lane Hospital; and, on September 1st, to the Citizens' Volunteer Hospital. The case appears upon the records of these different hospitals as a "gunshot wound of the left shoulder," and, at Turner's Lane, a fracture of the left clavicle is noted. On September 26th, the patient was transferred to St. Joseph's Hospital, Central Park, New York, where the following notes appear in the case book: "The ball entered, while he was stooping, over the outer portion of the left clavicle, passed through the lung of the same side, and lodged in the region of the left kidney. It was extracted on the tenth day, together with fragments of fractured bone. After the injury occurred he had hæmaturia, which continued eight or ten days. He has had cough and hæmoptysis from the beginning. The examination made on admission to this hospital reveals the following facts: 'Dullness and tenderness on percussion on the left side; respiration feeble all over the left lung posteriorly, and, at some situations, is entirely absent; over the anterior portion of the lung there is heard an occasional subcrepitant râle and sibilant ronchus. No distinct evidences of a cavity present themselves; the urine contains albumen, granular uriferous tube-casts, and blood corpuscles and pus globules in abundance.' October 10th, the hæmoptysis continues; the patient is failing in strength and becoming more emaciated. The treatment while in this hospital was quinine and aromatic sulphuric acid." This soldier was discharged from service October 16, 1863. Pension Examiner F. F. Burneister, of Philadelphia, reported, June 18, 1866: "A minie ball fractured the left clavicle and passed out on the left side of the back. The pensioner suffers with pain in the shoulder and partial paralysis of the left arm, interfering with its use." He was last paid in June, 1873.

CASE 514.—Corporal William H. Leach, Co. F, 1st United States Sharpshooters, aged 21 years, received a gunshot wound through the body at Gettysburg, July 2, 1863. He was removed to the Seminary Hospital, and, on July 26th, to the Cotton Factory Hospital, at Harrisburg. Acting Assistant Surgeon Lewis Post states that "the ball passed through the left hypochondriac region, between the two lower ribs, and fractured the lower rib of the right side and injured one or both kidneys. He complained of much pain in the back, and for eighteen days after the reception of the injury voided bloody urine. Cooling applications were still kept to the back, and the wounds dressed with simple cerate twice each day. The bowels moved regularly without medicine, and pulse was soft and natural. An opiate was occasionally administered at night. By August 14th, the wounds had nearly healed and the urine was natural; the patient complained of nothing but slight weakness in the back. August 24th: For three days the patient has been restless, and during the night passed pus from the bowels, and again voided bloody urine. Rest, sedatives, and mucilaginous drinks were ordered, and by September 16th he was able to walk out and was considered doing well." Leach was discharged from service January 6, 1864, and pensioned. Pension Examiner T. B. Smith, of Washington, reported, January 15, 1864: "The ball entered the abdomen over the middle third of the crest of the left ilium, passed through the loins, and emerged over the middle third of the crest of the right ilium. Another ball entered the abdomen below the edge of the second floating rib, three inches from the mesial line, and is supposed to be embedded in the muscles of the spine. This wound probably connected with the cavity of the intestine, as pus and sanious matter is found in the stools. He is disabled by reason of much difficulty in flexion of the spinal column, probably owing to rigidity and contraction of its muscles. The discharges of pus, &c., from the wound give rise to occasional attacks of diarrhoea, which temporarily disables him for labor. His general health is good and will improve slowly, but, I think, permanently." This pensioner was paid in May, 1873.

CASE 515.—Acting Assistant Surgeon L. L. Tozier reports that "Private James Brady, Co. C, 10th New York, aged 23 years, was admitted into the Ladies' Home Hospital, New York, June 8, 1861, having been shot while attempting to desert. A pistol ball entered the back, passed through the upper part of the left kidney, and lodged under the skin, in the eighth left intercostal space. When admitted he was much prostrated, his pulse was feeble and frequent, and his urine very bloody. Cold-water dressings were applied to the wound, and stimulants and a diuretic given, with extra diet. On the 11th, the ball was extracted through an incision. The urine was not as highly colored, and the patient was improving slowly. June 25th, the stimulants have been discontinued; the wound in the side has healed; that in the back nearly so." Brady was returned to duty June 27, 1861, but does not appear upon the Pension Roll, which is probably due to the circumstances attending the reception of the injury.

CASE 516.—Private W. S. Weaver, Co. E, 100th Indiana, aged 20 years, received a wound of the abdomen at Missionary Ridge, November 25, 1863. He was removed to the field hospital of the 4th division, Fifteenth Corps, thence to Bridgeport, to Cumberland, Nashville, whence he was furloughed January 18, 1864. On February 26, 1861, he entered the City Hospital at Indianapolis, suffering with diphtheria. On March 6th, he was transferred to the Soldiers' Home, and, on the 11th, to the hospital at Madison. Previous to his admission to the latter place, the injury was not supposed to have implicated more than the abdominal walls. Surgeon G. Grant, U. S. V., at Madison, states that "the ball entered the left side about one inch above the anterior superior spinous process of the ilium, perforated the left kidney, and was cut out of the back nearly opposite its entrance. The wounds are apparently healed, but he complains of much pain in the left renal region, and goes around with his body flexed in that direction, and says that he has had frequent hæmaturia. His urine does not show it at this time." Weaver was discharged from service April 21, 1864, and pensioned. Examining Surgeon George W. Mears, of Indianapolis, reported, April 22, 1864, that "the ball entered the abdomen in the left hypochondriac region and passed downward and backward, and is supposed to have lodged against the body of the third lumbar vertebra. Bloody urine was *constantly passed* at first, and, recently, *occasionally passes*. His back is very weak, and he cannot straighten it without great pain about the region of the kidney; his left leg is very weak, and walking a short distance disables him." Pension Examiner Louis Humphreys, of South Bend, reported, June 16, 1870: "The ball penetrated the left side, seven inches anterior to the spine, at the anterior border of



the lower rib, passed backward, and lodged against the vertebral body opposite the crest of the ilium, from which it was subsequently extracted. The wound healed tardily. From injury of some of the nerves of motion given off from that portion of the spine, partial paralysis exists of the lower left extremity, so as to render him quite lame at times. Walking or standing produces pain in the lumbar region and in the entire left lower limb. Hence he is unable to perform manual labor."

CASE 517.—Lieutenant F. C. Hume, Aide to General Cary, was wounded near Deep Bottom, July 27, 1864, by a conoidal ball, which entered the body three inches to the right of the median line and two and a half inches above the umbilicus, escaping at a point directly opposite, the same distance from the spinal column. He was taken at once to the Receiving and Wayside Hospital, Richmond. The register states: "July 28th: The patient has excruciating pain in the region of the right kidney; the urine, yesterday, was bloody, and to-day there is inability to pass it; twelve grains of hydrate of chloral and two grains of extract of hyoscyami given. July 29th: Bowels irritable; vomiting and tympanitis; enema of castor oil and water. July 30th: Condition improving; two grains of hydrate of chloral and one-half a grain of opium was ordered every two hours. He was transferred August 27, 1864, with every prospect of recovery."

CASE 518.—Private George Davis, Co. D, 18th Illinois, was admitted into the depot general hospital at Cairo, July 14, 1862, with a "shot wound of the left kidney, received at Fort Donelson, February 15, 1862." Assistant Surgeon S. Hamilton, U. S. V., further states that Davis was discharged from service August 15, 1862, and that his right leg was disabled. Dr. W. A. Burke, of Cairo, also certified that there was a "gunshot wound in the region of the right kidney, which disabled the right leg." A claim for pension was rejected for want of evidence that the disability occurred in the line of duty.

CASE 519.—Private J. A. Stewart, Co. H, 101st Ohio, aged 25 years, wounded at Stone River, December 31, 1862, by a shell fragment, was treated first in the field hospital of the 2d division, Fifteenth Corps, then at Nashville, then at Louisville, then at Jeffersonville, then at Madison, then at Camp Denison, whence he was discharged from service. The diagnoses are very varied, but they all agree that there was a severe wound in the left lumbar region, with dysuria. Some reference to nephritis or gravel appears in several of the hospital reports. Surgeon W. Varian, U. S. V., is very definite in pronouncing the case a recovery from a shot wound of the kidney.

Besides the foregoing twelve cases of recovery from shot wounds believed to implicate the kidney,<sup>1</sup> among the recoveries from wounds of the liver there were six instances in which the kidney likewise was supposed to be interested. These were the cases of Galloway (380), Little (387), Patterson (393), Sharer (397), Searle (402), and Williams (404). In the cases of Adams (289), who had stercoral fistula, and of Stanley (298), who voided a ball at stool, the left kidney in the former, and, in the latter, the right kidney, were reported to have been implicated. The only additional information obtained of the case of Private Groff, Co. D, 61st Pennsylvania, recorded in the preliminary report in Circular No. 6, page 27, as a possible recovery from a shot wound of the left kidney, shows that he is not a pensioner. There were five other instances of recovery from shot wounds believed to involve the kidney:

CASES 520-524.—Sergeant W. H. Penn, Co. E, 13th Iowa, wounded at Atlanta, July 22, 1864. Acting Assistant Surgeon J. M. Adler diagnosticated an injury of the right kidney. Pension Examiner J. Windell, of Des Moines, says: "Shot wound of back, with congestion of kidney." Pension last paid March 4, 1873. Private James Fraser, Co. H, 22d Illinois, wounded at Stone River, December 29, 1862, was discharged and pensioned April, 1863. Acting Assistant Surgeon T. W. Colescott states that the wound was "in the lower outer border of left hypochondrium, the ball passing through the left kidney and out close to

<sup>1</sup> Recoveries from shot wounds of the kidney are quite frequently recorded by modern writers on military surgery: thus, BAUDENS (*Clin. des Plaies d'armes à feu*, 1836, p. 346) gives three examples from the campaigns in Algeria: 1st, Ben-Gil-Ali, an Arab, shot wound of diaphragm, left kidney, and descending colon. 2d, Sergeant C——, of the Zouaves, oblique perforation in the left flank, April 1, 1833, with fracture of the tenth rib. Hæmoptysis and hæmaturia; no pain or retraction of the testis. The hæmaturia began to subside after the third day, and the urine was clear in a week. 3d, Corporal S——, 17th Light Infantry, was shot through the left lumbar region, April 15, 1836. Free hæmorrhage from the exit wound. Forty days after, a probe catheter entered six inches and evacuated an accumulation of pus. Dysuria, retracted testicle, but no hæmaturia. The patient was convalescent. BECK (*Chir. der Schussverletzungen*, 1872, S. 543) records two fortunate cases in the Franco-Prussian war of 1870. BILLROTH (*Chirurgische Briefe*, 1872, S. 188) records a recovery, Case 31, Lieut. Ciffre, 74th French infantry. SOGIN (*Kriegschirurgische Erfahrungen*, 1872, S. 96) records the case of Ernest Krause, wounded at Gorze, August 16, 1870, by a ball which entered eight centimetres to the right of the spinous process of the eleventh dorsal vertebra, injuring the right kidney, and probably the liver; recovery in about six months. STROMMEYER (*Marinen. u. s. w.*, S. 639) relates the case of a Danish officer shot in the right side under the short ribs, the ball passing out near the spine, just below the twelfth rib; on the next day bloody urine, and on the fifth day urine, passed from the wound of exit; a concreted size of an orange kernel passed, two months after the reception, per urethram, while the patient suffered severe pain; recovery. Dr. A. B. COOK (*Louisville Medical Gazette*, 1859, Vol. 1, p. 159) reports a recovery from a pistol shot through the body, in the case of John D——, an athletic Irishman, aged 23. The ball was believed to have passed through the larder of the left lung, the diaphragm, and the external border of the left kidney. Hæmaturia came on suddenly on the ninth day, and it was inferred that a slough separated at that date. There was acute pain in the left testicle, and along the corner of the wound. Dr. S. B. PARSONS, an homœopathist, records (*Western Hom. Observer, and Chicago Med. Investigator*, 1865, Vol. II, p. 51) a recovery from a pistol shot in the abdomen in the case of James D——, aged 23, the kidney being supposed to be injured. Dr. J. W. BROOKS records (*Chicago Med. Jour.*, 1872, Vol. XXIX, p. 519) the case of W. C——, aged 30, who recovered after being shot through the body with a Derringer ball. Shock, with hæmatemesis, and hæmaturia followed, which, with the direction of the ball, were supposed to "point unmistakably to the entering of the stomach and left kidney by the ball." It is also mentioned that "after the first sixteen hours he had no pain whatever." PENDLETON (*New Orleans Journal of Medicine*, 1868, p. 707) relates a recovery from a pistol shot wound of the kidney: G. H. P——, shot in December, 1868, in the right side, about two and a half inches from the umbilicus. Hæmaturia for several days. On the seventh day the patient voided about a gill of pure red blood, with little or no urine. He continued



the left side of the fourth lumbar vertebra; there is some abdominal effusion." Pension Examiner C. T. Jones states, in May, 1867, that the pensioner seems to have recovered his health, but complains of suffering from bloody discharges on slight exertion. This pensioner was last paid March 4, 1873. The three others are not on the Pension Roll. Private Joel E. Simpson, Co. D, 4th Minnesota, reported by Surgeon J. G. F. Holston, U. S. V., as having received a shot wound of the left kidney at Inka, September 19, 1862. Private M. Howe, Co. D, 34th Massachusetts, wounded at Piedmont, June 5, 1864, reported by Surgeon T. B. Reed, U. S. V., as "a wound of kidney." Discharged on expiration of service, January 20, 1866. Private M. Arms, Co. C, 22d Illinois, wounded at Stone River, December 31, 1862. Acting Assistant Surgeon Thomas W. Coleseott states that the "ball passed just below the ninth rib and emerged at the right side of the intervertebral space, between the last dorsal and first lumbar vertebrae, cutting the left kidney." Private Arms applied, but his claim was rejected for want of information.

Altogether some particulars are noted of twenty-six alleged instances of recovery from shot wounds of the kidney. In thirteen, the right, and in twelve, the left kidney was involved; in one case, this point is not mentioned. The details of the symptoms and progress of the cases are, for the most part, very unsatisfactory. Hæmaturia is reported as present in fifteen of these cases. The escape of urine by the external wound can rarely be inferred from the meagre memoranda of the attendant symptoms. Urinary fistula of long duration is reported in one case only. In a few cases, pus and phosphatic deposits in the urine were observed for considerable periods. Various forms of dysuria are referred to; and lumbar pains, muscular rigidity, partial paralysis, and other disabilities are reported. Of the twenty-six, fifteen are pensioners.

Hæmaturia is the most constant sign in injuries of this group, and directs attention to the kidney in those cases of general peritonitis in which dysuria and the escape of urine by the wound, or the signs of urinary extravasation are absent; as in the following case, reported by Assistant Surgeon G. A. Mursiek, U. S. V.:

CASE 525.—Sergeant James A. B——, Co. I, 8th Illinois Cavalry, aged 29 years, of good constitution, was admitted to Stanton Hospital, September 25, 1862, with a shot wound of the abdomen, received on September 22d at Jack's Shop, near Madison, Virginia. The ball entered just below the margin of the last right rib. On admission, the wound presented a ragged appearance. He complained of pain in the abdomen, which was tympanitic; the bowels were constipated; pulse 130 and quick, respirations thoracic and 26 per minute; the expression of countenance was natural. His urine contained blood. He was ordered a grain of opium every three hours, and beef-tea at discretion, and simple dressings to the wound. On the 26th the condition was unchanged; the dose of opium increased to two grains every two hours; the urine continued bloody. On the 27th he appeared somewhat better; pulse 120, respirations 22. On the 29th the bowels moved spontaneously; the stool contained some blood. On September 30th, in the morning, the pulse was 116, respirations 20. At five o'clock P. M., the abdominal pain and tympanitis had increased; pulse 120, respirations 22; his countenance expressed great anxiety. Resumed two grains of opium every two hours. On October 1st the patient was much easier; pulse 116, respiration 18; tympanitis and pain diminished. In the afternoon, he had an evacuation from the bowels containing blood. At five o'clock P. M., the pulse was 110, respirations 14. On October 2d the patient's appearance was improved, but he was somewhat drowsy; the pupils were not contracted; pulse and respirations unchanged in frequency. On the morning of October 3d the pupils were contracted to one-half their natural size; pulse 110, respirations 11; tympanitis slight; drowsiness marked. On the 4th, in the morning, the pulse was 120, respirations 12; tympanitis increased; ordered a third of a grain of sulphate of morphia every two hours. In the afternoon, the pulse was 130 and feeble, respirations 14; tympanitis augmented since morning; pupils not contracted; the patient was sinking. Morphine continued, with sherry added, one-half ounce every two hours. On October 5th the pulse was

to void blood in smaller quantities during the second week; complete recovery. JULES LUYB (*Gazette Médicale de Paris*, Juin 20, 1857, T. XII, p. 404) cites the case of a patient who died at the age of 29. Nine years previously he had received a shot wound in the lumbar region, the ball passing out in the right subspinal region. For twenty-four hours the urine passed from the wound. A large quantity of urine was drawn off by the catheter. No unusual symptoms followed. Three weeks before his death intense fever and general œdema appeared, with symptoms of acute tubercularization. At the autopsy a mass of fibrous material was found to fill the wound into the substance of the kidney. Left kidney shrivelled; right kidney enlarged. RICHARDSON (*West. Jour. of Med. and Surg.*, Louisville, 1841, Vol. VI, p. 28) reports a recovery from a shot wound of the right kidney; ball entered on the right of the median line, and escaped between the last rib and sacro-iliac junction; discharge of bloody urine on the first day; recovery in one month. EDMUNDS (J. J.), *New York Monthly Review of Med. and Surg. Sci., and Buffalo Med. Jour.*, Vol. XV, No. III, August, 1859, p. 149: An escaping convict was struck in the back by a ball, which is alleged to have "passed through the bowels, wounded the left kidney, and lodged in the abdominal muscles about two inches above and to the left of the umbilicus." Shock; hæmaturia; peritonitis, if any, circumscribed. Complete recovery in twelve days. DUPUYTREN (*Leçons Orales*, T. VI, p. 481) relates that a man was received at Hôtel-Dieu, in July, 1830, with a shot wound in the flank, with a single orifice, through which urine escaped, and manifested no other grave symptom, and left the hospital a fortnight subsequently, convalescent, and ultimately recovered completely. LANGENBECK (*Nosologie und Therapie der chirurgischen Krankheiten*, Göttingen, 1830, B. IV, S. 583) relates a case of perforation of kidney and pelvis; urine escaped from the wound, and blood passed by the urethra, and later, pus from wound and also from urethra; wound closed in thirty days; recovery. The details of the case cited from M. LÉMOYNE, in *Note 2*, on page 163, were communicated to the *Société de Chirurgie*, October 20, 1867: Delos, 6th regiment of the line, aged 26, wounded before Sebastopol, November 5, 1855, one shot communicating the left thigh, a second perforating the left hypochondrium. Death, January 10, 1855. The cicatrix in the left kidney was as described in the notes. Other examples will be noted further on.

<sup>1</sup> LIDELL (J. A.), *Injuries of the Abdominal Viscera by Firearms, etc.*, in *Am. Jour. Med. Sci.*, 1867, Vol. LIII, p. 336.

128 and feeble, respirations 18, and much embarrassed; morphia continued; allowance of wine doubled. At six o'clock p. m., pulse 133 and scarcely perceptible, respirations 22. He died at midnight. Autopsy, eighteen hours after death: the body emaciated; the abdomen protuberant; a large ragged wound about one inch in diameter, in the right hypochondriac region, immediately below the margin of the ribs. On opening the thorax, the heart and left lung appeared normal but forced somewhat to the left by a large effusion of blood into the right pleural cavity. The lower lobes of the right lung were compressed and flattened, and sections immediately sank in water. Both the pulmonary and costal pleura were covered with a thick layer of whitish-yellow, recent lymph. An abscess which had formed between the oblique and transverse abdominal muscles had burrowed up under the right crus of the diaphragm and opened into the right pleural cavity. The liver appeared normal; the intestines and stomach distended. The great omentum and mesentery loaded with extravasated blood of a dark color. Immediately below the *caput coli* was a large abscess, which burrowed along the *psaos magnus*, and down among the muscles of the back. It was lined throughout by a thick layer of false membrane, and, in its lower part, immediately against the sacrum, was found a cylindro-conical ball, somewhat flattened. It had, in its course, perforated the ascending colon and lower end of the right kidney, and fractured the transverse process of the third lumbar vertebra. The kidney presented a ragged wound at the lower end; the surrounding cellular tissue had become much thickened, and lined by a layer of lymph, forming part of the wall of the abscess. The kidney, on section, appeared of a pale-pink hue and granular, softened and flabby, the pyramids almost entirely effaced, except one, at the upper extremity, which was of a dark brownish hue; its tubes were distinct; the pelvis was of a greenish color, its veins much distended with blood. In the accompanying wood-cut (Fig. 126), the ball is represented in the direction in which it traversed the kidney, not in the locality in which it was found.

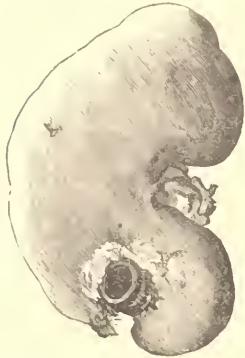

FIG. 126.—Right kidney torn by a cylindro-conical ball. *Spec.* 1735. (Reduced to one-third.)

brownish hue; its tubes were distinct; the pelvis was of a greenish color, its veins much distended with blood. In the accompanying wood-cut (Fig. 126), the ball is represented in the direction in which it traversed the kidney, not in the locality in which it was found.

CASE 526.—Private J. Rodgers, Co. G, 53d Ohio, at Kenesaw Mountain, June 27, 1864, was struck, by a musket ball, two inches below the angle of the left scapula. The ball penetrated the pleural cavity, and emerged through the sixth left intercostal space. Admitted to the field hospital of the Fifteenth Corps, at Barton's Iron Works, on June 30th; he breathed with difficulty, and had severe pain; his countenance was pale and anxious; the pulse 85. Stimulants and an anodyne were administered. Surgeon J. C. Hilburn, 57th Indiana, reports that, "On July 1st, the symptoms were aggravated by retention of urine. A catheter was introduced, and four pints of urine tinged with blood were drawn off. A lesion of the left kidney was now apparently demonstrated. On July 2d, the patient seemed much easier; urine passed naturally, mixed, however, with much pus and blood. On July 3d, the patient complaining of extreme pain in the chest and abdomen, emollient cataplasms were applied to the bowels; urine unchanged. July 4th, the pain becoming very severe, with increased difficulty of breathing, all treatment was suspended, and the patient died July 5, 1864."

CASE 527.—Acting Assistant Surgeon A. P. Crafts reports that "Private Evan Evans, Co. F, 151st New York, aged 40 years, was wounded at Mine Run, November 27, 1863, by a conoidal ball, which entered at the middle third of the left seventh rib, fractured it, and passed into the body. On December 4th, he was admitted into the 3d division hospital, Alexandria. There was paralysis of the bowels, but nothing else to indicate the course of the ball or the amount of injury to the internal organs, except great prostration, with occasional vomiting. Water dressings were applied, and castor oil and injections were given, and stimulants and tonics were administered. Death resulted December 22, 1863. A *post-mortem* examination, made twelve hours after death, showed great discoloration of the bowels; the liver, lungs, and spleen were healthy. The ball grazed the apex of the kidney, passed directly through, perforated the body of the seventh dorsal vertebra, and lodged close to the spine."

CASE 528.—Private Henry Meyer, Co. C, 5th Wisconsin, aged 25 years, was wounded at the Wilderness, May 7, 1864, by a conoidal ball, which penetrated the right side of the abdomen. On the 12th, he was admitted into the 3d division hospital at Alexandria. Simple dressings were applied to the wound. He died May 30, 1864. Surgeon Edwin Bentley, U. S. V., states that "the ball penetrated the right side of the abdomen, passed through the kidney, and lodged posteriorly to the duodenum, between that and the descending aorta. Death from peritonitis, caused by extravasation of urine into the peritoneal cavity."

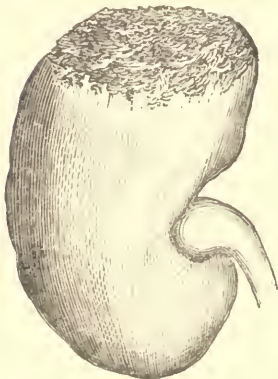


FIG. 127.—Shot laceration of the right kidney. *Spec.* 3703.

CASE 529.—Private Lewis E. Tickle, Jackson's Virginia Artillery, aged 22 years, received shot wounds of the lumbar region and right arm at Tenallytown, July 13, 1864. On the 27th, he was admitted into Lincoln Hospital, Washington. Acting Assistant Surgeon N. A. Robbins states that "when admitted the patient was in a hopeless condition. There was paralysis of the lower extremities, and he passed both urine and feces involuntarily. Stimulants and tonics were given, and *mix vomica*, quinine, and iron were exhibited freely. He lingered until August 4th, when he died from gradual exhaustion." Assistant Surgeon J. C. McKee notes as the cause of death, upon the monthly report, "severe buckshot wound of the kidney."

CASE 530.—Surgeon John Trenor, jr., U. S. V., reported that "Private Thomas W—, Co. B, 127th New York, aged 43 years, was admitted into the hospital at Beaufort, December 10, 1864, with a perforating gunshot wound of the back, received at Pocatigo the previous day. The ball had entered to the left of the spine, opposite the first lumbar vertebra, and emerged five inches to the right of the spine. Simple dressings were applied to the wound. Death resulted December 16th. At the necropsy the ball was found to have carried away the apex of the right kidney (Fig. 127). The spinal column was uninjured."



CASE 531.—Sergeant Frederick Littig, Co. H, 146th New York, aged 25, was wounded at Six Mile House, near Petersburg, August 19, 1864. He was taken to the hospital of the 2d division, Fifth Corps, and was transferred to Washington on the 24th, and admitted into Lincoln Hospital. Acting Assistant Surgeon G. S. Stebbins notes a "gunshot wound of the chest, involving the kidney," and states that "the patient had suffered so much from the wound previous to his admission that he was very badly reduced; there was also paralysis of the bladder and lower extremities. He was constantly delirious, and had involuntary discharges for several days, both from the bowels and bladder. Stimulants, tonics, and nourishing diet were given, and a grain each of acetate of lead and opium was administered to control internal hæmorrhage. Sulphate of morphia in solution to allay pain, and strychnine to overcome the paralysis of the bladder, were also given. He continued to fail in strength rapidly, and died on September 5, 1864, from complete exhaustion." The injury was on the right side.

CASE 532.—Sergeant F. S. Moyer, Co. K, 51st Pennsylvania, aged 34, was wounded at Spottsylvania, May 12, 1864, by a conoidal ball, which entered above the crest of the ilium and lodged. He was taken to the hospital of the 3d division, Ninth Corps. On the 26th, he was removed to Lincoln Hospital. Assistant Surgeon J. C. McKee notes the injury as a "shot wound of the left kidney, the ball lodging in the organ," and states that pyæmia was developed June 10th, and, although tonics and stimulants were freely administered, the patient died June 16, 1864.

CASE 533.—Private A. Wolf, Co. H, 87th Pennsylvania, wounded at Monocacy, July 9, 1864, entered hospital at Frederick on the 10th. Acting Assistant Surgeon W. S. Adams reports that the matter discharged from the wounds had the odor both of feces and of urine. On the 11th, there was slight tympanitis, but no tenderness on pressure; the bladder was empty. A discharge of urine and feces from the wound continued until death, July 14, 1864. An autopsy, ten hours after, showed that the ball, passing through the left gluteal muscles, thence through the sciatic notch, the bladder, the ileum, the ascending colon, and right kidney, lodged against the spinal column. The patient was much prostrated on admission, yet survived this terrible series of lesions five days.

CASE 534.—Private G. W. Ryerson, Co. F, 9th Maine, aged 20 years, received a shot wound of the left side at Petersburg, June 30th, was taken to the base hospital of the Eighteenth Corps, and died July 9, 1864. Surgeon C. H. Carpenter, 148th New York, thus describes the necropsy: "External examination showed the chest full and resonant; no difference perceptible on either side; no more than the usual amount of dullness as the spine or dorsal region was approached. A penetrating wound was seen passing through the tegument between the eighth and ninth ribs, midway between the sternum and spine, fracturing the ninth, from which the omentum was protruding nearly one inch. Between the sixth and seventh ribs, and nearly two inches anterior to a line drawn from axilla to trochanter, was a punctured wound entering the cavity of the thorax. On opening the thoracic cavity the lungs were found uninjured. Slight adhesion had taken place above the point of puncture and of penetrating wound through the diaphragm. On opening the abdomen, the intestines were found to be intact, the liver extending three inches to the left of the median line; the left kidney *torn from its seat, and nearly reduced to a pulpy mass*; the ball passing onward, downward, inward, and backward, until it rested beneath the psoas muscle just below the crest of the ilium, one and one-fourth inches to the left of the last lumbar vertebra." Thus the patient survived a very grave lesion of the kidney nine days.

CASE 535.—Private Edward H. Richard, Co. K, 51st Pennsylvania, aged 24 years, received a wound of the chest and abdomen at Petersburg, August 19, 1864. He was treated at a field hospital for a few days, and was transferred to Washington, entering Lincoln Hospital on the 24th. Acting Assistant Surgeon G. S. Stebbins states that "on admission the patient, of a naturally weak constitution, was very much reduced in strength, from exposure and suffering. The ball entered the left thoracic cavity, penetrated the diaphragm, wounded the left kidney, and emerged immediately over the spinal column. Internal hæmorrhage occurred, and continued for several days. Acetate of lead and pulverized opium were given, with topical applications of ice-cold water, to control the hæmorrhage. On September 8th, the wound became gangrenous; nitric acid was applied, and morphia was administered, and stimulants and tonics were given freely. The gangrene extended, finally involving the spinal cord and its investments, and causing death on September 10, 1864."

CASE 536.—Private S. N. Daily, Co. F, 11th Infantry, aged 19, was wounded at Gettysburg, July 2, 1863. He was taken to the field hospital, where the injury was recorded as a "gun-shot wound of the hip; fracture." On the 24th, he was admitted into the Cotton Factory Hospital at Harrisburg, where Acting Assistant Surgeon Lewis Post reports: "The ball entered the right side, fractured one of the floating ribs, passed anterior to the spine, and injured the left kidney. On admission, there was considerable prostration, with fever, and much tenderness in the region of the left kidney. There was also incontinence of urine, with painful and bloody discharges; pulse frequent. August 10th, the course prescribed was strictly antiphlogistic, with rest. The bowels were kept soluble with oil or sulphate of magnesia. Mucilaginous drinks were given, with opiates at night when necessary. For a few days past there has been considerable suppuration, with a feeble pulse. The febrile symptoms have entirely subsided, and he is now under a tonic course and is allowed a more liberal diet, which is doing good work. August 24th, the wounds are doing well. Healthy granulations are being formed. The pulse is more full and less frequent. The suppuration is diminishing, and he sleeps well. September 26th, there is but little suppuration from the wound, and the patient continues to improve. He sleeps well at night, and occasionally walks out. No medicines are given, and but light dressings are advised. On September 23th, he had a severe chill, followed by fever and congestion of the left lung. Antiphlogistics and counter irritants were at first resorted to, followed with sedatives and tonics. He gradually failed, and died October 4, 1863."

CASE 537.—Private Elden Townsend, Co. F, 7th Maine, aged 19 years, received a wound of the left side at Spottsylvania, May 12, 1864. He was removed to the hospital of the 2d division, Sixth Corps, where the injury was treated as a flesh wound. On May 25th, he was transferred to Lincoln Hospital, Washington. Acting Assistant Surgeon E. L. Bliss reports that "the ball had entered just beneath the eleventh rib and six inches from the spinal column. From the first, the patient suffered great mental depression, which continued until his death. The pulse was full and hard, and the skin dry and parched. The tongue was coated and inclined to redness about its edges; the bowels were constipated, and the appetite very poor. These symptoms

<sup>1</sup> CARPENTER (C. H.), *Boston Med. and Surg. Journal*, 1865, Vol. LXXI, p. 112.



continued without change until about July 23d, when they all became gradually aggravated, with the exception of the pulse, which was weak and rapid. This course continued until the skin was excessively husky, the tongue red, dry, and cracked, and the stomach so irritated that food and medicine were constantly rejected. Death resulted, from exhaustion, July 6, 1864. No tympanitis nor tenderness of the bowels were present at any time. The treatment was tonic and stimulating." An autopsy was made by Acting Assistant Surgeon H. M. Dean, who furnishes the following record: "The patient was very much emaciated; *post-mortem* rigidity well marked; the ball on entering had opened the diaphragm at its attachment, slightly injured the lower lobe of the left lung, passed behind the left kidney, lacerating it somewhat; it then coursed backward and a little downward, breaking off the left transverse process of the first lumbar vertebra, and was found with its apex between the spinous processes of the first and second lumbar vertebra; the lower lobe of the right lung was slightly engorged, but was otherwise healthy; the left lung was healthy, with the exception of the laceration by the ball, above referred to; weight of right lung, twelve ounces; of left, ten and a half ounces; the heart was flabby, and in the right side was a medium-sized fibrinous clot; the left side contained a smaller one; the valves were healthy; the heart weighed nine and a half ounces; the spleen was softer than usual, and weighed eight ounces; liver anæmic, weight sixty-six ounces; the right kidney was partially congested, and weighed seven and a half ounces; the left kidney was very anæmic, and had a laceration across its posterior surface, near its middle, and was much smaller than its fellow; it weighed five and a half ounces."

The comparative frequency of the association of wounds of the liver and of the right kidney has already been adverted to, and six instances have been noted among the recoveries from shot wounds of the liver. These lesions were conjoined also in nine of the fatal cases that have been enumerated, as in three cases detailed on page 134; the cases of Corporal Coffin (124) and of Bugler William B——, figured on page 136; and four others enumerated among the fatal complicated cases of wounds of the liver, viz:

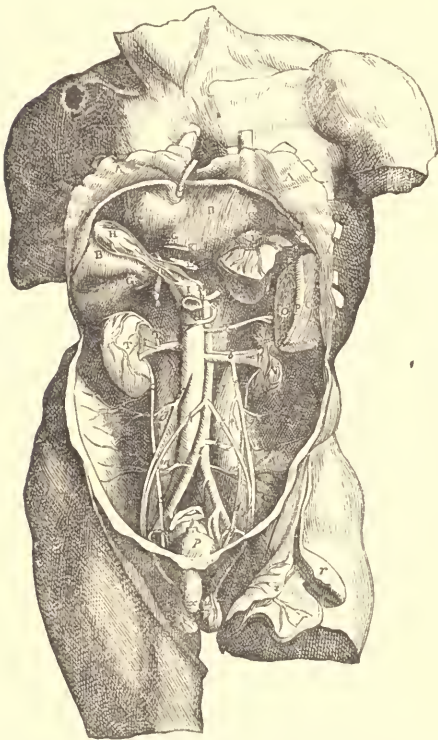


FIG. 128.—Some of the relations of the kidneys, spleen, and blood-vessels. [After VESALIUS, *Figura vigesima—quinti libri*.]<sup>1</sup>

CASE 415.—An autopsy reported by Surgeon C. W. McMillan, 1st East Tennessee, in the case of Corporal Bailey, 45th Pennsylvania, wounded at Blue Spring, October 12, 1863, showed that a conoidal musket ball entered the right sixth intercostal space, passed through the anterior portion of the right lobe of the liver, wounded the right kidney, and lodged between the bodies of the tenth and eleventh dorsal vertebrae. The patient died six days after the reception of the wound. The abdominal cavity was filled with coagulated blood and serum. The peritoneum and bowels presented a dark appearance. CASE 429.—Assistant Surgeon H. R. Silliman reports that Corporal S. B. Davis, 8th Tennessee Cavalry, was shot by a sentinel, April 12, 1864, at Fort Delaware. The ball entered the right lumbar region, perforated the right kidney and the liver. Death from internal hæmorrhage followed in a few hours. CASE 450.—Sergeant S. L. Lynn, 7th New Jersey, received a shot perforation of the chest and abdomen, November 6, 1864. First treated at the Second Corps hospital; he was transferred to Armory Square, at Washington, where Acting Assistant Surgeon T. H. Stewart states that the ball, entering the right seventh intercostal space anteriorly, passed backward and downward through the lung, diaphragm, liver, and kidney, "as was indicated by the difficult breathing, profuse discharge of bilious matter, and bloody urine," and emerged to the right of the second lumbar vertebra. The surface was icteroid. Death, December 15, 1861. CASE 481.—Private J. Woods, 10th New York Cavalry, on April 24, 1863, was struck by a carbine ball, which entered on the chondral junction of the right seventh rib, passed downward and backward through the lobe of the liver and the right kidney, and emerged two inches from the spinous process of the third lumbar vertebra. Assistant Surgeon L. W. Bliss, 10th New York Cavalry, reports that this wound was fatal in twenty hours. In cases that were fatal on the sixth and thirty-ninth days, respectively, there were no evidences of efforts toward reparation of the renal lesions. Indeed, pathologists generally have found little to say on this subject.<sup>2</sup>

On page 156, examples of associated lesions of the spleen and left kidney have been noticed. Two analogous cases may be found in the *First Surgical Volume*, pages 446 and 589. The six cases thus complicated were fatal, though one patient lingered for five weeks.

<sup>1</sup> This illustration, in which the right kidney is higher than it is usually represented, was photographed on wood from the copperplate opposite page 402, in the Leyden edition of VESALIUS, of 1725. The original wood-cut drawing, according to tradition from TITIAN'S pencil, is on page 370 of the Basel edition of 1542.

<sup>2</sup> KLEBS (*Beiträge zur pathologischen Anatomie der Schusswunden*, Leipzig, 1872, S. 100) observes: "Regarding shot injuries of the kidneys, I have little to say, as I have not observed any cases of recovery. In the two fatal cases at Carlruhe, after fourteen and eighteen days, respectively, no interstitial new formations were found."

Wounds of the kidney conjoined with wounds of the intestines, already exemplified by CASES 424, 452, 457, 529, 533, *supra*, were observed also in the two following cases:

CASES 538 and 539.—Surgeon George C. Bennet, 1st New York Mounted Rifles, reports that "Sergeant G. F. Wilson, Co. E, was wounded, January 9, 1863, by a conoidal leaden ball, which entered the hypogastric region, passed upward, backward, and to the right, and lodged on the external surface of the quadratus lumborum muscle. The intestines were much lacerated, and fecal matter issued from the orifice of the wound. The urine was sanguinolent. The ball passed through the right kidney, and was extracted from immediately beneath the cellular tissue. The patient was brought into camp and died ten minutes after." Surgeon S. J. W. Mintzer, U. S. V., reports that "Lieutenant George A. Hosmer, 2d Kentucky Cavalry, was admitted into the hospital at McMinnville, October 5, 1863, with a penetrating shot wound of the abdomen, the ball passing through the small intestines and the right kidney. He was in a moribund condition and died the same day."

Shot wounds of the kidney are not infrequently complicated with fractures of the vertebral column, as Surgeon John A. Lidell, U. S. V., in the instructive paper<sup>1</sup> on injuries of the spine, already cited, records the particulars of the following case:

CASE 540.—Private J. W. Smith, Co. K, 116th Pennsylvania, aged 19 years, received a shot wound in the right lumbar region, at Salem Church, May 30, 1864. Admitted to Stanton Hospital June 4th. There was ischuria renalis, with partial paraplegia. He died June 14, 1864. The ball had traversed the bodies of the second and third lumbar vertebræ and perforated the right kidney, which was almost disintegrated. The peritoneum was everywhere highly inflamed, the intestines almost gangrenous; the bladder was filled with bloody pus.

Similar complications have been noted in CASES 501, 525, 527, and 529.<sup>2</sup> The frequency of fractures of the lower ribs in connection with renal injuries has also been exemplified. The following is another instance:

CASE 541.—Acting Assistant Surgeon A. H. Halbertstadt reports that "Sergeant Charles Clyde, Co. K, 20th Pennsylvania Cavalry, aged 25 years, was admitted into the post hospital at Pottsville, December 17, 1863, having been wounded at Pottsville the same day. A buckshot had passed through the tenth rib two inches to the left of the spine, the upper portion of the kidney, and lodged under the skin in front of the chest. Another ball had passed through the head of the tibia and opened the knee-joint. The missile was removed from under the integument. Quinine, tincture of opium, and stimulants were administered, and nourishing diet ordered. Pyæmia developed December 25th, and death occurred January 6, 1864. The *post mortem* revealed the course of the ball as described. Pus had collected in the left pleural cavity, and there were metastatic abscesses in the left kidney."

Nineteen other fatal cases of shot wounds of the kidney appear on the returns. Six of the patients succumbed in the first few days, from shock or hæmorrhage; two lingered for seven and nine months, and died worn out by protracted suppurations. The dates of injury and of death are enumerated in the following list:

CASES 542-561.—Pt. H. Bacon, Co. E, 9th Kentucky, Murfreesboro', January 1st, wounded through both kidneys; died January 5, 1863. Pt. T. Boardman, Co. F, 64th New York; Reams's Station, August 25, 1864; prisoner; paroled; died March 28, 1865. Pt. W. W. Booty, Co. F, 112th New York; Cold Harbor, June 3d; died June 13, 1864. Pt. W. S. Bruce, Co. H, 6th Iowa Cavalry; Aldie, June 17th; died June 21, 1863. Corp'l D. Brown, Co. D, 165th New York; February 21st; died February 21, 1863; Pt. W. Cochran, Co. K, 11th Pennsylvania Cavalry; Ashby's Gap, December 17th; died December 28, 1864. Pt. I. Eaton, Co. B, 10th Pennsylvania; Gettysburg, July 2d; died July 3d, 1863. Pt. M. Holder, Co. B, 11th Georgia; Knoxville, November 29th; captured; died December 16, 1863. Pt. E. Howard, Co. C, 17th Infantry; Wilderness, May 8th;

<sup>1</sup> LIDELL (J. A.), *On Injuries of the Spine, including Concussion of the Spinal Cord*, in the *Am. Jour. Med. Sci.*, 1864, XLVIII, p. 314.

<sup>2</sup> In a note on pages 162-3, eleven examples of recoveries from alleged punctured or incised wounds of the kidney are enumerated, to which may be added a twelfth, recorded by PURMANS (*Lorber-Kraut.*, u. s. w., 1692, S. 416); a soldier, Müller, of Captain Kettwich's company, received a stab-wound of the left kidney; retention of urine; finally bloody urine; which escaped with great force on the fifth day; complete recovery in six weeks. Another case is found in FORESTUS (*Obs. et Cur. Med.*, Francof., 1614, Lib. XXV, Obs. 20); a youth of twenty, stabbed in the right kidney, had retention for six days; after hot fomentations, he passed a quantity of bloody urine, with clots, and had a rapid convalescence. An interesting case by Dr. DUPUY, of New Orleans, is recorded in the sixty-fourth volume of the *Journal général de médecine* of SÉDILLOT and VAIDY: A man stabbed with a sharpened foil in the right lumbar region; had acute pain, and voided nearly pure blood from the urethra; acute circumscribed peritonitis and nephritis followed; he recovered under an energetic antiphlogistic treatment. On pages 166-7, sixteen recoveries from supposed shot wounds of the kidney are cited; it is not difficult to adduce others, and it is surprising that Dr. HAMILTON (*Lectures, Am. Med. Times*, Vol. IX, p. 14, and *Treatise on Md. Surg.*, p. 367) should instance M. LEGOUËT'S case at Sebastopol as the only example within his knowledge. HENSEN'S fifty-ninth observation (*op. cit.*, 3d ed., p. 422) is of unquestionable authenticity, and has been pronounced the most singular on record as illustrating the whole series of symptoms of injuries of the kidney: An officer, shot through the right side of the body, December 9, 1813; was in extreme agony, and voided bloody urine. He soon became delirious, and venesection was practised several times. He suffered intense pain in the right shoulder. In seven weeks he was removed to England. Fever was again lighted up, and a tumor formed at the site of the posterior wound. The swelling was punctured a fortnight after, and discharged six ounces of pus of a urinous odor. The pain shifted to the testicle and afterward to the penis. The flowing of matter continued great and savored of urine, and there was much suffering from frequent and painful micturition. In July, a piece of cloth was discharged from the urethra. After this, complete recovery ensued. DEMME (*Mil.-Chir. Studien*, 1861, B. II, S. 151) says: "One of my colleagues at the Ospedale San Francesco observed a case of shot wound of the kidney, in which a piece of cloth from the soldier's uniform passed by the urethra; examination proved the cloth to be impregnated with epithelial detritus." OBERAZZ TÜRKE (*SCHMIDT'S Jahrbücher*, 1866, B. 129, S. 213) relates the case of a man wounded by three buckshot, the third entering two inches from the spine and an inch below the right twelfth rib, perforating the peritoneum twice, wounding the kidney, and bruising the intestine. recovery in two and a half months.



died May 22, 1864. Pt. D. Macfagan, substitute; in deserting, November 28th; died November 29, 1864. Pt. H. MacNeil, Co. C, 54th Ohio; Shiloh, April 6th; died May 23, 1862. Pt. J. Markham, Co. I, 70th New York; Williamsburg, May 6th; died May 23, 1862. Pt. J. Morlock, Co. K, 37th Indiana; Murfreesboro', January 3d; died January 16, 1863. Pt. P. Mower, Co. M, 1st Pennsylvania Cavalry; Culpeper, September 13, 1863; died July 3, 1864. Pt. S. H. Parcells, Co. L, 12th New York Cavalry; Moseley Hall, N. C., March 30th; died April 17, 1865. Pt. A. Perkins, Co. I, 11th New York Cavalry; Memphis, March 15th; died March 15, 1865. Corp'l L. Specknagel, Co. B, 25th Ohio; Murfreesboro', December 31, 1862; died January 1, 1863. Pt. J. Sperry, Co. K, 141st Pennsylvania; Chancellorsville, May 3d; died May 19, 1863. Lieut. W. E. Weyrick, adjutant 44th Illinois; Dallas, May 26th; died July 7, 1864.

Though there were several instances of lodgement of balls in the kidney, and cases of laceration without communication with the peritoneal sac, there appear to have been none in which the attendant circumstances were thought to require nephrotomy or to warrant the operation of extirpation of the kidney.<sup>1</sup> Urinous infiltration in the lumbar cellular tissue does not appear to be common after shot wounds. The reason probably is, that the eschars, lining the track, protect the parts until a limiting wall of inflammatory exudation has taken place. Hence it seems unwise to enlarge the exit wounds at first; but later, the free incision of the phlegmonous accumulations likely to form in the loins constitutes a most important part of the treatment.<sup>2</sup> The possibility of retention of the coagula in the bladder should be an object of solicitude, and a large catheter and vesical injections should be used early, if indicated. That the kidney may recover from any very considerable lesions, if the complications can be averted, is now well established. Professor Socin and Mr. Fayerer have recently furnished additional proof.<sup>3</sup>

<sup>1</sup> Professor BILLROTH (*Chirurgische Briefe aus den Kriegs-Lozavellen zu Weissenburg und Mannheim*, 1870, Berlin, 1872, S. 205) remarks: SIMON gave it as his opinion, "that it might be advantageous, in uncomplicated cases of injury of the kidney, where the latter suppurated—cases almost invariably fatal—to extirpate the injured kidney. \* \* \* I would not hesitate to perform this operation, should an opportunity offer." The successful case on which Professor SIMON based his opinion, is recorded in the *Deutsche Klinik*, 1870, S. 137: A woman of 46, who had undergone ovariectomy eighteen months previously, had a renal fistula. On August 2, 1869, at Heidelberg, Professor G. SIMON extirpated the left kidney. The patient was able to leave her bed in six weeks. Dr. J. T. GILMORE, of Mobile (*Am. Jour. of Obstetrics*, May, 1871), removed, in December, 1870, an atrophied kidney from a negro, aged 33, five months advanced in pregnancy. The organ was fed by a single small vessel, which was ligated. The woman recovered without aborting. These, and six other cases, are collated in the *American Journal of the Medical Sciences* for January, 1873, Vol. LXV, p. 278, viz: Dr. PEASLEE'S case (*PEASLEE, On Ovarian Tumours*, 1872, p. 158), the extirpation of a solid renal tumour, April, 1868; death from peritonitis fifty hours afterward. Dr. SCHETELLE'S case (*Archiv für Gynäkol.*, 1870, S. 146, quoted by PEASLEE (*l. c.*, p. 158)). Dr. MEADOW'S case (*British Med. Jour.*, 1871, Vol. II, pp. 66, 73), a renal mistaken for an ovarian cyst and extirpated; death from hæmorrhage from the pedicle on the sixth day. Mr. DURHAM'S case (*Brit. Med. Jour.*, 1872, Vol. I, p. 565), a woman of 43, who had undergone nephrotomy for suspected calculus disease two years previously, was not relieved of hæmaturia, severe pain, etc., and on May 14, 1872, at Guy's Hospital, the right kidney was extirpated, and found to be healthy; the patient died. Dr. PETERS'S case (*New York Med. Jour.*, 1872, Vol. XVI, p. 473), William S. B——, aged 36, had purulent discharges from the bladder, with a tumour in the right loin, and was supposed to have calculous pyelitis; the kidney was extirpated May 7, 1872; death in sixty-five hours afterward. Professor VON BRUNS'S case, reported by Dr. LINSER (*Württemberg. Correspondenz Blatt* 1871, B. XXI, No. 14), of a man with urinary fistula following a shot wound received December 2, 1870; a portion of the left kidney was extirpated, March 23, 1871, and death resulted ten hours subsequently. The viscus was so bound down by adhesions that its complete removal was impracticable. The right kidney was found gravely diseased. The editor, for some reason, does not include the case of Dr. E. B. WOLCOTT, of Milwaukee, reported by Dr. CHARLES S. STODDARD, of East Troy, Wisconsin (*Med. and Surg. Reporter*, 1861, Vol. VII, p. 126); J——, aged 58, underwent extirpation of a tumour in the right hypochondriac region, which, on removal, weighed two and a half pounds, and presented "undoubted evidence of its being a kidney, from a small portion of its upper portion, which had not degenerated, showing the tubules and a portion of the pelvis." The patient died from exhaustion fifteen days after the operation. Nephrotomy for the removal of calculi or of foreign bodies, or nephrolithotomy, erroneously ascribed to HIPPOCRATES (*de internis affectib.*, Cap. XV), is the subject of one of HEVIN'S erudite memoirs (*Mém. de l'Acad. de Chir.*, T. III, pp. 238-331), in which materials for a score of modern monographs may be found. LAFFITTE (*Mém. de l'Acad.*, T. II, p. 233) reports what he considers a successful instance. Another is ascribed to PETER MARCHETTI, an operation on Mr. Hobson, the British consul at Venice. It is described in the *Philosophical Transactions*. Professor GROSS (*System*, Vol. II, p. 710) tells us that Professor GUNN, of Chicago, has performed nephrotomy on account of the supposed presence of a renal calculus, finding no stone, but relieving temporarily the patient's distressing pain and nausea. Professor N. W. DAWSON (*The Clinic*, November 2 and 16, 1872), in the case of a woman of 50, extracted a calculus from the pelvis of the left kidney. The patient survived the operation five days.

<sup>2</sup>The literature of traumatic affections of the kidneys is very meagre. The dissertation of GITTERRI'S, *De rentum vulnere. et qui huic succedit, cruento mictu*, Lipsiæ, 1596, would appear to be the only special treatise on the subject. CHOPART, *Des maladies des voies urinaires*, Paris 1791, 2me partie, p. 13, has a sensible chapter, *des plaies des reins*, and cites the instances of recovery by FALLOPIUS, DODONEUS, VALERIOLOA (*Lib. II, Obs. 8*), and LA MOTTE. In his fifty-third epistle, article 40, MORGAGNI describes the dissection of a tailor, stabbed in the right kidney, March 24, 1742, "on the very day the resurrection of our Saviour was celebrated, a circumstance which made the fact more heinous." References to other special cases have been indicated in preceding notes.

<sup>3</sup>FAYERER (J.), *Clinical and Pathological Observations in India*, London, 1873, p. 591: Patient died of tetanus sixteen days after an extensive laceration of the kidney, running up into the hilum, with other injuries. No peritonitis. SOCIN (A.), *Kriegschir. Erfahrungen*, Leipzig, 1872, S. 95: case of "shot wound received August 16, 1870; the patient was alive in March, 1871. I did not succeed in learning the details of his death, which occurred shortly after March; but I was informed that the missile was found encysted in the kidney." On page 20, *supra*, note 2, specimens of ruptured kidney are enumerated, and, among them, Prep. 748 of the Museum of the New York Hospital shows the thorough cicatrization in three weeks of an almost complete division of the kidney (RAY'S *Cat.*, p. 297). Prep. 4, of Series XI, of St. George's Hospital, shows a cicatrix in the right kidney from a laceration resulting from an accident eighteen months before death (*Cat.*, p. 530). Preparations illustrating mechanical lesions of the kidney are very rare. The Army Medical Museum possesses only the examples of shot injuries noted, and specimens 592, 593, 594, 1052, 1105, 1106, and 1125 of the Medical Section, of renal calculi. In the Museum of the New York Hospital, specimen 749 shows a deep punctured wound of the convex border of the kidney, not involving the pelvis. The patient succumbed in five days to other injuries, and there is no attempt at repair.



*Wounds of the Supra-renal Capsules* may be briefly referred to in this connection, not because of any supposed relation between these organs and the kidney, further than that of contiguity; but for the sake of convenience only, since, in our present ignorance of the functions of these bodies, it is impracticable to assign their true relations. In a case mentioned on page 569 of the preceding volume,<sup>1</sup> the ball, after fracturing the ninth right rib, traversing the left lung and diaphragm, lodged in the left supra-renal capsule. The patient lived four weeks, although both the pleural and abdominal cavities were opened. As he survived so long, it is to be regretted that a more detailed clinical record was not made, that it might be possible to decide how far the icteroid discoloration of the skin and other symptoms, referred to pyæmic infection, may have been associated with pigment deposit in the skin, or the bronzing described by Dr. Addison;<sup>2</sup> or if the destruction of one capsule was attended by the retention in the circulation of some poisonous substance, which, as Dr. Brown-Séguard<sup>3</sup> suspected, it may possibly be the office of these organs to remove. But the most careful pathological observation is unlikely to reveal functional relations that have eluded the researches of the most practiced and sagacious physiologists.

CASE 562.—Private H. C. H——, Co. B, 1st Maine Heavy Artillery, wounded at the Wilderness, May 6, 1864, was sent to Washington, and entered Lincoln Hospital on May 26th. The symptoms are described only on the 30th and on June 2d:



FIG. 130.—Section of ninth right rib, from which more than two inches of the body of the bone were driven into the left lung by a conoidal musket ball. Spec. 2423. [Half-size.]

"A musket-ball wound, one inch below the inferior angle of the left scapula, enters the pleural cavity; there is no exit wound; the patient is very weak; the wound is unhealthy in appearance; a probe passes readily for a long distance

through the wound; there is pyæmia; the respiration is hurried; there is considerable dullness on percussion over the left side; several sequestræ were removed from the scapula." On June 2d, there was "bloody oozing from orifice of the wound; no hæmorrhage from the mouth or bowels." Death, June 3, 1864, twenty-eight days after the reception of the wound. At the autopsy "a central portion of the ninth left rib, about two and three-fourths inches long (FIG. 130), was found broken off and driven into the substance of the left lung, having become firmly adherent to the lung by fibrinous bands (FIG. 131). The ball penetrated the left lung and diaphragm and was found flattened but concealed, because entirely encysted in the supra-renal capsule over the left kidney." It is erroneously stated in the minute in the *First Surgical Volume* that the ball penetrated both pleural cavities. The thoracic and abdominal were the two cavities penetrated. The lower lobe of the left lung was partly hepatized, partly carnified. The pulmonary and costal pleuræ were greatly thickened by profuse layers of lymph and false membrane. There had been hæmothorax, and the level of the dark decomposing grumous fluid was mapped out by stains on the serous sac (FIG. 131). The fragment of rib driven in upon the lung exactly supplies the loss of substance from the shaft of the bone. The three specimens were forwarded to the Museum by J. Cooper McKee, with the following memorandum: "Specimen 2423 exhibits the two extreme portions of the fractured rib; 2424 shows the middle portion of the rib attached to the left lung, which it has penetrated; 2425 is the upper part of the kidney with the supra-renal capsule, containing the ball itself, yet undisturbed. The ball penetrated the left lung and diaphragm and was found flattened and concealed, because entirely encapsulated in the supra-renal body."

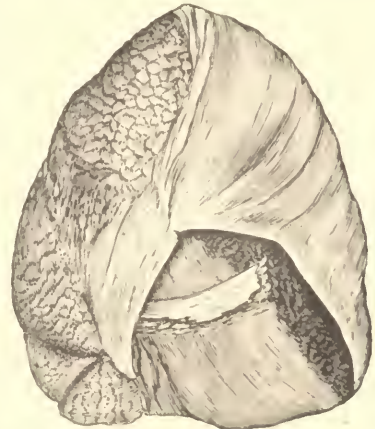

FIG. 131.—Left lung, with a portion of the ninth rib embedded in it. The thickened pleura is cut away to expose the cavity in which altered blood was effused. Spec. 2424.

<sup>1</sup> See *First Surgical Volume*, Chap. V, p. 569, FIG. 229. In this very remarkable case there was no hæmoptysis, not much oppression of breathing, scarcely any hæmorrhage, no disorder of the trophic functions, and comparatively little shock at the outset, the reverse of what would be anticipated from Kölliker's observation, that the supra-renal capsule is more highly supplied with nerves than any other glandular structure, and that the nervous branches are derived from the sympathetic, pneumogastric, and phrenic nerves. The patient died of pyæmia. The dissection was made by Dr. Schoney, detailed by Dr. McKee to make autopsies at Lincoln Hospital.

<sup>2</sup> ADDISON, *On the Constitutional and Local Effects of Disease of the Supra-renal Capsules*, London, 1856; HALEY, *An Experimental Enquiry into the Function of the Supra-renal Capsules*, *Med. Chir. Rev.*, Am. ed., 1858, Vol. XXI, pp. 169, 389; WILSON, *Diseases of the Skin*, 4th ed., p. 557 LISTER, *Proc. Royal Soc.*, No. 27; HUTCHINSON, *Med. Times and Gaz.*, 1856, Nos. 297, 299; VULPIAN, *Gaz. Hebdomadaire*, Mars 9, 1858.

<sup>3</sup> BROWN-SÉQUARD, *Jour. de la Physiologie*, Vol. I, 1858, p. 160; PHILIPPEAUX, *Comptes Rendus de l'Acad. des Sciences*, 1856, 1857; GRATIOLLET *Comptes Rendus*, 1856.

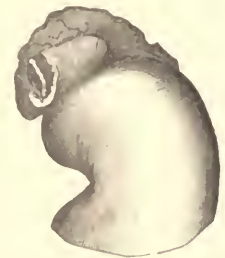

FIG. 129.—Section of the left kidney, with a conoidal musket ball lodged in the supra-renal capsule. Spec. 2425, A. M. M.

WOUNDS OF THE OMENTUM, MESENTERY, AND BLOOD-VESSELS.—Those cases of penetrating wounds of the abdomen in which the most important lesions are limited to the serous membranes or blood-vessels rarely come under treatment. Some observations that might be included in the first group have been recorded under the head of penetrations without visceral injury (p. 35). The cases in which lesions of the blood-vessels were the most important feature have not been well studied or classified, for the obvious reason that most of the patients perish before help can be accorded, and are left with the slain on the field. Moreover, the pernicious doctrine of Jourdan,<sup>1</sup> that surgery is powerless in lesions of the blood-vessels of the belly, had too much currency, and most surgeons felt exonerated from exposing and securing wounded vessels within the abdomen, and at liberty to "rely on general measures," or to employ tents and styptics. The evils of such temporization will be more fully indicated in treating of *hæmorrhage* and of *abdominal effusions*. On page 38, *supra*, the distinctive symptoms that Ravaton ascribed to wounds of the omentum are quoted. Few other authors<sup>2</sup> attempt to separate them from the phenomena common to cases of traumatic peritonitis. Apart from the numerous instances of protrusion of the unwounded omentum, which will come up for consideration under the head of complications of penetrating wounds of the abdomen, the returns of the war present at least one remarkable example of a shot lesion of the omentum, the penetration being probably a secondary accident:

CASE 563.—Private L. S. P.—, Co. E, 3d North Carolina, received wounds of the left ankle and left side, at Antietam, September 17, 1862. He was treated at the field hospital, and, on the 29th, was transferred to hospital No. 1, Frederick, under the care of Assistant Surgeon I. H. Searle, 25th New York, who states: "The first ball inflicted a transverse wound in the left

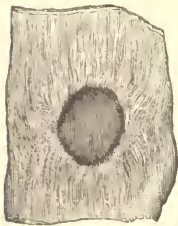

FIG. 132.—A portion of integument from the loin, including a circular shot cicatrix. *Spec.* 852. [Reduced to one-half.]

ankle; the second entered just anteriorly and below the twelfth rib on the left side. Amputation above the ankle was deferred only on account of the patient's weakness. He had tenderness over the abdomen to some extent, and constipation. He was treated with stimulants, tonics, and opiates, with cold-water dressings to the wound. He died October 29, 1862." A *post-mortem* examination was made twelve hours after death, and Acting Assistant Surgeon W. W. Keen, jr., obtained three specimens: "The ball which wounded the abdomen had passed between the internal and external oblique muscles to the other side of the abdomen, two and a half inches to the right of, and above, the umbilicus. It had there probably ulcerated through the walls of the abdomen, since there was a small abscess and the walls of the abdomen and peritoneum were firmly glued together. There were also, at this point, as well as over the diaphragmatic surface of the liver, some traces of the effects of peritonitis. The ball was found in the left lumbar region posteriorly (the patient lay mostly upon the left side), in the fold of the omentum, lying in about one-half an ounce of serum, and was surrounded by some peritoneal bands. The folds of the omentum when lifted hold the ball most beautifully within their grasp." The specimen, imperfectly represented in the wood-cut (FIG. 133), is described by Assistant Surgeon Woodhull<sup>3</sup> as "a portion of the omentum magnum, in the folds of which is lodged a conoidal bullet slightly misshapen from having glanced against the brass plate of the soldier's waist-belt." The second preparation, sent by Dr. Keen, and very imperfectly represented in FIG. 132, consists of a rectangular portion of the integument from the right (?) lumbar region, exhibiting a circular depressed smooth cicatrix an inch in diameter, composed of granulation tissue, with a thin, shining, epidermal covering. "The ball was found," Dr. Keen writes, "in the left lumbar region. I am under the impression that it entered in the right lumbar region, but I am not sure. My memorandum simply says: 'Skin of

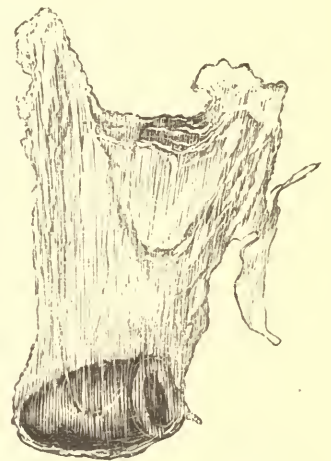

FIG. 133.—Conoidal ball held in the folds of the omentum magnum. *Spec.* 1926.

<sup>1</sup>JOURDAN, *Dict. des Sci. Méd.*, T. II, p. 317. See *First Surgical Volume*, p. 521, note.

<sup>2</sup>The dissertations of RIVINUS (*De omento*, Lipsiæ, 1717), REBMANN (*De omento sano et morbo*, Argent., 1753), HALDER (*De morbis omenti*, Göttingen, 1786), and VALLOT (*De morbis omenti*, Besançon, 1792) may be consulted, but without much satisfaction. The article EPIPLOON, by CHAUSSIER and ADELON, in the *Dict. des Sci. Méd.*, T. XII, p. 461, is more instructive. DORSEY taught (*Elements of Surgery*, 2d ed., 1818, Vol. 1, p. 99): "Wounds of the omentum or mesentery seldom occasion trouble, except from their bleeding; when practicable, the bleeding vessels are to be secured by ligature, and the ligature in every instance left out at the external wound."

<sup>3</sup>WOODHULL (A. A.), *Catalogue of the Surgical Section of the Army Medical Museum*, 1866, p. 490. The history of this case having been filed with specimen 766, specimen 1926 was not identified at the date of the printing of the Catalogue, and Dr. Woodhull fortunately inserted the note: "It is a matter of regret that the particulars of this unique case have been lost. Any one having cognizance of it is requested to communicate with the Surgeon General"—a request with which Drs. R. F. WEBER and W. W. KEEN, jr., immediately complied.



lumbar region—minié ball in omentum?" The abdominal wound had completely healed, and appears to have been remotely, if at all, related with the fatal termination of the case, which took place six weeks after the reception of the two injuries. "There was no irritation or peritonitis caused by the ball in the omentum, as I remember." Dr. Keen states, \* \* "The wound of the ankle was the cause of death." The perforation of the left ankle is preserved in the Museum, as specimen 766 of Section I. The ball, crushing the outer malleolus and astragalus, and grooving the calcaneum, has caused disorganization of the joint.

One, or two examples only of wounded omentum, with protrusion, need be referred to here, as the subject will recur presently, in considering *visceral protrusions*.

CASE 564.—Private Lewis Vetter, Co. I, 1st New York Artillery, aged 32 years, was wounded at Chancellorsville, May 3, 1863. He remained at the field hospital until the 7th, when he was transferred to Finley Hospital, Washington. Here, Assistant Surgeon William A. Bradley, U. S. A., recorded the injury as a "shot wound of the right side." On June 2d, the man was transferred to Satterlee Hospital. The following notes of the case appear upon the case-book: "Gunshot wound of the anterior wall of the abdomen; the ball entered about one inch above the crest of the right ilium. The patient states that a portion of omentum protruded about six inches from the wound, and that the protrusion was tied and replaced. The ligature still remains. Sulphate of copper dressings. June 16th, traction on the ligature was commenced by adhesive strips, and water dressings were applied to the wound. On the 18th, the ligature came away. The patient had some diarrhoea on the 19th. On the 20th, cerate dressings were applied." The case appears to have progressed favorably, and on July 27th Vetter was returned to duty. He is not a pensioner.

A remarkable example of protrusion of the omentum through a shot wound is related by Assistant Surgeon Sternberg, at page 250 of Circular No. 3, 1871. The protrusion took place through a ragged orifice in the left hypochondrium, caused by the oblique impact of a ball at short range. After a three-days journey of over a hundred miles, the officer who received this injury arrived in camp. The epiploon was then covered with florid granulations, and bathed in pus, and adhered to the margins of the orifice. It was removed by Dr. Sternberg with a wire *écraseur*, and recovery ensued without an unpleasant symptom. The specimen, which weighs three ounces, is represented in the wood-cut (FIG. 134).

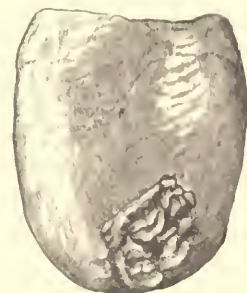

FIG. 134.—Portion of excised omentum. Spec. 5521. [Half size.]

Instances of ruptures of the blood-vessels of the abdomen have been referred to on page 21, *supra*, and examples of wounds of the mesenteric, epiploic, and epigastric arteries have been mentioned<sup>1</sup> on pages 9, 10, 42, 62.

Wounds of the mesentery are commonly disregarded in presence of the lesions of the intestine to which it is attached, or of the vessels it seems to distribute.<sup>2</sup> FIGURE 49, page 71, *supra*, shows how it may share in perforations of the bowel. Specimen 505 of the Medical Section of the Museum is "a piece of mesentery, in which an opening has been formed, through which several feet of the lower part of the ileum passed, and subsequently became strangulated."<sup>3</sup>

In an interesting case, reported by Surgeon W. S. Edgar, 32d Illinois, the division of both epigastric arteries could be recognized in a patulous shot channel above the pubes. There appears to have been no bleeding:

CASE 565.—"John D. Murphy, a prisoner of war, was wounded while attempting to escape the guard. The ball entered at one inguinal region and emerged at the other, cutting through the entire abdominal wall, from one side to the other, about half an inch above the pubes. It severed the epigastric artery on either side, and produced a gaping wound about eight inches in length, exposing plainly the pelvic viscera. The patient was admitted into the post hospital at Cairo on June 30, 1864, and returned convalescent to the military prison on July 21, 1864."

It will be more convenient to continue the subject under the succeeding head.

<sup>1</sup> Consult also MILIN, (*Preussische Vereinszeitung*, 1844, No. 8) and EMMERT (*Lehrbuch der Speciellen Chirurgie*, Stuttgart, 1862, S. 248).

<sup>2</sup> MORGAGNI (*De sed. et caus.*, Patavii, 1765, Epist. LIV, art. 35, p. 282) relates that a foreigner was stabbed in the abdomen with a sharp thin sword; he died on the fifth day. Of the autopsy MORGAGNI remarks: "And the wound had reached to the intestine colon, about four inches below the spleen, but had injured it only superficially; and from thence, without injuring any other intestine, it had reached to the mesentery, which, for this reason, was not only found to be wounded, but tumid."

<sup>3</sup> WOODWARD (J. J.), *Catalogue of the Medical Section of the Army Medical Museum*, 1867, p. 55; Case of Private C. C.—A 8th Wisconsin.



COMPLICATIONS.—Penetrating wounds of the abdomen may be attended by the following complications, viz: hæmorrhage, foreign bodies, visceral protrusions, abdominal effusions, and traumatic peritonitis:

*Hæmorrhage.*—The bleeding which attends penetrating wounds of the abdomen may proceed either from the vessels which supply the walls, from the parenchyma of the viscera,

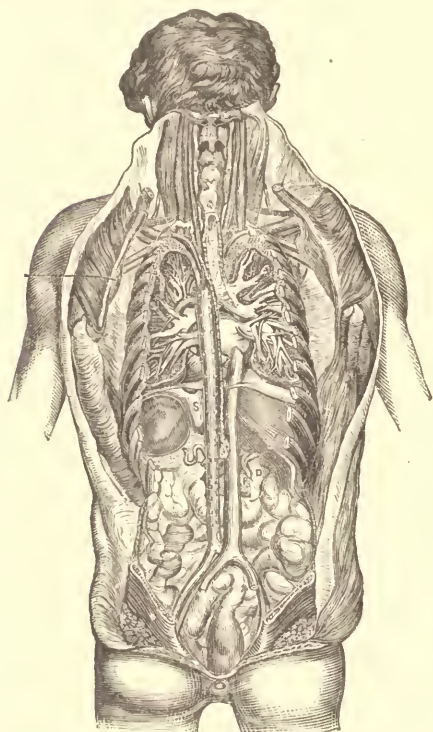


FIG. 135.—Posterior view of the viscera of the thorax and abdomen, designed specially to show the relations of the blood-vessels. [After SIMSON, *Med. Anat.*, Pl. XIV.]

or from the great vessels, in which event the cases rarely come under treatment, and from the secondary branches which supply the viscera. Enthusiasts have cherished and proclaimed the conviction that the surgical lessons of the war, deduced from a great wealth of materials, would embrace solutions of many of the higher surgical problems; but the thoughtful reader, while not disregarding those grave subjects, on which experience was acquired on so large a scale, will, perhaps, look for some of the more important teachings in provinces that rarely engage the attention of systematic writers. In treating of wounds of the chest, we saw that the abandonment of rigid antiphlogistic treatment in such injuries, though sanctioned, was not brought about by the experience of our war, but was only a part of general professional progress, while the practical acquisitions really resulting from our experience were to be sought in our better knowledge of the limits of operative interference with fractures of the bony case, with thoracic effusions, and with lesions of the contained parts. In wounds of the belly, likewise, we must look for improvements among matters of detail, to which didactic authors devote but little space.

In the *First Surgical Volume*,<sup>1</sup> a series of cases was adduced which displayed, in a very impressive manner, the dangers of regarding bleeding from the internal mammary and intercostal arteries as a trivial affair. Not less than twenty one instances were detailed of recurrent bleeding from these vessels, and seventeen of these cases terminated fatally. The cases recorded with wounds of the abdomen furnish other instances:

CASE 566.—Surgeon John Drye, 6th Kentucky Cavalry, reports that "Private John T. Minor, Co. I, 6th Kentucky Cavalry, was wounded, while on picket at Hopkinsville, Kentucky, December 21, 1864, by the accidental discharge of a Spencer rifle. An elongated ball entered one inch to the right of the umbilicus, passed inward through the intestines, and out close to the spine, dividing the lowest intercostal artery. He died the same day, from internal hæmorrhage.

CASE 567.—Private C. H. S——, Co. E, 2d Michigan, aged 17 years, was wounded at Petersburg, June 17, 1864, and was taken to the Ninth Corps Hospital, where it was found that a ball had entered two inches above and to the left of the ensiform cartilage, and passed out in the left hypochondriac region. The injury was regarded as a flesh wound, and the patient was sent to Washington, entering Emory Hospital June 24th. Acting Assistant Surgeon E. B. Harris reports that "he was much exhausted, on his arrival, from loss of blood and exposure in transit to this point. Pulse 98 and feeble; skin hot; bowels constipated; urine scanty and high colored. There was slight hæmorrhage when the patient arrived in hospital, and extensive ecchymoses and swelling of the left side, extending to the axilla [interstitial hæmorrhage], attended with some difficulty of breathing." \* \* \* "The patient was bathed and cleansed, and placed in bed, with the wound in a depending position and dressed with iced water. The bowels were opened with sulphate of magnesia; spirits of nitric ether, with a nourishing diet and stimulants, and an anodyne at night, were directed. On June 25th, the patient had slightly improved, having rested quietly during the night; bowels opened; cold-water dressings continued, with laxatives. On June 27th, the wound was discharging slightly a very offensive matter. On June 30th, the wound discharged pus with slight traces of blood;

<sup>1</sup>On pages 523, 525, and 548-552.

no abatement of swelling in the side; breathing more free. On July 1st, the swelling of the side was less, the breathing easier; the cold-water dressings were continued, and nourishing diet and stimulants were given. On July 2d, the wound discharged pus and blood; treatment continued, with anodyne at night. On July 3d, in the morning, the patient was apparently improving. At two in the afternoon, secondary hæmorrhage set in profusely, and was supposed to proceed from branches of the internal mammary artery; patient lost considerable blood; his countenance was sunken, with a haggard expression; breathing short and hurried; bowels tympanic, and the meteorism rapidly increasing; pulse 120 and feeble; ice-water dressings were applied, and sponges saturated with the solution of the persulphate of iron were passed into each wound, and compresses applied over them; stimulus was given and the patient kept on his back." [These measures appear not to have controlled the bleeding.] Dr. Harris resumes: "On July 4th, no particular change; some hæmorrhage again; no change in treatment, save repeating the compression and persulphate of iron to suppress the bleeding; gave a mild laxative to open the bowels in hope of removing the tympanitis, which was accomplished, with relief to the difficulty of breathing. On July 5th, on exposing the wound, there was no bleeding; gave stimulants, with nourishing food, and an anodyne at bedtime. On July 6th, at three in the morning, hæmorrhage set in, and the patient expired in a very few moments. *Post mortem*: The ball had made furrows through the cartilages of the fourth, fifth, and sixth ribs, and, passing down, had carried away portions of the seventh and eighth ribs, and passed out opposite the spleen. Found that the hæmorrhage must have been produced from the musculo-phrenic and superior epigastric arteries, as their mouths were exposed. Found the pericardium altered from the diseased parts contiguous to it, and also partially filled with blood. Also found the transverse portion and upper part of the descending colon were gangrenous; also a portion of the peritoneum contiguous to the wound and diseased parts. There was extensive inflammation of the soft parts extending to the axilla. The lower part of the left lung and parts contiguous were highly congested. There were traces of a nutmeg appearance in the left lobe of the liver, which was slightly inflamed. The stomach, heart, right lung, and the upper part of the left lung were normal in appearance. There was also found a mass of coagulæ, pus, spiculæ of bone, and pieces of cartilage in a sac between the points of entrance and exit of the ball. A preparation of the anterior extremities of five ribs, the fifth to the ninth inclusive, with the costal cartilages, was forwarded to the Museum by Surgeon N. R. Mosely, and is mounted as specimen 2809. "The seventh and eighth ribs are fractured at their extremities, and are necrosed."—(*Cat.*, p. 77.)

It is difficult to conceive of a more perplexing conjunction of circumstances than was here presented. The propinquity of the ball-track to the pericardium, the hazard of displacing the shattered fragments of the ribs in such vital relations, might well arouse the gravest solicitude of the most experienced surgeon. The excellent Goyrand tells us<sup>1</sup> that the ligation of the internal mammary "may be done with facility in the first three intercostal spaces, presents some difficulties in the fourth, is very difficult in the fifth, and nearly impracticable in the sixth." It is quite possible that, in this case, the difficulties of ligating the vessel at the seat of the wound might have proved insurmountable. In this event, it would have been proper, upon the recurrence of the bleeding, to tie the artery in the third intercostal space. But the urgent indications for ligation were obviously unheeded, and the skilful anatomist in charge of the hospital was not, apparently, consulted. The disastrous results of reliance on Monsel's salt in serious arterial bleeding were, once more, conspicuously exposed. Here is another instance:

CASE 563.—Assistant Surgeon E. McClellan reports that "Private W. Bachus, Co. E, 142d New York, aged 36 years, wounded at Bermuda Hundred, May 12, 1864, was shot through the abdomen. The ball entered posteriorly in the left lumbar region, two inches from the spine, and passed obliquely forward and inward, and was extracted from beneath the skin on the right side. He was treated at the Tenth Corps Hospital till May 19th, and was then admitted to Hampton Hospital. From June 7th to 11th, there were lost from twenty to twenty-five ounces of blood from recurring bleeding from an intercostal artery. The bleeding was each time arrested by plugging the wound with lint and styptics. Death, June 12, 1864."

It is essential to have correct views in this matter. In treating of wounds of the walls of the belly, on pages 9 and 10 of this chapter, I have earnestly insisted on the dangers of trusting to palliative measures in bleeding from the epigastric, circumflex, iliac, mammary, and lumbar arteries, and have adduced a deplorable series of six fatal cases (CASES 34-39) in exemplification of the perils of temporizing with such accidents. These positive examples are more impressive than any language. Hæmorrhage from these vessels is not common, it is true, after division by shot. We have seen, in CASE 565, how both epigastrics may be torn across without consecutive bleeding; and know that much larger trunks, as the brachial, or even the femoral, when divided by shot, are sometimes as completely occluded

<sup>1</sup>GOYRAND (d'Aix), *Clinique Chirurgicale*, 1870, p. 223, and *Mém. de l'Acad. de Méd.*, 1832.



as if treated by torsion. But this natural hæmostasis is not uniformly brought about in shot wounds, and, in punctured or incised wounds, seldom; and when bleeding does take place, it must not be trifled with. In 1790, Dr. James Carmichael Smyth enumerated, in the Society for promoting Medical Knowledge, ten cases in which death resulted from hæmorrhage, in consequence of the epigastric artery, or some branch of it, having been wounded in the operation of paracentesis<sup>1</sup>. Mr. South and Professor Hamilton<sup>2</sup> have also adduced examples in illustration of this accident. The disastrous results of wounding the epigastric artery in the course of the operation for strangulated hernia are well known. I cannot approve the course of Lawrence and of some other writers, in representing that the dangers of this accident have been exaggerated.<sup>3</sup> The recent works on ovariotomy by Dr. Peaslee and by Mr. Wells contain several examples of hæmorrhage<sup>4</sup> succeeding that operation, which instructively exemplify the importance of exposing and of directly securing the bleeding points. The sixty-eighth and sixty-ninth observations of Sanson's monograph<sup>5</sup> on traumatic hæmorrhages are instances in which the fatal results of division of the epigastric artery by stabs might readily have been arrested by the ligature. C. J.

<sup>1</sup> SMYTH, *Medical Communications*, 1790, Vol. II, p. 482. Dr. SMYTH encountered this accident in his own practice, and mentioned it to Dr. WILLIAM HUNTER, who said it was new to him. A twelve-month after, Dr. SMYTH observed a second instance, and, on enquiry, learned that Mr. WATSON, of the Westminster Hospital, had seen the accident three times; Mr. HOWARD, of the Middlesex Hospital, twice; and Mr. HOWARD, of Argyle street, twice; and that a patient had recently died at St. Thomas's Hospital from the same cause. The editor of the *Communications* remarks that two of the above cases had been related by Messrs. FORD and PEARSON, and had been the subject of public conversation at meetings of the society several years previously. The St. Thomas's Hospital case may have been that related by SOUTH, in his additions to *Chelius* (*op. cit.*, Am. ed., Vol. III, p. 207). Including two referred to by Dr. THOMAS WATSON (*Lectures on the Principles and Practice of Physic*, Vol. II, p. 399), SOUTH groups together five cases; but it is not practicable to determine whether or not they are identical with those enumerated by SMYTH.

<sup>2</sup> Dr. HAMILTON's patient recovered; but the case illustrates impressively the serious nature of this accident (see p. 9, note 2, *supra*) and the importance of fixed rules of treatment. The operator relates the circumstance as follows:

"We desire to mention, however, that we have once wounded the epigastric artery while operating for the relief of ascites, and that the hæmorrhage was made to cease by pressure. \* \* The instrument, a trocar, was inadvertently carried about two inches to the left of the median line—a few inches below the umbilicus. The water escaped freely and without being colored with blood. As the canula was being slowly withdrawn, however, and when its extremity had fairly escaped from the peritoneal cavity, but was still held by the muscles and skin, a clear, bright-red stream of blood began to flow through the instrument. The stream nearly filled the canula. It was at once apparent what had happened, but an occurrence so unexpected left us for a moment undecided what course to adopt. Pushing the canula fairly into the cavity again, it was observed that the stream of blood ceased at once, and that colorless serum again escaped. This, happily, confirmed our suspicion that the vessel was lying so far from the peritoneum in the substance of the rectus muscle that it had not emptied itself into the peritoneal cavity, and perhaps might not if the canula was withdrawn. While we were deliberating, and before the canula was carried back into the belly, the patient had lost over a quart of blood. The instrument was now withdrawn, and the external bleeding at once ceased almost entirely. A graduated compress was prepared and laid directly over the wound, and this was secured in place by a broad and firm bandage. On the following day a slight bleeding occurred, from the bandage having become displaced while the patient was asleep, but it never returned." \* \* \*  
*A Treatise on Military Surgery*, by F. H. HAMILTON, 1865, p. 374.

"\* \* But when the trocar was nearly withdrawn, its distal extremity having escaped from the cavity of the peritoneum, but still remaining beneath the skin, a stream of arterial blood, nearly filling the canula, flowed from its open extremity. Alarmed, and uncertain how to proceed, I permitted the canula to remain in this position until nearly a pint of blood had escaped, thinking it better that it should flow outwardly than inwardly, and hoping that it would cease spontaneously. In this I was disappointed; and, finally, I thrust the canula farther in, and the bleeding at once ceased. Preparing then a graduated compress, the trocar was again slowly withdrawn, and, arresting its extremity where it had been arrested before, the phenomenon was repeated—the blood flowed in a full stream. Removing it entirely, blood continued to trickle quite freely over the skin. The compress and a firm bandage were then applied, and the bleeding ceased altogether. The recovery was as complete and rapid as usual in such cases; and, several months later, having occasion to tap her again, I discovered that my first operation was made three or four inches to the right of the median line." \* \* \*  
*The Principles and Practice of Surgery*, by FRANK HASTINGS HAMILTON, A. M., M. D., LL. D., 1872, p. 765.

The following are accepted rules, as formulated by Mr. POLLOCK, Vol. II, p. 429, HOLMES'S *System*, 1861 (the italics are the author's): "We would lay it down as a rule, firstly, that in punctured wounds of the abdominal wall, if any hæmorrhage be present, but not sufficient in amount to justify or indicate an enlargement of the wound for the purpose of applying a ligature to the bleeding vessel, the exit of the flowing blood through the orifice of the wound from the injured artery or vein should not be checked by outward applications. By far the least of two evils will be rather to allow the blood an escape externally, than by external appliances to insure its accumulation in the tissues surrounding the wound. We would lay it down as a rule, secondly, that if hæmorrhage be at all free, the wound should be enlarged sufficiently to allow the bleeding vessel to be secured, and no dependence should be placed on pressure to restrain such hæmorrhage." Whether the puncture in this case cited, of the operation termed by Mr. Erichsen "the simplest in surgery," was "two inches to the left" or "four inches to the right of the median line;" whether the hæmorrhage amounted to "nearly a pint," or to "over a quart;" whether the operator was "for a moment undecided," or "alarmed, and uncertain how to proceed," for an indefinite period,—the employment of a compress, involving the hazard of internal or of interstitial hæmorrhage, should not be held up for imitation.

<sup>3</sup> LAWRENCE (*a Treatise on Ruptures*, 5th ed., 1828, p. 270) and SHARP (*Critical Enquiry*, etc., 1754, p. 31). BOYER, also (*op. cit.*, T. VI, p. 256), thought lightly of this accident, but had occasion to modify his opinion; for VIDAL (*Path. Ext.*, T. IV, p. 251) relates that he saw him subsequently divide the epigastric in herniotomy on two occasions, succeeding, it is true, in arresting the bleeding. But SCARPA (*Sull' ernie*, p. 41) gives a fatal case; A. COOPER (*op. cit.*, p. 53) another, in Mr. STERRY'S practice; and a case by Mr. DAVIE, in which the patient recovered after being reduced very low. GUNZ (*Observations anatomico-chirurgiques de herniis*, Lipsiæ, 1744) tells us that he heard of two fatal cases in Paris. HEY (*Pract. Obs. in Surgery*, 3d ed., p. 161) gives an instance in which he had great difficulty in controlling the bleeding. ARNAUD (*Mémoires de Chirurgie*, etc., 1768, T. II, p. 781) invented a special tennaculum for this accident. For general observations on its dangers, without specified cases, consult BERTRANDI (*Traité des opérations*, 1784, p. 29), RICHTER (*Anfangsgründe der Wundarznehkunst*, Göttingen, 1801, B. V, S. 309), and I EBLANC (*Précis d'opérations de chirurgie*, Paris, 1775, T. I, p. 51).

<sup>4</sup> PEASLEE, *Ovarian Tumors, their Pathology, Diagnosis, and Treatment, especially by Ovariotomy*, New York, 1872, p. 497. WELLS, *Diseases of the Ovaries, their Diagnosis and Treatment*, New York, 1873, p. 270. "In Mr. WELLS'S eleventh case, very free hæmorrhage took place on the tenth day, from a small artery that had apparently been wounded in passing the lowest suture. He applied a ligature, and the bleeding ceased."

SANSON, *Des hæmorrhages traumatiques*, Paris, 1824, p. 281.



M. Langenbeck relates an instance of fatal hæmorrhage from a slight stab in the belly, where the bleeding was found to proceed from the ascending branch of the left colic artery. The treatment had consisted in the application of a broad body bandage.<sup>1</sup> Malgaigne encourages<sup>2</sup> a reliance upon direct compression in punctured wounds of the blood-vessels of the abdominal wall. But an examination of the evidence must satisfy the reader that there is ample foundation for the prudent counsels of Professor Gross and Mr. Pollock, who advise ligation or acupressure as the only safe resources.

*Foreign Bodies.*—Examples have been adduced of the lodgement of balls in almost all parts of the abdomen, in the vertebræ, muscles, and connective tissues, in the stomach, intestines, liver, kidney, pancreas, supra-renal capsule, and omentum.<sup>3</sup> Here is an additional illustration (Fig. 136), contributed by Surgeon J. A. Lidell, U. S. V. In most instances these missiles have been removed after death. The old precept of LeDran, that when balls are lost in the capacity of the belly, one need not amuse himself by hunting for them, was corroborated by Percy's statements that projectiles are sometimes innocuously encysted in the abdominal cavity, and sometimes harmlessly eliminated by stool, and has remained a rule generally observed. But Baudens earnestly contested its validity, and adduced instances in which he succeeded in extracting balls lodged in the psoas muscle or the vertebræ, and maintained that, in this region as elsewhere, the removal of foreign bodies when practicable should be the rule. M. Legouest adheres to this opinion, and those practitioners who permit the introduction of the finger for exploration of shot wounds of the belly cannot well refuse to sanction the removal of foreign substances that may be detected in such examination. The two following examples of the lodgement of foreign bodies in the abdominal cavity are somewhat remarkable:



FIG. 136.—Ball extracted after death from the body of the second lumbar vertebra, six days after it had traversed the fore-arm, left thorax, diaphragm, and left kidney.—Spec. 3076.

CASE 569.—Private W. Billinger, 19th New York Battery, aged 24 years, was wounded at Spottsylvania, May 12, 1864, by a minié ball. He was taken to the field hospital of the 2d division, Ninth Corps, and on May 25th was transferred to Lincoln Hospital. On June 2d, pyæmia developed, and resulted fatally on June 9, 1864. Iron and quinine, alternated with brandy, constituted the medicinal treatment. At the necropsy it was found that the ball had struck between the posterior border of the acetabulum and the lesser sacro-ischiatic notch, passing obliquely upward and forward, fracturing the acetabulum, and rebounding from there, flattened and bent down in an ununiform fashion at its apex. It was found hooked in a mesenteric pouch below the duodenum. The omentum was disorganized, and the small intestines were covered with grayish exudations; the mucous membrane of the stomach was congested. This case furnished specimen 2493 of the Museum, and there will be occasion to revert to it in treating of fractures of the pelvis. Assistant Surgeon J. C. McKee reports the case.

CASE 570.—Private J. Ives, Co. I, 15th New York, aged 20 years, received a lacerated wound of the gluteal region by the explosion of torpedoes at Bachelor's Creek, May 26, 1864. He was admitted to Foster Hospital, at New Berne, on the same day. He was supposed to be only slightly wounded until the sixth day, when blood and pus passed with his urine. On the tenth day, fecal matter escaped from the wound. The bowels had moved freely, and without pain, from the first. On the twelfth day, profuse hæmorrhage occurred. The wound was plugged with lint saturated in a solution of persulphate of iron, but the hæmorrhage escaped through the rectum, and continued at intervals until death, June 8, 1864, fourteen days after the injury. At the autopsy, ten hours after death, it was found that, from sloughing of the wound, two branches of the gluteal artery were opened about half an inch from the bifurcation; the canal or track of the wound passed through the great sciatic notch, and a fragment of a splinter, five and a half inches long, which had been broken off, was found lying within the abdominal cavity, having penetrated the descending colon about twelve inches above the rectum and passed out three inches higher, and was forced against the inner wall of the pelvis, on the right side, with such force as to broom up the end about half an inch, wounding the sciatic nerve in its course, in which situation it remained, transfixing the colon and lying behind the bladder, without giving rise to inflammation of the colon or peritoneum. The bladder was much thickened and inflamed, and contained considerable pus; death seemed to have resulted from secondary hæmorrhage, and not from the wound or the presence of the foreign body. The case is reported by Surgeon C. A. Cowgill, U. S. V.

<sup>1</sup> LANGENBECK (C. J. M.), *Nosologie und Therapie der Chirurgischen Krankheiten*, 1830, B. IV, S. 595.

<sup>2</sup> MALGAIGNÉ, *Manuel de Médecine Opératoire*, 7ème éd., 1861, p. 560.

<sup>3</sup> In the vertebræ: CASES of McDonald, Hogan, Flaherty, and Joseph R —, pp. 411-4, of the *First Surgical Volume*, and CASE 496, p. 155, *supra*. In the muscles, CASES 186, 197, 200, 302, 499, 445, and 321, pp. 47-141, *supra*; in the fascia and connective tissue, CASES 305, 307, 471, 414, 230; in the stomach, CASE 196; in the intestines, CASES 294, 295, 296, 297, 298, 299, 300, and CASE A<sup>2</sup> on page 101; in the liver, CASES 199, 318; in the pancreas, CASES 505, 418; in the kidney, CASES 525, 532; in the supra-renal capsule, CASE 562; and in the omentum, CASE 563, *supra*.

*Visceral Protrusions.*—Being subjected to a constant equable pressure by their muscular walls, the abdominal viscera, when these are divided, follow the line of least resistance and are liable to protrude. This condition is of such importance that generic distinctions are determined, in the classification of penetrating wounds of the abdomen, by its presence or absence. It is especially common in incised and large lacerated wounds; comparatively infrequent in punctures and in shot wounds. Still, it has been seen that even the fixed viscera occasionally protrude through the orifices made by shot. Examples have been adduced of protrusions of wounded portions of the liver, spleen, and pancreas, and it was observed that, in the case of these solid viscera, adhesions formed speedily at the orifice, intra-peritoneal extravasation was avoided, and the injured part being removed by sloughing or excision, the complication might be regarded as a favorable one. The intestines and epiploon protrude more frequently, especially the latter. The mode of dealing with the protruded gut is tolerably well settled; but much discussion, with which the reader is probably familiar, has arisen regarding the proper management of the protruded omentum. Sometimes, with a recumbent position and relaxation of the abdominal muscles, the protruded parts return without difficulty. If not readily reduced, the general surgical practice is in accordance with the precept of Boyer,<sup>1</sup> to return the omentum whenever it is intact, and to enlarge the orifice if necessary to accomplish this purpose. Ravaton taught that it was very bad practice to cut off the protruding omentum, "a deadly and cruel manœuvre, contrary to reason and experience."<sup>2</sup> Pipelet has collected a few instances of its ill effect,<sup>3</sup> but I find more in which it has been practiced with impunity.<sup>4</sup> Larrey advises that the protruding omentum should not be returned, and

<sup>1</sup> BOYER, *Traité des maladies chirurgicales*, 5e éd., T. VI, p. 38.

<sup>2</sup> RAVATON, *Pratique moderne de la Chirurgie*, 1776, T. II, p. 210, and *Chirurgie d'Armée*, 1768, p. 486.

<sup>3</sup> PIPELET, *Mémoire sur la ligature de l'épiploon*, in *Mém. de l'Acad. de Chir.*, 1757, T. III, p. 394.

<sup>4</sup> 1. GALENUS (*Omnia que extant*, Froben, 1567, T. I, Lib. IV, p. 274, *de usu partium*. &c.) remarks: "Sicut et nos id (omentum) aliquando fere totum abscidimus illud gladiatorum ita vulnerato. Ille vero homo sanatus est cito." 2. FORESTUS (*Obs. et cur. chir.*, Francofurti, 1611, Lib. VI, Obs. 7, p. 13); a youth, A. J.—, in December, 1562, was stabbed with a knife in the left side of the abdomen; the protruding omentum, without being ligated, was cut off by a young, inexperienced surgeon, "ad quem cum venissem, objurgavi temerarium chirurgum ob crassam ejus ignorantiam;" recovery in about two months. 3. RICHER (*Eph. nat. cur.*, Dec. II, Ann. VI, 1687, Obs. CXCVIII, p. 395) relates that he was called to see a peasant, Hering, aged 50, who had been stabbed in the left hypogastrum. The protruding omentum had been cut off before his arrival by a surgeon of the village Osthoven. "Ipsum vehementer objurgavi, quod non omni conatu repositionem tentasset, vel ad minimum ante abscissionem, ut solet fieri in simili casu, ligasset." The patient recovered entirely. 4. LARREY (*Mém. de Chir. Mil. et Comp.*, 1812, T. III, p. 261) relates that the dragoon, Bernard, received a sabre wound in the right inguinal region; hæmorrhage from epigastric, and protrusion of omentum; the protruding portion was extirpated; recovery in six weeks. 5. ACKERLY'S case (*London Med. Gaz.*, 1837, Vol. XX, p. 549) has been cited in note 2, pp. 162-3, *ante*. 6. HOMBERG (RICHTER'S *Chir. Bibliothek*, Göttingen, 1779, B. V, S. 152) records a case of a young man, aged 15, stabbed in the abdomen. A large piece of omentum protruded, and was cut off two hours after the reception of the injury; recovery in four weeks. 7. NEUMAN (*American Med. Intelligencer*, 1841, p. 164); a negro, Leven, on February 25, 1840, received a stab wound in the abdomen an inch and a half below the navel; a portion of the omentum, protruding nearly two inches, was ligated and cut off; recovered in a few weeks. 8. COATES (*Med. Gazette*, N. S., Vol. V, 1847, p. 933) records that J. Allen, aged 14, was stabbed, on October 14, 1847, in the abdomen, between the ninth and tenth ribs. A ragged portion of the omentum about three inches in length protruded, and was cut off; the wound healed in ten days. 9. GUSHEE (*Boston Med. and Surg. Jour.*, 1847, Vol. XXXV, p. 80) relates that a man, aged about 30, cut himself in the abdomen, seized the protruding omentum and cut off a portion measuring one hundred and forty-four square inches. "At the end of four weeks the patient was up and well." 10. HEWSON (*Medical Examiner*, 1851, Vol. VII, p. 567) records the case of a colored woman, Lloyd, aged 21, stabbed on June 21, 1851, in the left groin. A piece of the omentum, the size of the palm of a hand, protruded; a double ligature was passed through the mass, which was then cut off close to the integuments; recovered in six weeks. 11. COLEGROVE (*Boston Med. and Surg. Jour.*, 1859, p. 249) cites a case of removal of the entire omentum by Dr. STAUNTON. A German woman, aged 30, was, on June 30, 1858, attacked by a cow, the horn of the animal penetrating the abdomen two inches above and to the right of the umbilicus; the bowels protruded, and also the torn and lacerated omentum; the latter was removed; recovered in less than three months. 12. MILLNER (*New Orleans Jour. of Med.*, 1869, Vol. XXII, p. 177) was called, on May 27, 1868, to see a negro, Alick, who had been stabbed in the left iliac region one inch above the anterior superior spinous process of the ileum; the omentum, severely lacerated, protruded six inches; a ligature was passed around and the protruding portion cut off; recovery in one month. 13. WILLARD (*Med. and Surg. Reporter*, 1870, Vol. XXIII, p. 281) cites the case of a patient of Dr. GARRETSON, who had been stabbed in the abdomen; a portion of omentum protruded and was afterward torn and bruised; it was cut off and allowed to remain in the wound; recovery. 14. HOWE (*The American Med. and Surg. Jour.*, August, 1855, Vol. VII, p. 331) relates that, on May 13, 1855, James C—, aged 23, was stabbed above and a little to the left of the abdomen; a portion of the omentum, much lacerated, protruded; the lacerated portions were clipped off, one piece being twelve inches long and four inches broad; recovery in two weeks. 15. KLOMAN (*Phil. Med. Times*, November, 1872, Vol. III, No. 55, p. 101) states that a boy, aged 10, fell upon an iron railing, one point penetrating the abdomen; in disengaging the boy a piece of the omentum, considerably lacerated, was dragged from the wound; protruding portion ligated and cut off; recovery. 16. GIBBES (*Transactions of the South Carolina Med. Ass.*, 1872, and *Am. Jour. of Med. Sci.*, 1873, Vol. CXXIX, N. S., p. 200); knife wound in left hypochondrium, through which omentum protruded; ligation and excision of six inches of protruding omentum; recovery in about forty days. 17. BAUDENS (*l. c.*, p. 346); case of Ben-Gil-Ali, cited in note on page 106, *supra*; a portion of the omentum protruded and was removed. 18. Mr. NUNSELEY (*Medical Times and Gazette*, 1860, Vol. I, p. 132) showed, at the meeting of the Pathological Society of London, March 20, 1860, a portion of omentum which had been successfully removed after protrusion



Guthrie, Robert, and Baron H. Larrey have earnestly sustained this precept.<sup>1</sup> Many illustrations in favor of either view might be adduced,<sup>2</sup> and the circumstances attending particular cases will determine the practitioner's conduct in adopting the one or the other. If the protruding omentum is intact and readily reducible, it should be returned; otherwise, it is safer to leave it protruding than to enlarge the wound in the peritoneum for its reduction, or to incur the hazard of intra-abdominal effusion from its lacerated vessels. Left externally, the epiploic protrusion will generally shrivel gradually and waste, and will be apparently retracted within the abdominal cavity. Sometimes, on the contrary, the mass becomes tumefied and is invaded by suppuration or gangrene. It may then be advantageously incised, or partially removed by the *écraseur* or the knife. This operation is not dangerous if deferred until adhesions at the orifice have formed a barrier to the extension of inflammation. CASES 236 and 276, of Lieutenant Deichler and Private Marker, on pages 77 and 91, and the instance from Dr. Sternberg's practice, referred to on page 175, exemplify the advantages of deferred interference. Except in extended lacerations, amounting to eviscerations almost, epiploic protrusions are as rare after shot

through a wound of the abdomen. 19. There is also a case reported by SAVIARD (*Nouveau recueil d'observations chir.*, Paris, 1702, p. 102): A woman aged 31, was wounded with a sword on the right side of the hypogastric region; omentum and seven inches of ileum protruded; gut returned, omentum ligated and a piece of the size of a pullet's egg cut off; the wound healed, but the woman died shortly afterward of diarrhoea. At the autopsy the omentum, intestine, and peritoneum were found united together. 20. Dr. DEWES (*Med. Times and Gaz.*, 1862, Vol. I, p. 611) relates a successful case of ovariotomy, with removal of large portion of omentum.

<sup>1</sup> LARREY (D. J.), *Clinique chirurgicale*, T. II, p. 497; GUTHRIE, *Wounds and Injuries of the Abdomen*, London 1847, p. 15; ROBERT (A.), *Mém. de l'Acad. de Méd.*, 1845, T. XI, p. 664; LARREY (H.), *Bull. de la société de chir.*, ébancé, Avril 17, 1850, T. I, p. 620.

<sup>2</sup> GUTHRIE (*On Wounds and Injuries of the Abdomen*, etc., 1847, p. 12) cites four instances: 1. Evan Thomas, aged 17, stabbed September 1, 1828, immediately above the umbilicus; the protruding omentum was returned; the wound united in a week. 2. A soldier, wounded with a lance at Albuhera, in the right lower part of the belly; the omentum protruded and was reduced, and a ligature applied to the epigastric; recovered. 3. A Spanish soldier, stabbed at Madrid, in 1812, near and below the umbilicus; the protruding omentum was reduced; the wound healed. 4. A Spanish soldier, shot at the battle of Toulouse; a small ball perforated the abdomen and carried with it a portion of the omentum; the latter gradually diminished, and finally was drawn into the wound of the abdomen; recovered. 5. LARREY (*Mém. de Chir. Mil. et Camp.*, 1817, T. IV, p. 278) relates the case of M. de L—, a young officer, wounded in August, 1815; the protruding omentum was gradually returned; recovered in a few months. 6. IDEM (*l. c.*, T. III, p. 436) cites the case of Etienne Belloc, aged 26, wounded with a sabre, April 1, 1811; the omentum protruded and formed a tumor, which gradually diminished and returned within the abdominal cavity. 7. RAYATON (*Chirurgie d'Armée*, Paris, 1768, p. 497) relates the case of a servant of a captain of dragoons, who was cut with a hunting knife in the umbilical region; part of the omentum had escaped; it was ligated, and separated in a few days; the wound healed in thirteen days. 8. BIRKETT (*Lancet*, July 1867, Vol. II, p. 9); a policeman, aged 27, was stabbed in February, 1866, in three places; the third wound being situated in the left iliac region, about half an inch above and internal to the anterior superior spinous process of the ilium; the omentum, which protruded, was ligated; it separated in a few days, and in three weeks the wound had healed. 9. BAUDENS (*Clinique des plaies d'armes à feu*, 1836, p. 315); a soldier of the 28th regiment, shot in the abdomen; omentum protruded from both wounds; re-union and recovery. 10. FAYRER (*Clinical and Pathological Observations in India*, London, 1873, p. 576); a Bengalee boy, aged 5, on August 25, 1871, fell on a glass shade, which broke under him, causing four transverse parallel wounds; a portion of the large intestine and some omentum protruded; the viscera were returned and the wounds closed with wire sutures; well by December 20, 1871. 11. KEY (A.) (*Guy's Hospital Reports*, Vol. I, 1836, p. 580); J. E—, aged 18, stabbed in the left side; a portion of omentum, four inches long, protruded, which was allowed to remain outside, and sloughed off; recovered. 12. EARLE (*London Med. Gazette*, 1829, Vol. III, p. 27); William W—, aged 21; punctured wound of right side of abdomen, with protrusion of omentum; wound enlarged and omentum returned; recovery. 13. BERTOLET (*Medical Examiner*, 1851, Vol. VII, N. S., p. 489); a boy, aged 12, gored by a bull; about ten inches of colon and a portion of lacerated omentum protruded; shreds of omentum chipped off and viscera returned; complete recovery. 14. BLACKLOCK (*Monthly Jour. of Med. Sci.*, Edinburgh, 1852, Vol. XV, p. 30); J. W—, aged 10, fell upon a broken wash-hand basin, cutting the abdominal wall; the greater part of the small intestines, the transverse arch of the colon, and the omentum immediately protruded; viscera reduced; recovery in twenty-five days. 15. LOVE (*Medical and Surgical Reporter*, 1860, Vol. IV, p. 271); an Irishman, aged 41, was stabbed in the umbilical region to the left of the median line; the protruding omentum was returned; no peritonitis; recovery. 16. HECKFORD (*Lancet*, 1864, Vol. II, p. 120); a sailor, aged 23, stabbed in the left side of the abdomen; the omentum, which protruded three inches, was returned; recovered in three weeks. 17. DILLON (*Med. and Surg. Reporter*, 1871, Vol. XXIV, p. 382); J. Reed received a stab below the umbilicus, from which six inches of the omentum protruded; membrane returned, and recovery rapid. 18. LÉPINE (*Bulletin de l'Académie Royale de Méd.*, 1843-4, T. IX, p. 146); a laborer was struck in the abdomen by a ball; the stomach, enormously distended, the omentum and the transverse colon escaped; viscera returned; patient recovered, and was well nearly twenty years later. 19. BOULWARE (*Boston Med. and Surg. Jour.*, 1867, Vol. LXXV, p. 161); P. S—, a laborer, aged 28, stabbed in the right inguinal region; bowels protruded and were returned; recovered in twelve days. 20. EARLE (*Lancet*, 1833, Vol. I, p. 763); a boy fell upon a bottle, the fractured glass cutting the abdomen; the protruding intestine was returned; recovery. 21. MIDDLETON (*Canada Med. Jour.*, 1866, Vol. II, p. 453); a young man wounded in the abdomen by the blade of a scutching machine; about a yard of intestines protruded and was returned. 22. WOOSTER (*Pacific Med. and Surg. Jour.*, 1858, Vol. I, p. 391); T—, aged 35, stabbed below and to the right of the navel; protrusion of loop of small intestine; viscera returned; well in four weeks. 23. CHEESMAN (*New York Jour. of Med.*, 1841, Vol. IV, p. 117); G. S—, aged 24, wounded two or three inches to the right of the umbilicus; omentum protruded and was returned; recovery in two weeks. 24. LUCE (*Med. and Surg. Reporter*, 1859-60, Vol. III, p. 290); a pregnant woman was gored by a cow; the lower part of the abdomen was torn eleven inches; a large mass of intestines protruded; they were returned, and the woman recovered without serious complications. 25. CRAWFORD (*Med. and Surg. Reporter*, 1870, Vol. XXIII, p. 525); O. L—, aged 16, gored by the horn of a cow two inches below the umbilicus; two feet of ileum and lower border of omentum protruded and were returned; recovery. 26. BUNCE (*Lancet*, 1846, Vol. I, p. 363); a boy, aged 5, fell upon a pair of shears; ten inches of intestine escaped; wound and were returned; recovery. 27. RAPHAEL (*Am. Med. Times*, Vol. VI, 1863, p. 89); T. C—, aged 20, stabbed in the enlarged and viscera returned; recovered in twelve days. 28. IDEM (*l. c.*, p. 89); J. D—, aged 40, cut in the hypogastric region; two feet of intestines protruded; wound enlarged and gut returned; recovery in a month. 29. HALL (*Am. Jour. of Med. Sci.*, 1869, Vol. LVIII, p. 79); H. B—, aged 32, cut, on January 3, 1868, near the navel; eighteen inches of the small intestine escaped; wound enlarged and bowel returned; well in less than three weeks.



wounds as they are common after stabs. Very rarely the omentum protrudes through the orifice made by a pistol ball, as in the following example, in which the advantages of an expectant treatment are illustrated:

CASE 571.—Corporal Sylvanus Lathrop, Co. F, 1st Michigan Cavalry, aged 22 years, was wounded at Winchester, September 19, 1864, by a revolver ball, which entered the left iliac region two inches above Poupart's ligament and one and a half inches to the right of the anterior superior spinous process of the ilium, passed backward, and emerged between the body of the fifth lumbar vertebra and the posterior superior spinous process of the ilium. He was removed to the Cavalry Corps Hospital, where he remained until October 29th, when he was transferred to the hospital at Cumberland. Acting Assistant Surgeon S. B. West reports that "a considerable piece of the omentum protruded and sloughed off." His health was good, and the wound was discharging healthy pus and healing. He was returned to duty January 16th, and discharged from service July 24, 1865, and pensioned. Pension Examiner David Clark, of Flint, Genesee County, Michigan, reported, in March, 1870, that "in consequence of the wound the patient suffers from a partial paralysis of the left leg and weakness of the back. The left leg is somewhat smaller than its fellow. The power of rotating the body on the hips is impaired, and the response of the muscles in rising from a sitting posture, or in attempting to lift, is uncertain, causing him to fall if thrown out of a perpendicular line."

A single example of early excision of a portion of protruded omentum is presented by a fatal case; and the unfavorable result, if not expedited, does not appear to have been retarded by the operation:

CASE 572.—Acting Assistant Surgeon T. H. Stuart reported that "Private G. Webster, Co. E, 6th Maine, aged 23 years, was admitted into Armory Square Hospital, Washington, November 9, 1863, with a penetrating wound of the abdomen, received at Rapidan Station on the 7th. The ball entered one inch to the left of and a little above the umbilicus, passed inward and backward, and emerged from the loins one and a half inches from the spine. A portion of the omentum, half the size of the hand, protruded and was strangulated so that it could not be returned, and was removed with a scalpel at three o'clock in the afternoon. He died at six o'clock on the same day."

In most of the cases of shot wounds attended by protrusion of the omentum, there were other grave or mortal complications. In the histories of the four following cases, fatal at the end of two or three days, the epiploic protrusions are prominently mentioned:

CASE 573.—Private Calvin Drury, Co. D, 30th Ohio, was wounded at Mission Ridge, November 25, 1863, by a conoidal ball, which penetrated the right side of the abdomen. Surgeon John Moore, U. S. A., states that he was admitted into the field hospital of the 2d division of the Fifteenth Corps. "The omentum protruded, and was returned and the opening closed. He died November 28, 1863."

CASE 574.—Acting Assistant Surgeon W. M. Dorran reports that "Private Henry Eggemyer, 4th Ohio Battery, was admitted into the Union Hospital, Memphis, September 28, 1863, having been accidentally wounded the day previous by the explosion of a shell in a caisson, on which he was seated while the battery was disembarking. On examination it was found that one fragment had entered the right chest and fractured the eighth rib near its junction with the cartilage; another penetrated the abdominal cavity a little to the right of the median line and about two inches above the umbilicus, permitting the protrusion of a portion of the omentum about the size of a walnut. There was also a fracture of the left ulna and a contused wound of the right thigh. The patient had suffered great pain in the chest for two hours after the reception of the injury. When admitted his breathing was labored, respiration about 50 per minute, and pulse 120. Morphine was given to ease the pain, and, through the night, one grain of opium and one-eighth of a grain of tartar emetic were given in a pill every three hours. September 29th, respiration labored; he suffers no pain, but speaks in monosyllables and with difficulty. Death resulted September 30, 1863.

CASE 575.—Private James Howard, Co. F, 43d U. S. Colored Troops, was admitted into the field hospital of the 1th division, Ninth Corps, July 30, 1864, with a shell wound of the abdomen, received at Petersburg the same day. The omentum protruded from the wound. Simple dressings were applied. He died August 1, 1864. The case appears upon a list of casualties signed by Surgeon James P. Prince, 36th Massachusetts.

CASE 576.—Assistant Surgeon J. G. Murphy, U. S. V., reports that "Captain R. B. Kellogg, Co. A, 15th Iowa, aged 28 years, was admitted into the officers' hospital at Beaufort, January 14, 1865, with a shot wound of the abdomen, received on the skirmish line, near Port Royal, the same day. The ball entered on the left side, about four inches posterior to the crest of the ilium, passed transversely through the ilium and peritoneum, and emerged one inch to the left of and two inches below the navel, carrying out through the exit wound a portion of the omentum. Simple dressings were applied. This officer was much prostrated by the shock of his injury, and died January 16, 1865, from its effects."

Five other cases, in which this complication is mentioned, terminated fatally within twenty-four hours:

CASES 577-581.—Surgeon J. M. Woodworth, 1st Illinois Light Artillery, records the following two cases of protrusion of the omentum upon the list of casualties at the battle of Ezra Chapel, Atlanta, July 23, 1864: 1. Major T. J. Ennis, 6th Iowa, shot wound, from the loins through the abdomen; omentum protruding; simple dressings; he died eight hours after the reception of the injury. 2. Captain T. S. Elrick, Co. D, 6th Iowa: shot wound of belly; large mass of omentum protruding; death the same day. 3. Surgeon Garrettson L. Carliart, 31st Iowa, reports that "Private Thomas Darnell, Co. E, 13th Illinois, was admitted into the hospital of the 1st division, Fifteenth Corps, June 30, 1863, with a shot wound of the abdomen, received at Vicksburg the

same day. The omentum magnum largely protruded. He died July 1, 1863." 4. Surgeon John A. Spencer, 69th New York, reports that "Private Patrick Sheridan, Co. A, 69th, New York, was wounded near Petersburg, June, 1864; the ball comminuted the left elbow-joint, fractured the seventh rib, and lodged in the abdomen; the omentum protruded; death, June 17, 1864." 5. Assistant Surgeon J. S. Billings, U. S. A., reports that "Sergeant M. Gaynor, Co. D, 88th New York, was wounded at the Wilderness, May 6, 1864; the omentum protruded from the wound; death resulted the same day."

In the treatment of protruding intestine, the rules of practice are well settled. Unless disorganized, it must be replaced, the exit wound being enlarged for the purpose, if requisite. If it is wounded, recourse must be had to enteroraphy. Protrusion of the bowel after shot wounds is uncommon; but some remarkable instances have been cited.<sup>1</sup> The four following are examples of recovery after this complication:

CASE 582.—Corporal Leroy Jordan, Co. C, 110th Ohio, was wounded at Cold Harbor, June 3, 1864, by a conoidal ball, which entered the right side at a point between the iliac and umbilical regions. He was treated in hospitals at Washington and Columbus, and discharged from service May 12, 1865. Pension Examiner Samuel S. Gray reported, June 15, 1865, that "the missile cut through the walls of the abdomen, allowing the bowels to protrude. The wound has healed, leaving a large cicatrix; the wall of the abdomen is weakened and tender."

CASE 583.—Private Daniel Miller, Co. E, 66th New York, received a wound of the left side of the abdomen at Antietam, September 17, 1862. Surgeon C. S. Wood, 66th New York, states that "the missile opened the cavity of the abdomen so that the meso-colon protruded. Cold-water dressings were applied." He was transferred to the hospital at Frederick, September 23d, where, without information of Dr. Wood's observation, the case was regarded as a flesh wound in the left flank. The patient convalesced rapidly, and was discharged from service January 20, 1863. His name does not appear on the Pension Roll.

CASE 584.—Private Patrick Powers, Co. F, 28th Massachusetts, received a shot lacerated wound of the abdomen a little above and to the right of the umbilicus, at Bull Run, August 30, 1862. On September 4th, he was admitted into the 3d division hospital at Alexandria, under the charge of Surgeon Edwin Bentley, U. S. V., who reports that "the bowels protruded from the wound. They were replaced, and adhesive straps, compress, and bandages applied. He was discharged December 13, 1862, at which time an unnatural opening in the muscles still existed." Pension Examiner S. L. Sprague, of Boston, reported, March 7, 1868: "He has hernia at the place of the wound, the tumor being now the size of a small hen's egg. The scar is an inch long, and, on feeling with the finger, is depressed in a ring whence the intestine protruded. Lifting or coughing increases the tumor. He cannot labor or do anything requiring much effort. Disability three-fourths and wholly permanent."

CASE 585.—Sergeant B. Vincens, Co. C, 6th Georgia, was admitted into the Receiving and Wayside Hospital, Richmond, September 30, 1864, with a wound of the right side of the abdomen, received at Fort Harrison the day previous. The following notes of the case appear upon the hospital case-book: "A conoidal ball entered two inches above Poupart's ligament, and one inch internal to the ilium, and lodged. When admitted, the patient was cold and pale; the bowels protruded through the wound to the extent of one and a half inches; no lesion of the gut could be detected. The intestines were replaced by manipulation without enlarging the wound, and the orifice was closed by sutures and adhesive straps. Stimulants and opiates were ordered. October 1st, no action of the bowels has taken place since the reception of the injury; urine passed freely and without pain. October 2d, an enema of warm water and castor oil was given, which produced three or four evacuations; abdomen somewhat swollen. On the 6th, the wound commenced suppurating. Fætid matter escaped, and there was considerable gastric disturbance but little fever. October 9th, some improvement; fætid matter continually escaped from the wound; no natural evacuations. On the 22d the patient felt better; his appetite was improved, and the edges of the wound had assumed a healthy appearance. Opium, quinine, and bismuth had been given at different times. On October 25th, he was transferred."

After the bowel is replaced, the abdominal wound should be securely closed. The quilled suture, as recommended on page 4, *supra*, accomplishes this effectually; but the button suture, devised by Dr. Bozeman,<sup>2</sup> answers still better. In cases of this group, if anywhere, the plan advocated by Drs. Chisolm, Michel, and Howard, of refreshing the edges of shot wounds, and seeking union by first intention,<sup>3</sup> may be advantageously instituted. In most instances, however, the extent of internal injury will preclude any hopeful interference, as in the following cases:

CASES 586-589.—Lieut. B. E. Kelley, Co. G, 1st Rhode Island, Chancellorsville, May 3, 1863; Pt. H. Richardson, Co. C, 1st Connecticut, Petersburg, August 17, 1864; Pt. J. W. Slider, Co. A, 13th Ohio, Petersburg, August 21, 1864; Serg't H. Burt, Co. A, 77th New York, Cedar Creek, October 19, 1864. In these four cases the bowels protruded after shot wounds and were replaced and retained by strapping, death resulting within a day or two.

<sup>1</sup> The cases of Major Power, CASE 163, page 34, and that of Lieutenant Carter, CASE 284, page 91, are examples of recovery. CASES 22- and 229 (pp. 72 and 73) are instances of protruding wounded intestine treated unsuccessfully by enteroraphy. CASE 231, page 75, is also an instance of protruding wounded intestine.

<sup>2</sup> BOZEMAN (N.). *Account of a New Mode of Suture*, in the *Louisville Review*, 1856, Vol. I, p. 75.

<sup>3</sup> Consult the references in note 1 to p. 514. *First Surgical Volume*.

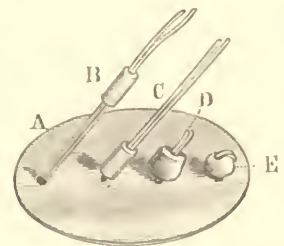


FIG. 137.—Bozeman's button suture.



*Hernia.*—The liability to ventral hernia involved by wounds of the abdominal parietes have been discussed in the first section of this chapter, and exemplified by CASES 92–95. Fewer examples are observed after penetrating wounds; because the recoveries from those injuries are not numerous, and because the peritoneal adhesions inseparable from reparation are an obstacle to protrusion. It is proposed to consider the general subject of hernia as a cause of disability, discharge, and pension, in a chapter in the *Third Surgical Volume*;<sup>1</sup> but it is of interest to notice here some specific examples of traumatic herniæ, and, if not strictly relevant, to adduce the nine instances of kelotomy and two operations for the radical cure of hernia that appear on the returns.

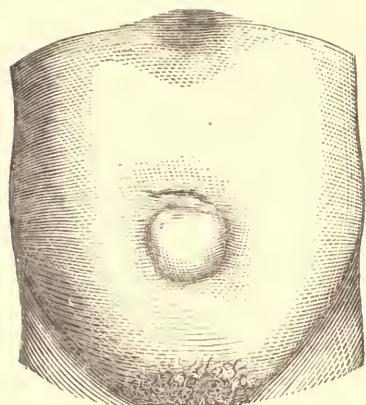


FIG. 138.—Ventral hernia consequent on a shot wound. Spec. 2279. [Plaster-cast.]

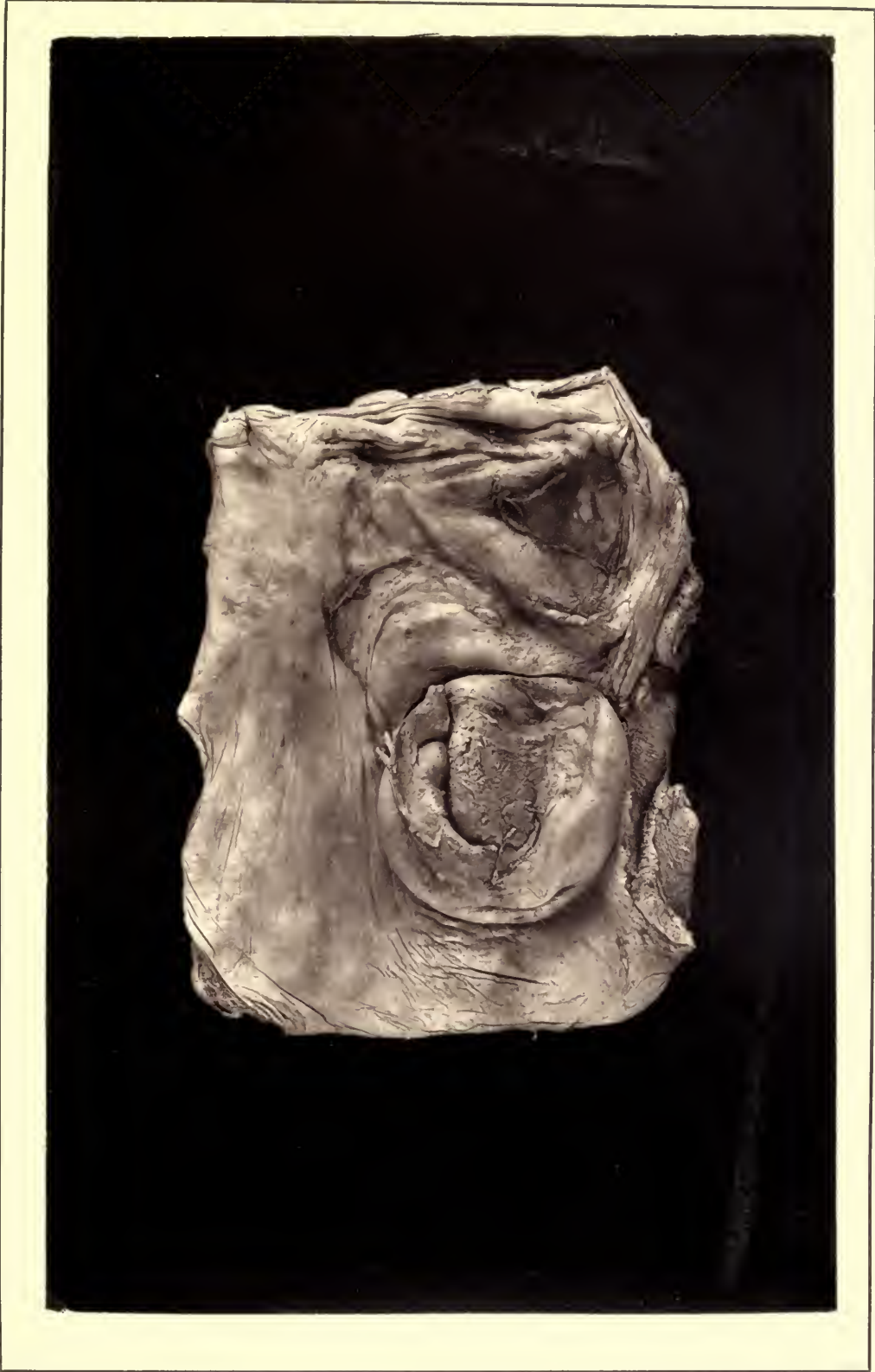CASE 590.—Private W. W. Wilbur, Co. D, 7th New York Heavy Artillery, was wounded at the Wilderness, May 5, 1864, by a musket ball, which struck to the left of the umbilicus and inflicted a furrowed penetrating wound. He was sent to the Ira Harris Hospital, at Albany, August 25, 1864. The wound healed readily, but the walls of the abdomen were so much weakened that a ventral hernia formed. Professor J. H. Armsby had prepared and sent to the Museum a plaster cast, which admirably shows the condition of the parts. It is imperfectly illustrated in the adjacent drawing (FIG. 138).

In a case of intestinal obstruction, of which the nature was not determined during life, the dissection after death (PLATE X) referred the symptoms to the strangulation of a small knuckle of the jejunum, which had protruded through a fissure at the margin of the left rectus, where the conjoined tendon had been weakened or divided by the passage of a ball.

CASE 591.—Corporal John F——, Co. D, 2d New York Cavalry, was wounded at Aldie, June 17, 1863, and admitted into the Mansion House Hospital, Alexandria, on the next day. Acting Assistant Surgeon W. Leon Hammond reports: "On admission he complained of severe headache; his pulse was frequent and hard, his tongue clean and moist. He passed his water freely, but stated that he had had no evacuation of the bowels for several days. The ball had entered in the left inguinal region in front of and a little above the external ring, had severed the pectineus muscle, struck the body of the pubic bone, glanced, and was lost in the body, its direction and course being unknown. Pressure of the hand over the abdomen developed no pain. There was tenderness over the lumbar region, which the patient attributed to bruises received when he was thrown from his horse on receiving the wound. A dose of castor oil was ordered. June 18th, no evacuation of the bowels had taken place. The cephalalgia was increasing; there was much heat about the head, and the face and cheeks were red and hot. To be more sure of the diagnosis before venturing on further treatment, I examined the rectum, but found no feces or obstructions. I then injected the rectum myself in order to ascertain the nature of the complication. The first pint of water was retained; the second pint remained also; but a third overflowed, and was free from any admixture of feces or blood. June 19th: In the afternoon the patient began to be troubled with hiccough and nausea; paregoric was given and quiet enjoined. June 20th: Hiccough and nausea somewhat abated; in the afternoon, vomiting set in, first of water, then of bile; laudanum was ordered, to be repeated during the night. June 21st: The laudanum was not given, through the interference of a female nurse. The injury was now thought to be in the abdomen, and that the intestines were ruptured, and opium, with absolute abstinence from food and drink, was directed. June 22d: Has paroxysms of hiccoughing, and vomited fecal matter. On the morning of the 23d, he seemed to rally, and asked for some stimulants, and took a draught of brandy and iced-water; he relished it and appeared more quiet; the vomiting and hiccough continued, and the patient became very much prostrated and slightly delirious. During the evening of the 24th, the pulse ran up very high; hippocratic face. Death resulted June 25th, at eleven o'clock A. M. At the autopsy, the ball was found embedded in the body of the pubis or horizontal ramus, close to the cotyloid cavity. A portion of the jejunum protruded through a fissure at the base of Hesselbach's triangle, constituting an internal inguinal hernia, and was strangulated. This hernia was small and made no tumor perceptible to the touch; no correct diagnosis could be made before death." The preparation from this remarkable case, Specimen 1604 of Section I of the Museum, is represented by PLATE X, the photo-relief print opposite.

<sup>1</sup>TABLE CI, p. 646, of the *First Medical Volume*, gives the number of discharges of white soldiers for hernia as 9,602, and TABLE OXII, p. 717, reports 258 discharges for the same cause from the colored troops, a total of 9,360 cases. This is believed to be much less than the real aggregate of discharges for this cause, not only because of the incompleteness of the reports from which the consolidations were made, but because the 27,141 unclassified discharges doubtless include many in which hernia was the unspecified disability. Commissioner J. H. BAKER (*Report of Com. of Pensions*, 1871, p. 8) states that "the whole number of pensioners paid on account of hernia is 3,183," and adds that "it is not improbable that a considerable proportion of these cases are fraudulent, despite the extraordinary care taken to prevent their enrollment." The tabular statement in the report (p. 20) gives the cases of single hernia as 2,710, and of double hernia as 513, or an aggregate of 3,383. It is impracticable to ascertain what proportion were alleged to be of traumatic origin.





Ward phot.

Am. Photo-Relief Printing Co., Philada.

PLATE X. HERNIA OF THE JEJUNUM THROUGH A SHOT PERFORATION.

No. 1604. SURGICAL SECTION.



The accepted doctrine that wounds of the diaphragm, whether in the fleshy or tendinous part, never unite, but remain with their edges separated ready for the transmission between them of any of the loose viscera (Guthrie<sup>1</sup>), is confirmed by the following case of strangulated phrenic hernia:<sup>1</sup>

CASE 592.—Private Christopher C——, Co. B, 107th Pennsylvania, aged 22 years, was wounded at Gettysburg, July 2, 1863, by a musket ball, which penetrated the left wrist and the lower part of the left chest. He was taken to the hospital of the 2d division of the First Corps. The details of the progress of the case are not recorded further than by indications that, after grave symptoms from fracture of the ribs and pulmonary lesions, the patient slowly convalesced, and recovered sufficiently to be transferred for modified duty in the Veteran Reserve Corps. He was attached to the 39th company of the 2d battalion. On November 11, 1863, he was admitted into Lincoln Hospital, at Washington, for remittent fever. The case was attended by anomalous symptoms which are not described in detail, and terminated fatally November 15, 1863. Acting Assistant Surgeon H. M. Dean gives the following account of the *post-mortem* examination: “Autopsy sixteen hours after death: height, five feet eight inches; rigor mortis well marked; body not much emaciated. Parts *in situ*: Right lung extended from clavicle to fifth intercostal space, and lacked one and a half inches of meeting the median line; left lung, a small portion only visible, extending from first to second ribs, and lies directly in the median line; both lungs well adapted to the costal surface of the thorax; the rest of the thorax of left side was filled with the stomach, which was greatly distended with air, and extended one and a half inches to the right of the median line; on removing the sternum, it bulged up an inch above the level of the thorax; apex of heart one-half inch to the right of the median line; liver extends two and a half inches to the left of the median line; fundus of the gall-bladder visible; small intestines collapsed and contained little or no air; spleen highly injected, of a dark purple-reddish color; colon unusually distended with flatus. Brain perfectly healthy; little or no fluid in the lateral ventricles; weight, forty-nine and a half ounces. Oesophagus purple color throughout; trachea filled with a very tenacious, blackish-gray sputa; bronchi filled completely with this secretion. The apex of the first lobe of the right lung was the seat of gray tuberculous deposit; the whole lung was of a uniform dark-red color; crepitated under pressure, permeated with air throughout; this lung performed the whole aeration of the blood; weight of right lung, fifteen ounces. The left lung was very much compressed, the upper lobe being five lines thick, the lower, nine lines; both were everywhere of a dark flesh color on section, with the exception of the border of the first lobe, which was of a light flesh color; a section of it sank in water; weight of left lung, eight and three-quarter ounces; the left lung was firmly united to the ribs and diaphragm by very firm fibrinous adhesions. Pleura not thickened; no trace of pus anywhere. The eighth, ninth, tenth, and eleventh ribs were fractured about three and a half inches from their corresponding cartilages; these were all, but the eleventh rib, united. The heart, four inches long by three and a half inches wide at base, somewhat pyramidal in shape—the apex being at the root of the pulmonary artery; the base behind the two sides was formed by the right and left ventricles; the organ had evidently been much compressed during life; no clot in the right side; the left side contained a very small venous clot, and a small quantity of venous blood; the right ventricle, two and a half lines thick; the left ventricle, nine lines thick; pericardial fluid, two drachms. The stomach was of a large dimension, being eleven inches long, six inches wide, three inches deep; it was entirely contained in the left thorax, with the exception of the cardiac extremity, which was in the abdominal cavity; the tumor was of a globular shape, owing to the manner in which the stomach had been forced through the opening of the diaphragm; this opening was opposite to the eighth rib, and in close proximity to it; the opening was two and a half inches long, in a line with the transverse horizontal diameter of the body, and embraced, besides the cardiac extremity of the stomach, two portions of the transverse colon—a large horse-shoe loop being contained in the thorax. The liver, ten and a half inches long, eight inches wide, two and a half inches thick; intense dark-blue color, with a slight shade of purple; acini almost obliterated, the organ having a dull flesh color on section; intensely injected with dark venous blood, a large quantity of which flowed out on pressure. (Bronze liver.) The bile in the gall-bladder measured ten drachms, of an intense black color in mass, but of a dark brown when poured out; no sediment; very viscid. The spleen, four and a half inches by three inches; unusually firm—taking some force to push the finger through the parenchyma; darkish-purple mulberry color; weight, four and a half ounces. Pancreas, nine inches by one and a half inches at head; flesh color; weight, two and a half ounces. Kidneys: Right kidney, four and a quarter by two and a quarter inches; intensely congested; weight, five ounces; left kidney, four and a quarter by two and a quarter inches; same appearance as right; weight, four and three-quarter ounces. Intestines greatly congested throughout, as seen from the peritoneal surface; of a stone color; mucous membrane dark-purplish red; solitary glands not enlarged. Peyer's patches inconspicuous. In the large intestine the mucous surface was of a dark purple; the glandular organs were not diseased. The ball entered on a level with the sixth rib on the left side, two inches below the nipple, traversed the diaphragm, and passed out two inches lower down, and six inches posterior to the wound of entrance.” The weight of the viscera, on lifting the preparation from the alcohol in which it is immersed, withdraws them from the thoracic cavity. Hence, in FIGURE 139, drawn from a photograph of the preparation, the relations of the parts are but imperfectly represented.

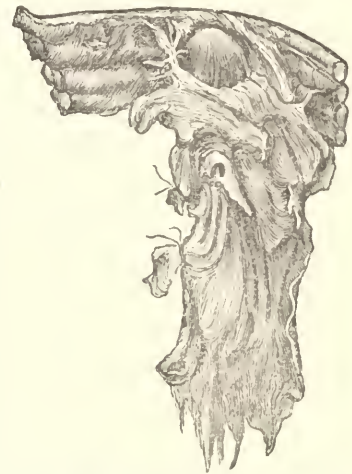

FIG. 139.—Preparation from a case of diaphragmatic hernia.—Spec. 1789.

<sup>1</sup> In the Museum of the British Army Medical Department preparations 1152 and 1153 represent diaphragmatic herniae (WILLIAMSON'S *Cat.*, p. 155). At St. Bartholomew's, Specimen 74 of Series XVII is an example (*Cat.*, p. 334). At the New York Hospital Museum, Specimens 406 and 407 are both examples of traumatic phrenic hernia (*Cat.*, p. 189). In the Boston Medical Improvement Society's Museum, 493, a dry preparation, is a hernia, though an old stab wound of the diaphragm (*Cat.*, p. 141).



*Herniotomy.*—Nine operations for strangulated hernia were reported. The protrusions were all inguinal or scrotal, five left, four right; nearly all were old reducible herniæ, getting down and becoming strangulated through carelessness. In all the operations the sac was opened, and the stricture was generally found at the neck. In one instance, a branch of the epigastric was cut; in another, the gut was punctured; in both, ligatures were applied; but in the case of the wounded intestine the ligature slipped, and there was fatal intra-abdominal effusion. Five operations resulted successfully, one being for the relief of an inflamed epiplocele:

CASE 593.—Private W. Chase, Co. M, 2d Wisconsin Cavalry, aged 23 years, was admitted to Gayoso Hospital, Memphis, January 2, 1865, with symptoms of strangulation from a direct inguinal hernia, which was ascribed to a strain received in a fall from a horse, June 4, 1864. There was intense pain in the tumor and over the belly, and, without unnecessary delay, Acting Assistant Surgeon W. D. Hall decided to operate. Chloroform being given, an oblique incision, five inches in length, was made over the sac, through the integument, superficial fascia, intercolumnar fascia, conjoined tendon of transverse and internal oblique cellular tissue. The protrusion was still firmly held by annular folds of peritoneum. After much hesitation, and a renewed careful attempt at taxis, a probe-pointed bistoury was passed through the peritoneum and an incision half an inch in length was made, which permitted the reduction of the protruding intestine, which was much engorged, but not in an unfit condition for replacement. The patient was kept on low diet, and aconite and veratrum viride were administered in small doses. The pulse, which had been at 90, was reduced to 60. Recovery was rapid, and in twenty-eight days complete.

CASE 594.—Private P. Fountain, Co. B, 8th Louisiana (afterward 47th U. S. Colored Troops), on August 17, 1863, was brought to the regimental hospital with strangulation of a right scrotal hernia, that had existed for nine years. The tumor was of the size of a cocoa-nut. Taxis, under chloroform, being unavailing, Surgeon N. N. Horton,<sup>1</sup> 8th Louisiana, performed kelotomy, opening the sac, which contained omentum and knuckles of small intestine somewhat congested. The stricture being divided, the protrusion was readily returned. The wound was closed by five stitches, and dressed with a T-bandage, and full doses of opium were administered. No untoward symptoms ensued. The wound healed rapidly, and on September 1, 1863, the patient was returned to duty. Assistant Surgeon L. P. Fitch, 8th Louisiana, reports that he was discharged at Vicksburg, June 15, 1864, on account of hernia.

CASE 595.—Discharged Private W. H. Henington, Co. K, 32d Wisconsin, on May 28, 1865, was admitted to the general hospital at Hilton Head with symptoms of strangulation, that had lasted for four days, of an oblique right scrotal hernia. Assistant Surgeon R. S. Reber, U. S. V., administered chloroform, and, failing in taxis, proceeded with the operation, as the abdominal tenderness, vomiting, hiccough, and other symptoms were too urgent to admit of delay. The sac was opened; a knuckle of small intestine extended to the bottom of the serotum, and was tightly strictured at the internal ring. The stricture being divided, the protrusions were replaced without difficulty. The external pudic branch of the epigastric artery was ligated. The threatening symptoms were at once allayed, and the patient convalesced without any untoward circumstance, and was returned to duty June 18, 1865.

CASE 596.—Corporal F. Markle, Co. M, 2d New York Heavy Artillery, was admitted to hospital at Camp Nelson, Kentucky, October 5, 1864, with symptoms of strangulation from an irreducible tumor in the left inguinal canal. The tumor was inflamed and painful; the abdomen was tender. Surgeon Daniel Meeker, U. S. V., proceeded, on October 6th, to give chloroform to practice kelotomy; the sac being opened, the protrusion was found to be omental. It was replaced; the grave symptoms subsided, and the man returned to duty January 17, 1865.

CASE 597.—Private J. A. Tracy, Co. D, First Veteran Reserves, aged 29 years, was admitted to Armory Square Hospital, March 14, 1864, with strangulated hernia. The left side of the scrotum was distended by a tumor and was very painful on pressure. Efforts at reduction by taxis, already vainly essayed by the medical officer at Camp Rush, were renewed under chloroform, without success. As the vomiting and abdominal tenderness had mitigated after the anæsthetic and the administration of a dose of morphia, it was decided to await the arrival of the surgeon in charge. The next morning, March 15th, Surgeon D. W. Bliss, U. S. V., had the patient placed in a warm bath for half an hour, and then, under chloroform, again employed persevering taxis, unavailingly, and then proceeded with the operation of herniotomy. An incision, four inches long, was made over the long axis of the tumor, extending to the course of the spermatic cord, and the various coverings of the sac were successively divided. The point of stricture was found at the internal ring, and was relieved by a slight incision, which was followed by the descent of a considerable loop of intestine, somewhat discolored. The protrusion was carefully replaced within the abdominal cavity, and a few sutures and straps were applied, and maintained by a T-bandage and compress. The patient was placed in bed, and ordered an opium pill every three hours. Except from abdominal pain, which was relieved by enemata containing sulphuric ether, there were no untoward symptoms. The patient was kept on a farinaceous diet, with opiates, and on the sixth day had a dose of castor oil, which operated kindly. After this convalescence was uninterrupted, and on April 21st the patient was discharged on furlough, and on July 1, 1864, was returned to duty. He was discharged July 14, 1865, and pensioned. Examiner J. R. Beck, of Lancaster, Ohio, reported, August 17, 1869, that the hernia was reducible, but required the constant use of a truss. The pension was suspended June 30, 1873, "no response having been received from the pensioner for two years."

<sup>1</sup> Dr. HORTON, in the *Am. Med. Times*, 1863, Vol. VII, p. 216, gives a full account of this case, describing the hideous torture to which this hernial protrusion was ascribed.

### Four unsuccessful operations for strangulated inguinal enterocele were reported:

CASE 598.—Private J. Z. Kivett, Co. 1L, 2d East Tennessee, was admitted to Jarvis Hospital, April 18, 1864, with oblique left inguinal hernia. He was convalescent from pneumonia, and presented symptoms of strangulation. The tumor extended well down in the scrotum. Symptoms of strangulation were very urgent, and ether being administered, and taxis unavailing, Acting Assistant Surgeon B. B. Miles laid open the sac, May 11, 1864, divided the stricture, which was very tense, and replaced the protruding gut, which was indurated and congested. Traumatic peritonitis supervened, and was treated by opium, with stimulants. Death, May 17, 1864. At the autopsy, the colon was found thickened, and perforated about eighteen inches from the ileo-cæcal valve.

CASE 599.—Private N. Moore, Co. 125, 2d battalion, Veteran Reserve Corps, was admitted to Main Street Hospital, Covington, with oblique right inguinal hernia. On May 5th, Surgeon A. M. Speer, U. S. V., found the tumor immensely large—at least six feet of intestine in the scrotum, besides a mass of omentum. The symptoms of strangulation being very grave, chloroform was administered, and the usual operation was performed, the stricture being found in the neck of the sac, opposite the external ring. On May 8th, the tumor again protruded during a fit of coughing, and was replaced with some difficulty. On May 9th, alarming signs of traumatic peritonitis arose, and the case terminated fatally on the following day, May 10, 1864.

CASE 600.—Private J. A. Robbins, Co. I, 143d Pennsylvania, under Dr. J. M. Da Costa's care for a functional cardiac disorder, at Filbert Street Hospital, January 12, 1864, presented the symptoms of strangulated hernia. Acting Assistant Surgeon A. D. Hall was summoned at eleven o'clock at night and found a moderate-sized irreducible inguinal hernia. The patient had worn a truss habitually, but had carelessly left it off. His legs were drawn up, but his countenance expressed little pain. Taxis under ether had been tried. Gentle efforts were again made by Dr. Hall. Then the man was ordered two grains of opium, and an operation was deferred till morning. The further progress of the case is described by Dr. Hall: "At nine the next morning the same state of affairs existed, and, assisted by Dr. E. L. Duer, I proceeded to operate. The incisions were made layer by layer carefully. On opening the sac, quite a mass of omentum was found in a healthy condition. There was trifling effusion in the sac, and no adhesions. About twelve or fourteen inches of intestine were in the sac, of a ruby color, merely deeply congested, without any signs of inflammation or sphacelus; the external ring was enlarged by an incision directly upward. At the internal ring the stricture was so tight as to admit with difficulty the tip of the little finger on which to cut as a director. This stricture had to be incised several times before it would permit the return of the bowel. A slight puncture of the bowel, not penetrating more than the muscular coat, was discovered. *It bled quite freely, and a ligature was put around it.* It was supposed that the bowel must have been injured by riding up under the knife in the tight stricture. The stricture being relieved, the bowel was returned first, and followed by the omentum. At one stage of the operation the ether produced alarming symptoms; suddenly the face became livid, the respiration gasping, and then almost ceased. Asphyxia being imminent, the tongue was pulled forward; ammonia applied to the nostrils, artificial respiration put into practice, and galvanism applied to the cervical spine and præcordia. The patient slowly rallied; the edges of the wound were brought together with silver sutures, a compress and spica bandage were applied, and one hundred drops of laudanum ordered after the effects of the ether had passed off. The operation occupied about an hour. The patient was made comfortable in bed; it was enjoined that his diet should consist of a tablespoonful of arrowroot every third hour, and nothing else. Four hours after the operation he was quite comfortable, had no pain, was unaffected by the opium, had been dozing a little, pulse 114, good; face expressive of ease and relief. He was to have the opium in doses of twenty-five drops of the tincture every hour until sleep was produced. At half-past nine in the evening he was doing well. No pain in abdomen, felt quite easy; had not slept much; pupils showed no evidence of being affected by the opium; did not seem sleepy, and had slept but little, although lying quietly. At half-past three in the morning I was called up to see him, as he had had a convulsion, followed by rigidity. I found him in a comatose condition, with labored respiration. He had talked to the head nurse at two o'clock and said that he felt very comfortable, and a half hour later he had the convulsive attack. He continued to sink, and died at five in the morning. At the autopsy eight hours after death, the membranes and veins of the cerebral sulci were found much congested. The lateral ventricles contained yellowish serum; each choroid plexus congested; the right lung was pale externally, congested internally; the left lung pale anteriorly, deep purplish congestion of lower lobe posteriorly—this portion yet floated in water. Bloody serum was found filling the pelvic cavity. The strangulated portion of the intestine had not recovered itself; it was still of a deep-red color; patches of fresh lymph were scattered near the mesenteric attachment; the folds of the intestine were glued together; *the ligature had come away from the little wound of the intestine, and it was covered with a recent clot*; the omentum was bound together in a firm globular mass by inflammation; the peritoneum about the internal ring was marked by deep spots of ecchymosis."

CASE 601.—Private A. Soethig, Co. 48, 2d battalion, Veteran Reserve Corps, aged 42, was admitted to Armory Square Hospital, September 21, 1864, with right inguinal hernia of two years' standing, during which period the protrusion had frequently descended into the scrotum and been with considerable difficulty returned by the patient's own efforts. There were now symptoms of strangulation of no great severity. The man was placed in a hot bath, and taxis was unavailingly practiced. The symptoms became more urgent, and on September 22d Surgeon D. W. Bliss performed the usual operation and reduced the protrusion. Opium pills and a nourishing diet. Death, October 10, 1864.

The pathological preparations in these cases were not forwarded to the Museum, which possesses, however, at least one excellent illustration of the appearance of an old reducible hernia after protracted strangulation (FIG. 140). It was contributed by Dr. L. J. Draper:

CASE A<sup>4</sup>.—J. W.—, a negro man of 40, with reducible right oblique inguinal hernia of twelve years' standing, was unable to reduce his hernia, August 17, 1869, and symptoms of strangulation soon appeared. Dr. L. J. Draper, of Washington, was summoned, and, failing in taxis under chloroform, directed the tumor to be covered with ice during the night and the lower bowel to be opened by enema. On August 18th, taxis was again tried by Dr. W. Lee and by Dr. Draper, and again in the



evening by these surgeons, assisted by Dr. W. B. Drinkard. It was then decided to cover the tumor with extract of belladonna, and to give a fourth of a grain of sulphate of morphia every two hours during the night. Up to this time, nothing had been retained upon the stomach. The morphia was likewise rejected, and on August 19th, at ten in the forenoon, had made little

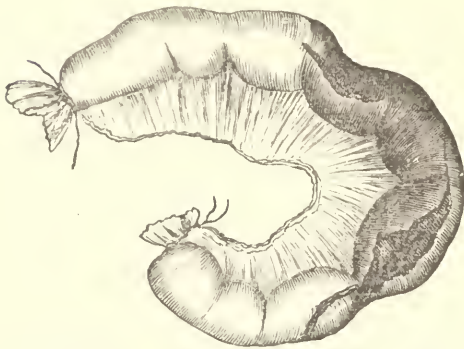


FIG. 140.—Semi-gangrenous loop of ileum from a strangulated hernia. *Spec. 55906.*

impression on the system. Dr. Draper describes the termination of the case as follows: "He was then put under the influence of chloroform, and, after a last effort at reduction by taxis, the tumor was laid bare, the sac opened, and the external and internal rings both enlarged so that the finger would pass readily into the abdomen. But one knuckle of intestine had passed into the sac, which was returned without difficulty; but the omentum of which the tumor was principally composed was so congested and swollen as to be returned only with great difficulty. It was thus much discolored, but apparently not gangrenous, or it would have been removed. After the operation the hicough and vomiting continued, the latter becoming fecal: the patient sank rapidly, and died at 9 P. M. the same day. *Post-mortem* made at 10 A. M. the following day, and six inches of ileum removed. It was much discolored and semi-gangrenous, but showing plainly the points of constriction. The failure of the operation is attributed to the excessively hot weather, and the postponement of the operation for twenty-four hours in the hope of reducing by taxis. Another illustration of the importance of operating early, when satisfied that it must be done." See wood-cut (FIG. 140).

Two unsuccessful operations for the radical cure of reducible inguinal herniæ were reported:

CASE 602.—Private W. P. Hayden, Co. K, 100th New York, aged 36, was admitted to hospital at Buffalo, June 25, 1864, with left direct inguinal hernia of two years' standing. Dr. Sanford Eastman, on August 24th, introduced a silver ligature through the inguinal canal, after the method of Professor J. H. Arnsby, with the view of inducing adhesive inflammation and preventing a recurrence of the protrusion. Serious inflammatory symptoms ensued, but were relieved by a cataplasm of powdered elm. The ulterior result was unfavorable, the patient being compelled to maintain the hernia by a truss. He was discharged, for disability, January 19, 1865.

CASE 603.—Sergeant P. O'Connell, Co. G, 2d Missouri, aged 37 years, was admitted to the Brown Hospital, at Louisville, May 6, 1864, with a reducible oblique inguinal hernia of the left side. His general health was perfect. On May 14th he was placed under chloroform, and Assistant Surgeon B. E. Frayer, U. S. A., operated, for the radical cure of the hernia, by Syme's method. No untoward symptoms ensued, and recovery was almost complete, on his transfer to Jefferson Barracks, July 11, 1864. Returned to duty August 16th; he was discharged September 29, 1864. The hernia appears to have returned, as Pension Examiner J. Bates, of St. Louis, reported, October 10, 1865, that there was "left inguinal hernia in the scrotum." His application for pension was rejected for want of evidence that the disability was incurred in the line of duty.

An ingenious instrument, devised by Medical Inspector G. T. Allen, U. S. A., for a modification of the operation by invagination for the radical cure of reducible hernia, was presented by him to the Museum<sup>1</sup> Dr. Greenville Dowell, of Galveston, also donated an instrument employed by him for the same purpose.<sup>2</sup>

*Abdominal Effusions.*—The extravasations that are sometimes associated with penetrating wounds of the belly may be considered in the following order: 1. Effusions of blood; 2, of bile; 3, of urine; 4, of alimentary or stercoral matters, and of entozoa; 5, of pus; 6, of gas.

It has been seen, in the second section, that similar effusions sometimes result from contusions and ruptures. They are furnished by the different reservoirs contained in the abdomen, by lesions of the vessels, by morbid secretions of the serous membrane, by the ruptures of abscesses, aneurisms and cysts, and may be divided into primary and consecutive effusions. The former comprises effusions of blood and of the various gaseous,

<sup>1</sup> These instruments are numbered 1428 and 6094, respectively, in Series XXVIII. Here also may be seen patterns of the apparatus of WITZLER, WOOD, ROTHMUND, PARKER, and others. See an article by Dr. DOWELL in the *Texas Med. Jour.*, 1873, Vol. I, p. 233.

<sup>2</sup> For the bibliography of Hernia, the articles of RICHERAND and of RAIGE DELOIME (*Dict. des Sci. Méd.* XXI, p. 168, and *Dict. de Méd.* XV., p. 328) may be consulted. Some of the points specially alluded to in this subsection are considered by the following authors: HESSELBACH, *Über den Ursprung und das Fortschreiten der Leisten- und Schenkelbrüche*, Würzburg, 1814, p. 17; BOEHMER, *De herniis abdominalibus*, Halae, 1780; THURM-EISEN, *De hernia ventriculi*, Basil. 1777; KIRSCHBAUM, *De hernia ventriculi*, Argentorati, 1749; FIELTZ, *Ein Darm- und Netzbauchbruch (Entero-piilocle ventralis) nebst dessen Behandlung*, in SODER'S *Journal*, 1801, B. III, St. 3, S. 447; LAFOND, *Considérations sur les hernies abdominales, sur les bandages herniaires enzigrades, et sur des nouveaux moyens de s'opposer à l'anéurisme*, Paris, 1821; CLOQUET, *Recherches anatomiques sur les hernies de l'abdomen*, Paris, 1817-19; SCHMIDTMANN, *Von einem geheilten Magenbruch*, in RUST'S *Magazine*, 1825, B. XVIII, H. I, S. 155; WHEEL-WRIGHT, *A case of hernia ventriculi from external violence, wherein the diaphragm was lacerated*, in *Medico-chirurg. Transactions*, London, 1819, Vol. VI, p. 374; PIPELET, *Remarques sur les signes illusoirs des hernies épiploïques*, in *Mém. de l'Acad. Roy. de Chir.*, T. V, p. 613.



liquid, and solid contents of the hollow organs or accidental cavities within the abdomen; the latter are due to the morbid secretions induced by the presence of irritating matters, or result from traumatic inflammation. Essentially variable in their nature, the cases of each group of effusions must be separately examined.

*Blood.*—Effusions of blood in the abdominal cavity may be either arterial or venous, and may proceed from injuries of the aorta and its branches, from lesions of the vena cava and portal vein and their ramifications, or from wounds of the viscera, particularly the liver and spleen. Over a score of examples may be found among the preceding abstracts.<sup>1</sup> The following is a rare instance of extra-peritoneal extravasation from the rupture of a large traumatic aneurism:

CASE 604.—Sergeant Winslow A. Morrill, Co. A, 16th Maine, was wounded at Gettysburg, July 3, 1863, by a conoidal ball, which entered the chest at the right nipple and lodged. He was taken to the field hospital of the First Corps, where the wound was dressed simply. On the 19th he was transferred to the hospital at York, whence Acting Assistant Surgeon A. E. Carothers reports that "at the date of admission the patient was in a very low condition; his pulse was rapid and feeble, skin covered with cold perspiration, tongue dry and red. There was some delirium, and the patient complained of great pain in the lumbar region, with painful and difficult urination. There were symptoms of pyæmia, but, under the liberal use of tonics and stimulants, his condition improved and hopes were entertained of his recovery. About August 1st, after the excitement of meeting his wife at the hospital, he rapidly grew worse, presenting the same symptoms as at first, and a pulsating tumor was distinguished in the umbilical region, which steadily increased in size. He gradually sank, and died August 12th from anæmia. A slight convulsion occurred in articulo mortis. An autopsy was made nine hours after death: The ball entered at the right nipple, passed inward, downward, and backward, struck the spinal column about the eighth dorsal vertebra, passed through the diaphragm by the side of the sheath of the aorta, and lodged in the body of the fifth lumbar vertebra half an inch to the right of the median line. In the aorta, immediately above the point of lodgement of the ball, was found a large aneurismal sac, partially emptied, and there was a large quantity of coagulated blood beneath the peritoneum, on the left side of the spine, amounting to nearly two pounds. The pncuonic inflammation had entirely subsided, and the aorta elsewhere was healthy. The right ureter, which passed over the sac of the bullet, was obliterated."

The doctrine of the circumscription of effusions due to the reciprocal equable pressure of the parietes and viscera, advanced by the celebrated Petit, the younger, has been the theme for much discussion,<sup>2</sup> in which the disputants have not always commanded respect for their knowledge of physical laws. This reproach cannot be addressed to the refutation of Petit's hypothesis, in Velpeau's masterly paper on effusions in the abdomen, in the first part of the dictionary in thirty volumes; where it is demonstrated, by clinical facts and by experiments, that the collection of the blood in circumscribed depots occurs only when a small quantity is extravasated and adhesions form in the vicinity, and that when

<sup>1</sup> In the *First Surgical Volume*, among the cases of fractures of the lower vertebrae, see CASES of James S —, p. 440; of W. A —, p. 441; of W. B — and John McD —, p. 445; of J. D —, p. 449; and, in this volume and chapter, CASES 206, 212, 221, 225, 238, 302, 304, instances of circumscribed or diffused effusions of blood from the mesenteric veins or small arteries; CASES 311, 414, 424, 434, 455, 457, of effusions from lesions of the liver; CASES 459 and 502, of wounds of the spleen; and CASE 506. Doubtless, in many of the other cases enumerated, blood was copiously poured out, although the circumstance is not particularly specified in the reports.

<sup>2</sup> HORLACHER, *De lethaliitate vulnerum abdominis cum extravasatis conjunctorum*, Onoldi, 1837; JOBERT, *Des collections de sang et de pus dans l'abdomen*, Thèse, Paris, 1836; MORGAGNI, *Opera omnia*, Bat., 1765, Lib. IV, Epist. 54, Art. 14, p. 279; BONETUS, *Sepulchretum*, Genevæ, 1700, T. III, Lib. IV, Sect. 3, *De vulneribus*, Obs. 25, p. 362; RUYSCII, *Observationum anatomico-chirurgicarum centuria*, Amstelodami, 1691, Obs. 43, 84, and 85; DUNCAN, *The History of a Discharge of Blood to a great Extent, by tapping*, in *Med. and Phil. Comment.*, by a Society in Edinburgh, London, 1777, Vol. V, Pt. I, p. 181; ELLER, *Nützliche und Auserlesene Med. und Chir. Anmerkung*, n. s. w., Berlin, 1730, S. 138; PEIT, *Essai sur les épanchemens et en particulier sur les épanchemens de sang*, in *Mém. de l'Acad. de Chir.*, Paris, 1743, T. I, p. 237, and T. II, p. 92; GARENGEOT, *Sur les épanchemens dans le bas-ventre*, in *Mém. de l'Acad. de Chir.*, Paris, 1753, T. II, p. 115; VACHER, *Observations de Chirurgie sur un espèce d'emphyème, fait au bas-ventre avec succès en conséquence d'un épanchement*, Paris, 1737; LAMOTTE, *Traité complet de Chirurgie*, Paris, 1771, T. II, p. 122, Obs. CCXLIV; JORDAN, *Épanchemens dans le sac du péritoine*, in *Dict. des Sci. méd.*, en 60, Paris, 1815, T. XII, p. 420; PELLETAN, *Clinique Chirurgicale*, Paris, 1810, T. II, p. 98; LECLERC, *Épanchement sanguin déterminé par l'ulcération d'un vaisseau abdominal et suivi de la mort dans l'espace de trois heures*, in *Arch. gén. de méd.*, 6me ann. 1828, T. XVIII, p. 281; BELL, J., *Discourses on the Nature and Cure of Wounds*, Edinburgh, 1795, Pt. II, p. 95; DESOER, *Sur l'épanchement de sang dans l'abdomen produit par cause externe*, Thèse de Paris, 1815; RAVATON, *Chirurgie d'Armée*, etc., Paris, 1768, Obs. XXV, p. 498; CABROL, A., *Alphabet anatomique avec plusieurs observations particulières*, Genevæ, 1662; BLANDIN, *Diversæ in abdomen liquidorum effusiones*, Paris, 1827; FOURCADE (L.), *Étude clinique, anatomique et expérimentale de l'épanchement de sang dans l'abdomen, par cause externe*, Thèse de Paris, 1829; LARREY, *Mém. de Chir. mil.*, Paris, 1812, T. III, p. 334; CRUVEILLIER, *Anat. path. du corps humain*, Paris, 27e liv., p. 5; VOLLGNANI, *Ex vehementi illius abdominis lethaltas*, in *Eph. Nat. Cur.*, 1670, Ann. I, Obs., XXI, p. 82, cites a case of bloody effusion in the abdominal cavity from a blow of the horns of a deer; PHELICH, *Chirurgische Beobachtungen*, Leipzig, 1795, B. I. S. 128; MEITENS, *Diss. vulnus pectoris complicatum cum vulnere diaphragmatis et arterie mesentericæ inferioris*, Argent., 1758; BROWN, WM., *Case of fatal hæmorrhage into the abdomen*, in *Edinburgh Med. Jour.*, Vol. I, p. 552; PORTER, *Case of Penetrating Wound of the Abdomen*, in *Edinburgh Med. Jour.*, Vol. IV, Pt. II, p. 1064; BIRKETT, *Laceration of the Spleen, Death in a few hours from Internal Hæmorrhage*, in *Lancet*, 1864, Vol. II, p. 716; SABATIER, *Médecine opératoire*, Paris, 1822, T. II, p. 147; MOREHEAD, *General peritonitis from a penetrating wound of the liver and effusion of blood into the abdomen*, in *Courby's India Journal*, 1830, Vol. V, p. 206; VELPEAU, *Épanchemens dans l'Abdomen*, in *Dict. de Méd.*, T. I, p. 187.

furnished copiously by the laceration of a large vessel or of a vascular organ, it may permeate to all parts of the abdominal cavity. Commonly it gravitates toward the pelvis or the iliac fossæ, the relations of the duplications of the peritoneum greatly influencing its localization. On the right side of the mesentery, the folds of the peritoneum are so arranged as to convey the effused blood on inclined planes toward the right iliac fossa; if the blood is poured out from a wound on the left side, it is more likely to run down into the pelvic cavity. Sudden copious bleeding within the abdominal cavity is indicated by the well-known signs of hæmorrhage: feebleness of pulse, faintness, pallor, cold extremities, cold sweats, etc.; but slow, gradual bleeding may continue unsuspected to a dangerous or fatal extent,<sup>1</sup> so slight are the symptoms induced by it. When the blood is principally circumscribed, partly by coagulation and partly by the compression of the walls and the viscera, adhesions form around it by the agglutination of the serous surfaces or the exudation of false membrane. Then consecutive symptoms arise, due to the presence of the effusion as a foreign body. The extravasated blood may be slowly absorbed, or it may excite or aggravate traumatic peritonitis. Here is a case in which a patient survived for seven weeks a shot perforation of the abdomen with limited extravasation of blood:

CASE 605.—Private Daniel Wills, Co. D, 2d West Virginia Cavalry, aged 19 years, received a wound of the lumbar region at Five Forks, April 5, 1865. He was conveyed to the depot field hospital of the Cavalry Corps, and, on the 8th, was transferred to Stanton Hospital, Washington. He gradually sank, and died May 23, 1865. An autopsy was made twelve hours after death by Acting Assistant Surgeon W. Bryan, who reports as follows: "The original wound was enlarged by an incision in the direction of the course of the ball, which had passed into the abdomen from the fourth lumbar vertebra, having opened the abdominal parietes on the right side. A collection of dark fluid, apparently blood and pus, to the amount of one pint, was found in the right hypogastric region. An incision was made over the crest of the pubis, and the ball was found lodged in the tissues."

A case illustrating the diffusion of the effused blood, and the absence of peritoneal inflammation, is found in the records of Douglas Hospital:

CASE 606.—Private James Reed, Co. D, 1st U. S. Sharpshooters, was wounded at Rapidan, November 7, 1863, and was admitted to the field hospital of the 1st division, Fifth Corps, on the same day. He was transferred to Washington, and admitted to Douglas Hospital on November 9th, and Assistant Surgeon W. Thomson, U. S. A., reported as follows: "At the time of admission he was much prostrated, but there were no symptoms of peritonitis. He died November 13, 1863. At the autopsy, the ball was found to have entered the right side three inches above the anterior superior spinous process, passed through the internal iliac and psoas muscles, and then escaped as far as the integument, whence it had been removed by incision from the sacro-iliac symphysis. The intestines were not wounded, but were deeply stained by the effused blood. Death seemed to have been caused by the prostration of so severe a wound, as no traces of peritonitis or pyæmia were found."

The following is an example of fatal bleeding from the internal iliac vein:

CASE 607.—Private John Dudley, 103d U. S. Colored Infantry, aged 32 years, was wounded in a skirmish in Kentucky, August 29, 1864, and was admitted to West End Hospital, Cincinnati, on August 30th, where he died on the same day. The case is reported by Acting Assistant Surgeon R. Bartholow<sup>2</sup> as follows: "On examination, found a wound of the right hip which was supposed to be the entrance of the ball, and another wound anteriorly in the right iliac region, supposed to be the orifice of exit. Patient was very weak; pulse rapid; respiration also rapid; skin cold and dry; the abdominal muscles were firmly contracted, and the lower extremities drawn up. He evinced great suffering when pressed upon the abdomen, and vomited freely. At 2 o'clock P. M. hæmorrhage took place from the anterior wound, but was arrested by placing the patient on his back, but commenced again, however, when he was lying on his right side. There was also great irritability of the bladder; but no urine passed when the catheter was introduced. Morphia and one ounce of whiskey were given every four hours, and applications of warm water were made over the abdomen; he was unable to take food. Autopsy sixteen hours after death: There was considerable saggillation posteriorly and about the neck, and swelling of the neck anteriorly. Upon laying open the cavity of the abdomen, a clot of blood was found effused on the anterior surface of the intestines, and entangled in it was the skin of a grape. The peritoneum was red and injected, but there was no exudation of false membrane; the cavity of the abdomen was filled with blood. Upon removing the intestines and tracing the course of the ball, it was found to have entered through the ischiatic notch, divided the internal iliac vein, impinged upon the right lateral portion of the bladder, and made its exit in the right iliac region. The ball also passed through the lower portion of the ileum about twelve inches from the ileo-cæcal valve."

<sup>1</sup>FOLLIN, in an article replete with sound and sagacious observations, mentions an instance in which death resulted from the puncture of some of the terminal ramifications of the mesenteric artery by a bayonet, and the hæmorrhage was not suspected until revealed by the autopsy. *Des Epanchemens traumatiques de l'abdomen*, in *Dict. encyclop. de Sci. Méd.*, T. 1, p. 171.

<sup>2</sup>BARTHOLOW (R), *Cincinnati Lancet and Observer*, 1864, Vol. VII, p. 596.

In the treatment of intra-abdominal bleeding, the surgeons usually adopted the general measures for combating hæmorrhage commended by systematic authors, excepting venesection and cupping over the belly: that is, absolute immobility, occlusion of the external wound, and the application of refrigerants, with sinapisms to the extremities, and, internally, cold acidulated or saline drinks, opiates, and, sometimes, preparations of digitalis, veratrum viride, or gallic acid. Phlebotomy, still recommended by leading French and German authorities on this subject, was rejected even more uniformly than in intra-thoracic hæmorrhage. When internal bleeding proceeds from the vessels of the abdominal walls, the ligature is, of course, the safe and indispensable remedy. On page 177 and elsewhere I have dwelt upon the disastrous results of neglecting this paramount resource. In this direction, I believe that operative interference should be carried to the extreme verge of the limits that prudence enjoins. Instances are not wanting in which branches of the mesenteric, epiploic, gastric, and colic arteries have been successfully ligated. Where there is protrusion of the wounded, solid viscera, with oozing from the lacerated surfaces, a ligature in mass may be requisite. If the finger, introduced into a penetrating wound in the belly, recognizes the warm jet of a bleeding vessel, the point must be exposed and secured. It would be more rational to ligate even the cava or aorta, than to stuff the wound with lint saturated with persulphate of iron, as was done in more than one mortal hæmorrhage. The cases of intra-abdominal bleeding that are not immediately mortal, from lesion of the great vessels, and that are not amenable to mechanical treatment, form a small group in which the surgeon is reduced to the general measures for combating hæmorrhage already indicated. Should these means, of which rest and ice-poultices are the chief, prove successful, three additional indications arise: to promote absorption of the effused blood, to oppose the recurrence of bleeding, and, under some circumstances, to evacuate the extravasation. If the utility of such resolvents as cupping and cataplasms is not demonstrated, it is certain that the second indication may be fulfilled by maintaining absolute repose, with a light, reparative diet, of a nature to leave little residue,<sup>1</sup> for immobility of the intestine also is essential, and must be assured by opiates. There is reason to apprehend that here, and in other circumstances in which recurrence of hæmorrhage was imminent, a want of caution in the administration of brandy and other stimulants was a point open to criticism in the practice of some surgeons. The evacuation of the effused fluid may become necessary, where it forms a circumscribed tumor, augmented by inflammatory products. No example of the sort is found on the reports; but the surgeon encountering such a case may judiciously follow the practice inculcated by Velpeau, of a free incision in preference to puncture, as advised by Vacher.

In this connection may be noted a few instances in which tapping was required for non-traumatic effusions, dependent on morbid secretion:

*Paracentesis.*—Four instances only of tapping were reported; whence it may be inferred that the cases of ascites following diarrhœa or malarial fever that required this operation were comparatively rare:

CASE 608.—John Davidson, powder boy, Co. A, Marine Artillery, was admitted into the Ladies' Home Hospital, New York, February 23, 1863, suffering from hydropsy. The following notes of the case appear upon the hospital case-book: "He was on board the gunboat Picket when she was blown up, September 9, 1862, and received a fracture of the left leg with considerable contusion of the soft parts. He was treated at the hospital at New Berne, and was furloughed for twenty days, and came to New York in the latter part of January, remaining at a sailors' boarding house until his admission into this hospital. He had diarrhœa during all the time he was at the hospital at New Berne, and until his arrival in New York, when it ceased. On

<sup>1</sup> Milk diet, recommended particularly by Dr. ASHURST (*Princ. and Pract. of Surg.*, p. 368), is excellent.



admission, the abdomen was much enlarged; fluctuation was distinct, and the veins of the abdomen were turgid. He was still lame from the injury to the leg, considerably emaciated, and obliged to keep his bed from debility. There was some œdema of the lower extremities. Hydragogue cathartics were given repeatedly, with the effect of reducing for the time, to some extent, the abdominal effusion; but the relief being only temporary, paracentesis was resorted to on March 24th, with much relief. The liquid, however, re-accumulated, so that in a few days the abdomen was as much enlarged as before the operation. The treatment, aside from tapping, consisted of muriate tincture of iron and nutritious diet. March 29th, the vertical diameter of the liver, as ascertained by percussion, appears to be normal; there are no signs of cardiac disease. It does not appear that this patient has been so situated as to be able to drink spirits to much extent. He states that he has drunk only very little occasionally. On July 22, 1863, Davidson was transferred to Lovell Hospital, Portsmouth Grove, whence he was discharged from service October 29, 1863, "because of ascites, most likely from tubercles in the mesentery, contracted in line of duty. Fracture and dislocation of left tibia." Pension Examiner R. H. Tuft, of Elkton, Maryland, reported, December 14, 1868, that Davidson was "blown up by the explosion of the gunboat Picket, receiving internal injuries which resulted in debility and chronic diarrhœa. This condition has been kept up by exposure and bad whiskey." His claim for pension was rejected!

CASE 609.—Private John W. Tarton, Co. I, 94th New York, aged 35 years, was admitted into the depot field hospital of the Fifth Corps at City Point, March 15, 1865, suffering from dropsy. On March 23d, he was transferred to Harewood Hospital, Washington, and on April 17th to Stanton Hospital. On May 7th, Surgeon B. B. Wilson, U. S. V., administered chloroform and performed paracentesis, removing two gallons and one pint of fluid. The patient was in good condition. Dr. Wilson, on May 28th, repeated the operation, withdrawing fluid to the amount of three gallons and three pints. The patient was rather debilitated, and required the administration of stimulants during the operation. The abdominal parietes appeared to be in good condition. Death resulted from peritoneal inflammation on June 16, 1865.

CASE 610.—Private John Tacket, Co. B, 14th Kansas Cavalry, aged 45 years, was admitted into the hospital at Pine Bluff, April 29, 1865, from his regiment, suffering from chronic diarrhœa. Assistant Surgeon F. F. Foster, 13th Illinois Cavalry, reports that "on June 27th, there was enlargement of the liver and abdominal dropsy. The patient was anæmic, and the abdomen was much distended with fluid. Paracentesis abdominis was performed. A tonic course of treatment was then pursued, but the abdomen again became distended. He died September 10, 1865, from dropsy resulting from hepatic disease."

CASE 611.—Private Titus H. Flanders, Co. K, 153d New York, aged 48 years, was admitted into the regimental hospital, April 16, 1865, suffering with acute diarrhœa. The progress of the case is not noted, but, on July 17th, he was transferred to Marine Hospital, St. Louis, whence Surgeon A. Hammer, U. S. V., reported that ascites had supervened. The patient was very feeble and the abdomen much distended. On July 21st, Dr. Hammer performed paracentesis abdominis, evacuating nine pints of fluid. Diuretics, diaphoretics, and stimulants were administered. Death, July 31, 1864.

Acting Assistant Surgeon J. P. Hachenburg transmitted a drawing of a trocar, designed to preclude the admission of air in paracentesis by a syphon attachment to the canula.

*Bile.*—In two notes on page 21 the principal recorded clinical observations on the effects of extravasation of bile from rupture of the gall-bladder or of the biliary ducts are referred to, and in the series of one hundred and seventy-three shot wounds of the liver (CASES 312–484) are some illustrations of the results of effusion of bile in the peritoneal cavity, and others may be found in the works referred to in the note.<sup>1</sup> The elevated position of the biliary reservoir and canals, and the fluidity of the secretion, and its persistence after lesions of the excretory apparatus, are circumstances that would seem to ensure the diffusion of the bile over the intestinal mass in the event of wounds or ruptures of the gall-bladder or ducts. In a case of wound of the gall-bladder that Sabatier observed, intense peritonitis was rapidly developed; the belly swelled quickly, with great tension and pain in the hypochondrium. On the third day a prominence was noticed in the right iliac region, and Sabatier introduced a trocar and gave vent to a dark-green odorless fluid, supposed to be pure bile. Authors have repeated Sabatier's description; and it has been commonly held that extravasation of the acrid bile would necessarily irritate the serous membranes to a degree involving mortal peritonitis. The instances of

<sup>1</sup> LAURENREITH, *De sanantibus forsan vesiculae felleæ vulneribus*; E. LITTRÉ, *Blessures des voies biliaires*, in *Dict. de Méd.*, T. V, p. 232; HARLAN (G. C.), *On Wounds of the Liver*, in *North Am. Med. Chir. Rev.*, 1859, Vol. III, p. 701; HERLIAS, *Expériences sur l'ouverture de la vésicule du fiel*, in *Jour. gén. de Méd.*, 1757, T. XXVII, p. 463; FRYER, *Extravasation of Bile into the Cavity of the Abdomen, etc.*, in *Med. Chir. Trans.*, 1813, Vol. IV, p. 330, and *Medical and Phys. Jour.*, 1815, Vol. XXXII, p. 152; MAVER (L.), *Die Wunden der Leber und Gallen-blase*, München, 1872, Sn., 47, 61, 77; AVICENNA, *Canon medicinarum*, Venetiis, 1700, Lib. III, Fenn. 14, Tract. 3, p. 14; PÉTIU, *Sur les tumeurs formées par la bile retenue dans la vésicule du fiel, et qu'on a souvent prises pour des abcès au foie*, in *Mém. de l'Acad. Roy. de Chir.*, Paris, 1713, T. I, p. 170; BLASIUS, *Observationes in d. rarioris*, Amst., 1677, P. II, n. 4; LE GROS CLAEK, *Cases illustrées de lésions de l'Abdomen*, in *Lancet*, 1864, Vol. I, p. 68; WILKS, *Liverrot of the Liver, with Formation of an Abscess below it and the Diaphragm, perforat of the latter*, in *Lancet*, 1861, Vol. II, p. 736; PORTAL, *Cours d'anatomie médicale*, Paris, 1803, T. V, p. 121; LIETAUD, *Historia Anat. med.*, Parisiis, 1767, Obs. 910–911, p. 211, refers to cases related by SALMUTH and HOFFMANN; SABATIER, *Méd. opératoire*, Paris, 1822, T. II, p. 153; SUGART, *The Use of Bile in the Animal Economy*, in *Phil. Transactions*, Aor., & c., by FAMES and MARTYN, London, 1734, Vol. VII, p. 571; CALLISEX, *Syst. Chir. Hodiernum*, Vol. I, p. 718.

recovery recorded by Fryer and Frank are contested by Chelius and others, and it has been sought to explain the exceptional case of Parroisse, referred to on page 137, by supposing that the ball gained admission to the gall-bladder by ulceration. Callisen pointed out that extravasation might be prevented in wounds of the gall-bladder by previous accidental adhesions of the organ to the peritoneum, a suggestion practically applied in the operative treatment proposed for biliary calculi. The experiments on animals by Höring and Herlin and by Campaignac indicate that the intensity of the irritant action of bile effused in the peritoneal cavity has been overrated,<sup>1</sup> and some of the facts observed during the war point in the same direction. In the complicated case of Coffin (CASE 424, p. 136), hyperacute peritonitis terminated fatally in fifteen hours; but in the cases of Alleger and Kingsbury (CASES 408, 449), with equally extensive extravasation of bile, life was prolonged for five and eight weeks. In the following case the patient survived twenty days:

CASE 612.—Private *Haywood Painter*, Co. A, 24th North Carolina, was wounded at Petersburg, March 24, 1865. He was admitted to field hospital at City Point on the following day, and March 29th was transferred to Washington, where he was admitted to Lincoln Hospital on the 30th. The history of the case up to the time of death was reported by Acting Assistant Surgeon N. A. Robbins, and the autopsy by Acting Assistant Surgeon F. P. Arthur, as follows: "Gunshot wound of back-ball entering near the crest of the right ilium, and probably penetrating into the cavity of the abdomen. He suffered a great deal of pain from time to time; the wound also suppurated pretty freely; he grew weaker daily, and finally died, from the consequent exhaustion, on the 13th of April, 1865." Autopsy record: "Height, five feet ten inches; external appearance very much jaundiced; ball entered three inches to the right of the spine on a level with the crest of the ilium, passed forward through the muscles of the back, penetrated the cavity of the abdomen, and ruptured the gall-bladder; the ball was found lying loose posterior to bladder; lower lobes of both lungs very much congested; pleural adhesions on right side; heart healthy; abdominal viscera very much discolored by bile; intestines not wounded."

In the case of Green (CASE 436, p. 139), a shot perforation of the right lobe of the liver, with division of a large branch of the hepatic duct, though there was generalized peritonitis, and probably an incessant escape of bile, the patient survived forty-four days. In such cases, Campaignac advised ligation of the ducts, and Herlin extirpation of the gall-bladder, adducing the results of experiments on animals in support of these propositions.<sup>2</sup> Bohn and Kaltschmidt<sup>3</sup> held that life might be extended for some length of time without the cystic bile, and that this, when effused in the abdomen, did not of itself bring on any immediate danger; but the view promulgated a century later by Sabatier has prevailed, and subsequent facts appear to modify it only as to the intensity of the inflammation resulting from extravasation of bile. It has been stated that the report of a recovery from a shot wound of the gall-bladder in *Circular 3*, page 50, was a clerical error; in the recovery recorded on page 140 (CASE 316), in which this lesion was alleged, the diagnosis was probably erroneous.

*Urine.*—The absence of examples of urinary extravasation in the cases of wounds of the kidney or ureter, that come under treatment, has been adverted to on page 162. This complication is so rare that, according to Velpeau, Morgagni could cite only the example adduced by Piccolomini. Instances of extra-peritoneal urinary infiltration are adduced on page 20. That the effusion of urine within the peritoneum is more irritating

<sup>1</sup> In a case of rupture of the gall-bladder observed by ROGERS (*GROSS'S Elem. of Path. Anat.*, 1845, p. 665), the patient survived the escape of the fluid sixty hours. In one recorded by DRAKE (*Western Jour. of the Med. and Phys. Sci.*, 1834, Vol. VII, p. 520), death took place at the end of the third day. In four of the cases recorded in LESUEUR'S thesis, life was destroyed in a few hours; the fifth survived four days. A case described by SKEETE (*London Med. Jour.*, 1785, Vol. VI, p. 274), terminated fatally at the end of the sixth week. TRAVERS (*Inquiry, etc., op. cit.*, p. 72) mentions two fatal cases, without specifying their duration. See cases in MORGAGNI'S *Epistolæ Anatomice*, Ep. II, Art. 96, *Op. omn.*, Patavii, 1765, T. II, p. 85, and in VAN SWIETEN, *Comm. in Boerhaave*, Parisiis, 1755, T. I, p. 475.

<sup>2</sup> The certainty of an inevitably fatal result from expectation may justify extreme surgical boldness, and, with FOLLIN, I would refrain from censuring this proposition; but, as that excellent surgeon remarked, it is to be feared that the damage inflicted by the bile already extravasated would render interference nugatory.

<sup>3</sup> BOHN, *De vulnerum renuntiatione*, Lipsiæ, 1689, cap. 4. KALTSCHMIDT, *De vulneribus hepatis*, Jena, 1735.

than the extravasation of any other secretion is unquestioned. Such an accident is almost uniformly fatal in from two to twelve days. Yet, in thirty-seven cases collected by Houel,<sup>1</sup> there were two instances of recovery. The subject will be reverted to in treating of injuries of the bladder.

*Feces, etc.*—Escape into the peritoneal cavity of the alimentary, stercoral and gaseous matters ordinarily contained in the digestive tube, and occasionally of lumbrici and other entozoa, are complications resulting from ruptures and spontaneous perforations of the intestines as well as from wounds, so frequent as to come under the observation of every practitioner. The relations to the extravasation of the form and extent of the solution of continuity, of the state of repletion or vacuity of the intestine, of the formation of adhesions, and of the interposition of epiploic laminæ, have been exemplified by cases of ruptures and of wounds (pp. 22 and 62). It has been contended that after wounds of the intestine this extravasation "takes place much less frequently than might have been expected."<sup>2</sup> Two instances of multiple shot wounds of the intestine are adduced by Mr. Erichsen, in which no fecal effusion took place, although the intestines contained much stercoraceous matter, and were largely lacerated, and the patients survived two days. One or two such exceptional instances (CASES 225 and 226, p. 71) are found on the reports of the war. Sometimes the subject is passed over in silence; but a multitude of such examples as the following appear:

CASE 613.—Sergeant Daniel H. Bird, Co. I, 1st West Virginia, was wounded at Murfreesboro', September 11, 1863, while sleeping in his tent. He was treated in regimental hospital until he died, on September 13th. Surgeon D. Baguley, 1st West Virginia, reported: "Ball entered the left lumbar region and passed to the right side, from whence it was extracted, having perforated the intestines in its course. The contents of the intestines were extravasated into the abdominal cavity and fatal inflammation resulted."

If, by the fortunate adhesions or occlusion by interposition of the omentum or of contiguous viscera, fecal effusion was temporarily arrested, it was liable to be provoked by moving the patient, as in the following case:

CASE 614.—Private John Piercefield, Co. II, 91st Ohio, aged 33 years, was wounded at Winchester, July 20, 1864, by a conoidal ball. He was treated in a field hospital until the 24th, when he was admitted to hospital at Cumberland, where he died two hours after admission. The following report of the case was made by Acting Assistant Surgeon C. H. Ohr: "The ball entered near the sternal end of the cartilage of the tenth rib, at the upper edge on the right side, and, passing down through the abdomen, lodged in the muscles of the right hip three and a half inches below the crest of the ilium and three inches behind the tip of the great trochanter, whence it was extracted immediately after his admission here. The patient had been some four or five hours delayed on the road from Martinsburg, without even the necessary supply of water. His skin was cold and clammy; pulse 96, small, weak, and thready; voice hoarse and weak; respiration laborious, short, and hurried; bowels constipated; ejects stimulants immediately after swallowing; extremities cold. The extreme prostration of the patient prevents the acquisition of any information as to his previous treatment, and, from the disposition to emesis with the near approach of death, nothing was administered but a little whiskey and water, which was not retained. Autopsy, fourteen hours after death, showed the abdomen tensely swollen, peritonitis with adhesion of the bowels, and the peritoneal sac extensively studded with patches of pus and freely covered with fecal matter from the numerous perforations of the intestines. The tediousness of separating the adhesions and the offensive condition of the subject prevented a minute tracing of the track of the ball or preservation of portions of the perforated intestines."

CASE 224, on page 71, is another instance of delayed extravasation, the symptoms of intense peritonitis coming on during transportation, and terminating fatally on the eighth day. There is yet another group of cases, which John Bell has admirably described, in which the patient goes on well till the eighth or tenth day, the intestines having only been bruised in the rapid passage of the ball, and then the hurt part sloughs off, and the

<sup>1</sup> HOUEL, *Des plaies et des ruptures de la vessie*, Paris, 1857, p. 50. The recoveries were reported by SYME (*Lancet*, 1848, Vol. 1, p. 289) and by Dr. WALTER, of Pittsburg (*Med. and Surg. Reporter*, 1862, Vol. VII, p. 153).

<sup>2</sup> ERICHSEN, *The Science and Art of Surgery*, 6th ed., 1872, Vol. I, p. 508. The case of Dunn, p. 449, *First Surgical Volume*, CASES 217, p. 69, 219, 220, p. 70, 224, p. 71, and 303, p. 103, *supra*, are examples of the rapidly fatal peritonitis following fecal effusion after shot wounds. CASES 206, p. 62, and 233, p. 76, illustrate the same condition after stab wounds. CASE 216, p. 68, is a remarkable illustration of a large circumscribed fecal effusion in a case in which life was prolonged for four weeks.



æces are poured out into the cavity of the abdomen, and there is a sudden interruption of the stools, and as sudden a tension and swelling of the belly, with vomiting, hiccough, and speedy death.

Salzmann, Heister, Poland,<sup>1</sup> and a few others have referred to the escape of entozoa from wounds of the bowel. Travers (*op. cit.*, p. 27) considers this a peculiar case, to which no reasoning on the effusion of inanimate matter can apply. CASES 172, 215, 221, and A<sup>5</sup>, on pages 42, 68, 71, and 206, furnish illustrations of this rare accident.<sup>2</sup>

After a solution of continuity of the digestive tube, the conditions under which faecal effusion within the peritoneal cavity fails to ensue appear to be: First, that the orifice shall not exceed three lines in extent,<sup>3</sup> when reduced by muscular contraction. The eversion and pouting of the mucous membrane may be sufficient to occlude such an aperture, whether its direction is transverse, oblique, or longitudinal. Secondly, if the lesion of the intestine is in parts of the duodenum or colon uninvested by peritoneum, the effusion will be interstitial or external. Thirdly, the edges of the orifice in the intestine may immediately adhere to the peritoneal lining of the parietes, and the extravasation will then take place externally; or adhesions may form with neighboring coils of intestine, or with the surfaces of the solid viscera, or the aperture may be closed by the apposition of the omentum or mesentery. Lastly, the vulnerating instrument may inflict such violence as to annihilate the peristaltic action of the bowels, when the intestine may be lacerated in many places, without effusion taking place. Under all other circumstances, faecal extravasation is the inexorable sequence of a perforation of any magnitude, for the digestive tube is never absolutely empty. The uniform equable pressure with the beneficent tendencies that John Bell and Travers so earnestly and wisely insisted on, favors the accidental formation of adhesions; but it must be steadily held in view that unless occlusion is immediately effected through the agencies adverted to or by surgery, faecal effusion *must* result, unless the muscular coat is paralyzed. Argument to prove that the contents of the bowel must follow the line of least resistance and escape through an orifice in the bowel large enough to permit their escape would appear to be supererogatory. Yet some writers mistake the explicable exceptions to this rule for the rule itself. Physicians do not question that perforation of the bowel following ulceration will almost inevitably be followed by effusion. That extravasation almost infallibly results from ruptures of the intestine without external wounds is not doubted. Travers ably explained why effusion should not take place in many punctured wounds. It has latterly been alleged that faecal extravasation is uncommon in shot wounds of the intestine. Mr. Erichsen's assumptions (*op. cit.*, 1859, 1st Am. ed., p. 328; 6th ed., 1872, Vol. I, p. 509) on this subject, in which Petit's exploded hypothesis on the circumscription of faecal effusions is revived, have been almost literally copied, without acknowledgment, by Surgeon-Major Williamson (*Mil. Surg.*, 1863, p. 104), whose familiarity with the morbid anatomy of shot wounds of the abdomen might have been expected to have deterred him from endorsing statements so widely at variance with the results of sound theory and of practical experience. The teachings of Ballingall,<sup>4</sup> and careless interpretations of the

<sup>1</sup> SALZMANN (J.), *De chirurgia curtorum*, Argent., 1713; HEISTER, *Gen. Syst. of Surg.*, 1769; POLAND, *Guy's Hosp. Rep.*, 1858, Vol. IV, p. 149.

<sup>2</sup> In CASE 207, p. 64, lumbrici escaped through the external wound, and in CASE 283, p. 94, a similar escape of another worm, the trichocephalus dispar, was observed. BAUDENS, DE LISLE, and BRUOT give similar instances.

<sup>3</sup> The experiments of Professor GROSS are decisive on this point. They are succinctly detailed in his *System* (5th ed., Vol. II, p. 663), and are more elaborately stated in his exhaustive *Inquiry* (*op. cit.*, p. 10). A synopsis of the results appears in note 4, page 60, *supra*.

<sup>4</sup> BALLINGALL (*Outlines of Military Surgery*, 5th ed., p. 352): "Extravasation of the contents of the bowel within the peritoneum is by no means so liable to occur as speculative writers would lead us to imagine."

experiments of Travers, and of John Bell's eloquent exposition of the salutary effects of the uniform equable pressure, may have misled Mr. Erichsen, Mr. Teale, and Dr. Williamson into the support of this unsafe doctrine, to which it would be sufficient to oppose the authority of John Hunter,<sup>1</sup> of Velpeau,<sup>2</sup> of Jobert,<sup>3</sup> and of Professor Gross,<sup>4</sup> if it was impracticable to refute it by appealing to facts. It would be easy to multiply examples from the records of the war; but as it might be objected that these were selected cases, the fallacious assumption of the rarity of fecal effusion after shot wounds of the digestive canal may be preferably controverted by adducing instances from other writers.<sup>5</sup>

That extravasated alimentary or stercoral matters may become encysted, and, producing circumscribed abscesses, may be discharged externally or into the intestinal canal, is doubtless true; but such facts are among the rarest of exceptions. The instance observed by Archer (p. 43, *supra*, note) of an incised wound of the stomach, with escape of its contents into the peritoneal cavity, and recovery after the discharge in the groin of an abscess containing portions of cabbage, is one of the most remarkable.

Such instances of extravasation of lymph, from division of the thoracic duct or of the reservoir of Pecquet, as Morgagni details in the fifty-fourth epistle, and as Sandifort, Portal, Scherb, and Lieutaud have described, were not observed. As Velpeau observes, such effusions are doubtless possible, but it may fearlessly be asserted that their existence has never been satisfactorily demonstrated. My observations have not confirmed those of Dr. Williamson in regard to the displacement of the wounded gut,<sup>6</sup> but are in accord

<sup>1</sup> HUNTER (*Gunshot Wounds*, *op. cit.*, p. 545), in the paragraph preceding that in which he relates the exceptional instance of the officer wounded in the Hyde Park duel. lays down the general principle that a ball striking one of the abdominal viscera will produce effects of two kinds, and the first "is common to them all, viz: their contents or extraneous matter escaping into the cavity of the abdomen."

<sup>2</sup> VELPEAU (Article *Épanchements dans l'abdomen*, in *Dict. de Méd.*, 1832, T. 1, p. 201), after recalling that fecal effusions often result from ruptures of the alimentary tube, adds: "les plaies pénétrantes en sont une cause encore plus fréquente."

<sup>3</sup> JOBERT, treating of wounded in the revolution in Paris in July, 1830 (*Plaies d'armes à feu*, 1833, p. 215), gives an instance of fecal effusion, and remarks: "les matières fécales s'épanchent souvent dans le ventre, et il en résulte une péritonite mortelle."

<sup>4</sup> GROSS (*System*, etc., 1872, Vol. II, p. 664): "In gunshot wounds of the bowels, and in incised wounds attended with severe contusion, the eversion of the mucous coat is generally very slight, and sometimes even absent. Owing to this circumstance, wounds of this description, even when very small, are extremely prone to be followed by fecal extravasation and fatal peritonitis." Mr. POLLOCK (Mr. HOLMES'S *System*, 1870, Vol. II, p. 671) justly observes: "All the experiments by Mr. TRAVERS, Dr. GROSS, and others lead to this conclusion, that, upon the infliction of a wound of the intestine, some escape of feculent fluid, though perhaps a very small quantity, takes place, and is the chief cause of the subsequent peritonitis."

<sup>5</sup> Only in a small proportion of the observations of fatal shot wounds of the alimentary canal recorded by authors are the *post-mortem* appearances described, and in these the presence of fecal effusion is seldom specified, probably because, as TRAVERS remarks, "the extravasation of fecal matter seems to have been regarded as a consequence so inevitable of a rupture of the bowel, that the notice of the former circumstance after the mention of the latter probably approached somewhat in the writer's idea to the nature of an identical proposition." Many writers on military surgery seldom detail fatal cases. PURMANN and LARREY, for example, who are especially full and instructive in treating of wounds of the abdomen, adduce only examples illustrating the successful efforts of nature or intervention of art. Notwithstanding, from the comparatively small number of recorded fatal shot perforations of the intestine, it is possible to collect many instances of fecal effusion. Thus, BECK (*Die Schusswunden*, 1850, S. 216) records five dissections of soldiers who died after the battle of Vicenza from shot wounds of the intestine; large fecal intraperitoneal extravasation was present in all. These patients perished on the second and third, and one on the fourth day. And SCHWARTZ (*Beiträge zur Lehre von den Schusswunden*, 1854, S. 125) gives the autopsies of H. S., wounded at Altenhof, April 21, 1848, with fecal effusion and hyperacute peritonitis, ending fatally in twenty-four hours, and of A. F., 31st Prussian regiment, wounded April 23, 1848, at Schleswig, who survived a fecal effusion from shot perforation of the small intestine five days. LOHMEYER (*Die Schusswunden*, 1859, S. 160) records the autopsy of Lieutenant H., wounded September 12, 1850, who died from fecal extravasation from a shot wound of the colon. Assistant Surgeon HORSER, U. S. A. (*Circular* No. 3, S. G. O., 1871, p. 48), records a case of fecal extravasation following a shot perforation of the colon, fatal in a few hours. SOGIN (*Kriegschir. Erfahrungen*, 1872, S. 95) gives the autopsy of Fille, shot through the colon at Gravelotte, August 18, 1870; died with fecal effusion. FISCHER (H.) (*Kriegschir. Erfahrungen*, 1872, S. 129), records an example of fecal effusion from shot wound of the colon and small intestine in the case of Thodkein, 13th Prussian regiment, wounded August 14, 1870; fatal in four days. BAUDENS (*Plaies d'armes à feu*, p. 335) describes the autopsy of a case of shot wound of the colon with fecal effusion. FERRIER (*Traité des plaies d'armes à feu*, 1844, p. 268) mentions a single fatal case of shot wound of the small intestines, in which five convulsions presented each two perforations; a large fecal extravasation excited peritonitis, terminating fatally in twenty-four hours. SÉBILLOT (*Campagne de Constantine*, 1838, p. 157) details a fatal case of fecal effusion from a shot wound of the intestine, and adds: "Nous perdîmes ainsi pendant le reste de la campagne tous ceux qui présentèrent des plaies pénétrantes abdominales, et ni les heureuses adhérences sur lesquelles on compte pour prévenir l'épanchement, ni la pression mutuelle des viscères ne purent empêcher dans aucun cas cette termination funeste." BERTHERAND (*Campagne d'Italie*, 1860, p. 97) reports the case of Lieut. Col. V., who received a shot wound of the small intestines at Solferino, causing fecal effusion and death in forty-eight hours.

<sup>6</sup> Surgeon-Major GEORGE WILLIAMSON observes (*Military Surgery*, 1863, p. 112): "It is curious to remark, on *post-mortem* examination of a case of direct gunshot perforation of the abdomen, that the intestine is wounded in many places considerably removed from the direct course of the ball. Is this removal of wounded portions of intestine from the line of the ball due solely to the natural peristaltic action, or to something more than this, as the result of the injury? Probably the latter influence is considerable; as it has been remarked, and I believe truly, that under perforation of the intestines by ulceration there is not only contraction in calibre, but marked shortening of the intestinal canal. This action beyond the peristaltic may be expected, and really appears to follow equally perforations by injury and disease, thus explaining the withdrawal of the wounded points of intestine from the line of the ball, as indicated by the orifices of entrance and exit."



with those of Baudens and of Legouest, that in shot wounds of the abdomen the intestinal lesion is usually found just behind the entrance orifice in the parietes. Further investigation of this point is desirable. Theoretically, there appears to be no reason why the contraction of the longitudinal fibres should not produce displacements in addition to those resulting from peristaltic and antiperistaltic movements.

*Pus.*—Effusions of pus into the peritoneal cavity may be primary, depending on the extravasation of the contents of abscesses; or consecutive, as exudations resulting from peritonitis. The following cases, though not very characteristic, have been classified in this category:

CASE 615.—Private W. H. Sanborn, Co. A, 12th Massachusetts, aged 22 years, received a perforating wound of the chest and abdomen at the Wilderness, May 7, 1861, by a conoidal ball. He was treated in the field hospital until the 12th, when he was transferred to Armory Square Hospital, Washington. On May 26th, he was sent to the hospital at Chester. Surgeon T. H. Bache, U. S. V., reports that, "when admitted, the wounds were almost healed and his general health was good; on the fourth or fifth day following, he was taken with a chill, followed by hot accelerated pulse, and had these rigors daily for two or three days, with slight diarrhœa, epistaxis, tenderness in right iliac fossa and over the liver, and about this time pseudomemena appeared over the abdomen; he was progressing favorably until the evening of June 9th, when his pulse was 110, full and bounding; and on the next day he was still failing; the skin cold and clammy, and pulse barely perceptible; he died at five o'clock P. M. Autopsy: The missile had entered near the eighth rib, on the left side of the chest, and made its exit above the fifth rib on the right side, about four inches from the sternum. The serous cavities were filled with grumous-looking pus, and the liver much enlarged and displaced; a large cavity was found on the under surface of the right lobe, capable of containing thirty-two ounces of pus; the track of the ball through the liver from entrance to exit was well marked; the glands of Peyer were much enlarged, and there was considerable congestion of the intestines."

CASE 437 (see p. 132).—Private E. Holbrook, Co. F, 16th New York, aged 24 years, was wounded at Chancellorsville, May 3, 1863. He was treated in field hospital until May 8th, when he was admitted into Stanton Hospital, Washington. Acting Assistant Surgeon G. A. Mursick reported, on the Medical Descriptive List, that the patient was paraplegic when admitted, and urine and feces passed involuntarily; his pulse was small and feeble, and respiration thoracic; he had never spit blood. He was much prostrated, and had a troublesome bed-sore. These symptoms continued until May 10th, when they assumed a typhoid type. On May 12th, there was effusion into the right pleural cavity, and some cough; the tongue was coated and dry. On May 19th, the pulse was 110 and feeble, and was gradually growing weaker; had very little appetite; bed-sore increasing in size. On the 24th he had a chill, and, on the 28th, the abdomen became tympanitic, with pain and constriction. He died on the following day, at 5 o'clock A. M. The treatment had consisted of cold applications to wounds, with tonics, stimulants, and nutritious diet. *Post-mortem* examination showed that the ball had entered the back, passed through the body of the tenth dorsal vertebra, traversed the cavity of the abdomen, passing between the aorta and ascending cava, perforated the diaphragm and liver, and lodged in the intercostal space between the seventh and eighth ribs."

CASE 616.—Private George Johnson, Co. H, 116th Ohio, aged 19 years, was wounded at Piedmont, June 5, 1864, and admitted to Confederate hospital at Stanton on June 7th. Assistant Surgeon W. Grumbein, 20th Pennsylvania Cavalry, reported as follows: "Wounded by three balls, one of which struck the crest of the ilium and entered the abdominal cavity; another struck the thigh over the trochanter. The wounds were not considered dangerous at first. The suppuration was profuse and unhealthy. The patient was of a scrofulous diathesis, and was weakened to a great extent by diarrhœa, which could not be checked by medicine. Hæmorrhage took place toward the last, which nothing but steady pressure would check. He remained sensible until he died, July 13, 1864. The *post-mortem* examination showed that the psoas and iliac muscles were entirely dissected and in an advanced state of putrefaction; so also was the pelvic fascia; the peritoneum was of a mottled appearance, bordering on a scarlet color. The course of the ball was not discovered on account of the disorganized state of the tissue. In the left iliac fossa was found about a pint of coagulated blood and pus."

CASE 617.—Private William A. Dickey, Co. B, 13th Tennessee Cavalry, aged 27 years, was wounded at the assault on Fort Pillow, April 12, 1864, and on the 11th was admitted into the hospital at Mound City. The following report of the case was made by Surgeon Horace Wardner, U. S. V.: "April 17th, the patient complained much of pain in the left side and back; the abdomen was swollen and tympanitic and very tender. Warm-water fomentations were applied, and also anodynes, under the influence of which he sometimes rested tolerably well. About June 1st fluctuation was detected in the left lumbar region, and, on the 3d, this was relieved by incision, about sixteen ounces of dark-gray and very offensive pus being discharged. He sank rapidly, and, on the 4th, hicough set in and continued until June 6th, when he died. Autopsy sixteen hours after death: Rigor mortis perfect; body much emaciated, and abdomen swollen. The ball entered four inches to the right of and one inch above the umbilicus, passed obliquely downward and to the left, between the internal oblique and transversalis muscles, near to the pubis; it then passed upward and backward, striking the posterior superior spinous process of the ilium, producing a zigzag fracture two and a half inches in length, and lodged on the left side of the last lumbar vertebra below the transverse process. The ilium was denuded of periosteum in a space two or three inches in diameter. The peritoneum, omentum, descending colon, and rectum were black, and had been much inflamed, and there were appearances of congestion along the whole intestinal canal. The kidneys were normal and the spleen somewhat congested; the liver was not examined; stomach appeared healthy; peritoneal adhesions very extensive; and about three ounces of dark, stinking pus was found between the psoas muscle and the ilium."



CASES 125, 212, 304, 307, 414, and 449, on pages 24, 67, 104, 135, and 136, *supra*, furnish better examples of this complication, and a great number may be found in the authors cited in the note.<sup>1</sup> In the cases of peritonitis attended by a copious effusion of pus that have come under my observation, there was less pain than in those associated with pseudomembranous exudation, or, still worse, with fecal effusion.

*Air or Gases.*—Air, in rare instances, may accumulate, to a small extent, in the peritoneal cavity through a long, narrow wound in the parietes, and somewhat less rarely through perforations of the lung and diaphragm. The extravasation of intestinal gases is a very common, if not a uniform, result of a division of the walls of the alimentary canal. Dr. F. H. Hamilton<sup>2</sup>—who has thoughtfully discussed the subject of abdominal effusions, and whose authority might have been added to those invoked in confirmation of the frequency of fecal escape after shot wounds of the bowels—suggests three explanations of the mechanism of these extravasations: First, that by admission of air through the track of the wound the peritoneal surfaces, normally in absolute contact, may be separated, and an intra-peritoneal air space may be formed, into which the contents of the intestine, impelled by peristaltic action, may be freely found. Secondly, holding that “the intestines contain always a certain amount of gas,”<sup>3</sup> Dr. Hamilton conceives that immediately on the reception of a wound the muscular tunics of the intestines vigorously contract and expel this confined gas; the intestine collapsing, and the gas having gained admission to the peritoneal cavity, the fluid and solid contents of the intestine readily follow. Thirdly, the fecal matter may be displaced and carried forward by the missile precisely as any other substance lying in its way. There can be no question that sudden meteorism is the most constant and characteristic symptom of rupture of the intestinal walls. Jobert’s<sup>4</sup> claim, that it is of pathognomonic value, is, perhaps, exorbitant; for, as Mr. Le Gros Clark<sup>5</sup> observes, in his very able and discriminating analysis of the semeiology of traumatic abdominal lesions, severe contusions of the belly with shock are ordinarily accompanied by tympanitis and constipation, referable to the suspension of function of the ganglionic nerves; yet the sudden apparition of this symptom, conjoined with other circumstances, as bloody stools or vomiting, may convert the presumption of a solution of continuity in the intestine very nearly into a certainty. The decomposition of the fluids in deep wounds of the loins sometimes evolved gases that permeated the connective tissues, and constituted a variety of emphysema. Effusion of the gaseous contents of the bowels attended many of the cases that have been narrated; CASES 224 and 226 may be particularly referred to.<sup>6</sup>

<sup>1</sup> FABRICIUS HILDANUS, *Opera omnia*, Francofurti ad Mœnum, 1646, Cent. II, Obs. LVII; BLASIUS, *Observationes med. rariores*, Amstelod., 1677, Pt. I, n. 10; BECKER, *Abscessus abdominis effusione curatus*, in *Eph. Nat. Cur.*, 1670, ann. I, p. 198, obs. LXXXII; LIEUTAUD, *Historia anat. med.*, Paris, 1767, L. I, Obs. 721; THOM, *Erfahrungen und Bemerkungen aus der Arzney-Wundarzney-und Entbindungswissenschaft*, Frankfurt, 1799, p. 174; SALZMANN, J. R., *Varia observata anatomica*, Amst., 1669; OSLANDER, *Denkwürdigkeiten für die Heilkunde und Geburtshülfe*, Göttingen, 1794, B. I, S. 101; CAVALLINI, *Collezione istorica di casi chirurgici*, etc., Firenze, 1762, I, p. 283; HAUTESIERCK, *Recueil d'observations de médecine des hôpitaux militaires*, etc., Paris, 1766 and '72, p. 329; FABRICIUS, *Curatio juvenis prægravidæ musculorum abdominis inflammatione et periculosa effusione puris laborantis*, Helmst., 1749; BÉGIN, *Mém. sur l'ouverture des collections purulentes et autres développées dans l'abdomen*, in *Jour. univ. hebdom. de méd. et de chir.*, 1830, T. I, p. 417; CROWTHER, *Case of Abscess in the Abdominal Muscles which terminated fatally*, in *Edinburgh Med. and Surg. Jour.*, April 1, 1806, Vol. II, p. 129.

<sup>2</sup> HAMILTON (F. H.), *Lectures on Gunshot Injuries of the Abdomen*, in *Am. Med. Times*, 1861, Vol. VIII, p. 229.

<sup>3</sup> Doubtless gases are constantly found in all parts of the intestines, as M. LONGET (*Traité de Physiologie*, 1861, T. I, p. 152) and Dr. FLINT (*The Physiology of Man*, 1867, Part II, p. 379) agree; but, under normal conditions, they abound only in the large intestine, the mephitic gases being confined to the colon by the action of the ileo-cæcal valve. In vivisections, and in opening the abdomen in animals just killed, far less distention of the small intestines is observed than in dissections made some hours after death.

<sup>4</sup> JOBERT (DE LAMHALLE), *Traité théorique et pratique des maladies chirurgicales du canal intestinal*, 1829, T. I, p. 60.

<sup>5</sup> CLARK (F. LE G.), *Lectures on the Principles of Surgical Diagnosis*, p. 268.

<sup>6</sup> Consult CLÉMENT (*De l'épanchement d'un liquide or d'un gaz comme accid. des plaies de l'abdomen*, Paris, 1839); BLANDIN (*Diversæ in abdomine effusiones*, Paris, 1827); GUYON (*Épanchements dans l'abdomen*, in *Dict. encyc. des sci. méd.*, 1864, T. I, p. 167); ROKITANSKY (*Lehrbuch der Pathologischen Anatomie*, Wien, 1856, B. III, S. 146).

*Traumatic Peritonitis.*—A most frequent and most fatal complication, common to penetrating wounds and ruptures without external lesions, and, in a less degree, to parietal wounds, is inflammation of the peritoneum. “You perceive,” said John Bell, in the third of his incomparable *Discourses*, “you perceive that a lecture on wounds of the abdomen must be a lecture on inflammation of that cavity, and of the various ways in which it is produced.” And here it may be remarked that, in awarding the credit due this brilliant man for his account of peritonitis, it must be remembered that this affection was not previously distinctly recognized,<sup>1</sup> and that the merit of distinguishing it from visceral inflammations has been claimed for the immortal Bichat, who wrote six years subsequently. It is probable that traumatic peritonitis differs from what is termed the idiopathic form mainly in a less liability to become diffused. While fully recognizing the dangers of spreading inflammation from mechanical violence to the peritoneum, it must be remembered that a limitation of the inflammation by salutary adhesions more commonly ensues. It seems to be well established that in more than half of the fatal cases of ovariectomy, no signs of peritoneal inflammation are discovered after death.<sup>2</sup> Effusions are the most common cause of general traumatic peritonitis; yet, as has been exemplified, this is not the necessary result of effusions of blood and pus, while, in rare instances, even the more irritating extravasations of fæces, bile, and urine may cause only circumscribed peritonitis. Shot wounds implicating the small intestines almost always cause fæcal effusion<sup>3</sup> and consequent acute peritonitis, while in similar lesions of the colon these complications are often avoided. Baudens and M. Legouest state that the hyperacute generalized peritonitis resulting from this cause is generally fatal within twenty-four hours. The patients of this group observed during the war often lived until the second or third day, and thirty-six and forty-eight hours would be near the average limit.<sup>4</sup> The pathogeny of peritonitis is strictly analogous to that of pleuritis and of pericarditis (Niemeyer); there is hyperæmia, then a loss of epithelium, and a migration of colorless blood-corpuscles leading to new formation of young connective tissue in the membrane, which causes a velvety appearance; then the surface is covered with fibrinous exudation containing young cells in variable number; then follow sero-fibrinous exudations in great variety.

Traumatic peritonitis usually begins with severe pain at the seat of injury, rapidly extending over the entire abdomen. This is especially observable if there is effusion. If

<sup>1</sup> I speak advisedly. TONNELÉ (*Arch. gén. de méd.*, T. XII, p. 463) has adduced some observations of HIPPOCRATES referable to puerperal and chronic peritonitis; MORGAGNI, in his thirty-eighth epistle, describes some of the anatomical lesions of peritonitis; and VOGEL, in 1764, and CULLEN, in 1782, gave a place in nosology to peritonitis; but it is plain that the disease was not understood at the latter date, for CULLEN wrote (*First Series of the Practice of Physic*, Chap. VIII, § 384): “I have given a place in our Nosology to the Peritonitis. \* \* \* It is not, however, proposed to treat of them here; because it is difficult to say by what symptoms they are always to be known.” CHOMEL (*Dict. de Méd.*, 1811, T. XXIII, p. 559) ascribes to BICHAT the credit of describing peritonitis as a distinct affection from enteritis and other visceral phlegmasia, in the same sense that pleuritis is distinct from pneumonia. But the *Anatomic générale* was not published until 1801, and JOHN BELL'S *Discourses* were printed in 1793-5. JOHN HUNTER doubtless appreciated the subject aright; yet, in his treatise, he dwelt principally on the reparative adhesive inflammation, and alluded only once and briefly (*op. cit.*, 1794, p. 545) to diffuse peritonitis as a consequence of effusions: “Universal inflammation of the peritoneum will take place, attended with great pain, tension, and death.” [Since writing the above, I have recalled two other passages in the first part of HUNTER'S work (*On the Blood, Inflammation, and Gunshot Wounds*, 1794, pp. 244-246), too long for quotation, but affording incontestable proof of HUNTER'S correct appreciation of this subject. It is not improbable that JOHN BELL derived his view from his illustrious cotemporary; his publication dating 1793-5.]

<sup>2</sup> Of 51 deaths from ovariectomy reported by Dr. PEASLEE (*Ovarian Tumors*, 1872, p. 33e), 12 resulted from peritonitis, or 23 per cent. Of 150 deaths from the same operation, collected by Dr. J. CLAY (*Appendix to KIWISSE'S Lectures*, p. CXXXIII), 64, or 42.6 per cent. were from peritonitis. Of 128 deaths in Mr. WELLS'S table (*Diseases of the Ovaries*, 1873, pp. 402-428), 50, or 39 per cent. In 49 deaths recorded by Dr. ATLEE (*Gen. and Dif. Diag. of Ovarian Tumors*, 1873), the cause of death is not uniformly specified; the fatal result is ascribed to peritonitis in only eight instances.

<sup>3</sup> SOCIN (*Kriegschirurgische Erfahrungen*, 1872, p. 94) remarks: “Die meisten Schussverletzungen des Darmes führen zum Austritt von Kothmassen in die Bauchhöhle und zu rasch tödtlicher Peritonitis.”

<sup>4</sup> I cannot resist the conclusion that our cases survived rather longer, on an average, than those described by the French authors, nor the impression that this postponement of the fatal issue was due to abstinence from the blood-letting deemed essential, in such cases, by our colleagues in France. On the ordinary duration of traumatic peritonitis, I may quote some well-considered remarks of Dr. PEASLEE: “Acute peritonitis proves fatal in twelve to twenty-four hours, and on to the eighth day; nearly one-fourth of the whole number dying on the third day alone, and nearly two-thirds of the whole within the first seventy-two hours. Asthenic peritonitis proves fatal from the ninth up to the twenty-first day, or even later.”—PEASLEE, *Ovarian Tumors*, 1872, p. 351.



the inflammation is propagated from a wounded viscus, its progress is more insidious; the pain, heretofore limited to the vicinity of the injured organ, gradually increases and extends. In all cases, there is general depression along with the pain, and subsequently fever; but the commencement is not marked by a severe chill followed by febrile reaction, as in peritonitis from infection or the rheumatic dyscrasia. The pain is the most constant and characteristic symptom; the slightest pressure increases it, so that the patient is intolerant of the weight of the bed-clothes even, and fixes the diaphragm to prevent its descending pressure in respiration, and draws up the lower extremities to relax the abdominal muscles, an attitude the artist has well represented in PLATE IV (*opp.* p 77). For a like reason, the patient speaks in a low tone, and dreads the hiccough and disposition to vomit that commonly attend this condition, or the slightest cough, or any change of posture. Tympanitis comes on early, almost immediately, if there is fecal effusion. Its cause is not clear, but is ascribed partly to the expansion of the contained gases, through paralysis of the muscular coat, partly to their retention, rather than to the decomposition of the intestinal contents. Constipation and scantiness or retention of urine, feebleness and frequency of pulse, a rapid alteration and contraction of the countenance, are the remaining more prominent symptoms. In the earlier stages, it is asserted that auscultation sometimes detects a friction sound,<sup>1</sup> and percussion is occasionally an auxiliary in diagnosis in cases of effusion. The temperature has been found generally to rise to 105° or more.<sup>2</sup> The mental faculties commonly remain unusually clear until near the close, when sometimes the mind becomes cloudy, and the patient grows apathetic or delirious. At the same time, the pulse becomes very frequent and thready, the countenance is profoundly altered, the surface is bathed in a clammy sweat, and the patient soon succumbs. A few hours are sufficient for the development and catastrophe in this series of symptoms;<sup>3</sup> but the fatal termination usually takes place from the third to the fifth day. In the rare instances in which diffuse traumatic peritonitis terminates in resolution, the disease gradually assumes a chronic form, and progresses through a slow convalescence, leaving visceral adhesions and other anatomical alterations, which cause much subsequent suffering, and admit of a great liability to relapses. Schwartz observes<sup>4</sup> that the gravity of the symptoms of traumatic peritonitis is sufficient to mask the minor signs indicative of the lesions of particular viscera, and that a diffuse inflammation of this membrane precludes all differential diagnosis. The distinction between circumscribed peritonitis and the traumatic visceral phlegmasia with which it is commonly associated, is not less impracticable.<sup>5</sup>

To avoid iteration, the subject of the complications of abdominal injuries may here be concluded, and the treatment of traumatic peritonitis may be considered in connection with the concluding remarks on the treatment of injuries of the abdomen.

<sup>1</sup> "Aussil le frottement péritonéal n'est perçu que dans certains cas de péritonite, et surtout de péritonite tuberculeuse."—BARTH et ROGER, *Traité prat. d'auscultation*, 3<sup>e</sup> éd., 1850, p. 526. Consult DESPRÉS (*Mém. de la Soc. anat.*, June, 1834); CORRIGAN (*On the Mechanism of Friction Sounds*, in the *Dublin Jour. of Med. Sci.*, November, 1836); BRIGIT (*Med. Chir. Trans.*, 1835, Vol. XIX, p. 176), and DESPRÉS (*Thèse inaug.*, Paris, 1840).

<sup>2</sup> It is now a subject of investigation, whether very grave visceral traumatic lesions of the abdomen are not attended by a constant lowering of the animal temperature. Should this prove to be true, it would probably be found that in such cases peritoneal inflammation was not present.

<sup>3</sup> One or two peculiarities of the symptoms may be noted: The vomiting is commonly a regurgitation without co-operation of the diaphragm. Singultus is sometimes the earliest symptom, and may continue throughout, becoming an exerting complication a few hours before death. The thirst is sometimes insatiable. The meteorism is so great as to force the diaphragm upward until the liver and heart ascend to the third rib, and great dyspnoea, with cyanosis, is indeed.

<sup>4</sup> SCHWARTZ (*Beiträge zur Lehre von den Schusswunden*, 1854, S. 123) remarks: "As regards the progress of penetrating shot wounds of the abdomen, the symptoms of peritonitis always occupy a prominent position; so much so, that a symptomatology, indicating the simultaneous injury of single viscera, such as the liver, spleen, stomach, etc., becomes impossible."

<sup>5</sup> Consult RINDELEISCH, *On the Morbid Anatomy of Serous Membranes*, in *A Manual of Pathological Histology*, Dr. BAXTER'S translation, New Sydenham Society, 1872, Vol. I, p. 309; PEYRE, *Diss. sur la péritonite traumatique*, Montpellier, 1823, Thèse 58; MOUILLÉ, *Considérations générales sur la péritonite traumatique*, in *Mém. de méd., de chir. et de phar. mil.*, 1860, Juillet; NUSSBAUM, *Traumatische Peritonitis*, in PITHA und BILLROTH.



FREQUENCY OF WOUNDS OF THE ABDOMEN.—Serrier has sought to determine,<sup>1</sup> by collecting observations from various authors, the relative liability of different regions of the body to injury from shot wounds, and concludes that wounds of the belly ordinarily constitute about 6.6 per centum of the whole number of wounds coming under treatment. Serrier does not specify the sources whence his figures are derived, and for the safe employment of the numerical method his data are inadequate. I have, therefore, computed, from the authors mentioned in note 2, the proportion of wounds of the belly to the aggregate in eighty-nine thousand seven hundred and thirty-one cases, and found the ratio to be 3.8 per cent. TABLE I, on page 6, sets forth the number (4,577) of abdominal injuries in one hundred and six thousand eight hundred and forty-six cases of shot wounds, comprised in the partial field returns of the last year of the war. The ratio is 4.28 per centum. Naturally, the field returns give a larger percentage than those of fixed hospitals, because of the excessive early mortality of grave shot wounds of the belly. Again, if to the 4,821 cases of wounds of the abdominal parietes recorded in TABLE II, p. 8, be added the 52 injuries of viscera without external wounds, rendered in TABLE III, p. 26, and the 3,717 cases of penetrating wounds of the abdomen included in TABLE IV, further on an aggregate of 8,590 injuries of the abdomen, derived from statistical returns embracing 253,142 cases, is obtained, the ratio of injuries of the abdomen being 3.3 per centum, or about one case in twenty-nine. In considering these averages, the reader will bear in mind the restrictions in the classification of abdominal injuries observed in this chapter, most wounds of the pelvis and all flesh wounds of the lower dorsal region being excluded. The most extended observations on the seat of injury in those slain in battle are by Generalarzt Loeffler, on the Prussians killed in action in Schleswig in 1864. Similar, though more limited observations, by Inspector General Mouat, Dr. Bertherand, Surgeon Lidell, and the editor of this work, are of importance from the great rarity of authentic comparisons of this sort.<sup>3</sup> All the observations amount to six hundred and ninety-seven cases. Excluding seventy-three by Dr. Bertherand, in which the ratio of abdominal wounds is so large as to suggest either error in observation or some special liability to injuries of this class in Algerian warfare, the remaining six hundred and twenty-four cases present, with tolerable uniformity, a percentage of deaths from injuries of the abdomen of about ten or eleven per cent. of the aggregate killed in action.

It will be observed that, so far as the fragmentary data at present attainable permit an approximative estimate, about a tenth of those slain in battle perish from injuries of the abdomen, and that from three to four per cent. of the wounded who come under treatment are wounded in the abdomen.

<sup>1</sup> SERRIER (*Traité des plaies d'armes à feu*, ouvrage couronné (médaille d'or) par M. le Ministre de la guerre, en 1844, p. 30). From an analysis of 784 cases, subdivided into twenty-one groups, the author finds wounds of the abdomen (52) seventh in the order of frequency, and slightly less common than those of the chest (53).

<sup>2</sup> The cases are taken from Dr. MATTHEW'S official report of the British wounded in the Crimea (*op. cit.*, T. II, pp. 257-8-9), 10,279 cases, 368 wounds of abdomen; from M. CHENU'S Crimean report (*Camp. d'Orient*, p. 627), total 34,306, abdomen 665; M. CHENU'S report of the Italian War of 1859 (*Camp. d'Italie*, T. II, p. 830), aggregate 17,054, abdomen 917; from M. BERTHERAND (*Camp. de Kibylie*, p. 314), total 1,422, abdomen 51; from DEMME, Italian War (*Studien*, S. 19, Oestreicher), 8,500, abdomen 515; *Idem* (*op. cit.*, S. 20, Franzosen), 8,595, abdomen 595; from Inspector General MOUAT'S (*Army Med. Dept. Rept. for 1865*, Vol. VII, p. 489) report of New Zealand War, total 415, abdomen 23; from Herr LOEFFLER, Danish War of 1864 (*Generalbericht*, u. s. w. S. 54), total 1,968, abdomen 103; from Dr. STROMEYER (*Erfahrungen über Schusswunden im Jahre 1866*), total 1,394, abdomen 30; from statistics of the Bohemian War of 1866; Generalarzt BECK (*Die Schusswunden*), total 238, abdomen 6; Dr. MAAS, *Kriegschirurgische Beiträge*, 1870), total 212, abdomen 11; from the Franco-German War of 1870; Herr BECK (*Chirurgie der Schussverletzungen*, 1872, S. 519), total 4,344, abdomen 106; Professor H. FISCHER (*For Metz. op. cit.*), total 875, abdomen 33; Dr. KLEIS (*Beiträge*, u. s. w. 1872, S. 4), total 129 autopsies, abdomen 12.

<sup>3</sup> The figures are: LOEFFLER (*Generalbericht*, table quoted in *First Surgical Volume*, page 603), killed 387, struck in abdomen 41, or 11.4 per cent; MOUAT (*Army Med. Dept. Rep.*, Vol. VII, p. 473), killed 118, abdomen wounds 11, or 9.3 per cent; LIDELL (*Circular* No. 6, S. G. O., 1865, p. 39), killed 143, abdomen wounds 5, or 11.6 per cent; OTIS (*First Surgical Volume*, p. 602) killed 76, abdomen wounds 9, or 11.7 per cent; BERTHERAND (*Camp. de Kibylie*, 1854, pp. 92 and 147), killed 73, abdomen wounds 21, or 28.7 per cent. Twenty of M. BERTHERAND'S cases, with a large preponderance of wounds of the belly, were collected by his assistant Dr. BEZES.

MORTALITY OF WOUNDS AND INJURIES OF THE ABDOMEN.—Before proceeding to comment upon the comparative fatality<sup>1</sup> of abdominal injuries, it will be proper to present, in a tabular form, the statistics of the penetrating wounds of the abdomen that have been considered in the foregoing section:

TABLE IV.

*Numerical Statement of the Cases of Penetrating Wounds of the Abdomen returned during the War.*

WOUNDS.		Cases.	Died.	Recovered.	Unknown.	Ratio of mortality of determined cases.	
Without known injury to the Viscera.	Punctured and Incised.....	13	4	9	.....	30.7	
	Shot.....	19	7	12	.....	36.8	
With injury to the Viscera, of known character.	Punctured and Incised.....	14	12	2	.....	85.7	
	Stomach.....	79	60	19	.....	75.9	
		Intestines.....	653	434	118	51	80.3
	Liver.....	173	108	62	3	63.5	
	Spleen.....	29	27	2	.....	93.1	
	Shot wounds* of the	Pancreas.....	5	4	1	.....	80.0
		Kidney.....	78	51	26	1	66.2
		Blood-vessels, Omentum, and Mesentery.	54	47	7	.....	87.0
Supra-renal Capsule.....	1	1	.....	.....	100.0		
With visceral injuries, of which the nature and extent were not determined with exactness.	Shot.....	2,599	2,226	186	187	92.2	
Aggregate.....	3,717	3,031	444	242	87.2		

Adding the aggregates in the foregoing table to those in TABLES II and III, the total number of cases of injuries of this region, including flesh wounds, visceral injuries without

<sup>1</sup> In the Crimean War, in the British Army, "where penetration of the abdominal cavity by gunshot injury was considered to be beyond doubt death was the rule, recovery the rare exception, only nine patients (including both officers and men) having survived out of one hundred and twenty where this was believed to have taken place, and even of this small number some of the cases were not unequivocal." MATTHEW (*op. cit.*, Vol. II, p. 328): The mortality rate then, where an approximation to accuracy obtained in the returns, was 92.5. In the French Army, M. CHENU (*op. cit.*, *Camp, d'Orient*, p. 197) records the results of one hundred and twenty-one penetrating shot wounds of the abdomen, of which one hundred and eleven, 91.7 per cent., resulted fatally. As regards the Italian campaign of 1859, M. CHENU in his official report (*Statistique Med. Chir. de la Camp. d'Italie*, 1869, T. II, p. 489) states that "the penetrating wounds of the abdomen, very grave usually, gave a great mortality on the field, and an equally great mortality in the hospitals. Without speaking of the inflammatory complications which these injuries induced, we will say that all degrees of gravity were observed—visceral lesions, visceral protrusions, etc.—but we have found only rare and incomplete abstracts of observations transmitted to the chief medical officer." M. CHENU then presents thirty-two abstracts of cases. These brief but interesting notes record the disabilities resulting from two bayonet wounds, three cases of contusion, and twenty-seven penetrating shot wounds. Among the latter are included one instance of alleged lesion of the stomach, two of the liver, one instance in which a ball was voided at stool, four cases of wounds of the bladder, four cases of fecal fistula, in one of which Dupuytren's operation for abnormal anus was unsuccessfully practiced. M. CHENU then tabulates (p. 493) two hundred and fifty-seven cases of penetrating wounds of the abdomen, of which two hundred and forty-six were cases of shot wounds, with one hundred and sixty-three deaths, or a death rate of 66.2 per cent. Of the twenty-two classes into which M. CHENU distributes the injuries he discusses, the fifth is assigned to injuries of the abdomen. The sixth to the tenth classes include injuries of the sacro-lumbar, iliac and gluteal, inguinal, genital, and anal regions. In these five classes instances of wounds involving the abdominal cavity are evidently included, but to what extent is not apparent. DEMME (*Militär-Chir. Studien*, 1861, B. II, S. 121) professes to give an analysis of two hundred and fifty-nine shot wounds of the abdomen, observed in the North Italian hospitals in 1859. Of these sixty-four were penetrating wounds, and forty terminated fatally, a mortality rate of 62.5 per cent. Of these, thirty-seven, with nineteen deaths, a death rate of 51.3, were unattended by visceral injury. Of twenty-seven cases complicated by visceral lesions, twenty-one were fatal, or 77.7 per cent. The precision of these summaries would be admirable, if they inspired confidence.

\* Some of the cases in this category are duplicated, triplicated, or oftener repeated, as involving several viscera. To avoid the error in the aggregate which would otherwise result, I have subtracted equivalent numbers of recoveries and deaths from the undetermined visceral injuries. The 1,072 complications of wounds of the stomach, liver, etc., occurred in 928 individuals; the differences (144 cases, 117 deaths, 23 recoveries, 4 cases unaccounted for) are deducted from the columns opposite visceral injuries not determined with exactness.

external lesions, and penetrating wounds, was eight thousand five hundred and ninety.<sup>1</sup> In sixteen hundred and ninety of these the result was not ascertained. Of the remaining sixty-nine hundred, thirty-three hundred and twenty-seven<sup>2</sup> died, or 48.21 per cent.; or, roughly, about half of all the cases reported as shot wounds of the belly, and nine in ten of those reported as penetrating wounds proved fatal. The published statistical information regarding the mortality of penetrating shot wounds of the belly in other wars is meagre. The returns having pretension to precision are collated in the following table:

TABLE V.

*Showing the Number of Penetrating Shot Wounds of the Abdomen on the Occasions named, and from the Authorities quoted, with the Ratio of the Mortality.*

ACTION, &c.	Wounds.	Died.	Ratio of Mortality.
Peninsular War (Alcock).....	19	18	94.7
Revolution in Paris in 1830 (Ménière).....	21	14	66.6
Revolution in Paris in 1848 (Baudens, 6; Jobert, 11; Huguier, 4; Roux, 4; Escalier, 2).....	27	21	77.7
New Zealand War (Mouat).....	15	14	93.3
French in Algeria (Bertherand, Sédillot).....	32	28	87.5
French in Algeria in 1854 (Bertherand).....	7	7	100.0
British in India (Balfour).....	38	32	84.2
French in Crimea (Chenu).....	121	111	91.7
British in Crimea (Matthew).....	120	111	92.5
French in Italy in 1859 (Chenu).....	246	163	66.2
Austrians and Italians, after Solferino (Demme).....	64	40	62.5
Prussians in Danish War of 1864 (Lœffler).....	103	59	57.2
Danes in Danish War of 1864 (Lœffler).....	89	57	64.0
Prussians in Six-Weeks War (Maas).....	10	4	40.0
Prussians at Langensalza (Stromeyer).....	17	9	52.9
Prussians at Landeshut (Biefel).....	5	1	20.0
Germans in Franco-Prussian War (Billroth 8, Beck 73).....	81	61	75.3
Germans near Metz (Fischer 5).....	5	3	60.0
Germans at siege of Paris (Kirchner 32, Mosetig 4).....	36	34	94.4
Germans at Massy (Rupprecht 3), at Wörth (Christian 16).....	19	16	84.2
Germans in Reserve Hospital at Carlsruhe (Socin 7), Düsseldorf (Graf 4).....	11	7	63.6
French at Sedan (Desprès 6, MacCormac 7), at Strasburg (Tachard 10, Poncet 15).....	38	36	94.7
French at siege of Paris (Boinet 12, Berenger-Feraud 6, Mundy 4).....	22	15	68.1
Aggregate.....	1, 146	861	75.1

<sup>1</sup> The figures for the separate categories are: Of thirty-three hundred and seventy-three determined flesh wounds of the abdomen, 266 deaths, or 7.8 per cent.; of fifty-two cases of external wounds without visceral injuries, 30 deaths, or 57.6 per cent.; of thirty-four hundred and seventy-five determined penetrating wounds of the abdomen, 3,031 deaths, or 87.2 per cent.

<sup>2</sup> The writings of ALCOCK, MÉNIÈRE, BAUDENS, MOUAT, BERTHERAND, SÉDILLOT, CHENU, MATTHEW, DEMME, LÖFFLER, MAAS, STROMEYER, BIEFEL, BILLROTH, BECK, FISCHER, SOCIN, MACCORMAC, from which many of the above statistical facts are derived, have been already cited. The later statistics are from the following writers: KIRCHNER (C.) (*Ärztlicher Bericht über das Königlich Preussische Feldlazareth im Palais zu Versailles während der Belagerung von Paris vom 19 September, 1870, bis 5 März, 1871*, Erlangen, 1872); MOSETIG (V.) (*Erinnerungen aus dem Deutsch-Französischen Kriege, in Der Militärarzt*, 1872, Nos. 1, 5, 7, 10, 12, 17, 20); RUPPRECHT (*Militärärztl. Erf. während des Deutsch-Französischen Krieges im Jahre 1870-71*, Würzburg, 1871, S. 59); CHRISTIAN (J.) (*Relation sur les plaies de guerre observées à l'ambulance de Bitschwiller, in Gazette méd. de Strasbourg*, 1872, No. 22); GRAF (E.) (*Die Königl. Reservelazareth zu Düsseldorf während des Krieges, 1870-71, Elberfeld, 1872*); DESPRÈS (A.) (*Rapport sur les travaux de la 7e ambulance à l'armée du Rhin et l'armée de la Soire, Paris, 1871, pp. 46, 56*); TACHARD (E.) (*Réflexions pour servir à l'histoire de la chirurgie en campagne, in Gaz. des Hôpitaux*, 1872, Nos. 58, 60, 67); PONCET (F.) (*Contribution à la relation méd. de la guerre de 1870-71, in Montpellier Médical*, Dec. 1871, p. 537); BOINET (*Service chirurgical, Bulletin de la Société française de secours aux blessés militaires des armées de terre et de mer*, No. 14); BÉRENGER-FÉRAUD (*Des blessures de l'abdomen observées dans la 2<sup>me</sup> division des blessés au Val-de-Grace pendant le siège de Paris, in Montpellier Médical*, Novembre, 1871); MUNDY (*Service médico-chirurgical de l'ambulance du Corps législatif. État et mouvement des militaires blessés traités dans cette ambulance du 19 Septembre, 1870, au 31 Janvier, 1871, in Gaz. des Hôp.*, 1871, No. 149).



It is certain that the aggregates in this table with small mortality rates, as those reported by Drs Billroth, Biefel, and Maas, represent insulated groups rather than fair averages, and consequently reduce the mortality ratio unduly, and it is probable that the returns from the Italian War are too incomplete to give adequate expression to the deadliness of shot wounds of the belly.<sup>1</sup> Moreover, several of the authorities quoted include in their returns wounds of the pelvis, which, as will appear in the next chapter, are far less fatal than wounds of the abdomen.

The comparatively small category of cases of recovery after indubitable shot penetration of the abdomen may be arranged in three divisions: The first, and largest group, would include the cases of perforation of the large intestine in parts uncovered by peritoneum, followed by recovery with or without abnormal anus. The second, a group so small that the absolutely authenticated examples can be counted on the fingers, comprises the instances of wounds of the solid or membranous viscera, with extravasation of their contents within the peritoneal cavity. In the third division would be placed the cases of recovery after undoubted penetration or perforation of the peritoneal cavity without visceral injury, or, as it would be safer to say, with very slight visceral injury. On rigorous examination, these also would probably be found few in number. To the instances adduced in an early portion of this Section (pp. 31-40) should be added the following observation by Dr. J. J. B. Wright:<sup>2</sup>

CASE 1\*.—"Private Edward Pfan, of the permanent party of the garrison at Carlisle Barracks, was wounded in a skirmish with the rebel pickets, near Hagerstown, Maryland, on the 6th day of July, 1864. He was transported on a litter to the hospital of the post on the 11th, five days after the infliction of the wound. A minié ball had penetrated the back three inches to the right of the spinal column, three-fourths of an inch above the crest of the ilium, and two inches below the margin of the false ribs; its course was perpendicular to the line of the body, and it was extracted from beneath the integuments in front of the abdomen, distant two and a half inches from the umbilicus, in a line with the superior posterior spinous process of the ilium. By means of opiates and the use of nutritious food, leaving but small material for the formation of feces, his bowels were kept in a state of perfect quietude until July 20th, fourteen days after the reception of the wound, when a large, healthy fecal discharge occurred, without any admixture of blood or pus. On July 25th, his bowels were again moved, and subsequently, during his convalescence, he had healthy alvine dejections as often as every other day. Purulent matter of offensive smell and ichorous character was discharged from both orifices up to the 18th of August, when both healed kindly. Nothing occurred during the history of the case to interrupt the progress of cure, except the supervention of an abscess in the walls of the abdomen immediately below the site of the wound, caused by the extraction of the bullet. Pfan is now entirely convalescent, and will be returned to duty in a few days. There can be no doubt that in the above case a minié ball of large size passed directly from rear to front through the belly, almost through the centre of the intestines as they lie coiled up in the abdomen. It is inconceivable how the bowels could have escaped rupture in several of their folds, and yet the case presented no evidence of their integrity of structure having been impaired, no fecal matter being discharged from either orifice, and no pus per anum. It is very certain that the ball passed in a direct line from its place of entrance to its lodgement in front, and was not deflected. Of this fact I fully satisfied myself by a careful examination when the case was first presented to my notice."

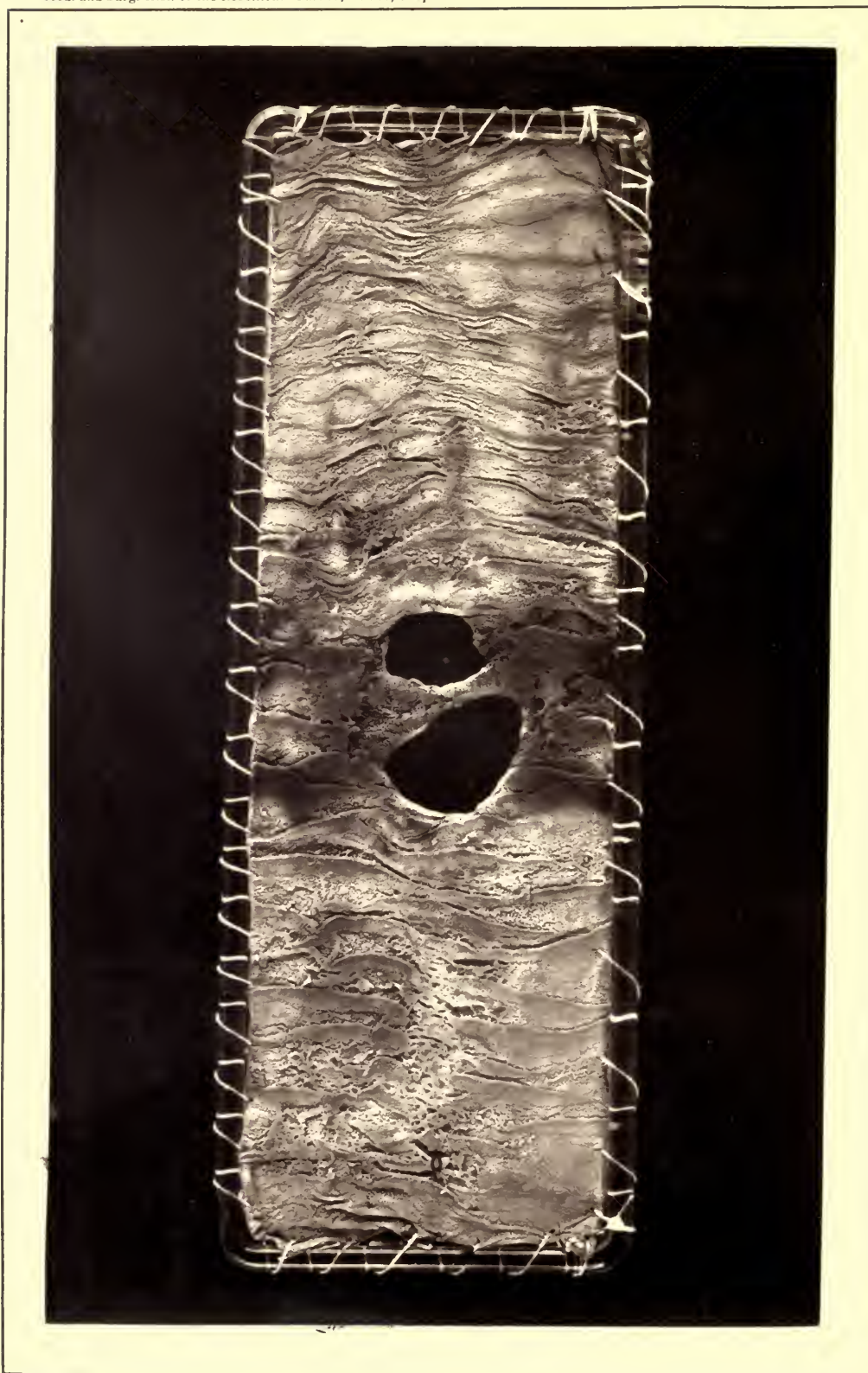
This instance, with those previously cited, proves that Malgaigne's denial of penetrating wounds of the abdomen without visceral injury can only be accepted in a restricted sense. The almost marvellous examples of impalement, of which some of the most curious have been recorded by Dr. J. B. S. Jackson,<sup>3</sup> demonstrate the slight degree of visceral injury that may sometimes attend penetrating wounds of the abdominal cavity

<sup>1</sup>The reader can compare with the remark ascribed by Dr. CHESLUM to Sir CHARLES BELL, "that, although abdominal wounds bore a fair relative proportion to other wounds immediately after a battle, a few days sufficed to remove them; so that, by the end of the first week, there was scarcely one to be seen," the following observations of Herr LIEPFELER (*Generalbericht*, u. s. w., 1867, s. 49) after the Schleswig-Holstein War: "On the field of battle the chest wounds were the most fatal; and also in those patients that reach the hospital, the wounds of the chest are more fatal than the wounds of the head. The wounds of the abdomen and pelvis, as regards the immediate fatality, give way to the above two classes, but surpass them already in the first two days. They are, of all shot injuries, the deadliest; fortunately they are not the most frequent."

<sup>2</sup>This abstract is taken from the monthly report of Carlisle Barracks for August, 1864, from Brevet Brigadier-General J. J. B. WRIGHT, Surgeon U. S. A. It is remarkable that the same graceful pen that long ago indited the report, well known in surgical annals, of a recovery after shot perforation of the chest (the case of General Shields, related in a letter from Dr. WRIGHT, printed in HAMILTON'S *Practical Treatise on Military Surgery*, 1861, p. 157), should also describe one of the very few satisfactory examples of shot perforation of the belly without visceral injury.

<sup>3</sup>JACKSON (J. B. S.), *Boston Med. and Surg. Journal*, 1857, Vol. LV, p. 387. See also: SARGENT (J.) (*Am. Jour. Med. Sci.*, 1853, Vol. XXV, p. 385); KEMPER (C. R.) (*Stethoscope*, 1854, Vol. IV, p. 9); HOME (Z.) (*Boston Med. and Surg. Jour.*, 1840, Vol. XXII, p. 69); BAILEY (T. P.) (*Charleston Med. Jour. and Review*, 1853, Vol. IX, p. 604); DIX (W.) (*London Med. Repository*, 1826, Vol. III, p. 317).

LIBRARY  
UNIVERSITY OF  
CALIFORNIA.



Ward phot.

Am. Photo-Relief Printing Co., Philada.

PLATE XI. RUPTURE OF ILEUM BY THE KICK OF A MULE.

No. 6269. SURGICAL SECTION.



Without a rigid analysis, of which the outlines have been thus indicated, the statistics of injuries of the abdomen are liable to be very misleading; and, as deductions from these statistics directly influence practice,<sup>1</sup> it is of the utmost importance to discriminate the different forms of injury in estimating the mortality of wounds of the belly.

CONCLUDING OBSERVATIONS.—In treating, in the second Section, of ruptures of the intestine, allusion was inadvertently omitted to an interesting observation by Dr. Chisolm,<sup>2</sup> of secondary perforation of the descending colon following a contusion by a spent shell. In rupture of the small intestine, intra-peritoneal extravasation appears to be inevitable. An account of another interesting example of an injury of the description, with the pathological specimen, has been contributed to the Museum by Dr. Hartigan:<sup>3</sup>

CASE A<sup>5</sup>.—Dr. J. F. Hartigan, assistant coroner, presented to the Army Medical Museum the specimen of ruptured ileum, represented in PLATE XI opposite, with the following notes of the case and autopsy: "William S——, a coal-barge hand, aged 16 years, was kicked in the abdomen by a mule on June 23d, at eight in the morning, and died twenty hours afterward, at four o'clock A. M. of June 24, 1873. The attendants stated that the lad suffered extreme pain, with nausea and vomiting immediately after the injury, and that Dr. Wise, from the Navy Yard, came and prescribed for him. At the autopsy, ten hours after death, there was found general redness of the peritoneum, the omentum and mesentery being deeply injected, and the coils of the small intestines and of the colon being hyperæmic. There was copious fecal extravasation, but no effusion of blood. There were many lumbricoid worms lying free in the abdominal cavity. There was tympanitis, with extensive distention; before the cadaver could be sewn up it was necessary to puncture the intestines. The seat of external injury was in the right iliac region, and was indicated by a slight contusion, with slight ecchymosis in the abdominal muscles. Two preparations were obtained, one of contusion and partial rupture of the transverse colon [6270, Sect. I, A. M. M.], and one of laceration of the ileum [6269, Sect. I, A. M. M.]" Dr. John C. Wise, of the Government steamer Tallapoosa, politely furnished the following clinical notes of the case: "I was requested this afternoon (June 23, 1873) to visit a lad about 14 years of age, frail constitution, but in previous good health—an employé on a canal barge—who had been kicked, about eight o'clock A. M., by a mule in the right groin. I saw him about six o'clock P. M. Inspection revealed the ecchymosis made by the toe and points of the iron shoe; diffused redness and pain extending over the entire abdomen; the pulse was quick and wiry, (? ) that on face of inflammation below the diaphragm; the skin very dry; the respiration costal, short, and frequent, deeper inspiration being exceedingly painful; there was nausea and slight vomiting; the lips were very dry and everted, showing the teeth; the eye was brilliant and the countenance anxious; the intellect was clear, questions being intelligently answered. Suffering was so intense as to cause the little sufferer to cry aloud, complaining of tightness of the abdomen and great thirst; the patient lay upon his back with the thighs in strong flexion. I ordered stupes to cover the abdomen, soaked in camphorated soap liniment, tincture of arnica, and laudanum, an ounce of each, and to take a pill every hour containing a grain each of calomel and opium; bits of ice were given to allay thirst. This treatment was continued till eight o'clock with no signs of improvement, and, a little later, symptoms of collapse were manifest. The pulse was almost imperceptible at the wrist, and had lost its wiry character. The hands, feet, and surface generally was cold; the respiration frequent, the countenance pinched, and the mind wandering; tympanitic sounds over the abdomen, but no distention of the bladder. Carbonate of ammonia and brandy were now resorted to, but in vain; the symptoms advanced, and the patient died twenty hours after the occurrence."

In view of the invariable and, it would appear, necessary fatality of such cases, the question arises of the propriety of abdominal incision for the removal of the extravasated

<sup>1</sup> The advocates of the do-nothing system base their arguments mainly on the number of recoveries from penetrating wounds of the abdomen that take place under what they term "the general plan of treatment," and as illustrations they commonly adduce instances belonging to the first or third of the divisions indicated on the preceding page, instances that, for the most part, are to be regarded as examples of wounds of the abdominal viscera in parts without the peritoneal cavity, or else as penetrations without visceral injury. But it is to the last degree illogical to adduce such instances as indicating the course of treatment appropriate to *wounds of the viscera within the peritoneal cavity*. In the preceding pages the editor has sought to analyze the different varieties of this last group and to estimate the comparative mortality of wounds of the liver, spleen, and kidneys, and of the alimentary canal, and it is believed that those who will take the trouble to examine the evidence will be unable to resist the conclusions that, while recoveries from wounds of the liver are more frequent than was formerly believed, and wounds of the spleen and kidney occasionally, and those of the colon frequently, terminate favorably, the rarity of recoveries from wounds of the stomach and small intestine treated without operative interference is extreme.

<sup>2</sup> CHISOLM (J. J.) (*A Manual of Military Surgery*, 1861, p. 354): "Sergeant E. L. Davis, Co. C, 7th battalion S. C. V., was injured on the 10th of July, during the bombardment of Battery Wagner, by the explosion of a shell. Two days afterward, when he entered the general hospital, he complained of pain in the left lumbar region, where he had been struck. There was no ecchymosis present, although there existed some tumefaction—not, however, sufficient to excite any apprehension. There was slight abrasion about his face and right side. Six days after the injury, he having suffered much with pain, fluctuation was detected in the lumbar region. A puncture was made, which discharged a large quantity of pus, and with it, fecal matter. Some of this escaping into the cellular tissue of the loin and buttock induced a phlegmonous condition, with rapid sloughing of cellular tissue. Although free incisions were made, the sloughing could not be checked. It extended in every direction, until one vast sloughing cavity occupied half the trunk, from the ribs to the trochanter, and from the vertebral column to the pubis. An autopsy revealed a double rupture in the descending colon, with opening parallel to the areolar fibres, which had permitted the free escape of fecal matter into the cellular tissue, between the bowel and quadratus lumborum muscle. Collecting in quantity, it had separated and disorganized the tissues as low as Poupart's ligament, forming a large sac distinct from the peritoneal cavity, and separated from it only by the peritoneum. In this the iliac artery was lying bare. Had the forces not escaped in the loin it would have dissected to the groin, as the fecal cavity was bounded below by Poupart's ligament."

<sup>3</sup> Since CASE 119, illustrated by Plate I, was printed on page 23, Dr. Hartigan has published it in abstract, with comments, in the *Medical and Surgical Reporter*, 1873, Vol. XXVIII, p. 457.

matter, and the practice of enteroraphy. The tendency of progressive surgery, as indicated by the undertakings for the removal of abdominal tumors, and of intestinal obstructions,<sup>1</sup> as well as for the extraction of foreign bodies and for the treatment of wounded intestines, is in this direction, and it appears probable that *laparotomy*, if that may be the correct general term for abdominal sections, will henceforward be employed with increasing frequency, not only in the treatment of morbid growths, but in obstructions and wounds of the abdominal organs.

DIAGNOSIS.—The mass of evidence that has been reviewed contains little regarding the symptomatology of injuries of the abdomen, and contributes only indirect aid in the problems of differential diagnosis.<sup>2</sup> The numerous examples of unsuspected lesions revealed after death testify indirectly to the truth of the maxim that there is no absolute distinctive sign of wounds of either of the abdominal viscera, save the escape externally of its secretion or its contents. The observations indicate the uncertainty of hæmatemesis and bloody stools as signs of wounds of the alimentary canal, and bring prominently in view the importance of sudden meteorism as a symptom of perforation of the bowels.<sup>3</sup> Abundant evidence is produced to refute the doctrine, still taught in most text-books, that general peritonitis is an almost uniform result of penetrating wounds of the abdomen; the absence of this complication having been verified by numerous autopsies. On the other hand, no information is furnished on the important question of the state of the animal temperature in grave abdominal injuries,<sup>4</sup> and there is a remarkable absence of any comments on the obscure subject of shock. As a general rule, shock is more profound and persistent in grave wounds of the abdomen than in wounds of any other region; yet the diagnostic value of this symptom is diminished by the fact that it often supervenes after simple contusions without organic lesion, and its intensity or continuance even are not standards by which the nature of the injury can be determined. It is of the utmost importance to discriminate the collapse due to syncope from internal bleeding from true shock. Vomiting and retention of urine are common but not constant accompaniments of injuries of the abdomen, and by themselves have little significance. Persistent localized pain is very suggestive; but grave visceral injury is sometimes attended by comparatively

<sup>1</sup> Consult on this interesting subject an able article by Dr. SAMUEL WHITALL (*Gastrology for Intestinal Occlusion*, in the *New York Medical Journal*, 1873, Vol. XVIII, p. 113); also Dr. STEPHEN ROGER'S elaborate paper on *Intussusception* (*Trans. New York State Med. Soc.*, 1872). The erudite HEVIN, in his *Recherches historiques sur la gastrotomie, ou l'ouverture du bas-ventre, dans le cas de Volvulus, ou de l'intussusception d'un intestin*, in *Mém. de l'Acad. Roy. de Chir.*, 1768, T. IV, p. 201, adduces many instances and arguments from the older writers in favor of laying open the abdominal cavity for the relief of strangulation, intussusception, and obstruction of the bowels from various causes. The Academy, it is understood, compelled HEVIN to modify, in his published essay, the favorable conclusions which he deduced from the facts and arguments he collected; so that while his memoir commences with the observation that the ancients had proposed many very useful operations that the moderns had neglected or abandoned altogether, at the end he is reserved in his advocacy of abdominal sections. One of the earliest distinct propositions to lay open the abdomen was made by BARBETTE, in his *Chirurgia sive Heelkonst na de hedendaagse practyk beschreeven*, Amsterdam, 1657. The Latin version, in the edition of 1693, is as follows: "Annon etiam præstaret, facta dissectione musculorum et peritonæi digitis susceptum intestinum extrahere, quam certe morti agrotantem committere?" Compare BONETUS (*Polyalthes sive Thesaurus medico-practicus*, Geneva, 1692, Lib. IV, Cap. 26, § 58, p. 510, and also in the *Sepulchritum*, Geneva, 1700, Lib. III, Sec. XIV, T. II, p. 228), a dissertation by VELSE (*De mutuo intestinorum ingressu*, Lugd. Bat., 1742), and PLATER (F.) (*Præceps medicæ*, Basil, 1736, T. II, Cap. XIII).

<sup>2</sup> SOCIN (*Kriegschir. Erf.*, 1872, S. 89) observes that "the injuries of the abdomen and its contents are of a peculiar diagnostic interest, and severely test the surgeon's sagacity. But, with the keenest diagnosis, the treatment does not gain correspondingly in precision. Frequently we must be satisfied with very general therapeutic indications, and much must be left to kind nature, who sometimes proves herself truly amiable, an indulgent helpmate to the surgeon."

<sup>3</sup> Tympanitis may also arise without any physical lesions as a consequence of simple contusion, the concussion of the ganglionic nerve centres leading to temporary paralysis of the muscular coat of the bowel.

<sup>4</sup> CLARK (F. LEG.) (*Lectures on the Principles of Surgical Diagnosis*, London, 1870, p. 288) observes: "As regards temperature, I cannot say I have been fortunate enough to obtain any results which satisfy me of its value in determining the presence of visceral lesion, and still less the locality of that lesion. Of the fact that the temperature is depressed in these injuries, as well as in contusion, there can be no doubt; but I have not succeeded in verifying, from my own observation, the remarks of the writer of an article on 'Animal Heat in Surgical Diseases,' in the *Nouveau Dictionnaire de Médecine et de Chirurgie pratique*, viz: that the depression of temperature is in proportion to the proximity of the lesion, be it from internal strangulation or other cause, to the stomach. Certainly the intensity of the shock seems to bear a direct ratio to this relation, and, inasmuch as depressed vitality is accompanied by a proportionate degradation of temperature, in this way the observation referred to may be explained."



little pain. In reviewing the injuries of the several viscera, the chief diagnostic signs of injury in each, so far as they are known, have been alluded to; but it is obvious that this is a field in which there is still much to be learned.

TREATMENT.—In the general management of wounds of the abdomen, venesection was abandoned, as far as can be learned, in the armies on either side, even more completely than in the treatment of wounds of the chest.<sup>1</sup> There were those who still placed confidence in the controlling power of mercurial preparations over inflammation, and the administration of calomel formed part of the treatment in many cases. Surgeon E. Swift observed several apparently desperate cases of traumatic peritonitis, which terminated favorably under the method commended by the elder Larrey, of inunction with gray ointment after vesication of the entire surface. But, in all cases, opium was the main resource. The facility with which its salts could be exhibited hypodermically was gratefully appreciated in the numerous cases of this class in which the stomach rejected all medicine. Suppositories also afforded an excellent means of administering opium in injuries of the abdomen.<sup>2</sup> Apart from the general advantages of this invaluable remedy, in cases of wounds of the abdominal viscera, by arresting peristaltic action, it aided in securing the rest of the wounded part, the first condition in the reparation of all traumatic lesions. Diffuse inflammation once established, however, neither this nor any other remedy was of avail,<sup>3</sup> an experience repeated in the recent Franco-German War.<sup>4 and 5.</sup> But traumatic peritonitis is often circumscribed, and when localized in immediate proximity with the wound or ball-track, it is unattended by general reaction, and the local reaction may be protective only, not transgressing the plastic stage, and serving simply to establish adhesions which may guard against effusions into the peritoneal cavity. Even when less strictly circumscribed, when effusion has taken place, local traumatic peritonitis may still exert a beneficent protective influence, by encysting the foreign matters extravasated into the peritoneal cavity by plastic exudations. To restrain inflammation within these salutary limits, absolute rest is the most important indication, the patient being suffered neither to be moved nor to move himself; and hence the best contemporaneous surgeons strongly insist that men with penetrating wounds of the abdomen shall be permanently treated as near as practicable to the spot where they fall. Every rod they are transported

<sup>1</sup> Only four instances of blood-letting were observed in the returns, viz: Two cases in which venesection was practised: CASE 234, p. 76, and CASE 497, p. 155; and two cases of cupping: CASE 338, p. 138, and CASE 367, p. 131. The old views on this subject are well known; they are expressed by THOMPSON (J.) (*Report of Obs., etc., after Waterloo*, 1816, p. 106): "It cannot be too frequently repeated that copious blood-letting and the use of the antiphlogistic regimen, in all its parts, are the best auxiliaries which the surgeon can employ in the care of all injuries of the viscera contained within the cavity of the abdomen." But forty years later, in the Crimean War, it was discerned by the British surgeons, at least, that the antiphlogistic treatment formerly in vogue was no longer applicable. Thus, MATTHEW (*Med. and Surg. Hist.*, etc., p. 329) observed: "In none of these cases does general blood-letting appear to have been indicated, and it was employed in very few instances." After the Austro-Prussian War of 1866, NEUDÖRFER wrote (*Handbuch der Kriegschirurgie*, 1867, S. 731): "As regards blood-letting, the majority of the later French surgeons, as well as some of the Germans, who cannot shake off the fetters of the older French tradition, still cling to venesection; but the majority of German and American and English surgeons, formerly staunch supporters of venesection, have now abandoned it."

<sup>2</sup> There is hazard in exorbitant doses of opium, and an instance was noted, in the reports, in which the patient apparently perished immediately from narcosis, rather than from the direct effects of the wound; but practitioners of ordinary experience and discretion will seldom err in this direction.

<sup>3</sup> FISCHER (H.) (*Kriegschir. Erf., Vor Metz*, 1872, S. 131) remarks: "Gegen die diffuse peritonitis kämpften wir mit Opium und Mercur vergeblich." (Against diffuse peritonitis we vainly battled with opium and mercury.)

<sup>4</sup> In the Franco-German War of 1870, according to Professor SOGIN (*Kriegschirurgische Erfahrungen*, Leipzig, 1872, S. 95), "the treatment consisted of topical applications of ice, injections of morphia, with opium internally; with no solid food whatever." Professor H. FISCHER, of Breslau (*Kriegschirurgische Erfahrungen*, Erlangen, 1872, S. 131), states that: "The treatment of shot wounds of the abdomen was solely symptomatic. Absolute rest, with sparing liquid diet, and opium internally, until the inflammation subsided."

<sup>5</sup> GORDON (C. A.) (*Lessons in Hygiene and Surgery from the Franco-Prussian War*, London, 1873, p. 140) reports that "the statistics of the Franco-Prussian War support the generally fatal character of gunshot wounds penetrating the cavity of the abdomen." But his acquaintance with such statistics appears to be limited, extending to only twenty-nine cases, gleaned from M. DESPRÉS and Mr. MACCORMACK. The interpretations of the Crimean and American statistics by this writer being in several instances obviously erroneous, his conclusions respecting the Franco-German experience may be received with distrust. The most important lesson conveyed by his work is the danger of generalizing from insufficient data. LOSSEN (H.) (*Kriegschir. Erf. aus den Baracken Lazarethen zu Mannheim, Heidelberg und Carlsruhe*, 1870-71, in *Deutsche Zeitschrift für Chirurgie*, B. U) contends that, "as long as the entire material of shot wounds, including killed and wounded, is not taken in consideration, apparently inexplicable differences of percentages will be the result of statistics."



adds to the formidable peril they have already to encounter.<sup>1</sup> Food and drink, save a little ice or cold water, are to be absolutely interdicted at first, and then the blandest nutriment, such as milk, may be sparingly allowed. The reports indicate that this rigid regimen was not always enforced, and that the absolute rule forbidding the early employment of purgatives was sometimes neglected, and that these errors had disastrous consequences. The position of the patient is of importance. If there is a single wound, the patient should lie in that posture that will place the orifice downward and favor the approximation and adhesion of the viscera to its edges. If the abdomen is perforated, it will usually be best to make the exit orifice dependent. When there is evidence that a viscus is wounded, the parietal wound must always be left open, except in cases in which enterotomy is practised. No advantageous effects were obtained by local depletion<sup>2</sup> or by emollient fomentations at an early period; but extended and protracted applications of ice over the entire abdomen were believed, in several instances, to have exerted a decided influence in moderating inflammation. The majority of surgeons esteem moderate compression by a circular bandage useful. Dr. Neudörfer regards the gypsum bandage as peculiarly adapted to this class of injuries. If the stomach or small intestines are divided, there is no reasonable presumption that fecal extravasation and consequent hyperacute generalized peritonitis can be averted unless by operative interference. Under these circumstances, therefore, the surgeon should enlarge the wound, carefully cleanse the cavity, and unite the solutions of continuity in the wounded viscus by sutures.<sup>3</sup>

<sup>1</sup> STABSAZI BÄHR (*Deutsche Klinik*, 1871, B. XXIII, S. 406) remarks: "Days at least are required to cause death from peritonitis alone: fecal matter passed into the peritoneum does its work quicker. Were the wound in the wall of the abdomen sufficiently large to allow the contents of the peritoneal sac to escape freely, it would be comparatively easy to cleanse the cavity and to keep it clean. The patient might assume the knee-elbow position to empty the peritoneal sac, while the viscera are to be kept back by a gauze bandage and the wound of the gut is to be closed by suture. In future those wounds must be cared for on the battle-field, and the surgeon must come prepared to lay open and enlarge the wound of the abdominal wall."

<sup>2</sup> At the beginning of this chapter (p. 2) it was observed that the experience of the war induced surgeons to modify, in some essential particulars, the rules laid down by GUTHRIE and endorsed by TRIPLETT in relation to the management of injuries of the abdomen. There are twenty-one of these well-known aphorisms (GUTHRIE'S *Commentaries*, l. c., p. 612; TRIPLETT'S *Handbook*, l. c., p. 86). The validity of the fifth, sixth and seventh, restricting the employment of sutures in incised wounds of the abdomen, is no longer recognized by practical surgeons. The ninth, on the management of protruding omentum, is too absolute. The aphorisms from the tenth to the seventeenth inclusive are excellent, and their value has only been confirmed by more extended observation. The three following conclusions relate to wounds of the pelvis rather than of the abdomen proper. The twenty-first aphorism, enjoining a rigorous antiphlogistic regimen, with the general and local abstraction of blood, and the exhibition of mercury, is utterly at variance with the therapeutical doctrines now commonly accepted.

<sup>3</sup> Besides the works of ALBUCASIS, ALBERTI, ASHHURST, BOERHAAVE, BILGUEE, BOHN, BEAUMONT, BALLINGALL, BAUDENS, BOYER, BÉRARD, BELL, BRESCHET, BROCA, BERTRANDI, BECK (B.), BRYANT, BILLROTH, CELSUS, COOPER, CALLISEN, CHISOLM, DIEMERBROECK, DUPUYTREN, DENANS, DESAULT, DORSEY, DONAU, DEMME, DURHAM, ETTMÜLLER, ERICSSON, EMMERT, FABRICIUS, FALLOPIUS, FLAJANI, FISCHER, FAYRE, GALEX, GARENGOT, GOUFFES, GUTHRIE, GUNTHER, GÉLY, GROSS, ITALY ABBAIS, HOLLEBIUS, HEISTER, HALLER, HÉVIN, HEENSEN, HERMANS, HENRICH, HUNTER, HAMILTON, JOBERT, JENCKER, KLEBS, LE DIAN, LANGENBECK, LITTRE, LAMOTTE, LIETTAUD, LOHMEYER, LONGMORE, LEMBERT, LIGOUFEST, LE GROS CLARK, MORGAGNI, MARJOLIN, MACLEOD, MATTHEW, MARCUS, NEUDÖRFER, NÉLATON, PARÉ, PURMANN, PERCY, PLOCCQUET, POLAND, POLLOCK, PIRGOFFE, RHAZES, RICHTER, REYBARD, RAVATON, STAHLPART VAN DER WIEL, SCHLICHTING, SCULTETUS, SEIDELIUS, SCHENCKIUS, SCARPA, SABATIER, STROMEYER, SOGIN, TULPIUS, TIEFFENBACH, TEICHMEYER, TEN HAARF, THOMSON, TRAVERS, VIDUS VIDIUS, VAN SWIETEN, VOGEL, VIGLA, VELPFAU, VIDAL, VOLKMAN, WARREN, and WEBER, and others, referred to in the preceding pages, the following may be consulted: BECK, *Zur Behandlung der penetrirenden Bauchwunden*, in *Deutsche Klinik*, 1857, S. 3; BATY, *Plaies de l'abdomen*, 1838, thèse de Paris; BODELIO, *Plaies pénétrantes de l'abdomen*, 1831, thèse de Paris; PENASSE, *Sur les contusions de l'abdomen*, 1831, thèse de Paris; GIRARDIN, *Essai sur les indications et le traitement des plaies pénétrantes de l'abdomen*, 1829, thèse de Strasbourg; TOMMEUR, *Plaies du bas-ventre*, 1806, thèse de Paris; GAULTIER, *Plaies pénétrantes de l'abdomen*, 1810, thèse de Paris; AUBRIET, *Plaies de l'abdomen*, 1815, thèse de Paris; CANDY, *Plaies pénétrantes de l'abdomen*, 1824, thèse de Paris; LITTRE (A.), *Observations sur des plaies du ventre*, in *Mém. de l'Acad. des Sci. de Paris*, 1705, p. 32; CANDY, *Plaies pénétrantes de l'abdomen avec issue de viscère*, Thèse, Paris, 1821; THOMP, *Cases Illustrative of the Beneficial Effects of the Opium Treatment in Injuries and Operations interesting the Intestines and Peritoneum*, in *Dublin Hosp. Gaz.*, 1857, Vol. IV, p. 161; JOUET, *Plaies pénétrantes de l'abdomen. Sutures. Guérison*, in *Gaz. des Hôpitaux*, 1855, p. 158; ELLIS, *On Injuries of the Abdomen*, in the *Lancet*, 1831-5, Vol. II, p. 751; ROUBARD, *Utilité de l'application du froid dans le traitement des plaies pénétrantes du bas-ventre*, Thèse, Paris, 1808; RICHERAND, *Obs. sur l'obscurité du diagnostic dans les plaies pénétrantes de l'abdomen*, in *Jour. de méd., chir., et pharm.*, par CORVISART, etc., 1803, T. II, p. 352; CHAMAISSON, *Considérations sur les plaies du bas-ventre, suivies de quelques observations particulières à l'odeur*, Thèse, Montpellier, 1815; EICHHOFF, *De vulnera abdomini penetrantium lethaliitate*, Berolini, 1829; FABRICIUS, *Medicinisches-gerichtliches Facl der Tödtlichkeit einer puncti: renden Bauchwunde, mit Vorfall und Verletzung, nebst Erinnerungen aus der chirurgischen Lehre von der Darm- und Bauchnath*, Mainz, 1824; CARPENTIER, *Quelques considérations sur les plaies pénétrantes de l'abdomen avec issue de epiploon*, Thèse, Paris, 1870; BRUN (R. A.), *Des dangers des plaies par instruments tranchants non-pénétrantes du bas-ventre*, Paris, Thèse, 1858; FOCKE, *Diss. de abdominalis vulneribus*, Göttingæ, 1798; MARRIGUES, *Dissertation sur les plaies du bas-ventre*, Paris, 1778; VERGÈZ, *Plaie d'arme à feu pénétrant dans le bas-ventre*, in DESAULT, *Jour. de Chir.*, Paris, 1791, T. II, p. 66; GOYAND, *Plaies pénétrantes de l'abdomen et procédé de suture nouvelle, pour la guérison des anses contre-nature*, Thèse, Paris, 1870; PITHA und BILLROTH, *Handbuch der Allgem. und Spec. Chir.*, B. III, Avesch. V. S. 169; WALTER (J. GOTTLIEB), *De morbis peritonæi*, Berlin, 1785; BICHAT, *Anat. gén.*, Nouv. éd., 1812; LÉNNEC, *Histoire d'inflammation du péritoine*, in CORVISART'S *Jour. de méd., chir., et pharm.*, Frenclider, an X, et Vendémiaire, an XI (August and September, 1802); PINEL, *Nosographie philosophique*, 6<sup>e</sup> éd., 1818, T. II, p. 328; PICARD (A. L.), *Diss. sur la peritonite*, Paris, 1811.

## CHAPTER VII.

### INJURIES OF THE PELVIS.

The injuries of the pelvis<sup>1</sup> that will be considered in this chapter are shot fractures of the innominate bones, sacrum, and coccyx, wounds of the contained parts, principally of the bladder and rectum, and wounds of the genital organs. Of other wounds of the external soft parts, those of the inguinal and iliac regions have been included with flesh wounds of the abdomen, and those of the gluteal and sacral regions will be more conveniently considered in connection with flesh wounds of the back, a category that might appropriately have been included in the fourth chapter, and, because found encumbered with many instances of penetrations of the chest and abdomen, reserved until these should be eliminated, to form, with the observations on wounds of the hips and buttocks, a supplementary eighth chapter. Nine or ten examples of fractures of the pelvis by crushing or by falls are reserved in like manner for a separate chapter, which it is proposed to devote to the simple and compound fractures not caused by shot. These reservations made, there remain for examination a large and important class of cases, which, with the exception of a few operations for non-traumatic affections, and a single instance of bayonet injury, are examples of shot wounds exclusively. Some instances will appear in which the abdominal as well as the pelvic organs were implicated; for, though it was designed that all cases in which the peritoneal cavity was primarily involved should be considered in the last chapter, such was the multitude and variety of the instances to be analyzed, that strict conformity with the arbitrary boundaries established was probably sometimes unattained. And here, as elsewhere throughout this work, while the advantages of a rational systematic classification are conceded, adherence to nosological forms and the requirements of the nomenclatures in vogue are held subordinate to the main purpose of putting in evidence the principal facts. These will not always occupy the places where their relations would most advantageously appear, defects due not so much to the extent of the materials as to their variety, and to the diversity of the sources from which they have been collected, disadvantages which copious indices may in some measure relieve, an atonement the patient reader will surely find at the close of the work. In the *First Surgical Volume*, in the fourth chapter, six cases are related among the injuries of the spine that were, at

<sup>1</sup>The older anatomists described the innominata, sacrum, and coccyx as appendages of the vertebral column or of the lower extremities. REALDUS COLUMBUS (*De re anatomica*, 1559) appears to have been the first to compare the assemblage of these bones to a basin or pelvis (*pelvis*, L., πυελος, G.): *Pelvis imaginem elegantissimè conformant, quæ utero, vesicæ, ac intestinis tutiùs continendis à naturâ parata est.* After him, anatomists uniformly described the hypogastric cavity containing the bladder and rectum, and the uterus in woman, as the *pelvis*. Thus, VERHEYEN (*De anatomie corporis humani*, Louvain, 1693): *Pelvis insignis cavitas in quâ continentur vesica et intestinum rectum, atque uterus in mulieribus.* GALEN described as *anonyma* the great pair of bones forming the anterior and lateral walls of this cavity; whence the ordinary designation of innominate bones, *ossa innominata*. It was CELSUS (L. VIII, cap. 1, et cap. 10; item L. II, c. 7) who denominated them *coxæ*, or haunch bones (*ossa coxarum*), from κοχῶνη, the part near the pudenda and anus.

the same time, instances of shot fracture of the pelvis. In the preceding chapter of this volume, thirty-four examples of shot fracture of the pelvis are included with wounds of the abdominal viscera. In the distribution of the cases to be considered in this chapter into three sections, it appears inadvisable to adopt any unvarying principle of classification. Many of them present a variety of lesions. A case of wound of the bladder or rectum, for instance, may be simultaneously an example of fracture of the pelvis, and of wound of the genitals; and while its position should generally be determined by the gravity or rarity of the principal lesion, other considerations may render a different grouping desirable. It may be advantageous to colligate dissimilar cases with a single important feature in common: all of the examples of foreign bodies in the bladder, for instance, or all the cases of traumatic stricture of the urethra, though they may be associated with a variety of complications. Besides these intentional departures from a systematic classification, abstracts of cases misplaced through editorial oversight, or from typographical exigencies, will violate the requirements of a rigorous method.

A general view of the injuries of the pelvis, within the restricted limits assigned, discloses noteworthy contrasts to the injuries of the abdomen lately under consideration. In the pelvic injuries there is a far less formidable fatality than in penetrating wounds of the belly. It may be roughly stated that while the mortality of shot penetrations of the abdomen greatly exceeds 75 per cent., that of shot wounds of the pelvis is in inverse proportion, more than three-fourths of the cases exempt from grave visceral lesions terminating in recovery. Of about eight hundred shot fractures of the ilium, complicated and uncomplicated, reported during the war, over six hundred resulted favorably. In wounds of the belly, traumatic peritonitis is the chief cause of danger; in wounds of the pelvis, purulent infiltration, cellulitis with gangrene, urinary infiltration, necrosis with exfoliations and protracted suppurations, paralysis, and pyæmia, are the more common causes of death. Though it is often impracticable to establish an exact diagnosis in deep wounds of the pelvis, the degree of obscurity is less than in analogous lesions of the abdomen; the contained parts are more accessible to exploration; their functions are known, and their disorders cognizable. In wounds of the belly, the limits within which the reparative efforts of nature can be assisted by art are extremely restricted. In wounds of the pelvis, interference for the removal of dead bone, the extraction of foreign bodies, the liberation of confined fluids, the ligation of wounded vessels, or the restoration of obliterated canals, is not infrequently required.

Larrey, Hennen, Guthrie, Ballingall, Tripler, and most of the writers on military surgery of the last generation, treat of injuries of the pelvis in connection with wounds of the abdomen, and Dr. Neudörfer, Dr. F. H. Hamilton, and others, persevere in this classification;<sup>1</sup> but Dr. Stromeyer, Generalarzt Beck, Professor Socin, Professor H. Fischer, M. Legouest, Mr. Blenkins, Mr. Birkett, and the majority of contemporaneous writers on war surgery, prefer to describe the injuries of the pelvis separately.

Porter tells us<sup>2</sup> that, in the war with Mexico, injuries of the pelvis were esteemed "exceedingly dangerous;" and Dr. Stromeyer observes<sup>3</sup> that, in the war in Schleswig-

<sup>1</sup> The form of Inspector General TAYLOR'S classification, presented by Deputy Inspector General LONGMORE as that employed in the British Army (*Medico-chir. Trans.*, Second Series, 1871, Vol. LIV, p. 20), makes no provision for shot fractures of the pelvic bones unless complicated with injury to the abdomen. In the *Surgical History of the Crimean War*, Dr. MATTHEW (*op. cit.*, Vol. II, p. 327) adds to the class of "gunshot wounds of the abdomen" two orders or subdivisions, one for "rupture of viscera without external wound," and one for "fracture of the pelvis, not being at the same time wounds opening the cavity of the abdomen."

<sup>2</sup> PORTER (J. B.), *Surgical Notes of the Mexican War*, in *Am. Jour. Med. Sci.*, 1852, Vol. XXIII, p. 30: "Wounds of the pelvis and parts adjacent are exceedingly dangerous."

<sup>3</sup> STROMEYER (L.), *Gunshot Fractures* (STATHAM'S translation, Am. ed., 1862, p. 41).



Holstein, "such injuries were always very dangerous." This attribute may be predicated, with proper qualifications, of mechanical lesions of any portion of the body; but I think that the reader, in analyzing the material to be set before him, will be impressed by the severity of the injuries compatible with recovery, that the parts in this region will sustain, rather than by their extreme danger.

In the first section it is proposed to select from the large category of reported shot fractures of the pelvis a sufficient number to fully illustrate the varieties of this group of lesions, and the operations they occasionally require. In the second section, mainly devoted to wounds of the bladder and rectum, some notice will be taken of the surgical diseases of those parts, and penetrations without visceral injury will also be considered, and lesions of the blood-vessels, and ligations. As the discussion of injuries of the bladder will occupy much space, injuries of the urethra, with the subject of traumatic stricture, will be relegated to the third section, on injuries of the genital organs.

## SECTION I.

### SHOT FRACTURES OF THE PELVIC BONES.

There is great diversity in the direction, extent, and gravity<sup>1</sup> of the lesions produced by the impact of projectiles upon the bones of the pelvis. Contusions, grooving of a single lamina, cleanly cut perforations, sinuous canals through the cancellated structure, comminutions with widely radiating fissures, or detachment of fragments, are varieties to be again subdivided, according to the injuries of the soft parts with which they may be associated. Balls are sometimes deflected by the oblique planes of the ossa innominata; sometimes they split or flatten on the laminae; often they are impacted in the spongy tissue, and often completely traverse the osseous girdle in all directions. Missiles may impinge either on the exterior of the bony basin, or, penetrating the soft parts in the inguinal, iliac, or lumbar regions, through the notches, or foramina, or the perineum, they strike the inner surfaces of the pelvis. Hence an important distinction, according as the splinters detached by the ball, the primary sequestra of Dupuytren, are driven within the pelvic cavity or outwardly. The difference in gravity in shot perforations of the chest, according as the ball fractured a rib on entering, or traversed an intercostal space and either avoided the bony case altogether or fractured the rib only in emerging, was pointed out in the fifth chapter; and Dr. Pirogoff informs us<sup>2</sup> that in the late Franco-German war the significance of these conditions made much impression. I have mentioned<sup>3</sup> that Surgeon J. H. Brinton drew my attention to this important distinction in 1864, and finding no earlier reference to it, I think the great merit of exposing it should be conceded to him. The cases to be adduced will show that an analogous rule obtains in shot penetrations of the pelvis.

<sup>1</sup> The compilers of the Confederate Manual (*A Manual of Military Surgery, prepared for the use of the Confederate States Army*, Richmond, 1863, p. 61) regarded the prognosis of shot fractures of the pelvis very gloomily: "When portions of the pelvic parietes are fractured by heavy projectiles, very protracted abscesses generally arise, connected with necrosed bone, and the vital powers of the patient are greatly tried by the necessary restraint and confinement. The great force by which these wounds must be produced, and the general contusion of the surrounding structures, cause a large proportion, sooner or later, to prove fatal, notwithstanding the peritoneal cavity may have escaped. Even apparently slight cases, as where a portion of the crest of the ilium is carried away by a shell, or ball lodged in one of the pelvic bones, often prove very tedious from the long-continued exfoliations and abscesses which result."

<sup>2</sup> PIROGOFF, *Bericht ueber die Besichtigung der Militair-Sanitätsanstalten in Deutschland, Lothringen und Elsass im Jahre, 1870*, Leipzig, 1871.

<sup>3</sup> *First Surgical Volume*, p. 428.

In striking the pelvis, large solid shot, unless impinging very obliquely, occasion such frightful disorders that death ensues before inflammation has time to set in; the soft parts are lacerated or pulpified and the bones comminuted. The condition is that described in treating of injuries of the cranial bones, as *écrasement*, or smash. Grapeshot or shell fragments may occasion similar lesions; but instances will be adduced where life has been prolonged for a considerable time after formidable mutilations by these missiles. Musket balls cause a very great variety of comminutions. Even slight shot fractures of the pelvis are long in healing: the necrosed parts maintain obstinate fistulæ; the form of the sequestra is unfavorable to their elimination; operative interference is often advantageous in expediting or consummating this process. Laugier<sup>1</sup> lays much stress upon the remarkable accidents that result from detachment of the spines of the ilium or pubis or of the tuberosity of the ischium. The muscles attached to these tuberosities losing their fixed points of insertion, their contraction displaces the moveable fragment, and a separation takes place analogous to those observed in fractures of the olecranon or patella. By position, something may be effected favoring ligamentous union. In fractures of the anterior iliac spine, for example, the sartorius should be relaxed by flexing the lower extremities; in fractures of the tuberosity of the ischium, the thigh should be extended.

SHOT FRACTURES OF THE ILIUM.—From its greater size and more exposed position, the ilium<sup>2</sup> is more subject to fracture than the other portions of the innominate bone. Its injuries are also generally more accessible to exploration.<sup>3</sup> The variety in form of these lesions has already been noted. The crest or spines may be notched or detached,<sup>4</sup> and injuries analogous to the detachment of epiphyses in long bones may be caused; or the wing of the bone may be cleanly perforated, as represented in the print opposite (PLATE XXXVI); or the ball may penetrate one lamina and remain impacted, as in a specimen in the Dupuytren Museum; or may split and rest astride the bone, as in a preparation in the Museum of Val-de-Grace, figured on page 419 of M. Legouest's work; or may entirely detach the iliac portion of the innominate from the ischium and pelvis, as in another preparation at Val-de-Grace, represented in M. Legouest's FIGURE 52; or shatter the bone in various directions,<sup>5</sup> as shown in many of the succeeding wood-cuts; or the ball may bury itself in the thick, spongy portions of the ilium, or tear away the coccyx, as in Andouillé's observation.<sup>6</sup>

The eminent Dr. Stromeyer insists upon two facts in relation to these injuries, that were corroborated by the experience of our war, and should be remembered in framing a prognosis, viz: the liability to pyæmia, and the greater danger where the missiles entered posteriorly and traversed the thick gluteal muscles, before fracturing the bone, the long shot-tracks favoring purulent infiltration and sloughing, when dilatation by deep incisions was of little avail.

<sup>1</sup> LAUGIER (S.), Article *Plaies du bassin*, in *Dict. de Méd.*, 1833, T. V, p. 70.

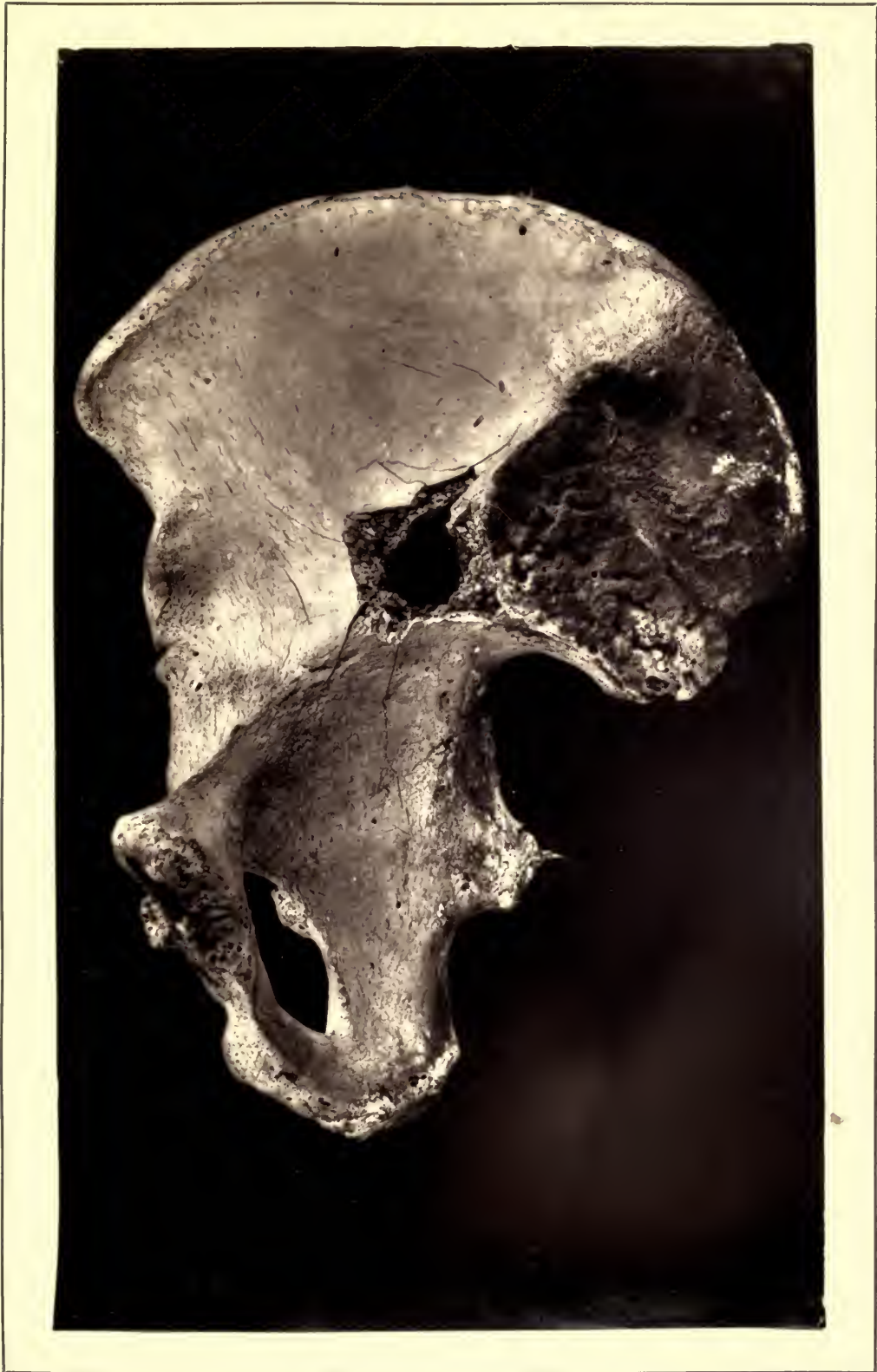<sup>2</sup> Ilium, from its supporting the *ilia*, or flanks; or, according to DUNGLISON (*Dict. Med. Sci.*, 1860, p. 490), from its seeming to support the ileum (*εἰλω*, I twist); or possibly from the curved or twisted form of its crest.

<sup>3</sup> DUVERNEY (*Traité des Maladies des os*, Paris, 1751, T. II, p. 279) is said by the erudite MALGAIGNE to have been the first to describe fractures of this bone. He gives a good account of them, and one has no inclination to question his claim to priority.

<sup>4</sup> STROMEYER refers to this group of cases as exceptions to the ordinary gravity of shot wounds of the pelvis: "These injuries were always very dangerous, excepting those where the crest of the ilium was struck and shattered. These cases almost always ended favorably, the inflammation being moderate, so also the subsequent suppuration; the sequestra were removed gradually after suppuration had fully commenced, and only the discharge of tertiary sequestra in some degree hindered the cure. As a rule, in these cases, the bullet had not penetrated deeply, or it was easily removed. Indeed, one case proved favorable where the bullet had comminuted the anterior superior and inferior spines of the os ilium, and had lost itself in the neighborhood of the horizontal ramus of the pubes, where it yet remains."—*Gunshot Fractures*, STATHAM'S Translation, Am. ed., p. 42.

<sup>5</sup> Dr. F. H. HAMILTON, though lavish in censure of M. LEGOUEST for proposing to enlarge abdominal wounds in order to stitch the wounded intestine or to remove balls, makes a discrimination in favor of the removal of bone splinters in fractures of the pelvis (*A practical Treatise on Fractures and Dislocations*, 3d ed., 1866, p. 339): "If the fracture is compound, and the fragments have penetrated the belly, the wound should be enlarged, and, as far as possible, every piece of bone should be removed."

<sup>6</sup> ANDOUILLE, *Mém. de Vaccin. de chir.*, 1753, T. II, p. 488.



Ward phot.

Am. Photo-Relief Printing Co., Philada.

PLATE XXXVI. SHOT PERFORATION OF THE RIGHT ILIUM.

No. 2869. SURGICAL SECTION.





Among fourteen hundred and ninety-four cases of shot fractures of the pelvic bones reported during the war, the ilium was implicated in eight hundred and twenty-nine. There were also three hundred and ninety-five cases, recorded as shot fractures of the pelvis or of the os innominatum, of which a considerable, but indeterminable, proportion undoubtedly interested the ilium. In seven hundred and ninety-nine of the eight hundred and twenty-nine cases, the ilium was alone involved; while, in thirty instances, the pubis, ischium, and more frequently the sacrum, and sometimes the pelvic viscera, were simultaneously injured.

There is a group of cases which are often mistaken for, and proclaimed as recoveries from, shot perforations of the abdomen, in which the position of the orifices of entrance and exit favors such an hypothesis, though the ball-track is, in reality, entirely without the peritoneal cavity, and passes through the muscles and the broad wing of the ilium. An example is figured in PLATE V, opposite page 81, and the facts of that and similar cases may introduce us to the series of particular instances of shot fractures of the pelvic bones:

CASE 618.—Commissary Sergeant George E. Corson, 1st Battalion, 17th U. S. Infantry, was wounded at the battle of Spottsylvania, May 12, 1864, by a conoidal musket ball, which entered six inches to the left of the umbilicus, and passed directly backward, fracturing the crest of the ilium. He was taken to the Fifth Corps Hospital, and four days subsequently was sent in an ambulance to Belle Plain, and thence to Washington, where he was admitted to Judiciary Square Hospital. There was no symptom of peritonitis at any time, and the wound gave little trouble, except from the rather copious suppuration attending it. In the latter part of July, 1864, Sergeant Corson was ordered to the headquarters of his regiment, at Fort Preble, Maine. On August 29th, he was discharged from service. On October 10, 1864, he was appointed a hospital steward, and was assigned to clerical duty in the Office of the Surgeon General. In December, 1865, the entrance and exit wounds were still open. From time to time fragments of necrosed bone escaped. It was impossible to pass a probe through the track of the wound without causing pain. There was but slight suppuration. This steward remains on duty in the Surgeon General's Office at this date, August 2, 1873. He now enjoys comparatively good health, and suffers but slight inconvenience from his injury. The appearance of the cicatrices is shown in the right-hand drawing of PLATE V, opposite page 81, *ante*.

CASE 619.—Major H. A. Barnum, 12th New York, was wounded at Malvern Hill, July 1, 1862, by a conical musket ball, which entered midway between the umbilicus and the anterior superior spinous process of the left ilium, passed through the middle of the ilium, and emerged posteriorly. The wound was regarded as fatal, and the patient was left in a field hospital. On July 2d, he was captured and taken to Libby Prison, a distance of eighteen miles, in an express wagon. On July 17th, he was taken to Aikin's Landing in an ambulance, a distance of seventeen miles, and exchanged. He was conveyed by water to Albany, and thence, by rail, to Syracuse, New York. At no time were any symptoms of peritonitis manifested. On October 1st, Major Barnum went to Albany, where Dr. March dilated the anterior wound by an incision and extracted several fragments of the ilium, and directed that a tent should be worn. Promoted to the command of the 149th New York, Colonel Barnum took the field in January, 1863. He wore the tent about a month, when the anterior wound healed. About the middle of March, a large abscess formed and evacuated itself at the site of the anterior wound. In April, Dr. March again cut down to the ilium, and introduced a tent. No loose fragments of bone were found. The colonel resumed his duties, and commanded his regiment at Gettysburg. In January, 1864, another large abscess formed and discharged posteriorly. The orifice was enlarged by Dr. L. D. Sayre, of New York, and a seton of oakum was passed from before backward through the entire track of the ball. This was worn for several weeks, when Surgeon M. K. Hogan, U. S. V., substituted a seton of candle-wick, which was gradually reduced in size, and finally replaced by a single linen thread. The photograph, of which a reduced copy is presented in the wood-cut (FIG. 141), was taken at the Army Medical Museum in August, 1865. The wound still discharged slightly, and the thread seton was still worn. Promoted to be a brigade commander, General Barnum was almost continually in the field for the next two years. He participated in the campaigns of Atlanta, Georgia, and Carolina, was shot through the right forearm at Kenesaw Mountain, and received a shell wound of the side at Peach Tree Creek. Since the close of the war General Barnum has enjoyed comparatively good health, and has actively participated in political affairs.



FIG. 141.—Fistula following a shot perforation of the flank and left ilium. [From a photograph.]

CASE 620.—Private W. A. Harkness, Co. K, 7th Rhode Island, aged 35 years, was wounded at Cold Harbor, June 3, 1864. At the regimental hospital the injury was recorded as a "wound of the bowels." On the 7th, he was transferred to Carver Hospital, Washington, whence Surgeon O. A. Judson reported the case as a "flesh wound of the abdomen." On September 26th, he was admitted into Lovell Hospital, Portsmouth Grove, and discharged the service January 26, 1865. Surgeon Charles O'Leary, U. S. V., notes upon the monthly report as follows: "Gunshot wound of the abdomen; the ball passed beneath the umbilicus, injuring the bone by escaping through the ilium. A painful tumor marks the track of the ball." He was pensioned, and Examining Surgeon Robert Millar, of Providence reported, January 21, 1870, that the "ball entered the abdomen at the median line, about two inches above the pubes, passed outward toward the left side, fracturing the left ilium at the anterior superior spinous process, and emerged about two inches beyond. The irritation seems to have extended to the bladder, and if he stands he has a constant desire to urinate; any heavy lifting produces pain and fulness in this region. He also has pain at the seat of the fracture, which has recently increased, probably owing to some necrosed spiculae of bone. He says that he can perform no hard labor which requires standing or lifting." He was last paid on December 4, 1872.

CASE 621.—Lieutenant Colonel John M. Hedrick, 15th Iowa, was wounded near Atlanta on July 22, 1864, and after Surgeon William H. Gibbon, of his regiment, had applied a primary dressing, he was transferred to the hospital of the Seventeenth Army Corps, thence was admitted into hospital at Chattanooga, where Surgeon J. H. Phillips, U. S. V., records the injury as a flesh wound of the back. Thence this officer was sent to hospital at Louisville on August 10th, where Surgeon A. T. Watson, U. S. V., records "gunshot wound of left forearm and of left hip." He was mustered out of service on August 11, 1866, and was pensioned. On September 4, 1867, Pension Examiner W. S. Orr reports: "A musket ball carried away the left transverse process of the fifth lumbar vertebra, penetrated the os ilium of the same side near its connection with the sacrum, and emerged through the ilium near its anterior superior spinous process. The wound has been followed by extensive exfoliation of the ilium, which has not yet entirely ceased. Disability total." Promoted to a colonelcy, and brevetted a brigadier for gallantry, this officer subsequently regained his strength, and, in 1872, visited Washington, in tolerably robust health.

CASE 622.—Musician J. Dalley, Co. H, 53d Pennsylvania, aged 28 years, was wounded at Fredericksburg, December 13, 1862. He was treated in the field, and at Armory Square Hospital, Washington, and was discharged from service March 6, 1863. The certificate of disability, signed by Surgeon D. W. Bliss, U. S. V., states that there was a "gunshot wound of the left side; the ball entered through the skin over the liver, passed obliquely downward and backward through the ilium, two inches below the crest. Necrosis of ilium." Dalley was pensioned, and was paid to March 4, 1869, when his pension was discontinued.

CASE 623.—Private W. H. Davis, Co. F, 15th Ohio, aged 22 years, was wounded at Kenesaw Mountain, June 23, 1864, by a conoidal ball. On June 27th, he was admitted to No. 1 hospital, Chattanooga, from the field, with "gunshot wound of the abdomen," and, on July 1st, he was transferred to Nashville, to hospital No. 2, in charge of Surgeon J. E. Herbert, U. S. V., the injury being recorded as "gunshot wound in umbilical and sacral region." On the 27th he was furloughed, and on November 25th was admitted to Brown Hospital, at Louisville, where Assistant Surgeon B. E. Fryer, U. S. A., recorded the case as a "gunshot fracture of the crest of the left ilium." On the 30th he was transferred to Madison, and on January 6, 1865, to Columbus, Ohio, and Surgeon S. S. Schultz, U. S. V., described the injury as "gunshot wound of the abdomen, injuring the crest of the left ilium." This soldier was discharged the service on February 14, 1865, his disability rated at three-fourths. Pension Examiner A. H. Hewetson, of St. Clairsville, reported, March 31, 1865: "Ball passed from a point about two inches above and a little to the right of the superior spinous process of the ilium to the left sacro-iliac symphysis; several pieces of bone were discharged. The hip is painful and the spine weak, so that when the weight of the body is thrown upon the left limb it is violently agitated. He suffers considerable pain of a nervous character before changes in the weather; disability three-fourths, to some extent temporary." This pensioner was last paid to June, 1873.

CASE 624.—Private J. J. Smith, Co. E, 2d Georgia, aged 30 years, was wounded at Gettysburg, July 3, 1863. He was cared for at the Third Corps Hospital until the 28th, and then transferred to Camp Letterman. Acting Assistant Surgeon Rowand reported that "a minié ball entered a half inch below the umbilicus, passed on under the integuments, and escaped at the upper edge of the right os innominatum, fracturing the crest of the ilium, a portion of which it carried away. The missile then passed through the middle third of the right arm, fracturing the humerus. The arm was amputated on July 4th, by circular operation. The after treatment consisted of cold-water dressings, with stimulants and tonics." The patient convalesced rapidly, and on October 1st was transferred to West's Buildings Hospital, Baltimore, and on November 12th to City Point, for exchange.

CASE 625.—Private J. N. Kaufman, Co. G, 151st Pennsylvania, aged 21 years, was wounded at Gettysburg, July 1, 1863. He was removed to the field hospital of the 3d division, First Corps, and, on the 11th, was transferred to Camden Street Hospital, Baltimore. Surgeon Z. E. Bliss, U. S. V., states that "the ball entered the left side above the crest of the ilium, passed superficially across, and emerged below the margin of the ribs, about four inches from the umbilicus. When admitted, there was free discharge from the upper orifice." On July 24th, the patient was transferred to Harewood Hospital. Acting Assistant Surgeon L. Dorsey noted on the medical descriptive list that "the ball entered the abdomen about one inch below the last rib of the left side, and passed out above the posterior superior spinous process of the ilium. The patient was discharged from hospital August 12, 1863, at which time the wound was nearly healed." Kaufman was pensioned, and Examining Surgeon D. L. Beaver, of Reading, reported, September 28, 1863, as follows: "The ball struck opposite, three inches off [from the median line?], passed directly backward, and made its exit through the upper portion of the left ilium. The wounds are both discharging, and there is great induration at the ilium. Swelling and irritation exist, showing that the bone is affected. Disability three-fourths; may change." This pensioner was last paid in March, 1873.

CASE 626.—Corporal I. N. Porter, Co. E, 154th New York, aged 25 years, was wounded at Pine Knob, June 15, 1864. In the field hospital at Chattanooga, at Cumberland Hospital, Nashville, and at Clay Hospital, Louisville, the injury is noted as a "shot wound of the abdomen." On August 9, 1864, he was admitted into hospital at Cleveland, and discharged from service



March 6, 1865. Surgeon George M. Sternberg, U. S. V., states upon the certificate of disability that there was a "gunshot wound of the right colon, with fracture of the ilium." Pension Examiner H. C. Taylor, of Brocton, N. Y., reported, November 10, 1866: "Gunshot wound in the abdomen, the ball passing entirely through from a point a little to the right of the umbilicus to a point in the back a little below the kidney. The disability has of late increased. He is unable to perform manual labor and, in my opinion, the disability is complete." Pension paid to March, 1873.

In this group,—often confounded with shot perforations of the abdomen,—of penetrations in the iliac region with fracture of the crest or wing of the ilium, it would be possible to adduce many instances of recovery; but these may here suffice, as others will appear in further subdivisions of the subject. Though very uncommon, there were examples of recovery after shot lesions involving both iliac bones:

CASE 627.—Private C. C. Condra, 3d Tennessee, was admitted into the general hospital at Paducah, Kentucky, for a gunshot wound through both ilia, received on February 5, 1863. Pyæmia was developed on March 8th. It was successfully treated with quinia and iron, anodynes and stimulants.

CASE 628.—Major Jacob Scheu, 7th New York, aged 34 years, was admitted from City Point to Armory Square Hospital on May 7, 1865, for a shot perforation of the pelvis, received at South Side Railroad on May 2d. A conoidal musket ball had entered three inches below the centre of the crest of the right ilium, passed through the pelvis anterior to the sacrum, and emerged at a corresponding point on the opposite side. On admission, he suffered intense pain; there was incontinence of urine and paralysis, but increased sensitiveness of the lower extremities, with slight contraction of the extensor muscles of the foot. The wound had nearly closed, but suppuration had taken place along nearly its whole length. After enlarging each wound slightly, several loose pieces of bone were removed from both, and an abscess beneath the gluteal muscles was evacuated. Perfect rest was enjoined; poultices were applied; stimulants and anodynes administered. The patient was transferred to De Camp Hospital on August 18th. By September 15th, he was improved; there was a slight discharge from both wounds, and the atrophied limbs could easily be moved about in bed. This officer was discharged the service on April 18, 1866. He was subsequently a patient of Dr. Charles A. Leale, who states, November 14, 1867: "The patient has good use of his limbs and can walk easily; he has slight paralysis of one leg."

Lateral perforations in front of the vertebral column, implicating both innominate, must commonly be attended with fatal visceral injuries; but a ball passing parallel to the sacrum may readily notch both of the iliac crests posteriorly, where they project beyond the sacral spine, and such injuries are not necessarily very grave. Two instances approximating to this description, the cases of Russell and Woodbury, will be found with the histories of the fractures of the sacrum.

In the early dressing of shot fractures of the ilium it is sometimes necessary to remove very large detached fragments, as in the following instance:

CASE 629.—Private W. J. Gibson, Co. G, 102d Pennsylvania, aged 20 years, was wounded at the Wilderness, May 5, 1864, by a six-ounce grapeshot, which entered the front of the abdomen a little below a line drawn from the umbilicus to the anterior superior spinous process, and about three inches from the border of the right ilium, and passed through the middle of the ilium, carrying before it a portion of the bone more than two inches square; both the ball and the fragment of bone lodged in the gluteal muscles. He was removed to the field hospital of the 2d division, Sixth Corps, where Surgeon George F. Stevens, 77th New York, administered chloroform, and removed, through an extensive incision along the nates, the missile and the fragment of bone which lay in proximity. The borders of the large opening in the ilium were smoothed by means of the bone forceps somewhat enlarging the orifice.

The wound was then brought together, and water-dressings applied. He passed through the hard experience of the wounded of the Wilderness, being drawn in an army wagon two nights and a day over rough roads, and for several days received little or no care. [The above notes of the case appear on a special report furnished by the operator.] On May 25th, the patient was removed to Lincoln Hospital, Washington, and on July 28th, to the hospital at Pittsburg, where he was transferred to the Veteran Reserve Corps, January 30, 1865. He was discharged June 19, 1865, and pensioned. Examining Surgeon D. N. Rankin, of Alleghany City, reported, July 5, 1865, that "the missile entered the right iliac region and fractured the right ilium. Great deformity of the parts and a partial loss of the use of the right leg resulted. He has had poor health since the reception of the injury." This pensioner died October 7, 1866. Dr. Stevens had prepared and sent to the Museum a ferrotype of the specimens removed, which are represented, of the size of nature, in the adjacent drawings (FIGS. 142 and 143).

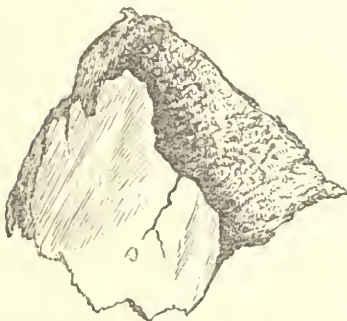

FIG. 142.—Fragment of right ilium carried away by a grapeshot. [From a photograph.]




FIG. 143.—Grapeshot that produced the foregoing fracture, and then lodged in the buttock.

On examining the shot fractures of the ilium<sup>1</sup> somewhat in the order of the extent of the osseous lesions, the collection of the Army Medical Museum will afford a variety of illustrations. Partial fractures, involving one lamina, notchings of the crest or epiphyseal fractures, and embedded balls, may first be selected for notice:

CASE 630.—Sergeant William L.—, Co. D, 10th New York Cavalry, aged 25 years, was admitted to hospital at Alexandria on October 15, 1863, having received a gunshot wound at Bristoe's Station on the previous day. The ball entered the left groin one-half inch to the outside of the femoral artery and half an inch below Poupard's ligament, extending backward; the probe could be passed toward the pelvic cavity for a distance of five inches, but the ball could not be found. At the time of admission there were no symptoms of injury of the abdominal viscera; his general health was good, and there was no derangement of the functions. On October 16th, he was attacked with a violent diarrhœa and had passages of a light-green color; the pain in the groin was slightly relieved and the diarrhœa was partly controlled on the next day, and, on the 19th, he had a slight chill, and there was a yellow discoloration of the skin around the wound; pulse 100, and feeble; patient weak; diarrhœa more severe. The yellow discoloration of the skin increased, and, by the 21st, was decided and general over the whole body and whites of the eyes. On the 22d, the bowels were regular as to the number of passages, but of a loose character and light-green color; pulse 100, and feeble; he had a severe chill, and died five minutes afterward, death being caused by pyæmia. The *post-mortem* examination showed that the ball had struck the os innominatum and caused a compound impacted fracture of a portion of the bone, two inches square, above the acetabulum. The ball had passed into the pelvic cavity, and was found lying directly under the bladder. The whole course of the intestinal canal as well as the stomach was found highly congested. An abscess was found in the right lobe of the liver containing two and a half ounces of pus, and the whole organ was softened. All the abdominal viscera were congested. The specimen (FIG. 144) consists of the iliac portion of the left acetabulum and adjacent bone, with a conoidal ball (FIG. 145), which has contused the internal surface of the ilium just below and behind the anterior inferior spinous process, and was contributed, together with the history, by Acting Assistant Surgeon J. Hunt Stillwell.

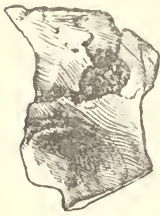

FIG. 144.—Shot fracture of the inner lamina of the left ilium. Spec. 1743.



FIG. 145.—Ball taken from the pelvic cavity.

CASE 631.—Private D. G.—, Co. F, 56th Pennsylvania, aged 33 years, was wounded at South Side Railroad, October 27, 1864, by a conoidal ball, which entered over the crest of the left ilium and emerged two inches to the right of the spinal column. He was sent to City Point, thence to Alexandria, Virginia, where he was admitted to hospital on November 2d. "He complained of severe pain; there was no paralysis either of sensation or of motion in the lower extremities, and he micturated freely. Water-dressings were applied, opiates administered, and a half diet with extras was allowed. A few days before the 13th, the patient had a chill, which was followed by fever, low muttering delirium, quick and feeble pulse, icteric hue of the skin, and breath of a saccharine odor. Supporting treatment was of no avail; he gradually grew worse, and died November 13, 1864. Noticeable at the *post-mortem* examination, thirty-four hours subsequently, were the great degree of rigidity, slight emaciation, saggillation posteriorly, and the fœtid odor of a dark, peculiar fluid emitted from the cancellated structure of the injured ilium. There was half an ounce of serum in the left pleura; the upper lobes of the left lung were congested posteriorly; the lower lobe congested and indurated, and portions of it splenified, with numerous abscesses the size of a millet-seed in its substance. The upper and lower lobe of the right lung were congested and indurated posteriorly, with an abscess the size of a pea and numerous smaller ones in their substance. The bronchi were inflamed; the pericardium contained two ounces of fluid, and there was a large yellow clot in the right auricle, which extended into the pulmonary veins. The omentum was thickened; the peritoneum drier than usual; the small intestines congested externally. Their surfaces felt clammy, and, in the left iliac region, they were slightly adherent to each other and to the lower part of the rectum by a few shreds of recently deposited lymph. The spleen and kidneys were paler than usual. The liver was paler than usual posteriorly, indurated and darker than usual anteriorly. The gall-bladder contained two ounces of very dark inspissated bile. The wounds did not penetrate the abdominal cavity, but on removing the descending colon suppuration was found to have extended to the outer coat of the intestine posteriorly." With the foregoing notes, Surgeon E. Bentley, U. S. V., contributed to the Museum a section of the injured ilium, which is represented in the adjacent figure (FIG. 146).

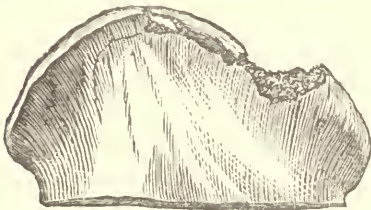


FIG. 146.—Upper portion of the left ilium, with a shot fracture of its crest. Spec. 3108.

CASE 632.—Corporal T. Forbush, Co. A, 3d Iowa, was wounded at Shiloh on April 6, 1862, by a musket ball, which entered an inch and a half behind the trochanter major and lodged in the dorsum of the ilium. He was sent to his regimental hospital at Bolivar, and was attended by Assistant Surgeon B. F. Keables, 3d Iowa. The wound healed with the ball impacted,

<sup>1</sup>Of twenty-four cases of shot fractures of the ilium in the Fourteenth (Bavarian) Army Corps, during the Franco-German War of 1870, recorded by Generalarzt BECK (*Chirurgie der Schussverletzungen*, Freiburg, 1872, S. 549), nineteen recovered and five died. Professor SOCIN (*Kriegschirurgische Erfahrungen*, 1872, S. 37) records six cases of this injury, with one death. Professor H. FISCHER, of Breslau (*Kriegschir. Erf.*, Erlangen, 1872), records eight cases, with one death. In the Bohemian War of 1816, however, Dr. BECK (*Kriegschir. Erf.*, Freiburg, 1867, S. 251) had five cases of shot fractures of the ilium, of which two were fatal. In the Italian War of 1859, Dr. DEMME (*Studien*, 1861, B. II, S. 168) records six cases of shot fractures of the ilium, with two deaths. RAYFON (*Chirurgie d'Armée*, 1768, p. 140) relates a case of recovery from a shot perforation of the ilium; BAUDENS (*Clinique des plaies d'armes à feu*, 1836, p. 339) gives two such cases. CHIPPAULT (*Fract. par armes à feu*, 1873, p. 75, Obs. LXXX and LXXXI) records two cases of shot fracture of the left ilium: Pivot-Taffut, trumpeter, 27th marching regiment, Ardenay, December 2, 1870, perforation near anterior superior spine, convalescence; Simon Petit, 59th regiment, Beaugency, December 7, 1870, shot fracture, extraction of necrosed fragments, amelioration. BERTHERAND (*Camp. de Kab.*, 1862, p. 29) gives one fatal case of shot fracture of the ilium, and two others in which he does not report the result, a total of fifty-five cases, with twelve deaths, a mortality of 21.8 per cent.



and the patient so far recovered as to re-enlist as a private in the 11th Infantry, December 4, 1862. He served with his regiment in Georgia, and made the march from Atlanta to Washington. The wound having reopened in April, 1866, he was admitted into hospital at Fredericksburg. Surgeon Charles Paige, U. S. A., made an exploratory incision, and discovered the ball almost completely embedded in a new osseous tissue, but the propriety of removing it was considered doubtful. The patient was sent with his regiment to Camp Grant, Richmond, and was returned to duty October 4, 1866. He was discharged from service November 2, 1866.

Rarely, however, are balls impacted in the ilium the sources of so little irritation.<sup>1</sup> Ordinarily, osteitis may be anticipated, and, eventually, caries and necrosis, unless the patient should perish from pyæmic infection, as occurred in the first of the following cases:

CASE 633.—Private M. S——, Co H, 116th Pennsylvania, aged 30 years, having sustained a gunshot fracture of the left ilium at Cold Harbor on June 3, 1864, was sent to Alexandria, and admitted to Sickles Hospital on June 12, 1864, in a weak and exhausted condition. Simple dressings were applied to the wound; tonics, stimulants, and anodynes were administered, and a full diet was allowed. A spicula of bone was removed on June 26th, after which improvement took place. On July

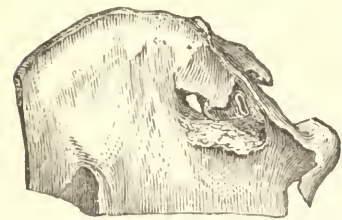


FIG. 147.—Section of the left ilium, fractured by a conoidal musket ball which is embedded near the crest. *Spec.* 3312.

14th, bed-sores appeared over the sacrum; on the 18th, a large spicula of bone was removed from the left anterior superior spinous process of the ilium. On August 2d, there was dysuria, with high-colored urine, which disappeared under appropriate treatment. On August 17th, the patient went to Philadelphia on seven days' leave of absence. His subsequent history is as follows: August 26th, sinking with exhaustion; wound has opened and discharges unhealthy pus; bed-sores increased in size and exceedingly foul. September 1st, pyæmia rapidly setting in; abscess appears before the anterior superior spinous process of the ilium. Death occurred September 8, 1864. At the autopsy, pus

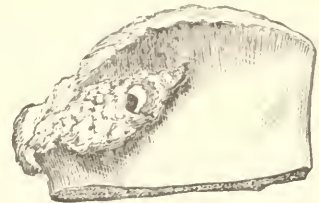


FIG. 148.—Exterior view of the specimen.

was found in the peritoneum, and a conoidal musket ball rested on the internal iliac unsele. Acting Assistant Surgeon E. Neal forwarded to the Museum the pathological preparation, represented by the wood-cut (FIGS 147, 148). "The fragments are irregularly attached by callus, but the track of the ball is carious. The inner face of the ilium shows slight osseous deposits beyond the line of fracture."—(*Cat.*, p. 227.)

CASE 634.—Surgeon W. L. Baylor, P. A. C. S., in a special report, states that "Captain P. Poindexter, Co. I, 14th Virginia, aged 36 years, having been wounded in a skirmish before Suffolk in May, 1863, was sent to Petersburg, and admitted into the Washington Street Hospital in June. He had been struck by shrapnel in eight places. Six of these wounds were flesh wounds of the extremities; the other two were fractures of the ilia. The balls were embedded in the bone. The wounds of the extremities were not long in healing. After two weeks' attention, he was sent into the country and passed into the hands of another physician, who removed a ball from the right ilium. The patient died of exhaustion on October 28, 1863."

CASE 635.—Private A. W——, Co. F, 27th Indiana, aged 21 years, was admitted to hospital at Aquia Creek, May 15 1863, for a wound received at Chancellorsville on May 3d. A conoidal musket ball had passed through the centre of the ilium, burying itself in the sacrum within a line of the vertebral canal. The patient having been made a prisoner, his wound was neglected for eleven days, his fare during that time consisting of crackers and bread, and he suffered from protracted dorsal decubitus. On June 14th, he was sent to Washington and admitted to Douglas Hospital. Here he rallied after the administration of tonics, stimulants, and a nourishing diet; but in a few weeks failed again, and died July 8, 1863. An autopsy was made by Acting Assistant Surgeon Carlos Carvallo, who contributed to the Museum the interesting pathological preparation (FIG. 149), and notes of the case: "The ala of the ilium, for a space of nearly three inches square, is missing; externally, the perforation is fringed with foliaceous callus; internally and posteriorly, a border nearly an inch wide is necrosed and nearly separated; inferiorly, a longitudinal fissure extends parallel with the anterior wall of the ischiatic notch; and the sacrum near the iliac junction is carious and has lost much tissue by absorption."

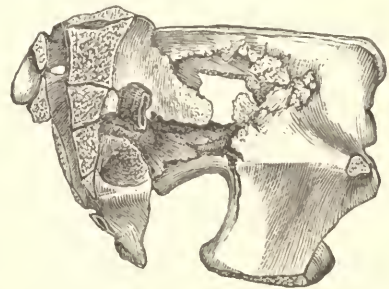


FIG. 149.—Section of left os innominatum, and longitudinal half of sacrum, with an impacted conoidal ball. *Spec.* 1641.

The frequency with which balls are embedded in the ilium is considerable. In fifty-two of the recoveries from shot fractures of the ilium balls were extracted, and in many of these cases the missiles were firmly wedged in the bone. In seventeen of the autopsies, balls were found impacted in the ilium.

<sup>1</sup> Experience fully confirms the justice of GUTHRIE'S precept on this subject: "Balls which lodge in these flat bones may often be removed, and the comfort of the patient assured, by a timely operation, instead of proving the source of much torment and misery for many years by their being allowed to remain."—*Commentaries*, 6th ed., 1855, p. 597.



Elsewhere examples will be given of the extraction of projectiles impacted in the ilium. Balls lodge most readily, of course, in the spongy parts of the bone, and, in very rare instances, may become innocuously encysted. There is a specimen in the Dupuytren

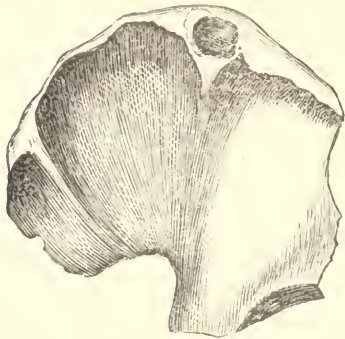


FIG. 150.—Upper half of the right ilium. Ball impacted in the iliac crest. (*Musée Dupuytren.*) [After LEGOUÉST.]

Museum, represented in the wood-cut (FIG. 150), where a ball impacted in the iliac crest has led to very little local mischief. A yet more remarkable example is illustrated by FIGURE 151. The preparation was taken from a soldier wounded at the battle of Leipzig, October 18-19, 1813, who died in Paris, in 1843, from an affection unconnected with his injury. A fistulous opening on the left hip had never cicatrized. The ilium is much thickened, the roughness of the crest and other points of muscular attachment is much exaggerated. There are many osteophytes, and, in short, all the indications of chronic osteitis.

In extensive comminutions, though death from shock commonly takes place soon after the infliction of the fracture, patients occasionally withstand an astonishing amount of injury, as in the following case, which appeared to be progressing favorably until recurring intermediary hæmorrhage from one of the lumbar arteries supervened:

CASE 636.—Corporal H. M——, Co. C, 22d Pennsylvania Cavalry, aged 21 years, having been wounded in a skirmish near Martinsburg, July 30, 1864, was sent to Frederick, and admitted to hospital on July 5th. Acting Assistant Surgeon J. C. Shimer reports that a “fragment of shell had entered behind the left ilium, fracturing and severely comminuting its crest, forcing

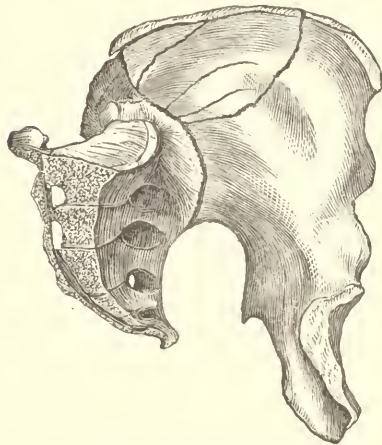


FIG. 152.—Left os innominatum and section of sacrum fractured by a shell fragment. *Spec.* 3813.

and firmly embedding the fragments in the lumbar muscles and against the left side of the lumbar vertebra: there was incomplete paraplegia: the pulse was somewhat excited, but the appetite tolerably good and the bowels regular. The fragment of shell had been removed on the field. Anodynes, friction of the lower extremities with alcohol, the removal of a spicula of bone from the wound, and antiseptic dressings were employed. On the 10th, the pain at the seat of injury had subsided, but at times there were excruciating pains along the course of the left sciatic nerve. July 15th, general condition had deteriorated. There was, however, an absence of pain; healthy granulations had appeared at the bottom of the wound covering the broken bone, and the bowels were apparently normal. On the 20th, the patient was sinking; his countenance anxious, pulse accelerated

and feeble, tongue pale, respiration quickened. July 21st, hæmorrhage occurred from one of the lumbar arteries amounting to twenty ounces, and causing great enfeeblement. It was checked by compression, but recurred on the 22d to the amount of eight ounces. An effort was made to remove the fragments of bone and to secure the ruptured vessel. Some spiculæ were removed; but the larger fragments could not be separated. A clot was allowed to form, and the bleeding ceased. The patient died July 23, 1864. On *post-mortem* examination nothing abnormal was found in the viscera. The pelvis was terribly shattered.” (FIGS. 152, 153). “There is a fracture of the posterior superior third of the ilium, one line of which extends from the posterior inferior spinous process of the crest two inches behind the anterior superior spinous process. The fragment thus broken off is bisected by a fracture running at right angles, and of the posterior fragment the inferior half is missing.”—(*Cat.*, p. 227.)

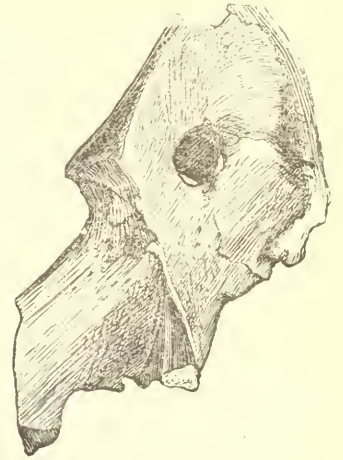

FIG. 151.—Shot perforation of the left iliac fossa. (*Musée Dupuytren.*) [After LEGOUÉST.]

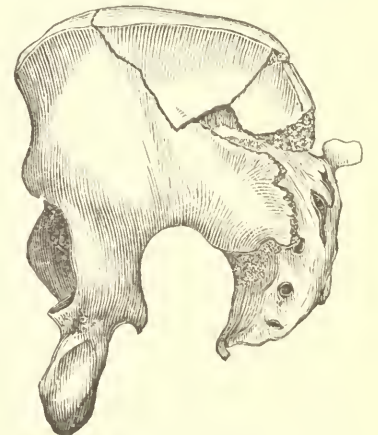


FIG. 153.—Exterior view of the same specimen.

CASE 637.—Private A. W. P——, Co. F, 3d Vermont, aged 21 years, was wounded at Boonesboro', July 10th, and entered hospital at Frederick on July 12, 1863. Acting Assistant Surgeon W. S. Adams reports that "A conoidal musket ball, which entered just above the anterior superior spinous process of the left ilium, passed downward, backward, and inward, struck the superior border of the great ischiatic notch and fractured the ilium, and passed out through the left side of the fourth and fifth bones of the sacrum. Delirium ensued on the 16th; wet cups were applied to the temples and behind the ears; warm

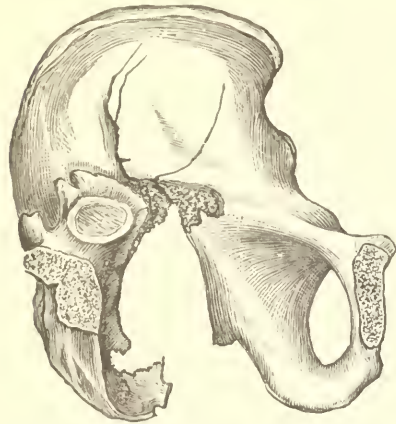


FIG. 154.—Sacrum and left os innominatum fractured by a musket ball. *Spec.* 3526.

fomentations and sinapisms to the lower extremities. The delirium continued, with complete anorexia and urinary trouble, and, on the 17th, a quart of bloody urine was drawn by a catheter. The abdomen subsequently became tympanitic. On the 19th, there were well-marked symptoms of pyæmia. In treating this case diuretics, stimulants, tonics, and anodynes were administered. The patient died July 22d, 1863. The *post-mortem* examination revealed an abscess in the right lung; the left lung and kidney much congested; there were evidences of peritonitis; the coats of the bladder were thickened, and its internal surface was covered with lymph; the external coat of the rectum was in a state of

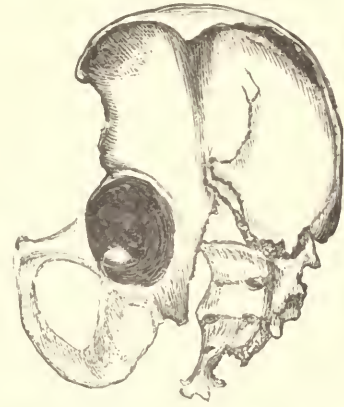


FIG. 155.—Exterior view of the same specimen

ulceration." The pathological preparation (FIGS. 154, 155), consisting of the sacrum and left os innominatum, showing an absence of nearly two square inches of the inner surface of the ilium just anterior to the sacral articulation, a longitudinal tracture extending three inches toward the crest of the ilium, and a fissure two inches toward the anterior superior spine, was contributed to the Museum by Dr. Adams, with the foregoing notes.

CASE 638.—Private H. Rice, Co. G, 25th Illinois, aged 38 years, wounded in the right ilium by a rifle ball, at Merryville, in December, 1863, was admitted into hospital at Knoxville on December 16th. He was transferred to Nashville on April 24, 1864, and admitted to Cumberland Hospital. Assistant Surgeon W. B. Trull, U. S. V., reports that the wound was treated by simple dressings, and that a general stimulating treatment was pursued; but the case progressed unfavorably and terminated fatally on July 4, 1864, from "nostalgia." This singular cause of death is assigned in two separate reports, without explanation.

CASE 639.—Private B. M. P——, Co. I, 126th Ohio, aged 21 years, was wounded at the Wilderness, May 6, 1864, and admitted to Douglas Hospital, Washington, on May 26th, where he died of pyæmia on the 28th. The following notes of the case,

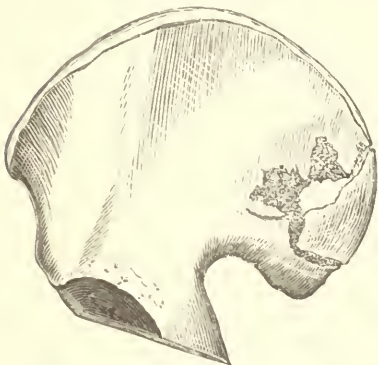


FIG. 156.—Section of the left ilium obliquely perforated by a musket ball. *Spec.* 3531.

with the specimen, were contributed by Assistant Surgeon W. Thomson, U. S. A.: "The ball entered just within the left posterior superior spinous process of the ilium and escaped over the dorsum of the bone. When admitted, the patient was delirious and had a rapid, feeble pulse, a dry tongue, and an icteroid hue of the whole body. No examination was made of the lungs, but the symptoms clearly indicated his death to be due to pyæmia." The specimen is represented in the adjacent wood-cuts (FIGS. 156, 157), the long shot canal from the sacro-iliac junction internally to near the middle of the dorsum externally being imperfectly indicated.

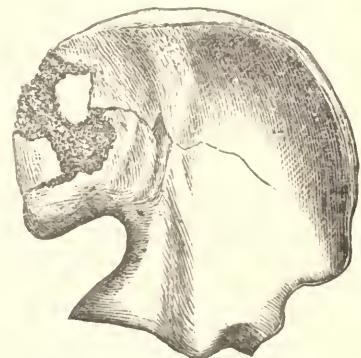


FIG. 157.—Reverse of the same specimen.

CASE 640.—Sergeant G. W. Feistel, Co. K, 200th Pennsylvania, aged 22 years, was wounded at Fort Steadman, on March 25, 1865, by a conoidal ball, which entered above and one inch to the left of the pubic symphysis, grazing the upper side of the os pubis, passed outward and backward, and emerged on the outer side of the left buttock. He was admitted into field hospital, and transferred, on April 7, 1865, to Alexandria. Surgeon E. Bentley, U. S. V., reports that, "on the 12th, he had chills, which became severe and frequent, and there was a profuse discharge of fetid pus from the wound. On the 14th, the patient was delirious; involuntary evacuations of the bowels and bladder occurred; he passed into a state of stupor, and died on April 17, 1865. During the treatment, the patient was stimulated and nourished. At the autopsy, the skin was very yellow; a considerable quantity of very offensive pus was found between the os pubis and the peritoneum, also in a cavity outside the pubic bone. The left lung was healthy; the lower lobe of the right hepated, its middle and upper lobes crepitant. There was very yellow lymph on the lower lobe of the right lung, but no adhesion. The heart was large; the pericardium distended with serum. The liver was large and pale; the spleen large; the ileum injected, and there was a tubercle (?) in the right kidney the size of a pea."



CASE 641.—Private *J. H. C.*—, Co. G, 2d North Carolina, was wounded in a skirmish at Kelly's Ford, November 7, 1863, and was admitted to Cavalry Corps field hospital on the same day; on the 23d, was received into Lincoln Hospital, Washington, and died December 28, 1863. Assistant Surgeon Harrison Allen, U. S. A., contributed to the Museum the diseased portion of the innominate, with the following notes: "The autopsy, four and a half hours after death, showed that the ball had entered two and a half inches above the anterior superior process of the ilium and passed directly from before backward and slightly downward, making its exit at the posterior inferior portion of the ilium two inches below the crest. The ilium was fractured at the point of entrance and exit of the ball, and was entire between these points. In the iliac fossa an irregularly

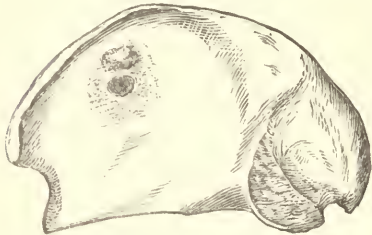


FIG. 158.—Ventral view of appearance after a shot perforation of the right ilium. Spec. 2015.

shaped abscess was observed extending beneath the iliac fascia and downward toward the crural opening, internally over the psoas muscle, undermining it and separating it from its attachments, the muscle appearing to traverse the abscess. The cavity extended the entire length of the crest of the ilium, and contained about two ounces of pus of a dark mahogany color, and very offensive. The anterior wound of the ilium connected with the iliac fossa by a fissure in the fracture, and the pus had discharged freely through this opening during life."

Assistant Surgeon A. A. Woodhull, U. S. A., remarks (*Cat.*, p. 25): "The specimen (FIGS. 158 and 159) consists of the greater portion of the right ilium. The bone is perforated near its crest, two inches posteriorly to the anterior superior spinous process, as if by a buckshot. The track of the ball is carious, but on the lower external surface is a large fringe of spongy callus. Surrounding the internal orifice is a small quantity of new bone. Just above the posterior superior spinous process is a contused wound three-fourths by one and one-fourth inches, over which the outer surface is wanting, and which retains a corresponding involucrum."

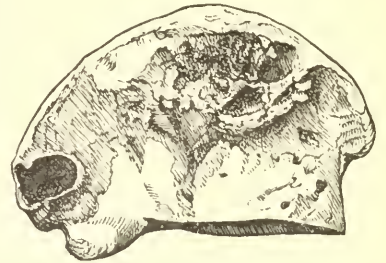


FIG. 159.—The exterior view of the same specimen, showing the shot canal fringed with osteophytes, and the cavity of an abscess of bone.

CASE 642.—Private Isaac N——, Co. A, 155th Pennsylvania, aged 23 years, was wounded at Fredericksburg, December 12, 1862, by a ball and three buckshot, one of which passed through the ilium, and another entered the crest. He was admitted to Harewood Hospital on the 13th. Acting Assistant Surgeon W. A. Harvey reports that a buckshot was removed, and the patient was treated with nitric acid, iron, brandy, etc., and that the wound was kept open with tents. The patient died January 31, 1863. Dr. Harvey sent to the Museum the specimen represented in the wood-cuts (FIGS. 160, 161). A buckshot had perforated the dorsum about its centre, and another lodged in the outer border of the crest near the superior extremity of the insertion of the latissimus dorsi; the borders of the perforating fracture are necrosed, and the bony tissue in which the ball lodged is carious.

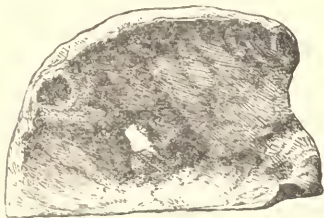

FIG. 160.—Upper two-thirds of the right ilium, showing a shot perforation and a carious cavity, from which a small ball was extracted. Spec. 988.

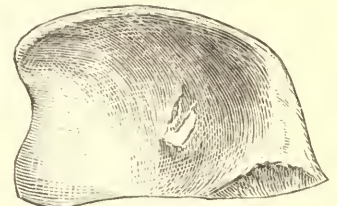


FIG. 161.—External view of the same specimen.

CASE 643.—Private R. H. R——, Co. H, 24th New Jersey, was wounded at Fredericksburg, December 19, 1862, and on the 17th was transferred to Harewood Hospital. Acting Assistant Surgeon W. A. Harvey reports that "the ball was removed on December 20th, when the diagnosis was made of fracture through the left ilium. The patient died December 28, 1862. *Post-mortem* examination revealed a fracture of the ilium, and a large mass of coagulum between the bone and iliacus muscle, and two fragments of bone driven in. Pus and coagulated blood had burrowed into the cavity of the pelvis." The specimen (FIGS. 162, 163) was contributed to the Museum by Dr. Harvey. Assistant Surgeon Woodhull remarks (*Cat.*, p. 226): "The external fracture embraces nearly two square inches of surface, and the internal fracture nearly four square inches. One square inch of bone is missing, and the fractured portion of the inner table is bent inward; the border of the fracture is necrosed."

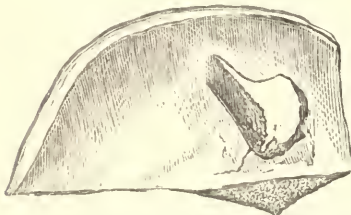

FIG. 162.—Superior half of left ilium perforated by a conoidal ball above the sacral articulation. Spec. 985.

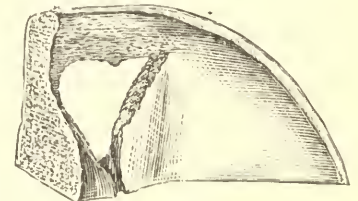
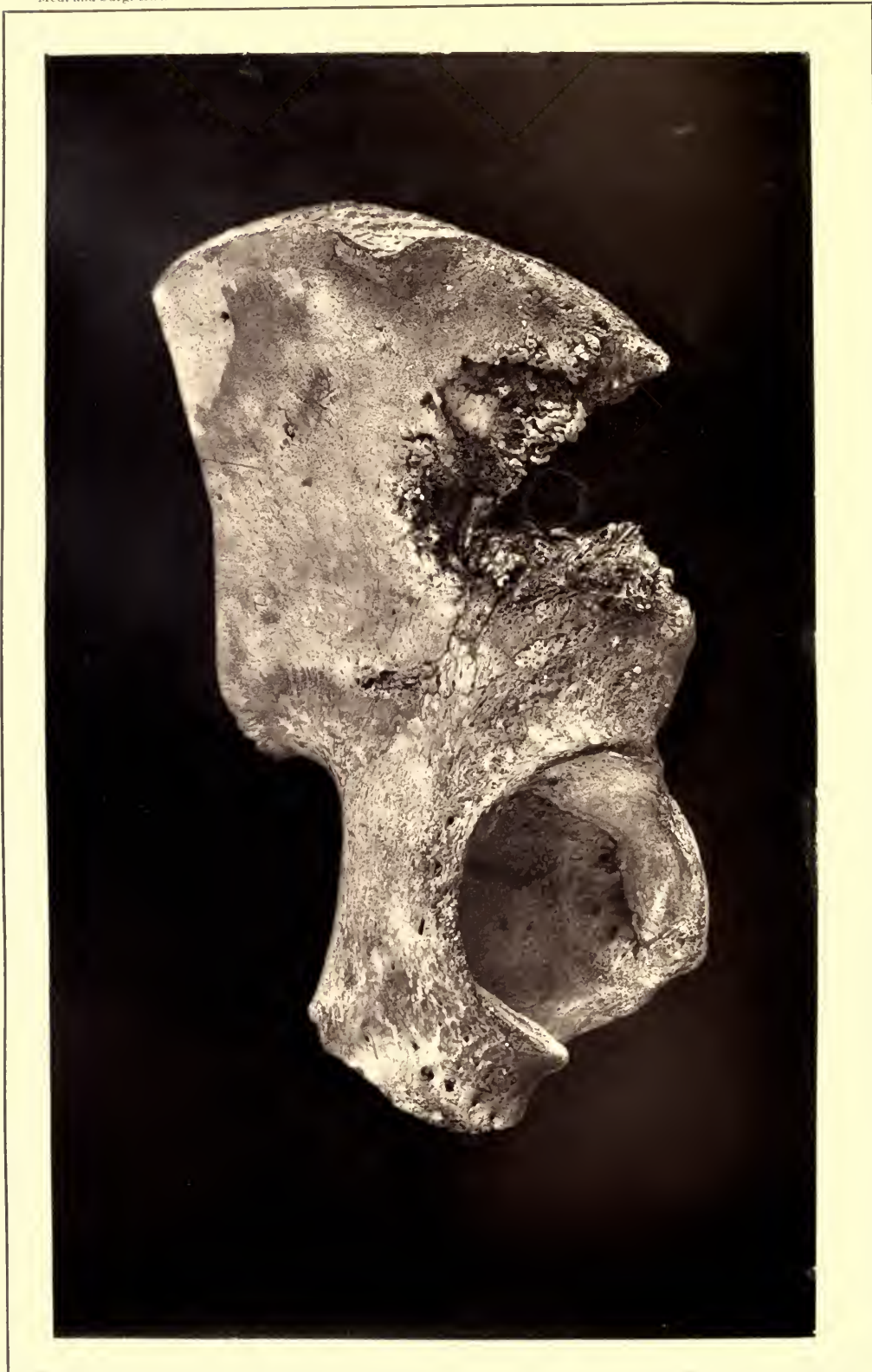

FIG. 163.—Dorsal aspect of the same specimen.

CASE 644.—Private *T. J. I.*——, Co. E, 31st Georgia, aged 18 years, was wounded at Monocacy Junction, July 9, 1864, by a conoidal ball, which penetrated the right hip and passed through the upper border of the ilium without penetrating the abdominal cavity. He was sent to Frederick, and admitted into hospital on the 10th. Acting Assistant T. E. Mitchell reported that "the wound continued to suppurate freely, and tonics and stimulants were administered. On the 25th, the patient was attacked with diarrhoea, which lasted about ten days, but yielded finally to astringents. After this, his appetite became good







Ward phot.

Am. Photo-Relief Printing Co., Philada.

PLATE XXXIV. CARIOUS SHOT FRACTURE OF THE RIGHT ILIUM.

No 3900. SURGICAL SECTION.

and his strength increased. The part of the ilium through which the ball passed became necrosed, and several small sequestra were discharged. On August 20th, a fragment, three inches in length by one-half inch in width, was removed. The parts around the wound of exit sloughed, and pus burrowed downward along the venter of the ilium till September 8th, when it penetrated the abdominal cavity. Hyperacute peritonitis ensued, and the patient died on September 10, 1864. At the *post-mortem* examination the abdominal cavity was found filled with pus, an abscess having burst into the cavity. The bone in the vicinity of the wound was much necrosed. The pathological specimen, represented in the photo-relief print opposite (PLATE XXXIV), was contributed to the Museum by Dr. Mitchell. It consists of "the anterior half of the right innominatum, comminuted at the anterior superior process of the ilium, where a wedge-shaped fracture, two inches in depth by the same base, with loss of substance, has been caused by a conoidal ball. The fractured edges are torn and carious. On both surfaces is a layer of periosteal deposit nearly separated. The bone immediately adjacent to the fracture is necrosed and partly detached." (*Catalogue*, 1866, p. 226; description of specimen 3900, XI, A. B. b, 11.)

CASE 645 —Private Joseph S——, Co. C, 1st Wisconsin Cavalry, aged 29 years, was wounded at Dandridge, January 17, 1864, by a conoidal ball, which entered the right hip anteriorly at the superior portion of the ilium, ranging inward and downward. On the next day he was admitted to Asylum Hospital at Knoxville, where simple dressings were applied, opiates, astringents, and tonics administered, and the ball was extracted some time in April. On August 12th, the patient was transferred to the Clay Hospital, Louisville, and thence, on the 23d, to Harvey Hospital, Madison, where the following report of the case was made by Surgeon H. Culbertson, U. S. V.: "A sinus had opened over the right pubis, which discharged unhealthy pus; the right foot was turned out, and the leg and foot were swollen from effusion of serum. Chronic diarrhœa and dysuria supervened,

followed by extreme emaciation, and he died on August 13, 1865. At the examination, twenty-four hours after death, the pubic sinus was found leading to the bladder, and along the inner face of the right ilium; the bladder was ulcerated at points in its outer coats and through the three coats at one point, and its mucous coat was generally discolored, softened, and in a state of chronic inflammation. At the seat of the fracture of the ilium fragments of the inner table of the bone had been driven in by the missile, and were feebly attached by new bone; the track of the ball was carious and the orifice raised by new osseous deposits. The head of the femur was partially dislocated and ankylosed against the iliac margin of the acetabulum. The articular surfaces were softened and partially absorbed, and the inner surface of the femur was eroded. The specimen consists of the sacrum, right os innominatum, and upper portion of the femur, and is represented by the wood-cuts (FIGS. 164 and 165).

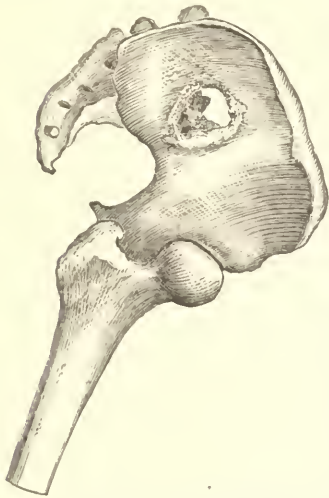


FIG. 164.—Caries and subluxation of the head of the right femur, in a case of shot perforation of the ilium. *Spec.* 3232.

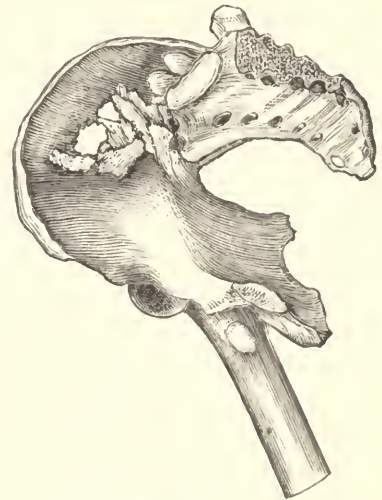


FIG. 165.—Interior view of this specimen.

In a large proportion of the cases, the side on which the injury was inflicted was specified, and the results, as set forth in the following tabular statement (TABLE VI), indicate that, notwithstanding the partial protection afforded by the canteen, haversack, and side-arms, there was a predominance of injuries of the left hip of about 10 per cent., the ratio in which the right ilium was struck being 44, and that of the left 56, per cent. of the determined cases.

TABLE VI.

*Indicating the relative Liability of the Right and Left Ilii to Shot Injury.*

RESULT OF SHOT FRACTURES OF THE ILIUM.	Cases.	Right Ilium.	Left Ilium.	Both Ilii.	Side not Specified.
Recovery .....	594	224	269	3	98
Death.....	192	64	95	2	31
Undetermined .....	10	2	5	1	2
Aggregates.....	796	290	369	6	131



The three following cases illustrate the greater danger of shot fractures of the posterior spinous processes of the ilium than of lesions of the same magnitude of the anterior processes. The three patients apparently perished from pyæmia, two a fortnight after being wounded, one at the expiration of four weeks.

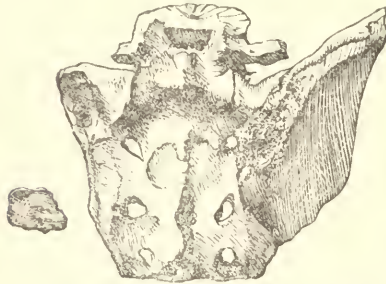

FIG. 166.—Superior portion of sacrum, posterior portion of right ilium, fifth lumbar vertebra, and battered conoidal ball which fractured the three bones. *Spec.* 1650.

Surgeon G. A. Mursick, U. S. V., reported that "a piece of shell entered his left side, fracturing the crest of the ilium, and passed backward to the lumbar vertebrae; the wound presents a ragged appearance, and is about one and a half inches in diameter; there is complete loss of motion and partial loss of sensibility in the left lower extremity; there is paralysis of the bladder, and relaxation of the sphincter ani, the urine being retained, and two stools passed involuntarily. He complained of pain in the abdomen and left foot; pulse 80, full and quick. The treatment consisted of applications of simple dressings to the wound, the administration of opiates, and drawing off of the urine by the catheter. October 1st: He passed his urine this morning without the aid of a catheter, and retains his feces; the wound is suppurating; he is very restless and is suffering great pain; some pieces of bone were removed from the wound this morning; opiates were given, and a flaxseed poultice was applied to the abdomen. October 6th: The pain in the abdomen is slight, but is more severe in the foot, and he is very restless. October 12th: There has been but little change in his condition; he has some irritative fever, and has but little appetite; he is emaciated, and his pulse is frequent and feeble. October 16th: He is gradually failing in strength; the tongue is dry and furred; bowels constipated; the pain in the foot continues. An enema was given to move the bowels. October 18th: He has had a severe chill during the night, and has fever this morning; the tongue is dry and brown; the pain in the abdomen still remains, with slight tympanitis. Opiates, tonics, and stimulants were given. On the 19th, he had rigors, and on the 20th, he had a slight hæmorrhage from the wound; the rigors continued, and the skin was of a yellow hue; there was nausea and vomiting, respiration was embarrassed, and there were sibilant sounds in the posterior part of the lungs. On the 21st, he had rigors and slight delirium. He died October 22, 1863.

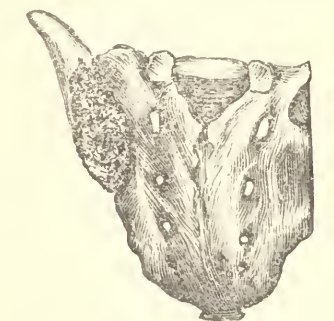

FIG. 167.—Sacrum and portion of the left ilium, the dorsal portion of the spine of the latter shattered by a shell fragment. *Spec.* 1519.

lodging with some pieces of bone in the muscles of the back. The lungs were congested, and contain a number of small abscesses; none were found in the liver. The other abdominal viscera were healthy. The heart presented evidences of an old pericarditis, and the mitral valves were thickened." The specimen (FIG. 167) consists of the sacrum and posterior part of the left ilium. A portion of the ilium in the region of the posterior spines has been carried away by a fragment of shell, and the neighboring bone is necrosed. It was contributed to the Museum by Surgeon John A. Lidell, U. S. V.

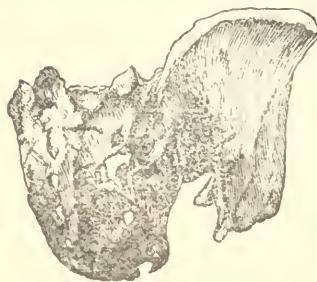


FIG. 168.—Shot fracture of the posterior inferior spinous process of the right ilium. *Spec.* 3532.

CASE 646.—Private J. C. M——, Co. G, 116th Pennsylvania, aged 18 years, was wounded at Reams's Station, August 25, 1864, by a minie ball, which shattered the crest of the right ilium just above the posterior superior spinous process, fractured the spinous process of the fifth lumbar vertebra, passed across to the opposite side, and lodged below the crest of the left ilium. He was sent from a field hospital, on the 26th, to Emory Hospital. He suffered intense pain from the time of admission, and on September 1st gangrene set in. The treatment consisted of detergent topical applications, and the administration of anodynes and stimulants, with nourishing diet. He died September 7, 1864. The autopsy, made the next day, disclosed the course of the ball as above stated. The specimen (FIG. 166) was contributed, with the foregoing history, by Acting Assistant Surgeon H. G. Bates.

CASE 647.—Private A. B——, Co. M, 63d North Carolina, aged 35 years, was wounded at Madison Court-House, September 22, 1863, by the explosion of a shell, and was admitted to Stanton Hospital, Washington, on the 25th. Assistant Surgeon G. A. Mursick, U. S. V., reported that "a piece of shell entered his left side, fracturing the crest of the ilium, and passed backward to the lumbar vertebrae; the wound presents a ragged appearance, and is about one and a half inches in diameter; there is complete loss of motion and partial loss of sensibility in the left lower extremity; there is paralysis of the bladder, and relaxation of the sphincter ani, the urine being retained, and two stools passed involuntarily. He complained of pain in the abdomen and left foot; pulse 80, full and quick. The treatment consisted of applications of simple dressings to the wound, the administration of opiates, and drawing off of the urine by the catheter. October 1st: He passed his urine this morning without the aid of a catheter, and retains his feces; the wound is suppurating; he is very restless and is suffering great pain; some pieces of bone were removed from the wound this morning; opiates were given, and a flaxseed poultice was applied to the abdomen. October 6th: The pain in the abdomen is slight, but is more severe in the foot, and he is very restless. October 12th: There has been but little change in his condition; he has some irritative fever, and has but little appetite; he is emaciated, and his pulse is frequent and feeble. October 16th: He is gradually failing in strength; the tongue is dry and furred; bowels constipated; the pain in the foot continues. An enema was given to move the bowels. October 18th: He has had a severe chill during the night, and has fever this morning; the tongue is dry and brown; the pain in the abdomen still remains, with slight tympanitis. Opiates, tonics, and stimulants were given. On the 19th, he had rigors, and on the 20th, he had a slight hæmorrhage from the wound; the rigors continued, and the skin was of a yellow hue; there was nausea and vomiting, respiration was embarrassed, and there were sibilant sounds in the posterior part of the lungs. On the 21st, he had rigors and slight delirium. He died October 22, 1863. Autopsy, eighteen hours after death, showed well-marked rigidity, body emaciated, and skin of a yellow hue. A piece of shell had struck the posterior part of the crest of the ilium, breaking off some pieces, and, passing backward behind the colon, it struck the upper part of the sacrum, fracturing it, and also the body, laminae, and transverse processes of the fourth and fifth lumbar vertebrae, and partially divided the spinal cord.

CASE 648.—Sergeant Walter S——, Co. I, 109th New York, aged 24 years, was wounded at the Wilderness, May 12, 1864, and admitted to the field hospital of the 3d division, Ninth Corps, on the same day, and, on the 26th, transferred to Douglas Hospital, Washington, where he died on May 27, 1864. The surgeon in charge reported: "Death was caused by pyæmia. This man must have been treated at Fredericksburg after his injury; he had well-marked pyæmia on admission, and died from that cause a few hours after. There was no examination of the lungs, but his external hue, sweet-smelling breath, delirium, and nervous prostration, left no doubt as to the nature of his disease." The specimen (FIG. 168) consists of the sacrum and right ilium; the spongy portion of the ilium near the sacral junction is fractured over a space one and a half inches square, and the sacrum is fractured at the second intervertebral notch as though by the impact of a ball, and was contributed, with the foregoing report, by Assistant Surgeon William Thomson, U. S. A.





Ward phot.

Am. Photo-Relief Printing Co., Philada.

PLATE XXXV. FRACTURE OF THE LEFT OS INNOMINATUM BY A SHELL FRAGMENT.

No. 4130. SURGICAL SECTION.



CASE 649.—Private *J. L. E*——, Co. A, Cobb's Georgia Legion, aged 35 years, was wounded at Sailors' Creek, Prince Edward's, Virginia, April 6, 1865. He was admitted to the field hospital of the Fifth Corps on April 14th, and was transferred to Washington, on the steamer *State of Maine*, on the 18th, and received into Lincoln Hospital on the 19th. Assistant Surgeon *J. P. Arthur* reported: "Gunshot fracture of the left ilium, missile entering two inches from the sacro-iliac synchondrosis, passing through into the pelvis, where it remained. The patient died from hæmorrhage April 28, 1865. The specimen consists of the sacrum and left os innominatum. A fragment of shell, one inch and a half by two inches, has perforated the ilium near its centre and caused a complete fracture of the bone from the level of the base of the sacrum. The specimen was contributed by Assistant Surgeon *J. C. McKee*, U. S. A. In the photo-relief print opposite (PLATE XXXV) the sacrum has been dismounted to give a better view of the venter of the ilium.

CASE 650.—Private *O. W. Goodale*, Co. G, 10th Vermont, aged 20 years, was wounded at Petersburg, April 2, 1865, and taken to a hospital of the Sixth Corps. On the 11th, he was transferred, by City Point, to Harewood Hospital. Surgeon *W. A. Child*, 10th Vermont, Assistant Surgeon *J. Sykes Ely*, U. S. A., and Surgeon *R. B. Bontecou*, U. S. V., in charge of the several hospitals, reported a shell wound of the right hip, with fracture of the ilium, without particulars of the treatment. The patient being transferred to Sloan Hospital, Montpelier, on May 12th, Surgeon *Henry James*, U. S. V., reported as follows: "Shell wound of the right side of the pelvis, involving the ilium. Compound comminuted fracture of the crista near the anterior superior spinous process. Pieces of bone were removed at the time of the injury. The patient says the wound opened into the pelvic cavity. When admitted, the wound was healthy and discharging a little. It was three inches long and two and a half inches wide. He was much emaciated, and was not able to walk. May 20th, the wound was healing fast; his appetite was good, and he was seemingly improving. The treatment consisted of cold-water dressings to the wound and the administration of opiates and stimulants. On June 10th, he went home on furlough, at which time the wound was doing well and healing rapidly; but when he returned the wound was discharging, and was phagedenic, with tendency to sloughing. He was discharged the service September 11, 1865; disability total." Pension Examiner *N. W. Braley*, of Chelsea, Vermont, reported, October 3, 1865: "Struck by a shell in the right hip, carrying away the front portion of the ilium, and consequently detaching those muscles that are inserted in that portion of the bone and making it difficult for him to walk. The wound has not healed in consequence of the ragged surface of bone left; disability total, and temporary." And on September 4, 1867, Dr. *Braley* again reported that "there is quite an excavation, and loss of strength in the hip-joint and muscles about the joint." On December 6, 1871, the Examining Board at Concord reported as follows: "Motion of hip-joint impaired while in hospital; during his recovery from the wound he coughed and emaciated; the cough has continued ever since. He is now pale and poor in flesh. There is dulness on percussion, and absence of the respiratory murmur over a large portion of the lung." Dr. *Austin Durkee*, of Franklin, reported that this pensioner "died of consumption December 20, 1871. His wound was an open one, and discharged freely until about eight months prior to his death; about that time the wound dried and the disease settled upon his lungs, thereby causing his death."!

CASE 651.—The leading facts in the following case were reported to this office from Carver Hospital and the Pension Bureau, but the interesting details will be presented in the language of the brave soldier himself, from a letter, accompanying his photograph, which he sent to Dr. *J. S. Billings*. Commissary Sergeant *Erskine Carson*, Co. I, 73d Ohio, was wounded at Bull Run, August 30, 1862: "I was wounded," he states, "about half-past four in the afternoon. At the time I was hit, the regiment was in line of battle, firing upon the rebels and receiving their fire, and I was standing on the line of the officers, partly leaning on a musket, with both hands near its muzzle, with the right foot to the rear, something like a 'parade rest.' A space of about the distance of two files happened to be opened directly in front of me, through some confusion into which the left of the company had fallen. I had suspended from my neck and hanging upon my left side a large rubber coat, compactly rolled in a round bundle, with the end projecting toward the enemy. The ball, hitting me first, perforated two folds of this gum coat, then striking and passing through the end of a Britannia metal flask lying on its narrow side in my blouse pocket, coming out about half of the length of the flask and in a different direction from that it entered, entering my body on the left side, as seen in the photograph (FIG. 170), not knocking me down, but turning me half-face to the left, and passing through somewhat obliquely; the ball carried with it a piece of the flask of about the size and shape I have tried to draw here (FIG. 169), and drove the fragment through nearly to the edge of the posterior wound (FIG. 171). But the ball, going through my body and through my haversack, which at the time was full of biscuit, spent its force upon the last cover of the haversack. I walked about seventy-five yards after I was wounded, but with great pain and a continual sense of giving way of my left side. I was conveyed to Carver Hospital, Washington, the third day after being hurt. I think it was about two weeks after my arrival in hospital that Surgeon *J. M. Palmer* probed my wound, posteriorly, and brought out the piece of flask (FIG. 169). A day or two before, however, a piece of bone (FIG. 172) was taken out. From that time up to November 1, 1862, about eight or ten pieces of bone were taken out or spontaneously made their appearance. One or two small pieces were taken out in December,




FIG. 169.—Portion of metallic flask detached by a bullet.

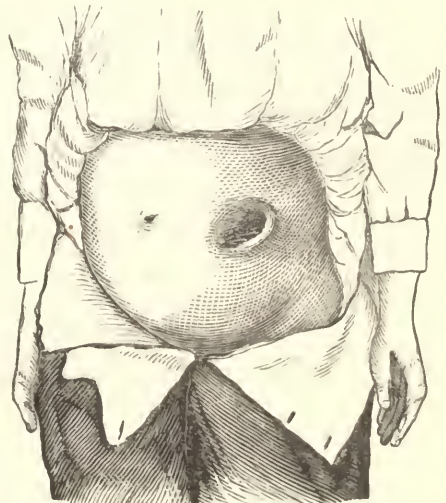


FIG. 170.—Cicatrix of entrance wound in a case of shot perforation of the ilium. (From a photograph.)

1862. The anterior wound was probed only two or three times in hospital, and the probe most frequently took the direction of the ball. The probing of the posterior wound took different directions several times, coming abruptly against the bone, and

sometimes the probe entered the body a sufficient distance to have passed through the bone. It is my best recollection that whilst probing the posterior and anterior wounds at the same time the probes never came in collision; and once, I remember, the probe entering the anterior orifice undoubtedly passed through the bone. Once or twice, the probe entering the posterior wound ran almost straight up the body. Neither wound has been probed since January 1, 1863. The last piece of bone came out of the anterior wound in March, 1863—some four pieces coming out of that wound altogether, the largest a honeycombed bit about the size of a gold dollar. Both wounds suppurate always, alternating, however. The anterior wound at times seems entirely closed and healed up; but at the end of ten days, generally, it opens and suppurates to the amount of one and a half



FIG. 171.—Cicatrix of the posterior wound in the foregoing case of shot perforation of the ilium.

tablespoonfuls each day. Neither wound has ever healed permanently, and for the past two and a half years the quantity of discharge has been about the same as mentioned. Formerly, the quantity was greater. I used crutches from January 1, 1863, to June 1, 1863; but it was not until the fall of 1864 that I felt justified in taking much exercise. Since June, 1865, I have ridden a great deal on horseback, suffering no inconvenience whatever, though going forty miles at a trip, the suppuration neither increasing nor diminishing. This spring, however, the anterior wound has been more annoying to me than ever before, more pain in it and soreness, but only when suppuration has been going on from this wound. It is particularly uncomfortable when I am feverish. For about six weeks after I was wounded I could not draw a long breath without great pain in the anterior wound. I am very certain that about the latter part of April, 1866, a piece of the dark-blue trowsers I had on when wounded came out of the anterior wound. The threads were found upon the inside bandage directly next my body,—I have had on no blue clothes since the battle. For the first ten days I was in hospital the surgeon treated me as though afraid of inflammation of the bowels." Sergeant Carson was discharged from service October 30, 1862, and pensioned. Pension Examiner John H. Oliver, of Cincinnati, reported, January 14, 1863, that "the ball entered the abdomen four inches to the left of the umbilicus, passed obliquely backward and outward through the left ilium, and

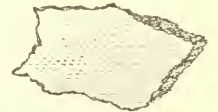

FIG. 172.—Tertiary sequestrum from the ilium.

made its exit opposite the centre posteriorly, causing compound fracture of the bone. The wound is still open at exit and entrance, and occasionally discharges spicula of bone, rendering the left thigh and leg at present useless; he may recover the use of the limb in part. Disability total, and permanent." The pensioner was last paid June 4, 1873.

Cases of shot fracture of the ilium in the vicinity of the cotyloid cavity are sometimes very obscure; and even pathological preparations do not always suffice to determine whether the joint was primarily or secondarily affected. In CASE 645, and in the following instance, lesions of the acetabulum resulted in luxations of the head of the femur:

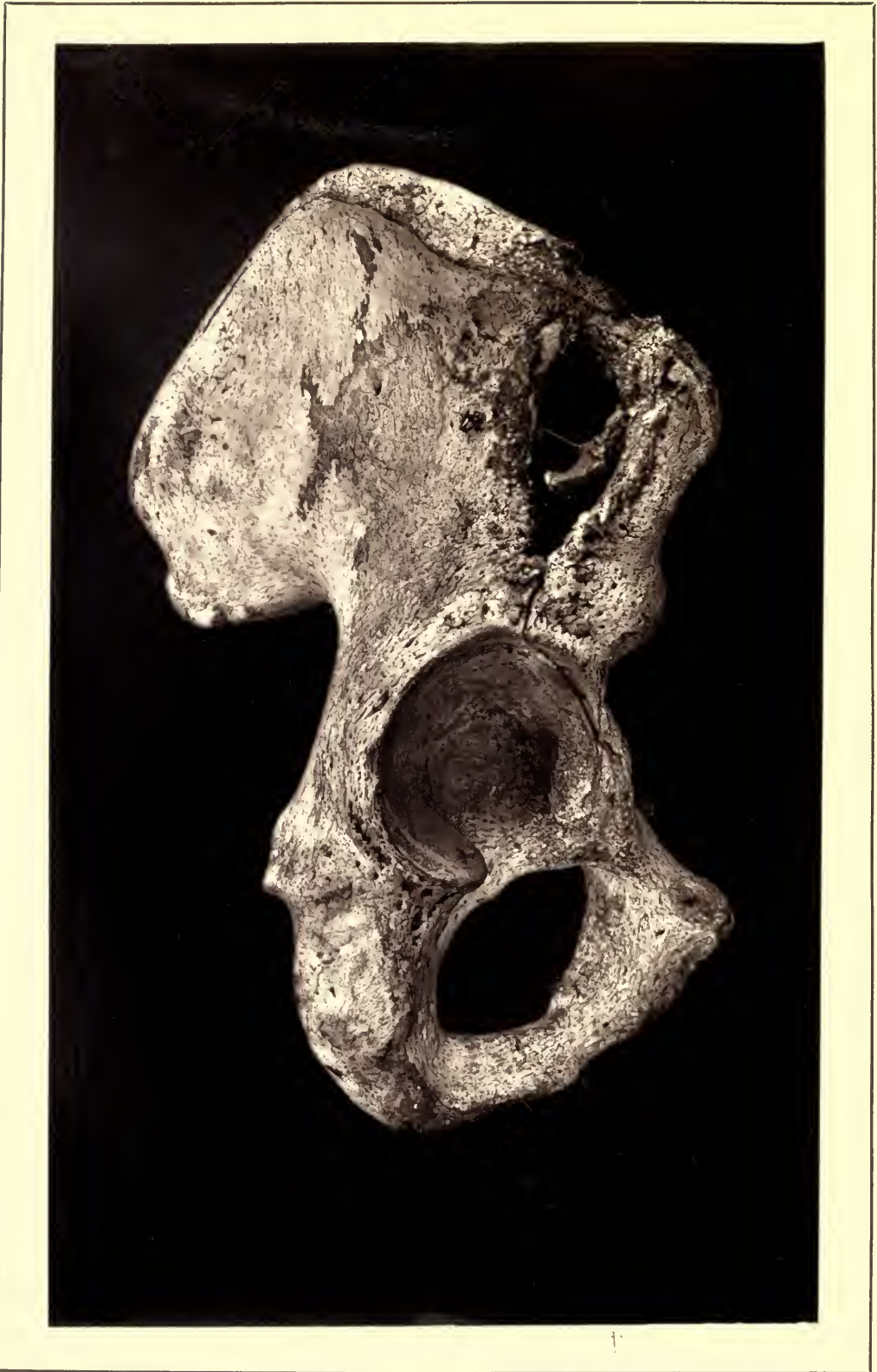CASE 652.—Private F. H. Bacon, Co. A, 22d Massachusetts, was wounded at Gaines's Mills, June 26, 1862, by a ball, which entered just below the anterior inferior spinous process of the right ilium, and escaped from the buttock about two inches from the anus. It was thought the rim of the acetabulum might possibly be fractured. On July 21st, he was admitted from the hospital transport Louisiana into hospital at Baltimore. He was discharged from service on September 26, 1862, for loss of motor power of the right lower extremity, the disability being rated as total. On December 17, 1863, Pension Examiner Oramel Martin reports: "The limb can be shortened two inches, and a crepitus may be felt by bearing on it or pushing it back when the soldier is in a sitting posture. The patient can walk with a cane, but the leg and thigh are much atrophied." Pension Examiner J. B. Treadwell, of Boston, reported, April 3, 1872: "The ball entered two inches below the anterior superior process and emerged at the centre of the right natis, fracturing the neck of the femur. There is two inches of shortening. The right lower extremity is smaller and softer than the left. He is very lame, and is unable to lift more than fifteen pounds. Disability total, and of the third grade."

Among many illustrations of the varied lesions resulting in primary and secondary traumatic arthritis, five cases of slight shot injury of the iliac portion of the acetabulum are reported in Circular 2, S. G. O., 1869.<sup>1</sup> It is not proposed to enter here upon the injuries of the hip-joint further than to ask attention to the small group of instances in which fissures extend into the cotyloid cavity from shot fractures of the ilium. The Museum possesses a beautiful example of this in specimen 172. A vertical shot canal, three inches long, extending from the crest of the ilium to within an inch of the acetabulum, is connected with the latter by a deep fissure. The fissure did not extend through the articular cartilage, and apparently excited very little inflammatory disturbance in the

<sup>1</sup> Circular No. 2, S. G. O., 1869, *A Report on Excisions of the Head of the Femur for Gunshot Injury*, p. 89 et seq., CASES 160-164. Consult also CASE 150 and CASE 272, and an article by Dr. LEWIS HEARD, *Gunshot Wound of the Hip*, in the *Boston Med. and Surg. Jour.*, 1863, Vol. LXVIII, p. 439.







Ward phot.

Am. Photo-Relief Printing Co., Philada.

PLATE XXXVII. CARIES AND NECROSIS AFTER A SHOT PERFORATION OF THE LEFT ILIUM, WITH A BALL-FRAGMENT SUSPENDED IN THE SHOT CANAL, AND A FISSURE EXTENDING INTO THE COTYLOID CAVITY.

joint. The borders of the canal are, in some places, fringed with osteophytes, and in others are carious or necrosed. The pathological preparation is figured in the photo-relief print opposite (PLATE XXXVII).

CASE 653.—Private Henry Reens, Co. I, 30th Massachusetts, aged 18 years, was wounded at Ceder Creek, October 19, 1864. He was treated at the field hospital for several weeks, and on November 12th was transferred to a hospital at Frederick; thence, on the 18th, to Filbert Street Hospital, Philadelphia, where Surgeon T. B. Reed, U. S. V., noted a "gunshot wound through the crest of the ilium;" thence to Turner's Lane Hospital, whence Surgeon R. A. Christian reported attacks of epilepsy. The patient was discharged from McClellan Hospital June 4, 1865, and pensioned. This pensioner visited the Army Medical Museum April 3, 1867, when the following notes of the case were obtained by Assistant Surgeon E. Curtis, U. S. A.: "The ball entered just to the outside of the anterior superior spinous process of the ilium of the right side, passed outward and backward, and emerged about six inches from the point of entrance. The man stated that the wounds became gangrenous at the field hospital at Winchester, that he was unable to walk for five months, and that numerous pieces of bone were removed from both orifices, one being two inches long. The wound did not heal for five months, and the orifice of exit reopened two or three times, but no more bone was discharged. At present, the anterior cicatrix is adherent to the bone; the posterior cicatrix is movable. Motion of the hip-joint causes pain, and the muscles resist powerfully any attempt to move the thigh; there is, however, limited motion. The knee, also, is somewhat stiff, and can be flexed but very slightly. He walks by swinging the pelvis, keeping the knee-joint immovable, and moving the hip-joint very slightly. The ankle-joint is stiff, and the toes drawn up by the extension. He never had any abscesses in the hip, and probably no disease of the joint except the false ankylosis from long confinement." A photograph of the patient was made, which is No. 177 of the *Surgical Photograph Series*, and is drawn on a reduced scale in the adjacent wood-cut (FIG. 173). The Pension Examining Board at New York reported, February 14, 1872, that "the ball struck the right side of the abdomen, and, passing through the crest of the ilium, emerged posteriorly six inches from the wound of entrance. The anterior cicatrix is adherent to the bone. He is now suffering from epileptiform convulsions. From the history and circumstances of the case we believe that the convulsions are due to disease of the nerve centres, the result of an ascending neuritis, having its origin in a nerve within the wound. Disability total, third grade. Weight, 120; age, 26; respiration and pulse normal."

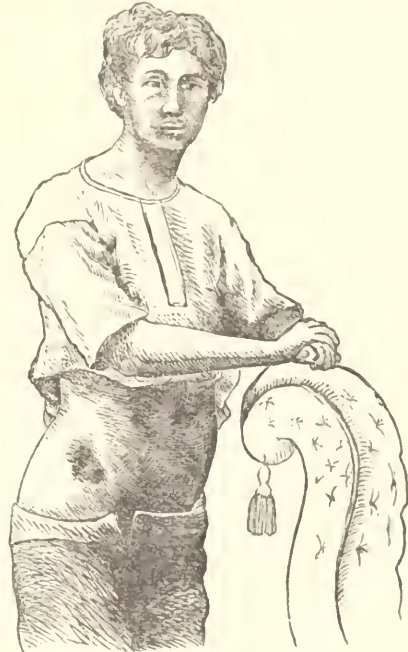

FIG. 173.—Cicatrix of a shot perforation of the ilium. [From a photograph.]

*Caries and Necrosis.*—The frequency of these terminations of the osteitis induced by shot fractures is so great that Dr. Stromeyer concludes that the preservation of life after these grave injuries of the pelvis is not always to be reckoned good fortune, the patients leading ailing and painful lives,<sup>1</sup> exposed to the recurrence of suppuration, and liable to fatal complications from slight accidents, as in the following case:

CASE 654.—Private John D——, Co. C, 51st New York, aged 41 years, was wounded at Antietam, September 17, 1862, by a conoidal ball, which entered between the anterior spinous processes of the left ilium and escaped just exteriorly to the lowest third of the sacrum. He remained in a field hospital until October 2d, when he was removed to Camp A Hospital, Frederick. "He was greatly exhausted, and the wound discharged unhealthy pus profusely, and the countenance was hectic. Stimulants and nutritious diet were freely given for a fortnight without materially altering his condition, when he began slowly to regain strength. The wound, however, continued to suppurate freely." He convalesced sufficiently to be able to walk about, but received a severe fall on December 14th, after which he gradually grew worse, and died December 24, 1862. All along he had suffered pain in the course of the sciatic nerve, but had referred none to the articulation. The neuralgia was excruciating after the fall. The specimen (FIG. 174) was contributed to the Museum by Assistant Surgeon W. M. Notson, U. S. A. The exterior surface of the ilium one inch above the acetabulum is grooved by the bullet; the walls of its track are thickened by new bone, and interiorly a sinus has perforated the bone nearly three inches, and has opened by ulceration the fundus of the acetabulum.<sup>2</sup>

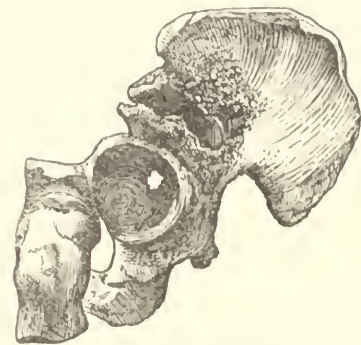


FIG. 174.—Carious shot canal in the left ilium. Spec. 934.

<sup>1</sup> ANGER (*Traité iconographique des maladies chirurgicales*, 1<sup>re</sup> monographie, *Luxations et fractures*, p. 17) figures the right ilium notched and perforated by a conical ball, which has largely splintered the bone. The specimen is taken from a soldier wounded at Solferino, June 24, 1859, who died in Paris in 1864, in Nélaton's ward, from protracted suppuration.

<sup>2</sup> Compare CASE 187, Circular No. 2, S. G. O., 1869, p. 92.



CASE 655.—Private *Alison Simpson*, Co. F, 49th North Carolina, aged 18 years, was wounded at Antietam, September 17, 1862, and appears to have been treated at Hospital No. 5, Frederick. On October 25th, he was transferred to Camden Street Hospital, Baltimore. Acting Assistant Surgeon E. G. Waters reported that "a musket ball entered the right iliac fossa one and a half inches internally to the crest of the ilium, passed directly backward and outward, perforating the bone and fracturing it extensively, and escaped posteriorly. October 27th, a number of denuded, detached, and entirely dead fragments of bone were removed through the anterior opening, to the great comfort and benefit of the patient. The discharge continued abundant and offensive for some weeks; but, as the strength and vigor of the patient returned, it improved rapidly in character and diminished in quantity. By February 14, 1863, the wound had healed and the patient was sent to the South. Some contraction of the tissues in the neighborhood of the wound existed at this time, preventing him from resting the entire sole of his foot on the ground."

The Pension Roll affords many illustrations of the protracted suppurations following chronic caries and necrosis induced by shot injuries of the bones of the pelvis. The following are some examples:

CASE 656.—Private M. G. Jones, Co. I, 5th New York, was wounded at Manassas, August 30, 1862, and taken prisoner; and was subsequently paroled and sent to Annapolis, and, on November 15th, was admitted to the General Hospital under charge of Surgeon T. A. McParlin, U. S. A., where the following report was made: "The ball entered the abdominal walls three inches above the symphysis pubis, passing over to the right side, making a wound five inches in length. The anterior superior spinous process of the ilium was impinged upon, and pieces of bone had been removed. The wound has healed, but the patient is lame, and complains of great pain in the lumbar region and can bear no pressure on the abdomen." On January 28, 1863, he was discharged the service. Pension Examiner S. D. Willard, of Albany, New York, reported, October 24, 1863: "Ball struck the crest of the ilium and tore across the abdomen. There is lameness and disability on movement involving the action of the sartorius muscle." This pensioner was paid to June 4, 1872.



FIG. 175.—Ball and necrosed fragments from the left ilium. *Spec.* 1794.

CASE 657.—Private C. Daly, Co. A, 62d New York, received a shot fracture of the pelvis at Gettysburg, July, 1863. He was admitted to a field hospital of the Sixth Corps on the 4th, and on the 26th was transferred to Baltimore, to Patterson Park Hospital. A musket ball had entered posteriorly two inches below the crest of the left ilium, shattering this bone considerably, and passed in the opposite direction, and was found buried in the muscles of the right side, immediately below the bone. It was removed by Surgeon S. D. Freeman, U. S. V., with several pieces of bone, the largest of which were taken from the left ilium near its vertebral and sacral articulation. The patient convalesced, and was discharged from service March 19, 1864. The specimen (FIG. 175), consisting of a conoidal ball and thirteen fragments of necrosed bone, was contributed by the operator, with the foregoing narrative. Examining Board of Surgeons J. F. Ferguson, M. K. Hogan, T. F. Smith, W. F. Dunning, and Charles Phelps, of Newport, reported November 8, 1871: "There is a long, deep, adherent cicatrix in the gluteal region; the movements of the back are interfered with; disability three-fourths. Also gunshot wound of the left hand, between the metacarpal bones of the middle and ring fingers, near the metacarpal phalangeal joint, weakening the middle and ring fingers; disability one-fourth. Disability for both wounds total and permanent." This pensioner was last paid to June 4, 1873.

CASE 658.—Private C. Dunbar, Co. D, 10th Massachusetts, aged 24 years, was wounded at Fredericksburg, May 3, 1863, by a conoidal musket ball, which entered the upper part of the left natis, passed anteriorly, and lodged. He was sent to New York, and admitted into the Central Park Hospital on May 17th. Soon after the reception of the wound, both testicles became painful and inflamed and remained so for three or four days. On June 29th, an incision, similar to that recommended for ligation of the external iliac artery, was made upon a hard substance lying half way between the anterior superior spinous process and the symphysis pubis, and half an inch above Poupart's ligament; it proved to be the ball, which was removed, with three small pieces of bone. The after treatment consisted of simple dressings, with quinine and whiskey. The patient rapidly convalesced, and returned to duty on September 23d; discharged from service November 24, 1863, on surgeon's certificate of disability, and pensioned. On April 28, 1870, Pension Examiner P. H. Humphrey reported: "There is necrosed bone, and many pieces have been extracted. He complains of lancinating pains in his groin and hip-joint. It almost entirely incapacitates him for labor. Disability total."

CASE 659.—Lieutenant J. Swallow, 51st Pennsylvania, was wounded at Fredericksburg, December 13, 1862, by a conoidal musket ball, which passed through the right ilium near the crest, and emerged posteriorly through the sacrum. On March 24, 1863, he was admitted to the officers' hospital, Annapolis. Surgeon B. A. Vanderkief, U. S. V., reported that there were indications of extensively diseased bone; the general health was good, and the discharge from the wound free. The wound was poulticed; the patient exercised moderately in the open air, and took quinia and iron. Several pieces of bone were removed with forceps on May 23d; two large pieces were taken away on June 22d; large fragments were extracted on July 6th; and, on September 9th, some came away. The wound continued open and discharged, with very little inflammation, and the patient walked with the aid of a crutch. He was improving rapidly at the date of his discharge from the service, March 15, 1864. He was pensioned, and on April 7, 1865, the pension was increased. Pension Examiner W. Corson reports, November 4, 1872, that "the wounds are healed. The pensioner is, and has been since the receipt of the injury, uniformly lame. Heavy lifting, or prolonged exercise on foot, is followed by soreness and increased disability. The general health is good, and there is no appreciable atrophy of the limb. The disability is rated as total."



CASE 660.—Captain Thomas C. Spackman, Co. E, 198th Pennsylvania, aged 38 years, was wounded at Gravelly Run, March 29, 1865, and sent to a field hospital of the Fifth Corps, where he remained until May 1st, when he was transferred to Armory Square Hospital, Washington. Assistant Surgeon C. A. Leale, U. S. V., reported a "gunshot wound of the left hip; a conoidal ball entered one inch above the trochanter major and made its exit one inch to the left side of the anterior superior spinous process of the ilium. The ball passed through the ilium an inch below the anterior superior spinous process. When admitted, he was suffering considerable pain from a large abscess that had formed on the crest of the ilium, which had been punctured at City Point. A free incision into it evacuated the pus and permitted the removal of several small splinters of bone; a poultice was then applied. Stimulants, anodynes, and beef extract were given. June 20th: The wound still discharges. By the use of the probe I discovered several small pieces of bone on the inner side of the ilium; I passed a seton of oakum through the wound, and, in forty hours, drew it through with small pieces of bone entangled; applied a poultice and treated the case as before. On June 26th, he left the hospital to go to Philadelphia, having been mustered out May 29th. At this time the wounds looked healthy and discharged but a very small quantity of pure pus. He had a flesh wound of the left leg, which sloughed a little after he was admitted. It was so slight then that he did not mention it to me; when he left, this was also healthy. It was on the left leg, two inches below the knee, on the lateral aspect." This soldier was discharged the service June 26, 1865. Surgeons E. A. Smith, T. S. Harper, and J. Collins reported, November 6, 1872, that "the ball shattered the pelvic bones, resulting in five openings, which discharge pus freely at this date, with pieces of bone continually coming away. The necrosis of the pelvis is very extensive, and the condition of the applicant is 'such as to incapacitate him for performing any manual labor, but not such as to require constant personal aid and assistance.' He is able to dress his wound, but he is very offensive both to himself and to others; disability total." This pensioner was last paid up to March 4, 1873.

CASE 661.—Private John D. Wolff, Co. A, 14th Connecticut, aged 37 years, was wounded at Morton's Ford, February 6, 1864. He was admitted to a hospital of the Second Corps, and was subsequently treated in Alexandria, New York, and New Haven, and was discharged from service June 11, 1865. The records of the above hospitals furnish no details of the progress of the case. He received a pension until March, 1867, when he enlisted in Co. E, 42d Infantry (V. R. C.), at which date the pension was discontinued, though renewed at the date of discharge, April 2, 1869. Examining Surgeon Thomas B. Reed, of Philadelphia, reported, April 26, 1869, that "the ball entered to the inner side of the crest of the ilium and passed through and out near the sacro-iliac symphysis. The wound is still open and occasionally discharges dead bone; the limb is weakened and much impaired. He has slight double inguinal hernia, but does not wear any truss. He is much debilitated, and unable to earn a living by manual labor." Examining Surgeon Philip Leidy, of Philadelphia, reported, in July, 1869, as follows: "The ball entered the upper angle of the left iliac region at the anterior superior spinous process, passed inward, and emerged near the sacro-iliac junction of the same side, fracturing the ilium. The wound at the point of entrance is still open and discharging freely, due to the presence of necrosed bone. The applicant is under treatment at the Episcopal Hospital in this city. His general health is good and does not seem to be influenced by the existing condition of the wound, though he is disabled directly from performing manual labor for any length of time. The diseased bone is not extensive (though it will not permit of surgical interference) and may be discharged by the natural process at any time, when the pensioner will be relieved altogether. There is no constitutional cause acting in his case." In February, 1871, the Pension Examining Board at Philadelphia reports that there is "necrosis of the ilium. The wound of entrance is fistulous and discharges profusely. When the discharge ceases for a few days he becomes sick." In September, 1872, they reported that the wound of entrance was still discharging freely because of the presence of carious bone. This pensioner was last paid to June 4, 1873.

CASE 662.—Sergeant J. H. Whitney, Co. B, 9th New York, was wounded at Antietam, September 17, 1862, and was treated at Locust Spring by Surgeon T. H. Squire, 89th New York, who reported that "a musket ball entered the left gluteal region at a point three inches below the crest of the left ilium and three and a half inches from the median line of the sacrum, and remains in some unknown part of the body. There is no paralysis, or trouble of the bowels or bladder." On January 23d, the patient was sent to Smoketown, and, on May 10th, to hospital No. 1, Frederick, where the report of Assistant Surgeon R. F. Weir, U. S. A., is substantially the same. This soldier was discharged June 11, 1863, and pensioned. Examiner Charles Rowland, of Brooklyn, reported, on March 24, 1864, that "a rifle ball entered the left hip, fracturing the left os ilium, the ball traversing downward, and was supposed to have lodged near the os sacrum, where it still remains. At times it is exceedingly painful, rendering the soldier's health precarious." On June 18, 1869, Pension Examiner W. W. Potter, of Washington, reported that "a large cicatrix exists upon the left buttock, near its centre, with an opening through which pus is constantly discharging. The opening indicates the point of entrance of a minie ball, which has perforated the ilium obliquely from left to right. There are no indications of its exit, and the missile has undoubtedly lodged within the cavity of the pelvis; patient states that portions of the bone have been exfoliated, and that the discharge of pus has been constant since the injury was received, which indicates necrosis of some of the pelvic bones. Some fibres of the sciatic nerve appear to have sustained injury affecting the sensation and motion of the left lower extremity. He presents an anæmic appearance, and there is liability to a fatal termination at any time. Disability total, and probably permanent." This pensioner was last paid to March 4, 1873.

CASE 663.—Sergeant P. Ryan, Co. H, 15th U. S. Infantry, aged 21 years, was wounded at Atlanta, August 7, 1864, and was treated in a field hospital of the Fourteenth Corps until September 3d, when he was sent to Chattanooga, registered as a case of "gunshot wound of left side," and thence, on October 29th, to hospital No. 3, at Nashville, where Surgeon J. R. Ludlow, U. S. V., recorded the case as a "gunshot fracture of the left ilium." This soldier was subsequently in hospital at Jeffersonville and Camp Dennison, and discharged the service April 7, 1865, and pensioned. Examiner W. M. Evans, of Ashtabula, Ohio, reported, July 31, 1867, that "the wound through the ilium is discharging considerably, and frequently a small piece of spongy bone comes away; some nineteen pieces have been thus discharged, according to the statement of the applicant. He is weak, pale, and emaciated. This wound is probably not a permanent affair, as it will heal when the carious bone is removed; disability total." This pensioner was last paid March 4, 1873.

In view of the persistence of Sergeant Ryan's fistula for nine years already, and the experience of the Leipzig pensioner mentioned on page 218, whose fistula remained open for thirty years, it appears unsafe to predict that such lesions will not prove "permanent." Endless, *intarissable*, are the epithets by which Bégoin and M. Legouest find that such fistulæ may commonly be characterized. The following are analogous examples:

CASE 664.—Lieutenant James Peacock, Co. D, 87th Massachusetts, aged 33 years, was wounded at Fort Steadman, March 25, 1865, and was sent to a Ninth Corps hospital, where Surgeon M. K. Hogan, U. S. V., noted "Gunshot wounds of both thighs." Transferred to the depot field corps hospital. Assistant Surgeon Samuel Adams, U. S. A., remarked, March 31st, that the "ball entered two inches to the right of the umbilicus and came out at the middle of the crest of the ilium. No hæmorrhage from the bowels; no abdominal tenderness; no fever; clean tongue; appetite good; no sleep;" and, on April 1st, "pulse good; no fever; countenance bright." This officer appears subsequently to have been treated in quarters. He was honorably discharged June 12, 1865, and pensioned. Examiner Oramel Martin, of Worcester, reported that his disability was "total and permanent. A ball hit about two inches to the right of the umbilicus, passed through the abdomen and out through the centre of the right ilium. The bone is diseased and the wound discharges pus. Exercise which brings the muscles of the abdomen into action creates great lameness, from the adhesions."

CASE 665.—Private E. H. Jones, Co. H, 14th New York Heavy Artillery, aged 17 years, was wounded at Petersburg, July 3, 1864. His injury was recorded at a hospital of the Ninth Corps, by Surgeon M. K. Hogan, U. S. V., as a "gunshot wound of the left hip." Sent to City Point, and thence, on July 6th, to David's Island, New York; this soldier remained at De Camp Hospital until October 15th, and was then sent to the general hospital at Rochester. He was registered as convalescent from a "gunshot fracture of the crest of the left ilium," and was discharged from service April 3, 1865, and pensioned. Examiner Thomas M. Flandrau, of Rome, reported, September 16, 1870: "A rifle ball entered the hip three inches to the left of the spinal column, fracturing the crest of the ilium. The position of the ball was not ascertained until December, 1869, when it was extracted from the buttock by enlarging a fistula near the tuberosity of the left ischium. Bone was removed shortly after the wounding; none since. The wound of entrance did not heal until after the ball was extracted. There is now an ugly fistulous opening over the tuberosity of the ischium, situated in a deep ulcerated cleft, the remains of the incision, which discharges constantly. From the sensitiveness of the part, a probe could not be passed to any great depth. The main trouble is from the inflamed state of the fistula. The man cannot sit on that buttock, walk nor stoop, without occasioning pain and some inflammation. Time and proper surgical treatment will probably benefit him." This pensioner was paid March 4, 1873.

Examples might be multiplied; but the foregoing, conjoined with instances adduced in other subdivisions, sufficiently illustrate the difficulty in healing of shot fractures of the ilium,<sup>1</sup> the complications arising from denudation and caries, and from irritation of branches of the sacral and sciatic nerves and consequent neuralgia, paralysis, or muscular atrophy. Many patients sink under these exhausting influences; purulent infiltration, pyæmic or septicæmic infection being ordinarily the proximate causes of dissolution. In the recorded fatal cases there is, unfortunately, a paucity of detailed necroscopical memoranda.

CASE 666.—Private Joseph D. Hammer, Co. D, 142d Pennsylvania, aged 24 years, was wounded at Gettysburg, July 1, 1863. He was removed to the field hospital, where he remained until the 14th, when he was sent to Baltimore and admitted into Camden Street Hospital. Acting Assistant Surgeon E. G. Waters reported that "when admitted his general condition was good. A minié ball had entered the right hip just above and behind the great trochanter, passed inward, and lodged in the ilium posterior to and above the acetabulum. He was urged at this time to submit to an operation for the removal of the bullet, but he declined, and nothing further was done at the time. August 27th, the patient was seized with a severe rigor, great constitutional disturbance, and intense pain in the vicinage of the ball. On visiting him the next morning, he implored me to extract the missile, which was done accordingly. I apprehended that he was already suffering from pyæmia, which proved to be true. The bullet was found impacted in the ilium, and had to be loosened with the elevator before it could be detached. A large fragment of that bone was likewise withdrawn. The joint was not involved, its movements continuing free. August 29th, slept indifferently, notwithstanding a full dose of morphia. August 30th: Pulse irritable; no appetite; had a severe rigor. He took quinine and carbonate of ammonia, with morphia. September 2d: No improvement; no appetite; but takes beef essence with milk-punch, as ordered; gets his tonic, with eight ounces of whiskey, daily. September 6th: Treatment the same; another severe rigor; morphia at night, under which he sleeps tolerably well; skin constantly bathed in sweat; pulse very frequent, soft, and irritable. September 8th: Observed at my visit to-day that he had become suddenly and universally jaundiced; much inclined to sleep; complained of no pain, but expressed himself as feeling comfortable; pulse very small, and too rapid to count; body bathed in sweat, as it has been for several days, necessitating frequent changes of clothing; remedies persevered in to no purpose, and he sank at 11 P. M. Necropsy, twelve hours after death, revealed the ilium badly crushed and the superincumbent tissues in a gangrenous condition. The liver and kidneys were the only organs examined. The former had a yellow patch of considerable extent on its anterior aspect, penetrating several lines into its parenchyma; the latter were healthy. I attributed this man's death to his obstinate refusal to have the bullet extracted soon after his admission; certainly its removal at that time, with the comminuted fragments of bone, would have diminished risks of ulterior accidents."

<sup>1</sup> Professor C. F. LOHMEYER (*Die Schusswunden*, Göttingen, 1859, S. 141) remarks: "A speedy cure, after shot injury of the pelvic bones, I have seen but once."



CASE 667.—Sergeant James F. Barnes, Co. E, 24th Wisconsin, aged 31 years, was wounded at Mission Ridge, November 25, 1863. He was admitted on the same day to hospital No. 2, Chattanooga, under the charge of Surgeon Franklin Irish, 77th Pennsylvania, who noted the injury as a "shot wound of the groin." On January 29, 1864, he was transferred to hospital No. 3, Nashville, whence Assistant Surgeon Frederick W. Byers, 93th Illinois, reported that "on admission the patient was much emaciated and anæmic, and had suffered with diarrhoea for two weeks. The ball had entered near the anterior inferior spinous process and had passed backward upon the dorsum of the ilium and lodged. The wound of entrance had closed. There were bed-sores upon the back and hip, and an incision three inches long had been made behind the trochanter, from which unhealthy pus flowed. Stimulants and tonics were administered, and by February 10th the general condition was improved. On February 29th, the diarrhoea was mitigated but not arrested. On March 4th, the ball was extracted through an incision in front of the acetabulum. There was a free discharge of unhealthy pus from the wound, which gave no evidence of healing. The bed-sores were washed with a solution of permanganate of potash. March 15th, there was no improvement in the wounds, and the discharges from the bowels were more frequent. March 20th: Patient becoming gradually weaker, and the discharge from the wounds and bed-sores less copious but more fetid; no healthy granulations. He died March 27, 1864. Autopsy eighteen hours after death: No rigor mortis; there was a large bed-sore over the left hip, and the surrounding skin and subjacent tissues were ecchymosed; the wound of the hip was nearly closed externally; an incision laid open a cavity extending beneath the gluteal muscles; the ball had slightly fractured the anterior margin of the ilium; no pus was found in the cavity, but a dark, very fetid, pulsatious matter, which also covered the bed-sores. The right lung was healthy, but a portion of the substance of the apex of the left lung, about the size of a hen's egg, was broken down into a putrilage resembling in appearance and smell the contents of the cavity in the hip; a clot of blood could be traced from the pulmonary artery to the cavity; there was no surrounding hepatization or other evidence of inflammation. Heart healthy, containing fluid blood; small clots; mucous membrane of the ileum abraded."

CASE 668.—Private F. Pannour, Co. F, 1st Sharpshooters, aged 23 years, wounded at Cold Harbor, June 3d, was sent to Washington, and admitted into the Carver Hospital on June 11, 1864. Surgeon O. A. Judson, U. S. V., reports that "a rifle ball had entered the right side about an inch and a half above the groin, had passed transversely backward, producing incomplete fracture of the neck of the right femur, passed through the ilium, and had emerged about one inch above the right natis. On June 26th a very large quantity of pus, which had collected in the pelvis and burrowed in beneath the superficial fascia in the gluteal region, was evacuated. Free incisions were made and tents of lint drawn through. At the time of operation the patient was much exhausted. Stimulants and a nutritious diet were prescribed." These measures were unavailing, and death from exhaustion ensued June 29, 1864.

CASE 669.—Private H. Petzerick, Co. B, 100th Pennsylvania, aged 30 years, was wounded at Petersburg, March 26, 1865, and sent to the Ninth Corps hospital, and thence transferred to Slough Hospital, Alexandria. Surgeon E. Bentley, U. S. V., records, April 6th, that "a conoidal ball had passed through the posterior portion of the crest of the left ilium, through the body of the last lumbar vertebra, and through the right ilium just above its articulation with the sacrum. There was paralysis of the bladder and of the lower extremities. Cold-water dressings were applied to the wound, and the urine was drawn off with a catheter. The case terminated fatally on April 8, 1865. On autopsy the membrane of the spinal cord was found to be exposed, but not torn; the abdominal viscera were but slightly inflamed."

CASE 670.—Private A. Ecker, Co. A, 74th Pennsylvania, aged 37 years, wounded at Gettysburg July 1st, was admitted to Camp Letterman Hospital on July 25, 1863. A conoidal musket ball had entered at the upper part of the right sacro-iliac junction, splintering portions of the sacrum and ilium. The patient's general condition was improving, but he was troubled at times with sciatica. On August 24th, the ball, with fragments of clothing, was removed. From this time till September 1st, the wounds improved. From September 10th till October 1st, the patient was not doing so well; no loose sequestra could be found. Slow improvement took place from October 1st to the 9th. On November 15th, the patient was transferred to York. He died of exhaustion on December 22, 1863.

*Pyæmia or septicæmia*, the prominent causes of death in nine of the cases already recorded in different parts of this section, were also the immediate causes of fatality in the three following cases; and in thirty-three, altogether, of the two hundred and eleven fatal cases:

CASE 671.—Private Levi Carter, Co. K, 13th Ohio Cavalry, aged 21 years, was wounded at Petersburg, April 9, 1865. He was sent from City Point to Baltimore on April 22d, and entered Jarvis Hospital. Assistant Surgeon DeWitt C. Peters, U. S. A., reported that "a gunshot wound of the left side was complicated by a fracture of the ilium. Symptoms of pyæmia developed on April 28th. Beef-tea, stimulants, and other restoratives were perseveringly, but unavailingly, administered, and the case terminated fatally April 30, 1865. At the autopsy metastatic abscesses were found in the lungs."

CASE 672.—Private D. B. Doxtater, Co. E, 115th New York, aged 20 years, was wounded, May 2, 1864, at Olustee, Florida, and was admitted, on February 26th, to hospital No. 1, Beaufort, South Carolina. Assistant Surgeon C. E. Goddard reported that "a ball struck the highest point of the crest of the left ilium and passed out at the external border of the left psoas magnus muscle. The patient did well, under simple dressings with extra diet and stimulants, until March 13th, when the wound discharge diminished, and there was a slight chill, followed by febrile reaction. The stimulants were increased in quantity, and an opiate at bedtime was ordered. On March 14th, the patient was much worse, and had a severe chill; the pulse was small and rapid, and the discharge scanty and sanguinolent. On March 15th, the respiration was labored, the pulse smaller and quicker, the skin of a bright yellow hue, and there was a tendency to colliquative diarrhoea. Death took place March 16, 1864. The mesenteric glands were filled with pus."

CASE 673.—Corporal A. A. Rich, Co. G, 122d New York, aged 21 years, was wounded before Petersburg, March 25, 1865. He was transferred from a field hospital of the Sixth Corps to Mount Pleasant, Washington, April 2, 1865. Assistant



Surgeon H. Allen, U. S. A., entered the case on the quarterly report of wounded as a "gunshot flesh wound of the left lower extremity; the ball entered the gluteal region two inches to the left of the coccyx and passed inward." On the special report on pyæmia, Dr. Allen states that, "on April 3d, symptoms of pyæmia were ushered in by a slight rigor. Two fifteen-grain doses of sulphate of quinia were given, with an interval of eight hours. On April 5th, there was a severe rigor. On April 6th, the patient was put under chloroform and the wound was enlarged to explore the track and position of the ball. There was a severe chill in the evening; the countenance was sallow, the conjunctiva yellow, and the breath had the odor of hay. There were severe chills on April 7th and 8th, and on the 9th troublesome hiccough, which was relieved by a blister to the epigastrium, the raw surface being dressed with a half grain of sulphate of morphia in powder. Later in the day he was restless and slightly delirious, and had involuntary rice-colored dejections. On April 10th, he was comatose and sinking rapidly, and died April 11, 1865. Pus was found in the lower lobes of both lungs in considerable quantities. The other organs were healthy.

*Excisions of Portions of the Ilium.*—Operations for the removal of necrosed portions of the ilium are mentioned by some of the older surgeons, by LeDran<sup>1</sup> (1731), Arrachart<sup>2</sup> (1766), Boucher<sup>3</sup> (1776), Theden<sup>4</sup> (1782), Manné<sup>5</sup> (1789), and Weidmann<sup>6</sup> (1793); and since excisions have become an established surgical resource, writers treating of excisions of the trunk have usually alluded to the possible necessity of trephining or partial excision in the innominate bone. The ilium has received much less attention, however, than its homologue, the scapula. A correspondence might be instituted between the two, parallel to that between the femur and tibia among long bones, in adaptability to excision. That the tibia and scapula admit of mutilations to an extent that would surely prove fatal in the femur and ilium, is partly due to absence of the thick muscular investments which cover the latter bones. Hennen<sup>7</sup> was averse to interference with shot fractures of the ilium; but his experience of such cases appears to have been very limited, and led him to conclusions now known to be erroneous, for the mortality of these injuries has been proved to be comparatively small, and the advantages of removing the irritation induced by impacted balls or diseased bone has been demonstrated. Yet, with all of the practical precepts of this wise teacher, this caution of Hennen's should be borne in mind; for while judicious interference is often required in this group of cases, imprudent and ill-considered operations are nowhere more disastrous. The extraction of impacted balls, the removal of primary sequestra, the extraction of loose exfoliations, the scraping or gouging of carious canals, must be widely discriminated from formal excisions; and Professor Malle, with justice, contends that it was not without doing violence to surgical idiom that

<sup>1</sup> LEDRAN (*Observations de Chirurgie*, Paris, 1731, T. II, p. 265, Obs. XCV) relates a case of caries of the ilium, on a colonel of infantry, on whom M. LEAULTÉ, after cauterizing the bone, broke away the carious part with forceps. LEDRAN, also, in *Traité ou Reflexions tirées de la Pratique sur les Playes d'Armes à feu*, Paris, 1737, in the chapter *Des Playes aux os des isles*, gives the following precept: "Si la balle ayant percé l'os, n'avoit pas pénétré bien avant dans le bassin, et qu'elle fût arrêtée dans le tissu cellulaire du péritoine, ou bien dans la face interne de l'os, entre lui et les muscles qui le tapissent intérieurement; enfin si elle n'étoit pas loin, ce qu'il est quelquefois possible de connoître avec la sonde ou le doigt, il faut, pour l'ôter, agrandir l'ouverture de l'os, soit avec le trépan exfoliatif, soit avec la gouge, soit avec les tenailles incisives."

<sup>2</sup> ARRACHART (*Mém. dissert. et obs. de chirurgie*, Paris, 1805, p. 269, *Observation sur une carie de l'os des isles et de l'os sacrum*, lue à l'Académie de Chirurgie en 1766), relating the case of Lecoq with caries of the ilium following fracture, remarks that it was decided to apply the actual cautery in order to "hâter la chute des esquilles. Cette opération fut répétée de huit ou huit jours jusqu'à trois fois." The patient, who had been suffering for over a year, recovered rapidly.

<sup>3</sup> PERCY's precept is as follows (*Man. du chir. d'Armée*, 1792, p. 139): "Si une balle après avoir percé l'os des isles n'étoit pas allée trop loin dans le bassin, qu'elle se fût fixée dans le tissu cellulaire du péritoine ou dans les muscles psoas et iliaque, et qu'il fût possible de la reconnoître avec le doigt ou la sonde, il faudroit, pour l'extraire, augmenter l'ouverture de l'os par quelque un des moyens ci-devant énoncés et même le trépan, comme l'a fait, dans une autre circonstance, M. BOUCHER (Il est chirurgien à la Flèche. Voyez les *Seances publiques de l'Académie de Chirurgie*, année 1776, page 66), si le siège de la balle ne correspondoit pas à cette ouverture." I cannot refer to BOUCHER'S paper.

<sup>4</sup> THEDEN (*Neue Bemerkungen und Erfahrungen zur Bereicherung der Wundarzneikunst*, Berlin, 1782, B. II, S. 49) remarks: "Sometimes the ball remains half in the ilium. \* \* \* The wound is to be freely opened, the bone to be laid bare without touching the ball, aside of which an opening in the bone is to be made either with the trepan or with a rasping iron, or, if you have neither, by shaving with a piece of glass. Insert into the opening an iron lever and prize the ball outward. I have successfully used this method in such a case."

<sup>5</sup> MANNÉ (*Traité élémentaire des maladies des os*, Toulon, 1789, p. 186) remarks: "S'il y avoit fracture avec esquilles, à l'os ilium, on feroit les incisions nécessaires pour relever les pièces enfoncées, et extraire celles qui seroient détachées; s'il y en avoit qui ne pussent pas être relevées avec des élevatoires ou des pince, on trépaneroit la partie voisine, pour avoir la facilité de les relever, et d'extraire des corps étrangers s'il y en avoit. On est aussi quelquefois obligé de trépaner pour donner issue au pus d'un abcès formé entre l'os et le muscle iliaque."

<sup>6</sup> WEIDMANN, *Diss. de necrosi ossium*, Francofurti, 1793, p. 111.

<sup>7</sup> HENNEN (*Mém. Mil. Surg.*, 2d ed., 1829, p. 419) declares: "I have never witnessed a recovery from an injury of this description, nor have I seen one, where the performance of any operation, much less the application of a trephine, as proposed by Boucher in the Memoirs of the French Academy for 1776, could have been of use. The picking away of splinters, or other sources of irritation, is all that I have ventured to do in the few cases that have come under my care, trusting the remainder to proper regimen and dressings, and to the sanative powers of nature."

Velpau and Oscar Heyfelder confounded them all under the latter term. During our war, operations of some sort were practiced on the ilium in one hundred and fifty-one instances, and many analogous examples are found in the modern annals of European surgery. In two of our cases trephining was practiced:

CASE 674.—Corporal A. Knoth, Co. E, 41th Illinois, aged 25 years, having been wounded by a conoidal ball at Atlanta, Georgia, on August 6, 1861, was admitted into the field hospital of the 2d division, Fourth Corps. The ball had entered the right ilium about an inch and a half behind the anterior superior spinous process, and about one inch below the crest, passed downward and backward, and had lodged. The patient was transferred, on August 17th, to Chattanooga; on August 23d, to Nashville; September 8th, to Louisville; November 30th, to Madison; and on July 30, 1865, to Camp Butler, Illinois. In the early stages of the case the wound became gangrenous. At the hospital at Madison, Surgeon J. H. Rauch, U. S. V., detected the ball by means of a Nélaton probe properly curved. It lay underneath the psoas magnus, below the ilio-pectineal line, near the sacro-iliac symphysis and the external iliac artery. On February 21, 1865, the patient was chloroformed; a crucial incision, directly across the external opening, was carried down upon the dorsum of the ilium; the flaps were dissected up, revealing the bone much thickened. An opening was made with a trephine and enlarged by a chisel, downward and backward, an inch and a half in length. After repeated trials, the ball was extracted. The wound was left open; cold-water dressings were applied; gentle aperients occasionally given, and a bottle of ale was allowed daily. The constitutional condition was very good; by March 30, 1865, the patient was almost well. He was discharged from service August 30, 1865, with "loss of use of right leg and lameness of hip-joint." The disability was rated as total. On January 11, 1870, Pension Examiner H. M. Seymour reports: "In the summer of 1869 the wound reopened, and the patient was obliged to spend several months in the county hospital at Chicago. The wound is now closed, but is liable to reopen. Disability total, of uncertain duration."

Another instance of the perforation of the ilium by the trephine, to facilitate the removal of a ball, was reported by Surgeon John A. Lidell, U. S. V., who has printed an interesting detailed account of the case elsewhere:<sup>1</sup>

CASE 675.—Corporal A. Millhaupt, Co. C, 24th Wisconsin, aged 33 years, wounded at Chancellorsville May 3, 1863, was sent to Washington, and admitted into Stanton Hospital on June 15, 1863. A conoidal musket ball had entered three inches below the crest of the left ilium and lodged. The wound healed readily, and the patient was furloughed on June 29th; but the wound reopened soon after. Upon readmission, Surgeon J. A. Lidell, U. S. V., detected the ball with a Nélaton probe, and, on December 16th, dilated the wound and enlarged the perforation of the ilium made by the ball, removing a button of bone with the trephine, and extracted the ball with a strong necrosis forceps. Pyæmia supervened, and terminated fatally December 31, 1863.

Operations of various degrees of magnitude for the removal of primary or tertiary sequestra, of balls and other foreign bodies, and of carious bone, were not infrequent. An early example was recorded by the distinguished Tripler:

CASE 676.—Surgeon Charles S. Tripler, U. S. A., in his monthly report from St. Mary's Hospital, Detroit, October, 1863, relates the following observation: "Captain W. H. Rexford, 24th Michigan, was wounded, at the battle of Gettysburg, by a conoidal ball, which struck him about one inch posterior to the anterior superior spinous process of the right ilium, passed into the cavity of the pelvis, and again made its exit through the ilium just above the sciatic notch and immediately anterior to the sacro-iliac synchondrosis, and lodged in the gluteal muscles, from whence it was removed a few days after the battle. The patient's general health had become quite good; but the wounds showed but little disposition to heal. At length the presence of dead bone having been revealed at the posterior opening by means of the probe, it was decided to attempt its removal. The patient being placed under the influence of chloroform, the injured portion of the ilium was exposed. Necrosed bone having been removed through the opening made by the ball in its exit, the finger was readily introduced into the pelvic cavity. The operation produced no appreciable ill effect on the general condition of the patient. One week after the operation, a piece of cloth, probably from the pants, about one inch long and half an inch wide, enveloping a splinter of bone nearly an inch long, made its way out from the cavity of the pelvis. Patient is now doing exceedingly well." Examining Surgeon J. A. Brown, of Detroit, Michigan, reported February 25, 1864: "Ball entered the ilium near the anterior superior process, perforated it twice, and was extracted near the attachment of the gluteus maximus. Result: Destruction of the ilium, atrophy of right leg; great debility and incurable deformity; wound still open; disability total, and probably incurable."

CASE 677.—Private Joel Mixon, Co. F, 19th Maine, aged 35 years, was wounded at North Anna River, May 23, 1864, and was treated in a field hospital of the Second Corps until the 29th, when he was sent to Mount Pleasant Hospital, Washington. Assistant Surgeon C. A. McCall, U. S. A., reported: "Gunshot wound of the right ilium, fracturing the bone severely. The ball entered over the dorsal side of the ilium, passing through obliquely upward and inward, and making its exit through the abdominal muscles one-third of the space from the ilium to the umbilicus. The discharge was offensive. On June 10, 1864, Acting Assistant Surgeon M. C. Mulford excised two and a half inches of the ilium, extending from the superior spinous process down into the body of the ilium, following the course of the fracture, and smoothing off the ragged edges of the bone. At the time of the operation his general condition was good. The inflammation of the wound and putrid discharge, with slight rigors, decidedly indicated the extension of inflammation to the peritonæum. The operation was followed by a copious, thin, dark-colored discharge from the deep and extensive wound. Light and nutritious food, with tonics, were given. The patient died on June 17, 1864, from peritoneal inflammation and gangrene."

<sup>1</sup> LIDELL. *On Gunshot Fractures of the Pelvis*, in *Am. Med. Times*, 1864, Vol. viii p. 135.

CASE 678.—Colonel A. J. Warner, 10th Pennsylvania Reserves, was wounded at Antietam, September 17, 1862. He was struck by a conoidal musket ball an inch obliquely below and behind the anterior superior spinous process of the right ilium. There was not much bleeding or faintness, and the colonel was able to dismount without assistance. The ball was found to have perforated the ilium very obliquely from before backward and inward, and was out of reach of the finger or probe. After his wound was dressed, he was sent to Hagerstown, and thence, early in October, to Washington, when Surgeon Meredith Clymer, U. S. V., found that a series of chills had attended the separation of the eschars and the formation of pus, and that the inflammatory reaction had in a measure subsided, the shot orifice discharging freely. There was nothing to indicate an abdominal complication. A careful search having failed to detect the missile, the treatment was limited to general measures until December, when, on account of the persistent lumbar neuralgia, and of symptoms indicative of confined matter, Surgeon Clymer, in consultation with Surgeon J. B. Brinton, U. S. V., determined on a more extended exploration. Except in removing some bits of necrosed bone, this search was unavailing, though carried as far as prudence would permit, and no further operative interference was undertaken until February 6, 1863. In the meantime, Colonel Warner suffered from recurring abscess-formation, and acute pain at intervals; but, endowed with an iron constitution, his general health deteriorated less than is common under such circumstances, and there was no threatening of pyæmic infection. On February 6, 1863, this officer was placed under the influence of chloroform, and Surgeon Brinton made an incision upon the dorsum of the ilium and freely exposed the orifice of entrance in the bone. The walls of the shot canal were then chiseled and gouged away, and, after a protracted search, the ball was detected near the sacro-iliac synchondrosis, very firmly embedded in the spongy substance of the ilium. After many unsuccessful attempts with various forceps, it was at last extracted with a strong pair of pincers, and with it bits of clothing and of bone. The ball, which Colonel Warner retains in his possession, was split at the apex, and a piece of bone was wedged in the fissure. The operation occupied nearly three hours. Considerable, but not excessive, inflammatory action ensued after the operation; but the local pain was diminished, and in a few weeks the wounds showed a disposition to cicatrize. In a few months they healed up, but reopened at intervals for the discharge of phlegmonous abscesses, provoked by small exfoliations. The colonel was able to resume his command at Gettysburg, and was subsequently transferred to the command of the 17th regiment of the Veteran Reserve Corps and brevetted a brigadier general. He continued to suffer from occasional pus-formations at the seat of injury until the end of 1866, when the cicatrices became firmly adherent to the dorsum of the ilium, and free from sensitiveness, except in damp weather. His ordinary weight of one hundred and eighty pounds gradually augmented to two hundred pounds. He was pensioned. Examiner G. O. Hildreth, of Marietta, reported, November 2, 1867, the shot perforation of the ilium, and subsequent extraction of the ball, and stated that: "He suffers from neuralgic pain around the wound, and on the outside of the leg in the course of the sciatic nerve, especially in cold and damp weather." In October, 1873, the editor met this officer and learned the foregoing facts, many of which had not been placed on record.

CASE 679.—Private George R. Brookius, Co. D, 16th Michigan, aged 22 years, was wounded at Gaines's Mill, June 27, 1862. He remained at the field hospital until July 20th, when he was conveyed, on the hospital steamer Louisiana, to Baltimore, and admitted into the Camden Street Hospital. Here Acting Assistant Surgeon E. G. Waters reported as follows: "A conical bullet, about one ounce and a quarter in weight, entered the right buttock, passed horizontally forward through the dorsum of the ilium about three inches below its crest and the same distance from the sacrum, and lodged within the cavity of the pelvis. The external wound healed sufficiently in a few weeks to admit of his going out into the city daily. The external wound opened again from time to time, and, on one of these occasions, Assistant Surgeon J. T. Calhoun, U. S. A., whose patient he then was, desired me to see him. I discovered satisfactorily, with an ordinary probe (the Nélaton instrument had not then been introduced), a foreign body lying within the cavity. A few days afterward, through the transfer of Dr. Calhoun to West's Buildings Hospital, the patient came under my care. He readily consented to an attempt at removal of the foreign body. Accordingly, on April 9, 1863, he was put under chloroform, and, after an hour's effort, during which it was necessary to chisel away much bone in order to reach its locality, the bullet was successfully seized and removed. It seemed to have pushed before it the long wall of the pelvis, and laid at the bottom of a tubular cavity of bone, fully four inches from the external surface. No accident followed the operation, and, on July 1, 1863, he left the hospital, cured, for his home, having been discharged from service." This man was pensioned. Drs. A. Farnsworth and A. B. Spinney, of East Saginaw, Michigan, reported, July 30, 1863, that the "ball struck upon the right posterior iliac region about two or three inches to the right of the junction of the last lumbar vertebra with the sacrum, fractured the bone, and, passing through, lodged upon the internal surface of the right ilium. There is much lameness of the spine and right hip; coldness and numbness of the limb, caused by injury of the nerves." He was last paid December 4, 1872.



FIG. 176.—Conoidal ball compressed and curved by impact on the vertebral processes and ilium. *Spec. 4623.*

CASE 680.—Private J. Stiehler, Co. G, 184th Pennsylvania, aged 18 years, was wounded at Deep Bottom, Virginia, on August 14, 1864, by a conoidal ball, which entered to the right of the last dorsal vertebra, passed inward and downward through the dorsum ilii, and lodged in the right iliac fossa. Being sent to Washington, he was admitted into the Emory Hospital on the 17th. On the 19th, Surgeon N. R. Moseley, U. S. V., removed the ball (FIG. 176) through an incision of two inches, with small pieces of the vertebral process and crest of the ilium. The subsequent treatment consisted of cold-water dressings, tonics, stimulants, and a nutritious diet. The patient was doing well by September 30th; he was returned to duty on December 7, 1864, and was mustered out of service on July 14, 1865, and pensioned. He was paid to September 4, 1872, and the disability was then rated as one-half, and permanent.

CASE 681.—Corporal J. R. Morris, Co. K, 114th Illinois, aged 21 years, was wounded at Tupelo, July 15, 1864, by a minie ball. He was treated in a field hospital of the Sixteenth Corps, and thence, on July 21st, sent to Memphis, to Adams's Hospital. Assistant Surgeon J. M. Study, U. S. V., reported: "Gunshot wound of the left ilium. \* \* \* Portions of the fractured ilium were removed. There were no symptoms of wounded intestines, and no difficulty in the passages from the bowels. He has slight fever in the afternoon; has no pain, and the wound discharges freely. The fever yielded to antiperiodics. The patient did well until attacked with symptoms of pyæmia, August 6th. He died August 9, 1864."



CASE 682.—Private H. Redmond, Co. I, 1st Mississippi Marine Brigade, aged 22 years, was accidentally wounded at Alexandria, Louisiana, April 15, 1861. He was sent, on the hospital steamer Woodford, to New Orleans on May 10th, and admitted to Jackson Barracks Hospital. Thence he was transferred, on July 23d, to the Marine Hospital, St. Louis, where Surgeon Adam Hammer, U. S. V., reported as follows: "Gunshot wound by a round ball, which entered one inch below the anterior superior spinous process of the ilium and passed outward and obliquely upward to the angle of the tenth rib, passing between the muscles and skin, forming a canal thirteen inches in length. On July 24th, there was a slight degree of inflammation and suppuration, and the canal was then enlarged, and several pieces of the ribs and os ilium were extracted and simple dressing applied. He deserted January 19, 1865."

CASE 683.—Private D. Roarke, Co. H, 22d Massachusetts, was admitted to National Hospital, Baltimore, on July 21, 1862, with a shot fracture of the right ilium. On August 5th, a necrosed fragment (FIG. 177) was extracted by Surgeon A. B. Hasson, U. S. A. The patient convalesced, and was discharged for disability October 21, 1862, and pensioned. He re-enlisted in the Veteran Reserve Corps June 29, 1864. His application for pension alleges that he was wounded at Gaines's Mills June 27, 1862, by a ball, which "took out a piece of the hip bone; also in the right shoulder with a shell, and lay on the battle-field for fifteen days, and was taken prisoner and carried to Richmond, and received no medical treatment until August 5, 1862." Pension Examiner G. S. Jones reported, February 7, 1863, that "a portion of the crest of the ilium has been removed, in consequence of which he has soreness and pain in the parts." This pensioner was last paid to April, 1873.

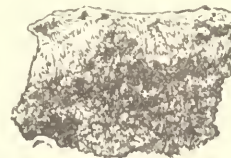

FIG. 177.—Curious fragment of the right ilium. *Spec.* 421.

CASE 684.—Private J. A. Addison, Co. G, 61st New York, was wounded at White Oak Swamp, June 25, 1862, and treated in regimental hospital until July 3d, when he was sent to the National Hospital, Baltimore. Necrosed fragments of bone were removed on August 12th, and the man was discharged for disability on September 16, 1862. He re-enlisted August 25, 1864, and was again discharged June 16, 1865. Surgeon A. B. Hasson, U. S. A., sent to the Museum, with the foregoing particulars, a specimen of the exfoliation removed (FIG. 178). It consists of a fragment, three-fourths of an inch square, from the ilium, the laminated surface of which appears to have been partially fractured as if by a nearly spent ball. Pension Examiner L. H. Robbins, of Lincoln, Nebraska, reported, August 31, 1871: "Ball entered at the upper edge of the superior spinous process of the ilium, fracturing it and passing into the cavity. There has been a constant discharge through a fistulous opening in the wound, causing great debility, and rendering him unable to perform manual labor; the disability will probably be permanent." He was last paid to June 4, 1873.



FIG. 178.—Necrosed fragment taken from the ilium. *Spec.* 431.

CASE 685.—Sergeant H. Oswald, Co. M, 24th New York Cavalry, aged 23 years, was wounded at Cold Harbor, June 3, 1864, and sent to Alexandria on the 8th, and thence to Philadelphia, entering Mower Hospital on the 29th. Here Acting Assistant Surgeon B. Barr reported: "The ball entered the left groin, passing through the left ilium, and lodged near the trochanter major, whence, on July 9th, it was removed, with several pieces of bone, by Acting Assistant Surgeon W. P. Moon. The patient did well after the operation. Simple dressings only were used. Wine, brandy, milk-punch, and beef-tea were administered as freely as the patient could take them." Surgeon J. Hopkinson, U. S. V., contributed the pathological specimen, No. 3619, consisting of sixty-three small osseous fragments, some necrosed, others constituted by new osteophytes, weighing in the aggregate eighty grains. The ball remained in the soldier's possession. He is not a pensioner, being recorded a deserter.

CASE 686.—Private B. Cook, Co. I, 63d Pennsylvania, aged 18 years, was wounded at White Oak Swamp, June 30, 1862, by a musket ball, which grazed the outer surface of the right arm midway between the shoulder and elbow, and by a fragment of shell, which fractured the crest of the right ilium. He was admitted on the hospital steamer Louisiana, on July 20th, as a paroled prisoner of war, and transferred to Baltimore, where he was admitted to Camden Street Hospital on the 21st. At this time he was feeble, and was treated with water-dressings locally, and tonics and stimulants. On August 24th, the necrosed surfaces of the ilium were removed with the gouge, and small fragments that continued to separate were frequently removed subsequently. On November 21, 1862, he was discharged the service cured, there being at this time some contraction of the upper muscles of the thigh, and the foot could not be kept long on the ground without inconvenience. The specimen (FIG. 179) consists of six small fragments of dead bone from the ilium, and was contributed, with the history, by Dr. Waters, and transmitted by Surgeon L. Quick, U. S. V. Pension Examiner G. McCook, of Pittsburg, reported, February 16, 1863: "Locomotion is considerably impaired; the case will be probably improved by time; disability one-half." The pensioner was last paid in November, 1863. No subsequent report to the third auditor.

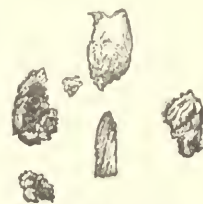

FIG. 179.—Necrosed fragments removed after a shot fracture of the ilium. *Spec.* 432.

When a missile perforates the ilium and lodges under or in the iliacus or psoas muscles, Baudens teaches<sup>1</sup> that it is safer to seek the ball through an incision similar to that made for ligation of the common iliac artery, rather than to enlarge the shot canal in the ilium or to trephine the bone.

<sup>1</sup> BAUDENS (*Clin. des plaies d'armes à feu*, 1836, p. 298) teaches: "Il faudrait alors faire agir le tire-fond obliquement à leur surface, et peut-être même le rejeter, pour recourir au trépan. Ce moyen est également conseillé pour retirer les balles profondément engagées, et dont la présence ferait redouter la formation d'abcès et de fûtes purulentes fistuleuses. Cette perte de substance osseuse aurait le double avantage d'ouvrir une facile issue à la suppuration et de préparer ainsi les voies à la guérison. Dans une circonstance où à l'aide d'une sonde j'avais pu suivre, à travers une perforation de l'os iliaque du côté droit, le trajet d'une balle jusque dans la substance du muscle psoas où elle s'était arrêtée, j'ai rejeté le trépan, et j'ai préféré arriver directement et bien plus sûrement au projectile en ouvrant l'abdomen par une incision courbe, faite dans le pli de l'aîne, comme pour la ligation de l'artère hypogastrique."

There is reason to believe that in some cases of limited caries, after shot fracture, in subjects of sound constitution, palliative measures may be followed by radical cures. The orifice or orifices of the shot canal being kept open, and the fistulous track gently stimulated and kept free from minute exfoliations by detergent injections, cicatrization may ensue, without the risk of removing the osseous wall. When, as in the following case, a formal excision would involve breaking down the inner lamina of the ilium the operation becomes very hazardous:

CASE 687.—Colonel Joseph B. Kiddoo, 22d Colored Troops, aged 30 years, was wounded in an engagement before Richmond, October 27, 1864. Surgeon Charles G. G. Merrill, 22d Colored Troops, recorded the injury as a "lacerated wound of the back by a minie ball." On October 29th, this officer was sent to Chesapeake Hospital, near Fort Monroe. Assistant Surgeon E. McClellan reported the injury as a "shot wound in the lumbar region, involving the spine." The particulars of the case are not found on the hospital registers or case-books. On January 11, 1865, Colonel Kiddoo was transferred from the hospital and was treated in quarters at Washington. On September 4th, he was brevetted a major-general of volunteers; on July 28, 1866, he was commissioned lieutenant-colonel of the 43d Infantry; on December 15, 1870, he was retired from active service with the full rank of brigadier-general, U. S. A. In Washington, this officer was attended by Assistant Surgeon Notson, U. S. A., and it is believed that a memorandum of the facts of the case was furnished by him for the files of the Surgeon General's Office, but no record of this paper has been found. In the autumn of 1866, Assistant Surgeons Thomson and Billings saw the case in consultation with Dr. Notson, and an operation was determined on for the removal of dead bone or other sources of irritation. Dr. Billings has kindly furnished the following minute of his recollection of the circumstances: "When seen by Drs. Thomson, Notson, and myself," Dr. Billings writes, "there was a fistulous opening near the anterior superior spine of the left ilium, from which from half an ounce to an ounce of pus discharged daily. Exercise produced pain in the sacro-iliac junction, with tendency to cramp in the posterior muscles of the left thigh. A canal with bony walls, about the size of a goose-quill, was found to lead from the opening downward, backward, and inward, the probe passing freely for about eight inches. The outer opening was enlarged by incision, and the edge of the bony canal was cut away with the bone-gouge forceps. Several scales of dead bone were removed from the canal and its walls were scraped out with a raspator. It was then thoroughly syringed out, and the patient was directed to lie on his abdomen as much as possible for a few days, to keep the opening at the lowest point. Subsequent treatment consisted in syringing the canal with a very dilute solution of carbolic acid. The wound entirely closed, and gave him no trouble for two or three years. I believe it has since opened once or twice." Notwithstanding the occasional inconvenience arising from his wound, it is gratifying to know that General Kiddoo, in 1873, nearly ten years after the reception of his injury, enjoys tolerable health, and is enabled to engage in laborious professional avocations.

CASE 688.—Private H. G. Bigelow, 15th Massachusetts, was wounded at Antietam, September 17, 1862. A musket ball, which struck just below the anterior superior spinous process of the left ilium, channelled the crest of the bone, and escaped near the sacro-iliac junction an inch below the posterior superior process, carrying some splinters out of the orifice. On September 22d, his surgeon (the lamented Haven, killed a few months afterward at Fredericksburg) made an incision three inches long midway between the entrance and exit orifices, and removed several fragments of shattered bone, of which three were seen each at least an inch long, three-quarters of an inch in width, and of the entire thickness of the ilium. In December, the patient was removed to his home in Berkshire County, and was attended by Dr. Frank A. Cady, who has published an interesting history of the case at this stage.<sup>1</sup> In January, 1863, there was pus suppurating from the orifices of entrance, incision, and emergence, with occasional escape of necrosed bone. On January 27, 1863, Mr. Bigelow was promoted to a lieutenancy. The shot canal was daily syringed with a dilute solution of nitrate of silver. On March 15th, the wounds had cicatrized, and the lieutenant reported for duty, and was transferred to the Veteran Reserves, and resigned August 28, 1863, and was pensioned. On May 2, 1871, Examiner T. B. McNett, of Grand Haven, Michigan, reported that "numerous pieces of bone had been discharged through a fistulous opening, and a constant drain of pus had seriously affected his health. He is a bookkeeper by profession, but will have to resign his position on account of ill health."

CASE 689.—Private J. A. Cole, Co. H, 25th Iowa, aged 23 years, was wounded at Arkansas Post, January 11, 1863, and was conveyed on the hospital transport Louisville to the Adams Hospital at Memphis. A musket ball had struck the posterior superior process of the left ilium and buried itself in the bone, whence it was extracted soon after the reception of the injury. On April 10, 1863, Acting Assistant Surgeon T. T. Smiley cut down through the indurated tissues near the wound entrance and removed a number of loose pieces of necrosed bone, and then, with the gouge and rachine, scraped cleanly the neighboring carious bone, leaving a cavity of the size and shape of half an egg divided longitudinally. Dr. Smiley has printed an account of the operation, with a prognosis that was unhappily not verified.<sup>2</sup> The patient was transferred to Lawson Hospital, St. Louis, April 17, 1863, and, on June 9th, was sent to Kookuk, when he was discharged from service September 6, 1864, Surgeon M. K. Taylor, U. S. V., certifying that there was "atrophy of the gluteal muscles and loss of sensation throughout the entire left leg." The pension records show that this pensioner died January 30, 1865.

An analysis of the one hundred and fifty-one operations on the ilium shows eighty-two instances of removal of bone, thirteen of removal of ball with bone-splinters, fifty-five of extraction of balls, and one of extraction of a piece of cloth. In four of the cases

<sup>1</sup> CADY (F. A.), *Gunshot wound*, in *Extracts from the Records of the Berkshire District Medical Society*, *Boston Med. and Surg. Jour.*, 1863, Vol. LXVIII, p. 286.

<sup>2</sup> SMILEY, *Gunshot Wounds from Arkansas Post*, in *Boston Med. and Surg. Jour.*, 1863, Vol. LXIX, p. 154.

of removal of bone and in two of the ball-extractions, portions of clothing also were removed. Of the eighty-two operations for the removal of bone, eight consisted in the primary extraction of splinters, and of these cases three resulted fatally; two were instances of formal trephining, one proving fatal and the other failing to effect a permanent cure; fifty-seven, with six deaths, were secondary operations, consisting of the removal of exfoliations or of large pieces of necrosed bone, or of the application of the gouge or chisel to carious parts; and fifteen were extractions of sequestra at unspecified dates. Of the thirteen examples of removal of balls<sup>1</sup> with bone splinters, two were primary, one resulting fatally; ten, with one fatal instance, were secondary; and one case, with a favorable termination, was of uncertain date. Of the fifty-five ball extractions, fourteen, with five fatal terminations, were primary; thirty-two, with six deaths, were secondary; and nine operations, with three deaths, were of undetermined date. In a single case, a piece of cloth only was removed at a long interval after the injury. In the aggregate, there were twenty nine fatal cases, or the small percentage of 19.2; twenty-four primary operations, with nine deaths; one hundred and two secondary, with fourteen deaths; twenty-five of undetermined date, with six deaths. In other words, the mortality of the cases in which operative interference<sup>2</sup> was undertaken was less than the mean mortality of shot fractures of the ilium, computed from the eight hundred and nineteen known cases with two hundred and eleven deaths, or 25.7 per cent.

Sufficient evidence has been adduced to prove that authors have erred in representing shot fractures of the ilium as being dangerous, and to indicate that the prognosis of Percy should be re-established.<sup>3</sup> Professor Hannover, from researches among the Danish invalids, appears first to have noticed this error of the moderns.

<sup>1</sup> PIROGOFF (*Grundzüge*, u. s. w., 1864, S. 835) remarks: "If the bone be at all accessible, I advise, during the period of suppuration, instead of a tedious, uncertain, and dangerous extraction, the resection of the bone which holds the missile."

<sup>2</sup> LISFRANC (*Précis de méd. opérat.*, Paris, 1846, T. II, p. 518) remarks: "Chez le malade qui tout récemment a reçu un coup de fusil près du bois du Meudon, M. VICTOR BAUD a enlevé un fragment osseux assez considérable provenant de cette crête." HEYFELDER (J. F.) (GÜNTHER, *Lehrbuch von den Blutigen Operationen*, 1860, B. IV, S. 2) successfully removed, at Erlangen, in 1847, a necrosed portion of bone, three inches long, from the ilium at the antero-internal margin of the ischiatic notch. In a case in which a ball penetrated the ilium an inch below the middle of the crest, and many bone splinters could be felt deep in the wound, and the ball was supposed to have lodged, Dr. LÄTER (*Preuss. Med. Vereinszeitung* XVIII, 1849) enlarged, two months after the reception of the injury, the shot channel with a trephine, introduced a finger, and removed splinters of bone; the ball could not be found; the patient recovered in seven months. HEYFELDER (J. F.) removed (*Beiträge zur Operat. Chir.*, in *Deutsche Klinik*, 1858, B. X, S. 204), December 23, 1857, the necrosed anterior superior spine of the ilium with a chain saw, in a patient whose pelvis had been fractured in a railway accident; death occurred two days after the operation. Dr. NEUDÖRFER (*Handbuch der Kriegschir.*, 1867, S. 804), in the case of Josef Haeba, a Tyrolean sharpshooter, shot in the ilium at Solferino, June 24, 1859, on December 13, 1859, enlarged the shot channel with a chisel; the ball was not found, but on cutting away several osteophytes and a point of bone which obstructed the entrance of the shot canal, necrosed fragments were removed; recovery in two months. Dr. ROUX (J.), in CHENU (*Statistique méd. chir. de la campagne d'Italie en 1859 et 1860*, Paris, 1860, T. II, p. 505), records the case of A. Duprez, wounded at Magenta, June 4, 1859, in the left flank. In October an incision was made, the trephine applied, and the ball with difficulty removed with pineers. Inflammation, œdema, etc., supervened, and the patient died January 3, 1866. DEMME (*Studien*, Würzburg, 1861, B. II, S. 171) gives the case of G. B., wounded at Solferino, June 24, 1859; the ball entered the ilium and was said to have been extracted at the ambulance station; several pieces of bone had been removed; the patient was failing from consecutive caries and suppuration. On October 5th, Dr. NEUDÖRFER removed the carious portion of the anterior crest of the ilium and extracted a piece of ball that had remained; the patient made a good recovery. Dr. NEUDÖRFER makes no mention of this incident. SIEBERT (*Statistik der Resektionen ausgeführt von Professor F. RIED*, Jena, 1868, S. 38) states that a triangular piece of necrosed bone was removed from the right ilium with the osteotome by Dr. RIED; recovery. VASLIN (*Étude sur les plaies par armes à feu*, Paris, 1872, p. 100) relates the case of E. Dumard, wounded near Orleans, December 2, 1870, in the right ilium. On March 26, 1871, M. LÉON LABRÉ made a free incision and enlarged the shot canal with a gouge and mallet and removed the ball; the patient left the hospital on July 8, 1871. Professor SOGIN (*Kriegschirurgische Erfahrungen*, 1872, S. 97) remarks that in the case of Désiré Blot, wounded at Gravelotte, August 18, 1870, Professor HEINE made a partial resection of the crest of the ilium; several necrosed fragments of bone were afterward removed, and the wound did not completely close until the 142d day.

<sup>3</sup> Baron PERCY (*Man. der Chir. d'Armée*, 1792, p. 242) taught that "Les fractures des os des fesses ne sont pas dangereuses." In departing from this precept HENKES has been followed by most modern surgeons: Thus, Dr. STROMEYER (*Maximen*, u. s. w., 1855, S. 655) asserts that: "Injuries of the pelvis must be considered as dangerous as injuries of the head." DEMME (*Studien*, B. II, S. 176) gives the same opinion. GUTHRIE (*Lectures*, etc., 1847, p. 60) observes that: "Although frequently fatal, they are not usually so at the moment." Dr. LOHMEYER (*Die Schusswunden*, 1850, S. 147) declares: "Death is the most frequent result of shot fractures of the pelvis." Dr. OCHWADT (*Kriegschir. Erf.*, 1865, S. 351) announces that: "According to our observations we must consider shot wounds of the pelvis, with or without injury to the viscera, very dangerous." On the other hand, M. HUGUET (*Des plaies d'armes à feu*, etc., 1819, p. 132) contends that in comparison with wounds of the head, chest, and abdomen, "Celles du bassin sont moins mortelles, même avec lésion des organes qu'il contient." Herr BECK (*Kriegschir. Erf.*, 1867, S. 250) has found "the results various, but not as fatal as generally supposed;" and Dr. NEUDÖRFER (*Handbuch, &c.*, 1867, S. 763) errs in the opposite direction in declaring that: "Shot wounds of the pelvis, without injury to the viscera, are never fatal, and not even dangerous, but as a rule heal slowly." Professor HANNOVER (*Die Dänischen Invaliden*, 1870, S. 20), than whom few have more carefully studied the remote results of injuries, has arrived at the conclusions enunciated in the text.



Though the limits that would be assigned to this subject by the usual nosological classifications have been transgressed, the materials relating to it have by no means been exhausted. The Catalogue of the Surgical Section will direct the student, in addition to those that have been presented, to many interesting examples in the Museum, of shot fractures of the ilium and of the destructive and reparative processes consequent on them, and particularly to the specimens marked 2488, 3525, 3872, and 6313. One of these,

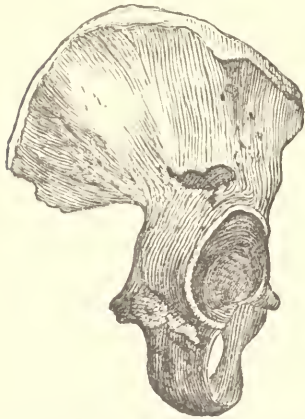


FIG. 180.—Ball split and resting astride of the outer table of the right ilium (*Musée du Val-de-Grace*). [After LEGOUËST.]

of which there is no available drawing, illustrates the splitting of a ball upon the outer lamina of the ilium,<sup>1</sup> and closely resembles the preparation (FIG. 180), already alluded to, as figured by M. Legouëst. In treating of the injuries of the hip-joint there will be occasion to revert to some of these illustrations. Many interesting abstracts of war cases of shot fracture of the ilium have appeared in the journals or in surgical treatises: Surgeon J. Bryan, U. S. V., has related<sup>2</sup> the case of Private J. B. Edgar, convalescent after necrosis following a shot fracture of the crest of the right ilium. The lamented J. Mason Warren recorded<sup>3</sup> a difficult ball extraction in the case of Private W. O. Young, 1st Massachusetts, through a track leading for several inches through the gluteal muscles, to a chipped fracture at the inner edge of the great sciatic notch, an excruciating neuralgia being relieved by the removal of the missile. Other instances will occur to those who study the annals of war surgery<sup>4</sup> or follow the current of periodical surgical literature.<sup>5</sup>

<sup>1</sup> Professor P. F. EVE states (*Nashville Jour. of Med. and Surg.*, 1867, Vol. II, p. 232) that this splitting of the ball upon the ilium occurred also in the case of Governor G. MacDuffie, of South Carolina, wounded in a duel. The position of the missile was not detected, and the statesman died from irritation induced by its presence, in 1851.

<sup>2</sup> BRYAN (J.), *Gunshot wounds in the Army—Injuries of the Pelvis*, in *Boston Med. and Surg. Jour.*, 1862, Vol. LXVI, p. 49.

<sup>3</sup> WARREN (J. M.), *Surgical Observations, with Cases and Operations*, Boston, 1867, Obs. CCCXXVIII, p. 551.

<sup>4</sup> The eleven following cases, in which the results are recorded by authors, may be added to the fifty-five determined cases enumerated in the note to page 216: BORDENAVE (*Précis de plusieurs observations sur les plaies d'armes à feu en diff. parties*, in *Mém. de l'Acad. Roy. de Chir.*, Paris, 1753, T. II, p. 522) relates a successful case of a shot fracture of the ilium, treated by PLANQUE. HENNES (*Princ. of Mil. Surg.*, 1829, p. 450) cites a case treated by Dr. THOMSON: An officer, wounded in the ilium by a ball, "where it remained above two years, until violent inflammation having been excited by dancing, it was luckily discovered, and extracted with considerable difficulty"—recovery. GUTHRIE (*Commentaries*, 6th ed., London, 1855, p. 507) gives four cases of recoveries of fractures of the ilium: Colonel Wade, wounded at Albuhera, in 1811; General Hercules Packenham, wounded at Badajos, April 6, 1812; Colonel Wilson, shot at Chippewa, July 5, 1814; and a soldier wounded at Salamanca; also one fatal case, John Bryan, wounded near Quatre-Bras, June 17, 1815. LARREY (H.) (*Hist. chir. du siège de la citadelle d'Anvers*, Paris, 1833, p. 167) records a case of recovery after comminuted shot fracture of the ilium. JOBERT (*Plaies d'armes à feu*, Paris, 1833, p. 224) narrates the case of R——, a recovery from shot fracture of the ilium. VASLIN (*Étude sur les plaies d'armes à feu*, 1872, p. 98) cites two cases (Obs. XXVII and XXVIII) of shot fractures of the ilium, at the engagements at Villiers-sur-Marne, and near Orleans, December 2, 1870; the former case was fatal, the latter terminated successfully. M. CHENU (*Camp. d'Orient, op. cit.*, p. 200 *et seq.*) gives abstracts of the cases of twenty pensioners, with shot fractures of the ilium; and (*Camp. d'Italie, op. cit.*, T. II, p. 507) similar abstracts of cases of no less than forty-five men pensioned for disability arising from this cause.

<sup>5</sup> KIMBALL (G.) (*Boston Med. and Surg. Jour.*, 1849, Vol. XL, p. 40) relates the case of Private G. Church, Massachusetts Volunteers, wounded at Molino del Rey, September 27, 1847, by a ball which fractured the ilium. Surgeon R. S. SATTERLEE, U. S. A., made an immediate but unsuccessful search for the ball. The patient was discharged from hospital in five months. Epileptic paroxysms frequently recurring, in October, 1848, Drs. GUTTEAU and KIMBALL enlarged a fistulous sinus leading toward the anterior superior spinous process and extracted the ball. The epileptic seizures thenceforward ceased, and the patient was convalescent at the date of the report. HAMILTON (P. II.) (*Am. Med. Times*, 1864, p. 217, and *Treatise on Mil. Surg.*, 1865, p. 328) records six fortunate cases of shot penetration in the inguinal region, in five of which the pelvic bones were supposed to be interested (Cases of Grant, Knoll, Haynes, a soldier of the 51st Georgia, and Private T. Walter); [Grant's case was a shot perforation of the ilium, treated at Frederick; a piece of dead bone was extracted. He was examined for pension, but dropped for some informality; he had incontinence of urine. Knoll was transferred to Fort Wood for exchange. Haynes recovered from a shot fracture of the left ilium, was pensioned, and, in March, 1873, suffered from weakness and numbness in the back and left lower extremity. Of Walter and the Confederate soldier no records appear.] MERCER (*Chicago Med. Jour.*, 1870, Vol. XXVII, p. 676, and note 1 to p. 107, *ante*) gives a case of elimination of a fragment of ilium by the anus after a shot fracture. BIGHAM (C. B.) (*Boston Med. and Surg. Jour.*, 1871, N. S., Vol. VII, p. 58) records a case of grooved shot fracture of the left ilium, with fecal fistula and lodgement of the ball in the buttock, in the case of J. M——, aged 26, treated at the "International Ambulance," at Nancy. RANKIN (*Surgical Cases*, in *Am. Jour. Med. Sci.*, 1864, Vol. XLVIII, p. 67) prints a case of recovery from a shot fracture of the left ilium: Case of Private Rosebury, Co. K, 93d Pennsylvania. WELLS (W. L.) (*Med. and Surg. Reporter*, 1863, Vol. XV, p. 433) publishes the case of Private J. Strunk, Co. G, 142d Pennsylvania, wounded at Petersburg, June 21, 1864, treated at McClellan Hospital for a shot fracture of the right ilium, died January 29, 1865, after diffuse suppuration. O'MEAGHER (W.) (*Gunshot Wounds of Pelvis*, in *Am. Med. Times*, 1862, Vol. IV, p. 6) reports a fatal shot perforation of the ilium, with intestinal lesions. FERRY (C.) (*Confederate States Med. and Surg. Jour.*, 1864, Vol. I, p. 77, Obs. 46 and 47) records two examples of recovery from shot fracture of the wing of the ilium. BUTLER (W. H.) (*Buffalo Med. and Surg. Jour.*, 1864, Vol. III, p. 459) records a case of shot fracture of the ilium, with vesical complications. ROBBINS (*Proc. Clinico-Path. Soc.*, in *Am. Jour. Med. Sci.*, 1868, Vol. LV, p. 124) prints a report of the same case.

It was found to be peculiarly important, in this group of injuries, to explore the shot canal thoroughly before inflammatory swelling supervened, and to remove all splinters and foreign bodies; but the treatment may be more conveniently considered after examining the injuries of other pelvic bones.<sup>1</sup>

SHOT FRACTURES OF THE PUBIS. — Eighty-six cases appear on the returns as partial or complete shot fractures of this bone. The average fatality of these injuries was much greater than attended corresponding lesions of the ilium, as forty-three, or half of the patients, died. Fourteen of the cases, at least, were complicated with lesions of the bladder, and at least eleven with lesions of the rectum;<sup>2</sup> and other cases were associated with injuries either of the penis, testis, prostate, spermatic cord, femoral vein, or crural nerve. In the case of Corporal F—, related on page 184 (CASE 588), the ball was found embedded in the horizontal ramus of the pubis,<sup>3</sup> near the rim of the acetabulum, as represented in FIGURE 181.<sup>4</sup> No other part of the bone has enough spongy texture to readily admit of the impaction of projectiles, and, in most of the preparations that have been preserved, balls have notched<sup>5</sup> the horizontal or perpendicular ramus, as in the specimen represented by FIGURE 182, from a case of perforation of the bladder and rectum, that will be related hereafter. The pubis is a tough bone, and, according to specimens examined by me, seldom much splintered by shot. In two examples of its fracture by crushing weights, that have come under my observation, the absence of comminution was also remarkable.<sup>6</sup> The distri-

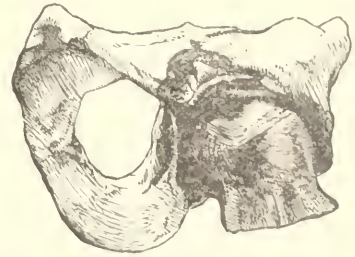


FIG. 181.—Ball embedded in the ramus of the left pubis. Spec. 1603.

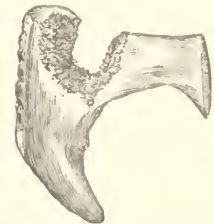

FIG. 182.—Inner surface of right pubis, the horizontal ramus notched by a musket ball. Spec. 3751. [Half-size.]

<sup>1</sup> The Museum of the Boston Society for Medical Improvement (*Cat.*, 1847, p. 45) possesses a shot fracture of the ilium from Waterloo, Specimen 199. The *Musée Dupuytren* has the two perforations figured on p. 218 (FIGS. 150, 151, *supra*), presented by Baron DUPUYTREN (*Cat.*, 1842, p. 24). The *Musée Vrolik* (*Cat.*, 1865, p. 327) possesses the left innominate of a soldier, the external lamina cleanly perforated, the internal more splintered; the ball entered the peritoneal cavity. FISCHER (H.) figures (*Kriegschir. Erf.*, TAF. IV, 24) a fine specimen of shot fracture of the posterior crest of the left ilium. The Museum of the College of Surgeons of Edinburgh (*Cat.*, 1836, p. 24) possesses an ilium, Specimen 198, XX. D, struck by a small rifle ball. In the Hunterian Museum, in Series LXIV, Specimen 2916 A, is the greater part of the right ilium shattered by shot, from a British soldier, wounded at Sebastopol, August 17th, who died September 2, 1855. (*Desc. Cat., Supplement 1*, 1863, p. 91.)

<sup>2</sup> This is probably much less than the real proportion of visceral complications. Many cases are reported of wounds of the bladder and rectum "with fracture of the pelvis," but without specification of which bone of the pelvis.

<sup>3</sup> DUVERNEY (*Traité des mal. des os*, 1751, T. I, p. 283) has, according to MARGAIGNE, priority in describing fractures of the pubis also. According to his observations, and those of NIVET (*Bull. de la Soc. Anat.*, 1837, p. 194), of MARET (*Obs. sur les fract. des os du bassin*, in *Mém. de l'Acad. de Dijon*, 1774, T. II, p. 85), of A. COOPER (*A Treatise on Dislocations and Fractures of the Joints*, 4to, 1823, p. 105), of WHITAKER (*Am. Jour. Med. Sci.*, 1857, Vol. XXXIV, p. 283), uncomplicated fractures of the pubis are not dangerous; but the shot fractures are rarely uncomplicated.

<sup>4</sup> The examples of shot fractures of the pubis recorded by authors are not very numerous. TULPIUS (*Observationes medicæ*, Lugduni Bat., 1716, Lib. IV, Obs. XXX, p. 323) relates a successful case of shot fracture of the os pubis, with injury of the bladder. GUTHRIE (*Wounds and Inj.*, etc., 1847, p. 67) refers to a case treated by Dr. WALTZ, and recorded in GRAEFE and WALTHER'S *Journal*: the ball passed through the os pubis and bladder; slow recovery. BERTHERAND (*Camp. de Kabylie*, 1852, p. 298) records two fatal cases of shot fractures of the pubis: Riçois, trumpeter, 54th voltigeurs, wounded June 24, 1857, died August 27th; and P—, 75th of the line, wounded June 27th, died July 21, 1857. Both succumbed from purulent infiltration and pyæmia. LOHMEYER (*Die Schusswunden*, 1859, S. 141) records a rapid recovery of a soldier of the 6th Schleswig-Holstein battalion, wounded October 4, 1850, from a shot fracture of the descending ramus of the os pubis; and a fatal instance, at the same engagement, in a soldier of the 11th battalion, in whom the tuberosity of the ischium was likewise involved, and death ensued from pyæmia. BECK (*Chir. der Schussverletzungen*, 1872, S. 554) describes a fracture of the horizontal ramus of the left os pubis from a splinter from a hand grenade; death from septicæmia. H. FISCHER (*Kriegschirurgische Erf.*, 1872, S. 184) gives two fatal cases of shot wound of the os pubis: one of the patients died of pyæmia; in the other case the hip-joint was involved. RUPPRECHT (*Militärärztliche Erfahrungen*, 1871, S. 60) relates a case of fracture of the os pubis, fatal in thirty-three days from pyæmia. DOW (T. C.) (*Nashville Jour. Med. and Surg.*, 1867, Vol. III, p. 161) relates the case of J. B—, Co. H, 3d Tennessee, wounded February 24, 1865, a shot fracture of the left os pubis, complicated with wound of the bladder. An operation for urinary fistula was practiced by Professor P. F. EVE, M. D., two years later. Dr. CHISOLM (*Manual of Mil. Surg.*, 3d ed., 1863, p. 352) records a recovery from a complicated shot fracture of the right os pubis, in the case of Private Moore, Co. E, Palmetto Sharpshooters, wounded June 29, 1862, before Richmond. Dr. MACLEOD (*Notes on the Surgery of the Crimean War*, 1868, p. 275) gives two cases of recovery after shot fractures of the pubic bone. Professor HANNOVER (*Die Dänischen Invaliden aus dem Kriege 1864*, S. 20) records a recovery after shot fracture of the pubis, with false ankylosis of the hip. A total of fifteen cases, with seven deaths, or 46.6 per cent.

<sup>5</sup> Dr. J. H. PACKARD (*Proc. Path. Soc., Phila.*, 1862, in *Am. Jour. Med. Sci.*, 1862, Vol. XLIV, p. 109) records also an autopsy in a case of shot fracture of the pubis, in which this notching of the bone without fissuring was observed.

<sup>6</sup> Compare also a specimen in Dr. NELL'S Cabinet, figured by Professor GROSS (*System*, 5th ed., 1872, Vol. I, p. 969, FIG. 130), and an article by Dr. J. W. LODGE (*Extensive Fracture of the Pubic Bones*, in *Am. Jour. Med. Sci.*, 1865, Vol. I, p. 404).



bution of the ligaments and fascia partly account for this. When the loss of substance or displacement is not great, repair appears to progress rapidly, and caries seems to follow shot fracture less frequently than in the ilium. In fourteen or more of the cases, bone splinters were picked out early; in seven, balls were removed; in two, other foreign bodies were extracted. Peritonitis supervened in seven cases, and nine patients, at least, perished from pyæmia. The last complication being more frequent in shot fractures of the ilium than in those of the pubis, while the mortality of the latter was double that of the former, the causes of the difference are explained by the greater frequency of sloughing of the pelvic fascia, of injuries of vessels and nerves, and of urinary and fecal extravasation, in the pubic fractures. The illustrated CASES 691 and 698 exemplify what appears to be the most common form of shot fractures of the pubis:

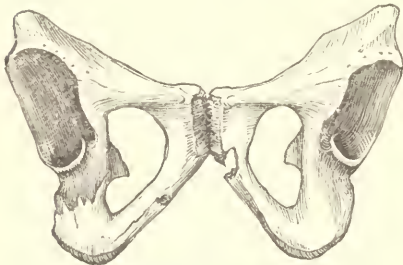

FIG. 183.—Anterior halves of the ossa innominata, the left pubis notched by a ball. *Spec.* 4076.

CASE 690.—Private H. C——. Co. H. 15th New York Heavy Artillery, aged 29 years, received a wound at South Side Railroad, on March 31, 1865, from a conoidal ball, which entered the left groin two and a half inches internally to the anterior superior spinous process of the ilium, and emerged at the right natis, fracturing the left ramus of the pubic bone, and cutting across the membranous portion of the urethra. He was sent to Washington, and admitted into Emory Hospital on April 5th. The catheter could not be introduced, and on the 6th the urine escaped from the posterior wound. On the 12th, diarrhœa set in, and death followed on April 14, 1865. The autopsy revealed "sphacelus of the peritoneum and a deposit of plastic lymph on the internal coats of the bladder." A portion of the bones of the pelvis, showing the lesion in the pubic bone, was contributed to the Museum, with the foregoing history of the case, by Acting Assistant Surgeon L. M. Osmon (FIG. 183).

A permanent cure after a shot fracture of the pubis was obtained in the following case, which derives interest also from the difficulties attending the detection and extraction of the ball:

CASE 691.—Lieutenant-Colonel Charles L. Pierson, 39th Massachusetts, was wounded at an engagement near the Six-mile House, Weldon Railroad, August 18, 1864, and was taken to the 3d division hospital of the Fifth Corps. Surgeon L. W. Read, U. S. V., reported "a gunshot wound penetrating the pelvic cavity." The Massachusetts Adjutant General<sup>1</sup> states that the wound was considered mortal. The following day the colonel was sent to the depot at City Point, where Surgeon W. L. Faxon, 32d Massachusetts, described the injury as a dangerous shot wound of the abdomen. On September 16th, the late Assistant Surgeon J. Sim Smith, U. S. A., saw the patient, and included this case in an important report made by him on the usefulness of the Nélaton probe, relating the circumstances as follows: "Lieutenant-Colonel Pierson, 39th Massachusetts, who had been wounded August 18th, by a ball, which had penetrated the pubis on the right side, near the symphysis, and entered the pelvis, stated that at the time he was shot he was standing erect, and that after receiving the wound he walked some distance. When I saw him, he was lying on his back, with his thighs flexed upon the abdomen, which was tender and tympanitic, with an ecchymosis extending over the iliac and hypogastric regions. He had well-marked symptoms of peritonitis and cystitis, with a profuse and fœtid discharge from the wound. After complete anæsthesia had been induced, a flexible catheter was passed into the wound to ascertain the course of the ball. It was found that after it had passed through the pubis and penetrated about two inches obliquely to the left, it had turned still more to the left and passed transversely across the pelvis. A Nélaton probe, with a flexible shaft bent to suit the course of the wound, was then entered without difficulty for about

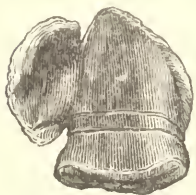


FIG. 184.—Conoidal ball battered in fracturing the right pubis. *Spec.* 2241.

eight inches, and upon its removal the metallic lustre upon the porcelain bulb was very distinct. Being still uncertain as to the exact locality of the ball, the probe was again introduced, and it was found that pressure made upon the left side, behind the trochanter major, caused the probe to be thrust from the wound. Upon cutting directly down behind the trochanter, the ball was found lying almost in direct contact with, and upon the outer side of, the femur. The extraction of the ball was followed by a free discharge of fœtid pus, and in a day or two his condition improved, and he is now recovered." The missile (FIG. 184) was sent to the Museum by Dr. Smith. Promoted to a colonelcy, this officer was honorably discharged January 4, 1865, and pensioned. The Pension Record states that, on March 5, 1865, the wound was still open and discharging, and the disability was rated at three-fourths, and probably not permanent. The wound subsequently healed soundly, and, after May 15, 1868, the colonel ceased to draw a pension.

There was a single example of tetanus among the forty-three fatal cases of this group. It appears not to have occurred among the two hundred and eleven fatal cases

<sup>1</sup> SCHOLLER (W.) (*Annual Report of the Adjutant General of the Commonwealth of Massachusetts for the year ending December 31, 1864*, Boston, 1865, p. 850): "Lt. Col. Pierson, now colonel, received a wound at that time supposed to be mortal, and was helped off the field."



of specified shot fractures of the ilium, though a number of instances are recorded in the category of fatal shot injuries of the innominate bones in which the part injured is not indicated.

CASE 692.—Private T. B. Ballou, Co. C, 24th Michigan, aged 23 years, was wounded at Gettysburg, July 1, 1863, by a conoidal ball, which entered at the right hypogastrium one inch from the linea alba, passed backward and downward, and, fracturing the right pubic bone, emerged from the right natis one inch from the anus. He had urinated half an hour previously or the ball would have penetrated the bladder. The patient was admitted into Camp Letterman Hospital. Acting Assistant Surgeon W. B. Jones reported that: "On August 7th, he had a severe attack of gastric remittent fever, with vomiting and persistent nausea. Several splinters of bone were removed from the anterior wound, also some pieces of clothing and part of a button. The patient was allowed a generous diet; quinia and sweet spirits of nitre were administered, and poultices were applied." He was transferred to the Cotton Factory Hospital, Harrisburg, on October 12th, and died November 26, 1863, as reported by Acting Assistant Surgeon W. S. Woods, of traumatic tetanus.

The four following instances of tetanus following shot injuries of unspecified portions of the innominate were reported:

CASES 693-696.—Captain Henry C. Hatfield, 34th Ohio, received a lateral shot perforation through the pelvis, at Fayetteville, Virginia, on September 19, 1862. With other wounded he was sent to Gallipolis, Ohio, having been transported forty-five miles in a wagon and the remaining distance in a bateau. Tetanus appeared on the 15th and proved fatal on September 19, 1862. Private G. Cummings, Co. H, 86th New York, aged 31, wounded at Spottsylvania, May 10, 1864; tetanus supervened May 17th, and resulted fatally May 19, 1864. Private W. T. House, Co. D, 46th Tennessee, wounded at Nashville, December 16, 1864; tetanus and death, January 6, 1865. Private J. M. Soules, Co. G, 2d New York Mounted Rifles, wounded June 18, 1864, at Petersburg, and died July 4, 1864, from tetanus.

As will be more fully exemplified in the next section, vesical complications often attended shot fractures of the pubis. In the following case of shot fracture of both pubes, complicated by lodgement of the ball, the bladder was only indirectly implicated:

CASE 697.—Private D. D——, Co. D, 14th Connecticut, aged 22 years, was admitted, from City Point, Virginia, to Stanton Hospital, Washington, on March 30, 1865, for a wound received at Hatcher's Run on March 25th. A conoidal musket ball had entered the upper third of the right thigh anteriorly, passed upward and inward into the pelvis, striking the descending ramus of the right pubis just below the symphysis, contusing the corresponding bone on the left side, passing over the membranous portion of the urethra, striking against and knocking off a fragment of the spine of the ischium, impinging on the sacrum at the insertion of the coccygeus, and finally lodged in the gluteus maximus. The shock of injury was reported to have been inconsiderable, and the patient complained of no other inconvenience than pain and tenderness in the hypogastrium, with a persistent inclination to evacuate the bowels. The external wound, apparently healthy, discharged dark, bloody pus, of a decided fecal odor; the functions of the bladder were normal: the patient hopeful; pulse good, at about ninety. The pelvic irritation and tenesmus were temporarily relieved by an enema of soap and water, and cold-water dressings were applied to the wound. During the week following, there was but little change in the patient: irritation of the rectum and peritoneum supervened, with costive bowels. These symptoms were again relieved by the injection. The discharge from the wound assumed more the character of laudable pus, but still preserved its fecal odor. The patient's condition remained unchanged till April 15th. The position of the ball, which at first was not sufficiently distinct to justify an incision, now became more evident, the tumefaction around it having increased until the irritation began to affect the general system. Determining to remove the ball, Surgeon B. B. Wilson, U. S. V., chloroformed the patient, and made an incision over its point of lodgement; but the missile, which was distinctly felt previous to the incision, could not be found. The presence of the ball at a distance of about seven inches from the orifice being revealed by means of a Nélaton probe, several ineffectual efforts were made to grasp it. A small fragment of necrosed bone was removed. On the morning of April 16th the ball was found in the bed, having gravitated out during the night; the urine was high-colored and loaded with mucus; pain and tenderness extended over the whole abdomen. The administration of morphia in solution, and sweet spirits of nitre, with stimulants and a nutritious diet, afforded partial relief till April 20th, when pyæmia set in. On the 23d, the symptoms had increased; involuntary evacuations took place; the patient sank, and died on April 25, 1865. The autopsy, twenty-four hours subsequently, revealed marked cystitis and peritonitis, with commencing gangrene in those portions of the peritoneum covering the bladder and rectum. The pelvis (FIG. 185), with the missile attached, and the history of the case, were contributed by Surgeon B. B. Wilson, U. S. V. The ball, mounted in the left sciatic notch, does not appear in the figure.<sup>1</sup>

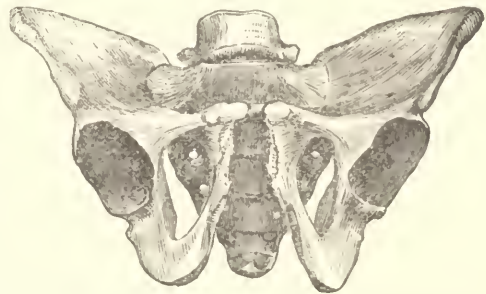

FIG. 185.—Pelvis, showing a shot-fracture of the pubis. *Spec.* 4171.

There were no cases which could be strictly classified as excisions of the pubis, though, in several cases, splinters of bone were picked out primarily, and, in others, carious

<sup>1</sup> Dr. D. WEBSTER PRESTISS has published (*Am. Jour. Med. Sci.*, 1865, Vol. I, p. 400) an extended account of this case, with remarks.

bone was removed, or necrosed fragments were extracted.<sup>1</sup> The more important of these cases were associated with lesions of the ischium or bladder, and will be detailed hereafter. In one of them, a fragment of the pubis became the nucleus of a calculus. A case of caries, illustrated by a specimen, may conclude the subject for the present:

CASE 698.—Private Daniel L.—, Co. F, 23d Ohio, aged 22 years, was wounded by a conoidal ball at Halltown, August 25, 1864. He was treated in field hospital at Sandy Hook until the 29th, when he was admitted to the hospital at Frederick. The following notes of the case were furnished by Acting Assistant Surgeon T. O. Cornish: "The patient could tell nothing of his condition and treatment until he came under my charge on September 17th. At this time he was evidently sinking; the brain was sluggish and the mind wandering; pulse 120; skin sallow. Tonics, stimulants, and anodynes were administered, and poultices applied to the wound. On the 18th he had a chill, and the unfavorable symptoms increased daily until death resulted, on September 20, 1864. An examination, made eighteen hours after death, revealed an injury of the superior border of the horizontal ramus of the right pubis. Pus had penetrated through the obturator foramen into the cavity of the pelvis, and also into the hip-joint; the femoral vein was not examined. All the viscera were apparently healthy. The pelvic portion of the peritoneum was congested." The specimen (FIG. 186), which consists of the right pubis, exhibiting a carious condition of the horizontal ramus after partial gunshot fracture, was contributed by Acting Assistant Surgeon R. W. Mansfield.

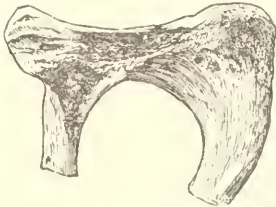


FIG. 186.—Caries of the ramus of the right pubis. *Spec. 3819.* [Half-size.]

SHOT FRACTURES OF THE ISCHIUM.—These injuries were somewhat less frequent and less fatal than analogous lesions of the pubic bone, the aggregate of instances recorded being seventy-three, of which thirty-one, or 42.4 per cent, resulted fatally. Eight cases were complicated by lesions of the bladder, and four with wounds of the rectum. One of the fatal cases illustrates what large projectiles may occasionally be buried and concealed in the deep tissues. The adjoining wood-cut (FIG. 187) represents a fragment from the apex of a 20-pounder shell. A soldier, attempting to crack nuts upon the unexploded missile on the field of Antietam, by way of carrying out a wager with a comrade, had terrible proof that the charge had not been withdrawn. This fragment "tore his perineum, lacerated for two inches the membranous portion of the urethra, and upturned the left ischium."<sup>2</sup> The unfortunate man soon perished from shock. This bulky mass was found between the ramus of the ischium<sup>3</sup> and the adductors of the thigh. One border of the speci-

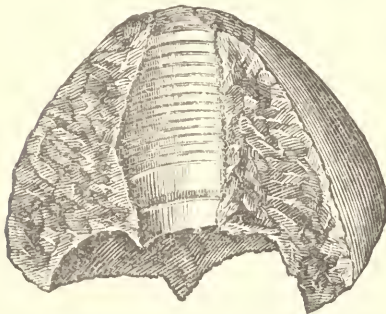


FIG. 187.—Fragment of a shell extracted from the ischiatic region. *Spec. 4457.* [Reduced one-half.]

men is a section drawn longitudinally through the centre, showing a diameter of more than three and a half inches. The other border is at nearly right angles, three inches from the apex." The walls are an inch and one-fourth thick, and the specimen weighs thirty-two and one-half ounces. It was contributed to the Museum by Surgeon E. W. McDonnell, U. S. V.

<sup>1</sup> In 1863, Dr. OSCAR HEYFELDER (*Lehrbuch der Resectionen*, Wien, S. 317) tabulated five instances of so-called resection of the pubis. With sundry inaccuracies, the following instances appear to be referred to: MARET (*Mém. de l'Acad. de Dijon*, 1774, T. II. p. 85): A cart-wheel passed over a young lady, age 18 years, and fractured the os pubis; an incision was made and that portion of the right os pubis removed which forms the symphysis and the descending ramus joining the ischium; reproduction of new bony substance followed, which entirely supplied the loss of the removed portion. COOPER, A. (*Surgical Essays*, Am. ed., Philadelphia, 1821, Vol. I, p. 162), on March 13, 1817, successfully removed, with Macheil's and Hey's saws, a large exostosis from the os pubis of a German, H. W. Bromer, aged 21. Professor GEORGIO REGNOLI of Pisa, in 1830 (GÜNTHER, *Lehre von den Blutigen Operationen*, 1860, B. IV, S. 2), removed an exostosis of the descending ramus of the os pubis by three blows of the chisel and mallet; recovery in one month. LISFRANC (*Précis de méd. opérat.*, Paris, 1846, T. II. p. 550) remarks: "J'ai vu DUPUYTREN extirper une esquille volumineuse résultant d'une fracture de la branche horizontale du pubis." MAYER (*Deutsche Klinik*, 1856, S. 202), in 1847, scraped a portion of the descending ramus of the os pubis with a coarse file for caries, with indifferent results. He intended to excise the descending ramus, but the interference of the patient's relatives and of another physician prevented it.

<sup>2</sup> Ischium, *ἰσχίον*, strictly the cotyloid cavity; a term derived by some etymologists from *ἰσχύς*, strength, and by others from *ἰσχω*, I arrest, Germanic, *Sitzbein*.

<sup>3</sup> STROMEYER (*op. cit.*, p. 42) has the following observations on shot-fractures of the ischium: "Comminuted fractures of the ischium were equally dangerous. \* \* \* I have seen one case of injury of the ascending branch of the ischium end favorably after extraction of large tertiary sequestra. The contusions of the ischia also had very bad consequences, and gave rise to obstinate suppuration and hectic fever."

In favorable cases, patients recovered tardily from shot fractures of the ischium,<sup>1</sup> convalescence being hindered by caries and abscess-formations. A single instance may exemplify this, and other illustrations may be selected from the fatal cases in order that pathological preparations may show the varieties of fracture.<sup>2</sup>

CASE 699.—Private *J. I. Ship*, Co. F, 4th Virginia, aged 19 years, wounded at Antietam, September 17, 1862, was sent to Frederick and admitted into general hospital. Acting Assistant Surgeon A. V. Cherbonnier reports that "a conoidal ball had entered the left groin and emerged in the posterior middle third of the thigh, fracturing the tuberosity of the ischium in its course. On admission, the patient suffered excruciating pain; there was a thin and very offensive discharge from the wound. Chloroform was administered and large fragments of the ischium were removed, about half a pint of pus being discharged during the operation. The wound was dressed with a yeast poultice, and the patient was supported by means of quinia, brandy, and a good diet. He improved after the operation, and by December 20th was in good condition; the wound was filling up and suppurated slightly. On December 24th, a small abscess opened near the pubes. Necrosed bone was discovered by means of the probe; but the patient's health was good and the wounds improving. He was transferred, December 29, 1862, to hospital No. 1." He steadily convalesced, and was transferred for exchange March 4, 1863.

CASE 700.—Private T. Carson, Co. I, 27th Pennsylvania, aged 40 years, was wounded at Mission Ridge, November 25, 1863, and made a prisoner. On his release, he stated that a musket ball had passed through both buttocks, and that it was thought that the tuberosity of the ischium, and perhaps the trochanter of the left femur, were fractured. He was confined at Atlanta until exchanged, February, 1864, and was then sent to hospital at Chattanooga, entering on February 18th. The external orifices of the wounds were healed. The patient died from exhaustion on February 28, 1864. Assistant Surgeon John D. Johnson, U. S. V., sent to the Museum a preparation of the fractured ischium (FIG. 188), and reported that at the autopsy there was extensive necrosis of the ischium, with erosion of the cartilaginous rim of the acetabulum, and slight caries of the great trochanter, with wasting and alteration of the surrounding soft tissues.

CASE 701.—Private *C. W. M.*, Co. B, 14th North Carolina, aged 21 years, was wounded at Antietam, September 17, 1862, by a musket ball, which entered the cleft of the nates one and one-fourth inches above the anus, passed in the vicinity of the hip-joint, and emerged in front of the great trochanter; he also received four gunshot wounds of the other leg, one missile clipping the crest of the tibia. He was left upon the field, and was subsequently removed to hospital, where he was treated until the 29th, when he was transferred to Frederick. Assistant Surgeon R. F. Weir, U. S. A., reports: "Buck's apparatus was applied; there was but little pain. On October 14th, the patient was still comfortable, though his appetite was poor and pulse 118. A slight hæmorrhage occurred on the following day, ceasing, however, of its own accord. He failed rapidly, and died at midnight, October 17, 1862. Upon a dissection of the parts the missile was found to have grazed the tuberosity of the ischium and plunged through the great trochanter, splitting off the head, neck, lesser trochanter, and four inches of the shaft of the femur; ossific matter was abundantly deposited between the fragments and along the edges." The specimen (FIG. 189) was contributed to the Museum by Dr. Weir. On the outer surface of the tuberosity is a circular portion of necrosed bone with a clearly defined line of separation, having a diameter of one and three-fourths inches, the evident result of contusion.

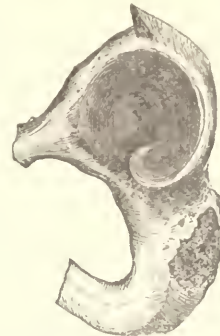

FIG. 188.—Shot fracture of the left ischium.—Spec. 3101.

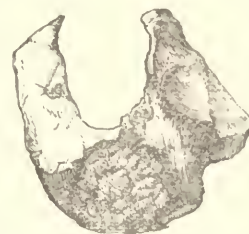

FIG. 189.—Necrosis of the left ischium after shot contusion. Spec. 882. [Half size.]

<sup>1</sup> The following are some of the references by modern military surgeons to shot fractures of the ischium: *BILGEBER (Chirurgische Wahrnehmungen, Berlin, 1763, S. 365)* relates that Private Menz was shot at Lauenrdorf, in 1759, by an iron ball, which fractured the right ischium; profuse suppuration ensued; two months later a large piece of bone and the ball were removed; suppuration continued for six weeks, when the wound closed. *JOBERT (Plais d'armes à feu, Paris, 1833, p. 234)* remarks that he saw at Saint Cloud a case of fracture of tuber ischi, which had not yet quite healed in six months. *CHENU (Statistique méd. chir. de la camp. d'Italie, Paris, 1869, T. II, p. 507)* details the case of Avenant, 84th line regiment, wounded at Solferino, June 24, 1859, by a musket ball, which fractured the ischium; several pieces of bone escaped; recovery took place with false ankylosis of the hip-joint. *MATTHEW (op. cit., p. 33)* gives the particulars of three cases of shot-fracture of the ischium; two recovered in about six months; a third proved fatal after profuse suppuration; in the latter the descending ramus of the os pubis was found fractured. *BAIDENS (Des plaies d'armes à feu, 1849, p. 229)* gives an abstract of the case of Menry; shot fracture of the ischium; splinters successfully removed. *SCHWARTZ (Beitäge zur Lehre, u. s. w., 1854, S. 136 and 137)* gives two fatal cases of shot fractures of the ischium; in one the internal iliac vein was injured. *DEMME (Studien, u. s. w., 1861, B. II, S. 173)* cites four cases of fractures of the ischium; two fatal, and two recoveries. Among the pensioners examined by Dr. Hannover (*Die Dänischen Invaliden aus dem Krieg, 1864, S. 20*) was one shot in the ischium, who suffered from atrophy of the lower extremity of the injured side. *BECK (Chirurgie der Schussverletzungen, 1872, S. 552 and 556)* mentions three successful and one fatal case of shot fractures of the ischium. *SOCIN (Kriegschir. Erf., 1872, S. 97)* records a case of fracture of the ischium with a favorable result. *CHIPAULT (Tract, par armes à feu, 1872, p. 74)* relates two cases of recovery after shot fractures of the ischium: *Obs. LXXVIII, Foché, 33d regiment, wounded at Poupry, December 24, 1870, splinters extracted from left ischium, rapid convalescence; Obs. LXXIX, Benehey, 33th regiment, Nonneville, December 2, 1870, removal of fragments from shot fracture of left ischium, recovery.*

<sup>2</sup> At the Museum of the Pennsylvania Hospital, Specimen 1113 shows a fracture of the ischium by a round ball, a fragment an inch long being broken off the postero inferior part of the rim of the obturator foramen; the patient died from hæmorrhage from the divided femoral vein.—(*Cat.*, 1869, p. 26.) The Warren Anatomical Museum possesses a Specimen, 1052, presented by Dr. R. M. Hodges, of comminution of the tuberosity of the right ischium and incomplete fracture of the left pubis by a pistol ball. The patient, who underwent a thigh amputation also for shot injury of the knee, also survived twenty-two days.—(*Cat.*, 1870, p. 178.) In the same collection, Specimen 1054, is a shot fracture of the tuberosity of the left ischium, also presented by Dr. Hodges. In the Edinburgh Museum, Specimen 197, XX, D, is a shot perforation of the ramus of the ischium. The patient survived the injury a considerable time, and died from hydatids of the liver.—(*Cat.*, 1836, p. 24.)

<sup>3</sup> Erroneously described in the Catalogue of the Surgical Section, p. 223, as the right ischium.



Impaction of balls in the ischium appears to take place in a fair proportion of cases.<sup>1</sup> The Museum possesses two examples of the sort, and others are recorded in which the missiles were extracted:

CASE 702.—Private Silas W——, Co. A, 23d New Jersey, aged 21, was wounded at Chancellorsville, May 3, 1863. He was treated in the regimental hospital until the 8th, when he was sent to Douglas Hospital, Washington, whence Acting Assistant Surgeon C. Carvallo made the following report of the case: "The ball entered the right gluteal region, perforated the innominate bone near the sacro-iliac symphysis, and entered the pelvic cavity without apparently injuring the viscera; the patient could pass water without difficulty or pain, the urine being of a natural color; his bowels were in good order but somewhat costive. May 12th, he became feverish; thirsty; dry tongue and skin, and accelerated pulse; a solution of nitrate of potash was administered. He continued feverish, and, on the 17th, an emulsion of turpentine was given, which relieved him considerably at first and smoothed his tongue, but it soon became dense, hard, and furred, as before. On the 19th, he had a slight chill, ascribed to the cold draught of an open window, and quinia, morphia, and stimulants were given. On May 20th, there was great stupor and the patient was delirious, talking while asleep. An abscess was opened at the roots of the second and third phalanges of the right foot; there was also a metastatic abscess in the left elbow. Turpentine emulsion was given three times a day, and sulphate of quinine one hour after each dose of the emulsion. On May 23d, secondary hæmorrhage occurred, supposed to proceed from the sciatic artery, or from a muscular branch of the gluteal artery. Stupes of lint compressed into the wound stopped the hæmorrhage after the escape of some five or six ounces of blood. On the next day there was stupor, and stertorous breathing, and incontinence of urine; the wound discharged serous-purulent blood, and the gluteal region was infiltrated with the same. He died at one o'clock P. M., May 24, 1863. At the *post-mortem* examination, five hours after death, the ball was traced to the pelvis, where it lay loosely in the bone; there was no wound of the pelvic viscera, nor any evidence of pyæmia in the lungs, liver, spleen, or kidneys.<sup>2</sup> The specimen (FIG. 190) is from a wet preparation of the right ischium, much shattered directly behind the acetabulum by a conoidal ball, which is mounted in the notch through which it penetrated. The preparation was transmitted, with Dr. Carvallo's memoranda, by Assistant Surgeon W. Thomson, U. S. A.

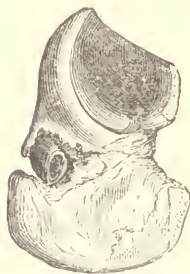

FIG. 190.—Shot fracture of the right ischium. *Spec.* 1245. [Reduced to one-third.]

CASE 703.—Dr. Redfern Davies, a volunteer surgeon from Birmingham, England, makes the following report of a case of shot fracture of the ischium and death from chloroform, in a Confederate soldier, first treated at Middletown, and then transferred to Hospital No. 1 at Frederick, where Dr. Davies was stationed: "*William L*——, Co. E, 23d North Carolina, aged 24 years, was wounded at South Mountain, September 12, 1862. The ball entered his groin very near the femoral artery and made its exit at the tuber ischii, fracturing the latter. Admitted October 22d; had bad bed-sores, laying the spine bare, and severe chronic diarrhœa, and had lost flesh. October 28th, chloroform was administered to remove the fragments of the ischium. No cardiac disease existed so far as known, but the heart was not examined. The chloroform was administered by Dr. A. [Acting Assistant Surgeon W. S. Adams] on a pocket handkerchief, which was pressed firmly against the mouth of the bottle, which was then inverted. Plenty of air was given, and the handkerchief was wet with chloroform but once. About a minute after the administration of the chloroform was begun almost complete relaxation was produced and two stertorous respirations were observed, when the handkerchief was immediately removed. The pulse up to this time was undisturbed; the patient then took some ten or twelve deep and rather rapid inspirations, with thickened pulse, when respiration suddenly ceased; the pulse continued for six or eight beats, which were slower and feeble, and then suddenly ceased. Artificial respiration was immediately resorted to by Marshall Hall's ready method, which produced distinct respiration, but no pulsation. Having kept it up for about twenty minutes without result, the case was given up as hopeless. *Post-mortem*, three hours after death: The body warm; no rigor mortis whatever; the chest and abdomen were opened and the blood was observed to flow from the veins, not being coagulated. In the pleural cavities there was no effusion; in the pericardium there were about two fluid ounces of effusion, without any pericarditis. On removing the calvarium, the veins of the dura mater and the pia mater were very much engorged with dark-colored uncoagulated blood; in the arachnoid space there was about two ounces of fluid. The substance of the brain was unusually firm on section and normal in appearance; there were from four to six drachms of fluid in the lateral ventricles; the cerebellum, pons Variolii, and medulla were normal. The right and left auricles of the heart were immensely distended with very dark uncoagulated blood; the ventricles full of the same, but not distended. The coronary openings were so large that the tip of the little finger could be introduced; all the valves were healthy, but the substance of the heart was somewhat flabby, especially on the right side. Six hours after death there was still no rigor mortis." The specimen (FIG. 191) of the fractured ischium, showing a round ball firmly embedded in the tuberosity, was sent to the Museum. A small fragment of bone just above the missile, and against which it appears to have impinged, is crossed. The ischium is not completely fractured, but the region of lodgement is much splintered. A sample of the chloroform used was sent to the laboratory of the Surgeon General's office. The case will be reverted to in the chapter on anaesthesia.

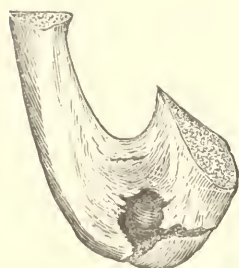

FIG. 191.—Round ball impacted near the tuberosity of the right ischium. *Spec.* 819.

<sup>1</sup> Respecting balls lodged in the ischium, Dr. NEUDÖRFER relates (*Handbuch der Kriegschirurgie*, 1867, S. 806) the case of M. Hamsel, 3d Jaegers, wounded at Custoza in June, 1866; the missile fractured the ischium and lodged; several unsuccessful attempts were made to extract the ball; the patient died February 9, 1868. At the autopsy the ball was found lying loosely in a cavity formed by new osseous exudation. Dr. NEUDÖRFER remarks: "Had I risked the removal of the inner portion of the wreath of osteophytes, the ball could have been readily removed at the first attempt, and the patient would probably be alive to-day." Dr. NEUDÖRFER presents (FIG. 67) a beautiful drawing of the pathological preparation.

<sup>2</sup> Through a clerical error in the report, and a misprint in the *Catalogue of the Surgical Section*, 1866, p. 227, the lesion has been ascribed to the ilium instead of the ischium.

The greater number of the cases in which preparations were preserved were examples of partial fracture, followed by caries and necrosis. These cases appear to have been frequently complicated by pyæmia. Shot contusions were followed by caries in two cases:

CASE 701.—Private W. Keith, Co. A, 14th Infantry, was struck by a musket ball at Gaines's Mills, June 22, 1862. Surgeon J. L. Le Conte, U. S. V., records that he was sent to Chester, Pennsylvania, where it was found that the missile had entered just above the ramus of the pubis, two inches to the right of symphysis, passed between the bladder and rectum, and emerged at the left sacro-sciatic notch. A chronic subacute inflammation of the bladder ensued, and a portion of the injured ischium became necrosed. Surgeon Charles Page reports that this soldier was discharged, for the disabilities above described, December 29, 1863. His name is not on the Pension List.

CASE 705.—Private Michael L——, Co. K, 18th Wisconsin, aged 19, was wounded at Corinth, October 3, 1862, by a minié ball, which entered the right groin three inches from the spine of the pubis, and passed through the obturator foramen, grazing and carrying away a portion of the neck of the ischium, and emerging at the right buttock one and a half inches from the natal fissure. On November 30th, he was admitted to hospital at St. Louis, and was doing well up to December 16th, when symptoms of pyæmia appeared, which developed quickly, and he died on December 22, 1862. The specimen (FIG. 192) was contributed, with the foregoing history, by Surgeon John F. Hodgen, U. S. V., and consists of the right ischium and pubis. The inner face of the ischium above the tuberosity and below the acetabulum is grazed by the passage of the ball. The fractured surface is carious; the outer border has a slight osseous deposit upon it.

In the following cases, and in eight others, portions of carious or necrosed bone were removed, and in eight cases balls were extracted:<sup>1</sup>

CASE 706.—Private J. L. D. O——, Co. K, 14th Connecticut, aged 37 years, was wounded at Fredericksburg, December 12, 1862, by a round ball and two buckshot, which passed through the penis and scrotum into the left ischiatic region and emerged just above the sacrum. He was admitted into the field hospital of the 1st division, Ninth Corps, and was transferred to Douglas Hospital, Washington, December 26th. Assistant Surgeon C. C. Lea, U. S. A., reported as follows: "At the time he was wounded he was sitting on the ground with his legs bent under him, and was shot by a sharpshooter about fifty feet to his front. When admitted, the wounds in the penis and scrotum were suppurating, and the tunica vaginalis of the right testicle was completely exposed; these wounds cicatrized slowly, especially that in the penis, which was retarded by frequent painful erections. By March 18th, all the wounds were closed except that in the right ischiatic region, where the suppuration was kept up by necrosis of the ischium, which the bullet had grazed in its passage, several sequestra of bone having come away and others still separating. The patient had been feeble and required constant stimulation; he also had an occasional attack of severe diarrhœa. No change occurred until April 5th, when pleuro-pneumonia supervened, accompanied by such debility and collapse that the patient, already enfeebled by the profuse suppuration, rapidly sank, and died on April 10, 1863. The treatment consisted of removal of fragments, dressing, and administration of tonics and stimulants, with nourishing diet. The autopsy, made fifteen hours after death, revealed the following: In the chest there were recent adhesions on both sides, densest on the right side, where the disease had been chiefly observed before death; nearly a pint of serum was effused in the right pleural cavity and about three ounces in the left. The left lung was crepitant, the right densely congested and sank at once in water. Liver fatty and enlarged, spleen and kidneys normal, intestines sodden and congested; no ulcers detected. The ischium was found to be fractured near its junction with the pubes, but so many fragments had been removed, and the remainder of the bone was carious to such an extent, as to obscure the original line of fracture; the necrosis extended to within one-sixth of an inch of the hip-joint, which was yet intact." The specimen (FIG. 193) consists of the right ischium, badly fractured between the acetabulum and the tuberosity. The shattered bone is carious, and much diminished by absorption and loss of fragments; it was contributed by Assistant Surgeon W. Thomson, U. S. A.

CASE 707.—Private W. S. Fulton, Co. F, 98th Ohio, was wounded at Jonesboro', September 1, 1864, and was first treated in a field hospital of the Fourteenth Corps by Surgeon W. C. Daniels, U. S. V. The patient was transferred, on October 30th, to the general hospital of the Army of the Cumberland, at Atlanta, and placed under the care of Assistant Surgeon M. C. Woodworth, U. S. V. Subsequently he was sent to Nashville, and thence, on January 26, 1865, to Gallipolis, where he died February 11, 1865. The reports of the field surgeons and of Surgeons Breed and Herbst, U. S. V., at Nashville, substantially agree with the more minute account given by Surgeon L. R. Stone, U. S. V., at Gallipolis. "The ball," Dr. Stone relates, "entered the right hip one inch posterior to the great trochanter, and emerged at the left groin, having fractured the right ischium, and perhaps the ramus of the corresponding pubis."

<sup>1</sup> Professor P. F. EVE (*Cases of Gunshot Wounds*, in the *Nashville Jour. of Med. and Surg.*, 1867, Vol. 11, p. 229) relates a case of extraction of ball from near the tuberosity of the ischium, four years after the reception of the injury: W. C. Draughton, 14th Tennessee, was wounded at Seven Pines, May 30, 1862, the ball entering the lower part of the belly; the missile could not be found; the wound healed, but re-opened several times, and a small piece of bone was discharged. In September, 1864, the bladder became irritable, and two rough calculi, one the size of a pea, were discharged. In March, 1866, pus freely escaped during efforts at micturition or defecation. After several unsuccessful attempts, the ball was finally removed on April 30, 1866, by a long pair of forceps, and the wound healed completely in a few weeks.

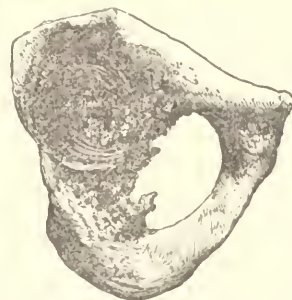

FIG. 192.—Right ischium injured by a ball. Spec. 1012.

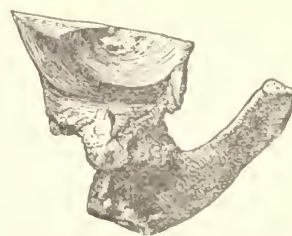


FIG. 193.—Caries and necrosis of the ischium from shot fracture. Spec. 1060.



Pelvic cellulitis, with deep suppuration, commonly attended shot fractures of the ischium, and, with its attendant chills, appears to have been sometimes confounded with pyæmia, also a frequent complication. Shot fractures of the ischium were in several instances associated with injuries of the femur, the latter then ordinarily becoming the dominant lesion:

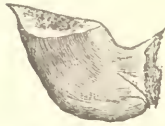

FIG. 194.—A portion of the left ischium contused and fissured by a musket ball. *Spec.* 987.

CASE 708.—Private J. B.—, Co. F, 131st Pennsylvania, aged 29 years, having been wounded at Fredericksburg on December 13th, was sent to Washington, and admitted into Harewood Hospital December 18, 1862. Surgeon Thomas Antisell, U. S. V., reports that "A conoidal musket ball had entered at the sacro-iliac symphysis, passed through the gluteal muscles on the dorsum ilii, and lodged in the perineum within an inch of the anus, from which position it was extracted. The patient died from the conjoined effects of hæmorrhage and extensive suppuration." A preparation from this case, a portion of the left ischium, contused and carious on its inferior posterior surface, was contributed to the Museum by Acting Assistant Surgeon W. A. Harvey, and is figured in the adjoining wood-cut (FIG. 194)

CASE 709.—Private Frank G.—, Co. K, 105th Pennsylvania, aged 28 years, was wounded on May 3, 1863, by a bullet, which struck over the symphysis pubis and came out at the left buttock. He was admitted to Carver Hospital on May 9th, and "remained without bad symptoms, although unable to use his limb, until the 18th, when he began to complain of pain in the hip and to lose his appetite. On the 16th, one-fourth of a grain of morphine, with one grain of quinine and a little

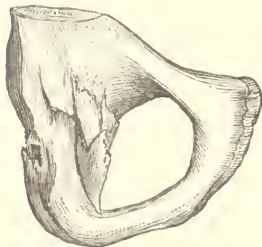


FIG. 195.—Internal view of the left pubis and ischium, showing a partial shot fracture of the body of the latter. *Spec.* 1212.

blue mass, was given every three hours. This had no other effect than to irritate his stomach and to cause vomiting. On the 17th, tincture of iodine was freely painted over his hip, and a poultice was applied. On the 18th, morphia was again administered, and the patient was transferred to a water-bed. The pain in the hip was not, however, relieved by these measures. On the 20th, the irritability of stomach being great and but little nourishment being taken, lime water and milk was administered with good effect. A liniment containing chloroform and acornite was applied over the parts. The sufferings of the patient became much less than they had been, but he was continually sinking, and finally died on the 21st, at about 7 o'clock A. M. At the autopsy, the course of the bullet was traced from its point of entrance over the symphysis pubis. It had passed across the ramus of the bone, furrowing it slightly across the obturator foramen, and through the body of the ischium. It then passed through the soft parts. The bones injured were taken out and preserved. Pus was found in the hip-joint." The above history was contributed by Acting Assistant Surgeon B. F. Craig, who treated the case. The pathological preparation, showing the fracture of the ischium (FIG. 195), was transmitted to the Museum by Surgeon O. A. Judson, U. S. V., in charge of Carver Hospital.

CASE 710.—Private J. W. S.—, Co. H, 155th Pennsylvania, aged 19, was wounded at Hatcher's Run, February 6, 1865, and was admitted to the field hospital of the 1st division, Fifth Corps, on the same day, and, on the next, removed to City Point. On the 14th he was transferred to Point Lookout, where he was treated until July 24th, when he was sent to Washington, where he was treated in various hospitals until May 1, 1866, when he was transferred to the post hospital under the charge of Assistant

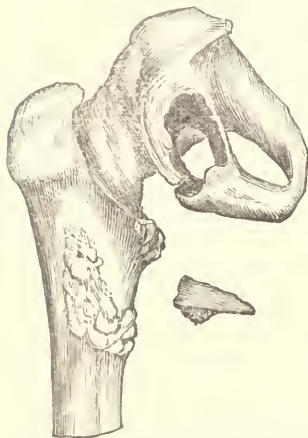


FIG. 196.—Bones of the left hip-joint, showing shot fractures of the ischium and femur. *Spec.* 2557.

Surgeon W. Thomson, U. S. A., who reports that "When admitted the patient was very weak and pale, and suffering from an old gunshot fracture of the ischium, and also from diarrhœa, with distressing nausea and vomiting after taking food or medicine. He stated that he had reclined on the right side altogether for many months; there was considerable œdema of the right arm, side, and leg, with pitting on pressure. The discharge from the wound was not profuse, but offensive and dark colored. These untoward symptoms increased steadily, despite all attempts to support the vital powers, and he died from exhaustion on May 20, 1866. Autopsy, seven hours after death, revealed: The right lung almost entirely cannified, weighing nine ounces, and compressed by three pints of serous fluid. There were considerable pleuritic adhesions in the side. Left lung healthy, with very slight effusion within the pleural cavity; heart very small, weighing six ounces; liver enlarged, hard, and paler than normal; kidneys and spleen healthy. Stomach the seat of numerous small ulcers which entirely perforated the mucous membrane; these were mostly toward the lesser curvature and rather nearer the pyloric orifice. No lesion of the large or small intestines." The specimen (FIG. 196) was forwarded to the Museum by Dr. Thomson, and consists of a wet preparation of the left hip-joint. The femur was partially fractured on the posterior surface below the trochanter minor, at which part several of the fragments were attached, and a loose fragment from which is mounted with the specimen. The ischium is perforated through the tuberosity on nearly the same plane as the obturator foramen."—(*Cat.*, p. 228.)

CASE 711.—Private D. H. Anderson, Co. G, 115th Indiana, was wounded at Blue Springs, October 10, 1863. He was sent, on October 12th, to Asylum Hospital, Knoxville, where Surgeon C. W. MacMillan, 1st East Tennessee, reported that "the ball entered two inches behind the left great trochanter, fractured the ischium, and made its exit at the left border of the anus. Secondary hæmorrhage occurred from a small arterial branch in the shot canal on October 18th, and was controlled by compression by pledgets of lint, saturated by solution of the persulphate of iron." He died October 20, 1863, from pyæmia. The cavity of the pelvis was found filled with fetid pus at the autopsy.



A number of the fractures of the ischium and of the pubis were complicated by wounds of the genital organs:

CASE 712.—Private *J. B. F.*—, Co. D, 42d Virginia, aged 25 years, was wounded at Petersburg, April 2, 1865, and was admitted to field hospital, 3d division, Ninth Corps, on the same day, whence he was transferred to Douglas Hospital, Washington, on the 6th, where he is reported to have received "a gunshot wound of the penis, scrotum, and upper portion of the right thigh, the bullet having grazed the os ischium in its course. The case progressed without any very unfavorable symptoms until the 15th, when he was seized with a severe chill; several chills occurred on the following day, and, on the 17th, he had two chills, and also pleurisy of the left side, with excessive pain. On the 20th he had a chill, and the subsequent sweats were increased in severity. He died from pyæmia on April 21, 1865. At the autopsy, the pleural cavities were found to contain about a pint of yellow colored liquid, with floating shreds of lymph, and the lungs were filled with pyæmic abscesses in various stages, their exterior surface covered with flakes of yellow lymph." The preparation of the injured bone (FIG. 197), with the ischiatic portion of the acetabulum chipped by a bullet, and scrotum, were contributed, with the foregoing history, by Assistant Surgeon W. F. Norris, U. S. A.

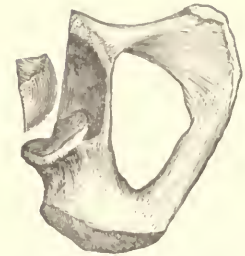

FIG. 197.—Portion of the right os innominatum, the edge of the cotyloid cavity chipped by a bullet. *Spec.* 1391.

*Excisions of Portions of the Ischium and Extraction of Foreign Bodies*—As indicated by some of the preceding abstracts, the extraction of bone splinters often formed a part of the primary dressing of shot wounds attended by fracture of the ischium, and the removal of carious or necrosed bone was frequently required in these cases.<sup>1</sup> In some cases, as in the two following, foreign bodies were extracted together with the bone sequestra:

CASE 713.—Private O. T. Whitaker, Co. H, 103d Ohio, aged 22 years, was wounded at Resaca, May 14, 1864, and was admitted to general hospital, Chattanooga, from the field, on the 17th, and transferred to No. 1, Nashville, on June 2d, where Surgeon B. B. Breed, U. S. V., reported: "Gunshot fracture of the tuberosity of the right ischium; the ball entered the right buttock, passed downward and inward through the perineum, and emerged at the external aspect of the upper third of the left thigh. On November 26th, the patient was placed under the influence of chloroform, and Acting Assistant Surgeon M. L. Herr removed a portion of a bayonet-scabbar, one and a half inches long and about three-fourths of an inch thick, by an incision in the perineum. The lower portion of the bayonet itself, an inch long and one-fourth of an inch in thickness, together with the tuberosity of the ischium, were also removed through an incision on the lateral aspect of the natis directly opposite the ischium. At the time of the operation there was a profuse discharge of pus, with necrosed scales of bone, from three fistulous openings, one in the perineum, one in the right natis, and another in the internal surface of the right thigh; his constitutional condition was good. Water dressings were applied, and the wound healed rapidly." The patient was transferred, on May 6, 1865, to hospital at Jeffersonville, whence he was discharged the service, June 1, 1865, and pensioned. Examiner J. Strong, jr., of Elyria, reported, June 14, 1865, that: "Pus and bone were discharged for eight months. He can now move with difficulty on crutches. The muscles and tendons are very weak and contracted. Disability total, and probably temporary." This pensioner was paid on June 1, 1873.

CASE 714.—Private A. Piatt, Co. B, 104th New York, was wounded at Gettysburg, July 1, 1863, by a conoidal ball, which entered about three inches to the right of the anus, penetrated the gluteal muscles, and fractured the ischium behind the acetabulum, and injuring the rim of the cotyloid cavity enough to allow the head of the femur to slide up on to the dorsum of the ilium. He was treated in a field hospital of the First Corps until July 13th, when he was transferred to West's Buildings Hospital, Baltimore; thence, on the 22d, to Patterson Park Hospital. On September 2d the ball was extracted, and several splinters of bone were removed by Acting Assistant Surgeon G. W. Pay. The patient recovered, with two inches shortening of the limb, and was transferred to the Veteran Reserve Corps on October 31, 1863. On November 14, 1863, he was discharged and pensioned. The missile and bone fragments removed, contributed to the Museum by the operator, are represented in the wood-cut (FIG. 198). Examining Surgeon F. J. Ames, of Mount Morris, reported, October 2, 1836: "Ball entered at the right of the termination of the spinal column, passing through the gluteal muscles, and so injured the right hip-joint that it is now completely obliterated, the head of the femur riding upon the hanch-bone. The limb is shortened three and a half inches, and he is unable to perform manual labor; disability total." This pensioner died April 15, 1870.



FIG. 198.—Flattened bullet and twelve bits of necrosed bone from the right ischium. *Spec.* 1795.

<sup>1</sup>The category of so-called excisions of portions of the ischium is not large. MAUSOUR (*Questions de chirurgie: Exposé des div. méth. chir. et de l'extraction des corps étrangers introduits ou formés dans les différents cavités*, Montpellier, 1812, p. 164) relates a case of caries of the ischium he treated, in 1769; with the actual cautery he extracted a fragment of the ischium as large as a small chicken-egg. FRÜCKE, of Hamburg, removed, with a chisel, the carious tuberosity of the ischium, according to Dr. GÜNTHER (*Lehrv. von den Blut. Operat.*, 1860, B. IV. S. 2). At the operation the pudic artery was divided and tied by Dr. GÜNTHER; the patient recovered. DEMME (*Studien*, Würzburg, 1861, B. II. S. 174) gives the case of Czankola, shot at Solferino, June 24, 1859. Dr. NEUDÖRFER, on September 29, 1859, resected the tuberosity of the ischium, with a surprisingly successful result. Oberstabsarzt BIEFEL (in LANGENBECK'S *Archiv für Klin. Chir.*, 1869, B. XI. S. 419) records the case of a lieutenant of the 41st Prussian infantry, wounded at Kreppehof, June 27, 1861, three inches from the right trochanter; trismus and other tetanoid symptoms supervened, and continued until August. On October 10th, a cloth-wad and bone splinter were removed, and a few days later the ball was found impacted in the inner side of the tuberosity, surrounded by new osseous depositions, which were gouged out and the ball released.

**SHOT FRACTURES OF THE SACRUM.**—Though placed more superficially than the innominate bones, the sacrum<sup>1</sup> is less liable to fracture from ordinary external violence than the latter, because of its thickness, spongy texture, and the mode in which it is braced by the pelvic girdle and the vertebral column.<sup>2</sup> These conditions afford no exemption from shot fractures, to which the bone is exposed in proportion to its magnitude, though much shielded by its surroundings, except on the spinous surface. Paré<sup>3</sup> states that he had many times seen the sacrum fractured by bullets and the subjects recovered, but if the fracture involved the spine, *à peine le malade peut éviter la mort*, the old master appearing less sound than usual in his prognosis. Three interesting cases of shot fractures of the sacrum are recorded<sup>4</sup> in the fourth chapter of the *First Surgical Volume*. Two of these are illustrated by pathological preparations, one of which is represented in the wood-cut (Fig. 199). The third was an example of recovery after the extraction of a ball impacted in the bony pyramid. The total number of cases reported was one hundred and forty-five. In three of them the result has not been determined. Of

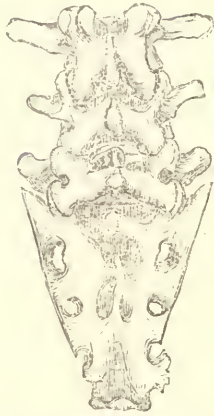

FIG. 199.—Sacrum and last lumbar vertebra, with a deformed round ball lodging in the spinal canal. *Spec.* 1198.

the remaining one hundred and forty-two, sixty-two, or 43.7 per cent., were fatal. It was common for one or both the projecting posterior spines of the ilium to be fractured simul-

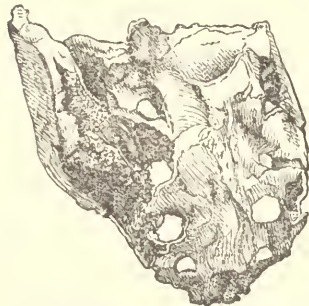

FIG. 200.—Shot fracture of the sacrum and ilium. *Spec.* 1353.

taneously with the sacrum, as in the preparation illustrated by FIGURE 200, and in those represented on page 222, and elsewhere in this section. Among the cases of recovery from shot fracture of the sacrum, were four in which the bladder was penetrated. In nine instances the rectum was wounded, and eight of these cases resulted favorably. In addition to the complications attending shot injuries of the innominate, paralysis and other disorders referable to lesions of the nerves were common after shot fractures of the sacrum. One or two examples of recovery may precede the fatal cases that furnished specimens of the various forms of these fractures:

**CASE 715.**—Private William Woodbury, Co. C, 15th Massachusetts, aged 30 years, was wounded at Antietam, September 17, 1862. He was treated in the Hoffman House Hospital, near the field, and at Satterlee Hospital, Philadelphia, and was discharged from service March 24, 1863, and pensioned. Examiner Oramel Martin, of Worcester, reported, May 11, 1863, that "the ball struck the right ilium two inches below its crest and three inches back of the anterior superior spinous process, passed through the bone and upper part of the pelvis, and out at the upper part of the attachment of the left ilium with the sacrum. The wound still discharges where the ball entered, and several pieces of bone have been discharged. Stooping causes him pain." This pensioner was paid to March, 1873.

**CASE 716.**—Lieutenant S. W. Russell, Co. B, 49th New York, and A. D. C. Sixth Corps, aged 26 years, was wounded at Rappahannock Station, November 7, 1863. On the 9th he was admitted into Armory Square Hospital, and on February 3, 1864, was transferred to Seminary Hospital, Georgetown, under the charge of Surgeon W. H. Ducachet, U. S. V. The case is noted upon the hospital register as "gunshot wound of the back. The ball entered the crest of the ilium on the left side and passed through the ilium of the right side, slightly injuring the lumbar vertebra." On February 19th, he was transferred to Kalorama Hospital on account of varioloid; was furloughed for sixty days March 7th, and returned to duty May 16, 1864. He was discharged from service June 27, 1865, and pensioned. Pension Examiner Julius Nichols, of Washington, reported, June 30, 1865, that "the ball entered the left hip, passed across the upper portion of the sacrum, and emerged from the right hip. The surface of the sacrum was fractured. The wound is unhealed. He will probably recover. Disability total for two years." This pensioner was last paid June 4, 1873.

<sup>1</sup> Sacrum, *sacr*, from having been offered in sacrifice, or from its propinquity to the genitals; German, *Heiligenbein oder Kreuzbein*. PAULUS EGINETA (ADAMS'S translation, 1846, Book VI, Sect. XCVIII, Vol. II, p. 455) speaks of simple and compound fractures of this bone, and their treatment.

<sup>2</sup> PATESSIER, Article *Fractures du sacrum*, *Dict. des sci. méd.*, 1820, T. XLIX, p. 318; MALGAIGNE, *Mém. sur les fractures du sacrum et du coccyx*, *Jour. de chir.*, 1846.

<sup>3</sup> PARÉ, *Œuvres*, éd. Paris, 1599, *Livre des fractures*, Chap. XLII, p. 443.

<sup>4</sup> Cases of Corporal L. P.—, page 447; of Private Michael H.—, p. 449 (*Spec.* 1198); and of Lieutenant W. A. C. Ryan, p. 461.



Pyæmia appears to have been nearly as common a complication as in shot injuries of the ilium. It was reported as the cause of death in eight of the sixty-two fatal cases, or 12.9 per cent. Cases that furnished specimens<sup>1</sup> may be mainly selected as examples:

CASE 717.—Private H. A. Lutes, Co. K, 74th Indiana, aged 21 years, was wounded at Chickamauga on September 19, 1863, by a conoidal musket ball, which entered at the centre of the dorsum of the left ilium, passed transversely across the sacrum, fracturing its spinous process, and emerged at the posterior crest of the right ilium. The patient had involuntary discharges from the bowels, but no paralysis of the lower extremities. The wound was dressed simply; tonics and stimulants were administered. Death, October 12, 1863, of pyæmia. Assistant Surgeon T. C. Norton, U. S. V., reported the case.

CASE 718.—Private George F——, Co. A, Purnell Legion, aged 23 years, was wounded at Cold Harbor, June 3, 1861, and was treated in the depot and division field hospitals until June 12th, when he was transferred to Washington and admitted to the Douglas Hospital. At this time he was suffering from partial paraplegia. He died from well-marked pyæmia on June 21st. The discharge from the wound was a dirty serous fluid. Autopsy: The ball was found in two pieces in the sacro-sciatic notch, having perforated the sacrum to the right of the median line; both lungs contained extensive pyæmic patches filled with yellow fluid; the liver and spleen were softened, and the latter enlarged. There had been icterus before death. The specimen (FIG. 201) consists of the sacrum, perforated a little to the right of the median line, at the junction of the fourth and fifth vertebrae, the internal wound being the larger, and was contributed together with the foregoing history, by Assistant Surgeon W. Thomson, U. S. A.

CASE 719.—Private W. M. Basto, Co. H, 137th New York, aged 25 years, was wounded at Wauhatchie on October 28, 1863. He was admitted from the field to a hospital at Chattanooga on the 29th. A missile had entered just above the left trochanter major, struck the innominate just above the acetabulum, causing a fracture, which extended toward the anterior superior spinous process and horizontally across the dorsum, passed through the sacro-iliac synchondrosis, exposing the cauda equina, and comminuting the sacrum. There ensued paralysis of the lower extremities, and involuntary evacuation of the bowels accompanied with frequent chills. Death, November 8, 1863.

CASE 720.—Private B. R——, Co. K, 37th Wisconsin, aged 41 years, was wounded at Petersburg, July 30, 1861, by a conoidal ball. Assistant Surgeon William Thomson, U. S. A., reported that "he was admitted to Douglas Hospital on August 3d, and died, after symptoms of pyæmia, on August 10th. There was no paraplegia before death, but for three days after admission the catheter was required, after which time his water passed freely. The internal organs were not examined, but death was preceded by chills and other characteristic symptoms." The specimen (FIG. 202) was sent to the Museum by Dr. Thomson, with the foregoing memorandum.

CASE 721.—Private A. S. Mabie, Co. A, 7th New Jersey, aged 23 years, received, at North Anna, May 24, 1861, a perforating wound of the pelvis by a musket ball, and was sent to a field hospital of the Second Corps, where Surgeon O. Everts, 20th Indiana, noted the character of the wound, and observed that there were no indications of injury of the peritoneal cavity, or of the bladder or rectum. The patient was sent to Washington on May 30th, and was treated at Mount Pleasant Hospital. Assistant Surgeon C. A. McCall, U. S. A., reported that the ball entered the groin below Poupard's ligament, near the anterior inferior iliac spine, and, passing backward, made its exit through the sacrum. The case progressed very favorably, considering the extent and gravity of the injury, until August 30th, when a chill ushered in a fatal attack of pyæmia. Quinia was given, with stimulants and a sustaining regimen, and the threatening symptoms appeared for a few days to be held in check; then chills recurred with greater intensity, and the patient died September 10, 1864. No autopsy was made; but the symptoms pointed unmistakably to pyæmia as the cause of death.

CASE 722.—Private James M. S——, Co. I, 22d New York, aged 19 years, was wounded at West Point, Virginia, May 7, 1862, and was treated in the regimental hospital until the 14th, when he was sent to Judiciary Square Hospital, Washington, whence Assistant Surgeon Calvin G. Page reported as follows: "Gunshot wound of the lumbar region near the nates, and also through the lower part of the right chest. When admitted, there was a large discharge of pus from the wounds, to which poultices were applied. Tonics, stimulants, and opiates were also administered. On the 18th, there was some fever; the bowels were loose, pulse full, and urine scanty, with some dysuria. Frictions of the whole surface with alcohol and water were ordered. On the 22d, the urine was still bloody; the bowels were regular; the patient was flighty at night; the pulse was full; he perspired freely at night, and had a small appetite. He died on May 23, 1862. Post-mortem section of the injured parts showed a deep wound of the sacrum, plunging the bone." The portion of the sacrum injured is represented in the wood-cut (FIG. 203). It was sent to the Museum by Dr. Calvin G. Page.<sup>2</sup>

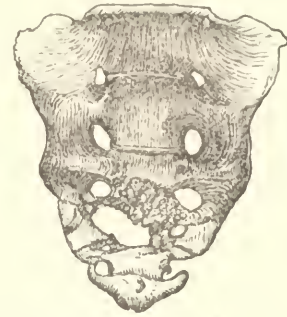


FIG. 201.—Shot perforation of the sacrum. Spec. 3568.

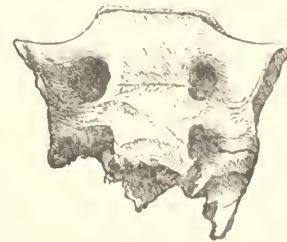

FIG. 202.—Upper two thirds of sacrum obliquely fractured by a musket ball. Spec. 3566.

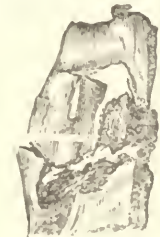

FIG. 203.—Right half of the sacrum grooved by a ball. Spec. 230.

<sup>1</sup>Herr FISCHER (H.) (*Kriegschirurgische Erfahrungen* Erlangen, 1872, S. 132, and TAFEL IV, 23) describes and figures a shot fracture of the sacrum in the case of Bielefeld, 53d Prussian Infantry, wounded August 8, 1870, died October 5, 1870. The *Musée Dupuytren* contains a preparation of the pelvis (No. 15, *Cat.*, 1842, p. 24) with a ball lodged in the second right sacral foramen; the specimen is figured by M. LEGOUËZ (*Chirurgie d'Armée*, 2<sup>me</sup> éd., p. 419). Dr. STROMAYER (*Maximen der Kriegsheilkunst*, 1855, S. 654) has a sacrum from a patient wounded at Fredericia, who, eight months after the injury, was convalescent when dancing brought on a fatal attack of pyæmia.

<sup>2</sup>The *Catalogue of the Surgical Section*, p. 227, erroneously credits the specimen to Surgeon Charles Page.



A case of transverse perforation of the sacrum, the fatal issue proximately due to bed-sores, an instance of crash with remarkable absence of shock, two examples of embedded balls, and a case fatal from secondary hæmorrhage,<sup>1</sup> may continue the survey of this group:

CASE 723.—Corporal Amos E. C——, Co. H, 110th Pennsylvania, aged 18 years, was wounded at Chancellorsville, May 3, 1863. Acting Assistant Surgeon Carlos Carvallo reports that “a conoidal musket ball, which entered the left buttock behind and above the great trochanter of the left side, emerged through the left side of the sacrum. The patient remained in the hands of the enemy for nine days, during which time his wounds were entirely neglected. On June 14th, he was sent to

Washington and admitted to Douglas Hospital, being very nervous, weak, and anæmic. There were bed-sores at the long projections of the hips, back, and sacrum, so that it was impossible to lay him in a comfortable position. The ball was extracted by Acting Assistant Surgeon J. E. Smith. The trunk was supported by rings of India-rubber and gutta-percha, padded with cotton and feathers. The medical treatment was expectant. The case progressed as follows: June 21th, anorexia. 25th, bowels costive. 27th, epididymitis of the left testicle, caused by the pressure resulting from the weight of the right thigh while lying on his left side. 28th (morning), catarrh of the stomach; (evening), acute bronchitis, fever, flatulence, pain in the stomach. 29th, bowels costive, bleeding of the gums, dysphagia, gums red and inflamed. July 7th, the inflammation has nearly subsided. The patient died July 9, 1863. On *post-mortem* examination pleuritic adhesions were found, but no signs of peritoneal inflammation. The sacrum (FIG. 204) was perforated, with loss of substance, at the junction of the fourth and fifth vertebrae. The fractured bones were carious, and there was a slight osseous deposit on the inner surface of the sacrum.”

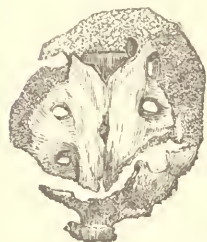

FIG. 204.—Sacrum grooved transversely by a musket ball.—*Spec.* 1612.

CASE 724.—Surgeon L. A. James, 4th Ohio Cavalry, reported that Private W. Ball, 1st Ohio Cavalry, at Elk River, July 2, 1863, had the upper part of the sacrum crushed in by an unexploded twelve-pound shell, which lodged in the left iliac fossa, whence, with some difficulty, it was extracted. This man lived four hours after the reception of the injury, being perfectly conscious until a short time before dissolution.

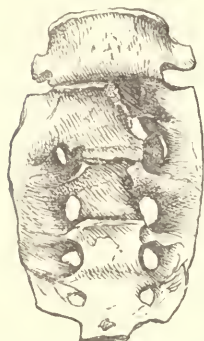


FIG. 205.—Sacrum and last lumbar vertebra. A ball is impacted in the left sacral foramen. *Spec.* 2002.

CASE 725.—Private G. A. L——, Co. I, 1st Pennsylvania, aged 23 years, was wounded at Spottsylvania, May 10, 1864, and taken to a field hospital of the Fifth Corps. On the 14th, he was transferred to Carver Hospital, Washington. Acting Assistant Surgeon U. Sweet reported as follows: “The missile entered about two inches to the left of the sacrum, passing a little downward and to the right, fracturing the sacrum, and remaining in the wound. When admitted, the patient was not much emaciated; there was great pain and tumefaction of the abdomen; the bowels were constipated, and there was complete retention of the urine. The bladder was greatly distended with urine; the pulse about 140; tongue thickly coated with dark-colored fur; sordes on the teeth. There was partial paraplegia. The catheter was introduced and the bladder relieved. The missile was searched for unsuccessfully. Opiates were then administered. He continued to sink, and was perfectly unconscious. The pulse was at 160. He died May 15, 1864.” The specimen contributed to the Museum by Dr. Sweet is represented in the accompanying wood-cuts (FIGS. 205, 206).

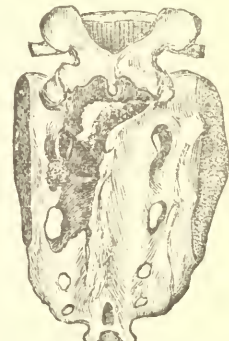


FIG. 206.—Posterior view of the same specimen.

CASE 726.—Private H. J. Nearing, Co. A, 15th New York Cavalry, aged 22 years, was wounded near Winchester, July 24, 1864. The regimental Assistant Surgeon M. A. Halstead and Surgeon J. Boone, Maryland Volunteers, reported a shot wound of the right hip, penetrating the sacrum. The patient was sent from Sandy Hook Hospital, on July 30th, to Baltimore, and entered Jarvis Hospital the next day. Assistant Surgeon D. C. Peters reports that there was “secondary hæmorrhage to the amount of six ounces from a traumatic aneurism, on August 7th,” and that the bleeding was “restrained by persulphate of iron and compression; but recurred on August 8th, and was restrained by the same means. Death, August 10, 1864, from spinal meningitis.” Acting Assistant Surgeon B. B. Miles made an autopsy, twenty-four hours after death, and reported that “the ball was found to have struck the right side of the sacrum and then to have lodged. The parts surrounding the injury were in a gangrenous condition. The lower part of the spinal cord was softened and of a dark appearance.”

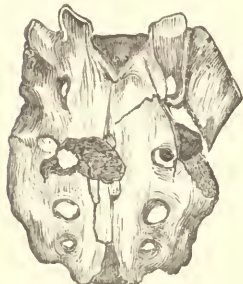

FIG. 207.—Sacrum, with a ball impacted at the left second intervertebral notch. *Spec.* 2542.

CASE 727.—Private Peter K——, Co. G, 91st New York, aged 32 years, having been wounded at the engagement at the South Side Railroad on April 1st, was sent to Washington, and admitted to Douglas Hospital on April 6, 1865. A conoidal musket ball had entered the buttock nearly on a level with the second vertebra of the sacrum, about four inches to the left of the spinous process of the vertebra, passed through the sacral portion of the spinal canal, and lodged in the right wing of that bone, near its junction with the ilium. There was complete paralysis of the bladder and of the rectum, with constant hæmaturia; but no paralysis of the lower extremities. On April 8th, the patient failed rapidly, and became partially insensible. He died from exhaustion April 9, 1865. The specimen (FIG. 207) was contributed by Dr. W. F. Norris, U. S. A.

<sup>1</sup> KOCH (*Notizen über Schussverletzungen*, in LANGENBECK'S *Archiv*, 1873, B. XIII, S. 569) notes two cases from Noisseville analogous to CASES 725, 726, viz.: Fischer, 1st Prussian Infantry, ball lodged in sacrum August 31st, death October 2, 1870; Mercier, 62d French Infantry, shot fracture of sacrum August 31st, death from hæmorrhage from gluteal artery, November 11, 1870.

Shot fractures of the sacrum<sup>1</sup> are represented in the Museum by not less than sixteen specimens, of which eight of the most interesting have been already figured. A few other examples may be added:

CASE 728.—Private P. McC——, Co. H, 1st Louisiana Cavalry, aged 20 years, was wounded at Carrion Crow Bayou, Louisiana, November 3, 1863. He was treated on the field until the 8th, when he was admitted to University Hospital, New Orleans, where he died November 22, 1863. The following report of the case, together with the specimen, was furnished by Assistant Surgeon P. S. Conner, U. S. A., in charge: "Gunshot fracture of the sacrum, the missile passing obliquely from the left, entered near the median line at the junction of the second and third lumbar vertebrae, and escaped into the pelvis through the right portion of the second vertebra. The sacrum was completely fractured transversely at that point." The specimen (FIG. 208) is figured in the adjoining wood-cut.

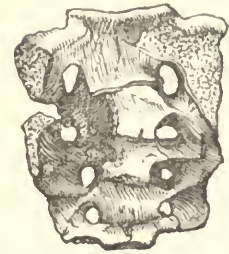

FIG. 208.—Shot fracture of the sacrum. Spec. 3001.

CASE 729.—Private W. M. R——, Co. F, 58th Virginia, aged 22 years, received a wound in the abdomen at Winchester, July 20, 1864; a musket ball penetrated the back five inches above the anus and one inch to the left of the median line and lodged. The wound was dressed in the field hospital, and, on the 23d, he was admitted into the hospital at Cumberland, and the case reported by Surgeon J. B. Lewis, N. Y. V., as follows: "The wound looked irritated and was attended with much pain; it was examined under the use of chloroform and the ball traced obliquely upward and forward, having broken down the sacrum and spinous processes of the lower lumbar vertebrae. The discharges were very thin and fetid; he suffered much, but there was no paralysis or loss of sensation; he has had retention of urine, requiring the daily use of the catheter; he did not rest well, but felt well otherwise. July 25th, he was very restless and suffered great agony from the wound, the oedymosis and discoloration of which were disappearing rapidly; suppuration was profuse and offensive. But little change occurred in the condition of the patient up to August 6th, when light tetanic spasms occurred, with delirium and unconsciousness, and continued with increasing severity, and, on the 8th, opisthotonic spasms recurred at frequent intervals; the pupils were largely dilated and fixed, and he was unconscious and unable to take food or medicine. The case was complicated with diarrhoea, requiring the use of astringents and opiates, for which diarrhoea mixture was given during the day and solutions of morphia at night; cold-water dressing was applied to the wound; tonics and stimulants were administered, and nourishing diet ordered. He died August 8, 1864. *Section cadaveris* twelve hours after death: Rigor mortis well marked; the back in the vicinity of the wound was livid and offensive; the ball was found about three inches from the point of entrance above and to the right of the spinous process of the lumbar vertebra, embedded in the muscular tissue; the spinous processes were broken through and the spinal column in a suppurating condition. The cerebrum and cerebellum were also suffused and injected with blood throughout their entire extent; the right kidney was partially broken down by an abscess, and the left was congested and enlarged; old adhesions of the peritoneum and bowels marked the extreme of inflammatory action. No other viscus was examined." Dr. Lewis forwarded the specimen (FIG. 209), which consists of a wedge-shaped portion of the sacrum, showing a fracture into the vertebral canal at the second sacral vertebra, and the first and second spinous processes broken away.

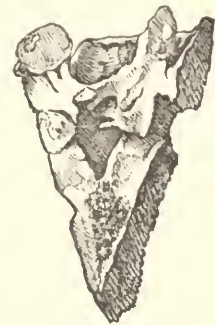

FIG. 209.—Shot penetration of the sacral canal. Spec. 4258.

CASE 730.—Private Peter C——, Co. E, 73d Pennsylvania, aged 26 years, was wounded at Chancellorsville, May 3, 1863, by a conoidal musket ball, which perforated the third sacral vertebra at its junction with the ilium and embedded itself within the pelvis. He was sent to Washington, and admitted into Douglas Hospital on May 7th. Acting Assistant Surgeon H. L. W. Barrett describes the progress of the case: "There was no paralysis or disturbance of function. Water dressings, morphia, and a nourishing diet constituted the treatment. There was no constitutional indication of serious injury till May 19th, when a slight fever occurred, followed by much prostration. On the following day, the constitutional disturbance was more marked; the pulse being 100, the tongue of a dark-brown color, and the skin hot but moist. The bowels and urine were natural; the discharge of pus free, with no discoloration from the wound, and the patient slept well. On May 21st, he became much worse; the pulse being at 120, with jaundice, sordes, loose bowels, dry skin, obtuse mind, moaning, and restlessness; the pulse rose to 125. On May 22d, the skin was dry and of a dark-yellow color; decubitis dorsal; there was a free dark discharge from the wound; the tongue was dark, and there was hicough; death, May 22, 1863." At the necropsy, eighteen hours subsequently, "the ball was found embedded in a portion of the clothing, and enclosed in a sacculated membrane just within the pelvis, none of the viscera of which were injured. Both the ilium and sacrum were fissured and comminuted, several large pieces being driven inward. The case is remarkable for the absence of peritonitis and paralysis, the patient being able to get in and out of bed to stool, and having no tenderness or tympanism of the abdomen even to the last." Assistant Surgeon W. Thomson, with these comments, transmitted the pathological specimen (FIG. 210).

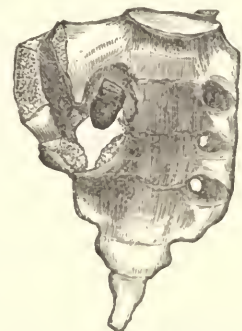

FIG. 210.—Sacrum and adjoining portion of right ilium, and bullet which perforated the former. Spec. 1245.

<sup>1</sup> While references to shot fractures of the pelvis abound in the writings of military surgeons, observations in which the seats of the lesions are described with precision are not very numerous. DESPORT (*Traité des plaies d'armes à feu*, Paris, 1749, p. 323) mentions the recovery of a soldier of the Nivernois regiment, shot in the upper portion of the sacrum; a large incision was made and the ball removed with pincers. BIROT (*Hist. de l'état et de progrès de la chir. mil.*, 1817, p. 138) gives the case of Sarbeuf, 10th brigade, shot through the sacrum and rectum; several pieces of bone came away; recovery in about one month. HENSEN (*Princ. of Med. Surg.*, 1829, p. 449) states that Mr. HAMMICK showed him a preparation from a patient



*Excisions of Portions of the Sacrum.*—About half an inch of the lower end of the sacrum may be removed without opening the sacral canal. The spinous apophyses may also be resected. The interval between the apophyses and the lateral foramina is only about half an inch, so that it is not easy to resect the lamina. The spinous processes or lower extremity are most readily excised by the cutting bone-forceps; the remaining parts of the bone are more conveniently attacked by the ruzine, gouge, or cockscomb saw.

CASE 731.—Surgeon N. R. Derby, U. S. V., was wounded, during the Red River Expedition, in April, 1864. The following notes of the case appear upon a monthly report of No. 1 hospital, Alexandria, Louisiana, signed by Surgeon James Roberts, U. S. V.: "The wound was produced by a large round ball, which entered over the rough surface of the first sacral bone and near the posterior right sacral foramen. The finger passed through a circular opening into a cavity of the pelvis. The direction was forward, downward, and outward; the situation of the ball was not found. Three pieces of the sacrum and some pieces of clothing were extracted at the time of the examination, which was made while the patient was under the influence of chloroform. On April 30th, the patient was conveyed, on a water-bed, to the hospital steamer R. C. Wood." On May 12th, he was admitted into the hospital at Mound City, whence he was transferred to Jeffersonville June 1st. Surgeon Derby was mustered out of service July 27, 1865, and pensioned. Examining Surgeon W. M. Chamberlain, of New York, reported, May 5, 1866: "The ball entered the cavity of the pelvis through the sacrum. The injury has resulted in partial sensory and motor paralysis of the right lower extremity, obliging him to walk with a crutch and cane; there is also some neuralgic disturbance."

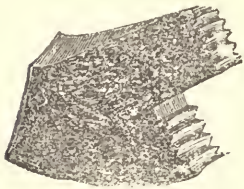


FIG. 211.—Shell fragment extracted from the sacrum. *Spec.* 4459.

CASE 732.—Private Charles A. Trask, Co. H, 13th Massachusetts, was wounded at Antietam, September 17, 1862, by a fragment from a spherical case-shot, which fractured the pelvis and lodged in the sacrum. He was conveyed to a field hospital, where the missile was extracted. On September 20th, he was transferred to Hagerstown, and, on the 29th, to Chambersburg, where he died in the early part of October, 1862. The missile (FIG. 211), showing a section of the orifice for the fuze, and weighing two and two-third ounces, was contributed to the Museum by Surgeon E. McDonnell, U. S. V.

CASE 733.—Private W. Bell, Co. F, 121st Pennsylvania, was wounded at Gettysburg, July 1, 1863. A ball entered just below the left posterior superior iliac process and lodged. The patient was sent to Broad and Cherry Streets Hospital, where Surgeon John Neill, U. S. V., reported the general health excellent, a fortnight after the injury. "On introducing the finger an extensive fracture of the sacrum was recognized, a large piece being movable; the ball had passed downward and toward the right. There was no paralysis or paresis, and the evacuations were natural. Several large fragments of bone were removed, evidently belonging to the sacrum. By October 1st he had made a good recovery, without a bad symptom." He was discharged July 10, 1865, and pensioned. The Pension Examining Board reported, May 1, 1872, substantially, that the ball, passing through the sacrum, lodged in the right hip; and that there was loss of bone, adherent cicatrix, numbness of both legs, especially the left, and pain on change of weather.

CASE 734.—Corporal M. Moore, Co. G, 8th Ohio, aged 23 years, was wounded at Gettysburg, July 3, 1863, and was taken to the Second Corps hospital. Surgeon Isaac Scott, 7th West Virginia, reports that "a ball entered the pelvis a little to the left of the spine, and between the fourth and fifth sacral vertebra." The patient was transferred to McKim's Mansion Hospital, July 13th. Acting Assistant Surgeon A. Hartman reports that "there were several secondary hæmorrhages externally during the 14th. He also complained of pain in the abdomen, and became delirious. Death resulted July 15, 1863. *Section cadaveris:* The course of the ball was in a line drawn from the point of entrance to the crest of the pubis. There was considerable blood effused into the pelvis, apparently from the lateral sacral and small branches given off from the anterior trunk of the internal iliac. The peritoneum bore evident marks of inflammation. The ball (FIG. 212) was found just posterior to the bladder." The missile was transmitted to the Museum by Surgeon L. Quick, U. S. V.



FIG. 212.—Ball found in the pelvic cavity after death. *Spec.* 671.

shot by a musket ball through the side of the sacrum, three inches above the point of the coccyx; the missile penetrating obliquely upward, and being passed by stool two months after the injury; this patient survived two years. [Compare note 1, p. 107, *supra*, where it is erroneously stated that HENNEZ specifies only the cases there referred to. This is probably one of the instances he had in mind in writing: "Other cases of a similar nature have come to my knowledge."] The same author (*l. c.*, p. 450) gives the case of an officer shot through the sacrum at the siege of Badajos in 1812, the injury resulting fatally. LARREY (D. J.) (*Mém. de chir. mil. et camp.*, 1817, T. IV, p. 298) quotes a case from the *Saltzberg Gazette* of 1812; a ball entered through the os pubis and escaped through the sacrum; urine and fecal matter escaped from the posterior wound, and urine only from the anterior; the patient recovered. LARREY (*l. c.*, T. IV, p. 309) also relates the case of a German soldier shot through the sacrum in 1800; the ball lodged in the bladder, and was removed by Dr. LANGENBECK ten years afterward. GUTHRIE (*Lectures*, etc., 1847, p. 67) records that a French officer was shot at Salamanca through the sacrum, urine escaping from the entrance and exit wounds; death followed in three days, from peritonitis. ROIX (*Considérations cliniques sur les Blessés qui ont été reçus à l'Hôpital de la Charité*, 1830, p. 33) gives the case of a man of 20, shot through the sacrum; paralysis of bladder and rectum ensued, and death in seven or eight days. HUTIN (*Fragmens historiques et médicaux sur l'Hôtel national des Invalides*, Paris, 1851, p. 75) tabulates three instances, in which invalids were admitted to that hospital with balls embedded in the sacrum. JOBERT, *Plates d'armes à feu*, 1833, p. 220) relates the case of T——, shot in the base of the sacrum, in the revolution in Paris, July, 1830; the ball was removed, and the patient slowly recovered. CHENU (*Statistique méd. chir. de la camp. d'Italie*, 1869, T. II, pp. 510, 512) records four cases of shot fractures of the sacrum resulting favorably. BECK (*Kriegschir. Erf.*, 1867, S. 253) cites one successful and one fatal case of fracture of the sacrum; in the latter, the ball lodged in the bone, and an unsuccessful attempt to forcibly remove the missile was made; death from pyæmia. The same writer (*Chirurgie der Schussverletz.*, 1872, S. 553-555) adduces four cases of shot fractures of the sacrum with favorable terminations. Professor SOCIN (*Kriegschir. Erf.*, 1872, S. 98) relates two cases of shot fractures of the sacrum; recovery in three and eighteen weeks; in the latter case the ball lodged; ball and many bone splinters were removed. CHIPAULT (*Tract. par armes à feu*, 1872, p. 77) relates two cases (*Obs.* 82 and 83); recovery after shot fracture of the sacro-spinal processes. PURMANN (*Fünfzig Sonder- und wunderbare Schusswunden Curen*, 1721, *Obs.* VII) records the case of Sergeant Eulenberg, shot through the sacrum, at Stettin, July, 1677; four days after, the ball passed at stool.



Dr. Francis H. Brown, in a valuable paper,<sup>1</sup> read before the Middlesex Medical Society, has recorded two cases of shot fracture of the sacrum, in one of which a shell fragment was deeply embedded in the body of the bone and was with some difficulty extracted:

CASE 735.—Private J. O. Churchill, Co. E, 11th Massachusetts, was wounded near Bristoe Station, August 30, 1863, and sent to Judiciary Square Hospital at Washington. Surgeon Charles Page, U. S. A., reports a shot wound directly over the sacrum. On passing the finger through the lacerated soft parts, a fragment of metal was felt an inch below the surface, thoroughly impacted in the body of the sacrum, and requiring considerable force for its dislodgement. There was retention of urine, and a catheter was introduced; once relieved, the bladder resumed its normal functions. The patient had no paralysis or other indication of spinal concussion. He was able to sit up at the expiration of a fortnight, and in a month was about the wards. He was transferred to the Filbert Street Hospital on December 11, 1862, and discharged from service March 20, 1863, for a "shell wound of sacrum." His name does not appear on the Pension Rolls.

What was formerly regarded as an indispensable implement in extracting bullets from bone, the old-fashioned *tire-fond*, was rarely or never used, and, indeed, was not included in the outfit of the field or dressing cases of the surgeons of either army. That it is occasionally requisite is shown by the following case, in which the screw of a ramrod served as a substitute:

CASE 736.—Private J. McDonald, Co. K, 11th Connecticut, was wounded near Petersburg, June 18, 1864. He was admitted to the hospital of the 2d division, Sixth Corps. On examination by Surgeon S. F. Chapin, 139th Pennsylvania, the ball was discovered "firmly embedded in the body of the sacrum, beyond the reach of forceps, and was extracted by means of a common ramrod, a piece of which remains in the bullet as when taken out." There was great prostration from shock, and the patient died the same day, June 18, 1864. The specimen, as represented in the wood-cut (FIG. 213), was forwarded by Dr. Chapin to the Museum, with the foregoing memoranda.

CASE 737.—Surgeon J. J. Chisolm relates (*Manual of Military Surgery*, 3d ed., 1863, p. 356) that "in the case of Private E. J. Mattheus, of the 26th Alabama Regiment, a youth of 14 years, who, when returning from a fifth charge against a Yankee battery during one of the battles of Richmond, was shot in the back, the ball entered through the sacrum an inch from its spinous processes and one inch below the level of the crest of the ilium. Eight months after the reception of the wound he applied to me for relief, as he had a constant discharge of pus from both the wound in the back and a fistulous passage in the left groin. Upon examination with a probe, which passed in four inches, traversing the sacrum, the foreign body was detected, the bulb of the probe entering the cup of the minié ball. By using a gouge, the orifice through the sacrum was enlarged sufficiently to allow the ball being drawn from the pelvic cavity. The case recovered."

Besides the seven foregoing examples of operations upon the sacrum for the removal of injured or diseased bone or the extraction of impacted projectiles, five others have previously been incidentally noticed,<sup>2</sup> and the examination of injuries of the bladder and rectum will present several others. There were in all twenty-five such operations.<sup>3</sup> In one instance the trephine was employed.

CASE 738.—Private H. F. Norcross, Co. C, 25th Massachusetts, aged 20 years, was wounded at Drury's Bluff, May 16, 1864. He was sent to Hampton Hospital. Assistant Surgeon Ely McClellan, U. S. A., recorded a shot penetration in right gluteal region. The patient was removed to DeCamp Hospital, June 10th; to Readville on October 19th; and to Dale Hospital, Worcester, on October 25, 1864. The track of the ball had been traced to the right side of the second sacral segment, and the missile was apparently deeply embedded in the bone. On March 9, 1865, Acting Assistant Surgeon E. B. Lyon reported that "there was an open sinus on the right buttock communicating with the lodgement of the ball in the sacrum, and discharging freely. The constitutional condition was comparatively good. Ether was administered, and an oblique incision, six inches in length, was made, exploring the orifice in the sacrum. A trephine was then used to enlarge the orifice in the bone. The ball was divided and removed in seventeen parts. Simple dressings were applied. On March 31st, the wound was healing kindly." He was discharged from service July 10, 1865, when Surgeon C. N. Chamberlain, U. S. V., rated the physical disability at one-fourth, resulting from a "gunshot perforation of the sacrum, with loss of tissue and an extensive cicatrix." This soldier was pensioned. The Examining Board of Boston reported, September 18, 1873: "Wound of upper part of right buttock, near the cleft. In consequence of the cicatricial tissue he suffers pain and lameness. The cicatrix is tender, and open most of the time, and is discharging at present. The disability continues at one-half."



FIG. 213.—Conoidal ball extracted by a ramrod. Spec. 1123.

<sup>1</sup> BROWN (F. H.), *Surgical Cases*, in *Boston Med. and Surg. Jour.*, 1863, Vol. LXVII, p. 492. The second case, that of Private Durfee, is noted further on.

<sup>2</sup> Another report in the case of Pt. W. Ambrosier, printed on page 458 of the *First Surgical Volume*, and in the *Cincinnati Lancet and Obs.*, 1864, Vol. VII, p. 595, indicates that the sacrum shared in the injury, and that the removal of fragments reported was from the spinous process of the sacrum.

<sup>3</sup> The few following cases are recorded by authors: PERMANN (*Funffzig Sonder- und wunderbare Schusswunden Curen*, Frankfurt, 1721, Obs. XXV, p. 191) relates the case of M. Friedrich, of Captain Götzen's company, shot through the sacrum, at Greifswalde, November 23, 1678, and states that he removed a large piece of the os sacrum on the third day, and eighteen small pieces during the first four weeks. Professor ROTHMUND (RIEDEL, *Die Resectionen der Knochen*, Nürnberg, 1860, S. 242) is said to have successfully removed a necrosed piece of the os sacrum, three by four and a half

**SHOT FRACTURES OF THE COCCYX.**—This form of injury has received some attention from military surgeons on account of Andouillé's disquisition already noticed, which is printed in the second volume of the celebrated *Memoirs of the French Academy of Surgery*.<sup>1</sup> It is hardly necessary to observe that the osseous lesion is ordinarily a subordinate element in the gravity of shot injuries of this group. Van Onsenoort and Ollier<sup>2</sup> extirpated the coccyx for caries, and Nott<sup>3</sup> and Simpson<sup>4</sup> performed the same operation with impunity for neuralgia, and Mr. Bryant<sup>5</sup> has safely separated the muscular attachments.

Seventeen cases of shot fracture of the coccyx, of which six, or 35.3 per cent., were fatal, were reported during the war. In twelve cases, with five deaths, the coccyx was the only bone involved; four cases, terminating favorably, had attendant fractures of the sacrum; two, one of which was fatal, were associated with fractures of the pubis.

In four of the seventeen cases, the rectum was penetrated; in three of these four cases, the bladder was also injured. The two fatal cases of this group<sup>6</sup> fall in this last category, which, moreover, comprises all the instances in which shot fracture of the coccyx was associated with injury of the bladder.

**CASES 739-744.**—Five of the six cases of shot fracture of the coccyx alone that terminated favorably, were those of Private G. W. Busch, Co. A, 2d Illinois, wounded at Chancellorsville, May 2, 1863, discharged April 4, 1865; Private W. L. Fischer, Co. D, 1st Mississippi Marine Brigade, wounded at Rodney, December 4, 1863, discharged from service May 31, 1864; Private P. Doyle, Co. G, 16th Kentucky, wounded at Atlanta, July 20, 1864, duty, January 7, 1865; Corporal E. H. Shermer, 105th Co., 2d Battalion V. R. C., Stone River, December 31, 1862, discharged April 12, 1864; Private B. Jones, Co. D, 176th New York, wounded at Cedar Creek, October 19, 1864. The sixth case was that of Denegan, which will be detailed separately. Of these five, Busch alone is pensioned; the application of Doyle is pending. Private Busch was treated in hospitals at Chattanooga, Nashville, Jeffersonville, and Mound City. It is from the last-named hospital that Surgeon Horace Wardner, U. S. V., returns the fullest account of the case. Pension Examiner Churchman, of Chillicothe, reports that in this case the ball was extracted from the vicinity of the left sciatic nerve, and that the left lower extremity is permanently lamed in consequence of injury to the nervous trunk. Private Shermer's case was complicated with wound of the rectum and fecal fistula, and discharge of necrosed bone. Private Jones appears on the records of Jarvis Hospital as a transverse shot perforation of both buttocks, with fracture of the coccyx, complicated by secondary hæmorrhage, arrested by compression. The hæmorrhage was relieved by Assistant Surgeon D. C. Peters to "traumatic aneurism of the internal pudic artery."

**CASE 745.**—Private S. Denegan, Co. E, 58th Massachusetts, aged 22 years, was wounded at Cold Harbor, June 1, 1864, and sent to Alexandria, where he was admitted into St. Paul's Church Hospital, June 7, 1864. Acting Assistant Surgeon A. W. Tryon reports: "A gunshot fracture of the coccygeal bones, wounding the rectum; the ball entered the gluteal muscle about four inches to the right of the os coccygis and passed directly across, making its exit from the gluteal muscle of the opposite side about the same distance from the coccyx. Blood and pus from the wound flowed through the anus, and small quantities of fecal matter worked out at the openings of the wound. The patient had been much debilitated by a severe persistent diarrhœa. He was supported by milk-punch made with brandy. Quinia, iron, and tannin, with opium pills, were administered. On June 20th, the edges of the wound became gangrenous, and a patch directly over the coccyx, an inch above the ramus, sloughed out, making another opening. Bromine was applied to the livid edges of the wound, and a separation of the slough soon followed, and the wound began to exhibit a healthy action. On July 1st, he was greatly improved. July 6th, he was suddenly taken with a chill in the afternoon, and at night he had another. Next morning erysipelatous inflammation, extending along the integument of the hips and down on his thighs, was progressing very rapidly. A high febrile movement accompanied this attack. Two grains of sulphate of quinia, with half a drachm each of simple syrup and tincture of the sesquichloride of iron, was ordered every four hours, with a local wash of acetate of lead and opium. On the following day the febrile movement was not so high, and milk-punch was resumed. The erysipelatous inflammation kept extending, but soon began to fade and go down around the wound. In about ten days it entirely disappeared. The patient's appetite and strength improved. The tincture of

inches, with the osteotome. Mr. JOHN COUPER (*Misc. Cases, in Clin. Lect. and Rep. of Lond. Hosp.*, 1867-8, Vol. IV, p. 270) records a case of extraction of an iron ball from the sacrum, twenty-one years and a half after the reception of the injury. The man was struck at Moodkee, in December, 1845. Several unsuccessful attempts to extract the ball from its lodgement near the middle of the sacrum were made. In 1867, the missile was successfully extracted, and weighed four hundred and fifty grains, and was thickly coated on the surface with sulphurets. CHAMPEAUX (*Gazette Salulaire*, 1769, No. 31, p. 3) relates the case of a woman injured by a fall, which caused necrosis of the sacrum; the bone was laid bare and more than twenty pieces of bone were removed by means of the forceps.

<sup>1</sup> ANDOUILLE (*Mém. de l'Acad. de Chir.*, 1753, T. II, p. 488) states that in Flanders, at the battle of Raucon, October 11, 1746, a Hanoverian soldier was struck by a musket ball, which entered at the junction of the pubis with the ilium, notched the bone, traversed obliquely the cavity of the pelvis, perforated the rectum, and destroyed the lower part of the sacrum and part of the coccyx.

<sup>2</sup> VAN ONSENOORT'S case is cited by VELPEAU (*Méd. opérat.*, 1839, T. II, p. 641), and by RIED (*Die Resectionen der Knochen*, 1860, S. 242), O. HEYFELDER (*op. cit.*, S. 318), and others who appear to quote VELPEAU. VAN ONSENOORT'S *Operative Heelkunde*, Amsterdam, 1822, is styled *ein schr gutes Compendium*, by BERNSTEIN. OLLIER, *Traité exp. et clin. de la Régénération des Os*, 1867, T. II, p. 186.

<sup>3</sup> NOTT, *New Orleans Medical Journal*, 1844, Vol. I, p. 58.

<sup>4</sup> SIMPSON (J. Y.), *Medical Times and Gazette*, 1861, Vol. I, p. 317.

<sup>5</sup> BRYANT (T.), *Medical Times and Gazette*, 1860, Vol. I, p. 393.

<sup>6</sup> These cases, of Tweedy and of Baggs, will be detailed in the second section of this chapter, with fatal shot wounds of the bladder.



iron and quinine was continued in the same doses, repeated at longer intervals. The opening into the rectum seemed to have closed before the attack of hospital gangrene, for there was no fecal matter in the wound and no discharge of pus by the anus. Several pieces of bone were removed, and about the middle of August the patient had sufficiently recovered to stand up, though with pain. He had no further drawbacks, and, by October, could hobble about. The wound did not close till about the last of November. He still walked with great difficulty. At the request of the patient he was discharged December 17, 1864." This man's name is not on the Pension Roll.

Some others of the eleven cases resulting favorably presented complications of interest:

CASES 746-750.—The five cases of recovery from shot fracture of the coccyx associated with fractures of the sacrum or pubis, were those of Colonel A. S. M. Morgan, 63d Pennsylvania, wounded at Fair Oaks, May 31, 1862, mustered out and pensioned April 18, 1863; Private Frank Davy, Co. K, 100th New York, wounded at Fort Wagner, July 18, 1863, discharged and pensioned January 30, 1865; Private D. A. Barton, Co. G, 21st Wisconsin, wounded at Resaca, May 14, 1864, discharged and pensioned December 8, 1864; Corporal G. Simonson, Co. B, 16th Michigan, wounded at Spottsylvania, May 8, 1864, discharged June 16, 1865, and pensioned; Corporal J. Daly, Co. F, 56th Massachusetts, wounded at Cold Harbor, June 2, 1864, mustered out July 14, 1865. In the case of Colonel Morgan, Pension Examiner G. McCook, of Pittsburg, reports that the rectum was injured, and that the disability is permanent. The particulars of the case of Private Frank Davy are correctly related, under the title of "Sergeant Hank Davy," in the *American Med. Times*, 1864, Vol. VIII, p. 301, and in his *Treatise on Military Surgery*, 1865, p. 351, by Medical Inspector F. H. Hamilton, U. S. A. The case was complicated by fracture of the pubis, abscess, and secondary stercoral fistula. Pension Examiner Loomis, of Buffalo, reported, in February, 1865, that the pubis was carious and the motor functions of the left lower extremity considerably impaired. In Private Barton's case, Examiner J. S. Canaday, of Brooklyn, Iowa, reported, July 6, 1871, that "the ball carried away a portion of the coccyx. I find the sacral nerves damaged, so that locomotion to any considerable extent is impossible." In the case of Corporal Simonson, Examiner D. Clark, of Flint, reported, May 7, 1863, that the "ball entered the left hip about three inches back of the crest of the ilium, passed nearly horizontally through the lower part of the os sacrum, separating the coccyx, and emerged through the right hip at about a corresponding point, injuring the spine and plexus of nerves, especially on right side, causing irregular and imperfect innervation, with partial paralysis of right leg, with inability to raise weights, and difficulty in rising from a reclining to an erect position, with spasmodic action of the limbs, and, at times, inability to walk."

There were six fatal cases of shot fracture of the coccyx:

CASES 751-754.—Three of the six fatal cases of shot fracture of the coccyx were those of Private H. Glynes, Co. B, 10th Vermont, wounded at Cold Harbor, June 1st, died June 18, 1864, at Armory Square, Washington; Private L. F. McCrary, Co. H, 9th Alabama Cavalry, wounded at Lafayette, Georgia, June 24th, died September 18, 1864; Private W. M. Thaker, Nelson's Battery, wounded at Pocotaligo, October 22, 1862, died November 12, 1862, with erysipelas and pneumonia. Of one of the remaining fatal cases some details will be given here, and the others will be described in the next section. Corporal J. K. Phillips, Co. B, 6th Maine, aged 26 years, was wounded at Boonesboro', July 9, 1863, and admitted to hospital at Frederick on July 12th. Assistant Surgeon M. Hillary, U. S. A., reported that "the ball entered the right buttock, passed through transversely, making its exit on the opposite side. The patient complained of pain in the right gluteal region, and the surrounding parts were slightly swollen. On the 18th, the right buttock was still more swollen, the skin was glossy, and there was great heat and tension. A cataplasm was applied, and, at 3 o'clock P. M., after consultation held with Dr. Wier, an incision, eight inches long, was made down to the fascia, which was also incised upward and downward with the probe-pointed bistoury. The tissues had a gangrenous aspect, and a quantity of gas escaped from the incision. On the 19th, gangrene rapidly extended, involving the entire right gluteal region. Active stimulation was of no avail, and the patient died in the evening of July 19, 1863. At the autopsy, three hours after death, the muscles of the gluteal region were found disorganized, the connective tissue hanging in shreds like tow. Near the sciatic notch the parts assumed a more normal appearance. On tracing, with difficulty, the track of the ball, it was found to have become subcutaneous in the middle, where a portion of the coccyx was broken off; the track continued through the left buttock. Some bits of tin, such as are used in the Belgian rifle cartridge, were picked out of the shot track."

In the case of Baggs, related further on, a ball is said to have been found embedded in the coccyx.

Though less rare<sup>1</sup> than simple fractures, shot fractures of the coccyx are sufficiently uncommon<sup>2</sup> to justify reference to every authentic individual case. In the foregoing examples, attendant visceral lesions were less frequent than would be anticipated from the anatomical relations. The variety of the complications of shot fracture of the coccyx precludes the establishment of any special rules of treatment. The early removal of sequestra or foreign bodies is, of course, indispensable. Free, though cautiously directed, incisions, to prevent the burrowing of pus, may be requisite. Extreme attention to

<sup>1</sup> BAUDENS (*Clinique des plaies d'armes à feu*, Paris, 1836, p. 416) relates that a soldier of the 3d line was shot, at Stenali, by a ball which carried off a portion of the os coccyx and lacerated the anus; ball removed by counter-incision; recto-vesical fistula; recovery.

<sup>2</sup> PURMANN (*Fünffzig Sonder- und wunderbare Schusswunden Curen*, Frankfurt, 1721, Obs. XXXI, S. 237) relates that, at the siege of Wolgast, 1675, Private P. Günther, of General Götze's regiment, was shot through both buttocks and the os coccygis et ilionis; wound very painful; ball removed by incision from left buttock; recovery.



cleanliness, to the prevention of fæcal accumulation in the rectum, and the confinement of inflammation-products in the shot canal, and watchfulness of the state of the bladder, are precautions that must not be overlooked.

SHOT FRACTURES OF THE PELVIC BONES IN GENERAL.—The reason advanced by Mr. Birkett, in his excellent paper<sup>1</sup> on injuries of the pelvis, in support of the assertion that "it would be idle to write a systematic description of the dislocations and fractures of each pelvic bone separately," does not apply to shot fractures which are seldom combined with luxations. It has been found advantageous to group the cases of shot fracture of the several bones, although not infrequently more than one were interested. In TABLE VII, an approximate expression is given of the extent to which the fractures of the several bones exceed the number of individual cases of shot injury.

Referring to CASES 692–696, it may be remarked that tetanus appears to have been an infrequent complication of shot fractures of the pelvis. There is some ground for supposing that it oftenest attended lesions in the sacral region:

CASE 755.—Private H. A. Durfee, 55th Ohio, wounded at Bull Run on August 30, 1862, was sent to Washington and admitted into Judiciary Square Hospital. A ball had entered on a level with the fifth lumbar vertebra two inches to the right of the median line, and was not found. From the date of his wounds the patient had entire paralysis of the nerves of motion and sensation of the left lower extremity; the right was moved as in health, and was normally sensitive to any stimulus. Two days after entrance, and six days after the wound, opisthotonos occurred. This condition lasted, more or less marked, until his death. During the entire treatment the patient passed his urine and feces involuntarily, in bed. He stated that he knew when the urine was dribbling away, but of the fæcal discharges he had no knowledge. From his entrance this patient gradually failed. He died September 12, 1862. At the autopsy the ball was found to have perforated the upper sacral vertebra laterally from right to left, and to have lodged beneath that portion of the sacral plexus formed by the last lumbar and first sacral nerves.<sup>2</sup>

Dr. Brown remarks that the lesions of the nerves revealed by the autopsy in this case, rendered intelligible the phenomena observed during life. The injury of the portion of the sacral plexus contributing to the greater sciatic and the internal pudic nerves, and to the numerous branches to the muscles of the thigh, accounted for the incontinence of urine and of fæces, and the paralysis of the left lower extremity.

Prolapsus of the rectum is referred to as a possible consequence of shot fracture of the sacrum:

CASE 756.—Private L. Schœnfield, Co. B, 8th New York, was admitted from the field to regimental hospital at Stafford Court-house on September 14, 1862, for a gunshot wound of the sacrum, probably received at Manassas on August 29th. He was sent to Washington, and discharged from service on December 3, 1862, at which time there was prolapsus ani and pain in the legs, the disability being rated at one-half by Surgeon M. Frochlich, 8th New York. This man was transferred to Alexandria on September 23, 1863. He is not a pensioner.

If the diagnoses of several observers are unquestioned, shot contusions of the pelvic bones would appear to involve less serious results than like injuries of the long bones:

CASE 757.—Major J. S. Ritchie, 209th Pennsylvania, aged 28 years, was wounded at Petersburg, April 22, 1865, and was taken to the hospital of the 3d division, Ninth Corps. Surgeon A. F. Whelan, 1st Michigan Sharpshooters, and Surgeon W. O. Macdonald, U. S. V., regarded the injury as a shot wound of the thigh and groin. The patient was sent to Armory Square Hospital, where Assistant Surgeon C. A. Leale, U. S. V., made the following report of the progress of the case: "Admitted to Armory Square April 24, 1865. Ball entered below the tuberosity of the ischium, passed through the gluteal muscles, along the inner aspect of the femur near the inner and upper space of Scarpa's triangle, was deflected by the fascia lata, and made its exit at the crest of the pubis one inch from the symphysis; the bladder was not injured. Suppuration had taken place along the whole length of the wound, and a large abscess had formed below Poupert's ligament. The anterior wound was slightly enlarged and the pus evacuated, and opiates, stimulants, and beef-tea were given. In July, the ischium was found to be necrosed. I removed two pieces of bone from the posterior, and one piece from the anterior wound. Several pieces of cloth have come away with the pus at different times. The posterior wound extends several inches from the surface and passes through the gluteal muscles to the bone. The anterior wound has nearly closed. Has had no unpleasant symptoms of lower extremity." Surgeon D. W. Bliss reported that this officer was discharged July 11, 1865. He was pensioned. Examiner J. L. Suesserott stated, April 11, 1866, that "the abdominal parietes have been greatly weakened, and hernia may yet result." This pensioner was last paid March 4, 1873.

<sup>1</sup> BIRKETT (J.), *Injuries of the Pelvis*, in HOLMES'S *System of Surgery*, 1870, Vol. II, p. 709.

<sup>2</sup> BROWNS (F. H.), *Surgical Cases*, in the *Boston Med. and Surg. Jour.*, 1863, Vol. LXVII, p. 492.

It would seem that it was a common error to regard too lightly the divisions of the soft parts attending shot fractures; but experienced surgeons recognized the gravity of extensive lesions of the muscular tissues. There were sometimes shot perforations of the ilium, which proved fatal from shock, though unattended by any visceral lesion, as in the following case:

CASE 758.—Corporal Thomas Young, Co. I, 99th New York, was wounded during the siege of Suffolk, April 14, 1863, by a conoidal ball, which struck the left breast a little internal to the nipple, and passed downward and backward under the great pectoral muscle, and made its exit through the crest of the left ilium at a point almost midway between its anterior and posterior spines. He was at once carried to the regimental hospital. From the moment of the infliction of the injury there was extreme collapse and that general appearance of alarm and anxiety so indicative of penetrating wounds of the abdominal cavity. He seemed to suffer no pain, but complained of an incessant desire to micturate, which continued unrelieved after the urine was drawn off by the catheter. The treatment consisted in stimulants, opium, enemata, and simple dressings, with occasional fomentations. He never rallied, but sank and died within twenty-four hours from the receipt of the injury. Surgeon J. Wilson, 99th New York, states, on the monthly report, "I traced the course of the ball after death. It passed at first almost directly downward, tearing up the great pectoral, external and internal, oblique and transversalis muscles; winding backward and outward, it fractured the crest of the ilium, and emerged by a ragged opening about midway between its anterior and posterior superior spines, at the point where the transversalis muscle was torn. The peritoneal cavity was opened to a very limited extent, but none of the viscera were wounded, nor was there any hæmorrhage into the pelvic cavity to account for the frequent and painful efforts to micturate, as taught by Baudens. There was slight effusion into the peritoneal cavity, but only a trace of inflammatory action."

The following is a synopsis of the reported cases of shot fracture of the pelvis:

TABLE VII.

*Numerical Return of Fourteen Hundred and Ninety-four Cases of Shot Fractures of the Pelvis reported during the War.*

CLASSIFICATION OF MEN INJURED.					CLASSIFICATION OF BONES INJURED.				
SHOT FRACTURES.	Total.	Recov-eries.	Deaths.	Result unk'wn.	SHOT FRACTURES.	Total.	Recov-eries.	Deaths.	Result unk'wn.
Ilium.....	799	595	194	10	Ilium.....	829	608	211	10
Pubis.....	72	38	34	.....	Pubis.....	86	43	43	.....
Ischium.....	59	39	20	.....	Ischium.....	73	42	31	.....
Sacrum.....	110	59	48	3	Sacrum.....	145	80	62	3
Coccyx.....	13	7	6	.....	Coccyx.....	17	11	6	.....
Two or more pelvic bones.....	46	21	25	.....	.....	.....	.....	.....	.....
Unspecified pelvic bones.....	395	159	217	19	Unspecified pelvic bones.....	395	159	217	19
Aggregates.....	1,494	918	544	32	Aggregates.....	1,545	943	570	32

*Excisions of Portions of the Pelvic Bones.*—The observations that have been adduced, and others that might be cited, teach emphatically the importance of removing detached fragments of bone after shot fracture of the pelvic bones, and of using energetic means for the removal of impacted balls. They equally demonstrate the occasional necessity of the excision of carious bone and of the removal of necrosed sequestra.<sup>1</sup> Such instances as CASE 687 indicate that what is requisite may sometimes be accomplished by gouging out the diseased cancellous walls of the shot canal, a plan of *évidement* that M. Ollier and his disciples have reduced to a method. Sub-periosteal excisions may also be advantageously employed. In one instance, M. Ollier has known the ischeo-pubic ramus to be

<sup>1</sup> Regarding resections of the pelvic bones, consult the systematic treatises and magazine articles already cited, and particularly: JAEGER (*Operatio resectionis*, Erlange, 1832, p. 18); LISFRANC (*Précis de médecine opératoire*, Paris, 1846, T. II, p. 543); MALLE (*Traité d'anatomie chirurgicale*, Paris, 1855, p. 220, *Resection des os du bassin*); FEIGEL (*Chirurgische Bilder*, Stuttgart, 1856, S. 401, *Die Resection am Darmbeinraude*, Tafel XXIV); ENMERT (*Lehrbuch der Speciellen Chirurgie*, Stuttgart, 1862, S. 553, *Resectionen der Hüftbeine*); RIED (F.) (*Die Resectionen der Knochen*, Nürnberg, 1860, S. 242); HEYFELDER (O.) (*Lehrbuch der Resectionen*, Wien, 1863, S. 313); GÜNTHER (*Lehre von den Blutigen Operationen*, 1860, S. 2); SÉDILLOT (*Traité de méd. opérat.*, Strasbourg, 1865, 3<sup>me</sup> éd., p. 498); OLLIER, *Traité exp. et clin. de la Régénération des Os*, 1867, T. II, 180; LARGHI, *Operazioni sotto-periosteae e sotto-capsulari*, Torino, 1855.



regenerated after an operation of this sort. The instruments most generally serviceable in these operations are the gouge and the gnawing bone-forceps (PLATE XLI, FIG. 3). Some practical surgeons attach great importance to the projection forward of the jaws, like the teeth of a rodent or the beak of a rapacious bird. The pattern in the new Army cases is excellent, and preferable to the form advised by the late Professor Nélaton. On the other hand, the curved gouge of M. Legouest is handier (PLATE XLI, FIG. 4) than that supplied in our Army set. It will seldom be necessary to divide the laminar portion of the pelvic bones to a greater extent than can be accomplished by these instruments. Where it is necessary, as in removing the crest of the ilium or the tuberosity of the ischium, Heine's osteotome (PLATE XLI, FIG. 1) is more convenient than Hey's or the chain-saw. It is hard to think of a condition in which the trephine would be a serviceable instrument.

INJURIES OF THE PELVIC LIGAMENTS.—In several instances, in which missiles traversed the pelvic ligaments and there was reason to believe that the sacral, sciatic, or crural nerves were uninjured, chronic rheumatic pains, with local tenderness, ensued,

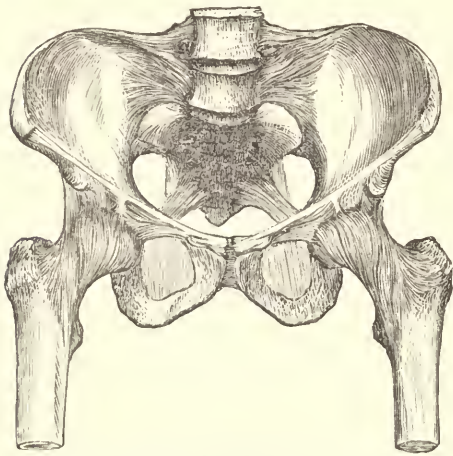


FIG. 214.—Ligamentous preparation of an adult male pelvis. *Spec. 19, Sect. IV, A. M. M.*

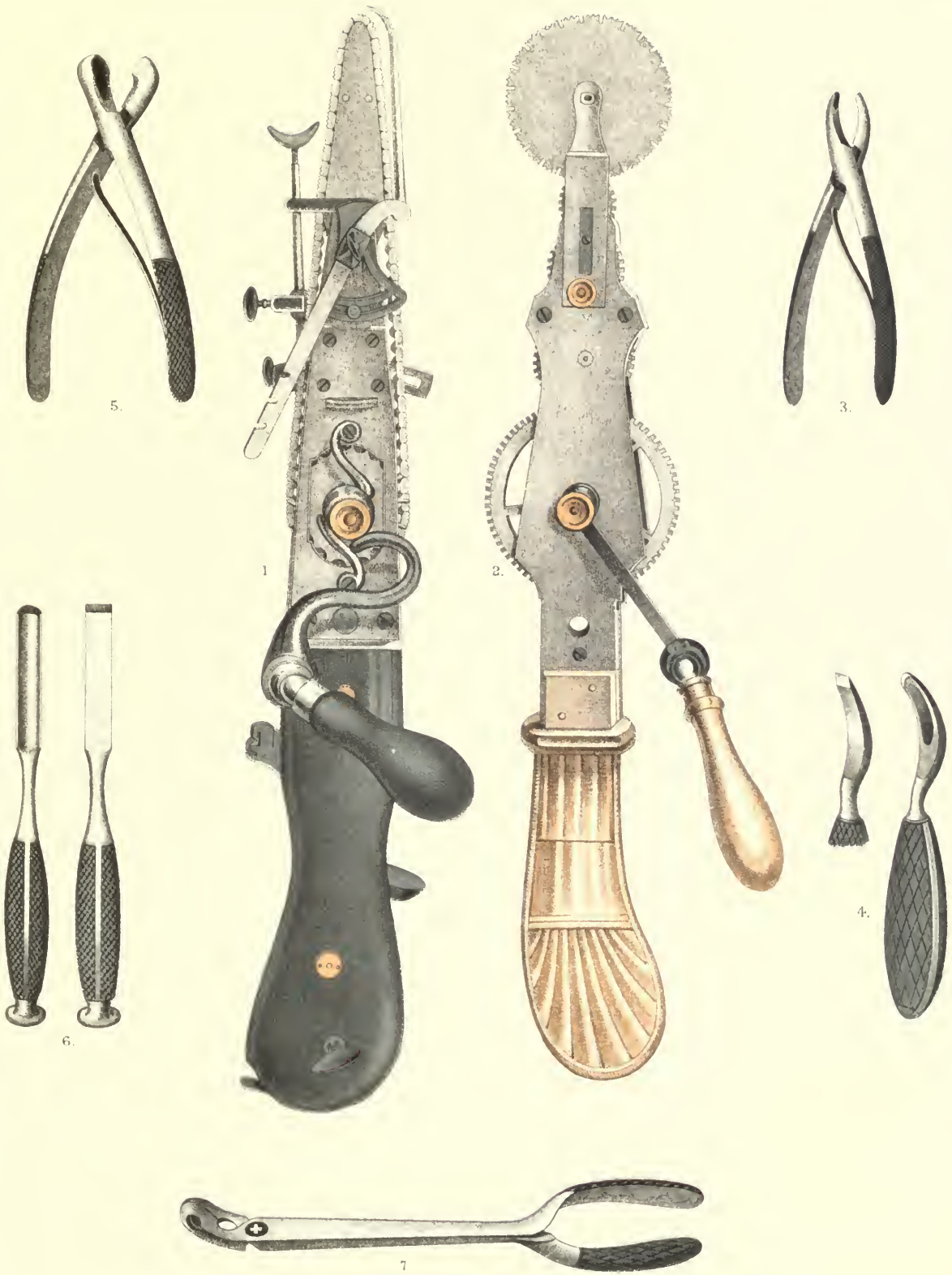
symptoms that might plausibly be referred to the lesions of the fibrous tissue. The denegation of the sensibility of ligaments, so long maintained by Haller and his disciples, though refuted by Bichat, had a lingering influence upon pathologists, until, from 1857 to 1866, Rüdinger, Kölliker, Sappey, and Hénocque<sup>1</sup> demonstrated the distribution of the nerves, arteries, and veins of the ligaments as satisfactorily as other histologists had demonstrated those of the cornea. The pelvic ligaments have been studied in their obstetrical relations, and with reference to luxations; but their mechanical lesions have been little investigated, and no information meriting record was communicated during the war on the subject, which is alluded to here to indicate the

desirableness of further observation and research.<sup>2</sup>

<sup>1</sup> Consult WINSLOW (*An Anatomical Exposition of the Structure of the Human Body*, 6th ed., Edinburg, 1872, Vol. I, p. 153); WEITBREICHT (*Syndesmologia sive Historia Ligamentorum Corporis humani*, Petropoli, 1742); MONTEFALCON (*Art. Ligament*, in *Dict. des Sci. Méd.*, 1818, T. XXVIII, p. 179); HÉNOQUE (*Art. Ligaments*, in *Dict. encyclopéd. des Sci. Méd.*, 1869, 2<sup>e</sup> série, T. II, p. 557). On the nerves of ligaments, compare RÜDINGER (*Die Gelenk-nerven des menschlichen Körpers*, Erlangen, 1857); RÄUBER (*Vater'sche Körperchen der Bänder und Periostnerven*, 1865); KÖLLIKER (*Handbuch der Gewebelehre*, 4te Auflage, 1863); SAPPEY (*Traité d'Anatomie Descript.*, 1867, T. I, p. 556); ADAMS (W.) (*On the Reparative Process in Human Tendons after Division*, London, 1860).

<sup>2</sup> PAULUS ÆGINETA (*Sydenham Society ed.*, London, 1846, T. II, p. 454); PETRUS DE ARGELATA (*Chirurgia*, Liber VI, cap. 7, Venetiis, 1480, *de fractura ossis ultima caudæ*); VERDUC (*Pathologie de Chirurgie*, 1703, p. 400, *de la fracture de l'os sacrum et du coccyx*, and p. 401, *de la fracture de l'os innominé*); PETIT, (J. L.) (*Traité des maladies des os* 3<sup>e</sup> éd., 1735, T. II, p. 106); MANNÉ (*Traité élémentaire des maladies des os*, Toulon, 1789, p. 183, *de la fracture des os du bassin*); DUVERNEY (*Traité des maladies des os*, 1751, T. I, p. 279); CRÉVE (*Diss. de fracturis ossium pelvis*, Mougant, 1792); LUTENS (*Manuel des opérations chir.*, Gand, 1826, p. 107, *fracture des os du bassin*); DORSEY (*Elements of Surgery*, Philadelphia, 1818, Vol. I, p. 141); ADELMANN (*De fracturis ossium pelvis*, Fuldae, 1835); MARET (*Obs. sur les fractures des os du bassin*, in *Mém. de l'Acad. de Dijon*, 1774, T. II, p. 85); BOYER (*Traité des mal. chirurg.*, Paris, 1845, 3<sup>e</sup> éd., T. III, p. 145); SANSON (*Fractures des os du bassin*, in *Dict. de méd. et de chir.*, in XV, Paris, 1832, T. VIII, p. 484); JACOB (*De fracturis ossium pelvis*, Lipsiæ, 1861); HEINRICH (*De fracturis ossium pelvis*, Halis Saxonum, 1858); SÉVEILLÉ (*Nouvelle doctrine chirurgicale*, Paris, 1812, T. II, p. 249); MALGAIGNE (*Traité des fractures et des Luxations*, Paris, 1847, T. I, p. 634; and *Mém. sur les fractures du sacrum et du coccyx*, in *Journal de chirurgie*, Juin, 1846); LAUGIER (*art. Plaies du bassin*, in *Dict. de méd.*, in XXX, Paris, 1833, T. V, p. 69); CLOQUET and A. BÉRARD (*Fractures des os du bassin*, in *Dict. de méd.*, in XXX, Paris, 1830, T. V, p. 71); HAFA (*De fractura ossium pelvis*, Diss., Halis Saxonum, 1864); PÉFIT (*Œuvres complètes*, Paris, 1864, p. 150, *de la fracture des os des îles et pubis*); NÉLATON (*Éléments de Path. chir.*, Paris, 1844, T. I, p. 702, Art. XII, *fractures des os du bassin*); RICHTER (A. L.) (*Fractura pelvis*, in BLASIUS, *Handwörterbuch der gesammten Chirurgie*, Berlin, 1837, B. II, S. 487); STROMEYER (*Maximen*, Hannover, 1855, S. 646, *Verletzungen des Beckens*); DEMME (*Studien*, u. s. w., Würzburg, 1861, B. II, S. 154, *Die Schusswunden des Beckens*); CHENU (*Rapport, etc., pendant la campagne d'Orient*, Paris, 1865, p. 198, *Blessures de la région iliaque et fessière*); STROMEYER (*Erfahrungen über Schusswunden im Jahre 1866*, Hannover, 1867, S. 44); BECK (*Kriegschirurgische Erfahrungen während des Feldzuges 1866*, Freiburg, i. B., 1867, S. 217); IDEM (*Chirurgie der Schussverletzungen*, Freiburg, 3. B., 1872, S. 544); SOCIN (*Kriegschirurgische Erfahrungen, gesammelt in Curlsruhe, 1870 und 1871*, Leipzig, 1872, S. 97); FISCHER (H.) (*Kriegschirurgische Erfahrungen, Vor Metz*, Erlangen, 1872, S. 131); LEGOUEST (*Traité de Chirurgie d'Armée*, Paris, 1872, p. 415); VASLIN (*Étude sur les plaies d'armes à feu*, Paris, 1872, p. 98); FANO (*Traité élémentaire de Chirurgie*, Paris, 1869, T. I, p. 383); ENGEL (*Beiträge zur Statistik des Krieges von 1870-71*, Berlin, 1872).





D. W. Williams & Son, Phila.

- 1. Heine's Osteotome.
- 2. Scie à Mollet.
- 3 5. Guawing bone forceps.

PLATE XLI. INSTRUMENTS FOR RESECTION.

- 4. Legoues's curved gouge and chisel
- 6. Gouge and chisel U.S.A. pattern
- 7. Nélaton's bone forceps.



## SECTION II.

## INJURIES OF THE PARTS CONTAINED IN THE PELVIS.

This section will be mainly devoted to a consideration of the cases of injuries that were reported during the war, of the bladder and rectum, and of the blood-vessels, nerves, and connective tissues contained in the cavity of the pelvis, and of the derangements consequent upon such injuries. But other disorders of the pelvic organs requiring surgical intervention, such as calculus, retention of urine, fistula and hæmorrhoids, that come only indirectly under the head of injury, will also be discussed briefly or at some length.

The frequency with which active therapeutic measures may be advantageously employed in physical lesions of the organs of this region, contrasts strongly with the comparatively rare occasions where such measures can be hopefully employed in injuries of the contents of the other great cavities. Although exceptions have been adduced and examined at great length, it has been seen, in preceding chapters, that wounds of the encephalon were, for the most part, followed by mortal coma,—that wounds of the parts contained in the thorax were very fatal, dyspnoea, cold extremities, and a faltering pulse being the deadly signs,—that wounds of the viscera of the abdomen proper were generally mortal, either from shock or from diffused peritonitis, revealed by collapse, intense pain, vomiting, meteorism. In the pelvic cavity, however, only those injuries involving the great blood-vessels and the part of the bladder covered by the peritoneum, are necessarily beyond the resources of art.

Notwithstanding their complexity, it will be convenient to group the cases to be considered according to the part in which the most important lesion is situated, and the section will therefore be subdivided, and injuries of the connective tissues without lesion of the viscera will be first examined, then injuries of the bladder, of the prostate, of the rectum, and of the blood-vessels and nerves.

SHOT PENETRATIONS OR PERFORATIONS WITHOUT VISCERAL INJURY.—Projectiles traverse or deeply penetrate the pelvic more frequently than the abdominal cavity, without

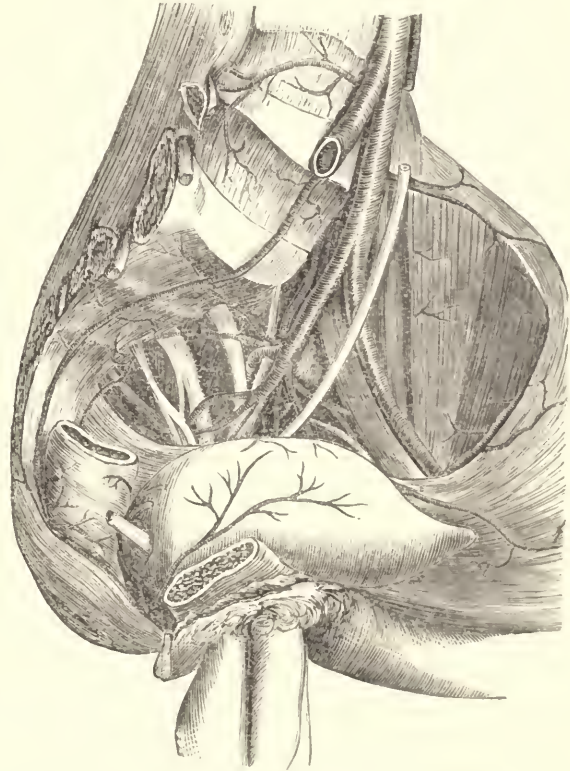


FIG. 215.—Viscera, blood-vessels, and nerves of the pelvis. [After ANGER.]



injury to the viscera. The review of shot fractures of the pelvic bones has already afforded some examples of this.<sup>1</sup> Sometimes, though very rarely, balls pass from the inguinal to the gluteal region, or the reverse, through the ischiatic notch, without interesting the bones, vessels, or viscera. The following are three of these fortunate exceptional instances:

CASE 759.—Private Daniel Brown, Co. A, 5th Pennsylvania Reserves, aged 28 years, was wounded at Fredericksburg, December 13, 1862, by a conoidal musket ball, which entered the left groin near Poupart's ligament, passed directly through the pelvic cavity, and escaped through the gluteal muscles of the same side. He was sent to Annapolis, January 11, 1863, and was subsequently transferred to Harrisburg, and to Patterson Park Hospital, Baltimore, on November 1, 1864. Here he is recorded as "convalescent, and returned to duty on April 2, 1864." The patient was afterward admitted into Augur Hospital, Alexandria, at Carver Hospital, Washington, at Philadelphia on May 5th, and was discharged the service on June 11, 1864, and pensioned. On February 1, 1871, the pension examiner reports that "there is a tender cicatrix in the groin, impairing the usefulness and motion of the limb, which is atrophied. The disability is rated as three-fourths and probably permanent."

CASE 760.—Private J. A. Smith, Co. D, 25th New York, was wounded, on May 1, 1863, at Chancellorsville, by a conoidal musket ball, fired at a distance of not more than thirty yards. The projectile entered nearly over the left abdominal ring, traversed the pelvic cavity, and made its exit at the upper part of the right buttock. He walked one hundred yards after he was hit. There was quite free bleeding from the anterior wound. He was treated in the Twelfth Corps Hospital. There were no symptoms of peritonitis. The appetite was good, the bowels regular, the functions of the bladder perfect. By the 21st of May his wound was entirely healed, and he was discharged from service by reason of the expiration of his term of enlistment. The drawings, reduced copies of which are presented by the adjacent wood-cuts (Figs. 216, 217), were made at Fredericksburg by Hospital Steward Stauch, under Surgeon J. H. Britton's supervision, a few days after the infliction of the injury. If the course of the ball was correctly reported, the appearances are the reverse of those commonly observed, the supposed entrance wound being the largest and most lacerated. The ball evidently passed through the sciatic notch, and the small amount of mischief inflicted is very remarkable. Smith applied for a pension, and, on November 4, 1866, Dr. J. H. Helmer, of Lockport, New York, reported: "Ball entered just above

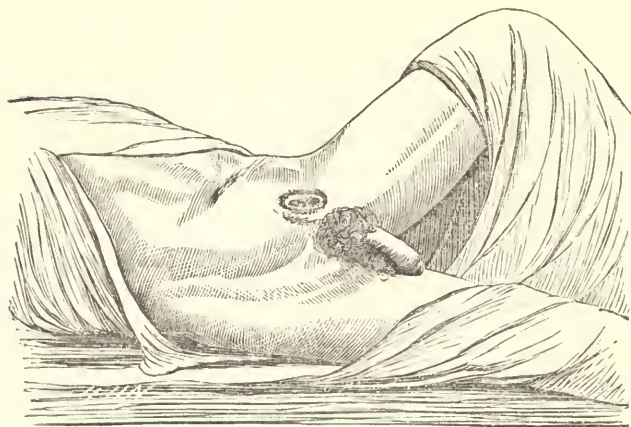


FIG. 216.—Entrance wound of a shot perforation of the pelvic cavity.

Poupart's ligament on the left side, and came out through the centre of the right natis, at first (as he states) occasioning a disturbance in the bladder, which has now entirely subsided. The muscles of the limb and pelvis do not appear to have suffered from the wound. There has been no discharge of bone at any time. The cicatrices are small and colorless. I do not see wherein any disability is produced;" and Smith's application for pension was rejected November 27, 1866.

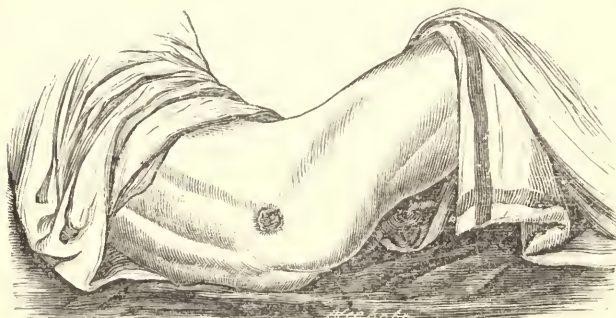


FIG. 217.—Exit wound of a shot perforation of the pelvic cavity.

experienced a constant, dull pain through the pelvis. Examiner D. B. Nelson reports, April 30, 1866, that the pensioner's spermatic cord and testes were injured from the effects of the wound. September 4, 1873, the same examiner reported that from injury of the left spermatic cord there was frequent pain in the left testis, and permanent disability.

<sup>1</sup> Analogous instances were observed in the late Franco-German War. Thus FISCHER (II.) (*Kriegschirurgische Erfahrungen*, 1872, S. 135) relates the case of Zirotzki, 1st Prussian Jagers, shot at Forbach, August 14, 1870. The ball entered to the left of the penis and escaped on the right side, an inch and a quarter behind the trochanter; the pelvic cavity was perforated, but there were no symptoms of injury of the viscera; there was slightly painful micturition, owing, perhaps, to compression from extravasation of blood. The patient recovered without peritonitis.

The three following cases are of the same general character, though less exempt from complications. In the first, the great sciatic nerve appears to have been injured; the second would be quite in point but for the contradictory pension record of lesion of the genital organs; in the third case, there was injury of the ischium, and some secondary lesion, at least, of the bladder:

CASE 762.—Corporal J. S. Francks, Co. F, 68th Pennsylvania, received shot wounds in the left groin and right foot at Gettysburg, July 2, 1863. He is registered at the field hospital on July 4th, and, on August 5th, at Camp Letterman, whence, on October 1st, he was sent to Satterlee Hospital. Surgeon I. I. Hayes, U. S. V., reported that "a ball, entering above the left crus of the penis, passed out through the right buttock." This patient was discharged the service April 11, 1864, and pensioned. It would appear that the missile traversed the pelvic cavity, passing through the sciatic notch, without seriously injuring the viscera. Examiner James Cummins, of Philadelphia, reports, March 20, 1867: "Ball entered left side and root of penis and came out of right hip, resulting in hernia at wound of entrance and total paralysis of right foot; probably permanent."

CASE 763.—Private B. Jones, Co. G, 141st Pennsylvania, was wounded at Chancellorsville, May 3, 1863. He was sent from the field on June 14th, to Fairfax Seminary Hospital, where it is recorded that a "Minié ball entered the left groin, and was removed, on June 22, 1863, by Surgeon D. P. Smith, U. S. V., by a counter-opening through the left buttock, without untoward complications." The projectile (FIG. 218) was contributed to the Museum, and is "the lower half of a conoidal ball, irregularly and jaggedly flattened over the cupped portion." This soldier was discharged from service January 8, 1864, and pensioned. Pension Examiner W. H. Read, of Honesdale, Pennsylvania, reported September 21, 1867, that this pensioner had received a shot wound of the thigh, lacerating the penis and testicle, and suffered from muscular pains and contractions. His disability was reported as continuous in 1873.



FIG. 218.—Half of a flattened ball that traversed the pelvis. *Spec. 2728.*

CASE 764.—Dr. G. Treskatis, of Albany, reported to the Surgeon General the following case, under the title *Spontaneous elimination of a rifle ball*: "Private Frederic Rolf, Co. I, 52d New York, aged 20 years, was wounded in front of Petersburg, June 16, 1864, while lying on the abdomen, the regiment being ordered to lie down. The ball entered the right natis about one inch to the right of the anus, near the ischial tuberosity. He was immediately removed to the field hospital. He lost a great deal of blood, so that he fainted several times during the transportation. In the hospital, the wound was examined by Surgeon Wolf, and, as the ball could not be found, a poultice was applied. Violent inflammation soon ensued, the whole thigh being greatly swollen and preventing him from using either the hip or knee-joints. The patient, after four days, was removed to Portsmouth Grove, R. I., and placed under the care of Dr. Paine, who examined the wound several times without being able to find the ball, the probe being introduced its whole length. A violent diarrhoea set in soon after the arrival, weakening the patient still more; he had no appetite, and slept little; when sleeping he always laid on the abdomen; the wound in the meanwhile began to suppurate, the whole limb being still very painful and tender, and altogether precluding walking. The patient had great difficulty in retaining the urine, and was obliged to pass water very often. While in the act of micturition he experienced great pain, extending from the pubis to the back, along the crest of the right ilium; pus discharged very freely at the same time from the wound, and the urine was continually of a red color. A few small splinters of bone came away during the next four weeks. The diarrhoea was checked by astringents, especially by tincture of the sesquichloride of iron, after about four weeks, when his general health began also to improve, appetite and sleep returning; he was also able to walk about in the ward, without, however, using the right hip-joint at all, swinging the whole right side of the pelvis forward. The patient was transferred, August 25, 1864, to the Albany General Hospital, and placed under the care of Dr. Smith. His wound was examined repeatedly, but the ball could not be found. Dr. Smith states that the probe always entered the wound-canal in a straight direction. At the end of October, Dr. Smith removed a piece of bone of the size and shape of a thumb-nail. The patient felt greatly relieved after the operation; he began to walk without a cane, using both hip and knee-joints, although the symptoms of irritation of the bladder still persisted, he being obliged to pass water every ten or fifteen minutes, by drops, which were always tinged red. The wound still remained open, discharging serous pus. For the micturition diuretics were prescribed, mainly buchu. He was transferred to the Veteran Reserve Corps April 17, 1865, and put on guard duty in the month of May. Inflammation was rekindled, in consequence, as he believes, of wearing the waist-belt, which caused him great distress. An epithelial membrane had formed over the wound. Pain and tenderness increased; he felt severe lancinating pain in the vesical region, aggravated by exercise. He states that the delicate cicatrix was ruptured, and that a free discharge of pus followed, giving him some relief. The cicatrix reformed, and aggravating pain and dysuria ensued, and he therefore intentionally ruptured it again. This condition of things continued till the end of 1865, when he found it necessary to reopen the fistula every week, which operation was always followed by a free discharge of pus and decrease of pain. The patient was transferred to the culinary department in August, 1865. He was honorably discharged November 24, 1865. The symptoms of irritation of the bladder continued till January, 1866, when they ceased entirely. He had also pain in the right inguinal region, accompanied by a sensation as if something was pressing against the bladder; the other functions remained undisturbed, his general health having been very good. On March 16, 1866, the wound began to inflame again; while stooping to the ground he felt something moving up toward the external orifice of the wound; on examining it with his finger he felt a hard substance protruding from it. Thinking it might be the ball, he extracted it himself by means of his thumb and a pen-knife; it was an Enfield rifle musket ball, as described in page 88 of Circular No. 6, FIG. 96, c. The base protruded first. The ball was nearly intact in its shape, with the exception of a slight flattening of the apex, as if the ball had struck sideward a hard substance. The wound closed after two days. I saw the man several times afterward, and he stated that he felt perfectly well, and was able to walk a great deal without experiencing the slightest difficulty. He has no pain whatever, and enjoys excellent appetite and sleep." This man is not a pensioner.



The following account of a case of shot penetration of the pelvis without visceral injury, the missile pressing on the prostate, causing dysuria, and being removed by perineotomy, has been communicated by Dr. C. L. Hubbell, of Troy, late Surgeon 12th New York:

CASE 765.—At the engagement at Hanover Court-House, May 27, 1862, Dr. Hubbell writes: "Being assigned by Surgeon G. H. Lyman, U. S. V., medical director of the Fifth Corps, to a field hospital known as 'Dr. Kinney's house,' after having attended to the most urgent cases of our own wounded, my attention was called to a wounded Confederate, whose name I did not learn, aged about 40, a private in the 38th North Carolina Regiment, who was groaning with pain in the region of the bladder and unable to pass his urine. He was shot when in line of battle, early in the engagement, about one o'clock P. M., and was taken prisoner, together with several of his wounded companions and the surgeon of his regiment, in a charge made by our forces shortly afterward. The ball entered about three inches above the left trochanter major, in a direction obliquely backward and upward, and must have passed around in front of the femur and pelvis, up to the position which it reached, as there was no fracture of the pelvis. Suspecting, from the inability to pass his urine, that the ball had lodged near the neck of the bladder, and there being no evidence of it externally, I passed my finger into the rectum and felt the bullet distinctly, just between the prostate gland and the rectum. I at once explained to the patient the nature of the operation to be performed for his relief, to which he readily assented, and said he did not wish to take chloroform or to have his hands and feet tied by bandages. Placing him in the position for lithotomy, and proceeding precisely as in the lateral operation for stone, with the fore-finger of the left hand as a guide and without the grooved staff and beaked knife of the lithotomist, I soon reached the bullet, and without the loss of much blood. Seizing the ball and extracting was the work of a moment, and as soon as the membranous portion of the urethra was passed a full stream of urine spirted out from the meatus of the urethra. The relief was complete. This man was carried the next day to Gaines's Mill in an ambulance-wagon, and I heard a week afterward that he was doing well, and that after the third day the urine passed freely without the use of the catheter. I have no doubt as to his entire recovery, for the rectum and bladder were uninjured. The ball was a conical one, of the largest size used in the Springfield musket, and was a good deal battered at the small end."

Many such observations as the following appear on the reports, without mention of visceral complication either in the clinical or necroscopic records. They are too vague to have much weight:

CASE 766.—Private Walter R. Davis, Co. G, 12th Massachusetts, aged 19 years, was wounded at Fredericksburg, December 13, 1862, and admitted into the hospital of the 2d division, First Corps. The injury was registered as a "flesh wound of the groin." On the 19th he was admitted into the 3d division hospital, Alexandria. Surgeon Edwin Bentley, U. S. V., reports that "the ball entered immediately beneath the external abdominal ring, on the left side, passed backward and to the right, through the pelvic cavity at the great sciatic notch. The intestine protruded through the wound of entrance. The bowel was replaced, the opening closed by compress and bandage, and large doses of opium were given to allay pain and control the peristaltic action of the bowels. He died December 25, 1862. The autopsy showed peritoneal inflammation extending over the parietal layer as high as the umbilicus, and over the bladder and rectum. There was also purulent inflammation of the abdominal and pelvic muscles."

The following case, for which a place was not found in treating of shot wounds involving the peritoneal cavity, may be compared with the more fortunate instance of intestinal protrusion, CASE 163, recorded on page 34:

CASE 767.—Sergeant Cyrus J. Spicer, Co. I, 11th Missouri, was wounded at Vicksburg, May 22, 1863, by a conoidal ball, which entered the left inguinal region and lodged. He was removed to the hospital of the 3d division, Fifteenth Corps, and, on the next day, was placed on board the hospital steamer City of Memphis and conveyed to Memphis, where he was admitted into Jackson Hospital on the 28th. Surgeon E. M. Powers, 7th Missouri Cavalry, reports that "when admitted the symptoms were generally favorable, pulse normal, and appetite good. Water dressings to the wound, and nourishing diet constituted the treatment. June 5th, appetite poor. June 14th, symptoms unfavorable, and the patient sinking very fast; considerable hectic with rigors, and much pain in the left leg. He died at four o'clock P. M., June 15, 1863. An autopsy was made four hours after death. There was considerable pus and sanious matter collected under the deep fascia, and great destruction in and about the wound. The patient evidently died from the above cause and exhaustion consequent on a suppurating wound."

In CASES 630 and 702 of the last section, the pelvis was deeply penetrated without visceral injury. These, with CASES 758 and 761 of this section, are four of nineteen cases found in a diligent search for examples of shot penetrations of the abdomen without visceral injury. Eleven of the nineteen proved to be instances of penetration of the pelvic, rather than the abdominal, cavity. Four have been detailed; the seven others were the following:

CASES 768-774.—1. Surgeon A. D. Gall, 13th Indiana, reports that Corporal C. Ruck, Co. D, 13th Indiana, was wounded, May 15, 1863, by a ball, which entered the right iliac fossa, and was cut out of the right buttock; "there was no sign of injury of the bowel or bladder;" death thirty-four hours after the injury. 2. Private A. Mulloy, Co. A, 11th Infantry, wounded at



Fredericksburg, December 13, 1862. A conoidal musket ball entered near the coccyx and lodged in the pelvic cavity. Treated in Washington and Philadelphia hospitals; died January 9, 1863. Assistant Surgeon R. R. Taylor, U. S. V., reported that at the autopsy the rectum and bladder were found uninjured. 3. Private H. Widger, Co. I, 1st Minnesota, aged 24, was wounded at Gettysburg, July 2, 1863. Acting Assistant Surgeon W. M. Welch reported, from Camp Letterman, that "a musket ball entered the right side of the pelvis at the spine of the ilium, and emerged through the bone at the sacro-iliac junction, wounding none of the viscera." The man was discharged and pensioned. Examiner H. L. Hodge, February 1, 1864, reported that this pensioner walked with difficulty, and suffered in damp weather. He was on the roll June 4, 1873. 4. Private J. F. Bonner, Co. C, 14th Pennsylvania, aged 32, wounded at Fredericksburg, December 13, 1862, is reported by Acting Assistant Surgeon J. H. Jamar to have received a shot perforation from the inguinal region to the buttock of the same side, "evidently traversing the pelvis and escaping through the greater ischiatic foramen" without any visceral complication. Treated in Philadelphia; he was discharged, May 3, 1863, without pension. 5. Sergeant J. McPeeters, Co. A, 3d Pennsylvania Cavalry, aged 31, was wounded at Mine Run, November 27, 1863. Assistant Surgeon C. H. Alden reports that a musket ball passed through the pelvis without injuring any viscera, but probably with lesion of the sciatic nerve, the lower extremities being partially paralyzed. This soldier was discharged and pensioned April 6, 1864. 6. A soldier of the 26th Ohio was wounded, at Sewall Mountain, by a large musket ball entering just above the pubic bone, and passing downward and backward without injuring the bladder or rectum. Surgeon H. Z. Gill, U. S. V., reports that this man recovered. 7. Private *W. R. Green*, a Confederate prisoner, wounded on the picket line at the Blackwater, December 12, 1862, was treated in the regimental hospital of the 13th Indiana. Surgeon A. D. Gall reports that the missile entered one inch to the right of the sacrum, passed apparently through the great ischiatic notch, and emerged half an inch above the symphysis pubis. Neither the intestines nor bladder were wounded. The patient was transferred, in a favorable condition, December 30, 1862, to the hospital of the 11th Pennsylvania Cavalry.

The complicated fractures furnish some illustrations for this group.<sup>1</sup> Thus, Surgeon J. W. Foye, U. S. V., stated that a ball, after fracturing the acetabulum, innocuously passed through the pelvic viscera; and Assistant Surgeon R. Bartholow, U. S. A., reported an instance of fracture of the ischium into the cotyloid cavity, the missile passing afterward between the rectum and prostate without lesion of either.<sup>2</sup> Other less complicated examples are found in the records of shot wounds of the pelvis. Those most carefully reported are as follows:

CASE 775-779.—1. Sergeant C. H. Anderson, Co. K, 25th Wisconsin, wounded at Atlanta, July 22, 1864. Surgeon H. Culbertson, U. S. V., reported that a musket ball entered the white line two inches above the pubes, passed obliquely downward and emerged at the left great ischiatic notch, and lodged behind the trochanter major, without injuring the bladder, vessels or nerves. The patient entered Harvey Hospital at Madison, and, on December 20, 1864, was sent to modified duty in the Veteran Reserve Corps. He was discharged and pensioned September 13, 1865. On December 1, 1872, Examiner J. W. B. Wellcome, of New Ulm, reported the track of the ball as the reverse of that above described, and that injury of the sacral plexus and of the sacral ganglion had caused weakness of the lower limbs and pain in the neck, chest, and head. The spermatic cord was enlarged and the testis sensitive. 2. Private J. B. Simpson, Co. F, 42d Indiana, aged 22, was wounded at Chicamauga, September 20, 1863, and treated in hospitals at Nashville, Louisville, and Madison. Acting Assistant Surgeon T. J. Pearce reported that "the ball passed through the pelvis, entering the left natis and emerging at the right groin; there was no injury of the viscera, blood-vessels, or nerves." This soldier was discharged and pensioned October 17, 1864. Examiner W. S. Wilburn, of Princeton, reported February 12, 1870, the disability from the pelvic injury as slight; but the pensioner was disabled by other wounds. 3. Lieutenant J. M. Roberts, 7th Wisconsin, was wounded at Five Forks, April 1, 1865, by a ball which struck near the symphysis pubis and lodged in the buttock near the left ischial tuberosity, without injury of the bladder. This officer was discharged and pensioned. Examiner J. H. Hyde, of Lancaster, states, August, 1866, that the missile perforated the os pubis and emerged at the tuberosity of the left ischium, leaving the left leg partially paralyzed. 4. Private J. Allen, Co. E, 13th Ohio, aged 23, was struck at Stone River, December 31, 1862, by a ball which entered above the tuberosity of the left ischium, and, according to Acting Assistant Surgeon A. E. Heighway, "passed between the bulb of the urethra and the bladder, and escaped through the right groin." Discharged June 12, 1863. 5. Private Jacob Mark, Co. A, 5th Indiana Cavalry, was wounded at Buffington Bar, by a ball which entered an inch to the right of the end of the sacrum and emerged through the right pubic bone. Surgeon W. H. Gobrecht, U. S. V., reported, after a careful exploration, that "the rectum, bladder, and spermatic cord escaped injury. The case progressed favorably, and the man was discharged February 13, 1864."

Shot penetrations of the pelvic cavity without visceral injury appear, then, to be much less infrequent than corresponding wounds of the abdomen.<sup>3</sup>

<sup>1</sup> In the cases of pelvic fracture, 681, 692, 697, 698, projectiles are reported to have penetrated deeply without wounding the viscera.

<sup>2</sup> These cases, of Private Reuben S——, Co. K, 13th Illinois, and of Private Martin P——, Co. K, 6th Maine, which furnished Section I, specimens 2174 and 1653, respectively, will be detailed with shot injuries of the hip joint.

<sup>3</sup> THOMSON (*Report of Obs. in Mil. Hosp. in Belgium*, 1816, p. 110) adduces examples of this group observed after Waterloo: "Several cases of wound in the region of the pelvis occurred, in which it appeared to us that balls had passed through that cavity, without injuring either the bladder or intestines. In one case at Brussels, the ball had entered on the right side of the symphysis pubis, and had passed out of the middle of the right buttock. This patient complained much of pain, and had a considerable degree of fever; but there had been neither fecal nor urinous discharge. In another case which we saw at Antwerp, the ball had taken, as nearly as possible, the same direction; and having neither wounded the intestines nor bladder, seemed to have produced very little constitutional or local injury."

INJURIES OF THE BLADDER.—Apart from those produced by the manipulations of the surgeon,<sup>1</sup> injuries of the male bladder are rarely observed in civil practice. When the distended reservoir ascends above the pubes, it is exposed to external violence in the hypogastric region; but ordinarily it is screened by the strong pelvic bones. These are an insufficient protection from the projectiles of modern warfare, and hence wounds of the bladder are not uncommon in military practice. A military surgeon, the famous Larrey,<sup>2</sup> wrote the first systematic account of them, and those who have since treated of the subject have largely profited by his masterly observations and reflections.<sup>3</sup> Thomson, Hennen, Guthrie, S. Cooper, C. J. M. Langenbeck, Dupuytren, Baudens, and Legouest have added some interesting observations.<sup>4</sup> In 1851, M. Demarquay read to the Surgical Society of Paris an extended paper on shot wounds of the bladder, which was analyzed and criticized in an elaborate report by MM. Chassaignac, Giralès, and H. Larrey. In 1855, in the second edition of his work on the bladder,<sup>5</sup> Professor Gross discussed its physical lesions with his accustomed erudition and discernment, presenting many facts derived from American experience. In 1857, M. Houel printed an exhaustive memoir on wounds and ruptures of the bladder in general.<sup>6</sup> Larrey was the first to place prominently in view that while all accidental injuries of the bladder are extremely serious, those produced by shot are less dangerous than others, and suggested, in explanation, that the tissues are so crushed by projectiles that eschars are produced, protecting, in a measure, the connective tissues from urinary infiltration. He also put in evidence the important bearing on the prognosis, of the state of plenitude or vacuity of the bladder, at the moment of injury. The cases of vesical injury recorded during the war were numerous and instructive, and belonged almost exclusively to the group of shot wounds. They, happily, exemplify recoveries when the outer tunic only was injured, or one wall was pierced, or the organ was completely transfixed—and complications of pelvic fractures, of foreign bodies, and of wounds of the rectum.

<sup>1</sup> VIDAL, *Traité de Path., ext. et de Méd. Opérat.*, Troisième éd., 1851, T. IV, p. 709: Il y a plus des plaies de la vessie faites par le chirurgien que des plaies dues à des accidents."

<sup>2</sup> LARREY (D. J.) (*Mémoire sur les Plaies de la Vessie et sur certains Corps étrangers restés dans ce Visère*, printed in 1817, in the fourth volume of the *Mémoires de Chirurgie Militaire et Campagnes*, p. 284 et seq., and reproduced, in 1822, in the *Clinique chirurgicale*, T. II, p. 503. In his exordium, LARREY observes: "Toutefois, il n'existe encore rien de complet sur les plaies de la vessie." This is quite true, though CHESSELDEN (*Treatise on the High Operation*, 1723), MORAND (*Traité de la Taille*, 1728, p. 224), GARENGEOT (*Traité des op.*, 1731), DESPORT (*Traité des Plaies d'armes à feu*, 1749, p. 319), and PERCY (*Mém. du Chir. d'armée*, 1792, p. 246) had reported some important cases, and the learned LOUIS had briefly summed up the principal points of the question in two pages of his *Dictionnaire de Chirurgie* (1767), and CHOPART (*Traité des Mal. des Voies urinaires*, 1792, T. II, p. 88) had made some instructive remarks on the subject.

<sup>3</sup> LARREY begins his memoir with the remark that "the ancients considered shot wounds of the bladder as mortal," and cites the well-known aphorism of HIPPOCRATES, S. VI, xviii, Κύστιν διακοπέντη \* \* θανατώδες, *Cui persecta vesica, lethale*. LARREY would have been the last to impute to his predecessors erroneous doctrines in order to achieve an easy victory in exposing their fallacy; but his followers have committed this fault, in giving an unduly general application to his remark. The ancients generally did not consider wounds of the bladder as necessarily or absolutely fatal. ARISTOTLE (*Hist. animal.*, Chapt. 15) expressly states that wounds near the neck may unite, and GALEN relates a case of recovery from wound of the bladder, and, in commenting on this very aphorism of HIPPOCRATES, contends that the latter does not use θανατώδες in the sense of *absolutely fatal*, but meaning rather *very dangerous*. For a critical disquisition *qual modis vulnera dicantur lethalia*, the reader may consult SEBITZ (*Problema exanimis vulnerum*, Strasburg, 1633, Pars II, 78). Assuredly, after CELSUS (*De re medica*, ed. Lugd., 1592, L. VII, p. 671), the ancients could not regard wounds of the bladder as fatal, since a method of cystotomy is taught there. FALLOPIUS (*Op. gen.* Venet., 1607, T. II, p. 397), FORESTUS (*Obs. et Cur. chir.*, Francofurti, 1611, Lib. VI, Obs. V, in scholia, p. 12) JEROME OF BRUYSSWYKE (*Handywarke*, 1525, Cap. 51), GEBSSORFF (*Feldbuch der Wundt-Artzney*, Frankfurt, 1551), and SCHLICHTING (*Traumatologia*, 1748, p. 87), and others of the middle age, taught the curability of wounds of the bladder, and for the most part advised that its wounds should be stitched up.

<sup>4</sup> HENXEN (*Principles*, 3d ed., 1823, p. 425); GUTHRIE (*Commentaries*, 5th ed., 1855, p. 603, *Lectures*, etc., 1823, p. 64); COOPER (S.) (*Article Bladder*, in *Dict. of Pract. Surg.*, Am. ed., 1838, p. 180); LANGENBECK (C. J. M.) (*Nosog. und Therap. der Chir. Krankh.*, 1830, B. IV, S. 580); DUPUYTREN (*Leçons orales de clin. chir.*, 6d. 1830, T. VI, p. 482); BAUDENS (*Clin. des plaies d'armes à feu*, 1836, p. 365); LEGOUEST (*Chir. d'Armée*, 2d éd., 1872, p. 421).

<sup>5</sup> GROSS (S. D.), *A Practical Treatise on the Diseases, Injuries, and Malformations of the Urinary Bladder, the Prostate Gland, and the Urethra*, 2d ed., Philadelphia, 1855, p. 124: "It is remarkable," Professor GROSS observes "how little information is to be found, in systematic treatises on surgery, on wounds of the bladder. From their silence, one would suppose that their authors were either totally unacquainted with the subject, or that they were afraid to discuss it."

<sup>6</sup> M. DEMARQUAY'S paper appears in the *Mémoires de la Société de Chirurgie*, 1851, T. II, p. 289, and is followed by the *Rapport sur les plaies de la Vessie par Armes à feu*, par MM. H. LARREY, CHASSAIGNAC, and GIRALÈS. M. HOUEL'S paper (*Des plaies et des ruptures de la Vessie*, 1857, 8vo, pp. 79) is, I regret, known to me only through citations by FOLLIN, NÉLATON, and others.



*Ruptures of the Bladder.*—No unequivocal instances of rupture of the bladder by blows, falls, crushing weights, or the impact of large spent projectiles, were reported. Dr. F. H. Hamilton asserts<sup>1</sup> that the latter cause has produced rupture of the bladder; but I can discover no satisfactory evidence<sup>2</sup> of the correctness of this statement. Percy reviewed<sup>3</sup> the examples of rupture of the bladder recorded in his time, and, in 1857, M. Houel<sup>4</sup> published thirty-seven instances of traumatic rupture, produced generally by blows upon the hypogastrium, by falls, or by the passage of carriage-wheels; but in no instance by the impact of spent projectiles. Nor does Dr. Lidell, in his important paper<sup>5</sup> on rupture of the pelvic viscera, published since the war, record an example of this description.<sup>6</sup>

*Punctured, Incised, and Lacerated Wounds.*—No sword, lance, or bayonet wounds involving the bladder were reported, and the only cases belonging to this group were examples of punctures of the bladder for retention of urine, or of cystotomy with a therapeutic purpose. Accidental wounds of the bladder by sharp instruments<sup>7</sup> and lacerations<sup>8</sup> are rare. A few fortunate instances are collected in the notes.

<sup>1</sup> HAMILTON (F. H.), *A Treatise on Military Surgery*, 1865, p. 323.

<sup>2</sup> The only case in which this lesion is reported to have taken place is that of Private Levi Fletcher, Co. D, 2d Minnesota, aged 20, whom Surgeon D. L. HANB, 2d Minnesota, states to have suffered "a rupture of the neck of the bladder, at Bull Run; discharged August 24, 1861," and pensioned. The examiner, Dr. W. A. PENNIMAN, of Minneapolis, reported, March 28, 1863, that the injury was caused by a "spent cannon ball," and that "the disability arose from injury done to the neck of the bladder [The examiner does not entertain the hypothesis of rupture, and probably accepted the pensioner's allegation of the cause of injury], producing inability to retain the urine, with frequent pains in that region. Disability one-half, and probably not permanent." The disability appears to have proved persistent, however, as the pensioner was paid ten years later, June 4, 1873. A rupture of the bladder by a spent projectile would be extraordinary; a recovery from such an accident would be marvellous.

<sup>3</sup> Article *Crévasse*, in *Dict. des Sci. Méd.*, 1843, T. VII, p. 349, cites cases from BONETUS, W. HUNTER, FRYE, OSIANDER, etc. Consult, also HARRISON'S paper in the *Dublin Journal of Medical Science*, 1836, Vol. IX, p. 349; Dr. S. SMITH'S *Contributions to the Statistics of Rupture of the Urinary Bladder*, in the *New York Journal of Medicine*, in which seventy-eight cases are analyzed, cases of rupture from muscular compression during parturition, etc., being included; and Dr. THOMP'S *Observations*, in the *Dublin Quarterly Journal of Medical Science*, 1868, Vol. XLVI, p. 306.

<sup>4</sup> HOUEL (C.), *Des plaies et des ruptures de la vessie*, Thèse d'agrégation, Paris, 1857. The ruptures were nearly equally divided in position between the anterior and posterior walls: Fifteen were in the posterior wall and communicated with the peritoneum; twelve were in the anterior wall without communicating; three were lateral, two communicating, and one non-communicating; two were at the summit of the bladder; one was a double rupture, interesting both the anterior and posterior walls; the seat of the upper ruptures was not specified, but they communicated with the peritoneum. Only two of the cases resulted favorably. See page 194. *supra*.

<sup>5</sup> LIDELL (J. A.), *On Ruptures of the Abdominal and Pelvic Viscera, especially the Bladder*, in the *Am. Jour. Med. Sci.*, 1867, Vol. LIII, p. 340.

<sup>6</sup> The tradition of such accidents comes from HENNES, who remarks (*Princ. of Mil. Surg.*, 3d ed., p. 433): "Paralysis of the bladder is a common effect from blows of shells; \* \* \* rupture also sometimes occurs without any external solution of continuity." It is rarely that this learned and exact writer bases his statements on analogy instead of observation.

<sup>7</sup> For examples of punctured or incised wounds of the bladder resulting favorably, compare: 1. GALEN (*De locis affectis*, p. 4), the case of a young man in Mitylene, recovering from a sword thrust in the bladder. 2. WÜRZT (*Pract. der Wundarznei*, Basil, 1595), the case of the sailor Jacob, stabbed in the bladder in 1581; urine escaped through the wound for three days, and recovery followed. 3. STALPART VAN DER WIEL (*Obs. rar.*, 1687, Vol. I, p. 317, Obs. LXXXI), a recovery from a sword thrust through the bladder, in a man at the Hague. 4. PERMANN (*Lorberkrantz*, 1692, S. 422) gives the case of C. Böttcher, stabbed through the neck of the bladder by a knife, and convalescent after two months. RUYSH (*Op. om.*, 1737, T. I, p. 63) tells of a Hollander stabbed in the bladder, at Amsterdam, who recovered after grave complications. 5. BÜCKING (BALDINGER'S *Neue Magazin*, Leipzig, 1782, B. IV, S. 225) relates the case of Bolms, a farmer, impaled on a sharp stick, in 1781, who recovered after suffering from recto-vesical fistula a long time. 6. LARREY (*Clin. Chir.*, 1829, T. II, p. 504; *Mém. et Camp.*, T. IV, p. 288) gives the case of Ferrier, who recovered after a Cossack had thrust a lance through his bladder. 7. BATAILLE (A. S.) (*Rec. de Mém. de Méd. Chir. et Phar. Mil.*, 1821, T. IX, p. 281) records the case of a soldier of the 38th French Infantry, who recovered in six weeks, after a sabre had passed through his bladder, entering above the pubis at the left of the white line, and passing obliquely downward through the right sciatic notch, and pushed through to the hilt. 8. SCHÜTTE (*Med. Zeitung*, Berlin, 1810) records the case of a man of 20, impaled on a sharp stake, which penetrated the bladder through the perineum; urine escaped by the wound, and then rapid recovery ensued. 9. BRESCIANI DE BORSA (*Saggi di Chirurgia teorico-practica*, Verona, 1843, p. 39) tells of a youth stabbed in the hypogastrium with a knife; a catheter brought away a great deal of blood; recovery was rapid and complete. 10. VAN HOLSBECK (*Schmidt's Jahrbücher*, 1856, B. XC, S. 330) gives a case of recovery from a stab wound of the bladder, in a woman wounded October 20, 1864. 11. GREENAWAY (E.) (*Clin. Lect. and Rep., London Hospital*, 1864, Vol. I, p. 185) records the case of Thomas B——, aged 19, whose bladder was punctured by the tine of a hay-fork, June 29, 1863. Blood flowed copiously by the urethra; a catheter brought away a pint of fluid, two-thirds blood; catheter left in; a convalescence rapid. 12. MAAS (*Kriegschir. Beiträge*, 1870, S. 20) relates the case of Buhl, 17th Austrian Sharpshooters, wounded at Nachod, by a lance thrust through the bladder, June 27, 1866; rapid recovery without complications. 13. TYRRELL (*Proceedings of Sacramento Med. Soc., in Pacific Med. and Surg. Jour.*, 1868-69, Vol. II, p. 452) reports a case of stab wound in the right groin, the knife penetrating the bladder, as indicated by copious bleeding from the methra; rapid recovery. 14. GIBBS (O. C.) (*Buffalo Med. and Surg. Jour.*, 1870-71, Vol. X, p. 161) relates the case of a Swede, aged 55, whose rectum and bladder were transfixed by a sharp stake; profuse hemorrhage; recovery in a few weeks.

<sup>8</sup> Recoveries from traumatic lacerations of the bladder in males are very infrequent. The following are instances: 1. SCHENCKIUS (*Obs. med. rar.*, 1609, p. 554) records a case related to him by PLATEY'S: H. T——, a follower of the King of Navarre, was gored in the hypogaster by a steer; urine escaped from the wound; recovery. 2. SCHLEIKE, a regimental surgeon (RICHTER'S *Bibliothek*, 1772, B. II, 4, S. 48), relates that a soldier, falling from a tree, was impaled on a picket fence; farmers saved off the picket and carried the man to the hospital. Dr. SCHLEIKE extracted the picket, the size of a man's arm; it had entered the left side, perforated the bladder, and fractured the last right false rib. Profuse suppuration ensued; pieces of bark escaped; the patient recovered, after a tedious illness of fifteen months. 3. LARREY (*Clin. Chir.*, T. II, p. 505, and *Mem. et Camp.*, T. IV, p. 289) records the case of a soldier gored by a bull at a Festa at Burgos, in 1808. The sharp horn penetrated the right groin, came in contact with the distended bladder, and tore its exterior coat; there was hernia of the bladder, but its cavity was not opened; there was profuse hemorrhage. A catheter was retained in the bladder until cicatrization was complete. LARREY saw this man afterward at Madrid, perfectly well.



*Concussion of the Bladder.*—Apart from the paralysis of the bladder resulting from spinal concussion, Dr. F. H. Hamilton states<sup>1</sup> that the organ may be paralyzed by the concussion of shot upon the parietes of the abdomen, and adduces this example:

CASE 780.—Private William Graham, 12th New York, was wounded at Blackburn's Ford, July 18, 1861, by a charge of buckshot striking above the pubes. The shot were extracted by Surgeon A. B. Palmer, 2d Michigan Volunteers. The patient was seen by Brigade Surgeon F. H. Hamilton, U. S. V., and was found to have paralysis of the bladder. "On introducing the catheter, the urine was observed not to be bloody. There was no evidence, therefore, that the bladder had suffered any lesion. There was no paralysis in any other portion of the body. The bladder resumed its functions completely after a few days."

No analogous examples were reported. However, Mr. Blenkins declares<sup>2</sup> that "paralysis of the bladder is not an uncommon result of blows from shot or large pieces of shell, and rupture of the bladder when in a state of distension may occur without being accompanied by corresponding injury to the external parts." Without discussing the frequency of vesical paralysis, it may be surmised that the possibility of rupture from the cause assigned is, so far, conjectural, though theoretically probable.

SHOT WOUNDS OF THE BLADDER.—Injuries of this group, though very dangerous, were in many instances followed by more or less complete recoveries. In one hundred and eighty-three reported cases, eighty-seven patients, or 47.5 per cent., survived; though a large majority suffered from grave disabilities, and many from distressing infirmities, which have resulted fatally in a few cases, after years of suffering. The statement in the preliminary report,<sup>3</sup> regarding the uniform fatality of shot perforations of the bladder above the pubes or through the pubic bones, in the cases then examined, must therefore be partly set aside by the results of later investigation.

Histories have been published of a number of very satisfactory recoveries after shot wounds of the bladder, received during the war. Dr. John A. Lidell,<sup>4</sup> in a paper already frequently cited, details an instance, a case of perforation from the left of the hypogastrium to the right buttock, with escape of urine from the supra-pubic orifice. Professor W. H. Van Buren has recorded<sup>5</sup> a case in which the missile pursued a similar course, traversing the distended bladder, and recovery rapidly followed, without ultimate derangement of the function of the bladder. Professor F. H. Hamilton states<sup>6</sup> that General Robert E. Potter was "shot through the bladder, at Petersburg, in 1865, by a rifle ball, which entered above the pubes, from which injury he has made a complete recovery." In an oblique perforation of the pelvic cavity by a ball entering in the right inguino-hypogastric region, passing through the bladder, and emerging through the sciatic notch, March 11, 1863, the patient made a satisfactory recovery, served afterward in the Veteran Reserves, and, in 1872, was a pensioner, with comparatively slight disabilities.<sup>7</sup> Another instance of recovery after shot perforation of the bladder, in the case of Corporal Brownlee, is related in the *First Surgical Volume*, p. 488. The early history of another example of

<sup>1</sup> HAMILTON (F. H.), *A Treatise on Military Surgery and Hygiene*, 1865, p. 323.

<sup>2</sup> BLENKINS (G. E.), Additions to article *Gunshot Wounds*, in the eighth edition of S. COOPER'S *Diet. of Practical Surgery*, 1861, Vol. 1, p. 835.

<sup>3</sup> Circular 6, S. G. O., 1865 (*Reports on the Extent and Nature of the Materials available for the Preparation of a Medical and Surgical History of the Rebellion*, p. 27): "Gunshot wounds of the bladder, when the projectile entered above the pubes or through the pubic bones, have proved fatal, so far as the records have been examined. There are many examples of recovery, however, from injuries of the parts of the bladder uncovered by peritonium." With the qualifying clause, the statement nearly represents the truth as now approximated.

<sup>4</sup> LIDELL (J. A.) (*Am. Jour. Med. Sci.*, 1867, Vol. LIII, p. 365), case of Sergeant J. H. Post, Co. H, 61st New York, wounded at Spotsylvania, May 12, 1864. He was discharged June 6, 1865. He is not a pensioner. Dr. F. H. HAMILTON (*Princ. and Pract. Surg.*, p. 117) states that he saw this man in 1869, and that his health was completely restored, though there was still a fistula at the exit orifice.

<sup>5</sup> VAN BUREN (W. H.) (*Gunshot Wound of Bladder*, in the *New York Med. Jour.*, 1865, p. 162), case of L. L. Jones, aged 46, wounded in the New York riots, July, 1863.

<sup>6</sup> HAMILTON (F. H.), *Principles and Practice of Surgery*, 1872, p. 118.

<sup>7</sup> The case of Private Samuel Stewart, Co. B, 40th Indiana, reported by regimental surgeon Dr. ISRAEL B. WASHBURN, in *Am. Jour. Med. Sci.*, 1866, Vol. LII, p. 118. Pension Examiner A. Coleman reported, April 13, 1867, that "there was still occasional discharge of pus with the urine; the gluteal muscles were slightly affected."

satisfactory recovery is related by Dr. D. Rankin.<sup>1</sup> The ball entered the left (?) iliac fossa, probably perforated the fundus of the bladder, and emerged at the right buttock; a troublesome urinary fistula ultimately closed, and the man enjoyed tolerable health ten years after the reception of the injury. Dr. J. D. Jackson has also recorded a recovery.<sup>2</sup>

The following patients are reported as having recovered with persistent urinary fistulæ:

CASE 781.—Private R. Butchers, Co. H, 72d New York, aged 20 years, was wounded at Mine Run, November 27, 1863, and was treated on the field till December 5th, and then transferred to hospital at Alexandria. Surgeon E. Bentley, U. S. V., reported the case as a "gunshot wound of the bladder, mainly on the left side; ball removed on the field; simple dressings; discharged the service, October 14, 1864, for gunshot wound of the bladder; disability total." Pension Examiner Staple, of Winona, reported, September 4, 1872, that "there is a fistulous opening from the urethra in front of the scrotum; also a sinus at the back of the scrotum, on the right of the perineum, which is from the bladder; there is necrosis of the pelvic bones; disability total." This pensioner was paid in June, 1873.

CASE 782.—Private R. Carey, Co. I, 99th Ohio, was accidentally wounded at McMinnville, Tennessee, July 15, 1863. Surgeon J. F. Woods, 99th Ohio, reported as follows: "The ball passed from a point immediately below the horizontal ramus of the pubis, and external to, but opening into, the sheath of the left spermatic cord, incising the base of the bladder and chipping bone from the tuberosity of the ischium of the opposite side, the ball emerging in this line from the soft parts. The shock was moderate and the hæmorrhage slight; the hypogastric region was dull on percussion; the catheter returned from the bladder loaded with blood, but without discharge of urine. Portions of clothing, hair, and spicula of bone were found in the track of the wound and in the scrotum. These foreign matters were carefully removed and simple dressings were applied. Various attempts were subsequently made, by manipulation with, and injection of water through, the catheter, to break up and remove the coagula and to secure a passage of urine by this channel, but all have failed. Fourteen days passed, and the posterior orifice still gave free exit to the urine without infiltration or sloughing, and without an unfavorable symptom save the indication of a probable vesical fistula. The patient is rapidly recovering." In August, the patient was transferred to general hospital at McMinnville, and Surgeon S. J. W. Mintzer, U. S. V., reported that the case was still progressing favorably, although the urine still escaped through the wound of exit. The patient had, however, full control over the movement of the bladder, and the wound of entrance had healed. A fistulous opening would probably remain. On September 11th, the patient was transferred to Cumberland Hospital, and discharged the service October 26, 1863. Pension Examiner J. Colby, of Defiance, reported, September 1, 1870, that "the ball entered half an inch to the left of the symphysis pubis, taking its course slightly downward, backward, and to the right, passing through the os pubis, the anterior inferior portion of the bladder, the neck of the bladder, and os ischium, and passing out one and a half inches to the right of the lower point of the os coccyx. These wounds have never healed. The urine continually escapes from both openings, diffusing into the cellular tissue, causing inflammation and physical disturbance requiring surgical and medical assistance." On September 4, 1873, he reported: "The neck of the bladder has never united, and the urine dribbles away and is diffused in the cellular tissues, thus passing off through fistulous openings. The principal one is in the front part of the perineum and two others are in the right natis. Manual labor produces fever and inflammation of the affected parts; disability total." This pensioner was last paid in June, 1873.

CASE 783.—Private G. W. Hannah, Co. A, 39th Kentucky, aged 34 years, was wounded at Cynthiana, June 12, 1864, by a conoidal ball. Surgeon J. G. Hatchett, U. S. V., reports that the missile "entered the right buttock three inches from the anus, and emerged at the left groin just above the pubic arch." On June 15th, the patient was admitted to hospital at Covington, and was discharged October 7, 1864, and pensioned. January 14, 1870, Examiner S. V. Feror, after describing the course of the ball, states that "the wound involved the bladder, so that the urine passed out at the entrance and exit orifice of the ball, and still passes out at the hip, where a fistulous opening is left. The discharge of urine by the natural channel is often bloody and contains mucus, especially after an attempt to work. The pensioner has to sit down in order to pass water; he suffers more or less constant pain, which is increased by exertion."

CASE 784.—Corporal W. H. Reed, Co. A, 127th New York, was wounded at Pocotaligo, December 9, 1864, the regimental surgeon, Dr. G. R. Cutler, noting a "wound of the hip." Removed to a hospital at Beaufort, Surgeon John Trenor, U. S. V., records that "the ball had penetrated the bladder and lodged." Assistant Surgeon W. R. Ray, U. S. V., corroborates this report, and states that the patient was discharged May 17, 1865. The Examining Pension Board at New York reports, June 12, 1872: "Ball entered the left groin over the femoral artery, penetrating the neck of the bladder. There is a deep depression at the point of entrance. The ball has never been removed. The urine passed through the wound for three months after the wound was received. About three years ago the wound opened, a piece of bone came out, and at that time the urine again passed through the aperture. The limb is very weak, and he is unable to perform any hard labor with that limb, or to walk any distance without great pain. Disability total, and permanent." This pensioner was last paid in July, 1873.

The presence of dead bone was the irritating cause, in most instances, of the persistence of fistules. But sometimes there appears to have been no foreign source of irritation, and the sinuses remained open, apparently from the transformation of their walls into tissue indisposed to union. No attempt to procure union by operative interference was reported.

<sup>1</sup>RANKIN (D.) (*Surgical Cases*, in *Am. Jour. Med. Sci.*, 1864, Vol. XLVIII, p. 67): Case of Private W. Rosenberg, Co. K, 93d Pennsylvania, wounded at Fair Oaks, May 31, 1862; discharged and pensioned October 25, 1862. Dr. RANKIN records the recovery prematurely. Examiner G. P. Lineaweaver, of Lebanon, reported, October 11, 1870, that the cicatrix of the entrance wound was in the *right* iliac fossa; that the pensioner had suffered for three years from urinary fistula; but that the sinuses then closed firmly, and no other vesical trouble remained but slight incontinence. In May, 1873, this invalid applied for increased pension.

<sup>2</sup>JACKSON (J. D.), *Am. Jour. Med. Sci.*, 1869, Vol. LVII, p. 281.



CASE 785.—Private C. Schaffer, Co. B, 4th Iowa Cavalry, aged 22 years, was wounded in a skirmish near Memphis, December 14, 1864. Assistant Surgeon J. Studley, U. S. V., reported from Adams Hospital that "a ball passed through the right ilium, perforated the bladder, and that the wound was treated by simple dressings." On May 23, 1865, the patient was transferred to the Overton Hospital, where Assistant Surgeon J. P. Wright recorded the entrance of the ball as above, and added that it emerged through the left pubis. This soldier was discharged June 14, 1865, and pensioned. Examiner S. N. Pierce reported, June 13, 1869, that "the urine passes from the bladder through the openings caused by the ball. There is profuse suppuration from the wound; emaciation, and prostration—so great that the pensioner is confined to his bed and requires the services of an attendant. Disability is rated as total, and permanent." The records further show that this pensioner died July 24, 1869.

CASE 786.—Private J. H. Wesson, Co. H, 6th Tennessee Cavalry, was wounded at Salem, Mississippi, October 8th, and sent to Washington Hospital, Memphis, November 1, 1863. Assistant Surgeon J. P. Wright, U. S. A., reported that "a ball had perforated the sacrum, rectum, bladder, and os pubis. There was a fistulous opening near the symphysis, which discharged urine. Several small pieces of bone were removed in the course of treatment, and the patient improved." On April 10, 1864, he was sent to a small-pox hospital for varioloid; was returned on May 4, 1864; and transferred to Gayoso Hospital on May 15, 1865, and discharged the service September 27, 1865, his disability rated as total. There is no pension record in the case.

CASE 787.—Private M. A. Wetherwax, Co. D, 4th New York Heavy Artillery, aged 20 years, was wounded at Petersburg, April 2, 1865, and sent to the Slough Hospital, Alexandria, April 8th. Surgeon E. Bentley, U. S. V., reports: "Gunshot wound through buttock, penetrating the bladder. The treatment pursued consisted of simple dressings, opiates, and low diet." This man was discharged the service August 31, 1865, and pensioned. On April 15, 1867, Pension Examiner R. C. McEwan reported the "existence of a urinary fistula, through which urine passes during micturition. The left testicle is inflamed, large, and tender on pressure, causing pain in the groin and inability to stand long on the feet. The patient resorts to opiates for relief of pain, and at times has considerable swelling of the feet and limbs. He is unfitted for manual labor." The disability is rated as total, and of uncertain duration. On February 28, 1868, Examiner J. G. Bacon, of Saratoga, reported that "the ball entered the right buttock, passed obliquely across the lower portion of the pelvic cavity, and emerged at the anterior surface of the right thigh two inches below the groin. The bladder was injured, and a urinary fistula followed, which still remains, its outlet being near the junction of the penis with the scrotum. The left testis is enlarged and inflamed, causing great and continued pain, which requires the constant use of opiates. The general health has deteriorated very much, owing to the severe nature of his injury. He passes blood frequently, is greatly debilitated and emaciated, thinks he will not long remain on earth." Dr. Bacon recommended an increase of pension, which was allowed, to date from June, 1866, and was last drawn by the pensioner June 4, 1873."

Other patients recovered after suffering from recto-vesical fistulæ, which closed early in some instances, and, in others, remained pervious for long periods. Some of these cases will be detailed here, and others with wounds of the rectum:

CASE 788.—Private P. Janisch, Co. E, 20th Wisconsin, aged 24 years, was wounded at Prairie Grove on December 7, 1862. The case is briefly noted by Surgeon Ira Russell, U. S. V., at Fayetteville, and Assistant Surgeon W. Short, 26th Indiana, at Springfield, Illinois, as a severe shot wound of the hip, for which the patient was discharged May 15, 1863. Dr. James Diedendorf, of Milwaukee, in a letter to the Surgeon General, May 16, 1866 reports the facts of the case as follows: "The ball entered one inch to the left of the anus, passed through the rectum and bladder beneath the ramus of the ischium, and emerged in the right groin, causing recto-vesical fistula. Faecal matter was discharged from the opening for about four months; after that it took the natural course. Urine still continues to discharge from the fistula. The patient was obliged to use a catheter for six months. He was treated in Smith's Hospital for three months, where Dr. Carpenter introduced a catheter regularly for six weeks. He says that when he left the Fayetteville Hospital he was not allowed to take the catheter, which he had then learned to pass for himself. He is at present able to perform some light work. Urine continues to discharge from the groin, more particularly in the morning, when the bladder is somewhat distended; in the after part of the day it passes by the urethra with an occasional leakage." This man was pensioned. He presented his photograph to this office (*Card Photographs*, S. G. O., Vol. I, p. 22), showing a small fistula opening externally one inch below the right inguinal ring. Examiner W. C. Spalding, April 21, 1870, reports: "There is now a fistula formed from the groin through the neck of the bladder and rectum, so that the urine, while the bladder is being emptied, passes through the groin, penis, and rectum. His general health is poor." The disability is rated as total, of the second grade, and permanent. This pensioner was paid June 4, 1873.

CASE 789.—Lieutenant G. W. Blake, Co. K, 2d Iowa, was wounded at Corinth on October 3, 1862. He was attended by Surgeon A. B. Campbell and H. Wardner, U. S. V., and by Acting Assistant Surgeon W. R. Burke. The early history of the case is compiled from casualty lists and an unsigned clinical report. A ball entered just above the left pubis, half an inch from the symphysis, passed backward, downward, and outward, perforating the bladder and rectum, and escaped through the sacrum and gluteal muscles an inch and a half from the upper edge, and one inch from the spine of the sacrum. He was treated in a field hospital of the Army of West Tennessee, and at Cairo. A catheter was introduced through the urethra, but no effort was made to close either shot opening. From both orifices feces and urine escaped freely; there was considerable inflammation about the external wounds, which subsided in a few days. After a time both wounds closed, and the feces and urine passed through the natural channels. The patient was furloughed October 19, 1862, and discharged from service May 27, 1864, and pensioned. On June 19, 1864, Pension Examiner P. M. McLaren reports "the original wounds of exit and of entry are healed; but there is an opening through the upper part of the scrotum in which the probe detects dead bone, and from which dead bone is being discharged." This pensioner was paid in June, 1873.

CASE 790.—Private W. Estee, 5th Massachusetts Battery, was wounded at Gettysburg, July 2, 1863. A musket ball perforated the pelvis from the right buttock to the right groin. Gas and faecal matter escaped by the anterior wound. On July



13, 1863, he was sent to Jarvis Hospital, Baltimore. Assistant Surgeon D. C. Peters, U. S. A., who has printed an account of the case elsewhere,<sup>1</sup> observed that "the abdomen was tender and tympanitic, the knees drawn up, the breathing difficult. A catheter introduced into the bladder brought away a small quantity of urine mingled with soluble fecal matter. With cataplasms, enemata, diluents, and the free use of opiates, the patient improved. There was a stercoecal fistula, but it closed in a few weeks, and the functions of the bladder and bowel were completely restored." On September 18th he was furloughed, and, on December 7th, entered Mason Hospital, Boston, convalescent. He was discharged and pensioned December 23, 1863. In December, 1872, Examiner G. S. Jones stated that there was dysuria; otherwise, the pensioner's health was satisfactory.

CASE 791.—Private *M. Mooney*, Co. E, 19th Virginia, was wounded at Chapin's Bluff, November 18, 1863, and sent to Chimborazo Hospital. The ward-surgeon recorded the following notes of the case: "A ball entered near the lower part of the sacrum, one inch to the right of the median line, passed forward and downward through the base of the bladder and the prostatic portion of the urethra, emerging under the arch of the pubis, impinging on its right ramus, and wounding the right crus of the penis. He was urinating at the time. The ball also passed through the left thumb. On admission, urine was dribbling from both wounds. On November 20th, there was considerable fever and cough; very little urine passes by the natural passage of the urethra. A slough had opened the rectum on the 26th; urine and fecal matter passed from both wounds. In December a gum catheter was several times passed into the bladder, disclosing spasmodic contraction of its sphincter; the excretions were regular and the appetite good, but there was considerable emaciation. On December 30th, a little urine passed by the urethra." The case progressed as follows: "January 15, 1864: Fecal matter but no urine passes by the posterior wound; a little urine from the anterior wound; patient furloughed. 30th: Anterior wound closed; urinates only by the urethra. February 2d: Anterior wound reopened and urine escaping therefrom; constitutional symptoms present. 10th: Feces ceased to discharge; the anterior wound closed. March 1st: The anterior wound reopens, but closes by the 10th. 15th: Posterior wound open and fecal discharge from the same; there is also diarrhœa. 20th: Serous discharge from the posterior wound. 30th: Less irritability of the bowels. April 16th: Transferred to Chimborazo No. 2; both wounds open; sero-purulent discharge; frequent attacks of diarrhœa, and exfoliation from the pubes. The treatment pursued was mainly expectant."

In very few instances were the recoveries complete. Making every allowance for exaggerations in the pension reports of disabilities, where the ulterior histories can be traced, it is rare to find the functions of the bladder perfectly restored after shot injury:

CASE 792.—Private *G. W. Pitt*, Co. G, 37th Wisconsin, aged 29 years, was wounded at Petersburg, July 23, 1864, and sent to a Ninth Corps Hospital. Surgeon M. K. Hogan, U. S. V., reports that "a conoidal musket ball entered one inch behind and above the trochanter major, passed inward, fracturing the ilium and penetrating the bladder, and lodged, and could not be found." The patient was sent, by City Point, August 1st, to Mount Pleasant Hospital, furloughed on August 12th, and transferred, November 12th, to Harvey Hospital, Madison. Surgeon H. Culbertson, U. S. V., reports that the wound was then healed, and that the ball had been extracted from the anterior inferior spinous process of the ilium. The soldier was discharged March 18, 1865, and pensioned. In May, 1865, Examiner A. M. Danton reports that the pensioner is quite lame and unable to labor. He rates the disability at three-fourths, and of uncertain duration. On September 4, 1873, Examiner G. M. A. Brown reported that "a fragment of shell passed across and through the muscles of the left hip. The use of the leg is much impaired. Disability continues three-fourths." This pensioner was paid June 4, 1873.

CASE 793.—Private *L. Schroder*, Co. G, 1st Louisiana, aged 41 years, was wounded at Port Hudson, June 14, 1863, and was registered by Surgeon W. B. Reed, U. S. V., from a field hospital of the Nineteenth Corps, as a case of "gunshot wound of right knee and of belly." He was transferred to New Orleans, and Surgeon Francis Bacon recorded only the wound of the knee, and returned the man to duty August 16, 1863. On November 2, 1864, this soldier entered University Hospital with chronic diarrhœa, and, on January 5, 1865, was transferred to St. Louis Hospital, where Surgeon A. MacMahon, U. S. V., reported "an old gunshot wound of the bladder," and the patient was discharged February 28, 1865. He was pensioned, and Examiner G. Kellogg reported that he "suffered from anuresis and chronic cystitis." Examiner D. Mackay reported that the pensioner died October 19, 1870, "from the effect of a gunshot wound penetrating the bladder."

CASE 794.—Private *W. H. Sibbald*, Co. F, 1st New York Dragoons, aged 21 years, was wounded April 15, 1862, at Suffolk. Assistant Surgeon E. McClellan reports that he entered Hampton Hospital, April 15, 1863, with shot perforation of the pelvis, and was returned to duty August 23, 1863. On October 21, 1863, he was admitted to the 2d division hospital at Alexandria. Surgeon T. Rush Spencer, U. S. V., reported the case as a "gunshot wound of the intestines." The ward-attendant, Acting Assistant Surgeon J. P. Rossiter, notes that "a musket ball entered the left hip from behind, and made its exit just above the symphysis pubis and a little to the right, injuring the bladder, so that urine escaped from the wound. On admission the wounds were healed, and the patient was doing well." On October 30, 1863, he was sent to De Camp Hospital, David's Island, whence Assistant Surgeon J. Sim Smith, U. S. A., reported him returned to duty, November 19, 1863. This man was discharged from service January 8, 1864, and pensioned. On January 15, 1863, Examiner G. R. Crockett reported that: "He complained of dysuria and inability to retain his urine at times, and of pain in the region of the bladder, and inability, from pain, to walk or stand long. The disability has increased from cystitis following gunshot wound. There is increased difficulty in voiding the urine." On January 15, 1873, the same examiner gives substantially the same report, adding that the dysuria has increased.

Besides the six cases of recovery from shot wounds of the bladder noted at the beginning of this subsection, and the fourteen cases briefly detailed, CASES 704 and 747 of the first section of this chapter were instances of recovery from shot fractures of the

<sup>1</sup>PETERS (D. C.), *Gunshot Wound of Intestines and Bladder*, in *Am. Med. Times*, 1864, Vol. VIII, p. 3.

pelvic bones complicated by injury of the outer wall of the bladder without penetration. To these twenty-two cases may be added fifteen, in which foreign bodies complicating shot wounds were successfully removed by cystotomy. As this series includes some of the most complete and satisfactory examples of recovery from shot wounds of the bladder that were reported, it may be well here to examine these, and to resume, on page 283, the consideration of the cases in which operations were not performed. Twenty-one lithotomy operations will be recorded, of which four were fatal or doubtful, and two were unconnected with the war.

FOREIGN BODIES IN THE BLADDER.—Shot wounds of the bladder are not uncommonly complicated by the presence of foreign bodies in the cavity of the organ. Either the projectile itself, or fragments of bone, may primarily penetrate and lodge within the viscus, or may find their way thither by ulcerative absorption. Less frequently, portions of clothing, bits of hair or of integument, or fragments of wood, are driven in. Moreover, the cystitis resulting from shot wounds is likely to induce the formation of calculi, without the presence of any foreign nuclei. Examples of all of these varieties of vesical concretions were observed during, or subsequent to, the war. These extraneous bodies are sometimes extracted through the wound by which they entered, and sometimes they are discharged by the natural channel. No instances of small bullets thus escaping by the urethral canal were reported, though such have been observed;<sup>1</sup> but several examples were given of splinters of bone eliminated by this passage.<sup>2</sup> Most frequently, however, these foreign bodies became encrusted and have to be removed by operation. The annals of the war, or donations to the Museum, furnish twenty-one examples of lithotomy for the removal of concretions consequent on wounds of the bladder. In twelve, these were found about projectiles from fire-arms; in one, about an arrow-head; in three, upon bone splinters; in three, on inspissated mucus, or blood, or with no recognizable nucleus; in two, respectively, upon a bit of cloth and upon a tuft of hair.

<sup>1</sup> The following instances of small projectiles voided by the urethra after penetrating the bladder may be cited: 1. ELSCHOLTZ (J. S.) (*Ephem. Nat. Cur.*, Ann. IX and X, Nürenberg, 1693, Abs. LXXXV, p. 229) relates that a certain captain received a ball in the right side, penetrating the bladder; the wound healed, but there was a sense of weight around the pubes, and, after much tenesmus, a ball, "of the kind termed *Lauff-Kugel*, equal in size to a garden-pea," was passed the urethra. This case is quoted by BONETUS, DEMARQUAY, DIXON, and others. MM. CHASSAIGNAC, GIRALDÈS, and H. LARREY (*Rep. sur les plaies de la Vessie par armes à feu*, in *Mém. de la Soc. de Chir.*, 1851, T. II, p. 339) cite from STALPART VANDER WIEL, a case said to be reproduced by THOMAS BARTHOLOINUS, which I cannot find in the editions I have examined of either of these authors. (THOMAS BARTHOLOINUS, by the way, died in 1680, and the first edition of Stalpart's earliest publication [*Zeldsame danmerkingen*, etc.] was printed in 1686.) The citation is as follows: "At the siege of our city (Copenhagen), a soldier in the pay of Sweden received in the epigaster (*sic*) a small bit of sharp iron (termed here *skraz*), of the kind with which cannon are still charged. The wounded man was carried, with five hundred others, to a neighboring city, and there received surgical aid. This morsel of iron was voided with the urine, contrary to general expectation, with atrocious pains, which gradually subsided. This man was promptly restored, by the care of Surgeon Cornelius, very skillful in his art. I think the iron fragment engaged in the urethra from the wounded bladder, for I do not see that it could arrive thither by an easier route." MANGETUS (*Bibl. chir.*, Geneva, 1721, Vol. I, p. 71) relates the case of a youth, who, while hunting, received a charge of small shot in the groin. Pus and shots were voided by the urethra. The patient sank under the protracted suppuration and died. To these old instances may be added a modern one, recorded by Dr. C. D. STICKNEY (*Boston Med. and Surg. Jour.*, 1855, Vol. LI, p. 360): Edward James, a painter of New Bedford, Massachusetts, was accidentally shot in the right of the hypogastrium by a Colt's pistol, June 7, 1854. He had excruciating vesical tenesmus, and voided urine mixed with blood. A catheter introduced soon after the accident evacuated two ounces of bloody urine. A few hours subsequently a catheter was again introduced, and the urine drawn was not bloody. Two days afterward, after much pain and straining, the ball was expelled from the urethra. Dr. L. BARTLETT also observed this remarkable case.

<sup>2</sup> A few examples may be added to those adduced in the text, of the elimination by the urethra of splinters of bone driven into the bladder: 1. LARREY (*Clin. Chir.*, 1829, T. II, p. 518): Case of Lieutenant Burnot, 26th Infantry, wounded at Hanau, October 30, 1813. A musket ball, dividing the right spermatic cord, perforated the bladder and rectum. Urine and feces escaped by the posterior wound. As the wounds cicatrized the urine resumed its natural channel, and fragments of bone were voided by the urethral canal. Complete recovery ultimately ensued. BRIOT (*Histoire de l'état de la chir.*, 1817, p. 150) alludes to seeing this case. 2. DOUGLAS (J.) (*Edinburgh Surg. and Med. Jour.*, 1817, Vol. XIII, p. 313) relates the case of Captain S——, who received a shot perforation of the bladder, at Chippewa, July 5, 1814. A piece of bone passed by the urethra. After protracted suffering, this officer completely recovered. 3. HENNEX (*Principles*, 1829, p. 429) records the case of T. D——, a soldier wounded at Waterloo, June 18, 1815. A ball grazed the horizontal ramus of the pubis, perforated the distended bladder, and came out at the buttock of the same side. The wound gradually healed, and, with the urine discharged from the urethra, bony grit was passed, which was collected and amounted to three drachms in weight; the largest piece was flat like a coin, and of the size of a split pea. 4. MATTHEW (*Med. and Surg. Hist.*, 1. c., Vol. II, p. 331) gives the case of J. Griffith, 57th regiment, aged 26, wounded on June 18, 1855, by a musket ball, which entered the left buttock and escaped about three inches above the pubis, an inch to the right of the median line; urine escaped from both wounds; seven weeks after the reception of the injury three small fragments of bone passed by the urethra, and two pieces of bone escaped by the anterior wound; the patient recovered. 5. BARKER (A. E.) (*Med. Press and Circular*, 1872, Vol. I, p. 182) relates the case of Peter S——, aged 21, observed in the clinic of Professor BESCH, of Bonn, wounded at Bapaume, January 3, 1871, an oblique shot perforation of the pelvis. A splinter of bone obstructed the urethra and was removed by forceps.



*Vesical Calculi formed about Projectiles.*—Examples of this sort have been recorded by Dionis, Cheselden, Covillard, Percy, and others. Several of the concretions are preserved in museums. One of the most interesting<sup>1</sup> is represented in the adjacent wood-cut (FIG. 219). In 1792, Chopart enumerated<sup>2</sup> the examples that had been recorded prior to his time, and, in 1850, Mr. James Dixon enumerated<sup>3</sup> sixteen instances in which such concretions had been removed by lithotomy, three in which bullets, forming nuclei of stones, were found in the bladder after death, and one in which the bullet was small enough to be voided by the urethra. American experience has added thirteen instances of cystotomy for the removal of projectiles or of concretions formed about them, and three European instances may be added to the collection by Mr. Dixon,<sup>4</sup> making thirty-two recorded examples of this group.



FIG. 219.—Vesical calculus formed about a musket ball (*Museum der Josef's Akademie*). [After PODRAZKI.]

<sup>1</sup> Professor PODRAZKI (*Fremde Koerper, in der Harnblase, in von PITHA und BILLROTH, Handbuch, B. III, Abt. H. S. 81*) states that the pyriform concretion is formed about a leaden ball and weighs one ounce five drachms and ten grains, and is composed of phosphate of lime, magnesia, and ammonia. It is from a soldier wounded in the pubes. Part of the projectile remained impacted in the bone; the other part was exposed in the vesical cavity, and formed a nucleus for the deposition of phosphates. EURLICH (*Chir. Beobachtungen, B. I, S. 208*) speaks of seeing it before 1795.

<sup>2</sup> CHOPART, *Des plaies de la vessie, in his Traité des Maladies des Voies Urinaires, 1792, p. 92.*

<sup>3</sup> DIXON (J.), *In Medico-Chirurgical Transactions, 1850, Vol. XXXIII, p. 197.*

<sup>4</sup> According to COVILLARD (*Observations Iatrocirurgiques, éd. THOMASIN, 1791*): (1.) PELLOTIER successfully removed by lithotomy a calculus the size of a pigeon's egg from the bladder of a nobleman, who had received a shot wound in the hypogastrium five years previously. This operation dates probably about 1633. DIONIS (*Cours d'Opérations, 1708, p. 170*) relates that (2.) FRÈRE JACQUES, in 1698, successfully operated at Versailles on an Irishman who had carried a ball in his bladder for four or five years. CHESSELDEN (*Treatise on the High Operation, 1723, PLATE X*) figures a calculous concretion deposited about a ball, which entered the bladder through the back part of the thigh, and was removed by (3.) RIDOUTE, four or five months after the infliction of the wound. MORAND (*Opuscules de chirurgie, 1772, T. II, p. 26*) states that his father (4.) "had removed from an invalid soldier, by the ordinary operation of lithotomy, a stone which had for a nucleus a musket ball, which had entered the soldier's bladder by a shot wound received in the hypogastrium many years previously, who recovered from the operation." Elsewhere (*op. cit., p. 248*) MORAND speaks of having seen a case of this description, referring probably to his father's case. (5.) BORDENAVE (*Précis de plus. Observat. sur les Plaies d'Armes à feu en différentes parties, in Mém. de l'Acad. de Chir., 1753, T. II, p. 522*) relates that DUVERGÉ saw a young man who had been shot by a pistol at the pubic attachment of the right rectus. The abdomen was tense, and there was retention of urine and a tumor in the perineum. DUVERGÉ punctured the fluctuating perineal tumor with the trocar of FOUCHER; a great quantity of sanguineous urine escaped. Cutting on the canula into the bladder, DUVERGÉ withdrew the ball, a rag from the shirt, and many coagula. The patient was bled nine times, and recovered after "a mediocre convalescence." PERCY (*Man. du Chir. d'Armée, 1792, p. 446*) also adduces this case, and it has been erroneously accredited by some writers to DEVERGÉ. (6.) GARENGEOT (*Traité des Opérations de Chir., 2d éd., 1741, p. 170, Obs. XI*) records an instance in which MARECHAL performed lithotomy on an officer wounded in the vesical region ten years previously, and removed a stone having a musket ball as its nucleus. (7.) C. J. M. LANGENBECK (*Nosol. und Therap. der Chir. Krankh., 1850, B. IV, S. 590*) records a case in which a ball perforated the sacrum and rectum and lodged in the bladder. Urine and blood passed by the rectum. The entrance wound healed in a month, and, a fortnight later, urine and pus ceased to be discharged from the anus. There was frequent painful and sometimes involuntary micturition. Small calculi were discharged from the urethra six weeks after the reception of the injury. LANGENBECK performed lithotomy and removed a calculus enclosing a ball (Kugel von Steinmasse eingeschlossen) and adherent to the wall of the bladder. This is probably the same case that LARREY (*Clin. Chir., 1829, T. II, p. 529*) refers to LANGENBECK, stating that the operation was performed at the Wertheim Hospital, ten years after the injury, with success, and that the operation was of the size of a small hen's egg. DEMARQUAY (*Mém. sur les Plaies de la Vessie par Armes à feu, 1851, Obs., VII*) gives a long history of this case, stating that the subject of the operation was Charles Klein, a Prussian soldier, 25 years of age, wounded December 11, 1800, near Burgenbroeck. There is reason to believe that the interval between the injury and operation was much less than that recorded by LARREY. (8.) SOUTH (*Notes to CRELUS'S System of Surgery, Am. ed., 1847, Vol. I, p. 529*) records the operation of lithotomy of the elder CLINE, February 20, 1812, on a sailor, who, in July, 1811, received a shot perforation of the right ilium an inch above the sciatic notch. He was taken to a hospital at Cadiz, and suffered with retention of urine for five days, when he was relieved by the withdrawal from the urethra of a roll the size of a goose-quill and two inches in length, consisting of fragments of shirting and of trousers. The fistula in the lip had healed in January, 1812. A month later, CLINE operated, removing an encrusted flattened ball, encysted on the left side of the bladder, and with a small portion of bone adhering to it. The man recovered very quickly. The ball is in the Museum of St. Thomas's Hospital. (9.) LARREY (*Clin. Chir., 1829, T. II, p. 530*) relates that on August 4, 1812, he successfully performed lithotomy in the case of Lieutenant Guenou, 92d Infantry, wounded at Witepsk, August 3, 1812. The ball had entered the right groin, notched the ramus of the pubis, and passed obliquely downward and inward into the bladder. When struck with a sound, the impression of impact was very feebly transmitted to the hand. After consultation with RUES and others, LARREY practiced perineal lithotomy, and the ball was presented to the patient in less than two minutes. It was subsequently deposited in the Museum of the *École de Médecine*, at Paris, where it may still be seen, partly covered with earthy phosphates. "On y voit une petite portion d'os incrustée," LARREY remarks that this envelope demonstrated the facility that would have attended injections of quicksilver, a measure advocated by some of the consultants. After the operation, a small piece of bone and a fragment of clothing with black coagula, escaped from the wound. The bladder was washed out by emollient injections, and nothing hindered convalescence except a slight arterial hemorrhage on the second day, requiring a ligature. (10.) GUTHRIE (*Lectures, etc., 1847, Case 116, p. 69, and Commentaries, etc., 6th ed., p. 109*) relates the case of the soldier of the King's German Legion, wounded at Waterloo, June 18, 1815, and sent, by Staff-Surgeon CAMPBELL, to the York Hospital at Chelsea, where (with Duguet, the French soldier GUTHRIE had amputated at the hip) he became the object of great attention. "The ball entered a little way above the pubes and lodged. The symptoms which immediately followed were by no means severe, although he had passed a little bloody urine at first." In September, GUTHRIE, in the presence of a concourse of military medical men, removed a concretion composed, as Dr. MARCET ascertained, of triple phosphates deposited upon a flattened musket ball. Mr. GUTHRIE kept the specimen in a little box, and annually exhibited it to his class. One year, leaving it on the table after his lecture, he returned to find that some one, who never returned it, had borrowed the specimen. (11.) LARREY (*Clin. Chir., 1829, T. II, p. 537*) relates the case of Captain J. M. Rémy, 108th Infantry, aged 50 years, wounded at Waterloo, June 18, 1815, the projectile striking the left hypochon-



It is believed that the particulars of the following case, briefly noted in the Museum Catalogue,<sup>1</sup> have not heretofore been published:

CASE 795.—Lieutenant William Palmer, Co. E, 35th Massachusetts, aged 27 years, was wounded at Antietam, September 17, 1862, and taken to Locust Springs Hospital. The following report of the case was transmitted by the late Assistant Surgeon G. M. McGill, U. S. A.: "A conoidal ball entered over the left ilio-pubic eminence, and, breaking the body of the left pubis, passed inward, downward, and to the right, penetrated the bladder near its summit, lodging in its cavity. Urine escaped from the wound of entrance, and the surrounding tissues were swollen. The patient complained of severe pain on the inside of the left thigh; there was irritative fever, with diarrhoea, and rapid emaciation. The presence of the ball in the bladder was detected on September 21st. On September 25th, the patient was chloroformed and placed upon a firm table in the position for lithotomy. Aided by Assistant Surgeon G. H. Leonard, 51st New York, and others, I then made an incision, two inches in

diameter, notching the anterior extremity of the tenth rib, and passing toward the pubes. He was taken to Jemappes. Much blood and stercoraceous matter passed from the wound. He was thence transferred to the English hospital at Brussels, where he was frequently visited by LARREY, then a prisoner of war. Fæcal matter frequently passed with the urine. At the end of July a phlegmonous abscess formed in the right groin, and a few days after there was a copious discharge of purulent matter, with a urinous odor, by the wound. In December, 1815, the health of this officer was nearly restored; the abnormal anus had closed, and the dysuria had almost disappeared; but there was still a painful feeling of dull weight between it and the pubis. In 1821, this symptom was aggravated, and Captain Rémy went to Paris and consulted LARREY, who, in consultation with RIBES, decided to cut down upon the supposed site of lodgement of the ball. The officer was quite stout, and it required a deep incision between the white line and left pyramidalis to reach a cyst, which contained no traces of a projectile, but a little orifice admitting a probe leading to a hard body between the left pubis and the body of the bladder. Largely incising the fibrous wall of the cyst, LARREY was enabled to extract, with a polypus forceps, the foreign body, which proved to be an ounce ball encrusted with a circular layer of calculeous matter. This officer recovered perfectly in a month, and LARREY heard from him long after, in the enjoyment of good health, at his home in the provinces. (12.) SOUBERBIELE (*Bulletin de la Société d'Émulation*, 1821, p. 450) records the case of Duprel, 135th Infantry, wounded at Lützen, May 2, 1813, the missile striking the left flank, notching the false rib, and passing obliquely downward and inward behind the pubes, where it lodged, and could not be detected. The wound closed, the patient convalesced, and pursued his ordinary avocations until the close of 1815, when a phlegmonous tumor formed behind the horizontal ramus of the left pubis. A few weeks subsequently the patient experienced a sensation of laceration, followed by painful micturition and the disappearance of the tumor, and passed blood and pus by the urethra. Subsequently he suffered from symptoms of calculus, and once a surgeon, on sounding him, felt a concretion; but when preparations for an operation were made the calculus could not be felt, and the undertaking was deferred until 1821, when, at the Hospital St. Antoine, SOUBERBIELE, having demonstrated the presence of the calculus, performed lateral lithotomy, and removed a fragment of a shell (*biscain*) weighing four ounces and two drachms, covered with successive calcareous layers, disposed in divergent rays, with a rough surface. A perfect cure rapidly ensued. LARREY (*Clin. Chir.*, T. 11, p. 535) and many other authors have cited this case. (13.) BALLINGALL (G.) (*Outlines of Military Surg.*, 5th ed., 1855, p. 357) remarks that "a staff-surgeon in the service underwent an operation for the removal of a ball from the bladder, which was successfully accomplished." Mr. DIXON (*Med. Chir. Transactions*, 1850, Vol. XXXIII, p. 199) states that he was informed by CUSACK that this operation was done by COLLES, of Dublin, six or seven months subsequent to the reception of the shot-wound, and that the case is identical with that accredited to CRAMPTON by GUTHRIE. (14.) BALLINGALL (*op. cit.*, p. 357) refers to "a more recent case, a ball encrusted with calculeous matter, of which a cast is to be seen in the Museum [of the Edinburgh Royal Infirmary], was successfully extracted, although in the first instance an operation was considered fruitless, in consequence, as I have been informed, of the ball, which had entered from behind, having lodged under the pubis and become partially encysted." Mr. DIXON (*Med. Chir. Trans.*, 1850, p. 199) states that in this case CUSACK operated eighteen months after a shot perforation of the sacrum and extracted the ball from the left side of the prostate. In a discussion in the Royal Medical and Chirurgical Society, March 26, 1850 (*The Lancet*, 1850, Vol. 1, p. 423), Dr. C. DE MORGAN referred to a case obviously identical with this, occurring in the practice of Sir CHARLES BELL: "An Irish gentleman was wounded by a musket ball in the hip. The usual symptoms of a foreign body in the bladder presented themselves, and the body was distinctly detected by a sound. The bladder was cut into, but no foreign body was found. A subsequent operation was performed by Mr. CUSACK, and a bullet removed. It was supposed that the missile got into the bladder by ulceration, and that in the first operation it had fallen into the cavity it had originally occupied." Mr. W. V. PETTIGREW "had seen the subject of this case lately; he was quite well." (15.) LEWIS (W.) (*The Lancet*, 1824-30, Vol. 1, p. 31) reports the case of John Roden, a lad of 11 years, shot on November 5, 1828, by a pistol charged with a stone bullet. The missile, "after penetrating a door, entered the left thigh, and afterward passed into the bladder." Mr. LEWIS extracted several pieces of wadding, but was unable to detect any other foreign body. Great inflammation, with excreting dysuria, supervened; but, after a few weeks, the wound healed, while symptoms of calculus became aggravated. On June 23, 1829, Mr. LEWIS practiced lithotomy, and extracted a "marble, considerably increased in size by the deposition of calculeous matter adhering firmly to it." The boy recovered without an unfavorable symptom, and subsequently enjoyed perfect health. (16.) BAUDENS (*Clin. des Plaies d'Armes à feu*, 1836, p. 384, Obs. IV) relates the case of a volunteer in the 67th French Infantry, who, July 15, 1831, was struck by a ball, which, after notching the pubic arch, perforated the anterior wall of the distended bladder. There was no exit orifice, and the urine escaped by the pubic wound. A sound introduced by the urethra detected a foreign body in the bladder. BAUDENS enlarged the entrance wound and practiced supra-pubic cystotomy, and extracted a ball and a splinter of bone from the bladder. The patient rapidly recovered. (17.) HUTCH, the old chief-surgeon of the Hôtel-des-Invalides (*Mém. sur la nécessité d'extraire les corps étrangers et les esquilles*, Paris, 1851, p. 18, Obs. VIII) records the case of a pensioner, Dupont, wounded in Spain in 1808, the ball entering the right buttock. Thirty-two years subsequently, while a gendarme at Rheims, this man underwent lithotomy, and a calculus, having a ball for its nucleus, was successfully extracted. (18.) Mr. JAMES DIXON (*Med. Chir. Trans.*, 1850, Vol. XXXIII, p. 197) read to the Royal Medical and Chirurgical Society, March 26, 1850, a paper by Assistant Surgeon E. M. MACPHERSON, 9th Royal Lancers, entitled *A Case of Gunshot Wound, and Subsequent Extraction of a Bullet from the Bladder*. The case was that of a private, W. West, 24th Regiment, aged 22 years, shot in the left buttock at Chillianwallah, January 13, 1849. He felt such severe pain in the left testis as made him at first suppose that part to be the seat of injury. The ball-track, which was supposed to pass through the ischiatic notch, healed without difficulty; but there was a urethritis, ascribed at first to an old gonorrhœa; but pain on micturition increasing, a sound was passed, and a foreign body in the bladder detected. August 30, 1849, Mr. MACPHERSON practiced lateral lithotomy, and extracted from the bladder an iron ball weighing an ounce and thirty-eight grains. It was encrusted with a thin layer of sandy deposit. By the end of October the patient was convalescent. WILLIAMSON (*Med. Surg.*, 1863, p. 119) and other authors have cited this case, GUTHRIE (*Comm.*, etc., p. 610) being unable to learn the operator's name. (19.) Dr. NEIDÖRFFER (*Handbuch der Kriegschirurgie*, 1867, S. 808) records the case of Joseph Itseli, of the Prince Wasa Regiment, wounded at Solferino, June 24, 1859, by a ball that entered the right sciatic notch and injured the bladder. On July 27th, Dr. NEIDÖRFFER, by lateral lithotomy, extracted from the bladder the ball (FIG. 220), slightly encrusted on one side, smooth and greasy on the other. The patient made a perfect recovery. Sir G. BALLINGALL (*op. cit.*, p. 357), after referring to the cases of FRÈRE JACQUES, COLLES, CUSACK, and MACPHERSON, states that the last was detailed by Mr. DIXON. "to

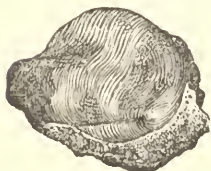

FIG. 220.—Encrusted bullet removed from the bladder by lithotomy. Weight 465 grs. [After NEIDÖRFFER.]

whom we are indebted for notices of fifteen other cases in which a similar operation had been performed." This is literally true, Mr. DIXON's collection including the operations by FRÈRE JACQUES, COLLES, and CUSACK. Dr. F. H. HAMILTON (*Treat. on Mil. Surg.*, 1865, p. 372, and *Princ. and Pract. of Surgery*, 1872) erroneously states that BALLINGALL "collected nineteen cases in which balls, having entered the bladder, have subsequently been removed." BALLINGALL alludes to sixteen only.

<sup>1</sup> WOODBULL (A. A.), *Catalogue of the Surgical Section of the Army Medical Museum*, 1866, p. 601, description of specimen 4394.

length, from the wound transversely to the right, parallel with the pubes. Upon reaching the peritoneum, it was found easy to push that membrane aside, as it was detached, with fragments of the pubic bone adhering to it. The orifice made in the bladder was now discovered, and was sufficiently enlarged, and the ball was extracted by dressing forceps. Afterward most of the bone fragments were removed, with the exception of two of the largest, firmly adherent to the peritoneum. A catheter was introduced by the urethra with the object of drawing off urine, and the wound of operation was dressed with a tube, in order that any excess of urine might flow away readily. In the course of a week the mode of dressing was changed, and simple dressings were applied to the wound of operation. By this time the wound of the bladder had closed, for urine came wholly by the catheter. The patient was very pale and feeble, his pulse was rapid and weak, he had little appetite, and a slough formed, notwithstanding the most careful dressing, at the root of the penis anteriorly. I was ordered away from the field hospital of the Ninth Corps, in which this officer lay, on the 8th of October, at which time I considered his case, although a critical one, yet one that was likely to recover." It appears from the report of Surgeon T. H. Squire, 89th New York, that the sloughing continued to extend, and in spite of the most careful sustaining measures the patient sank exhausted, and died October 13, 1862. The extracted missile was sent to the Museum; one aspect is represented by the wood-cut (FIG. 221), and the opposite by FIG. 3 of PLATE VII. The ball, irregularly compressed at its base and presenting near the apex two ragged depressions, weighed one ounce and two grains Troy. At the bottom of the conical cavity in the base of the ball is a white encrustation, which was more considerable before the specimen had been handled and transferred. It consists of ammoniaco-magnesian phosphate. The bone fragments were lost.

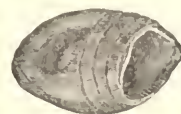

FIG. 221.—Cylindrical ball taken from the bladder. Spec. 4394.

The late Dr. R. A. Felton, of Colonel Dockery's Arkansas regiment, is reported<sup>1</sup> to have performed, unsuccessfully, the high operation of lithotomy, in 1862, at an Iuka hospital, for the removal of a ball from the bladder of a soldier wounded about two months previously.

Dr. J. L. Forwood, of Chester, Pennsylvania, has had the good fortune to successfully remove musket balls from the bladder in two cases, which have been briefly related in a report to the Surgeon General:<sup>2</sup>

CASE 796.—Private T. Lindsay, Co. F, 69th Pennsylvania, aged 43 years, was wounded at Gettysburg, July 2, 1863, while in a kneeling posture, by a ball which, after passing through his canteen, entered the thigh. Surgeon H. Jones, U. S. V., reports that he was treated at Camp Letterman, from August 5th to November 5, 1863, for a gunshot wound penetrating the pelvis, and was then transferred to Newton University Hospital, Baltimore. Surgeon C. W. Jones, U. S. V., reports that "a ball passed into the pelvic region, causing incontinence of urine, and impairing the motions of the hip-joint," and that the patient was discharged from service January 18, 1864. On his return home to Chester, Pennsylvania, he suffered many of the symptoms of stone in the bladder, for which he was treated from time to time, until February, 1866, when an operation for strangulated hernia, the result of dyspnoea, became necessary. On April 12, 1866, the operation of lithotomy was performed by Dr. J. L. Forwood, when, most unexpectedly, an irregularly shaped ball, coated with a phosphatic deposit, was removed from the bladder. This concretion and nucleus weighed 768 grains. The operation was successful. There is no pension record in the case. The specimen is in Dr. J. L. Forwood's cabinet.

CASE 797.—Private T. S. Mason, Co. K, 198th Pennsylvania, aged 50 years, was wounded near Hatcher's Run, March 31, 1865. Surgeon W. L. Faxon, 32d Massachusetts, reported that "a conoidal ball entered through the pubic arch and lodged in the bladder." The patient was removed to City Point, and thence to Lincoln Hospital, at Washington, where Assistant Surgeon J. C. McKee, U. S. A., reported that "a minié ball, entering just above the pubis, over the bladder, penetrated and lodged," and that the patient was discharged from service June 9, 1865, and pensioned. This pensioner returned to his home in Chester, Pennsylvania, and, in December, 1867, Examiner M. Emanuel, of Linwood, reports: "Ball is still lodged in the cavity of the abdomen, causing continued discharge from the seat of the lodgement. He is unable to lift, and incapacitated for manual labor. In February, 1869, the wound healed up and the patient thought himself well; but in February, 1870, vesical trouble, with bloody urine, appeared. On April 16th, the operation of lithotomy was performed by Dr. J. L. Forwood, who removed a conoidal musket ball weighing one ounce and a quarter, and having two small pieces of phosphatic deposit attached. On May 30th, the patient was up and about, but the wound had not entirely healed. There were no symptoms of calculus until six weeks before the operation, notwithstanding there seems but little doubt of the ball having been in the bladder prior to that time. September 6, 1873, Examiner Thomas S. Christ, of Chester, reported that "in this case the ball entered just above the pubes and lodged. Five years and sixteen days after the reception of the injury, I assisted Dr. Forwood in removing the ball from the bladder."<sup>3</sup> This specimen also is in Dr. Forwood's large collection.

In a letter dated November 29, 1873, Dr. J. L. Forwood expressed his intention to "present the two minié balls, taken from Mason and Lindsay, to the Army Medical Museum, with their surgical histories, at once." It is much to be regretted that these

<sup>1</sup> WALLIS (J. D.), *Nashville Jour. of Med. and Surg.* 1867, N. S., Vol. II, p. 502. An unknown soldier received, at Corinth, October 4, 1862, a penetrating shot wound above the right pubis. Four weeks afterward urine escaped from the wound, and symptoms of calculus appeared. It was supposed that a ball, lodged in the muscular coat of the bladder, had made its way by ulceration into the cavity. About November 26th, 1862, Dr. Felton practiced supra-pubic lithotomy and removed a large round ball, probably from shrapnel. The patient survived the operation only 24 hours.

<sup>2</sup> FORWOOD (J. L.), CASES DCCHI and DCVI, in *Circular 3*, S. G. O., 1871, pp. 259, 261.

<sup>3</sup> Dr. Christ adds that there is an interesting account of this case in the *Philadelphia Press* of April 18, 1870.



rare specimens will not be received in season to permit engravings of them to be prepared for insertion in this place. If practicable, they will be figured in a later portion of the section.

The following, though not strictly a "war case," was, at one time, treated at the military hospital at Fort Cottonwood, and is interesting in this connection,<sup>1</sup> and must serve as the fifth of the series of cases of bullets extracted by lithotomy:

CASE A<sup>6</sup>.—James Mitchell, aged 34 years, a Scotchman, employed on the Leavenworth and Denver Railroad, received accidentally, in April, 1864, a pistol shot, penetrating the left sacro-iliac synchondrosis, and lodging. He was taken to the post hospital at Fort Cottonwood, and placed under the care of Assistant Surgeon James N. LaForce, 7th Iowa Cavalry. The patient stated that during his six weeks' sojourn in hospital he suffered great pain in the rectum, and had difficulty in micturition. In October, 1864, he went to his home in Iowa. In June, 1865, he consulted Dr. J. C. Hughes, at Keokuk, who carefully explored the bladder and rectum without finding any foreign body. In February, 1868, he again consulted Dr. Hughes, and a sound introduced into the bladder at once revealed the presence of a large calculus. On February 22, 1868, in the presence of the medical class of the Iowa University, Professor J. C. Hughes performed the bilateral operation for lithotomy of Dupuytren. The calculus was too large to be removed, although the prostate was divided as freely as was consistent with safety. The concretion was therefore crushed by a lithotrite. After extracting the fragments, the bullet that had formed the nucleus was found and removed. The fragments consisted of phosphates, and, when aggregated, formed a calculus of the size of a large

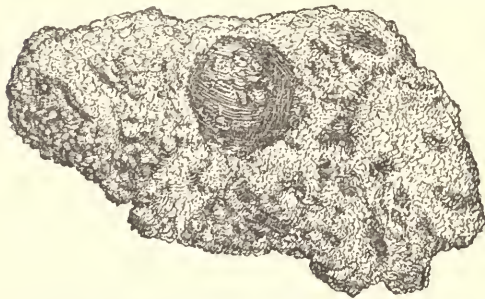


FIG. 222.—Vesical calculus formed about a ball. [From a photograph.]

hen's egg. The long-standing irritation induced by the concretion had resulted in the formation of sinuses, one of which constituted a recto-vesical fistula, and there were suspicious indications of a tuberculous diathesis, and at the date of the report, one year after the operation, the prospect of recovery was unpromising. [Since the foregoing abstract was placed in type, a photograph of a section of the concretion removed in this case has been received at the Museum through the kindness of Professor Hughes. It is carefully copied in the accompanying wood-cut (FIG. 222). In a letter to the editor, Dr. Hughes states that "the stone was crushed in its removal, but has been put together with as much care as possible. I trust the photographer's print will prove satisfactory. I had lost sight of the case and its history, further than the publication referred to, the patient having left the city. Upon enquiring of an acquaintance of his, who resides here, I learn to-day (November 26, 1873), that he died of small-pox, in 1871, in one of the eastern cities."]

The remarkable instance of successful removal of a fragment of a grenade from the bladder, by Surgeon J. F. Randolph, is already well known.<sup>2</sup> Whatever else may be thought of the reduction of the pension of the subject of this operation, it is gratifying to know that, nearly ten years subsequent to the operation, he enjoyed such good health that this saving in government expenditure was deemed suitable.

CASE 798.—The principal facts, already published, are as follows: "Private Conrad Lotes, Co. A, 23d Indiana, was wounded at Vicksburg, June 25, 1863, attended by his regimental surgeon, M. Brucher, and Surgeon G. R. Weeks, U. S. V., and sent, on the hospital transport R. C. Wood, to St. Louis. A portion of a hand-grenade had entered the right buttock two inches from the end of the coccyx and penetrated the bladder. On April 2, 1864, the foreign body was removed by lateral lithotomy, at Jefferson Barracks, by Surgeon J. F. Randolph, U. S. A. The patient recovered rapidly, and was discharged and pensioned June 17, 1864." His ulterior unpublished history is found in the Pension Records. In September, 1865, Examiner W. A. Clapp reported that there was "incontinence of urine." On October 4, 1871, a board of examiners reported that there was "a slight traumatic stricture in the membranous portion of the urethra, and the right testicle is adherent to the scrotum; disability total, of the third grade." The pensioner was in fair health, and, on Examiner J. O. Stanton's report, his pension was reduced in September, 1873. The concretion, contributed to the Museum by Dr. Randolph, is numbered 88 in the Surgical Section, and is well represented in FIG. 2 of PLATE VII, the quadrilateral shell fragment. It weighs an ounce, six drachms, and twenty-four grains Troy; its original weight of two ounces five grains having been reduced by the crumbling of the investing phosphates. These consist almost wholly of the triple phosphate of ammonia and magnesia.

Brevet Colonel Alexander N. Dougherty, Commandant of the New Jersey Home for Disabled Soldiers at Newark, in 1863 successfully removed from the bladder of a soldier, wounded three years and four months previously, a round iron ball encrusted with

<sup>1</sup> An abstract of the case has been published by Professor J. C. HUGHES, M. D., in the *Iowa Medical Journal*, 1869, Vol. V, p. 98.

<sup>2</sup> RANDOLPH (J. F.), *Case in which a Fragment of a Shell encrusted with Calculous Matter was extracted from the Bladder by Lithotomy*, in the *Am. Jour. Med. Sci.*, 1864, Vol. XLVIII, p. 271; *Gunshot Wounds of the Genito-Urinary Organ*, in Circular No. 6, S. G. O., 1865, p. 29; *Catalogue of the Surgical Section of the Army Medical Museum*, 1866, p. 492; FRANKLIN'S *Science and Art of Surgery*, 1867, Vol. 1, p. 706.





Ward, phot.

J. Boon, lith.

VESICAL CALCULI FORMED UPON PROJECTILES.

Fig. 1. Med. Dir. Dougherty's Case (Spec. 5520)  
 Fig. 2. Surg. J. F. Randolph's Case (Spec. 88)  
 Fig. 3. Dr. G. M. M. Gillis' Case (Spec. 1394)

Fig. 4. Prof. E. T. Miles's Case (Spec. 5019)  
 Fig. 5. Dr. Cabot's Case  
 Fig. 6. Prof. E. M. C. Gurte's Case (Spec. 6203)

Fig. 7. Dr. W. H. Forwood's Case (Spec. 5931)



phosphatic depositions<sup>1</sup> The concretion was exhibited to the New York Pathological Society and donated to the Army Medical Museum. It is represented in the first figure of PLATE VII:

CASE 799.—Private W. Cockerott, Co. D, 190th Pennsylvania, aged 38 years, was wounded at Fort Gregg, Petersburg, April 2, 1865. The injury was recorded by the assistant regimental surgeon, D. T. Baldorf, and by Surgeon H. C. Levensalee, 8th Maine, as "a severe gunshot wound of the testicle." The patient was sent to Hampton Hospital. He informed Assistant Surgeon E. McClellan, U. S. A., that normal and painless evacuations of the bladder and bowels had taken place half an hour after the reception of the wound, and that pieces of the pubic bone had been removed, and frequent unavailing efforts made to find the ball. He was transferred, on August 23d, to Mower Hospital, where he was discharged, by Surgeon L. Taylor, U. S. A., for gunshot wound of the abdomen, with fracture of the pelvis, and expiration of time of service, September 23, 1865, and pensioned. Examiner J. H. Clark, of Newark, reported, February 12, 1867, that "the ball entered the abdomen just above the symphysis pubis and lodged in the pelvis; considerable bone escaped. The ball seems to have lodged in the lower end of the vertebrae. The patient's back is weak; he cannot sit long at a time, cannot stoop, and can do no work; he has to get on his knees to get down; the wound still discharges; the kidneys are deranged; he walks slowly and cautiously, and finds it difficult to rise up or to walk immediately afterward. Disability total, and permanent." On May 30, 1867, this pensioner entered the Soldiers' Home, at Newark, for treatment for herpes zoster. At this time the wound had healed, difficult micturition having occurred simultaneously with its closure. A sound failed to reveal the presence of any extraneous substance in the bladder. A week afterward he was discharged; but in a few weeks he returned to say that the wound had reopened, and that, in consequence, he had experienced entire relief. Nothing more was heard from him until July 13, 1868, when he was readmitted, the wound having closed and his old symptoms having grown worse. A foreign body was now readily detected by physical exploration, and the urine was heavily loaded with pus, and at times was bloody. On August 31, 1868, the patient was cut for stone by Dr. A. N. Dougherty, and a vesical calculus was removed, the nucleus of which was an iron ball (*Spec.* 5520). The encrustations consisted of uric acid and triple phosphates, and the specimen, when recent, weighed one ounce and twenty-three grains avoirdupois. The encrustations were chiefly on one side, giving the concretion the shape of a cock's-comb. The operation employed was the one lately recommended by Sir William Ferguson, and consisted in making a superficial cut, as in Dupuytren's bilateral method, semi-circular, the convexity forward, half an inch in front of the anus, with the extremities of the wings equidistant between the anus and the ischium. When, in the dissection, the membranous portion of the urethra was reached, the cut in the prostate was made as in the lateral. The incision described above is said to afford more ample room for the fingers than the usual lateral cut. The only untoward feature of this case was that, although the urine began to flow wholly by the urethra as early as the fifteenth day, there was, as late as December 20, 1868, a fistulous track leading toward the bladder, but discharging no urine. The patient was healthy looking, although he stated that there was still some pus in his urine. In June, 1873, the Pension Board at Newark reported that this man had ascites, with extreme emaciation.

Dr. Samuel Cabot, of Boston, in November, 1871, removed, in fragments, a large phosphatic calculus from the bladder of a soldier, shot through the sacrum at Gettysburg, more than eight years previously. A conical musket ball was the nucleus of the concretion, which is now in the cabinet of the Boston Society for Medical Improvement. Through the kindness of Professor J. B. S. Jackson, a photograph of the specimen was prepared for the Army Medical Museum.<sup>2</sup> This is copied in the fifth figure of PLATE VII:

CASE 800.—Private F. H. McIntosh, Co. A, 1st Massachusetts, aged 21 years, was wounded at Gettysburg, July 2, 1863. Surgeon H. James, U. S. V., records that he was treated at the Seminary Hospital until July 15th, for a "gunshot wound of the back." He entered Mason Hospital, Boston, on July 21th, and Acting Assistant Surgeon W. E. Townsend reported a "penetrating shot wound of the pelvis, the ball still remaining in the pelvic cavity," and, subsequently, that "the patient was discharged March 5, 1864, with inability to walk without a crutch, and total disability." The history of the progress of the case may be condensed from the admirable account recorded by Dr. Cabot: "Three weeks after the reception of the wound, a probe was passed through the entrance orifice at the left of the spine of the second sacral segment, across the pelvis, to the os pubis. The bullet could not be detected by a Nelaton probe or by burr drills, but a scale of lead and twenty-three fragments of bone were removed. Early in September, 1863, an abscess pointed an inch above the horizontal ramus of the left pubis. When this was incised, a sinus extending along the pectineal line to the sacrum was revealed. Free drainage thus established, no further treatment was pursued. The left leg became flexed on the thigh, but sufficient extension was recovered to permit locomotion after a year. For five years there was pain in the sacral region and in the course of the sciatic nerve, but none in the anterior part of the pelvis, till 1870. Necrosed fragments escaped from both orifices of the sinuses, which discharged pus, but never urine or feces. In the summer of 1869, the orifices healed, and all symptoms disappeared except the sciatic pain. Toward the close of 1870, painful and frequent micturition began, and augmented until the patient was unable to work, and incontinent ended in a constant dribble from his urethra. On November 25, 1871, the patient was etherized at the Massachusetts General Hospital, and Dr. Cabot performed lateral lithotomy. The stone was brittle, and the firm pressure requisite to remove one of its size and the diminished cohesion due to the hard nucleus, caused its fracture. Chemical examination of the calculus showed it to be composed principally of phosphate of lime; it also contained some carbonate of lime, the triple phosphates of

<sup>1</sup> Notices of this case are printed in the *Newark Daily Advertiser*, September 12, 1868; *New York Med. Gaz.*, 1868, Vol. I, p. 762; *Med. and Surg. Reporter*, 1868, Vol. XIX, p. 255; Circular 3, S. G. O., 1871, p. 259; *Am. Eclectic Med. Rev.*, 1870, Vol. V, p. 278.

<sup>2</sup> A full and interesting report of the later history of this case is printed in the *Proceedings of the Boston Society for Medical Improvement*, in the *Boston Med. and Surg. Jour.*, 1872, N. S., Vol. IX, p. 169.



ammonia and magnesia, and uric acid. The patient had a good night, and took nourishment well the following day. A continuous stream of warm water was passed through a catheter into his bladder for ten minutes, and several coagula and calculous fragments were washed out of the perineal opening. A catheter was retained in the bladder. The wound healed rapidly. On January 13, 1872, the patient was reported well. On September 3, 1873, the Pension Examining Board at Boston reported that "the ball entered the back about three inches from the sacrum, plunging the tissues, and entered the pelvis just to the right of the sacrum, injuring the bone in its course. The cicatrix is three inches in length and quite tender. Anteriorly at the lower part of the abdomen, just over the bladder, is a cicatrix, the result of an abscess undoubtedly caused by the presence of the bullet, that has been removed from the bladder by perineal section, forming the nucleus of a stone. Is obliged to wear a urinal, being unable to hold his water. This incontinence is total. Suffers from pain in bladder and bowels, which have lost their tone. Has lost some twenty or twenty-five pounds of flesh. Disability total, third grade." The concretion is represented in FIG. 5 of PLATE VII.

As these pages are passing through the press, there is reported yet another example of lithotomy, by Dr. S. W. Hamilton, of Columbus, Ohio, for the removal of an encrusted bullet, ten years subsequent to a shot wound of the bladder:

CASE 801.—Colonel Alvin C. Voris, 67th Ohio, was wounded in an assault on Fort Wagner, Morris Island, July 18, 1863. Surgeon M. S. Kittinger, 100th New York, reported that a musket ball penetrated the left inguinal region. Surgeon J. J. Craven, U. S. V., records that this officer was received on the Hospital Steamer *Cosmopolitan*, July 27, 1863, taken northward, and granted leave of absence. There is no record of the treatment of the injury at this period. Brevetted Brigadier General of Volunteers, for gallantry, December 8, 1864, this officer was honorably mustered out December 12, 1865. He did not apply for pension. In the *Cincinnati Times*, November, 1873, it is stated that General Voris had long suffered with an affection of the bladder at his home at Akron, Ohio, and that Professor S. W. Hamilton, of Columbus, on exploration detected a foreign body and performed lithotomy, when a battered Enfield rifle bullet of the usual size was extracted from the bladder. The *Akron Beacon* states that the physicians in attendance reported that the patient had progressed very favorably since the operation, and predicted his speedy recovery. The reporter states that the theory of the entrance of the ball into the bladder was that it had lodged in the muscular coat of the upper part of the organ, and that by gravitation and ulcerative absorption it gradually worked into the cavity. The operator, Dr. S. W. Hamilton, will doubtless print an authentic account of the case.

Several interesting examples of calculus resulting from shot injury of the bladder occurred to the Confederate medical officers. Dr. Hunter McGuire, medical director of General Jackson's Corps, Professor F. T. Miles, Dr. J. Francis King, and Professor J. J. Chisolm have contributed to the Army Medical Museum the encrusted projectiles and calculi which they successfully removed. Several of these are figured in PLATES VII and VIII. The instances of extraction of balls by lithotomy will be noted here; and the cases of removal of vesical concretions following shot wounds, and found about bone or cloth, or having no distinct nuclei, will be referred to further on:

CASE 802.—"Private *George L. Shrimp*, Co. C, Palmetto Sharpshooters, aged 25 years, was wounded at the second battle of Manassas, August 30, 1862, by an ounce ball from spherical case. The ball perforated an oil-cloth folded around a small tent-fly, and the belt of his cartridge-box, entering the body about an inch to the left of the spine and about two inches below the last rib, and penetrating the cavity of the abdomen. He remained at the field infirmary four or five days, when he was transferred to hospital at Warrenton, where he remained until October 20th, when he obtained a furlough to his home in Anderson District. He rejoined the Army about March, 1863, and served to the close of the war. He was present at the surrender of General Lee's Army at Appomattox, on April 9, 1865, and then returned to his home, where he has been actively engaged in farming, suffering no inconvenience from his wound until May 28, 1867. On this day he was plowing in the field, when he felt something drop somewhere in his abdomen. He was immediately seized with violent irritation of the bladder, and great pain and difficulty in voiding urine. He was considerably alarmed, and came the next day to consult me: after detailing the symptoms, I told him he had some foreign body in his bladder. He then informed me of the wound, and showed me the cicatrix of entrance of the ball. I then gave the opinion it was the ball in the bladder. I sounded the bladder in presence of Dr. A. Evans, and immediately struck the ball. On August 3, 1867, I performed the usual lateral operation and extracted an ounce ball, slightly flattened on one side, and covered with minute shining crystals of phosphate of lime; about one-sixth of the circumference of the ball was covered with a thick deposit of the same salt. How did the ball get into the bladder? It certainly was not free in the cavity of that viscus prior to May 28th, when he distinctly felt it drop, for up to that time not a single one of the usual symptoms indicated its presence. It could not have penetrated at the time of receiving the wound, or there would have been mortal extravasation of urine into the cavity of the abdomen. The only rational explanation is, that the ball perforated the external coats, pushing the internal before it, without producing any solution of continuity in that coat, thus preventing any escape of urine until the outer tunics united and closed the opening. The ball was suspended in the walls of the bladder by the invaginated mucous membrane for nearly five years. By its weight it probably induced absorption of the thin membrane, and wore its way gradually through by attrition, until it dropped into the bladder. The deposit on the ball shows that a portion of the ball was exposed to the urine long before it dropped into the bladder." With the foregoing narrative, clipped from a Carolinian newspaper, Professor F. T. Miles presented to the Museum the remarkable specimen, numbered 5019 in the Surgical Section, and represented in FIG. 4 of PLATE VII. It is a round, ounce, leaden ball, partially encrusted with ammoniaco-magnesian phosphate and the phosphate of lime.

Quite recently, Dr. J. Francis King, of Wilmington, North Carolina, successfully removed a ball coated with phosphates, from the bladder of a man wounded eight years ago, at the battle of the Wilderness, the missile perforating the ilium and lodging in or near the walls of the bladder for a long period, entering the cavity of the organ by ulcerative absorption about four months before the operation of lithotomy was performed. Dr. King presented the encrusted ball, represented by FIGURE 223, to the Museum with the following notes of the case:

CASE 803.—“*J. J. Canady*, ex-Confederate, born in Onslow County May 22, 1839, enlisted in Co. E, 3d North Carolina regiment, in 1861, under command of Captain Redd, and was sent to Virginia in May, 1862. From this date to the time he was wounded he was engaged in seven battles, but was unhurt until May 5, 1864, when, at the battle of the Wilderness, while in a kneeling position, taking cartridges from his box, he was shot through the left ilium about one and a half inches from its sacral articulation. Being unable to rise, he was compelled to lie on the ground about three hours, till assisted by the ambulance corps. He was carried to a field hospital, where he remained twenty-four hours, and was then sent to Orange Court-House. Sojourning there a night and day, he was sent by rail to a hospital at Staunton, where he remained two months, and was then discharged and sent back to his home in North Carolina. During this time he suffered great pain, with difficulty of urinating, having to void the bladder very frequently, the urine being always mixed with much blood and pus. He was greatly emaciated, and with great difficulty reached his home. His bowels were always regular; he was unable to do any manual labor for months, though the blood ceased passing shortly after his return home. Pus continued to be mingled with the urine, and at irregular intervals his sufferings were great for two or three weeks at a time. In February, 1873, while in a stooping position, he experienced a sudden and severe pain, with great desire to micturate; but found it impossible to do so until he placed himself on his back. Afterward he was compelled always to adopt this position to relieve the bladder, and began to pass blood with the urine and pus. His health became rapidly worse, and in May, 1873, he came to Wilmington to obtain advice. I first saw him on May 18th, much emaciated, suffering great pain in the bladder, passing clotted blood and pus with a small quantity of urine about every hour; the left testicle very tender and painful and much swollen. After general treatment, on May 24th I made an examination with a sound and digital examination by the rectum, discovered the ball, found the bladder and rectum very tender, hard, and tense. On June 1st, assisted by Drs. Anderson, Lane, and Love, I placed the patient in a position for lithotomy. Dr. Lane administered chloroform, Dr. Anderson holding the grooved staff. I performed the lateral operation, preferring it from having before performed it seven times successfully. When the membranous portion of the urethra was reached I found it thickened and contracted, passed the scalpel down to the prostate, and then, with a probe-pointed bistoury, divided it sufficiently to admit my finger, removed the staff, and passed a long pair of polypus forceps into the bladder. After exploring, the ball was found and extracted (FIG. 223). Its base end was covered with deposits of phosphate of lime. But very little blood was lost in the operation, and the patient soon rallied from the effects of the chloroform. He was placed in bed, and did well until the next day, when he was seized with a severe chill followed by high fever. I immediately began giving tonics and stimulants, with good nourishing diet, and everything went on well. The wound kindly healed on the fifteenth day, the flow from the wound having ceased; urine passed freely and easily by the urethra. Five weeks after the operation the patient was again a well man, and returned to his home with perfect control over the bladder.”



FIG. 223.—Encrusted ball removed from the bladder by lithotomy. Weight, one ounce twelve grains Troy. Spec. 6292.  $\frac{1}{2}$ .

The following case is the more interesting from the spontaneous fracture of the concretion prior to its removal:<sup>1</sup>

CASE A7.—John Ely, aged 40 years, was accidentally shot, in 1867, by a large pistol ball, which struck above the right trochanter major. Ineffectual efforts were made to find the ball, which was supposed to have lodged in the pelvic cavity. The patient was confined to bed for a month, having no trouble with his bladder during his confinement. He resumed his avocation as a laborer, and, eight months afterward, suddenly experienced symptoms of stone. For the next two years paroxysms of dysuria and vesical tenesmus, with excessive suffering, recurred with increasing severity. In one of the paroxysms a sensation of something giving way was followed by a discharge of urine from the rectum. Afterward there was incontinence, the urine dribbling constantly from the urethra, and discharging more freely by the anus. On December 3, 1870, the patient entered the College Infirmary in Richmond, and the lateral operation for lithotomy was performed by Professor Hunter McGuire, and the ball and fragments of a spontaneously fractured calculus were removed. On December 31st, the perineal wound was closed, and the patient was convalescent. On January 15, 1871, the recto-vesical fistula had closed, and the functions of the bladder were again normal. Professor H. McGuire contributed to the Army Medical Museum the interesting specimen from this case. It is numbered 6203 in the Surgical Section. The relations of the fragments to the bullet were obvious, and it was not difficult to reconstruct the calculus in the shape it probably presented prior to its spontaneous fracture. The concretion thus restored weighs 690 grains Troy. It is well depicted in FIG. 6 of PLATE VII. It is of a light-gray color, and consists mainly, apart from the leaden nucleus, of triple phosphate.

To these cases of concretions formed about projectiles from fire-arms may be added the remarkable case of calculus formed about an arrow-head, and successfully removed

<sup>1</sup> This case is fully related and discussed in a paper entitled *Extract from a Clinical Lecture at the Medical College of Virginia, in a Case of Gunshot Wound of the Bladder, followed by Stone*. By HUNTER MCGUIRE, M. D., Professor of Surgery, Virginia Medical College, in the *Virginia Clinical Record*, 1871, Vol. I, p. 46.



by Assistant Surgeon W. H. Forwood, U. S. A., as already reported in Circular 3, Surgeon General's Office, 1871, page 260.<sup>1</sup> The principal points are here recapitulated:

CASE 804.—In 1862, Sitamore, a Kiowa chief, aged 42 years, in a fight near Fort Larned, with Pawnees, was wounded, by an arrow, in the right buttock. The shaft was withdrawn, the iron head being left deeply embedded. He passed bloody urine immediately afterward, but the wound soon healed, and, for six years, he continued to engage in the chase without inconvenience. In August, 1869, he applied to Assistant Surgeon W. H. Forwood, U. S. A., at Fort Sill, with unmistakable signs of calculus. On August 23, 1869, Dr. Forwood removed, by lateral lithotomy, the large concretion represented by FIG. 7 of PLATE VII. The calculus was egg-shaped, and six hours after removal, before being sawn, weighed nineteen drachms avoirdupois, and was found to consist of a uniform deposit of triple phosphate about an iron arrow-head. The patient was almost convalescent on the eighth day, when his band carried him to his camp, sixty miles away, where an epidemic of fever was prevailing. He died nineteen days afterward.

*Calculi having Nuclei of Bone, and Encrusted Bone-splinters.*—It was observed by Hennen, that “depositions of calcareous matter are often formed in the bladder after its coats have been injured by a wound;” and, he adds, “a splinter of bone is, in most cases, found to be the nucleus of the deposition of calculous matter.”<sup>2</sup> Hennen figures a concretion of this sort (FIG. 227), and adverts to a case in Dease's practice. Sir Henry Thompson refers to a calculus in the Museum of the Royal College of Surgeons, having a nucleus of bone. It was presented by Sir William Blizard, as removed by dilatation from the female bladder by Mr. Allaway; but no further history of the specimen exists. A section of this concretion is represented in the wood-cut (FIG. 224). In a case in which Professor P. F. Eve removed by cystotomy, in 1846, from the bladder of a negro woman, a calculus having a nucleus of bone, there had been a fracture of the pubis by a fall from a stable-loft; the nucleus was a fragment of the pubis, and the concentric deposits are reported to have consisted mainly of uric acid. Although Hennen declares calculous formations about bones to be common after shot wounds,<sup>3</sup> published examples are not numerous, and the three instances resulting from the experience of the war are of unusual interest.

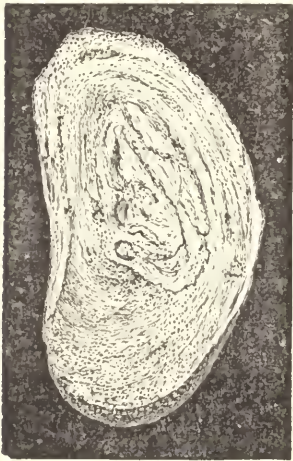

FIG. 224.—Fusible calculus deposited on a piece of bone. [After Catalogue of Animal Concretions, in the Museum of the Royal College of Surgeons. Series VIII, H, a, 11. PLATE II, FIG. 7.] †

<sup>1</sup> In an interesting letter to the editor, January 14, 1873, Dr. W. H. FORWOOD corrects several errors in the report in Circular No. 3, 1871, p. 260; *i. q.*: “*Litimore* should be SITAMORE. SIT, in the Kiowa language, signifies *Bear*, and this chief was of the ‘royal family’ of Bears, of whom are famous: SIT-ANK, Sitting Bear, SIT-ANTA, White Bear, SIT-AMORE, Sleeping Bear, SIT-AMGEAR, Stumbling Bear.” Secondly, the concretion weighed 1140 grains after removal, and its reduction to 815 grains, as recorded in the Circular, is explained by its division by a coarse saw, and subsequent inspection and handling by a multitude of Indians.

<sup>2</sup> HENNEN (J.), *Principles of Military Surgery*, 3d ed., 1829, p. 432.

<sup>3</sup> It is remarkable that such distinguished writers on military surgery as Dr. J. A. LIDELL and Professor F. H. HAMILTON, and such an eminent lithologist as Sir HENRY THOMPSON, should refer to instances in which bone formed the nucleus of a calculus as of almost unexampled rarity. Remark, in a case of lithotomy at University College Hospital (*The Lancet*, 1872, Vol. I, p. 851), the great utility of a light flat-bladed lithotrite to

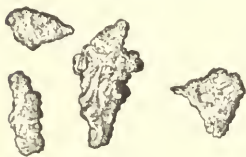

FIG. 225.—Portions of bone removed from the bladder by lithotrite from a man of 40 years. (After THOMPSON.) †

measure and accurately diagnosticate vesical concretions, even when their removal by lithotry was not contemplated, Sir HENRY THOMPSON described a case of a man of 40 years, whom, in June, 1865, he had sounded and found to have stone, and had then, as usual, introduced a lithotrite to ascertain the precise size of the calculus, and remarked that the mass did not feel like stone, and withdrew, for examination, a bit, which proved to be bone. The calculus was small, and on June 27th and 30th the phosphatic matter and bone were crushed together. The bony portions are represented in FIGURE 225, from a cut in *The Lancet*, drawn from the originals. The smaller pieces were removed by the lithotrite; the larger was impacted in the urethra, and was removed by forceps. Sir HENRY THOMPSON also narrated the case of W. D—, a lad of 15 years, who had been crushed by a carriage wheel passing over his pelvis four years previously, and had suffered at first from hæmaturia and vesical inertia, and subsequently from the passage of grit and of a bit of bone, on March 6, 1871, and been successfully operated on by lithotomy. In this case, before performing the lateral operation, a fragment of bone was withdrawn by the lithotrite, and the form and dimensions of the concretion were accurately determined. The bone-fragment and calculus are represented of the size of

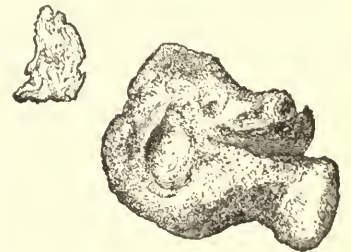


FIG. 226.—Calculus formed about a nucleus of bone. (After THOMPSON.) †



Dr. W. C. Livingston, in August, 1865, removed a large oval calculus having a bone splinter as its nucleus, and two encrusted bone fragments, from a soldier who had received a shot perforation of the bladder fifteen months previously:

CASE 805.—Sergeant George E. Shafford, Co. G, 83d New York, aged 24 years, was wounded at the Wilderness, May 6, 1864, and made a prisoner. He was admitted to the Annapolis General Hospital, September 26, 1864, from the flag of truce steamer New York. Surgeon B. A. Vanderkief, U. S. V., records a "shot wound of the right groin, and diarrhoea." He suffered greatly with vesical irritation. He was transferred to Co. B, 97th New York, and discharged January 6, 1865, and pensioned. He returned to his home in New York, and, on August 6, 1865, consulted Dr. W. C. Livingston, who learned from the sergeant that the missile, supposed to be a minié musket ball, had entered at the right inguinal ring, passed through the bladder, and emerged at the middle of the sacrum. Urine dribbled constantly from the anterior wound. He lay under canvas until June 10th, when he was sent to hospital at Lynnhburg, under the care of Assistant Surgeon H. C. Chalmers, P. A. C. S. About July 1st, urine began to pass by the urethra. By the middle of September, both openings had closed. Soon afterward he began to experience symptoms of calculus. On August 18th, Dr. Livingston, assisted by Dr. Markoe and others, performed the median operation for lithotomy, and removed an oval calculus and two fragments of bone encrusted with calcareous matter. In the course of ten days the urine passed entirely by the urethra, and the patient made a rapid recovery. The fragments of bone were probably chipped off from the pubis, in which a notch could be felt. On sawing the oval calculus, the nucleus was found to consist of a fragment of bone.<sup>1</sup> The Pension Examining Board of New York refer to a feature of the case unmentioned in the other reports, a stercoral fistula, from wound of the rectum. A report dated April 6, 1870, states: "Ball entered just below Poupert's ligament on the right side, passed through the bladder and rectum, and emerged three inches above the anus. In consequence of foreign material remaining in the bladder, vesical calculus formed, which has been removed by median operation. A complete fecal fistula remains. Disability total, third grade, and permanent. He also has a reducible indirect inguinal hernia, of which we are unable to state the origin." This pensioner was last paid June 6, 1873.

nature in FIGURE 225, copied from a cut in *The Lancet*. The concretion consists of a bone nucleus largely encrusted by phosphates. After relating these cases, Sir HENRY THOMPSON refers to preparation H, a, 11, of Section VIII, in the Museum of the Royal College of Surgeons, a large phosphatic calculus removed by ALLAWAY from the bladder of a woman, having a piece of bone in the centre, and to *Specimen*



FIG. 227.—Ammonio-magnesian phosphatic calculus formed about a splinter of bone. [After HENNEN.]  $\frac{1}{2}$ .

5041 of the Army Medical Museum, at Washington, as the only additional recorded examples of vesical calculus with a nucleus of bone. On the presentation to the New York Pathological Society, January 25, 1866, by Dr. LIVINGSTON, of the concretion from Sergeant Shafford's case, a phosphatic calculus with a nucleus of bone, it is reported (*The Medical Record*, 1866-67, Vol. I, p. 186) that "Dr. LIDELL remarked that the case, so far as his knowledge extended, was a unique one." And "Dr. HAMILTON stated that a number of cases were reported in which balls found an entrance into the bladder and lodged; but he had never heard of an instance in which fragments of bone had been driven into the organ in the manner described by Dr. LIVINGSTON. It is surprising that there did not occur to these teachers either the case of shot wound of the bladder in which Staff-Surgeon DEASE removed calculi having splinters of bone for nuclei (HENNEN'S *Principles of Military Surgery*, 1829, 3d ed., p. 432), and the concretion represented of the size of nature in the fifth figure of PLATE III, in the edition of 1820 of Hennen's work, and copied in the adjacent wood-cut (FIG. 227), or the two more recent instances recorded by LEROY D'ÉTHOLLES, or several others recorded in the annals of surgery.

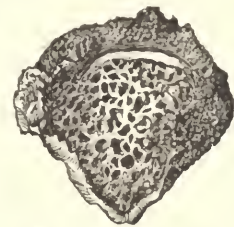


FIG. 228.—Cut surface of a calculus with porous bone for a nucleus. Weight 434 grs. [After NEUDÖRFER.]  $\frac{1}{2}$ .

M. LEROY (*L'Union Médicale*, 1853, T. VII, p. 412) cites the cases: "De deux blessés de février et de juin, 1848, dont le bassin fut traversé par des balles qui détachèrent et poussèrent dans la vessie des esquilles d'os, lesquelles devinrent des noyaux de pierre. M. LEROY céra les concrétions calculeuses et coupa les portions d'os avec un instrument décrit page 251 de son *Recueil de mémoires*." M. H. LAUREY (*Rapport sur les plaies de la vessie*, in *Mém. de la Soc. de Chir.*, 1851, T. I, p. 369) states that his illustrious father, after the siege of Acre, operated on an officer who had received a shot perforation of the bladder and rectum, and successfully removed a calculus formed about a fragment of the pubic bone. Professor P. F. EVE (*Southern Med. and Surg. Journal*, 1846, Vol. II, p. 587) records an operation for lithotomy on a negro, and the removal from the bladder of a piece of bone three-fourths of an inch square, coated with deposits of uric acid. BERTHERAND (*Campagnes de Kabylie*, 1862, p. 111) relates the case of B——, 1st Zouaves, shot through the bladder, June 19, 1854, at Taourirt, by a ball, which entered the upper part of the left thigh near the crural arch, and made its exit through the right buttock. There was copious bleeding by the urethra and by the posterior wound. The patient was sent to the Dey Hospital at Algiers, and slowly convalesced, a urinary fistula persisting anteriorly. In November, 1854, a calculus was extracted through the fistula. It was bean-shaped, and consisted of a small splinter of bone, encrusted with concentric layers of phosphate and carbonate of lime. After its passage the fistula closed, and the soldier recovered perfectly. A case recorded by Dr. NEUDÖRFER (*Handbuch der Kriegschirurgie*, Leipzig, 1867, p. 811), the concretion being figured above (FIG. 228), was published since the remarks by Drs. LIDELL and HAMILTON on Dr. LIVINGSTON'S operation. It is that of Franz Scharowitz, 21st Infantry, wounded at Skalitz. The concretion, formed about a porous fragment of bone, was removed at a garrison hospital at Vienna, June 23, 1866, by Herr NEUDÖRFER, by lateral lithotomy. This soldier made a rapid recovery. Dr. B. B. LEONARD (*Cincinnati Lancet and Observer*, 1871, Vol. XIV, p. 520) relates the case of F. Hines, aged 8 years, who underwent supra-pubic lithotomy in April, 1871. A calculus weighing three and a half ounces was removed from the bladder, with a piece of bone as a nucleus; a speedy recovery ensued. PODRAZKI (*Wiener Medizinische Wochenschrift*, 1865, S. 1765-1780) records the case of an Austrian officer, Lieutenant P. A——, wounded at Solferino, June 24, 1859, by a ball, which entered through the left buttock and perforated the rectum and bladder. Urine escaped from the wound and the rectum. The ball could not be found. The wound healed in four weeks; but on March 20, 1862, the patient was admitted to Professor VON PITHA'S clinic with symptoms of calculus. ALLARTON'S operation was successfully performed with the expectation of finding a ball, but instead a heavily encrusted, rough-surfaced piece of bone about one inch in diameter was removed. Notwithstanding an attack of pleuritis, the patient recovered, completely in seven weeks. Professor GROSS (*Elements of Pathological Anatomy*, 1845, p. 721) has in his cabinet a calculus presented by Dr. JETTOS, of Summer County, Tennessee, containing three of the caudal vertebrae of a squirrel. The concretion was removed from the bladder of a man of thirty-five, addicted to nefarious practices. In the eighth and ninth examples in the antecedent note (p. 269) on calculi formed about bullets, cases of operations by CLINE and LARREY, portions of bone were included in the concretions. Specimen 2136, Section IV, in the Edinburgh Museum, is a vesical calculus having a nucleus of bone, from a case of shot wound of the pelvis (*Cut.*, 1836). The concretion was presented by Dr. JOHN THOMSON. TULLIUS (*Obs. med.*, Leyden, 1716, p. 323) tells of a shot wound of the bladder that cicatrized; but difficulty of micturition ensued, which was ascribed to a calculus. After death, a large fragment of the os pubis and three calculi were found in the bladder. Two other examples are noted further on.

<sup>1</sup>The later history of this case is reported by Dr. W. C. LIVINGSTON in the *Proceedings of the New York Pathological Society*, January 25, 1866; in the *Medical Record*, 1867, Vol. I, p. 185. The case is referred to, also, in Dr. T. M. MARKOE'S article in the *New York Med. Jour.*, 1867, Vol. V, p. 30, *Obs.* XVI.—in Dr. F. H. HAMILTON'S *Principles and Practice of Surgery*, 1872, p. 118.

Dr. C. Terry, of Columbus, Georgia, has recorded<sup>1</sup> a case of successful lithotomy for the removal of calculi formed about splinters of the sacrum, driven into the bladder of a soldier, by a shot perforation of the pelvis, seven months prior to the operation:

CASE 806.—[This abstract is condensed from the detailed account printed by Dr. Terry.] Private *J. A. Miller*, Co. E, 39th Alabama, was wounded near Atlanta, July 28, 1864. A conical musket ball perforated the sacrum near the left sacro-iliac junction, passed through the bladder, and made its exit through the horizontal ramus of the right pubis. He was treated at a hospital at Atlanta for a fortnight, and entered Walker Hospital, Columbus, September 5, 1864. The anterior wound had healed. The urine passed partially by the posterior wound. Abscesses formed on the right side of the scrotum, and there was sloughing, ascribed to injury of the spermatic vessels. Several small bits of bone and calcareous concretions passed by the urethra. The posterior wound remained open, and pieces of bone were discharged through it. There was much pain in the pelvis, and suffering during micturition. Three months after the reception of the injury, Dr. Terry was induced to explore the urinary canal with a sound. A grating sensation was felt, and an operation was determined on. March 3, 1865, a straight staff was passed down to the membranous portion of the urethra, when a piece of bone an inch and a half long, covered with calcareous matter, was found lying transversely embedded in the muscles. This fragment being removed, the canal, much deflected and adherent to the pelvis, was traced to the prostate, which was sufficiently incised to admit the passage of the finger into the bladder, and several more pieces of bone encrusted with calcareous matter were removed. A concretion the size of a filbert was found encysted, and this also was removed. The bladder was then thoroughly washed out. The calcareous matter was very soft, and much detritus was washed away. It was thought the fragments removed would fill the palm of the hand. The patient improved for a month, then calcareous matter and necrosed bits of bone were discharged by the urethra, and there was great vesical irritation. The hospital being broken up on the cessation of hostilities, the patient went to his home. On June 29, 1865, Dr. Terry visited him and performed lithotomy by the lateral method, and removed several small pieces of bone and three calculi. One was of the size of the egg of the guinea-fowl, the other two of the size of a hickory-nut. Mr. W. J. Land, chemist, analyzed them, and found them to consist almost entirely of phosphate of lime, with slight traces of oxalate, deposited upon small nuclei of bone. The patient rapidly recovered, but a perineal fistula remained. This was treated by catheterization and cauterization, and after eighteen months it closed, without contraction of the canal of the urethra. On April



FIG. 229.—Calculus formed about a nucleus of bone. *Spec.* 6327.  $\frac{1}{4}$ .

26, 1866, the patient had regained control of the bladder and was pronounced well. [Since the foregoing abstract was placed in print, Dr. C. Terry has had the great kindness to transmit the further history of this case, and to donate the only one of the four calculi remaining in his possession to the Army Medical Museum. A section of it is represented in the adjacent woodcut (FIG. 229). It is an oval calculus, an inch in the largest, and nine and thirteen-sixteenths of an inch, respectively, in the transverse diameters, and consists of a uniform deposit of ammoniaco-magnesian phosphates about a splinter of compact bone half an inch long. "I regret exceedingly, Dr. Terry writes, that I am able to send you but a very small specimen of the calculi removed from Miller. After his complete recovery, he was in Columbus, and begged for the large calculus removed at the first operation, wishing to preserve it as a memento of his war history. I gave it to him, with a phial full of small pieces, and a splinter of bone on which a concretion was deposited. The largest piece (FIG. 229) is the remains of the largest calculus extracted at that operation. It has stood for six or seven years in a phial on a shelf in my office, and has been inquired for so frequently, and shaken about in the bottle, that the outer soft layers have crumbled away. I now regret exceedingly that I did not preserve it more carefully, for it will hardly serve your purpose for adequate pictorial representation, though it may serve to show you the character of the deposit. The after history of the case may interest you: Miller remained for about two years without virility, when this function rapidly returned, and he married, and informed me that he had no difficulty in his conjugal relations. He married a widow with two children; but, after two years, has had no issue. Eighteen months since I saw him in excellent health, weighing one hundred and eighty pounds.]

FIGURE 2 of PLATE VIII represents the large calculus formed about a splinter from the left pubis, successfully removed, by Dr. H. McGuire, from the bladder of a soldier, three years and four months subsequent to a shot perforation of the organ. The details of the case have been already published;<sup>2</sup> the principal facts are as follows:

CASE 807.—Private *M. C. H.*—, — Virginia, aged 23 years, was wounded at the engagement at McDowell, May 8, 1862. A musket ball, striking the horizontal ramus of the left pubis, perforated the bladder and rectum, and emerged through the right ischiatic notch. He was sent to Staunton, and remained in the general hospital there four months. Urine mixed with blood and pus passed through both entrance and exit wounds; feces often escaped through the posterior wound. During the third week several bone fragments were discharged in defecation. In thirty-five days the exit wound closed, and urine was voided by the urethra. Urine continued to be partly discharged by the anterior wound, but this orifice gradually closed. In September, 1862, he was able to get about on crutches. In September, 1865, he applied to Dr. H. McGuire with symptoms of stone in the bladder. A sound revealed the presence of a large calculus (*Spec.* 5041). Lateral lithotomy was performed. The stone was found adherent to the cicatrix in the posterior wall of the bladder. After its removal the patient rapidly regained his usual health, without an untoward symptom.

<sup>1</sup> TERRY (C.), *Remarkable Case of Gunshot Wound of the Bladder, requiring two Operations of Lithotomy*, in the *Richmond Medical Journal*, 1866, Vol. II, p. 169.

<sup>2</sup> MCGUIRE (H.), *Gunshot Wound of the Bladder and Rectum, and subsequent operation for Stone in the Bladder*, in *Proc. of Richmond Acad. of Med.*, in *Richmond Med. Jour.*, 1868, Vol. V, p. 279. Compare also Circular No. 3, S. G. O., 1871, p. 258, CASE DCCII, and *London Lancet*, 1872, Vol. I, p. 851, *Clinical Remarks on Lithotomy*, by Sir HENRY THOMPSON.



In some cases of cystitis following shot injury of the bladder, and complicated by the penetration of bone splinters into the cavity of the viscus, calculi are formed, but, singularly enough, not upon the bone fragments, but without any foreign substance that can be recognized as having afforded a nucleus about which the concretion has accumulated. Such an instance occurred to Surgeon D. W. Bliss, U. S. V., in the case of Mahay, who died at Armory Square Hospital, fourteen months after the reception of a shot perforation of the bladder, with fracture of the pubis. Bits of necrosed bone had been discharged through the urethra. At the autopsy, two large phosphatic calculi of homogeneous composition were found in the bladder. They are represented in the first figure of PLATE VIII, and the particulars of the case will be found in the series of the fatal shot perforations of the bladder. Surgeon J. J. Chisolm, C. S. A., also had a case of this description, in which he successfully performed lithotomy, and had the kindness to present a section of the calculus<sup>1</sup> to the Army Medical Museum. Dr. Chisolm has detailed the case in his excellent manual.<sup>2</sup> The concretion is shown in FIG. 3 of PLATE VIII.

CASE 808.—Private *R. S. Moore*, Co. E, Palmetto Sharpshooters, was wounded at Frazer's Farm, June 29, 1862. The ball notched the crest of the right pubic bone and escaped through the right buttock. Urine escaped through both orifices, none by the urethra. The exit wound closed in a few weeks; the entrance wound was maintained as a urinary fistula until the date of operation in May, 1863. During this period bits of bone and calculous matter were discharged through the urethra. In December, 1862, symptoms of stone. The communication of the fistula with the bladder was very direct. With some difficulty Dr. Chisolm removed an encysted calculus, formed about a pasty nucleus, with no trace of a foreign body (*Spec.* 4712). The abdominal sinus healed promptly after the operation, and the patient rapidly recovered.

As there is no mention of a foreign nucleus in the following case, it may be inferred that none was observed:

CASE 809.—This case is fully reported<sup>3</sup> by the operator, Dr. R. L. Madison, in the *Richmond Medical Journal*. The leading facts are as follows: "Sergeant *S. F. P.*—, Co. C, 1st Virginia Cavalry, aged 25 years, was wounded at Front Royal, August 16, 1864. A ball entered above the left trochanter major, perforated the ischium and bladder, and lodged subcutaneously on the anterior surface of the right thigh. It was removed through an incision by Surgeon Owen. Urine passed through the wound. At the expiration of a fortnight, Dr. Dorsey introduced and maintained a catheter in the bladder. In February, 1865, the patient was convalescent from his wound, but symptoms of calculous disorder had appeared. On May 19th, Surgeon R. L. Madison performed bilateral lithotomy and removed a soft calculus, which was crushed in extraction. The patient made a good recovery." The concretion is described as large and friable.

The following instance of successful lithotomy, by Dr. Benjamin W. Robinson, for the removal of calculi consequent on a shot wound of the bladder, belongs either to this category or to that embracing calculi with nuclei of bone. The concretions are stated to have been composed of phosphate of lime. The abstract is abridged from a report by Dr. Fessenden:<sup>4</sup>

CASE 810.—Private *John W. Gardener*, Co. F, 24th North Carolina, aged 25 years, was wounded at the battle of Fredericksburg, December 13, 1862. A conoidal musket ball entered just above the pubis and passed out through the body of the ischium. He was sent to a hospital at Richmond, and, a week subsequently, was sent to his home in Cumberland County, North Carolina. He was admitted to the Fayetteville Hospital, November 1, 1863. Urine passed through the orifices of entrance and exit; there were bed-sores, with extreme emaciation, debility, and pain. With careful treatment the general condition

<sup>1</sup> The specimen is one-half of a nearly globular vesical calculus an inch in diameter. It weighs fifty grains Troy; the original weight of the entire calculus is unknown. Its exterior is of a slightly reddish gray, soft, porous, and granular. It is seen to be composed of a homogeneous structureless mass, presenting to one side of the centre a comparatively large irregular cavity, which was originally filled with a soft pasty mass forming the nucleus of the calculus. It is of a muddy gray color, soft, granular, porous, and structureless throughout. A small quantity of the dust from the calculus heated on platinum blackened and cleared up with some loss, and dissolved in hydrochloric acid without effervescence; the solution neutralized with ammonia and treated with oxalate of ammonia gave no precipitate. A fresh portion was soluble in boiling water to the extent of about one-third of the quantity used; the residue was insoluble in liquor ammonia, but readily dissolved on acetic acid, from which it was precipitated by ammonia as a gelatinous deposit containing numerous crystals of triple phosphate. The solution in boiling water gave a deposit on cooling; boiled with liquor potassæ it gave off ammoniacal vapors; treated with hydrochloric acid it gave a precipitate which, under the microscope, was found to consist of crystals of uric acid. It may be inferred that about two-thirds of the calculus consisted of triple phosphate, and one-third of urate of ammonium.

<sup>2</sup> CHISOLM (J. J.), *A Manual of Military Surgery*, 3d ed., 1864, p. 352.

<sup>3</sup> Report of a Case of Gunshot Wound of Bladder, with Recovery, followed by Calculus—Its successful Removal by Lithotomy. By R. L. MADISON, M. D., late Surgeon Virginia Military Institute,—in the *Richmond Med. Jour.*, 1866, Vol. II, p. 487.

<sup>4</sup> FESSENDEN (B. F.), *Report of Surgical Cases in General Hospital, Fayetteville, North Carolina, in the Confederate States Medical and Surgical Journal*, 1864, Vol. I, p. 115.



improved until, on November 10th, it was deemed prudent to explore the bladder, when the instrument came in contact with a calculus with a sharp, clear, very audible sound. The urine gave a white deposit, which was found, on analysis, to consist of phosphate of lime. The patient was put on a course of tonics, with mineral acids and a moderate allowance of stimulants. On February 13, 1864, Dr. B. W. Robinson, in the presence of Drs. Haigh, McRae, and others, practiced bilateral lithotomy, using Dupuytren's lithotome, and four calculi were successively and readily extracted. The largest weighed an ounce; the aggregate weight of the four was two and seven-sixteenths Troy ounces. The operation was followed by the happiest results. The wound of operation and the entrance wound soon healed. May 2, 1864, convalescence was so far established that the patient, greatly improved in health, was able to walk about. There was a slight fistula at the exit orifice, but no urine passed through it, and health and strength were in a great measure restored. [In a letter to the editor, dated Fayetteville, December 3, 1873, Dr. B. W. Robinson says: "I regret my inability to send you the calculi taken from *Gardener*. My office was sacked about the close of the war, and these and many other treasured objects were scattered and destroyed. The subject of the operation, who lives not very far from here, is a hale, hearty man. He has married since, and has several children."]

Bits of clothing driven into the bladder were ordinarily eliminated by the urethra or by the wound-canal; but in one instance, occurring in the practice of Surgeon D. W. Bliss, U. S. V., a foreign body of this description became the nucleus of a calculus.<sup>1</sup> This concretion is represented by FIGURE 4 of PLATE VIII. The facts of the case, as compiled from the reports of nine surgeons,<sup>2</sup> are as follows:

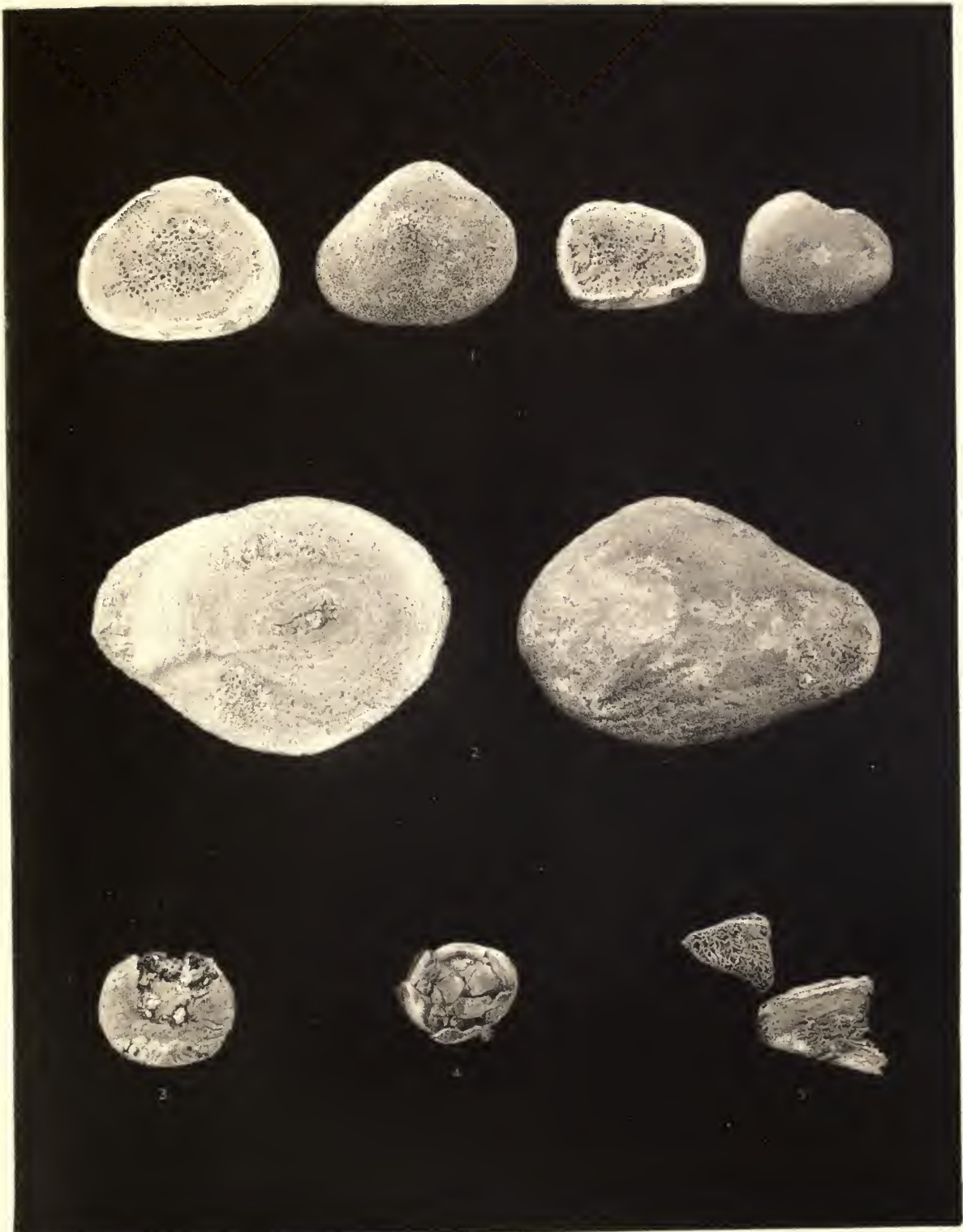
CASE 811.—Private Sherman E. Perry, Co. K, 16th New York, aged 27 years, was wounded near Salem Church, in General Sedgwick's advance at the battle of Chancellorsville, May 3, 1863, and made a prisoner. A conical ball penetrating his canteen, entered the groin, and, passing backward and to the right, made its exit at the right lesser sciatic notch, lodging under the skin. His body was inclined forward when he was struck, and he fell to the ground on receiving the wound, and believes that there was copious bleeding. He soon rose and walked forty rods to a small house. On May 7th, the ball was extracted by one of the medical officers of the 121st New York, who was also a prisoner, and who continued in attendance until May 12th, when Perry was taken with others to United States Ford, paroled, and delivered to the provost marshal, and placed under the care of Surgeon L. W. Oakley, 2d New Jersey, at the Sixth Corps hospital at Potomac Creek, who reported that no urine was passed by the urethra for eight days, but that blood and urine passed freely through the wound. Surgeon H. Janes, U. S. V., remarked that "the ball entered the left groin,<sup>3</sup> passed through the bladder, and emerged through the right sciatic notch," and that "the urine passed through the anterior wound till May 29th, through a catheter kept in the bladder." At the end of May, Dr. Janes reports that "the wound is now healing." On June 13th, the patient was sent to Washington on a hospital transport steamer, and entered Army Square Hospital the same day. Surgeon D. W. Bliss, U. S. V., reported that "the wound had nearly healed. A flexible catheter was constantly retained in the bladder for about four weeks previous to his admission, and continued for three or four days afterward, about which time, on withdrawing the catheter, a piece of blue cloth immediately followed, which was rolled upon itself, and was being very nicely encrusted with fine sand, serving as a nucleus for the formation of a stone. On June 21st, and after the introduction of a catheter, a small flat piece of bone passed through the urethra. It was well known that something yet remained in the bladder from the fact of his having pain and difficulty in urinating, and at times the urine would suddenly cease to flow; which condition of things continued until July 21st, when he experienced unusual pain in attempting to urinate, and the cause soon became apparent in the shape of a stone, measuring about three-fourths of an inch long and half an inch in diameter, which resembled a peanut more than anything else in size, shape, and color. He suffered very severe pain during its passage to the fossa navicularis, from which place it was extracted with a small forceps." On September 9th, the evidence of further deposits in the bladder being conclusive, and giving the patient trouble, Dr. D. W. Bliss, surgeon in charge, performed the lateral operation for stone and removed a soft calculus of a flat oval shape, three-fourths of an inch long, one-half inch wide, and one-fourth inch thick, the nucleus of which seemed to be cloth.<sup>4</sup> Weight, twenty-three grains. "September 19th: The patient has done well up to date." On October 28th, the patient was transferred to New York, and admitted to DeCamp Hospital. Assistant Surgeon J. Sim Smith, U. S. A., reports him convalescent from a shot wound of the bladder, and furloughed October 31st. Acting Assistant Surgeon Mason F. Cogswell reported Perry as admitted to the post hospital at Albany, November 3, 1863, with a "gunshot flesh wound of the abdomen," and as

<sup>1</sup> Examples of calculi formed about cloth or textile fabrics are extremely rare; 1. NICOLAS TULPIUS (*Obs. med.*, 1716, Lib. III, Cap. IX, p. 195) relates the case of a West Indian youth, who had been gored by a buffalo in the hypogastric region, with lesion of the bladder. The wound healed, but calculous symptoms supervened and lithotomy was performed, and a stone removed having as a nucleus a piece of lint, a part of a tent used in dressing the lacerated wound. 2. HUTIN (*Mém. sur la nécessité d'extraire les corps étrangers*, 1851, p. 16, Obs. IV) relates the case of Marsat, shot, in 1808, above the right pubis, the ball perforating the bladder and emerging at the left buttock. Urine passed at first through both wounds, which afterward gradually closed. In 1827, PASQUIER, aided by YVAN, practiced lithotomy and removed three calculi, each with a piece of cloth as a nucleus.

<sup>2</sup> Portions of the history of this case have been published by W. H. BUTLER, M. D. (*Buffalo Med. and Surg. Jour.*, 1864, Vol. III, p. 459), and republished by H. A. ROBBINS, M. D. (*Am. Jour. Med. Sci.*, 1868, Vol. LV, p. 124).

<sup>3</sup> Surgeon H. JANES, U. S. V., and Pension Examiners T. B. SMITH, H. C. BATES, and S. L. PARMELEE state that the ball entered the *left* groin, which is, doubtless, true (see *Cat. Surg. Sect.*, A. M. M., 1866, p. 493). Acting Assistant Surgeons W. H. BUTLER and H. A. ROBBINS describe the entrance orifice as on the *right* side. Drs. BLISS, J. S. SMITH, and M. F. COGSWELL do not specify the point of entrance.

<sup>4</sup> This specimen consists of a flattened ovoid vesical calculus measuring  $\frac{1}{16} \times \frac{1}{16} \times \frac{3}{16}$  inches and weighing 23 grains Troy. Its exterior is of a light reddish gray color, compact, and smooth, but extremely soft and granular. It has been broken open and is seen to be composed of a nucleus and one coat. The nucleus comprises about one half of the whole calculus, and is composed of matted cotton cloth mixed with crystals of triple phosphate. (*McC. Spec.* No. 161, S. S.) The coat of the nucleus is made up of numerous concentric laminae, and is very friable. It agrees with the description of the exterior in physical characters. A small quantity heated on platinum blackened but cleared up with little loss, and dissolved in hydrochloric acid without effervescence. The solution nearly neutralized by ammonia, and heated with oxalate of ammonia, gave no precipitate. Under the blowpipe it is infusible. A fresh portion was insoluble in boiling water and liquor ammonia, but was entirely soluble in acetic acid, from which it was precipitated by ammonia as a gelatinous deposit containing numerous crystals of triple phosphate.—(*McC. Spec.* 162, S. S.) (*Spec.* 1687, *Surg. Lect.*)



Ward, 1864

J. Brien, 1864

VESICAL CALCULI REMOVED AFTER SHOT WOUNDS.

Fig. 1. Surg. D. W. Bliss's Case (Spec. 2567)

Fig. 3. Prof. J. J. Chisolm's Case (Spec. 4624)

Fig. 2. Dr. H. M. Graves's Case (Spec. 5011)

Fig. 4. Dr. D. W. Bliss's Case (Spec. 3633)

Fig. 5. Dr. R. F. Weens's Case (Spec. 6211)





“discharged from service January 22, 1864.” This soldier was pensioned. Examiner J. B. Smith, of Washington, reported, April 2, 1834: “Ball entered above left pubis, perforated the bladder and pelvis, and passed out of the right buttock. Operation for stone in the bladder was done, and the nucleus found to be a portion of dress carried thither by the ball. He has now lameness of the right lower limb and incontinence of urine. General health good; disability two-thirds; will probably improve.” Examiner C. C. Bates, of Potsdam, reported, September 12, 1865: \* \* \* “There is lameness in the back, extending down the left thigh as far as the knee; the left thigh has a palsied feeling. He has never been free from a burning pain extending from the scar in the left groin into the bladder; hips are very weak; the bodily health otherwise pretty good.” The same examiner reported, November 29, 1869, that this pensioner “suffers severe pains, every two or three weeks, in the abdomen, and excessively severe in the bladder and urethra, extending to other parts while passing water. There is always much trouble in urinating, and during these exacerbations he can neither lie, sit, nor stand still. He has used *uva ursi* infusion every day during the past year, consuming nearly five pounds of the leaves. His urine leaves always a whitish sediment, and sometimes contains pure blood. All these symptoms have increased since his discharge. The disease is permanent. \* \* \* He works a little at the carpenter’s trade. \* \* \* The paroxysms last several days.” On September 10, 1872, the same examiner reports that this pensioner “has chronic *cy-titis*, following gunshot wound of the bladder. Frequently the pain in making water becomes intense and burning. \* \* \* The kidneys are now diseased. \* \* \* The pensioner’s habits are correct.” On September 5, 1873, Examiner S. L. Parmelee, of Gouverneur, after describing the wound and operation, adds that this pensioner “still has symptoms of stone; occasionally passes blood; a good deal of sediment in the urine; also tenderness of the abdominal scar, and of the inside of the thigh. His disability continues total.”

In one instance, recorded<sup>1</sup> by Dr. Thomas M. Markoe, in his important paper on *Median Lithotomy*, a tuft of curly hair, carried from the right pubic region into the bladder by a ball, formed a nucleus of a calculus, the ball itself passing through and emerging at the left sciatic notch. The following is Dr. Markoe’s interesting narrative of the case:

CASE 812.—“Henry Smith, a German, aged 30 years, was admitted to the New York Hospital about the middle of August, 1833, with some symptoms on the part of the bladder, which had followed a wound of that organ, received August 9, 1862, at the battle of Cedar Mountain. The ball had entered in front, a little to the right of the median line, about an inch above the pubes, passing through the part of skin covered with hair. It passed nearly through the body, and was cut out behind over the left sciatic notch, through which it had probably taken its course. For a week, urine flowed out through both wounds, but, after a long course of tedious suffering, the opening gradually healed, and has since remained soundly cicatrized. Owing to some difficulty in passing water, which the patient cannot explain, the catheter was employed daily during ten months. The act of micturition continued to be painful, with great irritability of the bladder, and, in fact, all the symptoms of stone gradually developed themselves. On admission, his general condition was feeble and irritable, with great distress in the region of the bladder, urine dark colored and containing a good deal of pus. A sound immediately detected the presence of a calculus, apparently of large size. The median operation of lithotomy was performed on the 25th of August. The incision was carried well back and made quite free, under the conviction that the stone was of considerable size. The prostate was easily dilated and the forceps readily seized the stone, but, unfortunately, in attempting to extract it, it broke, and the numerous fragments required frequent introduction of the instrument for their complete removal. By care and patience, however, the bladder was entirely cleared, and well washed out by a stream of warm water. The hemorrhage was quite insignificant. August 26th, has been very comfortable, and has had some good sleep. His urine did not flow for about three hours after the operation, and then, by a voluntary effort, he passed several ounces through the wound. Since then it has dribbled away most of the time, though he has partial control of it. August 28th, can hold his water four hours without inconvenience. There is now no dribbling from the wound. When he wishes to pass water, a large portion of it comes through the urethra. From this time his progress was not interrupted by a single bad symptom. The water all passed by the urethra at the end of a week. The wound healed rapidly, and he was discharged, cured, about the end of September. The stone was found to have for a nucleus a tuft of curly hair of the pubes, which had been carried into the bladder by the ball and there left, while the ball itself passed through.”

In the twenty-one foregoing lithotomy operations, seventeen were successful, three fatal, and, in one, the result has not transpired. Of thirteen cases in which missiles were removed, there were ten in which these were leaden bullets, three of the round, and seven of the conical variety; six of the ten balls were very slightly encrusted, while four formed the nuclei of large stones. In three cases the projectiles were of iron, a canister-shot, a grenade fragment, and an arrow-head, all coated with thick calcareous depositions. In eight cases, in which bone, cloth, hair, or soft organic matters had constituted the nuclei, the calculi were of medium or large dimensions, and commonly very friable. In six cases of this last series, of what may be termed traumatic calculi, there were no obvious contra-indications to lithotripsy. In all of the encrustations and concretions the ammoniaco-magnesian phosphate prevailed, and several were almost exclusively composed of this triple salt; in others, phosphate of lime, urates, and organic matters were present.

<sup>1</sup> MARKOE (T. M.), *Median Lithotomy*, in *New York Med. Jour.*, 1867, Vol. V, p. 23.

in limited proportions. The remark of Marcet,<sup>1</sup> that vesical concretions of this sort are uniformly of the *fusible* species—composed, that is, of nearly equal proportions of phosphate of lime and of the triple phosphate of ammonia and of magnesia—is not sustained by my observations, which rather tend to show that, in such concretions, the bone-phosphate is often altogether absent, and that the triple phosphate uniformly predominates. It may subserve the convenience of the reader to have the dates and principal circumstances of these operations in a tabular form.

TABLE VIII.

*Descriptive Numerical Statement of Twenty-one Cases of Lithotomy for the Extraction of Projectiles or Traumatic Vesical Calculi.*

No.	DATE OF—		PATIENT.	OPERATOR.	INJURY.	OPERATION.	RESULT.	AUTHORITY.
	Injury.	Operation.						
1	Sept. 17, 1862	Sept. 25, 1862	Lieut. W. Palmer, E. 35th Mass.	Dr. G. M. McGill, A. S.	Shot wound over left pubis.	Supra-pubic.	Died Oct. 13, 1862.	S. G. O. Records.
2	Oct. 4, 1862	About Nov. 20, 1862	Unknown soldier.	Dr. Felton.....	Shot wound above right pubis.	Supra-pubic.	Died 24 hrs after op.	WALLIS, in <i>Nash. Med. Jour.</i> , 1867, 11, p. 562.
3	July 2, 1863	April 12, 1866	Priv. T. Lindsay, P. 69th Penn.	Dr. J. L. Forwood	Shot wound of pelvis..	Lateral.....	Recovery ..	Circ. 3, S. G. O., 1871, p. 259.
4	Mar. 31, 1865	April 16, 1870	Priv. T. S. Mason, 198th Penn.	Dr. J. L. Forwood	Shot wound through pubic arch.	Lateral.....	Recovery ..	<i>Ibid.</i> , p. 261.
5	In April, 1864	Feb. 22, 1868	J. Mitchell.....	Prof. J. C. Hughes	Shot w'd of sacro-iliac junction.	Bilateral....	Recovery ..	<i>Iowa Med. Jour.</i> , 1869, V, p. 98.
6	June 25, 1863	April 2, 1864	Priv. C. Lotes, A, 23d Ind.	Surg. J. F. Randolph.	Shot wound at end of coccyx.	Lateral.....	Recovery ..	<i>Am. Jour. Med. Sci.</i> , 1864, p. 271.
7	April 2, 1865	Aug. 31, 1868	Priv. W. Cockroft, D. 199th Penn.	Dr. A. N. Dougherty.	Shot w'd over pubes ..	Lateral.....	Recovery ..	Circ. 3, S. G. O., 1871, p. 259.
8	July 2, 1863	Nov. 25, 1871	Priv. F. H. McIntosh, A, 1st Mass. Col. A. C. Voris, 67th Ohio.	Dr. Samuel Cabot	Shot wound of pelvis..	Lateral.....	Recovery ..	<i>Boston Med. and Surg. Jour.</i> , 1872, p. 169.
9	July 18, 1863	..... 1873	.....	Dr. S. W. Hamilton	Shot w'd in left groin..	( )	( )	<i>Akron Beacon.</i>
10	Aug. 30, 1862	Aug. 3, 1867	Priv. G. L. Strimp, Palmetto SS.	Prof. F. T. Miles	Shot w'd left of spine..	Lateral.....	Recovery ..	Operator's report.
11	May 5, 1864	June 1, 1873	J. J. Canady.....	Dr. J. F. King...	Shot w'd thro' left ilium	Lateral.....	Recovery ..	S. G. O. Records.
12	In 1867	Dec. 3, 1870	John Ely.....	Prof. H. McGuire	Shot w'd near right trochanter.	Lateral.....	Recovery ..	<i>Virg. Clin. Rec.</i> , 1871, p. 46.
13	In 1862	Aug. 23, 1869	Sitamora, a Kiowa	Dr. W. H. Forwood, A. S.	Arrow w'd thro' right buttock.	Lateral.....	Died Sept. 19, 1869.	Circ. 3, S. G. O., 1871, p. 260.
14	May 4, 1864	Aug. 18, 1865	Sergt. G. E. Shafford, G. 83d N. Y.	Dr. W. C. Livingston.	Shot w'd of right groin	Median.....	Recovery ..	<i>Med. Rec.</i> , 1867, p. 185.
15	July 28, 1864	June 29, 1865	Priv. J. A. M——, E. 39th Ala.	Dr. C. Terry.....	Shot perf. of sacrum...	Lateral.....	Recovery ..	<i>Richmond Med. Jour.</i> , 1866, p. 169.
16	May 8, 1862	Sept., 1865	Priv. M. C. H——	Prof. H. McGuire	Shot w'd of left pubis..	Lateral.....	Recovery ..	<i>Richmond Med. Jour.</i> , 1868, p. 279.
17	June 29, 1862	May, 1863	Priv. R. S. Moore, E. Palmetto SS.	Dr. J. J. Chisolm	Shot wound of crest of right pubis.	Supra-pubic.	Recovery ..	<i>CHESOLM, Mon. of Mil. Surg.</i> , p. 352.
18	Aug. 16, 1864	May 19, 1865	Sergt. S. F. P——, C. 1st Va. Cav.	Dr. R. L. Madison	Shot perf. of ischium..	Bilateral.....	Recovery ..	<i>Richmond Med. Jour.</i> , 1866, p. 487.
19	Dec. 13, 1862	Feb. 13, 1864	Priv. J. W. Gardner, F. 24th N. C.	Dr. B. W. Robinson	Shot w'd above pubis.	Bilateral.....	Recovery ..	<i>Conf. States Med. and Surg. J.</i> , 1864, p. 115.
20	May 3, 1863	Sept. 9, 1863	Priv. S. E. Perry, K, 16th N. Y.	Surg. D. W. Bliss	Shot penetration above left pubis.	Lateral.....	Recovery ..	S. G. O. Records.
21	Aug. 9, 1862	Aug. 25, 1863	Henry Smith.....	Dr. T. M. Markoe	Shot penetration above right pubis.	Median.....	Recovery ..	<i>N. Y. Med. Jour.</i> , 1867, p. 23.

In thirteen cases, the concretions are preserved in the Army Medical Museum, as follows: 1-4394; 3-6329; 4-6330; 6-88; 7-5220; 10-5019; 11-6292; 12-6203; 13-5931; 15-6327; 16-5041; 17-4712; 20-1687. The Museum preserves also photographs of the concretions in CASES 5 and 8. In seven instances, conical leaden balls were extracted, forming the nuclei of large phosphatic concretions in CASES 8, 9, and 12, and but slightly encrusted in CASES 1, 3, 4, and 11. In three instances, round leaden balls were extracted, with extensive deposits in CASE 5, and a slight partial coating only in CASES 2 and 10. In three cases, the missiles were of iron, and were all largely encrusted (CASES 6, 7, and 13). In three concretions formed about bone, CASES 14, 15, 16, the phosphatic depositions were large. In the five remaining cases, 17 to 21 inclusive, the concretions were of medium size, varying according to the duration of the calculous symptoms. Three were supra-pubic, twelve lateral, three bilateral, one unspecified, and two median operations.

*Lithotomy for ordinary Vesical Calculi.*—To conclude what is to be said of lithotomy, a digression may be permitted to mention the operations that were reported of the removal of stones of spontaneous or non-traumatic origin. These were but three in number, and only two of them were performed on the persons of soldiers:

CASE 813.—Private Michael Laman, 5th New York Independent Battery, aged 33 years, was admitted to Summit House Hospital, Philadelphia, April 4, 1865, with "calculous and incontinence of urine." Surgeon J. H. Taylor, U. S. V., reports that "on April 24th, the patient was chloroformed and the lateral operation for lithotomy was performed by Acting Assistant Surgeon O. Shittler. A straight scalpel was used in dividing the several tissues and the prostate gland. Three calculi of phosphate of lime, about the size of filberts, were removed. At the time of operation the patient's constitutional condition was good. The after treatment consisted of simple dressings, dilute nitric acid, extra diet, tonics and stimulants." The patient was mustered out on June 27, 1865. Not a pensioner.

<sup>1</sup>MARCEZ, *An Essay on the Chemical History and Medical Treatment of Calculous Disorders*, 1817, p. 75.

In a report on the diseases of the British army in the Spanish Peninsula, Sir James McGrigor remarks on the infrequency of calculous disorders in soldiers,<sup>1</sup> and Hutchinson<sup>2</sup> has treated of the rarity of such affections in seamen; but Yelloly<sup>3</sup> has shown that the tendency of any particular class of persons to be affected with such complaints is exceedingly small, especially during the period of active exertion in adult age.<sup>4</sup>

CASE 814.—Private Joseph Reisinger, Co. L, 8th New York Cavalry, aged 19 years, was admitted to Armory Square Hospital, April 22, 1863, and returned to duty October 26, 1863. In transmitting to the Museum the beautiful specimen of mulberry calculus represented in the wood-cut (FIG. 230), Surgeon D. W. Bliss, U. S. V., gave the following history of the case: "Said Reisinger is a cooper by trade, born in the city of Rochester, New York, and has lived in Rochester and its vicinity until he enlisted in military service, August 30, 1862. He has had slight pain, on urinating, at intervals for the past five years. During these paroxysms he had constant desire to micturate, after which there was severe pain under the glans penis and along the track of the urethra. He was almost entirely free from the above symptoms from March, 1862, to October, 1862, when, on doing duty as a mounted man, he suffered extreme pain at every motion of the horse. Was not excused from duty at any time in consequence of his complaints of urinary trouble. He was taken ill with typhoid fever, January 1, 1863, and was sent to his regimental hospital at Belle Plain, and transferred to hospital at Hope Landing about February 1, 1863. On April 22, 1863, he was transferred to Armory Square Hospital. An examination was instituted on the 22d of June, and a stone detected by means of the sound. On June 29th, lithotomy was performed by the lateral incision, the patient being perfectly anesthetized by the inhalation of chloroform. No untoward symptoms have occurred to the present date, July 3, 1863, the patient expressing himself as 'cured, but a little sore.' The wound rapidly and kindly granulated."

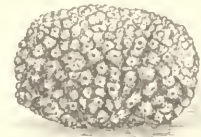


FIG. 230.—Mulberry calculus successfully removed by lithotomy. *Spec. 1334.*

CASE 815.—Surgeon Samuel D. Turney, U. S. V., reports that Peyton, a negro lad, aged 14 years, was admitted into the Murfreesboro' General Hospital, October 5, 1864, with symptoms of vesical calculus. On October 20th, Surgeon Turney performed the lateral operation, and extracted a concretion consisting of mixed phosphates, and weighing one ounce and three drachms. Urine passed by the urethra on November 1, 1864, and November 25, 1864, Peyton was discharged, cured. On November 25, 1873, Dr. Turney transmitted to the Museum a specimen purporting to be the calculus removed on this occasion; but, on examination, it was found to be a pyriform mass consisting of carbonate of lime and sand, possibly a cast of this calculus.<sup>5</sup>

*Other Examples of Shot Wounds of the Bladder.*—Akin to the examples of projectiles within the bladder encrusted with phosphatic deposits, is an instance of a ball, which, after perforating the bladder, lay in a fistulous track, exposed to encrustation by the urinous salts:

CASE 816.—Private T. Winans, Co. B, 28th Illinois, age 22 years, was wounded at the battle of Shiloh, April 6, 1862. Surgeon R. Nicholls, U. S. V., reported that he was "admitted to the hospital at Quincy, May 7, 1862, with a gunshot fracture of the neck of the left femur. The ball entered three inches below and two inches behind the anterior superior spinous process of the left ilium, passed through the bladder, and lodged in the region of the sacrum. Treatment by Buck's method." This man was discharged from service December 6, 1862, with the accompanying remark over an illegible signature: "Hip ankylosed; general health good. About the fracture as above, I have my doubts." The patient receives a pension. On February 6, 1872, Pension Examiner J. H. Ledlie reports, "several pieces of dead bone have been removed. Some months since a tumor presented itself near the anus. This suppurated, and upon opening it a large conical leaden ball was found, *half of which was covered with what appeared to be the salts of the urine.* Urine was freely discharged through the opening for several weeks. At present this is all healed. There is ankylosis of the hip-joint, shortening of the limb one inch and a half, atrophy of the whole limb, and constant pain along the sciatic nerve, which is much increased by walking." Disability is rated total and permanent.

*Extraneous Bodies Escaping by the Urethra.*—It was remarked, on page 268, that several instances were recorded of the elimination of fragments of bone by the urethra,

<sup>1</sup> Compare BALLINGALL (*Outlines of Mil. Surgery*, 5th ed., 1855, p. 359), where Sir J. McGrigor's report is quoted; SMITH (R.) (*A Statistical Inquiry into the Frequency of Stone in the Bladder, in Great Britain and Ireland*, in *Med. Chir. Trans.*, 1821, Vol. XI, p. 1).

<sup>2</sup> HUTCHINSON (A. C.), *On the Comparative Infrequency of Urinary Calculi among Seafaring People*, in his *Practical Observations on Surgery*, 2d ed., London, 1826, p. 308.

<sup>3</sup> YELLOLY (J.), *Remarks on the Tendency to Calculous Diseases*, in the *Philosophical Transactions of the Royal Society*, 1829, Part I, p. 55.

<sup>4</sup> Medical Inspector A. L. GHON, U. S. N., informs the editor that the records of the Naval Bureau of Medicine and Surgery show that calculus is almost unknown in the United States Navy. COOLIDGE (R. H.) (*Statistical Report on the Sickness and Mortality of the Army of the United States*, 1860, p. 323) records 47 cases of calculus, in the twenty years, 1840-60, in an aggregate force of 187,141 men. WOODWARD (J. J.) (*Med. and Surgical Hist. of the War of the Rebellion*, Part I, Vol. I, Table C, p. 641) records 2,613 cases of "stone and gravel" among the white troops in the period 1861-66, in an aggregate of 5,825,480 cases of disease, and (Table CXI, p. 712) 359 such cases in an aggregate of 629,354 cases of disease among the colored troops, in the period 1861-66. It is probable that not only instances of calculus and of sabulous urinary depositions were returned in this category, but many cases of dysuria of almost every variety.

<sup>5</sup> Dr. TURNEY was naturally deceived by the concretion forwarded to him from Murfreesboro', externally resembling the uric acid calculus he had removed. In a letter to the editor, this surgeon laments that he is "the victim of blunders," and refers to page 289 of the *First Surgical Volume*, in which, in a case of trephining, he is by implication made responsible for the statement "a silver plate was inserted." Dr. TURNEY assuredly made no reference to this absurd popular superstition, the statement appearing on a case-book of hospital No. 2, of Nashville, February 25, 1865, having apparently escaped the vigilance of the officer in charge, Surgeon J. E. Herbst, U. S. V.



though none were reported of the passage of small bullets by that canal. Two years after the war, Assistant Surgeon J. V. Lauderdale observed a case of the latter variety:

CASE A<sup>s</sup>.—Private John Rich, Co. M, 2d Artillery, aged 22 years, was admitted to the post hospital, Presidio of San Francisco, California, on August 4, 1867, suffering from the effects of a pistol ball fired by a barkeeper, who shot at him while his back was turned toward him and at a distance of ten feet. "The ball entered the pelvis at a point exactly midway between the posterior superior spine of the ilium and the tuberosity of the right ischium. There was but little hemorrhage from the external wound. The patient was conveyed at once to the hospital, about half a mile away from the scene of the affray. An unavailing attempt was made to find the ball by probing the external wound. There being no unusual pain or other discomfort from the presence of the ball, its extraction was not again attempted. Hopes were entertained that the ball did not go deeper than the bone, and had probably rebounded. Soon the patient had an urgent desire to void urine, but without being able to do so. A catheter was introduced and a pint of bloody urine was brought away. A few hours later the desire to urinate recurred, and the same atony of the bladder existed. The catheter brought away a quantity of urine, but less tinged with blood than that



FIG. 231.—Pistol ball voided by the urethra. *Spec.* 6382. †

first removed. The patient complained of a little pain in the region of the external wound, which was readily quieted by small doses of morphia. Cold-water dressings were applied, and the wound presented nothing more than a slight puncture of the integument. August 9th: The bowels were moved to-day with an ounce of castor oil; the wound has a healthy appearance, with but little discharge of healthy pus; the bladder has recovered its normal tone, and the patient passes healthy looking urine: when the catheter was introduced the last time, yesterday, it came in contact with a foreign body, supposed to be about the size and weight of the missing pistol ball. August 10th: To-day the patient observes, when he would void his urine in an upright position, that some obstruction offers itself, but meets with no difficulty if he makes water while lying in a horizontal position. It was thought to be too soon for any operation for the removal of the foreign body by lithotomy, as injury might be done to the tissues recently penetrated by the ball. August 19th: This afternoon, while the patient was urinating, he felt a foreign body engaging itself in the lower portion of his urethra, and which caused the flow to cease; making a straining effort he drove this body so near the meatus that he could feel it on the under side of the penis with his fingers; by a little manipulation he succeeded in urging it along the urethral channel nearly to the meatus; here the canal proved to be too narrow for its further progress; a thin narrow-bladed bistoury was passed in the meatus and carried flatwise past the body, then its edge slightly turned upon the constricting fibres of the urethra; a little cutting sufficed, and a delicate pair of forceps being passed down and engaging the body, the missing pistol ball (FIG. 231) was extracted; weight of ball, eighty-four grains; patient recovered without a single unfavorable symptom, and, on the 2d of September, was doing duty in the light battery."

As indicated on page 268, the escape of fragments of bone by the urethra was more common. It will be remembered that this took place in CASES 808 and 811, in which cystotomy was subsequently practised.<sup>1</sup> In a fatal case, to be detailed hereafter, the case of Mahay, pieces of bone were discharged through the urethra; in another case, large bone fragments (PLATE VIII, FIG. 5) occupied the cavity of an abscess connected with the urethra; and in a third case, bone fragments impacted in the urethra were extracted, by Dr. Thomas G. Morton, by perineal section. In the following case, the escape of scales of bone persisted for a long period:

CASE 817.—Private A. Rennicker, Co. D, 209th Pennsylvania, was wounded at Petersburg, March 25, 1865. He was treated in a field hospital, in the Fairfax Seminary Hospital, and in the McClellan Hospital after May 21st, where Assistant Surgeon Samuel Adams, U. S. A., reported as follows: "Gunshot penetrating wound of the bladder; the ball entered the left groin and passed out through the left buttock; urine came through the wound of entrance; no fever; tongue clean; sleeps well; appetite good; no pain in the wound." This soldier was discharged June 29, 1865, and pensioned. Examiner E. A. Smith reported on that date that "the ball entered the left iliac region and passed through the bladder, and out at the middle of the right buttock; he now passes calculi, and suffers great pain in the left testicle." His disability ceased in September, 1867, but subsequently appears to have returned, as Examiner J. S. Suesserott, of Chambersburg, reported September 4, 1873, that he was "still passing small pieces of bone through the urethra, and that the left testicle was subject to periodical swellings." The disability was rated as total.

It has been already shown, on page 277, that the frequency of the presence of bone, as a foreign body in the bladder, has been underestimated.<sup>2</sup>

<sup>1</sup> In CASES 785 and 800, bone fragments were removed with the projectiles; and in CASES 784, 786, and 789, fragments of bone were removed or escaped, but probably through wounds or fistulous tracks. See Note 2, p. 268, *supra*.

<sup>2</sup> To the nineteen instances of bone fragments in the bladder adduced on pp. 277 *et seq.*, the following may be added: 1. ASHIER (*Des corps étrangers, qu'on a trouvés dans la vessie, servant de noyau à la pierre*, Thèse à Paris, 1830, p. 18) relates the case of a girl who had dysuria after a fall, with fracture of the ischium, and passed several bone fragments by the urethra. Eight years afterward she underwent lithotomy, and two calculi with nuclei of bone were extracted. 2. WARNER (*Cases in Surgery*, London, 1760, p. 221, Case XXXV) relates a case in which he removed from the bladder of a woman a calculus the size of a pigeon's egg, having a piece of bone as a nucleus. The concretion broke in removal, and the bone fragment was found to weigh sixteen grains. 3. Professor BULL (*Blasenstein mit einem Knochenfragment als Kern*, in HENSEL and PFEUER, *Zeitschrift für rationelle Medicin*, 1859, S. 82) records the case of a farmer of 29, stabbed in the right buttock, the knife penetrating the rectum and bladder. The wound healed in four weeks; but the man never recovered his health, and died after four years. In the bladder was found an adherent cicatrix and a calculus weighing six and a half ounces, and having as a nucleus a piece of bone one by two centimetres. Near the cicatrix, the pelvis was carious.

In two Confederate cases, recorded respectively by Dr. J. Theus Taylor<sup>1</sup> and Dr. John D. Jackson,<sup>2</sup> the passage of fragments of bone by the urethra in the course of convalescence is described. The original reports, from which the following brief abstracts are condensed, may be profitably consulted:

CASE 818.—A Texan soldier was wounded at Mansfield, April 8, 1864. The ball notched the symphysis pubis and emerged at the left side of the coccyx. Neither the urethra nor rectum were injured, but urine escaped freely from both orifices. The constitutional symptoms were grave for some days. A gum-elastic catheter was maintained in the bladder, though frequently withdrawn and cleansed. The entrance wound healed in four, and exit wound in eight, weeks. After its closure there was cystitis from the presence of foreign bodies, and Dr. Taylor was repeatedly "on the point of cutting into the bladder to relieve it of the foreign bodies that were evidently the cause of the trouble, but concluded to wait and try systematic dilatation of the urethra. One morning, a large-sized bougie having been introduced, and the urine having been long retained, the patient was made to stand up and lean forward so as to enable him to exercise the greatest possible ejaculatory power. The bougie was then withdrawn, and was followed by a wad of foreign matters, consisting of *portions of clothing<sup>3</sup> and of bone*, which was violently projected from the bladder with a torrent of urine. For several days smaller particles came away." The youth then rapidly recovered, and went home cured in July, 1864.

CASE 819.—Private *Michael Tipps*, Co. A, 17th Tennessee, aged 21 years, was wounded at Mill Spring, January 19, 1862. Surgeon W. A. Gentry, of his regiment, stated that a ball traversed the pelvis, through the sacrum and horizontal ramus of one of the pubic bones, perforating the rectum and bladder. The patient was transported in an army wagon one hundred and sixty-five miles over a very rough mountainous road to Winchester. Urine and feces and many bone fragments passed through both orifices for several weeks, and then the wounds gradually closed. Dr. John D. Jackson examined this man for discharge, November 26, 1863, and found the wound cicatrized. The patient stated that after the orifices closed he *passed small pieces of bone through the urethra*, and that even then, twenty-two months subsequent to the injury, bits of bone were occasionally passed by the canal, and he displayed several pieces of spongy bone corresponding with the cancellated tissues of the pubic bone.

When it is remembered that, of thirteen cases in which projectiles were removed from the bladder, there was probably direct complete penetration in six only, and that in seven cases the missiles entered by ulcerative absorption, and, in two instances, were extracted within the last year, and further, that the escape of small necrosed sequestræ has been observed many years subsequent to the primary injury of the pelvis and bladder, it may be inferred that instances of calculi formed on bone fragments or balls may still be looked for among the invalids surviving shot wounds in the pelvic region, of whom, according to the last report of the Pension Office, a considerable number remain on the rolls. The comparative frequency with which missiles, after

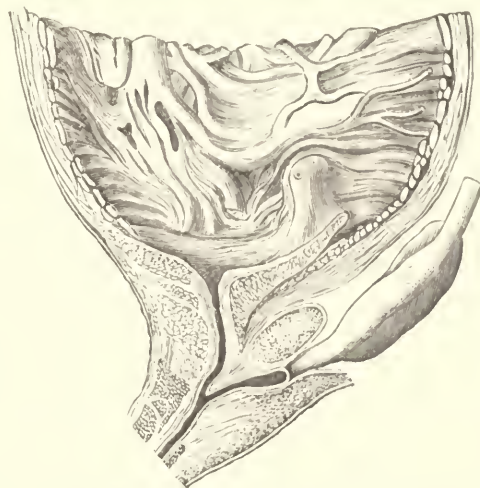


FIG. 232.—Median section of the lower part of the bladder, showing the outer and inner muscular and the mucous coats, the long muscles of the urethra and the orifice of the latter, the muscles of the trigonum vesicæ, the external and internal sphincters, the prostate gland with its sinns, the right vesicula seminalis, and beginning of the vas deferens. [After HENLE.]<sup>4</sup>

<sup>1</sup> TAYLOR (J. T.), *Gunshot Wound of Bladder, Recovery*, in the *Southern Jour. Med. Sci.*, 1867, Vol. II, p. 29.

<sup>2</sup> JACKSON (J. D.), *Gunshot Wound of Bladder and Rectum*, in the *Am. Jour. Med. Sci.*, 1869, Vol. LVII, p. 281.

<sup>3</sup> 1. It will be remembered that in the elder CLINE'S case of cystotomy for the removal of a ball (page 230 *ante*, *Note*, Obs. 8), a roll of shirting and cloth was discharged from the urethra prior to the operation. 2. HENSEX (*Princ. Mil. Surg.*, 3d ed., p. 426), remarking that "if extraneous matters carried into the bladder are of a soft and yielding nature, or of a small size, the natural flow of the urine often carries them out," adduces the instance of John Rowan, 50th regiment, wounded at Vera in the Pyrenees, July 25, 1813, the ball passing through the skirt of his coat and entering the body above the tuberosity of the left ischium; the wound healed, and 138 days from the date of its infliction, after drinking to excess of the wine of the country, after straining for a half-hour, he shot out from the urethra a substance coiled up in the shape of a fragment of bougie, nine lines in length and three in breadth, which proved to be a faded red piece of cloth with its lining; its texture was unaltered, and there was no calculous deposit on it. GUTHRIE (*Comm.*, 5th ed., p. 695, and *Lectures*, Case 98) also adduces this case: "A soldier of the light division, etc." 3. COLLES (*Lectures on the Theory and Practice of Surgery*, Am. ed., Phila., 1845, p. 133) records a case in which, "after a deal of effort, a piece, or rather two pieces, of cloth, which were rolled up into a ball and had lodged in his urethra, were shot out." This is the case of the Irish gentleman from whose bladder COLLES removed a ball (Compare CASE 13 in *Note* on p. 270 *ante*). COLLES claimed the case in his sixteenth lecture, and exhibited the ball, which bore no marks of enervation. 4. Quite recently M. PERRIN (*Ann. Med. de Paris*, 1872, T. XXVII, p. 600) reported to the Surgical Society of Paris the case of a man of 40, impaled on the broken leg of a chair, which penetrated the base of the bladder through the rectum. Thirty days subsequently, the recto-vesical laceration was healed. A fortnight subsequently there was retention, relieved by the expulsion, after severe straining, of a roll of cloth, a fragment of this man's trousers.

<sup>4</sup> HENLE (J.), *Handbuch der Anatomie des Menschen*, Braunschweig, 1866, B. I. S. 332.

traversing the pelvic parietes, are arrested in the wall or cavity of the bladder, is accounted for not only by the loss of momentum of the projectile, but by the sudden contraction of the bladder, and by the resistance of the urine it may contain. In the larger proportion of cases, the ball moves with sufficient velocity to surmount these obstacles and to produce a double perforation. If the perforation interests a part of the bladder covered by peritoneum, there is no reason to anticipate other than a fatal termination; but if both orifices are below this, and free egress for the urine is provided, through a catheter or through the shot tracks, recovery may be looked for, under favorable conditions, in a considerable proportion of the cases. As was illustrated on page 267, the recoveries are for the most part incomplete. Here are two examples, however, of shot wounds of the bladder, in Confederate soldiers, where very perfect recovery is alleged:<sup>2</sup>

CASE 820.—Dr. R. Barksdale relates<sup>1</sup> that he saw a Confederate soldier of a North Carolina regiment, wounded at Fredericksburg, December 13, 1862, who had walked a mile and a half to the rear of Marye's Heights after receiving an antero-posterior shot perforation of the bladder, the ball entering the white line half an inch above the pubes, and emerging through the middle of the sacrum. Urine escaped from both orifices, and could be expelled also from the urethra. A gum-elastic catheter was introduced and retained in the bladder, and a quarter of a grain of morphia was given. No bad symptoms ensued. In four weeks both wounds were healed, and the man walked to Hamilton's Crossing on his way home, being allowed three weeks' furlough before resuming his military duties. The absence of particulars of the ulterior history of this unknown soldier, and the remote date at which the facts were chronicled, detract from the value of this otherwise interesting narration.

CASE 821.—Private *John L. Fore*, Co. H, 14th Virginia, aged 35 years, was wounded at Gettysburg, July 3, 1863. Acting Assistant Surgeon James Newcombe reported that "a ball entered the posterior and inner aspect of the right natis, and emerged through the scrotum on the left side." The motions and urine passed through both openings and also through the natural channels, the urine escaping in the alvine discharges. There was little hemorrhage. Surgeon Henry James, U. S. V., observed the case and reported it as a "wound of the perineum and bladder, with abnormal anus." Dr. Newcombe states that "profuse suppuration soon became established, but the wounds granulated healthily, and the urine had almost ceased to escape by the wound on the tenth day, the cessation being gradual; the feces followed the same course, though more slowly. No inflammatory fever followed the injury, no catheter was introduced, and no medicine was exhibited except an occasional opiate. August 10th: At present the patient appears to be progressing rapidly toward complete recovery; the secretions pass through the natural channels. October 6th: He is fairly convalescent, and will be transferred to a general hospital." This man was sent to West's Buildings Hospital, whence Surgeon T. H. Bache, U. S. V., reports that he was paroled, November 12, 1863.

<sup>1</sup> BARKSDALE (R.), *Gunshot Wound of the Bladder, remarkable Recovery*, in *Virginia Clinical Record*, 1873, Vol. III, p. 367.

<sup>2</sup> References to cases of recoveries from shot wounds of the bladder recorded in surgical annals, that have not been noticed in other connections, will be here briefly enumerated: 1. CABROL (*Alphabet. anat. avec plus. obs. partic.*, Geneva, 1602, Obs. XXVI); a soldier shot through both walls of the bladder, at Pzenas; CHOPART alludes to the case (*Mémoires des voies urinaires*, 1792, T. II, p. 88). 2. RIVERIUS (*Op. med. urin.*, 1679, Obs. comm. No. V); soldier shot at Tarascon, through bladder and sacrum. 3. MANGETUS (*Bibl. chir.*, 1721, T. III, p. 678); Reiche, a student; shot perforation of the bladder, in May, 1680. 4. LARREY (D. J.) (*Mémoires de Chir. mil. et camp.*); a mason at Lausanne, treated by MESLIN, for a shot wound of the bladder with injury of the epigastric artery; there is a fuller account in MORAND's *Opuscules*, T. II, p. 27. 5. DESPORT (*Traité des plaies d'armes à feu*, 1719, p. 319); a soldier shot in the bladder, at Gnastalla, September 19, 1734. 6. BORDENAVE (*Précis*, etc., in *Mémoires de l'Académie de chir.*, 1753, T. II, p. 523); a soldier treated by PONÉYÉS, at Charleroi, for shot wound of the bladder, August 2, 1746; PÉRY refers to this case (*op. cit.*, p. 216). 7. BOURIENNE (*Journal de Méd.*, T. XXXIX, p. 426); a grenadier, Lavigne, shot through the bladder, near Cassel, July 24, 1762. 8. GUÉRIN (MORAND, *Opusc.*, T. II, p. 27) treated Lieutenant Corneillon, shot through the neck of the bladder, at St. Sébastien; there was much blood extravasated in the bladder; CHOPART (*op. cit.*, p. 93) and DEMARQUAY (*op. cit.*, p. 308) relate this case. 9. WALTZ (*Gräfe und Walther's Journal*, about 1800), according to GUTHRIE (*Lectures*, p. 67), successfully treated a pistol-ball perforation of the bladder. 10. SOUTH (*Notes to Chelius*, Am. ed., Vol. I, p. 528) relates the case of Colonel A——, wounded before Alexandria, a grape-shot passing through the rectum and bladder; the projectile is preserved in St. Thomas's Hospital Museum. 11. LARREY (D. J.) (*Mémoires de Chir. mil. et camp.*, 1812, T. II, p. 162); Chaumette, 22d mounted chasseurs, shot through the bladder and rectum, at Tabre, in 1799; and also 12. Case of Corporal Dacé, 9th line regiment, shot wounds of bladder and rectum, at Acre, in 1799, 13. Private Desjardines, 32d demi-brigade, shot perforation of the bladder, at Acre, in 1799, complicated by gangrene and fistula; and 14. (In *Clin. chir.*, 1829, T. II, p. 520, citing from the *Salzburger Gazette*); case of shot perforation of puòis and bladder. 15. (*Ibid.*, p. 515); a grenadier, wounded in Austria, in 1801; and 16. A soldier of the same corps, wounded at Eslingen, a fearful shot laceration of the bladder. 17. HENRIEN (*Précis of Mil. Surg.*, 3d ed., 1829, p. 439); case of Labiche, 7th French dragoons, wounded at Waterloo, through the bladder; air escaped by the urethra. 18. GUTHRIE (*Commentaries*, 5th ed., p. 607); Captain Steigh, 100th regiment, shot perforation of bladder, at Chippewa, July 5, 1814. 19–21. GUTHRIE (*Lectures*, etc., p. 66 *et seq.*); cases of French soldiers wounded at Almaraz, at Tonlouse; of J. Sordis, wounded at Waterloo; BRUCE's case of Thompson, 5th regiment; BOUTFLOWER's case of a cavalry soldier at Salamanca; and Captain M——, wounded at Ciudad Rodrigo. 25. GAULTIER (in SÉDILLON's *Journal*, T. XLII, p. 170); a soldier shot through the bladder, in the Valencia expedition, July, 1808; M. DEMARQUAY (p. 301) cites this case. 26. CHAMALSON (*Causid. sur les plaies du Bas-ventre*, Montpellier, 1815, Obs. IV, p. 13); corporal, 5th Miners, shot through the bladder, May 13, 1810. 27. FLEURY, cited by M. DEMARQUAY (p. 300); case of Fourvel, a youth of 18, with a shot wound of the wall of the bladder, converted into a penetration by the separation of the eschar. 28–30. BAUDENS (*Clin. des plaies d'armes à feu*, 1836, p. 367); A——, 59th regiment, shot through the ilium and bladder, October 12, 1833, at Bongie; at page 384, of a soldier of the 3d regiment, shot, at Stodi, through the coccyx, rectum, and bladder; there was escape of gas and feces through the urethra; and, at page 229, the case of Tomillier, in July, 1848. 31. PAOLI (*Gaz. Méd. de Paris*, 1848, p. 108); case of Mett, aged 38, shot wound of the bladder, November 30, 1811. 32. M. DEMARQUAY (*Mémoires sur les plaies de la vessie par armes à feu*, in *Mémoires de la Soc. de Chir.*, 1851, T. II, p. 324) reports an interesting case from his own practice: Oudiné, a national guard, shot through the pubis, the iliac artery, spermatic cord, and bladder and rectum, June 24, 1848; forty-one small fragments of bone, carried into the bladder, were extracted by the forceps; after many grave complications, he recovered with an urinary fistula. DEMARQUAY reports the same case in the *L'Union Méd.*, 1851, p. 107. 33. B. BECK (*Die Schusswunden*, 1850, S. 227); a shot perforation of the bladder in an Austrian chasseur, in 1849. 34. MACFADYEN (*Notes on Surgery of the Crimean War*, 1858, p. 271); Private Griffith, 55th British Regiment, shot penetration of the bladder, before Sebastopol, in 1855. 35–37. CHENEY (*Report of the*



The cases of recovery in the Union Army, of which precise details are accessible, with few exceptions were associated with serious disabilities; and several discharged and pensioned invalids succumbed finally to the remote effects of their injuries.

CASE 822.—Corporal S. D. Carrier, Co. B, 4th Vermont, aged 26 years, was wounded at Fredericksburg, December 13, 1862, and received treatment in Mount Pleasant Hospital, Washington, until March 21, 1863, and afterward in the general hospital at Brattleboro', where he was discharged on May 11th on account of "gunshot wound of the bladder." Pension Examiner E. V. Watkins, of Newbury, Vermont, reported, September 13, 1872, that "the wounds [meaning, probably, the cicatrized sinuses connected with them] were situated as follows: One immediately through the os pubis, and also through the bladder, coming out on the left side of the backbone; one through the left testicle, and passing out also on the left side of the spine; one through the left groin, passing through the rectum; and another in the right inner thigh. The disability consists in great irritability of the bladder, with pain in that region; an inability to retain the urine, in consequence of permanent contraction and a chronic inflammation of the neck of the bladder; also a weakness of the rectum or paralysis resulting from the passing through of the ball, very much impairing the functions of that portion of the bowels; and a loss of use of the right leg from the wound in the thigh. Finally, he has frequent calls to urinate, attended with very severe pain, especially after taking exercise or cold, and at such times is obliged to take to his bed. He has defective circulation and symptoms of paralysis." Examiner J. F. Burns, of Brainerd, Minnesota, reported, September 16, 1873, the injuries as described, and adds: "He cannot retain his urine, and has to use a bougie to keep the bowels open, and has partial paralysis of both legs; his disability is total." He was last paid to June 4, 1873.

CASE 823.—Private D. P. Grubb, Co. B, 48th Ohio, was wounded at the battle of Stone River, December 31, 1862. Surgeon W. P. Johnson, 18th Ohio, records his treatment for shot wound of the bladder, at Murfreesboro', till March, 1863, and Surgeon C. McDermont, U. S. V., reported his admission to Cumberland Hospital, Nashville, with a shot wound involving the pelvis, bladder, and rectum, and his discharge for "recto-vesical fistula, consequent on shot wound," December 9, 1863. Not a pensioner.

CASE 824.—Sergeant E. F. Yeaton, Co. D, 5th New Hampshire, aged 25 years, was wounded at Cold Harbor, June 3, 1864, and was admitted to the 2d Division Hospital, Alexandria, on the 12th, where Surgeon E. Bentley, U. S. V., in charge, recorded the case as a "gunshot perforating wound of the bladder, with injury of the pubic bone; ball lodged; simple dressings." He was discharged, on account of wounds and expiration of service, November 28, 1864, and pensioned. Examining Surgeon J. N. Wheeler, of Dover, New Hampshire, reported, January 31, 1865: "Yeaton presents a wound of the bladder caused by a bullet. The ball entered just above the pubes in the median line and lodged, after penetrating the bladder. The wound is not yet fully healed, and he is still confined to his bed. Disability total, and uncertain as to duration." The records of the Pension Office show that this pensioner died on May 23, 1865.

*Camp, d'Orient*, 1865, pp. 194, 195, and 205; cases of Guil, Lallemand, and Morton, recoveries from shot wounds of the bladder. 38-40, CHENEY (*Camp, d'Italie*, T. II, pp. 493, 494, 502); cases of Bourmet, Dato, and of Grondeau, recoveries from shot wounds of the bladder; Dato had also a penetration of the rectum, and voided the ball at stool. 41, LÖFKE (*Kriegschir. Aphorismen*, in LAXGENBECK'S *Archiv.*, 1866, B. VIII, S. 83); case at Sonderburg, treated by Dr. VOLMER, the ball perforating the bladder and rectum, exciting but little inflammation. 42, OCHWADT (*Kriegschir. Erf. während des Krieges gegen Dänemark* 1864, Berlin, 1865, S. 346); case of Private G. I——, 64th Prussian regiment, shot through the rectum and bladder, June 23, 1864; pubis slightly injured, and fragments removed. 43, P. MENDE, acting as a volunteer surgeon at Würzburg, communicated to the *Boston Med. and Surg. Jour.*, 1867, Vol. LXXV, p. 529, the case of John Graef, 8th Bavarian rifles, with shot perforation of the base of the bladder, received at Rosbrunn, July 22, 1866. 44, 45, F. H. LOVELL, in a communication to the *Lancet* (December 1, 1866, Vol. II, p. 603), reports two cases of recovery from shot wounds of the bladder, in the Bohemian War of 1866, which are noted by H. FISCHER in the *Handbuch* of VON PYTHA and BILLROTH, B. I, Abth. II, S. 252. 46, 47, K. FISCHER (*Militärärztliche Skizzen*, 1867, S. 63) records two cases of recovery from shot wounds of the bladder in a soldier at Gütseinh, and in a soldier treated in another Silesian hospital. 48, VOLKMANN (*Über einige Fälle von geheilten penetrirenden Bauchwunden*, in *Deutsche Klinik*, 1869); case of Ratschinsky, 45th Prussian regiment, shot perforation of the bladder, at Trautemau, August 21, 1866. 49, 50, STROMEYER (*über Schusswunden*, in Jahre 1866, S. 43) records two cases of recovery from shot wounds of the bladder. 51, 52, H. BECK (*Chir. der Schlussverletzungen*, 1872, S. 561); cases of F——, 1st Baden, shot through the bladder, at Nuits, December 8, 1870; and of B——, 48th French infantry, who received a similar wound, at Wörth, August 6, 1870. 53-56, MACCORMAC (*Notes and Recollections*, etc., 1871, p. 74); case of Hautefeuille, aged 22, shot through rectum and bladder, at Sedan, September 1, 1870, at the English hospital. Dr. MACCORMAC also saw two cases at a Belgian ambulance, and one at Bazailles, under the care of Dr. JUNCKER, all with urinary fistula, and likely to recover. 57, SOGIN (*Kriegschir. Erf.*, 1872, S. 98); case of E. Arnold, shot perforation of bladder, at Gravelotte, August 18, 1870. 58, 59, ENGEL (*Beiträge zur Statistik des Krieges von 1870 bis 1871*) gives two cases of recovery from wounds of the bladder. 60-63, STEINBERG, (*Die Kriegslazarethe und Baracken von Berlin nebst einem Vorschlage zur Reform des Hospitalwesens*, Berlin, 1872) relates six cases of shot wounds of the bladder; one died, and one was still under treatment. 64, KIRCHNER (*Ärztlicher Bericht über das Königlich Preussische Feldlazareth im Palast zu Versailles während der Belagerung von Paris vom 19. September bis 5. März*, 1871, Erlangen, 1872) narrates one recovery and five fatal cases of shot wounds of the bladder. 65, REDARD (*Gazette des Hôpitaux*, 1872, p. 100); case of E——, aged 27, 90th line regiment, shot through the bladder and rectum, at Paris, September 30, 1870. In these sixty-five cases, the evidences of penetration of the bladder were incontrovertible, and convalescence was fairly established when they were reported as recoveries. In many instances, however, fistules or other distressing infirmities rendered the recoveries incomplete, what may be termed survivals rather than true recoveries. American cases of recovery from shot wounds of the bladder, other than those cited as observed during the war, are few. 66, W. G. BRECK (*Virginia Med. Jour.*, 1857, Vol. VIII, p. 461) records the case of C. Fairbanks, aged 20, shot in the pubic region, August 25, 1854, recovery after extensive exfoliation of the bone; the case is interesting from the supposed regeneration of a portion of the pubis. 67, GRINSTEAD (*St. Louis Med. and Surg. Jour.*, Vol. XV, p. 489); case of N. Long, aged 7, shot wound of bladder, July 4, 1857. 68, J. S. ATHON (*Cincinnati Jour. of Med.*, 1866, p. 118); John B——, aged 9, shot wound through bladder, in January, 1865. 69, DAYMAN (I. J.) (*Northwestern Med. and Surg. Jour.*, 1854, N. S., Vol. III, p. 301) records the case of J. H——, shot wound of left buttock; a pint of blood passed by the urethra; bloody urine drawn by catheter for two days; no escape for urine by wound; sound detected a ball in the bladder; patient declined an operation, and recovered without bad symptoms; anterior history not recorded. 70, KOERPER (J. F.) (*GROSS, System*, etc., 5th ed., Vol. II, p. 718); perforation from right buttock to left groin by a conical musket ball traversing the distended bladder of a young man; urine passed by posterior wound for six days; recovery, without fistula, in six weeks. 71, JANEWAY (E. G.) (*Proceedings of the New York Pathological Society*, April 9, 1873, in the *Medical Record*, Vol. VIII, p. 344) presented to the society a round musket ball taken from the bladder of Joseph Hassenfratz, aged 51, who died of asthma, January 5, 1873, nineteen years after receiving an accidental shot wound in the buttock. Before death, a faint click revealed the presence of a metallic foreign body in the bladder. In the slightly hypertrophied wall of the bladder there were no signs of the point of penetration. There was a cicatrix in the hip. There were three small pouches in the posterior wall; the ball lodged in one of them, but was easily displaced, and fitted either of the others. The somewhat flattened ball was slightly encrusted at one small place. The deposit was believed to be composed of *urates*.

In appreciating the partial recoveries from shot wounds of the bladder, the effects of the lesions of the pelvic bones and rectum, with which they were so frequently associated, must be allowed due weight.

CASE 825.—Private C. A. Warren, Co. H, 17th Maine, aged 36 years, was wounded at the Wilderness, May 6, 1861, and was treated in the 3d division hospital of the Second Corps, by Surgeon O. Evarts, U. S. V., for a "gunshot penetrating wound of the abdomen." On May 28th, the patient was sent to Armory Square Hospital. Acting Assistant Surgeon F. P. Richards described that "the ball entered at the anterior superior spinous process of the right ilium, and injured the ascending colon and fundus of the bladder. He passed both feces and urine through the upper wound until June 5th, when the feces ceased to pass through the wound and he had natural alvine passages. On July 2d, a consultation was called, and a No. 5 catheter was passed by the urethra, through which the urine flowed freely; but, on July 3d, the catheter slipped out, and the parts were too much tumefied to allow of its being replaced. On July 8th, a flexible No. 5 catheter was passed and the urine again flowed freely; but, on July 9th, this catheter came out, though tied tightly to both abdomen and thighs; the parts were very much tumefied." Surgeon D. W. Bliss, U. S. V., reported that this man was "discharged the service May 16, 1865, for urinary fistula; disability total." The Pension Records state that Dr. James G. Sturgis, late assistant surgeon 17th Maine, reports, on the application for widow's pension: "Wounded by a minie ball, which entered the abdomen in front of the right hip, passing through the neck of the bladder, through the rectum, and through the sacrum. The wound never healed, but discharged from the time of injury until death. He was never able to leave his bed from the time of injury, being brought home on a couch. My knowledge of the above facts were derived from being with him and dressing his wounds at the battle of the Wilderness, and attending him after his arrival home until his death, which occurred March 1, 1867."

CASE 826.—Private David Tappen Sharp, Co. E, 40th New York, aged 20 years, was wounded at the Wilderness, May 6, 1861. There is no field memorandum in records of the 3d division, Second Corps, in which the regiment was brigaded. The wounded man was received at Armory Square Hospital, May 28th. Surgeon D. W. Bliss, U. S. V., reported that the "ball entered at the pubic region and made its exit at the sacrum," and that the soldier was "discharged from service, August 16, 1864, for paralysis of bladder from gunshot wound." He was pensioned. The New York Pension Board, Drs. Deming, Smith, Hogan, and Phelps, reported, April 3, 1872: "The ball entered the right groin and emerged through the left natis. The urine still passes through the opening in the groin. Extensive varicocele. There is constant inflammation of the groin where the ball entered, caused by the oozing of the urine. Disability total, third grade, and permanent." This invalid died August 1, 1873. In a letter to the Surgeon General, Dr. Elisha Harris, registrar, transmitted a memorandum of the case by Dr. J. Shrady, from which the following extracts are made: "The case of Mr. Sharp is one of the curiosities of surgery, and, so far as I know, unique. He was wounded through the right groin in the battle of the Wilderness, May, 1861, the ball passing through the bladder and *some folds of the intestines*, and emerging at the coccyx. He was seen by many surgeons, both civil and military who have taken a deep interest in his case. Also the Surgeon General would be much pleased to know the result as a contribution to the surgical history of the last war. May I ask the favor of revising my diagnosis by an autopsy, or do I infringe upon the prerogatives of the coroner. If I do so infringe, please pass over the case to him, with the request that I be informed of the time of the inquest." \* \* \* On November 21, 1873, Dr. Elisha Harris, registrar, transmitted Dr. John Shrady's notes of the autopsy in this case, held thirty hours after death: "Present, Drs. Forbes, Cosine, Brockway, Reed, Ellison, and myself. Body only fairly nourished; thorax not opened, but no pulmonary symptoms evident during life. Liver and kidneys healthy. Surface of peritoneum coated with lymph, generally in form of flakes; fluid inconsiderable. Bladder thickened and contracted to the capacity of only two ounces, with a perforation opening externally in the right groin. The adhesions surrounding the orifice of the cicatrix were attached to the right ramus of the pubes. The course of the ball, which caused the wound, was not distinctly traced, owing to the decomposition, which was hastened by the high temperature of the season and the recumbent position of the body. There was also a reducible scrotal hernia of the right side, omental in character, and a thickened appendix vermiformis, but no perforation of substance or other solution of continuity."

CASE 827.—Private Wilson Robinson, Co. C, 7th New York Heavy Artillery, aged 27 years, was wounded at Topotomoy Creek, May 29, 1861, and taken to the 1st division hospital, Second Corps, where Surgeon James E. Pomfret, of his regiment, reported a "penetrating shot wound in the right groin." Surgeon E. Bentley, U. S. V., records the case at Alexandria, from June 12th to October 11th, when the patient was sent to Ira Harris Hospital, Albany. Assistant Surgeon J. H. Arnsby, U. S. V., reports that "he was discharged, June 19, 1865, on account of a gunshot fracture of the pelvis, the ball passing through the pelvis and bladder. There is caries of bone, and the trunk is flexed. The right leg is of little use. General health is impaired, and the man is unable to earn a subsistence." He was pensioned, and Examiners R. B. Bontecou and W. H. Craig, September 20, 1873, reported the case as "a gunshot wound of the right groin, the ball entering the ramus of the right pubis, fracturing that bone and wounding the bladder. A fistulous opening still continues to discharge urine in the groin. The pensioner has been confined to his bed the past nine months, and requires the constant attention of another person. Disability total, first, grade." This pensioner was paid to June 4, 1873.

CASE 828.—Private B. F. White, Co. C, 6th Kansas, aged 22, probably wounded at Dry Wood, September 2, 1861, is reported by the regimental surgeon, Dr. J. B. Woodward, as "admitted to the general hospital at Fort Scott, January 1, 1862, with *rubus schlopetium*, and discharged July 10, 1862." The Department Register states that he was discharged by "Medical Director-General J. E. Quidor, for wound of the bladder, causing the urine to pass by the rectum." In applying for a pension, the applicant alleged that a "ball had passed through the small of the back, ranging forward, and that another ball had passed through the left thigh." The application was rejected on the ground of insufficient evidence. Examiner A. Fuller, of Lawrence, then reported, March 21, 1870: "Gunshot entering at the right of the point of the sacrum, passing through the neck of the bladder, and still lodged beneath the integuments of the abdomen below the umbilicus, disabling him from active exercise or labor; disability total and permanent." Some time after this, and prior to April 5, 1871, this invalid soldier died. The precise date and cause of death have not been ascertained.



It will be sufficient to enumerate briefly the larger proportion of the remaining cases reported as recoveries from shot wounds of the bladder:

CASES 829-833.—Private K. S. Davis, Co. I, 104th Ohio, aged 21 years, was wounded near Atlanta, August 6, 1864. Surgeon E. Shippen, U. S. V., reported a penetrating shot wound of the pelvis. Surgeon F. Meacham, U. S. V., and Surgeon J. H. Rauch, U. S. V., reported the case as a shot wound of the bladder. This soldier was returned to duty January 17, 1865; discharged June 17, 1865, and pensioned. Examiners Z. E. Bliss, Wooster, and Boise, of Grand Rapids, reported, September 16, 1873, that "the ball entered the left groin just anterior to the anterior superior process of the ilium, passed downward and inward, remaining lodged in the body, disabling him by weakening the thigh, and causing rheumatic pains." Private W. Ford, Co. H, 126th Ohio, aged 31 years, was wounded at Winchester, September 19, 1864. Surgeons R. Sharpe, 15th New Jersey, and W. A. Barry, 9th Pennsylvania, reported the injury as a gunshot flesh wound of the groin or thigh. At Jarvis Hospital, Assistant Surgeon D. C. Peters, U. S. A., reported "a gunshot wound of the bladder," and the man's transfer to the Veteran Reserves, January 20, 1865, and discharge and pension June 29, 1865. Examiner W. D. McGregor, of Steubenville, reported that "he was wounded first in the left arm, \* \* \* ; the wound does not trouble him much at present. \* \* \*. A second shot struck in front of the left leg three inches below the hip-joint, and, passing inward, it came out in the left groin; striking again, it passed through the upper part of the scrotum, and was taken out of the right groin. The wounds are painful during exercise and changes of weather, in consequence of the injury to the nerves; disability one-third and probably permanent." Pensioner paid to June 3, 1873. Private F. Gonzalalo, Co. K, 9th New Hampshire, aged 26 years, was wounded at Poplar Grove, September 30, 1864. Surgeon J. Harris, 7th Rhode Island, reported a shot wound of the scrotum. Surgeon E. Bentley, U. S. V., adds that the urethra was injured. The patient was discharged September 8, 1865, and pensioned. Examiner J. Phillips, of Washington, reported, July 23, 1866: "The ball entered the right thigh, passed through the scrotum, injuring the urethra and right testicle. There are several openings in the scrotum, through which, he says, the urine flows." Examiner T. F. Smith, of New York, reported, September 6, 1873, that "a ball passed through the right testis and left hip, making its exit through the posterior aspect of the hip-joint; the bladder must have been perforated, as the only discharge of urine is through the wound of the testicle; the wound in the hip-joint interferes with locomotion; there is thickening and induration of the scrotum." Sergeant J. Scott, Co. D, 94th New York, was wounded at Bull Run, August 29, 1862. Assistant Surgeon C. A. McCall, U. S. A., regarded the injury as a flesh wound of the back. Acting Assistant Surgeon M. F. Coggswell reported it as a "gunshot wound through the pelvis, penetrating the bladder and rectum." This man was discharged February 26, 1863. Examiner E. S. Lansing, of Watertown, reported, March 26, 1863: "Ball passed into the pelvis on the left side, injured the bladder, and passed out on the right side near the trochanter major, doing extensive injury; disability total. The pensioner was paid to June 4, 1873; there is no later account of his condition. Private J. H. Springstead, Co. D, 10th New York, was wounded at Spottsylvania, May 12, 1864. Seven surgeons report this case, with sundry discrepancies in details, but the injury appears to have been regarded by most, as a shot penetration of the pelvis without visceral injury. This man was discharged and pensioned July 16, 1865. Examiner T. B. Smith, of New York, reported, September 16, 1873, that "the ball entered the left gluteal region and made exit at the outer aspect of the right thigh, wounding the bladder in its passage. He is troubled with incontinence of urine; power of locomotion in right leg is impaired; disability one-half."

CASES 834-845.—Private A. Keller, Co. A, 203d Pennsylvania, was wounded at Fort Fisher, January 15, 1865. Surgeon N. S. Barnes, U. S. V., reported a shot wound of sacrum, Assistant Surgeon D. Bache, a shot wound of the bladder, from McDougall Hospital, where the patient remained longest, and whence he was discharged, July 6, 1865. Corporal G. S. Harger, Co. I, 10th Massachusetts, aged 24 years, was wounded at Spottsylvania, May 18, 1864, and made prisoner and paroled to Annapolis, where Surgeon B. A. Vanderkift reported that the "ball entered the right buttock and passed forward, wounding the rectum, urethra, and bladder, and emerged through the upper third of the left thigh." This soldier was sent to Boston, well, April 15, 1865, for muster out. Private J. Gorman, Co. K, 82d Pennsylvania, aged 20 years, was wounded at Cold Harbor, June 3, 1864. Surgeon E. B. Kelly, 95th Pennsylvania, reported the case as a shot wound of the abdomen, and Assistant Surgeon S. A. Storrow, U. S. A., reported, from Filbert Street, Philadelphia, that the ball "penetrated the bladder." This soldier was returned to duty August 16, 1864. Captain T. S. Beall, 51st Georgia, was wounded near Knoxville, November 29, 1863. Surgeon A. M. Wilder, U. S. V., reported that "a ball passed through the bladder." Private E. Estep, Co. F, 4th Ohio, aged 22, was wounded at Chancellorsville, May 3, 1863. Surgeon Justin Dwinelle, 106th Pennsylvania, reported, "gunshot wound through back and bladder;" Surgeon A. Heeger, U. S. A., at Point Lookout Hospital, reported "wound of left hip and bladder." Lieutenant E. Thompson, 2d Massachusetts Cavalry, aged 22, was wounded at Winchester, September 19, 1864. Surgeon A. P. Clarke, U. S. V., reported a "severe bullet wound of the bladder." This officer was mustered out July 20, 1865. Private G. B. Akerman, Co. B, 67th Pennsylvania, aged 20 years, wounded in attempted desertion, October 20, 1864, is reported by Surgeon Z. E. Bliss as having received "a gunshot wound of the right hip, the ball passing internally, wounding the bladder." He was returned to duty May 20, 1865. Private D. Sulch, Co. K, 8th Pennsylvania Reserves, wounded and captured before Richmond, June, 1862, was reported by the Confederate officials as having received "a gunshot wound of the bladder." Private A. Winne, Co. C, 33d Ohio, was wounded at Perryville, October 3, 1862, Surgeon J. G. Hatchitt, U. S. V., reported that he received "a gunshot wound of the bladder." He was discharged on certificate of total disability, February 15, 1863. Corporal J. McKee, Co. I, 85th Indiana, was wounded, March 5, 1863; reported on the field casualty list as "shot through the hip and bladder." Private T. D. Strickland, Co. A, 11th Georgia, is reported, by Surgeon A. M. Wilder, U. S. V., as having received a "gunshot wound through the neck of the bladder," at Knoxville, November 29, 1863. Private D. W. Davis, Co. L, 1st Massachusetts Heavy Artillery, aged 21 years, was wounded at Spottsylvania, May 19, 1864. Assistant Surgeon J. C. McKee, U. S. A., reported "a gunshot wound of left ilium, ball penetrating neck of bladder." Acting Assistant Surgeon Stephen Smith also reports the case as a "gunshot wound through bladder," without comments. None of the above twelve are pensioned.



M. Demarquay holds that there may be shot contusions and lacerations of the outer tunics of the bladder, with secondary penetration of the cavity upon the separation of the eschars, and adduces an observation by Fleury in support of this view, which MM. H. Larrey, Chassaignac, and Giraldés<sup>1</sup> hesitatingly admit. Facts appear to sanction the belief that such lesions of the external coats occasionally result from shot injury, and that secondary penetration of the vesical cavity, upon the separation of the eschars, may or may not result. The following are possibly instances of this sort, though the evidence of vesical lesions is inconclusive:

CASE 846.—Private R. Hussey, Co. A, 6th Maine, aged 24 years, was wounded at Chancellorsville, May 3, 1863. He was sent on a hospital steamer to Douglas Hospital on May 8th, and Acting Assistant Surgeon H. L. W. Burritt reported that "the ball entered just inside of the anterior inferior spinous process of the right ilium, passed directly across the pelvis, apparently just outside of the deep fascia and very near the bladder, and came out nearly in the same position opposite its entrance; the bowels moved freely; there was some pain with a little blood in the urine, which was drawn once by the catheter; castor oil and whiskey were given, with full diet. May 15th: The abdominal tenderness and urinary difficulty subsided; no fever at any time; some injury to the bladder. 21st: Remains the same; no irritation or fever; wound suppurates healthily and is healing rapidly; pulse 78; skin moist and bowels regular; some pain and passage of blood with the urine; an anodyne diuretic was given. 25th: Improving; no irritation of the bladder or bowels; no fever, pain, or swelling; the discharge has nearly stopped, and the wounds are closed except at one small point. June 3d: Wound healed; no pain in bladder, which was evidently contused by the passage of the ball; appetite and general health good." He was transferred, on May 16th, to West's Buildings Hospital, Baltimore, and subsequently to Point Lookout, whence he was sent to duty November 15, 1863. He served in the Veteran Reserve Corps, and was discharged January 31, 1866. Pension Examiner B. Johnson, of Dover, Michigan, reported, April 16, 1866, that in consequence of the wound he was unable to perform any labor which required lifting or much exertion, and rated his disability as three-fourths and permanent. He was pensioned from the date of his discharge, and was last paid to June 4, 1871, and since then has not been heard from.

CASE 847.—Private Philip Matties, Co. H, 23th Wisconsin, aged 23 years, was wounded at Resaca, May 15, 1864. The injury is described as a shot wound of the abdomen at a field hospital of the Twentieth Corps, and at Chattanooga, Nashville, and Jefferson Barracks, in similar terms, with the addition that the missile entered the left groin, passed downward and lodged; but at the Swift Hospital at Prairie-du-Chien, where the patient was admitted April 29, 1865, Acting Assistant Surgeon F. W. Kelley states that the "ball passed into the pelvic cavity, injuring the bladder, and has never been found." This soldier was discharged, June 30, 1865, without pension.

*Fatal Shot Wounds of the Bladder.*—M. Demarquay complained that materials for the treatment of the pathological anatomy of shot wounds of the bladder were absolutely lacking. The experience of late wars would be expected to contribute toward supplying

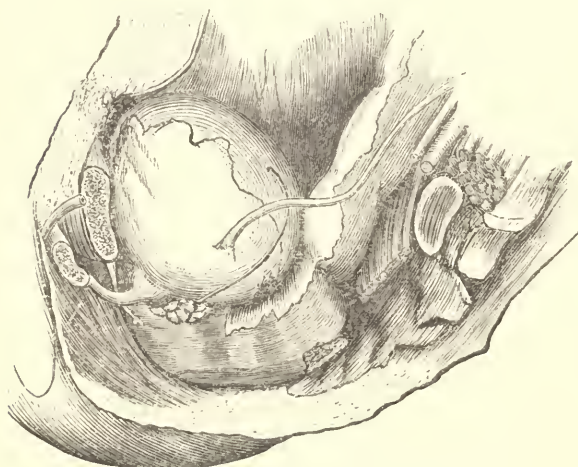


FIG. 233.—Shot perforation of the bladder and rectum.

this deficiency. In our war, in cases of this group, a certain number of autopsies were made, and some interesting pathological preparations were preserved for the Army Medical Museum. The descriptions of the appearances observed were commonly very brief, but several of the preparations speak for themselves. Of cases described in detail, oblique perforations were the most numerous, the missile entering a groin and passing out at the buttock of the opposite side, or, in about equal proportion, traversing this track in the reverse direction. Many illustrations have been given already of cases in which balls pursued this general

course, sometimes passing through the notches or foramina, sometimes penetrating the bony walls. In other cases, the perforations were antero-posterior, or the reverse, implicating

<sup>1</sup> *Mémoires de la Société de Chirurgie*, 1851, T. II, pp. 300 and 335.

commonly the pubes or sacrum, or both. The simplest shot perforation is that through the obturator foramen and sciatic notch, where the ball can hardly avoid the great vessels in some part of its track. The single instance of this sort recorded was promptly fatal:

CASE 848.—Captain Richard H. Kimball, Co. K, 12th Massachusetts, was wounded, August 30, 1862, by a ball, which entered the right obturator foramen, passed through the bladder, and emerged through the left greater ischiatic notch, cutting the pyriformis. He survived the injury only a short time. The missile (FIG. 234) was cut from the gluteal muscles previous to embalming the body, and was placed in the Museum, with the foregoing memorandum, by Acting Assistant Surgeon F. Schafhirt.




FIG. 234.—Missile from a fatal case of perforation of the bladder. *Spec.* 4036.

CASE 849.—Private C. Wolver, Co. H, 24th New York, aged 20 years, was wounded at Centreville on August 30, 1862. Acting Assistant Surgeon W. H. Butler<sup>1</sup> reports that "a musket ball entered above the pubis one inch to the right of the median line, passed obliquely to the left and downward, and escaped four inches above the coccyx and three inches to the left of the spinous process." The patient was admitted to the Union Chapel Hospital September 1st. The posterior wound had closed, but from the anterior there was an almost constant flow of urine, notwithstanding the retention, from the first, of a catheter in the urethra. The pulse was 125. A difficulty in passing the catheter was finally overcome by withdrawing the stylet gradually after the catheter passed under the pubis, and giving it an upward tilt on the inner end. Cleanliness was enforced; a nutritious diet was given, with opium in full doses. The bowels were confined till September 9th, when the tongue became thickened and coated, and the patient complained of oppression in the bowels. An enema of warm water was followed by a normal evacuation. A marked jaundice ensuing on the 10th, a mercurial cathartic, followed in six hours by castor oil, was administered, with the effect of producing a free and painless evacuation. On the 11th, sherry wine in the yolk of an egg was given every four hours; at bed-time, ipecac with quinia and blue pill. The patient was quiet till the latter part of the night, when he became restless and delirious. Stimulants and opiates were continued on the 12th; clots of blood were expectorated during the day and at night; respiration was accelerated, and the pulse 140; failure occurred gradually, and the patient died on the morning of September 13, 1862. Three hours afterward, the cadaver was yellow and emaciated, rigor mortis was well marked, the bowels tympanitic, and the eyes sunken. There was well-marked saggillation on the back, neck, and thighs, and the pupils were remarkably dilated. The external appearance of the superior wound was very dark and dry. On cutting through the abdominal walls a slight fracture of the superior part of the pubis was discovered, some small pieces of bone being detached; ulceration had taken place to a considerable extent beneath the parietes of the abdomen and to the right of the bladder. A small piece of bone was driven into the bladder from the os pubis. The walls of the bladder were thickened at least one inch, and its capacity lessened about one half. The ball was found to have passed through the left side of the bladder and through the upper part of the ischiatic notch. The outer wound was completely closed, and could not be forced open. The lungs were normal anteriorly; on the left the lobes were covered with plastic lymph, and the cavity of the chest and the pericardium were filled with serum of a dull yellow color. The liver was much enlarged; the kidneys normal; the spleen congested. Externally the heart presented a normal appearance, but its cavities were filled with thick and tenacious fibrinous bands. This was particularly marked in the right auricle, the mass on being removed taking casts of the veins well up into the head. The stomach and intestines were healthy." The specimen, contributed to the Museum by Dr. Butler, is represented in the adjoining wood-cut (FIG. 235). The perforation is completely cicatrized, its site being indicated by a large depressed scar.

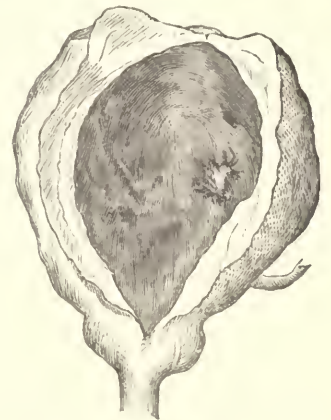

FIG. 235.—Shot perforation of the urinary bladder. *Spec.* 510.

CASE 850.—Private *Fleming P.*—, Co. K, 6th Georgia, aged 23 years, was wounded at Antietam, September 17, 1863, and was sent to a field hospital. Surgeon H. S. Hewitt, U. S. V., records that he was admitted to Frederick Hospital No. 5 on October 4th. Acting Assistant Surgeon A. V. Cherbonnier gives the following particulars of the case, which first came under his notice on October 18th: "The patient had been struck by a round bullet, which entered a little above the tuberosity of the right ischium, passed through the bladder near its neck, and made its exit near the inferior anterior spinous process of the right ilium. He suffered great pain; the abdomen was tense, and sensitive to the lightest touch; there was severe pain in the perineum, constant unavailing desire to void the urine, and an abscess was forming over the pubis. Urine mixed with pus dribbled from both orifices. With some difficulty a catheter was introduced, and offensive matter was drawn off to the amount of a few ounces, mingled with a slight quantity of urine. Fomentations were applied to the abdomen; then compound cathartic pills were given, and the wounds were carefully cleansed. On October 19th, the patient had passed a more comfortable night; the abdomen was less tense and painful; pain in the perineum not complained of. Urine with pus passed through the catheter, which he introduced himself. He complained very much of the abscess forming over the pubis. The wound was thoroughly washed, and dressed with simple cerate; fomentations were continued over the abdomen, a flaxseed-meal poultice was applied over the forming abscess, and a grain of morphia was ordered if the bowels should be open. October 20th: The patient had passed a sleepless though not a restless night, and had two copious stools; the pubic abscess pointing, was opened with a lancet and discharged copiously, affording great relief; all unpleasant sensations about the abdomen were much, if not entirely, relieved. The urine was much clearer, but still mixed with pus. The patient looks more cheerful and feels much better, with appetite returning; he ate some chicken-broth with a little chicken. Treatment the same. October 23d: His condition is improving; he thinks himself able to go home; the urine is voided almost entirely through the catheter; the wounds

<sup>1</sup>BUTLER (W. H.), *Three Cases of Gun-shot Wounds of the Bladder*, in the *Buffalo Med. Jour.*, 1864, Vol. III, p. 456.



are looking healthy. October 25th: He complains of much pain in the right groin along the track of the spermatic cord; another abscess is forming, and the opening over the pubis is suppurating; a small piece of bone was removed therefrom; his general health is improving. October 27th: I opened the abscess in the right groin; he had complained incessantly of it, and much pus was discharged therefrom, and also pieces of clothing; flaxseed-meal poultices to all the wounds were ordered; much less pus passed through the urethra; a full dose of castor-oil was ordered. October 28th: The patient is much better and does not complain of pain, but is unable to sleep; two grains of opium were ordered. November 1st: The patient is better; he has rested well, and his appetite is good. November 12th: He is slowly but surely improving, and the wounds are closing. November 15th: The bladder is resuming its power; the wound in the groin is closed. November 19th: The posterior wound or point of exit is closed; the patient is quite cheerful and contented, though the two remaining wounds are suppurating and he still uses his catheter. December 7th: He has had a good night's rest, which was procured through the aid of a half grain of sulphate of morphia, and he feels comparatively well. December 8th: He has slept well without morphia; passed urine by the catheter; some of the urine again escapes from the lower wound, which troubles his mind; an explanation cheered his spirits, and he sank into an easy slumber. December 11th: He is occasionally fretful, but is easily reconciled to his condition; the wounds have closed up again; patient cheerful and improving. December 15th: He is improving, but still draws his urine by the catheter. December 19th: He has left off the use of the catheter and passes his urine without any trouble; the urine is still mixed with some pus, and some of it, though little, escapes through the wound again; his general health is good. December 22d: He is improving, and walked and sat up awhile to-day; to-night he complains very much about his bed-sore, and an air pillow and poultice were applied. December 25th: He is still improving, and gets up awhile every day. December 28th: He complains of diarrhœa; ordered pills of quinine, Dover's powder, rhubarb, and carbonate of iron." On the 29th, the man was transferred to Hospital No. 1, where Assistant Surgeon R. F. Weir, U. S. A., continued the report as follows: "January 10th: The patient is evidently slowly failing; he continues very irritable; the pulse is 115 and very weak, and the tongue furred, brown, and rather dry; much difficulty is experienced in getting him to take his medicine, and, at times, it seems almost impossible for him to swallow; fears are entertained that tetanus will supervene; the mucous membrane of the mouth is covered with aphthous ulcers; he has constant pain over the course of the urethra, and the passage of calculi is suspected; on introducing the catheter it was found to grate over some hard substance near the neck of the bladder; this was thought to be a piece of bone (FIG. 5, PLATE VIII) which had been forced into the bladder from some point of the urethra previous to his admission. A consultation was held, but, owing to the patient's prostrate condition, it was thought advisable not to remove the foreign body; enemata of beef-tea with brandy were ordered. January 16th: The patient is very feeble; his pulse is slow and weak, and the tongue red at the edges and coated in the centre; bowels regular; skin dry and hot; he has a great desire for water, and great difficulty in swallowing medicine and nourishment; the wounds are not in good condition, and the urine escapes from the openings; there is considerable trouble experienced in introducing the catheter.

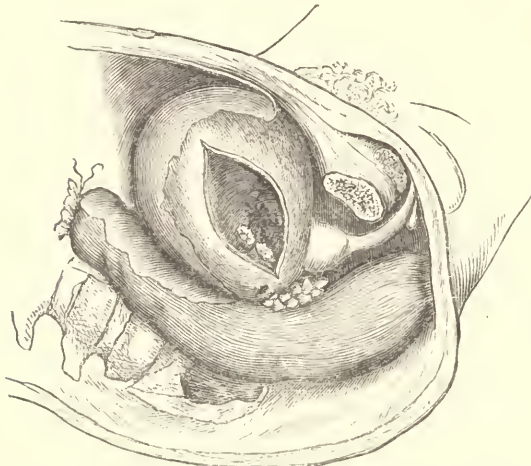


FIG. 236.—Drawing of a wet preparation of the pelvic viscera showing the wound in the bladder made by a ball which entered through the right ischium and escaped above the left pubis. Also the bone fragments near the neck of the bladder. *Spec.* 3,075.

January 24th: The patient is slowly improving and the pulse is somewhat better; the tongue is cleaning up and the bowels are regular. January 27th: The patient seems more comfortable this morning; he rested well last night; the wound was dressed with simple cerate and the bed-sores dressed with a poultice; he is improving. January 28th: The patient has considerable cough, and I ordered an anodyne; the pulse is quite weak; he has not so much trouble in swallowing; the tongue is coated and the breath fetid; the bowels are becoming more regular. January 29th: The patient is very weak this morning, and I ordered a blister to his chest, as he complained of severe pain there, and coughs very much; he continued to gradually sink until about three o'clock P. M., when he died. Examination ten hours after death, showed the body much emaciated. The track of the ball is as follows: The point of entrance is found to be half-way between the trochanter major and the tuberosity of the ischium of the right side; the exit is just above the root of the penis, on the abdomen. In the track of the wound, commencing at the ramus of the right side, the tuberosity of the ischium was splintered at its lower aspect. A portion of necrosed bone was found in this place. Below the border of the symphysis pubis on the left side, the descending ramus of that side was also found much comminuted; it had not been completely fractured transversely; the ball had apparently been deflected near the median line. The superior, lower, and anterior parts of the pubis to one and a half inches from the median line was found in a state of necrosis, with destruction of cartilage; this formed the posterior wall of an abscess, in the cavity of which was found necrosed bone and fragments of bone, three of which, about the size of the thumb-nail, were located in a passage communicating with the upper floor of the urethra, just posterior to the triangular ligament; these were obstructions to the urethra, and were noticed during life on all passages of the catheter; this explains the injury to the catheters during life. The abscess above was of the capacity of from four to six ounces; all the urinary tracts opened to it. The second opening was on the upper portion of the right thigh near the scrotum; the third and fourth on the left thigh a short distance below Poupart's ligament. The other portions of the urethra were not found involved. The bladder was slightly diminished in size, and the walls were but little thickened; the mucous membrane, however, was very much congested near the base and was almost in a sloughing condition; embedded in it were numerous flattened, roughened deposits of phosphate, and one smooth particle about the size of a pea. The kidneys presented similar deposits, and were mottled, and presented in places the appearances of fatty degeneration, but there



was no material difference in size and color. The lower lobe of the left lung was inflamed, and the inferior mesentery engorged and enlarged." A wet preparation of the pelvic viscera from this case, forwarded to the Museum by Dr. Weir, is imperfectly delineated in the foregoing drawing (FIG. 236). The artist has not succeeded in representing the abscess and false passages between the pubis and prostate, or the form of the bone fragments. The latter are accurately drawn, of the size of nature, in FIG. 5 of PLATE VIII.

CASE 851.—Sergeant H. B.—, Co. K, 5th Minnesota, aged 21 years, was admitted into hospital at Nashville, December 16, 1864, for a wound received at Franklin the previous day. Assistant Surgeon C. C. Byrne reports that "a conoidal ball passed through the rectum an inch above the verge of the anus, through the bladder, and then fractured the right os pubis, escaping upward without opening the peritoneal cavity." The fractured pubis is represented by FIG. 182, p. 237, and a cursory examination would suggest that the course of the ball was the reverse of that described, the loss of substance being much greater on the inner surface of the horizontal ramus. But a closer inspection indicates the correctness of Dr. Byrne's hypothesis, the greater loss of substance of the inner table being obviously due to the oblique impact and deflection of the projectile. The clinical report continues: "The wounds were dressed simply, and opium was administered. Feces and urine escaped from the wound of entrance. The patient sank slowly, and died from exhaustion and peritonitis, December 29, 1864." A preparation of the pelvic viscera (FIG. 237), exhibiting the track of the ball, was contributed to the Museum by Acting Assistant Surgeon H. C. May. The integument from the groin is tilted upward, at right angles to its proper plane, so as to exhibit, in the drawing, at A, the exit orifice made by the ball.

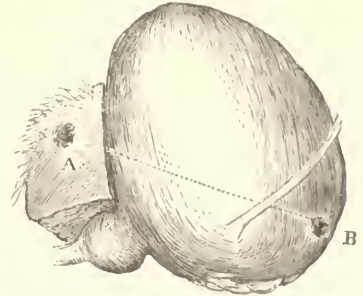


FIG. 237.—Preparation of a shot perforation of the bladder and rectum. *Spec. 3752.*

CASE 852.—Corporal L. T. Relyea, Co. A, 9th New York, aged 28 years, was wounded near Petersburg, June 18, 1864, and sent to a field hospital of the Fifth Corps, and was recorded by Surgeons Reed and Faxon as a case of flesh wound of the hip. On July 19th, he was transferred to City Point, and sent thence to Washington, and admitted into Stanton Hospital on July 1st. Surgeon John A. Lidell, U. S. V., reported the case as a "gunshot wound of the bladder and rectum." Ice dressings were applied, and stimulants administered, with tonics. Death, July 2, 1864, from peritonitis.

CASE 853.—Lieutenant F. A. Morrell, Co. K, 10th New York, was wounded at Fredericksburg, December 13, 1862. Assistant Surgeon A. E. VanDuser, 10th New York, reports that "a rifle ball had entered upon the left hip, passed through the bladder, and lodged. At the same time he received this wound a spent shell struck him in the right subclavian region." This officer was sent to the Seminary Hospital, Georgetown, on December 17th. Surgeon J. H. Brinton, U. S. V., entered on his note-book: "When admitted, had dulness, suberepitant râle, occasionally a dry sibilant râle; pulse 120, weak and feeble; sleeps badly. January 9, 1863: Catheter; much better; pulse 96; appetite tolerable. January 14th: Pulse 96; bowels good; had a slight chill; urine passed through the posterior opening made by the ball. After January 9th, a catheter was kept in the bladder; his condition improved; pulse 96; appetite tolerable." Acting Assistant Surgeon H. W. Ducachet reported that after the middle of January this officer's condition gradually deteriorated, and that he died February 4, 1863.

It must not be overlooked that patients may recover from the vesical injury and perish from intercurrent disease:

CASE 854.—Private M. Jones, Co. F, 25th Wisconsin, was wounded, July 22, 1864, near Atlanta, and was taken to hospital No. 3, at Rome, Georgia. Surgeon G. F. French, U. S. V., states that "a ball from a sporting rifle perforated the bladder and lodged in the right inguinal region, where its presence caused the formation of an abscess. The missile gradually worked its way to the surface, and was extracted September 11, 1864." The ball represented in the wood-cut (FIG. 238) was sent to the Museum by Surgeon French. The patient suffered from chronic diarrhœa, and Surgeon J. H. Grove, U. S. V., reports that he died of this malady September 23, 1864.




FIG. 238.—Battered round rifle ball that penetrated the pelvis, lodged, and was discharged from an abscess. *Spec. 3293.*

CASE 855.—Private W. B. Wait, Co. K, 108th New York, aged 28 years, was wounded at Monocacy, July 9, 1864. Acting Assistant Surgeon G. M. Paullin reports that "a conoidal ball entered the left buttock about two inches above the tuberosity of the ischium, passed upward and forward, perforated the rectum, severed the prostatic portion of the urethra, fractured the ramus of the pubis of the same side, and emerged at a point about an inch and a half to the right of the penis. He was admitted from the field into hospital at Frederick on July 11th. His general condition was good, and he complained of but little pain; the appetite was good. On introducing the catheter by the urethra, an obstruction was found near its prostatic portion which interrupted the further progress of the instrument, and upon introducing the finger into the rectum it came into immediate contact with the catheter. The male catheter being withdrawn, a female catheter was introduced by the rectum through the wound in the urethra into the bladder, where it was retained by means of a T-bandage; but proving of little or no advantage it was removed, as the urine emptying from the urethra into the rectum was discharged with the feces. On July 12th, symptoms of peritonitis supervened; the pulse increasing from 75 to 100, with extensive tympanitis. Wet cups were applied to the abdomen, subsequently a cantharidal plaster. On the following day the patient was much more comfortable, all the symptoms of peritonitis having abated. The symptoms having increased on the 17th, a poultice of hops and flaxseed was applied to the abdomen. On the 18th the patient was somewhat better; the tympanitis had subsided. There was little change by the 30th; he complained of no pain; his appetite for light articles of food was quite good, yet the patient failed gradually; delirium and subsultus came on, and he died on August 14, 1864. The bladder, rectum, pubis, and ramus of the ischium were dissected out *en masse* at the *post-mortem*, but were so disorganized and lacerated as to be scarcely recognizable. The ramus of the pubis of the right side was somewhat comminuted."

The next case furnished the calculi represented in FIGURE I of PLATE VIII, and presents several other features of great interest, such as the passage of bone fragments by the urethra, the persistent fistulous orifice in the right wall of the bladder, the ligamentous union of the fractured pubis, and the concentric hypertrophy of the muscular tunic.

CASE 856.—Private John M——, Co. H, 101st New York, aged 19 years, was wounded at the second battle of Bull Run, August 29, 1862. He was taken to Armory Square Hospital. Surgeon J. H. Brinton, U. S. V., made a memorandum of the case in his note-book, with diagrams indicating the position of the entrance and exit wounds. Reduced copies of these drawings are represented in FIGS. 239 and 240. The missile, probably a conical musket ball, entered over the horizontal ramus of the right pubis an inch from the symphysis, and, passing downward and a little outward, emerged through the right buttock.

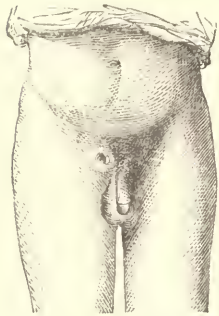


FIG. 239.—Entrance wound of a shot perforation of the pubis.

Surgeon D. W. Bliss, U. S. V., forwarded a report of the case. After giving the military description and seat of injury, the report continues: "Several pieces of bone, at different periods, passed through the urethra, and although he has never been perfectly free from pain, sometimes of the most severe character, his appetite and strength long continued good. The wounds made by the entrance and exit of the ball would close up for a longer or shorter period, and again open and discharge urine, pus, and blood; and, when uniting, the contents of the bladder would pass quite as freely through these fistules as through the urethra. He generally urinated freely, but never without pain, referred to at times as very severe; the urine always albuminous, muco-purulent, or bloody, and in considerable quantities. During the earlier part of the treatment a catheter was retained in the bladder, and attempts have been made, at different later periods, to reintroduce it, but were attended with unendurable suffering. The catheter never seemed to be of much benefit. The patient has suffered much pain, referred to the kidneys, at different periods, which was allayed by cupping, warm fomentations, and opiates. About six weeks ago

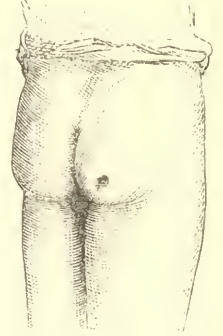


FIG. 240.—Exit wound in the same case.

(September 15, 1863) he was placed under the influence of ether, and the anterior wound was dilated and an irregularly shaped piece of bone was extracted, and, at the same time, a stone was distinctly felt, but it was not deemed prudent to operate for its removal at that time. Since then, he has been gradually failing, and he died on the evening of October 24, 1863.<sup>1</sup> At the autopsy, on the following day, it was discovered that the course of the ball varied but little from the foregoing description. The

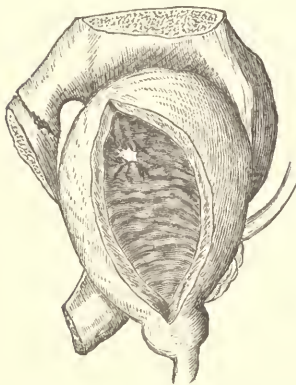


FIG. 241.—Fistule from shot perforation of the bladder, with fracture of the right pubis and ischium. Spec. 1758.

bladder was greatly contracted, and the walls or coats were three-eighths of an inch in thickness, and the cavity was nearly filled by two stones, one weighing two drachms ten grains, the other three drachms fifty-seven grains, or, conjointly, six drachms seven grains. Several pieces of necrosed bone were removed from the point of exit of the ball." The two calculi here referred to were sent to the Museum, and were numbered 2567 of the Surgical Section. They are represented of the size of nature in FIG. I, PLATE VIII. The bladder and injured portion of the right os innominatum were also forwarded, and constitute the highly interesting specimen represented in the wood-cut (FIG. 241). There is ligamentous union of the fracture of the horizontal ramus of the pubis. The fractured ischium is united by callus and so much deformed as to be a puzzling study. The thickened bladder adheres to the pubis and ischium, and its wall appears to have been perforated at one point only, the opening remaining widely pervious. The missile probably struck the viscera while distended, and produced a single laceration on its right lateral wall. In Dr. J. H. Brinton's note-book there is a memorandum of a visit to the patient, January 3, 1863: "Patient is nearly well. He complains of pain at the anterior wound when he draws a long breath, and of constant pain in the glans penis, and frequently pulls at the prepuce. Appetite good. Pieces of bone were discharged some five or six days since through the posterior opening, and some little pieces came through the urethra, the size of a



FIG. 242.—Fragment of necrosed bone expelled through the urethra. [From a drawing by Dr. J. H. BRINTON.]

grain of rice, and ragged. One piece was expelled which was larger, about half an inch in length and nearly quarter of an inch in width (FIG. 242). There was great pain in micturition. The catheter has, at various times, been introduced."

CASE 857.—Private H. C. Hotchkiss, Co. H, 90th New York, aged 18 years, was wounded at Cedar Creek on October 19, 1864. Assistant Surgeon J. Homans, U. S. A., reported that a musket ball fractured the ilium and ischium, and penetrated the bladder and lodged in the muscles of the opposite side. The patient was sent to the Sheridan field hospital, and thence to Baltimore. On October 26th he entered Newton University Hospital, where Surgeon R. N. Pease, U. S. V., reported there ensued "peritonitis, cystitis, and sloughing of the sciatic artery, and death, October 30, 1864."

As in the foregoing cases, in a majority of the ninety-six fatal cases of shot wounds of the bladder likewise, the complication of fracture of one or more of the pelvic bones

<sup>1</sup> A duplicate of this report is found on a case-book of Armory Square, without signature. The substance of it has been published, more or less literally, by Dr. W. H. BUTLER (*Buffalo Med. and Surg. Journal*, 1864, Vol. III, p. 458), and by Dr. H. A. ROBBINS (*Am. Jour. Med. Sci.*, 1868, Vol. LV, p. 125), both formerly employed at Armory Square as acting assistant surgeons.



was present. This statement must be submitted, in place of an exact determination of the frequency of this complication, the fractures being specified in twenty-eight cases only.

A number of the cases, five at least, of fatal shot wounds of the bladder were complicated by the graver injury of fracture of the neck of the femur with destruction of the hip-joint. The following may be particularly noticed here as explaining a mistaken reference,<sup>1</sup> of a Museum specimen:

CASE 858.—Private *J. P. Cavanagh*, Co. F, 17th South Carolina, was wounded at Antietam, September 17, 1862. He was treated with other wounded prisoners on the field until October 9th, when he was sent to hospital No. 1, at Frederick, and placed under the care of Dr. Redfern Davies, who made the following note of the injury and autopsy: "The external wound was beneath the left

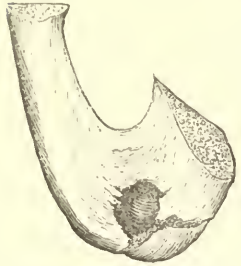

FIG. 243.—Ball embedded in the inner part of the right ischium. *Spec.* 819.

trochanter-major, which, with the adjacent shaft of the femur, was much comminuted. The joint was apparently injured. A probe passed freely into the bladder. The mine escaped partly by the wound and partly by the natural channel. The general condition was pretty good. October 14th, since a careful examination, three days ago, the patient has rapidly grown worse. He died on October 15, 1862. *Scetio calaveris*: Trochanter-major pulverized; trochanter-minor extensively comminuted; shaft of femur at its junction with trochanter and neck comminuted, the fragments held together by periosteum. The ball passed through the thyroid foramen. A finger passed readily into the bladder from the wound. Beneath the periosteum, in the pelvic cavity, there was extensive sloughing and destruction of the soft parts. The peritoneum covering the intestines was injected. The bladder was perforated in two places. The bullet was found fixed in the tuberosity

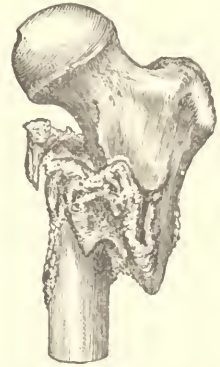

FIG. 244.—Partly consolidated shot fracture below the trochanters of the left femur. *Spec.* 798.

of the right ischium, its base only visible. The ischium was comminuted." [There can be no doubt that the specimen 819 referred to, and figured (FIG. 191) on page 242 *ante*, CASE 703, of *William Laws*, really belongs to this case, which also furnished the specimen No. 798 (FIG. 243) of partly consolidated shot-fracture of the left femur below the trochanter. On referring to the abstract of case 703, it will be observed that the ball perforated the ischium, *making its exit* near the tuberosity of the ischium. In the case of *Cavanagh*, the ball, after fracturing the left femur (FIG. 244), embedded itself in the body of the right ischium, and a careful review of the reports of Dr. Redfern Davies and of Acting Assistant Surgeon W. W. Keen, jr., leaves no room for doubt that specimens 798 and 819 were both obtained from the case of *Cavanagh*.]

The following is also an instance of fracture of the neck of the femur conjoined with injury of the bladder, and is interesting from the vesical lesions having been apparently secondary, as in the cases adverted to on page 290, the penetration of the bladder resulting from consecutive sloughing:

CASE 859.—Sergeant W. Spendlove, Co. E, 1st New York Cavalry, aged 25 years, was wounded at Piedmont, June 5, 1864, and was taken prisoner, and a few days afterward admitted to a Confederate hospital at Stanton. Assistant Surgeon W. Grumbeln, 20th Pennsylvania Cavalry, made the following special report of the case: "He was wounded in the left hip by a piece of shell; the wound in the soft parts was extensive, and the trochanter and neck of the femur comminuted; by probing the wound the lower end of the upper portion could be distinctly felt, having the appearance of a direct fracture; the lower portion was more oblique. A great number of pieces of bone were taken out and suppuration removed others. It was decided to wait until the suppurating stage was fully established and then resect the bone. At the time when the operation should have been performed, however, pulmonary symptoms had made themselves manifest, of a very ambiguous nature, precluding all hopes of a successful termination of the case. The patient sank daily, and phthisis pulmonalis was fully established. By enquiring into his previous history, I ascertained that he has had a dry hacking cough for some time, and also has had hæmorrhage from the lungs. For the last three weeks of his sickness, his urine was bloody and contained some pus. He died July 13, 1864. *Post-mortem* appearances: The external wound looked red and healthy, not at all indicating the degree of injury existing within. On laying open the joint there was no sign of reparation, the tissues forming a dark sloughing mass. Notwithstanding the small quantity of matter that escaped through the opening the cavity was filled with coagulated blood, and communicated with the bladder by a fistulous opening through the obturator foramen. The piece of shell was not extracted. It was supposed that it had not lodged in the wound, but that a splinter of bone penetrated toward the bladder, injuring its coats, which afterward sloughed through. The right lung seemed healthy, but the left lay in a pool of matter and was very much disorganized."

<sup>1</sup> The two specimens arrived together from Frederick. The ischium appears to have been forwarded by Dr. REDFERN DAVIES, the femur by Dr. W. W. KEEN, jr., and the two were numbered 798. (See *Catalogue of A. M. M.*, 1863, p. 41.) The ischium was then transferred to No. 819 (*Ibid.*, p. 42). In the quarto *Catalogue* of 1866, p. 281, Specimen 798, not conforming to the history to which it was referred, is classified as of unknown origin, and No. 819 is referred to the case of *William Laws*. The memoranda accompanying the specimens are well calculated to deceive; but a careful comparison of numbers and letters proves, beyond question, that there was no pathological preparation forwarded in the case of *William Laws*, and that the two preparations 798 and 819 belong to the case of *Cavanagh*.



Like CASE 859, and those adduced on page 290, the following is an instance of secondary penetration of the bladder by ulceration, the progress of the lesions having been explained by an autopsy:

CASE 860.—Private D. Smith, Co. I, 57th New York, aged 30 years, was wounded at Gettysburg, July 2, 1863, and treated at the Seminary and Camp Letterman hospitals. Assistant Surgeon S. B. Sturdevant, U. S. V., reported: "He was admitted August 8, 1863, having been wounded by a minié ball entering the body on the left side of the spine near its junction with the sacrum, touching, in its passage, the last lumbar vertebra, passing into the cavity of the pelvis in a line downward and forward, and between the lower end of the middle of the rectum and the base of the bladder; the ball was not extracted. The patient had been doing well since the injury, aside from the emaciation which gradually took place, until the morning of September 4th, when prostration suddenly ensued, and simultaneously with it a considerable quantity of urine and pus was discharged from the rectum. Death resulted on September 8, 1863, from exhaustion, consequent on the injury. Simple dressings, tonics, stimulants, and nourishing diet were prescribed from the time of his entrance into the hospital until his death. A *post-mortem* examination was made in this case, when it was discovered that at the point where the ball had touched the anterior portion of the rectum and the posterior wall of the bladder in its passage between them, ulceration had taken place involving all the coats of the bladder, and that part of the rectum lying contiguously to the bladder, making a communication which had allowed a free passage of urine into the rectum. Only a small amount of pus was seen, and there was no disorganization of the pelvic viscera beyond the ulceration as above described."

*Urinary infiltration* was the cause of death in a large proportion of cases of shot wounds of the bladder.<sup>1</sup> If the urine gained access to the serous sac, fatal peritonitis resulted; if it permeated the pelvic fascia, sloughing or diffuse suppuration was less promptly, but almost as surely, mortal.

CASE 861.—Private F. Smith, Co. I, 10th New York, was wounded at Bull Run, August 28, 1862, was sent to Ryland Chapel Hospital, at Washington, in September. Assistant Surgeon V. B. Hubbard, U. S. A., reported that "a minié ball penetrated the bladder through the right ilium and lodged. Urine was extensively infiltrated into the surrounding tissues, and escaped with pus from the wound, especially during paroxysms of coughing and during defecation. A catheter was introduced into the bladder and maintained in position till death. There was a scanty flow of urine through the catheter, and during the last few days it was intimately mixed with pus. The surrounding tissues were much discolored, and would have sloughed extensively had the patient survived a violent irritative fever, of which he died September 14, 1862."

CASE 862.—Private J. Smith, Co. A, 10th New York, wounded at Bull Run on August 28, 1862, was sent to Washington, and admitted into hospital on September 2d. Assistant Surgeon V. B. Hubbard, U. S. V., reported that a ball entered the pelvis at the left sacro-iliac synchondrosis and lodged. There ensued complete paralysis of the bladder, and no urine was voided save by the use of the catheter, which was retained in the bladder and gave issue to an intimate mixture of blood and urine in about equal proportions. The genitals were œdematous; the tissues of the pelvis were infiltrated with urine, and escaped from the wound with the pus. The patient died on September 19, 1862. The symptoms and termination of this case were very similar to those of Private Frank Smith, who died five days previously from a similar wound.

The coincidence of shot perforations of the bladder and rectum,<sup>1</sup> already repeatedly exemplified, is further illustrated by the three following cases, two of which have been alluded to on page 252. The subject will be more fully considered in the following subsection, on wounds of the rectum:

CASE 863.—Private R. Baggs, Co. F, 1st West Virginia, was wounded on November 27, 1863. Surgeon D. Bagley, of his regiment, reports that "a pistol ball entered the right groin, penetrated the bladder, and passed through the rectum, establishing a communication between them, which caused the greater part of the urine to be voided by the rectum. A catheter was introduced and retained in the bladder for some days. At length inflammation was manifested, and the patient rapidly sank, and died on December 17, 1863, twenty days from the time he was wounded. The *post-mortem* revealed a gangrenous condition of the bowels, with extravasation of urine. The ball had entered the fundus of the bladder and passed through on the opposite side into the rectum, and was embedded in the coccyx."

CASE 864.—Private A. Tweedy, Co. I, 79th New York, aged 26 years, was wounded at Blue Springs, Tennessee, on October 11, 1863. Surgeon C. W. McMillin, 1st Tennessee Mounted Infantry, reports that "a ball entered half an inch to the right of the symphysis pubis, crushing the ramus, tearing the bladder and rectum, and making its exit through the coccyx." The patient was sent to the Asylum Hospital at Knoxville, October 12th, and died October 15, 1863. The autopsy revealed "extensive inflammation from infiltration of urine; the intestines adhered to each other and to the abdominal peritoneum."

CASE 865.—Private H. F. Potter, Co. M, 1st Pennsylvania Cavalry, was wounded at Brandy Station, and was sent to Annapolis, on the steamer Platonic, June 9, 1863. Surgeon B. A. Vanderkief, U. S. V., reported that "a ball entered the right buttock, passed forward through the ilium, rectum, and bladder, and lodged." Death, July 15, 1863, from urinary infiltration.

<sup>1</sup>JARVIS (N. S.) (*Surgical Cases at Monterey*, in *New York Jour. of Med.*, 1847, Vol. VIII, p. 156) records a fatal example of shot fracture of the ischium, in the case of Private Capers, Baltimore Battalion, with urinary fistula at the pubes and urino-stercoral fistula in the buttock, terminating fatally on the sixteenth day. The same author records the case of Private Young, 1st Tennessee, wounded at Monterey, September 21, 1846, who died, on the twenty-third day, from a diagonal shot perforation of the bladder and rectum without pelvic fracture.

Nearly all of the fatal cases of shot wounds of the bladder in which accounts of the morbid appearances were reported are detailed in the preceding pages, though a few instances relating to the subject will be found in succeeding subsections on wounds of the prostate gland and on wounds of the urethra. Surgeon J. A. Lidell, U. S. V., has published<sup>1</sup> the history of a case of transverse double shot perforation of the bladder, fatal at the end of the third week, and described the agglutination of the intestines and other viscera "by greyish-white or ash-colored, soft, plastic exudation, the product of recent diffuse peritoneal inflammation." Dr. E. G. Janeway has printed<sup>2</sup> a very interesting account of dissection of a bladder, in the hypertrophied walls of which a round leaden ball had been sacculated for nineteen years. In a letter to the Surgeon General, Surgeon J. G. F. Holston, U. S. V., referring to an autopsy<sup>3</sup> of a soldier shot in the pelvis, remarks that "post-obit examination proved the existence of a perforation of the bladder, though not a drop of urine had escaped externally, neither had he suffered that excruciating anguish generally the accompaniment of the extravasation of urine into the peritoneal cavity." Dr. B. B. Miles, in his reports of autopsies at Jarvis Hospital, describes<sup>4</sup> the appearances observed in a case of diagonal shot perforation of the bladder terminating fatally on the thirty-third day. Examples of the effects of shot wounds of the bladder complicated with lesions of the viscera of the abdomen proper, have been adduced under previous headings, as, for instance, CASE 533, on page 169, CASE 637, on page 219, CASE 645, on page 221, CASE 690, on page 238; CASES 690 and 697 may also be compared. An analysis of the observations of shot wounds of the bladder observed during the war, teaches that when such lesions are limited to the portions of the bladder uninvested by peritoneum, they will heal readily, provided no foreign sources of irritation are present, and a ready exit for the urine<sup>5</sup> is afforded by natural or artificial channels, so that the organ may remain in that state of rest the healing process requires. The wrinkled

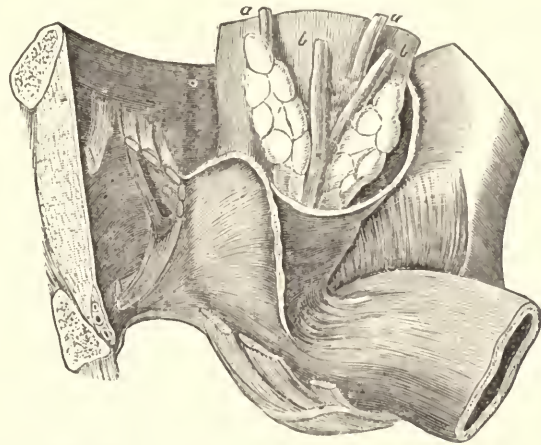


FIG. 245.—Section showing the pelvic viscera near the anterior wall of the pelvis, the rectum turned back: *a a*, ureters, *b b*, vasa deferentia. The relations of the fasciæ, muscles, and iliac vessels and nerves are also well shown. [After HENLE, *Handbuch der Eingeweidelehre*, B. I, S. 33*e*.] 3.

<sup>1</sup> LIDELL (J. A.), *On Rupture of the Abdominal and Pelvic Organs, especially the Bladder, including those occasioned by Fire-arms*, in *Am. Jour. Med. Sci.*, 1867, Vol. LIII, p. 367, Case X, of Private W. Hesling, Co. I, 9th Cavalry, wounded May 30th, died at Stanton Hospital, June 20, 1864.

<sup>2</sup> JANEWAY (E. G.), *Proceedings of the New York Pathological Society*, April 9, 1873, in *The Medical Record*, Vol. VIII, p. 344. The chief points are stated at the end of the note on page 287, *supra*.

<sup>3</sup> Case of Private J. Ingold, Co. A, 68th New York (Cameron Rifles), wounded on picket, October 12, 1861, died at Alexandria, October 14, 1861.

<sup>4</sup> Case of Sergeant H. J. Tucker, 1st New York Independent Battery, wounded at Cedar Creek, October 19, 1864, died November 21, 1864: "The ball fractured the left pubis near the symphysis, passed through the bladder, and fractured the spine of the right ischium. Near the ball track, the peritoneum was discolored and in a gangrenous condition; there was slight effusion of blood in the peritoneal cavity. The coats of the bladder were indurated and the mucous coat was ulcerated at some points, and the muscular tunica was disorganized in spots. The serotum was infiltrated with effused blood. The kidneys were congested, the liver and spleen were normal."

<sup>5</sup> COLLES (*Lectures on the Theory and Practice of Surgery*, Am. ed., Phila., 1845, p. 133) remarks: "In gunshot wounds of the bladder urine is never effused." BECK (*Chirurgie der Schussverletzungen*, 1872, S. 562) cites four fatal cases of shot wounds of the bladder. At the autopsy, in the case of B——, 2d Baden Grenadiers, after opening the peritoneum, a reservoir filled with urine, ichor, and gas was found; ichorous exudations were found in the pelvic cavities of the other cases. STROMAYER (*Maximen*, n. s. w., S. 660) recites at length a case of shot wound of the bladder. Urine in very small quantities continued to ooze slowly into the cavity of the abdomen, as indicated by continued vomiting and cold extremities, while there were hardly any signs of peritonitis. A "spitzkugel" had opened the bladder, the point remaining in the bladder. The ball had been pushed back by a catheter just enough to allow the urine to escape into the peritoneal cavity, as was demonstrated by the autopsy. SEUDÖRFFER, (*Handbuch der Kriegschir.*, 1867, S. 814) relates the case of Wischnai, 9th Hussars, shot in the abdomen in February, 1854; death, March 10, 1854. At the autopsy, the missile was found to have grazed the external coat of the bladder, and, passing between the bladder and rectum, to have entered Douglas's space, escaping to the right of the glutens; secondary opening of the bladder; the peritoneum above the bladder and the adjacent connective tissue was thickened and infiltrated with urine and pus, and covered with phosphates; beyond this space no peritonitis.



form of cicatrix usually remaining is represented by FIGURE 245; but, after the lapse of time, all marks of perforation by a small projectile may be obliterated, as in Dr. Janeway's observation. The viscus usually contracts adhesions to the adjacent tissues at the seat of injury, and, when there is pelvic fracture, is often united to the bone by adventitious fibrous tissue, as in CASE 856. Such adhesions involve unpleasant dragging sensations when the bladder is distended. When large fistules are established, communicating with the cutaneous surface of the groin or perineum, or with the cavity of the rectum, their walls acquire an epithelial lining continuous with the mucous coat of the bladder. It is alleged that persistent fistulous communications with the small intestine have been observed.<sup>1</sup> I have never seen an anatomical demonstration of this, and have looked in vain for a satisfactory description of such a condition. More or less hypertrophy of the muscular tunic is observed when patients survive mechanical lesions of the bladder for any considerable length of time. If the injury is near the neck, and its effects seriously impede micturition, the consequent muscular hypertrophy is proportionally exaggerated. The cases in which extravasation of urine into the peritoneal cavity was clearly established proved speedily fatal. The observations of Syme, Chaldecott, and Walters<sup>2</sup> indicate, however, that the undecomposed urine does not necessarily act as a mortal irritant to the serous sac, and suggest a therapeutic expedient, to be considered hereafter. Diffuse infiltration of urine between the deep pelvic fasciæ had consequences varying with the extent and direction of the infiltration; generally, more or less sloughing of connective tissue was induced, and abscesses, and pyæmic or septicæmic infection often followed.<sup>3</sup> Projectiles lodging in the cavity of the bladder are apt to induce chronic cystitis, with ammoniacal urine and phosphatic deposits, which usually encrusted the foreign body. It was noticeable that iron missiles were more quickly coated than those of lead, and that silver catheters maintained in the bladder were very soon encrusted, phenomena suggestive of an explanation partly chemical, partly mechanical. Projectiles lodged more frequently in the walls of the bladder than in the cavity, and, in some instances, induced no functional disturbance, until, by ulcerative absorption, they intruded into the cavity. If the tissues were tolerant of the presence of these metallic foreign bodies in some situations, it was otherwise with detached fragments of bone. These, if driven into the cavity of the bladder, sometimes became the nuclei of calculi; if lodged in the walls or surrounding tissues, they invariably induced abscesses and fistulous communications with the exterior. Coagulated blood and mucus, and hair likewise, served as nuclei for phosphatic concretions in the bladder. MM. H. Larrey, Chassaignac, and Giraldés assert (*l. c.*, p. 336) that coins

<sup>1</sup> Compare Dr. PETERS'S observation, CASE 793, and the cases recorded by KÉRAUDREN (P. F.) (*Causes des Mal. der Marins*, 1817) and by FLEURY (DEMARQUAY'S *Mém.*, p. 300).

<sup>2</sup> CHALDECOTT (*Provincial Medical Journal*, London, 1846, p. 333); case of John Phillips, wine-merchant in Dorking, aged 50; the distended bladder ruptured by violent contact with a post. SYME (*Contributions to the Pathology and Practice of Surgery*, 1818, p. 303, reprinted from the *Edinburgh Monthly Jour. of Med. Sci.*, 1848, Vol. VIII, p. 502); a youth of 17, in Benjamin Bell's practice; bladder lacerated by a fall on a sharp piling; recovery after free extra-peritoneal incisions. WALTERS (A. G.) (*Case of Rupture of the Bladder, treated by Abdominal Section*, in the *Med. and Surg. Reporter*, 1862, Vol. VII, p. 153); case of John Bolland, aged 22, rupture of the bladder from a kick, a case largely reprinted at home and abroad.

<sup>3</sup> ATCHLEY (*Extravasation of Urine in a Child, following Rupture of the Urethra from a Blow*, in *Lancet*, 1871, Vol. II, p. 677); BIRKETT (*Case of Extravasation from Urine from Ruptured Urethra*, in *Lancet*, 1856, Vol. I, p. 230); WICHMANN (J. E.) (*Ideen zur Diagnostik*, Hannover, 1792-1802, B. III, S. 44); OSIANDER (F. B.) (*Neue Denkwürdigkeiten*, n. s. w., Göttingen, 1797, B. I, St. 2, S. 302); CAGNION (*Infiltration d'urine à la suite d'un contusion au périnée*, in DESAULT, *Journal de Chir.*, Paris, 1792, T. I, p. 373); SABATIER (*Méd. opératoire*, Paris, 1822, T. II, p. 156). WALLACE (*Extravasation of Urine from Rupture of the Urethra by a Fall*, *Lancet*, 1856, Vol. I, p. 230); BONETUS (*Sepulchritum*, Genevæ, 1700, Lib. III, Sect. XXIV, Obs. XII, p. 631); MONTAGU (C.) (*A Case of a Rupture of the Bladder from a Fall*, in *Med. Communications*, London, 1790, p. 284); OILENROTH (JR.) (*Von einer bey starker Quetschung des Beckens zerplatzten Urinblase*, in THIEFEN, *Neue Bemerkungen und Erfahrungen*, Berlin, 1795, B. III, Beob. 3, S. 128); CHOPART (*Traité des maladies des voies urinaires*, 1792, T. II, pp. 89, 94); GUYON (Article *Abdomen*, in *Dict. encyclop. des Sci. Méd.*, 1869, T. I, p. 174); LAUGIER (Article *Vessie*, in *Dict. de Méd.*, en 30, Paris, 1846, T. XXX, p. 741); HOLT, (*Lancet*, 1866, Vol. I, p. 457) cites two cases of extravasation of urine, one from retention, the other from external injury; DITTEL (*Harninfiltration*, in VON PETHA und BILLROTH, *Handbuch der Allgemeinen und Speciellen Chirurgie*, 1872, B. III, Abth. II, S. 187); PETIT (*Des épanchemens dans le Bas-ventre*, in *Mém. de l'Acad. Roy. de Chir.*, 1753, T. II, p. 101); CLEMENT (*De l'épanchement d'un liquide ou d'un gaz comme accident des plaies du bas-ventre*, Thèse à Paris, 1839, p. 20).



and buttons, as well as bone fragments, may be driven into the bladder by shot. The possibility is obvious, but, as there is no evidence that such foreign bodies ever have been thus introduced, the remark is hardly in conformity with that scientific precision to be anticipated from such a source, that exactness which surgical investigators should ever esteem a sacred obligation.<sup>1</sup>

In connection with considerations on the pathological anatomy of shot wounds of the bladder, may be inserted representations of the encrusted projectiles already referred to on page 271, in detailing the cases of Mason and Lindsay, CASES 796 and 797. These interesting specimens were kindly transmitted by Dr. J. L. Forwood, but, it will be remembered, not in season to admit of the insertion, in the proper place, of engravings to illustrate them. FIGURE 246 represents the concretion removed from the bladder of Lindsay (CASE 796), a flattened conoidal ball, largely encrusted with triple phosphate,<sup>2</sup> successfully extracted by lateral lithotomy two years and nine months subsequent to the reception of a shot wound of the pelvis. In December, 1873, seven years and eight months subsequent to the operation, Lindsay enjoyed fair health, and was employed as a weaver in a factory at Upland, Delaware County, Pennsylvania. FIGURE 247 represents the encrusted conoidal ball with limited deposits of triple phosphate, successfully removed from the bladder of Mason (CASE 797, p. 271) five years after the reception of a shot wound of the pelvis.<sup>3</sup> Mason was also well in December, 1873, pursuing his avocation as a fisherman on the Delaware. Dr. J. L. Forwood is "firmly of the opinion that the ball was not in Mason's bladder until six weeks prior to the operation." "I knew him very well," Dr. Forwood continues, "and for years after his return from the army I saw him every few days. There was a puckered cicatrix in the centre of the pubic arch. There were no symptoms of calculus whatever. Six weeks prior to the operation, while he was fishing for sturgeon in Delaware Bay, he suddenly felt a stinging sensation in the hypogastrium and a desire to urinate, and passed a little blood with his urine. Calculous symptoms supervened immediately afterward. Mason left his boat and came home to Chester and consulted me, and, on sounding him, I detected what I believed to be a ball. The operation followed as soon as his consent was obtained. There was no chronic inflammation in this case, an evidence, in my estimation, of the correctness of my hypothesis that the ball had a brief residence in the cavity of the bladder. Mason had a quick recovery, and subsequently enjoyed uninterrupted good health."<sup>4</sup>

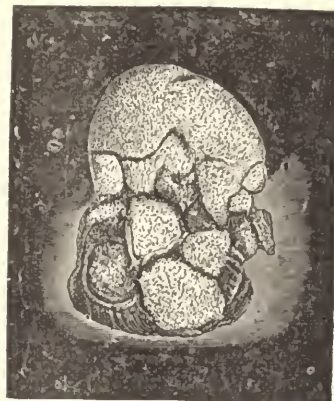


FIG. 246.—Vesical calculus having a deformed conical ball as a nucleus. Spec. 6329.  $\frac{1}{2}$ .




FIG. 247.—Conoidal musket ball removed from the bladder. Spec. 6330.  $\frac{1}{2}$ .

<sup>1</sup> Professor LONGMORE (HOLMES'S *System*, 1861, T. II, p. 68) directly, and GUTHRIE (*Lectures*, p. 70) by implication, state that: "PERCY removed a ball and a portion of shirt from the bladder." PERCY simply recounts such an operation by DUVERGÉ (p. 269, *supra*).

<sup>2</sup> The greatest length of the rounded encrustation and ball together, as they probably were placed in the bladder, was about 38 millimetres. The weight of the ball and investing matter is 631 grains Troy. The encrustation consists almost entirely of ammoniaco-magnesian phosphate; there is, however, a trace of phosphate of lime.

<sup>3</sup> The encrusted missile weighs 496 grains Troy. The encrustation is of unmixed ammoniaco-magnesian phosphate.

<sup>4</sup> In addition to the thirty-two examples of balls extracted from the bladder already noticed, I find a thirty-third instance in WIERRER (*Neueste Vorträge der Professoren der Chirurgie und Vorstände der Krankenhäuser zu Paris über Schusswunden*, Sulzbach, 1849, S. 76, note): Major G——, of Würzburg, was shot in the groin in the Russian campaign of 1812, and the wound healed without serious derangements. Fifteen years subsequently, this officer began to suffer from calculous symptoms. In the latter years of his life he could micturate only by strongly flexing the thigh and leaning the trunk to the opposite side. He died of an affection of the heart, in 1836. At the autopsy, a ball was found in the coats of the bladder near the neck; half of the missile, projecting into the cavity of the bladder, was covered with calcareous deposit an inch long by half an inch in width, the concretion acting as a valve over the urethral orifice. The encrusted ball was presented by Dr. WIERRER to the Anatomical Museum in Würzburg.

Dr. J. L. Forwood more than compensated for the delay in forwarding the specimens from the cases of Lindsay and Mason, by transmitting the specimen and history of a third case, an instance of shot contusion of the bladder, followed by the formation of a cystic oxide calculus, which was successfully extracted by lithotomy:

CASE 863.—Sergeant William McMonegle, Co. A, 12th New Jersey, received an injury at the battle of Chancellorsville, May 3, 1863. Dr. J. L. Forwood, of Chester, reports that the sergeant's statement was that, while in the act of firing, a piece of shell struck the butt of his musket, and that he was knocked down and remained insensible for half an hour, when he rallied and rejoined his regiment. After the battle, he reported to the regimental surgeon and was off duty for three weeks. The monthly report of Surgeon A. Satterthwait, 12th New Jersey, for May, 1863, mentions by name only those of the command who

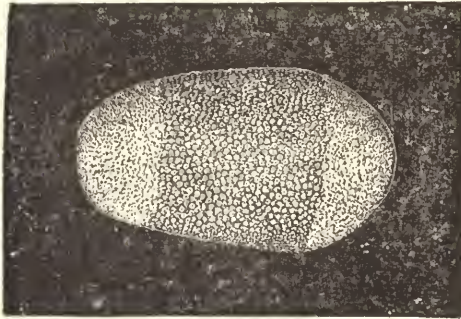


FIG. 248.—Cystic oxide calculus removed from a discharged soldier. *Spec.* 6334.  $\frac{1}{2}$ .

were killed at Chancellorsville, and this case is not reported on the Corps casualty lists; but these omissions by no means invalidate the soldier's personal narrative, which proceeded to recount that, on recovering from his swoon, he felt a severe pain in his back, and one week afterward a stinging pain in the bladder, accompanied by partial retention of urine. He was not placed under medical treatment, and a month subsequently his urine was voided with difficulty and pain, and sometimes dribbled away involuntarily. These symptoms never abated; but rather increased steadily up to the period at which, years afterward, he underwent lithotomy. At the battle of Gettysburg, July 3, 1863, Sergeant McMonegle was wounded in the forearm and was sent to West's Buildings Hospital, where Surgeon George Rex, U. S. V., recorded his admission without indication of the nature of the injury, and added that this soldier was sent to modified duty as a guard at the Park, July 24, 1863, and to duty October 21, 1863. The sergeant stated that after rejoining his regiment he suffered so much with pain in urinating that he was off duty half the time. The urine would dribble away uncontrollably, and he would be mortified at dress parade

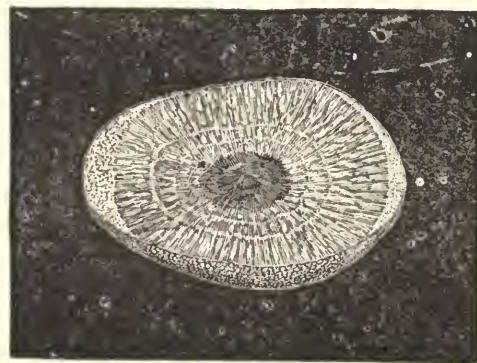


FIG. 249.—Section showing the internal structure of *Spec.* 6334.

by the stains on his trousers. He was discharged on the expiration of his term of service, in August, 1865, and returned to his home in Woodbury, unable to work, and suffering with such painful vesical symptoms as to be deprived of rest at night. He was treated by Drs. Clark and Howell, of Woodbury, but did not improve, and, in 1867, removed to Chester. Drs. C. J. Morton and Roland explored the bladder with sounds without detecting the presence of a calculus. Then, for a year, the patient was under the care of Dr. Delworth, of Chester, and his symptoms were not alleviated. Then he applied for treatment at the clinic of the University of Pennsylvania, but when Professor H. H. Smith was about to explore the bladder with a sound, the sergeant's courage forsook him and he escaped from the table. He came under Dr. J. L. Forwood's observation in this wise: As the Doctor was pursuing a country drive, he saw a man on the road with a wheelbarrow, who presently set down his barrow, and lying down in the pathway on his side, endeavored to void his urine, apparently with extreme distress, so that when the Doctor stopped and enquired the cause of his suffering, he said: "I wish the ground would open and let me in!" He readily accepted Dr. Forwood's advice, and, on exploration, a sound at once detected a calculus of medium size. On November 20, 1869, the ordinary operation of lateral lithotomy was performed; the concretion (FIG. 248) was easily grasped and extracted. The after-treatment presented no unusual incidents; convalescence was uninterrupted and rapid. In December, 1873, McMonegle was enjoying good health and was employed in a foundry at Chester. The calculus, weighing, after drying, two hundred and fifty-eight grains Troy, is a remarkable and beautiful example of a cystic oxide concretion, capped at the extremities of the long axis by deposits of triple phosphate. The exterior (FIG. 248) and the appearances on section (FIG. 249) are accurately represented in the accompanying wood-cuts. The calculus and the principal memoranda from which the foregoing abstract was compiled were contributed by the operator, Dr. J. L. Forwood, to the Army Medical Museum.

In this case, cystitis and possibly consequent calculous deposition is referred to a blow upon the hypogastrium, which, beyond cavil, appears to have temporarily paralyzed the contractile power of the bladder. The case, in the latter point of view, confirms the observation of Dr. F. H. Hamilton (CASE 780) on this effect of contusions in the hypogastrium. M. Legouest and Mr. Blenkins agree with Professor Hamilton<sup>1</sup> as to the frequency of this

<sup>1</sup> HAMILTON (F. H.) (*Princ. Mil. Surg.*, 1865, p. 324). LEGOUEST (L.) (*Traité de Chirurgie d'Armée*, 2<sup>me</sup> éd., 1872, p. 423), who also teaches that, "Les gros projectiles \* \* lorsqu'ils frappent obliquement sur l'abdomen ou le bassin, peuvent rompre la vessie." BLENKINS (Additions to Article *Gunshot Wounds*, in the eighth edition of COOPER'S *Dictionary*, 1861, p. 835): "Paralysis of the bladder is not an uncommon result of blows from shot or large pieces of shell, and rupture of the bladder when in a state of distention may occur, without being accompanied by corresponding injury to the external parts." WILLIAMSON (*Mil. Surg.*, 1863, p. 118) notes a case of incontinence of urine from a contusion by a spent round shot.



result, of which I find no evidence, and sustain also the supposition that shell contusions produce ruptures of the bladder, of which the experience of our own and other late wars has afforded no instance, the nearest analogous example being the case reported by Mr. Prescott Hewett,<sup>1</sup> of rupture of the bladder by a blow of a bar of iron on the hypogastrium.

The only pathognomic sign of wound of the bladder is the escape of urine by the artificial opening. Pain, frequent micturition, and bloody urine are uncertain signs; indeed, the source of hæmaturia, in abdominal injuries, is often very obscure. The diagnosis rarely presents difficulties, save in regard to the extent and nature of the complications. A glance at Quain's familiar plate (FIG. 250) suggests that these must of necessity be frequent and varied; shot wounds of the bladder unattended by injuries either of the pelvic bones, the rectum, the blood-vessels, or genital organs, being rarely observed. Restlessness, anxiety of countenance, lumbar pain, tenesmus, hæmaturia, a rapid pulse, and low temperature are usual, but not invariable, accompaniments of wounds of the bladder.<sup>2</sup> Contrary to general opinion, M.

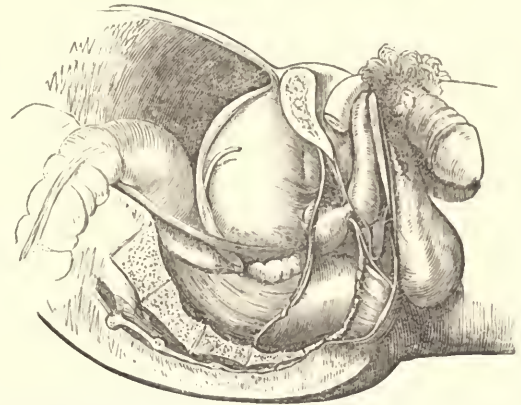


FIG. 250.—Side view of the viscera of the male pelvis. [After WILSON.]

Demarquay (*l. c.*, p. 293) has established, by repeated actual measurements, that distention of the bladder does not elevate the recto-vesical duplicature of the peritoneum, the distance from the extremity of the cul-de-sac to the perineum remaining at 7 or 8 centimetres, whether the bladder is full or empty. Accepting these measurements, there is difficulty in believing that this peritoneal fold escaped perforation in some of the cases of recovery. Among the fatal cases were several of men shot in prone or stooping postures, the missiles entering the nates or perineum (FIG. 251) and passing through the fundus of the bladder into the abdominal viscera, causing extravasations and mortal peritonitis. In the treatment of wounds of the bladder, our surgeons had no confidence in the prevention or cutting short of inflammatory accidents by depletion, and directed their efforts to the mitigation of the complications caused by urinary infiltration.<sup>3</sup> To restore the passage of the urine by the natural channel, to prevent consecutive distention of the organ, to evacuate blood accumulated in its cavity, and to diminish as much as possible the escape of urine through the tissues, were the objects held in view, and mainly sought by the aid of the catheter. Cystoraphy, though recommended by M. Legouest, was not practiced.

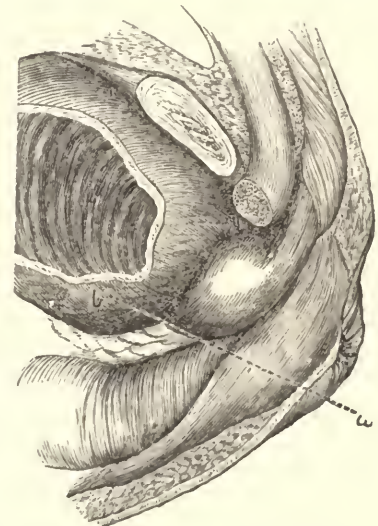


FIG. 251.—Drawing to show the direction of a shot penetration of the bladder nearly in a line with the long axis of the body. [Altered from BOUGERY.]

<sup>1</sup> HEWETT (P. G.), *Ten Cases of Ruptured Bladder*, in *Transactions of the Pathological Society of London*, 1850-52, Vol. III, p. 229.

<sup>2</sup> Compare M. LE GROS CLARK'S discriminating observations on the diagnosis, *Lect. on the Principles of Surg. Diag.*, 1870, p. 335.

<sup>3</sup> FISCHER (H.) (*Schussverletzungen der Bauchhöhle*), in VON PITHA und BILLROTH, *Handbuch der Allgemeinen und Spec. Chir.*, B. I, Abth. II, S. 252) remarks: "Shot wounds of the bladder are more frequent and dangerous, when the organ is distended and the ball enters from behind. Generally, diffuse peritonitis, copious infiltration of urine, and gangrenous inflammation soon develop themselves. But adhesions and closing of shot wounds of the bladder with double perforation even have been observed. \* \* Shot wounds of the anterior wall of the bladder need not open the peritoneum."



No instance of protrusion of the bladder after shot wounds was reported; indeed, Samuel Cooper's observation of three cases of traumatic cystocele, after the battle of Waterloo, remains unparalleled in modern warfare. As the bladder rarely protrudes and its shot perforations are seldom simultaneously single and communicating with the exterior by short and direct canals, the cases admitting of the easy application of sutures must be very infrequent. Some of the many survivors with vesical fistulæ might, perhaps, hope for relief by cystoraphy. Early incisions were rejected, as facilitating rather than obviating urinary infiltration; but, after this had taken place, incisions for evacuation of urine and pus and gangrenous connective tissue were often practiced with the most beneficial results.

Poney's practice<sup>1</sup> having suggested, and Chopart's writings<sup>2</sup> inculcated, the advantages of catheterization in shot wounds of the bladder, the elder Larrey attached great importance to this feature in the treatment. In accordance with Larrey's precepts, the introduction and maintenance of a catheter throughout the progress of treatment was regarded as of imperious and uniform necessity in wounds of the bladder; but, as many lithotomists came to doubt the utility of maintaining a tube in the prostatic wound after

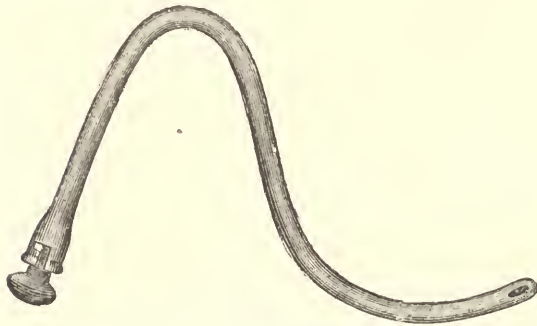


FIG. 252.—Squire's catheter à demeure. Spec. 4688.  $\frac{1}{2}$ .

cystotomy, and then to discard this expedient as superfluous and occasionally hurtful, so, as experience in the management of wounds of the fundus of the bladder has augmented, some surgeons have become skeptical regarding the necessity or advantage of keeping an instrument in the bladder. Baudens appears to have first suggested<sup>3</sup> that the presence of a catheter might prove a hindrance to the healing process. In a case reported by Professor Van Buren,<sup>4</sup> already alluded to on

page 264, he advantageously refrained from the employment of a catheter; and Herr Beck's later experience<sup>5</sup> inclines him to the view that catheterization should not form a routine part of the treatment. On the other hand, the judicious use of the catheter constitutes, in many instances, the most essential therapeutic resource. Surgeon T. H. Squire, 89th New York, who has paid special attention to the subject, attaches great importance to the continuous maintenance of a catheter, and, in a case that will be described with Wounds of the Urethra, devised an instrument with a special curve (FIG. 252), adapted to the pendulous portion of the urethra. A French elastic catheter is, I think, preferable.

<sup>1</sup> In BORDENAVE'S *Observations sur les Plagues par Armes à feu*, in the *Mém. de l'Acad. de Chir.*, 1753, T. II, p. 523. In the case of a soldier shot in the bladder at Charleroi, "M. Poney's voyant que les urines ne sortaient point par le voie urinaire, eut recours à la sonde, qui devient très-utile pour débarrasser la vessie des urines, et procure l'issue de quelques petits caillots et de portions membraneuses."

<sup>2</sup> CHOPART (*Traité des Mal. des voies urinaires*, 1792, T. II, p. 93): "Il faut souvent, et même dès le premier tems introduire par l'urètre une sonde dans la vessie, soit pour procurer l'issue de l'urine ou quelques caillots de sang qui y sont retenus, soit pour détourner ce liquide de ces plaies."

<sup>3</sup> BAUDENS (*Clin. des plaies d'armes à feu*, 1836, p. 368): "Cette fistule, comme on le voit, s'est établie et guérie par les seules forces de la nature, dont les efforts salutaires ont été un instant arrêtés par l'introduction de la sonde. Ce qui prouve qu'il est des cas où il faut savoir s'abstenir de l'introduction de la sonde dans la vessie, et que la présence de celle-ci n'est pas indispensable pour la guérison des fistules urinaires."

<sup>4</sup> VAN BUREN (W. H.) (*New York Medical Journal*, 1865, Vol. I, p. 105): "The continuous presence of a catheter in the urethra and bladder of a man, already suffering from a most serious wound, is no trifling addition to the burden he has to bear, and although, in deference to all high authorities, from Chopart and the Larreys to Legouest and Hamilton, the use of the instrument is properly regarded as the rule in gunshot wounds of the bladder, the result of this case demonstrates that the rule may be occasionally disregarded to the advantage of the patient." In this case, Professor VAN BUREN states that: "The temperature, during the first two weeks of his confinement, was never below 80°, varying from this to 92°." An astonishing observation, about which there must have been some mistake!

<sup>5</sup> BECK (B.) (*Chirurgie der Schussverletzungen*, 1872, S. 559) advises the use of the catheter only where there is retention. An elastic catheter, or, better still, one made of tin, may be introduced, perineal section being practiced, if catheterization is otherwise impracticable. He describes his change of view as follows: "Ich habe in frühesten Zeit der Ansicht gegolten, der Katheter müsse augenblicklich nach der Verwundung eingeführt werden, ich bin aber seit vielen Jahren davon zurückgekommen."

It is important to leave the orifice free, and to renew the instrument every two days, until the cure is complete. Opium, by the stomach and by enema, and frequent warm baths, greatly mitigate vesical irritation, and, if the extent and direction of the wounds admit of it, washing out the bladder by tepid injections is very serviceable. After the first few days, the bowels should be kept soluble, by diet if practicable, by laxatives if necessary.<sup>1</sup>

WOUNDS OF THE PROSTATE.—While so much has been written on enlargements and other diseases of the prostate,<sup>2</sup> Velpeau and Vidal<sup>3</sup> are among the few authors who have treated of its injuries in a systematic manner, although in all treatises on the pathology of the urinary organs, or on operations on the urethra or bladder, considerations respecting the physical lesions of the prostate necessarily hold an important place. From the point of view of the military surgeon, the general custom of omitting any special mention of wounds of the prostate might well be followed, for incised wounds are considered in treating of cystotomy; and such is the complexity of shot wounds of the pelvis, that there are few that interest the prostate without, at the same time, implicating parts less tolerant of injury. Still, in a work of the magnitude of this history, it is convenient to multiply subdivisions, and as one case was reported in which a ball lodged in the prostate, and others in which this organ was the principal seat of injury, it is not amiss to form a separate group, though the cases included in it might have been placed with the account of injuries of the bladder or of the urethra. Of the pathology of the seminal vesicles and Cowper's glands (FIG. 253) little is known. Civiale, Lallemand, and Faye<sup>4</sup> have collected a few examples of calculus, of suppurative inflammation, and of tubercle in these organs. In a case of shot wound involving these parts,<sup>5</sup> there was persistent priapism. The direction of the wound-track, ischuria, excessive pain in defeca-

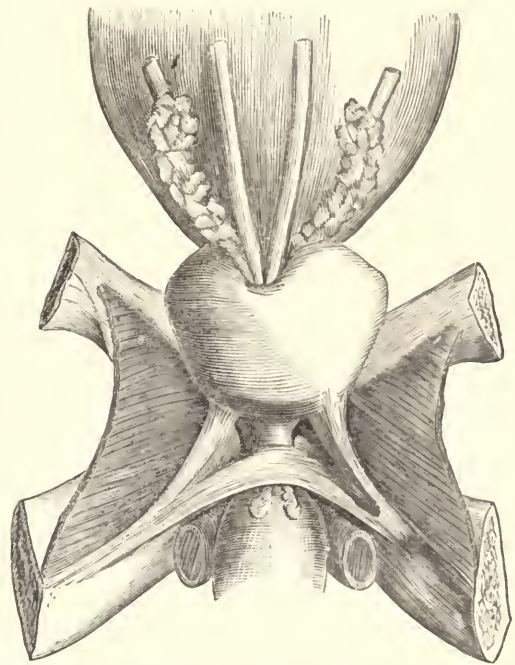


FIG. 253.—Prostate, seminal vesicles, and bulb of the urethra seen from behind, and showing also Cowper's glands, the ischio-prostatic ligaments, and middle perineal fascia, sections of the corpora cavernosa, and the external obturator muscles. [After ANGER.]  $\frac{2}{3}$ .

<sup>1</sup> Few, if any, pathological preparations of shot wounds of the bladder are preserved outside the Army Medical Museum; at least I have not found such in the collections I have examined or the catalogues to which I have access. In many museums, there are numerous specimens illustrating wounds or cicatrices after cystotomy or vesical puncture; and examples of ruptured bladder, in which the Army Medical Museum is deficient, are not uncommon elsewhere. Preparations exhibiting stabs or lacerations of the bladder are uncommon. At the Warren Museum, No. 2482 is the bladder of a child transfixed by a bay-hook (J. B. S. JACKSON'S *Cat.*, p. 521). At Guy's, 2104<sup>00</sup> is a bladder pierced by a catheter, and 2104<sup>75</sup> shows a stab in the posterior wall. At St. George's Museum, No. 35, in Series IX, shows a laceration of the rectum and bladder by the broken leg of a chair (*Cat.*, p. 412); No. 4, of Series XII, shows a stab wound of the bladder, and No. 6, same series, shows a puncture of the bladder by a catheter (*Cat.*, p. 543).

<sup>2</sup> PROSTATE, —πρῶ, before, ἵστημι, to stand; Lat., *Glandula prostata*; Ger., *Vorstehdrüse*.

<sup>3</sup> VELPEAU (A. L. M.) (*Plais de la prostate*, in *Dict. de méd.*, en 30, 1842, T. XXVI, p. 134), a lucid, exhaustive essay of ten pages, in the best style of the master. VIDAL (AUG.) (*Traité de path. ext. et de méf. opérat.*, 5<sup>me</sup> éd., 1861, T. IV, p. 707) devotes a chapter of his classical work to this subject, reproducing in the main his valuable paper from the *Annales de Chirurgie Franc. et étrang.*, 1841, T. II, pp. 31 et 206. EMMERT (C.) (*Lehrbuch der Specillen Chirurgie*, 1862, B. III, S. 708) has one short paragraph on *Wunden der Prostata*. COSTELLO has a short article on *Wounds of the Prostate*, in the third volume of the *Cyclopedia of Practical Surgery*. Systematic writers generally refer only incidentally to one group of wounds of the prostate, those from within outward, in treating of the contusions and false routes made in catheterization, the punctures and incisions purposely made in operations. In the journals, an occasional observation of physical lesions of the prostate is found; thus: MONOD (*Blessure de la prostate dans la ponction vésicale sus-pubienne*, in *Gazette des Hôpitaux*, 1855, No. 121, p. 484).

<sup>4</sup> CIVIALE (*Traité pratique sur les maladies des organes génito-urinaires*, 3<sup>me</sup> éd., 1858, T. II, p. 503); LALLEMAND (*Des maladies des organes génito-urinaires*, Paris, 1825); LAMPERHOFF (*Diss. de vesicularum natura et usu*, Berlin, 1835). The chief observers were ALBERTS, CRUVEILHIER, DALMAS, and MITCHELL. FAYE (*Diss. de vesiculis seminalibus*, Christiana, 1841).

<sup>5</sup> Case of Private M. Perkins, Co. K, 6th Maine, wounded near Fredericksburg, May 3, 1863. The ball chipped the left acetabulum and ischium, and passed through the thyroid foramen, between the rectum and prostate; he lived thirty-eight days; there was persistent priapism for many days.



tion, and signs detected on catheterization and exploration by the rectum, may sometimes suffice to establish the diagnosis of a lesion of the prostate; there is no pathognomonic sign. Abstracts are given of two fatal cases, and of one which had a favorable termination:

CASE 867.—Sergeant H. Ford, Co. F, 67th New York, was wounded at Fair Oaks, May 31, 1862, and was admitted to Douglas Hospital on June 4th. Assistant Surgeon Warren Webster, U. S. A., reported that "a ball entered on the posterior part of the thigh two inches below the lower portion of the sacrum and three inches to the right of the median line, passed forward and inward, apparently through the lesser ischiatic notch, and lay embedded in the neck of the bladder or the prostatic portion of the urethra. A sound introduced into the bladder comes in contact with the ball near the neck of the bladder. Water injected into the bladder passed out through the wound. The urine, having a foetid smell, and being mixed with pus, was discharged by means of a catheter. June 12th, hæmorrhage from the urethra, apparently venous in character, occurred this afternoon, and one quart of blood was lost; ice was applied to the perineum until the hæmorrhage ceased. A pill, containing half a grain of opium and three grains of sugar of lead, was given every two hours. June 14th, the hæmorrhage has not returned, and the patient now passes his water without difficulty; there is still a foetid discharge of pus and urine from the wound. On June 15th, hæmorrhage from the wound occurred again to the amount of one quart. June 17th, the patient has bled several times since the 15th, always from the wound, and had much trouble about passing his urine. He died at eleven o'clock P. M. Examination ten hours after death, showed that the ball had passed inward, fracturing the spine of the ischium, detaching the lesser sacro-sciatic ligament, wounding the internal pudic artery, and was embedded in the prostatic gland."

CASE 868.—Private Charles C——, Co. A, 30th Iowa, aged 24 years, was wounded at Vicksburg, May 22, 1863. He was placed on a hospital transport and taken to Memphis, and admitted to Jackson Hospital on May 27th. Acting Assistant Surgeon S. H. D. Garretson made the following report of the case: "The ball entered midway between the trochanter major of the left femur and the apex of the os coccygis, and made its exit in the right femoral region one inch below Ponpart's ligament. Patient stated that very profuse hæmorrhage occurred immediately after the reception of the wound. Urine escaped from both entrance and exit wounds, but none from the urethra. At every considerable motion of the patient blood escaped from the femoral opening of the wound despite the pressure of compresses. Slight diarrhœa, accompanied by deep jaundice, occurred on the 30th. On June 4, 1863, the patient expired. *Post-mortem* revealed that the prostate gland above the floor of the urethra and at its junction with the bladder was cut away; that the right ramus of the os pubis was shattered to fragments; and that the femoral vein was either originally cut or had afterward sloughed from the effects of the injury. There was not much infiltration of urine among the pelvic tissues. At the request of Assistant Surgeon E. M. Powers, U. S. V., in charge of the hospital, the bladder, prostate gland, and femoral vein were dissected out, and accompany this condensed history of the case." The pathological preparations were transmitted to the Museum by Surgeon W. Watson, U. S. V., and one is represented in the accompanying wood-cut. In the preparation of the urinary bladder (FIG. 254) there is a large loss of substance at the fundus, which appears to have been made in removing the viscus. The destruction of tissue in the prostate is greater than represented by the wood-cut. The preparation of the femoral vein will be represented in the subsection on wounds of the blood-vessels. The orifice in the vessel is very large.

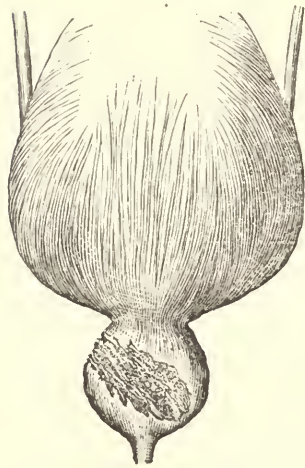


FIG. 254.—The prostate channelled and disintegrated by a musket ball. *Spec.* 2093.  $\frac{1}{2}$ .

CASE 869.—Private E. Holloway, Co. E, 1st Delaware, aged 18 years, was wounded at Morton's Ford, February 6, 1864, and was admitted to the field hospital of the Second Corps, where Surgeon F. A. Dudley, 14th Connecticut, reported: "Gunshot wound, lacerating the prostatic portion of the urethra. March 4th, the ball was extracted through the left natis. March 15th, the urine now flows from the anterior wound." On March 24th, the patient was transferred to the 2d division hospital, Alexandria, and the injury was recorded as a penetrating wound of the bladder. The patient was transferred to Tilton Hospital on August 20th, and thence transferred to the Veteran Reserve Corps, January 28, 1865, and discharged without pension.

CASES 791 and 855 are also instances of shot lesions of the prostate;<sup>1</sup> another example, CASE 899, will be found on page 313, and still another with Wounds of the Urethra.

<sup>1</sup>Special works on the diseases of the prostate, where the effects of mechanical lesions are sometimes incidentally adverted to, are those by HOME (E.) (*Pract. Obs. on the Treatment of the Diseases of the Prostate Gland*, London, 1811); his paper, on the *Middle Lobe*, is in the *Philosophical Transactions*, 1806; WILSON (J.) (*On the Male Urinary Organs*, London, 1821); AMUSSAT (*Leçons sur les rétentions d'urine et les mal. de la prostate*, Paris, 1832); DUGA (*Étude pour servir à l'hist. des mal. de la prostate*, Thèse de Montpel., 1833); VERDIER (G. E.) (*Obs. et Réflex. sur les phlegmas. de la prostate*, Paris, 1838); MERCIER (L. A.) (*Essai sur un nouv. moyen de diagn. des divers déform. de la prostate*, in the *Arch. gén.* 3<sup>e</sup> série, 1839, T. V, p. 209); LEROY (D'ÉTIOLLES) (*Considérat. anat. et chir. sur la prostate*, Paris, 1840); STAFFORD (*On the Prostate*, 2d ed., London, 1845); CAUDEMONT (*Des engorgemens de la prostate*, 1847, Thèse de Paris, 198); ADAMS (J.) (*Anat. and Dis. of the Prostate Gland*, London, 1853); GELLIE (*De l'hypertrophie de la prostate, etc.*, Thèse id., 1854, No. 149); BÉLAUD (*Des mal. de la Prostate*, thèse d'aggr., Paris, 1856); COULSON (*On the Diseases of the Bladder and Prostate Gland*, 5th ed., London, 1856); HODGSON (*The Prostate Gland*, London, 1856); LEDWICH (*Inflammation of the Prostate*, in the *Dublin Quart. Jour.*, 1857, Vol. XLVII); JAPIN (*De l'hypertrophie de la prostate*, Th. de Paris, 1857, No. 155); TAGAND (*De la prostatite aigue*, 1858, id., No. 131); DAUSSURE (*De l'hypertroph. de la prostate*, id., No. 136); DELHOMME (*De la prostatite aigue*, id., 1859, No. 87); GUERLAIN (*De la prostatorrhée*, 1860, id., No. 237); THOMSON (II.) (*Diseases of the Prostate*, Jacksonian prize-essay for 1860, 4th ed., Phila., 1873); MALSANG (*Prostatite*, Th. de Paris, 1865, No. 141); DESCUBES (*Sur les abcès de la prostate*, 1866, id., No. 185); DODEUIL (*Sur les alt. sénile de la prostate*, 1866, id., No. 8); LUSCHKA (*Das vordere Mittelstück der Prostata und die Aberration derselben*, in VIRCHOW: *Arch. d. path. anat.*, 1865, S. 592); VERNEUIL (*Ectopie congen. part. de la prostate*, in *Arch. gén.*, 6<sup>e</sup> série, 1866, T. VII, p. 660); GOULEY, (J. W. S.) (*Diseases of the Prostate*, Chapter XI of his work on *Dis. of the Urinary Organs*, 1873, p. 253); GÉTIQUES (*Quelques considérations sur la prostate*, Paris, 1828).

WOUNDS OF THE RECTUM.—Of the traumatic affections of this region described by systematic writers, those made by pointed or cutting instruments are commonly produced by the surgeon, and will be noticed under the head of operations. The rectum<sup>1</sup> may be lacerated in defecation, or by the penetration of sharp fragments of bone into the intestine with the fæces; such accidents usually induce fistules of the anus, which will be examined further on. Dieffenbach<sup>2</sup> and others have known the clumsy introduction of a clyster-syringe to produce perforation of the rectum, and the injection of the liquid of the enema into the cellular tissue, a very dangerous accident. Serious lesions are sometimes consequent upon the introduction of bulky or irritating foreign bodies into the rectum with a therapeutic or criminal purpose; such cases will be considered under the head of foreign bodies. Shot wounds of the rectum are not infrequent, though rarely uncomplicated; they are scarcely mentioned by Mayo and others, who have treated specially of the injuries and diseases of the rectum; but claim the serious attention of the military surgeon, for the safety and the comfort of the patient largely depend upon the judgment and skill with which their treatment is conducted. This subdivision will, accordingly, be mainly occupied with the examination of the cases of this group reported during the war; but recorded operations for fistules, hemorrhoids, foreign bodies, etc., will also be chronicled.

One hundred and three cases of shot wounds of the rectum were reported, of which forty-four, or 42.7 per cent., resulted fatally. In forty-six cases concomitant fractures of the pelvic bones are distinctly noticed, the osseous lesion being specifically referred to the pubis in eleven cases, to the sacrum in nine, to the ischium in four, to the coccyx in four. By implication, however, the reports indicate the existence of pelvic fractures in a much larger proportion than forty-six of one hundred and three cases; indeed, there is nothing in the observations to contradict the theoretical considerations from which the extreme rarity of shot wounds of the rectum without pelvic fracture might be deduced. Pelvic cellulitis, and septicæmia<sup>3</sup> from fæcal infiltration, diffuse suppurations and other consequences of osseous lesions, and secondary bleedings from injury of the branches of the iliac arteries, were the complications that most commonly preceded a fatal termination in this group of cases. The wood-cut (Fig. 255) indicates

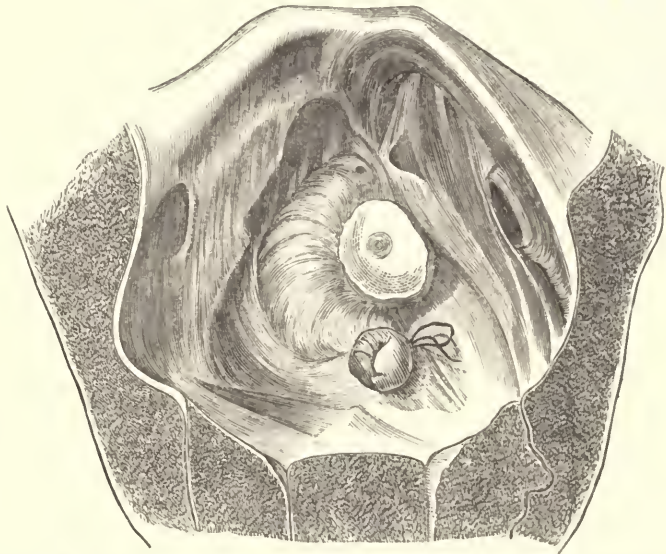


FIG. 255.—Section of the pelvis, according to Désormeaux, showing a portion of the rectum, a portion of the bladder at the neck, the pelvic aponeuroses, etc. From BOUVIER'S inaugural thesis. [After ANGER.] 4.

the extreme rarity of shot wounds of the rectum without pelvic fracture might be deduced. Pelvic cellulitis, and septicæmia<sup>3</sup> from fæcal infiltration, diffuse suppurations and other consequences of osseous lesions, and secondary bleedings from injury of the branches of the iliac arteries, were the complications that most commonly preceded a fatal termination in this group of cases. The wood-cut (Fig. 255) indicates

<sup>1</sup> RECTUM, a latin word, preserved in the English, French, Spanish, and Italian languages, notwithstanding its unfitness, to designate the third and last portion of the great intestine; Gr. *Ασπυγαν*, Gn. *Mastdarm*.

<sup>2</sup> DIEFFENBACH, in *Journal für Chirurgie und Augenheilkunde*, B. IX, S. 142.

<sup>3</sup> BECK (B.) (*Chirurgie der Schussverletzungen*, 1872, S. 554) regards shot wounds of the rectum as not dangerous in themselves, though often attended by mortal complications. He adduces four cases having a favorable issue and five fatal cases, and remarks of the latter that "death ensued in consequence of extensive osseous lesions involving the head of the femur, the acetabulum, etc., or else from injuries of the vessels, particularly of branches of the internal iliac; or, finally, from septicæmia consequent upon the infiltration of fæces." Further on (S. 555) the same author advises "not to search in blind channels for the missile, as it frequently passes spontaneously with the fæces."



the relations of the rectum to the pelvic fasciæ, and explains the liability of the fæces, retained by the contractions of the sphincters, to be widely diffused along the aponeurotic planes when the gut is perforated. Thirty-four of the cases, of which fourteen were fatal, are known to have been complicated with wounds of the bladder. Many of these cases have been detailed in the subsection on wounds of the bladder.<sup>1</sup> Some examples of comparatively satisfactory recovery<sup>2</sup> after shot wounds of the rectum will first be examined :

CASE 870.—Private *W. A. Colton*, Co. F, 42d Mississippi, was wounded and captured at Gettysburg, July 3, 1863. Surgeon *A. J. Wood*, 2d Wisconsin, reported a gunshot wound of the pelvis. The patient was transferred to De Camp Hospital. Surgeon *J. Simons*, U. S. A., reported that "a ball entered the left ilium about three inches posteriorly to the anterior superior spinous process, and emerged about an inch to the left of the anus." Acting Assistant Surgeon *A. W. Brockway* stated that "fecal matter came from each orifice; the man was in a very weak condition on admission; pulse small, at 110 and very weak, and he was much reduced in flesh. He had moderate diarrhœa, and the discharge from the wounds was copious. He was put upon stimulants and beef-tea, with opium; the diarrhœa was soon relieved. The wounds were dressed with oakum alone, and kept well washed; he soon began to mend, and the wound of exit closed in three weeks; the wound of entrance healed in the middle of September. Two or three small fragments of necrosed bone had come away. The general health of the patient rapidly improved, and he was sent to Fortress Monroe about the 1st of October, 1863, to be exchanged; he was then in apparently perfect health."

CASE 871.—Corporal *J. W. Alexander*, Co. B, 10th West Virginia, aged 22 years, was wounded at Cedar Creek, October 19, 1864, and, on the 23d, was admitted into the Patterson Park Hospital, Baltimore, where Acting Assistant Surgeon *M. Kempster* reported that "the ball entered about two and a half inches to the right of the anus, and, passing obliquely upward, had penetrated the rectum at a point three and a half to four inches above the anus. The patient had a profuse diarrhœa, and was considerably debilitated; fecal matter passed through the artificial anus continually, making the man a loathsome object. An astringent was administered, good diet given, and the wounds were dressed with dry oakum. October 26th: The patient complained yesterday of pain and swelling an inch anterior to the anus, and this morning there is an opening there, which also discharges fecal matter; none is discharged by the anus. Stimulants were given, and also anodynes to relieve the acute pain. October 28th: The patient is somewhat improved; the last opening carries off all the fecal discharges, thus relieving the original opening made by the ball. The diarrhœa is somewhat better; the discharges are less frequent, but thin. November 1st: The diarrhœa is nearly well, and the opening made by the ball is healing, and, since the discharge has been checked, the opening anterior to the anus is closing and the fecal discharge passes naturally. The opening anterior to the anus is syringed with cold water at each dressing, and the man appears clean and healthy. The diet throughout has been low, and no solids whatever have been given. November 10th: The wound made by the ball is nearly healed; the other is closing fast; no fecal matter has been discharged from it for five or six days; the diarrhœa is entirely checked. The object has been to keep the bowels somewhat constipated, and the result thus far has been satisfactory; his general condition is very good. The wounds have entirely healed, but the parts are yet a little tender. There has been no further treatment beyond limiting the diet and dressing the wounds with dry oakum." This soldier was returned to duty January 17, 1865. He is not a pensioner.

CASE 872.—Private *G. W. Parks*, Co. A, 16th Pennsylvania Cavalry, aged 30 years, was wounded at Po River, May 9, 1864, was treated in the Cavalry Corps Hospital, and subsequently transferred to the Second Division Hospital at Alexandria, where Surgeon *E. Bentley*, U. S. V., reported: "Admitted, May 24th, with a gunshot wound of the upper third of the left thigh and right natis, the ball passing through the rectum. Simple dressings were used, the wound healed, and he was furloughed on November 7th. He was readmitted on November 30th, and was discharged the service on May 30, 1865, on certificate, with complete disability, the consequence of gunshot wounds of both thighs, bladder, and rectum." Examiner *C. H. Dana*, of Tunkhannock, reported, March 15, 1872, that the "ball entered the upper and inner portion of the left thigh, passed under the pubic arch, and made its exit just under the ischium of the right side, passing through the rectum and neck of the bladder. The wounds of the rectum and bladder soon healed, but the wounds at the points of entrance and exit of the ball would heal for a time and then open. They now remain constantly open, and continually discharging pus, and sometimes blood, submitting him to great inconvenience, producing weakness and considerable pain on exercising. Disability three-fourths and probably permanent." This pensioner was paid to June 4, 1873.

CASE 873.—Sergeant *J. F. McGill*, Co. D, 25th New York Cavalry, aged 21 years, was wounded at Woodstock, October 8, 1864. On the 11th, he was transferred to the depot hospital at Winchester, and on December 5th, to Frederick. Acting Assistant Surgeon *T. E. Mitchell* reported that "a small conical ball passed through the fleshy part of the thigh at the upper third, through the perineum and lower part of the rectum, and came out near the left sacro-iliac articulation. When he was admitted at Frederick, the wound of exit was discharging but little; his bowels moved once or twice a day, with but little pain; ten grains of tartate of iron thrice daily, with milk-punch, constituted the general treatment. He continued to improve until the 20th, when a discharge of fecal matter occurred from the wound of exit, accompanied with loss of appetite, and smarting pain in the track of the wound. It lasted but three days, when the fever subsided, his appetite returned, and the condition of his bowels became quite regular, being moved but twice in twenty-four hours." He was transferred to New York, January 7, 1865, and was discharged from service, at McDougall Hospital, June 13, 1865. He is not a pensioner.

<sup>1</sup> Compare CASES 786, Wesson; 788, Jamisch; 789, Blake; 790, Este; 791, Mooney; 805, Shafford; 807, M. C. H.—; 810, Gardner; 821, Fore; 822, Currier; 823, Grubb; 825, Warren; 832, Scott; 835, Harger; 851, H. B.—; 852, Relyea; 855, Wait; 860, D. Smith; 863, Baggs; 864, Tweedy; 865, Potter.

<sup>2</sup> STROMEYER (L.) (*Maximen*, etc., 1855, p. 668) asserts that: "Injuries of the rectum occur generally in shot wounds of the lower portions of the sacrum, and, of themselves, are not dangerous."

The relative proportion of cases of complete perforation of the pelvis by balls, and of cases of penetration with lodgement, has been only approximately ascertained. If instances of subcutaneous lodgement are included, the latter group would have a considerable numerical predominance. The following are some instances of lodgement, with extraction of the projectiles through incisions:

CASE 874.—Sergeant A. G. Buchanan, Co. I, 139th Pennsylvania, aged 29 years, was wounded at Chancellorsville. He was sent from a Sixth Corps hospital to Stanton Hospital. Surgeon J. A. Lidell, U. S. V., records a shot wound of the right buttock, and the patient's transfer to Satterlee Hospital, June 17, 1863. Acting Assistant Surgeon L. K. Baldwin reported that "a conoidal ball entered the right natis nearly on a level with the anus, penetrated to the depth of seven inches, and lodged. When admitted, he was suffering a great deal of pain in and around the wound, from which there was a profuse discharge of unhealthy pus. Several shreds of clothing came away with the discharge, much to the relief of the patient. On July 10th, an examination revealed the lodgement of the ball between the tuberosity of the ischium and the anus. It had gravitated to this point and become so painful as to render its extraction necessary. An incision made between the tuberosity of the ischium and the anus failing to reach the ball, another was made through the rectum, at the verge of the anus, when the ball was easily reached and extracted with the forceps. The bowels were then locked up for a week, and the wound was dressed with cold water. At the end of this time it was found that the opening made through the rectum had entirely healed, and no fecal matter passed through it when his bowels were moved. By August 8th, the opening made in the fossa and the wound of entrance were almost entirely healed. The patient, having suffered severely from the pain attendant on the wound and long confinement to which he was subjected, now began to slowly regain his health and strength." He was returned to duty on March 23, 1864, transferred to the Veteran Reserve Corps January 28, 1865, and was mustered out January 29, 1865, and pensioned. The Examining Board at Pittsburg, Drs. McCook, McCandless, and Wishart, reported, June 7, 1871, that this pensioner was permanently disabled by the injury received from "a ball, which entered the middle of the right gluteus muscle and passed toward the median line, cutting the rectum, and injuring the sphincter ani." The missile (FIG. 256), was presented to the Museum by Dr. L. K. Baldwin.

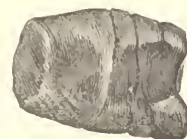

FIG. 256.—Compressed and mutilated musket ball extracted through the rectum. *Spec. 4429.*

CASE 875.—Private L. M. D. Crane, Co. G, 3d Michigan, aged 26 years, was wounded at Chancellorsville, May 3, 1863. Surgeon E. L. Welling, 11th New Jersey, reported his admission to a Third Corps field hospital with a shot wound of the left hip. He was sent to Armory Square Hospital, and Acting Assistant Surgeon R. S. L. Walsh reported that the ball entered four inches posterior to the anterior superior spinous process of the left ilium and lodged. It evidently passed through the rectum, as, in giving an injection, part of this would pass out of the wound. He was very much exhausted from the discharge and the formation over the right ischium of a large abscess, which was opened on June 4th, to his great relief. There was a great discharge of pus, but the ball was not found as was expected. June 21th: Patient doing well with the exception of a bed-sore. September 12th: A spherical case-shot was removed from the right natis by the surgeon in charge. September 24th: Patient doing well. He received a furlough in January, and was readmitted in March, and, on July 2, 1864, was discharged the service. The missile, represented in the wood-cut (FIG. 257), is a round iron ball from spherical case, and was transmitted to the Museum, with the foregoing memorandum, by Surgeon D. W. Bliss, U. S. V. Examiner H. O. Hitchcock, of Kalamazoo, reported, October 17, 1864, that "there is loss of power in the left leg, and constant pain in the left leg and back, with severe constipation." He rates the disability at three-fourths and temporary. Examiner E. Amsden, of Allegan, reported, September 4, 1873: "The ball was extracted from near the tuberosity of the right ischium, causing considerable injury to the gluteal muscles. Disability three-fourths, not permanent."




FIG. 257.—Iron case-shot removed from right buttock, after perforating the rectum. *Spec. 4429.*

CASE 876.—Private F. Gleaser, Co. G, 8th New York Heavy Artillery, aged 25 years, was wounded at Petersburg, June 22, 1864. Surgeon J. F. Dyer, 19th Massachusetts, and Surgeon W. F. Burmeister, 69th Pennsylvania, reported from a Fifth Corps hospital that "he had received shot wounds of the right or of both hips." The patient was sent to Judiciary Square, when Assistant Surgeon A. Ingram, U. S. A., recorded, July 1, 1864, that "the ball, passing through the right hip, perforated the rectum." Transferred to Rochester, November 26, 1864, the patient was reported, by Acting Assistant Surgeon A. Backus, as "having a fistulous opening communicating with the rectum, caused by a minic ball, which entered the right buttock, and was extracted from the perineum at the field hospital before Petersburg." This soldier was discharged from service July 25, 1865, for total disability. He appears not to have been pensioned.

CASE 877.—Sergeant D. K. Brinson, Co. H, 13th Georgia, aged 21 years, was wounded at Gettysburg, June 1, 1863. He was treated in the Seminary Hospital until July 30th, and then transferred to Camp Letterman, where Acting Assistant Surgeon J. Newcombe reported: "The ball entered the left groin and was excised from near the point of the right buttock. There was considerable hæmorrhage from the anterior or wound of entrance, but scarcely any from behind though the ball was almost immediately removed. The rectum, however, was wounded, and its contents escaped through the posterior wound; this ceased altogether after the lapse of a week. The bladder escaped unburnt. August 7th: The wounds are now nearly healed and give no inconvenience, and the patient walks out daily; he is quite convalescent. Tonics and full diet were given and the wound dressed. On August 20th, he was suffering from diarrhoea, which was relieved in a few days by the use of astringents and opiates. September 15th: The patient is quite well as regards general health, but has not recovered the perfect use of his limb; he experiences some difficulty in flexing the thigh upon the abdomen." On September 16th, he was transferred to West's Buildings Hospital, whence he was paroled September 25, 1863.



*Stercoral Fistule after Shot Wounds of the Rectum*—The occurrence of abnormal anus after shot perforation of the rectum was not infrequent, and there was, perhaps, a greater persistency in fecal fistulæ in this region than in those communicating with the colon through the fleshy parietes. The frequently attendant osseous lesions satisfactorily account for this, the discharges from carious bone and the occasional escape of sequestra keeping open sinuses that might otherwise contract and close:

CASE 878.—Private E. Machenbach, Co. E, 4th Missouri Cavalry, aged 25 years, was wounded at Mine Creek, Kansas, October 25, 1864. Surgeon F. V. Dayton, 2d New Jersey Cavalry, reported a slight shot wound of the left hip. The patient was treated at Mound City, by Surgeon E. Twiss, 15th Kansas Cavalry, until January 15, 1865, and then transferred to Fort Leavenworth, where Surgeon G. W. Hogeboom, U. S. V., recorded a "wound of the left hip and thigh by a conoidal ball, which penetrated the abdomen." On April 24, 1865, this soldier was discharged and pensioned for "gunshot wound through the left ilium;" disability rated as total. Examiner J. Bates, of St. Louis, reported, on May 1, 1865, that the wound of exit was still suppurating and there was lameness, which would probably improve. This invalid never drew his pension, but subsequently enlisted in the 29th Infantry. On March 30, 1863, Surgeon G. E. Cooper, U. S. A., reported that he had been in hospital at Fort Monroe suffering from the effects of a wound through the sacrum, implicating the rectum, and causing a fistulous sinus, through which the feces passed when the bowels were at all soluble. He was returned to duty with his company at Alexandria, March, 1863.

CASE 879.—Private W. H. Aucker, Co. B, 1st Minnesota, aged 22 years, was wounded at Gettysburg, July 2, 1863, by a minié ball, which entered the right thigh two inches above and one inch posterior to the right trochanter major, penetrated the right ilium, passed across the body, wounded the rectum, and emerged two inches external to the left sacro-iliac synchondrosis, having penetrated the left ilium from the inner surface. He was received into the field hospital on the 3d, and, on July 26th, was transferred to Camp Letterman Hospital. Assistant Surgeon H. E. May, 145th New York, reported that, "on admission, the wound of entrance was healed; that of exit still open, and discharging fecal matter. He had lain upon his face almost the whole time since the reception of the injury. His appetite was good; he slept well, and suffered very little pain." On November 7th, he was transferred to Newton University Hospital, Baltimore, on April 25, 1861, to De Camp Hospital, New York, and discharged from service June 4, 1864. Dr. A. L. Lowell, of the Pension Office, has furnished the following memoranda in the case: "Certificate of discharge states: Gunshot wound of the right hip and abdomen, the ball passing through the intestines. Certificate of examining surgeon, September 15, 1864: The wound is not healed; subject very feeble. July 24, 1866: Partial artificial anus where the ball passed out. The use of the legs is much impaired. Ingesta and small seeds pass out at times through the wound of exit of the ball. April 12, 1869: An artificial anus still exists, and at times the contents of the bowels pass out through the opening; he cannot endure hard labor, especially in walking, as both legs are affected. December 6, 1871: When the wound is open, wind passes through the opening on the left side; when closed, air infiltrates the surrounding parts; he has frequent discharges of blood and pus from the rectum; the parts are very sensitive to pressure; the left leg is somewhat atrophied, with lessened nervous sensibility; all efforts at manual labor are painful."

CASE 880.—Corporal E. H. Shermer, Co. H, 74th Ohio, was wounded at Stone River, December 31, 1862. Three slugs entered the left buttock, passed through to the right, lodged there superficially, and were removed by the surgeon of the field hospital [Surgeon George D. Beebe, U. S. V.], where he remained two days, and was thence transferred to Hospital No. 9, Nashville, and was about five weeks under the care of Surgeon Stegman, 2d Missouri; he was then sent to New Albany, and, five months later, to Madison, where his wounds healed, and on November 27, 1863, he was transferred, by Surgeon Gabriel Grant, U. S. V., to the Veteran Reserve Corps. He was discharged the service, April 12, 1864, from Cliffburne Barracks, Washington. Dr. Adams Jewett, Pension Examiner at Dayton, reports: "Exactly how long he was under treatment, my notes do not record; he says that fecal matter was discharged from both wounds for about four and a half months, and that a piece of bone came out about ten months after he was wounded, and that his feces sometimes passed involuntarily. On April 16, 1864, I examined him for pension. In the left gluteal region, six inches in front of the median line of the sacrum and seven inches below the crest of the ilium, is a cicatrix as large as a dollar, and in the right gluteal region a smaller scar also, about six inches in front of the median line of the sacrum and eight inches below the crest of the ilium. In sitting, he rests upon the edge of the chair, bearing his weight on one tuberosity of the ischium; he says that sitting square causes pain at the end of the backbone; he says he has not full power to retain the contents of the bowels, especially if there is any tendency to diarrhoea; he is considerably lamed, and looks of infirm health. He was examined September 30, 1865, when his general health seemed improved, and he was less lame, but found much difficulty in walking over uneven ground; he complained of pain in the lower part of the back, hips, and thighs; the control of the alvine evacuations is improved but not perfect; he still sits upon the edge of the chair, though he can sit squarely for a time by help of a cushion." This pensioner was paid to June 4, 1873.

CASE 881.—Private H. Shafer, Co. A, 116th Ohio, aged 21 years, was wounded at Winchester, June 13, 1863. He was transferred from the field hospital to Jarvis Hospital, Baltimore; on April 26th, to DeCamp Hospital, New York; and on June 9th, to the Seminary Hospital at Columbus, Ohio. Assistant Surgeon G. Saal, U. S. V., reported: "Gunshot wound; ball entered right hip; exit at pelvic region; fecal fistula in the left groin; simple dressing and compresses." Transferred, August 27, 1864, to Camp Dennison, and afterward treated in Tripler Hospital. Discharged February 4, 1865; disability three-fourths. Pension Examiner W. Walter, of Woodfield, reported, May 13, 1867: "At Winchester, June 13, 1863, he received a gunshot wound in the rear of the left hip, entering within one inch of the spine, passing through the pelvis, and making its exit in the left groin near the scrotum, causing weakness of the left leg and back. In my opinion he is for the greater part incapable of obtaining subsistence by manual labor; disability three-fourths, probably permanent." This pensioner was paid to March 4, 1873.

In the next case, it appears quite likely that the sigmoid flexure, rather than the rectum, was implicated, and, from the scanty indications in the report, it may be inferred that eversion and prolapsus of the intestine at the entrance orifice had supervened:

CASE 882.—Private H. P. Stoddard, Co. F, 2d Vermont, aged 24 years, was wounded at Savage Station, June 29, 1862. Transferred to Broad and Cherry Streets Hospital, thence to Marine Hospital, Burlington. The first detailed account of the injury is given by Acting Assistant Surgeon S. W. Thayer, who reports that "the ball entered to the left of the penis, passed through the pubis, rectum, and ilium, and came out a little to the left of the anus. He passed feces through both openings for several weeks." This soldier was discharged July 30, 1863, and pensioned. Examiner C. M. Chandler, of Montpelier, reported, September 4, 1873: "A discharge from the wound over the pubic bone is now uncomfortable and disagreeable. There is quite a growth at the entrance wound. The ball entered through the left pubis and made its exit through the buttock of the same side. There is an artificial anus, and the disability continues total."

In the following cases, the patients succumbed to the constitutional drain involved by the irritation maintained by persistent stercoral fistules:

CASE 883.—Private B. H. Clark, Co. A, 32d Massachusetts, aged 18 years, was wounded at Spottsylvania, May 12, 1864, by a conoidal ball, which entered the pelvis and perforated the rectum; he also received a wound of the head. He was treated in a field hospital, and on the 18th was transferred to Stanton Hospital, Washington; was furloughed on June 30th, and admitted into Dale Hospital, Worcester, July 5th. At each of the above hospitals a shot injury of the rectum was recorded. On November 14th, the patient was transferred to the Soldiers' Rest, Boston, where Acting Assistant Surgeon W. E. Townsend reported that "two fistulous openings were left by the wounds, through which feces passed." He was discharged the service December 8, 1865, and applied for a pension, stating in his declaration "that he was unable to leave his bed or help himself in any way." He died April 17, 1866, at the Home for Discharged Soldiers, in Boston.

CASE 884.—Private E. D——, Co. F, 120th New York, aged 36 years, was wounded at Spottsylvania, May 10, 1864, and admitted to Harewood Hospital on the 13th, the injury being noted as a wound of the left groin by canister shot. He was discharged, April 25, 1865, for total disability from a gunshot wound of the left groin, by Surgeon R. B. Bontecou, U. S. V., who transmitted to the Museum the photograph copied in the wood-cut (FIG. 258). Pension Examiner J. H. Clarke, of Newark, reported, July 31, 1867: "The ball entered the left side of the abdomen opposite the crest of the ilium. It seems to have found its way outside the small intestines and to have penetrated the rectum. The ball was removed from this situation. Before its removal, however, the fecal matter seems to have found its way out. Now the wound presents the appearance of an artificial anus; indeed, fecal matter was manifest to the sight and smell when I visited him to-day. He says that he defecated by the anus every week or two, but that the contents of the bowels continually find exit by this abnormal orifice. His general health is good. He has been in the hands of good surgeons, who see no chance of his recovery. It would seem impossible that surgical interference should avail to close the orifice in the rectum. Eight pieces of bone have been discharged; the ulcer looks as if more might appear. Were not the rectum penetrated, I should suppose recovery possible. He is now, of course, very helpless, and requires constant attendance and the performance of disgusting services; blood frequently passes from the anus. Disability total and permanent. The records show that this pensioner died on June 18, 1869.

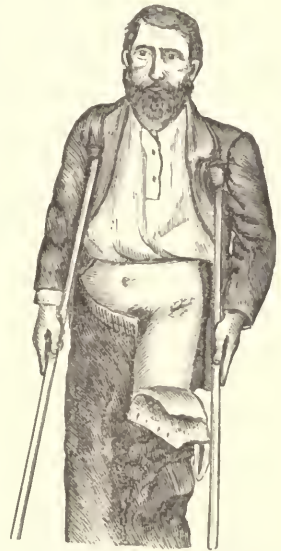

FIG. 258.—Stercoral fistula of the rectum. [From a photograph.]

CASE 885.—Sergeant Rufus G. Hayward, Co. B, 4th Vermont, aged 19 years, was wounded at Fredericksburg, December 13, 1862, and was treated in field hospital until the 18th, when he was admitted to Mount Pleasant Hospital, and thence furloughed on May 12, 1863. On August 5th, he entered the Brattleboro' Hospital. Surgeon E. E. Phelps, U. S. V., reported a "gunshot wound; ball perforating abdomen, but not lodging, with lesion of intestines." This patient was discharged the service October 30, 1863. Pension Examiner S. Newell, of St. Johnsbury, Vermont, reported, November 4, 1864, " \* \* \* : "Gunshot wound, ball entering the left side, wounding the intestines and bladder; urinary fistula and artificial anus resulted. He is in failing health; will probably terminate fatally in a few months;" and on November 23, 1869, Examiner C. C. Calhoun reported: "I attended Rufus G. Hayward occasionally after his discharge up to the time of his death, which occurred on August 10, 1869, so that I was familiar with his disease up to his death. He had two abscesses on his left side, which broke out and became running sores; and, by a breaking of the colon or large intestine, there was a constant discharge of fecal matter up to the time of his death, rendering him helpless; he had also three abscesses in his back constantly discharging; an entire loss of use of left arm and leg, so that he was wholly unable to dress and undress himself, all occasioned by gunshot wounds received in action."

CASE 886.—Corporal A. Young, Co. C, 8th Ohio, aged 35 years, was wounded at Mine Run, November 27, 1863, sent to Alexandria, and discharged May 7, 1864, by Surgeon T. R. Spencer, U. S. V., for "gunshot wound of the abdomen, perforating the cavity and wounding the bladder and rectum, and chronic cystitis resulting therefrom." This soldier applied for pension, September, 1864, Examiner G. K. Thompson certifying that a ball had passed from the left groin through the bladder and rectum, and that a rectal fistula persisted; and, subsequently, that the patient died December 5, 1864. Dr. Myers, of Bucyrus, certified, in support of the application of the heirs for pension, that the shot wound of the bladder and rectum was the sole cause of his death.



In the two preceding cases and in the following case, there were vesico-intestinal fistules, and the details reported do not clearly indicate how far the communications with the bladder contributed to the fatal results, or whether the vesical or the rectal injuries should be considered the dominant lesions:

CASE 887.—Lieutenant G. Robinson, Co. H, 70th New York, was wounded at Gettysburg, July 2, 1863, and was treated in a field hospital for some days, and the case noted as a gunshot wound of the bowels and lumbar region. The records of the Pension Office state that "this officer received a minié ball through the lower part of his head, fracturing his jaw, in the Peninsular campaign; he recovered, and was wounded in the back at Gettysburg, and was treated in Baltimore, at the house of Mayor J. L. Chapman. He was discharged the service March 5, 1864, for disability." Dr. J. E. Culver, of Hudson County, New Jersey, reports that "Lieutenant Robinson died August 3, 1864, from a gunshot wound received at the battle of Gettysburg; the ball having passed through the bladder and rectum, producing injuries which made recovery impossible."

A review of cases of pensions after shot wounds of the rectum, indicates that paralysis with incontinence of the fæces, or obstinate constipation, stricture, muscular contractions and atrophy, sinuses leading to carious parts of the pelvis, and recurrent abscesses were among the remote disabilities resulting from injuries of this group:

CASE 888.—Private J. W. Huntoon, Co. D, 4th Vermont, was wounded at Chancellorsville, May 3, 1863. He was admitted to a field hospital of the Sixth Army Corps at Potomac Creek, as a paroled prisoner, on May 13th, and, on June 14th, was transferred to Hammond Hospital, at Point Lookout, where Acting Assistant Surgeon R. N. Wright reported: "Admitted with a wound by a minié ball through the pelvic region, perforating the rectum. The fæces were discharging through both wound orifices. There was total loss of motion and sensation in the lower extremities; his spirits were good; constitution recuperative and energetic. Sulphate of quinia in three-grain doses was given every three hours, and doses of one-sixteenth of a grain of strychnia until he had taken four doses. Stimulating diet was given. August 30th: The patient is now so far improved that with the aid of a cane he walks about without difficulty; he has a good appetite, sleeps well, and will soon be in a condition to travel. Stimulants were administered occasionally, as circumstances required, and simple dressings were applied to the wounds. In my opinion, his wounds will unfit him for military duty for some time if not permanently." He was discharged the service at Convalescent Camp, December 31, 1863. Examiner A. W. Giddings, of Anoka, reports, September 4, 1873: "Gunshot wound in the right thigh, upper third. The ball passed through the rectum, paralyzing the sphincter muscles of the rectum and the bladder, so that he is unable to retain either fæces or urine. Labor causes the cicatrix in the rectum to become irritated and bleed, followed by soreness. He also has loss of sensibility in the right thigh and in the lumbar region. He is obliged to grasp the penis with his hand to enable him to get up and walk across the floor without a discharge of urine; disability total." His pension was paid him September 4, 1873.

CASE 889.—Corporal S. G. Hodgens, Co. D, 10th Pennsylvania Reserves, was wounded at Oak Grove, June 30, 1862. He was sent to Broad and Cherry Streets Hospital, July 29th, and Acting Assistant Surgeon John Neill made the following special report of the case: "Admitted with a gunshot wound of the sacrum; the ball entered behind near the middle of the sacral bone, in an oblique direction from left to right, and has not been removed. He states that about two weeks before admission some fecal matter was discharged from the wound, which only occurred once, and nothing of the kind has been noticed since. Examination of the rectum reveals no injury of the gut, and the presumption is that the ball passed obliquely downward, burying itself in the gluteal muscles on the right side. At the time of admission his health was very poor; the wound was slightly inflamed, and discharged a small amount of pus. Several spiculae of bone were removed from the wound, and he complained of a deep-seated dull pain in the gluteal region on the right side, between the tuberosity of the ischium and the trochanter major and passing down the thigh. The wound was dressed for a few days with flaxseed poultices, followed by warm-water dressings, and a good diet, tonics, and stimulants were ordered. Under this treatment his health improved very rapidly. The wound looks well and is almost healed. His fecal discharges have been perfectly natural since his admission to the house, and he is now able to walk around the ward." He was discharged the service December 5, 1862. Examining Surgeon John R. Willson, of Washington, Pennsylvania, reported, December 16, 1863: "A musket ball entered the lower part of the sacrum near the junction of the coccyx, penetrating the sacrum and lacerating the rectum; the wound is now nearly healed, but leaves a weakness of the back, which is disappearing; disability probably temporary." Examiner W. D. Craig reported, September 1, 1872: "The ball struck the sacrum about three inches above the extreme point of the os coccygis, and passed downward on the right side of the anus, lodging about four inches from the place of entrance, where it still remains embedded in the gluteal muscles. There is from half an ounce to an ounce of pus discharged from the wound every day. The ball is a constant source of nervous irritation. The limb is very painful and cannot bear much exertion. The soreness, nervous irritation, and loss of motive power have increased very much within the last two or three years." His pension was last paid to September 4, 1873.

CASE 890.—Private J. Ipes, Co. L, 6th Ohio Cavalry, aged 39 years, was wounded at Petersburg, June 8, 1864. Surgeon W. B. Reznor, at a cavalry corps hospital, and Surgeon T. R. Spencer, U. S. V., at an Alexandria hospital, recorded a severe shot wound of both buttocks. The patient was transferred to Filbert street, Philadelphia, July 13, 1864, where a fracture of the pelvis was diagnosed; and was transferred to Satterlee Hospital, July 19th, where Surgeon I. I. Hayes, U. S. V., recorded a severe shot wound of both buttocks and rectum, and the patient's discharge for total disability, June 10, 1865. Surgeon J. E. McDonald, U. S. V., gives a similar certificate, without specifying the nature of the disability.

Abstracts of several other cases of incomplete recovery from shot wounds of the rectum will further exemplify the disabilities consequent on such injuries, when complicated by vesical lesions or by pelvic fractures. FIGURE 255, on page 305, and the adjacent wood-cut (FIG. 259),

the latter drawn from a section of the pelvis of a frozen cadaver, may remind the reader of the relations of the rectum to the other parts contained in the pelvis and to the bony walls. The feces retained by contraction of the superior sphincter almost of necessity overflow through a perforation in the upper part of the gut. Hence Dupuytren advised<sup>1</sup> a division of the sphincter under these circumstances, a practice occasionally adopted by our surgeons, with most satisfactory results, and which has been much employed by Doctors Simon, Fischer, Fehr, and

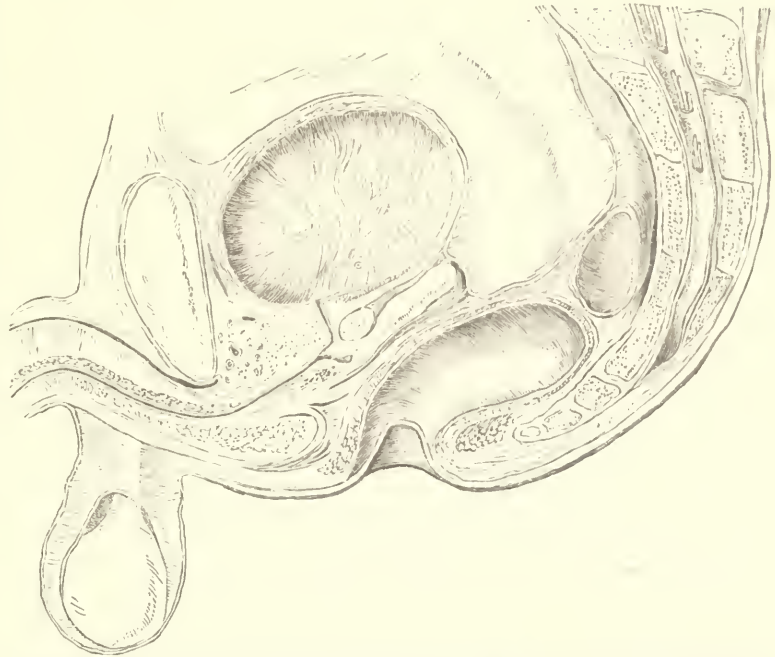


FIG. 259.—Median section of the pelvis of a frozen adult male cadaver, showing the pubic symphrosis, the divided tunics and cavity of the bladder, with the orifices of the ureter, the prostate, the urethra, cavernous and spongy bodies and testis, the rectum with its external and internal sphincters, the recto-vesical duplicature of the peritoneum, and the pelvic fasciæ. [AFTER HENLE.]

others, in the late Franco-German war, as will be more particularly noticed in speaking of the treatment of this group of injuries.

CASE 891.—Private M. Sullivan, Co. K, 93d Illinois, aged 39 years, was wounded at Chattanooga on November 25, 1863. Surgeon J. S. Prout, 26th Missouri, records "a gunshot wound through both hips and bladder." Surgeon J. Perkins, U. S. V., at the general field hospital reported a "shot wound of the gluteal region, the ball coming out at the right groin." At Nashville, Surgeon C. W. Horner, U. S. V., records "a severe gunshot fracture of the pelvis, the ball perforating the bladder and rectum." At Jeffersonville, Surgeon M. Goldsmith, U. S. V., reported "a gunshot wound of right groin." At Madison, Surgeon G. Grant reported "gunshot wound of both hips." At Camp Butler, Illinois, Surgeon A. B. Campbell, U. S. V., recorded "a gunshot wound of the right hip, the ball perforating the bladder and rectum," for which injury the patient was discharged May 30, 1865, and pensioned. Examiner C. C. Latimer, of Princetown, reported, September 16, 1869, that "the ball entered the left ischium, passing through the bladder and rectum. He is wholly helpless, and confined to a chair or to his bed all the time, and having a dozen or more urinary fistulae, through two or three of which feces passed." His disability was rated as total and of the first grade. This pensioner was paid to June 4, 1873.

CASE 892.—Private W. H. Bulla, Co. F, 2d Iowa Cavalry, was wounded at Farmington, Mississippi, May 9, 1862, the injury being described on the field record as a "wound of the thigh and rectum, by ball." He was conveyed on the hospital steamer D. A. January to St. Louis, and thence to Jeffersonville, where he was admitted to hospital on the 14th, and furloughed on May 22, 1862. He was promoted to a lieutenancy on February 21, 1864, and mustered out of service May 15, 1865, and pensioned. Examiner Henry Frasse reported: "The ball entered the lower third of the right thigh; passed upward and inward from the posterior face of the femur, and is now lodged in the thigh; the thigh is atrophied and weak. A second ball entered on the right side of the anus, and was cut out from the coccygeus. Whenever the bowels move, the feces pass out involuntarily. The third ball passed just under the patella and lodged on the tibia, and was cut out of the left leg. His general health is excellent; disability total." The lieutenant's pension was paid him September 4, 1873.

CASE 893.—Private H. Rinker, Co. B, 48th Pennsylvania, aged 25 years, was wounded at Petersburg, April 2, 1865, and was sent to Washington, where he was admitted to Carver Hospital on the 5th. Surgeon O. A. Judson, U. S. V., noted the injury as a "gunshot fracture of the sacrum and wound of rectum." This soldier was discharged, June 28, 1865, in consequence of the injuries. Pension Examiner J. G. Kochler reported, June 20, 1866: "Received a slight gunshot wound over the lower spine. The wound is now closed and he is able to labor; disability temporary." Rinker's claim for pension was rejected on account of the report of absence of disability.

<sup>1</sup> DUPUYTREN, *Lçons Orales*, 2<sup>me</sup> éd., T. VI, p. 471.



The first of the five following cases, though the ulterior history is unknown, would appear to have been an instance of recovery with an unusually small amount of disability. In the second case, there was stricture, and, in the third, paralysis of the sphincter; while the CASE 897 is a recovery with the alleged complication of shot fracture of the great trochanter, and CASE 898 a rapid recovery after fracture of the pubis:

CASE 894.—Private *J. W. Brannon*, Co. B, 22d Georgia, aged 18 years, was wounded at Gettysburg, July 3, 1863. He was treated in Seminary Hospital until the 27th, and transferred to Camp Letterman, where Acting Assistant Surgeon H. H. Sutton reported: "The patient was wounded by a minié ball, which entered a little above the left hip-joint, passing through the ilium and sacrum and through the rectum, and passing out a little higher on the opposite side. On admission, he had much pain in the posterior part of the pelvis and a difficulty in passing urine, but did not need the passage of the catheter. There is a free discharge from the openings of the wounds; he has diarrhœa; otherwise, his health is good. Perfect rest was enjoined, extra diet given, and iron, quinine, acetate of lead, opium, and ipecac administered. August 12th: The diarrhœa has stopped, and the patient is slightly improving in other respects; the discharge from the opening made by the exit of the ball is still free; stimulant and tonic treatment continued. August 25th: The patient is improving daily; there is a little soreness about the pelvis, which, however, is not increased by a little walking. The wound made by the entrance of the ball has nearly healed; that by the exit discharges slightly. The same treatment was continued and full diet given, and, by September 3d, the patient feeling well, and the wound being healed, he was allowed to walk a little." He was transferred to West's Buildings Hospital on October 6th, and paroled on November 12, 1863.

CASE 895.—Private *J. M. Latta*, Co. B, 29th Iowa, was wounded at Jenkins Ferry, Arkansas, April 30, 1864, and was reported by Surgeon L. Nicholson, of his regiment, as mortally wounded by a shot perforation of the pelvis. On June 16th, he was admitted to hospital at Camden with "gunshot wound of the pelvis," but there is no record of treatment or disposition. He was mustered out of service on June 17, 1865. Pension Examiner D. H. O. Linn, of Magnolia, Iowa, reported, August 27, 1870: "The ball entered the left groin and passed directly backward, making its exit in the left hip. In its course it seems to have partially paralyzed the rectum, so that to effect a passage he has to resort to a powerful cathartic or enema. It also seems to have injured some of the muscles and nerves in this region, so that walking a short distance produces stiffness of the leg and considerable pain at the knee." *J. H. Rice*, late assistant surgeon 29th Iowa, in an affidavit made July 18, 1870, testifies that he has frequently been consulted in this case, and describes the wound as follows: "The ball entering near the left groin, passing over the edge of the pubis, and coming out through the left natis. Said wound frequently breaks, and discharges for several weeks in succession." This pensioner was paid to June 4, 1873.

CASE 896.—Sergeant *F. M. Simon*, Co. H, 105th Ohio, aged 30 years, was wounded at Perryville, Kentucky, October 8, 1862. He was treated in hospitals at Perryville and Louisville, where the injury was noted as a gunshot wound of side and hip, respectively, and finally at Gallipolis, whence he was discharged the service March 8, 1863, for "gunshot wound of the pelvic cavity." Examiner *E. Mygatt*, of Poland, reported, May 7, 1863: "The ball entered the glutei muscles two inches to the left of the anus and one inch above its line, passed obliquely through the rectum, crossing the perineum, and, passing under the right pubis, emerged through the adductor muscles of the right thigh one and a half or two inches below the groin." Examiner *John McCurdy* reported, September 6, 1872: \* \* "The result is stricture of the rectum, paralysis of the sphincter, and an almost constant discharge of pus and fœces, thus rendering a very frequent change of dressing necessary; the right limb is much atrophied, caused by its limited motion on account of the wound." On September 8, 1873, he again reports that "there is a stricture of the rectum at the seat of the wound, and an abscess below the rectum and ischium of the right side, and paralysis of the sphincter ani and consequent inability to retain the contents of the rectum; pus is almost constantly passing away with the fœces; disability total." This pensioner was paid to September 4, 1873.

CASE 897.—Private *T. J. Doughman*, Co. G, 89th Ohio, aged 28 years, was wounded at Chickamauga, September 20, 1863. He was treated in hospital at Chattanooga and afterward at Hospital No. 3, Nashville, where the case was reported as a "gunshot wound of both hips and fracture of the ilium," and he was furloughed February 19, 1864. He was discharged while on furlough, February 29, 1864, and on the certificate of discharge Assistant Surgeon *J. V. Anderson*, 15th Indiana, records: "Compound comminuted fracture of the right and left ischium, the missile also dividing the rectum." Examiner *E. Mead*, of Cincinnati, reported, June 11, 1864: "The ball entered the left thigh at the great trochanter, passing entirely through the posterior portion of the pelvis, and, making its exit at a point nearly opposite in the right thigh, fracturing the ischii; one piece of bone was removed; large cicatrices of bed-sores exist; he is obliged to use crutches." Examining Surgeons *J. F. White* and *W. J. Wolfley* reported, August 2, 1871: "The ball entered, grazing and fracturing the left great trochanter, passed through the rectum, and emerged in the right buttock." Examiner *G. K. Taylor* reported, September 11, 1873, that he had several cicatrices from wounds, one of which, unhealthy, tender, and discolored, covered the entire coccyx; there were also numerous cicatrices over the back resulting from bed-sores. He was paid to September 4, 1873.

CASE 898.—Private *William D. Bush*, Co. G, 13th Georgia, was wounded at Gettysburg, July 2, 1863. He was taken to Seminary Hospital on July 3d, and transferred to Camp Letterman on August 2d, where Acting Assistant Surgeon H. H. Sutton reported as follows: "A minié ball entered the left groin three-fourths of an inch below Poupart's ligament and two inches from the spine of the pubis, shivering the horizontal ramus; it then passed through the lower part of the pelvis, wounding the rectum, and made its exit through the greater sacro-ischiatic notch. October 10th: The passage of feces from the posterior wound had ceased and the wound was nearly healed, and the suppuration from the anterior wound was free and healthy; his general health was good." He continued to improve until November 10th, when he was convalescent, and was transferred to West's Buildings Hospital. On November 12th, Surgeon *T. H. Bache*, U. S. V., reports that he was paroled and sent to City Point for exchange.

Though the subject is commonly passed over very cursorily by authors, the large proportion of pensioners invalidated on account of disabilities resulting from this division of injuries of the pelvis, admonishes us that the surgery of the rectum merits much consideration from military surgeons. The relation of cases in which patients have survived such injuries, only to endure afflicting infirmities, will therefore be continued. In the four following cases, fistules persist, either urinary, stercoral, or communicating with diseased bone:

CASE 899.—Private T. Fordham, Co. H, 18th New York, aged 31 years, was wounded at Drury's Bluff, May 16, 1864, and sent to Hampton Hospital on the 18th. He was transferred to McDougall Hospital, New York, on July 12th, and the injury was noted by Assistant Surgeon S. H. Orton, U. S. A., as a "gunshot wound of the pelvis," for which he was treated until October 27, 1864, when he was discharged the service for "recto-vesical fistula," being totally disabled. On May 1, 1867, Examiner B. J. Morris, of Plattsburg, reported: "The ball entered the pelvis just above the anus, passing through the rectum and penis, injuring the prostate gland, causing total inability to retain the urine, which continues to pass through the wound. He is totally unfit for work." On September 4, 1873, Examiner T. B. Nichols, of Plattsburg, reported him as "so injured in the pelvic region, where the urethra was cut through by a musket ball, that he has no control of his water; his clothes are always wet; he cannot labor, and it is no small job to care for him; an addition of six dollars per month to his pension, although bringing no relief to his misery, would be some consolation." This pensioner was paid June 4, 1873.

CASE 900.—Private I. Irons, Co. F, 14th New Jersey, aged 25 years, was wounded at Cold Harbor, June 1, 1864. He was sent to Washington, and was treated in Judiciary Square Hospital until the 19th, when he was transferred to Douglas Hospital, where Assistant Surgeon W. F. Norris, U. S. A., reported the case as a "penetrating gunshot wound of the rectum, the ball entering the lower portion of the abdomen at the root of the penis, grazing the arch of the pubis, and emerging at the left buttock." He was discharged the service August 18, 1865, for "gunshot wound of the pubis and rectum;" disability total. Examining Surgeon M. D. Benedict reported, August 19, 1865: "A musket ball entered the pubis and passed obliquely backward through the abdomen, emerging through the left natis, fracturing the pubis and ischium, and perforating the intestine. The wounds are open and fistulous, and feces are still discharging through them." Examiner Charles Hodge, jr., reports, October 29, 1866: "A ball entered the lower part of the abdomen, breaking the pubis at the symphysis and cutting the suspensory ligament of the penis. Several pieces of bone have been discharged from the anterior wound. The ball passed inward and to the left, and made its exit from the back about one and a half inches from the middle of the spine; both wounds are still open, as well as several others caused by abscesses connected with the wound, and the contents of the bowels are discharged through them. The left leg is so contracted, owing to the cutting of large nerves by the ball, that he can but just touch the toe to the ground, but cannot bear any weight on it when he is lifted up on his crutches. He is confined to his bed, and constantly requires the personal aid and attention of another person; disability total." His pension was increased to twenty-five dollars a month, and was last paid September 4, 1873.

CASE 901.—Private F. E. Hodgman, Co. I, 24th Michigan, aged 32 years, was wounded at Gettysburg, July 1, 1863. On September 2d, he was admitted to Camp Letterman Hospital, where Assistant Surgeon H. C. May, 145th New York, reported as follows: "Wounded by a minié ball entering the left groin and emerging at a point one inch posterior to the right trochanter major, wounding the rectum in its course. November 4th: No history of case previous to October 12th; passed fecal matter through both wounds. During the last four weeks there has been no fecal passage from the wound of exit, and none from the wound of entrance for two weeks past; the wound of exit is closed; the wound of entrance is still open; general health good; transferred November 5th." He was admitted to Newton University Hospital on the following day, and, on July 24, 1864, transferred to general hospital at Cleveland, Ohio, whence he was discharged the service March 8, 1865. Examiner W. M. Eames, of Ashtabula, reported, October 28, 1865: "The wound was caused by a ball striking the thigh near the point of exit of the femoral artery, and passing backward and downward till it pierced the rectum and passed out at the natis on the opposite side. The wound still discharges though more than two years have elapsed, and the rectum has not yet healed. The secretions of the bowels, especially gases, still pass into the wound and cause great trouble. He is very lame, and the wound is quite painful." The same surgeon reports, September 4, 1873: "He was struck by a ball in the left groin, which passed through the body and out at the left buttock; the injury has affected the muscles of the left leg so as to produce cramps and almost constant neuralgic pain, and is liable to bring on lameness; the rectum is still sore, and gives evidence that there is a fistulous opening by occasionally suppurating and by constant soreness; disability three-fourths and permanent." This pensioner was paid to September 4, 1873.

CASE 902.—Private D. C. Feathers, Co. B, 14th West Virginia, aged 23 years, was wounded at Cloyd's Mountain, May 9, 1864. He was probably taken prisoner, as he was first recorded as having been admitted to No. 1 Hospital, Annapolis, from the steamer *George Lowry*, on October 9th. On November 26th, he was transferred to Camp Parole, and furloughed in January, 1865; readmitted, transferred to Patterson Park Hospital, and again admitted to Camp Parole, where he was discharged April 11, 1865. Surgeons James C. Fisher and W. D. Stewart, U. S. V., reported the case as a "gunshot wound of the pelvis, involving the rectum," and Surgeon Stewart, in the certificate for discharge, stated: "Gunshot wound of the right hip; the ball entering and passing through the right os innominatum and pelvis, the injury resulting in caries of the bones." Examiner J. Nichols, of Washington, reports, April 14, 1865: "Gunshot wound in the region of the right hip, the ball passing thence into the bowel, perforating the gut. The wound remained open for two months. The parts are yet very weak, though healed, and the joint nearly useless." Examiner Thomas Kennedy, of Grafton, West Virginia, reported, September 30, 1873: "The ball remained in the body; the cicatrix is one inch in diameter; the muscles are shrunk and cicatrix depressed; disability one-half." This pensioner was paid to September 4, 1873.



In the next four cases, three of the pensioners had faecal fistulae,<sup>1</sup> and one suffered from partial stricture of the rectum. In two of the cases, contraction of the muscles and partial paraplegia of one of the lower extremities augmented the disabilities:

CASE 903.—Private D. Ploss, Co. D, 112th New York, aged 25 years, was wounded at Cold Harbor, June 1, 1864, transferred from a field hospital, and, on the 7th, was admitted to Mount Pleasant Hospital, Washington, where Assistant Surgeon C. A. McCall, U. S. A., noted a "gunshot wound of the pelvis, the ball passing through the rectum." He was furloughed August 15th, but did not return, and was reported as a deserter. He was subsequently admitted to hospital at Fort Porter, New York, whence he was discharged, on a certificate of disability, July 6, 1865. Examiner O. H. Simons reported, November 15, 1872: "Wound of both hips; the ball entered immediately above the external abdominal ring of the left side, and made its exit through the right natis, about four inches above the anus. The wound at the point of entrance has closed; that of exit still remains open, and gives passage to flatus and faecal matter, though only at times." On September 4, 1873, the same examiner reports that "an artificial anus exists at point of entrance, through which faecal matter passes, rendering him, at times, an object of disgust even to himself. Labor brings on attacks of diarrhoea. He is a feeble looking man and unfit for the performance of any manual labor; disability total." This pensioner was paid to September 4, 1873.

CASE 904.—Private W. Peabworth, Co. K, 4th Kentucky, aged 24 years, was wounded at Chickamauga, September 19, 1863. Surgeon W. C. Otterson, U. S. V., reports, from Hospital No. 8, Nashville, that "a round musket ball entered the body two inches above and inside of the anterior superior process of the left ilium, and came out behind two inches from the right sacro-iliac articulation. Four months after the injury neither wound has healed, though the general health is good, and there is a fair prospect that the patient will go through life with two abnormal anuses. Faecal matters are occasionally discharged through either wound. The bowels move through the natural channel with a fair degree of regularity. Discharged, February 23, 1864." He was pensioned, but there is no further medical evidence other than a certificate by Assistant Surgeon J. P. Liddall, 22d Indiana, of the same tenor as Dr. Otterson's report.

CASE 905.—Private J. Sears, Co. B, 8th Michigan, was wounded at Chantilly, September 1, 1862, and sent to Baptist Church Hospital, Alexandria, September 6. Acting Assistant Surgeon W. Leon Hammond reported as follows: "Wounded by a ball, which entered the left anterior femoral region at the iliac portion of the saphenous opening one and a half inches below Poupart's ligament, and passed downward and backward across the iliacus, perforating the rectum, and passed out of the right great sacro-sciatic notch, and finally emerged from the gluteal region two inches from the coccyx, leaving an orifice which became an artificial anus. The treatment consisted of emollient enemata twice daily; injection of the wound-track with largely diluted tincture of iodine; injection of solution of morphia to relieve the neuralgic pains, and compression. The artificial anus closed by the healing process in forty-seven days." This soldier was discharged from service December 12, 1862, as totally disabled. Examiner W. B. Thomas reported, June 13, 1863: "The ball entered immediately beneath the middle of Poupart's ligament of the left side, traversed the body, wounding the rectum, and passed out three inches from the spinal column, through the right of the gluteus muscle." Examiner B. D. Ashton reported, September 23, 1873, that "the ball entered the left groin, passing through the rectum and out at the coccyx; the rectum contracted and the internal sphincter adhered to the coccyx. The passage for the faeces is small; the left leg is partially paralyzed; disability one-half and permanent." The pensioner was paid September 4, 1873.

CASE 906.—Private A. White, Co. H, 21st Massachusetts, was wounded at Chantilly, September 1, 1862. He was admitted to Baptist Church Hospital, Alexandria, on the 5th. Acting Assistant Surgeon W. Leon Hammond reported that "a minié ball entered the right gluteal region one inch above the trochanter major, passing through the right great sciatic notch, perforating the rectum and passing out of the left great sacro-sciatic notch, and emerging at the left natis two and a half inches from the axis of the sacrum, producing an artificial anus. For nine days after admission the faecal evacuations passed entirely through the left wound, after which faecal discharges began to pass both from the wound and rectum and continued to do so for five days, when the artificial anus closed. The treatment consisted of an enema twice every day, and injection of the wound with cold water, afterward warm water, and, finally, with diluted tincture of iodine. After each injection, I applied strong compression along the track of the wound. The patient walks with the foot everted and pendant, with no control over the foot; flexion and extension of the foot is impossible, but flexion and extension of the thigh and leg are perfect." On December 5th, he was transferred to McDougall Hospital, and was then discharged from service December 18, 1862. Examiner A. Lambert, of Springfield, reported, March 16, 1863, that "he was shot through the right hip above the great trochanter, injuring the spine and intestine, so that faecal matter passed from the wound in the left buttock, and the right leg is partially paralyzed. The ball seems to have entered just above the great trochanter, and issued from the left buttock just above the cleft of the nates, and to the left of the spine; disability total." This pensioner was last paid to March 4, 1867. A letter from his mother, dated November 4, 1873, states that he was lost in the ship "Everesta" in a voyage from Fayal to America; date not given.

CASES 908, 909, 910, on the next page, relate also to pensioners, one suffering with rectal stricture and two with stercoral fistulae.<sup>2</sup> There were not wanting, however, cases

<sup>1</sup> BLANCO (*Guerison de la fistule anale par la sonde à demeure*, in *Journal des connaiss. méd.-chir.*, No. 2, 1867) adduces a shot penetration through the perineum into the rectum, the ball producing a wound 3-4 centimetres broad and 7 centimetres long, which became a troublesome faecal fistula. A rubber cylinder was inserted, its upper extremity reaching beyond the internal wound orifice in the rectum; the faeces passed through the tube, and the injury, which had previously resisted all efforts at healing, closed rapidly. It is difficult to conceive of the tolerance of such a cylinder by the bowel, even after division of the sphincters; and this expedient must be regarded as curious rather than as of practical utility.

<sup>2</sup> MASSAKOWSKY (PAUL) (*Statistischer Bericht über 1415 französische Invaliden des deutsch-französischen Krieges 1870-1871*, in *Deutsche Zeitschrift für Chirurgie*, 1872, B. I, S. 321). In eight cases of injuries of the pelvic viscera, the rectum was injured five times, the rectum and bladder twice, and the bladder alone once. In the three latter cases urinary and faecal fistulae remained.

in which fecal fistulæ in this region closed spontaneously, and at as early a period as shot perforations of the upper part of the large intestine are sometimes observed to close.

CASE 907.—Private J. W. Smith, Co. K, 76th Ohio, was wounded, while on the steamer *Louisiana*, at the engagement at Arkansas Post, January 11, 1863, and was admitted to hospital at Memphis on the 19th, with a gunshot wound of the thigh. He was transferred to hospital at Mound City in April, and Surgeon Horace Wardner, U. S. V., reported that "a musket ball struck the left hip near the origin of the gluteal muscles and passed through the rectum. The ball was lost in the muscular substance. Fæcal matter passed through the opening at intervals for three weeks. The treatment consisted of the application of simple dressings to the wound; the discharge continued until April 1st, when the wound-orifice healed, after which he walked about for two weeks, and the wound then reopened and continued discharging at intervals until April 14th. He was received into this hospital on April 23d, weak and considerably emaciated. Treatment: Simple dressings externally and anodynes internally. No efforts were made to find the ball except by probing, his lungs being so diseased, and he being so emaciated and reduced in strength, that it was not considered prudent to subject him to any severe operation. He did well, and was able to walk about at the time of his discharge from service May 15, 1863." His name is not on the Pension Roll.

CASES 908-914.—Private M. Nengebaur, Co. B, 11th New Jersey, aged 20 years, was wounded at Petersburg, June 16, 1864. Surgeon O. Evarts, 20th Indiana, reported a shot perforation of both hips. Surgeon A. F. Sheldon, U. S. V., from Campbell Hospital, reported a shot perforation of the rectum. Assistant Surgeon J. T. Calhoun, U. S. A., from the Ward Hospital, Newark, confirmed the diagnosis of the field surgeon. Pension Examiner J. H. Clark reported, July 17, 1865, that "the ball entered the left natis and passed out at a corresponding point on the right, passing through the rectum, producing constriction, and making defecation difficult." Examiners Woodhull, Osborne, and Mercer reported, September 11, 1873, "wound of gluteal region of each side, injury of rectum." Private O. T. Spencer, Co. H, 1st Pennsylvania Artillery, aged 30, was wounded at Fair Oaks, May 31, 1862. Surgeon E. Shippen, of his regiment, reported a gunshot wound of the pelvis. This soldier was discharged for disability by Acting Assistant Surgeon A. C. Bournonville, October 22, 1862. Examiner C. C. Halsey reported, June 26, 1868, that "the ball entered the right iliac region and passed out through the right buttock. The entrance orifice remains open, constantly discharging pus; there is a fistulous passage into the bowels, which do not move unless stimulated by enemata. Fluid injected into the rectum and fæcal matter often pass through the wound, and pus passes by the rectum. The original disability has increased, and the patient requires constant personal aid and attention." The same examiner reported, September, 1873, that the disabilities were undiminished. Private N. W. Halsey, Co. C, 37th Massachusetts, aged 33, was wounded at the Wilderness, May 6, 1864. Assistant Surgeon J. C. McKee reported, from Lincoln Hospital, "a shot wound of the perineum and rectum," and sent the man to modified duty in the Veteran Reserves, March 29, 1865. He was discharged and pensioned June 29, 1865. Examiner E. Wright, of Lee, reported, January 14, 1868: "Ball entered right thigh, passed in front of the femur, penetrated the pelvis, wounding the rectum, and escaped through the right natis; has fistula, causing much inconvenience; disability probably temporary." This pensioner was paid September 4, 1873. Private C. Sparks, Co. A, 21st New York Cavalry, aged 26, is alleged to have been wounded at Fort Fisher, February 17, 1865. Surgeon B. A. Vanderkief, U. S. V., reported, from Annapolis, that this man was transferred, convalescent from chronic diarrhœa, to Baltimore, February 27, 1865. Surgeon A. Chapel, U. S. V., reported, March 2, 1865, from West Buildings Hospital: "Ball entered right gluteal region, back part, passed through the rectum, and made its exit at left gluteal region; wound received, February 17, 1865, at Fort Fisher. Furloughed March 3, 1865, to report to chief mustering officer for muster out." This man has not filed an application for pension. Private M. Kenney, Co. K, 2d Cavalry, aged 27, was shot in a street affray at Washington, September 19, 1861. He was taken to the E Street Infirmary. Medical Cadet E. R. Hutchins recorded<sup>1</sup> that a pistol ball entered the left buttock, passed through the rectum, and emerged in the inner right femoral region. The finger introduced in the rectum discovered a ragged wound about three and a half inches from the anus. Fæcal matter passed by the orifice in the thigh. On September 22d, the sphincter was divided; but feces continued to pass by the wound in the thigh until October 4th, when the natural evacuations took place, with great relief. The wound-track in the thigh was unavailingly dilated with compressed sponge to promote elimination of fragments from the ischium, and on February 19, 1862, an incision was made and some pieces of necrosed bone were removed. Assistant Surgeon S. H. Storrow, U. S. A., reports that this man recovered completely, and was discharged July 9, 1862. Private C. Fandy, Co. B, 5th Louisiana, aged 27, was wounded and captured, August 29, 1864, at Smithfield. Surgeon M. S. Love, P. A. C. S., reported "a gunshot wound through both thighs and rectum." Surgeon A. Chapel, U. S. V., reported, from West's Buildings Hospital, that "the ball entered the left thigh at Poupard's ligament, and came out of the right buttock, having cut through the rectum. Recovered, and sent to Point Lookout, January 8, 1865, for exchange." Lieutenant S. Harrison, Co. B, 5th Louisiana, aged 24, was wounded at Winchester, September 19, 1864. Surgeon W. S. Love, P. A. C. S., reported "G. S. W. of side." Surgeon A. Chapel, U. S. V., reported, from West's Buildings, "gunshot wound of left hip, the missile passing through the rectum." The patient was transferred to Fort Delaware, May 10, 1865.

Forty of the fifty-nine cases of recoveries from shot wounds of the rectum have been noted in this subsection, fifteen<sup>2</sup> with wounds of the bladder, and four<sup>3</sup> with shot fractures of the pelvis.

*Fatal Shot Wounds of the Rectum.*—Of the forty-four reported instances, seven<sup>4</sup> have been detailed among the fatal cases of wounds of the bladder, and five on pages 309, 310. Abstracts of thirteen other instances will be related here, including the one fatal

<sup>1</sup> HUTCHINS (E. R.), *Boston Med. and Surg. Journal*, 1862, Vol. LXV, p. 255, Vol. LXVI, p. 113.

<sup>2</sup> Viz: CASES 786, Wesson; 788, Janisch; 789, Blake; 790, Estee; 791, Mooney; 805, Shafford; 807, II—; 812, Smith; 819, Tipps; 821, Fore; 822, Carrier; 823, Grubb; 825, Warren; 828, White; 835, Harger.

<sup>3</sup> Viz: CASES 742, Shermer; 745, Denegan; 746, Morgan; 747, Davy.

<sup>4</sup> Viz: CASES 851, B—; 852, Relyea; 855, Wait; 860, D. Smith; 863, Baggs; 864, Tweedy; 865, Potter.



case (924) in the group of nine shot-fractures of the sacrum with lesion of the rectum (compare 246), and two (922, 927) of the three fatal cases of shot-fracture of the ischium with wounds of the rectum. The third fatal case of this group (Murphy) will be detailed on page 326, with Wounds of the Blood-vessels. In one case, death resulted from tetanus:

CASE 915.—Private I. Catherall, Co. A, 15th New Jersey, was wounded at Gettysburg, July 3, 1863, and sent to Philadelphia, to South Street Hospital, on the 8th. Acting Assistant Surgeon J. R. Tryon reported that "he was wounded by a minie ball, which passed in a little to the left of the extremity of the coccyx, entering the pelvic cavity through the lesser sacro-sciatic foramen, and lodging in front of the rectum and behind the bladder. The ball remained untouched until the 9th, the day he arrived at this hospital, when, on probing the wound with my fingers, it was detected and immediately removed, together with a considerable amount of his clothing. The man remained quiet and comfortable that night under the influence of a laudanum enema and a poultice to the wound. On the morning of the 10th, he seemed quiet, and suffered no pain; he was kept in bed, and ordered a light nutritious diet, and had a laudanum enema at bed-time. On the 11th, he complained of slight numbness and stiffness of the jaws with some pain in the wound, and a large poultice was ordered to be applied wet with tincture of opium. A grain of opium was given every hour, also egg-punch and beef-tea, and a half grain of sulphate of morphia thrice daily. July 12th, is no better this morning; treatment continued; this afternoon he is perfectly rigid; the bowels have been freely moved, but a communication is found to exist between the wound and the rectum; some pleurothotonos and opisthotonos. The wound is freely discharging and looks better. He died on the morning of July 13, 1863. An autopsy revealed the extent of the wound as above stated, and a large rent in the rectum."

The fatal termination in the next case was due to intermediary hæmorrhage from a hæmorrhoidal artery. Another instance will be found with Wounds of Blood-vessels.

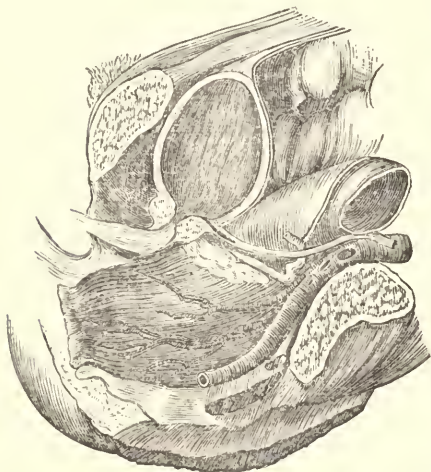


FIG. 260.—Section of the pelvis, showing the distribution of the hæmorrhoidal arteries. [After ANGER.]

CASE 916.—Private L. S. Dyer, Co. E, 31st Ohio, aged 17 years, was wounded at Murfreesboro', June 2, 1863. Surgeon J. R. Arter, of the 31st Ohio, thus referred to the injury: "One case of gunshot wound of the hip will likely prove fatal. The ball struck the left ilium one inch above and in front of the acetabulum, passing directly across in front of the sacrum, through the rectum and out through the right ilium at a point corresponding to where it entered." He was admitted to the general hospital at Murfreesboro' on the same day, and Surgeon J. Y. Finley, 2d Kentucky Cavalry, reported as follows: "Gunshot wound; the ball passing through the great sacro-sciatic notches and injuring the rectum. The fæces were passed for some time through the channel formed by the passage of the ball. Secondary hæmorrhage occurred on July 20th, probably from the middle hæmorrhoidal artery (FIG. 260). Persulphate of iron was used as a styptic, and lint applied as a compress, but death resulted on the same day. No pyæmia existed." The case may be compared with the instances of shot-fracture of both ilia, on page 215, and illustrates the comments there submitted respecting lateral horizontal perforations of the pelvis in front of the sacrum. It is true that there was a difference of opinion between the two surgical attendants as to whether the missile perforated both ilia, or traversed the great ischiatic notch on either side. Either of these forms of injury is sufficiently rare to be remarkable. One is inclined to accept the report of the field surgeon, who had the better facilities for exploration of the shot track with the finger, and of detecting the fracture he describes with precision.

CASE 917.—Lieutenant S. H. Anderson, Co. B, 34th Mississippi, was wounded at Atlanta, May 14, 1864. Surgeon D. C. O'Keefe reports:<sup>1</sup> "Gunshot wound, ball entering near upper and posterior border of right os innominatum, passing obliquely downward, through the upper portion of the rectum, toward the left thigh, and lodging. On admission, patient was suffering intense pain, with daily febrile exacerbations and constant fecal discharges from wound, which was suppurating very freely. Patient continued in this condition until May 30th, when diarrhœa set in, which continued, except when controlled by opiates and astringents, until his death on June 5, 1864."

CASE 918.—W. Shaw, Co. K, 95th New York, aged 19 years, was admitted to Harewood Hospital on May 20, 1864, for a shot fracture of the pelvis, received at the Wilderness on May 5th. A ball had entered near the superior process of the left ilium and emerged in the middle of the gluteal region. The patient's general health was good; the wound, apparently healthy, discharged moderately. Small pieces of bone were removed, and by July 10th the wound of exit was healed and the discharge from the anterior opening was healthy. Improvement continued till September 1st, when the patient complained of pain in the left groin. On the 10th, extended necrosis of the ilium was detected by the probe; from this time the discharge from the wound increased; the patient sank gradually, and died, from exhaustion and diarrhœa, on February 5, 1865. On *post-mortem* examination, the visceral portion of the peritoneum was found adherent on the left side to the parietal portion; the descending colon, adhering to the fascia ilea, was perforated, and communicated with an abscess below the psoas and iliacus muscles, which were atrophied, and the ilium was soft and diseased. There was inflammation of the rectum and of the mucous membrane of the bowels; the other organs were healthy.

<sup>1</sup>O'KEEFE (D. C.), *Surgical Cases of Interest, treated at Institute Hospital, Atlanta, Georgia, in May and June, 1864, in the Confederate States Medical and Surgical Journal*, 1865, Vol. II, p. 26.

Another case of lateral perforation of the rectum, that may be compared with CASE 916, proved fatal three and a half years after the injury:

CASE 919.—Private H. Johnson, Co. M, 1st Massachusetts Heavy Artillery, aged 23 years, was wounded at Spottsylvania, May 19, 1864, and admitted to Lincoln Hospital on May 22d. Assistant Surgeon J. Cooper McKee, U. S. A., reported as follows: "The wound of entrance was at the outer upper portion of the glutens maximus muscle; the exit, in a straight line on the other side, directly opposite, the missile perforating in its course the upper portion of the rectum. The wounds have alternately healed up, and have then broken out afresh, with the occasional passage of flatus and the evacuation of feces through both openings, and sometimes with a tendency to slough. This patient was furloughed and readmitted during the month of November, and, on January 18, 1865, secondary hæmorrhage occurred from the gluteal artery or its branches, which was arrested by compression with a T-bandage tightly applied around the abdomen and scrotum; no hæmostatic was found necessary. No pyæmia existed. The patient perfectly recovered, and, on March 31, 1865, was discharged the service." In accordance with a request from the Surgeon General of Massachusetts, Dr. Stephen Traey, of Andover, gives the following certified history of the case: "The above-named soldier was of a healthy family, and, so far as I can learn, without any hereditary predisposition to any disease whatever. He was a stout, healthy man, weighing about 165 pounds at the time he was wounded, in May, 1864. The wound was that of a musket ball passing entirely through the pelvis laterally, involving the rectum to such an extent that the feces passed through the external opening for six months or more. At the time of his discharge, in March, 1865, his condition may be briefly described as follows: The wound was still discharging pus somewhat copiously; also gas escaped from the intestine through it; emaciation considerable; he could walk only by the aid of crutches; appetite and digestion good. In June, 1865, he had gained so that he could walk by the aid of a cane; appetite and digestion good. The discharges from the wound continued much as at the time of his discharge; there was no increase of flesh, and he had a slight hacking cough. In September, 1865, his appetite and digestion continued good, and he had gained some in strength but had not gained in flesh; the discharges from the wound and the cough continued without material change. December, 1865: Since last date, he has continued to lose flesh slowly and his strength has not increased; the cough and expectoration have increased; the discharges from the wound continue; he now complains of shortness of breath; the evidences of pulmonary tuberculosis are more complete and unmistakable; the appetite and digestion are good. March, 1866: His appetite and digestion are excellent, but in other respects he has failed very perceptibly since last date; the cough and expectoration have increased very much; he has had chills and night-sweats for several weeks; during the month he has had pulmonary hæmorrhage several times, the quantity being estimated at one pint. From this date, his cough and expectoration constantly increased; his strength and flesh continually decreased, and the discharges from the wound continued unchanged. His appetite and digestion continued remarkably good, but nothing of note occurred until July, 1867, when he had a diarrhœa which confined him to his bed for some two weeks. He rallied from this so that he walked and rode out a few times, but soon became so weak that he was unable to sit up, and gradually failed in all respects, excepting that his appetite and digestion continued remarkably good, until his death, on December 10, 1867. I have only to add that I am perfectly certain that the death of the above-named soldier was the legitimate and direct result of, and was directly and solely caused by, the wound he received as above named, and for which he was discharged and pensioned." The statements of the pension examiner agree with Dr. Tracy's in regard to the character of the wound.

CASE 920.—Private Luther M. B——, Co. I, 1st Massachusetts, aged 18 years, was wounded at Bull Run, August 30, 1862, and remained on the field until September 6th, when he was admitted to Georgetown College Hospital, where Assistant Surgeon J. M. Brown reported that "it was found that the ball had entered a short distance behind the great trochanter of the right side, and, passing directly through the rectum, had left a fistulous opening. A compress was placed over the wound, the rectum washed out twice daily, and supporting treatment was employed. On September 30th, the side of the left thigh began to swell, and from its inflamed condition had the appearance of containing an acute abscess. On October 1st, the patient began to sink rapidly, and the whole of the thigh assumed a distended, brawny appearance, and, after some hours of delirium, he died at about eight in the evening. At the autopsy, it was found that the ball, after perforating the rectum, had passed onward and fractured a portion of the body of the left ischium and the acetabulum. The tissues were found to be greatly infiltrated by coagula and a small amount of fecal matter. This condition was observed to reach nearly down to the knee, and readily accounted for the swollen condition of the limb during life. The capsular and round ligaments were softened and almost absorbed." The injured portion of the left ischium (FIG. 261) was contributed to the Museum, with the foregoing notes, by Assistant Surgeon J. M. Brown, U. S. A. The acetabular portion of the innominatum was not preserved.

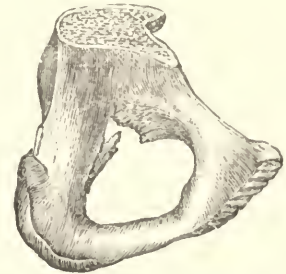


FIG. 261.—Lower portion of the left os innominatum, showing a shot fracture of the outer border of the thyroid foramen. *Spec.* 116.

CASE 921.—Private John A. Harter, Co. E, 146th New York, aged 29 years, was wounded at the Wilderness, May 12, 1864, and was sent to Carver Hospital on the 14th. Acting Assistant Surgeon P. C. Gilbert reported: "The ball entered to the right of the spine, three inches below the false ribs, and made its exit at the posterior part of the upper third of the thigh. May 15th: There is no peritonitis or injury of the medulla spinalis. Patient is pale, weak, and has a bad diarrhœa. There is an extensive and unwholesome discharge from the upper opening of a feculent character. Milk diet was given, with ten ounces of whiskey every twenty-four hours, and an ounce of castor-oil, with fifteen drops of tincture of opium, was ordered to be taken immediately. As soon as the operation from the above prescription was over, the following was ordered: One grain of sulphate of morphia, five grains of tamin, three grains of cayenne pepper, and ten grains of sulphate of quinia; to be made into ten pills, one to be taken every four hours. May 16th: The diarrhœa has ceased; the appetite is poor, but the general condition of the patient is improved. The wound remains the same as yesterday. Milk diet and whiskey continued. At six o'clock P. M. he took whiskey reluctantly; and milk-punch was ordered during the night. On the 17th, 18th, and 19th, stimulating treatment was continued, but the patient sank gradually, and died May 20, 1864."



Fæcal infiltration in the pelvic connective tissues and consequent exhausting suppuration appear to have led to the fatal terminations in the two preceding cases; in the two following, the bladder was implicated:

CASE 922.—Sergeant T. A——, Co. C, 119th New York, aged 26 years, was wounded at Chancellorsville, May 2, 1863, and treated in a field hospital of the Eleventh Corps, at Brook's Station, until the 25th, when he was sent to Alexandria and admitted to the Second Division Hospital. Acting Assistant Surgeon T. C. Barker reported as follows: "Gunshot wound in the left natis, extending toward the lower part of the rectum. He entered the hospital in the evening with low typhoid delirium, and the wound was not suspected or discovered until the next morning. Neutral mixture was given every four hours, and low diet ordered. May 26th: Respiration abdominal; thoracic sounds dull; one ounce of urine drawn off by the catheter; pulse 120 and feeble. Stimulants were given and turpentine stupes applied to the thorax. May 27th: More feeble; pulse 140; his urine has been drawn off twice daily; some has passed involuntarily each day; treatment continued. May 28th: Fæcal matter passes occasionally through the wound; the pulse 140; two grains of sulphate of quinia every three hours, and aromatic sulphuric acid with whiskey was ordered. On the 29th, a probe was passed through the wound into the rectum just above the sphincter, and out at the anus. Enemata of soap and water was given, and turpentine stupes were applied to the pubic and umbilical regions; the quinine was discontinued late at night. The patient grew more feeble and unconscious, and was sinking; there was tenderness and some fulness in the pelvis and lower abdomen, indicating peritoneal inflammation. He died May 30, 1863."

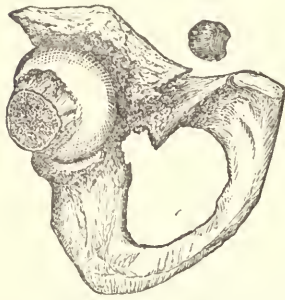

FIG. 262.—Lower portion of the right innominate and head of the femur; the thyroid portion of the acetabulum was fractured by a round ball, and caries ensued. *Spex.* 1183.  $\frac{2}{3}$ .

Surgeon E. Bentley, U. S. V., forwarded a more complete history with the pathological preparation represented in the cut (FIG. 262) and notes of the autopsy: "Upon exposing the lungs, a few purulent deposits, the size of pustules, were found posteriorly. The heart was flabby and very pale, the inner surfaces of the cavities being almost bloodless. The liver, spleen, pancreas, and kidneys were natural; the stomach was apparently healthy, and the small intestines were generally normal in appearance. The great omentum was somewhat injected and coated with plastic lymph, which had been freely exuded, agglutinating the intestines in many places. Approaching the pelvis, the signs of peritoneal inflammation became more marked. The bladder and rectum showed the effects of intense inflammation; indeed, their tissues were incipiently gangrenous. The track of the ball was traced from its entrance in the left buttock, above the tuber ischii downward and forward, to the left side of the rectum, above the sphincter, perforating the gut and emerging from its right side below the peritoneal fold. It then entered the bladder on the right side of the fundus and passed onward to the upper and outer margin of the right thyroid foramen, fracturing the pubis, and opening the capsular ligament and grooving the anterior part of the head of the right femur, and finally lodged between the external vastus and rectus femoris, six inches below the head of the femur."

CASE 923.—Lieutenant S. Hamner, Co. I, 5th North Carolina Cavalry, aged 38 years, was wounded at Cold Harbor, June 3, 1861, and was admitted to Chimborazo Hospital on the same day. Assistant Surgeon W. W. Dickie, U. S. A., recorded the following notes of the case: "Wounded by a conoidal ball, which entered about the centre of a triangle formed by the symphysis pubis, the superior spinous process of the left ilium, and the umbilicus, passed through the bladder and rectum and descending colon, and lodged in the gluteus muscles, from whence it was cut out. The urine passed through the wound of entrance, and blood was drawn off when the catheter was introduced. On June 6th, there was a small discharge of bloody urine, with great pain; fever diminishing, and no appetite. On the 7th, a large quantity of feculent matter was discharged with urine from the abdominal wound; the pulse was full and strong. No material change occurred up to the 13th, when peritonitis supervened, and death ensued June 16, 1864."

CASE 924 was complicated by diphtheria, constitutional, it may be presumed, rather than local. Diphtheritic infection of wounds and blistered surfaces was indeed very uncommonly observed during the war in the military hospitals of either the Union or Confederate armies:

CASE 924.—Sergeant E. R. Harrington, Co. H, 15th Massachusetts, aged 23 years, was wounded at Cold Harbor on June 3, 1864. He was sent to Armory Square Hospital. Surgeon D. W. Bliss, U. S. V., reported that "the injury was caused by a missile which entered the right buttock an inch and a half above and behind the trochanter-major, passed through the sacro-sciatic notch across the pelvis between the rectum and sacrum, and emerged at a point nearly corresponding on the opposite side." The patient was sent to New York, and admitted to the Central Park Hospital on June 9th. Surgeon B. A. Clements, U. S. A., reported that "the wounds were apparently healthy; but the discharge of fæcal matter continued for a month. For two weeks after admission, there occurred but two passages from the rectum, and these were small compared with those which passed through the wounds. In the course of the third week the discharge through the right wound ceased, and the opening commenced to close from the bottom; the general health improved steadily; the discharge took place entirely from the anus, and everything looked promising till July 23th, when the patient was seized with diphtheria, of which he died in twenty-four hours. The treatment pursued in this case was chiefly expectant—enemata, tonics, stomachics, and a full diet. The autopsy revealed the existence of diphtheria and acute pericarditis; a wound of the rectum on its posterior surface, the opening left being large enough to admit the little finger; and a fistulous track, substantially walled in by adhesions, and communicating the opening in the gut with the exit wound. There were strong indications of the ultimate closure of this wound." Fuller details of this case have been published by Dr. G. F. Shrady.<sup>1</sup>

<sup>1</sup>SHRADY (G. F.), *Wound of Rectum*, in *Am. Med. Times*, 1864, Vol. IX p. 79.

Many of the fatal cases of shot perforation of the rectum, possessing possibly features of interest, were briefly recorded as deaths from exhaustion, without memoranda of autopsies or any references to the morbid anatomy:

CASES 925-928.—Lieutenant J. Zoller, Co. L, 2d New York Artillery, was wounded at Deep Bottom, August 14, 1864. Surgeon James E. Pomfret, 7th New York Artillery, reports that the injury was regarded at the field hospital as a flesh wound of the right buttock. At the Seminary Hospital, Georgetown, Surgeon H. W. Ducachet, U. S. V., stated that a "conoidal ball entered at the right sacro-coccygeal junction, perforated the rectum, and emerged at the right of Poupart's ligament; the patient died from exhaustion February 16, 1865." Private T. G. Horton, Co. K, 65th Indiana, was wounded at Fort Fisher, February 17, 1865. Surgeon E. Shippen, U. S. V., reported a "severe shell wound of the right thigh and hip." Surgeon A. Chapel, U. S. V., reported, from West's Buildings Hospital: "Missile entered back part of right gluteal region and passed through the rectum; the patient died April 14, 1865." Lieutenant Colonel H. McKay, 180th Ohio, aged 27 years, was wounded at Kinston, March 9, 1865. Surgeon C. A. Cowgill, U. S. V., reported, from Foster Hospital, New Berne: "Ball entered lower margin of left ischium and passed out through the right pubis, wounding the bladder and rectum; died March 13, 1865." Private L. Markmore, Co. I, 60th Ohio, aged 40 years, was wounded at the Southside Railroad, October 2, 1864. Assistant Surgeon Clinton Wagner, U. S. A., reported, from Beverly Hospital: "Missile entered right hip, passed between the coccyx and the tuberosity of the ischium, through the rectum, and emerged through the left obturator foramen, and thence, deflected by the fascia, passed down the thigh nearly to the knee-joint. Death, October 21, 1864, from exhaustion."

The assertion, on page 291, that in shot perforations through a thyroid foramen and sciatic notch "the ball can hardly avoid the great vessels in some part of its track," is not, perhaps, too absolute; but Cases 928 and 922 and the instance cited below,<sup>1</sup> prove that the vessels may escape in shot penetrations of the obturator foramen. It is, perhaps, unsafe to set limits to the immunity the resiliency of the arteries occasionally affords them. An example of shot penetration through the thyroid foramen, fatal from secondary bleeding from a hæmorrhoidal artery, will be found with Wounds of the Blood-vessels.

Guthrie lays down, at the close of his classical commentaries,<sup>2</sup> that there may be shot lesions of the rectum unattended by injury to any other organ *within the pelvis*. This is literally true, though the instance given, of Captain Gordon of the Navy, is not very satisfactory, since in that case there were vesical trouble and partial paraplegia, and "small pieces of bone came away." Such an injury can hardly be inflicted otherwise than as illustrated by the diagram (FIG 251) on page 201, the missile entering perpendicularly to the axis of the pelvis. This is reported to have occurred in the case of a celebrated general officer killed at Chantilly, September 1, 1862. Retreating, with his body inclined over his horse's neck, amid a volley from the enemy's advance, a ball, it is alleged, entered the anus and lodged in the lung. No external wound was visible, and the nature of the injury was not surmised until the body was embalmed.

The instances adduced in this subsection adequately exemplify the complications attendant on shot wounds of the rectum. It is plain that lesions of this portion of the intestinal canal have not the grave consequences of injuries of the upper bowels, but are to be compared with injuries of those portions of the ascending and descending colon uncovered by peritoneum. Fæcal extravasation outside the peritoneal cavity, while not involving the mortal peril of intra-peritoneal effusion, is yet a grave complication, and ever impending in shot wounds of the rectum. Our surgeons were not ignorant of the means by which Dupuytren advised that the tendency to stercoral infiltration in such cases should be obviated; at least, in several instances (CASES 874, 876, 912) they resorted

<sup>1</sup> FEHR (*Behandlung der Schussverletzungen im Allgemeinen*, in LANGENBECK'S *Archiv*, 1873, B. XV, S. 330) relates the case of Corporal H——, 1st Prussian G. L. regiment, shot through the right foramen ovale, the ball traversing the lower part of the rectum and escaping at the great sciatic notch. Fæces passed through the wound of exit. Death on the eleventh day. Dr. FEHR adds: "The wounded man might have been perhaps saved by the immediate splitting of the external sphincter; but I never thought of this until after the war, when an analogous case was cited to me which Simon had successfully treated in this manner."

<sup>2</sup> GUTHRIE (G. J.), *Commentaries on the Surgery of the War in Portugal*, 6th ed., 1855, § 420, p. 611: "The rectum may be wounded without any other organ being wounded within the pelvis; of this I have seen several instances."



to division of the sphincters.<sup>1</sup> But from the comparatively large number of cases of persistent stercoral fistulæ found among the pensioners, it would appear that this practice was not as general as it might advantageously have been. Why the unanimity of surgeons as to the proper treatment of anal fistulæ should be broken in view of traumatic cases, is

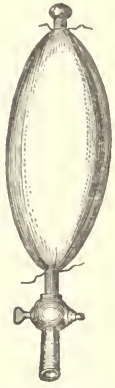

FIG. 263.—Compressor for hæmorrhage in the rectum. [After BUSHE.] †

curious. The same phenomenon has been observed in the Franco-German War of 1870. Professor Simon, of Heidelberg, in a paper that has attracted much attention,<sup>2</sup> while proclaiming that the principle of averting fecal accumulation and infiltration by division of the sphincters had long been recognized, expresses his astonishment that he was almost alone during the campaign as far as he could learn, in resorting to this expedient. Stricture of the rectum was not reported to have been a common consequence of shot injury. Dr. Neudörfer thinks<sup>3</sup> that such a complication may generally be averted by the judicious employment of bougies. The frequency of recto-vesical fistulæ after shot injury would naturally suggest a resort to sutures;<sup>4</sup> but it does not appear that any plastic operations were performed. Hæmorrhage was not a frequent complication of shot wounds of the rectum. Some of the more



FIG. 264.—Tube of BUSHE'S compressor.

serious examples will be adduced with Wounds of the Blood-vessels. In a recent review of this subject, in the great systematic treatise of Billroth and Von Pitha, Herr Esmarch<sup>5</sup> highly approves of the instrument proposed long since by our countryman, Dr. Bushe (Figs. 263, 264), a bladder introduced into the rectum and dilated by ice-water percolating from a tube, a form of compressor originally devised by Dr. Bushe for the suppression of hæmorrhage after lithotomy.<sup>6</sup> But in serious hæmorrhages it is unsafe to rely on any resource but the ligature. The gut must be dilated by a fenestrated speculum and the bleeding orifice exposed, when the vessel may be seized by a long artery forceps and tied. This difficult operation has been described, with figures of suitable instruments, by Dr. Bodenhamer,<sup>7</sup> in a recent article replete with sound observations. The actual cautery as a hæmostatic should be left to the farriers, save in the exceptional cases in which, by galvanic cauteries or other instruments of precision, it can be applied directly to the

<sup>1</sup> DUPUYTREN (*Leçons Orales*, T. VI, p. 471), speaking of shot wounds of the rectum, observes: "Dans ces cas, les matières stercorales retenues par les sphincters dans le rectum, refluent nécessairement de manière à passer continuellement par les ouvertures des plaies, ce qui les entretient pendant un temps fort long. Je pense que le meilleur moyen à employer dans ces circonstances serait de fendre largement et profondément les sphincters de manière à donner un très-libre et très-facile écoulement aux matières stercorales à mesure qu'elles arrivent dans le rectum; alors les ouvertures accidentelles faites aux autres points du rectum se cicatriseraient bien plus promptement, puisque les matières stercorales ne s'y présenteraient plus."

<sup>2</sup> SIMON (*Über die künstliche Erweiterung der Anus und Rectum*, in LANGENBECK'S *Arch.*, 1872, B. XV, Heft 1, S. 109) remarks: "During the last war I have observed several shot wounds of the rectum, and have treated three patients myself. In two cases, where, after a six weeks' treatment by other surgeons, fæces still escaped through the wounds, and where the patients were extremely reduced from fecal abscesses, burrowing of pus, and fever, the splitting of the sphincter backward induced a cure in a short time. The escape of fecal matter ceased immediately after the operation, and in fourteen days the wounds had healed. In the third case, the fistulous wounds refused to heal in spite of repeated incisions, and the regular operation for fistula became necessary." This paper was read at the first congress of German military surgeons at Berlin, April 13, 1872. In the course of it Professor G. SIMON promised a future extended monograph "*Über Mastdarmschüsse*." FISCHER (H.) (*Kriegschir. Erf.*, 1872, S. 136) says: "Exceedingly commendable appears to me the proceeding lately introduced by SIMON, of cutting the sphincter in cases of shot perforation of the rectum with escape of fæces by the wound." SOGIN (*Kriegschir. Erf.*, 1872, S. 98) adduces an instance in which this practice was successfully adopted.

<sup>3</sup> NEUDÖRFER (J.) (*Handbuch der Kriegschirurgie*, 1867, S. 791, *Verletzungen des Mastdarmes*): "Such traumatic strictures should not be allowed to form. Insert gutta percha bougies, which may be made daily, as needed, of gradually augmented calibre, and left in place for a half-hour or hour twice daily, taking care that bulky fæces do not accumulate above the stricture."

<sup>4</sup> LOHMEYER (*Die Schusswunden*, 1859, S. 172) remarks: "When the bladder and rectum are injured, the edges of the wounds of the two organs may unite, \* \* allowing the urine to pass by the rectum, and fæces and even solid substances, such as cherry kernels, etc., to pass into the bladder and out through the urethra." Compare Specimen 153, St. Thomas's Hospital Museum (*Derc. Cat.*, Vol. II, p. 305).

<sup>5</sup> ESMARCH (P.) (*Verletzungen des Mastdarmes*, in VON PITHA und BILLROTH, *Handb. der Allg. und Spec. Chir.*, 1872, B. III, Abth. II, Lief. 5, S. 49) teaches that: "On account of the great danger of such hæmorrhages [*from the hæmorrhoidal arteries*] it is the duty of the surgeon to go to work with inexorable determination. At every operation performed on the rectum with the knife, each severed vessel should be most carefully ligated." Further on, Herr Esmarch cautions the young operator against reliance on tampons, and commends BUSHE'S compressor (Figs. 263, 264).

<sup>6</sup> BUSHE (G.). *A Treatise on the Malformations, Injuries, and Diseases of the Rectum and Anus*, New York, 1837, p. 185, PLATE IX, FIGS. 11 and 12.

<sup>7</sup> BODENHAMER (W.). *Traumatic Hæmorrhage of the Rectum*, in *The Medical Record*, 1872, Vol. VII, p. 361.

wounded part, or be employed to sear varicose surfaces, as after the operation of excision of hemorrhoids. Complications aside, wounds of the rectum are found to heal very readily.<sup>1</sup>

*Anal Fistula.*—In the *First Medical Volume* of this History, at pages 639 and 711, it is stated that there were reported twenty seven hundred and seventy-six cases of fistula-in-ano in about six and a half million (6,454,853) cases of disease, among the white and colored troops; and, on pages 617 and 717, there are recorded five hundred and twenty discharges and eleven deaths from this affection, in a mean strength of 531,920 men. Sixty-two operations for fistula ani were reported.<sup>2</sup> There is no mention of failure of the operation in any instance, and all of the patients recovered, and forty-two were returned to duty. In one case the ligature was employed; in the others, the ordinary operation by incision was practiced. Acting Assistant Surgeon J. J. Black freely excised the callous edges of the sinus in one case, in which no consequent abnormal constriction of the anus is mentioned. Surgeon A. Hammer, in a case complicated by extensively ramifying sinuses, cauterized with nitric acid, with advantage, as he believed. In two cases, injections with tincture of iodine had been unavailingly employed. Fistulas consequent on abscesses resulting from shot wounds are not included in this category, except possibly in the following instance, in which inflammation may have been propagated from a wound in the buttock:

CASE 929.—Private *W. Varner*, Co. B, 60th Georgia, aged 29 years, was wounded at Monocacy, July 9, 1864. He was treated at Frederick until the 25th, and then transferred to West's Buildings Hospital. Surgeon A. Chapel, U. S. V., reported "a gunshot flesh wound of the upper third of the left thigh. By September 2d the wound had healed, and the patient was detailed as nurse. Abscesses formed near the anus, resulting, about September 15th, in fistula-in-ano. On November 5th, I operated upon the fistula, dividing the sphincter ani muscle with a probe-pointed bistoury. The case progressed favorably, and the man was transferred to Fort McHenry in December, and returned for exchange January 2, 1865."

The suggestion of Sabatier<sup>3</sup> and Ribes<sup>4</sup> as to the position of the internal orifice appear to have been commonly borne in mind; while, as to the order of formation of the internal orifice in complete fistula, the observations confirmed the view set forth by Mr. Ashton,<sup>5</sup> rather than either of the antagonistic doctrines of Brodie<sup>6</sup> and Syme.<sup>7</sup>

*Anal Fissure.*—Instances of this painful affection were reported as successfully treated by incision, and several surgeons spoke approvingly of the treatment by rupture of the sphincter by sudden forcible dilatation.

<sup>1</sup> ESMARCH (F.) (*Verletzungen des Mastdarms*, in VON PITHA und BILLROTH, *Handb. der Allg. und Spec. Chir.*, 1872, B. III, Abth. II, Lief. 5, S. 40) declares: "Every extensive wound of the rectum is to be considered as severe, and often as mortal." Elsewhere (S. 45) he remarks: "In time of war shot wounds of the rectum occur not infrequently, although rarely without complications. I have observed two cases in which the ball passed through both buttocks, perforating the posterior wall of the rectum. Both recovered, although feces continued to escape for a long time through the wounds of entrance and exit."

<sup>2</sup> Abstracts of these cases may be referred to in the Register of Miscellaneous Operations, S. G. O., Vol. II, p. 246 *et seq.*, under the following names: Privates Adams, 18th Connecticut; Altridge, 140th New York; Bentley, 24th Wisconsin; Beryer, 19th Pennsylvania Cavalry; Bruekman, 4th Wisconsin Cavalry; Campbell, 71st Pennsylvania; Clinterson, 93d New York; Clark, 7th Massachusetts; Culling, 2d V. R. C.; Comstock, 121st New York; Cowley, 112th Illinois; Hospital Steward Cox, 1. S. A.; Privates Curtis, 20th Iowa; Dalton, 2d Colorado Cavalry; Donnohoe, 57th Massachusetts; Dumb, colored camp follower; Gordon, 19th Michigan; Haas, 96th Pennsylvania; Hardy, 29th Iowa; Henfler, 152d New York; *Hight*, 25th Virginia Battery; Holbrook, 99th Pennsylvania; Hutchinson, 9th New Hampshire; Jessup, 11th V. R. C.; Kelly, V. R. C.; Kneeskern, 44th New York; Krug, 13th Missouri Militia; Lafarge, 2d Massachusetts Cavalry; Letterman, 108th Illinois; Louis, Purnell (Maryland) Legion; McCarthy, 139th New York; McClure, 82d Pennsylvania; McFarland, 1st D. C. Cavalry; McNally, 41st New York; Martin, 56th Illinois; Martin, M., 173d Ohio; Miller, V. R. C.; Milton, 72 Illinois; Colonel Morton, 81st Ohio; Privates Nipe, 105th Pennsylvania; O'Brien, 8th New York Cavalry; O'Keefe, 5th New York; Phelps, 12th New Hampshire; Richau, 5th Illinois Cavalry; Riggs, 85th Pennsylvania; Richey, 4th Pennsylvania Cavalry; Roseau, 5th Ohio; Russell, 72d Illinois; Ryan, 6th V. R. C.; Slavan, 125th New York; J. Smith, 116th Pennsylvania; L. P. Smith, 4th Maryland; J. Smith, 7th Massachusetts; Summers, 14th Indiana; Swartwood, 75th Indiana; Tucker, 119th Illinois; Tynan, 12th V. R. C.; Vandler, 4th Michigan; Von Blessing, 37th Wisconsin; N. C. Wilson, 4th South Carolina Cavalry; S. Wilson, 1st V. R. C. Nineteen of these men were discharged and forty-two returned to duty. The operators were Drs. W. F. Norris and J. H. Thompson, three cases each; Drs. Carvallo, Hammond, Miles, Wurdner, and Siebold, two cases each; Drs. Agnew, Balser, Black, Brockman, Chapel, Culbertson, Dougherty, Ellis, Farron, Green, Hood, Hubbard, Holmes, Herbst, Highland, Hutton, Jackson, Judson, Ligler, Longnecker, Mursiek, Manfred, McKee, Neff, Owen, Sweet, Stahl, Taylor, Tolzier, Wilson, and Young, one each.

<sup>3</sup> SABATIER, *De la Médecine Opératoire*, 1822, T. II, p. 350.

<sup>4</sup> RIBES, *Quarterly Journal of Foreign Medicine and Surgery*, 1820.

<sup>5</sup> ASHTON, *Prolapsus, Fistula-in-Ano, and other Diseases of the Rectum, their Pathology and Treatment*, 3d ed., 1870, p. 31.

<sup>6</sup> BRODIE (B. C.), *Diseases of the Rectum*, 3d ed., p. 25 (Vol. III, p. 533 of Mr. HAWKIN'S edition of *The Works*).

<sup>7</sup> SYME, *The Diseases of the Rectum*, Edinburgh, 1838, p. 23.



A single case of cancer of the rectum was reported, the diagnosis having been based on a microscopical investigation. The subject of the case was an officer, who recovered; whence it may be inferred that he suffered only from a non-malignant hemorrhoidal tumor. Of diseases of the rectum it is unnecessary to speak at length. The reports added nothing to the information contained in the excellent works on the subject.<sup>1</sup>

*Hæmorrhoids.*—The frequency of piles, as indicated by the monthly sick reports, is expressed by the consolidated tabular statements of the *First Medical Volume*. There were reported 60,953 cases of piles with 40 deaths, in an aggregate of 6,451,853 cases of disease among the troops; and 1,598 men of a mean strength of 531,920, were discharged for disability resulting from hæmorrhoids. Only nineteen instances of operative interference for the removal of piles were reported, and none of the fatal cases are included in this category. Excision was practiced in two cases of external piles. Internal tumors were removed by the ligature in twelve, by the *écraseur* in three, and by excision followed by nitric acid cauterization, in two instances. Ten of the men operated on were returned to duty, and nine were discharged for disability. Incisions for fistulæ and excisions for piles were regarded by many surgeons as minor operations, not to be recorded on the monthly reports. Of the different modes of operating for internal piles, ligation was the most popular—for the wholesome dread of hæmorrhage<sup>2</sup> in wounds of the rectum was as great as ever. But excision with cauterization had many advocates. A variety of clamps were used, that of Professor N. R. Smith, or Mr. H. Smith's similar instrument,<sup>3</sup> with the blades guarded by ivory (FIG. 265), having the preference.

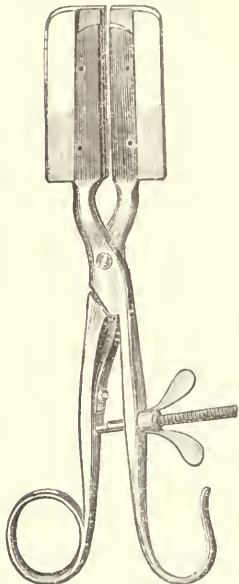


FIG. 265.—H. Smith's clamp. [After SMITH.]

*Foreign Bodies.*—The reports during the war presented few instances of foreign bodies impacted in the rectum, whether swallowed or imprudently or mischievously introduced from without. In the case of General D——, Surgeon Basil Norris removed a bone fragment (FIG. 266) that had lodged transversely above the sphincter for twelve days, inducing great irritation. Among the many valued contributions to the Army Medical Museum by Professor J. B. S. Jackson,<sup>4</sup> Specimen 5961 is a cast of a stone five and a quarter inches long and three inches wide, which a sailor of 45 years forced into his rectum during an attack of dysuria. The gut was ruptured, and the foreign body was successfully removed from the peritoneal cavity through an incision in the umbilical region, an instance even more remarkable than the extraordinary examples of foreign bodies in the rectum adduced by Morand and others.<sup>5</sup>



FIG. 266.—Rib of rabbit extracted from the rectum. Spec. 951.

<sup>1</sup> MAYO (H.) (*Observations on Injuries and Diseases of the Rectum*, London, 1833); QUAIN (R.) (*The Diseases of the Rectum*, London, 1855); CURLING (*Observations on the Diseases of the Rectum*, London, 1863), &c., &c.

<sup>2</sup> ESMARCH (P.) (*Verletzungen des Mastdarmes*, in VON PITHA und BILLROTH, *Handb. der Allg. und Spec. Chir.*, 1872, B. III, Abth. II, Lief. 5, S. 51) observes: "Is the locality of the bleeding vessel known, it is safer to introduce the finger and to compress the bleeding orifice until the hæmorrhage completely ceases, which generally occurs in ten minutes. Should hæmorrhage recur, the bleeding vessel should be ligated at all hazards."

<sup>3</sup> SMITH (H.), *The Surgery of the Rectum*, 3d ed., 1871, p. 105.

<sup>4</sup> JACKSON (J. B. S.), *Desc. Cat. of the Warren Anat. Museum*, 1870, p. 467; Preparation 2237 is "a portion of the rectum showing the mechanical injury that was done by the passage of a bougie. From a gentleman, aged 60." Dr. JACKSON remarks: "The above is only one of several cases I have seen in which the passage of some instrument in the rectum has been the immediate cause of death."

<sup>5</sup> MARCHETTIS (P.) (*Observationum medico-chir. rar. sylloge cum tractat. III. de ulceribus et fistulis ani*, Patav., 1664, Cap. 7); MORAND (*De plusieurs observations singulieres sur des corps étrangers, les uns appliqués aux parties naturelles, d'autres insinué dans la vessie, et d'autres dans le fondement*, in *Mém. de l'Acad. de Chir.*, 1757, T. III, p. 605); HEVIN (*Précis d'obs. sur les corps étrangers arrêtés dans l'œsophage, etc.*, in *Mém. de l'Acad. Roy. de Chir.*, 1743, T. I, p. 540).

While preparations of malignant growth and of foreign bodies in the rectum abound in museums, there are very few specimens of wounds, and especially of shot wounds,<sup>1</sup> of this portion of the intestine.

WOUNDS OF THE BLOOD-VESSELS AND NERVES.—Physical lesions of the great vascular and nervous trunks distributed in the pelvis have been little studied, for they generally are mortal before surgery can intervene.

In army practice, cases of this group will present not very infrequently the gravest problems to the practitioner. The first ligation of the common iliac, it will be remembered, was made by William Gibson,<sup>2</sup> to arrest hæmorrhage from a shot wound. The Museum possesses an example (FIG. 268), contributed by Dr. James Robarts, of perforation of the right primitive iliac by a pistol ball. The patient lived twelve minutes after the reception of the wound; so that, had a surgeon been near, it would have been possible to tie the vessel above and below the wound. Bogros,<sup>3</sup> in Velpeau's presence, dissected a subject with a similar wound. Larrey records<sup>4</sup> a case of sword puncture of the iliac vein and artery treated, apparently with success, by provisional compression

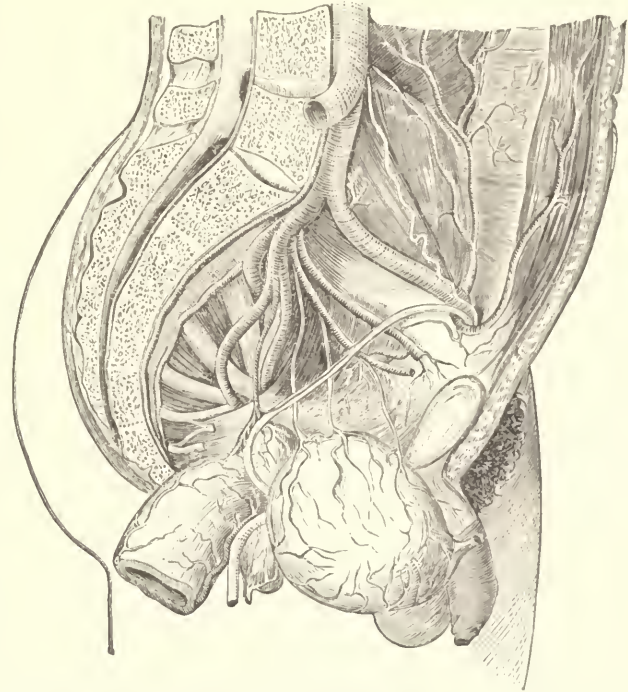


FIG. 267.—Arteries of the pelvis. [After LÉVELLÉ, in SAPPÉY'S *Anat. Disc.*, T. II, p. 640.]

and the method of Valsalva. Such instances are exceptional; but injuries of the branches of the pelvic vessels and nerves, sciatic, pudic, and gluteal, often come under treatment, and their management requires the utmost discrimination. It is proposed to relate here abstracts of some cases in which the diagnoses were not fairly made out, instances of wounds or ligations of the primitive iliac artery and of the hypogastric artery and its branches, and cases of injury of the sciatic and crural nerves. Mention of the injuries and numerous operations on the external iliac artery will be deferred.

*Punctured and Incised Wounds.*—The following case and one on page 335, a case of ligation of the common iliac, belong to this category:

CASE 930.—The following record appears on the case-book of the City Hospital, St. Louis, Surgeon John T. Hodgen, U. S. V., in charge: "Private Adam Schomaecker, Co. E, 4th Cavalry, aged 27 years, of temperate habits, was admitted into hospital on May 2d, with a bayonet wound of the left side received at Cairo, April 25, 1852, whilst attempting to pass the guard. He suffered extreme pain in the left thigh and leg, which swelled largely. He died June 27, 1852. At the *post-mortem* examination the blade of the bayonet was found to have entered the superior portion of the thigh, passed through the sciatic notch, injuring the sciatic nerve, and wounding a branch of the internal pudic artery; whence a false aneurismal sac had formed. The sac had become diffused through the whole pelvic cavity, forcing the rectum to one side, greatly displacing the sigmoid flexure of the colon, rendering defæcation difficult and painful. The aneurismal cavity contained about three quarts of blood."

<sup>1</sup> Specimen 1892 of Guy's Hospital Museum (*Path. Cat.*, 1857, p. 75) is a "rectum perforated in two places from gunshot wound which injured the obturator nerve." In the same museum, 1877<sup>00</sup> is a portion of rectum perforated by a bougie; 1877<sup>00</sup> and 1877<sup>00</sup> are similar preparations. In the Warren Anatomical Museum, 2267 (*JACKSON'S Cat.*, p. 167) is an analogous specimen. At St. Thomas's Hospital (*Desc. Cat.*, 1859, p. 305) are several preparations of stricture of the rectum, No. 153 showing ulceration and recto-vesical fistula induced by cherry stones.

<sup>2</sup> GIBSON (W.). *Case of a wound of the common Iliac artery.* in *The American Med. Recorder*, 1820, Vol. III, p. 185.

<sup>3</sup> VELPEAU, *Nouv. Élém. de Méd. Opérat.*, 2<sup>me</sup> éd., 1839, T. II, p. 164.

<sup>4</sup> LARREY (D. J.), *Clin. Chir.*, 1829, T. III, p. 156; Case of Corporal J. Fleury; apparently the external iliac vessels were wounded.



*Shot Wounds.*—Though it is proposed to defer the consideration of lesions and ligations of the external iliac, some instances will be given of wounds of its branches. It is hardly possible to unduly multiply illustrations of the management of wounded blood-vessels.

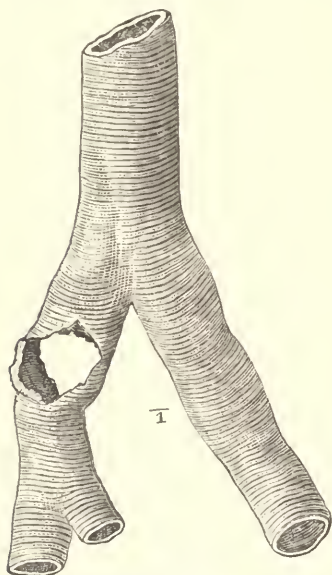


FIG. 268.—Shot perforation of the right primitive iliac artery. *Spec.* 6336. 1.

CASE 931.—Sergeant E. S. Fisher, Co. D, 40th New York, aged 21 years, was wounded at Spottsylvania, May 12, 1864. Surgeon O. Evarts, 20th Indiana, from a Second Corps hospital, reported "a gunshot wound of right hip." The patient was sent to Columbia Hospital, May 16th. Surgeon T. R. Crosby, U. S. V., recorded, "a gunshot flesh wound at the crest of the right ilium. On May 29th, there was hæmorrhage, amounting to eight ounces, from the circumflex ilii. The hæmorrhage was easily controlled by pressure, but the patient, already much exhausted, succumbed the same day."

CASE 932.—Private G. Edwards, Co. A, 155th Pennsylvania, aged 26 years, was wounded at Petersburg, June 18, 1864. Surgeon W. R. De Witt, U. S. V., reported, from a Fifth Corps hospital, "gunshot wound of left hip." The patient was sent to Alexandria, and thence to Broad and Cherry Streets Hospital, when Assistant Surgeon T. C. Brainerd, U. S. A., reported: "The ball entered at the left hip and was extracted from over the sacrum. There was comminuted fracture of the left innominatum; pus is discharging from both wounds and from the rectum. On July 22d, there was hæmorrhage to the amount of eighteen ounces, proceeding apparently from the circumflex iliac artery. The bleeding was arrested by the application of the solution of the persulphate of iron, with compression. Hæmorrhage to the extent of twelve ounces recurred, and resulted fatally on July 23, 1863."

CASE 933.—Corporal W. Matthews, Co. C, 11th Tennessee, aged 23 years, wounded by a minie ball at Hatcher's Run, February 6, 1875, was treated in the depot at City Point until the 12th, and then sent to Hammond Hospital, at Point Lookout. Surgeon G. L. Sutton, U. S. V., reported a "gunshot flesh wound of the left hip; the ball entered the anterior surface just over Poupart's ligament, and passed backward and outward, making its exit near the trochanter major. On the 13th, 14th, 15th, 19th, 26th, and March 2d, hæmorrhages occurred from the circumflex iliac artery, but not more than

eight ounces of blood were lost at any one time. The hæmorrhages on the first three days mentioned ceased spontaneously; in the other three instances it was arrested by application of persulphate of iron. Blue mass pill, quinine, and stimulants were given. Pyæmia was present on February 25th. He died on March 3, 1865."

CASE 934.—Private *Joseph S. Haden*, Co. E, 13th Georgia, aged 23 years, was wounded at Gettysburg, July 1, 1863, treated in Seminary Hospital until August 2d, when he was transferred to Camp Letterman Hospital. Acting Assistant Surgeon J. A. Newcombe reported: "Wounded by a minie ball entering the pelvis at the left groin, and making its exit near the tuber ischii of the left side; neither the bladder nor rectum were injured. His general health was much impaired; the discharge offensive and ichorous. He improved from August 10th to 15th. On the 21st, he had diarrhœa with watery evacuations, which were bloody on the next day; the skin was icteroid, and the countenance pinched. The evacuations on the 24th were bloody, and contained a good deal of mucus; the tongue was tremulous, and the teeth covered with sordes. His passages were involuntary on the 26th. On the 25th, hæmorrhage from the wounds was controlled by compressing the external iliac. He died August 30, 1863."

*Wounds of the Internal Pudic Artery.*—The following examples may be added to those adduced on pages 256 and 304:

CASE 935.—Sergeant C. Moulton, Co. D, 2d Maryland, aged 24 years, was wounded at Poplar Grove Church, September 30, 1864. He was admitted into hospital No. 2, Annapolis, from the steamer *George Leary*, on October 9th. The following notes of the case were made by Surgeon G. S. Palmer, U. S. V.: "Gunshot wound of the trochanter and neck of the left femur by a minie ball, which, entering the outer aspect of the trochanter major and emerging at the inner aspect, passed through the serotum. On October 12th, 13th, 14th, and 15th, hæmorrhages occurred from the internal pudic artery, with a loss of three ounces of blood in each of the first two instances, four in the third, and six in the last. Persulphate of iron, compress, and bandages were used, but death resulted on October 15, 1864."

CASE 936.—Private *P. Smith*, Co. G, 25th Alabama, aged 35 years, was wounded at Franklin, November 30, 1864, and was treated on the field until December 16th, when he was admitted into hospital No. 1, Nashville. Surgeon B. B. Breed, U. S. V., reported: "Gunshot flesh wound on the inner and posterior aspect of the right natis. On February 9, 1865, hæmorrhage occurred from the internal pudic artery to the extent of six ounces; this was arrested by the application of persulphate of iron. On the morning of the 15th, hæmorrhage recurred, and, patient being extensively reduced, it proved fatal before it could be arrested. The case was under the care of Acting Assistant Surgeon W. J. R. Holmes."

CASE 937.—Private *W. S. Rouse*, Co. E, 2d Wisconsin, was wounded at Gettysburg, July 1, 1863, and was treated in White Church Hospital. Surgeon G. M. Ramsay, 95th New York, reported: "Gunshot wound of the left thigh and perineum. Hæmorrhage occurred, on July 11th, probably from the internal pudic artery. The location and condition of the wound forbidding the operation of ligation, it was treated by compression and styptics. The quantity of blood lost was sixteen ounces, and the patient died on the following day. It was considered probable that there was internal hæmorrhage, but, as no *post-mortem* was held, this was not determined."

Hæmorrhage was the most important complication in many cases of wounds of the pelvis in which the precise source of bleeding was not determined. It was not always decided even whether the branches implicated were of the external or internal iliac.<sup>1</sup> In no region was the application of the cardinal rule of tying a wounded vessel above and below the seat of injury more difficult of application, and in none were the consequences of a neglect of this principle more disastrous.

CASE 938.—Private Henry M——. Co. B, 8th New York Cavalry, aged 35 years, was wounded at Raccoon Ford in September, 1863. His injury is recorded as a flesh wound of the groin in the casualty lists of the Army of the Potomac for September 13, 14, and 15, 1863. He was sent to Lincoln Hospital, entering September 17th, and was attended by Acting Assistant Surgeon W. C. Flowers, who made the following report of the case: "Wounded, September 15th, at Raccoon Ford. Was kneeling with left foot forward when wounded. A minié ball struck the outer part of the left thigh four inches below the anterior superior spinous process of the ilium, passed inward and slightly upward across the perineum, rupturing the urethra, fracturing the right ischium extensively, and finally escaped two inches behind the right trochanter major. Soon after the injury there was extreme pain in the parts, accompanied with ischuria. He had not passed urine for over forty-eight hours. The urine, intermixed with blood, oozed slowly from the wound of entrance. The bladder was much distended. After much trouble, however, a catheter was passed, after many fruitless attempts had been made to introduce it, and he remained quiet for three or four days. During this period, he had slight fever; tongue dry and slightly furred; much wandering at night, and, forty hours before his decease, he had a severe hæmorrhage, the blood escaping from the wound of entrance in such quantities as to permeate the bed. Nothing was done to arrest it, since, through the carelessness of the night watch, the accident was unnoticed until active bleeding had ceased. After this he failed rapidly, and died on the evening of September 27, 1863, having had a slight return of the hæmorrhage within the hour preceding his death." Assistant Surgeon H. Allen, U. S. A., reported the autopsy as follows: "Examination ten hours after death showed good muscular development and very marked rigidity. The parts *in situ* showed that the right lung extended from the first to the fifth rib, and the left from the first to the third rib, and both were bound to the ribs by adhesions. The apex of the heart was on a level with the fourth rib; the liver extended three inches to the left of the median line; the stomach was conspicuous; transverse colon natural, and the omentum was loaded with fat. The œsophagus was of a pale color, yellowish at its lower portion; the mucous membrane of the trachea was pale; the bronchial gland at the bifurcation of the trachea was enlarged, thickened, of a blackish color, and softened. The right lung was affected with lobular pneumonia, the lobules being especially prominent at the apex, where, upon the latero-posterior surface of the first lobe, a number of lobules were seen covered by a thin layer of recently exuded lymph. The parenchyma between these affected portions was apparently healthy, excepting that of the third lobe, which was markedly congested; the left lung was similarly affected; the first lobe, however, having been more congested than the lower. Sections of the hepaticized lobules sank in water; the weight of the right lung was twenty-one and of the left twenty-four ounces. The heart was four and a half inches wide by five and three-quarters inches long; the right side contained a large, soft, black clot, and a smaller white one was found upon the left side; the valves were healthy; the pericardium contained one ounce of fluid of the color of blood. The liver weighed fifty-six ounces and was pale, and the capsule readily separated; the bile was healthy and of a rich ochre-red color. The spleen was very soft and of a dark flesh color, and weighed eight ounces. The right kidney, four and three-quarters by two and a half inches, was flaccid and exceedingly pale; the only appearance of a sanguineous line appearing at the base of the pyramidal bodies. Cortical substance and mamille very pale. Weight of right, six ounces; of left, seven and a quarter ounces. Pancreas, nine inches long, two inches wide at head, healthy. Intestines healthy throughout. Brain healthy; cavity of arachnoid filled with an unusually large amount of fluid. The specimen sufficiently explains itself. It would be well to remark, however, that no ball was found. Extending from the ischium of the right side down the inner side of the corresponding thigh, a long ragged track was detected, measuring ten inches in length, lined with a thick black sloughing membrane. It was situated deep in the muscles of the limb. Its existence had not been detected during life." FIG. 269—a indicates the entrance orifice.

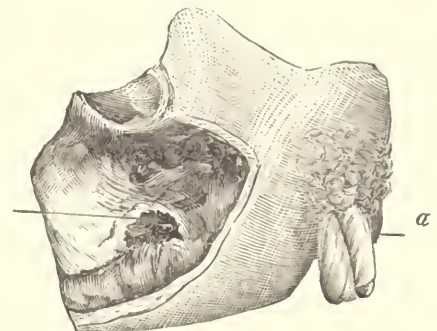


FIG. 269.—Lateral view of a preparation from a case of shot perforation of the perineum. Sp. c. 1746.

CASE 939. Private S. Robinson, Co. I, 3d New Hampshire, was wounded at Drury's Bluff, May 13, 1864. Surgeon J. J. Craven, U. S. V., from a field hospital of the Tenth Army Corps, reported that "a musket ball penetrated the right thigh and serotum." The patient was sent to Hampton Hospital, Fort Monroe, on the 15th. Assistant Surgeon Ely McClellan, U. S. A., reported a "gunshot wound, the ball entering the left hip in front of the trochanter and emerging at the root of the penis, on the right side of the serotum. On the 28th and 29th, hæmorrhage occurred from one of the branches of the profunda or pudic arteries, and about two pounds of blood was lost. The femoral artery, about three-fourths of an inch from Poupard's ligament, was ligated. Hæmorrhage recurred fifty-six hours after the operation, and the patient died June 2, 1864."

<sup>1</sup> For operations on the branches of the iliac arteries, consult J. BELL's famous case (*Disc. on Wounds*, 1795, p. 78); SYME (*Obs. on Clin. Surg.*, 1851, p. 169); VÉLPEAU (*Méd. opérat.*, 1839, T. II, p. 162); UHDE (*Deutsche Klinik*, 1853, B. V. S. 175); GIESNER (*Lehre von den Blut. Op.*, 1863, B. IV, S. 11); PACKARD (J. H.) (*A Hand-Book of Operative Surgery*, 1870, p. 167); GUTHRIE (*Commentaries*, 6th ed., 1865, p. 27); LADELL (J. A.) (*On the Wounds of Blood-vessels, Traumatic Hæmorrhage, Traumatic Aneurism, and Traumatic Gangrene*, New York, 1870, p. 219); LIZARS (J.) (*A System of Practical Surgery*, Edinburgh, 1838, Vol. I, p. 104).



Of secondary bleeding from the obturator or hemorrhoidal vessels or their branches the following are probably examples. CASE 911, already alluded to on page 316, is of peculiar interest on account of the course of the ball through the thyroid foramen and sciatic notch:

CASE 940.—Sergeant J. H. Warford, Co. A, 124th New York, aged 23 years, was wounded at Sailor's Creek, April 6, 1865. He was treated in Second Corps hospitals until the 22d, and then sent to Jarvis Hospital. Assistant Surgeon D. C. Peters, U. S. A., reported: "Gunshot wound of the right thigh, the ball entering about two inches below Ponpart's ligament and three inches from the spine of the pubis. On June 12th, hæmorrhage to the extent of two ounces occurred from the external pudic artery, being caused by sloughing from gangrene. The vessel was ligated in the wound. There was no return of the hæmorrhage." He was transferred, on July 24th, to Hicks Hospital, and thence discharged, August 26, 1865. Pension Examiner W. P. Townsend, of Goshen, reported, October 17, 1865, that "a ball penetrated the right thigh in the inguinal space, and passed through the limb one inch behind and below the trochanter major; he had gangrene in the wound. There is now a fistula discharging. From injury to the muscles the limb is contracted on the pelvis. He walks on crutches. Disability total." Examiner J. Gordon reported, September 17, 1873, that "the cicatrix at point of entrance is very large, and sensitive from the effects of hospital gangrene. There is also much adhesion of muscles, fascia, and skin, with some contraction. Disability three-fourths."

CASE 941.—Private J. A. Murphy, Co. C, 17th Virginia, aged 20 years, was wounded at Williamsburg, May 8, 1862, and was treated in a field hospital until the 17th, when he was sent to Cliffburne Hospital, Washington. Assistant Surgeon John S. Billings, U. S. A., made the following special report of this case: "He was wounded while in a kneeling position: the ball entered the external aspect of the thigh five inches below the trochanter major, and then, passing upward and inward, lodged in the buttock of the opposite side. When admitted he was cheerful and comfortable, presenting no symptoms worthy of notice. May 25th: As he began to complain of pain and tenderness in the left natis, an incision was made and the ball found, after a little search, embedded in the fibres of the gluteus maximus. June 1st: He has been going on well up to this date, when a sudden and copious discharge of blood from the anus occurred. A weak solution of persulphate of iron was given in enema, which readily checked the hæmorrhage. Small doses of opium were given internally, and the patient was restricted to milk diet. June 3d: Hæmorrhage took place from the wound made for the purpose of extracting the ball, and also from the rectum; the persulphate was again resorted to, and followed by an opium suppository, as he complained of intolerable tension and pain. Good nourishment was given, with one grain of opium and ten drops of tincture of iron every four hours. He perspired freely. Up to June 15th, he slowly and steadily improved; no more hæmorrhages taking place, and the discharges being natural, with the exception of containing, now and then, a small clot of blood. The wound made by the entrance of the ball had entirely healed; the discharge from the wound made to extract the ball was purulent and copious, but contained no blood. On the evening of the 14th, however, hæmorrhage occurred from the rectum, not very profuse, but sufficiently so, in his feeble condition, to utterly prostrate him. The same remedies were employed with the effect of checking the hæmorrhage, and beef-essence, brandy, etc., were given. June 16th: Has been very slightly improving up to this date, when hæmorrhage again occurred from the bowels, and he died in half an hour. Examination six hours after death: The ball was found to have passed upward from the point of entrance in the thigh. It entered the pelvis at the obturator foramen, passing directly through the rectum, broke off the spinous process of the ischium of the opposite side, and lodged in the fibres of the gluteus medius. The bleeding vessel was one of the inferior hæmorrhoidal arteries; the space between the sacrum and rectum was filled with coagula; the recto-vesical fold was elevated and its peritoneal surface was dark in color. The autopsy was made by Dr. E. Curtis."

*Wounds and Injuries of the Sciatic Artery.*—The examples of lesions of this vessel that were reported were fatal. Cases recorded further on were treated—by Professor Brainard, by ligation of the primitive iliac; by Surgeon A. B. Mott, by tying the hypogastric; by Surgeon W. Clendenin, by the application of the actual cautery. Two cases, here related, were treated by Surgeons Crosby and Duval, by ligation of the sciatic, apparently by single proximal ligatures.<sup>1</sup>

CASE 912.—Private H. C. Leslie, Co. M, 7th New York Artillery, aged 18 years, received a shot wound at Cold Harbor, June 3, 1864, and, after some treatment in a field hospital of the Second Corps, was removed to Washington and admitted into Columbia Hospital on the 8th. Surgeon T. R. Crosby, U. S. V., noted "a gunshot wound of the sciatic artery, from which hæmorrhage occurred on the 16th, to the extent of twenty-five ounces; the artery was then ligated. He died June 19, 1864."

CASE 943.—Private W. R. Carrington, Co. H, 2d South Carolina, was wounded at Cedar Creek, October 19, 1864. He was sent, on October 20th, to the Prisoner's Hospital, at Winchester, in charge of Surgeon W. S. Love, P. A. C. S., who reported a "wound by a conoidal musket ball which comminuted the transverse process of the sacrum. Hæmorrhage from the sciatic artery occurred on November 3d, and the vessel was ligated by Dr. Duval (Confederate) and the ball was extracted. Death, November 4, 1864."

<sup>1</sup> DUGAS (L. A.), *Aneurism of the Ischiatic Artery—Ligature of this Vessel, and consequently of the Primitive Iliac Artery; with Remarks, in the Southern Med. and Surg. Jour.*, 1859, Vol. XV, p. 652. This important paper contains a translation of an abstract of Professor SAPPÉY'S case of ligation of the sciatic. The student should further consult: BOUSSON (F.) (*Mém. sur les Lésions des artères fessière et ischiadique, et sur les opérations qui leur conviennent*, in *Gaz. Méd. de Paris*, 1815, T. XIII, p. 161); DUBAY (*Lettre sur un nouveau procédé pour la ligature de l'artère fessière*, in *Gaz. Méd. de Paris*, 1815, T. XIII, p. 219); DIETERICH (*Das Aufsuchen der Schlagadern behufs der Unterbindung*, etc., Nürnberg, 1831); ZANG (*Darstellung blutiger Heil- Operationen*, Wien, 1823, B. 1, S. 294); SHAW (J.) (*A Manual for the Student of Anatomy*, 1825, p. 119).

In connection with a report of CASE 679, page 232 *ante*, Acting Assistant Surgeon E. G. Waters observes: "These wounds of the buttock are eminently dangerous, on account of the risk of wounding the gluteal or sciatic arteries. I lost two men from hæmorrhage from this cause, men wounded at Spottsylvania, who lay in adjoining beds in my ward at Camden Street Hospital." The following is doubtless one of the cases referred to:

CASE 944.—Private J. Harris, Co. E, 49th Pennsylvania, aged 24 years, was wounded at Spottsylvania, May 9, 1864. He was treated in a Sixth Corps hospital until the 13th, then sent to Campbell Hospital, and on the 16th to Camden Street Hospital. Surgeon Z. E. Bliss, U. S. V., reports: "Gunshot wound of the right foot and thigh. One bullet entered behind the right great trochanter and passed inward and backward; the other grazed the dorsum of the right foot. Examination revealed that the great trochanter was injured. The patient did well until June 27th, when hæmorrhage of an alarming character occurred. It was supposed to proceed from the sciatic or pudic arteries. Twenty-five ounces of blood were lost. The bleeding was checked by compression, the indications to search for and tie the vessel not being sufficiently clear to warrant operative interference. He sank, and died June 29, 1864. An autopsy six hours subsequent to death revealed an immense accumulation of blood under the gluteus maximus of the same side, and the sac of what had been a traumatic aneurism. The sciatic nerve and pudic arteries seem to have been divided. The bullet was found lodged in front of the second sacral vertebra."

It is probable that the following, the only other fatal case of wound of the buttock in the ward at the period mentioned, is the second instance that Dr. Waters had in mind:

CASE 945.—Private J. Stafford, Co. C, 1st New Jersey, aged 24 years, was wounded at Spottsylvania, May 10, 1864. He was sent to Emory Hospital, May 13th. Surgeon N. R. Moseley, U. S. V., reported a "shot wound of the right lumbar region." The patient was transferred to Camden Street Hospital on May 16th. Surgeon Z. E. Bliss, U. S. V., reported that the "ball struck the right flank above the crest of the ilium and lodged in the right natis. Death, May 23, 1864, from the effects of the wound."

An instance of fatal bleeding from the sciatic artery was observed at Hampton Hospital:

CASE 946.—Lieutenant C. E. Hammond, Co. D, 6th Connecticut, aged 28 years, was wounded at Weirbottom Church, June 16, 1864. Assistant Surgeon Ely McClellan, U. S. A., reported that "he was admitted to the Chesapeake Hospital on the 19th, for a gunshot wound of the back and hip by a conoidal ball, and died from secondary hæmorrhage from the sciatic artery on June 27, 1864."

*Wounds of the Ilio-Lumbar Artery.*—Case 168, on page 36 *ante*, and the following are examples of fatal bleeding from this branch of the posterior trunk of the hypogastric:

CASE 947.—Private G. D. Vinson, 18th Tennessee, aged 20 years, wounded at Fort Donelson, February 14, 1862, was received into the City Hospital, St. Louis, on March 4th, where Surgeon J. T. Hodgen, U. S. V., reported that "he had received a gunshot wound of the right ilium. Hæmorrhage occurred from the ileo-lumbar artery, on date of admission, to the extent of thirty ounces, and recurred at intervals until death supervened on March 24, 1862."

*Wounds and Ligations of the Gluteal Artery.*—Two instances were recorded of bleeding from this vessel successfully treated by compression, and eleven at least in which this resource was unavailing; and also two instances in which the vessel was successfully ligated,<sup>1</sup> and three which proved fatal after ligation:

CASE 948.—Private George Allen, Co. I, 2d New York Heavy Artillery, was wounded at White Oak Swamp, August 14, 1864. He was treated on the field until the 23d, when he was admitted into Satterlee Hospital, Philadelphia. Surgeon I. I. Hayes, U. S. V., reported: "Gunshot flesh wound of the right buttock. A hæmorrhage of from three to five ounces occurred on August 25th, from the deep branches of the gluteal artery; the bleeding occurred to the same extent on the 28th. In both instances it was arrested by compression made by a compress and roller. The wound had nearly healed, when, on January 13, 1865, he was transferred to the Veteran Reserve Corps." Allen is not a pensioner.

CASE 949.—Private T. Patterson, Co. G, 31st Illinois, was wounded at Vicksburg, June 26, 1863, and treated in a hospital of the Seventeenth Corps, for a "shell wound of the right hip," until July 29th, and then transferred, by the steamer R. C. Wood, to St. Louis, and admitted into Jefferson Barracks Hospital, August 1st. Surgeon J. F. Randolph, U. S. A., reported a "gunshot wound of the gluteal muscles; hæmorrhage occurred from the gluteal artery on September 5th and 16th. This man was discharged from service, April 29, 1864," and pensioned. Examiner John W. Mitchell, of Illinois, June 22, 1865, reported that "a piece of shell carried away a portion of the left buttock; he had gangrene and exfoliation of the pelvic bone; the cicatrix was large and deep; the attachments of the muscles were injured by sloughing; the hip-joint was very weak, and the muscles of the leg atrophied. Disability was rated total." This pensioner was paid June 1, 1873.

<sup>1</sup> NEUBÖRFLER (*Handbuch der Kriegschirurgie*, 1867, B. II, S. 1108) says: "No contemporary surgeon has exposed this vessel on the living subject, and such an operation would hardly ever come to be carried out, since compression of the artery, digital compression of the aorta, and artificial coagulation of blood offer a series of resources that may be substituted for deligation."



Illustrations of fatal bleeding from wounds of the gluteal artery or of its branches were unhappily numerous.<sup>1</sup> The following instances may supplement those already cited.<sup>2 and 3</sup>

CASE 950.—An unknown Union soldier, probably wounded at Spotsylvania, was admitted to Judiciary Square Hospital, May 19, 1864. Assistant Surgeon Alexander Ingram, U. S. A., reported "a gunshot wound of the buttock. Soon after the patient's admission, profuse and uncontrollable hæmorrhage from the gluteal artery supervened, and proved fatal, May 19, 1864."

CASE 951.—Private J. Hull, 27th New York Battery, aged 27 years, was wounded at Petersburg, June 18, 1864. Surgeon M. K. Hogan, U. S. V., reported, from a Ninth Corps hospital, "ball in right hip." The patient was sent to Columbia Hospital on June 24th. Surgeon T. R. Crosby, U. S. V., reported that "pyæmia was well developed on June 25th, and the case was tending toward a fatal termination, when fatal secondary hæmorrhage from the gluteal vessels supervened, July 2, 1864."

CASE 952.—Private J. Ford, Co. H, 67th Indiana, was wounded at Grand Coteaux, November 3, 1863, treated on the field in a hospital of the Thirteenth Corps until the 13th, when he was admitted into St. James Hospital, New Orleans, whence Assistant Surgeon S. H. Orton, U. S. A., reported: "Gunshot wound of the right thigh. The ball injured the gluteal artery, the hæmorrhage from which it was impossible to control, and death resulted on December 6, 1863."

CASE 953.—Lieutenant W. J. Cockburn, Co. H, 120th New York, aged 28 years, was wounded at Gettysburg, July 3, 1863, and admitted into a First Corps hospital on the same day. The following report was made by Surgeon W. B. Chambers, 97th New York: "Wounded by a conoidal ball passing into the pelvis. On July 10th, there was hæmorrhage from the gluteal artery to the extent of twelve ounces, and recurred on the 17th, the bleeding having been arrested in both instances by pressure." He was transferred to East Walnut Street Hospital, Harrisburg, on the 21st, whence Acting Assistant Surgeon R. H. Sailer reported that "he died July 22, 1863, from secondary hæmorrhage."

CASE 954.—Private R. H. *McCracken*, Co. L, 13th South Carolina, aged 24 years, was admitted into Chester Hospital on July 19, 1863, having been wounded at Gettysburg on the 3d. Surgeon E. Swift, U. S. A., reported that "a conoidal ball entered the back, coursing down to the left hip, which was fractured. On August 2d, hæmorrhage, to the extent of thirty-two ounces, from the gluteal artery, resulted in the patient's death on the same day."

CASE 955.—Private J. S. Greer, Co. F, 7th North Carolina, was admitted into Chester Hospital on July 17, 1863, for a wound received at Gettysburg, July 3d. This case is recorded as a "gun-shot wound of the left hip. The patient had three attacks of hæmorrhage from the gluteal artery; the last attack, on July 29th, resulted in the loss of from twelve to fifteen ounces of blood, causing death on the following day." The case is reported by Surgeon E. Swift, U. S. A.

CASE 956.—Lieutenant J. B. Korman, Co. A, 23d Kentucky, aged 25 years, was wounded at Dallas, May 26, 1864, treated on the field until June 6th, and then admitted into hospital at Chattanooga. He was thence transferred to the Officer's Hospital, at Nashville, June 10th. Surgeon J. E. Herbst, U. S. V., made the following report of the case: "Gunshot wound of the left hip; the ball, entering from behind, passed forward and fractured the ilium of the same side. The ball was detected by a probe, but there was such a depth of tissues, and the missile was so firmly embedded in the bone, as to baffle all attempts to extract it. Hæmorrhage from the gluteal artery occurred on the 15th, and twenty-four ounces of blood were lost. The bleeding recurred on the following day to the amount of twelve ounces, and in both instances was controlled by pressure. Pyæmic chills were not decided. He died from pyæmia on June 20, 1864."

CASE 957.—Corporal E. John, Co. D, 99th Ohio, was wounded at Marietta, June 21, 1864. Treated first at Fourth Corps hospital, where Surgeon J. D. Brumley, U. S. V., believed that the hip-joint was opened. This patient was sent to Chattanooga on the 25th. Assistant Surgeon C. C. Byrne, U. S. V., reported that "he was struck by a piece of shell in the right gluteal region and a deep wound was produced. On June 24th, hæmorrhage from the right gluteal artery occurred, while the patient was on the cars; the amount of blood lost was not ascertained. The bleeding recurred on the 29th to the extent of twenty ounces; the blood coagulating, arrested the hæmorrhage. The patient died July 4, 1864."

CASE 958.—Private J. Preston, Co. A, 122d New York, aged 17 years, was wounded near Fort Stevens, July 12, 1864, and was sent to Mount Pleasant Hospital. Assistant Surgeon C. A. McCall, U. S. A., reported: "Severe wound of the right thigh by a musket ball. On July 30th, hæmorrhage occurred from the gluteal artery and four ounces of blood were lost. The patient stated that he had bled slightly five or six times, but that the bleeding had been easily arrested by compression. He died of pyæmia, August 18, 1864."

CASE 959.—Private J. Ragan, Co. M, 1st Massachusetts Artillery, aged 21 years, was wounded at North Anna River, June 1, 1864, and received treatment in a field hospital of the Second Corps until the 11th, when he was admitted into Lincoln Hospital. Assistant Surgeon J. C. McKee, U. S. A., recorded: "Wound in the right gluteal region by a minié ball. Hæmorrhage from the gluteal artery occurred several times after his admission, and death resulted July 5, 1864."

CASE 960.—Private H. *Treadwell*, Co. G, 61st North Carolina, was wounded at Morris Island, August 26, 1863. He was admitted into hospital No. 4, Beaufort, on September 1st. Assistant Surgeon John Trenor, jr., U. S. V., reported: "Flesh wound of the left thigh by a rifle bullet, which entered the buttock and passed close to the head of the femur, and made its exit opposite to the anterior face of the femur, passing between the head and ramus of the ischium. Hæmorrhage from the gluteal artery took place on September 8th to the amount of thirty-five ounces; it was controlled by a free application of persulphate of iron on the orifices of the wound. The bleeding did not recur. The patient was probably forty or forty-five years of age and in a miserably debilitated condition, and had never fully rallied from the first shock of the wound. He died September 12, 1862."

<sup>1</sup> In the *Surgical Memoirs of the War of the Rebellion*, collected and published by the United States Sanitary Commission, 1870, p. 210, a case of secondary hæmorrhage from the gluteal artery, observed by Prof. P. F. EVE, is recorded: Case of L. T. *Sherrill*, Co. K, 18th Alabama, shot through the right nates, September 20, 1863. Hæmorrhage occurred October 9th, and was restrained by pressure. Death, October 11, 1863.

<sup>2</sup> CASES 631, p. 216; 648, p. 222; 702, p. 242.

<sup>3</sup> Compare GUTHRIE (*On the Diseases and Injuries of the Arteries*, London, 1833); HODGSON (*A Treatise on the Diseases of the Arteries and Veins*, 1845, p. 397).

It was stated, in six instances, that ligatures were placed on the cardiac side of wounds of the gluteal artery. Two of the patients recovered.<sup>1</sup> Dr. J. H. Brinton has transmitted, January 27, 1874, an account of a ligation of the gluteal in the case of Colonel A. J. Warner, partially detailed on page 232:

CASE 678 (*Continued*).—"On the 6th of February following, another attempt was made by Surgeon Clymer to find the ball. The patient having been anesthetized, an incision fully four inches in length was made over the track of the ball, which corresponded nearly with the centre of the gluteus maximus muscle. The line of the incision was parallel to the fibres of the muscle. The subjacent parts were freely divided, and the ball was eventually found embedded in the substance of the ilium on the line of the posterior inferior spine, and just above the upper border of the great sacro-sciatic notch. It was removed without any very serious difficulty. During the manipulation, however, the gluteal artery was started. The hæmorrhage at first was very severe, apparently uncontrollable. The jet of blood possessed great force, and seemed to fill the large cup-shaped cavity of the wound in an instant. At the request of Dr. Clymer, I took charge of the bleeding. My first impulse was the ligation of the internal iliac, so difficult seemed any attempt upon the deeply seated bleeding vessel. A moment's reflection, however, led me to search for the latter, when, thrusting my finger to the bottom of the wound, I could readily feel the impulse of the jet of blood. I then requested Assistant Surgeon Moss, U. S. V., to plug the wound with the end of a dry towel. This was done; at the expiration of a few seconds I quickly removed the plug, and while so doing was so fortunate as to see the gaping orifice of the main trunk of the gluteal artery, as that vessel emerged through the great sacro-sciatic foramen. I immediately compressed the trunk with the end of my index finger against the upper bony rim of the notch, thus arresting the hæmorrhage instantly and completely. The seizure of the vessel with an artery forceps and its ligation was then an easy matter. No further hæmorrhage, to any extent, occurred in this case; the ligatures separated in due time, and the patient made a happy recovery."

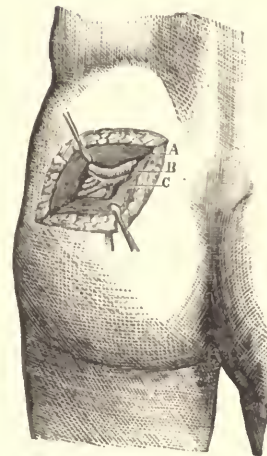


FIG. 270.—Ligation of the left gluteal. [After FOLLIS]. A—gluteus maximus; B—gluteal artery; C—gluteal veins.

CASE 961.—Private R. West, Co. B, 104th Illinois, aged 31 years, was wounded at Atlanta, August 7, 1864, by a minié ball. He was treated on the field and in hospitals No. 1, Chattanooga, and No. 1, Nashville, where he was admitted on the 17th. Surgeon B. B. Breed, U. S. V., reported a "severe flesh wound of the right side. Hæmorrhage from the gluteal artery ensued on September 19th to the amount of eight ounces. The vessel was ligated in the wound, the proximal end being tied; no hæmorrhage recurred. The wound was treated with simple dressings. The patient was transferred, December 20, 1864." On January 10, 1865, he was admitted into hospital at Jefferson Barracks, thence discharged the service, February 5, 1865. Pension Examiner C. Hard, of Ottawa, reported, April 1, 1865, that "the ball entered the right side at an angle of the floating ribs, and passed through to the right, producing extensive sloughing and adhesion of the muscles, almost disabling the right leg, and rendering him very lame." Examiner A. C. Rankin reported, September 19, 1863, that "West was shot in the right side just below the last true rib; the ball passed downward and came out about the end of the coccyx. He has had hospital gangrene in his wound, which destroyed a large portion of the muscles of the hip. There is a large cicatrix extending from the crest of the ilium to the end of the coccyx, and several others on the hip and thigh, caused by abscesses. He has a hitch in his walk, from the muscles of his hip being adherent to each other. Disability is total." This pensioner was paid to September 4, 1873.

In a case of excision of the head of the femur<sup>2</sup> and in the two following cases, bleeding from the gluteal was controlled by proximal ligatures:

CASE 962.—Private G. W. M. Johnson, Co. I, 32d Tennessee, aged 20 years, was wounded at Fort Donelson, February 15, 1862, and was sent to St. Louis. He entered the City Hospital on February 21st. Surgeon J. T. Hodgen, U. S. V., reported, "wounded in the left hip. On March 12th, hæmorrhage occurred to the amount of twenty-five ounces, probably from the gluteal artery. The vessel was tied, and the ligature afterward separated. On March 24, 1862, death ensued, but was not occasioned by recurrence of hæmorrhage."

CASE 963.—Sergeant J. Morrison, Co. A, 102d Illinois, aged 27 years, was wounded at Resaca, May 15, 1864, and received slight treatment for a shot wound of the left arm in a field hospital of the Twentieth Corps, previous to his admission into No. 8, Nashville, on the 25th. On the same day he was transferred to Brown Hospital, Louisville, where Assistant Surgeon B. E. Fryer, U. S. A., reported as follows: "Gunshot wound of both buttocks; no laceration. On June 17th the patient was placed under chloroform, and the left gluteal artery was ligated. He was much reduced from a copious hæmorrhage immediately before the operation. He reacted somewhat, and was ordered nutritious diet and stimulants. On the third day after the operation he had a chill, which was followed by well-marked pyæmic symptoms. He died from pyæmia, July 3, 1864. *Post-mortem* examination revealed pus in both the elbow and the right shoulder-joints, and also in the right knee; but there were no thrombi in the veins."

<sup>1</sup> Compare the case of CARMICHAEL (*Wound of the Gluteal Artery and an Account of the Operation for Securing it*, in the *Dublin Med. Jour.*, November, 1833); GUTHRIE (*Commentaries*, 6th ed., p. 270). Note also THREDEX (J. C. A.) (*Neue Bemerkungen und Erfahrungen*, 1872, B. I. S. 83) a case of fatal recurrent bleeding from a shot wound of the gluteal artery treated by compression; and the case of JEFFREY (*Cyclopædia of Pract. Surgery*, 1841, Vol. I. p. 278). BECK (*Chirurgie der Schussverletzungen*, 1872, S. 546) says that in shot wounds of the buttock, complicated with bleeding, absolute rest will often be adequate, the patient being made to lie upon the belly. He mentions the case of an officer with such a wound, with recurrent hæmorrhage arrested by position and compression, and thinks that ligation will be rarely required in shot wounds of the buttock.

<sup>2</sup> CASE of Private J. Melear, Co. A, 8th Michigan Cavalry, reported in Circular 2, S. G. O., 1869, p. 25.



In a case of shot fracture of the ilium complicated by bleeding from a branch of the gluteal, Dr. Bentley endeavored to carry out the sound practice of placing ligatures above and below the wounded portion of the vessel:

CASE 961.—Private R. C. Davidson, Co. K, 6th Maryland, aged 16 years, was wounded at Petersburg, April 2, 1864. Surgeon W. A. Childs, 10th Vermont, at the Third Division Hospital of the Sixth Corps, reported a shot wound of the right hip. The patient was sent to Slough Hospital, Alexandria. Surgeon E. Bentley, U. S. V., reported: "Shot wound of right hip, and flesh wound of the right arm. The ball entered above and without the anterior superior spinous process of the ilium, and emerged above the great sciatic notch. The patient was in excellent condition on his admission, on April 7th. The wound in the hip, which was by far the graver injury, cleaned off nicely with simple water dressings. On April 13th, about six ounces of blood was lost from the exit wound in the hip; the hæmorrhage was readily checked by pressure over the gluteal artery, indicating that it proceeded from a branch of that vessel. On April 15th, bleeding recurred in the morning to the extent of four or five ounces. At four in the afternoon, Dr. Bentley cut down and tied the gluteal artery and several of its branches, and the hæmorrhage was completely controlled. Stimulants were cautiously administered in small and frequently repeated doses, and he rallied rapidly after the operation. He was placed on a highly nutritious regimen. He rested well on the succeeding night, and passed a good day on the 16th. He continued to do well on the 17th and 18th; but, on the 19th, at half past two in the morning, the nurses aroused the ward officer by reporting a fresh bleeding, and nearly a quart of blood was lost before the hæmorrhage was checked. He gradually sank, and died April 19, 1864. At the autopsy, eighteen hours after death, the right ilium was found denuded over a space of two by four inches, and fractured just below the anterior superior spinous process."

Evidently lesions of the gluteal artery and its branches are not insignificant.<sup>1</sup> It is probable that, when the blood-vessels are fairly severed, properly adjusted compression will control bleeding from them in almost all cases; but when an artery the size of the gluteal is but partly divided, so that it cannot retract and be closed by the natural process of hæmostasis, then the only safe resource is the treatment insisted on by Guthrie, and the practitioner must at all hazards accomplish the difficult operation of placing ligatures on the vessel above and below the seat of injury.

*Wounds and Ligations of the Internal Iliac or Hypogastric Artery.*—Primary lesions of this vessel rarely came under treatment; but several instances were reported in the war, in which it was opened secondarily by sloughing. Wounds of its larger branches,<sup>2</sup> as has been seen, were not uncommon, and, on three occasions, for bleeding from them, ligatures were placed on the hypogastric, on the principle of Anel's operation. Two of these cases are printed on page 332, the third on page 334. The complexity and frequent variability in the distribution of this vessel<sup>3</sup> renders the diagnosis of its lesions to the last degree obscure. Some cases of injury of the vessel were reported, however, as follows:

CASE 965.—Private S. Ryder, Co. D, 5th Michigan Cavalry, aged 29 years, was wounded at Hanover town, May 28, 1864, and treated in a field hospital of the Fifth Corps until June 4th, when he was admitted into Emory Hospital. Surgeon N. R. Moseley, U. S. V., reported: "Wound of the left thigh by a minié ball. On the 18th, hæmorrhage occurred from the internal iliac to the extent of three ounces, and the patient died, on June 19, 1864, from accumulation of blood in the abdomen."

CASE 966.—Private S. Martin, Co. F, 101st Ohio, aged 19 years, was wounded at Stone River, December 31, 1862, and, on January 9, 1863, was admitted into hospital No. 5, Nashville, with a "gunshot wound of the left side of the abdomen. On January 16th, hæmorrhage to the amount of thirty ounces occurred from the internal iliac artery, and death resulted on January 17, 1863." The case is reported by Assistant Surgeon I. D. Wylie, of the 35th Illinois.

CASE 967.—Sergeant H. Osgood, Co. D, 83d New York, was wounded at Fredericksburg, December 13, 1862. Surgeon C. J. Nordquist, 83d New York, reported "a gunshot wound of the hip." The patient was sent to Lincoln Hospital, and was admitted December 23d. Surgeon H. Bryant, U. S. V., reported: "Gunshot wound of pelvis; fracture of the superior spinous process of the left ilium, and probably wounding a lumbar nerve and the internal iliac artery." Tetanus supervened, December 25th. On December 28th, profuse secondary hæmorrhage took place, and death the same day."

<sup>1</sup> On operations on the gluteal and ischiatic arteries, besides the authorities cited, the reader may consult an article by the solid FOLLIN (*Traité élémentaire de pathologie externe*, 1869, T. II, p. 489); also a paper by BLASIUS (*Eigenthümlicher Schmerz beim Gluteal-Aneurysma*, in *Deutsche Klinik*, 1859, B. XI, S. 105); and a case by CAMPBELL (G. W.) (*Ligation of Gluteal Artery for Traumatic Aneurism*, in *Brit. Am. Jour.*, Vol. III, p. 103).

<sup>2</sup> "La brièveté, la profondeur de la situation de l'iliaque interne doivent rendre ses lésions fort rares, car nous n'en connaissons pas d'exemple."—BÉRARD (A.), *Plaies des vaisseaux iliaques*, in *Dict. de Méd.*, T. XVI, p. 230.

<sup>3</sup> "The internal iliac artery descends from the front upper part of the sacro-iliac junction to the lower part of the same articulation. In this descent it is bounded behind by the sacral plexus of nerves and gives off several arterial trunks; but the manner by which the last is accomplished is much varied in different subjects. For the most part, it is an inch or more long before any important branches leave it; it is then frequently divided into two principal trunks, an anterior and posterior, from which proceed the several branches that supply the internal and the external parts of the pelvis. The rule of origin of the secondary trunks from these two principal ones, even when the latter exist, is not fixed; for sometimes they arise from one, sometimes from the other, and then again from the trunk of the hypogastric itself."—HORNER (W.), *Special Anatomy*, 6th ed., 1843, Vol. II, p. 253.

The subject of wounds of the iliac blood-vessels has been very fully and ably discussed by Dr. J. A. Lidell.<sup>1</sup> An illustration adduced by him, and a few other examples may be cited before detailing the instances of deligation of this trunk:<sup>2</sup>

CASE 968.—Surgeon M. M. Stimmel, 26th Ohio, reports that "Private Abel Mock, Co. K, 26th Ohio, was admitted into the field hospital of the 6th division, Army of the Ohio, May 27, 1862, having been wounded the same day while on picket near Corinth. A musket ball entered the abdomen in the left inguinal region, about two inches above the centre of Poupart's ligament, and passed obliquely backward to the point of exit, near the lower margin of the iliac fossa. The descending colon was perforated, and, when I first saw the patient, protruded some six or eight inches from the wound, allowing the escape of fecal matter. This man died, fifteen hours after the reception of the wound, from immediate hæmorrhage. There was no post-mortem examination, but in my opinion the ball was not deflected from a straight line in its passage. Some of the important branches of the iliac artery were doubtless divided. The bladder was evacuated a few minutes before the wound was received, else it must have been perforated."

CASE 969.—Private J. Lotters, Co. K, 37th Ohio, was wounded at Princeton, West Virginia, May 16, 1862. Surgeon C. Schenek, 37th Ohio, reported the injury as severe. Surgeon J. F. Gabriel, U. S. V., stated that the "ball passed through the right upper portion of the sacrum. The wounded man entered the post hospital at Raleigh, West Virginia, May 23th, and died June 6, 1862. At the autopsy it was found that the missile had wounded the posterior trunk of the internal iliac artery and embedded itself in the right iliacus internus muscle. The immediate cause of death was secondary hæmorrhage."

CASE 970.—Private E. Ryan, Co. K, 137th New York, aged 45 years, was wounded at Gettysburg, July 2, 1863. Surgeon J. M. Farmington, 137th New York, reported "a gunshot wound of the hip." The patient was placed in the Twelfth Corps Hospital. Surgeon H. E. Goodman, 28th Pennsylvania, reported that the "ball passed through the sacrum. On July 17th, hæmorrhage to the amount of twelve ounces occurred from a branch of the internal iliac. This patient died July 18, 1863. The pelvis was filled with blood. The missile was not found."

The actual cautery was unavailingly employed as a hæmostatic in the following case:

CASE 971.—Private Oliver M. Heath, Co. G, 6th New Hampshire, aged 23 years, was wounded at the second battle of Bull Run, August 31, 1862, and was sent to Emory Hospital, September 6, 1862. Surgeon W. Clendenin, U. S. V., reported: "*Vuln. sclopeticum*: Death, September 16, 1862." This, doubtless, is the case reported in full by Surgeon Clendenin in the *Sanitary Commission Memoirs*. It is there stated that "the ball entered the buttock near its centre, passing through the glutei muscles, perforating the os innominatum and lodging in the pelvic cavity." \* \* "The case progressed well until the morning of the twelfth day, when blood began to ooze from the wound, at first slowly, but during the day it became more copious. Styptics, compression, etc., were used persistently, but without much success; hæmorrhage supervened from time to time until the patient's life was seriously endangered thereby. The wound was enlarged for the purpose of ligating the vessel: but, failing to find the bleeding vessel, the surgeon (Surgeon W. Clendenin, U. S. V., was in charge) applied the actual cautery, by which the hæmorrhage was arrested. On the succeeding day, profuse bleeding again supervened; the actual cautery was again applied very thoroughly, but without effect, and the wound was subsequently twice cauterized, yet the hæmorrhage continued. The patient died on the sixteenth day from the loss of blood. *Post-mortem* examination: The bullet had passed through the ilium, and was found lying upon the floor of the pelvis. It had wounded in its course the deep superior branch of the gluteal artery (external to the ilium), and, within the pelvis, the posterior trunk of the internal iliac artery. The first blood had undoubtedly come from the deep superior branch of the gluteal, which was arrested by the cautery. The subsequent bleeding was from the posterior trunk of the internal iliac, and, consequently, it was beyond the reach of the cautery."

<sup>1</sup> *Surgical Memoirs of the War of the Rebellion, collected and published by the United States Sanitary Commission*, New York, 1870. Consult the memoir on *Traumatic Hæmorrhage*, already cited, by Brevet Lieutenant Colonel JOHN A. LIDELL, U. S. V., Vol. I, Section I, Chapter XI, p. 219, Case LXXII.

<sup>2</sup> 1. STEVENS, of Santa Cruz, has the merit of priority in ligating the internal iliac, for aneurism, December 27, 1812. The account of his successful operation in the case of "Mailla, a negro woman from the Bambara country, \* \* the property of the heirs of P. Terral, esq.," may be found in the *Med. Chir. Trans.*, 1814, Vol. V, p. 421. This woman died ten years subsequently, and Professor OWEN dissected the pelvic blood-vessels, and the preparation was deposited in the Museum of the Royal College of Surgeons (*Disc. cat.*, 1848, Vol. III, p. 218, Series XXXV, No. 1596). The setæ, and not the gluteal, as supposed, had been the seat of aneurism. The operation has now (1874) been repeated at least twenty times: 2. On May 12, 1817, by ATKINSON (*Med. and Phys. Jour.*, Vol. XXXVII, p. 267), in the case of T. Cost, aged 29, with gluteal aneurism, who died, partly from hæmorrhage, nineteen days after the operation. 3. AVERILL (*Op. Surg.*, 1825, p. 55) is authority for the statement, that a Russian surgeon was poisoned by the ezar for successfully accomplishing the third ligation of the internal iliac on the living subject. I suspect this to be the operation commonly ascribed to ANEYD, of St. Petersburg (see *Am. Med. Recorder*, 1824, Vol. VII, p. 814). 4. Specimen 1504<sup>90</sup> of Guy's Hospital shows a ligation of the internal iliac by R. C. THOMAS, esq., of Barbadoes. The vessel is plugged with coagula above and below the ligature. The preparation was given by THOMAS to A. COOPER (*Cat. of Path. Prep. at Guy's Hospital*, 1860, Vol. I, *Circul. System*, p. 81). 5. S. POMEROY WHITE, of Hudson, New York, tied the left internal iliac successfully for gluteal aneurism, in the case of a tailor, Volkenburg, aged 60, October 23, 1827 (*Am. Jour. Med. Sci.*, Vol. I, p. 304). NEUDÖRFER and other Europeans erroneously cite this as "Hudson's case." 6. ALTMÜLLER, of Cassel, ligated the internal iliac, June 21, 1831, in the case of a woman, M. E. Truppé, with gluteal aneurism. The patient lived eighty-three days (*Deutsche Klinik*, 1853, B. V, s. 175). 7. VALENTINE MOTT (*Am. Jour. Med. Sci.*, 1837, Vol. XX, p. 13) performed successfully the second American ligation of the internal iliac, December 29, 1834, in the case of R. Charlton, aged 38, a colored man, with gluteal or ischiatic aneurism. 8. Dr. ZENONI TORACCHI tied the internal iliac, April, 1844, for traumatic or gluteal aneurism, in the case of a soldier of 36, who survived the operation twelve hours (*Gazzetta Medica Toscana*, August, 1844, as cited in the *Arch. gén. de Méd.*, 4<sup>e</sup> série 1846, T. XI, p. 314). 9. Dr. H. J. RIGGLOW (*Am. Jour. Med. Sci.*, 1849, Vol. XXII, p. 29) tied the internal iliac for traumatic aneurism, September 30, 1848, in the case of an Irish woman, stabbed in the buttock by her husband. Death from peritonitis, October 7, 1848. 10. Dr. G. KIMBALL (*Am. Jour. Med. Sci.*, 1850, Vol. XX, p. 92), in the case of A. Wentworth, aged 55, with aneurism, tied the internal iliac, November 19, 1849. The patient died, from recurrent hæmorrhage, December 6, 1849. 11. The operation by TRIPLER (*Am. Jour. Med. Sci.*, 1854, Vol. XXVII, p. 365), a ligation of the right gluteal and afterward of the internal iliac, November 13, 1853, in a man cut in the buttock, is well known through GUTHRIE'S severe criticism (*Commentaries*, 6th ed., p. 270). The patient survived the operation three days. 12. SYME'S instructive account of his successful ligation of the left internal iliac, in the case of F. S——, aged 22, with aneurism, is recorded in his *Observations in Clinical Surgery*, Edinburgh, 1861, p. 165. 13. The relation of a case in which SYME tied successfully, November 20, 1861, the common, external, and internal iliaes,



Dr. J. W. Thompson, of Paducah, prints, in the *Nashville Medical Journal*,<sup>1</sup> the history of a ligation of the internal iliac, from which the following abstract is made:

CASE 972.—Private *Thomas P.*—, 16th Tennessee Cavalry, was wounded at Harrisburg, Mississippi, July 10, 1864, and entered Forrest Hospital a few days subsequently. The left buttock had been penetrated by a minié ball. For four or five days there was moderate bleeding from the wound; but, on July 26th, the hæmorrhage suddenly became alarmingly copious. Dr. Thompson endeavored to tie the gluteal artery, from which the hæmorrhage was supposed to proceed. He reached the bleeding vessel and placed a ligature around it, but the coats were so much decomposed that the thread cut through. Dr. Thompson, in consultation with Drs. S. N. Denham, D. H. Bryant, H. Branham, and Russell, decided to tie the hypogastric. Anæsthesia being induced, an incision was made from a point an inch above and internal to the anterior superior spinous process of the left ilium, obliquely downward to the internal abdominal ring. The dissection was completed on the grooved director until reaching near the cavity of the abdomen. The peritoneum was then separated from the iliac fossa and pressed toward the linea alba. Dr. S. N. Denham then passed a ligature around the internal iliac about half an inch from its origin from the primitive iliac. The hæmorrhage was arrested instantly upon tightening the ligature. The patient was much prostrated by the anæsthetic, and it was necessary to pretermit its employment before the operation was completed. The after treatment consisted of opiates, with a mild nourishing diet. The symptoms were at first favorable; no evidence of peritoneal inflammation arising. On the sixth day there was a sudden gush of blood, and death ensued in a few minutes, August 1, 1864. Dr. J. W. Thompson asserts that this is the eleventh example of ligation of the hypogastric, and remarks that from the intricate anatomical relations of this vessel, its ligation is an operation of exceeding difficulty.

CASE 973.—Sergeant-Major E. Raymond Fonda, 45th New York, aged 28 years, was wounded at Drury's Bluff, May 7, 1864, by a minié ball, which entered one inch to the right of the coccyx, passed upward and out to within half an inch of the surface, just above the trochanter major of the right side. The ball was cut down upon and removed on the same day; it did not injure the bone. The wounded man was treated in a field hospital until the 10th, when he was admitted into Hampton Hospital, Fort Monroe; thence transferred to New York, and admitted to Ladies' Home Hospital on the 23d of May. Surgeon A. B. Mott, U. S. V., reported: "When admitted, the patient was very much emaciated; the wound healed unhealthy and inflamed, the discharges thin and offensive, and there was a disposition to slough. The sloughing increased on the 26th; the discharge was sanious and thin, the patient weak and restless. On the 28th, the wounds were still unhealthy in condition and showing evidence of gangrene. June 1st: The discharge was slightly increased and the wound painful. Five ounces of sherry wine daily, with extra diet, was ordered. On the 8th, the wounds were still painful, and the discharge continued to look unhealthy. Hæmorrhage occurred on the 13th, coming probably from the sciatic artery; persulphate of iron was applied and the wound plugged. On the 14th, there was a very profuse hæmorrhage, which was arrested by persulphate of iron with pressure. Hæmorrhage recurred on the 15th, and was checked by the application of Lambert's tourniquet with compresses. The patient was much reduced in strength; pulse 130. Beef-tea and five ounces of sherry wine were given and frequently repeated during the day. There was no hæmorrhage the next day; beef-tea and wine continued. The patient was much better on the 17th; his pulse 100. After consultation, it was decided that the only chance for the patient's recovery would be to ligate the right internal iliac artery. He was put under the influence of a mixture of chloroform and ether, and the operation was performed by Surgeon A. B. Mott, U. S. V. The hæmorrhage was immediately checked. Quite an extensive slough had already taken place where the ball was extracted; the parts looked healthy. Beef-tea and five ounces of brandy were given frequently during the day. On June 20th, an enema of warm water and castile-soap was administered; beef-tea, oysters, and brandy were given. The wounds were doing well on the 29th, and brandy and good diet continued. On July 2d, the patient's pulse was 80, his general condition better. One-half ounce of castor-oil was given, producing a gentle movement of the bowels. The ligature came away on the 6th, followed by hæmorrhage, which very much reduced the patient; pulse 130. Brandy and good diet were continued. There was no hæmorrhage on the 9th; brandy continued to be given. The patient was gaining strength by the 13th; wine and good diet were given. Again, on the 18th, hæmorrhage occurred very freely, almost exhausting the patient; his pulse was 150. On the 21st and 22d, hæmorrhage recurred, frequently during the latter day; pulse was very weak and rapid. He died at six o'clock p. m. on July 22, 1864. The necropsy showed the external incision nearly healed, except a small opening which led to the ligated portion of the artery. The adjacent parts had become adherent, forming a gangrenous sac containing about one ounce and a half of pus and coagulated blood; the proximal end of the artery had sloughed to the bifurcation."

after opening the sac of an iliac aneurism, in the person of a seaman, R. L.—, aged 31, is recorded in the Proceedings of the London Medico-Chirurgical Society (*Med. Times and Gaz.*, N. S., Vol. I, 1862, p. 625). 14. Of Mr. HIGGINSON'S unsuccessful ligation of the internal iliac for hæmorrhage from the gluteal, I have not found the original version. It is described in the Proceedings of the Liverpool Medical Society, April 5, 1863 (*Med. Times and Gaz.*, 1863, Vol. I, p. 330). 15. Dr. T. G. MORTON (*Pennsylvania Hospital Reports*, 1868, Vol. I, p. 209) describes a successful ligation of the left internal iliac, in the case of J. Miles, aged 21, with gluteal aneurism. 16. The original account of a successful ligation in 1869, of the internal iliac for diffused gluteal aneurism, by Professor C. GALLOZZI, of Naples (*Considerazioni sul un caso di guarigione di ligatura dell'arteria iliacca interna*), in the case of a youth, D. Gramatico, I have not seen. It is cited in VIRCHOW, HIRSCH, and GÜRTL'S *Jahresbericht*, 1869, B. II, S. 312, and in the *British Medical Journal*, January 22, 1870. 17-19. To the foregoing are to be added the three unsuccessful ligations of the internal iliac practiced by Drs. MCKEE, J. W. THOMPSON, and A. B. MOTT, added in the text, and, possibly (20), an operation ascribed by GÜNTHER (*Lehre von den Blut. Op.*, 1860, S. 9) and others to EVERETT, which I am unable to verify. Professors GROSS and ERICHSEN ascribe an unsuccessful operation to J. Kearney Rodgers, and Dr. ASHURST places "ROGERS" among the unsuccessful operators on this vessel. J. K. RODGERS was present at Dr. V. MOIT'S operation. D. L. ROGERS (*Cases in Surgery*, Newark, 1849, p. 93) tied the *external* iliac for inguinal aneurism, and the *Cyclopædia of Practical Surgery*, 1841, Vol. I, p. 278 states that: "Mr. Rogers has published a case in which he was also successful" in tying the gluteal artery. It does not appear that either of these surgeons ligated the hypogastric. POWER (*Anat. of the Arteries*, etc., Am. ed., 1862, v. 286) erroneously includes GÜNTHER'S ligation of the common iliac in this category. There is a paper by FICK (*Diss. exhibens historiam commemorabilem deligationis arteriæ iliacæ internæ*, Cassel, 1836) which professes to give a statistical summary of the earlier ligations of the hypogastric; but GÜNTHER (B. IV, S. 9) justly deprecates the confusion this writer has brought about, by including cases of deligation of the common and external with those of the internal iliac artery.

<sup>1</sup> THOMPSON (J. W.), *Ligation of the Internal Iliac Artery*, in the *Nashville Jour. of Med. and Surgery*, N. S., 1866, Vol. I, p. 108.

*Wounds and Ligations<sup>1</sup> of the Common Iliac Artery.*—As it has been demonstrated that wounds of the aorta are not always, of necessity, immediately mortal (pp. 15, 24 *ante*), it might be inferred, *a fortiori*, that wounds of the great secondary trunk would not be invariably attended by immediate fatal bleeding. Illustrations of this truth are, however, very rare. One instance was reported of shot wound of the right common iliac, fatal on the second day:

CASE 974.—Private E. R. Smithers, Co. G, 142d New York, aged 23 years, was wounded near Petersburg, June 18, 1864, and, on the following day, was admitted into Hampton Hospital, Fort Monroe. Assistant Surgeon Ely McClellan, U. S. A., reported as follows: "Gunshot wound of the right natis, the ball passing into the pelvis at the sacro-iliac symphysis. On June 20th, hæmorrhage occurred from the common iliac artery; there was a loss of three quarts of blood, and death ensued June 21, 1864. A *post-mortem* examination was made, and the ball was found lodged at the superior sacro-iliac symphysis, and the common iliac artery wounded."

To the three examples of ligation of the common iliac referred to in the preliminary report of 1865,<sup>2</sup> a fourth instance must be added, to complete the contribution of the war-experience to this division of what the European writers term "high surgery." The fourth example was an operation by the lamented Brainard,<sup>3</sup> which was, in a restricted sense, successful. A detailed account of this case has been already published:

CASE 975.—Colonel Joseph R. Scott, 19th Illinois, was wounded at the battle of Murfreesboro', December 31, 1861. A musket ball entered the thigh just below the groin, at the outer side of the femoral vessels, grazed the inside of the femur, and came out at the buttock. At the time of the injury there was hæmorrhage, which was controlled, as was supposed, by pressure on the femoral artery. The compression was continued for three weeks, during which time no hæmorrhage recurred. The wound suppurated and some small scales of bone came out at each orifice of the wound. He was sent to his home in Chicago, and did very well, although the wound remained open behind until April 5th, when a small tumor formed in front, which was opened. A day or two after, a hæmorrhage took place from both openings. On April 9th, at night, a copious bleeding was partly controlled by pressure, but recurred at intervals. On April 10th, Professor Brainard was summoned, and applied a compressor over the femoral. This seemed to arrest the bleeding; but in about two hours it returned, and was so great as to threaten death, and Dr. Brainard resolved to tie the external iliac, not doubting, from the history of the case, that the hæmorrhage proceeded from branches of the profunda femoris, close to its origin. With the aid of Professor Freer and the Drs. Hurlburt, the external iliac was tied by Lisfranc's method; but the bleeding was as profuse as ever, and it became evident that the ischiatic artery was the one giving blood. The danger was urgent, and Dr. Brainard at once extended his incision upward and outward and placed a ligature on the common iliac. The wound in the thigh was then enlarged, and a great quantity of coagula turned out. Warm applications were made to the limb, and brandy and broth ordered. On April 11th, the limb was cool, but not cold; pulse 100; nausea troublesome. On April 12th, pain and tenderness in the left renal region; pulse 120; wounds beginning to suppurate. On April 24th, ligature came away from external iliac, and, on May 1st, from common iliac. The wound of operation was healed on May 12th. He remained in good condition until July, the posterior wound still discharging pus and small bits of necrosed bone. At this date, he was attacked by colliquative diarrhœa, followed by typhoid fever, and died on July 8, 1863.

It is to be regretted that the report of Surgeon A. J. Phelps, U. S. V., of the casualties in the Fourteenth Corps at Stone River, does not supply the omission of Dr. Brainard in relation to the side on which the injury was inflicted. Surgeon Phelps records the case

<sup>1</sup> To Dr. STEPHEN SMITH'S elaborate summary (*A Statistical Examination of the Operation of Deligation of the Primitive Iliac Artery, embracing the Histories (in abstract) of Thirty-two Cases, in the Am. Jour. of Med. Sci., N. S., 1860, Vol. XI, p. 17*), Professor GÜRLT (LANGENBECK'S *Arch.*, 1862, B. III, S. 6) has added (33), a fatal case observed by himself, in LANGENBECK'S *Klinik*; and another (34), by RÜNGER, of Marlburg (FICK, *Diss. ex. historiam commem. deligationis arteriæ iliacæ*, etc., Cassel, 1846). A few others have since been reported, viz: 35. DELISLE (*Statistical Sanit. and Med. Rep. for the Year 1860*, London, 1862, p. 453); artery tied June 25th, 1859; death in 13 weeks. 36. BICKERSTETH (*Edinburgh Med. Jour.*, July, 1862); T. A., aged 39; operation for tumor March 4, 1862; ligation came away April 6th; patient recovered. 37. SYME (*Med. Times and Gaz.*, June 14, 1862, p. 625); R. L.—, seaman, aged 31, successfully treated for iliac aneurism by opening the sac and tying the common, external, and internal iliac arteries. 38. COCK (GUY'S *Hospital Reports*, London, 1864, 3d Series, Vol. X, p. 207); Wm. W.—, aged 27; successful ligation of right common iliac for aneurism, June 30, 1863. 39. MCKINLAY (W. B.) (*Edinburgh Med. Jour.*, 1864, Vol. IX, Part II, p. 208); successful ligation of external, and afterward common iliac, in the case of George T.—, aged 30. 40. HARGRAVE (W.) (*Dublin Med. Press*, 1865, Vol. II, p. 163); fatal case of ligation of the left common iliac for tumor in the left iliac fossa in a man aged 43. 41. BAXTER (A. J.) (*Chicago Med. Jour.*, 1865, Vol. XXIII, p. 460) ligated, July 22, 1865, the right common iliac for aneurism of the abdominal aorta; death, July 22, 1866. 42. MAUNDER (*Med. Times and Gaz.*, Oct. 26, 1867, p. 458) tied the right common iliac in a case of inguinal aneurism; patient died seven days after the operation. 43. CZERNY (BILLROTH, *Chir. Briefe*, u. s. w., Berlin, 1872, S. 131) tied successively the external, the common iliac, and the aorta, in a case of shot fracture of the upper third of femur, in a soldier wounded August 4, 1870; death in a few hours. 44. LADUREAU (*Réc. de mém. de méd. milit.*, October, 1871) ligated the common iliac in a case of spontaneous aneurism in a man aged 40; death on the 30th day. 45. W. MORRANT BAKER (*Saint Bartholomew Hosp. Reports*, 1862, Vol. VIII) tied the common iliac in a youth of 17, for aneurism in the gluteal region; death in 40 hours. 46. BUSCH (F.) (LANGENBECK'S *Archiv. für Klin. Chir.*, 1873, B. XV, S. 481), on May 18, 1870, ligated the common iliac in the case of a butcher accidentally stabbed in the right iliac region; death on the 40th day after the operation.

<sup>2</sup> Circular No. 6, S. G. O., 1865, p. 78.

<sup>3</sup> BRAINARD (D.), *Ligation of the Common Iliac Artery*, in the *Chicago Medical Journal*, 1864, Vol. XXI, p. 57. Reprinted in the *Am. Jour. Med. Sci.*, 1864, Vol. XLVII, p. 565, in the Sanitary Commission Memoirs, and elsewhere.



as a "gunshot wound of the groin and thigh." From the allusion to "pain in the left renal region," in Dr. Brainard's report, it may possibly be safe to infer that the shorter and deeper left primitive iliac was the trunk ligated. Of the three other ligations of the common iliac, full histories have been published of two. Dr. J. Cooper McKee's operation has been only briefly noted in the preliminary report and in the Museum Catalogue.<sup>1</sup>

CASE 976.—Private John Hardy, Co. H, 95th New York, aged 25 years, was wounded at Weldon Railroad, August 20, 1864, and, on the 24th, was admitted into Lincoln Hospital, Washington. Acting Assistant Surgeon E. W. Atwater reported: "This patient came into my ward in good condition; his wounds discharging healthy pus freely. He continued to improve until the night of September 5th, when the officer of the day was called to arrest hæmorrhage from his wound; this was promptly done by plugging the wound with lint saturated with persulphate of iron. I saw him at my usual morning visit, when the dressings were removed and others applied, without a return of the hæmorrhage. The hæmorrhage recurred on the night of September 6th, and again on the 8th and 11th. At a consultation held with the surgeon in charge on the 6th, it was decided that the gluteal artery was wounded. The patient was given more nourishing diet, with stimulants, and the wound was kept closed and cold applied to the parts externally. On the 12th, it was decided to ligate the internal iliac, and this was done

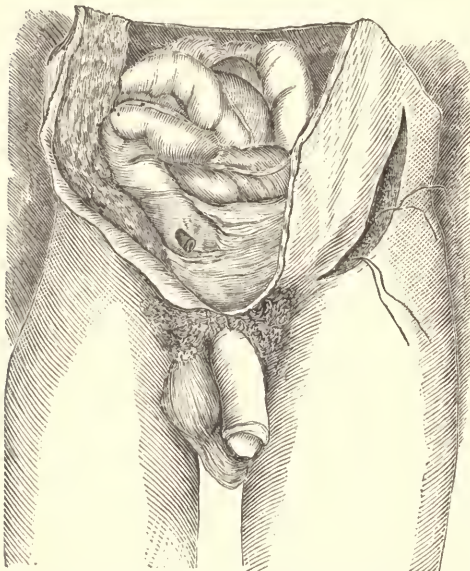


FIG. 271.—Drawing from a photograph of the cadaver in McKee's case of ligation of the internal and common iliaes. The left half of the pelvis and upper femoral regions are preserved in the Museum as Specimen 3464, Sect. I.

at four o'clock P. M. The wound was then opened and the bleeding was as free as before; a ligature was immediately applied to the common iliac, when the hæmorrhage seemed to be arrested. The patient was taken back to his bed at six o'clock and two grains of opium were given him, and one grain ordered to be given hourly until he was easy; during the night he took six grains. Beef-tea and brandy were administered freely. On the morning of the 13th, he was doing well. Beef-tea and brandy were continued; the temperature of the left leg was kept up by cans filled with warm water. At six o'clock P. M., he had another hæmorrhage from the wound, after which he continued to grow worse. Brandy and carbonate of ammonia were administered freely during the night, but without effect. The patient died at eight o'clock A. M., September 14, 1864." The *post-mortem* examination was made by Acting Assistant Surgeon H. M. Dean, who reported that "the œsophagus and trachea were normal. Both lungs were perfectly normal; the right weighed ten ounces, the left, eight and a half ounces. Pericardium normal. The right side of the heart contained a medium sized fibrinous clot, the left side a small one; the parenchyma and valves were healthy; the organ weighed ten ounces. The spleen was firm and somewhat enlarged, and weighed fourteen and a half ounces. The liver appeared normal, and weighed fifty-nine and a half ounces. He had a gunshot wound of the left gluteal region; a minié ball, passing through the walls of the pelvis, was found lying in the pelvic cavity, against the wall of the right side. By carefully raising the intestines from the pelvic cavity the ball was raised with them, and appeared to be protruding from the large intestine, the apex and one-half of the ball being visible. There was a small quantity of blood in the pelvic cavity. There was an

incision seven inches in length, commencing about three and a half inches from the median line on the left side, just below the ribs, passing downward, parallel to the median line, about five and a half inches, when it was made to course slightly inward. The internal iliac artery and the common iliac were ligated, and the ligatures were *in situ*. The track of the ball was not examined" It is proper to add to the reports by Drs. Atwater and Dean, that both of the ligations were made by Assistant Surgeon J. Cooper McKee, in charge of Lincoln Hospital at this date. With a wet preparation of the injured parts, Dr. McKee forwarded to the Museum a photograph<sup>2</sup> made from the cadaver at the autopsy. It is represented of reduced size in the wood-cut (FIG. 271). In the brief narrative of this case in his quarterly report of surgical operations, Dr. McKee mentions that "very little blood was lost in the course of the operation."

A full account of a ligation of the right common iliac artery for diffuse aneurism, resulting from a bayonet stab inflicted seven months previously, implicating the anterior trunk of the right internal iliac, has been published by the operator, Professor Ralph N. Isham, of Chicago.<sup>3</sup> A synopsis of the report is presented here, with a diagram to indicate the line of incision. Though the artery was brought into view in Dr. Isham's operation, the novice must not be betrayed by this drawing into the supposition that such

<sup>1</sup> Circular No. 6, S. G. O., 1865, p. 78, and *Cat. of the Surg. Sect. of the Army Medical Museum*, p. 461.

<sup>2</sup> *Contributed Photographs Army Medical Museum*, Vol. II, p. 5.

<sup>3</sup> ISHAM (R. N.), *Ligation of the Primitive Iliac Artery for Traumatic Aneurism*, in the *Chicago Medical Journal*, 1866, Vol. XXIII, p. 222, and reprinted in *The Medical Record*, 1867, Vol. I, p. 193.

a fair view of the vessel is commonly obtained in operations on the living subject, or in dissections on the injected cadaver. Even in thin subjects the vessel is very deep. In the shrunken wet preparation from Dr. McKee's patient, the distance from the surface to the seat of ligation is over five inches. In a ligature of the internal iliac, Syme, "finding that any attempt to bring the vessel into view would be quite impracticable, proceeded to pass the needle under it with such guidance as was afforded by a very distinct perception of its coats."<sup>1</sup>

CASE 977.—Surgeon John Groening, 35th Wisconsin, reports that Private August Tapka, Co. H, 25th Wisconsin, was accidentally wounded by a bayonet thrust, at Camp Washburne, Milwaukee, March 18, 1864, and was returned to duty July 12, 1864. Surgeon Samuel Kneeland, U. S. V., reports that this soldier was admitted to University Hospital, New Orleans, August 29, 1864, with a bayonet stab in the right gluteal region, and that he was furloughed September 19, 1864. Acting Assistant Surgeon R. N. Isham reported that he entered the Marine Hospital, Chicago, September 30, 1864, and died October 11, 1864, and sent a report of the progress of the case from which the following abstract is prepared: There was bleeding to the amount of fifteen ounces at the time of injury. The urine, which was drawn by the catheter for four days subsequently, contained much blood. Great swelling in the iliac fossa and right buttock occurred immediately. He was sent to his regiment, in Arkansas, after two months, but he could hardly walk with the aid of a cane. He suffered from what he described as a "hammering pain" in the tumor, which was observed to pulsate. Topical applications, made at the hospital whither he was sent, in New Orleans, failed to afford relief. On his admission to the Chicago hospital, he was suffering great pain in the tumor and right lower extremity. He was anæmic and presented the constitutional symptoms attending great loss of blood. The tumor was red and glistening, and extended from the crest of the right ilium to the natal fold. The cicatrix of the bayonet stab was nearly in its centre, and beside it was a puncture recently made for exploration by a surgeon on the transport steamer. The puncture was dilated to the size of a half dollar and filled with coagula, through which, October 2d, arterial blood escaped. There was numbness of the limb and dysuria. A bruit, but no audible pulsation, was perceptible on auscultation. On October 2d, an injection of solution of perchloride of iron was resorted to, with temporary arrest of the hæmorrhage, and injections were repeated on recurrences of the bleeding. It was decided to tie the common iliac. On October 7th, the patient being placed under chloroform, assisted by Surgeon L. H. Holden, U. S. A., and Acting Assistant Surgeon Terry, Dr. Isham proceeded to the operation. A curvilinear incision was made from in front of the extremity of the twelfth rib downward and forward to the crest of the ilium (FIG. 272), and along the crest, terminating near the anterior superior spinous process. The muscles and transverse fascia were successively divided, and, the peritoneum being held out of the way by two fingers, the deep wound was enlarged to the extent of the external incision. The peritoneum was lifted uninjured by the hand, together with the intestines, and the vessel was exposed to view, not a drop of blood obscuring the parts. The ureter was lifted with the peritoneum. A Mott's artery needle was passed under the vessel. The tightening of the ligatures not only arrested the circulation in the limb, but diminished the tumor, so that its tense surface became flaccid. The wound was closed; the limb was enveloped in cotton and placed in an easy position, and warm-water bottles were arranged near it; a half grain of morphia was given, and oyster-broth. He had a good night, and the limb was of natural temperature. Pulse 113. A dose of four drops of tincture of veratrum viride was given at seven in the morning; at eight in the evening the pulse was reduced to 80 beats. October 9th: Pulse 90; the discharge from the sac being offensive, the clots were turned out, and the sac was injected with a solution of permanganate of potassa. October 10th: Discharge from sac very offensive. October 11th: Died at ten A. M. The autopsy revealed no evidence of peritonitis. A well-organized clot extended from the seat of ligation to the aorta. The wound was in the anterior trunk of the internal iliac, within the sacro-ischiatric notch. The walls of the enormous sac were gangrenous. There were no appearances to account for the hæmaturia.

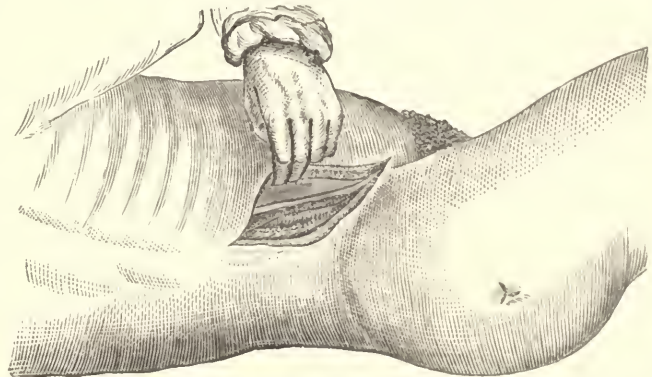


FIG. 272.—Diagrammatic drawing of the incision in Isham's case of ligation of the right primitive iliac artery, for a bayonet stab inducing traumatic aneurism of the anterior trunk of the internal iliac.

Dr. Isham was satisfied, after the autopsy, that the method he adopted was preferable to "the old operation," an opinion to which the editor, for one, cannot subscribe.

The history of the fourth instance of ligation of the common iliac artery reported during the war, has long been before the profession, and has excited less discussion and criticism than the extraordinary nature of the treatment might naturally have elicited.

An examination of the pathological preparation (FIG. 273), or a perusal of the operator's

<sup>1</sup> SYME, *Observations in Clinical Surgery*, Edinburgh, 1861, p. 167.



narrative of the case, leaves no room to doubt that this was an example of aneurismal varix, and that the deviation from the general rule of placing a ligature above and below the wounded part of the artery was not advantageous.<sup>1</sup>

CASE 978—Private G. W. Clark, Co. I, 4th New Jersey, aged 24 years, was admitted to the regimental hospital at Warrenton, August 31, 1863. Assistant Surgeon B. A. Watson, 4th New Jersey, gives no diagnosis, but records that the patient was transferred to general hospital at Washington, September 7, 1863. He entered Armory Square Hospital, September 15th. Surgeon D. W. Bliss, U. S. V., records the case as "venous congestion; patient transferred to Newark, November 12, 1863." He entered Ward Hospital, Newark, November 13, 1863, and in the monthly report Acting Assistant Surgeon A. M. Mills recorded the diagnosis: "Edema and varix of the left thigh." In the surgical report by Surgeon George Taylor, U. S. V., for the quarter ending March 31, 1864, the history of the case is recorded substantially as printed in the *American Journal of Medical Sciences*, 1864, Vol. XLVIII, p. 36. An outline of the narrative will suffice: In 1855, this man was accidentally wounded by the blade of a pocket-knife plunged into the inner part of the left thigh two inches below Poupart's ligament. He stated that there was free bleeding at the time, readily arrested by compression, and that the wound healed, and he resumed his avocation as a farmer, at the end of a week. No subsequent trouble arose until August, 1863, when a swelling of the calf of the left leg was observed, and pain was experienced in the left inguinal region. The swelling augmented, and the patient was sent to general hospital at the dates already noted. On December 26, 1863, Acting Assistant Surgeon J. B. Cutter observed an aneurismal thrill on firm pressure of the hand on the tumefied thigh, and a bruit over the tumor on auscultation. Surgeon G. Taylor and others verified these observations, and it was decided that the external iliac artery should be ligated. On February 6, 1864, anesthesia being induced by a mixture of chloroform and ether, Acting Assistant Surgeon J. B. Cutter made an incision five inches in length, commencing outside of the left external abdominal ring and curving upward to a point an inch above the anterior superior process of the ilium, divided the oblique and transverse muscles, and ligated the external iliac. Copious venous hæmorrhage during the operation, was ascribed by Dr. Cutter to "obstruction of the femoral vein by the aneurismal sac." The ligature came away on March 12th. On March 31st, the patient was reported by Dr. Cutter as "weak and debilitated from long confinement to bed, sitting up for an hour or so. Has not attempted the use of his leg as yet." In the surgical report from Ward Hospital for the quarter ending October 31, 1864, Assistant Surgeon J. Theodore Calhoun, U. S. A., transmits a narrative substantially the same as that printed in the *American Journal of Medical Sciences*, 1865, Vol. I, p. 392. It is stated that "since the beginning of June the limb had become enormously distended;" that "previous to the operation the thigh measured thirty-seven inches in circumference;" that "a number of openings on the thigh had lately put on a gangrenous appearance." Surgeon G. Taylor being still in charge of the hospital, it was determined to ligate the common iliac, and, on September 17, 1864, the operation was performed by Acting Assistant Surgeon J. B. Cutter. Anæsthesia being induced, "an incision was made six inches in length just above the old incision made for the ligation of the external iliac artery. The abdominal muscles were carefully divided until the fascia transversalis was brought plainly into view; it was found firmly adherent to the peritoneum, which was thickened and fastened to the surrounding parts. It was found impossible to separate the peritoneum and get behind it; so the peritoneal sac was opened, and the artery secured in that way. The wound was brought together with silver sutures and adhesive plaster, and was dressed as is usual with wounds containing a ligature. The superficial hæmorrhage was very abundant, but was of a different character from that of the previous operation. With very little trouble the veins were secured by ligature, and the operation proceeded without further inconvenience." September 18th: The patient passed a pretty comfortable night. The temperature of the limb has not fallen at all. Warm applications have been made to the foot only. There is great diminution in the size of the limb; it is fallen away about one-third. September 19th: Considerable tenderness of the abdomen. Limb still diminishing in bulk; is about half its former size. September 20th: Vomiting; labored respiration. September 21st: Death.  *Sectio cadaveris* : "Eighteen hours after death the whole surface of the

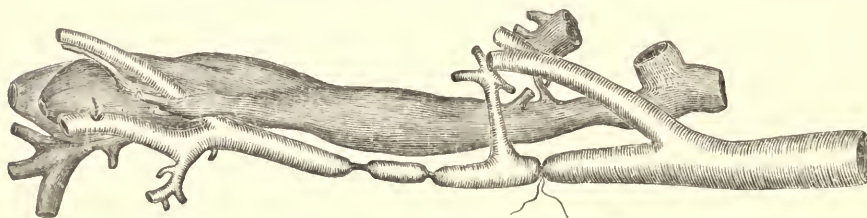


FIG. 273.—Aneurismal varix of the femoral vessels, showing, with the varicose veins, a portion of the aorta, the iliacs, with a ligature upon the left common trunk, and a constriction where a ligature has been placed on the left external iliac, and two constrictions of the femoral, due, apparently, to imperfection in the injection. *Spec.* 3597.  $\frac{1}{15}$ .

peritoneum was coated with lymph, and there was a small collection of serum. The lymph in some places was in flakes; in other situations it was the consistency of thick gruel, closely resembling pus. No adhesions between the lips of the wounds." The vessels were removed and injected. The preparation was sent to the Army Medical Museum by Assistant Surgeon J. Theodore

Calhoun,<sup>2</sup> who took charge of the hospital in October, 1864. A photograph of the preparation is included in the *Photographs of Surgical Cases and Specimens*, S. G. O., Vol. II, p. 24, and a reduced copy of this print is presented in the accompanying woodcut (FIG. 273).

<sup>1</sup> CUTTER (J. B.). *Successful Ligation of External Iliac Artery for Traumatic Aneurism of the Femoral, with a Statistical Table, showing the Results of the Operation of Tying the External Iliac Artery*, in the *Am. Jour. Med. Sci.*, 1864, Vol. XLVIII, p. 36. CUTTER (J. B.). *Ligation of the Common Iliac Artery: Sequel of Case of Ligation of External Iliac Artery for Aneurism of the Femoral Artery*, in *Am. Jour. Med. Sci.*, 1865, Vol. I, p. 391.

<sup>2</sup> As this excellent officer and esteemed gentleman is dead, the editor refrains from publishing the letter, filed in this Office, in which he comments on the operation. The specimen is erroneously accredited, in the *Catalogue of the Surgical Section of the Army Medical Museum*, p. 46), to Assistant Surgeon Clinton Wagner, U. S. A.

Few surgical precepts appear better established than that which inculcates that in arterio-venous aneurisms,<sup>1</sup> if the tumor is stationary, all operative interference should be avoided; but if interference is imperative, the artery should be tied on either side of the wound in it.<sup>2</sup> The foregoing case is an additional argument for the prescription of the methods of Hunter and of Anel in the treatment of this form of aneurism.<sup>3</sup>

*Wounds and Ligations of the Spermatic Artery.*—Lesions of this branch of the aorta will again claim attention with Wounds of the Testis. A single instance of bleeding arrested by compression, and a case in which the artery was tied, may be adduced here:

CASE 979.—Sergeant H. Frazier, Co. E, 28th Massachusetts, aged 41 years, received a wound at Fort Steadman, March 25, 1865, and was sent to a field hospital of the Second Corps. He was transferred to Stanton Hospital, Washington, on the 30th. Surgeon B. B. Wilson, U. S. V., reported: "Wound of the penis, left testicle, and upper third of the left thigh. There was hæmorrhage on April 4th, from the left spermatic artery, with a loss of twenty-four ounces of blood. The artery was not ligated, as the bleeding was controlled by pressure. Simple dressings to the wound and stimulating treatment were employed. He recovered, and was discharged May 30, 1865." He is not a pensioner.

CASE 980.—Color-Sergeant E. W. Crippen, Co. C, 27th Illinois, aged 29 years, was wounded at Missionary Ridge, November 25, 1863, and admitted into a field hospital of Sheridan's Division, Fourth Corps. Surgeon F. W. Lytle, 36th Illinois, transmitted the following account of the case: "The left testicle was shot away by a musket ball, leaving the tunica albuginea, with the cord, hanging through a ragged wound in the scrotum. The same ball made a wound in the left thigh through the skin. One ball, thought to be the same, entered behind the internal malleolus of the left ankle and passed out near the centre of the heel and near the sole of the foot. The spermatic artery was ligated on the 28th, and the debris of the testicle removed; the edges of the wound were pared and united by sutures, leaving an opening for discharge. On December 1st, the patient was doing well, union having taken place in the scrotum by first intention. He complained of great pain in the ankle, the parts around which were swollen, doughy, erythematous, immovable, and extremely painful. The parts were freely laid open and poultices applied; the constitutional irritation was considerable. The leg was suspended in an anterior splint. December 9th: Parts in about the same condition, only they were suppurating freely. The pain in the ankle was intense and produced a great deal of constitutional irritation. Poultices were applied, morphia was administered, and generous diet allowed. On the 14th, no change in the appearance of the ankle, which was discharging freely. The patient lost about six ounces of arterial blood by hæmorrhage from the wound; the bleeding ceased without any interference. His appetite was bad and he had a chill: his tongue was coated with a dirty whitish fur. Milk-punch was freely given, with generous diet. The following day the patient was very low; the chill he had on the previous day, not being very well marked was more like a rigor. Quinine and stimulants were freely given. He had hiccough during the night before, and all the day of the 17th. His pulse was scarcely perceptible, and he was profoundly prostrated. On the 18th, he was about the same; hiccough ceased during the night; hippocratic countenance. Hæmorrhage, on the 19th of December, 1863, to the amount of at least one pound, from the ankle, was arrested by persulphate of iron, but the patient died on the same day."

The bleeding from the posterior tibial was, of course, the important and mortal complication in this case. It is improbable that simple hæmorrhage from the spermatic artery should ever present serious difficulties.

In the foregoing review of the reported cases of wounds and ligations of the arteries of the pelvis, a group of practical importance, comprising the wounds and ligations of the external iliac, has been reserved for future consideration.

<sup>1</sup> Arterio-venous aneurism was first noticed by SENNERT (*Opera omnia*, Parisiis, 1641, Lib. V, Cap. XLIII, p. 797) (for the vague passages cited from PARÉ, ANDREA DE LA CRUCE, and FABRICIUS HILDANUS are of little moment); but the true nature of the affection was first discovered by WILLIAM HUNTER (*Med. Obs. and Inquiries*, 1757, Vol. I, p. 323; *Idem*, 1762, Vol. II, p. 390; *Idem*, 1767, Vol. III, p. 110; *Idem*, 1771, Vol. IV, p. 285). The pathology of the different varieties of aneurism by anastomosis has been worked out, however, by contemporaneous surgeons, and especially by those of the school of Paris. The student may profitably consult the dissertation of MORVAN, *de l'anévrysme variqueux* (Thèse de Paris, 1847, No. 41); and the theses of HENRY (*Considérations sur l'anévrysme artériovoineux*, Paris, 1856, No. 70) and of GOUPEL (*De l'anévrysme artériovoineux*, Paris, 1855) are also of value. The subject is carefully treated in the systematic work of BROCA (*Des Anévrysmes*, Paris, 1856, p. 24). The principal facts of interest to the military surgeon have been collated by BARDELEBEN (K.) (*Über das traumatische Aneurysma arterio-venosum. Beobachtung eines solchen nach Schussverletzung*, Inaug. Diss., Berlin, 1871).

<sup>2</sup> Dr. G. W. NORRIS (*Am. Jour. Med. Sci.*, 1843, Vol. V, p. 27) records an instance in which he successfully put this method in practice, and adds some very instructive comments on the treatment of arterio-venous aneurisms. Dr. NORRIS'S operation was for aneurism at the bend of the elbow; but a recent case, in which Mr. JAMES SPENCE, of Edinburgh, successfully treated a traumatic varicose femoral aneurism by ligating the artery above and below the wounded part, is strictly in point. The history of the case, which strikingly exemplifies what has been insisted on in the text as the correct conduct under such conditions, is printed in the *Edinburgh Medical Journal*, July, 1869, and is reprinted in the *American Journal of Medical Sciences*, October, 1869, Vol. LVIII, p. 562.

<sup>3</sup> FOLLAN (*Traité élémentaire de Path. externe*, 1865, T. II, p. 374) collected ten instances of arterio-venous aneurisms of the lower extremity, of which five were treated by placing a ligature on the carline side of the aneurism. All five ended fatally. He collected also nine examples of arterio-venous aneurisms of the upper extremity treated in like manner: three terminated fatally; there were relapses in five cases, and a cure was reported in one case. After the suspension of the current of arterial blood by a proximal ligature, the venous blood still entering the distal portion of the artery may block up the vessel and lead to gangrene, or else anastomoses restore the circulation in the distal portion, and a relapse occurs.



*Wounds of Veins.*—A few instances were reported in which injury of the veins of the pelvis was the most important complication. It may be supposed that lesions of the common iliac vein, or of its two principal tributaries, would be almost immediately mortal;<sup>1</sup> though an instance has been given at page 190 (CASE 657) of a patient surviving for over twenty-four hours a shot division of the internal iliac vein. In wounds of the external iliac vein or of the femoral vein near its entrance into the pelvic cavity, should the primary bleeding be controlled, gangrene of the lower extremity does not necessarily ensue immediately. In the following case, already cited by Dr. Lidell,<sup>2</sup> the patient survived seventeen days, and in CASE 984, on the next page, the fatal termination was as long delayed:

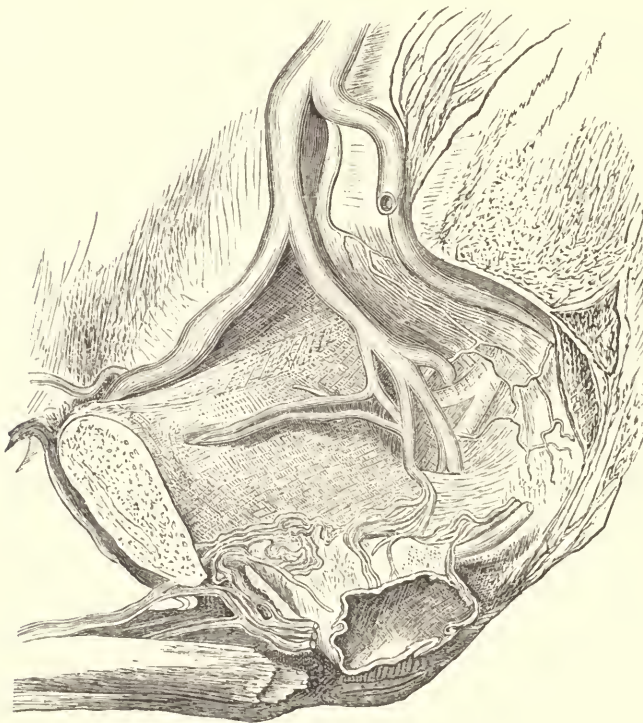

FIG. 274.—The veins of the pelvis. [After HENLE.]  $\frac{1}{2}$ .

Hæmorrhage of consequence from the lesser veins must be a rare event. In a single instance in the reports, attention is directed to bleeding from a gluteal vein:

CASE 983.—Private W. J. Parry, Co. I, 88th Illinois, aged 31 years, wounded at Chickamauga, September 20, 1863. The injury was recorded by Surgeon J. W. Foye, U. S. V., as a "gunshot wound of the right hip," and the patient was sent to the City Hospital at Chicago, whence Acting Assistant Surgeon J. A. Jackson reported a "wound of the right gluteal veins and flesh wound of the right hip. The patient was furloughed April 6, 1864, readmitted, and transferred to the Veteran Reserve Corps on August 7, 1864." Examiner Henry W. Lyman, of Chicago, reported, March 21, 1868: "Ball entered the space between the trochanter major and the tuberosity of the ischium; it did not pass through, and is said to have been allowed to remain. There is what seems to be a thickening of the fibrous tissues behind the trochanter. The adjacent bones were not fractured. He cannot stoop over without throwing his leg back, and then only with pain. Disability two-thirds and permanent." In an examination for an increase of pension Examiner J. S. Hidden reported, December 17, 1873, that "a musket ball entered the

CASE 981.—Private D. Wilson, Co. F, 110th Ohio, aged 44 years, was wounded at Fort Steadman, March 25, 1865, and was sent to Armory Square Hospital on March 28th. Assistant Surgeon C. A. Leale, U. S. V., reported that "a ball entered the right thigh at the middle of the sartorius border of Scarpa's triangle, cutting across the femoral vein, and passed beneath the ramus of the pubis, fracturing it across the perineum, and lodged deeply in the gluteal muscles. Hæmorrhage followed continuously, and at times was checked by styptics. When admitted he was delirious, and his limb was infiltrated with serum. He died, April 11, 1865, of asthenia. The necropsy showed the bone in the track of the ball very much comminuted, and the femoral vein partly closed by adhesive inflammation and filled with emboli."

Venous hæmorrhage was an important intercurrent feature in the following case:

CASE 982.—Private J. Schulthasis, Co. D, 15th New York Heavy Artillery, was wounded at Viner's Farm, Virginia, May 31, 1864, and was admitted into Douglas Hospital, Washington, on June 4th. The following report was made by Assistant Surgeon W. Thomson, U. S. A.: "Gunshot fracture of trochanter major and pelvis. There was hæmorrhage to the extent of two ounces, on the 7th, from the hæmorrhoidal veins; the bleeding ceased spontaneously, and did not recur. Pyæmia appeared on the 15th, resulting fatally on June 21, 1864."

<sup>1</sup> Compare, in the *First Surgical Volume*, the cases and remarks on pages 468 and 519, and wounds of the cavæ, and, in the *Second Surgical Volume*, CASE 434 on page 13F.

<sup>2</sup> LIDELL (J. A.), *On Wounds of the Veins*. This is the title of the fifth chapter of the important paper on Wounds of the Blood-vessels already frequently cited in this Section. Dr. S. W. GROSS's statistical monograph on the wounds of veins and the applicability of the ligature in such injuries is printed in the *American Journal of the Medical Sciences*, 1867, Vol. LIII, p. 305. Other authorities on the subject are: LANGENBECK (B.) (*Beiträge zur chirurgischen Pathologie der Venen*, in *Archiv, für Klin. Chirurgie*, 1861, B. I, S. 1); TRAVERS (*On Wounds and Ligatures of Veins*, in *Surgical Essays*, Am. ed., 1821, p. 167); OLLIER (*Des plaies des veines*, Thèse de concours d'agregation, 1837); AMUSSAT (*Recherches expérimentales sur les blessures des artères et des veines*, Paris, 1843); HOFFMANN (A.) (*De la ligature des veines*, Thèse, Paris, 1856); NICAISE (*Des plaies et de la ligature des veines*, Paris, 1872); BLASII'S (*Über seitliche Venenligatur*, Halle, 1871); STAUB (A.) (*De ligatura venarum laterali*, Inaug. Diss., Berlin, 1862); PICHEL (Das Venensystem in seinen krankhaften Verhältnissen, Leipzig, 1843-44).

fleshy portion of the right hip, six inches downward and backward obliquely from the superior spinous process of the ilium, and was never extracted. There is atrophy of the muscles, exercise producing pain and cramps down the thigh to the knee; inability to raise the foot over anything without great effort. During the past year numbness and partial paralysis has set in and is on the increase; it is permanent in the present degree." This pensioner was paid September 4, 1873.

Lesions of the femoral vein presented some features of interest clinically and from the point of view of the pathological anatomist; but most of these cases may be suitably considered either in the chapter on wounds of the lower extremities, or in treating, further on, of phlebitis or pyæmia. A single illustration may be presented (FIG. 275) of a shot wound of the femoral vein, as the case to which it belongs has been already related (CASE 868) at page 304. This patient survived thirteen days, though there were repeated copious venous hæmorrhages. The subject of the following case lived eighteen days:

CASE 984.—Private J. Shephard, Co. D, 9th Iowa, was admitted into the field hospital of the 2d division, Sixteenth Corps, on October 9, 1864, having been wounded by a conoidal ball at Allatoona on the 5th. Surgeon Joseph Pogue, 66th Illinois, reported that "the ball entered below the pubis and made its exit at the right trochanter major, making a very severe wound. The discharge from the wound was of a sanious purulent character, frequently accompanied by venous hæmorrhage, the latter becoming more copious daily. He died October 23, 1864. Autopsy twelve hours after death: Ball passed in on the left side of the scrotum above the testicle, and out anterior to the trochanter major of the right femur; it had severed the spermatic cord of the right testicle, passing posterior to the femoral vessels. The track of the ball was extensively ulcerated; the femoral vein severed, and containing purulent matter."

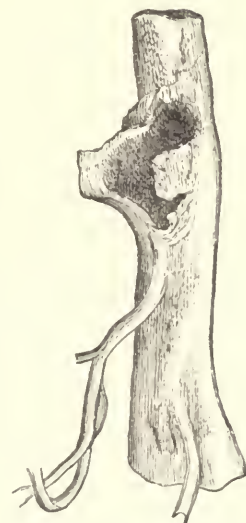


FIG. 275.—Shot laceration of the right femoral vein. *Spec.* 2094.  $\frac{1}{2}$ .

*Wounds of Nerves.*—It is altogether probable that there were instances of injuries of the pelvis in which the most important pathological elements were constituted by lesions of the sacral plexus of the sciatic and crural nerves or of smaller branches. It may be doubted, however, whether there were many such cases in which the attendant or resulting phenomena were described with the precision requisite in a study of such obscurity. The editor, at least, has hitherto been unable to accomplish any satisfactory analysis of the material bearing on the subject, and must be content to adduce some abstracts of cases which may possibly be of service to other investigators, and to again refer to the labors of Dr. S. Weir Mitchell<sup>1</sup> and Drs. Morehouse and Keen. Specimen 3538, of the Army Medical Museum,<sup>2</sup> from a shot laceration of the crural nerve, was preserved, by Dr. William Thomson, from a patient who survived the injury twenty-five days and died of tetanus, and a drawing illustrating its pathological histology will be given in treating of Tetanus, in the *Third Surgical Volume*. Dr. Larue,<sup>3</sup> aided by Professor Robin, has been studying shot lesions of the nerves during the Franco-Prussian War.

CASE 985. —Private B. Cunningham, Co. B, 51st Ohio, aged 21 years, was wounded at Stone River, December 31, 1862, and was treated in hospitals on the field at Nashville, New Albany, and Madison, entering the last July 24, 1863. Surgeon A. M. Wilder, U. S. V., reported as follows: "Wounded by a rifle ball, which entered from behind at the middle third of the right thigh, then passed forward and downward through Hunter's canal, wounded the great sciatic nerve, and emerged from the anterior aspect of the thigh. At the time of injury the profuse hæmorrhage was controlled only by the application of the tourniquet. His lég was flexed upon his thigh and cannot be straightened; he complained of much pain in the heel, toes, and dorsum of the foot; the leg was somewhat numb and was not painful. The wound was entirely healed at the time of his admission, and the man's general health was very good; he slept well at night without anodynes. A wash composed of fluid extract of aconite, chloroform, tincture of opium, and diluted alcohol, gave great relief to the pain. The left limb presented every appearance of "paralysis agitans," which was probably occasioned by reflex action of the nervous system." He was transferred

<sup>1</sup> In the work by Dr. S. WEIR MITCHELL (*Injuries of Nerves and their Consequences*, Philadelphia, 1872), and in the reports resulting from the associated labors of Drs. MITCHELL, MOREHOUSE, and KEEN (Circular No. 6, S. G. O., 1864, on *Reflex Paralysis*, and *Gunshot Wounds and Other Injuries of Nerves*, Philadelphia, 1864), will be found the most valuable data supplied by the experience of the war in regard to injuries of the nerves of the pelvis, and, indeed, to injuries of the nerves in general.

<sup>2</sup> WOODHILL (A. A.), *Catalogue of the Surgical Section of the Army Medical Museum*, 1866, p. 510: Private A. F——, Co. F, 31st Maine; wounded at the Wilderness, May 6th, died May 31, 1864.

<sup>3</sup> LARUE (E.), *Étude clinique sur les blessures des nerfs par les armes à feu*, *Gazette d. s. Hôpitaux*, Janvier 6, 1872, p. 9.



to Ohio, and admitted to Seminary Hospital, Columbus, September 13, 1861, and was discharged on September 20th. Acting Assistant Surgeon W. H. Drury certified: "Paralysis of the right leg and hyperæsthesia, caused by wound of the popliteal nerves." Examining Surgeon T. H. Smith, of New Philadelphia, reported, December 23, 1867: "Wounded by a ball passing through the thigh, wounding the femoral nerve. The foot is so drawn that the toes point downward, and he cannot flex the foot at the ankle. I think the disability is permanent. The limb does not seem to have the sense of feeling." The Examining Board at Dayton, Surgeons A. Jewett, A. S. Dunlap, and J. B. Beck reported, September 9, 1873, that the "ball entered the right thigh posteriorly, rather to the outer side, and came out on the front and inner side about the middle of the thigh. The tendo-achilles is greatly contracted, so that the heel will not touch the ground, and the foot is held firmly nearly at a right line with the leg." This pensioner was paid September 4, 1873.

CASE 986.—Private R. H. Blue, Co. E, 73d Indiana, aged 25 years, was wounded at Lost Mountain, June 16, 1864. From hospitals at Chattanooga, Nashville, and Madison, Drs. McGowan, Herbst, and Rauch described the case as a shot wound implicating the abdominal walls on the right side, and possibly complicated with fracture of the right ilium. This soldier was discharged May 30, 1865, and pensioned. Examiner S. J. Weldon, Covington, Indiana, reported, January 6, 1872: "Gunshot wound of the right side, fracturing the ribs. The ball entered about two inches above the crest of the ilium, remaining in the body; its location is not detected, but I believe it to be embedded in the lumbar muscles; it interferes with the ability to lift, walk, or run, and renders him unable to follow his occupation as a farmer. The numbness indicates either pressure upon some of the sacro-lumbar nerves or lesion of them." On September 5, 1873, Dr. Weldon further reports: \* \* \* "The disability consists of lameness of the right leg, numbness, and loss of muscular power in that limb. Disability one-half." This pensioner was paid September 5, 1873.

CASE 987.—Private R. Nelson, Co. B, 119th Pennsylvania, was wounded at Chancellorsville, May 3, 1863. The injury was reported as a shot perforation of the pelvis, from the Sixth Corps Hospital, the Hammond, Satterlee, and Turner's Lane Hospitals, lesions of the ilium and rectum being noted at some of the hospitals. This man was discharged from Turner's Lane, December 23, 1864, for "total disability from partial paralysis of the left lower extremity, from gunshot wound of the left hip." Examiner H. Lenox Hodge reported, at that date, "a gunshot wound appears to have involved both hips, and also the pelvis, passing through the rectum. The left leg is shrivelled and paralyzed, probably in consequence of injury to the nerves." Examiner S. Lovell, Attleboro', Pennsylvania, reports, September 3, 1873: "A minié ball passed into the pelvis near the left acetabulum, perforating the rectum. He was for a long time unable to use his left leg. His system is still much shattered from the effects of the wound. His left leg shows, by the flaccid condition of its muscles and by its shrunken appearance, that he depends but little on it for walking. That he is but the wreck of his former self is evident, but I cannot see that his disability has increased materially. I think his disability permanent in its present degree, and that it has not been caused or protracted in any way by vicious habits; disability total." This pensioner was paid June 4, 1873.

CASE 988.—Private A. Kates, Co. A, 19th Infantry, aged 24 years, was wounded at Chickamauga, September 19, 1863. He was treated in a Fourteenth Corps field hospital until the 29th, when he was sent to hospital at Chattanooga, and there the injury was noted as follows: "Gunshot wound; the ball entered to the left of the spine and four inches above the tuberosity of the ischium, and emerged two inches below and outside of the anterior superior spinous process of the ilium; the posterior portion of the ilium was probably slightly injured. The patient was in a good condition when admitted." He was transferred to Indianapolis, and discharged April 1, 1865. Acting Assistant Surgeon J. Saunders, of Fort Wayne, March 16, 1865, certified: "Perforating gunshot wound of the pelvis, implicating the hip-joint." Examiner J. P. Dodds, of Bloomington, stated, April 17, 1865: "The ball entered about the middle of the left side of the sacrum, passed transversely forward, and was extracted by making a deep incision at the outer inferior edge of the left ilium. The missile shattered, somewhat, the bones of the pelvis, it appears, from the many pieces of bone, small spiculae, and scales that have been removed. It appears, also, that the missile injured the nerves, as evinced by the persistent pains in the back, hip, and knee, interfering with free and natural movement of the lower limb, and undue susceptibility to cold and so forth. At the point of the ball's ingress there is a pit of about two-thirds of an inch in depth. The wound seems now to be closed and healed. His disability is three-fourths." No account of this pensioner has been received since September 4, 1866.

CASE 989.—Corporal P. Carlin, Co. E, 125th Ohio, aged 21 years, was wounded at Missionary Ridge, November 25, 1863. At Chattanooga, Nashville, and Parkersburg, the case was reported as a shot wound of the left groin or hip, by Surgeons F. Irish, G. Perrin, J. W. Foye, and W. A. Banks; fracture of the pelvis being also noted at some but not all of the hospitals. This soldier was discharged November 18, 1864, and pensioned. Examiner G. O. Hildreth, of Marietta, reports, September 4, 1866: "A musket ball entered the left lower part of the abdomen and lodged behind the left femur near the hip-joint. It seems to have fractured the upper end of the femur. Complete ankylosis of the hip-joint exists; also partial ankylosis of the left knee-joint. The stiffness of the knee seems to have been the result of inflammation that followed the injury. He is unable to pull on a sock or boot, as the knee does not bend enough to enable him to touch the foot. He complains of coldness and numbness of the left foot; also of pain about the hip and down the outer side of the thigh, probably from injury of the sciatic nerve. The leg is somewhat shortened; the foot is turned out, but bears flat on the ground when walking. The flexion of the knee is sufficient to admit of walking. There seems to be a movement in the pelvis, but not in the hip-joint. He says exercise is always painful, and, though he goes about more or less, he does not engage in regular labor." Examiner John W. Trader, of Sedalia, stated, September 9, 1869: "The muscles of the thigh are atrophied, and from the injury done to the sciatic nerve there is severe pain upon any unusual or active exercise." He further reported, September 4, 1873, a "gunshot wound of the left hip, the ball entering the left hypochondriac region, ranging downward and outward, making its exit through the glutæus muscles, dislocating the hip. The hip-joint is completely ankylosed, and the knee partially. The muscles of the leg are very much atrophied. The injury completely disqualifies him for manual labor; disability total." His pension was last paid to September 4, 1873.

CASE 990.—Corporal J. H. Beadle, Co. F, 55th Illinois, was wounded at Shiloh, April 6, 1862, and was treated in hospital at Quincy, Illinois, where Surgeon R. Nicholls, U. S. V., reported that "he was wounded by a musket ball, which entered over the centre of the sacrum, fracturing it at its junction with the ilium, and passed out below the anterior superior spinous process.

He was discharged December 6, 1862, at which time he walked about; the wounds were discharging at both the orifices of entrance and exit of the ball, with bare bone to be felt at the point of entrance." On the certificate of disability appear the following notes by Dr. Nicholls: "The ball entered the body of the right spinal column, fractured the sacrum at the sacro-iliac junction, and emerged three inches above and behind the trochanter major of the right femur." Pension Examiner Geo. F. Wright, Canton, Illinois, reported, August 5, 1871: "Musket ball entered the left hip posteriorly an inch from the left margin of the sacrum, passed through the bone, ranging forward and outward toward the right side, and passed through the right ilium near the centre of the bone. Important nervous communications were severed, causing paralysis of important muscles in both the hip and thigh. Corporeal labor causes great pain in the parts; the lower extremities are weak, and his disability is total." This pensioner was paid September 4, 1873.

CASE 991.—Private R. Weaver, Co. K, 45th Pennsylvania, aged 38 years, was wounded at Cold Harbor, June 3, 1864, and treated in a field hospital until June 7th, when he was transferred to Harewood Hospital, where Surgeon R. B. Bontecou, U. S. V., reported a severe shot wound of the right inguinal region, and had prepared a photograph, which was forwarded to the Museum and is copied in the wood-cut adjacent (FIG. 276). On May 30, 1865, this invalid soldier was discharged the service and pensioned. Examiner J. Levergood, of Lancaster, reported, March 6, 1869, that "he was originally pensioned for a gunshot wound of the right inguinal region. The wound was an exceedingly serious and dangerous one, in consequence of which the whole limb has become somewhat atrophied. At present, he gives every indication of laboring under confirmed phthisis; he has cough, expectoration, pains in the chest, loss of appetite, pallid countenance, and is greatly emaciated; he is in a precarious condition." Examiner J. B. Hower, of Marietta, reported that Weaver died April 25, 1869, and that "he had been suffering from a gunshot wound in the right groin and hip, causing partial paralysis of the right leg. The spinal cord was also more or less affected, and there were several ulcers on his body, caused by the impurity of his blood, a consequence of the poison infused into his system by said shot wound."



FIG. 276.—Cicatrix of a shot wound followed by paralysis. [From a photograph.]

CASE 992.—Captain E. E. Brasher, Co. I, 14th Indiana, was wounded at Antietam, September 17, 1862, and was treated in a Second Corps hospital, and subsequently at the Avenue House, Washington, Surgeon T. Antisell, U. S. V., reporting the case as a "gunshot wound through the left iliac region, in consequence of which he is unable to perform the duties of an officer. He has done no duty since he was wounded. There is partial loss of motion and sensation of the left lower extremity, which, on account of the injury to the nerve, is likely to be permanent." This officer was discharged from service December 19, 1862, but re-entered the Army as captain in the 120th Indiana Volunteers, and was promoted to the rank of major, and subsequently killed in action at Franklin, November 30, 1864.

CASE 993.—Private T. W. Buck, Co. E, 7th Virginia, aged 23 years, was wounded at Gettysburg, July 3, 1863. He was treated on the field until August 21st, when he was admitted to Camp Letterman Hospital. Acting Assistant Surgeon H. H. Sutton reported: "A ball from a Sharp's carbine entered the left side of the sacrum at the third segment, passed in the pelvis and there lodged. The ball in its passage injured the sacral plexus of nerves, and consequently the leg of the corresponding side became paralyzed; but the natural feeling and movements of the limb were gradually returning when the patient was admitted. His general health was good; the wound gave much pain at times from the forming of abscesses; there was a continued discharge, but the amount was small. Stimulants and tonics were given, and the wound was dressed with simple cerate, alternated when necessary by flaxseed-meal poultices. On September 1st his condition was unchanged, and the same treatment continued. His condition was still unchanged on the 15th." On the following day he was transferred to West's Buildings Hospital, whence he was paroled, September 25, 1863.

CASE 994.—Private W. D. Cole, Co. E, 23d Massachusetts, aged 42 years, was wounded and captured at Drury's Bluff, May 16, 1864. He was admitted into Hospital No. 1, Annapolis, on August 14th, from the steamer New York, with partly healed wounds of the abdomen, right hip, and left arm. He was transferred to Camp Parole, and thence to Rulison Hospital on December 6th. Assistant Surgeon John Bell, U. S. A., reported that he was "discharged March 23, 1865," and remarked that "this is a case of very extensive cicatrices of the abdominal walls, the result of wounds from buckshot at short range, and is complicated with injury of the sciatic nerve." Examiner J. G. Metcalf, of Mendon, reported, April 5, 1867: "The wounds were not entirely healed under ten months; he has been lame in the right leg from the date of injury. At this time, the side of the cicatrix is frequently painful, and the right leg becomes more lame upon exercise; he cannot labor at light work without pain." Surgeons H. Crane, J. B. Treadwell, and Hugh Doherty, Examining Board at Boston, reported, April 6, 1873: "Ball entered the abdomen at the left of the umbilicus, and emerged through the tensor vagina femoris on the opposite side, without entering the abdominal cavity. The walls of the abdomen are sensitive at all times, and severely so if extended." This pensioner was paid September 4, 1873.

CASE 995.—Private J. Carmody, Co. H, 16th Michigan, aged 22 years, was wounded at Cold Harbor, June 3, 1864. He was sent from a Fifth Corps hospital to Lincoln Hospital on the 12th. Assistant Surgeon J. Cooper McKee, U. S. A., reported: "The ball entered two inches behind the anterior superior spinous process of the ilium, and in the track of the gluteal nerves. Patient may have been exposed to cold while on the field and on transports. There is no proof that a nerve was injured. On June 10th, tetanus appeared; narcotics were freely used both internally and hypodermically, and bromide of potassium, in one-drachm doses, was also tried. Ice was applied to the wound without benefit. The spasm was arrested, but by what agency it is hard to state. Death resulted June 15, 1864."



CASE 996.—Private J. Elliott, Co. C, 30th Ohio, aged 22 years, was wounded at Missionary Ridge, November 27, 1863, and admitted into a Fifteenth Corps field hospital. Surgeon J. M. Woodworth, 1st Illinois Light Artillery, reported: "Gunshot wound; the ball passed through both hips, fracturing the sacrum. Fragments of bone were removed, four hours after the injury, by Surgeon P. Bonner, 47th Ohio; no anæsthetic was used. He was doing well on the twenty-fifth day." On December 22d, he was admitted into a hospital at Chattanooga, with a "gunshot wound of both hips;" transferred, and admitted into No. 1, Nashville, with a "wound of the right hip and partial fracture of the ilium." He was transferred to hospital at Jeffersonville, March 23d, thence to hospital at Madison, April 8th, and, on September 9, 1864, he was discharged the service. Examiner William Blackstone, of Athens, reported, February 20, 1865: "His disability arises chiefly from partial paralysis and wasting of the flexor muscles of the right leg, caused by a wound inflicted by a musket ball which injured the gluteal muscles, the right ischium, and the great sciatic nerve of the right side. He is also disabled by ulcers, caused by frost-bite, on the side of first, second, and fifth toes of his right foot." Another report, from Examiner C. L. Wilson, of December 30, 1867, states: "Partial paralysis and atrophy of the muscles of the right hip, from a gunshot wound which injured the right ischium and right great sciatic nerve; also, occasional ulceration and constant tenderness of the right foot and toes from frost-bite. The effect of the wound and the frost-bite combine to make him lame and unable to perform fully his labor as a farmer." Surgeons S. M. Smith, E. B. Fullerton, and J. W. Hamilton, examining Board at Columbus, transmitted the following on September 5, 1873: "Wounded through both hips, the ball striking and entering the left side, passing through the right side deep in the tissues, and wounding the bone—the ilium. The muscles of the right limb are emaciated."

Of the subjects of the twelve foregoing abstracts, one died of tetanus, one was subsequently killed in action, one died after four years of suffering; a fourth, a pensioner, is probably dead, as no account of him has been received at the Pension Office for seven years; a fifth, a Confederate, has not been heard from since the date of his parole; but seven remain under the inspection of the pension examining surgeons, and it is to be hoped that the ulterior histories of these cases will be carefully observed. Besides these twelve examples of the results of shot injuries of the nerves of the pelvis in this and in the preceding section, fifteen instances in which nerve lesions were an important element are recorded among the cases of injury of the pelvic bones or viscera,<sup>1</sup> and two analogous instances may be found in the fifth chapter of the *First Surgical Volume*.<sup>2</sup> These twenty-nine examples present a great variety of illustrations of the phenomena of direct and reflex paralysis, paresis, and muscular atrophy. The latter was the most frequent of the morbid conditions they had in common, the expression "the lower extremity was shrunken and useless" occurring in many of the reports.

The relation between lesions of the nerves and alterations of the muscular tissue has been of late a favorite subject of pathological enquiry.<sup>3</sup> Without entering on the subject here, it may be remarked that in most of the foregoing cases prolonged inactivity of the limb would alone adequately account for a considerable degree of muscular atrophy. In the treatment of traumatic neuralgia, Dr. Mitchell<sup>4</sup> found constitutional alterative remedies insufficient. In cases of old neuritis or sclerosis, iodide of potassium and, more rarely, corrosive chloride of mercury were administered, with little if any advantage. Quinine and arsenic were equally ineffective, save in so far as they might be of use in combating the malarious element, that especially fostered neuralgia. Whatever constitutional means tended to restore the lowered tone of the system, appeared to diminish the intensity and frequency of recurrence of the neuralgic trouble. M. Legouest<sup>5</sup> employs in traumatic neuralgia narcotic fomentations and friction, cold-water douches, simple or medicated vapor baths, and hypodermic injections of morphia or atropia, with advantage sometimes, often without benefit. In the paralyzes, faradization is the main resource.

<sup>1</sup> CASES 239, Mills, p. 78; 274, Cook, p. 89; 290, Tucker, p. 100; 653-654, Reens, D—, p. 225; 662, Whitney, p. 227; 678-679, Warner, Brookins, p. 232; (*In text*) Young, p. 236; 739, 745, Busch, Denegan, p. 252; 748, 754, Barton, Phillips, p. 253; 755, Durfee, p. 251; 758, Young, p. 255.

<sup>2</sup> CASES of Private Thomas D—, Co. F, 1st Michigan, page 445, and of Private T. K—, Co. A, 6th Cavalry, page 448.

<sup>3</sup> VULPIAN (A.), *De l'atrophie des muscles qui se produit sous l'influence des lésions traumatiques ou analogues aux nerfs. Action trophique des centres nerveux.* (Comptes rendus de l'Académie des Sciences, 8 Avril, 1872) "Jusqu'à quel degré cette influence trophique est-elle indispensable au tissu musculaire? Question à étudier. Quel est le mécanisme intime de cette influence? Question qui me paraît sans solution possible, dans l'état actuel de la science."

<sup>4</sup> MITCHELL (S. W.), *Injuries of Nerves and their Consequences*, 1872, p. 270.

<sup>5</sup> LEGOUEST (L.), *Chirurgie d'Armée*, 2ème éd., 1874, p. 677.

## SECTION III.

## ON INJURIES OF THE GENITAL ORGANS.

Wounds of the genital organs may be considered as a subdivision of injuries of the pelvis.<sup>1</sup> As observed in warfare, they constitute a comparatively small group,<sup>2</sup> and are not very dangerous, though important because of the disabilities they induce, and their influence on the moral faculties.<sup>3</sup>

It may be remarked that the names of only a small proportion of those who recovered from wounds of the genital organs are found upon the Pension List; and, in this comparatively small number, the causes of disability assigned are often foreign to the lesions of the organs of reproduction that probably constituted the real causes; hence there are very few detailed histories of cases of injury of this class.

We shall examine, first cases of wounds of the penis;<sup>4</sup> secondly, at some length, wounds of the urethra, with cases of traumatic stricture and operations for organic stricture, subjects that have been separated, for convenience sake, from their more natural relations with injuries of the bladder and prostate; and lastly, injuries of the scrotum, testis, and spermatic cord.

WOUNDS OF THE PENIS.—These injuries were not very rare; they were commonly inflicted by cutting instruments or by shot. The examples reported during the war were of all grades of severity, from removal of the prepuce to ablation of the entire organ.

*Incised Wounds.*—These comprised accidental, voluntary, criminal, and therapeutical mutilations,—and one instance of a bayonet wound of the penis. There were reported fifty-two operations for phymosis—thirty-one by circumcision, and twenty-one by slitting up the prepuce on the dorsal surface. Only seven of these operations were practiced on account of congenital elongation and contraction of the prepuce; eight were performed for phymosis incident to gonorrhœa; and twenty-one to expose condylomata or chancres. In some of the cases of the latter group, very serious consequences ensued from the inoculation of the exposed raw surfaces, and in several instances sloughing phagedæna invaded

<sup>1</sup> In the classification in use in the British Army these injuries constitute a distinct class. MATTHEW, the surgical analyst of the Crimean War, observes that "there appears no very sufficient reason for separating these wounds from those of the pelvis, except as showing the increased mortality invariably induced by lesion of bone in this as in other situations."

<sup>2</sup> Thus, M. CHENU (*Camp, d'Orient*, p. 206) reports 205 such cases in 34,306 wounded, or .06 per cent. In the British Army, in the same campaign, the proportion was .07 per cent., or 74 in 10,279 determined cases. M. CHENU (*Camp, d'Italie*, T. II, p. 518) records 87 cases in 17,054, or .05 per cent., and Dr. B. HECK (*Chir. der Schussverletz.*, 1872, S. 160) mentions 24 cases in 4,344, or .05 per cent.

<sup>3</sup> "Mutilations of the genital organs," observes M. LEGUEST (*Chir. d'Armée*, 1872, p. 708), "have a marked influence upon the moral faculties of the subjects affected by them. Many thus wounded are a prey to a profound sadness that impels them to suicide. The loss of the testes is more easily tolerated than the total ablation of the penis, the latter no longer permitting sexual relations. Some surgeons have raised the question if, in cases where, the testes remaining intact, the virile member has been carried away at the root, castration should not relieve the despair of the mutilated sufferers, by extinguishing desires it is impossible to gratify. Nous pensons," continues M. LEGUEST, "que la question doit être résolue négativement; le temps apporte avec lui l'indifférence ou l'oubli, si, par des artifices dont l'histoire des perversions génésiques reuferme de nombreux et tristes exemples, la passion érotique ne parvient pas à tromper la nature."

<sup>4</sup> "Est autem penis," writes DIEMERBROECK (*Op. om., Med. et Anat.*, Ultrajecti, 1865, Cap. XXIII, p. 123), ("quæ etiam Priapus, Virga, Mentula, Veeetrum, Coles, et Membrum virile, aut genitale, Græcis τυλος, clavus, et στυλος, caulis, ac πος, penis, nominatur), pars organica ad seminis in uterum injectionem primario, et secundario ad urinæ excretionem comparata. Hic est ille Priapus hortorum naturalium profectus (quem respirari colit mulier juvenisque puella) Incantator ille maximus, qui suo fascino femininum sexum miris modis effascinare solet. Hæc est illa pars, quæ naturas virgines dementare, honestas sæpe feminas abripere, tristes et melancholicas exhilarare, ac novo vigore perfundere valet; qui suo contactu frigidus mulieres calefacit, suo ingressu soporosas suscitât, suo attritu torpidus alacres facit, atque ad summum voluptatis culmen evehit; ino quæ tenellas juvenculas dulci suo allatu erassiores et ventriosas reddere, ac insipientes puellas sapientiores, atque etiam matres lactantes facere potest."



the wounds thus rashly and reprehensibly inflicted. Some of the medical men employed in the hospitals apparently regarded syphilitic patients as having no rights. In one instance circumcision was practised by means of an *écraseur*. In most of the operations the divided mucous membrane and integument were united by silver wire sutures, in a few cases of circumcision, by *serres-fines*. One case resulted fatally, the unhappy result being ascribed to the co-existence of disease of the valves of the heart. A number of operations for the removal of warty growths were reported, and several unimportant cases of division of the frenum, and of enlargement of the meatus. 'The case of bayonet wound' was as follows:

CASE 997.—Private A. Fritz, Co. F, 14th Infantry, was admitted to DeCamp Hospital, at David's Island, March 10th, 1865. Assistant Surgeon W. Webster reports that he was suffering from "the effects of bayonet wounds of the back and penis, received at Fredericksburg, February 11, 1864." No further particulars are recorded except that this soldier was "transferred to the headquarters of his regiment at Fort Trumbull, Connecticut, April 12, 1865."

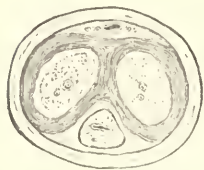


FIG. 277.—Transverse section of the flaccid adult penis; showing the dorsal artery and vein, the network of the cavernous bodies, and the spongy body enclosing the urethra. [After HENLE.]  $\frac{1}{2}$ .

Two severe self-inflicted incised wounds of the penis in insane soldiers were noted, and there were several instances of similar injuries occurring in brothels,<sup>2</sup> one luckless subject having the penis maliciously amputated about two inches from the crura. The vascular supply of the penis in the flaccid (FIG. 277) and the turgid state (FIG. 278) is indicated in the accompanying wood-cuts.

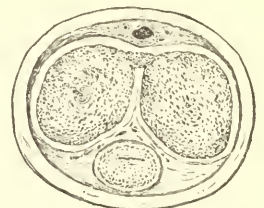


FIG. 278.—The same parts as in the foregoing figure, the organ being in a state of erection. [After HENLE.]  $\frac{1}{2}$ .

The chief requirements in wounds of the penis are to stanch the bleeding, and to dress the solution of continuity in such a manner that there shall be no obstacle to the evacuation of the urine. It is recommended to tie the dorsal artery and the arteries of the corpora cavernosa<sup>3</sup> when wounded, if they can be found; but they rarely furnish jets after shot wounds. Le Dran,<sup>4</sup> who appears to have had considerable experience in amputations of the penis, observed that they rarely spirted when cut across. Guthrie says:<sup>5</sup> "I have not had occasion to tie an artery, even when the penis has been as good as amputated." However, in cases of criminal mutilations, more particularly,<sup>6</sup> dangerous hæmorrhage has occurred. It may usually be controlled by cold and pressure. Schmucker commends<sup>7</sup> pressure with agaric. Boyer, Guthrie, and Dupuytren<sup>8</sup> advise compression by a circular bandage on a catheter introduced in the urethra. M. Legouest<sup>9</sup> prefers to this effective and harmless plan the employment of a styptic solution of perchloride of iron. Professor Gröss<sup>10</sup> would substitute acupressure.

<sup>1</sup> If DEMME'S reports be accepted, bayonet wounds of the penis were common in the Italian Campaign of 1859. In his *Studien* (B. II, S. 161) he remarks: "While in bayonet injuries I repeatedly noticed copious bleeding, it was absent in all shot wounds of the cutis of the penis that came under my notice. Even lacerations and perforation of the corpora cavernosa caused only little secondary bleeding."

<sup>2</sup> PIROGOW (Grundzüge der Allgemeinen Kriegschirurgie, 1864, S. 616) states: "In the Russian prisons I examined judiciously several such mutilated persons. The silly sect, which bases its belief on the passage in the gospel of St. Matthew, Chap. XIX, 12, practices the mutilations on children only. But about twenty years ago the sect attempted to spread their creed among the Cossacks of the Don, when the authorities interfered. Of twelve of these fanatics that I examined, I found five with the genitals shaven closely to the body. The amputation of the penis had been performed without introducing a catheter into the urethra, and castration without ligation of the spermatic arteries, but, as it seemed, with torsion of the spermatic cords."

<sup>3</sup> LANGENBECK (C. J. M.), *Nosol. und Therap. der Chir. Krankh.*, Göttingen, 1830, B. I, S. 319.

<sup>4</sup> LE DRAN (*Traité des Opérat. de Chir.*, 1742, p. 207: "Il est rare que le sang sorte en jet, à moins que ce ne soit d'une artère un peu grosse. S'il y en a une qui donne, j'y fais une ligature avec l'aiguille enfilée. Le sang qui donne sort pour l'ordinaire des corps caverneux comme d'une éponge qu'on presseroit, ainsi on ne peut l'arrêter que par le styptique soutenu de la compression."

<sup>5</sup> GUTHRIE, *Commentaries, etc.*, 6th ed., 1855, p. 594.

<sup>6</sup> CHELUS, *Von den Wunden des männlichen Gliedes*, in seinem *Handbuch der Chir.*, Achte Auflage, Heidelberg, 1857, S. 537. PALLUCI, *Observat. sur la séparation du pénis*, Paris, 1750, p. 247.

<sup>7</sup> SCHMUCKER, *Vermischte Chir. Schriften*, 1782, B. III, S. 238.

<sup>8</sup> BOYER, *Traité des mal. chir.*, 5<sup>me</sup> éd., 1849, T. VI, p. 794; GUTHRIE, *op. cit.*, p. 594; DUPUYTREN, *Leçons orales*, T. VI, p. 507.

<sup>9</sup> LEGOUEST (*Chirurgie d'Armée*, 2<sup>me</sup> éd., 1872, p. 436). There is a suggestion of the unreliability of this plan in the sentence that follows: "Enfin, si l'hémorrhagie persistait encore, il faudrait avoir recours à la cautérisation par le fer rouge."

<sup>10</sup> GRÖSS (S. D.), *A System of Surgery*, 5th ed., 1872, Vol. II, p. 873. This plan, unless in practice it should be found to lead to erections, would be unexceptionable.

*Shot Wounds.*—Three hundred and nine cases were reported of shot injuries of the penis, in which it is not mentioned that the urethra was interested. A very small proportion of these cases were uncomplicated. The most frequent complications were wounds of the scrotum and testes, wounds of the perineum and thighs, wounds of the pelvic walls or viscera. The cases involving laceration of the urethra are separately examined in the succeeding subsection. Of the three hundred and nine cases of shot wounds of the penis, forty-one or 13.2 per cent. terminated fatally. The great majority of these fatal cases were complicated by graver injuries elsewhere, particularly by fractures of the pelvis or femur. The fatality of the less complicated cases was due, in two instances, to tetanus, and in several to small-pox, pneumonia, pericarditis, and other intercurrent affections. One instance is mentioned of an uncomplicated shot wound resulting fatally from pyæmia.<sup>1</sup> Two observations by Surgeon S. W. Gross, U. S. V., and by the late J. Mason Warren,<sup>2</sup> teach that projectiles may be innocuously encysted in the cavernous portion of the penis:<sup>3</sup>

CASE 998.—Private D. P——, Co. A, 16th Infantry, “received a wound of the penis, at the battle of Shiloh, April 7, 1862. Being immediately removed from the field and placed upon a hospital boat, I did not see him until six weeks subsequently, when I examined him with a view to a discharge from the service. I found that the ordinary conical ball had become encysted in the right corpus cavernosum, the point of the missile presenting to and being about one inch from the pubes. He stated that a good deal of inflammation had ensued, but that no efforts were made to extract the ball by his attendant in the hospital at Evansville, Indiana. He was a married man and the father of four children, but had not had an erection since he was wounded. As the ball gave him no pain, I could not induce him to have it removed. He wished to be discharged on account of lumbago, but the cause was deemed insufficient.” This soldier was discharged July 23, 1864.

CASE 999.—A sailor, thirty years of age, was wounded, at Pensacola, Florida, in April, 1862, by a musket ball, which entered the outer and upper part of the left thigh, passed through the limb, emerging near the root of the scrotum, and again entered and disappeared. He was sent to the Marine Hospital at Chelsea. In May, Dr. Fox discovered the ball in the left corpus cavernosum. It gradually worked over to the right side. The man had no difficulty in urinating, and no pain during erection. The apex of the conoidal ball was toward the body. On May 30th, Dr. Fox invited Dr. Warren to witness the removal of the foreign body. “It was firmly held by the fingers, and then cut down upon. The skin was first divided, then the strong fibrous covering of the cavernous body, and although the incision was quite free, the foreign substance resisted the use of ordinary forceps, the elastic force and suction of some of the tissues operating to prevent its extraction. The wound being now held well open, a pair of bullet forceps were introduced, and the ball slowly extracted as if from a bed of India rubber. There was no violent rush of blood from the erectile tissues, but a slow, continued discharge as from a large vein. This was controlled by means of a sponge and bandage. A gradual suppuration, with apparent elimination of the sac, formed around or pushed before the foreign body, followed, and the patient is now recovering in the most satisfactory manner. The case is interesting from its rarity and for the practical facts which it teaches in regard to the danger from interference with the erectile tissue, which at first would appear likely to be more considerable.”

There were other instances of balls lodging in the penis, and removed by excision; but these were cases of primary extraction:

CASE 1000.—Acting Assistant Surgeon W. I. C. Duhamel records the case of a “soldier wounded at the second battle of Bull Run, August 30, 1862, by a heavy conoidal ball, which entered the gluteal muscles, passed along the perineum, and lodged in the root of the penis, whence it was extracted through an incision by Dr. Duhamel, assisted by Surgeon C. McMillan, U. S. V., at the field hospital at Fairfax Station. The case was lost sight of and the result of the injury remains unknown.” The missile (FIG. 279), which weighed 835 grains and presented a very trivial derangement of form, was contributed by the operator to the Army Medical Museum.



FIG. 279.—Ball excised from the penis. Spec. 3146. 1.

CASE 1001.—Private J. Brainard, Co. C, 18th Massachusetts, aged 28 years, was wounded at Cold Harbor, June 3, 1864. He was treated on the field, at Alexandria, and afterward at McDougall Hospital, where Assistant Surgeon H. M. Sprague, U. S. A., reported: “A gunshot wound of the right thigh and of the penis. The missile, a conoidal musket ball, remained in the cavernous portion of the penis for fifty-two hours, when it was excised at the First Division Hospital of the Fifth Corps. He was furloughed July 7, 1864, and, failing to report, was recorded as a deserter August 6, 1864.” The report of the Adjutant General of Massachusetts states that this man was transferred to Co. B, of the 32d regiment, and discharged June 29, 1865.”

<sup>1</sup> Case of Corporal W. J. U——, Co. F, 7th New Hampshire, wounded at Deep Bottom, October 27, 1864. Death, November 21, 1864.

<sup>2</sup> GROSS (S. W.), *Interesting Cases of Gunshot Wounds*, in *Am. Med. Times*, 1863, Vol. VIII, Case II, p. 137; compare, also, Circular 3, S. G. O., 1865, p. 29. WARREN (J. M.) *Ext. from Rec. of Boston Soc. for Med. Improvement*, in *Boston Med. and Surg. Jour.*, 1862, Vol. LXXVI, p. 476, and in *Surgical Observations, with Cases*, 1867, p. 552.

<sup>3</sup> NEUDÖRFER (*Handbuch der Kriegschirurgie*, 1867, S. 799) is rather incredulous regarding the encystment of foreign bodies in the penis, but cites the case reported by Dr. GROSS as proof of the possibility of such an occurrence.



In a third case, a musket ball was excised from the corpus cavernosum after traversing the right buttock. The particulars of this case are mainly derived from the report of the pension examining surgeon, who furnished a drawing, which is copied in the wood-cut (FIG. 280), to illustrate the course of the ball:

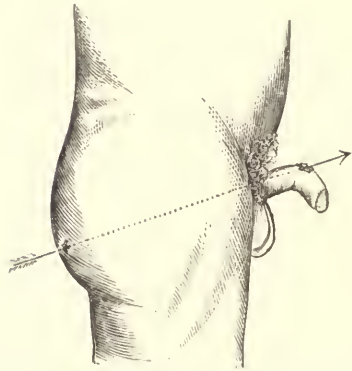


FIG. 280.—Diagram of the course of a ball excised from the penis.

CASE 1002.—Private J. H. A——, Co. H, 1st New Jersey, was wounded at Salem Creek, May 3, 1863, and was reported missing in action. Assistant Surgeon A. Haltzuff, U. S. A., reported, however, that he was brought to Judiciary Square Hospital on May 8th, and transferred to Christian Street Hospital, in Philadelphia. Here Surgeon J. J. Reese, U. S. V., records that the patient had “a shot wound of the right buttock, the ball having been excised from the dorsum of the penis.” The patient was again transferred on September 23d, and, on June 2, 1864, mustered into the Veteran Reserve Corps, and finally discharged and pensioned. Examiner J. B. Coleman, of Trenton, reported, March 20, 1868: “Ball entered a little to the outside of the ischium, passed inward, upward, and forward, through the gluteus magnus, quadratus femoris, and the inner edge of the long adductor muscles, back of the spermatic cord, and lodged in the corpora cavernosa of the penis, from which point it was extracted by incision. The shock to the sciatic nerve caused the right hip to be weak, and impaired its motions to the extent of fully one-half or even entire disability.” With his report, Dr. Coleman transmitted a diagrammatic drawing of the course of the ball, which is faithfully copied in the wood-cut (FIG. 280). This pensioner was paid to September 4, 1872.

The five foregoing are the only instances reported in which balls were found lodged in the penis. It may be inferred that such a lesion will be seldom observed. Except in a virile organ of extraordinary dimensions,<sup>1</sup> the corpora cavernosa scarcely afford space for the encysting of a large musket ball. Their strong fibrous envelope is likely to deflect a projectile, and if the latter penetrate, it will probably lacerate the tissues and pass on. Few of the reported cases of shot wounds of the penis present any circumstances of interest. The following may serve as illustrations of this class of reports:

CASE 1003.—Private R. C——, Co. B, 24th Michigan, aged 31 years, was wounded at Gettysburg, July 2, 1863. At York, on the 19th, Surgeon H. Palmer, U. S. V., noted: “Gunshot wound of the scrotum and penis; simple dressings; furloughed August 19th; readmitted September 13th, and returned to duty October 14, 1863.” This soldier was discharged June 28, 1865, and pensioned. Examiner J. A. Brown, of Detroit, reported, September 17, 1866: “Ball entered at the root of the penis, passed to the left, through the hip, back of the head of the femur. The result is lameness in the thigh or groin, attended with much pain and tenderness in the groin. Disability is one-half and permanent.” Surgeons Brown, N. W. Webber, and J. F. Noyes, the Detroit Examining Board, reports, September 5, 1873: “A ball struck the dorsum of the penis, wounding it, and, passing to the left, wounded the left thigh in its upper third. There is slight difficulty in voiding urine, and lameness of the left thigh. His disability is one-half.” This pensioner was paid September 4, 1873.

CASE 1004.—Corporal P. Reynolds, Co. I, 105th Ohio, aged 42 years, was wounded at Chickamauga, September 19, 1863. He was treated in the following hospitals: Field hospital, Fourteenth Corps, No. 14, Nashville, and No. 15 and Taylor, Louisville, being returned to duty, from the latter, February 15, 1864. The injury had been noted as a gunshot wound of “privates,” “scrotum,” and “external genitals,” respectively. He was admitted to hospital at Camp Chase on May 23, 1864, with “gunshot wound of the left hip, with injury to the joint,” and was discharged May 30, 1864. Surgeon S. S. Schultz, U. S. V., certified: “The ball entered the penis on the left side one inch from the root, and escaped three inches to the left of the anus; the entire left lower extremity is slightly paralyzed; he has also incontinence of urine, at times quite troublesome. Both difficulties, paralysis and enuresis, have not improved for four months, but are becoming rather aggravated. He is not fit for the Veteran Reserve Corps. Disability three-fourths.” Examiner W. Wiley, Fond-du-Lac, reported, October 14, 1873: “Ball entered at the root of the penis and passed out three inches external to the coccyx. There is considerable adhesion of the muscles; disability three-fourths.” This pensioner was paid on September 4, 1873.

<sup>1</sup> Among extraordinary examples of development of the penis may be mentioned the instance adduced by GIBBON (*The History of the Decline and Fall of the Roman Empire*, Chap. t. L), who alludes to the preternatural gift of Mahomet, and adopts the style of St. GREGORY NAZIANZEN (*εὐαγγέλιον Ἱεροκλέος τρισκαίδεκάτων ἀθλον*, Orat. III, p. 108) in stating that the apostle might rival the thirteenth labor of Hercules. The testimony of MARACCI (*Prodromus Alcoran*, p. IV, p. 55) is quoted, “sibi robur ad generationem, quantum triginta viri habent inesse jaletaret: ita ut unica hora posset undecim feminis *satisfacere*,”—and the exclamation of Ali, who washed the prophet’s body after death, is cited from Albufeda: “O propheta, certe penis snus cœlum versus erectus est.”—(In *Vita Mohammed*, p. 140.) HORNER was accustomed to exhibit a large injected penis from the Wistar Museum collection, with the remark that it formerly pertained to a South Sea Islander; and that the missionary who obtained it stated that when the organ became turgid, the derivation of blood from the systemic circulation was so great as to induce syncope. Though there are many exact series of measurements of the urethra, few anatomists give definite statements of the normal dimensions of the penis. SPIGELIUS (*Op. omnia*, Amsterdami, 1645, L. I, Chap. X) says, “in an adult man the penis, when erect, should be six inches long and four inches in circumference.” Two injected preparations in the Army Medical Museum (*Sect. IV*, Nos. 20, 21) divested of integument, measure in length, respectively, from the meatus to the pubis, six and a half inches and five and a half inches; from the extremity to the termination of either crus, nine and three-quarters and eight and three-quarters inches; in circumference, varying less than two lines in any part, the measurements are: four and three-quarters, and four and one-quarter inches. PAULLINUS (C. F.) (*Ephem.*

Erections are a great hindrance to the healing of wounds of the penis, especially of those that implicate the cavernous tissue. They tend to induce hæmorrhage, and necessarily break up incipient adhesions and retard reunion. Hence everything promoting sexual excitement must be sedulously avoided in these cases. The parts should be lightly dressed; the patient should lie on a hard bed, and have a spare regimen, and should be exhorted to shun lascivious thoughts. Camphor, in pill or enema, may be often advantageously employed:

CASE 1005.—Private J. Q. Erwin, Co. H, 27th Massachusetts, aged 19 years, was wounded near Petersburg, May 6, 1864. He was sent to Hampton Hospital, where the injury was recorded as a "gunshot wound of the penis and scrotum." July 17th, the patient was transferred to Filbert Street Hospital; October 28th, returned to duty, and discharged and pensioned June 15, 1865. Examiner G. C. Lawrence, of North Adams, reported, May 15, 1866: "A minie ball entered at the root of the penis on the right side, passing downward and backward, and was extracted from the posterior part of the thigh. The wound is healed, leaving a hernia which escapes into the scrotum near the base of the penis. His disability is one-half and permanent." This pensioner was paid on June 4, 1873. The remarks on the coincidence of hernia and shot wounds, on page 13, may be compared.

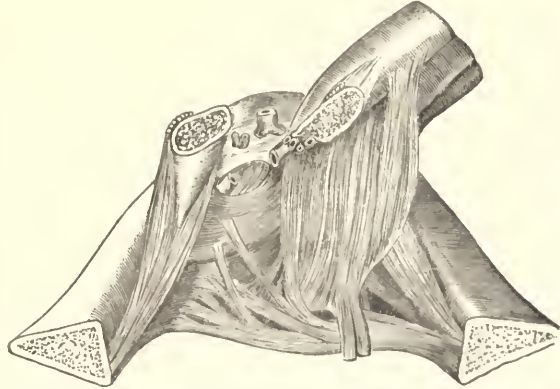


FIG. 281.—The pubic arch and root of the penis. The right corpus cavernosum is divided transversely, showing the dorsal artery, nerve, and vein, the corpus spongiosum and urethra, and the urethral muscles and ligaments. [After HENLE.]

CASE 1006.—Private J. M——, Co. B, 7th Maine, aged 19 years, was wounded at the Wilderness, May 5, 1864, and was treated on the field, in a Sixth Corps hospital, for a "gunshot wound of the left thigh and testicles." On May 8th, he was admitted into Emory Hospital, where the injury was noted, by Surgeon N. R. Moseley, U. S. V., as a "gunshot wound of the testicle and penis," and was thence transferred to New York to Grant Hospital, July 21st. Surgeon A. H. Thurston, U. S. V., recorded "wound of the testicle and penis; furloughed September 30th, readmitted October 30th, and returned to duty December 30, 1864." This man was discharged the service May 14, 1865. On the certificate of disability, signed by Assistant Surgeon A. S. Packard, 1st Maine, appears "shot wound through the upper third of the left thigh, involving the testicle and sciatic nerve." On application for pension, M—— alleges that he received a gunshot fracture of the femur, that splenæ of bone were discharged from the wound, and that he was confined and treated for eleven months in Emory and Willett's Point hospitals; but he makes no mention of any injury to the genito-urinary organs, nor does any of the examining surgeons allude to such injury. Examiner B. Bussey, jr., of Houlton, Maine, reports, March 7, 1866: "Compound fracture of the left thigh by a shot. His leg is weak, and there is loss of power in the flexor muscles in the patient's foot, and his toes drag on the ground in walking. His disability has increased from one-third to three-fourths by reason of progressive atrophy of muscles of the leg from the knee down."

But few examples were reported of amputation of the penis for shot injury:

CASE 1007.—Private Lyman N. C——, Co. B, 53d Illinois, aged 24 years, was wounded at Atlanta, July 21, 1864. Surgeon W. W. Welch, 53d Illinois, reported "a lacerated shell wound of the penis and scrotum." The patient was sent to the general field hospital of the Seventeenth Corps, where Surgeon J. G. Miller, 11th Iowa, made a similar injury, and noted the patient's transfer to Rome, October 20th. On December 3, 1864, he was admitted to hospital at Jeffersonville, and Surgeon M. Goldsmith, U. S. V., reported: "Gunshot wound of penis; amputation of penis July 21, 1864. Sent to Provost Marshal for insubordination March 29, 1865." This soldier was returned to his regiment April 21, 1865; admitted to Foster Hospital, New

*Nat. Cur.*, Norimbergæ, 1687, Dec. II, An. V, App., p. 51, Obs. LXXVII) relates that his father saw, at Spire, a country youth with a truly monstrous penis "two spans in length," "*mentula duas robusti viri spithamas longa*!" BLAW (J. F.) (in a paper *de monstrosa penis magnitudine*, in the continuation of the *Ephemerides*, 1712, Cent. I, p. 338) relates, among others, the case of a Salzburg soldier named Herbst, examined by a jury of surgeons. This man's pendulous penis extended to the knee, and equalled in size the turgid penis of a stallion: "*quam veretrum equi turgidum*." DIEMERBROECK (*l. c.*, p. 123), discussing at length the dimensions of the penis, only recapitulates vulgar traditions on the subject: "*Vulgo brevioris stature viri nec nan qui a Venere abstemii vivunt, item nasuti seu magno naso præditi (hinc ex nasi magnitudine de magnitudine penis, ut etiam ex oris magnitudine in mulieribus, de earum pudendi magnitudine iudicari posse, sibi persuadere solent salaciores viri et mulieres, secundum hos versuculos*:"

*Ad formam naris nossetur mentula maris:*

*Ad formamque oris nossetur res muliebris.*"

Ut et stolidi, stupidiq; ac fatui, majore pene donati traduntur." HANNÆUS (D. G.) (*Ephem. Nat. Cur.*, Dec. II, An. VIII, 1689, Obs. CXIV, p. 251), remarking that Nature is sometimes prodigal and again niggardly in the distribution of her gifts, relates that he once saw two sons of Mars "satellites Veneris sedulos, quos Lamprosaenum deum ad sui imaginem fixisse crederes. Horum alter veretrum habet, tam longum et læetosum, ut ipsum Priapum in ruborem daret; sed serotum modicum. Alteri est curta virga supellex; sed seroti apparatus tantus, ut hinc recipiendo vix par sit pileus." PETRONIUS (A. P.) (a chaplain of Pope GREGORY XIII. in his work *De nobis Gallico*, 1565, L. II, Cap. 15) thought that the size of the penis was an index of mental endowment: "*magnum penem dicit indicare ingenium durum et stolidum, asinino simile*." SPICELIUS (*Opera que extant omnia*, Amsterdam, 1645, Lib. I, Cap. X, p. 19) considered a great development of the virile organ as disadvantageous in the function of fecundation: "*major mentula,*" inquit, "*vulvam potius replet magnitudine, quam uterum faciendo semine*. Est etiam ineptior ad Venerem, quam neque animosè aggreditur, nec diu sustinet, victis pondere masculis, qui rigidam hastam tenent. Parva contra, et salacior est, et fecundior, quia stillando cervicem uteri, magis prolecat feminarum semen, et durtissimè pugnam perferi."



Berne, April 26th; transferred to Mower Hospital, Philadelphia, May 8th, and returned to duty May 18, 1865. He was mustered out of service July 22, 1865, having been promoted first sergeant, and reduced at his own request. His name does not appear on the Pension List.

In lacerations of the integuments of the penis, if close apposition of the divided parts is effected, owing to the vascularity and looseness of the tissues, union is rapidly accomplished, if inflammatory action is kept within bounds. In some instances, as in the following, sutures are requisite, even in shot lacerations, to ensure adequate approximation :

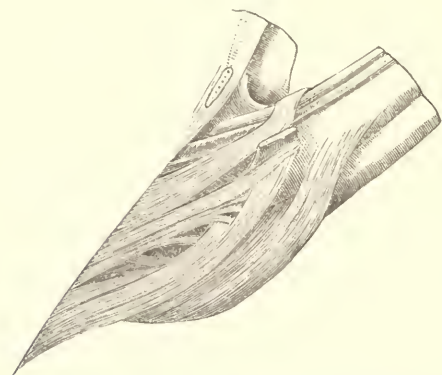


FIG. 282.—Profile view of the root of the penis, the integuments removed to show the disposition of the ligaments, muscles, arteries, and veins. [After HENLE.]  $\frac{1}{2}$ .

CASE 1008.—Private J. M——, Co. A, 54th Ohio, was wounded at Dallas, May 26, 1864, and was taken to a hospital of the Fifteenth Corps. Surgeon J. M. Woodworth, 1st Illinois Artillery, reported “a lacerated gunshot wound of the integuments of the penis and scrotum; the wounds had been united on the field by Surgeon J. N. Barnes, 116th Illinois.” This patient was subsequently treated at Ackworth, and at Rome, Georgia. Surgeon J. B. Potter, 30th Ohio, reported that there was a shot flesh wound of the left thigh in addition to the wounds of the genital organs. The patient recovered, and was mustered out with his regiment, August 15, 1865. His name does not appear on the Pension List.

In illustration of this class of injuries, Professor F. H. Hamilton<sup>1</sup> adduces the interesting case of a soldier of the 94th New York, with three buckshot perforations of the penis, implicating the urethra. Some examples belonging to this group are collected in the next subsection, which indeed comprises the major

portion of the notable cases of wounds of the penis.

Dr. Smiley has published<sup>2</sup> the histories of two cases of shot perforations of the penis without lesions of the urethra, though complicated by other graver injuries. Boyer<sup>3</sup> has discussed the limits within which reunion of wounds of the penis may be anticipated, and his discouraging conclusions are adopted by most systematic writers. Baudens<sup>4</sup> treats fully of this subject, citing several valuable observations, and, in adverting to those deformities of the penis liable to ensue after shot-wounds with much loss of substance,

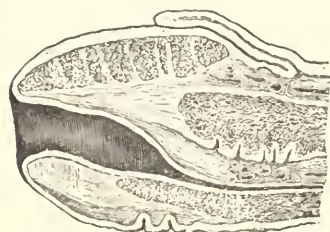


FIG. 283.—Longitudinal median section of the distal extremity of the penis, showing the corpus cavernosum glandis and fossa navicularis, the commencements of the corpus cavernosum and corpus spongiosum and urethra, and the duplicatures of integument. [After HENLE.]  $\frac{1}{2}$ .

describes an operation by which he rectified the axis of the organ, in a case of lateral distortion, by cutting out a wedged-shaped piece from the opposite cavernous tissue. There will be occasion to revert to plastic operations in this region in the next subsection. Even when there is no lesion of the urethra, the use of the catheter is of essential importance in wounds of the penis, the inflammatory swelling often causing retention unless this precaution is observed. Several pension examining surgeons remark upon the liability of cicatrices of shot wounds of the penis to inflame from slight causes of irritation. M. Toulmouche, who has written an elaborate

<sup>1</sup> HAMILTON (F. H.), *Gunshot Wounds of the Penis*, in the *Am. Med. Times*, 1864, Vol. IX, p. 61.

<sup>2</sup> SMILEY (T. T.), *Twenty Cases of Gunshot Wounds*, in the *Boston Med. and Surg. Jour.*, 1863, Vol. LXVIII, p. 416; Cases of Private C. Idall, Co. F, 47th Pennsylvania, and of Leitzinger, Co. A, 55th Pennsylvania.

<sup>3</sup> BOYER (*Traité des mal. chir.*, 5th éd., 1849, T. VI, p. 794) states that he once saw a man, whose wife, in a paroxysm of jealous fury, had mutilated him by cutting off his penis while asleep, and who suffered greatly from constriction of the divided extremity of the urethra. This eminent surgeon held that if two-thirds of the cavernous bodies were divided, it would be hopeless to attempt reunion, and that the proper course would be to complete the amputation, an opinion reproduced by BÉRARD (*Dict. de Méd.*, 1843, T. XXIII, p. 430). VIDAL (*Traité de path. ext.*, 5th éd., 1861, T. V, p. 260), and NÉLATON (*Élém. de path. chir.*, 1859, T. V, p. 668). But VÉDRESSE (*Considérations générales sur les lésions traumatiques du pénis*, in the *Rec. des Mém. de méd., de chir. et de phar. mil.*, 1860, 3e série, T. III, p. 209) relates an instance in which the child-wife of a young Arab was so cruelly importuned by her husband that she attempted to amputate his penis with a razor, dividing more than two-thirds of the transverse diameter of the organ, including a partial division of the spongy portion and urethra. Nevertheless reunion took place, and the functions of the penis were not seriously impaired.

<sup>4</sup> BAUDENS (M. L.), *Clinique des plaies d'armes à feu*, 1836, p. 406.

paper on the medico-legal relations of wounds of the genital organs,<sup>1</sup> remarks that the subject is dealt with cursorily in systematic treatises on his specialty. So far as it relates to wounds of the penis, this observation is applicable to treatises on military surgery also. Hennen and Guthrie barely allude to these injuries, and Larrey's long chapter on lesions of the generative organs is mainly devoted to injuries of the testis.<sup>2</sup> In truth, when lesions of the urethra and plastic operations are separated from this category, little remains to be commented on.<sup>3</sup> Contusions or ruptures of the cavernous bodies and strangulations of the penis are rarely observed in military practice.<sup>4</sup> Amputations of the penis should be restricted to cases of cancer. Even in the most hopeless cases of injury, there is little risk in awaiting what the reparative powers of nature may accomplish; and it is needless to sacrifice any tissue by the knife. In amputation for malignant disease, Mr. Hilton's modification of dividing the urethra and spongy body a little in front of the division of the corpora cavernosa, and then slitting up the urethra, and stitching the flaps to the integument, is an improvement on the old "clean sweep," which was often followed by contraction of the urethral orifice. Mr. Bryant<sup>5</sup> has found the galvanic cautery the most eligible instrument for ablation of the penis.

**WOUNDS OF THE URETHRA.**—The cases of this category were of much interest, involving the important complications of traumatic stricture, false routes, urinary fistules,

<sup>1</sup>TOULMOUCHE (A.) (*Étude médico-légale des blessures intéressant les organes génitaux chez l'homme*, in *Annales d'Hygiène*, 1868, 2<sup>e</sup> série, T. XXX, p. 110). DEVERGIE (A.) (*Méd. légale théorique et pratique*, 2<sup>e</sup> éd., 1840, T. II, p. 299) devotes but a page and a half to the subject; BECK (*Elem. of Med. Jurisprudence*, 5th ed., 1835, Vol. II, p. 220) dismisses it in two lines. It is curious to note that CÆLUSUS, in the twenty-third chapter of the sixth book, *de obscenarum partium vitiiis et curationibus*, speaks of the vocabulary of the Greeks on this subject as tolerable, while that of the Romans was gross: "Neque tamen ea res a scribendo deterere me debuit." he adds. So the vernacular terms in every language seem more indelicate than foreign expressions of precisely similar import.

<sup>2</sup>HENNEN (J.) (*Princ. Mil. Surg.*, 3d ed., 1829, p. 450); GUTHRIE (G. J.) (*Commentaries, etc.*, 6th ed., 1855, p. 594); LARREY (D. J.) (*Clin. Chir.*, 1829, T. III, p. 57). Brief observations on the subject may be found in DUPUYTREN (*Leçons Orales*, 1839, 2<sup>e</sup> éd., T. VI, p. 500). MENDÈRE (*L'Hôtel-Dieu en 1830*, p. 368) cites four cases of shot wounds of the penis. APPIA (P. L.) (*The Ambulance Surgeon*, 1862, p. 168) relates a surprising case of longitudinal transit of a ball along the corpus cavernosum. DEMME (*Studien*, B. II, S. 160. *Schusswunden der Röhre*) details five cases of shot wounds of the penis. EMMERT (*Lehrbuch der Chir.*, 1852, B. II, S. 704); SOCIN (*Kriegschir. Erfahr.*, 1872, S. 100), and NEUDÖRFER (*Handbuch der Kriegschir.*, 1867, S. 798) each devote several pages to the subject. COLE (J. J.) (*Mil. Surg.*, 1852, p. 84) gives a case of mutilation of the penis by a cannon shot, with some sensible reflections on injuries of this group. FANO (*Traité élém. de chir.*, 1869, T. II, p. 1004, *Blessures du pénis*) satisfactorily summarizes what is known on the subject. GILLETTE (*Blessures des parties génitales*, in *Arch. Gén.*, 1873, Vol. XXI, p. 322) gives four cases from Metz.

<sup>3</sup>Four cases of complicated shot wounds of the penis have already been cited in the two preceding sections: CASES 706, p. 243; 712, p. 245; 762, p. 259, and 791, p. 267. NOURIS (L.) (*Case of Gunshot Wound of the Penis*, in the *Am. Jour. Med. Sci.*, 1867, Vol. XLVII, p. 281) has recorded the case of Private J. L. Williams, Co. D, 96th Pennsylvania, wounded at Chancellorsville, who recovered, with little deformity, from a severe shot laceration of the penis. FULTON (H. R.) (*Gunshot Wound of the Penis, with the Results*, in the *Med. and Surg. Reporter*, 1860, Vol. IV, p. 517) relates the history of Hugh C—, accidentally shot through the penis by a pistol-ball. The bleeding is said to have demanded two ligatures; recovery took place with traumatic hypospadias. ANNAN (S.) (*Cases of Gunshot Wounds, with Remarks*, in DUNGLISON'S *Am. Med. Intelligence*, 1839, Vol. II, p. 3) describes, among cases observed in the Baltimore riot of August, 1835, a severe shot wound of the penis advantageously treated by sutures. The subject is alluded to with extreme brevity at pages 11, 13, 21, and 261 of the *Appended Documents to the First Part of this history*. BERTHERAND (*Gazette des Hôpitaux*, 1861, No. 10, p. 32) relates that a large dog bit off and swallowed the penis and scrotum of a French Zouave in Algiers; a portion of the penis was found in the dog's stomach. STROMEYER (*Maximen der Kriegsheilkunst*, 1855, S. 667) cites the case of an artilleryman, who, while washing himself, was bitten by a horse, the integument of the entire periphery of the pendulous portion of the penis being torn off, except near the corona, where a slight attachment remained. The surgeon first called in stitched on the glove-finger of skin wrong end behind, when the surgeon in charge of the hospital arrived and replaced the integument properly; but, though carefully approximated by sutures, the part perished. A similar case is reported by ERICHSEN (*Science and Art of Surgery*, 6th ed., 1872, Vol. I, p. 515). On the anatomy of the penis consult: MÜLLER (*Med. Zeitung des Vereins für Heilkunde in Preussen*, No. 48); KRAUSE (HECKER'S *Annalen*, February, 1834); WILSON (E.) (*Cyclop. Anat. and Phys.*, Vol. III, p. 909); STEIN (A. W.) (*The Histology and Physiology of the Penis*, in *New York Med. Jour.*, 1872, Vol. XV, p. 595).

<sup>4</sup>Cases of rupture or laceration of the corpora cavernosa, with excessive infiltration of blood, occasionally result from malicious violence inflicted on the erect organ, or from the accident described as "missing the mark" in coition. Professor P. F. EVE (*Remarkable Cases in Surgery*, 1857, p. 373 *et seq.*) has industriously collected a series of extraordinary examples of this nature, including the two instances reported by V. MOIT (*Trans. New York Acad. of Med.*, 1851, Vol. I), G. C. BLACKMAN'S cases (*Cincinnati Jour. of Med.*, 1866, Vol. I, p. 316), and Dr. PETER PARKER'S case, reported by Dr. W. S. W. RUSCHENBERGER (*Am. Jour. Med. Sci.*, 1849, Vol. XVII, p. 410). But the exhaustive monograph on this subject is by DEMARQUAY and PARMENTIER (*Des lésions du pénis déterminées par le coït*, Paris, 1861). TRYE (C. B.) (*Med. Communications*, 1790, Vol. II, p. 158. *Case of Rupture of the Corpora Cavernosa Penis*) details an instance that exemplifies the impropriety of making incisions to liberate the effused blood in these cases. HUGUIER (*Bulletin de la Société de Chir.*, T. III, p. 514) narrates a case, complicated with rupture of the urethra, which proved fatal from urinary infiltration. Professor EVE (*op. cit.*, p. 376 *et seq.*) has also collected a variety of examples of strangulation of the penis by rings, bottles, etc.

<sup>5</sup>BRYANT (T.) (*The Practice of Surgery*, 1872, p. 599). ZIELEWICZ (J.) (*Ueber die Amputation des Penis mit der galvanocaustischen Schneide-schlinge*, in LANGENBECK'S *Archiv.*, 1870, B. XII, S. 580) has an elaborate paper on this subject. Compare also PHILIPPEAUX (*Traité pratique de la cauterisation*, 1856, p. 479). VELPEAU (A. L. M.) (*Nouv. Élém. de méd. opérat.*, 2<sup>e</sup> éd., 1839, T. IV, p. 340) says: "Je ne puis terminer sans faire observer que, toute simple qu'elle est, l'amputation de la verge manque néanmoins rarement d'avoir des suites assez fâcheuses. Si les malades qui s'y soumettent guérissent à peu près constamment au bout de quinze, vingt, trente jours, bon nombre n'en tardent pas à être tourmentés par les idées les plus sombres, un fond de tristesse dont rien ne peut les tirer: de telle sorte que les uns finissent par se détraire, que d'autres succombent assez souvent à leur accablement moral, au moment où on pouvait le moins s'y attendre."



foreign bodies, and delicate operations of catheterization, urethroraphy, urethroplasty, and the extraction of foreign bodies. The danger of injuries of this group varies according to their seat in the penile, serotal, membranous, or prostatic portions of the urethra, increasing with the distance from the urethral meatus.



FIG. 284.—Sir Astley Cooper's urethra forceps. [After FERGUSON.]

As the bladder is approached, the urethra acquires additional investments and the risk of urinary infiltration augments. Under the fossa navicularis the canal of the urethra is covered only by its proper membranes, and frequent operations for enlarging the meatus demonstrate the innocuity of wounds of this

locality. Further on, in the pendulous portion, the urethra is invested by spongy erectile tissue, a loose connective tissue, and the skin; then, it is in relation with the scrotum; then, traversing the triangular ligament and middle perineal aponeurosis, and, passing between the latter and the upper perineal fascia, it reaches the prostate. The practical consequences of lesions of the prostatic portion of the urethra have already been exemplified. They were due mainly to contact of the urine with the wound and its infiltration in neighboring parts. These accidents are less frequent and less grave in wounds of the membranous and penile portions of the urethra, in which the urine can usually be retained, and its contact with the wound can be avoided by the judicious use of the catheter; or, at all events, such contact need only take place at comparatively remote intervals. If infiltration occurs, it is located in a cellular tissue widely separated from the peritoneum by numerous layers of fascia, whereas in wounds of the neck of the bladder or the prostate the great serous membrane is in dangerous proximity. The difficulty of reuniting wounds of the urethra, inversely to their danger, augments with the distance from the bladder, fistules near the distal extremity of the pendulous part being especially intractable. The remark at the commencement of this chapter (p. 209), that the injuries of the pelvis to be examined, with the exception of a few operations for non-traumatic affections and a single case of bayonet wound, were examples of shot wounds exclusively, was too unqualified. CASES 930, 977, and 997 were examples of bayonet wounds, and CASE 978 was an instance of puncture by a knife-blade; in this subsection a case of sabre-wound occurs, and examples of rupture of the urethra from violence not inflicted by shot.<sup>1</sup> Systematic writers commonly subdivide wounds of the urethra into those from without inward, and those from within outward. The military surgeon is chiefly concerned with those of the first group; but some examples of the second will be encountered; for, apart from the accidents of catheterization, the frequency of wounds inflicted with a therapeutic purpose, by internal urethrotomy or by forced dilatation, has, of late years, rapidly increased. In examining first the shot wounds, and subsequently those produced by other causes, there will be occasion to exemplify the complications of traumatic stricture, foreign bodies, false routes, urinary fistules, and the operations of catheterization, suprapubic, perineal, and rectal puncture of the bladder, urethrotomy, urethroraphy, and urethroplasty.

*Shot Wounds.*—These were attended by complete or partial division of the canal of the urethra, and varied in their character according to the portion of the urethra interested

<sup>1</sup> The remark was really applicable to the cases of the first section only. It was based upon the reiterated assurances of the clerk in charge of the assorted documents, who thought the inquiry applied to the papers belonging to the section and not to those of the chapter. The editor, doubting this assertion, made repeated searches for other cases of incised and punctured wounds; but the memoranda were not brought to light until it was too late to suppress the erroneous statement here corrected, and for which this apology is made.

and the extent of the attendant complications; for they were rarely uncomplicated. There were a hundred and five cases in this category, of which twenty-two were fatal. Abstracts of seven of these cases have been already recorded.<sup>1</sup> The fifteen remaining fatal cases were attended by grave complications. The proximate causes of death are indicated in the foot-note;<sup>2</sup> and we may proceed with an examination of the different varieties of cases of recovery from shot wounds of the urethra, noticing first the cases of *Traumatic Stricture*:

CASE 1009.—Private J. Smith, Co. G, 101st Indiana, was wounded at Chattanooga, September 22, 1863, and was treated in a field hospital and afterward at Cumberland Hospital, Nashville, where the case was noted as a "gunshot wound of the bladder and testicle." He was furloughed December 25th, and admitted to hospital at Madison, March 11, 1864. Acting Assistant Surgeon D. W. Flora then reported that "he was accidentally wounded while lying flat upon his face, the ball entering the perineum and perforating the bladder near the neck, passing out in the left inguinal region. He states that the urine was discharged from both wounds for some time after the reception of the injury. He was discharged the service on April 9, 1864, his general health being fair and his wounds healed." Examiner B. S. Woodworth, of Fort Wayne, reported, November 3, 1865, that "the ball entered the perineum midway between the anus and scrotum, striking the ramus of the pubis on the left side, and penetrated the bladder. There is a slight stricture, the wound probably having affected the urethra. Disability is three-fourths." This soldier was pensioned, and paid to June 4, 1873.

CASE 1010.—Private O. H. Moore, Co. A, 2d New York Cavalry, aged 25 years, was wounded at Leeompte, April 4, 1864, and was treated in the University Hospital, New Orleans, and Ira Harris Hospital, at Albany. Assistant Surgeon J. H. Armsby, U. S. V., states that he was "admitted, September 21, 1864, with a gunshot wound of the abdomen and bladder; there was a profuse discharge of glairy pus from the sinuses, and the patient was weak and irritable. On January 22, 1865, Acting Assistant Surgeon E. H. Ferris made an incision two inches in length through the gluteal muscles and extracted the ball." The patient was "discharged for disability, July 6, 1865, his general health being good, and he being able to earn partial subsistence." Examiner W. H. Miller, of Sandy Hook, reported, July 19, 1865: "The ball entered the left buttock, passing through to the other, and was removed from near the anus in January, 1865. The place from which the ball was extracted is yet unhealed and discharges; the wound will probably heal; he complains that it affects his urinary organs." Examining Board of Surgeons R. B. Bontecon, W. H. Craig, and C. H. Porter, of Albany, reported, October 2, 1863: "The ball entered the middle of the left gluteal region and passed through the pelvis and neck of the bladder, lodging in the right side of the perineum, against the ramus of the right ischium, from whence it was removed. The proximity of the track of the wound to the membranous portion of the urethra has caused stricture, and obliged him to resort to frequent dilatations of the urethra to void his urine. Disability continues at total." His pension was last paid him June 4, 1873.

CASE 1011.—Private Peter Lins, Co. B, 9th Pennsylvania Reserves, was wounded at Antietam, September 17, 1862, and was treated in hospitals at Frederick, Philadelphia, and Pittsburg, until December 1, 1863, when he was transferred to the Veteran Reserve Corps. He was subsequently discharged and pensioned, and Examiner W. W. Herron, of Allegheny City, reported, January 15, 1867, that "the ball penetrated the right hip over the tuberosity of the ischium, fracturing it, and escaping through the upper part of the left thigh. The urinary organs were so injured by the passage of the ball that he cannot urinate without the use of the catheter." October 19, 1867, Examiner G. McCook, of Pittsburg, reported to the same effect, and, on September 9, 1873, Pension Examining Board A. G. McCandless, J. W. Wishart, and W. Wilson, of Pittsburg, reported that "the ball entered the right buttock and passed across to the left side, opening the urethra, and coming out on the inner side of the left thigh. He is obliged to use a catheter continually. His disability continues at total." This pensioner was last paid to June 4, 1873.

<sup>1</sup> 1. CASE 630, Private H. C—, Co. H, 15th New York Artillery, p. 298; 2. CASE 823, Private D. P. Grubb, Co. B, 48th Ohio, p. 287; 3. CASE 850, Private Fleming P—, Co. K, 6th Georgia, p. 291; 4. CASE 855, Private W. B. Waite, Co. K, 10th New York, p. 293; 5. CASE 867, Sergeant H. Ford, Co. F, 67th New York, p. 304; 6. CASE 868, Private Charles C—, Co. A, 30th Iowa, p. 304; 7. CASE 938, Private Henry M—, Co. B, 8th New York Cavalry, p. 325.

<sup>2</sup> 1. Corporal A. J. Hartmann, Co. K, 97th Pennsylvania, aged 25, wounded at Milford, May 20th; ball traversed perineum and urethra; died June 3, 1864, from urinary infiltration. 2. Private J. Meyer, Co. E, 32d Indiana, wounded at Nose's Creek, Georgia, June 17th, in penis and perineum; died July 21, 1864, from septicaemia. 3. Sergeant J. Mintun, Co. H, 67th Ohio, wounded at Fort Wagner, July 18th, in left thigh and perineum, the urethra being divided; died August 11, 1863, from exhaustive suppuration. 4. Private G. Cummings, Co. H, 80th New York, aged 31, wounded at Spottsylvania, May 10th, oblique shot perforation from right natis to left testis, lacerating the urethra; died May 19, 1864, from tetanus. 5. Private A. G. Stinwell, Co. G, 5th North Carolina, wounded and captured at Spottsylvania, May 12th; shot fracture of right femur and division of the urethra by the same ball; died June 4, 1864, from surgical fever and shock. 6. Corporal J. Moran, Co. E, 39th Massachusetts, wounded at Southside Railroad, March 31st, shot fracture of left femur, the urethra severed by the same ball; died August 7, 1865, exhausted; an attack of pleuro-pneumonia gave the *coup de grâce*. 7. Private C. Griner, Co. I, 3d Delaware, wounded at Petersburg, April 1st, shot fracture of femur and laceration of scrotum and urethra; chills, delirium; death, April 19, 1865, "exhaustion." 8. Private M. Smith, Co. F, 38th Virginia, wounded at Spottsylvania, fracture of upper third of left thigh by a conoidal ball, which passed through both thighs and lacerated the urethra; excision of head of left femur; death, May 13, 1864 (compare CASE XLV, p. 43, Circular 2, S. G. O., 1869, and *Spec. 5500*, Sect. I. A. M. M.). 9. Corporal J. Bishop, Co. B, 22d Alabama, wounded at Chickamauga, September 19th, shot fracture of right femur, the ball traversing the bulbous part of the urethra and the soft parts of the left thigh; died October 8, 1863 (*vide Confed. States Med. and Surg. Jour.*, 1864, Vol. I, p. 77). 10. Private E. C. Hoff, Co. A, 1st Minnesota, wounded at second Manassas, August 31st, shot fractures of both femurs with wound of the perineum and injury to the membranous part of the urethra; death, October 12, 1862, from "exhaustion." 11. Corporal P. K. Priece, Co. D, 32d Colored Troops, wounded at Pocotaligo, December 6th, shot perforation of penile portion of urethra and wound of left thigh; death, December 31, 1864, from urinary infiltration. 12. Private H. Strauss, Co. F, 145th New York, wounded at Chancellersville, May 3d, shot perforation of the pelvis from the left buttock to the left side of the scrotum, dividing the urethra; phlebitis and dry gangrene ensued, and terminated fatally, July 24, 1863. The three fatal cases, of English, Bobbit, and Stewart will be related in detail.



Ordinarily the introduction and maintenance of a catheter constitutes the most important part of the treatment of a shot wound interesting the urethra; but it often happens that, after a certain stage, of variable duration, the presence of a catheter is

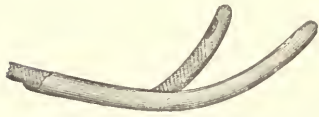

FIG. 285.—Mercier's instrument for avoiding false passages. It is a silver catheter, hollow up to the dotted line; beyond this is a solid portion which enters the false passage. A small gum catheter is passed along the instrument and issues at the orifice in its concavity to traverse the urethra beyond the false passage occupied by the extremity of the instrument. [After THOMPSON.]  $\frac{1}{2}$ .

prejudicial to the process of cicatrization.<sup>1</sup> It is possible that in such a case as that following, it would have been practicable to have avoided the entrance of the catheter into the wound-track by employing M. Mercier's ingenious plan (FIG. 285) of passing a small gum catheter through a fenestra in the hollow metallic instrument first introduced. The false passage being filled by the metallic fascia, the gum catheter projecting laterally might be guided into the true canal, and when fairly lodged in the bladder the metallic catheter could be withdrawn.

CASE 1012.—Private J. N. Fugate, Co. F, 55th Illinois, aged 21 years, was wounded at Kenesaw Mountain, June 27, 1864. Surgeon J. B. Potter, 30th Ohio, at one of the Fifteenth Corps field hospitals, reported "a gunshot wound of both thighs and scrotum." Acting Assistant Surgeon M. M. Shearer made the following report of the case from the hospital at Barton Iron Works: "The patient having been removed from an erysipelas ward, where he had been suffering from erysipelatous inflammation of the wound for fourteen days, it was found that the ball had entered on the anterior surface of the left thigh, immediately over the upper third of the sartorius muscle, five and a half inches below the origin of the muscle and two and a half inches below the centre of Poupart's ligaments, ranging inward, upward, and backward, passing beneath the tendons of the pectineus and the adductors and deep perineal fascia, piercing, in its course, the corpus spongiosum of the penis and partly severing the membranous portion of the urethra; from this point the missile ranged downward, outward, and backward through the right thigh, passing posterior to the femur, and lodged beneath the integuments, whence it was extracted. The urine discharged copiously through the entrance wound at every attempt to micturate, none escaping through point of exit. The wound suppurated freely. Ordered simple cerate dressing to the wounds, and muriated tincture of iron and milk punch to be administered thrice daily. July 8th, patient's general condition excellent; appetite good. July 9th, urine still discharges through the wound in right thigh; wound in left thigh healing kindly. A metallic catheter was introduced and the urine was drawn off morning and evening. But little urine passed through the wound during the day. July 10th, entrance wound nearly closed; exit wound healing kindly. A gum-elastic catheter was introduced and left permanently in the bladder." For the next four days the catheter was maintained in the bladder, being removed and cleansed every twenty-four hours; during this period no urine escaped by the entrance wound. On July 14th, there was difficulty in replacing the catheter. Even after chloroform was administered it was impracticable to reach the bladder, the extremity of the instrument passing into the wound-canal notwithstanding the utmost care and caution in manipulation. Urine again passed through the wound, causing great pain. There was but little constitutional disturbance. Repeated unsuccessful attempts were made, during the next few days, to conduct a catheter into the distal portion of the urethra. On July 18th, a small abscess pointed behind the scrotum, and, on incision, a small piece of cloth was found and extracted. On July 27th, the urine passed wholly by the urethra; the general health of the patient was good, and he was furloughed by Surgeon A. Goslin, 48th Illinois. He entered the hospital at Quincy, November 11, 1864, and Surgeon D. G. Brinton, U. S. V., recorded that "a conical ball had entered the sartorius muscle anteriorly, and passed through the urethra and right gluteal muscles. He has some difficulty in voiding his urine. Transferred to Veteran Reserve Corps, February 13, 1865." He was on duty, in the 34th company, at Mound City Hospital, when Acting Assistant Surgeon J. A. McCoy reported that he was discharged, August 14, 1865, being unfit for service on account of a urinary fistula. He was pensioned, and Examiner J. J. Caldwell, of Dallas, Iowa, reported, September 4, 1873, that "the ball took effect a little below the left groin, passed through the bladder, and came out on the opposite thigh about two inches below the hip-joint. He suffers from pain in the region of the bladder, and has difficulty in passing his urine, and has resorted to a catheter twice in the last few months. He is unfit to perform any severe manual labor. Disability third grade."

CASE 1013.—Private M. S. Clark, Co. I, 1st Iowa Cavalry, was wounded at Chalk Bluffs, Missouri, May 2, 1863, and was admitted to the regimental hospital at Lake Springs. Assistant Surgeon C. H. Lathrop, 1st Iowa Cavalry, recorded "gunshot wound in the penis, the ball passing near the spermatic cord and wounding the urethra, thence passed into the right thigh." This soldier was transferred, on May 5th, to Post Hospital, Cape Girardeau, whence Surgeon H. A. Martin, U. S. A., reported as follows: "Shot wound of scrotum and left testis, involving the urethra. There was an immense extravasation of blood and urine, for which free incisions were successfully made; for two weeks urine passed by the wound only, but the wound then closed fully and urine passed entirely through the urethra. He was returned to duty twenty-nine days after the reception of the injury." Clark is not a pensioner.

<sup>1</sup> DUPUYTREN (*Leçons orales*, 1839, T. VI, p. 514) taught that shot wounds of the urethra should ordinarily be treated by the introduction and maintenance of a catheter, the external surface of the wound being covered by compresses covered with simple cerate. But he adds: "Il ne faut pas croire cependant que la sonde à demeure dans la vessie soit toujours un moyen infallible de guérison. A une certaine époque, il arrive quelquefois qu'elle nuit plus qu'elle ne sert, on voit la cicatrisation s'arrêter, et en l'ôtant, celle-ci se fait très-rapidement. Un individu reçut dans les journées de juillet un coup de feu qui lui ouvrit l'urètre à la racine de la verge. Il fut reçu à l'Hôtel-Dieu dans le service de M. BRESCHET; on lui mit une sonde à demeure dans la vessie; il la conserva pendant son séjour à l'Hôtel-Dieu et à la maison de convalescence de Saint-Cloud pendant plus de trois mois. A cette époque il n'était pas encore guéri, car la plaie de l'urètre subsistait encore. Pensant alors que ce malade était en nombre de ceux auxquels la sonde nuit dans ces cas-là plus qu'elle ne sert, je l'ôtai, et en peu de jours la guérison se fit." SOGIN (*Kriegschir. Erfahrungen*, 1872, S. 100), in his description of the wounded after the engagements before Metz, observes: "There were four cases of shot wounds of the urethra. \* \* \* The urinary fistules closed in from five to seven weeks without use of the catheter. Extensive infiltration did not occur."

In shot wounds of the penile portion of the urethra the diagnosis is obvious. Lesions of the deeper part are suggested by the escape of blood from the meatus, by the passage of sanguinolent urine from the meatus and the wound, by scalding pain in the wound and canal following a shot penetration in the course of the urethra, and by indications derived from the employment of the catheter. The latter signs also discriminate solutions of continuity in the deep parts of the urethra from those in the bladder. Moreover, the escape of urine by the wound-track is intermittent in lesions of the urethra, except in cases of incontinence; whereas, in penetrations of the bladder, the urine dribbles constantly away. Micturition is usually easy immediately after a laceration of the urethra; but, through inflammatory swelling and spasmodic contraction, the excretion of urine soon becomes difficult, and often impossible. Infiltrations of blood and urine, which are reckoned among the early accidents of lacerations of the urethra, are peculiarly liable to be followed by retention, though in shot wounds attended with much loss of substance such infiltrations are less common than in other varieties of rupture.

In the cases treated without incisions, it is difficult to estimate the extent of loss of substance involved in the urethral laceration; and the degree of contraction in many of the cases of traumatic stricture is left to conjecture, from the omission from the reports of reference to the size of instruments that could be passed through the constricted part:

CASE 1014.—Captain B. Q. A. G——, Co. B, 10th Indiana Cavalry, wounded at Chancellorsville, May, 1863, was treated in a cavalry corps hospital near Aquia Creek. Assistant Surgeon J. H. Knight, 3d Indiana Cavalry, reported: "The ball entered at the right side of the scrotum, and, injuring the right testis, passed through the left thigh. He is recovering rapidly." Captain G—— was promoted lieutenant colonel of 10th Indiana Cavalry, January 7, 1864, and was reported wounded at Florence, South Carolina, September 13th. He was admitted, October 13, 1864, to No. 6, New Albany, with an "injury to the right testis and urethra," and returned to duty November 20th. In April, 1865, he was sent to Grant Hospital, Cincinnati, for examination, and was discharged the service April 25, 1865, and pensioned. Examiner E. R. Hawn, of Leavenworth, reported, September 11, 1871: "Gunshot wound of both testes. The ball entered the right testis near the centre, passing through it and cutting the under side of the penis, opening the urethra, and entering the left testicle at the upper part, and passing through it. The wound involves the spermatic cord and causes pain. The wound of the urethra causes stricture at the point of the wound. He is at times subject to incontinence of urine from the effects of the wound; disability total." This pensioner was paid to September 4, 1873.

CASE 1015.—Sergeant T. Parker, Co. K, 69th New York, aged 26 years, was wounded at Deep Bottom, August 16, 1864. He was taken from the field and admitted into Satterlee Hospital, Philadelphia, on the 20th. Assistant Surgeon B. Bache, U. S. A., reported the following particulars in the case: "Wounded by a minié ball, which entered the perineum anterior to the anus, and, passing forward, made its exit near the middle of the upper third of the right thigh, passing external to the femoral artery, and producing a wound of the bulb of the urethra. He passes his urine through the posterior wound and some through the anterior wound, but none through the urethra. The private parts are very much congested. By August 30th, the wound was cleaning finely, though suppurating profusely. On October 3d, the wound being nearly closed, a catheter was placed in the urethra, with some difficulty because of stricture. The treatment had consisted, throughout, of water dressing and nourishing diet." The patient recovered, and was discharged June 6, 1865, and pensioned. Examiner J. L. Hodge, in a report of June 7, 1865, says: "A shot wound of the right thigh, scrotum, and urethra has impaired the usefulness of the thigh and left him with a bad stricture of the urethra." Examiners C. Phelps, J. F. Ferguson, and M. K. Hogan, on June 22, 1870, reported: "Ball entered the right thigh, upper and anterior aspect, passed through the perineum, and emerged before the opposite side. He has traumatic stricture and incontinence of urine." The same board reports, September 9, 1873, that this pensioner "is much troubled with incontinence of urine and seminal emissions; disability three-fourths."

CASE 1016.—Private C. W——, 34th Massachusetts, aged 35 years, was wounded at Cedar Creek, October 13, 1864. He was sent to Winchester, and, on the 18th, transferred to Camden Street Hospital, Baltimore, where Surgeon Z. E. Bliss, U. S. V., noted "a gunshot wound of the left testis and urethra." Thence, February 17, 1865, this soldier was sent to Dale Hospital. Surgeon E. H. Chamberlain, U. S. V., reported "gunshot wound of the left testis—severe; testis removed October 14, 1864," and, on the certificate of disability, "gunshot wound of perineum and scrotum, injuring the urethra and left testicle; wound not healed." Examiner O. Martin, of Worcester, reported, November 12, 1868: "A ball hit inside of the right buttock just above the anus, passed through the lower portion of the pelvis, cut through the penis, severing the urethra, and carried away the left testicle; venereal powers weakened; freedom of motion of the body impaired from adhesions; disability total and permanent." Examiner G. W. Morse, on September 6, 1873, reported: "Ball passed through the right testis, coming out at the root of the penis, rupturing the urethra, and carrying away the left testicle; he had urinary fistula for four months; now there is pain in the back and region of the wound; pain and tingling on passing urine; and pain in the abdomen when he works. He cannot do any work that requires him to stoop. There is stricture of the urethra, caused by the ball having passed through the scrotum; disability total." This pensioner was paid to September 4, 1873.



Contraction of the canal necessarily attends the cicatrization of shot wounds of the urethra in a degree commensurate with the loss of substance, unless the narrowing is resisted by the presence or frequent passage of unyielding tubes. Even then the tendency to contract remains. It is different with traumatic stricture due to inflammation of the contiguous tissues, when the integrity of the canal has not been destroyed. The super-vention of stricture, after an interval of five years, in the first of the following cases, is remarkable:

CASE 1017.—Lieutenant H. C. P——, Co. H, 21st Pennsylvania Cavalry, was wounded at the engagement at Hatcher's Run, October 27, 1864, and sent to the Second Division Hospital, Cavalry Corps. Assistant Surgeon E. J. Marsh, U. S. A., recorded a "flesh wound of the left thigh." The patient was transferred to hospital at City Point, and furloughed November 7th. On December 5, 1864, he was registered with wounded volunteer officers at Washington. Acting Assistant Surgeon F. S. Barbain notes the injury as "a gunshot flesh wound of the scrotum and left thigh;" and adds that this officer was "discharged February 8, 1865, readmitted March 4th, and discharged the service April 9, 1865."—S. O. 62, § 19, A. G. O. Dr. H. W. Sawtelle, of the Revenue Marine Service, states that in this case the sciatic nerve was injured, and that there was for a long time pain and sensitiveness in the course of this nerve. He adds that during the treatment an abscess formed in the scrotum, requiring evacuation by a trocar, and that after retirement from service this officer experienced no inconvenience from the injury until the spring of 1870, when scalding on micturition, and a diminution in the size of the stream of urine was observed. Catheterization thrice weekly was employed for nearly a twelve-month, with great benefit. In January, 1873, Dr. Sawtelle examined this pensioner, and detected "a slight stricture corresponding with the exit of the ball. A system of gradual dilatation by bougies was advised, and under this treatment steady improvement took place." Dr. W. P. Johnson and Examiner J. O. Stanton, of Washington, certified that the stricture was, in their opinions, of traumatic origin.

CASE 1018.—Corporal B. H. Wood, Co. B, 154th New York, aged 24 years, was wounded at Chancellorsville, May 3, 1863. He was sent from an Eleventh Corps hospital, on the transport *Mary Washington*, to Stanton Hospital, where Surgeon J. A. Liddell, U. S. V., reported a "gunshot wound resulting in urinary fistula." On June 20th, the patient was removed to Carver Hospital, where Surgeon O. A. Judson, U. S. V., recorded a "shot wound of the urethra." At DeCamp Hospital, November 21, 1864, Assistant Surgeon J. S. Billings, U. S. A., reported this man as "returned to duty." On April 29, 1865, this soldier was sent from a Twentieth Corps hospital, by the hospital Steamer *S. R. Spaulding*, to McDougall Hospital, New York, and Assistant Surgeon S. H. Orton, U. S. A., reported that he was discharged for traumatic stricture of the urethra, June 12, 1865, and pensioned. Examiner O. A. Tompkins, of Randolph, reported, May 1, 1872: "The ball entered at the right side of the root of the penis, passed backward and inward through the urethra, and emerged at the centre of the left natis three inches from the anus. There now remains permanent stricture of the urethra." An increase of pension was recommended.

CASE 1019.—Private J. Metzler, Co. A, 44th Illinois, aged 32 years, was wounded at Resaca, May 14, 1864, and was treated in hospitals at Chattanooga, Nashville, and Louisville; again in No. 8, Nashville, from October 27th; and transferred to Brown Hospital, November 30th, where a wound of the penis was first reported; thence to Jefferson Barracks, where Assistant Surgeon H. B. Tilton, U. S. A., noted a "stricture of urethra from gunshot wound." This soldier was transferred to the Veteran Reserve Corps, January 11, 1865; discharged October 17, 1865, and pensioned. Examiner S. Wagenseller, of Pekin, reported, April 30, 1867: "One wound in the wrist, ball entering the back part of the hand, passing through the wrist-joint, fracturing the bones; he has not full control of the motion of the joint. In the other wound, the ball struck the penis on the left side in front of the scrotum, passing out from the right gluteal muscles. He urinates with great difficulty, water dripping away slowly; disability one-half and permanent." This pensioner was paid to the date of his death, July 31, 1871.

CASE 1020.—Captain John M——, 79th New York Militia, aged 38 years, was wounded at Bull Run, July 21, 1861, and again August 30, 1862. On the last occasion he was taken prisoner and remained in the hands of the enemy for eight days. He was paroled and rejoined his regiment, and was promoted major November 17, 1862, and lieutenant-colonel February 17, 1863. He was mustered out at the expiration of his term of service, May 31, 1864, and pensioned. Surgeon J. E. MacDonald, U. S. V., formerly of the 79th New York, July 5, 1865, makes the following statement: "At the battle of Bull Run, July 21, 1861, Mr. M—— received a very serious wound from a musket ball, which perforated the apex of the left chest and lung and fractured the left scapula. He made a rapid recovery, however, from so severe a wound, and reported for duty in an extremely short time." \* \* "At the second battle of Bull Run, August 30, 1862, Mr. M—— received a wound from a minié ball, which passed through the right natis, the scrotum, and the urethra. On this occasion, the nature of the wound did not permit him to escape from the field, and he remained eight days in the hands of the enemy. Much to the surprise of many surgeons, myself among the number, he survived to be removed to Washington, and again to be of service to his regiment. I have carefully examined his condition recently, and find that he is still obliged to make frequent use of the catheter to relieve his bladder, and often suffers from both incontinence and retention of urine. It is my opinion that he will never cease to be subject to temporary difficulties of like nature." Examiner T. F. Smith reported, January 30, 1866: "A ball perforated the apex of the left lung, fracturing the left scapula, in consequence of which he has not full power of the left arm; disability from this, one-fourth. Another ball passed through the right natis, scrotum, and urethra. He is obliged to use a catheter continually in order to draw off the urine. Whenever he performs hard labor the wound breaks open. He is unable to walk but a short distance. Disability from this, three-fourths." The same examiner, September 17, 1873, reports: "Ball entered over middle third of the left clavicle and made exit over the inner border of the middle third of the left scapula; no disability. Ball entered to the left of the scrotum in the groin, cutting the urethra, and made its exit from the right natis. He is obliged to use a catheter to draw off the urine; locomotion considerably interfered with; disability total." This pensioner was paid December 4, 1873.

Continuing the examinations of traumatic stricture consequent on shot wounds of the urethra,<sup>1</sup> there will be next noted four examples of stricture of the penile portion of the canal, and one in which the seat of contraction is indefinitely indicated:

CASE 1021.—Private S. D——, Co. I, 26th Pennsylvania, aged 45 years, was wounded at Spottsylvania, May 12, 1864. He was sent to Emory Hospital on the 25th, and the injury was recorded as a "wound of the left testis and penis by a minié ball." On June 11th he was transferred to Camden Street Hospital, and mustered out June 18, 1864. Examiner H. E. Goodman reported, October 8, 1869: "The wound of the applicant has resulted in the loss of the left testis and slight wound of the end of the penis. The cicatrix of the scrotum is well marked, and the testis is entirely absent. The meatus of the urethra is contracted by reason of the cicatrix, causing, however, little trouble. He states that before the loss of the testis he had one child, and has had none since; his wife is healthy. He has the same desire as formerly for sexual intercourse; the discharge is thin, watery, and of very slight amount. I was under the impression that the spermatic cord of the right testis was obliterated, and I examined the semen eight hours after copulation, and found it of very slight amount, thin, and watery as stated, and having live spermatozoa but fewer in number than in ordinary semen. He states that he has pains when lifting or doing heavy work." This pensioner was paid September 4, 1873.

CASE 1022.—Private W. Rahlman, Co. C, 24th Wisconsin, aged 49 years, was wounded at Adamsville, May 17, 1864, and treated in a Fourth Corps hospital. Surgeon W. P. Pierce, 88th Illinois, reported a "gunshot flesh wound of the left hip and scrotum." The patient was sent to Chattanooga on the 23d, and thence to Nashville, Louisville, and Jefferson Barracks, and to Keokuk on December 4th, where Surgeon M. K. Taylor, U. S. V., reported: "Gunshot wound of the left thigh, the ball entering on the outer posterior aspect, three inches below Poupart's ligament, piercing the upper part of the scrotum, and occasioning a severe abraded wound of the penis an inch posterior to the glans." This soldier was discharged June 10, 1865. Examiner G. W. Perrine, of Milwaukee, reported, February 7, 1866: "He received a flesh wound from a rifle ball which entered the fold of the left natis, passed through behind the bone, emerged on the inside of the thigh, thence through the scrotum and penis; all of which wounds are healed and have been for over a year." October 24, 1866, Dr. Perrine continues: "The increased disability is caused, I should think, by an injury to the sciatic nerve. At times he is very lame, and can lift but very little, and often has cramps. Of this, I have satisfactory evidence from others, as well as from Rahlman himself. He did not represent himself, at the first examination, as bad as he was." Examiners E. Kramer, J. H. Sterns, and R. B. Brown reported, November 12, 1873, that "the leg is lame, and there is a stricture of the urethra, caused by a wound."

CASE 1023.—Private E. W. Knapp, Co. F, 157th New York, aged 44 years, was wounded at Gettysburg, July 1, 1863. The case was recorded at Camp Letterman as a "wound of the genitals by a minié ball." The patient was sent, July 24th, to Harewood Hospital. Acting Assistant Surgeon J. Carrier reported: "Ball entered at the posterior part of the head of the penis and passed upward, making its exit at the anterior part. The wound healed, and this soldier was returned to duty September 22, 1863." He was discharged July 6, 1865, and pensioned. Examiner P. B. Havens, of Hamilton, reported, November 26, 1867: "Gunshot wound through penis, producing constant irritation of the kidneys, liver, and heart, through irritation of the spinal cord, and weakness of the spine, the urine passing off seven or eight times during the night. He is unable to do common labor; disability permanent." Examiner D. D. Chase, of Morrisville, September 6, 1873, reported: "Wound of the penis; the ball penetrated just posterior to the glans. There is slight contraction of the urethra, and painful and difficult micturition."

CASE 1024.—Private E. Robbins, Co. I, 16th Illinois, aged 26 years, was wounded at Windsor's Farm, North Carolina, March 16, 1865. Surgeon E. Batwell, 14th Michigan, reported, from a hospital of the Fourteenth Corps, "a gunshot wound of the penis and pubes." The patient was sent to New Berne, where Surgeon C. A. Cowgill, U. S. V., reported, April 5th, "a shot wound of the penis and scrotum." On April 13th the patient was sent to McDougall Hospital, whence he was discharged, May 31, 1865, for "shot fracture of symphysis pubis, the ball having passed through the penis and scrotum," according to the certificate of Assistant Surgeon S. H. Orton, U. S. A. This soldier was pensioned. Examiner S. N. Pierce, of Iowa, reporting, December 15, 1871: "An ounce musket ball entered directly at the symphysis pubis, and, passing backward around the thigh, lodged on the posterior of the left thigh, where it remained two years. Some exfoliation from the femur resulted. The applicant suffers much from difficulty in passing urine, and frequently requires to use a catheter. There is pain, referred to the neck of the bladder, and some atrophy of the left thigh. The strength of this extremity is reduced." This pensioner was paid March 4, 1873.

CASE 1025.—Private J. O'Brien, Co. D, 7th New York Artillery, aged 18 years, was wounded at Tolopotomy Creek in June, 1864. He was sent to Douglas Hospital on June 12th. The injury was recorded as a "gunshot wound of the upper third of the thigh and of the penis—severe." The patient was furloughed August 23d, readmitted, and discharged June 3, 1865, and pensioned. Examiner J. Doekstader, of Sharon Spa, reported, June 22, 1866: "The ball nearly cut his penis off, so that it hung by a fragment of skin; but, after a good deal of trouble, the organ was saved." Examiner J. I. Sweet reported, December 2, 1873: "Gunshot wound of the left thigh and penis. The ball passed through the penis just above the glans, then passed through the thigh, while in a standing position, severed the sartorius, grazed the femoral artery, injuring the nerves, and struck the bone, producing enlargement of the bone." This pensioner was paid December 13, 1873.

<sup>1</sup> Histories of several cases of shot wounds of the urethra have appeared in the medical journals. It will suffice to refer to them without recapitulating the details: 1. PARRY (J. L.) (*Gunshot wound, involving the membranous portion of the urethra*, in the *Phil. Med. and Surg. Reporter*, 1866, Vol. XIV, p. 6); case of J. Y——, aged 32, wounded at the second battle of Manassas, successfully treated by the catheter à demeure. 2. SEMMES (A. J.) (*Gunshot wound of the gluteal region and of the urethra*, in *New Orleans Med. and Surg. Jour.*, Vol. XIX, 1866-67, p. 69); case of Private W. McC——, 52d North Carolina, wounded May 3, 1863; the urethra was lacerated in front of the triangular ligament; when inflammation had subsided, a catheter was maintained in the urethra; rapid convalescence. 3. MCSCROFF (C. S.) (*Gunshot wound of the urethra—Removal of a broken catheter*, in the *Am. Med. Times*, 1863, Vol. VII, p. 181.)



Doubtless, when pensioners made no complaint of dysuria, the existence of traumatic stricture was sometimes overlooked by the pension examiners; and, often, less stress was laid upon this cause of disability than would be anticipated from the nature of the antecedent injuries:

CASE 1026.—Private M. McCarthy, Co. D, 83d Pennsylvania, was wounded at Gaines's Mills, June 27, 1862. He was taken prisoner, and subsequently paroled and sent north, and was admitted into Broad and Cherry Streets Hospital, Philadelphia. Surgeon John Neill, U. S. V., reported: "A ball entered on the left side, on a line with the penis, below the arch of the pubes, and, passing obliquely backward, made its exit in the right of the buttock, immediately behind the great trochanter. When admitted, July 31st, his general condition was pretty good; whenever an attempt was made to evacuate the bladder, the urine passed freely from the wound in front; some also passing from the urethra. No catheter was employed in the treatment of the case; a warm-water dressing was applied to the wounds and a good diet ordered. The wound of exit healed rapidly with very little discharge; that of entrance of the ball granulated slowly, and urine continued to flow until October 1st, at which time the wound had cicatrized, and the patient was convalescent without a bad symptom." On November 12th the patient was transferred to Chester, and thence returned to duty January 23, 1863. He was discharged from service February 11, 1863, and pensioned. The certificate of disability recommends discharge by reason of "varicose veins of left leg;" and the adjutant general endorsed on the same, May 22, 1873: "This man was entitled to discharge by reason of gunshot wounds." Examiner W. M. Chamberlain, March 6, 1863, reported: "The ball entered the left groin, and, passing through the scrotum, issued on the external surface of the right hip. There is, probably, some stiffness and soreness after much exertion, but it is hardly a cause of disability, in my judgment." Examiner J. L. Stewart states, January 10, 1870: "Gunshot wound through the scrotum and the root of the penis, from the left side, passing through the right hip, resulting in weakness and stiffness of the same." Drs. J. L. Stewart and W. M. Wallace reported, February 7, 1872: "Gunshot wound entering on surface of scrotum, immediately above the left testicle, passing out, as stated by applicant, at a small mark on the surface of the gluteal muscles of the right side, producing some abrasion and contraction at point of entrance." The same board, with the addition of Dr. H. Strickland, September 4, 1873, reports: "Mark of gunshot wound of the left groin; ball entering the left groin on a line with the penis, passing through just below the neck of the bladder, making exit on the right hip opposite the lower edge of the glutei muscles, producing pain upon motion of the limb; disability three-eighths." This pensioner was paid to September 4, 1873.

CASE 1027.—Private A. Bordeaux, Co. F, 14th Ohio, aged 17 years, was wounded at Atlanta, August 5, 1864. He was treated for a gunshot wound of the scrotum in a Fourteenth Corps hospital; thence sent to No. 2, Chattanooga; thence to No. 3, Nashville; and finally to No. 6, New Albany. Here Acting Assistant Surgeon E. S. Crosier reported the injury as a "gunshot wound of the scrotum and perineum," and that the right testicle had been removed, under chloroform, by Surgeon G. E. Sloat, 14th Ohio, on the field, on the day of injury. This soldier was discharged July 11, 1865, and pensioned. His attending physician, Dr. Joel Greene, testified as follows, May 3, 1873: "Gunshot wounds of the penis, testes, perineum, and rectum, causing the loss of the right testicle, and producing such contraction and derangement of the tissues that he is, from time to time, unable to empty his bladder without the aid of a physician." Examiners S. S. Thorn and S. H. Bergen, of Toledo, reported, August 6, 1873: "Ball entered from the front, striking the penis, removed part of the glans, and, passing through the scrotum, destroyed the right testis; thence through the perineum, emerging at the centre of the anus. The urethra was wounded by the ball. The applicant passes water with difficulty, frequently requiring the use of a catheter. The bladder was evidently injured at the neck by the same missile; he has suffered from cystitis ever since; he evacuates the contents of the bladder frequently. Disability is three-fourths." This pensioner was paid September 4, 1873.

CASE 1028.—Private J. Roe, Co. C, 4th New Jersey, aged 49 years, was wounded at Gaines's Mills, June 27, 1862. He was admitted into Fourth and George Streets Hospital, Philadelphia, on July 30th, where Acting Assistant Surgeon J. B. Bowen reported: "A round ball entering the left thigh below the superior spine of the ilium, passed through the thigh, through the scrotum, right testicle, and right thigh, cutting the spermatic cord and urethra. When wounded he was taken prisoner and sent to Richmond and confined there for three weeks. When admitted to this hospital, the wound was neglected and in a bad condition, urine escaping through the opening in the urethra and the right testis protruding. The man improved from the first, and the wounds healed, with atrophy of the testis." This soldier was discharged from service December 22, 1862. Examiner C. Hodge, jr., of Trenton, reported, October 27, 1873: "Ball entered the left hip immediately in front of the joint, passing downward and inward through the thigh, entered the scrotum, destroying both testes, then entered the right thigh on the inner side, and made its exit from the posterior surface of the thigh. He is not able to work at all. Disability total and, to a degree, permanent."

The rarity of any notice, in the reports, of the early symptoms attending shot wounds of the urethra, must be regretted. It is impracticable to determine definitely in what

<sup>1</sup> In considering the treatment of shot wounds of the bladder, it has been seen that unanimity of opinion regarding the uniform necessity of maintaining a catheter permanently no longer prevailed. Similar doubts as to the expediency of the continued employment of the catheter in lacerations of the urethra have emanated from high authorities. The opinions of DUPUYTREN and of SOUIN have been already cited (p. 352, *note*). PROGGER (*Grundzüge der Allgemeinen Chirurgie*, 1864, S. 614) enquires: "In traumatic ruptures of the urethra, should the catheter be introduced immediately? I am not in favor of it, even in cases of retention. \* \* I make deep incisions through the infiltrated integument and subjacent cellular tissue. If a rupture of the bulbous part is detected, I split the scrotum in the raphe, separate the two testes and lay open the ruptured part." BECK (*Chirurgie der Schussverletzungen*, 1872, S. 566) says: "By the introduction of a catheter the surgeon should convince himself whether the urethra is permeable or not. If permeable, allow the pewter or rubber catheter to remain for a short time; if impermeable, make an incision in the median line of the perineum, search for the wounded urethra, and introduce the catheter. An incision should not be feared, but the catheter should be used with the greatest caution."

proportion of cases retention of urine occurred early, and the supervention of other primary complications are seldom mentioned. It would appear, from the silence of the reporters on the point, that primary hæmorrhage to any troublesome extent was unusual. There were several instances, however, in which this accident was recorded:

CASE 1029.—Corporal J. Snodgrass, Co. G, 14th West Virginia, aged 32 years, was wounded at Halls town, August 26, 1864. He was admitted into hospital at Frederick, and Acting Assistant Surgeon J. H. Bartholf reported: "Shot passed through the buttock, taking the urethra in its course, from which he had profuse hæmorrhage at the time, and recurring at intervals during three days. He was admitted here on September 14th, and was then in very good condition; the scrotum was ecchymosed; there was no passage of urine through the wound at any time, and, apparently, there had been no infiltration of urine. He recovered rapidly, walking about by September 25th, and was furloughed October 3d. at which time the wound was healed." He was readmitted, and was transferred to Mower Hospital November 17th, and thence sent to duty on the 28th. He was discharged June 27, 1865, and pensioned. Examiner S. A. Walker, of West Union, reported, June 1, 1863: "Ball entered right thigh, through head of adductor longus, passed through the perineum, rupturing the urethra, and out a little below the left tuber ischium; for awhile urine passed through the wound: his back is so weak that he cannot work; disability total and permanent." Examiner E. D. Safford reported, February 15, 1869, that \* \* "he is a constant sufferer from vesical irritation." Dr. M. S. Hall certifies, August 6, 1869: "The ball entered the right groin, or a little below it, and passed upward, backward, and transversely, so that it came out a little back of the left trochanter; in its course it passed near the neck of the bladder, partly cutting off the urethra and some of its blood-vessels. I think the pudic artery must have been cut. He passed his water, for the first three days, from the opening made by the ball—this is his statement to me. But the effects of this wound at the present time are: Great irritation of the neck of the bladder, producing severe incontinence of urine; great pain in the back and perineum, so that if he rides on horseback, or walks, or stands on his feet, it is aggravated to great suffering; and inability to labor. Since he has been wounded he has constantly had rheumatism of the back (lumbago), to such an extent at times that he is helpless. This is often his condition when it is cold and damp. Last June he had an abscess in the gluteal region of the left hip, and I was of the opinion that it was from the effects of the wound. \* \* Disability total." This pensioner was paid September 4, 1873.

CASE 1030.—Private J. L. Williams, Co. D, 96th Pennsylvania, aged 35 years, was wounded at Chancellorsville, May 3, 1863, and admitted into Mount Pleasant Hospital on the 8th. Assistant Surgeon C. A. McCall, U. S. A., reported a "gunshot wound of the penis and scrotum, the ball laying open the urethra two inches in front of the external meatus, passing out below, and entered the left groin below Poupart's ligament, making its final exit to the left of the coccyx. On May 15th and 16th, hæmorrhage occurred from the artery of the corpus cavernosum to the amount of two ounces, and was arrested by pressure upon the artery." He recovered, and was transferred to Philadelphia on June 2d, and admitted into McClellan Hospital,<sup>1</sup> whence he was finally discharged the service. On the certificate of disability Acting Assistant Surgeon J. G. Murphy states: "A shot wound of the penis, scrotum, and back, the ball passing in at the centre of the glans just above the urethra, and out one inch beyond, entered the scrotum, and, after running around the pelvis, at last emerged an inch above the anus. He has also incontinence of urine." Examiner J. G. Kochler, of Schuylkill Haven, reported, September 12, 1863: "Ball entered at the glans penis, passed through a portion of the urethra, lacerating it, through the scrotum, and then through the muscles of the lower part of the abdomen, making its exit at the upper part of the sacrum. At present, there is partial ankylosis of the knee-joint and stiffness of the leg at the groin; pain over the lower spine; incontinence of urine, and total inability to labor. The disability is rated total and permanent." This pensioner was paid June 4, 1871.

Another instance of primary hæmorrhage after a shot wound of the urethra, will be found with the instances of urinary fistula of the penile portion of the urethra.

It is hardly necessary to call attention to the frequent association of injuries of the urethra and of the testes:

CASE 1031.—Private H. S. W——, Co. B, 29th Iowa, aged 25 years, was wounded at Jenkins Ferry, Arkansas, April 30, 1864. Surgeon S. H. Sawyer, 36th Iowa, reported that this soldier "received a gunshot wound of the penis and scrotum, and fell into the hands of the enemy." Assistant Surgeon W. L. Nicholson, 29th Iowa, who appears to have remained with the captured wounded, makes a similar entry on the register of the Camden Hospital, Arkansas, June 28, 1864, adding, "still in hospital in the hands of the enemy." On March 1, 1865, the patient was sent to the Marine Hospital, New Orleans, from Camp Distribution, a depot for exchanged soldiers. Surgeon J. Booke, U. S. V., reported a "shot wound involving the penis and testes." This soldier was discharged May 26, 1865, and pensioned. Examiner J. N. Penn, of Des Moines, reported, June, 1866: "A ball passed through the penis and destroyed the right testicle, entered the groin, passed through the right thigh, injuring the muscles and the periosteum of the femur." Examiner J. W. Martin, of Red Oak, reported, September 4, 1873: "Gunshot wound of right thigh and testicle; the ball passed through the back part of the thigh, carried away the right testicle, and cut through the penis an inch and a half back of the glans. The wound in the thigh weakens it and interferes with free motion; the scrotal cicatrix is tender; there is tenderness also in the track of the spermatic cord. The injury to the penis contracts the urethra, producing stricture, so that he suffers extremely in micturition. His general health is sensibly affected, and his sufferings are severe; disability one-half." This pensioner was paid September 4, 1873.

<sup>1</sup> Acting Assistant Surgeon I. NORRIS, jr., has reported this case from McClellan Hospital (*Am. Jour. Med. Sci.*, 1864, Vol. XLVII, p. 281), stating that "a urinary fistula existed for some time, \* \* which, however, finally closed."



So little information regarding stricture resulting from shot wounds is recorded, even by writers treating specially of traumatic lesions of the urethra,<sup>1</sup> that it is of interest to notice all the instances reported during the war, however scanty may be the details ascertained.<sup>2</sup>

CASE 1032.—Private G. H. Shæffer, Co. G, 115th Pennsylvania, aged 25 years, wounded at Spottsylvania, May 12, 1864, was admitted into Washington Hall Hospital, Alexandria, on the 25th. Surgeon T. Rush Spencer, U. S. V., reported "gunshot wound of the testicles by a conoidal ball." The patient was furloughed on June 6th, and, on July 2d, was received into Filbert Street Hospital, Philadelphia, convalescent, whence he was returned to duty July 10th. He was discharged July 27, 1864, and was pensioned March 31, 1871. Dr. A. G. B. Hinkle, of Philadelphia, certified, March 16, 1872, that he had "removed a minié ball from the scrotum of this invalid, June 19, 1861." Examiner E. A. Smith reported, April 3, 1872: "The ball struck the penis about the middle, and, passing downward, was extracted from between the testes. He now suffers from stricture of the urethra, painful erections, etc. The disability has not increased on account of wounds, but the applicant is suffering from phthisis pulmonalis in its second stage, as shown by general emaciation. He formerly weighed 159 pounds. He has hæmorrhage night-sweats, prostration, cough, etc., and there is a cavity in the left lung; and it would appear as if a recent general deposit of tubercle had taken place. He is unable to entirely wait upon himself, and has done no work since December, 1871, having been confined to his room. Disability total." This pensioner was paid September 4, 1873.

CASE 1033.—Private G. E. Douglass, Co. E, 157th New York, aged 29 years, was wounded at Chancellorsville, May 3, 1863, and was sent to Washington to St. Aloysius Hospital. He was transferred, October 17th, to Harewood Hospital. Acting Assistant Surgeon C. F. Trautmann reported from Harewood: "A minié ball entered near the left os pubis, and, passing directly backward, wounding in its course the urethra, made its exit through the right buttock about an inch and a half from the anus. When admitted the wound was healed, but the patient had difficulty in voiding urine, and was not able to walk any distance without causing inflammation of the parts injured." He was discharged for gunshot wound of the urethra, disability three-fourths, and was pensioned. Examiner B. Smith, Washington, reported, December 28, 1863: "Ball entered the root of the penis to the left of the symphysis pubis, and passed through the pelvis, wounding the urethra. Catheterism was rendered necessary for about four months; some constriction of the canal remains, as he frequently has dysuria, and dull pains through the pelvis. A stricture may ultimately result from the injury and entitle him to an increased pension." On March 12, 1866, Examiner H. C. Gazlay reported: \* \* "The wound has healed externally, but abscesses gather and break as often as once in six weeks, discharging bloody matter from the urethra, accompanied by severe pains. This pensioner has also soreness and tenderness of the left testis, and much pain, at times, extending along the spermatic cord to the abdomen; also heat and swelling of the testis during each occasion of the formation of pus. At these times micturition is difficult and painful." Examiner J. W. Lawrence, September 30, 1869, states that the bulb of the urethra and the prostate gland were wounded, and that there is constant and increasing inflammation in the prostate, which will suppurate and then discharge every month or two, but is never entirely well. The last report of this case is from Examiner C. H. Evans, and is dated September 11, 1873: "The wounded man is unable to assume a standing position for a long time without severe pain in the urethra. He has an occasional attack of retention of urine and is obliged to use the catheter. His urine frequently contains pus."

CASE 1034.—Private L. W. Bailey, Co. K, 38th Massachusetts, aged 27 years, was wounded at Opequan, September 19, 1864. Surgeon E. T. Hoffman, 90th New York, reported that "a minié ball struck the hip and severely lacerated the urethra." Surgeon S. P. Wagner, 114th New York, reported that this patient was transferred from the Nineteenth Corps Depot Hospital to Frederick, October 12th. Assistant Surgeon R. F. Weir, U. S. A., recorded the patient's admission at that date, with a "shot perforation from the left buttock to the right groin, involving the urethra, and resulting in traumatic stricture. The urethra was fully dilated, and the wound healed, April 27, 1865, and the soldier was returned to his regiment," and discharged June 27, 1865.<sup>3</sup> No record of application for pension, December 4, 1873.

CASE 1035.—Private J. B. Milner, Co. C, 17th Indiana, aged 26 years, was wounded at Selma, April 7, 1865; was admitted into Kennedy Hospital, Mobile, with a "gunshot wound of the abdomen," on May 4th. He was transferred to hospital at Mound City, May 21st. Surgeon H. Wardner, U. S. V., noted: "Wound of pelvis, ball entering at the left crus penis, passing obliquely back and to the right, severing the urethra, then, grazing the tuberosity of the ischium, it emerged in the right posterior gluteal region. When he was admitted the wound was healed." This patient was sent to Madison and admitted into Hospital No. 3, June 9th, and registered as having received a "gunshot wound of the abdomen and perineum." He was returned to duty July 17, 1865. It does not appear that he has applied for a pension.

<sup>1</sup> Thus, Dr. C. PHILLIPS, the fourth chapter of whose *Traité des maladies des voies urinaires*, Paris, 1860, p. 226, treats *Des lésions traumatiques de l'urèthre*, alludes to shot lacerations only by saying that DUPUYTREN (*Leçons orales*, 2e éd., 1833, T. VI, p. 514) "has given one example of partial destruction of the urethra by a projectile." FRANC (J.) (*Observations sur les lésions de l'urèthre par cause traumatique*, Paris, 1840), BEANEY (J. G.) (*Traumatic Stricture of the Urethra*, Chapt. VIII, of *Orig. Contrib. to the Pract. of Operat. Surgery*, Melbourne, 1859, p. 77), and VOLLEMIER (*Lésions traumatiques de l'urèthre*, Chap. X, de sa *Traité des mal. des voies urinaires*, 1868, p. 461) almost equally ignore traumatism from shot.

<sup>2</sup> A few instances of shot wounds of the urethra are detailed in various reports from the Franco-German War of 1870. Thus, SCHÜLLER (M.) (*Kriegschir. Skizzen aus dem deutsch-französischen Kriege 1870-71*, Hannover, 1871, S. 32) remarks: "A small shot wound of the fleshy parts, across the perineum, just the root of the penis, healed with a urethral fistula." BECK (B.) (*Chir. der Schussverletzungen*, 1872, S. 566) cites two cases of shot wounds of the urethra, in which urinary fistulae remained for a long time, but no external urethrotomy was not considered necessary. BERTHOLD (E.) (*Statistik der durch den Feldzug, 1870-71, invalide gewordenen Mannschaften des 10 Armee-Corps*, in *Deutsche Militärärztliche Zeitschr.*, Jahrg., I, S. 466) mentions two cases of wounds of the urethra. In one of the latter the urinary fistula in the urethra remained open nearly a year; a stricture remained which would not admit of the finest catheter; only by strong muscular effort a very fine jet of urine escaped. LOSSEN (H.) (*Kriegschir. Erf. aus den Barackenzazarethen zu Muenheim, Heidelberg und Karlsruhe, 1870 und 1871*, in *Deutsche Zeitschrift für Chir.*, 1873, B. II, S. 20) cites three cases of shot wounds of the urethra.

<sup>3</sup> Adjutant General's Report of Massachusetts for 1864-5, Vol. II, p. 808.

There were a few instances in which the existence of shot laceration of the urethra<sup>1</sup> was incontestably demonstrated, and yet complete reparation was reported to have taken place at an early period.<sup>2</sup> It may be questioned, however, if the results would appear as satisfactory could the ulterior histories of these cases be traced:

CASE 1036.—Private *A. B.*——, a Confederate soldier, aged 18 years, was wounded at Pea Ridge, March 10, 1862. Surgeon W. C. Otterson, U. S. V., reports that “a round musket ball entered the perineum midway between the scrotum and the anus, and passed forward and upward, dividing the urethra, and coming out above the symphysis pubis. Urine passed by the wounds for five days, and afterward by the urethra, and in three weeks the wound was almost healed.”

CASE 1037.—Private *S. C. Jarvis*, Co. C, 5th Kentucky Cavalry, aged 25 years, was wounded at Shiloh, April 6, 1862, and was admitted into City Hospital, St. Louis, April 19th. Surgeon J. F. Hodgen, U. S. V., reported: “Wounded by a pistol ball, which struck the root of the penis, passing in an outward and downward direction, coming out behind the trochanter of the right leg. When admitted, he was in good condition; appetite fair; bowels regular; much pain in the wound; scrotum and penis swollen, and urine passed from the wound at the root of the penis. The wound was cleansed and wet cloths applied. April 25th: Wound in the same condition; urine passing from the wound, causing much pain; urethra examined with a probe and found partially closed with granulations. A small catheter was applied, and from this date the wounds were dressed with a solution of tannin into which fresh lint was dropped, and applied to the wound every hour. Iron and quinine were given internally. June 2d: Wound entirely closed since middle of May; penis somewhat swollen.” This prisoner-of-war was sent to the Provost Marshal August 20, 1862.

CASE 1038.—Private *M. O.*——, Co. D, 17th Illinois, aged 24 years, was wounded at Shiloh, April 6, 1862, and received treatment in hospital at Savannah, and, subsequently, at Quincy, Illinois, where Surgeon R. Nicholls, U. S. V., reported: “Gunshot wound; the ball entered two inches in front and half an inch above the left trochanter major, traversed both thighs, and, dividing the urethra in its course, made its exit one inch behind the right trochanter major. September 12th: Wound healed, but he complains of pain at the origin of the right adductor muscles, and is unable fully to straighten the right thigh. The left thigh is painful when fully flexed, but has improved in this respect considerably.” He was discharged the service September 22, 1862. It does not appear that he ever applied for a pension.

CASE 1039.—Private *A. Drake*, Co. A, 77th New York, was wounded at Antietam, September 17, 1862. He was sent to Satterlee Hospital. Acting Assistant Surgeon N. Hickman and W. F. Atlee made the following report: “He was admitted into this hospital on September 26th, suffering from a wound produced by a minié ball, which penetrated the right natis near the tuberosity of the ischium, and, passing forward and inward, traversed the whole length of the perineum, cutting, in its course, the urethra at its membranous portion, and finally lodged in the epididymis of the right side, whence it was extracted, on October 5th, by an incision from below, extending upward. The patient stated that, immediately after he was wounded, he was sent to a temporary hospital, where he received no attention save the occasional introduction of a catheter into the bladder.<sup>3</sup> Upon his arrival at this hospital he was at once put in a horizontal position, and a metallic catheter was inserted into the bladder and allowed to remain about a fortnight, when it was found that the urine flowed naturally through the urethra. The wound, of course, was dressed by the usual mode. About a week subsequently, a severe inflammation set up in the testes and scrotum, which was combated by the constant application of cloths wet with ice-water. All the concomitant symptoms, such as pain, want of sleep, costiveness, etc., were relieved by the usual remedies. On October 25th, the left testis was diminishing in bulk, and the patient’s urine continued to drop from him; he received no treatment. On the 30th, two drops of tincture of nuxvomica were ordered three times a day. A catheter was introduced into the bladder without difficulty on December 2d, and by the 4th both wounds were healing; there was considerable atrophy of the left testis, and incontinence of urine when he made any effort, but he retains it when at rest. He had pain in his testicles when he walked, and also when voiding his urine; his health was good. On December 8th, this patient left the hospital without permission and enlisted in the 2d Cavalry.” He has never applied for a pension.

CASE 1040.—Private *A. Morrison*, Co. H, 61st Alabama, was wounded and captured at Smithfield, August 29, 1864. At West’s Buildings, Baltimore, Surgeon A. Chapel, U. S. V., reported “a slight gunshot wound of the urethra.” This soldier was transferred, cured, to Fort McHenry for exchange, November 19, 1864.

CASE 1041.—Corporal *C. R. Jackson*, Co. B, 6th Kansas Cavalry, was wounded at Mazzard’s Prairie, July 27, 1864. Surgeon J. S. Redfield, of his regiment, reported a “shot wound of the pelvis,” and the patient’s transfer to Fort Smith, where Surgeon C. E. Swasey, U. S. V., recorded “a gunshot wound of the left thigh and scrotum.” This soldier was discharged November 18, 1864. In applying for pension he attested, under oath, that “a ball entered the left buttock and passed under the pubes, coming out near the end of the penis, destroying the urethra,” a statement substantially corroborated by the company commander.

<sup>1</sup> NFALE (H. ST. J.) (*Chirurgical Institutes*, 1805, p. 218) must have met with numerous examples of wounds of the urethra during the War of the American Revolution. He says: “If the end of the penis has been shot off, we must put a cannula into the beginning of the urinary canal, of a convenient length and thickness to prevent not only the orifice from being contracted in its diameter, but also to hinder it shrinking up and concealing itself amidst the fleshy parts, as I have seen happen, in three instances, during the campaigns in America.”

<sup>2</sup> BECK (B.) (*Chir. der Schussverletzungen*, 1872, S. 565): “In wounds of the penile portion of the urethra, where there is neither infiltration nor involuntary escape of urine, it depends on the extent of the injury whether a complete cure is possible, or whether a fistula remains. Repeatedly I have noticed complete recoveries.”

<sup>3</sup> The editor, seeking, as far as practicable, to give the hospital reports textually, does not exclude passages of criticism, even when obviously unjust. In the case under consideration, one might enquire, if the field surgeons were so skilful or fortunate as to introduce a catheter through a ruptured urethra, what further “attention” in the way of primary treatment was demanded?



In other instances, like the following, of alleged speedy recovery after shot wound of the urethra, it is not clear that the canal was in reality lacerated. As Herr Beck observes,<sup>1</sup> the urethra is endowed with a resiliency analogous to that of the arteries, and may escape serious injury though lying in the apparent course of a ball:

CASE 1042.—Private *J. Jones*, Co. F, 6th Alabama, aged 22 years, was wounded at Fisher's Hill, September 25, 1864, and captured. Surgeon *W. A. Barry*, 98th Pennsylvania, reported "a wound in the testicles by a minié ball." Surgeon *A. Chapel*, U. S. A., reported that this patient was admitted to West's Buildings Hospital, October 13th, with a "gunshot wound of the scrotum and urethra, involving the loss of the left testis. The wounds healed kindly, and the soldier was transferred for exchange, cured, to Fort McHenry, December 9, 1864."

An example of a traumatic stricture consequent on a sabre wound will be recorded under the head of Urethroraphy; and other instances, resulting from other causes than shot wounds, will be noted in subsequent subdivisions. Many illustrations of traumatic stricture from shot wounds will appear in the following subsections, and general observations on the treatment and results of this affection will be deferred until after the presentation of these cases:

*Urethral Fistules*.—A large number of shot lacerations resulted in fistules that were distinguished as penile, scrotal, perineal, or rectal-urinary fistulæ, according to the point of outlet. The urethro-rectal fistules were the rarest, those of the penile portion of the urethra the most intractable. In connection with urethral fistules resulting from other causes than shot injury, there will be occasion to revert to this topic and to refer to their treatment under the heads of Dilatation, Cauterization, Urethrotomy, Urethroraphy, and Urethroplasty. The causes favorable to the formation of fistules after shot lacerations of the urethra are, in the first place, extensive loss of substance of the entire canal, of which this complication is perhaps an inevitable consequence; secondly, partial loss of substance with urinary infiltration; thirdly, ulceration, promoted sometimes by the injudiciously protracted maintenance of an instrument in the urethra; fourthly, the lodgement of foreign bodies; fifthly, the obstruction of the canal anteriorly to the wound by traumatic stricture. There is commonly little trouble in the diagnosis of such fistules. Escape of urine demonstrates their presence, and a probe introduced through the fistulous track reveals its extent and direction; and, if a sound can be carried through the urethra and brought in contact with the probe, the relations of the artificial canal are readily recognized. There is usually but one opening into the urethra, but the cutaneous outlet of the fistule is frequently multiple. Numerous and varied examples were reported.

CASE 1043.—Private *H. Siegfried*, Co. L, 7th Pennsylvania Cavalry, aged 33 years, was wounded at Dallas, May 26, 1864, and was treated in a cavalry corps field hospital for a "gunshot wound of the hip, scrotum, and penis," and, on June 7th, was sent to Chattanooga, and thence transferred to Hospital No. 19, Nashville, June 18th, returned to duty December 3, 1864, and discharged May 6, 1865, and pensioned. Examiners *W. Blackwood* and *W. R. Grove*, of Lancaster, reported, September 24, 1873: "The ball entered the right natis and passed out two inches below the groin, wounding the penis. There is an opening near the glans penis, through which the urine escapes; also paralysis of the foot. Disability total and permanent." This pensioner was paid June 4, 1873.

CASE 1044.—Private *C. H. Terry*, Co. A, 12th New Jersey, aged 29 years, was wounded at Petersburg, June 16, 1864. He was treated in a field hospital of the Second Corps, and, on the 26th, was admitted to Lovell Hospital, Portsmouth Grove, with a "gunshot wound of the scrotum," and, on October 4th, was transferred to Ward Hospital, Newark, and thence returned to duty January 26, 1865. He was discharged June 23, 1865, and pensioned. Examiner *Q. Gibbon*, of Salem, reported, July 15, 1865: \* \* \* "Fistulous opening of the urethra above, through which the urine passes in micturition; pain in the lower pelvis upon active exertion." Examiners *J. B. Coleman*, *C. Hodge, jr.*, and *W. W. L. Phillips*, of Trenton, certified, September 6, 1873: "Musket ball passed through the lower part of the penis behind the glans, then through the middle line of the scrotum below the spermatic cord, and finally tore through the groin, lacerating it severely; disability total." This pensioner was paid September 4, 1873.

<sup>1</sup> BECK (B.) (*Chir. der Schussverletzungen*, 1872, S. 565) remarks: "Although the urethra, on account of its elasticity, frequently eludes projectiles, solutions of its continuity occur by seton and furrowed shot wounds."

Like other shot wounds of the genital organs, many of those interesting the urethra were complicated, as in the following fortunate examples of fistules consequent on shot wounds of the pendulous portion of the urethra, and associated with injuries of the femur:

CASE 1045.—Private T. B. Blunden, Co. H, 157th New York, aged 40 years, was wounded near Savannah, December 6, 1864. He was sent to Hilton Head on the 12th with a "gunshot wound of the penis and flesh wound of the thigh," and treated until February 26th, when he was granted leave of absence for a month, to report for duty at the expiration of his furlough. He was discharged December 27, 1865, and pensioned. Examiner H. C. Gazlay, of Cortland, reported, October 6, 1866: "Ball pierced the lower portion of the glans penis, carrying away a portion of the urethra, and injuring the femur, so that an artificial passage is left near the orifice. The ball then entered the inner hamstring of the right thigh, striking the femur, and making its exit at the right natis. Three pieces of bone were discharged, and the sinus is now healed; two or three buckshot passed through the scrotum, injuring the right testis, which is swollen and painful. He has constant pain during micturition. The muscles of the right hip and thigh are sore and painful, so that he walks with difficulty; any motion of the limb causes pain; disability total." This pensioner was paid September 4, 1873.

CASE 1046.—Private M. M. P——, Co. K, 100th Indiana, aged 23 years, was wounded at Bentonville, March 22, 1865. He was treated at New Berne for a "gunshot wound of the penis and scrotum," and transferred to De Camp Hospital, April 27th. The hospital record is as follows: "Gunshot wound of the penis, scrotum, and left thigh. The prepuce and glans penis were perforated, and a fistulous opening into the urethra remains. On May 18, 1865, Acting Assistant Surgeon H. Sanders circumcised the prepuce, the patient taking chloroform. The man was discharged July 26, 1865, and pensioned." Examiner D. W. Hinson, August 22, 1866, reported: "Ball entered the penis, passing through, and, playing havoc with the left testicle, fractured the left femur.[?] The muscles are, of course, contracted. His disability is one-half and permanent." Examiner J. Colby reported, September 16, 1873: "The ball entered the dorsum of the glans penis and passed out on the posterior surface one and a half inches above the glans, cutting the urethra, which has not united, passed through the left thigh close to the body, entering the front and inner side, and out at the lower part of the left natis. Manual labor produces pain in the leg and hip, and soon wearies the leg; disability one-half."

The variety of fistula with several external orifices, rarer in the penile than in the perineal portion of the urethra, is exemplified by the following case:

CASE 1047.—Private W. T——, Co. B, 28th Massachusetts, was wounded at Gettysburg, July 3, 1863. No record of the treatment of this case is found prior to the patient's admission into St. Paul's Hospital, Alexandria, May 13, 1864, where he was discharged July 1, 1864. In the certificate of disability, June 21, 1864, Surgeon T. R. Spencer, U. S. V., describes a "mutilation of the penis by gunshot, followed by urethral fistula and incontinence of urine." Examiner G. S. Jones, of Boston, reported, September 12, 1866: " \* \* "Fistulous openings now exist in the wounded parts, through which urine is ejected; the parts are in a bad condition." Examiners J. B. Treadwell, H. Chase, and H. Doherty reported, September 4, 1873, when this pensioner was paid: " \* \* "The urine passes altogether from the openings caused by the wound, and not through the natural passage. \* \* Disability total."

The following appears to have been an instance of fistula of the pendulous portion of the urethra; but the later history is wanting:

CASE 1048.—Private I. L——, Co. A, 17th Infantry, aged 19 years, was wounded at Gettysburg, July 3, 1863. At Seminary Hospital, on the same day, the injury was noted as a gunshot wound of the scrotum. At Camp Letterman, July 29th, Surgeon H. James, U. S. V., reported: "Gunshot wound of the glans penis; the ball severed the left spermatic cord and made its exit at the upper third of the right thigh." Acting Assistant Surgeon J. K. Shivers reported: "August 31st: This patient has required no treatment since he has been under my charge. The urine at times flows through the orifice, but as a general thing he draws it off by means of a catheter. He had a slight diarrhoea upon one occasion, which was relieved by the administration of a pill of opium and camphor, since which time he has been doing well. On September 2d, he was ordered a wash of subacetate of lead and tincture of opium." On September 4th, he was admitted into Sixteenth and Filbert Streets Hospital, and was sent thence, on September 12th, to Fort Columbus, and discharged on the expiration of his term of enlistment. He has not applied for a pension.

The methods employed, if any, to close penile fistules, were seldom described in detail. In CASE 1051, cauterization and stitches were employed, and several examples of more methodical plastic procedures are mentioned further on. The essential prerequisite of removing all obstructions in the canal anterior to the fistulous opening, appears to have been duly appreciated:

CASE 1049.—Private M. Keating, Co. D, 42d Pennsylvania, aged 33 years, was wounded at Bull Run, August 30, 1862. He was treated in hospitals at Washington, Baltimore, Point Lookout, and Philadelphia, entering Mower Hospital on October 1, 1863, and being discharged the service therefrom, June 21, 1864. Surgeon J. Hopkinson, U. S. V., on certificate of disability dated June 14, 1864, stated: "Necrosis of pubis, and urethral fistula, from gunshot wound." Disability one-third. Examining Surgeon H. L. Hodge, of Philadelphia, reported, June 21, 1864: "On account of gunshot wound of the pelvis his general health had been much impaired. The anterior wound still remains open, and urine passes through it continually; disability total." There is no record of this man since September 4, 1865, when he last drew his pension.



Were it feasible, it would be desirable that the many invalids with fistules of the penile portion of the urethra should be assembled under the care of an adept in plastic surgery. Such cases as the following might admit of relief by operations judiciously planned and skilfully executed, and, if necessary, perseveringly repeated:

CASE 1050.—Private C. H. Van Epps, Co. C, 26th Iowa, aged 30 years, was wounded at Chattanooga, November 27, 1863. After having received treatment in hospital at Bridgeport, and afterward at Nashville, this soldier was transferred to the Veteran Reserve Corps, February 4, 1864. On February 24, 1866, Examiner A. B. Ireland, of Comanche, Iowa, reported: "The ball passed through the groin, penis, and thigh. The wound in the groin and thigh have healed, but the natural orifice of the penis is, I think, permanently closed, so that the urine passes out about half way up the side of the penis, through a very small orifice, almost drop by drop, or in a very small stream, the pensioner requiring about ten minutes to urinate." On September 4, 1873, when this invalid was paid, Dr. Ireland added that "the wounds of the side and thigh give but little trouble; urine still discharges from the wound half way up the side of the penis, through two orifices now instead of one; disability three-fourths."

CASE 1051.—Private C. H——, Co. I, 35th Illinois, aged 24 years, was wounded at Chickamauga, September 19, 1863. He was treated in hospitals at Nashville, Evansville, and Quincy, having been admitted into the latter on December 26th. Acting Assistant Surgeon I. T. Wilson reported: "A minic ball passed through the left side of the scrotum and body of the penis, entering the latter about an inch and a half behind the glans, passing through the inferior portion of the glans. The wound healed, leaving an opening at least half an inch into the urethra, and the glans to some extent were bound down to the prepuce below by attachment to it. The urine was voided by the use of the catheter during the process of healing, and can be forced through the natural passage when closing the artificial orifice with the finger. Attempts have been made to close up this orifice—first by cauterization, and then by stitches, both proving ineffectual; the stitches having broken out in a few hours by an erection of the organ." The wounded man was returned to duty March 11, 1864, and, on the 23d, was admitted into Lawson Hospital, St. Louis; thence he was transferred to Jefferson Barracks, and again admitted into hospital at Quincy on July 9th. Dr. Wilson further noted that "the wounds are healed, but an orifice is left on the under side of the penis, communicating with the urethra." This soldier was mustered out September 3, 1864. He is not a pensioner.

The great difficulty in closing wounds of the urethra with less of substance, when situated in the penile portion of the canal, already adverted to, is further exemplified in the following cases, and under the head of Urethroplasty:

CASE 1052.—Captain O. M. F——, Co. B, 60th New York, was wounded at Atlanta, August 1, 1864, and was treated in a Twentieth Corps hospital, where Surgeon H. E. Goodman, U. S. V., recorded a "gunshot wound of the left hand and flesh wound of the testicle." At the Officers' Hospital, Nashville, and the Grant Hospital, Cincinnati, the case was registered as a "gunshot wound of the penis and of the left hand." This officer was discharged the service November 29, 1864, and pensioned. Examiner C. H. Bates, of Potsdam, reported, July 17, 1867: "Was wounded by a ball in the index finger, causing its amputation at the middle of the first phalanx. A ball also wounded the penis, opening the urethra just posterior to the corona glandis, and just to the right of the frænum. The opening is like a button-hole in shape, one-third of an inch in length, and allows the escape of half the urine during micturition. The ball also wounded the left testis, causing its immediate removal. General health good." Examiner S. F. Sherman, of Ogdensburg, reported, September 6, 1873: "Fistulous opening back of glans, through which urine and secretions pass; disability one-half." This officer's pension was paid to September 4, 1873.

CASE 1053.—Corporal T. Garvin, Co. H, 94th New York, aged 43 years, was wounded at Hatcher's Run, February 7, 1865, and was treated in a Fifth Corps hospital for "severe gunshot wound of the genitals," and transferred to Newton University Hospital, Baltimore, on the 11th, where the following was noted: "Gunshot wound of the penis, right testicle, and right thigh, the ball emerging from the gluteal region, lower parts, fracturing the femur." The wound was dressed with cold water, and the right lower extremity was placed in Buck's apparatus, and counter-extension was made by pulley and weights, with favorable results. The patient was removed to Jarvis Hospital May 25d. Assistant Surgeon D. C. Peters, U. S. A., recorded a "gunshot wound of the penis, right testicle, and right thigh, involving the femur," and stated on the certificate of disability, "gunshot wound of penis, right testicle, and upper third of femur; urine escapes through the lower opening of the penis; he has some union of limb, but about three inches shortening; disability total." This invalid was discharged June 11, 1865, and pensioned. Examiner Geo. W. Cook, of Syracuse, reported, April 25, 1866: "Bullet struck the glans penis, passing downward and backward through the urethra, producing hypospadias, through which the urine is voided; thence into the right thigh, fracturing the same. About four inches of the femur has been resected."(1) The attending physician, Dr. A. Welch, states, August 16, 1869, in an affidavit, that, to the time of his death, "Garvin was laboring under severe pain and difficulty from a wound which he received in the right hip, passing through the joint and through the testicle, destroying the hip-joint, producing a shortening of the limb and an open wound, from which pus and splinters of the bone and joint were discharging to the time of his death," January 3, 1869.

CASE 1054.—Private Ernest S——, Co. E, 2d New Jersey, aged 36 years, was wounded at South Mountain, September 13, 1862. Assistant Surgeon H. A. Dubois reported, from the hospital at Birkettsville: "A musket ball penetrated the penis, testis, and thigh. By the end of September the patient was convalescent." He was discharged from Ward Hospital, Newark, November 10, 1865, and pensioned. November 21, 1868, Examiner J. O. Sterns, of Elizabeth, reported: "A ball passed through the penis just back of the glans and destroyed the left testis. The hole through the body of the penis remains open and the urine passes involuntarily at the artificial orifice." The Trenton Examining Board, September 5, 1873, gives substantially the same statement as that of Dr. Sterns.

When a shot perforation of the urethra results in a fistula at the corona, or but a few lines posterior to it, and attempts to close the artificial opening fail, it may be proper to produce artificial epispadias or hypospadias by connecting the meatus and fistula by an incision.<sup>1</sup>

CASE 1055.—Private S. W. Simerl, Co. B, 21st Missouri, aged 27 years, was wounded at Pleasant Hill, Louisiana, April 9, 1864. He was sent from a hospital of the Sixteenth Corps on May 3d, on the steamer R. C. Wood, to Adams Hospital, Memphis. Surgeon J. G. Keenon, U. S. V., reported a "gunshot wound; ball entering the glans penis and passing through the scrotum and right thigh." This soldier was returned to duty September 20, 1864, and discharged and pensioned April 19, 1866. Examiners W. Jones and A. S. Long, of St. Joseph, reported, November 2, 1870: "Gunshot wound of the right testis and right thigh, the shot having passed through the glans and prepuce, causing deformity of the glans. The urethra remains open from the meatus to the posterior portion of the fossa navicularis. The missile passed through the right testis, which is atrophied and adheres to the scrotum, and entered the right thigh, passing through obliquely, and producing excessive muscular injury. There is a deep adherent cicatrix both at the entrance and exit of the shot, with partial contraction of the injured muscles, resulting in imperfect use of the right leg; disability total and permanent." Examiner G. R. Baldwin, of Fort Scott, September 8, 1873, writes that "the urethra is split open to the corona and its surfaces are inflamed. The scrotum becomes excoriated, in warm weather, at the seat of the cicatrix." This pensioner was paid September 4, 1873.

Fistules were ascribed, in some instances, to the prolonged use of sounds. The dangers to be apprehended from this cause, once underestimated, are now adequately appreciated. The cautions expressed by Dupuytren, and Drs. Pirogoff, Socin, and Beck, have been cited in the notes to pages 352 and 356. Dr. Gouley has, more recently, adduced illustrations of the ill effects of the protracted retention of catheters.<sup>2</sup>

CASE 1056.—Colonel Joshua L. C——, 20th Maine, was wounded at Petersburg, June 17, 1864, and taken to the hospital of the 1st division, Fifth Corps. Surgeon W. R. DeWitt, jr., U. S. V., reported that "a conoidal ball penetrated both hips, and was extracted," and that Surgeon M. N. Townsend, 41th New York, was detailed to accompany the patient to City Point, when, by direction of Surgeon E. B. Dalton, U. S. V., he was placed on the hospital transport Connecticut and conveyed to Annapolis, and promoted Brigadier-General of Volunteers and Brevet Major-General. Surgeon B. A. Vanderkief, U. S. V., reported that he "reached the hospital at that place very comfortably on June 20, 1864, with a shot wound involving both buttocks and the urethra." The progress and treatment does not appear on the hospital case-books, but in a letter to Surgeon J. H. Brinton, U. S. V., September 4, 1864, Dr. Vanderkief states: "I send you a catheter used by Brigadier-General J. L. C——, U. S. V. As you will perceive, it is covered by a calculeous deposit. This catheter was but five days in the bladder, and was repeatedly covered in the same way. I think it a very important specimen, illustrating the necessity of often renewing catheters when they are to be used *à demeure*. The history you shall get when the patient is discharged." The specimen referred to is accurately represented, of half-size in the wood-cut (FIG. 286). The patient was brought September 20, 1864, and mustered out January 15, 1866, and pensioned. The promised report of the case was not received. From Pension Examiner O. Mitchell's report, September 18, 1873, it appears that "the ball entered the right hip in front of and a little below the right trochanter major, passed diagonally backward, and made exit above and posteriorly to the left great trochanter. The bladder was involved in the wound at some portion, as the subsequent history of escape of urine from the track of the wound and its extravasation testified. He very often suffers severe pain in the pelvic region. The chief disability resulting indirectly from the wound is the existence of a fistulous opening of the urethra, half an inch or more in length, just anterior to the scrotum; this often becomes inflamed. The greater part of the urine is voided through the fistula, the fistula itself resulting from the too long or too continuous wearing of a catheter. No change has resulted since the last examination; disability total." This invalid was paid to June 4, 1873, at \$30 a month.




FIG. 286.—Catheter encrusted by phosphates. Spec. 2512.  $\frac{1}{2}$ .

CASE 1057.—Private A. Longley, Co. E, 19th Maine, aged 17 years, was wounded at Petersburg, November 27, 1864. He was treated in hospitals on the field, at City Point, Washington, and Augusta, where he was admitted to Clay Hospital on April 3, 1865, and thence discharged the service May 15, 1865, for "gunshot wound of the left thigh, fracturing the bone, and involving the scrotum and glans penis; disability one-half." Examiner C. W. Snow, of Skowhegan, reported, September 24, 1866: "Ball passed through the thigh, grazed the scrotum, and passed through the penis, cutting off the urethra about half an inch back of the glans penis. The urine is discharged at the openings on either side of the penis, a small part only escaping at the natural channel." The same surgeon reports, February 5, 1873: "As the result of wearing a catheter too long after receiving the wound, the urethra burst near the root of the penis. It has a sac-like enlargement there, from which the urine does not discharge without pressure. A small quantity remaining creates irritation, and has produced a discharge resembling catarrh of the bladder. The trouble is on the increase; disability three-fourths." This pensioner was paid June 4, 1873.

<sup>1</sup> NEUDÖRFER (J.) (*Handb. der Chir.*, 1867, 8, 816) relates a case in point: "F. Krump, 27th Austrian Infantry, was wounded at Oversee, in 1859. The ball passed through the thigh and penis, dividing the urethra immediately behind the glans." Herr NEUDÖRFER split up the urethra between the meatus and the fistula, "transferring the man into an hypospadias, but obtaining a notable amendment in the stream of urine."

<sup>2</sup> GOULEY (J. W. S.), *Diseases of the Urinary Organs*, New York, 1873, p. 128.



The following complicated case of penile urethral fistula offers several interesting features, among which the immediate retention of urine and early hæmatocele are noticeable:

CASE 1058.—Private W. E. Vandermark, Co. I, 120th New York, was wounded at Chancellorsville, May 3, 1863, and was treated in a Second Corps field hospital until the 9th, when he was admitted into Armory Square Hospital. Surgeon J. H. Brinton, U. S. V., noted as follows: "The ball entered on the left buttock four inches behind the great trochanter, and passed up the penis from the base to the right portion of the corona glandis, where it emerged. There had been a collection of urine in the scrotum, which had been freely laid open. The urine passed by the meatus, by the wound of exit, and by the artificial opening in the scrotum. A catheter was used, and the wound did well." This patient was transferred to New York Harbor, October 29th, and returned to duty December 8th, but was soon sent to Convalescent Camp, and thence to Campbell Hospital, Washington, February 9, 1864, and registered as a case of "gunshot wound of the penis and scrotum." He was transferred to the Veteran Reserve Corps in March, and was finally discharged November 15, 1865, and pensioned. The following special report of this case was made, on June 13, 1871, by Dr. H. W. Sawtelle: "He was wounded by a conoidal ball and buckshot, which struck the left gluteal region three and a half inches posterior to the trochanter major, and, passing to the right and forward, emerged anteriorly through the genital organs, in four pieces—one from the right side of the penis, just behind the corona glandis, which was thought to have followed the course of the urethra; another through the left testis; and two through the body of the penis close to the scrotum. The scrotum soon became enormously distended with blood, which was evacuated on the field twenty-four hours after the injury. From the first the patient was unable to void the urine, and the use of a catheter produced such intense pain during each evacuation of the bladder that the administration of chloroform was necessary from May 4th to July 17, 1863. Two small pieces of bone discharged from the wound of the penis at the scrotum, through which opening the urine partially escaped for one year. I saw this man in March, 1871, and found the wounds healed, except the one at the cervix penis, where a small fistulous opening existed, through which urine escaped. The motions of the hip-joint were somewhat circumscribed, so that he walked with a slight limp; his general health was good. He had suffered continuous pain in the urethra and hip; it was much aggravated in damp weather, and micturition increased the pain in the urethra. The invalid stated that he had been obliged to suspend his business as a driver of a milk-wagon on account of the greatly increased pain and swelling it caused in the hip and wounded testis." Pension Examiner J. O. Stanton, of Washington, reported, May 15, 1872: "Ball entered the left natis and made its exit on the left side of the scrotum and right of the penis, cutting the urethra in its course. His disability is total." September 9, 1873, Examiner Stanton continues: "The left testis is now slightly swollen and tender. Urine still passes through the fistulous opening on the right side of the penis just behind the glans. Shot wound of the inner portion of the upper third of the right thigh; this wound does not disable him at present." This pensioner was paid on September 4, 1873.

The rarity and intractability of fistules of the pendulous portion of the urethra resulting from shot injury,<sup>1</sup> are sufficient reasons for presenting the details of the foregoing sixteen cases.

*Deep Urethral Fistules.*—In this group, examples will be presented of fistules resulting from shot injuries of the bulbous, membranous, and prostatic portions of the urethra, and designated scrotal or perineal fistules, according to the seat of the external orifices. Urethro-rectal fistules will be subsequently noticed. Deep urethral fistules resulting from organic lesions are much more common than fistules of the pendulous urethra; but this proportion is not maintained after shot injury:

CASE 1059.—Private L. P. Johnson, Co. C, 4th U. S. Colored Troops, was wounded at Neuse River, February 22, 1865, and was conveyed by the hospital steamer S. R. Spaulding to Baltimore, and admitted to McKim's Mansion Hospital, March 3d. Surgeon L. W. Reed, U. S. V., reported a "gunshot wound of the right natis, the ball passing in and perforating the urethra." He was discharged for disability on May 27, 1865. Examining Board of Surgeons S. S. Thorn and S. H. Bergen, of Toledo, Ohio, reported, September 4, 1873, that "the ball entered the perineum on the right side, wounding the membranous portion of the urethra, and produced an extensive and almost impassable stricture. A perineal fistula, communicating with the canal, exists, and he passes urine through both the fistula and the urethra; retention of urine frequently occurs. His general strength is greatly reduced, and his disability continues and is rated as total." This invalid received his pension June 4, 1873.

CASE 1060.—Private J. Dambach, Co. K, 32d Missouri, aged 38 years, was wounded at Resaca, May 14, 1864, and was treated on the field, and afterward in hospitals at Chattanooga, Nashville, and Jeffersonville, for gunshot wound of the scrotum, and was discharged from service at the latter place, May 30, 1865, and pensioned, May, 1871. Board of Examiners Drs. J. C. Whitehall and F. G. Porter, of St. Louis, reported, May 1, 1872: "He has deep-seated urethro-perineal fistula, and loss of erectile power of the penis, with partial destruction of the left testis, and deformity of the scrotum, from the effects of a gunshot wound through the penis and scrotum, causing extensive laceration of both. The disability is no doubt permanent. There is constant dribbling of urine, which frequently produces excoriation of the parts, and in warm weather gives rise to an exceedingly offensive odor; disability total." The pensioner was paid to September 4, 1873.

<sup>1</sup>CHENE (J. C.) (*Rapport, etc., Camp d'Orient*, p. 205) records the case of Le Dain, 2<sup>e</sup> Zouaves, shell wound of scrotum, resulting in urinary fistula. In the report, *Campagne d'Italie*, 1859, T. II, pp. 519, 520, M. CHENE records four cases of shot wounds of the urethra: Desreumaux, 23<sup>e</sup>; Paulet, 49<sup>e</sup>; Verdet, 100<sup>e</sup>; Rossignol, 23<sup>e</sup> de ligne. The two former recovered with traumatic stricture; the two latter with fistules of the penile portion of the urethra.

In the first of the three following instances of perineal urethral fistula resulting from shot injury, a plastic operation, indefinitely described, was unavailingly performed. In the second case, the inference is that, after a long period, the fistula closed, at least temporarily. The details of the third case are very imperfect:

CASE 1061.—Private Jacob R——. Co. D, 8th Infantry, aged 27 years, was accidentally wounded, February 2, 1865, and immediately admitted into Chester Hospital. Surgeon Thomas Hewson Bache, U. S. V., reported: "Shot wound of left buttock. The ball entered about three inches from the anus, passed upward, was then deflected from the right pubis, glanced downward through the scrotum, destroying the right testis. The perineum and right groin were much ecchymosed and swollen. Urine passed in small quantity through the perineal opening. The urethra was severed in the membranous portion of the urethra. At mid-day no urine had passed and the bladder was much distended. After unsuccessful attempts at catheterization, it was decided to puncture the bladder above the pubes, owing to the state of the perineum. Urine to the amount of thirty-five ounces was thus drawn off, leaving the patient comfortable. On April 15th, perineal section and urethrotomy was practiced, and a silver catheter was introduced through the urethra; there was slight hæmorrhage. The patient was much prostrated, but rallied upon stimulation, and gradually improved, and was discharged, April 25, 1865, as cured." Pension Examining Surgeon G. W. Perrin, of Milwaukee December 16, 1866, transmitted to this office three interesting photographs of this case (*Card Photographs*, S. G. O., Vol. II, p. 22), and stated that "the ball first struck a tree, and then glancing, hit the left buttock, and came out through the scrotum and perineum in three pieces. The right testicle escaped through one of these openings, and was replaced when the wound was dressed at Chester Hospital, nine miles from the scene of the accident. The testis was subsequently destroyed by suppuration. The ball in its passage cut the urethra. In consequence of this, there was no discharge of urine for two days; at the expiration of this time the bladder was tapped over the pubis, and a catheter was kept in the bladder through this opening for two days, when, through the carelessness of the attendants, it was allowed to come out. Then the urine escaped through the wound in the urethra. This state of things continued until April 14th, when an operation was performed by Dr. Benton assisted by Dr. Bache and others, for the purpose of restoring the urine to its natural course through the urethra. This operation was to a great extent successful, for the urine ceased to pass from the wound for fourteen days, and while the catheter remained in the urethra. When it was removed, the poor fellow was doomed again to disappointment, for a portion of the urine again took its old passage through the wound in the urethra, and so continued to escape by the fistula on February 8, 1866. About July 28, 1865, the patient was removed to Chesnut Hill Hospital, where he remained about five weeks. He then returned to Milwaukee, and was received and cared for at the Soldiers' Home of that place. His general health, at that time, was very good. Some time in the spring of 1865 another operation was performed by Drs. Nauman and Marks, I believe, with the same anticipations and somewhat better results than the first, so much so, that the urine has never returned to its unnatural outlet through the fistula in the urethra. This wound is now closed; but when the catheter was removed, the opening made by the surgeon through the perineum had not healed. He is now able to retain the urine at will; when he voids the urine, however, he is obliged to close the perineal opening with the fingers, and the urine mostly passes by the urethra, but a portion always escapes through the perineal opening. Probably another operation skilfully performed would cure the difficulty entirely. Enclosed I send you photographs of R——." See the wood-cut (FIG. 287), copied from one of the photographs. There is no pension record in the case.

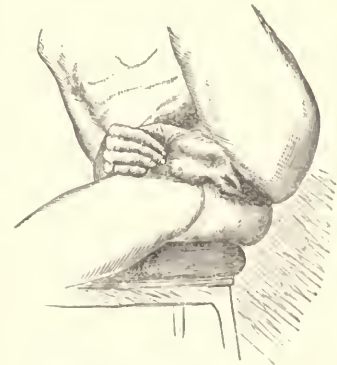


FIG. 287.—Perineal fistula after shot wound and urethrotomy. (From a photograph.)

CASE 1062.—Corporal J. Campbell, Co. F, 25th Illinois, was wounded at Stone River, December 31, 1862, and was treated in hospital at Nashville, and thence transferred to No. 3, Louisville, April 23, 1863. The case was noted by Acting Assistant Surgeon T. W. Colscott as a "gunshot wound through the scrotum and urethra, the ball emerging to the right of the os coccyx." On May 10th, the patient was sent to Hospital No. 3, New Albany, when he convalesced, and was returned to duty on August 17th. He was finally discharged from service September 5, 1864, and pensioned. Examiner D. L. Jewett, of Watseka, reported, November 11, 1872: "The bullet struck on the inner border of the gluteus maximus muscle, and, passing obliquely forward, struck the pubic arch, dividing the urethra; the bones forming the arch were materially injured; then glancing downward, the ball passed between the testes and through the scrotum. The point of entrance is still open; pus is often discharged with pieces of decayed bone; the wound was a very severe one. The muscles and nerves are so affected as to render manual labor impossible." Examiner A. C. Rankin reported, February 15, 1873, that this man "was shot through the pelvis; the ball carried away a portion of the glans penis, passed in between his testicles, entered the urethra, passed through the base of his bladder, and came out through the tuberosity of the ischium of the right side. The skin has adhered to the ischium, making a very deep cicatrix. His urine passed out through both wounds for four months. His greatest trouble is in working or carrying weights. He walks as though his hips were strapped together." Disability total and permanent. This pensioner was paid September 4, 1873.

CASE 1063.—Private H. Greenway, Co. C, 88th Pennsylvania, aged 32 years, was sent, by Surgeon A. S. Coe, 147th New York, from a Fifth Corps hospital to Lincoln Hospital with remittent fever. Assistant Surgeon J. C. McKee, U. S. A., reported that this patient had an intractable stricture of the urethra, and that he was transferred to Chester, May 13, 1865. Surgeon T. H. Bache, U. S. V., reported: "Traumatic stricture of the urethra, with perineal fistula, consequent, according to the patient's statement, upon a shot wound received in the naval service, at Point Lookout, April 9, 1864, prior to the man's enlistment in the Army. He was not benefited by treatment, and was discharged July 10, 1865," of course without pension.



Whether the urinary fistule, in the following case, had a vesical or urethral internal orifice, was not determined at the autopsy. Dr. Brinton's opinion, that the communication was with the urethra, appears the most plausible:

CASE 1064.—Private G. C. Rimmill, Co. E, 1st Vermont Cavalry, aged 18 years, was wounded in a skirmish at Waterloo Bridge, on the Rappahannock, August 29, 1862. He was sent to Washington, and admitted to Armory Square Hospital. The regimental and hospital records simply chronicle the injury as *vulnus sclopeticum*, Surgeon D. W. Bliss reporting that the man was discharged for this cause, November 19, 1862. Surgeon J. H.

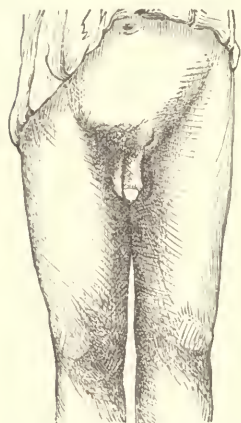


FIG. 288.—Entrance wound of a shot perforation of the pelvis. From a drawing by Dr. J. H. BRINTON.

Brinton's note-book, however, and the report of the pension examiners furnish some particulars of the nature and progress of the case. "The ball entered," according to the report of February 21, 1863, of the Pension Examiners Drs. R. Clark and L. A. Richmond, of Hartland, Vermont, "just above the pubes, a little to the right of the symphysis, and emerged at the right side of the coccyx, near the tuberosity of the ischium, passing through the bladder and the intestine near the coccyx. At present he has urinary fistula, with total inability to stand or walk. His disability is total, probably for life." Surgeon J. H. Brinton, U. S. V., who examined the patient at Armory Square and made drawings of the seat of the wounds (FIGS. 288, 289), reported that "the day after the reception of the injury urine escaped from the orifices of the wounds of entrance and exit. After two weeks, the entrance wound (FIG. 288) healed, but urine continued to flow from the exit wound (FIG. 289). At this date, September 14th, the patient slept badly, his bowels were constipated, the pulse at 140, feeble and irregular; little or no pain on pressure over the abdomen. There were two urethral fistulae, one underneath the root of the penis and the scrotal junction, and one in the perineum. The ball probably divided in its course the membranous or prostatic portion of the urethra, or the neck of the bladder. For a month subsequently, all the urine was discharged through the orifice

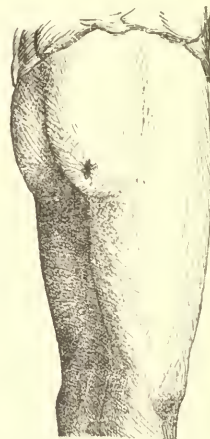

FIG. 289.—Exit wound of a shot perforation of the pelvis. From a drawing by Dr. J. H. BRINTON.

through which the ball emerged. This orifice gradually contracted, and, six weeks after the injury, only a third or fourth part of the urine escaped by it, the remainder being passed by the meatus." Leaving the hospital, November 19, 1862, the patient went to his home at Hartland, Windsor County, Vermont, and no further information has been received respecting him except the report already given of the pension examiners, and an announcement of his death, September 28, 1863.

In the preceding as in several other instances, shot lesions of the urethra were associated with pelvic fractures.<sup>1</sup> Equally common was the association of injuries of the urethra and of the femur. It will be recalled that this complication was observed in CASES 1045, 1046, and 1053. It was present also in the three following cases:

CASE 1065.—Private W. Catchpole, Co. C, 7th New York Artillery, aged 19 years, was wounded at Petersburg, October 11, 1864. He was treated in a Second Corps hospital, then at City Point and Annapolis, and, on April 10, 1865, was sent to West's Buildings Hospital, at Baltimore. He was transferred to Jarvis Hospital in May; to Hicks Hospital in July; and, finally, to Fort McHenry Hospital, February 20, 1866. Assistant Surgeon C. Peters, U. S. A., noted as follows in this case: "Gunshot wound of the pelvis, involving the membranous portion of the urethra; the femurs were complicated, and dead bone came away from both openings. The treatment was expectant and supporting; stimulants were given and simple dressings employed." This invalid was discharged April 13, 1866, and pensioned. Examiner W. M. Wright, of Baltimore, reported, June 28, 1866: "The ball entered about four inches below the crest of the ilium on the left side, and passed obliquely upward and across, partially dividing, in its course, the urethra in its membranous portion, wounding the sciatic nerve, and passed out, fracturing the lateral surface of the os sacrum. His right leg is paralyzed and wasted, and the knee and ankle-joints are ankylosed. The wound of the urethra has not healed, and he passes his urine partly through the wound of entrance. His general health is tolerably good, and is improving; he can move about a little on crutches." Examiner C. McDermott, of Hampton, on May 15, 1872, reported: "He was shot through the upper third of both thighs, through the perineal space, by a musket ball, which wounded the urethra and produced a fistula. Abscesses formed on the inner side of both thighs and on the outer side of the right thigh, which continue to discharge. The original wounds of entrance and exit of the ball have never healed, and these, also, discharge purulent matter. When he urinates the urine discharges from six orifices, which are suppurating ulcers located at the original wounds and at points of the abscesses. Many fragments of bone have been discharged from the openings, indicating extensive necrosis of the femur. Both lower limbs are contracted; the left one so badly, that when he stands on crutches it does not touch the floor. The long-continued irritation of these ulcers, with the constant and copious discharge of pus, has produced extreme debility and emaciation. This wounded man cannot stand alone or dress himself, and requires careful attendance and frequent change of dressings to prevent his person from being offensive. When placed on his crutches he can walk a short distance, but is confined, for the most part, to his bed or an easy chair. There is no hope of any improvement in his present condition; his disability is rated total."

<sup>1</sup> DURAND (J.) (*Quelques considérations sur les fractures de s pubis*, Thèse à Paris, 1863) cites six cases of fracture of the os pubis, in which the urethra was injured or lacerated by bone fragments. Two were fatal, four recovered; in two cases strictures remained; and in two, the *boutonnrière* became necessary.

Apart from the urethral lesion, the case next related is invested with interest as a remarkable example of successful excision in the shaft of the femur. In the succeeding similarly complicated case, conservation was effected by expectant measures:

CASE 1066.—Private A. Shock, Co. A, 4th Pennsylvania, aged 23 years, a stout and healthy man, was accidentally wounded, March 10, 1862, and was sent to Union Hospital, Georgetown. Assistant Surgeon J. S. Billings, U. S. A., made the following special report of the case: "Eighteen hours before admission, this man was accidentally shot by a soldier standing about ten paces to his left, and was struck by a minié ball at the left side of the junction of the penis with the scrotum, the missile dividing the spongy tissue and urethra, then, perforating a fold of the scrotum, into the right thigh at a point about two inches below the crest of the pubis, and passed out at the posterior and external aspect of the thigh, three inches below the great trochanter, having shattered the femur in its transit. Slight hæmorrhage had followed. Prior to admission, three short splints had been bound to the injured thigh. After careful examination and consultation with Surgeon A. N. McLaren, U. S. A., it was determined to attempt conservation of the limb. I accordingly enlarged the orifice of exit freely and removed all detached fragments of bone, preserving as much periosteum as practicable, and removing sharp points of the lower fragments with cutting forceps. Perhaps four and a half inches of the continuity of the shaft, from the trochanter downward, were thus removed. The splintering did not extend to the neck of the bone. The patient was placed on a fracture-bed and the limb was suspended by means of Smith's anterior splint. I then, with some difficulty, introduced a large silver catheter into the bladder and drew off the urine. The instrument was allowed to remain 24 hours. Water dressings were applied to the wounds, and, when reaction had fairly taken place, a grain of sulphate of morphia was given. On March 15th, the patient was calm and suffered no pain, but had an anxious, frightened look. The bowels had not been moved since the accident. Pulse 110; moderately strong. He was ordered a mercurial cathartic, to be followed by an enema. At eight p. m. he was slightly delirious; the pulse was very weak, and the frightened expression more marked; the bowels had not acted. Beef-essence and brandy were given freely, and a terebinthinate enema was administered. On March 14th, at 7 A. M., the condition was worse; pulse scarcely perceptible; bowels constipated; abdomen tympanitic. To take a mixture of tincture of ergot, half an ounce, tincture of camphor, one drachm, to be repeated every two hours. The terebinthinate enema to be repeated. At noon there was improvement; the pulse 95, and stronger; the bowels freely open; the countenance natural; the consciousness fully restored. To have milk-punch, beef-extract, etc. March 16th: Has had a comfortable night. For the first time, complains of pain in the wound; suppuration is commencing. The wet lint-compresses were covered by oiled silk. The stimulant and supporting treatment was continued, with small doses of morphia. March 17th: Thin sanious offensive pus was copiously discharged. Tongue furred, red tip and edges; pulse 110, weak. March 18th: A large wire-wove padded splint was applied to the posterior surface of the thigh, a fenestrum having been cut opposite the orifice of the exit wound. For the next few weeks he remained very comfortable, the suppuration diminishing and becoming healthy in character. The wound of the urethra slowly granulated and closed, about three-fourths of an inch of a portion of the circumference of the canal having sloughed away. An abscess formed over the tuberosity of the right ischium; it was incised and discharged healthy pus. On May 10th the patient was in good condition, sleeping well, enjoying a good appetite, with regular bowels, and freedom from pain. A small fistulous opening still exists in the urethra, but is slowly closing under occasional applications of a crayon of nitrate of silver. Both the entrance and exit orifices of the shot perforation of the thigh have closed. The abscess in the nates is still discharging. Callus has been thrown out in good quantity. The limb presents several inches shortening. At this date the patient was sent to the Seminary Hospital, where I saw him on July 20, 1862, in excellent general health. The urethral wound had entirely cicatrized. A trifling sinus still exists in the thigh." Surgeon J. R. Smith, U. S. A., reported that this patient entered Seminary Hospital on May 12, 1862, and, after reviewing the early history of the case, continues: "The limb did not seem to prosper under this treatment [by Smith's anterior splint]. In addition to profuse suppuration, the pus burrowed and the thigh was painful. I accordingly changed the treatment, extending the limb on a water-bed, elevated the foot so as to secure counter-extension by the weight of the body. June 3, 1862, the patient was rapidly improving." This soldier was discharged October 10, 1862, and pensioned. Examiner J. M. Adler, of Philadelphia, September 8, 1868, after recapitulating the course of the ball and the particulars of the injury, added: "Compound comminuted fracture of the femur, with great obliquity of union and loss of portion of the shaft of the bone, resulting in five to six inches shortening." Examiners H. E. Goodman, T. H. Sherwood, and J. Collins reported, September 8, 1873: "Ball divided the urethra near the scrotum and entered the thigh near the perineum, exit behind the great trochanter; fracture of the femur. Result: Fistula, atrophy of right testicle, and four inches shortening of femur; disability total."

CASE 1067.—Private M. Fitzmaurice, Co. B, 170th New York, aged 22 years, was wounded at Petersburg, June 17, 1864, and was sent, on the transport Connecticut, to hospital at Annapolis. Acting Assistant Surgeon W. P. Willis reported: "He was struck by a minié ball in the right hip, the missile passing through the pelvic cavity, injuring the urethra, and producing compound comminuted fracture of the left femur in its upper third. He is doing very well at present. The flesh wound was treated by dry dressings and the fracture by sand-bags." This patient was furloughed October 27th, entered McDougal Hospital November 30th, and was discharged June 16, 1865. Surgeon E. P. Vulliamy, U. S. A., examined this man for enlistment in the Veteran Reserve Corps, and reported "a minié ball entered the outside of the left thigh about two inches below the trochanter major, breaking the femur, and passed through both thighs on a line a little above the perineum, and passed out about one inch in front of the right trochanter major. His bladder was paralyzed for four months after the injury, requiring the almost daily use of the catheter. The fractured extremity was treated with sand-bag supports in place of splints, and in two months the patient was able to walk by the aid of crutches. In seven months his wounds healed up entirely. A few small pieces of bone came from the wound of entrance in the discharges. The fractured femur is bent outward considerably and is shortened two inches; there is no difference in the size of the lower extremities. He says he has no pain, and has suffered no damage in his general health in consequence of his injuries." This soldier served in the Veteran Reserves until March 25, 1867, and was then pensioned. This pensioner was examined by Dr. G. S. Gale in 1863, and by Dr. W. M. Chamberlain in 1869, but no additional facts of interest were reported. Fitzmaurice is reported to have died July 31, 1871.



The reader will note, in the first of the three following cases, that, as has been so frequently observed in the reports of shot wounds of the pelvis, the supervention of hernia is adduced as an effect of the injury. In CASE 1069, the course of the ball is remarkable:

CASE 1068.—Private J. M. Kelley, Co. K. 1st Ohio Artillery, aged 24 years, was wounded at Gettysburg, July 1, 1863, and was sent to Seminary Hospital. On the 24th he was transferred to Camp Letterman, where Acting Assistant Surgeon E. A. Koerper reported: "A minié ball entered opposite the right sacro-iliac symphysis, passing forward and outward, and lodging somewhere behind the trochanter major; the sacrum and ilium were both fractured, as several pieces were discharged. August 16th: Has had diarrhœa for several days, but it is now checked. August 21st: Improving daily. November 9th: Wound nearly healed." He was transferred, November 17th, to Camp Dennison, Ohio, and finally discharged February 4, 1864, and pensioned. The certificate of disability, given at Columbus by Acting Assistant Surgeon T. C. Tipton, recorder of a board of examiners, stated: "Gunshot wound of the pelvis, lodging in the opposite pubic bone, resulting in partial paralysis of the lower extremities." Examiner G. O. Hildreth, of Marietta, June 11, 1864, reported: "The ball entered the pelvis from behind, on the right side, near the sacrum, and has not been removed. It seems to have passed over near to the left ischium, as a fistula has formed in the perineum. The right hip-joint is affected, and motion is difficult and painful. He was confined to his bed until the middle of April. The leg is improving somewhat, and he can walk a few rods at a time." In an application for increase of pension Kelley states, September 5, 1867, that "a minié ball struck from behind, entering at the right sacro-iliac junction, and afterward ulcerated out through the perineum. About a year after the reception of the wound hernia occurred. Last spring an abscess formed around the wound of entrance." Dr. Hildreth again, April 2, 1868, reports this case: "He was wounded in the pelvis, the ball entering the dorsum of the ilium, right side, near the spine or sacrum, and emerging in the perineum or left groin. The bladder or urethra was injured, as proved by the escape of urine. The wound of entrance has closed since last summer. The motion of the hip is not much impaired; the leg is weak and painful. He complains of pain in the perineum from exercise, and suffers from pain down the thigh, like sciatica; also from pain in the right side of the abdomen above the internal abdominal ring. He has left inguinal hernia." Dr. Hildreth makes the next biennial examination, and, in reporting it, says that the ball "came out subsequently in the left groin. Left scrotal hernia occurred in 1864 as an effect of the injury, and still continues. The wound of the pelvis has greatly impaired the strength and use of the right leg. Disability total." This pensioner was paid December 4, 1873.

CASE 1069.—Corporal W. G. Denton, Co. E. 8th Michigan, aged 21 years, was wounded at Petersburg, June 24, 1864, and sent at once to a Ninth Corps hospital. Surgeon P. A. O'Connell, U. S. V., reported: "Ball entered three inches below and to the outer side of the right nipple, and made its exit at the raphe of the scrotum, superficial to the pubes, thence, wounding the urethra, made its exit." He was transferred to Alexandria on July 4th. Surgeon T. Rush Spencer, U. S. V., noted: "Ball entered over the cartilage of the ninth rib, passing obliquely downward, wounding the bladder, and emerged at the scrotum near the left testicle. Urine is escaping from both passages." He was transferred, January 21, 1865, to Harper Hospital, Detroit, and was discharged August 21, 1865, Surgeon A. Wynkoop, U. S. V., reporting that "a ball entered the right side at the ninth rib, passing down, severing the urethra, and carrying away the left testicle, making a false passage for the urine." Examiner M. L. Greene, of Pontiac, reported, August 8, 1866, that the "penis was useless for all purposes, and the urine passes through the fistulous opening at the exit point of the wound." Examiner C. Earl reported, September 4, 1873: "Rifle ball entered at the eighth rib and came out at the perineum, severing the urethra about one inch and a half from the neck of the bladder. The urine is voided through a fistulous opening entirely. Disability total."

CASE 1070.—Private D. Ferris, Co. I, 12th Massachusetts, aged 19 years, was wounded at Antietam, September 17, 1862. Surgeon J. Maclean Hayward, 12th Massachusetts, reported that "a round ball entered the left buttock and emerged from the right groin." The wounded man was sent to the Smoketown Hospital, and Surgeon B. A. Vanderkief reported that he recovered from a shot wound of the bladder, and was discharged from service, December 19, 1862, and pensioned. He re-enlisted, June 7, 1863, and served till May 7, 1864, when he was sent to Cuyler Hospital, at Germantown. Assistant Surgeon H. S. Schell, U. S. A., states that this man was "well until March, 1864, when he fell astride the round of a ladder. This accident was followed by an abscess in the perineum, and difficulty in passing water. The cicatrix in the buttock became swollen and was lanced, and urine escaped from it. On June 1st, Dr. Dunton passed a large bougie through two strictures in the urethra, while the patient was under the influence of chloroform and ether. The instrument was not introduced into the bladder. The patient was much relieved, having had some difficulty in passing urine previously. June 2d, the same bougie was passed into the bladder while the patient was under the influence of the same anæsthetic. After this, during the day, he could pass only a few drops of blood when he attempted to urinate. June 3d, eight o'clock A. M.: He has made no urine since yesterday; efforts at catheterization were entirely unsuccessful until two and a half o'clock P. M., when the instrument was finally passed into the bladder, and it was discovered that the difficulty of catheterization had been produced by an old false passage. The catheter was kept in the bladder for six days, when it was removed, the water being passed not only through but around it. June 6th to 24th: After the removal of the instrument he passed his urine very freely; his general condition was long very feeble, but he has now nearly recovered his usual health. His urine is not passed quite as freely as when the catheter was removed; he passes it both by the opening in the perineum and by the penis. June 30th: The general health of the patient is improving; the urine escapes through the perineal fistula; a catheter was introduced morning and evening." Ferris was furloughed September 7, 1864, and transferred to Mower Hospital, May 10, 1865. Assistant Surgeon C. Wagner, U. S. A., reports that the patient was not treated by operation at Mower Hospital, and that he was discharged from service, June 29, 1865, on account of "urinary fistula following a gunshot wound of the bladder." He was pensioned. Examiner G. S. Jones, of Boston, reported, December 5, 1865, that "the bladder has been penetrated, and a fistulous opening now exists near the anus from which urine escapes. No urine passes through the urethra." This pensioner was paid to September 4, 1866.

From the continual discharge of the seminal secretion with the urine, through the perineal fistula existing in the following case, the existence of an abnormal communication between the remaining testis or vas deferens and the urethra has been surmised:

CASE 1071.—Captain R. S——, Co. D, 72d Pennsylvania, aged 24 years, was wounded at the Wilderness, May 6, 1864. He was treated in a field hospital for a "gunshot wound of the testicle," and was transferred, on the 20th, to Armory Square, where Surgeon D. W. Bliss, U. S. V., described the injury as a "gunshot wound of the perineum and urethra." Subsequently, this officer was transferred to the hospital at Camac Woods. Acting Assistant Surgeon W. Camac reported: "Admitted on May 22d, having been wounded by a round ball, which entered to the left of the left cord of the testicle, passed across and struck the urethra, opened it, and passed down behind the scrotum, outward to the right side of the perineum, and down and out over the tuberosity of the right ischium. The left testicle was carried away; the right, uninjured; the urethra was opened for at least two inches of its length. The wound was then granulating. About half of the urine escaped through the opening; the other half passed in a good stream from the natural channel. The parts were so irritable as to preclude the use of a catheter, and the cure was entrusted to granulation, as after lithotomy, a watch being kept for any constriction. The parts were greatly swollen; the general condition of the patient's system was good; pulse fair. Milk-punch was given lightly, with full diet; poultices were applied, and the patient kept quiet. On the 24th, he was doing well; on the 26th, his bowels were opened by an enema, and the rectum seemed clear. There was much pus from the perineum, it having been opened by incision, but there was no sign of infiltration. The ligature on the cord had not then come away; the pus was healthy and suppurating in the whole track of the wound very freely. On the 29th, an abscess opened on the left side of the scrotum; a cataplasm was placed over the whole wounded surface. For a day or two lotions of lime water had been used. A weak solution of permanganate of potash was thrown into the cavities. The urethra was granulating finely; no instrument was used; the stream of urine from the end of the penis was very good, and the flow from the fistulous opening was diminishing. May 31st: He was doing very well, but was not a good patient. There was still much pus from the perineum; the ligature was still on the whole cord, and, therefore, was not expected to come away soon. On June 5th, the urine was dribbling from the fistulous opening to about one-tenth the whole amount. He was doing well on the 7th, and the pus was diminishing in quantity and was healthy; there was no trouble in micturition. An enema was used. The ligature came away on the 8th, and there was a decided general improvement in the last two days. On the 13th, the wound in the perineum was nearly healed; the scrotal wound was healed; the urethra was granulating finely, and the escape of urine was diminishing. The dressing consisted of lime water; extra diet was ordered, and the patient's general health was excellent. The fistula continued to granulate finely; on the 21st, only a few drops of urine escaped from it, and there was a full stream through the natural channel; the patient walked about comfortably. July 1st: While the patient urinates, a drop or two, now and then, comes out at the junction of the scrotum and penis. From this point down, about one inch and a half of the urethra has been carried away, and there is no defined canal; but a passage to the bladder is pervious and the stream natural. It was impracticable to get a bougie into the bladder, as the canal starting from the glans penis goes to the junction of the scrotum and penis, and then into the cavity opening into the scrotum formerly occupied by the left testicle. The general health was good; the officer walked everywhere; apparently, he could perform full duty, and there was no tendency to further contraction; therefore it was decided not to interfere unless some inconvenience should arise. When the risk of contraction is over caustic might close the fistulous orifice." This officer was transferred to Annapolis on July 31st, and mustered out August 24, 1864. Examiner J. H. Gallagher, of Philadelphia, reported, January 16, 1866, that, "Cutting away a portion of the prepuce, the ball entered the body of the penis, passed into the urethra and out, and was extracted through the natis. There is a fistulous opening through the urethra from which there is constant oozing of urine, the bladder being involved in the injury, causing weakness. The pensioner has lost the scrotum and left testicle. He states that the right testis frequently becomes swollen and painful, producing a serous discharge from the fistule; he complains of general lassitude and weakness." Examiners H. E. Goodman, T. H. Sherwood, and J. Collins, September 4, 1873, reported: "Loss of left testicle, and urethral fistula, and one of the perineum on the right side. Urine and spermatic fluid are discharged. The disability continues total." This pensioner was paid September 4, 1873.

To the thirteen foregoing examples of scrotal or perineal urethral fistules from shot injury, should be added CASE 831, an instance of multiple scrotal fistules, and three cases recorded under the head of Urethrotomy. Of sixteen cases of vesico-cutaneous fistules recorded,<sup>1</sup> only six opened in the perineum.

*Urethro-rectal Fistules.*—The rarest variety of urethral fistules is constituted by those communicating with the rectum.<sup>2</sup> In the subsections on wounds of the bladder and of the rectum, thirteen examples<sup>3</sup> were adduced of persistent vesico-rectal fistules resulting from shot injury. Urethro-rectal fistules from this cause were less frequent and less obstinate. The anatomical relations of the urethra to the intestine involve less liability of the establishment of intercommunication between the canals, and should they be

<sup>1</sup> CASES 781-2-3-4, on page 265; 785-6-7, on page 266; 797, p. 271; 808, 810, p. 279; 826-7, p. 228; 856, p. 291; 858-9, p. 295; 869, p. 304.

<sup>2</sup> VOILLEMIER (*Traité des mal, des voies urinaires*, 1868, p. 423), in treating of urethral urinary fistules, observes: "Les fistules qui s'étendent de l'urètre au rectum sont plus rares; elles forment une espèce toute particulière qu'on n'observe guère qu'à la suite de la taille péricule." The Professor had occasion to modify this opinion during the siege of Paris in 1870-71, as indicated by the observation cited from M. GILLETTE, on the next page.

<sup>3</sup> CASES 788, 789, 790, 791 on pages 266, 267; 823, p. 287; 825, 828, p. 288; 860, p. 296; 876, p. 307; 885-6, p. 309; 887, p. 310; 899, p. 313.



connected by a ball track, there is not the constant dribbling of urine which opposes the closure of recto-vesical fistules, and fæces intrude less readily than into the bladder. The five cases reported during the war that may possibly be referred to this category illustrate these remarks. In CASE 1072, the urethro-rectal fistula appears to have closed spontaneously a year after the injury. In the next case, pus without urine passed by the fistules; the communication between the urethra and rectum was not incontestable. In the three cases on page 371 the fistules were recurrent rather than permanent.<sup>1</sup>

CASE 1072.—Private James Dervin, Co. H, 4th Rhode Island, aged 25 years, was wounded at Antietam, September 17, 1862, and sent to the Ninth Corps Hospital at Locust Springs. Surgeon T. H. Squire, 89th New York, states that "a musket ball entered the skin about two inches back of the tuberosity of the left ischium and one and a half inches from the median line, and, passing forward across the perineum, came out at the lower part of the scrotum, half an inch to the right of the raphe. At present (December 8th?), the posterior wound is discharging laudable pus, and the anterior is healed; but there are two consecutive openings still higher, on the side of the scrotum, which originally gave vent to the matter consequent on active inflammation of the testis or of some other tissue contained in that side of the scrotum. This man was taken from the field the second day after the fight, and having had no discharge from the bladder, and because a catheter could not be introduced, the bladder was punctured through the rectum by Surgeon M. Storrs, 8th Connecticut, and the urine has been passing through that puncture, more or less, ever since, especially if a catheter is not introduced frequently, as it has been as a general thing. The gum catheter is now to be left in the canal, and I am in hopes that the recto-vesical fistula will heal. Occasionally of late, during a movement of the bowels, the urine has been expelled voluntarily by the urethra. The patient now is improving, but he has not stood upon his feet since the injury, and he complains that his limbs are stiff and sore, and unable to support him in the erect posture. By further investigation, I discovered that the urethra, near the bulb, was laid open by the ball, and that urine escaped through the scrotum through this wound for many days. December 8th: When the patient makes water, the greater portion of it comes by the anus, probably by a communication between the membranous portion of the urethra and the rectum, either made primarily by the ball or consecutively by infiltrative inflammation and ulceration. I must send for a rectum speculum and a special catheter, and endeavor to heal this urethro-rectal fistula." \* \* In a second case-book, Dr. Squire continues the report of the case, probably in January, 1863: "For nine weeks past a secondary fistulous opening has existed at the point of the buttock, communicating, by a tortuous sinus, behind the rectum, with the ball route; thus the case is complicated by a fistula in ano behind and a recto-urethral fistula in front, both kept open by the excretions of the kidneys and of the bowels. Heartily sick of this temporizing treatment I have been pursuing fruitlessly, I administered chloroform, and, passing in the grooved staff at the entrance wound and out at the fistulous orifice in the natis, I laid open the intervening tissues by an incision five inches long and an inch and a half deep. Then, passing the staff from this cut into the rectum, through the track of the ball, and out at the anus, I also laid open the intervening tissues here. It is my intention to use the knife in the recto-urethral fistula by and by, in hopes of obtaining union from the bottom, and thus making a complete cure of this disagreeable case. In the meantime, the patient must wear a catheter or have one introduced every twelve hours." The patient was transferred to No. 1 Hospital, Frederick, January 20, 1863, when Assistant Surgeon R. F. Weir, U. S. A., recorded the existence of a urinary fistula, without comment, and the man's transfer to Jarvis Hospital, June 16, 1863. Assistant Surgeon D. C. Peters, U. S. A., transferred the patient to Hammond Hospital, July 3, 1863. Acting Assistant Surgeon M. A. Booth reported: "Gunshot wound of the perineum; ball lodged in the scrotum, injuring the testis, and was extracted at the Frederick Hospital, February 14, 1863, by Dr. North. There is a fistulous opening into the urethra. August 21st: Catheter dispensed with; fistula closed. August 25th: Has taken cold from lying on damp ground; has fever and dysuria, with soreness over the region of the bladder; urine is somewhat bloody. August 30th: Cystitis improving; the urine is nearly free from mucus and albumen; there is some phosphatic deposition. September 15th: The urine is alkaline, and there is a superabundance of triple phosphates; reaction alkaline. September 22d: Improvement continued; recommended for discharge." The patient was sent to duty January 16, 1864, and, on February 8, 1864, was admitted into Mount Pleasant Hospital from Camp Convalescent. He was furloughed and readmitted, and returned to duty May 24, 1864, and discharged October 15, 1864, and pensioned. Examiner H. W. Rivers, of Providence, reported, May 30, 1868, that "the ball entered the left buttock about three inches to the left of the anus, passed through the urethra, and came out at the scrotum, wounding the right testis. The injury causes incontinence of urine and severe pain on exercise." This pensioner was paid on June 4, 1873.

CASE 1073.—Private D. Ennes, Co. D, 8th Ohio, aged 21 years, was wounded at Cold Harbor, June 3, 1864, and was admitted to Armory Square Hospital on the 8th, the injury being rated as a "gunshot wound of the scrotum." He was returned to duty June 29th, and discharged the service July 13, 1864, and pensioned. Examining Surgeon A. H. Agard, of Sandusky, reported, June 1, 1866: "Was wounded by a ball in the left of the scrotum, passing backward and wounding the testis, urethra, and rectum. He now suffers some pain along the track of the ball, and has occasional discharges of matter from the urethra and rectum." Dr. Agard reports, November 15, 1871: "His increase of disability results from a numbness and pain in the left thigh, resulting from the wounding of nerves, I think a reflex action in the sciatic nerve or branches; disability total." Examiner J. B. Ford reported, on examination for increased pension, December 21, 1871: "Right testis gone; ball passed into the upper part of the left hip or thigh, whence it was extracted after fifteen months. The left thigh is weak and motion impeded, and he is unable to be much on his feet; disability total." The pension was increased, and paid to September 4, 1873.

<sup>1</sup> GILLETTE (*Remarques sur les blessures par armes à feu observées pendant le siège de Metz (1870) et celui de Paris, 1871*, in *Arch. gén.*, 1873, T. XXI, p. 322) cites a case of shot wound of the perineum with recto-urethral fistula. The penis was tumefied; vesical catheterization impossible; there was infiltration with emphysema of the perineum, scrotum, and penis; numerous deep incisions were made; death.

In two of the three following examples of urethro-rectal fistules,<sup>1</sup> the abnormal canal closed early; the third is persistent, apparently requiring operative interference:

CASE 1074.—Private O. Hitt, Co. E, 105th Ohio, was wounded at Perryville, October 8, 1862, and was admitted into Antioch Church Hospital on the same day. Assistant Surgeon C. V. Fowler, 105th Ohio, noted "a gunshot wound of the perineum and urethra, urine passing from the wound." The patient was transferred to Hospital No. 12, Louisville, December 1st, where Surgeon R. L. Stanford, U. S. V., reported "gunshot wound through the right hip, injuring the urethra." This soldier was discharged December 11, 1862, Dr. Stanford recording on the certificate of disability "gunshot wound an inch to the right of the coccyx, the ball passing through the rectum into the bladder, making a fistula through which the urine passes in large quantities." Examiner C. D. Griswold, of Cleveland, December 9, 1833, reported: "Gunshot wound, the ball entering posteriorly between the nates near the os coccygis, passing forward and injuring the bladder and rectum, resulting in irritability of the bladder and pain from locomotion." Examiner J. W. Fally, March 6, 1873, reported: "Three or four times a year the parts inflame, suppurate, and discharge by the rectum; while that is going on he is laid up." Dr. Fally, in reporting the biennial examination, December 22, 1873, says: "The feces and urine are now voided regularly; the parts are well healed; his general health has much improved; disability total." This pensioner was paid to December 4, 1873.

CASE 1075.—Acting Assistant Surgeon John Neill, in charge at Broad and Cherry Streets Hospital, Philadelphia, reported that "Private W. H. Disbrow, Co. D, 5th New York, aged 19 years, was wounded at Gaines's Mills, June 27, 1862, and taken prisoner, and subsequently paroled and sent North. He was admitted, on July 29th, with a gunshot wound of the bladder and intestines, the ball having penetrated the abdomen in front just above the pubes, and remained in the body. At the time of admission, urine dribbled from the wound. He stated that for several days after the injury his urine poured from the wound in a stream, and that occasionally a small quantity of feces also passed. His general condition was good. He was discharged the service August 7, 1862." Examiner T. Franklin Smith, of New York City, reported, September 20, 1873: "Ball entered the right groin and was removed from the perineum, involving the urethra. Locomotion is affected in consequence of tenderness and pain in both legs and testicles. Disability continues at one-half." This pensioner was paid in July, 1873.

CASE 1076.—Private R. E. B——, Co. F, 6th New Jersey, aged 26 years, was wounded at Williamsburg, May 5, 1862, and treated at Mill Creek till sent to the Filbert Street Hospital, Philadelphia. October 14th, Acting Assistant Surgeon E. L. Duer reported: "He received a ball from behind, entering about one inch to the left of the anus and the same distance from the point of the coccyx. The missile traversed the urethra from its membranous portion to near the base of the glans, completely disorganizing the parts, and emerging on the right side of the urethra. Hæmorrhage ensued to exhaustion, but, by reason of a good constitution and fortunate conveyance, he rallied, and was placed in hospital. The urine passed mostly through the posterior wound for several weeks. The case came under my care about two months subsequently, when the urine merely trickled out after being at stool or after voiding it by the natural channel, which, by the way, he experienced no trouble in effecting. The posterior wound at its orifice had nearly healed. I passed a large-sized catheter sufficiently well into the bladder to draw off the urine, but could not bring down the shaft of the instrument to the axis of the body, nor could the patient retain it comfortably for more than a few minutes. The point of resistance seemed beyond the wound, though the patient states that he had never had anything like stricture previously. The treatment consisted in enlarging the posterior wound, and injecting dilute iodine and weak solutions of nitrate of silver, at the same time that a tent was kept introduced into the posterior wound and a catheter introduced occasionally. The edges of the anterior wound rapidly contracted under the stimulus of nitrate of silver. The perineal wound in the urethra has evidently nearly closed from the fact of there being but an occasional drop passing posteriorly, but yet the fistulous disposition of the wound is still remaining. Pure iodine has been injected and a drainage tube kept in for a short time, by which it is hoped to accomplish a cure. November 20th: Under the treatment detailed, the posterior wound has closed up, and, with the exception of the fistula behind the glans, the patient seems quite cured. The missile was supposed to be a minié ball, fired from a distance of only twenty yards. The sensation was that of having a red-hot iron poked through the wound. The fistula will be treated by operation in a few days. January 21, 1863: There has never been any disposition to erection of the penis since the reception of the wound." This soldier was discharged March 16, 1863, and pensioned. Examiner W. Jewell reported, March 24, 1863: "Musket ball in the left hip, passing through the penis, entering the urethra, and coming out on the right side of the virile member. The wound is healed in part, leaving an opening or fistula into the urethra, which gives rise to incontinence of urine; disability total;" and on September 7, 1865, he again reported, "The improvement warrants a reduction of disability to one-half." Examiner P. Leidy, August 29, 1865, stated: \* \* "There is a fistulous opening communicating with the urethra from without at the point of exit of the ball, through which the urine passes in voiding, constituting hypospadias, which has increased, as also the pain and tenderness of the whole region included between the point of entrance and exit of the ball. His general health is fair; disability total." In October, 1867, Examiner J. M. Adler gave a similar description of this soldier's wound and result, and added: "The posterior wound becomes inflamed, at times suppurates and opens, and the urine escapes through it. The consequent irritation from the urine interferes greatly with locomotion and manual labor, and the deformity is great and probably incurable." Examiners E. A. Smith, T. S. Harper, and G. C. Harlan reported, February 1, 1871: "Ball entered the left buttock about an inch to the left of the coccyx, and, ranging forward, passed through the soft parts, slightly wounding the neck of the bladder, and made its exit through the side of the penis. Discharge still continues from both entrance and exit wounds. When urinating, a portion passes through the wound in the side of the penis, and if attempts to micturate in erect position be made, a portion of the urine passes from both wounds." September 24, 1873, Examiners T. Sherwood, H. E. Goodman, and James Collins reported: "Shot wound of right groin and left hip, resulting in urinary fistula from the penis and anus. The pensioner is practically emasculated, and the discharge is offensive. The disability is equivalent to the loss of a limb in consequence of the disgusting nature of the complaint."

<sup>1</sup>Urethro-rectal fistules consequent on shot wounds are not referred to in the writings on military surgery the editor has consulted. Concerning such fistules due to other traumatic causes, the reader may compare: JOURDAN (Art. *Fistule*, *Dict. des sci. méd.*, 1816, T. XV, p. 627); BÉRARD (A) (*Les fistules uréthro-rectales*, in *Dict. de M. d.*, 2<sup>e</sup> éd., 1846, T. XXX, p. 123); DESAULEY (P. J.) (*Traité des mal. des voies urinaires*, An. VII, p. 295); FAGUELSKI (*De fistulis urinariis*, Berol., 1822); JAMAIS (A.) (*Manuel de path. et de chir.*, 1870, 2<sup>e</sup> éd., 1870, T. II, p. 835).



*Fatal Shot Wounds of the Urethra.*—Of the morbid anatomy of shot lesions of the urethra, scarcely anything is definitely known. The Army Medical Museum shares in the poverty of European pathological collections in respect to preparations illustrating this form of injury. Nineteen of the twenty-two fatal cases in which the urethra was wounded by shot are enumerated on page 351, two others are noted on this page, and the remaining case with the operations of external perineal urethrotomy. The causes of death may be indicated, in a general way, as: hæmorrhage, in three cases; urinary infiltration in eight, in two of which the signs of peritonitis were pronounced; surgical fever, with profuse suppuration, in nine, including three cases complicated with fracture of the femur; tetanus and phlebitis with gangrene, each in one case. There were several autopsies; but little information was derived from them, owing to the disorganized condition of the parts examined. The Museum possesses a preparation (FIG. 290) of shot perforation of the urethra, contributed by Dr. R. K. Stone, with the following memorandum:

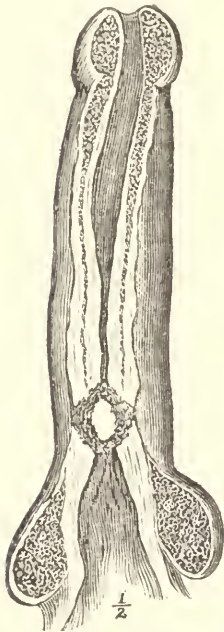


FIG. 290.—Shot perforation of the penis, dividing the urethra. Spec. 902.

CASE A<sup>9</sup>.—"Mr. CORN. H——, one of two clerks, bosom friends, in Washington, in 1862, married a charming person, and took lodgings, at which his friend was a frequent and welcome visitor. After some months, annoyed by his comrade's assiduities near his wife, Mr. H—— returned unexpectedly, during office hours, to his bed-chamber, and became the unhappy witness of the infidelity of his wife, actually beholding the *stylum in pyride*. He avenged himself with a Derringer pistol, aiming with such precision that the ball entered the raphe of the scrotum of the preoccupied paramour, traversed the penis forward and upward, and lodged in the pubic bone. Profuse hæmorrhage was quickly followed by hyperacute peritonitis, and the wounded man expired after thirty-six hours of agony."

Occasions where the urethra is exposed to such oblique, postero-anterior, shot perforations should be exceedingly rare. Scant details were reported of two fatal cases of shot laceration of the urethra, the one complicated by urinary extravasation, the other by phlegmonous abscesses near the urethra.

CASE 1077.—Private C. Stewart, Co. G, 16th Pennsylvania Cavalry, aged 19 years, was wounded at Shepardstown, July 16, 1863. He was treated in a cavalry corps hospital until the 20th, and then sent to Camden Street Hospital. Acting Assistant Surgeon E. G. Waters reported: "A musket ball entered the dorsum of the penis near its base, passed backward and onward through the scrotum, and entered the left thigh through its anterior and inner aspect, about two inches below Poupart's ligament. His condition was reasonably good on admission, but the penis and scrotum assumed a gangrenous appearance, and, on the 23d, he was found pulseless at the morning visit, exceedingly restless, his countenance anxious and livid, thirst insatiable, and the thigh throughout its extent enormously swollen. The entire surface of the body emitted a cadaveric and offensive odor. This assemblage of symptoms, together with a slight hæmorrhage from the wound in the thigh, occasioned apprehensions of injury to the urethra and either the femoral or profunda blood-vessels. He sank and died at ten o'clock in the evening. The next morning about half a gallon of sanious fluid was observed to have escaped from the wound in the thigh; this discharge, saturating the table on which the body lay, formed a large pool on the floor of the dead-house. The corpse was so offensive that no examination could be made."

CASE 1078.—Private P. S. Bobbitt, Co. A, 47th North Carolina, was wounded at Gettysburg, July 3, 1863, and sent to Seminary Hospital, where Surgeon A. J. Ward, 2d Wisconsin, reported a "shot wound of the urethra." The patient was moved to Camp Letterman Hospital August 5th, where Acting Assistant Surgeon E. P. Townsend reported that "the ball entered to the right and above the symphysis pubis, and passed out through the muscles of the back above the pelvis, and to the left of the sacrum. The urine was discharged entirely from the posterior wound. But little was known of this patient's previous history. On admission, he had an exhausting diarrhoea with entire loss of appetite, being unable to retain the least nourishment on his stomach. Attempting to pass a catheter, a stricture was found about two lines beyond the glans penis. This being finally passed, and a gush of pus instantly filling the catheter, a second and impassable stricture was reached at the neck of the bladder. The treatment pursued was expectant. The patient failed, and died of exhaustion on October 20, 1863."

Of the eighty-three reported cases of recoveries from shot wounds of the urethra, some details have been furnished of twenty-six resulting in stricture, of thirty-eight with the superadded complication of fistula, and of seven without recorded permanent lesions

of the canal. The three following cases may be added to the last-named category; in each, the effects of the urethral lesions appear to have been slight:

CASE 1079.—Private J. Lawler, Co. A, 9th Massachusetts, was wounded at Spottsylvania, May 12, 1864, and, after treatment on the field, was sent, on the 18th, to Douglas Hospital, the injury being noted as a "gunshot wound of the perineum, lacerating the urethra." He was transferred, June 16th, to McDougal Hospital, New York, furloughed, and, on July 17th, was admitted into Mason Hospital, Boston, whence he was discharged July 2, 1864, and pensioned. Examiner G. S. Jones, of Boston, August 1, 1861, reported: "The wound was in the natis and scrotum. The ball entered the right buttock and emerged near the right external abdominal ring, injuring the bones of the pelvis and the right testis. He is now quite lame." Captain McGonnigle, late of Co. A, 9th Massachusetts, on oath attests that said Lawler was wounded "by a ball and two buckshot in his right groin and testicles." Surgeon A. N. McLaren, U. S. A., examined this man for enlistment in the 42d Veteran Reserve Corps, on July 17th, and reported: "Gunshot wound; ball entering about an inch and a half to the right of the anus, through the perineal muscles and right testicle, and impinging upon the right side of the pubic arch, escaping at this spot; the wound is healed." He was re-enlisted, receiving his pension to that date.

CASE 1080.—Corporal E. Carpenter, Co. D, 10th New York Artillery, was wounded at Petersburg, July 7, 1864. Surgeon S. A. Richardson, 13th New Hampshire, reported, from an Eighteenth Corps hospital, that this man was struck "by a minié ball, which passed through the right thigh and penis, and was sent to Fort Monroe, July 13th," and transferred to Lovell Hospital, Rhode Island. Surgeon L. A. Edwards, U. S. A., recorded a "shot wound of right thigh, penis, and scrotum," and the patient's transfer to Troy. Surgeon G. H. Hubbard, U. S. V., recapitulated the foregoing diagnosis, and reported this soldier's discharge, April 18, 1865, for "disability resulting from loss of muscle from the anterior portion of the thigh, unfitting him for service in the Veteran Reserves." Examiner W. A. Anderson, of Wisconsin, reported, October 8, 1867: "A musket ball passed through the glans penis and upper third of the right thigh anterior to the femur. In hospital, gangrene destroyed much muscular tissue in the track of the wound, leaving a cicatrix involving half the circumference of the limb. There is great contraction, and the limb is slightly atrophied, and he complains of pain and weakness in the knee, which, I should think, might result from such a wound. He follows his business as a farmer." This pensioner was paid June 4, 1873.

CASE 1081.—Private J. S. O——, Co. F, 115th New York, was wounded at Newmarket Heights, September 29, 1864. He was sent from a Tenth Corps hospital on October 2d to Hampton, where Assistant Surgeon Ely McClellan reported a "gunshot wound of the scrotum involving the urethra," and the patient's transfer to Grant Hospital, New York, October 18, 1864. Surgeon A. H. Thurston, U. S. V., reported this man's transfer to the Veteran Reserves, January 25, 1865. No application for pension has been made.

*Urinous Infiltration and Free Incisions.*—Extravasation of urine from shot lacerations of the urethra gives rise to two forms of accidents.<sup>1</sup> When freely infiltrated into the perineal and scrotal tissues, there is rapid swelling with discoloration, and great constitutional disturbance. There is also a chronic form, when the urine slowly permeates the connective tissue, producing a brawny tension of the part and, ultimately, urinous abscesses. In both forms, free incisions,<sup>2</sup> for the evacuation of the urine and disorganized tissues and exudations, constitute the important and essential remedy:

CASE 1082.—Lientenant M. N. N——, Co. C, 47th North Carolina, aged 24 years, was wounded at Gettysburg, July 3, 1863, and was sent to De Camp Hospital on the 19th. Acting Assistant Surgeon E. W. Edwards reported that "the ball entered the posterior aspect of the right natis, passed forward and inward, wounding the urethra, and made its exit through the right upper part of the scrotum without wounding the spermatic cord or testis. The antecedent treatment had consisted of a free perineal incision, through which the urine flowed. When admitted, the patient was very feeble and much emaciated; he could control his bladder, but when the urine was voided it passed entirely through the exit wound and the fistule in the perineum made by the above-mentioned incision. The left half of the scrotum had sloughed, leaving the testicle bare. The patient was allowed a generous diet, with sherry and porter; the parts were kept clean, and the testis wrapped in a linen compress covered with simple cerate; a No. 8 steel bougie was passed every other day, with some difficulty at first, and allowed to remain for ten minutes. The patient began at once to improve, and, at the end of thirty days, the urine flowed entirely by the natural passage. The passing of the sound, however, was continued up to the time of his discharge. The scrotum reformed, the wounds and fistula healed kindly, and when he was transferred, on October 20, 1863, he was, to use his own words, 'as good a man as ever he was.'" On October 24th, this officer was sent to Bedloe's Island for exchange.

CASE 1083.—Private G. Walters, 1st New York Sharpshooters, was wounded in the perineum, at Suffolk, in April, 1863. Assistant Surgeon J. K. Hasbrouck, New York Sharpshooters, reported that a musket ball entered the left buttock and penetrated the pelvic cavity; and that the patient was sent to the hospital of the 6th Massachusetts. Surgeon Walter Burnham, of that regiment, reported that "an incision was made into the urethra, the same as for lithotomy, to communicate with a wound of the canal in order to prevent the general infiltration of urine escaping from the wound in the hip." Death, April 16, 1863.

<sup>1</sup> For an excellent exposition of the effects of acute and chronic extravasation of urine in traumatic injuries of the urethra, consult a clinical lecture at St. Bartholomew's Hospital by Mr. W. S. Savory, F. R. S., in *The Lancet*, January 17, 1874, Vol. I, p. 79. The early use of the catheter is deprecated.

<sup>2</sup> MATTHEW (T. P.) (*Surg. Hist. of the British Army in the Crimea*, etc., 1858, Vol. II, p. 334) records the case of J. Slothers, 21st regiment, aged 22, wounded June 18, 1855, by a musket ball, which entered the left side of the scrotum, divided the urethra, and passed out at the right buttock. A catheter could not be introduced. Free incision into the perineum was made, and an elastic catheter introduced into the bladder through the vesical portion of the divided urethra. Death, June 27, 1855.



*Injuries of the Urethra not caused by Shot.*—Except when caused intentionally or accidentally in surgical manœuvres, these are uncommon. Occasionally, however, they are inflicted under the inspiration of insanity, malice, jealousy, or mischief,<sup>1</sup> of which some examples have been given in treating of wounds of the penis. A single instance of sabre wound of the urethra was reported:

CASE 1084.—Trumpeter J. D. Hall, 10th Ohio Cavalry, was wounded before Fort Donelson in January, 1862, by a sabre thrust through the buttock and perineum. His record for the next three years cannot be traced. Surgeon S. S. Schultz, U. S. V., reported that this soldier was admitted to the post hospital, Camp Chase, May 2, 1865, with traumatic stricture of the urethra, caused by a wound received three years previously. He was transferred to Tripler Hospital, at Columbus, May 5, 1865, where Surgeon J. D. Knight, U. S. V., reported: "This soldier is suffering from stricture of the urethra, produced by a wound from a sabre, received at Fort Donelson. The wound was sewed up immediately after the reception of the injury. Discharged May 30, 1865." The name of this soldier does not appear on the Pension List.

The following remarkable example of eversion of the corpus spongiosum, obstructing the urethra by a cylindrical fleshy mass, recalls the extraordinary case that occurred to Mr. Hilton, at Guy's Hospital,<sup>2</sup> in 1867:

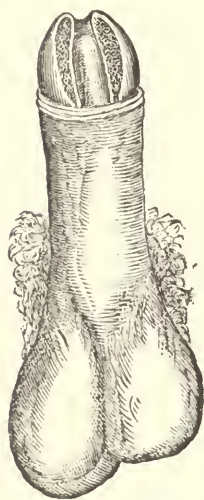


FIG. 291.—Fleshy excrescence in the fossa navicularis, resulting from an old laceration of the corpus spongiosum.

CASE 1085.—Private J. Looney, Co. I, 2d East Tennessee, aged 22 years, was admitted into Asylum Hospital, Knoxville, May 29, 1864, with chronic diarrhœa. He was transferred, on July 25th, to Holston Hospital, and Surgeon H. L. W. Burritt, U. S. V., reported: "Traumatic stricture of the urethra, with vascular excrescence. The patient states that when he was a boy his penis was crushed by a fall between two mill-stones. The urethral canal is tortuous and will not admit the passage of the smallest catheter. There is such complete phymosis that it amounts nearly to occlusion; the probe grates along some hard obstruction and fails to detect a canal for a greater distance from the orifice than about one-fourth of an inch. He frequently urinates incompletely and painfully; his water escapes by drops; he complains of nothing but the mechanical difficulty. July 25th: Circumcision was practised to overcome the phymosis; then a portion of the under part of the glans penis was incised enough to expose a hard cartilaginous tumor, occupying and obstructing the meatus urinarius. This tumor was excised without difficulty, the patient being anesthetized by chloroform. The operation was performed by Surgeon John Shady, 2d East Tennessee. July 30th: The catheter that had been placed in the urethra was removed; the patient urinates with natural freedom, and has, so far, had not a single untoward symptom. August 2d: No change, except that the organ is somewhat less sensitive to the contact of instruments. August 25th: No longer keeps his bed, and has been doing light duty around the hospital; the glans is marked by several sulci, radiating from the meatus as a centre; no difficulty in micturition." This soldier was returned to duty August 31, 1864. He is not a pensioner. The appearance of the cylindrical fleshy tumor, occupying an inch or more of the urethra from the fossa navicularis backward, and exposed by laying open the canal, is represented in the annexed wood-cut (FIG. 291), from a pencil sketch.

CASE 1086.—Private C. A. Maxon, Co. C, 130th New York, aged 23 years, was admitted into David's Island Hospital, New York Harbor, November 15, 1863, with atony of the bladder. Acting Assistant Surgeon J. L. Van Norden reported: "The patient was below the medium size, and of healthy appearance. He stated that since his earliest recollection he had experienced at intervals a want of power in the bladder to expel its contents, and that there never was sufficient contractile power to enable him to throw his water any distance. After a march of two days, some six months since, he arrived at Yorktown in an exhausted condition; says that he first came to himself on the boat going to Washington when he found that he had been insensible for five days. At this period his urine was drawn by catheter for the first time. Arriving in Washington, he was placed in barracks, where he had retention of urine for two days. He was then sent to Judiciary Square Hospital, where, a day after his arrival, a number of surgeons tried to relieve him by catheterization. Failing in this attempt, puncture of the bladder was advised, when the patient requested to be allowed to try the introduction of the catheter. This being granted, he forced the instrument in and drew off the contents of the bladder. Since then he has not been able to pass his water without a catheter, which he uses thrice daily. On examination, a false passage was found, but a No. 12 sound could be passed without difficulty. The urine flowed from the bladder without force; the passage of instruments is followed by considerable constitutional disturbance, depriving him of sleep the night following their use. On November 22d, the patient had facial erysipelas, for which tincture of iron was prescribed. Under this treatment the disease, which had surrounded and partly closed the right eye, quite disappeared by the 26th. The mine was still passed by the catheter on November 29th." This man was discharged the service January 29, 1864, for "stricture of the urethra and false passage." He is not a pensioner.

<sup>1</sup> The American Indians sometimes torture their victims by ablation of the penis. For numerous and varied examples of mutilations, consult Dr. CHEEVERS (*Man. of Med. Jurisprudence for India*, 1870, p. 493, etc.). Dr. WILLIAMSON (*Mil. Surg.*, 1863, p. 120), to "illustrate the tricks that soldiers play on each other," cites the case of Hussey, 18th Regiment, whose companions, while he was drunk, inserted a piece of cane a foot long and tied it in the urethra. Compare Note 2, on page 344, and DEVERGIE (*Médecine Légale*, 1840, T. II, p. 300); MAHOT (*Des ruptures de l'urèthre*, Paris, 1838); THIBAUT (*Des plaies contuses de l'urèthre*, Thèse, Paris, 1863, No. 4).

<sup>2</sup> In that well-known case, described and figured by Mr. BIRKETT (*An. of the Organs of Generation*, in HOLMES'S *System*, etc., 1870, Vol. II, p. 735) and by Mr. BRYANT (*Practice of Surgery*, 1872, p. 600), the subject was a man of fifty, bitten by a stallion when nineteen. A cylindrical fleshy mass, an inch and a quarter long and a third of an inch thick, projected from the meatus.

Other complications of injuries of the urethra and operations will now be considered, whether connected with shot or other traumatic lesions or with surgical diseases:

*Foreign Bodies.*—The urethra may be obstructed by foreign bodies descending from the bladder, or introduced by the meatus, or driven into the canal by projectiles. Arrested in the urethra, they cause dysuria and inflammatory symptoms, and their extraction becomes imperative. The foreign bodies expelled from the bladder may be either calculi or bone fragments, as exemplified in CASES 806, 808,

817, 819, 849, 850, 856; or small projectiles, as in CASE A<sup>8</sup>, page 284; or pieces of cloth, as in CASES 811, 818; or possibly of other foreign substances that have been driven into the bladder.<sup>1</sup> In very rare cases, projectiles are arrested either within the urethra or in such a position in the contiguous tissues as to press against and obstruct the canal,<sup>2</sup> as in CASES 765, 867; and, in other instances, equally rare, fragments of clothing or other foreign bodies may be driven before the missile and lodge in the urethra, as in CASE 1087. The foreign bodies introduced into the urethra by the meatus are either fragments of broken surgical implements, or of substances introduced by patients for the purpose of relieving retention, or else objects as varied as the perverted fancies of onanists. The Army Medical Museum contains many illustrations of the several varieties of foreign bodies that obstruct the male urethra. Among them are seventeen specimens of calculi,<sup>3</sup> expelled or extracted from the canal after detention for periods of varied duration,—splinters of bone impacted in the urethra, as represented in the fifth figure of PLATE VIII, and by wood-cut 242,—a pistol ball, extracted by delicate forceps, and delineated of natural size by FIGURE 231,—several fragments of catheters, bougies, and other instruments, of which one illustration is given on the next page,—bits of twigs, straws, and wires, employed in futile attempts to relieve retention of urine,—melon-seeds, hair-pins, crochet-needles, and sundry other objects introduced into the urethra in order to excite erotic sensa-

tions.<sup>4</sup> For a detailed description of these, reference must be made to a future edition of the Catalogue of the Surgical Section of the Museum; but one or two examples of each



FIG. 292.—  
HUNTER'S  
OR HALES'S  
forceps.



FIG. 293.—  
VIDAL'S  
curette.

<sup>1</sup> Four instances of projectiles engaged in the urethra are enumerated in Note 1, p. 268, and five instances of similar obstruction by bone fragments are mentioned in Note 2, on the same page. In Note 3, p. 285, four cases of obstruction of the urethra by pieces of cloth are cited. The following references may be added: HUSSEY (E. L.) (*Obstruction of the Urethra, a Piece of Bone impacted, ten Years after Injury of the Pelvis*, in the *British Med. Jour.*, March 23, 1867, Vol. I, p. 318); PAGET (J.) (*Separation by direct Violence of a Portion of Bone from the Arch of the Pubes, and its impaction in the anterior Wall of the Urethra, giving rise to Retention of Urine and other Symptoms of Stricture*, in the *Med. Times and Gaz.*, 1865, Vol. II, p. 442). A piece of bone, two-thirds of an inch long, partially encrusted with phosphates, was removed by perineal section from the urethra of a middle-aged man, whose pelvis had been injured by a mass of falling earth.

<sup>2</sup> EVE (P. F.) (*A Pistol-ball shot into the Urethra and extracted by Incision*, in the *Nashville Jour. of Med. and Surg.*, 1867, Vol. II, p. 232) relates an interesting observation of a bullet lodged beyond the membranous portion of the urethra, near the prostate; perineal section on a grooved staff was practised, the foreign body was removed, and the patient, a negro, recovered without a bad symptom.

<sup>3</sup> *Specimens* 587, 4667, 4830, 4983-4-5-6-7-8, 5457, 5476-7, 5522-3, 5562, 5868, 6200. Of these specimens, nine consist mainly of uric acid or urates, six of oxalate of lime, and two of carbonate of lime. Several of the specimens comprise from two to six separate concretions. *Specimen* 4850, constituted by one hundred and fourteen hemp-seed and uric acid calculi, passed by the urethra without becoming impacted, is not included in this series.

<sup>4</sup> On foreign bodies in the male urethra, consult the various treatises on calculous disorders, and on the extraction of foreign bodies, and, also, GROSS (S. D.) (*Foreign Bodies in the Urethra*, Chapt. VII of his *Pract. Treat. on Dis. Inj. and Malform. of the Urin. Bladder, Prost. Gland, and Urethra*, 1855, p. 828); LEE (C. C.) (*Remarks on the Path. and Treatment of Urethral Calculi and of Foreign Bodies in the Urethra*, in the *New York Med. Jour.*, 1867, Vol. VI, p. 97); LESPINE (L. B.) (*Sur les corps étrangers qui prennent naissance dans les voies urinaires*, Thèse de Paris, 1815); GEORGE (V. P. M.) (*Des diverses voies par lesquelles les corps étrangers peuvent pénétrer dans les organes urinaires*, Thèse de Paris, 1838, No. 368); BOURDON (R.) (*Quelques considérations sur les corps étrangers des organes géno-urinaires*, Thèse de Paris, 1871, No. 195); LEROY D'ETIOLLES (*Sur l'extraction des corps étrangers solides autres que les calculs*, Paris, 1843); GÜNTNER (*Chir. Beobachtungen. Fremde Körper in der Harnröhre*, in *Memoirabilien*, 1869, B. XIV, 7, S. 158); FOUCHER (*Sur les corps étrangers introduits dans l'urèthre et dans la vessie*, in *Bull. g'n. de Thérap.*, 1860, T. LIX, p. 493); PAILLET (*Des corps étrangers de la vessie et de l'urèthre*, Thèse de Paris, 1852, No. 186); DEMARQUAY et PARMENTIER (*Des corps étrangers*



variety may be briefly alluded to here. The particulars of a case which furnished two of the specimens of urethral calculi, on account of the eminent position of the subject of it, possess extrinsic interest:

CASE A<sup>10</sup>.—President Andrew Johnson, in August and September, 1867, suffered intensely from the frequent recurrence of paroxysms of lumbar pain, dysuria, and other symptoms of nephritic colic; symptoms which his physician, Dr. Basil Norris, U. S. A., ascribed to the passage of a renal calculus. After a few weeks' intermission, about the middle of October, another attack of difficult micturition, with tenesmus and great pain, announced that the calculus had entered the vesical end of the urethra. The pain was mitigated by the use of hypodermic injections of sulphate of morphia. On the second day of the paroxysm, the calculus could be felt in the serotal portion of the canal, and Dr. Norris proposed to attempt its extraction by the aid of a curette or forceps; but the patient objected to operative interference; and, as micturition, though difficult and painful, was still accomplished sufficiently to avert any dangerous vesical accumulation, the expectant and anodyne treatment was continued. During the night the calculus was expelled, and, at the morning visit, the patient handed the concretion (FIG. 294 *b*) to his attendant, remarking that he might exclaim with the old Greek philosopher: *Εὐρηκα!* The urethral irritation at once subsided, and, on the same day, the President undertook a journey to Boston. The calculus, weighing six grains Troy, was a hard tuberculated ovoid concretion, consisting almost wholly of oxalate of lime. In the spring of 1869, after a similar train of symptoms, a second, somewhat smaller, calculus (FIG. 294 *a*) was spontaneously expelled. While it was engaged in the urethra, the pain was so excessive that Dr. Norris was summoned to Greenville; but, upon his arrival, March 9, 1869, the offending concretion had escaped. The patient recuperated as rapidly as on the first occasion, and has since enjoyed immunity from calculous disorder. The second concretion was similar in weight, color, and composition to the first, but of irregular form, as indicated in the wood-cut (FIG. 294 *a*).

It is unnecessary to reproduce the illustrations of the bone-fragments and bullets voided by the urethra. They may be found on pages 284 and 294. The details of a case in which urethrotomy was resorted to, in order to extract the extremity of a large flexible catheter (FIG. 295) broken off in an attempt at dilating a dense stricture anterior to the scrotum, will be related in the next quinquennial report of surgical cases in the Army. The incision in the pendulous portion of the urethra was closed, with difficulty, six weeks after the operation.

An abstract has been already published<sup>1</sup> of a case in which a broom-straw (FIG. 296), broken off in the urethra in a patient's attempt to relieve a distressing attack of retention of urine, was removed through an anti-scrotal incision by Assistant Surgeon J. H. Bartholf, U. S. A. The nature of foreign bodies that lodge in the urethra, and the positions they may occupy, are so varied, that the surgeon is often called on to improvise a plan for their removal, and it is impracticable to formulate general rules for their extraction. When impacted near the meatus, it is often possible to remove them with ordinary forceps, a division of the urethral orifice frequently facilitating this procedure. A bent probe will often answer the purpose when the foreign body lies near the free end of the urethra, or the body may be caught in the metallic loop, long since proposed by Marini (FIG. 297). By palpating the canal the exact position of the foreign body can be determined, and then, if it is lodged in the pendulous part, by deflecting the urethra, the loop may be slipped over the foreign substance and made to extract it, if its size and form permit. In many cases, however, such simple means will be unavailing, and it will be necessary to employ more complicated contrivances, or even, as has been seen, to have recourse to urethrotomy.

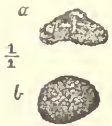


FIG. 294.—Two mulberry calculi passed by the urethra: *a*, Spec. 5562; *b*, Sp. 4830.



FIG. 295.—Fragment of rubber catheter removed by urethrotomy. Spec. 5965.




FIG. 296.—Broom-straw removed by urethral section. Spec. 5527.

*introduits dans l'urèthre*, in *Gaz. hebdom.*, 1857, T. IV, p. 23; GRUBE (W.) *Beiträge zur Casuistik der Steine und Divertikel der männlichen Harnröhre*, in *Berliner Klin. Wochenschrift*, 1867; CUTTER (E.) *Case of Urethral Calculus*, in *Boston Med. and Surg. Jour.*, October 6, 1870; PHILLIPS (C.) *(Des corps étrangers introduit dans l'urèthre, Chap. VII. de son Traité des mal. des voies urinaires, 1860, p. 666)*; RELIQUET *(Opérat. nécessitées, par un gravier ou un calcul dans l'urèthre, Chap. VI. de son Traité des op. des voies urinaires, 1871, p. 572)*; CUTTER (E.) *(Case of Urethral Calculus, in Bost. Med. and Surg. Jour., October 6, 1870)*; ANNANDALE (T.) *(Case of Multiple Calculi in the Urethra, in Brit. Med. Jour., 1869, p. 399)*; GONTARD *(Sur des portions d'os sortis de l'urèthre, in Jour. de Méd., 1757, T. VI, p. 107)*; BOINET *(Mém. sur un procédé nouveau, etc., pour l'extraction des corps aigus introduits dans l'urèthre, in Jour. des connaissances médico-chir., 1847, T. II, p. 145)*.

<sup>1</sup> In Circular 3, S. G. O., 1871, p. 255: Case of Private J. Kline, Co. C, 11th Infantry.

Jules Cloquet substituted for Marini's loop (FIG. 297) a silver canula and wire noose.<sup>1</sup> Professor Voillemier regards the so-called Hunter's forceps (FIG. 292) as the best instrument for the extraction of calculi from the urethra.<sup>2</sup> In some of its innumerable modifications, this instrument has been largely employed in the removal of foreign bodies from the urethra or bladder, constituting, indeed, under the designation *bilabe* or *trilabe*, the essential part of the apparatus with which modern lithotomy was successfully practised at the end of the first quarter of the present century. The reliable Vidal considered his curette (FIG. 293), consisting of a flattened silver canula with a button pushed forward by a stylet, as one of the best means of extracting foreign bodies from the urethra, and I have used it successfully more than once, for this purpose; but, with all the curettes, the difficulty of getting behind the foreign body is sometimes



FIG. 297.—Marini's metallic urethral loop.  $\frac{1}{2}$ . [After HEISTER, PLATE XXIX, FIG. 7.]

insuperable. With a view of eluding it, Ravaton<sup>3</sup> invented a jointed curette, designed to be insinuated between the foreign body and the urethra (or the auditory canal) while straight, a button afterward being projected laterally by the movement of a slide. Leroy modified this contrivance (FIG. 299), and it has been further improved by the admirable instrument-maker Charrière.<sup>4</sup> It is the basis of the urethral lithotrites of Dubowitzky and of Nélaton. The varieties of urethral forceps that have been recommended are almost innumerable. The form used by Sir Astley Cooper (FIG. 281, p. 350) is celebrated rather for the success of its application by that great surgeon than as an invention; for it had been known for two centuries. The instrument has been improved by Weiss, and forms part of the armamentarium of British surgeons.<sup>5</sup> It is more useful for the extraction of small bodies from the bladder than from the urethra. The construction of the urethral forceps of Sir Henry Thompson is beautiful; but the slender blades have a feeble grasp. The action of the lever forceps of Robert and Collin is more effective; but the latest and best instrument of this description is probably that fabricated by M. Mathieu<sup>6</sup> (FIG. 298)

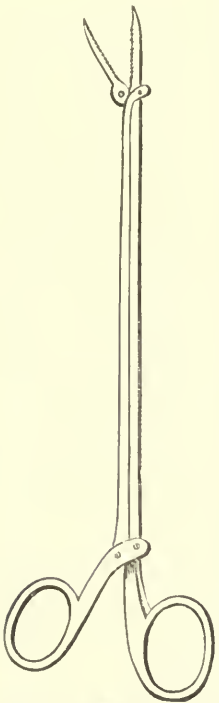


FIG. 298.—M. MATHIEU'S urethral forceps

insuperable. With a view of eluding it, Ravaton<sup>3</sup> invented a jointed curette, designed to be insinuated between the foreign body and the urethra (or the auditory canal) while straight, a button afterward being projected laterally by the movement of a slide. Leroy modified this contrivance (FIG. 299), and it has been further improved by the admirable instrument-maker Charrière.<sup>4</sup> It is the basis of the urethral lithotrites of Dubowitzky and of Nélaton. The varieties of urethral forceps that have been recommended are almost innumerable. The form used by Sir Astley Cooper (FIG. 281, p. 350) is celebrated rather for the success of its application by that great surgeon than as an invention; for it had been known for two centuries. The instrument has been improved by Weiss, and forms part of the armamentarium of British surgeons.<sup>5</sup> It is more useful for the extraction of small bodies from the bladder than from the urethra. The construction of the urethral forceps of Sir Henry Thompson is beautiful; but the slender blades have a feeble grasp. The action of the lever forceps of Robert and Collin is more effective; but the latest and best instrument of this description is probably that fabricated by M. Mathieu<sup>6</sup> (FIG. 298)



FIG. 299.—Articulated curette of LEROY (d'Étiolles).  $\frac{1}{2}$ .

<sup>1</sup> GÜNTHER (*Lehre von den Blut. Op.*, Leipzig, 1860, B. IV, S. 443) cites cases in which HANEKROTH, of Siegen, in 1811, and DIEFFENBACH extracted urethral calculi by wire-loops (*Drahtschlinge*), HANEKROTH using a fine piano-string. DESCHAMPS (F. J.) (*Traité hist. et dogmat. de la taille*, 1826, T. IV, p. 222) states that he had frequently successfully used a bent probe.

<sup>2</sup> VOILLEMIER (*Traité des mal. de l'urèthre*, 1868, p. 509). HALES (*Statistical Essays*, 1733, Vol. II, p. 257) believed himself the inventor of this instrument, and many surgical critics have accorded him the credit of it. Yet an almost identical apparatus was figured long before him by FABRICIUS HILDANUS in the *De lithotomia vesicæ liber*. Cnp. XXVII, p. 755, Francofurti, 1646 (*Delineatio speculi ad extrahendos calculos e virga*), and by SCULTETUS (*Armamentarium chirurgicum*, Francofurti, 1666, Tab. XVI, Fig. 3, p. 25). It is, indeed, only the simplified reproduction of the instrument employed by FRANCO (*Traité très ample des hernies*, Lion, 1561, p. 147) and by ANDREAS DELLA CROCE (*Chirurgia universalis perfetta di tutti le parti pertinenti alchirurgia*, Venezia, 1574) for the extraction of small calculi from the bladder. FRANCO spoke of the instrument as invented long before him: "The first inventor," he said, "must have had more *loz* than I: for, as it is commonly said, it is easier to modify advantageously an invention than to invent it."

<sup>3</sup> *Pratique moderne de la Chirurgie*, Paris, 1776, T. I, p. 378, et pl. IV.

<sup>4</sup> See a figure and description in PHILLIPS, *Traité des maladies des voies urinaires*, 1860, p. 621, Fig. 90. For details of LEROY'S instrument, compare VOILLEMIER, *op. cit.*, p. 508.

<sup>5</sup> FERGUSSON (W.), *A System of Practical Surgery*, 5th ed., 1870, p. 710. WEISS'S *Illustrated Catalogue*, 1863, Pl. XXIV, Fig. 7.

<sup>6</sup> MATHIEU, *Pince uréthrale à double levier et à branches parallèles*, in *Bull. de l'Acad. de Méd.*, Séance d'Octobre 10, 1871, and in *Gaz. des Hôpitaux*, 1871, No. 114.



It is more prudent to resort to incision of the urethra for the removal of foreign bodies, rather than to incur very serious danger of injuring the canal by persistent efforts at extraction; for incised longitudinal wounds of the urethra generally heal without fistules. Friable bodies too large to traverse the urethra, and especially impacted calculi, may often be advantageously treated by crushing and removal in fragments. This is a very old operation. It is described in detail by Abulkasim<sup>1</sup> (A. D. 1100), by Franco (1591), and by Ambroise Paré, who, as is too often the case, neglects to acknowledge his indebtedness to his predecessors. Though practised by Fischer, it was regarded by surgeons generally as of merely historical interest, until the invention of lithotripsy recalled attention to it.<sup>2</sup> Civiale perfected a urethral lithotrite (Fig. 300), which, in skilful hands, is sometimes very serviceable. The great difficulty consists in passing the female blade behind the concretion. This is sometimes avoided by strongly depressing this blade, and, if the foreign body is in the pendulous part of the urethra, by bending the penis abruptly (Fig. 302), as advised by Reliquet and long before by Paulus Ægineta.<sup>3</sup> With the most careful manipulation, however, the female blade will sometimes strike against the foreign body and press it backward. Nélaton sought to evade this obstacle by having fabricated, by M. Mathieu, a lithotrite with a jointed female blade. The objection to this instrument is that it has not sufficient strength to crush a really hard calculus; and, if such a one is seized and cannot be pulverized or disengaged, the difficulty of withdrawing the instrument may place the operator in an awkward dilemma. Ingenious instruments have been designed for cutting, bending, and otherwise facilitating the extraction of pins, bougie-fragments, and the like. Unless habituated to the use of such implements,<sup>4</sup> the surgeon will prefer, in difficult cases, a clean longitudinal incision to the risk of lacerating the canal.




FIG. 300.—CIVIALE'S urethral lithotrite. [After M. CHARRIÈRE'S pattern.]



FIG. 301.—NÉLATON'S jointed urethral brisé pierre. [After M. MATHIEU'S pattern.]

<sup>1</sup> ALBU'CASIS (*De Chirurgia*, Oxon., 1778, cura JOHANNIS CHANNING. Lib. II, Sect. LX, p. 289): "Dein sumas filum, et cum illo ligato virgam subter calculum, ne forte in vesicam calculus revertat. Deinde intronittas ferrum perforans (terebram) cum lenitate in penis foramen donec ferrum perforans ad ipsum calculum pervenerit; et terebram cum manu tua revolve in ipsum calculum paulatim, et tu conator perforationem ejus, donec illum calculum penetraveris per alterum latus. Equidem urina illico liberata erit. Deinde cum manu tua constringe reliquias calculi, ab exteriori parte virgæ, illæ etenim perforatæ sunt, et cum urina oducentur: et sanatus erit æger; si voluerit deus excelsus."

<sup>2</sup> Compare FRANCO (*Traité des hernies*, 1561, p. 116); PARÉ (*Œur. compl.*, Liv. VIII, Chap. XLII); FISCHER (C. D.) (*De calculo vesicæ urinariæ in urethram impulso et singulari encheiresi absque sectione exempto*, Erford. 1744); DUBOWITZKY (in PHILLIPS, *op. cit.*, p. 620), etc.

<sup>3</sup> RELIQUET (*Traité des Opérations des Voies Urinaires*, Paris, 1871, p. 586); PAULUS ÆGINETA. ADAMS'S ed., London, 1846, Book VI, Sect. LX, Vol. II, p. 356.

<sup>4</sup> GÜNTHER (*Lehre von den Blut. Operat.*, 1860, B. IV, S. 442 et seq.) enumerates not less than sixteen modes of elimination of foreign bodies from the urethra, citing illustrations of each from numerous authors. It will suffice cursorily to hint at the subdivisions: 1. Spontaneous (FABRICIUS HILDANUS, CIVIALE); 2. After suppuration (BARTHOLINUS, STEIGER); 3. By manipulation (FR. JACQUES); 4. Copious drinking of diluents (SIR CH. BELL); 5. Pushing back into the bladder (DEMARQUAY); 6. Dilatation by bougies (SIR CH. BELL, DELPECH, AUMONT); 7. Injection of liquids (WIGAN, SCHREGER); 8. Insufflation of air (TROUSSET); 9. Suction (FOURCROY, CHOPART); 10. Removal by special instruments (FRIBBE, V. AMMON, HUNTER, WEISS, DUBOWITZKY); 11. Curette (TARLER, MOHLENHEIM); 12. Trituration by forceps and stylet (AMUSSAT); 13. Crushing (DEMARQUAY, MURER); 14. Wire and metal loops (HANCKROTH, DIEFFENBACH); 15. Forceps (SEYDL, CIVIALE, DE LAMOTTE, SÉGALAS); 16. Incisions (BRODIE, SABATIER, BOULI, MURAT, DEMARQUAY, etc.)

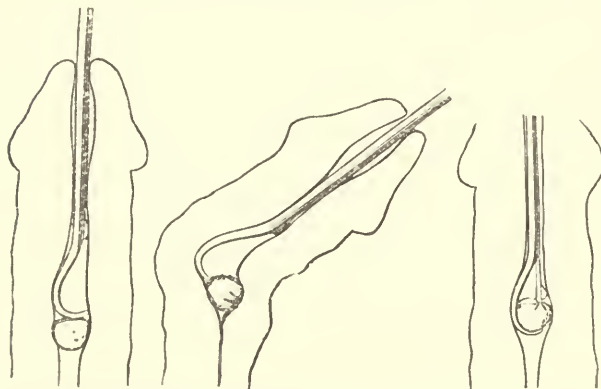


FIG. 302.—Diagrams illustrating the introduction of a lithotrite and the seizure of a urethral calculus. [After RELIQUET.]

The rarity of the complication of traumatic lesions of the urethra by foreign bodies has been pointed out on page 375, and the instances reported of foreign bodies in the urethra consequent upon wounds of the bladder are there enumerated. A rare instance of shot wound of the urethra, with a piece of cloth impacted in the canal, was recorded, and another in which Surgeon C. S. Muscroft, U. S. V., successfully extracted a broken catheter from the canal with the aid of forceps.<sup>1</sup>

CASE 1087.—Private T. J. Kinnear, Co. D, 13th Indiana, was wounded near Suffolk, April 13, 1863, and sent to the regimental hospital, where Surgeon A. D. Gall, 13th Indiana, noted a "gunshot wound near the anus, wounding the urethra, produced by a conical rifle ball, which entered on the right and a little anterior to the anus, passing upward and forward a short distance, and wounding the urethra; the ball, however, dropped out of the wound and was found in his clothing. The urine, during micturition, passes out of the wound—at first in large quantities, but considerably less now. The patient is doing well, and seems to be recovering without any other unfavorable complication. This man had also a flesh wound over the metatarsal bones of the left foot, which was quite severe, but is doing well: treatment, cold-water dressings." Surgeon T. H. Squire, 89th New York, reported: "He was wounded while skirmishing in front of the enemy; having first received a wound in the foot, he was upon his hands and knees trying to escape from his dangerous situation, when a second ball struck exactly in a line corresponding to that of the usual incision for the lateral operation of lithotomy, on the right side of the body, about two inches from the anus. The patient was conveyed in a light cart about one mile to the hospital at Suffolk, where his trousers were removed from him while he was in a sitting posture on the edge of a chair, and, while this was being done, the ball dropped on the floor. Soon after this the patient undertook to urinate, but the effort caused him so much pain that he desisted until the next day, when he was compelled to evacuate the bladder. At this time most of the urine escaped by the wound. Subsequently, during micturition, the water escaped in both directions, about half one way and half the other; but at the present time, June 7th, only a very small portion of it escapes through the false passage, and the wound is nearly healed. About six weeks after the injury, a piece of his drawers, of cotton fabric, was forced out of the meatus by the stream of urine. A purulent discharge has, all along, been going on from the meatus as well as from the wounds. It is probable that the urethra was wounded in the membranous portion. The catheter has not been used at any time, and, virtually, the case has been left entirely to the efforts of nature, and its progress thus far has been favorable." This man was sent to Chesapeake Hospital May 12th, and transferred to the Veteran Reserve Corps September 1, 1863. He has not applied for a pension.

CASE 1088.—[An extended account of the early history of this case has been published<sup>2</sup> by the attending medical officer, Assistant Surgeon B. C. Brett, 21st Wisconsin. The following memoranda are compiled from the hospital and pension records.] Corporal J. Sheets, Co. I, 101st Ohio, was wounded at Murfreesboro', December 31, 1862, and was sent to a Fourteenth Corps hospital, in charge of Surgeon J. L. Teed, U. S. V. A musket ball had entered the right buttock and passed out at the left side of the scrotum, dividing in its passage the membranous portion of the urethra. There was great œdema of the scrotum, with interstitial extravasation of blood, extending to the inguinal and pubic regions. The urine could be voluntarily retained, but, on micturition, it escaped chiefly through the scrotal wound. A catheter was introduced into the bladder and cold lotions were applied to the wound-orifice. On January 3, 1863, two free incisions were made into the tunica vaginalis, and pus and decomposed urine were freely discharged from the tumefied scrotum. In the next two days the walls of the scrotum sloughed anteriorly, leaving the testes bare. On January 21st, the vesical extremity of the catheter was found encrusted, and its calibre was nearly obliterated by phosphatic deposition. It was removed and cleaned, and replaced by another instrument. On January 24th, this was found similarly encrusted and clogged, and a smaller gum-elastic instrument was substituted. On January 25th, in withdrawing this instrument it broke, and about a third of the distal extremity remained in the urethra, where its open extremity could be felt by a probe. The ward medical officer, Assistant Surgeon B. C. Brett, 21st Wisconsin, being baffled in attempts to extract the foreign body, Surgeon C. S. Muscroft, U. S. V., succeeded in grasping the end of the broken fragment with a long narrow bullet forceps, and safely extracted it. The perineal wound was drawn together by adhesive straps with a view of obliterating it. On January 27th the patient had a chill, and a large perineal abscess formed, and, on February 1st, this was incised, a vast amount of pus being liberated. He was transferred, as reported by Surgeon J. T. Finley, 2d Kentucky, to the general field hospital at Murfreesboro' on March 21st, and not discharged "cured," on February 2d, as published by Assistant Surgeon Brett. April 2d, this man was furloughed, and September 26, 1863, transferred to Co. A, 15th Veteran Reserves (Gen. Ord. 320, A. G. O., 1863), and discharged June 30, 1865, and pensioned. Examiner C. W. Backus, of Three Rivers, reported that "he has chronic conjunctivitis, and sclerotic inflammation, etc.," without adverting to the disability from wounds. In his application for increase of pension, the pensioner states under oath that he was "wounded by gunshot, the ball passing through the body, coming out below the left groin, severing the water passage, causing the lower part of the scrotum to slough off, and severing and injuring the muscles of the left leg so as to leave the same weak and ready to give out when standing." This pensioner was paid September 4, 1873.

Complex instruments are unlikely to be required for the removal of foreign bodies connected with shot wounds of the urethra; for, if accessible, they may be extracted through the wound, and otherwise, it is better to resort to incision, for the canal will not be in a condition to permit tedious and painful manœuvres.

<sup>1</sup> For instances of bougies breaking in the urethra, consult: MASON (E.) (*Stricture of the Urethra; Breaking of a Bougie in the Urethra*, in *Am. Jour. Med. Sci.*, 1869, Vol. LVIII, p. 391); BANCROFT (*Stricture of the Urethra; Extraction of a broken fragment of a Gutto-percha Bougie*, in *Bost. Med. and Surg. Jour.*, 1873, Vol. 10, p. 206); and HARTS-HORNE (H.) (*Phila. Med. Times*, 1874, Vol. IV, p. 432).

<sup>2</sup> BRETT (B. C.), *Removal of broken Catheter from Bladder*, in the *Am. Med. Times*, 1863, Vol. VII, p. 181.



*Treatment of Wounds of the Urethra and of Traumatic Strictures and Fistules.*—The immediate introduction of a catheter into the bladder, if it is possible to pass one, has long been regarded as indispensable<sup>1</sup> in wounds of the urethra, and was the established rule of practice during the war. When this was accomplished and foreign substances were removed, the edges of wounds were approximated over the catheter by adhesive strips,<sup>2</sup> and a compress of lint completed the dressing.<sup>3</sup> Agreed thus far, surgeons differed widely in opinions respecting the period of retention of the instrument, or whether it should be retained at all. Some experienced practitioners advised that the catheter should be introduced only often enough to prevent repletion of the bladder, and a growing disapprobation of protracted maintenance of instruments was undeniable. A similar modification of former views is observable in the writings of cotemporaneous European military surgeons.<sup>4</sup> On the other hand, there may be noted a greater confidence in the advantages of early and free perineal and scrotal incisions when the ball-track communicating with the urethra is tortuous and deep and the danger of urinous infiltration and abscess imminent.<sup>5</sup> The immediate introduction of a catheter after a shot laceration of the urethra will often present great difficulties to the field surgeon, pressed for time and unprovided with a variety of catheters. Nevertheless the attempt must be made, with the utmost caution and delicacy of manipulation, without waiting until the desire to urinate is urgent. M. Voillemier teaches<sup>6</sup> that a medium sized silver catheter is the best for the purpose, and the pocket-case always affords such an instrument. A full-sized flexible catheter, always at hand in the hospital knapsacks or field-companions, is the instrument preferred by most of our surgeons, and approved by M. Legouest.<sup>7</sup> If the operator is foiled, attempts may be repeated with small flexible catheters; and if even a filiform instrument can be inserted, it may be used as a conductor (FIG. 303) for an instrument of larger calibre. Sometimes the difficulty of introducing even the smallest instrument is invincible, and then it is imprudent to incur the hazard of making false passages by insisting on catheterization. If there is retention of urine, and interference is imperative,

<sup>1</sup> LARREY (D. J.) (*Mém. de Chir. mil.*, 1812, T. II, p. 164); LEGOUEST (*Chir. d'Armée*, 1872, p. 434); GUTHRIE (*Lect.*, etc., 1847, Conclusion 18; *Commentaries*, 1855, 5th ed., p. 614); TRIMMER (*Handbook*, etc., 1861, p. 87); CHISOLM (*Man. of Mil. Surg.*, 1864, p. 350); MATTHEW (*Hist. Brit. Army in Crimea*, Vol. II, p. 334); BECK (*Chir. der Schussverletz.*, 1872, S. 566).

<sup>2</sup> HENNEN (*Princ. of Mil. Surg.*, 3d ed., 1829, p. 450) remarks: "Wounds of a most distressing nature, but fortunately not very common, occur in the perineum, and in the organs of generation. In the first class, the elastic gum catheter is of the utmost assistance to us. In the few cases which I have met with a perfect cure was effected by its employment, together with that of small adhesive straps to bring the lips of the urethra together, and light easy dressings, particularly finely scraped dry lint, without the aid of any scarifications whatever; the latter application, with an occasional emollient poultice, has generally brought the wounds of the genitals to a healthy state."

<sup>3</sup> THOMPSON (J.) (*Report of Observations, etc., after the Battle of Waterloo*, 1816, p. 111) remarks: "We saw one case at Brussels, and another at Antwerp, in which a ball had carried away a considerable portion of the inferior surface of the urethra, with a portion in one of the cases, of the anterior part of the scrotum. In both instances catheters were introduced, by which the urine was discharged, and the granulations forming on the edges of the wounds very properly drawn together by means of adhesive straps placed over these catheters."

<sup>4</sup> See notes on pages 352, 356, and 373. STROMEYER (L.) (*Maximen der Krügsheilkunst*, 1855, S. 662) observes: "Open injuries of the urethra from shot wounds heal readily, as I have several times witnessed, without leaving a fistule or requiring the maintenance of a catheter." Treating of ruptures of the urethra, MR. J. BIRKETT (*Holmes's System, etc.*, 1870, Vol. II, p. 727) says: "A catheter should not be secured in the bladder, for when this is done the urine may ooze along the canal, by the side of the instrument, and become extravasated into the tissues about the site of the laceration. Besides, the presence of the instrument stretches the urethra and tends to keep the divided fissures apart."

<sup>5</sup> The treatment of urinous infiltration from shot injury of the urethra by free perineal and scrotal incisions has been approved and practised equally by the older and more modern military surgeons. Thus, BILGUER (J. U.) (*Chir. Wahrnehmungen*, 1763, S. 356) cites the case of Ratsch, wounded at the battle of Prague, May 6, 1657; the ball, entering at the root of the penis, perforated the urethra and the *corpora cavernosa*. No urine passed for four days. The penis and scrotum were swollen and highly inflamed; urine passed through the wound on the fourth day; the scrotum was opened and a copious collection of urine and pus was allowed to escape; recovery. STROMEYER (L.) (*Maximen*, u. s. w., 1855, S. 663) records a case of shot laceration of the urethra observed at Hadersleben, in 1849, three days after an assault on Fridericia. The ball entered on the left side of the penis and severed the membranous portion of the urethra, dragging it from its attachments. Dr. STROMEYER made a free and deep incision to the urethra, relieving the infiltration, found the ball, and introduced a catheter through the vesical portion of the urethra. The patient died, fifteen days after the injury, of pyæmia. Dr. STROMEYER regrets that he had not seen the injury in its earlier stage and made a precise diagnosis. He would not, he says, have attempted to introduce a catheter.

<sup>6</sup> VOILLEMIER, *Lésions traumatiques de l'urèthre*; *loc. cit.*, p. 470.

<sup>7</sup> LEGOUEST (L.) (*Chirurgie d'Armée*, 2<sup>e</sup> éd., 1872, p. 434): "L'introduction d'une sonde laissée à demeure dans la vessie est la première indication qui se présente dans les solutions de continuité de l'urèthre: elle a pour but d'empêcher la rétention d'urine et l'infiltration urinaire, et de prévenir les rétrécissements. La sonde doit être de gomme élastique et d'un calibre aussi considérable que possible."

it is safer to have recourse to perineal section, or to puncture of the bladder, expedients to be hereafter considered. Occasionally, when it is impracticable to pass a catheter by the meatus, because of the entanglement of the extremity of the instrument in the lacerated canal, it is feasible to gain the bladder through the vesical portion of the urethra. This accomplished, the free end of the catheter may be engaged in the anterior portion of the urethra, through the wound, and carried forward through the meatus, and the continuity of the canal may thus be re-established. If it is possible to introduce a catheter<sup>2</sup> before the bladder voluntarily or involuntarily voids itself, the dangers of inflammatory swelling and of urinary infiltration will be largely diminished.<sup>3</sup> Unhappily, in war-surgery, this salutary prophylactic measure is seldom practicable. If the bladder happens to be distended when the urethra is torn by a ball,<sup>4</sup> the soldier will yield to the desire to micturate, and the urine will pass through the lacerated wound. Confidence is no longer reposed in the general and local blood-letting, by which the older surgeons sought to avert the inflammatory complications incident to this form of injury, and it is the more necessary to insist on such other means of moderating inflammation as are likely to be effective. Absolute rest should be conjoined with a severely restricted diet. Diluent mucilaginous drink should be given in moderation; for it is unwise to vex the urinary passages by inordinate secretion. Opium and camphor by the mouth or in suppository are of great advantage in allaying irritation. The bowels should be kept soluble by saline laxatives. Warm baths are grateful and useful.

Assuming that a catheter has been passed to the bladder, the question arises of the duration of its retention, and this must be determined by the attendant circumstances. If the laceration of the urethra is ante-scrotal, it will be prudent to let a full-sized gum-elastic catheter remain in for twenty-four hours, and



FIG. 303.—Improved catheterization on a conductor. [After GAUJOT et SPILLMANN.] 3.

<sup>1</sup> GAUJOT et SPILLMANN, *Arsenal de la Chirurgie Contemporaine*, Paris, 1872, T. II, p. 693, Fig. 1367. Compare also the figure in M. MAISON-NEUVE'S article in the *Gazette des Hôpitaux*, 1852, p. 311.

<sup>2</sup> To the circumstances under consideration the emphatic language of CIVIALE is especially applicable: "Le cathétérisme est une opération importante, puisqu'elle décide parfois de la vie des malades. \* \* Les difficultés dont elle est entourée, sont aussi sérieuses que les accidents qu'elle peut produire."

<sup>3</sup> "As far as precept without practice can impart instruction on this subject, the inexperienced practitioner will find M. VOLLEMIER a reliable guide. Treating of traumatic lesions of the urethra, the eminent surgeon of Hotel Dieu says (*op. cit.*, p. 476): 'The surgeon should sound the patient as early as possible, without waiting until the latter wishes to urinate. He will select a medium-sized silver catheter, which he can direct more surely than a flexible instrument. Having introduced it into the meatus, he will push it forward very gently, having care to make its extremity follow the upper wall of the canal, which is generally preserved even in the midst of the most serious lacerations. If he reaches the bladder safely, he may immediately replace the metallic catheter by another of caoutchouc, which the patient will more easily tolerate. But, if the catheterization has been troublesome, he will refrain from this change, for he may encounter new obstacles, and be less fortunate than in his first attempt. He will leave in the silver catheter for a day or two, to give the tissues time to mould themselves, as it were, upon it, and will then only attempt to replace it by a flexible catheter. But, however experienced one may be in practising catheterization, he cannot always introduce a silver catheter, and will be compelled to resort to flexible catheters of different forms and sizes, and trust a little to chance. After many gropings, one often succeeds in passing a very small instrument; this is already something gained. It must be left in place, its free extremity scrupulously kept open. As it does not fill the canal, and is of too small calibre to empty the bladder rapidly, the urine, if the patient has an urgent desire to urinate, will pass without it, and reach the wound. This accident is very common. A large catheter maintained in the bladder is the best means of preventing it; but this does not always obviate the difficulty; sometimes it even promotes it by irritating the bladder and inducing contraction. When there is this vesical intolerance, a very soft catheter, which has had a proper curve given it, should be chosen, and care should be taken to insert it only just beyond the neck of the bladder, and to leave its free extremity unplugged.'

<sup>4</sup> The diversity of opinion expressed by writers on military surgery respecting the average condition of the soldier's stomach in battle (see notes to pp. 41, 57) as regards repletion or vacuity, is paralleled by their antagonistic dogmas in relation to the average state of the bladder. LARREY (D. J.) (*Mém. de chir. mil. et camp.*, 1817, T. IV, p. 285) believed that the bladder would generally be found distended in action: "La chaleur de l'action et sa durée les détournent du soin de verser leur urine; ce liquide s'accumule dans la vessie qui offre alors, en remplissant le bassin, une telle surface que la cause vulnérante ne peut entrer dans cette boîte osseuse sans toucher ou entamer ce viscére." Dr. CHISOLM (*A Manual of Mil. Surg.*, 1864, p. 352) observes: "Fortunate it is for men going into battle that the excitement under which the troops are at that time laboring causes a continual dropping from the ranks to urinate, so that rarely does a soldier go into battle with his bladder full. In this physiological fact lies the safety of many a man, as the contracted bladder, concealed behind the pubis, in the cavity of the pelvis, often escapes injury from the passage of a ball, which, were the organ distended, would assuredly traverse it." Dr. CHISOLM appears to forget that, under the circumstances he depicts, the immunity of the bladder, the ball pursuing the same course, is purchased at the expense of a perforation of the peritoneal cavity.



then introduce such a catheter as can be passed with the least inconvenience, whenever the patient desires to urinate, until cicatrization has so far progressed that the contact of the urine is no longer irritating. The reintroduction of an instrument can rarely present serious difficulty when the laceration is in the penile portion of the canal; the irritation excited by the permanent retention of an instrument can here be safely avoided. When a shot wound involves the bulbous or membranous portions of the urethra, the problem is more complex. The dangers from protracted retention of a catheter and the difficulty of replacing it when withdrawn are alike augmented. It is generally inculcated that, in such cases, a catheter should be left in, unless its presence induces intolerable irritation, until cicatrization has fairly commenced. Yet this precept is maintained less positively than formerly,<sup>1</sup> and is rejected by many. There is a middle course, that has not been sufficiently tested experimentally to decide on its value: It is possible to withdraw the catheter, as soon as it occasions discomfort, over a long filiform conductor,<sup>2</sup> which might remain<sup>3</sup> without

<sup>1</sup> Sir BENJAMIN C. BRODIE, speaking of perineal fistules (*Lectures on the Diseases of the Urinary Organs—Works*, 1865, Vol. II, p. 441), says: "I formerly have advised the patient never to void his urine without the aid of the catheter, but I am now inclined to believe that the irritation thus kept up tends, on the whole, to delay rather than to expedite the cure. At other times I have kept the patient in bed for some weeks, with an elastic gum catheter constantly in the urethra and bladder; but I cannot say that, with my present experience, I have much more faith in this mode of treatment than in that which I have just mentioned. After a few days, the urine generally begins to flow by the side of the catheter, which does not, therefore, answer the purpose for which it was introduced, of preventing its escape by the sinus. Then in many cases the catheter has the effect of a seton, causing an abundant suppuration of the urethra, and the purulent discharge, finding its way into the sinus, prevents it from closing as much as it would be prevented by the contact of the urine."

<sup>2</sup> There is rarely difficulty, as I have found by repeated experiment, when either a silver or gum catheter is introduced into the bladder, in inserting through one of the eyes a small whalebone guide-bougie, with a spiral bulbous tip, or a filiform gum conductor, its conical tip abruptly bent. By sewing or tying the proximal end of such a guide to a straight stylet, the catheter may be withdrawn over it, leaving a guide to the bladder.

<sup>3</sup> The use of cylindrical tubes for the relief of retention, or for exploring the bladder through the urethra, dates from remote antiquity. Thus, HIPPOCRATES (*περί ροδίων* I, 6, ed. LITTRÉ, T. VI, p. 150) counts a physician unskilful who cannot sound the bladder: "μηδ' ἐς κύστιν ἀδίσκον καθέτρα δυνάσθαι καθίναν." Termed by the Greeks catheters (κῆθηρα, I thrust in), "Græci catheterem vocant," GALEN (*De locis affect.*, Lib. I, Cap. I, ed. Basileæ, 1561, p. 5), they were designated by CELSUS (Lib. VII, Cap. 26, *De urina reddenda difficultate*: "Ergo aneae fistulae fiunt, etc.) and his contemporaries, fistulae; and were made of copper or brass, of three sizes for men, of fifteen, twelve, and nine finger-breadths in length, and of two sizes for women, of nine and six finger-breadths, respectively. Catheterism is mentioned by ÆTIUS (*Tetrabiblos*, ed. Lugduni, 1549, p. 601) and other Greeks; but none described the operation fully except PAULUS ÆGINETA (Lib. VI, Sect. LIX, Syd. Soc. ed., Vol. II, p. 351). By the Arabians, the instrument was called *syringa* or *algatie*. The latter term has been borrowed by the French, who apply this name and the synonyme *sonde* to the instrument denominated catheter by English-speaking peoples, and use the term catheter for the instruments we term stiffs and sounds. ANTYLLUS (A. D., 350, cited by ORIBASIVS) and HALY ABBAS (A. D. 994, *Tract.* LIX, Cap. 45, *De mingendi arte cum cathetiro*, ed. Lugduni, 1523) briefly mention catheterism. ALBUCAZIS (*Chirurgia*, Lib. II, Cap. LIX, ed. CHANNING, p. 279) commends a catheter of silver: "ex argenteo conficitur; sit vero tenue, glabrum, concavum uti pennæ avis cannulla." He follows the description of PAULUS as to its use, and also figures an instrument for injecting the bladder, a silver tube with the bladder of a ram attached. RHAZES (A. D. 923, in his *Continens*, ed. Venetiis, 1506, *Liber* X, p. 220) gives a fuller account of catheterism than any of the mediæval writers. He insists on the importance of having a smooth rounded vesical extremity to the instrument, a flexible stylet, and small lateral perforations: "quum caput ipsius cannullæ est læve et planum, hujus foramina in lateribus parva et multa, in quibus non poterit ingredi sanguis coagulatus neque sanies penitus ex parvitate ipsorum - et eo ut sunt multa foramina, si opilatur unum, urina ingreditur per aliud: et omnino ingreditur per aliquod ipsorum. Et si ei fuerit difficultas ex aliqua particula saniei coadunata, in cannulla instrumenti habeas acum ingredientem in ipsa cannulla," etc. RHAZES recommends also (Lib. X, Cap. 3, p. 220), in some cases, a flexible leaden catheter of his invention: "instrumentum urinativum confectum de plumbo ut torqueatur et involvatur ad foramen: quum vitandus est dolor." AVICENNA (A. D. 978-1036) first mentions, as known before his time (*Canon*, Lib. III, Fen. XIX, *Tract.* II, Cap. 9, ed. Venet., 1564, p. 879), flexible catheters, composed of animal or vegetable tissues: "Syringarum melior est illa quæ conficitur ex levioribus corporibus et magis susceptilibus flexionis." Though the idea of flexible instruments was not entirely abandoned, they were little used for several succeeding centuries. LASSUS (*De la Médecine Opératoire*, Paris, An. III (1794), T. I, p. 439, et. Pl. III, Fig. 1) saw at the museum at Portici a medium-sized (mm. 4) copper catheter, with a double curve, like an italic *~*. This instrument was taken from the ruins of Pompeii, and therefore dated A. D. 79 at least. I had copied the figure given of it by MM. VOULLEMIER and GAUCJOT (FIG. 304 a) before meeting with the drawing of LASSUS's, which represents the beak with a single eye on the concavity, larger and more oval than the double lateral foramina now in vogue. Many other catheters were subsequently found in the ruins of Pompeii, and are now preserved in the *Museo Borbonico*, in Naples. They are of bronze, varying in calibre and curvature; several are rectilinear. As anatomical knowledge advanced, surgeons essayed to adapt instruments to the curvature of the urethra at different ages, and catheters were designed in great variety. There were innumerable modifications in form and calibre, and in the fenestration of the vesical extremity. FRANCO (*Traité des hernies*, 1561, p. 113) and AMBROISE

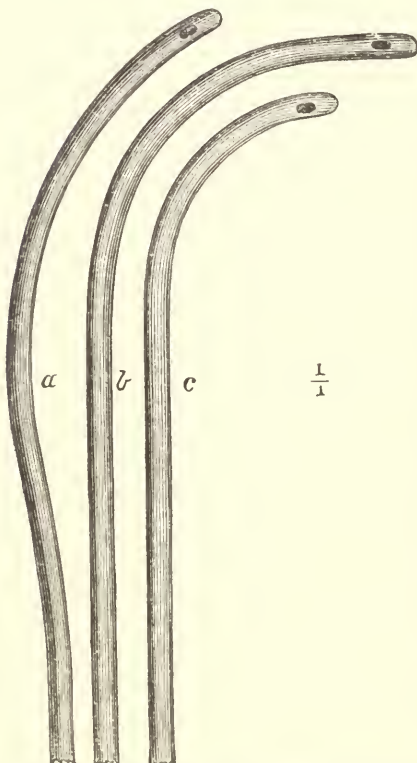


FIG. 304.—Patterns of metallic catheters: a, catheter found at Pompeii; b, Gély's model; c, Heurteloup's model.

causing irritation, to serve as a guide for the replacement of a catheter. If the lacerated urethra will tolerate the presence of such a guide, a soft rubber catheter, open at the vesical end, may be passed over it as often as is necessary to relieve the bladder; and the dangers of infiltration on the one hand, and, on the other hand, of irritation from protracted retention of a catheter, may be avoided. The gravity of the disorders consequent on urinary infiltration is such that the aid the catheter may afford in obviating them will be only relinquished with extreme reluctance.

Thus far it has been assumed that a catheter has been introduced in the first instance; but it cannot be denied that, in many shot lacerations of the urethra, the surgeon may fail to introduce a catheter, not only in his hasty attempts on the field, but under more favorable circumstances, when provided with a variety of instruments and enabled leisurely and perseveringly to employ the most dexterous manipulation. In a very valuable paper on the treatment of contusions of the perineum attended with lacerations of the urethra, printed, in 1870, in the tenth volume of the *New York Medical Journal*, Dr. Stephen Rogers teaches that the passage of a catheter is impossible in cases of transverse lacerations of the urethra, but that longitudinal lacerations do not oppose an equally insurmountable

PARÉ (*loc. cit.*, T. II, p. 464) figure several very similar to forms now in use; others with an orifice at the vesical extremity, which can be closed by a bulbous stylet; others again with a single eye on the convexity, or with double lateral eyes on either side. TOLET (*Traité de la lithol.*, 5th ed., 1708, p. 113) approvingly describes a semi-circular catheter used by MARECHAL, identical with that reproduced in the present century by RÉCAMIÈRE as a novelty. J. L. PETIT (*Œuvres complètes*, ed. Prévost, 1844, p. 779) invented an S-shaped catheter, for use when a protracted retention of an instrument was necessary. It resembles that which Dr. Squire has latterly recommended (FIG. 252, p. 302), and was much used prior to the invention of gum-elastic catheters. PETIT also used an S-shaped catheter without eyes, open at the vesical end, but provided with an obturator, a pyriform button at the end of

a stylet. GARENGEOT complains that it was used everywhere in Europe except in the country of its inventor.

HEISTER (*Institutiones chir.*, Amstelad., 1739, T. II, p. 324, Pl. XXIX, Figs. 3 et 4) used a catheter (FIG. 306) which bent backward before bending upward, a curve formerly termed *panse* or *paunch*, and figured in 1683 by TOLET, very suggestive of the catheters not long since extolled by M. BENIQUE (*De la rétenc. d'urine et d'une nouv. méthode pour introduire les bougies et les sondes dans la vessie*, Paris, 1829). All of these catheters, save the leaden instrument of RHAZES, were rigid, and necessarily exercised injurious pressure at some point, if long retained in the urethra. To obviate this difficulty, VAN HELMONT (*Opusc. med. inaudita*, Colon, 1634, *Liber de Lithiasi*, Cap. VII, p. 703) devised catheters of chamois leather, varnished with glue, and provided with a whalebone bougie. RICHARD WISEMAN (*Ser. Chir. Treatises*, 2d ed., 1692, Vol. II, pp. 427-8) assisted VAN HELMONT in a difficult case, in which this instrument was used, and describes the same. TROJA (*Mem. sur la construction des catheters flexibili*, p. 263) substituted dog-skin covered with layers of oil of copal, polished with pumice-stone. FABRICIUS (ab Aquapendente) had catheters of softened horn prepared ("at ego imaginatus sum magis flexibile corpus, et illam ex cornu paravi."—*Opera chirurg.*, Lugduni, 1723, p. 537). These instruments were liable to speedy deterioration, especially by impregnation with calcareous salts. SOLINGEN (*Manuale operation der Chirurgie, etc.*, Amsterdam, 1684, p. 244) designed an ingenious catheter fashioned at the vesical extremity like the ordinary catheter; but composed, from an inch from this point, of silver riband rolled spirally into a cylinder. RONCALLI (*Historie morborum*, Brixia, 1741, fol. p. 59) improved this instrument, which he named the vermicular catheter, by narrowing the silver riband and covering the cylinder with waxed silk, and thus obtaining greater flexibility and smoothness. In 1768, MACQUER (*Mém. de l'Acad. des Sci.*, p. 209), having dissolved caoutchouc in ether, proposed to make catheters of this substance, and the jeweler BERNARD carried the idea into execution. For a time he made catheters and bougies of spiral wire covered with caoutchouc; but soon substituted for the metallic thread a frame-work of linen or silk. This was a step in advance, yet BERNARD'S catheters were hard and friable, and not infrequently left a fragment in the urinary passages. BERNARD sought to avoid this danger by reducing the proportion of caoutchouc. TROJA, THIEDES (*Neue Bemerkungen und Erfahrungen*, u. s. w., 1782, B. II, S. 150), and other ingenious surgeons had prepared, from caoutchouc, catheters far superior to any previously known. Now a-days, that substance is no longer an ingredient in the composition of so-called gum-elastic catheters; the coating of the silken-thread frame consists of linseed oil associated in various proportions with resins of copal or of turpentine. The complicated processes of manufacture are clearly and minutely detailed by VIDAL (*Path. ext.*, T. IV, p. 664). MM. FÉRIER, and LASSÈRE have brought the fabrication of these catheters to great perfection. GUTTA-percha, suggested by a physician of Singapore and commended by Dr. H. J. BIGELOW (*Boston Med. and Surg. Jour.*, 1849, Vol. XI, p. 9), and balata (an article with properties intermediate between encaoutchouc and gutta-percha, prepared from the milky juice of the *sapota Mulleri*. *Zeitschr. des allg. oerterr. Apoth. Ver.*, 1869, S. 525, from *Sitzungsber. der Kais. Acad. der Wiss.* LIX), enjoyed a fleeting reputation as material for catheters. Instruments composed of them were hard and frangible, in short, inferior and dangerous. In the last few years, caoutchouc has again come in vogue, in the shape of vulcanized rubber. Catheters of this substance are far softer and more pliable than those of gum-elastic. They are very useful for persons

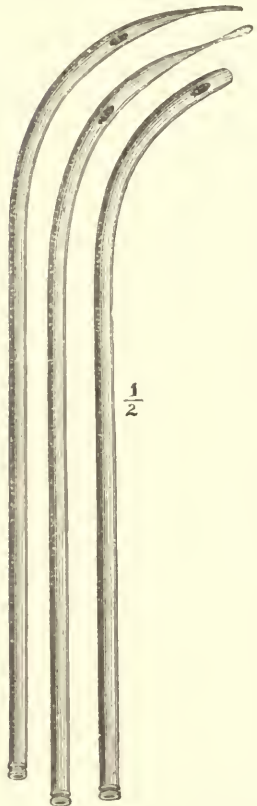


FIG. 305.—Curved gum-elastic catheters: a, conical; b, olivary; c, cylindrical.

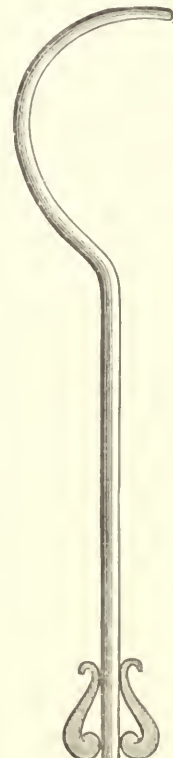

FIG. 306.—HEISTER'S catheter.  $\frac{1}{2}$ .



obstacle, and that all lacerations of the urethra are therefore not impassable, and that "it must be accepted as the proper practice to determine, at the earliest moment after the injury, whether the sound can be readily, or with any moderate effort, passed into the bladder." Dr. Rogers cites, in confirmation of his view, Sir Henry Thompson's remark,<sup>1</sup> that when retention occurs from laceration of the urethra "instruments can rarely be used to relieve it, without the hazard of inflicting some additional laceration." The opinion of these eminent authorities, that a catheter can rarely pass through a lacerated urethra except by accident, while meriting the most thoughtful consideration, is yet not fully sustained by the experience acquired in shot lacerations. In a considerable proportion of these cases (in which, it is true, the extent of the lesions was not reported, and, perhaps, not ascertained, with precision) instruments were carried through the lacerated canal, apparently with gentleness, and the bladder was reached, without having recourse to forced catheterization. The passage of a catheter, with a view of averting infiltration,<sup>2</sup> should,

who have to catheterize themselves, and in cases where a catheter is to be worn for several days; for they are retained with less inconvenience than harder and less flexible instruments, and long resist the action of the urine. These great merits are accompanied by disadvantages. The walls have to be very thick (FIG. 307) that they may not collapse on the slightest pressure and obliterate the calibre of the tube. Consequently the calibre of the



FIG. 307.—Longitudinal section of the vesical extremity of a vulcanized rubber catheter  $7\frac{1}{2}$  mm. in diameter.

tube and the eyes, or eye, for there is usually only one, must be comparatively small, and obstruction by blood or mucus is easy. Such catheters are too supple to overcome the least obstacle. If a stylet is used to give firmness, it is necessary to increase the thickness of the wall of the cul-de-sac, lest it be perforated, and then the stylet no longer reaches the end of the catheter, but is preceded by a flexible appendage, deviated by the slightest obstruction, and not subject to the surgeon's direction.—VOILLEMIER. Nevertheless, the occasions on which these catheters will be found very useful are numerous. Patients wearing them can walk about without inconvenience and with very slight risk of inducing ulceration in the urethra; and their comparative inalterability is of great importance. The importance of the curvatures given to catheters to adapt them to the urethra at different ages and under varied diseased conditions, has been exaggerated and unduly depreciated by interested partisans. GÉLY, of Nantes (*Moniteur des Hôpitaux*, 1854, T. II), AMUSSAT (*Leçons sur les rétentions d'urine, etc.*, 1832), HEURTELOUP (FIG. 304 c), and others, have made careful anatomical investigations concerning the normal curvature of the male urethra at different ages, with a view of determining the proper corresponding curve. DESCHAMPS (*Traité hist. et dogmat. de la Taille*, 1824, T. I, p. 211) unjustly derided such refinements, alleging that there was little variation in the normal curvature of the urethra. The advantages of varying the form and size of catheters are now duly appreciated. For ordinary purposes, cylindrical instruments are used with a gentle curve, like that of the old Roman instrument (FIG. 304, a) or the catheters used by DESAULT and BOYER. In old persons, it is desirable to have a more abrupt curve. GÉLY commends a curvature of one-third of a circle of 12 centimetres (FIG. 304, b). The artist has failed to continue the curve quite to the beak, as should be done; HEURTELOUP (FIG. 304, c) insisted on a curve of one-fourth of a circle of 8 centimetres; LEROY considered the fourth of a circle of 12 centimetres the proper curve. In cases of enlarged prostate, and for purposes of exploration, the abrupt curve proposed by LEROY, or the elbow-like (*coudée*) bend suggested by MERCIER, are of great value. The form of the vesical extremity of the catheter is also advantageously varied. Ordinarily, the catheter is cylindrical, with two oval lateral eyes near the beak (FIG. 305, c); but when the canal is obstructed, the instrument may have a conical or olivary termination (FIG. 305, a, b) advantageously. For special purposes, catheters are also made open at the vesical extremity, or grooved or tunnelled, to admit of being used with a conductor. Catheterization upon a conductor will doubtless be more generally appreciated as a resource in urethral lacerations. BUSCH (W.) (*Notiz über eine einfache Vorrichtung, welche den Wechsel des Katheters bei Harnröhrenwunden im Damme erleichtert*, in LANGENBECK'S *Archiv. für Klin. Chir.*, 1863, B. IV, S. 36) laid before the Association of Surgeons and Scientists at Bonn, in the fall of 1857, an apparatus similar, but, as he claims, superior to that described by M. DEMARQUAY in the *L'Union méd.*, Mars 4, 1858, p. 102. M. DEMARQUAY remarks: "Comme il faut échanger les sondes tous les huit ou dix jours, il importe de se servir de sondes ouvertes aux leur extrémités, afin de faire pénétrer une bougie dans l'intérieur de la vessie. Pour rendre cette opération plus facile, j'ai fait construire des bougies en baleine, comme celles employées généralement par M. Guyon; seulement je leur donnais plus de longueur. Une fois qu'une de ces bougies avait pénétré à travers la sonde dans la vessie, j'étais cette dernière tout doucement, et en la fendant de la partie superficielle vers la partie profonde." Dr. Busch continues: "My catheters have also no openings at the side, but are open at each extremity. At the vesical end, the catheter is somewhat conical, and has an orifice a little more than a line in diameter. A silver stylet is fitted as closely to the catheter as the stylet of a trocar to its canula. This strong rod should be double the length of the catheter, with a mark just visible at the free extremity of the catheter when the stylet is inserted through the entire length of the latter. When it is desired to change the catheter, the long stylet is inserted until the mark corresponds with the edge of the free end of the catheter, indicating that the stylet has entered the vesical orifice. The catheter is then withdrawn over the rod, more readily than by the tedious process involved by DEMARQUAY'S apparatus. The vesical portion of the catheter being slightly conical, it hugs the stylet closely, and reaches the bladder without detriment to the wounded urethra. The new catheter being placed, the stylet is withdrawn." Catheters are variously numbered, according to their calibre, by the American, English, and several French scales; indeed almost every specialist, now-a-days, has his special gauge. It is, therefore, well to have a measure available for any scale. FIGURE 308 represents a convenient instrument, purchased from Mr. Tiemann for the Museum, under the barbarous name of "pupillometer." No doubt, korameter (*κόρη, cœra, pupilla*) would be a less hybrid appellation. The instrument however designated, is as useful for the measurement of catheters as of pupils.

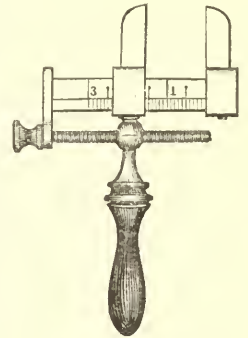


FIG. 308.—Catheter gauge.

<sup>1</sup> THOMPSON (H.), *The Pathology and Treatment of Stricture of the Urethra and Urinary Fistula*, 2d ed., 1858, p. 121.

<sup>2</sup> VOILLEMIER (*Traité des mal. des voies urinaires*, 1868, pp. 475, 476) observes: "La gravité des plaies contuses de l'urèthre gît surtout dans l'infiltration d'urine. La première indication thérapeutique à remplir doit donc être de prévenir cet accident en plaçant une sonde à demeure dans la vessie." \* \* "Dans les cas, les plus simples en apparence, de plaie contuse de l'urèthre, le cathétérisme est encore une opération délicate. L'irrégularité de la déchirure, le gonflement inflammatoire qui ne manque pas d'arriver quelques heures après l'accident, la compression du canal par le sang épanché dans les tissus voisins, sont autant d'obstacles qu'il n'est pas toujours facile de surmonter. Aussi faut-il prendre les plus grandes précautions si l'on veut éviter de faire une fausse route, ou tout au moins d'agrandir la plaie."

therefore, always be the first aim of the surgeon in cases of laceration. Whether the catheter is introduced or not, it is unquestioned that, upon the first sign of the supervention of urinary infiltration, the importance of deep incisions is paramount. When it has proved impracticable to prevent the mischief, it is only by this means that its extension can be arrested. CASES 1013, 1082, 1083, among others, illustrate the happy effects of opportune incisions.<sup>1</sup> In shot lacerations of the urethra the great variety of direction of the ball-tracks will indicate modifications in the seat and direction of the incisions. Sometimes they may be confined to the perineum; sometimes they must extend to the scrotum and penis, and elsewhere. The surgeon must make sure that the decomposing urine is nowhere

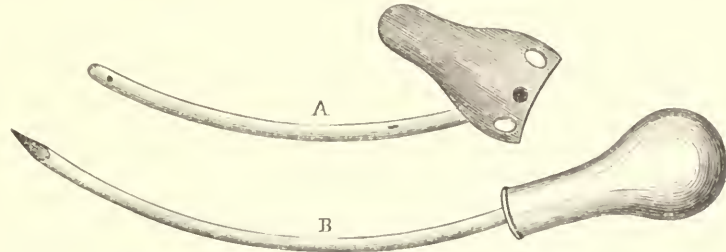


FIG. 309.—FLURANT'S recto-vesical trocar. [Reduced one-half from the author's drawing.<sup>2</sup>]

confined in the cellular tissue, and should so place the incisions as to make the urethral laceration communicate with the surface as directly as practicable. The urine will then probably escape freely through the torn urethra, and no further immediate local treatment will be requisite. Should there be retention, however, it will be necessary either to guide a catheter through the lacerated urethra, or to puncture the bladder. There is variance of opinion as to the best course to adopt. Surgeon M. Storrs, 8th Connecticut, in such an emergency (CASE 1072), preferred vesical puncture by the rectum.<sup>3</sup> This is a comparatively safe operation; but the supra-pubic puncture is more in favor, especially since the aspirating trocars have come into general use.

From this cursory consideration of the treatment of recent lacerations of the urethra, it is necessary to pass to an examination of the measures required in the management of traumatic stricture, an almost uniform complication of cases that do not terminate fatally,

<sup>1</sup> Regarding the importance of free perineal incisions in these cases, consult Dr. STEPHEN ROGERS'S article, already cited (*New York Medical Journal*, 1870, Vol. X, p. 370); the references to the opinions of M. SAVORY and Drs. PROGOFF, BECK, and STROMEYER, on pages 356, 373, 380 *supra*; and also to CHARLES BELL (*A Treatise on the Diseases of the Urethra, etc.*, p. 305), to BRODIE (*Works*, Hawkins's ed., 1865, Vol. II, p. 421), to GUTHRIE (*Anat. and Dis. of the Urinary and Sexual Org.*, Am. ed., p. 127), and a valuable paper by Dr. W. HUNT (*Traumatic Rupture of the Urethra, recent and chronic*, in *The Med. Times*, Phila., 1870-71, Vol. I, p. 173), where eight cases of laceration are detailed, with judicious comments.

<sup>2</sup> FLURANT'S paper and plate may be found in POUTEAU'S *Mélanges de Chirurgie*, Lyons, 1760 (*Nouvelle Méthode de pratiquer la Ponction à la Vesie*, p. 500, and Pl. I. Fig. 1). LE BLANC (*Œuvres Chirurgicales*, 1779, T. I, p. 106) reproduces the description of the operation, with a different figure of the instrument.

<sup>3</sup> The operation for the relief of the retention by recto-vesical puncture was devised and practised by FLURANT, at the Charity Hospital, at Lyons, in 1750. He successfully operated on a man of sixty-two years, with impassable stricture. In 1752, he again operated, and the patient succumbed from causes foreign to the operation. In 1757, he performed a thoroughly successful vesical puncture by the rectum, in the presence of his colleague, CHARMETTON (SABATIER, *Méd. opérat.*, ed. 1822, T. II, p. 375). FLURANT used a straight trocar in his first two operations; but then had made the instrument figured in the text (FIG. 309), somewhat after the model of the trocar for supra-pubic puncture of Frère CÔME. The operation appears not to have been warmly advocated, until a century later. LE BLANC (*Œuvres*, etc., 1779, T. I, p. 112) relates that in a desperate case of retention, in a man of sixty-three, with hiccough, the belly tense as a drum, the extremities cold, he punctured the rectum, "avec le trois-quarts de M. FLURANT \* \* en suivant les procédés prescrits par lui \* \* et le malade fut rappelé de la mort à la vie." In the *Philosophical Transactions*, Vol. LXVI, 1776, Part I, p. 578, Dr. ROBERT HAMILTON, of Edinburgh, in a letter to Sir JOHN PRINGLE, gives an "account of a suppression of urine cured by a puncture made in the bladder through the anus." REID (*An Enquiry into the Merits of the Operations used in obstinate Suppressions of Urine*, London, 1778) and KLOSSE (*De paracentesi vesicæ urin. per intest. rectum*, Jena, 1791) advocated this method of vesical puncture. FRANK (*De curandis homin. morb.*, Lib. VI, p. 542) and SCHEMMING (S. TH.) (*Über die tödtlichen Krankheiten der Harnblase und Harnröhre*, 1822) relate instances in which skillful surgeons attempted the operation, and it was found after death that the trocars had perforated the urethra without entering the bladder. These skillful surgeons must have been exceptionally awkward on the occasions referred to; for, with ordinary care, this operation, in the words of its modern advocate, Mr. EDWARD COCK, of Guy's Hospital, is "safe, easy of accomplishment, and without danger as to its consequences." The evidence has been very fully presented by Mr. COCK in his papers in the *Mélico-Chirurgical Transactions*, 1852, Vol. XXXV, p. 153, and in *Guy's Hospital Reports*, 1866, p. 267. The references to the operation by BRODIE (*Lect. on Dis. of the Urinary Organs*, London, 1849); by H. THOMPSON (*Path. and Treatment of Strict.*, 1858, p. 333); by CHARLTON (*Med. Times and Gaz.*, 1861, Vol. I, p. 277); by Mr. T. BRYANT (*Guy's Hosp. Rep.*, 1862, 3d ser., Vol. VIII, p. 201, and *Practice of Surgery*, 1872, p. 592); and by M. PHILPPART (*Gaz. des Hôp.*, 1866, p. 102), will reward consultation. The objections urged against the operation are the alleged liability to suppuration between the bladder and rectum, which is improved,—the probability of persistence of fistulous communication, which experience amply disproves,—and the possibility of injuring the seminal vesicles, with consequent trouble with the testes, a very rare accident. The operation, though seldom required, affords the inexperienced practitioner a much safer means of relieving the bladder than perineal incisions or punctures.



and to the treatment of fistules. As it is desired to adduce, at this point, the information furnished by the reports in regard to the treatment of ordinary organic strictures also, a digression must be allowed for that purpose, and then the principal methods of operative interference in stricture, by dilatation or incision, will be examined.

*Organic Stricture.*—The monthly reports of sickness and mortality of the army, for the period of the war, recorded an aggregate of two thousand five hundred and eighty-one cases of strictures of the urethra, with eight deaths, and two hundred and forty-seven discharges for physical disability.<sup>1</sup> It is impracticable to determine whether examples of traumatic stricture were comprised in these numerical returns. The aggregates of mortality and of discharges would indicate that they were not included in any considerable proportion. Apart from mechanical injuries, and from rare malformations and malignant affections, the causes of stricture are inflammation and syphilis. About one hundred thousand cases of gonorrhœa and eighty thousand cases of syphilis were returned on the sick reports<sup>3</sup> for the period under consideration. Details of cases of organic<sup>4</sup> stricture consequent on gonorrhœa or syphilis were rarely reported. The three following abstracts, and three that will be found with the cases of external perineal urethrotomy, are among the few exceptions:

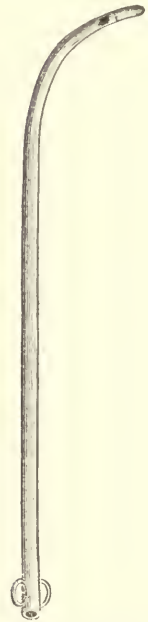

FIG. 310.—BOYER'S conical catheter.<sup>2</sup> [From M. CHARBRIÈRE'S pattern.]<sup>3</sup>

CASE 1089.—Private P. Slater, Co. B, 7th U. S. C. T., was admitted to Corps d'Afrique Hospital, January 29, 1866, with syphilis. Acting Assistant Surgeon C. Lodge reported that, "on admission, the patient was very low, with cold sweats and hiccough; there was a tumor in the hypogaster, and the penis was swollen and of a purplish color, and there was phymosis, with incipient gangrene of the prepuce and glans. A director was introduced and the prepuce freely incised. A catheter passed into the urethra encountered a false passage, made by previous attempts at catheterization. This being avoided, the catheter was forced through the stricture, free bleeding taking place, and a large quantity of ammoniacal urine was drawn off. The penis was enveloped in compresses wet with zinc lotion, and subsequently with dilute nitric acid lotion and charcoal poultices; a generous diet was ordered, with anodynes. For a few days the patient was semi-delirious and almost collapsed, his urine dribbling away involuntarily. Some time after admission, an abscess formed in the groin and opened spontaneously, leaving a large sloughing sore, from which, the man insisted, urine was discharged. Another abscess formed in the perineum, from which urine unmistakably

issued, yet still it passed in a small stream by the natural channel. Gangrene attacked one foot. A line of demarcation formed above the ankle, and the superficial parts above sloughed. He now contracted discrete variola. In April he was improving, the inguinal sores being healed and the ulcerated surface on the foot being nearly well. He lost by sloughing two inches of the penis. His urine passes mainly by the natural channel, but there is a fistulous opening from the urethra at the seat of stricture, and the patient has iritis. He will probably have to undergo urethrotomy for his stricture at some future time. He was transferred, convalescent, June 25, 1866." This convalescent was sent to Sedgwick Hospital, Greenville, where Assistant Surgeon A. Hartsuff, U. S. A., reported that "he died, July 7, 1866, from the sequelæ of small-pox."

<sup>1</sup> See *First Medical Volume*, TABLES C, p. 636, CI, p. 646, CXI, p. 710, CXII, p. 716 = 2,438 cases of stricture and 7 deaths among white, and 143 cases and 1 death among colored troops; 241 discharges from white, and 6 from colored troops.

<sup>2</sup> BOYER, *Traité des mal. chir.*, T. IX, p. 238.

<sup>3</sup> *First Medical Volume*, *loc. cit.*, pp. 636, 710; Gonorrhœa, white troops 95,833, colored 7,060=102,893; Syphilis, white troops 75,382, colored 6,207=79,589. Should it be assumed that the 2,581 cases of stricture were derived from these 182,482 venereal cases, the ratio would be nearly 1 in 75; but such an assumption would require numerous corrections.

<sup>4</sup> It is often stated that the ancients were ignorant of strictures, and that this affection was unobserved until the prevalence of syphilis in the middle age; but NAUCHE, in his excellent inaugural dissertation (*Nouvelles recherches sur la rétention d'urine par rétrécissement organique de l'urètre*, Paris, An. IX, 1800), proves that, although PAULUS ÆGINETA and ALBUCAZIS, who, of the ancients, treated most fully of urinary disorders, scarcely alluded to stricture, the disease was recognized and described by many of the old writers, as; HIPPOCRATES (*Aph.*, Lib. IV, aph. 80); ALEXANDER OF TRALLES (*Op. omn.*, Basil, 1723, Lib. III, Cap. XXXVIII, p. 251); ÆTIUS (*Tetrabiblos*, Sermon. III, Cap. XXI, p. 689); PLINY (*De re med.*, Lib. XXIII, Cap. 9, etc.); AVICENNA (*Arab. med. princ.*, canon medicine, Venet., 1608, Sen. XIX, Tract. II, p. 489); and especially RHASES (*Op.*, Venet, 1542, Lib. XXIII, Fol. 240). STILLING avers (*Die Rationelle Behandlung der Harnröhren-Stricturen*, Cassel, 1870, S. 165) that HELIODORUS (a surgeon of Rome in the time of Trajan, A. D. 96, whose fragmentary works are found in VIDUS VIDIVS, COCCHIUS, and more fully in ORIBASIVS—the passages, *Περὶ συστρωθῆσις οὐρήθρας*, are in Cardinal MAI'S Vatican edition, and, still better, in the edition supervised by DAREMBERG and BUSSEMAKER, and printed by the French Government in 1862; *Œuvres d'Oribase, texte grec en grande partie inédit, collationné sur les manuscrits, traduits pour la première fois en français*, pp. 472, 473, 474) practiced urethrotomy, writing of carnosities: "Ἀεὶ οὖν σκόδασι τῷ στενῷ τὴν σάρκα ἐκτέραντι," "Then it becomes necessary with a narrow and sharp stylet to cut out the flesh." It was not until the eighteenth century that the subject was investigated in monographs and systematic treatises. The following is a partial bibliography, many papers being designedly omitted as referred to elsewhere: PIETRE (*Ergo urethre angustia nocent cathartica*, Paris, 1614); BENEVOLO (*Nuova proposizione intorno alla caruncula dell' urethra*, Firenze, 1724); DABAN (*Obs. chir. de l'urètre, trait. suivant la nouvelle méthode*, Paris, 1748); LE DRAN (H. F.) (*Rec. d'obs. chir., sur les mal. de l'urètre*, Avignon, 1748); ANDRÉ (*Diss. sur les mal. de l'urètre, qui ont besoin des bougies*, Paris, 1751); GOUILLARD (Y.) (*Mém. sur les mal. de l'urètre*, Montpellier, 1751); ALIBES (*Traité des mal. de*

Naturally, the three cases recorded in detail were altogether exceptional. The case of syphilis with stricture and false-passages, just related, was very complicated; in the next case, ante-scrotal stricture with fistula was supposed to have no venereal antecedent; and, in the third case, stricture resulting from gonorrhœa was situated in the membranous part of the canal.

CASE 1090.—Private T. M. Peterson, Co. D, 32d C. T., aged 25 years, was treated, by Surgeon C. M. Wight, 32d C. T., at the regimental hospital on Morris Island, for "inflammation of the penis and scrotum," from July 12th to August 31, 1861, and then sent to Hospital No. 3, Beaufort, Surgeon J. Tremor, jr., U. S. V., recording the case as one of "dysuria and hypospadiæ." December 14th, at Hospital No. 2, Beaufort, Assistant Surgeon J. G. Murphy, U. S. V., noted "inflammation of the kidneys," and the patient's "discharge, June 5, 1855, on account of urinary fistula on posterior part of penis." This man was pensioned. Examiners Goodman, Collins, Harlan, Sherwood, Harper, and Smith reported, January 24, 1872, as follows: "He states that on Morris Island, in 1864, he had an attack of stricture, and that there was afterward an infiltration of the scrotum and penis, which was lanced by the attending surgeon. He has at this time a fistulous urethra, the urine escaping from two openings at the base of the penis and on either side of the raphe of the scrotum. He is compelled to wear a rubber bag on account of the constant dribbling. He alleges that he has never had gonorrhœa. Disability total and permanent." This pensioner was paid March 4, 1873.

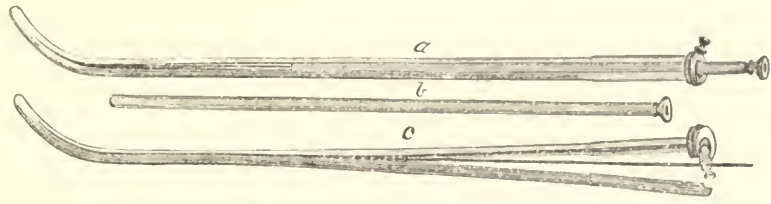


FIG. 311.—PERRÈVE'S dilatateur.<sup>1</sup> [Reduced from the inventor's drawing.]

CASE 1091.—H. Boles, quartermaster's service, aged 21 years, was admitted into Post Hospital, Washington, June 4, 1866. Assistant Surgeon W. Thomson, U. S. A., reported: "Double stricture of the urethra, following gonorrhœa of several months' duration; the stricture existing since July, 1865. There was one firm and myielding stricture in the spongy portion of the urethra, and another one, less tense, in the membranous portion; there was no discharge from the urethra; there was incontinence of urine. On June 5th, Acting Assistant Surgeon G. P. Hanawalt commenced dilating the stricture by means of silver sounds, introduced twice daily, no anæsthetic being used. The patient's constitutional condition was good at the time, and there was but little sensibility of the urethra, which had been already treated by Dr. R. K. Stone with Holt's dilator. In the evening, a No. 1 sound was introduced with slight difficulty. On the following day, a No. 2 sound was carried into the bladder, and a No. 3 into the first stricture. On the 7th, the No. 3 was passed into the bladder. On the 10th and 11th, there was traumatic urethritis from too frequent catheterism. He left hospital on the 12th, but returned on the 20th, and was discharged from hospital June 25, 1866, his treatment being continued as an out-door patient. On the 27th, the next to the largest sound was introduced. On July 3d, the patient himself introduced a large-sized bougie without difficulty. He was cured in twenty-eight days, urinating in a full stream."

*Urethre*, Paris, 1755); ARNAUD (G.) (*Plain and Easy Instructions on the Dis. of the Urethra*, 1763); FOOT (J.) (*Crit. Inquiry into the ancient and mod. Manner of treating the Dis. of the Urethra*, London, 1774); GRÉGIN (*Diss. sur les mal. de l'urèthre*, Paris, 1780); HUNTER (J.) (*On Venereal Diseases*, London, 1786); CHOPART (*Traité des mal. des voies urin.*, 1792, T. II, p. 626); DESAULT (*Journal de Chir.*, 1791, T. II, p. 361); HOME (E.) (*Pract. Obs. on the Treatment of Strictures of the Urethra*, London, 1795); BERLINGHIERI (A. V.) (*Abhandl. über die Verengerungen der Harnröhre*, in HARRLESS'S *N. Jour. der ausländ. med. chir. Literatur*, B. I, St. I, S. 7); LARBOND (P.) (*Rech. sur le rétrécissement chronique de l'urèthre*, Paris, 1805); WHATELY (*An Improved Method of Treating Strictures of the Urethra*, London, 1804); LEHMANN (G. T.) (*Diss. de curandis urethrae stricturis*, Lipsiæ, 1810); KLEMMANN (*De curandis urethrae stricturis chronicis*, Erlangæ, 1811); BELL (CH.) (*On Diseases of the Urethra*, etc., London, 1811); HOWSHIP (J.) (*Pract. Observat. on the Diseases of the Urinary Organs*, London, 1816); PETIT (A.) (*Mém. sur la rétention d'urine, produit par le rétrécissement du canal de l'urèthre*, Paris, 1818); ARNOTT (J.) (*Treatise on Stricture of the Urethra*, London, 1819); BINGHAM (R.) (*Pract. Essays on Strictures of the Urethra and Diseases of Testicles*, London, 1820); COURTRAY (C. B.) (*Pract. Observat. on the Disease of Stricture, recommending an improved System of Treatment*, London, 1822); DUCAMP (TH.) (*Traité des rétentions d'urine, causées par le rétrécissement de l'urèthre*, Paris, 1825); DUBOUCHET (H.) (*Petit Traité des rétentions d'urine, causées le plus fréquemment par un ou plusieurs rétrécissements du canal de l'urèthre*, etc., Paris, 1823); MACILWAIN (G.) (*A Manual of the Treatment of Strictures in the Urethra*, London, 1824); LALLEMAND (L.) (*Observations sur les maladies des organes génito-urinaires*, Paris, 1825); PROUT (W.) (*An Inquiry into the Nature and Treatment of Diabetes, Calculus, and other affections of the Urinary Organs*, London, 1825); SCHÖNEMANN (E. A.) (*De strictura urethrae*, Berol., 1826); ECKSTRÖM (*Ars-Berättelse om Svenska Läkarsällskapets Arbeten*, 1825, Stockholm, 1826); KILMER (W.) (*Über die radicale Heilung der Harnröhrenverengerungen*, etc., Anchen, 1828); CASTEL (J. J.) (*Diss. sur les rétrécissements du canal de l'urèthre*, Thèse à Paris, 1829); HAMMICK (S. L.) (*Pract. Remarks on Amputations, Fractures, and Stricture of the Urethra*, London, 1830); ALIZARD (C.) (*Sur le rétrécissement organique de l'urèthre*, Thèse à Paris, 1831); SAULSOHN (S.) (*De urethrae stricturis*, Berlin, 1833); CORNAY (J. E.) (*Des rétrécissements organiques de l'urèthre*, Thèse à Paris, 1836); RAEHLMANN (A.) (*De urethrae virilis strictura organica*, Bonnæ, 1840); KUGLER (*Pract. Abhandlung über die Verengerung der Harnröhre*, Wien, 1843); LEROY D'ÉTIOLLES (*Urologie. Des angusties ou rétrécissements de l'urèthre*, Paris, 1845); IVANICHICH (V.) (*Über die organische Verengerung der Harnröhre und ihre vollkommenste Behandlung*, Wien, 1846); BÉNIQUÉ (J.) (*La dilatation des rétrécissements de l'urèthre*, Paris, 1849); CIVIALE (J.) (*Traité prat. sur les mal. des organes génito-urinaires*, Paris, 3e éd., 1858); SEYDEL (*Die Stricturen der Harnröhre*, Dresden, 1854); THOMPSON (H.) (*The Pathology and Treatment of Stricture of the Urethra*, 2d ed., London, 1858); BIRD (F.) (*Du traitement des rétrécissements de l'urèthre*, Thèse à Paris, 1855); FAERBER (H.) (*De curandis urethrae stricturis*, Diss. inaug., Gryphus, 1855); PRO (J.) (*Anatomie pathologique des rétrécissements de l'urèthre*, Thèse à Paris, 1856); SCHMIDT (F.) (*De urethrae stricturis*, Diss., Gryphus, 1857); HARRISON (J.) (*The Pathology and Treatment of Stricture of the Urethra*, London, 1857); HOUDART (S.) (*Nouv. Héilung der Harnröhrenverengerungen*, Frankfurt a. M., 1859); SMITH (H.) (*On Stricture of the Urethra*, London, 1857); HOUDART (S.) (*Nouv. procédé de dilatation des rétrécissements du canal de l'urèthre*, Thèse à Paris, 1860); FLAYARD (C.) (*Consid. sur les traitements des rétrécissements organiques de l'urèthre*, Montpellier, 1866); FRANCK (M.) (*Étude sur les rétrécissements organiques du canal de l'urèthre et sur leurs modes de traitement*, Thèse à Paris, 1871).

<sup>1</sup> PERRÈVE (V.). *Traité des rétrécissements organiques de l'urèthre* (Prix d'Argentueil). Paris, 1817, p. 178.



Noting thus briefly the influence of gonorrhœa and syphilis in causing organic stricture—for the general subject of venereal affections is reserved for consideration in the *Third Surgical Volume*—attention is recalled to the fact that in the eighty-three reported cases of recovery from shot injuries of the urethra, stricture was an almost uniform if not inevitable result.

*Dilatation and Divulsion.*—In the treatment of all urethral strictures, not excluding those of traumatic origin, the method of gradual dilatation holds the most important place.<sup>1</sup> It is required uniformly; the expedients of forcible dilatation and incision being subsidiary, and useless unless associated with it. In the great majority of cases of organic stricture, gradual dilatation alone suffices, a truth first fully set forth by John Hunter, through deductions from the anatomical characters of strictures, and the mode of action of bougies. It is equally unquestionable that there are many cases in which gradual dilatation is inadequate; and most of the examples of traumatic stricture belong to this category. For the

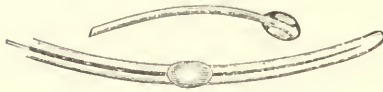

FIG. 312.—SHEPPARD'S dilatator.

<sup>1</sup>The plan of dilating strictures by special combinations of sliding tubes appears to be a corollary of the idea of catheterism on a conductor, an expedient employed and commended by DESAULT, of which I find no earlier mention. CIVALE, who should have known better, erroneously ascribes (*Nouvelles considérations sur la rétention d'urine*, 1823, p. 41) to NAUCHE the credit of first introducing a catheter on a conductor. NAUCHE'S inaugural thesis was published Messidor, An. IX (June, 1801). He does not appear to have employed this method, but substantially copies (*Nouvelles recherches sur la rétention d'urine*, Paris, An. IX, p. 59) the words of his master, DESAULT, in commendation of it. DESAULT not only advised, but put in practice, the operation, as is proved by the following citation from his lecture at Hotel-Dieu (*Journal de Chirurgie*, 1792, T. III, p. 132): "D'ailleurs, si l'on craignoit de rencontrer quelque difficulté à passer la seconde sonde, il seroit facile d'obvier à cet inconvénient, en se servant de sondes ouvertes par les deux bouts: on introduiroit la première au moyen d'un stilet à bouton, et avant de la changer, on la garniroit d'un stilet, long d'environ deux pieds, que l'on enfonceroit de quelques lignes dans la vessie; puis on retireroit la sonde sur le stilet qu'on laisseroit à sa place, et sur lequel on conduiroit ainsi, sans peine et avec sûreté, une nouvelle sonde." This passage is reproduced in the *Traité des Maladies des Voies Urinaires*, An. VII, p. 310, and in the *Œuvres chirurgicales*, 3<sup>re</sup> éd., par XAVIER BICHAT, 1813, T. III, p. 314. PLESSMANN (*La Médecine puerpérale et des accidents de la maternité*, Paris, 1797) practised this method, acknowledging that he learned it of DESAULT. PICHAUZEL also advocated this method, and received a prize for his paper, in 1810, from the Academy of Medicine of Bordeaux (THOMPSON'S *Jacksonian Prize Essay on Stricture*, 1st ed., 1852, p. 199). Though useful in many emergencies besides those attending stricture, particularly in cases complicated by false routes or by lacerations, this plan appears to have been neglected for many years. It was revived by AMUSSAT (*Leçons sur les rétentions d'urine*, 1832), who used a long fine whalebone guide. It was recommended by RIGAL (*De la destruction mécanique de la pierre*, etc., 1829, p. 29). After this, many surgeons, apparently quite independently of one another, adopted this principle to the dilatation of strictures. A guide being passed, successive tubes were slid over it. In his description of his "compound catheter," in the *London Medical Gazette*, 1841, Vol. XXVII, p. 916, Dr. BUCHANAN, of Glasgow, figures a series of sliding tubes, which he had used since 1831, in the treatment of obstinate stricture, and which he regarded as identical with the "new surgical instrument," described and figured at page 651 of the same journal, by Mr. J. C. FOULKES, of Liverpool. Dr. BUCHANAN'S instruments were made by PETER AITKIN, instrument-maker of Glasgow. The New York instrument-makers sell at the present day a very handsome series of sliding bulbous-tipped tubes, under the name of "AIKEN'S urethral set." GRAVES (*System of Clinical Medicine*, Dublin, 1845, Vol. I, p. 555) and Dr. WILMOT (*On the Treatment of Stricture*, in *Dublin Quart. Jour. Med. Sci.*, 1857, Vol. XXXIII, p. 310) states that Mr. HUTTON, of the Richmond Hospital, employed a similar method in 1835. It is remarkable, as Sir HENRY THOMPSON has frequently pointed out, how often the application of this principle has been regarded as a new invention, and the priority of DESAULT overlooked. In 1845, M. MAISONNEUVE read to the Paris Academy of Sciences (*Compte rendu, Séance du Janvier 13, 1845*) his *Mémoire sur un moyen très-simple et très-sûr de pratiquer le cathétérisme dans les cas même les plus difficiles*. The simple means consisted of a very fine supple bougie, a gum-elastic catheter open at both ends, and a silken or metallic thread to guide the catheter upon the bougie, as illustrated by FIGURE 303, p. 381, *supra*. In several successive papers (*Gaz. des Hôp.*, 1852, p. 310; *Ibid.*, 1855, p. 295; *Ibid.*, 1858, p. 101) M. MAISONNEUVE defended the method of catheterism on a conductor, or catheterism à la suite, as he sometimes designated it, as the easiest and surest and most generally applicable of all methods of reaching the bladder in cases of obstruction of the urethra. The value and originality of this plan were warmly contested, especially by MM. LENOIR and GERALDÈS, whose criticisms may be found in the debates of the *Société de Chirurgie* in 1855 *et seq.* The fact remains that nearly all the dilators, urethrotomes, and analogous urethral instruments now fabricated by the French makers are provided with M. MAISONNEUVE'S conducting bougie. In 1851, Mr. T. H. WAKLEY (*The Lancet*, 1851, Vol. I, p. 121) presented to the Medical Society of London his "new instrument for the cure of stricture" (FIG. 313), consisting of a small catheter with a removable thumb-slide, a conducting rod to be screwed to the catheter, and a series of graduated silver and elastic tubes. Mr. TEEVAN states (*Lancet*, 1873, Vol. II, p. 5) that SOLLY used an elastic catheter, open at both ends, which he slid along a cat-gut bougie. According to PHILLIPS (*Traité des mal. des voies urin.*, 1860, p. 426), PASQUIER employed the same plan. Dr. GOULEY (*Dis. of the Urinary Organs*, 1873, p. 54) has insisted on the superiority of capillary whalebone bougies as conductors. Whalebone was used for stylets by VAN HELMONT (*De lithiasi*, Amstelod., 1652, p. 70E) and for bougies by ALLIÈS (*op. cit.*, 1755, p. 103). The latter rejected this material as hard and liable to cause bleeding. GUILLOX (*De la Stricturetomie intra-urétrale*, 1857, p. 20, etc.) repeatedly advocated the advantages of filiform whalebone bougies in the *Gazette Médicale*, February 14, 1832, the *Revue Médicale*, 1839, T. I, p. 311, and elsewhere. He believed that, by the assistance of these guides, forced catheterism or vesical puncture might always be avoided. BRIGGS (J.) (*The Treatment of Stricture of the Urethra by Mechanical Dilatation*, London, 1845, p. 39), in narrow constrictions, used capillary whalebone bougies softened by warm water and curved by insertion in a catheter.

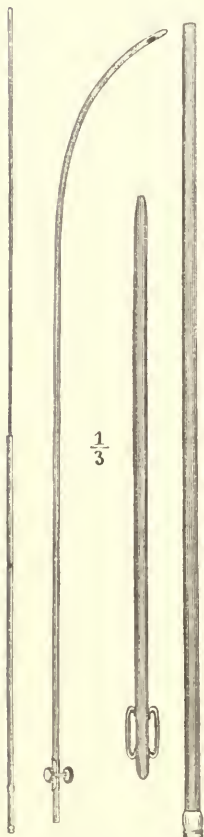


FIG. 313.—WAKLEY'S stricture instruments. [After WEISS; *Cat.*, Pl. XXV.]

prevention of constrictions after injuries of the urethra, frequent mechanical dilatation of the canal is the only available prophylactic measure; but, if there is much loss of substance, the tendency to contraction will not be overcome. Traumatic strictures will therefore require, more frequently than others, recourse to incisions. The different modes of forcible dilatation, by conical sounds or more complex adaptations of the wedge principle, will probably be rarely found applicable to cicatricial constrictions. No cases of traumatic stricture were reported in which this plan was adopted. But, in the treatment of ordinary strictures, many medical officers, and especially Surgeon J. R. Smith, U.S.A., approved of rapid dilatation<sup>1</sup> and divulsion. The latter wrote:



FIG. 314.—Dilator or divulsor of MALLEZ.

“In regard to stricture of the urethra I would like to put on record my opinion, acquired by considerable experience, that the practice of dilating strictures of the urethra by the ordinary bougie is very and unnecessarily slow, and is not a radical cure—relapses occurring in the majority of instances. I recommend that a Holt’s dilator be issued with the personal sets of instruments.”

The simplest mode of mechanical dilatation of stricture is by means of large conical sounds or catheters, instruments of progressively increasing calibre being successively introduced. This plan, fiercely attacked and stigmatized as “forced catheterism,” has

<sup>1</sup>Instruments susceptible of mechanical expansion after being passed through a stricture were suggested in the last century (STILLING, *op cit.*, p. 334); but none of them appear to have been of practical utility prior to that described by LUXMOORE (*On Stricture of the Urethra*, London, 1809, p. 23), a cylindrical tube, the intra-urethral part separating into four blades, which were expanded by a screw at the outer end. It was used for very gradual dilatation.

In 1831, GUTHRIE (*Anat. and Dis. of the Urin. and Sexual Organs*) used a three-bladed dilator, made by WEISS, on the principle of Sir ASTLEY COOPER’S urethral forceps (FIG. 284 ante). These instruments were inapplicable to narrow strictures. In 1847, PERRÈVE made known (*op cit.*, p. 178; see FIG. 311) his ingenious instrument for the rapid dilatation and rupture of strictures. In 1847 also, MICHELÉNA (*Des rétrécissements de l’urèthre*, Thèse de Paris, 1847, No. 29) and, two years later, RIGAUD (*De la dilatation instantanée des rétrécissements de l’urèthre au moyen d’un instrument nouveau, Catheter dilateur parallèle*, in *Gaz. méd. de Strasbourg*, 1849, p. 32) designed urethral dilators very similar in mechanism (FIGS. 315, 316). In both, the blades are separated by a series of jointed-levers, and both are defective in that the valves, in opening, must slide in inverse directions. The instrument-makers greatly improved these dilators. M. MATHIEU, particularly, designed a pattern (FIG. 317) in which the distension of the urethra at the meatus is obviated, a pattern much imitated by the English and American makers. One of these instruments was purchased for the Museum from Tiemann & Co., under the name of “ATLEE’S Dilator,” and the same instrument is advertised by GEMRIG (*Illustrated Cat.*, p. 73) as “PANCOAST’S Stricture Dilator.” In the last twenty-five years, the modifications of urethral dilators have been numerous, and some of them felicitous. Professor GROSS (*System, etc.*, 5th ed., 1872, Vol. II, p. 290) considers the instruments proposed by HOLT, VOILLEMIEU, and RICHARDSON as the best. Mr. HOLT described his modification (FIG. 321) in 1852 (*The Lancet*, 1852, Vol. I, p. 146), and in the second edition of his monograph (*On the Immediate Treatment of Stricture of the Urethra*, 1862) recorded many instances in which it had been advantageously employed. M. VOILLEMIEU’S instrument (FIG. 320) was described in 1836 (*Un nouveau dilateur cylindrique*, *Bull. de l’Acad. de Méd.*, T. XXXII, p. 289). Mr. H. W. RICHARDSON’S “dove-tailed dilator” was described and illustrated in his article on “the instantaneous method of treating stricture of the urethra” (*Dublin Quart. Jour. Med. Sci.*, 1868, Vol. XLVI, p. 74). Many other dilators have their advocates. Dr. DITTEL, the author of the important chapter on stricture in the *Handbuch* of BILLROTH and VON PITHA (*op. cit.*, 1872, B. III, Abth. 2, S. 123), commends his own, which is similar to that of M. VOILLEMIEU. A modification of the MICHELÉNA instrument, that has been much approved, was proposed by Sir H. THOMPSON, in 1863 (*Med. Times and Gaz.*, Vol. I, p. 461). In the same year, Mr. P. C. SMYLY (*Dublin Quart. Jour. Med. Sci.*, February, 1863, Vol. XXXV, p. 80) suggested the addition of the “railway catheter” principle to his modification of PERRÈVE’S dilator. In 1896, Dr. C. O. ASPRAY (*The Lancet*, Vol. II, p. 146) printed cases in illustration of his modification. In 1898, M. MALLEZ (*Bull. de l’Acad. etc., Gaz. des Hôp.*, p. 95) devised an instrument (FIG. 314 supra) in which the sliding-button plan is revived. This is essentially the plan of Dr.

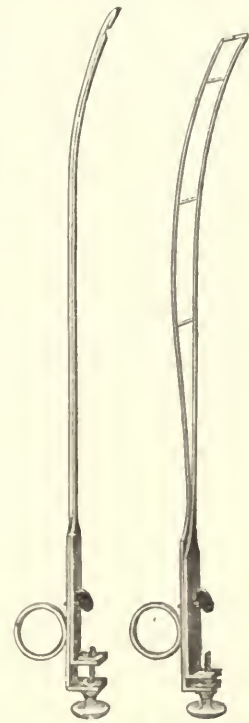


FIG. 317.—M. MATHIEU’S dilator. [From the maker’s model.]  $\frac{1}{2}$ .

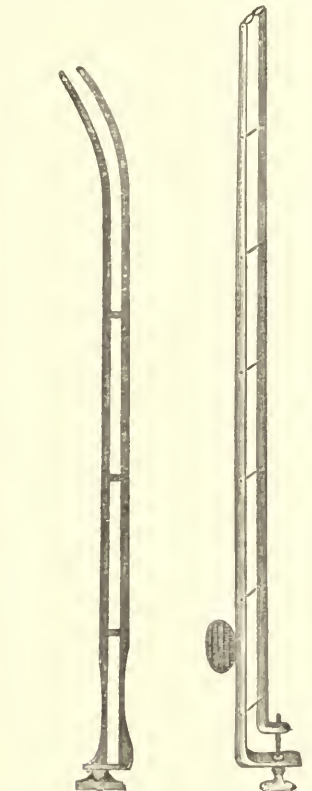


FIG. 315.—MICHELÉNA’S dilateur. [After the inventor’s drawing.]  $\frac{1}{2}$   
 FIG. 316.—RIGAUD’S dilateur.  $\frac{1}{2}$ .

<sup>1</sup>Instruments susceptible of mechanical expansion after being passed through a stricture were suggested in the last century (STILLING, *op cit.*, p. 334); but none of them appear to have been of practical utility prior to that described by LUXMOORE (*On Stricture of the Urethra*, London, 1809, p. 23), a cylindrical tube, the intra-urethral part separating into four blades, which were expanded by a screw at the outer end. It was used for very gradual dilatation.



long retained the confidence of practical surgeons. Desault, by the earnestness with which he insisted on its advantages, as it were appropriated this method. Chopart fully agreed with Desault, and Boyer (FIG. 310); systematized, so to speak, the plan of rapid dilatation.



FIG. 318.—Dilatateur of SÉGALAS.  $\frac{1}{3}$ .

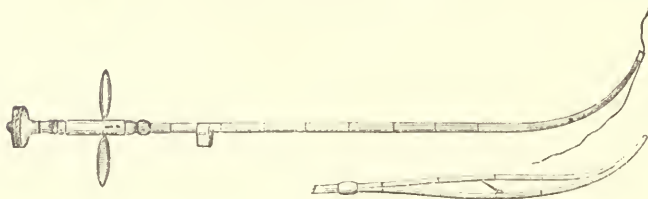


FIG. 319.—Dr. GOULEY'S modification of Sir H. THOMPSON'S Expander.

Mayor,<sup>1</sup> of Lausanne, by his exaggerations and exclusiveness, brought discredit on this method; yet it is approved, in our own time, by such solid authorities as Professor Gross and M. Voillemier. The series of graduated nickel-plated sounds, issued in the army sets, is well suited to the treatment of stricture by forcible dilatation. Continuous dilatation,

involving the patient's confinement in bed, was rarely employed in army practice;<sup>2</sup> and the treatment of stricture by cauterization was regarded as obsolete. In the few cases in

SHEPARD, of Stonehouse, a grooved catheter with a metallic *traveller*, as figured on page 388 (FIG. 312), only the dilator of M. MALLEZ, like all the more modern instruments of this class, is provided with a conductor. Of these various forms of instruments, some are effective in stretching, expanding, or over-distending strictures, and others accomplish their rupture, splitting, or division.



FIG. 320.—M. VOILLEMIE'S divulsor. [After VOILLEMIE.]

The mechanical construction of the best of these implements has been perfected to that degree, that the dangers of making false routes, or of pinching the mucous membrane between the valves, need not cause a skilful manipulator serious apprehension; but the risk of constitutional disturbance, after rupture of the urethra, cannot be eliminated by any improvements in the mechanism by which the tissues are torn. It is commonly conceded that the general application of forcible ruptures to urethral strictures is an abuse. In the exceptional cases in which rupture may be of advantage, the modifications of PERRÈVE'S instrument (FIG. 311) afford the best means of effecting it. The modification by Mr. HOLT (FIG. 321) has enjoyed, perhaps, the widest popularity; that recommended by M. VOILLEMIE (FIG. 320) acts with more security.

<sup>1</sup> MAYOR (M.). *Sur le cathétérisme simple et forcé, et sur les rétrécissements de l'urètre et les fistules urinaires*, Paris, 1836, p. 509. Three years earlier (*Jour. des Connaissances méd-chir.*, October, 1833), MAYOR had recommended that instruments of large size should be first employed in the treatment of strictures however narrow. RUST (*Theoretisch-practisches Handbuch der Chirurgie*, 1835, B. XV, S. 339, *Note*) advocated the same error less extravagantly. Both authors erred in generalizing a fact long familiar to practical surgeons, namely, that in many cases of dysuria a catheter of medium or large calibre is more readily introduced than a small one. FABRICIUS HILDANUS (*Opera que extant omnia*, Francofurti, 1644, *De lithotomia vesicæ*, Cap. 3, p. 712) noted this, and explained it by the liability of small sounds to catch in the lacunæ and rugosities of the urethra, which would be unfolded by the rounded extremities of large sounds: "Vidi enim aliquando, me instrumento parvo ad Vesicam penetrare non potuisse, cum tamen magnum et crassum citra ullum impedimentum et obstaculum immissum fuerit: causa est, quia tenerum ac gracile instrumentum infraactibus ac rugis Virgæ impingit: crassum vero Urethram dilueit, et per se aperit." LE DRAN (*Traité des Opérat. de Chir.*, Paris, 1742, p. 289) remarked that "dans les gens difficiles à sonder, une petite algalie peut percer la tunique interne de l'urètre, et faire de fausses routes, ce que ne peut faire une plus grosse." CHOPART also (*Traité des maladies des voies urinaires*, 1792, p. 434) taught that moderately large instruments traverse the urethra more readily, with less hazard of false passages, and with less pain, than those of small diameter. BOYER and PHYSICK and many others reiterated these precepts, but only with reference to the catheterism of the unobstructed urethra.

<sup>2</sup> Much ingenuity has been expended in preparing bougies capable of expansion after introduction into strictures. Of these, cat-gut bougies have enjoyed the most credit. They appear to have been first proposed by TURQUET DE MAYERNE (*Op. med.*, ed. J. BROWNE, 1703, p. 134), and were extolled by LE DRAN (*Traité des opérations de Chirurgie*, 1742, p. 359) and by FOOT (*A Critical Enquiry into the Ancient and Modern Manner of treating the Disease of the Urethra, with an improved Method of Cure*, London, 1774, p. 51). BENJAMIN BELL (*System of Surgery*, 1784, Vol. II, p. 215) refers erroneously to WILLIAM DEASE, of Dublin, as the inventor. Cat-gut bougies are praised by CLOSSI'S (*Über die Luetsche, 1797*), RICHTER (*Anfangsgründe der Wundarzneikunst*, 1802, B. IV, S. 275), and later by JASSAY, MONTAIN, IVANCHICHI, DITTEL, and many others. The following papers indicate some of the materials for bougies particularly recommended in this country: MCDOWELL (W. A.) (*An Account of the Use of the Bark of the Slippery Elm Tree (Ulmus fulva) for Bougies, etc.*, in the *Western Jour. of the Med. and Phys. Sci.*, 1838, Vol. XI, p. 371); WATERS (W.) (*Case of Stricture cured by*




FIG. 321.—Mr. BARNARD HOLT'S dilator. [From WEISS'S pattern.]

*Bougies of the Bark of the Slippery Elm Tree (Ulmus fulva)*, in the *Am. Jour. Med. Sci.*, 1839, Vol. XXV, p. 321); BIGELOW (H. J.) (*Employment of Gutta-percha in the Treatment of Strictures*, in the *Boston Med. and Surg. Jour.*, 1819, Vol. XI, p. 9); CABELL (P. H.) (*An easy mode of constructing Bougies*, in the *Am. Jour. Med. Sci.*, 1856, Vol. XXXII, p. 578); BATCHELOR (J. P.) (*History of Compressed Sponge for the Treatment of Strictures of the Urethra*, in the *New York Jour. of Med.*, 1859, Vol. VI, p. 301). Several Scotch surgeons have recommended the stems of algae, particularly of *laminaria digitata*, or sea-tangle, as a material for bougies, shrinking when desiccated, yet retaining great tenacity, and readily absorbing moisture and swelling up. Dr. SLOAN, of Ayr (*Glasgow Med. Jour.*, Vol. X, p. 281), and Mr. COLLIS, of Meath Hospital (*Dublin Jour. Med. Sci.*, 1861, Vol. XXXIV, p. 373), have insisted on the utility of this material for purposes of dilatation. Compare NEWMAN (R.) (*The Med. Record*, 1872, Vol. VII, p. 270).

which continuous dilatation was essayed, some ingenious efforts were made to adapt mechanical means of dilatation to the constricted portion of the urethra alone. These were substantially repetitions of the much-modified instruments of Ségalas (Fig. 318), or of Ducamp<sup>1</sup> (Fig. 322), and the practical results were unimportant. In short, for progressive gradual dilatation of strictures graduated elastic or metallic sounds were alone of real utility. Surgeon T. H. Squire, 89th New York, and Assistant Surgeon J. W. S. Gouley, U. S. A., devoted much attention to traumatic and organic strictures, and, since the war, have enriched our literature by important contributions on the subject.<sup>2</sup> Surgeon J. H. Brinton, U. S. V., often employed Mr. Holt's instrument for rapid dilatation, and had great confidence in the method in



FIG. 322.—Air or water dilatator. [After DUCAMP.]

<sup>1</sup>DUCAMP (TH.) (*A Treatise on Retention of Urine caused by Strictures in the Urethra*, translated by W. H. HERBERT, M. D., New York, 1827, PL. IV, FIG. 2). IDOM (*Traité des retent. d'urine causées par le rétrécissement de l'urèthre*, Paris, 1822). Compare also COSTALLAT (*Essai sur un nouveau mode de dilatation*, Paris, 1831, p. 109). SÉGALAS, besides his cannula, divided in one portion into several elastic blades, which separated by the action of a rod governed by a screw, proposed (*Traité des rétentions d'urine et des autres affections, qui se lient aux rétrécissements de l'urèthre*, Paris, 1828, p. 138) dilatation by the distention of a little bag of goldbeater-skin by air or water. This plan, of much older date than SÉGALAS or DUCAMP, has often been revived, only to result in disappointment.

<sup>2</sup>SQUIRE (T. H.) (*Synopsis of some Important Improvements in the Treatment of Obstinate Organic Stricture of the Urethra and Urinary Fistulae*, in *The Boston Med. and Surg. Jour.*, 1867, Vol. 77, p. 401); THE SAME (*Proceedings of Elmira Academy of Medicine*, September, 1870); THE SAME (*Vertebrated Prostatic Catheter*, in *Am. Jour. Med. Sci.*, 1871, Vol. LXII, p. 333); THE SAME (*Verteb. Prost. Cath.*, in *Am. Jour. Med. Sci.*, 1872, Vol. LXIV, p. 433); THE SAME (*Advantages of the Vertebrated Catheter in Prostatic Retention*, in *The Medical Record*, 1873, Vol. VIII, p. 4); GOULEY (J. W. S.) (*Clinical Lectures on the Diagnosis and Treatment of Stricture of the Urethra*, in *The Medical Record*, 1870, Vol. V, pp. 29, 54, 73, 101); THE SAME (*Discussions of the Urinary Organs*, 8vo., New York, 1873). Dr. GOULEY has brought very prominently before the profession the advantages of capillary whalebone bougies as conductors for catheters and sounds employed in the treatment of tortuous and eccentric strictures. The vesical extremity of the catheter is grooved or "tunnelled" (see Fig. 323 b, and Fig. 324, 3), and when the whalebone guide has passed the obstacle, its free end is slipped through the tunnel of the sound, which is then slid down to and through the contraction. This very valuable device has been adapted to urethrotomes, dilators, stiffs, and other urethral instruments.

In the language of Mr. TEEVAN (*Lancet*, 1873, Vol. II, p. 5), who has adopted and modified it (FIG. 324), it must be regarded as "a beautiful and useful" addition to surgical resources in the treatment of stricture. Mr. TEEVAN'S modification consists simply in cutting out a longitudinal piece of the catheter (FIG. 324, 2) instead of grooving it, and is, therefore, inapplicable to stiffs, sounds, and instruments for urethrotomy, to all of which Dr. GOULEY has extended his plan. Acrimonious discussions have arisen respecting the priority of invention of this important improvement, some writers contending that the merit of suggesting it is due to Dr. W. H. VAN BUREN. The editor would not intervene in this controversy, "*non nostrum lanias componere lites*," but may state that while, as has been abundantly shown in previous references, neither catheterism on a conductor nor whalebone bougies are novelties, yet the perforation or tunnelling of the vesical extremities of urethral instruments, to adapt them to sliding on a guide, is undeniably an innovation, of which the editor, for his part, had seen no suggestion prior to the publications of Dr. GOULEY. Several of the urethral instruments devised by Dr. SQUIRE have been received with much favor. The gold or silver tubes, denominated *uriducts*, proposed for continuous dilatation of rebellious strictures of the first and second portions of the urethra, may be worn, according to Dr. SQUIRE, without discomfort. A case is adduced of a patient who "wears it all the time, and feels no more inconvenience from it than one does from a plate of false teeth in the mouth." These instruments are figured in Dr. SQUIRE'S article in the *Boston Medical and Surgical Journal*, Vol. LXXVII, p. 462. The uriduct designed for the continuous dilatation of strictures of the third portion of the urethra is the S-shaped catheter is represented on page 362 (FIG. 252 *ante*), devised by Dr. SQUIRE to meet the exigencies of the case of Devin (CASE 1072, p. 370). In a letter to the Surgeon General, of January 19, 1866, Dr. SQUIRE

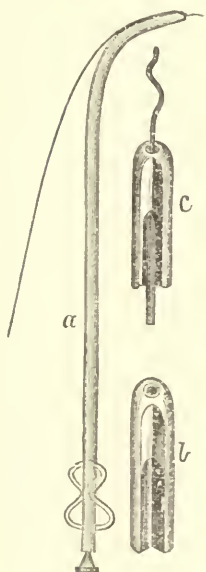


FIG. 323.—Dr. GOULEY'S tunnelled catheter. [After GOULEY.]

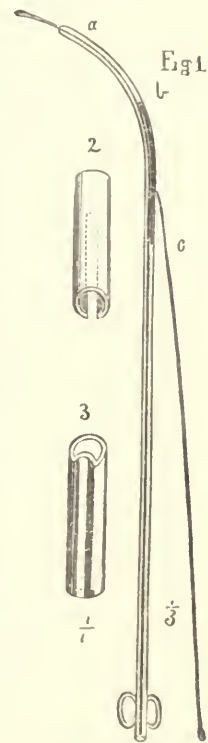


FIG. 324.—Mr. TEEVAN'S modification of Dr. GOULEY'S tunnelled catheter. [After TEEVAN.]

(recognizing the utility of a vesical siphon as early as 1834) called attention to the following advantages of this double curved catheter: "It keeps its place in the canal itself, thus rendering unnecessary the unscientific and unsatisfactory adjuncts usually employed. It conforms exactly to the natural direction of the urethra, and imposes no restraint upon the urinary organs. Being in the form of a siphon, it empties the bladder while the patient is lying supine in bed, a thing which the silver catheter of single curve will not do." The jointed or vertebrated catheter proposed by Dr. SQUIRE for the relief of retention of urine from enlargement of the prostate has been approved by many surgeons, particularly by Dr. L. A. SAYRE (*Trans. Med. Soc., State of New York*, 1871, p. 293). Dr. S. CARO (*The Med. Record*, 1871, Vol. VI, p. 523); and Dr. S. COWAN (*Am. Jour. Med. Sci.*, 1874, Vol. LXVII, p. 35). Professor GROSS (*System, etc.*, 5th ed., 1872, Vol. II, p. 743) and Dr. ASHBURST (*Princ. and Pract. of Surg.*, 1871, p. 893) refer to Dr. SQUIRE'S prostatic catheter; and Professor F. H. HAMILTON (*The Princ. and Pract. of Surg.*, 1872, p. 811) states that he has "employed this instrument in a few cases, and \* \* \* found it to answer its purpose exceedingly well," but apprehends danger from liability of the links to become detached in the bladder, and does not perceive plainly the advantages of the instrument over an ordinary flexible catheter.



properly selected cases. In army practice generally, recourse was seldom had to the over-distending and splitting of strictures. Indeed a callous stricture was regarded as a disqualification for military duty, warranting a soldier's discharge. There is no record of the employment of divulsion in cases of traumatic stricture.

*Urethrotomy.*—Although there is imperfect historical evidence that the Greeks and Arabians practised scarifications of the urethra, and that, toward the middle of the sixteenth century, the Neapolitan surgeon, Alfonsus Ferri, and Ambroise Paré, and Francisco Diaz,<sup>1</sup> employed cutting instruments to penetrate impassable obstructions in the urethra, and Allié and Vigurie performed similar operations two centuries later, and although external urethrotomy, alleged to have been first described by Aretæus, A. D. 80, was occasionally practised after Solingen's operations (*circa* 1673), yet it is unquestioned that dilatation and cauterization were the only methods of enlarging strictures commonly employed until the second quarter of the present century. A familiarity with the principal varieties of this operation is essential to a correct understanding of the treatment of stricture, and the subject will be considered somewhat at length.

*Internal Urethrotomy.*—The operations comprised under this denomination are twofold: those of puncture or incision of urethral obstructions from before backward, or what

<sup>1</sup>Herr STILLING, in his exhaustive critical treatise *Die Rationelle Behandlung der Harnröhren-Stricturen*, adduces satisfactory evidence that HELIODORUS (a Greek practitioner in Rome, in the first century, a contemporary of JUVENAL, who mentions him in the tenth Satire) employed such scarifications of the urethra as the moderns would designate internal urethrotomy. ALBUCASIS approved of such an operation, and figured (*Chirurgia*, ed. Oxon., p. 112) a little scalpel suitable for its performance.

AMATUS LUSITANUS (*Curatio medicamentum*, Cent. II, III, IV, Lugduni, 1565-67-80, Cur. XXIII, p. 168) appears to have incised the urethra by a blade concealed in a canula, in the case of a child with congenital atresia, about 1540. FERRI (*De caruncula sive callo que cervicis vesicæ immusculatur*, Lion, 1553) is perhaps the first to definitely recommend, as a general practice, the treatment of strictures by perforation by sharp or pointed stylets. PARÉ (*Œuvres*, loc. cit., T. II, p. 569) describes several instruments for internal urethrotomy, and figures two of them. He used, and even permitted patients to use, a sound roughened at the end, to rub against callous strictures, after the fashion of a file. He employed, also, a straight canula with large oblong lateral eyes, with cutting edges (FIG. 325 A). Pressed against strictures or vegetations, by a rotary movement the instrument was made to cut them away. His second instrument (FIG. 325 B) was a curved catheter, the open distal extremity closed by a button on a stylet. The instrument being passed down to a stricture, the button was projected, and then drawn back, with a view of dividing the stricture between the sharp edges of the canula and button. DIAZ, who practised at Madrid in 1576, figures a cutting catheter "instrumento cissorio de nuestra invencion" (FIG. 326). A pointed stylet, which was thrust out of the end of the canula, is not represented in the figure. Though he declares the instrument safe, DIAZ advises that it should be used only in extreme cases: "deste instrumento tenemos de usar como de remedio estremo que no ay otro."—(*Tratado nuevamente impresso de todas las enfermedades de los riñones y vesica*, Madrid, 1588, p. 170.) In 1603, TURQUET (THEODORUS OF MAYERNE) was expelled from the Faculty of Paris, and called a "grand fourbe" by GUY PATIN, for successfully operating on HENRY IV, by perforating a callous stricture, so desperate and foolhardy was the operation considered. MAYERNE, who went to England, and became surgeon to JAMES I, records the fact with excusable exultation: "Scirpo acuto, imo et cathetere argenteo penetravi felici successu (in Rege Henrico IV, Gallie), non tamen sine dolore, sed eo tutius, quo diligentius celebrata fuerant universalia." (TURQUET DE MAYERNE, *Op. med.*, ed. BROWNE, London, 1703, p. 137.) The parenthesis is recorded by MAYERNE on the margin. ALLIÉS, according to his son (*Traité des mal. de l'urèthre*, 1755, p. 72), treated urethral fistules by first relieving strictures in front of them by means of perforation. According to CUOPART (*Traité des mal. des voies urinaires*, 1792, T. II, p. 328), VIGUERIE, of Toulouse, failing to relieve a troublesome stricture by HUNTER's method of cauterization, perforated the obstruction with a trocart, and cured the patient. All of these operations were of the nature of forced catheterization or of puncture of the urethra rather than methodical urethrotomy, and dilatation and cauterization remained the only methods of treating strictures in common use. In 1795, PHYSICK designed a lancetted catheter for the division of strictures from before backward, and in succeeding years repeatedly performed this operation with success.—(DORSEY, *Elements of Surgery*, 1813, Vol. II, p. 149.) He used a straight or curved canula, according to the location of the stricture. These instruments are represented by FIGURES A1 and 2, of PLATE XII, copied from DORSEY's drawings. In 1819, ARNOTT (*Treatise on Strictures*, London, 1819) proposed two urethrotomes, one with a circular blade, the other with two lateral blades. Their value appears not to have been tested. In 1823, M'GHIE, a naval surgeon (*Suggestions in Surgery*, in *Edinb. Med. and Surg. Jour.*, 1823, Vol. XIX, p. 361), suggested an instrument closely resembling PHYSICK's, but having the improvement of a conical conductor in advance of the blade. In 1824, AMUSSAT presented to the Paris Academy the first of a series of urethrotomes contrived by him. In 1827, STAFFORD presented to the Westminster Medical Society (*The Lancet*, 1828, Vol. I, p. 397) his lancetted catheter (FIG. 311), which attracted much attention at the time. It uses were more fully discussed by the inventor in later publications: STAFF-

FORD (R. A.) (*A Series of Observations on Strictures of the Urethra, with an Account of a New Method of Treatment*, London, 1828; and *Further Observations on the Use of the Lancetted Stilettes in the Cure of Strictures of the Urethra, with Additional Cases*, 1829; and *On Perforation and Division of*

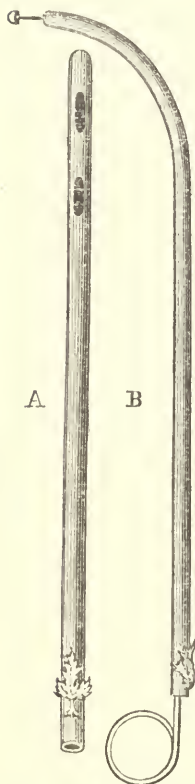


FIG. 325.—PARÉ'S cutting sound. [After PARÉUS.]



FIG. 326.—Cutting urethral canula of DIAZ.

is now known as antero-graduate urethrotomy, and incision of permeable callous strictures from behind forward, or retrograde urethrotomy. There have been few, if any, examples of the application of this method of treatment to traumatic strictures. In these, external urethrotomy was resorted to if any operative interference was attempted. In the treatment of old intractable organic strictures, however, internal urethrotomy was regarded as a valuable resource. The necessity of incisions in these difficult cases has long been recognized. The instruments

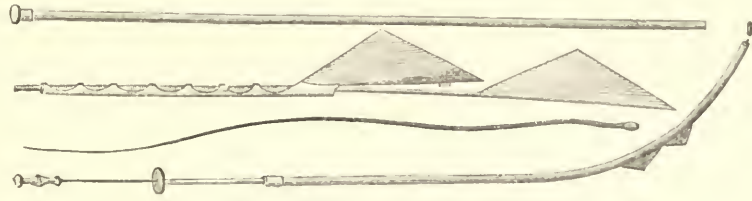


FIG. 327.—Antero-graduate urethrotome of M. VOILLEMIER.

Physick devised for the purpose are represented in FIGURE A of PLATE XII, and Jameson's urethrotome and that of Chew are shown in FIGURES C and D of the same plate. The rude mechanism of these instruments partly accounts for the slowness of prudent surgeons in accepting internal urethrotomy as a legitimate means of dealing with intractable strictures. For many years, it was considered unsafe to incise strictures except in the antescrotal portion of the canal; but the instruments of precision now in use, the urethrotome of M. Voillemier (FIG. 327), and that of M. Maisonneuve (FIG. 330) partic-

Permanent Strictures, London, 1836). Meanwhile the introduction of lithotomy, in 1820, necessitated the frequent enlargement of the meatus by incision, to facilitate the introduction of instruments, and sometimes the division of strictures in the fossa navicularis, and CIVIALI designed a sheathed knife for this purpose, and LEROY, of course, prepared a special instrument of somewhat different pattern; since when sundry surgeons have devised complex

means of effecting these simple incisions, each one extolling his special "meatotomy." The next real improvement in urethrotomy was by JAMESON, of Baltimore, who, in 1827 (simultaneously with STAFFORD's publication in the *London Medical and Physical Journal*, October, 1827), described and figured (*Am. Med. Recorder*, October, 1827, Vol. XII, p. 329, *Practical Observations on Strictures of the Urethra*, by HORATIO G. JAMESON, M. D.) a urethrotome with a broad sliding blade, guarded by a sheath, analogous in principle, though inferior in construction, to the best antero-graduate urethrotomes now in use. A portion of Dr. JAMESON'S drawing is reproduced in PLATE XII, FIG. C. 1, 2. Already, in two essays on stricture (*Am. Med. Rec.*, 1824, Vol. VII, pp. 251, 687), JAMESON had described cases in which he had successfully operated, in 1820 and 1821, on intractable strictures by internal incision. Unfortunately, these three most instructive as well as learned essays were published before the time when Edinburgh reviewers required, "Who reads an American book?" and for many years escaped due recognition. AMUSSAT (*Arch. gén. de Méd.*, 1824, T. IV, pp. 31, 547), as early as 1823, presented to the Paris Academy an instrument (FIG. 329) for scarifying callous strictures. It was subsequently described by his brother-in-law, A. PETIT (*Leçons sur les rétentions d'urine causées par les rétrécissements*, 1832, p. 143). Henceforward it is necessary, in the enumeration of urethrotomes, to distinguish between instruments designed to penetrate and divide strictures from before backward, or antero-graduate, those acting from behind forward, or retrograde urethrotomes, and those making slight incisions, or scarifications. DZONDI (*Instrument für innere Urethrotomie*, in *Geschichte des Klin. Inst. für Chir.*, Halle, 1818, Taf. II) used, in 1818, an instrument resembling PHYSICK'S, for puncturing strictures, and DIEFFENBACH (HECKER'S *Literar. Annalen*, u. s. w., 1826, S. 165-169) later employed an ingenious instrument at one dilating and cutting; but DIEFFENBACH appears to have had little confidence in this plan of treatment, for he soon laid it aside. In 1826, DESPINEY, of Bourg, reported (*Arch. gén. de Méd.*, T. XI, p. 146) two successful cases of strictures in the pendulous part of the urethra treated by incision. RYAN (*London Med. and Surg. Jour.*, 1835, Vol. VIII, p. 240) states that "a lancet, covered by a catheter, was also used, about thirty years ago, by Sir CHARLES BLICKE, of St. Bartholomew's Hospital, and by Mr. NAYLER, of Gloucester." These operations, and one by GRINDEL, of the London Hospital, are said to have been done according to PHYSICK'S method, and with unfavorable results, especially in Mr. NAYLER'S case, in which there was severe hemorrhage. DÖRNER (*Vorschlag eines neuen Mittels gegen hartnäckige Harnröhrenverengerungen*, in SIEBOLD'S *Chiron.*) wrote upon the "new method" of urethrotomy as early as 1806. In 1828, Dr. E. R. CHEW (*Description of an Instrument for dividing Strictures of the Urethra*, in the *North American Med. and Surg. Jour.*, Vol. V, p. 341) published an account of a urethrotome of his invention, with a drawing by S. G. MORTON (which is copied in FIGURE D of PLATE XII). This instrument was used and recommended by Dr. R. HARLAN (*Case of Stricture of the Urethra operated upon with Mr. CHEW'S Instrument*, in the *North Am. Med. and Surg. Jour.*, Vol. V, p. 341). In 1830, GUILLOIS (*Gaz. des Hôp.*, T. IV, No. 98, 1831, and *Revue médicale*, 1839, T. I, p. 299) presented to the Paris Academy his urethrotome, and subsequently complained that this instrument had been copied by LEROY without acknowledgment. REYBARD, in 1833, proposed the first of the many urethrotomes that bear his name (*M. m. sur les rétrécissements de l'urèthre*, Lyons, 1833). The instruments he finally advocated for the method that received the Argenteuil prize in 1852, were retrograde urethrotomes, of which two patterns are represented further on (FIG. 335). LEROY (d'Étiolles), in his *Traité d'angusties*, 1845, describes several urethrotomes, some of which had been presented to the Paris Academy as early as 1837. One of these instruments is represented by FIGURE 332. It is a canula with an olivary expansion at the terminal extremity, concealing a blade, arranged with the ingenuity in details characteristic of this inventor. In 1844, Surgeon R. J. DODD, U. S. Navy, recommended (*Am. Jour. Med. Sci.*, N. S., Vol. VII, p. 374) an "improved catheter-bougie" or what is now termed an antero-graduate urethrotome. This instrument, adapted to scarifications rather than deep incisions, is copied from the author's drawing, in FIGURE F, PLATE XII. In 1847, Dr. MARTIAL DUPERRIS, of Havana (*Mém. sur les rétrécissements organiques de l'urèthre*, Paris, 1847), recalled attention to the urethrotome figured in the wood-cut (FIG. 328) on page 395, which he had devised as early as 1833, while practising in New Orleans (*Considérations nouvelles sur*

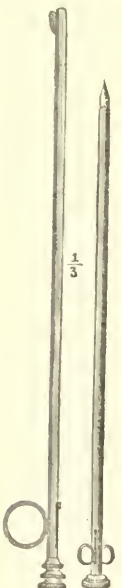


FIG. 328.—STAFFORD'S urethrotome. [Reduced from a drawing of the author's.]




FIG. 329.—AMUSSAT'S scarificator.

les rétrécissements de l'urèthre, Lyons, 1833). The instruments he finally advocated for the method that received the Argenteuil prize in 1852, were retrograde urethrotomes, of which two patterns are represented further on (FIG. 335). LEROY (d'Étiolles), in his *Traité d'angusties*, 1845, describes several urethrotomes, some of which had been presented to the Paris Academy as early as 1837. One of these instruments is represented by FIGURE 332. It is a canula with an olivary expansion at the terminal extremity, concealing a blade, arranged with the ingenuity in details characteristic of this inventor. In 1844, Surgeon R. J. DODD, U. S. Navy, recommended (*Am. Jour. Med. Sci.*, N. S., Vol. VII, p. 374) an "improved catheter-bougie" or what is now termed an antero-graduate urethrotome. This instrument, adapted to scarifications rather than deep incisions, is copied from the author's drawing, in FIGURE F, PLATE XII. In 1847, Dr. MARTIAL DUPERRIS, of Havana (*Mém. sur les rétrécissements organiques de l'urèthre*, Paris, 1847), recalled attention to the urethrotome figured in the wood-cut (FIG. 328) on page 395, which he had devised as early as 1833, while practising in New Orleans (*Considérations nouvelles sur*



ularly, permit the division of strictures in the sub-pubic region with as much regularity as those of the penile portion of the urethra. If, as Desault said, the simplicity of an operation is the measure of its perfection, the division of deep strictures by the urethro-

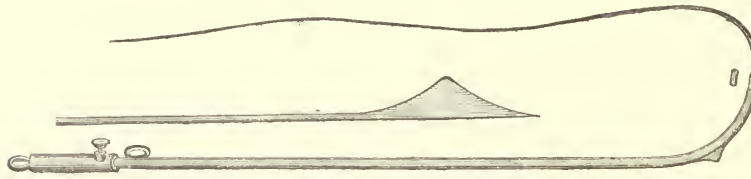


FIG. 330.—Urethrotome of M. MAISONNEUVE.

tome of M. Maisonneuve must be esteemed a felicitous solution of the problem involved. In moderately skilful hands, the filiform conductor effectively guards against operating on false routes, and the objec-

tions urged, that this bougie is liable to curl up and present its point at the meatus, or to be cut by the knife, are not sustained by experience. There is a certain risk of wounding unconstricted portions of the urethra by the unguarded blade of this instrument, and M. Voillemier supplied his urethrotome (FIG. 327) with a shield. A limited number of these urethrotomes, manufactured (with so-called modifications) by New York and Philadelphia instrument-makers, were issued to army medical officers. No special cases of internal urethrotomy in the bulbous and membranous portion of the urethra were reported. The

*le rétrécissement du canal de l'urètre et sur de nouveaux instruments de scarification*, in *Bull. de Therap. méd. et chir.*, 1839, T. XVII. p. 41). This instrument is, as the inventor designed, a scarificator only, and is adapted to the treatment of such strictures only as permit the introduction of an instrument of two and a half or three lines in diameter. Dr. ARNTZENIUS, of Amsterdam (*Verhandlung over de organische Gebreken der Urethra*, Utrecht, 1840), though doubting the safety of urethrotomy in deep-seated strictures, proposed an ingenious instrument for urethral incisions from before backward. M. RATTIER (*Gaz. des Hôp.*, 1843, p. 420) presented to the Paris Academy an antero-grad urethrotome, which, like many others, was seldom, if ever, of practical utility. Indeed, until many years later, all modes of puncture, scarification, or incision from before backward of urethral strictures were regarded as very hazardous unless confined to the pendulous portion

of the urethra; but the division from behind forward of callous strictures that would admit the passage of an instrument of medium size, or what is now termed retrograde urethrotomy, was considered much surer and safer, and many instruments were devised for accomplishing this operation. In 1845, PÉTREQUIN transmitted to the *Acad. roy. de méd. de Belgique* his memoir: "*Sur l'emploi d'un nouvel urethrotome dans le traitement des rétrécissements de l'urètre, d'après des recherches particulières d'anatomie path. sur les coarctations uréthrales*." PÉTREQUIN reported five successful cases; his retrograde urethrotome was denominated quadrilateral; it did not come into general use. The urethrotome of IVANCHICH, represented in the annexed wood-cut (FIG. 331), is praised by Dr. WENZEL LINHART (*Compendium der Chir. Operationstehre*, Wien, 1862, p. 901), and is said to be much employed by German surgeons. It is an ingenious but complicated instrument. Herr STILLING (*Zur Inneren Urethrotomie*, Berlin, 1866), in a severe and somewhat ungenerous criticism, undertakes to show that it is merely a derivation from STAFFORD'S instrument. A description, with figures, of a urethrotome of VERNIES, which met with academic approbation, may be found in the *Gazette des Hôpitaux*, 1848, p. 320. In the second edition of his treatise on operative surgery, of 1855, Professor SÉDILLOT (*Traité de méd. op.*, 3<sup>me</sup> éd., 1866, p. 554) intimated that "the really useful discovery surgeons require, would be a urethrotome adapted to the division from before backward of such strictures as can be penetrated by a filiform bougie. The real practical difficulty is to pass and dilate very narrow strictures. Months, indeed, are sometimes lost, and the greatest obstacles are encountered, before recourse can be had to the urethrotomes hitherto proposed, which require an opening of several millimetres, at least, for their admission. Were it possible to bring to bear on the constriction a cutting blade, using the bougie that had passed the stricture as a conductor, the patient and surgeon would be spared much time and trouble. I have made some

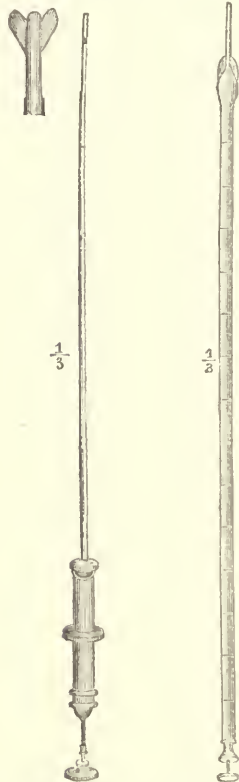


FIG. 331.—Urethrotome of IVANCHICH. FIG. 332.—Urethrotome of LEROY.

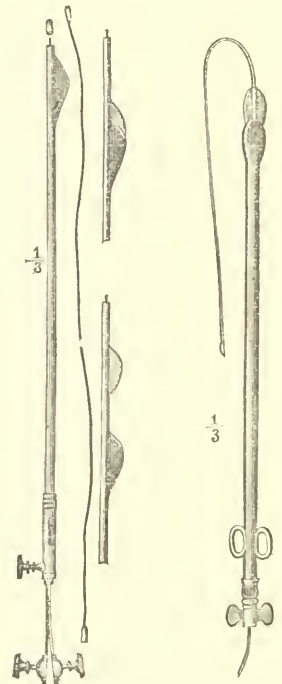
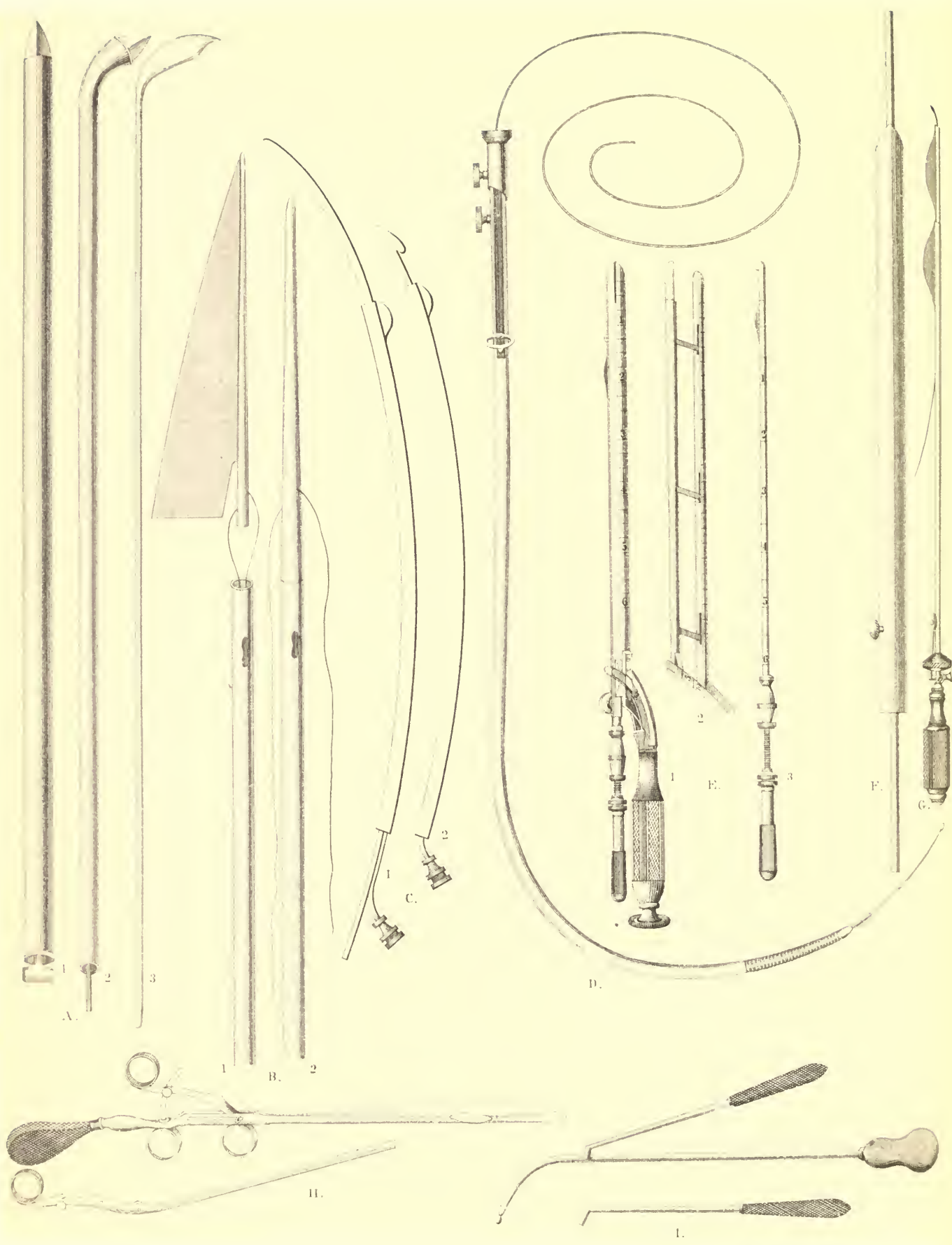


FIG. 333.—SÉDILLOT'S urethrotome. FIG. 334.—BONNET'S urethrotome.

essays in this direction, and, notwithstanding the imperfection of my instruments, will allude to them in order to indicate the way toward which our researches should be directed." The conditions on which Professor SÉDILLOT insisted, BONNET (*De l'incision d'avant en arrière des rétrécissements du canal de l'urètre*, par PHILIPPEAUX, *Gaz. des Hôp.*, 1848, p. 40c) sought to supply by a urethrotome (FIG. 334) furnished with a metallic conductor; but







A. Physick's lancetted catheters.  
 B. Physick's conducting bougie.  
 C. Jameson's urethrolome.  
 D. Chew's lancetted catheter

PLATE XII. URETHRAL INSTRUMENTS.

I. Hewitt's gorget for external urethrotomy.

E. F.N.Oliver's dilating urethrolome  
 F. Dodd's scarificator.  
 G. Gonley's urethrolome.  
 H. Hammer's urethrolome.

inferences from the general allusions to the subject are, that rupture, or divulsion, was preferred to incision in the treatment of obstinate post-serotal strictures, being so sure and easy of execution with the improved instruments, that, in some minds, it became a question whether this method would not eventually supersede internal urethro-

tomy altogether. The instruments for incision and rupture of strictures very gradually attained their present excellence; and it is interesting to note that American ingenuity has been creditably illustrated in their successive improvements. In proof of this assertion, it is only necessary to call attention to the various urethral instruments figured in PLATE XII, opposite. It will not be difficult to recognize, in the bougie conductor (FIG. B, 1, 2) which Physick used in 1796, an anticipation of the filiform conductors so much approved half a century later. In Jameson's anterograde urethrotome of 1828 (FIG. C, 1, 2), the blade is shielded in the fashion now most commended; and in Chew's instrument, also proposed in 1828, are found several of the devices subsequently held of value; while the urethral instruments of recent American invention happily combine those ingenious



FIG. 335.—Urethrotome of Herr STILLING or of M. BOINET.

his instrument was not a great improvement on that proposed twenty years before by STAFFORD. M. RICORD (*Traité pratique des mal. vénériennes*, 1838, p. 746) employed internal urethrotomy from an early period of his practice; but very guardedly, and rather by scarification than deep incision. The instrument made for him, in 1839, by M. CHARBIÈRE, is represented in the accompanying wood-cut (FIG. 337). CIVITALE (*De Urethrotomia, ou de*

*quelques procédés peu usités de traiter les rétrécissements de l'urètre*, 1849), on rare occasions, used an anterograde urethrotome of simple construction, for the division of strictures in the pendulous portion of the urethra only; and subsequently invented the retrograde urethrotome (FIG. 339) which is commonly known by his name, having come into quite general use. To apprehend clearly the value of REYBARO'S urethrotomes, it is necessary to consult the voluminous report by ROBERT (*Bull. de l'Acad. de Med.*, 1851-52, T. XVII, p. 1097) of the commission that adjudicated the Argenteuil prize in 1852. The commission decreed the prize to the dissertation of REYBARO because: "On y trouve un point de départ nouveau, basé tout à la fois sur l'anatomie, la physiologie pathologique et l'expérimentation. Enfin, une série de déductions conduisent logiquement l'auteur à rejeter les moyens de traitement connus, et à proposer une thérapeutique nouvelle dont il démontre l'efficacité par des faits nombreux. M. REYBARO a réalisé le perfectionnement les plus importants pour la cure des rétrécissements de l'urètre." In 1853, REYBARO published his *Traité pratique des rétrécissements du canal de l'urètre*, in which are figured two of the instruments (FIG. 336) with which he practised his deep and free incisions. These were followed by hæmorrhage, or dangerous febrile attacks, or other disastrous results, often enough to raise a prejudice against internal urethrotomy in any form; yet the view for which REYBARO contended—that incisions of strictures to be of use must be extended through the indurated tissue—was just; and he was not the first reformer to insist extravagantly upon his innovation. Subsequently, in 1853, M. MAISONNEUVE (*Gaz. des Hôp.*, 1853, p. 581) sought to put the same idea in execution by using Frère COME'S lithotome as a urethrotome; but the dangers of such an application being demonstrated, M. MAISONNEUVE (*Séance de l'Acad. des Sci.*, May 14, 1855) devised the simple and effective urethrotome (FIG. 330) now in general use, suggested, as the inventor observes, by the mode of catheterism on a conductor he had proposed ten years before. The urethrotome of M. BOINET, with a metallic guide (FIG. 335), was an improvement on that of BONNET, but was not much used after the invention of M. MAISONNEUVE'S simpler instrument, with its filiform elastic conductor; though LINHART (*Compendium der Chir. Operationslehre*, 1862, S. 895) states that a similar instrument, suggested by Herr STILLING, was recommended in Germany. The urethrotomes of M. MARQUEZ (*Note sur un coarctolôme*, *Gaz. méd. de Strasbourg*, 1856, p. 131), of Sir W. FERGUSON (*A System of Practical Surgery*, 1857, 4th ed., p. 779), of M. MERCIER (*Recherches sur le traitement des maladies des organes génito-urinaires considérées spécialement chez les hommes âgés*, etc., 1856, p. 421), of Professor GROSS (*A Pract. Treat. on the Dis., etc. of the Urinary Bladder, the Prostate Gland, and the Urethra*, 1855, p. 791), and of Dr. LINHART (*Beschreibung eines Urethrotoms*, in *Verhandl. der Phys. med. Gesellschaft in Würzburg*, 1858) have had their advocates, but have not come into general use. Dr. W. F. WESTMORELAND, of Atlanta (*Strictures of the Urethra*, in the *Nashville Jour. of Med. and Surgery*, 1854, Vol. VII, p. 91), commented favorably on the method of REYBARO, and proposed a urethrotome furnished with a metallic guide, which is figured by Dr. J. F. BUMSTEAD (*Path. and Treatment of Venereal Diseases*, 1864, p. 309). M. FAVROT (*Gaz. des Hôp.*, 1859, p. 56) submitted a three-bladed urethrotome, which is of historic interest merely. The anterograde urethrotomes of Dr. G. A. PETERS (PLATE XII, FIG. E, 3) and of Sir H. THOMPSON (*Path. and Treatment of Stricture of the Urethra*, 1858, p. 138; and *The Value of Internal Incision in the Treatment of Obstinate Strictures of the Urethra*, *Lancet*, 1859, Vol. II, p. 784), on the other hand, have been

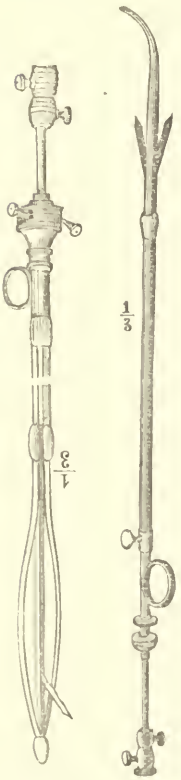


FIG. 336.—Urethrotomes of REYBARO.



FIG. 337.—M. RICORD'S scarificator.



FIG. 338.—Scarificator of Dr. PUTIERIS.

and the value of internal incision in the treatment of obstinate strictures of the urethra, *Lancet*, 1859, Vol. II, p. 784), on the other hand, have been



modifications that later experience has approved. Some surgeons are disposed to restrict the application of antero-internal urethrotomy to strictures in the pendulous portion of the urethra, but recommend the incision from behind forward of constrictions more

deeply seated. The urethrotome of Civiale (FIG. 339) is esteemed one of the most serviceable; but operators are now enabled to select from a great variety of such instruments. There is little

or no evidence regarding the applicability of internal urethrotomy in strictures consequent on shot injuries. Among the cases of fistules, were a number in which the urethra was nearly or completely impermeable in advance of the abnormal opening, and in some of these instances internal urethrotomy might have been the best means of restoring the calibre of the canal; but there is no evidence that the experiment was ever tried. Dilatation and external incision appear to have been the only modes of operative interference with traumatic stricture.

*External Perineal Urethrotomy.*—The number of instances in which external

much employed. Two other urethrotomes, that have been used, are figured below (FIGS. 340 and 341) as the urethrotomes of MM. TRÉLAT and CHARRIÈRE. Dr. BRON (*Gazette med. de Lyon*, 1859) disputes priority of invention in the details of these instruments, and, indeed, their proposers make

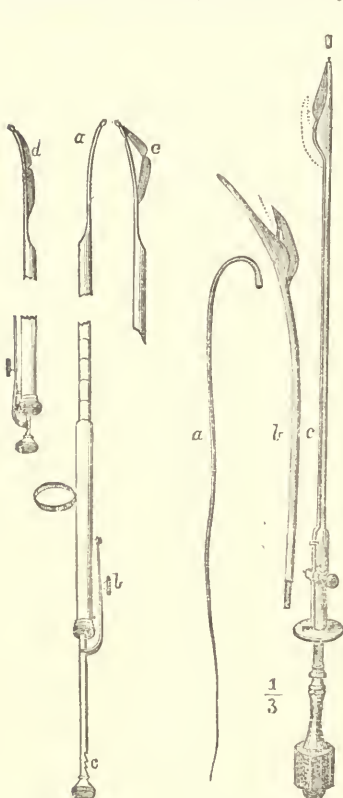


FIG. 340.—TRÉLAT'S urethrotome. FIG. 341.—Urethrotome of CHARRIÈRE.

no claim of originality, but have very ingeniously adapted and combined the serviceable features in the instruments of other inventors, and have made urethrotomes that may be used indifferently to divide strictures from before backward and from behind forward. An account of the instrument of M. TRÉLAT will be found in the *Gazette des Hôpitaux*, 1863, p. 300. CHARRIÈRE'S instrument was shown to the Paris Academy in November, 1852 (*Gazette médicale*, 1852, p. 755). Both of these urethrotomes have, however, undergone many modifications, and, as here represented (FIGS. 340 and 341), are supplied with filiform guides and other recent mechanical improvements. Urethrotomes have been continued with curved rotating blades for the excision rather than incision of strictures that permit the passage of a small cannula. The urethrotome of M. MALLEZ (FIG. 342) is of this sort, and is intended for use with very narrow strictures. It is difficult to make these curved blades effective. An ingenious though complicated urethrotome with a catheter attached, invented by M. J. CHARRIÈRE (*Nouvel urethrotome à lame cachée, et porte-sonde*, *Gazette des Hôpitaux*, 1864, p. 87), is shown in FIGURE 343. Latterly the advantages of combining incision with divulsion, in certain cases, has attracted attention, and an instrument devised for this purpose by Dr. F. N. OTIS (*New York Med. Jour.*, 1872, Vol. XV, p. 159, and Vol. XVII, p. 281) is figured on PLATE XII, FIG. E, 1, 2, 3. Already Dr. A. HAMMER, of St. Louis (*Gaz. des Hôp.*, 1854, p. 127), had sought to accomplish this by an instrument resembling the lithotome of Frère COME (PLATE XII, FIG. H), and supplied with a blunt as well as a sharp concealed blade. Dr. C. D. MASTIN, of Mobile (*Report on Internal Urethrotomy*, 1871), has recommended a modification of the antero-internal urethrotome of M. MAISONNEUVE, which is not unlike the urethrotome perfected by Professor SÉDLICZKY, represented by FIGURE 333. Of the retrograde urethrotomes, that of CIVIALE (FIG. 339), or some of

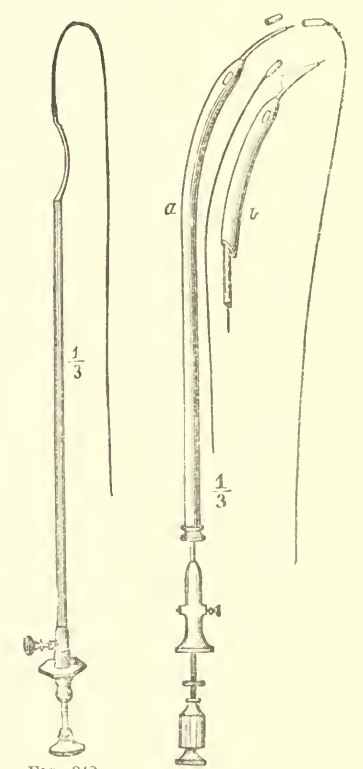


FIG. 342.—Urethrotome of M. MALLEZ. FIG. 343.—CHARRIÈRE'S urethrotome porte-sonde.

its modifications, has been most employed. M. CAUDMONT'S instrument is, perhaps, the best of this class. M. HORION (*Des rétentions d'urine*, 1863), M. BEYRAN (*De l'uréthrotomie dans le traitement des rétrécissements de l'urètre*, in *L'Union méd.*, 1865, p. 148), and many others, have invented urethrotomes, some of which display great ingenuity. If slight ameliorations in details, in the fabrication of urethral instruments, have sometimes been unwisely claimed as real inventions, the practical importance of many such slight improvements must, none the less, be recognized. Although in operations in this region, as elsewhere, more depends upon the judgment and skill of the surgeon than upon the instruments he uses, yet nowhere, not even in operations on the eye, is nicety of mechanism in the instruments more essential. The progress in this direction must be esteemed among the more important advances in modern surgery.

incisions<sup>1</sup> were resorted to for the relief of stricture appears to have been small. In regard to the cases of traumatic stricture, this is the more remarkable, because so many of them were attended by fistules; there being no less than forty-eight examples of this distressing complication. Only seven operations of external perineal urethrotomy were reported, and but four of these were performed on account of consequences of shot injury. The first of this series was a division of a traumatic stricture a month subsequent to the injury:

CASE 1092.—Corporal G. Walter, Co. D, 95th Pennsylvania, aged 39 years, was wounded at the Wilderness, May 5, 1864. He was admitted to the Second Division Hospital, Alexandria, on the 26th. Acting Assistant Surgeon J. Cass made the following report of the case: "Gunshot wound of the scrotum, dividing the urethra. The wound is healed, leaving a permanent stricture, and in June, 1864, Acting Assistant Surgeon C. P. Bigelow performed the median operation for stricture by incision through the raphe, three inches in length, into the urethra. The general condition of the patient was favorable; the anæsthetic used was sulphuric ether. After the operation the catheter was introduced and allowed to remain." On October 29th, he was transferred to McClellan Hospital, Philadelphia, where he was treated for the wound, which was still open. He was discharged June 1, 1865. Surgeon L. Taylor, U. S. A., on certificate of disability stated that "he was wounded in the right thigh, right testicle, and urethra, the ball making its exit through the left thigh." Examiner J. Lenox Hodge reported, June 5, 1865: "The wound has impaired the usefulness of the right thigh and has left him with a tight stricture of the urethra, which obliges him to wear a catheter all the time." Examiner J. S. Crawford reported, September 17, 1873: "The projectile entered the back part of the right thigh, passed upward and outward and made its exit in the middle of the thigh, and, entering the scrotum, passed through it, cutting the urethra, and came out on the left side below the hip-joint. One testicle is entirely removed, the other is atrophied. He has to wear a tube that reaches above the opening in the urethra; disability three-fourths." This pensioner was paid to September 4, 1873.

There can be little doubt, that a successful operation for perineal section described by

<sup>1</sup> The history of external perineal urethrotomy has been obscured by juristic discussions chiefly on the merits of SYME'S operation. An immense amount of rubbish has been debited regarding the nature of the operation denominated *boutonnaire*; the "patriotic bias" has been unbecomingly manifested; much unwarranted egotistical assumption, and much ignorant and malignant detraction, has been displayed. Yet the historical facts remain, to be traced readily enough by the unprejudiced student. It is unquestionable that incisions in the perineum for the relief of retention of urine or of stricture, or of foreign bodies impacted in the urethra, were practised, in very early times, under the name of perineal puncture, section, urethrotomy, or *boutonnaire*. It is equally clear that important distinctions may be pointed out between these exceptional operations, and the modern methodical operations of external perineal urethrotomy upon a grooved staff, and of external perineal urethrotomy without a conductor. Perineal urethrotomy in some shape is probably coeval with lithotomy; but the first distinct mention of it, as a separate operation, appears to be contained in ARETEIUS (*De curatione acut. et duntur. morborum*, ed. BOERHAAVE, Lugduni Bat., 1735, Lib. II. p. 111, *de curatione acutorum vesicæ affectuum*), who, A. D. 80, speaking of calculi impacted in the urethra and causing retention, advised that they should be cut down upon and removed. "Ἴν' δὲ ἀπορος μὲν ἢ ἡ τῶνδε ἰητρῶν, θηήσκη δὲ ἀδύνησι ἀνθρώπος, ταμνεν τὴν τριχάα καὶ τὸν τῆς κυστιῶς τραχήλον, ἕς τε τὴν τὸν λιθὸν ἐκπτῶσιν" (at si expedi. medicatio nequit, homine doloribus consumitur, locum cum. qui sub glande est, cervicemque vesicæ incidit, ut lapis excidat). The context shows that this was a familiar operation at that time. Ten years later, HELIODORUS (*loc. cit.*, Lib. XLV) commends a similar operation for scleroma with retention: "πρῶς δὲ τῷ ὄσχει, τὸν ὑπὸ τὸ σκληρίωμα τόπον διαρῆν χρῆ, συνδιαιρούμενον τῷ περινεῷ τοῦ τραχήλου τῆς κυστιῶς, ἵνα κατὰ ἐπιτηδέουσιν γυνηται ῥύαί" (If, on the contrary, the scleroma was situated near the scrotum, the region below the tumor should be divided, including in the incision the neck of the bladder and perineum, in the avowed purpose of leaving a urinary fistula.) OMBASIUS (*Opera*, ed. STEPHANI, 1567, *Synopses*, Lib. IX, cap. XXXII, p. 146), in the fourth century (circa A. D. 360), advises a similar perineal urethral incision for removal of conglua: "Spatium quod inter anum et pudendum interjacet, quod perineum dicitur, secare, quemadmodum in vesicæ calculo consueverit, atque ita grumis educere." In the sixth century (A. D. 550), ÆTHIUS (*Tetrabiblos*, Lugduni, 1549, p. 692) repeats this recommendation: "Sic vero neque sic grumi dissolvantur, interepedimentum inter anum et pudendum, perineum Græcis dictam, inferne dissecare oportet, quemadmodum in calculosa vesicæ est prædictum, et eductis grumis de cetero." In the following century (A. D. 650), PAULUS ÆGINETA (*Syd. Soc.*, ed. ADAMS, 1844, Vol. I, p. 546) apparently quotes this advice, though without acknowledgement: "If there be coagulated blood in the bladder [which cannot be dissolved by methods recommended, then] we must make an incision in the perineum, as in the cases of calculus, and, having removed the clots of blood, accomplish the cure in a proper manner." The same precept reappears in the writings of the Arabians. RHAZES, of Bagdad (A. D. 850-923), (*Continet.*, ed. Venet., 1506, Cap. X, p. 215, *De agrolutibus renium et vesicæ*), speaking of dysuria caused by blood conglua, remarks: "Et nisi dissolvatur, aperitur exitura cum ferro." AVICENNA (*Opera*, Venet., 1598, Lib. III, cap. VI, p. 832), after describing the use of the catheter in cases of retention, advises no further operative interference, but says that others have adopted a perineal section: "Quando urine fit difficultas \* \* \* est aliquis qui ingeniatur, et in eo, quod est inter anum et testiculos scissuram efficit parvam et ponit in ea cannulam ut egrediatur." It was not, however, until GIOVANNI, of Cremona, and his disciple MARIANO SANTO, established and popularized the operation of lithotomy by the major apparatus, that this form of urethrotomy came into common use. All of these citations refer to instances of what the old French surgeons would call *la boutonnaire*, and henceforward minute directions were given for the operation. The patient was to be placed in the position for lithotomy. A grooved staff was to be introduced. An assistant raised the testes. The operator, taking the handle of the staff in his left hand, made the convexity of the curve of the staff to project in the perineum; then, holding his knife as a writing pen, he was to make, back of the scrotum, on the median line, or slightly to the left of the raphe, a longitudinal incision, descending nearly to the anus and intersecting the urethra for the extent of an inch or an inch and a quarter. Then, laying aside the knife, he took a gorget and introduced it along the groove of the staff, through the perineal wound, to the bladder, and then withdrew the staff. The gorget, in its turn, served as a guide to carry a full-sized tube into the bladder (VOLLEMIER, *op. cit.*, p. 311). Many would restrict the term external urethrotomy to cases in which the operation was done with a view of dividing a stricture. Great confusion has arisen from this distinction having been observed or neglected by different writers. THEVENIN (of Paris) does not treat specially of strictures; but in speaking of retention of urine (*Œuvres contenant un traité des tumeurs, etc.*, Paris, 1678, Cap. CXXI, p. 167) he describes this operation: "L'opérateur fera une incision avec le bistouri entre l'anus et le scrotum," and he added an improvement; for instead of using a gorget, after dividing the urethra on a grooved staff, he glided along the groove of the catheter a stylet which served as a conductor for the introduction of a tube into the bladder, and avoided the extension of the urethral incision toward the prostate. The remarkable operation by MOISSIN,




FIG. 314.—SYME'S grooved staff.



the late J. Mason Warren (*Surgical Observations*, 1867, p. 235, Case CXXXIII), was performed upon the subject of the following observation, although no name is mentioned in Dr. Warren's report:<sup>1</sup>

CASE 1093.—Private R. Nelson, Co. K. 29th Massachusetts, aged 20 years, was wounded at Fort Steadman, March 25, 1865. From a Ninth Corps field hospital, Assistant Surgeon S. Adams, U. S. A., reported: "Gunshot wound of the perineum, severing the urethra; the ball entered the perineum in front of the anus, and came out through the pelvis and scrotum, dividing the urethra; the urine passed through the posterior wound; simple dressings." Dr. A. T. Fitch, April 1st: "Pulse good; much fever; tongue clean; appetite good; no sleep; not much pain." On April 3d, this patient was transferred to City Point, and, on the 7th, to Alexandria, whence he was discharged May 31, 1865, and pensioned. Examiner G. S. Jones, of Boston, reported, June 19, 1865: "The ball entered the penis, passed through the right testis and neck of the bladder, and emerged from the left natis near the cleft. A fistulous opening now exists, from which his urine escapes. The right testis is atrophied, and its functions are evidently greatly impaired. The disability is total and permanent, and biennial examinations are evidently not required." This pensioner was paid September 4, 1873.

In this case, three months after the reception of the injury, the posterior portion of the urethra was found involved in a mass of cicatricial tissue, and a bougie introduced at the meatus emerged at a fistule near the anus. Perineal section was performed, and great difficulty was experienced in finding the orifice of the urethra that led to the bladder. The gristly mass was divided, and a large catheter was introduced. There was immediate relief; but the ulterior result was less satisfactory than had been anticipated. In the

in 1662 (*Wiseman's Chir. Treat.*, 1676, Book VII, Chap. VI, p. 76), which some authors regard as the first recorded example of external urethrotomy without a conductor, will be again referred to. Surgeons were not deterred from attempting perineal section when it was impracticable to pass a grooved staff because of the contraction of the urethra. Thus COLOET (F.) (*Traité de la Taille*, 1727, p. 241) relates several instances in which he incised the perineum and divided the urethra without a guide, "sans règle et sans appui," especially a case in which he successfully operated on a notary of the parliament of Paris. In this case there were three perineal fistules, which might have facilitated the operation. CIVIALE (*Les mal. des organes génito-urinaires*, 3<sup>me</sup> éd., 1858, T. II, p. 323) refers this particular operation, by FRANÇOIS COLOET, to June 28, 1687. In the treatise on *Diseases of the Urinary Organs*, by Dr. GOULEY, which is issued to medical officers, such an excellent historical summary is supplied of the progressive improvements made in effecting perineal incisions, whether for the relief of stricture or of retention, that it is almost a work of supererogation to recapitulate the bibliography of the subject at this period. Among the writers of the last century adduced by this author and by Professors VOLLEMIER and STILLING may be particularly noted: TOLET (*Traité de la lithotomie*, 1681, and the English translation by Lovell, 1683, Cap. XXI, p. 146); SOLINGEN (*Mannliche opération de chirurgie*, Amsterdam, 1863), and the citations from the same in STALPART VAN DER WIEL (*Obs. rur. méd. anat.*, 1687, T. II, p. 410); PALFEN (*Anat. du corps humain*, Paris, 1726, p. 174); DIONIS (*Cours d'opérations de chirurgie*, 4<sup>me</sup> éd., 1750, p. 195), and LA FAYE in his notes to DIONIS (*op. cit.*, p. 211); LE DRAN (*Traité des opérations de chirurgie*, 1742, p. 368); COL DE VILLARS (*Cours de chirurgie dicté aux écoles de méd.*, Paris, 1747, T. IV, p. 221); ASTRUC (*De morbis veneris*, 1738, p. 242), and MUZZEL (F. H. L.) (*Medicinische und chirurgische Wahrnehmungen*, Berlin, 1714, S. 113). The importance of including the indurated tissue in the urethral incision was well recognized by J. L. PETIT: "All those on whom I practised the boutonnière on account of retention of urine," he says, "regained freedom of the canal, provided the stricture was comprized in the incision." (*Mém. de l'Acad. de Chir.*, éd. Fossone, T. II, p. 17.) HUNTER's operation for perineal fistula (*Treatise on the Venereal Disease*, London, 1788, p. 160) is memorable in the history of this operation. His renowned contemporaries, DESAULT, SHARPE, and CHOPART, condemned perineal incisions, which, apparently, were undertaken about this period so injudiciously that external urethrotomy, discontinued by these masters, fell into desuetude among European surgeons. The operation was revived in this country by STEVENS (*The Medical and Surgical Register, consisting chiefly of Cases in the New York Hospital*, 1818, Vol. I, p. 75), and soon afterward JAMESON, whose papers are elsewhere cited, D. L. ROGERS (*Philadelphia Med. and Phys. Jour.*, Vol. XIX, p. 186), and J. C. WARREN (*Boston Med. and Surg. Jour.*, 1829, Vol. II, p. 321) described cases of its successful performance; and, later, at the New York Hospital, between 1838 and 1843, external perineal urethrotomy was not infrequently performed. Meanwhile some British surgeons, CHEVALIER, GUTHRIE, ARNOTT, and BRODIE, especially, endeavored to raise external urethrotomy from the discredit into which it had fallen; but it remained an exceptional operation until 1844, when SYME, with great earnestness, recalled professional attention to it and placed its advantages in a new light, maintaining, indeed, that all cases of urethral obstructions that were not curable by dilatation should be treated by internal incision. SYME simplified the operative method, and greatly improved the instruments for performing it. His guide staff, as used by his Edinburgh disciples, is figured in the wood-cut, FIG. 344, on the preceding page. The importance of including in the incision not only the strictured portion of the urethra, but a portion of the uncontracted canal, was established by the researches of SYME and of CIVIALE. The objection to SYME's metallic conductor, that the operator was exposed to the danger of entering and cutting upon a false passage, has been obviated by the employment of filiform gum conductors or of capillary whale-bone guides. A great improvement, suggested by Mr. AVERY, consists in passing a loop of silk through each edge of the incised urethra. Other details in the manual of the operation have been perfected by contemporaneous surgeons.

<sup>1</sup> Regarding American experience in external perineal urethrotomy, besides the systematic works by Drs. GROSS, MORLAND, and GOULEY, and papers already cited, the following articles may be consulted, viz: A series of seven cases of traumatic stricture successfully treated by this plan by J. MASON WARREN (*Surgical Observations, with Cases and Operations*, 1867, p. 234 et seq.); LENTE (F. D.) (*Perineal Section for Stricture of the Urethra*, in the *New York Jour. of Med.*, 1855, Vol. XIV, p. 220; also *Surgical Statistics of the New York Hospital*, in *Trans. Am. Med. Assoc.*, 1851, Vol. IV, p. 330, containing a tabular statement of the results of twenty-seven operations of perineal section); HALSEY (W. S.) (*Strictures of the Urethra treated by SYME'S Method*, in the *Am. Jour. Med. Sci.*, 1858, Vol. XXXVI, p. 72); MAURY (R. B.) (*Traumatic Stricture; Perineal Urethrotomy without a Guide*, in the *Medical Record*, 1866, p. 417); VAN BUREN (W. H.) (*Clinical Lectures on Traumatic Stricture*, in the *Med. Record*, 1865, pp. 180, 278); ASHURST (J., jr.) (*Traumatic Stricture complicated with perineal Fistula; Treatment by external Division*, in *Am. Jour. Med. Sci.*, 1866, Vol. LII, p. 81); WHITEHEAD (W. R.) (*Perineal Urethrotomy*, in the *Med. Record*, 1866-67, Vol. I, p. 491); GHION (A. L.) (*Stricture of the Urethra, etc., Perineal Section, Recovery*, in the *Am. Jour. Med. Sci.*, 1868, Vol. LV, p. 556); CREAMER (J.) (*External perineal Urethrotomy*, in the *New York Med. Jour.*, 1869, Vol. IX, p. 139); BURKE (G. M.) (*Perineal Section for impermeable Stricture*, in the *Western Jour. of Med.*, 1869); GAVIN (M. T.) (*Case of impacted urethral Calculus; External Urethrotomy*, in the *Boston Med. and Surg. Jour.*, 1870, Vol. VI, p. 118); INGALLS (W.) (*Urethral Calculus; Retention of Urine; External Urethrotomy*, in *Boston Med. and Surg. Jour.*, 1871, Vol. VII, p. 93); HEWIT (H. S.) (*Perineal Urethrotomy*, in the *Med. Record*, 1871-72, Vol. VI, p. 316); OTIS (F. N.) (*Remarks on Stricture of the Urethra of extreme calibre*, in the *New York Med. Jour.*, 1872, Vol. XV, p. 152); TAYLOR (B. F.) (*Operation for Stricture of the Urethra, with Remarks*, in the *New Orleans Med. and Surg. Jour.*, 1850-51, Vol. VII, p. 339); HUNT (W.) (*Traumatic Rupture of the Urethra, recent and chronic*, in the *Medical Times*, Phila., 1870-71, Vol. I, p. 173); BRIDSON (C. K.) (*Contributions to the Surgery of the Male Urethra*, in the *Med. Record*, 1872, Vol. VII, p. 219).

next case, perineal section of a traumatic stricture<sup>1</sup> was practised five months after the injury, and, for a time, the operation promised well; but, afterward, a fistule persisted for three years, though it appears, ultimately, to have closed spontaneously; a rare result.<sup>2</sup> It is not strange, if the absorbing duties of military surgeons during time of war is considered, that so few operations of this class were then reported, nor that several of them should have been practised in civil hospitals. There were, indeed, more cases of external urethrotomy reported in the five years succeeding<sup>3</sup> than during the war; and army experience of the treatment of traumatic stricture must be owned to be limited.<sup>4</sup>

CASE 1094.—Sergeant S. W. Shadle, Co. D, 11th Pennsylvania, aged 22 years, was wounded at the Wilderness, May 6, 1864. He was sent to Finley Hospital on May 26th. The following entry appears on the unsigned hospital case-book: "Shot wound of the right testis, and also injury to the urethra. The testis was removed on the field, May 7th. On June 30th he was furloughed, after which he was readmitted. The wound healed, but produced stricture of the urethra, for which an operation by external perineal section was performed by Surgeon G. L. Hancock, U. S. V., on October 1st. December 8th: The patient is doing well; the catheter is kept in the bladder; the wound of operation has commenced healing since the application of official iodine ointment on lint. The wound, which was very indolent at the time, was stopped with the charpie thus prepared. Extra diet and porter were given. On the 10th, a small orifice had made its appearance at the root of the penis on the under side, and communicated internally into the urethra. Cataplasms were constantly applied to the testis. By the 16th the new opening just mentioned was quite healed. Iodine ointment was continued, and calomel was given internally. The opening at the root of the penis which closed on the 16th was again open on the 28th. This was caused probably, by the use of a silver catheter a second time, elastic ones not being used in the hospital. A sulphate of quinine pill was given every two hours. On the following day the remaining testis was inflamed and was quite hard and painful; severe pains also extended to the cord. The patient was attacked by severe chills, followed by fever, probably of a malarial character; and the tongue was loaded with a yellow coating. Wine and tonics were given. By January 5, 1865, the patient was much improved; the chills had ceased, and the inflammation in the testis had subsided. But little change took place from this date to February 6th; catheterization was continued; the discharge from the wound had nearly ceased, and the patient's health, generally, was good." This man was discharged August 3, 1865, and pensioned. Examiner M. D. Benedict reported, August 4, 1865: "A musket ball entered the scrotum and was extracted from the perineum. The right testis was extirpated. The urethra was wounded, and there remains a fistulous opening of the urethra anterior to the scrotum, through which fistula the urine passes in part." Examiner J. S. Crawford reported, January 6, 1868: "The projectile struck the scrotum and carried off the right testis, wounded the urethra in its upper third, and also the perineum. Urine passes through a fistulous opening in the upper third of the urethra. The left testis is now swelled and inflamed. In erection of the penis, chlorde occurs, from the adhesive inflammation of the urethra. His amorous desires are not destroyed. The fistulous opening in this case certainly could be closed by a proper operation, and I endeavored to persuade him to have it done. Successfully done, the operation would remove the unpleasant feature in this man's case." The same surgeon continues, September 15, 1873, by saying that "the pensioner has incontinence of urine at night; through the day he has to micturate often, and he has neuralgia in the back as the result of the wound. The fistulous opening is closed; the incontinence occurs from partial paralysis of the sphincter muscles, and his disability is total." This pensioner was paid September 4, 1873.

The next case was very complicated, and perineal section was practised, on the tenth day after the injury, for the removal of a bone fragment and the relief of infiltration

<sup>1</sup> BILLROTH (TH.) (*Chir. Briefe aus den Kriegslazarethen in Weissenburg und Mannheim*, 1870, S. 206) speaks of a case of "shot wound through the perineum with laceration of the urethra, August 4, 1870; obliteration of the latter; tedious discharge of urine by the perineal fistula only. September 20th, I performed external urethrotomy, and introduced a catheter by the urethra. On November 15th, Herr LOSSEN had the kindness to write to me: By the urethrotomy the wound of operation has healed some time since. Patient has, for four weeks, urinated through the urethra, and catheterizes himself." Herr LOSSEN (*Kriegschr. Erf. aus Mannheim, Heidelberg, und Karlsruhe*, in *Deutsche Zeitschrift für Chir.*, 1873, B. II, S. 21) gives the patient's name as Johan Markewitsch, 46th Prussian regiment, and adds: "Both shot wounds granulated finely after the operation. About the middle of October, 1870, urine passed through the urethra for the first time. Wound cicatrized rapidly. In November, the patient introduced the catheter twice daily, but was able to pass urine without it." Dr. LOSSEN saw this patient at Schwetzingen about the middle of January, 1871: "The anterior shot wound had become fistulous again and passed urine in drops. Further information is wanting." BECK (B.) (*Chirurgie der Schwerverletungen*, 1872, S. 566) states that, in the Bavarian Corps, "thrice, external urethrotomy was successfully performed for retention of urine and infiltration in consequence of injury or traumatic stricture, no retarding complications occurring." FLEURY (C. F.) cites a successful case of external perineal urethrotomy after shot injury, from the Franco-German War (*Fistules urinaires, pelviennes et fémorales, suite d'un coup de feu, uréthrotomie externe sans conducteur.—Guérison*, in *Gaz. des Hôp.*, 1871, No. 41).

<sup>2</sup> WILLIAMSON (G.) (*Mil. Surg.*, 1863, p. 118) mentions two cases of invalids from the Indian Mutiny, under the care of Assistant Surgeon Smith, 9th Lancers, very similarly wounded by balls traversing the left testis and wounding the urethra, perineal fistulae resulting. "The fistulous openings in the canal closed entirely, and the natural passage remained undiminished in size, allowing a full-sized catheter to pass with ease into the bladder."

<sup>3</sup> Compare the *Report on Surgical Cases in the Army*, Circular 3, S. G. O., 1871, Cases DCXCII, DCXCIV, p. 254; DCXCV, p. 255.

<sup>4</sup> BILLROTH (TH.) (*Chirurgische Erf.*, Zürich, 1860-67, in *Arch. für Klin. Chir.*, 1869, B. X, S. 532) gives eleven cases of traumatic strictures of the urethra, caused by falls on the perineum. Six of the patients came under treatment early and were successfully treated by gradual dilatation. In a boy of eleven, with a stricture of one year's standing, a very fine catheter was successfully introduced; after the second insertion, fatal uræmia supervened. In four cases—nine weeks, two years, four years, twenty years after the injury, respectively—bougies could not be introduced. In the last three, complicated with urethral fistules, external urethrotomy was performed and catheters were introduced. Death from uræmia took place, respectively, on the seventh, second, and third days after the operation. In the fourth case, while attempting to introduce a catheter, the instrument passed through the weak cicatrix into the space between the bladder and symphysis pubis; the attempt was discontinued; fatal perivesical infiltration of urine resulted.



rather than for traumatic stricture, and the observations, already alluded to on page 284, should, perhaps, have been classified under the head of perineal incisions rather than as an example of external urethrotomy. Thus far the experience of the latter operation for the consequences of shot injury has been extremely limited.

CASE 1095.—Private E. English, Co. I, 67th New York, aged 21 years, was wounded at Fair Oaks on June 1, 1862. He was sent to the Fifth Street Hospital, Philadelphia, on June 8th, and Acting Assistant Surgeon A. C. Bournonville reported the progress of the case substantially as follows: A round ball had struck on the right buttock, entered the pelvis, fracturing the spine of the ischium, passed through the bladder at the neck, through the right obturator foramen, splintering the descending ramus of the pubis, and emerged on the thigh (passing under the femoral vessels) at the apex of Scarpa's triangle. The femoral vessels were uninjured, but the crural nerves were implicated. On admission, the patient was much prostrated; the right leg was paralyzed and much swollen; urine passed from the wound of exit, and urine and pus from the wound of entry. On passing a sound into the bladder a hard foreign body could be felt. On June 11th, Acting Assistant Surgeon T. G. Morton made a perineal section, three days after the patient's admission, and a catheter was introduced and allowed to remain. A fragment of bone three-fourths of an inch long, which had worked its way through the bladder into the urethra, was extracted on June 13th. Stimulants, tonics, and opiates were subsequently prescribed. The urine flowed freely through the catheter. On June 19th, a large flow of dark clotted blood from the bladder escaped from the wound of exit and from the section. The patient died from extreme exhaustion on June 26, 1862.

Three instances were reported of operations of external perineal urethrotomy<sup>1</sup> in cases of strictures of non-traumatic origin:

CASE 1096.—Private P. Martin, Co. II, 88th New York, aged 30 years, was admitted into Finley Hospital, April 20, 1864. On the regimental monthly report for April, signed by Surgeon R. Powell, one case of disease of the urinary and genital organs is noted, without comment. Surgeon G. L. Pancoast, U. S. V., reported, from Finley: "Stricture of the urethra since April 15th. He could not void water except by drops, and no instrument of any kind could be passed. His general health was very good. On September 28th, chloroform was administered, the stricture was laid open by a cut from without, and a large silver catheter was then passed into the bladder. The patient did well, and was returned to duty January 8, 1865."

CASE 1097.—Private J. Ewing, Co. II, 49th Pennsylvania, aged 35 years, was admitted into Cuyler Hospital, May 20, 1861, with amputation at the right shoulder-joint performed eight months previously. He was furloughed a short time in June, and subsequently he was treated for stricture, and Assistant Surgeon H. S. Schell, U. S. A., reported as follows: "Stricture of the urethra following an attack of gonorrhœa seven years prior to admission. The stricture was impermeable, and the perineum was the seat of several fistulous openings. On November 15th, the patient was chloroformed, and Acting Assistant Surgeon B. Rohrer performed the operation of perineal section. A grooved director was introduced into the urethra as far as the point of stricture, which was anterior to the bulb: and the stricture was then divided by an external incision, one inch in length, through the raphe of the perineum. At the time of the operation the constitutional condition of the patient was good. A No. 8 catheter was introduced immediately after the operation, and left in for a few days. The case progressed favorably, and, by December 20th, the wound was firmly healed, the fistulæ closed, and a No. 8 catheter could be passed without difficulty." He was furloughed December 20th, readmitted, and discharged the service January 16, 1865.

CASE 1098.—Private W. Walton, Co. G, 28th Massachusetts, aged 25 years, was admitted into General Hospital at Boston, November 29, 1861. Assistant Surgeon Edward Cowles, U. S. A., noted: "Stricture of urethra of six years' standing. External perineal urethrotomy was practised by Dr. Henry J. Bigelow, December 14, 1861. The patient had considerable hæmorrhage from the wound on the 15th, 17th, 18th, and 19th, 'probably from the artery of the bulb.' Grave symptoms began to appear on the 24th, with probable deep pelvic inflammation. Death ensued December 29, 1861."

This scanty series of operations for external perineal urethrotomy does not indicate the estimation in which this resource was held by army surgeons. Its value was highly appreciated; the risks attendant on it<sup>2</sup> were not regarded as great in comparison with those of other operations on the urethra. The lamented H. S. Hewit devised an instru-

<sup>1</sup>The contributions of American writers comprise some valuable additions to the literature of the operative treatment of urethral stricture. Among them are papers by: HORNER (W. E.) (*Fistula in perineo, with considerable loss of substance, cured by Lunar Caustic*, in the *Phila. Jour. of Med. and Phys. Sci.*, 1824, Vol. IX, p. 141); JAMESON (H. G.) (*On the Treatment of Stricture of the Urethra by Perineal Section, with Cases*, in the *Am. Med. Recorder*, 1824, Vol. VIII, p. 121; also *Practical Observations on Stricture of the Urethra*, *Ibid.*, 1828, Vol. XII, p. 329; also *Case of Stricture of the Urethra treated by Perineal Section*, in the *Maryland Med. Recorder*, 1829, Vol. I, p. 177). Dr. JAMESON was a pioneer in this country in promoting a rational operative treatment of intractable urethral strictures. Besides advocating and practising external perineal urethrotomy, he revived DESAULT'S plan of catheterization on a conductor, which, after falling into disuse for half a century, is now again in vogue. CHEW (E. R.) (*Description of an Instrument for dividing Strictures of the Urethra* (with a plate), in the *North Am. Med. and Surg. Jour.*, 1828, Vol. V, p. 311); WRIGHT (J. A.) (*Case of impermeable Stricture, operated on through the Urethra, with the Suggestion of a new-shaped Catheter*, in *Charleston Med. Jour.*, 1852, Vol. VIII, p. 799); DUGAS (L. A.) (*On the Treatment of Stricture of the Urethra*, in the *Southern Med. and Surg. Jour.*, 1855, Vol. XI, p. 645); CHESLUM (J. J.) (*Perineal Section for impermeable Stricture*, in the *Charleston Med. Jour.*, 1857, Vol. XIII, p. 301); BERGE (J. H.) (*Dilatation of Strictures in the Urethra*, in *Am. Med. Monthly*, 1862, Vol. XVII, p. 419); BROWNE (W.) (*Incision of Stricture of the Urethra*, in *The Stethoscope*, 1851, Vol. I, p. 625); STEIN (A. W.) (*Retention of Urine*, in *New York Med. Jour.*, 1874, Vol. XIX, p. 464).

<sup>2</sup>BILLROTH (TH.) (*Chirurgische Erfahrungen*, Zürich, 1860-67, in *Arch. für Klin. Chir.*, 1869, B. X, S. 532) observes: "It is a well-known fact that in cases of serious disease of the bladder, ureters, and kidneys consequent on old strictures, operative interference, even by the introduction of a catheter, is not without danger. The alternatives are the rejection of such operations or the risking of them, hoping for exceptionally favorable results."

CASE 1129.—Private T. J. F——, Co. A, 51st Pennsylvania, aged 19 years, was wounded at Spottsylvania, May 12, 1864. Surgeon M. K. Hogan, U. S. V., reported, from a Ninth Corps hospital, "gunshot wound of the right thigh and testicles; testicle removed." On the 25th, this patient was sent to Armory Square Hospital, and remained under treatment until September 24th; when transferred to Satterlee Hospital the medical officer in charge of Ward G reported: "Shell wound of the right thigh and groin, carrying away the right testicle; poultices and simple dressings were applied. By February 6, 1865, he had so far recovered as to be recommended for duty with his regiment, and was transferred to another ward. A piece of the shell still remained deeply buried in the wound near the situation of the femoral artery; and, on February 16th, Acting Assistant Surgeon W. F. Atlee made an incision about one inch long and extracted the piece of shell. There was but little hæmorrhage, and no ligatures were used. The anæsthetic used was one part chloroform to three of ether. When the operation was performed the wound was somewhat inflamed. Flaxseed poultices and cerate dressings were applied to the wound, and the patient did well until April 20th, when an abscess began to form on the inner side of the thigh below the wound. The parts were painted with tincture of iodine, and, on the 27th, the abscess opened and discharged a quantity of bloody pus. On May 11th, there were syphilitic warts all over the corona of the glans penis." This soldier was mustered out June 24, 1865, and pensioned. Examiner T. J. Harper, of Philadelphia, May 3, 1871, reported: "A ball entered the right inguinal region a few lines above the middle of Poupart's ligament, causing a suppurating wound, which still continues to discharge, resolution never having taken place since he was wounded. Immediately after having received the above-described wound, while being carried from the field of battle, he received several other wounds by the bursting of a shell, one fragment of which carried away the right testicle, and another fragment caused wounds in the upper and middle thirds of the right thigh, which is now covered with numerous cicatrices. Disability from these wounds has increased." This pensioner was paid September 4, 1873.

CASE 1130.—Captain E. S——, Co. I, 17th Missouri, aged 37 years, was wounded at Arkansas Post, January 11, 1863. He was treated at a Fifteenth Corps hospital and at the Officers' Hospital, Memphis, for "chronic diarrhœa," and was returned to duty on July 6, 1863. On July 21, 1864, he entered Main Street Hospital at Covington; a board of surgeons reported: "Gunshot wound of the lower extremity and scrotum." This officer was discharged July 27, 1864, and pensioned. Examiner J. Bates, of St. Louis, reported, September 3, 1864: "Ball passed through the upper fleshy portion of the left thigh and through the scrotum, and out through the fleshy part of the right thigh." Examiner J. Baker, of Jefferson City, January 15, 1872, reported: "A ball passed through the left testicle and right thigh; the testicle has entirely disappeared, leaving the adjacent structures in an irritable condition, so that occasionally the parts become inflamed and ulcerated." \* \* \* Dr. Baker again reported, September 4, 1873: "Wounded by a ball in the left testicle, which was afterward removed. The ball then penetrated the right thigh, and passed out near the trochanter major. He is unable to bend the thigh to the abdomen, and suffers from lameness and inability to take active exercise; the cicatrix of the scrotum is tender; disability three-fourths."

CASE 1131.—Private S. S——, Co. F, 48th Illinois, aged 18 years, was wounded at Fort McAllister, December 21, 1864, and sent to hospital at Beaufort on the next day, and registered: "perforating gunshot wound of the left testicle and right thigh by a conoidal ball; testicle removed." On January 1, 1865, this patient was sent by hospital steamer to De Camp Hospital, New York, and thence, by rail, on March 18th, to Quincy, Illinois. Acting Assistant Surgeon D. C. Owen reported: "Wounded by a minié ball, which totally destroyed the left testicle; thence, entering the right thigh, the ball passed through the gluteal muscles; both wounds are healed; full diet was given; the patient improved slowly, and, May 17, 1865, was discharged and pensioned." Examiner Joseph Robbins, of Quincy, reported, May 18, 1865: "Ball struck the scrotum, took out the left testicle, entered the right thigh on the inside, passed obliquely through and out on the outer side posteriorly. The leg is weak, and soon becomes weary when exercised; he has pain and weakness in the left groin, aggravated by exertion; disability three-fourths." Examiner A. T. Barnes, of Centralia, reported, February 9, 1872: \* \* \* "The testicle being destroyed entitles him to one-half pension, and the wound in thigh to one-fourth; the spermatic cord is also painful, the pain being annoying rather than severe." This pensioner was paid September 4, 1873.

*Excisions of the Testis for Shot Injury.*—Sixty one, or about one in nine, of the cases of shot injury of the testis were treated by extirpation of the injured organ. In twenty-five the right testis, in thirty-one the left, and in three both testes were removed; in two cases this point was not specified. The mortality of these cases was 18 per cent. In the cases treated by expectation, the mortality was 11.9 per cent.:

CASE 1132.—Private James L——, Co. B, 10th Infantry, was wounded at the Wilderness, May 12, 1864, and sent to a Ninth Corps hospital. Surgeon M. K. Hogan, U. S. V., reported: "Gunshot wound of testicle, necessitating castration." May 26th, this soldier was transferred to Lincoln Hospital, and registered as a case of "loss of left testicle, excised for gunshot wound." He was sent to Patterson Park, Baltimore, convalescent, on June 6th, and returned to duty July 22, 1864. No application for pension.

CASE 1133.—Sergeant Samuel B——, Co. G, 70th Ohio, aged 25 years, was accidentally wounded at Columbia, South Carolina, February 18, 1865. He was admitted to a Fifteenth Corps hospital on the same day. Acting Assistant Surgeon J. W. Brewer reported: "Gunshot wound of the right thigh, injuring the scrotum and wounding the left testicle; the injured testis was removed by Acting Assistant Surgeon G. M. Wilson." The patient was transferred to Foster Hospital, New Berne, April 4th, and thence to Grant Hospital, New York, on the 16th; was returned to duty June 2d, and discharged from service August 14, 1865, and pensioned. Examiner Thomas W. Gordon, of Georgetown, Ohio, reported, August 14, 1865: "The ball entered the inside of the left thigh in the upper third, carried away the left testicle and injured the right one, passed into the upper third of the right thigh, and was removed from its posterior side through the glutei muscles. An abscess was afterward found in the middle third of the thigh, inside, and the muscles sloughed. The leg is a little diminished in size by the loss of nervous and muscular power, and is thereby weakened." This pensioner was paid September 4, 1873.



The two foregoing abstracts, and six on this and three on the succeeding page, relate to excisions of the left testis,<sup>1</sup> which is probably more exposed than its fellow to shot injury, in a degree inadequately expressed in the statistical summary on page 355:

CASE 1134.—Sergeant L. J.—, Co. I, 134th New York, aged 18 years, was wounded at Gettysburg, July 1, 1863. Surgeon H. Janes, U. S. V., reported: "Severe gunshot wound of the genitals and removal of the left testicle." On July 16th the sergeant was sent to Annapolis, and, on October 5th, was registered as "convalescent from an excision of the left testis for gunshot wound, and returned to his regiment." He was discharged June 10, 1865, and pensioned. Examining Surgeon J. R. Doekstader, of Sharon Spa, reported, February 3, 1870: "Gunshot wound in the left testicle, which was removed on July 4, 1863. The ball in its course penetrated the soft parts in the neighborhood, ascending into the region of the groin. It has made sad inroad upon his health." Dr. J. S. Swart reported, January 2, 1872: "Wound of left testicle, which is entirely removed. No inconvenience from the castration as regards his health. The disability is permanent in its present degree." Surgeons R. B. Bontecou, W. H. Craig, and C. H. Porter reported, September, 1873, that the "ball passed through the left testis, which was removed, and also injured the museles on the under side of the left thigh."

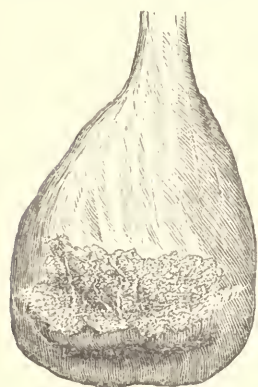


FIG. 356.—Shot wound of the left testis. Spec. 2560. ♀.

CASE 1135.—Private James E. L.—, Co. C, 105th Pennsylvania, aged 21 years, was wounded at the Wilderness, May 6, 1864. A conoidal musket ball perforated the scrotum and inflicted a slight wound in the thigh. The left testis was so much injured that it was excised on the field by Surgeon J. Ebersole, 19th Indiana. The patient was sent to Harewood Hospital May 26th, and transferred to Jarvis Hospital June 6th, thence convalescent to Camp Parole, July 19th, and returned to duty August 23, 1864. He was promoted sergeant and served till the muster out of his regiment, and was honorably discharged and pensioned July 11, 1865. He was in good health, though rated as totally and permanently disabled, in July, 1872. The injured testicle was contributed to the Museum, and is represented in the wood-cut (Fig. 356).

CASE 1136.—Sergeant Oscar T.—, Co. I, 77th New York, aged 24 years, was wounded at Spottsylvania, May 12, 1864. Surgeon S. J. Allen, 4th Vermont, reported that "a ball entered the outer side of the right thigh, passed through, and wounded the left testicle. On the same day the injured testis was removed. The patient entered Carver Hospital May 24th. He was furloughed June 25th, and returned to his regiment to be mustered out January 30, 1865. June 11, 1870, Pension Examiner W. H. Miller reported that this man "complained of pain in his left thigh when he labored hard; that he was not able to retain his urine as long as formerly; and that the disability was not increased to more than three-fourths."

CASE 1137.—Lieutenant-Colonel Benjamin G. B.—, 2d Pennsylvania Heavy Artillery, aged 38 years, was wounded at Petersburg, June 30, 1864. Surgeon Horace Luddington, 100th Pennsylvania, reported that a conoidal ball penetrated the left testis and perineum. The wounded officer was placed under the influence of chloroform and the disorganized testis was excised. The patient was sent to the Seminary Hospital, at Georgetown, August 3, 1864, recovered, and was furloughed on August 23, 1864. He was discharged the service November 19, 1864. Examiner James Neil reported, April 30, 1867, that "this pensioner has lost his virile power and has partial paralysis. The disability is rated as total and permanent." Examiner T. F. Smith reported, September 23, 1873: "Constant pain in scrotum, extending to the groin."

CASE 1138.—Private L. B.—, Co. C, 2d Wisconsin, aged 23 years, was wounded at the Wilderness, May 5, 1864, and taken prisoner. He was exchanged, September 26, 1864, and sent on the steamer New York to an Annapolis hospital, where Surgeon B. A. Vanderkeift noted a "gunshot wound of the scrotum, destroying the left testicle." After furlough, this soldier entered Swift Hospital, Prairie Du Chien, November 24, 1864. Acting Assistant Surgeon W. F. Kelley reported: "Gunshot wound of the right hip and perineum; the ball entered at the root of the penis on the left side and lodged in the left hip. The patient states that, under the circumstances, the wound did well. He lay on the battle-ground for thirty-two days with very little treatment, was removed to Gordonsville and remained eleven days, and then was removed to Lynchburg. On May 6th, the ball was cut out by a Confederate stretcher-bearer, and, on May 13th, Surgeons Thompson and Phillips (prisoners on the field) removed the left testis." On admission, the wound was discharging and inclined to slough, but speedily amended, and the soldier was transferred to the Veteran Reserve Corps, April 13, 1865; discharged July 29, 1865, and pensioned. On July 5, 1871, Examiner J. Conant, of Prairie Du Chien, reported: "The ball entered on the left side and just above the penis, and injured the left spermatic cord and testicle, so that it became necessary to remove the latter." Examiner S. G. Armstrong reported, September 20, 1873: "Gunshot wound at the left external abdominal ring, causing castration of the left testicle." The reports of the examiners indicate that this pensioner's disabilities arise principally from the effects of wounds in the thigh and forearm.

CASE 1139.—Corporal A. C.—, Co. E, 61st New York, aged 21 years, was wounded at Hatcher's Run, May 31, 1865, and sent to City Point. Acting Staff-Surgeon J. Aiken reported: "Gunshot wound of the penis and scrotum. A conoidal ball passed through the prepuce and glans penis, the left testis, and the fleshy part of the left thigh. The testis was split by the ball and lay bare. The patient was enfeebled by irritation and suffering, which had been excessive. On April 5th, chloroform was administered, and an operation was practised by Acting Staff-Surgeon W. J. Burr, by removal of the left testis and part of the glans penis, paring the edges of the scrotum, which had sloughed considerably, and uniting them with sutures. The parts healed slowly by granulation, and by April 21st were nearly well." The corporal was sent to duty April 26th, transferred to Carver Hospital, May 2d; to Whitehall, Bristol, May 27th; to De Camp Hospital, July 14th, and thence mustered out July 26, 1865. No application for pension.

<sup>1</sup>CASE 1016, p. 353, and CASE 1054, p. 362, were instances of primary ablation of the left testis; and other examples will be recorded as CASES 1149, 1152, 1153, p. 412; 1158, 1160, 1161, 1163, 1164, 1168, and 1169, p. 413.

Eventually the three following cases resulted fatally; but a connection between the operation, or the injury even, and the fatal termination, is apparent in *CASE 1142* only.<sup>1</sup>

*CASE 1140.*—Corporal E. A. P——, Co. I, 1st Massachusetts Artillery, aged 17 years, was wounded near Petersburg, June 16, 1864, and sent from a Second Corps hospital, on July 4th, to Judiciary Square Hospital. Assistant Surgeon A. Ingram, U. S. A., reported: "Wound through the right buttock and left testicle; the testis has been removed on the field." This soldier was twice furloughed, readmitted, and returned to duty November 30th; discharged June 2, 1865, and pensioned. He states that "a minié ball entered at the testicle and passed out through the fleshy part of the right thigh, at Petersburg, June 16, 1864, and that, on March 31, 1865, he was again wounded, at Hatcher's Run, by a musket ball, which entered near the right shoulder-blade, passing through or near the spine, and that after remaining about a month the ball was taken out near the left shoulder-blade." Examiner A. Garcelon, of Turner, reported, April 23, 1866: "Loss of left testicle, and injury of the adductor muscles of the thigh, interrupting free progression. Injury of spine near lower angle of the scapula, causing weakness of the upper extremities; disability three-fourths." This pensioner died September 23, 1867.

*CASE 1141.*—Private James Knight, Co. A, 63d Ohio, was wounded at River's Bridge, South Carolina, February 3, 1865, and was admitted to a Seventeenth Corps hospital, where Surgeon J. A. Follet, 39th Ohio, noted "gunshot wound of abdomen and privates; left testis excised by Surgeon Arthur B. Monohan, 63d Ohio." This patient was sent to hospital at Beaufort on February 6th, where Surgeon J. Trenor, jr., reported that "he died of pyæmia, on February 10, 1865."

*CASE 1142.*—Private Samuel F. G. Yeomans, Co. G, 2d New York Mounted Rifles, aged 18 years, was wounded at Petersburg, June 19, 1864, and sent to a Ninth Corps hospital. Surgeon James Harris, 7th Rhode Island, reported a "gunshot wound of the thigh and scrotum; castration of the left testis." This soldier was transferred to Lovell Hospital, Portsmouth Grove, June 26th, and died, July 11, 1864, from the effects of chronic diarrhæa.

The next series of abstracts are of cases of excision of the right testis:

*CASE 1143.*—Private J. P——, Co. F, 119th New York, aged 26 years, was wounded at Chancellorsville, May 2, 1863. He was taken prisoner, released, and, about May 15th, received into the Log Hospital, near the deserted battle-field. Surgeon George Suckley, U. S. V., reported: "Shot wound of scrotum, lacerating it so as to expose the right testis, which was disorganized. The testis was removed on May 12th. The patient was sent to Columbian Hospital, May 15th, and four days afterward to Mower. The wound did well till July 20th, when an ulcer appeared on the penis, which healed under a mild zinc lotion. On September 30th, the patient was able to do light duty, and was recommended for the Invalid Corps December 22, 1863. It is noted that the influence of the sexual passion in this case has suffered abatement." No application for pension.

*CASE 1144.*—Corporal W. N. C——, Co. H, 10th Vermont, aged 22 years, was wounded at Mine Run, November 29, 1863, and sent to Hallowed Hospital, Alexandria, December 4th. Surgeon E. Bentley, U. S. V., reported: "Gunshot wound of the right testicle. Ball cut out December 7th, and testicle removed." On September 9, 1864, the patient was sent to Smith Hospital, Brattleboro'; returned to duty December 27th; discharged March 9, 1865, and pensioned. Examiner D. W. Hazelton, of Cavendish, reported, April 25, 1866: "Ball first passed through and destroyed the right testicle, entering the thigh on the inside close to the body, passing through, making its exit from the right buttock. The wound is still discharging, and fragments of bone come away from time to time. The wound is painful, and very troublesome in the act of sitting; disability total." Drs. H. Pierpont and C. A. Gallagher, of New Haven, reported, September 3, 1873: "Ball entered from before through the adductor longus muscle, passed backward, and emerged from the gluteus minimus muscle. The wound of exit is open occasionally, and also abscesses in the inner portion of the thigh near the perineum. He is troubled much the most during warm weather." This pensioner was paid September 4, 1873.

*CASE 1145.*—Corporal C. S——, Co. A, 2d New Jersey, aged 27 years, was wounded at Spottsylvania, May 12, 1864, and sent, on the 26th, to Alexandria. "Shot wound; the ball passed through the right testis. Both testicles were much injured, greatly inflamed, and exquisitely painful. On May 28th, the patient being chloroformed, the right testicle was excised by Surgeon Edwin Bentley, U. S. V. With simple dressings, and nourishing diet and tonics, the case progressed favorably, and, by June 30th, the wound was healing kindly." This soldier was furloughed July 27th, readmitted, and transferred, November 1st, to Beverly, New Jersey, and returned to duty January 8, 1865, and, February 6th, discharged and pensioned. Examiner T. H. McReynolds, of Cincinnati, January 16, 1867, reported: "Ball entered the anterior aspect of the scrotum one-fourth of an inch to the right of the raphe, passed through, and lodged against the left ischium, whence it was afterward removed. The right testis had been excised, and there is considerable induration of the scrotum, and a varicose condition of the veins of the left side. He has lameness and neuralgic pains of the left leg; continued walking or other exertion causes painful swelling of the scrotum, and his disability is three-fourths and permanent." Examiner G. K. Taylor, September 29, 1873, reported: "Loss of right testis; left testis is enlarged and painful, and the veins are varicose. There is a small thickened cicatrix just in front of the left tuber ischii; also a healthy, small, unimportant cicatrix on the left natis. His disability is undiminished."

*CASE 1146.*—Sergeant Robert D——, Co. F, 49th Pennsylvania, aged 22 years, was wounded at Spottsylvania, May 10, 1864. Surgeon E. B. B. Kelly, 95th Pennsylvania, reported "a shot wound of the scrotum, with laceration of the right testis, which was excised at the field hospital of the 1st division, Sixth Corps." The patient was treated at Lincoln and Jarvis Hospitals until August 22d, and was returned to duty from Annapolis, by Surgeon B. A. Vanderkilt, U. S. V., September 13, 1864. This soldier is not a pensioner. At several hospitals the injury was referred to the left testis.

<sup>1</sup> The prudent advice of PARE: *Des plaies en particulier*, Liv. 8<sup>me</sup>, Chap. XXXVI regarding the treatment of wounds of the testis, will bear repetition: "Or quant aux playes des Testicules et parties genitales, parce qu'elles sont necessaires à la generation, et qu'elles font la paix en la maison, on les conservera le plus soigneusement qu'il sera possible, y procedant ainsi que l'on verra estre necessaire, suivant la doctrine donnee par cy devant, diversifiant les remedes selon les accidens qui viendront."



The two following cases relate to primary excisions of the right testis, and are followed by a series of five primary operations, two on the right and three on the left testis:<sup>1</sup>

CASE 1147.—Lieutenant C. D. H——, Co. C, 47th Massachusetts, aged 40 years, was wounded at the Wilderness, May 6, 1864. Surgeon W. H. Ducachet, U. S. V., from the Seminary Hospital, Georgetown, where this officer was received May 12th, reported: "Gunshot wound of penis, scrotum, and right thigh. The right testis was removed on the field, May 7th. The patient states that the scrotum was very much lacerated. The wound of the thigh was slight. The patient says that the operation was performed by Surgeon Nathan Hayward, 20th Massachusetts. This officer's wound healed readily, and he was furloughed June 4, 1864, and discharged October 13, 1864. Examining Surgeon David Choate, of Salem, November 12, 1864, reported: "The ball struck the right testicle in front, passed into the right thigh near the perineum, and escaped from the right natis a little below the centre. Considerable sloughing followed near the wound of entrance in the thigh; the loss of substance is now apparent. The thigh is emaciated; he suffers from almost constant tenderness and sense of soreness, with frequent pains on the outer side of the thigh, and also pain in the four lesser toes, evidently neuralgic; there is partial loss of power in the whole limb, which is apt to drag in walking, requiring constant care to avoid stumbling; it is especially difficult for him to ascend stairs, and exercise and fatigue cause pain, and the right foot and ankle swell at night. The right testicle is gone. He is slowly improving, but his disability is total." Another report, from the Examining Board at Boston, Surgeons Chase, Foye, and Treadwell, is dated November 2, 1870: "Ball passed through the right side of the glans penis, carried away the right testicle, then passed through the gemellus muscles, injuring the tibial nerve, producing, at times, much sensitiveness along the course of that nerve. His disability is reduced to one-half." This officer received his pension September 1, 1873.

CASE 1148.—Lieutenant J. W. R——, Co. H, 61st Pennsylvania, was wounded at Spottsylvania, May 12, 1864. Surgeon S. J. Allen, 4th Vermont, reported, from the 2d division, Sixth Corps, a "gunshot flesh wound of the left thigh and the left testis, requiring removal of the latter." This officer was sent to Washington and treated in hospital until May 27th, when he was furloughed. On July 21st, he entered Hospital No. 1, Annapolis, and returned to duty on the following day. He was mustered out at the expiration of his term of service, September 13, 1864, and pensioned. Examining Surgeon T. S. Harper, of Philadelphia, reported, August 10, 1869: \* \* "He received a wound of the genitals, a ball having entirely shot away the right testicle. Although a great loss to him personally, and disqualifying him for marital duties, I cannot perceive that the result of his wound adds to or increases his disability to perform manual labor." It is gratifying to observe that this rigorous interpretation of the law was overruled, and to find this officer, December 27, 1871, an applicant for increase of pension. Examiners T. S. Harper, T. S. Sherwood, E. A. Smith, J. Collins, and G. C. Harlan then reported "gunshot wound of the upper portion of the right thigh, chipping the femur and destroying the right testis, so that he is unable to make positive engagements for business; he has no sexual desire, and has no children." In an examination made in September, 1873, when this pensioner was paid, the board rated his disability at one-half for the thigh wound and one-half for the loss of the testis.

CASES.—In the following instances of shot wounds of the testis the injured organ was excised, and the patients recovered and were pensioned: 1149. Private R. J——, 125th Illinois, was wounded at Kenesaw, June 27, 1864, in the left testis; and immediate castration was practised by Surgeon C. H. Mills, 125th Illinois. The patient was transferred to the Veteran Reserves, November 19, 1864, and discharged July 5, 1865. Examiner W. Somers reported, May 15, 1869, that "the ball, in addition to destroying the testis, passed through the right thigh; the outer side of the thigh is paralyzed." Examiner A. Kratz reported, September 6, 1873, that the disability was undiminished. 1150. Private D. L. M——, 64th Ohio, was wounded at Murfreesboro', December 31, 1862, in both thighs and right testis. Assistant Surgeon H. P. Anderson, 64th Ohio, removed the portion of the testis remaining. Discharged January 27, 1863. Examiner C. M. Johnson, March 1, 1872, reported: "The ball passed through the upper part of left thigh, injuring the sciatic nerve, and, passing through the scrotum, injured the lower extremity of the left testis and entirely destroyed the right." This pensioner was paid December 4, 1873. 1151. Private F. S——, 9th Iowa, aged 27 years, was wounded at Dallas, May 27, 1861. Surgeon J. Pogue, 66th Illinois, recorded extirpation of right testis for shot wound. This soldier was discharged May 29, 1865. Examiner H. Ristine, of Marion, reported, September 5, 1873: "The ball passed through the left testicle, injuring it to such an extent as to require its removal, and through the muscles of the posterior part of the right thigh, which are so much injured as to somewhat impair the use of the limb in walking." Paid June 4, 1873. 1152. Private J. W. B——, 205th Pennsylvania, was wounded at Petersburg, April 2, 1865. Surgeon M. F. Bowers, 209th Pennsylvania, reported: "Gunshot wound of thigh and scrotum; left testicle removed." This soldier was discharged July 14, 1865, and pensioned. Examiner D. L. Beaver, of Reading, reported, January 29, 1872, that "a ball passed through both thighs and scrotum, injuring testicles, one of which was removed immediately; the other remains intact and was healthy until lately; it is now painful to touch, and wasting away. Erection and power of coition are very slight; there is but small desire left, and this will probably soon disappear; disability total." 1153. Private J. B——, 16th Maine, aged 19, was wounded at Hatcher's Run, February 7, 1865. Surgeon D. C. Chamberlain, 94th New York, reported: "Severe gunshot wound of the genitals, and castration of the left testicle." This pensioner was paid September 4, 1873.

<sup>1</sup> Instances of excision of the testes for shot injury are rarely mentioned by early writers on military surgery. My notes include none prior to the present century; but I have not searched exhaustively. A few references are given here, and in foot-notes further on: LARREY (D. J.), in his *Clinique chirurgicale*, T. III, p. 58, observes: "Lorsque l'un des testicules est atteint par un projectile, de manière à être dénué de ses tuniques ou désorganisé dans une grande partie de sa substance, il faut nécessairement en faire l'extirpation. C'est en effet la conduite que nous avons tenue dans plusieurs circonstances dont nous avons parlé dans autres articles." The cases are not specified in other articles. SEDGWICK, in *Med. Chir. Zeitschrift*, 1804, B. III, S. 472, cites a case: "Heilung einer Schlusswunde am scrotum welche die Castration des rechten Testicles erforderte." THOMSON (J.) (*Report of Obs., &c., after the battle of Waterloo*, Edinburgh, 1816, p. 112) remarks: "We saw several cases also in which balls had passed through one or both testes. In one case, in which a ball had removed a portion of the scrotum, the right testis protruded at first through the opening, but it was afterward replaced by an operation. In another case, the left testis having been exposed in a similar manner, became of so large a size that it was deemed necessary to remove it. We saw one young man affected with violent hysterical paroxysms, in whom a musket ball, having passed through both testes, had occasioned great swelling and pain of these organs. A very common wound was that in which a musket ball, entering by the scrotum on the left side, had passed through it and the posterior part of the right buttock.

It was observable that there was less hesitancy in applying for pension on the part of those injured in the testes, than in those in whom the penis was mutilated.<sup>1</sup> Nevertheless there were a number of cases of ablation of the testes in which no application for pension has been reported, as in the eleven following cases:

CASES 1154-1164.—Of cases of excision of the testis on account of shot injury, without subsequent applications for pension, the following instances were reported: 1. Private M. W——, 19th C. T., aged 19, wounded at Petersburg, July 10, 1864; immediate removal of right testis by Surgeon F. M. Weld, 27th C. T.; duty, November 8, 1866. 2. Corporal A. Y——, 10th New Jersey, aged 34, wounded at Snicker's Gap, in right testis and hip, July 24, 1864; on August 19th Assistant Surgeon L. D. Miller, 1st New Jersey, excised the injured testis; duty, November 28. 3. Corporal J. M. H——, 31st Illinois, wounded at Atlanta, July 22, 1864, in the right thigh and testis; Surgeon H. McKeenan, 17th Wisconsin, performed primary ablation of the testis; this soldier was discharged on expiration of term, November 7, 1864. 4. Color-Sergeant E. W. B——, 19th Massachusetts, wounded at Fredericksburg, December 13, 1862; Surgeon J. H. Taylor, U. S. V., reported that the right testis was removed for shot injury; duty, April 23, 1863. 5. Corporal P. K——, Co. E, 115th Pennsylvania, wounded at Gettysburg, July 1, 1863; Surgeon C. K. Irwin, 72d New York, reported: "Left testis excised for shot injury; duty, July 11, 1864." 6. Private I. W. H——, 2d Louisiana, was wounded at Port Hudson, May 27, 1863; Surgeon F. Bacon, U. S. V., reported: "Removal of right testis for gunshot wound; duty, February 7, 1864." 7. Private R. R——, 64th New York, aged 35, was wounded at Fair Oaks, June 1, 1862. Acting Assistant Surgeon A. C. Bournonville reported: "Wound of left side of scrotum, left testis and cord; left testis removed on the field; discharged, July 27, 1862." 8. Corporal James S——, 28th Massachusetts, aged 18, was wounded at Chantilly, September 1, 1862. Surgeon W. Clendemin, U. S. V., reported: "Gunshot wound of the left testicle, the ball passing through the fleshy part of the left thigh; the testes were much swollen, the left testis protruding. On September 12th, the patient was chloroformed and the testis was removed. On the 14th, he was no better; the parts were swollen and erysipelatous. Tincture of iron was given thrice daily, wine and chlorate of potassa were given, and lead lotions were applied." The case progressed favorably, and the patient was well December 4, 1862, and was returned to duty.<sup>2</sup> 9. Private J. P——, 1st New Jersey Cavalry, aged 25, was wounded at Weldon Railroad, August 23, 1864. Surgeon R. B. Bontecou, U. S. V., recorded the following, September 12th: "Gunshot wound of the right testicle; removed on the field on day of injury; operator unknown. By September 30th, the wound was nearly healed. Furloughed October 11th; November 30, 1864, deserted." 10. Private J. H. I——, 4th Virginia, was wounded at Petersburg, March 25, 1865. Surgeon W. L. Baylor, P. A. C. S., recorded: "Wounded in the left testis by a minié ball; the testis was removed, March 26th, by myself, assisted by Drs. J. P. Smith and J. T. Kilty. This soldier was nearly well when he left hospital, April 1, 1865." 11. Private E. F. B——, 101st Ohio, was wounded at Jonesboro', August 31, 1864. Surgeon M. G. Sherman, 9th Indiana, recorded: "Shot wound of privates; left testicle removed by Surgeon T. M. Cook, 101st Ohio." Discharged June 12, 1865.

*Fatal Cases of Excision of the Testis.*—Of sixty-one cases of excision of the testis for shot injury, eleven, or 18 per cent., resulted fatally. The following examples indicate the proportion in which death was traceable to the operation. There were five ablations of the testis for traumatic lesions not produced by shot, with one death; and eleven cases of removal of the testis for disease, with two deaths:

CASE 1165.—Private G. Cornick, Co. F, 7th Wisconsin, aged 23 years, was treated in a Fifth Corps hospital for a wound received at Spottsylvania, May 11, 1864. He was sent to Washington on the 15th and admitted into Emory Hospital, where Surgeon N. R. Moseley, U. S. V., reported: "Gunshot wound of the scrotum, with laceration and protrusion of the right testicle. The parts became gangrenous, and there was severe constitutional disturbance from the infiltration of pus in the right iliac region. The wound was ragged and the turgid testis was assuming a gangrenous appearance, and there was great tenderness of the abdomen. Chloroform and ether were administered to the patient on the 19th and the right testis removed, the operation being followed by cold-water applications to the wound. Peritonitis set in on the same day; it was treated with calomel, opium, brandy, and turpentine stupes to the abdomen;" but unavailingly, as the case terminated fatally on May 23, 1864.

CASES.—The following complicated cases of excision of the testis for shot injury also proved fatal: 1166. Private G. C——, 7th Wisconsin, wounded at Spottsylvania, May 11, 1864, in right testis, which became gangrenous, and was excised by Surgeon N. R. Moseley, U. S. V. Death from peritonitis, May 23d. 1167. Captain A. J. S——, 9th New Hampshire, was wounded at Spottsylvania, May 18, 1864. Surgeon M. Hogan, U. S. V., reported: "Shell wound with extensive laceration, and castration of one testis." Death, May 20, 1864. 1168. Corporal C. P. D——, 6th Vermont, aged 26 years, wounded at the Wilderness, May 5, 1864. Surgeon O. Evarts, 20th Indiana, noted: "Wound of head and testis; castration of left testis May 6th." Died, from fracture of skull, June 3d. 1169. Private A. J. B——, 37th Wisconsin, aged 27 years, wounded at Petersburg, July 30, 1864, in "right thigh and scrotum." Surgeon A. F. Whelan, 1st Michigan Sharpshooters, removed left testis. Death, August 6th. 1170. Sergeant A. C——, 12th Pennsylvania, aged 16 years, was wounded at Cold Harbor, June 2, 1864. Surgeon C. H. Chamberlain, U. S. V., recorded: "Wound of perineum and testes; removal of one of them." The patient died July 17, 1864. 1171. Private J. H——, 74th Illinois, wounded at Marietta, June 27, 1864. Surgeon E. H. Bowman, 27th Illinois, reported: "Testis destroyed; excision." Death, July 8, 1864.

<sup>1</sup> SOCIN (A) (*Kriegschr. Exf.*, 1872, S. 100) gives the case of H. Fenslage, wounded at Görzce, by a ball passing through the penis, then through the scrotum, lacerating the testis. The wound of the penis healed in nineteen, that of the testis in fifty-one days. Professor SOCIN distinguishes this as a "complete perforation of the penis without injury to the urethra, owing perhaps to the small size of the Chassepot projectile, or possibly to an exceedingly large German calibre."

<sup>2</sup> The report of the Adjutant General of Massachusetts, 1865, p. 572, shows this man was subsequently captured, and that he died in Richmond, March 13, 1864.



*Excision of both Testes.*—This operation is still frequently performed,<sup>1</sup> according to Curling, by oriental barbarians; but is rarely resorted to, even in Italy, among civilized communities, except on account of hopeless disorganization of the testes by injury or disease. When the testes are badly lacerated by shot, some military surgeons<sup>2</sup> are of opinion that primary ablation<sup>3</sup> is preferable to an expectant treatment because of the greater rapidity of recovery after operation. Three cases were returned in which both testes<sup>4</sup> appear to have been removed for shot injury, although the reports are somewhat vague:

CASE 1172.—Thomas Fisher, an unassigned substitute recruit of the 16th Pennsylvania Cavalry, aged 24 years, having received gunshot wounds of the left thigh, right hand, and both testicles, at the Soldiers' Rest, Washington, September 9, 1864, was taken to Judiciary Square Hospital, anesthetized, and both testicles were excised, and the right hand was amputated a little above the wrist (see *Specimen* 3210, Sect. I, A. M. M.), by Acting Assistant Surgeon J. F. Thompson. During September the patient progressed favorably, but he died October 16, 1864, from exhaustion from surgical fever.

CASE 1173.—Lieutenant J. A. V——, Co. A, 153d New York, aged 32 years, was wounded at Cedar Creek, October 19, 1864. A Sixth Corps hospital register states: "Gunshot flesh wound of the left thigh and both testes by a minie ball. On October 23d, Assistant Surgeon J. G. Thompson, 77th New York, excised the right testis. Charcoal poultices, followed by simple dressings, were applied, and the case progressed favorably, so that by November 7th the patient was able to walk about." November 19th, this officer was sent to the National Hospital, Baltimore, thence to the Annapolis Officers' Hospital; on the 23d granted leave of absence, and readmitted January 25, 1865. Acting Assistant Surgeon J. H. Longenecker reported: "This officer had suffered from a gunshot wound of the scrotum, with loss of the right testicle; and also from a wound of the upper third of the left thigh by a minie ball, which entered at the right side of the scrotum, carrying away the right testicle, entering again at the upper third of the left thigh, passing backward, and emerging at the tuberosity of the ischium. The wounds are healed and require no treatment." This officer was honorably mustered out and pensioned, February 18, 1865. Examiner P. R. Furbeck, of Gloversville, reported, May 7, 1866: "Was wounded by a minie ball passing through the scrotum, destroying both testicles, and thence through the left thigh. He has since been subject to some pain in the thigh and at the end of the right spermatic cord, and has not regained his strength; disability one-third, probably permanent." Examiner B. B. Kelley, September 24, 1873, reported: "The ball passed through the scrotum, destroying both testicles; a portion of the right testis still remains; the ball entered the inner side of the thigh and came out about two inches below the trochanter major, splintering the back part of the femur, pieces of which were taken out at the point of exit. The action of the limb is interfered with by the passage of the ball, causing lameness when use is continued, as in walking all day; disability one-third."

CASE 1174.—Private R. W. C——, Co. C, 33d Iowa, was wounded at Jenkins' Ferry, Arkansas, April 30, 1864, and taken prisoner. He was admitted into hospital at Camden, Arkansas, where Assistant Surgeon W. L. Nicholson, 29th Iowa, reported: "May 11th, castration of testicles while in the enemy's hands." This man was discharged July 6, 1865, and is now an applicant for pension. He states that he was treated, while a prisoner, in Confederate hospitals at Princeton, Camden, and Magnolia, Arkansas. Examiner A. A. Dye, of Lamar, Missouri, February 18, 1874, reports an examination of claimant: \* \* "The thigh wound was produced by a ball, which struck the scrotum in front, carrying away the right testicle, entering the right thigh at a point opposite, and made its exit three inches below and an inch posterior to the trochanter major. There is weakness of the limb, with anaesthesia of the parts supplied by the obturator nerve." This man also received a wound of the leg, and a pension for total disability is recommended.

One example was reported of excision of both testes in a case of laceration not resulting from shot injury:<sup>5</sup>

CASE 1175.—Private W. Lucas, Co. E, 1st Virginia Battalion, aged 45 years, was wounded and captured at Farnville, April 7, 1865, and sent to the Second Corps hospital at City Point on April 13th. Acting Staff-Surgeon John Aiken reported: "Contused wound of the abdomen and testes by running against an abatis. Both testicles were severely injured, and the scrotum entirely sloughed away from them. On April 14th, Acting Assistant Surgeon W. J. Burr removed both testicles, and also an extensive slough from the scrotum. On April 18th, an abscess, which had formed in the inguinal region, was opened. Inflammation of the lungs supervened, and the patient died April 24, 1865."

<sup>1</sup> TIMÆUS (*Med. epistole et consilia*, Lipsie, 1665, Lib. III, casus XLVI) relates a case of ablation of both testes for inflammation, observing that the patient lived at the date he wrote: "quantum mutatus ab illo Ilectore."

<sup>2</sup> BILLROTH (TH.) (*Chir. Briefe aus den Kriegslazarethen*, u. s. w., 1872, S. 206) observes: "Of two cases of shot lacerations of the testicles that I treated (Nos. 37 and 38), I performed castration *lege artis* in one; in the other I only removed the torn tissues and clotted blood; the former patient recovered more rapidly than the latter, and suffered far less."

<sup>3</sup> BECK (B.) (*Chir. der Schussverletz.*, 1872, S. 597) cites four cases of shot wounds of the testicles from the campaigns of Werder's Bavarian Corps. Two recovered with atrophy; two, wounded at Wörth, August 6, 1870, underwent immediate castration by Dr. BECK, and recovered rapidly, one being well in a fortnight.

<sup>4</sup> MATTHEW (P. P.) (*Surg. Hist. of Brit. Army in Crimea*, etc., 1858, Vol. II, p. 335) notes four cases of shot wounds of the scrotum and testicles. In the case of an officer, the wound in the scrotum was brought together with hair-lip pins and twisted suture; in another case the ball lodged in the body of the left testicle and was cut out; in the third case the entire body of one testicle was removed by a fragment of shell, but the wound healed readily; in the fourth, the testis was only slightly wounded, but at the end of five months had nearly disappeared by absorption, and that of the opposite side was diminished in bulk.

<sup>5</sup> HIPPOCRATES (*Aph. VI. 28* and 30) gives those who have lost the testes the consolation that they are unlikely to suffer from gout. Εἰδὼς ὅτι οὐ πολλαχρῶς αἰεὶ φασακροῦ γίνονται. For an extended commentary on this subject, with citations from the Greek poets, who personified Podagra as the daughter of Bacchus and Venus, compare ADRIAN SPICERUS, *Opera omnia*, Amsterd., 1645, T. II, p. 69.

The forty-three cases immediately preceding the last abstract, and CASE 1016, on page 353, and CASE 1094, on page 399, are all of the sixty-one operations of excision of the testis from shot injury of which any particulars of moment are recorded.

CASE 1176.—Private J. H. Berry, Co. A, 9th Maine, aged 18 years, was wounded at Fort Wagner, July 18, 1863, admitted into hospital at Morris Island with a "gunshot wound of the privates," and, on the next day, sent to Hospital No. 3, Beaufort. Surgeon David Merritt, 55th Pennsylvania, reported: "Gunshot wound of external genitals; a minie ball, tearing open the scrotum on the right side anteriorly, passed through the thigh posteriorly, and was extracted, on the field, from the gluteal muscles. Had the testicle been put in the scrotum and sutures used, thereby closing the scrotum, the result of the case might have been different; but, after waiting a few days, and applying cool and soothing lotions, the resulting condition was such that invited surgeons and myself deemed an operation necessary, and castration was accordingly performed. This case, with all major amputations, was sent north on the steamer *Cosmopolitan*, and was doing well when last seen." On July 30th, the patient was admitted into McDougall Hospital, thence transferred to Lovell Hospital, returned to duty April 18th, and discharged September 27, 1864, and pensioned. Examiner W. H. Page, of Boston, reported, September 12, 1865: \* \* "A ball struck the right testis, which testicle has been removed, passed into the inner side of the right thigh, and came out at the lower border of the *gluteus maximus* behind." Examiners G. S. Jones, on September 11, 1865, and J. B. Treadwell, Hugh Doherty, and Horace Chase, on September 18, 1873, reported substantially as above, rating the soldier's disability at three-fourths. The pensioner was paid to December 4, 1873.

*Atrophy of the Testis*<sup>1</sup> was naturally a very common result of shot injury:<sup>2 and 3</sup>

CASE 1177.—Private E. C——, Co. E, 17th Ohio, aged 22 years, was wounded at Chickamauga, September 19, 1863. He was sent from a Fourteenth Corps hospital, on the 25th, to Hospital No. 16, Nashville, where the injury was noted as a "gunshot wound of the left testicle, the ball passing through." On March 15th he was sent to Brown Hospital, Louisville, and similarly registered. On March 31st he was transferred to Madison; thence to Camp Dennison, and was discharged, on certificate of Surgeon W. Varian, U. S. V., September 8, 1864, for "atrophy of the left leg, gunshot wound of the scrotum, and expiration of service," and pensioned. Examiner W. H. Corwin, of Lebanon, reported, June 10, 1872: "A musket ball passed through the left testicle, in which he suffers sharp pains; these pains extend to the groin, up the left side, and across to the right side, over the region of the stomach. He has pains also in the left arm and leg, which pains are succeeded by numbness and partial paralysis. He cannot with his left hand hold up an ordinary-sized chair for two minutes." Examiner J. L. Drake reported, September 8, 1873: "A musket ball passed directly through the left testicle, the point of entrance being in front, that of exit behind. There is enlargement of the spermatic cord and external veins of the scrotum, with tenderness, weight, and pain in the testicle. Disability one-half." This pensioner was paid September 4, 1873.

CASES.—Atrophy of the testis after shot injury was observed in the following instances: 1178. Private W. B. G——, 35th Iowa, was wounded at Tupelo, July 16, 1864. Assistant Surgeon J. C. G. Happersett, U. S. A., reported: "Gunshot wound of both thighs, penis, and scrotum; duty November 17, 1864." Discharged May 6, 1865, and pensioned. Examiner C. Hershe, of Muscatine, reported, July 20, 1865: "Ball entered two and a half inches above right knee and emerged from the upper part of the thigh, then passed through the penis and divided the cord of the left testis, making its exit half an inch below joint of left hip; was in kneeling posture when the wound was received." The same examiner reported, in December, 1867, that the "left testicle is wasted to nothing, or nearly so. His penis is very much deformed, and cords of his leg are getting shortened, so that he is lame; disability total." Paid March 4, 1873. 1179. Corporal A. K——, 8th New Jersey, aged 38, was wounded at Petersburg, June 16, 1864. Surgeon J. F. Dyer, U. S. V., reported: "Gunshot wound of hip and testis." Duty February 6, 1865. Discharged July 17, 1865. Examiner A. W. Woodhull, of New Jersey, reported, July 13, 1867: "Ball entered left groin, passed through scrotum, and came out about four inches below Poupart's ligament. Both testes are now atrophied; the patient has consumption; disability total." Death from phthisis, February 11, 1868. 1180. Private W. W. Bailey, 11th Vermont, was wounded at Petersburg, June 2, 1864. Veteran Reserve Corps, November 25, 1864. Discharged July 31, 1865. Examiner D. W. Hazelton, of Cavendish, reported, February 25, 1866: "Gunshot wound, first of penis, cutting off a portion of the glans, injuring the left testis so that it has completely atrophied, and, further, of left thigh." Examiner W. S. Robinson, in his report, alluding to wound in scrotum and testis, says: "Testicle of left side lost by the wound." Paid September 4, 1873. 1181. Private A. W——, 14th Connecticut, aged 24, was wounded at Morton's Ford, February 6, 1864. Discharged June 14, 1865. Examiner R. M. C. Lord reported, December 22, 1866, that the "ball passed through scrotum and right thigh. Almost complete atrophy of both testes." Paid September 4, 1873. 1182. Private H. E. Davis, 2d New York Mounted Rifles, was wounded before Petersburg, June 17, 1864. Discharged February 12, 1865, Surgeon G. L. Pancoast, U. S. V., certifying: "Gunshot wound of scrotum and right thigh; unfit for Veteran Reserves; disability two-thirds." Examiner D. H. Decker, of Monticello, reported, September 8, 1873: "Atrophy of left testis; both are sensitive. The injury to the thigh produces a peculiar gait; disability total and permanent." Paid September 4, 1873.

<sup>1</sup> BERTHOLD (*Statistik der u. s. w., invalide gewordenen Mannschaften des 10. Armee-corps, in Deutsche Militairärztliche Zeitschrift* 1872, B. I, S. 466), describing the disabilities of eighteen hundred and four invalids, states: "There were four shot injuries of the testicles. \* \* The injured testicles all became atrophied."

<sup>2</sup> WYLLIAMSON (G.) (*Military Surgery*, 1863, p. 117) observes: "Wounds of the testicle and spermatic cord are not infrequent, and usually heal rapidly; but the portion which remains is often of little use, although the patient does not like to lose it." He cites two cases: Forbes, 66th Regiment, wounded at Delhi, June 18, 1857; ball through left testicle, pubis, and bladder; recovery; and Young, 75th Regiment, shot at Delhi, September 14, 1857; musket ball passing through the urethra, left testis and left thigh, emerging at left buttock; left testis sloughed away; urethral fistula closed spontaneously.

<sup>3</sup> CHENEU (J. C.) (*Rapport, etc., pendant la camp. d'Orient*, 1865, p. 267) cites eleven cases of recoveries from shot wounds of the testicles, with loss of one testicle in six, and atrophy in four cases. 1033 (*Stat. med. chir. de la camp. d'Italie en 1859 et 1860*, T. II, p. 518 et seq.) gives thirteen cases of recoveries from shot wounds of the testicles, with loss of one testicle in eight, and atrophy in three cases. It is not specified whether the loss of the testes was due solely to the effect of projectiles or to subsequent ablation by the knife.



An analysis of the five hundred and eighty-six cases of shot injury of the testis leads to the conclusion that there has been gross exaggeration in the statements heretofore made regarding the influence of such lesions on the *morale* of invalids. A decent aversion to publicity as to their mutilations is the only marked characteristic the editor has observed in the numerous cases brought to his notice.

The following are the only examples of the profound melancholy and suicidal tendency sometimes attributed to the loss of the testes that have been found in the records:

CASE 1183.—Private J. A——, Co. F, 1st Michigan Cavalry, aged 22 years, was admitted to Judiciary Square Hospital, January 11, 1864. Assistant Surgeon A. Ingram, U. S. A., reported that “an accidental wound, received prior to enlistment, had deprived this soldier of both testes and left a urethral fistula, which persisted in spite of various attempts to obtain reunion. Profound melancholia had resulted, and the patient was unfit even for modified duty in the Veteran Reserves. He was discharged May 3, 1864.”

CASE 1184.—Private H. C. Chamberlain, Co. K, 36th Massachusetts, aged 28 years, was wounded at Spottsylvania, May 12, 1864. He was treated in a Ninth Corps hospital for a “wound of scrotum,” and, on the 28th, was sent to Fairfax Seminary Hospital, where Surgeon D. P. Smith, U. S. V., noted a “wound of the scrotum, with loss of testicle, by a conoidal ball.” This soldier was furloughed October 7, 1864, and discharged May 29, 1865. Examiner E. F. Upham, of Massachusetts, reported: “Left testicle extirpated in consequence of a wound from a ball. There is extreme tenderness of the spermatic nerve and vessels, which by reflex nervous action causes general debility; there is also spinal irritation in the lumbar region, and the system is suffering from excessive fatigue and partial sunstroke; the joint effects of the injuries cause excessive nervous irritability, and, at times, partial aberration of mind.” Dr. Upham subsequently testifies, in an affidavit, that when the above-named soldier came home on furlough from Fairfax Seminary Hospital he was insane; and that after his discharge he committed suicide, November 24, 1866, by standing before an approaching engine, which passed over him and destroyed life.” This man’s pension was allowed until the date of death, and, April 11, 1870, the pension was continued to the father of the deceased.

It is unusual for malingerers to attempt to simulate diseases of the testis, yet the following apparently represents an instance of the kind:

CASE 1185.—Private H. C. Gardner, Co. B, 95th Pennsylvania, aged 24 years, is alleged to have been wounded at Antietam, September 17, 1862. There is no record of his case prior to April 14, 1863, when he was received at Hospital No. 1, Frederick, with “anasarca.” At Jarvis Hospital, whither he was subsequently sent, an “injury to the side by a spent ball” was registered. From Hammond Hospital, Point Lookout, where the patient was sent on July 3d, Acting Assistant Surgeon W. F. Buchanan reported: “This wounded man stated that he was struck by a spent cannon ball in the region of the spleen and stomach; and, while being carried off the field, a shell exploded, wounding his right testis, since which time it has healed and become much atrophied. He states that he has had hæmoptysis and hæmatemesis. His lungs were auscultated and percussed, and were found in good condition. He complains of swelling of the injured testis and the abdomen during damp weather or when taking long walks. There is no apparent swelling at present. On September 10, 1863, after a board of survey, this man was returned to duty.”

Fungous protrusion from the testis<sup>1</sup> and sloughing of that organ and of the scrotum were rare. There was one example of what Von Ammon terms *oscheoplasty*:<sup>2</sup>

CASE 1186.—Private M. E. C——, Co. B, 5th New Hampshire, aged 22 years, was wounded at Farmville, April 7, 1865, and was treated in a Second Corps hospital, and thence sent to City Point. Acting Staff-Surgeon J. Aiken reported: “Gunshot wound, the ball passing through the right testicle and left thigh, causing sloughing of the scrotum and testis. On April 13th the injured testicle was removed, the sloughing tissue of the scrotum excised, and the edges freshened and united by sutures by Acting Staff-Surgeon W. J. Barr.” The patient did well, and was transferred to Armory Square Hospital, May 19th. Surgeon D. W. Bliss, U. S. V., reported: “Gunshot wound of the scrotum and left thigh, the ball grazing the anterior surface of the right side of the scrotum, destroying the right testicle, passing behind the left, and making its exit about the junction of the scrotum and integument of the left thigh, near the outer surface of the same.” The patient was transferred to Webster Hospital, Manchester, June 26th, and was mustered out July 25, 1865, and pensioned. Examiner H. Powers, of Morrisville, Vermont, September 30, 1865, reported: “Shot through the testicles; right one removed, the other disabled; the ball then passed through the upper third of the left thigh, shattering the bone and injuring the nerves, causing the loss of sensation in part of the flexor muscles of the thigh.” Examiner E. J. Hall, September 29, 1873, reported: “The ball struck the right thigh near the scrotum, passed through the right testicle into the left thigh. The right testis was removed and the left has become considerably atrophied; it is quite painful, and occasionally becomes inflamed. The muscles of the thigh on the outer side have become somewhat contracted.” This pensioner was paid September 4, 1873.

<sup>1</sup> Referring to shot wounds of the testis, HENNEK (Princ. of Mil. Surg., 3d ed., 1829, p. 451) remarks: “In some instances, the scrotum has sloughed extensively, leaving the testis quite uncovered; in others, the testis has thrown out, with great rapidity, a fungous protrusion. In some of these fungous cases I have seen the whole tribe of escharotics employed in vain, and the ultimatum of castration has been adopted. This is a remedy often unnecessary, for, by removing the fungous growth with the knife, and cautiously dissecting away the excrescence in slices until we come to the sound structure, the parts frequently heal up with the usual dressings.”

<sup>2</sup> AMMON (F. A. V.), Die Plastische Chirurgie, u. s. w., Berlin, 1842, p. 255.

ment to facilitate the performance of the operation. This apparatus is figured in PLATE XII, opposite page 395, as FIGURE I. It has not come into general use.

*Urethroraphy and Urethroplasty.*—Notwithstanding the comparatively large number of cases of urethral fistules reported, few instances are noted in which methodical plastic procedures<sup>1</sup> were undertaken. The following may be compared with those cited on p. 362:

CASE 1099.—Private E. Olney, Co. G, 44th New York, aged 29 years, was wounded at Spottsylvania, May 8, 1864, and, on the 17th, was admitted to Harewood Hospital. He was transferred to Satterlee Hospital, Philadelphia, on July 20th, where the following history of the case is recorded on the case-book of that hospital: "Gunshot wound of the scrotum; loss of half of the penis by gangrene and slough; fistulous opening at base of penis anteriorly; edges of fistula pared and united by silver sutures. November 2d: Has some pain of head and lumbar region at times; urine passes too freely. December 15th: Is improving and growing fat. He continued to improve, but had occasional headache and pain in the back, and, on January 16th, was acting as ward-master. January 26th: Swelling and abscess of scrotum. On February 3d, he was furloughed for twenty days, but, not returning, was reported a deserter. On April 27, 1865, he was again admitted. May 10th: There were troublesome fistulous openings of the scrotum, allowing the escape of urine. June 14th, 1865: Improved, and recommended for discharge. Surgeon J. E. McDonald, U. S. V., certified: "Wound of penis and scrotum; ablation of penis, and fistulous opening into the bladder." This soldier was pensioned. Examiner T. O. Seudder, of Rome, reported, October 5, 1865: "A rifle ball passed through the penis and left side of the scrotum. One-half of the penis was amputated; wound healed. There is still inflammation of the mucous membrane of the bladder, and dribbling of urine; disability total." This pensioner was paid at the Detroit Agency, September 4, 1871; since which time nothing has been heard from him.

CASE 1100.—Private W. G. McK——, Co. G, 94th New York, was wounded at Manassas, August 29, 1862, and sent to Judiciary Square Hospital. Of several wounds by buckshot, three penetrated the urethra. Surgeon F. H. Hamilton, U. S. V., states<sup>2</sup> that the surgeon in charge of the hospital [Surgeon Charles Page, U. S. A.], after two of the three abnormal orifices of the urethra had closed spontaneously, succeeded in closing the remaining fistula, near the meatus, by refreshing the edges of the fissure and bringing them together by sutures, completely restoring the form of the organ. This soldier was returned to duty January 23, 1863. He has not applied for pension.

CASE 1101.—Private C. Meninger, Co. I, 119th Pennsylvania, aged 25 years, was wounded at the Wilderness, May 5, 1864. From Douglas Hospital, Washington, where the patient was admitted on the 25th, he was transferred to Haddington Hospital, Philadelphia, June 1st. Surgeon S. W. Gross, U. S. V., reported: "Wounded by a minié ball; antero-posterior perforation of the anterior third of the penis, and wound of the right groin. Before his coming here the penis had retained its usual shape, but no attention was paid to the urethra. June 2d: Wound in groin suppurates freely; it is five inches long and appears to have been one inch deep. Under the frænum there is a sinus communicating tortuously with the urethra; through this the urine escapes *guttatim*, irregularly. A straight bistoury, entering the meatus one inch and a half, reached the urethral stricture; a gum catheter being introduced, urine passed freely. Slight suppuration on the 17th. The following day, the catheter being removed, urine flowed freely. The urethra is reclosed, June 30th, and urine again passes through the sinus. On July 21st the patient was chloroformed, and Acting Assistant Surgeon L. E. Nordman made an incision from the meatus urinarius one inch and a half anteriorly downward. A silver catheter was passed up, and the divided parts approximated by four silver sutures over the fixed catheter. There was some hæmorrhage, but no vessels required tying. July 22d: The bladder is occasionally emptied by unplugging the catheter. On the 24th the sutures were removed and adhesive straps applied; little swelling existed, and some sleep was enjoyed. The incision line was not quite healed by August 8th, and a bougie was introduced to prevent the closing of the urethra." Meninger was discharged the service March 25, 1865; he is not a pensioner.




FIG. 345.—NÉLTON'S urethroplastic method.  $\frac{1}{2}$

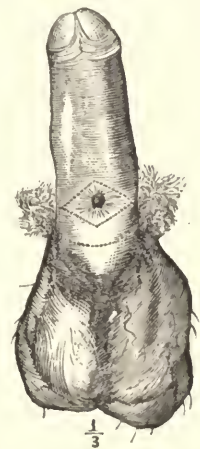


FIG. 346.—Incisions for urethroplasty. [After DILLTEL.]

<sup>1</sup> On urethroraphy and urethroplasty consult: A. COOPER, EARLE, DELPECH, and BRODIE, cited elsewhere, and DIEFFENBACH (J. F.) (*Heilung widerwärtlicher Oeffnungen der vorderen männlichen Harnröhre*, mit Abbild., in *Zeitschrift für die gesammte Medicin*, Homburg, B. II, S. 1). This remarkable memoir is translated in the *Dublin Jour. of Med. Sci.*, 1836, Vol. X, p. 273, the *Gaz. méd. de Paris*, 1836, p. 802, and *Arch. gén. de méd.*, 1836-37, 2<sup>e</sup> série, T. XIII, pp. 69, 206). See also DIEFFENBACH (*Die Operative Chirurgie*, Leipzig, 1845, S. 526); SÉGALAS (*Lettre à DIEFFENBACH sur une uréthroplastie*, Paris, 1840); RICORD (*Uréthroplastie par un procédé nouveau*, in *Ann. de la chir. franc. et étrang.*, 1841, p. 62, et *Gaz. méd.*, 1843, p. 163); ALLIOT (F.) (*Obs. cliniques*, in *Gaz. Méd. de Paris*, 1834, p. 348); GOYRAND (*Gaz. méd. de Paris*, 1843, p. 172); VIDAL (*Path. ext. et Méd.*, Thèse de Paris, 1854, No. 254); BRUNEAU (*Des fist. urin. uréth. chez l'homme*, *Ibid.*, No. 327); LE GROS CLARK (*Large Opening into the ant. part of the Urethra*, *Phila. Med. and Phys. Jour.*, Vol. XIX, and *Surg. Essays and Cases in Surgery*, Newark, 1849, p. 122); VON AMMON (F. A.) (*Die Plastische Chirurgie*, Berlin, 1842, S. 269); RICORD (*Nouvelle observation pour servir à l'histoire de l'uréthroplastie*, in *Gaz. méd.*, 1850, p. 779); NEIDÖRFFER (J.) (*Handbuch der Kriegschirurgie*, 1867, S. 216), Case of Reiter, 15th Jægers, shot at Solferino, June 21, 1859, through the root of the penis with great loss of substance; successful urethroraphy.

<sup>2</sup> HAMILTON (F. H.), *Lecture on Gunshot Wounds of the Penis*, in *Am. Med. Times*, 1864, Vol. IX, p. 61, and *Treat. on Mil. Surg.*, 1865, p. 386.



Attempts to close urinary fistules by the Indian method of borrowing integuments from the neighboring parts, were made by Sir Astley Cooper,<sup>1</sup> in 1818, and by Delpech, in 1830, with partial success. The flaps were taken from the scrotum. Delpech also operated by taking flaps from the inguinal region and the integuments of the penis.<sup>2</sup> Dieffenbach's elaborate illustrated paper, translated in the Dublin Journal, in 1836, by Swift, proposed several urethroplastic operations by the French method of *glissement*. Viguric, Alliot, Ségalas, Clark, and Ricord also described operative procedures, some of which are illustrated by FIGURES 346 and 347. The most successful operation appears to be that of Nélaton (FIG. 345), and I have thought it was not impossible that its success was due to a cause analogous to that on which hinges the result of operations for anal fistules and of staphyloraphy. If the reader will turn to page 343, to the wood-cut 282, borrowed from Henle, he may be reminded that the transverse incisions in Nélaton's operation would divide the muscles surrounding the root of the penis, much after the fashion of Sir W. Fergusson's incisions in cleft-palate; and it is possible that this explains the greater success of this than of Dieffenbach's plan, with longitudinal incisions. The three cases mentioned on the preceding page, and CASE 1061, on page 365, are the plastic procedures on account of the consequences of shot wounds of the urethra reported during the war. Another instance of urethroplasty occurred in a more common form of perineal laceration:

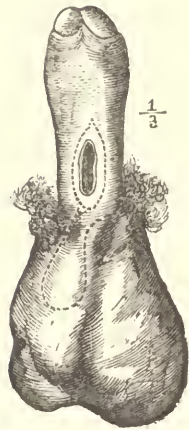


FIG. 347.—Urethroplasty by scrotal flap.

CASE A<sup>10</sup>.—Peter F.—, quartermaster department, aged 21 years, was admitted into the post hospital at Washington on May 1, 1866, with two fistules of the membranous portion of the urethra, the result of a severe lacerated wound of the perineum, caused by a fall astride of a plank.

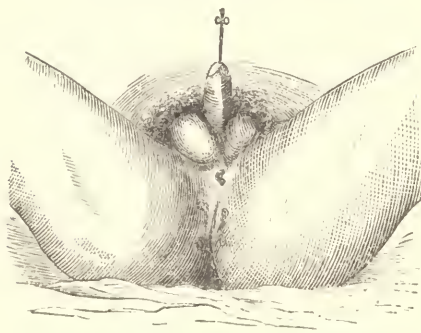


FIG. 348.—Partially successful urethroplasty for perineal fistula. [From Phot. 181, Vol. IV, p. 31, *Sur. Phot. Ser.*, A. M. M.]

Canterization of the edges of the fistules by bromine, nitrate of silver, and the actual cautery, was at intervals unavailingly essayed. A plastic operation had already been performed by Dr. N. S. Lincoln, without success. On June 3d, Assistant Surgeon W. Thomson, U. S. A., pared the edges of the apertures and approximated them by silver sutures. A catheter was retained in the bladder, the urethra having been dilated freely by the daily use of bougies. There was dysuria and frequent micturition on the following day, and, on the 6th, the sutures were removed. The posterior orifice appeared to have closed; but it reopened, and recourse was again had to cauterization, without advantage. There was such loss of substance, nearly a third of the cylinder of the urethra being destroyed, that the restoration of the canal was a very difficult problem. After a few weeks, the callous edges of the fistules were again refreshed and approximated by sutures, which soon tore out, and it was discovered that the patient had received visits after this, as after the former operation, from a young woman to whom he was affianced, whose tender ministrations induced a local hyperæmia very prejudicial to the success of any plastic procedure.<sup>3</sup>

The recent employment of the vesical siphon in the treatment of urinary fistules<sup>4</sup> has obviated one of the great difficulties in the successful management of these lesions. M. Voillemier essayed to prevent the contact of the urine with the edges of the fistule by utilizing the capillary attraction of a few cotton threads passed through a catheter. M. Panas has shown that a small rubber tube, long enough to be used on the principle of the siphon, will effectively drain the bladder.

<sup>1</sup> COOPER and TRAVERS, *Surgical Essays*, 1st Am. from 3d London ed., 1821, p. 380.

<sup>2</sup> DELPECH, *La Lancette française*, T. IV, p. 285 et T. IX, pp. 277-8.

<sup>3</sup> BOYER (*Traité des mal. chir.*, T. IX, p. 270) relates the case of "un chef d'escadron de trente-six ans, affecté d'une fistule longue de 3 lignes et située au devant des bourses. Après qu'une sonde eut été introduite dans la vessie, on fit l'avivement avec le bistouri; les bords de la plaie furent parfaitement réunis par trois points de suture. Mais le malade, qui avait une femme jeune et jolie, ayant eu l'imprudenc de la faire coucher avec lui, il éprouva une forte érection qui tirailla les points de suture. Il survint du gonflement, de l'inflammation, et le troisième jour, les parties embrassées par les fils furent divisées. Aussi l'opéracion n'eut aucun succès; elle fut même nuisible en ce qu'elle contribua à l'agrandissement de la fistule.

<sup>4</sup> GRIPAT (H.), *Du Siphon vésica dans le traitement des fistules urinaires par la soude à demeure*, Paris, 1874.

Deplorable as it is to abandon a patient to the necessity of voiding his urine through an artificial perineal apparatus, and to a calamity that annihilates the sexual and social relations of life, there appears to be no alternative when the entire circumference of the urethral canal is destroyed to the extent of an inch or more, and an irremediable fistula is left. Twenty or thirty pensioners, or more, afflicted with this infirmity, should be provided each with at least two urinals, to preserve them from contracting a repulsive urinous smell. Professor Gross, at page 403 of the second edition of his treatise on the urinary organs, figures several urinals, shaped somewhat like Florence flasks, and capable of holding about twelve ounces. Latterly, the inconvenience of the bag shape has been avoided by having a long caoutchouc tube descending along the outer seam of the trousers. The contrivance of Gariel (FIG. 350) is probably the best of the metallic urinals. It is readily maintained in place, and has been approved by the experience of numerous invalids. Sometimes it is possible to dispense with an external urinal by using such an apparatus as that devised by Mr. Oliver Pemberton<sup>1</sup> (FIG. 349).

As indicated on page 372, there are now at least thirty-eight sufferers from urethral fistules consequent on

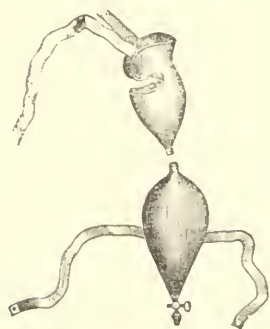

FIG. 350.—GARIEL'S URINAL.

shot wounds received during the war of the rebellion. In Germany, pensioners with urinary fistules receive the largest sum accorded to any class of sufferers.<sup>2</sup> In this country, no discrimination has yet been made in behalf of these unfortunates. It has been suggested, on page 362, that they should be assembled, to receive such succor as art can afford, from some one skilled in this branch of surgery.

In operations on the urethra, for strictures or for fistules, there are two sources of danger, of which the prudent practitioner is always regardful. These are urethral fever<sup>3</sup> and false routes.<sup>4</sup> A knowledge of the utility of quinine in the former affection, and the

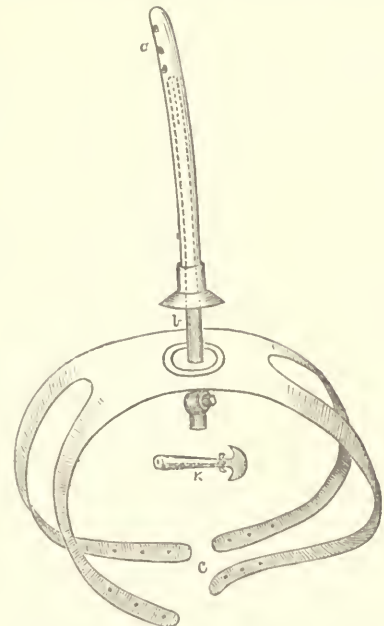


FIG. 349.—PEMBERTON'S PERINEAL CAULIA: a, silver tube, not unlike a female catheter; b, inner caulium closely fitting the outer, and provided with a faucet, opened by the key k; c, elastic thigh-straps to be attached to a body-band.

<sup>1</sup> Mr. O. PEMBERTON (*On Traumatic Destruction of the Urethra, and its Relief by a suitable Apparatus in the Perineum*, in *Lancet*, 1861, Vol. I, p. 258). Mr. PEMBERTON reviews the annals of surgery, and finds that, while they afford some scanty materials leading to the conclusion that a limited destruction of the urethra has been repaired, there is no evidence that a new canal has ever been permanently formed where the entire calibre of the urethra has been destroyed for the space of an inch. EARLE'S case (*Pract. Obs. in Surgery*, London, 1823, pp. 197, 211), in which an inch of the urethra was wanting, and a cure was effected after three operations, a new passage being formed by common integument, no mucous membrane being visible. The subject three years subsequently was reported as able to expel urine by the meatus in a full stream, as having married and become a father. In HOUSTON'S case (*Dublin Jour. of Med. Sci.*, Vol. VIII, p. 11), the evidence that the entire circumference of the urethra was destroyed is defective. In BRODIE'S case (*Works*, HAWKINS'S ed., 1865, Vol. II, p. 449), an artificial passage was made to supply the loss of three-quarters of an inch of the urethra; but the permanence of the cure is not established. In SYME'S case (*H. THOMPSON'S Path. and Treatment of Stricture*, 1st ed., p. 36c), failure resulted from the contraction of the new passage, formed of common integument. Consult further: LAPEYRE (*Sur un régénération du canal de l'urètre totalement détruit par une gangrène de cause interne*, in *VANDEMONDE'S Recueil*, Paris, 1757, T. VI, p. 281); PÉTREQUIN (J. L.) (*De la ponction prostatique de la vessie, et de la restauration de l'urètre dans un cas de destruction de ce canal par une contusion violente du périnée*, in *Bull. de l'Acad. de Méd.*, Paris, 1858-59, T. XXIV, p. 613); and FINE (*Observation d'une rétention d'urine produite par un rétrécissement de l'urètre et guérie par un procédé opératoire particulier*, in *Jour. gén. de méd.*, etc., par SEDILLOT, Paris, 1810, T. XXXIX).

<sup>2</sup> BERTHOLD, *Stat. der durch den Feldzug, 1870-71, inval. gewordenen Mannschaften des 10 Corps*, in *Deutsche Mil. Zeits.*, 1872, B. I, S. 433.

<sup>3</sup> Consult MAUX (E.) (*Des accidents fébriles et des phlegmasies qui suivent les opérations pratiquées sur le canal de l'urètre*, Paris, 1861); ROSEK (*Das sogenannte Urethralfieber*, in *Archiv der Heilkunde* von WUNDERLICH, ROSEK, und GRIESINGER, 1867, S. 246); BANKS (W. M.) (*On certain rapidly Fatal Cases of Urethral Fever after Catheterism*, in *Edinb. Med. Jour.*, 1871, p. 1074); MALHERBE (*De la fièvre dans les mal. des voies urinaires*, 1872).

<sup>4</sup> Consult DITTEL (*Falsche Wege der Harnröhre*, in *Handbuch der Allg. und Spec. Chir.*, 1872, B. III, Abth. 2, S. 185); VOLLEMBER (*Fausse Routes*, Chap. IX, de son *Traité des maladies des voies urinaires*, 1868, p. 456). See BECK (*Chir. der Schussverletzungen*, 1872, S. 567) for an instance of false passage after shot injury of the urethra.—the case of a subultra of Garibaldi, on whom Dr. THOMANN performed suprapubic puncture of the bladder. Consult also Mr. BURKETT'S article, and the references in the works of HOWSHIP, DUCAMP, WHALEY, GUTHRIE, and MERICIER.



expedients for the ready recognition of the latter, are comparatively recent advances. The diagnosis of strictures is now made with approximate precision by the use of properly

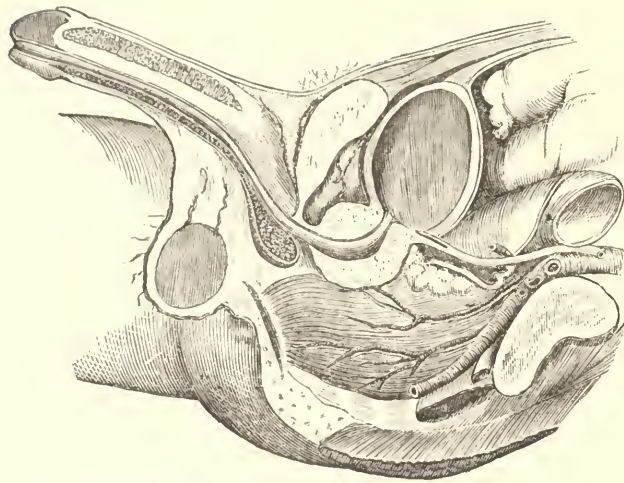


FIG. 351.—Normal relations of the adult male urethra. [After BOUGERY.]

contrived bulbous sounds. Sir Charles Bell's invention<sup>1</sup> has been happily modified by M. Leroy and others (FIG. 355), and the acorn-pointed gum bougies now generally employed afford the best means of appreciating the locality and extent of strictures. Impressions with wax or other material give no accurate information respecting the nature of strictures,<sup>2</sup> and the various urethrosopes<sup>3</sup> have not brought such aid to pre-

cision in diagnosis, as was anticipated. Electrolysis has been discarded as valueless.<sup>4</sup> In the exploration of narrow strictures, filiform bougies of gum or

FIG. 352.—Capillary whalebone bougie.

<sup>1</sup>BELL (CHARLES). *A System of Operative Surgery*, 1st ed., 1807, Vol. I, p. 104; 2d ed., 1814, Vol. I, p. 70.  
<sup>2</sup>Consult ARNOTT (J.) (*Treatise on Strictures*, 1819, p. 76); DUCAMP (*Traité des rétentions*, etc., 1822, p. 176); MERCIER (*Recherches anat.*, etc., in *Gaz. Méd.*, 1845, p. 145); CIVIALE (*Traité prat.*, etc., 1842, p. 148); BIGELOW (H. J.) (*Boston Med. and Surg. Jour.*, 1849, Vol. XI, p. 9).  
<sup>3</sup>In the *Philadelphia Journal of the Medical and Physical Sciences*, 1827, Vol. XIV, p. 409, may be found an erudite review, by Dr. ISAAC HAYS, of the various instrumental devices, that were known at that date, for illuminating, in living bodies, dark cavities having external openings. The instrument of BORRINI, of Frankfort, and the unfavorable reports thereon of the Josef Akademie and Faculty of Vienna (*Bull. de la Soc. méd. d'Émulation*, Avril, 1808) are referred to, and the "urethro-cystic speculum" presented by SÉGALAS, December 11, 1826, to the Paris Academy of Sciences, as well as the speculum of BOMBOLZINI for the exploration of the bladder, stomach, large intestines, and uterus; and a full description, with a figure, is presented of an endoscope designed, in 1824, by Dr. JOHN D. FISHER, of Boston. Twenty years later CAZENAVE (*Nouveau mode de l'exploration de l'urèthre*, etc., Bordeaux, 1845) and AVERY (*Dublin Med. Press*, December, 1845), at the Charing-Cross Hospital, experimented on the ocular inspection of strictures in the pendulous portion of the urethra. M. DESORMEAUX (*Note sur un instrument à l'aide duquel on voit dans l'intérieur de l'urèthre*, *Bull. de l'Acad. de Méd.*, November 29, 1853, *Gaz. des Hôp.*, p. 573, *Gaz. Méd.*, p. 770), in 1853, first described his ingenious though complicated endoscope, and subsequently detailed the improvements he successively adopted (*De l'endoscope et de ses applications au diagnostic et au traitement des affections de l'urèthre et de la vessie*, 1865). The paper of Dr. F. H. CRUISE on *The Utility of the Endoscope as an Aid in the Diagnosis and Treatment of Disease* (*Dublin Quart. Jour. of Med. Sci.*, 1865, Vol. XXXIX, p. 329), illustrated by a chromolithograph of the appearances of stricture viewed through a tube, if it does not vindicate its title, contains some interesting historical information regarding endoscopy. Dr. R.

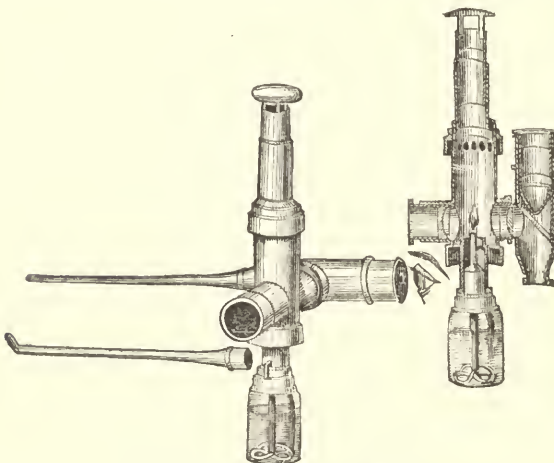


FIG. 353.—Endoscope of DESORMEAUX.

NEWMAN's essay (*The Endoscope*, in the *Trans. Med. Soc.*, New York, 1870) is profusely illustrated by wood-cuts and lithographs, and abstracts of cases in the writer's practice. The endoscope of Dr. P. S. WALES, U. S. N., is figured by Professor GROSS (*System*, etc., 5th ed., Vol. II, p. 715) with the observation that, "after a fair trial with this instrument, surgeons have very generally concluded that it is practically of little utility." M. VOULLEMIER, Sir H. THOMPSON, and Herr STILLING accord a similar verdict in regard to the instrument of M. DESORMEAUX. Dr. GOWLEY (*loc. cit.*, p. 23) and Drs. VAN BUREN and KEYES (*A Practical Treatise on the Surgical Diseases of the Genito-urinary Organs*, 1874, p. 75) agree that the light rubber canula proposed by Professor F. N. OTIS, illuminated by a suitable concave reflector, will answer every practical purpose to which urethroscopy is now applicable. A pattern is deposited in the Army Medical Museum (*Spec.* 4903, SECT. I). Other urethrosopes have been proposed by Herr GRÜNFELD (*Zur endoskopischen Untersuchung der Harnröhre*, in *Wiener Med. Presse*, 1874, S. 225) and by M. LANGLEBERT (*Gaz. des Hôpitaux*, 1868, p. 463).  
<sup>4</sup>The early efforts of CRUSSELL (*Die electrolytische Heilmethode*, in *Neue med.-chir. Zeit.*, 1847), and the pretensions of MIDDELDORFF (*Die Galvano-caustik*, Breslau, 1854), of BRENNER (*Untersuch. und Beobacht. auf dem Gebiete der Electrotherapie*, 1868), and of MM. MALLEZ and TRUPIER (*De la guérison des rétrécissements de l'urèthre par la galvanocaustique chimique*, 2<sup>m</sup> éd., 1870), and of a pupil of the latter, M. BAUTISTA (*De la galvanocaustique chimique comme moyen de traitement des rétrécissements de l'urèthre*, 1870) have been experimentally reviewed by Professor MEREDITH CLYMER, late Surgeon U. S. V. (see GOWLEY, *op. cit.*, 1873, p. 55), and by Dr. E. L. KEYES (*Practical Electrotherapeutics*, in *New York Med. Jour.*, 1871, Vol. XIV, p. 586) with results worse than negative, and suggestive of the lesson, that it is unwise to strike heavy blows in the dark.

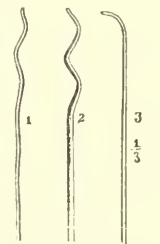


FIG. 354.—Contorted filiform bougies: 1, 2, after LEROY; 3, after B. BELL.

Dr. R. NEWMAN's essay (*The Endoscope*, in the *Trans. Med. Soc.*, New York, 1870) is profusely illustrated by wood-cuts and lithographs, and abstracts of cases in the writer's practice. The endoscope of Dr. P. S. WALES, U. S. N., is figured by Professor GROSS (*System*, etc., 5th ed., Vol. II, p. 715) with the observation that, "after a fair trial with this instrument, surgeons have very generally concluded that it is practically of little utility." M. VOULLEMIER, Sir H. THOMPSON, and Herr STILLING accord a similar verdict in regard to the instrument of M. DESORMEAUX. Dr. GOWLEY (*loc. cit.*, p. 23) and Drs. VAN BUREN and KEYES (*A Practical Treatise on the Surgical Diseases of the Genito-urinary Organs*, 1874, p. 75) agree that the light rubber canula proposed by Professor F. N. OTIS, illuminated by a suitable concave reflector, will answer every practical purpose to which urethroscopy is now applicable. A pattern is deposited in the Army Medical Museum (*Spec.* 4903, SECT. I). Other urethrosopes have been proposed by Herr GRÜNFELD (*Zur endoskopischen Untersuchung der Harnröhre*, in *Wiener Med. Presse*, 1874, S. 225) and by M. LANGLEBERT (*Gaz. des Hôpitaux*, 1868, p. 463).  
<sup>4</sup>The early efforts of CRUSSELL (*Die electrolytische Heilmethode*, in *Neue med.-chir. Zeit.*, 1847), and the pretensions of MIDDELDORFF (*Die Galvano-caustik*, Breslau, 1854), of BRENNER (*Untersuch. und Beobacht. auf dem Gebiete der Electrotherapie*, 1868), and of MM. MALLEZ and TRUPIER (*De la guérison des rétrécissements de l'urèthre par la galvanocaustique chimique*, 2<sup>m</sup> éd., 1870), and of a pupil of the latter, M. BAUTISTA (*De la galvanocaustique chimique comme moyen de traitement des rétrécissements de l'urèthre*, 1870) have been experimentally reviewed by Professor MEREDITH CLYMER, late Surgeon U. S. V. (see GOWLEY, *op. cit.*, 1873, p. 55), and by Dr. E. L. KEYES (*Practical Electrotherapeutics*, in *New York Med. Jour.*, 1871, Vol. XIV, p. 586) with results worse than negative, and suggestive of the lesson, that it is unwise to strike heavy blows in the dark.

whalebone (Figs. 352, 354) are of the utmost utility. Benjamin Bell appears to have first perceived the advantage of abruptly bending the extremity of bougies in dealing with eccentric strictures. The seeming paradox that in operations on the urethra the surgeon should forget his anatomy, has its truthful side; but only those who have a good stock of anatomical knowledge to be temporarily ignored, should undertake operations on the urethra. (Fig. 351.)



FIG. 355.—SIR CHARLES BELL'S bulbous probe.

INJURIES AND DISEASES OF THE TESTIS.—The instances reported of contusions, contused wounds, and lacerations of the testis<sup>1</sup> from shot injury, numbered five hundred and eighty-six; a few cases of wounds of the testis from other causes were reported; and numerous examples of hydrocele or of hæmatocele of alleged traumatic origin. Orchitis was very common among the troops in garrison, and syphilitic diseases of the testis were not rare. Other morbid alterations of the testis were comparatively infrequent. Attention will be invited mainly to the shot lesions, and the other traumatic affections and the diseases will be cursorily noticed. Wounds of the testes are less frequent than might be anticipated from their exposed position. Their mobility and rounded form, and the suppleness of the tissues investing them, explain the facility with which these organs escape injury (Velveau).<sup>2</sup>

*Shot Injuries of the Testis.*—Of the five hundred and eighty-six cases of this group, by far the largest proportion consisted of lacerated wounds of one or both testes, and the majority of these were complicated by concomitant wounds of either the penis, thighs, perineum, or pelvis. There were sixty-six fatal cases, the deaths resulting in most instances from the complications. Three hundred and forty cases, in which the seat of injury was precisely specified, presented one hundred and thirty-six examples of wounds of both testes, ninety-five cases of wounds of the right, and one hundred and nine of wounds of the left testis. Wounds of the testis commonly caused acute pain, radiating to the loins, and were generally attended by faintness, and often by vomiting. It has been asserted that severe contusions of the testes may occasion shock of fatal severity. I have not met with unequivocal evidence that an instance of this sort has been observed. In one of the reported cases, death was, indeed, ascribed to a shot contusion of the testes;<sup>3</sup> but the fatal event ensued a fortnight after the reception of the injury, and there is nothing in the report to oppose the supposition that there was some concomitant mortal complication.

<sup>1</sup> TESTIS, Gr., ὀρχίς; Lat., *Testiculus*, from *testis*, a witness, as testifying to virility; PLEDITUS, Lib. III, Fab. 11 (*Eunuchus ad Improbum*):

"En, ait, hoc unum est, cur laborem validus,  
Integritates testes quia desunt mihi."

Compare JUVENAL, Sat., Lib. II, Sat. 6, 339, and MARTIAL, Epig., Lib. IV, Epig. 24, 5.—Fr., *Testicule*; It. and Sp., *Testicolo*; Germ., *Hode*.

<sup>2</sup> On wounds of the testis consult VELPEAU (*Plaies du testicule*, *Dict. de Med.*, 1844, T. XXIX, p. 434); COOPER (A.) (*Obs. on the Structure and Diseases of the Testis*, 2d ed., 4to, 1841, p. 79); CURLING (T. B.) (*A Pract. Treatise on the Diseases of the Testis*, etc., 2d Am. ed., 1856, Chapt. III); KALTSCHMID (*Diss. de testiculo per varias operationes sub præfecto militum post vulnere antichæ infelicis successu curato*, Jene, 1762); SEHITZ (*Erwägen vulnere singularum*, Argentorati, 1633, Pars III, § 159 et seq.); BOYER (*Traité des mal. chir.*, Paris, 1849, T. VI, p. 700, *Des plaies des testicules*); DEMME (H.) (*Studien*, 1861, B. II, S. 165, *Schusswunden des Hodensacks*).

<sup>3</sup> Case of Private J. Meehan, Co. B. 90th Illinois, was injured at Mission Ridge, November 25, 1863. Surgeon W. W. Bridge, 46th Ohio, reported, from the field hospital of the 4th division, Fifteenth Corps, "a severe contusion of the testicles by a minie ball; death, December 9, 1863, from the injuries." A case reported by Dr. W. SCHLESER, in CASPER'S *Wochenschrift für die gesammte Heilkunde*, 1842, No. 41, S. 683, under the title *Pödeliche Tödtung durch Quetschung der Hoden*, was believed by the author to be a unique example of sudden death from contusion of the testis. In 1836, a healthy man, engaged in a fray, shrieked out, fell into convulsions, and died in five minutes. The only injury found was the rupture of both spermatic arteries and veins at the internal rings, produced by the testicle having been pulled down by one of those with whom the man was fighting. The case is cited by Messrs. CURLING (*loc. cit.*, p. 100) and PAGET (*Brit. and For. Med. Rev.*, January, 1844) as a remarkable evidence of the sympathy of the vital organs with the testes.



*Shot Lacerations of the Testis.*—About four-fifths of the shot injuries were perforations or grave lacerations of the testis. Nineteen examples of this form of injury have been presented in preceding subdivisions.<sup>1</sup> Thirty other instances, selected from cases of recovery without operative interference, will be related here:

CASE 1102.—Private A. B——, Co. C, 5th Michigan, was wounded at Fair Oaks, May 31, 1862, and sent to Balfour Hospital, Portsmouth. Assistant Surgeon H. L. Sheldon, U. S. A., noted: "Gunshot wound: the ball passed through the scrotum, causing extensive laceration." The patient was transferred to St. Mary's Hospital, Detroit, February 8, 1864. Acting Assistant Surgeon D. O. Farrand reported: "Transferred to the Veteran Reserve Corps, March 22, 1864, for gunshot wound of the left testicle and right thigh, producing permanent lameness and constant neuralgia." This man was mustered out June 17, 1865, and pensioned. Examiner W. B. Thomas reported, June 28, 1869: "Ball passed through the upper and posterior portion of the right thigh, and thence through the scrotum, wounding the left testicle. The testis is very much atrophied and painful. The muscles of the thigh are atrophied and weak and considerably contracted, producing considerable lameness." Examiner D. Clarke reports, September 11, 1873, that "the ball passed through the left testicle, and thence just back of the head of the right femur. In consequence of this wound he has a weakness in those parts, which debars him from lifting and any laboring occupation. His disability is three-fourths." This pensioner was paid on September 4, 1873.

CASE 1103.—Private Andrew B——, Co. E, 1st West Virginia Artillery, aged 38 years, was wounded at Buckhannon, August 30, 1862. The early history is not recorded. At Cumberland, September 9, 1863, Surgeon J. B. Lewis, U. S. V., reported: "Wounded by a carbine ball, which penetrated the scrotum below the centre of the right side, and made its exit near the raphe at about the same line, chipping the lower extremity of the right testis and bruising the left. The treatment consisted of topical applications of ointments, and occasional cleaning with castile soap-suds during the process of granulation. The cicatrix broke open and the ulcerative process recurred several times. The wound has now been healed for more than three months; the testes are both extremely tender and sensitive to the touch." This man was transferred, convalescent, February 1, 1864, to hospital at Parkersburg, returned to duty April 2d, and mustered out of service December 23, 1864. Not a pensioner January 4, 1874.

CASE 1104.—Private John H. L——, Co. D, 1st Maryland Battery, aged 28 years, was wounded at Gettysburg, July 3, and was treated in Seminary Hospital till the 28th, when he was sent to West's Buildings Hospital. Surgeon George Rex, U. S. V., reported "gunshot wound, causing the loss of the left testicle. On August 5th, an abscess in the scrotum was opened. The case progressed favorably, and the wound was nearly healed when the man was paroled, August 22, 1863."

CASE 1105.—Private Jonathan C——, Co. F, 87th Indiana, aged 31 years, was wounded at Chickamunga, September 20, 1863. Surgeon P. A. Cleary, U. S. V., reported, from Hospital No. 3, Chattanooga, a "gunshot wound of the penis and scrotum;" and was subsequently treated in hospitals at Nashville, Louisville, New Albany, and Jeffersonville, and mustered out May 30, 1865, and pensioned. Examiner N. Sherman, of Plymouth, Indiana, reported, April 28, 1866: "Applicant received a ball destroying the right testicle, and, passing into the right thigh behind the adductor longus muscles, came out near the inferior portion of the os coeconomy, causing pain and sickness upon slight exertion. Disability temporary." Examiner W. Hill reported, September 4, 1873: "Gunshot wound of the right testicle, scrotum, and inside of the right thigh on a line with the lower portion of the testicle. There is adhesion of the scrotum with the testicle, tenderness in the cicatrix, and pain along the spermatic cord. Disability total."

CASE 1106.—Private H. D——, Co. H, 45th Pennsylvania, was wounded at Cold Harbor, June 3, 1864. Surgeon James Harris, 7th Rhode Island, reported, from a Ninth Corps hospital, a "gunshot wound of the scrotum." Thence the patient was transferred to Carver Hospital, remaining under treatment until September 9th, when he was sent to Satterlee Hospital. Surgeon I. I. Hayes, U. S. V., reported: "Gunshot wound of the lower extremity and genital organs: the ball entering the scrotum and destroying the left testicle, passed onward, entering the upper third of the right thigh on the internal side, and coming out on the posterior and internal aspect of the same, the distance between entrance and exit wounds being about four and a half inches." The wound healed and the patient was returned to duty January 5th, and, on May 16, 1865, he was discharged and pensioned. Examiner N. Parker, of Lawrenceville, reported, October 15, 1870: "Gunshot wound of the left testicle and atrophy of the right; injury of the sciatic nerve and partial paralysis of the right lumbar region, with a difficulty in stooping. Disability seven-eighths." This pensioner was paid September 4, 1873.

CASE 1107.—Private James M. P——, Co. I, 29th Ohio, aged 25 years, was wounded in the hip at Dug Gap, May 8, 1864, and, after treatment in hospitals at Nashville, Louisville, and Camp Demison, was returned to duty on October 4th. On November 9th, he was again wounded at Bardstown, and sent to Clay Hospital, Louisville, and transferred, on December 19th, to West End Hospital, Cincinnati, where "wounds of the scrotum, penis, and left thigh" were noted; thence he was sent, April 20, 1865, to Camp Demison, and mustered out and pensioned, June 21, 1865. Examiner W. M. Eames, of Ashtabula, January 9, 1866, reported: "It is supposed that Perkins has a minié ball lodged near the femoral artery, at the upper third of the thigh, which causes contraction of the muscles and occasional severe spasmodic action of the muscles of the thigh and leg, and also interferes very much with locomotion. He was also wounded in the natis, penis, and testes, which wounds are a source of considerable trouble and inconvenience, the former having caused abscesses and extensive exfoliation and lameness." In a certificate dated September 12, 1867, the same physician reports: "He received a musket ball through the left thigh, which passed backward to the hip-bone, striking the ischium and splintering it, and remaining in some ten months; also one through the penis and left testicle, and a minié ball in the left thigh near the side of the femoral artery, which ball is lodged near the sciatic nerves. Disability total." This pensioner was paid September 12, 1867, and a claim for further increase of pension was pending in 1873.

<sup>1</sup> CASES 1013, p. 352; 1014, 1016, p. 353; 1021, p. 355; 1028, p. 356; 1041, p. 357; 1032, p. 358; 1039, p. 359; 1042, p. 360; 1016, 1048, p. 361; 1052, 1053, 1054, p. 362; 1055, p. 363; 1060, p. 364; 1061, p. 365; 1072, p. 370; 1079, p. 373.

Neuralgia and atrophy of the organ are the most frequent causes of complaint with pensioners for shot injuries of the testis.<sup>1</sup> It is curious to note the various estimates of the gravity of these disabilities :

CASE 1108.—Private Thomas Johnson, Co. G, 27th Ohio, aged 19 years, was wounded at the battle of Kenesaw Mountain, June 18, 1861, sent to a Sixteenth Corps hospital at Marietta, and thence to Hospital No. 19, Nashville, where Surgeon W. H. Thorn, U. S. V., reported, June 29th, "gunshot wound of the right testicle;" thence the patient was transferred to Jeffersonville, July 7th, where Surgeon M. Goldsmith, U. S. V., gave a similar description of the injury. When convalescent, this soldier was sent to Camp Dennison, and discharged at the expiration of his term of enlistment, August 30, 1864. Examiner J. W. Gustine, of Panora, Iowa, reported, July 16, 1869: "A severe flesh wound of the scrotum and buttock; ball entered the scrotum above the right testicle, near the cord, and passed out through the gluteal muscles of the left side. There is neither induration nor thickening of the parts; the wound is beaded, and the health is good; no disability." On this certificate the applicant's claim for pension was rejected, July 29, 1869.

CASE 1109.—Private W. R——, Co. F, 6th Maryland, aged 21 years, was wounded at the Wilderness, May 5, 1864, treated on the field until the 26th, and sent to Harewood Hospital, and thence to Satterlee, May 31st. Surgeon I. I. Hayes, U. S. V., noted a "gunshot wound of the genital organs," and the patient's transfer to Baltimore, to Camden Street Hospital, July 8th. Surgeon Z. E. Bliss, U. S. V., reported: "Ball grazed the anterior aspect of the right thigh, at the upper third; entered the scrotum, injuring both testicles and the inner aspect of the left thigh." This man was returned to duty October 8, 1864, and discharged July 6, 1865, and pensioned. Examiner T. Owings, of Baltimore, reported, October 26, 1866: "Gunshot flesh wound of both thighs, and through the right testicle, destroying it; right leg somewhat disabled by contractions at the point of the wound; disability one-half and permanent." Drs. H. E. Goodman, T. H. Sherwood, and J. Collins, at Philadelphia, reported that the "ball passed across the thighs and destroyed the right testicle; disability total." This pensioner was paid September 4, 1873.

CASE 1110.—Private S. A. F——, Co. I, 1st Massachusetts Artillery, aged 19 years, was wounded at Cold Harbor, June 1, 1864. He was sent from a Second Corps hospital to Lincoln Hospital on June 7th, and the case was registered as a "shot wound of the right testis and thigh." The wound granulated kindly under simple treatment; the patient convalesced rapidly, and, after two furloughs, he was returned to duty, February 3, 1865. He was discharged and pensioned, August 16, 1865. Examiner David Choate, of Salem, reported, November 12, 1866: "Ball passed through the right half of the scrotum, and, probably, through the right testicles; re-entered the inner surface of the thigh, and escaped behind, an inch below the junction with the natis. He suffers chiefly from pain and weakness in the loins and pain in the groins, especially after such work as lifting or reaching up, and is frequently obliged to quit work. The pain continues on into the night. The testis is much reduced in size and altered in form—dumb-bell shaped—as though part gone, and swells if he takes cold or receives an injury. There is some dribbling of urine after micturition; the wound through the thigh occasions but slight inconvenience; disability one-half." Examiner C. A. Carlton, in an examination for increase of pension, September 17, 1873, after describing the wound as above, adds: "Right testicle completely wasted; he complains of almost constant pain in the testis, extending up to the back, and is aggravated by lifting or walking. Disability total."

CASE 1111.—Sergeant M. G——, Co. I, 117th New York, aged 31 years, was wounded at Drury's Bluff, May 16, 1864. At an Eighteenth Corps hospital, a "gunshot flesh wound of the right thigh and privates" was noted; at Fort Monroe, on the 19th, a "gunshot wound of the testicles." On July 12th the patient was transferred to McDougall Hospital, and sent, September 2d, convalescent, to Rochester, and thence returned to duty, January 24, 1865; discharged June 8, 1865, and pensioned. Examiner H. B. Day, of Utica, reported, June 29, 1865: "The ball passed through the scrotum from left to right near the root of the penis, and through the right thigh. There is but little left of the right testicle; several small pieces of bone have been discharged from the wound in the thigh in the last eight days. He is quite lame, and walking is painful; disability two-thirds." Examiner J. W. Randall reported, when this pensioner was paid, September 4, 1873: "A ball entered the left side of the scrotum, passed through the right testicle, and entered the right thigh about two inches from the pubic bone, passing posterior to the femur, and came out near the tuberosity of the ischium. The testicle is atrophied, and the cord contracted and painful. Disability three-fourths."

CASE 1112.—Private J. F. Alexander, Co. F, 40th Indiana, aged 20 years, was wounded at Kenesaw Mountain, June 27, 1864. Surgeon E. H. Bowman, 27th Illinois, from a Fourth Corps division hospital, reported a "gunshot flesh wound of the hip and scrotum," and the patient's transfer to Hospital No. 2, Chattanooga, and admittance on July 3d. After treatment at Hospital No. 19, Nashville, the patient was sent to Brown Hospital, Louisville, September 4th, and the injury was noted as a "gunshot flesh wound of the right buttock, thigh, and testicle." The patient convalesced, was furloughed, and finally mustered out December 21, 1865, and pensioned. Examiner M. H. Bonney, of Lebanon, reported, August 9, 1868: "This man was wounded in the scrotum, the right testicle being implicated. While in Texas he contracted ague, which left him paralyzed, so that he was not able to labor. I think the ague was the cause of the paralysis." Examiner J. K. Bigelow reported, September 29, 1869: "Ball passed through from just posterior to the right great trochanter to the inner aspect of the thigh, where it made its exit, passing thence through the scrotum, injuring the right testicle and causing an ugly cicatrix attaching the scrotum to the testicle, which, in addition to a profound malarial influence, has developed a peculiar nervous prostration which resembles chronic alcoholism. His habits are correct. I am of the opinion that his disability at the above rate, three-fourths, is wholly permanent." He was paid to September 4, 1873.

<sup>1</sup> For published cases of wounds of the testis not cited elsewhere, consult PURDY (A. E. M.) (*Cases of Gunshot Wounds*, in *Am. Med. Times*, 1863, Vol. VI, p. 66); THOMSON (W.) (*Cases of Hospital Gangrene*, Case VII, in *Am. Jour. Med. Sci.*, 1864, XLVII, p. 185); HAMILTON (P. H.) (*Gunshot Wounds of the Scrotum and Testes*, in *Am. Med. Times*, 1864, Vol. IX, p. 61); HOMANS (J., jr.) (*Gunshot Wound of the Testis and Femur*, in *Boston Med. and Surg. Jour.*, 1865, Vol. LXXII, p. 15).



CASES.—In the following shot injuries of the testis pensions were allowed: 1113. Private W. McC——, 38th Ohio, was wounded at Missionary Ridge, November 25, 1863. Assistant Surgeon H. T. Legler, U. S. V., reported, January 4, 1864: "Gunshot wound of right thigh and testis." Discharged September 17, 1864. Examiner W. Ramsay reported, April 16, 1873: "Ball entered left thigh, passed through serotum and right thigh; one testis entirely destroyed." Pension paid September 4, 1873.

1114. Private J. G——, wounded at Chickamauga, September 19, 1863. Duty at Camp Chase April 7, 1864. Discharged December 5, 1864. Examiner S. W. Jones, Leavenworth, reported, April 11, 1865, "destruction of left testis." Examiner H. S. Roberts, September 5, 1873, reported: "Ball destroyed left testis and wounded the adductor muscles of the left thigh." Paid September 4, 1873.

1115. Private J. R. S——, 3d Vermont, aged 26, wounded at the Wilderness, May 5, 1864. Surgeon E. E. Phelps, U. S. V., reported: "Gunshot wound of external genitals." Duty December 27, 1864. Mustered out June 19, 1865. Examiner J. E. Stickney, of New Hampshire, reported, January 30, 1866: "Gunshot wound through left thigh and testis." Examiner H. A. Cutting reported, October 8, 1873: "Gunshot wound of left thigh; left testis shot away, causing abscess; now healed." Paid to September 4, 1873.

1116. Sergeant W. G. B——, 5th Vermont, aged 21, was wounded at the Wilderness, May 5, 1864. Surgeon O. A. Judson, U. S. V., recorded, May 11th, "gunshot wound of serotum." Duty July 9, 1864. Discharged July 10, 1865. Examiner L. D. Ross, Vermont, reported, December 21, 1865: "Wounded in left thigh and testicle, a portion of latter carried away; wound has healed, uniting serotum and testis." Dr. A. P. Beldeu, of New York, corroborates above, adding: "And at times all the ease he gets is to lie flat on his back for two or three days at a time." Disability total. Paid September 4, 1873.

1117. Private C. R. Fiske, 4th Vermont, aged 22, was wounded at the Wilderness, May 5, 1864. Surgeon S. J. Allen, 4th Vermont, records: "Shot in the left testicle." Assistant Surgeon J. C. McKee, U. S. A., reported, May 25th, "gunshot wound of left testis and right nates." Duty July 29, 1864. Discharged July 13, 1865. In his declaration for pension, applicant states that the "ball carried away his left testicle, passing round hip, coming out in fleshy part of buttock; that after these wounds healed he had fistula in ano." Examiners Porter and C. L. Allen, at Rutland, reported, February 1, 1871: "Testicle was removed, for injury, at the time the wound was received. There is fistula in ano." Paid September 4, 1873.

1118. Private J. M. W——, 188th Pennsylvania, aged 17, was wounded at Cold Harbor, June 3, 1864. Veteran Reserve Corps, October 8, 1864. Discharged August 8, 1865. Examiners J. McCook and J. W. Wishart, of Pittsburg, reported, February 1, 1871: "Ball entered below glutei, passed behind femur, and out on inner side of thigh, injuring left testis." Same board reported, May 1, 1872, "destruction of left testis." Paid September 4, 1873.

1119. Private G. P——, 9th U. S. C. T., aged 36, wounded at Deep Bottom, August 17, 1864. Surgeon J. H. Taylor, U. S. V., reported, August 20, "gunshot wound of left thigh and testicle." Discharged May 27, 1865. Examiner J. Cumiskey, of Philadelphia, reported, June 12, 1865: "Ball entered inner side of left thigh and passed through left testis and head of penis; testis entirely destroyed and leg slightly contracted from wound in thigh." Examiners G. W. Fay, H. W. Owings, and A. W. Dodge reported, November 1, 1871: "Loss of left testis; cicatrix on inner aspect of left thigh, which is slightly atrophied." Paid December 4, 1873.

1120. Private D. W. S——, 114th New York, aged 30, was wounded at Winchester, September 19, 1864, and discharged August 8, 1865. Examiner I. Spencer, of New York, reported, September 29, 1866: "The first ball passed through both thighs and the serotum, destroying the left testis." Examiner V. W. Mason reported, November 30, 1868: "Ball entered lower and posterior part of left hip, destroying left testis, and passed out at upper and outer part of right thigh." Paid December 4, 1873.

1121. Private D. H——, 13th Michigan, aged 32, was wounded at Chickamauga, September 19, 1863. Surgeon B. Cloak, U. S. V., recorded, November 11th: "He received six wounds, viz: Wound of left thigh, two wounds of the right; another ball carried away the glans penis and one testis; wound of right shoulder, and gunshot fracture of three fingers of right hand." Duty August 9, 1864. Discharged March 9, 1865. Examiner E. Ansdan reported, September 4, 1873: "First, loss of fingers; secondly, loss of testes and an opening inside of prepuce; thirdly, bayonet wound in thigh. In addition there is gunshot wound of thigh, one of left shoulder, and one of natis." Paid September 4, 1873.

1122. Private S. M. Y——, 5th Illinois, aged 25, was wounded at Chickamauga, September 19, 1863. Assistant Surgeon B. E. Fryer, U. S. A., reported: "Gunshot wound of right thigh, ball passing through both testes." Duty September 13, 1864. Discharged January 16, 1863. Examiner R. Barney, of Missouri, reported, March 12, 1872: "Gunshot wound of the forearm, right thigh, and testicles." This pensioner was paid September 4, 1873.

1123. Private J. F. W——, 13th Pennsylvania Cavalry, was wounded at Samaria Church, June 24, 1865. Surgeon T. R. Spencer, U. S. V., reported: "Gunshot wound of the right testis and groin." Duty March 15, 1865. Discharged July 14, 1865. Examiner J. S. Crawford, of Williamsport, reported, January 13, 1869, that "the testis was entirely removed; lameness of leg from injuries to muscles." The same examiner reported, August 7, 1872: "The serotum is healed soundly."

1124. Private G. P——, 15th New York Heavy Artillery, was wounded at Spottsylvania, May 19, 1864. Surgeon J. Hopkinson, U. S. V., reported: "Gunshot wound of left testis and right thigh." Duty September 29, 1864. Discharged April 3, 1865. Examiners Phelps, Smith, and Deming, of New York, reported, February 5, 1873: "Ball carried away left testis, passing through right thigh." 1125. Private J. B. W——, 105th New York, was wounded at Fredericksburg, December 13, 1862. Surgeon O. A. Judson, U. S. V., reported, June 2, 1863: "Discharged for gunshot wound of both thighs and left testis; disability total." Examiner H. T. Montgomery reported, March 1, 1866: "A ball passed through both thighs and the left testis." Paid June 4, 1873.

1126. Quartermaster Sergeant G. S. S——, 2d Sharpshooters, aged 32, was wounded at Spottsylvania, May 13, 1864. Duty September 1, 1864. Discharged February 20, 1865. Examiner L. D. Ross reported, September 8, 1866: "Wound caused by ball, destroying left testis, passing through right thigh." Special Examiner A. L. Lowell reported, April, 1871: "A ball carried away left testis, entering at perineum, emerging from right natis; wounds fully healed." Paid June 4, 1873.

1127. Private J. V. J——, 2d Maine, aged 30, was wounded at Fredericksburg, December 13, 1862. Discharged June 4, 1863. Examiner J. C. Weston reported, June 10, 1863: "Applicant received shell wounds in both thighs and right testis, the latter being destroyed. All the muscles in front of right thigh, down to the bone, appear to have been severed." Disability total. Paid September 1, 1873.

1128. Private J. A. B——, 8th Michigan Cavalry, aged 33, was wounded at Henrysville, November 23, 1864. Discharged May 12, 1865. Assistant Surgeon D. O. Farrand reported: "Gunshot wound through left testis, ball penetrating right thigh, and is lodged there." Examiner Dorsch, September 4, 1873, added, "ball came out, after four years, below the seat." Disability total. Paid December 4, 1873.

*Injuries of the Spermatic Cord* were not infrequently referred to in connection with shot wounds of the genitals. CASES 979 and 980, on page 237, have been adduced as instances of ligation of the spermatic artery,<sup>1</sup> an operation rarely required,<sup>2</sup> though described in routine by systematic writers.<sup>3</sup> The five following are examples of shot lesions of the spermatic cord:

CASE 1187.—Sergeant C. Upjohn, Co. E, 191st Pennsylvania, aged 21 years, was wounded at Laurel Hill, Spottsylvania, May 12, 1861. Surgeon D. W. Read, U. S. V., reported, from a Fifth Corps hospital, a "shot wound of the right thigh and scrotum." The patient was sent to Lincoln Hospital, and transferred, June 14th, to York, and on July 5th to Broad and Cherry Streets Hospital, and thence returned to duty April 11, 1865, and discharged May 30, 1865, and pensioned. Examiner J. Cumiskey reported, September 27, 1866: "Applicant was wounded by a ball passing upward through the front of the right thigh and cutting through the spermatic cord, coming out of the penis, and, according to the applicant's statement, entirely destroying all virile power in that organ. Though he is not thereby disabled for manual labor, I think his permanent injury of the procreative organs should be considered, and a pension granted." Examiner T. B. Reed reported, July 31, 1867: "The applicant is suffering from gunshot wound of the thigh at the upper third. The wound was a large, ragged laceration, and gangrene and sloughing followed, leaving a large adherent cicatrix, which has a tendency to discharge from time to time. The leg is very much weakened, its use and power are much impaired, and he cannot stand or walk on it any length of time. His disability is three-fourths and permanent." This pensioner died July 3, 1873.

CASE 1188.—Private J. E. Gleason, Co. I, 27th Michigan, aged 30 years, was wounded at Spottsylvania, May 12, 1864. He was treated in hospitals on the field, at Fairfax Seminary, City Point, and Beverly, no mention being made in any of these hospitals to injury of the testes. He was afterward sent to Detroit, and admitted into Harper's Hospital on December 23d. Acting Assistant Surgeon D. O. Farrand noted a "gunshot wound of the testicles by a minié ball." This soldier was discharged May 23, 1865, and pensioned. Examiner L. W. Pasquelle, of St. John's, May 18, 1866, reported that "one buckshot passed into the scrotum on the left side and cut the spermatic cord off; the testicle is almost absorbed; the wound is not yet healed. He has also a flesh wound of the left thigh." In an examination for increase of pension, April 27, 1867, this physician also states that the "wound is still discharging large quantities of fetid pus every twenty-four hours; so excessive is the discharge that he is too weak to work." In a renewed claim for increase of pension, March 26, 1871, the pensioner stated, under oath, that he was wounded "by a bullet and buckshot in the groin and testicles; the bullet entering the left groin, and, passing downward, coming out on the inside of the left leg. The buckshot, two in number, passing into the testicles, from whence they have since been taken." In a biennial examination, September 5, 1873, Dr. Pasquelle says the testicle "is shrivelled and useless, and painful at times from the injured nerve connected therewith; disability total." This pensioner was paid on September 4, 1873.

CASE 1189.—Private G. M. Oberly, Co. D, 129th Pennsylvania, was wounded at Chancellorsville, May 3, 1863, and was treated in the field hospital of the 3d division, Fifth Corps, until the 19th, when he was transferred to Campbell Hospital, where Surgeon J. H. Baxter, U. S. V., reported the case as a "gunshot wound of the pelvis," and returned the man to duty June 3, 1863. Pension Examiner Edward Swift, of Easton, reported, February 19, 1868, that "the ball had entered the upper part of the scrotum on the left side, injuring the spermatic cord and the os pubis, and passed out two inches above the anus and one inch to the left of the sulcus. He remained under treatment for more than a year. In August, 1863, I removed a splenium of bone from the anterior orifice, one and a half inches long by about one-fourth of an inch thick. The last fragment of bone came away in July, 1864. The left testicle is nearly absorbed. September 8, 1867: He continues feeble and is unable to take much active exertion." On July 23, 1868, he reported that "he still has considerable pain in the region of the wound, and is much debilitated from its effects. He has been unable to attend to any business since receiving the wound; disability total and permanent." This pensioner was paid to June 4, 1873.

CASE 1190.—Private W. H. L——, 70th New York, was wounded at Gettysburg, July 2, 1863. Veteran Reserve Corps, January 31, 1864. Discharged June 27, 1864. Examiner J. T. Keables, of Michigan, reported, February 15, 1870: "Ball entered middle third of right thigh, passed through right side of scrotum, injuring testicle, entered left thigh, and passed through. Examiner I. S. Wakefield reported, September 4, 1873, as above, adding: "severing the spermatic cord."

CASE 1191.—Corporal S. C. T——, Co. C, 3d Michigan, aged 27 years, was wounded at the Wilderness, May 5, 1864, and was sent from a Second Corps hospital, May 24th, to Harewood. Surgeon R. B. Bontecou, U. S. V., reported: "Gunshot wound of the testicles and of the upper third of the left thigh." At McClellan Hospital the same record was made, with the additional statement that "the ball carried away the right testis; the soldier was returned to duty, cured, November 22, 1864." He was discharged July 5, 1865, and pensioned. Examiner L. W. Pasquelle, of Michigan, November 12, 1867, reported: "The ball cut off the spermatic cord and the artery running to the right testicle; the testicle is entirely destroyed; the ball passed out on the right side of the rectum, injuring it slightly; disability one-half." The same examiner reported, September 5, 1873, substantially the same as above, except: "Ball passed through left side of rectum, destroying the sphincter muscle and causing much trouble in controlling the movement of the bowels."

<sup>1</sup> Allusions to ligations of the spermatic artery, except in cases of castration, are rare. SOEIX (*Kriegschir., Erf.*, 1872, S. 50) cites a case: Mohamed-ben-Raute, 12th Tirailleurs, shot at Würth, August 6, 1870, through the left side of the scrotum and the soft parts of the right thigh. There was profuse bleeding on the eighth day, and the spermatic was ligated by Professor HECKER. BECK (*Chirurgie der Schwerverletz.*, 1872, S. 306), in a list of ligations practised by him, mentions one of the spermatic artery. MALGAIGNE also (*Revue méd.-chir.*, Juillet, 1859) gives a case of ligation of the spermatic artery for a traumatic aneurism of the dorsal artery of the penis.

<sup>2</sup> LOHMEYER (*Die Schusswunden*, 1859, S. 174) observes: "If the injury to the spermatic cord is followed by copious bleeding, it becomes necessary to ligate the spermatic artery; the testicle of the injured side becomes atrophied, but its extirpation, as advised by DUPUYTREN, even when it is injured, is entirely unnecessary, as it offers no advantages and only causes the patient useless speculations as to his condition."

<sup>3</sup> LANGENBECK (J. J. M.) (*Nosologie und Therapie der chir. Krankh.*, 1839, B. IV, S. 511) observes: "Injuries of the spermatic cord necessitate ligation, and considerable lacerations of testicles, castration."



*Contusions of the Testis.*—Bruises of the testes, especially by compression of the organs against the pommel of the saddle, were common among mounted men, and the origination of hydrocele and hæmatocele was often ascribed to this accident. Brief abstracts of shot contusions of the testis are noted below. In notes on pages 405 and 419 evidence is adduced that negatives the doctrine that grave contusions of the testis are necessarily attended by extreme shock:

CASE 1192.—Private J. Purit, Co. I, 4th Cavalry, received a contused wound of the testicles from a shell, at Chapin's Farm, September 30, 1864. He was sent, October 4th, to hospital at Fort Monroe, and returned to duty November 28, 1864.

CASE 1193.—Private Harman Bosaek, Co. A, 24th Illinois, aged 25 years, was wounded at Chickamauga, September 19, 1863, and sent to a hospital at Louisville. Surgeon R. R. Taylor, U. S. V., reported "a severe contusion of the testis by a spent ball." The patient was transferred to Quincy. Surgeon R. Nicholls, U. S. V., reported: "The testicle was swollen and inflamed. The inflammation subsided after the application of iodine, linseed poultices, and rest. Duty on January 26, 1864."

CASE 1194.—Corporal T. Fitzgerald, Co. K, 72d New York, aged 23 years, was wounded at Gettysburg, July 3, 1863. Surgeon A. B. Ward reported that he was taken to Seminary Hospital with a wound of the right thigh. Transferred, July 11th, to Summit House Hospital. Acting Assistant Surgeon T. G. Hunt reported "a bruise of the testes by shell," and the patient's transfer to Mower Hospital on July 29th. Here Surgeon J. Hopkinson, U. S. V., reported that "the injury to the testis was received by a large solid shot striking a rail on which the soldier was sitting. With a suspensory bandage, he gradually improved, and did duty as a sentry after September 9th, and was sent to his regiment November 23, 1863."

*Sarcocele*, in one hundred and thirty-eight cases, and unspecified diseases of the testis, in two thousand two hundred and twenty-eight cases, were noted on the monthly reports;<sup>1</sup> but details were given of very few of these cases. Specimen 3654 furnished the Museum<sup>2</sup> with a good example of cystic disease of the testis, and the following case illustrates the effects of chronic inflammation:

CASE 1195.—[The following memoranda of the ablation of a diseased testis, supposed to be affected by tuberculous degeneration, are gleaned from a voluminous report by Acting Assistant Surgeon A. W. Tryon, who presented the pathological specimen to the Army Medical Museum.] Recruit H. D. Taner was received at Grosvenor Hospital, Alexandria, March 4, 1865. He related a long story of a fall in January, 1863, astride the walking-beam of a lake steamer, whence contusion and laceration of the perineum and scrotum, and confinement to bed for four months, and a surgical operation of unknown nature. Recovering, he had served a year as engineer on a steamboat, had then enlisted at Toledo, been ordered to Todd Barracks, arrested, tried, and imprisoned for desertion; sent to King's Street Hospital on account of a scrotal enlargement, again imprisoned, and finally sent to Grosvenor Hospital, under Dr. Tryon's care, with "acute orchitis." The scrotum was poulticed. On March 23d, an abscess on right side opened and discharged. On April 2d, "the operation of emasculation of the right testis was performed." "Ice and warm poultices were applied alternately, the former for one hour, the latter for two hours, for the next six days, and iodide of potassium and infusion of cinchona were administered internally. On April 22d, the scrotal incision was nearly healed." On April 24, 1865, "the patient was transferred to Sickles Barracks feeling quite well," and was discharged May 8, 1865, for "excision of right testicle for strumous disease." On examination of the removed testis, "tuberculous inflammation was found to have attacked the lower end of the tunica vaginalis, and there was tuberculous deposit throughout. The testis was much broken down by inflammatory action; but on microscopical examination it was found to be non-malignant." [On microscopical examination of this specimen (FIG. 357) at the Museum, after hardening in alcohol, disintegration of the tubular structure by tuberculosis was not observed. The tunica vaginalis and surrounding structures were thickened and enlarged by inflammatory exudations.]

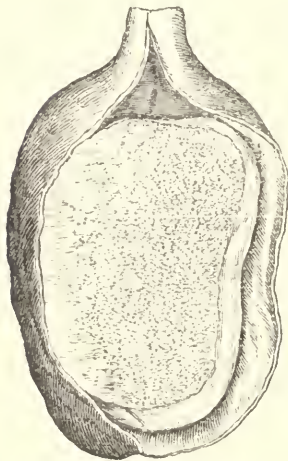


FIG. 357.—Section of right testis enlarged by chronic inflammation. Spec. 4066.

Instances of traumatic displacement of the testis were published<sup>3</sup> by Surgeon J. W. Thompson, of Paducah, and Assistant Surgeon E. J. Hall, 1st Vermont Cavalry. In the editor's opinion, the facts adduced do not conclusively establish these malpositions as examples of dislocation from violence rather than of congenital cryptorchid.

<sup>1</sup> *First Medical Volume*, pp. 640 and 712.

<sup>2</sup> *Cat. of the Surg. Sect.*, 1866, p. 493, Specimen 3654: "The left testicle enormously enlarged and excised entire. The organ, when removed, weighed two and a quarter pounds." Operation by Assistant Surgeon S. J. BUMSTEAD, 29th Illinois, in the case of W. Slaughter, aged 50.

<sup>3</sup> THOMPSON (J. W.) (*A Case of probable Dislocation of the Testicle*, in *The Nashville Jour. of Med. and Surg.*, 1866, Vol. 1, p. 39); Case of Private E——, 3d Kentucky. HALL (E. J.) (*Dislocation of the Testicle*, in *The Med. and Surg. Reporter*, 1867, Vol. XV, p. 304); Case of Private X——, Co. E, 1st Vermont Cavalry.

WOUNDS OF THE SCROTUM.<sup>1</sup>—These lesions, when uncomplicated, are attended by little pain or danger, and may be generally regarded as trivial. The extensibility of the tissues permits large solutions of continuity to be readily approximated, and even when there has been great loss of substance, reparation is commonly surprisingly rapid. Even trifling wounds, however, are liable, in vitiated constitutions, to be attacked by erysipelatous inflammation or the curious affection termed acute œdema of the scrotum,<sup>2</sup> and in such cases prompt interference is requisite, with free incisions and ferruginous preparations. Several instances of balls lodging in the scrotum,<sup>3</sup> without injuring the contained parts,<sup>4</sup> were reported:

CASE 1196.—Private S. Kratzer, Co. D, 25th Indiana, was wounded at Shiloh, April 6, 1862, by a ball, which entered just below the anterior superior spinous process of the ilium, passed under the sartorius muscle, through the abdominal ring, and then into the scrotum. On July 14th he was admitted, from Savannah, into hospital at St. Louis. Surgeon T. McMartin, U. S. V., reported that the ball was extracted from the scrotum, through an incision, before the patient's admission. By September the wound had nearly healed. This soldier was discharged October 14, 1862, and pensioned. Examiner J. W. Crooks, of Rockport, reported, April 17, 1863: "The ball having entered the left thigh, passed through the muscles into the lower part of the abdomen, and was finally taken out of the scrotum. He is at times quite lame." Examiner E. Mead, of Cincinnati, reported, January 24, 1865: "The ball entered the left thigh three inches below and anterior to the trochanter major, passed inward, through the thigh, anterior to the femur, thence into the left testicle, from which it was extracted. The triceps extensor femoris and sartorius muscles and the body of the testicle were injured. There is partial ankylosis of the hip-joint, and the power of locomotion is considerably impaired. Injury to muscular structure has resulted in contraction; pain in the testicle occurs frequently." Examiner H. S. Woods, of Cannehon, reported, September 15, 1873: "The ball passed in through the fleshy part of the thigh and into the lower part of the abdomen, injuring the cord of the left testicle and causing it to become soft and enlarged, which prevents his walking to a great extent."

CASE 1197.—Private William L.—, Co. G, 33d Pennsylvania, was wounded at Bull Run, August 30, 1862. Assistant Surgeon Warren Webster, U. S. A., reported that he entered Douglas Hospital September 7, 1862. A conoidal musket ball had entered the gluteal muscles two inches back of the great trochanter, passed inward and downward under the neck of the femur, and lodged in the scrotum. He had been made a prisoner, had been paroled, and had remained on the battle-field five days. When admitted, an abscess had formed in the scrotum. This was opened, and its cause was found in a ball, which was extracted. October 29th, the wounds were doing very well, and had nearly healed. There was some rigidity of the muscles of the thigh. The patient was discharged from service November 14, 1862. On July 15, 1871, Pension Examiner W. S. Walsh reported "a cicatrix remaining, about one inch in diameter. The pensioner has considerable difficulty in walking, cannot ride a horse, and suffers pain at times. His disability is rated at one-half and permanent."

CASE 1198.—Private J. B. Van Armes, Co. K, 106th New York, aged 23 years, was wounded at Petersburg, April 2, 1865. Surgeon W. A. Child, 10th Vermont, reported a shot wound of the pelvis. Assistant Surgeon J. S. Ely, U. S. V., at the Sixth Corps Hospital, reported a wound of the thigh and testes. Assistant Surgeon W. F. Norris, U. S. A., reported that this man was admitted into Douglas Hospital, June 19th, from Judiciary Square,—a conoidal ball had been extracted from the scrotum on April 24th, twenty-two days after the reception of the wound. Atrophy of the left testicle ensued. The patient was discharged from service on July 3, 1865, and was pensioned. In September, 1871, Pension Examiner B. F. Sherman reports that this invalid suffered no disability from the wound in the leg. The left testicle was atrophied; the right apparently healthy; disability one-half and permanent.

Another case, recorded as a shot wound of the scrotum, appears to have been complicated by incarcerated serotal hernia:

CASE 1199.—Sergeant G. W. Fox, Co. A, 112th New York, aged 33 years, was wounded at Chapin's Farm, September 29, 1864, and admitted on the same day to a Tenth Corps hospital with "a gunshot wound of the scrotum." He was sent thence to Hampton Hospital, October 1st, and transferred to New York to Grant Hospital, October 18th. He was returned to duty December 3d, and discharged June 13, 1865. In his application for pension, March 20, 1871, the sergeant states that "he was shot through the bag containing his testicles, rather on the left side, severing the cords; that he was obliged to wear a false bag for a number of years; that said wound was about a third of the distance from his body." \* \* Examiner J. H. Whitehouse, of Michigan, January 1, 1872, reported this man as totally and permanently disabled from "strangulated serotal hernia, caused by the striking of a spent ball. It inflames at times and becomes painful."

<sup>1</sup> SCROTUM, Gr., *σάβρυκος*, bursa testium, scrotum, by metastasis from "scortum, quod pellem significat" (FACIOLATI); "sacculus e pelle quo testiculi continentur." Fr., *Bourses*; Gr., *Hodensack*; Old Eng., *Cods*, "from Saxon *Coðde*, a case or husk in which seeds are lodged."—S. JOHNSON.

<sup>2</sup> LISTON (R.), *Remarks on the Acute Form of Anasarous Tumour of the Scrotum*, in the *Medico-Chirurgical Transactions*, 1839, Vol. XXII, p. 288, may be profitably consulted on this subject.

<sup>3</sup> Among the paintings in the Edinburgh Museum, No. 2951 is a sketch, from Sir CHARLES BELL'S collection, of a man wounded in the scrotum (*Cat.*, 1836, p. 361). The ball went through both testicles without touching the thighs. There is more inflammation, a larger wound, and a greater quantity of slough, on the side on which the ball passed out. Two cases of shot perforation of the scrotum are recorded in Circular 3, S. G. O., 1871, p. 56. There was not excessive shock in either case, and both patients speedily recovered.

<sup>4</sup> GLANDORF (M. L.) (*Speculum chirurgicum*, Bremen, 1619) cites a case of shot wound of the scrotum: the ball cut out from the opposite thigh.



*Hydrocele*.—Fifteen hundred and eighty-six cases of hydrocele, with seven deaths, were returned on the monthly reports of sick and wounded,<sup>1</sup> and ninety-four cases of discharge<sup>2</sup> for disability arising from this affection. On the surgical reports, twenty-seven cases of operations for hydrocele<sup>3</sup> were reported, three of which terminated fatally. The causes of death in four other cases returned numerically, are not given. The cases of operations will be briefly noted:

CASES.—When not otherwise specified, it will be understood that the operations consisted in puncture and an astringent injection of the sac of the tunica vaginalis, usually of dilute tincture of iodine. The name of the surgeon, the date of operation, and the disposition made of the patient, will be noted if recorded: 1200. Private T. B. Blizzard, Co. K, 26th Pennsylvania, was treated, at Chester, November 2, 1862, by seton and by incision. On March 18, 1863, Acting Assistant Surgeon B. Stone reported that this man had been tapped, at Harrison's Landing, August 20, 1862, for hydrocele ascribed to a contusion received at the battle of Williamsburg. This soldier was transferred to the 99th Pennsylvania, was wounded at Petersburg, March 25, 1865, and mustered out July 1, 1865. 1201. Private W. Henderson, Co. G, Punell Legion, aged 34; operated on at Frederick, August 16, 1862, by Assistant Surgeon R. F. Weir; fell into enemy's hands. 1202. Nurse A. Merrins, at Satterlee Hospital, November 5, 1862, was operated on by Professor S. D. Gross, and returned to duty December 5, 1862. 1203. Private J. Simms, Co. A, 11th Missouri, aged 40, operated on at Quincy, October, 1862, for traumatic hydrocele of left side; nearly a pint of serum was drawn off; duty December 8, 1862. 1204. Private Cordeman, 55th Pennsylvania; hydrocele prior to enlistment; entered regimental hospital at Hilton Head in November, 1862, and Surgeon D. Merritt, 55th Pennsylvania, tapped the tumor and evacuated a "pint and a half of straw-colored fluid;" returned to duty radically cured. 1205. Private J. Shisler, Co. B, 84th Pennsylvania; Assistant Surgeon J. S. Waggoner, 84th Pennsylvania, operated at Culpeper, September, 1863; discharged—date not given. 1206. Private R. Goss, Co. I, 69th Pennsylvania, operated on at Alexandria, January 11, 1863, by Surgeon C. Page, U. S. A., for hydrocele of right side, by incision and the introduction of a seton; cured; duty June 13, 1863. 1207. Sergeant J. M. Hotz, Co. B, 7th Maryland, aged 61; fourteen ounces of yellow serum from right tunica vaginalis evacuated by Acting Assistant Surgeon A. W. Holden, at Frederick, September 19, 1863; intense inflammatory action; cured, and discharged September 19, 1864. 1208. Private A. Bourke, Co. F, 7th Kansas Cavalry, aged 25; at St. Louis Marine Hospital, July 12, 1864, Surgeon A. Hammer, U. S. V., operated for double hydrocele; duty September 6, 1864. 1209. Corporal J. J. Garner, Co. F, 10th New Jersey, aged 25; at McLellan Hospital, April 15, 1864, Acting Assistant Surgeon J. G. Murphy operated, without injection; effusion; returned to duty February 8, 1865. 1210. Private J. Irvin, Co. L, Michigan Engineers, aged 59; operated on at Madison, April 1, 1864, by Acting Assistant Surgeon W. B. Greene; discharged October 8, 1864. 1211. Private J. Flanigan, Co. C, 14th Michigan, aged 40; Acting Assistant Surgeon D. O. Farrand punctured the left vaginal tunic, at St. Mary's Hospital, Detroit, June 5, 1864; the disease recurred; discharged August 10, 1864. 1212. Private G. A. Potter, Co. B, 1st New York Cavalry, aged 40; at Frederick, May 16, 1864, Acting Assistant Surgeon J. H. Bartholf punctured the right tunic and evacuated ten ounces of serum. 1213. Private W. W. Spearin, Co. G, 6th Vermont, aged 32; Acting Assistant Surgeon E. G. Waters punctured the hydrocele, August 20, 1864; modified duty in the Veteran Reserves September 15, 1864. 1214. Private H. A. Shorepe, Co. E, 7th Maryland, aged 24; hydrocele of left side of six months' standing; punctured at Jarvis Hospital, Baltimore, August 6, 1864, by Acting Assistant Surgeon E. G. Waters; recurred; transferred to Veteran Reserves October 2, 1864. 1215. Private J. Walker, Co. L, 5th New York Cavalry, aged 23; operated on by Acting Assistant Surgeon B. Rohrer, at Cuyler Hospital, February 24, 1865; deserted March 27, 1865. 1216. Sergeant L. L. Sweet, Co. I, 37th Iowa; scrotum enlarged for several years; swelling ascribed to a bruise received on a rail-car; Acting Assistant Surgeon I. Z. Hall tapped and evacuated "three pints of water" from the tunica vaginalis; discharged April 22, 1865, with atrophy of testis. 1217. Private L. Doty, Co. H, 38th Massachusetts, aged 25; encysted hydrocele; Acting Assistant Surgeon W. S. Adams operated at Frederick, February 18, 1865; cured, and discharged on expiration of service, June 30, 1865. 1218. Private J. Robertson, Co. L, 2d Iowa Cavalry, aged 45; operated on at St. Louis Marine Hospital, by Surgeon A. Hammer, U. S. V., for hydrocele of left side, July 12, 1864; eleven ounces of serum evacuated; duty August 3, 1864. 1219. Farrier R. Stetson, Co. K, 2d Massachusetts Cavalry, aged 43; operated on at Jarvis Hospital, October 29, 1854, by Medical Cadet H. McElderry, U. S. A., for hydrocele of six months' duration, ascribed to a fall from a horse; transferred to Veteran Reserves, Co. 72, October 16, 1864. 1220. Private R. Rawlins, Co. H, 142d New York, aged 18; operated on at Troy, March 17, 1865; mustered out June 13, 1865. 1221. Private P. McVeigh, Co. D, 106th New York, aged 42; Acting Assistant Surgeon E. R. Ould operated at Frederick, February 9, 1865, by incision; discharged June 6, 1865. 1222. Private E. Longcoy, Co. M, 21st New York Cavalry, aged 19; Acting Assistant Surgeon T. C. Cornish operated at Frederick, March 23, 1865; discharged, cured, May 19, 1865. 1223. Private J. Grosskloss, 39th Ohio, aged 31, was wounded at Atlanta, July 22, 1864, and was discharged and pensioned June 19, 1865. Examiner G. O. Hildreth, of Marietta, reported that a ball penetrated the soft parts of the left thigh and the scrotum, and lodged somewhere near the ramus of the ischium. In 1871, the same surgeon reported that the ball was removed in the autumn of 1866, and that in the winter of 1870 hydrocele was developed on the left side, doubtless from the chronic irritation resulting from the shot perforation of the scrotum. The hydrocele was operated on, but reappeared the following year. The case is related in detail, and there appears to be no reason to doubt the relation between the injury and the disease.

<sup>1</sup>These cases were returned in reports of an aggregate of six million four hundred and fifty-four thousand eight hundred and thirty-four cases (white troops, 5,825,480; colored, 629,354 = 6,454,834), occurring in a mean strength of five hundred and thirty-one thousand nine hundred and twenty (white troops, 468,275; colored, 63,645 = 531,920). See *First Medical Volume*, pp. 611, 712.

<sup>2</sup>The discharges were from a total number of discharges for physical disability of two hundred and twenty-three thousand five hundred and thirty-five (discharges from white troops, 215,312; from colored, 8,223 = 223,535). See *First Medical Volume*, pp. 648, 718.

<sup>3</sup>The library of the Surgeon General's Office is rich in papers on hydrocele, to which the catalogue supplies references. Among the classical authorities are: BERLANDI (*Mém. sur l'Hydrocele*, in *Mém. de l'Acad.*, 1757, T. III, p. 84); POTT (P.) (*Pract. Remarks on the Hydrocele*, London, 1762);

The causes of the fatal terminations of three operations for hydrocele were reported respectively as: old age, meningitis, and pneumonia, the cases exemplifying the old lesson of grave consequences from trivial surgical interference:

CASE 1224.—Private J. Burley, Co. D, 37th Iowa, aged 61 years, was admitted to Adams Hospital, Memphis, July 29, 1864, with remittent fever. He was transferred to Jefferson Barracks, and thence, convalescent, to Keokuk, August 20, 1864. Surgeon M. K. Taylor, U. S. V., reported: "Hydrocele of the left side. The parts were much enlarged with thickening of the wall of the tunica vaginalis. On August 20th, the patient was anesthetized by a mixture of chloroform and ether; the sac was punctured and its contents evacuated by a trocar, and a dilute solution of bromine was then injected. The patient was of feeble habit." The hospital register adds: "Died September 4, 1864, of hydrocele and old age."

CASE 1225.—Private J. H. Ellis, Co. F, 7th Wisconsin, aged 21 years, was admitted to Hospital No. 1, Frederick, March 5, 1863. Surgeon R. F. Weir, U. S. A., reported: "Hydrocele; died April 7, 1863, of meningitis." Acting Assistant Surgeon Alfred North furnished a history and pathological preparation (Fig. 358) from this case: "On March 11th, this patient was operated on, by Dr. North, for hydrocele. The sac was punctured and the following injection was thrown in: *Tinct. Iodini*, ℥ʒij, *Iodidi Potass.*, ʒij.—M. No dressing applied. March 12th: Moderate amount of inflammation established. March 16th: Swelling of scrotum subsiding. Lest the inflammation excited might be insufficient to insure the success of the operation, tincture of iodine was painted outside. March 20th: Pulse quick and weak; tongue slightly furred; skin dry and warm; bowels rather costive; compound cathartic pill and castor oil ordered. March 25th: Patient has improved; says his scrotum pains him little; appetite poor; there has been slight excoriation of the integuments covering the scrotum, but no signs of erysipelas. March 30th: Patient not so well; says that he has had a chill, and is this morning quite feverish; pulse full; tongue coated and dry; skin dry and hot; appetite poor; bowels inclined to constipation; the scrotum appears to be doing well and is still smaller. March 31st: There are small ulcers here and there over scrotum; parts red and much swollen; ordered as a local application an ounce of simple cerate, with ten grains each of powdered opium and acetate of lead rubbed in; patient is taking ale and generous diet. April 2d: Has had no chill since last note; complains of severe headache, and has no appetite; bowels inactive; patient quite morose; ordered eight grains of compound cathartic pill, U. S. P. April 4th: Scrotum has diminished in size, and in every respect looks to be doing well; general condition about the same; there is still some slight cerebral disturbance; feels quite weak, and has scarcely any appetite. April 5th: Cerebral symptoms more strongly marked; pupils much dilated; pulse 110 and feeble; nausea and vomiting; bowels are moved only by the action of purgatives; seems unwilling to answer questions; ordered cups to temples, hot bricks to feet, purgatives and diaphoretics. April 6th: Patient worse, and above symptoms continue; ordered a blister to the nucha and an enema of a drachm of spirits of turpentine, in two ounces of mucilage; scrotum looks about the same; ordered cups behind the ears; five P. M., patient is comatose; ordered head shaved and cold applications. April 7th: Patient now and then answers a question; pulse very weak; ordered beef-tea to be freely given, and a wine glass of milk-punch every two hours; has had two fecal evacuations since last P. M. April 8th: Assistant Surgeon R. F. Weir, U. S. A., being called, ordered patient's head to be shaved and cold cloths applied; bowels are opened and scrotum looks to be doing well, but patient is delirious and fast failing. April 9th: Patient continued to fail, and at half-past eleven P. M. died. *Post mortem* twelve hours after death: *Rigor-mortis* well marked. Upon opening the chest, the right lung was found hepaticized, the outer surface being filled with miliary tubercles. In the upper portion of the middle lobe a mass of tubercular matter the size of a pullet's egg was found in a softened condition; throughout the entire lung tubercles were scattered. Left lung in the same condition. Thymus gland filled with softened tubercular matter. Liver somewhat enlarged and highly congested. Kidneys highly congested and capsule firmly adherent to the organ. Brain: Membranes highly congested; blood-vessels distended with dark-colored pus; substance of brain highly congested, especially the white substance. Removed the tunica vaginalis and contents of right side, this being a hydrocele which was operated upon by Dr. North twenty-nine days antecedent to death. On opening the sac, it was found to contain four ounces of albuminous serum. The tunics were somewhat thickened; there were no adhesions to be found at any point."

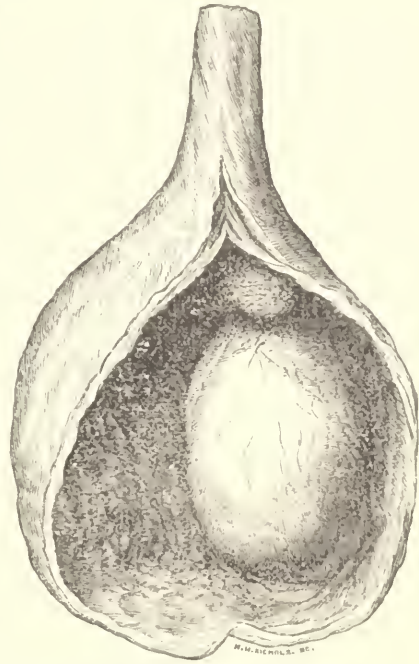


FIG. 358.—Hydrocele of the left tunica vaginalis. *Spec.* 4079.

CASE 1226.—Private D. L. Glimes, Co. K, 31st Wisconsin, aged 38 years, was admitted to Hospital No. 1, Nashville, November 10, 1864, with hydrocele. Surgeon B. B. Breed, U. S. V., reported that, "on November 13th, Acting Assistant Surgeon W. L. Herr operated for the radical cure of the hydrocele, evacuating eight ounces of fluid and inserting a seton. The hydrocele was cured, but pneumonia supervened, and terminated fatally December 16, 1864."

EARLE (*Treatise on the Hydrocele*, London, 1791); DEAN (W.) (*Obs. on the different Methods for the radical Cure of the Hydrocele*, Dublin, 1782); BELL (B.) (*Treatise on the Hydrocele, on Sarcocoele, and other Diseases of the Testes*, Edinb., 1793); MONRO (A.) (*Of Hydrocele, Hematocele, etc.*, in *Edinb. Med. Essays*, Vol. V, p. 299); BRODIE (B. C.) (*Remarks and Obs. on Diseases of the Testicle*, in *London Med. and Phys. Jour.*, 1825); HOLBROOK (J.) (*Practical Obs. on Hydrocele, etc.*, London, 1825); BENEDICT (*Bemerkungen über Hydrocele, Sarcocoele, und Varicocele*, Leipzig, 1831); BLANDIN (PH. F.) (*Hydrocèle*, in *Dict. de méd. et chir. prat.*, 1833, T. X, p. 108); VELPEAU (*Dict. de méd.*, 1837, T. XV, p. 442); GERDY (*Considérations pratiques sur l'hydrocèle et le sarcocèle*, in *Arch. gén. de méd.*, 1838, 3<sup>e</sup> sér., T. I, p. 57); BERAUD (*Considération sur l'hématocele ou épanchement sanguin du scrotum*, in *Arch. gén. de méd.*, 1851, 4<sup>e</sup> sér., T. XXV, p. 224). Consult, also, *opuscules* 1061, Sect. I, A. M. M.



*Varicocele*.—Recruiting regulations require military surgeons to attach considerable importance to the affection thus designated.<sup>1</sup> Fourteen hundred and fifteen men are reported as discharged from service, during the war, on account of this form of disability.<sup>2</sup> But operations for this affection were not common. In a special report, Surgeon J. R. Smith, U. S. A., remarks:

"I have operated six times for varicocele, five of the cases being citizens, and one a soldier named Howard, of Co. E. Battalion of Engineers. He is reported as a case of varicocele in one of my monthly reports from Jefferson Barracks, but the report of the operation was forgotten. These varicoceles were all of the left side, were operated on by subcutaneous ligature, and were all successful."

The bias that leads advocates of discharged soldiers to refer physical disabilities to traumatic causes, has been adverted to in treating of hernial protrusions; it is not less noticeable in the reports of other varieties of scrotal enlargements:

CASE 1227.—Private E. Haines, Co. G, 41st Ohio, aged 36 years, was wounded at Rocky Face Ridge, May 9, 1864. Surgeon R. D. Lynde, U. S. V., reported, from a Fourth Corps hospital: "A shell contusion of the right shoulder." Surgeon F. Sadler, U. S. V., made a similar report from Chattanooga, and recorded the patient's transfer to Nashville, whence he was returned to duty, May 20th, by Surgeon R. R. Taylor, U. S. V. On June 6, 1864, this soldier was admitted to Hospital No. 1, McMfreesboro', where Surgeon H. H. Seys, 15th Ohio, recognized a "gunshot contusion, producing varicocele of the left side." This man was sent to duty July 4th, and discharged November 2, 1864. In his application for pension, he states that he was severely wounded at Stone River, December 31, 1862, in his right arm; at Chickamauga, September 19, 1863, in the left leg; and at Buzzard Roost, as described above. He says of this injury that he "was struck by a piece of shell on the brisket, and the shock was so severe as to injure the groin and entire hip, and also to cause the left testis to swell badly, rendering it painful."

The best modern authorities are adverse to operative interference with varicocele, advising, in serious cases, suspensory bandages.<sup>3</sup> A very good suspender is that recently

<sup>1</sup> Varicocele, a term of hybrid formation (*varix* and *κήλη*), is commonly understood to imply a varicose enlargement of the veins of the spermatic cord. Yet some authors define the affection as a dilatation of the veins of the scrotum, and term varices of the spermatic veins *Cirsocele* (*κίρσος* and *κήλη*), a distinction known to CELSUS. Drs. VAN BUREN and KEYES (*A Practical Treatise on the Surgical Diseases of the Genito-Urinary Organs*, 1874, p. 468) declare that: "Varicocele is constituted by a varicose enlargement of the pampiniform plexus and veins of the cord." In army practice, varices of the spermatic cord, epididymis, or scrotum would probably be classified under the head of varicocele, in making reports.

<sup>2</sup> On the monthly reports of sick and wounded, there were recorded seven thousand two hundred and seventy (7,270) cases of varicocele, with one (1) death (*First Medical Volume*, pp. 639, 711); and there were fourteen hundred and fifteen (1,415) discharges (1,390 white and 25 colored soldiers) from this form of disability (*Ibid.*, pp. 647, 717). The mean strengths and aggregates from which these cases were derived are specified in note 1, p. 420.

<sup>3</sup> CHAPMAN (*Varicose Veins, their Nature, Consequences, and Treatment*, 1856, p. 49) justly appreciates the objections to which the operations for ligation of the spermatic veins are obnoxious: "Phlebitis, once provoked, is so little under our control, that \* \* \* I cannot bring myself to believe that any surgeon is justified in deliberately encountering so formidable a risk, remote as he may deem it, for the sake of an advantage which is at best merely transitory." And, in the latest work on the subject, received since the foregoing observations were in print, Professor VAN BUREN and Dr. KEYES (*A Practical Treatise on the Surgical Diseases of the Genito-Urinary Organs*, 1874, p. 471) declare that "all the operations proposed for varicocele have been attended by fatal consequences, and it is unsurgical to endanger life for a disease in itself harmless." Dr. ASHURST (*The Principles and Practice of Surgery*, 1871, p. 936) believes that the operation for the radical cure of varicocele "can only be justifiable in exceptional cases." Professor GROSS

(*System*, etc., 5th ed., Vol. II, p. 837), after practising strangulation of the veins by the twisted suture in fifteen cases, was led to abandon the operation because one of his patients "unexpectedly perished from phlebitis and pyæmia." The editor of these pages was a witness, in 1851, of the fatal consequences of ligation of the spermatic veins, in two cases, in the hands of VIDAL, a skilful advocate of the operation, and author of an important monograph relating to it (*De la cure rad. du varicocele*, etc., Paris, 1850). Dr. J. H. BRINTON, in an elaborate paper (*Description of a Valve at the Termination of the right Spermatic Vein in the Vena Cava, with Remarks on its Relations to Varicocele*, in *Am. Jour. Med. Sci.*, 1856, Vol. XXXII, p. 111), explains the greater frequency of varicocele on the left side by the absence, in the spermatic vein of that side, of a valve (FIG. 359) found by him uniformly present near the origin of the right spermatic vein in the adult male human subject. EMMERT (*Lehrbuch der Chir.*, 1862, B. III, S. 866) corroborates this observation. CURLING (*A Pract. Treatise on the Diseases of the Testis*, Am. ed., 1856, p. 348) compiles statistical returns from the British Army Medical Department showing that there were 3,911 recruits rejected for varicocele in the ten years ending March 31, 1853, of whom 3,360 had the disease on the left, 282 on the right, and 269 on both sides. MARSHALL (II.) (*On the Enlisting, Discharging, and Pensioning of Soldiers*, 2d ed., Edinburgh, 1839, p. 32) asserts: "Cirsocele seldom occurs, except on the left side. I do not recollect having ever seen a well-marked case of it on the right side, although I have examined nearly 30,000 recruits." It is of historical interest to recall that DELPECH, an eminent surgeon of Montpellier, was assassinated, October 29, 1832, by a man whom he had treated for varicocele. The murderer, Demptos, had understood that DELPECH had been consulted by the relatives of a person he wished to marry, and had given an intimation that a matrimonial engagement was, under the circumstances, undesirable (*The London Med. Gazette*, 1833, Vol. XI, p. 223, and *Annuaire Médico-Chirurgical*, 1833, septième année, p. 635). Compare, on this subject: FRIEBSCH (*Über die Radicalcur der phlebetas spermatic. int. oder die sogenannte Varicocele*, Freiburg, 1839); NÉLATON (*Considérations sur la varicocele*, in *Gaz. des Hôp.*, 1858, p. 451); THOMSON (L. R.) (*Varicocele treated by Pressure*, in *Monthly Jour. of Med. Sci.*, 1849, Vol. IX, N. S., Vol. III, p. 195); BLANDIN (P. F.) (Article *Varicocele*, in *Dict. de méd. et chir. prat.*, 1836, T. XV, p. 540); MOUTON (Article

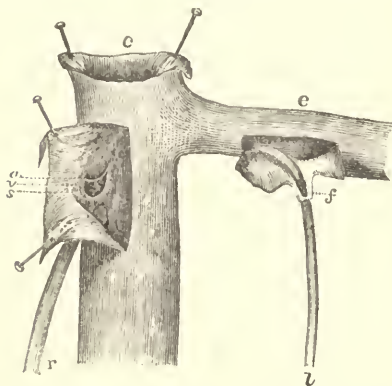


FIG. 359.—Dissection of the vena cava, emulgent and spermatic veins, showing the right spermatic valve. [After BRINTON.]

635). Compare, on this subject: FRIEBSCH (*Über die Radicalcur der phlebetas spermatic. int. oder die sogenannte Varicocele*, Freiburg, 1839); NÉLATON (*Considérations sur la varicocele*, in *Gaz. des Hôp.*, 1858, p. 451); THOMSON (L. R.) (*Varicocele treated by Pressure*, in *Monthly Jour. of Med. Sci.*, 1849, Vol. IX, N. S., Vol. III, p. 195); BLANDIN (P. F.) (Article *Varicocele*, in *Dict. de méd. et chir. prat.*, 1836, T. XV, p. 540); MOUTON (Article

suggested by Mr. Morgan,<sup>1</sup> of Dublin, which is figured in Mr. Thomas Bryant's excellent manual of surgery, and is useful in various affections of the testis.

CONCLUDING OBSERVATIONS.—A retrospect of the several subjects discussed in this chapter, with a summary of the different groups of cases, will be of convenience here. The lists of the different groups of injuries of the pelvis sum up as follows:

TABLE IX.

*Numerical Statement of Three Thousand One Hundred and Seventy-four Cases of Injuries of the Pelvis reported during the War.*

NATURE OF INJURY.	CASES.	RECOVERIES.	DEATHS.	RESULT UNKNOWN.
Shot fractures of the pelvis.....	1,494	918	544	32
Punctured and incised wounds.....	15	12	3	
Shot penetrations of the pelvic cavity without known injury to the viscera.....	38	25	13	
Shot wounds of the bladder.....	185	89	96	
Shot wounds of the prostate.....	8	4	4	
Shot wounds of the rectum.....	103	59	44	
Wounds of pelvic nerves and blood-vessels.....	179	94	85	
Shot wounds of the penis.....	300	268	41	
Shot wounds of the urethra.....	105	83	22	
Shot wounds of the testis.....	586	520	66	
Shot wounds of the spermatic cord.....	32	30	2	
Shot wounds of the genital organs indefinitely described.....	120	104	13	3
Total.....	3,174	2,206	933	35

The cases of shot fractures of the pelvis are accounted for on page 255; brief abstracts are presented of 140 instances, of which 136 are classified according to the bone chiefly injured (72 cases being referred to the ilium, 9 to the pubis, 16 to the ischium, 24 to the sacrum, and 15 to the coccyx), while abstracts of 4 cases illustrate complications of shot fractures of the pelvis. There were specified 1,545 shot fractures of the several pelvic bones; but these occurred in 1,494 patients, as above indicated. The mortality rate

*Cirrocèle*, in *Dict. des sci. méd.*, T. V); HÉLOT (J.) (*Du varicocèle et de sa cure radicale*, in *Arch. gén. de méd.*, 1844, 4<sup>e</sup> sér., T. VI, p. 1, and T. VIII, p. 287); GAGNEBÉ (*Dilatation variq. des veines*, 1830); LANDOUZY (H.) (*Du varicocèle*, 1838); BRESCHE (G.) (*Mém. sur une nouvelle méth. de trait. et de guérir le cirrocèle et le varicocèle*, in *Gaz. méd. de Paris*, 1834); BÉBARD (A.) (Article *Varicocèle*, in *Dict. de méd.*, 1846, T. XXX, p. 553). There are in the library of the Surgeon General's Office many theses on varicocèle; *e. g.*, papers by DELAGENESTE, GAULTIER-DUPARRAY, HACQUE, HENRY, BOISSEL (H.), BRIOUX, BUREAU (E.), CHAUMAS (E.), CODET (C.), GARCIA (F.), GERHARDT, (C. H.), JANVIER (E.), JEANSELME (J. L. G.), JOSEPH (G.), LEE (H.), LETORSAY (H.), LITZICA, POUZET (J.), PRINHAIRE, SCHWERING, SELTMANN, STRAUBE, and TRANDAFIRESCO. Mr. CURLING, who, in his *Practical Treatise on Diseases of the Testis*, and paper on the *Testicle*, in the *Cyclopædia of Anatomy and Physiology*, sums up most of what is known on this subject, recalls the measurements of CRIVEILLIER (*Anatomie descriptive*, 1834, T. II, p. 731), who found the adult human testicle to measure two inches in length, an inch in breadth, and eight lines in thickness.—Sir ASTLEY COOPER's estimate (*loc. cit.*, p. 12) of a long diameter of two inches, a transverse diameter of one and a half inches, a lateral diameter of one inch and one eighth,—and records the mean dimensions of the testicle, according to his own measurements, as an inch and three-quarters in length, an inch and a quarter across, and an inch in thickness. Sir A. COOPER stated the average weight of the testicle at one ounce. MECKEL (*Manuel d'Anatomie gén., desc., et path.*, 1825, T. III, p. 621) makes it four drachms "c'est-à-dire sa substance, débarrassée de toutes les enveloppes." Mr. CURLING found a mean of these two estimates, or about six drachms, to be the ordinary weight of the sound testicle in a healthy adult, which nearly accords with KRAUSE'S measurements (*Vermischte Beobacht.*, in MÜLLER'S *Archiv für Anat. Phys. und Wissensch. Med.*, 1837, S. 23), who found the mean weight in five instances 334.4 grains. LAITH (*Mém. sur le testicule humain*, Paris, 1832) and HUSCHKE (*Encyclopédie Anatomique*, T. V, p. 347) have especially investigated the anatomy of the seminiferous tubules, which the former estimated at 840 in number, with a mean length of the united ducts of 1.750 feet. It must not be forgotten that Sir A. COOPER, whose beautiful preparations of the testicle are preserved in the Museum of the Royal College of Surgeons of England, succeeded in filling these tubules with size injection, an achievement other anatomists have failed to imitate. Mr. CURLING states that spermatozoon are not infrequently found in the testes of men over seventy years of age, and the procreative faculty is sometimes retained to a still more advanced period of life, as in the remarkable instance of Thomas Parr, of Shropshire, who attained the great age of 152 years, and whose body was dissected, in 1635, by the illustrious HARVEY. It is related by BETTUS (*De ortu et natura sanguinis*, London, 1669, p. 320): "Genitalibus erat integris, neque retracto pene neque extenuato, neque seroto distento ramice aquoso ut in decrepitis solent, testiculis etiam integris et magnis."

<sup>1</sup>MORGAN (On the Treatment and Cure of Varicocèle by Suspension of the Testis, in the *Dublin Quart. Jour. of Med. Sci.*, 1869, Vol. 48, p. 490), BRYANT (T.) (*The Practice of Surgery*, 1872, p. 644).



ascribed to the cases of pelvic fracture<sup>1</sup> appears exorbitant; but when interpreted by the figures in TABLE VII. and the facts adduced regarding fractures of the several bones, it is plain that the seemingly excessive fatality arises from including in this group cases undoubtedly complicated with grave visceral lesions.<sup>2</sup> Some remarkable examples of excisions of portions of the pelvic bones were adduced, and in PLATE XLI various forms of cutting forceps, rowel saws, chisels, gouges, and other osteotomes used in these operations were figured. The cases of punctured and incised wounds of the pelvis are briefly adverted to on page 350, and five abstracts are published of instances of this group. The other ten cases were comparatively trivial.<sup>3</sup> A few remarkable examples of shot penetrations of the pelvic cavity without known injury of the viscera were next presented, followed by an exposition in detail of the important material relating to wounds of the bladder. Reference was made to several complete recoveries after shot wound of the bladder, and among them to the case of General R. B. Potter, of which a more definite account has since been obtained:

CASE A<sup>11</sup>.—Major-General Robert B. Potter, U. S. V., commanding the Second Division of the Ninth Corps, while endeavoring to rally the assaulting column on the Petersburg Heights, after the mine-explosion, June 30, 1864, was struck by a musket ball, which traversed the pelvic cavity from a point above and slightly to the right of the symphysis pubis, to the outer side of the left buttock. The axis of the wound indicated that the missile passed near the upper curve of the great sciatic notch. Urine escaped from the shot orifices, but there was no evidence of pelvic fracture. The field surgeons regarded the case as desperate; but the patient, whose courage and intelligence were as conspicuous in the hospital as on the field, argued that, if no bones were broken, his chances of recovery were better than those of patients subjected to lithotomy. The event vindicated these provisions. The flow of urine by the wounds soon ceased; the wounds cicatrized, and in the course of a few weeks the cure was complete. This gallant officer was honorably mustered out of service January 15, 1866, and made no application for pension. In January, 1874, being in Washington, he had the kindness to permit several medical officers at the Surgeon-General's Office to verify (by the cicatrices) the course of the ball, and it was ascertained that there was no functional vesical disorder, or, indeed, any inconvenience consequent on the formidable injury received.

The reference, on page 264, to the foregoing case, and to other complete recoveries from shot wounds of the bladder, is followed by instances of partial recovery of patients left with urinary fistules. Then follows a remarkable series of examples of foreign bodies in the bladder, including several in which encrusted projectiles were removed from its cavity, and others in which missiles, or the substances driven in by them, as bone, hair, clothing, etc., became the nuclei of vesical calculi. No instances were reported of encrusted bullets found in the bladder after death.<sup>4</sup> Such cases are extremely rare. Cases

<sup>1</sup>In this tabular statement, as in TABLE IV, on page 202, difficulties arise from the attempt to account in a tabular form for the fate of a given number of individuals, some of whom were recipients of several of the different varieties of injury enumerated. Should there be apparent contradictions, it is believed that the aggregate mortality is correctly set forth. At all events, the tables are compiled from actual count of the individual cases, by name.

<sup>2</sup>It has been shown, for example, that shot fractures of the ilium are not necessarily very fatal injuries unless complicated by penetration of the abdominal cavity. It was in the category of cases returned as "gunshot fractures of the pelvis" (without specification of the parts immediately injured) that the large mortality rate appears. Now most of these cases were returned from field hospitals, and there is evidence that very many of them were attended by visceral injuries, though the evidence was not sufficiently definite to permit a separation and classification of these cases.

<sup>3</sup>Compare CASES 930, p. 323, 977, p. 335, 978, p. 336, 997, p. 344, 1085, p. 374 *ante*. Of the ten remaining cases of this category, five were instances of bayonet stabs, two of accidents from broken chamber-pots or urinals, and three from other analogous accidental injuries.

<sup>4</sup>Mr. DIXON (*Med. Chir. Trans.*, 1850, Vol. XXXIII, p. 199) cites, as examples of calculi formed about bullets and found in the bladder after death, the case communicated to FABRICIUS HILDANUS (*Op. que ext. omn.*, Frankofurti, 1645, Cent. III, Obs. LXVII, p. 250) by PAULUS OFFREDUS, in which a calculus the size of a hen's egg, deposited about a ball, was found in the bladder thirty years after the reception of the wound. HILDANUS says that no suffering was experienced for fifteen years; for the last fifteen years of his life the patient suffered greatly. HILDANUS says nothing of an attempt at extraction. Mr. DIXON adduces as distinct cases the observations of BARTHOLINUS and BINNINGER. They appear to be identical with each other and with the original observation by SEGER, of Turin. BARTHOLINUS (*Epist. Med.*, Hagæ, 1644, *Epist.* XXXV) speaks of a case related to him by SEGER, of a calculus the size of an egg, encrusting a ball, found in the bladder after death. BONETUS (*Sepulchritum*, Geneva, 1700, T. II, L. III, p. 58) quotes this case from SEGER, and adds that BAUHN had shown the specimen to him. BINNINGER (*Obs. et Curat. Med.*, 1673, p. 401), who adduces many observations from BARTHOLINUS, describes, in similar terms, an instance of a calculus formed about a ball. Had this been a distinct case, the omnivorous BONETUS would probably have recorded it. There may be added to these cases a very interesting observation by Dr. JAMES W. ROBINSON (*Medical Examiner*, 1855, Vol. XI, p. 328): A man of 35 years was shot through the sciatic notch, in Texas, in 1862, the missile lodging. He was treated, in hospitals in Cincinnati and Pittsburgh, for vesico-rectal fistula, and died in October, 1853. At the autopsy a large musket ball was found in the bladder, surrounded by a calcareous deposition four times as large as the ball. The specimen was in possession of Dr. ROBINSON, at Warfordsburg, Pennsylvania. MATTHEW (T. P.) (*Med. and Surg. History of the British Army in the Crimea*, Vol. II, p. 332) remarks that "in the 20th regimental hospital a musket ball was detected, during life, lodged in the urinary bladder, but the case speedily proved fatal."

of calculi formed about bone-fragments were shown to be less exceptional than recent authorities have supposed. Instances of the successful removal of such concretions by lithotomy, and *post-mortem* examples likewise were adduced.<sup>1</sup> A case of calculus consequent on shot injury, a tuft of hair the nucleus of the stone, was then quoted,<sup>2</sup> and operations for calculus of non-traumatic origin were adverted to. Reverting to shot injuries of the bladder, examples illustrating their pathological anatomy were presented; the paucity of the materials available on this topic being acknowledged. Since the remarks on page 290 were put in type, information has been received of the fatal termination of another case of this series, with the following notes of the autopsy:

CASE 827 (*Continued*).—Dr. A. Vanderveer, of Albany, states that pensioner Robinson died October 25, 1873, and avers that the direct cause of his death was penetrating gunshot wound of the bladder with a resulting fistula, attended with intense pain and cystitis. The same physician furnished the following report of an autopsy made by him twenty-four hours after death: "Wilson Robinson, aged 35, American. *Post-mortem* rigidity well marked. Bed-sore back of and below the trochanter major, on the right side. Cicatrix and mouth of fistula below Poupart's ligament near the pubic symphysis on the right side, one-third way from the symphysis pubis. Body much emaciated. The course of the ball was just below Poupart's ligament near the pubic symphysis on the right side, and passing through the horizontal ramus of the pubic bone entered the posterior portion of the bladder, passed out and through the tuberosity of the ischium on the left side, was then deflected upward, and finally lodged behind the trochanter major of the left femur, where it was found firmly encased in a fibrous covering. The bladder was divided in two parts by cicatricial tissue and fibrinous bands—apparently the portion of the bladder through which the ball had passed. The anterior half of the bladder contained a large calculus, the posterior portion a smaller one. The calculi were soft and phosphatic in character. The fistulous track on the right side connected with the bladder just in front of the opening of the right ureter by a small valvular orifice. The coats of the bladder were much thickened. The ureters were dilated so as to admit the passage of the little finger. The pelves of the kidneys were dilated, and there was slight contraction of the parenchyma; the general structure of the kidneys, however, was normal. The capsules were not adherent and tore up easily. The thoracic viscera were healthy. Encephalon not examined."

Injuries of the prostate were next briefly noticed, and eighteen pages were then devoted to an examination of wounds and diseases of the rectum.<sup>3</sup> In shot perforations of the rectum,<sup>4</sup> the advantages of following the analogy suggested by the treatment of anal fistules, by freely incising the sphincters, was insisted on. It was shown that the number of pensioners with traumatic stercoral fistules, or with stricture or paralysis of the rectum, was so large as to invite serious attention to this group of injuries. The fifth and last subdivision of the second section, on wounds of the pelvic blood-vessels and nerves, included abstracts of some remarkable operations on the great arterial trunks.

<sup>1</sup> Compare notes on pp. 277 and 284, and CASES 841 and 850. Professor BRENS, of Tübingen (*Über Schussverletzungen mit Eindringen von Fremdkörpern und nachträglicher Steinbildung, in Deutsche Zeitschrift für Chir.*, 1873, B. III, S. 520), cites the case of J. S.—, 2d Würtemberg regiment, shot at Bonheil, November 30, 1870. The ball entered immediately above the left pubic bone and escaped through the left buttock; urine issued from both orifices. Several small fragments of bone escaped from the anterior wound, but finally both wounds healed. On July 21, 1871, lateral lithotomy was performed, and a concretion removed, formed about a fragment of bone one by three centimetres. Among the detritus was found a bit of cloth from the uniform, a centimetre square. The patient was convalescent a fortnight after the operation. STROMEYER (L.) (*Handbuch der Chir.*, B. II, S. 712) states that he: "saw in the summer of 1865, in Professor ESMARCH's clinic, a young soldier from whose bladder the professor had removed, in a peculiar manner, a number of encrusted bone-splinters. The missile had comminuted the horizontal ramus of the left pubis, passed through the bladder and rectum, and escaped posteriorly. Dr. ESMARCH enlarged the deep narrow fistule above the ramus by the use of *laminaria digitata*, and removed, partly with forceps, partly by injections, in repeated operations, bone-splinters and encrustations, which filled a four-ounce glass. The injections were made, with the irrigator, by the urethra, forcing out water and small osseous fragments through the fistule."

<sup>2</sup> Examples of vesical calculi having nuclei of the epidermal tissues or appendages are exceedingly rare. KENMANN (*De calculis in corpore humano reperitis*, Tiguri, 1565, Cap. XI) relates that, in 1558, C. von Bernheim was shot in the bladder; urine escaped for eleven weeks through the wound, which then healed. Subsequently symptoms of calculus supervened, and lithotomy was practised, and a stone removed having a fragment of skin as a nucleus. "Purgata vesica, liberataque a reliquis sordibus, calculus, viscositate, sanie et aliis que de globo bombardico, lotii armonia consumpto, supererant et orificium vesicæ obstruxerant." The piece of skin was flexible, two straws thick, and the width of a finger. SCHENKLIUS (*l. c.*, p. 554) cites this case.

<sup>3</sup> Two patterns of an ingenious and convenient duck-bill speculum for exploration of the rectum, devised by Colonel J. H. BAXTER, Chief Medical Purveyor, U. S. A., were donated to the Museum (*Specimens* 6438, 6439, Ser. I, A. M. M.) too late for description in connection with this subject.

<sup>4</sup> Balls penetrating the rectum, or entering by ulcerative absorption, are sometimes passed at stool. CASE 169, p. 37, was possibly an example of this sort. Dr. W. F. THIBALLS (*Gunshot Wound in the Back—Bullet passed by Rectum Twenty-four Hours after, in The Cincinnati Lancet and Observer*, 1867, Vol. X, p. 664) relates the case of a negro, aged 18 years, shot December 21, 1866, through the transverse process of the third lumbar vertebra, the ball entering the rectum, and being discharged with the feces twenty-four hours afterward. In the *First Surgical Volume* (pp. 515, 508) instances are recorded of balls voided at stool, and in the preceding chapter of this volume (pp. 35, 37, and pp. 98-102, and notes on pp. 106-7) twenty-eight such instances are enumerated. Two of these were from GUTHRIE, though one of them was earlier described by HENNEN. GUTHRIE elsewhere relates yet a third case (*On Wounds and Injuries of the Abdomen and Pelvis*, 1847, p. 70, Case 112), in which the missile appears to have entered the rectum; a French soldier, wounded at Salamanca by a ball, which passed in by the side of the sacrum and lodged on the sixth day passed the missile by the anus. Thus there appear to be at least thirty recorded examples of war-projectiles voided at stool.



In the third section, after referring briefly to wounds of the penis,<sup>1</sup> wounds of the urethra were discussed in detail, the large number of pensioners with traumatic stricture or urinary fistules demanding special examination of this subject. The question of the propriety of maintaining a catheter after wounds of the urethra was discussed,<sup>2</sup> and the recent improvement in the treatment of urethral fistules by the use of the vesical siphon<sup>3</sup> was noted. In PLATE XII, opposite page 395, figures, copied from original plates, are grouped together to demonstrate the creditable share of American surgeons in advances in the operative surgery of the urethra.<sup>4</sup> It was suggested that the pension list indicated many cases of disability possibly susceptible of alleviation by urethroplasty. In the large group of cases of shot wounds of the testes, it was concluded that castration had not infrequently been resorted to unwisely. Complaints of neuralgia were made by many of the pensioners invalided for injury of the testes.<sup>5</sup> The cases of hydrocele,<sup>6</sup> cirsocele, and diseases of the testes were simply enumerated. It was shown that injuries of the pelvis were deserving a separate consideration, and that the gravity of shot wounds in this region had been exaggerated by many writers, conclusions in the main confirmed by the researches of writers on the surgery of the latest European war.<sup>7</sup>

<sup>1</sup>Space was not found on the pages devoted to wounds of the penis for an enumeration of the pathological preparations illustrating this subject in the Army Medical Museum and in other collections. In SECTION I, A. M. M., *Specimens* 3000, 3010, 3017, are groups of prepuces "amputated for syphilis," and contributed by Acting Assistant Surgeon R. THOMAS (*Cat., l. c.*, p. 494). No. 1645 is an amputated penis, studded with venereal warts, donated by Acting Assistant Surgeon T. H. STILLWELL. No. 4843 is a penis affected with cancer, amputated in 1870, by Dr. R. K. STONE. No. 4844 is a fine illustration of the effects of rupture of the urethra. No. 5463 is a portion of the penis affected by epithelioma, and amputated, in 1868 (prior to the notoriety of eundurango), by Dr. D. W. BLISS. In the Pennsylvania Hospital Museum (*Cat.* 1869, p. 110), Specimen 1680 is the "self-amputated penis of a man of 59 years. In the Museum of the Boston Society for Medical Improvement (*Cat.* 1847, p. 221), Specimen 705 is a penis studded with venereal warts and affected with phymosis, and amputated by Dr. C. H. STEADMAN. Specimens 706, 707, 708, of the same collection, illustrate removals of the penis for cancer or for syphilis. In Guy's Hospital Museum (*Cat.* 1857, Vol. II, p. 148), Specimen 2427<sup>0</sup> consists of the penis and testes of a man, extirpated by himself, from religious motives. (See the Gospel according to St. MATTHEW, *Chap.* XIX, 12.) In the Museum of St. Bartholomew's Hospital (*Cat.* 1846, Vol. I, p. 413), Specimen 38 of Series XXX is a prepuce affected by epithelioma. A penis, removed by self-mutilation, is preserved (Series XIII, Specimen 1) in the Museum of St. George's Hospital (*Cat.* 1866, p. 576). A number of preparations of portions of the penis amputated for disease may be found in the Museum of the Royal College of Surgeons of England (*Disc. Cat.*, 1849, Vol. IV, p. 383 *et seq.*).

<sup>2</sup>In a dissertation published in 1873 (*Inconvénients des sondes à demeure*), M. J. A. QUIROS presents the following conclusions, which probably express the views taught at present in the school of Paris: 1. "Si, dans certains cas, on est obligé de laisser un corps étranger dans l'urèthre, il faut le faire le moins possible et employer des sondes souples. 2. Dans les cas de maladie de la prostate et de la vessie, qui exigent l'emploi de ces instruments, il faut préférer, s'il est possible, que les malades se sondent eux-mêmes toutes les fois que cela devient nécessaire. 3. Laisser après les opérations pratiquées sur le canal, la sonde le moins longtemps possible et se servir des instruments qui ne forcent pas l'urèthre. 4. Préférer, dans les cas des fistules urétrales, le cathétérisme répété, s'il était possible. 5. Dans les rétrécissements, la dilatation arrivée à un certain degré, il faut cesser la dilatation permanente, et avoir recours soit à la dilatation temporaire, à l'uréthrotomie ou à la division, selon les cas."

<sup>3</sup>GRIPAT, *Du siphon vésical dans le traitement des fistules urinaires*, Paris, 1873.

<sup>4</sup>Some American contributions on genito-urinary surgery are referred to in notes on pp. 398 and 400. Among many other papers may be consulted: BLISS (J. C.) (*A Dissertation on Permanent Strictures of the Urethra*, New York, 1815); M'JUNKIN (J. B.) (*Case of Wound of the Genitals*, in *Am. Jour. Med. Sci.*, 1834, Vol. XV, p. 123); BETTON (TH. F.) (*Laceration of the Urethra from a Fall on the Perineum, with consequent Retention of Urine, for which Operation of Puncturing the Bladder was performed*, *ibid.*, 1836, Vol. XIX, p. 389); HAYS (I. L.) (*On Laceration of the Urethra*, *ibid.*, 1836, p. 392); MORRISON (M.) (*Urinary Fistula*, *ibid.*, 1838, Vol. XXII, p. 323); ANNAN (S.) (*Laceration of Urethra*, *ibid.*, 1839, Vol. XXIV, p. 314); SMITH (N. R.) (*Paracentesis vesicae for Relief of Suppression caused by Rupture of the Urethra*, *ibid.*, 1833, Vol. XXIII, p. 63); NORRIS (G. W.) (*Fistula in Perineo, following a Fall—Operation—Cure*, *ibid.*, 1843, N. S., Vol. V, p. 21); ATLEE (W. L.) (*Two Cases of Perical Operation on the Urethra*, *ibid.*, 1844, N. S., Vol. VIII, p. 358); RUSCHENBERGER (W. S. W.) (*Fracture of the Penis*, *ibid.*, 1849, Vol. XVII, N. S., p. 410). BURLINGHAM (H. D.) (*Compound Fracture of the Sacrum, followed by Discharge of Urine through the Wound: Recovery*, *ibid.*, 1868, N. S., Vol. LV, p. 362); SEELYE (S. D.) (*Fracture of Pelvis at Symphysis Pubis and Rupture of Bladder*, *ibid.*, 1868, N. S., Vol. LV, p. 111); MASON (E.) (*Stricture of the Urethra; Breaking of a Bougie in the Urethra; Perineal Section and Median Operation as for Stone, with Extraction of Bougie from the Bladder*, *ibid.*, 1869, N. S., Vol. LVIII, p. 391); GAY (G. W.) (*Stricture of the Urethra; Retention; Perineal Section*, in *Boston Med. and Surg. Jour.*, 1874, Vol. XC, p. 133); HODGES (J. T.) (*Gunsbot Wound through the Perineum*, in *The Medical Archives*, 1870, Vol. IV, p. 3-); SNEED (W. J.) (*Stricture of the Urethra—Internal Urethrotomy*, in *Nashville Jour. of Med. and Surg.*, 1873, Vol. XII, p. 275).

<sup>5</sup>ASHHURST (J.) (*The Princ. and Pract. of Surgery*, 1871, p. 929) states that galvanism has proved serviceable in such cases. Consult SARRAU (J.) (*Essai sur la névralgie du testicule*, Thèse, Paris, 1841); LAZARUS (J.) (*Über Neuralgie des Hodens*, in *Wiener Med. Presse*, 1872, No. 30); LABOUBÈNE (*Névralgies viscérales*, Paris, 1860); VAN BUREN (W. II.); KEYES (E. L.) (*A Practical Treatise on Surgical Diseases of the Genito-Urinary Organs*, 1874, p. 445); CULLERIER et RATIER (*Article Hémoorrhagie*, in *Dict. de méd. et de chir. prat.*, 1830, T. IV, p. 158).

<sup>6</sup>Sir A. COOPER (*Lect.*, etc., 1825, Vol. II, p. 92) gives the average quantity of fluid in hydrocele as from six to eight ounces, and adds: "The largest hydrocele I have heard of was that of Mr. GIBBON, the historian, from whom Mr. CLINE drew off six quarts of fluid."

<sup>7</sup>Thus, FISCHER (H.) (*Kriegschir. Erf.*, 1872, S. 136) says: "We have nothing essential to remark regarding the treatment of shot fractures of the pelvis, but were astonished at the large number of cases of severe shot injuries of the pelvis we observed while stationed at the Berlin barracks, the men returning from France completely cured. Among them were cases of recoveries where both bladder and rectum were injured. Therefore in such cases it is well not to despond too early." And SOGIN (*Kriegschir. Erf.*, 1872, S. 99) concludes: "On the whole, the results in cases of penetrating shot wounds of the pelvis and of fractures of the pelvis were much better than I had *a priori* anticipated. The treatment, though most carefully supervised, was extremely simple. In every instance, we endeavored to place the wounded man in such a position as to facilitate a continuous spontaneous discharge from the wound, and to avoid all obstructive dressings. This is frequently difficult of accomplishment; but, in these cases, the surgeon must not tire until he procures for each individual patient a well-upholstered mattress, cut out according to the seat of injury, and protected from infiltration of pus."

## CHAPTER VIII.

### FLESH WOUNDS OF THE BACK.

Before passing from the injuries of the trunk to the discussion of those of the extremities, it is necessary to refer briefly to wounds of the soft parts of the back.<sup>1</sup> Reference to this class of injuries would have been made in the fourth chapter of the *First Surgical Volume*, had it been practicable to sift the returns in season. As remarked already, on page 209, many cases recorded as "shot wounds of the back" were found to be, in reality, penetrations of the thoracic or abdominal cavities. It was determined, therefore, to reserve the cases of injuries of the dorsal soft parts,<sup>2</sup> and to advert to them together with cases of injury unattended by fracture of the hips and buttocks. As Dr. Matthew has remarked,<sup>3</sup> the limits of this group of injuries are not very clearly defined in the nosologies. It has been sought to include in this series the cases of wounds in the regions covered by the trapezius, latissimus dorsi, and gluteal muscles, that were not complicated by fractures or penetrations of the great cavities. These constituted from four to six per centum of the total number<sup>4</sup> of wounds received in action.

<sup>1</sup> Back (*bac* or *bæc*, Saxon; according to CRAIG and WORCESTER); German, *bach*; modern German, *Rücken*; Greek, *ῥωτός*; Latin, *dorsum*, *tergum*; French, *dos*; Italian, *dosso*. PEVET (*Diet. des Sci. Méd.*, T. X, p. 151, Art. *Dos*) says: "Le dos est une des parties du corps les moins exposées aux maladies: les plaies de cette partie sont peu graves, toutes les fois qu'elles ne pénètrent point dans l'intérieur de la poitrine ou de l'abdomen, ou qu'elles n'ont point atteint la moelle épinière; elles ne présentent d'ailleurs aucune indication particulière."

<sup>2</sup> HIPPOCRATES (ΠΕΡΙ ΕΑΚΩΝ, *Œuvres Complètes*, éd. LITTRÉ, 1849, T. VI, p. 429), in the twenty-third section of his work on wounds, treats briefly of those of the back, referring almost exclusively to those inflicted by the lash. After lacerations of the back by fustigation or other causes, he commends the application of cataplasms of boiled onions or squills, and, later, an ointment of goat's grease, or fresh lard, with oil, resin, and a salt of copper. Flogging in the United States Army was abolished by an act of Congress approved August 5, 1861, promulgated in General Order 49, for that year, of the War Department. Section 3 of the act reads: "And be it further enacted, That flogging, as a punishment in the Army, is hereby abolished." As indicated by a foot-note to the 87th ARTICLE OF WAR, "the infliction of corporeal punishment by stripes or lashes was forbidden by Act of May 16, 1812; but by Act of March 2, 1831, flogging was again officially authorized in cases of desertion. Flogging in the Navy was abolished September 28, 1850 (*Stat. at Large*, Vol. IX, p. 513).

<sup>3</sup> Dr. T. P. MATTHEW, the official annualist of the surgery of the British Army in the Crimea, records (*op. cit.*, Vol. II, p. 336) 323 cases of slight and severe "simple flesh contusions and wounds," with twenty deaths, under the head of "gunshot wounds of the back and spine." These 323 instances are from an aggregate of 7,669 determined cases. The proportion of shot flesh wounds of the back was, therefore, in this series, 4.21 per cent. DEMME (*Mil. chir. Studien*, 1861, B. I, S. 19), whose figures are so often to be skeptically regarded, states that, in the Italian War of 1859, among 8,500 wounded Austrians, 345 cases of wounds of the back and buttock were observed, or 4 per cent.; and among 8,595 wounded French, there were 170 cases of lesions of the back or buttocks, or 2 per cent. FISCHER (II.) (*Kriegschir. Erfahrungen*, 1872, S. 28) tabulates 20 cases of shot wounds of the back in a total of 875 wounded before Metz, or 2.2 per cent. MOYAT (*Med. and Surg. Hist. of New Zealand War*, in the British army medical report for 1865, p. 474) gives 17 cases of "wounds of muscles of the back" in a total of 415 wounded, or 4.0 per cent. MASSAKOWSKY (P.) (*Statistischer Bericht über 1415 Französische Invaliden des deutsch-französischen Krieges, 1870-71*) states: "Ninety-three cases of injuries of the pelvis were observed, of which fifty-six (or 4.9 per cent.) were injuries of the external soft parts, all implicating the buttocks, and in four instances perforating the latter from side to side. Some cases of large loss of substance from lacerations by shell fragments were worthy of mention. Four of these were really remarkable, for, notwithstanding the magnitude of the lesions, there was little general constitutional disturbance. I saw no instance in which the wounds had entirely healed, though cicatrization was rapidly going on in all. In four cases, the sciatic nerve was injured, with paralysis of the parts supplied by it." STEINBERG (*Die Kriegslazarethe und Baracken von Berlin*, 1872, S. 146) tabulates 8,531 cases of wounds treated in the Berlin Hospital in 1871-72, of which number 823, or 9.6 per cent., were flesh wounds of the trunk. It is fair to conclude that about one-half of these, or 4.8 per cent., were flesh wounds of the posterior parts.

<sup>4</sup> In a *Consolidated Statement of Gunshot Wounds* (Circular No. 9, S. G. O., July 1, 1863), Surgeon J. H. BRINTON, U. S. V., records the cases of shot flesh wounds of the *Trunk*, treated in the U. S. A. General Hospitals for the last four months of 1862, as 2,190 in number. Of these wounded, 91 died, 220 were discharged, 50 deserted, 76 were furloughed, 12 were exchanged, 686 were sent to duty, and 1,055 remained under treatment. The regions of the trunk implicated in these cases were not specified. The unpublished *Consolidated Statements* for the quarter ending March 31, 1863, give 2,280 "gunshot flesh wounds of the trunk," of which 49 were fatal. Of these wounded, 559 were sent to duty, and 187 were discharged; 617 are accounted for by furlough, transfer, and desertion, and 877 remained under treatment. The *Consolidated Statements* for the quarter ending June 30, 1863, present 2,060 cases of shot wounds of the trunk, with 50 fatal cases, 81 discharges, 574 transfers, furloughs, or desertions, 381 cases duly cured and returned to duty, and 971 cases remaining under treatment. It is obvious that more than a third of the cases in these numerical statements were liable to be counted over again in each quarterly return. The totals were, for the three quarters, 24,936, 22,657, and 25,334, and the percentages 10.4, 10.0, and 8.1, and, if half of the cases referred to the posterior part of the trunk, a proportion closely approximating that deduced from other sources is reached.



On the classified returns of wounds and injuries, on the form printed on page XV of the *Introduction to the First Surgical Volume*, returns made with approximate completeness during the last year of the war only, about six per centum of the aggregate<sup>1</sup> of cases were entered as "flesh wounds of the back and hips." Extracts from the greater number of these returns are consolidated in the following table:

TABLE X.

*Partial Numerical Statement of Shot Wounds of the Back and Hips, in the Field or Primary Hospitals in various Campaigns, during the last Year of the War of the Rebellion, 1864-65.*

BATTLE, ACTION, OR SERIES OF ENGAGEMENTS.  Names or Dates.	WOUNDS OF THE BACK AND HIPS.		MISSILES.		TOTAL WOUNDED.	PERCENTAGE OF WOUNDS OF THE BACK AND HIPS.
	Cases.	Deaths.	Large projectiles, cannon shot, shell, and bomb fragments, grape, and caustic.	Small projectiles, musket, carbine, rifle, pistol balls, and small missiles from shrapnel and canister.		
Army of the Potomac from May 4 to August 31, 1864.....	2,485	31	318	2,120	38,944	6.38+
Armies of the Cumberland, Tennessee, and Ohio during the campaign to Atlanta, from May 4 to September 8, 1864.....	1,336	32	175	1,116	23,308	5.73+
Armies of the Cumberland, Tennessee, and Ohio, and Cavalry, during General Hood's invasion of Tennessee, from October 25 to December 31, 1864.....	143	1	26	116	3,610	3.96+
General Sherman's campaign in 1865 through the Carolinas.....	91	2	.....	88	1,533	5.93+
Armies of the James and Ohio, etc., from Fort Fisher to Goldsboro', N. C., 1865....	51	2	8	30	1,075	4.74+
Army of the West Mississippi during the siege of Mobile, from March 26 to April 9, 1865.	68	1	23	41	2,111	3.22+
Army of the James during General Grant's campaign against Petersburg, from May 4, 1864, to April 9, 1865.....	909	14	180	696	16,120	5.63+
Engagements in the Shenandoah Valley, May 4 to Aug. 30, 1864.....	180	2	10	76	2,196	8.19+
Campaign in the Shenandoah Valley, Aug. 21 to Dec. 30, 1864.....	589	11	72	507	7,542	7.80+
Army of the Potomac from Sept. 1, 1864, to April 9, 1865.....	741	12	79	596	10,467	0.71+
Aggregate.....	6,593	108	891	5,386	106,846	6.17+

The total number of cases of shot wounds of the back (not implicating the spine or the thoracic or abdominal cavities) reported are summed up in the following table:

TABLE XI.

*Tabular Statement of Twelve Thousand Six Hundred and Eighty-one Cases of Gunshot Flesh Wounds of the Back.*

SEAT OF INJURY.	CASES.	DIED.	DISCHARGED.	DUTY.	UNKNOWN.
Returned as flesh wounds of the back, without other specification.....	3,486	172	383	2,641	290
Specified as over posterior thoracic region.....	990	51	162	724	53
Specified as over lumbar or posterior abdominal region.....	698	51	125	495	27
Returned as wounds of hips, buttocks, nates, or gluteal region.....	7,507	526	1,056	5,297	628
Aggregate.....	12,681	800	1,726	9,157	998

The returns conform closely to what might be inferred *a priori*, from the extent of surface exposed, as to the frequency of shot wounds of the fleshy parts of the thoracic,

<sup>1</sup>The conclusions in the preliminary surgical reports in Circular No. 6, S. G. O., 1865, were based on an analysis of 87,822 cases of wounds and injuries. Of these, 5,195 cases were classified as "gunshot wounds of the back." The aggregate of cases of shot wounds treated during the war of the rebellion, now tabulated on the registers of the Surgeon General's Office, with some approximation to precision, numbers 253,142, of which 12,681 are tabulated as gunshot wounds of the back, the percentage of cases referred to this category being five and three-quarters and five in the two counts.

lumbar, and gluteal regions of the back. Flesh wounds of the back, other than those inflicted by shot, and enumerated in the table, were uncommon.

*Punctured and Incised Wounds of the Back* were exemplified by fifty-six instances, of which twenty-one were cases of bayonet stabs, thirteen of sabre cuts,<sup>1</sup> and twenty-two of punctures or incisions by sundry weapons. None of these cases are recorded as terminating fatally, though in six the result has not been ascertained; forty-five were sent to duty, and five were discharged. Several of these cases were examples of severe, though not dangerous, sword wounds.<sup>2</sup>

*Shot Wounds of the Back* involving only the soft parts<sup>3</sup> were seldom mortal unless pyæmia or tetanus supervened, or some maltreated arterial bleeding. As the men were often ordered to lie down under artillery fire, large lacerations of the dorsal region were not infrequent. Commonly they healed rapidly:

CASE 1228.—Private Frederick S——, Co. A, 149th Pennsylvania, aged 19 years, was wounded July 13, 1864, in the entrenched lines before Petersburg, on the Fifth Corps front, by a large shell fragment, which tore away the dorsal integuments over a space at least six by eight inches, and severely lacerated the subjacent muscles, without injury, however, to the ribs or spine. Surgeon W. R. DeWitt, U. S. V., rendered the first attention to the patient. There was no bleeding, and the shock was comparatively slight, and, after taking restoratives and having the raw surfaces covered by a water dressing, the wounded man was taken to City Point. Here he was placed in the Fifth Corps Hospital, under the care of Surgeon W. L. Faxon, 32d Massachusetts. Here a colored drawing of the laceration was made by Hospital Steward Stauch, at that time detailed by Surgeon J. H. Brinton, at the hospitals of the Army of the Potomac, for the purpose of securing drawings of recent injuries. Only such tissues sloughed as were utterly disorganized by the projectile, and the large lacerated surface soon granulated kindly, so that after a month the patient was in a condition to be transferred northward, and entered the Whitehall Hospital, at Bristol, Pennsylvania, on August 15, 1864. Cicatrization progressed rapidly, and Assistant Surgeon W. H. Forwood, U. S. A., reported that the patient was furloughed on September 12, and readmitted on October 4, 1864, fairly convalescent. On January 23, 1865, this soldier was sent for modified duty in the Veteran Reserves, and on June 24, 1865, he was mustered out of service. From the pension record, it is inferred that neither this man nor his relatives have made application for pension. The accompanying wood cut (FIG. 360) is copied from the drawing by Stauch.

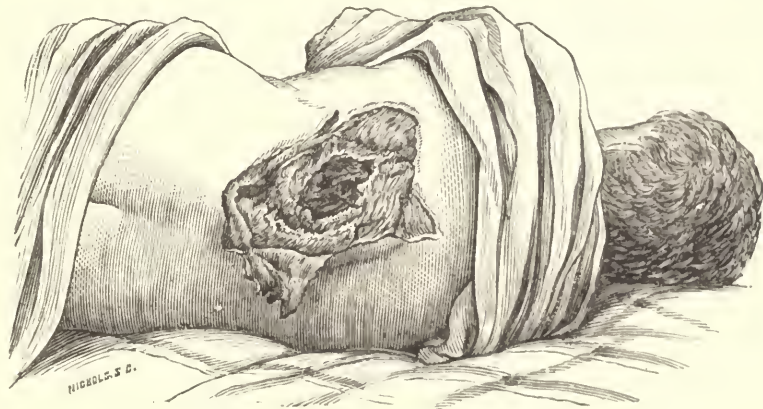

FIG. 360.—Laceration of the back by a shell fragment.

Sometimes, on the contrary, the reparative process was very slow after such lacerations, as would be anticipated from the nature of the vascular supply in this region.

<sup>1</sup> Of the thirteen reported cases of sabre wounds of the back, twelve were received in action, as follows: Pt. T. O'Rourke, K, 6th Pennsylvania Cavalry, Brandy Station, August 1st; duty, August 18, 1863. G. Radebaugh, H, 13th Pennsylvania Cavalry, Winchester, June 15, 1863; duty. Pt. J. Barber, K, 1st Colored Troops, September 30, 1864; duty. Pt. J. Jones, H, 11th Pennsylvania Cavalry, near Richmond, October 17, 1864; discharged. Pt. W. H. Cheeny, H, 5th Connecticut, Savannah, December 10, 1864; duty. Corporal H. H. Brownsmiller, H, 1st Pennsylvania Cavalry, Jetersville, April 5, 1864; discharged. Lieut. J. M. Corns, E, 2d West Virginia Cavalry, Five Forks, April 1st; duty, April 22, 1865. Pt. T. Gray, F, 2d West Virginia Cavalry, Five Forks, April 1st; duty, April 18, 1865. Pt. P. Gallagher, I, 9th Massachusetts, Gettysburg, July 24; duty, September 8, 1863. Serg't. T. Taylor, B, 10th New York Cavalry, Brandy Station, June 9th; duty, August 16, 1863. Pt. T. Dewyer, 4th Michigan, Fort Donelson; duty. Pt. C. A. Woods, A, 1st Pennsylvania Artillery, Petersburg, July 1, 1864; discharged. The bayonet stabs appear to have been inflicted, for the most part, by sentries or provost's guards, or in brawls, or through accident. One example only is specified as a wound received in action, and in this single case it does not clearly appear that the wound was inflicted by the enemy.

<sup>2</sup> Sabre wounds of the back are seldom referred to. BELGUER (*Chir. Wahrnehmungen*, 1763, S. 433) gives an instance in the Seven Years War (1756-63): A cavalryman, J. R —, retreating and leaning over his horse's neck, received two severe sword-cuts in the lumbar region. MORGAGNI (*De sed. et caus.*, 1765, Ep. LIII, p. 270) records an autopsy in a case of sabre-thrust in the back. A report by Surgeon S. W. GROSS, U. S. V. (*Am. Med. Times*, 1864, Vol. VII, p. 126), of a sword-stab in the left flank, penetrating the descending colon, has already been alluded to on page 75 *ante*.

<sup>3</sup> STROMEYER (*Maximen der Kriegsheilkunst*, 1855, S. 673) observes: "Shot wounds of the soft parts of the back have not an especial tendency to suppuration. But in long s-ton wounds it frequently occurs that they heal, and reopen after months and form a fluctuating tumor, which must be opened, as the thick skin of the back is only slowly perforated by the serous substance. Many surgeons err in trying to relieve the ailment by several small incisions or even punctures parallel to the spine; these afford no relief, and it is absolutely necessary to make an incision of several inches in length at a right angle to the spine."



There were some curious instances of long circuitous ball-tracks, and among the fatal cases were noted several in which the projectiles had lodged under the scapula. Other conditions being equal, flesh wounds in the flanks and buttocks had more gravity than those in the upper dorsal region.<sup>1</sup> In cases where large portions of muscles were torn away,<sup>2</sup> cicatrization was sometimes protracted for years:

CASE 1229.—Private John A. Tucker, Co. E, 17th Maine, aged 20 years, was wounded, by the explosion of a shell, at the battle of Chancellorsville, May 3, 1863. The integuments over the gluteal and lumbar regions were torn away, and, on the right side, a large portion of the gluteal muscles was removed. He was treated by Surgeon G. L. Welling, 11th New Jersey, at a hospital of the Ninth Corps, until reaction took place, when he was sent to Armory Square Hospital, at Washington, on May 8th. He suffered but little pain, and his appetite was good. He was ordered the best of diet, with porter; lint wet with a disinfectant lotion to the wound and an anodyne at night. The patient did well till the forenoon of May 15th, when he

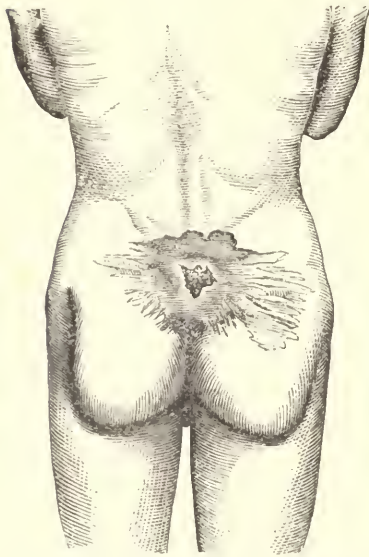


FIG. 361.—Appearance, nine years subsequent to the reception of the injury, of the ulcerated cicatrix of the wound depicted in PLATE IX. [From a photograph.]

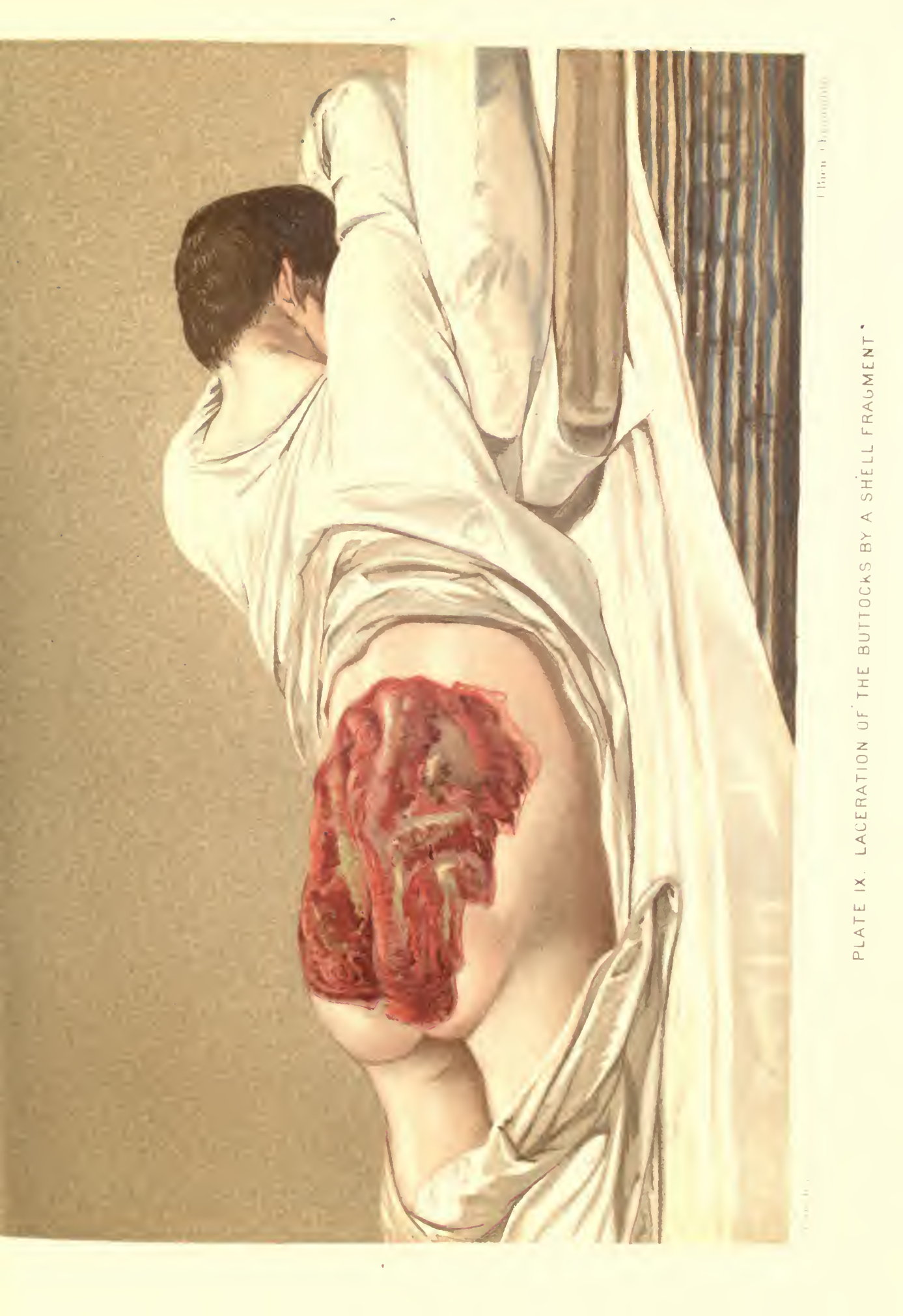complained of inability to separate his jaws, and of stiffness of the muscles of the neck. He took a full dose of morphia, but on the following day the trismus was more confirmed, and there was slight opisthotonos. The report makes the contradictory statement that there was no spasmodic action of the muscles. No trouble in deglutition or respiration. Turpentine stupes were applied to the neck, and the fourth of a grain of sulphate of morphia was given every four hours, with milk-punch. On May 15th, the jaws could be separated more, and there was less stiffness about the neck. On the 20th, there were frequent involuntary twitchings of the dorsal muscles. The wound was more painful. It was dressed with olive oil on cotton batting, and, later in the day, with a solution of morphia. The internal administration of morphia was continued. On the 21st and 22d, the symptoms continued to amend. The patient could separate his jaws and protrude his tongue. He had a fourth of a grain of sulphate of morphia every hour, applications of ice to the spine, and the wound was dressed every six hours with a lotion containing six grains of morphia. On the 22d, there was a dejection from the bowels. From this date the patient steadily improved. On July 10th, he received a furlough. He returned to the hospital on November 24, 1863. December 5, 1863, he was examined by Surgeon J. H. Brinton, U. S. V. The wound had cicatrized, except over a space the size of the palm of the hand, which surface was granulating kindly. The right buttock was flattened and wasted. The gait was feeble and uncertain. The general health appeared to be good. Very soon after the reception of the injury a colored drawing of the huge wound, which is very accurately reproduced in the chromolithograph opposite (PLATE IX), was executed by Hospital Steward Stauch, under Dr. Brinton's supervision. This soldier was discharged December 15, 1863, and pensioned. Examiner J. H. Jewett, of South Berwick, Maine, reported, November 30, 1870: "A shell wound over sacrum, of large extent; is not so well as formerly; the wound over the sacrum shows no disposition to heal, and in all probability will

remain an open ulcer. His weight is 130 pounds, the pulse 70, the respiration normal; disability total." In 1871, the editor of these pages addressed a note of enquiry to Mr. Tucker regarding the condition of his wound. His attorney, Mr. G. C. Yeaton, courteously responded to this letter, and transmitted a photograph and diagram of the cicatrix, which then bounded an irregular granulating surface three inches wide by two inches in height. The photograph is reproduced in the wood-cut (FIG. 361). For a long time the granulations on this raw surface had been indolent, and cicatrization had made no progress; there were no sinuses or fistulous tracks to indicate the existence of diseased bone or other internal cause of irritation. The invalid's general health was satisfactory. He described the discharge from the ulcer as "thick and creamy." The editor advised that M. Reverdin's plan of skin-grafting, on which Messrs. Bryant and Pollock had latterly reported so favorably, should be resorted to, but has not been informed whether this advice was followed.

The transplantation of portions of skin to facilitate the cicatrization of large granulating surfaces must be regarded, I think, as a very important modern advance in surgery, "rendering," as Mr. Bryant expresses it, "many cases curable that were not so previously, and facilitating the cure of as many more."

<sup>1</sup> BECK (B) (*Chir. der Schussverletzung* n, 1872, S. 448) is one of the few writers on military surgery who speak, at any length, of shot wounds of the soft parts of the dorsal region. He remarks, in substance, that when the fleshy covering of the back is injured, much depends on the depth to which the laceration of the muscles extends, the length of the shot channel, the amount of emulsion (as from large shot or shell fragments), or the degree of implication of the ribs or spine. Shot wounds limited to the areolar tissues and muscles mainly were of no special interest, unless attended by exceedingly large loss of substance or by a very long spongy ball track. Cases in which blood-vessels of the larger order and main branches of the nerves were contused or lacerated were more serious. The functions of the dorsal muscles were, in some cases, much impaired by shot lacerations. Many invalids of this class were unable to move freely, and complained of difficulty in breathing, stooping, turning the head; complications due, unquestionably, to cicatrices resulting from lacerated shot wounds that had either been attended by sloughing or had required incisions to relieve deep suppuration.

<sup>2</sup> FISCHER (G.) (*Dorf Floing und Schloss Vergaills*, in *Deutsche Zeitschrift für Chir.*, 1872, B. 1, S. 138) cites the case of a French soldier, who, while kneeling, was struck by a rolling cannon ball which tore away a piece of the buttocks the size of a dinner plate. In another instance, a piece as large as a man's hand was carried away. In both cases luxuriant granulations sprang up, and complete recoveries were to be expected.



J. Bern - (Lyon 1886)

PLATE IX. LACERATION OF THE BUTTOCKS BY A SHELL FRAGMENT.

1886





The value of M. Reverdin's interesting discovery<sup>1</sup> has been experimentally substantiated by Drs. Hodgen, Brinton, and others, in this country, and by Messrs. Pollock, Bryant, and others, in England. A wood-cut illustrating one of Dr. Hodgen's cases is

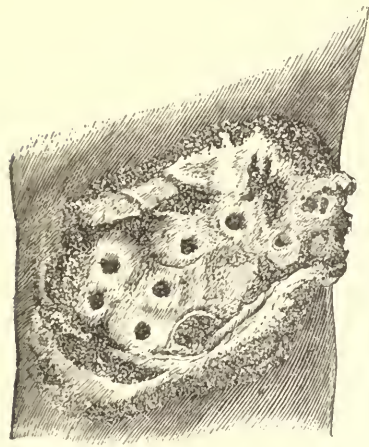


FIG. 362.—Skin grafting. [After HODGEN.]

copied in FIGURE 362, and FIGURE 363 is borrowed from Mr. Bryant. The two last-named surgeons have published very interesting accounts of the details of the different plans of skin grafting, with ingenious observations on the best methods of establishing centres of "cutification." FIGURE 361 represents the scissors recommended by Mr. Bryant for the removal of the sound skin. In a number of cases on the pension rolls, of indolent ulcers consequent upon extensive loss of tissue, there




FIG. 363.—Skin grafting. [After BRYANT.]

can be no doubt that this method of skin transplantation would prove invaluable. There are several examples, analogous to that detailed on the preceding page, of what would be termed healthy granulating surfaces remaining open for as long a period as ten years.

<sup>1</sup>M. REVERDIN made, November 24, 1869, at the Necker Hospital, in Paris, the successful experiment of transplanting two small portions of skin, taken from the right arm of a man thirty-five years of age, to a granulating ulcer on the left fore-arm of the same individual, the result of a laceration incurred in falling from a scaffold on October 16, 1869. The ulcer healed under this treatment, and on December 15, 1869, M. GUYON, in whose service the case was treated, read to the Surgical Society of Paris an account of this brilliant achievement, under the title: *Grefe épidermique*, *Bull. de la Soc. de Chir.*, December, 1869; *Gaz. des Hôp.*, Janvier 11, 1870, p. 15. In May, 1870, Mr. G. D. POLLOCK, of St. George's Hospital, London, followed this novel method of treatment, in the case of a girl of eight years, with a huge indolent ulcer of the thigh, resulting from a burn. Various modes of treatment, local and general, had been pursued, without any diminution of the unhealed surface, when the plan of transplantation of bits of skin from the abdomen was resorted to, with such signal success that a similar treatment was adopted in fourteen other cases. (*The Lancet*, 1870, Vol. II, pp. 680, 686, 707, and *Transactions of the Clinical Society*, 1871, Vol. IV, p. 37.) The *Transactions of the Clinical Society* for 1870, besides Mr. POLLOCK'S important paper, contains a report by Mr. G. LAWSON (*On the Transplantation of Portions of Skin for the Closure of large Granulating Surfaces*). The practice very soon became established as a great boon in the management of ulcers. In this country, Professor CHISOLM (*Skin Grafting*, in *Baltimore Med. Jour.*, 1870, Vol. I, p. 586), Dr. J. H. BRINTON (*The Med. and Surg. Rep.*, 1871, Vol. XXIV, p. 73), Drs. PORTER and COOLIDGE (*Epidermic Engrafting*, in *Rep. of Soc. for Med. Improvement*, in *Boston Med. and Surg. Jour.*, 1870, Vol. VI, p. 344), Dr. H. R. WILLIAMS (*On Healing Ulcers by Transplantation*, in *New York Med. Gaz.*, December 3, 1870), Messrs. BELT, HANDY, and BOLLES (*Cases of Transplantation of Skin*, in *Boston Med. and Surg. Jour.*, 1870, Vol. VI, p. 389), and many others, hastened to repeat M. REVERDIN'S experiment. Abroad, the practice was early imitated by Mr. STEELE (*On Transplantation of Skin*, in *Brit. Med. Jour.*, 1870, Vol. II, p. 621), Mr. PAGE (*Obs. on the true Nature of the so-called Skin Grafting*, *ibid.*, p. 655), Dr. MACLEOD (*Transplantation of Skin*, in *Glasgow Med. Jour.*, 1870-71, Vol. III, p. 339), FORT (*La greffe épidermique*, in *Gaz. des Hôp.*, 1870, No. 87, et *Gaz. méd. de Paris*, 1871, No. 41), PONCET (*Des greffes dermo-épidermiques*, *Lyon Medical*, 1871, Nos. 22 and 23), HOFMOKL (*Über Überpflanzung von Hautstücken*, in *Wiener Med. Presse*, 1871, No. 12), HEIBERG and SCHULZ (*Einiges über Hautverpflanzung*, in *Berlin Klin. Wochenschrift*, 1871, No. 10), LINDENBAUM (*Über die Transplantation*, n. s. w., *ibid.*, 1871, No. 11), NETOLITZKY (*Zur Casuistik der Hauttransplantation*, in *Wiener med. Wochenschrift*, 1871, No. 34). Many other references may be found in a summary in the *Biennial Retrospect*, 1871, Vol. I, p. 233, of the New Sydenham Society's publications, among which may be noted papers by DOBSON (*Med. Times and Gaz.*, Oct. 29, 1870, Vol. II, p. 500), GOLDIE (R. W.) (*Skin Grafting*, *Lancet*, 1871, Vol. I, p. 47), WOOD (M. A.) (*Skin Grafting*, *Brit. Med. Jour.*, 1871, Vol. I, p. 446), WILSON (W.) (*Remarks on Skin Grafting*, *Glasgow Med. Jour.*, 1871, p. 341). Professor FRANK H. HAMILTON (*Healing Wounds by Transplantation*, in *The Medical Gazette*, New York, 1870, Vol. V, p. 138) draws attention to a plastic operation proposed by him in 1845 (*Buffalo Med. and Surg. Jour.*, June, 1847, Vol. II, p. 308), in the case of a lad of 15, with an ulcer of the right calf and thigh. The plan had in view the "planting upon the centre of the ulcer a piece of new and perfectly healthy skin," taken "from the calf of the other leg (having secured the two together)." Dr. HAMILTON is reported as claiming the suggestion, "whether it be regarded as good or bad, as his own, viz.: the application of the plastic operation to old and indolent ulcers: yet he will postpone getting it patented until he learns how his Boston friends get along with their other patent." No operation was done in this case; but Dr. HAMILTON refers to an instance in which he successfully practised an operation of this nature, in 1854, in the case of Driscoll, an Irish laborer, the operation having been fully described in a paper entitled: "*Eltoplasty* (*ελεος*, ulcer, and *πλαστω*), or, *Old Ule rs treated by Anaplasty*," in the *New York Jour. of Med.*, 1854, Vol. XIII, N. S., p. 165. M. OLLER (*Lyon Médical*, 1872, T. IX, p. 464) regards Dr. HAMILTON as having anticipated M. REVERDIN'S discovery. On the other hand, Dr. JOHN WATSON (*Reclamation on the Treatment of Ulcers by Anaplasty*, in *New York Jour. of Med.*, 1854, Vol. XIII, p. 360) states that Dr. HAMILTON'S proposal had been by him "anticipated, on at least two occasions," citing an article in the *American Journal of the Medical Sciences*, 1844, Vol. VIII, p. 537, and his remarks on "*Atopoplasty*, or *Forehead-menting*," in Vol. I, p. 711 of the 1847 edition of Dr. TOWNSEND'S translation of VELPEAU'S *New Elements of Operative Surgery*. J. F. PALMER, an editor of HUNTER (*The Works of JOHN HUNTER*, F. R. S., 1837, Vol. III, p. 256), cites "BARONIO, *Degli insetti animali*, 1804,"

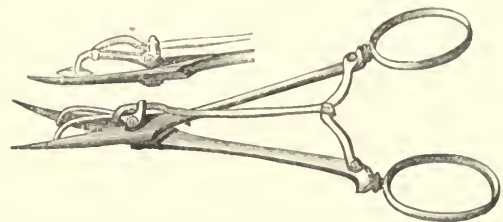


FIG. 361.—Scissors for transplanting sound skin, devised by Dr. MACLEOD. [After BRYANT.]



A fraction over six per centum of the cases returned as "gunshot flesh wounds of the back" proved fatal. The proximate causes of death in the eight hundred fatal cases recorded in TABLE XI are specified in three hundred and eighty cases. Eighty-three of these were complicated by other wounds. Of the remaining two hundred and ninety-seven patients, twenty-seven are said to have succumbed to tetanus,<sup>1</sup> thirty-three to secondary hæmorrhage,<sup>2</sup> and twenty-eight to gangrene. The fatal termination was ascribed to surgical or traumatic fever in seventeen cases, to erysipelas in eight, and to typhoid fever in thirty-one cases; to pyæmia or septicæmia in sixty-seven cases, to pneumonia or hepatitis (probable instances of embolism) in seventeen cases; to diarrhœa and dysentery in thirty-nine cases; and to peritonitis in seven. In one case, the administration of chloroform was thought to have brought about the fatal result. Two patients died from diphtheria, two from small-pox, and eighteen from various intercurrent diseases due to hospitalism and unconnected immediately with the traumatic affections. Analysis of this large series of gunshot flesh wounds corroborates the conclusions stated in a foot-note on page 7 of this volume, and indicates that the mortality of these non-penetrating wounds has been over-estimated by some European writers of acknowledged authority in matters pertaining to surgical statistics. Making every allowance for errors, and admitting that the aggregate may have been swelled by the admission to hospital of trivial cases of wounds of the integuments, the percentage of mortality remains much lower for this group of injuries than has been heretofore represented.<sup>3</sup>

in testimony of the successful transference of portions of integument from one part of an animal to another. In connection with JOHN HUNTER'S well-known experiments, Mr. POLLOCK and M. G. MARTIN (*De la durée et conditions d'adhérence des restitutions et transplantations cutanées*, Paris, 1873, No. 41) refer to the experiments of this Italian (BARONIO, G.) (*Ricerche intorno alcune riproduzioni che si operano negli animali così detti a sangue caldo, e nell'uomo*, Milan, 1818). A highly interesting disquisition on the transplantation of animal tissues was published, ten years ago, by Dr. P. BERT (*De la greffe animale*, Paris, 1863), an imperfect bibliography being appended to the paper. Consult further: MORALES (R.) (*A Successful Case of Transplantation*, in *New York Med. Rec.*, April 15, 1871); HOWARD (B.) (*Theory of Cure of Ulcers by Skin Grafting*, in *Proc. of Med. Soc. of the County of New York*, *New York Med. Jour.*, 1871, Vol. XIII, p. 466); BARTLETT (S. C.) (*Removal of entire Scalp: Wound healed by Skin Grafting*, in *Am. Jour. Med. Sci.*, 1872, Vol. LXIV, p. 573); HODGEN (J. T.) (*Cell or Skin Grafting*, in the *St. Louis Med. and Surg. Jour.*, July 10, 1871, p. 289); TRADER (J. W.) (*A Case of Skin Grafting*, St. Louis, 1871); WOODMAN (J.) (*Notes on Transplantation or Engrafting of Skin*, London, 1871); BARLOW (W. H.) (*On the Practice and Rationale of Skin Grafting*, in the *Manchester Med. and Surg. Rep.*, October, 1871); BRYANT (T.) (*The Practice of Surgery*, 1872, p. 431); CZERNY (*Haut-transplantation*, in *Wiener Med. Presse*, 1871, Jahrg. XII, No. 17, S. 439); MARQUEL (P.) (*Des greffes cutanées*, in *Lyon Méd.*, 1872, T. X, p. 76 (*et seq.*)); HOUZÉ DE LAULNOIT (*Quelques essais d'anaplastie à l'aide de greffes muqueuses*, etc., in *Gaz. hebdomadaire*, October 11, 1872, p. 662); PERCY (Article *Ente animale*, in the *Dict. des Sci. Méd.*, 1815, T. XII, p. 339).

<sup>1</sup> The date of the fatal termination is recorded in twenty-four of the twenty-seven cases. Excluding the two cases of Corporal J. Cantelon, Co. H, 4th Cavalry, and of Private J. Trainor, 2d Infantry, who survived fifty-four and forty-two days, respectively, the mean duration of life after the reception of the injury, in the twenty-two cases, was nearly twelve days. One patient, a soldier of an Alabama regiment, wounded at Gettysburg, died in four days; several died on the eighth day after the reception of the injury. Surgeon I. MOSES, U. S. V. (*Am. Jour. Med. Sci.*, 1864, Vol. XLVIII, p. 354), has published abstracts of several of these cases in his *Surgical Notes of Cases of Gunshot Injuries occurring near Chattanooga*.

<sup>2</sup> Some of these cases would, with more precision, be described as instances of intermediary hæmorrhage. Of the thirty-three, in thirty-two the fatal bleeding came on from the third to the eightieth day, the mean period being the thirtieth day. In the thirty-third case, that of Private W. H. Marsh, Co. K, 13th Illinois, wounded at Vicksburg, in 1862, there was a persistent fistula after a shot wound of the buttock, and, three years subsequently, the report states that uncontrollable venous hæmorrhage occurred, and proved fatal in twenty-four hours. It seems more probable that a gluteal or ischiatic aneurism gave way.

<sup>3</sup> Consult on this subject: BENSON (C.) (Article *Muscles of the Back*, in *The Cyclopædia of Anat. and Phys.*, Vol. I, 1835, p. 368); PETIT (Article *Dos*, in the *Dict. des Sci. Méd.*, 1814, T. X, p. 150); MORGAGNI (*De sedibus et causis morborum*, Patavii, 1765, Epist. LIII, art. 12, p. 270); BILGUER (J. U.) (*Chir. Wahrnehmungen*, 1763, S. 493); COLE (J. J.) (*Military Surgery*, 1852, p. 75); MATTHEW (T. P.) (*Med. and Surg. Hist. of the British Army in the Crimea*, 1858, Vol. II, p. 336); CHENU (J. C.) (*Camp. d'Orient*, l. c., 1865, p. 186); STROMEYER (*Mazimen*, 1855, S. 670); DEMME (*Studien*, 1861, B. II, S. 189); BIRKETT (J.) (in HOLMES'S *System*, etc., 2d ed., 1870, Vol. II, p. 708); NEUDÖRFER (J.) (*Die Schussverletzungen der seitlichen Weichteile der Wirbelsäule*, in *Handbuch*, l. c., 1872, S. 1743); FISCHER (H.) (*Rückenwunden*, in *Kriegschir. Erf.*, l. c., 1872, S. 111); and BECK (B.) (*Von den Verletzungen des Rückens*, in *Chir. der Schussverletz.*, 1872, S. 448).

## CHAPTER IX.

### WOUNDS AND INJURIES OF THE UPPER EXTREMITIES.

The comprehensive title prefixed to this chapter is adopted in order to conform to the plan commonly pursued by systematic writers; yet it is not designed to enter upon all the branches of the subject, but only to present a summary of the facts reported regarding sword and bayonet and other cuts and stabs and shot wounds. Such information as has been communicated respecting the various other injuries to which the upper extremity is exposed, such as bruises and sprains, burns, scalds, and frost-bites, luxations, and fractures from other causes than shot, it is purposed to set forth in the *Third Surgical Volume*.

Some particulars regarding the comparatively small proportion of reported cases of punctured, incised, and miscellaneous wounds and injuries, will be specified in succeeding subdivisions of this chapter; but attention will be invited mainly to the facts recorded respecting shot wounds of the upper extremities, a group of great importance, comprising, numerically, one-third, or perhaps more,<sup>1</sup> of all the cases of wounds received in action that came under the care of the hospital surgeon, and requiring, to a large extent, operative interference by excisions, amputations, or ligations of blood-vessels.

Reserving the account of the accidents and injuries not inflicted by war-weapons, the materials will be arranged, as far as practicable, on that generally accepted principle of classification of traumatic affections which bases the principal divisions on regional, and the subdivisions on structural, characters.<sup>2</sup> The detailed facts reported of punctured, incised, and shot wounds of the upper extremities will be distributed in eight subdivisions, treating, respectively, of flesh wounds, shot fractures of the clavicle and scapula, wounds

<sup>1</sup> The justification for this statement is found in the statement in TABLE XII, on the next page, compiled from the reports of the statistical writers who have paid most attention to the relative frequency of wounds in warfare according to region, and, at the same time, have had access to large groups of facts. It is, of course, impracticable to obtain anything more than an approximation to the total number of wounds received in action; yet the comparative ratios may be as accurate as if exact enumeration was approached.

<sup>2</sup> I have no hesitation in stating that on most points I fully concur in the high estimate that Professor T. LONGMORE (*On the Classification and Tabulation of Injuries and Surgical Operations in Time of War*, in *Med. Chir. Trans.*, 1871, Vol. LIV, p. 201 *et seq.*) has bestowed on the plan of classification proposed, in 1856, by Inspector-General J. R. TAYLOR, C. B. This plan, subject to some modifications suggested by experience, has long been favorably regarded by army surgeons in this country. In 1864, when new forms of surgical record books were issued to the hospitals (*Circular Letter*, S. G. O., January 20, 1864—See *Prefatory*, p. IV, *First Part, Med. and Surg. Hist. of the Rebellion*), a form, copied substantially from Inspector-General TAYLOR'S classification, was printed in each register, and commended to the surgeons "as a guide to them in recording the diagnoses of surgical cases," with the injunction that: "By following its general arrangement as closely as possible, it is believed that greater accuracy will be insured in the preservation of surgical data for consolidation, and opportunity will be afforded of comparing the surgical results obtained in this war with those arrived at during the Crimean and other campaigns." It was not the eulogy of the British classification that I have taken exception to in the notes on p. XXVI of the *First Surgical Volume*, and on p. 7 of this volume, but to what I regarded as grave misrepresentations of the nature of the American surgical statistics and of the mode of dealing with them. Surgeon General LONGMORE has latterly (*Am. Jour. Med. Sci.*, 1873, Vol. LXVI, p. 584) declared that his statement regarding the number of persons engaged in collating and arranging the surgical statistics of the American War was an "unintentional mistake," which he very much regrets, and I cheerfully accept this interpretation. The unguarded expression on page 6 of the preliminary report of Circular 6 is quite open to misapprehension, what was simply a list of books of record being termed a "classification." I have explained elsewhere (*Am. Jour. Med. Sci.*, 1868, Vol. LVI, p. 128) the circumstances under which that report was published a few months after the termination of the war, all pretension to completeness being repeatedly disclaimed.—G. A. O.



of the shoulder joint, shot fractures of the shaft of the humerus, wounds of the elbow joint, fractures of the ulna and radius, wounds of the wrist joint, shot fractures of the metacarpus and phalanges. Yet no rigorous adherence to classification will be attempted, and matters allied to the several subjects discussed, that it is desirable to place on record, will be intercalated in the different sections and subsections, as convenience may dictate.

So-called accidents are subject to fixed laws, and the remarkable uniformity in the proportion of injuries of the upper extremities to the aggregates of casualties on various battle-fields, as indicated in the following table, is not surprising :

TABLE XII.

*Collated Returns, indicating the Relative Frequency of Shot Wounds of the Upper Extremity, in the Aggregates treated in Hospitals.*

	AGGREGATE WOUNDED.	WOUNDS OF UPPER EXTREMITIES.	RATIO.
July, 1830, days in Paris and Lyons, etc. (SERRIER'S table).....	784	233	29.7
Crimean War (MATTHEW'S return).....	7,660	2,189	28.5
Crimean War (CHENU'S return).....	34,306	10,648	31.0
Italian War of 1859 (CHENU'S return).....	19,672	6,721	34.1
Italian War of 1859 (DEMME'S estimates).....	17,095	6,047	35.3
Danish War of 1861 (LOEFFLER'S tables).....	3,558	927	26.0
American War of the Rebellion (S. G. O. returns).....	253,142	84,718	33.4
Franco-German War (consolidated returns).....	24,788	7,916	31.9
Totals.....	361,005	119,399	33.0

The main subject of this chapter will be the shot fractures of the bones of the upper extremities, with the complications and operations thereby involved; but there will be much to be said also of the injuries implicating the soft parts, which were often followed by diffuse suppuration,<sup>2</sup> by disquieting hæmorrhages requiring ligation of the principal arterial trunks, by paralysies and pareses, and by other complications, which, in no inconsiderable number of cases, were treated by the extreme resource of amputation. It has been impracticable to do more than to approximate the relative frequency of shot wounds of the soft parts and of fractures of the upper extremities, and the distribution of the injuries, numerically, in the arm, forearm, and hand<sup>3</sup>

<sup>1</sup> These 24,788 cases are collected from the following authors: MACCORMAC (W.) (*l. c.*, p. 128), 610 cases; BILLROTH and CZERNY (*l. c.*, p. 208), 277; RUPPRECHT (*l. c.*, S. 8), 361; MÜHLBAUER (*Erfahrungen aus dem Feldzuge*, etc., in *Bayerisches ärztliches Intelligenzblatt*, 1871, No. 31, S. 374), 1,899; STEINBERG (*l. c.*, S. 146), 8,531; GOLTDAMMER (*Bericht über die Thätigkeit des Reserve-Lazaraths des Berliner Hülfsvereins*, in *Berliner Klin. Wochenschr.*, 1871, S. 139), 639; HEYFELDER (O.) (*Bericht über meine Wirksamkeit am Rhein*, in *Petersburg Med. Zeitschrift*, 1871, No. 1), 226; SOCIN (A.) (*l. c.*, p. 8), 643; MUNDY und MOSETIG (*Service méd.-chir. de l'ambulance du Corps législatif*, *Gaz. des Hôp.*, 1871, No. 149), 136; BECK (B.) (*Chir. der Schussw.*, 1872, S. 160), 4,344; FISCHER (H.) (*l. c.*, S. 28), 875; KIRCHNER (U.) (*Ärztlicher Bericht, n. s. w., im Palast zu Versailles*, Erlangen, 1872), 2,099; GRAF (E.) (*Die Königl. Reservelazareth zu Düsseldorf, Elberfeld*, 1872), 298; SCHÜLLER (M.) (*Kriegs-chir. Skizzen*, Hannover, 1871), 491; GROS (F.) (*Notice sur l'hôpital civil, etc., de Strasbourg*, *Gaz. méd. de Strasbourg*, 1872, No. 17), 148; BERTHOLD (*Deutsche Mil-ärzt. Zeitschrift*, 1872, B. I, S. 429), 1,804; and MOSSAKOWSKY (P.) (*Deutsche Zeitschrift für Chir.*, 1872, B. I, S. 324), 1,415.

<sup>2</sup> LOEFFLER (F.) (*General-Bericht über den Gesundheitsdienst*, Berlin, 1867, S. 145), in diffuse suppurations after shot wounds of the upper extremities, insists on the early opportune employment of the knife and syringe. He rebukes "the miserable custom of squeezing out pus, not yet entirely banished, though seldom observed," among the surgeons of the Danish War. Another abuse reprobated by Herr LOEFFLER in this connection is the carelessness of assistants in employing sponges, which he would gladly see superseded by some form of irrigating apparatus, in all traumatic cases; because, apart from the liability of septic infection, there is the liability of doing harm in passing sponges over tender granulating surfaces.

<sup>3</sup> The statistics of LOEFFLER, FISCHER, and SOCIN, though taken from a comparatively small number of cases, may be compared with the counts mentioned in note 4 of the following page. Herr LOEFFLER states (*General-Bericht*, n. s. w., *l. c.*, 1867, Th. I, S. 137) that of 927 cases of shot wounds of the upper extremities tabulated from the records of the Danish War of 1864 (the soft parts only being involved in 490 cases), the shoulder was interested in 265 instances, or 28.6 per cent., the upper arm in 270, or 29 per cent., the forearm in 188, or 20.3 per cent., the hand in 204, or 22 per cent. Herr H. FISCHER (*Kriegs-chir. Erf.*, 1872, S. 136) records 249 cases of shot injuries of the upper extremities. Of these, 119 were unattended by fracture. Of this group of shot flesh wounds, 60 were of the upper arm, 30 of the forearm, 29 of the hands, percentages of 50.4, 25.2, and 24.3, respectively. SOCIN (*Kriegs-chir. Erf.*, 1872, *l. c.*, S. F) tabulates 135 shot wounds of the upper extremities, of which 47 were flesh wounds. Of these, 28 were of the upper arm, 15 of the forearm, 6 of the hand—the proportions being 59.5, 27.7, and 12.8 per cent., respectively.

## SECTION I.

## FLESH WOUNDS OF THE UPPER EXTREMITIES.

The cases of this category were too numerous to permit any satisfactory analysis. Over fifty thousand cases,<sup>1</sup> or about a fifth of all the wounded reported *by name*, were returned as shot flesh wounds of the upper extremities. A minute examination of the individual cases in such a series could not be attempted;<sup>2</sup> yet it was practicable to check the lists in various ways, to eliminate duplicated cases and such as should have been returned as fractures, to select for printing many attended by important complications, and to have warrant for some general deductions of interest.

Thus, in examining two series, each consisting of one thousand carefully verified cases, taken in their order on the registers, it was found that the wounds of the left upper extremity slightly predominated, in the proportion of about six or seven per cent.<sup>3</sup> The cases specified as wounds of the shoulder constituted over one-sixth, those of the arm one-third, those of the forearm nearly one-fifth, and those of the hand more than one-fourth of the total number of shot wounds of the upper extremities.<sup>4</sup>

PUNCTURED AND INCISED WOUNDS.—There were sixty-nine examples of bayonet wounds of the fleshy parts of the arm, or forearm, or hand, and forty-four cases of similar injuries by other pointed weapons. There were eighty instances of sabre-cuts of the upper extremity, not involving the bones, and one hundred and sixty-four other cases of incised wounds of this region of sufficient gravity to be reported by name, and to require the confinement of the patient to hospital. About three-fourths of the patients with sword and bayonet wounds were early returned to duty,<sup>5</sup> and among the remainder there were no examples of fatal results traceable to the injuries. Among the cases of punctured and incised wounds not inflicted in battle, a number required the ligature of the principal arterial trunks, and several of these resulted fatally.

<sup>1</sup> The number of cases of shot flesh wounds of the upper extremities recorded on the registers of the Surgeon General's Office that are referred to this category at present (July, 1874) is 54,723, or about *two-thirds* of the total of 84,718 cases of shot wounds of the upper extremities. This aggregate of 54,723 cases is reached by summing up all cases of shot flesh wounds of the upper extremities entered by name, and taken from field reports and casualty lists, from the regular hospital reports, and from special reports. But it is known that a considerable number of this group of cases, recorded on the regular quarterly surgical reports from the hospitals, have not been transcribed on the registers, because it was impracticable to afford the clerical labor requisite for comparison and entry of the cases without multiplication. In the aggregate of 87,822 cases of war injuries published in Circular 6, 21,248, or about 24 per cent., were recorded as shot flesh wounds of the upper extremities. The ratio of the 54,723 cases here referred to that category to the aggregate of 253,142 registered cases is about 21 per cent. The reduction in the ratio is probably due to the subtraction of cases of fractures and penetrating wounds.

<sup>2</sup> The readers of these volumes are, doubtless, for the most part, conversant with muster-rolls and other statistical work, and it is hardly necessary to remind them that the advantages likely to accrue from such a critical analysis would not justify the clerical labor it would involve. The indices to the registers of shot flesh wounds of the upper extremities record 977 names of soldiers distinguished from their comrades by the name of *Smith*, and *Brown* and *Jones* and other familiar patronymics appear almost as frequently, so that it was a task of magnitude to make a list of these cases, avoiding reiterations.

<sup>3</sup> In the first thousand cases, 461 were of the right and 534 of the left side, and 5 of both sides; in the second thousand counted, 471 were of the right, 522 of the left side, and in 7 both extremities were wounded.

<sup>4</sup> The counts in the two series of a thousand cases, in which the part injured was specified, were as follows: Shoulder, 176 and 196, or 18.6 per cent.; arm, 337 and 340, or 33.8 per cent.; forearm, 297 and 187, or 19.7 per cent.; hands, 280 and 277, or 27.8 per cent.

<sup>5</sup> Of the 69 patients with bayonet stabs, 48 were returned to duty, 13 were discharged, 1 died in Andersonville prison from causes foreign to the injury, and in 7 instances the result was not ascertained. Of the 80 patients with sword-cuts, 58 went to duty, 17 were discharged, 1 died of phthisis while on furlough, and in 4 cases the termination was unknown.



*Ligation of the Brachial Artery.*—In two instances of punctured wounds of the arm implicating the brachial artery, the orthodox plan<sup>1</sup> of ligating the vessel above and below the wound was successfully practised:

CASE 1230.—Private D. Welcome, Co. D, 107th Illinois, aged 23 years, was accidentally wounded, August 18, 1864. Surgeon A. M. Wilder, U. S. V., states, in a *Report of cases collected during the Campaign in Georgia*, that this man received "a bayonet thrust at the bend of the left elbow, cutting the brachial artery. The vessel was ligated above and below the wound." The patient was sent to Nashville, and thence to Louisville, Jeffersonville, and Quincy, where Surgeons Chambers, Goldsmith, and Brinton noted his convalescence and discharge, July 2, 1865.

The second case was reported by Assistant Surgeon J. W. S. Gouley,<sup>2</sup> who mentions the ocular demonstration of recurrent distal hæmorrhage presented in the course of his operation.<sup>3</sup>

CASE 1231.—"Private J. Williams, Co. A, 6th Pennsylvania Cavalry, aged 26 years, of intemperate habits, while in a state of intoxication resisted arrest and attempted to use violence, and one of the men of the provost guard stabbed him with his sword in the upper part of the left arm, corresponding to about the lower third of the coraco brachialis muscle. Profuse hæmorrhage followed, and was arrested by the corporal of the guard, who applied a handkerchief tightly above and another below the wound. This was so cleverly done that the patient lost no blood until the dressing had been removed two hours subsequently, September 20, 1862, when he was conveyed to the hospital for treatment. On careful examination, it was ascertained that the brachial artery had been wounded, and without any farther delay an incision was made as for ligation of the brachial artery, and the vessel secured above and below the wound, and the portion between the two ligatures cut out. The *vena comites* were also tied by reason of their having been injured at the time of the accident. With the exception of considerable œdema of the forearm and arm, which was controlled by bandages, the case progressed well, both ligatures having come off on the eighth day. On October 16, 1862, the patient was ordered to report for duty, entirely well. The first ligature having been applied, the wound was carefully sponged and red blood distinctly seen jetting out of the mouth of the vessel from below, and that with considerable force, showing that the application of a ligature to the artery above the wound only would have been an insufficient, incomplete operation."

*Ligation of the Ulnar Artery.*—A single instance was reported of ligation of the cubital artery,<sup>4</sup> remarkable because of the failure of restoration of circulation in the little finger:

CASE 1232.—Private S. H. Davidson, 2d Iowa Battery, aged 19 years, was wounded March 24, 1864, near Memphis, by a bowie-knife. Surgeon J. G. Keenon, U. S. V., reported that there was "an incised wound of the right wrist, opening the joint and dividing the ulnar artery. The vessel was ligated, and the wound brought together by sutures, prior to the patient's admission to the Adams Hospital. The patient was faint from loss of blood on admission. Pounded ice was applied over the wound. The operator's name was unknown." On his next quarterly report, Dr. Keenon continues the history of this case: "Dry gangrene had occurred, and a line of demarcation had formed, in the case of the patient whose ulnar artery was ligated on March 22d, and, on April 13, 1864, Surgeon Keenon amputated the right little finger and head of the corresponding metacarpal bone. The patient rapidly convalesced, and was returned to duty June 8, 1864."

*Ligation of the Radial Artery.*—There was a single instance, likewise, in which this vessel was ligated on account of an incised wound:

CASE 1233.—Private L. Pump, Co. I, 1st Mississippi Cavalry, aged 39 years, was admitted into Adams Hospital, Memphis, July 21, 1864. Assistant Surgeon J. M. Study, U. S. V., reported an "incised wound of the anterior aspect of the left forearm, severing the radial artery; inflicted by the patient during a fit of delirium tremens. The tendons of the flexor muscles protruded. Acting Assistant Surgeon B. W. Coale ligated the radial artery. Gangrene set in thirty-six hours after the operation, and the patient died July 28, 1864."

In wounds of vessels of the calibre of the radial, ligation is commonly deemed indispensable, yet in an instance reported by Assistant Surgeon Frantz, bleeding from an incised wound of the radial is reported to have been controlled by pressure:

CASE 1234.—Private O. Jeffers, Co. B, 20th New York Cavalry, aged 18 years, was wounded at Portsmouth, Virginia, January 25, 1864. Assistant Surgeon J. H. Frantz, U. S. A., reports his admission into Balfour Hospital, from regimental hospital, February 6th, with "an incised wound of the left wrist, the radial artery severed, the hæmorrhage controlled by pressure. Transferred to New York, April 26, 1864." Assistant Surgeon Warren Webster, U. S. A., reports this man's admission to DeCamp Hospital, and death from intermittent fever, May 28, 1864.

<sup>1</sup>GUTHRIE (G. J.), *The Diseases and Injuries of Arteries, with the Operations required for their Cure*, London, 1830, p. 254.

<sup>2</sup>The portion of the artery excised was sent to the Museum, and was numbered 854 in the Catalogue of Surgical Specimens of 1863. The specimen had disappeared on the revision of the Catalogue in 1866. Dr. J. A. LIDELL has already published this case.

<sup>3</sup>SCHÜLLER (*Kriegschr. Skizzen*, 1871, S. 33), in a case of shot flesh wound of the arm, on the appearance of intermediary hæmorrhage, on the sixteenth day, successfully ligated the brachial artery high up, after an unsuccessful attempt to tie the vessel *in loco*. Bleeding recurred from the distal orifice of the vessel, but was controlled by compression.

<sup>4</sup>Compare M. FARABEUF'S *Précis de Manuel Opératoire, Ligatures des Artères*, Paris, 1872, p. 45, of which Dr. J. D. JACKSON, of Danville, has printed an excellent English version: *Ligation of Arteries*, Philadelphia, 1874, p. 69.

There were one or two cases in which the reports convey intimations that stabs in the arm, implicating the brachial artery, proved fatal from malpractice—compression and styptics having been resorted to instead of ligation.<sup>1</sup>

*Wounds of the Palmar Arches.*—There were no special reports of such cases from the Union Army,<sup>2</sup> but an instance was found in a series of clinical reports from a Confederate hospital in Petersburg, transmitted by Surgeon W. L. Baylor:

CASE 1235.—“Private C. W. Reynolds, Co. H, 3d Arkansas. Incised wound of superficial palmar arch and some small arteries in the palm. The bleeding was profuse and was stopped by pressure. An oblong compress reaching half-way to the elbow was laid over the track of the radial artery, commencing at the wrist, and one also over the ulnar. These were confined in place by bandage, the wound filled with lint, and the whole secured by a splint from the elbow to the point of the fingers; cerate dressings were used. The bandage was readjusted on the third day, the lint in the wound remaining. The bleeding ceased entirely on the sixth day, and most of the lint was removed from the wound, which was improving. The arm was kept in a sling until about September 24th, at which time the wound had healed, with some contraction of the palmar fascia.”

The treatment of wounds of the superficial and deep palmar arches<sup>3</sup> often suggests very embarrassing questions, on which surgeons of the highest authority differ in opinion.<sup>4</sup> The subjects of such injuries are very unfortunate if they have not the services of a surgeon possessed of the requisite skill and courage to thoroughly explore the wound at the outset.<sup>5</sup>

In the three hundred and fifty-seven cases referred to, of this group of punctured and incised wounds of the upper extremities, there were four deaths, and forty patients were discharged for disabilities resulting from their wounds. Two of the deaths were from neglected arterial bleeding, and two from causes foreign to the injuries received. The disabilities of the majority of those discharged were from contractions or adhesions consequent on diffuse abscesses or the division of muscular or tendinous tissues.

<sup>1</sup>For accounts of punctured and incised wounds of the upper extremities in American journals, compare: SMITH (A. G.) (*Operation for Aneurism of the Axilla*, in *Western Medical Gazette*, Cincinnati, 1833, Vol. I, p. 319); WHITE (G. H.) (*Successful Ligation of the Subclavian Artery*, in *Am. Jour. Med. Sci.*, 1838, Vol. XXIII, p. 351); WEIDENSTRAND (*Wound of Forearm; Division of the Radial Artery; Ligation; Erysipelas; Cure*, in the *New Orleans Med. Jour.*, 1844-5, Vol. I, p. 637); POST (A. C.) (*Wound of the Axillary Artery and Plexus of Nerves*, in *New York Jour. of Med.*, 1845, Vol. IV, p. 171); WOOD (P. G.) (*Wound of the Brachial and Ulnar Arteries. Ligation. Cure*, in *The Stethoscope and Medical Reporter*, 1856, Vol. I, p. 489); CHEVEBS (D. W.) (*Punctured Wound of the Wrist*, *Boston Med. and Surg. Jour.*, 1868, Vol. I, p. 282); GAY (G. H.) (*Wound of Arm with Injury of Large Vessels*, in *Boston Med. and Surg. Jour.*, 1873, Vol. X, p. 273).

<sup>2</sup>There were but two cases of punctured or incised wounds of the palm specially reported, viz.: Lieutenant J. S. Russell, 29th Missouri, treated at the Officers' Hospital at Lookout Mountain from November 14th to November 23, 1864; and Private J. W. Sowers, Co. F, 152d Pennsylvania, treated at Grant Hospital, New York, from March 10th to May 8, 1865. Evidence of troublesome arterial bleeding appears in neither case.

<sup>3</sup>ARNOTT (C. D.) (*On the Treatment of Wounds of the Palmar Arch*, in *The Lancet*, 1855, Vol. II, p. 141) remarks: “The principle I wish to inculcate is, that under no circumstances, in hæmorrhage from the palm, is deligation of the arterial trunks on the cardiac aspect to be deemed necessary or attempted. I am aware this will at present hardly find general favor. I am, however, certain of my fact, and, therefore, state it boldly.”

<sup>4</sup>Professor VON PITIHA (*Die Krankheiten der Extremitäten*, in V. PITIHA and BILLROTH, *Handbuch*, u. s. w., 1868, B. IV, Abth. I, Heft II, S. 116): “I saw several cases of exceedingly rebellious bleeding from cuts and stabs of the palm; two of these were brought to me, after numerous ineffectual attempts to stop the bleeding, in a profoundly anæmic condition, yet I was never forced to practise ligation, as the bleedings ceased, on removal of conglua, completely and permanently. \* \* The first thing to be done in such cases is to freely expose the bleeding vessel by enlarging the wound, and to boldly clear away all conglua. The irritation caused by the sponge and the admission of cool air frequently induces the gaping arterial wound to retract. The wound should not be immediately closed, but should be kept under close observation for some time.”

<sup>5</sup>Professor GUOSS (*System*, etc., l. c., 5th ed., Vol. I, p. 808) and Dr. AGNEW (*Med. and Surg. Reporter*, Philadelphia, 1873, Vol. XXIX, p. 367) advise that the general rule for the treatment of wounded arteries shall not be deviated from here, and that in recent punctured or incised wounds of the palmar arches the wound should be enlarged and both ends of the bleeding vessel tied, and the editor, for one, heartily applauds this advice. Mr. BRYANT (*The Practice of Surgery*, 1872, p. 223), while sanctioning such practice in wounds of the superficial arch, believes that in deep wounds “it is neither expedient nor justifiable to explore the palm for the purpose.” But the neglected cases are those that present the real difficulties, and in these, as VELPEAU (*Nouveaux Eléments de Méd. Opér.*, 1839, T. II, p. 173) remarks, “*tout réussit et tout échoue contre elles*”—compression, cauterization, neopressure, the ligation of the radial or ulnar or of both, and the ligation of the brachial, have all been employed, with reported successes and failures. VELPEAU, at the place quoted, cites many references on this subject, which it would be superfluous to recapitulate; but the student may be reminded, in addition, of LISTON'S observations (*Elements of Surgery*, 2d ed., 1840, p. 486); of an important paper by BOECKEL, in the *Gazette Médicale de Paris*, 1862, No. 3; of another by CROLY (G. H.) (*Wounds of Arteries in the Vicinity of the Wrist and Foot*, 1862); and of one Strasbourg and four Paris theses, viz.: BALANSA (*Des hémorrh. traumat. de la main*, 1852); DROUET (*Des plaies et des hémorrh. traumat. de la main*, 1855); PIREYRE (*Hémorrh. artér. traum. de la main*, Paris, 1863); LEGUERN (*Plaies de la paume de la main*, Paris, 1864); NAIL (*Des hémorrh. traum. de la main*, Strasbourg, 1860); and of the following additional references: COOPER (A.) (*Lectures*, 1829, Vol. III, p. 195); BÉCARD (A.) (*Plaies de la main*, in *Dict. de Méd.*, 1838, T. XVIII, p. 527); ARNOTT (D. C.) (*The Lancet*, 1858, Vol. II, p. 445); SKKY (C.) (*Report of a Case of Wound of the Palmar Arch*, in *The Lancet*, 1855, Vol. I, p. 574); SAVORY (*Wound of the Palmar Arch*, *The Lancet*, 1855, Vol. I, p. 653); NÉLATON (*Elem. de path. chir.*, 1859, T. V, p. 911); HORTELOUP (P.) (*Du Traitement des hémorrhagies de la main*, *Gazette hebdom.*, March 27, 1868, p. 194); CARABEC (L.) (*Messures et plaies de la paume de la main gauche par des fragments de verre*, etc., *Gazette hebdom.*, 1868, T. V, p. 294); LEVY (E.) (*Hémorrhagies de la paume de la main arrêtées au moyen de l'éponge préparée*, 1869); MIDDLEBORP (*Die Percutane Ligatur*, in *Preuss. Milit. Zeitung*, 1862, S. C.); MARTIN (G.) (*Études sur les plaies artérielles de la main et de la partie inférieure de l'avant-bras*, in *Gaz. des Hôp.*, 1870, No. 2). A sensible discussion of the treatment of these difficult cases may be found in the *Boston Med. and Surg. Journal*, 1847, Vol. XXXVI, p. 169; ELLSWORTH (P. W.), *Wound of the Palmar Arch*.



**SHOT WOUNDS.**—Of the vast number of cases included in this category, many were complicated by injuries of the trunk. Projectiles perforating the soft parts of the arm often wounded the thoracic or dorsal parietes or penetrated the chest, and wounds of the forearm and hand were frequently associated with superficial or deep wounds of the abdomen. Only the wounds limited to the soft parts of the upper extremity will be considered here.<sup>1</sup> Perhaps the most interesting of these were the cases attended by lesions of the larger arterial or nervous trunks, cases that possibly cannot be strictly denominated flesh wounds, yet are conveniently classified under this head. There were numerous cases, however, in which the bones and the principal vessels and nerves escaped, that were attended by such destruction of skin, muscle, tendon or ligament, as resulted either fatally or in very serious disabilities; and there were cases complicated by gangrene or by tetanus, and even instances in which amputation was practised for complicated injuries involving only the soft parts. Instances of each group will be cited.

*False Anchylosis.*<sup>2</sup>—Contraction and rigidity of the parts was an almost constant result of serious shot injuries of the soft tissues of the upper extremity, frequently attended by distortion of the limb, often by disordered sensation, and always by impairment of motor power. The following are examples:

**CASE 1236.**—Sergeant C. Newbert, Co. F, 2d Missouri, was wounded at Stone River, December 31, 1862, and was treated in Hospital No. 1, Murfreesboro', and No. 19, Nashville. Surgeon J. S. Foye, U. S. V., noted: "Gunshot wound of the left arm near the shoulder; loss of use of the elbow joint; atrophy." This soldier was discharged May 21, 1863, and pensioned. Examiner J. B. Cosgrove, of St. Louis, reported, May 23, 1863: "Gunshot wound of the left arm four inches from the shoulder joint, the ball passing through the soft parts without injuring the bone, destroying the deltoid muscle, the injury resulting in almost total loss of use of the arm and partial anchylosis at the elbow joint." Examiner W. M. Chamberlain reported, July 20, 1868: "Nearly the whole of the deltoid muscle was cut out by a cannon ball; the joint is ankylosed by contraction of the soft tissues, and the upper arm is useless." The pensioner was paid to March 4, 1874.

**CASE 1237.**—Corporal J. S. Stevenson, Co. K, 20th Indiana, aged 28 years, was wounded at Gettysburg, July 3, 1863, and was admitted to Satterlee Hospital on July 5th. Surgeon I. I. Hayes, U. S. V., noted: "Ball entered in front of the radius at the wrist joint and passed upward, traversing the fascia, and lodged at the inner side of the elbow joint." Stevenson was transferred to the Veteran Reserve Corps December 31, 1863, and discharged the service July 15, 1864, and pensioned. Examiner G. A. Mears, of Indianapolis, reported, July 15, 1864: "Ball entered anterior and inner surface of the forearm just above the wrist, and, ranging upward, made its exit on the anterior and outer surface of the arm at the elbow joint, in its progress slightly injuring the lower end of the radius, otherwise making an extensive flesh wound; this is now healed, but the arm is still weak and slightly flexed at the elbow." Examiner T. Blakeslee reported, September 5, 1873: "The ball traversed the entire length of the forearm; there now exists partial anchylosis of the elbow joint and slight contraction of the flexor muscles over the wrist; disability one-third." This pensioner was paid to July 15, 1864.

Hippocrates nearly approached the truth, probably, when he asserted that the more highly organized tissues after injury were repaired, but were not regenerated or reproduced as they were before;<sup>3</sup> yet his doctrine was forgotten for centuries, until revived by Fabre

<sup>1</sup> SOEIN (A.) (*Kriegschir. Zef.*, 1872, S. 101) says: "It is an error to believe that such wounds might be left in inexperienced hands, or that they heal without careful treatment. When a shot track passes through several superimposed layers of muscles, care is to be had that the injured parts do not displace themselves and obstruct the suppurating canal. Such displacements are of advantage only at the moment of injury, when, in some instances, they may prevent the admission of air and preclude all suppuration. Such examples of primary healing, although not extremely rare, are yet exceptional, and it is preferable to see from the start that the entire shot track remains open. Primary prophylactic draining of all long flesh shot tracks, even, may well be justified. If this be not done, and should hardships of all kinds, such as bad quarters, tedious transportation, cold during the first days, and so forth, exert injurious influences, the results will be acute inflammatory oedema, ichor, progressive suppuration along the fascia, and fever with pyæmic chills, and the 'slightly wounded man' will become 'an extremely sick patient' before he reaches the reserve hospital. An early deep incision into the abscesses that have formed, and a suitable position, combined with absolute rest of the injured part and a complete disinfection of the wound, will generally avert the threatening perils. But suppuration may continue for months. The frequent presence of various foreign bodies, such as small pieces of clothing, contribute to defeat a favorable result. The injuries inflicted by the so-called tabatière ball of large calibre appear to be especially liable to such complications. I found them comparatively frequent in the muscular tissues; their heavy weight (35 grams), and perhaps the construction of the altered Snider-gun, from which they are fired, are perhaps the causes of their low propulsive power. The missile has a large cavity, usually filled with a pastboard wad, which separates from the missile, remains lodged, becomes impregnated with wound secretions, and causes extremely fetid pus-formations. It also frequently occurs that this very blunt projectile carries with it into the wound large pieces of clothing."

<sup>2</sup> From ἀγκυλος crooked, curved; ἀίωσ, ἄγκωσ, Lat., unctus.)

<sup>3</sup> HIPPOCRATES: Ἄριστος ἢ ἐν τῷ σωματι, οὐκ ἐργάζεται, οὐτ' φέρει. Compare also, APHORISMS, *Sect.* VI, 19, and *Sect.* VII, 28, and refer to FABRE (*Mémoires où l'on prouve qu'il ne se fait point de régénération de chairs dans les plaies et les ulcères avec perte de substance*, *Mém. de l'Acad. de Chir.*, 1768, T. IV, p. 73); HILLEN (F.) (*Anatomie path. logique des cicatrices dans les différents Tissus*, in *Mém. de l'Acad. de Méd.*, Paris, 1855, T. XIX, p. 467); THIBESCH (*Die feineren anatomischen Veränderungen nach Verwundung der Weichtheile*, in PITHA and BILLROTH, *Handbuch der Allg. und spec. Chir.*, B. I., Abth. II, S. 543); BILLROTH (*Die Allg. u. spec. Chir., Path. and Ther.*, Berlin, 1866, Vorlesungen 6-12); PEARCE (SIR JAMES) (*Lectures on Surgical Pathology*, 3d Am. ed., 1871, Lecture 7-12).

in 1752, in memorable discussions in the French Academy of Surgery.<sup>1</sup> Supported by Louis and Pibrac, Fabre finally enforced the recognition of the ancient teaching, which substantially agrees with the results arrived at by Paget and Billroth and Thiersch with the more precise methods of modern science.

It is unnecessary to accumulate instances of uncomplicated shot lacerations of the upper extremities. The nature of the reports of such cases will be understood by the two following citations:

CASE 1238.—Private F. Farrington, Co. H, 3d Maine, aged 18 years, was wounded at Gettysburg, July 2, 1863, and was received into Satterlee Hospital on July 10th. Acting Assistant Surgeon F. L. O. Rochrig noted: "Wounded by a piece of shell, which struck the upper third of the left arm, causing a large and deep flesh wound. By August 8th, the condition of the wound was greatly improved; the motions of the arm, especially that of extension, were rather limited. This soldier was furloughed, and readmitted in September; but, having received no treatment during his absence, extension of the arm had become almost impossible." He was transferred to the Veteran Reserve Corps December 12, 1863, and was discharged October 27, 1864, and pensioned. Examiner E. Russell reported, May, 1866, that the muscles of the arm were contracted, and the arm weaker and more painful than two years before. Examiner J. B. Severy reported, September, 1873, that the pensioner could not extend his elbow beyond an angle of 130°, and the utility of the limb was greatly impaired. This pensioner was paid March 4, 1874.

CASE 1239.—Private S. Rayfield, Co. C, 9th Colored Troops, aged 19 years, was wounded at Chapin's Farm, September 29, 1864. On September 30th, he was admitted into Balfour Hospital, Portsmouth, whence Assistant Surgeon J. H. Frantz, U. S. A., reported: "Shell wound of left arm, extending from shoulder to elbow; discharged June 3, 1865." Examiner S. B. Kenney reported, September 23, 1869: "Injury caused by explosion of shell, a fragment striking the left arm, tearing the triceps muscle the entire length and injuring the bone. The contraction of the muscle affects the arm in its motions; it cannot be flexed quite to a right angle." On September 4, 1873, Dr. Kenney reported: "Deltoid muscle destroyed. Humerus injured and portions exfoliated. Use of arm very much impaired. Disability three-fourths." This pensioner was paid March 4, 1874.

*Atrophy or Deformity after Sloughing.*—This subject will be more fully illustrated hereafter, in treating of hospital gangrene. A few examples will suffice here:

CASE 1240.—Private T. E. Griffith, Co. B, 44th New York, was wounded at Gettysburg, July 2, 1863. Treated in regimental hospital until the 10th, when he was sent to Satterlee Hospital. Acting Assistant Surgeon M. S. Perry reported: "Flesh wound of the lower third of the left arm above the elbow. August 20th, he has hospital gangrene; the wound looks black, and emits the peculiar smell of gangrene. Poultices of charcoal and flaxseed were applied, and the parts touched every other day with pure nitric acid, and tonics were freely given. September 20th, the wound is almost healed, but the arm is weak. December 7th, returned to duty." This man was discharged September 23, 1864, and pensioned. In April, 1869, Examiner H. B. Day, of Utica, reported that the wound had never entirely healed, but opened every year, and was then open. In December, 1873, Examiner C. B. Coventry reported considerable loss of muscular tissue by gangrene, leaving a large cicatrix, causing weakness of the arm; disability one-fourth. This pensioner was paid March 4, 1874.

CASE 1241.—Corporal J. H. Bartine, Co. F, 11th New Jersey, was wounded at Gettysburg, July 2, 1863, and was treated in Seminary Hospital, and subsequently in Satterlee. Acting Assistant Surgeon T. G. Morton noted: "Gunshot wound of the shoulder; a round ball passed through the shoulder superficially. He did well until July 25th, when a gangrenous slough appeared, which spread until all the skin covering the muscle came away; the sloughing process continued; the entire muscle became involved and undermined, and subsequently came away, leaving an enormous cavity extending from the acromion to the insertion of the deltoid, and laterally its entire breadth. Under tonics, stimulants, porter, poultices, and the best of diet the patient improved, the slough separated, the cavity granulated and filled up, and is now cicatrizing over." On August 10, 1863, this soldier deserted, according to the hospital register, and was returned to duty, according to the State adjutant general's report. It appears that he has not applied for a pension.

In one of the cases of this group, Professor Joseph Leidy recorded the *post-mortem* appearances of so-called phlebitis with embolism:

CASE 1242.—Private C. M. Beadle, Co. C, 20th Maine, aged 30 years, was wounded at Gettysburg, July 2, 1863, and was admitted to Satterlee Hospital on the 10th, and died August 6, 1863. Acting Assistant Surgeon J. Leidy reported: "Examination August 7th. A vigorous looking man, aged about thirty years; he had had a gunshot wound of the left arm, and gangrene extended along nearly its whole length on the posterior part. The basilic and axillary veins were inflamed and thickened, and contained a clot which was undergoing puruloid change in its interior. The internal organs of the chest and abdomen were healthy, except that there were several patches of inflammation in the ileum; death probably resulting from the poisonous or irritative influence of the phagedæna or hospital gangrene." This patient came to Satterlee from the field hospital of the First Division of the Fifth Corps, where the records are silent concerning the early history of the case. Surgeon I. I. Hayes, U. S. V., states that the shot perforation of the muscles of the left arm was made by a conical musket ball.

<sup>1</sup> Compare GARENGEOT (*Traité des opérations de chirurgie*, 2<sup>m</sup> ed., 1841, T. I, p. 5); QUÉSSAY (*Traité de la suppuration*, Paris, 1749, p. 259); PIBRAC (*Remarques sur le traitement des playes avec perte de substance*, in *Mémoires de l'Académie Royale de Chirurgie*, 1768, T. IV, p. 330); LOUIS (*Mémoire sur la consolidation des playes avec perte de substance*, *ibid.*, T. IV, p. 106); CRUVEILLIER (*Traité d'anatomie pathologique générale*, Paris, 1849, T. I, p. 232).



*Pyæmia* was a not infrequent cause of fatality in the shot flesh wounds of the upper extremities, as will be fully exemplified in the chapter on that subject. A few brief illustrations will suffice here :

CASE 1243.—Private W. E. Vanever, Co. F, 15th Massachusetts, aged 34 years, was wounded at Antietam, September 17, 1862, and received at Filbert Street Hospital, Philadelphia, on September 26th. Surgeon W. M. Breed, U. S. V., reported: "Wound of the right shoulder and left hand; one wound, from a fragment of shell, is on the dorsal surface of the left hand, between the thumb and forefinger, tearing out the fleshy mass to the depth of a quarter of an inch, healing kindly under simple dressings. The other wound, from a conoidal ball perforating the right shoulder antero-posteriorly, the bullet passing out behind the teres major and teres minor muscles, not striking the chest, but evidently wounding the great nerves of the arm, as the limb is partially paralyzed; for, though sensation is perfect, motion is seriously interfered with. The case did well until about October 20th, when the suppuration became so profuse that the constitutional disturbance was great, and the case assumed the form of irritative fever of the most serious nature. \* \* He has had frequent chills; his pulse is feeble and quick; the tongue is dry; profuse and exhausting sweating, lasting several hours, occurs. He has been treated within the last few days by the administration of tonics such as tincture of iron, sulphate of quinia, and carbonate of ammonia, and stimulated by whiskey. The wound still suppurating freely; the general condition of the patient is not improving. This patient died November 5, 1862."

CASE 1244.—Private O. F. Curtis, Co. I, 1st Massachusetts Artillery, aged 25 years, was wounded at North Anna, May 19, 1864. He was sent to Washington, and, on May 23d, was admitted into Armory Square Hospital. Surgeon D. W. Bliss, U. S. V., recorded: "The ball entered the central portion of the left deltoid muscle and is still lodged. On June 3d, Acting Assistant Surgeon D. W. C. Van Slyck extracted the ball through the wound of entrance. On June 4th, pyæmia supervened. Tonics and stimulants were administered. The patient died June 8, 1864."

CASE 1245.—Sergeant J. F. Thatcher, Co. G, 15th New Jersey, aged 22 years, was wounded at Spottsylvania, May 12, 1864. Surgeon E. F. Taylor reported, from a Sixth Army Corps hospital, "a shot flesh wound of the left arm." On May 14th, this man entered Carver Hospital. Surgeon O. A. Judson, U. S. V., reported: "Gunshot flesh wound of the right forearm. An unsuccessful attempt was made to remove the missile, which the patient asserted had not been extracted. On June 3d, symptoms of pyæmia were developed; stimulants were freely given, together with sulphate of quinia, and an opiate at night. Death, June 8, 1864. The necropsy revealed pus in the axillary vein, pyarthrosis in the right elbow joint, and suppurative medullitis of both radius and ulna."

*Flesh wounds attended by Lesions of the large Blood-vessels.*—Many cases were reported in which it was thought necessary to tie the arterial trunks of the upper extremities<sup>1</sup> for the suppression of hæmorrhage from shot wounds of the soft parts. These cases will be enumerated in the order of the magnitude of the arteries ligated.

*Ligations of the Subclavian.*—There were four instances of ligation of the subclavian artery on account of shot flesh wounds, as follows:

CASE 1246.—Sergeant P. Smith, Co. E, 84th Pennsylvania, aged 33 years, was wounded at South Side Railroad, September 30, 1864, and was treated in hospitals on the field and at City Point, and thence transferred to New Jersey, and was admitted into Beverly Hospital on October 7th. Assistant Surgeon C. Wagner, U. S. A., noted: "Gunshot flesh wound of the right arm. Secondary hæmorrhage from the brachial occurred on the 12th, and ten ounces of blood were lost. Acting Assistant Surgeon J. C. Morton ligated the brachial, using chloroform as an anæsthetic; reaction was prompt. The parts were sloughing rapidly at the time, but the condition of the patient was favorable; he did well for several days, but the hæmorrhage recurred on the 21st, the patient losing fifteen ounces of blood; he was feeble; pulse 110; the subclavian artery was at once ligated by Dr. Morton, and the patient improved for some time, but ultimately died from exhaustion, November 22, 1864."

CASE 1247.—Corporal S. Staines, Co. C, 53d Pennsylvania, aged 25 years, was wounded at Gettysburg, July 2, 1863. Assistant Surgeon C. W. Spayd, 53d Pennsylvania, reported "a severe gunshot wound of the right arm," and the patient's transfer to Mower Hospital, July 7th. Surgeon J. Hopkinson, U. S. V., reported: "Flesh wound of the lower third of the right arm. July 23d, recurrent hæmorrhage from the brachial artery; artery ligated in the continuity. August 2d, amputation of the arm for secondary hæmorrhage. August 23d, hæmorrhage, caused by sloughing of the axillary artery, took place, necessitating the ligation of the subclavian artery; the operation was performed by Acting Assistant Surgeon C. R. McLean, beneath the clavicle." The history of the case is continued from an unsigned case-book of ward 12: "August 24th, pulse 100,

<sup>1</sup>LOEFFLER (*Generalbericht, u. s. w.*, 1867, S. 152) gives detailed accounts of nine cases of shot flesh wounds of the upper extremities attended with lesions of the blood-vessels. In one, primary bleeding, supposed to proceed from the axillary, was successfully and definitely controlled by pressure. In a second, primary hæmorrhage from the axillary, temporarily arrested by pressure, recurred, and ligation was successfully practised. In a third case, a shot lesion of the brachial, with secondary bleeding, was successfully treated by tying the axillary. In a fourth case, a like treatment was adopted for primary bleeding from the brachial, but fatal gangrene ensued. In a fifth case of the same nature as the fourth, amputation at the shoulder joint was unsuccessfully resorted to after gangrene had supervened on the ligation of the axillary. The sixth case was also a fatal shoulder joint amputation, practised on account of diffuse aneurism from shot wound of the brachial. The seventh case, fatal from pyæmia, was a ligation above and below the seat of injury of one of the dorsal branches of the radial artery. The eighth case was a successful ligation of the brachial for secondary hæmorrhage after a shot wound of the radial. The ninth case was a successful ligation of the brachial for secondary hæmorrhage from a shot wound of the lower part of the same vessel. At page 159, Herr LOEFFLER, after commenting on the difficulties of applying ligatures at the seat of injury in secondary bleedings from wounded arteries, makes the just observation that: "The ligation *in loco*, in recent shot wounds, is less difficult, and one would wish, with PROGOFF, that in all cases, where there is no doubt as regards the injury of an arterial trunk, ligation should be performed at the time of the first dressing, even if the primary bleeding has been checked."

and weak. Appetite bad. Stump as warm as the rest of the body. August 25th, placed upon a water-bed and ordered nourishing diet, iron, quinine, and wine. The patient continued to mend until six o'clock A. M., September 1st, when hæmorrhage occurred from the subclavian artery, and before assistance could be rendered the man died from loss of blood. *Scelio cuticæ* twenty hours after death: A neat dissection was made of the artery with its anastomosing branches. A plug, about one inch and a quarter in length and to all appearance well organized, was found at the proximal side of the ligature; the ligature came away by making slight traction. The hæmorrhage was found to have come from a small branch on the distal side of the ligature, which freely anastomosed with the supra-scapular branch of the thyroid axis. Pressure had been made on the proximal side of the ligature without stopping the hæmorrhage. A specimen preserved to be forwarded to Washington," was not received.

CASE 1243.—Sergeant E. O. Gates, Co. M, 4th New York Artillery, aged 22 years, was wounded at Cold Harbor, June 4, 1864. He was sent, June 7th, to Fairfax Seminary Hospital, and thence, on June 10th, to Mower Hospital. Surgeon J. Hopkinson, U. S. V., reported: "A shot wound at the upper third of the right arm, the ball passing antero-posteriorly; the wound sloughed, and secondary hæmorrhage from the brachial ensued June 25th. The patient was placed under chloroform, and Acting Assistant Surgeon W. P. Moon ligated the axillary artery. The patient did well until June 30th, when slight bleeding recurred. This was arrested by compression. On July 1st, hæmorrhage arose from the axillary, the artery having sloughed at the point of ligation. Acting Assistant Surgeon T. G. Morton enlarged the wound made for ligating the axillary, and tied the subclavian high up in the axilla; no anæsthetic was used; the patient was ensanguined, having lost about thirty ounces of blood, and, though stimulants were freely used, died in one hour after the operation." The specimen (FIG. 365) is "a wet preparation of the brachial, axillary, and subclavian arteries, the two latter ligated for secondary hæmorrhage." (*Cat. Surg. Sect., A. M. M., p. 454*). It was contributed by Acting Assistant Surgeon W. Scott Hendrie. Only the subclavian and axillary portions of the vessel are shown in the wood-cut, the distal end of the preparation being disorganized to that extent that it is difficult to determine what of the lesions and ligatures should be dated as *ante mortem*, and what were due to the dissector or anatomical preparer.

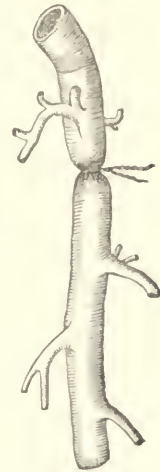

FIG. 365.—Preparation of the right subclavian artery and branches, ligated in the continuity. *Spec. 2545.*

The abstract of the fourth, and perhaps the most interesting, of the cases of ligations of the subclavian for shot wound unattended by fracture, is relegated to a future chapter, where the instructive illustrations belonging to it can also appear, in connection with other important observations of traumatic axillary aneurism<sup>1</sup> afforded by the experience of the war. It will avoid iteration to refer here cursorily to the treatment and literature of wounded arteries<sup>2</sup> as related to shot injuries of the axilla. In this work, the lower margin of the first rib is regarded as the line of demarcation between the subclavian and the axillary trunks. The reader who has consulted the twenty-five abstracts of cases of ligation of the subclavian in the *First Surgical Volume* need not be reminded that several might have been classified<sup>3</sup> with injuries of the soft parts of the upper extremities, with as much propriety as with wounds of the chest. A summary of all of the ligations of the subclavian reported during the war, will be presented further on.

<sup>1</sup> SOGIN (*Kriegschir. Erf.*, 1872, S. 49) gives three interesting cases of shot flesh wounds of the upper extremities with injuries of the blood-vessels, all terminating fatally. In the first, a shot perforation through the axillary folds, primary bleeding ceased spontaneously. On the eighth day there was no radial pulse. On the tenth day there was secondary bleeding, which was checked, but recurred during the night; digital compression of the subclavian was maintained for twenty-two hours; then ligation of the axillary above and below the injury was practised. Gangrene supervened, and the case terminated fatally on the seventeenth day after the injury. The second case was likewise a shot perforation of the axilla, with intermediary hæmorrhages on the fifteenth, sixteenth, and seventeenth days, when the subclavian was tied outside the scapeni. Bleeding recurred five days subsequently, and, though temporarily arrested, proved fatal on the twenty-sixth day after the injury, the ninth after the ligation. The third case was an example of consecutive traumatic aneurism. A ball passing through the scapular fold of the axilla and the upper arm injured either the axillary or brachial high up. Long afterward axillary aneurism supervened, and four months and a half from the date of injury the radial pulse disappeared. The subclavian was then tied. There was recurrent hæmorrhage on the twelfth and thirteenth days after the operation, and death on the fourteenth.

<sup>2</sup> An interesting *Report of a Case of Axillary Aneurism*, by Surgeon C. McDUGALL, U. S. A., was communicated in 1841, by Acting Surgeon General H. L. HEISKELL, to *The Maryland Medical and Surgical Journal*, 1841, Vol. II, p. 52. Dr. McDUGALL tied the left subclavian of Private J. Kane, aged 24, of Co. K, 4th Artillery, for complication attending a shot wound of the axilla. The case terminated fatally a week subsequently. The late Dr. NOTT, of Mobile, has recorded the case of C. L. Church, the left subclavian tied November 27, 1838, for false consecutive axillary aneurism; the patient lived till April, 1841—(NOTT, J. C., *Ligature of Subclavian Artery for the Cure of Axillary Aneurism caused by Gunshot wound*, in *Am. Jour. Med. Sci.*, 1841, N. S., Vol. II, p. 111.) The student will of course consult HERR KOCHE'S table (*Ueber Entbindungen und Aneurysmen der Arteria subclavia*, in LANGENBECK'S *Archiv für Klinische Chirurgie*, Berlin, 1869, B. X. S. 195), Dr. G. W. NORRIS'S statistics (*Contributions to Practical Surgery*, 1873, p. 222), the paper (in *Guy's Hospital Reports*, 1870, Vol. XV, p. 47) by the lamented POLAND, and the *Report* by Drs. PARKER, NORRIS, ARMSBY, and MUSSEY, in the eighteenth volume of the *Transactions of the American Medical Association*, 1867, p. 239). Other references to shot wounds in the axillary region without fracture, with ligation of the subclavian, are those of MOTT (V) (*Case in which the Right Subclavian Artery was tied just as it passes the Scapeni Muscles, for an Aneurism of the Axilla, from a Gunshot Wound*, in *New York Jour. of Med.*, 1845, Vol. IV, p. 16); WATSON (J) (*Case of Gunshot Wound in Left Axilla—Ligature of Left Subclavian, and, subsequently, Ligatures of Brachial and Subscapular Arteries*, in *Am. Jour. Med. Sci.*, 1851, N. S., Vol. XXI, p. 254).

<sup>3</sup> On p. 533 *et seq.* of the *First Surgical Volume*, CASES 1, 7, 10, 12, 13, 14, 15, 16, 18, 19, 20, 21, 22, of the series of cases in which the subclavian was tied, were instances in which the soft parts only were implicated, soft parts referable indifferently to the chest or upper extremity.



*Ligations of the Axillary Artery.*—There were fifteen ligations of the axillary because of shot flesh wounds of the upper extremities—with three recoveries and twelve deaths. It is noticeable that it was the right axillary that was thrice successfully tied, and that of the twelve fatal cases, eight were operations on the left axillary. One fatal case was a ligation on the right side, and in three cases the seat of ligature was not recorded:

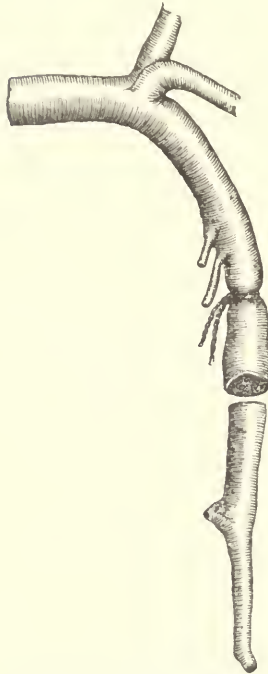


FIG. 366.—Preparation of an axillary artery a fortnight subsequent to ligation. *Spec.* 3679.

CASE 1249.—Corporal P. Yoho, Co. F, 116th Ohio, aged 30 years, was wounded at Winchester, September 19, 1864. Surgeon D. Bagnley, 1st West Virginia, reported a gunshot wound of the arm and back, and the patient's transfer to McClellan Hospital on September 27th. Acting Assistant Surgeon R. E. Brown reported: "A gunshot flesh wound of the middle and outer side of the left arm and left side of the back, by a mimié ball. The wound was in a sloughing condition at the time of his admission. He had intermediary hæmorrhage on October 4th, 5th, 6th, and 7th. The total quantity of blood lost was supposed to amount to thirty-six ounces. The first three hæmorrhages were controlled by a saturated solution of alum and persulphate of iron, and compresses of lint. The last hæmorrhage was so great that it became necessary to use the tourniquet to control it; during the day the entire arm and hand became excessively congested and inflamed, and the parts being in such a condition as to endanger the life of the patient, it was concluded, at the suggestion of Acting Assistant Surgeon E. Harts-horne, that Acting Assistant Surgeon W. L. Wells should ligate the left axillary artery at its third portion, which was done in a successful manner. The constitutional state of the patient was not good at the time of the operation; he was subject to intermittent fever, and was much debilitated. He seemed to progress favorably, and the wound began to look healthy until one week after the date of operation, when pyæmia set in and the discharge from the wound became very vitiated. The appearance of the wound became more abnormal, and the man gradually sank, dying on October 22, 1864. Examination proved that death was caused by pyæmia. The pleural cavity of the right side was literally filled with pus, and three small abscesses were found in the right lung." The specimen (FIG. 366), contributed by Surgeon Lewis Taylor, U. S. A., is a wet preparation of the left axillary artery, ligated in its third portion for secondary hæmorrhage. The artery is patulous, having been cut through by the ligature, which came away after death.

CASE 1250.—Corporal S. Richards, Co. M, 11th Pennsylvania, aged 25 years, was wounded at Ream's Station, August 25, 1864, and, on the 29th, was admitted into Mower Hospital, Philadelphia. Surgeon Joseph Hopkinson, U. S. V., noted: "Gunshot wound of the middle third of the left arm; the ball entered at the inner side of the arm, passed upward, and was extracted from the axillary space, on the field. The wound sloughed and secondary hæmorrhage occurred; and on September 5th the patient had lost about fifteen ounces of blood. On that date, Acting Assistant Surgeon W. P. Moon ligated the axillary artery in its continuity, using chloroform as an anæsthetic. The patient was in good condition at the time, and reaction was prompt. Simple dressings were applied to the wound, and stimulants administered freely. Profuse hæmorrhage set in on the 11th, due to sloughing of the artery at the point of ligation; the patient was very weak, and almost pulseless, from loss of blood. The wound was at once enlarged and the axillary ligated farther up. On September 14th, diarrhœa set in with violence; from that time the man failed rapidly, and died September 18, 1864."

The bleedings which necessitated these ligations were, in most cases, intermediary, occurring in the second or third week after the reception of the wounds. In three only of the series of fifteen cases<sup>1</sup> was the interval from the date of injury to that of hæmorrhage greater than thirty days.

CASE 1251.—Lieutenant-Colonel M. M. Dawson, 100th Pennsylvania, aged 33 years, was wounded at Petersburg, June 17, 1864. Surgeon M. K. Hogan, U. S. V., reported from a Ninth Corps hospital: "A shot wound of the left arm and left side of thorax; the ball extracted, and the patient sent to Washington, June 19, 1864" From Armory Square, Surgeon D. W. Bliss, U. S. V., reported: "A gunshot wound of the left shoulder, with contusion of the right breast. On June 27th, secondary hæmorrhage occurred to the amount of thirty ounces. The operation of tying the axillary artery was performed. After ligating the proximal extremity, hæmorrhage continued. The distal extremity was then secured by tying the brachial. A few hours after, hæmorrhage burst out afresh, and finally the patient died."

CASE 1252.—Sergeant F. Oldfield, Co. D, 10th Michigan, aged 33 years, was wounded at Atlanta, July 22, 1864. Not until August 7th was he received at Cumberland Hospital, Nashville. Surgeon B. Cloak, U. S. V., reported: "A wound of the upper third of the left arm. On August 10th, Acting Assistant Surgeon James C. Thorpe ligated the axillary artery just above the anterior circumflex. At the time, the parts were gangrenous and the patient was suffering from irritative fever. Nitric acid was effectively employed for the removal of the gangrenous parts. Tonics and stimulants, with good diet, were given, but with little benefit. The patient succumbed, from irritative fever, August 16, 1864."

<sup>1</sup> The bleedings were on the thirty-second, thirty-fourth, and thirty-ninth days, in these three cases; in the remaining cases, the hæmorrhages occurred from the second to the twentieth day, viz., in 15, 12, 10, 19, 7, 20, 17, 5, 6, 10, 11, and 2 days.

The two following abstracts are gleaned from the scanty reports of the Confederate hospitals filed in the War Department:

CASE 1253.—Private *H. C. Moore*, Co. A, 26th Georgia, was wounded in May, 1864 (probably at Spottsylvania), and was admitted to a Confederate hospital in Charlottesville. Professor *J. L. Cabell* recorded: "Gunshot wound of the left arm. On May 19th, secondary hæmorrhage occurred, and the axillary artery was ligated. Gangrene supervened, and the arm was amputated at the shoulder joint on May 23d. The patient died on the same day."

CASE 1254.—Private *W. A. Baggs*, Co. E, 20th Georgia Cavalry, wounded in June, 1864 (probably at Cold Harbor), was sent to Charlottesville. Professor *J. L. Cabell* recorded: "A gunshot flesh wound of the arm. On June 23d, secondary hæmorrhage from the axillary artery supervened, recurring at intervals on the 24th, and, on the 25th, the artery was ligated. This patient died June 28, 1864."

In a seventh case of ligation of the left axillary for shot wound interesting the soft parts, disarticulation at the shoulder was resorted to unsuccessfully:

CASE 1255.—Private *J. Lightfoot*, Co. E, 25th Massachusetts, aged 28 years, was wounded at Petersburg, August 10, 1864. Surgeon *J. B. Morrison*, U. S. V., reported, from an Eighteenth Corps hospital, "a shot wound of the left shoulder." On August 17th, this patient was sent to Satterlee Hospital. Acting Assistant Surgeon *L. K. Baldwin* described the injury as resulting from: "A musket ball, which entered the edge of the pectoral muscle, passed through the axillary space, and emerged near the edge of the scapula. The wound, at the time of admission, was apparently very slight and doing well. He continued to improve until August 27th, when a slight secondary hæmorrhage occurred from the wound of entrance, easily controlled by compression. Another hæmorrhage, of a much more serious nature, occurred on the 29th, also controlled by compression of the subclavian. An aneurism now began to form in the axillary and in the front of the shoulder, which increased gradually until September 17th, when the shoulder and parts in front of it were increased to more than twice their natural size. Great pain was also experienced from the tension of the parts and from the pressure on the axillary plexus of nerves; the arm was entirely paralyzed. After a careful examination, it was deemed advisable to lay open the parts and to ligate the injured vessel. An incision was made over the line of the axillary artery, which revealed, as soon as the tissues were divided, an immense clot, containing more than a half gallon of blood, which was turned out, exposing the artery for nearly its whole length. An opening was found in the artery, near its middle, caused by one side of the artery having been injured by the ball in its passage, having afterward ulcerated through. Ligatures were placed on the artery both above and below the seat of injury. The patient rallied well after the operation and continued quite easy for several hours; but the arm, being deprived of its source of nutrition, very soon began to show signs of gangrene, and, at the same time, to become quite painful. Things continued to grow worse, and forty-eight hours after the artery was ligated the arm was covered with blebs and was in a state of mortification, and it was deemed advisable to amputate it at the shoulder joint. This was done on September 19th, forty-eight hours after the ligation of the artery. The patient rallied after the operation, but sank and died at eleven o'clock that night. No autopsy was made." Specimen 3630 (*Cat. Surg. Sect.*, p. 459) is reported to have been derived from this case. It is a wet preparation, "showing great loss of substance from sloughing." The preparation as dissected and mounted is uninteresting.

The abstracts of the next three cases, of ligations on the cardiac side of wounded arteries, may be recorded for instruction rather than for imitation. The administration of stimulants to bleeding men is a wretched substitute for the observance of Guthrie's excellent precepts:<sup>1</sup>

CASE 1256.—Corporal *F. Hurd*, Co. F, 8th Maine, aged 24 years, was wounded at Fort Darling, May 16, 1864, and sent to Mower Hospital. Surgeon *J. Hopkinson*, U. S. V., reported that: "The ball entered the biceps and passed obliquely upward and inward, under the humerus, and emerged about two inches below the axilla. May 21st, wound sloughing; secondary hæmorrhage occurred from the left brachial artery, eighteen ounces of blood being lost. The patient was much prostrated from excessive discharge and loss of blood. Acting Assistant Surgeon *W. P. Moon* enlarged the anterior wound and ligated the proximal end of the brachial artery. \* \* The wound still continued to slough, and, on June 1st, hæmorrhage recurred from the brachial artery above the ligature, thirty ounces of blood being lost. Acting Assistant Surgeon *J. H. Jamar* administered ether and ligated the axillary artery. There was no reaction, and the patient died June 1, 1864, eight hours after the operation."

CASE 1257.—Private *Emanuel D. Miller*, Co. F, 90th Pennsylvania, was wounded at Bull Run, August 30, 1862, and was forwarded to Washington, where he was received into Mount Pleasant Hospital on September 1st. Assistant Surgeon *C. A. McCall*, U. S. A., noted: "Gunshot flesh wound of the arm. Secondary hæmorrhage from the brachial artery September 5th. Ligation of axillary artery September 6th. No recurrence of hæmorrhage. Collateral circulation established. Brandy and quinine administered. Death from exhaustion, at seven o'clock P. M., September 12, 1862."

CASE 1258.—Private *F. Friedeboldt*, Co. F, 5th Michigan, was wounded at Fair Oaks, May 31, 1862. On June 4th, he was admitted into Judiciary Square Hospital, Washington. Acting Assistant Surgeon *C. G. Page* reported: "The ball passed through the posterior portion of the upper arm without injury to the bones—extensive ecchymosis. June 10th, a free arterial hæmorrhage occurred; on removing the clots, extensive disorganization of the soft parts was found. The wounded brachial was not accessible. The axillary artery was tied high up. The subscapular was found very far forward, and was tied to prevent subsequent trouble. June 21st, both ligatures came away; feeble pulse detected in the radial artery. June 23d, a very profuse hæmorrhage occurred from the brachial, which was stopped by compression by a pad in the axilla. Troublesome hæmorrhages occurred on July 12th and 13th, and the patient died July 14, 1862."

<sup>1</sup> GUTHRIE, *Commentaries*, etc., 5th ed., 1855, p. 212 and p. 252, and *Dis. and Inj. of Arteries*, 1830, *passim*.



Bérard has well pointed out<sup>1</sup> that there is a wide discrepancy in the anatomical and surgical acceptations of the limits of the subclavian and axillary trunks. Hence a confusion of language, and a necessity to choose between the nomenclature of the anatomists and that of the surgeons. Bérard decides to follow the former; but it would appear more just that the opinions of practitioners on the living subject should prevail.

CASE 1259.—Private D. Smith, Co. C, 6th Pennsylvania Cavalry, aged 29 years, was wounded at Trevillian Station, June 12, 1864. Surgeon W. H. Rulison, 9th New York Cavalry, reported, from a Cavalry Corps hospital, "a gunshot wound of the left arm; serious." On June 21st, the patient was admitted into Finley Hospital, Washington. Surgeon G. L. Pancoast, U. S. V., noted, "a gunshot wound of the left arm; ball not extracted. Transferred June 28th." On June 29th, this soldier was admitted into Cuyler Hospital, Germantown. Assistant Surgeon H. S. Schell, U. S. A., reported: "A gunshot flesh wound of the left upper arm, apparently slight. The wound of entrance healed, that of exit nearly so; arm very painful, and enlarged at its upper third. July 16th, a traumatic aneurism of the left brachial artery had formed, which was first perceived about July 10th; the arm was greatly swollen and very painful, of a dusky hue, and threatened with gangrene. A superficial abscess had formed spontaneously. The patient was feverish and irritable from pain produced by rapid swelling of the arm. Acting Assistant Surgeon J. M. Leedom administered chloroform and ether, and ligated the brachial artery by the 'old operation' for aneurism, the sac being freely laid open, the clots turned out, and the vessel tied above and below its opening into the sac: hæmorrhage twenty ounces; extent of incision four and a half inches. The patient had a pyæmic rigor on July 17th, which did not recur. The wound was suppurating profusely. On July 21st, a copious hæmorrhage took place, twenty-one ounces of blood being lost. The bleeding was treated precisely as a secondary hæmorrhage from a wound, the vessel being freely exposed and ligated above and below the bleeding point by Dr. Leedom. July 25th, patient much worse; slight delirium; pulse 102; urine drawn off by catheter. July 26th, patient quite delirious. Sphincters relaxed, and involuntary discharges. Erysipelatous blush over arm and clavicular region. Ligatures all came away this morning. July 29th, consciousness fully restored; wound doing well. Bed-sore on inner condyle; the bone exposed. The hæmorrhage recurred on July 29th, and again on July 31st, and August 2d and 3d, sixteen ounces of blood being lost. On August 3d, the artery was again ligated in the axillary space. August 5th, bleeding to the extent of six ounces. Patient exhausted and depressed by repeated hæmorrhages and by suppuration: sloughing abscesses following erysipelas. Assistant Surgeon H. S. Schell amputated the left arm at the shoulder joint—flap from deltoid. The ligature of the 3d instant was left on the axillary artery. August 6th, hæmorrhage to the extent of eight ounces. Stump opened; blood apparently oozing from the tissues, and was checked by pressure and Monsel's salt. August 7th, ligature came away from the axillary artery at twelve o'clock M., a gush of blood following. The artery was immediately tied again, by Dr. Ashhurst, about three-fourths of an inch higher up, the incision being extended toward the clavicle. Hæmorrhage again occurred at eleven o'clock P. M. The vessel was again tied by Dr. Rohrer. August 8th, six o'clock P. M., ligature again became detached from the axillary artery, which was now tied still higher up, in fact almost up to subclavian region. The patient survived about two hours. The constitutional treatment employed throughout was profound quiet, with nutriment and stimulus graduated according to his condition."

Ligation of the axillary artery was only an incident in the next terrible case of pyæmia with pus formation in various large joints:

CASE 1260.—Private *W. Raper*, Co. G, 5th North Carolina, was wounded at Williamsburg, May 5, 1862. On May 9th, he reached Hygeia Hospital. Surgeon R. B. Bontecou reported: "Admitted with amputation of the right leg and a gunshot wound of the right arm, the ball entering at the outer border of the biceps in the lower third and emerging behind its inner border. The leg stump looked sloughy and was attacked with erysipelas. He was removed to a separate room in a distant portion of the building. Recovering from this, he was returned to one of the surgical wards in the early part of June, and soon complained of an abscess occupying the anterior of the right shoulder. There was little pain except on motion of the arm, but the swelling was large when my attention was called to it, and although the integuments were not discolored, yet fluctuation was so apparent and the wall so thin, I opened it, and a very large amount of pus, eight ounces, escaped. Three days after this, the assistant surgeon on duty enlarged the opening, and pus flowed again freely, and in a few hours quite a smart hæmorrhage occurred, which was repeated. I enlarged the opening, which was a little to the outside of the long head of the biceps, and could not find the bleeding point. Carrying my finger down the arm, I discovered a sinus suppurating, which led beyond my reach. This I instantly laid open and followed to its apparent termination, about one inch from the gunshot wound of the arm which had long since healed externally. Failing to find any wounded vessel, I ligated the axillary as high up as I could reach it, and the hæmorrhage ceased. Death ensued the day following (June 14, 1862), from exhaustion, and the *post-mortem* revealed an ulceration of the brachial artery at the situation of the bullet wound, in the lower third, communicating with the abscess above by a sinus along the edge of the biceps. The whole joint was disorganized and denuded of its cartilage; the scapula seemed to float in an inner abscess; the periosteum throughout its whole extent was nearly separated from it. This was likewise the case with the left scapula and joint, and the hip joints, each, were distended with pus."

In ten of the twelve foregoing cases of ligation of the axillary, proximal ligatures only were applied. In three of the cases, consecutive amputation was resorted to unavailingly; but this resource was successfully employed in one of the three succeeding fortunate cases. References to the copious literature of wounds of the axilla are omitted here.

<sup>1</sup>BÉRARD (P. H.), Article *Vaisseaux Axillaires*, in *Dict. de Méd.*, 1833, T. IV, p. 485.

The reports of pension examiners give some details of the three cases of recovery in this series<sup>1</sup>. In the first, a proximal ligature was applied twelve days after the reception of the injury; in the second, proximal and distal ligatures were placed one month after the shot perforation in the axilla; in the third, a proximal ligature was placed a week after the injury, and, hæmorrhage recurring, the arm was amputated:

CASE 1261.—Private W. Sobbee, Co. G, 61st Pennsylvania, aged 29 years, was wounded near Fort Stevens, July 12, 1864. Assistant Surgeon C. A. McCall, U. S. A., reported that "this soldier was received, July 13th, at Mount Pleasant Hospital, with a shot flesh wound of the right arm, a perforation of the fleshy parts by a minié ball from before backward and inward. On July 23d and 24th, hæmorrhage from the brachial artery supervened. Bleeding recurred four times, at least twelve ounces of blood being lost. On July 24th, Acting Assistant Surgeon A. Transue attempted to tie the brachial artery, which was found in such a condition as not to admit of ligature. The incision was extended in the axillary space, and the axillary artery was ligated. The incision measured three and a half inches. The arm was much swollen from compression by a tourniquet." The patient was transferred to Satterlee Hospital on August 9th, and was discharged November 10, 1864. Captain C. H. Bewley certified, January 30, 1869, that "the ball severed the main artery," and that "a handkerchief was tied immediately above the wound to stop the flow of blood." Examiner J. Cumminsky reported, April 24, 1869: "Wounded by a ball passing through the upper portion of the right arm, making a flesh wound only, but injuring the brachial nerve. The limb is very weak, and at times he suffers considerable pain." The pension examining board at Philadelphia reported, September 13, 1873: "Shot wound of the right arm, inner side, at upper third. Ligation of the brachial artery. No pulsations in either radial or ulnar. Hand numb in cold weather."

CASE 1262.—Private A. E. Williams, Co. B, 7th Michigan, aged 27 years, was wounded at Gettysburg, July 2, 1863. Surgeon D. W. Maull, 1st Delaware, reported, from a Second Corps hospital, a "shot wound of the right shoulder," and Surgeon A. J. Waid, 2d Wisconsin, noted the patient's transfer to Mower Hospital on July 7th. Surgeon J. Hopkinson, U. S. V., reported: "Flesh wound of the upper third of the arm. On August 4th, there was hæmorrhage from the axillary artery, which was ligated deep in the axilla, both ends being tied." The ward case-book furnishes the following notes: "Wounded in the middle third of the left arm and in the left side by a musket ball; a flesh wound. On July 7th, the discharge was profuse and offensive. The wounds were touched with creasote and wetted by a lotion of sulphate of copper. Good diet, iron, and brown stout were ordered. On July 21st, the entrance wound in the arm continued to discharge and looked badly. \* \* At ten o'clock at night, on August 3d, hæmorrhage commenced from the brachial artery, which was taken up. On August 4th, the patient was transferred, at the ward surgeon's request, to surgical ward No. 35." This soldier recovered, and was returned to duty April 25, 1864, and discharged July 7, 1864, and pensioned. In the declaration of the pensioner, made June 22, 1866, he states that he "was shot in the under side of the left arm," and "that about a month afterward the main artery of the arm became severed by sloughing off, when said artery was taken up. The arm, in consequence of said wound and the severing of the large artery, is very weak, nearly useless, and partially paralyzed; having but little sense of touch or feeling." Dr. M. S. Downer certified, June 14, 1869, that he had treated the pensioner: "The deltoid muscle is severed from the bone and the axillary artery is sloughed off. There is no pulse in the wrist whatever; the arm is partially paralyzed, the fingers are stiff, and in consequence of said wound the arm is nearly useless." Examiner D. F. Alsdorf, of Corunna, reported, September 5, 1873: "Ball entered the left side just below the scapula and passed through the posterior part of the axilla and through the fleshy part of the left arm. The wound was followed by extensive gangrene of the arm, which destroyed the muscles and left a large cicatrix with adhesions. The three lesser fingers are a little numb and not strong, and the arm weak and painful if used for hard labor."

CASE 1263.—Private T. Vancellete, Co. D, 3d Vermont, aged 21 years, was wounded at Lee's Mills, April 16, 1862, and was sent to Fort Monroe. Surgeon R. B. Bontecou, U. S. V., reported: "Admitted here with a gunshot wound of the middle of the right arm, the bullet entering the outer side of the biceps, and passing between that muscle and the humerus, escaped posteriorly through the triceps. There was great swelling of the arm and forearm, with exceedingly feeble pulse at the wrist in that arm. The wounds of the integuments and fascia did not at all correspond, and the fascia was distended with decomposing clots from the axilla to the elbow. To this circumstance, perhaps, the man owes his life, fatal hæmorrhage being prevented by the condition of the orifices. Free incision of the fascia on either side of the arm gave great relief, and the tumefaction and œdema of the forearm subsided in a great measure, and the pulse at the wrist became more distinct. Simple wet dressings were used, and supporting treatment. Hæmorrhage occurred twice, on April 18th and 23d. The axillary artery was tied, because the tissues below were greatly disorganized. Hæmorrhage again took place on April 25th, and amputation of the arm high up was made. The man was for many days in a very critical state, fainting on the slightest exertion, having lost great quantities of blood by the previous bleedings. He was well supported, and, notwithstanding some sloughing of the integuments covering the stump, he recovered, and was sent north about June 1st. I shall not soon forget the trouble experienced in finding the artery when search was made for it from the posterior wound. In fact, the tissues were so disorganized that the artery could not be distinguished by the eye, and the heart's action was so feeble that the pulsation could not be felt. The parts were so extensively denuded that the ligature was placed upon the axillary in sound tissues. Examination of the arm after the amputation showed absence of the brachial, for two inches of its course, by ulceration or wound; the hæmorrhage was from the distal end, near the bend of the elbow." This soldier was sent to New Haven, June 9, 1862, and Surgeon P. A. Jewett, U. S. V., recorded his discharge January 13, 1863. He was pensioned, and was paid March 4, 1874.

<sup>1</sup> Compare, on this subject, LARREY'S famous narrative of the case of General Dulong, shot through the right axilla, in Poland, in 1807. HOLYO-WAY (J. M.) (*Consecutive and Indeterminate Hæmorrhage from large Arteries after Gunshot Wounds, with a Report of Cases treated by different Methods, Appreciation*, in *Am. Jour. Med. Sci.*, 1865, Vol. I, p. 350). BRINTON (J. H.) (*Ligation of the Axillary Artery in the First Portion of its Course*, in *Am. Jour. Med. Sci.*, 1866, Vol. LII, p. 101). LIDELL (J. A.) (*On the Wounds of Blood-vessels, etc., op. cit.*, 1870, p. 64).



*Ligations of the Brachial Artery.*—This operation was resorted to, on account of shot flesh wounds of the arm, in at least seventy-six instances. A few cases will be detailed, and all reported will be tabulated. The right brachial was interested in thirty-eight, and the left in thirty-seven cases; in one case this point was not mentioned. Consecutive amputation was resorted to in nine cases, with success in only three of the nine. Twenty-one cases, or 27.6 per centum, terminated fatally, a terrible mortality. The bleedings for which the ligations were done were primary in thirteen cases; in thirty-three they occurred in the first fortnight after the reception of the injury, and, in some cases of sloughing, as late as the seventy-second day; the mean was about eighteen days:<sup>1</sup>

CASE 1264.—Private J. A. Heminger, Co. H, 67th Ohio, aged 18 years was wounded at Fort Darling, May 20, 1864, and was treated in a Tenth Corps field hospital until the 23d, Surgeon J. J. Craven, U. S. V., recording a "gunshot wound of the elbow." The patient was then sent to Hammond Hospital, Point Lookout. Surgeon A. Heger, U. S. A., noted: "Gunshot flesh wound of the lower third of the right arm. The wound became gangrenous, destroying the continuity of the artery and causing secondary hæmorrhage, during which there was a loss of eighteen or twenty ounces of blood. On July 24th, Surgeon Heger ligated the brachial artery above and below the wound." The soldier was discharged June 28, 1865, and pensioned. Examiner E. D. Peck, in February, 1867, described "a ball entering the right arm at the elbow and injuring the joint, so that he is unable to perform full labor." Examiner F. W. Firman, in September, 1873, reported that "the ball passed through the right elbow; joint slightly necrosed, and motion impeded." The reports of the pension examiners imply some osseous lesion which must have been of a secondary nature. The great difficulty of exact diagnosis in old injuries in the vicinity of the elbow joint is familiar to all practical surgeons.

CASE 1265.—Private M. Gillard, Co. K, 16th Mississippi, aged 27 years, was wounded and captured in an engagement on the Weldon Railroad, August 24, 1864. He was sent to Washington four days subsequently, and Dr. J. C. McKee reported, from Lincoln Hospital: "A shot flesh wound through the biceps muscle, with secondary hæmorrhage. On September 7th, Acting Assistant Surgeon J. Morris ligated the brachial artery about the middle third, and also a muscular branch, applying two ligatures to each. The brachial vein being found to be ulcerated, ligatures were applied above and below the opening. At the time of operation the parts in the vicinity of the wound were gangrenous, and the general condition of the patient was not very good." This prisoner recovered, and was transferred to the Old Capitol Prison, for exchange, on February 5, 1865.

CASE 1266.—Private A. Gilboa, Co. C, 8th Michigan Cavalry, aged 27 years, was wounded near Knoxville, January 29, 1864. Surgeon L. D. Griswold, 103d Ohio, reported a "flesh wound of the left arm." The patient was sent, February 11th, to Hospital No. 1, at Nashville. Surgeon C. W. Hornor reported that: "The ball entered the flexure of the left elbow joint one inch above the external condyle of the humerus, passed through the soft parts, and emerged at the upper and inner border of the forearm. The patient had had a hæmorrhage from the wound, on his journey from the battle-field, the night before admission, and another bleeding of six ounces occurred soon after his arrival at the hospital. The wound was discharging ichorous pus. The septum between the two openings was divided, and the bleeding found to be from the brachial artery, which was lacerated in two-thirds of its calibre. It was ligated above and below the seat of injury by Acting Assistant Surgeon H. C. May. The track of the ball was lined throughout with black sloughing shreds of decomposed tissues. The hæmorrhage did not recur, but much trouble existed below the joint from swelling of the tissues; and the wounded man being a very impatient person, perfect rest of the limb was impracticable, and a partially ankylosed joint was the result. On June 11, 1864, the patient was transferred to Louisville." This soldier was subsequently treated in Totten, St. Mary's, and Harper Hospitals, and discharged November 14, 1864, and pensioned. Examiner M. L. Greene, of Pontiac, reported, February 15, 1869: "The left elbow joint is completely ankylosed by a wound from a minie ball. The arm is semi-flexed, much wasted, and useless as far as the joint is concerned." This pensioner's condition was unchanged in October, 1873.

CASE 1267.—Private J. N. Downey, 6th Maine Battery, aged 21 years, was wounded at Petersburg, June 13, 1864. On June 22d, he was admitted into Carver Hospital, Washington. Surgeon O. A. Judson, U. S. V., reported: "Gunshot wound of the right forearm about four inches from the elbow, exit on wrist, producing extensive injury to muscles and tendons. July 6th, wound gangrenous, with extensive sloughing. Patient of a feverish habit and with small appetite. Acting Assistant Surgeon G. E. Brickett ligated the brachial artery. Nourishing diet, stimulants, and tonics were ordered. The wounds healed quite favorably." On June 27, 1864, this soldier was sent to Cony Hospital, Augusta, and was discharged June 3, 1865.

CASE 1268.—Private W. Ellis, Co. K, 9th New York Cavalry, aged 20 years, was wounded at Culpeper, August 1, 1863. He was sent to Washington, and entered Douglas Hospital August 2d. Assistant Surgeon W. Thomson, U. S. A., reported: "A shot flesh wound of the lower third of the right arm. On August 11th, there was secondary hæmorrhage from a branch of the brachial, and eight ounces of blood were lost. The hæmorrhage recurred on the 12th, and Acting Assistant Surgeon J. E. Smith ligated the brachial, the parts being so infiltrated that it was with difficulty that the artery was found. The patient was anæmic from the repeated hæmorrhages he had undergone. The wound healed kindly by granulation, treated with water dressings and adhesive straps, but there was a very slight contraction of the flexors of the forearm, owing to the neglect of the after treatment during his absence on furlough. He was returned to duty October 10, 1863." Not a pensioner.

<sup>1</sup> Leaving out the 13 cases of immediate hæmorrhage, the dates of bleeding were: In 2 cases on the 4th day, in 1 on the 5th, 1 on the 6th, 2 on the 7th, 4 on the 8th, 1 on the 9th, 5 on the 10th, 6 on the 11th, 4 on the 12th, 1 on the 13th, 4 on the 14th, 2 on the 15th, 3 on the 16th, 1 on the 17th, 4 on the 18th, 2 on the 19th, 2 on the 20th, 2 on the 21st, 1 on the 22d, 1 on the 26th, 1 on the 27th, 1 on the 31st, 1 on the 32d, 1 on the 33d, 2 on the 34th, 1 on the 35th, 1 on the 36th, 1 on the 41st, 1 on the 43d, 1 on the 65th, 2 on the 72d: in one instance the date of bleeding is not stated.

The five foregoing abstracts illustrate the results of ligature of the brachial for bleeding from shot injury, under very varied conditions; yet the subject has been so little studied that it is worth while to relate a few more cases in detail:

CASE 1269.—Sergeant W. McAllister, Co. F, 96th Pennsylvania, aged 30 years, was wounded at Spottsylvania, May 10, 1864. Surgeon E. F. Taylor, 1st New Jersey, reported from Sixth Corps Hospital "a shot flesh wound of the right forearm." On May 13th, the patient was transferred to Alexandria. Surgeon E. Bentley, U. S. V., reported, May 21st: "Forearm œdematous; the wound in tolerable condition, but filled with clotted blood. The patient was very weak, having lost a large amount of blood, about forty ounces. The brachial artery just above the bifurcation was tied. Eggs, milk, and beef-tea were ordered, and stimulants were prohibited. On June 6th, the brachial was again tied in the middle third, and the patient was somewhat improved. The ligature placed on the middle third of the brachial came away on June 27th, and the patient then improved rapidly." This soldier was discharged October 13, 1864, and pensioned. Assistant Surgeon S. B. Ward, U. S. V., noted, "had three attacks of secondary hæmorrhage." Examiner J. Nichols, of Washington, reported, October 13, 1864, "limb now perfectly useless." Examiner F. F. Burmeister reported, July 11, 1866, "atrophy, with the entire loss of the use of the arm." Examiner J. H. Oliver, of Philadelphia, reported, as the result of a special examination: "A ball had entered the anterior surface of the right forearm, upper third, ulnar side, passed upward and backward through the inner portion of the elbow joint, and made its exit from the inner posterior surface, immediately above the elbow, comminuting the articulating portions of the ulnar and humerus, wounding the nerves and vessels, and was followed by profuse hæmorrhage and ligation of the ulnar artery. The forearm was permanently semiflexed at an angle of 45 degrees, the hand, thumb, and fingers extended and entirely useless, the elbow and joints below being ankylosed." Examiners T. H. Sherwood, H. E. Goodman, and J. Collins reported, September 15, 1873: "Gunshot wound of the right elbow joint; the arm was partially ankylosed from contraction of the cicatrix. Ligation of brachial artery; hand useless."

CASE 1270.—Private A. B. White, Co. D, 1st District of Columbia Cavalry, aged 22 years, was wounded at Petersburg, June 17, 1864. He was sent, June 20th, to Mower Hospital. Surgeon J. Hopkinson, U. S. V., reported: "A shot flesh wound of the inner side of the upper third of the right arm. The wound sloughed and involved the brachial artery, and, on July 6th, hæmorrhage occurred to the amount of sixteen ounces, and Acting Assistant Surgeon J. M. McGrath enlarged the wound of entrance and ligated both ends of the artery. The hæmorrhage did not recur. On July 31st, the wound was entirely healed." This soldier was discharged December 29, 1864, having little use of the hand, and was pensioned. Examiner J. C. Weston, of Bangor, January 12, 1865, reported: "The ball entered in front of the arm four inches below the acromion and three inches below the axilla, cut the brachial artery, injured the median nerve, passed through and escaped behind the arm. An incision was made and the artery taken up and tied. He had gangrene in the wound, by which the muscles in the vicinity were injured, and there is diminution and induration of tissues. There are two cicatrices, one two inches long the other three and a half inches. Around the seat of the injury the limb measures one inch less in circumference than its fellow. The motions of the elbow joint are impaired. He can fully flex and extend the fingers, but his power of grasping objects is very feeble. He is afflicted with constant numbness and pain in the fingers and wrist joint, and the hand is nearly useless." This pensioner was paid March 4, 1874.

CASE 1271.—Private E. Potter, Co. H, 86th New York, aged 29 years, was wounded at the Wilderness, May 7, 1864, and sent to Washington. On the 11th, he was received into Douglas Hospital. Assistant Surgeon W. Thomson, U. S. A., noted: "Gunshot flesh wound across the flexure of the left humero-ulnar articulation. On May 17th, the patient was placed under the influence of ether and a ligature was placed on the brachial artery by Dr. Thomson, in the middle third of the vessel. The wound had been doing well, but the ball having injured the artery, secondary hæmorrhage had taken place to the amount of four ounces. His general health was good, the wound not being sufficiently severe to cause much constitutional disturbance. After the operation, the arm was covered with warm wet flannels and oiled silk. May 31st, patient doing well. June 16th, wound healed, with stiffness of the elbow joint; transferred to New York City." He was treated in DeCamp Hospital, and subsequently at Elmira; thence discharged the service May 12, 1865, and pensioned. The certificate of disability by Acting Assistant Surgeon J. K. Stanchfield, and also the report of Examiner J. W. Bellows, in October 1866, describe the injury as a gunshot fracture. The disability was rated one-half. This pensioner was paid March 4, 1874.

CASE 1272.—Private J. Grady, Co. K, 164th New York, aged 47 years, was wounded at Petersburg, June 16, 1864, and sent to Carver Hospital, where Surgeon O. A. Judson, U. S. V., recorded "a shot flesh wound through the right biceps." On June 28th, the patient went to Cuyler Hospital. The hospital record states that the ball passed between the brachial artery and the humerus. On July 2d, and again on the 4th, secondary hæmorrhage occurred from the brachial artery, three pints of blood being lost. Assistant Surgeon H. S. Schell, U. S. A., made an incision three and a half inches in length, and ligated the brachial artery; both ends of the vessel were tied. No anæsthetic was employed. There was no return of the hæmorrhage. "Grady was discharged February 6, 1865, for contraction of the biceps muscle," and was pensioned. Examiner E. Bradley, of New York City, reported, December 2, 1865: "Musket ball lacerated externally the soft tissues of the middle third of the right arm. Atrophy of the biceps and partial atrophy of the forearm and hand from diminished vascular and nervous supply has resulted. The limb has little strength, and is comparatively useless." Examiner Charles Phelps, August 9, 1867, noted: "Wound of right arm by musket ball; the orifice of entrance was enlarged, and the brachial artery tied. Pulsation is distinct in the superior profunda artery, which is much enlarged, but is feeble in the radial. Nutrition of the arm is well maintained, but in the hand it is much impaired, and the fingers have little strength in flexion." This pensioner is reported to have died October 30, 1870, from disease not referable to the injury.

The more important facts of the nine foregoing, and of sixty-seven other cases, are grouped in a tabular statement on the two following pages.



TABLE XIII.

Summary of Seventy-six Cases of Ligation of the Brachial Artery for Hemorrhage from Shot Injuries unattended by Fractures.

No.	NAME AND MILITARY DESCRIPTION.	DATE OF INJURY.	DATE OF HÆMORRHAGE.	PROBABLE SOURCE OF HÆMORRHAGE.	DATE OF OPERATION.	OPERATION AND OPERATOR.	RESULT.
1	Babeock, F., Sergeant, M, 6th Illinois Cavalry, age 21.	Feb. 21, 1864.	.....	Palmar arch.	Mar. 14, 1864.	Brachial ligated by A. A. Surgeon A. Sterling.	Duty, July 13, 1864.
2	Bergner, F., Private, B, 121st Pennsylvania, age 21.	May 25, 1864.	June 15, 1864.	Brachial artery.	June 15, 1864.	Brachial ligated above and below by A. A. Surg. E. DeWitt.	Duty, June 30, 1864.
3	Bettenhauser, C., Pt., I, 61st New York, age 23.	July 2, 1863.	Aug. 12, 1863.	Brachial artery.	Aug. 12, 1863.	Proximal end ligated in wound....	Vet. R. Corps, May 13, 1864.
4	Beverly, W. J., Pt., C, 17th Maine, age 27.	May 5, 1864.	May 23 and 24, 1864.	Brachial artery.	May 24, 1864.	Brachial ligated above and below by Ass't Sur. G. A. Mursieck, U. S. V.	Died July 2, 1864.
5	Bowman, G. W., Pt., C, 107th Illinois, age 22.	Aug. 6, 1864.	Aug. 6, 1864.	.....	Aug. 6, 1864.	Brachial ligated by Surg. A. M. Wilder, U. S. V.	Disch'd April 11, 1865.
6	Branagan, T., Private, B, 22d Massachusetts, age 19.	June 18, 1864.	July 20 and 24, 1864.	Brachial artery.	July 24, 1864.	Proximal end ligated in wound. A. A. Surg. H. Sanders.	Duty, Jan. 18, 1865.
7	Brooks, G., Pt., I, 9th Virginia.	Aug. 26, 1864.	Sept. 5, 1864.	Brachial artery.	Sept. 5, 1864.	Ligated above and below wound; A. A. Surg. T. J. Dunett.	Died Sept. 16, 1864.
8	Caden, L., Pt., C, 8th New Jersey, age 19.	June 16, 1864.	July 2, 1864.	Profunda minor.	July 2, 1864.	Brachial tied in wound by A. A. Surg. W. Hooper.	Duty, Jan. 12, 1865.
9	Carroll, J., Pt., E, 39th New York, age 28.	May 6, 1864.	May 12, 1864.	Brachial artery.	May 12, 1864.	Ligated at junction of axillary and brachial arteries by Acting Assistant F. G. H. Randolph.	Deserted July 28, 1864.
10	Cline, C. R., Pt., D, 7th West Virginia, age 23.	June 1, 1864.	June 15, 1864.	Brachial artery.	June 15, 1864.	Brachial ligated. Arm amputated June 21, 1864, by A. A. Surgeon H. D. Vosburg.	Died June 25, 1864.
11	Clark, Osear A., Pt., D, 21st Ohio, age 31.	July 9, 1864.	July 24, 1864.	Brachial artery.	July 24, 1864.	Brachial ligated by A. A. Surg. A. H. Hoy.	Discharged.
12	Coyle, Dan. O., Pt., K, 1st Wisconsin Cavalry.	July 27, 1862.	.....	.....	July 27, 1862.	Brachial ligated just above elbow..	Disch'd Oct. 25, 1862.
13	Davis, J. H., Pt., E, 39th U. S. C. T., age 21.	July 30, 1864.	July 31, 1864.	.....	July 31, 1864.	Left brachial ligated by incision in upper third of arm.	Deserted Jan. 19, 1865.
14	Davis, Wm., Pt., E, 3d U. S. Artillery, age 24.	Feb. 20, 1864.	Mar. 7, 1864.	Interosseous artery.	Mar. 7, 1864.	Brachial ligated in middle third by A. A. Surgeon J. T. Kennedy.	Duty, April 24, 1864.
15	Daniels, Lewis, Pt., B, 69th New York, age 26.	Mar. 28, 1865.	April 5, 1865.	.....	April 5, 1865.	Both ends of brachial tied..	Died April 12, 1865.
16	Downey, J. N., Pt., 6th Maine Battery, age 21.	June 18, 1864.	.....	.....	July 6, 1864.	Brachial tied by A. A. Surgeon G. E. Brackett. (See CASE 1267 ante.)	Disch'd June 3, 1865.
17	Donnelly, J., Pt., D, 16th Massachusetts, age 41.	May 12, 1864.	May 24, 1864.	Brachial artery.	May 24, 1864.	Brachial tied above and below for violent bleeding, patient having lost 2 qts. of blood in 3 minutes.	Disch'd Jan. 18, 1865.
18	Duffy, Hugh, Lieutenant, D, 155th New York, age 46.	June 3, 1864.	June 13, 1864.	Brachial artery.	June 13, 1864.	Ligation of brachial. Arm amputated June 21, 1864, by Surg. D. W. Bliss, U. S. V.	Disch'd Oct. 13, 1864.
19	Donnelly, E., Pt., C, 51st New York, age 29.	Sept. 17, 1862.	Oct. 3d, 5th, and 6th, 1862.	Brachial artery.	Oct. 6, 1862.	Brachial ligated above and below; Ass't Surg. W. Notson, U. S. A. Oct. 7, 1862; amputation of arm.	Died November 7, 1862, of pyæmia.
20	Ellis, Wm., Pt., K, 9th New York Cavalry, age 20.	Aug. 1, 1863.	Aug. 11 and 12, 1863.	Brachial artery.	Aug. 12, 1863.	Brachial ligated by A. A. Surgeon J. E. Smith. (See CASE 1268 ante.)	Duty, Oct. 10, 1863.
21	Estes, H., Pt., H, 11th Kentucky, age 18.	June 9, 1863.	June 13, 1863.	Palmar arches..	June 13 and 19, 1863.	Ligation of radial. Ligation of brachial by A. A. Surg. E. L. Green.	Disch'd Jan. 16, 1864.
22	Fisher, A., Corporal, G, 36th Massachusetts, age 18.	June 23, 1864.	.....	.....	June 22, 1864.	Ligation of brachial on field.....	Disch'd Dec. 23, 1864.
23	Flewelling, A., Pt., I, 29th Indiana, age 20.	April 6, 1862.	April 20, 1862.	Palmar arch...	April 21, 1862.	Ligation of brachial.....	Disch'd May 15, 1863.
24	Fritzehey, Wm., Sergeant, M, 12th Pennsylvania Cavalry, age 24.	Mar. 21, 1865.	April 23, 1865.	Brachial artery.	April 23, 1865.	Brachial ligated at middle third by Surg. J. B. Lewis, U. S. V.; bleeding recurred May 4, 10, and 14. Arm amputated May 14, 1865.	Disch'd June 27, 1865.
25	Frank, Ph., Pt., D, 5th Minnesota, age 27.	Dec. 16, 1864.	.....	.....	Dec. 23, 1864.	Brachial ligated.....	Duty, Sept. 4, 1865.
26	Gilboa, A., Pt., C, 8th Michigan Cavalry, age 27.	Jan. 29, 1864.	Feb. 11, 1864.	Brachial artery.	Feb. 11, 1864.	Brachial tied by A. A. Surg. H. C. May. (See CASE 1266 ante.)	Disch'd Nov. 14, 1864.
27	Girbach, A., Pt., B, 5th Pennsylvania Cavalry, age 26.	June 25, 1864.	Sept. 5 and 14, 1864.	Ulnar artery ..	Sept. 15, 1864.	Ulnar ligated Sept 5th; brachial Sept. 15th, by Ass't Surg. J. W. Meriam, U. S. V.	Disch'd May 16, 1865.
28	Gillard, M., Pt., K, 16th Mississippi Regiment, age 27.	Aug. 24, 1864.	Sept. 7, 1864.	.....	Sept. 7, 1864.	Brachial artery and vein ligated above and below by A. A. Surg. J. Morris. (See CASE 1265 ante.)	Sent to Old Captiv Prison Feb. 5, 1865.
29	Grady, James, Pt., K, 164th New York, age 47.	June 16, 1864.	July 2 and 4, 1864.	Brachial artery.	July 4, 1864.	Right brachial tied above and below by Ass't Surg. H. S. Schell, U. S. A. (See CASE 1272 ante.)	Disch'd Feb. 6, 1865.
30	Greaf, A., Corporal, D, 40th New York.	June 18, 1864.	July 23, 1864.	Radial artery..	July 23, 1864.	Ligation of brachial above its bifurcation—radial had been ligated previously.	Died July 25, 1864.
31	Hayward, R. G., Pt., B, 4th Vermont, age 19.	Dec. 13, 1862.	Dec. 31, 1862.	Brachial artery.	Jan. 1, 1863.	Brachial ligated.....	Disch'd Oct. 30, 1863.
32	Heminger, J. A., Pt., H, 67th Ohio.	May 20, 1864.	July 24, 1864.	Brachial artery.	July 24, 1864.	Brachial ligated above and below by Surgeon A. Heger, U. S. A.	Disch'd June 28, 1865.
33	Hercford, J., Pt., L, 6th Kansas Cavalry, age 18.	Oct. 22, 1864.	Oct. 22, 1864.	Brachial artery.	Nov. 27, 1864.	Brachial ligated at cardiac and distal end by Surg. A. C. Van Durn, U. S. V.	Disch'd July 6, 1865.
34	Heliker, R., Pt., G, 65th Ohio, age 25.	Nov. 25, 1863.	Dec. 6, 1863.	Brachial artery.	Dec. 6, 1863.	Brachial ligated above and below by Surg. A. W. Mahan, 64th Ohio.	Disch'd Oct. 6, 1864.
35	Hatmaker, J., Corp, B, 51st Ohio.	Nov. 24, 1863.	Nov. 24, 1863.	.....	Nov. 24, 1863.	Brachial ligated on field.....	Disch'd Oct. 4, 1864.
36	Herring, I., Pt., C, 53d C. S. A.	Nov. 25, 1863.	Nov. 27, 1863.	.....	Nov. 29, 1863.	Brachial ligated in middle third ..	Recovery* ..
37	Henderson, D. D., Pt., I, 15th Mississippi, age 21.	Feb. 12, 1865.	Feb. 24, 1865.	Brachial artery.	Feb. 24, 1865.	Left brachial ligated at upper third ..	.....
38	Howard, G., Pt., H, 8th New York Artillery, age 20.	June 3, 1864.	June 29, 1864.	Brachial artery.	June 29, 1864.	Brachial ligated above and below by A. A. Surg. E. L. Duer.	Died July 1, 1864.

\* Compare HOLLOWAY (J. M.), in *American Journal of the Medical Sciences*, 1865, Vol. I, p. 342.

No.	NAME AND MILITARY DESCRIPTION.	DATE OF INJURY.	DATE OF HÆMORRHAGE	PROBABLE SOURCE OF HÆMORRHAGE	DATE OF OPERATION.	OPERATION AND OPERATOR.	RESULT.
39	Huhn, H., Lieut., K, 44th Illinois, age 24.	June 27, 1864.	June 27, 1864.	Brachial artery.	June 27, 1864.	Ligation of brachial in wound on field, by Surg. H. E. Hasse, 24th Wis., and W. P. Pierce 88th Ill.	Disch'd Dec. 10, 1864.
40	Hurd, F., Corp'l, F, 8th Maine, age 24.	May 16, 1864.	May 21, 1864.	Brachial artery.	May 21, 1864.	Brachial ligated by enlarging the wound, by W. P. Moon, A. A. Surg. June 1st, axillary ligated by A. A. Surg. J. H. Jamar.	Died June 1, 1864.
41	Hurley, R., Pt., H, 158th New York.	Sept. 19, 1864.	Sept. 27 and 28, 1864.	Brachial artery.	Sept. 28, 1864.	Brachial ligated at upper third. Arm amputated below elbow Oct. 9, 1864, by A. A. Surg. Maury.	Disch'd Mar. 29, 1865.
42	Johnson, O., Pt., C, 33d Iowa.	July 4, 1863.	Aug. 4 and 5, 1863.	Radial, ulnar and brachial.	Aug. 5, 1863.	Right brachial ligated.	Died Aug. 13, 1863.
43	Marshall, H., Pt., F, 1st Michigan Cavalry, age 20.	May 28, 1864.	June 19 and 24, 1864.	Ulnar, radial, and brachial.	June 19, 1864.	Right brachial ligated. June 24th, arm amputated at upper third by A. A. Surg. S. B. Harris.	Died July 11, 1864.
44	McAllister, Wm., Sergeant, F, 96th Pennsylvania, age 30.	May 10, 1864.	May 21, 1864.	Brachial artery	May 21, 1864.	Brachial ligated just above bifurcation. June 6th, religated in mid. third by Sur. E. Bentley, U. S. V. (See CASE 1269 ante.)	Disch'd Oct. 13, 1864.
45	McIntire, A., Pt., M, 2d New York Artillery, age 22.	June 3, 1864.	June 15, 1864.	.....	June 15, 1864.	Right brachial ligated by Assistant Surg. T. R. Crosby, U. S. V.	Mustered out in Dec., 1864.
46	Moore, A. A., Pt., C, 53d Indiana, age 21.	July 21, 1864.	Oct. 1, 1864.	Radial artery.	Oct. 1, 1864.	Brachial ligated by Surgeon J. C. Morgan, 29th Missouri.	Disch'd May 11, 1865.
47	Morgan, L., Pt., D, 14th Michigan, age 22.	Mar. 20, 1865.	April 8, 1865.	Left brachial.	April 8, 1865.	Left brachial ligated at both ends.	Died April 13, 1865.
48	Morris, R., Pt., A, 149th Pennsylvania, age 25.	Oct. 27, 1861.	Nov. 13, 1864.	Radial artery	Nov. 13, 1864.	Right brachial ligated by Surg. N. R. Moseley, U. S. V.	Disch'd April 26, 1865.
49	Myers, H., Sergeant A., 23d Illinois.	May 3, 1863.	May 3, 1863.	Brachial artery.	May 3, 1863.	Brachial ligated by A. A. Surgeon J. Kirker.	Disch'd July 21, 1865.
50	Owens, E. G., Pt., H, 13th West Virginia, age 19.	Oct. 19, 1864.	Oct. 27, 1864.	Brachial artery.	Oct. 27, 1864.	Brachial ligated in wound by Surg. S. W. Gross, U. S. V.	Tr. to V. R. C., Mar. 25, 1865.
51	Parett, W. B., Pt., D, 5th Iowa, age 21.	Sept. 19, 1862.	Oct. 3, 1862.	Brachial artery.	Oct. 3, 1862.	Brachial ligate l.....	Disch'd Jan. 7, 1863.
52	Parmenter, R. B., Pt., A, 21st Michigan, age 32.	Dec. 16, 1862.	.....	.....	.....	Brachial ligated.....	Died Jan. 1, 1863.
53	Pierce, Geo. W., Pt., D, 20th Indiana.	Aug. 30, 1862.	Sept. 9 and 10, 1862.	Pulnar arches.	Sept. 10, 1862.	Brachial ligated.....	Disch'd Feb. 7, 1863.
54	Potter, E., Pt., H, 86th New York Vols., age 29.	May 6, 1864.	May 17, 1864.	Brachial artery.	May 17, 1864.	Brachial ligated at middle third by Ass't Surg. W. Thomson, U. S. A. (See CASE 1271 ante.)	Disch'd May 12, 1865.
55	Price, E., Corp'l, B., 39th New Jersey, age 22.	April 2, 1865.	April 6, 1865.	Ulnar artery.	April 6, 1865.	Ulnar ligated at 4 A. M.; brachial at 1.30 P. M., by Ass't Surg. H. Allen, U. S. A.	Disch'd July 27, 1865.
56	Quinn, J., Pt., C, 18th U. S. Infantry.	Dec. 31, 1862.	Dec. 31, 1862; Jan. 10 and 22, 1863.	Brachial artery.	Jan. 23, 1863.	Left brachial ligated at upper third.	Vet. R. Corps, July 8, 1863.
57	Rea, J. K., Pt., H, 102d Pennsylvania, age 17.	May 5, 1864.	May 14, 1864.	Brachial artery.	May 14, 1864.	Left brachial ligated. May 17th, arm amputated; Surg. C. Pnge, U. S. A.	Died Dec. 1, 1864.
58	Roberts, J., Pt., H, 24th New York Cavalry.	June 17, 1864.	June 28, 1864.	Brachial artery.	June 28, 1864.	Brachial ligated.....	Died July 8, 1864.
59	Saoni, C., Pt., I, 9th New Hampshire, age 23.	Sept. 13, 1864.	Oct. 10, 1864.	Brachial artery.	Oct. 10, 1864.	Brachial ligated in wound; one ligature; A. A. Surg. J. Sweet.	Died Nov. 13, 1864.
60	Shuck, J. L., Pt., G, 27th Ohio, age 21.	July 4, 1864.	July 11, 1864.	Brachial artery.	July 11, 1864.	Brachial ligated.....	Disch'd May 25, 1865.
61	Sipes, J., Serg't, K, 32d Ohio, age 24.	July 16, 1865.	July 17, 1865.	Brachial artery.	July 17, 1865.	Brachial ligated by Surgeon R. R. Taylor, U. S. V.	Disch'd Sept. 27, 1865.
62	Smith, Ph., Pt., E, 84th Pennsylvania, age 33.	Oct. 1, 1864.	Oct. 12, 1864.	Brachial artery.	Oct. 12, 1864.	Brachial ligated. Oct. 21st, bleeding recurred, and subclavian ligated. (See CASE 1246 ante.)	Died Nov. 22, 1864.
63	Smith, U., Pt., C, 15th Iowa, age 29.	Aug. 14, 1864.	Aug. 14, 1864.	Brachial artery.	Aug. 14, 1864.	Brachial ligated on field, in upper third.	Disch'd July 24, 1865.
64	Smith, T. J., Pt., E, 6th Iowa, age 22.	April 6, 1862.	April 24, 1862.	Brachial artery.	April 24, 1862.	Brachial ligated.....	Disch'd Mar. 19, 1863.
65	Smith, D., Pt., C, 6th Pennsylvania Cavalry, age 29.	June 12, 1864.	July 16, 1864.	Brachial artery.	July 16, 1864.	Brachial ligated; religated July 21st; axillary ligated Aug. 3d. Amp. of arm at shoulder joint Aug. 5th. Bleeding recurred, and axillary ligated Aug. 7th, and still higher on Aug. 8th. (See CASE 1259 ante.)	Died Aug. 8, 1864.
66	Sweeney, P., Pt., 2d New York Artillery, age 40.	Aug. 14, 1864.	Sept. 17, 1864.	Brachial artery.	Sept. 17, 1864.	Brachial ligated just above the crossing of the median nerve; Surg. N. R. Moseley, U. S. V.	Disch'd Feb. 3, 1865.
67	Torbet, C. L., Serg't, C, 2d Alabama, age 18.	April 9, 1865.	April 17 and 25, 1865.	Brachial artery.	April 17, 1865.	Brachial ligated by Surgeon A. McMahon, U. S. V.	Released on June 23, 1865.
68	Tuttle, F. M., Pt., B, 44th Illinois, age 23.	June 27, 1864.	July 17, 1864.	Brachial artery.	July 17 and 19, 1864.	Ligation of ulnar. Ligation of brachial; Surg. J. R. Ludlow, U. S. V.	Disch'd Feb. 28, 1865.
69	Vanderslice, J., Pt., D, 96th Pennsylvania, age 49.	June 3, 1864.	June 14 and 28, 1864.	Brachial artery.	June 14, 1864.	Brachial ligated by A. A. Surgeon D. Kennealy.	Died July 16, 1864.
70	Waite, W., Pt., E, 53d Ohio.	May 31, 1864.	May 31, 1864.	Brachial artery.	May 31, 1864.	Brachial taken up by Surg. I. N. Barnes, 116th Illinois.	Disch'd May 12, 1865.
71	Walker, H. H., Pt., A, 27th New York.	June 27, 1862.	Aug. 2, 1862.	Brachial artery.	Aug. 2, 1862.	Brachial ligated by Ass't Surgeon W. Thomson, U. S. A.	Died Aug. 3, 1862.
72	White, A. B., Pt., D, 1st D. of C. Cavalry.	June 17, 1864.	July 6, 1864.	Brachial artery.	July 6, 1864.	Brachial ligated by A. A. Surgeon J. M. Mcnath. (See CASE 1270 ante.)	Disch'd Dec. 29, 1864.
73	White, E. P., Pt., F, 19th Maine, age 21.	Mar. 31, 1865.	April 12, 1865.	Brachial artery.	April 12, 1865.	Brachial ligated by A. A. Surg. W. H. Evisgn.	Disch'd June 29, 1865.
74	Williamson, J., Corp'l, C, 111th Illinois, age 26.	Dec. 13, 1864.	Jan. 2, 1865.	Ulnar and brachial arteries.	Jan. 2, 1865.	Ligation of brachial; religated same day. Amputation of arm, upper third, Jan 7; A. A. Surg. H. Leamon.	Died Feb. 1, 1865.
75	Winnemore, E., Mus., K, 68th Pennsylvania, aged 21.	June 26, 1864.	Aug. 8, 1864.	Ulnar artery.	Aug. 8, 1864.	Brachial ligated by A. A. Surg. W. P. Moon.	Disch'd Jan. 13, 1865.
76	Wolfe, F., Pt., N, 9th New York Artillery, age 28.	Oct. 19, 1864.	Oct. 29, 1864.	Brachial artery.	Oct. 29, 1864.	Both ends of the brachial tied.....	Died Nov. 14, 1864.



In one of the cases enumerated in the preceding table, a preparation of the ligated brachial was preserved and transmitted to the Museum. Specimen 950 of the Surgical Section (*Cat.*, p. 461) is also an example of ligation of both extremities of the brachial for shot injury; but, unfortunately, the history of the case has not been identified. The other preparations of ligature of the brachial in the Museum are from cases of amputation:



FIG. 367.—Preparation showing ligations of the radial and brachial arteries. *Spec.* 5645.

CASE 1273.—Corporal A. Greaf, Co. D, 46th New York, aged 37 years, was wounded at Petersburg, June 18, 1864, and was treated in a Ninth Corps hospital, thence transferred to Harewood, and, on June 28th, to Satterlee. Acting Assistant Surgeon W. B. Corbit reported: "Gunshot flesh wound of the upper third of the right forearm. A minie ball entered about three inches below the external condyle of the humerus, on the dorsal surface, and emerged opposite; no bones were involved. The wound was in a sloughing condition, the patient anæmic and despondent. Nitric acid was applied to the wound and followed by flaxseed poultices, and extra diet was prescribed. By July 20th, gangrene had ceased to spread and healthy granulations had arisen, but the patient's despondency continued. On July 23d, a profuse hæmorrhage occurred from the radial artery, which was ligated. The surrounding tissues being very much disorganized and the bleeding still continuing, a ligature was put around the brachial just above the bifurcation. Stimulants, beef-tea, and tonics were freely given. Several minor hæmorrhages occurred next day, and the patient died, apparently from exhaustion, July 25, 1864." The specimen (FIG. 367), forwarded by Dr. Corbit to the Museum, is a wet preparation, showing the radial artery ligated just below, and the brachial artery just above, the bifurcation.

It is remarkable that all of the thirteen cases of ligation for primary hæmorrhage were successful.<sup>1</sup> In the series of thirty-three intermediary cases,<sup>2</sup> those in which the interval between the injury and recourse to ligation did not exceed fifteen days, there were nine deaths. Eleven of the twenty-nine secondary cases,<sup>3</sup> in which the interval from the date of injury to the date of ligation of the brachial ranged from sixteen to eighty-two days, terminated fatally. In one fatal case, the date of the ligation was not given. Four of the consecutive amputations belong to the intermediary, and five to the secondary group. In eight of the twenty-one fatal cases, ligatures were applied above and below the wounded point, and hæmorrhage recurred in one instance only. Bleeding recurred in at least seven of the thirteen cases of proximal ligation. The reported causes of death in these twenty-one fatal cases were: in seven cases, pyæmia; in eight, "exhaustion" from repeated bleedings; in two, gangrene; in one, intercurrent colliquative diarrhœa; in one, phthisis; and in two cases, this point was not reported. The seat of ligation was indicated in sixty cases, and unmentioned in twelve of the successful and four of the fatal cases. The artery was tied in the upper third in thirteen cases, with four deaths; in twenty-four cases, of which six were fatal, it was secured in the middle third; and in twenty-three cases, with seven fatal terminations, ligatures were applied near the bend of the elbow.<sup>4</sup> The surprisingly large mortality of the cases of ligation at the lower third is partly explicable by the fact that there are included in this category several instances of complicated wounds of the hand or forearm, and ligation of the brachial was but one of a series of operations. Of shot lesions of the brachial, much the larger proportion are attended by fracture of the humerus, with which the artery is in such close relation through the greater part of its course.

<sup>1</sup> See CASES 5, 12, 13, 22, 33, 35, 36, 39, 49, 56, 61, 63, and 70 of TABLE XIII.

<sup>2</sup> CASES 7\*, 9, 10\*, 11, 14, 15\*, 17, 18, 20, 21, 23, 25, 26, 28, 34, 37, 40\*, 41, 44, 45, 50, 51, 53, 54, 55, 57\*, 58\*, 60, 62\*, 67, 69\*, 73, 76\*; the fatal cases are indicated by asterisks.

<sup>3</sup> CASES 1, 2, 3, 4\*, 6, 8, 16, 19\*, 24, 27, 29, 30\*, 31, 32, 38\*, 42\*, 43\*, 46, 47\*, 48, 59\*, 64, 65\*, 66, 68, 71\*, 72, 74\*, 75.

<sup>4</sup> The instructions given by MALGAIGNE (*Manuel de Médecine Opératoire*, 7<sup>m</sup>e éd., 1861, p. 149), by Dr. J. H. PACKARD (*A Handbook of Operative Surgery*, 1870, p. 157), and by other systematic writers, for tying the brachial, leave nothing to be desired. Unless the arm is greatly tumefied, the vessel can be felt throughout its whole course, and only a very clumsy surgeon could miss it. At the lower third, the median basilic vein running parallel to it, and the internal edge of the tendon of the biceps, are almost certain guides, and, higher up, the inner edges of the biceps and coraco-brachialis afford indications not less sure. Many interesting details regarding ligations of the brachial may be found in M. L. TRUPPER'S article *Brachiale*, in the *Dictionnaire Encyclopédique des Sciences Médicales*, 1869, T. X, p. 447.

*Ligations of the Ulnar Artery.*—Ten instances were reported of ligations of the ulnar artery for shot wounds unattended by fracture. Three of these cases terminated fatally. One of the ligations was done for primary bleeding, three for early intermediary hæmorrhages incident to sloughing. The right forearm was interested in seven, and the left in three cases. Brief notes of eight of the cases are subjoined; the ninth has been already mentioned in the enumeration of cases of ligation of the brachial artery; and the tenth will be referred to among the ligations of the radial:

CASES: 1274.—Corporal *J. N. Freeman*, Co. H, 58th Virginia, aged 36 years, was wounded at Winchester, September 19, 1864. Surgeon *F. V. Hayden*, U. S. V., reports: "Shot flesh wound of the right arm, severing ulnar artery. Ligation of ulnar artery, September 19th, by Surgeon *Todd*, 13th Virginia." This soldier was subsequently treated at West's Buildings Hospital, Baltimore, and was transferred, October 25, 1864, to Point Lookout for exchange. 1275.—Sergeant *G. L. Bell*, Co. E, 10th Connecticut, was wounded at Kinston, North Carolina, December 15, 1862. Surgeon *E. P. Morong*, 2d Maryland, reported from Foster Hospital, New Berne: "Flesh wound of the right forearm: hæmorrhage on December 27th, sixteen ounces of blood being lost. The artery was cut down upon just above the bend of the elbow and ligated; the artery tied was the ulnar, there being high division of the brachial." [The hæmorrhage was not arrested by the ligation, since Dr. Morong states in another column of this report that] "the arm was amputated at its lower third, December 27, 1862. The patient lived seventy-four days after the operation, doing well up to within fourteen days of his death. At this time he learned that another had been appointed to the second lieutenancy of his company, to which he was himself entitled by right of promotion. His disappointment was great, and was, I believe, the immediate cause of his death, March 11, 1863." 1276.—Private *G. W. Booth*, Co. F, 1st Michigan, aged 26 years, was wounded in the engagement on the Weldon Railroad, August 21, 1864. He was sent from a Fifth Corps hospital, on the 27th, to Fairfax Seminary. Assistant Surgeon *H. Allen*, U. S. A., recorded: "Gunshot wounds of left forearm. A conoidal ball entered the outer side of the middle third of the forearm, on the anterior surface, passed transversely inward, and made its exit on the inner side. September 6th, at midnight, \* \* \* bleeding from the ulnar artery to the extent of eight ounces occurred, and recurred on the following morning, when an ounce of blood was lost. \* \* \* The track of the ball being exposed, by uniting the wounds of entrance and exit by a transverse incision, Dr. Allen turned out the clot and tied the ulnar artery above and below the aneurismal sac." The patient was transferred to Harper Hospital, Detroit. "He was discharged and pensioned, February 28, 1865." Examiner *J. W. Falley*, of Hillsdale, reported, May 20, 1874, "that he can neither open nor close the three outer fingers, and that the hand has been growing more and more useless." 1277.—Private *J. Carter*, Co. D, 11th Connecticut, aged 22 years, was wounded at Drury's Bluff, May 16, 1864. Assistant Surgeon *W. Webster*, U. S. A., reported from DeCamp Hospital: "A minie ball passed through the right forearm at its middle third. There was phagedenic sloughing and hæmorrhage from the ulnar artery, on June 2d, to the extent of twelve ounces. Acting Assistant Surgeon *O. W. Peck* ligated the ulnar artery." This soldier was discharged December 21, 1865, and is not a pensioner. 1278.—Sergeant *G. W. Shaw*, Co. H, 85th Pennsylvania, aged 42 years, was wounded at Bermuda Hundred, May 20, 1864. He was shot through the left forearm, and bleeding coming on, the ulnar artery was tied, June 12th, by Acting Assistant Surgeon *Pryor*. Discharged November 12, 1864, and pensioned. Examiner *F. C. Robinson*, of Uniontown, reported, September, 1866: "The muscles and tendons of the arm are so extensively injured that he is unable to open or close the hand, three of the fingers being permanently contracted and immovable, and the index finger and thumb can only be moved partially, and possesses but a slight degree of power." 1279.—Private *J. A. Clapper*, Co. G, 43d New York, aged 22 years, was wounded July 12, 1864. He received a shot perforation of the middle third of the left forearm, and was sent to Mount Pleasant Hospital, and thence, on July 20th, to Satterlee. Acting Assistant Surgeon *M. Lampen* reported that: "The wound measured three inches by four and was gangrenous. The patient's general health was tolerably good. A solution of permanganate of potassa was applied to the wound, which was dressed also with sugar. On August 2d, the slough was removed completely and the wound was healthy. On August 8th, the wound was sloughing again, and the patient was feeble, and sugar was applied as before, tonics being given internally. On August 10th, hæmorrhage occurred from the ulnar artery to the amount of six or eight ounces, and Acting Assistant Surgeon *W. Atlee* ligated the artery in the wound at both extremities. By August 20th, the slough was all removed, the wound was looking healthily, and the patient's health improving. On August 30th, he had a severe chill, followed by fever. August 31st, hæmorrhage occurred from a small artery and was arrested by compression. He had a chill during the night, and again on September 1st. Sulphate of quinia was given freely during the intermission. September 7th, the wound was sloughing again, and there was slight hæmorrhage, which was arrested by compression, and he had a chill in the morning. Chills recurred on the 8th and 9th. On the 11th, there was again a slight hæmorrhage, which was arrested as before; the patient was sinking rapidly; tonics and stimulants were administered. The next day he had a chill. On the 11th, hæmorrhage occurred from the ulnar artery to the amount of five ounces. The patient being too much exhausted to bear any operation, the tourniquet was applied to the arm to arrest the hæmorrhage, and was allowed to remain until the time of his death, which occurred at one o'clock P. M., September 14, 1861." 1280.—Private *G. Harbison*, Co. L, 2d Pennsylvania Artillery, aged 32 years, was wounded at Chapin's Farm, September 29, 1864. Surgeon *J. C. Fisher*, U. S. V., reported, from Camp Parole: "Shot wound of the lower third of the right forearm: hæmorrhage November 1st, from the ulnar artery. Assistant Surgeon *W. St. G. Elliott*, U. S. V., tied the proximal end of the artery November 2d, and, hæmorrhage recurring, a ligature was placed upon the distal end on November 3d. The patient recovered, with partial contraction of the index and middle fingers, and was transferred to Philadelphia February 8, 1865." Surgeon *J. Hopkinson*, U. S. V., reported that this soldier was discharged from Mower Hospital May 18, 1865, on account of "shot wound of the right wrist, with sloughing of the flexor muscles." He was pensioned, and on September 16, 1873, Examiners *A. G. McCandless* and *J. W. Wishart* reported: "The middle, ring, and little fingers of the right hand are closely contracted in the palm and cannot be opened, and there is but little power in the first finger and thumb.



The hand is wasted from want of use." 1281.—Private W. D. Wartenbee, Co. D, 100th Ohio, aged 23 years, was wounded at Wilmington, February 29, 1865. Surgeon S. J. W. Mintzer reported from the hospital at York: "Shot flesh wounds of the anterior surface of the right forearm, followed by extensive sloughing March 26, 1865. There was hæmorrhage from the ulnar artery; twenty ounces of blood lost. Acting Assistant Surgeon G. Byers tied both ends of the artery in the wound. The hæmorrhage did not recur." Discharged July 5, 1865. Not a pensioner.

In five of the ten cases, the artery was tied above and below the seat of injury. One of the patients died from pyæmia. In three instances, a proximal ligature only was applied. Two of the three patients died, one having undergone consecutive amputation; the third recovered, after consecutive ligation of the brachial. In the two remaining successful cases it is not stated whether one or two ligatures were applied.

*Ligations of the Radial Artery.*—The reported cases in which it was specified that the radial artery was tied on account of shot wounds unattended by fracture, numbered twenty. Eighteen will be briefly noted here—two, in which the brachial was tied consecutively,<sup>1</sup> having been already mentioned. Proximal ligatures were applied in eight, both proximal and distal ligatures in nine, while in three cases this point was not specified. Two were cases of primary, fifteen of intermediary, and three of secondary bleeding.<sup>2</sup> It is noticeable that in the four fatal cases proximal ligatures only were applied:

CASES.—There were two instances of ligation for primary bleeding: 1282.—Private W. C. Tate, Co. B, 56th Illinois, was wounded at Corinth, October 4, 1862, and sent to Mound City October 14th. Surgeon E. C. Franklin, U. S. V., noted: "Gunshot wound of the middle third of the right forearm, severing the radial artery and tendons of the supinator longus muscle. Ligation of the radial artery on the field. Returned to duty November 14, 1862." Tate is reported to have been lost on the steamer General Lyon, off Cape Hatteras, on the way to Illinois for muster out. 1283.—Private G. Smith, Co. H, 64th Ohio, was wounded at Marietta, June 16, 1864. Surgeon W. P. Pierce, 88th Illinois, recorded: "Gunshot wound of the left arm; radial artery divided. Ligation by Surgeon S. J. Young, 79th Illinois." The patient was subsequently treated in Cumberland Hospital and at Camp Demison, and was discharged December 3, 1865, and pensioned. Examiner W. Loughbridge, of Mansfield, Ohio, reported, July 3, 1872, that the radial nerve as well as the artery was wounded in this case, and that the extensors of the thumb and first two fingers are liable to spasmodic contraction from slight irritation. 1284.—Private D. Brown, Co. I, 7th West Virginia Cavalry, aged 18 years, was wounded at Wyoming, November, 1864. The radial artery was ligated five days after the reception of the injury, and the patient returned to duty in about a month. He was mustered out August 1, 1865, and re-enlisted December 11, 1866, in Co. K, 1st Infantry. Assistant Surgeon H. E. Brown noted "a deficient vitality in the left hand; he suffers from cold in it, and loss of power. The cicatrices from the wound and the operation are plainly visible." Not a pensioner. 1285.—Private Wm. Thompson, Co. E, 1st Maryland Legion, aged 24 years, was wounded at Cold Harbor, June 3, 1864, and sent to Alexandria June 9th. Surgeon E. Bentley, U. S. V., reported: "Gunshot flesh wound of the left forearm, the ball passing anterior to the bones. The radial artery was perforated, and from it considerable hæmorrhage occurred twenty-four hours previous to the operation. The tourniquet was applied at the time of hæmorrhage. On June 12th, the radial artery was ligated at wound, both ends of the artery being tied. Patient did well, and was returned to duty September 19, 1864." Not a pensioner. 1286.—Corporal J. A. Grundy, Co. F, 98th New York, aged 21, was wounded at Chapin's Farm, September 29, 1864. Surgeon J. J. Van Rensselaer, 98th New York, noted, "a gunshot wound of the left forearm," and the patient's transfer to Hampton Hospital on October 2d. The hospital register refers to "hæmorrhage from the radial and interosseous arteries to the amount of four ounces on October 9th; on the 10th, there was bleeding of five ounces, and on the 13th, of five ounces, checked, on each occasion, by compression and persulphate of iron and cold water applications. On the 16th, the radial artery was ligated in the wound, one end only being tied. There had been no recurrence of the hæmorrhage after the 13th. The patient died, on October 26th, from irritative fever." 1287.—Private L. Hathaway, Co. I, 25th Massachusetts, aged 24 years, was wounded at Cold Harbor, June 2, 1864. Surgeon S. A. Richardson, 13th New Hampshire, reported "a shot flesh wound of the upper fourth of the left forearm." The patient was sent to Alexandria, and on June 13th the radial artery was tied high up, by Surgeon Edwin Bentley, U. S. V. The parts were swollen, œdematous, and dark colored. The case progressed favorably, and the patient was discharged October 22, 1864, and pensioned. Examiner V. O. Taylor, of Athol, reported, September, 1873, "lameness of the arm not improved since last examination." 1288.—Corporal J. McIsaacs, Co. G, 5th Michigan, aged 21 years, was wounded at Spottsylvania, May 10, 1864, sent from a Second Corps hospital to Mount Pleasant, and thence, on May 20th, to Cuyler Hospital; the case was recorded by Assistant Surgeon H. S. Schell, U. S. A., as a gunshot flesh wound of the left forearm. May 21st, profuse hæmorrhage from the radial artery; eight ounces of blood lost. Acting Assistant Surgeon W. R. Duntun enlarged the wound and tied the radial artery above and below. The slough had not been discharged, and the surrounding parts were perfectly healthy. Hæmorrhage did not recur; ligatures came away on the 26th. Returned to duty August 12, 1864. 1289.—Private H. Greenly, Co. K, 34th New York, was wounded at Oak Grove, Virginia, June 30, 1862. Surgeon T. A. McParlin, U. S. A., reported from Annapolis, July 4, 1862: "Shell wound in right wrist. The wound sloughed and involved the radial artery, and, on July 10th, hæmorrhage to the amount of eighteen or twenty ounces took place. The

<sup>1</sup> CASES 21 and 30, in TABLE XLII—of Pt. H. Estes, Co. H, 11th Kentucky, and Corp'l A. Greaf, Co. D, 46th New York. CASE 1273, p. 450 *ante*.

<sup>2</sup> A good statistical table on wounds of the radial is contained in M. GUSTAVE MARTIN'S *Étude sur les Plaies artérielles de la Main et de la Partie inférieure de l'Avant-bras*, Thèse de Paris, 1870, No. 104, p. 3 *et seq.*

bleeding was arrested by cold, pressure, and styptics. On the 18th, the radial artery was ligated above the wound. The ligation was difficult on account of loss of blood and feeble pulsation. The wound healed, with a large cicatrix and contraction of the flexor muscles." Returned to duty October 29, 1862, and discharged the service January 10, 1863, and pensioned. Examiner H. B. Cole, of Wisconsin, reported, July 22, 1870, "partial ankylosis of wrist joint, and partial loss of use of thumb and index finger, with rheumatism of forearm." 1290.—Private J. Thomas, Co. G, 75th Illinois, aged 22 years, was wounded at Perryville, October 8, 1862. From New Albany Hospital No. 4, Acting Assistant Surgeon J. Sloan reported, October 14th: "Flesh wound of the middle third of the right forearm. October 20th, secondary hæmorrhage from the radial to the amount of twenty-four ounces; both ends of the artery were tied at the wound; no recurrence of the hæmorrhage. Discharged from service December 7, 1862." 1291.—Private M. O'Brien, Co. I, 169th New York, aged 24 years, was wounded at Petersburg, June 30, 1864. At Hampton Hospital there was noted: "Gunshot wound of the left forearm. July 14th, hæmorrhage to the amount of a quart from the radial artery. The artery was ligated in the wound July 15th; being tied above and below the bleeding point, just beyond the bifurcation of the brachial. Hæmorrhage recurred July 20th; loss of blood, two quarts; wound exposed to the air, and hæmorrhage ceased. Operator, Assistant Surgeon Edward Curtis, U. S. A. On August 2d, Acting Assistant Surgeon H. B. White amputated the arm at the middle third. \* \* The patient was transferred, October 6, 1864, to New York," and treated at Grant Hospital until February 11, 1865, when he was discharged and pensioned. The examiner's report, December 4, 1873, mentions no details of interest. 1292.—Private I. Miller, Co. K, 97th Pennsylvania, aged 25 years, was wounded in a skirmish in Virginia, May 20, 1864. Surgeon J. R. Everhart, 97th Pennsylvania, reported that the patient was sent from a Seventh Corps hospital to Hammond Hospital with a "shot wound of the left forearm; the ball passing through the radial side." The register of the Point Lookout Hospital states: "June 12th, Acting Assistant Surgeon S. H. Siebold ligated the radial artery above and below the wound. The patient recovered, and was transferred to the Veteran Reserve Corps April 12, 1865." Not a pensioner. 1293.—Private S. Hulse, Co. I, 84th Pennsylvania, aged 27 years, was wounded at Cold Harbor, June 3, 1864. Surgeon O. Everts, 20th Indiana, at a Second Corps hospital, reported: "Gunshot wound of the right forearm. The patient was sent to Hammond Hospital." The register states: "Hæmorrhage occurred from the radial on June 26th, with loss of nearly ten ounces of blood. The artery was ligated in its continuity above and below the point of hæmorrhage by Acting Assistant Surgeon J. Evans. Patient recovered sufficiently to go on furlough." He was transferred to Satterlee Hospital on August 16th, and deserted October 18, 1864. 1294.—Sergeant A. Knock, Co. B, 81th Illinois, aged 24 years, was wounded at Marietta, June 27, 1864, and sent to Nashville, to Cumberland Hospital, and thence transferred to Hospital No. 1 on the 14th. Surgeon B. B. Breed, U. S. V., noted: "Severe gunshot flesh wound of the left arm. On July 22d, hæmorrhage occurred from the radial artery to the amount of twelve ounces, and the artery was ligated in the wound, the proximal end only being tied. Gangrene supervened, involving the whole anterior aspect of the forearm and wrist joint, and, on July 24th, Surgeon R. L. Stanford, U. S. V., amputated at the lower third of the arm. Death ensued, from exhaustion from diarrhœa and suppuration, October 11, 1864." 1295.—Sergeant H. M. Beach, Co. C, 15th Minnesota, aged 31 years, was wounded at Nashville, December 16, 1864, and treated in Columbia Hospital until the 20th, and then sent to No. 4, New Albany, Indiana. Acting Assistant Surgeon S. J. Alexander noted: "The ball entered immediately above and within the outer condyle of the right humerus, passed downward, backward, and inward, injuring both the radial and ulnar arteries, fracturing no bones, and making its exit just below the internal condyle of the humerus. On January 10, 1865, hæmorrhage, of from sixteen to twenty ounces, took place from the radial and ulnar arteries. On the same day both arteries were ligated at the seat of injury, on the cardiac side, only one ligature being applied to each artery. The operation was performed by Acting Assistant Surgeon J. Sloan; hæmorrhage did not recur. The patient died January 28, 1865. Death was not the result of exhaustion, but was owing to the jaundiced and typhoid condition of the system." 1296.—Private R. Fisher, Co. K, 121st New York, aged 18 years, was wounded at Spottsylvania, May 10, 1864. Surgeon E. F. Taylor, 1st New Jersey, reported, from a Sixth Corps Hospital, a "shot wound of the lower third of the right forearm, nearly exposing the radial artery." The patient was sent to Armory Square, and later to Satterlee, where the register notes: "June 7th, secondary hæmorrhage from the radial; loss of blood, four ounces. The radial artery was tied at the upper and lower edges of the wound by Acting Assistant Surgeon A. A. Smith. Wound was sloughing from the effects of the contusion, some two and a half inches of the artery having been destroyed. Progress favorable; no recurrence of the hæmorrhage. Deserted December 1, 1864." 1297.—Sergeant G. H. Wrigthman, Co. L, 6th Michigan Cavalry, aged 23 years, was wounded at Hanover town, May 28, 1861, and sent to Emory Hospital June 4th. Surgeon W. R. Moseley, U. S. V., noted: "Shot wound of the right radial artery; ligation June 27th. Secondary hæmorrhage June 28th, amounting to six ounces; radial re-ligated in the wound at one end, with favorable result. Furloughed August 19, 1864. Deserted October 11, 1864." Not a pensioner. 1298.—Corporal W. C. Wright, Co. F, 107th New York, aged 21 years, was wounded at Atlanta, June 20, 1864, and sent to Nashville. Surgeon J. E. Herbst, U. S. V., noted, at Hospital No. 2: "Gunshot flesh wound of the right forearm; rupture of the radial artery; wound gangrenous. August 5th, artery tied by enlarging the wound by Acting Assistant Surgeon S. Blackwood." Duty July 13, 1865. Not a pensioner. 1299.—Private D. Ray, Co. I, 5th Connecticut, aged 22 years, was wounded at Dallas, May 25, 1864. Surgeon C. N. Campbell, 150th New York, reported, from a Twentieth Corps hospital: "A shot wound of middle third of left forearm; ball passing directly across, beneath the skin and fasciæ, slightly wounding the muscles." The patient was sent to Joe Holt Hospital, Jeffersonville. Surgeon H. P. Stearns, U. S. V., reports that on July 22d hæmorrhage to the amount of ten ounces, probably from a muscular branch of the radial, took place. The radial artery was ligated in the wound, both ends being tied. The patient recovered, and went to duty January 26, 1865. Not a pensioner.

The side injured was specified in each case, and the injuries were equally distributed, ten on the right and ten on the left side. Four cases terminated fatally; five patients were discharged; eight returned to duty; and three deserted. In two cases, a second ligation was practised, and, in two, resort was had to consecutive amputation. The bleedings were either primary or as late as the fifty-eighth day; the mean was nineteen days.



*Ligation of the Interosseous Artery*<sup>1</sup> for shot flesh wound of the forearm is represented in the reports by a single instance:

CASE 1300.—Private J. A. Forsyth, Co. G, 9th Maine, aged 21 years, was wounded near Petersburg, June 25, 1864. He was sent from a Tenth Corps hospital to Hampton Hospital. Assistant Surgeon E. McClellan, U. S. A., recorded: "Shell flesh wound of the left forearm. July 19th, hæmorrhage occurred from the interosseous artery, with loss of two ounces of blood. Both ends of the bleeding artery were ligated in the wound, on July 20th, by Assistant Surgeon E. Curtis, U. S. A. Hæmorrhage recurred on August 13th, and the patient died, from exhaustion, on the same day."

*A Ligation of the Superficial Palmar Arch* for shot wound was reported. The hospital and pension reports disagree regarding the complication of the injury of the soft parts by lesion of the bones:

CASE 1301.—Private R. D. Roberts, Co. F, 72d Illinois, aged 49 years, was wounded opposite Island 18, Mississippi River, March 9, 1864. He was sent to Adams Hospital, Memphis, on March 12th, from the steamer Hillman. Assistant Surgeon J. M. Study, U. S. V., reported that "a revolver ball entered about the centre of the right hand. On March 19th, the track of the ball was slit up. On March 27th, ligation of the superficial palmar arch was practised." Surgeon J. G. Keenon, U. S. V., reported "a revolver shot of right forearm, the ball entering about the centre of the palm of the hand and emerging at the upper third of the forearm. There was bleeding to the extent of eight ounces on March 22d, and, on March 27th, the superficial palmar arch was tied." This man was discharged and pensioned January 26, 1865. Examiner J. E. Ennis, of Iowa, reported, in 1866, contraction and loss of use of the fingers, from a "shattering of the radius and ulna." Examiner C. H. Lothrop, of Lyons, Iowa, reported, September 4, 1873, "perfect ankylosis of wrist joint." The pensioner stated that he had been attended at Memphis by Drs. Jessup and Hall. The second lieutenant of his company testified that while this soldier was returning to his regiment from a furlough, on the steamer Hillman, "when the boat was wooding on the Missouri shore, he was taken, and shot through his hand and wrist and arm by a guerrilla."

*Ligations of Branches* of the axillary and brachial, and ligations of the digital arteries, were, in a few instances, made the subjects of special reports. The anterior and posterior circumflex, the superior profunda, anastomotica magna, and the inner digitals of the index and middle fingers, are the minor arteries specified as ligated for shot wounds unattended by fracture.<sup>2</sup> Two of the cases of this group terminated fatally.<sup>3</sup>

*Flesh Wounds involving large Blood-vessels treated without Operation.*—A number of examples of shot wounds of the larger arterial trunks of the upper extremity were reported where ligatures were not applied; and many instances of opening of these vessels by ulceration or sloughing, consequent on shot injury, in which operative interference was not essayed. Nine cases of the former group were specially reported, and will be briefly recapitulated:

CASE 1302.—Lieutenant J. G. Miner, Co. K, 1st Kansas, was wounded at Tusculum, October 5, 1862. Surgeon A. Newman, 1st Kansas, reported, "a gunshot wound of the upper extremity, severing the axillary artery; death, October 5, 1862."

CASE 1303.—Private W. Hendrick, Co. F, 26th South Carolina, aged 22 years, was wounded May 20, 1864, and sent to a Confederate hospital in Petersburg. Surgeon W. L. Baylor reported that "a minie ball inflicted a flesh wound of the right shoulder; the axillary artery was believed to have been wounded. Hæmorrhage ensued on May 24th, and recurred on the 27th. The patient died June 1, 1864, from its effects."

CASE 1304.—Private C. W. Simpson, Co. B, 32d Massachusetts, aged 19 years, was wounded at Hatcher's Run, February 6, 1865, and was admitted to No. 1 Hospital, Annapolis, on February 17th. Surgeon B. A. Vanderkeift, U. S. V., reported: "Shot wound of the left shoulder, the ball passing through the axilla and wounding the axillary artery. On the 19th, there was slight hæmorrhage from the anterior opening; arrested by compression. It recurred during the evening more

<sup>1</sup> Compare an Account of the Ligation of the Interosseous Artery, by Assistant Surgeon G. M. STERNBERG, in Circular 3. S. G. O., 1871, p. 238.

<sup>2</sup> Cases of: 1. Private R. Yariek, G. 6th Michigan, wounded at Cold Harbor, June 3, 1864. Ligation of anterior circumflex of left arm at seat of injury. Discharged and pensioned. In September, 1873, Examiner J. G. LUZE of Saginaw, reported the arm "atrophied and weak." 2. Corporal A. Ward, F, 15th Massachusetts, aged 25, wounded at Gettysburg, July 2, 1863. Ligation of left posterior circumflex, at Saterlee, July 13th. Transferred to Veteran Reserves, and discharged July 28, 1864. 3. Corporal A. Detweiler, G, 15th Pennsylvania, aged 18, was wounded at Hatcher's Run, March 23, 1865. Ligation of right posterior circumflex artery, at Harewood Hospital, some time in April. Recovered, and was discharged June 16, 1865, and pensioned. There is a photograph of the patient in the Museum (*Contributed Photographs*, S. S., Vol. VII, p. 17). 4. Sergeant G. T. Zwick, I, 27th Michigan, aged 27, wounded at Spottsylvania, May 12, 1864. Ligation of left posterior circumflex, July 2d, at Chester. Death, July 15, 1864. 5. Corporal J. Foster, K, 2d Illinois, was wounded at Chickamauga, September 19, 1863. Ligation of the right anastomotica magna, September 29th. Death, October 9, 1863. 7. Private L. G. Williams, H, 84th Illinois, was wounded at Chickamauga, September 20, 1863. Proximal ligation of the left inferior profunda, October 8th. Discharged, and pensioned February 28, 1865. Examiner W. E. CRAIG, of Illinois, reported, September, 1873, that the wound had implicated the humeral artery, and that the motor powers of the hand were much impaired. 7. Private Z. Gantt, G, 27th North Carolina, was wounded at Petersburg, June 15, 1864. Ligation of the third digital artery by Assistant Surgeon E. CURTIS, U. S. A., July 20, 1864. 8. Private J. W. Turner, I, 126th Ohio, age 21, wounded at Spottsylvania, May 12, 1864. Ligation of second digital artery by Surgeon S. R. MOSELEY, U. S. V., May 22. Transferred to Veteran Reserves, January 17, 1865.

<sup>3</sup> CASES of Zwick and Foster, 4 and 5 of the preceding note.

profusely. The anterior and posterior openings were then enlarged, the clots removed, and fresh compresses, saturated with a solution of persulphate of iron, were applied and partially controlled the hæmorrhage; but it continued to weep until the 20th, when the patient became delirious, and continued so until the time of his death, February 22, 1865. Loss of blood thirty-two ounces. Supported throughout by beef-tea and brandy."

In a fourth case, reported as a wound implicating the axillary, the bleeding probably arose from the subscapular artery:

CASE 1305.—Private J. Shelley, Co. D, 107th Pennsylvania, was wounded at Fredericksburg, December 13, 1862, and was sent from a First Corps hospital to Washington, and admitted to Mount Pleasant Hospital December 21st. Acting Assistant Surgeon I. P. Myer reported: "The ball entered the arm on the internal side, about two inches below the head of the humerus, passed obliquely backward and slightly downward, toward the anterior border of the scapula, and was probably lodged in the axillary space. There was a collection of pus in the axilla, to which egress was given. On December 23d, secondary hæmorrhage supervened. There was hæmorrhage also on the subsequent evening. On December 26th, the patient was in a feeble, debilitated condition; pulse very frequent and weak; lips pallid from the repeated hæmorrhages; respiration quick and nervous. The blood and pus had burrowed beneath the muscles and tissues as far as the seventh rib and formed a large sac, from which a quantity of clotted blood and discharges of an offensive character were pressed out. The patient was too much prostrated to sit up a sufficient length of time to permit his wound to be dressed, being constantly bathed with perspiration. On January 2d, he was attacked with severe rigors; had a troublesome cough, with gelatinous spots mingled with blood: and fine crepitant râles through the lower portion of the right lung; pulse 100. A bistoury was passed into the huge fluctuating tumor, but the discharge consisted chiefly of clots of blood, only a very little pus escaping. January 3d, the wound was dressed and the sac emptied as near as possible of its contents, and the chest firmly bandaged. There was a return of the bleeding; checked by compresses. At eight o'clock that evening it recurred profusely; pressure upon the subclavian checked it. The wounds were then stuffed with charpie, sprinkled with powdered persulphate of iron, and the bleeding was controlled. January 4th, the patient was etherized, and a thorough examination of the wound was made. The finger was passed along the course of the wound, and pulsation was felt in the brachial artery; and through the incision in the axilla pulsation was recognized in the axillary artery; there was also pulsation in the radial. It was then inferred that the subscapular artery must be the source from which the hæmorrhage arose. The wound was again filled with charpie, over which compresses were placed, and in this condition the patient was allowed to remain undisturbed until January 7th, when the dressings were removed and the wounds cleared, and a large quantity of healthy pus entirely free from clots gushed forth; by gentle pressure the sac was effectually emptied, and a bandage was thrown tightly about the chest; pulse 100, and appetite improved. The sac was daily evacuated of its contents, and the bandaging continued. January 11th, while dressing the wounds this morning, a hard substance was discovered at the dependent portion of the sac, over which an incision was made, and a conical ball was extracted, that, no doubt, had lodged in the axilla, and had followed the burrowing blood and pus. It was extracted a little forward of a line dropped from the inferior angle of the scapula, and from the interspace of the seventh and eighth ribs. From this period the pulse began to diminish in frequency and the discharge to decrease in quantity. January 18th, to-day he sat up for several hours, for the first time since his illness. The discharge from the wound now amounts only to about two drachms during the twenty-four hours; pulse 88; appetite good; quite cheerful. January 24th, there is no more discharge; the patient is convalescing favorably." Shelley was discharged August 4, 1863, and pensioned. Examiner T. B. Smith, of Washington, reported, August 5, 1863: "Numbness, coldness, and loss of power of index and middle fingers and thumb of right hand, owing probably to nervous injury. Extension of arm imperfect through long rest." This pensioner died October 19, 1864. The cause of death is not known at the Pension Bureau.

Two cases were reported as instances of spontaneous healing of the brachial after shot injury. The evidence, however, is inconclusive:

CASE 1306.—Corporal T. Munroe, Co. K, 9th Illinois, was wounded at Chickamauga, September 20, 1863, and was sent to Nashville November 1st. Surgeon W. M. Chambers, U. S. V., noted: "Severe gunshot wound of the right arm, with injury to the brachial artery and nerves, and also a shot wound of the left arm. Discharged from service January 7, 1864, for paralysis of the right forearm in consequence of a cicatrix compressing the brachial artery and median nerve."

CASE 1307.—Private T. Hughes, Co. D, 1st Kansas, was wounded at Cross Bayou, Louisiana, September 14, 1863, and was admitted to Post Hospital, Natchez, Mississippi, on the following day. Surgeon B. F. Stephenson, 14th Illinois, noted: "Gunshot wound of the left arm. The ball passed beneath the radius and ulna and made its exit at the internal condyle of the humerus, severing the brachial artery. Secondary hæmorrhage September 16th; bleeding suppressed by compression. Duty, October 22, 1863." Not a pensioner.

In two cases, likewise, of shot injury of the radial, the bleeding was arrested without operative interference:<sup>1</sup>

CASE 1308.—Lieutenant J. Kelly, 23d Tennessee, aged 25, was wounded at Petersburg, June 17, 1864, by a conical musket ball. He was made a prisoner and was sent to Washington. Surgeon O. A. Judson, U. S. V., reported, from Carver Hospital, "a gunshot wound of the left forearm. The patient was transferred to Lincoln Hospital July 14th." Assistant Surgeon J. C. McKee, U. S. A., reported, "shot wound of left forearm, the radial artery severed. Transferred to Old Capitol Prison July 30, 1864."

<sup>1</sup> GUTHRIE (G. J.) (*On the Diseases and Injuries of Arteries*, London, 1830, p. 331) did not disapprove of attempts to treat wounds of the radial by compression. The shot lesion, if the artery is completely divided, is equivalent to torsion.



The next, the eighth of the series of shot flesh wounds interesting primarily the larger vessels of the upper extremity, of the cases treated without operation, was probably an example of division of the radial, with spontaneous cessation of the bleeding:

CASE 1309.—Captain *S. M. Rawlston*, Co. D, 6th Georgia Cavalry, aged 38 years, was wounded May 10, 1864, and entered Institute Hospital, Atlanta, May 19th. Surgeon D. C. O'Keefe recorded<sup>1</sup> a "Gunshot wound; the ball entering the left forearm anteriorly two inches from the elbow joint, and passing obliquely upward made its exit just above the olecranon process on the back of the arm. Great hæmorrhage followed the injury. There was no radial pulsation at the wrist. June 5th, the patient has done well up to this time; has had a chill, followed by fever; suppuration diminished; arm more painful; for this condition quinine was used in the forenoon; aperients and poultices to the arm were employed. June 13th, the parts around the elbow continue red, swollen, and painful; there is a free discharge of pus from the incision. From this time forward the patient steadily improved, and was furloughed July 29, 1864."

A case of hæmorrhage from the right interosseous artery was followed by gangrene and amputation of the thumb:

CASE 1310.—Private *S. Maxwell*, Co. A, 122d Ohio, aged 28 years, was wounded at Winchester, June 15, 1863, and sent to Newton University Hospital, Baltimore, on June 23d. Surgeon C. W. Jones, U. S. V., reported: "The patient was wounded by a minié ball entering anteriorly halfway between the wrist and elbow, and passing upward between the radius and ulna, lacerating the interosseous artery. On June 24th, a slight secondary hæmorrhage occurred, which was arrested by compression. On the 25th, a more marked hæmorrhage occurred. The wound was dilated and unsuccessful exploration made for the ball. An effort was also made to ligate the artery at the seat of injury, but it was so broken down that the effort proved a failure. Persulphate of iron was applied, with compression, which arrested the hæmorrhage and prevented its recurrence. In all, about twenty-four ounces of blood had been lost. On July 1st, the ball was removed by a counter opening posteriorly just below the elbow; the wound commenced healing very soon. On July 7th, the thumb became suddenly gangrenous, probably from obliteration of the interosseous artery, and a generally congested state of the arm interfered to a great extent with the circulation of the hand. The thumb was amputated at the middle of the metacarpal bone. On August 8th, the hand had entirely healed from the injury resulting from the amputation of the thumb; the wound of the arm was nearly well, though the destruction of the soft parts of the forearm was very marked." The amputated thumb was sent to the Museum by Dr. Jones, and is numbered 1692 of Section I (*Cat. Surg. Sect.*, 1866, p. 522).

*Sloughing involving the larger Blood-vessels.*—From various causes, many of the shot flesh wounds of the upper extremity, where no considerable vessel was implicated, assumed an unhealthy action, and the larger trunks were opened secondarily by ulceration.

*Hæmorrhage from the Subclavian or its Branches.*—One instance in which the main trunk, on the left side, was supposed to have been opened, was reported, and another where one of its principal branches gave way in a sloughing shot wound:

CASE 1311.—Sergeant *H. Allen*, Co. K, 77th New York, aged 33 years, was wounded at Antietam, September 17, 1862. He was sent from a Sixth Corps hospital to Harrisburg, probably on September 24th. Acting Assistant Surgeon J. P. Wilson reported that: "When admitted he was very weak from loss of blood; but by the use of tonics and styptics he appeared to rally until October 14th, when hæmorrhage to the extent of five pounds supervened. Brandy, styptics, plugging of the wound, and the actual cautery were employed unavailingly to arrest the bleeding. Ligation of the artery was not attempted, as, in the opinion of a number of surgeons who saw the case, it would have been entirely useless under the circumstances."

CASE 1312.—Corporal *L. Burnett*, 11th Mississippi, was wounded at Gettysburg, July 2, 1863. Surgeon H. Janes, U. S. V., reported "a gunshot wound of the breast," and added that the patient "was sent to the rebel field hospital, and was transferred to Chester Hospital July 19th. Surgeon E. Swift, U. S. A., reported: "A shell wound below the left clavicle, causing great destruction of the muscular tissue. On July 22d, there was profuse hæmorrhage from one of the branches of the left subclavian, which was imperfectly checked by compression and styptics. The patient died July 26, 1863, from the effects of the recurring hæmorrhages."

*Hæmorrhage from the Axillary or its Branches.*—Four cases were reported that appear to belong to this category:

CASE 1313.—Private *E. Wilson*, Co. E, 35th Missouri, aged 23 years, was wounded at Helena, July 2, 1863. He was sent to Gayoso Hospital, Memphis. Surgeon D. W. Hartshorne, U. S. V., reported: "A shot flesh wound of the left arm; hæmorrhage from the axillary artery, August 1st, nearly ten ounces of blood being lost. Death, August 7, 1863."

CASE 1314.—Private *E. J. Thompson*, Co. E, 82d Pennsylvania, aged 28 years, was wounded at Cold Harbor, June 3, 1864. He was sent directly to New York from White House Landing. Assistant Surgeon Warren Webster, U. S. A., reported, from De Camp Hospital: "A gunshot wound of the shoulder. On August 16th, hæmorrhage set in, proceeding apparently from the axillary artery. An attempt was made to find the bleeding point, but the patient expired during the exploration, August 16, 1864."

<sup>1</sup>O'KEEFE (D. C.), *Confederate States Medical and Surgical Journal*, 1865, Vol. II, p. 30.

In the next case, early bleeding from a branch of the axillary was followed by ulceration and mortal hæmorrhage from the main trunk:

CASE 1315.—Sergeant *W. T. White*, Co. B, 3d North Carolina, aged 22 years, was wounded at Petersburg, April 1, 1864. Treated at Sickel's Hospital, Alexandria. Surgeon *E. Bentley*, U. S. V., reported: "On admission there was slight hæmorrhage from small branches of the axillary, which was controlled by pressure, but recurred. Loss of blood, twenty-four ounces. Pulse small; patient too feeble to undergo the operation of ligation of the subclavian, which was the only one likely to afford relief, as the axillary artery had undoubtedly sloughed high up in the axilla. Death, April 29, 1864."

The happy effects of temporary compression under certain circumstances are illustrated by the following case:

CASE 1316.—Private *W. H. Bailey*, Co. F, 38th New York, aged 20 years, was wounded at Fredericksburg, December 13, 1862, and sent to Annapolis January 29, 1863. Surgeon *T. A. McParlin*, U. S. A., reported: "A gunshot wound, the ball passing through the front of the shoulder and out near the scapula. Gangrene took place at the orifice of the wound on January 18, 1863, and sloughing continued until February 26th. On March 9th, bleeding to the amount of twelve ounces took place, probably from injury to one of the thoracic arteries. Pressure was made by a pad and bandage over the subclavian for forty-eight hours, and bleeding was arrested." This soldier was discharged and pensioned. The Boston Pension Examining Board reported, September 8, 1873, that "the extremity was paralyzed and atrophied, the forearm two and a half and the hand a half inch smaller than their fellows."

Special reports were made in several cases of bleeding from the brachial or its branches, that were treated by compression and styptics:

CASE 1317.—Private *T. J. Young*, Co. F, 20th Maine, aged 30 years, was wounded at Gettysburg, July 2, 1863. He was sent to Summit House Hospital. Acting Assistant Surgeon *J. Gibbons Hunt* reported: "Phagedenic ulceration of the lower half of the left arm followed a shot flesh wound. Hæmorrhage, to the amount of sixteen ounces, took place on August 25th. It was arrested by persulphate of iron and decoction of logwood." He was discharged and pensioned September 19, 1863.

CASE 1318.—Sergeant *J. T. Robinson*, 122d Ohio, aged 26 years, was wounded at the Wilderness, May 6, 1864. He was sent to Washington, to Harewood Hospital. Surgeon *R. B. Bontecou*, U. S. V., reported: "He had a shot perforation through the right knee joint, and a flesh wound at the lower third of the right upper arm. What appeared to be a comparatively unimportant injury proved, in the sequel, a fatal accident. Bleeding from the wound in the forearm came on June 2d, as much as sixteen ounces of blood being lost. The hæmorrhage was arrested by compression of the brachial, but, in the patient's debilitated condition, the bleeding was mortal; and when the surgeon arrived and prepared to tie the artery the patient was moribund. He died June 2, 1864."

CASE 1319.—Private *D. Warner*, Co. B, 170th Ohio, was wounded at Snicker's Ferry, July 18, 1864, and was sent to Sandy Hook. Acting Assistant Surgeon *N. F. Graham* reported: "A shot wound of the left arm. Hæmorrhage from ulceration of the artery, August 1, 1864; compression used. Hæmorrhage recurred August 6th, and continued at intervals until death, August 12, 1864."

CASE 1320.—Colonel *G. Mihalotzy*, 24th Illinois, was wounded at Tunnel Hill, February 25, 1864. Surgeon *L. D. Harlow*, U. S. V., reported from the Officers' Hospital, Lookout Mountain: "A deep gunshot flesh wound of the right arm above the elbow. Hæmorrhage, amounting to sixteen ounces, from the anastomotica magna, took place on March 2d. Solution of perchloride of iron was applied. The patient died March 11, 1864, probably from pyæmia which succeeded the hæmorrhage."

CASE 1321.—Sergeant *J. Lawton*, Co. A, 13th Pennsylvania, aged 24 years, was wounded at Petersburg, June 15, 1864. Surgeon *T. H. Bache*, U. S. V., reported from Chester Hospital: "There was hæmorrhage from the anastomotica magna to the extent of six ounces on July 8th, consequent on a shot wound of the fleshy part of the middle third of the right arm. The bleeding was controlled by stuffing the wound with lint saturated with a solution of the persulphate of iron, and the patient recovered, and was returned to duty November 23, 1864." Not a pensioner.

CASE 1322.—Private *W. Jones*, Co. E, 4th Delaware, aged 24 years, was wounded at Petersburg, June 18, 1864, and sent to Washington. Assistant Surgeon *C. A. McCall*, U. S. A., reported from Mount Pleasant Hospital: "A superficial shot wound of the right arm near the elbow joint. Hæmorrhage occurred on July 23d and on August 9th, from a branch of the brachial artery, with a loss of ten ounces of blood. The bleeding was arrested by cold applications and compression." This soldier was returned to duty December 22, 1864. Discharged and pensioned, May 7, 1865, for muscular contraction.

CASE 1323.—Sergeant *G. Shapleigh*, Co. D, 5th New Hampshire, aged 28 years, was wounded at Gettysburg, July 2, 1863, and treated at Satterlee Hospital. Surgeon *I. I. Hayes* reported: "A shot flesh wound of the right arm. On July 20th, there was hæmorrhage from a muscular branch of the brachial to the amount of six ounces; it was arrested by compression."

CASE 1324.—Private *J. Ruhl*, Co. K, 88th Pennsylvania, aged 34 years, was wounded at Gettysburg, July 3, 1863. Acting Assistant Surgeon *W. V. Keating* reported, from Broad and Cherry Streets Hospital, Philadelphia: "A shot wound of the right arm followed by sloughing. On August 10th, there was bleeding to the extent of ten ounces from a muscular branch of the brachial; the bleeding was arrested by compression." This soldier was discharged and pensioned September 10, 1864.

CASE 1325.—Private *E. Powers*, Co. C, 4th Massachusetts Cavalry, aged 30 years, was wounded at Jacksonville, Florida, March 1, 1864, and was treated at Beaufort, South Carolina. Assistant Surgeon *C. E. Goddard*, U. S. A., reported: "A shot wound of the upper third of the left arm. On March 15th, there was hæmorrhage from a muscular branch of the brachial; treated successfully by compression." The patient recovered, and was discharged and pensioned October 4, 1864.



*Hæmorrhage from the Ulnar Artery or its Branches.*—Guthrie<sup>1</sup> taught that bleeding from the ulnar artery would be arrested spontaneously, if the vessel was completely severed. This is doubtless true; but a great liability to consecutive bleeding remains, and he is a rash surgeon who trusts a vessel of this calibre without a ligature, unless he employs torsion, acupressure, or some other substitute.

CASE 1326.—Private T. E. Curtis, Co. C, 10th Connecticut, aged 19 years, was wounded at Kinston, December 14, 1862, and was sent to New Berne. Surgeon E. P. Morong, 2d Maryland, reported: "December 25th, hæmorrhage from ulnar artery to the amount of seventeen ounces; tourniquet applied to the brachial arrested the bleeding;" recovery.

CASE 1327.—Private H. Olsen, Co. C, 56th Massachusetts, aged 18 years, was wounded at Petersburg, June 17, 1864, and was sent to Harewood Hospital July 20th. Surgeon R. B. Bontecon, U. S. V., reported a shot wound of the left hand, ball entering near the pisiform bone, and emerging at the side of the wrist, about an inch below. The ball was cut out August 1st. On August 9th and 10th, there were hæmorrhages to the amount of two ounces from branches of the ulnar. An incision was made for the purpose of finding the bleeding vessel, but without avail. No recurrence of bleeding. The patient did well and was returned to duty.

CASE 1328.—Private J. Carter, Co. D, 11th Connecticut, aged 22 years, was wounded at Drury's Bluff, May 16, 1864, and sent to DeCamp Hospital on May 22d. Assistant Surgeon W. Webster, U. S. A., reported: "A shot flesh wound of the right forearm at the middle third. On June 2, 1864, hæmorrhage, to the amount of twelve ounces, took place from the ulnar artery, but ceased after compression, and did not recur." This soldier was discharged December 21, 1865.

CASE 1329.—Private W. A. Dobbins, Co. B, 84th Illinois, aged 28 years, was wounded at Chickamauga, September 19, 1863. Surgeon C. W. Hornor, U. S. V., reported, from Hospital No. 1, Nashville, October 12th: "Shot flesh wound of the upper third of the left forearm. On November 23d, there was bleeding from a branch of the ulnar, which was arrested by compression of the brachial. The bleeding recurred, however, and the patient died May 23, 1864."

*Hæmorrhage from the Radial and its Branches.*—Four examples were specified:

CASE 1330.—Sergeant J. E. Brown, Co. K, 13th Mississippi, aged 31 years, was wounded at Gettysburg, July 2, 1863, and sent to the Twelfth Corps Hospital. Surgeon H. E. Goodman, 23th Pennsylvania, reported: "A gunshot flesh wound of the forearm, with hæmorrhage from the radial artery, July 14th." This soldier was paroled from West's Buildings Hospital September 25, 1863.

CASE 1331.—Corporal S. Lowery, Co. G, 92d New York, aged 25 years, was wounded at Petersburg, June 15, 1864, and sent to McClellan Hospital. Surgeon L. Taylor, U. S. A., reported: "A shot flesh wound of the left forearm at its lower third. Bleeding to the amount of two quarts, from the radial artery, took place on July 7th. It was checked by persulphate of iron and compression." The patient recovered, and was returned to duty December 3, 1864.

CASE 1332.—Private L. D. Varney, Co. B, 106th New York, aged 22 years, was wounded at Cold Harbor, June 3, 1864, and was sent to McKim's Hospital. Surgeon Lavington Quick, U. S. V., reported: "A flesh wound of the lower third of the left forearm near the wrist. The wound sloughed, and, on July 2d, hæmorrhage to the amount of one pint occurred from the radial artery; this was arrested by the application of powdered persulphate of iron, pressure, and ice." No recurrence of bleeding supervened, and this soldier was returned to duty November 28, 1864.

CASE 1333.—Private J. A. Campbell, Co. H, 81st Illinois, was wounded at Vicksburg, May 22, 1863. He was admitted at Church Hospital, Memphis. Surgeon G. R. Weeks, U. S. V., reported: "A gunshot wound of the left hand. On admission the entire palmar surface of the hand was covered with fetid sloughs, and the cavity of disorganized tissue extended nearly to the elbow. Bromine was freely applied, and the wound cleaned rapidly. On August 13th, hæmorrhage to the extent of thirty ounces took place from the radial. He died the same day. The autopsy revealed thrombi in the vessels leading to and from the heart."

*Hæmorrhage from the Interosseous Artery.*—Three instances were reported of serious bleeding from shot flesh wounds of the forearm, where the interosseous artery was believed to be consecutively implicated:

CASE 1334.—Sergeant N. Strain, Co. C, 9th Veteran Reserves, aged 28 years, was wounded at Fort Stevens, July 11, 1864. He was treated at Mount Pleasant Hospital. Assistant Surgeon C. A. McCall, U. S. A., reported: "Hæmorrhage of thirty-four ounces, from the left interosseous artery, on July 23d, following a gunshot wound of the forearm. The bleeding recurred on August 3d, and again on the 12th, and was arrested by compression, a finger being introduced into the wound." The patient was returned to duty.

CASE 1335.—Private S. Sharpe, Co. C, 4th U. S. Colored Troops, aged 20 years, was wounded at Deep Bottom, September 29, 1864. Assistant Surgeon J. H. Frantz, U. S. A., reported: "A shot perforating flesh wound of the forearm. At Balfour Hospital, on October 15th, eight ounces of blood were lost; but the bleeding was arrested by cold and compression."

CASE 1336.—Private C. Lake, Co. H, 10th New York Artillery, aged 27 years, was wounded at Petersburg, July 3, 1864. Assistant Surgeon J. H. Frantz, U. S. A., reported, from Balfour Hospital: "A gunshot flesh wound of the forearm. Bleeding to the extent of eight ounces took place on July 10th. It was controlled by compression, and there was no recurrence."

<sup>1</sup> See his work *On the Diseases and Injuries of Arteries, with the Operations required for their Cure*, London, 1830, p. 225: "In many cases of amputation at the wrist and forearm, in which I wished the patient to lose a certain quantity of blood, I have allowed either the radial or ulnar artery to bleed until it ceased."

Three cases of consecutive bleeding from the palmar arches,<sup>1</sup> due to sloughing consequent on shot injuries of the hand unattended by fracture, were reported without details. One proved fatal.

Serious results were reported from hæmorrhages from sloughing wounds implicating the digital arteries.<sup>2</sup> One fatal case was recorded; but the fatal termination was apparently due to pyæmic infection.

A few additional examples of hæmorrhage from collateral branches, inadvertently omitted in the preceding enumeration, may be noted here.

There were four reported instances of shot flesh wounds of the shoulder in which grave hæmorrhage arose, as was believed, from the supra-scapular branch of the subclavian, or from the subscapular arteries.<sup>3</sup>

There were two examples of fatal consecutive bleeding in shot flesh wounds of the right shoulder, in which it was supposed that the hæmorrhage proceeded from ulceration of the acromial thoracic artery.<sup>4</sup> A single instance was specified of serious bleeding from the inferior circumflex branch of the axillary.<sup>5</sup>

Examples have been given already<sup>6</sup> of hæmorrhages from branches of the brachial. Special reports were made, besides, of two instances of bleeding after shot injury of the superior profunda, one case proving fatal.

CASE 1337.—Private J. Johnson, Co. I, 39th Illinois, aged 18 years, was wounded at Bermuda Hundred, May 14, 1864. Surgeon A. Heger, U. S. A., reported: "On June 23d and 24th, bleedings of from ten to twelve ounces took place from a gunshot wound of the right axilla. The hæmorrhages proceeded from the superior profunda. Digital compression of the right subclavian was kept up night and day by the hospital assistants. There were slight recurrences of bleeding, however, and the patient died June 24, 1864."

Another instance of bleeding from the superior profunda is noted on the succeeding page. In these lesions of the branches of the axillary and brachial, as in many other circumstances, a precise knowledge of the topographical anatomy will guide the surgeon to a correct treatment; but this knowledge will be unavailing, unless, at the same time, he appreciates the true principles of the management of wounded arteries.

<sup>1</sup> CASES of Pt. J. Blanch, 123d New York, wounded at Petersburg, April 2, 1865; Surgeon B. B. WILSON, U. S. V., reported, from Stanton Hospital, that bleeding from the right superficial palmar arch on April 11th was successfully treated by compression. 2. Of Pt. G. M. Kidd, 46th Virginia, aged 41. In the records of the Confederate medical department, Vol. LXXIX, p. 63, it is stated that "he was wounded at Atlanta, August 4, 1864, and the left superficial palmar arch was opened by sloughing consequent on the wound, and profuse hæmorrhage occurred on August 12th, but was successfully controlled by compression." 3. Of Pt. J. C. Costley, Co. H, 3d Kentucky Cavalry; was wounded at Stone River, December 31, 1862. Surgeon J. SHRADY, 2d Tennessee, reported: "A shot wound traversing the palm, forearm, and arm, the missile lodging near the spine of the scapula. Hæmorrhage from the palmar arches January 12, 1863. Profuse bleeding; death, January 14, 1863."

<sup>2</sup> Corporal E. Stewart, 1st Missouri Cavalry, aged 22, was wounded at the Wilderness, May 5, 1864. Surgeon T. H. BACHE, U. S. V., reported from Chester Hospital, that "bleeding, to the extent of twenty-four ounces, took place on June 3d, from one of the digital arteries of the right hand, but was arrested by compression." Sergeant T. Rieger, Co. D, 119th New York, aged 28, was wounded at Gettysburg, July 2, 1863. Surgeon I. I. HAYES, U. S. V., reported: "A shot flesh wound of the left hand, with hæmorrhage from a digital artery, August 5th, to the extent of two ounces. It was arrested by cold and pressure; but pyæmia supervened, and death ensued August 19, 1863."

<sup>3</sup> CASES: Surgeon R. M. S. JACKSON, U. S. V., reported that Pt. H. G. Whitehead, Co. G, 141st New York, was wounded at Atlanta, July 20, 1864, and lost forty ounces of blood, September 25th, at Lookout Mountain, from a shot flesh wound of the right shoulder. The bleeding was supposed to proceed from the supra-scapular artery. The patient died a few hours after the bleeding. There were two deaths and one recovery in the three cases in which the bleeding was supposed to proceed from the subscapular; Surgeon L. TAYLOR, U. S. A., reported, from McClellan Hospital, that "Pt. J. F. Cole, Co. F, 35th Massachusetts, aged 23, was wounded at Spottsylvania, May 18, 1864. There was hæmorrhage from the subscapular artery on June 13th, following a shot wound of the left shoulder, and the patient died June 14, 1864." Surgeon H. S. STEARNS, U. S. V., reported from Paducah: "Pt. A. Young, Co. A, 22th Louisiana, was wounded at Chickasaw Bayou, December 29, 1862, by a shot perforation of the right shoulder. There was hæmorrhage on January 14th, from the subscapular probably. Death, January 15, 1863." Dr. STEARNS also recorded a case of recovery from secondary bleeding from this vessel: "Corporal E. W. Olney, Co. F, 13th Illinois, was wounded at Vicksburg, December 29, 1862. On January 14th, there was bleeding from the left subscapular artery. The shot track appeared to involve the soft parts only. The bleeding was arrested by the injection of a solution of perchloride of iron, and the patient made a rapid recovery."

<sup>4</sup> CASES of Pt. J. V. Snyder, Co. I, 12th Iowa, and of Pt. T. Snowberger, Co. E, 184th Pennsylvania; the former wounded at Tupelo, and treated at Adams Hospital, Memphis; Assistant Surgeon J. M. STUDY, U. S. V., reporting a mortal hæmorrhage from the acromial thoracic, estimating the amount of blood lost at sixty ounces. Death, August 12, 1864. The second patient was wounded at Petersburg, June 18, 1864, and died at Mount Pleasant Hospital, July 29, 1864. Bleeding from one of the right acromial arteries was temporarily arrested by styptics and compression; but the patient sank the same day.

<sup>5</sup> CASE of Sergeant J. Blackwell, Co. E, 24th Michigan, aged 20, wounded at Gettysburg. Surgeon I. I. HAYES, U. S. V., reported, from Sutterlee: "A shot flesh wound of the right axilla, followed, August 2, 1863, by profuse hæmorrhage from the inferior circumflex." Duty, March 24, 1864.

<sup>6</sup> See CASES 1320 *et seq.*, p. 457.



In a second case of consecutive bleeding from the superior profunda, a somewhat novel hæmostatic method was employed:

CASE 1333.—Private W. Getcher, Co. F, 1st Pennsylvania, aged 24 years, was wounded at Old Church, May 30, 1864, and sent to Philadelphia. Assistant Surgeon S. A. Storrow, U. S. A., reported a "gunshot wound of the right upper arm. Hæmorrhage of twelve ounces from the profunda major, June 14th. The clot being removed and the bleeding recurring, the wound was filled with subnitrate of bismuth, and compression was made by bandages from the wrist." The patient was transferred to Harrisburg, June 16, 1864, for muster out of service.

In a number of instances of bleeding consequent on shot wounds of the forearm, satisfactory results were ascribed to the use of compression, styptics, and the application of cold. Surgeon J. Curtis, U. S. V., reported two cases<sup>1</sup> to exemplify the utility of the persulphate of iron under such circumstances. Assistant Surgeon A. Ingram, U. S. A., reported an instance of hæmorrhage after a shot lesion of the superficialis volæ, arrested by the same means.<sup>2</sup> Reliance on such measures was not always rewarded by success, since in thirteen instances, at least, bleeding from minor branches led to a fatal termination. These cases will be briefly noted. But three were intermediary; in the others, the bleedings<sup>3</sup> were later than the first fortnight after the injury:

CASES 1339-1351.—Surgeon T. Antisell, U. S. V., reported that: "Major L. Schaumberger, 15th New York Artillery, was wounded at Hanover Court House, May 19, 1864, receiving a shot flesh wound of the right forearm. Profuse hæmorrhage took place, May 23th, and the officer died from its effects the same day." Surgeon W. L. Baylor, of the Confederate service, reported that: "Private A. Lusecomb, Co. G, 39th Illinois, was wounded at Bermuda Hundred, May 16, 1864, and captured. He was treated at Petersburg for a gunshot flesh wound of the right arm, and died May 26, 1864, from hæmorrhage, which compression failed to control." Acting Assistant Surgeon G. W. France reported that: "Private P. Borkvort, Co. C, 19th Illinois, was wounded at Vicksburg, January 2, 1863. He was sent to Nashville Hospital No. 7, with 'a lacerated gunshot wound of the left forearm. Hæmorrhage amounting to forty ounces, on January 16th, was controlled by compression of the brachial, and a second bleeding did not occur; but pulmonary trouble set in, and the case terminated fatally February 24, 1863.'" Medical Cadet O. M. Pray reported and printed<sup>4</sup> an account of the case of "*John Wiggall*, Co. F, 11th Virginia, aged about 25, \* \* \* wounded at Williamsburg, May 5, 1862," in the muscles of the right shoulder, by a musket ball. "Secondary hæmorrhage occurred about May 21st, from the anterior wound. A plug and compress were used for about three days, and then removed. On the 23th, another hæmorrhage took place, and again the wound was plugged. Patient was very weak. Slight hæmorrhage on the 29th. Death took place May 30th." Surgeon A. Hartsuff, U. S. A., reported that: "Private W. Bennett, Co. D, 11th Wisconsin, aged 38 years, was wounded at Fort Blakeley, April 9, 1865, and was treated, at Greenville, for a shot wound of the right forearm, and died from exhaustion, due to secondary hæmorrhage, April 29, 1865." Surgeon J. H. Taylor, U. S. V., reported that: "Teamster B. Fuller, Sixth Corps, was wounded near City Point, July 12, 1864. He had a shot flesh wound of the right shoulder. Secondary hæmorrhage took place August 2, 1864, and resulted in death." Assistant Surgeon C. A. McCall, U. S. A., reported that: "Private B. Atwood, Co. C, 1st New York Dragoons, aged 24 years, was wounded at Old Church, June 11, 1864, receiving a shot perforation of the left deltoid. Death from hæmorrhage, July 2, 1864." Surgeon A. J. Ward, 2d Wisconsin, reported that: "Private *E. Nall*, 53d North Carolina, was wounded at Gettysburg. A musket ball had penetrated the fleshy parts of the right shoulder. He died, July 23, 1863, from secondary hæmorrhage." Surgeon J. G. Hatchitt, U. S. V., reported that: "Corporal A. J. Ferris, Co. C, 10th Wisconsin, was wounded at Perryville, October 8, 1862, by a musket ball, which passed through the left shoulder without injuring the bones. Death, from secondary hæmorrhage, November 5, 1862." Surgeon S. J. W. Mintzer, 83d Illinois, reported that: "Captain *R. Stephenson*, a Confederate officer, aged 33 years, was wounded at an engagement near Fort Donelson, February 3, 1863, and made a prisoner. A musket ball passed through the lower part of the muscular walls of the right axilla without injuring any vessels or nerves of importance. On March 3d, and again on March 5th, there was profuse hæmorrhage, a thin dark-colored blood, that did not coagulate, flowing away. The bleeding continued, in spite of compression and the various other hæmostatics resorted to, until the date of the death of this officer, May 6, 1863." Assistant Surgeon E. McClellan, U. S. A., reported that: "Private N. E. Sweat, Co. E, 24th Massachusetts, aged 23 years, was wounded at Bermuda Hundred, May 18, 1864, a musket ball perforating the right pectoral and deltoid muscles. Death, from secondary hæmorrhage, June 26, 1864." The same medical officer reported that: "Private M. Bayard, Co. C, 116th Ohio, aged 23 years, was wounded at Hatcher's Run, March 30, 1865. A gunshot flesh wound of the left upper arm was followed, on May 27th, by secondary bleeding, which resulted fatally on the same day." Surgeon E. S. Cooper, U. S. V., reported that: "Private T. Maloy, Co. B, 62th New York, was wounded at Spottsylvania, May 10, 1864. A musket ball perforated the left arm without fracturing the humerus. Secondary hæmorrhage occurred, and was checked by the application of a tourniquet; but the bleeding recurred, and the patient died August 18, 1864."

<sup>1</sup> CASE of Pt. C. W. O'Key, Co. C, 6th Wisconsin, aged 23, wounded at Gettysburg, and treated at Cuyler Hospital for a shot wound grazing the right wrist. Hæmorrhage, on August 3d, was arrested by the Monsel salt. The case of Pt. A. F. Muller, Co. C, 6th Wisconsin, aged 23, was identical in the reported details.

<sup>2</sup> CASE of Pt. J. Dunkel, Co. D, 148th Penn., aged 33, wounded at Chancellorsville. Hæmorrhage from superficialis volæ, May 17, 1863. Duty.

<sup>3</sup> The dates of hæmorrhage were, in the thirteen cases, on the 9th, 10th, and 13th days in the three intermediary cases, and in the others the intervals were, respectively, 16, 20, 21 (in two cases), 22, 28, 30, 39, 57, and 111 days.

<sup>4</sup> Report of Mill Creek Hospital, Fort Monroe, in *Am. Med. Times*, 1862, Vol. V, p. 76.

**Flesh Wounds involving the larger Nerves.**—The reports specify ninety-six instances of shot flesh wounds of the upper extremities unattended by injuries of the bones or blood-vessels, but interesting large nerve trunks. The most detailed accounts of such cases are from the Christian Street Hospital, in Philadelphia, where, in May, 1863, wards were set apart for cases of traumatic affections of the nerves. Dr. Mitchell, Dr. Morehouse, and Dr. Keen had charge of these wards, and have published the results of their observations in several important papers. The first<sup>1</sup> and second<sup>2</sup> were prepared in association by the three observers. A third monograph<sup>3</sup> was printed by Dr. Mitchell, in 1867, on this subject; and, with the Baconian inspiration that every debtor to his profession should also be a help thereunto, this writer, in 1872, printed a systematic treatise<sup>4</sup> on

<sup>1</sup> *Gunshot Wounds and other Injuries of Nerves*, by S. WEIR MITCHELL, M. D., GEORGE R. MOREHOUSE, M. D., and WILLIAM W. KEEN, M. D., Philadelphia, 1864. In this valuable treatise, CASE 19 (p. 90), of Pt. J. Bieswänger, Co. B, 75th Pennsylvania, was an example of "gunshot wound of the left brachial plexus, with slight loss of sensation and paralysis of motion. Atrophy and contraction of numerous muscles, and joint lesions due to disuse," ensued. CASE 22, of Pt. A. Lawton (p. 94), Co. A, 4th Ohio, aged 20, wounded at Chancellorsville, was an instance of "gunshot wound of the brachial nerves, with slight loss of motion and sensation, with early burning pain, diseased joints, and acid sweats." The "vinegar sweats" are said to have "disappeared during the electrization of the arm, but probably not through its agency." CASE 23 (p. 98), of B. Graham, 5th Battery, Massachusetts Artillery, aged 22, was a case of "shell wound affecting the musculo-spinal nerve, with trivial loss of facility; but entire motor paralysis in the ultimate distribution of the nerve." CASE 24 (p. 107), of H. Weston, Co. E, 18th Massachusetts, aged 42, is the history of an "injury of the brachial nerves, resulting in nutritive changes and in burning and neuralgic pains." CASE 27 (p. 126), Pt. L. Monaghan, aged 26, wounded at Chancellorsville, May 3, 1863; "shell bruise of right brachial plexus; slight loss of motion; tonic spasm of the flexor carpi radialis, flexor carpi ulnaris, and palmaris longus, causing violent flexion of wrist; analgesia well marked; no loss of facility; section of tendons; relief." CASE 30 (p. 131), H. Gervaise, Co. F, 1st Vermont Cavalry, aged 20, shot, July 7, 1863, in the left arm, at the edge of the biceps, six inches above the internal condyle of the humerus; exit on postero-internal face of arm; ulnar and median nerves injured; "paralysis of motion; slight of sensation; contraction of flexors; relaxation under treatment; atrophy; claw-hand from paralysis of interossei; stinging pain in hand; great gain; interosseal paralysis alone remains; discharge, with prosthetic apparatus." CASE 31 (p. 148), Sergeant A. D. Marks, Co. C, 3d Maryland; shot wound of left brachial plexus; "paralysis of motion and sensation; muscular hyperaesthesia; intense burning in hand and arm; contracted extensors; relief;" discharged April 10, 1864.

<sup>2</sup> Circular No. 6, S. G. O., March 10, 1864 (*Reflex Paralysis*), by S. WEIR MITCHELL, M. D., GEORGE R. MOREHOUSE, M. D., and WILLIAM W. KEEN, Jr., M. D. CASE VII (p. 13), of Pt. M. Farrell, Co. I, 20th New York, aged 28, wounded at Fredericksburg, December 13, 1862, is an example of "wound of the deltoid; sensory and slight motor paralysis of right arm; 'speedy recovery.'"

<sup>3</sup> A. FLINT, M. D. (*Contributions relating to the Causation and Prevention of Disease, and to Camp Diseases*, New York, 1867, *Preface*, pp. V, VI), informs us that: "After the termination of the late war of the rebellion, the United States Sanitary Commission resolved to publish a series of volumes \* \* \* under the immediate direction of the medical committee of the Commission, the committee consisting of Professor WM. H. VAN BUREN, M. D., CORNELIUS R. AGNEW, M. D., ELISHA HARRIS, M. D., Professor WOLCOTT GIBBS, M. D., and Professor J. S. NEWBERRY, M. D. \* \* \* This volume is devoted to topics pertaining to medicine. \* \* \* The transportation of the sick and wounded, together with other kindred topics, and all those which belong to surgery are assigned to other volumes." The twelfth chapter of the volume thus prefaced, is a paper by Dr. S. WEIR MITCHELL, *On the Diseases of Nerves resulting from Injuries* (pp. 412-468), containing abstracts of a large number of cases observed at the "United States Army Hospital for Injuries and Diseases of the Nervous System." It is difficult to understand why this topic was supposed to have no relevancy to surgery. Perhaps the exclusive devotion to medicine of Professors GIBBS and NEWBERRY led them to regard the cases only in their relations to internal pathology. This important paper contains abstracts of the following "war cases" of shot flesh wounds of the upper extremities, with lesions of the nerves, unattended by injuries of the bones or blood-vessels: CASE I (p. 455), J. Albaugh, Co. G, 83d Pennsylvania, aged 19, wounded at Chancellorsville, May 5, 1863; ball passing through interosseal space of the right forearm; "partial loss of sensation; immobility of fingers and wrist owing to disease and adhesion; recovery." CASE II (p. 456), C. Behr, Co. K, 1st Minnesota, aged 26, shot at Gettysburg, July 2, 1863, in the left hand, between the thumb and forefinger, ball finally entering half an inch below the clavicle; "wound of brachial plexus; paralysis, atrophy, and contraction of numerous muscles; burning pain until wound healed; motions limited by general stiffening of the joints." CASE III (p. 457), G. T. Barnes, Co. D, 68th Pennsylvania, aged 25, wounded at Gettysburg, July 2, 1863, at the antero-superior angle of left axilla; axillary nerves injured; "extensive paralysis of forearm and hand; loss of sensation; great improvement under treatment; continued gain afterward." CASE V (p. 461), R. C. Phillips, Co. C, 4th New York, aged 20, wounded at Gettysburg, July 2, 1863; ball entered the left chest, and lodged in the left arm on a level with the posterior border of the armpit; two hours later the missile was cut out; axillary nerves injured; "total loss of motion; extensive atrophy; gradual gain; partial loss of sensation; slight causalgia and neuralgia; relief of both; tremors; great general gain." CASE VI (p. 463), D. Shiveley, Co. E, 114th Pennsylvania, aged 17, shot at Gettysburg, July 2, 1863; the ball entered an inch above the sternal end of the clavicle and escaped on the posterior part of the right arm two inches below the axilla; axillary nerves injured; "paralysis of motion; slight of sensation; burning on tenth day; great atrophy and contracted muscles; subluxation of fingers; nutritive changes; eczema in both palms; great improvement; discharged." CASE VII (p. 466), of H. Gervaise, has been mentioned as CASE 30, in Note 1.

<sup>4</sup> Dr. S. WEIR MITCHELL (*Injuries of Nerves and their Consequences*, 1872) cites the following instances of shot flesh wounds of the upper extremities, with lesion of the nerves: CASE 19 (p. 145), a private, "shot through the brachial plexus, became wildly excited, crying murder repeatedly, and accusing those near him of having shot him. He did not fall." CASE 20 (p. 145), "An officer, shot through the right median nerve, talked some what incoherently, \* \* \* had not the least remembrance of having been shot." CASE 21 (p. 145), a "wagonmaster, shot through the left ulnar nerve," destroying the trunk as well as the ulnar artery, resulting in loss of sense and motion. CASE 33 (p. 200), "H——, aged 39, shot July 2, 1863, through inner edge of the right biceps, half an inch above the internal condyle of the humerus; glossy skin, causalgia and neuralgia; joint disease; acid sweats; slight loss of tact; constitutional symptoms." CASE 34 (p. 204), of Monaghan has been mentioned as CASE 27, in a preceding note. CASE 35 (p. 207), J. D——, Co. F, 69th Pennsylvania, aged 23, shot in the left forearm behind the ulna, four and a half inches below the olecranon process; median and ulnar nerves involved; "paralysis of motion; none of sensation; rigid fingers from joint disease; neuritis and causalgia from tenth day; relief by blisters; eruptions above the limit of causalgia; red palm." CASE 37 (p. 209), G. L——, Co. C, 1st Minnesota, aged 31, wounded July 3, 1863; the ball entered the right biceps three and a quarter inches above the level of the internal condyle, and made its exit three and a quarter inches directly below, wounding the main artery and the ulnar and median nerves; "atrophy and contraction of flexor muscles; atrophy of all the hand muscles; neuro-traumatic arthritis; loss of sensation; moderate improvement; discharge." CASE 42 (p. 252), of H. Gervaise, has already been mentioned as CASE 30, in Note 1. CASE 47 (p. 290), J. H. Corliss, Pt., Co. B, 14th New York Militia, aged 27, shot at the Second Bull Run, August 29, 1862, in the left arm, three inches directly above the internal condyle; "injury of median and ulnar nerves; loss of motion; excessive causalgia; excision of four inches of median nerve; no relief." CASE 50 (p. 298), A. F. Swann, Captain, Co. C, 16th Pennsylvania Cavalry, aged 34, wounded at Cold Harbor, May 28, 1864, by a minié ball, which entered the left forearm two inches below the head of the radius, and made its exit just above the inner condyle



injuries of the nerves, dealing largely with the results of shot lesions of the arms. The special cases referred to by these authors are indicated in the footnotes, and it is proposed here to advert cursorily to the subject, as it must come up hereafter in connection with the shot fractures of the upper extremities, and is well deserving of separate consideration. Others have printed contributions on this subject from observations made in the Union and Confederate hospitals. The late Professor J. C. Nott, of Mobile, in a paper<sup>1</sup> published in 1866, promised an account of cases of shot injuries of the nerves; but did not live to fulfil this purpose. Dr. W. P. Moon published<sup>2</sup> several abstracts of cases of shot lesions of the nerves of the upper extremity unattended by fracture, one of which was an example of neurotomy for the relief of traumatic neuralgia. Drs. Mursick, Eve, Stewart, and Birdsall<sup>3</sup> have published observations of shot flesh wounds of the upper extremities interesting the nerves. As so many histories of cases of this category are thus accessible for reference, but few will be detailed here:

CASE 1352.—Private J. Carroll, Co. E, 61st New York, aged 28 years, was wounded at Antietam, and was treated in a Second Corps field hospital, and afterward at Satterlee. Acting Assistant Surgeon W. S. Halsey reported: "Admitted, September 27, 1862, with gunshot wound of the right arm, a buckshot passing under the skin just below the axilla, injuring the internal cutaneous nerve. On October 20th, I dissected carefully down to the internal cutaneous nerve, following the cicatrix, when the nerve was reached and examined. He attributed all his distress to that part. Nothing was found that resembled a foreign body; a hard and knotty substance, however, was felt along the course of the nerve, and seemed to be a part of it. This was cut out by dividing the nerve and removing about one-half inch. The wound had healed up, broken out again, discharging a large quantity of pus and a piece of cloth, and again closed. He complained of great pain along the inside of the arm and elbow, and, though somewhat relieved after the discharge of the cloth, the pain was still intense. Great relief followed the operation, but all power over the forearm was lost. From this time, he complained of sharp pain near the acromial process. The wound healed, but the pain in the shoulder continued. About December 13th, the pain in the arm and forearm gradually increased in severity. Belladonna plasters were used, and hypodermic injections of morphia in solution, giving relief for a limited period only. The cause of the pain was no doubt due to the injury to the nerve, and subsequently to the new cicatricial tissue, which bound the nerve down to the surrounding parts and by its contraction kept up a continual strain on it. The return of the old pain was probably due to the formation of a new cicatrix, acting in the same manner." The patient was discharged the service, on certificate of disability, on February 24, 1863, Surgeon I. I. Hayes, U. S. V., certifying to "partial paralysis of right arm, and neuralgia of the same." It does not appear that he ever applied for a pension.

*Injuries of the Brachial Plexus.*—Thirteen examples were specially reported of shot wounds implicating the brachial plexus, though unattended by injury of the bones or blood-vessels. Two of these have been published in detail, and are enumerated, with brief references to the eleven others, in the subjoined footnote.<sup>4</sup> Paralysis resulted in

---

of the humerus; "median nerve injured; causalgia; excision of three inches of the median nerve; entire relief." CASE 55 (p. 311), T. B. W.—, 23d Pennsylvania, aged 17, wounded at Gettysburg, July 2, 1863, by a ball, which entered the middle arm behind the brachial artery, three-fourths of an inch below the uppermost part of the axillary hollow; nerve lesions; "loss of motion and slight loss of sensation; relapse from neuritis, with contraction of flexors, and 'claw-hand,' recovery."

<sup>1</sup>NOTT (J. C.), *Contributions to Bone and Nerve Surgery*, Philadelphia, 1866. The author remarks: "I have, during the war, witnessed a number of cases of neuralgia following gunshot wounds and amputations, which I may work up at some future day, and can make room at present for but two cases, which are of unusual interest both for their novelty and practical bearings." The two examples of neuromata, for which room was made, were unconnected with war-surgery, and before the professor had worked up the examples of shot lesions of nerves *Mors pallida* overtook him.

<sup>2</sup>MOON (W. P.), *Cases of Gunshot Wound of Neck, Arm, Forearm, etc.*, in *Am. Jour. Med. Sci.*, 1868, Vol. LV, p. 54. CASE III. is that of Corporal J. Dixon, Co. F, 8th New York Artillery, a shot wound of the right forearm, in which, after an unavailing excision of a portion of the radial nerve by Dr. MORTON, amputation was practised. This report may be supplemented by the records of this Office, which show that "this man was discharged June 24, 1865, and pensioned, and was an applicant for increase of pension, August, 1874."

<sup>3</sup>MURSICK (G. A.) (*Report of a Case of Gunshot Injury of the Median and Internal Cutaneous Nerves*, in *New York Med. Jour.*, 1866, Vol. II, p. 174); EVE (P. F.) (*Cases of Gunshot Wounds*, in *The Nashville Jour. of Med. and Surg.*, 1867, Vol. II, p. 221); BIRDSALL (S.) (*Report of a Case of Wound of Median Nerve*, in *Philadelphia Med. and Surg. Reporter*, 1866, Vol. XV, p. 434); and STEWART (J. L.) (*Ibid.*, 1871, Vol. XXIV, p. 92).

<sup>4</sup>The case of Sergeant G. F. Barnes, Co. D, 68th Pennsylvania, has been already mentioned in the reference to Dr. S. WEIR MITCHELL'S paper in the *Memoirs of the Sanitary Commission*, 1867 (Vol. I, p. 413). The case of Sergeant J. Bieswänger, Co. B, 75th Pennsylvania, had also been adverted to in the enumeration of the cases detailed by Drs. MITCHELL, MOREHOUSE, and KEEN (*Gunshot Wounds and other Injuries of Nerves*, 1864, p. 90). Both of these men were pensioned. Examiner H. L. HODGE reported, April 6, 1864, in the case of Barnes, that: "On account of a gunshot wound of the left axilla the hand is perfectly useless, being without sensation and incapable of movement." The Pension Examining Board of Philadelphia reported, September 11, 1873, "paralysis of hand, equal to loss of it." In the case of Bieswänger, the Philadelphia Examining Board reported, August 23, 1871: "There is complete paralysis of the extensor muscles of the left hand, rendering his hand almost useless. He complains of severe neuralgic pains in the arm and hand." In September, 1873, the Board reported: "Atrophy of pectoral muscles; contraction of ring and little fingers; thumb deformed, and contracted on the palm." Information is found on the pension reports of five others discharged for disabilities resulting from shot lesions of the brachial plexus: Pt. S. R. Baker, Co. H, 38th Massachusetts, wounded at Winchester, September 19, 1864, was reported by Surgeon C. N. CHAMBERLAIN, U. S. V., from Dale Hospital, as a case of "shot injury to the left brachial plexus, with partial loss of use of arm and fingers." This soldier was discharged and pensioned, July 26, 1865. The Boston Pension Examining Board reported, September 5, 1873: "He has an aneurism of the

eight of the cases, and the patients were discharged from service, and seven were pensioned. Four patients recovered and were returned to modified duty. One patient died from tetanus.

*Injuries of the Circumflex, Musculo-cutaneous, and Musculo-spiral Nerves.*—Eleven instances were recorded of shot lesions of one or more of these nerve trunks. Two cases have been cited in detail. One patient succumbed from tetanus, and the record of the autopsy is appended. Other examples of the results of such lesions may be found among the cases already noted:

CASE 1353.—Private H. Quigley, Co. C, 1st Kansas, aged 28 years, was wounded at Wilson's Creek, August 10, 1861, and sent to St. Louis on August 17th. Assistant Surgeon S. M. Horton, U. S. A., reported: "The wound was caused by a minie ball, which perforated the arm at the middle of the right biceps, emerging through the posterior portion at the junction of the middle and lower thirds. In its course, the median and internal cutaneous nerves were lacerated. The wound healed kindly, but a neuroma was formed where the nerves had been wounded, embracing the two nerves at that point. The tumor was as large as a small walnut. The neuralgia that resulted was incessant, and of the most intense character. From one and a half to two grains of sulphate of morphia had to be given at night to afford the man any rest. Bathing the hand in cold iced-water during the day for four months afforded him very much relief, the hand feeling easy. But if the hand was permitted to become dry and warm, and a narcotic was not administered, the pain returned. After a furlough of thirty days, he returned in February with the hand much less painful, the neuroma having nearly disappeared. In one month he was sent as attendant to the hospital at Jefferson Barracks." He was discharged October 10, 1862, and pensioned. Examiner J. C. Whitehill, of St. Louis, reported, September 9, 1867: "The applicant was shot through the right arm, wounding the median and ulnar nerves, whence sensation is partially destroyed. The hand is deformed from muscular and tendinous contractions, and the arm is considerably smaller than the other. He has some use of the thumb and forefinger, but the whole hand is almost useless." In October, 1873, the St. Louis Pension Board reported substantially as above, describing: "Atrophy of the arm and forearm; contraction of all the fingers of the right hand on the palmar surface."

The autopsy in the fatal case of this category did not corroborate the view of some of the German pathologists,<sup>1</sup> that proliferation of the connective tissue of the white

brachial artery near the elbow joint. \* \* \* The circulation in the hand is weak; the fingers are very small and atrophied, but have good motion, although not much power." Pt. J. Mulhern, Co. A, 8th Kansas, aged 27, wounded at Chickamunga, September 19, 1863, is reported by Acting Assistant Surgeon S. F. FEW to have received a "shot wound of the right axilla, passing through and injuring the brachial plexus of the nerves." This soldier was discharged July 27, 1864, and pensioned. The discharge certificate stated that there was "partial paralysis of the limb and contraction of the muscles." Examiner C. ROWLAND, of Brooklyn, reported, December 12, 1864, that the "disability will soon be removed." The pensioner was last paid March 4, 1866, and hence it is probable that the prognosis of the examiner was verified. Pt. C. F. Pearson, Co. A, 40th Massachusetts, was wounded at Cold Harbor, June 1, 1864. Acting Assistant Surgeon JOHN STEARNS reported, from the hospital at Readville, Massachusetts: "A severe gunshot injury of the right brachial plexus by a musket ball. Partial paralysis of the limb ensued. The patient was discharged May 21, 1865." Examiner I. F. GALLOUPE reported, April 11, 1867, that: "A musket ball entered right arm three inches below the acromion, at the inner edge of the deltoid muscle, passed through the axilla, and made its exit from the back one inch from the spine, on a level with the inferior edge of the scapula. The bone was not injured. The arm is partially paralyzed. The thumb and first three fingers are numb, and can be but partially flexed with difficulty. The whole limb is weak, easily fatigued, and painful if much used." Dr. GALLOUPE, in two subsequent examinations, March 7, 1868, and September 9, 1873, reported substantially as in the foregoing statement. Corporal C. Haynes, Co. D, 33d Massachusetts, was wounded October 29, 1863. Acting Assistant Surgeon W. E. TOWNSEND reported, from Mason Hospital: "A gunshot wound from the brachial plexus, causing paralysis of the arm. Discharged February 16, 1864, and pensioned." Examiner A. S. McLEAN, of Springfield, Massachusetts, reported, November 2, 1868: "A ball, entering near the middle of the posterior edge of the left sterno-cleido-mastoides, emerged from the middle of the left trapezius, causing injury of the cervical plexus, and corresponding pain and weakness of the muscles supplied by some of its branches." Pt. J. W. Hollingsworth, Co. C, 18th Indiana, aged 22, was wounded at Cedar Creek, October 19, 1864. Assistant Surgeon C. H. ALDEN, U. S. A., reported: "A severe gunshot wound of the left arm, injuring the brachial plexus." The patient was discharged June 17, 1865, and pensioned. Examiner N. D. THOMAS, of Rockville, Indiana, reported, February 9, 1866, that: "The arm and forearm have atrophied until greatly reduced in size. He states that he suffers pain in the limb nearly all the time, and that he can use the limb but little." Examiner C. LEAVITT reported, March 4, 1870: "There are no contractions or adhesions, yet there is doubtless some weakness of the limb." The eighth soldier discharged for this form of injury was Pt. B. D. Libbey, Co. F, 20th Maine, aged 41, wounded at Gettysburg, July 1, 1863. Surgeon J. J. REESE, U. S. V., reported, from Christian Street Hospital: "A gunshot wound of the brachial plexus, producing paralysis agitans. Discharged November 30, 1864." The four cases returned to full or modified duty were: Pt. P. O'Sullivan, Co. F, 6th New York Artillery, aged 20, wounded at Cold Harbor, May 10, 1864. Assistant Surgeon C. H. ALDEN, U. S. A., reported: "A gunshot wound of the left shoulder, injuring the brachial plexus; the patient was transferred to the Veteran Reserves, October 27, 1864." Pt. H. C. Reynolds, Co. B, 75th Indiana, aged 20, was wounded at Chattanooga, September 21, 1863. Assistant Surgeon W. C. DANIELS, U. S. V., reported: "A ball passed through the muscular parts of the left arm, injuring the brachial plexus of nerves; causing partial paralysis." The patient was transferred to the Veteran Reserves, March 7, 1864. The Indian-apolis Board reported unfavorably on his application for pension, which was consequently rejected. Pt. T. Burns, Co. C, 69th Pennsylvania, was wounded at Mine Run, September 16, 1863. Assistant Surgeon C. H. ALDEN, U. S. A., reported: "A severe shot flesh wound of the right arm, with injury to the brachial plexus." The patient was returned to duty September 5, 1864. Pt. J. Dunbar, Co. F, 69th Pennsylvania, aged 23, was wounded at Gettysburg. Assistant Surgeon C. H. ALDEN, U. S. A., reported: "A severe shot wound of the right shoulder, with injury of the brachial plexus; at duty, March 2, 1864." The case that terminated fatally from tetanus was reported by Assistant Surgeon D. C. PETERS: "Pt. H. L. Prince, Co. F, 7th Maine, aged 18, was wounded at Cedar Creek, receiving a shot laceration of the left shoulder, involving the brachial plexus. Symptoms of trismus appeared on October 24, 1864, five days after the injury, and blisters to the spine, tartar emetic, opium, and stimulants were unavailingly employed, the case ending fatally October 25, 1864."

<sup>1</sup> ROKITANSKY (C.) (*Über das Auswachsen der Bindegewebs-Substanzen und die Beziehung desselben zur Entzündung*, Wien, 1854); DEMME (H.) (*Beiträge zur pathologischen Anatomie des Tetanus*, Leipzig, 1859); THAMMAYN (O.) (*Beiträge zur Lehre vom Tetanus, nach den neuern Untersuchungen über denselben*, in SCHMIDT'S *Jahrbücher*, 1861, B. 112, S. 210). HASSE (K. E.) (*Handbuch der Speciellen Pathologie und Therapie*, Erlangen, 1855, S. 602) expresses grave doubts of the correctness of this view.



medullary matter of the cerebellum, medulla oblongata, and spinal cord should be regarded as the constant anatomical lesion of tetanus. The eleven cases are mentioned below.<sup>1</sup>

CASE 1354.—Corporal J. S. Mills, Co. A, 57th Massachusetts, aged 22 years, was wounded at Fort Steadman, March 25, 1865, and was admitted to Mount Pleasant Hospital, Washington. Assistant Surgeon H. Allen, U. S. A., noted: "Gunshot flesh wound of left upper extremity. Traumatic tetanus appeared April 11th, and death ensued April 15, 1865.  *Sectio cadaveris*: Upon laying open the track of the ball, it was found that the external cutaneous branch of the musculo-spiral nerve had been wounded. The tissues were matted together, of a dark color, and filled with a bloody serum. The bone was denuded for a space as large as a shilling, but no fracture. All the other tissues and organs in a remarkably healthy condition. The wound had been allowed to close rapidly. The treatment consisted of morphia and brandy in large doses, counter-irritation to the spine, with liquor ammoniæ; and supporting the constitution with beef essence, egg-nog, etc. There was no evidence that the patient had been exposed to cold, draughts of air, dampness, or excessive heat."

*Injuries of the Median Nerve.*—Shot flesh wounds in which lesion of this nerve was regarded as the principal feature were reported in thirty-six instances, to three of which allusion has been made. Five of these patients were returned to duty; twenty-eight, of whom fourteen were pensioned, were discharged for disability; and three died. Three cases furnished specimens to the Museum. Two cases will be detailed, and the others concisely enumerated:

CASE 1355.—Private M. Hanighan, Co. I, 2d Infantry, was wounded at Gaines's Mill, June 27, 1862, and was sent to Douglas Hospital, Washington. Surgeon Peter Pineo, U. S. V., reported: "Patient entered this hospital on July 4th, with a gunshot wound of the left arm at the junction of the middle and lower thirds, involving the median nerve. The wound healed kindly, but left a neuralgic condition of the hand, which has thus far, December 13th, yielded to no treatment, either local or general. December 17th, he was operated upon by Surgeon P. Pineo, U. S. V., and one and a quarter inches of the median nerve was resected. At eight in the evening, the hand was very warm, and there was some pain; but the patient was too much influenced by ether to give a correct statement of his feelings. He was ordered half a grain of sulphate of morphia. On December 18th, he complained of soreness of the hand, with considerable pain; he had enjoyed some sleep the previous night. On December 19th, the patient complained of the sensitiveness of the hand, even to jarring caused by a person walking across the floor. On December 20th, the patient was removed to a separate room; he slept quite well last night. \* \* December 24th, no improvement. December 29th, his hand is more painful. After January 1, 1863, the patient thought he improved slowly, but that he would never get well if he remained in hospital, and his discharge was granted him. February 14, 1863, the patient then felt quite well, and said his hand pained him less than usual, and thought he would be able to get home without any trouble. He left for New York at three in the afternoon of the day of his discharge. The foregoing statement is given by Dr. Sutton, who has had the immediate charge of the case. An important point in this case is the fact that the patient always complained of pain in the extremities of the ulnar as well as of the median nerve, and while the pain was less in the extremity of the median after the operation, it was the same in the ulnar. Another point is, that a less amount of the nerve was taken away in this case than in that of Corliss, and the pain, though manifestly less, was not so complete as when double the amount of nerve tissue was removed." The specimen, consisting of one and one-fourth inches of the median nerve, was contributed to the Museum (*Cat. Surg. Sect.*, p. 499, Specimen 958). This soldier was pensioned, Surgeon Pineo recording on his certificate of disability: "Gunshot wound of arm, injuring the median nerve." This man re-enlisted May 14, 1867, and was discharged March 22, 1869, his pension being resumed from that date. Examining Surgeon W. W. Potter, of Washington, reported August 6, 1869: "A minie ball entered the outer lateral aspect of the left arm three inches above the bend of the elbow, direction inward, passing anterior to the humerus; the exit was from the inner lateral aspect of the arm. The median nerve has sustained injury near the point of exit of the missile, causing hyperæsthesia. The muscles are soft and atrophied, especially those of the hand, and the extremity is carried in an extended position, flexion being painful." Examining Surgeon J. O. Stanton, September 10, 1873, reported: "Cicatrices well healed; paralysis of forearm and hand; atrophy of the muscles; has no control of the left hand; disability total." The pensioner was paid June 4, 1874.

<sup>1</sup> CASES of: 1. Pt. H. C. Phillips, Co. C, 44th New York, cited as CASE V, in *Note 3*, p. 461 *ante*. 2. Pt. W. Gray, Co. B, 140th New York, aged 20 years, wounded at the Wilderness, May 5, 1864. Surgeon R. A. CHRISTIAN, U. S. V., reported from Turner's Lane Hospital: "Severe shot flesh wound of the left arm, involving the musculo-cutaneous nerve; discharged August 16, 1864." Not a pensioner. 3. Pt. H. Carneil, Co. G, 29th Wisconsin, aged 26, wounded at Murfreesboro', April 8, 1864. Surgeon H. CULBERTSON, U. S. V., reported from Harvey Hospital: "Gunshot flesh wound on the under face of the right arm on a level with the axillary fold, anteriorly, wounding the external cutaneous nerve, and inducing paralysis of sensation of the outer half of the left arm and forearm, the thumb, fore and middle fingers, with paralysis of motion of the biceps and brachialis anticus. The patient was transferred to the Veteran Reserves, October 7, 1864." A fourth case, 1352, and a fifth, CASE 1353, have already been adduced. 6. Lieutenant B. S. Fitch, Co. C, 157th New York, aged 19; Gettysburg, July 2, 1863. Surgeon J. W. PETTINOS, U. S. V., reported, from Camp Parole, Annapolis: "Gunshot flesh wound of the left forearm, involving the musculo-spiral nerve. The patient was returned to duty October 13, 1863." 7. Lieutenant S. C. Smith, Co. I, 1st Maine Cavalry; wounded at Rappahannock Station, October 3, 1863. Surgeon H. W. DUCACHET, U. S. V., reported: "Gunshot wound of the inner side of the right arm, with injury of the musculo-spiral nerve. The patient was returned to duty November 3, 1863." 8. Corporal J. F. Elliott, Co. G, 5th Wisconsin, aged 23; wounded at the Wilderness, May 4, 1864. Surgeon R. A. CHRISTIAN, U. S. V., reported: "Severe gunshot flesh wound of the left arm, involving the musculo-spiral nerve. The patient was returned to duty September 9, 1864." 9. Pt. W. H. Barkey, Co. K, 149th Pennsylvania, aged 22; wounded at Spottsylvania, May 12, 1864. Surgeon R. A. CHRISTIAN, U. S. V., reported: "Gunshot wound of the right arm, involving the musculo-spiral nerve. The soldier was transferred to the Veteran Reserves, October 27, 1864." 10. Pt. T. J. Orent, Co. L, 2d New York Artillery, aged 25; wounded at Cold Harbor, June 4, 1864. Surgeon R. A. CHRISTIAN, U. S. V., reported: "Gunshot wound of the middle third of the left arm, involving the musculo-spiral nerve. The patient was transferred to the Veteran Reserves, October 27, 1864." The eleventh case (CASE 1354) has been given in detail.

*Neurotomy* was resorted to in the next case, which furnished several specimens<sup>1</sup> to the Museum. Notwithstanding recent experiments, this appears a surgical resource to be entrusted only to practitioners possessing more than ordinary physiological knowledge:

CASE 1356.—Private B. Knox, Co. A, 1st Delaware Cavalry, aged 27 years, was wounded at Edward's Ferry, February 15, 1865, and on the 19th was received into Armory Square Hospital, Washington. Acting Assistant Surgeon H. E. Woodbury furnished the following special report: "The patient's injuries were, 1st: A gunshot flesh wound of the outer aspect of the lower third of the left thigh; ball extracted from anterior surface of knee just above patella. Also gunshot flesh wound of right arm; ball entered the outer aspect just below the elbow, and passed upward and inward through the biceps muscle. Point of exit about four inches above point of entrance. The ball in its course injured both the ulnar and median nerves. The wound of the thigh healed rapidly. A neuroma was formed on the ulnar; this I extirpated April 3, 1865, and sent the specimen, with history, to the Army Medical Museum at nearly that date. Temporary relief followed, but the pain returning, on April 7th the surgeon in charge tried separating the ulnar nerve. April 10, 1865, the patient still suffering, at his request it was decided to amputate. The patient was put under the influence of ether, and the surgeon in charge amputated. The patient seemed to be doing well until April 22d, when he had a severe chill. From this time the symptoms of the pyæmia were well marked. Sulphite of soda, iron, and quinine were freely given, with stimulants, but the patient firmly believed he would die, and gradually sank until April 28th, when he breathed his last."

CASES 1357 to 1390.—Pt. R. M. Whiteside, Co. F, 40th New York, aged 23, Gettysburg, July 2, 1863; median nerve injured; discharged August 16, 1864. Pt. J. O'Rourke, Co. E, 5th Michigan, Gettysburg, July 2, 1863; shot wound of median nerve of left arm; duty, May 7, 1864. Pt. L. Stucker, Co. H, 75th Pennsylvania, aged 38; Gettysburg, July 2, 1863; gunshot wound of median nerve; mustered out October 3, 1864. Corp. M. Irwin, Co. F, 57th Pennsylvania, aged 30; Gettysburg, July 3, 1863; shot wound of right median nerve, discharged October 31, 1864, and pensioned. Pt. R. H. Shumway, Co. G, 5th Wisconsin, aged 29; Fredericksburg, May 3, 1863; slight flesh wound of right median nerve; discharged July 26, 1864, and pensioned. Pt. M. Gossing, Co. F, 14th Connecticut, aged 22; Morton's Ford, February 1, 1864; shot wound of lower third of right arm; median nerve injured; discharged October 18, 1865. Corp. M. S. Ditson, Co. K, 20th Massachusetts, aged 24; Gettysburg, July 2, 1863; shot wound of median nerve; discharged January 8, 1864, and pensioned. Pt. M. Kennedy, Co. H, 90th Pennsylvania, aged 16; Wilderness, May 5, 1864; shot flesh wound involving median nerve; duty, February 7, 1865. Pt. W. A. Sturdy, Co. I, 18th Massachusetts; Bull Run, May 30, 1862; median nerve injured; discharged August 16, 1863, and pensioned. Pt. H. Vandever, Co. A, 5th Michigan, aged 35; Williamsburg, May 5, 1862; shot wound of median nerve; discharged September 25, 1864. Corp. C. H. Dinkins, Light Artillery, aged 31; Petersburg, July 18, 1864; injury of median nerve;<sup>2</sup> discharged March 1, 1865. Pt. M. Miller, Co. A, 111th Pennsylvania, aged 18; Peach Tree Creek, July 20, 1864; median nerve severed; discharged May 31, 1865. Pt. G. I. Grothers, Co. H, 22d New York Cavalry, aged 21; City Cross Roads, October 1, 1864; division of median nerve; discharged May 18, 1865. Pt. D. A. Patton, Co. E, 129th Illinois, aged 24; Peach Tree Creek, July 20, 1864; median nerve injured; discharged January 24, 1865, and pensioned. Pt. J. O'Brien, Co. K, 52d Illinois; Shiloh, April 6th, 1862; shot wound of left median nerve; erysipelatos inflammation; discharged September 22, 1862. Pt. L. Wheat, Co. I, 71st New York, aged 21; Bull Run, August 27, 1862; shot wound involving the median nerve; discharged June 17, 1865. Corp. J. Hossack, Co. A, 142d Pennsylvania, aged 26; Wilderness, May 5, 1864; shot wound of median nerve; discharged July 27, 1865, and pensioned. Pt. H. Griffl, Co. F, 8th Indiana, aged 23; Cedar Creek, October 19, 1864; shot injury of median nerve; discharged July 1, 1865. Pt. E. Bacon, Co. A, 20th Massachusetts, aged 25; Spottsylvania, May 12, 1864; median nerve injured; discharged August 29, 1865, and pensioned. Pt. U. Smith, Co. C, 15th Iowa, aged 23; Atlanta, August 14, 1864; shot injury of right median nerve; discharged. Serg't W. Peohlar, Co. D, 8th Maryland, aged 34; Spottsylvania, May 12, 1864; shot injury of the median nerve; duty, October 8, 1864. Pt. J. Rowland, Co. I, 45th Pennsylvania, aged 24; Spottsylvania, May 12, 1864; severe flesh wound of left arm, injuring the median nerve; discharged September 15, 1865, and pensioned. Corp'l T. Tucker, Co. D, 61st Pennsylvania, aged 27; Spottsylvania, May 12, 1864; shot wound of left median nerve; transferred to V. R. C., March 26, 1865. Pt. W. H. Nelson, Co. C, 184th Pennsylvania, aged 19; Cold Harbor, June 3, 1864; shot injury of right median nerve; transferred to V. R. C., March 17, 1865. Pt. John Repp, Co. B, 20th Pennsylvania, aged 32; Fort Harrison, September 29, 1864; shot wound of right arm and forearm, with injury of median nerve, and also shot wound of left arm, for which the arm was amputated; discharged January 29, 1866, and pensioned. Pt. F. Eos, Co. F, 93d Pennsylvania, aged 44; Wilderness, May 5, 1864; flesh wound of right arm, involving median nerve; discharged October 17, 1864. Corp'l B. Graham, mentioned as CASE 23, in note 1, on page 461 *ante*. Pt. H. Gervaise, cited as CASE 30, in note 1, on page 461 *ante*. Pt. G. L. Squiers, Co. C, 1st Maine, aged 32; Gettysburg, July 3, 1863; injury of median and ulnar nerves; discharged April 6, 1864, and pensioned. Pt. R. Macauley, Co. D, 71st Pennsylvania, aged 20; Wilderness, May 6, 1864; shot flesh wounds of right median and ulnar nerves; discharged March 17, 1865. Sergeant A. D. Marks (see CASE 31, in note 1, on page 461 *ante*). Pt. J. H. Corliss,<sup>3</sup> mentioned as CASE 47, in note 4, on page 461 *ante*. Pt. P. Lehman, Co. B, 42d Pennsylvania, aged 22; Antietam, September 17, 1862; shot injury of the left median nerve; death, September 25, 1862. J. H. Matthews, Co. F, 83d Illinois, wounded in the left arm, February 17, 1863; median nerve injured; traumatic tetanus; death, February 22, 1863.

<sup>1</sup> Specimen 4038 is an oblong neuroma (*Cat. Surg. Sect.*, p. 529); specimen 4056 (*ibid*) is a "wet preparation of portions of the median and ulnar nerves" \* \* after amputation \* \* "upon each of the nerves a slight neuromatous enlargement is noticeable." Specimen 4095 (*l. c.*, p. 502) shows "the soft tissues from the stump," in the foregoing case.

<sup>2</sup> HALLOWAY (J. W.), *Consecutive and Intermediate Hemorrhage*, etc., in *Am. Jour. Med. Sci.*, 1865, Vol. L, p. 340; CASE VII. Shot Injury of the Median Nerve.

<sup>3</sup> This case furnished Specimen 959, of Section I, of the Army Medical Museum, Surgeon P. Pinco, U. S. V., having excised "two inches of the median nerve, \* \* for excessive neuralgia of the palmar portion of the hand and fingers following a flesh wound of the left arm at the junction of the upper thirds."—(*Cat. Surg. Sect.*, p. 449.)



*Injuries of the Ulnar Nerve.*—Seventeen cases were reported, and ulterior information of thirteen of them is obtained from the pension reports. A plaster cast in the Museum, described at page 533 of the Surgical Catalogue, designates one of the cases.<sup>1</sup> The remainder will be briefly enumerated:

CASE 1391.—Corporal C. Hinds, Co. A, 9th New York Cavalry, aged 28 years, was wounded at Falling Waters, Maryland, July 7, 1863, and was left at Boonsboro' until January 11, 1864, when he was received into Armory Square Hospital. Surgeon D. W. Bliss, U. S. V., noted: "Gunshot wound of the left arm; ball entered the ulnar border of the arm three inches below the elbow joint, passed downward and outward, and made its exit four and a half inches from the point of entrance." He was discharged the service February 26, 1864, for "paralysis of the left forearm and hand from gunshot wound," and pensioned. Examiner C. S. Hurlbut, June 23, 1864, reported: "Wounded by a ball passing through the left forearm near the ulna, wounding or dividing the ulnar nerves, causing atrophy of the entire hand and paralysis of the ulnar side of the forearm and hand." This pensioner was paid March 4, 1874.

CASES 1392-1406.—Surgeon D. G. Brinton, U. S. V., reported the following two cases from the hospital at Quincy: 1. "Pt. J. M. Putnam, Co. F, 55th Illinois, age 24; wounded at Shiloh, April 6, 1862. Gunshot wound across the inner condyle of the right arm, injuring the ulnar nerve. The wound had healed on admission. The hand was partially paralyzed and the muscles of the forearm were atrophied." The patient was discharged September 4, 1862, and pensioned. Examiner G. W. Wright, of Canton, reported, December 9, 1872, that: "The ulnar nerve was divided, and a part of the hand is paralyzed as a consequence. The motion and strength of the joint is very much abridged." Examiner J. V. Harris reported, September 4, 1873, that the pensioner's condition was unchanged. 2. "Pt. C. Chapin, Co. E, 10th Illinois, aged 21; wounded at Kenesaw Mountain, June 20, 1864. Gunshot wound of the ulnar nerve, the ball striking the ulnar side of the right forearm. The three last fingers are flexed, the muscles contracted, impaired, and having a pricking sensation. The wound is nearly healed." This soldier was discharged from Camp Butler, July 15, 1865, and pensioned. Examiner J. Robbins, of Quincy reported, July 20, 1865, that: "A ball passed through the forearm at the junction of the middle and lower thirds, without fracturing it. The forearm and wrist are weakened from destruction of the muscles. One-half pension recommended." On January 27, 1866, the claimant stated that he had so far recovered from his disability that he declined to further prosecute his claim for pension. The next two cases were reported by Surgeon R. A. Christian, U. S. V., from Turner's Lane Hospital, Philadelphia: 1. Pt. J. Bagley, Co. G, 3d Massachusetts Cavalry, aged 28; "wounded at Winchester, September 19, 1864. Partial paralysis of the left arm from a slight gunshot flesh wound, with injury to the ulnar nerve." This patient was discharged September 4, 1865, and pensioned. 2. "Sergeant M. V. Collins, Co. A, 106th New York, aged 24; wounded at Monocacy, July 9, 1864. Severe gunshot flesh wound of the left elbow joint, dividing the ulnar nerve." This soldier was discharged June 22, 1865, and pensioned. Acting Assistant Surgeon S. F. Few reported, from the hospital at Fort Leavenworth: "Pt. L. H. Cole, Co. D, 9th Kansas Cavalry, aged 18; wounded on the way from Fort Scott, November 28, 1862. A ball entered the right forearm, passed between the shafts of the ulnar and radius, and emerged at the olecranon process, wounding the ulnar nerve, and resulting in complete ankylosis of the elbow joint and wasting of the limb." The patient was discharged May 23, 1864, and pensioned. In June, 1873, the pensioner's claim was suspended, no response having been received for two years. Surgeon D. P. Smith, U. S. V., reported, from Fairfax Seminary Hospital: "Sergeant C. Bosworth, Co. G, 16th Maine, aged 47; wounded at Fredericksburg, December 13, 1862. Paralysis of the left forearm, the result of a shot wound." The patient was discharged March 16, 1863, and pensioned. Examiner G. A. Wilbur, of Skowhegan, reported, March 5, 1866: "Flesh wound through the left arm, with injury to the ulnar nerve. He cannot now completely flex the fingers. The little and ring fingers are numb." Dr. Wilbur forwarded a photograph of the pensioner to the Museum (*Contributed Photographs*, Vol. 1, p. 11). Pt. D. Finn, Co. H, 34th Massachusetts, aged 23; wounded at New Market, May 15, 1864. Surgeon J. B. Lewis, U. S. V., reported, from Cumberland: "Gunshot flesh wound diagonally across the bend of the left elbow, with injury of the ulnar nerve; the ball was extracted before admission." The patient was discharged July 25, 1865, and pensioned. The Hartford Examining Board reported, September 11, 1873: "A little stiffness of the joint, and some weakness." Surgeon I. I. Hayes, U. S. V., reported, from Satterlee Hospital, Philadelphia: "Pt. H. Voight, Co. E, 13th Massachusetts; wounded at Antietam, September 17, 1862. Cicatrized gunshot wound of the right arm, with paralysis of the ulnar nerve. Necrosis involving different branches of the sympathetic nerve. Discharged April 18, 1863," and pensioned. Examiner G. S. Jones, of Boston, reported, December 21, 1867: "Partial paralysis of the left hand, which impairs its power and usefulness." Surgeon T. A. Antisell, U. S. V., reported, from Officers' Hospital, Washington: "Captain G. H. Wells, 1st New York Dragoons; wounded at Winchester, September 19, 1864. Gunshot wound, injuring ulnar nerve of the left arm. Discharged February 10, 1865," and pensioned. Examiner W. W. Potter, of Washington, reported, July 5, 1865: "Five abscesses have formed at different places as the result of the wound, and the operation of bisecting the ulnar nerve, for the relief of intense pain, had been made. This man is compelled to use subdermal injections of morphine for relief." \* \* In 1871, Captain Wells's condition was so much improved that his pension was reduced. Acting Assistant Surgeon G. K. Smith reported, from Officers' Hospital, Washington: "Lieutenant S. Gait, 10th New York Cavalry; wounded at Todd's Tavern, May 5, 1864. Gunshot wound of the right arm, with injury to the ulnar nerve." Discharged August 1, 1864, and pensioned. The Elmira Examining Board reported, September 4, 1873: "The ulnar nerve was injured and causes numbness of the little and ring fingers; he is unable to pursue his avocation of blacksmith." Surgeon H. Janes, U. S. V., reported, from Sloan Hospital, Montpelier: "Pt. C. Lapage, Co. C, 17th Vermont, aged 17; wounded at Lynchburg, April 2, 1865. Shot contused flesh wound of the left arm four inches above the elbow, injuring the ulnar nerve. The right hand is cold and partially paralyzed. Discharged June 24, 1865," and pensioned. Examiner A. L. Lowell reported,

<sup>1</sup>CASE of Pt. S. D. Barnum, Co. B, 141st Pennsylvania, which furnished Specimen 1817. This soldier was discharged November 30, 1865, and pensioned. Examiner C. M. TURNER, of Towanda, reported, September 4, 1873: "The fingers and hand are numb and destitute of voluntary motion. The arm and wrist are very weak, and atrophied in a degree."

March, 1871: "A fragment of shell, passing between the right arm and the body, barely grazed the inner margin of the biceps muscle, and there now remains a thin non-adherent cicatrix, which is healthy. I find no injury of function following the lesion. The limb is well developed and strong." Disability ceased. In the next four cases, no application for pension was made: Surgeon J. J. Reese, U. S. V., reported the two following cases from Christian Street Hospital: 1. "Sergeant C. A. Poulson, Co. G, 88th Pennsylvania; wounded at Gettysburg, July 2, 1863. Gunshot wound of the right ulnar nerve; paralysis and general debility." The patient was discharged December 16, 1863. 2. Pt. W. Gordon, Co. C, 26th Pennsylvania, aged 20; wounded at Gettysburg, July 2, 1863; "Gunshot wound of left arm, injuring the ulnar nerve and obliterating the brachial artery." This patient was transferred to Turner's Lane Hospital, March 14, and discharged June 18, 1864. Surgeon S. N. Sherman, U. S. V., reported, from the hospital at Grafton: "Private R. Middleton, Co. E, 21st New York Cavalry, aged 18; accidentally wounded June 1, 1864. Shot wound of the lower third of the left arm, injuring the ulnar nerve." Mustered out of service. Surgeon J. Moore, U. S. A., reported from the Ladies' Home Hospital, New York: "Pt. W. McNally, 15th New York Battery, aged 24; wounded at Cold Harbor, June 2, 1864. Gunshot wound, ball passing through the fleshy part of the right upper arm, cutting the ulnar nerve. There is loss of sensibility in the little finger." This soldier was discharged from service October 26, 1864.

*Injuries of the Radial Nerve.*—But two examples of this lesion unattended by fracture of the bones of the forearm were specified in the reports:<sup>1</sup>

CASE 1407.—Private John Donovan, Co. G, 17th Maine, was wounded at the Wilderness, May 6, 1864, and was admitted to hospital at York, Pennsylvania, May 21st, and discharged the service March 7, 1865, and pensioned. Surgeon A. N. McLaren, U. S. A., examined Donovan for the 42d Veteran Regiment, May 24, 1867, and reported: "Gunshot wound of left arm at junction of upper and middle thirds, through the flexor muscles; slight exfoliation of bone from edge of radius, and probable injury of radial nerve; also a sabre wound of right arm. Slight loss of sensation, but not of power, of first and second fingers. Sabre wound received at Mine Run, November, 1863. Both wounds perfectly healed." This man was finally discharged the service April 2, 1869, and again pensioned. Examiner F. L. Sprague, of Boston, reported, February 23, 1859: "The scar on the ulnar side is puffed out, and is soft and easily depressed by the fingers. It is sensitive." In September, 1873, the Boston Examining Board reported: "The fingers cannot be fully extended, and the movements of the wrist are restricted through atrophy of the muscles and adhesion of the tendons."

CASE 1408.—Corporal S. Berry, Co. B, 4th Vermont, aged 26, was wounded at Fort Fisher, March 25, 1865, and admitted to Sloan Hospital, Montpelier, April 14th. Surgeon Henry Jones, U. S. V., noted: "Gunshot flesh wound, right forearm; ball injuring radial nerve; discharged the service June 23, 1865, with partial paralysis of hand." Examiner J. F. Skinner, of Boston, reported, January 20, 1866: "The ball passed through the right arm at the junction of the middle with the upper third of the forearm, \* \* \* greatly injuring the nerve and muscles. There is great loss of nervous influence; the fingers cannot be extended nor flexed, and have but little power." Dr. Skinner reported, September 5, 1873, that: "The arm is wanting in power, and painful when used. The circulation is low in the arm below, requiring care to keep it warm in cold weather."

There were fourteen instances of shot flesh wounds of the upper extremities with lesions of the nerves, in which the injured nerve trunk was not designated. One of the patients was returned to duty, twelve were discharged, and, in one case, death resulted from tetanus.<sup>2</sup>

CASE 1409.—Private J. Roby, Co. G, 7th New Hampshire, aged 51 years, was wounded at Olustee, February 20, 1864, and was sent, with other wounded, to the hospital at Hilton Head. Assistant Surgeon J. E. Semple, U. S. A., reported: "A simple flesh wound of the left upper extremity, from gunshot, the nature of the missile being unknown. Symptoms of tetanus were observed soon after the patient's admission into hospital, and speedily became of the gravest character. On February 26th, opisthotonos supervened, and the symptoms becoming more violent, the case terminated fatally, February 28, 1864."

Commonly shot lesions of the larger nerves of the extremities do not immediately jeopardize life; but, as Matthew has well observed, "from the vast amount of misery and annoyance entailed, extending often over an indefinite period, their importance to the patient can hardly be exaggerated." The pathological anatomy of these lesions has, in later wars,<sup>3</sup> been carefully studied, and, with the bibliography of the subject, will be adverted to hereafter.

<sup>1</sup> M. NICAISE (Article *Bras*, in *Dict. Encyclopéd. des Sci. Méd.*, T. X, p. 503) alleges that in wounds of the arm the radial is the nerve oftens complicated "car à la partie inférieure il est situé à la face externe du bras." He appears to reason *a priori*, without discussing any considerable body of facts. Our returns indicate that lesions of the median nerve are the commonest, and those of the ulnar are next in frequency.

<sup>2</sup> Three instances of tetanus in cases of shot flesh wounds of the upper extremities, with lesions of the nerves, have already been cited: CASE of H. L. Prince, 7th Maine (the last case of note 4, on page 462); CASE 1354, J. S. Mills, 57th Mass., p. 464; and CASE 1390, J. H. Matthews, p. 465.

<sup>3</sup> KLEIS (E.) (*Beiträge zur Pathologischen Anatomie der Schusswunden*, Leipzig, 1872, p. 21), after citing a case of neuroma after injury of the ulnar nerve in a shot flesh wound of the arm, remarks: "The neuritis which here supervened, in consequence of the bruising of the nerve trunk, has disappeared; the regeneration of the nerve fibres has begun in the manner described by E. NEUMANN,—from the nerve ends, severed by blaise or cut, fine bundles of fibres were developed, and gradually united into a larger cylinder-axis, becoming enclosed in a common sheath. This regeneration can be best observed in cases of neuromata after amputation. The severe pains probably are closely connected with the proliferation of the connective tissue, for the nerve fibres as they grow are obstructed and pressed by the thickening interstitial tissue. The less the latter is, the easier and more perfect will be the regeneration of the nerve fibres."



AMPUTATIONS CONSEQUENT ON FLESH WOUNDS.—It has already appeared, in the review of the cases of shot wounds of the soft parts of the upper extremity implicating the blood-vessels and nerves, that the extreme resource of amputation was not infrequently adopted, either on account of primary hæmorrhages, of diffuse consecutive aneurisms, or of extended sloughing or suppuration, or of bleeding regarded as uncontrollable. These cases will be enumerated, for the most part in tabular form, in the order of the propinquity of the operations to the trunk.

*Amputations at the Shoulder Joint.*—Fourteen such cases were reported. Three have already been noted,<sup>1</sup> and one has been elsewhere published.<sup>2</sup> One was a primary operation,<sup>3</sup> seven were intermediary, and the other six secondary.<sup>4</sup> They may be summed up as follows:

TABLE XIV.

*Numerical Statement of Fourteen Amputations at the Shoulder for Complicated Shot Injuries unattended by Fracture.*

No.	NAME, AGE, AND MILITARY DESCRIPTION.	DATE OF INJURY.	NATURE OF INJURY.	DATE OF OPERATION.	OPERATION AND OPERATOR.	RESULT.
1	Bowers, J. W., Pt., D. 1st Maryland, age 35.	June 1, 1864.	Gangrene and secondary hæmorrhage after shot wound of left forearm. Carious bone could be felt with a probe.	July 8, 1861. March 22, 1865.	Flap amputation at the middle third; A. A. Surgeon A. McLetchie. Amputation at shoulder joint; A. A. Surgeon H. P. Yates.	Disch'd July 9, 1865. Died July 21, 1861.
2	Cape, J., Sergeant, K, 18th Mississippi, age 22.	July 3, 1863.	Sloughing consequent on shot wound of the right arm.	August 26, 1863.	Amputation of right arm at shoulder; Surgeon H. Hinkley, U. S. A.	Recov'd November, 1863.
3	Denton, F. M., Pt., H, 4th South Carolina, age 31.	May 28, 1864.	Shot perforation of left axilla; extensive diffuse aneurism.	Sept. 1, 1861.	Ligation of the left subclavian; amputation at shoulder joint; Assistant Surgeon J. C. McKee, U. S. A.	Died Sept. 2, 1864.
4	Draper, E., Pt., A, 3d Delaware, age 23.	March 31, 1865.	Shot wound of right axilla, with division of vessels; arm swollen, and wound in a sloughing condition.	April 9, 1865.	Amputation at the shoulder by Larrey's method; Assistant Surgeon W. P. Norris, U. S. A.	Died April 16, 1865.
5	Eaton, N. J., Corporal, H, 8th New York Artillery, age 21.	June 22, 1864.	Shot wound of right axillary artery. July 8th and 10th, hæmorrhage from recurrent branches	July 8, 1864.	Flap amputation at right shoulder joint; Surgeon R. B. Bontecou, U. S. V.	Died July 10, 1864. <i>Spec.</i> 6312, A.M.M.
6	Harver, S., Pt., E, 19th Ohio.	May 22, 1862.	Left arm lacerated by shell fragment; complete destruction of soft tissues.	May 22, 1862.	Amputation of left arm at shoulder, on field.	Disch'd July 17, 1863.
7	Irwin, S., Corporal, F, 67th Pennsylvania, age 23.	Sept 22, 1864.	Necrosis of shaft of the humerus consequent on burrowing of pus after a shot flesh wound of the arm.	October 28, 1864.	Ligation of anterior circumflex. . . . .	Disch'd Sept. 9, 1865.
8	Jasper, J., Pt., D, 5th Michigan.	May 31, 1862.	Gangrene of left arm following shot penetration, with lodgement and diffuse phlegmonous inflammation.	June 18, 1862.	Amputation of left arm at shoulder by Larrey's method; A. A. Surgeon D. W. Cheever.	Died June 21, 1862.
9	Lightfoot, J., Pt., E, 25th Massachusetts, age 28.	August 10, 1864.	Shot perforation of left axilla. . . . .	Sept. 19, 1864.	Amputation of left arm at shoulder joint; A. A. Surgeon L. K. Baldwin. (See CASE 1255 <i>ante</i> .)	Died Sept. 19, 1864. <i>Spec.</i> 3630, A.M.M.
10	McKissock, R., Pt., G, 4th New Hampshire, age 20.	Sept. 29, 1864.	Aneurism of right brachial, followed by mortification of the entire arm.	October 13, 1864.	Flap amputation at the right shoulder joint; Ass't Surgeon D. R. Brower.	Died October 14, 1864.
11	Moore, H. C., Pt., A, 26th Georgia.	May 12, 1864.	Gangrene of left arm, with secondary hæmorrhage.	May 23, 1864.	Left arm amputated at shoulder joint. (See CASE 1253 <i>ante</i> .)	Died May 23, 1861.
12	Page, F. A., Pt., K, 4th Vermont, age 19.	April 16, 1862.	Shot perforation of axilla; hæmorrhage; ineffectual attempts made to reach the vessel.	April 25, 1862.	Amputation at the right shoulder joint, and axillary artery secured; Surgeon R. B. Bontecou, U. S. V.	Disch'd Sept. 1, 1862.
13	Parker, J. B., Pt., I, 3d Maine, age 40.	May 5, 1864.	Shell laceration of anterior aspect of left arm near shoulder. May 28th, hæmorrhage from brachial artery and superior branches; pressure applied to subclavian artery for several hours.	May 28, 1864.	Amputation at the left shoulder joint; Surgeon D. W. Bliss, U. S. V.	Died May 30, 1864.
14	Smith, D., Pt., C, 6th Pennsylvania Cavalry, age 29.	June 12, 1864.	Traumatic aneurism of left brachial artery.	August 5, 1864.	Amputation of left arm at shoulder joint; Assistant Surgeon H. S. Schell, U. S. A. (See CASE 1259 <i>ante</i> .)	Died August 8, 1864.

Four of the operations were done on account of hæmorrhage, four for so-called traumatic aneurism, five for gangrene, and one for extensive consecutive necrosis of the humerus. There were eight deaths or 57.1 per cent., a high mortality rate for this operation.

<sup>1</sup> CASES 1253, 1255, p. 443, and 1259, p. 444.

<sup>2</sup> HINKLEY (H.), *Treatment of Hospital Gangrene, in Confederate States Med. and Surg. Jour.*, 1864, Vol. I, p. 131.

<sup>3</sup> Dr. B. BECK (*Chir. der Schussverletz.*, 1872, S. 572) sanctions the ablation of the upper extremity for shot injury unattended by fracture, under certain circumstances: "Should, for instance, the entire package of vessels in the axillary space be injured, the circumstances are far more unfavorable; since, from the anatomical relations, even if there is no uncontrollable bleeding, gangrene supervenes. In such cases, if the diagnosis is clearly established, it is preferable to amputate the limb, so as not to be compelled, after the appearance of gangrene or secondary hæmorrhage, to operate under far more disadvantageous circumstances. Frequently, in cases of such lesions, the soft tissues are extensively lacerated, and the diagnosis is facilitated, and indications are afforded that more manifestly justify the removal of the limb."

<sup>4</sup> The intervals between the reception of the injury and the date of operation were, respectively: 38, 51, 64, 9, 16, 0, 113, 18, 40, 4, 11, 9, 23, and 54 days; or, leaving out the primary operation, from four days to nearly four months. The mean was a little over 32 days.

*Amputation of the Upper Arm.*—The reported cases of amputation in the continuity of the upper arm, for complications of shot wounds unattended by fracture, numbered fifty-four. Most of the operations were practised either on account of hæmorrhage or of gangrene, principally for the former cause:

TABLE XV.

*Summary of Fifty-four Cases of Amputations in the Continuity of the Upper Arm, for Complicated Shot Injuries unattended by Fracture.*

No.	NAME, AGE, AND MILITARY DESCRIPTION.	DATE OF INJURY.	NATURE OF INJURY.	DATE OF OPERATION.	OPERATION AND OPERATOR.	RESULT.
1	Amonett, J. P., Pt., II, 50th Illinois.	April 16, 1862.	Shell laceration of the right arm.....	April 18, 1862.	Amputation of right arm eight inches from shoulder, on field.	Disch'd Sept. 4, 1862.
2	Bell, G. L., Sergeant, E, 10th Connecticut, age 34.	Dec. 15 1862.	Hæmorrhage after shot flesh wound of right forearm.	Dec. 27, 1862.	Flap amputation of right arm at middle third; Surgeon E. P. Marong, 2d Maryland. (See CASE 1275 ante.)	Died March 11, 1863.
3	Berry, H., Governm t employe, age 57.	Nov. 5, 1864.	Erysipelas and gangrene after shell wound of right forearm, with great destruction of soft parts.	Jan. 9, 1865.	Circular amputation of right arm at junction of upper and middle thirds; Surgeon J. Perkins, U. S. V.	Duty, May 9, 1865.
4	Best, J., Pt., F, 7th Indiana Cavalry, age 20.	Feb. 22, 1865.	Wound of left interosseous artery; "the limb as far as the elbow apparently a lifeless mass."	Feb. 26, 1865.	Flap amputation of left arm near the insertion of the deltoid muscle; Surgeon J. M. Study, U. S. V.	Disch. May 7, 1865.
5	Bowers, J. W., Pt., D, 1st Maryland, age 36.	June 1, 1864.	Gangrene and secondary hæmorrhage after shot wound of the left forearm.	July 8, 1864.	Flap amputation of left arm at middle third; A. A. Surgeon A. McLechle, March 22, 1865, amputation at the shoulder joint.	Disch'd July 9, 1865.
6	Brieknell, W., Pt., H, 19th Wisconsin, age 20.	June 27, 1864.	Shot flesh wound "of the entire extent of the left arm; parts swollen from hand to shoulder, and muscles torn."	June 28, 1864.	Circular amputation of left arm at upper third.	Disch'd Feb. 7, 1865.
7	Brown, T., Pt., C, 1st Massachusetts Artillery, age 50.	June 21, 1864.	Necrosis of humerus after flesh wound of the left arm.	Feb. 12, 1866.	Circular amputation of left arm near shoulder; Dr. J. F. Galloupe, late Surgeon 17th Massachusetts.	Recovered.
8	Caplinger, D., Pt., A, 15th West Virginia, age 40.	Mar. 31, 1865.	Gangrene after shot wound of the left hand.	May 1, 1865.	Amputation of left arm above elbow.	Disch'd Aug. 7, 1865.
9	Carr, S., Pt., C, 30th Ohio, age 20.	June 20, 1864.	Gangrene and hæmorrhage after flesh wound of the left arm.	July 13, 1864.	Flap amputation of left arm, middle third; Surgeon A. C. Swartzwalder, U. S. V.	Disch'd Sept. 23, 1864.
10	Chandler, W., Pt., D, 8th U. S. Colored Troops, age 34.	Feb. 20, 1864.	Gangrene following shot wound of the left arm.	Mar. 14, 1864.	Flap amputation of left arm, middle third.	Disch'd Dec. 26, 1864.
11	Clark, T. B., Corporal, G, 17th Ohio, age 26.	May 27, 1864.	Gangrene after shell contusion of the left hand.	July 10, 1864.	Circular amputation of left arm at middle third; Surg. S. E. Fuller, U. S. V.	Died Aug. 7, 1864.
12	Cline, C. R., Pt., D, 7th West Virginia, age 21.	June 1, 1864.	Shot injury of right brachial artery; hæmorrhage ensuing after ligation.	June 21, 1864.	Flap amputation of right arm, upper third; A. A. Surgeon H. D. Vosburg.	Died June 23, 1864.
13	Conrad, A., Pt., C, 8th Illinois Cavalry, age 27.	June 21, 1863.	Recurrent hæmorrhage after flesh wound of the left forearm.	July 9, 1863.	Flap amputation of left arm at lower third; A. A. Surgeon G. McCoy. (See CASE 1410 post.)	Died July 11, 1863.
14	Dougherty, T. H., Pt., H, 12th Indiana, age 22.	July 20, 1864.	Laceration of left ulnar artery; entire forearm gangrenous.	July 27, 1864.	Flap amputation, left arm, middle third; Surgeon W. H. Thorne, U. S. V.	Disch'd Nov. 25, 1864.
15	Darwood, H., Pt., I, 15th Infantry, age 17.	Aug. 8, 1864.	Hæmorrhage from radial artery, followed by gangrene.	Sept. 5, 1864.	Circular amputation, right arm, middle third; Ass't Surgeon T. A. McGraw, U. S. V.	Died Sept. 7, 1864.
16	Day, J., Pt., F, 1st Massachusetts Artillery, age 30.	Oct. 1, 1864.	Flesh wound of right arm, followed by sloughing.	Oct. 18, 1864.	Flap amputation of right arm, upper third; A. A. Surgeon G. A. Chesley.	Disch'd Mar. 23, 1865.
17	Donnelly, E., Pt., C, 51st New York, age 29.	Sept. 17, 1862.	Flesh wound of right arm; recurrent hæmorrhage after ligation of brachial.	Oct. 7, 1862.	Circular amputation of right arm; Ass't Surgeon W. M. Notson, U. S. A.	Died Nov. 7, 1862.
18	Duffy, H., Lieutenant, D, 155th New York, age 46.	June 3, 1864.	Shot wound of left brachial artery; hæmorrhage following ligation.	June 21, 1864.	Amputation of left arm, upper third; Surgeon D. W. Bliss, U. S. V.	Disch'd Oct. 13, 1864.
19	Emory, C. E., Lieutenant, F, 12th New Hampshire.	June 3, 1864.	Hæmorrhage from ulnar artery after wound of the left forearm.	June 26, 1864.	Amputation of left arm at middle third.	Died Aug. 1, 1864.
20	Eva, J. H., Pt., K, 106th Pennsylvania, age 42.	July 3, 1863.	Flesh wound of the left wrist, involving brachial and ulnar arteries; necrosis.	July 3, 1863.	Amputation just below elbow; Surgeon J. Aiken, 71st Penn. Oct. 23th, amputation six inches below the shoulder; A. A. Surgeon T. G. Morton.	Disc. Sept. 26, 1864. Spec. 2732, A.M.M.
21	Fish, C., Pt., A, 15th Maine, age 26.	April 8, 1864.	Secondary hæmorrhage after flesh wound of the right arm.	April 15, 1864.	Circular amputation, right arm, upper third; Surgeons B. Wilson, U. S. V., and M. D. Benedict, 75th New York.	Died May 18, 1864.
22	Fritzschey, W., Sergeant, M, 12th Pennsylvania Cavalry, age 24.	Mar. 21, 1865.	Recurrent bleeding after ligation of brachial artery.	May 14, 1865.	Amputation of left arm just above the point of ligation; Surgeon J. B. Lewis, U. S. V.	Disch'd June 27, 1865.
23	Gill, M., Quartermaster's employe, age 26.	Oct. 29, 1864.	Sloughing and mortification after flesh wound of the left forearm.	Nov. 20, 1864.	Circular amputation at lower third of arm; A. A. Surgeon G. L. Stockdell.	Duty, Feb. 27, 1865.
24	Gunther, G., Pt., B, 7th New York Artillery, age 25.	May 18, 1864.	Hæmorrhage following wound of the left forearm.	May 28, 1864.	Circular amputation of left arm at lower third; A. A. Surg. C. H. McQueston.	Disch'd July 18, 1865.
25	Heatherby, J., Pt., E, 11th West Virginia, age 35.	Oct. 28, 1864.	Gangrene and hæmorrhage after wound of the left forearm.	Jan. 1, 1865.	Circular amputation of left arm, middle third; Ass't Surgeon W. H. Banks, U. S. V.	Died Jan. 24, 1865.
26	Hooker, W. H., Sergeant, H, 142d New York, age 39.	June 29, 1864.	Shell contusion of the right elbow....	Aug. 15, 1864.	Flap amputation of right arm, middle third; Ass't Surgeon H. M. Sprague, U. S. A.	Disch'd Oct. 5, 1864.
27	Hooper, J. A., Pt., 10th Massachusetts Battery, age 20.	Oct. 14, 1863.	Shot injury to left brachial artery....	Nov. 1, 1863.	Circular amputation, middle third, left arm; Surg. N. R. Moseley, U. S. V.	Disch'd Feb. 17, 1864.
28	Howell, E., Pt., H, 9th Iowa Cavalry, age 20.	Sept. 6, 1864.	Median nerve and left brachial artery divided; hæmorrhage.	Nov. 15, 1864.	Flap amputation, middle third, left arm; Ass't Surg. L. Lycan, 54th Illinois.	Died Dec. 14, 1864.
29	Jarvis, A., Pt., G, 10th West Virginia, age 45.	Oct. 13, 1864.	Shot laceration of right brachial artery and ulnar nerve; hæmorrhage.	Oct. 28, 1864.	Circular amputation, right arm, middle third; Surg. J. B. Lewis, U. S. V.	Disch'd June 23, 1865.
30	Knock, A., Sergeant, B, 84th Illinois, age 36.	June 27, 1864.	Hæmorrhage and gangrene ensuing after ligation of the radial artery, in a wound of the left forearm.	July 21, 1864.	Circular amputation of the left arm; Surgeon K. L. Stanford, U. S. V.	Died October 1, 1864.



No.	NAME, AGE, AND MILITARY DESCRIPTION.	DATE OF INJURY.	NATURE OF INJURY.	DATE OF OPERATION.	OPERATION AND OPERATOR.	RESULT.
31	Knox, B. E., Pt., A, 1st Delaware, age 27.	Feb. 15, 1865.	Shot wound of the biceps muscle and the median nerve.	Apr 110, 1865.	Amputation of the right arm, upper third; Surgeon D. W. Bliss, U. S. V.	Died April 28, 1865.*
32	Leonard, H., Pt., II, 2d New Jersey Cavalry, age 24.	June 10, 1864.	Shot injury of the principal nerves of the left forearm, followed by phagedena and decomposition.	June 13, 1864.	Circular amputation of the right arm, middle third; A. A. Surgeon J. N. Sharp.	Died June 28, 1864.
33	Marks, J. C., Pt., D, 149th Pennsylvania, age 28.	May 10, 1864.	Shot injury to the nerves of the right arm. Resection of three-fourths of an inch of both the median and musculocutaneous nerves, by A. A. Surgeon G. A. Mursiek.	Oct. 23, 1864.	Flap amputation of the right arm at junction of upper and middle thirds; Surgeon J. A. Lidell, U. S. V.	Disch'd May 27, 1865.
34	Milton, J., Sergeant, II, 25th Ohio, age 26.	July 1, 1863.	Hæmorrhage from the brachial artery after a wound of the right arm.	Aug. 8, 1863.	Amputation of the right arm; A. A. Surgeon J. B. Smith.	Died August 19, 1863.
35	Millett, A. F., Pt., A, 17th Michigan, age 37.	Mar. 25, 1865.	Sloughing and gangrene following a shell contusion of the left forearm.	May 5, 1865.	Circular amputation of the left arm at middle third; A. A. Surg. H. Craft.	Disch'd June 23, 1865.†
36	Marshall, H., Pt., E, 1st Michigan Cavalry, age 20.	May 28, 1864.	Hæmorrhage consequent on injury to the ulnar and humeral arteries of the right arm. June 19th, ligation of the brachial artery.	June 24, 1864.	Amputation of the right arm at junction of upper and middle thirds; A. A. Surgeon W. P. Ensign.	Died July 12, 1864.
37	Moon, J. M., Pt., C, 19th Virginia, age 26.	May 12, 1864.	Shell laceration of inner surface of right elbow joint; bone laid bare.	May 31, 1864.	Circular amputation of right arm at junction of middle and lower thirds.	Died July 23, 1864.
38	O'Brien, M., Pt., I, 169th New York, age 24.	June 30, 1864.	Hæmorrhage recurring after ligation of the radial artery, in a shot flesh wound of the left forearm.	Aug. 2, 1864.	Amputation of the left arm at the middle third; A. A. Surgeon H. B. White. (See CASE 1291 ante.)	Disch'd Feb. 11, 1865.
39	Paive, W., Pt., K, 67th Ohio, age 24.	May 10, 1864.	Shot wound of left arm, severing the brachial artery and injuring the tissues of the elbow.	May 18, 1864.	Circular amputation of the left arm at the lower third; A. A. Surgeon J. H. Hill.	Died July 5, 1864.
40	Rea, J. K., Pt., II, 102d Pennsylvania, age 17.	May 5, 1864.	Gangrene and hæmorrhage after shot flesh wound of the upper third of the left arm. Brachial artery ligated May 14, 1864.	May 17, 1864.	Flap amputation of the left arm at the upper third; Surg. C. Page, U. S. A.	Died Dec. 1, 1864.
41	Rice, J., Pt., A, 20th Connecticut, age 22.	Mar. 19, 1865.	Shot wound of the right arm, severing the brachial artery; acute inflammation of the elbow joint.	May 7, 1865.	Circular amputation of the right arm, upper third; A. A. Surg. H. Sanders.	Disch'd Oct. 18, 1865.
42	Rieker, B., Pt., G, 6th Vermont, age 45.	May 5, 1864.	Gangrene following a shot flesh wound of the left wrist.	May 16, 1864.	Flap amputation of the left arm at the upper third; Surgeon E. Bentley, U. S. V.	Died May 22, 1864.
43	Sinclair, F., Pt., B, 8th Maine, age 28.	May 20, 1864.	Shot wound of the right brachial artery.	June 1, 1864.	Flap amputation of the right arm at the upper third; A. A. Surgeon M. Baldwin.	Died July 1, 1864.
44	Springer, R. B., Pt., L, 2d Iowa Cavalry, aged 31.	Sept. 1, 1864.	Gangrene after a shot flesh wound of the left hand.	Sept. 21, 1864.	Amputation of the left arm at the middle third; Confederate surgeon. Re-amputation about a month after.	Disch'd Dec. 20, 1864.
45	Stager, J., Corporal, E, 95th Pennsylvania.	May 3, 1863.	Shot flesh wound of the left arm, with probable destruction of the brachial artery.	May 9, 1863.	Amputation of the left arm at the upper third; Assistant Surgeon W. Thomson, U. S. A.	Disch'd Sept. 9, 1863.
46	Staines, S., Corporal, C, 53d Pennsylvania, age 25.	July 3, 1863.	Recurrent hæmorrhage after ligation of the brachial artery in a shot flesh wound of the right arm.	Aug. 2, 1863.	Amputation of the right arm at the upper third; A. A. Surgeon C. R. McLenn. (See CASE 1247 ante.)	Died Sept. 1, 1863.
47	Vancellote, T., Pt., D, 2d Vermont, age 21.	Apr 116, 1862.	Repeated hæmorrhages consequent on a shot perforation of the right arm. Axillary artery ligated April 23d.	Apr 125, 1862.	Amputation of the left arm, high up; Surgeon R. B. Bonicoun, U. S. V. (See CASE 1263 ante.)	Disch'd Jan. 13, 1863.
48	Vincent, C., Pt., D, 122d Ohio, age 19.	Nov. 27, 1863.	Secondary hæmorrhage from sloughing of the brachial artery in a shot perforation of the upper third of left arm.	Dec. 27, 1863.	Flap amputation of the left arm just below the shoulder joint; A. A. Surgeon C. P. Bigelow.	Died Jan. 6, 1864.
49	Waldo, A., Corporal, I, 35th Massachusetts, age 30.	May 19, 1864.	Shot wound of the left arm, injuring the brachial artery and dividing the tendons of the biceps muscle.	May 25, 1864.	Flap amputation of the left arm at the junction of the middle and upper thirds; Surg. D. W. Bliss, U. S. V.	Died June 7, 1864.
50	Wiener, X., Pt., D, 10th New York Cavalry, age 19.	Aug. 23, 1864.	Shot wound of the left elbow, injuring an arterial branch and producing an aneurism.	Sept. 4, 1864.	Flap amputation of the left arm at the lower third; Assistant Surgeon J. C. McKee, U. S. A.	Died Sept. 19, 1864.
51	Williamson, J., Corporal, C, 111th Illinois, age 26.	Dec. 13, 1864.	Recurrent hæmorrhage after ligation of the brachial artery in a shot wound dividing the ulnar and brachial arteries.	Jan. 7, 1865.	Flap amputation of the right arm at the upper third; A. A. Surg. H. Leaman.	Died Feb. 1, 1865.
52	Wright, W., Pt., C, 160th Pennsylvania, age 26.	June 3, 1864.	Dissection of all the muscles by burrowing of pus in a shot flesh wound of the left arm.	July 9, 1864.	Amputation of the left arm; A. A. Surgeon H. Leaman.	Died Dec. 20, 1864.
53	Featman, R., Pt., D, 50th Virginia, age 25.	Aug. 27, 1864.	Hæmorrhage following a shot flesh wound of right forearm, with division of the ulnar and radial arteries.	Aug. 29, 1864.	Circular amputation at the middle third of the right arm; Assistant Surgeon W. F. Richardson, U. S. A.	Died Sept. 27, 1864.
54	Zink, T., Pt., H, 45th New York, age 24.	July 2, 1863.	Sloughing, with great loss of soft parts, followed by secondary hæmorrhage and gangrene, in a shot wound of the left elbow joint.	July 15, 1863.	Circular amputation of the left arm at the lower third; Assistant Surgeon H. S. Scheil, U. S. A.	Disch'd Nov. 21, 1863.

There was an appalling mortality in this series. Half of the patients died. Three amputated primarily for grave shot lacerations, recovered. Of thirty-five intermediary operations, twenty-one (60 per cent.) resulted fatally. Of the sixteen secondary amputations, only ten had a successful issue. An analysis of the reports shows that amputation was resorted to on account of hæmorrhage in thirty-five of the cases. In eleven of them, ligation of a main arterial trunk had been already practised. The right limb was mutilated in twenty-one, and the left in thirty-three instances. Thirteen amputations were in the lower, twenty-three in the middle, and eighteen in the upper third, and it will be noticed how the mortality increased as the trunk was approached.

\* See *Specs.* 4038, 4050, and 4065, A. M. M.

† *Spec.* 152, A. M. M.

*Amputations of the Forearm.*—Fourteen cases were reported of amputation in the forearm on account of the consequences of shot flesh wounds:

TABLE XVI.

*Summary of Fourteen Amputations in the Continuity of the Forearm, for complicated Shot Injuries unattended by Fracture.*

No.	NAME, AGE, AND MILITARY DESCRIPTION.	DATE OF INJURY.	NATURE OF INJURY.	DATE OF OPERATION.	OPERATION AND OPERATOR.	RESULT.
1	Bentz, F., Pt., E, 100th New York, age 40.	May 7, 1864.	Shot wound of left hand, followed by gangrene.	July 5, 1864.	Flap amputation of left forearm at junction of middle and lower thirds; Ass't Surg. W. Webster, U. S. A.	Disch'd Sept. 27, 1864.
2	Cole, A., Pt., I, 4th Michigan, age 19.	May 6, 1864.	Shot laceration of right hand, between thumb and index finger; erysipelatous inflammation; profuse and fetid discharge.	May 31, 1864.	Flap amputation of forearm at middle third; A. A. Surgeon G. H. Dare.	Died July 1, 1864.
3	Hercules, C., Pt., G, 129th Illinois, age 37.	May 26, 1864.	Shot wound of left wrist and hand; infiltration of pus; abscess; ulna protruding; gangrene.	July 11, 1864.	Circular amputation of forearm at upper third; A. A. Surgeon George E. Walton.	Disch'd April 22, 1865.
4	Hurley, R., Pt., H, 159th New York, age 24.	Sept. 19, 1864.	Shot wound of right arm; brachial artery severed and ligated; gangrene of forearm.	Oct. 9, 1864.	Flap amputation in middle third of forearm; A. A. Surg. F. F. Maury.	Disch'd Mar. 29, 1865.
5	James, O., Pt., F, 1st Michigan, age 21.	June 22, 1864.	Shot wound of back of left hand; erysipelatous inflammation.	July 29, 1864.	Flap amputation of forearm at upper third; A. A. Surgeon A. Fran.	Disch'd Nov. 15, 1864.
6	Karbaek, W., Pt., E, 1st Miss. Mounted Rifles, age 21.	Feb. 13, 1865.	Shot laceration of superficial palmar arch; erysipelas and gangrene.	Feb. 26, 1865.	Circular amputation at middle third of forearm; A. A. Surg. R. W. Coale.	Disch'd May 14, 1865.
7	Kelley, W. G., Pt., E, 4th Rhode Island, age 55.	Sept. 17, 1862.	Shot wound of left forearm; hæmorrhage from interosseous; compression; recurrent bleeding.	Sept. 26, 1862.	Flap amputation of forearm at upper third; Surgeon C. W. Jones, U. S. V.	Disch'd Nov. 29, 1862.
8	Palmer, A., Pt., K, 73d Ohio, age 40.	July 3, 1863.	Shot wound above wrist; palmaris longus and flexor sublimis digitorum cut.	July 29, 1863.	Amputation of forearm by Ass't Surg. H. S. Schell, U. S. A.; hæmorrhage occurred, and radial ligated by A. A. Surg. D. Kennedy on the same day.	Died July 31, 1863.
9	Perry, Ch., Pt., H, 13th New Hampshire, age 28.	June 15, 1864.	Shot wound of left forearm, middle third; four inches of radius denuded; sloughing.	July 15, 1864.	Circular amputation of forearm above middle third; A. A. Surgeon J. W. McGrath.	Disch'd Mar. 2, 1865.
10	Pettigrew, M., Quartermaster's employé, age 16.	Sept. 24, 1864.	Shot flesh wound of right forearm	.....	Primary amputation of upper third of right forearm.	Recovery.
11	Ruber, C., Pt., F, 83d New York, age 20.	May 8, 1864.	Shot wound of left forearm; gangrene.	May 23, 1864.	Flap amputation of upper third of forearm; A. A. Surg. C. W. Koechling.	Died June 1, 1864.
12	Schleiker, N. N., Pt., K, 5th Michigan, age 39.	Aug. 28, 1864.	Shot wound of left hand and wrist; sloughing of muscles and tendons; gangrene.	May 23, 1865.	Circular amputation of forearm at junction of middle and upper thirds; A. A. Surg. D. O. Farrand.	Disch'd Oct. 3, 1865.
13	Seipp, G. W., Corporal, G, 1st Maryland, age 20.	May 19, 1864.	Shot wound of left middle finger; large abscesses of hand and under surface of forearm; carpal bones denuded.	June 3, 1864.	Flap amputation of forearm at middle third; A. A. Surgeon H. M. Dean.	Disch'd Sept. 24, 1864.
14	Sladden, R., Pt., F, 3d New Hampshire, age 29.	May 17, 1864.	Shot wound of left wrist; extensive sloughing; gangrene, and secondary hæmorrhage.	June 9, 1864.	Circular amputation of forearm at middle third; A. A. Surg. W. S. Ward.	Disch'd Nov. 8, 1864.

One primary and four secondary amputations resulted successfully. Of the nine intermediary cases, three were fatal. The mortality of more than 20 per cent. for forearm amputations was excessive, and probably, must be explained by pyæmic or septicæmic complications. Nine of the operations were on the left and five on the right side.

GENERAL OBSERVATIONS ON FLESH WOUNDS OF THE UPPER EXTREMITIES.—The facts set forth in the preceding section sufficiently attest the frequency and importance of the injuries of the upper extremities observed in the war of the rebellion. Punctured and incised wounds received in action were comparatively rare; those inflicted in affrays and brawls were more common; but there was no great fatality from this class of injuries. Venesection was obsolescent during the war, and there were no recorded examples of arterio-venous aneurisms at the bend of the elbow. Shot wounds of the upper arm, forearm, and hand were, perhaps, the most common accidents of battle.<sup>1</sup> They often resulted in diffuse inflammation and sloughing, and in disabilities due to muscular atrophy or loss of substance, to tendinous adhesions and contractions, and to other complications that will be briefly recapitulated. Notwithstanding the protected position of the principal arterial trunks on the inner sides of the bones, and the resiliency of these vessels, there were

<sup>1</sup> BIL' BOTH (Th.). (*Chir. Briefe*, u. s. w., 1872, S. 207) observes: "The injuries of the upper extremity, especially of the finger and hand, are, as you may convince yourself by the examination of transports of wounded, enormously frequent; they form a large percentage of the slightly wounded, and are especially adapted to transportation."



many examples of division or laceration of the arteries unattended by fracture, both by large and small projectiles; and yet more common were hæmorrhages from arteries that had been bruised by the passage of a ball, or ulcerated from proximity to a ball track. I have not been able to find any instance of fatal primary bleeding<sup>1</sup> from a shot lesion of the brachial or its branches. Of the cases of ligature of the brachial that furnished preparations to the Museum, the following may be cited:

CASE 1410.—Private A. Conrad, Co. C, 8th Illinois, aged 27 years, was wounded at Upperville, June 21, 1863. He was sent to Emory Hospital, at Washington. Acting Assistant Surgeon W. H. Ensign reported that: "A carbine ball, entering two inches above the left wrist joint, passed upward behind the bone nearly to the elbow joint. On admission, at Emory Hospital, the patient's arm was much swollen. On June 29th, the entrance wound was enlarged, and an unsuccessful search was made for the ball. Sinuses extended along the radius, which was denuded of periosteum in much of its extent. The forearm was bandaged and kept moistened with ice water. On June 30th, laudable pus was freely discharged. On July 2d, the situation of the ball was thought to be detected just below the elbow joint. The patient was gradually growing weaker. On July 3d, the position of the ball was plainly detected [compare *Specimen 1387*, Sect. I, A. M. M.], and it was proposed to cut down upon it, when hæmorrhage commenced from the point of entrance of the ball. A tourniquet was immediately applied to the brachial artery. The ball was then excised, and a bandage applied from the fingers to the elbow. The tourniquet was loosened, and the hæmorrhage did not return. On July 5th, the bleeding recurred. Compression was applied over the radial and ulnar arteries by means of bandages." On July 9th, Dr. Ensign being ordered away, Acting Assistant Surgeon G. McCoy took charge of the case, and "secondary hæmorrhage being frequent, there was nothing left but amputation, which was performed by antero-posterior flaps of the integument, with circular division of the muscles, just above the elbow. The patient was more cheerful, and his pulse came up; but exhaustion finally prevailed, and he died July 11, 1863."



FIG. 368.—Preparation of the left brachial two days after amputation. *Spec. 1386*.

Venous hæmorrhages of importance after shot wounds or other injuries of the upper extremities appear to have been infrequent; and no information was reported regarding the effects of shot lesions of the lymphatics of the arm. Many valuable observations were collected respecting shot lesions of the nerves, and some of the best recorded cases of causalgia, or "burning pain," and of "glossy skin," are derived from shot injuries of the soft parts of this region. Yet the proportion of such cases to the immense aggregate of shot wounds of the upper extremities was comparatively small, even less than observed, in another war, by Generalarzt Loeffler.<sup>2</sup>

It has seemed best to dwell on these flesh wounds of the upper extremity,<sup>3</sup> since few writers regard them as worthy of separate consideration. The elder Langenbeck is one of the exceptions.<sup>4</sup> MM. Desormeaux and Nicaise, in articles in the two new French dictionaries of medical sciences, treat systematically of wounds of the soft parts of the upper limb, and Dr. B. Beck has some sound observations on shot wounds of this category.<sup>5</sup>

<sup>1</sup> A most competent authority, Generalarzt LÖEFFLER, states (*Generalbericht über den Gesundheitsdienst*, u. s. w., 1867, S. 157): "Important primary bleedings from injuries of the larger blood vessels are rarely observed at the place of the first dressing, for the reason that, if the bleeding does not cease spontaneously or from provisional compression, the time from the reception of the injury to the arrival at the place of first dressing is more than sufficient to cause death from hæmorrhage." This of shot wounds of the upper extremities.

<sup>2</sup> The eminent writer just quoted observes (*l. c.*, S. 149), in treating of shot wounds of the upper extremities: "When the soft parts only are injured, the arterial and nerve trunks, protected by their sheaths, fortunately escape, as a rule. Regarding the latter, especially, the small number of nine injuries of the larger nerve trunks only in a total of five hundred shot flesh wounds of the soft parts \* \* conclusively proves that the nerves frequently escape the inroads of the *Spitzkugel* and the *Langblei*. In certain regions of the upper extremities the nerves are so much exposed, that the rarity of their lesion is remarkable." In Herr LÖEFFLER'S statistics the examples of important nerve lesions in shot flesh wounds of the upper extremities was 9 in 500 cases. In our records the proportion is much less, 96 cases in 54,729. No doubt many cases are unreported in the American statistics.

<sup>3</sup> MATTHEW (T. P.) (*op. cit.*, Vol. II, pp. 355, 356), in an aggregate of 7,660 cases, tabulates 2,189 cases of shot wounds of the upper extremities, as already stated in TABLE XII, page 434. Of these, 1,296 cases, or 59.2 per centum, were flesh wounds. DEMME (*Studien*, 1860, B. II, S. 201) remarks that of "2,000 cases of shot injuries of the upper extremities, in the Italian War of 1859, 1,325, or 66.2 per centum, were uncomplicated flesh wounds." FISCHER (H.) (*Kriegschirurgische Erfahrungen*, 1872, S. 136), in a total of 249 cases of shot injuries of the upper extremities, reports 119 cases, or 47.7 per centum, as uncomplicated shot wounds of the soft parts.

<sup>4</sup> LANGENBECK (C. J. M.) (*Nosologie und Therapie der Chirurgischen Krankheiten*, Göttingen, 1850, B. IV) devotes a chapter (III Capitel, S. 220) to flesh wounds of the upper extremities, treating specially of those complicated by wounds of the arteries and those treated by amputation.

<sup>5</sup> In treating of flesh wounds of the upper extremities, Dr. B. BECK (*Chir. der Schussverletzt.*, 1872, S. 572) remarks: "If the artery only is injured, and the bleeding may be controlled with almost entire certainty, the surgeon should strive for the conservation of the limb, even if the nerve is also wounded, and, in like manner, where the large veins are implicated." Dr. WILLIAM MACCORMACK, in his interesting *Notes and Recollections* (*l. c.*, p. 25) tabulates 63 shot wounds of the upper extremity unattended by fracture, treated at the Anglo-American Ambulance after Sedan, without a fatal case, and remarks: "The patients recovered well, with scarcely an exception, from simple flesh wounds." But elsewhere the danger of deductions from limited facts is recognized.

## SECTION II.

## FRACTURES OF THE CLAVICLE AND SCAPULA.

There appear in the reports twenty-three hundred and eighty-one cases of fractures of the clavicle<sup>1</sup> or of the scapula<sup>2</sup> unattended by primary lesions of ribs, head of humerus, or thoracic cavity. The vast majority are examples of shot fracture. A few instances of sabre and bayonet injuries of these bones will be noted. Ninety or more cases of simple or compound fractures of the collar bone or shoulder blade from blows, falls, railroad accidents, and the like, are reserved for the proposed chapter alluded to on page 209, on fractures not caused by shot projectiles.

The cases of shot fractures of the clavicle and scapula implicating the chest cavity have been adverted to in the fifth chapter of the *First Surgical Volume*, and abstracts of thirty examples are there presented, thirteen of fractures of either bone separately, and four of simultaneous fracture of both bones. In this section, the clavicle and scapula will be looked upon no longer as portions of the chest-parietes, but as portions of the upper limbs. The fractures on the left side had a slight numerical predominance.<sup>3</sup>

The returns indicate a comparatively moderate degree of danger to life from this class of injuries. Eliminating the risks of secondary implication of the viscera of the thorax, or of mischief to the great vessels and nerves therein, the mortality rate of injuries of the clavicle and scapula is small, amounting, in uncomplicated shot fractures of the clavicle to a little over 9 per cent., in analogous lesions of the scapula to 12.4 per cent., in simultaneous injuries of both bones to 23.3 per cent. The superficial situation of the clavicle accounts for the comparative innocuity of compound fractures of the bone unattended by lesions of the important organs in its vicinity.

A large number of alleged partial excisions of the clavicle and scapula were reported; but, on examination, many of these operations are discovered to be merely extractions of detached bone splinters, or the removal of fragments of necrosed bone. Attention will be called to some important exceptional cases.

*Sabre and Bayonet Wounds.*—One example was reported of bayonet fracture of the clavicle, and four instances of sabre incisions<sup>4</sup> and two of bayonet perforations of the

<sup>1</sup> Clavicle, Lat., *clavicula* (small key) ("Quod instar clavis scapulam eum sterno claudant ac firment."—DIEMERBROECK. *l. c.*, p. 550). Greek, κλειδός; German, *Schlüsselbein*; Italian, *clavicola*; French, *clavicule*.

<sup>2</sup> Scapula, the Latin equivalent for *shoulder blade*; VOSSIUS derives the name from σκαπτισθαί, to be hollow. DIEMERBROECK (*l. c.*, p. 550) remarks: "barbaris spatula dicta." Greek, ὠμοπλάτη; Fr., *omoplate*; Ger., *Schulterblatt*.

<sup>3</sup> In the proportion of a little over 4 per cent. There were 1150 fractures on the right, 1199 on the left, 11 of both sides, and in 21 instances this point was unspecified. Professor SOGIN (*Verletzungen der Extremitäten*, in *Kriegschir. Erf.*, 1872, S. 101) estimates that "both sides of the body are apparently equally exposed to hostile projectiles under the present manner of fighting; of 235 cases of shot wounds of the upper extremities, 116 were of the right and 119 of the left side."

<sup>4</sup> The epaulet of the officer and shoulder-scale of the enlisted man, though now ornamental appendages, were originally part of the defensive armor, to shield the shoulders from sword-cuts. See REES (A.) *The Cyclopædia or Universal Dictionary of Arts, Sciences, and Literature*, Philadelphia, Vol. XIII.



scapula; but, in several of these seven cases, the descriptions given were so indefinite as to leave doubt whether the osseous lesions were of a serious nature. However, the cases will be briefly recapitulated:

CASE 1411.—Private S. W. Billingsby, Co. K, 46th Indiana, was wounded at Belmont, November 7, 1861, and discharged for disability. He was subsequently, at Cincinnati, in January, 1867, examined for re-enlistment in the regular service by Acting Assistant Surgeon L. A. James, who noted, "bayonet fracture of the right clavicle."

CASE 1412.—Private J. Quinn, Co. G, 2d Missouri, was wounded at Chattanooga, September 19, 1863. Assistant Surgeon J. Powers, U. S. V., noted, at St. Louis, September 27th: "A punctured wound of the trunk, caused by a bayonet entering immediately over the inferior angle of the right scapula, not penetrating the chest." Returned to duty October 1, 1864.

Another example of bayonet injury of the scapula has been mentioned in the *First Surgical Volume*.<sup>1</sup> There were the following cases of sabre cuts of the scapula:

CASE 1413.—Sergeant J. Higgins, Co. G, 5th Cavalry, was wounded at Gaines's Mill, June 27, 1862. He is reported to have had a sword wound of the superior angle of the right scapula, for which he was treated in regimental hospital. He had other wounds, and was discharged. He was examined for re-enlistment in the regular service by Acting Assistant Surgeon J. Neill, at Philadelphia, in April, 1868, who reported that "no disability" then existed.

CASE 1414.—Private F. Boyer, Co. E, 18th Pennsylvania Cavalry, was wounded at Gettysburg, July 2, 1863, and sent to Cuyler Hospital, July 5th. Surgeon Josiah Curtis, U. S. V., reported, "an incised wound of the scapula." This man is reported to have "deserted, July 23, 1863."

CASE 1415.—Private C. A. Woods, Co. A, 1st Pennsylvania Artillery, was wounded at Petersburg, July 3, 1863. He was discharged, but, on July 10, 1866, was examined as a recruit for the 42d Infantry by Surgeon A. N. McLaren, U. S. A., who reported: "A sabre wound about an inch in length over the left scapula, just below the centre of the spine. This man had also an inguinal hernia of the left side, the result of a fall received while climbing the enemy's breastworks at the same time and place."

A fourth case,<sup>2</sup> complicated by a sword wound of the cranium, is mentioned on page 20 of the *First Surgical Volume*.

**Shot Fractures of the Clavicle and Scapula.**—Contrary to the general impression,<sup>3</sup> shot fractures of the clavicle or of the scapula unattended by penetration of the chest are not infrequent in modern warfare. The cases reported from the war of the rebellion are summed up in the following tabular statement:

TABLE XVII.

*Numerical Statement of Two Thousand Two Hundred and Eighty Cases of Shot Fractures of the Clavicle and Scapula unattended by Penetration of the Chest or Lesion of the Humerus.*

NATURE OF SHOT FRACTURE.	CASES.	DUTY.	V. R. C.	DISCHARGED OR PAROLED.	DIED.	UNDETERMINED.
Of the clavicle.....	527	242	46	188	44	7
Of the scapula.....	1,444	598	94	554	177	21
Of the clavicle and scapula.....	105	18	3	58	21	2
Of clavicle or scapula near the shoulder, the fracture not precisely specified..	204	83	4	48	69	.....
Aggregates.....	2,280	941	147	848	314	30

Although the mortality in this group was less than 14 per cent., more than half of those injured were found incapacitated for further duty. Examples have been adduced of shot fractures of the clavicle and scapula associated with penetration of the pleural cavity; but the cases not thus complicated are too numerous to be passed over without further comment.

<sup>1</sup> Case of Private R. Dorsey, Co. E, 17th West Virginia, *First Surgical Volume*, p. 469.

<sup>2</sup> Private P. Lucas, Co. G, 1st New York Cavalry, wounded at Winchester, June 13, 1863.

<sup>3</sup> FISCHER (H.) (*Kriegschirurgische Erfahrungen, Vor Metz, 1872*, S. 142), speaking of fractures of the scapula and clavicle, remarks: "How such wounds are possible without injury to the lung, or without opening of the pleural cavity, is difficult to conceive." LÖFFLER (*Generalbericht über den Gesundheitsdienst, 1867*, S. 162) tabulates 66 cases of fractures of clavicle or scapula without penetration of the pleural cavity, in a total of 2,355 cases, a still larger percentage of this class of cases than in the war of the rebellion, where the percentage was only 0.9, or 2,280 cases in 253,142.

*Shot Fractures of the Clavicle.*—The Museum possesses twenty-one illustrations of this form of injury, including examples of transverse fractures (FIG. 369), of oblique and comminuted fractures, of caries and necrosis following shot lesions, of fractures with attempts at repair more or less successful, and of sequestra or fragments removed from the clavicle. Some of these specimens have been figured already;<sup>1</sup> others will be shown in connection with the abstracts of cases now to be related. Of the few writers that have treated specially of shot fractures of the clavicle, some have exaggerated their dangers,<sup>2</sup> and others have underestimated the frequency of grave complications.<sup>3</sup> A century ago, Ravaton<sup>4</sup> appreciated more justly than recent authors the gravity of these injuries. Several examples of complicated shot fractures of the clavicle were detailed in the third, fourth, and fifth chapters.<sup>5</sup> Some instances of uncomplicated fracture will be cited here:

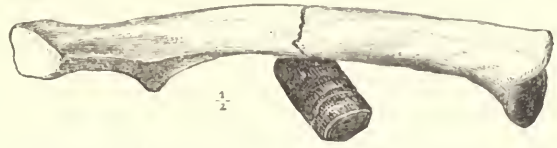


FIG. 369.—Transverse fracture of the middle of the right clavicle by a conical ball. *Spec.* 1210.

CASE 1416.—Private G. D. Baxter, Co. G, 110th New York, aged 41 years, was wounded at Gettysburg, July 2, 1863. Surgeon H. Janes, U. S. V., noted, "a gunshot fracture of the right clavicle." On October 5th, the patient was sent to Philadelphia. Acting Assistant Surgeon C. B. King forwarded to the Museum, from Turner's Lane Hospital, the missile by which the patient was struck. It is a round iron ball, weighing 257 grains, probably a spherical-case shot, and is numbered 4509 of the first section of the Museum. Dr. King described it as "entering at the inner third of the clavicle, fracturing this bone, and lodging under the pectoral muscle near the axilla. The ball was not extracted until May 3, 1864." On July 15th, the patient was sent to Haddington Hospital, and discharged and pensioned September 28, 1864. He re-enlisted June 4, 1865, in the Marine Corps, and was again discharged June 3, 1869. His pension was restored from that date. Examiner J. F. Hall, of Portsmouth, reported, January 29, 1873: "The applicant has a scar over the right clavicle. The bone was fractured, and, he says, severed, and pieces of bone came out. There are two or three scars below the clavicle; also one on the right arm, a little below the shoulder. \* \* The scars are all healed and apparently sound. The adhesions in the healing of the fractured clavicle give some embarrassment in the use of the arm." Dr. Hall reported, September 4, 1873: "There are troublesome adhesions, with considerable difficulty in raising the right arm." The pensioner was paid June 4, 1874.

CASE 1417.—Private D. Crowther, Co. C, 13th Massachusetts, was wounded at Bull Run, August 30, 1862, and was admitted to Filbert Street Hospital, Philadelphia, on September 30th. Acting Assistant Surgeon W. M. Breed, U. S. V., reported: "He was struck by a fragment of shell over the left pectoral muscle, fracturing the clavicle at its middle third, with an external wound an inch in length over but not communicating with the bone. There was considerable ecchymosis over the seat of injury. It was dressed loosely, at first, with Fox's apparatus, and afterward, as the tenderness subsided, the apparatus was tightened up. The bone has consolidated with half an inch overlapping." The patient was discharged January 19, 1863, on certificate of disability, for "partial loss of use of the left arm from shell wound of the shoulder." Not a pensioner.

In the five hundred and twenty cases of this group the mortality rate was small, but slightly exceeding 8 per centum. More than half of the patients were returned to duty, and about a third of the number were discharged; and, as their names do not appear on

<sup>1</sup>In the *First Surgical Volume*, viz: *Spec.* 2194, as FIG. 219, p. 483; *Spec.* 137, as FIG. 242; *Spec.* 3760, as FIG. 243. Cases of partial excision are exemplified by *Specimens* 3844, 372, 4332, in FIGS. 256, 257, 258, of that volume.

<sup>2</sup>NEUDÖRFER (J.) (*Handbuch der Kriegschirurgie*, 1872, S. 1116) states: "While the simple fracture of the clavicle is comparatively the least important of that of any of the long bones, uniting readily with complete preservation of the functions of the arm, we must class the shot fractures of the clavicle with the, relatively, most severe and dangerous injuries; they are even more dangerous than the fractures of the upper arm." GOLDON (C. A.) (*Lessons on Hyg. and Surg.*, 1873, p. 144), generalizing from a case of simple fracture, a shot wound in the clavicular region, at Sedan, and another at Flöing, infers that: "These few cases furnish no just estimate of the rate of occurrence of this injury, but rather point out their extreme fatality."

<sup>3</sup>BECK (B.) (*Chir. der Schussverletz.*, 1872, S. 641), treating of shot fractures of the clavicle, says: "If there are no special indications, no serious injuries of the vessels or nerves by deep-seated splinters, the healing should be left to nature without operative interference. Resections, as a rule, aggravate the condition by causing a large deficiency of bone. The less the wound and bones are manipulated, the better the result. I have, indeed, in my earlier campaigns, successfully practised resections in cases of comminuted fractures; but, judging from my later experience, the cases would have terminated successfully, without operation, at an earlier period." Generalarzt BECK believes that: "Fractures of the clavicle are rarely accompanied by serious injuries of the neighboring blood-vessels; but more frequently by lesions of the nerves."

<sup>4</sup>RAVATON (*Chirurgie d'Armée*, Paris, 1768, p. 200) entitles his twentieth chapter: "De la cure de coups de feu qui fracturent la clavicle," and details three interesting cases of shot fractures of the clavicle, from the battle of Dettingen, June 16, 1743, and adds some judicious reflections on the frequency, danger, and treatment of this form of injury.

<sup>5</sup>Compare, in the *First Surgical Volume*, the cases of: Corporal L. Shaw, G, 35th Ohio, p. 407; Sergeant G. E——, A, 2d Texas Cavalry, p. 432; Pl. C. Berry, I, 28th New Jersey, p. 474; Sergeant Samuel A——, 125th Pennsylvania, p. 482; Pl. Andrew G——, I, 5th Michigan, Sergeant Lemuel A. J. B——, I, 27th Mississippi, and Pl. Edward Osborn, II, 9th Pennsylvania Reserves, p. 483; Major G. N. Lewis, 12th Connecticut, p. 494; Pl. Monroe P. Sanders, F, 93d Pennsylvania, p. 499; Unknown soldier, p. 522; Pl. John B——, D, 51st Illinois, p. 523; William S——, a scout, p. 546; Pl. Adam Grimm, D, 7th Connecticut, p. 547; Pl. E. C. Melley, K, 2d West Virginia Mounted Infantry, p. 555; Pl. W. S. Jenne, B, 6th Vermont, 585; Pl. *Allman M. P——*, C, 34th Virginia, p. 588.



the pension roll, some of these were not seriously disabled. It is highly probable that many cases were returned under this head that a rigorous analysis would have excluded; and in many of the cases rightly classified, the clavicle was but slightly clipped or grooved by the projectile, at its acromial extremity. Slight injuries of the sternal extremity were prone to result in necrosis:

CASE 1418.—Lieutenant J. J——, Co. E, 5th Tennessee, was wounded at Mission Ridge, November 25, 1863, captured and taken to Chattanooga. On February 16, 1864, he was transferred to Nashville. Acting Assistant Surgeon P. Peter reported:

"He was suffering from a large abscess over the left clavicle, and another over the symphysis pubis, the latter discharging very freely. The patient was greatly emaciated and very much exhausted, feverish, and with very poor appetite. He was put upon egg and milk diet, milk punch, and wine. He died from exhaustion February 23, 1864." The sternal half of the necrosed collar bone (FIG. 370) was transmitted to the Museum with the foregoing report. The concomitant caries of the pubic bone lends color to the suspicion that the disease of the clavicle may, if not due to syphilis, have been aggravated by a syphilitic taint.

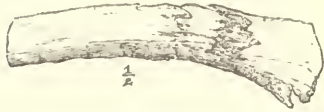

FIG. 370.—Sternal half of the left clavicle necrosed after shot contusion. *Spec.* 2193.

It has been surmised that the nerves suffer oftener than the blood-vessels in shot fractures of the clavicle.<sup>1</sup>

CASE 1419.—Sergeant J. V. Flansburg, Co. E, 97th New York, aged 23 years, was wounded at Bull Run, August 30, 1862. On September 7th, he was admitted into Columbian College Hospital, Washington. Surgeon T. R. Crosby, U. S. V.,

reported: "A minié ball passed in about two inches behind and below the posterior fold of the axilla, and was taken out in front, about the middle of the clavicle. The clavicle was fractured and the brachial plexus injured. Discharged January 30, 1863, with imperfectness of the shoulder joint," and pensioned. Examiner C. B. Coventry, of Utica, reported, September 15, 1873: "There is weakness and tenderness and spasm of the muscles." Surgeon C. Page, U. S. A, forwarded the missile to the Museum. It is "a conoidal ball, exceedingly misshapen by being compressed and bent upon itself, with jagged extremities and longitudinal grooves on one side and a comparatively smooth surface on the other. Removed from among the fragments of the clavicle, having entered above the angle of the left scapula" (*Cat. Surg. Sect.*, p. 657), and weighs 404 grains. It is represented of half size in the annexed wood-cut (FIG. 371).

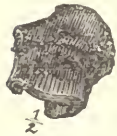

FIG. 371.—Missile flattened on the clavicle. *Spec.* 4505.

*Excisions of the Clavicle.*—Some observations on this subject have been presented in the fifth chapter, in connection with shot wounds of the chest. Ten examples were adduced, including two instances of extirpation of the clavicle,<sup>2</sup> and five of partial excisions

<sup>1</sup> M. CHEXY (*Op. cit. Camp. d'Orient*, p. 209) tabulates 103 cases of shot fracture of the clavicle, with 41 deaths; but undoubtedly these must include many instances of chest wounds. STEINBERG (*Die Kriegslazarethen und Baracken von Berlin*, 1872, S. 149) notes 44 cases of fracture of the clavicle, with two deaths, in an aggregate of 8,531 wounded. GILLETTE (*Blessures par armes à feu observées pendant le siège de Metz*) details one case of shot fracture of the right clavicle, in an armorer aged 46 years, which resulted fatally from the burrowing of pus.

<sup>2</sup> In thirty published cases of extirpation of the clavicle, of which I will presently give references, there were fifteen operations practised on account of caries or necrosis, ten for morbid growths usually designated osteosarcomata, and four on account of the immediate results of injuries. Of the latter category, only two were performed on account of shot injury. These were the two cases referred to in Chapter V, both complicated by injuries of the pleural cavity. It would be interesting, if further details could be had of the case reported by Professor J. L. CABELL, of which a memorandum is printed in the *First Surgical Volume*, p. 557. An account of the second extirpation of the clavicle for shot injury, by Surgeon General J. C. PALMER, of the Navy, is printed in the *Am. Jour. Med. Sci.*, 1865, Vol. XLIX, p. 357. In 1874, Dr. PALMER contributed to the Museum a preparation, No. 6213, Sect. I, from this case. It consists of the right scapula, upper third of humerus, and first and second ribs. The fragments of the comminuted clavicle were not preserved. The ribs are fissured; the humerus is uninjured; the superior angle of the scapula, the part where the supraspinatus is attached, and that smooth portion of the spine over which the trapezius glides, have been carried away by the projectile. The note on page 557 of the *First Surgical Volume*, on extirpations of the clavicle, is incomplete, and contains some errors. Professor GROSS is right in referring to REMMER the operation in 1732, reported by KULMUS (J. A.), *De exostosi stomatode claviculari, ejusque felici sectione* (printed in HALLER'S *Disp. chir.*, 1756, T. V, p. 655); but this operation was not an extirpation, but a partial excision for exostosis. Dr. FUQUA'S operation likewise was not a removal of the entire bone, for the operator states: "The inner extremity was exposed; not all of it, however, was found diseased, and it was determined to remove only the carious part" (*Maryland and Virginia Med. Jour.*, 1860, Vol. XV, p. 359). These corrections made, the recorded complete excisions may be enumerated in chronological order: 1. (1811-1813 [4]) MCCREARY (C), removal of the entire clavicle for serofulous necrosis in a lad, who survived the operation thirty-five years. JOHNSON (J. H.) (*New Orleans Med. and Surg. Jour.*, 1870, Vol. VI, p. 474) states that this operation was done at Hartford, Kentucky, on May 4, 1811. Professor H. H. SMITH (*Princ. and Pract. of Surg.*, 1863, Vol. II, p. 335) gives the date as 1813, adducing as authority Professor GROSS'S *History of Kentucky Surgery*, p. 180. 2. (1823) MEYER, of Zürich (*Encyclop. Wörterbuch der med. Wissenschaften*, B. 29, S. 96, and v. GLEFFE and v. WALTHER'S *Journal*, 1833, B. XIX, S. 71), successfully removed the entire clavicle, for caries, in the case of a man aged 34. 3. (1828) MOTT (V.) (*An Account of a Case of Osteosarcoma of the Left Clavicle, in which Excision of that Bone was successfully performed*, in *Am. Jour. Med. Sci.*, 1828, Vol. III, p. 100). 4 and 5. (1825-1832) WUTZER (OHSBACH), *De resectione claviculari*, Bonn, 1831, p. 6) in 1825, and again in 1832, performed the operation for caries. 6. (1832) WARREN (J. C.) (*Removal of Clavicle in a state of Osteosarcoma*, in *Am. Jour. Med. Sci.*, 1833, Vol. XIII, p. 17), a fatal case. 7. (1834) ROTX (MIQUEL, *Bull. gén. de Thérap.*, 1834, T. VI, p. 216) is said to have extirpated a carious clavicle, the case terminating fatally on the third day. 8. (1835) MAZZONI, of Pisa (*Gaz. méd. de Paris*, 1838, p. 460), successfully excised the clavicle in a child four years of age. 9. (1836) TRAVERS (B.) (*Removal of the Clavicle*, in *Med. Chir. Transactions*, 1838, Vol. XXI, p. 135), a successful operation, in a boy of 10, for a tumor referred to an injury in a fall from a wheelbarrow. 10. (1838) BRANGINI, of Pistoja (*Gaz. méd. de Paris*, 1838, p. 460), a case of successful extirpation for necrosis in a youth of 15; MIQUEL alleges that the bone was regenerate. 11. (1838) KUNST (*Über den totalen Verlust des Schlüsselbeines*, in *Deutsche Klinik*, 1850, B. II, S. 263), another of the few traumatic cases: "C. Angles, aged 36, a day laborer, able to follow his avocations after complete removal of the clavicle, injured by a blow from a stick." 12. (1852) WEDDERBURN (A. J.) (*Total Removal of the Collar Bone for Caries*, in *New Orleans Month. Med. Rev.*, 1852, Vol. II, p. 1), a successful operation. 13. (1853) BARTLETT (E. M.) (*Report of Case of Exostosis of the*

in cases in which projectiles had penetrated the thorax; and three instances of partial excisions were cited also,<sup>1</sup> in cases unattended by lesions of the pleural cavity<sup>2</sup> that might more properly have found place in this section. These three, with the cases described in the six following abstracts, and twenty-two enumerated in TABLE XVIII, form a group of thirty-one partial excisions of the clavicle for shot injury.<sup>3</sup> The following is a fortunate instance of an early excision of the acromial extremity:

CASE 1420.—Private J. Baird, Co. C, 86th New York, aged 26 years, was wounded at Gettysburg, July 2, 1863, and was treated in a field hospital until the 23th, when he was transferred to Camp Letterman. Acting Assistant Surgeon W. L. Hays noted: "Ball entered middle third of the left clavicle, fracturing the bone, and passed out at the summit of the scapula posterior to the acromion process. A few days after receiving the injury the fractured pieces of bone were removed by the saw. When admitted into this hospital the two ends of the fractured bone were very much depressed, and the wound suppurating freely; his general health was not good. The wound was treated by cold-water dressings and acetate of lead and opium, and Fox's apparatus for fracture of the clavicle was applied. September 10th, general health very much improved; depression of shoulder much less than when admitted." On September 23th, the patient was transferred to Philadelphia, and was discharged September 13, 1864, and pensioned. Examiner A. Edelin, April 19, 1867, reported: "There is a loss of full half of the left clavicle from the centre outward, the parts having been resected, the result of gunshot wound, \* \* \* rendering the arm weak and ineffective." The reports of subsequent examinations, the last made in 1874, do not differ markedly from the foregoing. This pensioner was paid June 4, 1874.

In four of the operations, the portion excised is not specified; in eleven, the body of the bone, in thirteen, the acromial, and in three, the sternal portions, were removed. Nine operations, with one death, were primary; eight, with one death, were intermediary; seven, with two deaths, were secondary; in seven cases, with two deaths, the dates of operation were not recorded. The excisions were on the left side in seventeen, and on the right in thirteen cases; in one instance, this point was not specified. Eight of the patients recovered and were returned to modified duty; fifteen were discharged; six died; and in two

*Clavicle, and its Extirpation*, in *St. Louis Med. and Surg. Jour.*, 1851, Vol. XII, p. 64; good results. 14. (1854) OWENS (J. A.) (*Osteosarcoma of the Clavicle, operation*, in *New Orleans Med. and Surg. Jour.*, 1854-55, Vol. XI, p. 164), a successful operation. 15. (1856) BLACKMAN (G. C.) (*Removal of the Entire Clavicle*, in *The Western Lancet*, 1856, Vol. XVII, p. 336), a successful operation for caries, in the case of J. B.—, aged 42. 16. (1857) CURTIS (C. R. S.) (*Extirpation of the Entire Clavicle*, in *Am. Jour. Méd. Sci.*, 1857, Vol. XXXIV, p. 350), an operation for malignant disease, in the case of Elizabeth P.—, aged 20; recovery from the operation, but reproduction of the cancer. 17. (1857) NÉLATON and RICHARD (See OLLIFFE, *Traité expériment. et clin. de la régénér. des os*, Paris, 1867, T. II, p. 174). The first-named excised the outer half of the clavicle of a woman for caries, and a few months later, RICHARD removed the remaining sternal portion; the patient died a year subsequently. 18. (1859) ESMARCH (F.) (NISSEN, *Diss. de resectione*, Kilia, 1859, p. 7), a successful operation for osteosarcoma. 19. (1860) HEYFELDER (J. P.) (*Totale Resec. des linken Schlüsselbeines*, in *Deutsche Klinik*, 1860, B. XII, S. 291), a fatal complete excision for caries in a girl, Aphymia Segorowa, aged thirteen. 20. (1860) GUNN (M.) (*Case of \* Extirpation of Clavicle*, in *Chicago Med. Jour.*, 1868, Vol. XXV, p. 301). 21. (1864) A FIELD SURGEON (*Med. and Surg. History of the War of the Rebellion*, 1870, Part I, Vol. II, p. 557), a primary excision of the clavicle for shot comminution, recorded by Professor J. L. CABELL; the patient survived eleven days. 22. (1864) PALMER (J. C.), (See TRYON, *Excision of the Right Clavicle*, in *Am. Jour. Med. Sci.*, 1865, Vol. XLIX, p. 357), a second case of total excision for shot injury, in the case of a sailor, aged 19 (*Specimen 6213, A. M. M.*). 23. (1866) BOWE (H.) (*Case of Removal of the Entire Clavicle*, in *Med. Times and Gaz.*, 1866, Vol. II, p. 194), a successful operation, in the case of K. Kloete, a colored child, aged 7, for caries consequent on injury by a blow. 24. (1867) IRVINE (J. W.) (*On a Case of Excision and Regeneration of the Entire Clavicle*, in *The Lancet*, 1867, Vol. I, p. 206): This was a successful operation, in the case of George W.—, aged 16, with necrosis of the right clavicle following an attack of rheumatic fever. 25. (1868) MORIN (D.) (*Resection de la clavicle pour un carcinome*, in *Gaz. méd. de Lyon*, 1868, No. 8, p. 93), a successful operation in the case of a young child. 26. (1868) DAWSON (W. W.) (*Excision of the Entire Clavicle*, in *Cincinnati Lancet and Observer*, 1868, Vol. XI, p. 1), a successful operation for necrosis, in the case of J. Black, aged twenty. 27. (1869) COOLEY (F.) (*Removal of the Entire Clavicle for Osteosarcoma*, in *Leavenworth Med. Herald*, 1869, Vol. III, p. 302), a successful operation in the case of John Scott, aged thirty. 28. (1870) VARICK (T. R.) (*A Case of Subperiosteal Resection of the Clavicle*, in *New York Med. Record*, 1870, Vol. IV, p. 510), a case in which the bone was regenerated as was believed. 29. (1870) EVE (P. F.) (*Excision of the Clavicle—Death on the Sixth Day*, in *Nashville Jour. of Med. and Surg.*, 1871, Vol. I, p. 68): Case of J. Smith, aged 12, with an "enchondroma of a semi-malignant nature." 30. (1870) BRITTON (D.) (*Extirpation of Clavicle*, in *Med. Times and Gaz.*, 1870, Vol. I, p. 551): A successful removal of a "cancerous tumor" of the left clavicle, in the case of Samuel Smith, aged thirty-five. The recorded cases of extraction of the necrosed sequestra are numerous. CHAMPION (*Congress. à l'Hôtel-Dieu*, 1802) relates that the elder PELLEFAN extracted the "entire" clavicle in the case of a child with abscess of the shoulder following small-pox, and that the bone was reproduced. Analogous cases in the practice of MOREAU and of COSME D'ANGERVILLE are related in BORDENAVE'S memoir on exostosis, in the fifth volume of the *Mém. de l'Académie de Chirurgie*, 1774, p. 361.

<sup>1</sup> Cases of Sergeant J. H.—, and Private J. H. N.—, on page 559, *First Surgical Volume*, and of Corporal W. H. Husky, on page 560. These, with the six cases detailed here, and twenty-two enumerated in TABLE XVIII, constitute the thirty-one illustrations, found in the reports, of partial excisions of the clavicle after shot injury, unattended by penetration of the thorax.

<sup>2</sup> SCHWARTZ (H.) (*Beiträge zur Lehre von den Schusswunden*, 1854, S. 199) cites three cases of shot fractures of the clavicle, and remarks: "If there is a comminuted fracture of the clavicle, all loose fragments should be immediately removed and all sharp points should be cut from the bone. \* But never be beguiled to remove more than the extreme points of the bone. \* \* Allow nature to manage, and you will soon see exuberant granulations cover all parts of the bone. \* \* Resection of the clavicle should be rejected, therefore, unless the splintering is so extensive as to involve either the acromial or sternal joint."

<sup>3</sup> On excision of the clavicle, compare, in addition to the authorities already cited: JÄGER (in RUST'S *Handbuch der Chirurgie*, B. VI, S. 396), who proposes partial excision of the bone as a preliminary measure to ligation of the first part of the subclavian; MALGAIGNE (J. F.) (*Manuel de Méd. Opér.*, 7<sup>me</sup> ed., 1861, p. 240; CHASSAIGNAC (E.) (*Traité clin. et prat. des opér. chir.*, 1861, T. I, p. 661); RICHTER (Article, *Clavicle*, in *Nouveau Dict. de Méd. et de Chir. Pract.*, 1868, T. VIII, p. 42); FERGUSON (W.) (*A System of Pract. Surg.*, 4th ed., 1870, p. 281); WAGNER (A.) (*Über den Heilungsprozess nach Resection und Extirpation der Knochen*, Berlin, 1853, S. 26. New Sydenham Society's translation, Vol. V, p. 139).



instances the result was undetermined. Examples of several varieties of partial excision of the clavicle<sup>1</sup> are appended:

CASE 1421.—Corporal J. Schrawger, Co. F, 2d Iowa, aged 34 years, was wounded at Fort Donelson, February 15, 1862. He was sent to the Third Street Hospital, at Cincinnati, and discharged and pensioned July 10, 1862. Examiner J. C. Hupp, of Wheeling, reported, September 5, 1863: "Gunshot wounds in left side, neck, and shoulder. One ball entered the sternocleidomastoid an inch above its sternal insertion, and escaped through the scapula above its spine. Another ball fractured the clavicle in its upper third, where it lodged, and whence it was extracted in July, 1862. The first wound is cicatrized. Several marks of abscesses are to be seen about the shoulder and region of scapula. The clavicle is ulcerated, and an open ulcer exits below the clavicle." Corporal Schrawger subsequently entered the Veteran Reserve Corps, and was appointed a Sergeant in the 2d battalion. On September 30, 1864, he was sent to Seminary Hospital, Columbus, Ohio. Assistant Surgeon G. Saal, U. S. V., noted: "Gunshot fracture of clavicle, with injury to spine of scapula. Fragments of lead remained in the shoulder, perceptible by means of a probe, one piece being embedded on the under side of the acromial end of the clavicle. Fistulous openings exist through and below the clavicle. On February 20, 1865, Acting Assistant Surgeon C. E. Boyle trephined the clavicle and removed the lead fragment, weighing about three drachms, also several small pieces from the supra-scapular fossa, together with necrosed bone. The wound closed rapidly after the operation, and the fistulæ diminished greatly in size and depth. The patient was returned to duty to Camp Chase on March 20, 1865, his wound being nearly well, with prospect of complete cure." On June 19, 1865, he is reported by Surgeon J. D. Knight, U. S. V., as having "died of erysipelas" at Tripler Hospital, Columbus, Ohio.

CASE 1422.—Sergeant W. V. Taylor, Co. G, 66th Ohio, aged 25 years, was wounded at Peach Tree Creek, July 20, 1864. About November 10th, he was transferred to Nashville. Surgeon B. B. Breed, U. S. V., noted: "Gunshot fracture of the acromial end of the left clavicle by a minié ball. On August 4th, excision of two and a half inches of the acromial end of the bone was performed by Assistant Surgeon J. H. Long, 5th Indiana Cavalry, through an incision three inches long over the superior border of the clavicle. The wound healed without any untoward symptoms." The patient was sent to Columbus, and mustered out of service December 15, 1864, and pensioned. Examiner J. S. Carter, of Urbana, Ohio, reported, November 14, 1865: "A ball entered at the middle of right clavicle, passed through the shoulder and out at the upper portion of the scapula. The wound is still discharging. He has very little motion of the joint. He also received at Gettysburg a wound in the head, at the upper portion of the frontal bone. About one inch of both tables of the skull has been removed. Dr. B. B. Leonard, of West Liberty, Ohio, states: "That this pensioner came under his care several months after being mustered out of service, and that on passing a probe through the wound of the shoulder he detected a foreign body which he supposed to be bone, but on removal proved to be half of a conoidal ball, weighing a half ounce, also that the wound healed readily." This pensioner was paid July 4, 1873.

<sup>1</sup>Of partial excisions of the clavicle, I find thirty-eight instances recorded, with some details, in surgical annals. There are others briefly alluded to, and others, again, complicated by excisions of portions of the scapula or humerus. Of the thirty-eight cases that will be enumerated here, eleven or twelve were operations consequent on shot injuries. These operations were by VELPEAU, STROMEYER (2), SCHWARTZ, D. AÏRES, PARAVICINI, BECK, LÜCKE, GUILLERY, BOCKENHEIMER, and DESPRÈS. An operation, in 1719, by CASSEBOHM, was on a soldier aged 28; but it is not stated whether or not it was practised on account of shot injury. It was successful, and, if included in this category, there would be twelve partial excisions of the clavicle for shot injury, with two deaths. Dr. O. HEYFELDER (*Lehrbuch der Resectionen*, 1863, S. 300) tabulates eighteen cases of partial excision of the clavicle, six of the diaphysis, five of the sternal and seven of the acromial portion. I am unable to verify the case referred to M. CHASSAIGNAC; several antecedent cases are omitted, and the succeeding decennium has supplied many other instances. It is an incomplete chronological enumeration of operations of this group. 1. (1715) PETZOLD (C.) (*Obs. med.-chir. select.*, Breslau, Obs. LXII, p. 126), an excision for necrosis, in a child of nine. 2. (1719) CASSEBOHM (*Acta, med. Berlin*, Vol. I, Dec. II, p. 98), according to RIED (F.) (*Die Resectionen*, 1860), removed three inches of the body of the clavicle, in the case of a soldier, aged 28, who recovered with good use of the arm. 3. DAVIE, according to SIR ASTLEY COOPER (*A Treatise on Disloc. and Fract.*, etc., 2d ed., 1823), excised an inch and a half of the sternal extremity of the clavicle for a compound luxation, and the patient recovered with perfect use of the arm. 4. (1830) VELPEAU (*Nouv. Élémt. de Méd. Opér.*, 1839, T. II, p. 571) successfully excised the acromial end of the clavicle in a case of shot fracture, in the French revolution of that year. 5. (1834) ROUX (as reported by HUTEAUX, *Resection des ext. artic. des os*, etc., Thèse, 1834, p. 18) successfully excised two inches of the acromial end of the clavicle for caries, in the case of a man of forty-one. GERDY (*De la resect. des ext. artic. des os*, 1839, p. 19) also mentions this case. 6. (1837?) CARUS (according to NOODT, *Das Osteotom*, 1838, S. 63) excised successfully the middle portion of the shaft of the clavicle, in a man aged forty-one. 7 and 8. NOODT also relates that two successful excisions of the diaphysis of the clavicle were performed by SADLER and WELZ, and Dr. HEYFELDER accepts these cases; but no references are given. I cannot discover the writings of SADLER; but have examined those of four Doctors WELZ: Edward, Adolphus, Joseph, and Robert (compare BERNSTEIN, *Bibliothek*, S. 217; *Cat. Library, S. G. O.*, Vol. II, p. 884), without finding this case. Is it not possible that the Bavarian physician was misled by the report of an operation on one of the victims of the disaster at the Sadler's Wells theatre, in North London? 9. (1838) REGNOLI (G.) (*Annali medico chirurgici di Roma*, Vol. 1, p. 32), in a case of necrosis of the sternal end of the clavicle, in a man of forty, practised a successful excision. 10. (1840) MALOGO (*Giornale per servire di progressi della patologia e della materia medica*, Feb. 1840) successfully removed the outer two-thirds of the clavicle, in the case of a boy of seven years. 11. (1843) ASSON (M. A.) relates (in the *Giornale dei progressi della patol.*, etc., 1843, as quoted in the *Arch. gén. de méd.*, 1844, 4<sup>me</sup> série, T. V, p. 374) a successful excision of the sternal extremity of the left clavicle, in a man of forty-four, for syphilitic caries. 12. (1844) BLANDIN (P. F.) (*Bull. de la Soc. Anat. de Paris*, 1844, T. XIX, p. 332) excised nearly the whole of a necrosed clavicle, in the case of a medical student, who recovered with good use of the corresponding arm. 13. (1845) CHAUMET (*Resection de la clavicle pour un sarcome vasculaire*, in *Gaz. méd. de Paris*, 1846, p. 209) records a successful case, frequently quoted as an extirpation of the clavicle. The outer two-thirds appear to have been removed. 14. (1848) EVE (P. F.) (*Removal of four and a half inches of the Clavicle—patient fully recovered*, in *Southern Med. and Surg. Jour.*, N. S., 1848, Vol. IV, p. 158) relates an instance of partial excision of the left clavicle, for necrosis following a blow from a stick, the case of "Ned. a very powerful young man, belonging to Mr. H——" 15. (1848) POTTER (H. G.) (*Excision of the Clavicle*, in *The Lancet*, 1849, Vol. I, p. 392), in the case of Agnes T——, aged 42, with disease of the left clavicle following rheumatism, removed the greater portion of the bone; "about half an inch of the sternal end was left attached to the sternum." The editor of *The Lancet* (*op. cit.*, February 5, 1857, p. 132) very carelessly states that "the whole of the clavicle was excised by Mr. POTTER," evidently not taking pains to verify his references to his own journal. 16. (1848) SÉDILLOT (CH.) (*Traité de méd. opérat.*, etc., 1865, T. I, p. 499) excised a portion of the clavicle for osteitis, with excellent result. 17. (1849) GROSS (S. D.) (*System of Surgery*, 5th ed., 1872, Vol. II, p. 1078) successfully excised "nearly the whole of the left clavicle" from a lad of thirteen. 18–19. (1849–1851) STROMEYER (L.) (*Maximen der Kriegschirurgie*, 1855, S. 687) observed two cases of shot fracture "in which resection in the continuity of the clavicle became necessary. In one case, not seen until the eighth day, \* \* the outer fragment had been driven into the brachial plexus and caused the most excruciating pains, which extended even to the other arm.

FIGURES 256 and 257, on page 559 of the *First Surgical Volume*, illustrate pathological preparations of excised portions of the collar bone, and on page 522 of that volume a good example of longitudinal splintering of the right clavicle by a musket ball is delineated. The annexed wood-cut represents the partial repair of an oblique shot fracture:

CASE 1423.—In a tabular statement of operations practised at the City Hospital, St. Louis, from September, 1861, to October, 1862, Surgeon J. T. Hodgen, U. S. V., reported a case of resection of the clavicle resulting fatally. No particulars are given. About the same date, Dr. Hodgen contributed to the Museum Specimen 309 of Section I (*Cat. Surg. Sect.*, p. 73), which lacks any recorded memorandum. It is possible that this specimen (FIG. 372) is from the case of excision referred to. It is described by Dr. Woodhull as: "The inner two-thirds of the right clavicle after an oblique comminuted fracture at the junction of the outer thirds. A bony fragment, with the inner portion ensheathed with callus and the outer extremity necrosed, projects upward and outward from the outer border of the bone. On the outer portion of the sternal concavity there is a thin deposit of callus."

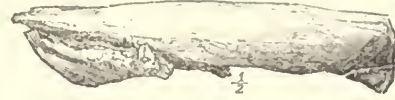

FIG. 372.—Inner thirds of the right clavicle splintered by shot, and probably excised (i) *Spec.* 309.

CASE 1424.—Corporal L. Bartel, Co. K, 4th Massachusetts Cavalry, aged 23 years, was wounded at Beanfort, July 16, 1863. On November 4th, he was sent to Portsmouth Grove, Rhode Island. Assistant Surgeon W. F. Cornick, U. S. A., reported, from Lowell Hospital: "Gunshot fracture of left clavicle; the ball perforated the left scapula and emerged anteriorly, fracturing the clavicle at its middle third. The wound is sloughing, and small abscesses have formed near the edge of the wound, yielding apparently healthy pus. The edges of the wound are everted and callous, and caries of the clavicle was discovered by probing. The patient was restless and suffering much pain. On January 20, 1864, Acting Assistant Surgeon E. Seyffarth placed the patient under ether and excised a portion of the clavicle, cutting along its middle portion to the extent of two inches, avoiding as much as possible all the attachments of muscles, dissecting off and gouging out the diseased bone to the amount of one inch and a half in length and to the depth of half the diameter of the clavicle. The gouge and cutting forceps were used for the operation. The patient rested well after the operation. On the third day he had regained appetite, and healthy granulations were springing up. On the ninth day, the bone, as far as denuded from periosteum, was covered to the margin of excavation. Steady and rapid improvement continued. On March 1st, the wound had healed, and though callus was still prominent, the patient had perfect use of the arm. He had perfectly recovered on March 25th, and was returned to duty on May 6, 1864." On December 3, 1864, he was mustered out and pensioned. Examiner J. Mackie, of New Bedford, reports, November 13, 1871: "Ball entered over left clavicle and came out at left scapula, fracturing both bones. Resection of part of the clavicle was performed in consequence of the wound. The left arm is now atrophied and weak, and almost useless. He cannot hold a fork, or dress himself without assistance."

causing immobility of both. \* \* The operation brought amelioration, but did not prevent death from pyæmia. In the second case, secondary hæmorrhage led to the resection. The bleeding ceased after the removal of splinters and the resection of fragments, without the discovery of injury to the large blood-vessels. Here, also, death from pyæmia ensued, probably caused by bleeding." Dr. STROMEYER continues: "I only cite this case to add the remark, that in case of secondary bleeding from the injured or contused subclavian artery, if not rapidly fatal, the resection of the clavicle solely paves the way for the ligation." PRUGOFF (N.) (*Grundzüge der Allgemeinen Kriegschirurgie*, 1864, p. 774) says: "Several times I have observed severe hæmorrhages in cases of shot fractures of the clavicle; but they were arrested by rest and cold compress, if they did not occur from the lung. Other surgeons advise to resect the fractured ends for the purpose of finding the source of the bleeding, and to ligate the subclavian." 20. (1850) SCHWARTZ (H.) (*Beiträge zur Lehre von den Schusswunden*, 1854, S. 199) relates the case of W. E—, a Saxe-Weimar soldier, shot through the left clavicle. The greater part of the diaphysis was successfully excised. 21–22. (1852–1853) LANGENBECK (B.) is reported (LÜCKE, *Beiträge zur Lehre von den Resektionen*, in LANGENBECK'S *Arch.*, 1862, B. III, S. 306) to have practised two successful partial excisions of the clavicle for necrosis in these years. 23. (1856) TOLAND (H. H.) (*On the Reproduction of Bones*, in *Pacific Med. and Surg. Jour.*, 1858, Vol. I, p. 8) reports a successful excision of the sternal extremity of the clavicle, in a sailor with syphilitic caries. 24. (1857) AYLES (D.) (*Gunshot Wound of the Shoulder—Two and a half inches of the Clavicle removed—Reproduction and Complete Recovery*, in *New York Jour. of Med.*, 1857, Vol. II, p. 16) records a successful excision, with partial reproduction, in the case of a man of 62 years, wounded by bird-shot. 25. (1857) COOPER (E. S.) (*Case of Osteosarcomatous Affection*, in the *Pacific Med. and Surg. Jour.*, 1858, Vol. I, p. 49) describes a successful excision of the clavicle. In a note on page 557, *First Surgical Volume*, this case is wrongly referred to 1837. 26. (1857) KÜCHLER (H.) (*Resection von Vier fünftel des Schlüsselbeines*, in *Deutsche Klinik*, 1859, B. XI, S. 412) performed a partial excision of the clavicle, on a man of 22 years, on account of a carcinomatous tumor; the case terminated fatally. 27. (1857) HEYFELDER (J. F.) (*Resection des Schulterendes des linken Schlüsselbeines*, in *Deutsche Klinik*, 1857, B. IX, S. 199) records a fatal excision, in the case of a soldier, aged 28, of the acromial extremity of the left clavicle. 28. (1858[?]) ROTHMUND (A.) is reported (REID, *Die Resektionen*, u. s. w., 1860, S. 269) to have performed a successful partial excision of the clavicle, in a case of caries following simple fracture. 29. (1858) GAY (J.) (*Disease followed by Fracture of the Clavicle—Operation—Recovery*, in *Med. Times and Gaz.*, 1858, Vol. I, p. 61) records the case of W. B—, a man of 35, with abscess over the acromial part of the clavicle. 30. (1859) PARAVICINI (DENME, *Studien*, 1860, B. II, S. 217) resected the acromial end of the clavicle, in a case of shot fracture, in the Italian campaign of that year. "Seven weeks after the operation the wound had entirely healed. The resected ends were connected by a firm, hard, fibrous cord." 31. (1859) BOWMAN (W.) (*Medullary Tumor of the Clavicle; successful Removal, with the outer Half of the Bone*, in *The Lancet*, 1859, Vol. I, p. 132). 32. (1860) FUQUA (W. N.) (*Excision of the Clavicle*, in *The Maryland and Virginia Med. Jour.*, 1860, Vol. XV, p. 358) records a successful excision of the outer part of the clavicle, for caries, in an Irish laborer, forty years old. 33. (1864) BECK (H.) (LANGENBECK'S *Archiv.*, 1864, B. V, S. 232) cites a case of shot wound, a cannon ball laceration of muscles and brachial plexus; a large portion of bone removed to prevent injury to blood-vessels and pleura. 34. (1870) LÜCKE (A.) (*Kriegschirurgische Erf.*, u. s. w., Bern, 1871) tabulates among the operations performed at the hospital at Darmstadt, a successful case of excision of the body of the clavicle for shot injury. 35. (1870) GUILERY (*Présentation des blessés*, in *Bulletin de l'Acad. de Méd. de Belgique*, 1871, T. V, p. 91) cites a case of partial excision of the clavicle for shot injury, with subsequent exfoliation of the larger part of the remaining portion. 36. (1870) BOCKENHEIMER is stated to have done a successful operation of this sort (CASPARI, *Mittheilungen aus dem Reservelazareth II zu Frankfurt a. M.*, in *Deutsche Klinik*, 1870, B. XXII, p. 452); M—, aged 26, shot at Billingen, September 22, 1870; the clavicle was fractured and the greater part of the bone excised; good recovery. 37. (1871) SENN (N.) (*Excision of Clavicle for Osteosarcoma*, in *North Western Med. and Surg. Jour.*, 1871–72, Vol. II, p. 259) records a successful removal of a tumor of the outer part of the left clavicle, in the case of J. A—, a Bohemian, 13 years of age. 38. (1871) DESPRÉS (A.) (*Rapport sur les Travaux de la 7<sup>e</sup> ambulance, Campagne de Sedan*, Paris, 1871, p. 46) tabulates a successful case of partial excision of the clavicle for shot injury. It would probably not be difficult to find other examples of partial excisions of the clavicle for disense. I have enumerated only these encountered in searching for excisions for shot comminutions.



It appears that in traumatic osteomyelitis of the clavicle, as in other long bones, morbid action is liable to extend to the sound parts, after the portions that have undergone structural alteration have been removed:

CASE 1425.—Private A. D. Kelley, Co. H, 45th Ohio, aged 22 years, was wounded at Kenesaw Mountain, June 27, 1864. He was sent to Nashville on July 20th; Surgeon B. B. Breed, U. S. V., reported: "A shot fracture of the left clavicle, with resection of the acromial end. Gangrene made its appearance on September 12th, but was arrested by two applications of bromine." The patient was transferred to Jeffersonville, and discharged May 27, 1865, and pensioned. Examiner W. H. Phillips stated, in 1867: "A ball fractured the left clavicle and passed obliquely backward, emerging at the posterior and superior angle of the left scapula. The wound was followed by gangrene, and a portion of the clavicle, amounting to one-half its length, was removed. The wound is still open, and discharging from beneath the pectoral muscles and in the axilla. The shoulder joint is drawn out and atrophied, and useless from want of support by the clavicle." This pensioner died July 19, 1863.

TABLE XVIII.

*Summary of Twenty-two Cases of alleged Excisions of Portions of the Clavicle after Shot Injury.*

N	NAME, AGE, AND MILITARY DESCRIPTION.	DATE OF INJURY.	NATURE OF INJURY.	DATE OF OPERATION.	OPERATION AND OPERATOR.	RESULT.
1	<i>Broyles, B. F.</i> , Pt., F., 9th Alabama, age 19.	May 3, 1863.	Minié ball fractured the clavicle and lodged in the axilla; missile extracted.	May 9, 1863.	The wound over the clavicle was enlarged, and the fractured ends removed by means of a Hey's saw.	Sent home June 9, 1863.
2	<i>Bull, J.</i> , Corporal, C, 53d Georgia, age 24.	May 5, 1864.	Compound comminuted shot fracture of the scapula end of the left clavicle.	May 5, 1864.	Excision of two-thirds of the acromial end of the clavicle; Surg. J. J. Knott, P. A. C. S.	Recovered.
3	<i>Cheney, D. J.</i> , Pt., F, 31st Ohio, age 21.	Nov. 25, 1863.	Shot fracture of the left clavicle.	May 10, 1864.	"Excision."	Discharged September 21, 1864. Not a pensioner.
4	<i>Clark, H. C.</i> , Pt., B, 37th Massachusetts.	April 6, 1865.	Fracture of the left clavicle by a minié ball.	April 6, 1865.	"Excision."	Discharged October 6, 1865. Not a pensioner.
5	<i>Cox, J.</i> , Pt., D, 14th North Carolina.	June 2, 1864.	Fracture of the right clavicle by a minié ball.	.....	Excision of the middle third of the clavicle.	Recovered rapidly. Furloughed July 15, 1864.
6	<i>Curley, M.</i> , Sergeant, F, 2d Delaware.	July 2, 1863.	Shot perforation of left shoulder, fracturing the clavicle.	.....	Excision of two-thirds of the clavicle.	Disch'd June 28, 1864. Arm almost entirely useless, and shoulder joint partially ankylosed.
7	<i>Decker, M.</i> , Pt., D, 6th Wisconsin.	May 12, 1863.	Shot fracture of the outer third of the right clavicle; minié ball.	May 12, 1864.	Extraction of missile and removal of the outer third of the clavicle.	Duty, December 17, 1864. Arm permanently weakened.
8	<i>Gliek, W. H.</i> , Corporal, B, 5th Iowa.	Nov. 25, 1863.	Musket ball fractured the left clavicle.	Nov. 25, 1863.	Excision of the distal third of the clavicle; Surgeon E. G. McGorrick, 9th Iowa.	Veteran Reserve, Feb. 7, 1864. Motion and strength of arm much impaired; neuralgic pain in shoulder joint.
9	<i>Goodfellow, M. A.</i> , Lieut., E, 53d Illinois, age 21.	July 21, 1864.	Musket ball perforated right shoulder, fracturing the middle third of the clavicle.	July 21, 1864.	Excision of two inches of the middle third of the clavicle.	Disch'd March 30, 1865. Shoulder partially ankylosed, arm wasted, nearly useless. Death from pleuro-pneumonia December 14, 1870.
10	<i>Hoard, W. F.</i> , Pt., B, 33d North Carolina.	July 1, 1863.	Musket ball struck the right clavicle near its middle, fracturing it in both directions.	July 9, 1863.	Excision of the whole of right clavicle with the exception of one inch of its humeral end.	September 10th. Use of the arm regained. Paroled.
11	<i>Jackson, L. C.</i> , Pt., H, 14th Tennessee, age 22.	Dec. 13, 1862.	Comp'd fracture of the sternal half of right clavicle; missile lodged at sterno-clavicular articulation; necrosis.	Feb. 8, 1863.	Resection of one inch of the clavicle and removal of the missile.	Wound healed rapidly. Furloughed March 9, 1863.
12	<i>Myers, J. D.</i> , Pt., F, 28th North Carolina, age 34.	Sept. 1, 1863.	Gunshot wound of the right shoulder and back.	Oct. 7, 1863.	Fragments removed, and the acromial end of the clavicle excised.	Recovered.
13	<i>Phillips, H.</i> , Pt., K, 148th Pennsylvania, age 18.	Aug. 15, 1864.	Shot perforation of the right shoulder, with fracture of the clavicle and scapula.	Aug. 19, 1864.	Excision of one-fourth of an inch of the clavicle and removal of several fragments; Surg. N. R. Moseley, U. S. V.	Discharged June 18, 1865. Not a pensioner.
14	<i>Pursley, L.</i> , Pt., C, 19th Indiana.	May 5, 1864.	Fracture of the left clavicle by a minié ball.	May 5, 1864.	Excision.....	Disch'd October 19, 1864. Use of the shoulder joint impaired.
15	<i>Sanders, J. G.</i> , Corporal, B, 18th Ohio, age 19.	Dec. 15, 1864.	Compound comminuted shot fracture of the middle portion of the right clavicle.	Dec. 16, 1864.	Excision of two and a half inches of the clavicle; A. A. Surgeon M. N. Benjamin.	Discharged June 14, 1865. An applicant for pension.
16	<i>Schneider, G.</i> , Pt., G, 5th Cavalry.	July 28, 1864.	Gunshot wound through left shoulder, fracturing the clavicle and scapula.	Aug. 29, 1864.	Removal of the middle third of the clavicle; A. A. Surg. H. Sanders.	Disch'd October 18, 1864. Shoulder joint weak and painful.
17	<i>Scott, Z. S.</i> , Sergeant, G, 89th Indiana, age 25.	April 9, 1864.	Minié ball passed through the right shoulder, fracturing the clavicle.	April 26, 1864.	Excision of three inches of the middle third of the clavicle.	Died June 12, 1864.
18	<i>Shirley, W.</i> , Pt., E, 13th Indiana.	Dec. 13, 1861.	Shot fracture of the left clavicle and first rib.	.....	Clavicle divided, with Hey's saw, one inch from its acromial extremity, and disarticulated at the sternum.	Died February 19, 1862.
19	<i>Spaulding, G. W.</i> , Pt., D, 52d Indiana.	April 6, 1862.	Gunshot fracture of the middle third of the left clavicle.	.....	Excision of two-thirds of the whole clavicle at its middle portion; Surg. E. C. Franklin, U. S. V.	Died May 7, 1862, from the effects of sloughing produced by erysipelas.
20	<i>Thayer, M.</i> , Pt., A, 16th Connecticut.	Sept. 17, 1862.	Musket ball perforated the left shoulder, fracturing clavicle.	.....	Excision.....	Discharged Jan. 12, 1863. Partial disability of arm.
21	<i>Wicker, N. S.</i> , Pt., C, 50th Illinois.	Nov. 25, 1863.	Severe shot wounds of right shoulder and thigh.	Nov. 25, 1863.	Excision of clavicle.....	Died November 28, 1863.
22	<i>Wilkins, W. D.</i> , Sergeant, F, 15th South Carolina.	July 3, 1863.	Gunshot fracture of the right clavicle.	.....	Excision.....	.....

The reader must collate, with the instances presented in the foregoing tabular statement and the six abstracts that precede it, two cases of extirpation of the clavicle, and five of partial excision of the bone where shot fracture accompanied penetration of the thorax, and of three unattended by primary lesion of the chest cavity, that have been detailed<sup>1</sup> in the *First Surgical Volume*. The conclusions to which he would probably be led by an analysis of the reports of these thirty-one cases, were all the details at his disposition, would probably be, that extirpation of the clavicle for shot injury is seldom if ever called for; that, as in shot fractures of other long bones, detached splinters should always be immediately extracted, and that, as elsewhere, necrosed osseous fragments should invariably be removed at the earliest practicable moment. It is probable that instances may occur, in which it may become necessary to excise portions of the clavicle in order to reach wounded blood-vessels beneath it.

*Shot Fractures of the Scapula.*—Of fourteen hundred and twenty-three determined cases, one hundred and seventy-seven terminated fatally. Hennen long since observed<sup>2</sup> that shot lesions of this bone, if they did not implicate the thoracic cavity or shoulder joint, were not, comparatively, perilous; facts accumulated by later observers<sup>3</sup> have confirmed his judgment, and the data consolidated in TABLE XVII conclusively establish this point. The fatal results which were not in large proportion, could usually be traced to secondary affections of the chest or shoulder, probably due to some undiscovered fissures extending to the glenoid cavity, or unsuspected injury to the thoracic walls; or else might be referred to those complications that attend all, even the slightest, traumatic affections. The commoner forms of shot fracture of the scapula associated with shot penetrations of the chest have been exemplified in the fifth chapter of the preceding surgical volume.<sup>4</sup> Further illustrations, derived from cases not thus complicated, will be offered

<sup>1</sup> *First Surgical Volume*, pp. 557, 558, 559, and 560.

<sup>2</sup> HENNEN (J.) (*Principles of Military Surgery*, 3d ed., 1829, p. 394): "The injuries of the scapula itself are not of a very serious nature. Balls make a clean passage through its broad plate, and the splinters occasioned by them are easily removed." SERRIER (*Traité de la Nature, des Complications et du Traitement des Plaies d'Armes à feu*, Paris, 1844, p. 222 et seq.) treats quite fully of shot fractures of the shoulder blade, holding that they are not very dangerous in themselves, and insisting on the importance of extracting detached splinters of bone. In the valuable publication containing the communications made to the Paris Academy of Medicine, in 1848, by Professors ROUX, VELPEAU, MALGAGNE, BÉGIN, and others, on shot wounds. BAUDENS (*Des Plaies d'Armes à feu*, Paris, 1849, p. 222) cites instances of shot fractures of the scapula observed in the military hospitals during the French revolution of that year. JOHN THOMSON (*Report of Observations \* \* after the Battle of Waterloo*, Edinburgh, 1816, p. 149) gives similar testimony. He mentions three cases of shot fractures of the scapula; all the patients recovered. The scattered observations recorded by the older military surgeons are of the same tenor. Thus BORDENAVE (*Précis de plus. obs. sur les playes d'armes à feu en différentes parties*, in *Mém. de l'Acad. de Chir.*, 1753, T. 1, p. 533) relates an interesting case of comminution of the scapula by a cannon ball, successfully treated by M. DESPELETTE; and RAVATON (*Chirurgie d'Armée*, 1768, p. 246 et seq.) gives three examples of shot fractures of the scapula (Obs. LIII, LIV, and LV) resulting favorably.

<sup>3</sup> SCHWARTZ (H.) (*Beiträge zur Lehre von den Schusswunden*, 1851, S. 139, u. s. w.) details five severe cases of shot fractures of the scapula that came under his notice, of which four terminated fatally. He remarks that: "The most careful treatment is required when there is consecutive burrowing pus. No attempt should be made to press out the pus; but to allow free escape, the shot opening must be dilated. Should the burrowing continue, its extent should be ascertained by the sound, and limited by deep and large incisions. \* \* If one incision is insufficient, one should not hesitate to make several, and should not be frightened at the extent and the depth of the wound, but should cut down to the ribs even." From the civil commotions in Paris, in 1830, JOBERT (de Lamballe) (*Plaies d'armes à feu*, 1833, pp. 319, 320) cites eight cases of shot fractures of the scapula, and remarks: "Par son état spongieux l'omoplate peut être perforée dans tous ses points avec une facilité étonnante. La saillie de ses apophyses spongieuses les expose à être enlevées en partie, sans fracture du reste de l'os, ou à être perforées, comme on l'a observé plusieurs fois sur l'épine de l'omoplate et l'aeromion. En portant le doigt à la surface de ces apophyses, on sent un vide, une place ronde, qui indique le passage de la balle et la perte de substance. La largeur et le défaut d'épaisseur du scapulum l'exposent à des perforations analogues à celles que l'on pourrait faire sur un papier fortement tendu." M. CHENE' (*op. cit. Camp. d'Orient*, p. 209) tabulates 106 instances of shot fractures of the scapula, with 33 deaths, a fatality of 31.1 per cent.; but the cases complicated by chest penetration are not discriminated. Dr. G. WILLIAMSON (*Mil. Surg.*, 1863, p. 127) infers, from his experience in India, that: "Fractures of the scapula are not dangerous, unless they shatter the neck of the bone, or cause a fissure into the joint. Abscesses are apt to form under the fascia of the back, and require to be laid freely open by incision." Inspector-General MOUTAT (*op. cit. Special Rep. from the New Zealand War of 1863*, etc., in *Statist., Sanit. and Med. Reports*, London, 1867, Vol. VII, p. 494) records five cases of recovery after shot fractures of the scapula, and observes that: "None of the cases have had extensive injuries; but here again, as in the cases of fractured clavicle, after exfoliation and centralization, the mobility of the shoulder joint is interfered with, and a man's usefulness as a soldier is injured." Dr. C. A. GORDON (*Experiences of an Army Surgeon in India*, London, 1872, p. 28) cites an example of a shot fracture of the right scapula, with a favorable result.

<sup>4</sup> Museum specimens of shot fractures of the scapula are illustrated by wood-cuts in the *First Surgical Volume*, in the cases of Pt. J. P.—, FIG. 211, p. 475; of Pt. F. T.—, FIG. 212, p. 475; of Pt. W. F.—, FIG. 213, p. 476; of a soldier wounded at the First Bull Run, FIG. 221, p. 481; of a prisoner at Fort Donelson, FIG. 222, p. 485; of Pt. G. W.—, FIG. 223, p. 485; of Pt. Thomas L.—, FIG. 224, p. 485; of Pt. Edward L.—, FIG. 225, p. 486; of Pt. Patrick F. W.—, FIG. 252, p. 551; of Pt. F. E. Bickett, FIG. 259, p. 562; of Pt. J. B.—, FIG. 290, p. 563; of Pt. George R. M.—, FIG. 261, p. 563; of Pt. Morris O.—, FIG. 263, p. 564, removal of necrosed portions of the right scapula; of Pt. J. P.—, FIG. 264, p. 564 (an addendum to the case detailed on p. 475); of Pt. W. A. Forbush, FIG. 265, p. 564, also noticed on p. 475; and, lastly, of Corp'l Sam'l A. C.—, FIG. 274, p. 576.



here; but first some instances of recovery<sup>1</sup> will be presented, with reference to the position of the external wounds in this group of cases:

CASE 1426.—Assistant Surgeon W. H. Forwood, U. S. A., was wounded in the cavalry engagement at Brandy Station, October 8, 1863. He was sent to Washington on October 15th, and placed in Douglas Hospital. Assistant Surgeon W. Thomson recorded a "gunshot fracture of the right scapula," and the extraction of the missile on the date of the patient's arrival. On October 27th, Dr. Forwood was so far convalescent as to be able to travel to his home in Pennsylvania, and soon afterward he resumed active duty in the field. He now (1874) suffers comparatively little inconvenience from this serious shot fracture.

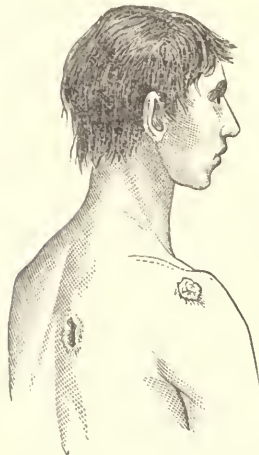

FIG. 373.—Shot perforation, with fracture of the spine of the scapula. [From a photograph.]

CASE 1427.—Private F. Reager, Co. F, 93d Pennsylvania, aged 18 years, was wounded at Petersburg, March 25, 1865, was treated in a Sixth Corps Hospital, and thence sent to Washington. Surgeon R. B. Bontecou, U. S. V., noted: "Admitted to Harewood Hospital, April 2, 1865, suffering from a gunshot wound through the upper portion of the back and the right shoulder, fracturing the spine of the scapula, and making its exit over the inner angle of the right scapula. On admission, the constitutional state of the patient and the condition of the injured parts were good. The patient progressed favorably under simple dressings and a nourishing supporting diet throughout, and the parts had entirely healed when he was discharged, May 30, 1865." The photograph, from which the wood-cut (FIG. 373) is taken, was contributed from Harewood by Surgeon Bontecou. In his application for pension, Reager makes oath that he "was wounded through the right shoulder by a minie ball; that it seriously injured him, and materially interferes with him in the performance of his daily labor, at times altogether incapacitating him therefor." His claim for pension was suspended June 30, 1873, in consequence of no response having been received for two years.

CASE 1428.—Private J. Whitlatch, Co. B, 7th West Virginia, aged 19 years, was wounded at Petersburg, April 1, 1865, and sent to Washington, to Carver Hospital. Surgeon O. A. Judson, U. S. V., noted: "Gunshot wound of right shoulder. Ball entered superiorly, near the acromion process, passed downward and backward, and lodged near the inferior angle of the scapula, producing compound comminuted fracture of the spine of the scapula. The wound became greatly swollen and very painful. On April 9th, the patient was placed under the influence of sulphuric ether, and sequestra of the fractured spine of the scapula were removed by Acting Assistant Surgeon J. S. Wentz, who also extracted the missile by enlarging the original wound. Favorable progress followed the operation. The wound continued to improve rapidly. No unfavorable complications occurred except exfoliation. Discharged from service on June 12, 1865, necrosis of the scapula following the injury." Examiner J. C. Hupp, of Wheeling, reports, on April 30, 1866: "Ball entered the top of right shoulder, passed through the right scapula parallel with its spine, extensively fracturing that bone in the region of the fossa infra-spinata, portions of which have been removed. A deep cicatrix, four inches in length, exists below and parallel with the spine of the scapula. Right shoulder painful and enfeebled." The Examining Board of Wheeling reports, on September 12, 1873: "The ball was subsequently extracted from the scapula near its posterior edge, etc. Disability rated one-half."

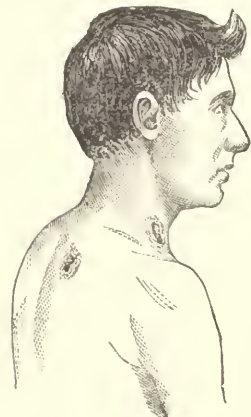

FIG. 374.—Entrance and exit wounds in a shot perforation of the right scapula. [From a photograph.]

CASE 1429.—Private J. Anderson, Co. E, 207th Pennsylvania, aged 22 years, was wounded at Petersburg, April 2, 1865, and was treated in a Ninth Corps Hospital, and thence transferred to Washington. Surgeon R. B. Bontecou, U. S. V., noted: "Admitted to Harewood Hospital April 6th, suffering from gunshot wound of the right shoulder, the ball entering one inch above the clavicle, making its exit near the spine of the scapula, fracturing the same. On admission, the condition of the injured parts and constitutional state of the patient were good. Result favorable. Patient was doing well when transferred." The photograph copied in the wood-cut (FIG. 374) was taken at Harewood, and contributed by Surgeon Bontecou. The patient was subsequently treated in Whitehall and Mower Hospitals, and was discharged from the latter September 9, 1865, and pensioned. Examiner W. M. Cornell, Philadelphia, September 11, 1865, reported: "The use of the arm is totally destroyed. The wound has not yet healed, and it is not possible to say how the case may be a year hence; but at present he is unable to labor." March 18, 1874, Examiner W. B. Rich reported: "Ball entered right side of neck, passed through shoulder, and came out near the top of the right scapula, fracturing the scapula, lacerating the muscles, tendons, blood-vessels, and nerves. The wound in the neck became gangrenous; extensive sloughing; exfoliation of bone from the scapula. The disability in this case was partial loss of use of the right arm; the shoulder dropped nearly three inches; there was partial paralysis of the arm and of the side of the neck; there was a large cicatrix on the side of the neck, and frequent eruptions on the skin." This pensioner was paid June 4, 1874.

Many illustrations of recent shot-perforations of the scapula might be selected from

<sup>1</sup> Surgeon H. ST. JOHN NEALE (*Chirurgical Institutes of Gunshot Wounds*, 2d ed., London, 1855, p. 164 *et seq.*), who served "formerly in H. M. 5th Infantry and 16th Light Dragoons, in the late war in North America," publishing "for the Service and Benefit of the Brave Warriors in Arms in Defence of our Country," devoted several pages to "*Remarks on wounds of the scapula, or shoulder blade*," and made some judicious observations on the subject. He held that if an oblique shot broke only the scapular spine, there was no reason to be apprehensive of bad symptoms, provided the surgeon followed the ordinary rule of treatment. If the bone was perforated, bits of clothing and of bone were likely to be driven in, and then "we should make bold incisions. \* \* \* If any large splinters are separated (which, however, but seldom happens) it is proper to extract them. Mr. PAUSCH, Surgeon-major of the regiment De Knyphausen, of the allied army in America, desired me to see Captain Van Passewitz, a gallant officer of the above corps, who was wounded in the right scapula by a grape shot, fired from a cannon during the reduction of Fort Washington, on the 20th of

photographs in the Museum; but the two wood-cuts opposite, the following sketch, and another figured on the next page, show the more common varieties of such shot tracks:<sup>1</sup>

CASE 1430.—Private H. Yore, Co. B, 20<sup>th</sup> Pennsylvania, aged 40 years, was wounded at Petersburg, April 2, 1865. He was admitted to a Ninth Corps hospital, and the ball was extracted. On the 5th, he was transferred to Harewood Hospital. Surgeon R. B. Bontecou, U. S. V., reported: "The missile entered the left shoulder, fractured the acromion process, and lodged in the supra-spinous space of the scapula. Small fragments of bone have been extracted from time to time. The wound did well." On May 18th, the patient was transferred to Satterlee Hospital, Philadelphia, and, on June 21, 1865, was discharged the service and pensioned. Examiner G. W. Smith, of Hollidaysburg, Pennsylvania, July 19, 1866, reported: "Ball entered the belly of the deltoid muscle, carrying away a process of the left scapula and the superior border of that bone, causing lameness and some disuse of the arm and shoulder." Examiner W. M. Findley, of Altoona, September 4, 1873, reported: "His disability entitles him to an increase of pension. \* \* Motion upward is much impaired; lifting weights is painful; disability three-fourths." This pensioner was paid to June 4, 1874. The photograph copied in the wood-cut (FIG. 375) was taken at Harewood, and contributed to the Museum by Dr. Bontecou.

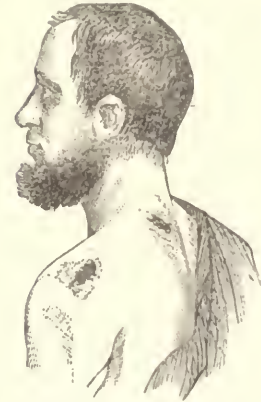

FIG. 375.—Entrance and exit shot wounds in a case of fracture of the left acromion.

CASE 1431.—J. Bettinger, aged 42 years, a soldier from Co. C, 4th New Jersey, discharged on account of hernia, arrived at Baltimore on his way home, on February 6, 1862, and was shot on the evening of the same day by a sentinel, who mistook him for a deserter. Two days afterward he was admitted to Camden Street Hospital. Acting Assistant Surgeon E. G. Waters reported: "The ball entered the back of right shoulder about four inches from the joint, struck the spine of the scapula, glanced off, fractured the coracoid process, detached the glenoid cavity, and made its exit in front, below the clavicle, without having injured the vessels or the humerus. On February 11th, pieces of clothing were removed, also pieces of bone embracing the entire coracoid process. On the 17th, typhoid symptoms appeared; pulse irritable; respiration labored; tongue dry and cracked; abdomen much distended and tender; discharge offensive and unhealthy. Cold-water dressings slightly impregnated with a solution of chlorinated soda were applied. Alcoholic stimulants, quinine, and beef-tea were given, and stupes of turpentine were applied to the abdomen. On February 29th, the tenderness of the abdomen had diminished; the tongue was coated but moist, the pulse was at 93. A small piece of the acromion made its way to the orifice of the wound and was removed. The patient was excessively wakeful, and opium was ordered. On June 18th, the anterior and posterior orifices of the wound were still open and discharging freely; there were also extensive sinuses. One of these could be traced laterally, having its orifice near the insertion of the deltoid; another communicated with the axilla, forming a large abscess. These were laid open. No necrosed bone could be detected. The treatment adopted was moderately stimulant and tonic, with nourishing diet. Simple dressings were applied, and the arm bandaged from hand to shoulder. On July 4th, there was an attack of erysipelas in the arm and shoulder, which readily yielded to treatment. On August 14th, the shoulder was observed to be flattened, and the head of the bone could be felt in the axilla, as usual after unreduced dislocations of the shoulder joint. The posterior orifice had ceased to discharge for several weeks; the anterior one was still suppurating slightly, but was nearly healed, and no sinuses were observable. The patient had considerable use of the limb, which will doubtless prove serviceable. He experienced no such pain as generally occurs when the head of the humerus presses on the brachial plexus. On September 17th, he was sent home quite cured, and enjoying extensive mobility of the arm." This man was a pensioner until January 19, 1871, when he died. Examiner D. L. Beaven, of Reading, reports, September 28, 1867: "He was injured in the pelvis by falling on a stump while aiding in building a fort at or near Camp Seminary, in 1861, which resulted in leaving something like an irritable condition of the bladder, from which he has to micturate frequently both night and day; suffers pain in consequence. Was also accidentally wounded at Baltimore, while on his way home, by a musket ball, which passed through the right shoulder. Is unable to raise his arm to his head; otherwise can use it."

November, 1776, near the banks of the Hudson's [*sic*] river, in the Province of New York. \* \* The ball had struck him in an oblique line, had shattered the spine of the blade bone, and also fractured its body. The muscles were much lacerated, and appeared all jagged and torn. Although the surgeon had made a considerable dilatation, it was soon found necessary to make still larger incisions. In the space of a month, several splinters of the bone came away with the dressings. An unfavorable suppuration continued to attend this wound for a long time, and seemed to threaten a gangrene; but by the free use of the Peruvian bark, and of opium, with a proper attention to the general treatment of the wound, this brave officer was again restored to his health. In the space of fourteen weeks he had taken upwards of four pounds of Peruvian bark. Many cases similar to the above might be stated which occurred during the campaigns in America, but a repetition of them is needless."

<sup>1</sup> The following practical observations by HENNES (*Principles of Military Surgery*, 3d ed., 1829, p. 396) should be pondered: "There is a class of wounds in the neighborhood of the scapula, which, though not of a threatening nature at first, yet often and unexpectedly have a fatal termination. These are principally occasioned by gunshot, but sometimes by punctured wounds, which directly open the infra-scapular vessels, or cause them subsequently to slough and pour forth their contents internally; giving to the eye the appearance of very trifling hemorrhage, but filling the whole sub-scapular space with blood, which makes its way down to the very loins by infiltration, and there causes deep abscesses and even gangrene. The long and distant range of parts through which the blood passes prevents the detection of the cause immediately; and, indeed, could we even discover it, I am not aware of any effectual mode of securing the bleeding vessels. In the cases I have met, the blood has been effused in large quantities, and has descended nearly to the sacrum, dissecting the interstices of the muscles completely, and giving to the posterior part of the thorax and the loins that appearance said by VALENTIN (*Recherches critiques sur la Chir. modern*, Paris, 1772) to designate sanguineous effusions into the sac of the pleura." The deductions from the facts set forth in TABLE XVII are corroborated by observations in other wars. Thus Professor H. FISCHER (*Kriegschir. Erf.*, 1872, S. 141), referring to shot fractures of the scapula, remarks: "As a rule these patients recovered without serious hindrance. Of eight cases, but one died, from purulent infiltration, a mortality of 12.5 per cent. Herr LOEFFLER, in his exact statistical work (*Op. cit.*, 1867, S. 162) chronicles forty-two shot fractures of the scapula, with seven fatal cases, or 16.6 per cent. M. GILLETTE (*Remarques sur les blessures par armes à feu observées pendant le siège de Metz*, 1870, etc., in *Arch. gén. de Méd.*, 1873, IV<sup>e</sup> sér., T. XXI, p. 312), with a happy facility in generalizing from a few facts, states that: "Ces blessures ne sont pas extrêmement graves, mais elles sont très-longues à guérir en raison des abscesses," and cites several cases of this group.



The pension records indicate that impairment of the functions of the shoulder joint was, as might be anticipated, a frequent consequence of shot fractures of the scapula, even in those cases in which the articulation was not primarily or directly involved:




FIG. 376.—Entrance and exit shot wounds in a case of fracture of the right clavicle and scapula. [From a photograph.]

CASE 1432.—Corporal W. T. Symons, Co. G, 16th Maine, aged 23 years, was wounded at Fredericksburg, December 13, 1862, and was treated in a First Corps field hospital, and subsequently in Prince Street Hospital, Alexandria, where Surgeon T. Rush Spencer, U. S. V., noted: "Admitted, December 19th, with gunshot wound of the right clavicle." He was discharged February 20, 1863, Dr. Spencer certifying that there was "Necrosis of the right scapula and clavicle, and inability to raise the right arm; results of gunshot wound. He is totally disabled from obtaining his subsistence from manual labor." Examiner Robbins, of South Norridgewock, Maine, April 28, 1863, reported: "The ball entered just above the right clavicle, fracturing it slightly, passing out through the supra-spinous fossa of the right scapula. The wound is yet suppurating, and occasionally discharges pieces of bone. The arm is very much limited in its motions." On March 5, 1866, G. A. Wilbur, late Surgeon 11th Maine, contributed a photograph of Symons, represented in the wood-cut (FIG. 376), and reported that "pieces of bone, one of which is supposed to be from the glenoid cavity, have come away," and the front wound was still discharging. Examiner C. W. Snow, September 4, 1873, reported: "Gunshot wound of apex of right lung, with fracture of the scapula. Impaired motion of shoulder joint; respiration slightly obstructed." This pensioner was paid to June 4, 1874.

In rare instances, there was troublesome hæmorrhage from shot wounds in this region,<sup>1</sup> necessitating recourse to the ligature, or even sacrifice of the upper extremity.

CASE 1433.—Private J. S——, Co. G, 1st Potomac Home Brigade of Cavalry, aged 31 years, was wounded at Maryland Heights, July 6, 1864. He was sent to Frederick. Assistant Surgeon R. F. Weir, U. S. A., reported: "A shot wound of the left shoulder, with partial fracture of the spine of the scapula. Hæmorrhage occurred on July 19th, and again on the 20th, from the dorsalis branch of the subscapular artery, to the amount of eight ounces. The bleeding was temporarily arrested by compression. On July 24th, the artery was ligated in its continuity. This patient was transferred, convalescent, to Mower Hospital, and thence, December 6, 1864, sent to duty. He was mustered out and pensioned June 28, 1865. Examiner C. H. Ohr reported, December 1, 1869: "Wound by a minie ball, which entered the left shoulder on its posterior aspect two inches below the acromion. It carried away much of the spine, passed through the scapula, and made its exit opposite the spinous process of the fourth dorsal vertebra. The motions of the scapula are restricted by the laceration and cicatrization of the \* \* muscles, and the power of the arm is much weakened and impaired. There is, recently, throwing off of dead bone, as shown by a fistulous opening midway the spine of the scapula."

In shot fractures of the scapula, the lodgement of balls was very frequently observed:

CASE 1434.—Private W. H. Holmes, Co. F, 17th Infantry, was wounded at Fredericksburg, December 14, 1862, and was sent to Washington, and admitted to Stanton Hospital on the 17th. Surgeon J. A. Lidell, U. S. V., noted: "A gunshot wound of the right shoulder, the ball entering midway between neck and shoulder joint, passing under the scapula, and remaining lodged." This soldier was discharged February 3, 1863, and pensioned. On April 7, 1863, Examiner G. S. Jones, of Boston, reported: "His wound was at the top of the right scapula, six inches from the acromion process, and the ball is lodged among the tissues. He is unable to extend his arm at a right angle, and its other motions are impaired." In November, 1864, Examiner J. B. Bell reported that the disability had increased, from the presence of the ball under the scapula. On January 6, 1870, Mr. Holmes, in response to a communication from this Office, stated: "I was wounded while lying down on the ground, on the heights facing the enemy; the bullet entered just back of the right shoulder, near the outer third of the spine of the scapula. The bullet was probed for at Fredericksburg, as also at Stanton Hospital, without success. I was discharged from the service at Stanton Hospital and went to St. Luke's Hospital, New York. During my stay at St. Luke's, three large pieces of bone were taken out; the wound closed in nine months. \* \* Dr. G. E. Buckett, Acting Assistant Surgeon at Kennebec Arsenal, extracted the bullet on November 1, 1869. Abscesses had formed under the arm during the past summer, attended with a great deal of pain and inability to use the arm; it was a whole minie bullet, well flattened, and lying upon and attached to the third rib. It had not probably changed its position, having passed through the upper portion of the scapula, back of the clavicle, downward and forward against the rib." Examiners J. W. Toward, W. B. Lapham, and I. H. Stearns, December 6, 1871, reported: "Ball entered on top of shoulder, badly shattering bone and integument; passed down and came out below the right axilla. There is an immense cavity from loss of substance at the seat of wound. The arm and shoulder are very weak and lame, and the movement of the arm is greatly impaired. All labor is performed with pain; can do but little work of any kind with right hand." On September 4, 1873, the same Board reported: "The bone above the spine of the scapula is wanting, having come away after the wound. The action of the muscles arising from and attached to that portion of the bone is destroyed to a great extent. The arm may be used for ordinary purposes with care, but with any unusual strain the arm will be useless for a time from soreness and lameness." Pension paid June 4, 1874.

<sup>1</sup> See also CASE 1458, on p. 490, and in the *First Surgical Volume* the cases of Pt. E. Pilger, p. 539, and J. Moser and J. Mackey, on p. 554.

The following case is interesting in several points of view, but particularly as demonstrating that the lumbar ecchymosis, regarded by Valentin and Larrey as of diagnostic value, and even as pathognomonic of penetration of the thoracic cavity, may attend wounds external to it—a much disputed point, to some extent discussed in a note on page 575 of the *First Surgical Volume*:

CASE 1435.—Private C. Ely, Co. K, 11th Pennsylvania Cavalry, aged 19 years, was wounded in a skirmish near Suffolk, Virginia, March 19, 1863. Surgeon G. C. Harlan, of this regiment, described the case as follows: "He was shot with a minie ball in the right shoulder, while mounted, March 17th, at Franklin. Wound of entrance in the anterior fold of axilla. Ball extracted below the spine of the scapula, having passed between the bone and its vessels, ploughing a deep groove in the neck of the former, and passing through the body of the scapula. There was not much external hæmorrhage, but enormous effusion between the muscular planes, extending to the spine behind, and dissecting up, and distending, the pectoral muscles in front, inducing a great tumefaction about the shoulder joint. The head of the humerus was apparently uninjured. Cold-water dressings were applied. March 19th, swelling about the same; warm-water dressings substituted for the cold. April 9th, patient up and walking about with his arm in a sling. Wound has discharged very little. The extravasated blood is for the most part absorbed. As the swelling subsided, a displaced piece of bone could be felt under the skin on the outside of the arm, just below the head of the humerus. April 15th, the patient was sent to hospital at Fort Monroe. He had slight motion of the arm, but free motion of the forearm and hand." This soldier was discharged June 15, 1863, and pensioned. Examiner H. Roberts, of Providence, reported, July 3, 1871: "The ball entered in front, fracturing the acromion process, which is now drawn downward. The ball came out, apparently through the scapula just below the spine. At present Mr. Ely is unable to raise his arm up to a level with the shoulder, or put it behind him; neither can he put it up to his head except in front. Rotation of the arm not equal to half of the natural limits. The powers of the arm and shoulder are greatly reduced, and the muscles in the region of injury are tender, contracted, and shrunken." Ely was examined by the Scranton Board, Drs. A. Davis and R. A. Squires, September 5, 1873, and September 2, 1874; no material change was reported. He was paid June 4, 1874.

Several instances were reported of hospital gangrene<sup>1</sup> attending shot fractures of the shoulder blade. The prominent scapular spines, like the ridges of the innominate and sacrum, subject the overlaying soft parts to such pressure as peculiarly predisposes them to sloughing. A brief abstract, accompanied by a sketch from a photograph, may serve as an example:

CASE 1436.—Sergeant J. M. J——, Co. E, 12th Louisiana, aged 23 years, was wounded at Franklin, November 30, 1864, and was sent to Hospital No. 1, Nashville, from the field hospital, on December 20th. Surgeon B. B. Breed, U. S. V., February 20, 1865, contributed the photograph represented by FIG. 377, with the following history: "Gunshot fracture of the left scapula by a conoidal ball. Gangrene appeared on December 24th, and two applications of bromine were made. December 27th, cured." Further particulars of the progress of the case are not furnished, but the patient was transferred to the Provost Marshal, March 27, 1865, for parole.

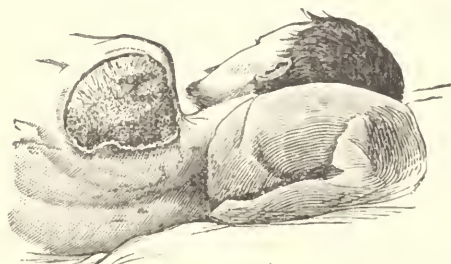


FIG. 377.—Gangrenous ulcer succeeding a shot fracture of the left scapula. [From a photograph.]

False ankylosis of the shoulder joint often occurred after shot fractures of the spine of the scapula; when the articulation was not injured primarily.

CASE 1437.—Corporal A. B. Clark, 2d Wisconsin, aged 24 years, was wounded at Bull Run, July 21, 1861. He was treated at Benton Barracks, Missouri, until November 1, 1862, when he was discharged and pensioned. Surgeon James Irwin, 8th Iowa, certified on the discharge paper as follows: "Gunshot wound; ball struck the left scapula, fracturing a portion of the spine, including the acromion process. Use of shoulder joint destroyed; portions of bone continue to discharge. The ball has not been extracted." This man re-enlisted in the Veteran Reserves. On March 29, 1864, he entered St. Mary's Hospital, Detroit. Acting Assistant Surgeon D. O. Farrand reported: "Wound by conoidal ball, which entered from behind, passed forward and through the spine of the left scapula, and lodged just below the clavicle, immediately above the subclavian artery. On April 5, 1864, the ball was removed by making about the same incision as for ligation of the subclavian artery; chloroform was used. At the time of operation the patient was worn out by constant pain from presence of the ball, and he was much emaciated." He recovered, and was returned to duty June 1, 1864, and was finally discharged April 3, 1865, resuming his pension. In 1867, Examiner Louis Davenport reported: "It is impossible to raise the arm more than six inches from the body, or place the left hand to the mouth." The Detroit Examining Board reported, February 7, 1872: "The muscles of the arm are atrophied; this atrophy is increasing. \* \* The ankylosis is complete, so that he is unable to move the joint at all. The atrophy of the muscles is of such an extent as to produce extreme weakness of the hand and arm. The limb hangs useless at his side." This pensioner was paid March 4, 1874.

<sup>1</sup> JOBERT (A. J.) (*Plaies d'armes à feu*, 1833, p. 321) relates an example of shot fracture of the scapula, in which gangrene repeatedly supervened, insisting on the utility of lemon juice in such cases: "Ce même homme nous offrit aussi un exemple de pourriture d'hôpital, survenue à la suite d'un écart de régime. Cet accident se renouvela chez lui plusieurs fois, quand il avait eu quelques rapports avec sa maîtresse; on parvint toujours à dissiper les symptômes, aussitôt qu'ils apparurent, par l'application du citron."



Of the consequences of shot fractures of the scapula,<sup>1</sup> secondary implications of the pleural cavity were the most fatal; but consecutive disease of the shoulder joint the most frequent. A case in which each of these complications was believed to be present may be cited:

CASE 1438.—Private G. S. Livingston, Co. I, 1st Vermont Cavalry, aged 32, was wounded at Reams Station, June 23, 1864. He was made a prisoner, was exchanged and sent, August 15th, to Camp Parole, Annapolis, from Richmond, and on October 3d he was furloughed. He entered Sloan Hospital, Montpelier, on February 20, 1865. Surgeon H. Janes, U. S. V., contributed a photograph showing the entrance and exit wounds in this case (*Card Photog.*, S. G. O., Vol. II, p. 5), with the following history: "This man was wounded by a minie ball, which entered one inch to the right of the spine, passed horizontally to the right and emerged just behind the point of the shoulder, fracturing the scapula and opening the shoulder joint. The wound was nearly healed at the time of his admission to Sloan Hospital. He continued to improve during his sojourn in this hospital, and was discharged July 19, 1865, in good health. Wounds healed; ligamentous ankylosis of the shoulder joint, with little use of the arm." Examiner A. L. Lowell, of Coventry, reported, August 28, 1870: "A musket ball struck the back between the spinous process of the fourth dorsal vertebra and the posterior margin of the right scapula, and passing upward and outward through the subscapularis muscle, emerged at the posterior margin of the acromion process. A portion of the acromial end of the scapular spine was fractured and the acromion was abraded by the bullet. The supra-spinatus and infra-spinatus muscles are atrophied by disuse. The pectoral muscles of the right side also show diminished volume and strength from the same cause. The humerus, although susceptible of slight rotation on its axis, is held fast to the scapula by fibrous adhesions about the scapulo-humeral articulation, and cannot be extended from the body. The scapula is also bound to the costal walls by adhesions, resulting from inflammatory action. The functions of those muscles, vessels, and veins presiding over the nutrition and efficiency of the right forearm and hand are not materially impaired. The hand is well used. The right side of the chest, especially under the scapula, is dull on percussion, and the respiratory action is feeble and expiration is prolonged, with well-marked pectoriloquy. The respiratory action of the left lung is exaggerated. The subject suffers from cough and dyspnoea on slight over-exertion or excitement. The respiratory action is largely abdominal, the walls of the chest exhibiting little motion. The face is pale, and the entire physical aspect is one of debility. The clinical thermometer shows 99½ degrees. The wound reopens from time to time for escape of exfoliated bone. From the fact that the bullet passed so near the thoracic walls, if not really penetrating them at the period of primary lesion, I form the opinion that from the contiguity of a severe wound the pleura and lung became seriously impaired, and it is now my view that the subtending pleura and lung tissue are bound to the costal pleura by adhesions. The pensioner alleges that immediately after being shot blood was freely raised and expectorated. The physical signs are rather those of hepatisation of the middle lobe of the lung, with pleuritic adhesions. I find no symptoms of hydrothorax. The respiratory action at the lower lobe still remains, although feeble; disability total." Examiner J. C. Rutherford, September 4, 1873, reports: "Right shoulder completely shattered, with considerable of the scapula. Complete ankylosis of the shoulder joint; arm firmly flexed at the side; has but little use of the right hand; often has abscesses form on his back near the shoulder, which are very painful and debilitating. Pensioner says, in his declaration, the wound has discharged a greater portion of the time, and thirty-one pieces of bone have been extracted." This pensioner was paid to June 4, 1874.

Balls sometimes traversed the upper dorsal region in close proximity to both scapulæ, but fracturing only one:

CASE 1439.—Private L. Mills, Co. A, 3d Maryland, was wounded at Antietam, September 17, 1862, and sent to Washington, to the Patent Office Hospital, September 28th, and thence to Carver Hospital, January 17, 1863. He was discharged March 26, 1863, for disability, Surgeon O. A. Judson, U. S. V., certifying that there was: "A wound of both shoulders by gunshot, disabling the patient in the use of each of his arms." Examiner P. B. Smith, of Washington, reported, March 26, 1863: "The ball entered behind the left shoulder joint, traversed the back beneath the scapula, and was cut out from the posterior part of the upper third of the right arm. The ball was removed five months after the reception of the injury. The general health is good. A large abscess formed beneath the right scapula, and a sinus fourteen inches in length." Assistant Surgeon E. F. Bates, U. S. V., contributed to the Museum the flattened musket ball that inflicted the fracture in this case, and had split probably on the spine of the left scapula, and passed across the back beneath the right scapula, and down the right arm to near the middle of the external aspect of the deltoid, whence it was extracted by Dr. Bates. The projectile is represented in the adjoining wood-cut (FIG. 378).



FIG. 378.—Round musket ball, with an impacted bone fragment. *Spec.* 295. 1-1.

There were reported twelve examples of shot fractures of both scapulæ unattended by penetration of the thoracic cavity; three fatal, and nine terminating favorably. These cases were attended by exfoliations and necroses of greater gravity than those in which

<sup>1</sup>Preparations of shot fractures of the scapula are probably not infrequent in such collections as those at Netley, at Val-de-Grace; but comparatively few are recorded in the catalogues of other museums of pathology. At the Edinburgh Museum (*Cat.*, 1836, p. 21) there are two specimens (199 and 201 XX, D), from the battle of Corunna. In the Hunterian collection there are also two specimens, numbered 2920 and 2926, one described at Vol. V of the Catalogue (1849), p. 24; and the other in the first supplement (1863), p. 92. The St. George's Hospital Museum has a specimen of shot perforation of the left scapula (*Cat.*, 1866, p. 65), numbered 215, of Series I. In the Guy's Hospital collection there is one specimen, marked 109735, described on page 67 of Dr. WILKES'S catalogue of 1863. In the Pennsylvania Hospital Museum are two preparations of shot fractures of the scapula (*Cat.*, 1869, p. 17; compare also *Proc. Path. Soc.*, Phila., June 27, 1866, Vol. II, p. 237). In the Museum of the Boston Society for Medical Improvement (*Cat.*, 1847, p. 37), specimen 161 is from a sailor of the frigate *Guerrière*, whose shoulder blade was shattered by a grape shot. In the pathological cabinet of the New York Hospital (*RAY'S Cat.*, 1860, p. 64), preparation 96 is a shot fracture of the right scapula.

only one shoulder blade was interested; yet the mortality from this form of injury was not large.<sup>1</sup> Fractures of the spinous processes of the upper dorsal vertebræ were noted in most of the cases that were reported in detail.

CASE 1440.—Private G. W. Stacks, Co. C, 17th Iowa, aged 28 years, was wounded at Tilton, Georgia, October 13, 1864, and was treated in Hospital No. 1, Chattanooga, from November 1st to 6th, when he was furloughed. On February 24, 1865, he was sent to Keokuk. Surgeon M. K. Taylor, U. S. V., noted: "Compound comminuted gunshot perforating fracture of both scapulae. Ball entered posteriorly beneath the spine of the right scapula, and emerged posteriorly above spine of the left scapula." The patient was discharged August 26, 1865, and pensioned. Examiner W. L. Orr, of Ottumwa, November 16, 1867, reported: "The original wound was caused by a musket ball, which struck the spine of the right scapula about three inches back of the acromion process, shattering the bone extensively, passed through the spinous process of the first dorsal vertebra, and emerged through the superior costa of the left scapula. Exfoliation of the right scapula is now going on, rendering muscular exertion of the arm impracticable." Paid June 4, 1874.

The next case is remarkable for the length of the seton-track the projectile is reported to have described:

CASE 1441.—Private A. Wilson, Co. A, 163d New York, aged 39, was wounded at Fredericksburg, December 13, 1862. He was sent to Stanton Hospital on Christmas day, and remained there until March 27, 1863, when he was transferred to Ladies' Home Hospital in New York. He was sent to the Invalid Corps, July 29, 1863. Surgeon A. B. Mott, U. S. V., reported: "He was wounded by a shell, which grazed the acromial process of the left side, passing along the upper border of the scapula, across the vertebral column opposite the second and third dorsal vertebra, then along the upper border of the scapula of the right side, fracturing its spine, making a wound six inches in width and sixteen in length. Remained in hospital at Falmouth for two weeks, when he was sent to Stanton Hospital, remaining there until transferred to this hospital. The wound had healed up, except near the fracture of the spine of the right scapula. The wound was kept clean, and the patient was put upon tonics. On May 8, 1863, the wound was healed, but the cicatrix was very sensitive to the touch." This soldier was discharged July 11, 1865, and pensioned. Examiner E. Bradley reported, July, 1865, that: "A piece of shell hit him just above the spine of the right scapula, and passing through the tissues and directly across the back, fractured the spine of the scapula; the muscles were severely torn and injured. The wound was healed, but the motions of the right arm were interfered with." Examiners McCullom and Leighton reported, September 8, 1873, that "the right scapula was fractured, impairing the free action of the arms."

CASE 1442.—Corporal F. Schwab, Co. A, 44th Illinois, aged 43 years, was wounded at Kenesaw Mountain, June 27, 1864. He was taken prisoner, but after his exchange, May 24, 1865, he was sent to Camp Chase, and thence to Tripler Hospital at Columbus. Surgeon J. D. McKnight, U. S. V., reported: "A gunshot wound of the posterior walls of the chest, fracturing both scapulae." The patient was discharged May 9, 1865, and pensioned. Acting Assistant Surgeon J. M. Evans reported: "A wound of the posterior walls of the chest, fracturing both of the shoulder blades and the spinal processes of the fifth and sixth vertebra, \* \* \* causing lameness to such an extent that he will be unfit for military duty." Examiner G. P. Wood reported, October 12, 1865: \* \* \* "A ball struck the right shoulder, injuring the scapulae, and breaking the spinous processes of the dorsal vertebra, weakening the shoulder and back." This pensioner was paid June 4, 1874.

CASE 1443.—Private W. P. Chase, Co. D, 2d Massachusetts, aged 25 years, was wounded at Antietam, September 17, 1862, and admitted to hospital at Camp Curtin on September 20th. Acting Assistant Surgeon J. P. Wilson reported: "Gunshot wound of both shoulders." The patient was discharged and pensioned November 11, 1862. Acting Assistant Surgeon J. B. Crawford reported that: "The ball entered over the middle of the left scapula, fractured the spinal process of the fifth dorsal vertebra, and made its exit at the lower border of the right scapula." Examiner O. Martin, of Worcester, October 10, 1864, reported: "The ball passed through the centre of the left scapula, and out through the right near its lower angle. The right scapula is diseased from the injury, and pieces of bone are being discharged, with large quantities of pus. There is no defect in the motion of the shoulder joint." Subsequent reports state that elimination of necrosed bone continued. This pensioner was paid June 4, 1874.

CASE 1444.—Private S. McMurray, Co. C, 11th Pennsylvania Reserves, was wounded at South Mountain, September 14, 1862. He was discharged and pensioned. December 3, 1862, Surgeon C. W. Jones, U. S. V., reported that: "A ball entered the right scapula, causing partial ankylosis of both shoulder joints." Examiner A. M. Neyman reported, January 30, 1869: "The left arm is seriously disabled for work of any kind; the disability is caused by a gunshot wound through the bodies of both of the scapulae; the disability will probably increase; it has increased since the last examination." This pensioner was paid June 4, 1874.

CASES 1445-1448.—Private J. Shank, Co. F, 2d Infantry, aged 25 years, was shot through the left shoulder at Rappahannock Station, November 7, 1863. Surgeon D. W. Bliss, U. S. V., reported that: "The missile passed through the muscles of the back, and emerged through the right shoulder, fracturing the spines of both scapulae." This soldier was returned to duty July 30, 1864, and is not a pensioner. Private J. Powell, Co. F, 30th Colored Troops, aged 39 years, received at Petersburg, July 30, 1864, "A shot wound of the right and left scapulae." Surgeon E. Bentley, U. S. V., reported that this soldier was returned to duty February 1, 1865; not a pensioner. Private W. H. Perry, Co. H, 36th Massachusetts, was struck at the Wilderness, May 6, 1864, by a musket ball, and Surgeon P. A. Jewett, U. S. V., noted that both scapulae were injured by the missile. This soldier was returned to duty October 2, 1864, and was not pensioned. Sergeant N. Brown, Co. C, 7th Colored Troops, aged 21 years, was hit at Deep Bottom, August 14, 1864. Assistant Surgeon Ely McClellan, U. S. A., reported that: "The ball fractured right and left scapulae. The patient convalesced, and returned to duty December 12, 1864." Not a pensioner.

<sup>1</sup> References to shot fractures of both scapulae are exceedingly uncommon in authors: BONET (*Corps de Médecine et de Chirurgie*, Geneva, 1679, T. II, Obs. 49, p. 24) cites a case observed by Borel, in which both scapulae were shattered by a bullet.



In the three fatal instances of shot fractures involving both scapulæ,<sup>1</sup> the patients succumbed, five to eight weeks after the reception of their injuries, from hospital gangrene or pyæmia. An abridged memorandum of these cases is appended:

CASES 1449-1451.—Private R. J. Ives, Co. B, 189th New York, aged 33 years, was wounded at Hatcher's Run, March 29, 1865, was taken to a Fifth Corps field hospital, where the ball was extracted. On April 3d, he was sent to Washington to Harewood Hospital. Surgeon R. B. Bontecou, U. S. V., reported: "A gunshot wound, the ball having entered over the middle of the superior edge of the right scapula, and was extracted near the middle of the left scapula; the left scapula was badly fractured and the right slightly injured. On admission the condition of the injured parts and the constitutional condition of the patient were tolerably good. The patient did tolerably well until April 20, 1865. After that date the parts became gangrenous, the whole length of the wound being involved in the sloughing. The patient sank, and died May 16, 1865." Private D. Way, Co. K, 1st New Hampshire Cavalry, received, at Petersburg, June 15, 1864, "Shot fractures of both scapulæ. He died July 20, 1864," as reported by Assistant Surgeon E. McClellan, U. S. A. Private N. T. Flewellyn, Co. E, 31st Maine, aged 22 years, was wounded at Spottsylvania, May 12, 1864. Surgeon T. R. Crosby, U. S. V., reported a "shot fracture of both scapulæ." Death July 10, 1864.

Preparations of shot fractures of the scapula, already illustrated, are enumerated on page 481. Some further examples will be adduced, PLATE XLV opposite representing one of the most remarkable of those in the Museum.

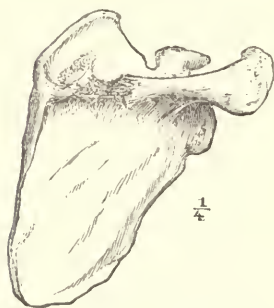

FIG. 379.—Shot fracture of the spine of the right scapula. *Spec.* 2186.

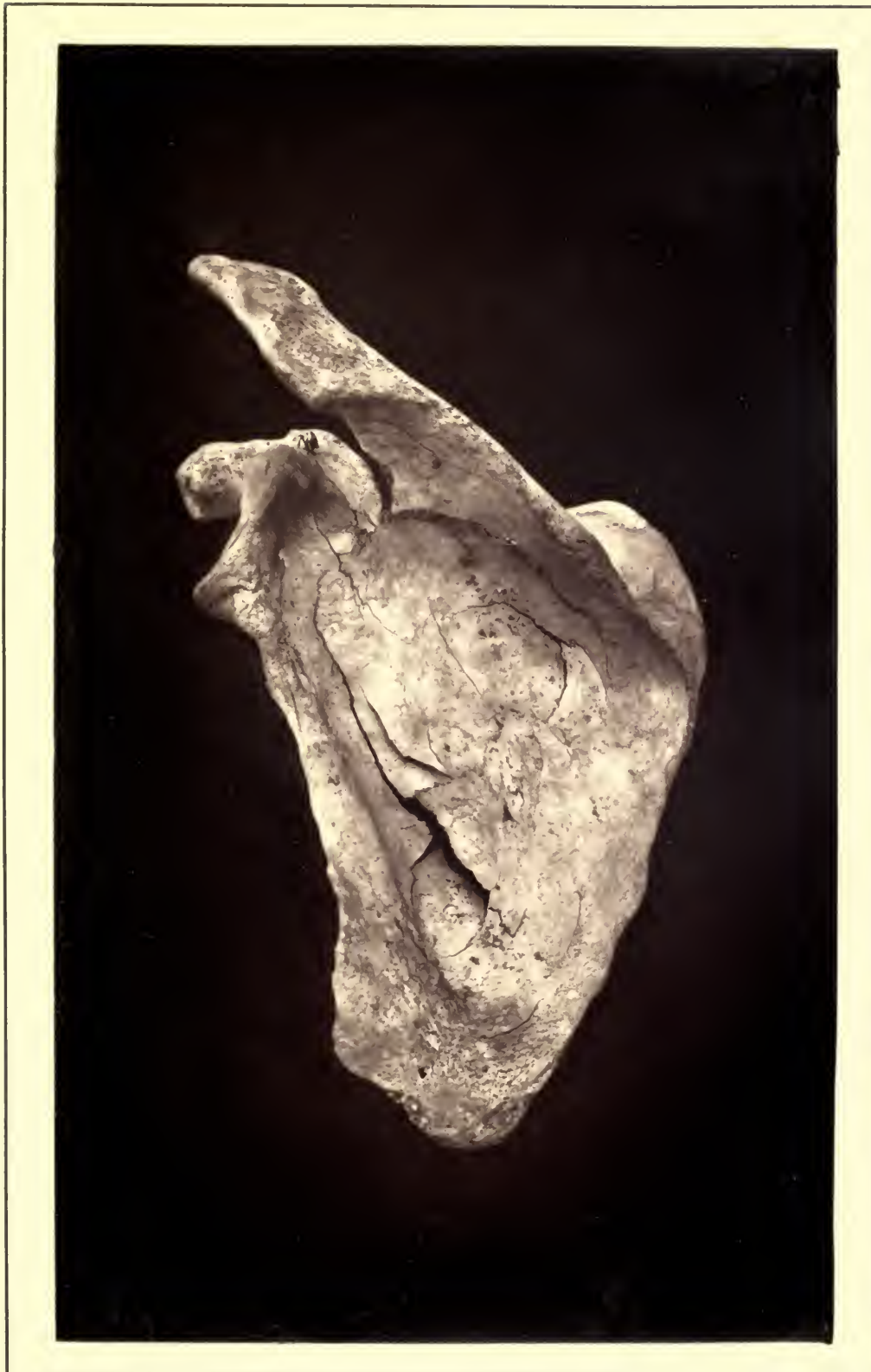CASE 1452.—Private N. O——, Co. D, 1st Florida Cavalry, was wounded at Mission Ridge, November 25, 1863, and was admitted to Prison Hospital, Nashville, on December 7th, and thence transferred to Hospital No. 1, January, 1864. He died of pneumonia, January 27th. Surgeon C. W. Horner, U. S. V., noted: "Post-mortem twenty-four hours after death: External appearance, moderate emaciation, with a general ecchymosed appearance of the back. On examination of the wound, it was found that the ball which produced it passed through the spine of the scapula." The specimen (FIG. 379) consists of "The right scapula, the posterior portion of the spine carried away by a bullet, which appears to have passed from below upward. Two slight fissures exist in the lower plate. The whole posterior surface of the bone shows marks of periosteal disturbance." The specimen was contributed by Acting Assistant Surgeon Preston Peters.

CASE 1453.—Private W. A. S——, Co. B, 13th Indiana, aged 27 years, was wounded at Petersburg, July 30, 1864. He was sent to a Ninth Corps hospital, where Surgeon T. S. Christ, 45th Pennsylvania, reported, "gunshot wound of the thorax, removal of pieces of bones." The wounded man was sent, on the following day, to City Point, and thence, on August 3d, to the Douglas Hospital, at Washington. Assistant Surgeon W. Thomson, U. S. A., reported: "This man was struck by three musket balls. One entered the left side an inch below the border of the left axilla, and escaped near the acromial extremity of the clavicle. A second ball penetrated the left supra-spinous fossa, and was removed after death. Striking the spine it caused remarkable fissuring of its base. A third ball, splitting on a rib, had penetrated the thoracic cavity between the ninth and tenth left ribs, and at the autopsy one-half of the missile was found just within the pleural cavity, and the other portion in the apex of the left lung. The autopsy revealed the usual evidences of traumatic pleuro-pneumonia." The scapula, forwarded to the Museum by Dr. Thomson, and represented in PLATE XLV opposite, is described by Dr. Woodhull (*Cal. Surg. Sect.*, 1866, p. 74) as "fractured by a bullet, which first impinged against its anterior border just below the glenoid cavity, and then struck the spine at the junction of the acromion, and was extracted from the supra-spinous fossa. A deep longitudinal fracture nearly separates the spine from the dorsum of the bone. The coracoid process is nearly split off, and the whole inferior plate is occupied with fissures, none of which directly communicate with the original fracture, but which together nearly destroy the bone."

One of the remotely fatal cases of shot fracture of the scapula was in the person of a medical officer:

CASE 1454.—Surgeon C. Newhaus, 29th New York, aged 43 years, received, at Bull Run, August 30, 1862, a gunshot wound of the right shoulder, which fractured the clavicle and the acromion process of the scapula. He was mustered out on November 13, 1862, and pensioned. In his affirmation, April 8, 1864, he stated that: "After his removal from the hospital on the battle field to Washington, he was treated by Surgeon Stæhli, of the 7th New York. He remained in Washington fifteen days, when he was removed to Brooklyn." Dr. R. Stæhli, late Surgeon 7th New York, certified in November, 1864, that this was a shot injury "causing a double fracture of the right clavicle and perforation of the scapula," and that it is his opinion "that said injury necessarily must impair the mobility of the right arm in a high degree, even if healed in the most favorable manner." Examiner C. Rowland, of Brooklyn, reported, November 4, 1864: "The above applicant alleges that he was wounded by a rifle ball entering under the right clavicle, and making its exit near the acromion process of the right scapula, causing a partial loss of the upward motion of the arm. He alleges that he cannot lift any weighty substance. It is a serious disability in manual labor, but, in his profession, will not incommode him very greatly." This pensioner died July 23, 1866. The cause of his death is not known at the Pension Bureau.

<sup>1</sup>Specimens 699 and 817, Section I, A. M. M., mounted together, afford a fine illustration of shot fracture of both scapulæ; but the preparation cannot easily be portrayed either by engraving or photography. DR. PAUL BECK GODDARD contributed three specimens with an abstract, which is printed at page 435 of the *First Surgical Volume*. Compare *Cal. Surg. Sect.*, 1866, pp. 60 and 75, and the remarks on pp. 435 and 436 of the preceding surgical volume.



Ward phot.

Am. Photo-Relief Printing Co., Philada.

PLATE XLV. COMMUNED SHOT FRACTURE OF THE LEFT SCAPULA.

No. 3585. SURGICAL SECTION.





These fractures, as observed in fatal cases, are, of course, of almost infinite variety. According to the part implicated, whether body or apophyses, and the date when the patients succumb, the recent comminutions, the attempts at repair,<sup>1</sup> or the destructive changes, present unlike appearances:

CASE 1455.—Sergeant F. H. H——, Co. A, 121st Pennsylvania, was wounded at Gettysburg, July 1, 1863, and sent, July 13th, to Broad and Cherry Streets Hospital, Philadelphia. Acting Assistant Surgeon H. M. Bellows reported: "A ball had entered on the right side of the chest over the third rib, two inches from its sternal extremity, passed around the chest, and had escaped behind, through the inner border of the scapula, about two inches above its apex. On admission, he was anæmic and very much broken down in health; his pulse was feeble and frequent, his tongue furred, and his countenance was of a dusky hue. The wound of entrance looked well; but that of exit was sloughing and discharging ichorous pus freely, and the soft tissues over and around the scapula were boggy. Milk-punch and beef-essence, with tonics, were freely administered, and the wounds were dressed with fermented poultices. July 18th, the sloughing continued, with indications of erysipelas. Crucial incisions, three inches in length, were made through the wound, and the deeper tissues were found to be involved. The parts were cauterized with nitric acid. On July 22d, he had several chills, followed by profuse diaphoresis and vomiting. Sinapisms were applied over the abdomen, and one drop of creasote was given in mucilage, as required. July 25th, the patient has been vomiting daily, and suffering from chills, followed by great exhaustion. This condition continued until August 2d, when he died. A *post-mortem* examination was made eight hours after death: In each lung a few scattered tubercles were found at the apices, with some hypostatic congestion at the bases. All the other organs were healthy. On examining the course of the wound, it was found that the ball had run around on the upper border of the third rib and passed out behind. A large abscess occupied the under surface of the scapula, which bone was, in part, denuded of its periosteum. There was another abscess in the superior spinous fossa; the coracoid process was necrosed. Death had evidently resulted from extreme exhaustion dependent on his condition." The specimen (FIG. 380) was forwarded to the Museum by Acting Assistant Surgeon W. V. Keating, and consists of "the right scapula fractured on the anterior border near the inferior angle. \* \* The fractured edges are necrosed, and both surfaces of the lower portion of the scapula are coated with an osseous layer."—*Cut. Surg. Sect.*, 1866, p. 74.

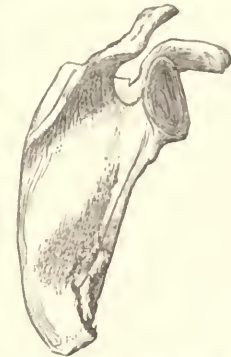

FIG. 380.—Right scapula coated with osteophytes after shot fracture. *Spec.* 2792.

In the foregoing case the patient survived a month; in the next, a fortnight only:

CASE 1456.—Corporal C. D. S——, Co. H, 100th New York, while on picket at the upper end of Folly Island, on the night of April 10, 1863, was wounded and taken prisoner by a scouting party of the enemy. Surgeon F. L. Dibble, 6th Connecticut, reported: "As his wound was severe, he was left by the enemy on the field, and was taken to the regimental camp three hours afterward. On April 11th, he was removed to the hospital steamer *Cosmopolitan* by Surgeon M. S. Kittenger, 100th New York, and his wounds were examined. A conical rifle ball had entered over the anterior superior edge of the deltoid just above the acromial end of the right clavicle, and, passing backward and inward, had emerged at the middle of the spine of the scapula. The scapula was extensively injured and several fragments were extracted, one of them being nearly an inch square; they were chiefly portions of the spine of the scapula. The degree of injury to the clavicle was not accurately ascertained. The shoulder joint was thought to be uninjured. The hæmorrhage from this wound was inconsiderable. A second wound, also from a rifle ball, entered at the middle of the under surface of the left heel, passed upward and a little inward, shattered the calcaneum and the inner malleolus, and made its exit above the latter prominence. Amputation was performed by the circular incision just above the malleoli, the condition of the soft parts not justifying the operation of Mr. Syme. The foregoing was transcribed from a report by Surgeon G. A. Otis, 27th Massachusetts, in charge of the steamer *Cosmopolitan*. The patient was removed from the transport into Hospital No. 1, Beaufort, April 16, 1863. On that day, and the succeeding one, both wounds remained in good condition, the stump showing evidence of immediate union of the flaps. The third day after admission, his condition was not so favorable, and the stump commenced to have an ashy appearance and was highly sensitive. Sloughing of the integuments to a considerable extent followed, and the surface of the wound never afterward assumed a healthy appearance. All this time the wound in the shoulder discharged profusely, and quite a number of pieces of bone were removed. On April 25th, a severe rigor seized the patient, followed by heat of the skin and great perspiration. During the day the skin and conjunctiva took on a yellow hue, and, on the 26th, he experienced another chill and complained of pains in the abdomen. At this time he became delirious, the delirium being low and muttering. On April 27th, pneumonia set in, and the cellular tissue of the right arm became infiltrated and greatly distended with fluid. He gradually sank until April 30th, when he died. After death I removed the clavicle and the remains of the scapula, which I send with this." The specimen (FIG. 381) exhibits "the right scapula, struck near its acromial end by a bullet which emerged through its spine, shattering a large portion of the bone. The joint was opened, and the glenoid cavity slightly fractured."—*Cat. Surg. Sect.*, 1866, p. 96.

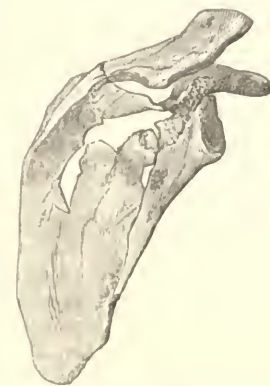

FIG. 381.—Shot fracture of the right scapula. *Spec.* 1188.

In this case, it was surmised that the shoulder joint was not interested primarily, and

<sup>1</sup>Observations of regeneration of the scapula in man have been recorded by CHOPART and KLENCKE, and RUDOLPH and KORTEN report the same phenomenon in the horse. (See WAGNER, *Über den Heilungsprozess nach Resektion und Extirpation der Knochen*, Berlin, 1853, S. 29.)



in the succeeding case, it would appear to be certain that the original lesion did not extend to the articulation. The subject of arthritis consequent on injuries in the vicinity of joints, must be reserved for future consideration. Unhappily, as will be more apparent in treating of injuries of the other large joints, the examples were so numerous, that it is necessary to avail of every opportunity of introducing illustrations, to be referred to in the subsequent general discussion:

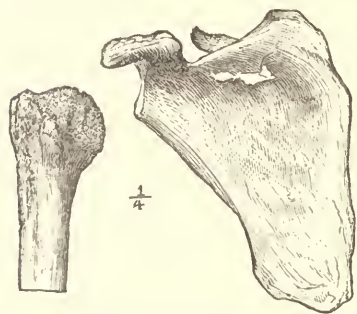


FIG. 382.—Shot fracture of the right scapula, with consecutive traumatic arthritis. *Spec.* 3581.

CASE 1457.—Private G. F. Watson, Co. K, 7th Wisconsin, aged 27 years, was wounded at the Wilderness, May 5, 1864. Surgeon C. N. Chamberlain, U. S. V., reported, from a Fifth Corps hospital, "a gunshot wound of the back." On May 12th, the patient was admitted into Douglas Hospital, Washington. Assistant Surgeon W. Thomson, U. S. A., reported: "This soldier was struck, on May 5th, by a conoidal ball, which fractured the scapula. He died, July 2<sup>nd</sup>, of profuse suppuration and chronic diarrhœa. At the necropsy, the mucous membrane of the large intestine was found thickened and ulcerated." Dr. Thomson contributed the specimen (FIG. 382) of "The right scapula, fractured in the supra-spinous fossa, and the upper portion of the humerus, the head of which is entirely absorbed. The joint does not appear to have been implicated in the original injury, but became destroyed by the resulting inflammation. There is a border of necrosed bone at the seat of fracture, and a slight osseous deposit near by, but no attempt at repair in the joint."—*Catalogue of the Surgical Section*, p. 96, 1866.

In a case of shot fracture of the scapula, after unavailing temporization with styptics, ablation of the limb at the shoulder was practised, as a preliminary measure to extirpation of the shoulder blade,<sup>1</sup> an operation the patient's condition did not permit:

CASE 1458.—Private I. B——, Co. B, 60th Ohio, aged 19 years, was wounded at Po River, May 9, 1864. He was sent to a Ninth Corps hospital, and thence to Washington on the 13th. Surgeon J. A. Lidell, U. S. V., from Stanton Hospital, reported: "Gunshot wound of left shoulder. Ball entered below the clavicle and border of trapezius muscle, and passing downward and backward, fractured the scapula. Secondary hæmorrhage took place on May 27th, 28th, and 30th, and was controlled on each occasion by the application of solution of persulphate of iron. Tonics and stimulants were administered, and ice dressings were applied. On the 29th, the ball was extracted through an incision made along the inner border of the scapula. On May 31st, hæmorrhage again occurred, and was so profuse, both from the wound as well as from the point where the missile was extracted, that amputation was considered necessary with a view of extirpating the scapula and securing the bleeding vessel, which was diagnosed to be either the subscapular or supra-scapular artery. After the patient had been placed under the influence of sulphuric ether, Acting Assistant Surgeon C. H. Osborne amputated the arm at the shoulder joint. The operation was accompanied by very little loss of blood, but the hæmorrhage had been so profuse previously, that the patient never fully rallied. Death supervened on the same day, May 31, 1864. The autopsy showed extensive stellated fracture of the scapula, and the supra-scapular artery was found divided near its passage over the bone. The internal organs were normal."

An instance in which a musket ball was lodged beneath the scapula is not without interest. Such cases were not very uncommon;<sup>2</sup> and were very frequently mortal.

CASE 1459.—Private G. H. Hamilton, Co. E, 5th Maine, aged 20 years, was wounded at Rappahannock Station, November 7, 1863. Surgeon D. W. Bliss, U. S. V., forwarded the missile that inflicted the wound to the Army Museum with the following memorandum: "The ball entered the middle third of the right clavicle, producing a complete fracture of the same, and otherwise lacerating the contiguous soft parts; ball remaining in. Two days had elapsed from the time of his receiving the wound to his being received into this hospital, when he was very much prostrated, and had not recovered from shock. His shoulder was very much swollen, and the head of the humerus was dislocated downward into the axilla. His system failing to respond to the most stimulating and thorough treatment, he died on the 14th of November, five days after admission. On *post-mortem*, after twenty-four hours, the ball was found lodged beneath the scapula, completely enclosed in a portion of the uniform coat. The lungs presented a congested condition, but not sufficiently so to account for his death; neither can the cause of his death be looked for in the amount of lesion in the surrounding parts. It was apparently the result of the shock received, or of nervous prostration." The projectile, as shown in the wood-cut (FIG. 383), is a longitudinal half of a conoidal ball, flattened, with inverted edges. A smaller fragment is attached. (See *Cat. Surg. Sect.*, 1866, p. 610.)

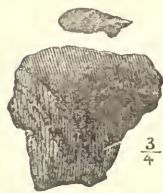

FIG. 383.—Portions of a conoidal ball split and flattened on the clavicle. *Spec.* 1560.

*Shot Fractures of the Scapula and Clavicle* simultaneously were usually, but not invariably, attended by lesions of the large adjacent blood-vessels or nerves, or of the pleural cavity or lung tissue. Two examples are subjoined of such contemporaneous

<sup>1</sup> The case may be added to the long list of examples of the folly of awaiting a third hæmorrhage before interfering.

<sup>2</sup> Compare, in the *First Surgical Volume*, CASES of G. W——, p. 485, W. H. Burns, p. 496, and H. Milleneth, p. 590; and (further on) others that will be detailed among the excisions of the head of the humerus.

fractures unattended by direct lesions of the chest cavity; because there are preparations in the Museum to illustrate them. It is rarely that such cases are noticed in surgical annals,<sup>1</sup> and, although the wood-cuts represent the specimens imperfectly, it seems best to place these observations on record:

CASE 1460.—Corporal C. F——, Co. D, 13th Iowa, aged 29 years, was wounded near Kenesaw Mountain, July 8, 1864. On July 12th, he was admitted into the field hospital at Rome, Georgia. Surgeon G. F. French, U. S. V., reported: "Gunshot wound of the right shoulder; the ball entered over the outer third of the clavicle, fractured it, wounded the external jugular vein, fractured the acromion process, and emerged over the anterior angle of the scapula. Nothing of his previous history was known. He died July 23, 1864. Autopsy eight hours after death: General appearance sallow and jaundiced. Upon examination of the viscera of the thorax the right lung was found normal, but extensive exudation of yellowish-green curdy pus covered the surface of the left lung, which was glued to the ribs by recent inflammation of the pleura; the parenchyma of the lung was congested. The left side of the thorax contained about one quart of yellowish-green curdy serum. The heart was normal but not contracted, and contained no clot. The liver was slightly enlarged, and exhibited circumscribed spots of fatty degeneration. The spleen was enlarged and its substance apparently normal. The kidneys were somewhat above their normal size; substance friable; the capsule separated with unusual facility. The form of the pyramids, as shown by a longitudinal section, was encroached upon, and in some instances entirely obliterated by fatty degeneration, which was so apparent as to be seen by removing the capsule from any part of the surface. There was extensive burrowing of pus, and suppuration in both the supra- and infraspinous fossae, involving also the cervical glands, some of which suppurated. In the external jugular vein were found half a dozen oval, white, opaque bodies, exuded beneath the mucous coat, near the upper valves, and about one-fourth of an inch in diameter. The vein was thickened in the vicinity, and softened; it was of a livid color, and contained a dark red, moderately firm thrombus, continuous throughout the diseased track, which was about three inches in length. The subclavian vein did not seem to have been implicated in the inflammation. The portal veins were of a bright red color, congested, and softened in the mucous coat. A few congested spots of inflammation were found in both the superior and inferior vena cava, particularly marked near its bifurcation into the common iliaes. In the middle portion of the vena cava were four or five deeply congested and elevated spots of irregular outline, one-sixteenth of an inch in diameter, encircled by a white ring, which appeared to be owing to the loss of substance from the middle coat of the vein. This appearance may still be seen in a section from the vena cava (*Spec.* 6455)." Dr. French contributed an osteological preparation from this case (*FIG.* 384), which consists of "the right clavicle with its acromial end clipped off, and the acromion fractured at its junction with the spine."—*Cat. Surg. Sect.*, p. 76.

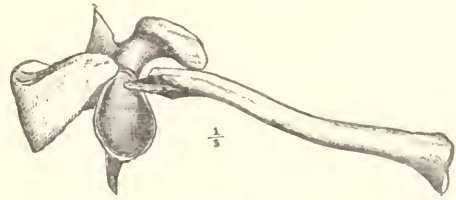


FIG. 384.—Shot fracture of the right acromion process and of the outer extremity of the clavicle. *Spec.* 3381.

CASE 1461.—Sergeant T. B——, Co. H, 5th Cavalry, was wounded at Gaines's Mill, June 27, 1862. He fell into the enemy's hands, was paroled, and sent, July 30th, to the Episcopal Hospital, Philadelphia. Acting Assistant Surgeon R. A. Cleeman reported: "Wounded by a musket ball, which entered the left shoulder about two and a half inches from the acromial process and just above the spine of the scapula; it came out at a point opposite the junction of the inner fourth with the outer three-fourths of the clavicle, producing a fracture of that bone. When admitted into the hospital he was in a low condition, with a chronic diarrhoea. The ends of the fragments of the collar bone were raised up by the side of the trachea, threatening to puncture the skin, which was very much inflamed. There was also extensive burrowing of pus over the great pectoral and supra-spinatus muscles. Owing to his condition, the ordinary apparatus for fracture could not be applied. The diarrhoea was checked and patient apparently improved; but the improvement did not last. The patient expired September 29, 1862. A *post-mortem* examination discovered the right lung filled with tubercles; the left was much smaller than the right, and affected in only two or three places with tubercle. The acromion was separated from the scapula and the clavicle broken; the diseased condition extended into the shoulder joint; the head of the humerus and the upper part of its shaft were carious. The first rib was diseased on its superior aspect, and the left lung adhered to its inferior aspect." The specimen (*FIG.* 385) consists of the "left clavicle, scapula, and upper half of the humerus. The clavicle is transversely fractured near the middle, the sternal half of the bone being much necrosed and exhibiting a certain amount of ensheathing callus on the internal surface. The head of the humerus is eroded, carious, and partly absorbed. The coracoid and acromial processes and upper part of the glenoid fossa are badly fractured, the place of the coracoid being occupied by a small irregular spike of new bone directed inward. The articular surface is carious and absorbed. The humerus was accidentally fractured through the surgical neck after death." (*Cat. Surg. Sect.*, 1866, p. 96.) The preparation was forwarded to the Army Museum by Acting Assistant Surgeon A. C. Bournonville.

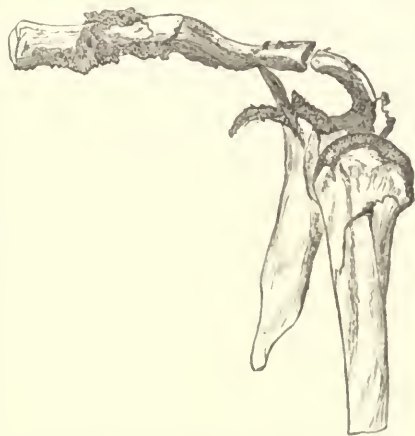

FIG. 385.—Shot fracture of the left clavicle and scapula, with consecutive disease of the shoulder. *Spec.* 234.

<sup>1</sup> MONDALON (*Sur un plaie d'arme à feu, avec fracture de l'omoplate et de la clavicle, etc.*, in *Jour. de méd. chir. pharm.*, etc., Paris, 1764, T. XXI, p. 246) relates a case of shot fracture of the scapula and clavicle; four pieces of the scapula were immediately removed, a fifth not until the fifteenth day; recovery.



*Excisions of Portions of the Scapula.*—This subject has been adverted to in the fifth chapter of the preceding volume, and some cases of partial excisions of the scapula,<sup>1</sup> in patients who suffered also from wounds of the chest cavity, are there detailed. There were no examples of removal of the entire scapula,<sup>2</sup> either with or without preservation of the arm. But there were reported not less than forty-nine cases of partial excision after shot fractures of the scapula, believed to be unattended by penetration of the chest. A few of these will be detailed, and the remainder will be tabulated:

CASE 1462.—Captain G. W. Lawton, Co. C, 4th Michigan Cavalry, was wounded in the right shoulder at Dallas, May 24, 1864. From a field hospital and a depot hospital at Chattanooga he was transferred, on June 10th, to the Officers' Hospital at Nashville. Surgeon J. E. Herbst, U. S. V., reported: "Gunshot fracture of the left scapula, the ball lodging; the parts were uninfected and painful, and the patient was somewhat feverish. On June 13th, he was chloroformed, and the ball was extracted, and the scapula trephined through an incision two inches long, made through the integuments, the trapezius and infra-spinatus muscles, about one inch external to the inner border of the scapula. Granulations sprang up readily, and a week after the operation the patient left the hospital on furlough. On October 21st he returned, and on December 1st he rejoined his command for duty." On July 1, 1865, Captain Lawton was mustered out, and pensioned. In a letter from Hagerstown, Maryland, dated June 14, 1866, Dr. Herbst describes him "as being in excellent health." Examiner L. O. Woodman, of Paw Paw, Michigan, reports, November 1, 1866: "A ball entered the right shoulder just below the clavicle and near the joint, passed through the scapula, and was extracted near its angle. The axillary plexus of nerves was injured by the missile, causing a partial paralysis of the right arm." In 1873, Examiner Keables, of Michigan, reported the arm as nearly useless.

<sup>1</sup> The following examples were cited, viz: CASES of P. J. P——, H, 14th Indiana, p. 475; Pt. F. E. Bickett, F. 5th Connecticut, p. 562; Pt. Geo. R. M——, E. 84th Pennsylvania, p. 563; Pt. Morris O——, D, 8th Infantry, p. 564. In the case of Bickett, Surgeon BRYANT is mentioned as the operator, in accordance with the hospital report (see *Cat. Surg. Sect.*, A. M. M., 1866, p. 79); but the editor has been informed by several persons who witnessed the operation that Assistant Surgeon HARRISON ALLEN, U. S. A., was the operator, a fact confirmed by Dr. ALLEN, personally, March 10, 1873. This, which furnished specimen 1050, was by far the most extensive of any of the excisions of the scapula reported with precision.

<sup>2</sup> The tabular statement of excisions of the entire scapula, of Dr. STEPHEN ROGERS (*Am. Jour. Med. Sci.*, 1868, Vol. LVI, p. 367), much copied in English and German works, includes 25 cases of total, and 31 cases of partial excisions. Among the 25 examples of extirpation of the scapula, CASES 10 (CÆTANI BÉY) and 15 (LARBÉY) are identical, and only 24 total excisions are in reality noted, an error that would have been avoided had references been given in this otherwise excellent table. To the partial excisions specified in Dr. ROGERS'S table many instances might now be added, and the number of total excisions has increased to 41. The 17 cases of total excision that may be added to those enumerated by Dr. ROGERS are: 1. A case by Professor W. PURDIE, who states (*Princ. and Pract. of Surg.*, 3d ed., 1873, p. 812): "On the 18th of September, 1856, I removed from a female, seventy years of age, the whole of the scapula, leaving the upper extremity. The patient recovered slowly, with a tolerable use of her arm, but she fell into bad health, and died on the first of December." 2. An operation practised February 17, 1857, originally reported by M. SOUPAÏT in the *Ann. de la Soc. méd. de Gand* (*Stance du 17 Juillet, 1857*), and cited in M. MICHIAUX'S article, *De l'ablation totale de l'omoplate, etc.*, in the *Gaz. Méd. de Paris*, 1866, T. XXI, p. 277. This was a removal of the scapula for malignant disease, after a previous disarticulation at the shoulder; there was fatal recurrence of carcinoma, and the patient succumbed July 12, 1857. 3. The same writer states (*loc. cit.*) that: "M. le Professeur DEROUBAIX (de Bruxelles) m'a rapporté également le fait d'un individu auquel il avait successivement pratiqué pour une tumeur de mauvais nature, d'abord la résection de la tête de l'humérus, puis la désarticulation scapulo-humérale, et enfin, l'extirpation totale de l'omoplate." The cancerous disease recurred fatally in the lungs. 4. LÜCKE (A.) (*Beiträge zur Lehre von den Resect.*, in *Arch. der Klin. Chir.*, 1862, B. III, S. 306) relates that, in 1860, Professor B. von LANGENBECK having, in the case of a man of 23, extirpated the humerus on account of an osteosarcomatous tumor, on the recurrence of the disease, extirpated the scapula and an inch and a half of the clavicle, the patient surviving eighteen months. 5. A successful case, in the person of a man named Messick, with necrosis of the shoulder blade, is recorded in the *Dublin Med. Press*, November 13, 1861, under the title: "An useful Arm left after the Removal of the entire Scapula." The operator's name is not recorded. 6. BIRD (J. D.) (*On a Case of Excision of the Scapula, Head of the Humerus, and part of the Clavicle, for Malignant Disease*, in *The Lancet*, 1865, Vol. II, p. 696) records an instance of successful extirpation of the scapula, by two successive operations, in the person of Ellen L——, injured by a fall; operations performed in 1863 and 1864, in which the head of the humerus, the entire scapula, and a portion of the clavicle were removed. 7. JACKSON (V.) relates (*Amput. of the right arm at the Shoulder joint, with Excision of the Scapula*, in *Brit. Med. Jour.*, 1869, Vol. II, p. 322) an operation on Samuel C——, aged 35, "struck by an engine-buffer in 1864;" a fatal case. 8. HAMILTON (F. H.) states (*Princ. and Pract. of Surgery*, 1872, p. 395) that he excised the entire scapula in February, 1866, "for necrosis resulting from a gunshot injury," and that "the patient recovered with a very useful arm." He refers to a tabular statement in the *New York Med. Jour.*, 1869, Vol. VIII, p. 440, where the case is numbered 59, without details. In Vol. III, p. 147, of the same journal, the case is alluded to. In the account in the *Med. and Surg. Reporter*, 1866, Vol. XIV, p. 372, of the proceedings of the New York Pathological Society, it is stated that: "Prof. HAMILTON presented a scapula, which had been removed entire from a soldier who had been wounded at Fredericksburg by a shell. Necrosis of the scapula ensued, necessitating its entire removal with the acromion and coracoid processes. The patient has power to use the coraco-brachialis and biceps, also tolerably well the triceps and deltoid. He is able to carry the arm without a sling, although attachment of these muscles is simply to cicatricial tissue, there having been no formation of new bone." 9. An unsuccessful extirpation of the scapula, with ablation of the upper extremity, in 1867, in the case of a boy of 12, is recorded by McLEOD (K.) (*Case of Medullary Tumor of the Arm; Amputation of the Limb and Scapula*, in the *Edinburgh Med. Jour.*, 1869, Vol. XV, I, p. 567). 10. POLLOCK (G.) (*St. George's Hospital Reports*, 1869, Vol. IV, p. 223) publishes two cases of resection of the shoulder blade; in the second, the case of O. G——, aged 47, the entire scapula was removed, with a fatal result; in the former, nearly the entire bone was removed. 11. Dr. D. M. SCHUPPERT has described (*Excision of Entire Scapula, with Preservation of a useful Arm*, in *New Orleans Jour. of Med.*, 1870, p. 90) an instance of successful total excision of the shoulder blade, in the case of a woman of 36, Theresa B——. 12. WATSON (P. H.) has recorded (*Edinburgh Med. Jour.*, 1869, Vol. XV, p. 124) an "amputation of the scapula along with two-thirds of the clavicle, and the remains of the arm." 13. HAMILTON (F. H.) (*Amputation of Arm and Scapula for Colloid of Scapula*, in the *Medical Record*, 1871, Vol. VI, p. 141) also removed the scapula, with the upper extremity, in the case of G. Hanna, with a tumor following a blow from falling earth. 14. LOGAN (S.) recorded the case of P. Janvier, aged 33 (*Excision of the Left Scapula subsequently to Resection of the Head of the Humerus of the same side*, in *Richmond Med. Jour.*, 1872, Vol. XIV, p. 131). Disease of the bone had resulted from blows. The operation is said to have resulted successfully, and to have been a total excision, practised in 1871. 15. Mr. C. STEELE, at the meeting of the British Medical Association at Plymouth, in August, 1871, read an account of an "Excision of the Scapula," in the case of Charles Bees, a boy operated on, at the British Infirmary, for malignant disease, unsuccessfully. Professor SPENCE, who has done so much to advance our knowledge of the treatment of surgical affections in the region of the shoulder, records (*The Dublin Jour. of Med. Sci.*, 1873, Vol. LV, p. 508) the case of John Dow, aged 68, whose right scapula Mr. SPENCE excised February 21, 1872. The patient recovered, and an interesting plate of the appearances of the cicatrices and of the tumor removed accompany the paper. 17. JEFFERSON (C. S.) (*Excision of the Scapula and nearly the entire Clavicle for malignant Disease*, in *The Lancet*, 1874, Vol. I, p. 759) records a successful excision of the scapula in the case of Miss

This case is detailed, because it must slightly modify a preceding statement<sup>1</sup> respecting trephining of the shoulder blade. The next case is curious, as attended by a consecutive luxation of the head of the humerus from traumatic arthritis:

CASE 1463.—Private E. Post, Co. E, 11th New York, aged 35 years, was wounded at Bull Run, July 21, 1861, and received into Hallowell Hospital, Alexandria, on the following day. Assistant Surgeon W. Thomson, U. S. A., noted: "The ball entered between the superior and inferior angle of the left scapula. Erysipelas and profuse suppuration followed, and resulted in a state of profound exhaustion. On a careful examination, by Assistant Surgeon R. L. Sheldon, on August 18th, the head of the humerus was found dislocated and beneath the clavicle, and the acromion and coracoid processes of the scapula were discovered to be fractured. An incision was made in the track of the ball beneath the spine of the scapula, and the bone was found with a track cut through its thickness, the spine comminuted at the acromion. A large portion of the acromion was removed, and the displaced coracoid process was restored to its position. Numerous fragments of bone were removed, and the roughened edges of the divided scapula were resected with Hey's saw. The constitutional improvement consequent upon this severe operation was wonderful. On September 9th, the patient was sent to his home in New York in good condition, his wound having closed." The man was discharged on certificate of Surgeon R. S. Satterlee, U. S. A., on December 27, 1861, and remained a pensioner until November 8, 1865, when he died. The missile that caused the fracture in this case appears to have split upon the bone. Two small fragments of the ball, supposed to have been extracted at the time of the excision, were contributed to the Museum, in 1867, by Dr. Thomson, and constitute specimen 4948 of Section I.—See *MS. Cat.*, 1867, p. 46.

S——, aged 20, successfully operated on December 14, 1873. There are two other cases of total excision of the scapula tabulated by an anonymous writer in the *New York Medical Journal*, 1869 (Vol. VIII, p. 434 *et seq.*). It is stated, on the authority of his nephew, that Dr. TWITCHELL, of Keene, New Hampshire, in 1838, removed "the scapula, arm, and part of clavicle." The patient "died some months afterward from redevelopment of the disease." Dr. E. KRAKOWITZER is said to have removed, in 1868, "the scapula five years after amputation at the shoulder joint" for enebondroma; the patient "died seven days after the operation, of exhaustion. \* \* The case was communicated by that surgeon, who will report in future in detail." Moreover, in the *Med. Times and Gaz.*, 1857, Vol. II, p. 155, it is related that an "excision of the entire scapula has been performed lately, with success, by Dr. CRAWFORD, of Ayr. Very little blood was lost. The patient was under the influence of chloroform for forty-five minutes." The references to the twenty-four cases of total excision of the scapula enumerated by Dr. STEPHEN ROGERS are as follows: 1. (1808) CURMING (R.), a successful ablation of the arm, scapula, and clavicle, after an accidental shot injury, in a male adult. (See C. HUTCHISON, in *London Med. Gazette*, 1830, Vol. V, p. 273.) 2. (1835) CROSBY (as reported by S. ROGERS, *Am. Jour. Med. Sci.*, 1868, Vol. LVI, p. 367) extirpated the scapula in an adult, previously amputated near the shoulder, and recurrent disease proved fatal. 3. (1837) MUSSEY (R. D.) (*Removal by Dissection of the entire Shoulder Blade and Collar Bone*, in *Am. Jour. Med. Sci.*, 1837, Vol. XXI, p. 390), a successful case of repeated operations for malignant disease. 4. (1838) McCLELLAN (G.), in the case of a boy of 17 years, removed the scapula, arm, and part of the clavicle, with a fatal result. The case is described and the preparation figured in Dr. McCLELLAN'S work (*Princ. and Pract. of Surgery*, Phila., 1848, p. 412). 5. (1838) GAËTANI BEY (*Mém. de l'Acad. de Méd.*, 1841, T. IX, p. 96) describes a disarticulation at the shoulder, with extraction of the scapula and resection of the clavicle, in the case of a lad of 14 years, who recovered. This is the case frequently, but erroneously, ascribed to LARREY, in 1838, and is a flagrant example of the propagation of error in the careless reproduction of statistics. 6. (1841) Professor RIGAUD (*Extirpation du scapulum en totalité avec la moitié externe, de la clavicle pratiquée le 9 May, 1841, pour un cas d'ostéophyte gélatineux*, Strasbourg, 1850, and *Gaz. méd. de Strasbourg*, 1844) reported a successful extirpation of the shoulder blade in a man 51 years old. 7. (1845) MUSSEY (R. D.) removed successfully the arm and scapula, in a case of osteosarcoma. (See S. ROGERS, in *Am. Jour. Med. Sci.*, 1868, Vol. LVI, p. 368.) The patient is stated to have survived nine years. I can find no other published account of the case. 8. LEWIS (W.) (*New York Med. Jour.*, 1868, Vol. VIII, p. 437) had an unsuccessful amputation above the shoulder for machine injuries, the scapula being removed. 9. (1847) FERGISSON (W.) (*Med. Chir. Trans.*, 1848, Vol. XXXI, p. 309) excised the scapula, in the case of a discharged soldier, aged 23, who had undergone amputation at the shoulder two years previously. 10. (1855) Professor B. von LANGENBECK removed the entire scapula for malignant disease, in the case of a boy of 12 years. (See FOCK, *Extirpation et resection scapulae nebst Mittheilung betreffender Beobachtungen aus der chir. Klinik des Hrn. B. Langenbeck*, in *Deutsche Klinik*, 1855, B. VII, S. 38.) The case proved fatal three and a half months subsequently. 11. (1856) HUYFELDER (J. F.) (*Beiträge zur Operativen Chirurgie*, in *Deutsche Klinik*, 1857, B. IX, S. 188) recorded the fatal case of Jakow Trifanoff, aged 40; the entire scapula removed for caries. 12. (1856) SYME (J.) (*On the Disarticulation of the Scapula from the Shoulder joint*, read before the *Med. Chir. Soc.*, February 24, 1857, in *Med. Times and Gaz.*, 1857, N. S., Vol. XIV, p. 249, and *Lancet*, 1857, Vol. I, p. 243, and *Excision of the Scapula*, Edinburgh, 1864, p. 11) recorded the first instance of removal of the entire scapula in Great Britain. The patient, a woman of 70, succumbed two months after the operation. 13. (1858) JONES (G. M.) of Jersey, in the case of a girl of 15; removed the entire scapula for caries, preserving the arm. The case is related in *The Medical Times and Gazette*, 1858, Vol. LXVII, pp. 633 and 657, and *Med.-Chir. Trans.*, 1859, Vol. XLII, p. 7, with a drawing of the scapula. 14. (1860) NIEPCE, in the case of a man of 30, injured by machinery, successfully removed the left arm, scapula, and clavicle. (See *Bulletin de l'Acad. de Méd.*, 1864-5, Vol. XXX, p. 723.) 15. (1860) HAMMER (A.), in the case of a girl of 18, relates a "Successful Extirpation of Entire left Scapula and acromial end of the Clavicle, with Preservation of the Arm," in the *St. Louis Med. Reporter*, 1866, Vol. I, p. 1. The disease recurred fatally nine months subsequently. 16. (1860) SCHUB (F.) (*Abhandlungen aus dem Gebiete der Chirurgie und Operationslehre*, Wien, 1867, p. 679, and *Wiener Med. Wochenschrift*, 1860) relates a successful extirpation of the scapula, in a child of 8 years. 17. (1862) SYME (J.) reports the case of T. G——, aged 43, who had already undergone excision of the head of the humerus, and who recovered, with perfect mobility of the upper extremity, after excision of the entire scapula and a portion of the clavicle. 18. (1862) BUSCH (W.) (*Lehrbuch der Topographischen Chirurgie*, 1864, Abth. III, S. 19) successfully removed the scapula and a part of the clavicle in a young girl, whose arm had been amputated previously for cancer. 19. (1863) SYME (J.) (*Excision of the Scapula*, Edinburgh, 1864, p. 30) recorded yet a third case of extirpation of the scapula. In this, the case of Mr. K——, aged 40, a portion of the clavicle, and the arm, were removed, as well as the scapula. 20. (1864) BUCK (G.), in an adult male, removed the scapula and part of the clavicle, the arm having been previously exarticulated. Recovering from the operation, the patient succumbed some months afterward from the recurrence of cancer. 21. (1864) Professor MICHAUX, of Louvain, in an extended memoir *De l'ablation totale de l'omoplate en conservant le reste du membre supérieur*, in the *Gaz. Méd. de Paris*, 1865 (Nos. 16, 17, 18), has related the case of Théodore Laurens (*Encephaloidé de l'omoplate; resection totale de l'os, avec conservation du membre supérieur, etc.*, *loc. cit.*, T. XXI, p. 313), a lad of 15, who recovered from the operation, but died ten months afterward from recurrence of cancer. 22. (1865) Sir W. FERGISSON relates a second case of temporarily successful extirpation of the shoulder blade in the case of a girl of 19 (*Removal of the Entire Scapula for malignant disease—Case now under treatment*, in *The Med. Times and Gazette*, 1865, Vol. II, p. 87, and at p. 574, again, where a report of the further progress of the case is promised). 23. (1867) A third operation by Sir W. FERGISSON was on a man of 40, with a tumor resulting from injury (*Removal of the Scapula, Upper Extremity, and Part of the Clavicle*, in *Med. Times and Gazette*, 1867, Vol. II, p. 465, and *The Lancet*, 1867, Vol. II, p. 552); the case resulted fatally on the third day. 24. (1867) ROGERS (S.) (*Case of Excision of the Entire Scapula, etc.*, in *Am. Jour. Med. Sci.*, 1868, Vol. LVI, p. 359) removed successfully the entire scapula, in a girl of 7, and reported the case with the important memoir that has been so frequently cited.

<sup>1</sup> *First Surgical Volume*, p. 564; "No instance was reported of trephining the scapula." The operations of MARESCAL and DUBREUIL are referred to in that connection.



The excisions were for the most part confined to the apophyses.<sup>1</sup> In the thirty-six cases in which the parts removed were specified, the acromion, or portions of the spine, were removed in thirty, the coracoid in one, and portions of the body of the bone in five. The following is an example of a successful removal of the upper angle:

CASE 1464.—Private B. Lammond, Co. H, 159th New York, aged 43 years, was wounded at Fisher's Hill, September 22, 1864. He remained at a field hospital for eight days, and was then sent to Sheridan Hospital, and thence, on October 10th, to Mower Hospital. Surgeon J. Hopkinson, U. S. V., noted: "Gunsbot wound of right shoulder. The ball entered anteriorly near the middle of the clavicle, passed beneath that bone downward and backward, and came out through the superior angle of the scapula. The soft parts became swollen and painful; the bone was necrosed and the wound discharged profusely. The patient was chloroformed, and Acting Assistant Surgeon J. M. McGrath, on October 14th, excised the superior angle of the scapula through a  $\wedge$ -shaped incision made along the superior and internal border of the scapula, four inches long in each direction. Three and a half inches of bone were removed. Prompt reaction followed, and the patient made good progress after the operation." On June 10, 1865, he was discharged and pensioned. Examiner C. Rowland, of Brooklyn, August 8, 1865, reported: \* \* "Many pieces of bone have been extracted. The arm is painful and much impaired in its motion." This pensioner was paid September 4, 1873.

The Museum possesses a specimen,<sup>2</sup> figured on page 562 of the preceding surgical volume, from a patient from whom Dr. Harrison Allen removed the greater portion of the left scapula, necrosed after shot fracture; and an instance of removal of the body of the scapula by Professor F. H. Hamilton, practised after the war, and consequently not reported to this Office, will be discussed further on.<sup>3</sup> But by far more common were those cases in which portions of the acromion, or of the spine, were removed:

CASE 1465.—Private W. Everitt, Co. F, 83d Pennsylvania, aged 22 years, was wounded at Malvern Hill, July 1, 1862, and conveyed to Union Chapel Hospital, Washington. Acting Assistant Surgeon W. H. Butler noted: "A ball entered the left shoulder anteriorly, two inches from its outer aspect, and apparently passed below the clavicle, between the coracoid and acromion processes, shattering the latter at its junction with the spine of the scapula. Six days after the reception of the injury the ball was excised. On July 9th, when admitted, the patient experienced but little pain while quiet, but considerable pain on motion. Cold-water and simple-cerate dressings were applied. Healthy suppuration was going on steadily. Several days after admission, the patient complained of increasing pain. On July 15th, pieces of clothing were extracted. On the 17th, Surgeon R. H. Coolidge, U. S. A., assisted by Surgeons Stone, Bliss, Page, and Bigelow, decided to operate. The acromion was dissected out, and the spine was cut close down and tapered down, to remove all roughness, by bone forceps. Two arteries were ligated. The flaps were brought together with four deep stitches, and long and broad strips of adhesive plaster from the arm to the opposite shoulder. The straps were renewed daily, and sufficient cold-water lotions were used to keep the parts moist. From July 21st, some tendency of the pus to burrow began to show itself. This was prevented by compresses. The man was discharged from service on September 3, 1862," and pensioned. Examiner J. Ross, of Knox, Pennsylvania, reported, September 6, 1873: "No power to raise his arm. Has but little use of the arm, as it rests close to his body, and cannot be moved without pain. Is unfit to perform labor, and ought to have his pension increased."

<sup>1</sup> Very few examples of excision of the scapula for shot wounds are found in the annals of military surgery: CHAMPION (L.) (*Traité de la résection des os cariés dans leur continuité, ou hors des articulations*, Paris, 1815, p. 47) remarks: "J'ai été dans le cas d'enlever avec le ciseau la moitié interne de l'épine de l'omoplate, laquelle était cariée depuis plus d'un an par suite d'un coup de feu," and adds: "En 1796, j'avais déjà secondé M. SOMMEILLER, chirurgien à Aneerville, dans l'excision de l'angle inférieure du même os." The cases of VELPEAU (*Nouv. élém. de méd. opérat.*, 1839, T. II, p. 571) and LEGUEST (*Traité de chirurgie d'armée*, 1872, 2<sup>me</sup> éd., p. 325), and the case tabulated by MATTHEW (*l. c.*, Vol. II, p. 368) have already been noted on page 565 of the *First Surgical Volume*. NEUBÜRGER (J.) (*Von der chirurgischen Abtheilung des K. K. Garnison-Spitales No. 1, zu Prag, in Oesterreich. Zeitschr. für prakt. Heilkunde*, 1862) resected, in 1862, a portion of the acromion and of the body of the scapula, in the case of a *Jäger*, who, in an attempt to commit suicide, shot himself through the *pectoralis major* and shoulder, shattering the scapula. The patient recovered without any untoward circumstances; but the functions of the arm remained limited. LÖFFLER (F.) (*Generalbericht*, u. s. w., 1867, S. 166) relates the case of E. Rice, 4th Prussian regiment, wounded at Düppel, April 6, 1864; fracture of scapula and clavicle; secondary hæmorrhage; resection of portion of the scapula; ligation of the subclavian; death. Dr. LÖFFLER adds: "The bony lesion in this case was of little importance. To prevent, as far as possible, the cause of a fatal issue, namely, secondary bleeding during the period of suppuration, it is well, in cases of deep shot wounds of this kind, to apply ice, if it can be had, for as long a period as possible, whether the osseous lesion be important, slight, or inappreciable. It has been a question if it may not be best in such cases, in order to arrest the bleeding, to excise the scapula from the infraspinous fossa, to search for the bleeding subscapular artery and to ligate at the seat of injury. As may be imagined, it is exceedingly fortunate if the operation fulfils its object." FISCHER (H.) (*Kriegschir. Erf.*, 1872, S. 142) records the case of Dumont, 76th French regiment, wounded August 6, 1870; the entire upper half of the comminuted scapula was resected, and the patient recovered with ankylosis of the shoulder joint. BECK (B.) (*Chir. der Schussverletz.*, 1872, S. 898) details three cases of excisions of portions of the scapula. In the case of S ———, 78th French line, the acromion and part of the scapular spine were excised; the patient recovered with good use of his arm, but died shortly afterward of dysentery. In the second case, the spine of the scapula was removed; and in a third, the acromion process was excised; there was extensive suppuration in the two latter cases; but the patients recovered. The four cases reported by M. CHIPAULT (*Fractures par armes à feu*, 1872, p. 82) have already been cited in the *First Surgical Volume*, p. 565. MUNDY and MOSETIG (*Servicé méd.-chir. de l'ambulance du corps législatif*, in *Gaz. des Hôp.*, 1871, No. 149) report a successful case of secondary excision of a portion of the scapula for necrosis. LEISRINK (H.) (*Notizen aus dem Reservelazareth Seemannshaus in Hamburg*, in *Archiv für Klin. Chir.*, 1872, B. XIII, p. 682) relates the case of C. Th ———, of the 17th Dragoons, wounded August 18, 1870, through the right shoulder. On December 6, 1870, one-half of the scapula was excised; on the next day transfusion of blood was made; the patient died nine days after the operation.

<sup>2</sup> *Catalogue of the Surgical Section of the Army Medical Museum*, 1866, p. 79.

<sup>3</sup> *Vide Med. and Surg. Reporter*, 1866, Vol. XIV, p. 372, and *New York Med. Jour.*, 1869, Vol. VIII, p. 440.

Many of the operations in this group were for necrosis following shot fracture, and bore more resemblance to the usual proceedings for the extraction of sequestra, if I may quote Mr. Holmes's discriminating language,<sup>1</sup> than to formal operations for excision. Although the removal of portions of dead bone was commonly a simple and inoffensive procedure, it was sometimes attended by fatal results:

CASE 1466.—Corporal S. A. Durburn, Co. D, 49th Ohio, aged 24 years, was wounded at Dallas, May 27, 1864, and sent to Nashville, thence to Louisville, and subsequently to Columbus. Assistant Surgeon G. Saal, U. S. V., from the Seminary Hospital, noted: "Gunshot wound of left shoulder. Ball entered near the head of the humerus, fractured the acromion process and spine of the scapula, and passed out at its inferior angle. When admitted, on June 17th, the patient was prostrated from secondary hæmorrhage, and his pulse was hardly perceptible. An injection of persulphate of iron was thrown into the wound, and the hæmorrhage was thus controlled. Stimulants and beef tea were freely administered. A counter opening was made, giving relief to the local symptoms. The greater part of the spine of the scapula being in a necrosed condition was removed, together with a portion of the acromion process, by Acting Assistant Surgeon W. H. Drury. On June 25th, symptoms of pyæmia set in. From the effects of this the patient died on June 29, 1864."

Other detailed cases, of which the following may serve as an example, amounted to little more than extractions of primary sequestra:

CASE 1467.—Private J. Flick, Co. C, 5th New Jersey, aged 30 years, was wounded at Chancellorsville, May 3, 1863. He was sent to Campbell Hospital, Washington, and transferred, May 17th, to Central Park Hospital. Acting Assistant Surgeon S. Smith reported: "Gunshot fracture of the right scapula. The wound is located just beneath the acromion process and extends backward and downward in the direction of the spine of the scapula. A probe detects loose pieces of bone. On May (?), the patient was etherized, and the wound laid open freely in the course of the spine of the scapula to the extent of four inches, exposing a large number of fragments of bone, pieces of clothing, and a flattened minié ball. The pieces of bone removed consisted of nearly the whole acromion process and portions of the spine of the scapula. The tissues were found to be very much contused. The cavity was cleansed and filled with lint. The patient did well after the operation. There was profuse discharge from the wound. On December 1, 1863, when this soldier was discharged, the wound had not completely healed, and the motion and strength of the shoulder joint was considerably impaired." This man is a pensioner. Examiner W. M. Chamberlain, of New York, reports, July 7, 1874: "A ball entered behind right acromion and issued near inferior angle of right scapula, causing extensive fracture thereof. The scapula is still much enlarged. The arm cannot be fully raised, is somewhat atrophied and much debilitated." The New York Examining Board reported, September 5, 1873: "There is a large cicatrix over the spine of the right scapula, thin, depressed, and closely adherent. It interferes with the movements of the shoulder joint. Disability rated one-half."

TABLE XIX.

*Summary of Forty examples of alleged Excisions of Portions of the Scapula after Shot Injury.*

NO.	NAME, AGE, AND MILITARY DESCRIPTION.	DATE OF INJURY.	NATURE OF INJURY.	DATE OF OPERATION.	OPERATION AND OPERATOR.	RESULT.
1	Adams, P., Pl., H, 6th New Hampshire.	July 2, 1864.	Gunshot fracture of the left scapula.	July 2, 1864.	Excision of the acromion process.	Disch'd June 12, 1865. Atrophy of the deltoid muscle; motion of arm slightly impaired.
2	Bridemyer, C., Pt., E, 70th Indiana.	June 15, 1864.	Gunshot fracture of the left scapula.	June 15, 1864.	Excision; Surgeon J. Bennett, 19th Michigan.	Died, September 10, 1864. Not a pensioner.
3	Civitan, M., Corp'l, F, 21st Georgia.	.....	Comp'd comminuted fracture of the right scapula by a musket ball which lodged in the neck.	Date of injury.	Partial excision of the scapula and extraction of the ball.	Undetermined.
4	Conley, T., Pt., B, 7th Michigan, age 21.	August 14, 1864	Shot fracture of the left scapula; minié ball.	Aug. 14, 1864.	Excision of the acromion process; Surgeon G. Chaddock, 7th Michigan.	Discharged January 18, 1865. Not a pensioner.
5	Covey, R., Pt., I, 29th Pennsylvania, age 27.	July 2, 1863.	Compound fracture of the spine of the right scapula by a minié ball.	Jan. 24, 1864.	Excision of a portion of the spine of the scapula; Surgeon H. Palmer, U. S. V.	Discharged September 5, 1864. Anchylosis of shoulder joint.
6	Coughlin, P., Pt., G, 20th Massachusetts, age 21.	May 6, 1864.	Gunshot fracture of the right scapula.	May 6, 1864.	Excision.....	Disch'd July 14, 1865. Fistulous opening near seat of wound; motion of arm restricted.
7	Crosby, P. L., Pt., F, 14th Infantry.	June 20, 1864.	Conoidal ball passed through the left shoulder, fracturing the acromion process and superior angle of the scapula.	July 3, 1864.	Excision of the acromion process; Surgeon A. F. Sheldon, U. S. V.	Died, July 20, 1864, from exhaustion.
8	Deeker, J., Corp'l, H, 68th New York.	August 29, 1862.	Gunshot fracture of the spine of the left scapula.	.....	Excision of a portion of the spine of the scapula.	Disch'd Jan. 19, 1863. Partial anchylosis of shoulder joint.
9	Doyle, A. H., Sergeant, K, 26th Massachusetts.	Dec. 13, 1862.	Musket ball fractured the outer third of the spine of the right scapula.	.....	Excision.....	Veteran Reserves, June 1, 1863. Arm useless for manual labor; inability to flex forearm.
10	Findley, W., Pt., E, 94th Ohio, age 26.	May 14, 1864.	Gunshot fracture of the right scapula.	May 14, 1864.	Resection....	Discharged November 29, 1864. Unable to elevate the arm or move it at the shoulder without assistance; tendency to inflammation about seat of injury.

<sup>1</sup> In his excellent paper on *Excision of Bones and Joints*, in the second edition of the *System of Surgery*, edited by him, 1871, Vol. V, p. 609.



No.	NAME, AGE, AND MILITARY DESCRIPTION.	DATE OF INJURY.	NATURE OF INJURY.	DATE OF OPERATION.	OPERATION AND OPERATOR	RESULT.
11	Fogle, M., Pt., I, 118th Pennsylvania.	May 7, 1864.	Gunshot fracture of the right scapula.	May 7, 1864.	Excision.....	Died May 15, 1864.
12	Gates, S. H., Capt., K, 50th Georgia.	May 12, 1864.	Gunshot injury of the right scapula.	.....	Excision of the outer end of the acromion process.	Furloughed May 16, 1864.
13	Graham, J., Pt., F, 11th Pennsylvania Reserves.	May 3, 1864.	Fracture of the acromion process of the left scapula by a minié ball.	May 9, 1864.	Acromion process removed; Surg. W. Lyons, 11th Pennsylvania Reserves.	Deserted February 11, 1865. Not a pensioner.
14	Henderson W., Pt., D, 36th Wisconsin, age 18.	Sept. 29, 1864.	Shot perforation of the right shoulder, with fracture of the acromion process.	Sept. 29, 1864.	Excision of acromion process; Surgeon D. W. Maul, 1st Delaware.	Veteran Reserves, April 1, 1865. Partial ankylosis of shoulder joint; muscular action much impaired.
15	Hinks, E. A., Capt., C, 19th Massachusetts.	June 3, 1864.	Gunshot fracture of the spine of the right scapula.	June 3, 1864.	Excision of a portion of the scapula; Surgeon J. P. Dyer, 19th Massachusetts.	Disch'd October 7, 1864. Motion of the shoulder joint much impaired.
16	Johnson, E., Serg't, C, 55th Pennsylvania.	June 3, 1864.	Shot perforation of the left shoulder by a minié ball.	June 3, 1864.	Excision of spine, a portion of the acromion process, and a large portion of the body of the scapula; Surg. D. Merritt, 55th Pennsylvania.	Disch'd March 22, 1865. Arm reduced in size and its motions restricted.
17	Keller, D. J., Pt., K, 24th Michigan, age 18.	July 1, 1863.	Fracture of the right scapula and dislocation of the humerus by a fragment of shell.	.....	Excision of the upper portion of the scapula.	Disch'd April 25, 1864. Unable to raise the arm or flex it at the elbow without assistance.
18	Killam, G. W., Pt., K, 3d Vermont.	August 21, 1864.	Shot fracture of the upper border of the left scapula; missile lodged.	Aug. 21, 1864.	Extraction of the missile and removal of three inches of the upper border of the scapula; Surg. G. T. Stevens, 77th N. Y.	Disch'd June 12, 1865. Motion of arm somewhat impaired.
19	King, J., Pt., H, 155th New York.	June 3, 1864.	Gunshot fracture of the left scapula.	June 3, 1864.	Excision; Surgeon F. Douglas, 170th New York.	Died, June 14, 1864, from erysipelas.
20	Metice, J., Pt., C, 32d Maine.	June 22, 1864.	Fracture of the right scapula by a minié ball.	.....	Resection.....	July 14th, hemorrhage, to the extent of sixteen ounces, from the supra-scapular artery. Died July 16, 1864.
21	McManus, M., Pt., G, 149th New York, age 19.	July 3, 1863.	Gunshot fracture of the acromion process of left scapula.	July 3, 1863.	Excision of acromion process. Interrupted sutures applied and arm flexed on trunk.	Veteran Reserves, March 7, 1865. Not a pensioner.
22	Moore, J., Pt., K, 26th Ohio.	June 14, 1864.	Comminuted shot fracture of the lower portion of the right scapula.	July 2, 1864.	Excision of two inches of the lower portion of the scapula; Assistant Surg. G. W. Burke, 46th Pennsylvania.	Died July 30, 1864.
23	Owen, E. P., Corp'l, A, 50th Illinois, age 22.	Oct. 5, 1864.	Minié ball perforated the left shoulder, fracturing the clavicle and scapula.	Nov. 30, 1864.	Excision of one-fourth of spine of scapula at its superior border; Surg. B. B. Breed, U. S. V.	Disch'd July 14, 1865. Motions of the shoulder impaired.
24	Palmer, A. H., Pt., G, 100th New York.	Aug. 21, 1863.	Shell laceration of the face and left shoulder, with fracture of the scapula.	Aug. 21, 1863.	Removal of part of the scapula.	Duty, September 5, 1864. Shoulder lame and painful.
25	Parrish, G., Corporal, E, 2d Michigan.	Nov. 24, 1863.	Shot fracture of right scapula by a minié ball.	Nov. 24, 1863.	Excision; Surg. J. B. Prince, 36th Massachusetts.	Duty, October 17, 1864. Atrophy of muscles of the arm and shoulder.
26	Picard, G., Pt., E, 102d New York.	Sept. 17, 1862.	Gunshot fracture of the right scapula.	.....	Excision of a portion of the scapula.	Disch'd December 19, 1862. Not a pensioner.
27	Ritchey, L., Pt., H, 7th Iowa.	Nov. 7, 1861.	Gunshot fracture of the left scapula.	.....	Excision of a portion of scapula; Surg. E. C. Franklin, U. S. V.	Returned to duty; unable to carry much weight on the shoulder.
28	Rollo, A., Sergeant, H, 8th Michigan.	May 12, 1864.	Severe fracture of left scapula by a shell fragment.	May 12, 1864.	Removal of the coracoid and acromion processes, together with the spine and head of scapula; Surg. W. Shurlock, 51st Pennsylvania, and A. F. Whelan, 1st Michigan S. S.	Died May 21, 1864.
29	Satterfield, A., Pt., E, 1st Maryland, E. S.	July 3, 1863.	Fracture of the right scapula by a musket ball.	July 4, 1863.	Excision of the acromion process; Surg. G. B. LeCompte, 1st Maryland, E. S.	Died July 20, 1863.
30	Shidler, S., Sergeant, E, 11th Ohio.	Nov. 25, 1863.	Gunshot fracture of the acromion process of right scapula.	Nov. 25, 1863.	Excision of three inches of bone.	Died December 2, 1863.
31	Sommers, J. C., Sergeant-major, 5th Louisiana.	June 14, 1863.	Gunshot wound of the left shoulder.	.....	Excision of the spine of the left scapula.	Detailed for duty as wagonmaster, March 8, 1864; loss of the use of the left arm.
32	Sowrs, A. H., Pt., E, 51st Indiana, age 22.	Dec. 16, 1864.	Shot fracture of the spine of the right scapula.	Dec. 20, 1864.	Excision of the lower portion of the spine of the scapula; A. A. Surgeon M. L. Herr.	Died January 31, 1865.
33	Stevens, P., Pt., E, 51st Iowa, age 44.	May 17, 1863.	Fracture of the left scapula by a conoidal ball.	June 9, 1864.	Removal of a portion of the spine of the scapula; Surgeon A. Hammer, U. S. V.	Disch'd October 31, 1864. Any effort at ordinary manual labor irritates the seat of injury.
34	Swinton, G., Sergeant, D, 95th New York.	June 2, 1864.	Shot fracture of the spine of the right scapula.	.....	Excision of the spine of the scapula.	Veteran Reserves, April 25, 1865.
35	Thomas, J., Corp'l, G, 46th New York.	May 18, 1864.	Conoidal ball fractured the left scapula.	May 18, 1864.	Excision; Surgeon J. S. Ross, 11th New Hampshire.	Not a pensioner.
36	Thompson, E. C., Sergeant-major, 57th Pennsylvania, age 26.	May 5, 1864.	Shot perforation of left shoulder, with fracture of the acromion process of the scapula; also fracture of the inferior angle of the maxilla.	May 5, 1864.	Excision of the entire acromion process and removal of fragments from inferior maxilla.	Died May 22, 1864.
37	Tolmay, J., Pt., K, 11th New Hampshire, age 22.	May 18, 1864.	Gunshot fracture of the spine of the right scapula; conoidal ball.	May 18, 1864.	Removal of the spine of the scapula; Surgeon J. S. Ross, 11th New Hampshire.	Disch'd October 31, 1864. Shoulder joint weakened.
38	Walker, J., Pt., H, 40th New York.	March 30, 1865.	Shell wound of the left shoulder, fracturing the scapula.	March 30, 1865.	Excision of a portion of the spine of the scapula.	Discharged June 16, 1865. Not a pensioner.
39	Wilson, C., Pt., C, 7th New Jersey.	July 3, 1863.	Conoidal ball fractured the right scapula.	.....	Excision.....	Duty, December 4, 1863. Not a pensioner.
40	Winslow, C., Lieutenant-colonel, 5th New York.	June 2, 1864.	Conoidal ball comminuted the spinous process of the left scapula and carried away a portion of the acromion process.	June 19, 1864.	Excision of the acromion process.	Necrosis of the head of humerus; symptoms of septic poison. Died July 7, 1864.

The forty cases noted in the foregoing tabular statement, six detailed immediately before, and three<sup>1</sup> recorded in the *First Surgical Volume*, were returned as resections of the scapula; evidently with much latitude of interpretation, on the part of some of the reporters, as to what constituted a formal excision. In these forty-nine cases the operations were practised on the right scapula in twenty-three, on the left in twenty-six. The date of operation was specified in thirty-nine cases. There were twenty-three primary operations, with six deaths; fourteen intermediary, with six deaths; two successful secondary operations. There was one death among the undated cases, making thirteen in all or 27 per cent. Of the thirty-six survivors, twelve returned to full or modified duty, and twenty-four were discharged.

In addition to these forty-nine cases of removal of splinters, of excision of portions of the apophyses or of the body of the scapula, or of extraction of necrosed sequestra, were not less than forty-two cases of removal of portions of the acromion, or coracoid, or neck of the scapula practised in operations that will be found classified with excisions of the head of the humerus.

*Partial Excision of the Clavicle and Scapula.*—Ten cases were returned in this category; one is detailed, and the others are tabulated.

TABLE XX.

*Summary of Nine Cases of alleged Excision of Portions of both Clavicle and Scapula after Shot Injury.*

No.	NAME, AGE, AND MILITARY DESCRIPTION.	DATE OF INJURY.	NATURE OF INJURY.	DATE OF OPERATION.	OPERATION AND OPERATOR.	RESULT.
1	Holland, P. F., Pt., A, 3d Pennsylvania Reserves.	June 27, 1862.	Musket ball perforated the right shoulder, fracturing the clavicle and scapula.	.....	Removal of a portion of the clavicle and scapula	Disch'd October 28, 1862. Partial ankylosis of the shoulder joint.
2	King, A., Pt., C, 5th New Jersey.	Nov. 5, 1861.	Conoidal ball fractured the acromion process of the right scapula and the acromial end of the clavicle.	Nov. 5, 1864.	Excision of the acromion process and the outer fourth of the clavicle; Surgeon H. F. Lyster, 5th Michigan.	Discharged June 9, 1865. Not a pensioner.
3	Northway, W. J., Pt., D, 79th Indiana.	Dec. 13, 1862.	Gunshot fracture of the left shoulder blade.	Dec. 13, 1862.	Excision of the external half of the clavicle, the spine of the scapula, and a portion of the acromion process; Surgeon J. S. DeBenneville, 11th Pennsylvania Reserves.	Died January 1, 1863.
4	Page, R., Pt., I, 23d U. S. Colored Troops, age 25.	July 30, 1864.	Fracture of the right shoulder blade by a minié ball.	July 30, 1864.	Removal of the external end of the clavicle and the coracoid process of the scapula; Surg. J. H. Ross, 11th New Hamp.	Discharged June 8, 1865. Moderate use of the arm, with prospects of further improvement.
5	Padgett, A. W., Pt., K, 109th New York.	May 25, 1864.	Shot perforation of the left shoulder, with fracture of the clavicle and spine of the scapula	May 25, 1864.	Excision; Surg. A. F. Whelan, 1st Michigan Sharpshooters.	Disch'd August 16, 1865. Arm disabled mainly by injury to the deltoid muscle, causing adhesion at the seat of injury.
6	Painter, A., Pt., C, 5th Artillery.	Dec. 13, 1862.	Gunshot fracture of the left shoulder blade.	Dec. 13, 1862.	Excision of external half of the clavicle, the spine of scapula, and a portion of the acromion process; Surg. J. S. DeBenneville, 11th Penn. Reserves.	Died January 1, 1863.
7	Pahner, W. H., Sergeant, D, 1st New York Artillery, age 23.	May 31, 1864.	Comp'd comminuted shot fracture of the acromial end of the left clavicle and acromion process of the left scapula; ball lodged.	May 31, 1864.	Missile extracted and excision performed; Surgeon W. S. Thompson, U. S. V.	Discharged May 18, 1865. Arm perished, and, together with the joint, totally disabled.
8	Pate, J. M., Pt., K, 18th Texas Cavalry, age 22.	Sept. 20, 1863.	Gunshot compound fracture of the left shoulder blade.	Sept. 21, 1863.	Resection of the clavicle and coracoid process of scapula.	.....
9	Petrie, G., Pt., B, 162d New York, age 41.	July 26, 1864.	Minié ball perforated the right shoulder, fracturing the clavicle, the acromion process, and spine of the scapula.	Aug. 10, 1864.	Excision of portion of the acromion process, the acromial end of the clavicle, and the spine of the scapula; A. A. Surgeon C. C. Elm.	Disch'd Oct. 11, 1865. Motions and power of arm impaired. Extensive consolidation of the tissues about the shoulder joint.

There were two fatal cases in this group. The operations were primary in eight instances, and among these the fatal results occurred. The operations were practised on the right and left sides, in equal proportion. The eight survivors were discharged for

<sup>1</sup> CASES of Private J. P.—, p. 475, Private Bickett, p. 562, and Private G. R. M—, p. 563.



physical disability. A tenth case of excision of portions of both clavicle and scapula, in which the operative interference appears to have been extended and effective, is fully detailed on this page. Most of these operations were manifestly removals of splintered parts of the outer half of the clavicle—of the acromial process, and of the spine of the scapula. In two cases, however, the coracoid process was excised:

CASE 1462.—Captain Abraham Kaga, Co. K, 20th Ohio, was wounded at Raymond, May 12, 1863, and treated at a field hospital. Surgeon E. L. Hill, 20th Ohio, reported: "A conical ball entered near the centre of the right clavicle, comminuting it and the acromion process and neck of the scapula, lodging just beneath the skin behind and external to the acromion. He was put under the influence of chloroform early, and I removed the ball, and, enlarging both wounds, resected the clavicle, acromion, and scapula from the centre of the clavicle outward; two and a half inches of bone were removed, the remaining ends being squared off by bone forceps. The acromion, badly comminuted, was removed by detaching the fragments from the periosteum, which was left as far as possible. The articulating surfaces of the clavicle, acromion, and glenoid cavity, although broken, were not opened into the joint, and after trimming off by forceps, were left in apposition. Not less than two inches of the body of the scapula, the spine, and acromion were entirely removed. The operation was a very tedious and formidable one. But little blood was lost; the only artery cut, the circumflex, was secured at once. Although for an hour and a half under the anæsthetic, he bore it excellently, and rallied finely. Considerable venous oozing continued for twenty-four hours from small branches. Assistant Surgeon Kay, 124th Illinois, in whose charge the wounded were left at Raymond, reported that this officer was doing well on the 28th of May. He was paroled with other wounded. On June 3d, I learned that he was doing well, and was anxious to be moved forward." Captain Kaga was discharged from service January 6, 1864, and pensioned. Examiner J. Phillips, of Washington, reported, March 13, 1867: "Exsection of the acromial end of clavicle, about one half its extent, and of the acromion process of scapula. The arm is much impaired in strength, and totally unfitted for manual labor. Disability total." Examiner F. Brewer, of Waynesville, Missouri, reported, September 13, 1873: "Fragments of this bone [the right scapula] are still discharged occasionally, and the right arm is practically disabled." This pensioner was paid September 4, 1874.

The fifty-nine instances above alluded to, constitute a large addition to the recorded statistical information on partial excisions of the clavicle and scapula for injury, but suggest few practical reflections on the subject that have not been referred to on pages 567 and 562 of the preceding volume. It may be remarked that the lines of incision, indicated by writers on this class of operations,<sup>1</sup> were not commonly followed in military practice, the position of the entrance and exit wounds, and relations of the detached or diseased portions of bone, regulating the direction and extent of the incisions.

It must also be stated, that two instances of alleged extirpation of the scapula<sup>2</sup> after shot injury came to the notice of the writer, but without such details as could warrant their incorporation with the official records. It is not necessary to modify the antecedent

<sup>1</sup> HEYFELDER (O.), *Lehrbuch der Resectionen*. Wien, 1863, S. 281. BECKEL'S translation of the same work, Paris, 1863, PLATE VII.

<sup>2</sup> In a case-book of the Confederate Surgeon General's office, Dr. H. L. THOMAS, of Richmond, makes the following entry: "Surgeon B. G. DYSORT, 3d and 4th Missouri, reports the case of *F. H. Smith*, Corp 1, Co. B, 3d and 5th Missouri regiments, wounded June 27, 1861, in the left shoulder. Scapula taken out, head of humerus resected on the same day. June 30th, yet in field infirmary." It is, of course, impossible to judge of the nature of the operation thus briefly recorded. The complete excision of the scapula after shot fracture, by Professor F. H. HAMILTON, and the published references thereto, are noted on page 492 (*note* § 8). Dr. HAMILTON has had the kindness to send a memorandum of the case, which, with an extract from his note of transmittal, is appended: " \* \* I have delayed answering your note, hoping that I would find the specimen. It was presented to the New York Pathological Society, and I have never seen it since, and I am unable to find it. The following has been copied from the Bellevue Hospital records. To the account given in the hospital record, I can only add that the periosteum was preserved, during the operation, with a great deal of care; but, up to the period when I last saw him, no bone had been reproduced. This fact I mentioned in my report to the Society. He was able to use his arm pretty well. I regret that I am unable to procure for you any more complete notes. Perhaps he is a pensioner, and you may find some account of his case in the pension records. \* \* If I learn anything more about the case, I will let you know." \* \* Enclosed in this note is the following extract from Bellevue Hospital records, First Surgical Division, 1863: "*Excision of Scapula*; William Murphy, aged 33; native of Ireland. Was admitted with the following history: At the battle of Fredericksburg, December 13, 1862, this patient received two wounds; a musket ball and buckshot entering just above the shoulder in front, and a grapeshot striking the scapula just below the spine. Six days after the battle, the head and several inches of the shaft of the humerus were removed, according to his statement. The wounds healed and remained so until about two months previous to his admission, when fistulous openings appeared over the scapula. When admitted he had limited motion in the arm; there were four or five fistulous openings over the scapula through which dead bone could be felt. No bone had ever been discharged. February 10, 1866, Dr. HAMILTON made a crucial incision over the scapula, and finding that almost the whole scapula was necrosed, he removed the whole bone. The tissues are very much indurated and vascular. A few ligatures were applied, and the wound filled with lint, and hæmorrhage controlled by pressure. February 13, 1866, dressings removed; suppuration free. February 19th, wound looks well; granulations plentiful and healthy. April 1st, wound almost entirely healed; has more motion of arm now than previous to operation." Following Dr. HAMILTON'S suggestion, careful search was made at the Pension Office. The name of "William Murphy" appears on the Pension Roll not less than sixty times; but the following entry was believed to be identified with the case referred to by Dr. HAMILTON: "Private William Murphy, Co. G, 73d New York (transferred from Co. A, 163d New York), aged (in 1873) 40 years; wounded at Fredericksburg, December 13, 1862, and discharged and pensioned March 2, 1865." Examining Surgeon THOMAS FRANKLIN SMITH reported, May 15, 1865: "A grapeshot wound of left shoulder, destroying a portion of the scapula, and also of the shoulder joint, so that he is unable to use his arm." On September 10, 1866, Dr. T. F. SMITH reports: "The loss of almost the entire left scapula, the result of a gunshot wound. There is great flattening of the shoulder, and the arm and shoulder are very much atrophied and weak. The arm is of but little or no use." Examining Surgeon W. M. CHAMBERLAIN reported, August 29, 1869: "The head of the left humerus and a large portion of the scapula have been exsected. The arm is stationary at

statement, that the annals of military surgery afford no instance of excision, for shot injury, of the *entire* scapula with preservation of the upper extremity; but there is a probability that Dr. Dysort's operation involved a large portion of the bone, and evidence that, in Professor Hamilton's case, a considerable part of the shoulder blade was successfully removed. It is proper, also, to refer to Mr. Cole's case,<sup>1</sup> in India, the description implying that the scapula, with the upper extremity, was removed after a shot comminution.

Although, as in shot comminutions of other flat bones, operative interference may occasionally be demanded,<sup>2</sup> yet, weighing all the evidence, it is obvious that extensive excisions of the scapula for injury can seldom be required as primary operations.<sup>3</sup>

Reverting to the cases of shot fracture of the clavicle and scapula in which no formal operations were performed, some interesting complications may be remarked. False traumatic aneurisms are common enough; but true aneurisms succeeding contusion by shot are very rare. A case classified in this group is believed to have been thus complicated. It is to be regretted that it was impracticable to trace its ulterior history:

CASE 1169.—Private *E. Reynolds*, Co. E, 7th Louisiana, aged 25 years, was wounded at Monocacy Junction, July 9, 1861, and received into Frederick Hospital on the following day. Acting Assistant Surgeon T. E. Mitchell reported: "A minié ball entered the back part of the left shoulder in the suprascapular fossa, traversing the neck, perforating the scapula, fracturing the clavicle, and making its exit on the anterior part of the neck a little to the right of the median line, and one and a half inches below the pinnæ Adami. The wounded man having been placed under care of Dr. Graves, Surgeon, C. S. A., progressed favorably. Under the application of cold-water dressings the anterior wound healed in the course of two weeks. On July 20th, the patient, while feeling over his neck, detected a buzzing sound, as he described it, to which he called the attention of the doctor, and which was at first sight supposed to be an abscess; upon close examination, however, it was found to be an aneurism of the subclavian artery between the omo-hyoid and scalenus anticus muscles, of small size and rather indefinite outline. The pulsation was quite perceptible, and the *bruit* was of a whizzing or purring character, which could be heard distinctly on auscultation as well as felt by the hand. Yet the patient experienced no peculiar sensations, other than a slight pain in the forearm and elbow, with total loss of motion, except in the fingers. The pulse at the wrist was unaffected. On August 5th, when the patient came under my care, I discovered an abscess external to the artery, and in close proximity to the aneurismal tumor, but external to it. This had begun to form on August 1st, and was opened by Assistant Surgeon R. F. Weir, U. S. A. A few spiculae of bone were removed and a moderate quantity of bloody pus was evacuated. The wound healed nicely, and the patient required no other treatment than to be kept quietly on his back in bed. By August 20th he was well enough to be permitted to sit up with his arm in a sling. On August 28th, the fracture of the clavicle had united, the posterior wound had closed, and the patient was permitted to walk about the ward. From this time, the tumor evidently decreased in size. On November 9th, though all tumefaction had left the parts, it was found that the strong aneurismal sound still continued, but was more circumscribed, and limited to the region of the lowest part of the carotid. The thrill could be felt over a space commencing from the clavicle, running upward nearly two inches, and transversely to a distance of one and a half inches. The sternomastoid was apparently overlying the tumor, which was evidently again increasing, its pulsations becoming visible. It had also

the shoulder joint and atrophied." The New York Examining Board, Drs. W. O'MEAGHER, C. PHELPS, and P. TREADWELL, reported, March 15, 1871: "Inner extremity of clavicle dislocated upward." Dr. T. F. SMITH reported, September 23, 1873: "There is a large adherent radiate cicatrix 5 × 5 inches over left scapula; there is great loss of bone substance; extension is impossible." This pensioner died June 24, 1874. The cause of his death is not known at the Pension Bureau. Further confirmation of the identity of this pensioner with the subject of Dr. HAMILTON'S operation has been found, since the foregoing memoranda were printed, in a special report by Surgeon E. P. VOLLUM, U. S. A., of examination of applicants for admission to the Veteran Reserve Corps, dated 115 Cedar Street, New York, February, 1867: "William Murphy was discharged from Co. G, 73d N. Y. Vols., as a private. He was wounded at Fredericksburg, December 13, 1862, by a grapeshot striking the posterior face of his left shoulder, carrying away some of the soft parts and shattering the scapula. At present, there is an extensive cicatrix occupying the back of the left shoulder, perfectly healthy in appearance, and the motion of the shoulder joint is considerably impaired. The man says that he has experienced no bad effect on his general health from the wound, which took five months to heal up. Fragments of the scapula were removed by Surgeon A. B. MORT, U. S. Vols., and Medical Inspector P. HAMILTON. Passed for V. R. Corps."

<sup>1</sup> COLE (J. J.), *Military Surgery, or Experience of Field Practice in India*, London, 1852, p. 110, Case XXVIII. The author states: "This injury appears to have been occasioned by a four-pounder. The ball impinged upon the head of the humerus, shattered it, smashed the acromion process, fractured the clavicle, and split the scapula to pieces. The shoulder joint is irreparably injured, the extremity itself is forever gone, and demands to be removed *en masse* from the trunk." He goes on to describe the mode of operation for an amputation above the shoulder, including the extirpation of the shoulder blade and resection of the clavicle; but whether this operation was undertaken is not indicated; nor is any intimation given of the result of the case.

<sup>2</sup> LOHMEYER (*Die Schusswunden und ihre Behandlung*, 1850, S. 193) remarks: "The splintering of the body of the scapula, as a rule, heals readily, and does not necessitate operative interference, though such treatment has been undertaken by B. v. LANGENBECK."

<sup>3</sup> On page 565 of the preceding surgical volume, some account is given of operations by MM. CHIPVAULT and CHARPIGNON, for excision of the shoulder blade, in the Franco-German War, and further information is there collated regarding this operation. But it does not appear to have found favor. DEMME (H.) (*Studien*, 1861, B. II, S. 219), speaking of shot fractures of the scapula, in the Italian campaign of 1859, observed that: "Operative interference, resection, which has, now and then, been practised in earlier wars, did not, as far as I know, become necessary in the Italian War." The following references on excision of the shoulder blade may be consulted: STERN (L.) (*Über die Resection des Schulterblattes*, Erlangen, 1852); FELSING (E. F.) (*Die Resection des Schulterblattes*, Giessen, 1863); PÉTREQUIN (J. E.) (*Mém. sur une méthode opérat. propre à amputer l'omoplate, en respectant le moignon de l'épaule et conservant les mouvements du bras*, in *Bull. de l'Acad. de Méd.*, 1859-60, T. XXV, p. 28-3); FREYNER (A.) (*Über die Resection des Schulterblattes*, Würzburg, 1846).



been ascertained that the subclavian was not the vessel injured, but the carotid, being proven by the fact that direct pressure over the course of the carotid, about three and a half inches above the clavicle, would cause a cessation of all thrill. The patient was transferred to Baltimore on December 23d. He had received no treatment for about a month, and the tumor had remained about the same size for several weeks." Surgeon A. Chapel, U. S. V., from West's Buildings Hospital, reported in this case: "Ball entered at the posterior part of the left shoulder, touched the left carotid artery, and escaped to right of the larynx, producing aneurism." The patient was transferred to the Provost Marshal, for exchange, February 11, 1865.

The burrowing of pus in the dorsal and lumbar regions was another important complication in the cases of this group, and was returned as the cause of death in one instance.

Pyæmia was specified as the cause of death in thirty-four of the three hundred and fourteen fatal cases; secondary hæmorrhage in eighteen cases; hospital gangrene in twelve; erysipelas in seven; tetanus in five, were the next most frequent causes of mortality. Nine patients were reported to have succumbed to secondary pulmonary trouble, five to variola, one to cerebro-spinal meningitis, twenty-six to fevers or bowel complaints contracted in hospital. In two-thirds of the cases, the causes of death were unspecified.

There is little to be remarked regarding the treatment of shot fractures of the shoulder blade.<sup>1</sup> After the arrest of bleeding, on the rare occasions requiring it, the removal of foreign bodies or of detached structures become such, it was only requisite to keep the parts at rest, supporting the arm by the side, that its weight might not further displace the mutilated fragments of the scapula. The conventional treatment of fractured scapula by an axillary pad and the bandage of Velpeau was seldom resorted to, if ever.

The bibliography of fractures of the clavicle and scapula<sup>2</sup> is meagre. The greater part of what has been published on excisions of these bones,<sup>3</sup> has been adverted to in preceding references. A further statement, confirming the report that Professor Hamilton's excision of the scapula was an extirpation, is subjoined.<sup>4</sup>

<sup>1</sup> In DOYER'S classical system (*Traité des mal. chir.*, 5<sup>e</sup> éd., 1845, T. III, p. 159), in PATISSIER'S article *Omoplate* (*Dict. des. sci. méd.*, 1819, T. XXXVII, p. 246), in BÉRAUD'S article with the same title (*Dict. de méd.*, 1810, T. XXII, p. 68), in LONSDALE'S treatise (*Pract. Treat. on Fractures*, 1838, p. 191), and in many other general and special surgical works, something may be found on fractures of the scapula, but comparatively little on shot fractures. PETIT and DESAULT, GURLE, MALGAIGNE, and HAMILTON treat fully of the subject, and two special dissertations are found in the Surgeon General's Library, namely: BROCKENHUIS (G. A.) (*De fractura colli scapulæ et processus coracoidei*, Jenæ, 1862) and PUTZ (J.) (*Über die Brüche des Schulterblattes*, Greifswald, 1865); but references to shot injuries are exceedingly rare. Most of the cases detailed by military surgeons have been referred to in the preceding notes of this section. It may be observed that the "judicious remarks" ascribed to NEALE, on page 482, are almost literally translated from LEDRAN (*Traité ou Reflexions tirées de la Pratique sur les Playes d'Armes à feu*, 1737, p. 160), who devotes four pages to shot wounds of the clavicle and scapula. DESPORT (*Traité des Playes d'Armes à feu*, 1749, p. 226 et seq.), observing that shot injuries of the shoulder blade must be, for the most part, considered with chest penetrations, nevertheless has a separate appendix, *des plaies de l'omoplate*, and details at length the case of a soldier, of the Roussillon regiment, wounded at the siege of Pizzighetone, by a cannon ball, that "tore away the arm, the upper half of the scapula, and the greater portion of the clavicle, besides fracturing the third rib." Happening to be in the trenches that day, DESPORT was near the soldier when he was struck, and there was so much bleeding, that he says: "*Je fis donc la ligature de tous les gros vaisseaux.*" The patient was seen by the celebrated FERREIN, and then sent on to a hospital at Lodi, whence M. DELAIRE informed DESPORT: "*qu'il avoit été fort bien guéri.*" If DESPORT really ligated the subclavian in this case, he anticipated KEATE'S operation by more than half a century. The siege of Pizzighetone, a fortified place near Cremona, in the famous quadrilateral, was a part of the war waged in Lombardy, between Charles VI and the French and Spaniards, which began in 1733, and ended, in 1735, with the cession of the Neapolitan provinces to Spain. Hence DESPORT'S case of avulsion of the arm, and portions of the clavicle and scapula, antedate the remarkable observation of CHESELDEN (*The Anatomy of the Human Body*, 7th ed., 1750, Tab. XXXVIII, p. 321), the case of Samuel Wood, whose arm, with its scapula, was torn off, by a rope winding around it \* \* in the year 1737.

<sup>2</sup> PAULUS ÆGINETA (see Sydenham Soc. translation, Vol. II, p. 450); PARÉ (*Œuvres complètes*, éd. MALGAIGNE, 1840, T. II, Liv. XIII, Chap. IX, p. 309); DUVERNEY (*Traité des maladies des os*, Paris, 1751, T. I, p. 221); DUMONT (A.) (*Les fractures du corps de l'omoplate*, Strasbourg, 1863); LOTZ-BECK (*Die Fracturen des Schulterblattheils*, in *Deutsche Klinik*, 1867, B. XIX, S. 430); VON PITHA (*Die chirurgischen Krankheiten der Extremitäten*, Erlangen, 1868, S. 16); ANGER (B.) (*Traité iconograph. des mal. chir.*, 1865, p. 112, et planches 27, 28). The article *Clavicula*, in the 6th volume of the *Dict. des Sci. Méd.*, 1813, T. V, p. 308 (the sixty volume French dictionary), is by the celebrated PETIT, and that in the *Dict. de Méd.*, 1834, T. VIII, p. 89 (the thirty volume dictionary), by Professor LAUGIER. But an exhaustive dissertation on lesions of the clavicle is published by Professor RICHET, in the *Nouv. Dict. de Méd. et Chir. Prat.*, 1868, T. VIII, p. 1, with a bibliographical appendix by M. DESPRÉS.

<sup>3</sup> An additional case of extirpation of the scapula has appeared in the journals since the foregoing lines were put in type: SCHNEIDER (R.) (*Extirpation der linken Scapula wegen eines Sarkoms*, in *Berliner Klin. Wochenschrift*, Aug. 3, 1874, S. 377) removed, December 3, 1873, the entire scapula, for disease in a lad six years old. The wound healed; but, in March, 1874, the tumor reappeared, and the boy died, April 20, 1874.

<sup>4</sup> The references on page 492 (*note 2*, § 8) and on page 498 (*note 2*) were printed, and stereotyped, when the following letter was received (November 21, 1874) from Professor HAMILTON: "I am unable to furnish you with any more complete account of the case of Wm. Murphy (excision of scapula) than is supplied by the records of Bellevue Hospital. The operation was made in the presence of a number of medical gentlemen, and the fact that the entire scapula was removed does not admit of doubt. The person described in your mem., is, there is no question, the same as the man operated upon by me. Possibly the specimen, or some further account of it, may yet be found. If it is, it will be sent to you. If any bone was actually found by the pension examiners corresponding to the scapula, then it was reproduced from the inflamed and thickened periosteum—all of which was left. This supposition is not improbable, although, when I last saw him, no portion of the bone had been reproduced." This interesting case affords, perhaps, a solitary example of a successful extirpation, for the results of shot injury, of the scapula, with preservation of the upper extremity. The operation was performed more than three years after the reception of the injury, and the pensioner survived more than eight years.

## SECTION III.

## WOUNDS OF THE SHOULDER JOINT.

Shot wounds only are to be considered in this section. There were no reported instances of punctured or incised wounds implicating the shoulder joint,<sup>1</sup> and the sprains, and luxations, and fractures from other causes than shot injury, that were recorded, will, as already intimated, be noticed in a future chapter. Classical authors commonly divide wounds of the joints into non-penetrating and penetrating. M. Legouest justly observes,<sup>2</sup> that the former group might, with greater propriety, be designated "peri-articular" wounds, and several recent writers on military surgery have concurred in his opinion. The systematic nomenclature further subdivides these wounds into those caused by pointed, or cutting, or contusing weapons.<sup>3</sup> The latter, of course, are concerned in treating of shot injuries. The few general observations communicated regarding wounds of the larger joints must be relegated to a subsequent part of the work. The many facts reported respecting shot injuries of the scapulo-humeral articulation, treated either on the expectant plan, or by excision, or by amputation, and of operations at the joint demanded by injuries in its vicinity, will amply fill this section.

The reported examples of shot wounds interesting the joint, without injury of the bones, were comparatively few, comprising only seventy-two cases. There were thirteen hundred and twenty-eight cases in which the articular extremities of the humerus or scapula were primarily involved, and the results were ascertained in all save fourteen. In nearly one-half of the cases, excision of the head of the humerus was practised; in three-eighths of them, expectant treatment was adopted; in one-eighth, the limb was removed. The mortality in the three groups averaged nearly one-third. The categories of excisions and amputations comprise, however, by no means all the instances of such mutilations that were reported. Excisions of the upper extremity of the humerus, and ablations of the arm at the shoulder, were often practised when the articulation was not immediately involved. For statistical purposes, it will be convenient to place these cases in three subdivisions, corresponding to the treatment by expectant measures, excision, or amputation that were employed. There will then be added to the fourteen hundred cases of primary shot injury of the shoulder, nine hundred and twenty-eight cases in which operations were performed, at the articulation, for shot injuries in its proximity. And thus will be

<sup>1</sup> The *region* of the shoulder joint, as remarked by Dr. M'DOWELL (*Cyclopædia of Anat. and Phys.*, Vol. IV—1, 1817, p. 571), cannot easily be assigned precise limits. Anteriorly separated from the pectoral region by the "coraco-deltoid groove" of VELLEUR, defining the narrow space between the deltoid and great pectoral muscles, it is limited above by the projection of the acromion and outer end of the clavicle. Posteriorly, it is confounded with the scapular region; inferiorly, it is bounded by the folds of the axilla. In this section it is proposed to consider only wounds of the shoulder joint itself. The synonymy of "shoulder joint" is as ill defined as the limits of the region: "*articulation scapulo-humérale*" and "*Schulter-gelenk*" are the ordinary French and German equivalents.

<sup>2</sup> LEGOUEST (L.), *Traité de Chirurgie d'Armée*, 2<sup>ème</sup> ed., 1872, p. 442.

<sup>3</sup> BONNET (A.), *Traité des Maladies des Articulations*, Lyon, 1815, T. I, p. 254.



aggregated twenty-three hundred and twenty-eight cases, as nearly as can be ascertained from the returns, of shot injuries directly, or indirectly, involving the shoulder joint, to be discussed in this section, comprising, it may be recapitulated, cases of wounds implicating the ligaments and strong tendons that strengthen them, the bursal sacs and synovial sheaths near the joint; cases of penetration of the joint without known fracture; cases of fracture of the articular extremities of the scapula and of the humerus, or of both; and cases of fracture of the shaft of the humerus, or of lesions of the soft parts of the region, in which amputations or excisions at the shoulder were practised

**WOUNDS TREATED ON THE EXPECTANT PLAN.**—Apart from the shot injuries of the shoulder complicated by lesions of the thorax, and those that have been classified with fractures of the clavicle and scapula, were five hundred and seventy-seven cases in which the scapulo-humeral joint was interested by shot projectiles and operative interference was not attempted.

**Wounds unattended by Fracture.**—There were few instances of the penetration of the joints by shot projectiles without injury to the articular extremities of the bones. In more than fifty thousand cases of shot wounds of the upper extremity, but two hundred and twenty-five were recognized as wounds of the shoulder, elbow, or wrist, without fracture. Of these, seventy-two were returned as wounds of the shoulder joint without fracture.<sup>1</sup> Some of them appear to be examples of contusions of the ligaments, cartilages, or synovial membrane, without actual penetration of the joint, a form of injury which, as Generalarzt Beck has justly remarked,<sup>2</sup> some surgeons have, without warrant, called in question. Others appear to have been fairly referred as shot penetrations of the articulation without osseous lesion. Six of the seventy-two cases proved fatal—in two instances, from pyæmia, and, in the remaining four, death was ascribed to “the effects of the wound of the joint.” Thirty six of the patients were discharged from service for disability, in the shape of false ankylosis for the most part. Thirty were sent to their regiments, or to modified duty. Nearly all of the cases are reported briefly, and none with particulars that seem to require citation. Yet, while there were few detailed abstracts of such cases, the experience of all surgeons who had a large field of observation, proved that shot wounds of the soft parts in proximity to the shoulder joint<sup>3</sup> were deserving of the gravest consideration.<sup>4</sup> The reader cannot have overlooked the fourteen cases of exarticulations at

<sup>1</sup> LÖFFLER (F.) (*Generalbericht über den Gesundheitsdienst im Feldzuge gegen Dänemark*, 1864, Berlin, 1867, p. 280) remarks that, among the cases of wounds of the shoulder joint, “there was not a single one of injury of the capsule only; in all were either the head of the humerus, the acromion process of the scapula, or the head and the glenoid cavity injured.” Yet an eminent authority, LONGMORE (T.) (*Articles, Gunshot Wounds*, in HOLMES'S *System of Surgery*, London, 1861, Vol. II, p. 73), assures us that: “Joints may be contused or opened by projectiles, without apparent lesion of any portion of the bones entering into their composition; but these are exceptions to the usual order of such cases from gunshot.”

<sup>2</sup> BECK (B.) (*Chirurgie der Schussverletzungen*, 1872, S. 575) observes: “The opinion of a few, that there are no shot joint-contusions, that, in cases of swelling of the joint with effusion, perforation exists, is entirely false, and can only be excused on the ground that these persons had not occasion to examine recent wounds, and to convince themselves of the fact that the joint was not opened, nor to watch the injury from the date of its infliction until its final development. In several instances—apart from digital examination, by which the wound track could be distinctly followed between the capsule of the joint and the outer covering—I have been enabled to clearly establish this by subsequent operation, and to satisfy myself of the fact by ocular inspection. For instance, in a case of shot wound of the shoulder, pronounced by several colleagues as penetrating the joint and indicating operative interference, I diagnosticated non-penetration, and convinced myself of the correctness of my opinion by the resection of the acromion, which became afterward necessary, finding that the capsule was intact, and that the missile had passed over the entire length of the joint, against the shoulder blade.”

<sup>3</sup> SOCIN (A.) (*Kriegschir., Erfahrungen*, 1872, p. 102) says: “In like manner, the shot wounds of the integument and tissues in proximity of the joints deserve great attention, as we are never certain that the joint capsule has not been grazed or opened; or even if this had not been the direct result of the injury, that opening of the joint may not occur, secondarily, because of stagnation of pus in the shot canal. It is known that such articular injuries frequently exist, for a long time, without any special symptoms, until, all at once, acute suppurative synovitis, with all its attending hazards, supervenes.”

<sup>4</sup> NEUBÜFFER (J.), in treating of shot wounds of the shoulder, remarks (*Handbuch der Kriegschir.*, 1872, S. 1126): “It occurs, that wounds that do not open the joint primarily, injure the same to such an extent that, in a short time, complete suppuration of the joint ensues;” and, referring accordingly to a special case, he adds: “the joint was contused and wrenched, and filled with extravasated blood; but not penetrated; but for all that, more severely injured than from a simple penetration of the capsular ligament.”

the shoulder on account of shot wounds in the neighborhood of the shoulder, tabulated on page 468. Nor will the instances, to be noted further on, of decapitation of the humerus, for necrosis consequent on peri-articular wounds,<sup>1</sup> escape attention. Dr. Hodges observes that ankylosis of the scapulo-humeral articulation from disease is of extreme rarity;<sup>2</sup> and it might be inferred *a priori* that in a ball-and-socket joint, permitting movement, under normal conditions, in almost every direction, ankylosis should occur infrequently. The laxity and capaciousness of the capsular ligament are in correspondence with the freedom of motion this articulation enjoys. Yet, if the reports of the pension examiners are correctly interpreted, it is not uncommon to find cicatricial bridles, or other lesions consequent on peri-articular shot wounds of the shoulder, seriously impairing the mobility of the joint. When the wounded are numerous after an action, precedence has to be accorded to the grave cases of shot fracture and of penetration of the great cavities, and those wounded in the upper extremities, unless their injuries are severe, may receive little immediate attention. But a comparatively slight shot injury near the shoulder, or, indeed, near any of the larger joints, readily excites inflammations of the most serious nature, if neglected. The proper treatment of shot wounds of this group consists in preventing, by support and immobilization of the arm, and cold lotions to the seat of injury,<sup>3</sup> the irritation and possible phlegmonous inflammation that might supervene, if the joint was not kept at rest, and protected from all irritant causes.

**Wounds attended by Fracture of the Bones composing the Shoulder Joint.**—There were returned five hundred and five cases of this description, in which operative interference was not undertaken. The results were that about half of the patients were discharged for disability, less than a fourth were sent to their regiments, or to modified duty, and somewhat less than a third died.<sup>4</sup> There were many examples in which the acromion, or coracoid, or borders of the glenoid cavity, or the head of the humerus were shattered, that reached a favorable termination. Some instances of these and other varieties of injury of this group will be detailed, and among them are some cases that have led military surgeons to doubt if operative procedures were invariably called for<sup>5</sup> in shot fractures at the shoulder. An attempt to establish direct numerical comparisons between the results of expectant treatment, excisions, and amputations, after shot frac-

<sup>1</sup> LEGUEST (L.) (*Op. cit.*, p. 443) has some very interesting comments on the gravity of shot wounds in the vicinity of the joints. He points out the probability of contusion, or of loss of substance, of the ligamentous or tendinous tissues, lighting up inflammation of the joint. He mentions how a "commotion profonde des éléments de l'articulation" may likewise lead to arthritis. He comments on the inflammations that supervene when the soft parts about a joint are torn away by projectiles. In conclusion, he remarks: "Les projectiles, sans ouvrir immédiatement les articulations, peuvent déterminer la gangrène des tissus frappés: l'ouverture de la cavité articulaire survient consécutivement à la chute des eschares," and adds: "l'inflammation immédiate ou consécutive de la capsule articulaire est l'accident le plus à craindre des plaies péri-articulaires."

<sup>2</sup> HODGES (R. M.), *The Excision of Joints*, Boston, 1861, p. 25 (The Boylston prize-essay for that year). Dr. HODGES states that, in 1855, there were "in the museums of London and Paris but four specimens illustrating such a condition."

<sup>3</sup> SOCIN (A.) (*Kriegschir. Erf.*, 1872, S. 102), treating of shot injuries in the vicinity of the scapulo-humeral articulation, declares that "in all doubtful cases, even, the joint must be kept steady, and this is best accomplished by a fenestrated gypsum or silicated bandage. The limb should be elevated. I have the carbolized bandage covered with an ice bag until the wound is healed, and do not allow the patient to leave his bed until complete cicatrization has taken place."

<sup>4</sup> The exact numbers are: Discharged, 247; duty, 119; died, 139.

<sup>5</sup> Professor HUNTER MCGUIRE, of the Medical College of Virginia, in the course of "*Clinical Remarks on Gunshot Wounds of Joints, delivered January 10, 1866, at Howard's Grove Hospital*" (*Richmond Med. Jour.*, 1866, Vol. I, p. 148), expresses the following opinion: "Gunshot wounds of the larger joints, involving the ends of the bones, almost invariably demand operative interference. When it occurs in the upper extremity, and the injury to the soft parts is not too extensive, the larger vessels of the limb being unhurt, and you think the patient's general condition justifies the operation, you should resort to excision in preference to amputation. I refer to the general health of the patient, because it is necessary to consider this, as well as the nature and extent of the injury, before deciding the character of the operation. I believe the shock and traumatic fever following excision of joints is greater than that of amputation. Recovery is certainly slower, and the system is never heavily taxed by suppuration. This is always profuse, even in the cases which recover most rapidly; and I found it usually necessary, not only to husband all the patient's strength, but to assist him, during the latter part of the treatment, with tonics and stimulants. Another thing you must remember: this matter, which I tell you is so abundant, sometimes collects in the wound and seriously interferes with the cure. This is especially liable to happen when the wound is not dependent, and cleanliness is not observed. You should try to prevent it, or if it does happen, make a free and early opening and let it out. The results of this operation at the elbow and shoulder joints are usually very gratifying."



tures at the shoulder, would probably be undertaken only by some sciolist or dabbler in statistics, since the injuries involved are so variable in nature and extent, that the terms of comparison cannot be fairly ascertained, and any strict application of the numerical method is impracticable. Such attempts have been characterized as caricatures of the inductive mode of reasoning. Yet, if the student will bear in mind that famous aphorism of Morgagni: "*Non numerandæ sed perpendendæ sunt observationes,*" which was so useful a commentary on the "*Ars tota in observationibus*" of Hoffmann, and will compare like cases, or series of similar cases, carefully making such restrictions and qualifications as the various groups of facts require, the mass of information collected may be fruitfully studied. It has been thought best to include in this section many cases in which fragments of bone, or of clothing, or other foreign bodies, were removed; such procedures being part of the proper dressing, and not formal operations. Mr. Thomas Bryant has politely said<sup>1</sup> that "the experience and knowledge of wounds of joints which the civil surgeon acquires must necessarily be somewhat limited, and it is to his military brethren that he generally turns for the information he may desire, as to the symptoms, results, and treatment of such injuries." In the particular group of wounds of joints under consideration, it is indubitable that the military surgeons have accumulated a great mass of observations, which, it may be hoped, will prove of use, when discussed by such writers as the one just cited and his compeers, although their imperative field duties may have compelled the army surgeons often to record their cases in a hasty and imperfect manner. The surgeons attached to armies early after the introduction of fire-arms, who have left us any account of their experience, have not failed to dwell upon the danger and mortality of shot injuries of the larger joints, citing many of their examples, as was the custom of the times, from the great personages thus wounded,<sup>2</sup> yet, incidentally, mentioning some of the subordinates.<sup>3</sup> In later wars, the fatality of these injuries was fully recognized and their danger perhaps overestimated. John Bell does not hesitate to pronounce all openings into inflamed large joints fatal;<sup>4</sup> and, until recent years, few have called the rule in question, or presented

<sup>1</sup> BRYANT (T.) *On the Diseases and Injuries of the Joints*, 1859, p. 182.

<sup>2</sup> Thus AMBROISE PARÉ (*Œuv. compl.*, éd. MALGAIGNE, 1841, T. III, p. 723) tells us that: "Toutes les playes faites aux grandes jointures, et principalement des playes contuses, estoient mortelles," and cites the case of a king of Navarre, shot in the shoulder joint, in 1562, and refers (*op. cit.*, T. II, p. 311) to similar cases of Monsieur de Guise and Count Philibert, all terminating fatally. DESPORT (*Traité des playes d'armes à feu*, 1749, Chap. IV, p. 235) treats *des plaies des articulations*, and, in speaking of *plaies de l'articulation de l'épaule*, declares that: "elles sont presque toujours mortelles, lorsque le fracas est grand; cependant on peut tenter l'amputation à lambeau faite dans l'artiele." RAVATON deserves credit for early recognition that conservative measures might sometimes suffice in shot injuries of the shoulder. He cites a case (*Chirurgie d'Armée, ou traité des plaies d'armes à feu*, 1762, p. 267) of a shot fracture of the shoulder treated on the expectant plan, and remarks: "Le succès avantageux qu'a eu le traitement de cette fracture de la tête de l'humérus, celui d'un nombre d'autres de même espèce, que j'ai vu depuis, prouve que le précepte qu'on avoit établi les siècles derniers, d'amputer à l'artiele dans tous ces cas, précepte que j'avois adopté, et que bien des chirurgiens suivent encore aujourd'hui, est sujet à plus d'une exception." And BILGUER, in his famous memoir on the rarity of the necessity of amputation (Halle, 1761), and LA MARTINIÈRE (*Mém. de l'Acad. de Chir.*, 1768, T. IV, p. 1) commenting on BILGUER, have something to say regarding shot wounds of the shoulder, treated on the conservative plan.

<sup>3</sup> Some of the older surgeons furnish observations on the expectant treatment of shot fractures of the shoulder, the only alternative for amputation from the middle of the eighteenth century until the time of the MOREAUX and of LAUREY. Thus BOUCHER (*Obs. sur des playes d'armes à feu compliquées de fracture, aux articulations des extrémités ou au voisinage des ces articulations*, in *Mém. de l'Acad. Roy. de Chir.*, 1753, T. II, p. 287) remarks: "Les grands accidens ne demandent pas toujours les grandes opérations;" and, on page 299, *Obs.* IX, relates the case of a lieutenant, wounded, at Fontenoy, through the head of the humerus, from whose shoulder M. GUFFROY removed, at various periods, pieces of bone; the patient recovered. On page 391, he gives a similar case of a soldier wounded at Ramillies. This was in 1753; and ten years later, J. M. BILGUER (*Chir. Wahrnehmungen*, 1763, p. 420) gives the case of a grenadier, wounded at Kesterlitz, in Bohemia, August 22, 1762, in which the head and shaft of the right humerus and the glenoid cavity were shattered. Surgeon WINKLER successfully extracted a number of fragments through an incision. BILGUER (*l. c.*, p. 420) further relates that Surgeon BROWN preserved the arm, in cases of shot fracture at the shoulder, of two soldiers, named Pritzelke and Horn, wounded in the Seven Years War, in 1762. A few years later, J. L. SCHMUCKER (*Vermischte Chir. Schriften*, Berlin, 1782, B. III, p. 301) relates a case of shot fracture of the head and neck of the left humerus and the glenoid cavity of the scapula, in which, in 1778, he dilated the posterior wound and removed fractured pieces of bone; the patient made a good recovery. On page 82, he argues against the then accepted doctrine of "amputating the limb in cases of splintering of the head of the bone, with the supposition that sphacelus of the member and death must otherwise ensue." Soon after, DOLIGNON (*Sur une plaie d'arme à feu*, in *Jour. de méd. chir., pharm., etc.*, 1786, T. LXVI, p. 47) described a case of shot fracture of the shoulder, where the head of the humerus, the acromion, and the acromial end of clavicle were fractured, in which, after removal of pieces of bone, the patient, a girl of 16, recovered with full use of the arm.

<sup>4</sup> BELL (J.) (*Discourses on the Nature and Cure of Wounds*, 1795, Part III, p. 12): "The wounds of the joints are so dangerous by their high inflammation, that they may be fairly enough compared with wounds of the great cavities, neither can bleeding appease the inflammation, nor opium

exceptions sufficiently weighty or numerous to invalidate it. But it is now known, in regard to the shoulder joint, at least, that favorable results may be obtained after shot penetrations, without resorting to formal operations.<sup>1</sup> Some examples will illustrate this:

CASE 1470.—Private J. Keenan, Co. H, 65th New York, aged 37 years, was wounded May 12, 1864, at the battle of Spottsylvania, and was sent to a Second Corps hospital, and thence to Douglas Hospital, May 27th, where Assistant Surgeon W. F. Norris, U. S. A., reported: "This man was struck by a musket ball, that entered a little below and in front of the acromial process of the left scapula, and, passing inward and downward, committed the head of the humerus, and made its exit at the posterior fold of the axilla. The constitutional condition was satisfactory. The wounds were discharging pus, mixed with synovia, quite freely. A digital exploration indicated that the head of the humerus was almost pulverized; but that there were no considerable fissures extending into the diaphysis. Upon consultation, it was decided to make a free incision into the joint to permit the removal of fragments and a free discharge from the wound. But the patient earnestly deprecated any operative interference, and, in obedience to his wishes, he was put to bed and allowed a generous diet; while, except to keep the arm at rest, to facilitate free discharge from the wounds, and to apply dressings of cold water, no local treatment was instituted. Under these measures, the patient steadily improved. Fragments of necrosed bone occasionally came away. As convalescence progressed, passive motion of the joint was made whenever the wounds were dressed. On January 20, 1865, the wounds were entirely healed. The patient had good use of his arm, and could perform most varieties of manual labor. The power of the deltoid was unimpaired, yet there was sufficient ankylosis to prevent the patient from putting his hand to his head or raising his elbow to a level with the shoulder. The result is certainly more satisfactory than the average result in excisions of the head of the humerus." A photograph of the patient was prepared at the Museum, July 9, 1865. A reduced copy is given in the annexed wood-cut (FIG. 386). This soldier was transferred to the Veteran Reserves May 1st, and discharged November 21, 1865, and pensioned. Examiner J. Neil, of New York, reported, April 17, 1866: "Shot fracture of the head of the left humerus, resulting in impeded motion of the joint in all directions, with partial muscular atrophy; disability three-fourths; likely to improve slowly." This pensioner's claim was suspended January 30, 1873, in consequence of no response having been received from him for two years.

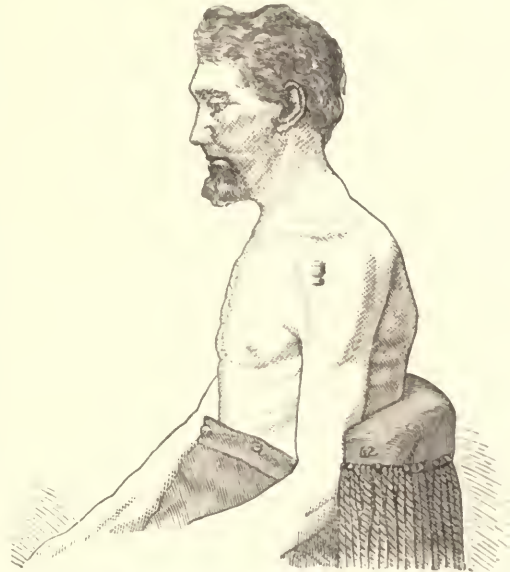

FIG. 386.—Results of conservative treatment in case of shot fracture of the head of the humerus. [From Photograph 62, *Surgical Series*, A. M. M.]

CASE 1471.—Private J. Jordan, Co. B, 12th Ohio, aged 30 years, was wounded at South Mountain, September 14, 1862, and was admitted to Hospital No. 1, Frederick, on the 16th. Acting Assistant Surgeon W. W. Keen, jr., made the following special report: "The ball entered the right arm just below the neck of the humerus, antero-externally, and emerged immediately below the clavicle at the junction of the outer and middle thirds, fracturing, probably, the head of the scapula. On October 7th, erysipelas set in, with the formation of pus about the wound of entrance. Dressed with lead and opium wash; quinine, iron, and stimulants given freely. October 16th, erysipelas entirely disappeared; free discharge of pus from the wound of exit, and of a healthy character. 19th, condition decidedly improving; pus very healthy; sitting up. 23d, there is some passive motion, but it gives him pain to pass the elbow upward; head of humerus fractured; crepitus distinct; also a piece of the coracoid broken off; a small piece of the bullet was extracted. November 5th, shoulder painful, so that he cannot sit up; no union of fragments; some deep burrowing of pus, which was evacuated by the introduction of a tent. 8th, strength failing somewhat, so that I increased the stimulants, the brandy to one ounce every two hours, and ordered beef tea freely; pulse 120. 10th, somewhat stronger; pulse 102. 11th, pulse 98, and stronger." The patient was discharged the service December 20, 1862, and pensioned. Examiner James Putney, of Kanawha, West Virginia, reported, in 1863, that: "His present condition is the result of a gunshot wound, the ball entering at the inferior posterior part of the deltoid muscle and coming out under the clavicle, fracturing the head of the humerus, producing ankylosis of the joint, and suppuration and exfoliation of the bone." Examiner T. F. Smith, of New York, reported, in 1873, that the pensioner was unable to place his hand on his head, and that the arm was considerably weakened, with nearly complete ankylosis of the shoulder joint. The pensioner was paid June 4, 1874.

relieve the pain,—nor bark nor diet support him under the vast discharge. We here pronounce more freely the opinion \* \* \* that openings into inflamed joints are fatal, and though there are in every book cases of ankylosed joints, we cannot but remember, that for one that has escaped by ankylosis, thousands have died. In this case—viz: of wounded joints—bleedings, poultices, and emollient fomentations constitute almost the whole that surgery can do. The wounds are to be dilated, the fragments of bone extracted, the patient laid quiet, and the limb as easy and soft as may be; nothing should be suffered to disturb him; he should have large opiates given him to abate the irritation and excessive pain;—and though bleeding may, perhaps, be allowable at first, yet our chief difficulty lies in supporting the strength of the patient during the tedious cure."

<sup>1</sup> Still more clearly in the recent European wars than in our own. Thus, BECK (B.) (*Chir. der Schussverletz.*, 1872, S. 528), who, as medical director of the Bavarian army corps, saw much field surgery, remarks: "Deducting the incurable cases, that required no further assistance from art, and those in which primary exarticulation at the shoulder had been performed, we treated, in our field or general hospitals, forty-six cases of injuries of this nature. In twenty-eight, expectant therapeutic measures were employed, with surprisingly favorable results, as only two of the wounded of this class perished; one, in consequence of tetanus, and the other, who had been left in our hands, in a very bad condition by French surgeons, was no longer a proper subject for an operation."



CASE 1472.—Private B. Buckley, 47th New York, aged 46 years, was wounded at Olustee, Florida, February 20, 1864, taken prisoner, and sent from Camp Parole to hospital at Annapolis, where Surgeon G. S. Palmer, U. S. V., reported: "Gunshot wound of right shoulder." This soldier was discharged January 16, 1865, and pensioned. He re-enlisted April 5, 1867, and the facts in his case are first reported on his examination for the Veteran Reserve Corps by Surgeon E. P. Vollum, U. S. A.: "A bullet entered under right acromion process, thence through head of humerus, and escaped near the angle of right scapula, after passing through that bone. A month after the injury, while a prisoner at Tallahassee, Confederate Surgeons Gidons and Clark removed several fragments of the head of the humerus. The injury and incisions repaired in eight months, when he was furnished by Dr. Hudson with an apparatus that kept the humerus well up in the glenoid cavity. This he wore for twelve months with very great advantage, and to it he attributes the restoration of the use of his arm. He now has all the motions belonging to the arm except raising the deltoid, and this he has to about one-quarter the natural extent, and it is improving. There is about an inch of shortening. The injured arm is considerably wasted, but there is no pain in it." This soldier was passed for the Veteran Reserve Corps, after having been pensioned from January 16, 1865, to March 18, 1867. He was discharged a second time, April 2, 1869, and pension continued. On examination for renewal of pension, Examiner G. S. Gale, of New York, reported, July 17, 1869: "The ball fractured the humerus near the head of the bone, and resection was made, with loss of two inches of bone, shortening of arm, and loss of motion at shoulder joint; the hand is useful in light work." Examiner P. Treadwell, of New York, reported, December 21, 1869: "The arm is of little use." Examiner J. F. Ferguson, of New York, reported, January 12, 1870: "For purposes of manual labor the arm is useless; flexion of arm extremely limited; there is little power in contracting the hand." Examiner T. F. Smith, of New York, reported, September 9, 1873: \* \* \* "There has been no reproduction of bone; arm and hand are useless for manual labor; disability total."

CASE 1473.—Private G. Dayspring, Co. H, 51th Pennsylvania, aged 26 years, was wounded at Piedmont, June 5, 1864. On December 7, 1865, he was admitted into Harewood Hospital, Washington. Surgeon R. B. Bontecou, U. S. V., reported: "Admitted suffering from gunshot wound, antero-posteriorly, of right shoulder, ball perforating head of right humerus. The patient was taken prisoner, but was recaptured by the Union forces and sent to hospital at Stanton; was again captured by the rebels and taken to Richmond, and was placed in Hospital No. 21, where he remained three months; was then paroled and sent to St. John's Hospital, Annapolis, remaining under treatment two months, and then was transferred to Camp Parole Hospital, remaining two months, and was again transferred to the Clairville Hospital, and about one month after his admission to that hospital was discharged from the U. S. service. The patient states that repeated search was made for the ball at the above-mentioned hospitals, but with exceptions of some spiculae of bones which were removed at intervals, the ball could not be found. On admission to this hospital the constitutional state of the patient was tolerably good, but the wound discharging profuse sanious pus. The wound was carefully examined, and the ball found lodged and impacted in the upper part of the anterior border of the right scapula, near its neck; the ball was extracted by Surgeon R. B. Bontecou, U. S. V., in charge of hospital, December 18, 1865. Anæsthetic, sulphuric æther and chloroform. The patient is doing very well, parts granulating finely, with fair prospects of a good recovery. The patient has, for some months, been a messenger in the Q. M. G. Office, with good use of his arm, but was annoyed by the constant discharge, which induced him to seek relief at this hospital." This soldier was pensioned from the date of his discharge, March 27, 1865, Surgeon J. B. Lewis, U. S. V., certifying on his discharge: "Paralysis of right arm, by reason of gunshot wound of right arm near the shoulder." Examiner J. Phillips, of Washington, September 25, 1866, reported: "Gunshot wound of right shoulder joint; there is retraction of the muscles of the shoulder, and he cannot raise the arm far from the side. The movements of the elbow and wrist are perfect." In September, 1869, Examiner W. W. Potter reported: "Portions of the humerus and scapula have exfoliated, and the movements of the joints are very much circumscribed;" and in March, 1870, certifies that: "A number of cicatrices exist, evidencing necrosis of the humerus and exfoliation. Crepitus now present at acromio-clavicular articulation." On August 5, 1874, Examiner H. Richings reported that there was then almost complete ankylosis of the joint, there being the least possible motion discernible." This pensioner was paid to September 4, 1874. A photograph of the pensioner, made at the Museum in 1871, is numbered 306, *Surgical Photograph Series*.

CASE 1474.—Private B. Oekart, Co. A, 103d New York, aged 30 years, was wounded at Antietam, September 17, 1862, and was treated in a farm house near the field for two weeks; thence removed to the Ninth Corps Hospital at Loenst Point, where he remained under treatment until January 18, 1863, when he was transferred to hospital at Smoketown, Maryland. Surgeon T. H. Squire, 89th New York, reported: "A musket ball entered the skin, just below the point of the acromion on the left shoulder, and came out in the hollow corresponding to the outer concavity of the clavicle, shooting over a couple of inches of skin, entering again near the middle of the clavicle, fracturing the bone at its most prominent point, and, passing on, grazed the skin of the neck, doing no further damage. The shoulder joint does not appear to be opened, and the compound fracture of the clavicle seems to be the most serious part of the injury. The lungs are not implicated; patient doing well. Subsequent observation makes it conclusive that the cavity of the shoulder joint was opened. December 31st: to-day, with a small but strong forceps, I removed a piece of bone seven-eighths of an inch in length and half an inch in width from the inside wound at shoulder. It was doubtless the acromial end of the clavicle." On April 27th, the patient was sent to Hospital No. 1, Frederick. Assistant Surgeon R. F. Wein, U. S. A., reported: "A rifle ball entered the shoulder half an inch external to the coracoid process, passed through the anterior portion of the joint, fracturing the head of the humerus, emerging two inches below the acromial end of the clavicle, fracturing this bone, and emerged at the anterior aspect of the neck. He remained all night on the field, was removed next day to a barn, and from thence to a farm house, where he remained two weeks. Patient states that several portions of bone were removed from the clavicle. The shoulder was paralyzed. The patient was removed to Locust Spring Hospital, where he remained three months; fragments of humerus and clavicle were removed from time to time. On admission to this hospital the wound over the clavicle was nearly closed; wound of joint healed; complete ankylosis of the shoulder exists. The patient is otherwise in good health." The patient was transferred to Jarvis Hospital, Baltimore, on June 16th, and was discharged the service July 20, 1863, for ankylosis of the shoulder consequent on the injury, and pensioned. Examiner W. W. Potter, Washington, D. C., June 13, 1870, reported: "Complete ankylosis of the left shoulder joint from a gunshot fracture of the head

of the humerus, with one and a half inches shortening of the arm. The middle third of the left clavicle was fractured at the same time, and some deformity of that bone now exists." Examiner R. G. Jennings, of Little Rock, reported, September 4, 1873: "Left arm two inches shorter than the other. Shoulder joint ankylosed; arm weak; muscles soft and flabby." This pensioner was paid June 4, 1874.

CASE 1475.—Private A. Boniface, Co. E, 140th Pennsylvania, aged 41 years, was wounded at Spottsylvania, May 12, 1864. Sent from a Second Corps hospital, three days afterward, to Washington; he was furloughed from Lincoln Hospital, and on October 19th received at a hospital at Pittsburg, where Surgeon J. Bryant, U. S. V., recorded: "A gunshot wound of the left shoulder, fracturing the scapula, clavicle, and humerus." This man was discharged December 29, 1864, for "Paralysis of arm; ball entering upper portion of the left shoulder, and making its exit at the posterior surface of the scapula," and pensioned. The Pension Examining Board of Pittsburg reported, September 6, 1873: "Ball entered over acromial process of left shoulder, fracturing it, and passed out over the scapula. Power to elevate arm impaired; disability one-half." Examiner James J. McCormick, December 3, 1873, reported: "The form of the shoulder is changed. The arm can be raised only to a horizontal position. It can be drawn forward but not backward. The arm near the axilla measures half an inch less than the right arm." This pensioner was paid June 4, 1874.

CASE 1476.—Private B. Hilt, Co. H, 20th Maine, aged 19 years, was wounded at Gettysburg, July 2, 1863, and was sent to Satterlee Hospital on July 11th. Surgeon I. L. Hayes, U. S. V., noted: "Gunshot wound of the head of the left humerus." Acting Assistant Surgeon W. W. Keen, jr., made the following special report: "The patient, occupation, farmer, in service one year, was admitted to Ward No. 2, July 11, 1863. A ball entered the arm externally one and a half inches below the acromion, and emerged under the middle of the left clavicle, completely shattering the head of the humerus. He states that no special inflammation followed the wound, and that prior to his admission nothing had been done save that cold water was applied. He had spit no blood. On admission the wound of entrance was small, and not very freely open to the head of the bone; the wound of exit was large and deep. The clavicle was partially exposed on the anterior and inferior aspect, and granulating admirably. His strength was good; pulse rather quick, but good; ordered extra diet and milk twice daily; bandaged the arm to the chest to insure quiet, and inserted a sponge tent into the wound of entrance and applied cold-water dressings. July 18th, the discharge has been healthy, but his strength seems failing; he can only sleep sitting up, and his shoulder 'feels heavy.' The wound of entrance I dilated still further by the knife, and removed several loose pieces of bone; one piece covered with articular cartilage; ordered milk diet, punch, and egg-nog, and elevated the arm by a sling to relieve the 'weight' complained of. July 19th, pulse 123 and pretty good; appetite good; ordered tincture of chloride of iron, fifteen drops, and sulphate of quinia, two grains, three times a day, with three-eighths of a grain of morphia at night. July 22d, the pus is burrowing anteriorly above the axilla and in front of the joint. Made a counter opening down to the head of the bone, evacuating considerable pus, and removing some fragments of bone. August 1st, removed more bone; wounds are remarkably healthy. The exposed portion of the clavicle is pinkish and is being covered by the soft parts; the pus is abundant and healthy, and his strength, appetite, and pulse are all improving." The patient was transferred to Cony Hospital, Augusta, June 17, 1864, and was discharged from service November 23, 1864—"gunshot fracture of the head of left humerus; disability total," being noted on his papers. Examiner James B. Bell, of Augusta, January 31, 1865, reported: "Complete ankylosis of the shoulder joint; wound still open and discharging freely; arm at present entirely useless, but its usefulness in time will be partially regained." Examiner F. G. Parker, Presque Isle, Maine, September 8, 1873, reported: "Wound of entrance two inches below and behind the head of the left humerus, fracturing that bone, and passing beneath the muscles; exit beneath the margin of and fracturing the clavicle. There are also cicatrices where pieces of bone have been extracted; general weakness of entire joint, and much atrophy of the muscles." The disability is rated total. This pensioner was paid June 4, 1874.

CASE 1477.—Private W. Heckles, 106th New York, aged 22 years, was wounded at Monocacy, July 9, 1864, and two days after sent to Frederick. Assistant Surgeon R. F. Weir, U. S. A., reported: "Wounded by a minié ball, which entered the right arm, posteriorly, at about the junction of the upper and middle third, and, the arm being elevated in the act of firing, passed obliquely forward, badly comminuting the humerus, and grazing the anterior rim of the glenoid cavity anteriorly, and emerged at a point about half an inch below and three inches from the humeral end of clavicle. Patient's general condition was good, his health robust. The wound of entrance was immediately enlarged, and all the loose fragments, several in number, removed, after which an angular tin splint was applied, having an opening in the bottom, through which dressings were applied to the wound and the pus allowed exit. The splint was suspended by cords from the cross-ties of the barrack. In this condition the patient continued, suffering no other complications than burrowing of pus through the tissues in proximity to the wound, relieved always by free incisions, and the occasional exfoliation of small fragments of bone, until furloughed, February 9, 1865. At this date, necrosis was going on in the head and upper third of the humerus, small fragments of which had been removed. There was very slight motion in shoulder joint, indication of permanent ankylosis." This soldier was discharged May 9, 1865, and pensioned. Examiner H. C. Austin, of New York, reported, May 23, 1865: "There is total loss of use of right arm, \* \* \* with ankylosis of the shoulder joint." Examiner B. F. Sherman, of Ogdensburg, reported, March 27, 1868: "Ankylosis of the shoulder joint, and disease of the shaft of the humerus, from which there is now, and has been most of the time, a constant discharge. Disability total." This pensioner was paid December 4, 1873.

CASE 1478.—Sergeant C. E. Spragne, 41th New York, aged 30 years, was wounded at Gettysburg, July 2, 1863. Surgeon A. B. Ward, 2d Wisconsin, reported a "shot wound of the left shoulder." The patient was transferred to Camp Letterman, July 31st, and to Satterlee, October 12th, where Acting Assistant Surgeon W. B. Jones recorded that "a minié ball entered the centre of the left shoulder joint anteriorly, passing backward and outward, emerging at the posterior part, completely shattering the head of the humerus. A few splinters of bone had been removed prior to entrance. A large abscess formed at the middle of left arm and was opened. August 5, 1863: Several large spiculae were removed from the anterior wound. August 19th: Several more large fragments were removed from both wounds. Upon probing, it was found that nearly the entire head and surgical neck were wanting." At four different dates, in August and September, like operations for removal of bone fragments



are recorded, and, on October 3, 1863, the removal of "three large spiculæ, part of the shaft of the humerus," is reported. This soldier was discharged March 11, 1864, for "loss of left arm. Disability total." Examiner P. Stewart reported, August 4, 1867: "Entire ankylosis of left shoulder joint, with considerable deformity." Examiner T. F. Smith, of New York, reported, September 17, 1873: "Extension of shoulder joint limited, seven-eighths; muscles are atrophied; strength of arm materially diminished; disability total." This pensioner was paid December 4, 1873.

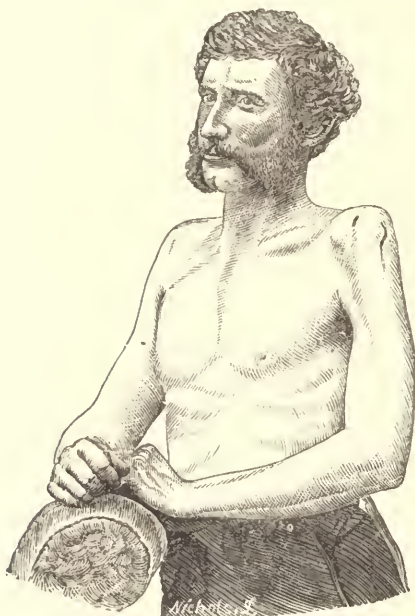

FIG. 387.—Cicatrices after a shot perforation of the left shoulder. [From a photograph.]

CASE 1479.—Lieutenant D. H. Cortelyou, Co. E, 6th New York Cavalry, aged 22 years, was wounded at Bottom Bridge, June 3, 1864. He was sent to Armory Square Hospital, Washington, on June 10th. Acting Assistant Surgeon D. C. W. Van Slyck reported: "Gunshot wound of the neck and left shoulder by a musket ball, which entered the right side of the neck, at the base, and was extracted, on the field, from the outer aspect of the left shoulder. On June 13th, Surgeon D. W. Bliss, U. S. V., examined and probed the wound. The upper border of the left scapula was found to be shattered. A counter opening was made in the left supra-scapular space, and exit thereby given to a gathering of pus. Dr. Bliss was unable to decide at this time whether or not the shoulder joint was involved. On June 25th, a counter opening for exit of pus was made on the anterior aspect of the left arm two inches below the shoulder joint. Patient has had persistent diarrhœa since admission." On July 26th, Lieutenant Cortelyou went on a leave of absence. On November 24, 1864, he entered the Officers' Hospital at Annapolis. Here Surgeon B. A. Vanderkief, U. S. V., removed, on several occasions, necrosed fragments of bone, constituting, according to the report, the major part of the head of the humerus. On March 18, 1865, the lieutenant was discharged the service. In December, 1867, he visited the Army Medical Museum, and a photograph was made, to illustrate the appearance of the injured shoulder. This photograph is copied in the adjacent wood-cut (FIG. 387). He had then a very useful arm. He was commissioned in the Ninth Cavalry, May 15, 1867. He was promoted to a first lieutenancy July 31, 1867. This officer was placed on the retired list, with the full rank of a captain of cavalry, December 15, 1870, on account of disabilities resulting from wounds received in action, in conformity with the act of Congress of August 3, 1861. (See ARMY REGISTER, 1874, p. 168.) Acting Assistant Surgeon J. H. Longenecker, who had charge of the case at

Annapolis, mentions that another abscess formed, in the early part of January, 1865, which, when incised, discharged over twenty ounces of pus. The photograph from which the cut is copied is 191 of the Surgical Series.

CASE 1480.—Corporal J. C. Hilberg, 5th Maryland, was wounded at Antietam, September 17, 1862, and sent to Camden Street Hospital on September 21st. Acting Assistant Surgeon E. G. Waters recorded: "A minic bullet entered the left shoulder one and a half inches above the anterior fold of the axilla and one inch from the margin of the glenoid cavity, passed downward and outward, fracturing the bone at the surgical neck, extensively comminuting the shaft, and lodged under the integuments, on the outer aspect of the arm, six inches below the joint. The ball was extracted on the same day, and the arm sustained in a splint. September 23d: The arm was immensely swollen near the seat of injury, the tissues livid, and pus had accumulated in quantity. This was relieved by a free incision, and bran and yeast poultices." From a more detailed printed report of this case,<sup>1</sup> it appears that, two weeks after the opening of the abscess, "lateral splints were applied, and the forearm was supported in a sling. In two months, union had become firm. February 6, 1863, the discharge had ceased; union firm, without superabundance of callus. The contour of the arm was natural and the tissues healthy in appearance." The patient was transferred to Hammond Hospital, July 3, 1863. Assistant Surgeon M. C. Miller, U. S. V., reported, August 18, 1863: "An abscess on the inner side of the arm, near the original wound." This was opened, and a large quantity of thin, fetid pus escaped. The abscess was reported healed on July 28th, but discharge was going on from the original wound. This discharge continued until October 28, 1863, when Surgeon H. Heger, U. S. A., removed two pieces of dead bone, each about an inch in length, "cribriform, flat, and irregular in outline." On January 14, 1864, the patient was sent to Convalescent Camp. He was discharged April 29, 1864, and pensioned. Examiner W. H. Clendenin, of Baltimore, reported, October 22, 1868: "A wound, now open, on the left arm, near the shoulder. The ball entered the pectoralis major muscle, then passed through the axilla, traversing the deltoid and biceps muscles, shattering the humerus in its course. Wasting of the muscles and loss of power in the arm. Slight contraction of the fingers. Occasional neuralgia. Small spiculæ of bone have passed, and more, I think, will come away." Examiners H. W. Owings, C. H. Jones, and A. W. Dodge reported, September 17, 1873: "Ball entered the inner triangle of the left shoulder near the acromion process, and made its exit on the anterior aspect of the left arm, causing a compound fracture of the humerus, upper third, and necessitating a resection of four inches of bone. Cicatrix extensive and adherent to bone. Use of arm very much impaired. Disability total." This pensioner was paid December 4, 1873.

At the Pension Bureau, many cases are reported as excisions or resections that were examples merely of elimination or extraction of necrosed bone. Doubtless it is often difficult for the pension examiners to decide, at a period remote from the injury, on its precise nature; and an opinion is formed from hearsay, that may sometimes be contradicted

<sup>1</sup> DARR (G. H.), *Conservative Treatment in Gunshot Fractures*, in *Am. Med. Times*, 1863, Vol. VI, p. 209.

by conclusive recorded evidence. The case just reported, for example, has been cited as an illustration of the propriety of abstaining from operative interference in some shot fractures of the shoulder. At the close of the subsection some remarks will be found on the expectant treatment of shot fractures at the shoulder. The next case introduces, incidentally, an ingenious apparatus (FIG. 388) improvised by Dr. George C. Harlan, and successfully employed in a shot comminution of the head of the humerus:

CASE 1481.—Private D. M. Moore, Co. I, 11th Pennsylvania Cavalry, aged 25 years, was wounded at Franklin, March 17, 1863, and was treated in the regimental hospital until August 13, 1865, when he was discharged the service and pensioned. Surgeon G. C. Harlan, 11th Pennsylvania Cavalry, made the following special report: "Wounded, while charging the enemy's pickets, on horseback. Gunshot wound by minié ball in right shoulder. Examined a few hours afterward at the regimental hospital in Suffolk. Compound comminuted fracture just below the neck of the right humerus. Bone much shattered, but vessels uninjured. Head of humerus entirely separated from shaft, and several small fragments lying loose between them. Shaft of humerus fissured below the wound, and head apparently split into several pieces. Ether was administered, and the injury carefully and thoroughly examined in consultation with Surgeons Hand, Humphreys, and Kneeland. After some hesitation it was decided not to resect for the following reasons: It could not be determined that the joint was actually opened, as the fracture did not appear to extend through the cartilage. The injury extended so low that at least four inches of the bone would have been lost by an operation; the patient was young and healthy and in a favorable condition for treatment, and should a secondary operation be necessary there would be a better chance of preserving the periosteum, loosened by suppuration, and reproducing bone. Cold-water applications were accordingly made. The next day there were constant oozing of blood, a good deal of tumefaction, and great pain at the slightest motion. To secure perfect rest and favorable position I applied a long narrow splint to the outside of the arm, extending from a point four or five inches below the elbow to the wound, and continued by an iron bracket to a point four or five inches above the shoulder, making extension from the first point by means of strips of adhesive plaster applied to the lower third of the arm, and counter-extension from the second by strips applied to the chest and back obliquely, and passing over a block above the acromion. A bandage was lightly applied over the arm and a splint from the elbow to the wound, which was left open for the application of cold-water dressings. This was frequently removed without disturbing the position of the limb. March 19th, oozing of blood much diminished; no increase of swelling; pulse a little accelerated; very slight febrile action. Scarcely any increase of temperature locally; no pain. 20th, scarcely any change; ordered sulphate of magnesia in small and repeated doses. 21st, skin and pulse natural; bowels freely moved; a good deal of sanious discharge from the lower wound; applied poultice to this, and continued cold-water dressing to arm and shoulder. April 1st, suppuration well established, moderate, and healthy; several small pieces of bone extracted from the lower opening to-day; he has had little or no pain, and sleeps well without anodyne. April 9th, more bone extracted with forceps; to have ale at dinner. 18th, sitting up; discharge decreasing; some union of fracture. A few days after this date he was sent to his home in Pennsylvania on thirty days' furlough, and on his return was detailed as mail carrier. He continued upon this duty until the regiment was mustered out, after the war. There was almost constantly a slight discharge from the wound, and occasionally small pieces of bone were removed, only one requiring an excision. November 9, 1867, called at my office to-day; says his arm has given him very little trouble since he left the army; is now milling, but has been employed in farming, ploughing, etc. The last piece of bone came away about a year ago; can raise the arm to a right angle with the body, but not higher, from want of sufficient power in the deltoid; perfect motion in every other direction. On superficial inspection no signs of the injury but four small scars, and a slight atrophy of the deltoid. No shortening of the arm was detected by careful measurement. A piece of lead the size of a split pea just underneath the skin about the insertion of the deltoid, and another lower down a little deeper. No tenderness produced by either." Examiner P. S. Clinger reported, April 23, 1866: "Was struck in the right arm, the ball penetrating near the shoulder joint and fracturing the os humeri. Ankylosis of shoulder joint; muscles agglutinated; wound open." A Board, convened at Lancaster, composed of Drs. W. Blackford and W. R. Grove, September 3, 1873, reported: "Wound open; arm emaciated." This pensioner was paid June 4, 1874.

CASE 1482.—Private B. Delihan, Co I, 8th Louisiana, aged 23 years, was wounded at Petersburg, April 2, 1865. On May 12th, he was admitted into Hammond Hospital, Point Lookout, from Richmond. Surgeon J. L. Sutton, U. S. V., noted a "gunshot flesh wound of left shoulder." He was transferred to Armory Square Hospital in July, to Stanton Hospital in August, and finally to Harewood, where Surgeon R. B. Bontecou, U. S. V., reported: "Admitted, September 13, 1865, partially convalescent from gunshot wound of the left shoulder, the ball passing through, shattering the head of the humerus. On admission to this hospital the constitutional state of the patient and condition of injured parts were tolerably good; wounds still discharging pus and small fragments of dead bone. No operation was performed in this case, and it apparently was left to nature; patient is able to be about, and, although he has as yet no use of the left arm, the prospects of his having a good and useful limb are very favorable. The articular surfaces of the shoulder joint are not injured." The patient was released February 6, 1866, through the Provost Marshall.

It has been observed, on page 503, that about one-third of the shot injuries involving the shoulder joint, that were treated on the expectant plan, proved fatal; and the subject



FIG. 388.—HARLAN'S bracketed splint for fractures of the upper extremity of the humerus. [From a drawing.]



would be imperfectly illustrated without detailed accounts of some of the fatal cases. There was, of course, great diversity in the nature of these injuries. In some the bones near the joint were shattered or fissured by large projectiles, or their fragments; in others, missiles from small-arms penetrated the joint, grooving or comminuting the articular extremities, sometimes remaining impacted in the humerus or scapula, or embedded in the soft parts, but more frequently perforating the joint.

CASE 1483.—Private A. L——, Co. A, 95th New York, aged 21 years, was wounded at Spottsylvania, May 12, 1864. First treated in hospital at Fredericksburg, he was sent, on May 26th, to Lincoln Hospital, at Washington. Acting Assistant Surgeon A. Ansell recorded: "The patient, when admitted to my ward, was exceedingly emaciated and low from the excessive discharge which was taking place from the wound. He stated that the ball had hitherto eluded discovery, and I unsuccessfully endeavored to discover it. He had good, generous diet, quinine, and iron, yet he gradually sank, and died on June 23d. He had no signs of pyæmia." Acting Assistant Surgeon H. M. Dean made an autopsy, and furnished the following notes: "He had been wounded by a minie ball entering three-fourths of an inch below the sterno-clavicular attachment of the

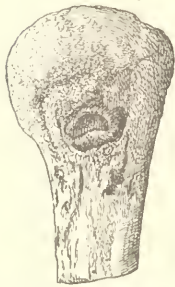

FIG. 381.—Musket ball impacted in the head of the left humerus. *Spec.* 2696.

left clavicle, passing outward to the left, and backward over the second rib, and was found embedded in the upper portion of the left humerus, anterior surface, close to the groove which receives the long head of the biceps muscle. The head of the humerus was found to be entirely denuded and carious; as was also the articulating surface of the left scapula. A large cavity beneath the left scapula was found filled with a sanious pus. On opening the thoracic cavity, the right lung was found attached to the wall by slight fibrous adhesions, apparently recent; lower posterior portion of the right lung was congested; the rest of the lung was healthy. The posterior portion of the left lung was also congested, and in the anterior portion a few small abscesses were found; the rest of the lung was healthy. The right auricle of the heart contained a large black clot extending down to the ventricle, which became more fibrinous. The left ventricle contained a small black clot; \* \* spleen healthy; liver apparently healthy; brain healthy. The rest of the organs not examined." The specimen (FIG. 389) consists of the superior third of the left humerus six weeks after injury. "A conoidal ball, which entered three-fourths of an inch below the sternal attachment and passed over the second rib, is embedded in the humerus near the bicipital groove. A piece of cloth driven before the bullet yet lodges with it. The articular surface is carious, the shaft is necrosed in the line of fracture below, and there is no attempt at repair."—(*Cut. Surg. Sect.*, A. M. M., 1836, p. 94.) Dr. Dean was the contributor.

CASE 1484.—Private Henry C S——, Co. C, 116th Illinois, aged 20 years, was wounded at Vicksburg, May 22, 1863, and was sent to Memphis on the hospital steamer City of Memphis, Assistant Surgeon W. D. Turner, 1st Illinois Light Artillery, in charge, noting a "gunshot wound of the left shoulder." The patient was admitted into Gayoso Hospital on May 27th. Assistant Surgeon W. Watson, U. S. V., made the following record of the case: "Wounded by a round ball through the posterior border of the deltoid, ranging downward and forward, shattering the head of the left humerus. There had been an incision three and one-half inches long through the deltoid for excision of the head of the bone, in which union by first intention had already taken place. It had been closed by sutures and adhesive straps, and was in excellent condition. The patient stated that the operation was performed on May 22d, and two inches of the head of the bone were then removed. The prominence of the acromion process and an apparent depression below it seemed to verify the statement, and, as the patient complained when it was handled, no further examination was deemed necessary. The wound was dressed with simple cerate and adhesive straps, and the arm supported by a broad sling. The symptoms continued favorable until June 8th, when the man had rigors and fever, with symptoms of inflammation, which soon developed itself, forming an abscess on the inner side of the shoulder, which pointed and was opened just below the outer third of the clavicle; pus to the amount of six ounces was evacuated. The symptoms were relieved, but there was still some swelling of the arm; some diarrhœa. June 14th, another abscess is forming in the lower third of the arm; the discharge is very free from the opened abscess, but very little from the incision through the deltoid. Diaphoretics were administered, a solution of creasote injected into the abscess, and a pill containing two grains of opium and one grain of camphor given every four hours to check the diarrhœa. June 19th, abscess opened and eight ounces of pus discharged; treatment continued. 20th, erysipelas made its appearance; considerable swelling about the elbow; patient looks haggard and exhausted. Twenty drops of muriated tincture of iron every two hours, with one ounce of wine, were given; tincture of iodine was applied to the arm, and compound solution of bromine injected into the wound. 21st, disease stationary; arm discharging freely; tongue dry; treatment continued. 22d, symptoms unchanged, but general appearance of the patient is better. 27th, erysipelas has entirely subsided; the discharge is very free, and evidently from dead bone. Pills of citrate of quinia and iron were given every four hours; the wine was increased to two ounces, and the abscesses were injected with the solution of creasote. 29th, the patient is slightly improved in his general appearance; treatment continued. July 3d, patient has failed and is now losing his appetite. Continued the pill of quinine and iron, and gave two ounces of whiskey every two hours. The treatment was continued, but the patient gradually failed until July 8th, when he died. *Post-mortem* examination showed that the head of the bone had been injured but not removed; the joint was entirely disorganized; the head of the humerus sphacelated, as also the glenoid cavity of the scapula. I am inclined to the opinion that had the excision been performed when the inflammation first developed, the chances of saving the man's life would have been increased." Dr. Watson forwarded the pathological preparation, which consists of the "head of the left scapula and the upper portion of the humerus. A round bullet passed through the head of the humerus, which, in the specimen, is necrosed and much absorbed. The glenoid cavity is eroded and enlarged. The greater tuberosity is more spongy than natural, and numerous small foramina perforate every portion above the epiphysal line."—(*Cut. Surg. Sect.*, 1835, p. 95.) The specimen is numbered 2083 of the Surgical Section.

The instances of shot injuries interesting the shoulder joint and chest cavity simultaneously were not infrequent; but patients rarely survived such lesions,<sup>1</sup> and the following mention of a case that did not terminate fatally until seven weeks after the reception of the injury may be regarded as exceptional:

CASE 1485.—Private William A——, Co. A, 1st Delaware, aged 30 years, was wounded at Farmville, April 7, 1865. He was removed from the field to City Point, thence to Annapolis, and on May 11th was transferred to Baltimore. Assistant Surgeon DeWitt C. Peters, U. S. A., reported: "Admitted to Jarvis Hospital May 12th, with a gunshot wound of the right shoulder. On admission, the original wound, which was about an inch below the acromial process of the scapula, was nearly healed, but there were several other openings which discharged a considerable amount of pus, and there was considerable burrowing of pus under the scapula and adjacent muscles, which discharged freely on pressure. Crepitus could easily be detected in the joint, and there being a point of entrance and none of exit of the ball, together with the presence of symptoms of pneumonia, it was supposed that it had fractured the humerus and lodged in the pleural cavity instead of lodging in the muscles. About May 20th, his shoulder and arm were attacked with erysipelas, which was exceedingly obstinate, and finally extended to his mouth and fauces. All these symptoms gradually grew worse, until he died, May 28, 1865. An autopsy was made, twenty-four hours after death. On examination, the left lung was found very large, as though distended with air, but the substance of the lung was normal. The lower lobe of the right lung was found hepatized, and the upper lobe intensely congested. The external border of the upper lobe was found to contain a cicatrix, evidently made by the ball in its course, and further examination revealed a minie ball in the right pleural cavity. The heart, liver, spleen, and kidneys were in a normal condition. Examination of the wound showed that the head of the humerus had been pierced by the ball, disorganizing the glenoid cavity, fracturing the coracoid process of the scapula, and entering the right pleural cavity between the second and third ribs." Dr. Peters contributed the specimen, which is imperfectly represented in the adjacent woodcut (FIG. 390), of the upper third of the right humerus. Dr. Woodhull remarks (*Cat. Surg. Sect.*, 1866, p. 95): "The anterior portion of the head is carried away. \* \* The head is thoroughly carious." Surgeon D. W. Maull, 1st Delaware, from a Second Corps hospital, Acting Staff-Surgeon J. Aiken, from City Point, and Surgeon B. A. Vanderkief, U. S. V., from Annapolis, give brief reports of the early history of the case, mentioning, however, no particulars that are not comprised in the report from Jarvis Hospital.

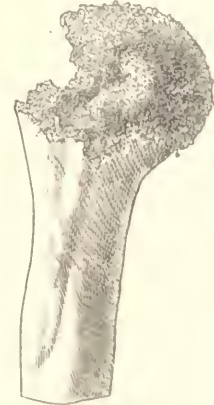

FIG. 390.—Head of humerus six weeks after shot fracture. *Spec.* 2541.

The four following are examples of fatal results from shot fractures implicating both bones of the scapulo-humeral articulation;<sup>2</sup> the scapula suffering most in all. Three of the patients perished from pyæmic infection, and one appears to have succumbed from hæmorrhage from the subscapular artery:

CASE 1486.—Private I. M. F——, Co. B, 12th New Hampshire, aged 31 years, was wounded at Chancellorsville, May 3, 1863. He was sent from a Third Corps hospital on May 9th to Harewood Hospital at Washington. Surgeon T. Antisell, U. S. V., recorded: "A fracture of the head of the humerus, the glenoid cavity, acromial process, and spine of scapula." Acting Assistant Surgeon W. A. Harvey reported more minutely: "A gunshot wound by a minie ball, entering the lower border of the axilla anteriorly, passing through, beneath the shoulder joint, opening the capsular ligament, fracturing the head of the humerus and a segment of the glenoid cavity, passing along through the scapula, \* \* emerging at the posterior border. \* \* On the 13th, the patient had a chill, followed by irritable fever and delirium, and he died May 17, 1863." Dr. Harvey forwarded to the Museum a specimen from this case, consisting of the left scapula and upper portion of the humerus. It is numbered 1128 of the Surgical Section of the Museum, and is described in the catalogue of 1866, at page 96. Acting Assistant Surgeon N. C. Stevens reported that at the autopsy no evidence that reparation had commenced was observed.

CASE 1487.—Corporal P. B——, Co. C, 88th Pennsylvania, aged 43 years, was wounded at Antietam. On September 27, 1862, he was admitted to Race Street Hospital, Philadelphia, and Acting Assistant Surgeon A. Trau reported: "Shot through axilla dextra. When admitted no fracture could be detected. On September 30th, profuse hæmorrhage occurred, supposed to come from the subscapular artery. There was frequent recurrence of the hæmorrhage notwithstanding the introduction of pledgets saturated with Monsel's salt into the wound. Death ensued on October 7th. *Pathological anatomy*: Extensive sloughing; laceration of the capsular ligament; abrasion of the humerus below its neck; fracture of the neck of the scapular and articular surface of the glenoid cavity and the upper portions of the external border of the scapula." The preparation, contributed by Dr. Trau to the Museum, is described by Dr. Woodhull (*Cat. Surg. Sect.*, 1866, p. 97) as "the right scapula and upper portion of the humerus. The glenoid fossa is fractured, and the border of the scapula immediately below it is carried away, as if by a missile that crushed the lesser tuberosity, fissuring the shaft." The specimen is numbered 239.

<sup>1</sup> MATTHEW (T. P.) (*Op. cit.*, Vol. II, p. 350) informs us that during the period of the Crimean War, when precise surgical returns were rendered in the British Army, there were seventeen cases of shot penetration or perforation of the shoulder joint, and that three patients treated without operation died, while fourteen were treated by resection. Dr. MATTHEW observes that the only cases treated on the expectant plan were apparently "complicated with some injury to the contents of the chest."

<sup>2</sup> ANDREWS (E.) (*Complete Record of the Surgery of the Battles fought near Vicksburg, December 27, 28, 29, and 30, 1862*, Chicago, '83, 4 pp. 28, 29) records thirteen cases of shot injury of the shoulder joint. One case was successfully treated on the expectant plan. In six instances, resection of the joint was performed, the patients doing well when they left the field hospitals. In the remaining six cases, recourse was had to amputation at the shoulder joint, two cases of this category proving fatal.



CASE 1488.—Corporal *G. S.*—, Louisiana Guard Artillery, aged 34 years, was wounded at Rapidan Station, November 7, 1863, and was captured and sent to Washington, entering Lincoln Hospital. Assistant Surgeon H. Allen, U. S. A., reported: "A conoidal ball struck him in the left shoulder and passed from right to left and from above downward, grazing the skin of the chin in its course, and lodging in the deltoid muscle. He entered the hospital on the 14th, and the ball was removed on the same day. An attempt was made to save the limb, since but a small portion of the humerus appeared to be involved, perfect motion of the joint being obtained at the time of examination. Symptoms of pyæmia supervened too late for surgical interference. He died November 30th. Autopsy forty-eight hours after death: Rigor mortis absent; emaciation not marked. Parts in situ: Right lung extended from first to fifth ribs and forward to within half an inch of the median line; the left extended from the first to the fifth ribs and forward to the junction of the cartilages with the ribs; position of heart natural; stomach conspicuous; liver extended three and a half inches to the left of the median line. The œsophagus and trachea were healthy, the latter somewhat injected. In the right lung, adhesions were found over the third lobe; the lung was of a bluish-grey color. The anterior part of the lung was apparently healthy. The third lobe was covered with a thin layer of lymph; near the apex of this lobe, two abscesses about the size of a filbert were seen; the periphery of these abscesses was of a yellowish, and its centre of a bright mulberry, color. On cutting open the lobe it was found to be carnified, the parenchyma being of a dark purplish red, much compressed, without crepitation; twelve drachms of purulent fluid were found in the pleural cavity; weight of right lung 27 ounces. The left lung was covered from apex to base with old adhesions, greatly congested; no abscesses; no pleurisy; weight 28 ounces. Heart healthy; weight 10 ounces. Liver rather pale, firm, no abscesses; healthy. Bile, 7 drachms, viscid, and of a brownish color. Spleen, mulberry color, very firm; weight 24 ounces. Pancreas, brain, and intestines healthy. Kidneys, right, very soft and paleish; left, similar to that of right side; weight  $7\frac{1}{2}$  ounces. The wound: The ball entered between the clavicle and the coracoid process of the scapula, and was removed by an incision made just above the insertion of the deltoid muscle into the humerus. The ball in its passage fractured the great tuberosity of the humerus. By inflammatory action the joint had become involved; the cartilage had been destroyed. The periosteum on the outer surface of the humerus beneath the great tuberosity was easily detached for about two inches in length, the head of the bone being friable. The under surface of the coracoid process was also denuded of periosteum. A collection of pus had formed in the axilla and surrounding parts." The pathological preparation was forwarded to the Museum by Dr. Allen. It consists of "the left scapula and upper half of the humerus, thirty-five days after injury. The greater tuberosity is fractured by a conoidal ball, and a line of necrosis is established along its lower border. There is partial fracture of the anatomical neck, and the head is friable. The inferior surface of the acromion is eroded. There are two fissures in the lower wing of the scapula." (*Cat. Surg. Sect.*, 1866, p. 93.) The preparation is illustrated in the adjacent wood-cut (FIG. 391). There is another specimen from this case, a battered ball, with bone splinters, preserved as Specimen 1424 of Section I, described on page 615 of the Catalogue of 1866.

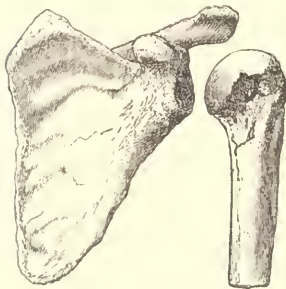


FIG. 391.—Shot fracture of the scapulo-humeral articulation three weeks after injury. *Spec.* 1952.

CASE 1489.—Private *J. L. M.*—, Co. C, 31st Georgia, aged 21 years, was wounded at Gettysburg, July 1, 1863, and three days after sent to Hospital No. 1, at Frederick. Acting Assistant Surgeon W. S. Adams reported: "Wounded by a minie ball, which entered on a line with the acromial end of the clavicle, one inch and a half below, passing backward and downward through the shoulder joint, grooving its way through the inferior border of the scapula, extensively comminuting the same. Up to date of admission, cold-water dressings had been applied. The patient was first seen by me on July 9th; his general condition was fair; no inflammation about the seat of injury; motion of the head of the bone gave but little pain. July 11th, the patient was etherized and a thorough examination of the parts made, and a number of fragments of the scapula removed; cold-water dressings continued. Ordered stimulants, tonics, and generous diet. July 14th, patient's condition fair; pulse 85; appetite good. July 17th: this morning the patient had a severe chill, followed by fever; ordered four grains of sulphate of quinia every four hours; other treatment continued. At six in the evening there was another slight chill. July 18th, patient's appetite failing; bowels regular; pulse 115; another chill at eleven in the morning, and a recurrence at nine at night.

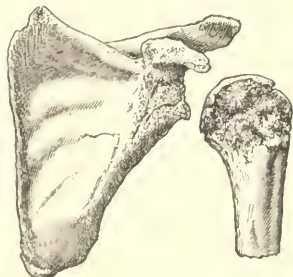


FIG. 392.—Preparation from a shot fracture of the scapulo-humeral articulation. *Spec.* 2869.

July 21st, has had two chills since last date; pulse 130; much depression of spirits; complains of weight in the cardiac region; has slight diarrhœa; appetite poor. July 22d, pulse 130, and feeble; countenance anxious; profuse diarrhœa. July 24th, patient has had two chills since last note; pulse 160, and very feeble; respiration much hurried; is evidently sinking. July 25th, died at ten o'clock this morning. Autopsy four hours after death: On opening the chest, the lungs collapsed but slightly. The left lung was completely filled with pyæmic abscesses from the size of a pullet's egg to that of a chestnut. The right lung was slightly congested and contained a few small abscesses. Each side contained about eight ounces of sero-purulent fluid. The heart was of normal weight. The liver presents a remarkably light-yellowish appearance; weight four pounds and eight ounces. Spleen much congested; kidneys soft, flabby, and very much congested; intestines healthy. The upper half of the humerus and the scapula were removed. The ball was found to have passed through the head of the humerus, dividing it into two parts, thence through the scapula just posterior to the glenoid cavity." The case is noticed in the *Catalogue of the Surgical Section*, 1866, p. 95, and one view of the specimen is given in the adjacent wood-cut (FIG. 392).

While it was of the utmost importance to keep the joint at rest, after shot fracture at the shoulder, it was observed that there was great danger in tight bandaging of the arm, and that any constricting apparatus liable to interfere with the circulation had, as

Dr. Stromeyer has remarked, a "fatal facility" in inducing gangrene or some other unfavorable complication.<sup>1</sup> It was observed, also, that in addition to the harm done to the limb from this cause, inflammation might extend, through contiguity, to the chest, although no direct lesion connected the injury at the shoulder with the thoracic cavity.<sup>2</sup>

CASE 1490.—Corporal C. F. C——, Co. L, 9th New York State Militia, aged 31 years, was wounded at Antietam, September 17, 1862, and admitted into Hospital No. 1, Frederick, on the 25th. Acting Assistant Surgeon W. W. Keen, jr., furnished the following notes of the case: "A ball entered two inches below the spine of the scapula and emerged one inch and a half below the acromion, shattering the head and upper part of the neck of the humerus. October 10th: Great œdema of the arm, for which two lateral incisions six inches in length were made; he had also a very bad bed-sore when he came under my charge, this date. October 19th: The arm has been bandaged up to the shoulder, with but little effect; no union has taken place, but his general condition is evidently improving. Iron, quinine, and stimulants were given, and the bed-sore was poulticed. October 26th: The slough is separated from the bed-sore; the arm is in a rather better condition; his general health is better. He was placed two days ago on a water-bed. November 1st: Patient complained this morning, for the first time, of a pain in the right chest; on percussion, dullness of both upper and lower parts of the right lung was found, and, on auscultation, crepitus corresponding to dullness and bronchial respiration. Solution of acetate of ammonia, syrup of ipecac, and morphia were given, with brandy and water more freely. November 2d: The dullness has extended throughout the entire right lung, with large mucous râles corresponding heard rather faintly, and crepitation has begun in the lower lobe of the left lung; sputum rusty pulse 120, and very feeble; respiration only 20, but labored. Diagnosis: Pneumonia with œdema and pleurisy; ordered dry and wet cups, and stimulants more strongly. After noon he sank more rapidly from the œdema, which greatly increased, and at seven o'clock p. m. the patient died. Autopsy eight hours after death: The right pleural cavity was filled with nearly a quart of serum and lymph. In the right lung there was an old tubercular cavity at the apex, as large as a walnut, with milary tubercles throughout the upper lobe, as proved by the microscope; an abscess was found at the lower part of the lung; nearly all the rest of the organ was filled with serum, and sank in water. The lower portion of the left lung also sank in water. The heart was normal, but about one ounce of serum was found in the pericardium. The head of the humerus was found to be shattered and, in part, pulverized, and it was split for some three inches downward. The lower edge of the glenoid fossa was also splintered off and the cartilage gone entirely from its surface. Amputation had been deferred only because the patient's strength was not sufficient at any time to warrant it." The specimen (FIG. 393) consists of the upper half of the left humerus, one and a half months after injury. The head and surgical neck are shattered, and an oblique fracture, with little comminution, extends two inches down the shaft. The head is carious and the line of fracture is bordered by necrosed bone, but there is no attempt at repair, excepting a minute deposit of callus at one point. It was contributed by Acting Assistant Surgeon W. W. Keen, jr., and the description is given in the *Catalogue Surgical Section*, 1866, p. 96, by Assistant Surgeon A. A. Woodhull, U. S. A.



FIG. 393.—Shot fracture of head of left humerus. Spec. 811.

In the following, as in CASE 1487, hæmorrhage was the immediate cause of death. In seventeen of the five hundred and five cases, mention is made of serious bleeding from the subscapular, suprascapular, and circumflex, or other large arterial branches; fourteen of these cases terminating fatally—all instances of intermediary hæmorrhage.

CASE 1491.—Private G. T. B——, Co. B, 12th South Carolina, was wounded at Gettysburg, July 2, 1863, and sent to Chester Hospital. Assistant Surgeon Brinton Stone, U. S. V., reported: "Admitted, July 9th, from the battlefield of Gettysburg. The wound was diagnosed as implicating the shoulder joint. The patient's condition not justifying an operation, supporting treatment was resorted to, and he gradually improved until July 22d, when secondary hæmorrhage occurred, apparently from a branch of the axillary artery. It was controlled by pressure; next day the hæmorrhage returned, but was controlled; but owing to the loss of blood the patient died of exhaustion on the same day. The *post-mortem* examination revealed complete disorganization of the shoulder joint. The anterior circumflex artery was found to have been opened by ulceration." The specimen is described by Dr. Woodhull (*Cat. Surg. Sect.*, 1866, p. 94, No. 2063) as "The upper half of the right humerus, grooved in the greater tuberosity and posterior part of the head by gunshot, three weeks after the injury. The articulating surface is thoroughly disorganized. A fissure on the posterior portion of the shaft is curiously and delicately bordered by necrosis." The catalogue accredits the specimen to Dr. Fisher, but it appears to have been simply forwarded by him.

The preceding abstracts (1470–1491) fairly represent the reports received of the five hundred and five cases of shot fractures at the shoulder, treated on the expectant plan. There will be an opportunity hereafter to compare the results with those of cases treated

<sup>1</sup> MACCORMAC (W.) (*Notes and Recollections of an Ambulance Surgeon*, 1871, p. 96) mentions this remark as made to him personally by the celebrated Generalstabsarzt STROMEYER, who had a *Feld-Lazareth* at Ploing, near Sedan, in September, 1870.

<sup>2</sup> HAMILTON (F. H.) (*A Treatise on Military Surgery*, 1865, p. 392) observes: "In case a ball has entered the humerus near the shoulder joint, and it is proposed to save the arm without resection, the external wound should be made free, the small loose fragments should be picked out carefully; and, for the rest, the case should be treated in the manner best calculated to prevent inflammation. Sutures, adhesive straps, bandages, and splints are inadmissible. Absolute rest and cool-water lotions are the important remedial agents. \* \* In general too much has been attempted; the bandages have been applied too tightly and perseveringly, and sometimes at the sacrifice of the limb. We employ, usually, in these cases a single splint, made of felt, leather, or gutta percha, long enough to extend over the top of the shoulder on the one hand and to the lower part of the elbow joint on the other, and broad enough to encircle one-third of the circumference of the arm."



by excision, or amputation. Here, however, it should be remarked, that the small mortality (of less than a third) given by the returns, as the result of expectant measures in shot fractures at the shoulder, must be considered with reference to the fact that the cases of least severe injury were usually selected for this mode of treatment. In analyzing the reports of the hundred and thirty-nine fatal cases, it was found that the immediate cause of death was referred to pyæmia in thirty-seven instances,—to hæmorrhage in fourteen,—to hospital gangrene in seven,—to phlegmonous erysipelas in five,—to tetanus in five. Nearly half of the fatal cases are thus accounted for. Of the remainder, some appear to have died from the effects of protracted suppuration, some from "surgical fever," others from intercurrent pulmonary disease; while, in many instances, no indication of the cause of death is assigned. In thirty-five of this series of cases, there were extractions of necrosed fragments of bone. In several of these, the missile, portions of clothing, or other foreign bodies were likewise removed. Six of these belong to the group of fatal cases.

Judging from the published reports of Confederate surgeons, in many instances necessarily hasty and fragmentary, as all battle-field returns must be, expectant measures after shot fractures at the shoulder were rarely trusted to by medical officers of the southern armies.<sup>1</sup> The question whether excision or amputation afforded the best means of preserving life was mainly considered, and the possibility of a successful result without operative interference was seldom entertained.

It was, indeed, at the date of the war, the generally accepted doctrine among military surgeons, that a shot penetration of the shoulder joint involved the necessity of excision or of amputation.<sup>2</sup> And, with less unanimity, this view is still maintained. While the naked statistics present the expectant method of dealing with shot injuries at the shoulder

<sup>1</sup> READ (J. B.) (*Report on Wounds of Large Joints, made to the Confederate States Association of Navy and Army Surgeons, in the Southern Med. and Surg. Jour.*, 1866, Vol. XXI, p. 200). The reporter states that: "Gunshot wounds of the scapulo-humeral articulation are to be resected in all cases in which the head of the bone is injured, and the blood-vessels and nerves that pass to the arm are intact." After discussing excisions for shot injury, Dr. READ remarks (*loc. cit.*, p. 200): "Comparing the result of these cases with that of wounds of this articulation treated without excision, we find seventeen—three cures, six deaths, and five useless ankylosed limbs, and six cases in which the result is not stated." Some inadvertence or misprint must occur here, as *twenty* rather than *seventeen* cases are particularized. Such reports are misleading, and distrust arises regarding the precision of the estimate on which may have been based the succeeding statement that: "The percentage is less than that given for amputations at the shoulder joint." MCGUIRE (H.) (*Clinical Remarks on Gunshot Wounds of Joints, in The Richmond Med. Jour.*, 1856, Vol. I, p. 148) observes: "Gunshot wounds of the larger joints almost invariably demand operative interference," and regards excision or amputation as the only alternatives in severe shot injuries at the shoulder joint. CHISOLM (J. J.) (*A Manual of Military Surgery*, 1854, p. 375), treating of shot injuries at the shoulder joint, discusses the relative advantages of excision and amputation, and regards excision or amputation as the only alternatives in severe shot injuries of the shoulder joint. WARREN (E.) (*An Epitome of Practical Surgery*, 1863, p. 371) pronounces positively in favor of resection in compound fractures of the head of the humerus. NOTT (J. C.) (*Contributions to Bone and Nerve Surgery*, 1856) and other Confederate surgeons who have written on shot injuries at the shoulder, refer to resections and amputations as the alternatives. Thus the anonymous compilers of *A Manual of Military Surgery for the use of the Confederate States Army* [reported to have been Drs. TALLEY, PETICOLAS, PEACHY, and DUNN, medical officers actively employed in the Confederate hospitals] declared that: "If the shoulder or elbow joint be much injured, but the principal vessels have escaped, the articulating surfaces and broken portions should be excised."

<sup>2</sup> SMITH (S.) (*Handbook of Surgical Operations*, 3d ed., 1862, p. 258), a work "prepared at the suggestion of several professional friends, who early entered the medical staff of the Volunteer Army," reiterates, in a third edition, that "if the shoulder or elbow joint be much injured, but the principal vessels have escaped, the articulating surfaces and broken portions should be excised," restating the opinions of many eminent authorities. Thus, DUPUYTREN (*Leçons Orales de Clinique Chir.*, 1839, T. V, p. 476) teaches: "Quand une balle, en pénétrant dans une articulation en a déchiré largement les ligaments, labouré les surfaces osseuses, et brisé ses surfaces en plusieurs fragments, les accidents inflammatoires les plus violents ne tardent point à arriver, et le malade y succombe presque toujours; aussi, le seul parti raisonnable à prendre dans ces cas-là, c'est de pratiquer le plus tôt possible l'amputation du membre, ou la résection des extrémités articulaires." JOBERT (A. J.) (*Plais d'armes à feu*, 1833, p. 239) declares: "En un mot, je n'ai vu aucune plaie d'armes à feu d'articulation, un peu étendue, pardonner aux blessés; ils finissaient tous par succomber à l'abondance de la suppuration et aux accidents inflammatoires, si une main hardie ne retranchait la partie qui était l'origine de tant de maux." LARREY (H.) (*Hist. chir. du siège de la citadelle d'Anvers, in Rec. de mém. de méd., de chir., &c.*, 1833, T. XXXIV, p. 282) writes: "On avait établi en principe la nécessité de l'amputation dans tous les cas de plaies pénétrantes des articulations par armes à feu, et ce principe, malgré quelques faits exceptionnels, s'est développé de jour en jour par l'expérience." BALLINGALL (G.) (*Outlines of Military Surgery*, 5th ed., 1855, p. 396) observes: "Injuries of this joint from musket or grape-shot are often a sufficient ground for the removal of the arm at its articulation with the scapula, or more frequently for the excision of the head of the humerus." BAUDENS (*Clinique des plaies d'armes à feu*, 1836, p. 449) admits that "Quand, en pareille circonstance, on n'a pas eu recours à quelque opération chirurgicale, il survient des caries et des accidents articulaires qui à la longue sont mortels." STROMEYER (L.) (*Maximen u. s. w.*, 1855, p. 694) judges: "According to my view, resection is indicated in every case in which injury of the bone with opening of the shoulder joint is ascertained." LEGOUËST (L.) (*Traité de Chir. d'Armée*, 1863, p. 624) said: "On peut dire que toutes les plaies des grandes articulations par les projectiles, nécessitent soit la résection, soit l'amputation immédiate." TRIFLER (C. S.) (*Handbook for the Military Surgeon*, 1861, p. 59) taught: "If a wound of the humerus is limited to the head, exsect; if it extends to the shaft, amputate." It would be easy to multiply citations on this subject; but iterations will be avoided by presenting the comparisons between expectant measures, conservative treatment by excision, and the ultimate resource of ablation of the limb, at the conclusion of the chapter.

in a somewhat favorable light, a survey of the individual cases fails to increase our confidence in this mode of treatment. It is true that in more than two-thirds of the cases returned in this category, a happy result is alleged; yet, in some instances, the precision of diagnosis may be questioned; and, in others, such incisions and extractions of sequestra were made as were almost tantamount to excisions. There can be no question, however, that in exceptional cases of shot fracture at the shoulder, expectant treatment, under judicious supervision, may result most favorably. This had been surmised by Boucher, Schmucker, and Guthrie; but few surgeons had the hardihood to abstain from amputation or excision. A remarkable example, however, is found upon the records of this office, in which, several years before the late war, a good result was secured, in a shot perforation of the shoulder, without operative interference:

CASE A<sup>12</sup>.—Private Christopher C. Frayser, Co. C, 1st Dragoons, aged 22 years, was wounded, May 27, 1856, at the Big Bend of Rogue River, in Oregon, in a fight with Indians. Dr. C. H. Crane, U. S. A., reported: "He was struck, at short range, by a large round rifle ball of the so-called Harper's Ferry make. The head of the humerus was fractured, two or three pieces were detached, and the upper part of the shaft of the bone was broken in fragments. It was at first supposed that it would be necessary to amputate at the shoulder joint. But, owing to peculiar circumstances—the detachment being surrounded by a large number of Indians, and under fire for thirty hours; and as, furthermore, there was but little hæmorrhage, and but slight constitutional disturbance, nothing more was done than to remove all loose fragments of bone, pieces of clothing, and other foreign bodies, and to keep cold-water applications to the wound. This man continued to do well, and was transported, with other wounded men, by me, in a canoe, for a distance of fifty miles, on a river in which obstructions and rapids were numerous, and he had a rough transit. He was then transported over more than fifty miles of precipitous mountain paths, on mule-back, and, three weeks after the reception of the wound, he was placed, in good condition, in the post hospital at Fort Orford, Oregon. I saw him some months subsequently, at Fort Vancouver, Washington Territory, and his wound was nearly healed. He told me that a number of small pieces of bone had come away during the first two months; and that then the wound had healed. He had some use of his arm when I saw him. I afterward heard that he made a good recovery, and had an excellent use of his arm." Surgeon C. H. Laub, U. S. A., reported, from Fort Vancouver, that this soldier was discharged February 9, 1857. The records of the Pension Office show that he went to his home in Fayetteville, North Carolina, and received his pension. The loss of the records of the Southern pension agencies, after the outbreak of the war, precludes the possibility of tracing the progress of the case. Dr. B. W. Robinson, of Fayetteville, wrote, in 1874, that the man had left that place.

Scattered through the imperfect annals of military surgery, other instances may be found in which abstention from operative interference, after shot fracture at the shoulder, was judged expedient;<sup>1</sup> but those in which the diagnosis was clearly made out, that had a favorable termination, are very rare; and the foregoing case has appeared to the compiler

<sup>1</sup> Although the later have been numerous, some of the earlier were important. Among them is one related by DORSEY (J. S.), who, after remarking (*Elements of Surgery*, 1818, 2d ed., Vol. II, p. 312) that "injuries from musket balls penetrating the capsular ligament, attended with fracture and destruction of the head and adjacent parts of the humerus, and wounding the axillary artery, require immediate operation," states that "GENERAL SCOTT, of the United States Army, happily recovered from such a wound, and has a very useful arm." Whatever skepticism military surgeons of the present day may entertain, regarding the wound of the axillary artery of the venerated officer thus mentioned, they will feel indebted to DORSEY for recording an account of the supposed nature of the injury. In the *Memoirs of Lieut.-General SCOTT*, LL. D., written by himself, 1864, Vol. I, p. 145, among the incidents of the battle of Niagara, or Lundy's Lane, the autobiographer relates the injuries of the commanding officer of the American forces. He was seeking to succor a brave soldier who had fallen at his side, and "had become a corpse as he fell," when, "in the next second or two, SCOTT, for a time, as insensible, lay stretched at his side, being prostrated by an ounce musket ball through the left shoulder joint. He had been twice dismounted and badly contused, in the side, by the rebound of a cannon ball, some hours before. Two of his men, discovering that there was yet life, moved him a little way to the rear, that he might not be killed on the ground, and placed his head behind a tree—his feet from the enemy. This had scarcely been done, when he revived and found that the enemy had again abandoned the field. Unable to hold up his head from the loss of blood and anguish, he was taken in an ambulance to the camp across the Chippewa, when the wound was stanch and dressed." The twelfth chapter of General SCOTT's autobiography further describes the shot wound of his shoulder, and the opinions of Drs. PHYSICK, DORSEY, and GIBSON regarding it, and explains how the latter surgeon's advice denied him "the opportunity of sharing in JACKSON'S brilliant victories near New Orleans." A distinguished medical officer, who served with General SCOTT in Mexico and subsequently, informs the editor that: "He suffered occasionally from neuralgic pains in said shoulder." It appears certain that there was no ankylosis or aneurism. Surgeon PAPENDICK (SCHMUCKER'S *Vermischte Chir. Schriften*, 1782, B. III, S. 301), of the Pomeiske dragoons, in the case of a soldier, wounded, November 25, 1778, by a shrapnel shot in the left shoulder, causing great destruction of bone, treated the case by extracting fragments of the scapulo-humeral articular extremities, and the man made a satisfactory recovery. GUTHRIE (*Commentaries, etc.*, 1853, 6th ed., p. 124) describes four cases of shot fracture at the shoulder treated conservatively: Lieutenant Madden, wounded at Badajoz, in 1812, a musket ball lodging in the head of the humerus;—Masters, 40th Regiment, with a musket ball lodged in the head of the humerus, April 12, 1814, at Toulouse;—Private Oxley, 23d Regiment, a musket ball grooving the head of the humerus, at the battle of Toulouse;—and Lord Seaton, with a nearly similar wound, at the assault on Ciudad Rodrigo, January 19, 1812. All four recovered, with stiffness at the shoulder; but with useful forearms, and some motion of the upper arms. GUTHRIE (*Treatise on Gunshot Wounds*, 1827, p. 482), referring to these cases, remarks: "These cases may all be considered fortunate. I have seen others in which part of the head of the humerus came away, and the arm has been preserved. I have also seen such cases ultimately terminating in amputation. The only and unsuccessful case of the shoulder joint, after the battle of Toulouse, was of this nature." A few pages further on, GUTHRIE refers to the case of Burnet, 92d Regiment, Chitty, 95th Regiment, and a third similar case, of shot comminution of the head of the humerus, at Waterloo, treated on the expectant plan, and vouches for the correctness of the remarks which JOHN THOMSON (*Report of Obs., etc., after Waterloo, op. cit.*, 1816, p. 150) published regarding these cases.



of these volumes of special significance, as an early illustration of real expectant conservative treatment of shot fractures at the shoulder, in which the propriety of abstaining from operative interference was justified by the results.

Larrey and Baudens<sup>1</sup> approved of an expectant treatment of these injuries under certain conditions. Professor Sédillot, Dr. B. Beck, and others,<sup>2</sup> have adduced instances in which shot fractures at the shoulder have been managed advantageously without operative interference. The more recent European experience<sup>3</sup> would appear, indeed, to justify surgeons in regarding the expectant treatment in these injuries more favorably than heretofore. Facilities for transportation, and propinquity to base hospitals, may partly explain the good results recorded by German and French surgeons in cases of shot wounds of this articulation. And it may be remarked, that sufficient time has not yet elapsed to admit of an approximative determination of the relative usefulness of limbs treated by expectation or excision in that campaign, after shot penetration at the shoulder.

<sup>1</sup> BAUDENS (L.) (*Clinique des plaies d'armes à feu*, 1836, p. 449) remarks: "J'ai vu souvent l'articulation scapulo-humérale traversée par des balles; et dans un cas, le plomb était demeuré au milieu de la tête articulaire." SIMON (G.) (*Prager Vierteljahrsschrift*, 10ter Jahrgang, 1, S. 168) relates a case in which a bullet healed in the head of the humerus, without the latter forming an adhesion to the shoulder blade. SÉDILLOT (*Du traitement des fractures des membres par armes de guerre*, in *Arch. gén. de méd.* 4<sup>e</sup> sér., 1871, T. XVII, p. 389) remarks: "La présence ou le passage d'une balle dans la tête de l'humérus n'empêche pas le malade de conserver son membre, et, quoiqu'il soit parfaitement indiqué d'extraire le projectile et les autres corps étrangers libres. On possède des exemples de guérison dans des cas où cette extraction n'avait pas été pratiquée. Nous avons assisté à une désarticulation du bras, faite par LARREY, sur un invalide qui portait, depuis vingt ans, une balle enclavée dans l'extrémité spongieuse de la tête de l'humérus où elle avait fini par déterminer des accidents inflammatoires de la plus grande gravité."

<sup>2</sup> BECK (B.) (*Chir. der Schussverletzungen*, 1872, S. 580) observes: "By absolute rest, appropriate position, and corresponding bandages: by immovability; by constant application of cold; by an anti-phlogistic regimen; by incisions, extended—in cases of severe tension of the capsule with perilous suppuration—even into the synovial sac, for the purpose of allowing the accumulated fluid to escape; by well-timed openings of burrowing abscesses; by extraction of loose splinters or fragments; by the administration of opium; by subcutaneous injection of morphia in cases of severe pains, the injury may frequently be controlled and even a cure, with usefulness of the limb, comparatively limited, indeed, may be accomplished, as we have frequently observed during the late war." SCHÜLLER (M.) (*Kriegschir. Skizzen*, u. s. v., 1871, S. 36), after citing several successful cases of expectant treatment of shot fracture at the shoulder, insists on the diagnostic importance of a knowledge of the precise position and attitude in which the injury was received, adding: "An allusion to this well known point would be superfluous, if it did not occur in every war that physicians, who never saw them before, have to treat shot wounds; and, with the eyes of the layman, may mistake peri-articular wounds for joint penetrations, and even, as was lately illustrated in the *Letter of Dr. VON BREUNING* in *Deutsche Klinik*, No. 38, 1870, are liable to open the joint to perform resection. Fortunately in this instance it was noticed just in time \* \* that the head of the humerus was uninjured." On the other hand, SOGIN (A.) (*Kriegschir. Erf.*, 1872, S. 154), speaking of the treatment of shot wounds of the shoulder joint, observes: "I consider it an error to postpone resection, in case of suppuration of the joint, until it appear that life itself is periled. The two cases cited, in which I thought myself justified in so doing, were bitterly regretted." Similar testimony is borne by other surgeons. Thus: RUPPRECHT (L.) (*Militärärztliche Erfahrungen*, Würzburg, 1871, S. 61) remarks: "Of the shot fractures of the shoulder joint, one case was fatal; phlebitis and purulent infiltration precluded an operation that ought, perhaps, to have been practised primarily." COUSIN (A.) (*Hist. chirurgicale de l'ambulance de l'école des ponts et chaussées, in L'Union Méd.*, 1872, T. XIII, p. 126) cites five cases of shot fractures of the shoulder joint, with four deaths, and observes: "Des 4 blessés qui moururent, 1 seul subit la résection de l'extrémité articulaire de l'humérus. Tous succombèrent à l'infection purulente."

<sup>3</sup> Several surgeons who have treated of the condition of invalids after the late Franco-Prussian War, seem inclined to think that the results, as regards the conservation of the motion of the arm, are more favorable in cases treated on the expectant plan, than in those dealt with by excision. MOSSAKOWSKY (P.) (*Statistischer Bericht über 1415, französische Invaliden*, in *Deutsche Zeitschrift für Chir.*, 1872, B. I, S. 333) observes: "As a general thing, it is my impression, that the cases of wounds of the shoulder joint that were conservatively treated, and healed with ankylosis \* \* showed better functional results than the cases treated by resection." BERTHOLD (*Statistik der durch den Feldzug, 1870-71, invalide geordneten Mannschaften*, u. s. v., in *Deutsche Militärärzt. Zeitschrift*, 1872, B. I, S. 469) remarks: "Comparing the preliminary results of the healing process of the five cases of resection with the four cases conservatively treated for shot wounds of the shoulder joint, the results of the latter have been more favorable as regards the ability to use the arm for occupations at the present date," although he adds: "The examination of the invalids took place about seven months after the injury, a period too early to allow conclusions regarding the end-results of the case." But there was much diversity of opinion. BILLROTH (TH.) (*Chir. Briefe aus den Kriegslazarethen in Weissenburg und Mannheim*, 1870, Berlin, 1872, p. 210) declares: "As, in cases of resections, you can have no control as regards the prospective functions of the arm, especially when a large portion of bone is to be excised, it is always better for the patient to escape with an ankylosed joint, without resection, than to have a dangling joint after resection." LANGENBECK (B.) (*Chir. Beobachtungen aus dem Kriege*, Berlin, 1874, S. 116) contends: "If it be true that ankylosis of the shoulder joint enhances the usefulness of the rest of the extremity, and especially of the hand, we would be obliged, in shot injuries of the shoulder joint, to constantly strive for the accomplishment of ankylosis." But he adds: "The presumption that ankylosis \* \* would bring about greater usefulness of the arm than could be had with a shoulder joint, even with limited motion, rests upon a fallacy, occasioned by a neglect to take into consideration the various degrees of severity of shot wounds of the shoulder joint. \* \* The shot injuries of this articulation that heal with ankylosis are, in all respects, injuries of a minor degree." The same author, at another page (*op. cit.*, S. 113) cites nine successful cases of shot wounds of the shoulder joint treated on the expectant plan, the patients recovering "completely with conservation of good motion of the arm," and remarks: "Whether, with the adoption of the conservative treatment of shot wounds of the shoulder joint during the last war (Franco-German, 1870-71) more special attention was paid to the preservation or re-establishment of good motion of the joint, I do not know, but doubt very much, as I several times noticed that surgeons, content to have saved the patient's life and arm, feared the methodical institution of passive motion. It is certain that the results of the cases of conservative treatment of shot wounds of the shoulder joint above cited challenge greater attention to the side of conservative surgery." But Professor LANGENBECK concludes (*loc. cit.*, p. 154) that "the expectant treatment in cases of severe shot fractures, such as those in which I performed resection, can never be carried out successfully; sooner or later, during the period of infiltration or suppuration, unless you allow the patient to perish, you will see before you the alternative of either resection or amputation." LOHMEYER (C. F.) (*Die Schusswunden und ihre Behandlung*, 1859, S. 192) argues that "the attempt to leave the healing of such wounds to Nature only, is always very hazardous, as most of the patients, if they do not perish of pyæmia, become so debilitated, by continued suppuration and repeated formation of abscesses, as to be brought to the verge of the grave." FISCHER (H.) (*Kriegschir. Erf.*, 1872, p. 147) observes: "The perforating shot injuries of the shoulder joint were, at first, all conservatively treated. In two cases, we were compelled to adhere to the conservative treatment, while, in the meantime, the patients fared so badly that operative interference did not appear justifiable. Both died."

Some of the precautions to be observed in attempting an expectant treatment, after these injuries, such as absolute rest, a restricted diet, and the other requirements of an antiphlogistic regimen, have already been incidentally adverted to, in commenting on the cases selected for detail, of the five hundred and five, returned on the reports of the war. If these prophylactic measures were not enjoined, the patients fared badly, as attested by numerous clinical histories. In addition, the necessity of scrupulous attention to the removal of all foreign bodies, including projectiles, fragments of clothing and of bone, and blood-clots also, was largely exemplified. Moreover, there were frequent illustrations of the importance of early free incisions, for the relief of pus-formations in and about the joint; and, in some cases, the utility of drainage was much insisted on.

Mr. MacCormac, in his notes<sup>1</sup> on the surgery of the French-German campaign of 1870, does good service in giving prominence to the utility of an axillary pad or cushion in shot fractures of the upper extremity of the humerus. I take the liberty of copying his illustrations (Figs. 394, 395) of the dressings used by that "veteran authority in military surgery," the renowned Dr. Stromeyer. A similar dressing, rendered familiar to our surgeons by Dr. Fox's apparatus for fractured clavicle,<sup>2</sup> was much employed, not only in the cases treated on the expectant plan, but in those in which recourse was had to excision. There can be no question of the utility of some appliance of this description, judiciously adjusted. Surgeon G. C. Harlan indicated, in the apparatus figured on page 509, how it was possible to avoid the dangers of tight bandaging of the upper arm in these shot fractures, and yet to secure the advantages of extension and counter extension,<sup>3</sup> by means of a bracketed splint with vertical adhesive strips; and the practical value of this suggestion will not fail to be appreciated. If immobility of the limb can thus be provided for, and the displacement inwards of the upper part of the humerus,

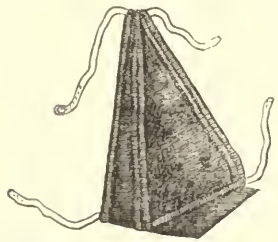


FIG. 394.—STROMEYER'S axillary pad. [After MACCORMAC.]

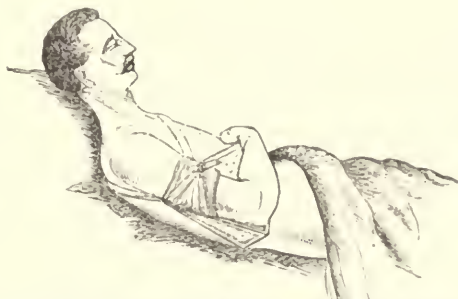

FIG. 395.—STROMEYER'S cushion as applied for shot fracture of the upper extremity of the humerus. [After MACCORMAC.]

<sup>1</sup> MACCORMAC (W.) (*Notes and Recollections of an Ambulance Surgeon*, etc., 1871, p. 97) says: "He [STROMEYER] has himself told me, so highly did he estimate the value of this cushion, that he considered it the most valuable appliance he had invented during his life, which is very strong language from a man who, like him, has done so much for surgical science." And Mr. MACCORMAC adds: "I have tried this mode of treatment myself, and found it to answer every purpose. The cushions are very readily made, and can be manufactured of different sizes. A very good size is one in which the sides measure about fourteen or fifteen inches in length." There must be a misprint or mistake here, since the distance from the one in which the sides measure about fourteen or fifteen inches would be inconveniently long. MACLEOD axillary fold to the inner condyle rarely exceeds, even in tall persons, ten inches, and a pad of fifteen inches would be inconveniently long. MACLEOD (G. H. B.) (*Notes, etc.*, 1858, p. 304), commenting on Dr. STROMEYER'S recommendation to make the trunk the splint in fractures high up in the humerus, declares: "As pus commonly burrows, and has to be evacuated on the inner aspect of the arm, it is difficult to carry such an idea into practice." The validity of the objection is not apparent. BALLINGALL (G.) (*Outlines of Mil. Surg.*, 5th ed., 1855, p. 376) dwells on the importance of a pad in the axilla. PASSAVANT (G.) (*Bemerkungen aus dem Gebiete der Kriegschirurgie*, Berlin, 1871, S. 30), remarking on the inutility of bandaging in shot fractures of the upper extremity of the humerus, states that: "I know of no better treatment than by STROMEYER'S pad, upon which the fractured arm rests without any bandaging. \* \* \* This pillow does, according to my view, better service than any bandaging, either in the sitting or prone posture." And this author cites a number of cases in support of his opinion.

<sup>2</sup> NOURIS (G.) (*Practical Surgery*, by ROBERT LISTON, with *Notes and Additional Illustrations*, Philadelphia, 1838) gives the earliest description I have seen of this apparatus, which "was introduced into the practice of the Pennsylvania Hospital in 1828, by Dr. Fox" (*loc. cit.*, p. 47), and is now so generally employed. (See SMITH (H. H.) *Minor Surgery*, 1859, p. 217, and SAUGEST (F. W.) *On Bandaging, etc.*, 1862, p. 129.) The axillary pad, it is hardly necessary to remark, was used at least as early as the seventh century by PAULUS ÆGÆTA (*See Book VI, Syd. Soc.*, ed. 1846, Vol. II, p. 486.) Yet "the ball of soft wool placed in the arm-pit, and secured with a bandage and sling," was but a rudimentary notion, imperfectly fulfilling the indications so well met by the coniform pillows of FOX and Dr. STROMEYER.

<sup>3</sup> Unless Dr. HARLAN'S suggestion meets the difficulty, the remarks of THILLAYE (*Traité des Bandages et Appareils*, 3ème éd., 1815, p. 262) must still have force: "Les auteurs qui ont écrit sur les Bandages, n'ont donné aucune description des appareils convenables pour cette fracture. LEDRAN (*Mém. de l'Acad. de Chir.*, 1768, T. IV, p. 623), DAVID (*Mém. sur les contre-coups, etc.*, en *Prix de l'Acad.*, T. XI, p. 308), MOSCATI (*Mém. de l'Acad. de Chir.*, 1768, T. IV, p. 619), et DESAULT (*Jour. de Chir.*, T. II, p. 145), ayant senti la difficulté d'entourer circulairement le lieu de la fracture, et la nécessité de mettre le membre dans une immobilité complète, ont décrit plusieurs bandages qui ont rempli les indications qu'ils se proposaient."



through the action of the pectoralis and latissimus dorsi, be guarded against by a pad in the axilla, little more surgical intervention will be needed, save what may be requisite to provide for free egress for foreign bodies and inflammatory exudations.<sup>1</sup> The methods employed by some European military surgeons, such as the introduction of tents of sponge, or of laminaria, or of drainage tubes,<sup>2</sup> were not much resorted to; but, in one or two instances the mode of dilating sinuses, suggested by Dr. G. K. Smith, by a tent watch-spring, described and figured at page 580 of the *First Surgical Volume*, was employed; but free incisions appear to have proved the best mode of dealing with the suppurations in and about the joint. The methods of securing immobility of the upper arm by means of wire-gauze splints, or of gypsum bandages,<sup>3</sup> were (as far as can be learned from the reports) neither practised nor recommended. Indeed the authorities most regarded,<sup>4</sup> disapproved of the use of splints and bandages in this group of cases. If it was possible, without placing the patient's life in jeopardy, to save for him a useful hand and forearm,<sup>5</sup> much was achieved. Even if ankylosis at the shoulder ensued, or if a dangling limb, united by long ligamentous attachments, was left, with muscles of the upper arm atrophied from disuse, the sufferer had reason for congratulation if even partial usefulness of the hand could be retained. The mortality in this series, amounting to 27.5 per centum only, was much less than the average of similar cases elsewhere published.<sup>6</sup> Conceding the widest margin for errors in diagnosis, and supposing that many of the cases were instances of peri-articular wounds, the death rate would remain remarkably low. The probable explanation of this fact is to be sought in the very large proportion of severe cases in which recourse was had to excision. Comparatively little has been written<sup>7</sup> on the expectant treatment of shot wounds of the shoulder joint, and the limited bibliography

<sup>1</sup> SÉDILLOT (*Du traitement des fractures des membres par armées de guerre*, in *Arch. gén. de méd.*, 1871, VI<sup>e</sup> sér., T. XVII, p. 389) remarks: "L'immobilité, dans le cas de conservation, est le moyen le plus efficace. Le pus trouve une issue par l'ouverture de sortie, s'il en existe, ou par celle d'entrée; l'éponge préparée, le laminaria servent à entretenir et à dilater les plaies. Les collections sont ouvertes par des petites ponctions déclinées maintenus béantes par des drains, si l'écoulement spontané ou par pressions répétées ne suffit pas."

<sup>2</sup> NEUDÖRFER (J.) (*Handbuch der Kriegschirurgie*, 1872, S. 1134), commenting on the possibility of treating successfully comminuted shot fracture of the shoulder joint by the expectant method, insists "upon the immediate and careful removal of all fragments" and the "insertion, into the cavity, of a drainage tube of large calibre," as only in this manner "all further operative interference, such as exarticulation or resection, may be avoided; and a more useful arm may be obtained than by a successful resection of the articulation."

<sup>3</sup> PIROGOFF (N.) (*Grundzüge der Allgemeinen Kriegschirurgie*, 1864, S. 798) and SZYMANOWSKY (J.) (*Handbuch der Operativen Chirurgie*, 1870, B. II) claim that the gypsum bandage secures the desired immobility; and BECK (B.) (*Chirurgie der Schwerverletzungen*, 1872, S. 583, 585) cites three cases of shot fractures of the shoulder joint treated on the expectant plan, in which this bandage was employed to good advantage, but generally not until "inflammation and suppuration had diminished." DEMME (H.) (*Studien*, B. II, S. 221) remarks: "Complete immobility of the joint during transportation should be secured. Unfortunately of the apparatuses recommended none fulfil this desideratum, and we must frequently be satisfied with position. The application of a cap-shaped splint seems advisable."

<sup>4</sup> HAMILTON (F. H.) (*A Practical Treatise on Fractures and Dislocations*, 1856, 3d ed., p. 229), remarking that intra-capsular fractures of the upper extremity of the humerus are generally compound, and, from the extent of the injury, often demand resection or amputation of the entire arm, says: "If an effort be made to save the arm, splints will not be applied, and the treatment will have little or no reference to the existence of a fracture; it will be directed only to the reduction or prevention of the inflammation, etc."

<sup>5</sup> LANGENHECK (B.) (*Chir. Beobachtungen aus dem Kriege*, 1874, S. 115) remarks: "There is no doubt, that, in cases of the upper extremity, the main issue should be the preservation of the usefulness of the hand and fingers. The shoulder joint may be ankylosed or loose, the elbow joint may be ankylosed at a right angle; the arm remains, nevertheless, for the invalid of inestimable value, and cannot be replaced by any prosthetic measure, as long as full use of the hand has been preserved. I cannot believe that the invalids examined by HANNOVER and KRATZ, who declared that they would rather have the arm amputated than to be troubled with their 'lame limbs,' were in earnest, nor can I believe that a surgeon, aside from the danger of the operation, could consent to exarticulate the arm at the shoulder joint on account of lameness or complete uselessness of the arm, as even the lamed arm, which swings like a pendulum powerless at the side of the body, serves to retain the equilibrium of the body."

<sup>6</sup> Dr. J. CHRISTIAN, in one of an interesting series of papers on the wounded of the French-German War of 1870-71 (*Relation sur les plaies de guerre observées à l'ambulance de Bischwiller*, 1870-71, in *Gaz. méd. de Strasburg*, 1872, p. 279), records twenty-four shot wounds of the shoulder joint, of which twenty-one were treated on the expectant plan. Eight of those had a fatal result. This writer dwells on the tendency to burrowing of pus in these cases. From various other European writers on military surgery, I have collected one hundred and sixty-four instances of shot wounds of the shoulder joint with fracture, treated on the expectant plan. Of these, eighty-two, or fifty per cent., had a fatal termination. The sources from which these cases were collected will be found in a tabular statement at the end of the chapter.

<sup>7</sup> Several articles, from which the student may derive assistance, have not, however, been cited; for example: the article in TODD's *Cyclopædia*, 1847-9, Vol. IV, p. 577, by Dr. ROBERT ADAMS, on *Abnormal Conditions of the Shoulder Joint*, and the fourth chapter of Dr. R. W. SMITH'S well-known *Treatise on Fractures in the Vicinity of Joints*, 1847, p. 176. BIEFEL (R.) (*Kriegschir. Aphorismen von 1866*, in *Arch. für Klin. Chir.*, Berlin, 1869, Band XI, S. 426) has some remarks on the subject; and in the classical works of BOYER, COOPER, DUPUYTREN, and NÉLATON, compound fractures involving the shoulder are discussed. Professor ESMARCH, of Kiel, in his celebrated work *Über Resektionen*, u. s. w., 1851, S. 51, has some observations on the expectant treatment of shot fractures at the shoulder; and Professor HANNOVER, of Copenhagen, in his valued treatise *Das Endresultat der an Dänischen Verwundeten* u. s. w., in *Med. Jahrbücher des Oesterreich. States*, B. 18, 1869, S. 109-137, also adverts to this subject.

of the subject has been somewhat fully referred to in the preceding and subjoined foot-notes. The question of the safety and comparative advantages of attempting expectant treatment, after shot fractures of the articular extremities of the humerus and scapula, requires further investigation. It is proved that under judicious management the results of expectant measures as to life and limb may be most satisfactory. It remains to be shown that, under the ordinary conditions of war-surgery, immediate operative interference may not be the safest plan. While the opinion offered in my preliminary report<sup>1</sup> of 1865 may have been expressed too emphatically, as deduced from insufficient data, it may still be held that the proportion of cases of shot fracture at the shoulder in which an expectant treatment is expedient, is comparatively small, and that recourse should generally be had to excision, unless concomitant injuries of the blood-vessels or nerves, or extended lesions of the soft parts, or of the shaft of the humerus, render amputation imperative.

EXCISIONS AT THE SHOULDER.—The cases of excision at the shoulder for shot injury that were reported during the war were so numerous that, if their discussion does not definitively settle the questions regarding operative interference in such cases, they furnish, at least, a mass of evidence unprecedentedly large<sup>2</sup> towards the solution of the problems presented by this interesting subject. The histories of no less than eight hundred and eighty-five cases were reported, and the results, as to fatality, have been ascertained in all save nine.<sup>3</sup> It would appear that six hundred and seventy of these operations were for direct shot injury of the articulation,<sup>4</sup> two hundred and fifteen either for shot fracture in near proximity to the joint, or for consecutive caries or necrosis.<sup>5</sup> It was thought inex-

<sup>1</sup> Circular 6, S. G. O., 1865, p. 55. It is there stated that: "Of 36 cases of gunshot fracture of the head of the humerus, selected as favorable cases for the expectant plan, and treated without excision or amputation, 16 died, or 44.4 per cent., a ratio in favor of excision of 11.36 per cent." Evidently this is a flagrant instance of generalization from insufficient data, inasmuch as 505 cases were reported of shot fractures at the shoulder treated expectantly, with a fatality of 27.5 per centum only; and with every allowance for erroneous diagnoses, the expectant plan makes a better numerical showing than I formerly believed possible. I am the more penitent for the hasty conclusion in the preliminary report, because it has misled several trusted surgical authorities. Among others, Dr. ASHURST (*Princ. and Pract. of Surgery*, 1871, p. 165), relying on these statistics, states that "expectant treatment gave worse results than either [excision or amputation], the mortality, even in selected cases, being as high as 44.4 per cent."

<sup>2</sup> From all the sources of information I have been enabled to consult, printed, manuscript, and verbal, including the doubtful cases of PERCY, LARREY, and GUTHRIE, the cases reported from the Paris revolutions of 1830 and 1848, and the Antwerp siege of 1831, from the French campaigns in Algiers, from the hostilities in Schleswig-Holstein, from the war in Lombardy in 1848-49, from the Crimean war, from the Italian campaign of 1859, from the New Zealand war of 1863-5, from the Danish war of 1864, from the Austro-Prussian "six-weeks' war" of 1866, from the returns of the French-German war of 1870-71, that had reached this country at the close of the year 1874, and, finally, from nearly a hundred cases communicated in writing or verbally, I have succeeded in collating less than five hundred and fifty examples of excision at the shoulder from shot injury, apart from those here tabulated, or less than two-thirds of the aggregate here recorded.

<sup>3</sup> A citation from an article in the *American Journal of Medical Sciences*, 1868, Vol. LVI, p. 128, may be permitted here: "The report on the nature and extent of the materials available for a surgical history of the war, included in Circular No. 6, S. G. O., 1865, was published in October of that year, a few months after hostilities had closed, and was professedly a preliminary and prefatory report, in which all pretension to completeness was repeatedly disclaimed. \* \* And, on every page, [it] endeavors to show the impracticability of gratifying the natural desire of the public for immediate information as to the results of the surgery of the war, without the greatest sacrifices of accuracy or completeness. In relation to a few of the surgical questions of especial interest \* \* an attempt was made to satisfy professional impatience, by giving tabular statements of all the facts on these subjects then in the possession of the Bureau, so far as was consistent with the space and time to which the compiler was restricted. But these were supplied with the reiterated caution that the results were incomplete, and that deductions from them were premature." That the preliminary report has been mistaken in Europe, as well as in this country, for the official surgical history, is a fact of which I am often reminded. Dr. F. LÖFFLER (*Generalbericht* u. s. w., 1867, S. 288), citing Circular 6, emphasizes a criticism on the statistics of shoulder joint excisions: "Five hundred and seventy-five resections of the shoulder joint! That is undoubtedly quite a number, such as would admit of generalization. It is the number to be found in the official report of the American war of the Union. But in sixty-seven cases the result was not ascertained." [The last italics are the editor's.]

<sup>4</sup> Six of these remain undetermined. Two hundred and twenty-three, or 33.58 per cent., terminated fatally.

<sup>5</sup> The result of three cases is unknown. In two hundred and twelve determined cases, there were eighty-three deaths, a mortality of 39.15 per centum, more than five per centum greater than in those cases in which the joint was directly injured.



pedient to segregate these groups; but more desirable to classify the cases according to the portions of bone removed, as in TABLE XXI, and in relation to the primary, intermediary, or secondary dates of the operations:

TABLE XXI.

*Numerical Statement of Eight Hundred and Eighty-five Cases of Excisions at the Shoulder Joint after Shot Injury.*

PARTS EXCISED.	OPERATION.				TOTAL.
	PRIMARY.	INTERMEDIARY.	SECONDARY.	UNDETERMINED DATE.	
The upper extremity of the humerus, with parts of either clavicle or scapula, or of both.	20	11	10	1	42
Part of the head.....	3	3	6	2	14
Head of the humerus.....	175	55	26	17	273
Head, with portion of the shaft.....	293	155	50	19	517
Excision at shoulder; parts not definitely distinguished.....	27	.....	.....	12	39
Aggregates.....	518	224	92	51	885

The different groups will be further analyzed, with details and figured illustrations of the more important cases in which such data were available, and tabular statements of the remainder.

**Excisions of the Head of the Humerus with Portions of the Clavicle or Scapula.**—The forty-two reported cases of this group, enumerated just above, will be more fully tabulated further on, in TABLE XXII. In three cases, the operations consisted in decapitations of the humerus with removal of the outer portion of the clavicle; in thirty-six, of excision of the upper extremity of the humerus and of portions of the processes of the scapula; in three, of excisions of the extremities of the three bones next the joint. Of the thirty-six cases in which the head of the humerus together with portions of the shoulder blade were removed, the parts of the scapula excised are specified with precision in thirty-three. The acromion, and sometimes portions of the spine, were excised in seventeen cases; the head or neck, in eleven cases; the coracoid, in two cases; while, in three instances, coracoid, acromion, head of scapula,<sup>1</sup> as well as head of humerus were excised, these latter, in reality, being entitled to be styled excisions of the shoulder joint. It is remarkable that the mortality, in the reported cases of this group, is less than that returned for simple decapitations of the humerus after shot fracture, scarcely a fourth terminating fatally. There were twenty primary, eleven intermediary, and ten secondary operations, and one successful instance of unspecified date. The appearance of the limb in one of the successful intermediary cases is represented by FIGURE 2 of PLATE XIII, opposite, and wood-cuts showing the results of several of the primary and secondary operations are intercalated in the text further on.

Detailed abstracts of six cases that furnished illustrations to the Museum may precede, in inverse order, the tabular summary. One was a secondary, two were inter-

<sup>1</sup> LÆFFLER (F.) (*Generalbericht*, u. s. w., Berlin, 1867, S. 290) remarks: "Fracture of the head of the humerus with injury of the articular portion of the scapula was comparatively frequent in shot wounds of the shoulder joint. This complication makes the prognosis of excision of the joint more serious, but is not a counter indication. In case of comminution, the surgeon is compelled to remove, after the resection of the head of the humerus, the fragments of the glenoid process. If there are only fissures, the question arises, whether it be advisable to excise the head or processes surrounding the glenoid cavity of the scapula. In our three cases, which recovered, this was not considered advisable. The progress of these cases, it must be admitted, was hindered by tedious burrowing of pus."

FIG I

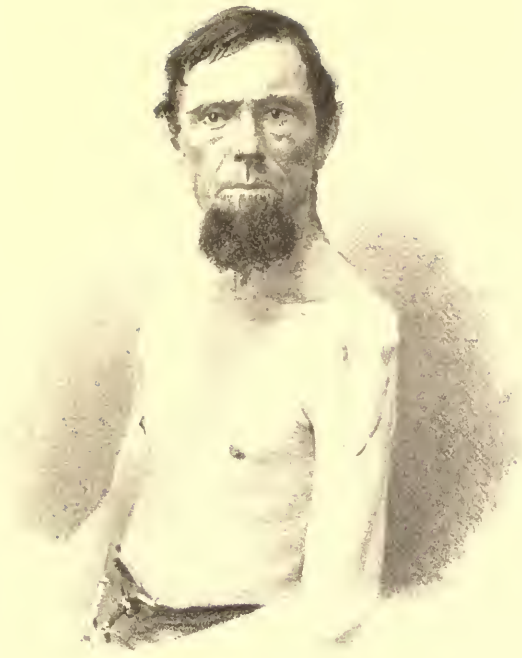

FIG II

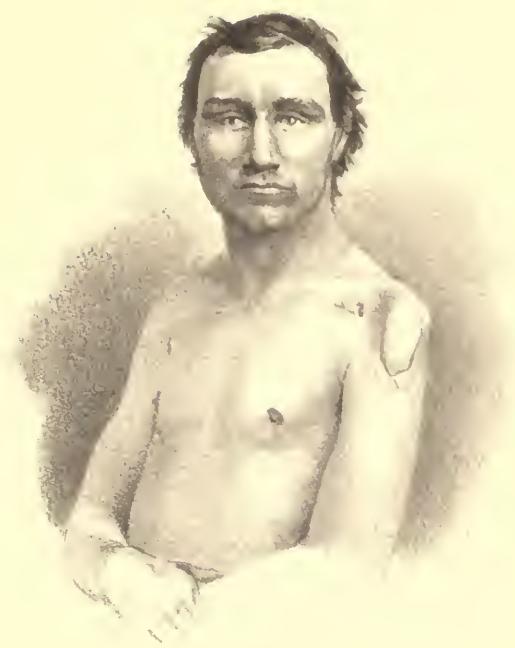

FIG III

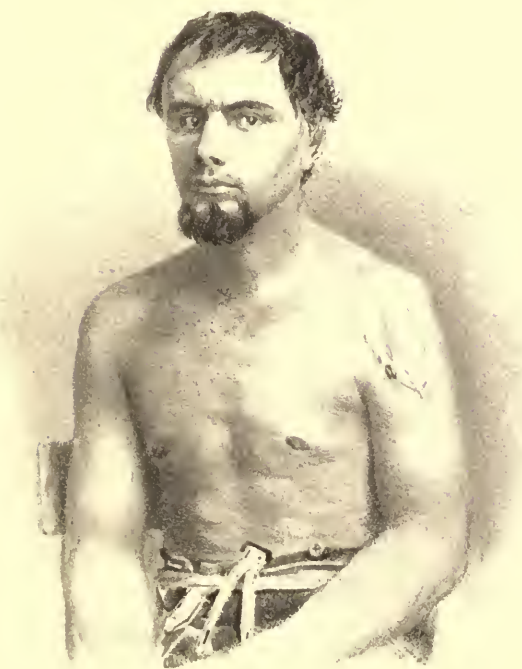

FIG IV



E. M. Wells del

J. Bien lith

RESULTS OF EXCISIONS OF THE HEAD OF THE HUMERUS.

FIG I Private Martin Kelly

FIG III Sergeant Jacob Yakey

FIG II Private R. Jones SPEC 259 A M M

FIG IV Private J. K. Clark SPEC 633 A M M





mediary, and three primary operations. A secondary case, where the patient survived an excision involving a large portion of the clavicle as well as the head of the humerus, was carefully illustrated by Surgeon R. B. Bontecon, U. S. V., and detailed as follows:

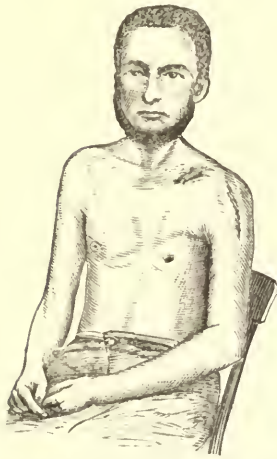

FIG. 396.—Cicatrices after an excision of the head of the humerus and portion of the clavicle for shot fracture.

CASE 1492.—Private John Harvey, Co. F, 29th Massachusetts, aged 21 years, was wounded at Petersburg, June 17, 1861, treated in a Ninth Corps hospital, and thence sent to Washington, and admitted into Harewood Hospital June 21st, suffering from a shot wound of the left arm. The ball entered at the upper third of the arm, passing upward, grooving the head of the humerus, and fracturing the left clavicle. On admission, the injured parts were in good condition, but the patient was very weak from excessive suppuration. On the 25th, the ball was extracted from under the fractured clavicle. On July 17th, the patient was etherized, and Surgeon R. B. Bontecon, U. S. V., excised the head of the humerus and about three inches of the left clavicle, which was denuded and protruding. The patient did well under supporting treatment. He was discharged from service February 18, 1865, on certificate of discharge for disability from "resection of the humerus and three inches of the sternal end of the clavicle." The foregoing notes, with two photographs taken at Harewood Hospital, representing the appearances of the shoulder after recovery, together with the portion of the humerus removed, were contributed to the Museum by Dr. Bontecon. The photographs give a tolerably good idea of the form of the cicatrices (FIG. 396) and of the extent of the incisions. The pathological specimen (FIG. 397) consists of the shattered head of the humerus. "A line of demarcation, crossing the epiphyseal line, encircles a necrosed portion of the specimen."—*Cat. Surg. Sect.*, 1865, p. 100. Examiner T. Hooper, of Fall River, Massachusetts, reported in September, 1866,

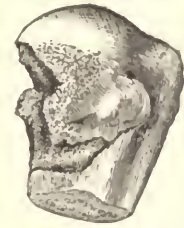

FIG. 397.—Head of left humerus excised for shot fracture. *Spec.* 3047.

that the arm was ankylosed and useless, could not be moved in any direction, was still painful, and the patient thought it would have been better had it been amputated. This pensioner died on December 29, 1869.

If the foregoing case be reckoned successful, and, unquestionably, the patient's life was prolonged for several years by the operation, the ten secondary operations give the favorable showing of a mortality rate of only twenty per cent. In the two fatal cases,<sup>1</sup> the patients succumbed after several months of profuse suppurative inflammation.

Of the eleven intermediary cases, the results were far less favorable, inasmuch as six patients died. Several of the survivors enjoyed comparatively good use of their limbs:

CASE 1493—Private R. Jones, Co. D, 67th New York, aged 22 years, was wounded, May 12, 1864, at the battle of Spottsylvania, and sent to a Sixth Corps hospital, in charge of Surgeon E. F. Taylor, 1st New Jersey. He had been struck by a conoidal musket ball, which comminuted the surgical neck of the humerus and the coracoid process of the scapula, and lodged just below the clavicle. He was removed to Fredericksburg, and thence to Washington, and was admitted to Carver Hospital, May 16th. At that date, the shoulder was highly inflamed and the arm greatly swollen. On May 17th, the patient was placed under the influence of ether, and the head and two inches of the shaft of the humerus, and the fragments of the coracoid process (FIG. 398) were removed, through a U-shaped incision, by Surgeon O. A. Judson, U. S. V. The case progressed rapidly toward recovery, and without any unfavorable complications. Attention was paid to supporting the elbow in order to approximate the upper extremity of the humerus to the glenoid cavity, and the wound was kept open for a time by dossils of lint. The coraco-brachialis and the short head of the biceps doubtless formed new attachments at the base of the coracoid process. A photograph of the patient was taken December 1, 1864 (*Surg. Ser. Phot.*, A. M. M., Vol. I, p. 17), at which date the cicatrix was perfectly sound, and the patient's control over the movements of the limb eminently satisfactory. Jones was discharged December 12, 1864, and pensioned. Drs. A. Parr and W. Bell, of New Brighton, England, reported, October 20, 1868: "Excision of the shoulder-joint on the left side, and consequently he has lost the use of the left arm, and will never regain it." This pensioner was paid December 4, 1873. The shattered excised portions of bone are represented in the annexed wood-cut (FIG. 398), and the appearance of the limb is represented in PLATE XIII, FIG. 2 (opposite page 520), by a drawing reduced from a photograph prepared at the Army Medical Museum in 1864. In a brief history, found after the compilation of the foregoing statement of the case, Dr. Judson says that: "Treatment consisted in introducing a siphon of lint into the wound to promote drainage. The end of the humerus was brought up as near to the glenoid cavity as possible by adhesive straps and bandage." The case is No. 25 in TABLE XXII.

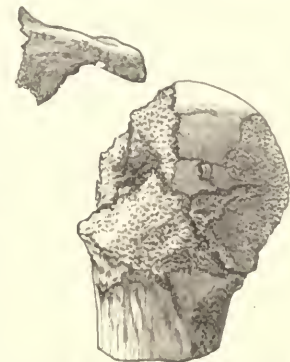

FIG. 398.—Excised head of humerus and coracoid process after shot fracture at the left shoulder. *Spec.* 2479.

<sup>1</sup>Harris and Jenkins, Nos. 15 and 23 of TABLE XXI, p. 521. The immediate causes of death are not reported. Both patients were in crowded hospitals in unhealthy climates.



An abstract of another successful intermediary operation has been published by the lamented Surgeon George Derby, 23d Massachusetts,<sup>1</sup> and is noted as the ninth case in the tabular statement on page 524.

In four of the six fatal intermediary operations, the unfavorable termination was ascribed to pyæmia. The most detailed example is the following:

CASE 1494.—Private B. M——, Co. H, 99th Pennsylvania, aged 23 years, was wounded at the Wilderness, May 6, 1864. He was sent from a Second Corps hospital to Washington, to Finley Hospital, and arrived May 11, 1864, with a "gunshot wound of the right shoulder, fracturing the acromion and coracoid processes and injuring the head of the humerus and spine of the scapula." "On May 24th," Surgeon G. L. Pancoast, U. S. V., reported, "he had a chill of an hour's duration. On the 25th, chloroform was administered and resection of the head of the humerus and excision of the fractured processes and fragments of the spine of the scapula were performed. At the time of the operation the condition of the injured parts was very unfavorable; the shoulder very much swollen, though not very painful; the patient's pulse was small and quick. Copious suppuration followed, together with frequent and watery stools, uncontrollable by opiates or astringents. Stimulants and nutritious diet were given. Death, June 3, 1864." Dr. Pancoast forwarded to the Museum the head of the humerus and portion of the acromion, which are represented in the adjoining wood-cut (FIG. 399), and are described (*Cat. Surg. Sect., A. M. M., 1866, p. 90*) as consisting of the "head of the left humerus obliquely excised through the surgical neck. The extremity of the acromion is mounted with the specimen. Pieces of the scapular spine were also removed, but are not preserved. The head is grooved transversely across its anterior face." The case is numbered 30 in the tabular statement. It an autopsy was had in the case, no report was communicated to the Surgeon General's office.



FIG. 399.—Head of left humerus and portion of the acromion excised after shot fracture.—*Spec. 2466.*

In the other two intermediary operations that terminated fatally, and which are enumerated as CASES 12 and 33 in TABLE XXII, gangrene and recurrent consecutive hemorrhage were assigned as the cause of death.

Among the twenty primary operations in this category, two terminated fatally, and, in a third case, the result could not be ascertained—a very favorable exhibit. In two of the seventeen successful instances, detailed clinical reports were transmitted, and photographs of the patients were forwarded to the Museum:

CASE 1495.—Brigadier General E. B. Brown, U. S. V., was wounded at Springfield, Missouri, January 8, 1863, by a musket ball at short range. Surgeon S. H. Melcher, U. S. V., reported: "The ball entered the left arm four inches below the apex of the shoulder, striking the humerus at the surgical neck, severing the long head of the biceps, passing upward and backward, splintering the shaft and fracturing the head of the humerus, striking the lower edge of the glenoid cavity, which it also fractured, and lodging just back of the neck of the scapula. I performed the operation for excision forty-four hours after the injury. The incision was V-shaped, and the head of the humerus and shaft of the bone, measuring five inches in all, and a small portion of the articular surface of the scapula, were removed. The wound healed by granulation, and, by January 31, 1863, was closed, except a small opening which discharged a moderate amount of pus. The limb was gradually shortening, and was, at that date, two inches shorter than the other. By a sling supporting the elbow, he used the fore-arm readily, and was daily walking about town. In five weeks after the battle he made the journey from Springfield to Sedalia, riding daily five to ten miles on horse-back, holding the reins in his left hand. In the fall of 1864 he was continually in the saddle, and commanded his brigade in the famous pursuit of Price by Pleasanton." This officer resigned his command November 10, 1865, and was pensioned from that date. On November 21, 1870, Dr. Melcher forwarded the photograph copied in the cut (FIG. 400), showing the condition of the arm and shoulder at that time, nearly seven years after the operation. He stated that this officer "had wonderful use of the entire arm; being able to chop wood, to play billiards, to support his fowling-piece at the shoulder while shooting, and to be constantly engaged in active out-door employment." As is usual in these cases, the pension examining surgeons' reports conflict with that of the operator. Examiner J. Bates, of St. Louis, reported, January 9, 1866: "Arm almost entirely useless;" and in September, 1873, a board, consisting of Examiners Porter, Hill, and Whitehill, reported "want of power in the arm, and deformity." A pension of thirty dollars a month was paid this officer as late as March, 1874.

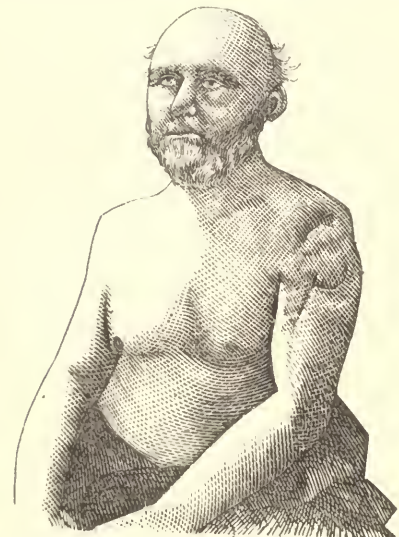

FIG. 400.—Appearance of a case of excision of the shoulder joint seven years after the operation. Phot. 301, Surg. Sect., A. M. M.

<sup>1</sup>DERBY (G.), *Case of Resection of the upper third of the Humerus*, in the *Boston Med. and Surg. Jour.*, 1863, Vol. LXVIII, p. 358. A photograph of this pensioner is preserved at the Museum (*Card. Phot. Surg. Sect., Vol. II, p. 6*), and an attempt was made to get a drawing from it; but the illustration was too unsatisfactory to warrant the insertion of a wood-cut.

Another strictly primary case suggests the fallacy of the dictum that operations of this class should not be performed on the battle-field,<sup>1</sup> and illustrates also the utility of a suspensory apparatus, when judiciously applied and intelligently worn:

CASE 1493.—Lieutenant I. N. Hawkins, Co. C, 73d Ohio, aged 22 years, was wounded at Atlanta, August 5, 1861. Surgeon W. C. Bennet, U. S. V., reported: "A minié ball fractured the right humerus, passed through the glenoid cavity, and was lost beneath the scapula. Resection was performed by Surgeon H. A. Langdon, 79th Ohio." This officer was sent to Nashville, and, on November 10th, came under the care of Surgeon J. E. Herbst, U. S. V., who noted: "Gunshot fracture of the right humerus in the upper third, penetrating the shoulder joint. On August 5th, the head and two inches of the shaft of the humerus were excised through a linear incision five inches in length. The patient states that he was in good condition at the time of the operation. The after-treatment consisted of simple dressings and supporting splints, and the patient did well." On November 27th, Lieutenant Hawkins was transferred to Cincinnati, and was treated in Grant Hospital until February 8, 1865, when he was returned to duty. On May 15, 1865, he was discharged the service and pensioned. In his declaration, the pensioner states that he was also wounded at Bull Run, August 30, 1862, in the right arm above the elbow, slightly fracturing the humerus, and on October 29, 1863, at Lookout Valley, was wounded in the left ankle, causing a severe flesh wound. Commissioner of Pensions J. A. Morgan, April 28, 1868, sent to the Surgeon General's Office, at the request of Mr. Hawkins, a photograph, copied in the wood-cut (FIG. 401). In the accompanying memorandum it is stated that: "He had good use of the arm from the elbow down. He writes legibly. Dr. Waddle, of Chillicothe, Ohio, had examined him some two weeks before, and said that there was no union of bone, or cartilage formed in place of that removed." Surgeon E. D. Hudson, who furnished this pensioner with a suspensory apparatus, stated that the arm was shortened half an inch; that the wound was soundly healed, with a deep sulcus underneath the acromion. The arm was useless for lack of leverage; the functions of the hand and forearm were, however, normal. This pensioner was paid March 4, 1874, at his home at Austin, Minnesota. There are several other reports of the case, the latest by Pension Examiner R. A. Barnes, of Austin. They substantially confirm and reiterate the foregoing facts.



FIG. 401.—Cicatrix in a case of excision of the head of the humerus.

The next primary case exemplifies a removal of the acromial process, and, as well, an excision of a portion only of the head of the humerus, a group of rare operations, of which fourteen instances will be enumerated in TABLE XXIII, on page 528.

CASE 1497.—Private P. Hogan, Co. K, 4th Infantry, aged 23 years, was wounded at Gettysburg, July 2, 1863. Assistant Surgeon B. Howard, U. S. A., reported from a Fifth Corps hospital: "A minié ball entered at the outer border of the deltoid, striking the head of the left humerus, and fracturing its outer third, and also the adjacent part of the acromion process, the ball lodging in the glenoid cavity. I made an incision parallel with the posterior border of the deltoid down to the joint, turned out the head of the humerus, and, instead of removing it entire, made a clean section both of it and of the acromion process, leaving the inner two-thirds of the head of the humerus and the corresponding portion of the acromion." On July 25th, the patient was transferred to the Cotton Factory Hospital at Harrisburg, and, on September 1st, to Fort Columbus, New York, where he was discharged October 10, 1864. Assistant Surgeon P. S. Conner, U. S. A., noted upon the certificate of disability: "Physically not suitable for the Veteran Reserve Corps." He was pensioned. Examiners G. C. Ashman and T. C. Miller, of Cleveland, reported, September 8, 1873: "There has been a gunshot wound of the left shoulder, the ball entering on the outer aspect, passing inward, and lodging in the joint, whence it was removed. There is loss of the acromion process of the left scapula to the extent of one and one-half inches, and loss of a portion of the head of the humerus and glenoid fossa of the scapula. Disability arises from the partial ankylosis of the left shoulder joint, which is such as to prevent full extension of the arm and rotation. Disability rated total." The specimen (No. 1377), contributed by Dr. Howard, is described, at page 85 of the *Catalogue of the Surgical Section of the Museum*, of 1866, as: "A section one-third of an inch in thickness, excised from the outer portion of the head of the left humerus for fracture. A portion of the conoidal ball is attached. A section of the acromion, which was made at the same time, has not been preserved."

It is impracticable to take space to detail the remaining thirty-six cases of excisions involving the different bones of the shoulder; but the more important particulars regarding them are set forth in the descriptive numerical statement on the following page.

<sup>1</sup>In a *Report of the Associate Medical Members of the Sanitary Commission on the Excision of Joints for Traumatic Cause*, Cambridge, 1862, "respectfully recommended by the Commission to the medical officers of our army now in the field," it is stated, at page 22, that: "Excisions of large joints are never to be practised on the battle-field, or under conditions that will require the immediate transportation of the wounded." The motives that led the eminent gentlemen who signed this report to volunteer advice to the field surgeons are worthy of all praise; but their judgment, on this point, has not been confirmed by those who had improved the best opportunities for observation.



TABLE XXII.

*Summary of Forty-two Cases of Excisions of the Upper Extremity of the Humerus, together with Parts of either Clavicle or Scapula.*

No.	NAME, AGE, AND MILITARY DESCRIPTION.	DATE OF INJURY.	NATURE OF INJURY.	DATE OF OPERATION.	OPERATION AND OPERATOR.	RESULT.
1	Benson, W. H., Pt., K, 45th Pennsylvania, age 26.	May 6, 1864.	Gunshot fracture of the left scapula and the head of the humerus.	May 27, 1864.	Excision of the head of the humerus and a portion of the scapula, by Surgeon A. F. Sheldon, U. S. V.	Disch'd September 11, 1864, and pensioned. In October, 1873, disens'd bone was discharging; arm useless.
2	Boynton, O. F., Pt., C, 14th Wisconsin.	March 27, 1865.	Comminution of the right scapula, involving the head of the humerus, by a shell fragment.	Mar. 27, 1865.	Excision of the head of the humerus and the acromion process of the scapula, by Surg. E. Powell, 72d Illinois.	Died April 9, 1865, of erysipelas.
3	Brown, E. B., Brigadier General, U. S. V.	Jan. 8, 1863.	Musket ball fractured the left shoulder joint and the shaft of the humerus and severed the long head of the biceps.	Jan. 10, 1863.	Excision of the head and a portion of the shaft of the humerus, and a small piece of the glenoid cavity of the scapula, by Surgeon S. H. Melcher, Missouri S. M.	Disch'd November 10, 1865, and pensioned. "wonderful use of the entire arm." See Case 1495.
4	Burgdorff, A., Pt., K, 149th New York, age 35.	July 20, 1864.	Lacerated wound of left shoulder joint by shell fragment; bones considerably fractured.	July 21, 1864.	Removal of the head of the humerus and portions of the clavicle and scapula.	Disch'd May 30, 1866, and pensioned; arm nearly immovable at shoulder joint.
5	Carter, R., Pt., K, 2d Georgia, age 34.	May 3, 1863.	Gunshot fracture of the clavicle and the head, neck, and shaft of the humerus.	May 4, '3.	Excision of one and a half inches of the sternal end of clavicle, and the head, neck, and two and a half inches of the shaft of the humerus.	Died June 19, 1863, from exhaustion following hemorrhage.
6	Chamberlain, T., Pt., G, 30th Ohio, age 21.	Sept. 14, 1862.	Conoidal ball fractured the right shoulder joint.	.....	Excision of the head of the humerus and the spine of the scapula.	Disch'd January 9, 1863, and pensioned; arm shortened one and a half inches.
7	Coy, G. W., Sergeant, D, 56th Massachusetts, age 28.	June 17, 1864.	Compound fracture of the left shoulder joint by a shell fragment.	June 17, 1864.	Resection of the head of the humerus and superior portion of the scapula, April 15, 1865, superior epiphysis and diaphysis removed piece-meal with pliers, by Ass't Surgeon G. M. McGill, U. S. A.	Disch'd June 5, 1865, and pensioned; arm useless.
8	Creighton, J. D., Pt., F, 12th Massachusetts.	August 29, 1862.	Gunshot fracture of the right shoulder joint.	Oct. 16, 1862.	Head and two and a half inches of the humerus and a portion of the acromion removed, by A. A. Surgeon J. M. McCalla.	Disch'd June 11, 1863, and pensioned. November, 1870, wound frequently breaks out.
9	Dunham, J., Pt., 3d New York Cavalry.	August 20, 1862.	Head of left humerus and the glenoid cavity comminuted by a conoidal ball.	Sept. 18, 1862.	Removal of neck of the scapula and head and shaft of the humerus to the junction of the middle and upper third, by Surgeon G. Derby, 22d Mass.	Discharged September 28, 1863, and pensioned; limb shortened three inches; union wholly muscular.
10	Durning, J., Pt., I, 12th New York, age 33.	Ap' 16, 1865.	Shot fracture of right shoulder joint; necrosis of the head of the humerus.	May 12, 1865.	Excision of the head of the humerus and a portion of the scapula, by A. A. Surgeon G. W. Van Voast.	Died May 25, 1865, of pyæmia.
11	Fulton, H. D., Pt., E, 30th Indiana.	Sept. 19, 1863.	Canister shot comminuted the head of the left humerus, the glenoid cavity, and the acromion process of the scapula.	Nov. 1, 1863.	Excision of the head of the humerus, the glenoid, and the acromion, through a linear incision, by Ass't Surgeon C. F. Haynes, U. S. V.	Disch'd April 22, 1864. October, 1868, useful arm.
12	Garland, A. M., Pt., H, 5th New Hampshire.	June 1, 1862.	Ball comminuted right clavicle at its outer third, grazed the head of the humerus, and was lost in the tissue of the arm.	June 26, 1862.	Excision of the head of the humerus and the acromial end of the clavicle, by Ass't Surg. H. L. Sheldon, U. S. A.	Died June 18, 1862. <i>Spec.</i> 4922, A. M. M.
13	Goedwin, R. S., Pt., A, 11th Massachusetts, age 25.	May 3, 1863.	Compound fracture of the right shoulder joint by grapeshot.	May 3, 1863.	Excision of end of the clavicle, the superior process of the scapula and the head and part of the shaft of the humerus.	Disch'd November 10, 1864, and pensioned. September, 1873, arm useless.
14	Halford, H., Pt., A, 8th Michigan, age 39.	Sept. 1, 1862.	Shot fracture of the head and neck of the left humerus; fragments of bone embedded deep in the joint.	Dec. 14, 1862.	Removal of extremity of the acromion and portions of the head of the humerus, by A. A. Surgeon W. A. Crover.	Disch'd April 6, 1863, and pensioned; arm emaciated and useless. <i>Spec.</i> 1023, A. M. M.
15	Harris, S. S., Pt., G, 70th Indiana, age 26.	May 15, 1864.	Musket ball fractured the spine of the left scapula, the glenoid cavity, and the head of the humerus.	June 22, 1864.	Removal of three inches of the upper end of the humerus, the acromial process, and part of the spine, and also of the body of the scapula, through a straight incision, by Ass't Surg. H. T. Legler, U. S. V.	Died August 14, 1864, at the field hospital at Bridgeport, Alabama.
16	Hartman, J. C., Pt., C, 4th Iowa Cavalry, age 45.	June 10, 1864.	Gunshot fracture of the left shoulder joint.	June 17, 1864.	Excision of the head and neck of the humerus and portions of the scapula forming the glenoid cavity, by A. A. Surgeon W. D. Hall.	Died June 24, 1864, of pyæmia.
17	Harvey, J., Pt., F, 29th Massachusetts, age 21.	June 17, 1864.	Musket ball destroyed about one-third of the inner side of the articular surface of the left humerus and the extremity of the clavicle.	July 17, 1864.	Removal of three inches of the clavicle and the head of the humerus through the surgical neck, by Surgeon R. B. Bon-tecon, U. S. V.	Discharged February 18, 1865, and pensioned; arm useless. <i>Spec.</i> 3047, A. M. M.
18	Hawkins, I. N., Lieutenant, C, 73d Ohio, age 29.	August 5, 1864.	Gunshot fracture of the right shoulder joint.	Aug. 5, 1864.	Excision of the acromion process of the scapula and the head and three inches of the shaft of the humerus, by Surg. H. H. Langdon, 79th Ohio.	Disch'd June 2, 1865, and pensioned; disability total and permanent.
19	Hayes, E., Lieutenant Colonel, 24th Ohio, age 31.	May 8, 1864.	Conoidal ball fractured the head of the right humerus and perforated the shoulder joint.	May 8, 1864.	Excision of a portion of the glenoid cavity and the head of the humerus, by Surgeon A. K. Fifield, 17th Ohio.	Disch'd November 4, 1864, and pensioned; muscular atrophy; arm and hand entirely disabled.

No.	NAME, AGE, AND MILITARY DESCRIPTION.	DATE OF INJURY.	NATURE OF INJURY.	DATE OF OPERATION.	OPERATION AND OPERATOR.	RESULT.
20	Hogan, P., Pt., K, 4th Infantry, age 26.	July 2, 1863.	Coronoid ball fractured the head of the left humerus and the acromion process of the scapula, and lodged in the cavity of the joint.	July 5, 1863.	Excision of the outer third of the head and the corresponding part of the acromion process, by Assistant Surgeon B. Howard, U. S. A.	Disch'd October 10, 1864, and pensioned; arm nearly useless. <i>Spec.</i> 1377, A. M. M.
21	Horton, R. E., Sergeant, E, 6th N. Y. Cavalry, age 30.	Sept. 19, 1864.	Musket ball passed through the right glenoid cavity and fractured the head of the humerus	Sept. 19, 1864.	Removal of the head and three inches of the shaft of the humerus, with the articulating surface of the scapula, by Surgeon A. P. Clark, 6th New York Cavalry.	Disch'd August 22, 1865, and pensioned; useful arm.
22	Inge, R., Pt., B, 1st Tennessee, age 23.	Aug. 8, 1863.	Gunshot fracture of the right shoulder joint.	Aug. 8, 1863.	Resection of the head and two inches of the shaft of the humerus, the coracoid and acromion processes, a portion of the spine anterior and inferior border of the scapula, and a portion of the glenoid cavity, by A. A. Surgeon A. Sterling.	Escaped February 18, 1864. <i>Spec.</i> 2090, A. M. M.
23	Jenkins, L., Pt., H, 24th Colored Troops.	July 10, 1863.	Contused wound of the shoulder joint, with partial fracture of the head of the humerus, caused by a piece of plank, which was struck by a shell.	.....	Secondary excision of the head and two inches of the shaft of the humerus, and the head and neck of the scapula.	Died April 25, 1864. <i>Spec.</i> 2724, A. M. M.
24	Jones, J., Pt., A, 11th Connecticut, age 25.	June 11, 1864.	Minié ball fractured the head of the left humerus, the coracoid process, and the body of the scapula.	June 23, 1864.	Excision of the head of the humerus, the coracoid process, and portion of the articulating end of the scapula, by A. A. Surgeon R. Ottman.	Died June 26, 1864. <i>Spec.</i> 3265, A. M. M.
25	Jones, R., Pt., D, 67th New York, age 22.	May 12, 1864.	Comminuted fracture of the surgical neck of the left humerus and the coracoid process of the scapula by a musket ball.	May 17, 1864.	Head and two inches of the shaft and fragments of the coracoid removed, through a V shaped incision, by Surg. O. A. Judson, U. S. V.	Disch'd Dec. 12, 1864, and pensioned; arm useless for manual labor. <i>Spec.</i> 2479, A. M. M., and Fig. 2, PLATE XIII.
26	Lyon, R., Sergeant, E, 49th Virginia, age 23.	Oct. 19, 1864.	Gunshot fracture of the left shoulder.	Oct. 19, 1864.	Removal of the acromion process and the head of the humerus, by Surgeons Morfitt and C. H. Todd, 13th Virginia.	Transferred for exchange February 16, 1865.
27	Marsh, N. P., Ft., C, 39th New Jersey, age 34.	Dec. 19, 1864.	Fracture of the right humerus, scapula, and clavicle by fragment of shell.	Dec. 19, 1864.	Removal of the head and one and a half inches of the shaft of the humerus, the coracoid process of the scapula, and the head of the clavicle, by Surg. L. W. Bliss, 51st New York.	Discharged July 8, 1865, and pensioned; arm powerless.
28	Mead J., Pt., K, 12th Wisconsin, age 23.	June 24, 1863.	Minié ball passed through the shoulder joint, destroying it.	On field.	Excision of part of the glenoid cavity and the head of the humerus.	Disch'd Aug. 21, 1863, and pensioned. March, 1870, arm useful from the elbow down.
29	Miller, M., Pt., K 119th New York, age 28.	June 15, 1864.	Musket ball comminuted the upper third of right humerus and injured the scapula.	Sept. 10, 1864.	Head and portion of the shaft of the humerus, four inches in all, and the acromion process of the scapula, removed through a linear incision, by Surg. M. Goldsmith, U. S. V.	Disch'd July 23, 1865, and pensioned. April, 1869, arm shortened nearly four inches, and useless.
30	M——, B., Pt., H, 91th Pennsylvania, age 23.	May 5, 1864.	Gunshot fracture of the acromion and coracoid processes of the right shoulder, with injury of the head of the humerus and the spine of the scapula.	May 25, 1864.	Excision of the head of the humerus through the surgical neck, and the fractured processes and fragments of the spine of the scapula, by Surg. G. L. Pancoast, U. S. V.	Died June 3, 1864. <i>Spec.</i> 2466, A. M. M.
31	Raymond, W. B., Corporal, K, 7th Wisconsin, age 17.	Feb. 7, 1865.	Gunshot wound of the right shoulder, involving the joint.	Feb. 27, 1865.	Excision of the head of the humerus and the acromion process of the scapula, through a V-shaped incision, by A. A. Surgeon W. W. Bidlach.	Disch'd June 27, 1865, and pensioned; muscular atrophy; motion at the elbow joint is nearly perfect.
32	Sampson, I., Pt., I, 79th Illinois.	Nov. 30, 1864.	Coronoid ball passed through the left shoulder joint, shattered the head and neck of the humerus, and fractured the head of the scapula.	Jan. 7, 1865.	Removal of the head and diseased portions of the scapula and the head of the humerus, by Surgeon J. R. Ludlow, U. S. V.	Disch'd March 14, 1865, and pensioned; perfect use of hand and forearm.
33	Sanford, J. E., Pt., D, 7th Massachusetts, age 24.	May 6, 1864.	Gunshot fracture of the right humerus, extending into the shoulder joint.	May 30, 1864.	Removal of the head and three inches of the shaft and a portion of the acromion, through a straight incision, by A. A. Surgeon F. W. Kelly.	June 7th, secondary hemorrhage; ligation of circumflex artery. Died June 16, 1864, from recurrent hemorrhage.
34	Shansville, V., Pt., K, 14th Louisiana, age 27.	Aug. 25, 1864.	Shell fragment fractured the left shoulder.	Aug. 25, 1864.	Removal of the head of the humerus and the acromion process of the scapula, by Surg. Ditton, 14th Louisiana.	Retired March 13, 1865, for disability, by Retiring Board.
35	Shreeve, D. H., Pt., F, 88th Illinois, age 43.	Nov. 25, 1863.	Acromion process of the left scapula, and the head and shaft of the left humerus shattered by a musket ball.	Nov. 26, 1863.	Excision of the head and four inches of the shaft of the humerus and a portion of the scapula, by Surgeon F. W. Lyttle, 36th Illinois.	Disch'd February 21, 1865, and pensioned.
36	Stökel, J. F., Pt., E, 6th New Jersey, age 22.	May 6, 1864.	Minié ball passed directly through left shoulder joint, fracturing the articular surface of the head of the humerus and the acromion of the scapula, and dividing the long tendon of the biceps.	July 12, 1864.	The head of the humerus and three-fourths of an inch of the acromion removed, through a straight incision, by Surgeon G. A. Mursick, U. S. V.	Disch'd October 6, 1864, and pensioned; "shoulder joint destroyed."
37	Sullivan, E., Pt., F, 20th Massachusetts, age 18.	May 12, 1864.	Coronoid ball fractured the left shoulder joint.	May 12, 1864.	Removal of the head of the humerus, the acromion process, a portion of the spine of the scapula, and the missile, by Surg. N. Hayward, 20th Massachusetts.	Disch'd January 17, 1865, and pensioned; arm powerless and nearly useless.



No.	NAME, AGE, AND MILITARY DESCRIPTION.	DATE OF INJURY.	NATURE OF INJURY.	DATE OF OPERATION.	OPERATION AND OPERATOR.	RESULT.
38	Thomas, E. M. D., Pt., G., 8th Louisiana, age 30.	Aug. 25, 1864.	Gunshot fracture of the left shoulder joint.	Aug. 25, 1864.	Excision of the head of the humerus and the acromion process of the scapula, by Surgeon J. N. K. Monmonier, 8th Louisiana.	Transferred for exchange February 16, 1865.
39	Unknown, Pt., 6th New York Cavalry.	June 11, 1864.	Conoidal ball fractured the head of the left humerus and the scapula.	June 11, 1864.	Removal of the head of the humerus, fragments of the scapula, and ball, through a straight incision, by Ass't Surg. J. W. Williams, U. S. A.	The patient fell into the hands of the enemy. <i>Spec.</i> 2333, A. M. M.
40	Way, J., Pt., G., 9th Colored Troops, age 19.	Sept. 29, 1864.	Gunshot wound of the left shoulder joint.	Jan. 9, 1865.	Head of the humerus and a portion of the acromion process of the scapula removed, through a straight incision, by A. A. Surg. F. E. Martindale.	Disch'd July 3, 1865, and pensioned; arm useless for labor.
41	Webster, A. G., Pt., H., 7th Maine, age 20.	June 10, 1864.	Musket ball crushed the head of the left humerus and passed through the glenoid cavity, shattering the head of the scapula.	June 10, 1864.	Excision of the head and neck of the humerus and two-thirds of the head of the scapula, by Surgeon G. T. Stevens, 77th New York.	Disch'd December 2, 1864, and pensioned; cannot extend hand to mouth.
42	Weller, L., Pt., G., 12th Virginia, aged 21.	June 11, 1864.	Gunshot fracture of the head of the left humerus, the glenoid cavity, and the neck of the scapula.	June 29, 1864.	Excision of the head, one inch of the shaft of the humerus, with a portion of the scapula, through a straight incision.	August 30, 1864, condition favorable; furloughed; recovered.

It will be observed that there were ten fatal, and one undecided case, and that there was an excessive fatality in the eleven intermediary operations. The ten deaths were ascribed to consecutive hæmorrhage in two instances, to pyæmia in five, to erysipelas in one; in the two remaining cases the proximate causes of death can only be surmised.

Thirty-six of the patients were Union, and six Confederate soldiers, and five of the latter<sup>1</sup> recovered and were sent home, faring even better than their opponents.

**Partial Excisions of the Head of the Humerus.**—While the extraction of fragments of the shattered head of the humerus was common, formal excisions of portions of the head were seldom attempted. Such operations were approved by Baudens,<sup>2</sup> whose services in promoting the employment of excisions of joints in military surgery have been insufficiently appreciated. Few other authors have even mentioned them. There were fourteen examples reported, of which two will be detailed:

CASE 1192.—Private Robert Wilson, Co. D, 6th Connecticut, aged 24 years, was wounded at Pocotaligo, October 22, 1862, and was admitted into Hospital No. 1, Beaufort, on the 24th. Surgeon R. B. Boniecou, U. S. V., furnished the following special report of the case: "This patient was admitted with a gunshot wound of the left shoulder, the ball entering anteriorly, midway between the acromion and coracoid processes, and grazing the internal aspect of the head of the humerus deeply at its union with the neck of that bone. No other wound was made, and the ball was not discernible through the wound. A considerable swelling under the pectoralis, near the clavicle, with tenderness and green discoloration, indicated the possibility that the ball was lodged there. Motion of the arm was painful; no crepitus, however. The swelling extended to the shoulder and arm, with some œdema of the fore-arm; radial pulse good. Wet dressings were kept applied until October 28th, when ice-bag and cerate dressings were substituted. On November 11th, the swelling having considerably subsided, I resected the head of the humerus by a transverse incision of the deltoid, and a perpendicular one from it down the posterior part of the arm. The chain saw was applied, after dissecting back the soft parts to a very small extent, and without dividing the attachment of any other muscle, the long head of the biceps having been shot away. Ice and cerate were continued, with oiled lint in the wound. When the joint was laid open, pus in considerable quantity came away. A track was discovered leading inward under the clavicle, but the ball could not be found. The swelling soon very much diminished, and the patient expressed himself as very well. On November 6th, there was increase of pain, and evidently more swelling in the infra and supra-scapular regions, with tenderness and well-marked fluctuation, but no discoloration. The clavicle is difficult to recognize, the parts are so tense and swollen. A poultice to cover the whole shoulder and neck was ordered, and a laxative of castor oil, and half-diet. On November 7th, the patient was doing well; the discharge of pus was copious; full diet, with a half-pint of beer at noon and night, was directed. On November 8th, the patient was doing well, but as he had not slept well the previous night, ten grains of Dover's powder was ordered. On the 10th, the abscesses in the neck and underneath the pectoral muscle having discharged

<sup>1</sup> In a letter dated Williston, Fayette County, Tennessee, March 25, 1874, to Surgeon General Barnes, Mr. Richard Inge remarks that the operation at the Overton Hospital was "A complete success. I am writing with the arm, a masterpiece of surgical skill." He fears that the case may have been lost sight of, after his escape from prison. He announces that he is on his way to his native city of London, but is willing to visit Washington (asking only that Government, against which this foreigner had fought for several years, should supply transportation). His chirography is so good as to be almost as remarkable as his impudence.

<sup>2</sup> BAUDENS, *Mémoire sur la Résection de la tête de l'humerus*, dans le *Recueil de Mém. de Méd. de Chir. et de Phar. Militaires*, 1855, 2<sup>ème</sup> série, 1855, T. XV, p. 180.

through the shoulder wound, the poultices were discontinued; and the surfaces of the deltoid, which had torn from the sutures and were gaping, were approximated with straps, and the whole limb was enveloped in lint and dry tow. On November 18th, the abscess of the neck and breast suppurated less. On November 26th, suppuration was again quite copious, and there was indistinct fluctuation above the clavicle, and also in the pectoral region, midway between the nipple and the left clavicle. Some wads of clothing were this day removed by the dresser, as they were projecting from the wound. The lips of the wound were drawn together gently by straps, and charpie was applied. The patient was permitted to dress and to walk about, and felt better than when in bed. On December 1st, the abscess over the clavicle was opened and a considerable quantity of pus escaped. I was unable to discover the ball, as I had hoped. A poultice was applied to this abscess. On December 10th, the abscess midway between the nipple and clavicle was opened and there was a free discharge of pus. A probe could be passed under the clavicle and all through the axilla, which was one vast pus-bag. I could not discover the ball. The patient walked about, and was off the bed the greater part of every day. On December 29th, this man had gained flesh; his wounds were nearly closed, and there was but little discharge. He was sent northward on the steamer *Star of the South*. He entered hospital at Fort Wood, December 31, 1862, and was thence sent to New Haven, and transferred to the Veteran Reserves, September 30, 1863, and subsequently discharged and pensioned, September 4, 1864. At Fort Wood, Dr. Bontecou saw this soldier, in July, 1863, "quite well, and with a useful arm." (See FIG. 402.) Examiner W. H. Trowbridge, of Stamford, July 8, 1867, reported: "Applicant is so crippled as to be unable to use his left shoulder. He suffers much pain, and his general health is permanently affected." On February 17, 1874, Mr. Wilson visited the Army Medical Museum, and stated that in October, 1864, while leaping to the ground from a fence, the ball became dislodged, and was removed by Dr. Hulburt, of Stamford. The excised portion of the humerus from this case was contributed to the Museum by the operator, Dr. Bontecou, and is represented in the adjacent wood-cut (FIG. 403). The line of section is oblique, crossing the anatomical neck. This pensioner was paid March 4, 1874.

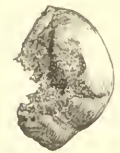

FIG. 403.—Portion of the head of the left humerus excised for shot-fracture. Spec. 2029.

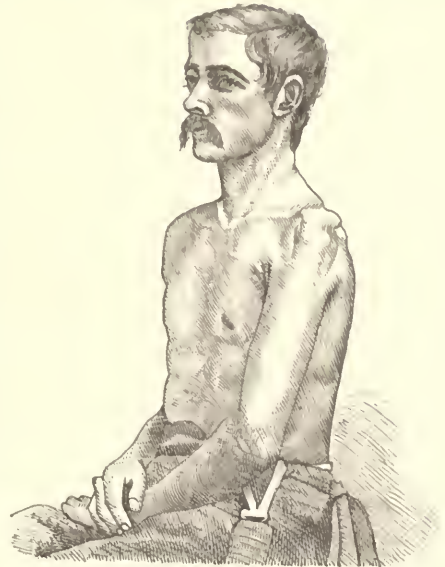

FIG. 402.—Result of excision of the head of the left humerus for shot-fracture. [From a photograph.]

Dr. Bontecou reported the following case also; and appears to have earnestly concurred in the sound doctrine of Malgaigne and of Baudens, that the surgeon is not at liberty to sacrifice the smallest portion of tissue which it may be practicable to save:

Dr. Bontecou reported the following case also; and appears to have earnestly concurred in the sound doctrine of Malgaigne and of Baudens, that the surgeon is not at liberty to sacrifice the smallest portion of tissue which it may be practicable to save:

CASE 1499.—Corporal H. Hatfield, Co. B, 14th New York Heavy Artillery, aged 23 years, was wounded at Fort Steadman, March 25, 1855, and was received into the Ninth Corps hospital at City Point; thence transferred to Washington, and admitted into Harewood Hospital on April 2d. Surgeon R. B. Bontecou, U. S. V., reported: "Gunshot wound of the right shoulder, the ball entering near the distal extremity of the clavicle and passing out below the acromion process of the scapula, injuring the head of the humerus. The wound was somewhat inflamed and discharging freely. On May 8th, the patient was placed under the influence of ether, and a small portion of the head of the humerus was resected. Simple dressings were applied, and supporting treatment ordered, with favorable result." The patient was doing well when discharged from service, July 2d, 1855. He was pensioned from this date, and was paid to March 4, 1874; but there are no records of the biennial examinations on file in the Pension Office. The photograph represented in the wood-cut (FIG. 405), together with the specimen (FIG. 404), preserved in the Army Medical Museum, was contributed by the operator, Dr. Bontecou. The specimen is described by Dr. Woodhull as "a portion of the head of the right humerus excised for gunshot, and consists of a section one-half inch in its greatest thickness, completely carious, and retaining but a small part of the articular surface."—*Cat. Surg. Sect.*, 1856, p. 97. A further search of the record of this pensioner, who resides at Perry City, New York, indicates that the result of the operation must have been tolerably satisfactory, since,



FIG. 404.—A portion of head of right humerus excised after shot injury. Spec. 4343.

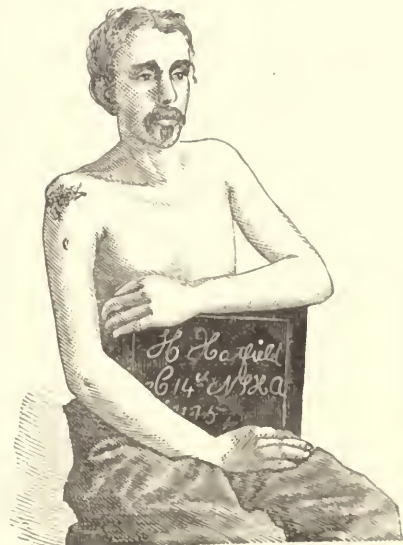


FIG. 405.—Cicatrices after an excision at the shoulder. [From a photograph.]

September 4, 1871, a reduction was made in his pension. Examiner M. M. Brown, of Ithaca, reported, December 23, 1873, that there was "complete ankylosis" [at the shoulder]; that the arm was "shortened one and a half inches, and the muscles of the arm are much atrophied, and the movements of the arm very limited." The pensioner's request for increased assistance was recorded, "to date from March 4, 1874." In May, 1874, Examiner M. L. Bennett, of Watkins, reported the disability as very serious.



There is an interesting specimen in the Museum, contributed by Dr. B. Howard, U. S. A., that illustrates this special operation,<sup>1</sup> although, as complicated by an excision of the clavicle, the case is classified elsewhere. It is one of the few osteological preparations in the collection, from cases of primary excisions limited to the epiphysis.

The results in this series attest, at least, the comparative safety of free openings into the shoulder joint after shot injury, but do not prove that, when the head of the humerus is grazed or grooved by a ball, it is safer to slice off the injured portion rather than to decapitate the bone. Ankylosis was too frequent to permit much to be said in favor of partial excisions in this region:

TABLE XXIII.

*Summary of Fourteen Cases of Partial Excisions of Head of the Humerus after Shot Injury.*

No.	NAME, AGE, AND MILITARY DESCRIPTION.	DATE OF INJURY.	NATURE OF INJURY.	DATE OF OPERATION.	OPERATION AND OPERATOR.	RESULT.
1	Caldwell, J., Lieut., F, 61st Pennsylvania.	Aug. 21, 1864.	Ball shattered about one-half of the head of the humerus	Aug. 21, 1864.	Shattered portion of head removed with gouge, by Surg. G. T. Stevens 77th N. York.	Disch'd September 3, 1864; not a pensioner December 4, 1874.
2	Dennison, W. J., Corporal, Thompson's Independent Battery.	Sept. 17, 1862.	Head of the right humerus deeply notched.	Oct 4, 1864.	Head partially resected, by Surg. H. S. Hewitt, U. S. V.	Disch'd November 21, 1862, and pensioned. Sept., 1874, unable to elevate arm beyond level; arm useless for manual labor.
3	Fulton, W. J., Pt., A, 1st Pennsylvania Cavalry age 22.	July 10, 1863.	Fracture of head of left humerus.	July 11, 1863.	Excision of sharp points and removal of fragments from head.	Disch'd Sept. 9, 1864, and pensioned. April, 1873, arm useless for manual labor.
4	Gissel, W. S., Pt., E, 5th Maryland.	Sept. 17, 1862.	Shot wound of right shoulder.	.....	Wound enlarged and shattered fragments excised.	Died November 10, 1862.
5	Harrington, M., Pt., B, 11th Infantry, age 23.	July 2, 1863.	Conical ball passed through head of left humerus; also, wound of right arm.	Nov. 20, 1863.	Posterior half of head excised, by A. A. Surgeon, A. D. Hall.	Disch'd April 5, 1864; pensioned. March, 1874, both arms much weakened in use of muscles.
6	Hatfield, H., Corp'l, B, 14th New York Heavy Artillery, age 23.	Mar. 25, 1865.	Head of right humerus fractured.	May 8, 1865.	Portion of the head of the humerus excised, by Surgeon R. B. Bontecou, U. S. V.	Disch'd July 25, 1865; pensioned. May, 1874, muscular atrophy; has very little motion of arm or forearm. <i>Spec.</i> 4343, A. M. M.
7	Jones, S. W., Pt., M, 12th Pennsylvania Cavalry, age 18.	July 25, 1864.	Inner half of the head of the left humerus much shattered.	Aug. 15, 1864.	Excision of inner half of the head, by A. A. Surgeon J. Dickson.	Disch'd June 30, 1865; pensioned. September, 1873, complete ankylosis of left shoulder joint and muscular atrophy.
8	Jones, W., Corp'l, K, 100th New York, age 22.	April 2, 1865.	Right shoulder joint fractured by a conoidal ball.	Sept. 15, 1865.	Two-thirds of the head of the humerus excised, by Ass't Surg. J. H. Armsby, U. S. V.	Disch'd January 15, 1866, and pensioned. Sept., 1873, ankylosis of shoulder joint and muscular atrophy; can use hand for writing. <i>Spec.</i> 588, A. M. M.
9	Mahon, D., Pt., D, 57th New York.	Sept. 17, 1862.	Shot wound of left shoulder.	Oct. 1, 1862.	Partial resection of head of humerus.	Duty. January 21, 1863. Not a pensioner in December, 1874.
10	McNalley, T., Corp'l, B, 62d Pennsylvania.	May 3, 1863.	Fracture of head of right humerus; loose fragments of bone became necrosed. The same ball destroyed the left eye and fractured the superior maxilla.	July 29, 1863.	Half of the head excised by straight incision through deltoid, by Ass't Surgeon W. Thomson, U. S. A.	Disch'd July 13, 1864, and pensioned. May, 1873, unfitted for all manual labor. <i>Spec.</i> 1683, A. M. M.
11	Robbins, S., Pt., D, 42d Illinois.	Nov. 25, 1863.	Head of the left humerus fractured; parts indurated; fistulous openings.	Aug. 16, 1864.	A large portion of the head excised, by A. A. Surgeon J. Sloan.	Disch'd December 23, 1864, and pensioned. April, 1872, complete and permanent ankylosis at shoulder joint.
12	<i>Sargent, A. H.</i> , Pt., F, 4th Texas, age 25.	July 3, 1863.	Ball split the head of the right humerus longitudinally and from right to left.	.....	Anterior portion of the head of the humerus removed.	Purloughed October 14, 1863.
13	Wilson, R., Pt., D, 6th Connecticut, age 24.	Oct. 22, 1862.	Ball entered between acromion and coracoid processes and lodged in the head of the left humerus.	Nov. 1, 1862.	Superior and greater portion of head excised, by Surgeon R. B. Bontecou, U. S. V.	Disch'd September 4, 1864, and pensioned. Sept., 1873, loss of use of arm. <i>Spec.</i> 2029, A. M. M.
14	Yeazell, S., Pt., B, 66th Ohio, age 19.	June 15, 1864.	Conical ball passed through the right shoulder joint and scapula.	June 16, 1864.	One-half inch of the head removed with the chain saw, by Surg. J. W. Broek, 66th Ohio.	Mustered out March 3, 1865, and pensioned. Sept., 1873, partial stiffness of the joint, and pain upon motion.

An analysis of this brief tabular statement is almost superfluous.

It will not escape the reader's attention that but one of the cases terminated fatally, that three were primary, three intermediary, and six secondary operations, and that in two cases the date of operation was undetermined, and that one of these was the single fatal case. Of the nine pensioners in this category, it is reported that two preserved serviceable arms while ankylosis or "a useless arm" is recorded in seven instances.

<sup>1</sup> *Specimen* 1577, SECT. I, A. M. M. The details of the case are given on p. 523 (CASE 1497), and the operation is tabulated as No. 20 in TABLE XXII.





FIG. I.



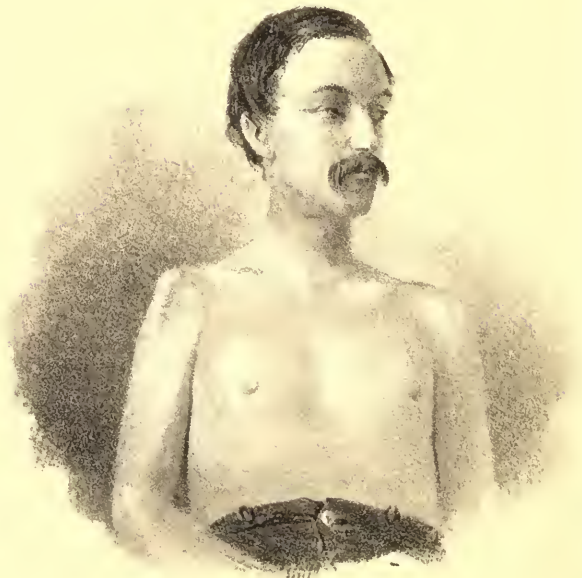FIG. II.




FIG. III.




FIG. IV.



E. M. Wells del.

J. B. Knapp lith.

### RESULTS OF EXCISIONS OF THE HEAD OF THE HUMERUS

FIG. I. Lieut. Jacobs. SPEC. 1767 A.M.M.  
 FIG. II. Private W. A. Henderson.

FIG. III. Private Reardon. SPEC. 1768 A.M.M.  
 FIG. IV. Lieut. C. T. Rand.

**Primary Decapitations of the Humerus for Shot Injury.**—Two hundred and seventy-three operations were referred to this group. A few will be detailed, and all of the series will, in TABLES XXIV and XXV, be enumerated, with such particulars as space will permit.

§ *Successful Cases.*—There were one hundred and nineteen survivors of whom a large proportion retained a useful hand and forearm, and several a serviceable upper arm:

CASE 1500.—Sergeant C. F. Rand, Co. K, 12th New York, aged 21 years, was wounded at Gaines's Mill, June 27, 1862. There is no hospital record of the case until the patient's arrival at Philadelphia; but, twelve years subsequently, the injured man stated that: "He laid on the field all that night, and was carried to the general field hospital at Savage's Station the next morning. There was free bleeding from the wound. At Savage's Station the head of the humerus was excised, either by Surgeon E. Bentley, 12th New York, or by Acting Assistant Surgeon J. Swinburne. From this station, he was sent to Richmond." He complained of the road and river transportation. After discharge from the prison hospital he stated that he was exposed at the dock until the arrival of the transport Daniel Webster, on which he was conveyed to Philadelphia. He entered Satterlee Hospital on July 30, 1862, and was discharged a month subsequently and pensioned, Surgeon I. I. Hayes certifying: "Resection of shoulder, necessitated by shot wound." This pensioner re-enlisted in the Veteran Reserves, and was appointed in November, 1863, a second lieutenant, and assigned, in May, 1864, to duty at Douglas Hospital. Assistant Surgeon W. Thomson, U. S. A., had prepared a photograph, which is copied in Figure 4 of PLATE XIV, opposite page 529, and furnished a copy to the Museum with the following memorandum: "This officer can use his arm at table, and plays well on the banjo." On January 1, 1868, Lieutenant Rand was discharged. Examiner John Root, of Batavia, New York, in June, 1869, reported: "The arm hangs by the muscles and ligaments, and for manual labor is of no use;" and, in September, 1873, Examiner J. O. Stanton reported: "About three inches of shortening of the limb. Cannot raise the arm. Has little use of the hand." This pensioner was paid in September, 1874. He availed of the opportunities afforded by his assignment to hospital duty to study medicine, and, receiving a diploma from one of the medical colleges in Washington, became a practitioner there. In addition, he occupies a responsible position in the Post Office Department. The result of the primary excision in this case is very satisfactory.

Another case, represented on PLATE XIV, was reported by the operator as simply a primary decapitation of the humerus, though subsequent reports would indicate that several inches of the shaft were removed. It is probable that consecutive necrosis and the elimination of tubular sequestra may account for the discrepancies in the report:

CASE 1501.—Corporal W. A. Henderson, Co. K, 1st U. S. Sharpshooters, aged 21 years, was wounded at Kelly's Ford, November 7, 1863. Surgeon J. W. Lyman, U. S. V., reported, from a Third Corps hospital: "A gunshot fracture of the head of the right humerus, with resection of three inches." This patient was sent to Washington, and entered Douglas Hospital November 9th. Assistant Surgeon W. Thomson, U. S. A., reported: "Resection of right shoulder joint. This man was discharged May 3, 1864." Dr. Thomson sent to the Museum a photograph, which is represented in FIGURE 2 of PLATE XIV, opposite page 529, with a statement that the "arm is useful, the patient can feed himself, and take his hat off." This corporal was pensioned. Examiner W. A. Jackson, of Lapeer, Michigan, November 26, 1865, reported: "The ball entered at the tuberosity of the right humerus and came out one inch below the coracoid process of the right scapula, completely comminuting the upper portion of the humerus. Four inches of the bone is lacking. The muscles of the right side of the chest both front and back are shrunk, leaving the right side of the thorax looking like a skeleton. The lung on the right side, below the clavicle, gives a dull sound on percussion, and the right side of the chest does not fill well in the act of respiration, and he is not able to make use of the right arm and hand." This pensioner was paid September 4, 1874.

CASE 1502.—Sergeant C. A. Winsor, Co. A, 6th Wisconsin, aged 22 years, was wounded at Gravelly Run, March 31, 1865. Surgeon A. S. Coe, 147th New York, reported from a Fifth Corps hospital: "A wound of the right shoulder by a minié ball." On the same day the head of the humerus was excised by Surgeon John C. Hall, 6th Wisconsin, through a straight incision parallel to the axis of the arm. On April 3d, the patient was sent to Washington, and entered Columbian Hospital, and, May 4th, was transferred to Judiciary Square Hospital. Surgeon E. Griswold, U. S. V., reported: " \* \* Admitted with resection of right shoulder, performed on the field. \* \* On May 14th, the wound was attacked with erysipelas, which, in a few days, subsided." On June 13, 1865, this soldier came to the Army Medical Museum, and a photograph was made, which is copied in FIGURE 2 of PLATE XVIII, opposite page 544. There was "nearly complete cicatrization, and promise of a comparatively useful arm." He was discharged July 16, 1865, and pensioned. Examiner J. Nichols, of Washington, July 20, 1865, reported: "Had resection of the head and two and a half inches of the shaft of the right humerus, with margin of glenoid cavity. Arm useless for labor. Examiner H. C. Taylor, of Chataqua, New York, November 10, 1866, reported: "The wound not soundly healed; occasionally suppurates; is very painful. Arm nearly useless. I think amputation would be preferable under the circumstances." The "biennial" pension report of 1873, made by Examiner C. Hurd, of Ottawa, Illinois, elicited no new facts. This pensioner was paid June 4, 1874.

CASE 1503.—Private J. M. Davis, Co. C, 10th Georgia, aged 19 years, was wounded at Gettysburg, July 3, 1863. He stated that, at a field hospital for Confederate prisoners, resection of the head of the left humerus had been performed by Surgeon J. J. Knott, P. A. C. S. On July 25th, the patient entered Camp Letterman hospital. Acting Assistant Surgeon H. H. Sutton noted: "A minié ball fractured the left humerus two inches below the shoulder joint. Resection of the head of the humerus was performed. When admitted the patient was very feeble; wound suppurating very freely; arm much swollen; had trouble-



some diarrhœa. August 15th, diarrhœa checked. August 20th, erysipelas. September 2d, erysipelas disappeared; health improving; discharge from wound diminished. September 15th, arm still swollen. October 15th, transferred convalescent.<sup>1</sup> This soldier was sent to West's Buildings Hospital, Baltimore, on October 15th, and paroled November 12, 1863. In 1869, the operator, Dr. Knott, forwarded to the Army Medical Museum a photograph of the patient (*Card Photographs, Surg. Sect., A. M. M., Vol. I, p. 7*) with a copy of a letter received from him, stating: \* \* \* "In the first place, the part of Nature to form a bone was nothing more nor less than a mere gristle attaching itself to the shoulder and to the end of the bone, which is about five inches down the arm. The end of the bone feels somewhat ragged, as though it never had been sawn off, though I think that roughness was caused by a decaying of the bone during my long sickness at Gettysburg. My arm is as limber as a rag, and as sound as any flesh. When I think of the strength and use of my arm, I feel under many obligations to you; for I have been told that you contended for the operation, while the others opposed it and were in favor of cutting the arm off at the shoulder. I use it to a good advantage in ploughing, hoeing, and cutting with an axe. I have never tried particularly to see how much I could raise from the ground, but to show some gentlemen, one day, that I had strength in it, I raised a coil of rope from the floor of a grocery store, which (the merchant said) weighed about one hundred and twenty-five pounds; it didn't feel very heavy. I find a greater difficulty in striking or nailing overhead than anything that I have ever tried."

Preparations of primary decapitations of the humerus after shot injury were rarely preserved. The Museum has but five from the hundred and seventy-five operations.<sup>1</sup>

CASE 1504.—Lieutenant-Colonel W. M. L.—, 89th New York, aged 23 years, was wounded at Fair Oaks, October 27, 1864. He was sent from an Eighteenth Corps hospital to Hampton Hospital. Surgeon D. G. Rush, 101st Pennsylvania, contributed the specimen (FIG. 406) with the following history: "Wounded by a musket ball, which entered immediately outside of the right coracoid process and passed backward and outward, making its exit through the back part of the deltoid muscle, below the posterior border of the acromion, and involved the head of the bone by passing directly through the top of it. He was admitted to hospital at Fort Monroe, October 29th, and I removed the head of the bone on the same date by making a V-shaped flap incision. The head was enucleated, and sawed off through the surgical neck by a chain saw. This operation was followed by perfect recovery. The treatment consisted in cold-water irrigation, nourishing diet, tonics, stimulants, etc." This patient was discharged May 15, 1865, and pensioned. Examiner W. H. Johnson, of Johnstown, New York, January 23, 1866, reported: "He has not the use of the arm, although he has the use in part of his fingers."

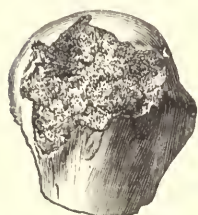


FIG. 406.—Head of the right humerus primarily excised for shot fracture. *Spec. 3802.*

In September, 1867, Examiner C. C. P. Clark, of Oswego, reported "the humerus badly diseased and the arm entirely useless." In September, 1869, Acting Assistant Surgeon W. P. Buel, Petersburg, Virginia, certified: "I find that the wound is still open and discharging purulent matter, proving that the bone is still exposed." This pensioner died May 9, 1874. Dr. J. H. Claibourne, of Petersburg, states that: "His death was caused directly by hæmorrhage from the lungs, indirectly by pulmonary abscesses, the result of a protracted drain upon his system by the wound in his shoulder, which wound had never healed, but required dressing daily, and discharged more or less pus, sanious matter, and necrosed bone," and that "there were some three or more openings upon the surface of the shoulder anteriorly," and "that the distal end of the clavicle had also the appearance of having been involved, either in the primary or secondary accidents of the wound." \* \* \* "Had frequent attacks of inflammation of the lung, abscesses, and hæmoptysis, often endangering his life." \* \* \* "The lung in the wounded side was almost exclusively affected," etc. The wound of the shoulder was recognized by the Pension Bureau as the remote cause of death.

CASE 1505.—Private T. Donohue, Co. K, 123d New York, aged 19 years, was wounded at Peach Tree Creek, July 20, 1864. Surgeon C. N. Campbell, 150th New York, reported, from a Twentieth Corps hospital: "Gunshot wound of left shoulder,

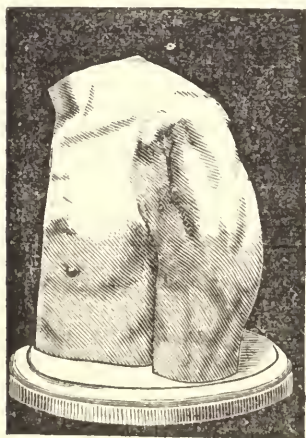

FIG. 407.—Copy of a plaster cast in a case of excision at the shoulder after shot injury. *Spec. 4203.*

resection of head and neck of humerus," and a further report states: "Surgeon J. Chapman, 123d New York, excised the head of the humerus." Four days subsequently the patient was transferred to Nashville, where he remained till the end of August, and then went to Louisville, and entered Brown Hospital, where Dr. B. E. Fryer, U. S. A., recorded: "A shot fracture of the head and neck of the left humerus. Excision was made through a straight anterior incision of about four inches, on the field, and the wound was nearly healed when the patient was admitted here." After a few days this soldier was sent to New York, and entered the Ira Harris Hospital, May 3, 1865. Professor J. H. Armsby reported the excision as heretofore narrated, and contributed to the Museum a plaster cast of the mutilated limb, which is represented in the adjacent wood-cut (FIG. 407). It is described (*Cat. Surg. Sect., 1866, p. 538*) as a cast of the left shoulder [taken] about one year after a primary excision of the head of the humerus. There are two large circular cicatrices on the anterior face of the upper portion of the arm, which is somewhat flattened but not otherwise deformed." Examiner J. S. Delavan, Albany, July 12, 1865, reported: \* \* \* "The upper part of the limb is, of course, entirely useless. The operation is the most successful I have ever seen." Examiner W. S. Searle, of Troy, in 1866, reported the limb as "of no service in manual labor." In September, 1873, Examiner W. S. Austin, of Oxford, Kansas, reported that: "The deltoid muscle and those adjacent are atrophied, and the arm is useless for the purposes of manual labor." This pensioner was paid June 4, 1874.

Three of the recovered cases are illustrated in the lithographic plates.<sup>2</sup>

<sup>1</sup> *Cat. Surg. Sect., 1866, Specimens 3802, 5749, of cases of recovery, and 2838, 1062, and 4023, of fatal cases.*

<sup>2</sup> See FIGURES 2 and 4, of PLATE XIV, opposite page 529, and FIGURE 2, PLATE XVII, opposite page 544.

TABLE XXIV.

*Summary of a Hundred and Nineteen Cases of Recovery after Primary Decapitation of the Humerus for Shot Injury.*

No.	NAME, AGE, AND MILITARY DESCRIPTION.	DATE OF INJURY.	NATURE OF INJURY.	DATE OF OPERATION.	OPERATION AND OPERATOR.	RESULT AND REMARKS.
1	Adams, T., Corp'l, I, 80th Illinois, age 20.	July 4, 1864.	Head of right humerus shattered.	July 4, 1864.	Head, through straight incision, by Surg. S. H. Kersey, 36th Indiana.	Disch'd Jan. 26, 1865; pensioned. Sept., 1873, arm hangs powerless; has some use of the hand. Resigned July 26, 1865. Good use of forearm. Not a pensioner. Transferred to Provost Marshal, March 27, 1865.
2	Agnus, F., Lieut., 5th New York.	June 27, 1862.	Right humerus comminuted.	June 27, 1862.	Head excised, by A. A. Surg. J. Swinburne.	Disch'd Sept. 27, 1864; pensioned. Some use of arm; can flex elbow and bring hand to chest. Resigned March 30, 1863; pensioned. Sept., 1873, arm useless for manual labor.
3	Armstrong, W. M., Serg't, D, 20th Mississippi, age 24.	Nov. 30, 1864.	Head of right humerus fractured.	Nov. 30, 1864.	Head excised	Disch'd Dec. 16, 1864; pensioned. Sept., 1873, atrophy of muscles of upper part of arm.
4	Baker, W. H., Lieut., C, 7th Tennessee, age 22.	June 3, 1864.	Comminuted fracture of head of right humerus.	June 3, 1864.	Head excised through a horse-shoe incision in deltoid	Disch'd May 17, 1865; pensioned. August, 1874, movements of shoulder greatly impeded. Disch'd May 31, 1865; pensioned. September, 1873, use of arm totally destroyed.
5	Baleom, H. A., Serg't, D, 6th Maine, age 25.	May 10, 1864.	Ball passed through neck of right humerus.	May 10, 1864.	Head excised, by Surg. Dickson, 14th Louisiana.	Disch'd April 4, 1865; pensioned. September, 1873, total loss of use of left arm.
6	Baneroff, P. S., Lieut., E, 111th Pennsylvania, age 32.	Sept. 17, 1862.	Right humerus fractured near the shoulder joint.	Sept. 17, 1862.	Excision of head and neck	Disch'd June 15, 1865; pensioned. Sept., 1874, arm hangs helpless.
7	Barkley, A. J., Pt., D, 32d Iowa, age 22.	April 9, 1864.	Right humerus fractured	April 9, 1864.	Head excised	Retired February 4, 1865.
8	Barnes, J. H., Pt., K, 4th Michigan.	Sept. 30, 1864.	Wound of right shoulder joint by a minié ball.	Sept. 30, 1864.	Head excised, by Surg. W. R. DeWitt, U. S. V.	Disch'd June 21, 1864; pensioned. September, 1873, the whole arm is nearly useless.
9	Barrett, G., Pt., Purcell Legion, age 37.	Aug. 18, 1864.	Fracture of upper portion of left humerus.	Aug. 18, 1864.	Head excised, through straight incision, by Surgeon A. A. White, 8th Maryland.	To Provost Marshal, January 27, 1865.
10	Bell, H. W., Corp'l, A, 14th Virginia, age 33.	July 3, 1863.	Fracture of head of humerus.	July 3, 1863.	Head excised, by Surgeon C. J. Bellows, 7th Ohio.	Disch'd Dec. 12, 1864; pensioned. February, 1871, cannot elevate arm; motions of hand good.
11	Bevard, H., Serg't, E, 61st Ohio, age 23.	July 26, 1864.	Fracture of left humerus; the ball emerged through the scapula.	July 26, 1864.	Head excised	Recovery.
12	Billmire, C. W., Pt., G, 63d Ohio, age 20.	July 27, 1864.	Comminution of right shoulder.	July 27, 1864.	Head, through a three-inch incision, by Surgeon A. B. Monahan, 63d Ohio.	Disch'd Dec. 10, 1864; pensioned. January, 1872, arm useless for manual labor.
13	Bofo, A. G., Pt., H, 8th Georgia, age 26.	July 2, 1863.	Wound of right shoulder joint.	July 3, 1863.	Head of humerus excised	Disch'd May 4, 1865; pensioned. Sept., 1873, no use of arm, and but little of forearm and hand.
14	Booker, D., Pt., K, 4th Ohio Cavalry, age 23.	June 3, 1864.	Fracture of right shoulder joint.	June 3, 1864.	Head excised, by Surgeon A. Satterthwaite, 12th N. Jersey.	Recoverd, with good motion and partial use of arm.
15	Bowen, G. W., Serg't, B, 1st Georgia, age 24.	Nov. 30, 1864.	Gunshot wound of shoulder.	Dec. 1, 1864.	Head excised over anterior aspect.	Disch'd Dec. 24, 1864; pensioned. Sept., 1873, loss of use of arm.
16	Brogan, P., Pt., I, 69th Pennsylvania.	May 12, 1864.	Fracture of head of right humerus.	May 12, 1864.	Head excised, by Surgeon M. Rizer, 73d Pennsylvania.	Transferred for exchange.
17	Brown, B. F., Pt., F, 38th Georgia, age 21.	Dec. 13, 1862.	Comminuted fracture of head of humerus.	Dec. 14, 1862.	Head excised	Paroled November 12, 1863.
18	Bryan, P., Corp'l, A, 93d Illinois, age 33.	Nov. 25, 1863.	Fracture of left shoulder	Nov. 25, 1863.	Upper portion of humerus excised, by Surg. J. R. Mohr, 10th Iowa.	Disch'd Nov. 16, 1863; pensioned. Disability total, third grade.
19	Bush, N., Pt., C, 60th New York, age 25.	May 26, 1864.	Shot fracture of the upper third of right humerus.	May 26, 1864.	Head excised, by Surgeon H. B. Whiton, 60th New York.	Disch'd Jan. 10, 1866; pensioned. Disability total, third grade.
20	Campbell, T. M., Pt., C, 17th Mississippi, age 27.	Dec. 11, 1862.	Wound of right shoulder joint.	Dec. 11, 1862.	Head excised through anterior longitudinal incision.	Disch'd Dec. 29, 1864; pensioned. Sept., 1873, loss of use of arm.
21	Colburn, T., Pt., M, 2d Connecticut Artillery, age 28.	June 22, 1864.	Fracture of right humerus	June 22, 1864.	Excision of head, by Surgeon G. L. Potter, 145th Pennsylvania.	Transferred for exchange.
22	Cray, L., Corp'l, D, 9th Minnesota, age 21.	Dec. 15, 1864.	Conoidal ball lodged in head of left humerus, shattering the bone.	Dec. 15, 1864.	Head excised through perpendicular excision in front.	Disch'd Aug. 25, 1865; pensioned. May, 1867, cannot extend arm; limb useless for manual labor.
23	Davis, J. M., Pt., C, 10th Georgia, age 19.	July 3, 1863.	Head of the left humerus comminuted.	July 4, 1863.	Head excised at surgical neck.	Paroled November 12, 1863.
24	Dibble, A. H., Pt., F, 53d New York.	May 3, 1863.	Fracture of upper fifth of right humerus, and injury of right wrist joint.	May 4, 1863.	Excision of head of humerus; gangrene and sloughing. July 22, 1863, arm amputated at shoulder joint.	Disch'd Nov. 16, 1863; pensioned. Disability total, third grade.
25	Dickerson, A., Serg't, D, 25th Georgia.	Dec. 7, 1864.	Fracture of head of the right humerus.	Dec. 8, 1864.	Excision of head through incision over anterior aspect.	Transferred for exchange, February 24, 1865.
26	Dixon, H. W., Capt., 6th S. Carolina Cavalry, age 34.	Oct. 7, 1864.	Ball passed through anatomical neck.	Oct. 8, 1864.	Head excised through straight incision.	Paroled October 31, 1864.
27	Donohue, T., Pt., K, 123d New York, age 19.	July 20, 1864.	Head and neck of left humerus fractured.	July 21, 1864.	Head and neck excised, through straight incision, by Surg. J. Chapman, 123d New York.	Disch'd July 12, 1865; pensioned. Sept., 1873, arm useless for manual labor. Spec. 4203, A. M. M.
28	Downs, J. E., Pt., E, 9th U. S. C. Troops, age 24.	Sept. 29, 1864.	Fracture of the neck of right humerus; capsule slightly opened on outer side.	Sept. 29, 1864.	Head and neck of humerus, by Surg. J. R. Weist, 1st U. S. Colored Troops.	Disch'd Jan. 10, 1866; pensioned. Disability total, third grade.
29	Dustin, S. B., Pt., K, 117th New York, age 34.	June 27, 1864.	Upper part of left humerus comminuted; joint involved.	June 27, 1864.	Head excised through linear incision.	Disch'd Dec. 29, 1864; pensioned. Sept., 1873, loss of use of arm.
30	Ellison, R., Serg't, E, 3d Georgia, age 23.	Aug. 21, 1864.	Fracture of upper third of humerus.	Aug. 21, 1864.	Head and neck of bone excised.	Transferred for exchange.
31	Emery, W. H., Lieut., C, 19th Maine, age 24.	May 6, 1864.	Fracture of the left shoulder	May 6, 1864.	Head excised, through a vertical incision, by Surgeon G. Chaddock, 7th Michigan.	Disch'd Oct. 13, 1861; pensioned. Sept., 1873, partial muscular atrophy of arm and forearm.
32	Eve, L. H., Corp'l, A, 6th Missouri, age 24.	Dec. 28, 1864.	Wound of left shoulder joint.	Dec. 28, 1864.	Head removed, by flap operation, by Surg. D. W. Hartshorne, U. S. V.	Disch'd June 6, 1865; pensioned. Sept., 1873, muscles of arm atrophied; but little use of arm.
33	Everett, J., Pt., F, 55th Pennsylvania, age 32.	June 18, 1864.	Fracture of left shoulder joint.	June 18, 1864.	Head excised, by Surg. G. T. Stevens, 77th New York.	Disch'd Jan. 2, 1865; pensioned. Sept., 1873, is unable to raise the hand; the arm hangs helpless.



No.	NAME, AGE, AND MILITARY DESCRIPTION.	DATE OF INJURY.	NATURE OF INJURY.	DATE OF OPERATION.	OPERATION AND OPERATOR.	RESULT AND REMARKS.
34	Farmer, W. M., Pt., F, 82d Indiana, age 21.	Feb. 25, 1864.	Fracture of upper portion of left humerus.	Feb. 25, 1864.	Head excised, by Surgeon W. Lemon, 82d Indiana.	Disch'd Nov. 9, 1864; pensioned. Sept., 1873, unable to perform long-continued labor.
35	Fellhager, J., Pt., C, 27th Pennsylvania, age 47.	Nov. 25, 1863.	Fracture of head of left humerus.	Nov. 26, 1863.	Head excised.....	Disch'd June 11, 1864; pensioned. Sept., 1873, the arm is of no use to the pensioner.
36	Foot, A., Lieut., B, 14th Infantry.	Aug. 18, 1864.	Fracture of shoulder joint.....	Aug. 18, 1864.	Head excised, by Surg. F. M. Flaudrau, 146th New York.	Returned to duty; promoted Captain January 18, 1865. Retired from service, Nov. 5, 1866.
37	Foster, S. C., Pt., D, 56th Massachusetts, age 21.	May 21, 1864.	Fracture of upper third of left humerus.	May 25, 1864.	Head and neck excised.....	Disch'd June 19, 1865; pensioned. Sept., 1873, disability equal to loss of hand for purposes of manual labor.
38	Fredenburg, G. W., Pt., B, 11th Connecticut, age 27.	May 16, 1864.	Head of right humerus fractured.	May 18, 1864.	Head, at anatomical neck, thro' straight incision, by Surg. D. Satterlee, 11th Connecticut.	Disch'd Mar. 23, 1865; pensioned. Ap'l, 1874, can extend arm from body to an angle of about 35°.
39	Gibson, W. A., Pt., B, 16th Alabama, age 23.	Nov. 29, 1864.	Fracture of the head of the left humerus.	Nov. 29, 1864.	Head excised, by Surg. D. S. S. McMahon, 7th Texas.	Transferred for exchange February 24, 1865.
40	Godfrey, P., Pt., E, 10th N. Carolina Artillery, age 20.	May 29, 1864.	Fracture of head of humerus..	May 29, 1864.	Head and neck of humerus excised.	Escaped October 23, 1864.
41	Griffis, J. F., Pt., F, 9th Alabama, age 21.	July 3, 1863.	Shell fracture of right humerus near surgical neck.	July 4, 1863.	Head excised, by Surg. H. A. Minor, P. A. C. S.	Paroled November 12, 1863.
42	Ham, J., Pt., A, 1st North Carolina Cavalry.	June 9, 1863.	Wound of right shoulder joint.	June 10, 1863.	Head and neck excised through straight incision.	Retired February 14, 1865.
43	Hanniski, G., Pt., I, 46th New York, age 29.	Sept. 30, 1864.	Shot wound of right shoulder.	Sept. 30, 1864.	Head excised, by Acting Staff Surgeon A. T. Fitch.	Disch'd Mar. 22, 1865; pensioned. Sept., 1873, non-union of bone; arm useless.
44	Hays, M., Pt., C, 151st New York, age 33.	May 12, 1864.	Upper portion of right humerus fractured.	May 12, 1864.	Head excised, by Surg. J. R. Cotes, 151st New York.	Disch'd July 28, 1865; pensioned. Sept., 1873, the extremity dangles by his side.
45	Haywood, M. H., Ft., C, 125th New York, age 44.	Oct. 7, 1864.	Fracture of right humerus....	Oct. 7, 1864.	Head excised, by Surg. J. W. Wishart, 140th Pennsylvania.	Disch'd Mar. 28, 1865; pensioned. Sept., 1873, arm useless for all purposes of manual labor.
46	Henderson, W. A., Pt., K, 1st Sharpshooters.	Nov. 7, 1863.	Fracture of right humerus....	Nov. 7, 1863.	Excision of head of humerus. See CAS; 1501, p. 529.	Disch'd May 8, 1864; arm useful, can take off his hat. Nov., 1866, arm useless for purposes of manual labor; pensioned.
47	Hendrickson, W., Pt., C, 143d New York, age 39.	Sept. 14, 1863.	Fracture of head of left humerus.	On field.	Excision of head.....	Disch'd Feb. 13, 1864. Not a pensioner in June, 1874.
48	Hiser, W., Pt., K, 1st Ohio Cavalry, age 21.	Aug. 20, 1864.	Comminuted fracture of head of left humerus.	Aug. 23, 1864.	Head and neck of humerus excised.	Disch'd Ap'l 17, 1865; pensioned. Died Aug. 17, 1866, from the effects of a gunshot wound of left lung. <sup>9</sup> (9)
49	Houston, J. P., Capt., K, 5th Minnesota.	Dec. 15, 1864.	Head of right humerus comminuted.	Dec. 16, 1864.	Head excised, by Surg. V. P. Kennedy, 5th Minnesota.	Disch'd Sept. 26, 1865; pensioned. Has not been heard from since 1865.
50	Hyde, R., Pt., B, 3d Maine, age 28.	May 31, 1862.	Fracture of head of humerus.	On field.	Head and portion of surgical neck, through vertical incision down the deltoid, by Surgeon D. Prince, U. S. V.	Disch'd Feb. 15, 1863. Not a pensioner in Nov., 1874.
51	Jackson, J. A., Pt., B, 28th Alabama, age 18.	Sept. 19, 1863.	Fracture of head of humerus.	Sept. 19, 1863.	Head excised at the surgical neck.	Recovered.
52	Jackson, R., Pt., B, 42d Virginia.	Mar. 25, 1865.	Fracture of left shoulder.....	Mar. 25, 1865.	Excision of head of humerus..	Paroled May 6, 1865.
53	Jackson, S. R., Lieut., G, 1st Maine Cavalry.	Oct. 27, 1864.	Fracture of left shoulder joint.	Oct. 27, 1864.	Head of humerus excised.....	Disch'd Mar. 15, 1865; pensioned. Limb useless. Died February 11, 1873.
54	Kaath, F., Pt., H, 5th New York, age 20.	Sept. 17, 1862.	Ball passed through head of left humerus.	Sept. 20, 1862.	Head excised through a V-shaped incision, by Surg. G. C. Humphreys, 9th N. York.	Disch'd May 5, 1863. Considerable motion at joint, forearm as useful as ever. Died May 6, 1864.
55	Kidder, J. E., Pt., C, 75th Indiana, age 30.	Sept. 19, 1863.	Wound of left humerus.....	Sept. 19, 1863.	Head excised, by Surg. J. A. Stillwell, 23d Indiana.	Disch'd Jan. 19, 1864; pensioned. Sept., 1873, unable to move arm outward from body on account of union of scapula and humerus.
56	Kingsley, G. W., Pt., 4th Massachusetts Battery.	Aug. 5, 1862.	Ball burrowed itself in the upper part of the humerus.	Aug. 7, 1862.	Excision of head, by Surgeon W. K. Brownell, 12th Connecticut.	Disch'd Oct. 16, 1862; pensioned. Died November 9, 1870.
57	Kirk, C., Corp'l, D, 1st Maine Artillery, age 29.	Nov. 4, 1864.	Comminuted fracture of the head of the left humerus by a conoidal ball.	Nov. 4, 1864.	Removal of head of humerus at surgical neck, by Surg. W. B. Reynolds, 2d Sharpshooters.	Disch'd Ap'l 27, 1865; pensioned. Sept., 1873, arm weak and of but little use.
58	Lewis, W. M., Lieut.-Colonel, 89th New York, age 23.	Oct. 27, 1864.	Gunshot fracture of the head of the right humerus.	Oct. 29, 1864.	Excision of the head through the surgical neck, through a V-shaped incision, by Surg. D. G. Rush, 101st Penn.	Disch'd May 15, 1865; pensioned. Died May 9, 1874, of hæmorrhage from lungs. Spec. 3802, A. M. M.
59	Liebman, L., Pt., I, 7th Wisconsin, age 17.	Feb. 7, 1865.	Minié ball fractured the head of the right humerus.	Feb. 7, 1865.	Resection of the head of the humerus, by Surgeon D. C. Ayres, 7th Wisconsin.	Disch'd July 3, 1865; pensioned. Sept., 1873, disability total.
60	Lipscomb, W. A., Serg't, C, 5th South Carolina, age 30.	Sept. 12, 1864.	Shot fracture of the head of the left humerus.	Sept. 13, 1864.	Resection of the head of the humerus.	Furloughed; doing well.
61	Little, T., Lieut., 1st Maine Cavalry, age 20.	April 6, 1865.	Gunshot wound of the right shoulder joint, ball lodging in the head of the humerus.	April 6, 1865.	Excision of the head of the humerus, through a straight incision, by Surgeon G. W. Colby, 1st Maine Cavalry.	Disch'd Aug. 1, 1865; pensioned. Sept., 1873, forearm and hand seriously atrophied and weak.
62	Livingston, R. N., Capt., F, 118th New York, age 19.	May 16, 1864.	Shot injury of the left shoulder joint.	May 16, 1864.	Excision of the head of the humerus.	Returned to duty June 17, 1865. July 1, 1866, arm and hand atrophied and useless; pension'd.
63	Lynn, J. W., Pt., C, 52d Ohio.	June 27, 1864.	Shot wound of the left humerus at about the insertion of the deltoid.	June 27, 1864.	Removal of the head of the humerus.	Disch'd May 1, 1865; pensioned. Sept., 1873, disability total, third grade.
64	McClellan, J. F., Pt., B, 122d Ohio, age 23.	Nov. 27, 1863.	Minié ball perforated the right shoulder, fracturing the head of the humerus.	Nov. 28, 1863.	Excision of the head of the humerus through a straight incision four inches in length.	Disch'd May 2, 1864; pensioned. Hand and arm permanently useless for labor.
65	Maher, W., Pt., D, 67th Ohio, age 30.	Aug. 14, 1864.	Conoidal ball passed transversely through the head of the left humerus, opening the joint.	Aug. 14, 1864.	Head of the humerus excised, through a longitudinal incision, by Surgeon C. M. Clark, 39th Illinois.	Disch'd May 25, 1865; pensioned. Sept., 1873, arm hangs useless by his side.

No.	NAME, AGE, AND MILITARY DESCRIPTION.	DATE OF INJURY.	NATURE OF INJURY.	DATE OF OPERATION.	OPERATION AND OPERATOR.	RESULT AND REMARKS.
66	May, S. H., Lieut., D, 10th Louisiana, age 23	July 1, 1863.	A minié ball passed directly through right shoulder joint.	July 1, 1863	Removal of the head of the humerus	Transferred for exchange October 27, 1863.
67	Mealus, W. H., Pt., F, 186th New York.	April 2, 1865.	Gunshot fracture of the right shoulder joint.	April 2, 1865.	Excision of the head of the humerus, by Surgeon J. A. Hayes, 11th New Hampshire.	Disch'd June 12, 1865; pensioned. Sept., 1873, disability equal to loss of limb for purposes of manual labor.
68	Meek, T. J., Pt., M, Phillips's Georgia Legion, age 20.	Nov. 29, 1863.	Gunshot wound of right shoulder joint, fracturing humerus.	Nov. 29, 1863.	Resection of the head of the humerus.	Furloughed Sept. 23, 1864.
69	Merry, E. H., Pt., F, 9th Iowa.	May 19, 1863.	Gunshot wound of the left shoulder.	May 19, 1863.	Removal of bone, including the head of humerus, by Surg. M. W. Robbins, 4th Iowa.	Disch'd July 27, 1863; pensioned. Sept., 1873, has no control over the arm.
70	Merryman, J. R., Pt., D, 1st Maryland Cavalry, age 21.	July 22, 1864.	Shot fracture of the left humerus.	July 22, 1864.	Head of the humerus excised.	Transferred for exchange Sept. 21, 1864.
71	Mesley, C. L., Pt., G, 18th Infantry.	July 4, 1864.	Gunshot fracture of the right shoulder and wound of breast.	July 4, 1864.	Excision of head of humerus. Aug. 7th, circular amputation at the shoulder joint, by Asst Surg. T. McGraw, U. S. V.	Disch'd December 31, 1864, and pensioned.
72	Miller, H. J., Pl., C, 74th Illinois, age 19.	June 27, 1864.	Minié ball fractured the head of the left humerus.	June 27, 1864.	Head of humerus excised, by Surgeons H. E. Hane, 24th Wisconsin, and W. P. Pierce, 88th Illinois.	Disch'd Feb. 27, 1865; pensioned. Sept., 1873, has but very little use of the shoulder joint.
73	Miller, J. S., Corp'l, D, 79th Pennsylvania, age 21.	July 21, 1864.	Gunshot wound of the left shoulder joint.	July 21, 1864.	Removal of head of humerus.	Disch'd May 22, 1865; pensioned. Sept., 1873, arm hangs powerless at side.
74	Miller, T. B., Pt., I, 116th Pennsylvania, age 19.	June 2, 1864.	Minié ball passed through the right shoulder joint.	June 2, 1864.	Head of humerus removed, thro' longitudinal incision, by Surg. P. E. Hubon, 28th Mass.	Disch'd Jan. 17, 1865; pensioned. Sept., 1873, arm hangs dangling at side.
75	Mitchell, H. H., Pt., D, 25th Iowa, age 24.	Jan. 11, 1863.	Gunshot wound of the left shoulder.	Jan. 11, 1863.	Excision of head of humerus.	Disch'd April 10, 1863; pensioned. Sept., 1873, arm atrophied, weak, of little use for manual labor. Ret. red March 1, 1865.
76	Moore, W. A., Corp'l, E, 18th North Carolina, age 21.	Aug. 16, 1864.	Conoidal ball passed through the head of the right humerus.	Aug. 16, 1864	Excision of head of humerus, by Surg. W. S. Love, P. A. C. S.	Furloughed July 25, 1864.
77	Morell, W. J., Pt., H, 15th South Carolina, age 37.	Aug. 24, 1864.	Gunshot fracture of the left humerus.	Aug. 24, 1864.	Excision of head of humerus.	
78	Morris, T. J., Pt., F, 15th Iowa, age 30.	July 22, 1864.	Gunshot fracture of the head of the left humerus.	July 23, 1864.	Excision of head of humerus.	Disch'd July 24, 1865; pensioned. April, 1868, impaired strength of arm unfit him for active labor.
79	Murray, C., Pl., I, 15th Massachusetts, age 20.	July 3, 1863.	Shot fracture of the head of the right humerus.	July 4, 1863.	Excision of head of humerus, by Surg. H. E. Goodman, 28th Pennsylvania.	Disch'd Feb. 20, 1864; pensioned. Oct., 1873, shortened two inches; motions of shoulder limited. March, 1863, doing well.
80	Myers, J. B., Pt., F, 1st South Carolina, age 28.	Dec. 13, 1862.	Gunshot wound of the right humerus.	Dec. 13, 1862.	Resection of head of humerus.	
81	Myers, J. C., Pt., D, 61st Pennsylvania, age 21.	June 1, 1862.	Gunshot fracture of the head of the right humerus and of the scapula.	June 1, 1862.	Head of humerus excised, by Surg. R. M. Tindle, 61st Penn. June 17, 1862, amputation at should. joint, by Dr. W. Parker.	Disch'd Nov. 25, 1862; pensioned. Died December 31, 1863.
82	Neale, F. R., Serg't, D, 1st Cavalry, age 29.	April 1, 1865.	Gunshot fracture of the head of the left humerus.	April 1, 1865	Excision of head of humerus.	Disch'd July 20, 1865; pensioned. Oct. 1872, has considerable use of the arm.
83	Norton, G. D., Pt., K, 5th Connecticut, age 23.	May 15, 1864.	Minié ball fractured the head of the left humerus.	May 15, 1864.	Excision of head of humerus, by Surg. A. K. Fifield, 29th Ohio.	Disch'd Sept. 23, 1864; pensioned. Sept., 1873, unable to raise the arm from the side.
84	Nott, P. R., Pt., K, 89th Illinois, age 20.	June 21, 1864.	Shot fracture of the head of the left humerus.	June 22, 1864.	Head of left humerus removed, thro' a straight incision, by Surg. H. B. Tuttle, 89th Ill.	Disch'd Mar. 22, 1865; pensioned. April, 1873, can use his hand; arm useless for manual labor.
85	Palfrey, F. W., Colonel, 20th Massachusetts.	Sept. 17, 1862.	Canister shot fractured the left shoulder joint.	Sept. 18, 1862.	Resection of head of humerus, by Surg. N. Hayward, 20th Massachusetts.	Disch'd April 13, 1863; pensioned. Sept., 1873, limb useless for heavy manual labor.
86	Parcher, F. M., Pl., E, 8th Minnesota, age 22.	Dec. 7, 1864.	Conoidal ball fractured the head of the right humerus.	Dec. 8, 1864.	Head of humerus remov'd, thro' a slightly curved incision, by Surg. S. D. Turney, U. S. V.	Disch'd May 23, 1865; pensioned. Sept., 1873, the arm is useless.
87	Perkins, H. C., Pt., D, 49th Georgia, age 20.	July 2, 1863.	Comp'd fracture of upper third of right humerus by shot.	July 3, 1863.	Excision of head and part of the neck of the humerus	Recovered, with perfect use of the forearm.
88	Peters, J., Pt., K, 42d New York.	May 12, 1864.	Shot fracture of upper third of the left humerus.	May 12, 1864.	Excision of head of the bone, by Surg. S. H. Plumb, 2d N. Y.	Disch'd February 24, 1865, and pensioned.
89	Presley, J. G., Lieut.-Col., 25th South Carolina, age 31.	May 7, 1864.	Comp'd comminuted fracture of upper third of left humerus.	May 8, 1864.	Excision of head of humerus.	May 31st, transferred to State, doing well.
90	Punch, M., Pt., C, 29th Pennsylvania, age 23.	Oct. 27, 1863.	Compounded fracture of neck of right humerus, extending into the joint.	Oct. 29, 1863.	The severed head of humerus dissected and twisted from its socket, and sharp points of the lower fragm'ts removed with a chain saw, by Surg. J. A. Wolf, 29th Pennsylvania.	Disch'd July 16, 1864, and pensioned. Sept., 1873, muscular atrophy; has good use of hand. Spec. 5749, A. M. M.
91	Rand, C. F., Serg't, K, 12th New York, age 24.	June 22, 1862.	Gunshot fracture of the head of the right humerus.	.....	Head of humerus excised, by A. A. Surg. J. Swinburne. See CASE 1500, p. 529.	Disch'd Aug. 30, 1862. Appointed Lieutenant in Vet. Res. Corps in Nov., 1863, and discharged Jan. 1, 1868; arm useless for labor. See FIG. 4, PLATE XIV.
92	Rector, T. S., Serg't, A, 11th Virginia, age 22.	July 2, 1863.	Gunshot wound through the right shoulder joint.	July 3, 1863.	Resection of head of humerus.	Recovered, and paroled November 12, 1863.
93	Reed, J., Corp'l, F, 6th Maryland, age 22.	Nov. 27, 1863.	Conoidal ball fractured right lower jaw and the head of the right humerus.	Nov. 28, 1863.	Excision of head of the right humerus.	Disch'd Oct. 28, 1864; pensioned. Oct., 1873, arm perfectly useless.
94	Reeder, W. H., Corp'l, I, 3d Delaware, age 24.	June 19, 1864.	Comminuted shot fracture of the upper portion of the humerus.	June 19, 1864.	Wound enlarged and head of humerus excised, by Surg. J. H. Beach, 24th Michigan.	Disch'd Feb. 3, 1865; pensioned. January, 1872, cannot raise arm from side.
95	Reynolds, J. F., Pt., 2d Kentucky Cavalry.	Aug. 2, 1862.	Minié ball fractured the head of the left humerus and the spine of the scapula.	Aug. 3, 1862.	Removal of head of humerus, thro' a single vertical incision, by Surg. F. H. Gross, U. S. V.	Disch'd Oct. 28, 1862; pensioned. Feb., 1874, disability equal to loss of one hand for purposes of manual labor.
96	Rhines, J., Lieut., E, 88th Illinois, age 23.	June 27, 1864.	Shot fracture of left shoulder.	June 27, 1864.	Excision of head of humerus, by Surg's H. E. Hane, 24th Wis., and W. P. Pierce, 88th Illinois.	Disch'd Oct. 27, 1864; pensioned. Sept., 1873, arm useless.
97	Riley, J., Pt., E, 2d Ohio, age 18.	Oct. 8, 1862.	Conoidal ball fractured head of right humerus; also wound in right lung.	Oct. 8, 1862.	Excision of head of humerus.	Disch'd Feb. 15, 1863; pensioned. Died December 16, 1871; cause of death unknown.



No.	NAME, AGE, AND MILITARY DESCRIPTION.	DATE OF INJURY.	NATURE OF INJURY.	DATE OF OPERATION.	OPERATION AND OPERATOR.	RESULT AND REMARKS.
98	Robinson, A., Pt., E, 10th New Jersey.	May 19, 1865.	Minié ball fractured the head of the humerus.	May 19, 1865.	Removal of the head of the humerus on the field.	Disch'd July 19, 1865. Does not appear upon Pension Rolls.
99	Robinson, B., Pt., D, 39th Colored Troops.	July 30, 1864.	Shell fragment fractured the head of the left humerus.	July 31, 1864.	Resection of the head of the humerus, by Surg. D. Mackay, 2d Colored Troops.	Undetermined. Does not appear upon Pension Rolls.
100	Rutherford, G., Serg't, F, 2d Minnesota, age 25.	June 19, 1864.	Conoidal ball fractured the upper third of the left humerus.	June 19, 1864.	Resection of the head of the humerus, by Surgeon C. N. Fowler, 105th Ohio.	Disch'd June 21, 1865; pensioned. Oct., 1873, use of arm greatly impaired.
101	Scott, J., Pt., E, 29th Infantry, age 27.	July 30, 1864.	Shot fracture of the head of the left humerus; also wound of right arm and hand.	July 30, 1864.	Resection of head of humerus and amputation of right index finger, by Surg. D. Mackay, 29th Colored Troops. Dec. 3, 1866, amputation of left arm.	Disch'd June 26, 1865; pensioned. October, 1873, disability total, second grade.
102	Seullion, H., Corp'l, K, 99th Pennsylvania, age 22.	June 6, 1864.	Gunshot fracture of the left shoulder.	June 7, 1864.	Removal of the head of the humerus through an incision posteriorly.	Disch'd June 21, 1865; pensioned. Feb., 1873, arm useless for manual labor; able to grasp and lift small objects with hand.
103	Shafer, J. W., Pt., F, 33d Virginia, age 21.	Sept. 17, 1862.	Shot perforation of the right shoulder joint.	Sept. 17, 1862.	Excision of the head of the humerus, by Surg. — Smith, 33d Virginia.	Transferred for exchange August 19, 1864.
104	Shannon, J., Pt., I, 29th Ohio.	May 8, 1864.	Right humerus fractured by a minié ball.	May 8, 1864.	Head of the humerus excised, by Surgeon A. K. Fifield, 29th Ohio.	Disch'd May 4, 1865; pensioned. Sept., 1873, arm useless for purposes of manual labor.
105	Shelby, W., Pt., E, 8th Missouri.	May 17, 1862.	Compound shot fracture of the head of right humerus; also fracture of lower jaw.	May 17, 1862.	Head of the humerus removed, by Surgeon J. R. Bailey, 8th Missouri.	Disch'd Dec. 20, 1864; pensioned. August, 1873, arm useless for manual labor.
106	Sherman, E., Pt., G, 55th Ohio, age 19.	July 3, 1863.	Conoidal ball fractured the right humerus in its upper third.	July 4, 1863.	Excision of the head and neck of the humerus.	Disch'd Jan. 22, 1864; pensioned. Oct., 1873, has use of arm only from the elbow down. Cannot elevate arm.
107	Slayton, E. B., Pt., D, 112th New York, age 26.	June 1, 1864.	Gunshot wound of the left shoulder joint.	June 3, 1864.	Removal of the head of the humerus.	Disch'd Dec. 18, 1864; pensioned. Sept., 1873, arm useless for purposes of manual labor.
108	Smith, C., Pt., G, 42d Ohio, age 22.	Dec. 29, 1862.	Compound shot fracture of the head of the right humerus.	Dec. 29, 1862.	Head of the humerus excised, by Surg. J. Pomerene, 42d Ohio.	Disch'd April 22, 1865; pensioned. January, 1874, no fulcrum for movements of arm.
109	Smith, J. S., Corp'l, K, 14th New Hampshire, age 32.	Sept. 19, 1864.	Gunshot fracture of the head of the left humerus.	Sept. 19, 1864.	Removal of the head of the humerus through a straight incision.	Disch'd May 31, 1865; pensioned. Sept., 1873, disability rated total, third grade.
110	Stack, R., Pt., D, 6th Inf'try, age 30.	July 2, 1863.	Shot fracture of the head of the humerus.	July 3, 1863.	Excision of the head of the humerus.	Disch'd Sept. 11, 1865; pensioned. He died November 3, 1867.
111	Steel, S. S. W., Serg't, C, 135th Pennsylvania, age 36.	Sept. 21, 1864.	Shot fracture of the head of the right humerus.	Sept. 22, 1864.	Resection of head of humerus, by Surg. S. P. Chapin, 135th Pennsylvania.	Disch'd April 20, 1865; pensioned. Sept., 1873, there is crepitation at the shoulder joint when the humerus is moved.
112	Stewart, W. F., Corp'l, G, 127th Illinois.	Dec. 28, 1862.	Ball and buckshot fractured the head of the left humerus.	Dec. 28, 1862.	Head of humerus excised, by Surg. E. Andrews, 1st Illinois Artillery.	Disch'd April 2, 1863; pensioned. Sept., 1874, disability rated total, third grade.
113	Taylor, G. W., Major, 14th Alabama, age 27.	May 12, 1864.	Shot wound of right shoulder joint; missile passed through head of humerus.	May 12, 1864.	Excision of head of humerus through a V-shaped incision.	Recovered, and retired in Nov., 1864.
114	Ustick, A., Sergeant, K, 4th Ohio, age 27.	May 25, 1864.	Shot fracture of left shoulder joint.	May 25, 1864.	Removal of head of humerus, by Surg. S. H. Plumbe, 82d New York.	Disch'd June 21, 1864; pensioned. Sept., 1873, has not much use of arm; can partially flex and extend same.
115	Wedgewood, G. R. S., Pt., E, 8th Minnesota, age 25.	Dec. 7, 1864.	Compound comminuted shot fracture of the head of the right humerus.	Dec. 9, 1864.	Excision of head of humerus through a slightly curved incision.	Disch'd June 14, 1865; pensioned. March, 1867, arm useless for all practical purposes.
116	Weldon, J. J. C., Corporal, E, 4th West Virginia.	May 19, 1863.	Gunshot fracture of the left humerus.	May 19, 1863.	Excision of the head of the humerus.	Disch'd July 29, 1864, arm nearly useless for manual labor, in February, 1874; pensioned.
117	White, W., Corp'l, K, 59th Illinois, age 27.	Dec. 15, 1864.	Conoidal ball fractured the head of the right humerus.	Dec. 15, 1864.	Head of the humerus removed thro' a longitudinal incision.	Disch'd Sept. 14, 1865; pensioned. Oct., 1873, hand and arm useless.
118	Wilson, W. L., Pt., E, 104th Illinois, age 21.	July 20, 1864.	Shot fracture of the left humerus, involving the shoulder joint.	July 21, 1864.	Resection of the head of the humerus, by Surgeon R. F. Dyer, 104th Illinois.	Disch'd Feb. 28, 1865; pensioned. Sept., 1873, disability equivalent to loss of arm.
119	Winsor, C. A., Sergeant, A, 6th Wisconsin, age 22.	Mar. 31, 1865.	Head of the right humerus shattered by a conoidal ball.	Mar. 31, 1865.	Removal of head of humerus, through a straight incision, by Surgeon J. C. Hall, 6th Wisconsin.	Disch'd July 16, 1865; pensioned. September, 1873, arm nearly useless.

It is probable that among the hundred and nineteen reported examples of primary decapitation of the humerus for shot injury, there may have been instances in which portions of the shaft were removed; but it has been deemed proper to accept the statements of the operators. Fifty-six operations were on the right, and fifty on the left side; and, in thirteen instances, this point could not be determined. An endeavor has been made to include in this group only such excisions as were practised, so far as could be ascertained from the reported evidence, within seventy-two hours from the date of injury. The method of operation was reported in only about a fourth of the cases. A straight anterior incision was practised in twenty-three instances; in five cases the joint was exposed by raising either an oval or V-shaped flap; in two cases curved incisions at the outer margin of the deltoid were employed. In eighty-nine operations the mode of incision is not specified.

§ *Unsuccessful Operations.*—Fifty-six primary decapitations of the head of the humerus for shot injury were reported that had a fatal termination. Abstracts of three are given, and all of the cases are enumerated in the subjoined TABLE XXV, on the succeeding pages:

CASE 1506.—Private G. H. Fiske, Co. H, 8th New York, was wounded at Fair Oaks, May 31, 1862, and was sent to Washington and admitted to Judiciary Square hospital. Acting Assistant Surgeon D. W. Cheever forwarded, together with the pathological specimen, the following description and abstract of the case, by Acting Assistant Surgeon Calvin G. Page: "Specimen of humerus after excision of portion of the head of the humerus for gunshot wound, the missile entering over the sternum, and passing under the pectoralis major and through the humerus near the head of the bone, shattering the head, and passing out on the external side of the arm. The patient was wounded May 31, 1862; the operation was on the day of the injury. The man entered hospital June 4th; did well till August 5th, when bleeding commenced at the interior wound. August 7th, profuse hæmorrhage. On attempting to reach the artery by laying open the track of the original wound, and finding the vessel, the bleeding was so profuse that the patient died while operating. An ulcerated opening was found in the artery near the junction of the axillary and brachial. It appears to have occurred the sixty-sixth day after the accident. The exfoliated portions of the upper end of the lower extremity of the humerus and the processes of absorption of the glenoid cavity are well shown by a section thereof; at the point of ulceration the artery was adherent to the muscular tissues." Acting Medical Cadet Burt G. Wilder reported: "In searching for the artery, after death, it was cut so as to remove the upper border of the ulcerated opening, but the lower border is entire; a part of the deltoid is removed to show the cavity from which the bone was excised." The specimen (No. 1062, *Cat. Surg. Sect.*, 1866, p. 97) consists of "a wet preparation of the upper fourth of the left humerus. The head has been broken into several fragments, which have retained their vitality and become consolidated in new positions, with new muscular attachments. One of these consolidated fragments has been again fractured, possibly in the removal of the specimen. A formation, as if of a cyst surrounding a lodged bullet, appears in the outer and anterior region. The axillary artery presents a large opening from ulceration, indicating death from secondary hæmorrhage." The catalogue refers to the preparation as received without a history; but the foregoing notes of the case were subsequently identified.

Fractures at the shoulder by shell fragments, grapeshot, or other large projectiles, inflicting such limited injury as to permit excision, were uncommon. The following is an instance, which has furnished to the Museum one of the few specimens of primary decapitations of the humerus for shot injury:

CASE 1507.—Private J. A. F.—, Co. M, 21st North Carolina, was wounded at the assault on Fort Steadman, March 25, 1865, and was admitted to a Ninth Corps field hospital on the same day. Surgeon G. W. Snow, 35th Massachusetts, reported: "A grapeshot wound of the left shoulder, fracturing the head of the humerus. Resection of humerus and removal of grapeshot by Surgeon J. A. Hayes, 11th New Hampshire. Died March 31, 1865." The specimen, represented in the adjacent wood-cut (FIG. 408), is described (*Cat. Surg. Sect.*, 1866, p. 99) as: "The head of the left humerus, excised through the surgical neck. A bullet has grooved the external portion of the head, and two fissures extend in the inner articular surface. The bone bruised by the ball is carious. Received from a Ninth Corps Hospital."<sup>1</sup>

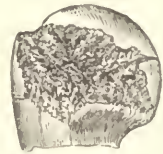

FIG. 408.—Head of left humerus, primarily excised for shot fracture. *Spec.* 4023.

CASE 1508.—Corporal H. Darragh, Co. K, 106th Pennsylvania, aged 40 years, was wounded at Petersburg, June 18, 1864, and, after treatment in the base hospital at City Point, was sent to Washington and admitted to Lincoln Hospital. Acting Assistant Surgeon J. F. Burdick reported: "The above soldier had undergone resection of the head of the humerus, and I saw him but once, and that was just previous to his death. The resection was performed prior to his admission to this hospital. He was very much emaciated; respiration was difficult; the arm was gangrenous. Death occurred July 14th. There is no record of treatment or diet. Medical Cadet Strickler informs me that he has had fifteen drops of tincture of chloride of iron three times a day, and simple water-dressing to the wound. Brandy was daily administered, at frequent intervals." The autopsy was made, on the day of the patient's death, by Acting Assistant Surgeon H. M. Dean, who contributed a pathological preparation from the case, with the following history: "Body is very much emaciated; *post-mortem* rigidity not very well marked; height five feet seven inches. The external surface of the right arm is gangrenous for a distance of six inches above the elbow. He has had a wound in the right shoulder, for which the head of the humerus has been resected. The upper extremity of the humerus, which was denuded for about half an inch, was drawn up by the muscles in contact with the glenoid cavity. The coracoid process of right scapula was also fractured. Wound slightly gangrenous. Right lung firmly adherent to the walls of the thorax and to the diaphragm. On section of the upper and lower lobes a large amount of a frothy fluid exuded. The lining membrane of the bronchi was very much congested. Left lung healthy. Right lung weighed twenty-one ounces; left, eleven and a half ounces. Spleen very much enlarged, firm, not pulpy, weighed nine ounces. Pericardium healthy. Heart: both ventricles contained a fibrinous clot; heart weighed nine ounces. Liver weighed fifty-one ounces, small and contracted; measured seven and a half by six and a quarter and three and a half inches; mottled and convoluted, more resembling the brain than the liver." The specimen consists<sup>2</sup> of "portions of right scapula and humerus, from a subject on whom excision of the head of the humerus had been performed in the field. The wound was gangrenous at the time of death, and the specimen shows no reparative effort."

<sup>1</sup>In regard to this and other primary operations done on March 25, 1865, Dr. SAMUEL ADAMS U. S. A., wrote: "I regret exceedingly that owing to the confusion caused by the whole army being then on the move, it was impossible to keep a record of these cases, and it is beyond my power to furnish the particulars now required. These men were all sent to the Depot Field Hospital at City Point, when the Corps moved to Burksville Junction on the 2d of April."

<sup>2</sup>Specimen 2838, *Catalogue of the Surgical Section, Army Medical Museum, 1865*, p. 25.



TABLE XXV.

Summary of Fifty-six Cases of Deaths after Primary Decapitations of the Humerus for Shot Injury.

No.	NAME, AGE, AND MILITARY DESCRIPTION.	DATE OF INJURY.	NATURE OF INJURY.	DATE OF OPERATION.	OPERATION AND OPERATOR.	RESULT AND REMARKS.
1	Anguish, H., Corp'l, I, 157th New York	July 1, 1863.	Gunshot fracture of the right shoulder.	July 1, 1863.	Excision of head of humerus.	Died July 31, 1863.
2	Black, F. G., Pt., D, 125th Illinois, age 24.	June 27, 1864.	Compound shot fracture of the left humerus.	June 27, 1864.	Removal of head of humerus.	Died July 5, 1864.
3	Blanchard, L. N., Pt., K, 8th N. York Artillery, age 26.	June 3, 1864.	Gunshot wound of right shoulder joint; also wound of hand.	June 3, 1864.	Excision of head of humerus on the field.	Died June 14, 1864.
4	Boothby, S., Lieut.-Col., 1st Maine Cavalry, age 30.	May 10, 1864.	Shot fracture of right humerus.	May 10, 1864.	Head of humerus excised, by A. A. Surgeon T. Siebold.	Died June 5, 1864, of pyæmia.
5	Boven, J. A., Pt., G, 59th Virginia, age 35.	Nov. 14, 1864.	Compound shot fracture of the right humerus	Nov. 14, 1864.	Excision of head of humerus.	Died November 19, 1864.
6	Burke, A., Pt., 18th N. York Battery.	July 1, 1863.	Shot fracture of the head and neck of the right humerus.	July 1, 1863.	Removal of head and neck of the humerus.	Died July 22, 1863, from hæmorrhage and erysipelas.
7	Burkhardt, G., Pt., H, 7th Illinois, age 25.	Mar. 24, 1863.	Wound of left shoulder joint, fracturing head of humerus.	Mar. 24, 1863.	Resection of head of humerus, by Surgeon J. Pogue, 66th Illinois.	Died May 4, 1865, of typhoid fever.
8	Choate, S. H., Pt., H, 61st Illinois, age 27.	Dec. 14, 1864.	Gunshot fracture of head of right humerus, the inner edge of the glenoid cavity, and the coracoid process. Missile lodged in chest cavity.	Dec. 16, 1864.	Head of the humerus removed at the surgical neck, by Surgeon S. D. Turney, U. S. V.	Died December 31, 1864, from the injury to the chest. Ball found, <i>post mortem</i> , in cavity of pleura, on diaphragm.
9	Darragh, H., Corp'l, K, 106th Pennsylvania, age 40.	June 18, 1864.	Shot fracture of upper third of right humerus.	June 18, 1864.	Excision of head of humerus.	Died July 14, 1864, from gangrene and pyæmia. <i>Spec.</i> 2838, A. M. M.
10	Davis, N. E., Lieut., F, 39th Illinois, age 21.	Oct. 13, 1864.	Conoidal ball comminuted upper portion of right humerus.	Oct. 13, 1864.	Removal of head of humerus, by Surgeon C. M. Clark, 39th Illinois.	Died Nov. 15, 1864, of pyæmia.
11	Douglas, A. P., Pt., K, 111th Pennsylvania, age 24.	July 20, 1864.	Minié ball fractured the right humerus.	July 20, 1864.	Head of humerus excised.	Died August 28, 1864.
12	Erwin, B. H., Pt., I, 70th Indiana.	July 2, 1864.	Fracture of the head of right humerus by conoidal ball.	July 2, 1864.	Excision of head of humerus.	Died July 2, 1864.
13	Fee, J. A., Captain, I, 48th New York, age 27.	June 28, 1864.	Gunshot fracture of the right shoulder.	June 28, 1864.	Excision of head of humerus; profuse suppuration and secondary hæmorrhage. July 13th, amputation at shoulder joint, by Surgeon D. G. Rust, 101st Pennsylvania.	Died July 15, 1864, from secondary hæmorrhage.
14	Fiske, G. H., Pt., H, 81st New York.	May 31, 1862.	Musket ball fractured head of left humerus and wounded the median vein.	May 31, 1862.	Excision of head of humerus.	Died Aug. 7, 1862, from hæmorrhage. <i>Spec.</i> 1062, A. M. M.
15	Fox, E., Pt., C, 8th Tennessee, age 37.	July 21, 1864.	Fracture of scapula and head of humerus by a conoidal ball.	July 21, 1864.	Excision of head of humerus.	Died August 26, 1864.
16	Fyfar, J. A., Pt., M, 21st North Carolina.	Mar. 25, 1865.	Grapeshot fractured the head of left humerus.	Mar. 25, 1865.	Removal of head of humerus through the surgical neck.	Died March 31, 1865. <i>Spec.</i> 4023, A. M. M.
17	Fulton, J., Corp'l, F, 14th Ohio, age 22.	June 14, 1864.	Ball passed through the head of left humerus.	June 14, 1864.	Excision of head of humerus, by Assistant Surg. J. Haller, 38th Ohio.	Died July 31, 1864, of exhaustion.
18	Gillam, W., Pt., D, 184th Pennsylvania, age 46.	June 3, 1864.	Shot fracture of head of left humerus.	June 3, 1864.	Excision of head of humerus, by Surg. M. Rizer, 72d Penn.	Died June 13, 1864.
19	Gillespie, M., Pt., C, 6th North Carolina, age 39	June 3, 1864.	Comminuted shot fracture of head of left humerus.	June 3, 1864.	Head of the humerus removed through a diagonal incision.	Died July 20, 1864, from exhaustion.
20	Glass, M., Corp'l, C, 2d Pennsylvania Artillery, age 22.	July 30, 1864.	Shot fracture of left humerus, upper third.	July 30, 1864.	Excision of head of humerus; ligation of subclavian artery, by Surgeon T. P. Oakes, 56th Massachusetts.	Died August 8, 1864, from exhaustion.
21	Green, J., Private, E, 59th Illinois.	June 20, 1864.	Gunshot fracture of shoulder.	June 20, 1864.	Resection of head of humerus, by Surgeon J. T. Wood, 99th Ohio.	Died June 26, 1864.
22	Green, N. S., Pt., A, 56th Massachusetts, age 28.	May 6, 1864.	Conoidal ball wounded the left shoulder joint.	May 6, 1864.	Excision of head of humerus on the field. June 5th, amputation of the arm at shoulder joint, by Surgeon R. B. Bon-tecon, U. S. V.	Died June 7, 1864, from exhaustion.
23	Habicht, L., Pt., C, 55th Virginia, age 24.	Oct. 1, 1864.	Gunshot wound of right shoulder joint.	Oct. 1, 1864.	Excision of head of humerus.	Died Oct. 14, 1864, from pneumonia and wound.
24	Hamilton, W., Pt., I, 23d Ohio, age 22.	Sept. 3, 1864.	Shot wound of right shoulder with great comminution of bone.	Sept. 5, 1864.	Excision of head of humerus, by Assistant Surgeon T. C. Smith, 116th Ohio.	Died September 13, 1864.
25	Handy, C., Sergeant, F, 79th Illinois, age 19.	June 1, 1864.	Shot fracture of head of right humerus.	June 1, 1864.	Head and neck of the bone excised, by Surg. S. J. Young, 79th Illinois.	Died July 4, 1864.
26	Hardengorf, R. D., Pt., E, 109th New York, age 21.	July 30, 1864.	Gunshot fracture of the right shoulder joint; also wound of breast.	July 30, 1864.	Excision of head of humerus, by Surgeon W. C. Shurlock, 51st Pennsylvania.	Died Sept. 3, 1864, of pyæmia.
27	Harrill, J. W., Sergeant, B, 26th Alabama, age 25.	July 3, 1863.	Fracture of right humerus by shot.	July 3, 1863.	Head of humerus excised, by Surg. H. E. Goodman, 28th Penn. July 12th, amputat'n of arm at shoulder joint.	Died July 21, 1863, from hæmorrhage.
28	Henderson, C., Pt., C, 158th New York, age 21.	Mar. 31, 1865.	Shot fracture of right humerus.	April 1, 1865.	Excision of head of humerus, by Surgeon C. M. Clark, 39th Illinois.	Died April 17, 1865, of irritable fever.
29	Hoch T., Sergeant, H, 17th Pennsylvania.	June 11, 1864.	Shot fracture of left shoulder joint.	On field.	Excision of head of humerus.	Died June 19, 1864, at Gordonsville.
30	Hopkins, E. N., Pt., H, 17th Pennsylvania.	June 24, 1863.	Minié ball fractured the right humerus.	June 27, 1863.	Excision of head of humerus.	Died June 27, 1863.
31	Humphrey, J., Pt., G, 1st Wisconsin, age 23.	May 30, 1864.	Gunshot fracture of the right shoulder.	May 30, 1864.	Excision of head of humerus.	Died July 11, 1864.
32	James, G., Pt., G, 75th New York.	June 14, 1863.	Shot wound of right shoulder.	June 14, 1863.	Removal of head of humerus, by Ass't Surg. W. W. Root, 75th New York.	Died September 3, 1863, from absorption of pus, producing a hectic condition.

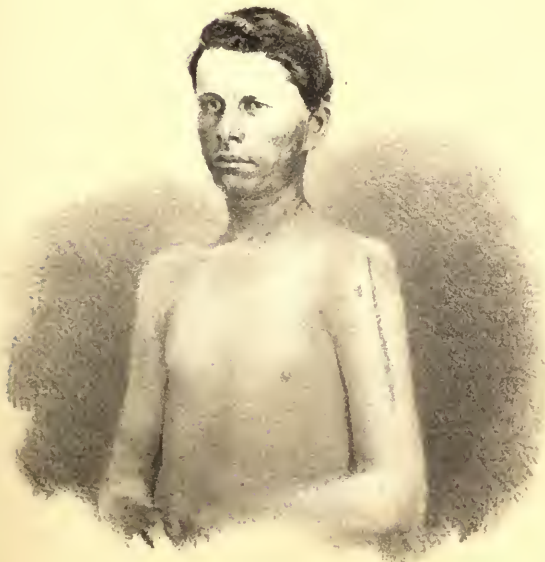FIG. I

FIG. II



FIG. III

FIG. IV



E. M. Wells del.

J. Bach. lith.

RESULTS OF EXCISIONS OF THE HEAD OF THE HUMERUS.

FIG. I. Captain J. P. Quindlen.

FIG. III. Sergeant J. H. Pratt.

FIG. II. Corporal J. B. Nicholson.

FIG. IV. Private J. E. Pwong. S.P.C. 1931 A.M.M.





NO.	NAME, AGE, AND MILITARY DESCRIPTION.	DATE OF INJURY.	NATURE OF INJURY.	DATE OF OPERATION.	OPERATION AND OPERATOR.	RESULT AND REMARKS.
33	Knommer, J., Pt., B, 82d Ohio.	Aug. 30, 1862.	Gunshot wound of neck of humerus.	Aug. 30, 1862.	Removal of head of humerus, by Surgeon J. Y. Cantwell, 82d Ohio.	Died November 2, 1862.
31	Lane, H. C., Pt., H, Purnell's Legion, Maryland Vols.	Aug. —, 1864.	Gunshot fracture of shoulder joint.	Aug. —, 1864.	Head of humerus resected, by Surgeon A. A. White, 8th Maryland.	Died September 8, 1864.
35	Lench, J., Pt., H, 2d Massachusetts.	April 20, 1864.	Gunshot wound of the right shoulder.	Apr'l 20, 1864.	Excision of head of humerus.	Died while a prisoner at Andersonville.
36	Leland, G. M., Lieut., E, 25th S. Carolina, age 28.	May 16, 1864.	Gunshot wound of left shoulder joint.	May 16, 1864.	Excision of head of humerus.	Died May 31, 1864, of pyæmia.
37	Logan, R., Pt., F, 51st New York.	Dec. 13, 1862.	Mimic ball fractured the head of the left humerus.	Dec. 13, 1862.	Excision of head of humerus.	Died Jan. 15, 1863, of pyæmia.
38	McCarthy, O., Pt., E, 106th New York.	June 2, 1864.	Shot fracture of left shoulder; also gunshot fracture of left leg.	June 2, 1864.	Head of humerus excised and leg amputated.	Died June 2, 1864, en route to hospital.
39	Mehamer, J., Pt., B, 55th Pennsylvania, age 34.	May 25, 1864.	Fracture of right humerus by a conoidal ball.	May 25, 1864.	Removal of head of humerus, by Surgeon D. Merritt, 55th Pennsylvania.	Died June 6, 1864, of pyæmia.
40	Malott, E., Pt., K, 62d Ohio, age 28.	April 2, 1865.	Conoidal ball fractured right humerus.	April 2, 1865.	Excision of head of humerus.	April 12th, erysipelas. April 18th, secondary hæmorrhage. Died April 20, 1865. Died October 23, 1864.
41	Monks, W., Pt., G, 15th New Jersey.	Oct. 19, 1864.	Gunshot fracture of left arm.	Oct. 19, 1864.	Excision of head of humerus.	Died October 23, 1864.
42	O'Tonnell, J., Pt., H, 9th New York, age 21.	Sept. 17, 1862.	Shot fracture of head and neck of left humerus.	Sept. 18, 1862.	Head of humerus removed, by Surgeon G. C. Humphreys, 9th New York.	Died September 28, 1862, from violent gangrenous inflammation of the wound.
43	Odor, B. F., Captain, K, 121st Ohio.	Oct. 8, 1862.	Shot fracture of humerus, involving the shoulder joint.	Oct. 8, 1862.	Excision of head of humerus.	Died October 10, 1862.
44	Reichter, G., Pt., B, 8th Maryland.	Aug. 21, 1864.	Gunshot fracture of the right shoulder joint and wound of left forearm.	Aug. 21, 1864.	Head of humerus removed, by Surgeon A. A. White, 8th Maryland.	Died Nov. 27, 1864, of Bright's disease.
45	Richardson, T., Pt., B, 150th New York.	May 15, 1864.	Gunshot wound of right shoulder; severe.	May 15, 1864.	Removal of head of humerus.	Died August 8, 1864, of pyæmia.
46	Roberson, J., Pt., F, 81st Pennsylvania, age 42.	June 18, 1864.	Wound of left shoulder joint by a conoidal ball.	June 18, 1864.	Head of humerus excised on the field.	Died July 14, 1864.
47	Shall, H., Corp'l, E, 45th Pennsylvania.	Sept. 14, 1862.	Gunshot wound of left shoulder.	Sept. 16, 1862.	Excision of head of humerus.	Died November 8, 1862.
48	Sloan, D., Pt., F, 11th Michigan.	Nov. 25, 1861.	Shot fracture of right humerus.	Nov. 27, 1863.	Resection of head and neck of the humerus.	Died Dec. 23, 1863, of ichthæmia.
49	Smith, G., Pt., A, 51st Pennsylvania, age 20.	May 6, 1864.	Conoidal ball fractured the head of right humerus.	May 6, 1864.	Removal of head of humerus.	Died May 29, 1864, of exhaustion.
50	Smith, S., Pt., A, 62d Pennsylvania.	May 9, 1864.	Fracture of left humerus by a conoidal ball.	May 9, 1864.	Resection of head of humerus on the field.	Died May 22, 1864.
51	Stephens, H. F., Corp'l, E, 27th Illinois, age 27.	Nov. 25, 1863.	Mimic ball fractured the surgical neck of the right humerus.	Nov. 27, 1863.	Head of humerus removed, by Surg. A. J. Phelps, U. S. V.	Died Jan. 14, 1864, of ichthæmia.
52	Stronou, B., Pt., B, 93d Pennsylvania.	May 5, 1864.	Shot fracture of neck of humerus.	May 5, 1864.	Head of the humerus excised.	Died May 5, 1864.
53	Stutzman, N., Pt., A, 50th Pennsylvania, age 20.	May 9, 1864.	Gunshot fracture of right humerus, involving the shoulder joint.	May 9, 1864.	Excision of head of humerus.	Died May 19, 1864.
54	Tedford, A. H., Pt., F, 4th Iowa.	Dec. 28, 1862.	Shot fracture of the upper extremity of the humerus.	Dec. 28, 1862.	Resection of head of humerus.	Died Feb. 6, 1863, of pyæmia.
55	Trafton, O., Pt., F, 32d Maine, age 32.	May 18, 1864.	Gunshot fracture of the left humerus.	May 18, 1864.	Removal of head of humerus.	Died May 29, 1864, exhaustion.
56	Woodhouse, C., Corp'l, G, 36th Colored Troops.	Sept. 29, 1864.	Comminuted fracture of the neck of left humerus, opening the joint.	Sept. 30, 1864.	Incision through deltoid and removal of head of humerus, by Surgeon J. R. Weist, 1st Colored Troops.	Died October 6, 1864.

The cause of death was stated in thirty-one of the fifty-six reports, and was ascribed to consecutive hæmorrhage in five cases, to pyæmia or septicæmia in eleven, and to "surgical fever" or "exhaustion" in fifteen, including a case in which the fatal event was referred to the effects of confinement in a prison hospital. The excisions were practised on the right side in twenty-nine, on the left, in twenty instances.

**Intermediary Decapitations of the Humerus for Shot Injury.**—Fifty-five operations are classified in this group. The results were far less satisfactory than in the preceding series, and corroborated the general rule forbidding operations during the inflammatory stage after injury, except under circumstances of exceptional urgency.

§ *Successful Cases.*—Twenty-one patients only, or less than forty per cent. of the fifty-five cases referred to in this category, survived. Two instances are detailed:

CASE 1509.—Private John Morrison, Co. F, 109th Pennsylvania, aged 35 years, was wounded at Cedar Mountain, August 9, 1862, and was admitted to Armory Square Hospital, Washington, on the 15th. Surgeon D. W. Bliss, U. S. V., made the following special report: "The patient had always enjoyed perfect health up to the time of the injury. When struck he was in the act of firing, the whole arm being raised on a horizontal plane, parallel to the shoulder, and the ball took effect in the surgical neck of the right humerus. He walked one mile, and was then taken in an ambulance to Culpeper, where he received surgical care. The wound was probed and search made for the ball, but to no purpose. Cold-water dressings were applied. On August



15th, the patient was sent by railroad to Washington and admitted to this hospital; he was extremely feeble and restless, with an anxious countenance and anorexia, entire indifference as to situation, pulse 110, the wound emitting copious sanguous discharge. Examination showed that the ball had produced a compound fracture of the humerus at the surgical neck, and ploughed a groove along the head, opening the capsule. The ball could not be found. There was considerable depression from effect of wound. Opiates and stimulants were administered, and tepid substituted for cold water. August 19th, resection was performed by Surgeon Bliss, assisted by Surgeons Clymer, Brinton, and Breed. The head of the humerus was excised by the V incision, disarticulated and removed; the shattered end of the shaft below the fracture was taken off, with the chain saw, to the length of an inch and a half, and the spiculae of bone embedded in the surrounding tissues carefully removed. The ball could not be found, nor its course traced, but it was supposed to be lodged in the axilla or thoracic walls. The incision was closed by interrupted sutures, and a tent introduced at the dependent point. Tepid-water dressings were applied; opiates in small and oft-repeated doses, alternated with brandy and beef tea, were given. September 1st, patient is improving; pulse at 90; healing by granulation has commenced. September 5th, the wound is rapidly granulating; the discharge is profuse but of a healthy character. Same treatment continued. September 7th, the arm is dressed with strips of adhesive plaster applied so as to form an easy and firm support. Patient is permitted to walk about through the ward. September 16th, patient still improving. October

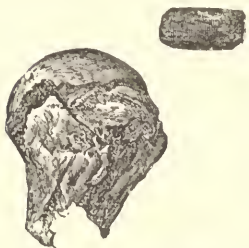

FIG. 409.—Excised head of humerus, with the missile that caused the fracture. *Specs.* 190 and 2432.

1st, patient is attacked with febrile symptoms; the discharges from the wound are less profuse. October 7th, the fever proved to be of the intermittent type, accompanied by anorexia and night sweating. These symptoms were controlled by powders containing sulphate of quinine, ipecac, opium, and tannic acid, one of which was given every three hours, and by minute doses of oxide of zinc. October 12th, patient complained of a tumefaction on the shoulder, which, on examination, was found to be extremely tender; it was small, hard, circumscribed, and situated an inch and a half below the middle of the spine of the scapula. An incision was made, and a conoidal ragged bullet was extracted; some pus of an unhealthy character escaped from the wound. The incision in the arm is nearly closed. October 25th, both incisions are nearly closed, and the general health of the patient is good." The specimen (FIG. 409), contributed by the operator, consists of "the head of the right humerus excised through the surgical neck. An elongated ball fractured the great tuberosity, crushing in the cancellated structure. A small portion of the anatomical neck is involved. The line of excision is very oblique. The missile is mounted with the specimen." This soldier was discharged from service December 12, 1862, and pensioned.

Dr. Bliss saw the man in Philadelphia in May, 1865, and reported that he had a useful arm. Examiner J. Neill reported, April 27, 1868, less favorably regarding the results of this excision. The Philadelphia Examining Board of 1873, Drs. Goodman, Sherwood, and Collins, describe "the arm swinging, dumb, and with little power; forearm weak."

CASE 1510.—Private C. Ross, Co. II, 90th Pennsylvania, aged 19 years, was wounded at Spottsylvania, May 10, 1861. He was treated in a Fifth Corps field hospital for a few days, and was then sent to Washington, and entered Douglas Hospital. Assistant Surgeon W. F. Norris, U. S. A., contributed the specimen (*Cat. Surg. Sect.*, 1866, p. 85, *Spec.* 4278), and a photograph represented by FIGURE 4 of PLATE XVIII, with the following history: "Admitted, May 14, 1864, with a comminuted fracture of the head of the left humerus. The patient had a good deal of irritative fever, and his strength appeared to fail rapidly under the profuse suppuration from the wound. It was, therefore, determined to resect the head of the humerus, and the operation was performed by Assistant Surgeon W. Thomson, U. S. A., then in charge of the hospital, by a straight vertical incision; there was but little loss of blood. The patient soon recovered from the shock of the operation, and continued steadily to improve in health and strength. The wound had entirely healed by the 20th of September. At this date, July 29th, 1865, he has a very useful arm, the motions and strength of the forearm, hand, and elbow joint being as good as in the uninjured side. He can raise the hand to the mouth." The patient was able to do good service in the kitchen and hospital from November, 1864, until August 21, 1865, when he was discharged from service and pensioned. The specimen consists of the head of the humerus in a number of small fragments, excised at the surgical neck. A card photograph, showing the appearance of the arm after recovery, stands with the specimen. Examiner W. W. Potter, of Washington, October 10, 1863, reported: "Has received a gunshot wound of the left shoulder; a minié ball transfixes the head of the humerus from before backward, rendering resection of four and a half inches of the humerus necessary, including the head of the bone, thus destroying the utility of the joint." The disability was rated as total. This man's pension was paid to the National Military Asylum, at Milwaukee, to September 4, 1874, he being an inmate of that Asylum. In September, 1873, a Board, consisting of Examiners E. Kramer, J. H. Stearns, and J. B. Brown, of Milwaukee, reported: "There was resection of the head of the left humerus with four inches of the shaft of the bone;" but the condition of the joint is left to conjecture. An analogous and contemporaneous case, treated on the expectant plan,<sup>1</sup> may be compared with this.

The more important reported facts respecting these successful intermediary excisions of the head of the humerus after shot injury, are incorporated in the succeeding tabular statement. It will be observed that the operations were on the right side in nine, and on the left in twelve instances. The method of operation was specified in eleven cases. In four, a flap was raised to expose the articulation; in seven, straight anterior incisions were employed. In several of the unspecified cases it is implied that the directions of the

<sup>1</sup> See CASE 1470, on page 505, *ante*, the case of Private J. Keenan (FIG. 386). A comparison of the results in these two cases led several surgeons of much experience in the excision of joints to modify, to some extent, their judgments regarding operative interference after shot comminutions of the head of the humerus.

incisions were determined by the position of the wounds, and were curvilinear, or made to conform to the position of the orifice or orifices made by the projectile.

TABLE XXVI.

*Summary of Twenty-one Cases of Recovery after Intermediary Decapitation of the Humerus for Shot Injury.*

No.	NAME, AGE, AND MILITARY DESCRIPTION.	DATE OF INJURY.	NATURE OF INJURY.	DATE OF OPERATION.	OPERATION AND OPERATOR.	RESULT AND REMARKS.
1	Boon, J. W., Pt., C, 73d Ohio, age 28.	Oct. 29, 1863.	Conoidal ball ploughed thro' the left humerus, comminuted the glenoid cavity, and split the scapula.	Nov. 14, 1863.	Removal of the head of the humerus at the surgical neck, and a few pieces of the comminuted scapula.	Disch'd Jan. 3, 1865; pensioned. September, 1873; loss of motion at shoulder, slight use of hand.
2	Burch, M., Pt., 7th Michigan Cavalry, age 21.	Nov. 24, 1864.	Minié ball fractured the clavicle and passed through the head of the right humerus.	Dec. 5, 1864.	Removal of a portion of the head of humerus, by A. A. Surgeon W. S. Adams, Dec. 22d, remainder of the head of humerus removed.	Disch'd June 8, 1865; pensioned. September, 1873, arm cannot be raised to horizontal position.
3	Clark, W. H., Pt., E, 34th Massachusetts, age 24.	May 15, 1864.	Musket ball passed through articulation of right shoulder, fractured the glenoid cavity, and grooved the head of the humerus.	May 22, 1864.	Head of the humerus excised thro' an S-incision, by Surgeon J. B. Lewis, U. S. V.	Disch'd Feb. 17, 1865; pensioned. April, 1874, power of arm seriously reduced; barely able to touch lips with tips of fingers. <i>Specs.</i> 4259, A. M. M.
4	Force, J. P., Captain, 11, 22d Colored Troops, age 30.	Sept. 30, 1864.	Conoidal ball transfixed the head of the left humerus.	Oct. 14, 1864.	Excision of the head of the humerus at the surgical neck through a V-shaped flap, by Surgeon D. G. Rush, 101st Pennsylvania.	Disch'd April 7, 1865; pensioned. September, 1873, disability total. <i>Specs.</i> 3801, A. M. M.
5	Ferguson, J. T., Sergeant, B, 8th Alabama, age 23.	Aug. 27, 1864.	Gunshot fracture of the head of the right humerus.	Sept. 15, 1864.	Head of the humerus removed through a linear incision.	September 30th, doing well; recovered.
6	Gage, W. M., Corporal, G, 8th Michigan, age 28.	May 5, 1864.	Shot wound of right shoulder joint, shattering the humerus badly and lacerating the soft parts; also wounds of right and left hands.	May 15, 1864.	Excision of the head of the humerus; amputation of the middle finger, left hand.	Disch'd May 5, 1865; pensioned. December, 1873, limb useless.
7	Kaney, J., Pt., D, 6th South Carolina, age 21.	Sept. 30, 1864.	Gunshot wound of right shoulder; the ball embedded itself in the head of the humerus.	Oct. 6, 1864.	Resection of the shoulder joint by semi-lunar method.	Furloughed November 2, 1864; wound healed.
8	Lawless, C., Pt., H, 4th Maryland, age 35.	Feb. 6, 1865.	Comp'd comminuted fracture of upper portion of the left humerus, with extensive injury to joint.	Feb. 28, 1865.	Wound enlarged and the head of the humerus removed, by A. A. Surgeon T. Siebold.	Disch'd Aug. 12, 1865; pensioned. October, 1866, cannot raise arm at all.
9	Lovejoy, P. R., Captain, G, 9th Maryland, age 43.	Oct. 18, 1863.	A large conoidal ball produced excessive comminution of the neck of the left humerus and also grazed its head.	Nov. 8, 1863.	Removal of the head of the humerus thro' a perpendicular incision, by Surgeon A. B. Hasson, U. S. A.	Disch'd Feb. 24, 1864; pensioned. March, 1866, prehensile power of hand nearly perfect.
10	McLane, P., Pt., I, 14th Virginia, age 20.	July 20, 1864.	Minié ball fractured inner margin of left glenoid cavity and lodged in head of humerus.	July 26, 1864.	Head of the humerus removed through an S-incision over the joint, by Surgeon J. B. Lewis, U. S. V.	Disch'd June 28, 1865; pensioned. September, 1873, is unable to raise arm from side, but had free use of forearm.
11	McNamara, J., Corporal, H, 3d Massachusetts Cavalry.	April 9, 1864.	Head of the left humerus shattered and scapula perforated by a musket ball.	April 17, 1864.	Head of the humerus excised through a straight incision in middle of deltoid, by Ass't Surg. S. H. Orton, U. S. A.	Disch'd June 16, 1864; pensioned. October, 1866, limb is entirely useless.
12	Morrison, J., Pt., A, 109th Pennsylvania, age 35.	Aug. 9, 1862.	Shot fracture of great tuberosity of right humerus, with slight involvement of the anatomical neck.	Aug. 19, 1862.	Excision of the head of the humerus at the surgical neck through a V-incision, by Surgeon D. W. Bliss, U. S. V.	Disch'd Dec. 8, 1862; pensioned. Sept., 1873, but little power in arm; forearm weak. <i>Specs.</i> 190 and 2432, A. M. M.
13	Nesbit, W. H., Pt., B, 12th Infantry, age 23.	May 6, 1864.	Conoidal ball passed obliquely through the neck of the right humerus and fractured the coracoid process of scapula.	May 26, 1864.	Resection of the head of the humerus, by Surgeon G. L. Pancoast, U. S. V.	Disch'd Sept. 25, 1864; pension'd. Sept., 1873, disability equivalent to loss of arm for purposes of manual labor.
14	Partch, O. H., Sergeant, C, 55th Illinois, age 24.	April 6, 1862.	Shot fracture of the head of the left humerus and wound of breast.	April 25, 1862.	Head of the humerus excised, by Surgeon J. T. Hodgen, U. S. V.	Disch'd Aug. 27, 1862; pensioned. October, 1873, the arm is greatly disabled.
15	Pierson, J. B., Pt., F, 4th Iowa Cavalry, age 18.	June 10, 1864.	Minié ball fractured the neck of the left humerus and split the head into the joint.	June 17, 1864.	Excision of the head and neck of the humerus, by a vertical incision through deltoid, by A. A. Surgeon J. A. Sharp.	Disch'd Sept. 16, 1864; pensioned. December, 1872, arm powerless and joint ankylosed.
16	Reisch, J., Pt., I, 108th New York.	Sept. 17, 1862.	Conoidal ball shattered head of left humerus, and caused a longitudinal fracture of the shaft of the bone.	Oct. 1, 1862.	Excision of the head of the humerus, by Surgeon J. B. Lewis, U. S. V. The missile was found impacted in its centre.	Disch'd Mar. 4, 1863; pensioned. September, 1873, limb hangs dangling and useless.
17	Riley, W. H., Pt., E, 3d West Virginia Cavalry, age 20.	August 7, 1864.	Head of the left humerus perforated by a conoidal ball.	Aug. 19, 1864.	Removal of the head of humerus through a semi lunar incision, by A. A. Surgeon W. B. Crain.	Disch'd June 12, 1865; pensioned. September, 1873, the arm cannot be raised upward from the body.
18	Ross, C., Pt., H, 90th Pennsylvania, age 19.	May 10, 1864.	Comminuted shot fracture of the head of the left humerus.	May 15, 1864.	Head of the humerus removed at the surgical neck, through a straight incision, by Ass't Surg. W. Thomson, U. S. A.	Disch'd Aug. 21, 1865; pensioned. Sept., 1873, disability equivalent to loss of hand for manual labor. <i>Specs.</i> 4278, A. M. M.
19	Sentell, E. H., Lieut., F, 160th New York, age 24.	Oct. 19, 1864.	Gunshot wound of right shoulder, badly fracturing the humerus.	Oct. 25, 1864.	Resection of the head of the humerus, by Acting Staff Surgeon N. F. Graham.	Disch'd April 5, 1865; pensioned. September, 1873, he has no use of the shoulder.
20	Smyser, H. E., Sergeant, B, 6th Wisconsin, age 34.	May 19, 1864.	Gunshot fracture of the head of the left humerus.	June 4, 1864.	Head of the humerus removed at the surgical neck, by Surgeon J. H. Beach, 24th Michigan.	Duty Sept. 9, 1864; commissioned Oct. 19, 1864, and mustered out July 14, 1865. Not a pensioner in December, 1874.
21	Wheeler, W. E., Captain, G, 73d New York, age 22.	May 10, 1864.	Gunshot wound of right shoulder joint; the missile passed through the head of humerus.	May 18, 1864.	Excision of the head of the humerus, by Surgeon H. W. Duchet, U. S. V.	Disch'd Aug. 23, 1864; pensioned. Died August 10, 1868.



§ *Unsuccessful Cases.*—Thirty-four intermediary excisions of the head of the humerus for shot injury resulted fatally. Abstracts of two of these are appended:

CASE 1511.—Sergeant J. P.—, Co. C, 4th Michigan, was wounded at Malvern Hill, July 1, 1862. He was sent to Washington, and entered Cliffburne Hospital. Assistant Surgeon J. S. Billings, U. S. A., reported: "Gunshot wound of the left shoulder. The ball entered over the coracoid process of the scapula, passed in a horizontal line outward and a little backward, and emerged, after splintering the head of the humerus. At the date of his admission, there was very little swelling of the part, slight discharge, and no constitutional symptoms. The patient could move the arm without difficulty or pain, and absolutely refused to have any operation performed. After ten days had elapsed, suppuration having greatly increased, the arm became brawny and œdematous, and hectic supervened. A probe was introduced; and the patient, having been informed that he would certainly die if the operation of excision of the head of the humerus were not resorted to, consented to have it done. On the afternoon of the same day, a semi-circular incision was made from the posterior edge of the wound to within an inch of the interior. The integument having been laid back, the furrow made by the ball and spicula detached in its passage were seen. Forcing the head of the bone out of the cavity, Dr. Billings removed it with the saw, just below the tuberosities. There was slight hæmorrhage from the deep-seated vessels, which were retracted beneath the capsule in such a way as to prevent their being twisted. The wound was left unclosed, stuffed with lint, and dressed with cold water. No recurrence of the bleeding took place during the night, but upon the removal of the charpie in the morning, there was a slight hæmorrhage, easily stopped by the persulphate of iron. The brawny feel had disappeared, together with the pain and œdema. From this period, until three days before his death, July 21st, the patient remained without any change of consequence taking place.

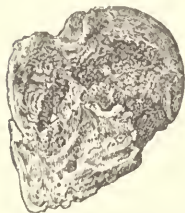

FIG. 410.—Head of left humerus, excised a week after shot fracture. *Spec.* 14.

Under the influence of the treatment adopted, he retained his strength to all appearance, and the power of his faculties. Suddenly, however, the edges of the wound broke down, its odor became very offensive, and subsultus and hectic supervened. Successive rigors, increasing in violence, set in, with short intermissions, and the patient rapidly succumbed. The autopsy disclosed no derangement of the viscera; no disease of the heart and lungs. The periosteum was not stripped off the bone of the wounded limb, but the brachial and cephalic veins opposite to the seat of the injury were thickened very much, and the axillary up to within an inch of the clavicle. One sinus, not of a metastatic character, was revealed, extending from the axilla along the upper third of the humerus. The patient died in the first stage of pyæmia." The specimen (FIG. 410) was one of the earlier contributions to the Museum (*Cat. Army Med. Mus.*, 1863, p. 9), and is represented in the adjacent wood-cut. It has been described (*Cat. Surg. Sect.*, 1866, p. 93) as: "The head of the left humerus, excised at the surgical neck after fracture by a conoidal bullet at the greater tuberosity, which, with the inner part of the anatomical neck, is carried away."

All of the cases of this category are enumerated in TABLE XXVII; yet details of another of those that presented features of interest, and afforded pathological specimens for the Museum, may be narrated more at length:

CASE 1512.—Private J. F.—, Co. C, 72d Pennsylvania, age 34 years, was wounded at Gettysburg, July 3, 1863. Surgeon H. Janes, U. S. V., reported a shot fracture of the left humerus, and the patient's transfer to Philadelphia on July 7th, where he entered Mower Hospital. Surgeon J. Hopkinson, U. S. V., reported the following memorandum: "When admitted, he was suffering from a gunshot wound of the left shoulder, implicating the head of the humerus. On July 22d, he was operated on by Acting Assistant Surgeon J. H. McClellan. An incision was made parallel to the long axis of the arm, through the centre of the deltoid muscle, four or five inches in length, commencing immediately under the acromion process. The capsular ligament being divided, an attempt was made to turn out the head of the humerus, but during the manipulation the head snapped from the shaft. The end of the shaft was then sawn off, and the head of the bone removed. The ball had passed through the surgical neck of the bone, or rather between that part and the head. The parts were brought together by silver wire sutures and adhesive strips, and dressed with compresses dipped in iced water." The subsequent minutes on the case book of the hospital are as follows: "July 23d, pulse 120, feverish, tongue slightly coated, bowels unmoved; a laxative administered. July 24th, bowels moved freely, rests very easily; slept well during the night by taking a quarter of a grain of sulphate of morphia; appetite good. July 25th, pulse full and soft; rested well during the night without morphia, but complains of pain in the bowels, and is feverish, with pulse at 130. The patient had a dose of sulphate of magnesia, and was ordered a draught of spirits of nitre and solution of acetate of ammonia, a tablespoonful to be taken every hour." After a daily clinical report of the condition of the pulse, appetite, dejections, etc., for the next few days, the hospital entries are resumed, on July 29th, as follows: "Pulse 105; left side erysipelatous from the shoulder to the groin. I believe this to be from the effect of water soaking down under him. Ordered a fracture bed and clean bed clothes. July 31st, doing well; side has improved in condition. August 4th, the patient continues to do well. Labarraque's solution is freely used this warm weather. August 6th, wound discharges freely. There was continued improvement to August 10th, and from that date to the 20th, a solution of sulphate of copper, ten grains to the ounce, was ordered to be injected in the parts as directed. August 26th, opened abscess in posterior part of side. September 2d, improving, though complaining of having chills through the night. Sulphate of

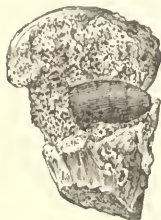

FIG. 411.—Carious head of left humerus, excised nineteen days after impaction of a musket ball. *Spec.* 2599.

quinia was ordered, with aromatic sulphuric acid, a pill to be taken every three hours. September 3d, discharge from shoulder and side very copious." \* \* The report proceeds to detail the topical applications and medication resorted to from day to day, stating that the patient, "in spite of stimulating treatment and diet," commenced sinking on September 8th; but lingered until September 27, 1863. The excised head of the humerus, delineated in the accompanying wood-cut (FIG. 411), was contributed to the Museum by the operator, and is described at page 101 of the Catalogue of 1866, of the Surgical Section.

So many illustrations of shot comminutions and of impaction of balls in the head of the humerus occur in this subsection, that it is unnecessary here to multiply examples; although this might be done easily, since, in eight instances, the excised fractured epiphyses are preserved in the Museum, and, in other cases, photographs of the pathological specimens and detailed abstracts of the cases are on file.

TABLE XXVII.

*Summary of Thirty-four Fatal Cases of Intermediary Decapitation of the Humerus for Shot Injury.*

No.	NAME, AGE, AND MILITARY DESCRIPTION.	DATE OF INJURY.	NATURE OF INJURY.	DATE OF OPERATION.	OPERATION AND OPERATOR	RESULT AND REMARKS.
1	Adams, T. J., Pt., G, 210th Pennsylvania.	Mar. 31, 1865.	Wound of right shoulder by a conoidal ball.	April 7, 1865.	Excision of head of humerus.	Died April 16, 1865.
2	Barry, P., Pt., D, 31th Massachusetts, age 20.	July 18, 1864.	Gunshot fracture of head of left humerus; joint opened.	July 23, 1864.	Excision of head of humerus through surgical neck, by Surgeon J. H. Boone, 1st Maryland.	Died August 4, 1864, from diarrhœa. <i>Spec.</i> 3186, A. M. M.
3	Blanchard, G. P., Lieut., D, 6th Maine, age 28.	May 10, 1864.	Gunshot wound of left shoulder; head of humerus crushed to pieces.	May 27, 1864.	Removal of head of humerus, by Surgeon H. W. Duechet, U. S. V.	Died August 6, 1864, from diarrhœa.
4	<i>Crumbacker, S.</i> , Sergeant, A, 35th Virginia Cavalry, age 44.	May 6, 1864.	Pistol ball passed through head of humerus, splitting the bone two and a half inches below the surgical neck.	May 11, 1864.	Head of the humerus excised through a V-shaped incision.	Died May 16, 1864, from effects of chloroform.
5	Deniston, I., Sergeant, D, 6th Michigan Cavalry, age 31.	June 2, 1864.	Gunshot wound of right shoulder joint, with slight comminution of head of humerus.	June 8, 1864.	Excision of head of humerus, by A. A. Surg. J. E. Dexter.	Died June 12, 1864, of pyæmia.
6	Dolhouser, A., Pl., I, 6th Illinois.	April 6, 1862.	Minié ball comminuted the neck of the left humerus.	Apr 130, 1862.	Head of humerus resected, by Surgeon R. Nichols, U. S. V.	Died May 27, 1862, of pyæmia.
7	Farrell, J., Pt., C, 72d Pennsylvania, age 34.	July 3, 1863.	Conoidal ball fractured head and shaft of humerus and embedded itself in the diaphysis.	July 22, 1863.	Head of humerus removed at surgical neck, by straight incision through deltoid, by A. A. Surgeon J. H. McClellan.	Died September 27, 1863, of pyæmia. <i>Spec.</i> 2599, A. M. M., and <i>Photo.</i> No. 100.
8	<i>Flowers, J.</i> , Pt., G, 15th Alabama.	Aug. 16, 1864.	Gunshot fracture of head of the right humerus.	Sept. 15, 1864.	Head of the humerus excised through a linear incision.	Died Sept. 22, 1864, from hæmorrhage.
9	Follet, S. O., Corporal, H, 7th Rhode Island, age 23.	May 11, 1864.	Conoidal ball passed through the shoulder joint and lodged in the head of humerus.	June 6, 1864.	Excision of head of humerus.	Died June 16, 1864, from hæmorrhage.
10	Glnze, S. S., Sergeant, B, 9th West Virginia, age 26.	Sept. 22, 1864.	Comminuted shot fracture of the head of left humerus and the inferior border of the glenoid cavity.	Oct. 17, 1864.	Excision of head of humerus at the surgical neck, by Ass't Surg. T. C. Brainard, U. S. A.	Died October 24, 1864, of exhaustion. <i>Spec.</i> 4122, A. M. M.
11	Gray, A., Pt., A, 188th Pennsylvania, age 37.	June 1, 1864.	Gunshot fracture of head of the left humerus.	June 13, 1864.	Excision of head of humerus through the surgical neck, by Surg. D. P. Smith, U. S. V.	Died July 11, 1864. <i>Spec.</i> 3303, A. M. M.
12	Haughaut, L., Pt., D, 3d New Jersey, age 40.	May 10, 1864.	Minié ball caused a deeply grooved fracture of the head of the right humerus; the fracture extended two inches down the shaft.	May 24, 1864.	Resection of head of humerus, by Surg. Z. E. Bliss, U. S. V.	Died June 9, 1864, of pyæmia.
13	Hetz, G., Pt., A, 75th Ohio, age 35.	May 3, 1863.	A large conoidal ball fractured and lodged in the head of the right humerus.	May 27, 1863.	Head of humerus excised at the surgical neck, by Surg. C. Page, U. S. A.	Died June 7, 1863, of pyæmia. <i>Spec.</i> 1206, A. M. M.
14	Hughes, A. J., Corporal, C, 25th Massachusetts, age 23.	June 3, 1864.	Gunshot fracture of the head of the left humerus.	June 13, 1864.	Removal of the head and neck of the humerus through a straight incision, by Surgeon E. Bentley, U. S. V.	Died June 23, 1864, of exhaustion.
15	Hughes, J., Pt., D, 23d Pennsylvania.	June 3, 1864.	Shot fracture of the head of the left humerus.	June 15, 1864.	Head of humerus removed, at surgical neck, thro' straight incision, by Surgeon E. Bentley, U. S. V.	Died June 21, 1864, of pyæmia.
16	Hunfield, H., Pl., H, 42d Indiana.	Oct. 8, 1862.	Musket ball passed through spine of scapula and fractured and lodged in the head of the humerus.	Oct. 24, 1862.	Excision of the head of the humerus through a V-shaped incision, by A. A. Surgeon J. Sloan.	Died October 29, 1862, of pneumonia.
17	Knappin, B. F., Captain, B, 44th Illinois.	June 23, 1864.	Gunshot fracture of the head of the left humerus.	June 27, 1864.	Excision of head of humerus, by Surgeons H. E. Hane, 21th Wisconsin, and W. P. Pierce, 88th Illinois.	Died July 4, 1864, of exhaustion.
18	Leery, J., Pt., H, 88th Pennsylvania, age 16.	Feb. 6, 1865.	Shot fracture of upper third of the left humerus.	Feb. 26, 1865.	Removal of head of humerus, a straight incision, by Ass't Surg. W. H. Gardner, U. S. A.	Died March 18, 1865, of exhaustion.
19	Lyons, E., Pt., E, 22d Massachusetts, age 23.	May 30, 1864.	Gunshot fracture of the left shoulder joint.	June 17, 1864.	Resection of head of humerus, by Ass't Surg. W. Webster, U. S. A.	Died July 14, 1864, of pyæmia.
20	McDonald, P., Pt., H, 69th Pennsylvania, age 24.	Dec. 13, 1862.	Gunshot wound of right arm.	Dec. 25, 1862.	Head of the humerus excised.	Died January 7, 1863, of pyæmia.
21	Mayes, S., Pt., F, 155th Pennsylvania, age 21.	Mar. 31, 1865.	Minié ball fractured the right clavicle, the coracoid process of scapula, and lodged in the head of right humerus.	Apr 12, 1865.	Excision of head of humerus at the surgical neck, by Surg. T. R. Crosby, U. S. V.	Died April 19, 1865, of exhaustion.
22	Mills, E. F., Pt., E, 12th New Jersey, age 26.	May 12, 1864.	Shot fracture of the head of the right humerus.	May 27, 1864.	Excision of head of humerus, by Surgeon G. L. Pamcoast, U. S. V.	Died June 13, 1864, from effects of operation.
23	Mulger, T., Pt., G, 20th Kentucky, age 30.	Oct. 8, 1862.	Minié ball passed through the head of the humerus.	Oct. 27, 1862.	Resection of head of humerus through a V-shaped incision, by A. A. Surg. J. Sloan.	Died October 29, 1862; did not rally from the shock of operation.



No.	NAME, AGE, AND MILITARY DESCRIPTION.	DATE OF INJURY.	NATURE OF INJURY.	DATE OF OPERATION.	OPERATION AND OPERATOR.	RESULT AND REMARKS.
24	Nix, J. L., Pt., F, 56th Georgia, age 26.	Sept. 14, 1862.	Shot fracture of left humerus and scapula.	Sept. 26, 1862.	Excision of head of humerus.	Died Oct. 4, 1862, from hæmorrhage.
25	Price, J., Sergeant, C, 4th Michigan.	July 1, 1862.	Conoidal ball splintered the head of left humerus.	July 13, 1862.	Head of humerus sawn off just below tuberosities, by Ass't Surg. J. S. Billings, U. S. A.	Died July 20, 1862, of pyæmia. Spec. 14, A. M. M.
26	Simms, J. M., Lieut., C, 10th Connecticut, age 25.	Dec. 14, 1862.	Conoidal ball injured the head of right humerus and glenoid cavity and lodged behind the scapula.	Dec. 20, 1862.	Removal of head and neck of humerus, by Surgeon M. T. Newton, 10th Connecticut.	Died Jan. 11, 1863, of pyæmia.
27	Slade, W. F. B., Lieut., I, 5th North Carolina, age 20.	May 5, 1862.	Head of right humerus splintered by shot.	May 25, 1862.	Removal of head of humerus, by Surgeon R. B. Bontecou, U. S. V.	Died June 5, 1862, of pyæmia.
28	Stewart, L. M., Pt., A, 142d Pennsylvania, age 23.	Dec. 13, 1862.	Shot fracture of the head of the right humerus.	Jan. 2, 1863.	Head of humerus excised. . . .	Died Jan. 15, 1863, of pyæmia.
29	Torwilliger, C., Pt., G, 21st Connecticut, age 22.	June 4, 1864.	Gunshot fracture of the left shoulder.	June 29, 1864.	Excision of head of humerus at surgical neck, by A. A. Surg. F. G. H. Bradford.	Died July 23, 1864, of typhoid pneumonia. Spec. 3145, A. M. M.
30	Van Douson, J., Pt., D, 14th New Jersey, age 39.	Oct. 12, 1864.	Shot comminution of head and neck of right humerus. Missile also fractured ribs, sternum, and clavicle, and lodged in lung.	Oct. 21, 1864.	Removal of head and surgical neck of right humerus, by A. A. Surgeon A. A. Smith.	Died Oct. 31, 1864, of pyæmia. Spec. 3633, A. M. M.
31	Ward, G. R., Pt., K, 11th Pennsylvania.	June 27, 1862.	A charge of buckshot, fired from behind into left shoulder, made a group of entrance and exit wounds.	July 20, 1862.	Excision of head of humerus, by Surgeon R. B. Bontecou, U. S. V.	Died July 30, 1862, from exhaustion and pyæmia.
32	Wilson, J. O., Pt., C, 11th Indiana, age 25.	June 15, 1863.	Shot wound of the left arm. . . .	June 20, 1863.	Head of humerus removed. . . .	Died Oct. 16, 1863, of pyæmia.
33	Woodman, J. M., Pt., D, 40th Ohio, 1864.	June 14, 1864.	Minié ball fractured the upper third of left humerus.	June 18, 1864.	Head of humerus removed, by Surg. J. T. Woods, 99th Ohio.	Died Sept. 26, 1864, of chronic diarrhœa.
34	Wyatt, J. M., Sergeant, D, 38th Wisconsin, age 35.	April 2, 1865.	Shot fracture of right humerus, extending into the shoulder joint.	April 9, 1865.	Head of humerus excised at the surgical neck.	Died April 18, 1865, of pyæmia.

The fatal results in most of these cases were referred, in general terms, to pyæmic infection, to exhaustion from suppuration, or to surgical fever;<sup>1</sup> but, in a few instances, the effects of chloroform and of secondary hæmorrhage were regarded as the proximate causes of death. The mean interval, in this series, between the dates of injury and fatality, was thirty-five days. In thirty of the operations, the side was specified, the right shoulder having been implicated in thirteen, and the left in seventeen. It may be inferred from the reports that in most of these cases the joint was exposed through interior incisions, usually made vertically from the acromion; though sometimes diverging, according to the position of the shot openings. In five instances, however, it is specified that the flap method was used, either by V-shaped or U-shaped incisions.

It will be noticed that the mortality rate (of 61.8 per cent.) is nearly twice as large as in the series of primary operations, and nearly 12 per cent. greater than in the succeeding category of secondary operations.

**Secondary Decapitations of the Humerus for Shot Injury.**—Twenty-six cases, operated on thirty days, or later, after injury, are here classified. The mortality was fifty per centum. The results in this limited series of operations by no means confirm the prevalent opinion that secondary excisions of the head of the humerus for injury are more successful than primary operations. But the group is too small to serve as a basis for deductions regarding this question. It will be found hereafter that if all of the *excisions of the upper extremity of the humerus for shot injury* be considered, the least mortality attended the secondary excisions. When all the evidence on the subject is adduced, this point will be fully discussed, and it will become obvious that conclusions regarding the various methods of dealing with shot fractures of the shoulder have been too hastily formulated.

<sup>1</sup>The proximate cause of death was specified in thirty two of the cases. One patient was believed to have died from the effects of chloroform, three succumbed from secondary hæmorrhages. In two cases, pneumonia, and in three, diarrhœa, was returned as the causes of death. In seven, "exhaustion from suppuration," and in sixteen "pyæmia" are recorded.

§ *Successful Cases.*—As heretofore, details and illustrations of a few of the tabulated cases will be presented. The specimen from the first is remarkable:

CASE 1513.—Private M. J——, Co. I, 5th Artillery, was wounded at Gettysburg, July 1, 1863. He was treated in the Seminary Hospital near the field, and at the Summit House Hospital, and was transferred to Mower Hospital on July 29th. Surgeon Lewis Taylor, U. S. A., reported: "Gun-shot wound of right shoulder by a conoidal ball, which entered posteriorly, a little above the axilla, and passed directly through, injuring the head of the humerus in its course. Simple dressings were applied to the wound until August 1, 1863, when Acting Assistant Surgeon C. R. McLean removed the head and one and a half inches of the shaft of the right humerus by a straight incision on the joint, length unknown. Chloroform was used, from which the patient reacted promptly. At the time of operation the condition of the patient was good and the wound in a healthy condition. Simple dressings were applied, and nourishing diet and stimulants ordered. No unfavorable symptoms occurred, the patient continuing to improve to the date of his transfer, September 23, 1863." The specimen (FIG. 412) consists of: "The head of the right humerus excised through the surgical neck. An excavation at the base of the great tuberosity, the shape and a little greater than the size of a conoidal ball, extends into the head of the bone. The walls of the cavity are perfectly smooth, as if formed by design, and there is no fissuring nor comminution connected with the injury. A very delicate periosteal deposit exists above the line of excision. Contributed by the operator."—(*Cat. Surg. Sect.*, 1866, p. 99.) This soldier was discharged from service November 5, 1863, and pensioned. Examiner E. C. Swift, of Easton, Pennsylvania, reported, November 14, 1863: "The wound is discharging very freely, and exfoliation is going on. A little motion of the joint exists, but ankylosis will probably take place." And again, on June 5, 1872: "The joint is entirely useless. The pain in the shoulder has increased, so that he suffers more at night with it." This pensioner was paid to March 4, 1874.

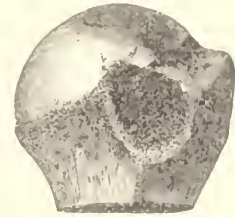


FIG. 412.—Excised head of humerus, with shot penetration without splintering. *Spec.* 2590.

TABLE XXVIII.

*Summary of Thirteen Cases of Recovery after Secondary Excisions of the Head of the Humerus for Shot Injury.*

No.	NAME, AGE, AND MILITARY DESCRIPTION.	DATE OF INJURY.	NATURE OF INJURY.	DATE OF OPERATION.	OPERATION AND OPERATOR.	RESULT AND REMARKS.
1	Campbell, R., Pt., K, 4th New York, age 28.	Dec. 13, 1862.	Minié ball shattered the head of the left humerus.	Jan. 17, 1863.	Removal of head of humerus through a V-shaped incision, by Ass't Surg. C. Wagner, U. S. A.	Disch'd Ap' 110, 1863; pensioned. Sept., 1873, arm nearly useless. <i>Spec.</i> 994, A. M. M.
2	Fuller, C. A., Lieut., C, 61st New York.	July 2, 1863.	Comp'd shot fracture of head of left humerus; also fracture of femur, followed by amputation.	Aug. 6, 1863.	Excision of head of left humerus, by Dr. E. King.	Disch'd December 16, 1863, and pensioned; has very free use of forearm and hand.
3	Harris, S., Pt., D, 169th New York, age 19.	May 16, 1864.	Gunshot wound of left shoulder.	July 1, 1864.	Head of the humerus excised through straight incision, by A. A. Surgeon T. H. Siebold.	Disch'd Feb. 8, 1865; pensioned. Sept., 1873, "arm almost powerless in some directions."
4	Johnson, M., Pt., C, 5th Artillery.	July 1, 1863.	Conoidal ball fractured head of right humerus.	Aug. 1, 1863.	Head of the humerus excised through surgical neck, by A. A. Surgeon C. R. McLean. CASE 1513 <i>supra</i> .	Disch'd Nov. 5, 1863; pensioned. Sept., 1873, disability total, 3d grade, and permanent. <i>Spec.</i> 2590, A. M. M.
5	Leatz, A., Lieut., B, 5th New York, age 26.	June 2, 1864.	Gunshot wound of left shoulder.	Jan. 3, 1865.	Excision of about one inch of head of humerus, by A. A. Surg. J. H. Longenecker.	Disch'd Aug. 21, 1865, and pensioned. Sept., 1865, has no use of his left arm.
6	McCann, E., Pt., B, 69th New York.	Dec. 13, 1862.	Shot fracture of head of left humerus; shaft splintered.	Sept. 13, 1863.	Removal of head of humerus, at surgical neck, through an S-incision, by Asst. Surg. C. R. Greenleaf, U. S. A.	Disch'd Sept. 21, 1864; pension'd. Died Jan. 13, 1867, of phthisis. <i>Spec.</i> 2592, A. M. M.
7	McClain, R., Corporal, C, 1st Sharpshooters.	Nov. 27, 1863.	Minié ball fractured outer portion of head of right humerus.	Dec. 30, 1863.	Excision of head of humerus, at the surgical neck, through straight incision, by Surgeon D. P. Smith, U. S. V.	Disch'd Feb. 22, 1864; pensioned. Sept., 1869, strength of arm greatly impaired. <i>Spec.</i> 1999, A. M. M., and <i>Photo.</i> 100.
8	Morris, W., Pt., I, 23d Virginia, age 23.	May 12, 1864.	Gunshot fracture of upper end of left humerus.	July 7, 1864.	Removal of head of humerus, by Surgeon R. B. Bontecou, U. S. V.	Recovered, and transferred for exchange, Nov. 1, 1864.
9	Naylor, C. H., Pt., I, 11th New Jersey, age 43.	May 3, 1863.	Shot fracture of head of left humerus and wound of right arm.	Aug. 16, 1863.	Head of the humerus excised through a straight incision, by A. A. Surgeon J. H. McClellan.	Disch'd Sept. 26, 1864, and pensioned. Sept., 1873, disability total, 3d grade. <i>Spec.</i> 2595, A. M. M.
10	Parrott, J., Pt., B, Purnell Legion, age 20.	Aug. 21, 1864.	Conoidal ball penetrated head of right humerus and was removed on field.	Oct. 15, 1864.	Head of the humerus removed through a straight incision, by A. A. Surgeon J. M. McGrath.	Disch'd Jan. 21, 1865; pensioned. Sept., 1871, disability total, 3d grade. <i>Spec.</i> 2435, A. M. M.
11	Turner, S., Corporal, G, 2d Michigan Cavalry.	Mar. 24, 1863.	Conoidal ball passed through the left shoulder.	June 11, 1863.	Excision of the head and neck of humerus thro' a straight incision, by Ass't Surg. C. C. Gray, U. S. A.	Disch'd Oct. 28, 1863; pensioned Dec., 1873, shoulder joint ankylosed; the elbow joint and forearm are free in their motions. <i>Spec.</i> 1912, A. M. M.
12	Waldron, C. A., Lieut., B, 2d Rhode Island, age 24.	May 6, 1864.	Conoidal ball fractured head of left humerus.	Sept. 27, 1867.	Excision of head of humerus through a V shaped incision, by Dr. H. W. Rivers. See CASE 1514.	Disch'd June 17, 1864; pensioned Dec., 1871, the arm is useless from injury to the muscles and nerves.
13	Williams, W. B., Pt., A, 2d Wisconsin, age 21.	May 4, 1864.	Shot fracture, with dislocation of the head of the right humerus.	June 20, 1864.	Excision of head of humerus through a longitudinal incision, by Surgeon H. Culbertson, U. S. V.	Disch'd July 27, 1864; pensioned March, 1874, "elbow and wrist are not affected, and the power of grasp is good."



It will be remembered that four of the operations were on the right, and nine on the left side. In seven instances, the excised portions of bone were sent to the Museum. See FIGURES 412 *supra* and 415 *infra*. In an eighth case, photographs of the part excised, and of the patient after recovery, were transmitted:

CASE 1514.—Lieutenant C. A. Waldron, Co. B, 20th Rhode Island, age 24 years, was wounded in the left shoulder at the Wilderness, May 6, 1861. This officer was treated in the Seminary Hospital, Georgetown, and subsequently in private quarters in Washington, and received a leave of absence, at the termination of which he was mustered out, June 17, 1864. Examiner C. G. McKnight, of Providence, reported, November 4, 1864: "Wounded in the left shoulder, the bone being shattered badly. The wound is still open and discharging; the arm is entirely useless." On April 1, 1868, Dr. H. W. Rivers, late surgeon 4th Rhode Island, who treated this officer after his discharge, reported:

"From the time of his being wounded he had very little treatment until he came under my charge. Pieces of bone continued to come away from time to time; several sinuses formed about the shoulder, and a constant fetid discharge was kept up. Mr. Waldron came under my notice about the first of September, 1867, and, after a careful examination of the parts, I advised him to have the head of the humerus excised. At this time, he was very much emaciated and run down. On September 27th, his general health having been improved by tonics and good diet, he presented himself for the operation. Assisted by Surgeons G. W. Carr, late of the 2d Rhode Island, and R. Miller, late of the 4th Rhode Island, and in presence of Dr. W. H. Hazard, of Wakefield, the patient being thoroughly under the influence of sulphuric ether, a V-shaped incision was made including the whole of the deltoid muscle. The flap thus made being dissected up, showed the head and upper portion of the humerus in a very carious condition. Several pieces, including the portion of the head not destroyed by caries, were detached and removed. The shaft was then sawn through and detached. A few pieces of carious bone were then removed by the gouge, and the parts brought together with six points of interrupted sutures. The wound was dressed with compresses wet with water, half a grain of morphia administered, and the patient put to bed. On September 28th, a solution of permanganate of potash was substituted for the water dressing. On October 3d, the patient was doing well, and from this date he continued to improve, the wound uniting almost by the first intention in three weeks from the date of operation. On March 20, 1868, he came to Providence to be photographed. His arm was found to be in a very useful condition, the

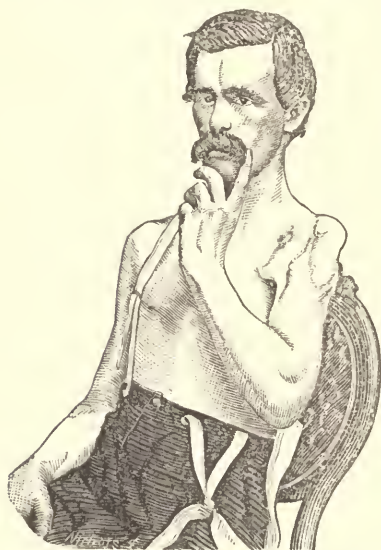


FIG. 413.—Cicatrices after a secondary decapitation of the humerus for shot injury. [From a photograph.]

wound having been long since healed. He was able to carry his hand to his mouth, tie his cravat, and to grasp with considerable power. His general health had improved, and he had gained fifteen pounds in weight since last October. The accompanying photographs show the result of the operation and the pieces of bone removed." The photographs are copied in the annexed wood-cuts (FIGS. 413 and 414). In December, 1871, Mr. Waldron was examined by a Board, who reported that his arm was useless from injuries to the muscles and nerves. His pension was paid March 4, 1874.



FIG. 414.—Fragments of left humerus.

One of the patients in this series<sup>1</sup> survived an amputation above the knee, in addition to the excision of the shoulder; his case will be detailed in the account of thigh amputations. Another succumbed from phthisis, although not until more than three years after the operation. The following is a good example of secondary excision of the head of the humerus with a ball embedded in it:

CASE 1515.—Corporal R. McClain, Co. C, 1st U. S. Sharpshooters, aged 31 years, was wounded at Mine Run, November 27, 1863, and was admitted to Fairfax Seminary Hospital, from a Third Corps field hospital, on December 4th. Surgeon D. P. Smith, U. S. V., contributed the specimen (FIG. 415) with the following notes: "Gunshot fracture of the head of the humerus.

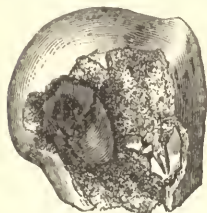


FIG. 415.—Ball impacted in head of right humerus. *Spec.* 1999.

The patient being able to use the arm in writing, the severity of the injury was not suspected until December 20th, when resection was performed by Surgeon D. P. Smith, U. S. V. No bad symptoms supervened." In the *Catalogue of the Surgical Section*, of 1866, the preparation is described: The specimen consists of "the head of the right humerus, excised through the surgical neck for a partial fracture at the posterior portion of the anatomical neck by a conoidal ball, which lodged." The patient was discharged February 22, 1864, and pensioned. Examiner G. R. Johnson, of Grand Rapids, reported, September 7, 1869: "A musket ball struck the right humerus about two inches below the shoulder joint, passed upward and buried itself in the head of the bone. In consequence of the injury to the bone, and of the resulting inflammation, the head of the bone and about one or one and a half inches of the shaft were excised. The result is that the movements and strength of the arm are greatly impaired." The pensioner was paid September 4, 1874.

<sup>1</sup> Case of Lieut. C. A. Fuller, 61st New York. This officer was wounded on the second day of the battle of Gettysburg, and underwent primary amputation at the lower part of the left thigh, by Surgeon C. S. Wood, U. S. V., at a Second Corps hospital.

FIG. I.



FIG. II.



FIG. III.

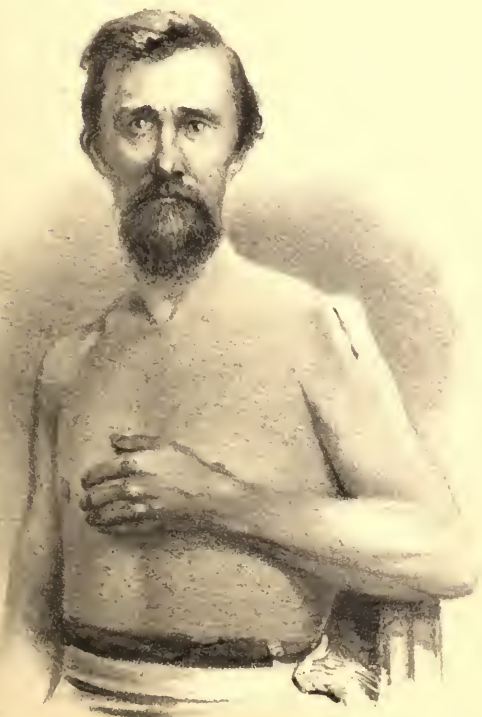


FIG. IV.



J. B. H. 4th

Win Bell phot

### RESULTS OF EXCISIONS OF THE HEAD OF THE HUMERUS.

FIG. I. Major T. G. Morrison

FIG. III. Private D. Singleton

Fig. II. See page 100

Fig. IV. See page 100





§ *Unsuccessful Cases.*—An equal number of cases terminated fatally. But in one of these there was a fracture of the first rib, and possibly the chest cavity was interested directly, or by extension of inflammatory action; and, in three instances, diarrhœa or dysentery, existing antecedently to the injuries or operations, were assigned as the causes of death. Eleven operations were on the right and one on the left side, the thirteenth case being undetermined, a result added to the evidence adduced on pages 537 and 544, as to the relative fatality of the operations on the right and left sides that fails to confirm the surmise of Professor Esmarch (*Über Resect.*, u. s. w., *op. cit.* s. 49) that the operation on the left side has a higher mortality rate than on the right; a suggestion, it is proper to add, very carefully qualified by that eminent surgeon:

CASE 1516.—Private W. S.—, 3d New York Independent Battery, aged 20 years, was wounded at Petersburg, March 25, 1865, and was admitted to Harewood Hospital, Washington, on April 2d. Surgeon R. B. Bontecou, U. S. V., reported: "Admitted April 2, 1865, suffering from a gunshot wound over the right scapula, the ball entering the deltoid muscle, injuring the head of the humerus, and making its exit near the spine. Resection of head of right humerus was performed, April 26th, through an incision about four inches long, over the deltoid muscle. At the time of the operation, the patient was very weak, and suffering from diarrhœa. An abscess had collected in the upper part of the arm, near the head of the humerus, and the parts were infiltrated with pus. The result was unfavorable, and the patient gradually sank, and died from exhaustion May 10, 1865." The operator, Dr. Bontecou, forwarded to the Museum a photograph of the patient (*Card Photographs*, Vol. II, p. 10), which is copied in the adjacent wood-cut (FIG. 416). It was taken soon after the operation, when a happier result was anticipated.



FIG. 416.—Incision and exit wound in a secondary decapitation of the humerus. [From a photograph.]

TABLE XXIX.

*Summary of Thirteen Fatal Cases of Secondary Excisions of the Head of the Humerus for Shot Injury.*

NO.	NAME, AGE, AND MILITARY DESCRIPTION.	DATE OF INJURY.	NATURE OF INJURY.	DATE OF OPERATION.	OPERATION AND OPERATOR.	RESULT AND REMARKS.
1	Beckwith, R. J., Pt., B, 12th N. York Cavalry, age 28.	Mar. 9, 1865.	Gunshot wound of the right shoulder.	May 5, 1865.	Excision of the head of the humerus.	Died May 12, 1865, of pyæmia.
2	Brooker, J. R., Pt., E, 11th South Carolina, age 39.	June 20, 1864.	Minié ball pierced the right humerus just below anatomical neck, making a round hole without fissure.	Aug. 3, 1864.	Excision of the head of the humerus through a V-incision, by Ass't Surgeon E. Curtis, U. S. A.	Died Aug. 11, 1864, from irritative fever.
3	Bryant, D. H., Pt., C, 7th Wisconsin, age 35.	May 8, 1864.	Gunshot wound of right shoulder joint; ball injured the head of humerus.	June 30, 1864.	Head of humerus removed at surgical neck, by A. A. Surg. C. F. Frautman.	Died July 4, 1864, from exhaustion after hemorrhage. <i>Spec.</i> 3018, A. M. M.
4	Burkhardt, H., Pt., E, 16th Louisiana.	Sept. 20, 1863.	Musket ball fractured the head of the right humerus.	Nov. 16, 1863.	Excision of head of humerus, by Surg. A. McMahon, 64th Ohio.	Died November 23, 1863, from diarrhœa.
5	Fitzgerald, B., Corporal, G, 73d Ohio, age 23.	Sept. 19, 1863.	Shot fracture of the right humerus, involving the shoulder joint.	Nov. 13, 1863.	Head of humerus excised at surgical neck, by A. A. Surg. G. P. Hasheuberg.	Died November 21, 1863, of pyæmia. <i>Spec.</i> 1925, A. M. M.
6	May, Jacob, Pt., 37th Ohio, age 18.	June 14, 1863.	Conoidal ball passed through the head of right humerus.	July 12, 1863.	Removal of head of humerus at the surgical neck, by Surg. J. G. Keenon, U. S. V.	Died July 23, 1863, of pyæmia. <i>Spec.</i> 1703, A. M. M.
7	Miller, G. A., Pt., E, 33d Indiana, age 21.	May 15, 1864.	Musket ball fractured the head of right humerus.	July 2, 1864.	Excision of head of humerus at surgical neck, by Ass't Surg. H. T. Logler, U. S. V.	Died August 8, 1864, of exhaustion.
8	Seale, J. P., Pt., D, 31st Mississippi, age 30.	Nov. 30, 1864.	Head of right humerus fractured by conoidal ball.	Jan. 14, 1865.	Head of humerus removed, by A. A. Surg. I. Sinclair.	Died March 3, 1865, of dysentery.
9	Stewart, W., Pt., 3d New York Battery, age 20.	Mar. 25, 1865.	Minié ball entered the deltoid muscle, injured the head of right humerus, and emerged near the spine.	Apr 26, 1865.	Head of the humerus removed through incision over deltoid, by Surgeon R. B. Bontecou, U. S. V.	Died May 10, 1865, from diarrhœa.
10	Stilwell, J., Pt., I, 1st Maryland Cavalry, age 21.	Aug. 16, 1864.	Shot fracture of head of left humerus; much disorganization of muscular tissues.	Sept. 21, 1864.	Head of the humerus removed through a straight incision, by A. A. Surg. J. C. Morton.	Secondary hæmorrhage Sept. 21; ligation of subclavian artery. Died September 23, 1864.
11	West, J., Pt., I, 37th New York, age 18.	June 30, 1862.	Round ball and buckshot grooved and fractured the head of the right humerus.	Aug. 1, 1862.	Excision of the head of the humerus at the surgical neck, by A. A. Surg. S. D. Gross.	Died August 20, 1862, of pyæmia. <i>Spec.</i> 388, A. M. M.
12	Wilson, M. L., Lieut., A, 123d New York, age 28.	May 6, 1864.	Gunshot wound of right shoulder and fracture of first rib.	June 10, 1864.	Removal of head of humerus, by Surgeon H. W. Ducahet, U. S. V.	Died June 19, 1864, of pyæmia.
13	Ziemer, W., Pt., H, 9th Wisconsin.	Sept. 30, 1862.	Minié ball fractured and lodged in head of humerus.	Nov. 1, 1862.	Excision of head of humerus.	Died Nov. 6, 1862, of pyæmia.



Eleven of the operations were on the right side. The joint was exposed by raising a flap, in one instance, and by linear incisions anteriorly, and parallel with the fibres of the deltoid, in seven cases; in five cases, this point is not noted. The following is a fatal case of that remarkable group of shot penetrations of the epiphysis without splintering, which appear to occur only in young subjects, and are very rare:

CASE 1517.—Private Jacob M——, Co. B, 37th Ohio, aged 18 years, was wounded at Vicksburg, June 4, 1863, and was treated in the regimental hospital until July 4th, when he was sent, on the hospital steamer D. A. January, to Memphis, and admitted to Adams Hospital. Acting Assistant Surgeon J. Thompson reported: "Gunshot fracture of the head of the right humerus. On examination, it was found that the ball had entered at the posterior portion of the deltoid muscle, passed directly

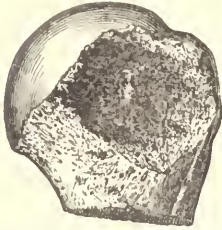

FIG. 417.—Head of the right humerus excised for shot injury. *Spec.* 1703.

through the head of the humerus, and came out at the anterior edge of the deltoid; wound suppurating very much; the patient is unable to move his arm; he has quite a yellow appearance of the skin and sclerotic coat of the eye: pulse 110. Excision of the head of the humerus was decided upon and was performed July 12, 1863, by Surgeon J. G. Keenon, U. S. V., by making a semilunar incision, dissecting up the deltoid, disarticulating the head of the bone, and sawing off the same at the anatomical neck with a chain saw. The bone was then placed in position, the flap retained by a few interrupted sutures, and dressed with cold water until suppuration was again established. Half a grain of morphia was then administered and the patient put to bed. July 13th, patient rested well last night; no treatment constitutionally. July 14th, wound looks well; pulse 112; bowels constipated; administered half an ounce of salts, which operated mildly. Evening, patient rather restless; pulse 118; half a grain of morphia ordered at bedtime. July 15th, patient rested very poorly last night; had violent rigors; pulse 110; month dry this morning; wound looks very well; suppurating; quinia ordered; discontinued cold water to wound and substituted simple dressings. July 16th, patient rested well last night; says he feels well; pulse now 100; wound suppurating nicely; ordered citrate of quinia, five grains three times a day, and beef tea, four ounces every three hours. July 17th, patient rested well last night; says he feels very well this morning; bowels rather constipated; ordered sulphate of magnesia, which operated about noon, and also tincture of chloride of iron, beef tea, and ale. July 20th, patient has had some severe rigors; pulse 105; tongue a little coated; skin moist; wound suppurating; continue iron, ale, quinine, and beef tea. July 21st, patient rested well last night; bowels moved this morning; continue treatment. July 22d, patient had severe rigors; quinine and Dover's powders ordered. July 23d, patient rested poorly last night; had severe rigors this morning; countenance quite dull; skin and eyes very yellow; wound still suppurating. Treatment: iron, beef tea, and ale, *ad libitum*. Progress unfavorable." Death resulted from pyæmia, July 23, 1863. The specimen (FIG. 417) was contributed to the Museum by Dr. Keenon, and consists of "the head of the right humerus excised at the surgical neck. The external portion of the head and anatomical neck on both sides of the epiphyseal line are occupied by a cavity the size of a walnut, with spongy and carious walls. There are no fissures in the head or shaft."—*Catalogue Surgical Section*, 1866, p. 100.

The statistics of the twenty-six secondary decapitations of the humerus for shot injury, unless accompanied by qualifying comments, would represent the operation too unfavorably;<sup>1</sup> since several of the cases proved fatal from causes foreign to the injury or operation.

**Decapitations of the Humerus for Shot Injury of Uncertain Date.**—Seventeen excisions at the shoulder, belonging to this subdivision, were reported without indication of the length of the period between the reception of the injury and the date of operation. The twelve successful, four unsuccessful, and one undetermined case are tabulated below, and a fatal case, and one of the successful cases are detailed at some length:

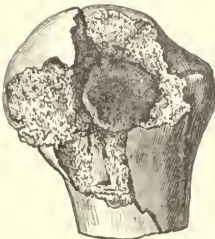


FIG. 418.—Ball impacted in the head of the right humerus. *Spec.* 5599.

CASE 1518.—Private J. M. M——, Co. F, 11th Georgia, was wounded at Gettysburg, July 3, 1863. He was sent to a field hospital for Confederates; but no account of the case is found recorded other than a memorandum by Surgeon H. James, U. S. V., giving the date of injury, and of transfer, and the note: "Ball in shoulder joint." The patient was transferred to David's Island, New York, on July 18th. Surgeon J. Simons, U. S. A., reported that he entered the DeCamp Hospital, July 22d, and died of pyæmia August 8, 1863. Dr. A. N. Brockway, of Harlem, New York, formerly Acting Assistant Surgeon at DeCamp Hospital, on September 10, 1868, transmitted to the Museum the excised head of the humerus from this case (FIG. 418), stating that: "The only history that I was able to obtain was that it belonged to a member of a Georgia regiment, and that the head of the bone was excised by Acting Assistant Surgeon J. W. Dickey, in August 1863, at the DeCamp Hospital, and that the patient shortly afterward died. I made diligent inquiry of the wardmaster, but could obtain no further history." This was probably an intermediary operation. The ball entering laterally has comminuted the head of the humerus and is impacted in its cancellous tissue. The specimen affords quite a typical example of those cases imperatively demanding excision.

<sup>1</sup> It is well known that many eminent surgeons have advocated secondary excisions at the shoulder as less hazardous than early operations; the data collected on the subject will be analyzed at the close of the section.

A successful case was illustrated by a photograph; but the reported details are otherwise, unfortunately, very imperfect:

CASE 1519.—Private B. E. Rice, Co. H, 7th Wisconsin, aged 31 years, was wounded at Gainesville, August 26, 1862, and was treated in the regimental hospital until August 30th, when he was transferred to Washington, and admitted to Columbian College Hospital, and discharged the service December 22, 1862, Surgeon T. R. Crosby, U. S. V., certifying to: "Gunshot wound, requiring resection of the head of the left humerus." On March 28, 1870, Dr. L. G. Armstrong, of Boscebel, Wisconsin, reported: "Gunshot wound, ball entering the shoulder joint from the front. Removed to Washington, D. C., Columbian College Hospital. Head of humerus excised after a number of days; secondary operation. Wound entirely healed in six months. Bones ankylosed, yet the arm cannot be raised from the side, admitting only of moderate forward and backward motion. The wound is healed soundly, yet large loss of tissue occurred. The humerus is two inches shortened. Arm can be used only from the elbow downward. Amount of neuralgic pain only trifling. General health but little influenced by the operation." Dr. Armstrong also forwarded a daguerreotype of Mr. Rice, taken March 21, 1870, which is copied in the wood-cut (Fig. 419). Examiner J. M. Jenkins, of Sibley, Iowa, reported, May 20, 1874: "Gunshot wound of left shoulder. Head and neck of humerus resected. Very large cicatrix; the deltoid, long head of biceps, infraspinatus, and pectoral muscles were, apparently, severed, and the nerves injured. The arm is shortened one and a half inches. The shoulder is very much atrophied, and the arm and forearm are somewhat smaller, and are easily chilled; he has but little use of the limb. Disability increasing, and may become total. The arm has but little motion, and the forearm and hand are very weak." Upon searching the case, it has been impracticable to obtain any important particulars of its earlier history. Surgeon D. Cooper Ayres, 7th Wisconsin, reported the admission of the patient to regimental hospital, with a "serious gunshot wound of the shoulder." Dr. Crosby does not describe the operation or mention the name of the operator. All of the reporters agree that the operation was on the left side. The position of the cicatrix is reversed in the daguerreotype, as copied in the wood-cut, and appears as of the right side. This is an error very liable to remain undetected in illustrations prepared by photography, even after careful scrutiny.

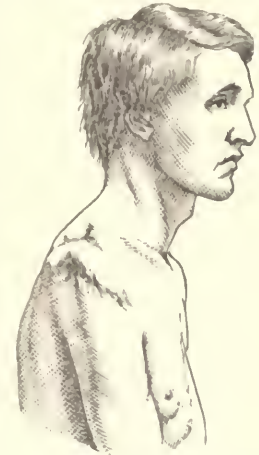

FIG. 419.—Cicatrices eight years after an excision of the head of the humerus.

TABLE XXX.

*Tabular Statement of Seventeen Decapitations of the Humerus for Shot Injury, in which the Intervals between the Dates of Injury and of Operation were not ascertained.*

NO.	NAME, AGE, AND MILITARY DESCRIPTION.	DATE OF INJURY.	NATURE OF INJURY.	DATE OF OPERATION.	OPERATION AND OPERATOR.	RESULT AND REMARKS.
1	Black, J., Pt., E, 51st Illinois, age 18.	June 27, 1864.	Comminuted shot fracture of left humerus.	.....	Excision of head of humerus.	Vet. Res. Corps, Sept. 4, 1864; not a pensioner in July, 1874.
2	Clout, W. W., Pt., I, 4th Georgia.	May 10, 1864.	Gunshot wound of right shoulder.	.....	Excision of the head of the right humerus.	Furloughed September 20, 1864.
3	Coggens, J., Pt., F, 5th New York Cavalry, age 21.	May 25, 1862.	Shot fracture of upper third of right humerus.	.....	Excision of head of humerus.	Disch'd September 17, 1862; not a pensioner in December, 1874.
4	Gozer, J., Pt., F, 89th Illinois, age 33.	Dec. 31, 1862.	Compound comminuted shot fracture of humerus.	.....	Removal of head and portion of the neck of the humerus.	Disch'd Ap' 129, 1863; pensioned, March, 1872, arm nearly useless.
5	Hayward, S. P., Pt., B, 6th Missouri, age 23.	Aug. 31, 1864.	Fracture of head of left humerus by fragment of shell.	.....	Head of humerus excised.	Disch'd May 19, 1865; pensioned, Sept., 1873, ankylosis of shoulder joint; loss of power of arm.
6	May, R., Pt., D, 19th Indiana, age 19.	Aug. 28, 1862.	Shot fracture of head of left humerus.	.....	Excision of head of humerus.	Disch'd November 23, 1862; not a pensioner.
7	Mulqueen, D., Pt., G, 6th Kentucky Cavalry, age 32.	April 6, 1865.	Conoidal ball fractured the left humerus.	.....	Resection of head of humerus, by a Confederate surgeon.	Discharged September 8, 1865, and pensioned; not heard from since March, 1866.
8	Prosser, O., Pt., A, 16th Louisiana.	Nov. 25, 1863.	Gunshot wound of shoulder.	.....	Excision of head of humerus.	Transferred to Provost Marshal February 20, 1864; recovered.
9	Rice, B. E., Corporal, F, 7th Wisconsin, age 19.	Aug. 30, 1862.	Conoidal ball penetrated the left shoulder joint.	.....	Excision of head of humerus. See CASE 1519.	Disch'd Dec. 22, 1862; pensioned, May, 1874, very little motion in arm; forearm and hand very weak. Photograph S. S., 267.
10	Smith, W., Pt., H, 173d N. York.	June 14, 1863.	Gunshot wound of right shoulder joint.	.....	Excision of the head and neck of the humerus.	Disch'd Mar. 7, 1864; pensioned, Sept., 1873, the limb is useless for manual labor.
11	Torbet, J. P., Pt., F, 3d Ohio, age 23.	Dec. 31, 1862.	Minié ball perforated the right shoulder, shattering the head of the humerus.	.....	Excision of head of humerus.	Disch'd Ap' 129, 1863; pensioned, Sept., 1873, result of operation excellent.
12	Van Scooter, A. B., Sergeant, H, 4th Michigan, age 31.	July 1, 1862.	Shot fracture of upper third of left humerus.	.....	Head of humerus excised, by Ass't Surgeon J. R. Smith, U. S. A.	Disch'd Dec. 19, 1862; pensioned, March, 1872, ankylosis of the shoulder joint.
13	Clapson, C., Corporal, A, 115th New York.	.....	Shot fracture of upper third of left humerus, involving joint.	May 27, 1863.	Excision of head of humerus.	Died June 16, 1863, of pyæmia.
14	Clark, W., Pt., K, 1st Massachusetts, age 34.	June 30, 1862.	Shot perforation of left shoulder joint; head of humerus badly fractured.	.....	Excision of head of humerus, by Surg. T. M. Getty, U. S. A.	Died July 21, 1862.
15	Roberts, L., Pt., H, 35th South Carolina.	.....	Gunshot wound of shoulder	.....	Excision of head of humerus.	Died October 26, 1864.
16	J. M. M——, Georgin Regiment, C. S. A.	July 3, 1863.	Minié ball embedded itself in the cancellous structure.	Aug. —, 1863.	Removal of head of humerus, by A. A. Surg. J. W. Dickey.	Died shortly after operation. Spec. 5599, A. M. M.
17	Gilburley, M., Pt., C, 14th Alabama.	Sept. 7, 1862.	Gunshot fracture of the right humerus at shoulder joint.	.....	Excision of head of humerus.	.....



**EXCISIONS OF THE HEAD AND PORTIONS OF THE SHAFT OF THE HUMERUS.**—Five hundred and seventeen cases were referred to this category, and are classified in four divisions. Two hundred and ninety-three were primary operations, one hundred and fifty-five intermediary, fifty secondary, and in nineteen cases the interval between the date of the injury and the date of the operation was undetermined.

**Primary Excisions of the Upper Extremity of the Humerus for Shot Injury.**—This large subdivision, when portions of the shaft as well as the head were removed, includes two hundred and ninety-three cases, with a mortality rate of only 27.3 per cent.

§ *Successful Operations.*—In a large proportion of the two hundred and thirteen successful operations the progress and details of the cases have been traced:



FIG. 420.—Cicatrix after excision of the head of the humerus.

CASE 1520.—Private S. B. Crane, Co. H, 13th Infantry, was wounded at Chickasaw Bayou, near Vicksburg, December 29, 1862, and was operated on in a Thirteenth Corps hospital, and thence sent on a transport to St. Louis, entering Lawson Hospital January 17, 1863. Surgeon C. T. Alexander, U. S. A., reported: "Gunshot fracture of the neck of the right humerus by a conoidal ball, which lodged at the superior angle of the scapula. Excision of the upper third, including the head, four inches in all, was performed on the field, December 29th, by Surgeon George S. Walker, 6th Missouri, through a linear incision, splitting the deltoid muscle." The patient recovered, and was discharged the service April 27, 1863. On September 5, 1864, Examiner John H. House, Independence, Iowa, reported: "The applicant received a ball through the right shoulder, shattering the head of the humerus and scapula, which required resection of three inches of the humerus. The vacancy is not replaced by new bone. He has no use of the arm, but can hold or carry any article in the hand; disability total." In September, 1868, the pensioner was sent to New York by order of Surgeon M. Mills, U. S. A., and was furnished by Dr. E. D. Hudson with an apparatus which greatly facilitated the movements of the arm. Prior to this he had full control over the forearm and hand, but the ligamentous attachments of the upper extremity of the humerus to the scapula were so long that the movements of the arm were very imperfect. The arm was shortened only one and a half inches, and its size was nearly normal, except that the deltoid was wasted from disuse. After the application of the apparatus, there was satisfactory power over the motions of the arm. The photograph, copied by the wood-cut (FIG. 420), was taken at this time, and contributed to the Museum by Dr. Hudson. The pensioner was paid March 4, 1874.

The flattening below the acromion, and atrophy of the brachial muscles, so common in these cases, is well exemplified in the following instance:



FIG. 421.—Appearance of cicatrix and limb two years after excision at the shoulder.

CASE 1521.—Private C. S. Wilson, Co. D, 3d Wisconsin, aged 21 years, was wounded at Averysboro', March 10, 1865, and was admitted into a Twentieth Corps hospital, where excision of the head of the right humerus was performed, through a straight anterior incision, by Assistant Surgeon H. M. Blood, 150th New York. The patient was subsequently treated in Foster Hospital, New Berne, and McDougal Hospital, New York, and was discharged from the latter, May 29, 1865, and pensioned. Examiner N. O. Hitchcock, of Kalamazoo, on February 7, 1867, forwarded the photograph of this soldier, as copied in the wood-cut (FIG. 421), with the following particulars: "The man was wounded by a minie ball, which passed through the right shoulder joint, shattering the upper part of the humerus. The operation was performed six hours after the infliction of the injury. The wound was not healed until October, 1866. The head and about three inches of the shaft, in all about four and one-half inches of the humerus, had been removed. There has been no restoration of bone. Motion at the shoulder is lost, but motion at the elbow is good, and the grasp of the hand is good. He can write quite well by moving the hand with the left one. He can chop wood pretty well; can drive horses with the hand, and can do any kind of work in which the shoulder is not required as a pivot or fulcrum." Examiner H. Neill, of Watonwan, reported, September 6, 1873: "Adduction and abduction, and the power of extending the arm at a right angle from the trunk, are wholly lost. The arm is shortened about three inches, and there is a partial atrophy of the arm." This pensioner was paid March 4, 1874.

The following is one of the seven cases<sup>1</sup> of this category illustrated by the lithographs on excision at the shoulder:

CASE 1522.—Sergeant Jacob P. Yakey, Co. D, 125th New York, aged 21 years, was wounded at Petersburg, June 22, 1864, and sent to a Second Corps hospital, where Surgeon D. H. Houston, 2d Delaware, reported that "he was struck by a conoidal ball, which entered the left

<sup>1</sup> CASES of Pt. Yakey (Fig. 3, PLATE XIII, op. p. 520), Lieut. Jacobs and Pt. Reardon (Figs. 1 and 3, PLATE XIV, op. p. 529), Captain Quindlen, Serg't Pratt, and Pt. Ewing (Figs. 1, 3, and 4, PLATE XVIII, op. p. 444).

shoulder at the anterior edge of the deltoid muscle, and fractured the humerus." On the same day Surgeon William S. Cooper, 125th New York, excised the head and three inches of the shaft of the left humerus through a V-shaped incision, the patient being under chloroform. The case progressed well. On June 28th, the patient was sent to Lincoln Hospital, and furloughed on September 17th, and discharged November 10, 1861. In January, 1865, he was admitted to a hospital at Troy as contract nurse. He had an abscess of the left arm, which was incised by Surgeon G. H. Hubbard, U. S. V., and a small fragment of necrosed bone was removed. After this the wound healed firmly. Sergeant Yakey was pensioned. Examiner W. S. Searle reported, July 6, 1865, "the arm is useless at present." Examiner A. Churchill, of Utica, reported, September 29, 1866, the injury and operation, and added: "There is still a running sore near the shoulder-joint, and another near the elbow-joint. The bone removed has not been reproduced; he has little control of the muscles of the arm, and the limb is of slight service for manual labor." Examiner C. B. Coventry, of Utica, reported, September 4, 1873, "almost total loss of use of the arm. Disability total." A photograph of the patient was made at Lincoln Hospital (*Contributed Surg. Phot.*, A. M. M., Vol. II, p. 13), which is copied in *Figure 3*, PLATE XIII, opposite page 520. There has been no application for a supporting apparatus in this case.

CASE 1523.—Sergeant B. Wilsey, Co. D, 4th New Jersey, aged 30 years, was wounded at Petersburg, April 2, 1865. On the 11th, he was sent to Washington, to Harewood Hospital. Surgeon R. B. Bontecou, U. S. V., noted: "Gunshot wound of left shoulder, the ball fracturing the head of the humerus. Resection of the head of the humerus was performed on the field on April 2d, through a straight incision in the long diameter of the deltoid muscle, about four inches of the shaft being also removed. The case progressed favorably under simple dressings, splints, and supporting treatment, and was doing well up to the end of June, 1865; but no osseous formation had taken place up to that date." On July 26th, he was sent to Ward Hospital, Newark, and thence discharged the service, August 30, 1865. Examiner E. A. Smith, of Philadelphia, September 4, 1865, reported that: "The wound of operation was then unhealed; there was ligamentous union, and he had all the motions of the forearm and hand." The pensioner was paid March 4, 1874. The wood-cut (FIG. 422) was taken from a photograph in the Museum (*Card Photographs*, Vol. II, p. 6). A letter from this pensioner, dated August 8, 1874, Berlin, Pennsylvania, states that the operation in this case "was performed by Surgeon R. Sharpe, 15th New Jersey, assisted by Surgeon B. A. Watson, 4th New Jersey. As to usefulness, it is of very little use. It has gathered and discharged several times. \* \* I can use the hand some. \* \* Several pieces of bone have lately come from it. It always has gathered about once a year until last winter, and since then, nearly every month."



FIG. 422.—Cicatrix after a decapitation of the humerus. [From a photograph.]

CASE 1524.—Private S. C. Allen, Co. A, 93d New York, aged 21 years, was wounded in the right shoulder by a piece of shell, at Spottsylvania, May 10, 1864. Primary excision of the upper extremity of the humerus was done at the hospital of the Third Division of the Second Corps, in charge of Surgeon O. Evarts, 20th Indiana. The name of the operator was not reported or remembered by the patient, who was sent to Washington, and received at Campbell Hospital on May 14th. Surgeon A. F. Sheldon, U. S. V., noted: "Gunshot fracture of the right humerus at the upper third. The head and five inches of the shaft of the humerus excised through an incision five inches in length. The operation was performed in a field hospital; operator unknown. The patient says he was in good health at the time, and that simple dressings were applied, and that the wound did well." A year subsequently, May 26, 1865, this soldier was transferred, convalescent, to hospital at Albany, and was discharged November 30, 1865, and pensioned. Assistant Surgeon J. H. Armsby, U. S. V., forwarded a picture of the pensioner, taken at the time of his discharge (*Contributed Surgical Photographs*, A. M. M., Vol. V, p. 10), and an excellent plaster-cast showing the cicatrices of the mutilated shoulder (*Spec.* 2845, A. M. M.), which Assistant Surgeon Woodhull has described<sup>1</sup> as: "A cast of the right arm, showing the results of primary excision. The head and about four inches of the shaft appear to have been removed. A broad, nearly straight cicatrix on the posterior surface of the arm embraces the wound of exit. A small cicatrix on the anterior surface involves the wound of entrance. The comminuted bone has evidently been removed through enlargement of the wound caused by the missile. There appears to be no bony union at the seat of operation. The shoulder is moderately full." On October 8, 1866, Dr. E. D. Hudson, of New York, fitted Allen with an apparatus, and forwarded the photograph, from which the wood-cut (FIG. 423) is taken, with the following report: "Arm very little shortened, very much atrophied; small fistulous ulcer. New growth of bone, two inches; interspace three inches. Functions of the forearm somewhat impaired; arm much debilitated. The apparatus is very gratifying, improving the functions of his arm, enabling him to carry his hand to his head." The reports of the pension examining surgeons, Dr. W. H. Craig, of Albany, in 1866, and Drs. Bontecou, Craig, and Porter, in 1873, add no new facts. The disability is regarded as total, in the phraseology of the Pension Office. This pensioner was paid March 4, 1874.

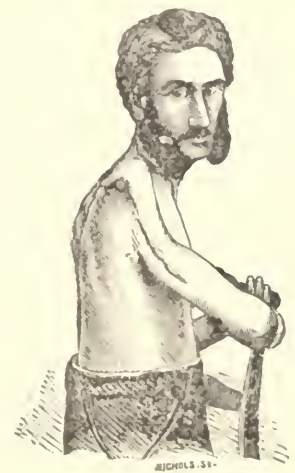

FIG. 423.—Cicatrix as it appeared two years and more after an excision of the upper part of the humerus for extensive comminution by a shell fragment. [From a photograph.]

<sup>1</sup> WOODHULL (A. A.), *Catalogue of the Surgical Section of the Army Medical Museum*, 1866, p. 537.



In many of the cases, the Museum possesses specimens of the parts excised, as well as illustrations of the appearances of the cicatrices:

CASE 1525.—Major T. G. Morrison, 66th Indiana, aged 33, was wounded at Big Shanty, October 4, 1864. Surgeon A. Goslin, 48th Illinois, in charge of the Fifteenth Corps Hospital, excised the head and four inches of the shaft of the right humerus, about eighteen hours after the injury, through a single straight incision, chloroform being used. The patient was sent to Atlanta, entering hospital on October 12th, and on October 29th was transferred to No. 1, Chattanooga, and to Officers' Hospital, Nashville, January 12, 1865. He was furloughed in March, and after some treatment at No. 6, New Albany, was finally discharged May 15, 1865, and pensioned. Examiner W. A. Clapp, of New Albany, August 31, 1865, reported: "Gunshot wound of the right shoulder; the ball passed through the head of the humerus. Resection of the head and four and a half inches of the shaft of the bone was subsequently performed. There is no bony union, and amputation will probably be the result. The wound is still suppurating." In March, 1867, Major Morrison visited the Army Medical Museum, and a photograph (Vol. IV, No. 176 S. S. *Phot. Series*) was taken, and is represented by *Figure 1* of PLATE XVIII. At the time of his visit the

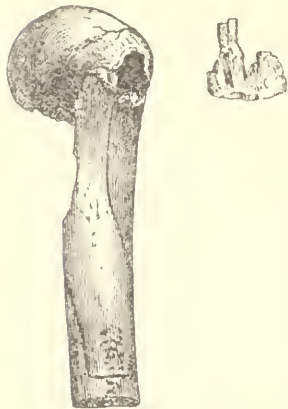

FIG. 424.—Excised upper extremity of the right humerus. [From a photograph.]

major had a tolerably good use of his hand and fingers; could write freely, and could flex the forearm at a right angle to the arm; pronation and supination were partially preserved. The major stated that in January, 1866, an exfoliation from the remaining portion of the humerus was removed by Drs. Crozier and Reed at New Albany, after which the wound soon closed. A photograph of the pathological specimen accompanies No. 176, and is represented by the adjacent wood-cut (FIG. 424). The specimen consists of five and a quarter inches of the upper extremity of the right humerus; the head is completely detached from the shaft at the base of the tuberosities, and there is loss of substance on the inner aspect of the surgical neck, involving nearly one-half of the bone and three inches in length. There is a cleanly cut hole just external to the base of the greater tuberosity, marking the point of exit of the ball; a detached fragment four inches in length extends from its posterior border, down the posterior aspect of the shaft, communicating at one part with the fracture on the internal aspect. The track of the ball is well marked through the cancellous structure of the base of the head. The head itself is not injured. This officer states that at the moment of injury he was using his field glass, the arm being raised at nearly a right angle with the body, the ball striking obliquely on the inner aspect of the surgical neck near the margin of the articular surface, passing directly through the bone outward and slightly upward, and emerging at the point above referred to, just external to the base of the greater tuberosity. Examiner W. A. Clapp, September 5, 1873, reported: "There is no restoration of bone, and the arm is almost entirely useless. The wounds are healed. The upper part of the right arm is very much attenuated and is perfectly flexible." The pensioner was paid June 4, 1874.

CASE 1526.—Bugler J. H. Ewing, Co. L, 8th Illinois Cavalry, aged 22 years, was wounded at Muddy Run, near Culpeper, November 8, 1863, and was taken to the Cavalry Corps Hospital, where he was operated on by Surgeon E. W. H. Beck, 3d Indiana Cavalry, who forwarded the specimen to the Army Medical Museum with the following history: "A large minié ball struck this man obliquely from the enemy's left, as he sat on his horse; his side fronting their line. The ball struck the inferior angle of the scapula, glancing upward in the direction of, and striking the neck of the humerus. About three inches of bone was broken into fragments and continuity destroyed; indeed there was the largest number of, and the smallest sized, pieces that ever came under my observation. I send you the largest pieces. It was with difficulty I got all the small fragments

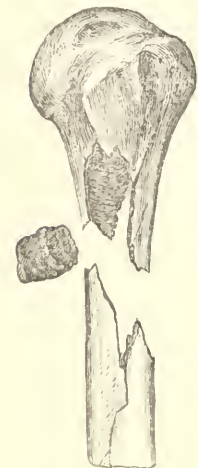

FIG. 425.—Excision of the upper extremity of the left humerus for shot fracture.—*Spec.* 1931.

extricated, so deeply and firmly were they embedded in the tissues around. The ligaments were broken, and the head of the bone partially displaced from the socket; a straight incision was the only one used. No large vessels or nerves were injured by either the ball or operation. Only one small surface artery was tied; very little blood was lost. The wound was closed by sutures and straps, save the necessary aperture. Circulation was good in the arm the next morning; the patient had slept; he took nourishment, and was lively and hopeful. On the 9th, he was sent twenty-two miles in an ambulance to the Corps Hospital." The specimen consists of the head and four and a half inches of the shaft of the left humerus, excised for comminution of the upper third by a conoidal ball, which is attached, battered. The humerus was partially dislocated, but the epiphysis is uninjured. A card photograph, showing the appearance after recovery, stands with the specimen, which is represented in the accompanying wood-cut (FIG. 425). On November 10th, two days after receiving the injury, the patient was admitted to Columbia College Hospital, Washington. In the middle of January, 1864, an abscess formed in the deltoid region, and a small fragment of necrosed bone was eliminated. By the end of January, the wound was entirely healed. On March 25, 1864, the hospital report states that Ewing could slightly flex the left forearm, and that the power of pronation and supination and of moving the hand was perfect. Ewing was discharged from service September 26, 1864. On June 25, 1865, he visited the Army Medical Museum, and a photograph was then taken, and is represented in *Figure 4*, PLATE XVII. He had little motion at the left shoulder joint, but the movements of the forearm were unimpaired. Examiner B. H. Long, of Mechanicsburg, Pennsylvania, November 15, 1866, reported that in consequence of the excision, "though the wound is now healed, his arm hangs helplessly at his side; no bone existing in the upper portion for a space of perhaps five inches. The arm is flexible in every direction, and requires a brace to prevent it from being a constant source of interruption." Examiner W. D. Scarff, of Bellefontaine, Ohio, September 6, 1873, states that the patient "suffers pain at times in the balance of the arm below the end of the humerus." The pensioner was paid December 4, 1873.

In the cavalry, there was a slight predominance of excisions at the right shoulder, attributed, by Dr. G. C. Harlan, to the advanced position of the pistol arm in mounted men.

CASE 1527.—Private George Howe, Co. F, 10th Michigan Cavalry, aged 19 years, was wounded at Flat Creek Bridge, Tennessee, August 24, 1864. On the next day he was admitted into Holston Hospital, Knoxville. Surgeon H. L. W. Burritt, U. S. V., furnished the following notes: "Gunshot fracture of the upper third of the right humerus, implicating the shoulder-joint. The ball entered the centre of the shoulder and emerged behind the posterior border of the deltoid near its insertion; severe hemorrhage from the wound. Forty-six hours after the injury, resection of the head and three inches of the shaft of the humerus was performed through a single straight incision from between the acromion and coracoid processes downward, of sufficient extent to expose the involved bone; the long head of the biceps was unimplicated, and was avoided by the scalpel; thirty-five fractured pieces of bone were removed. The anterior circumflex artery was ligated. Chloroform was used. Reaction was not very prompt, owing to previous loss of blood and a ride of twenty-three miles in an ambulance. At the time of the operation the pulse was 127, small and frequent, and feeble; patient complained of fainting from loss of blood; on the whole, he was rather indifferent to surrounding objects and much depressed. August 28th: He complains of the irksomeness of his supine position; in other respects, he expresses himself as being quite comfortable; the pulse is regaining its natural volume; suppuration already commenced; tonics and stimulants given freely. August 30th: If there be any change, it is for the better; appetite and spirits are fine. September 7th: Patient still improving; treatment continued. 12th: The surgical wound looks finely and is granulating; the ligature came away somewhere about a week since. 22d: The wound is nearly healed up, there being only one slight suppurating point; he eats quite heartily. 30th: Is doing well; wound closing; a solution of muriate of ammonia was applied externally; quinine and milk-punch given, with eggs, beef-soup, milk, and oysters for diet. October 23d: The wound is nearly closed, and there is but very little discharge, and no tenderness; pulse 85; feels well; symptoms all favorable; swelling about twenty-five per cent. in excess of the sound side." The specimen (FIG. 426), contributed to the Museum by the operator, consists of the head and two and one-half inches of the shaft of the right humerus. The epiphysis is not implicated, but the shaft is broken into many pieces. The patient was transferred, on October 26th, to Asylum Hospital; furloughed on the 31st; admitted into Harper Hospital, Detroit, on November 16th; furloughed and readmitted, and, finally, discharged from the service May 2, 1865, and pensioned. Examiner D. F. Alsdorf, of Michigan, reported, September 4, 1867: \* \* "Wound still discharging; he has been gradually losing the use of the shoulder joint since pensioned, and cannot raise the arm now at all. He can move the forearm and use it in eating, &c., but is totally disabled for manual labor." On October 4, 1869, Dr. Alsdorf reported that "all voluntary movements of the right arm are impossible; he can handle light articles; disability total." This pensioner was paid December 4, 1873.

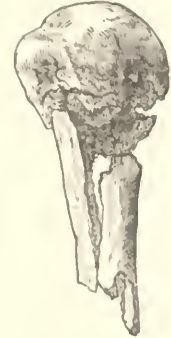

FIG. 426.—Upper portion of right humerus, primarily excised for shot fracture. *Spec.* 3405.

CASE 1528.—Private Martin F——, Co. I, 8th Illinois Cavalry, aged 20 years, was wounded at Jack's Shop, near Rochelle, Virginia, on September 22, 1863, and was admitted into the hospital of the Cavalry Corps. Surgeon A. Hard, U. S. V., transmitted the following history: "F—— was shot in the shoulder by a minié ball; he was stooping forward in the act of firing when he received the wound, the regiment being dismounted as skirmishers. A wet cloth or lint only was applied to the wound on the field. He was brought to Culpeper, some thirty miles, on the 23d, and was examined in presence of Surgeons Pancoast, medical director of the Cavalry Corps; Beck, surgeon-in-chief of the 1st Cavalry Brigade; Mitchell, in charge of Corps Hospital, and Acting Assistant Surgeons Rogers and Bliss. There was a unanimous decision in favor of resection. In their presence I performed the operation, making a longitudinal incision through the deltoid muscle, opening the joint with the scalpel, turning out the head of the bone and sawing it off as near the injured portion as possible, as the specimen will show. Only one small arterial branch required ligating. The wound was closed by sutures and adhesive straps, and no lint was inserted; this, in my judgment, being the better plan to pursue. Chloroform was employed during the operation. I have placed the ball in the specimen as nearly in the position in which it was found as could be arrived at." The specimen (FIG. 427) consists of the head and three inches of the shaft of the humerus, perforated through the surgical neck by a conoidal ball, and excised. The articular surface has sustained no loss of substance, but two fissures run through it, and another follows the line of the anatomical neck. The remainder of the specimen is much comminuted. Two days after the operation, the patient was transferred to Stanton Hospital, Washington. Acting Assistant Surgeon C. H. Osborne noted: "Condition of patient on admission was weak; wound suppurating freely; granulations healthy. November 1st, wound healing finely; appetite good; passive motion to be diligently employed. December 21st, wound entirely healed, with considerable mobility of the shoulder-joint; no fragments of bone were discharged during treatment; prospect flattering of recovery with a useful limb." The patient was furloughed in December; was readmitted, and finally discharged from service April 6, 1864, and pensioned. Assistant Surgeon T. W. Stull, 8th Illinois Cavalry, certified that F—— was wounded "by a musket ball which fractured the head and neck of the humerus of the right arm, rendering it necessary to resect at the shoulder joint." Examiner N. E. Ballou, of Illinois, January 10, 1867, reported: "Gunshot wound of the right shoulder, in which resection was had and four inches of the bone removed. The right arm is wholly useless for manual labor; there are issues on each side of the shoulder which discharge large quantities of pus." In his biennial report, September 4, 1873, Dr. Ballou makes no mention of the issues, but states that "the arm is shortened and is incapable of use." This soldier received his pension on December 4, 1873.

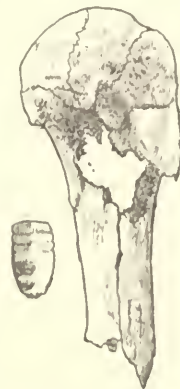

FIG. 427.—The head and three inches of the shaft of the humerus excised for shot fracture. *Spec.* 1715.

<sup>1</sup> Through an inadvertence, this specimen is described in the *Catalogue of the Surgical Specimens of the Army Medical Museum, 1866*, p. 87, as "the head and two and a half inches of the shaft of the left humerus."



A case belonging to this category, an example of successful excision after fracture of the upper part of the right humerus by a shell fragment, is of especial interest as illustrating how much of the humerus may sometimes be removed with comparatively satisfactory preservation of the functions of the arm. The elbow and forearm were well supported, and an excellent pseudarthrosis resulted:



FIG. 428.—Head and five and a half inches of the shaft of the humerus excised for shell fracture. *Spec. 1738.*

CASE 1529.—Private John F. Reardon, Co. C, 6th New York Cavalry, aged 22 years, was wounded at Culpeper, October 11, 1863, and entered Armory Square Hospital on the following day. Surgeon D. W. Bliss, U. S. V., found that his right humerus was shattered by a fragment of shell, which was removed from its lodgement under the deltoid muscle. It was four inches long, one inch broad, and weighed nine ounces. Surgeon Bliss excised the head and six inches of the shaft of the humerus through a straight incision on the outside of the limb. During the after-treatment the elbow was well supported. The patient recovered without a bad symptom, and with a remarkably useful limb. In March, 1866, Reardon was re-enlisted in the general service, and was assigned to duty as an orderly in the Army Medical Museum. From that date until the present (March, 1875) he has served continuously, suffering very little inconvenience from the mutilation he has undergone. Without difficulty he can place his right hand on the top of his head; he can lift a weight of two hundred pounds or more with the injured limb without pain. The movements of the forearm and hand are not in the least impaired, and there is great freedom of all the movements of the arm except abduction. The muscular development of the arm equals that of its fellow. No apparatus is requisite, and altogether the result is most satisfactory and successful. The case effectually disproves the dictum of the older military surgeons on the inutility of excisions of the humerus in cases in which it may be necessary to saw the shaft below the insertion of the deltoid. Reardon was pensioned. Examiner J. O. Staunton reported, December 9, 1873: "There is about three inches shortening of the arm; some atrophy of the muscles; a large cicatrix. He has some use of the hand when the elbow is supported; but the limb is useless for purposes of manual labor." The appearance of the excised portion of bone, presented to the Museum by Surgeon D. W. Bliss, is represented in the wood-cut (FIG. 428). The appearance of the limb is shown in FIG. 3 of PLATE XIV.<sup>1</sup>

The result of another case of this series, the pensioner having survived the injury and operation seven years or more, is illustrated on PLATE XVII, opposite page 536:

CASE 1530.—Captain J. P. Quindlen, Co. E, 81st Pennsylvania, aged 33 years, was wounded at Deep Bottom, August 16, 1864. He was admitted to a Second Corps field hospital on the same day, and excision of the head and three inches of the shaft of the right humerus was performed by Surgeon J. Wilson Wishart, 140th Pennsylvania. He was subsequently treated in Officers' Hospital, Camac's Woods, Philadelphia, and was furloughed in November, 1864. He was discharged from service May 15, 1865, and pensioned. Examiner Wilson Jewell, of Philadelphia, November 18, 1865, reported: "A ball penetrated the right shoulder joint. To save the arm the head of the humerus was removed by resection, but the arm is left powerless for manual or any other kind of labor, and the wound is still discharging." In June, 1866, Dr. Wishart contributed a photograph to the Museum exhibiting the condition of the arm, a print copied in *Figure 1* of PLATE XVII, with the following notes: "The dark spot upon the chest indicates the point of entrance of the ball; the two spots in the line of the cicatrix, the points from which there is still discharge. In a letter of May 21, 1866, Captain Quindlen says: "My right arm, measuring from the top of the shoulder to the tips of the fingers, is about two and a half inches shorter than the left arm. I can, with ease, lift my right hand to my mouth, and, with some trouble, put it on the top of my head, but cannot begin to strike out or strike the backs of my hands together; and can, with ease, lift about twenty-five pounds from the ground. My business is that of a house painter, but I can do but little at it with my right arm. I, to-day, would not give my right arm, poor as I am, for ten thousand dollars and all the artificial arms in the country. The discharge from my arm is at present very small, some days hardly perceptible, again, some days as much as a small teaspoonful." Dr. Francis Zerman, of Philadelphia, in an affidavit dated January 8, 1872, states that he attended on Mr. Quindlen, and that he "suffered from a severe wound in the right breast, which never healed, but continually discharged; that his lungs, in consequence of the severe depletion of the system, became affected; that he died November 8, 1871, and that the primary cause of his death was the wound above referred to."

A plaster cast and also a photograph of the cicatrix at the shoulder were furnished to the Museum in the following case, by Professor Arnsby, of Albany:

CASE 1531.—Sergeant J. H. Pratt, Co. F, 142d New York, aged 32 years, was wounded at Darbytown Road, October 27, 1864, and was taken to a Tenth Corps field hospital, where excision of the head of the humerus was performed by Surgeon N. Y. Leit, 76th Pennsylvania. On October 30th, the patient entered Hampton Hospital, and in May, 1865, was transferred north, and admitted to St. Mary's Hospital, Rochester, May 2, 1865, and July 6th was sent to Ira Harris Hospital, Albany, where he was discharged September 22, 1865, and pensioned. Assistant Surgeon J. H. Arnsby, U. S. V., contributed a plaster-cast (No. 2433 Surgical Sect., A. M. M.): "A cast of the left thorax and arm, ten months after a primary excision of three inches of the upper third of the humerus. The bullet appears to have entered posteriorly two inches below the summit of the shoulder, and to have passed out anteriorly, just above the outer fold of the axilla. The incision is six inches in length, and the cicatrix broad and irregular. The arm is somewhat atrophied at the junction of the upper thirds. It is not known whether

<sup>1</sup> An account of this case was published in the preliminary Surgical Report of Circular 6, S. G. O., 1865, p. 56, with an illustration which has been frequently reproduced, e. g. in BILLROTH and VON PITHA (*Handbuch*); FRANKLIN (E. C.) (*The Science and Art of Surgery*, 1867, Vol. I, p. 710); HAMILTON (F. H.) (*Princ. and Pract. of Surg.*, 1872, p. 394).

union occurred."—*Cat. Surg. Sect.*, 1866, p. 537. In June, 1867, Mr Pratt was supplied with a prothetic apparatus by Dr. E. D. Hudson, of New York, who reported a shortening of one inch, with considerable atrophy, and very limited power of motion. Dr. Hudson forwarded to the Museum a photograph of the patient, showing the appearance of the limb at this date, represented by Figure 3, PLATE XVII. The last certificate of examination is made by Pension Examining Surgeon N. E. Ballou, of Sandwich, as follows: "Gunshot wound of left shoulder, in which a resection of three inches of bone was had, including the head of the humerus. Arm shortened and manual labor performed with difficulty. The pensioner was paid December 4, 1873.

Caries of the shaft of the humerus was not infrequent after primary excisions of its upper extremity for shot fracture. In some cases, there were small but repeated exfoliations of bone; in others, a necrosed ring of bone was thrown off; in a few instances, the greater part of the diaphysis became necrosed. The following is one of the less serious cases:

CASE 1532.—Private G. D. Brockett, Co. C, 29th Ohio, aged 24 years, was wounded in the shoulder at Buzzard Roost, May 7, 1864; was operated on in a Twentieth Corps hospital, and thence, on May 12th, was sent to Hospital No. 1 at Nashville. Surgeon B. B. Breed, U. S. V., noted: "Excision of the right humerus; about three inches, including the head of the bone, being removed. Operation was performed on the field May 7th. Anæsthetic unknown. Patient recovered rapidly under local applications of water-dressing, and tonics, stimulants, and supporting treatment. The wound healed, leaving considerable motive power of the arm." On October 20th, the photograph represented in the cut (FIG. 429) was taken, and a print was contributed to the Museum by Dr. Breed. The patient was furloughed; and he was discharged from service July 22, 1865, and pensioned. Examiner J. H. Warren, of Ohio, May 10, 1866, reported the wound still discharging, and slight use of the hand, and on September 15, 1866, reported the arm as useless. Dr. J. L. Chapel, of Trumbull County, Ohio, certified, January 31, 1867: "I have been acquainted with G. D. Brockett, and have attended upon him since August, 1865. He has suffered, and is suffering, from necrosis of the middle third of the right humerus, caused by excision of the upper third of the bone, which was disarticulated and four inches taken out. The arm has continued to discharge pus, with occasional spiculae of bone, ever since the operation. The arm is of no utility as far as manual labor is concerned." This man's pension was increased, and he was paid March 4, 1874.

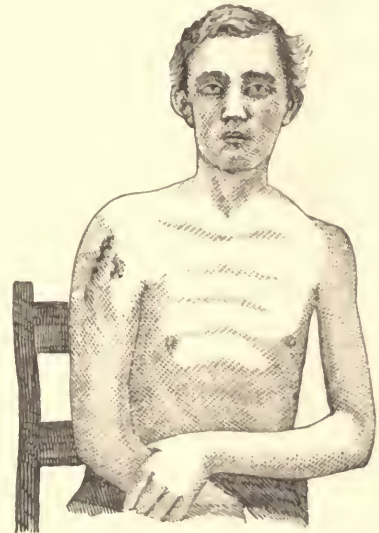


FIG. 429.—Appearance six months after excision of the upper part of the right humerus for shot fracture. [*Card Phot.*, S. G. O., Vol. II, p. 6.]

A successful case, illustrated in PLATE XIV, was a remarkable example of preservation of control over the motions of the arm after excision of a considerable portion of the upper extremity of the humerus, and especially of the power of abduction, usually lost after this operation:

CASE 1533.—Lieutenant Horace G. Jacobs, Co. G, 6th Maine, aged 18 years, was wounded at Rappahannock Station, November 7, 1863, by a conoidal ball, which entered the left shoulder posteriorly, two inches from the acromion process, fractured the upper extremity of the humerus, and made its exit an inch and a half below the middle of the clavicle. He was sent to Washington, and received at Armory Square Hospital. Surgeon D. W. Bliss, U. S. V., reported: "A ball, supposed to be conoidal, entered posteriorly two inches from the acromion process, passing through the head of the humerus, fracturing off the upper two-thirds of the head of the bone comminuting the inner portions and about two inches of the shaft of the humerus. Exit one and a half inches below the clavicle, at the middle third. November 16th, head of the humerus and about two inches of the shaft excised; the S-incision made through the soft parts; ordinary hæmorrhage; patient under chloroform. No vessels required ligation. The patient came out of the anæsthetic well. At the time of operation, the parts were swollen and ecchymosed; his constitutional condition was good, but he was somewhat feverish. The patient made a good recovery." The operator transmitted the pathological specimen (FIG. 430) to the Army Medical Museum. This officer was furloughed January 12, 1864, and, returning to Washington, was treated in quarters, by Surgeon T. Antisell, U. S. V. On May 28, 1864, the wound had healed, and Lieutenant Jacobs was discharged from service (S. O. 190, A. G. O.), and pensioned. Examiner A. G. Peabody, of Machias, Maine, reported substantially the facts already detailed regarding the injury and operation. Mr. Jacobs was subsequently employed in the office of the Commissary General of Subsistence. In January, 1865, he called at the Museum, and a photograph was taken of the injured shoulder. It is represented by the first figure in PLATE XIV, opposite page 529. At that time his control over the mutilated arm was more complete than in any other case of excision of the upper extremity of the humerus for shot injury that had come under observation at the Museum. He could put his hand on the top of his head and could lift a heavy weight. The amount of shortening was precisely three inches. The favorable result thus happily achieved was lasting; for, in January, 1875, Mr. Jacobs could use his arm even better than ten years before, and was on duty in the Treasury Department. His general health was excellent, and his control over the movements of the left arm was so perfect, that by any but a close professional observer the mutilation he had undergone would be unnoticed.

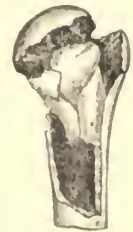

FIG. 430.—Excised upper extremity of the left humerus, shattered by a musket ball. *Spec. 1767.*



TABLE XXXI.

Summary of Two Hundred and Thirteen Cases of Recovery after Primary Excision of the Head and Portions of the Shaft of the Humerus for Shot Injury.

No.	NAME, AGE, AND MILITARY DESCRIPTION.	DATE OF INJURY.	NATURE OF INJURY.	DATE OF OPERATION.	OPERATION AND OPERATOR.	RESULT AND REMARKS.
1	Albert, M., Pt., G, 173d New York.	June 14, 1863.	Compound comminuted fracture of upper third of left humerus by a conoidal ball.	June 14, 1863.	Excision of five inches of bone, including the head, by A. A. Surgeon M. Schuppert.	Disch'd Sept. 29, 1863; pensioned. October, 1866, loss of motive power in right arm.
2	Algers, R. D., Pt., D, 1st N. York Engineers, age 23.	Aug. 28, 1864.	Shot fracture of the upper third of right humerus.	Aug. 28, 1864.	Removal of head and three inches of shaft through a straight incision.	Disch'd Mar. 11, 1865. Not a pensioner in Nov., 1874.
3	Allen, S. C., Pt., B, 93d N. York, age 21.	May 10, 1864.	Fracture of head of right humerus by shell; extensive muscular laceration.	May 10, 1864.	Head and four inches of humerus excised thro' a linear incision.	Disch'd Nov. 30, 1865; pensioned. Oct., 1873, arm useless for purposes of manual labor. <i>Spec.</i> 2845, A. M. M.
4	Allender, S. S., Pt., C, 124th Illinois.	May 22, 1863.	Comminuted shot fracture of upper third of left humerus.	May 22, 1863.	Removal of the head and upper third of the shaft of humerus	Disch'd Oct. 2, 1863; pensioned. Sept., 1873, has no power to move arm; has some use of fingers.
5	Anderson, W. J., Pt., A, 1st Georgia Sharpshooters, age 31.	Dec. 5, 1864.	Conoidal ball fractured the neck of the right humerus.	Dec. 5, 1864.	Head and two and a half inches of humerus resected.	Transferred for exchange, February 20, 1865, with comparatively useful arm.
6	Baker, L., Pt., —, 2d Rhode Island, age 25.	July 13, 1864.	Left humerus terribly comminuted below anatomical neck by a conoidal ball.	July 14, 1864.	Head and three inches of shaft excised through a straight incision, by Surg. E. Bentley, U. S. V.	Disch'd July 14, 1865. Not a pensioner.
7	Baldock, L., Pt., A, 110th Ohio, age 35.	June 3, 1864.	Minié ball passed thro' head and neck of left humerus and lodged in parietes of chest.	June 3, 1864.	Excision of head and shaft of humerus four inches below acromion, by Ass't Surgeon W. M. Houston, 122d Ohio.	Disch'd Apr 17, 1865; pensioned. Sept., 1873, disability total, third grade. <i>Spec.</i> 5655, A. M. M.
8	Barrett, W., Serg't, G, 6th Ohio Cavalry.	Sept. 1, 1863.	Shot fracture of left humerus.	Sept. 1, 1863.	Head and five inches of shaft of humerus excised through a straight incision.	Disch'd May 4, 1864; pensioned. Sept., 1873, disability total, third grade.
9	Barton, H., Pt., D, 28th Virginia, age 27.	Nov. 11, 1863.	Musket ball passed thro' left shoulder, fracturing the upper portion of the humerus.	Nov. 12, 1863.	Removal of superior portion of humerus, including the head; bone sawn across four inches from the anatomical neck, by Ass't Surg. P. M. Letcher, P. A. C. S.	August, 1864, limb shortened two inches; movements of forearm unimpaired. <sup>1</sup>
10	Berdel, J., Serg't, G, 47th Ohio, age 27.	June 1, 1864.	Conoidal ball fractured the upper third of left humerus.	June 1, 1864.	Head and upper third of humerus removed, by Surg. A. C. Messenger, 57th Ohio.	Disch'd July 13, 1865; pensioned. May, 1867, arm flexible in every direction. Died Oct. 10, 1871.
11	Betz, G. W., Serg't, H, 104th Ohio, age 27.	Nov. 27, 1864.	Fracture of upper third of left humerus by a conoidal ball.	Nov. 27, 1864.	Excision of head and three inches of shaft of humerus, by Surgeon J. H. Rodgers, 104th Ohio.	Disch'd June 25, 1865; pensioned. Sept., 1873, wound suppurates at times; arm useless.
12	Bigger, C. P., Lieut., A, 46th Virginia, age 21.	June 17, 1864.	Compound comminuted shot fracture of head and shaft of left humerus.	June 18, 1864.	Resection of head and three inches of shaft of humerus.	Recovered. Arm bids fair to be useful.
13	Bodge, G. E., Pt., B, 13th New Hampshire, age 22.	May 10, 1864.	Gunshot fracture of the right humerus.	May 11, 1864.	Excision of the head and three inches of shaft of right humerus	Disch'd Nov. 12, 1864; pensioned. Sept., 1873, disability total, 3d grade.
14	Booth, D. R., Pt., G, 3d Arkansas, age 21.	Sept. 20, 1863.	Shot fracture of the head of the right humerus.	Sept. 21, 1863.	Excision of the head and four and a half inches of shaft of humerus.	Retired February 9, 1865.
15	Boothman, W., Pt., B, 173d New York, age 18.	June 14, 1863.	Gunshot fracture of the right humerus; also fracture of lower maxilla.	June 14, 1863.	Excision of the head and two inches of the shaft of the humerus.	Disch'd Jan. 31, 1864; pensioned. Sept., 1873, "His arm is of no use to him."
16	Braushaw, D. W., Pt., A, 43d North Carolina.	May 25, 1864.	Conoidal ball fractured the left humerus.	May 25, 1864.	Excision of head and three inches of shaft of humerus.	Retired from service Jan. 2, 1865. Arm almost entirely useless, but had fair use of hand.
17	Brink, J. H., Pt. K, 11th Pennsylvania Cavalry, age 19.	May 21, 1863.	Shot fracture of upper third of right humerus.	May 21, 1863.	Excision of head and neck of right humerus, by Surgeon G. C. Harlan, 11th Pennsylvania Cavalry.	Disch'd Sept. 23, 1863; pensioned. Sept., 1866, arm hangs powerless at his side. <i>Photo.</i> 208, Surgical Series.
18	Bruckett, G., Pt., C, 29th Ohio, age 24.	May 7, 1864.	Compound shot fracture of the right humerus.	May 7, 1864.	Excision of the head and two inches of shaft of humerus.	Disch'd July 22, 1865; pensioned. Sept., 1866, arm useless for labor.
19	Brooks, W., Pt., G, 57th Indiana, age 38.	May 27, 1864.	Gunshot fracture of the head of the left humerus.	May 27, 1864.	Excision of the head and six inches of shaft of humerus, by Surgeon E. B. Glick, 40th Indiana	Disch'd May 18, 1865; pensioned. Sept., 1873, arm and hand useless.
20	Bryan, J. J., Pt., G, 6th Georgia.	May 16, 1861.	Comminuted shot fracture of the head and upper third of humerus.	May 17, 1864.	Head and three inches of shaft of the humerus removed, by Surgeon C. B. Gibson, C. S. A.	Transferred May 19, 1864; doing well.
21	Burger, S., Pt., A, 102d Illinois, age 30.	June 15, 1864.	Gunshot wound of right shoulder joint, ball passing thro' head of humerus.	June 15, 1864.	Excision of the head and four inches of shaft of humerus. June 20, 1867, arm amputated at shoulder joint, by Dr. M. Reese.	Disch'd Dec. 17, 1864; pensioned. May, 1874, extensive ulceration through intercostal muscles into pleural cavity; distressing cough.
22	Burns, John, Pt., A, 2d Massachusetts, age 21.	July 3, 1863.	Minié ball entered the left shoulder and embedded itself in the head of the humerus	July 4, 1863.	Excision of the head and two and a half inches of shaft of humerus, by Surgeon W. H. Heath, 2d Massachusetts.	Disch'd Oct. 27, 1863; pensioned. Sept., 1873, disability total, 3d grade.
23	Burns, W., Serg't, K, 37th Georgia, age 21.	Nov. 30, 1864.	Shot fracture of the left humerus.	Nov. 30, 1864.	Resection of the head and two inches of shaft of humerus.	Transferred for exchange, Feb. 11, 1865.
24	Carquville, W., Corp'l, I, 4th New York Cavalry, age 40.	Sept. 19, 1864.	Compound comminuted fracture of the left humerus by a conoidal ball.	Sept. 21, 1864.	Head and three inches of shaft of humerus excised.	Disch'd July 31, 1865; pensioned. Sept., 1873, arm useless.

<sup>1</sup>LETCHER (P. M.). Resection of Superior Third of Humerus, in *Confederate States Med. and Surg. Jour.*, 1864, Vol. I, p. 118.

No.	NAME, AGE, AND MILITARY DESCRIPTION.	DATE OF INJURY.	NATURE OF INJURY.	DATE OF OPERATION.	OPERATION AND OPERATOR.	RESULT AND REMARKS.
25	<i>Castlebury, Z.</i> , Pt., D, 33d Alabama age 19.	May 13, 1864.	Extensive comminution of the upper portion of the right humerus, involving the joint.	May 13, 1864.	Removal of head and upper portion of shaft of humerus, six inches in all.	Recovered June 25, 1864. <sup>1</sup>
26	<i>Charles, R. A.</i> , Serg't. A, 16th Pennsylvania Cav'ry.	Oct. 13, 1863.	Conoidal ball fractured head of the right humerus.	Oct. 16, 1863.	Excision of the head and four inches of shaft of humerus, by A. A. Surg. N. Barnes.	Disch'd June 3, 1865; pensioned. March, 1867, the arm is of no service for labor.
27	<i>Chisholm, A.</i> , Pt., A, 1st Confed'rato States Battery, age 17.	Aug. 19, 1861.	Gunshot wound of the right shoulder joint.	Aug. 20, 1861.	Excision of upper third of humerus through a simple longitudinal incision.	August 31st, doing well; recovered in October.
28	<i>Christian, S.</i> , Pt., —, 20th Massachusetts, age 23.	May 17, 1864.	Minié ball fractured the right shoulder.	May 17, 1864.	Removal of the head and a portion of shaft of humerus, by Surg. N. Hayward, 20th Massachusetts.	Disch'd Jan. 31, 1865; pensioned. Sept., 1873, muscular atrophy; arm useless.
29	<i>Clark, W.</i> , Pt., —, 20th Indiana Battery, age 28.	Oct. 28, 1861.	Head of left humerus badly shattered by gunshot.	Oct. 29, 1861.	Head and small portion of shaft of humerus excised, by Surg. G. E. Cooper, U. S. A.	Disch'd Aug. 4, 1865; pensioned. Sept., 1873, disability rated total, 3d grade.
30	<i>Cleghorn, J. E. F.</i> , Pt., K, 1st New Jersey Cavalry, age 27.	Nov. 27, 1863.	Shot fracture of head of left humerus.	Nov. 30, 1863.	Resection of the head and a small portion of the shaft of humerus, by Surgeon H. K. Clark, 16th N. York Cavalry. July 21, 1864, removal of remainder of humerus and the heads of radius and ulna, by A. A. Surg. J. B. Cutter.	Disch'd Oct. 20, 1864; pension'd. <sup>2</sup> Sept., 1865, arm hangs pendulous and useless. <i>Photos</i> 112, 148.
31	<i>Cockrell, R.</i> , Pt., H, 6th Mississippi, age 35.	Dec. 6, 1864.	Minié ball fractured the right shoulder.	Dec. 6, 1864.	Resection of the head and two inches of shaft of humerus.	Healed kindly. Transferred for exchange, March 1, 1865.
32	<i>Cole, S.</i> , Pt., G, 106th New York, age 19.	July 9, 1864.	Musket ball grooved the posterior portion of the head and shattered the surgical neck of the left humerus.	July 11, 1864.	Head and one and a half inches of the shaft of the humerus removed, by Ass't Surgeon R. F. Weir, U. S. A.	Disch'd June 13, 1865; pensioned. Sept., 1873, disability equal to loss of arm for manual labor. <i>Spec.</i> 3354, A. M. M.
33	<i>Connors, P.</i> , Pt., H, 13th New Jersey, age 43.	July 30, 1864.	Shot fracture of head of right humerus and wound of left forearm.	July 31, 1864.	Removal of the head and three inches of shaft of humerus.	Disch'd Sept. 20, 1865; pensioned. Sept., 1873, arm useless; disability total, 3d grade. <i>Spec.</i> 4356, A. M. M.
34	<i>Contant, E. H.</i> , Pt., A, 75th New York, age 23.	May 27, 1863.	Comp'd comminuted fracture of upper third of right humerus, involving joint, by canister shot.	May 27, 1863.	Excision of head and portion of shaft of humerus, by Surg. M. D. Benedict.	Disch'd June 18, 1865; pensioned. Sept., 1873, disability total, 3d grade. <i>Spec.</i> 2346, A. M. M.
35	<i>Cosgrove, M.</i> , Pt., B, 50th Massachusetts, age 36.	May 12, 1864.	Gunshot fracture of the upper third of the left humerus.	May 12, 1864.	Excision of the head and a portion of the shaft of the humerus, by Surg. T. F. Oakes, 50th Massachusetts.	Disch'd Jan. 16, 1865; pensioned. Sept., 1873, has fair use of forearm and hand.
36	<i>Costley, G.</i> , Serg't, K, 4th Colored Troops, age 27.	Sept. 29, 1864.	Conoidal ball fractured head of right humerus; also wounds of right hand and left hip.	Sept. 30, 1864.	Excision of the head and two inches of the shaft of humerus.	Disch'd April 4, 1865; pensioned. Sept., 1873, disability total, 3d grade.
37	<i>Crane, S. B.</i> , Pt., H, 13th Infantry.	Dec. 29, 1862.	Comminuted fracture of upper third of right humerus by a conoidal ball which lodged in scapula.	Dec. 29, 1862.	Removal of four inches of the humerus including the head, by Surgeon G. S. Walker, 6th Missouri.	Disch'd Ap'l 27, 1863; pensioned. September, 1873, arm useless for manual labor.
38	<i>Crousy, J.</i> , Pt., A, 69th Ohio, age 16.	May 14, 1864.	Shot fracture of upper third of the right humerus.	May 17, 1864.	Head and about two and one-half inches of the humerus excised.	Disch'd July 26, 1865; pensioned. July, 1874, able to flex forearm to right angle with arm. Grasp of hand feeble.
39	<i>Crites, S.</i> , Pt., E, 20th Indiana, age 21.	July 30, 1864.	Gunshot fracture of the left shoulder joint.*	July 30, 1864.	Head and three inches of the shaft of humerus removed through a straight incision.	Disch'd Oct. 6, 1864; pensioned. Sept., 1873, muscular atrophy of arm and forearm.
40	<i>Croft, M.</i> , Pt., A, 149th Pennsylvania, age 31.	June 1, 1864.	Minié ball perforated the left shoulder joint.	June 1, 1864.	Excision of the head and four inches of shaft of humerus, by Surg. W. Humphrey, 149th Pennsylvania.	Disch'd Aug. 23, 1865; pensioned. September, 1873, total loss of use of left arm for manual labor.
41	<i>Cross, J.</i> , Pt., A, 77th New York, age 34.	May 3, 1863.	Wound of right shoulder joint by a conoidal ball.	May 3, 1863.	Removal of the head and two and a half inches of shaft of humerus, by Surgeon G. T. Stevens, 77th New York.	Disch'd Sept. 12, 1863; pensioned. March, 1874, limb almost entirely useless.
42	<i>Decker, J. M.</i> , Pt., A, 7th Infantry, age 31.	July 2, 1863.	Musket ball perforated head of the right humerus.	July 4, 1863.	Excision of the head and one inch of the shaft of humerus.	Disch'd Ap'l 24, 1865; pensioned. Sept., 1873, disability total, 3d grade.
43	<i>Dekraker, M.</i> , Pt., A, 5th Michigan, age 24.	June 18, 1864.	Conoidal ball comminuted the head of the right humerus, opening the joint.	June 18, 1864.	Head and three inches of shaft of humerus resected, by Surg. H. P. Lyster, 5th Michigan.	Disch'd Mar. 29, 1865; pensioned. Dec. 7, 1870, has considerable use of arm.
44	<i>Dickenson, G.</i> , Serg't, K, 20th Connecticut, age 22.	July 3, 1863.	Extensive fracture of upper portion of right humerus by a fragment of shell.	July 5, 1863.	Excision of head and a small portion of the shaft of the humerus, by Surgeon J. A. Freemaq, 13th New Jersey.	Disch'd Aug. 18, 1865; pensioned. Sept., 1873, has about one-fourth ordinary motion in all directions.
45	<i>Dickson, R.</i> , Pt., D, 3d Maine.	June 1, 1862.	Wound of right arm and shoulder by conoidal ball and buck-shot.	June 3, 1862.	Excision of the head and five inches of shaft of humerus.	Disch'd Nov. 10, 1862; pensioned. March, 1874, disability total, 3d grade.
46	<i>Dillbridge, J. L.</i> , Pt., K, 23d Michigan.	May 14, 1864.	Comminuted shot fracture of upper extremity of right humerus opening the joint.	May 14, 1864.	Resection of the head and two inches of shaft of humerus, by Surg. U. S. Friak, U. S. V.	Disch'd June 9, 1865; pensioned. Jan'y, 1874, arm nearly useless.
47	<i>Dobell, J. D.</i> , Corp'l, C, 19th Illinois, age 24.	Sept. 29, 1863.	Shot fracture of head and neck of right humerus, with great laceration.	Sept. 23, 1863.	Head and two inches of the humerus removed, through a straight incision, by Surgeon W. P. Johnson, 1st Ohio.	Disch'd Ap'l 19, 1864; pensioned. Sept., 1864, arm useless and painful.
48	<i>Doelittle, M.</i> , Pt., E, 1st Michigan, age 28.	May 5, 1864.	Shot fracture of the right humerus beneath the internal edge of the deltoid.	May 5, 1864.	Excision of the head and a portion of the shaft of the humerus, four and a half inches in all.	Disch'd Sept. 12, 1864; pensioned. Sept., 1874, disability total, 3d grade.
49	<i>Dougherty, J. O.</i> , Pt., D, 155th Pennsylvania, age 27.	April 1, 1865.	Compound comminuted shot fracture of the head of the left humerus.	April 1, 1865.	Removal of the head and one and a half inches of the shaft of humerus.	Disch'd July 25, 1865; pensioned. Sept., 1873, can flex the elbow, and, to a slight extent, the fingers.

<sup>1</sup> O'KEEFE (D. C.), *Surgical Cases of Interest Treated at Institute Hospital, Atlanta, Ga., May and June, 1864 in Confederate States Medical and Surgical Journal*, 1865, Vol. 11, p. 30.

<sup>2</sup> CUTLER (J. B.), *Cases of Excision of Bones in Am. Jour. Med. Sci.*, 1866, Vol. 11, p. 129.



No.	NAME, AGE, AND MILITARY DESCRIPTION.	DATE OF INJURY.	NATURE OF INJURY.	DATE OF OPERATION.	OPERATION AND OPERATOR.	RESULT AND REMARKS.
50	Drake, J., Pt., G, 14th Ohio, age 28.	Sept. 1, 1864.	Musket ball comminuted the head of the left humerus.	Sept. 2, 1864.	Head and two and a half inches of shaft of humerus excised, by Surg. C. N. Fowler, 105th Ohio.	Disch'd June 25, 1865; pensioned. Sept., 1874, disability total, 3d grade.
51	Driscoll, D., Pt., I, 147th N. York, age 21.	June 18, 1864.	Gunshot fracture of the upper third of the left humerus.	June 18, 1864.	Head and one and a half inches of shaft of humerus excised, by Surg. A. S. Coe, 147th New York.	Disch'd May 15, 1865; pensioned. Sept., 1873, has no power to raise arm, but has some use of forearm.
52	Dulaney, — Colonel, 7th Confederate States Cavalry.	Aug. 14, 1864.	Extensive shot comminution of the head and upper portion of shaft of humerus.	Aug. 15, 1864.	Resection of the head and four or five inches of the shaft of humerus, by Dr. H. McGuire.	Recovered; can hunt, shoot, and play a good game of billiards. <sup>1</sup>
53	Dwyer, C., Pt., A, 1st Maryland Cavalry, age 23.	Aug. 16, 1864.	Comminuted shot fracture of the head of right humerus, with laceration of soft parts.	Aug. 16, 1864.	Head and two inches of the shaft of the humerus excised, by Surgeon C. M. Clark, 30th Illinois.	Disch'd April 11, 1865; pensioned. Sept., 1873, arm useless.
54	Edgar, W. D., Corp'l, K, 4th Ohio, age 25.	May 3, 1863.	Minié ball fractured the surgical neck of right humerus; missile lodged against the head of the bone.	May 5, 1863.	Head and upper third of humerus excised.	Disch'd Oct. 23, 1863; pensioned. Sept., 1873, arm hangs useless at side.
55	Eisele, P., Pt., I, 2d Missouri, age 34.	Nov. 25, 1863.	Shot wound of right shoulder joint; fracture of head of humerus.	Nov. 25, 1863.	Removal of the head and three inches of shaft of humerus, by Surg. A. McMahon, 64th Ohio.	Disch'd July 18, 1864; pensioned. September, 1873, limb nearly totally useless.
56	Ewing, J. H., Bugler, 8th Illinois Cavalry, age 31.	Nov. 8, 1863.	Conoidal ball fractured neck and shaft of the left humerus and injured the scapula.	Nov. 8, 1863.	Head and four and a half inches of the shaft of the humerus excised, by Surg. E. W. H. Beck, 3d Indiana Cavalry.	Disch'd Sept. 27, 1864; pensioned. Sept., 1873, the arm is almost useless. <i>Spec.</i> 1931, A. M. M., and <i>Photo.</i> 56.
57	Fisher, J., Sergeant, K, 17th Indiana.	June 25, 1863.	Conoidal ball passed through the head of the right humerus and lodged behind scapula.	June 27, 1863.	Head and two inches of shaft of the humerus removed, by Surg. I. Moses, U. S. V.	Returned to duty Jan'y 9, 1864.
58	Fisher, R., Corp'l, C, 7th N. York Artillery, age 27.	June 8, 1864.	Conoidal ball lodged in the head of the right humerus.	June 8, 1864.	Head and one inch of shaft of humerus removed, by Surg. J. W. Wishart, 140th Penn.	Disch'd May 25, 1865; pensioned. Died July 24, 1870, of phthisis. <i>Spec.</i> 381, A. M. M.
59	Fisher, T. T., Lieut., E, 27th Kentucky, age 22.	May 31, 1864.	Shot fracture of upper third of the right humerus, injuring the joint.	May 31, 1864.	Excision of head and two inches of shaft of humerus, by Surg. E. Shippen, U. S. V.	Disch'd Mar. 29, 1865; pensioned. Arm useless; can grasp with hand to a limited extent.
60	Fishley, C. H., Pt., D, 52d Ohio, age 20.	June 27, 1864.	Shot fracture of the head of the left humerus.	June 27, 1864.	Head and three inches of shaft of the humerus removed, by Surg. H. M. Duff, 52d Ohio.	Disch'd Jan. 31, 1865; pensioned. Sept., 1873, unable to extend arm or lift it from the body.
61	Fox, J., Pt., G, 27th Ohio, age 21.	July 4, 1864.	Minié ball comminuted upper articular extremity of right humerus.	July 5, 1864.	Resection of the head and four inches of shaft of humerus, by Surgeon A. B. Monahan, 6d Ohio.	Disch'd Aug. 3, 1865; pensioned. Sept., 1873, the arm cannot be extended or raised.
62	Francher, M., Pt., I, 8th Illinois Cavalry, age 25.	Sept. 23, 1863.	Head of the left humerus split and neck comminuted by a conoidal ball.	Sept. 23, 1863.	Head and three inches of shaft of humerus excised, by Surg. A. Hard, 8th Illinois Cavalry.	Disch'd April 6, 1864; pensioned. Sept., 1873, can perform little or no manual labor. <i>Spec.</i> 1715, A. M. M., and <i>Photo.</i> 125.
63	Francisco, H. C., Pt., A, 8th East Tennessee, age 20.	July 10, 1864.	Comp'd comminuted fracture of left humerus at anatomical neck by conoidal ball.	July 11, 1864.	Excision of the head and two inches of shaft of humerus, by Surg. J. H. Rodgers, 104th Ohio.	Disch'd Mar. 3, 1865; pensioned. Jan'y, 1874, muscular atrophy and total paralysis of left arm.
64	Frank, R., Pt., A, 11th Ohio, age 22.	Feb. 24, 1864.	Comp'd shot fracture of upper third of right humerus.	Feb. 24, 1864.	Head and four and one-half inches of humerus excised.	Disch'd Dec. 27, 1864; pensioned. Sept., 1873, extremity atrophied; grasp of hand feeble.
65	Fuller, A. C., Serg't, F, 58th Pennsylvania, age 29.	Sept. 29, 1864.	Comminuted shot fracture of the head of the left humerus.	Sept. 30, 1864.	Resection of the head and four and one-half inches of shaft of humerus.	Disch'd July 8, 1865; pensioned. Sept., 1874, shoulder tender and painful; arm useless.
66	Gammer, J., Corp'l, B, 80th Ohio, age 36.	Nov. 25, 1863.	Shot fracture of left humerus.	Nov. 25, 1863.	Excision of the head and two inches of shaft of humerus.	Disch'd May 13, 1864; pensioned. Sept., 1873, disability total, 3d grade.
67	George, T. C., Pt., B, 7th Wisconsin, age 22.	June 18, 1864.	Minié ball passed transversely through the left humerus two inches from shoulder joint.	June 19, 1864.	Excision of the head and three inches of shaft of humerus, by Surgeon D. C. Ayers, 7th Wisconsin.	Disch'd Feb. 9, 1865; pensioned. Sept., 1873, disability total, 2d grade.
68	Gibson, S. J., Pt., K, 31st Ohio.	Sept. 19, 1863.	Shot fracture of right humerus.	Sept. 19, 1863.	Excision of the head and four inches of shaft of humerus.	Disch'd Oct. 30, 1864; pensioned. Sept., 1873, disability one-half.
69	Gill, A. C., Pt., C, 20th Indiana.	May 12, 1864.	Severe wound of left shoulder by conoidal ball.	May 12, 1864.	Removal of the head and portion of the shaft of humerus, about seven inches in all.	Disch'd Dec. 27, 1864; pensioned. August, 1874, arm useless in the performance of manual labor.
70	Girst, J., Pt., B, 78th Illinois, age 28.	Sept. 1, 1864.	Conoidal ball fractured the upper third of the left humerus.	Sept. 2, 1864.	Head and three inches of shaft of the humerus excised, by Surg. A. Wilson, 113th Ohio.	Disch'd May 1, 1865; pensioned. Sept., 1873, arm hangs useless.
71	Goldston, W. A., Lieut., K, 1st Tennessee, age 25.	Aug. 6, 1864.	Comminuted shot fracture of head and upper third of shaft of humerus.	Aug. 6, 1864.	Head and five inches of shaft of the humerus removed, by Surg. A. M. Wilder, U. S. V.	Disch'd Sept. 26, 1864; pensioned. Sept., 1873, disability rated total.
72	Goodyer, J. H., Corp'l, F, 10th New York, age 22.	Feb. 6, 1864.	Oblique fracture through surgical neck of right humerus by conoidal ball.	Feb. 9, 1864.	Excision of the head and two inches of shaft of humerus, by Surg. J. Dwinelle, 106th Pennsylvania.	Disch'd Sept. 26, 1864; pensioned. Sept., 1873, disability equivalent to loss of hand for manual labor.
73	Graham, W. J., Pt., G, 100th Pennsylvania, age 19.	Aug. 19, 1864.	Minié ball comminuted the head and neck of the left humerus.	Aug. 19, 1864.	Removal of the head and two inches of neck of humerus, by Surgeon W. V. White, 57th Massachusetts.	Disch'd Mar. 29, 1865; pensioned. Sept., 1873, limb attenuated and atrophied.
74	Giant, W. R., Pt., B, 25th North Carolina, age 36.	May 26, 1863.	Comp'd comminuted shot fracture of left humerus; shaft fissured.	May 26, 1863.	Head and three and a half inches of shaft of humerus removed, by Surgeon C. H. Ladd, 56th North Carolina.	Recovery rapid. Writes, in 1871, that he "can plough, cut wood, and play the violin almost as good as ever."
75	Griffith, T. T., Pt., A, 59th Virginia, age 37.	May 8, 1864.	Shot fracture of upper extremity of the right humerus.	May 8, 1864.	Resection of the head and six inches of shaft of humerus.	Retired March 20, 1865.
76	Hall, D., Pt., E, 85th Indiana, age 24.	Nov. 18, 1863.	Minié ball lodged in the head of the left humerus, comminuting it greatly.	Nov. 18, 1863.	Head and two and a half inches of humerus excised, by A. A. Surgeon J. H. Green.	Disch'd May 18, 1864; pensioned. Sept., 1871, has no use of shoulder joint whatever.
77	Hall, J. M., Pt., H, 7th Texas, age 22.	Nov. 30, 1864.	Gunshot fracture of the left shoulder.	Nov. 30, 1864.	Excision of the head and two inches of shaft of humerus, by Surgeon J. R. Crane, 7th Texas.	Transferred to Provost Marshal. February 24, 1865.

<sup>1</sup>McGURE (H.), *Clinical Records on Gunshot Wounds of Joints, delivered, January 10, 1865, at Howard's Grove Hospital, in The Richmond Medical Journal*, 1866, Vol. 1, p. 119.

No.	NAME, AGE, AND MILITARY DESCRIPTION.	DATE OF INJURY.	NATURE OF INJURY.	DATE OF OPERATION.	OPERATION AND OPERATOR.	RESULT AND REMARKS.
78	Hammond, M., Serg't, Purcell's Battery, age 22	July 3, 1863.	Conoidal ball comminuted the upper portion of the left humerus.	July 3, 1863.	Excision of head and three inches of shaft of humerus by Surg. W. A. Greene, U. S. A.	Exchanged in Sept., 1863. Limb atrophied; use of hand and forearm perfect, that of arm somewhat impaired.
79	Hammond, W., Corp'l, K., 123th New York, age 44.	July 30, 1864.	Head and neck of right humerus badly comminuted, and circumflex artery partially divided, by a minie ball.	July 30, 1864.	Excision of the head and three inches of the shaft of the humerus, by Surg. H. F. Lyster, 5th Michigan.	Disch'd June 28, 1865; pensioned. Sept., 1873, limb useless for manual labor.
80	Hanna, T. R., Corp'l, G., 125th Ohio, age 43.	Nov. 30, 1861.	Shot fracture of upper third of the left humerus.	Dec. 1, 1861.	Excision of head and a portion of shaft of humerus by A. A. Surg. J. C. Thorpe.	Disch'd Sept. 25, 1865; pensioned. Died January 25, 1871.
81	Harbaugh, J. E., Pt., D, 6th Infantry, age 27.	May 3, 1863.	Comp'd comminuted shot fracture of the head of the right humerus.	May 3, 1863.	Head and one inch of shaft of humerus resected, by Ass't Surg. J. S. Billings, U. S. A.	Disch'd Nov. 11, 1863; pensioned. Dec., 1868, entirely unable to raise arm from body.
82	Harding, A. A., Lieut., G., 21st Wisconsin, age 25.	May 14, 1861.	Minie ball fractured the left humerus and penetrated the shoulder joint.	May 11, 1861.	Removal of head and two and a half inches of the shaft of humerus, by Surg. S. Marks, 25th Wisconsin.	Resigned Sept. 24, 1864; pensioned. Sept., 1873, complete loss of use of shoulder joint.
83	Hardy, J. K., Corp'l, E, 79th Indiana, age 28.	Nov. 25, 1863.	Shot fracture of upper third of the right humerus.	Nov. 25, 1863.	Head and one inch of the shaft of humerus resected, by Surg. C. Schussler, 6th Indiana.	Disch'd December 1, 1864, and pensioned.
84	Harlow, J. M., Pl., 1st Mass. Artillery, age 22.	June 16, 1864.	Shot fracture of the head of the left humerus; also wound of face with loss of right eye.	June 17, 1864.	Excision of the head and four inches of shaft of humerus.	Disch'd Nov. 9, 1864; pensioned. Sept., 1873, has limited use of arm.
85	Hartman, J., Pl., H, 187th Pennsylvania, age 39.	June 18, 1864.	Gun-shot wound of the left shoulder.	June 18, 1864.	Excision of head and upper third of humerus.	Disch'd Feb. 22, 1865; pensioned. Sept., 1873, arm totally useless.
86	Hatfield, E. P., Pt., C, 46th Ohio, age 27.	May 27, 1861.	Shot fracture of upper third of left humerus, extending into joint.	May 27, 1864.	Excision of the head and four inches of shaft of humerus by Surg. D. Halderman, 46th Ohio.	Disch'd Mar. 17, 1865; pensioned. Sept., 1873, disability total, 3d grade.
87	Hays, A. A., Pt., E., 8th South Carolina, age 24.	May 24, 1864.	Shot fracture of the head of the right humerus.	May 21, 1864.	Removal of head and three inches of shaft of humerus.	Recovered, and furloughed Aug. 27, 1864.
88	Heinrich, J., Pl., C, 12th Wisconsin, age 23.	Oct. 5, 1864.	Minie ball comminuted the upper portion of the left humerus, fractured four ribs, and injured lung.	Oct. 7, 1861.	Removal of the head and seven inches of the shaft of humerus and fractured portions of ribs, by Surg. J. J. Whitney, 18th Wisconsin.	Disch'd June 30, 1865; pensioned. Sept., 1873, has no control over the arm.
89	Helm, C. H., Pl., E, 31st Wisconsin.	Mar. 19, 1865.	Shot fracture of the head of the left humerus.	Mar. 19, 1865.	Resection of three inches of upper extremity of humerus, by Ass't Surg. M. T. Babcock, 141st New York.	Disch'd July 8, 1865; pensioned. Sept., 1873, disability equivalent to loss of hand.
90	Hennessey, J., Pl., E, 17th New York, age 18.	Sept. 1, 1864.	Comminuted shot fracture of the head of right humerus.	Sept. 3, 1864.	Head and three and a half inches of shaft of humerus removed, by Surg. E. Butwell, 14th Michigan.	Disch'd June 8, 1865; pensioned. Sept., 1873, arm useless for manual labor.
91	Hickenlooper, H., Corp'l, E, 6th Iowa, age 23.	Nov. 25, 1863.	Shot fracture of surgical neck of the right humerus; shaft splintered more than three inches.	Nov. 25, 1863.	Excision of head and neck of humerus, by Surgeon N. W. Abbott, 80th Illinois.	Disch'd Mar. 28, 1864; pensioned. Apr., 1872, can move arm inward and outward; has use of fingers and hand to some extent.
92	Hill, R. C., Pt., I, 57th Pennsylvania, age 23.	May 5, 1864.	Radiating fracture of the head of left humerus by a conoidal ball.	May 5, 1864.	Excision of head and a portion of the shaft of the humerus a little below the surgical neck, by Surgeon H. F. Lyster, 5th Michigan.	Disch'd Sept. 28, 1864; pensioned. Sept., 1873, disability rated total, 3d grade.
93	Holter, H., Pt., I, 25th N. Carolina, age 19.	June 17, 1864.	Comp'd comminuted shot fracture of right humerus.	June 18, 1864.	Removal of head and one inch of the shaft of humerus.	Furloughed July 28, 1864; doing well.
94	Holloman, N. P., Pl., H, 3d North Carolina, age 26.	July 2, 1863.	Conoidal ball fractured head of right humerus and lodged in the glenoid cavity.	July 3, 1863.	Removal of the head and four inches of shaft of humerus through a straight incision.	Recovered, and paroled November 12, 1861.
95	Holloway, J. P., Pt., A, 41st Virginia, age 22.	July 30, 1864.	A minie ball passed directly through left shoulder joint and shattered the head and shaft of the humerus.	July 30, 1864.	Excision of the head and two inches of shaft of humerus.	Recovered; retired from service January 23, 1865.
96	Howe, G., Pt., F, 10th Michigan Cavalry, age 19.	Aug. 24, 1864.	Comminuted shot fracture of upper third of right humerus, involving shoulder joint.	Aug. 26, 1864.	Head and two and a half inches of shaft of humerus removed, by Surg. H. L. W. Burritt, U. S. V.	Disch'd May 2, 1865; pensioned. Dec., 1873, arm useless for manual labor. Spec. 2405, A. M. M.
97	Hunt, T., Corp'l, D, 118th Ohio, age 46.	May 14, 1864.	Shot fracture of the head of the right humerus.	May 14, 1864.	Excision of head and four and a half inches of the shaft of humerus, by Surgeon C. W. McMillen, 1st E'st Tennessee.	Disch'd Dec. 8, 1864; pensioned. Sept., 1873, disability total, 3d grade.
98	Jacobs, H. G., Lieut., G, 6th Maine, age 18.	Nov. 7, 1863.	Conoidal ball perforated the head of left humerus, comminuting it, as also about two inches of the shaft.	Nov. 10, 1863.	Excision of the head and three inches of shaft of humerus, by Surg. D. W. Bliss, U. S. V.	Disch'd May 28, 1864; pensioned. Nov., 1864, wound still discharging. Biennial examination waived. Spec. 1767, A. M. M.
99	Jamison, J. A., Lieut., Claiborne's Staff, age 23.	Nov. 30, 1864.	Shot fracture of upper third of the left arm.	Dec. 1, 1864.	Head and two inches of shaft of left humerus removed, by Surg. J. R. Ludlow, U. S. V.	Recovered; transferred to Provost Marshal March 14, 1865.
100	Jarvis, T. J., Capt., B, 8th North Carolina, age 28.	May 14, 1864.	Shot fracture of upper third of right humerus.	May 14, 1864.	Resection of the head and four inches of shaft of humerus.	Recovered; furloughed August 10, 1864.
101	Jaycox, J. H., Corp'l, B, 143d New York, age 31.	July 20, 1864.	Head and upper third of the left humerus shattered by a conoidal ball.	July 21, 1864.	Excision of the head and five inches of shaft of humerus, by Surgeon H. K. Spooner, 61st Ohio.	Disch'd June 18, 1865; pensioned. Sept., 1873, muscular atrophy in region of wound. Spec. 4326, A. M. M.
102	Jenkins, A., Pt., D, 53d Ohio, age 24.	July 3, 1864.	Comminuted shot fracture of the left shoulder.	July 3, 1864.	Head and five inches of shaft of humerus removed, by Surg. A. C. Messenger, 57th Ohio.	Disch'd May 12, 1865; pensioned. Sept., 1873, disability for labor equivalent to loss of hand.
103	Jenks, J. G., Pt., F, 15th Infantry, age 17.	July 27, 1864.	Minie ball comminuted head of the right humerus.	July 27, 1864.	Head and two inches of shaft of humerus excised, by Surg. W. C. Jacobs, 81st Ohio.	Disch'd June 20, 1865; sept., 1873, limb useless for purposes of manual labor.
104	Johnson, J., Pt., A, 7th Colored Troops, age 23.	Oct. 13, 1864.	Shot fracture of upper third of the left humerus.	Oct. 15, 1864.	Removal of the head and three inches of shaft of humerus.	Disch'd Nov. 19, 1865; pensioned. Sept., 1873, arm swings helplessly at side.
105	Jordan, J., Corp'l, C, 69th Ohio, age 22.	May 14, 1864.	Conoidal ball shattered and lodged in the head of the left humerus.	May 14, 1864.	Head and two and a half inches of the humerus excised, by Surg. L. Shusser, 69th Ohio.	Disch'd Apr. 7, 1865; pensioned. Sept., 1873, slight motion at shoulder; arm useless for labor.



No.	NAME, AGE, AND MILITARY DESCRIPTION.	DATE OF INJURY.	NATURE OF INJURY.	DATE OF OPERATION.	OPERATION AND OPERATOR.	RESULT AND REMARKS.
106	Keeler, W., Pt., M, 8th New York Artillery, age 26.	June 23, 1864.	Compound comminuted fracture of the neck and upper third of the right humerus by a rifle ball.	June 23, 1864.	Excision of the head and two inches of shaft of humerus, by Surgeon A. Churchill 6th New York Artillery.	Disch'd Feb. 25, 1865; pensioned Oct. 1, 1866, for amputated shoulder joint, at Soldiers' Home, Philadelphia.
107	Keesley, P., Pt., A, 10th Illinois, age 24.	Mar. 21, 1865.	Shot fracture of upper third of the right arm; also three fingers of the right hand shot away.	Mar. 21, 1865.	Excision of the head and a portion of the shaft of humerus, four inches in all, by Surgeon W. A. Gott, 23d Wisconsin.	Disch'd July 17, 1865; pensioned Sept., 1874, not a pensioner.
108	Kennedy, H., Pt., G, 6th Missouri, age 22.	June 27, 1864.	Gunshot fracture of the right humerus.	June 27, 1864.	Resection of head and three inches of shaft of humerus.	Transferred to Provost Marshal December 8, 1864; considerable use of arm.
109	Kenyon, J. S., Pt., H, 8th New York Cavalry, age 19.	Aug. 25, 1864.	Compound shot fracture of the upper third of right humerus, involving joint.	Aug. 25, 1864.	Head and three inches of the shaft of humerus excised, by Surg. W. D. Ferguson, 8th New York Cavalry.	Disch'd Feb. 3, 1865; pensioned Sept., 1873, has only a very moderate use of the arm. <i>Spec.</i> 674 and 1370, A. M. M.
110	Kinnett, A. G., Pt., C, 37th Indiana, age 21.	May 27, 1864.	Minié ball comminuted the right humerus.	May 28, 1864.	Removal of the head and four inches of shaft of humerus.	Disch'd May 26, 1865; pensioned Oct., 1866, can grasp and lift light weights directly upward, but in no other direction.
111	Knapp, H. J., Pt., H, 29th Ohio, age 18.	May 8, 1864.	Shot wound of right humerus, badly shattering the head.	May 8, 1864.	Excision of the head and two inches of shaft of humerus, by Surgeon A. K. Field, 29th Ohio.	Disch'd May 19, 1865; pensioned Sept., 1873, shoulder weak and motions of arm greatly impaired.
112	Lahmers, C., Pt., E, 80th Ohio.	Nov. 25, 1863.	Minié ball fractured the head of the left humerus.	Nov. 25, 1863.	Head and one inch of shaft of humerus removed, by Surg. E. J. Buck, 18th Wisconsin.	Disch'd June 9, 1864; pensioned Oct., 1873, disability rated total, 3d grade.
113	Lamb, L., Pt., A, 28th Massachusetts.	Dec. 13, 1862.	Shot fracture of left shoulder joint.	Dec. 13, 1862.	Removal of the head and two inches of shaft of humerus.	Disch'd Nov. 2, 1864; pensioned. Died March 18, 1874.
114	Laney, L. B., Pt., B, 12th New Hampshire, age 35.	June 3, 1864.	Wound of the right shoulder joint by a conoidal ball.	June 3, 1864.	Excision of the head and three inches of shaft of humerus.	Disch'd June 19, 1865; pensioned Sept., 1873, has no control over hand.
115	La Rock, J., Pt., C, 9th Vermont, age 40.	May 12, 1865.	Extensive comminution of head of right humerus and laceration of soft parts by a minié ball.	May 13, 1865.	Excision of the head and two inches of shaft of humerus, by Surgeon C. M. Clark, 39th Illinois.	Disch'd Nov. 30, 1865; pensioned Sept., 1873, arm useless.
116	Lauer, G. C., Pt., E, 2d New Jersey, age 27.	May 3, 1863.	Shot fracture of head of right humerus.	May 3, 1863.	Excision of head and about four inches of shaft of humerus.	Disch'd May 5, 1864; pensioned Sep., 1873, total loss of use of arm.
117	Lenka, A., Pt., K, 198th Pennsylvania, age 21.	Mar. 29, 1865.	Comminuted shot fracture of upper portion of left humerus.	Mar. 29, 1865.	Head and one inch of the shaft of the humerus removed thro' a V-shaped incision.	Disch'd July 20, 1865; pensioned July, 1874, arm useless for manual labor.
118	Lewis, F., Sergeant, I, 93d Colored Troops.	June 16, 1864.	Conoidal ball perforated upper portion of right humerus; also shot wound of left forearm; primary amputation.	June 17, 1864.	Head and upper portion of the shaft of humerus removed, by Surgeon M. C. Lathrop, 98th Colored Troops.	Disch'd Jan. 20, 1866. Not a pensioner in Sept., 1874.
119	Lewis, J., Pt., F, 33d New Jersey, age 19.	June 22, 1864.	Minié ball passed directly thro' left shoulder joint, shattering the head of the humerus.	June 22, 1864.	Resection of the head and two and a half inches of shaft of humerus, by Surg. J. Riley, 33d New Jersey.	Disch'd Feb. 13, 1865; pensioned Sept., 1873, use of arm much impaired.
120	Lewis, N. J., Serg't, D, 38th North Carolina, age 18.	June 22, 1864.	Gunshot fracture of the head of humerus; also fracture of the right fibula.	June 23, 1864.	Head and three inches of shaft of humerus removed; also excision of six inches of right fibula, by Surgeon P. W. Young, 32d North Carolina.	Retired November 28, 1864.
121	Lloyd, J. W., Pt., G, 11th New Jersey, age 24.	July 2, 1863.	Conoidal ball entered the left arm about the middle, fractured humerus, and lodged in the head of the bone.	July 4, 1863.	Excision of the head and three inches of the shaft of the humerus.	Disch'd April 8, 1864; pensioned. Accidentally killed July 4, 1867; railroad accident.
122	Lord W., Sergeant, G, 25th N. York Cavalry, age 35.	Nov. 12, 1864.	Compound comminuted shot fracture of the head of left humerus.	Nov. 14, 1864.	Excision of head and one inch of the shaft of humerus, by Surgeon E. B. Nims, 1st Vermont Cavalry.	Disch'd June 20, 1865; pensioned. Died July 10, 1874. <i>Spec.</i> 3728, A. M. M.
123	McCue, J., Pt., E, 8th Illinois, age 23.	April 9, 1865.	Gunshot wound of the left arm.	April 9, 1865.	Excision of head and six inches of shaft of humerus, by Surg. J. B. Dickson, 47th Indiana.	Disch'd June 5, 1865; pensioned. Arm useless for manual labor.
124	McDonald, M. D., Lieut., C, 8th Alabama, age 25.	July 30, 1864.	Gunshot wound of left shoulder joint.	July 30, 1864.	Removal of the head and four inches of shaft of humerus.	Furloughed August 31, 1864; recovered.
125	McMurray, J. M., Pt., F, 123d New York, age 22.	July 20, 1864.	Gunshot fracture of the left shoulder joint.	July 22, 1864.	Excision of two and a half inches of the upper extremity of the humerus, including the head, by Surg. J. Chapman, 123d New York.	Disch'd Feb. 16, 1865; pensioned. Died February 15, 1872.
126	Mallory, T. F., Lieut., C, 8th South Carolina, age 20.	Sept. 17, 1862.	Fracture of the head of left humerus by shell fragment.	Sept. 18, 1862.	Head and a portion of the shaft of humerus, three inches in all, excised.	Sent to Provost Marshal Mar. 6, 1863. No bony union; pronation and supination nearly normal.
127	Martin, G., Pt., I, 5th Connecticut, age 35.	June 22, 1864.	Left humerus badly crushed by a conoidal ball.	June 23, 1864.	Excision of the head and two inches of the shaft of humerus, by Surgeon E. L. Bissell, 5th Connecticut.	Disch'd Aug. 31, 1866; pensioned. September, 1873; hand is well nourished; has fair power of grasp; can't lift heavy burdens.
128	Mason, J. S., Pt., F, 105th Ohio, age 20.	June 29, 1864.	Shot fracture of upper portion of right humerus.	June 29, 1864.	Removal of four and a half inches of the upper extremity of the humerus, by Surg. C. W. McMillen, 1st East Tenn.	Disch'd Nov. 12, 1864; pensioned. Sept., 1873, arm nearly useless for manual labor.
129	Mayer, F., Pt., B, 98th Pennsylvania, age 24.	June 18, 1864.	Shot fracture of the left humerus.	June 18, 1864.	Head and four inches of shaft of humerus excised through a straight incision.	Disch'd Sept. 21, 1864; pensioned. Aug., 1866, has some little use of hand and wrist.
130	Meek, G. N., Pt., B, 97th Indiana, age 25.	Aug. 16, 1864.	Minié ball fractured the head and shaft of the left humerus.	Aug. 16, 1864.	Resection of head and three inches of the shaft of humerus.	Disch'd June 9, 1865; pensioned. Sept., 1873, arm and shoulder atrophied; limb almost useless.
131	Miles, M. C., Pt., G, 48th Virginia, age 22.	July 2, 1863.	Minié ball perforated the left shoulder, fracturing the head and neck of the humerus.	July 5, 1863.	Excision of head, neck, and two inches of the shaft of the humerus.	Transferred for exchange Nov. 12, 1863; recovered.
132	Mingo, H., Pt., E, 2d New York Cavalry, age 32.	Nov. 12, 1864.	Compound fracture of the upper extremity of the right humerus by conoidal ball.	Nov. 12, 1864.	Excision of the head and three inches of shaft of humerus, by Surgeon J. W. Smith, 2d Ohio Cavalry.	Disch'd Dec. 5, 1865; pensioned. Oct., 1873, arm considerably atrophied; unable to perform most kinds of labor.

NO.	NAME, AGE, AND MILITARY DESCRIPTION.	DATE OF INJURY.	NATURE OF INJURY.	DATE OF OPERATION.	OPERATION AND OPERATOR.	RESULT AND REMARKS.
133	Morrison, R. A., Serg't, G, 83d New York, age 29.	Oct. 14, 1863.	Gunshot fracture of the head of right humerus and wound of the right forearm.	Oct. 17, 1863.	Excision of the head and two and a half inches of humerus, by Surg. E. Bentley, U. S. V.	Disch'd Feb. 13, 1864; pensioned. Sept., 1873, no bony reproduction; arm useless for manual labor.
134	Morrison, T. G., Major, 66th Indiana, age 31.	Oct. 4, 1864.	Conoidal ball comminuted the head of right humerus and split the shaft for a distance of four inches.	Oct. 5, 1864.	Head and four inches of the shaft of humerus removed, by Surgeon A. Goslin, 36th Illinois.	Disch'd May 15, 1865; pensioned. Sept., 1873, upper part of arm very much attenuated and perfectly flexible.
135	M——, M., Pt., G, 10th Illinois.	June 27, 1864.	Extensive comminution of the head of the humerus and glenoid cavity; ball lodged in neck of scapula.	June 27, 1864.	Excision of three inches of the upper extremity of humerus, and extraction of spicula from glenoid cavity and of ball from scapula, by Surg. G. C. Cooper, U. S. A.	Recovered rapidly, with a good and useful hand.
136	Nelson, P., Pt., B, 6th Wisconsin, age 30.	Aug. 19, 1864.	Musket ball fractured the head of the right humerus.	Aug. 21, 1864.	Removal of the head and two and a half inches of the shaft of the humerus.	Disch'd May 31, 1865; pensioned. Sept., 1873, arm completely useless.
137	Newell, T. J., Sergeant, E, 112th New York, age 36.	June 1, 1864.	Shot fracture of the left humerus.	June 1, 1864.	Removal of the head and a portion of shaft of humerus.	Disch'd Oct. 3, 1864; pensioned. Sept., 1873, arm useless.
138	Nicoll, D., Pt., E, Knapp's Penn. Battery, age 23.	Oct. 28, 1863.	Minié ball shattered the head of the right humerus and lodged.	Oct. 31, 1863.	Head and one-half inch of the shaft of the humerus excised thro' a Y-shaped incision, by Surgeon A. McMahon, 64th Ohio.	Disch'd May 17, 1865; pensioned. Aug., 1869, disability for manual labor equivalent to loss of limb. Spec. 3233, A. M. M.
139	Nixon, J., Pt., A, 24th New Jersey, age 32.	Dec. 13, 1862.	Minié ball fractured the lower, middle, and upper thirds of the left humerus and lodged in the glenoid cavity.	Dec. 13, 1862.	Excision of the head and upper third of the shaft of humerus, by Ass't Surgeon G. M. McGill, U. S. A.	Disch'd Ap'l 11, 1863; pensioned. Sept., 1873, limb permanently flexible and useless for labor.
140	O'Malley, P., Pt., K, 91st Pennsylvania, age 44.	Oct. 25, 1864.	Shot fracture of the head of the left humerus.	Oct. 25, 1864.	Excision of the head and three inches of the shaft of humerus.	Disch'd June 21, 1865; pensioned. Died August 2, 1865, from malarial disease.
141	O'Reilly, M., Pt., B, 3d Infantry, age 21.	July 2, 1863.	Conoidal ball perforated surgical neck of the left humerus; longitudinal fracture several inches down shaft.	July 3, 1863.	Removal of the head and two and a half inches of the shaft of humerus, by Ass't Surgeon B. Howard, U. S. A.	Disch'd Mar. 28, 1864; pensioned. Sept., 1873, no bony reproduction; arm useless for labor. Spec. 1376, A. M. M.
142	Ostrander, D. H., Captain, A, 108th New York.	Oct. 28, 1864.	Shot fracture of right shoulder joint; ball passed through the head of humerus.	Oct. 28, 1864.	Upper fourth of humerus, including the head, removed, by Surg. J. Scott, 7th West Virginia.	Disch'd Ap'l 17, 1865; pensioned. Dec., 1873, use of arm greatly impaired.
143	Page, G. W., Pt., 11th Massachusetts Bat'ry, age 26.	July 23, 1864.	Shot wound through the head of the left humerus.	July 23, 1864.	Excision of the head and five inches of shaft of humerus.	Disch'd Dec. 16, 1864; pensioned. Sept., 1873, arm and forearm atrophied; motions of hand and fingers good.
144	Parron, H. T., Pt., C, 26th Virginia, age 19.	June 15, 1864.	Compound shot fracture of the left humerus.	June 15, 1864.	Removal of the head and three inches of shaft of humerus.	Retired February 6, 1865.
145	Parrott, M., Corporal, A, 42d Indiana.	May 14, 1864.	Shot fracture of the upper portion of right humerus.	May 14, 1864.	Excision of five inches of upper extremity of humerus, including the head.	Disch'd Mar. 4, 1865; pensioned. July, 1866, arm pendulous and entirely useless.
146	Perry, R. C., Captain, B, 111th New York, age 29.	May 18, 1864.	Comminuted shot fracture of the head and continuity of the left humerus.	May 18, 1864.	Excision of the head and four inches of the continuity, by Surgeon A. N. Dougherty, U. S. V.	Appointed 1st Lieut. U. S. A. Jan. 22, 1867, and retired from active service Dec. 31, 1870, upon the full rank of Lieut.-Col. Recovered.
147	Phillips, J. F., Pt., D, 20th South Carolina.	July 28, 1864.	Conoidal ball fractured upper third of left humerus; lodged three inches above elbow.	July 28, 1864.	Excision of the head and three inches of shaft of humerus.	Disch'd April 3, 1865; pensioned. Sept., 1873, disability total, 3d grade.
148	Pomeroy, N. B., Corp'l, F, 27th Massachusetts, age 23.	May 16, 1864.	Shot fracture of left humerus by a conoidal ball.	May 16, 1864.	Head and three inches of shaft of the humerus resected.	Disch'd Sept. 22, 1865; pensioned. Sept., 1873, arm shortened and manual labor performed with difficulty. Spec. 2433, A. M. M.
149	Pratt, J. H., Sergeant, F, 142d New York, age 22.	Oct. 27, 1864.	Minié ball fractured the upper portion of left humerus; also wound of cheek.	Oct. 27, 1864.	Head and three inches of shaft of the humerus removed, by Surgeon N. Y. Leit, 76th Pennsylvania.	Disch'd May 15, 1865; pensioned. Died November 8, 1871.
150	Quindlen, J. P., Captain, E, 81st Pennsylvania.	Aug. 14, 1864.	A minié ball passed through the head of right humerus, fissuring the upper extremity of shaft.	Aug. 14, 1864.	Removal of the head and two inches of shaft of humerus, by Surgeon J. W. Wisbart, 140th Pennsylvania.	Disch'd Ap'l 30, 1864; pensioned. Jan., 1875, arm useless for labor. Specs. 1738 and 4699, A. M. M.
151	Reardon, J. F., Pt., C, 6th New York Cavalry, age 22.	Oct. 11, 1863.	Comp'd comminuted fracture of upper portion of the humerus by a fragment of shell.	Oct. 12, 1863.	Head and fractured portion of shaft of humerus removed, by Surg. D. W. Bliss, U. S. V.	Disch'd June 27, 1865; pensioned. Sept., 1873, arm useless; joint ankylosed.
152	Regan, T., Pt., F, 58th Illinois.	April 9, 1864.	Gunshot wound of right shoulder joint.	April 10, 1864.	Head and two inches of shaft of the humerus removed, by Surg. H. M. Crawford, 58th Illinois.	Disch'd Oct. 21, 1862; pensioned. Died in June, 1870.
153	Reilly, J., Pt., K, 5th New Jersey, age 40.	May 5, 1862.	Fracture of the head and upper part of the right humerus by a minié ball.	May 6, 1862.	Excision of the head and about two inches of the shaft of humerus.	Disch'd Dec. 31, 1864; pensioned. Died September 4, 1872.
154	Reynolds, J., Pt., E, 27th Michigan, age 51.	May 12, 1864.	Shot fracture of the head of right humerus.	May 12, 1864.	Excision of the head and about four inches of the shaft of humerus, by Surgeon S. S. French, 20th Michigan.	Disch'd Sept. 3, 1864. Not a pensioner in February, 1875.
155	Richard, C. A., Saddler, A, 10th Pennsylvania Cavalry.	Oct. 14, 1863.	Shot fracture of upper third of right humerus, extending into the joint.	Oct. 16, 1863.	Excision of the head and three inches of the shaft of the humerus.	Transferred for exchange March 1, 1865.
156	Richards, J. E., Captain, B, 2d Arkansas, age 27.	Nov. 30, 1864.	Comminuted fracture of upper extremity of left humerus.	Nov. 30, 1864.	Head and four inches of shaft of humerus resected, by Surg. McFadden, C. S. A.	Disch'd Mar. 18, 1864; pensioned. Sept., 1873, arm and hand useless. Spec. 1692, A. M. M.
157	Richardson, N., Pt., C, 27th Indiana, age 25.	May 3, 1863.	Conoidal ball passed through head of left humerus and was cut out from biceps muscle.	May 3, 1863.	Removal of the head and two and a half inches of the shaft of humerus, by Ass't Surg. B. Howard, U. S. A.	Disch'd Mar. 28, 1865; pensioned. Sept., 1873, arm useless for manual labor.
158	Robbins, W., Pt., K, 49th New York, age 16.	July 12, 1864.	Head and considerable portion of shaft of left humerus shattered by shot.	July 12, 1864.	Removal of the head and three and a half inches of the shaft of humerus, by Surg. G. F. Stevens 77th New York.	

<sup>1</sup> BATWELL (E.), Notes on Excisions, in The Philadelphia Med. and Surg. Reporter, 1864, Vol. XII, p. 201.



No.	NAME, AGE, AND MILITARY DESCRIPTION.	DATE OF INJURY.	NATURE OF INJURY.	DATE OF OPERATION.	OPERATION AND OPERATOR.	RESULT AND REMARKS.
159	Rodgers, J. W., Pt., II, 100th Pennsylvania.	Nov. 21, 1863.	Shot fracture of left shoulder joint.	Nov. 21, 1863.	Removal of the head and four and a half inches of shaft of humerus, by Surgeon J. P. Prince, 30th Massachusetts.	Disch'd Aug. 30, 1864; pensioned Sept., 1866, arm can be doubled upon itself six inches below glenoid cavity. Recovered.
160	Rodgers, W. F., Pt., II, 28th Alabama, age 30.	Sept. 19, 1863.	Shot fracture of the head of the right humerus.	Sept. 19, 1863.	Removal of head and a small portion of shaft of humerus.	Disch'd Oct. 3, 1864; pensioned Dec. 27, 1865, amputation of arm at shoulder joint, by Dr. H. S. Streeter.
161	Rosa, J. W., Pt., I, 2d N. York Artillery, age 24.	May 21, 1864.	Shell wound of the right shoulder, fracturing the humerus.	May 25, 1864.	Excision of the head and eight inches of shaft of humerus.	Disch'd Jan. 14, 1863; pensioned Sept., 1873, muscular action destroyed; arm very weak.
162	Rose, G. B., Pt., K, 11th Connecticut, age 21.	Sept. 17, 1862.	Fracture of the head and comminution of the neck of the left humerus by a musket ball.	Sept. 17, 1862.	Excision of the head and two inches of shaft of humerus through a U shaped incision, by Surg. M. Storr, 8th Conn.	Recovered. "Result beautiful, with very good use of arm."
163	Rudd, W., Pt., D, 47th Alabama, age 19.	May 6, 1864.	Minié ball buried itself in the head of the humerus, comminuting it.	May 7, 1864.	Three inches of bone, including the head of the humerus, removed, by Surgeon J. R. Burton, 47th Alabama.	October 1, 1863, recovered.
164	Ruth, A. M., Lieut., B, 2d South Carolina, age 23.	Aug. 1, 1863.	Minié ball passed through the head of the left humerus.	Aug. 1, 1863.	Excision of the head and two inches of shaft of humerus.	Disch'd Aug 25, 1865; pensioned Sept., 1873, arm swinging and useless.
165	Sands, T., Pt., F, 118th Pennsylvania, age 30.	Feb. 6, 1865.	Shot fracture of upper portion of left humerus.	Feb. 6, 1865.	Head and three inches of shaft of humerus removed by Surg. J. Thomas, 118th Pennsylv.	Disch'd June 17, 1865; pensioned Sept., 1868, has no use of arm.
166	Schmitz, H., Pt., K, 26th Iowa, age 29.	Oct. 16, 1864.	Shot fracture of the head of the left humerus.	Oct. 16, 1864.	Head and two inches of shaft of the humerus removed, by Surgeon A. T. Hudson, 26th Iowa.	Disch'd April 3, 1855; pensioned March, 1874, arm hangs useless at his side.
167	Schutte, H. W., Corporal, I, 105th Illinois, age 26.	June 22, 1864.	Comminuted fracture of head of right humerus by a round ball.	June 22, 1864.	Four inches of the upper extremity of humerus removed.	February, 1867, has good use of arm.
168	Scott, W. H., Pt., E, 12th Virginia, age 36.	Feb. 6, 1865.	Conoidal ball fractured head of left humerus.	Feb. 7, 1865.	Removal of the head and two inches of shaft of the humerus, by the Surgeon of the 12th Virginia.	Disch'd Jan. 1, 1868; pensioned Sept., 1873, arm is useless for manual labor.
169	Sears, H., Serg't, I, 131st New York, age 28.	May 27, 1863.	Comp'd comminuted shot fracture of upper third of the left humerus.	May 27, 1863.	Head and five and a half inches of shaft of humerus removed, by Surgeon M. D. Benedict, 75th New York.	Disch'd Sept. 15, 1864; pension'd Sept., 1873, necrosis of upper portion of remaining humerus.
170	Shaw, J. R., Pt., L, 3d New York Cavalry.	July 22, 1863.	Conoidal ball perforated head of right humerus and fractured the neck of the scapula.	July 23, 1863.	Head and two and a half inches of humerus excised, by Ass't Surg J. W. Gray, 9th New York.	Recovered, and exchanged January 8, 1865.
171	Slattery, M. J., Pt., D, 5th Louisiana, age 20.	July 9, 1864.	Comminuted fracture of head and neck of left humerus by musket ball.	July 10, 1864.	Resection of head and three inches of shaft of humerus, by Surg. C. H. Todd, C. S. A.	Disch'd Mar. 17, 1865; pensioned Sept., 1873, adherent cicatrix; arm useless.
172	Smith, A., Pt., Battery G, 1st New York Light Artillery, age 21.	Oct. 31, 1864.	Shot fracture of left humerus.	Nov. 1, 1864.	Excision of the head and two inches of shaft of humerus.	Disch'd May 25, 1865; pensioned Sept., 1873, limb devoid of strength and motion.
173	Smith, A. H., Pt., G, 20th Indiana, age 26.	May 25, 1864.	Shot fracture of right humerus.	May 25, 1864.	Head and three and a half inches of shaft of humerus removed.	May 18, 1865, every indication of a complete recovery. <i>Spec.</i> 4966, A. M. M.
174	Smith, L., Civilian, age 56.	Feb. 25, 1865.	Conoidal ball entered about two inches below head of left humerus, passed through joint under scapula and out.	Feb. 26, 1865.	Four inches and thirty-two pieces of bone removed, by Surgeon H. L. W. Burritt, U. S. V.	Disch'd July 10, 1865; pensioned Sept., 1873, arm atrophied and powerless; pseudoarthrosis.
175	Snyder, G., Pt., D, 91st Pennsylvania, age 41.	June 21, 1864.	Fracture of the upper third of the right humerus by minié ball.	June 21, 1864.	Head and three inches of shaft of humerus removed.	Disch'd June 12, 1865. Not a pensioner in December, 1871.
176	Soutbard, G., Pt., A, 121st Ohio, age 21.	Dec. 15, 1864.	Comminuted fracture of head and neck of left humerus, extending into joint; ball lodged in head of bone.	Dec. 16, 1864.	Head and three inches of shaft of humerus removed by Surg. F. W. Lytle, 36th Illinois.	Disch'd Dec. 20, 1864; pensioned March, 1871, disability total, 3d grade.
177	Spencer, W., Serg't, K, 55th Illinois, age 22.	June 23, 1864.	Fracture of upper portion of right humerus by fragment of shell.	June 23, 1864.	Four inches of humerus, including the head, removed, by Surgeon I. N. Barnes, 116th Illinois.	Disch'd Feb. 11, 1865; pensioned Sept., 1873, the arm is almost useless.
178	Staekhouse, J., Pt., D, 92d Ohio, age 36.	Feb. 25, 1864.	Compound shot fracture of the left humerus.	Feb. 26, 1864.	Head and one inch of shaft of humerus removed, by Surg. C. Soellheim, 9th Ohio.	Disch'd Feb. 1, 1864; pensioned Sept., 1873, arm powerless. <i>Spec.</i> 2996, A. M. M.
179	Stahl, J. S., Pt., H, 4th Wisconsin.	June 14, 1863.	Shot fracture of head of the left humerus.	June 16, 1863.	Excision of the head and two and a half inches of shaft of humerus, by A. A. Surg. F. Hassenburgh.	Disch'd June 8, 1865; pensioned Sept., 1873, has use of forearm and hand.
180	Stewart, J. P., Pt., F, 103d Illinois, age 24.	Feb. 15, 1865.	Shot fracture of upper extremity of left humerus.	Feb. 15, 1865.	Excision of four inches of upper extremity of humerus, by Surg. R. Morris 103d Illinois.	Transferred for exchange April 6, 1865.
181	Stewart, S. K., Pt., C, 6th Texas Cavalry, age 27.	Dec. 4, 1864.	Shot fracture of head of the left humerus.	Dec. 6, 1864.	Head and two inches of shaft of the humerus removed.	Disch'd Feb. 10, 1865; pensioned Sept., 1873, arm useless for manual labor.
182	Stewart, R., Pt., K, 139th Pennsylvania, age 29.	May 12, 1864.	Shot wound of the left upper extremity, opening the joint.	May 12, 1864.	Removal of the head and two inches of shaft of humerus.	Disch'd Nov. 18, 1864; pensioned Sept., 1873, motions of forearm and hand very limited.
183	Styers, J., Pt., A, 45th Ohio, age 28.	Nov. 18, 1863.	Minié ball fractured the upper portion of the right humerus.	Nov. 18, 1863.	Excision of three inches of the upper extremity of humerus.	Disch'd June 28, 1865; pensioned Sept., 1873, disability total, 3d grade.
184	Sulliger, T., Pt., F, 53th Ohio, age 28.	Aug. 10, 1864.	Comminuted fracture of head of right humerus by a minié ball.	Aug. 10, 1864.	Excision of the head and four inches of shaft of humerus.	Disch'd Aug 19, 1865; pensioned Sept., 1873, power of raising arm decidedly impaired.
185	Swoyer, J., Pt., C, 1st Illinois Artillery, age 25.	July 4, 1864.	Fracture of left shoulder joint by a conoidal ball.	July 4, 1864.	Excision of the head and a small portion of the shaft of humerus, by Dr. Miller, of Cincinnati.	Recovered April, 1864. Has good use of arm.
186	Sykes, I., Musician, Stuart's Cavalry.	July 3, 1863.	Extensive shot fracture of the head and upper half of the left humerus.	July 4, 1863.	Excision of the head and upper half of shaft of humerus, by Surg. Metcalf, C. S. A.	

<sup>1</sup> WILSON (J. S.), *Resection of Upper Half of Humerus*, in *Confed. States Med and Surg. Jour.*, 1864, Vol. I, p. 56.

NO.	NAME, AGE, AND MILITARY DESCRIPTION.	DATE OF INJURY.	NATURE OF INJURY.	DATE OF OPERATION.	OPERATION AND OPERATOR.	RESULT AND REMARKS.	
187	Taylor, A., Pt., G, 24th Massachusetts, age 18.	Aug. 18, 1864.	Conoidal ball perforated the neck of right humerus and fractured the shaft for two and a half inches.	Aug. 20, 1864.	Head and two and a half inches of the shaft of the humerus removed, by A. A. Surgeon J. A. Downer.	Disch'd Sept. 12, 1865; pensioned. May, 1866, there is some useful motion of forearm, but very little of the upper arm. Disability will probably increase.	
188	Taylor, J. C., Sergeant, D, 36th Illinois, age 28.	June 19, 1864.	Comminuted shot fracture of the head of right humerus.	June 20, 1864.	Head and two inches of shaft of humerus excised by Surgeons B. G. Pierce, 96th Ill., and H. E. Hasse, 24th Wis.	Excision of the upper half of humerus.	Recovered.
189	Thompson, E. S., Serg't, F, 11th Virginia.	May 16, 1864.	Shot fracture of upper portion of the right humerus	May 16, 1864.	Removal of nearly half of the bone, including the head.	Furloughed July 27, 1864, with a prospect of a useful arm.	
190	Trigler, J., Pt., B, 30th Virginia, age 22.	June 8, 1864.	Shot comminution of head and two inches of shaft of right humerus.	June 8, 1864.	Removal of three inches of upper portion of bone, including the head.	Disch'd Nov. 15, 1864; pensioned. Dec., 1873, arm entirely useless for purposes of manual labor. <i>Spec. 2625, A. M. M.</i>	
191	Tromley, J., Pt., H, 1st Michigan.	May 5, 1864.	Comminuted shot fracture of upper third of left humerus.	May 5, 1864.	Head and about two inches of shaft of humerus removed.	Disch'd June 27, 1865; pensioned. Sept., 1873, loss of power and use of arm.	
192	Van Riper, A., Sergeant, G, 39th New Jersey, age 46.	April 2, 1865.	Round ball comminuted head of the left humerus.	April 2, 1865.	Head and three inches of the shaft of humerus excised through a longitudinal incision.	Disch'd Aug. 28, 1865; pensioned. Sept., 1873, arm perfectly useless.	
193	Van Tassel, M., Pt., K, 5th Michigan, age 24.	June 16, 1864.	Fracture of the head and comminution of the shaft of the right humerus by buckshot.	June 15, 1864.	Head and two inches of shaft of humerus removed, by Surg. W. W. Bowlby, 3d New Jersey Cavalry.	Disch'd July 20, 1865; pensioned. Sept., 1873, motion and union to a limited degree; can elevate arm to a right angle; hyperaesthesia of hand and arm.	
194	Weikel, E., Pt., I, 18th Penn'a Cavalry, age 20.	June 15, 1864.	Gunshot fracture of the right shoulder joint.	June 22, 1864.	Excision of the head and two inches of shaft of humerus, by Surg. H. C. Johns, 129th Ill.	Disch'd April 8, 1865; pensioned. Sept., 1873, arm nearly useless.	
195	Wesner, J. K., Sergeant, K, 12th Illinois, age 26.	June 22, 1864.	Shot fracture of head of right humerus.	June 28, 1864.	Excision of head and four and a half inches of the shaft of humerus, by A. A. Surgeon J. Swinburne.	Retired March 18, 1865.	
196	Willett, M., Pt., E, 16th New York, age 28.	June 27, 1862.	Head of left humerus shattered by a musket ball; joint involved.	June 27, 1862.	Excision of the head and two inches of shaft of humerus, by Surg. J. T. Kimbly, 11th Ky.	Disch'd Dec. 16, 1864; pensioned. Sept., 1873, disability rated total.	
197	Williams, A. R., Pt., H, 1st South Carolina, age 19.	June 27, 1862.	Gunshot fracture of upper portion of left humerus.	June 27, 1862.	Resection of about three inches of bone through semi-lunar incision.	May, 1865, nearly healed.	
198	Williams, R. A., Pt., B, 11th Kentucky, age 38.	Aug. 6, 1864.	Shot fracture of left humerus at the surgical neck.	April 2, 1865.	Head and four inches of shaft of humerus removed, by Surgeons O. R. Freeman, 10th New Jersey, and B. A. Watson, 4th New Jersey.	Disch'd Aug. 31, 1865; pensioned. Sept., 1873, arm useless for manual labor.	
199	Williamson, W. T., Lieut., C, 1st Alabama.	Mar. 14, 1865.	Shot wound of shoulder joint; fracture of head and neck of humerus.	Mar. 16, 1865.	Excision of the head and three inches of shaft of humerus, by Ass't Surgeon M. M. Blood, 150th New York.	Disch'd May 29, 1865; pensioned. Sept., 1873, arm shortened about three inches and partially atrophied.	
200	Wilsley, B., Serg't, D, 4th New Jersey, age 30.	April 2, 1865.	Comp'd comminuted shot fracture of left humerus, involving the head.	May 6, 1864.	Resection of four inches of the upper extremity of humerus, including the head.	Disch'd June 11, 1864; pensioned. Sept., 1873, arm useless for manual labor.	
201	Wilson, C. S., Pt., D, 3d Wisconsin, age 21.	Mar. 16, 1865.	Musket ball perforated the right shoulder joint.	Feb. 7, 1865.	Head and three inches of shaft of humerus excised.	Disch'd May 16, 1865; pensioned. Sept., 1873, arm atrophied and powerless, and the disability equivalent to loss of the limb.	
202	Wilson, R., Pt., D, 10th Pennsylvania, age 23.	May 6, 1864.	Minié ball passed through left humerus near shoulder joint.	July 3, 1863.	Head and two inches of shaft of humerus excised.	October 31, 1863, recovered.	
203	Winters, M. K., Pt., E, 88th Pennsylvania.	Feb. 7, 1865.	Shot fracture of head of left humerus.	June 28, 1862.	Head and three inches of shaft of humerus resected, by Surgeon J. Swinburne.	Disch'd Oct. 1, 1862; pensioned. Sept., 1873, motions of forearm good; little abduction possible.	
204	Wise, J. H., Pt., I, 5th Virginia, age 19.	July 3, 1863.	Comminuted shot fracture of the head of left humerus.	June 22, 1864.	Excision of the head and three inches of shaft of humerus by Surgeon W. S. Cooper, 125th New York.	Disch'd Nov. 10, 1864; pensioned. Sept., 1873, almost total loss of use of arm.	
205	Wynkoop, H. J., Lieut., D, 13th New York.	June 27, 1862.	Rifle ball fractured the right humerus.	May 31, 1864.	Excision of three inches of the upper extremity of humerus, by Surg. M. Rizer, 72d Penn.	Disch'd Nov. 8, 1864. March, 1865, arm entirely useless.	
206	Yakey, J. P., Sergeant, I, 125th New York, age 21.	June 22, 1864.	Minié ball fractured the head of left humerus.	July 18, 1863.	Excision of head and nearly two inches of the shaft of the humerus, by Surgeon W. Hayes, U. S. V.	Disch'd Nov. 30, 1864; pensioned. Sept., 1873, joint ankylosed and muscles atrophied; cicatrix adherent to bone; arm of little use. <i>Spec. 1721, A. M. M.</i>	
207	Yeater, W., Pt., A, 184th Pennsylvania, age 16.	May 31, 1864.	Fracture of the upper third of the right humerus by a minié ball	Dec. 2, 1861.	Head and three inches of shaft of humerus excised, by Ass't Surg. E. J. Marsh, U. S. A.	Disch'd May 6, 1865; pensioned. Sept., 1873, arm useless for manual labor.	
208	Yellot, J. I., Captain, 1st Maryland.	July 18, 1863.	Conoidal ball shattered head and upper portion of shaft of left humerus; missile emerged on opposite side of chest.	April 14, 1865.	Removal of the head and three and a half inches of humerus, by A. A. Surg. W. S. Adams.	Disch'd Mar. 7, 1866. No command over arm or forearm. Not a pensioner.	
209	Yost, J. B., Serg't, A, 4th Penn'a Cavalry, age 23.	Dec. 1, 1864.	Shot fracture of the head and surgical neck of the right humerus.	May 24, 1864.	Excision of the head and two inches of shaft of humerus.	Disch'd May 17, 1865; pensioned. July, 1874, tolerably serviceable limb; no atrophy. Claim for increase of pension rejected.	
210	Yourall, T., Private, C, 3d Artillery, age 21.	April 14, 1865.	Comminuted fracture of upper part of left humerus by minié ball.	July 30, 1864.	Excision of the head and two inches of shaft of humerus, by Surg. G. S. West, C. S. A.	Recovered; furloughed Sept. 10, 1864.	
211	Zane, J., Pt., G, 69th Pennsylvania, age 33.	May 24, 1864.	Shot fracture of right shoulder joint.	Oct. 3, 1861.	Excision of the head and two and a half inches of humerus.	Disch'd June 2, 1865; pensioned. Dec., 1866, disability equal to loss of hand.	
212	Zeigler, J. H., Pt., H, 17th South Carolina, age 18.	July 30, 1864.	Shot fracture of upper third of right arm.				
213	Ziesse, A., Private, 16th Michigan, age 32	Sept. 30, 1864.	Comminuted fracture of the upper third of the right humerus, involving the shoulder joint, by a musket ball.				



Detailed abstracts of fourteen of the two hundred and thirteen reported successful primary excisions of the head and portions of the shaft of the humerus for shot injury precede the foregoing tabular statement; but the subject is of such interest and importance that some further examples from this group will be selected.

Surgeon George C. Harlan, 11th Pennsylvania Cavalry, adopted, in the following instance, an ingenious plan of counter-extension and of maintenance of the limb at rest:

CASE 1534.—Private J. Brink, Co. K, 11th Pennsylvania Cavalry, aged 19 years, was shot, as the regimental surgeon reports: "At short range, while mounted, by guerillas concealed in bushes by the way-side, May 22, 1863, near Windsor, about twelve miles from Suffolk, Virginia. He was taken immediately to the regimental hospital at Suffolk in an ambulance wagon. He was a good deal exhausted by hæmorrhage, which had been only partially checked, by a surgeon near at hand, with lint and bandage. The wound of entrance was in the median line of the right side of the chest two inches below the axilla. The wound of exit was in front of the shoulder, two inches and a half below the acromial end of the clavicle. The joint was not opened, but the humerus was terribly shattered below its head. He was etherized, and five inches of the bone, including the head, were removed by means of a free straight incision through the deltoid, the periosteum being carefully dissected from the fragments, and the sharp end of the bone sawed off squarely below the fracture by an ordinary amputating saw. Only one ligature was needed, and the wound was brought together by lead-wire sutures, except a space at the lower end, left as a drain, in which a piece of lint was inserted. A straight splint was applied to the back of the arm, which was loosely bandaged to the side by a roller. Morphia was administered freely, and water dressings applied to the wound. On May 22d, the patient was doing well;



FIG. 431.—Apparatus figured in Dr. Harlan's report of this case.

there was slight febrile action, yet a good deal of pain. The splint and bandages were removed, and extension was made from the lower end of the arm, and counter-extension by means of adhesive strips applied to the front and back of the chest and passing over a block above the shoulder, as suggested by Dr. H. Lenox Hodge in the treatment of fractured thigh.<sup>1</sup> These points were connected by an iron bar extending from several inches below the elbow to the back above the shoulder and bent at both ends (FIG. 431). This kept the limb in a favorable and comfortable position and maintained its length, and left the wound free for the application of dressings. He could now be moved in bed, or raised to the sitting posture, without pain. June 3d, doing well. The discharge has been profuse, but is diminishing.

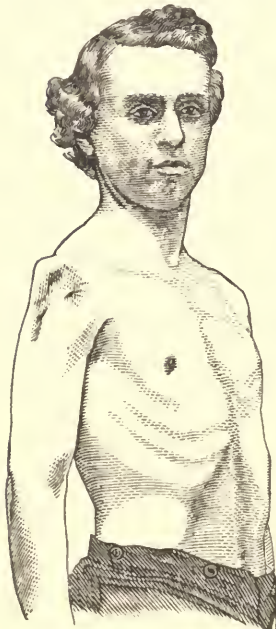


FIG. 432.—Cicatrix of an excision at the shoulder five years after the operation.

The wound gaped when the sutures were removed, on the fourth day, leaving a healthy granulating surface. He is taking punch and quinia, and full diet. June 8th, doing well; edges of the wound cicatrizing. June 9th, had a chill this morning; his tongue is coated, and he has dizziness and sick stomach. June 10th, the dizziness and nausea continue; the granulations have become pale and flabby, and the discharge dark and thin and sanious; pulse feeble, and expression anxious. These symptoms, in connection with the fact that a patient died of pyæmia in the same ward, on the 8th, left very little hope of recovery. Under active stimulation and most careful nursing, however, he gradually improved; and when the regiment received marching orders, was sent to general hospital, June 24th, still very feeble. March 13, 1868, Brink called at my office to-day. He has been employed for some time as a telegraph operator, always using the right hand at his work. He has perfect use of the forearm and hand, and partial use of the arm. He can place the hand on the opposite shoulder and carry it readily to the mouth in eating, when he always uses it by preference. The wounded arm is about an inch shorter than the sound one. Two inches and a half of new bone have been formed—its rounded extremity reaching to within an inch and a half of the acromion. It is flattened on its posterior surface and rounded anteriorly, and nearly equals the rest of the shaft in thickness. The pectoralis major, deltoid, and scapula muscles seem to be entirely wasted away, but the action of the coracobrachialis, biceps, and triceps is unimpaired, except, of course, by the want of support at the shoulder joint. He states that he was discharged from the Chesapeake Hospital on September 23, 1863; that the wound continued to discharge slightly for some time afterward; that he carried the arm in a sling for two months after leaving the hospital, and then commenced to use it; that he noticed the new bone harden rapidly after that time, but that it was not perfectly firm for a year and a half after the time when he was wounded." Dr. Harlan contributed a photograph of the patient (FIG. 432), taken some five years after the operation. The records of the Chesapeake Hospital confirm the patient's account. He entered there June 23d, and was discharged September 23, 1863. He was pensioned. Examiners C. Marr, of Scranton, and G. Urquhart, of Wilkesbarre, describe the injury and operation, and the last pension report states that the pensioner was paid March 4, 1874.

CASE 1535.—Private L. Baker, Co. B, 2d Rhode Island, aged 25 years, was wounded at Prince Street Prison, Alexandria, and was removed to the Third Division Hospital. The following was reported by the operator, Surgeon E. Bentley, U. S. V.: "Gunshot wound of the left shoulder. Ball entered in front, three inches below the point of the shoulder, passed backward

<sup>1</sup> GROES (S. D.), *System of Surgery*, 5th ed., 1872, Vol. I, p. 1011.

and upward, and emerged from near the acromion process. July 14th, excision of four inches of humerus, including head, by a straight incision six inches long; two ligatures; but little hæmorrhage. Anæsthetic: chloroform. The bone below the anatomical neck was terribly comminuted, part of it reduced almost to a powder, mixed with the blood and driven into the tissues. The soft parts, severely lacerated, bled freely after injury; bleeding checked by persulphate of iron and compress. The patient at the time of operation was somewhat weakened by confinement and loss of blood, but otherwise in fair condition. Water dressings. September 20th, wound doing well; abscesses have formed which have delayed the healing somewhat. Water and solution of sulphate of zinc has been the only local treatment. Stimulants internally. September 33th, wound nearly healed; in good health." The patient was transferred to the First Division Hospital on October 8th, and thence to Sickles Hospital, February 24, 1865, and was discharged the service, for disability, June 2, 1865. He has never applied for a pension.

CASE 1536.—Private L. Baldoek, Co. A, 110th Ohio, aged 30 years, was wounded at Cold Harbor, June 3, 1861. Surgeon William M. Houston, 122d Ohio, reported that: "A conoidal musket ball passed through the left deltoid muscle, and, striking the humerus at its surgical neck, a little anterior to the centre, passing slightly upward through the head of the bone, struck the bony wall of the chest, glanced downward, and was found lodged beneath the integuments, about half way down the side of the chest. The patient was immediately conveyed from the field to the hospital of the Third Division, Sixth Corps, and having been anæsthetized with chloroform, Surgeon W. M. Houston, 122d Ohio, assisted by Surgeon Robert Barr, 67th Pennsylvania, performed resection. A straight incision, about five inches long, was made, passing through the wound of entrance; the head of the humerus was disarticulated, and, by means of a chain saw, the shaft was sawn through at a point about four inches below the acromion process of the scapula, to which point the fractures extended. There was considerable blood lost, but no vessels were ligated. The patient reacted favorably. The wound was approximated with adhesive strips, and simple dressings were applied. On the succeeding day, he was conveyed in an ambulance wagon to White House Landing, and from thence to hospital in Washington, where he remained until August 17th, when he received a furlough for sixty days, and proceeded to his home, at Piqua, Ohio. At the expiration of his furlough, he went to Columbus, where he remained until March 7, 1865, when he was transferred to hospital at Camp Dennison. He was discharged April 14, 1865. The wound was entirely healed in eight months, reparation having been somewhat delayed in consequence of neglect and exposure after leaving hospital at Washington. At this date (November 30, 1865), Baldoek enjoys good health, but complains, occasionally, of pain in the shoulder and elbow.

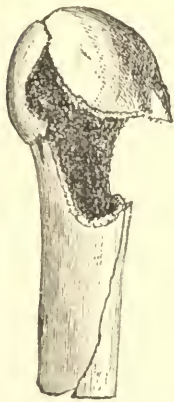


FIG. 433.—Excised upper extremity of the left humerus after shot fracture. *Spec.* 5655.

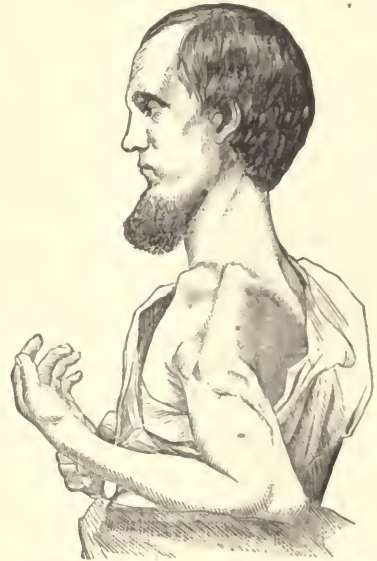


FIG. 431.—Cicatrix after an excision at the shoulder. [From a photograph.]

The sawn end of the humerus is about three inches from the centre of the glenoid cavity. The movements of the forearm and hand are unimpaired. He can apply his fingers to the top of the corresponding shoulder, and by inclining his head can touch any part of his face or head. He can carry an ordinary pail full of water with the injured member, and finds it very useful in hoeing and other light work." Together with this report, Dr. Houston forwarded to the Museum the excised portion of the humerus, which is represented in the wood-cut (FIG. 433). On June 25, 1865, Examiner Samuel S. Gray, of Piqua, forwarded the photograph represented in the wood-cut (FIG. 431) to the Museum, and a second photograph, showing another aspect of the cicatrix. Both of these photographs are mounted with the specimen.

CASE 1537.—Corporal J. H. Jaycox, Co. B, 143d New York, aged 31 years, was wounded at Peach Tree Creek, July 20, 1864. He was sent to a Twentieth Corps hospital, and, on the next day, the upper extremity of the left humerus was excised by Surgeon H. K. Spooner, 61st Ohio. On July 25th, the patient was transferred to Chattanooga. There is no report of his treatment there, although he remained there for several months. In December, 1864, he was sent to New York. Surgeon B. A. Clements, U. S. A., reported from St. Joseph's Hospital, that there had been a: "Gunshot fracture of the arm by a minié ball entering the upper third anteriorly, passing through and shattering the humerus, involving the head of the bone. Resection of the head and five inches of the shaft had been performed in the field hospital. \* \* \* When the patient arrived here, the incisions and wound were entirely healed. The patient has good use of his arm." This soldier was discharged June 16, 1865, and pensioned. Examiner J. L. Hasbroek, of Monticello, reported, March 9, 1867: "Its weight, with no other support than muscular and tendinous connections, causes the whole arm to become very much swollen, and worse than no arm. I should advise him to have it amputated, both for comfort and convenience." Examiner D. H. Decker, September 4, 1873, noted: "The muscles are somewhat atrophied in the region of the wound. There are no evidences of inflammation, and the operation of resection I deem perfectly successful." There is a plaster cast in the Museum from this case,<sup>1</sup> indicating a very satisfactory result.—(*Cat. Surg. Sect.*, 1836, p. 539.)

It has been heretofore suggested that many of the reports of pensioners regarding their disabilities must be received with grains of allowance, and that a humane indispo-

<sup>1</sup> Numbered 4326, *Surgical Section*, A. M. M. Many of the successive reports of the hospital surgeons or pension examiners recall Thackeray's exclamation: "How varied are the notions of critics!" Those conversant with the later writings of Professor B. V. LANGENBECK will not forget the passage quoted in a note on page 518, *ante*, where the advantages of a lamed and powerless upper limb are insisted on, since the member may, at least, serve to maintain the equilibrium of the body.



sition to deprive the mutilated men of the benefits of the laws enacted for their relief may possibly, in some instances, have unduly biased the pension examiners,—considerations that must always be held in view in judging of the accounts of the ulterior results of operations of this and similar groups. The estimates of the operator, of the patient, and of the government official regarding the merits of an operation often widely differ.



FIG. 435.—Cicatrix after excision of the upper extremity of the humerus. [From a photograph.]

also found in the bone close to the track of the ball." After the operation the patient was placed on the Hospital Transport Steamer City of Memphis and transferred to St. Louis. He was admitted to Lawson Hospital, January 17, 1833, doing well, and was discharged the service, and pensioned April 2, 1833. Examiner J. W. Trader, of Sedalia, Missouri, September 3, 1874, reported: "Gunshot wound of the left shoulder joint, and resection of the upper third of the humerus." The disability was rated total. The pensioner was paid September 4, 1874.

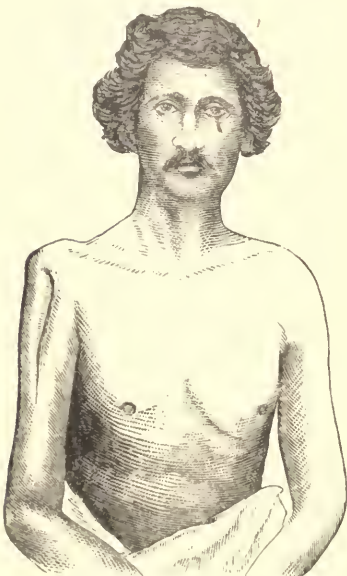


FIG. 436.—Cicatrix one year after excision at the shoulder.

CASE 1538.—Sergeant T. J. Newell, Co. E, 12th New York, aged 36 years, was wounded at Cold Harbor, June 1, 1864, and, on June 10th, was admitted into Harewood Hospital, Washington. Surgeon R. B. Bontecou, U. S. V., noted: "Admitted, with resection of the upper third of the left humerus in consequence of a gunshot wound; extent of injury unknown. Operation performed on the field, June 3d. On admission the constitutional state of the patient and condition of the injured parts were good; parts healing readily under treatment of simple dressing and a supportive nourishing diet, but with no restoration of bony structures; the muscles of the forearm and arm remain well developed and useful." Newell was discharged from service October 3, 1864, and pensioned. Examiner John Spencer, October 15, 1866, reported: "The whole upper half of the humerus, from the middle of the humerus to the humero-scapular junction, resected. The arm is useless above the hand and forearm; disability is permanent, and I cannot conscientiously rate it less than equal to loss of the hand." Examiner H. B. Osborn, on September 8, 1873, reported substantially as above, adding that the arm was still useless. This pensioner was paid March 4, 1874. The photograph from which the cut (FIG. 435) is taken was sent from Harewood Hospital, and is shown at page 8, Vol. II, *Card Photographs*. In a letter dated Sherman, New York, July 28, 1874, the pensioner remarks: "My arm is as useful to me as it ever will be; it often gathers and breaks, or rather it has to be lanced. \* \* I have the use of my hand, but cannot put it to my mouth only as I take the other hand. I can place it on the table and hold my fork, but cannot feed myself with it. \* \* My arm is of but little account, yet I would not have it off for anything."

CASE 1539.—Corporal W. F. Stewart, Co. G, 127th Illinois, aged 20 years, was wounded at Vicksburg, December 23, 1862, and on the same day was placed under chloroform, and Surgeon E. Andrews, 1st Illinois Light Artillery, excised the head of the left humerus. He reports that: "The head of the humerus was split by a bullet, fragments of which were found in the bone. A buckshot was also found in the bone close to the track of the ball." After the operation the patient was placed on the Hospital Transport Steamer City of Memphis and transferred to St. Louis. He was admitted to Lawson Hospital, January 17, 1833, doing well, and was discharged the service, and pensioned April 2, 1833. Examiner J. W. Trader, of Sedalia, Missouri, September 3, 1874, reported: "Gunshot wound of the left shoulder joint, and resection of the upper third of the humerus." The disability was rated total. The pensioner was paid September 4, 1874.

CASE 1540.—Corporal R. Fisher, Co. C, 7th New York Heavy Artillery, aged 32 years, was wounded at Cold Harbor, June 8, 1864. He was admitted to a Second Corps hospital, and, on the 10th, Surgeon J. W. Wishart, 140th Pennsylvania, excised the head and one inch of the shaft of the humerus by a straight incision through the middle of the deltoid. The patient was sent to Washington, and entered Armory Square Hospital on the 12th, and was finally discharged from service May 25, 1865. Surgeon D. W. Bliss, U. S. V., noted on his discharge papers: "Excision of right shoulder joint from gunshot wound." Assistant Surgeon J. H. Arnsby, U. S. V., in charge of Ira Harris Hospital, Albany, contributed to the Army Medical Museum a photograph of Fisher, taken at Albany, represented in the cut (FIG. 435), and also specimen No. 384, Section I, A. M. M. This specimen consists of a cast of the right thorax and arm, eleven months after the excision of four inches from the upper extremity of the humerus. The cicatrix is six inches in length, is parallel with the long axis of the arm, and has split the deltoid. The position whence the head of the humerus was removed is marked by a decided impression. Examiner R. L. Rea, of Chicago, December 17, 1866, reported: "Had four inches of the upper end of the right humerus removed; arm useless." The Chicago Board, Drs. W. A. Knox, J. M. Woodworth, and S. J. Jones, June 1, 1870, report: "Resection of four inches of the right humerus, including the head. No increase from this cause, but the applicant is in the last stage of tuberculosis, which was probably brought about by exposure in the service. Fisher died July 24, 1870. Dr. W. R. Marsh, formerly Surgeon 2d Iowa, testifies "that Fisher's death was caused by phthisis pulmonalis supervening upon a gunshot wound, etc., that the cicatrix of said wound indicates that the ball entered the right breast near the fourth rib and passed diagonally through the right lung and through the shoulder joint."

While multiplying illustrations of this most interesting advance in modern surgery, the general deductions from the statistical record must not be overlooked. The usual slight preponderance of operations on the left side is exhibited.<sup>1</sup> Consecutive amputation at the shoulder joint was called for in three cases.<sup>2</sup> Only ten instances have been heard from, at the close of a decennial period, of deaths subsequent to discharge on account of this operation. One hundred and fifty-eight of the mutilated men were pensioned. In twenty-two of the cases the excised portions of bone are preserved in the Museum.

CASE 1511.—Private A. Ziesse, Co. A, 16th Michigan, aged 32 years, was wounded at Poplar Grove Church, September 30, 1864. Surgeon W. R. DeWitt, jr., U. S. V., reports that he was struck by a minié ball in the right shoulder, and sent to a Fifth Corps hospital, and thence to City Point. Excision of the upper extremity was practised either on the field or at the base hospital. On October 7th, the patient was sent to Washington, and entered Lincoln Hospital. Assistant Surgeon J. C. McKee, U. S. A., reported: "Gunshot wound of the upper third of the right humerus, with comminution involving the shoulder joint. On October 31, exsection was made of the head of the humerus with about two and a half inches of the shaft. The name of the operator is unknown. The patient improved very rapidly after entering the hospital. By December 26th, the cicatrix was clean and free." Dr. McKee had a photograph prepared January 10, 1865 (*Contrib. Surg. Phot., S. G. O., Vol. II, p. 14*). It is copied in the adjacent wood-cut (FIG. 437). At that date this soldier had perfect use of his hand, but had little control over the movements of the arm and forearm. He was sent to Detroit and discharged, and pensioned June 2, 1865. Examiner J. B. Scovell, of Detroit, December 14, 1863, described the course of the missile as: "Carrying away the head of the humerus and destroying the use of the joint," etc. This pensioner was paid September 4, 1874.

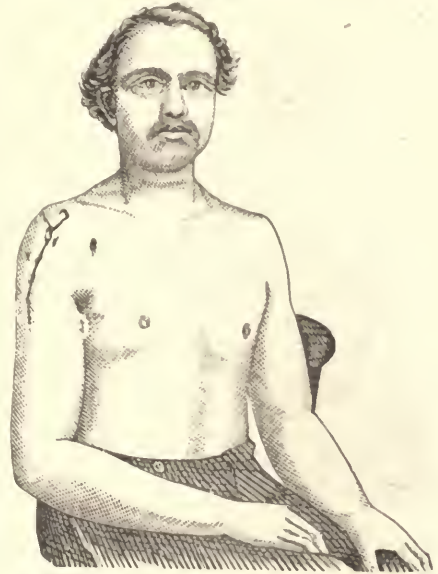


FIG. 437.—Cicatrix a fortnight after an excision at the shoulder. [From a photograph.]

Details of several of the operations enumerated in the tabular statement have been published already in the medical journals. References have been given to these abstracts whenever the cases have been recognized. Still later facts or illustrations have been received in some of these examples, as in the following:

CASE 1542.—Private R. C. Hill, Co. I, 57th Pennsylvania, aged 23 years, was wounded at the Wilderness, May 5, 1861. Surgeon O. Evarts, 20th Indiana, reported, from the hospital of the 3d Division of the Second Corps, that resection at the left shoulder was practised on the field for shot fracture. The patient was sent to Washington, and entered Finley Hospital. Surgeon G. L. Pancoast, U. S. V., corroborated the above report, and noted the favorable progress of the case, and the soldier's discharge for disability, September 28, 1864. Dr. H. F. Lyster, formerly Surgeon 5th Michigan, transmitted to the Surgeon General's Office, March 15, 1866, a copy of the report of this case, published in the *American Journal of the Medical Sciences* for October, 1865, and copies of the abstracts of two other cases there published, with daguerreotypes of the cicatrices.<sup>3</sup> Examiner G. McCook states, January 3, 1865, in regard to the pensioner, Hill: "He cannot lift his arm to his head, nor does he possess ability to use the arm at common labor." Examiner J. P. Hosack, of Mercer, Pennsylvania, December 25, 1865, reported: "From a wound of the shoulder joint, it had been considered necessary to perform resection of the head of the left humerus. Want of proper dressing, and suffering in the hands of the enemy for nineteen days, has left a very unfavorable result, much more so than usual from such operations. The deltoid muscle is entirely absorbed, and the end of the humerus is lodged in the axilla instead of in the glenoid cavity." On September 13, 1873, Dr. Hosack substantially reiterates this description, in reporting the biennial examination of the pensioner.

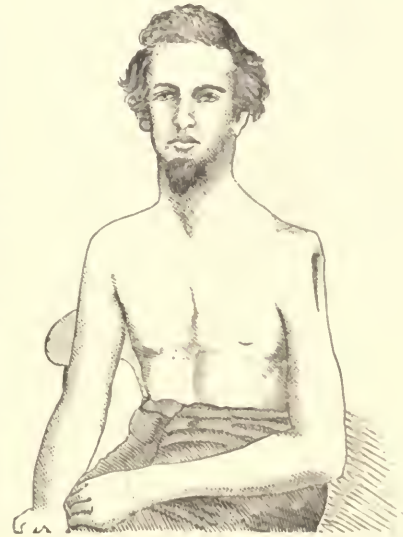

FIG. 438.—Cicatrix after an excision of the upper part of the left humerus. [From a daguerreotype.]

<sup>1</sup> In two hundred and five (205) of the two hundred and thirteen (213) operations enumerated in TABLE XXXI, the side implicated is reported, ninety-eight being on the right, and one hundred and seven on the left side. <sup>2</sup> CASES 21, 106, 161, Privates Burger, Keeler, and Rosa.

<sup>3</sup> LYSTER (H. F.), *Operations on the Shoulder, etc.* (*Am. Jour. Med. Sci.*, 1865, Vol. L, p. 362) The latter are enumerated as CASES 43 and 79 of TABLE XXXI. The abstracts are accompanied by drawings, and the EDITOR of the *American Journal* justly observes that "the figures, as represented in the daguerreotypes, from which the wood-cuts were engraved, seem to have been reversed." This error is rectified in FIG. 438, and in the cuts 442, 443, printed on page 567, engraved from the daguerreotypes furnished by Dr. LYSTER.



It was formerly thought inadvisable to excise the upper extremity of the humerus for shot injury when the injury extended far down the shaft,<sup>1</sup> but that precept has been repeatedly disregarded, with good results:

CASE 1543.—Corporal G. Martin, Co. I, 5th Connecticut, aged 35 years, received, at Marietta, June 22, 1864, a gunshot fracture of the left humerus. He was taken to a Second Corps field hospital, where, on the 24th, the head and several inches of the shaft were excised by Surgeon E. L. Bissell, 5th Connecticut. On September 2d, the patient was admitted to hospital at Chattanooga, and was subsequently treated in hospitals at Nashville, Jeffersonville, and New Haven. He was transferred from the latter to the Veteran Reserve Corps, April 23, 1865, and finally discharged the service August 31, 1866. E. D. Hudson, M. D., of New York, reported, May 24, 1866, that he had furnished Martin with an apparatus, and forwarded a photograph, represented in the wood-cut (FIG. 439), with the following statement: "Loss of six inches of the head and continuity of the humerus. Linear incision some seven inches in length. Arm shortened three inches and considerably atrophied; wound healed; deep fossa of cicatrix; hyperostosis from humeral end of the clavicle; hand and forearm normal; no command of forearm. Usefulness of the limb very satisfactory in lifting and pushing, and the forearm can be carried up beyond a right angle, and will improve by practice." On his application for pension, E. L. Bissell, M. D., certifies: "Martin was wounded at Resaca, in the right forearm, the wound being of such a nature as to enable him to continue with his regiment," and that at Marietta "he was severely wounded in the left shoulder. He was sent to the Brigade Hospital, Twentieth Corps, where an operation of resection of the head of the humerus was performed by myself. On or about June 27th, he was transferred to the hospital at Kingston, Georgia." Dr. Bissell also testifies that he finds "Martin has recovered from the operation, but that he has no control of the arm nor will he ever have." The Examining Board at Boston: J. W. Foye, J. B. Treadwell, and H. Chase, reported that "A gunshot entered the left shoulder from the rear, at the articulation, and passed through it. Two inches of the shaft of the bone, with its head, were removed, and the arm is useless and pendant." On September 5, 1873, the Board reported: "Hand is well nourished; he has fair power of grasp, but cannot lift heavy burdens; disability total."



FIG. 439.—Appearance of cicatrix two years after primary excision of the upper extremity of the humerus.

CASE 1544.—Private J. Trombly, Co. II, 1st Michigan, aged 23 years, was wounded at the Wilderness, May 5, 1864, by a minie ball, and taken to a Fifth Corps hospital, where excision of the upper extremity of the left humerus was performed by Surgeon J. Ebersole, 19th Indiana. "The head and a portion of the shaft of the humerus were removed through a longitudinal incision commencing at a point midway between the acromion and coracoid processes, and extending five inches down the coraco-brachialis, dividing the fibres of the deltoid, pectoralis major, and biceps muscles." The patient was sent to Washington, and placed in Harewood Hospital. The case progressed favorably, and in a few weeks the wound had healed, and "there was fair use of the forearm." At this time Dr. Bontecou had a photograph taken, from which the annexed wood-cut (FIG. 440) is copied. This soldier was discharged November 16, 1864, and pensioned. Surgeon Robert O. Abbott, U. S. A., directed him to report to Dr. E. D. Hudson, a skillful designer of surgical apparatus, with a view to the adjustment of some appliance to augment his control of the movements of the limb. Dr. Hudson, who has described the case,<sup>2</sup> stated: "The arm was of ordinary length, considerably atrophied, flexible, ungovernable by the will, unable to swing forward; pectoral muscle impaired; no effort at reproduction of lost part—functions of supinators, pronators, flexors, and extensors of the hand and fingers normal. With scapular and humeral appliance, oscillatory shoulder joint, and auxiliaries to pectoral muscle, he carries the arm forward across the chest, flexes the forearm to an acute angle, carries his hand nearly to his mouth—and departed with his trunk-valise in the hand of his mutilated arm, greatly rejoiced at his restored condition. With practice, he will so far regain the use of his arm as to hardly appreciate any loss." Drs. Brown, Noyes, and Webber, constituting a Pension Examining Board at

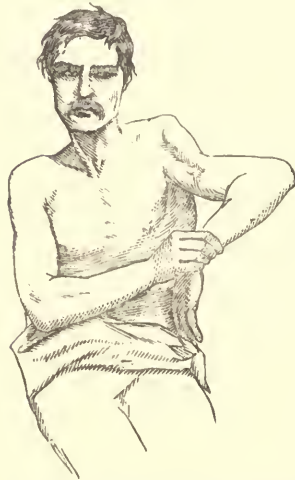

FIG. 440.—Cicatrix as it appeared a few months after an excision of the upper part of the left humerus for shot fracture.

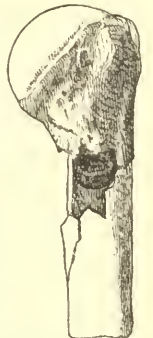

FIG. 441.—Excised upper extremity of humerus fractured by a ball that lies in the medullary cavity. Spec. 2625.

Detroit, Michigan, reported, December 17, 1873: "A resection of the upper extremity of the left humerus, about four inches of bone being removed." This is an under estimate, as shown by the specimen copied in the wood-cut (FIG. 441). It is reported in the *Catalogue of the Surgical Section*, 1866, p. 109, as a Chancellorsville specimen received without history, but was subsequently fully identified.

<sup>1</sup> The precise length of bone excised was specified in one hundred and ninety instances. The amount of the shaft removed, with the head, was stated as: half an inch in 1 case, an inch in 11 cases, an inch and a half in 10, two inches in 43, two and a half in 24, three in 46, three and a half in 7, four in 23, four and a half in 11, five in 7, five and a half in 2, seven or eight inches (or possibly, in one instance, nine) in 5 cases. In twenty-three cases, this point is not indicated. The insertion of the deltoid is usually described as at about the middle of the humerus (HENLE, SAYPEY, GRAY). In sixteen humeri just measured, from adult male skeletons in the Army Medical Museum, the extreme lengths were from twelve and a half to fifteen inches. The marks of the deltoid insertion were "about the middle," in all cases; but approaches the lower part of the middle third in proportion to the lengths of the upper extremity.

<sup>2</sup> HUDSON (E. D.), *Remarks on Excisions, with Cases and Plates*, New York, 1864, p. 12.

Other cases are illustrated by wood-cuts taken from photographs made under disadvantageous circumstances, as at camps or villages.

CASE 1545.—Corporal W. Hammond, Co. K, 120th New York, aged 41 years, was wounded at Petersburg, July 30, 1864. Surgeon F. F. Burmeister, 69th Pennsylvania, reported his admission on the following day, at the base hospital of the Second Corps, at City Point, with an excision of the upper extremity of the right humerus for comminution by a conoidal ball. The operation had been performed on the field by Surgeon H. F. Lyster, 5th Michigan, assisted by the regimental surgeon, W. Van Steenburg, 120th New York. The patient was transferred to Alexandria, August 11, 1864, and, progressing favorably under supporting treatment, was transferred to New York, March 23, 1865, and, after several other transfers, was discharged from McDougall Hospital, Fort Schuyler, June 28, 1865, and pensioned. An apparatus was furnished him May 26, 1866, by Dr. E. D. Hudson. On October 15, 1866, Examiner E. Bradley reported: "The hand is atrophied and cold; a good arm and no hand would be better than this pendulous and powerless arm and small cold hand." Examiner T. F. Smith reported, September 13, 1873: "The hand is cold and clammy."

CASE 1546.—Private D. Nicoll, Co. E, Knapp's Pennsylvania Battery, aged 23 years, was wounded at Wauhatchie Valley, October 28, 1863. He was removed to the field hospital at Chattanooga, where excision of the head and one-half inch of the shaft of the humerus was performed on the 30th by Surgeon A. M. McMabon, 64th Ohio. The patient was transferred to hospital at Murfreesboro' in November, and thence to New York, where he entered St. Joseph's Hospital, Central Park, March 30, 1864. Surgeon B. A. Clements, U. S. A., furnished the following history: "Minié ball entered at the outer aspect of the right shoulder and lodged, after shattering the head of the humerus. Operation October 30, 1863: A straight incision just external to the biceps tendon, apparently six inches long, with a small incision from the wound joining the long one, thus, Y. The head only appears to have been removed. The wound did well, but, the bone being necrosed, abscesses formed. It was over two months before he could leave his bed. After admission to this hospital, about May 10, 1864, several pieces of bone, and a disc of bone the whole calibre of the humerus, were removed. The result was very good. The arm is three-fourths of an inch shorter than its fellow. The upper extremity of the humerus is not drawn under the coracoid process. There is very little power in the deltoid. He can carry a bucket of water." In October, 1864, the patient was transferred to the Veteran Reserve Corps, and was finally discharged, and pensioned May 17, 1865, and was paid March 4, 1874. Examiner J. A. Young, of Monmouth, Illinois, reported, November 7, 1865, that: "The head of the right humerus, with about three inches of the shaft of the bone, has been removed; the pensioner is unable to elevate the arm or advance it without the assistance of the left hand. Forearm, hand, and fingers are in good condition." A plaster cast of the wounded limb (*Cat. Surg. Sect.*, 1866, p. 538, *Spec.* 3233), contributed by Acting Assistant Surgeon G. F. Shradly, is thus described in the Catalogue: "A cast of the right thorax and arm, showing the result of a primary excision of the head of the humerus, nearly a year after the injury. The wound of incision was, for six inches, parallel to the biceps tendon, joined by a smaller one from the wound of injury, making the whole Y-shaped. The cicatrix is about three inches in length and quite deep. \* \* \* The upper extremity of the humerus is not drawn under the coracoid process, and the arm is three-fourths of an inch shorter than its fellow."

CASE 1547.—Private M. Dekraker, Co. A, 5th Michigan, aged 24 years, was wounded at Petersburg, June 18, 1864. Surgeon O. Evarts, 20th Indiana, reported, from a Second Corps field hospital, a shot wound of the shoulder; and Surgeon A. F. Sheldon, U. S. V., recorded the patient's admission at Campbell Hospital, Washington, with "an excision of the head of the right humerus on the field," and his discharge March 27, 1865. The regimental surgeon and operator, Dr. H. F. Lyster,<sup>1</sup> has described the case at length in the article of the *American Journal of Medical Sciences*, Vol. L, p. 363, already cited. This soldier was pensioned. Examiner J. Nichols reported, March 29, 1865: "Wound yet unhealed and arm entirely useless; there will be partial restoration in six months." Examiners G. K. Johnson and Z. E. Bliss reported, December 7, 1870: "He has considerable use of his arm," and, in September, 1873, the same Board: "The arm is now one and three-fourths inches shorter than the left, and is necessarily much weakened." In another portion of their report it is stated that "the result is a very good one."

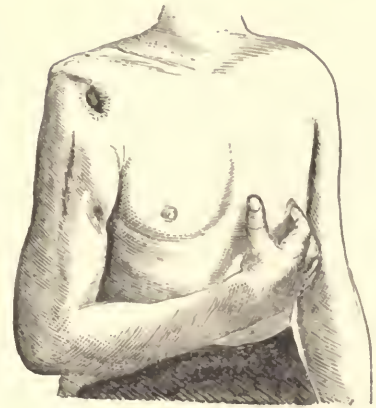

FIG. 442.—Cicatrix after primary excision of the upper portion of the right humerus. [From a photograph.]

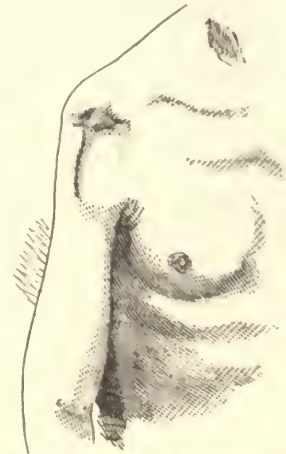

FIG. 443.—Cicatrix after excision of the upper extremity of the humerus.

<sup>1</sup> LYSTIEK (H. F.), *Operations on the Shoulder, etc.* (*Op. cit.*, *Am. Jour. Med. Sci.*, 1865, Vol. L, p. 364), remarks of the three primary excisions recorded by him: "These three cases were operated upon within a few hours after the injury had been sustained, and were all of a class where the necessity of active surgical interference is universally admitted. The only questions that arose were: Shall we amputate at the shoulder? or, Shall we resect the head and neck of the humerus? These questions cannot always be easily decided, and I have no doubt that arms have been sacrificed which could have been saved, and would have been, had the surgeons considered the operation for resecting as affording an equal chance for the patient's recovery. So far as my experience teaches me, though I have rarely seen the operation performed in the hospitals or in the field, the results of the only cases in which I have ever performed the operation have all been so favorable that they would seem to warrant the resection whenever the nature of the injury will allow, especially in recent gunshot wounds. In many instances the extent of fracture down the shaft of the humerus, the laceration of the muscular tissue, or the injury of the axillary vessels or axillary plexus of nerves, or, judging from the track of the ball, the anticipated sloughing of the brachial artery, will necessitate amputation at the shoulder without delay or hesitation. This is also very generally the case in shell wounds, owing to the extensive laceration or to the internal destruction of all the tissues of that region, even when the skin remains almost entire."



An instance of primary excision of the upper extremity of the left humerus after shot fracture, followed by necrosis of the shaft and disease of the elbow joint, and secondary extirpation of the remains of the humerus, and exsection of the upper extremities of the radius and ulna, has already been published.<sup>1</sup> The official report is appended:

CASE 1548.—Private J. E. F. Cleghorn, Co K, 1st New Jersey, aged 27 years, was wounded at Mine Run, November 27, 1863. Surgeon G. L. Pancoast, U. S. V., reported that this man was "received at the Cavalry Corps hospital the day of his injury, with a gunshot wound of the left shoulder." On November 30th, Surgeon H. K. Clark, 10th New York Cavalry, excised the head of the left humerus and a small portion of the shaft. No particulars of this operation were reported. Surgeon

E. Bentley, U. S. V., stated that the patient was transferred to Old Hallowell Hospital, at Alexandria, on December 5th. The injured limb was much inflamed, and "an abscess formed at the elbow joint. This was freely incised on December 7th, and the discharge of pus was very profuse. Simple dressings with a sustaining general treatment were employed for the next four months," when, on the approach of warm weather, the patient was removed to Ward Hospital, Newark. At this time the wound was healed, with the exception of a slight fistulous sinus, communicating with the sawn extremity of the shaft of the bone, although the entire shaft and condyles of the humerus subsequently became necrosed. Assistant Surgeon J. T. Calloun, U. S. A., reported that, "on July 21, 1864, the patient was placed under the influence of a mixture of ether and chloroform, and that Acting Assistant Surgeon J. B. Cutter removed the entire remaining portion of the humerus, including the elbow joint, making a straight incision the whole length of the arm on its outer aspect. No ligatures were applied. Silver sutures were used. Union by first intention took place nearly the entire length of the incision, and in three weeks after the operation was performed the patient was well and about. There was as yet no sign of the bone being renewed, although all of the periosteum that could be had been left." The result was satisfactory, and, on October 20, 1864, the man was discharged from hospital and army and pensioned. In November, 1864, an apparatus was fitted to the arm by Dr. E. D. Hudson, 693 Broadway, New York, who made a careful report of the case, stating that, after a comminution of the head of the left humerus by a minié ball, the upper third of the bone was excised at a field hospital, and that from consecutive disease, eight months subsequently the rest of the humerus, with the upper portions of the ulna and radius, were removed. The first operation appeared

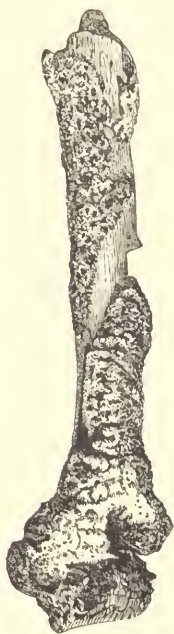

FIG. 444.—Necrosed diaphysis and lower epiphysis of left humerus, with parts of the ulna and radius, removed after an excision of the upper extremity of the bone for shot fracture.

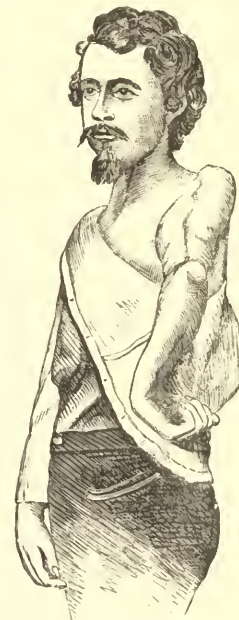

FIG. 445.—Appearance of limb two years after an excision of the humerus for shot injury.

to have been done through a straight anterior incision, the second through a longitudinal incision extending the length of the upper arm. Dr. Hudson remarked that the arm was healed, but "entirely flexile, muscles contracting zig-zag fashion, with contraction of an inch and a half, and much atrophy. There was no restoration of bone. There was strong power of flexion in the carpus and metacarpus, but the extensor antagonism was impaired." A detailed account of the ingenious apparatus, a sort of exoskeleton, devised by Dr. Hudson in this case, is printed in the paper cited from the *American Journal of the Medical Sciences*, 1866, p. 141, and is accompanied by a wood-cut. Drs. Cutter and Hudson sent several photographic illustrations of this case to the Museum. The pathological specimen removed in the second operation (FIG. 444) is copied, from a photograph, in the adjacent wood-cut. A photograph of the appearance of the limb two years after the secondary operation (FIG. 445) is also copied. The Pension Examiners express an unfavorable opinion of the results of this operation. Examiner C. Rowland, of Brooklyn, New York, does not hesitate to say that: "The arm is worse than useless, and the sooner it is amputated at the shoulder joint the better for the applicant." Examiner W. M. Chamberlain, of New York City, reported, September 10, 1866, that: "The limb hangs pendulous and useless." This pensioner was paid March 4, 1874. There are no late accounts of the condition of his limb at the Pension Bureau.

### Extirpations of the humerus<sup>2</sup> after caries following shot injury are very uncommon.<sup>3</sup>

<sup>1</sup> *Photographs of Surgical Cases and Specimens*, Washington, 1866, Vol. III, pp. 12 and 48; also a paper by Dr. J. B. CUTTER (*Am. Jour. Med. Sci.*, 1866, Vol. LI, p. 139).

<sup>2</sup> An honored teacher of surgery, Professor GROSS, states (*A System of Surgery*, 5th ed., 1872, Vol. II, p. 1088) that: "Professor LANGENBECK has, on several occasions, resected the entire humerus on account of gunshot injury." I have been unable to verify the cases referred to by Professor GROSS, and Professor B. von LANGENBECK (in his *Chirurgische Beobachtungen aus dem Kriege*, Berlin, 1874, S. 99), although he gives a summary of his operations, does not mention these. But he cites (*l. c.*, p. 140) a very interesting case, from the Franco-Prussian War, 1870-1871, in which, at different times, the head, the shaft of the humerus, and the elbow joint were removed. The case does not come strictly under this head, since the first operation was not primary, but it is too interesting to be unnoticed in this connection. It will be adverted to hereafter.

<sup>3</sup> It is possible that Dr. GROSS has reference to the following case, tabulated by Dr. C. HUETER (*Die Resectionen*, u. s. w., in LANGENBECK'S *Archiv.*, 1867, B. VIII, S. 99, No. 37), which was treated at the Royal clinic at Berlin, in 1865: "A boy, aged 6; dry caries of the head of the humerus with ankylosis of the joint; resection of the head of the humerus; periostitis of humerus and ulna; successive extraction of the diaphysis of the humerus, and of small sequestra of the epiphyses of the elbow and of the diaphysis of the ulna. Recovery." The name of the operator is not recorded.

*Primary Unsuccessful Operations.*—There were eighty cases referred to this category, of the two hundred and ninety-three primary cases referred to on page 548. The immediate causes of death are recorded in about half of the cases.<sup>1</sup> Twelve of the specimens are preserved in the Museum:

CASE 1549.—Private Nicholas C——, Co. C, 88th New York, aged 40 years, was wounded at Cold Harbor, June 3, 1864, and was admitted into a Second Corps hospital. Surgeon W. S. Cooper, 125th New York, reported: "Gunshot wound of the left arm; resection at the shoulder joint by Surgeon P. E. Hubon, 28th Massachusetts; simple dressings." On June 8th, the patient was transferred to Columbian Hospital, Washington, where Surgeon T. R. Crosby, U. S. V., noted: "Gunshot wound of the left breast; furloughed July 23, 1864; readmitted September 24th; furloughed November 3d." He probably died while on his way home, as his wife claimed a widow's pension from November 3, 1864, stating that her late husband was wounded in the breast by a musket ball, and that his arm was struck by a shell and the bone shattered from elbow to shoulder, and that he died on or about the above date, having been last heard from at Columbian Hospital, Washington. The specimen (FIG. 446) consists of the head and three and one-half inches of the shaft of the left humerus, excised for extensive comminution below the surgical neck. The capsule of the joint was opened. The pathological preparation was contributed to the Army Medical Museum by the operator.—(*Cat. Surg. Sect.*, 1863, p. 83)

CASE 1550.—Private C. L. Britton, Co. A, 22d Massachusetts, aged 27 years, was wounded at Cold Harbor, June 3, 1864. He was admitted to a Fifth Corps field hospital, where Surgeon W. R. DeWitt, jr., U. S. V., noted: "Gunshot wound. Resection of the head and shaft of the right humerus." Transferred to Washington, the patient entered Stanton Hospital on June 13th. Surgeon J. A. Lidel, U. S. V., recorded: "Gunshot wound of the right shoulder. Resection of the head and about three inches of the shaft of the humerus on the outer side; incision about eight inches in length; anæsthetic unknown. The operation was performed on the field, June 3d, by Surgeon Isaac H. Stearns, 22d Massachusetts; particulars unknown. The patient says he was in good condition at the time of operation. Treatment: Simple dressings, stimulants, and tonics. Patient doing well and wound granulating finely June 30, 1864." Pyæmia supervened, and death occurred July 9, 1864.

CASE 1551.—Private J. Houghley, Co. H, 116th Pennsylvania, aged 22 years, was wounded at Cold Harbor, June 3, 1864. He was admitted to a Second Corps field hospital, and thence sent to Washington and admitted to Harewood Hospital. Surgeon R. B. Bontecou, U. S. V., recorded: "Admitted June 7th, suffering from gunshot wound of the right arm, the ball entering the anterior surface about half-way down, fracturing and comminuting the shaft, and emerging at a point opposite on the posterior aspect. Resection of the head and about three inches of the shaft of the right humerus was performed, on the field, on June 3d, by Assistant Surgeon W. B. Hartman, 116th Pennsylvania. On admission, the condition of the injured parts was good. The bone was very much comminuted; the soft parts were healthy, suppuration not having set in. The constitutional state of the patient was also good. The wound occasioned by the resection filled up rapidly, with healthy granulations. The discharge of pus was not excessive. He was under a stimulating and supporting regimen, with occasional anodynes. June 28th, doing well. About the middle of July, the wound became very unhealthy, with profuse sanious discharge and some tendency to gangrene. There were no symptoms of pyæmia. The patient steadily sank, notwithstanding the free use of stimulants and a supporting nourishing diet throughout. He died July 25, 1864, of exhaustion."

CASE 1552.—Sergeant G. I. Cleaver, Co. L, 3d Indiana Cavalry, aged 27 years, was wounded near Knoxville, February 20, 1864, and was admitted to hospital on the following day. Surgeon A. M. Wilder, U. S. V., made the following special report: "Wounded by a conical bullet passing through the left arm at the upper third, producing a compound comminuted fracture of the humerus, extending into the joint. I removed the head of the humerus and fragments of bone to the extent of nearly three inches of the shaft, removing the sharp ends of the sound bone with a chain saw. The bullet was found in the wound. Very little blood was lost. The patient rallied well from the operation. This case was treated in Hospital No. 5, Knoxville, in charge of Assistant Surgeon H. L. Burritt, U. S. V., from whom I obtained the further history or termination of the case. February 20th, patient has vomited for twenty-four hours; no better; bowels regular; not much œdema; very little purulent discharge; patient looks cheerful; pulse 110. February 25th, pulse 112; skin and tongue in good condition; wound presents a sloughy appearance; some discharge of pus. February 26th, discharge of pus more; patient improved in appearance; no pain. February 27th, free suppuration; pulse 100; skin hot; complains of pain in the shoulder. March 8th, patient steadily improved from the date of last note. March 10th, patient worse; wound stops discharging pus but has a healthy look; slight chills, with vomiting (stomach has been irritable from the first); pyæmia feared. March 11th, typhoid symptoms developed; ichorous discharge from the wound; patient sinking rapidly; died at two o'clock P. M. The treatment was stimulant from the beginning." The specimen shown in the adjoining wood-cut (FIG. 447) was contributed to the Museum by the operator. It consists of the head and nearly four inches of the shaft of the left humerus excised for a severe fracture through the surgical neck. A conoidal ball tore the bone obliquely through the shaft with extensive splitting, but with little comminution, and lodged beneath the inner portion of the head. The articular surface of the bone was not injured, but the joint was opened.



FIG. 446.—Upper extremity of the left humerus excised for shot fracture. Spec. 2849.



FIG. 447.—Head and nearly four inches of the shaft of the left humerus excised for shot fracture. Spec. 2260.

<sup>1</sup> The assigned proximate causes of death were: Pyæmia, 13 cases; gangrene, 5; erysipelas, 4; exhaustion, 15; tetanus, 1; hæmorrhage, 3; intermittent fever, 1; phthisis, 2. In thirty-six cases no immediate cause of death is recorded.



TABLE XXXII.

Summary of Eighty Fatal Cases of Primary Excisions of the Head and Portions of the Shaft of the Humerus for Shot Injury.

No.	NAME, AGE, AND MILITARY DESCRIPTION.	DATE OF INJURY.	NATURE OF INJURY.	DATE OF OPERATION.	OPERATION AND OPERATOR.	RESULT AND REMARKS.
1	Alexander, T., Pt., A, 3d Iowa, age 23.	June 4, 1863.	Minié ball caused a compound fracture of the left humerus and passed through the left lung, just touching the vertebra.	June 5, 1863.	Head and three and a half inches of shaft of humerus excised, by Surgeon-General J. C. Hughes of Iowa.	Never rallied from effects of chloroform; died twenty hours after operation.
2	Allen, J. P., Pt., D, 45th North Carolina.	Sept. 9, 1864.	Shot fracture of left humerus below the surgical neck.	Sept. 11, 1864.	Excision of the head of the humerus, by Surgeon D. F. Wright, P. A. C. S.	Died September 13, 1864.
3	Babcock, D., Pt., B, 124th New York, age 19.	May 24, 1864.	Shot fracture of upper portion of right humerus, involving the joint.	May 24, 1864.	Head and four inches of shaft removed through a straight incision, by Surgeon S. H. Plumb, 82d New York.	Died June 8, 1864, of pyæmia.
4	Barnes, H. L., Pt., A, 34th Massachusetts.	June 5, 1864.	Fracture of head and neck of right humerus by a musket ball which lodged.	June 5, 1864.	Head and about three inches of shaft of humerus excised, by Dr. Baldwin, C. S. A.	Died June 16, 1864, of mortification.
5	Bazarth, J., Pt., A, 17th Iowa, age 23.	Oct. 13, 1864.	Minié ball caused extensive comminution of the head of the left humerus.	Oct. 14, 1864.	Removal of the head and a small portion of the shaft of the humerus through a single straight incision.	Died December 2, 1864, of exhaustion.
6	Beedy, O. E., Pt., C, 118th New York.	Sept. 30, 1864.	Oblique fracture of the right humerus by a musket ball which lodged in the bone.	Sept. 30, 1864.	Excision of the head and fractured portion of humerus, by Ass't Surg. J. W. Gray, 98th New York.	Died October 1, 1864, en route to General Hospital.
7	Boz, G. F., Pt., A, 17th Mississippi.	July 3, 1863.	Shot fracture of head of right humerus, and wound of right side of thorax beneath axilla.	July 4, 1863.	Excision of the head and three inches of the shaft of the humerus.	August 19th, great irritability of stomach, and diarrhœa; died August 21, 1863.
8	Branson, J., Serg't, A, 128th Indiana.	Aug. 12, 1864.	Shot fracture of upper third of left humerus.	Aug. 12, 1864.	Excision of the head and four inches of shaft of humerus, by Ass't Surgeon E. Lynn, 65th Illinois.	Died October 31, 1864.
9	Britton, C. L., Pt., A, 22d Massachusetts, age 27.	June 3, 1864.	Fracture of right shoulder by a shell fragment.	June 3, 1864.	Head and three inches of shaft of the humerus removed, by Surgeon I. H. Stearns, 22d Massachusetts.	Died July 9, 1864, of pyæmia.
10	Brockelbank, L. C., Pt., H, 4th N. Y. Artillery, age 25.	May 19, 1864.	Shot fracture of the right humerus.	May 19, 1864.	Head and three inches of the shaft of humerus removed.	Died June 10, 1864, of exhaustion.
11	Brownson, I. R., Capt., I, 14th Connecticut, age 37.	May 3, 1863.	Extensive comminution of neck of the right humerus by a conoidal ball which lodged.	May 3, 1863.	Entire upper third of the right humerus removed.	Died June 3, 1863, of exhaustion.
12	Cahill, N., Pt., C, 88th New York.	June 3, 1864.	Extremo comminution below surgical neck of left humerus by shot.	June 3, 1864.	Resection of head and three and a half inches of shaft of humerus, by Surgeon P. E. Hubon, 28th Massachusetts.	Died November 5, 1864. Spec. 2849, A. M. M.
13	Campbell, J. H., Pt., B, 28th Colored Troops.	July 30, 1864.	Comminuted shot fracture of head of left humerus with great laceration of soft parts.	July 30, 1864.	Excision of the head and five inches of shaft of humerus, by Surgeon G. J. Potts, 23d Colored Troops.	Died August 12, 1864.
14	Carlin, J., Pt., E, 73d Pennsylvania, age 37.	June 15, 1864.	Shot fracture of the right humerus.	June 15, 1864.	Head and upper third of the humerus excised.	Died June 22, 1864.
15	Carroll, M., Pt., K, 81st Pennsylvania, age 22.	June 4, 1864.	Compound shot fracture of the head of the left humerus; also fracture of the right humerus.	June 4, 1864.	Excision of the head and three inches of shaft of humerus, by Surgeon A. N. Dougherty, U. S. V. Amputation of right arm at middle third, by Surg. J. W. Wishart, 140th Penn'a.	Died June 14, 1864, of exhaustion.
16	Cleaver, G. F., Serg't, L, 3d Indiana Cavalry, age 27.	Feb. 20, 1864.	Oblique shot fracture through surgical neck of left humerus, extending into joint.	Feb. 20, 1864.	Excision of the head and four inches of the shaft of the humerus, by Surgeon A. M. Wilder, U. S. V.	Died March 11, 1864, of pyæmia. Spec. 2260, A. M. M.
17	Clements, J. O., Corp'l, E, 12th New Jersey, age 23.	May 3, 1863.	Shot fracture of the head of left humerus.	May 3, 1863.	Head and a portion of shaft of the humerus removed.	Died June 22, 1863.
18	Conner, W., Private, B, 62d Pennsylvania.	May 12, 1864.	Shot fracture of the head of — humerus.	May —, 1864.	Excision of the head and portion of the shaft of humerus on the field.	Died at the field hospital, May —, 1864.
19	Erwin, W., Captain, D, 11th Missouri.	April 1, 1865.	Shot fracture of the right humerus.	April 5, 1865.	Excision of upper five inches of the humerus, including the head, by Surg. M. W. Fisk, 11th Missouri.	Died April 7, 1865.
20	Finney, H., Pt., C, 18th Massachusetts, age 22.	May 9, 1864.	Shot fracture of the right humerus.	May 10, 1864.	Removal of head and portion of shaft of humerus.	Died June 26, 1864, of exhaustion.
21	Force, D., Private, I, 104th Ohio, age 34.	Aug. 6, 1864.	Minié ball fractured the upper extremity of the left humerus.	Aug. 6, 1864.	Head and six inches of shaft of the humerus removed, by Surgeon J. H. Rodgers, 104th Ohio.	Died Sept. 14, 1864, of pyæmia.
22	Grady, W. S., Major, 25th North Carolina.	June 30, 1864.	Compound shot fracture of upper third of right humerus and upper third of left radius.	June 30, 1864.	Four inches of the upper extremity of the humerus, including the head and neck, removed, by Surgeon F. N. Luckey, 25th North Carolina.	Died October, 1864, of bilious remittent fever.
23	Greenleaf, G. H., Pt., G, 9th Maine, age 20.	June 30, 1864.	Musket ball thoroughly comminuted the head and neck of the right humerus.	June 30, 1864.	Head and three and a half inches of shaft of humerus excised thro' a slightly convex incision, by Surgeon T. H. Squire, 89th New York.	Died August 9, 1864. Spec. 2788, A. M. M.
24	Grier, R. M., Pt., H, 1st Pennsylvania Rifles, age 20.	June 27, 1864.	Comminuted shot fracture of surgical neck of the left humerus; epiphysis uninjured; also wound through lung.	June 27, 1864.	Excision of the head and three inches of shaft of humerus, by Surgeon J. J. Comfort, 1st Pennsylvania.	Died July 11, 1864, of exhaustion. Spec. 4148, A. M. M.

No.	NAME, AGE, AND MILITARY DESCRIPTION.	DATE OF INJURY.	NATURE OF INJURY.	DATE OF OPERATION.	OPERATION AND OPERATOR.	RESULT AND REMARKS.
25	Griffin, J., Pt., D, 23d Wisconsin, age 21.	July 20, 1864.	Shot fracture of head of left humerus.	July 21, 1864.	Excision of the head and three inches of shaft of humerus.	Died July 29, 1864, of gangrene.
26	Grimes, J. M., Pt., D, 45th Alabama, age 19.	Nov. 30, 1864.	Shot fracture of upper third of right humerus.	Dec. 1, 1864.	Excision of the head and three inches of shaft, by Surgeon Ringgold, 45th Alabama.	Died Mar. 15, 1865, of erysipelas.
27	Hardinger, D., Pt., C, 100th Ohio, age 23.	Aug. 6, 1864.	Comminuted shot fracture of upper third of right humerus, involving joint.	Aug. 6, 1864.	Head and five inches of shaft of humerus excised, by Surg. O. A. Collamore, 100th Ohio.	Died September 27, 1864.
28	Haughley, J., Pt., H, 116th Pennsylvania, age 22.	June 3, 1864.	Minié ball fractured and comminuted the shaft of the right humerus.	June 3, 1864.	Head and three inches of shaft of humerus excised, by Surg. W. B. Hartman, 116th Penn.	Died July 25, 1864.
29	Higgins, J., Richardson's Battalion, Artillery.	June 6, 1864.	Missile comminuted the head of left humerus and lodged in the chest.	June 6, 1864.	Head and three inches of shaft of humerus removed by lateral incision through deltoid.	Died July 21, 1864, of pyæmia.
30	Hudson, W., Sergeant, D, 121st Pennsylvania, age 29.	Feb. 6, 1865.	Shot fracture of upper portion of the left humerus.	Feb. 6, 1865.	Head and two inches of shaft of the humerus removed.	Died February 22, 1865, of exhaustion.
31	Hall, D., Private, C, 81st Indiana.	June 12, 1864.	Shot fracture of upper third of humerus.	June 12, 1864.	Upper extremity of humerus excised, by Surgeon C. J. Walton, 21st Kentucky.	Died July 1, 1864.
32	Hopgood, R. H., Pt., D, 14th North Carolina, age 22.	May 4, 1864.	Musket ball comminuted the upper portion of humerus.	May 4, 1864.	Head and three inches of shaft of humerus excised.	Died June 5, 1864, of exhaustion.
33	Inge, J. F., Pt., B, 50th Virginia, age 26.	Aug. 5, 1864.	Shot fracture of upper third of the right humerus and partial fracture of scapula.	Aug. 5, 1864.	Excision of the head and one inch of shaft of humerus.	Died Aug. 10, 1864, of erysipelas.
34	Jerriss, J., Pt., D, 6th Wisconsin, age 21.	Feb. 6, 1865.	Fracture of the head of right humerus by a conoidal ball.	Feb. 8, 1865.	Head and upper portion of shaft of humerus excised.	Died Feb. 22, 1865, of tetanus.
35	Johnson, H., Pt., I, 111th Illinois, age 28.	May 28, 1864.	Compound fracture of upper third of right humerus by a conoidal ball.	May 28, 1864.	Head and upper third of shaft of humerus excised, by Act. Staff Surg. C. B. Richards.	Died July 14, 1864.
36	Jones, G. W., Pt., G, 61st Colored Troops, age 26.	July 15, 1864.	Severe shell wound of right shoulder.	July 15, 1864.	Removal of head and portion of the shaft of the humerus, by Ass't Surg. J. M. Study, U. S. V.	Died January 25, 1865, of consumption.
37	Kalrighter, H., Pt., D, 8th Maryland, age 24.	May 12, 1864.	Shot fracture of upper third of the left humerus.	May 12, 1864.	Excision of the upper extremity of humerus including the head.	Died June 5, 1864.
38	Keyes, A. F., Lieut., A, 8th Maine, age 25.	Oct. 27, 1864.	Extensive comminuted shot fracture of upper part of right humerus, periosteum stripped to capsular ligament.	Oct. 29, 1864.	Excision of the head and seven inches of shaft of humerus through a straight incision, by Surg. D. G. Rush, 101st Penn.	Died Nov. 15, 1864, of pyæmia. <i>Spec.</i> 3805, A. M. M.
39	Knau, L., Pt., C, 178th New York.	May 3, 1864.	Head and surgical neck of left humerus extensively shattered by a musket ball.	May 4, 1864.	Head and two and a half inches of shaft of humerus excised through a straight incision, by Ass't Surgeon J. Homans, jr., U. S. A.	Died May 6, 1864, during transportation.
40	Ladon, M., Pt., K, 63d New York.	Sept. 17, 1862.	Shot fracture of left humerus.	Sept. 17, 1862.	Excision of the head and four inches of humerus, by Surg. J. N. Lyman, 57th Penn.	Died October 22, 1862.
41	Lawson, G., Pt., A, 86th New York, age 35.	May 7, 1864.	Comminution of upper third of left humerus by a minié ball.	May 7, 1864.	Excision of the head and about two and a half inches of shaft of humerus. May 23d, secondary hæmorrhage from axillary artery; amputation at shoulder joint, by Surgeon R. B. Bontecou, U. S. V.	Died May 31, 1864.
42	McNeily, J. R., Captain, D, Hampton Legion, age 27.	June 13, 1864.	Shot comminution of the head and shaft of left humerus and coracoid process of scapula.	June 13, 1864.	Removal of three and a half inches of the humerus including the head.	Died June 17, 1864.
43	Mackin, J. H., Corporal, F, 153th Pennsylvania, age 22.	May 5, 1864.	Gunshot wound of left shoulder joint.	May 5, 1864.	Removal of head and a portion of the shaft through an incision made directly in front.	Died June 12, 1864, of exhaustion.
44	Martin, T., Pl., C, 25th New York.	April 1, 1865.	Shot fracture of upper third of the left humerus.	April 1, 1865.	Head and six inches of shaft of humerus excised, by a Confederate surgeon.	Died May 17, 1865. <i>Spec.</i> 4208, A. M. M.
45	Meek, J., Pt., C, 104th Ohio, age 33.	Feb. 20, 1865.	Fracture of upper third of left humerus by a shell fragment.	Feb. 20, 1865.	Excision of the head and three inches of the shaft of humerus.	Died Mar. 15, 1865, of pyæmia.
46	Mumford, J., Pt., C, 43d North Carolina, age 23.	May 16, 1864.	Gunshot wound of shoulder...	May 16, 1864.	Excision of the upper half of the humerus.	Died June 19, 1864.
47	Myer, N., Pt., K, 3d Indiana Cavalry, age 32.	Feb. 20, 1864.	Fracture of upper third of right humerus, extending into the joint, by a minié ball.	Feb. 20, 1864.	Head and six inches of shaft of humerus excised through a straight incision, by Ass't Surgeon H. L. W. Burritt, U. S. V.	Died February 25, 1864, of gangrene. <i>Spec.</i> 2227, A. M. M.
48	Nelson, P., Pt., H, 100th New York, age 26.	April 1, 1865.	Head of right humerus broken into several unequal fragments by shot; an oblique fracture extended down shaft.	April 1, 1865.	Head and two and a half inches of shaft of humerus removed, by Surgeon W. O. McDonald, U. S. V.	Died April 15, 1865, of erysipelas. <i>Spec.</i> 4139, A. M. M.
49	Page, D., Corporal, A, 33d Indiana, age 27.	June 22, 1864.	Comminuted shot fracture of four inches of upper extremity of right humerus; also wound of chest.	June 22, 1864.	Resection of the head and four inches of shaft of humerus.	Died July 7, 1864, of pyæmia.
50	Pelton, J. M., Lieutenant, C, 211th Penn'a, age 26.	April 2, 1865.	Shot fracture of head of left humerus; an oblique fracture extended through the surgical neck.	April 5, 1865.	Head and two inches of shaft of humerus removed, by Surg. W. O. McDonald, U. S. V.	Died April 14, 1865. <i>Spec.</i> 4161, A. M. M.
51	Peterson, J. H., Pt., E, 31st Colored Troops.	July 30, 1864.	Shot fracture of head of humerus, clavicle, and scapula.	July 31, 1864.	Head and three inches of shaft of the humerus excised, by Surgeon D. Mackey 29th Colored Troops.	Died September 15, 1864, of exhaustion.
52	Pickard, J., Pt., 7th Co. 1st New York Sharpshooters.	June 4, 1864.	Gunshot fracture of shoulder joint.	June 4, 1864.	Excision of head and one and a half inches of the shaft of humerus.	Died June 9, 1864.
53	Piekens, J., Pt., E, 14th New Jersey, age 30.	Nov. 27, 1863.	Fracture of the head of right humerus by a conoidal ball.	Nov. 27, 1863.	Excision of the head and three inches of shaft of humerus.	Died December 7, 1863. <i>Spec.</i> 2705, A. M. M.



No.	NAME, AGE, AND MILITARY DESCRIPTION.	DATE OF INJURY.	NATURE OF INJURY.	DATE OF OPERATION.	OPERATION AND OPERATOR.	RESULT AND REMARKS.
54	Poteat, F. L., Lieut., K, 47th North Carolina, age 26.	Aug. 25, 1864.	Minié ball shattered the upper third of the right humerus.	Aug. 25, 1864.	Excision of the upper extremity of the humerus, including the head, through a straight incision.	Died September 3, 1864.
55	Pratt, R. H., Sergeant, 11, 85th Indiana, age 36.	July 20, 1864.	Shot fracture of the right humerus.	July 20, 1864.	Excision of the head and three inches of shaft of humerus.	Died January 12, 1865; home on furlough.
56	Read, M., Pt., E, 7th Maine, age 31.	Sept. 19, 1864.	Head of left humerus badly shattered by a minié ball; articulation involved.	Sept. 21, 1864.	Excision of the head and a portion of shaft of the humerus through a V-shaped incision, by Ass't Surg. J. G. Thompson, 77th New York.	Died Sept. 30, 1864, of pyæmia and secondary pneumonia.
57	Risk, C. C., Pt., C, 13th Indiana, age 21.	Jan. 16, 1865.	Fracture of head of right scapula, coracoid process, and head of humerus, by shell fragment.	Jan. 17, 1865.	Head and one inch of shaft of humerus removed, by Ass't Surg. H. C. Merryweather, 5th Colored Troops.	Died February 27, 1865, of exhaustion.
58	Rutledge, H. H., Captain, A, 50th North Carolina, age 30.	May 16, 1864.	Extensive comminution of the head and upper third of left humerus by a conoidal ball.	May 17, 1864.	Head and four inches of shaft of humerus removed, through an oval incision, by Surgeon C. B. Gibson, C. S. A.	Died.
59	Ryan, P., Pt., H, 2d Massachusetts Artillery.	Apr. 20, 1864.	Compound comminuted shot fracture of the left humerus.	Apr. 20, 1864.	Head and two inches of shaft of humerus removed, thro' a semi-lunar incision, by Surg. C. H. Laid, 56th North Carolina.	Died April 20, 1865, while in the hands of the enemy.
60	Sessions, J. C., Sergeant, I, 2d Michigan, age 21.	June 17, 1864.	Grapeshot wound of left shoulder joint; humerus comminuted and soft parts and capsular ligament lacerated.	June 17, 1864.	Head and two inches of shaft of humerus removed, by Surgeon S. S. French, 20th Michigan.	Died Aug. 26, 1864, of exhaustion. <i>Spec.</i> 1992, A. M. M.
61	Shores, J., Pt., C, 61st Alabama, age 19.	June 3, 1864.	Comminuted shot fracture of the head of left humerus.	June 3, 1864.	Resection of the head and two inches of shaft of humerus.	Died July 6, 1864, of exhaustion.
62	Stott, A., Pt., E, 46th New York, age 45.	June 27, 1864.	Gnshot wound of right shoulder joint.	June 27, 1864.	Excision of the head and two inches of shaft of humerus, by Surgeon W. B. Fox, 8th Michigan.	Died July 6, 1864, from coma following gangrene.
63	Smiley, J. J., Corp'l, F, 27th Kentucky, age 20.	July 21, 1864.	Comminuted shot fracture of upper third of left humerus; joint not opened.	July 21, 1864.	Excision of the head and five inches of shaft of humerus, by Surg. A. M. Wilder, U. S. V.	Died August 23, 1864, of exhaustion.
64	Smith, F. M., Pt., A, 17th Ohio, age 22.	Aug. 10, 1864.	Shot fracture of the head of the right humerus.	Aug. 10, 1864.	Excision of the head and two and a half inches of the shaft of humerus.	Died December 14, 1864, of mortification of entire left leg; thrombi found in iliac veins; <i>post-mortem</i> .
65	Smith, J., Pt., K, 143d Pennsylvania, age 27.	May 5, 1864.	Conoidal ball fractured upper third of humerus.	May 6, 1864.	Head and portion of shaft of humerus removed by straight incision through deltoid, by a Confederate surgeon.	Necrosis, Nov. 3, amputation at shoulder joint; rupture of a large axillary aneurism; died Nov. 21, 1864.
66	Smith, J., Serg't, D, 21th New Jersey, age 33.	May 3, 1863.	A conoidal ball completely destroyed the head of right humerus and fractured the scapula.	May 3, 1863.	Removal of the upper third of the humerus, including the head.	Died May 31, 1863.
67	Smith, S. S. D., Pt., E, 4th Penn'a Cavalry, age 24.	Mar. 31, 1865.	Shot fracture of right shoulder joint.	Mar. 31, 1865.	Excision of about three inches of the upper extremity of the humerus.	Died April 11, 1865, of pyæmia.
68	Snowberger, T., Pt., E, 18th Pennsylvania, age 19.	June 18, 1864.	Musket ball fractured the head of the right humerus.	June 19, 1864.	Head and three inches of shaft of the humerus excised, by Surgeon S. H. Plumb, 82d New York.	Died July 29, 1864, of pyæmia.
69	Stidham, F. M., Pt., A, 46th Pennsylvania, age 23.	June 16, 1864.	Shot fracture of head of right humerus; the ball lodged in the chest.	June 17, 1864.	Excision of the head and two inches of shaft of humerus.	Died July 10, 1864, of hæmorrhage.
70	Stilwell, H. N., Pt., I, 142d New York, age 20.	Oct. 27, 1864.	Shot fracture of upper portion of right humerus; bone greatly shattered and ligaments about joint disrupted.	Oct. 27, 1864.	Head and six inches of shaft of humerus removed, by Surg. C. M. Clark, 39th Illinois.	Died Dec. 11, 1864, of phthisis following effects of operation.
71	Terry, M. A., Sergeant, C, 1st New York Dragoons, age 24.	May 31, 1864.	Shot fracture of right humerus, opening the shoulder joint.	June 1, 1864.	Excision of the head and three and a half inches of the shaft of humerus through a semi-circular incision.	Gangrene and erysipelas set in. Died Oct. 21, 1864.
72	Thomas, J. E., Pt., E, 85th Illinois, age 46.	July 19, 1864.	Shot fracture of left humerus, with laceration.	July 19, 1864.	Excision of the head and three inches of shaft of humerus.	Died December 10, 1864, of inflammation of lungs.
73	Towles, G. W., Lieut., B, 14th Alabama, age 21.	Sept. 29, 1864.	Gnshot fracture of left humerus and wound of lung.	Sept. 29, 1864.	Head and two inches of shaft of humerus removed.	Died October 4, 1864.
74	Vaughn, J., Pt., H, 3d Massachusetts Cavalry.	May 1, 1861.	Head and neck of the right humerus very much shattered by conoidal ball; also wound of lung.	May 2, 1864.	Head and two and a half inches of the shaft of humerus removed, by Surgeon J. A. Skilton, 87th New York.	Erysipelas supervened. Died May 7, 1864.
75	Wardell, C. P., Pt., E, 58th Massachusetts, age 35.	July 30, 1864.	Shot fracture of upper third of left humerus.	July 30, 1864.	Removal of the head and three inches of shaft of humerus.	Died Aug. 27, 1864, of pyæmia.
76	Welch, B. R., Sergeant, H, 1st District Columbia Cavalry, age 25.	Aug. 25, 1864.	Shot fracture of left shoulder and upper portion of humerus.	Aug. 25, 1864.	Excision of the upper extremity of the humerus, including the head.	Hæmorrhage Sept. 15th, amp. at shoulder joint, by A. A. Surg. I. G. Morgan. Hæmorrhage recurred. Died October 11, 1864. <i>Spec.</i> 3675, A. M. M.
77	White, W., Pt., B, 118th Ohio.	May 14, 1864.	Comminuted fracture of upper extremity of right humerus, opening the joint.	May 14, 1864.	Excision of the head and two inches of shaft of humerus, by Surg. C. S. Frink, U. S. V.	Died May 26, 1864.
78	White, R. A., Sergeant, C, 2d Arkansas.	Oct. 7, 1864.	Severe shot wound of the right shoulder.	Oct. 7, 1864.	Excision of the head and portion of the shaft of humerus.	Died November 7, 1864.
79	Wright, S. W., Sergeant, G, 75th Ohio, age 29.	Nov. 30, 1864.	Head and superior extremity of the shaft of left humerus extensively comminuted by shot.	Dec. 2, 1864.	Head and two and a half inches of shaft of humerus excised thro' an S-shaped incision, by Surgeon B. B. Breed, U. S. V.	Died December 4, 1864, of exhaustion.
80	Yerfas, S., Pt., I, 81st Indiana, age 36.	Dec. 16, 1864.	Extensive comminuted shot fracture of the head and shaft of the left humerus.	Dec. 18, 1864.	Removal of the head and two and a half inches of shaft of humerus, by Surgeon B. B. Breed, U. S. V.	Died January 1, 1865.

In three of these cases,<sup>1</sup> recourse was had to consecutive amputation at the shoulder.

CASE 1553.—Private J. Bazarth, Co. A, 17th Iowa, aged 23 years, was wounded at Tilton, Georgia, October 13, 1864, and was sent from Atlanta to Hospital No. 1, Chattanooga, where Surgeon J. H. Phillips, U. S. V., reported: "Gunshot fracture of the head of the humerus. The head of the bone was badly comminuted; the soft parts not much inflamed. On October 14th, resection of the left shoulder joint with removal of two inches of humerus; by a single straight incision, was performed on the field; operator unknown; chloroform was administered. The treatment was of a tonic and stimulating character, as well locally as constitutionally; the suppuration was, however, excessive; the end of the humerus necrosed, and the patient gradually sank. He died, from exhaustion, December 2, 1864."

The primary excisions of the upper extremity of the humerus for shot injury appear to give a mortality of somewhat less than 28 per cent. There was little difference in the relative fatality after injuries of the right or left shoulder.<sup>2</sup>

**Intermediary Excisions of the Upper Extremity of the Humerus for Shot Injury.**—There were one hundred and fifty-five cases of this order, in which portions of the shaft, as well as the head of the humerus, were removed.

§ *Successful Operations.*—Ninety-one patients of this subdivision survived. Abstracts of a number of these cases will precede and succeed the statistical enumeration in TABLE XXXIII, of intermediary excisions of the upper part of the humerus:

CASE 1554.—Private C. M. Wolff, Co. C, 5th New Hampshire, was wounded at Ream's Station, August 25, 1864, and treated in a Second Corps hospital until the 28th, when he was sent to Lincoln Hospital, at Washington. Acting Assistant Surgeon L. C. Dodge reported: "Wound produced by a minié ball, which entered on the anterior aspect of the left shoulder joint midway between the coracoid and acromion processes, passing directly backward, producing a compound comminuted fracture of the humerus, the ball passing completely through the bone at the surgical neck. The articulating surface of the humerus was not implicated. At the time of admission the arm was considerably swollen as far down as the elbow joint; otherwise, the condition of the patient was good. August 30th: Excision of the upper third of the humerus was performed to-day. A longitudinal incision six inches in length was made, commencing at the acromion process, and passing directly down to the posterior surface of the arm. The fragments of the bone were removed with the forceps, and the shaft of the humerus sawn through; the ordinary dressings were applied." Assistant Surgeon W. Lindsly, U. S. A., noted: "Ether was used as an



FIG. 448.—Posterior view of the head of the left humerus, excised for shot injury. *Spec.* 3161.

anæsthetic; six ligatures were used; operation performed by Acting Assistant Surgeon L. C. Dodge." The specimen (FIG. 448), contributed by the operator, consists of the head and one inch and a half of the shaft of the left humerus, excised. A conoidal ball entered the anatomical neck from the rear, fissured the articular surface and shattered the surgical neck, and remains embedded in the specimen. This patient was discharged from service December 3, 1864, and pensioned. E. D. Hudson, M. D., of New York,<sup>3</sup> published the following account of this case: "Three months after the operation his arm was healed—some atrophied; not shortened, very flexible, uncontrollable; having an interspace of two and a half inches, which nature had failed to restore; with inability to carry the arm forward across the chest; pectoral and deltoid muscles impaired; nerves, arteries, and functions of the forearm healthy; cannot flex the forearm much for lack of fixedness;

carries his forearm in a sling. With apparatus anatomically prepared and applied, scapular pad, and acromion process, a case for the arm attached to the scapular pad, with an oscillatory shoulder joint, and an aponeurotic case for the forearm united to that of the arm with ginglymoid joints; auxiliary straps of rubber webbing for the pectoral and biceps muscles (FIG. 449), he was able to flex the forearm, carry his hand to his head, pronate and supinate the hand, draw it partially across the chest, lift weights with forearm flexed, exercise the forearm, and will regain the use of his arm for ordinary vocations." On December 5, 1864, Examiner Julius Nichols, of Washington, reported: "Removal, by resection, of the head and three and a half inches of the shaft of the humerus; will be partially useful in time; requires perfect rest for one year." Examiner C. O. S. Gilman, of Salem, New York, reported, September 25, 1866: \* \* "he is unable to use the arm for any purpose; it often discharges at the joint; disability total and permanent." This pensioner was paid December 4, 1873



FIG. 449.—Apparatus employed in a case of excision at the shoulder. [From a photograph.]

<sup>1</sup> Namely: in CASES 41, 65, and 76, the cases of Lawson, Smith, and Welch. In all, the amputations were practised on account of hæmorrhage, intermediary in two instances, and in the third secondary, resulting from the rupture of an axillary aneurism nearly six months subsequent to the date of the injury and operation.

<sup>2</sup> Of the seventy-three operations in which this point was specified, thirty-eight were on the right, and thirty-five on the left side. The reader may compare, on this point, statistics alluded to, on pages 537, 544, 545, of this volume.

<sup>3</sup> HUDSON (E. D.), *Remarks on Excisions, with Cases and Plates*, p. 15.



Photographs were furnished of many of the subjects of intermediary excisions, and some have been copied in antecedent lithographs or in accompanying wood-cuts:

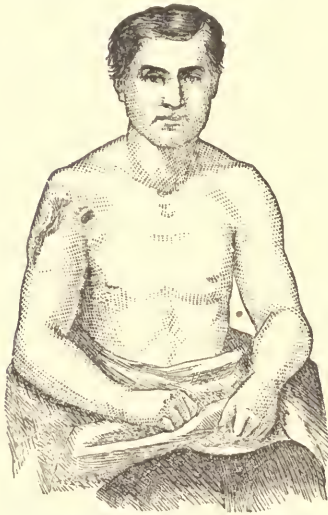


FIG. 450.—Cicatrix five months after an excision of the upper extremity of the humerus for shot fracture. [From a water-color drawing.]

CASE 1555.—Private H. Pierce, Co. B, 2d New York Mounted Rifles, aged 18 years, was wounded at Poplar Grove Church, September 30, 1864. Surgeon J. Harris, 7th Rhode Island, reported that this soldier was received at the hospital of the Second Division of the Ninth Corps with a shot wound of the right shoulder, and was sent to City Point. Surgeon W. O. McDonald, U. S. V., recorded his admission to the Ninth Corps base hospital, and transfer, on October 13th, to the Beverly Hospital, New Jersey. Here Assistant Surgeon C. Wagner, U. S. A., reported: "Gunshot wound of the right shoulder, fracturing the head of the humerus. On October 18th, resection of the head of the humerus was performed, removing two inches and a half of the bone. Chloroform was used; the patient reacting promptly. At the time of the operation the parts were suppurating freely, with considerable pain, and the patient was feverish, with loss of appetite; the pulse was at 110. Water-dressings were employed, and the man improved rapidly, and gave promise of having a useful arm." In March, 1865, Hospital Stewart Baumgras, U. S. A., having been sent to Beverly to make a drawing of Dr. Packard's case of reamputation at the hip,<sup>1</sup> made also a water-color sketch of Pierce (*Surg. Ser. Drawings*, A. M. M., No. 78), from which the wood-cut (FIG. 450) is copied. The patient was transferred to the Whitehall Hospital, Bristol, Pennsylvania, April 5th, and was discharged May 24, 1865, and pensioned. Examiner W. B. Alley reported, December 31, 1867: "The arm is shortened and feeble. It is better than a wooden one, for he has the use of his fingers and can handle papers, but cannot do any, or but little, manual labor, and has no trade or business. He claims that it pains him a large share of the time. I do not know how to rate this case; it is a permanent disability. I should say that he ought to have twelve or fifteen dollars a month." This pensioner was paid March 4, 1874.

CASE 1556.—Private D. Singleton, Co. F, 140th Pennsylvania, aged 30 years, was wounded at Spottsylvania, May 12, 1864, and was treated in a Second Corps field hospital, and thence sent to Washington, entering Carver Hospital on May 16th. He was operated on by Surgeon O. A. Judson, U. S. V., who reported as follows: "Gunshot wound of shoulder; conoidal ball lodged in head of humerus, splitting the head and detaching splinter. On May 27th, a straight incision was made through the deltoid, and the head and two inches of the shaft of the humerus was removed by a chain saw. Result favorable, the wound filling with healthy granulations." The patient was transferred, and admitted to hospital at Pittsburg on November 16, 1864, and on June 11, 1865, was discharged the service and pensioned. Examiner D. Stanton, of New Brighton, Pennsylvania, May 31, 1866, reported: "Minié ball lodged in the head of the humerus. The head and about two inches of the shaft excised May 20, 1864. There is now a space of about two and a half inches between the upper end of the shaft and the glenoid cavity. There is still necrosis of the bone. There is very slight voluntary motion of the arm, and limited use of the forearm and hand." On June 23, 1866, J. Wilson Wishart, late Surgeon 149th Pennsylvania, forwarded to the Army Medical Museum a photograph exhibiting the appearance of the injured limb at that time. The arm is supported at the highest point to which he could raise the elbow by voluntary efforts. This photograph is represented by *Figure 3* in PLATE XVIII. Dr. Wishart states: "During the present month Mr. S. called upon me at my office, and upon examination I found a slight discharge from the point indicated in the photograph by the dark spot at the junction of the upper and middle thirds of the cicatrix. Upon introducing a probe I discovered diseased bone, which, at his request, I removed on Thursday the 21st instant, through an incision in the upper part of the cicatrix. It proved to be a portion of the sawed surface of the humerus, which, with pieces previously discharged, completed about two-thirds of the circumference of the bone. A probe, introduced to the point whence the bone was extracted, entered a canal some two inches in depth, extending downward and to the inside of the humerus. Careful and repeated examination by myself and another surgeon failed to detect any communication with the humerus, or any more diseased bone. I am in hopes now that the wound will entirely close." In a certificate for increase of pension, January 16, 1867, Examiner Stanton reported: "There is now false joint, there being a space of two and a half inches between the upper end of the shaft and the glenoid cavity. The slight use of the hand is more than counterbalanced by the pain and soreness caused by its use. Important tendons were severed by the ball or by the knife of the surgeon." In September, 1873, a Board, convened at Pittsburg, and composed of Drs. A. G. McCandless, J. W. Wishart, and W. J. Elmore, reported: "The arm is useless for purposes of manual labor." The pensioner was paid June 4, 1874.

CASE 1557.—Corporal J. B. Nicholson, Co. I, 1st Wisconsin Cavalry, aged 33 years, was wounded at Pulaski, Tennessee, September 27, 1864, and was admitted to Hospital No. 3, Nashville, on October 1st, and was operated on by Surgeon J. R. Ludlow, U. S. V., who reported: "Gunshot wound of the left shoulder, the ball fracturing the upper third of the humerus and opening the shoulder joint. On October 11th, the patient was anesthetized by chloroform, and three inches of the bone were resected by a vertical incision of about four inches in length. The upper third of the shaft of the bone and its head were much shattered, while the soft parts were comparatively little injured. The health of the patient was excellent. Since the time of the operation the patient has rapidly improved without one bad symptom." He was transferred to Jefferson Barracks, Missouri, on December 6th; on the 16th, sent to hospital at Prairie du Chien; again sent to Nashville, and admitted to Hospital No. 14 on May 3, 1865, and finally discharged the service May 16, 1865, and pensioned. Examiner J. Diefendorf, of Milwaukee, in 1866, contributed a photograph of this pensioner, which is copied in *Figure 2* of PLATE XVII, and added the following notes: "The ball entered near the glenoid cavity in front of the left arm, injuring the socket and fracturing the neck and shaft of the humerus.

<sup>1</sup> PACKARD, *An Amputation at the Hip-joint*, in the *New York Med. Jour.*, 1866, Vol. II, p. 161.

Resection was performed, the soldier claims, of about four inches, including the head of the bone. It is, at present, about two and three-quarter inches shorter. The operator is entitled to credit in preserving the muscles, blood-vessels, and nerves. I [Dr. Dieffendorf] examined him July 20, 1865, for pension. He has improved since that period, so that he is now able to use his forearm freely, and able to feed himself, and perform considerable labor; he can raise about fifty pounds on a straight line by the use of his muscles, which do not appear to be diminished in size and vigor. He has good health and a vigorous constitution, and there is a fair prospect that the arm will be of great use to him." This pensioner died January 6, 1870. Examiner John A. Rice, of Morton, Wisconsin, reported that he attended this pensioner in consultation with his ordinary medical adviser, Dr. Miller; that "he found Nicholson suffering from an abscess of the shoulder at the spot where the joint had been removed; that the abscess was a direct consequence of the wound and surgical operation, and that said abscess resulted in pyæmia." Dr. D. McL. Miller, in his affidavit, dated July 14, 1870, corroborates the statements of Dr. Rice, and adds that "about eight weeks previous to the death of said Nicholson suppuration commenced in the spot where the shoulder joint had been removed."

CASE 1553.—Private J. Ruddy, Co. A, 63d New York, aged 32 years, was wounded at Petersburg, April 2, 1865. Surgeon F. M. Hammond, U. S. V., at the First Division Hospital of the Second Corps, and Acting Staff Surgeon J. Aiken, report simply that the patient had a shot wound of the left shoulder, and was sent on to Washington, where he was received into Harewood Hospital on April 4th. Surgeon R. B. Bontecou, U. S. V., reported: "Gunshot wound of the left shoulder and back, the ball entering at the head of the humerus and making its exit near the anterior portion of the scapula, fracturing the head of the humerus and the acromion process. On April 22d, the wound being in a suppurating condition, the patient was placed under the influence of ether, and the head and about four inches of the shaft of the humerus were removed. The after-treatment was supporting, with simple dressings, and the result was favorable." The photograph represented in the cut (FIG. 451) was taken while the patient was at Harewood Hospital, and was contributed to the Museum by the operator, Dr. Bontecou. This soldier was discharged from service July 12, 1865, and pensioned. Examiner J. S. Delevan, of Albany, reported, September 8, 1866: "Ball entered the left shoulder. The shoulder joint was resected, with a portion of the humerus. The limb cannot be used at all, excepting that the hand can be opened and shut, but he cannot carry anything in it. The elbow joint cannot be bent fully, and for all practical purposes it is useless to him, and in my opinion permanently so; disability total." Dr. P. F. L. Reynolds, of Albany, certified as follows: "Said John Ruddy died at Albany, June 3, 1865, from the effects of a gunshot wound; the ball which occasioned it having passed through the upper lobe of the left lung and out of the left shoulder, resulting in the wasting away of his system, and was the sole cause of his death."

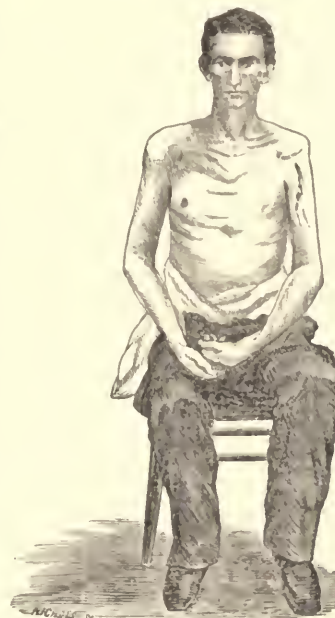

FIG. 451.—Cicatrix after an intermediary excision of the head of the humerus for shot fracture. [From a photograph.]

The two foregoing cases are classified with the successful intermediary cases, although the patients succumbed, respectively, five and three years subsequently to operations. In numerous instances it is difficult, because of conflicting testimony, to determine how far ultimate fatal results are to be attributed to injuries and operations. In this work, patients who survived severe operations until discharged, or pensioned, are classified as recovered.

CASE 1559.—Private J. K. Clarke, Co. E, 10th Pennsylvania Reserves, was wounded at Fredericksburg, December 13, 1862. Assistant Surgeon J. Barbour, 1st Pennsylvania, recorded a "gunshot wound near the shoulder." The patient was sent to Carver Hospital, December 18th. Surgeon O. A. Judson, U. S. V., reported that "the ball entered about three inches below the acromial process of the right side, passed upward and inward, fracturing a portion of the shaft and the head of the humerus badly. Resection was performed, January 7, 1863, by Surgeon J. Wilson, U. S. V. A U-shaped incision was made, and the head and about three inches of the shaft of the bone were removed by the chain saw. The wound was healed by the 1st of March. The local dressing was of water, with an occasional admixture of whiskey when the wound showed indications of indolence. At the date of operation the limb was much swollen, the discharge fetid and sanious, the skin hot, the pulse at one hundred, the tongue coated, with cephalalgia loss of appetite, and general depression." In a letter to Dr. J. H. Brinton, of May 2, 1863, Surgeon J. Wilson, U. S. V., stated: "The operation was performed January 6, 1863. I considered the case tending rapidly toward pyæmia. From the date of the operation the untoward symptoms began rapidly to subside. You will observe by the sketch [a drawing had been made, under Dr. Brinton's directions, by Hospital Steward Stauch, from which FIG. 4, PLATE XIII, is copied] that the sutures of the flap were inserted farther from the margin than usual. This I did that I might bring firmly together the soft parts, in order to secure as much union by the first intention as possible." Surgeon Wilson has published an extended narrative of this case, with accompanying observations on prolonged anæsthesia.<sup>1</sup> This soldier was discharged June 5, 1863, and pensioned. Examiner reported, June 4, 1863: "Ball unremoved, and probably is lodged beneath the scapula. Most of the motions of the arm are perfect, but it is powerless and useless for labor now." Examiner J. Voss, of Clarrington, reported, September 4, 1873: "The arm for use is worthless."

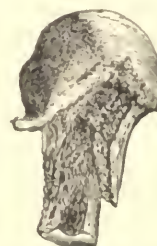

FIG. 452.—Upper extremity of right humerus excised for shot fracture. Sp. 633.

<sup>1</sup> WILSON (J.), *Case of Excision of shoulder-joint*, in the *Am. Med. Times*, 1863, Vol. VI, p. 232.



TABLE XXXIII.

*Summary of Ninety-One Cases of Recovery after Intermediary Excisions of the Head and Portions of the Shaft of the Humerus for Shot Injury.*

No.	NAME, AGE, AND MILITARY DESCRIPTION.	DATE OF INJURY.	NATURE OF INJURY.	DATE OF OPERATION.	OPERATION AND OPERATOR.	RESULT AND REMARKS.
1	Addison, J., Serg't, C, 23d Colored Troops, age 22.	July 30, 1864.	Shot fracture of the head of the right humerus.	Aug. 21, 1864.	Head and two inches of shaft of humerus removed through a straight incision, by Surg. E. Bentley, U. S. V.	Disch'd Sept. 7, 1865; pensioned. Disability total.
2	Arnold, F., Corp'l, F, 47th Pennsylvania, age 20.	Mar. 28, 1865.	Minié ball carried away half an inch of the articular surface of the left humerus.	April 5, 1865.	Head and one and a quarter inches of shaft of humerus excised thro' a straight incision, by A. A. Surg. W. S. Adams.	Disch'd July 11, 1865; pensioned. July 15, 1874, can earn one-half to three-quarter wages.
3	Basney, E., Pt, E, 2d Connecticut Artillery, age 16.	June 1, 1864.	Gunshot wound of right shoulder; missile lodged in head of humerus.	June 7, 1864.	Excision of the head and one inch of the shaft of humerus thro' an incision on external aspect, by Surg. E. Bentley, U. S. V.	Disch'd Oct. 22, 1864; pensioned. Sept., 1873, arm useless for manual labor.
4	Beck, J. L., Pt., I, 10th Illinois, age 22.	Mar. 8, 1865.	Shot fracture of upper third of the right humerus; sequestrum from joint escaping through wound.	April 5, 1865.	Excision of the head and four and one half inches of shaft of humerus thro' an elliptical incision, by Ass't Surg. W. Webster, U. S. A.	Disch'd July 8, 1865; pensioned. May, 1868, can feed himself with hand, but cannot perform manual labor.
5	Belger, M., Pt., B, 2d Michigan Cavalry.	Sept. 30, 1862.	Conoidal ball grooved the head of left humerus and lodged under the integument at back of neck.	Oct. 4, 1862.	Excision of the head and two inches of the shaft of humerus thro' a straight incision, by A. A. Surg. J. Sloan.	Disch'd July 3, 1863. Claim for pension rejected June 6, 1867. <i>Spec.</i> 342, A. M. M.
6	Bell, R., Pt., C, 3d Massachusetts Cavalry.	April 8, 1863.	Fracture of head and neck of right humerus by conoidal ball; fracture extended two inches downward.	April 18, 1863.	Excision of the head and three inches of shaft of humerus thro' single incision, by Surg. F. Bacon, U. S. V.	Disch'd June 23, 1864; pensioned. Oct., 1873, arm shortened three and a half inches; forearm can be flexed; can use hand and fingers.
7	Bickford, G., Pt, C, 11th New Hampshire.	Dec. 13, 1862.	Head of right humerus comminuted by a shell fragment.	Dec. 30, 1862.	Head and three and a half inches of shaft of humerus removed, by Surgeon D. W. Bliss, U. S. V.	Disch'd Oct. 7, 1863; pensioned. Oct., 1873, almost complete ankylosis of joint. <i>Spec.</i> 658, A. M. M.
8	Blakeman, A. C., Lieut., I, 6th New York, age 21.	May 12, 1864.	Shot wound through the head of the left humerus.	May 18, 1864.	Head and one and a half inches of shaft of humerus excised, by Surg. D. W. Bliss, U. S. V.	Disch'd Sept. 19, 1864; pensioned. Sept., 1873, has partial use of arm for manual labor. <i>Spec.</i> 274, A. M. M.
9	Bleecher, M., Pt., II, 79th Pennsylvania.	Oct. 8, 1862.	Fracture of right humerus, involving shoulder joint; ball lodged in surgical neck.	Oct. 22, 1862.	Excision of two inches of upper extremity of the humerus, including the head, by Surg. G. D. Beebe, U. S. V.	Disch'd April 7, 1863; pensioned. Oct., 1869, union is entirely unvascular; limb is useless for labor.
10	Booth, F., Pt., B, 86th New York.	Aug. 30, 1862.	Comminuted shot fracture of upper third of left humerus.	Sept. 8, 1862.	Removal of the head and four inches of shaft of humerus, by Surgeon J. H. Brinton, U. S. V.	Disch'd Nov. 1, 1862; pensioned. Sept., 1873, has moderate use of forearm and hand. <i>Spec.</i> 336, A. M. M.
11	Borger, F. A., Serg't, D, 8th Virginia, age 25.	July 3, 1863.	Minié ball perforated the neck of left humerus, producing a compound comminuted fracture.	July 21, 1863.	Head and portion of the shaft of humerus removed through an T-shaped incision.	Recovered; furloughed March 12, 1864.
12	Boyle, W., Pt., D, 59th Ohio, age 34.	April 7, 1862.	Shot fracture of the right humerus; scapula involved.	April 21, 1862.	Three and a half inches of upper extremity of humerus, including the head, removed, by Dr. G. C. Blackburn.	Disch'd Sept. 21, 1862; pensioned. Nov., 1873, disability total, third grade.
13	Bright, W., Pt., A, 12th Mississippi, age 25.	April 2, 1865.	Minié ball fractured the head of right humerus.	April 18, 1865.	Head and one inch of shaft of humerus excised through a V-shaped incision, by Surg. D. G. Kush, U. S. V.	Recovered; discharged from hospital June 29, 1865. <i>Spec.</i> 4211, A. M. M.
14	Bryant, G. H., Captain, D, 29th Wisconsin.	April 7, 1864.	Head of right humerus shattered by musket ball; longitudinal fracture thro' upper three inches of shaft.	April 17, 1864.	Head and three inches of the shaft of humerus excised by a straight incision thro' deltoid, by Surgeon F. Bacon, U. S. V.	Disch'd June 22, 1865; pensioned. September, 1873, arm cannot be raised from side, but is of some use. <i>Spec.</i> 3605, A. M. M.
15	Butler, W., Pt., G, 20th New York State Militia.	Aug. 30, 1862.	Musket ball extensively shattered the right humerus and comminuted the head of the bone.	Sept. 4, 1862.	Excision of the head and one inch of shaft of humerus, by Surg. E. Bentley, U. S. V.	Disch'd Nov. 10, 1863; pensioned. Sept., 1873, can, by exertion, raise hand to chin. <i>Spec.</i> 335, A. M. M.
16	Canfield, L. C., Pt., A, 15th Michigan, age 32.	Aug. 18, 1864.	Inner portion of head and neck of the left humerus carried away by musket ball.	Sept. 4, 1864.	Head and three and one-half inches of shaft of humerus removed, by Surg. A. Goslin, 48th Illinois.	Disch'd April 9, 1865; pensioned. Sept., 1873, disability total, third grade. <i>Spec.</i> 3487, A. M. M.
17	Clapp, G. C., Pt., G, 37th Massachusetts, age 35.	Sept. 19, 1864.	Upper third of right humerus shattered by minié ball.	Sept. 23, 1864.	Head and three and a half inches of shaft of humerus removed through a V-shaped incision, by Ass't Surgeon E. Curtis, U. S. A.	Disch'd April 13, 1865; pensioned. Sept., 1873, disability total, third grade. <i>Spec.</i> 3277, A. M. M.
18	Clark, J. K., Pt., E, 10th Pennsylvania Reserves.	Dec. 13, 1862.	Head and shaft of right humerus badly fractured; ball passed beneath scapula and could not be found.	Jan. 7, 1863.	Head and three inches of shaft of humerus removed through a V-shaped incision, by Surg. J. Wilson, U. S. V.	Disch'd June 6, 1863; pensioned. Sept., 1873, arm worthless for labor. <i>Spec.</i> 633, A. M. M.
19	Cleveland, J. J., Pt., K, 10th Connecticut.	Aug. 1, 1864.	Musket ball gouged the neck of right humerus and fissured the shaft.	Aug. 7, 1864.	Head and two inches of shaft of humerus excised, by Ass't Surgeon E. Curtis, U. S. A.	Disch'd Jan. 31, 1865; pensioned. Sept., 1873, wound opens and discharges at times; disability total, third grade.
20	Coolream, P., Pt., B, 61st New York, age 45.	May 8, 1864.	Ball passed antero-posteriorly through the head of the right humerus.	May 15, 1864.	Head and one inch of shaft of humerus excised, by Surg. E. Bentley, U. S. V. May 24th, ligation of axillary artery.	Disch'd Oct. 13, 1865; pensioned. Sept., 1873, ankylosis of humerus with scapula.
21	Cox, R. A., Pt., E, 14th West Virginia, age 29.	July 20, 1864.	Musket ball carried away the posterior half of the surgical neck and clipped the head of the left humerus.	Aug. 4, 1864.	Excision of head and neck of the humerus thro' an S-shaped incision over joint, by Surgeon J. B. Lewis, U. S. V.	Disch'd Mar. 27, 1865; pensioned. Sept., 1873, disability total, third grade. <i>Spec.</i> 4260, A. M. M.

NO.	NAME, AGE, AND MILITARY DESCRIPTION.	DATE OF INJURY.	NATURE OF INJURY.	DATE OF OPERATION.	OPERATION AND OPERATOR.	RESULT AND REMARKS.
22	Crawford, R. G., Pt., D, 139th Pennsylvania, age 22.	Mar. 25, 1865.	Comminuted fracture of the neck of the right humerus by a conoidal ball.	April 2, 1865.	Excision of the head and one inch of the shaft of humerus, by Surg. D. W. Bliss, U. S. V.	Disch'd July 3, 1865; pensioned. September, 1873, arm useless for manual labor. <i>Spec.</i> 4042, A. A. M.
23	Crippen, M. E., Pt., E, 47th New York, age 19.	Feb. 20, 1861.	Minié ball passed through the head of right humerus without injuring glenoid cavity.	Mar. 5, 1861.	Excision of the head and one and a quarter inches of shaft of humerus through a V-shaped incision, by Assist. Surg. W. R. Ramsey, U. S. A.	Disch'd Feb. 18, 1865; pensioned. Sept., 1873, non-union; disability total, 3d grade.
24	Criser, R. J., Sergeant, F, 11th Virginia Cavalry, age 25.	June 1, 1861.	Conoidal ball fractured the right humerus.	June 11, 1861.	Excision of the head and about four and a half inches of shaft of humerus.	Retired December 16, 1864.
25	Daily, R. H., Pt., G, 63d Pennsylvania, age 26.	May 8, 1861.	Shot fracture of left humerus.	May 26, 1861.	Head and portion of shaft of humerus removed, by Surg. R. B. Bonteeau, U. S. V.	Disch'd July 31, 1864; pensioned. Sept., 1873, power to elevate arm and shoulder lost.
26	Dinnen, J., Pt., E, 79th New York, age 39.	June 14, 1862.	Minié ball, after fracturing the inferior maxilla, entered the left shoulder joint.	July 10, 1862.	Head and one inch of the shaft of the humerus removed through a straight anterior incision, by Dr. T. M. Markoe.	Disch'd May 21, 1864; pensioned. Sept., 1873, disability equal to loss of arm for labor.
27	Dolan, J., Pt., D, 9th New York State Militia, age 30.	May 6, 1861.	Shot fracture of left humerus.	May 15, 1861.	Head and five inches of shaft of humerus excised, by Surg. A. F. Sheldon, U. S. V.	Disch'd July 23, 1865; not a pensioner in March, 1875.
28	Dolan, J., Pt., D, 63d New York, age 40.	Sept. 17, 1862.	Conoidal ball fractured the head of the left humerus; also fracture of upper jaw.	Intermediate.	Excision of the head and two inches of the shaft of humerus.	Disch'd Dec. 20, 1862; pensioned. Sept., 1867, arm atrophied, paralyzed, and almost useless. Died March 8, 1872.
29	Drown, B. F., Corporal, C, 5th Rhode Island Artillery.	Dec. 16, 1862.	Missile passed thro' the head and neck of the right humerus, fracturing the tuberosity.	Dec. 30, 1862.	Excision of head and portion of shaft of humerus through a semi-lunar incision, by Surg. E. P. Morong, 2d Maryland.	Promoted Lieut. in April, 1864; discharged Dec. 23, 1864; pensioned. Sept., 1873, forearm somewhat weakened; arm entirely useless.
30	Dumble, J., Pt., E, 3d New Jersey.	May 5, 1861.	Comp'd comminuted fracture of the upper portion of left humerus, involving the joint.	May 13, 1861.	Excision of the head and three inches of the shaft of humerus, by A. A. Surg. J. H. Thompson.	Disch'd Jan. 30, 1865; pensioned. Sept., 1873, has no shoulder power; arm shortened three inches.
31	Eberle, H., Pt., U, 28th Pennsylvania.	May 2, 1863.	Extensive shot fracture of the surgical neck and upper portion of left humerus.	May 17, 1863.	Excision of the head and four and a half inches of shaft of humerus, by Surg. D. W. Bliss, U. S. V.	Disch'd June 1, 1864; pensioned. Dec., 1869, disability total, 3d grade. <i>Spec.</i> 1262, A. M. M.
32	Figgins, G. C., Pt., G, 8th Illinois, age 25.	April 9, 1865.	Gunshot wound of the right shoulder joint.	April 9, 1865.	Excision of neck of humerus. May 3d, head and an inch of the upper extremity of the bone removed, by Surg. W. D. Murray, 161st New York.	Disch'd July 18, 1865; pensioned. Oct., 1873, arm shortened and motion and power diminished.
33	Fill, G., Pt., G, 75th Illinois, age 31.	June 1, 1864.	Shot fracture of the upper third of left arm.	June 8, 1864.	Excision of three inches of the upper extremity of humerus, including the head, by Surg. S. H. Kersey, 36th Indiana.	Disch'd June 8, 1865; pensioned. Sept., 1873, arm hangs powerless at the side.
34	Gregg, J., Sergeant, F, 69th Pennsylvania, age 24.	Nov. 27, 1863.	Shot fracture of head of left humerus near the greater tuberosity.	Dec. 25, 1863.	Excision of the head and one inch of the shaft of humerus thro' a straight incision, by Surg. D. P. Smith, U. S. V.	Disch'd Mar. 5, 1864; pensioned. Died Mar. 5, 1870, of injuries received by a fall from a building. <i>Spec.</i> 2002, A. M. M.
35	Hall, J. M., Pt., I, 27th Indiana.	Sept. 17, 1862.	Minié ball carried away the inner half of the head of right humerus.	Oct. 4, 1862.	Excision of the head and one inch of the shaft of humerus through a straight incision by A. A. Surg. J. H. Peabody.	Disch'd Dec. 17, 1862; pensioned. Sept., 1873, use of joint entirely lost; no ability to raise arm. <i>Spec.</i> 451, A. M. M.
36	Higgins, W., Pt., A, 11th Connecticut, age 18.	June 3, 1861.	Shot fracture of left humerus near the shoulder joint.	June 17, 1861.	Excision of the head and portion of shaft of humerus, by A. A. Surg. J. H. York.	Disch'd Dec. 16, 1865; died Dec. 28, 1865. <i>Spec.</i> 3304, A. M. M.
37	Horton, W. L., Lieutenant, 24th Massachusetts, age 24.	Mar. 14, 1862.	Conoidal ball comminuted the surgical neck and upper third of the right humerus.	Mar. 28, 1862.	Head and four inches of shaft of humerus removed through a straight incision, by Surg. S. A. Green, 24th Mass.	Resigned March 12, 1864; pensioned. Sept., 1873, good use of hand and forearm; no bony union.
38	Houston, T., Pt., I, 25th Illinois.	Dec. 30, 1862.	Minié ball passed directly thro' the neck of left humerus, fracturing the head and neck.	Jan. 12, 1863.	Excision of the head and neck of the humerus, about four inches in all.	Disch'd Mar. 7, 1863; pensioned. Sept., 1873, arm atrophied; can scarcely be moved in any direction.
39	Hyde, W., Pt., D, 2d Massachusetts, age 26.	July 3, 1863.	Conoidal ball fractured the head and neck of left humerus and comminuted the upper third of the shaft.	July 20, 1863.	Excision of the head and five inches of shaft of humerus through a crucial incision, by Surg. W. H. Heath 2d Mass.	Disch'd May 24, 1864; pensioned. Sept., 1873, arm useless.
40	Ingle, J., Pt., F, 15th New York Artillery, age 31.	May 12, 1864.	Comminuted shot fracture of upper third of left humerus.	May 21, 1861.	Excision of the head and three inches of the shaft of humerus through a longitudinal incision, by Asst. Surgeon J. C. McKee, U. S. A.	Disch'd Jan. 10, 1865; pensioned. Sept., 1873, necrosis still exists; arm useless for labor.
41	Johnson, G., Pt., I, 9th Colored Troops, age 17.	Sept. 29, 1864.	Surgical neck of right humerus considerably comminuted by shot; extensive laceration.	Oct. 27, 1861.	Head and three inches of shaft of humerus excised through a longitudinal incision, by A. A. Surgeon C. C. Ela.	Disch'd Dec. 6, 1865; pensioned. Sept., 1873, arm of little use as a means of performing labor. <i>Spec.</i> 2438, A. M. M.
42	Lamb, L. L., Pt., F, 83d Pennsylvania, age 21.	May 8, 1861.	Fracture of upper third of right humerus by a conoidal ball.	May 18, 1861.	Head and three inches of shaft of humerus excised, by Surg. E. Bentley, U. S. V.	Disch'd Dec. 16, 1864; pensioned. Sept., 1873, also unrelieved dislocation of left shoulder; disability equivalent to entire loss of both arms.
43	Lanham, N., Pt., G, 45th Georgia, age 48.	May 12, 1861.	Shot fracture of upper portion of right humerus.	May 22, 1861.	Excision of the head and upper portion of the shaft of humerus.	Released July 18, 1865.
44	Lauffer, J., Pt., C, 6th Connecticut, age 25.	June 17, 1861.	Fracture of left humerus by round musket ball.	July 5, 1861.	Excision of the head and four inches of shaft of humerus through a linear incision, by A. A. Surg. J. H. Jamar.	Disch'd Jan. 13, 1865; pensioned. Nov., 1872, muscular atrophy; inability to elevate arm. <i>Spec.</i> 3611, A. M. M.
45	Lee, H. L., Captain, G, 38th Virginia, age 35.	July 3, 1863.	Extensive shot comminution of head of humerus, with laceration of soft parts.	Aug. 1, 1863.	Excision of four inches of upper extremity of humerus, including head of the bone.	Recovered. Furloughed Oct. 15, 1863. "Bids fair to make a beautiful cure."



NO.	NAME, AGE, AND MILITARY DESCRIPTION.	DATE OF INJURY.	NATURE OF INJURY.	DATE OF OPERATION.	OPERATION AND OPERATOR.	RESULT AND REMARKS.
46	McMannus, S., Corporal, K, 22d Wisconsin, age 21.	July 20, 1864.	Comminution of head of right humerus and injury of glenoid cavity by bullet.	Aug. 20, 1864.	Excision of the head and four inches of shaft of humerus, by Surgeon H. Culbertson, U. S. V.	Disch'd Nov. 15, 1865; pensioned. Sept., 1873, muscular atrophy.
47	Martin, F., Pt., B, 16th Pennsylvania Cavalry, age 18.	May 23, 1864.	Shot fracture of the head of the right humerus.	June 6, 1864.	Excision of the head and three inches of the shaft of the humerus through a straight incision, by Surgeon A. F. Sheldon, U. S. V.	Disch'd Sept. 23, 1864; pensioned. Died Oct. 12, 1868.
48	Martz, W. H., Pt., D, 1st Pennsylvania Rifles, age 23.	Sept. 14, 1862.	Musket ball shattered the head of the humerus.	Sept. 18, 1862.	Excision of the head and two inches of the shaft of humerus, by Surg. G. C. Humphreys, 9th New York.	Disch'd April 8, 1863; pensioned. May, 1874, moderately useful arm for some purposes, but useless for his occupation.
49	Mason, R. B., Pt., I, 7th Michigan, age 25.	June 30, 1862.	Minié ball crushed the posterior part of the head of right humerus; fissures extended into the shaft.	July 19, 1862.	Head and four inches of shaft of humerus removed thro' semi-circular incision, by A. A. Sur. D. N. Rankin, assisted by Surgs. R. H. Coolidge, U. S. A., and J. H. Britton, U. S. V.	Disch'd Nov. 20, 1862; pensioned. Jan'y, 1874, muscular atrophy, and utter uselessness of arm for labor. Spec. 1, A. M. M.
50	Meneke, J., Corporal, C, 7th New York, age 32.	April 2, 1865.	Shot fracture of neck of right humerus.	Ap'l 14, 1865.	Excision of the head and four inches of shaft of humerus through straight incision, by Act. Staff Surg. W. J. Burr.	Disch'd Jan. 9, 1865; pensioned. Aug., 1866, arm pendulous and useless at side.
51	Mulvalo, P., Corp'l, C, 95th New York, age 37.	Feb. 8, 1865.	Fracture of the neck of right humerus by a minié ball.	Feb. 28, 1865.	Excision of head and three inches of shaft of humerus through a straight incision, by Ass't Surg. J. Vansant, U. S. A.	Disch'd Aug. 12, 1865; pensioned. Sept., 1873, disability total, 3d grade.
52	Neunzinger, F., Pt., D, 54th New York.	Aug. 28, 1862.	Extensive comminution of the left humerus, with separation of the head from shaft, by a conoidal ball.	Sept. 25, 1862.	Head and six inches of shaft of humerus removed, by A. A. Surg. J. Homans.	Disch'd April 6, 1863; pensioned. Sept., 1873, no union of bone; disability total, 3d grade. Spec. 155, A. M. M.
53	Nicholson, J. B., Corp'l, I, 1st Wisconsin Cavalry, age 33.	Sept. 27, 1864.	Head and upper portion of the shaft of left humerus badly comminuted by a musket ball.	Oct. 11, 1864.	Head and a portion of the shaft of humerus removed through a vertical incision, by Surg. J. R. Ludlow, U. S. V.	Disch'd May 16, 1865; pensioned. Died Jan. 7, 1870, of pyæmia, resulting from profuse suppuration at shoulder.
54	Pierce, H., Pt., B, 3d N. York Mounted Rifles, age 18.	Sept. 30, 1864.	Shot fracture of head of right humerus.	Oct. 18, 1864.	Excision of head and a portion of shaft of humerus, two and a half inches in all, by Ass't Surgeon C. Wagner, U. S. A.	Disch'd May 21, 1865; pensioned. Sept., 1873, loss of use of arm.
55	Potter, W. J., Pt., E, 185th New York, age 34.	Mar. 29, 1865.	Comminuted shot fracture of the right humerus, involving the shoulder joint.	April 5, 1865.	Excision of the head and two inches of shaft of humerus, by Ass't Surgeon H. Allen, U. S. A.	Disch'd June 1, 1865; pensioned. Died May 17, 1871, of pyæmia. Spec. 68, A. M. M.
56	Richards, F. M., Corp'l, F, 11th N. Hampshire, age 22.	May 12, 1864.	Comminuted shot fracture of upper third of right humerus; also wound of right thigh.	June 4, 1864.	Head and three inches of shaft of humerus removed through a straight incision.	Disch'd Ap'l 28, 1865; pensioned. May, 1874, cannot do over three-fourths ordinary labor.
57	Richardson, A. B., Pt., 23d Penn'a Cavalry, age 26.	Nov. 9, 1862.	Shot fracture of the head of left humerus.	Nov. 22, 1862.	Head and three-fourths of an inch of humerus removed, by Surgeon W. D. Wyner, 23d Illinois.	Disch'd June 2, 1864; pensioned. Sept., 1872, disability total, 3d grade.
58	Richetts, W. H., Pt., A, 13th Virginia, age 22.	June 27, 1862.	Conoidal ball lacerated capsule and split the right humerus in many fragments for three inches.	July 6, 1862.	Head and five inches of shaft of humerus removed through a perpendicular incision, by Surg. O. F. F. Manson, U. S. A.	March, 1864, very good use of arm; functions of forearm and hand perfect; writes well.
59	Riggs, G., Pt., E, 12th New Jersey, age 40.	May 3, 1863.	Musket ball shattered the acromial extremity of the clavicle and neck and upper portion of shaft of right humerus.	May 25, 1863.	Removal of the head and two inches of the shaft of the right humerus, by Ass't Surgeon C. A. McCall, U. S. A.	Disch'd Nov. 7, 1863; pensioned. Sept., 1873, disability equivalent to loss of hand or foot. Spec. 1190, A. M. M.
60	Risley, D. G., Capt., E, 9th Colored Troops, age 28.	Sept. 29, 1864.	Musket ball comminuted the superior extremity of right humerus; great laceration of soft parts.	Oct. 3, 1864.	Head and five inches of shaft of the humerus removed thro' a V-shaped incision, by Surg. D. G. Rush, 101st Pennsylvania.	Disch'd May 15, 1866; pensioned. Appointed Lieutenant U. S. A., July 28, 1866; retired Dec. 31, 1870, as Captain, U. S. A. Spec. 3804, A. M. M.
61	Rose, D., Pt., I, 8th New Jersey, age 18.	May 3, 1863.	Minié ball entered the inner aspect of the left arm, comminuting the bone up to its head.	May 16, 1863.	Excision of the head and three and a half inches of humerus, by Ass't Surg. C. A. McCall, U. S. A.	Disch'd June 19, 1865; pensioned. Sept., 1873, disability total, 3d grade. Spec. 1177, A. M. M.
62	Royal, W., Pt., H, 121st Pennsylvania.	Dec. 13, 1862.	Shot fracture of the upper portion of right humerus.	Dec. 18, 1862.	Excision of four inches of the upper extremity of humerus, including the head.	Disch'd July 23, 1863; pensioned. Sept., 1873, disability total, 3d grade.
63	Ruddy, J., Pt., A, 63d New York.	Mar. 31, 1865.	Head of the left humerus very much shattered by a conoidal ball.	Ap'l 22, 1865.	Excision of the head and a portion of shaft of humerus, by Surg. R. B. Bontecou, U. S. V.	Disch'd July 12, 1865; pensioned. Died June 26, 1868.
64	Shepherd, J. B., Lieut., 1st Missouri Artillery, age 24.	July 17, 1864.	Comminuted shot fracture of upper third of left humerus, badly splintering the bone and extending into the joint.	July 26, 1864.	Excision of the head and upper portion of shaft of humerus, by Ass't Surg. J. M. Study, U. S. V.	Disch'd July 25, 1865; pensioned. Sept., 1873, muscular atrophy and adherent cicatrix.
65	Shepler, J., Pt., B, 108th N. York, age 24.	June 3, 1864.	Comminuted shot fracture of the right humerus.	June 13, 1864.	Head and four inches of shaft of humerus removed through a longitudinal incision, by A. A. Surgeon A. Ansell. July 13th, amputation at shoulder joint, by Ass't Surg. J. C. McKee, U. S. A.	Disch'd Feb. 6, 1865; pensioned. Spec. 550, A. M. M.
66	Shirmeister, G., Corp'l, H, 54th New York, age 20.	Aug. 29, 1862.	Round musket ball passed through left shoulder joint, splintering head of humerus.	Sept. 3, 1862.	Excision of head and two and a half inches of shaft of humerus through a V shaped incision, by Surgeon C. Page, U. S. A.	Disch'd Sept. 15, 1864; pensioned. October, 1873, arm useless for labor.
67	Shockey, V., Corp'l, A, 8th Iowa, age 21.	Ap'l 27, 1865.	Comminuted fracture of the entire upper third of left humerus by shot.	May 4, 1865.	Excision of head and upper third of left humerus, by A. Surg. J. M. Study, U. S. V.	Disch'd Ap'l 10, 1866; pensioned. Oct., 1873, ankylosis of shoulder joint; use of arm destroyed.
68	Shufelt, L., Pt., C, 157th N. York, age 33.	July 1, 1863.	Conoidal ball fractured, and lodged in, the head of left humerus; fissures running down shaft.	July 7, 1863.	Head and four inches of shaft of humerus removed through a straight incision.	Disch'd Feb. 17, 1864; pensioned. Sept., 1873, arm of but little use.

No.	NAME, AGE, AND MILITARY DESCRIPTION.	DATE OF INJURY.	NATURE OF INJURY.	DATE OF OPERATION.	OPERATION AND OPERATOR.	RESULT AND REMARKS.
69	Singleton, D., Sergeant, F., 140th Pennsylvania, age 30.	May 12, 1864.	Conoidal ball lodged in head of left humerus, splitting it.	May 27, 1861.	Head and two inches of shaft of humerus removed through a straight incision, by Surgeon O. A. Judson, U. S. V.	Disch'd June 10, 1865; pensioned. Sept., 1873, arm useless for manual labor.
70	Smith, S., Pt., H., 150th Pennsylvania, age 36.	May 10, 1861.	Comp'd comminuted shot fracture of the head and shaft of the right humerus.	May 18, 1861.	Removal of head and three inches of the shaft of humerus through an S-shaped incision, by Surg. Z. E. Bliss, U. S. V.	Disch'd Jan. 7, 1865; pensioned. Sept., 1873, arm useless for labor.
71	Smith, W., Pt., D., 20th Pennsylvania, age 19.	June 5, 1864.	Fracture of the head of the left humerus by a conoidal ball.	July 6, 1861.	Removal of the head and three inches of shaft of humerus, by a Confederate surgeon, at Richmond.	Disch'd July 25, 1865; pensioned. Sept., 1873, arm hangs useless.
72	Sperry, C., Pt., C., 94th New York, age 19.	Aug. 30, 1862.	A minie ball split head of right humerus into three parts and separated the greater tuberosity at epiphysal line of union.	Sept. 4, 1862.	Removal of the head of the humerus, by A. A. Surgeon J. Hancock.	Disch'd Nov. 10, 1862; pensioned. Oct., 1873, good movement; fistulous opening discharging pus. <i>Spec.</i> 315, A. M. M.
73	Spindler, G., Pt., K., 14th Connecticut, age 33.	May 5, 1864.	Conoidal ball fractured the left humerus.	May 17, 1864.	Head and one and a half inches of shaft of humerus removed, by Surgeon A. F. Sheldon U. S. V.	Disch'd June 6, 1865; pensioned.
74	Sullivan, F., Pt., F., 5th New Hampshire, age 21.	June 3, 1864.	Fracture of the head of right humerus by a musket ball; shoulder dislocated; bone denuded of periosteum.	June 29, 1864.	Excision of the head and four inches of the shaft of humerus through a straight incision, by Surg. E. Bentley, U. S. V.	Disch'd Nov. 29, 1864; pensioned. Sept., 1873, arm useless. <i>Spec.</i> 2712, A. M. M.
75	Sweet, L. G., Pt., I., 17th New York, age 26.	Aug. 30, 1862.	Upper two-thirds of epiphysis of left humerus carried away and remainder broken into many fragments; capsule opened; also wound of left forearm, leg, and thigh.	Sept. 14, 1862.	Head and two inches of shaft of humerus removed through an S-shaped incision, by Surg. D. W. Bliss, U. S. V.	Disch'd Oct. 30, 1862; pensioned. Sept., 1873, muscular atrophy; disability total, 3d grade. <i>Spec.</i> 185, A. M. M.
76	Tincher, S. T., Pt., D., 14th Indiana.	May 6, 1864.	Shot fracture of right humerus and anterior and posterior border of glenoid cavity.	June 1, 1861.	Head and three inches of shaft of humerus excised through a straight incision, by Ass't Surg. J. C. McKee, U. S. A.	Disch'd Oct. 10, 1864; pensioned. Sept., 1873, disability total, 3d grade. <i>Phot.</i> 146, A. M. M.
77	Turner, J. H., Pt., E., 2d Florida, age 27.	May 5, 1864.	Comminuted shot fracture of upper third of left humerus.	May 15, 1864.	Head and four inches of shaft of humerus removed through a V-shaped incision.	Furloughed July 27, 1864; recovered.
78	Underwood, R. L., Pt., L., 6th Ohio Cavalry, age 19.	Mar. 31, 1863.	Minie ball passed through the neck of right humerus, fracturing and comminuting shaft.	April 6, 1865.	Excision of head and a portion of the shaft of humerus, by Surg. D. W. Bliss, U. S. V.	Disch'd July 21, 1865; pensioned. Amp. of arm at shoulder, July 10, 1867, by Dr. McDermont. <i>Spec.</i> 3492, A. M. M.
79	Verieker, W., Pt., E., 9th Massachusetts, age 22.	July 1, 1862.	Minie ball carried away one-third of head of left humerus, fractured the remaining two-thirds, and crushed the coracoid process of scapula.	July 18, 1862.	Removal of the head and half an inch of shaft of humerus and detached fragments of scapula, by Surgeon R. H. Coolidge, U. S. A., assisted by Surgeons J. H. Brinton and D. M. Rankin.	Disch'd Dec. 15, 1862; pensioned. So t., 1873, for purposes of manual labor the arm is almost entirely useless.
80	Wagner, E. F., Serg't, K., 12th Infantry, age 25.	June 27, 1862.	Shot fracture of the head and neck of the left humerus.	July 13, 1862.	Excision of the head and two and a half inches of shaft of humerus, by Ass't Surg. H. S. Sehell, U. S. A.	Disch'd Oct. 21, 1862; pensioned. Sept., 1873, loss of use of shoulder and limb.
81	Watkins, W. F., Serg't, A., 5th Michigan, age 46.	May 5, 1862.	Compound fracture of upper third of left humerus by a conoidal ball.	May 15, 1862.	Excision of the head and five inches of the shaft of humerus through a linear incision, by Surg. H. McLean, 2d N. York.	Disch'd Aug. 29, 1862; pensioned. Dec., 1873, indications of necrosis of bone; arm perfectly useless.
82	Watson, J., Pt., F., 1st Maryland Cavalry, age 24.	Aug. 16, 1864.	Head and upper part of shaft of left humerus very much comminuted by a conoidal ball.	Aug. 23, 1864.	Excision of the head and three inches of shaft of humerus, by A. A. Surg. C. T. Bullen.	Disch'd October 18, 1865. Had not been admitted to pension in August, 1874.
83	Weaver, S., Pt., G., 93d New York, age 25.	May 5, 1864.	Minie ball perforated the head of left humerus and emerged over the scapula.	May 12, 1861.	Excision of the head and two inches of shaft of humerus, by Surg. J. H. Thompson, 12th New York.	Disch'd Nov. 22, 1865; pensioned. April, 1867, arm cannot be extended without help from opposite arm.
84	Wendorff, A., Pt., B., 26th Wisconsin, age 18.	July 20, 1864.	Right humerus very much comminuted by a musket ball; shoulder joint involved.	July 29, 1861.	Excision of the head and three inches of shaft of humerus through a straight incision, by A. A. Surg. E. G. White.	Disch'd Jan. 9, 1865; pensioned. Sept., 1873, only backward and forward motion possible; three inches shortening and some atrophy.
85	Weston, S. B., Serg't, M., 1st Rhode Island Cavalry.	June 18, 1863.	Fracture of upper third of the left humerus by a conoidal ball.	July 3, 1863.	Excision of the head and two inches of shaft of humerus, by Surg. J. Wilson, U. S. V.	Disch'd Jan. 23, 1864; pensioned. Sept., 1873, upper arm useless; forearm comparatively so.
86	Whiteomb, W., Pt., B., 60th Ohio, age 23.	June 21, 1864.	Conoidal ball completely destroyed the integrity of head of right humerus and fractured the surgical neck.	July 5, 1864.	Head and one inch of shaft of humerus excised, by Surg. E. Bentley, U. S. V.	Disch'd June 1, 1865; pensioned. <i>Spec.</i> 2830, A. M. M., and <i>Phot.</i> 100.
87	Williams, O., Pt., K., 20th Michigan, age 20.	Nov. 18, 1863.	Shot fracture of upper third of the left humerus.	Nov. 30, 1863.	Head and five inches of shaft of humerus excised, by Surg. A. P. Hooker, 26th Mass.	Disch'd May 18, 1864; pensioned. Oct., 1869, uses forearm to feed himself; handles light articles.
88	Wolf, C. M., Corp'l, B., 5th New Hampshire, age 28.	Aug. 25, 1861.	Shot wound of left shoulder joint, with compound comminuted fracture of upper third of humerus.	Aug. 30, 1864.	Excision of head and about two inches of shaft of humerus through a longitudinal incision, by A. A. Surg. L. C. Doige.	Disch'd Dec. 3, 1861; pensioned. Sept., 1866, unable to use arm for any purpose. <i>Spec.</i> 3161, A. M. M.
89	Wombacker, F., Capt., E., 49th Pennsylvania.	May 12, 1864.	Conoidal ball perforated neck of right humerus, fracturing and splitting upper end of shaft.	May 31, 1864.	Excision of the head and three inches of shaft of humerus, by Surg. D. W. Bliss, U. S. V.	Disch'd July 15, 1865; pensioned. Sept., 1873, arm useless for manual labor. <i>Spec.</i> 2394, A. M. M.
90	Woods, E. H., Pt., G., 6th Maine, age 24.	May 3, 1863.	Upper portion of right humerus badly comminuted by a minie ball.	May 15, 1863.	Excision of the head and three and a half inches of shaft of humerus through a linear incision, by Ass't Surgeon C. A. McCall, U. S. A.	Disch'd Nov. 13, 1863; pensioned. Dec., 1866, arm almost useless for labor. <i>Spec.</i> 1118, A. M. M.
91	Yeager, J. F., Pt., F., 50th Pennsylvania, age 22.	May 9, 1864.	Comminuted shot fracture of the external border of the right scapula and head of the humerus.	May 16, 1864.	Removal of the head and two inches of shaft of humerus, and pieces of glenoid cavity and body of scapula, through a straight incision, by Ass't Surg. H. A. Cox, U. S. A.	Disch'd July 30, 1865; pensioned. Sept., 1873, arm totally useless for purposes of labor. <i>Spec.</i> 2235, A. M. M.



In two of the ninety-one operations above tabulated, consecutive amputation at the shoulder was practised; and, in another case, intermediary hæmorrhage necessitated the ligation of the right axillary artery. Seven of the ninety-one were operations on Confederate, and eighty-four on Union soldiers; and eighty of the latter were pensioned. The method of operation was specified in only forty-four instances, and was described as by straight anterior incision, in thirty instances—by U or V-shaped flaps, in seven—by a curvilinear or S-incision, in six—by a crucial incision, in one. Forty-seven operations were on the right, forty-two on the left, and two cases were undetermined. Five of the mutilated men died subsequently, at periods from six to ten years after operation. In thirty-four instances, pathological preparations were transmitted to the Museum:

CASE 1560.—Private E. H. Woods, Co. G, 6th Maine, was wounded at Chancellorsville, May 3, 1863, and was admitted to Mount Pleasant Hospital, Washington. Acting Assistant Surgeon E. Cones reported: "The patient, a very robust, muscular man, aged 24 years, was admitted May 8th. A minie ball had entered the outer anterior aspect of the shoulder, passed



FIG. 453.—Apparatus employed in case of excision at the shoulder. [From a photograph.]

backward and inward, and badly comminuted the upper portion of the humerus, the fracture extending up into the joint. Operation of resection of five and a half inches of the humerus with the head was performed, May 15th, by Assistant Surgeon C. A. McCall, U. S. A." The specimen (FIG. 454) consists of the head and three and a half inches of the right humerus. The anterior face of the shaft and posterior portion of the head are carried away, and the articular surface is split in two vertically. It was contributed by the operator. The patient recovered and was discharged the service, and pensioned November 13, 1863. At that date, Examiner T. B. Smith, of Washington, reported: "Ball entered the shoulder an inch below the coracoid process; and passed backward, fracturing the humerus in the upper portion. Resection of the head and about three inches of the shaft in consequence. Hand motions perfect, but unavailable for labor by reason of uselessness of the arm; may improve much in a couple of years." In November, 1865, Dr. E. D. Hudson, of New York, furnished this man with an artificial limb, and reported that there had been an excision of five inches of the shaft and head of the humerus through a linear incision, posteriorly, of the deltoid, and that the arm was shortened three-fourths of an inch, with slight atrophy. The general condition of the arm was excellent, the interspace being mainly filled with new growth of the continuity. The usefulness of the apparatus while under observation was very satisfactory. Dr. Hudson contributed a photograph, represented in the accompanying cut (FIG. 453), showing the mode of adaptation of the apparatus to the limb, and another giving a view of the patient, showing the cicatrix, which will be found on page 2, Vol. IX, *Contributed Photographs*, A.

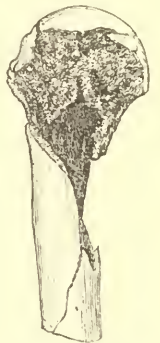

FIG. 454.—Upper extremity of right humerus excised for shot fracture. *Spec. 1118.*

M. M. In June, 1867, Examiner A. H. Agard, of Sandusky, Ohio, reported: "The excised end or stump has not formed a joint, but plays all about, rendering the arm quite useless for purposes of manual labor." The pensioner was paid March 1, 1874.

CASE 1561.—Private W. Vericker, Co. E, 9th Massachusetts, aged 25 years, was wounded at Malvern Hill, July 1, 1862, and was sent to Washington, and admitted to Epiphany Hospital on July 4th. Acting Assistant Surgeon D. N. Rankin reported: "Wounded by a minie ball entering at the outer side of the upper third of the humerus, passing obliquely upward, and carrying away one-third of the head of the humerus, also making a triangular fracture of the outer two-thirds of that part, the ball continuing in its course upward, crushing the coracoid process of the scapula, comminuting the humeral end of the clavicle, and making its exit immediately above the inner side of the supra-spinatus fossa. On the 18th of July, the operation of resection of the upper third of the humerus was performed by Surgeon R. H. Coolidge, U. S. A., assisted by Surgeon J. H. Brinton, U. S. V., and Acting Assistant Surgeon D. N. Rankin; he made the V-shaped incision, the point being upward; in dissecting up the flap large sinuses were discovered, especially one very large one, which was much more noticeable than the rest; it occupied the space between the ribs and clavicle, and when cut into discharged more than a pint of very unhealthy looking pus. All the pieces of comminuted bone were removed that could readily be taken away without complicating the operation, as it was supposed at that time that it would be impossible that the operation should prove successful, the system being in such a very bad condition, so much so that, in consultation, it was a very long time before it was fully decided upon to operate. The incisions were drawn together by sutures and adhesive plasters, with lint and a bandage over it, and a handkerchief sling to support the arm; the next day the cold-water dressing was commenced, and continued, though we found it necessary to put a felt splint on the elbow and forearm to assist in supporting the arm. Since the day the operation has been performed he has been improving rapidly; he has been taking the most nutritious food that could be gotten for him, such as beef essence, eggs, chicken soup, chickens, mutton, etc. He has been taking as tonics quinine, muriate tincture of iron, brandy, punch, porter, etc. His condition at this time, the 2d day of August, is certainly very cheering." The patient remained under treatment until December 15, 1862, when he was discharged the service and pensioned. Examiner G. S. Jones, of Boston, July 2, 1863, in a special report says: "The

head of the humerus has been resected, and a fistulous opening now exists, from which matter is discharging. The arm is now powerless and useless." In a letter dated December 25, 1865, Surgeon General Dale, of Massachusetts, reported that this man was employed as a farmer at North Bridgewater, Massachusetts; that there had been no fistulous openings or other inconveniences since the operation; that the man could put his hand to his head, and that the voluntary movements of the arm were otherwise eminently satisfactory. The South Abington Board, Drs. A. Millet and B. F. Hastings, report, September 6, 1873: "The ball entered the left shoulder joint and humerus of the left arm, fracturing the scapula, and passed out above the inner end of the clavicle. The motion of the shoulder joint is almost lost. The muscles about the shoulder and left arm are greatly atrophied and very adherent to the bone. For purposes of manual labor, the arm is almost entirely useless." A photograph of the specimen, shown as No. 121, Vol. III, *Phot. Ser.*, A. M. M., represents the head and one-half inch of the shaft of the left humerus. The inner portion of the head is carried away and the articular surface is eroded. This pensioner was paid September 4, 1874.

CASE 1562.—Captain D. G. Risley, Co. E, 9th Colored Troops, aged 28 years, was wounded in the arm at Deep Bottom, September 29, 1864, and, on October 3d, was received into Chesapeake Hospital, Fort Monroe. Surgeon D. G. Rush, 101st Pennsylvania, made the following special report of the case: "The missile entered the outer aspect of the arm, through the middle of the deltoid muscle, four inches below the head of the bone, producing unusual comminution, driving numerous fragments of the bone into the axilla and beneath the scapula, under which it passed and effected a hidden lodgement, where it still remains. The wounded man was carried off the field and did not arrive here until the morning of October 3d, at which time he was suffering from extreme pain and anxiety, having been told that he was not in a condition to bear amputation at the shoulder joint, which alone could save his life. He was emaciated and anæmic from an attack of miasmatic fever, from which he had just recovered. The soft parts were lacerated, swollen, everted, and painful; and the patient inclined to the belief that the wound was occasioned by a fragment of shell, but the lodgement remaining innocuous, tends to prove that it was a musket ball. On the afternoon of the day of his admission, I removed the head and fragments of the humerus, amounting to six inches, through a V-shaped incision, commencing immediately before and behind the acromion and terminating in the external wound. The comminuted fragments were first removed, carefully separating them from any attached periosteum, which, even though in shreds, was not removed. The next step was to detach the periosteum from the remaining fragment of shaft of bone attached to the head, which had partly been effected by the missile. The condition of the patient improved immediately, and by cold-water irrigation, tonics, moderate use of stimulants, and a very nourishing diet, he made a good recovery, being convalescent in six weeks after the operation. A large amount of callus was developed by the periosteum, producing a good substitute for the head of the bone, enabling the patient to perform considerable motion at the time of his discharge from hospital, January 25, 1865, with a fair prospect of future usefulness of the limb." Captain Risley was discharged from service May 15, 1865, for disability, and pensioned. On October 5, 1863, he was again commissioned as Second Lieutenant 42d Veteran Reserves. The adjoining wood-cut (FIG. 455) was taken from a card photograph, shown in Vol. II, page 9, *Card Photographs*, A. M. M. The specimen, No. 3804, *Surg. Sect.*, A. M. M., consists of the head and five inches of the shattered shaft of the right humerus excised. The epiphyseal portion is uninjured, but the remainder of the specimen is much broken. Contributed by the operator. Examiner D. H. Henry, of Elkhart, Indiana, reported, February 16, 1836, that "the arm and forearm at present are totally disabled."

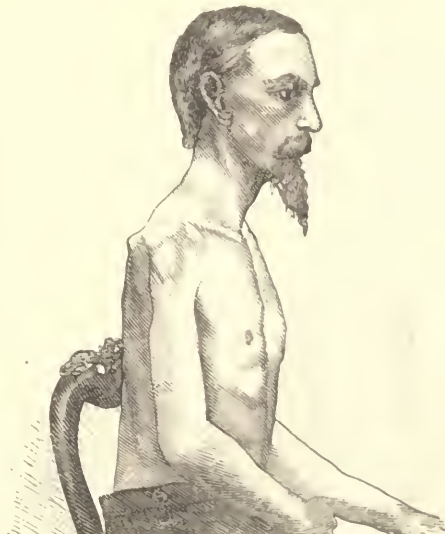

FIG. 455.—Cicatrix after intermediary excision of the upper extremity of the humerus. [From a photograph.]

CASE 1563.—Private *W. H. Ricketts*, Co. A, 13th Virginia, aged 22 years, was wounded at Gaines's Mills, June 27, 1862, and was admitted to Confederate Hospital No. 24, at Richmond, on the 28th. The case was recorded in Confederate Register No. 100, as follows: "A conoidal ball passed through the right arm near the shoulder joint, lacerated the capsule, and split the humerus in many fragments for three inches below the surgical neck. The head of the humerus was attached to a mere fragment; the glenoid cavity was uninjured. Great depression followed the injury. On July 5th, chloroform was administered, and excision of the head of the right humerus and five inches of the shaft by a perpendicular incision, was performed by Surgeon Otis Frederic Manson, P. A. C. S. After carefully removing all spiculae, the wound was closed by sutures, the limb placed upon a pillow, and cold-water dressings applied. The cure of the case was delayed by three separate attacks of erysipelas, the last of which occurred about August 22d; these yielded, however, to quinia and iron. March, 1864, the patient has very good use of his arm; the functions of the forearm and hand are nearly perfect; he writes well." A report of this case was published by the operator in the *Confederate States Medical and Surgical Journal*, Richmond, 1864, Vol. I, No. 3, p. 40, with a wood-cut of the patient showing the resulting cicatrix, and of the pathological specimen. An enlarged copy of the latter is represented by the adjacent cut (FIG. 456). Dr. Manson, in this publication, dated March, 1864, states: "The patient has now very good use of his arm; the functions of the forearm and fingers being almost perfect. He writes a beautiful hand, and, altogether, presents another of the many proofs of the value of this surgical expedient in preference to that formerly practised in such cases—amputation at the shoulder joint."

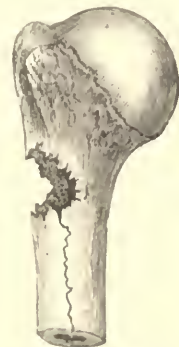

FIG. 456.—Excised upper extremity of right humerus. [Enlarged from a drawing in the *Conf. States Med. and Surg. Jour.*, 1864, Vol. I, p. 40.]



Periostitis, osteitis, and osteomyelitis of a portion or the whole of the remaining part of the humerus were not very infrequent after intermediary excision of the upper extremity of the bone; such examples were more common, however, among the fatal cases. The following is an instance of superficial caries of the diaphysis following periostitis:

CASE 1564.—Private R. B. Mason, Co. I, 7th Michigan, aged 25 years, was wounded at White Oak Swamp, June 30, 1862, and was sent to Washington, and admitted into Epiphany Hospital on July 4th. Acting Assistant Surgeon D. N. Rankin furnished the following report of the case: "Wounded by a minié ball, which entered at the outer side of the upper third of the humerus, passed obliquely upward, and through the posterior part of the head of the bone, causing several long fissures, extending three inches downward. The posterior part of the bone is likewise crushed to pieces; three large fragments are connected with the head and extend to the body of the bone; the fissures do not quite extend to the place where the bone was sawn off, the latter being about one-quarter of an inch farther down, the ball making its exit immediately below the acromion process. The patient having had pneumonia complicated with the wound, we were deterred from operating as soon as we wished. He was put on the best known treatment for pneumonia in order to get him in a better condition for operating; but we did not succeed

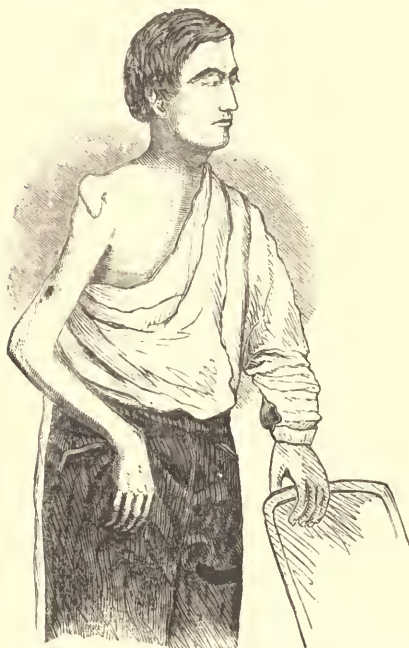

FIG. 457.—Appearance of cicatrix after intermediary excision of the head and portions of the shaft of the humerus, four years after operation. [From a photograph.]

very well in this particular, and finally concluded to operate notwithstanding his objectionable condition. We thought it was the only hope of saving his life, as the wound was suppurating largely, so much so, that it was telling severely upon his system. On July 19th, I performed the operation of resection of the head of the humerus, with the assistance of Surgeons J. H. Brinton, U. S. V., and R. H. Coolidge, U. S. A. The form of the flap made was the semicircular; it was necessary to remove about four inches of the humerus. The operation over, the man did very well for some ten days, at the end of which time his pneumonic symptoms returned as prominently as ever, assuming the character of phthisis pulmonalis; so much so, that at present his case is considered a very unpromising one." The specimen (FIG. 458) consists of the excised head and two inches of the shaft of the right humerus. A conoidal ball, entering the base of the great tuberosity, has shattered the surgical neck and extensively fissured the articular surface. Contributed by the operator. The patient remained under treatment until November 20, 1862, when he was discharged from the service and pensioned. Examiner H. O. Hitchcock, of Kalamazoo, reported, January 15, 1863: "There are now several fistulous openings along the humerus; there may be a necessity for amputation. The arm at any rate is more adapted for ornament than for use." On April 18, 1863, Dr. Hitchcock forwarded the photograph of the man, represented in the cut (FIG. 457), with the following notes: "For a year and a half after his discharge there were fissures still open and discharging, leading down to diseased bone and periosteum. The periosteum and surface of the bone had become diseased nearly to the elbow joint. An operation for scraping the diseased surface of the bone was followed by a complete and sound closure of all the sinuses. There is now complete ankylosis of the elbow joint. There has been no reproduction of bone where the bone was excised. No power exists to extend the arm upon the shoulder. There is a little control and use of the hand, as the man can write when the forearm is laid upon the table and the paper moved instead of the hand; this, however, can be continued only a few minutes. The photograph represents the case at this date." On a subsequent examination, in 1874, it is reported that "there is atrophy of the muscles of the shoulder and arm; ankylosis of the elbow joint, and that there are extensive cicatrices on the outer side of the arm from the shoulder to the elbow. The disability arising from the uselessness of the arm for the purpose of manual labor is rated total." Mason was paid March 4, 1874.

Similar exfoliations from the sawn end of the shaft, especially in the shape of necrosed rings of bone, were quite common:

CASE 1565.—Private J. M. Hall, Co. I, 27th Indiana, was wounded at Antietam, September 17, 1862, and was admitted to Hospital No. 2, Frederick. Acting Assistant Surgeon J. H. Peabody transmits the following history: "Upon an examination of the wound it was discovered that the ball had entered between the first and second ribs, about three inches to the right of the sternum, passing obliquely backward and outward, and making its exit at the external edge of the scapula, about an inch and a half below the acromion, fracturing the head of the humerus. Shoulder very much swollen and extremely painful at the time the patient was admitted; constitutional disturbance considerable; loss of appetite; pulse at 100. Waited until October 4th, hoping for a change; none having taken place, concluded to operate. Resected the head and one inch of the shaft of the humerus. Operation—straight incision. Patient did not lose an ounce of blood. Had to saw the bone twice, having found it denuded below the line of the first cut. October 28th, patient doing well; appetite good; wound entirely filled with healthy granulations. Treatment: wound kept open with lint; water dressing; granulations stimulated with basilicon ointment. The

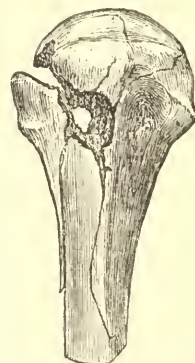

FIG. 458.—Upper extremity of right humerus excised for shot fracture. Spec. 1, A. M. M.

incision made in this operation had entirely healed six weeks after the operation. The patient now awaiting his discharge. Tolerable use of arm and forearm." The patient was discharged the service December 17, 1862, and pensioned. Examiner S. Hughes, of Greencastle, Indiana, reported, April 2, 1863: "The condition of the applicant is such as to be unable to move his right arm, the ball passing from the inside, near the outer third of the clavicle, through the shoulder joint, and out just below the scapula, fracturing upper third of humerus so much as to be necessary to remove some three inches of that bone at the joint; general health good." Examiner John S. Baker, of Osceola, Iowa, September 6, 1873, reported: "A number of spiculae of bone have since come out; impossible to raise the arm; use of joint entirely lost, and at times is very painful." The pensioner was paid December 4, 1873. The specimen, 451, *Surg. Sect.*, A. M. M., was contributed by the operator, and consists of "the head and one inch of the shaft of the right humerus excised. The inner half of the head was carried away by gunshot, and the specimen shows eight small fragments that were removed. The neck was sawn through in two places."

CASE 1566.—Private S. F. Tinsler, Co. D, 20th Indiana, aged 34 years, was wounded at the Wilderness, May 5, 1864, in the right shoulder, and was admitted to a Second Corps hospital, and thence sent to Washington, entering Lincoln Hospital May 30th. On June 1st, excision of the shoulder joint was performed by Assistant Surgeon J. C. McKee, U. S. A., who subsequently contributed the photograph represented by the cut (FIG. 459), and reported: "Ball entered the posterior surface of the head of the right humerus, passing forward, making its exit at the anterior surface, fracturing the head of the humerus and the anterior and posterior borders of the glenoid cavity. June 1st, excision of the head and three inches of the shaft of the right humerus through a straight incision, commencing at the coracoid process of the scapula and extending downward five inches. Ether was used as an anæsthetic. October 10th, parts entirely healed. Recovered." The patient was subsequently transferred to the Soldiers' Home, and was discharged the service January 24, 1865. He is a pensioner, and was paid June 4, 1874. His disability is rated total. The photograph from which the cut is copied is No. 146 of the *Surgical Section*.

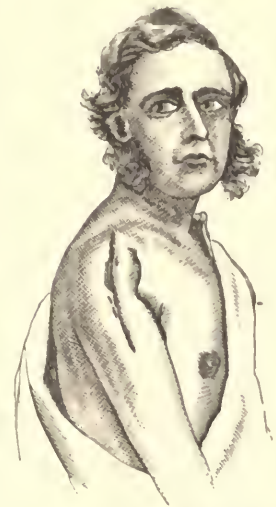

FIG. 459.—Appearance of cicatrix after intermediary excision of the head and three inches of the shaft of the right humerus. [From a photograph.]

When the joint is perforated antero-posteriorly by a small projectile, the posterior opening is of utility for purposes of drainage, and such cases are peculiarly adapted to the operation by a single anterior incision. The following is an illustration of this:

CASE 1567.—Corporal J. Mencke, Co. C, 7th New York, aged 32 years, was wounded at Petersburg, April 2, 1865, and was admitted to the Second Corps hospital at City Point, where resection of the head and neck of the humerus was performed by Acting Assistant Surgeon W. J. Burr. The patient was subsequently treated in Armory Square and Stanton Hospitals, Washington, and DeCamp Hospital, New York, and discharged the service January 9, 1866, and pensioned. In March, 1866, Assistant Surgeon Warren Webster, U. S. A., contributed the photograph represented by the wood-cut (FIG. 460), with the following report: "The patient received a compound comminuted fracture of the right humerus. A conoidal ball penetrated the anterior surface of the arm opposite the surgical neck of the humerus, traversed the bone in an antero-posterior direction, and emerged at the posterior fold of the axilla. He was twenty-four hours a prisoner after receiving the wound, during which time he received no treatment. On the 9th of April, he reached the Second Corps hospital at City Point, where, on the 13th of the month, he was rendered insensible by chloroform, and four inches of the humerus, including the head and upper portion of the shaft, were excised. The steps of the operation appear to have been those pursued by Langenbeck. The longitudinal incision was, however, commenced more internally than recommended by that operator, the surgeon having probably been influenced by the position of the wound, which occupied the line of the cut. Pasteboard appliances were used upon the patient until his transfer to Armory Square Hospital, Washington, where he arrived May 11, 1865. After that time, the limb was maintained in a straight position, supported by oakum and pillows. He was admitted to DeCamp Hospital September 4, 1865, at which time the case was progressing favorably. The existence of a posterior wound, permitting the free escape of pus in the recumbent posture, which, according to Esmarch,<sup>1</sup> is paramouly desirable in the operation by anterior incision, is believed to have essentially promoted recovery in this case. On the 25th of December, 1865, the accompanying photograph was taken at DeCamp Hospital. Although the knife, it would seem, was carried wide of the long tendon of the biceps, the preservation of the latter, if accomplished, proved of little practical value in this instance. An interval of nearly the extent of the removed bone exists between the humerus and the glenoid fossa. The member hangs like an inanimate mass at the man's side. He cannot raise the hand toward the mouth, nor does the deltoid enable him to abduct the arm in the slightest degree." Examiner James Neil, of Harlem, New York, August 16, 1866, reported: "The right arm hangs like a pendulum and is useless." The pensioner was paid March 4, 1874.



FIG. 460.—Appearance of the cicatrix eleven months after excision of the upper extremity of the humerus. [From a photograph.]

<sup>1</sup>ESMARCH (F.), *Über Resectionen nach Schusswunden*, Kiel, 1851, S. 46, and SLATHAM, abridged English translation of ESMARCH, London, 1856, p. 67.



§ *Intermediary Unsuccessful Operations*—Of the one hundred and fifty-five cases of intermediary excisions of the upper extremity of the humerus for shot injury, referred to on page 473, sixty-four had a fatal termination; a mortality rate of 41.2 per centum. Seven examples are detailed, and all the cases are summarized in the succeeding tabular statement:

CASE 1563.—Private T. McC——, Co. F, 2d New York Cavalry, aged 38 years, was wounded at Culpeper, September 13, 1863. He was sent to Washington, and on the following day admitted into Armory Square Hospital. Surgeon D. W. Bliss, U. S. V., reported the case as follows: "The patient is of a sanguine temperament, and was in good health up to the

time of the injury. A minié ball entered about four inches above the left nipple and emerged one inch and a half below the acromion process of the left arm, fracturing the humerus at the surgical neck. Wound quite painful. Lead wash was ordered to the shoulder, which was considerably swollen. The patient had the best diet possible, with wine thrice daily if he desired it. On September 17th, I resected the head and about three inches of the shaft of the humerus, the incision through the uncles being of an S-shape. Chloroform was used and a moderate amount of blood was lost. The muscles were considerably infiltrated with serum, and, after the removal of the bone, the inner part of the wound looked dark and unhealthy. The patient reacted well from the anæsthetic, and did not seem affected more than usual by the operation. The after treatment consisted in the administration of half-grain doses of opium with brandy every four hours. Lead and opium wash applied to wound, and best diet given. On the 18th, 19th, and 20th, a quarter of a grain of morphia was given at bed-time, and the lead and opium wash continued. On the 21st he complained of a want of appetite; the wound presented a gangrenous appearance. One-half of an ounce of tincture of cinchona was given three times daily, and warm-water dressings applied to the wound. September 22d: Bowels constipated; has had no operation for seven days; pulse increased in frequency and weak; complained of being cold; well-developed moist gangrene covered the incision and a sanious discharge flowed from the wound. A purple color pervaded the skin for some distance from the wound, the lips of which were glued by fibrinous bands, giving evidence of reparative action. One ounce of sulphate of magnesia was ordered at once, and half an ounce of tincture of cinchona given before meals, with the best diet. A warm poultice, made of pulverized cinchona and charcoal, yeast, and carrots, was applied every three hours, and beef tea and milk punch were given. In the afternoon he was unable to retain the milk punch,

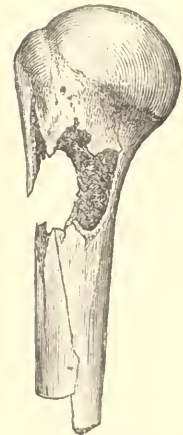

FIG. 461.—Excised head and three inches of shaft of humerus. Spec. 1730.

and a half ounce of brandy with two grains of carbonate of ammonia was substituted. The patient failed rapidly, and died at six o'clock A. M. of the 23d." The excised portion of the humerus was contributed to the Army Medical Museum by the operator (FIG. 461). The missile has perforated and almost entirely carried away the surgical neck. A number of fissures reach to, but do not transcend, the epiphyseal line. The fractures extend downward to the line of excision.

In one-third of the cases, the fatal result was ascribed to the invasion of pyæmia, and to exhaustion from burrowing of pus and profuse suppuration in fourteen instances:

CASE 1569.—Private Lyman C. B——, Co. E, 7th Maine, aged 23 years, was wounded at Ny River, May 18, 1864, and was admitted to a Sixth Corps hospital. On examination, a shot fracture near the neck of the humerus was diagnosed; splints and water dressings were applied. The patient was then sent to Washington, and entered Emory Hospital May 25th. Surgeon N. R. Mosely, U. S. V., noted: "Gun-shot wound of right arm; minié ball passed from before backward, through the deltoid muscle just above the insertion, fracturing the upper third of the humerus, the fracture extending into the joint. The bone was comminuted at the surgical neck. The soft parts were somewhat lacerated, with a sinus extending down the inner edge of the triceps, discharging dark ichorous pus. The patient was weak and debilitated from exposure on the field and during transportation. He was suffering much pain, and was desirous of having the limb amputated. On May 26th, the patient was placed under the influence of chloroform and ether, and Acting Assistant Surgeon S. W. H. Ensign excised the head and two and a half inches of the shaft of the humerus. The incision made was carried from the acromial process to the point of insertion of the deltoid. Adhesive straps were applied, with lateral felt splints and cold-water dressings, and the patient did well until May 28th, when a sinus was discovered descending from the shoulder down to the seventh rib, and extending over the greater portion of the side. A valvular incision was made into the abscess, which discharged about one pint of pus each day. He died on June 7, 1864, from progressive emaciation consequent upon the excessive discharge from the abscess." The pathological specimen is represented in the adjacent wood-cut (FIG. 462). It was contributed by Surgeon N. R. Mosely, U. S. V. It consists of the head and four and a half inches of the shaft of the right humerus excised for comminution of the upper third. A fracture occupies the anatomical neck in its outer half.

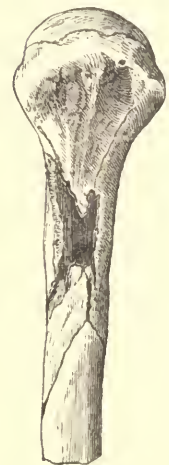

FIG. 462.—Excised upper third of right humerus. Spec. 2560.

In the succeeding summary (TABLE XXXIV) the sixty-four fatal intermediary cases are recorded alphabetically. Thirty-eight of these cases, and thirty-four of the preceding series, furnished pathological specimens to the Museum, or seventy-two of the one hundred and fifty-five cases. Intermediary operations were, for the most part, practised in permanent hospitals, which accounts probably for this remarkable preservation of the specimens.

TABLE XXXIV.

Summary of Sixty-Four Fatal Cases of Intermediary Excisions of the Head and Portions of the Shaft of the Humerus for Shot Injury.

No.	NAME, AGE, AND MILITARY DESCRIPTION.	DATE OF INJURY.	NATURE OF INJURY.	DATE OF OPERATION.	OPERATION AND OPERATOR.	RESULT AND REMARKS.
1	Anderson, H., Pt., H, 14th Indiana, age 22.	May 3, 1863.	Minié ball comminuted head of left humerus, driving one fragment into the parietes of chest; missile lodged in scapula.	May 27, 1863.	Head and one inch of shaft of humerus removed through a U-shaped incision, by Surg. O. A. Judson, U. S. V. Ball extracted.	Died June 1, 1863, of pyæmia. <i>Spec.</i> 1207, A. M. M.
2	Aumiller, J., Pt., C, 15th Infantry, age 24.	Aug. 7, 1864.	Shot fracture of upper third of the right humerus, extending into the joint.	Aug. 21, 1864.	Four inches of upper extremity of humerus, including head, through incision over deltoid, by A. A. Surg. W. H. Matlock.	Died Sept. 23, 1864, of pyæmia.
3	Becker, J. T., Pt., F, 4th Colored Troops, age 22.	July 21, 1864.	Musket ball split off two large pieces of the shaft of right humerus; fissures extended into shoulder joint.	July 30, 1864.	Excision of the head and two inches of the shaft of humerus through a V-shaped incision over deltoid, by Ass't Surg. n E. Curtis, U. S. A.	Died August 26, 1864, of exhaustion.
4	Besse, L. C., Pt., E, 7th Maine, age 23.	May 12, 1864.	Minié ball comminuted the right humerus at anatomical neck; fracture extended into joint.	May 26, 1864.	Head and four and a half inches of shaft of humerus removed, by A. A. Surg. W. H. Ensign.	Died June 8, 1864, of exhaustion. <i>Spec.</i> 2360, A. M. M.
5	Blair, S., Color Sergeant, C, 101st Pennsylvania.	May 31, 1862.	Musket ball shattered the neck and upper portion of shaft of humerus.	June 6, 1862.	Head and three inches of shaft of humerus removed through a U-shaped incision, by A. A. Surg. J. M. Brown.	Died July 12, 1862.
6	Bond, J. S., Pt., H, 1st Maryland.	Aug. 18, 1864.	Shot fracture of upper portion of right humerus.	Aug. 27, 1864.	Middle of head of humerus, with splinter of bone one and a half inches long attached, removed, by Surgeon A. A. White, 8th Maryland.	Died Aug. 30, 1864, from hæmorrhage from superior profunda. <i>Spec.</i> 129, A. M. M.
7	Bowen, J., Pt., F, 1st Sharpshooters, age 41.	May 12, 1864.	Portion of articulating surface of head of right humerus carried away by shot.	May 19, 1864.	Head and one inch of shaft of humerus removed through an S-shaped incision, by Surg. Z. E. Bliss, U. S. V.	Died June 15, 1864, of colic.
8	Brightbill, S., Pt., K, 209th Pennsylvania, age 30.	Mar. 25, 1865.	Inner fifth of the head of right humerus broken off by a conoidal ball; joint opened, ball impacted.	April 1, 1865.	Excision of the head and one inch of the shaft of humerus through a straight incision, by Surg. G. L. Hancock, U. S. V.	Died April 10, 1865, of pyæmia. <i>Spec.</i> 4282, A. M. M.
9	Britton, E., Sergeant, I, 69th New York, age 32.	Sept. 17, 1862.	A musket ball shattered the right humerus just below the surgical neck and lodged.	Sept. 28, 1862.	Head and three and a half inches of shaft of humerus through a linear incision, by A. A. Surgeon J. H. Bartholf.	Died October 27, 1862, of symptoms of pleuritis and pneumonia. <i>Specs.</i> 787 and 804, A. M. M.
10	Bullard, A., Pt., A, 37th N. Carolina.	Dec. 12, 1862.	Shot fracture of surgical neck of right humerus with extensive comminution of bone.	Dec. 29, 1862.	Excision of the head and three inches of the shaft of humerus, by Surg. H. Bryant, U. S. V.	Died Jan. 10, 1863, of pyæmia. <i>Spec.</i> 582, A. M. M.
11	Burk, E., Pt., I, 81st Pennsylvania, age 20.	May 12, 1864.	Shot fracture of the head of left humerus.	May 20, 1864.	Excision of head and two inches of shaft of humerus, by Ass't Surgeon A. Ingram, U. S. A.	May 28th, ligation of subscapular. June 2, pyæmic chill. Died June 28, 1864, of pyæmia.
12	Butler, J. L., Pt., G, 45th Pennsylvania, age 22.	June 3, 1864.	Compound comminuted fracture of the head of right humerus by a conoidal ball.	June 11, 1864.	Excision of the head and four inches of the shaft of humerus through a V-shaped incision, by Surg. O. A. Judson, U. S. V.	Died August 16, 1864, of chronic diarrhoea. <i>Spec.</i> 2944, A. M. M.
13	Byrd, R., Pt., E, 28th North Carolina, age 22.	May 12, 1864.	Shot fracture of left humerus, opening into the joint.	May 20, 1864.	Head and three inches of the shaft of humerus removed, by Ass't Surg. A. Ingram, U. S. A.	Died May 30, 1864.
14	Cadigan, M., Pt., G, 57th Massachusetts.	July 30, 1864.	Comminution of surgical neck of right humerus by a musket ball, which also fractured fifth and sixth ribs, and was found, <i>post-mortem</i> , in the abdomen.	Aug. 4, 1864.	Excision of the head and three inches of the shaft of humerus, by Surgeon A. P. Sheldon, U. S. V.	Died August 6, 1864. <i>Spec.</i> 2973, A. M. M.
15	Case, H. W., Serg't, H, 116th Pennsylvania, age 21.	May 12, 1864.	Shot fracture of the head of right humerus and acromial process of scapula.	May 29, 1864.	Head and four inches of shaft of humerus removed, by Surg. G. L. Hancock, U. S. V.	Died August 12, 1864. <i>Spec.</i> 2468, A. M. M.
16	Clemm, C., Pt., K, 79th Ohio, age 21.	Oct. 4, 1864.	Head of right humerus badly comminuted by a conoidal ball.	Oct. 18, 1864.	Removal of the head and two inches of the shaft of humerus through a single straight incision, by Ass't Surg. B. C. Brett, 21st Wisconsin.	Died April 21, 1865, of variola.
17	Crone, W., Pt., H, 15th Ohio, age 22.	Dec. 31, 1862.	Shot fracture of upper portion of humerus.	Jan. 23, 1863.	Removal of the upper part of humerus, including the head.	Died Feb. 13, 1863, of secondary hæmorrhage.
18	Darby, John, Pt., C, 36th New York, age 25.	July 1, 1862.	Comminuted fracture of the bones forming the right shoulder joint by a musket ball.	July 5, 1862.	Removal of the head and one inch of the shaft of humerus and the shattered fragments of the clavicle and acromial process, by Ass't Surg. J. S. Billings, U. S. A.	Died July 10, 1862, of gangrene.
19	Domrer, L., Pt., A, 5th Pennsylvania Cavalry, age 30.	June 15, 1864.	Comp'd comminuted shot fracture of the left humerus.	July 1, 1864.	Head and two and a half inches of shaft of humerus removed through a straight incision, by A. A. Surg. W. P. Moon.	Died July 14, 1864, of exhaustion. <i>Spec.</i> 3624, A. M. M.
20	Donaldson, W., Pt., C, 5th New Jersey.	May 5, 1862.	Compound shot fracture of the head of left humerus; also shot fracture of middle third of right thigh.	May 12, 1862.	Head and two inches of shaft of humerus removed, by Surg. E. B. Bontecou, U. S. V.	Died May 13, 1862.
21	Douglas, J., Pt., B, 4th New York Artillery, age 25.	May 19, 1864.	Shot fracture of the head of the left humerus.	May 26, 1864.	Head and one inch of shaft of humerus removed, by A. A. Surg. F. W. Kelly.	Died June 5, 1864, of pyæmia.
22	Dow, S. G., Pt., E, 31st Maine, age 19.	June 11, 1864.	Wound of left shoulder joint; ball passed through head of humerus.	June 19, 1864.	Excision of head and two inches of shaft of humerus through circular transverse incision across deltoid, by Surg. R. H. Bontecou, U. S. V.	Died July 7, 1864, of exhaustion. <i>Spec.</i> 3638, A. M. M.



No.	NAME, AGE, AND MILITARY DESCRIPTION.	DATE OF INJURY.	NATURE OF INJURY.	DATE OF OPERATION.	OPERATION AND OPERATOR.	RESULT AND REMARKS.
23	Elliott, C. H., Corp'l, D, 61st Pennsylvania.	May 31, 1862.	Minié ball entered right acromion and escaped at the insertion of deltoid, shattering the head of humerus; another ball fractured head of femur.	June 14, 1862.	Head and a portion of shaft of humerus excised, by Ass't Surg. H. L. Sheldon, U. S. A.	Died June 17, 1862, of pyæmia.
24	Emmert, J. W., Pt., F, 63d Tennessee, age 31.	May 14, 1864.	Shot fracture of the head of right humerus.	June 12, 1864.	Excision of head and four inches of shaft of humerus through a vertical incision seven inches long; synovial membrane of glenoid cavity removed.	Died July 9, 1864, of diarrhœa.
25	Evans, J., Pt., G, 21st Wisconsin, age 22.	Sept. 1, 1864.	Shot fracture of the head of left humerus.	Sept. 5, 1864.	Excision of the head and one and a half inches of the shaft of humerus.	Died February 3, 1865, of chronic diarrhœa.
26	Finn, M., Pt., A, 88th New York.	Sept. 17, 1862.	Comminution of the surgical neck of right humerus by a ball, which lodged and could not be found.	Sept. 28, 1862.	Excision of the head and four inches of shaft of humerus, by Ass't Surgeon A. K. Smith, U. S. A.	Died Oct. 9, 1862, of empyema. The missile was found, <i>post-mortem</i> , to have traversed the lung and lodged in it against spine of 11th costo-vertebral articulation. <i>Specs.</i> 382 and 960.
27	Frecht, J., Serg't, B, 122d Pennsylvania, age 24.	May 3, 1863.	Left humerus broken off at the surgical neck by shot; fissures running up into capsule.	May 9, 1863.	Head and three inches of shaft of humerus removed, by Surgeon T. Antisell, U. S. V.	Died May 13, 1863, of pyæmia.
28	Gage, M., Corporal, K, 94th New York, age 21.	Mar. 31, 1865.	Ball fractured the head of the right humerus and was cut out from between the clavicle and scapula.	April 21, 1865.	Excision of the head and one and a half inches of shaft of humerus through a straight incision, by A. A. Surgeon W. P. Moon.	Died May 6, 1865, of exhaustion.
29	Gibbons, E., Pt., L, 112th Pennsylvania, age 31.	June 23, 1864.	Musket ball passed through the head and upper portion of shaft of left humerus and lodged in deltoid.	July 20, 1864.	Excision of the head and upper third of shaft of humerus, by Ass't Surg. E. Curtis, U. S. A.	Died July 22, 1864, of exhaustion.
30	Hankin, J., Pt., H, 1st Michigan Sharpshooters, age 17.	June 17, 1864.	Fracture of the head of right humerus by a minié ball.	June 25, 1864.	Head and one and a half inches of shaft of humerus removed, by Surgeon R. B. Bontecou, U. S. V.	July 23d, ligation of the axillary artery. Died July 24, 1864, of secondary hæmorrhage. <i>Spec.</i> 3033, A. M. M.
31	Harrison, D. W., Pt., H, 13th Tennessee Cavalry, age 31.	April 12, 1864.	Head of left humerus badly comminuted by a musket ball; surgical neck shattered; also wounds of left lung and abdomen.	April 22, 1864.	Head and three and a half inches of shaft of humerus removed through a V-shaped incision, by Surg. H. Wardner, U. S. V.	Died May 4, 1864, of empyema and exhaustion. <i>Spec.</i> 3309, A. M. M.
32	Hill, J. A., Pt., A, 31st Maine, age 17.	April 2, 1865.	Minié ball fractured the neck and shaft of left humerus and was extracted from wound of entrance.	April 12, 1865.	Head and four inches of shaft of humerus removed through a vertical incision, by Surg. J. C. McKee, U. S. A.	Died Sept. 11, 1865, of exhaustion.
33	Honston, A. M., Pt., H, 12th New Hampshire, age 24.	May 3, 1863.	Fracture, with extensive comminution of upper third of right humerus, by an English conoidal ball.	May 8, 1863.	Excision of the head and three and one-half inches of shaft of humerus, by Surg. H. Bryant, U. S. V.	Died May 15, 1863, of pleuro-pneumonia. <i>Spec.</i> 1086, A. M. M.
34	Hughes, J., Corp'l, F, 1st Penn'a Cavalry, age 25.	Aug. 23, 1864.	Shot fracture of the head of the right humerus.	Sept. 5, 1864.	Head and four inches of shaft of humerus removed through a T-shaped incision, by A. A. Surg. W. P. Moon.	Died Sept. 27, 1864, of exhaustion. <i>Spec.</i> 3628, A. M. M.
35	Hutchins, W., Pt., D, 64th New York.	May 12, 1864.	Complete comminution of the surgical neck of the right humerus by shot.	May 27, 1864.	Removal of the head and four inches of shaft of humerus, by A. A. Surg. H. M. Dean.	Died June 7, 1864, of pyæmia. <i>Spec.</i> 2355, A. M. M.
36	Hutchinson, S. R., Corp'l, G, 95th Ohio.	Aug. 30, 1862.	Shot fracture of left humerus, involving shoulder joint.	Sept. 11, 1862.	Removal of three inches of upper extremity of humerus, including the head, by Surgeon H. Z. Gill, U. S. V.	Died in October, 1862, of chronic diarrhœa.
37	Kaskatter, L., Pt., G, 211th Pennsylvania.	April 3, 1865.	Musket ball passed transversely thro' anatomical neck of left humerus and emerged from middle of vertebral border of scapula.	Apr'l 14, 1865.	Head and three inches of shaft of humerus removed, by Surg. D. W. Bliss, U. S. V.	Died April 16, 1865, of exhaustion. <i>Spec.</i> 4094, A. M. M.
38	Killingsworth, J., Pt., I, 37th Mississippi, age 35.	Dec. 16, 1864.	Minié ball fractured head and split shaft of right humerus for two and a half inches.	Dec. 20, 1864.	Removal of the head and three inches of the shaft of humerus, by A. A. Surgeon F. B. Nofsinger.	Died Dec. 28, 1864, of exhaustion.
39	Lambert, A., Pt., E, 4th Maryland, age 45.	Aug. 20, 1864.	Shot perforation of right shoulder joint; anterior and inner portion of head of humerus carried away.	Aug. 31, 1864.	Removal of the head and one-half inch of shaft of humerus, by A. A. Surg. C. H. Bowen.	Died Sept. 5, 1864, of exhaustion. <i>Spec.</i> 3162, A. M. M.
40	Laskey, U. T., Pt., A, 7th Wisconsin.	Aug. 28, 1862.	Musket ball comminuted head and upper portion of the shaft of right humerus; shoulder joint implicated.	Sept. 23, 1862.	Excision of the head and portion of shaft of humerus, by Surg. E. Bentley, U. S. V.	Died October 2, 1862, probably from pyæmia.
41	Leonard, C. H., Pt., C, 10th New Hampshire, age 29.	May 7, 1864.	Comminution of surgical neck of right humerus by a minié ball; severe laceration of parts by bone fragments.	June 3, 1864.	Head and four inches of shaft of humerus removed through a straight incision, by Surg. B. A. Clements, U. S. A.	Died June 20, 1864, of pyæmia.
42	Levering, J. F., Pt., A, 5th Michigan, age 33.	Nov. 27, 1863.	Gunshot fracture of surgical neck of left humerus, not destroying continuity.	Dec. 14, 1863.	Excision of head and neck of left humerus thro' a straight incision, by Surg. D. P. Smith, U. S. V.	Died January 2, 1864, of pneumonia. <i>Spec.</i> 1998, A. M. M.
43	Lillie, D., Capt., I, 4th Vermont, age 26.	May 5, 1864.	Ball comminuted the head and neck of the left humerus and slightly fractured the glenoid cavity.	June 1, 1864.	Excision of the head and two inches of the shaft of humerus, by Surg. D. W. Bliss, U. S. V.	Died June 6, 1864, of pyæmia. <i>Spec.</i> 2420, A. M. M.
44	Liscomb, J. M., Pt., C, 1st Maine Artillery, age 18.	June 18, 1864.	Wound of right shoulder joint; ball fractured the head of the humerus.	July 18, 1864.	Head and one-half inch of shaft of humerus removed through a straight incision over deltoid, by Surgeon R. B. Bontecou, U. S. V.	Died August 11, 1864, of exhaustion. <i>Spec.</i> 3052, A. M. M.
45	McCloskey, D. L., Pt., K, 155th Pennsylvania, age 22.	May 10, 1864.	Shot fracture of left shoulder joint, involving head of the humerus.	May 14, 1864.	Removal of the head and three inches of shaft of humerus thro' a straight incision, by Ass't Surg. A. Dulaney, U. S. V.	Died June 16, 1864, from pleurisy.

NO.	NAME, AGE, AND MILITARY DESCRIPTION.	DATE OF INJURY.	NATURE OF INJURY.	DATE OF OPERATION.	OPERATION AND OPERATOR.	RESULT AND REMARKS.
46	McCriden, P., Pt., D, 63d New York, age 30.	June 16, 1864.	Fracture of upper third of left humerus by musket ball; head of bone involved.	June 23, 1864.	Head and three inches of shaft of humerus excised, by Surg. O. A. Judson, U. S. V.	June 29th, hæmorrhage; ligation. Died July 8, 1864, from exhaustion. <i>Spec.</i> 2337, A. M. M.
47	McCutchen, T., Pt., F, 2d N. York Cavalry, age 38.	Sept. 13, 1863.	Conoidal ball fractured surgical neck of left humerus.	Sept. 17, 1863.	Excision of the head and three inches of the shaft of humerus through an S-shaped incision, by Surg. D. W. Bliss, U. S. V.	Died September 23, 1863, of gangrene. <i>Spec.</i> 1730, A. M. M.
48	McQueen, J., Pt., K, 69th New York.	Sept. 17, 1862.	A conoidal ball fractured the neck and lodged in the head of the left humerus.	Oct. 9, 1862.	Head and three inches of shaft of humerus removed, by Surgeon S. Hewitt, U. S. V.	Died October 17, 1862, of irritative fever. <i>Spec.</i> 4040, A. M. M.
49	Merriam, W., Pt., L, 1st Maine Artillery, age 28.	June 21, 1864.	Minié ball passed directly thro' left shoulder joint; head and neck of humerus badly shattered.	July 12, 1864.	Removal of the head and three inches of shaft of humerus, by A. A. Surgeon F. G. H. Bradford.	Sank rapidly; died July 24, 1864. <i>Spec.</i> 3262, A. M. M.
50	O'Brien, P. J., Lieut., A. D. C., General Lander's Staff.	Feb. 20, 1862.	Pistol ball splintered head of left humerus; fracture extended into shaft.	Mar. 20, 1862.	Removal of the head and one and a half inches of shaft of humerus, by Surg. G. Suckley, U. S. V.	Died April 1, 1862, of tetanus. <i>Spec.</i> No. 17, A. M. M.
51	Parker, E., Pt., C, 21st Massachusetts, age 24.	Ap'l 18, 1862.	Bullet badly shattered the head of left humerus and emerged from axilla.	Ap'l 28, 1862.	Head and two inches of shaft of humerus resected through a perpendicular incision, by Surg. R. B. Hontecou, U. S. V.	Died June 7, 1862, of pyæmia.
52	Powers, W., Pt., B, 92d New York, age 24.	Oct. 27, 1864.	Head of right humerus and upper portion of shaft much comminuted by shot.	Nov. 3, 1864.	Head and two and a half inches of shaft of humerus removed thro' a longitudinal incision, by Ass't Surg. J. H. Frantz, U. S. A.	Died Nov. 22, 1864, of exhaustion. <i>Spec.</i> 3094, A. M. M.
53	Rambo, F. W., Pt., K, 50th Georgia.	Sept. 17, 1862.	Musket ball extensively shattered the shaft of humerus.	Sept. 25, 1862.	Head and four inches of shaft of humerus removed, by Ass't Surg. J. H. Bill, U. S. A.	Died December —, 1862.
54	Reynolds, P., Sergeant, 16th Massachusetts, age 32.	June 18, 1862.	Musket ball shattered the head of left humerus.	July 3, 1862.	Excision of the head and two inches of the shaft of humerus thro' a single straight incision, by A. A. Surg. S. Teats.	Died July 23, 1862, of pyæmia. <i>Spec.</i> 1006, A. M. M.
55	Reynolds, S. R., Capt., U. S. Vols., and A. A. G. 18th Army Corps, age 26.	June 3, 1864.	Conoidal ball gouged the tuberosities and split the head and shaft of the left humerus; ball lodged in head of bone.	June 8, 1864.	Excision of the head and three-fourths of an inch of shaft of humerus, by Surgeon D. W. Bliss, U. S. V.	Died July 30, 1864, of pyæmia. <i>Spec.</i> 2462, A. M. M.
56	Schafer, H., Pt., F, 51st Pennsylvania, age 36.	Mar. 25, 1865.	Comp'd comminuted fracture of right humerus, involving shoulder joint, by log hurled by cannon ball.	April 5, 1865.	Excision of the head and four inches and a half of shaft of humerus, by Ass't Surg. H. Allen, U. S. A.	Died May 4, 1865, of pyæmia. <i>Spec.</i> 152, A. M. M.
57	Scherman, J., Pt., G, 116th Pennsylvania, age 39.	May 12, 1864.	Minié ball entered below neck of left humerus and comminuted the shaft.	May 19, 1864.	Excision of the head and two inches of the shaft of humerus, by Surg. D. W. Bliss, U. S. V.	Died June 10, 1864. <i>Spec.</i> 2282, A. M. M.
58	Stannard, G. D., Pt., F, 17th Vermont, age 18.	Sept. 30, 1864.	Minié ball fractured and comminuted the left humerus and partially embedded itself in head of bone.	Oct. 16, 1864.	Head and upper portion of shaft of humerus removed through a straight incision, by Surg. L. Bentley, U. S. V.	Died Oct. 19, 1864, of exhaustion. <i>Spec.</i> 3289, A. M. M., and <i>Phot.</i> 37.
59	Strite, G., Pt., E, 83d Pennsylvania.	July 1, 1862.	Minié ball shattered surgical neck of right humerus.	July 7, 1862.	Head and three-fourths of an inch of shaft of humerus removed through a V-shaped incision, by Ass't Surg. J. S. Billings, U. S. A.	Died July 12, 1862, of pyæmia.
60	Thomas, H., Pt., H, 14th Indiana, age 24.	May 3, 1863.	Comminution of head of left humerus and fracture of shaft by a conoidal ball, which lodged in the glenoid cavity.	May 25, 1863.	Removal of head and a portion of the shaft of humerus thro' a straight incision, by Surg. O. A. Judson, U. S. V.	Died June 10, 1863, of pyæmia. <i>Specs.</i> 1208 and 4293, A. M. M.
61	Tyler, M., Pt., K, 140th New York, age 24.	May 5, 1864.	Shot fracture of greater tuberosity and adjoining parts of right humerus.	May 26, 1864.	Removal of the head and one inch of the shaft of humerus, by Surg. D. P. Smith, U. S. V.	Died June 3, 1864, of pyæmia. <i>Spec.</i> 3302, A. M. M.
62	Watson, W. J., Pt., E, 3d New Hampshire, age 19.	Aug. 16, 1864.	Head and upper portion of right humerus much comminuted by shot.	Aug. 30, 1864.	Head and three inches of shaft of humerus removed through longitudinal incision, by Ass't Surg. J. H. Frantz, U. S. A.	Died Sept. 14, 1864, of pyæmia. <i>Spec.</i> 1674, A. M. M.
63	Wheatly, J. H., Pt., C, 110th Ohio, age 44.	July 9, 1864.	Head and four inches of shaft of the right humerus shattered by a musket ball.	July 21, 1864.	Removal of the head and four inches of shaft of humerus, by Surg. G. S. Palmer, U. S. V.	Never recovered thoroughly from the shock of operation. Died July 24, 1864.
64	Wiggins, D. R., Pt., F, 1st Maine Artillery, age 33.	May 19, 1864.	Musket ball fractured the head of right humerus.	May 23, 1864.	Removal of the head and one inch of the shaft of humerus, by Surg. D. W. Bliss, U. S. V.	Died June 8, 1864, of pyæmia.

The large mortality was due chiefly to purulent infection and irritative fever. There were five instances of fatal secondary hæmorrhage with three ligations—two of the axillary, one of the subscapular,—one case of tetanus,—and several in which intercurrent diseases precipitated the result.<sup>1</sup> Thirty-three operations were on the right, and twenty-eight on the left side, while, in three cases, this point was overlooked. The result does not corroborate Professor Esmarch's surmise, already referred to,<sup>2</sup> respecting the greater mortality of operations on the left shoulder. Anterior vertical incision from the acromion downward

<sup>1</sup> The causes of fatality are reported thus: Pyæmia, 21 cases,—pleuro-pneumonia, 7, of which 3 were complicated by empyema,—secondary hæmorrhage, 5,—suppurative exhaustion, 14,—hospital gangrene, 2,—tetanus, 1,—shock, 1,—variola, 1,—diarrhœa, 4,—unspecified cases, with symptoms of surgical fever, 8.

<sup>2</sup> At page 545, *ante*. In the one hundred and fifty intermedialy excisions of the upper extremity of the humerus, in which the shoulder involved is specified, eighty were on the right, and seventy on the left side. The fatality was a trifle the largest on the right side—11.2 as compared with 40.0 per cent. on the left side. Compare ESMARCH, *Ueber Resectionen nach Schusswunden*, 1851, S. 49, and STATHAM'S *Abridged Translation*, 1856, p. 68.



was the operation most frequently adopted, having been employed in seventeen of the twenty-seven operations in which the method of excision was specified:

CASE 1570.—Captain S. R. Reynolds, Assistant Adjutant General, U. S. V., aged 26 years, was wounded at Cold Harbor, June 3, 1864. He was at once admitted to the Base Hospital, Eighteenth Corps, and, on June 6th, was sent to Washington, entering Armory Square Hospital June 8th. Surgeon D. W. Bliss, U. S. V., reported: "Gunshot wound; ball entered the left shoulder anteriorly and immediately below the acromial process. Another ball entered the right arm immediately below the shoulder joint, and passed outward and emerged externally, a little above the insertion of the deltoid muscle. Resection of the humerus was performed on the afternoon of his admission, chloroform being given; three vessels were tied. The ball had opened the joint and lodged in the head of the humerus, from which place it had been extracted. Simple dressings, nourishing diet, and stimulants were prescribed. July 1st, patient doing well; wound nearly healed." The patient was furloughed July 20th, and died, while at his home in New York, in the following August. The specimen represented in the wood-cut (FIG. 463) consists of "the head and three-fourths of an inch of the shaft of the left humerus excised. A conoidal ball striking between the tuberosities has gouged out a portion, and split the head and shaft vertically without fissures."—*Cat. Surg. Sect.*, 1866, p. 101. It was contributed by the operator, Dr. Bliss.

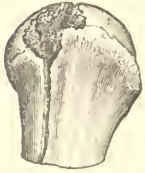

FIG. 463.—Head and small portion of shaft of left humerus excised for shot injury. *Spec.* 2462.

CASE 1571.—Private G. D. Starnard, Co. F, 17th Vermont, was wounded at Poplar Grove Church, September 30, 1864. Surgeon J. Harris, 7th Rhode Island, reported, from a Ninth Corps hospital: "Gunshot wound of left shoulder; application of splints." On October 11th, the patient was sent to Alexandria and admitted into King Street Hospital. Surgeon E. Bentley, U. S. V., reported: "Admitted with a gunshot wound of the left arm; the ball entered the posterior surface of the arm at the upper part of the middle third, fracturing the humerus. The arm was badly swollen. There was an incision, three inches in length, extending each way from the entrance of the bullet. The lips of the wound were everted and unsupported, indurated, and discolored. The patient stated that he had been etherized and the wound examined, but did not know whether the bullet or any bone had been removed. October 16th, profuse hemorrhage occurred from the wound, which reduced the patient nearly to a state of syncope; it took place so quietly that it was not discovered until the patient beheld the blood flowing out of his bed on the floor. He was etherized, the incision extended, and the upper part of the humerus removed. A battered minié ball was found so impacted in the posterior and inner aspect of the shaft, just below the anatomical neck. He had become so weakened by loss of blood that his pulse failed very rapidly under the influence of the ether, and for a little while was imperceptible at the wrist. Three ligatures were applied and the wound left open. Wine, ammonia, and mutton broth were given, and at five o'clock the wound was closed with sutures and adhesive plaster. The pulse increased, with hot skin, dry tongue, and great thirst. Cold water was applied to the wound, and one-half ounce of solution of morphia given every two hours until the patient slept. October 17th, severe chill, much thirst, hot and dry skin, quick and irritable pulse, lips pale, tongue glazed on centre, eyes of a pearly cast; he had hiccough, and the stomach rejected both food and stimulants except in very small quantities. The discharge from the wound was thin and offensive. Diluted chlorinated soda was applied. October 18th, patient felt rather more comfortable, otherwise much the same as the day before. October 19th, arm dressed in the morning; discharge thin and fetid. That portion of the wound marking the first incision was gangrenous, but the diseased muscle was apparently separating near the margin of the wound. In the afternoon hemorrhage again occurred, and considerable blood was lost before it was arrested. The whole wound became gangrenous, and at death the shoulder, as well as the wound, became much discolored. Hiccough was constantly present after the operation. He retained his senses till nearly the last, and died at six o'clock P. M., October 19, 1864." The specimen (FIG. 464) was contributed by the operator, Dr. Bentley, and



FIG. 464.—Head and upper portion of shaft of the left humerus excised for shot injury. *Spec.* 3289.

"consists of nearly the upper half of the left humerus excised for gunshot. A conoidal ball is firmly impacted just below the head; posteriorly the articular surface is eroded; a longitudinal fracture occupies the bicapital groove, and the posterior portion of the shaft is shattered."—*Cat. Surg. Sect.*, 1866, p. 111.

CASE 1572.—Private L. Domrer, Co. A, 5th Pennsylvania Cavalry, aged 30 years, was wounded at Petersburg, June 15, 1864. Surgeon J. J. Craven, U. S. V., reported from a Tenth Corps hospital: "Gunshot wound of left arm; simple dressings applied." The patient was transferred to Hampton Hospital, Fort Monroe, and, on June 21st, to Mower Hospital, Philadelphia. Acting Assistant Surgeon W. P. Moon reported: "This man was wounded by a conoidal ball, which entered at the outer edge of the insertion of the deltoid muscle, four inches below the articulation of the shoulder, and, passing obliquely inward and backward, made its exit on the inner surface of the arm, causing a compound comminuted fracture of the left humerus. The wound suppurated freely for several days, and was quite healthy. On July 1st, I concluded to perform excision of the shoulder joint. I made an incision, six inches in extent, from below the acromion to the external wound, and thence toward the internal border of the deltoid, and removed two inches of the humerus with the head of the bone. The wound was partially closed with silver sutures and adhesive plaster. Chloroform was used, and there was prompt reaction. The after treatment consisted of dry dressings, liberal diet, stimulants, and tonics. July 4th, pus burrowing into the axilla; compress and bandage applied. Patient had some diarrhoea, which was controlled by injections of opium. The discharge of pus was immense and continued for ten days. July 13th, the patient was unable to retain nutriment or stimulants. He died on July 14th, from exhaustion, the result of excessive discharge. *No post-mortem.*" The specimen (FIG. 465) was contributed to the Museum by Dr. Moon, and consists of the "head and two and a half inches of the shaft of the left humerus, excised for an oblique fracture with comminution through the surgical neck. The margins of the fracture are necrosed, and a very thin deposit of callus on the shaft has occurred."—*Cat. Surg. Sect.*, 1866, p. 107.

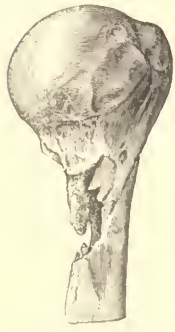

FIG. 465.—Head and portion of shaft of left humerus excised for shot injury. *Spec.* 3624.

There is frequent occasion to observe that shot penetrations of the shoulder, with lodgment of the missile, are far more dangerous than shot perforations:

CASE 1573.—Private D. B. W.—, Co. F, 1st Maine Heavy Artillery, aged 33 years, was wounded at North Anna River, May 19, 1864. He was sent to Washington, and admitted into Armory Square Hospital on May 23d. Surgeon D. W. Bliss, U. S. V., reported: "Gunshot wound of the shoulder; the ball entered about the anterior part of the right shoulder joint and fractured the humerus. On May 23d, the patient was anesthetized by chloroform, and I performed the operation of resection of the shoulder joint, hemorrhage being guarded against by an assistant pressing upon the subclavian artery. At the time of operation his constitutional condition was favorable. The after-treatment consisted of simple dressings and tonics. He died June 8, 1864." The specimen (FIG. 466) was contributed to the Museum by the operator, and consists of "the head and one and a half inches of the shaft of the right humerus excised. A conoidal ball lodged behind the greater tuberosity and split off the laminated structure over a triangular surface of which each side is one and a half inches."—*Cat. Surg. Sect.*, 1866, p. 104.

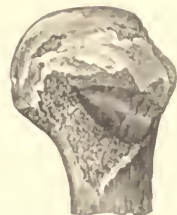


FIG. 466.—Head and one and a half inches of shaft of right humerus excised for shot injury. *Spec.* 2363.

The next and last of the seven detailed cases of unsuccessful intermediary excisions resulted fatally, from secondary hemorrhage from the right axillary artery:

CASE 1574.—Private J. H.—, Co. H, 1st Michigan Sharpshooters, aged 17 years, was wounded at Petersburg, June 17, 1864. Surgeon P. A. O'Connell, U. S. V., reported the patient's admission into a Ninth Corps hospital. Simple dressings were applied. On June 21st, he was transferred to Washington and admitted into Harewood Hospital. Surgeon R. B. Bontecon, U. S. V., reported: "Gunshot wound of right shoulder, the ball passing transversely from the outer to the inner surface, fracturing the head of the humerus. The parts were considerably swollen and discharging freely, and the patient was somewhat debilitated. June 25th, sulphuric ether was administered, and the head of the humerus was removed. The patient did very well, the wound healing finely, and the general health continuing good, until July 23, 1864, when hemorrhage occurred from the axillary artery to the amount of ten ounces. The artery was ligated, but the patient sank, and died from exhaustion on July 24, 1864. The treatment was supporting throughout." The specimen, represented by the wood-cut (FIG. 467), was contributed to the Museum by Dr. Bontecon. It consists of "the head and one and a half inches of the shaft of the right humerus excised. A battered conoidal ball is lodged in the anatomical neck within the bicapital groove. A vertical fracture divides the anterior third of the head."—*Cat. Surg. Sect.*, p. 104.

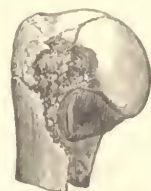

FIG. 467.—Upper extremity of right humerus excised for shot injury. *Spec.* 3033.

### Secondary Excisions of the Upper Extremity of the Humerus for Shot Injury.—

To this subdivision fifty cases are referred, of which twelve were fatal, a fatality of 24 per cent., a more favorable exhibit than is presented by the secondary decapitations of the humerus.

§ *Successful Operations.*—Thirty-eight patients of this class survived. Of the eight detailed abstracts that will be introduced, the first and third are remarkable because of the alleged reproduction, to some extent, of the excised portions of the diaphyses:

CASE 1575.—Private D. C. Lewis, Co. E, 11th Massachusetts, aged 21 years, was wounded at Bull Run, July 21, 1861, taken prisoner, and sent to Richmond, thence to Fort Monroe, where he was admitted into Hygeia Hospital on January 17, 1862. Surgeon R. B. Bontecon, U. S. V., noted: "Patient was suffering from gunshot wound of the left shoulder, the ball passing through the head of the humerus. Several fistulous openings communicated with the joint, scapula, and clavicle, and the whole shoulder was much swollen and indurated, the arm and forearm were much emaciated, and the general health broken down. In the latter part of January, or early in February, his health was so much improved by liberal diet that an operation was deemed advisable; and the head with about three inches of the shaft was resected. The V-shaped incision was employed on account of the situation of the fistules. I found great vascularity, and a cheesy condition of the parts, rendering it difficult to secure the vessels; there was also considerable difficulty experienced in removing the large irregular mass of bone in which the dead head, in three pieces, was enclosed. Gangrene attacked the wound, nearly proving fatal. In March, 1862, the patient became able to travel, and was transferred to his home in Boston. A new shaft had, at that time, supplied the place of the part removed, and some motion of the shoulder joint, with good condition of the limb, promised a favorable result." Dr. Bontecon transmitted a photograph of the patient when convalescent, from which the annexed wood-cut (FIG. 468) is taken (*Card. Phot. Surg. Sec.*, A. M. M., Vol. III, p. 9). This soldier was discharged October 23, 1862, and pensioned. Examiner G. S. Jones, of Boston, reported, August 10, 1863: "Anchylösis has taken place between the end of the humerus and the glenoid cavity of the scapula. The power and usefulness of the arm is impaired; disability is three-fourths." Mr. Lewis is now living in Nicaragua, Central America; his disability is reported to continue the same as formerly. His pension was paid March 4, 1874.

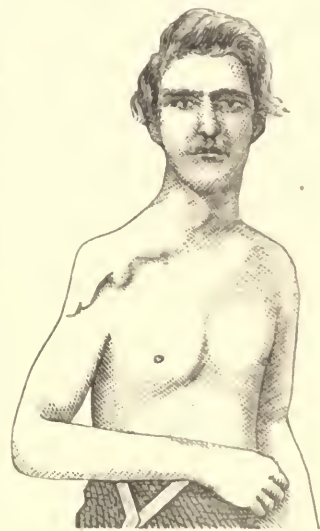

FIG. 468.—Centrix after a secondary excision of the head of the humerus for shot fracture.



The various results attending recovery after secondary excisions are well exemplified in the three following cases:

CASE 1576.—Private M. Kelly, Co. A, 16th Infantry, aged 46 years, was wounded at the battle of Stone River, December 31, 1862. Surgeon G. D. Beebe, U. S. V., reported, from a Fourteenth Corps hospital, "a shot wound of the left shoulder." The patient was sent to Nashville and entered Hospital 14, January 6, 1863. Surgeon F. Seymour, U. S. V., reported that a minié ball passed through the surgical neck of the left humerus, causing extensive comminution. After a general sustaining treatment, with simple dressings, the patient was in a condition to undergo an operation, and, on March 7, 1863, an operation for excision was performed. The head and neck, with fragments of the shaft, constituting about six and a half inches of the upper extremity of the left humerus, were removed through a V-shaped incision, severing the deltoid muscle. After the operation the patient progressed uninterruptedly to convalescence, and was discharged April 29, 1863, and pensioned. Surgeon J. H. Phillips, U. S. V., in charge of Nashville No. 14 Hospital, and Examiners J. Phillips and J. O. Stanton, of Washington, also reported the case substantially as above, Dr. Stanton adding, September 16, 1873, that "there is some atrophy of the muscles of the injured arm and of the forearm and hand. He cannot raise the arm." In September, 1865, Kelly was supplied with an apparatus by Dr. E. D. Hudson. He complained of this as "heavy and oppressive." This pensioner has long been employed as a doorkeeper at the Treasury Department at Washington. According to the observation of the editor of this work, he scarcely gave a fair trial to the ingenious apparatus designed by Dr. Hudson. The appearance of the cicatrix in this case is shown in FIG. 1 of PLATE XIII, opposite page 520, copied from a photograph furnished by Dr. Hudson.

CASE 1577.—Private J. H. K——, Co. B, 71st Pennsylvania, aged 21 years, was wounded at Gettysburg, July 3, 1863, and was treated in a field hospital until the 25th, when he was admitted into Camp Letterman. Surgeon Henry James, U. S. V., noted: "Wounded by a minié ball, which passed through the middle third of the left arm, causing compound comminuted fracture of the humerus. Resection was performed on July 6th. Anterior and posterior splints and water dressings applied. August 21st, the patient was steadily improving, and he was transferred convalescent, September 3d." On September 5th he was admitted into Satterlee Hospital, Philadelphia. Acting Assistant Surgeon T. G. Morton made the following special report of the case: "Kavanaugh was wounded by a piece of shell, which struck him on the outer edge of the deltoid and passed through the arm, splintering the bone, and was removed from the inside of the arm in close proximity to the axillary artery. A great many fragments of bone were removed at the corps hospital; some pieces were at least an inch in length. After his admission into this hospital the wound continued open. Necrosed bone was discharged and large portions were readily felt;



FIG. 469.—Head and part of shaft of left humerus excised for necrosis consequent on shot fracture. *Spec.* 2770.  $\frac{3}{4}$ .

the finger, passed in, could distinguish a cavity which seemed to be at or near the head of the bone. The wound was painful and the patient's constitution seemed to suffer. October 19th: The outer opening of the wound has an ugly appearance; it is about one inch in diameter and unhealthy in character; the finger can be passed up to the bone, which feels soft and rugged. The patient suffers great pain, especially at night, so much so as to wear upon his general health, which, for some time past, has been failing. There is daily fever, night-sweats, and loss of appetite. October 21st, condition not improving. I concluded to remove the cause of irritation, and accordingly made an incision down upon the diseased bone, through the external wound. The head of the bone was found to be very soft and the cartilage abraded; the shaft also was much diseased. The incision was extended, and I removed the head of the bone, with the old fractured portion, about three and one-half inches in length, which had not united and was in an unhealthy state. The only vessel requiring ligature was the circumflex artery, which bled profusely. The parts were carefully washed out, the wound brought together by silver sutures, and cold-water dressings applied. From the time of the operation all pain left him, and he improved rapidly in general health, and had not an unfavorable symptom. The head of the bone was in a broken-down condition and filled with pus. On the seventh day after the operation the patient was dressed and was out of his bed, and, on the tenth day, was walking about; at the end of six weeks the wound had entirely closed. The size of the arm has increased

since the operation, being now, February 1, 1864, nearly as large as the other; he has good use of it, and can perform light duty." The specimen (FIG. 469), contributed by the operator, consists of the head and two inches of the shaft of the left humerus. It shows the diaphysis much necrosed and the lesser tuberosity fractured. A moderate degree of callus has been thrown out on the lower extremity. This soldier remained under treatment until April 11, 1864, when he was discharged and pensioned. Surgeon I. I. Hayes, U. S. V., certified: "Total loss of use of the left arm, from resection of the shoulder joint for gunshot wound." Examiner F. F. Burmeister, of Philadelphia, reported, December 6, 1866: "A piece of shell having struck the left humerus near the head, caused the loss of about two inches and a half of the bone, resection having been performed, with the entire loss of the use of the whole arm. The applicant will never have use of the limb. The disability is permanent." This pensioner was paid December 4, 1873.

CASE 1578.—Sergeant Julius Sachse, Co. K, 2d Missouri, aged 24 years, was wounded at Chickamauga, September 19, 1863, and on the 25th was admitted from a Twentieth Corps hospital to No. 1, Nashville. The following report of the case was forwarded, with the specimen, by the operator, Assistant Surgeon Charles J. Kipp, U. S. V., through Surgeon C. W. Hornor, U. S. V.: "The ball entered at the posterior aspect of the right shoulder joint and made its exit anteriorly, about an inch and a half below the coracoid process, fracturing the head of the humerus and opening the joint. At the time of admission the shoulder was immensely swollen and very painful; the constitutional disturbance was comparatively slight. Ice was applied to the shoulder, and the intensity of the inflammation soon subsided. As statistics show that secondary excisions of this joint are followed by more favorable results than primary operations, it was decided to postpone excision, and, in the meantime, to treat the wound with ice-water dressings, and to inject a weak solution of permanganate salts into the joint thrice daily. Under this treatment the patient did well. On November 9th, I excised the head of the humerus and two inches of the shaft, making an incision four inches in length on the anterior aspect of the arm, using chloroform as an anæsthetic. The head of the humerus

was found very much comminuted, with loose pieces of bone in the glenoid cavity. Reaction was prompt. The inflammation following the operation was severe, but soon yielded to ice applications. The discharge from the wound was profuse and very fetid; the patient's general health was moderately good. Injection of a weak solution of permanganate salts in the wound, cold-water dressings to the shoulder, and the administration of nutritious diet and stimulants constituted the treatment. About December 8th, the patient had a severe rigor followed by high febrile reaction; the entire shoulder and arm became tumefied, hot, and painful; this continued for about a week, when the inflammation subsided. January 15th: Wound has now closed and the patient can move his arm without suffering much pain; he has considerable lateral motion, and can adduct his elbow about five inches from his body; there is but little deformity. The shoulder has the appearance of being luxated backward, and the shortening of the whole arm is about one inch and a half compared to its fellow." The specimen (FIG. 470) consists of a portion of the head and one inch of the shaft of the humerus. A segment one and a half inches in diameter remains of the head. The inner half of the shaft opposite the tuberosities has been absorbed. The patient was transferred to Louisville, May 5, 1864, and was admitted to Clay Hospital; he was sent to Jeffersonville on May 8th, and from there to No. 1, Madison, and was discharged July 8, 1864, and pensioned. Examiner J. B. Colgrove, of St. Louis, July 18, 1864, reported: "Gunshot wound of right shoulder; ball fractured the humerus; bone badly shattered; joint destroyed; total loss of use of arm. This man's pension was increased from May 10, 1873, and he died August 9, 1873." The cause of death is unknown.

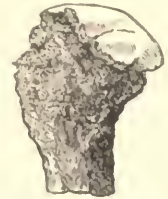

FIG. 470.—Excised head of humerus. Spec. 2180.

TABLE XXXV.

*Summary of Thirty-Eight Cases of Recovery after Secondary Excision of the Head and Portion of the Shaft of the Humerus for Shot Injury.*

NO.	NAME, AGE, AND MILITARY DESCRIPTION.	DATE OF INJURY.	NATURE OF INJURY.	DATE OF OPERATION.	OPERATION AND OPERATOR.	RESULT AND REMARKS.
1	Buekley, B., Pt., A, 47th N. York, age 47.	Feb. 20, 1864.	Compound comminuted shot fracture of the head of right humerus.	July 18, 1864.	Excision of head and four inches of shaft of humerus through a linear incision, by Surgeon Gileon, C. S. A.	Disch'd Mar. 27, 1865; pensioned. Dec., 1874, disability total, third grade.
2	Boazeman, H., Pt., F, 8th South Carolina, age 32.	July 1, 1863.	Minié ball entered head of left humerus and passed obliquely outward, fracturing the neck.	Aug. 17, 1863.	Excision of the head and two and a half inches of shaft of humerus, by Ass't Surg. T. J. Vance, C. S. A.	Paroled Sept. 25, 1863; recovered.
3	Brock, Peter, Corp'l, K, 28th Massachusetts, age 21.	July 2, 1863.	Fracture of the head of the left humerus and clavicle by a conoidal ball.	Oct. 20, 1863.	Excision of the head and five inches of the shaft of humerus through a straight incision, by Surg. H. James, U. S. V.	Disch'd Ap'l 21, 1864; pensioned. Sept., 1873, disability equal to less of arm for labor. Spec. 1941, A. M. M.
4	Chase, S. J., Pt., C, 111th New York, age 28.	May 5, 1864.	Minié ball passed through the head of right humerus, shattering it.	June 21, 1864.	Head and two inches of shaft of humerus removed through a vertical incision, by A. A. Surg. G. W. Fay.	Disch'd Mar. 23, 1865; pensioned. Sept., 1873, disability equal to less of arm for labor. Spec. 3465, A. M. M.
5	Clair, A., Pt., I, 4th Artillery, age 21.	Sept. 19, 1863.	Head of the left humerus perforated by a musket ball; shaft fissured.	Nov. 16, 1863.	Removal of the head and two inches of shaft of humerus through a straight incision, by Ass't Surg. C. J. Kipp, U. S. V.	Disch'd Sept. 15, 1864; pensioned. Feb., 1872, has partial use of forearm and hand. Spec. 2181, A. M. M.
6	Delan, M., Serg't, E, 2d Infantry, age 25.	Dec. 13, 1862.	Musket ball shattered the head of left humerus and lodged; shaft of bone split.	Mar. 6, 1863.	Excision of the head and two inches of shaft of humerus through a V-shaped incision, by A. A. Surg. J. Stearns.	Appointed 2d Lieut., 3d Infantry, Feb. 19, 1863. Retired Dec. 15, 1870. Spec. 999, A. M. M.
7	Dutton, O., Serg't, B, 20th Indiana, age 30.	May 12, 1864.	Minié ball fractured the left humerus just below surgical neck; head of bone dislocated.	June 28, 1864.	Head and two inches of shaft removed thro' a straight incision, by Surg. E. Bentley, U. S. V.	Disch'd Oct. 8, 1864; pensioned. Sept., 1873. "The arm is a useless appendage."
8	Eckelberger, J., Pt., L, 4th Penn'a Cavalry, age 20.	Aug. 16, 1864.	Four-fifths of the circumference of the bone carried away by a musket ball, which struck the neck of the right humerus.	Sept. 18, 1864.	Head and five inches of the shaft of the humerus removed through a straight incision, by A. A. Surgeon W. P. Moon.	Disch'd Ap'l 27, 1865; pensioned. Oct., 1866, arm and hand atrophied and useless. Drowned March 12, 1870.
9	Farnsworth, A. J., Pt., K, 12th Massachusetts.	Dec. 13, 1862.	Fracture of the left shoulder joint by a rifle ball.	June 6, 1863.	Excision of the head with the outer portion of the neck and shaft of humerus, by A. A. Surg. J. W. Cushing.	Disch'd Sept. 21, 1863; pensioned. Mar., 1874. "The arm is none of the best; some motion, though not a great deal."
10	Finch, S. F., Pt., D, 19th Indiana, age 34.	May 6, 1864.	Minié ball fractured the inner margin of right scapula and upper third of humerus.	June 15, 1864.	Excision of the head and three inches of shaft, by A. A. Surg. H. M. Dean.	Disch'd Feb. 27, 1865. Not a pensioner in August, 1874.
11	Fish, P., Pt., II, 43d New York, age 33.	May 6, 1864.	Comminuted fracture of the left humerus above the surgical neck by a conoidal ball; also wound of foot.	June 20, 1864.	Head and four inches of shaft of humerus removed through incision externally, by Surg. E. Bentley, U. S. V.	Disch'd April 6, 1865; pensioned. Sept., 1873, arm useless for labor.
12	Gahagan, J. W., Pt., H, 148th Pennsylvania.	May 3, 1863.	Shot fracture of the right humerus near the shoulder.	July 7, 1863.	Upper extremity of humerus removed just below surgical neck, by Ass't Surg. W. H. Gardner, U. S. A.	Disch'd Dec. 10, 1861; pensioned. Feb., 1874, ankylosis of joint; cannot raise arm.
13	Gravel, D., Pt., I, 142d New York, age 22.	May 20, 1864.	Shot perforation of left shoulder joint, with injury to the head of humerus.	Aug. 5, 1864.	Removal of the head and two inches of shaft of humerus through a V-shaped incision, by A. A. Surg. W. L. Welles.	Disch'd July 27, 1865; pensioned. Dec., 1871, reproduction of bone, shoulder joint completely ankylosed.
14	Greer, J. C., Pt., A, 12th South Carolina, age 19.	July 3, 1863.	Shot comminution of head of humerus and portion of the glenoid cavity.	Nov. 12, 1863.	Removal of four inches of upper extremity of humerus, including the head.	Returned to light duty August 28, 1864.
15	Harbaum, H., Corp'l, K, 37th Ohio, age 37.	May 16, 1862.	Fracture of left shoulder joint by a musket ball; head of the humerus fissured entirely through.	June 20, 1862.	Removal of the head and four inches of shaft through an L incision, by Ass't Surgeon H. Z. Gill, 11th Ohio.	Disch'd Aug. 15, 1862; pensioned. Died Jan. 28, 1865, from hemorrhage of lungs.



No.	NAME, AGE, AND MILITARY DESCRIPTION.	DATE OF INJURY.	NATURE OF INJURY.	DATE OF OPERATION.	OPERATION AND OPERATOR.	RESULT AND REMARKS.
16	Kavanaugh, J., Pt., B, 71st Pennsylvania, age 21.	July 3, 1863.	Upper third of left humerus shattered by a shell fragment.	Oct. 21, 1863.	Excision of the head and three and a half inches of the shaft, by A. A. Surg. T. G. Morton.	Disch'd April 11, 1864, and pensioned. <i>Spec.</i> 2770, A. M. M.
17	Kegerries, J. P., Pt., B, 2d Penn'a Artillery, age 19.	June 17, 1864.	Conoidal ball passed through the surgical neck of the right humerus.	Nov. 19, 1864.	Excision of the head and three inches of the shaft through a perpendicular incision, by Surgeon E. Bentley, U. S. V.	Disch'd May 28, 1865; pensioned. December, 1867, sequestrum six inches long removed, by Dr. J. L. Süsserott. <i>Spec.</i> 5741, A. M. M.
18	Kelly, J., Serg't, E, 6th Infantry, age 41.	Dec. 14, 1862.	Minié ball fractured the head of left humerus, opening the capsule.	Sept. 10, 1863.	Head and two and a half inches of shaft of humerus removed through an S-shaped incision, by Surg. D. W. Bliss, U. S. V.	Disch'd Dec. 18, 1863; pensioned. Oct., 1866, disability equal to loss of arm for purposes of labor. <i>Spec.</i> 1688, A. M. M.
19	Kelly, M., Pt., A, 16th Infantry, age 46.	Dec. 31, 1862.	Extensive comminuted fracture, through surgical neck, of the left humerus by a conoidal ball.	Mar. 7, 1863.	Six and a half inches of the humerus removed, including the head, through a V-shaped incision, by Surg. F. Seymour, U. S. V.	Disch'd April 29, 1863; pensioned. Sept., 1873, muscular atrophy of arm, forearm, and hand.
20	Kennier, B., Pt., I, 2d Massachusetts, age 27.	Sept. 17, 1862.	Shot fracture of head of right humerus by a minié ball; fracture extended down the shaft three inches.	Nov. 20, 1862.	More than a third of the upper portion of humerus removed, by Surgeon A. B. Hasson, U. S. A. Amputation at shoulder joint.	Disch'd April 24, 1863; pensioned. Enlisted in the V. R. C. Aug. 17, 1863. Disch'd Jan. 20, 1865.
21	King, R., Pt., D, 7th Wisconsin.	Aug. 29, 1862.	Minié ball shattered the left humerus through the anatomical neck.	Jan. 29, 1863.	Excision of the head and a portion of the shaft of humerus, by Act. Ass't Surgeon L. K. Baldwin.	Disch'd April 14, 1863; pensioned. Died Feb. 22, 1864. <i>Spec.</i> 2622, A. M. M.
22	Lewis, D. C., Pt., F, 11th Massachusetts, age 21.	July 21, 1861.	Shot fracture of the head of left humerus and comminution of the upper portion of shaft.	Feb. 7, 1862.	Removal of the head and three inches of the shaft, by Surg. R. B. Bontecou, U. S. V.	Disch'd Oct. 15, 1862; pensioned. Dec., 1873, arm useless for labor.
23	McCarthy, W., Sergeant, L, 24th N. Y. Cavalry, age 22.	Mar. 31, 1865.	Shot fracture of the head of the humerus, extending thro' the surgical neck.	June 8, 1865.	Removal of the head and three inches of the shaft of the humerus, by Surg. E. Griswold, U. S. V.	Disch'd Nov. 9, 1865; pensioned. Sept., 1873, disability total, 3d grade. <i>Spec.</i> 4236, A. M. M.
24	McTready, H., Pt., G, 15th Kentucky.	Sept. 19, 1863.	Bullet wound of the neck of the right humerus, comminuting the bone and opening shoulder joint.	Dec. 31, 1863.	Head and injured portion of the humerus removed through a straight incision, by Surg. R. G. Bogue, 19th Illinois.	Disch'd Jan. 14, 1865; pensioned. "Sept., 1868, motion of forearm moderately free; limb useless for actual work."
25	Middleton, J., Pt., A, 205th Pennsylvania, age 31.	April 2, 1865.	Shot fracture of the head of the left humerus.	May 9, 1865.	Head and two inches of shaft of humerus removed, by Surg. R. B. Bontecou, U. S. V.	Disch'd Sept. 23, 1865; pensioned. Nov., 1873, "incapacitated for labor." <i>Spec.</i> 4350, A. M. M.
26	Millard, W. A., Pt., G, 1st Tennessee, age 24.	June 26, 1862.	Musket ball perforated shoulder joint, carrying away one-third of head of humerus.	Sept. 14, 1862.	Excision of upper extremity of humerus at a point below the surgical neck.	Recovered: "useful joint."
27	Neville, L., Pt., I, 140th Pennsylvania, age 19.	May 12, 1864.	Shot comminution of the left humerus.	June 25, 1864.	Three and one-half inches and the head of humerus removed through a straight incision, by A. A. Surg. D. N. Rankin.	Disch'd Oct. 28, 1864; pensioned. Sept., 1873, "arm perfectly useless for all purposes of labor."
28	Parce, G., Pt., B, 44th Illinois, age 27.	Sept. 20, 1863.	Conoidal ball perforated upper third of the right humerus.	April 7, 1865.	Three and a quarter inches, including the head, removed, by Dr. E. Andrews. Aug. 2, 1867, and Oct. 3, 1867, five and a half inches of shaft excised, by Surgeon C. M. Clark, 39th Illinois.	Disch'd Sept. 30, 1864; pensioned. Sept., 1873, has slight use of fingers; arm useless for labor. <i>Spec.</i> 5657, A. M. M.
29	Pratt, B. W., Serg't, B, 7th New Hampshire, age 28.	July 18, 1863.	Shot fracture of upper third of left humerus.	Sept. 7, 1863.	Head and five inches of shaft of humerus removed, by A. A. Surg. J. B. Cutter.	Disch'd May 23, 1864; pensioned. Sept., 1873, limb useless for labor.
30	Queen, C. V., Pt., F, 59th New York, age 52.	Sept. 17, 1862.	Comminuted fracture of the left shoulder joint by a conoidal ball.	Oct. 26, 1862.	Excision of the head and three and a half inches of shaft of humerus through a straight incision, by Ass't Surg. J. H. Bill, U. S. A.	Disch'd Dec. 15, 1862; pensioned. Sept., 1873, has only partial use of the arm. <i>Spec.</i> 839, A. M. M.
31	Sachse, J., Sergeant, K, 2d, Missouri, age 24.	Sept. 19, 1863.	Shot fracture of the head and neck of the right humerus, with extensive comminution; shaft fissured.	Nov. 10, 1863.	Excision of the head and two inches of the shaft of the humerus through a straight incision, by Surgeon C. J. Kipp, U. S. V.	Disch'd July 10, 1864; pensioned. Died Aug. 9, 1873. <i>Spec.</i> 2180, A. M. M.
32	Seipel, H., Pt., H, 68th Pennsylvania, age 17.	May 3, 1863.	Shot fracture of left humerus by a conoidal ball.	July 8, 1863.	Excision of the head and three and a half inches of shaft of humerus, by A. A. Surgeon J. H. B. Met'ellan.	Disch'd Oct. 12, 1864; pensioned. Sept., 1873, arm useless for labor.
33	Sill, J., Pt., C, 25th Ohio.	Aug. 30, 1862.	Shot perforation of the left humerus at anatomical neck, with comminution of shaft.	Oct. 2, 1862.	Removal of the head and a portion of shaft of humerus, by Surg. D. W. Bliss, U. S. V.	Discharged; re-enlisted in V. R. C. and discharged Mar. 22, 1869; pensioned. April, 1872, arm useless for labor. <i>Spec.</i> 189, A. M. M.
34	Snow, F., Pt., C, 37th New York, age 21.	June 30, 1862.	Musket ball fractured the right humerus high up, completely comminuting bone.	Aug. 1, 1862.	Head and nearly four inches of shaft of humerus removed thro' a single perpendicular incision, by A. A. Surgeon S. D. Gross.	Disch'd Oct. 25, 1862; pensioned. Oct., 1863, some use of forearm and hand. <i>Spec.</i> 387, A. M. M.
35	Taylor, E. P., Pt., H, 19th Iowa, age 20.	Mar. 27, 1865.	Head of right humerus splintered by a musket ball, which lodged and was extracted through wound of entrance.	Ap' 28, 1865.	Upper extremity of humerus resected; section made one inch below surgical neck, by Ass't Surg. A. Hartsuff, U. S. A.	Disch'd June 5, 1865; pensioned. Sept., 1873, "arm useless."
36	Van Tassel, E., Pt., A, 120th New York, age 19.	May 3, 1863.	Shot wound of the left shoulder joint; head split and posterior fourth carried away.	June 24, 1863.	Head and one inch of shaft of humerus removed, through straight incision, by Assistant Surg. C. R. Greenleaf, U. S. A.	Disch'd July 31, 1865; pensioned. July, 1867, "total loss of use of arm." <i>Specs.</i> 1778 and 2596, A. M. M.
37	Wilkey, W. P., Pt., F, 4th New Jersey, age 19.	June 27, 1862.	Minié ball fractured upper third of the left humerus.	Sept. 1, 1862.	Head and upper third of shaft of humerus resected, by A. A. Surg. F. A. Keller.	Disch'd Jan. 24, 1863; pensioned. Sept., 1873, "By fixing elbow to side of body he can flex forearm and use some power." <i>Spec.</i> 890, A. M. M.
38	Winsor, J., Pt., F, 51st New York, age 27.	Dec. 13, 1862.	Shot fracture of the head of left humerus; ball passed under scapula and emerged.	Jan. 19, 1863.	Excision of the head and four inches of shaft of humerus, by Surg. T. Antisell, U. S. V.	Disch'd June 19, 1863; pensioned. Sept., 1873, "arm useless for purposes of labor."

Of the thirty-eight recoveries from secondary excisions of the upper extremity of the humerus after shot injury, above tabulated, thirteen were operations on the right, and twenty-three on the left side; in two Confederate cases, this point was not recorded. There was one instance of consecutive amputation at the shoulder, and one in which, by successive exsections, the entire shaft was removed.

CASE 1579.—Lieutenant Michael Dolan (retired), while 1st Sergeant of Co. E, 2d Infantry, and 25 years of age, was wounded at the battle of Fredericksburg, December 13, 1862. He was carried to the hospital of the 2d division of the Fifth Corps, whence Assistant Surgeon W. R. Ramsey, U. S. A., reported that "a musket ball penetrated the left shoulder; simple cold-water dressings were applied, and the patient was sent to a base hospital."

On December 16th, the patient entered Hammond Hospital, at Point Lookout, under the care of Acting Assistant Surgeon John Stearns, jr., who transmitted the following report, and published a duplicate of it.<sup>1</sup> "A minie ball entered left shoulder just inside acromial process of scapula and lodged just below the head of the humerus, splitting off about an inch of that bone at this place. Patient was much prostrated, and confined to bed long after entrance to hospital. When placed under ether for examination, the motion of joint was so good that it was pronounced uninjured. A second examination proved the extent of injury, but his condition did not warrant an operation until March 6, 1863, when the joint was exposed by flap-incision and about two inches of the humerus was removed, with the head. In a week after he was about as usual, and in four weeks from time of operation the wound



FIG. 472.—Cicatrix after an excision for shot injury. [From a Museum photograph.]

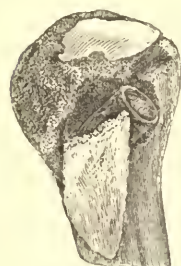

FIG. 471.—Carious excised head of left humerus, with an impacted conoidal ball. Spec. 999.

had healed, the patient progressing most favorably. An opening was made on the inner and posterior aspect of the arm to facilitate the escape of pus, which was slight and of perfectly healthy character. April 5th, everything progressing favorably." This operation was performed by Acting Assistant Surgeon John Stearns, jr., who contributed the specimen (FIG. 471) to the Museum. The catalogue of 1865, page 105, erroneously accredits the donation to Assistant Surgeon C. Wagner, U. S. A., who was in charge of the hospital. In February, 1863, Mr. Dolan was appointed 2d lieutenant of the 2d Infantry. July 23, 1863, he was transferred to the Annapolis General Hospital. Surgeon B. A. Vanderkeift, U. S. V., reports that he resumed duty August 11, 1863. He was promoted to a first lieutenantcy January 31, 1866, and retired, "for incapacity resulting from wounds received in the line of duty," December 15, 1870. In January, 1868, Mr. Dolan visited the Museum and permitted a photograph of the injured shoulder to be made. The picture is numbered 192 of the *Surgical Series of Photographs*, Vol. IV, p. 42. A reduced copy of it is presented by FIGURE 472. At this date, the lieutenant had a very useful arm.

CASE 1580.—Private Freeman S——, Co. I, 37th New York, aged 21 years, was wounded in the right shoulder in one of the battles before Richmond, June 30, 1862, and the ball was excised on the field. He was captured and incarcerated for three weeks, and then exchanged and sent to the Fourth and George Streets Hospital, Philadelphia. He was treated by Professor S. D. Gross, who forwarded the specimen from the case, represented in the adjoining wood-cut (FIG. 473), with the following report: "The patient, a stout, muscular man, received a gunshot wound of the right arm and shoulder. A round ball entered the back behind the vertebral border of the scapula, passed beneath the scapula, through the neck of the humerus, and emerged in front of the arm, four inches and a half below the head of the humerus. He was greatly debilitated when he arrived at our hospital on the 27th of July. On the 1st of August, I excised the head of the humerus along with nearly four inches of the shaft of the bone, which was completely comminuted, some of the splinters being driven in among the muscles. The greater portion of the shaft adherent to the head was necrosed at the time of the operation. In this case I made a single perpendicular incision, which was afterward united by metallic sutures. A considerable portion of the wound healed by the first intention, but there was a great deal of discharge for several weeks from the lower angle. Not a really untoward symptom occurred, and Snow was discharged from the hospital, October 20, 1862, in excellent health and flesh. The parts were perfectly cicatrized, and he had a very good use of the limb. A large amount of callus was thrown out from the extremity of the humerus." The specimen consists of the head and outer portion of the shaft of the right humerus, three and a half inches in length, excised two months after the injury. The articular surface was not involved, but the surgical neck was comminuted by a round ball. The specimen shows only the head and the large fragments attached. (See *Surgical Series of Photographs*, Vol. III, p. 24.) On October 25, 1862, Snow was discharged the service and pensioned. Examiner Nelson Peck, of Lyons, New York, reported, in 1863, that the upper arm was useless, but that "he had some use of the forearm and hand." The pensioner went to reside in Cambridge, Massachusetts, and his pension was successively increased, on January 6, 1866, and August 5, 1872, from \$8 to \$15, and then to \$18 per month. He was paid on March 4, 1874.

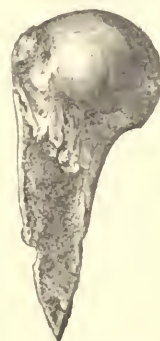

FIG. 473.—Excised head and part of the shaft of right humerus. Spec. 387.

<sup>1</sup> STEARNS (J., jr.), *A few Cases of Excision of the Elbow and Shoulder Joints*, in *Boston Med. and Surg. Jour.*, 1863, Vol. LXVIII, p. 252.



The two following cases are remarkable for the extent of consecutive removal of necrosed or carious portions of the shaft, with retention of the functions of the forearm. They may be compared, in regard to this feature, with the case of Cleghorn, described on page 568, where necrosis of the diaphysis and condyles followed a primary excision:

CASE 1581.—Private J. P. Kegerreis, Co. B, 2d Pennsylvania Heavy Artillery, aged 19 years, was wounded at Petersburg, June 17, 1864, and was treated in the hospital of the Ninth Corps, at City Point, until July 3d, when he was transferred to the 1st Division hospital at Alexandria. Surgeon Edwin Bentley, U. S. V., recorded: "Shot through right shoulder, the ball entering in front of the clavicle two inches from the acromial end, passing through the surgical neck of the humerus, and out near the centre of the deltoid muscle. November 19th: Excision of the upper part of the humerus, under chloroform, by a perpendicular incision from the acromion, through the deltoid, five inches in length, exposing the shaft of the bone, and sawing through the latter with a chain saw, and then disarticulating the head of the bone; length of bone removed, four and a half inches; long head of biceps not divided. He recovered slowly. At the time of operation, there was ankylosis of the shoulder, with slight swelling laterally, and much swelling in front; pus was discharging freely through the openings made by the ball, and at an incision in the anterior surface. The patient's condition was not very good; his constitution had evidently suffered from the excessive discharge from the wound; tongue coated; pulse 70; appetite poor. November 21st: Slight chill in the morning; pulse 120; beef tea. November 23d: Chill at 5 a. m.; pulse 128; at 1 p. m., another chill; pulse 130. Five grains of sulphate of quinia were given every eight hours, and milk punch. November 24th: Pulse 116; milk punch, beef tea, chicken broth. November 26th: Locally, water dressings and poultices, when painful. Opiates have been given to relieve pain and procure sleep. There has been gradual improvement since last date, and now, January 1, 1865, the patient sits up." On February 26th, this man was transferred to Sickel Barracks, and thence discharged, May 29, 1865, and pensioned. Dr. H. W. Sawtelle reported from the Pension Bureau, where the pensioner was then employed in clerical

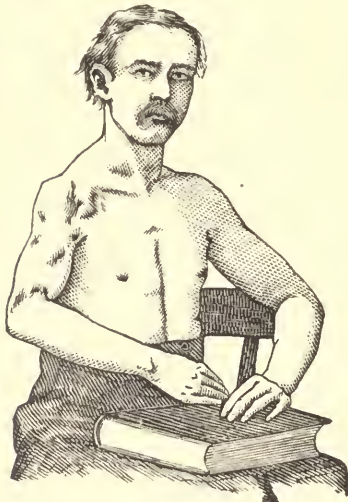


FIG. 474.—Cicatrices six years after an excision of the upper part of the humerus, followed by necrosis of the shaft. [From a Museum photograph.]

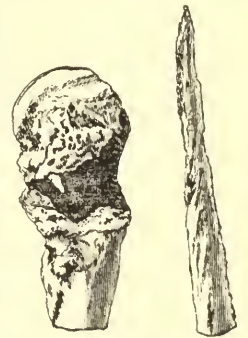

FIG. 475.—Excised carious upper end of right humerus, with a tubular sequestrum from shaft. Spec. 5711.  $\frac{3}{4}$ .

duty: "Pensioner states that, about one year after he left the service, nine fistulous openings discharged; the arm from elbow to shoulder becoming greatly enlarged, and his general health rapidly failing. December 17, 1857, Dr. J. L. Suesserott, of Chambersburg, removed a sequestrum of about six inches by enlarging the orifice from which it pointed, extending from the point of resection to the elbow, the patient being under the influence of nitrous oxide gas. He returned to his home, a distance of twenty miles, on the same day, no untoward symptoms occurring, and is now enjoying excellent health. The sinuses were all healed by April 1, 1868, and never reopened. The elbow joint is ankylosed in a semi-flexed position, and firm ligamentous union has taken place in the arm, so that the subject is able to lift about 135 pounds with the injured limb. Eleven well-marked cicatrices appear on the arm and side. The temperature of the limb is normal." The excised head, with a sequestrum of the shaft, is represented by the wood-cut (FIG. 475); it was presented to the Museum by Dr. Sawtelle. In April, 1868, Mr. Kegerreis called at the Museum, and a picture of the injured limb was made, and numbered 289 of the *Surgical Series of Photographs*, Vol. VI, page 39. (See FIG. 474.) This pensioner is still (May, 1875) employed as a clerk in the Pension Bureau, using his right arm with comparatively slight inconvenience.



FIG. 476.—Carious head and greater part of right humerus removed in three successive operations.

CASE 1582.—Private George P——, Co. B, 44th Illinois, aged 27 years, wounded in the arm at Chickamauga, September 19, 1863, was treated in hospitals on the field, and at Nashville, Louisville, Jeffersonville, Madison, and Quincy, arriving at the latter place July 27, 1864. Surgeon D. P. Brinton, U. S. V., reported that "a conical bullet had passed directly through the right humerus, at the upper third, in front. On admission, there was erythematic inflammation about the shoulder; it appears as though the bone might have been split into the joint. Simple dressings were applied to the wound, and tincture of iodine to the integuments about the shoulder; special diet given. August 6th, an opening was made from which pus flowed freely; wound still suppurating." He was discharged the service September 29, 1864, for disability on account of "gunshot wound of the right arm," and pensioned. The subsequent history of the case was furnished by C. M. Clark, late surgeon 39th Illinois, who reported: "Parce entered the Soldiers' Home Hospital, Chicago, in January, 1865, with caries of the upper third of the humerus, involving the head of the bone, with free discharge of pus from distinct sinuses on the dorsal surface of the arm. An operation for excision of the head was performed, April 7, 1865, by Dr. E. Andrews, when the head of the bone and a portion of the shaft were removed measuring three and three-quarter inches in all. The wound did not heal readily, erysipelas occurring, with considerable sloughing. I first saw the case June 13, 1867, at the time I took surgical charge of the Home. The arm was then swollen and painful, with discharge of sanious pus; denuded bone could be felt when the probe was introduced, and the patient was anxious for another operation, saying that he could not survive such torture as the limb constantly gave him. He was placed on full and

nutritious diet, with stimulus, receiving great benefit and gaining largely in flesh and strength. On August 2, 1867, he was placed under the influence of chloroform, and two and a half inches of the bone were removed by longitudinal incision on the outer surface of the arm. The bone removed was greatly diseased and shell-like in structure; the medullary cavity was greatly increased in diameter, and its contents bleeding very freely when section was made. The space occupied by bone prior to the previous operation was filled with cartilaginous matter, with some few points of ossific deposit. The wound was dressed after the usual manner, with sutures, adhesive strips, splint and bandage, and plenty of cold water. Several of the stitches were removed on August 7th, at which time the wound was doing nicely. By September 1st, the wound had nearly healed, and the man expressed himself as feeling first rate, and was able to use the arm to some extent. On September 15th, he had a chill, with subsequent fever, and from this date the arm became painful and commenced again to discharge. The probe detected more dead bone, and another operation was decided upon, which was performed October 3, 1867, when three inches more of the bone were removed, the portion removed presenting the same characteristics as the former piece. The wound healed readily, and ceased entirely to trouble him. In March, 1868, he could use the arm to some advantage, feed himself with it, and take off his hat. He left the Home in the latter part of March and went to his residence, since which time I have not heard from him." The specimen (FIG. 476) consists of the head and a portion of the shaft of the right humerus, removed in three operations, and in all eight and three-quarter inches, and was contributed by Dr. Clark, who performed the last two operations. A Board of Examiners, composed of W. C. Lyman, F. A. Emmons, and E. O. F. Roler, of Chicago, reported, September 15, 1873: "Removal of entire shaft of the right humerus, including the head of the bone and the condyles below; slight use of fingers; disability total." The pensioner was paid to March 4, 1874.

§ *Unsuccessful Operations.*—The excisions of the head with adjacent portions of the shaft reported as secondary procedures, and resulting fatally, were twelve in number:

CASE 1583.—Private Frederick K——, 14th Infantry, aged 31 years, was wounded at Spottsylvania, May 12, 1864, and entered Lincoln Hospital, Washington, on May 26th. Acting Assistant Surgeon A. Ansell reported: "When admitted, his wounds were healing very kindly, and he continued to do well until June 22d, when the limb began to swell, the lips of the wound having a phagedenic appearance, and he complained of severe pain in the shoulder. June 24th: He was removed to the operating room and the injury was examined under ether, when the shaft of the humerus was found to be so fearfully comminuted that resection was at once performed, by Assistant Surgeon J. C. McKee, U. S. A. The head and three and a half inches of the shaft were removed, and the wound was dressed with water dressings. He continued to do well until June 28th, at noon, when severe rigors supervened, accompanied by pain in the limbs, cough, and vomiting of bilious matter. His countenance became dull; he was at times delirious; the pulse was quick, small, and thready. Ordered five grains of carbonate of ammonia and fifteen grains of chlorate of potash every two hours, alternated with ten grains of sulphate of quinia in half an ounce of brandy. His respiration was hurried, at 40 a minute; he had pain in the left thorax; there was loud, small, and large crepitation in this region. The patient continued in this way, gradually failing, and expired at noon, June 30, 1864." The *post-mortem* examination was made by Acting Assistant Surgeon H. M. Dean, who forwarded the pathological specimen (*Cat. Surg. Sect.*, 1866, p. 109, *Spec.* 2719), with the following report: "Examination eight hours after death: Body not much emaciated. Had been wounded through the upper third of the arm. From the looks of the wound the ball entered two inches below the joint on the posterior surface, and was cut out immediately above the insertion of the pectoralis major muscle. Five and a half inches of the upper part of the humerus had been excised. Ligatures were still attached. The wound was in a sloughing condition, and there was no appearance of granulation. The glenoid cavity was normal. The upper extremity of the lower part of the humerus was denuded of its periosteum for one and a quarter inches."

CASE 1584.—Private T. T. P——, Co. A, 3d Michigan, aged 20 years, was wounded at Fair Oaks, May 31, 1862. He was sent to Christian Street, and thence to Haddington Hospitals, Philadelphia, and transferred, March 31, 1863, to Satterlee Hospital. Acting Assistant Surgeon J. H. Paekard reported: "Wounded by a ball of unknown character, passing through the left humerus from before backward, about four inches below the articulation of the shoulder. Several sinuses existed both in front of the arm and behind it, leading to dead bone. The orifice of exit of the ball had entirely closed. Pending arrangements for his removal to a Michigan hospital at Detroit, I proposed to him the extraction of the dead bone from his arm, and he readily consented. Accordingly, on the 9th of April, he was placed under the influence of chloroform, and the sinuses were laid open posteriorly so as to expose the affected portion of the bone. It was now found that the whole of the upper part of the humerus was so degenerated as to forbid all hope of its again becoming of use. The posterior incision was therefore continued transversely through the deltoid, so as to form an external flap, which, being raised up, the head of the humerus was freed from its articular connections, and the bone cut through below with bone nippers. Very little bleeding ensued, only three vessels needing ligation. Cold water was applied locally, and opium given to allay pain and promote sleep. He did very well until the night following April 16th, when he had what was considered a chill, followed by fever, with delirium and sweats. These symptoms proved the next day to have been the precursors of inflammation of the right lung. April 17th, I saw him at 6.30 P. M., and ordered six cut cups over the lower part of the right lung, beef essence and milk punch, with a febrifuge and anodyne mixture. Wound doing very well. On the 18th, Dr. Da Costa saw him, in consultation with me, and advised a mixture containing carbonate of ammonia, acetate of morphia, syrup of senega, and tincture of veratrum viride. Pulse ranging above 120; some delirium constantly; aggravated at night. 20th, Drs. Da Costa and Page saw him with me. His pulse was 136; tongue moist; slightly coated white. Bowels confined, abdomen excessively tympanitic, interfering with respiration, already impeded by the inflammation of the lung. I ordered an injection of spirits of turpentine, sixty drops in two ounces of starch water, every two hours; the brandy and milk to be given every hour. After two of the enemata, he became decidedly more comfortable, and his bowels were three times moved quite freely. All this time, the wound continued to do well. At two o'clock P. M., by order of the surgeon in charge of the hospital, the treatment was changed; a mixture of tincture of ergot, one ounce, and tincture of camphor, half an ounce, being prescribed, one drachm to be given every two hours. The brandy, etc., to be continued. April 21st,



some pain toward the base of the left chest; respiration more limited; pulse 136; countenance very unfavorable; delirium constant; no additional distention. No change in the treatment. 22d, Drs. Stille, Da Costa, and Halsey were ordered to consult with me in regard to the case. Upon examination, we found the pneumonia to have involved the left lung as well as the right. The physical signs of effusion into the pleuræ were also present. The patient's general condition was very bad; his pulse rapid and windy; his respiration impeded; his countenance anxious; his restlessness constant. The following treatment was ordered: half an ounce of brandy, with one and a half ounces of milk, every two hours at least; two ounces of beef essence every two hours; half a grain of aqueous extract of opium every three hours; the anterior surface of the chest to be painted with tincture of iodine. The patient, however, sank rapidly, and died the same day, at about five o'clock P. M." The following report of the *post-mortem* examination was made by Professor Joseph Leidy: "No restoration of the bone existed. Diagnosis of case, pneumonia; body large and rather fat; heart healthy; right pleural cavity contained about a quart of pus, the left about a pint of serum; right lung with comparatively recent pleurisy; the lower lobe covered with soft, yellowish, ragged pseudomembrane, and more or less adherent to the phrenic and costal pleuræ. More moderate pleuritic inflammation, with thin pseudomembrane, and partial attachments of the upper and middle lobes. Pleurisy of the left lung in a large circumscribed patch on the convex surface, about the size of the hand; the patch being adherent by recent pseudomembrane to the costal pleura. Both lungs, but especially their lower lobes, were affected with lobular pneumonia. The indurated masses, about the size of hickory nuts, were cream colored and infiltrated with pus. Some of the masses had broken down into cavities filled with pus. The bronchial mucous membrane throughout was inflamed. The abdominal viscera were all healthy. The lobular pneumonia was most probably metastatic inflammations and embolical in their origin." The specimen, No. 1875 of the Surgical Section, contributed by the operator, consists of "the head and three and a half inches of the shaft of the left humerus excised ten and a half months after injury, for perforation by gunshot of the surgical neck, followed by necrosis of the internal structures and a decided deposit of new bone internally. The specimen shows a portion of the shaft to have been removed by a trephine, of which there is no account in the history."—*Cat. Surg. Sect.*, 1866, p. 109.

TABLE XXXVI.

*Summary of Twelve Fatal Cases of Secondary Excisions of the Head and Portions of the Shaft of the Humerus for Shot Injury.*

NO.	NAME, AGE, AND MILITARY DESCRIPTION.	DATE OF INJURY.	NATURE OF INJURY.	DATE OF OPERATION.	OPERATION AND OPERATOR.	RESULT AND REMARKS.
1	Bennett, O. A., Sergeant, 1, 11th Virginia.	May 16, 1864.	Minié ball grazed the head of the humerus and emerged near the spine of the scapula.	June 29, 1864.	Four inches of the humerus, including the head, removed through a vertical incision.	Died July 6, 1864.
2	Cushing, W., Pl., B., 40th New York, age 24.	May 5, 1864.	Musket ball passed through the surgical neck of the right humerus, comminuting the head of the bone considerably.	June 11, 1864.	Excision of the head and three inches of the shaft through a straight incision, by A. A. Surg. H. B. Knowles.	Died July 16, 1864.
3	Kase, F. M., Pl., 14th Infantry, age 31.	May 12, 1864.	Comp'd comminuted shot fracture of the head and upper portion of shaft of the right humerus.	June 24, 1864.	Excision of the head and three and a half inches of the shaft, by Asst. Surg. J. C. McKee, U. S. A.	Did well until June 28. Rigors, vomiting, delirium. Died June 30, 1864, of pyæmia. <i>Spec.</i> 2719, A. M. M.
4	Henry, G., Sergeant, E, 35th Massachusetts.	Sept. 17, 1862.	Anterior portion of the surgical neck and lower portion of both tuberosities of right humerus carried away by shot.	Oct. 21, 1862.	Excision of the head and one-half inch of the shaft, by Asst. Surg. C. A. McCall, U. S. A.	Died November 3, 1862, of pyæmia. <i>Spec.</i> 330, A. M. M. <sup>1</sup>
5	Merriman, J., Pl., E, 155th Pennsylvania, age 26.	May 5, 1864.	Shot wound of right shoulder, fracturing the scapula and involving the shoulder joint.	June 15, 1864.	Excision of the head and one inch of the shaft, by Asst. Surg. W. F. Norris, U. S. A.	Died July 14, 1864; asthenia. <i>Spec.</i> 3559, A. M. M.
6	Minot, E. G., Pl., 1st Maine Artillery, age 25.	June 16, 1864.	Musket ball lodged in and fractured the head of left humerus and a part of the shaft.	Aug. 10, 1864.	Excision of the head and two inches of the shaft through incision over joint, by A. A. Surg. W. C. Flowers.	Died September 17, 1864, from pyæmia.
7	Peterson, T. F., Pl., A, 2d Michigan, age 20.	May 31, 1862.	Musket ball perforated the left arm from before backward, about two inches below the acromion.	Apr. 7, 1863.	The head and three and a half inches of the shaft excised, by A. A. Surg. J. H. Packard.	Died April 22, 1863, of pneumonia. <i>Spec.</i> 1875, A. M. M.
8	Robinson, L., Pl., E, 4th Colored Troops, age 29.	Sept. 29, 1864.	Shot fracture of the head of left humerus; portion of shaft and coracoid process of scapula also fractured.	Nov. 10, 1864.	Excision of the head and two inches of the shaft, by A. A. Surg. O. Warner.	Died November 14, 1864. <i>Spec.</i> 4003, A. M. M.
9	Spitler, S., Pl., K, 4th Ohio, age 19.	May 27, 1864.	Left humerus shattered below surgical neck without opening the joint; ball perforated left thorax.	July 19, 1864.	Head and four inches of shaft resected, by A. A. Surg. H. C. May.	Died July 26, 1864, of exhaustion. <i>Spec.</i> 3369, A. M. M.
10	Stiles, L. H., Pl., G, 9th Massachusetts, age 30.	Jan. 10, 1864.	Comp'd comminuted fracture of surgical neck of the left humerus by minié ball; same ball comminuted the lower maxilla.	Feb. 16, 1864.	Excision of the head and two and a half inches of the shaft through a V-shaped incision, by Surgeon O. A. Judson, U. S. V.	Died February 27, 1864; pyæmia. <i>Spec.</i> 2112, A. M. M.
11	Sweat, J., Pl., B, 58th Illinois.	April 9, 1864.	Shot fracture of left humerus by a minié ball.	May 20, 1864.	Excision of the head and one inch of the shaft through a vertical incision, by Surgeon J. G. Keenan, U. S. V.	Died May 24, 1864, of pneumonia.
12	Welch, J., Pl., C, 61st New York, age 20.	May 5, 1864.	Conoidal ball passed through the head of the left humerus, deeply grooving it.	Aug. 27, 1864.	Excision of the head and one inch of the shaft, by A. A. Surg. W. P. Moon.	Died Mar. 4, 1865, of pneumonia. <i>Spec.</i> 3618, A. M. M.

In seven of eleven cases in which the point was referred to, the operations were on the

<sup>1</sup> COUES (E.), *Excision of Head of Humerus*, in *The Med. and Surg. Reporter*, Philadelphia, 1862-3, Vol. IX, p. 231.

left side. Pyæmic infection appears to have been the most frequent cause of death. In eight of the cases, pathological preparations of the injured bones were transmitted to the Museum.

**Excisions of the Upper Part of the Humerus for Shot Injury of Undetermined Date.**—In nineteen of the five hundred and seventeen cases of excisions of the head with adjacent portions of the shaft of the humerus, after shot fracture, it was impracticable to ascertain the intervals between the dates of injury and of operation, either by the operators' or hospital reports, the pension examiners' reports, or by any other accessible sources of information. The recoveries, and the fatal cases, of which there were two only, will be summed up in a single tabular statement:

TABLE XXXVII.

*Summary of Nineteen Cases of Excision of the Head and Portions of the Shaft of the Humerus for Shot Injury, in which the Intervals between the Injuries and Operations were not ascertained.*

No.	NAME, AGE, AND MILITARY DESCRIPTION.	DATE OF INJURY.	NATURE OF INJURY.	DATE OF OPERATION.	OPERATION AND OPERATOR.	RESULT AND REMARKS.
1	Cromie, J., Captain, F, 12th New York, age 30.	June 27, 1862.	Shot fracture of right shoulder joint.	.....	Upper half of the humerus resected, by a Confederate surgeon, while a prisoner.	Disch'd April 7, 1863; pensioned. "Arm almost useless." Died August 9, 1870.
2	De Bank, W., Pt., D, 20th Connecticut, age 31.	May 3, 1863.	Comp'd comminuted fracture of head of the left humerus by a conoidal ball, which also wounded the lung and intercostal artery: aneurism.	.....	Head and more than one-third of the shaft removed while a prisoner at Richmond.	Disch'd Nov. 11, 1863; pensioned. Died January 30, 1864.
3	Enbank, J. N., Sergeant, C. S. Artillery.	Sept. 14, 1863.	Gunshot wound of the right shoulder.	.....	Excision of three inches of the upper extremity of humerus, including the head.	Recovered; furloughed January 12, 1864.
4	Faunce, P. C., Pt., I, 6th Ohio Cavalry, age 20.	May 4, 1864.	Shot fracture of left shoulder joint.	1864.	Head and about three inches of the shaft of humerus excised.	Disch'd Dec. 9, 1864; pensioned.
5	Fleming, J. A., Pt., G, 21st Illinois.	Dec. 31, 1862.	Comminuted shot fracture of the head and neck of right humerus.	.....	Head and a portion of the shaft, about three inches in all, removed, by Surg. R. G. Bogue, 12th Illinois.	Disch'd May 23, 1863; pensioned.
6	Gill, R. C., Pt., H, 13th Alabama, age 24.	May 12, 1864.	Musket ball passed through the left shoulder joint.	.....	Head and three inches of shaft of humerus excised.	Recovered; retired Feb. 13, 1865.
7	Hunter, N., Pt., C, 22d Michigan.	Sept. 19, 1863.	Shot fracture of right humerus; also wound of chest.	1863.	Excision of the upper third of the humerus.	Died October 8, 1863.
8	Kessler, C., Pt., I, 2d Wisconsin, age 26.	July 21, 1861.	Shot fracture of left shoulder, involving head of humerus.	1861.	Excision of the head and four inches of shaft, by Surgeon R. B. Bontecou, U. S. V.	Disch'd Feb. 4, 1862; pensioned.
9	Knot, F. R., Pt., G, 7th Virginia Cavalry.	.....	Shot fracture of the head and neck of the humerus.	May 31, 1864.	Excision of the head and four inches of shaft, by Surgeon C. B. Gibson, C. S. A.	Never rallied. Died May 31, 1864.
10	Quarier, M., Sergeant Major, 22d Virginia, age 26.	May 15, 1864.	Shot fracture of the shoulder joint.	1864.	Excision of the head and upper part of shaft of humerus.	Recovered; retired Dec. 3, 1864.
11	Ruggles, J., Pt., D, 121st Ohio, age 21.	Sept. 20, 1863.	Fracture of the head of left humerus by a minié ball.	.....	Removal of the head and one inch of shaft of humerus.	Disch'd Oct. 28, 1864; pensioned.
12	Saulsbury, J. L., Sergeant, D, 66th Georgia, age 19.	.....	Shot fracture of upper portion of humerus.	.....	Excision of the head and five inches of shaft of humerus.	Recovered; retired Dec. 3, 1864.
13	Scott, J. F., Pt., A, 21st North Carolina, age 24.	Aug. 28, 1862.	Fracture of upper portion of left humerus by a minié ball.	.....	Excision of the head and two inches of shaft of humerus.	Retired Feb. 18, 1865. Ankylosis of joint.
14	Shiney, A., Pt., I, 18th Massachusetts, age 33.	Aug. 30, 1862.	Shot fracture of left shoulder joint.	1862.	Excision of the head and three inches of shaft of humerus.	Disch'd Dec. 24, 1862; pensioned.
15	Shinn, W., Pt., K, 30th Illinois, age 30.	May 16, 1863.	Shot fracture of right humerus.	1863.	Excision of the head and a portion of the shaft of humerus.	Disch'd Oct. 15, 1863; pensioned.
16	Smith, T. B., Corporal, B, 93d Illinois, age 20.	May 16, 1863.	Shot fracture of upper third of left humerus.	.....	Excision of the head and a portion of the shaft of humerus through a straight incision.	Disch'd Oct. 7, 1864; pensioned.
17	Taylor, G. W., Pt., B, 53d North Carolina, age 24.	May 30, 1864.	Gunshot wound of shoulder, with fracture of upper portion of humerus.	1864.	Excision of the head and three inches of the shaft of humerus.	Furloughed July 16, 1864, cured.
18	Taylor, J. D., Pt., I, 3d Alabama Cavalry, age 19.	July 3, 1864.	Shot fracture of left humerus.	.....	Excision of head and upper extremity of shaft of humerus.	Recovered; retired Feb. 3, 1865.
19	Wilford, J. W., Pt., A, 43d North Carolina.	May 23, 1864.	Shot wound and fracture of the right arm.	.....	Excision of the upper half of the humerus.	Retired March 14, 1865.

**EXCISIONS AT THE SHOULDER; PARTS NOT DEFINITELY DISTINGUISHED.**—In thirty-nine of the eight hundred and eighty-five excisions at the shoulder for shot injury, the extent of bone removed was not precisely specified, and this and other imperfections in the reports precluded their distribution in the foregoing subdivisions. It is possible to state, however, that such dates were furnished as proved that twenty-seven of these operations were primary, and for the most part field cases. The recoveries and fatal cases will be tabulated together on the following page.



TABLE XXXVIII.

*Summary of Thirty-Nine Cases of Excisions after Shot Injury involving the Shoulder, in which the precise Portions of Bone removed have not been ascertained.*

No.	NAME, AGE, AND MILITARY DESCRIPTION.	DATE OF INJURY.	NATURE OF INJURY.	DATE OF OPERATION.	OPERATION AND OPERATOR.	RESULT AND REMARKS.
1	Allen, E., Pt., A, 59th New York.	July 3, 1863.	Shot wound of right shoulder.	July 3, 1863.	Resection of the shoulder joint.	Died July 15, 1863.
2	Anderson, M., Pt., E, 19th Illinois.	Sept. 19, 1863.	Shot wound of the left upper extremity.	Sept. 19, 1863.	Resection of the shoulder joint.	Died Sept. 29, 1863.
3	Barcroft, L. S., Pt., B, 18th Ohio.	Dec. 31, 1862.	Shot wound of the shoulder.	Dec. 31, 1862.	Excision.	Died February 5, 1863.
4	Barr, H., Pt., K, 117th New York, age 45.	Sept. 29, 1864.	Gunshot wound	1864.	Excision of the shoulder joint.	Died October 1, 1864, while a prisoner at Richmond.
5	Baufman, G., Pt., I, 73d Ohio, age 32.	Mar. 19, 1865.	Shot wound of right shoulder joint.	Mar. 19, 1865.	Excision at the shoulder.	Died March 28, 1865.
6	Bennett, D., Pt., G, 8th Pennsylvania Cavalry, age 31.	1864.	Shot wound of the shoulder.	1864.	Resection of the shoulder joint.	Died May 22, 1864, while a prisoner at Richmond.
7	Day, A., Pt., C, 23d Massachusetts, age 22.	1864.	Shot fracture.	1864.	Resection of the shoulder joint.	Died May 31, 1864, while in the hands of the enemy.
8	Day, W. H., Pt., F, 17th Maine.	July 3, 1863.	Shot fracture of right shoulder joint.	1863.	Resection of the shoulder joint.	Died August 31, 1863.
9	Day, W. H., Pt., 4th New York Battery.	July 3, 1863.	Fracture of left shoulder joint by a shell fragment.	July 3, 1863.	Excision of the shoulder joint.	( ? ) *
10	Douglas, E., Pt., B, 93d Illinois.	Nov. 25, 1863.	Fracture of shoulder by a conoidal ball; also wound of chest.	Nov. 25, 1863.	Excision, by Surg. J. R. Mohr, 10th Iowa.	Died December 20, 1863.
11	Eaton, W., Pt., C, 4th Massachusetts.	June 14, 1863.	Shot wound through left arm and left lung.	June 17, 1863.	Resection of the shoulder joint.	Died June 21, 1863.
12	Edel, E., Pt., M, 13th Pennsylvania Cavalry.	Oct. 12, 1863.	Shot wound of the left shoulder.	1863.	Resection of the left shoulder.	Died November 3, 1863.
13	Ellis, J., Pt., D, 81st Illinois.	May 22, 1863.	Fracture of right shoulder by musket ball.	May 22, 1863.	Resection of shoulder	Died June 19, 1863.
14	Fay, E., Pt., I, 5th North Carolina.	July 3, 1863.	Shot fracture of left shoulder joint.	1863.	Resection at the shoulder.	( ? )
15	Fussell, J. P., Pt., I, 9th Georgia.	Aug. 30, 1862.	Shot wounds involving right shoulder joint.	1862.	Resection of right shoulder.	Died September 11, 1862.
16	Gray, W., Pt., D, 10th Alabama.	1864.	Gunshot wound of the right shoulder joint.	1864.	Resection of joint.	( ? )
17	Green, C. B., Pt., A, 26th Massachusetts, age 25.	1864.	Wound of left shoulder joint.	1864.	Resection of shoulder.	Died June 24, 1864.
18	Hains, A., Pt., D, 91st New York.	June 14, 1863.	Severe buckshot wound of left shoulder.	June 18, 1863.	Resection of shoulder joint, by Surgeon W. G. Provost, 153th New York.	Died June 24, 1863.
19	James, J., Pt., D, 6th Virginia.	1864.	Gunshot wound of right shoulder.	1864.	Resection of the right shoulder joint.	Died August 6, 1864.
20	Kelly, J., Pt., K, 18th Wisconsin.	May 14, 1863.	Wound of left upper extremity.	May 16, 1863.	Excision of the left shoulder.	Died May 20, 1863.
21	Lamb, J., Pt., D, 30th Ohio.	June 17, 1863.	Wound of left shoulder.	June 17, 1863.	Resection of shoulder	Died August 13, 1863.
22	Lynch, J. B., Lieutenant, G, 58th Virginia, age 33.	May 3, 1863.	Wound of left shoulder joint.	May 3, 1863.	Resection of shoulder joint by deltoid flap.	Died June 1, 1863, of hæmorrhage.
23	Mitchell, C. T., Pt., 19th Indiana Battery.	Oct. 8, 1862.	Shot wound of the shoulder.	Oct. 8, 1862.	Resection of the shoulder joint.	Died Oct. 15, 1862, of hæmorrhage.
24	Narigan, J., Pt., E, 80th Ohio, age 22.	Nov. 25, 1863.	Shot wound of the chest, involving the shoulder joint.	Nov. 25, 1863.	Excision of the shoulder joint, by Surgeon E. J. Buck, 18th Wisconsin.	Discharged September 24, 1864; pensioned.
25	Pitt, L. N., Lieutenant, B, 2d North Carolina.	1863.	Gunshot wound of left shoulder.	1863.	Excision of the shoulder joint.	Transferred to general hospital, November 2, 1863.
26	Ream, B., Lieutenant, C, 7th Iowa.	Nov. 7, 1861.	Wound of right shoulder joint; also wound through lung.	Nov. 7, 1861.	Excision of the shoulder joint.	Died November 21, 1861.
27	Riley, V., Pt., C, 90th New York.	June 14, 1863.	Gunshot wound of the right shoulder.	June 14, 1863.	Resection of the shoulder joint.	Died June 24, 1863.
28	Ritchie, P., Corporal, K, 99th Pennsylvania.	Oct. 28, 1864.	Shot fracture of left shoulder; ball lodged in the dorsum of scapula.	Nov. 13, 1864.	Shoulder joint excised; thirty pieces of bone removed.	Disch'd July 1, 1865; pensioned.
29	Scoggins, J. B., Pt., K, 56th Georgia.	1864.	Wound of right shoulder joint.	1864.	Resection of the shoulder joint.	( ? )
30	Simmons, W. T., Pt., B, Palmetto Sharpshooters, age 22.	Oct. 7, 1864.	Shot wound of right shoulder joint.	Oct. 8, 1864.	Resection of the right shoulder joint.	Furloughed November 1, 1861.
31	Stansil, L., Sergeant, C, 8th South Carolina.	July 3, 1863.	Gunshot wound of left shoulder.	July 3, 1863.	Resection of the shoulder joint.	Died July 18, 1863.
32	Thoman, M. A., Lieut. Col., 59th New York, age 33.	July 2, 1863.	Wound of right shoulder.	July 2, 1863.	Resection of the shoulder joint, by Surg. N. Hayward, 20th Massachusetts.	Died July 11, 1863.
33	Wagner, J., Pt., G, 93d Illinois.	Nov. 25, 1863.	Shot fracture of right shoulder.	Nov. 25, 1863.	Excision of the shoulder joint, by Surgeon E. J. Buck, 18th Wisconsin.	Died November 29, 1863.
34	Watson, W., Pt., F, 5th South Carolina.	Oct. 29, 1863.	Shot fracture of humerus and scapula.	Oct. 29, 1863.	Resection of the shoulder joint, by Surgeon A. K. Fifield, 29th Ohio.	Died January 9, 1864.
35	White, W. P., Pt., A, 36th Alabama.	Nov. 25, 1863.	Gunshot wound of left shoulder.	Nov. 25, 1863.	Resection of the shoulder joint, by Surgeon A. T. Hudson, 26th Iowa.	( ? )
36	Winnacht, A., Pt., D, 32d Indiana.	Jan. 1, 1863.	Gunshot wound of left shoulder joint.	Jan. 1, 1863.	Resection of left shoulder joint.	Died February 24, 1863.
37	Winningham, J. W., Corporal, Hart's Battery.	1864.	Wound of left shoulder joint.	1864.	Excision of the left shoulder.	( ? )
38	Wright, W., Pt., G, 184th Pennsylvania.	June 22, 1864.	Shot fracture of left shoulder joint.	June 22, 1864.	Excision of the joint on the field, by Surgeon G. Chaddock, 7th Michigan.	Died July 10, 1864.
39	Wykert, E., Pt., B, 12th Ohio.	Dec. 31, 1862.	Wound of shoulder.	1863.	Resection of the shoulder joint.	Died March 28, 1863.

\* The interrogation marks denote those cases in which the ulterior results were not learned.

There were three recoveries after primary operations, and twenty-two fatal results; in two primary cases the terminations are unknown. There were seven cases with fatal results, and five with undetermined results, among the operations of unknown date.

CONCLUDING OBSERVATIONS ON EXCISIONS AT THE SHOULDER AFTER SHOT INJURY.—The opinions regarding this operation expressed in the preliminary surgical report, derived from the results of five hundred and eight determined cases, require some serious corrections, and other very slight modifications, since the additions made to the statistical data, and the more exhaustive analysis the entire material has undergone. The following consolidation will facilitate a review of the subject:

TABLE XXXIX.

*General Numerical Summary of the Eight Hundred and Eighty-five Excisions at the Shoulder, after Shot Injury, enumerated in the Seventeen preceding Tables.*

PARTS OF SHOULDER JOINT EXCISED.	PRIMARY.				INTERMEDIARY.				SECONDARY.				UNDETERMINED.				TOTALS.			
	Recovery.	Fatal.	Result not stated.	Total.	Recovery.	Fatal.	Result not stated.	Total.	Recovery.	Fatal.	Result not stated.	Total.	Recovery.	Fatal.	Result not stated.	Total.	Recovery.	Fatal.	Result not stated.	Aggregates.
Head, or Head and Shaft, with portions of either Scapula or Clavicle, or of both.	17	2	1	20	5	6	.....	11	8	2	.....	10	1	.....	.....	1	31	10	1	42
Partial Excisions of the Head of Humerus.....	3	.....	.....	3	3	.....	.....	3	6	.....	.....	6	1	1	.....	2	13	1	.....	14
Head of Humerus.....	119	56	.....	175	21	34	.....	55	13	13	.....	26	12	4	1	17	165	107	1	273
Head and portions of the Shaft of Humerus.....	213	80	.....	293	91	64	.....	155	38	12	.....	50	17	2	.....	19	359	158	.....	517
Excisions of Shoulder joint; bones not stated.....	3	22	2	27	.....	.....	.....	.....	.....	.....	.....	.....	.....	7	5	12	3	29	7	39
	355	160	3	518	120	104	.....	224	65	27	.....	92	31	14	6	51	571	305	9	885

In eight hundred and seventy-six cases the results as to fatality are known; in eight hundred and thirty-one of them, the stages at which the operation succeeded the injury are also determined. In three instances, the period of operation was stated, but not the final result; and, in six, both factors were wanting. The ratio of mortality in five hundred and fifteen primary excisions,<sup>2</sup> in which the results were ascertained, was 31.06 per cent., or more than 7 per cent. higher than indicated by the preliminary report. The terminations of each of the two hundred and twenty-four intermediary<sup>3</sup> operations were traced, and the death-rate amounted to 46.4 per cent., a sufficiently significant indication of the hazard attending operative interference during the inflammatory stage. The results of ninety-two

<sup>1</sup> Circular 6, S. G. O., 1865, p. 55. In this report, 575 excisions at the shoulder were reported, 252 primary, and 323 consecutive. The results, however, of 42 of the former, and of 25 of the latter, were undetermined; and the mortality rates of 23.8 for primary, and of 38.5 for consecutive, operations was deduced from 210 primary and 298 consecutive excisions, or 508 operations with ascertained results. Further investigation has disclosed that a large proportion of the 67 then undetermined cases eventually had a fatal result. The ratios of mortality now given may be regarded as near approximations to precise truth, inasmuch as the results as regards recovery or fatality are known in all save 9 of the 885 operations.

<sup>2</sup> There were 518 cases in the five groups into which the operations of this order were subdivided; the result was not ascertained in 3 instances. See TABLES XXI to XXV inclusive, and TABLES XXXI and XXXII. In the five groups, the fatality was distributed as follows: In the true excisions at the shoulder, in which portions of the scapula or clavicle were removed with the upper extremity of the humerus, there were but 2 deaths in 19 operations, or 10.5 per cent.; the partial primary excisions of the head were successful. Of 175 decapitations, 56 were fatal, or 32 per cent.; in 293 primary excisions of the head and portions of the shaft, the mortality rate was 27.3; in 25 primary cases in which the extent of excised bone was not specified, the fatality reached the formidable ratio of 88 per cent.

<sup>3</sup> A slight deviation was made, in tabulating the excisions, from the practice heretofore pursued by the editor in former publications in regard to the classification of amputations. Excisions practised on the day of injury, on the next day, and also on the third day, were rated as primary, whereas primary amputations were limited to those done within 48 hours from the reception of the injury. The distinction was made because the stage of reaction appeared to be longer delayed in the cases selected for excision than in the graver instances of injury demanding the ablation of the limb. In the four subordinate groups of intermediary operations the mortality rates were: For 11 shoulder joint incisions, 54.5; three partial excisions of the head without fatality; 55 decapitations, 61.8; for 155 excisions of head and portions of shaft, 41.3 per cent. These cases were likewise subdivided into four groups. The excisions of head with portions of clavicle or scapula had a mortality of 20; all 6 of the partial excisions were successful; 26 decapitations gave a fatality of 50; in 50 secondary operations of unknown extent, the ratio of mortality was 24 per cent.



secondary operations were also determined in every instance, and furnished a ratio of mortality of 29.3. Uniting the two groups of cases of consecutive operations, the mortality-rate was 41.4, instead of 38.5, per cent. as computed in Circular 6, from a series of cases numerically inferior to the present by almost one-third, and comprising nearly 12 per cent. of cases with unknown results. Of fifty-one excisions after shot fracture at the shoulder, enumerated in the foregoing table, some of the essential dates could not be ascertained,<sup>1</sup> although the final results were verified in forty-five cases, the latter series giving a ratio of mortality of 31.1 per cent.

Grouping the eight hundred and seventy-six excisions in which the results as to fatality were established,—for this point was determined in all save nine of the eight hundred and eighty-five operations,—the aggregate mortality was three hundred and five, or 34.8 per cent.<sup>2</sup> in the eight hundred and seventy-six determined cases. Even assuming that these nine cases all terminated fatally, the general numerical result would be but very slightly modified.

A more exhaustive analysis of these cases would be instructive, and, indeed, imperative, could it be accomplished without excluding the consideration of other kindred topics of equal importance. It would be interesting to inquire, for example, into the causes of a greater mortality after primary decapitations of the humerus after shot injury, than in excisions involving portions of the shaft as well as the head of the bone; and many similar questions might be profitably examined if there was space for their discussion.

It cannot be denied that the foregoing statistics give a very extended view of the merits of the operation of excision at the shoulder after shot injury, as compared with expectant treatment and with ablation at the joint, yet they do not comprise all the information on the subject that has been accumulated.

In addition to the foregoing examples which occurred either to Union soldiers or to Confederate soldiers treated in Union hospitals, the editor has been enabled to consult the record of a large number of Confederate cases, compiled by Dr. Howell L. Thomas, of Richmond, who, with great kindness, has contributed the register containing these observations to the archives of the Office of the Surgeon-General of the Army, at Washington. Access to many of the larger military hospitals of the Confederacy, and to the files of the Surgeon-General's Office, at Richmond, afforded Dr. Thomas unusual facilities for accumulating these data, yet he regretfully records, as quoted in a preceding volume of this work (PART I, VOL. 2, page 456, *Note 2*), the manifold imperfections of the reports, and meagreness of the record.<sup>3</sup> It is impracticable, from the facts detailed in these returns, to segregate, to any large extent, the primary and consecutive operations; and, in nearly half of the cases, the results are left to conjecture. Under these circumstances, it has been deemed inexpedient to attempt to group this series with those derived mainly from the reports of the Union surgeons. The total number of cases of excisions at the shoulder for shot fracture, recorded by Dr. Thomas, is two hundred and seventy-four; but seventy-three of these refer to cases treated at Union hospitals, and have been included in the preceding

<sup>1</sup> In most of these cases the dates either of the injury or of the operation were specified, one or the other being omitted, thus rendering it impracticable to determine the interval between the two. The single operation in this category involving the scapula was successful; 1 of the 2 partial excisions was fatal; 16 determined decapitations had a death-rate of 25 per cent.; 19 excisions of the upper extremity of the humerus had a mortality-rate of 10.5; the 7 determined cases in which the parts of bone removed were unspecified, all proved fatal.

<sup>2</sup> The mortality was distributed, in the five subdivisions, as follows: Excisions of head or head and shaft, with parts of clavicle or scapula, 40 determined cases, death-rate 24.3; in 14 partial excisions there was but 1 fatal case, or 7.14 per cent.; 272 decapitations gave a death-rate of 39.33; 517 excisions of head with upper part of shaft had a death-rate of 30.56; and 32 excisions of unspecified parts of the shoulder joint had a mortality of 90.6 per cent.

<sup>3</sup> "Brevity is a very commendable feature in clinical reports," says Dr. THOMAS; but conciseness must not be insisted on at the expense of completeness, else the cases may be robbed of all interest and the greater part of their value.

tabular statements.<sup>1</sup> There remain two hundred and one cases, of which the results have been definitely traced in seventy-five, a group including forty-three fatal cases and thirty-two recoveries. Twenty-three cases are returned as "furloughed," and probably a large proportion of these eventually survived, although some very grave cases were allowed to leave the hospitals for treatment at home. In one hundred and three cases, no satisfactory account of the results of the operations is afforded; hence it is not feasible to estimate the ratio of mortality in this interesting series. It is unnecessary to recapitulate the seventy-three instances already tabulated; they presented a very favorable percentage of recoveries. Of the remainder, a descriptive tabular statement is appended:

TABLE XL.

*Summary of Two Hundred and One Cases of Excision at the Shoulder, after Shot Injury, practised in the Confederate Army.*

No.	NAME, AGE, AND MILITARY DESCRIPTION.	DATE OF INJURY.	NATURE OF INJURY.	DATE OF OPERATION.	OPERATION AND OPERATOR.	RESULT AND REPORTER.
1	Ahrens, H., Pt., I, 1st Arkansas, age 35.	July 21, 1864.	Shot through the head of right humerus.	July 21, 1864.	Head excised.....	Surgeon S. T. Turner, 6th and 7th Arkansas.
2	Alexander, M. B., Pt., A, 5th Tennessee, age 25.	July 8, 1864.	Fracture of the right humerus at surgical neck.	July 8, 1864.	Shoulder joint excised.....	Surgeon J. M. Brannock, C. S. A.
3	Allen, A. A., Pt., D, 8th Georgia.	Oct. 7, 1864.	Wound in left shoulder joint.....	Oct. 8, 1864.	.....	Died November 19, 1864. Surg. P. F. Browne, C. S. A.
4	Allen, K. D., Pt., C, Ashcraft's command.	July 7, 1864.	Wound of left shoulder joint.....	July 7, 1864.	Lisfranc's method.....	Surgeon J. Button, C. S. A.
5	Allison, C. E. L., Lieut., A, 6th Florida.	Sept. 23, 1863.	Wound of shoulder joint.....	1863.	Head of humerus excised.....	Secondary hæmorrhage Nov. 1st; necrosis; recovered. Surg. F. Hawthorne, C. S. A.
6	Anderson, A. C., Sergt., G, 7th Texas, age 26.	July 22, 1864.	Comp'd comminuted fracture of head and shaft.	July 22, 1864.	Head and four inches of shaft excised.	Asst. Surg. D. T. Richardson, C. S. A.
7	Antry, D. Pt., I, 51st North Carolina, age 30.	May 20, 1864.	Fracture of head of humerus..	May 22, 1864.	Five inches of bone, including head, excised.	May 31st, doing well. Surgeon J. H. Pottinger, C. S. A.
8	Appelberry, F., Pt., C, 51st Tennessee.	July 22, 1864.	Fracture of upper portion of right humerus.	1864.	Head and neck and upper eighth, through longitudinal incision.	Doing well. Surg. L. C. Lyncheon, C. S. A.
9	Arrington, J. W., Pt., I, 12th North Carolina, age 20.	May 10, 1864.	Shot fracture of the head of the humerus.	May 10, 1864.	Excision of the head and two and a half inches of shaft.	May 20th, secondary hæmorrhage. Surg. R. J. Hicks, 23d North Carolina.
10	Asbell, W., Pt., C, 1st Delaware.	May 6, 1864.	Musket ball fractured head of humerus and second rib.	May 22, 1864.	Head excised through straight incision.	Died May 22, 1864. Surg. R. A. Lewis, C. S. A.
11	Beam, B. M., Pt., II, 33d Virginia, age 19.	May 3, 1863.	Shot wound through the upper third of humerus.	May 3, 1863.	Head excised.....	Surg. S. D. Smith, C. S. A.
12	Bean, T. J., Lieut., K, 16th Mississippi.	1864.	Shot wound of left shoulder joint.	1864.	Excision of shoulder joint.....	October 16th, transferred. Surg. S. E. Chaille, C. S. A.
13	Beardin, W. P., Pt., C, 44th Georgia, age 23.	May 6, 1864.	Shot fracture of head of the humerus.	May 6, 1864.	Excision of head; secondary hæmorrhage June 1; amputation at the shoulder joint.	June 30th, nearly healed. Confederate Surgeon Cabell.
14	Bell, E., Pt., II, 21st North Carolina, age 37.	June 7, 1864.	Wound of right shoulder; ball lodged in the bone.	June 7, 1864.	Excision of shoulder joint.....	August, 1864, recovered. Asst. Surg. R. O'Leary, C. S. A.
15	Beller, S. H., Pt., G, 5th Texas, age 30.	May 5, 1864.	Shot fracture of right humerus.	May 5, 1864.	Removal of the head and three inches of shaft.	July 23, 1864, furloughed. Asst. Surg. H. C. Chalmers, C. S. A.
16	Blackwell, G., Pt., C, 57th North Carolina, age 25.	May 5, 1863.	Head of humerus split by a conoidal ball.	May 5, 1863.	Removal of head and neck thro' straight incision into deltoid.	Died. Surg. C. S. Morton, 57th North Carolina.
17	Blevins, S., Pt., G, 30th North Carolina, age 17.	June 3, 1864.	Shot wound of the left shoulder joint.	June 3, 1864.	Excision of the head and upper third.	Retired March 31, 1865. Surg. O. P. Manson, C. S. A.
18	Postick, J. L., Lieut., 19th Arkansas, age 35.	July 22, 1864.	Shot fracture of right humerus and wound of posterior portion of chest.	July 23, 1864.	Head and superior third excised.	Died, July 31, 1864, from internal hæmorrhage. Surgeon W. E. Brickell, C. S. A.
19	Bowlin, S. C., Pt., Corbett's Battery, age 29.	May 15, 1864.	Comp'd comminuted fracture of head of the left humerus; grapeshot wound of thigh.	May 16, 1864.	Head and three inches of shaft excised.	Died June 8, 1864. Surg. G. G. Crawford, C. S. A.
20	Boyd, J. B., Lieut., E, 9th Tennessee, age 27.	1864.	Shot fracture of right shoulder.	Primary	Shoulder excised.....	February 3, 1864, nearly well. Surgeon D. Dupré.
21	Brandon, C. C., Pt., K, 13th Mississippi.	July 1, 1862.	.....	Primary	Shoulder joint excised.....	Died July 15, 1862. Surg. G. W. Carrington, C. S. A.
22	Brantley, J. M., Pt., A, 48th North Carolina, age 22.	Aug. 25, 1864.	Head of the left humerus and spinous process of the lumbar vertebra.	Sept. 18, 1864.	Head excised through straight incision.	Furloughed Oct. 8, 1864. Surg. F. Foulkes, C. S. A.
23	Breeden, J. H., I, 59th Virginia, age 18.	Aug. 28, 1864.	Fracture of the head of left humerus.	Aug. 28, 1864.	Head excised.....	Surgeon R. S. J. Peebles, C. S. A.
24	Brown, J. K., Sergt., Wyatt's Artillery, age 24.	June 3, 1864.	Through head of the right humerus.	On field	Head and four inches of shaft..	July 30, 1864, doing well. Surg. E. M. Seabrook, C. S. A.
25	Broox, J. A., Pt., F, 3d Georgia, age 28.	May 6, 1864.	Wound of shoulder joint.....	May 6, 1864.	Shoulder joint excised.....	Doing well. Surg. W. P. Fline, 3d Georgia S. S.
26	Bunks, F. M., Pt., K, 13th Arkansas, age 20.	Aug. 31, 1864.	Head of humerus.....	Sept. 7, 1864.	Head and two inches of shaft excised.	Transferred Sept. 17, 1864. Surg. S. E. Chaille, C. S. A.
27	Bush, J. P., Sergt., B, 2d Georgia, age 19.	July 20, 1864.	Fracture of head of humerus..	July 20, 1864.	Head excised.....	Surgeon W. H. Douglas, 2d Georgia.

<sup>1</sup> These seventy-three cases may be referred to as follows: Two in TABLE XXII; sixteen in TABLE XXIV; four in TABLE XXV; one in TABLE XXVI; two in TABLE XXVII; two in TABLE XXX; twenty-five in TABLE XXXI; eleven in TABLE XXXII; four in TABLE XXXIII; two in TABLE XXXV; one in TABLE XXXVI; one in TABLE XXXVII; one in TABLE XXXVIII.



No.	NAME, AGE, AND MILITARY DESCRIPTION.	DATE OF INJURY.	NATURE OF INJURY.	DATE OF OPERATION.	OPERATION AND OPERATOR.	RESULT AND REPORTER.
28	<i>Campbell, J. W.</i> , Pt., E, 48th Virginia.	Aug. 9, 1862.	Right humerus fractured within and external to shoulder joint.	Aug. 20, 1862.	Two and a half inches, including head, by Surg. W. Hay, C. S. A.	December 16, 1862, considerable motion of limb.
29	<i>Carpenter, J. W.</i> , Pt., I, 24th South Carolina, age 21.	May 16, 1864.	Shot wound of shoulder joint.	1864.	Head of bone excised.	Surg. W. G. McKenzie, C. S. A.
30	<i>Carr, E. T.</i> , Pt., F, 20th North Carolina, age 30.	May 9, 1864.	Shot wound of shoulder joint.	May 9, 1864.	Shoulder joint excised.	Died May 16, 1864. Surg. J. A. Bizzell, C. S. A.
31	<i>Carroll, T. H.</i> , 27th Georgia.	June 27, 1862.	Shot fracture of upper part of humerus.	June 29, 1862.	Excision of the head.	Recovered. Surg. J. A. S. Milligan, C. S. A.
32	<i>Champion, G. W.</i> , Pt., C, 2d Mississippi, age 23.	May 6, 1864.	Shot wound of shoulder joint.	1864.	Head and three inches of shaft removed.	Died, June 25, 1864, from erysipelas. Surg. J. R. Page, C. S. A.
33	<i>Clark, J. A.</i> , ———	July 1, 1862.	Shot wound of shoulder.	July 1, 1862.	Excision of shoulder joint.	Recovered. Surg. J. M. Halloway, C. S. A.
34	<i>Clemens, E. M.</i> , Sergeant, A, 12th Georgia, age 34.	June 14, 1864.	Humerus fractured extensively by shot.	June 14, 1864.	Head and neck and four inches of shaft removed.	July 18, 1864, furloughed. Surg. E. H. Smith, C. S. A.
35	<i>Clements, J. L.</i> , Pt., K, 6th South Carolina, age 24.	June 12, 1864.	Ball lodged in anatomical neck, splitting and comminuting surgical neck.	June 16, 1864.	Head and two inches of shaft removed.	October 26, 1864, furloughed; motion of hand and forearm perfect. Surg. J. L. Cabell, C. S. A.
36	<i>Cowdray, A.</i> , Pt., A, 30th Louisiana, age 31.	Aug. 7, 1864.	Shot fracture of right humerus	Aug. 7, 1864.	Excision of the shoulder joint.	October 30th, improving. Surg. A. H. Sneed, C. S. A.
37	<i>Creamer, J. W.</i> , Pt., F, 12th Georgia, age 25.	May 10, 1864.	Fracture of head of humerus; two inches of bone on anterior surface broken off.	May 11, 1864.	Broken fragments removed by resection.	-----
38	<i>Dalton, J. W.</i> , Pt., G, 54th Virginia, age 35.	May 15, 1864.	Shot fracture of the head of left humerus.	May 16, 1864.	Head and three inches of shaft removed.	Secondary hæmorrhage; died May 28, 1864. Surg. G. G. Crawford, C. S. A.
39	<i>Darden, E.</i> , Pt., F, 8th Louisiana, age 19.	May 4, 1863.	Head of right humerus and portion of glenoid cavity.	May 5, 1863.	Head and humerus, and portion of cavity.	Surgeon J. H. K. Monmonier, C. S. A.
40	<i>Davis, H. C.</i> , Pt., B, 37th Alabama, age 39.	June 18, 1864.	Head of the right humerus, by minié ball.	June 18, 1864.	Two and a half inches, including head, excised.	Furloughed in July, 1864. Surg. S. E. Chaillé, C. S. A.
41	<i>Davis, J. S.</i> , Pt., F, 2d South Carolina, age 28.	Oct. 19, 1864.	Wound of shoulder joint.	Oct. 19, 1864.	Shoulder joint excised.	December 1st, doing well. Surg. A. R. Meun, C. S. A.
42	<i>Dees, R.</i> , Pt., E, 5th Alabama, age 31.	Sept. 19, 1864.	Ball split head of right humerus and chipped off portion of the glenoid cavity.	Sept. 28, 1864.	Head excised through surgical neck.	Doing well October 1, 1864. Surg. J. H. Murray, C. S. A.
43	<i>Dennis, J. M.</i> , Corporal, B, 4th Alabama.	June —, 1864.	Comminuted fracture of the left shoulder joint within capsule.	1864.	Three inches of bone from articulation.	Surgeon A. R. Erstine.
44	<i>Dougherty, J.</i> , Pt., D, 8th Louisiana, age 28.	Sept. 14, 1863.	Fracture of head of the left humerus; ball penetrated chest.	Sept. 14, 1863.	Portion of anatomical neck.	Surgeon J. H. K. Monmonier, 8th Louisiana.
45	<i>Doyle, T.</i> , Pt., E, 2d Tennessee.	April 6, 1862.	Wound of left shoulder joint, followed by ankylosis.	Feb. 15, 1863.	Head of humerus excised.	Returned to duty May 4, 1863. Surg. P. F. Eve, C. S. A.
46	<i>Drapier, L.</i> , Pl., B, 5th North Carolina.	July 1, 1863.	Head of humerus fractured.	On field 1863.	Head excised through straight incision through deltoid.	Surgeon R. J. Hicks, 23d North Carolina.
47	<i>Dutton, S. D.</i> , Pt., E, 20th Alabama, age 24.	Aug. 4, 1864.	Fracture of head of the right humerus.	Aug. 4, 1864.	Head, through straight incision.	Surgeon W. E. Cochran, C. S. A.
48	<i>Earnheart, T.</i> , Pl., Ramsey's Artillery, age 19.	June 23, 1864.	Head of right humerus fractured; joint involved.	Primary 1864.	Three and a half inches of bone.	Furloughed July 30, 1864. Surg. J. S. Brint, C. S. A.
49	<i>Eldens, Z. P.</i> , Pt., G, 19th Arkansas, age 30.	Sept. 20, 1863.	Shot fracture of upper portion of right humerus.	Mar. 9, 1864.	Head and two inches of shaft removed.	Died March 29, 1864; erysipelas. Surg. G. G. Crawford, C. S. A.
50	<i>Edwards, J. A.</i> , Pt., A, 21st Georgia.	May 3, 1863.	Shot fracture of humerus, involving head of bone.	May 3, 1863.	Four inches of upper extremity removed by posterior external flap. (Lisfranc.)	Surg. L. G. Capers, C. S. A.
51	<i>Ellis, A. M.</i> , Pt., E, 1st Georgia, age 16.	June 15, 1864.	Musket ball chipped off head of right humerus and articular facet of scapula and lodged in joint.	June 15, 1864.	Head excised through linear incision.	Hæmorrhage from circumflex artery. Surgeon H. M. Darling, Stovell's Brigade.
52	<i>Ellison, A.</i> , Pt., D, 37th Mississippi, age 30.	July 22, 1864.	Shot fracture of head and two inches of right humerus.	July 22, 1864.	Removal of four inches of bone.	August 1st, doing well. Surgeon M. H. Nash, C. S. A.
53	<i>Erwin, W. B.</i> , Lieut., C, 9th Tennessee, age 28.	July 30, 1864.	Shot wound of head of right humerus.	July 30, 1864.	Head and three inches of bone removed through linear incision.	Gangrene; Sept. 30, 1864, not doing well. Surg. A. H. Sneed, C. S. A.
54	<i>Farr, J. F.</i> , Lieut., H, 5th South Carolina.	May 10, 1863.	Ball passed thro' shoulder joint, fracturing head of humerus.	May 10, 1864.	Excision of head and one inch of shaft by White's method.	July 10, 1864, doing well. Surg. M. Bellinger, C. S. A.
55	<i>Fitzgerald, T. W.</i> , Capt., K, 12th Alabama.	May 3, 1863.	Fracture of right humerus at anatomical neck, extending into joint, by grapeshot.	May 13, 1863.	Head excised through straight incision; posterior circumflex ligated.	Typhoid symptoms; died May 16, 1863. A. A. Surg. E. H. Wood, C. S. A.
56	<i>Foltz, H. J.</i> , Pt., D, 7th Virginia Cavalry, age 34.	May 6, 1864.	Shot fracture of upper portion of left humerus.	1864.	Primary excision of head and three and a half inches of shaft.	July 16th, furloughed. Asst. Surg. F. B. Shuford, C. S. A.
57	<i>Fordhove, Z.</i> , Pt., F, 2d Georgia, age 40.	June 22, 1864.	Shot fracture of head of the humerus.	June 22, 1864.	Excision of head.	Surg. J. M. Douglas, 2d Georgia.
58	<i>Fritzle, M. C.</i> , Corp., H, 19th Arkansas, age 22.	June 20, 186—.	Wound through right shoulder joint; fracture of head of bone.	June 20, 186—.	Head removed through single vertical incision.	Doing well August 1st. Surg. W. E. Bickell, 19th Arkansas.
59	<i>Fuller, W.</i> , Pt., D, 34th Georgia, age 26.	June 22, 1864.	Fracture of head of humerus.	June 22, 1864.	Head excised.	Surg. W. E. Brock, 34th Georgia.
60	<i>Gabbert, J. M.</i> , Sergt., D, 5th Virginia, age 25.	Aug. 9, 1862.	Head and shaft of the right humerus fractured; erysipelas and diarrhoea.	Sept. 21, 1862.	Head and two inches of shaft.	Arm amputated; died next day. Surg. J. L. Cabell, C. S. A.
61	<i>Gardee, P.</i> , Pt., 43d North Carolina, age 19.	July 1, 1863.	Head of right humerus penetrated.	July —, 1863.	Head and surgical neck through V-shaped incision.	Died, July 26, 1863, from secondary hæmorrhage. Surg. J. L. Cabell, C. S. A.
62	<i>Garner, F. W.</i> , Pl., G, 5th Georgia, age 48.	Nov. 23, 1864.	Head of the humerus fractured; flesh wound of elbow.	Nov. 24, 1864.	Head excised through linear incision.	Erysipelas. Surg. D. Herndon, C. S. A.
63	<i>Gay, J.</i> , Corporal, H, 14th Georgia, age 30.	May 23, 1864.	Head and shaft of the humerus fractured.	May 24, 1864.	Head and three inches of shaft through V-shaped incision.	Surgeon F. B. Henderson, 14th Georgia.
64	<i>Gay, M.</i> , Sergeant, H, 50th Georgia.	May 6, 1864.	Head of humerus fractured.	May 6, 1864.	Head excised.	Surgeon H. J. Parramore, 50th Georgia.
65	<i>Glenn, J. S. C.</i> , Sergt., K, 45th Alabama, age 40.	July 22, 1864.	Left humerus fractured.	July 23, 1864.	Head and two and a half inches of shaft excised.	August 31st, doing well. Surg. C. L. Herbert, C. S. A.
66	<i>Goff, M.</i> , Pt., G, 17th Alabama, age 30.	July 28, 1864.	Fracture of head and anatomical neck of left humerus.	July 28, 1864.	Head and neck through straight incision, posteriorly.	Died August 14, 1864. Surgeon S. V. D. Hill, C. S. A.
67	<i>Gordon, J. V.</i> , Pt., D, 16th Georgia, age 21.	Nov. 29, 1863.	Wound of right shoulder joint.	Nov. 29, 1863.	Resection.	Asst. Surg. J. B. Clifton, C. S. A.
68	<i>Grader, J.</i> , Pt., E, 16th South Carolina, age 38.	July 22, 1864.	Right humerus fractured at the neck.	July 23, 1864.	Head excised.	Surg. W. H. Cooper, 16th South Carolina.
69	<i>Graham, F. D.</i> , Sergt., K, 26th South Carolina, age 25.	May 29, 1864.	Upper third of the left humerus fractured.	May 21, 1864.	Head and four inches of shaft excised.	June 2d, secondary hæmorrhage. Surg. A. G. Lane, C. S. A.

No.	NAME, AGE, AND MILITARY DESCRIPTION.	DATE OF INJURY.	NATURE OF INJURY.	DATE OF OPERATION.	OPERATION AND OPERATOR.	RESULT AND REPORTER.
70	Gray, A. K., Pt., K, 21st Mississippi, age 26.	May 6, 1864.	Ball passed through surgical neck.	May 7, 1864.	Upper three inches of bone excised.	Died May 12, 1864. Surg. G. H. Peets, 21st Mississippi.
71	Gray, J. F., Pt., G, 3d Arkansas, age 26.	May 6, 1864.	Wound of left shoulder joint.	May 7, 1864.	Head excised through a V-shaped incision.	Furloughed July 28, 1864. Surg. B. M. Leiby, C. S. A.
72	Green, C. R., Pt., K, 32d Georgia, age 20.	Feb. 20, 1864.	Shot in head of left humerus.	Mar. 4, 1864.	Head excised.	Died March 17, 1864. Surgeon J. S. Morel, C. S. A.
73	Green, P., Lieut., E, 16th Tennessee, age 28.	July 20, 1864.	Comp'd comminuted fracture of upper third of humerus.	July 20, 1864.	Head through straight incision through deltoid.	November 1st, doing well. Surg. T. W. Leak, 16th Tennessee.
74	Green, P., Pt., B, 25th Texas, age 28.	May 27, 1864.	Fracture of humerus, head and neck of scapula.	1864.	Head of humerus and head and neck of scapula.	Surgeon A. A. Lawrence, 25th Texas.
75	Green, P., Pt., 1st Ohio Battery, age 27.	May 28, 1864.	Compound fracture of right humerus, high up.	May 29, 1864.	Upper two-thirds, including the head.	Died July 5, 1864. Asst. Surg. G. G. Roy, C. S. A.
76	Griffith, R. W., Pt., B, 45th Georgia, age 35.	May 3, 1863.	Upper third of humerus fractured.	On field.	Head through straight incision through deltoid.	Erysipelas; died of pyæmia, June 1, 1863. Surgeon J. Chambliss, P. A. C. S.
77	Haire, J. C., Sergt., D, 17th Georgia, age 26.	Sept. 19, 1863.	Fracture of head of humerus.	Oct. 9, 1863.	Four inches of bone, including head, removed.	Doing well. Surg. S. E. Chaillié, C. S. A.
78	Hall, T. M., Sergt., A, 37th Mississippi, age 30.	July 28, 1864.	Wound in right shoulder joint.	July 28, 1864.	Head of humerus excised.	Died. Surg. J. A. Groves, C. S. A.
79	Hankins, J. G., Pt., B, 35th Virginia, age 21.	May 16, 1864.	Shot fracture of surgical neck of right humerus.	May 17, 1864.	Head and five inches of shaft removed through perpendicular incision through deltoid.	Died from exhausting suppuration. Surg. S. E. Habersham, C. S. A.
80	Hart, J., Pt., E, 63d Virginia, age 67.	Sept. 20, 1863.	Ball completely crushed head of humerus.	Oct. 16, 1863.	Two inches of bone removed.	Jan. 1, 1864, complete recovery. Asst. Surg. T. J. McFarland, C. S. A.
81	Head, W. S., Pt., I, 17th Alabama, age 35.	Sept. 8, 1863.	Shot wound of left shoulder.	Sept. 8, 1863.	Head of humerus removed, together with fragments of bone.	Nearly well, and promises to have a useful arm. Surgeon D. L. Durden, C. S. A.
82	Hemwood, T. F., Pt., F, 44th North Carolina, age 33.	Oct. 14, 1863.	Neck of right humerus badly broken by shot.	Oct. 20, 1863.	Removal of the head through a V-shaped incision.	Furloughed Dec. 11, 1863, nearly well. Surg. J. L. Cabell, C. S. A.
83	Hill, W. G., Lieut., I, 28th Alabama, age 28.	July 28, 1864.	Shot wound of shoulder, involving head of humerus.	July 28, 1864.	Removal of head thro' straight incision.	Asst. Surg. J. W. Graham, 28th Alabama.
84	Hobard, J. H., Capt., Humphrey's Brigade, age 30.	May 6, 1864.	Shot wound of shoulder.	May 6, 1864.	Resection of head of humerus.	May 31st, improving.
85	Hopwood, A., Pt., G, 41st Virginia, age 28.	May 6, 1864.	Shot wound of the shoulder and hand.	May 7, 1864.	Head of humerus excised.	June 30th, nearly healed; perfect use of forearm. Surgeon P. B. Baker, 41st Virginia.
86	Holton, A. J., Sergt., A, 6th Alabama, age 24.	May 2, 1863.	Shot fracture of head of right humerus.	On field.	Head excised.	Died, July 27, 1863, of exhaustion. Surg. C. J. Clark, C. S. A.
87	Horn, J. A., Pt., B, 19th South Carolina, age 21.	July 22, 1864.	Shot wound involving shoulder joint.	July 22, 1864.	Removal of injured head thro' straight incision.	Furloughed Sept. 28, 1864. Surgeon W. H. Rankins, 19th South Carolina.
88	House, E. G., Pt., C, Cobb's Legion, age 19.	May 23, 1864.	Shot fracture of head of the humerus.	May 23, 1864.	Head excised at surgical neck.	Asst. Surg. H. S. Bradley, Cobb's Legion.
89	Howell, W., Pt., I, 15th South Carolina, age 37.	June 24, 1864.	Comp'd comminuted fracture of humerus and scapula.	June 24, 1864.	Head of humerus and spicula of scapula.	Doing well; "have some fear of necrosis of scapula." Surg. J. A. James, 15th South Carolina.
90	Hudson, B. F., Sergt., A, 4th Florida, age 28.	Sept. 20, 1863.	Fracture of head of the left humerus.	Sept. 25, 1863.	Head excised.	Died November 29, 1863. Surg. C. E. Michel, C. S. A.
91	Hudson, L., Lieut., K, 19th Alabama, age 36.	July 22, 1864.	Fracture of head of humerus.	July 23, 1864.	Head excised.	August 31st, doing well. Surg. C. Foxey, 19th Alabama.
92	Huff, J. T., Sergt., H, 53d Georgia, age 27.	July 21, 1864.	Wound through shoulder joint.	June 21, 1864.	Joint resected.	Died August 9, 1864.
93	Jenkins, J. A., Lieut., C, 51st Tennessee, age 30.	July 20, 1864.	Comminuted fracture of head and neck of right humerus.	July 20, 1864.	Head and surgical neck excised thro' straight incision.	August 1st, doing well. Surg. S. V. D. Hill, C. S. A.
94	Johnston, H. H., Sergt., B, 7th Texas.	Sept. 19, 1863.	Wound of right shoulder joint.	Oct. 14, 1863.	Head through perpendicular incision through deltoid.	Died Oct. 31, 1863, of pyæmia. Surg. W. P. Harden, C. S. A.
95	Jones, J., Pt., B, 121st New York, age 28.	May 10, 1864.	Fracture of head and surgical neck of humerus.	June 30, 1864.	Excision of four inches of bone.	July 1st, condition not good. Surgeon H. C. Chalmers, C. S. A.
96	Johns, J. B., Pt., C, 18th Tennessee.	May 26, 1864.	Compound fracture of humerus.	May 26, 1864.	Head and six inches of shaft excised.	August 31st, doing well. Surg. J. F. Grant, C. S. A.
97	Johnson, W. A., Pt., I, 44th Georgia, age 24.	May 10, 1864.	Ball passed through head of humerus, split bone for three inches, and shattered glenoid cavity.	June 29, 1864.	Three inches of humerus and detached fragments of scapula.	July 31st, pretty good use of arm. Surg. J. L. Cabell, C. S. A.
98	Kearns, P. J., Corporal, F, 114th Illinois, age 33.	July 14, 1864.	.....	July 14, 1864.	Shoulder joint excised.	Died of pyæmia, Aug. 9, 1864. Surg. W. C. Cavenaugh, C. S. A.
99	Key, D. L., Pt., D, 25th Arkansas, age 25.	June 28, 1864.	Shot fracture of left humerus.	1864.	Primary excision of shoulder joint and upper third of the shaft.	Asst. Surg. A. M. Walls, 25th Arkansas.
100	Kidd, C. H.	.....	Shot fracture of head of the humerus.	.....	Head removed.	.....
101	King, E. T., Pt., I, 47th Tennessee, age 22.	July 20, 1864.	Comp'd comminuted fracture of head and surgical neck of right humerus by conoidal ball.	July 20, 1864.	Head and neck removed thro' a straight incision posteriorly.	Recovered. Surg. S. V. D. Hill, C. S. A.
102	Kinsey, E. T., Sergt., B, 3d Mississippi, age 40.	July 20, 1864.	Head of the humerus badly fractured by shot; tissues lacerated.	July 25, 1864.	Head and upper third of shaft removed by vertical incision through centre of deltoid.	Sept. 11th, doing well. Surgeon W. T. McAllister, C. S. A.
103	Knight, W., Pt., C, 28th Tennessee, age 38.	July 7, 1864.	Compound shot fracture of the head of right humerus.	July 8, 1864.	Head removed through straight incision.	Oct. 31st, doing well. Surg. C. H. Wilson, 28th Tennessee.
104	Lawson, J., Pt., A, Palmetto Sharpshooters, age 16.	May 10, 1864.	Shot wound implicating shoulder joint.	May 10, 1864.	Excision of shoulder joint by straight incision thro' deltoid.	June 1st, doing well; furloughed June 6, 1864. Surgeon A. G. Lane, C. S. A.
105	Lee, G. W., Pt., H, 29th Alabama, age 27.	July 22, 1864.	Comp'd comminuted shot fracture of head of right humerus.	July 26, 1864.	Head and four inches of shaft excised.	August 1st, doing well; Sept. 5, 1864, furloughed. Surg. G. G. Crawford, C. S. A.
106	Lestie, I., Pt., B, 14th Georgia, age 18.	May 3, 1863.	Musket ball lodged in head of humerus.	On field.	Head and one and a half inches of shaft removed thro' straight incision.	May 9th, doing well; healthy granulations. Surg. J. Chambliss, C. S. A.
107	Libbitt, G. W., Pt., C, 35th North Carolina, age 19.	May 19, 1864.	Shot fracture of the humerus near shoulder.	June 1, 1864.	Head excised through straight incision.	Recovered. Surg. A. G. Lane, C. S. A.
108	Long, H., Lieutenant, B, 6th Louisiana, age 28.	Sept. 19, 1864.	Compound shot fracture of right humerus near surgical neck.	On field.	Head and two inches of shaft removed thro' vertical incision.	February 1, 1865, recovering; arm rapidly improving.
109	Long, W., Pt., C, 13th Georgia, age 22.	Sept. 19, 1864.	Fracture of head of the right humerus.	Sept. 29, 1864.	Shoulder joint excised.	October 30th, can use arm without trouble; furloughed Nov. 30, 1864. Surg. T. H. Fisher, C. S. A.



NO.	NAME, AGE, AND MILITARY DESCRIPTION.	DATE OF INJURY.	NATURE OF INJURY.	DATE OF OPERATION.	OPERATION AND OPERATOR.	RESULT AND REPORTER.
110	<i>Lynch, D.</i> , Pl., D, 65th Georgia, age 19.	Aug. 3, 1864.	Ball passed through head of humerus.	Aug. 3, 1864.	Head excised.....	Furloughed. Asst. Surg. W. H. Nardin, C. S. A.
111	<i>McCorquedale, N.</i> , Lieut., II, 3th Georgia.	Nov. 22, 1864.	Head of left humerus fractured.	1864.	Head and two inches of shaft through linear incision.	Died December 18, 1864. Surg. D. Herndon, C. S. A.
112	<i>McDaniel, W. H.</i> , A, 55th Tennessee, age 33.	July 28, 1864.	Compound fracture of neck of right humerus.	1864.	Head and four inches of shaft excised thro' linear incision.	Sept. 21, 1864, doing well. Surg. H. W. Brown, C. S. A.
113	<i>McDonald, D.</i> , Sergeant, F, Jeff. Davis's Legion.	Aug. 1, 1863.	Pistol ball through shoulder joint.	On field	Shoulder joint excised.....	Died Aug. 27, 1863. Surg. T. M. Palmer, C. S. A.
114	<i>McDonald, J.</i> , 1 L, I, 33d Alabama.	May 27, 1864.	Wound of left shoulder.....	.....	Head and part of shaft.....	July 1st, doing badly. Surg. F. Hawthorne.
115	<i>McElroy, J.</i> , Sergt., D, 29th North Carolina.	Sept. 19, 1863.	Compound fracture of head and neck of humerus.	Oct. 7, 1863.	Head excised.....	November 1, 1863, doing well. Surg. W. F. Westmoreland.
116	<i>McInnis, S. J.</i> , Pt., G, 8th South Carolina, age 21.	June 5, 1864.	Head of right humerus comminuted.	June 5, 1864.	Shoulder joint excised.....	June 30th, ball caused good deal of irritation about the lungs; recovered. Surg. J. P. Pierce, 8th South Carolina.
117	<i>McInoil, N.</i> , Pl., A, 29th Alabama, age 18.	.....	Head of left humerus fractured	.....	Head excised.....	July 1st, improving. Surg. J. A. Groves, C. S. A.
118	<i>McKinney, W.</i> , Co. C, 24th Georgia, age 23.	July 22, 1863.	Upper part of humerus comminuted.	July 23, 1863.	Upper part excised through straight incision.	August 31st, rather profuse suppuration. Surg. Leiby, C. S. A.
119	<i>McLinn, F.</i> , Pt., K, 60th Illinois, age 25.	Jan. 23, 1864.	Shot wound in right shoulder..	On field	Excision of shoulder joint.....	Died of exhaustion. Asst. Surg. G. G. Roy, C. S. A.
120	<i>McRee, G. W.</i> , Corporal, F, 33d Mississippi, age 32.	July 8, 1864.	Shot fracture of head of the humerus.	On field	Head and portion of shaft removed through linear incision.	Gangrene; Aug. 31st, no visible improvement. Surgeon E. J. Roach, C. S. A.
121	<i>Maddison, W. B.</i> , Private, Poague's Battery, age 34.	July 17, 1864.	Shot fracture of head, neck, and upper part of shaft of the left humerus.	July -, 1864.	Primary excision of the head, neck, and about five inches of shaft.	August 27, 1864, wound entirely healed. Surg. E. H. Smith, C. S. A.
122	<i>Manning, G.</i> , Pl., F, 1st Tennessee, age 23.	June 27, 1864.	Shot fracture of head of the humerus.	June 28, 1864.	Removal of the head through a straight incision.	Surgeon J. R. Buist, Mancy's Brigade.
123	<i>Massey, E. W.</i> , Pt., D, 2d Georgia Sharpshooters, age 22.	May 27, 1864.	Shot fracture of head of the left humerus through capsule, and down the shaft four inches.	1864.	Removal of the head and four inches of shaft by single incision through deltoid.	Died, June 18, 1864, from pneumonia. Surg. G. G. Crawford, C. S. A.
124	<i>Mayben, S. S.</i> , Corporal, G, 15th Arkansas.	June 30, 186-.	Shot fracture of head of the humerus.	July 1, 186-.	Removal of the head.....	In hospital, July 8th. Surg. J. A. Groves, C. S. A.
125	<i>Mayfield, T. J.</i> , Corporal, B, 33d Tennessee, age 34.	May 15, 1864.	Comp'd comminuted shot fracture of head of left humerus.	May 16, 1864.	Head and three inches of shaft removed.	Died, May 28, 1864, of typhoid fever. Surg. G. G. Crawford, C. S. A.
126	<i>Merrick, J. T.</i> , Pt., B, 4th Virginia, age 23.	1862.	Shot wound of shoulder.....	June 2, 1862.	Excision of shoulder joint.....	Recovery. Surg. E. H. Smith, C. S. A.
127	<i>Miller, J.</i> , Pt., G, 12th Virginia, age 31.	June 28, 1864.	Shot fracture of head of the left humerus, glenoid cavity, and neck of scapula.	June 29, 1864.	Head and one inch of shaft and a portion of scapula excised through straight incision.	August 30th, condition favorable; furloughed. Surgeon P. F. Browne, C. S. A.
128	<i>Mills, G. W.</i> , Pt., K, 39th Georgia, age 21.	May 15, 1864.	Compound shot fracture of head of left humerus.	May 16, 1864.	Removal of the head and two inches through a V incision.	May 26th, hemorrhage; doing well June 1; died June 7, 1864. Surg. G. G. Crawford, C. S. A.
129	<i>Mitchie, T. E.</i> , Pt., I, 33d North Carolina, age 23.	May 3, 1863.	Wound of left shoulder joint..	May 8, 1863.	Shoulder joint excised.....	Recovered. Surg. J. B. Strachan, C. S. A.
130	<i>Mixon, J.</i> , Pt., II, 7th Florida, age 22.	Sept. 2, 1864.	Wound of shoulder joint.....	Sept. -, 1864.	Joint excised.....	Furloughed Sept. 24, 1864. Surg. J. A. Groves, C. S. A.
131	<i>Montgomery, T. F.</i> , Pt., G, 38th Tennessee, age 25.	June 30, 1864.	Fracture of head of the left humerus.	June 30, 1864.	The superior extremity excised through vertical incision.	Asst. Surg. J. W. Beale, 38th Tennessee.
132	<i>Moore, A.</i> , Pt., G, 3d Virginia, age 19.	July 3, 1863.	Fracture of head of the left humerus.	On field	Head excised.....	Recovered. Surg. J. H. Pottinger, C. S. A.
133	<i>Moore, M. L.</i> , Pt., A, 58th North Carolina, age 26.	July 24, 1864.	Fracture of head of humerus; ball entered pleural cavity.	July 24, 1864.	Head and four inches of shaft through longitudinal incision.	August 1, 1864, doing well. Surg. M. H. Nash, C. S. A.
134	<i>Morris, F.</i> , Pt., E, 61st North Carolina, age 19.	Sept. 30, 1864.	Head of humerus fractured....	Oct. 2, 1864.	Head and three inches of shaft excised.	Profuse suppuration. Surg. S. Meredith, C. S. A.
135	<i>Moses, J. H.</i> , Pt., D, 28th Alabama, age 21.	July 28, 1864.	Fracture of neck of humerus; joint involved.	July 28, 1864.	Head and neck excised thro' straight incision.	Recovered. Asst. Surg. J. W. Graham, 28th Alabama.
136	<i>O'Neil, G. W.</i> , Sergt., G, 31st Georgia, age 22.	May 6, 1864.	Wound of right shoulder.....	May 7, 1864.	Head and two inches of shaft of humerus.	June 30th, wound healed. Surg. J. R. Page, C. S. A.
137	<i>Orr, G. F.</i> , Corp'l, I, 37th North Carolina, age 28.	May 2, 1863.	Shell divided right humerus and all except a small portion of soft parts.	On field	Shoulder by a V-shaped incision.	Transferred. Surg. C. Witsell, C. S. A.
138	<i>Park, W.</i> , Pl., I, 54th North Carolina, age 18.	June 7, 1864.	Wound of shoulder joint.....	June 7, 1864.	Two inches of bone excised...	June 8th, considerable venous hemorrhage; August 1st, improving. Asst. Surg. R. O'Leary, C. S. A.
139	<i>Padgett, J.</i> , Pt., E, 24th South Carolina, age 33.	Sept. 19, 1863.	Musket ball passed through surgical neck of humerus.	Oct. 3, 1863.	Excision of the head and four inches of shaft.	November 1st, general condition improving. Surg. H. W. Brown, C. S. A.
140	<i>Parton, T.</i> , Pt., D, 7th Arkansas, age 21.	July 22, 1864.	Shot fracture of right shoulder joint.	July 22, 1864.	Head removed through a V-shaped incision.	Surg. S. F. Turner, 7th Arkansas.
141	<i>Perry, W. J.</i> , Sergt., C, 42d Georgia, age 30.	May 15, 1864.	Compound shot fracture of the head of left humerus.	May 16, 1864.	Head and three inches of shaft removed by straight incision through deltoid, and another on posterior aspect.	May 29th, rigors; died June 2, 1864. Surg. G. G. Crawford, C. S. A.
142	<i>Peterson, A.</i> , Pt., D, 10th Georgia.	Nov. 22, 1864.	Shot fracture of head of the left humerus.	1864.	Head and one quarter of an inch of shaft removed thro' linear incision.	Surgeon D. Herndon, C. S. A.
143	<i>Phillips, J. N.</i> , Sergt., B, 10th Georgia, age 21.	May 3, 1863.	Shot fracture of head of the humerus.	On field	Head removed by straight incision through deltoid. June 26th, amputation two inches from glenoid cavity.	July 13th, hemorrhage from axillary; ligated; Aug. 3d, stump healed. Surgeon C. J. Clark, C. S. A.
144	<i>Pierson, J.</i> , Pt., E, 1st Alabama, age 16.	July 28, 186-.	Shot wound of right arm.....	July 28, 186-.	Excision of the shoulder joint..	Died. Surgeon J. A. Groves, C. S. A.
145	<i>Pinkley, M.</i> , Pt., C, 46th Tennessee.	July 28, 1864.	Compound shot fracture of the head of humerus.	July 28, 1864.	Excision of head.....	Asst. Surg. B. S. Barnes, 46th Tennessee.
146	<i>Powell, J.</i> , Pt., I, 3d Georgia, age 28.	June 11, 1864.	Shot fracture of left shoulder joint; also wound of the left lung.	June 12, 1864.	Removal of three inches of the upper extremity of humerus.	"Doing well when last heard from." Surg. E. B. Lewes, 3d Georgia.
147	<i>Ptolifno, J. H.</i> , Pt., II, 4th Texas.	Sept. 20, 1863.	Shot fracture of the upper portion of the humerus.	Oct. 12, 1863.	Excision of the head and three inches of shaft.	Secondary hemorrhage; recovered completely, with good use of forearm. Surg. F. Hawthorne, C. S. A.

No.	NAME, AGE, AND MILITARY DESCRIPTION.	DATE OF INJURY.	NATURE OF INJURY.	DATE OF OPERATION.	OPERATION AND OPERATOR.	RESULT AND REPORTER.
148	<i>Pullin, J. P.</i> , Pt., H, 44th Georgia, age 22.	May 10, 1864.	Shot fracture of head of the humerus.	May 11, 1864.	Excision of head.....	Surgeon A. Taylor, C. S. A.
149	<i>Fultz, H.</i> , Pt., D, 7th Virginia Cavalry.	May 6, 1864.	Upper third of humerus comminuted.	May 9, 1864.	Four inches of bone, including head, excised.	Surg. W. H. Benton, 7th Virginia Cavalry.
150	<i>Rains, M. W.</i> , Pt., 60th Georgia.	May 6, 1864.	Fracture of neck of humerus, extending into the joint.	May 7, 1864.	Head and four inches of shaft excised thro' straight incision.	Surgeon R. A. Lewis, C. S. A.
151	<i>Rainwater, J. A.</i> , Capt., E, 20th Mississippi, age 25.	Aug. 31, 1864.	Head of humerus fractured....	Aug. 31, 1864.	Head excised.....	Surgeon A. S. McKay, C. S. A.
152	<i>Ramsay, T. J.</i> , Pt., A, 19th Tennessee, age 23.	July 22, 1864.	Wound of right shoulder joint.	July 22, 1864.	Head and two and a half inches of humerus excised.	August 31st, doing well. Surg. B. Franklin, C. S. A.
153	<i>Ready, W.</i> , Pt., D, 50th Virginia, age 23.	1864.	Surgical neck of humerus comminuted.	1864.	Four and three-quarter inches of upper end excised.	Surgeon O. F. Baxter, C. S. A.
154	<i>Reinbert, J.</i> , Pt., 3d South Carolina Battery.	Sept. 14, 1862.	Wound of shoulder joint.....	Sept. 28, 1862.	Excised.....	Died October 5, 1862. Surgeon P. P. Lovrett, C. S. A.
155	<i>Rice, T.</i> , Sergt., 12th Tennessee, age 22.	July 22, 1864.	Ball penetrated right shoulder joint, fracturing humerus.	July 22, 1864.	Head excised to the anatomical neck.	Surgeon B. F. Dickinson, 12th Tennessee.
156	<i>Richardson, C.</i> , Pt., D, 58th Virginia, age 43.	May 12, 1864.	Wound of shoulder joint.....	May 25, 1864.	Head of humerus excised.....	Died June 7, 1864. Surgeon A. G. Lane, C. S. A.
157	<i>Richardson, J. P.</i> , Lieut., A, 10th South Carolina, age 23.	July 28, 1864.	Wound of shoulder joint.....	July 28, 1864.	Shoulder joint excised through straight incision.	Surgeon T. P. Bailey, 10th South Carolina.
158	<i>Rogers, R. R.</i> , Pt., D, 26th North Carolina, age 20.	July 3, 1863.	Ball passed through the right shoulder joint.	July 19, 1863.	Head of humerus excised, by Dr. Penchy, of Richmond.	Died Aug. 2, 1863, from erysipelas. Surgeon W. C. Dixon, C. S. A.
159	<i>Rose, D. A.</i> , Corp'l, K, 47th North Carolina.	1864.	Wound of shoulder joint.....	1864.	Shoulder joint excised.....	Died June 26, 1864, from extensive suppuration. Surgeon D. W. Thomas, C. S. A.
160	<i>Rowe, C. T.</i> , Pt., Sample's Battalion, age 28.	Nov. 25, 1863.	Wound of left shoulder joint..	Dec. 1, 1863.	Shoulder excised through vertical incision.	Dec. 19th, secondary hæmorrhage; died December 23, 1863. Surg. W. P. Harden, C. S. A.
161	<i>Rushing, E.</i> , Lieut., I, 37th Mississippi, age 21.	July 28, 1864.	Wound through left shoulder; head of humerus fractured.	July 28, 1864.	Articulation excised.....	Surgeon H. Estes, C. S. A.
162	<i>Rushing, J. R.</i> , Pt., E, 18th Tennessee.	May 26, 1864.	Compound fracture of humerus.	May 26, 1864.	Head and four inches of shaft excised.	May 27th, doing well. Surgeon J. P. Grant, C. S. A.
163	<i>Scott, A. A.</i> , Corp'l, H, 57th North Carolina.	Dec. 13, 1862.	Fracture of humerus just below shoulder joint.	Dec. 14, 1862.	Head and two and a half inches of shaft.	Died. Surgeon C. S. Morton, C. S. A.
164	<i>Serrath, D. J.</i> , Pt., H, 55th Alabama, age 25.	July 20, 1864.	Fracture of head of the right humerus.	July 21, 1864.	Head excised.....	Ass't Surgeon L. D. McReynolds, C. S. A.
165	<i>Shaggard, A.</i> , Pt., E, 44th North Carolina, age 24.	Oct. 14, 1863.	Comminuted fracture of three inches of the upper part of the humerus.	Oct. 23, 1863.	Head and three inches of shaft through incision along the inner edge of deltoid.	Furloughed Dec. 14, 1863; acquiring considerable use of arm. Surg. J. L. Cabell, C. S. A.
166	<i>Simons, H.</i> , Pt., K, 2d Arkansas, age 43.	Dec. 31, 1862.	Comminuted fracture of head and one inch of shaft of right humerus.	Jan. 13, 1863.	Head and one inch of shaft through straight incision.	Mar. 4, 1863, wound granulating. Surg. H. W. Brown, C. S. A.
167	<i>Smith, B. F.</i> , Pt., B, 37th Virginia Cavalry, age 27.	June 17, 1864.	Conical ball through head of humerus.	June 17, 1864.	Head through straight incision.	August 1st, doing well. Surgeon J. J. Terrell, C. S. A.
168	<i>Smith, F. H.</i> , Corp'l, B, 3d and 5th Missouri.	June 27, 1864.	Wound of left shoulder.....	June 27, 1864.	Scapula taken out; head of humerus resected.	Surgeon B. G. Dysort.
169	<i>Smith, J. P.</i> , F, 29th Alabama, age 25.	June 20, 1864.	Shot wound in left shoulder joint.	June 20, 1864.	Excision of shoulder joint....	Died July 4, 1864, of pyæmia. Surg. G. W. McDade, C. S. A.
170	<i>Sorter, S. H.</i> , Pt., F, 18th Georgia, age 24.	May 6, 1864.	Wounded severely in shoulder by shot.	May 7, 1864.	Excision of shoulder joint....	Surg. J. B. Brown, 18th Georgia.
171	<i>Stanton, A. J.</i> , Pt., B, 24th South Carolina, age 21.	.....	Head of the humerus and the glenoid cavity crushed by a ball.	.....	Fragments and two inches of shaft of humerus and a portion of glenoid cavity removed by perpendicular incision through deltoid.	Doing well. Surgeon W. P. Harden, C. S. A.
172	<i>Stanton, A. J.</i> , Pt., F, 18th Georgia, age 24.	May 6, 1864.	Shot wound of the left shoulder joint.	May 7, 1864.	Head removed through straight incision.	May 31st, doing well; stump healed. Surg. M. W. Houston, C. S. A.
173	<i>Summers, G. W.</i> , Pt., F, 32d Tennessee, age 30.	Aug. 18, 1864.	Shot fracture of left humerus..	Aug. 18, 1864.	Head and two inches of shaft removed.	Nov. 18, 1864, doing well. Surg. J. A. Groves, C. S. A.
174	<i>Summers, J. C.</i> , Sergeant-Major, 5th Louisiana.	June 15, 1863.	Shot wound of shoulder joint..	June 18, 1863.	Shoulder joint excised by Larrey's operation.	Recovered. Ass't Surg. T. S. Latimer, C. S. A.
175	<i>Sweet, S. L.</i> , Pt., C, 9th Tennessee.	Sept. 19, 1863.	Shot fracture of head of right humerus; same ball fractured superior maxilla.	Oct. 20, 1863.	Anatomical head removed thro' deltoid flap.	Nov. 30th, wound nearly healed. Surg. C. E. Michel, C. S. A.
176	<i>Tanner, E. J.</i> , Pt., B, Phillips' Legion, age 27.	Nov. 29, 1863.	Shot wound of shoulder joint..	Nov. 29, 1863.	Shoulder joint excised.....	Died.
177	<i>Taylor, J.</i> , Sergeant, A, 9th Arkansas, age 32.	July 28, 1864.	Shot fracture of head of the left humerus.	July 28, 1864.	Removal of head.....	Surgeon R. N. Price, C. S. A.
178	<i>Taylor, H. P.</i> , Pt., G, 1st Tennessee, age 27.	July 22, 1864.	Comp'd comminuted shot fracture of head of right humerus.	July 23, 1864.	Head excised through straight incision.	Surgeon J. R. Buist, C. S. A.
179	<i>Thomas, J.</i> , Pt., 7th South Carolina.	July 10, 1863.	Extensive destruction of tissue of head of humerus by shell.	Sept. 23, 1863.	Head by linear method.....	Sept. 29th, profuse hæmorrhage; the posterior circumflex ligated. Surg. W. C. Hollbeck, C. S. A.
180	<i>Thomas, J. P.</i> .....	Sept. 20, 1862.	Head of humerus fractured....	.....	Shoulder joint.....	Died Nov. 1, 1862. Surgeon F. Hawthorne, C. S. A.
181	<i>Thompson, J. J.</i> , Pt., G, 28th Georgia.	Dec. 13, 1862.	Fracture of upper third of the humerus.	On field	Head and two inches of shaft..	Sloughing. April 1st, improved. Surg. J. A. Milligan, C. S. A.
182	<i>Thompson, T. J.</i> , C, 3d South Carolina, age 30.	May 6, 1864.	Compound fracture of the head of humerus and the whole of the scapula.	1864.	Head of humerus and glenoid cavity.	Surg. J. Evans, 3d South Carolina.
183	<i>Toland, W. T.</i> , Pt., D, 22d Alabama, age 27.	July 28, 1864.	Compound fracture of head and surgical neck of humerus.	Aug. 11, 1864.	Head and five inches of shaft removed by curved incision.	Furloughed Oct. 13, 1864. Surg. H. W. Brown, C. S. A.
184	<i>Turner, J.</i> , Pt., 61st Virginia.	June 22, 1864.	Head and upper part of shaft of humerus.	June 23, 1864.	Head and one-half inch of shaft.	June 30th, doing well. Surgeon Powell, 61st Virginia.
185	<i>Vanderwood, W.</i> , H, 23d North Carolina, age 24.	May 3, 1863.	Head of humerus and glenoid cavity fractured.	June 28, 1863.	Two and a half inches of shaft and fragments of head of the humerus.	Aug. 1, 1863, improving rapidly. Surg. F. B. Henderson, C. S. A.
186	<i>Varnador, T.</i> , Pt., 15th Alabama, age 36.	June 4, 1864.	Wound of head of left humerus.	June 5, 1864.	Four inches of bone excised..	Furloughed Nov. 10, 1864. Surg. T. M. Palmer, C. S. A.
187	<i>Walker, J. H.</i> , Pt., F, 1st Georgia, age 20.	June 15, 1864.	Ball lodged in shoulder joint, chipping head of humerus and fracturing acromion.	June 15, 1864.	Head of humerus and acromial process thro' curved incision.	Surg. H. M. Darling, Stovell's Brigade.
188	<i>Walsh, J.</i> , Sergt., 15th Louisiana, age 35.	Aug. 29, 1862.	Fracture of shoulder.....	1862.	Upper third of humerus.....	Died September 12, 1862, of secondary hæmorrhage. Surgeon J. P. Chazell, C. S. A.



NO.	NAME, AGE, AND MILITARY DESCRIPTION.	DATE OF INJURY.	NATURE OF INJURY.	DATE OF OPERATION.	OPERATION AND OPERATOR.	RESULT AND REPORTER.
189	Waring, M. H., Sergt., G, 3d Florida.	May 28.	Shot fracture of head of right humerus.	May 29.	Head removed.....	Surgeon J. T. Holden, C. S. A.
190	Waterman, P., Pt., D, 20th North Carolina.	Sept. 14, 1862.	Shot comminution of head of humerus.	Sept. 14, 1862.	Three inches of upper extremity of humerus removed.	Surgeon R. J. Hicks, C. S. A.
191	Webb, H., Pt., E, 4th Mississippi, age 34.	July 9, 1864.	Fracture of head of right humerus and scapula by a minié ball.	On field.	Head of humerus and fractured portion of scapula removed.	Doing well. Aug. 1st, still in hospital. Surgeon C. A. Rice, 4th Mississippi.
192	Westwood, W., Pt., Carter's Artillery, age 28.	Sept. 14, 1863.	Extensive comminution of upper part of left humerus.	Sept. 15, 1863.	Portion of head through a curvilinear incision from coracoid to insertion of deltoid.	Sept. 27th, hæmorrhage. February, 1864, recovered. Surgeon B. F. Browne, C. S. A.
193	Whaley, I., Corp'l, H, 54th Alabama.	July 28, 1864.	Comminuted fracture of right humerus, splitting head from lesser tuberosity upward; fracture and comminution of the scapula one and a half inches above inferior angle.	1864.	Head and three inches of shaft and spicula removed.	Aug. 11th, hæmorrhage from deltoid branch. Aug. 12th, vessel ligated. Aug. 29th, prognosis favorable. Surgeon P. H. Otey, C. S. A.
194	White, A. L., Pt., I, 7th Georgia, age 22.	Oct. 7, 1864.	Shot wound of right shoulder joint.	Oct. 8, 1864.	Excision of shoulder joint.....	Dec. 30, 1864, still in hospital. Surg. B. F. Browne, C. S. A.
195	White, J. W., Lieut., I, 14th Alabama.	May 6, 1864.	Shot wound of shoulder joint..	May 6, 1864.	Excision of the head.....	Furloughed June 2, 1864.
196	Williams, G. W., Pt., G, 10th Texas, age 27.	May 27, 1864.	Comp'd shot fracture of right humerus involving shoulder joint.	1864.	Excision of head and four inches of shaft.	Ass't Surg. T. C. Foster, 10th Texas.
197	Williams, J. W., Pt., B, 19th Mississippi, age 24.	April 5, 1862.	Shot fracture of neck of the humerus; necrosis.	Feb. 18, 1863.	Thirteen pieces of bone with the articular head removed.	Duty. March 16, 1863, wound entirely healed. "Thinks he will ultimately regain the entire use of arm." Surg. J. Chambliss, C. S. A.
198	Wilson, E. T., Pt., A, 6th Texas, age 28.	May 27, 1864.	Shot fracture of surgical neck of humerus.	May 28, 1864.	Head and portion of shaft removed; two small muscular arteries divided and ligated.	May 30th, doing well. Assistant Surg. R. A. Smith, 6th Texas.
199	Wilson, J. H.....	186-.	Fracture of head of humerus...	Sec'd'y	Head excised.....	Recovered.
200	Workman, W. J., Pt., G, 44th North Carolina, age 21.	June 1, 1864.	Wound through shoulder joint antero-posteriorly.	June 2, 1864.	Shoulder joint excised.....	Furloughed July 26, 1864. Surgeon R. A. Lewis, C. S. A.
201	Youngblood, C. S., Pt., H, 2d Louisiana.	May 3, 1863.	Fracture of upper third of right humerus.	On field.	Head excised.....	Died May 10, 1863. Surgeon J. A. Milligan, C. S. A.

The two hundred and one operations above enumerated may be summed up as one hundred and thirty-four primary, twenty-eight intermediary, and ten secondary excisions at the shoulder for shot injury, together with twenty-nine cases of the same subdivision, although of uncertain date. The undetermined results are in large proportion, as the cases appear in the tabulation;<sup>1</sup> but many of the reports, especially those of the field cases, indicate that the patients were "doing well" when last accounted for; and the series tends to corroborate the evidence in favor of primary excisions at the shoulder for shot injury derived from the experience of other wars.<sup>2</sup> The numerical statement of Dr. Chisolm<sup>3</sup> is

<sup>1</sup>The figures are as follows: *Primary*, 134; recovered, 21—furloughed, 17—fatal, 25—unknown, 71. *Intermediary*, 28; recovered, 4—furloughed, 5—fatal, 9—unknown, 10. *Secondary*, 10; recovered, 4—fatal, 2—unknown, 4. *Operations of Undetermined Date*, 29; recovered, 3—furloughed, 1—fatal, 7—unknown, 18.

<sup>2</sup>Thus LÖFFLER (F.) (*General-Bericht*, u. s. w., 1867, S. 288) observes: "From a statistical point of view, it is undoubtedly the duty of the field surgeon, in cases of shot wounds of the shoulder joint, to excise the joint during the first forty-eight hours after the reception of the injury. Has this period passed, operative interference should be deferred until the end of the period of inflammatory reaction. But statistical results are hardly necessary to convince the field surgeon of the advantages of primary resection. If resections of the joints are acknowledged to be a means of diminishing the ratio of mortality notoriously following abstention from operative treatment, it is difficult to see why the operation should be delayed until the aspect of the case has really become threatening. \* \* \* More astonishing still is the assertion that nothing is gained by a primary resection. Less danger to life and shortening of the period of confinement by disease are certainly advantages worthy of consideration. Uncertainty regarding the diagnosis and accumulation of labor during the first days following a battle, already encroach sufficiently upon the time for primary resection." STROMEYER (L.) (*Maximen der Kriegsheilkunst*, 1855, S. 694) remarks: "According to my view, in every well-attested case of injury of the bone with opening of the shoulder joint, resection is indicated as the only method which will prevent the threatening danger of a suppurative inflammation." SCHWARTZ (H.) (*Beiträge zur Lehre von den Schusswunden*, 1854, S. 205), treating of shot fractures involving the shoulder joint, and illustrating the subject by his experience in the Schleswig-Holstein war, emphatically declares (the italics are his own): "All require the primary resection; the secondary should only be performed when the injury was overlooked in the first place, or if there was not time to resect during the first twenty-four hours." And, on page 207, he continues, after citing several excisions: "The last two cases teach obviously not only that anywise important cases of fractures of the humerus, extending within the capsular ligament, should be resected, but should be primarily resected." MACLEOD (G. H. B.), referring to excisions of the joints for shot injury (*Notes on the Surgery of the War in the Crimea*, 1858), avers: "So far as my observation went, primary excisions were much more successful than those done at a later date, both as regards the final results and the length of the period of convalescence." And DEMME (*Studien*, u. s. v., 1861, B. II, S. 224) argued to the same effect, and denies that excisions are more prejudicial to the transport of the wounded than unolested shattered limbs: "The condition of the soft parts more than anything else speaks in favor of primary resection. There is no considerable infiltration, no serious destruction of the joint, no burrowing of pus nor softening of the fibrous tissues, no fatty degeneration of muscles,—complications that are likely to follow expectant treatment, directed to symptoms, complications that sometimes persist after secondary resection, rendering the complete restoration of the functions of the arm impossible. \* \* \* The advocates of secondary operations lay great stress upon the fact, that it is difficult to estimate the extent of operative interference requisite in recent shot injuries; that there is danger of too much or too little being removed. This objection may have some foundation; but to say that the transport of the wounded after the operation is more dangerous to patients, and more difficult, is an error, and I am convinced that the contrary is the fact."

<sup>3</sup>CHISOLM (J. J.) (*A Manual of Military Surgery*, Columbia, 1864, p. 377), in a "Consolidated table of Resections, collated from records in the Surgeon-General's Office from June 1, 1862, to February 1, 1864,—prepared by Surgeon H. BAER, P. A. C. S.," accounting for 41 primary and 27 secondary excisions at the shoulder, after shot injury, with a percentage of fatality of 31.7 and 25.9, respectively.

at variance with this conclusion, representing the secondary excisions at the shoulder as the practice to be most advantageously followed. Before discussing this question, it is proper to refer to the excisions at the shoulder for shot injury done elsewhere. Of these, more than four hundred well-authenticated examples have been published, besides several score of analogous operations, described by some authors as excisions or resections at the shoulder; but not thus recognized by other writers. Only in the last thirty or forty years has the operation come to be regarded as one of the legitimate regular procedures of military surgery. The cases belonging to this period are classified in the following tabular statement:

TABLE XLI.

*Showing the Number of Excisions of the Upper Extremity of the Humerus for Shot Injury on the Occasions named, and from the Authorities quoted, with the Ratio of Mortality.*

ACTIONS AND AUTHORITIES.	CASES.	RECOVERIES.	DEATHS.	RESULTS UNDETERMINED.	RATIO OF MORTALITY.
Algeria and other occasions prior to 1855 (BAUDENS) <sup>1</sup> .....	14	13	1	.....	7.1
Austrians in Lombardy in 1848 (BECK).....	1	1	.....	.....	.....
Sleswig-Holstein, 1848-51 (ESMARCH and STROMEYER).....	19	12	7	.....	36.8
French in Algeria (BERTHERAND), 1854-56.....	1	1	.....	.....	.....
Crimean War, 1854-56, Russians (HÜBBENET).....	20	2	11	7	84.6
Crimean War, 1854-56, French (CHENU).....	42	18	24	.....	57.1
Crimean War, 1854-56, British (MATTHEW).....	16	13	3	.....	18.7
Italian War, 1859-60, French (CHENU).....	19	10	9	.....	47.3
Italian War, 1859-60, Austrians (DEMME).....	26	17	9	.....	34.6
New Zealand War, 1863-65 (MOUAT).....	9	9	.....	.....	.....
Danish War, 1864 (LÖFFLER).....	35	17	18	.....	51.4
Prussians in Six Weeks' War, 1866 (STROMEYER, BECK, BIEFEL, and MAAS.).....	13	7	6	.....	46.1
Army of the United States, 1865-70 (Circular 3).....	2	2	.....	.....	.....
Franco-German War, 1870-71, Germans (H. FISCHER, SOGIN, BECK, BILLROTH, RUPPRECHT, LÜCKE, SCHÜLLER, G. FISCHER, LOSSEN, STEINBERG, MAYER, ESTERLEN, KIRCHNER, KOCH, SCHINZINGER, STUMPF, MOSETIG, and GRAF). Franco-German War, 1870-71, French (PANAS, COUSIN, CHRISTIAN, PONCET, HERGOTT, F. GROSS, TACHARD, SÉDILLOT, CHIPAULT, and VASLIN). Franco-German War, 1870-71 (MCCORMAC, etc.).....	126	78	48	.....	38.0
.....	24	9	15	.....	62.5
.....	11	6	5	.....	45.4
.....	378	215	156	7	42.0

<sup>1</sup> BAUDENS (*Mém. sur la résection de la tête de l'humerus*, in *Rec. de mém. de méd., de chir.*, 1855, 2<sup>e</sup> sér., Vol. XV, p. 184); BECK (B.) (*Die Schusswunden*, 1850); ESMARCH (F.) (*Über Resectionen nach Schusswunden*, 1851, S. 41); STROMEYER (L.) (*Maximen*, 1855, S. 756); BERTHERAND (A.) (*Camp. de Kabylie*, 1862); HÜBBENET (C. V.) (*Die Sanitäts Verhältnisse der Russischen Verwundeten während des Krimkrieges in den Jahren, 1854-56*, Berlin, 1871); CHENU (J. C.) (*Camp. d'Orient*, p. 677); MATTHEW (T. P.) (*Op. cit.*, p. 376); CHENU (J. C.) (*Camp. d'Italie*, 1869, T. II, pp. 544-597); DEMME (H.) (*Militär-Chirurgische Studien in den Italienischen Lazarethen von 1859*, B. II, S. 226); MOUAT (*Med. and Surgical History of New Zealand War, in Army Med. Dept. Report for 1865*, Vol. VII, pp. 476-8); LÖFFLER (F.) (*Generalbericht*, u. s. w., 1864, S. 280-301); STROMEYER (L.) (*Erfahrungen über Schusswunden*, Hannover, 1867); BECK (B.) (*Kriegschir. Erf. während des Feldzugs*, 1866); BIEFEL (R.) (*Kriegschir. Aphor.*, von 1866, in *Arch. für Klin. Chir.*, Berlin, 1869, Vol. XI, S. 426 and 474); MAAS (H.) (*Kriegschir. Beiträge*, Breslau, 1870, S. 73); *Circular 3*, War Department, S. G. O., Washington, 1871, p. 226; FISCHER (H.) (*Kriegschir. Erf., Vor Metz*, 1872, S. 146); SOGIN (A.) (*Op. cit.*, S. 153); BECK (B.) (*Chir. der Schussverletzungen*, 1872, S. 583); BILLROTH (TH.) (*Chir. Briefe*, 1872, S. 213); RUPPRECHT (L.) (*Militärärztliche Erf.*, Würzburg, 1871, S. 15 and 61); LÜCKE (A.) (*Kriegschir. Fragen und Bemerk.*, Bonn, 1871, S. 105); SCHÜLLER (M.) (*Kriegschir. Skizzen*, Hannover, 1871, S. 11 and 10); FISCHER (G.) (*Dorf Floing und Schloss Versailles*, in *Deutsche Zeitschrift für Chir.*, 1872, B. I, S. 187); LOSSEN (H.) (*Kriegschir. Erf. u. s. w.*, in *Deutsche Zeitschrift für Chirurgie*, 1873, B. II, S. 40); STEINBERG (*Die Kriegslazarethe und Baracken von Berlin*, 1872, S. 148); MAYER (L.) (*Kriegschir. Mittheil.*, u. s. w., in *Deutsche Zeitschrift für Chir.*, 1873, B. III, S. 49); ESTERLEN (OTT, ESTERLEN, und ROMBERG) (*Kriegschir. Mittheilungen aus dem Ludwigsburger Reserve-Spital*, \* \* 1870-71); KIRCHNER (C.) (*Ärztlicher Bericht über das Königlich Preussische Feldlazareth im Palast zu Versailles*, Erlangen, 1872); KOCH (W.) (*Notizen über Schussverletzungen*, in *LANGENBECK'S Archiv für Klin. Chir.*, 1872); SCHINZINGER (A.) (*Das Reservelazareth Schwetzingen*, Freiburg, 1873); STUMPF (L.) (*Bericht über das Kriegsspital des St. Georg-Ritter Ordens zu Neuberghausen im Jahre 1870-71*, in *Bayerisches Ärztl. Intelligenzblatt*, 1872, Nos. 647, 655); MOSETIG (V.) (*Erinnerungen aus dem deutsch-französischen Kriege*, in *Der Militärarzt*, 1872); GRAF (E.) (*Die Königl. Reservelazarethe zu Düsseldorf während des Krieges*, Elberfeld, 1872); PANAS (F.) (*Mém. sur le traitement des blessures*, etc., in *Gaz. hebdom. de méd. et de chir.*, 1872, p. 389); COUSIN (A.) (*Hist. chir. de l'ambulance de l'école des ponts et chaussées*, in *L'Union méd.*, 1872); CHRISTIAN (J.) (*Relation sur les plaies de guerre observées à l'ambulance de Bitschwiller*, 1870-71, in *Gaz. méd. de Strassbourg*, 1871, p. 279); PONCET (F.) (*Contribution à la résection mé. de la guerre de 1870-71*, in *Montpellier médical*, 1872); HERGOTT (*Ambulance du Petit et du Grand-Séminaire pendant le siège de Strassbourg*, in *Gaz. méd. de Strassbourg*, 1870); GROSS (F.) (*Notice sur l'hôpital civil pendant le siège et le bombardement de Strassbourg*, in *Gaz. méd. de Strassbourg*, 1872); TACHARD (E.) (*Reflexions pour servir à l'histoire de la chirurgie en campagne*, in *Gaz. des Hôp.*, 1871); SÉDILLOT (*Du traitement des fractures des membres par armes de guerre*, in *Arch. gén. de méd.*, 1871, IV<sup>e</sup> sér., T. 17, p. 293); CHIPAULT (A.) (*Fractures par armes à feu*, 1872, p. 104); VASLIN (L.) (*Étude sur les plaies par armes à feu*, 1872, p. 76); MCCORMAC (W.) (*Notes and Recollections of an Ambulance Surgeon*, 1871, p. 130).



Apart from the references here tabulated, there have been published accounts, for the most part isolated, of particular instances of excisions at the shoulder for shot injury. Thirty-four of these, of which twenty-seven at least resulted favorably, are mentioned in the subjoined historical note.<sup>1</sup> An aggregate of four hundred and twelve cases is obtained by adding those included in the numerical statement on the preceding page. Or, laying

<sup>1</sup> Authors frequently mention THOMAS, of Pezenas, as the first who excised, in 1740, the head of the humerus; but it appears (SABATIER, *Mém. sur un moyen de suppléer à l'amputation du bras dans l'articulation*, in *Mém. de l'Institut National des Sci. et Arts*, Paris, An. XII (1804), p. 367) that THOMAS simply successfully extracted, for caries, in a girl, aged 4 years, a portion of the cylindrical part of the upper extremity of the humerus, about an inch and a half in length, and, the following day, the epiphysis forming the head of the humerus. The next case referred to is that of VIGAROUS, of Montpellier, said to have excised, in 1767 (GUTHRIE, G. J., *Gunshot Wounds*, 3d ed., 1827, p. 471, and PÉAN, J. E., *De la scapulo-galgie et de la résection scapulo-humérale*, Thèse, Paris, 1860, p. 45), the head of the humerus, for caries, in a lad of 17, who died shortly afterward; but, in a letter to M. SABATIER, an extract of which is published by the latter (*l. c.*, p. 373), M. VIGAROUS remarks: "Je n'ai point retranché la tête de l'os du bras." In 1768, CHARLES WHITE, of Manchester (*Cases in Surgery, with Remarks*, London, 1770, p. 57, and *Phil. Transactions*, 1770, Vol. LIX, p. 39), excised, for caries, the head of the humerus in a boy of 14; good motion of the limb being preserved. Three years later, in 1771, Dr. LENTIN (*Med. Chir. Bemerkungen*, 1771) successfully removed, for caries, the head and shaft of the humerus, with the exception of the lower two inches of the bone. From this time the operation was repeatedly and successfully performed by J. BENT, in 1771 (HUNTER, *Account of a Woman enjoying the Use of her right Arm after the Head of the os humeri was cut away*, in *Phil. Transact.*, 1774, Vol. LXIV, Part I, p. 353), who excised the head of the right humerus for caries, in a young girl, retaining perfect use of forearm;—by DANIEL ORRED, in 1778 (PERCIVAL (P.), *A Case in which the head of the os humeri was sawn off and yet the motion of the limb preserved*, in *Phil. Trans.*, 1779, Vol. LXIX, Part I, p. 6);—by MOREAU, the elder, in 1786 (MOREAU (P. F.), *Essai sur l'emploi de la résection des os*, Obs. I, 1816), in the case of a woman, aged 45, for caries; arm shortened two inches; good motion of forearm; and, by the same operator, in 1794 (*l. c.*, Obs. IV), in a widow, Moulin, aged 43, removing the head and shaft, 5½ inches in all; abscesses and fistulæ remained until her death, 10 years after the operation;—by the surgeon of the Cavalry regiment Lerris, in 1789 (PERCY et LAURENT, *Art. Résection*, in *Dict. des Sci. Méd.*, 1820, T. 47, p. 546), in a boy, aged 13, for caries. Several other cases are mentioned by the last named authors (PERCY and LAURENT), but it is impossible to reconcile their statements in the above article with others made by them in the article *Humerus*, *Dict. des Sci., Méd.*, 1818, T. XXII, pp. 36, 37, a fact that, in a measure, may account for M. SABATIER'S silence regarding them. PERCY et LAURENT (*Dict. des Sci. Méd.*, 1818, T. 22, p. 26) further declare: "Dès l'an 1794 nous présentâmes à feu notre collègue SABATIER, neuf exemples vivans de cette cure." [M. LEGUEST (*De la Chirurgie mil. contemporaine*, in *Arch. gén. de méd.*, 5e sér., 1859, T. XIII, p. 463) and Dr. R. M. HODGES (*The Excision of Joints*, 1861, p. 23) inadvertently cite nineteen operations, all accredited to PERCY.] PERCY complains that SABATIER, "le chirurgien, si justement célèbre fit dans la suite le sujet d'un mémoire où il ne jugea pas à propos d'en nommer l'auteur." But it is doubtful whether these cases were excisions, or mere removal of fragments; it would seem that at least some of them would have been reported in detail, especially as prior to that period no cases of excisions of the head of the humerus for shot injury are on record. The first case of excision for shot injury (the only series to be referred to hereafter in this note) that is reported in detail, is adduced by L. GROSSBOIS (*Diss. sur l'amputation du bras dans l'articulation avec des remarques et observations sur la résection de l'extrémité supérieure de l'humérus, etc.*, Paris, 1803, p. 34); Corporal Gaché, 18th regiment of the line, was shot through the right shoulder joint, at Roveredo, September 4, 1796; two days later he was admitted to the hospital at Verona. The head and a portion of the shaft were successfully excised by the author's brother, a noted surgeon in the French army. SABATIER, who is reported to have performed the operation of excision of the head quite frequently, describes, in his memoir to the Institute, the mode of operation, but does not claim to have practised it, although he carefully cites all authentic cases known to him. LARREY (D. J.), alleged to have operated in ten instances, remarks (*Rélation hist. et chir. de l'expédition de l'armée d'Orient*, 1803, p. 314, and *Mém. de Chir. mil. et camp.*, 1812, T. II, p. 174): "J'ai eu la bonheur de prévenir dix fois ces accidens, et d'éviter l'amputation qu'ils auraient nécessitée, en faisant l'extraction entière de la tête de l'humérus, ou des ses fragments;" but his cases were, undoubtedly, not cases of excisions, but removal of fragments, etc., as he remarks elsewhere (*Mém. de Chir. mil. et camp.*, 1812, T. II, p. 172): "Mais je n'ai point à m'occuper de la résection de la tête de l'humérus que je n'ai pas eu occasion de pratiquer; il me suffira d'avoir fait sentir la différence qui existe entre cette opération et l'extraction de la tête de l'humérus, séparée par une fracture de son col, ou réduite en fragments." The second authentic excision for shot injury was reported by M. PORET (*Obs. sur la résection de la moitié supérieure de l'humérus, après un coup de feu près l'articulation*, in *Jour. de méd. chir. phar.*, T. XXII, Juillet, 1811, p. 425), who excised the head of the humerus in the case of a soldier of the 95th regiment, who had been shot through the upper third of the humerus. The operation was performed on March 12, 1809, by M. PORET, in the presence of MM. LIXON, MANTEL, and FAYET. The patient recovered "toutes les fonctions se faisaient parfaitement bien." 3. According to JÆGER (*Operatio resectionis*, Erlangæ, 1832), WILLAUME, in 1812, successfully excised the head of the humerus. 4. MOREAU (P. F.) (*op. cit.*, 1816, Obs. 3) performed the operation on December 22, 1812, in the case of Sebastian Vilain, 63th of the line, who had been wounded in Spain, July 22, 1812; the head and four inches of the shaft were removed for caries; the patient recovered, with considerable use of the arm. 5. Dr. R. M. HODGES (*The Excision of Joints*, 1861, p. 24) records, on the authority of an eye-witness of this operation, that "In the United States it was first practised for gunshot wounds by Dr. Wm. Ingalls, of Boston, in the winter of 1812-13. The patient was a soldier in the United States Army, and he recovered with a tolerably useful limb. 6. Naval Surgeon BROWN, in 1814, excised the head of the humerus of Lieutenant Dunean of the Navy, wounded a few days before the battle of Plattsburgh, September 11, 1814, the patient recovering, with good use of the forearm. The case is detailed by Dr. H. HUNT (*Am. Med. Recorder*, 1818, Vol. I, p. 365). 7. S. MANN (J.) (*Med. Sketches of the Campaign of 1812, '13, '14*, Dedham, 1816, p. 208) cites the cases of two seamen of Commodore McDonough's fleet, wounded at the battle of Plattsburgh, September 11, 1814, by cannon balls; the fractured heads of the humeri were excised. 9. 10. LEGRAND (de Brège) (*Diss. sur la résection de la tête de l'humérus*, 1814) twice resected the head of the humerus for shot wounds, in 1814. 11. MOREAU (P. F.) (*op. cit.*, 1816, Obs. 5) excised the head of the left humerus in the case of Gautier, aged 24, wounded June 16, 1815; little use of the arm was retained. 12. W. R. MOREL, as reported by Sir J. MCGRIGOR (*Case of Gunshot Wound of the Shoulder joint*, in *Med. Chir. Trans.*, 1816, Vol. VII, p. 161), resected the head of the humerus, in the case of Th. Ellard, 18th Hussars, wounded at Waterloo, June 18, 1815. Recovery, with "little motion in the shoulder, but all the variety of motion of which the forearm and hand are capable." GUTHRIE (G. J.) (*A Treatise on Gunshot Wounds*, 1827, p. 470), in his chapter on "Excision of the Head of the Humerus," cites various cases from the British campaigns, 1810-1815, but, with the exception of the case of Ellard, above cited, they are all cases of removal of loose fragments. While the conservative treatment, as carried out by THOMAS, BOLCHER, and others, was practised extensively by military surgeons, the excision of the bone, as performed by WHITE, MOREAU, and others, was little favored by the former, and, as late as 1830, the eminent HENNEN (*op. cit.*, 3d ed., 1829, p. 30) remarked, that it was "not generally adopted;" and added: "I have never seen it performed on the field, and, in hospital practice, I have only seen one case of it. \* \* \* Upon the whole, I am inclined to think that the excision of the head of the humerus will be found to be an operation more imposing in the closet than generally applicable in the field." 13. 14. 15. BRIOT (*Histoire de l'état et de progrès de la chir. mil. en France*, 1817, p. 16) remarks: "M. BOTTIN a opéré une cure semblable à Barcelonne; M. COURVILLE une à Mayence; MM. PÉRET et LAFAYE ont également réussi, dans un cas extrêmement compliqué, à conserver le bras à une jeune soldat qui était à l'hôpital de St. Sébastien." 16. VERNET (*Letter autographe*, Bayeux, 1819) resected the shoulder joint for shot injury, but I have not been able to determine the result. 17. REYNAUD (YVAX) (*Résection de l'extrémité supérieure de l'humérus à l'occasion d'un coup de feu*, in *Arch. gén. de méd.*, 1827, T. XV, p. 464) excised the head of the humerus in the case of a marine, at Toulon, who had received two balls in the shoulder: "Là une nouvelle articulation s'est formée en 8 ou 9 mois, et aujourd'hui le malade peut exécuter des mouvemens dans tous les sens." 18. BRUCE (CH.) (*Three cases of Surgical Operations*, in *Lancet*, 1831, Vol. II, p. 742) relates the case of a soldier wounded at Phaleris, Greece, in May, 1827; resection of the head of the humerus was performed, but the patient died. 19. ROUX (J. N.), à Brignoles (*Gaz. méd. de Paris*, 1836, T. IV, p. 72), in 1836, excised the head of the humerus for shot injury, and the patient recovered.

aside fourteen instances in which the results were unknown or only partially determined, a series of three hundred and ninety-eight excisions at the shoulder for shot injury is collected, with two hundred and forty-two, or somewhat more than sixty per cent. of recoveries. Operations by Larrey, Percy, Guthrie, and others, referred by many writers to this category, have not been added to it, either because the operators explicitly declared that the cases could not be considered examples of formal excisions, or on account of some ambiguity in the records, or hazard of duplicating identical instances.<sup>1</sup> Although the period of operation in this series could not be determined with precision in more than half of the cases, the imperfect analysis was very favorable to primary excision.

Of the nine hundred and fifty-one completed observations of this operation reported from the American war,<sup>2</sup> there were six hundred and three recoveries, a percentage of 63.4. The distribution of these cases according to the period of operation is minutely explained on page 599, and it clearly appears that the mortality of the consecutive operations exceeded that of the primary in a proportion greater than ten per cent. The concurrent testimony of two such large bodies of facts affords a strong presumption in favor of primary excisions, although many surgeons entertain an opposite view.<sup>3</sup> There would probably be less difference of opinion if a ternary, instead of a binary, classification of operations<sup>4</sup> were more

with good use of forearm and some use of arm. 20. BADDELY (P. T. H.) (*Proceedings of Surgical Society of Ireland*, in *Dublin Med. Press*, Dec. 14, 1842) relates the case of a Hindoo soldier, aged 21, who had shot himself in the shoulder; secondary excision of the head of the humerus; recovery, with complete use of forearm and hand; can elevate the arm almost to a right angle with the body. 21. LERICHE (*Mém. de la Soc. d'émulation de Lyon*, 1842) successfully performed the operation. 22. STRATTON (TH.) (*Case of Gunshot Wound and Excision of the Head of the Humerus*, in *Edinb. Med. and Surg. Jour.*, 1846, p. 30) successfully excised the head of the humerus in a Chippewa Indian boy, aged 6, shot in the shoulder, in 1844; an intermediary operation. 23. WILLIAMSON (G.) (*Notes on Gunshot Injuries, etc.*, in *Dublin Quart. Journal*, 1859, Vol. XXVIII, p. 81) cites the case of John Morgan, shot at Idaliff, September, 1842; the head of the humerus was excised on June 22, 1844; patient "gradually regained power of motion in the arm." 24. Dr. BEITH, of the Royal Navy (*Gunshot Wound through the Shoulder Joint. Excision of the Head of the Humerus; Recovery, with Hinge-like Movement of the Articulation*, in *Lancet*, 1856, Vol. I, p. 207). 25. 26. WILLIAMSON (G.) (*loc. cit.*, p. 81) cites two successful cases from the Indian mutiny, 1858, one a primary, the other a secondary operation. 27. DYAS (W. G.) (*Resection of the Head of the Humerus for Gunshot Wounds*, in *Chic. Med. Jour.*, 1859, Vol. XVI, p. 764) removed the head of the humerus, shattered by gunshot, in the case of W. B.—; the result is not stated. 28. MATTHEW (T. P.) (*Stat. San. and Med. Reports of the Army Med. Department*, London, 1861, p. 399), in 1859, successfully excised the head of the humerus in the case of Fraser, 93d regiment. 29. EYE (P. P.) (*Nashville Jour. of Med. and Surg.*, July, 1860), the case of a young man, aged 16, accidentally shot in the shoulder; head of the humerus excised; recovery, with good use of limb, being able to raise the arm to a level with the clavicle. 30. V. PITHA (PODRAZKI, *Ueber Schusswunden*, in *Öster Zeitschrift, für prakt. Heilkunde*, B. VII, 1863) removed the head and portion of the shaft of the right humerus for shot injury; patient "does, with the fingers of this arm, the finest carving." 31. Chief Surgeon RIEDL (*Allgemeine Militärärztl. Zeitung*, 1864, Nos. 17, 18) removed the head of the humerus in the case of a soldier who had attempted to commit suicide; recovery, with good use of forearm and tolerable good use of arm. 32. Surgeon RUDGE, 9th Bengal Artillery (*Brit. Army M. D. Dept. \* \* Reports*, 1866, Vol. VI, p. 520), in 1865, excised the head of the humerus of a sapper shot through the axilla. The patient recovered, with good use of the forearm, and, "in fact, with very little exception, the entire use of the arm had been restored." 33. FITZGERALD (J. W.) (*Western Jour. of Med.*, 1869, Vol. IV, p. 112), in 1868, successfully removed the head of the left humerus, in a girl of nineteen, for comminuted shot fracture. 34. MINER (W. W.) (*Excisions Involving the Joints of the Upper Extremity*, in *Buffalo Med. and Surg. Jour.*, 1871, Vol. XI, p. 82) excised "the head, with the upper and middle two-thirds of the humerus," for gunshot injury of the shoulder; recovery, with perfect use of forearm, but very little motion of arm. I have endeavored in this note to refer only to isolated cases of excisions of the upper extremity of the humerus for shot injury, and the large number of cases collected from publications on special campaigns have been grouped in tabular form, see TABLE XII, p. 607.

<sup>1</sup> All this is explained, at as great length as space will allow, in the preceding note. I must say, however, that notwithstanding the disclaimer of the illustrious LARREY, several of his operations appear to me to have been excisions at the shoulder for shot injury, in the strictest sense. I cannot find, in either of PERCY's three articles, that he ever practised this operation after injury, although he collected a number of cases of excision for disease, and presented some of the recovered patients to the institute, and deserves much credit for his earnest advocacy of resections. The operations attributed by some writers to SABATIER, refer simply to those cases collected by PERCY. There are many other well known, authenticated cases, which, at first sight, might appear to be omitted in TABLE XI; but are, for the most part, grouped under the heads of the different campaigns, as the operations by Professor LANGENBECK, STROMMEYER, SCHWARTZ, etc., in the Dutchies, those of MAM. HAUDENS and LEGUEST, in the Crimea.

<sup>2</sup> The gross aggregate is one thousand and eighty-six operations, of which in one hundred and thirty-five instances the ultimate results were unknown or only partially known. While regarding the importance of such naked numerical statements and comparisons as vastly overrated, they appear to afford the only feasible mode of presenting in a small compass the results of such large numbers of cases.

<sup>3</sup> Thus SOCIN (A.) (*Kriegschir. Erf.*, 1872, S. 155), treating of excisions at the shoulder after shot fracture, while admitting that he has had no personal experience on the subject, opines that "primary resection should be confined to those cases in which extensive splintering of the bone can be diagnosed," but adds: "Should the considerably more favorable mortality-rate, observed in the American War (Circular 6), be confirmed, the field of primary resection should be extended, as, as a matter of course, the vital prognosis should be preferred to the functional." And HILLBOTH (T.) (*Chir. Briefe aus den Kriegs Lazarethen*, u. s. w., 1874, S. 210) contends that "primary resection is only to be practised when the splintering in the joint is very extensive." HODGES (R. M.) (*Exc. of Joints*, 1861, p. 29) strongly presents the arguments of the advocates of deferred operations. For the views of the writers on the other side, see the note on page 606.

<sup>4</sup> SWINGURSE (J.) (*Conservative Surgery*, in *Med. and Surg. Reporter*, Philadelphia, 1862-3, Vol. IX, p. 377) observes: "Now authors divide operations into primary and secondary. My experience induces me to make still another division, which is primary, secondary, and tertiary; the tertiary corresponding with the secondary operations of authors. It must be remembered that the stage which I designate as secondary is one of congestion and inflammation, where the capillary, small arteries, and veins become large reservoirs, and all the parts as a mass of distended blood vessels possessed of imperfect vitality. If, in this condition, any operation is performed, repairation goes on slowly, if at all; perhaps mortification and extensive sloughing of all the parts take place, and death follows, either from pyæmia, gangrene, exhaustion, or shock to the sensitive nervous system."



generally adopted.<sup>1</sup> It is a general rule, applicable to all excisions and amputations, that those practised during the intermediary or inflammatory stage are by far the most dangerous, and should never be performed except as compulsory operations. *If the patient survives this period* he generally attains a condition in which operations are tolerated even better than in full health, and the ratio of mortality of the true secondary or ulterior operations is less than that of immediate or primary operations. But how many patients perish in the experiment. Alcock has well observed that the mode in which authors have defined the several periods has had no small share in producing discrepancy of opinion on the subject.

Of the entire aggregate of one thousand and eighty-six excisions at the shoulder joint, reported from the American war, seven hundred and thirty-nine were practised on Union, and three hundred and forty-seven on Confederate soldiers. The mortality-rates of the completed cases<sup>2</sup> was 35.7 per cent. on the Union, and 39.4 per cent. on the Confederate side. In the latter group, however, the ratio is of little value, since the terminations of nearly two-fifths of the cases are unknown, yet, could they be ascertained, might greatly diminish or largely augment the proportion of deaths.

The side on which the excision was practised was recorded in eight hundred and seventeen instances. Four hundred and two were on the right, and four hundred and fifteen on the left side. One hundred and forty-six, or 36.6 per cent. of the former, and one hundred and twenty-four, or 29.8 per cent. of the latter, proved fatal; conclusions that reverse the inference of the celebrated Herr Esmarch, suggested by his earlier experiences in Schleswig-Holstein, that "the operation on the left side seems to give less favorable results than on the right."<sup>3</sup>

The slight numerical predominance of shot injuries of the left shoulder, too uniform in the various subdivisions to be accidental, has been ascribed to the exposed position of the left shoulder in firing, in the troops composing the great bulk of an army. Dr. George C. Harlan,<sup>4</sup> who served, with great distinction, with the cavalry, throughout the war, has

<sup>1</sup> We are indebted to BOUCHER for the proposition of a three-fold division of operations, according to the period at which they are performed. It appears in the second of his celebrated memoirs on shot wounds, published in 1753, in the second volume of the memoirs of the old French Academy of Surgery, at page 466. It is worth while to give a literal translation of his definitions: "I distinguish," he says, "three periods in which amputation may be practised: *Firstly*, the time immediately succeeding the infliction of the injury and preceding the development of complications. It is known that, after wounds by firearms, tension, inflammatory swelling, pulsations, acute pains, fever, etc., which are the ordinary consequences, do not appear immediately, and that these symptoms are more or less slow in presenting themselves, according to the size and complication of the wound, the temperament and constitution of the patient also having their influence. *Secondly*, the period when complications, being more or less developed, are more or less liable to affect the animal economy. *Thirdly*, the time when the grave complications have relaxed their violence, or have absolutely calmed down; the period that M. FAUCONNEAU requires in order to be able to operate with advantage." It must be remembered that BOUCHER'S judgment was formed after an immense experience of field surgery, at Ramilles and Fontenoi, and many other of the great battles in the Low Countries. RUTHERFORD ALCOCK (*Notes on Med. Hist. of the British Legion in Spain*, 1838, p. 66), quoting these definitions, declares that: "Against this division of periods nothing can be urged: they are distinct, successive, and easily appreciated, constant in their order, and generally with intervals very sufficiently marked." At the present day this classification is adopted by Drs. LÖFFLER, LEGUEST, BECK, BILLROTH, and many others.

<sup>2</sup> The result as to fatality was determined in seven hundred and thirty-six of the Union cases, the deaths numbering two hundred and sixty-three, or 35.7 per cent. In the series of three hundred and forty-seven Confederate cases, the terminations were ascertained in all but six of the one hundred and forty-six instances enumerated in the tables from XXII to XXXIX inclusive, and in seventy-five of the cases in TABLE XL, or in two hundred and fifteen Confederate cases altogether, with eighty-five deaths, or 39.4 per cent. The results of the large number of one hundred and thirty-two undetermined cases might, as has been already remarked, seriously modify these proportions.

<sup>3</sup> ESMARCH (F.), *Über Resektionen nach Schusswunden*, Kiel, 1851, S. 49: "Auffallend ist es, dass nach den statistischen Berechnungen die Operationen des linken Armes für das Leben des Verwundeten gefährlicher zu sein scheinen als die des rechten. \* \* \* Demnach würde sich die Sterblichkeit bei den Operationen am linken Arm zu denen am rechten, wie eins zu drei verhalten; indessen sind zu einem solchen Schlusse natürlich grössere statistische Untersuchungen erforderlich, da diese Verhältnisse von Zufälligkeiten abhängen können."

<sup>4</sup> In a letter to the editor, dated March 31, 1868, Dr. G. C. HARLAN, of Philadelphia, formerly Surgeon 11th Pennsylvania Cavalry, and chief medical officer of the Cavalry Division of the Army of the James, wrote: "I see you attribute the greater frequency of wounds of the left shoulder to the fact that it is advanced in the act of firing. [Referring to a remark on page 56, of Circular 6, S. G. O., 1865.] The rule seems proved by the exception: that in cavalry, the reverse is the case, so far as I have seen. You will notice that, in the cases I send you, the right side is the one injured in every instance. I can recall several others in which the case was the same. The right being the sword arm, is, of course, advanced in a charge, as well as in the use of the pistol." The reader may recall the case described by LARREY, of a famous swordsman, who had received a sword thrust in the left flank. The location of the wound puzzled LARREY, until he discovered that the grenadier was left-handed. Many other illustrations might be given of the effect of position on the location of wounds.

made the ingenious observation, that this rule is proved by an exception; since it can be shown that, in the cavalry, where the sword or pistol arm is advanced, the *right* shoulder is more frequently the seat of operation.

It is of interest to observe the steady increase in the relative frequency of excisions at the shoulder as the war progressed and the surgeons acquired experience.<sup>1</sup> The earnest recommendations of the medical directors doubtless had some share in leading the operators to resort to excision rather than amputation whenever practicable.<sup>2</sup>

The utility of the limb after excision of the shoulder joint for shot injury, though greater, in the majority of cases, than might be inferred from the reports of the pensioners, is generally less than is recovered in some instances of ankylosis after disease. Mr. Holmes, in his excellent paper on excisions, well describes the amount of motion obtained.<sup>3</sup> I have observed but two instances in which the power of abduction was nearly if not completely restored.<sup>4</sup> In the majority of cases that I have examined, motion in flexion, extension, and adduction was tolerably well preserved. I have met with no instance of true ankylosis.<sup>5</sup> In a large proportion of the cases, the functions of the forearm and hand were but slightly, and, in many, not at all impaired. Those who argue that the limb is useless after an excision at the shoulder because it dangles by the side, display a superficial appreciation of the considerations to be taken into account. Apart from the inestimable value of even a partial use of the hand, the mere weight of the limb, though its motor functions be completely destroyed, is of advantage in preserving the equilibrium of the body, and avoiding the distressing deformity consequent on ablation.

Pyæmia,<sup>6</sup> often accompanied by suppurative inflammation of the medullary cavity of the shaft, was the most frequent cause of death; and consecutive hæmorrhage next in

<sup>1</sup> In 1861, there were but two excisions at the shoulder for shot injury: Dr. BONTECOU'S successful case from the first battle of Bull Run (p. 597), and the unsuccessful case of Lieutenant Ream (p. 588), reported by Dr. J. H. BRINTON, from Belmont. In the case of Corporal K——, New York Volunteers, which furnished the Museum with Specimen 347, Section I, beautifully figured at page 113 of the Surgical Catalogue of 1866, a case that might be regarded as almost a typical one for decapitation of the humerus, Dr. GOULEY advocated that treatment in the consultations held at the time of the accident, July 26, 1861; but he was overruled, and reminded of HENSEN'S dictum. In 1862, there were 116 excisions at the shoulder, the partial return of shot wounds numbering 49,730. In 1863, there were 191 such operations, from a return of 55,377 shot wounds. In 1864, there were no less than 498 operations, the total return of shot injuries being 110,782. In 1865, with 18,320 cases of shot injury, there were 74 excisions at the shoulder. In 1866, 388 shot injuries were returned without any excisions at the shoulder. There was one excision in 1867, for an old injury, and three of unknown date, making the total of 885 excisions classified in Table XXXIX.

<sup>2</sup> In a note to General Orders 30, October 3, 1861, from General McCLELLAN'S Headquarters, Medical Director U. S. TRIPLER announced that: "The medical director desires that excision of the shoulder and elbow joints shall be resorted to, in preference to amputation, in all cases offering a reasonable hope of success."—(APPENDIX TO PART I, *Med. and Surg. Hist. of the War*, p. 60.) A recommendation of excisions of the head of the humerus instead of amputations at the shoulder joint is expressed in the report of Surgeon H. S. HEWIT, Medical Director of the Army of the Ohio.—(APPENDIX TO PART I, p. 311.) References are made in the same volume of appended documents to excision at the shoulder for shot injury, by Surgeon D. P. SMITH, U. S. V. (*op. cit.*, p. 24); by Surgeon R. MURRAY, U. S. A. (*op. cit.*, p. 38); by Surgeon J. B. BROWN, U. S. A. (*op. cit.*, p. 68); by Ass't Surgeon J. S. BILLINGER, U. S. A. (*op. cit.*, pp. 136 and 202); by Surgeon J. G. HATCHETT, U. S. V. (*op. cit.*, p. 255); by Surgeon C. J. WALTON, 21st Kentucky, (*op. cit.*, p. 264); by Surgeon W. GRINSTEAD, U. S. V. (*op. cit.*, p. 308); by Surgeon A. M. WILDER, U. S. V. (*op. cit.*, p. 319); by Surgeon E. P. SANGER, U. S. V. (*op. cit.*, p. 335).

<sup>3</sup> HOLMES (T.) (*A System of Surgery*, 2d ed., 1871, Vol. V, p. 667): "The arm can never, as it seems, be elevated beyond the horizontal line; while in many cases it hangs down, without any power whatever in the deltoid, at a greater or less distance from the scapula. But the movements of flexion, extension, and adduction are usually free; abduction can often be effected to the extent of raising the arm considerably from the side; and there is usually sufficient power in the forearm to carry heavy weights and perform many of the ordinary domestic tasks."

<sup>4</sup> Case of Lieutenant H. G. Jacobs, page 553, CASE 1533, and PLATE XIV, FIG. I, and the case of a pensioner who visited the Museum in May, 1875, whose name I cannot recall.

<sup>5</sup> RUPPRECHT (L.) (*Militärärztliche Erfahr.*, u. s. w., 1871, S. 62), speaking of secondary excisions of the head of the humerus, observes that: "The secondary operations were very much aggravated by deformities, gradually appearing after the injury, through thickening of the periosteum especially, and by extensive cavities succeeding abscesses. Immediately after the operation even, healing was retarded by pus formations, sometimes under the clavicle, in other instances under the scapula, again on the anterior aspect of the upper arm. Aside from the greater muscular atrophy, due to debility resulting from antecedent tedious suppurations and to pain and loss of sleep; apart, also, from the redundant granulations attending secondary operations, and resulting prejudicially in regard to the future usefulness of the limb, the disadvantages of secondary operations already adduced were of sufficient importance to permit us to declare that primary resection at the shoulder joint is preferable to the secondary operation."

<sup>6</sup> SÉDILLOT (*Du traitement des fractures des membres par armes de guerre*, in *Arch. gén. de méd.*, 1871, VI<sup>e</sup> sér. T. XVII, pp. 382-97), citing ten cases of excision of the head of the humerus, of which seven were fatal, ascribes this large mortality to the unfavorable hygienic and atmospheric conditions under which the operations were performed, and concludes: "Le plus sage est de n'entreprendre que des résections limitées à la tête et au col de l'humerus, de faire une incision peu étendue, de diviser l'os avec la scie à chaîne, qui exige moins d'espace; de fermer la plaie provisoirement avec quelques points de suture, et d'immobiliser le membre sans l'allonger ni le trop raccourcir, avec la précaution que l'extrémité, ossuse n'exerce aucune pression sur les parties molles. Si la diaphyse était fracturée et les désordres considérables, on pratiquerait immédiatement la désarticulation. Il ne faut pas oublier que la résection humérale guérit assez lentement et que la persistance d'une plaie exposée à des contagions infectieuses est, comme nous l'avons dit, une cause permanente de danger."



frequency as a source of fatality. There were seventy-nine fatal examples of the former, and sixty-seven of the latter, including eleven instances in which large arteries were consecutively ligated. There were twenty-seven cases of erysipelas, with fourteen deaths; twenty-four cases of gangrene, with fifteen deaths; and two fatal cases of tetanus.

It is unnecessary to say much of the mode of operation.<sup>1</sup> The anterior longitudinal incision, commonly known as Langenbeck's method, was the favorite procedure; though a number of operators preferred to raise a deltoid flap, or to connect a transverse oblique cut with the apex of the vertical incision. There were no reported instances of real subperiosteal excisions, nor any examples of reproduction of bone to any great extent.

The necessity of amputation after excisions at the shoulder seldom arose, ablation of the limb having been practised in but fourteen<sup>2</sup> of the thousand and eighty-six cases of excision. Eight of these consecutive operations resulted successfully, six fatally.<sup>3</sup> They were done at periods varying from nine days to three years from the date of accident.

<sup>1</sup> RUPPRECHT (L.) (*Militärärztliche Erfahr.*, u. s. w., 1871, S. 62) declares that: "The shoulder joint resection compared with other resections exhibits very satisfactory results. It demands the least special operative skill of any excision except that at the knee joint. It requires, in the after treatment, the least complicated bandaging; for, generally, a simple triangular sling suffices. Moreover, the patient commonly suffers less from the date of operation until recovery than after other excisions."

<sup>2</sup> Three of the cases will be found in TABLE XXIV, p. 531, etc.—(the periods recorded are the intervals between the excision and amputation): CASE 24, Dibble, gangrene, two months; CASE 71, Mesley, gangrene, one month; CASE 81, Myers, hæmorrhage, sixteen days. Three fatal cases are found in TABLE XXV, p. 536, etc.: CASE 13, Fee, hæmorrhage, a fortnight; CASE 22, Green, hæmorrhage, one month; CASE 27, Harril, hæmorrhage, nine days. Three successful cases occur in TABLE XXXI, p. 554, etc.: CASE 21, Burger, gangrene, three years; CASE 105, Keeler, chronic osteomyelitis, two years; CASE 161, Rosa, chronic osteomyelitis, nineteen months. Three fatal cases appear in TABLE XXXII, p. 570, etc.: CASE 41, Lawson, hæmorrhage, sixteen days; CASE 65, Smith, osteomyelitis with necrosis, six months; CASE 76, Weleh, hæmorrhage, twenty days. There is a case of recovery in TABLE XXXIII, p. 576; CASE 65, Shepler, gangrene, one month. Lastly, a successful instance occurs in TABLE XXXV, p. 591; CASE 23, Kerrier, osteomyelitis, three months.

<sup>3</sup> Besides the works cited in preceding notes, the observations on the subject in many of the later systematic treatises on surgery may be advantageously consulted, as well as the special publications enumerated in the following partial bibliography of excisions at the shoulder: AHLSTRUPPE (*De resectionibus*, Helsingfors, 1840); ALCOCK (R.) (*Observations on Injuries of Joints and their Treatment*, in *Med. Chir. Trans.*, 1840, Vol. XXIII, p. 243); BECK (H.) (*Zur Statistik der Amputationen und Resektionen*, in LANGENBECK'S *Arch. für Klin. Chir.*, 1864, B. V, p. 171); BLACKBURN (*An Essay on the Excision of Diseased Joints*, in GUY'S *Hospital Reports*, 1836, Vol. I, p. 274); BLANDIN (P. P.) (*Article Resection*, in *Diet. de méd. et de chir. prat.*, T. XIV, Paris, 1835, p. 248); BOUBNER (*Diss. de necessitate et utilitate cam in fructuris et luxationibus complicatis ossis portionem serræ discindendi quæ alterius repositionis obviat*, Strasbourg, 1776); BUTCHER (R. G. D.) (*On Excision of the Joints*, in *Dublin Journal*, February, 1857); CHAMPION (L.) (*Traité de la résection des os cariés dans leur continuité ou hors des articulations*, Paris, Thèse, 1815); DENOUE (E. S.) (*Essai sur l'utilité de la résection des os dans les membres*, Paris, 1812); DYAS (W. G.) (*Resection of the Head of the Humerus for Gunshot Wounds*, in *Chir. Med. Jour.*, 1859, Vol. XVI, p. 764); FLOURENS (*Théorie expérimentale de la formation des os*, Paris, 1847); FRANCKE (P. F.) (*Einiges über Gelenkresectionen der langen Röhrenknochen*, Diss., Leipzig, 1870); GERDY (J. V.) (*De la résection des extrémités articulaires*, Paris, 1839); GIRCOURT (G.) (*Essai sur l'histoire des plaies et de la résection de l'épaule*, Paris, 1873); GREEN (W. A.) (*Cases of Operation upon Diseased Joints*, in *Indian Annals of Med. Sci.*, April, 1855); HARPAY (G.) (*Med. Times and Gaz.*, Dec. 17, 1864, p. 664) exhibited to the Pathological Society of London a specimen from a case in which the head of the humerus and glenoid cavity of scapula had been excised 50 years before; HEIM (*Die Resektionen*, Würzburg, 1855); HEYFELDER (J. F.) (*Über Resektionen und Amputationen*, Breslau und Bonn, 1854); HEYFELDER (A.) (*Lehrbuch der Resektionen*, Wien, 1863); HODGES (R. M.) (*The excision of Joints*, Boston, 1861); IRUTER (C.) (*Die Resektionen*, u. s. w., in LANGENBECK'S *Arch. für Klin. Chir.*, 1867, B. VIII, p. 94); HUMMEL (*Über die Resection im Oberarmgelenk*, Würzburg, 1832); JÆGER (M.) (*Operation resectionis conspectu chronologico adunbrata*, Erlangæ, 1812); JÆGER (*Decapitatio ossis brachii in articulo humeri*, in RUST'S *Handbuch der Chirurgie*, 1831, B. V, S. 607); JEFFRAY (J.) (*Cases of the Excision of Curious Joints*, by H. PARK and P. F. MOREAU, Glasgow, 1806); KLITSKY (R.) (*Observations de résections pratiquées dans la continuité des os longs*, in *Gaz. méd. de Paris*, 1843, p. 183); KGLER (*Experimentu circa regenerationem ossium*, Göttingen, 1786); KYHAKOS (P. G.) (*De articuli humeri et cubiti resectione*, Berolini, 1851); LEGRAND (de Prègé) (*Diss. sur la résection de la tête de l'humerus*, 1814); LÜCKE (A.) (*Beiträge zur Lehre von den Resektionen*, in LANGENBECK'S *Arch. für Klin. Chir.*, 1862, B. III, S. 291); LYSTER (H. F.) (*Operations on the Shoulder, P. 1: Three successful consecutive Cases of Resection of the Shoulder Joint*, in *Am. Jour. Med. Sci.*, 1865, Vol. I, p. 362); MACGREGOR (J.) (*Case of Gunshot Wound of the Shoulder Joint*, in *Med. Chir. Trans.*, 1816, Vol. VII, p. 161); MEYER (G.) (*Über Resection und Decapitation*, Erlangen, 1829); MINER (W. W.) (*Excisions Involving the Joints of the Upper Extremity*, in *Buffalo Med. and Surg. Jour.*, 1871, Vol. XI, p. 82); MOHNS (J.) (*Beiträge zu den Resektionen der Knochen*, Jena, 1866); MOREAU (Fils) (*Obs. pratiques relatives à la résection des articulations affectées de carie*, Paris, An XI [1803]); MUHR (*Diss. de partibus ossium excindendis*, Berlin, 1823); PAUL (*Die Conservativ Chirurgie der Glieder*, Breslau, 1859); PÉAN (J. E.) (*De la scapulalgie et de la résection*, Thèse de Paris, 1869); PERET (de Montpellier) (*Sur la résection des extrémités articulaires*, Thèse de Montpellier, 1850); PETERSCHIK (*Diss. de resectione articulum extremis superioris*, Berolini, 1851); POBET (*Obs. sur la résection de la moitié supérieure de l'humerus, après un coup de feu près l'articulation*, in *Jour. de méd., chir., pharm.*, T. XXII, Juillet, 1811, p. 425); RIED (F.) (*Die Resektionen der Knochen*, Nürnberg, 1860); ROUX (P. J.) (*De la résection ou du retranchement de portions d'os malades, soit dans les articulations, soit hors des articulations*, Thèse, Paris, 1812); SCHILLBACH (E. L.) (*De exarticulatione ossis humeri*, Jena, 1850); SCHILLBACH (L.) (*Beiträge zu den Resektionen der Knochen*, Jena, 1861); SCHOLZ (*Amputation und Resection by Gelenkverletzungen*, Wien, 1866); SENFTLEBEN (H.) (*Beobachtungen und Bemer-Kingen über die Indikationen, den Heilungsprocess und die Nachbehandlung der Resektionen grösserer Gelenke*, in LANGENBECK'S *Arch. für Klin. Chir.*, 1862, B. III, S. 79); STEBUT (*De resectione amputationi comparata*, Dorpat, 1848); STEINLIX (*Über den Heilungsprocess nach Resection du Knochen*, Diss., Zürich, 1849); SYMB (*Treatise on the Excision of Diseased Joints*, Edinburgh, 1831); SYMB (*On the power of the Periosteum to form new bone*, in *Contributions to the Pathology and Practice of Surgery*, Edinburgh, 1848); SZYMANOWSKY (J.) (*Addimenta ad ossium resectionem*, Dorpati Livornorum, 1856); TERTOR (*Über die Wiedererzeugung der Knochen nach Resektionen by Menschen*, Würzburg, 1843); THORNTON (Surg. 9th Regt.) (*On Excision*, in *Reports of Crim. Med. and Surg. Soc.*, in *Med. Times and Gaz.*, Sept. 13, 1856, and Sept. 20, 1856); VERLEGHE (*Les résections osseuses*, etc., Bruxelles, 1853); VÖLCKER (C.) (*Beiträge zur Statistik der Amputationen und Resektionen*, in LANGENBECK'S *Arch. für Klin. Chir.*, 1863, B. IV, S. 576); WACHSER (G. H.) (*De articulis extirpandis imprimis de genu extirpato in nosocomio chirurgico academico Groninganz*, Groninga, 1810); WAGNER (A.) (*Über den Heilungsprocess nach Resection und Exirtipation des Knochen*, Berlin, 1853); WARREN (J. M.) (*Excision of the Shoulder Joint for Caries*, in *Am. Jour. Med. Sci.*, 1853, Vol. XXV, p. 346); WETZLAR (*De articuli resectione*, Bonn, 1832).

Something further will be adduced regarding the indications and comparative value of expectant measures, excisions, and amputations, for shot injuries near the shoulder, at the close of the Section.

## AMPUTATIONS AT THE SHOULDER.

Eight hundred and sixty-six examples of amputations for shot injury, by exarticulation at the shoulder joint, were reported. Fourteen of these, practised on account of complications attending injuries of the soft parts, have been enumerated in TABLE XIV, on page 468, in the first Section of this Chapter. Eight hundred and fifty-two cases will be referred to here, the results having been ascertained in all but twenty-eight.

SCAPULO-HUMERAL AMPUTATIONS AFTER SHOT FRACTURE.—A large proportion of these cases were primary operations, practised on account of shot fractures of the upper part of the humerus, generally with implication of the joint, and with such lesions of the soft parts as precluded a resort to excision. Others were performed on account of consecutive disease involving the upper arm.

<sup>1</sup>Amputation at this joint for gangrene was advised by HIPPOCRATES, HELIODORUS, GALEN, ABUL KASEM, PARÉ, HILLDANUS, and others. In 1642, PIGRAY (P.) (*Epitome des prec. de méd.*, 1642, p. 130, Chap. IX, *de la curation de sphacèle ou sidération*) observes: "Aucuns sont difficulté de couper dans la jointure ou près d'icelle, à cause des parties nerveuses: toutefois d'autant que l'on les coupe du tout et promptement, les accidents n'en sont pas si grands, j'en ay vu plusieurs qui ont bien succédé." BAIBETTE (P.) (*Thesaurus Chirurgie*, 3d Eng. ed., London, 1676), while speaking of the point of amputation, remarks: "Except the mortification hath extended itself to the uppermost parts of the arms or thighs; for then we are forced to take the joint itself;" but there is no evidence that he knew of any instance of scapulo-humeral amputation. PURMANN (M. G.) (*Lorbeer-Krantz*, 1692, B. III, S. 229) relates a case of amputation of the arm and adds: "Some say, the amputation can be most readily, and should be, performed in the joint nearest above the injury," but adds: "I have never performed this operation." In the *Jour. de méd.* de M. DE LA ROQUE, an 1686, Juin, p. 3, is related a case of gangrene of the arm, treated by Surg. LA GAREINE, and subsequently by another surgeon: "Qui prit une petite scie pour emporter l'os du bras; mais s'étant aperçu qu'il branloit vers son articulation avec l'épaule, il y donna quelques légères secousses, et l'os sortit facilement de sa boîte." The patient, a boy, recovered. MORAND (F. S.) (*Opuscules de Chirurgie*, 1768, T. II, p. 212) claims that his father first performed amputation at the shoulder joint: "C'est mon père qui a fait le premier cette opération aux *Invalides*, et c'est à tort que quelquesuns ont eu devoir l'attribuer à M. LEDRAN le père qui avoit été Chirurgien-major des Gardes Françaises. Il est vray que M. LEDRAN fit cette opération ensuite avec succès, mais il en accordoit lui-même la priorité à mon père." And LA FAYE, in his notes to DIONIS, *Cours d'opérat. de Chir.*, 1759, p. 758, ascribes the first operation to SALVADOR MORAN (i. e., SAUVÉUR FRANÇOIS MORAND). LEDRAN (H. F.) (*Observations de Chirurgie*, 1731, T. I, p. 315) relates that his father (in 1715) exarticulated the arm of M. Comaudeux for caries, in the presence of MM. ARNAUD, PETIT, and others, and that the patient recovered. GARENGEOT (*Traité des op. de chir.*, 1738, 2d ed., T. III, p. 455) describes the operation at length, and, on page 465, remarks that "le jeune Marquis de Coëtmadec, gentilhomme de Bretagne (evidently LE DRAN's patient) soit péri en six mois après la cure de cette amputation, quoique très-parfaitement guéri, mais par une abondance de sang." MILES (S.) (*The Elements of Surgery*, London, 1746, p. 178) states that DU VERNEY successfully exarticulated the arm, at Paris, on September 24, 1730, in the presence of BOERHAAVE. RAVATON (*Chir. d'armée*, 1768, Obs. LVI, p. 262) amputated the arm at the shoulder joint in a soldier wounded May 13, 1734, the case terminating fatally; and on page 266 (*Obs. LVII*) records a case of shot wound of the head of the humerus in 1744, and of successful exarticulation by a surgeon whose name he could not ascertain. HEISTER (L.) (*Institutiones chirurgicæ*, 1733, P. I, p. 510) describes the operation although he never performed it. SHARP (S.) (*A Treatise on the Op. of Surgery*, 1749, p. 230) observes: "There are in armies a great many instances of gunshot wounds of the arm near the scapula, which require amputation at the shoulder; but the apprehension of losing their patients on the spot by the hæmorrhage has deterred surgeons from undertaking it." LA FAYE (*Nouvelle méthode pour faire l'opération de l'amputation dans l'articulation du bras avec l'omoplate*, in *Mém. de l'Acad. de Chir.*, 1753, T. II, p. 242): "Depuis 1740, que j'ai lu ces réflexions à l'Académie, plusieurs célèbres chirurgiens ont adopté cette méthode et l'ont pratiquée à l'armée avec succès." FAURE (V. M.) (*Mém. en Prix de l'Acad. de Chir.*, 1819, T. III, p. 337) and BOUCHIER (*Obs. sur des playes d'armes à feu, etc.*, in *Mém. de l'Acad. de Chir.*, 1753, T. II, p. 463) exarticulated the arm of an English soldier, aged 25, shot through the shoulder joint, at Fontenoy, in 1745; the operation was performed 29 days after the injury; the man recovered. BEAUSSIER (*Sur une nouvelle manière de faire l'amputation du bras dans l'article*, in *Jour. de Méd., chir., pharm.*, Janvier, 1768, T. XXVIII, p. 530) observes: "J'ai vu faire deux fois l'amputation de l'humérus dans l'article; je l'ai faite une fois à l'armée, après un coup de feu, qui ne laissait que ce moyen de sauver le blessé." DAHL (P. H.) (*De humeri amputatione ex articulo*, in SANDIFORT, *Thesaurus dissertationum*, 1768, Vol. I, p. 37) exarticulated the arm at the shoulder. BROMFIELD (W.) (*Chirurgical Observations and Cases*, 1773, p. 209) performed the operation several times prior to his publication, and remarks: "I must acknowledge I had but little encouragement to do it at first, from those who had seen it performed repeatedly in the army." ALANSON (E.) (*Practical Observations on Amputations*, 1782, 2d ed., p. 180) records a successful case of exarticulation at the shoulder joint for shot injury, arm being blown off at the insertion of the deltoid. MICHELIS (*Briefve aus New York*, in RICHTER'S *Chir. Bibliothek*, Gottingen, 1782, B. VI, S. 125) saw, at Charleston, South Carolina, in 1778, a French soldier, wounded during Count Estaing's expedition against Savannah; the arm had been amputated at the shoulder joint and the patient recovered. Dr. JOHN WARREN performed the earliest exarticulation at the shoulder in this country, at the Boston Military Hospital, in 1791 (E. WARREN, in *Boston Med. and Surg. Jour.*, 1830, Vol. XX, p. 210); the patient recovered. Dr. R. BAYLEY (THACHER J.), *American Medical Biography*, 1828, Vol. I, p. 164), in 1782, successfully exarticulated the arm at the shoulder. Surgeon W. BURD, of the British Navy (*Annals of Med. for the year 1797*, Edinburgh, 1798, Vol. II, p. 282), exarticulated, on May 3, 1796, the arm of J. Moirieton, a French officer, shot in the right shoulder; the patient was discharged, cured, August 17, 1796. LARREY (D. J.) (*Mém. de chir. mil.*, 1812, T. II, 167) remarks: "Il s'en est présenté dix-neuf, qui ont nécessité l'amputation du membre à son articulation scapulo-humérale. Cette opération a eu un succès complet chez treize blessés; les six autres ont péri de la peste, ou des effets de la contagion portée par la cause vulnérante sur les organes intérieurs." FLEURY (*Observation sur une amputation du bras dans l'article*, in *Jour. de méd., chir., pharm.*, 1806, T. XII, p. 437) exarticulated the arm for shot wound in a boy of 12; the patient recovered after consecutive ligation of the axillary artery and vein. LARREY (D. J.) (*Mém. de chir. mil.*, 1812, T. III, p. 361) states that after the battles of Wagram and Eslingen he performed fourteen exarticulations at the shoulder, of which twelve were successful; and (l. c., T. IV, p. 432) remarks that, of a hundred and odd of his exarticulations at the joint, over ninety were successful. TROWBRIDGE (A.) (*Report of Extraordinary Cases of Amputation, read before the Med. Soc. of Jefferson County, New York*, in *The Medical Repository*, 1818, N. S., Vol. IV, p. 20) records two successful cases of exarticulation at the shoulder joint for shot injury. WHITEBRIDGE (J. B.) (*Case of Amputation at the Shoulder Joint*, in *The New England Jour. of Med. and Surg.*, 1816, Vol. V, p. 21) exarticulated the arm at the



TABLE XLII.

*Numerical Statement of Eight Hundred and Fifty-two Cases of Amputations at the Shoulder Joint after Shot Fracture.*

OPERATIONS.	TOTAL CASES.	RECOVERIES.	FATAL CASES.	RESULTS NOT SPECIFIED.	MORTALITY RATE, DETERMINED CASES.
PRIMARY.....	499	368	117	14	24.1
INTERMEDIARY.....	157	85	72	.....	45.8
SECONDARY.....	66	47	19	.....	28.7
OF UNSPECIFIED DATE.....	130	91	28	11	23.5
	852	591	236	25	28.5

**Primary Amputations at the Shoulder Joint.**—Only operations practised within forty-eight hours from the reception of the injury are included in this category. The results, ascertained in all but fourteen of the four hundred and ninety-nine cases, are remarkably good, more than three-fourths of the patients having recovered. Undiscriminating opponents of conservative measures might seek to found on this datum a serious argument. The series is large, yet less numerous, by one-third, than the primary excisions. It would appear that the well-known indications for primary exarticulation,—viz: a shot fracture of the upper extremity of the humerus, with lesion of the vessels or nerves; or, secondly, a fracture high up, with splintering extending below the insertions of the latissimus dorsi and great pectoral,—were not invariably respected; but, for the most part, the cases were well chosen, were such, in fact, as admitted of no alternative but ablation of the limb.

shoulder joint in a soldier of the 2d Artillery, wounded at Stoney Creek, Upper Canada, June 6, 1813; the patient died five weeks after the operation. GUTHRIE (G. J.) (*A Treatise on Gunshot Wounds*, 1827, 3d ed., p. 463) tabulates thirty-eight cases of amputation at the shoulder joint—nineteen primary and nineteen secondary; sixteen fatal and twenty-two recoveries. LAROCHE (*Rel. chirurg. des évènements qui se sont passés à Lyon, etc.*, in *Rec. de mém. de méd.*, 1835, T. XXXVII, pp. 102, 108) records two cases of amputation at the shoulder for shot injury; one patient recovered—the other perished. PINKNEY (N.) (*Report of some Operations performed during the late Cruise in the Pacific*, in *Am. Jour. Med. Sci.*, 1846, N. S., Vol. XII, p. 332) reports a fatal case of amputation at the shoulder joint for shot injury, at Callao, in June, 1843. PEASLEE (E. R.) (*New York Jour. of Med.*, 1853, Vol. X, p. 297) reports the case of a man who shot himself accidentally in 1845; Dr. PEASLEE amputated at the shoulder; recovery. Dr. E. JENNINGS (see letter to the editor of the *Annalist*, Vol. I, No. XXIII, p. 538) amputated the arm at the shoulder joint in a case of shot wound of the axilla; secondary hemorrhage and death ensued. Dr. JOHN WATSON (*Amputation at the Shoulder Joint*, in the *Annalist*, 1847, Vol. I, No. XVI, p. 371) exarticulated the arm at the shoulder joint, in 1847, in a case of injury of the right arm and hand, caused by the premature discharge of a cannon; the patient died. TRUPLER (CH. S.) (*Case of Secondary Hemorrhage after Amputation at the Shoulder*, in *New York Jour. of Med.*, 1849, N. S., Vol. III, p. 41) exarticulated the arm of a private of the 2d Infantry, wounded at Cherubusea, August 20, 1847—recovery. EVE (P. F.) (*Southern Med. and Surg. Jour.*, 1848, Vol. IV, N. S., p. 663) amputated, for shot injury, the arm of a black boy at the shoulder joint—recovery. HUGUIER (*Des plaies d'armes à feu. Communications faites \* \* par MM. les Docteurs BAUDENS, ROUX, etc.*, 1849, p. 143), in 1848, twice removed the arm at the shoulder joint for shot wounds; both patients recovered. MASSARENTI (MINELLI, *Frattura comminutiva dell'omero. Disarticolazione scapula-omero*, in *Bullettino dell' scienze mediche*, Bologna, 1850, Ser. 3, Vol. XVIII, p. 191) exarticulated at the shoulder joint, in the case of a soldier, aged 31, shot through the shoulder; the patient recovered. MAY (J. T.) (*Cases of Amputation*, in *Am. Jour. Med. Sci.*, 1851, N. S., Vol. XXII, p. 327) records a fatal case of amputation at the shoulder in a man accidentally shot by a fowling piece, in December, 1850. Mr. COCK (*Lancet*, 1852, Vol. II, p. 84), at Guy's Hospital, in 1851, exarticulated the arm at the shoulder joint, in the case of a leather-dresser, accidentally shot in the shoulder; the man recovered. BOLING (*Western Jour. of Med. and Sci.*, Vol. XIII, and *New York Jour. of Med.*, 1853, N. S., Vol. X, p. 21) exarticulated the arm for shot injury; patient died in six hours. COCHRAN (J.) (*A Case of Amputation at the Shoulder Joint*, in *The New York Jour. of Med.*, 1854, N. S., Vol. XIII, p. 43) successfully exarticulated the arm for shot injury, in the case of a young gentleman of South Brooklyn. HEYFELDER (J. F.) (*Deutsche Klinik*, 1855, B. VII, S. 495) exarticulated the arm at the shoulder for shot wound of the right forearm, in the case of Wasili Rilkooff, aged 27, wounded April 29, 1855; the case terminated fatally. HEYFELDER (J. F.) (*Deutsche Klinik*, 1858, B. X, S. 226) removed the arm at the joint in the case of A. Baum, accidentally shot in the shoulder, while hunting; the patient died. SANBORN (E. K.) (*Surgical Clinique at Castleton Med. College, in Boston Med. and Surg. Jour.*, 1859, Vol. LX, p. 35) exarticulated at the shoulder joint, in the case of a young man accidentally shot through the shoulder; the case terminated fatally. IRWIN (B. J. D.) (*Amputation at the Shoulder Joint*, in *Am. Jour. Med. Sci.*, 1859, N. S., Vol. XXXVIII, p. 350), in September, 1858, successfully exarticulated the arm of S. St. John, aged 24, shot in the shoulder by Mexicans. DUFFEE (W. J.) (*Amputation at the Shoulder Joint; Gunshot Wound*, in *Philadelphia University Jour. of Med. and Surg.*, Vol. XII, 1860, p. 394), in 1859, successfully exarticulated the arm at the shoulder for shot injury. IRWIN (B. J. D.) (*Gunshot Wound of Arm; Amputation at the Shoulder Joint*, in *Am. Jour. Med. Sci.*, 1861, N. S., Vol. XLII, p. 337) cites a case of exarticulation at the shoulder for shot injury; the patient died. MINER (J. F.) (*Clinical Remarks upon Surgical Cases in the Buffalo General Hospital—Gunshot Wound—Amputation at the Shoulder Joint*, in *Buffalo Med. and Surg. Jour.*, August, 1864, Vol. IV, p. 378): a young lad, shot through the upper portion of the right arm; recovery without accident. In *Circular* 3, S. G. O., 1871, pp. 188-189, are reported three cases of amputations at the shoulder joint for shot injury, by Assistant Surgeons D. L. HUNTINGTON and C. SMART, U. S. A., and Dr. OWENS, of Lynchburg. The two former were successful; the latter terminated fatally. BLACK (J. J.) (*Notes of some Surgical Cases*, in *The Western Lancet*, 1874, Vol. III, p. 291) exarticulated, in 1873, the arm at the shoulder for accidental shot injury; the patient recovered.

§ *Successful Operations.*—The details recorded regarding the three hundred and sixty-eight cases of this group are very scanty, consisting, for the most part, of little more than minutes of the injury and operation at field stations, notes of entrance and discharge from general hospitals, and reiterations of the facts by pension examiners. A few illustrations will precede the tabular enumeration of the cases:

CASE 1585.—Captain E. L. Severn, Co. K, 96th Pennsylvania, aged 27 years, was wounded at Spottsylvania, May 10, 1861. Amputation at the shoulder joint was performed by Surgeon D. W. Bland, 96th Pennsylvania, who reported: "The wound was caused by the explosion of a case-shot, fired from the guns of the enemy while the command were resting in line of battle. The shot wounded seven men, four of whom died in a few hours. The captain was brought to the rear immediately, and expressed a desire to have me sent for, and if an operation was to be performed I should do it. I had been detailed as Medical Inspector of the Corps, and felt some hesitancy in leaving my regular duties to perform an operation; however, I examined the wound and found the entire humerus completely comminuted, involving the elbow joint. A portion of the shell had passed through the top of the shoulder, carrying with it a considerable portion of the clavicle and superior part of the scapula. The subject was all that could be desired for a capital operation—young, perfect health, and strictly temperate. After consulting with several medical officers of the corps, the unanimous conclusion was for immediate removal of the arm at the shoulder joint, and as much of the clavicle and scapula as was seriously involved. Assistants were selected and assigned their respective duties; the patient was placed under the influence of chloroform, and I proceeded to remove the arm at the shoulder joint by making the superior flap from the body of the deltoid muscle, disarticulating the head of the bone, and cutting the lower flap from the muscle and integument on the inner side of the arm; ligatures were applied and all hemorrhage arrested. I then enlarged the wound over the clavicle by cutting in the direction of the bone, and after carefully removing the loose spiculae of bone I sawed off either end of the clavicle, there remaining about four inches of this bone. I then removed the fragments of the superior part of the scapula, cutting away all loose and damaged integument. I closed the wound over the clavicle and scapula by the interrupted suture. The removal of so large a quantity of bone and integument above the shoulder joint offered a fine opportunity for the escape of all secretions through the joint and at the most dependent portion of the flaps, thus very materially favoring a speedy and successful cure. At the completion of the operation, I administered one ounce of brandy with one grain of morphia. The operation took place in the midst of a dense wood, at five o'clock P. M., with the light from a half dozen candles. At midnight the wounded were loaded for Fredericksburg, and this patient, with hundreds of others seriously wounded, was sent twenty miles over corduroy roads, before the wound was examined or his condition inquired about. The discouraging circumstances under which the first instalment of wounded were sent to Fredericksburg are too fresh in the memory of every one to recount them. In sixty hours after the operation, the wound was dressed, and the subject made as comfortable as circumstances would permit; everything went favorably from this time on, and at the end of three weeks he was sent to Washington and placed in the Officers' Hospital, at Georgetown, under the care of the late Dr. Ducaet. This gentleman told the captain that he would get well, but assured him that he was one case out of ten thousand, remarking that it was the most extensive operation that ever came under his care. The captain recovered entirely, and is, to-day, enjoying good health, using his left hand and arm with about the same facility he used his right. The amount of discharge was considerable, but at no time was there any indication of the formation of abscesses. The opening formed by the exit of the ligatures was the drain for all secretions, and everything went on toward a rapid and successful cure." This officer was discharged from service August 17, 1864, his disability being rated as total and permanent, and was pensioned from that date. On March 22, 1867, Dr. Bland contributed a photograph of his patient, which is copied in the wood-cut (FIG. 477), and stated: "The patient is at present superintending a colliery and enjoys excellent health."

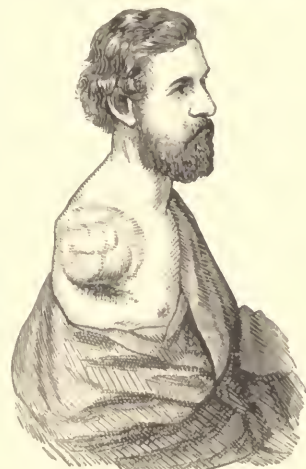

FIG. 477.—Stump after primary amputation at the shoulder joint.

CASE 1586.—Private A. E. H——, Co. F, 1st Maine Heavy Artillery, aged 21 years, was wounded at Yellow House, Virginia, October 2, 1864, and was sent to a Second Corps hospital. Surgeon O. Everts, 20th Indiana, noted: "Right arm fractured by shell. Amputation at shoulder joint." The patient was sent north, and was treated in hospitals at Beverly and Bangor, and was discharged from service from the latter place, August 30, 1865. Acting Assistant Surgeon J. S. Waggoner recorded: "Shell wound of right arm; amputation at the joint; nearly healed, with occasional discharge from a small orifice." The specimen (FIG. 478) was contributed by the operator, Surgeon D. S. Hays, 110th Pennsylvania. It consists of "the upper part of the right [the catalogue of 1833, p. 90, has it, inadvertently, the left] humerus amputated at the shoulder joint. The inner portion of the epiphysis is broken; an oblique fracture runs directly through the head and surgical neck, and several fissures extend over the articular surface." The Bangor Examining Board, Drs. R. K. Jones, J. C. Weston, and E. F. Sawyer, April 1, 1874, reported: "The limb was carried away by a shell wound, with the end of the acromial process of the scapula and probably the glenoid cavity of the scapula; the coracoid remains. The scar lies horizontally across the seat of shoulder; it is very sensitive. He wears a large shoulder pad, and a bandage to support the shoulder." This pensioner was paid June 4, 1874.

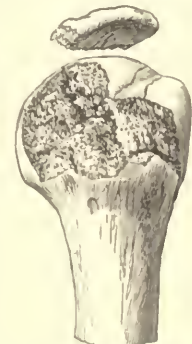

FIG. 478.—Shot fracture of the right acromion and head of humerus. *Spec.* 4115.  $\frac{1}{2}$ .

While, for the most part, the amputations at the shoulder were practised for fracture



implicating the articular surfaces, and attended by grave lesions of the soft parts in the vicinity, there were not a few instances of exarticulations for fractures of the diaphyses by small projectiles, where extensive longitudinal fissuring existed:

CASE 1587.—Private *D. S. Doggett*, Co. F, 35th Virginia, was wounded at Brandy Station, June 9, 1863. He was sent to Lincoln Hospital, at Washington. Acting Assistant Surgeon B. P. Brown forwarded the specimen (*Cat. Surg. Sect.*, 1866, p. 91, *Spec.* 1234), represented by FIG. 2, PLATE XLVI, with the following report: "Wounded in the right arm by a pistol ball passing from before backward through the humerus, about three inches below the head, producing considerable comminution, and lodging just beneath the integument at the lower border of the axilla. He came into this hospital, Ward 16, June 11, 1863. The arm was amputated at the shoulder joint, June 11th, at three o'clock P. M., by Surgeon G. S. Palmer, U. S. V." The specimen is described in the Catalogue as: "The right humerus amputated at the shoulder joint, for a compound fracture by a large pistol ball, at the upper thirds." The patient was transferred to Hammond Hospital, Point Lookout, on November 27, 1863, and assigned for exchange in March, 1864.

In the larger proportion of cases, however, the operation was practised on account of injuries produced by large projectiles—solid, or hollow and explosive:

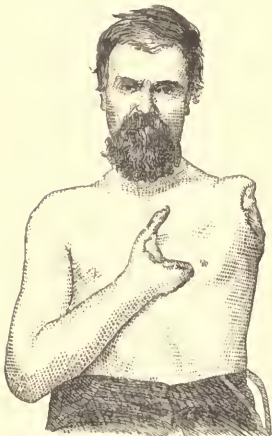

FIG. 479.—Cicatrice after amputations at left shoulder, and of fingers of the right hand. [From a photograph.]

CASE 1588.—Corporal J. J. F——, Co. K, 73d Indiana, aged 28 years, was wounded at Day's Gap, Alabama, April 30, 1863, while on a raid. The entire brigade was captured near Rome, Georgia, on May 3d. The regimental medical officers becoming separated from the men, there is no record of the patient until his discharge at Camp Morton, Indiana, October 19, 1863. Surgeon Seth T. Myers, 73d Indiana, certifies: "Discharged on account of a wound by a grapeshot, causing the left arm to be amputated at the shoulder joint, and the removal of the entire right hand with the exception of the thumb." This soldier was pensioned from the date of his discharge. His company commander certified: "\* \* \* his left arm was badly shattered near the shoulder by a grapeshot, and had to be amputated at the shoulder joint, and that at the same time and place his right hand was taken off, except his thumb, with shot or shell \* \* ." Examiner Luther Brusie, of Laporte, Indiana, February 5, 1866, furnished an ambrotype of the pensioner, represented by the cut (FIG. 479), and the following description: "The left arm was amputated at the shoulder joint. There is a total loss of all the fingers of the right hand, and a loss of all the metacarpal bones of the same hand except that of the little finger, and anchylosis of wrist." The pensioner applied for commutation for an artificial limb in 1870. He states that the operation was performed on the field by Assistant Surgeon W. M. Spencer, 73d Indiana, Dr. Peck, and Surgeon Seth T. Myers, immediately after the injury.

CASE 1589.—Private T. Cole, Co. B, 5th Michigan, aged 44 years, was wounded at the Wilderness, May 5, 1864. Surgeon O. Everts, 20th Indiana, in charge of a Second Corps field hospital, reported a "compound fracture of the arm," and "amputation May 5th." After treatment in Lincoln Hospital, Washington, the patient was furloughed, on June 21, 1864. On July 19th, he entered St. Mary's Hospital, Detroit. Acting Assistant Surgeon D. O. Farrand noted: "A gunshot wound of the right shoulder, passing through the surgical neck of the humerus. Flap amputation at shoulder joint; removal of the head of the humerus, in a field hospital, May 6th, by Surgeon Henry F. Lyster, 5th Michigan. The humerus was badly shattered. Progress was slow; the wound continued to discharge for a long time; simple dressings were employed. September 30th, the patient still under treatment." The patient was discharged from service October 1, 1864, and pensioned on account of "a gunshot fracture of the head of the right humerus and the lower border of the right scapula, which necessitated the amputation of the arm at the shoulder joint." The disability is rated total. The pensioner was paid December 4, 1874.

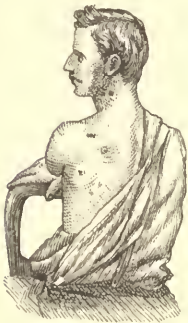

FIG. 480.—Cicatrix after an exarticulation at left shoulder, as it appeared a year after the operation.

Some examples of the character of the fractures of the humerus in the cases in which amputation was performed appear on the succeeding page.

CASE 1591.—Private G. H——, Co. D, 1st Massachusetts Heavy Artillery, aged 46 years, was wounded at the engagement near the Weldon Railroad, October 2, 1864. The case was registered at the 3d division, Second Corps, field hospital as a gunshot fracture of the arm. Surgeon O. Evarts, 20th Indiana, amputated at the shoulder joint, and sent to the Museum the pathological specimen represented by the wood-cut (FIG. 481). The patient subsequently entered Carver Hospital, at Washington. Surgeon O. A. Judson, U. S. V., noted: "Admitted October 31st, with gun-shot wound of the right arm. A conoidal ball passing, traversed through from before backward, producing compound comminuted fracture of the upper third of the humerus. Amputation of the right arm at the shoulder joint by the U-flap method was performed on the field October 3d. The result was favorable; the wound healing nicely upon admission. Treatment, simple dressing. Constitutional state, good. There has been no unfavorable complication in this case. Wound doing remarkably well at date of transfer, November 30, 1864." The specimen consists of "the upper half of the right humerus. The bone has been shattered throughout the upper third of its shaft, and was amputated at the joint."—(*Cat. of Surg. Sect., A. M. M., 1866, p. 91.*) The patient was treated in hospital at Readville, Massachusetts, until June 15, 1865, when he was discharged and pensioned. The records of the Pension Bureau do not furnish evidence as to the present condition of the stump. The pensioner was paid December 4, 1874. He received an artificial arm from Mr. Marvin Lincoln, June 3, 1855. The cicatrix was then in good condition.

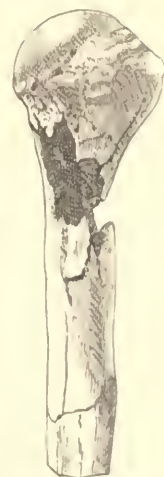

FIG. 481.—Upper extremity of the right humerus shattered by shot. *Spec. 4124.*

CASE 1592.—Private H. K. Atkinson, Co. G, 85th Pennsylvania, aged 47 years, was wounded in front of Petersburg, September 1, 1864. He was admitted to a Tenth Corps field hospital, and was operated on by Surgeon C. M. Clark, 39th Illinois, who reported: "Wounded by a spherical ball, twelve pounder. The ball struck the right arm midway between the elbow and shoulder joints, completely denuding the extensively fractured bone of its muscles and integuments, except in the axillary region, and a small strip of skin on the anterior surface of the arm. The artery, vein, and nerves were left intact, but exposed, and, to some degree, isolated from each other. The shock to the system had been extreme; however, the man managed to walk with assistance to my quarters, distance one-half mile. After giving him stimulants and some nourishment, a careful examination was made. The humerus had been carried away to the extent of some six inches from the head of the bone, except some few pieces that adhered to the remaining tissue. After consultation with Surgeon J. Westfall, 67th Ohio, I proceeded to remove the arm, after ligating the axillary artery; then, finding the head of the bone to be implicated, the capsular ligament was divided and it removed. The flap was made entirely from the axillary region, and was brought up so as to unite with the severed portion of integument over the acromial region. No anæsthetic was given. The flap was secured by silk sutures and adhesive straps, then cold-water dressing and a supporting bandage. He was put to bed in the field hospital, and remained under my care for two weeks, gradually improving in strength and the wound healing rapidly. At the expiration of this time he was sent to General Hospital, where he entirely recovered, and when I last heard from him he was at home and well." The patient was admitted to Hampton Hospital, Fort Monroe, September 23, 1864, and was subsequently treated at Grant Hospital, New York, and at Newark, New Jersey. He was finally discharged the service, and pensioned November 22, 1864. The pensioner declares: "A spherical case shot removed the arm from the shoulder." The pensioner was paid December 4, 1874.

CASE 1593.—Private C. W——, Co. K, 16th Massachusetts, aged 19 years, was wounded at Spottsylvania Court-house, May 9, 1864. Surgeon C. C. Jewett, 16th Massachusetts, amputated at the shoulder joint, on the field, and forwarded the specimen, represented by the wood-cut (FIG. 482), to the Museum. The patient was admitted to the 3d division hospital, Alexandria, on May 13th. Surgeon Page, U. S. A., recorded: "Gunshot fracture of right humerus. Immediate amputation at the shoulder joint. Transferred June 26, 1864, to Portland, Maine." The specimen consists of "the upper third of the right humerus, after disarticulation for fracture, with comminution in the upper third. The epiphysis has become completely separated in the preparation."—(*Cat. Surg. Sect., 1866, p. 92.*) The patient was treated in Cuy Hospital, Augusta, until July 12th, and then transferred to hospital at Readville, Massachusetts, under the care of Acting Assistant Surgeon J. Stearns, jr. He was discharged and pensioned November 19, 1864. The Brooklyn Board, Drs. M. K. Hogan, T. F. Smith, and J. F. Ferguson, August 19, 1874, certify: "Amputation of right arm at shoulder joint." The disability was rated total. The pensioner was paid March 4, 1875. He applied for commutation in lieu of an artificial limb.



FIG. 482.—Shot comminution of the right humerus in a young subject. *Spec. 123.*

CASE 1594.—Private L. W. H——, Co. I, 7th New Jersey, aged 27 years, was wounded at Spottsylvania, May 9, 1864. On the following day, amputation at the shoulder joint was performed by Surgeon C. C. Jewett, 16th Massachusetts. The specimen represented by the adjacent wood-cut (FIG. 483) was forwarded to the Museum by the operator. On May 14th, the patient entered King Street Hospital, Alexandria. Surgeon E. Bentley, U. S. V., recorded: "Shell wound of right arm. Amputation at shoulder joint by antero-posterior flaps. Patient says that the joint was badly fractured. Water dressings applied. Wound of amputation suppurated profusely. Stimulants and opiates given occasionally. Ligatures all away, and stump nearly healed, at time of transfer to Philadelphia, June 23, 1864." The patient was subsequently treated in the Christian Street and Broad and Cherry Streets Hospitals at Philadelphia, and was discharged and pensioned October 7, 1864. The pensioner declares "he received a wound from a shell, shattering the right arm, from the shoulder joint to the wrist, so badly that the next day the whole arm had to be removed." Surgeon C. Lehbach, 7th New Jersey, describes the fracture as inflicted by a canister-shot. This pensioner was paid December 4, 1874.



FIG. 483.—Comminution by shell fragment of upper half of right humerus. *Spec. 2,03.*



Two of the three following cases exemplify painful cicatrices from neuromatous enlargements. Two of them are illustrated by cuts from photographs prepared after the cicatrization of the mutilation; the second of these shows well the elevation of the mutilated shoulder, which is so characteristic of this amputation. It does not appear that the blood-vessels or nerves were implicated in either of these three cases:



FIG. 484.—Cicatrix after an amputation at the shoulder joint in a case in which the glenoid cavity was implicated. [From a photograph.]

was delayed until the 4th. He rejoined his regiment in January, 1864, with a good stump, but suffering from neuralgia, with enlargement of one of the nerves of the axillary plexus." This officer died September 17, 1864, and, on the widow's claim for pension, David McKinney, M. D., attested that he was the attending physician of Lieutenant Stokes, and that "the wound received by said Stokes was in his right arm, which was amputated at the shoulder joint. That upon his return home he was much reduced and his whole physical system much disordered, a condition superinduced by the suffering from the wound aforesaid. That for some months he continued prostrate and suffered intensely from the wound aforesaid, but subsequently recovered to such a degree as to be able to travel about, and in some measure direct his business affairs. He, however, suffered greatly from his wound at all times, and during the months of May, June, and July, 1864, the suffering from this cause became so great as to be beyond control by opiates and medicines that could be prudently administered, and rendered an operation necessary to remove the irritating cause. A second operation was, therefore, after due consideration and advice of eminent surgeons, performed by Drs. Dickson, Ritter, and others, of the City of Pittsburg, who removed a portion of the flesh and a mass of nerves from the cicatrix or face of the wound, which appeared to be the cause of the intense suffering. For a time he seemed to improve; the

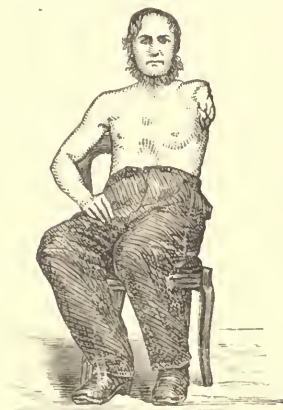

FIG. 485.—Cicatrix after amputation at the shoulder by transfexion. [From a photograph.]

intense suffering was relieved, but his system was so far reduced by former suffering and medicines taken to relieve the same as to be unable to rally and recover from the operation, and in a few days he began to sink; gangrene set in, and it was impossible to subdue it, and he died about three weeks after the operation." There appears to have been no autopsy in the case.

CASE 1597.—Private A. C. Chase, Co. C, 17th Vermont, aged 45 years, was wounded at Peeble's Farm, Virginia, September 30, 1864. He was sent to Washington from the field, and entered Lincoln Hospital. Surgeon J. C. McKee reported: "Admitted October 8th. Amputation at the shoulder, by the external lateral flap method, had been performed on the field, September 30th, for a shot fracture of the upper third of the humerus, near the joint." The patient was transferred to Sloan Hospital, Vermont, in December. Dr. H. Janes, formerly surgeon U. S. V., contributed, in 1875, a photograph, represented by the annexed cut (FIG. 485), with the following history of the case: "This soldier received a gunshot wound, fracturing the upper third of the left humerus. The arm was amputated at the shoulder joint, on the field, twelve hours after injury. The wound was slow in healing, and did not completely close until about six months after the operation. No accidents. Admitted to hospital at Montpelier, December 2, 1864. Discharged from the service June 12, 1865; disability two-thirds." This soldier was pensioned from the date of his discharge, and was paid December 4, 1874. He states that his arm was amputated in a Ninth Corps field hospital, and that he is ignorant of the name of the operator. Surgeon P. O. M. Edson and Assistant Surgeon J. H. Spohr were the medical officers of the regiment, which was attached to the 2d division of the Ninth Corps. Surgeon J. Harris, 7th Rhode Island, Surgeon W. A. Webster, 9th New Hampshire, and Surgeon J. S. Ross, 11th New Hampshire, were the principal operators in the Division at the period referred to.

One or two further examples may be adduced in illustration of the osseous lesions for which these amputations were performed for the most part. It will be observed that

whether the head or the shaft be fractured by musket balls, the splintering rarely crosses the epiphyseal line. Unless they are both shattered by a large projectile, or a small missile impinges directly at their junction, the epiphysis and diaphysis are seldom simultaneously fissured:

CASE 1598.—Private S. B——, Co. B, 85th Pennsylvania, aged 28 years, was wounded at North Anna, May 25, 1861. Surgeon J. Rawlings, 88th Pennsylvania, reported: "Gunshot fracture of the left humerus; amputation at the shoulder joint the following day." On May 29th, this soldier was transferred to Emory Hospital, Washington, where Surgeon N. R. Moseley, U. S. V., noted that "amputation of the left arm at the shoulder joint, by the oval flap method, was performed on the field. Treatment: Tonics and generous diet. June 30th, is still in hospital, improving gradually." Transferred, convalescent, to Philadelphia, to Christian Street Hospital, August 18th. This soldier was discharged November 3, 1864, and pensioned. Dr. Rawlings contributed to the Museum the preparation of the shattered head of the humerus, a view of which is presented in the annexed wood-cut (FIG. 486). Assistant Surgeon A. A. Woodhull, U. S. A. (*Cat. Surg. Sect.*, p. 90), remarks of it: "A conoidal ball, which has reversed itself, is embedded in the head of the bone, surrounded with shreds of clothing. The missile entered from the rear, shattered the greater tuberosity, and fractured the articular surface into several fragments. The fracture does not extend below the surgical neck." On July 18, 1870, this pensioner applied for and received commutation in lieu of an artificial limb, in accordance with the act making provision for mutilated soldiers. He certified that the cicatrix was sound at that date. He received his pension December 4, 1873.

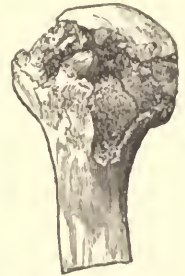

FIG. 486.—Posterior view of upper extremity of left humerus with an embedded reversed ball. *Spec.* 4125.

There were six instances, among the three hundred and sixty-eight successful primary exarticulations at the shoulder, in which portions of the acromial extremity of the clavicle, or fragments of the processes or body of the scapula, were removed at the time of amputation. All of these six cases were examples of comminution of the bones by large projectiles. The following is an illustration:

CASE 1599.—Sergeant G. W. Mears, Co. A, 6th Pennsylvania Reserves, aged 21 years, was wounded at Mine Run, November 27, 1863. This case is referred to on the Monthly Report by Assistant Surgeon J. K. Corson, of the regiment, as follows: "One case of shell wound of the left shoulder, in which the acromial process of the scapula and a portion of the clavicle and head of the humerus were much shattered. Amputation at the shoulder joint was performed twenty-four hours after the reception of the wound, and the fragments removed. Operator, Surgeon Charles Bower, 6th Pennsylvania Reserves, Chief Surgeon First Brigade, 3d division, Fifth Army Corps." The specimen, represented by the cut (FIG. 487), is described in the 1866 Catalogue, p. 92, as follows: "The upper third of the left humerus, which was disarticulated. The head and surgical neck were shattered by a conoidal ball, the fractures extending four inches down the shaft. Two and a half inches of the acromion, mounted with the specimen, was probably removed at the time of operation. Received from the Army of the Potomac." The patient entered Fairfax Hospital, Alexandria, December 4th, and was sent thence to Philadelphia, in May, 1864, and after treatment in Christian Street and Broad and Cherry Streets Hospitals, was finally discharged the service, June 11, 1864, and pensioned. His disability was rated total. He was paid June 4, 1874. The pensioner applied for commutation in lieu of an artificial limb, November, 1870, and stated that the cicatrix was then healthy. He had never worn any prosthetic apparatus.



FIG. 487.—Lesions consequent on a fracture of the left humerus by a shell fragment. *Spec.* 2531.

The method of operating that was most general was by transfixion and raising a large external flap, opening the articulation by the first incision, disarticulating, and then cutting the vessels and nerves in a short internal flap. But the oval methods of Larrey, Guthrie, and Scoutetten were also very often employed. In most of the cases the continuity of the humerus was destroyed near the shoulder, and strong-jawed forceps were useful in seizing the head of the humerus and turning it to facilitate its exarticulation. The importance of raising the arm from the side, that the operator or an assistant might have a hand in the axilla, to grasp the axillary artery at the instant of its division, was generally recognized. There was rarely much trouble in controlling bleeding. Indeed, primary exarticulation<sup>1</sup> at the shoulder for injury is a very simple operation. As much cannot be said of the intermediary and secondary operations.

<sup>1</sup>PIROGOFF (N.) (*Grundzüge der Allgemeinen Kriegschirurgie*, u. s. w., S. 771) is inclined to regard amputation at the shoulder joint for shot injury as a safer plan than excision; and claims that, in one regard, the latter is inferior even to the expectant conservative treatment, since it is "even more frequently complicated by rapidly increasing acute purulent oedema."



TABLE XLIII.

Summary of Three Hundred and Sixty-eight Cases of successful Primary Amputations at the Shoulder for Shot Injury.

NO.	NAME, AGE, AND MILITARY DESCRIPTION.	DATE OF INJURY.	NATURE OF INJURY.	DATE OF OPERATION.	OPERATION AND OPERATOR.	RESULT AND REMARKS.
1	Abbott, Wm., Pt., A, 58th Ohio.	Dec. 29, 1862.	Left humerus splintered by a musket ball.	Dec. 29, 1862.	Amputation at the shoulder by external flap method.	Discharged April 18, 1863, and pensioned.
2	Abraham, S. F., Pt., D, 56th Virginia.	June 3, 1864.	Fracture of surgical neck of the right humerus.	June 3, 1864.	Amputated, by Surgeon Rives, 56th Virginia.	Furloughed August 10, 1864.
3	Adams, J., Pt., 4th U. S. C. T., age 29.	Sept. 29, 1864.	Fracture of upper third of left humerus.	Oct. 1, 1864.	Amput'd by Lisfranc's method, by Surgeon A. H. Cowdrey, 37th U. S. C. T.	Discharged November 10, 1865; pensioned.
4	Adams, S. M., Pt., K, 12th Alabama, age 30.	July 1, 1863.	Shot through right shoulder, extensive comminution of humerus.	July 2, 1863.	Disarticulated at the shoulder by double flaps.	Recovered; paroled November 12, 1863.
5	Albertson, R., Pt., I, 14th Michigan.	Mar. 19, 1865.	Fracture of right humerus . . . .	Mar. 19, 1865.	Amputation, by Surgeon E. Batwell, 14th Michigan.	Discharged May 16, 1865, and pensioned.
6	Amsden, R. M., Pt., I, 11th Vermont, age 23.	Oct. 19, 1864.	Shot wound of the left shoulder joint, with much laceration.	Oct. 20, 1864.	Amputated after the battle at Cedar Creek.	Disch'd Aug. 12, 1865; pensioned.
7	Angel, H., Pt., 57th Ohio, age 19.	Sept. 2, 1864.	Wound of right arm by a cannon ball.	Sept. 2, 1864.	Amputation at the shoulder by the oval method.	Transferred to V. R. Corps, March 29, 1865; discharged June 30, 1865; pensioned.
8	Ashcroft, J., Sergt., K, 64th Ohio, age 31.	Nov. 25, 1863.	Shot fracture of head and portion of shaft of right humerus.	Nov. 27, 1863.	Amputated, by Surg. A. McMahon, 64th Ohio.	Disch'd Oct. 12, 1864; pensioned. Died Jan. 21, 1869, of "tubercular consumption resulting from the wound."
9	Atchinson, H. H., Pt., G, 85th Pennsylvania, age 47.	Sept. 1, 1864.	Fracture of middle third of right humerus by a 12-lb. spherical shot; bone denuded; artery, vein, and nerve intact.	Sept. 1, 1864.	Amputated, by Surgeon C. M. Clark, 37th Illinois; flap made entirely from axillary region.	Discharged November 22, 1864; pensioned.
10	Austin, A., Pt., D, 10th New York.	Aug. 30, 1862.	Laceration of the right arm, by cannon shot.	Aug. 30, 1862.	Amputated at the shoulder by external flap.	Disch'd Oct. 3, 1862; pensioned.
11	Bygby, T. B., Pt., C, 44th Virginia, age 19.	July 2, 1863.	Shot fracture of right humerus, shoulder joint involved.	July 3, 1863.	Amputated at the shoulder by Lisfranc's method.	Recovered; exchanged September 14, 1863.
12	Baker, * D., Pt., G, 19th Kentucky, age 21.	May 1, 1863.	Upper third of right humerus fractured; bone shattered.	May 1, 1863.	Amputated by Larrey's method, with an anterior V flap. . . . .	Discharged September 2, 1863; pensioned.
13	Ballard, J. A., Pt., K, 17th Alabama, age 25.	April 6, 1862.	Shot fracture of right humerus, high up.	April 7, 1862.	Disarticulation at the shoulder by transfexion.	Recovered; sent to military prison April 27, 1862.
14	Banks, G., Pt., B, 44th New York.	May 27, 1862.	Shot fracture of the left arm . .	May 29, 1862.	Amputation at the shoulder by Dupuytren's method.	Discharged September 23, 1862; pensioned.
15	Barber, G. W., Pt., E, 9th New Hampshire, age 23.	Dec. 13, 1862.	Shell fracture of left humerus, with great destruction of soft parts.	Dec. 13, 1862.	Amputation at the shoulder, by Surg. W. A. Webster, 9th New Hampshire.	Disch'd Mar. 13, 1863; pensioned.
16	Barbar, R., Pt., C, 42d Indiana.	May 30, 1864.	Shot fracture of left shoulder joint.	May 30, 1864.	Disarticulated, by Surg. B. F. Miller, 2d Ohio.	Disch'd Oct. 27, 1864; pensioned.
17	Barth, G., Pt., F, 4th Ohio. . .	May 2, 1863.	Shot fracture of left humerus, near the joint.	May 2, 1863.	Amputated at the shoulder, by Surg. C. S. Wood, 66th N. York.	Disch'd June 22, 1863; pensioned.
18	Baughan, M. T., Lieut., A, 5th Virginia, age 31.	July 3, 1863.	Upper portion and neck of the right humerus shattered; chest injured.	July 3, 1863.	Amputated at the shoulder, by a Confederate surgeon.	Recovered; exchanged March 3, 1864.
19	Bran, C. M., Lieut., G, 5th Texas, age 24.	July 3, 1863.	Shot fracture of the upper portion of the right humerus.	July 3, 1863.	Amputation at the shoulder by the flap method; abscesses formed.	Recovered; exchanged March 17, 1864.
20	Beek, J., Pt., I, 6th Connecticut, age 44.	Aug. 16, 1864.	Shot wound of right arm, with fracture of the humerus.	Aug. 17, 1864.	Disarticulation at the shoulder by the oval method.	Discharged September 4, 1864; pensioned.
21	Bell, A., Pt., A, 16th New York, age 29.	June 3, 1864.	Wound through left shoulder joint; humerus fractured.	June 3, 1864.	Amputation at the shoulder; flap method.	Disch'd Mar. 31, 1865; pensioned.
22	Bennett, R., Pt., F, 4th New Hampshire, age 18.	July 30, 1864.	Shot fracture of right shoulder . . . .	July 30, 1864.	Amputated, by Surgeon W. A. Webster, 9th New Hampshire.	Discharged January 20, 1865; pensioned.
23	Bernheisel, L., Pt., 5th Pennsylvania, age 25.	May 9, 1864.	Fracture of the upper third of right humerus by shell.	May 11, 1864.	Amputated at the shoulder, by Confederate Surg. Graham.	Disch'd May 1, 1865; pensioned.
24	Bertram, J., Sergt., II, 58th New York.	June 8, 1862.	Fracture of the left humerus at the surgical neck, with splintering.	June 8, 1862.	Amputated at the shoulder, by Surg. C. M. F. Muecke and Ass't Surg. C. Stein, 56th New York.	Disch'd Aug. 14, 1862; pensioned. Died January 15, 1874.
25	Bissell, E. B., Pt., K, 1st Vermont, age 20.	Oct. 27, 1864.	Right arm nearly severed close to the body by a cannon ball.	Oct. 27, 1864.	Amputated at the shoulder, by Ass't Surg. E. P. Fairman, 6th Vermont.	Disch'd July 25, 1865; pensioned.
26	Blackburn, W., Pt., D, 6th Wisconsin.	Feb. 6, 1865.	Shot fracture of upper third of left humerus.	Feb. 6, 1865.	Disarticulated at the shoulder by Larrey's plan.	Disch'd June 16, 1865; pensioned.
27	Blood, S. L., Pt., K, 11th Massachusetts, age 18.	May 5, 1864.	Right humerus fractured by a conoidal ball.	May 6, 1864.	Disarticulated at the shoulder; lateral flaps.	Disch'd July 25, 1865; pensioned.
28	Boethe, P., Pt., G, 1st Pennsylvania Reserve Artillery, age 34.	Feb. 7, 1864.	Fracture of head of right humerus; joint opened.	Feb. 9, 1864.	Disarticulated at the shoulder, by Surg. A. N. Dougherty, U. S. V.	Disch'd Nov. 18, 1864; pensioned. Spec. 2042, A. M. M.
29	Border, H., Pt., K, 133d Pennsylvania, age 18.	Dec. 13, 1862.	Shot wound of left arm, with comminution of bone.	Dec. 13, 1862.	Amputated at the shoulder, two hours after injury, by circular method.	Disch'd Mar. 27, 1863; pensioned.
30	Bowers, W., Pt., F, 5th U. S. Colored Troops, age 18.	Sept. 29, 1864.	Shot fracture of the left humerus and elbow joint.	Sept. 30, 1864.	Amputated at the shoulder, by Confederate Surg. Van Dell.	Disch'd June 8, 1865; pensioned.
31	Bowles, J. H., Pt., D, 1st Massachusetts.	Dec. 13, 1862.	Shell wound of the left arm in upper third.	Dec. 14, 1862.	Amputation, by Surg. J. M. Merron, 2d New Hampshire.	Disch'd Mar. 12, 1863; pensioned.
32	Box, J. P., Lieut., A, 147th New York, age 22.	July 3, 1863.	Shot wound through the left shoulder joint.	July 3, 1863.	Amputated at the shoulder by transfexion.	Discharged November 5, 1863; pensioned.
33	Boyd, J. H., Pt., E, 116th Illinois, age 19.	July 11, 1864.	Shot fracture of upper third of left humerus.	July 11, 1864.	Amputated at the shoulder, by Surg. A. C. Messenger, 57th Ohio.	Disch'd Oct. 24, 1864; pensioned.
34	Brailey, A. J., Sergt., E, 183d Pennsylvania, age 23.	June 18, 1864.	Shell wound of left arm, shattering the humerus.	June 18, 1864.	Amputated at the shoulder, by Surg. J. W. Wishart, 140th Pennsylvania.	Disch'd Oct. 12, 1864; pensioned.
35	Briant, G. R., Pt., A, 33d Indiana.	May 25, 1864.	Wound by a cannon ball; left arm shot away close to the shoulder.	May 26, 1864.	Amputated at the shoulder, by Surgeon R. F. Henece, 33d Indiana.	Disch'd Feb. 6, 1865; pensioned.

\* BRYANT (J.), *A Short Account of the "Mary Ann" Hospital, Grand Gulf, Miss., in The Am. Med. Times, 1863, Vol. VII, p. 4, CASE I.*

NO.	NAME, AGE, AND MILITARY DESCRIPTION.	DATE OF INJURY.	NATURE OF INJURY.	DATE OF OPERATION.	OPERATION AND OPERATOR.	RESULT AND REMARKS.
35	Brown, J. B., Pt., B, 37th Georgia, age 22.	Nov. 30, 1864.	Shot wound of right arm and juncture of the humerus.	Dec. 2, 1864.	Disarticulation at the shoulder by the double flap method.	Transferred to Provost Marshal for exchange, January 7, 1865.
37	Brown, G., Pt., K, 25th Ohio.	May 2, 1863.	Shell fracture of left humerus; laceration of soft parts.	May 3, 1863.	Amputation at the shoulder by the oval method.	Discharged November 18, 1863; pensioned.
38	Brown, G. L., Pt., G, 5th Massachusetts, age 28.	Mar. 29, 1865.	Fracture of head of humerus and acromial process by a fragment of shell.	Mar. 29, 1865.	Amputated by inner and posterior flaps, by Surg. W. Ingalls, 5th Massachusetts.	Disch'd Aug. 19, 1865; pensioned. Wound frequently breaks out and becomes a running sore.
39	Brown, J., Pt., E, 1st Maryland, age 33.	May 8, 1864.	Shot fracture of right humerus, with extensive fissuring and injury of vessels.	May 8, 1864.	Amputation at the shoulder by double flap method.	June 13th, secondary hæmorrhage, controlled by pressure on subclavian. Discharged May 23, 1864; pensioned.
40	Brown, P. J., Pt., I, 147th New York, age 25.	July 1, 1863.	Shot wound of left arm, the humerus splintered.	July 3, 1863.	Amputation at the shoulder, by a Confederate surgeon.	Promoted to lieutenant. Disch'd September 3, 1864; pensioned. Stump sound.
41	Brown, S., Pt., F, 7th Indiana, age 22.	May 6, 1864.	Shot fracture of upper third of right arm.	May 6, 1864.	Amputated at the shoulder, by Surgeon Geo. W. Now, 7th Indiana.	Sent to his regiment and mustered out Sept. 20, 1864; pensioned.
42	Brown, T. M. G., Pt., F, 48th New York, age 33.	July 30, 1864.	Shot fracture of right humerus	July 30, 1864.	Amputation at the shoulder by antero-posterior flaps.	Discharged November 7, 1864; pensioned.
43	Burk, A., Pt., F, 87th Pennsylvania, age 22.	June 2, 1864.	Wound of right arm, with fracture of the humerus.	June 2, 1864.	Amputation at the shoulder by transfexion.	Disch'd Nov. 12, 1864; pensioned. "Stump very tender; neuralgia pains upon pressure."
44	Burke, J., Pt., A, 5th Maryland.	Sept. 17, 1862.	Shot fracture of left humerus, with lesions of soft parts.	Sept. 18, 1862.	Amputation at the shoulder by antero-posterior flaps.	Disch'd Jan. 12, 1863; pensioned.
45	Burkhart, S., Pt., B, 88th Pennsylvania, age 28.	May 23, 1864.	Ball shattered the greater tuberosity, fractured the articular surface, and lacerated head of the humerus.	May 24, 1864.	Amputated at the shoulder by oval flap operation, by Surg. J. W. Rawlings, 88th Pennsylvania.	Discharged November 3, 1864; pensioned. Spec. 4126, A. M. M.
46	Burnham, W. J., Corp'l, K, 55th Pennsylvania.	Nov. 2, 1862.	Shell wound of right arm, with fracture of the humerus.	Nov. 2, 1862.	Amputated at the shoulder, by Ass't Surg. J. C. Lyons, 55th Pennsylvania.	Disch'd May 25, 1863; pensioned.
47	Bussey, J. P., Pt., C, 87th Indiana, age 29.	June 18, 1864.	Shot fracture of right arm at shoulder.	June 18, 1864.	Amputated by Surgeon C. E. Triplett, 87th Indiana.	Disch'd Nov. 2, 1864; pensioned. Pension Report says: "Two inches below shoulder joint."
48	Byers, J. K., Lieut., F, 121st Pennsylvania.	Dec. 12, 1862.	Shot wound through right arm and shoulder.	Dec. 14, 1862.	Amputated at the shoulder, by Surg. P. F. Whitehead.	Disch'd Oct. 14, 1863; pensioned.
49	Coll, D., Pt., Marine Corps, age 25.	May 22, 1864.	Shot wound of left arm, with comminution of the bone.	May 23, 1864.	Amputated at the shoulder, by Surg. Fletcher, C. S. A.	Disch'd Oct. 26, 1866; pensioned. Pension Board, March 20, 1873, certifies: "Large aneurism of subclavian above ligature."
50	Callahan, M., Pt., A, 30th Ohio, age 33.	July 22, 1864.	Shot wound of middle third of left arm, with splintering.	July 23, 1864.	Disarticulated at the shoulder by transfexion.	Disch'd Mar. 25, 1865; pensioned.
51	Cassell, M. M., Corp'l, K, 23th Georgia, age 25.	Nov. 30, 1864.	Shot wound of left arm, the humerus shattered.	Dec. 1, 1864.	Amputation at the shoulder by antero-posterior flap.	Sent to Provost Marshal January 31, 1865.
52	Cutlett, B. J., Corp'l, I, 55th North Carolina, age 19.	July 3, 1863.	Shot fracture of left humerus in upper third.	July 4, 1863.	Disarticulated at the shoulder by the oval method.	Exchanged March 3, 1864.
53	Chapel, M. H., Pt., K, 8th New York Heavy Artillery.	June 3, 1864.	Shot wound of left arm, the humerus fractured.	June 3, 1864.	Disarticulated at the shoulder, by a Confederate surgeon.	Disch'd Jan. 28, 1865; pensioned.
54	Charters, J., Pt., C, 5th Maine.	Sept. 14, 1864.	Accidental shot fracture of left humerus; ball passed through lung and emerged from the back.	Sept. 11, 1864.	Amputated at the shoulder by the circular method.	Both wounds healed without trouble. Discharged March 21, 1865; not a pensioner.
55	Chase, A. C., Pt., C, 17th Vermont, age 45.	Sept. 30, 1864.	Fracture of the upper third of the left humerus.	Sept. 30, 1864.	Lateral flap amputation at the shoulder.	Disch'd June 12, 1865; pensioned.
56	Choate, C., Corp'l, K, 16th Maine.	June 17, 1864.	Shell wound of right shoulder, the head of the humerus shattered.	June 19, 1864.	Disarticulation at the shoulder, by Surg. C. Alexander, 16th Maine.	Disch'd Dec. 7, 1864; pensioned.
57	Clark, L. E., Pt., I, 14th Ohio, age 18.	Sept. 1, 1864.	Comminuted shot fracture of upper third of left humerus.	Sept. 2, 1864.	Amputation at the shoulder by Lisfranc's method, by Surg. C. N. Fowler, 105th Ohio.	Disch'd Mar. 23, 1865; pensioned.
58	Clay, W. H., Pt., A, 6th Wisconsin.	Aug. 28, 1862.	Shot wound of right shoulder joint.	Aug. 30, 1862.	Amputated at the shoulder, by Surg. J. McNulty, U. S. V.	Disch'd Nov. 13, 1862; pensioned.
59	Coddington, E. H., Serg't, F, 14th Iowa.	Feb. 13, 1862.	Fracture of left humerus one inch below the head by grape-shot.	Feb. 14, 1862.	Amputation at the shoulder by the oval method.	Disch'd Aug. 15, 1862; pensioned. Shoulder weak and shrivelled; indistinct respiratory murmur over right lung.
60	Cole, T., Pt., B, 5th Michigan, age 44.	May 5, 1864.	Right humerus shattered at the surgical neck.	May 6, 1864.	Amputated at the shoulder, by Surgeon H. F. Lyster, 5th Michigan.	Slow progress. Disch'd Oct. 3, 1864; pensioned.
61	Coles, A. W., Pt., E, 30th Massachusetts, age 31.	Feb. 7, 1865.	Shot wound of upper third of left arm, with extensive comminution of the humerus.	Feb. 7, 1865.	Amputated at the shoulder by the double flap method, by Surgeon W. Thorndike, 30th Massachusetts.	Disch'd May 18, 1865; pensioned. Pension Examining Board, Jan. 6, 1875, states: "About 2 inches of the superior extremity of the humerus remain, but in dislocated condition."
62	Conlin, J., Pt., D, 49th Pennsylvania, age 31.	May 6, 1864.	Shot wound of left shoulder joint.	May 6, 1864.	Antero-posterior flap amputation at the shoulder.	Disch'd Dec. 4, 1864; pensioned.
63	Cornell, J. E., Serg't, I, 50th Georgia, age 27.	July 2, 1863.	Fracture of the left humerus by a large projectile.	July 3, 1863.	Amputation at the shoulder by Lisfranc's plan.	July 19th, gangrene of stump; sol. chlor. sod. applied; Dec. 8th, erysipelas over shoulder. Exchanged March 17, 1864.
64	Coppes, F., Lieut., C, 72d Pennsylvania.	May 6, 1864.	Shot wound of left arm . . . . .	May 8, 1864.	Amputation at the shoulder, by a Confederate surgeon.	Disch'd Sept. 9, 1864; pensioned.
65	Croft, W. N., Pt., C, 61st Georgia, age 23.	July 2, 1863.	Shot fracture of the head of the left humerus.	July 3, 1863.	Antero-posterior flap amputation at the shoulder.	Sent to Provost Marshal Sept. 10, 1863.
66	Crowder, J., Serg't, F, 40th Virginia, age 27.	July 3, 1863.	Upper third of right humerus fractured by a conoidal ball.	July 3, 1863.	Disarticulation at the shoulder by lateral flaps.	Exchanged March 3, 1864.
67	Cunningham, J., Pt., B, 11th Massachusetts.	Aug. 20, 1862.	Shot wound of left arm, involving the vessels and bone.	Aug. 30, 1862.	Amputation at the shoulder by double flaps.	Disch'd Oct. 15, 1862; pensioned.
68	Cunningham, F., Pt., H, 142d Pennsylvania.	Dec. 13, 1862.	Shot fracture of left humerus near the shoulder.	Dec. 13, 1862.	Amputation at the shoulder, by Surg. C. Bower, 6th Penn.	Disch'd Mar. 6, 1863; pensioned.
69	Daft, J. G., Pt., C, 14th New Jersey, age 21.	May 13, 1864.	Shot wound of right shoulder joint, humerus fractured.	May 13, 1864.	Amputation at the shoulder joint; flap operation.	Disch'd April 3, 1865; pensioned.
70	Dana, A., Corp'l, E, 2d U. S. Cavalry, age 27.	June 11, 1864.	Head and four inches of shaft of right humerus fractured by a conoidal ball.	June 11, 1864.	Amputation at the shoulder joint, by Ass't Surgeon J. W. Williams, U. S. A.	Walked about day after operation. Discharged and pensioned.



No.	NAME, AGE, AND MILITARY DESCRIPTION.	DATE OF INJURY.	NATURE OF INJURY.	DATE OF OPERATION.	OPERATION AND OPERATOR.	RESULT AND REMARKS.
71	Davis, T. R., Pt., C, 1st Texas Battalion, age 27.	June 14, 1863.	Shaft of right humerus comminuted to the shoulder joint by spherical case shot.	June 14, 1863.	Amputation at the shoulder joint by transfixion.	Sloughing; portion of spine of scapula and some tissue removed. Exch'd Jan. 25, 1864.
72	Dean, B. D., Sergt., A, 9th Louisiana.	Oct. 19, 1864.	Comp'd comminuted fracture of upper third of humerus.	Oct. 19, 1864.	Amputation at the shoulder by double flaps.	Sloughing arrested by turpentine and alcohol. Sent to Provost Marshal April 1, 1865.
73	Dean, J., Pt., I, 9th Pennsylvania.	Aug. 30, 1862.	Shell wound of the right arm.	Aug. 30, 1862.	Amputation at the shoulder by the circular method.	Disch'd May 27, 1865; pensioned.
74	De Condres, L. C., Corp'l, K, 16th Wisconsin.	Oct. 4, 1862.	Shot wound of the right arm, the humerus shattered.	Oct. 6, 1864.	Disarticulated at the shoulder, by Surg. S. P. Thornhill, 8th Wisconsin.	Disch'd Nov. 10, 1862; pensioned. Stump occasionally sore.
75	De Graffe, C., Pt., D, 61st New York.	Sept. 17, 1862.	Wound of the left arm by solid shot.	Sept. 17, 1862.	Amputated three hours after injury, by Surg. J. H. Taylor, U. S. V.	Disch'd Nov. 25, 1862; pensioned.
76	Demison, J. T., Corp'l, G, 67th New York, age 21.	May 6, 1864.	Compound fracture of neck of left humerus.	May 6, 1864.	Amputated at the shoulder, by Surg. Ph. Leidy, 119th Penn.	Disch'd July 4, 1864; pensioned. Died January 19, 1875.
77	Derstine, G. A., Pt., B, 16th U. S. Infantry.	May 24, 1864.	Right arm carried away by solid shot.	May 24, 1864.	Amputated at the shoulder by oval method.	Disch'd Sept. 30, 1864; pensioned. Died August 25, 1868, of pulmonary disease, caused by the wound.
78	Dewey, F., Pt., A, 36th Wisconsin, age 42.	June 18, 1864.	Shot fracture of upper third of left humerus.	June 18, 1864.	Disarticulated at the shoulder, by Surg. C. Miller, 36th Wis.	Disch'd Oct. 24, 1864; pensioned.
79	Dieck, A., Pt., B, 3d Missouri, age 32.	May 14, 1864.	Fracture of left humerus by a large projectile.	May 14, 1864.	Amput'd at shoulder, by Surg. A. T. Hudson, 20th Iowa.	Disch'd Sept. 10, 1864; pensioned.
80	Dietrick, G., Pt., C, 140th New York.	May 5, 1864.	Shot wound of right arm, the humerus shattered.	May 5, 1864.	Amputated at the shoulder, by a Confederate surgeon.	Disch'd Mar. 25, 1865; pensioned.
81	Dietzman, G., Pt., A, 17th Missouri.	May 12, 1863.	Fracture of the right humerus; shoulder joint involved.	May 12, 1863.	Amputated at the shoulder, by Surg. C. Forster, 58th Ohio.	Disch'd Aug. 8, 1865; pensioned.
82	Dobbins, T., Pt., E, 25th Missouri.	Sept. 20, 1861.	Left arm carried away clean from body, and two ribs fractured, by a six-pound ball.	Sept. 20, 1861.	Amputated at the shoulder, by Surgeon J. T. Hodgson.	Disch'd Mar. 22, 1862; pensioned.
83	Dodds, E., Sergt., C, 21st New York Cavalry.	Aug. 21, 1864.	Fracture of upper third of right humerus; shoulder joint involved; also fracture of maxillary bone.	Aug. 21, 1864.	Amputated by flap method, by Surgeon G. S. Dilts, 5th New York Heavy Artillery.	Disch'd July 5, 1865; pensioned.
84	Dougell, D. S., Pt., F, 35th Virginia.	June 9, 1863.	Right humerus fractured three inches below the head by pistol ball.	June 11, 1863.	Amputated at the shoulder, by Surg. G. S. Palmer, U. S. V.	Exchanged March 3, 1864. <i>Spec.</i> 1234, A. M. M.
85	Dolan, J., Pt., B, 26th Indiana, age 36.	June 18, 1864.	Wound of the left arm by grape, the bone shattered.	June 18, 1864.	Circular flap amputation at the shoulder.	Disch'd April 1, 1865; pensioned.
86	Dolph, W., Corp'l, D, 53d Pennsylvania, age 28.	July 2, 1863.	Head and upper portion of left humerus shattered by a conoidal ball.	July 2, 1863.	Amputation at the shoulder, by Surgeon C. S. Wood, 66th New York.	Disch'd Feb. 4, 1865; pensioned. Killed by railroad accident June 27, 1865.
87	Dersch, H., Pt., C, 48th Pennsylvania.	Sept. 17, 1862.	Shot fracture of upper third of left humerus.	Sept. 19, 1862.	Amputation at the shoulder by Larrey's method.	Disch'd Dec. 7, 1862; pensioned.
88	Doyle, P., Pt., K, 3d Delaware, age 30.	June 18, 1864.	Shot fracture of upper third of left humerus.	June 18, 1864.	Amputated at the shoulder by the flap method, by Surg. D. E. Wolfe, 3d Delaware.	Disch'd Mar. 29, 1865; pensioned.
89	Drake, J., Pt., D, 73d Ohio, age 24.	Oct. 29, 1863.	Shot fracture of left wrist, passing to the upper part of the humerus, involving the shoulder joint.	Oct. 31, 1863.	Amputated by the oval method, by Surgeon I. N. Hines, 73d Ohio.	Disch'd April 4, 1864; pensioned.
90	Dunbar, J. L., Pt., 37th Massachusetts, age 27.	April 7, 1865.	Fracture of right humerus at upper third by conoidal ball; parts crushed and lacerated.	April 7, 1865.	Amputation at the shoulder by Lisfranc's method.	Disch'd July 7, 1865; pensioned.
91	Dunkel, J., Pt., G, 115th Pennsylvania.	May 3, 1863.	Comp'd comminuted fracture of head and shaft of the right humerus.	May 3, 1863.	Amputation by the flap method, by Surg. C. S. Wood, 66th New York.	Disch'd Mar. 4, 1864; pensioned.
92	Dunn, J., Pt., I, 121st Ohio.	Mar. 19, 1865.	Shot fracture of right humerus, with injury of the vessels.	Mar. 19, 1865.	Amputation at the shoulder by transfixion.	Disch'd June 7, 1865; pensioned.
93	Dusenbury, G. W., Pt., E, 40th Indiana, age 21.	Dec. 15, 1864.	Fracture of upper third of left humerus by pistol ball.	Dec. 15, 1864.	Amputated at the shoulder, by Surg. T. L. Magee, 51st Ill.	Mustered out May 8, 1865; pensioned.
94	Eady, E. H., Sergt., B, 9th Louisiana, age 23.	Oct. 19, 1864.	Comminuted fracture of right arm.	Oct. 19, 1864.	Amputated at the shoulder, by Ass't Surg. E. P. Clark, 31st Massachusetts.	Released on parole, Feb. 15, 1865.
95	Eekinroth, H., Pt., G, 148th Pennsylvania.	May 2, 1863.	Comminuted fracture of head of the right humerus; joint opened.	May 2, 1863.	Amputated at the shoulder, by Surgeon A. N. Dougherty, U. S. V.	Disch'd Nov. 23, 1863; pensioned.
96	Egner, C., Pt., K, 8th Pennsylvania Cavalry, age 28.	April 7, 1865.	Comp'd comminuted fracture of head and upper portion of left humerus; also wound of chest.	April 8, 1865.	Amputation at the shoulder by the oval method.	Disch'd July 26, 1865; pensioned.
97	Eichler, C., Sergeant-major, 10th Minnesota, age 36.	Dec. 16, 1864.	Fracture of left arm by a cannon ball.	Dec. 16, 1864.	Amputated at the shoulder, by Ass't Surg. F. H. Milligan, 10th Minnesota.	Disch'd June 13, 1865; pensioned.
98	Ettinger, G., Pt., A, 13th Indiana.	Oct. 1, 1861.	Accidental shot wound of right arm, fracturing the bone.	Oct. 1, 1861.	Amputated at the shoulder, by Surg. A. D. Gall, 13th Indiana.	Disch'd Jan. 16, 1862; pensioned.
99	Evans, E. A., Corp'l, D, 8th Georgia, age 24.	July 10, 1863.	Head of right humerus shattered by conoidal ball.	July 10, 1863.	Amputation at the shoulder by Dupuytren's plan.	August 11th, gangrene; ligatures removed and nitric acid applied. Paroled Sept. 23, 1863.
100	Ewing, J., Pt., H, 49th Pennsylvania, age 35.	Apr 128, 1864.	Wound of right shoulder joint by a large projectile.	Apr 128, 1864.	Amputation at the shoulder, by Surg. Ph. Leidy, 119th Pennsylvania.	Disch'd Jan. 16, 1865; pensioned. Wound never healed; diarrhoea, consumption; and finally death occurred Feb. 25, 1867.
101	Fairfield, I. M., Pt., D, 27th Michigan, age 22.	June 3, 1864.	Shot wound of right shoulder; humerus crushed; great disorganization of surrounding parts.	June 3, 1864.	Amputated at the shoulder by oval flaps, by Surgeon A. F. Whelan, 1st Michigan Sharpshooters.	Disch'd May 11, 1865; pensioned. Died February 24, 1869.
102	* Fallon, E., Pt., 12th New York Battery, age 26.	May 30, 1864.	Comminuted fracture of head and upper third of humerus.	May 30, 1864.	Amputated at the shoulder by the lateral flap method.	Disch'd June 12, 1865; pensioned.
103	Fellew, S. H., Pt., C, 3d South Carolina.	July 3, 1863.	Upper third of left humerus shattered, and flesh wound of upper third of thigh.	July 5, 1863.	Amputated at the shoulder by the flap method.	Paroled September 25, 1863.

\* LYNSTER (H. F.), *Operations on the Shoulder*, in *Am. Jour. Med. Sci.*, 1865, Vol. L, p. 357.

NO.	NAME, AGE, AND MILITARY DESCRIPTION.	DATE OF INJURY.	NATURE OF INJURY.	DATE OF OPERATION.	OPERATION AND OPERATOR.	RESULT AND REMARKS.
104	Ferguson, H. C., Pt., G, 1st Virginia.	July 3, 1863.	Shot fracture of left arm and lesion of the brachial artery.	July 3, 1863.	Amputation at the shoulder by Larrey's method.	Necrosed portion of the neo-union process removed; retired Aug. 29, 1864. Disch'd Jan. 31, 1865; pensioned.
105	Ferner, N., Pt., M, 8th New York Heavy Artillery, age 21.	June 3, 1864.	Grapeshot wound of middle third of left arm.	June 4, 1864.	Amputation at the joint by circular method, by Surgeon J. L. Brenton, 8th Ohio.	Disch'd Oct. 21, 1863; pensioned.
106	Ferris, J. J., Corp'l, K, 73d Indiana.	Apr' 13, 1863.	Shot wound of the left arm and right hand; hand totally destroyed with the exception of the thumb.	Apr' 13, 1863.	Left arm amputated at shoulder, by Ass't Surgeons W. Spencer and S. F. Myers, 73d Indiana.	Disch'd Dec. 30, 1862; pensioned.
107	Fielding, C., Pt., A, 105th Ohio.	Oct. 8, 1862.	Fracture of right humerus, involving shoulder joint; arm nearly torn off by shell.	Oct. 10, 1862.	Amputation at the shoulder, by Surgeon C. N. Fowler, 105th Ohio.	Disch'd Aug. 9, 1862; pensioned.
108	Follos, R., Pt., K, 72d New York, age 19.	May 5, 1862.	Fracture of left arm by a large missile.	May 6, 1862.	Amputated at the shoulder, by Surgeon J. A. Skilton, 87th New York.	Disch'd Nov. 14, 1862, a neuroma at the lower portion of the cicatrix was excised by Dr. F. M. Markoe. Stump remains tender. Disch'd July 12, 1865; pensioned.
109	Forker, O. H. P., Serg't, H, 5th Illinois, age 23.	Dec. 16, 1864.	Shot comminution of head and upper third of left humerus.	Dec. 17, 1864.	Amputation at the shoulder by the antero-posterior flap method, by Asst. Surg. J. E. Link.	Disch'd Jan. 29, 1864; pensioned.
110	French, H. H., Serg't, F, 6th New York, age 28.	July 2, 1863.	Ball entered at anterior extremity of second rib and emerged at outer side of right arm, fracturing humerus.	July 4, 1863.	Antero-posterior flap amputation, by Surg. D. E. Kelsey, 6th New York.	Disch'd July 15, 1864; pensioned.
111	Fritzing, J., Pt., H, 61st Pennsylvania, age 49.	May 12, 1864.	Shot wound of right arm at upper third.	May 12, 1864.	Amputation at the shoulder by lateral flap.	Disch'd Mar. 26, 1863; pensioned.
112	Frizzell, W., Corp'l, H, 2d New York, age 21.	May 3, 1863.	Fracture of upper third of right arm by a conoidal ball.	May 3, 1863.	Amputated at the shoulder, by Ass't Surg. George King, 16th Massachusetts.	Disch'd Jan. 28, 1863, of disease of right lung, the result of wound. Disch'd July 27, 1863; pensioned. Died February 23, 1870.
113	Fulcher, G. W., Pt., H, 83d Indiana.	May 28, 1863.	Fracture of left arm by grapeshot.	May 28, 1863.	Amputated at the shoulder by double flap operation, by Surg. M. W. Robbins, 4th Iowa.	Right arm amputated at the shoulder joint. Oct. 5, 1862, amputation of left forearm at upper third. Disch'd Dec. 17, 1862; pensioned. Disch'd Aug. 5, 1864; pensioned.
114	Fuller, D., Pt., G, 53d Pennsylvania.	Sept. 17, 1862.	Shell wound of both arms, with fracture of right humerus.	Sept. 17, 1862.	Right arm amputated at the shoulder joint.	Exchanged August 21, 1864.
115	Gardner, J. E., Pt., B, 24th Iowa, age 21.	April 8, 1864.	Shot fracture of the head of the left humerus.	April 9, 1864.	Amputation at the shoulder by the oval method.	Disch'd June 21st, sloughing; nitrate of silver and chlorine applied. Disch'd Sept. 6, 1864; pensioned. Mustered out September 20, 1864; pensioned. Furloughed October 8, 1864.
116	Gawner, G. H., Pt., E, 7th Georgia.	Aug. 16, 1864.	Shot fracture of upper third of left humerus.	Aug. 16, 1864.	Flap amputation at shoulder, by the regimental surgeon.	Disch'd Dec. 23, 1862; pensioned.
117	Gates, G. W., Pt., F, 4th Maryland, age 36.	June 1, 1864.	Shot fracture of left humerus near shoulder joint.	June 2, 1864.	Lateral flap amputation, by Surgeon R. H. Robinson, 7th Maryland.	Amputated at the shoulder, by Surg. G. W. New, 7th Ind.
118	Garrison, S., Pt., A, 7th Indiana, age 23.	May 7, 1864.	Shot fracture of upper third of left arm.	May 7, 1864.	Amputated at the shoulder, by Surg. E. M. Waters, U. S. A.	Disch'd Dec. 23, 1862; pensioned.
119	Giles, J. P., Pt., L, 1st Texas.	Sept. 29, 1864.	Shot fracture of upper third of left humerus.	Sept. 29, 1864.	Amputated at the shoulder, by Surg. E. M. Waters, U. S. A.	Amputation at the shoulder, by Surgeon R. R. Meens.
120	Genevan, R. H., Corp'l, D, 3d Ohio.	Oct. 8, 1862.	Grapeshot wound of left arm, severing arm from body.	Oct. 8, 1862.	Amputation at the shoulder, by Surgeon R. R. Meens.	Fetid discharge at first; May 31st, convalescing. Aug. 25, 1863, abscess opened in axilla. Exch'd Mar. 3, 1864. Disch'd April 29, 1865; pensioned.
121	Glover, R. T., Pt., D, 43d Alabama, age 22.	May 17, 1864.	Shot fracture of the head of the humerus.	May 19, 1864.	Amputation at the shoulder ...	Disch'd July 29, 1865; pensioned.
122	Goodloe, D. S., Adjutant, 18th Mississippi, age 24.	July 2, 1863.	Comp'd comminuted fracture of upper third of left humerus.	July 2, 1863.	Amputation at the shoulder by Lisfranc's method.	Disch'd July 29, 1865; pensioned.
123	Goodrich, H. B., Pt., F, 14th Connecticut.	Aug. 25, 1864.	Shot fracture of left shoulder joint.	Aug. 26, 1864.	Amputation at the shoulder, by Surg. G. Chaddock, 7th Mich.	Disch'd July 29, 1865; pensioned.
124	Greer, C., Pt., A, 4th Delaware, age 31.	Oct. 8, 1864.	Fracture of left humerus by a cannon ball.	Oct. 9, 1864.	Flap amputation at shoulder, by Surg. A. A. White, 8th Maryland.	Disch'd July 29, 1865; pensioned.
125	Greyble, G. L., Pt., B, 93d Indiana, age 18.	Dec. 16, 1864.	Comminuted shot fracture of lower third of right humerus.	Dec. 17, 1864.	Flap amputation at shoulder, by Ass't Surg. G. E. Irwin, 93d Indiana.	Disch'd July 17, 1862; pensioned.
126	Griffith, T. P., Pt., I, 48th Illinois.	April 7, 1862.	Wound of right shoulder joint by a shell.	April 7, 1862.	Amputation at the shoulder by Larrey's plan.	Disch'd Feb. 5, 1864; pensioned.
127	Gutermann, C., Pt., F, 2d U. S. Infantry, age 30.	May 1, 1863.	Shot fracture of the head of left humerus.	May 1, 1863.	Amputation at the shoulder, by Ass't Surgeon J. S. Billings, U. S. A.	Mustered out May 15, 1863; pensioned. Disch'd Aug. 8, 1863; pensioned.
128	Gyger, A., Pt., A, 122d Pennsylvania.	May 3, 1863.	Shot wound of right shoulder joint.	May 3, 1863.	Amputated at the shoulder, by Surg. F. Reynolds, 88th N. Y.	Disch'd Feb. 21, 1865; pensioned.
129	Hacker, A., Corp'l, E, 93d Indiana.	May 22, 1863.	Fracture of left shoulder by a conoidal ball.	May 24, 1863.	Amputated at the shoulder, by Surg. M. W. Fisk, 11th Mo.	Disch'd Sept. 27, 1864; pensioned.
130	Hadlock, W., Pt., C, 6th Iowa, age 21.	Nov. 22, 1864.	Shell fracture of right humerus, high up.	Nov. 22, 1864.	Amputated at the shoulder, by Surg. R. Morris, 103d Illinois.	Retired from service September 21, 1864. Disch'd Dec. 6, 1864; pensioned.
131	Hallen, B. C., Pt., A, 36th Wisconsin.	June 18, 1864.	Shell fracture of upper third of left humerus.	June 18, 1864.	Amputated at the shoulder, by Surg. D. W. Maul, 1st Del.	Disch'd Oct. 9, 1863; pensioned.
132	Ham, E. C., Pt., B, 3d Virginia Cavalry.	June 21, 1864.	Shot wound of humerus, shattering its upper part.	June 21, 1864.	Amputated at the shoulder, by Surg. E. I. Habersham, U. S. A.	Disch'd Dec. 6, 1864; pensioned.
133	Hambke, A., Pt., H, 15th New York Heavy Artillery.	Aug. 18, 1864.	Shot fracture of left humerus.	Aug. 20, 1864.	Amputated at the shoulder by antero-posterior flaps.	Disch'd Oct. 9, 1863; pensioned.
134	Hannum, S., Corp'l, B, 2d Delaware.	July 3, 1863.	Shell fracture of left humerus; arm carried away.	July 3, 1863.	Amputation at the shoulder, by Dr. Higgins.	Convalescent October 1, 1862.
135	*Hardie, J. M. W., Pt., 17th Mississippi, age 19.	Sept. 17, 1862.	Conoidal ball comminuted the upper portion of the right humerus.	Sept. 17, 1862.	Flap amputation at the shoulder.	Disch'd Aug. 30, 1865; pensioned. Stump sensitive. Spec. 4115, A. M. M.
136	Hardy, A. E., Pt., F, 1st Maine Heavy Artillery, age 21.	Oct. 2, 1864.	Shell fracture of head and surgical neck of right humerus, acromial process of scapula, and probably glenoid cavity.	Oct. 2, 1864.	Amputated at the shoulder, by Surgeon D. S. Hays, 110th Pennsylvania.	Disch'd Dec. 20, 1864; pensioned. October 1, 1862, doing well.
137	Harrison, A. J., Lieut., H, 126th Ohio, age 26.	May 6, 1864.	Comp'd comminuted fracture of right humerus.	May 7, 1864.	Amputated at the shoulder, by a Confederate surgeon.	
138	*Harrison, W. H., Pt., Peyton's Virginia Battery, age 41.	Sept. 17, 1862.	Lower half of left arm torn off by a fragment of shell; no bleeding from torn vessels.	Sept. 18, 1862.	Flap amputation at the shoulder.	

\* See FISCHER, G. J., Report of Fifty-seven Cases of Amputation, in the Hospitals near Sharpsburg, Md., after the Battle of Antietam September 17, 1862, in *Am. Jour. Med. Sci.*, 1863, Vol. XLV, N. S., p. 48.



No.	NAME, AGE, AND MILITARY DESCRIPTION.	DATE OF INJURY.	NATURE OF INJURY.	DATE OF OPERATION.	OPERATION AND OPERATOR.	RESULT AND REMARKS.
130	Hawkins, W. H., Pt., 1, 21st North Carolina, age 36.	Sept. 19, 1864.	Comp'd comminuted fracture of upper third of left humerus and laceration of soft parts; joint involved.	Sept. 21, 1864.	Amputated at the shoulder by Larrey's method, by Surgeon E. L. Brevard, C. S. A.	Released April 18, 1865.
140	Hayes, G., Pt., F, 54th Massachusetts Colored Troops.	Feb. 10, 1865.	Right arm shattered, forearm torn away, both eyes destroyed by accidental discharge of a cannon.	Feb. 10, 1865.	Amputated at the shoulder, by Ass't Surg. N. S. Roberts, 21st U. S. Colored Troops.	Disch'd Sept. 8, 1865; pensioned. Wound healed, but tender.
141	Hayes, W. M., Pt., E, 20th Georgia Batt. of Cavalry, age 19.	June 11, 1864.	Shot wound of right arm, with fracture high up.	June 11, 1864.	Amputated at the shoulder, by Surgeon Metcalf.	Retired January 30, 1865.
142	Haynes, W., Pt., K, 3d East Tennessee, age 24.	May 14, 1864.	Comp'd comminuted fracture of upper third of right humerus; also wound of hip.	May 14, 1864.	Amputated at the shoulder, by Surgeon C. W. McMillan, 1st Tennessee.	Disch'd Feb. 23, 1865; pensioned.
143	Hazeltine, H. H., Pt., I, 4th Vermont, age 33.	May 5, 1864.	Comminuted fracture of left humerus by a grapeshot; soft parts much lacerated; joint involved.	May 6, 1864.	Flap amputation at the shoulder, by Surgeon D. M. Goodwin, 3d Vermont.	Disch'd Oct. 22, 1864; pensioned.
144	Heaton, S., Pt., F, 1st Pennsylvania Cavalry.	Nov. 12, 1862.	Shot wound of right arm, with humerus shattered.	Nov. 12, 1862.	Amputation at the shoulder, by Surgeon D. Stanton, 1st Pennsylvania Cavalry.	Disch'd Dec. 10, 1862; pensioned.
145	Hedick, A., Pt., B, 23d North Carolina, age 23.	May 3, 1863.	Shot fracture of right humerus, extending into joint.	May 5, 1863.	Flap amputation at shoulder.	Furloughed July 11, 1863.
146	Heistonbrittle, D., Pt., C, 44th New York, age 24.	Sept. 23, 1864.	Comp'd comminuted fracture of upper third of left humerus.	Oct. 1, 1864.	Amputation at the shoulder by the oval method.	Disch'd Mar. 14, 1865; pensioned.
147	Held, F., Sergeant, B, 56th Ohio.	May 16, 1863.	Shot fracture of right arm near the shoulder.	May 18, 1863.	Amputation at the shoulder by transfixion.	Disch'd Nov. 5, 1863; pensioned.
148	Hendrickson, L. C., Pt., K, 95th Pennsylvania.	June 1, 1864.	Shell wound of right arm, with lesion of the vessels.	June 1, 1864.	Flap amputation at the shoulder, by Surg. E. P. B. Kelly, 95th Pennsylvania.	Disch'd Dec. 5, 1864; pensioned.
149	Henesy, T. J., Pt., C, 10th Vermont, age 30.	Oct. 19, 1864.	Shot fracture of upper third of left humerus, extending into joint, and injury of scapula.	Oct. 19, 1864.	Double flap amputation, by Surg. T. A. Helwig, 87th Pennsylvania.	Disch'd May 27, 1865; pensioned.
150	Henry, O., Pt., F, 61st New York.	June 29, 1862.	Shell wound of right shoulder, with fracture.	June 29, 1862.	Amputation at the shoulder by the oval method.	Disch'd May 5, 1863; pensioned.
151	Hewins, G. W., Pt., E, 3d Wisconsin.	June 9, 1863.	Shot wound of left shoulder joint; humerus fractured.	June 9, 1863.	Amputation at the shoulder by Lisfranc's method.	Disch'd Oct. 7, 1863; pensioned.
152	Hicks, C. A., Pt., D, 11th Mississippi.	July 3, 1863.	Shot fracture of neck of right humerus.	July 5, 1863.	Amputation at the shoulder by double flaps.	September 30th, wound healed; discharged October 12, 1863.
153	Higgins, L., Pt., G, 148th Pennsylvania, age 31.	May 5, 1864.	Comminuted fracture of upper third of left humerus.	May 6, 1864.	Lateral flap amputation at the shoulder, by Surg. J. Ebersole, 19th Indiana.	Disch'd Jan. 23, 1865; pensioned. <i>Spec. 23, A. M. M.</i> Died Feb. 14, 1870.
154	Hill, J. A., Pt., A, 13th Illinois.	Dec. 22, 1862.	Fracture of left humerus by a fragment of shell.	Dec. 22, 1862.	Amputated at the shoulder, by Surg. S. C. Plummer, 13th Illinois.	Disch'd Feb. 19, 1863; pensioned.
155	Hobbs, G., Pt., D, 1st Mass. Heavy Artillery, age 46.	Oct. 2, 1864.	Compound fracture of upper third of right humerus.	Oct. 3, 1864.	U-flap amputation, by Surg. D. Everts, 20th Indiana.	Disch'd June 15, 1865; pensioned. <i>Spec. 3124, A. M. M.</i>
156	Holley, H. H., Pt., H, 26th Michigan, age 20.	May 12, 1864.	Shot fracture of neck and shaft of right humerus.	May 12, 1864.	Amputated at the shoulder, by Surg. J. W. Wishart, 146th Pennsylvania.	Disch'd Nov. 29, 1864; pensioned.
157	Hollowell, C. H., Pt., G, 1st Mississippi Mounted Marine Brigade, age 23.	June 2, 1864.	Wound of right arm by solid shot.	June 2, 1864.	Amputated at the shoulder, by Surg. J. Roberts, 1st Miss. Mounted Mar. Brigade.	Disch'd Jan. 10, 1865; stump healed; pensioned.
158	Honans, C., Corp'l, E, 30th New York, age 19.	May 9, 1864.	Head of left humerus fractured by a musket ball.	May 10, 1864.	Amputated at the shoulder, by Surgeon P. E. Hubon, 28th Massachusetts.	Disch'd Jan. 28, 1865; pensioned.
159	Hooper, W. H., Pt., K, 12th Massachusetts, age 27.	July 3, 1863.	Fracture of upper third of right humerus.	July 4, 1863.	Flap amputation at shoulder.	Disch'd April 11, 1864; pensioned.
160	Houck, A., Pt., B, 84th Pennsylvania, age 20.	Aug. 6, 1864.	Shot wound of right arm; bone shattered.	Aug. 16, 1864.	Flap amputation at shoulder.	Slight sloughing. Disch'd Sept. 2, 1865; pensioned.
161	Houghton, C. W., Lieut., C, 27th Michigan, age 28.	May 12, 1864.	Shot wound of left arm, with injury of bone and artery.	May 12, 1864.	Amputation at the shoulder by the oval method.	Disch'd Oct. 5, 1864; pensioned. Entered Veteran Reserve Corps April 8, 1865.
162	Houston, R., Serg't, A, 59th New York.	July 3, 1863.	Shell fracture of right humerus, with laceration of the soft parts.	July 4, 1863.	Amputated at the shoulder, by Surg. W. J. Burr, 42d New York.	Abscess formed. Disch'd Oct. 7, 1863. Entered V. R. C. Disch'd June 15, 1864; pension allowed but never called for.
163	Huenemann, J. B., Pt., I, 76th Ohio, age 24.	Aug. 26, 1864.	Shell fracture of the head of the left humerus.	Aug. 26, 1864.	Amputated at the shoulder, by Asst. Surg. D. Holderman, 46th Ohio.	Disch'd April 9, 1865; pensioned.
164	Huffmann, L. W., Pt., I, 7th New Jersey, age 27.	May 9, 1864.	Comminuted shell fracture of upper third of right humerus.	May 11, 1864.	Antero-posterior flap amputation, by Surg. C. C. Jewett, 16th Massachusetts.	Mustered out October 7, 1864; pensioned. <i>Spec. 2903, A. M. M.</i>
165	Hughes, P., Corp'l, F, 2d U. S. Cavalry, age 28.	May 31, 1864.	Shot wound of right arm above and below elbow joint, badly fracturing bones.	May 31, 1864.	Double flap amputation, by Asst. Surg. C. I. Wilson, U. S. A.	Returned to duty, and discharged from service April 1, 1865, and pensioned.
166	Hull, B., Pt., K, 9th New Jersey, age 23.	Dec. 16, 1862.	Upper third of left humerus shattered by grapeshot; soft parts, vessels, and nerves torn; no shock.	Dec. 16, 1862.	Double flap amputation at the shoulder, by Surg. Geo. A. Otis, 27th Massachusetts.	Jan. 16, 1863, wound cicatrized; transferred to V. R. C. Dec. 5, 1863. Discharged Sept. 9, 1864; pensioned.
167	Hurley, C., Pt., H, 1st South Carolina, age 24.	May 3, 1863.	Shot fracture of upper third of arm.	May 3, 1863.	Amputation at the shoulder by transfixion.	Exchanged July 3, 1863.
168	Hutchins, S., Pt., E, 2d New York.	Aug. 14, 1864.	Shot fracture of right humerus at the surgical neck, with wound of brachial.	Aug. 14, 1864.	Antero-posterior flap amputation.	Sept. 30, 1864, secondary hemorrhage; axilla artery ligated at the stump. Disch'd Nov. 22, 1864; pensioned.
169	Hutchinson, L. M., Pt., B, 21st South Carolina, age 22.	Aug. 21, 1864.	Shot wound of middle third of arm.	Aug. 21, 1864.	Flap amputation at shoulder.	Sent to Old Capitol Prison Nov. 26, 1864.
170	Hutton, E. R., Corp'l, C, 53d Illinois, age 21.	July 12, 1863.	Shot fracture of right humerus.	July 12, 1863.	Amputation at the shoulder by the oval method.	Disch'd Dec. 4, 1863; pensioned.
171	Ingle, W. H., Pt., K, 49th Ohio, age 22.	May 27, 1864.	Shot wound of left shoulder joint.	May 29, 1864.	Amputated at the shoulder, by Surg. H. B. Tuttle, 8th Illinois.	Disch'd Dec. 9, 1864; pensioned.
172	Jamison, J. H., Pt., E, 148th Pennsylvania.	May 12, 1864.	Shot fracture of right humerus.	May 13, 1864.	Flap amputation at shoulder.	Disch'd Oct. 7, 1864; pensioned.
173	Johnson, J., Pt., D, 2d Wisconsin.	Dec. 13, 1862.	Fracture of upper third of right arm by a cannon ball.	Dec. 13, 1862.	Flap amputation at shoulder.	Disch'd April 10, 1863; pensioned.

No.	NAME, AGE, AND MILITARY DESCRIPTION.	DATE OF INJURY.	NATURE OF INJURY.	DATE OF OPERATION.	OPERATION AND OPERATOR.	RESULT AND REMARKS.
174	Johnson, J. R., Pt., A, 15th New Jersey, age 32.	Aug. 18, 1864.	Shot fracture of middle third of right humerus.	Aug. 19, 1864.	Amputated at the shoulder, by Asst. Surg. W. T. Smith, 2d Rhode Island.	Disch'd July 10, 1865; pensioned.
175	Jones, A., Serg't, I, 8th New York, age 35.	Oct. 27, 1864.	Fracture of upper third of the right humerus.	Oct. 28, 1864.	Amputated at the shoulder, by Asst. Surg. Gibbs, U. S. A.	Returned to duty March 9, 1865; mustered out; pensioned.
176	Jones, W. M., Pt., B, 80th Illinois, age 25.	May 14, 1864.	Shell fracture of the left shoulder joint.	May 14, 1864.	Amputated, by Surgeon J. D. Brumley, U. S. V.	Disch'd July 5, 1864; pensioned.
177	Julian, M., Pt., D, 2d Ohio	Oct. 8, 1862.	Wound of right arm.	Oct. 8, 1862.	Amputated at the shoulder, by Surg. B. F. Miller, 2d Ohio.	Disch'd Feb. 23, 1863; pensioned.
178	Kaufman, N., Pt., H, 5th Ohio, age 23.	May 25, 1864.	Shot fracture of right humerus.	May 26, 1864.	External flap amputation at the shoulder, by Surgeon W. R. Longshore, 117th Penn.	Disch'd Nov. 30, 1864; pensioned.
179	Keane, P., Pt., I, 124th New York, age 25.	June 16, 1864.	Shot wound of right arm, with injury of bone and vessels.	June 16, 1864.	Flap amputation at shoulder.	Disch'd Sept. 1, 1864; pensioned.
180	Keller, C. W., Pt., E, 145th Pennsylvania.	May 12, 1864.	Shot fracture of left humerus in upper third.	May 12, 1864.	Amputated at the shoulder, by Surg. J. W. Wishart, 140th Pennsylvania.	Disch'd June 8, 1864; pensioned.
181	Kelleher, J., Capt., C, 20th Massachusetts, age 35.	May 13, 1864.	Shell fracture of right shoulder joint; also wound of maxilla.	May 18, 1864.	Amputated, by Surg. N. Hayward, 20th Mass.; portions of clavicle and scapula were removed at the same time.	Mustered out July 30, 1864; pensioned.
182	Kennedy, R. V., Pt., A, 57th Pennsylvania.	July 2, 1863.	Shot fracture of left arm, with much splintering.	July 2, 1863.	Amputation at the shoulder.	Disch'd Dec. 3, 1863; pensioned.
183	Kent, H. A., Corp'l, B, 91st Ohio, age 34.	June 17, 1864.	Shell wound of left arm near the shoulder joint.	June 18, 1864.	Flap amputation at shoulder.	June 29, 1864, symptoms of gangrene. Disch'd Sept. 28, 1864; pensioned.
184	Kerling, J., Pt., B, 29th New York.	Aug. 29, 1862.	Shot wound of left arm, with lesions of bone and vessels.	Aug. 29, 1862.	Amputation at the shoulder by transfexion.	Disch'd Mar. 31, 1863; pensioned. Died Sept. 7, 1862.
185	Kidder, M. W., Pt., F, 147th New York, age 33.	June 18, 1864.	Shot wound of right arm and fracture of humerus.	June 19, 1864.	Amputated, by Ass't Surgeon J. B. Hall, 6th Wisconsin.	Disch'd Nov. 29, 1864; pensioned.
186	Killoran, M., Corp'l, H, 170th New York.	May 24, 1864.	Shot fracture of right humerus, high up.	May 25, 1864.	Amputated, by Surgeon W. J. Barr, 43d New York.	Disch'd Mar. 17, 1865; pensioned.
187	Kilpatrick, R. L., Lieutenant-Colonel, 5th Ohio, age 48.	May 2, 1863.	Shot fracture of right humerus and shot wound of left thigh.	May 4, 1863.	Amputation at the shoulder by antero-posterior flaps.	Disch'd Aug. 17, 1863. Appointed Captain 42d Infantry July 28, 1866. Retired Dec. 15, 1870; pensioned.
188	King, W. C., Serg't, D, 12th Kentucky Cavalry, age 37.	Nov. 18, 1863.	Wound of right arm, with fracture near shoulder.	Nov. 18, 1863.	Amputated at the shoulder, by Surg. R. L. Stamford, U. S. V.	Disch'd Oct. 6, 1864; pensioned.
189	Kipler, M., Pt., 8th New York Heavy Artillery, age 23.	June 3, 1864.	Shot fracture of head of right humerus.	June 4, 1864.	Flap amputation at the shoulder by double flaps.	Disch'd Sept. 24, 1864; pensioned.
190	Kline, J., Pt., B, 8th New York Cavalry, age 28.	Aug. 25, 1864.	Comp'd comminuted fracture of right arm.	Aug. 26, 1864.	Amput'd at shoulder, by A. A. Surg. John Goldsborough.	Disch'd Aug. 2, 1865; pensioned.
191	Knight, T. K., Serg't, A, 1st Georgia, age 32.	Nov. 30, 1864.	Shot wound of left arm and fracture high up.	Dec. 1, 1864.	Amputation at the shoulder by the oval plan.	Sent to Provost Marshal March 7, 1865.
192	Lacy, J., Pt., I, 36th Massachusetts, age 21.	Oct. 19, 1864.	Shot fracture of right shoulder joint.	Oct. 20, 1864.	Amputation at the shoulder by transfexion.	Disch'd Aug. 7, 1865; pensioned.
193	Lafontaine, A., Pt., H, 1st Maine, age 26.	Mar. 25, 1865.	Shell wound of right shoulder joint.	Mar. 25, 1865.	Amputation at the shoulder by external flap.	Disch'd May 31, 1865; pensioned.
194	Lahey, M., Pt., F, 2d U. S. Infantry.	June 27, 1862.	Shell wound of left arm, bone and soft parts injured.	June 29, 1862.	Amputated at the shoulder, by a Confederate surgeon.	Disch'd Sept. 16, 1862; pensioned.
195	Lamb, P., Pt., A, 61st New York.	June 1, 1862.	Gunshot wound of left shoulder.	June 2, 1862.	Amputation at the shoulder by transfexion.	Disch'd Sept. 18, 1862; pensioned.
196	Lehmann, J., Pt., E, 4th Texas, age 23.	Sept. 17, 1862.	Left arm carried away by a grapeshot.	Sept. 17, 1862.	Amputation at the shoulder by double flaps.	Two abscesses opened in axilla. Discharged Nov. 30, 1862.
197	Leonard, G., Corp'l, G, 47th New York, age 21.	Sept. 5, 1863.	Shell fracture of left arm, with much laceration.	Sept. 5, 1863.	Amputation at the shoulder by Larrey's method.	Disch'd Dec. 30, 1863; pensioned. Died of Bright's disease, May 23, 1868.
198	Long, H. F., Pt., I, 17th Pennsylvania Cavalry.	May 31, 1864.	Shot fracture of left humerus.	June 1, 1864.	Amputation at the shoulder by double flaps.	Disch'd Nov. 28, 1864; pensioned.
199	Losey, H. P., Pt., A, 103d Ohio, age 21.	May 14, 1864.	Shot fracture of upper third of left humerus.	May 14, 1864.	Amput'd at shoulder, by Surg. L. D. Griswold, 103d Ohio.	Disch'd Sept. 26, 1864; pensioned.
200	Loucks, C. H., Pt., G, 53d Pennsylvania, age 42.	Mar. 31, 1863.	Shot fracture of left humerus, shoulder joint involved.	Mar. 31, 1863.	Amputated, by Surg. W. H. Raymond, 26th Michigan.	Disch'd June 13, 1865; pensioned.
201	MacNulty, W. A., Serg't, A, 10th New York.	Dec. 13, 1862.	Shell wound of right arm, shattering all the bones about the shoulder joint.	Dec. 13, 1862.	Amputated at shoulder; scapular end of clavicle, neck of scapula, and two portions of blade of scapula, about three inches in length, removed by Surg. C. S. Wood, 60th N. Y.	Mustered out May 2, 1863; pensioned. Stump very tender.
202	Mangan, J., Pt., D, 15th New Jersey, age 34.	May 12, 1864.	Comminuted fracture of middle third of right humerus.	May 13, 1864.	Amputated by double flap method, by Surgeon H. A. Minor, C. S. A.	Copious hemorrhage. Disch'd May 16, 1865; pensioned. Died Nov. 8, 1869.
203	Marguet, M., Pt., C, 116th Pennsylvania.	Dec. 13, 1862.	Shot wound of left arm, with injury to the bone and vessels.	Dec. 13, 1862.	Amputation at the shoulder by the oval method.	Disch'd July 24, 1865; pensioned.
204	Mark, F., Pt., A, 2d Missouri Light Artillery, age 26.	May 26, 1861.	Both arms torn off by accidental discharge of cannon.	May 26, 1861.	Left arm disarticulated at shoulder; right forearm amputated three inches below elbow, by Dr. Schmidt.	Disch'd Oct. 17, 1861; pensioned. Stumps in good condition.
205	Martin, D. W., Corp'l, C, 1st New Jersey, age 31.	May 5, 1864.	Fracture of left shoulder joint by a large projectile.	May 6, 1864.	Amputation at the shoulder by transfexion and external and internal flaps.	June 29, 1864, large abscess opened. Sent to his State, his time of service having expired June 23, 1864; pensioned.
206	Martling, R. F., Serg't, F, 119th New York, age 42.	July 1, 1863.	Shot fracture of left shoulder joint.	July 2, 1863.	Flap amputation at shoulder.	In September, 1864, carious bone removed. Disch'd March 11, 1865; pensioned.
207	Mason, W. P., Pt., C, 1st Vermont Cavalry, age 18.	July 3, 1863.	Shot wound of right arm.	July 4, 1863.	Amputation at the shoulder by Larrey's plan.	Disch'd Mar. 3, 1864; pensioned.
208	Mathews, P., Pt., I, 20th Massachusetts.	July 3, 1863.	Compound fracture of the left humerus.	July 4, 1863.	Amputated at the shoulder, by Surgeon N. Hayward, 20th Massachusetts.	Recovered; not a pensioner.
209	Mattis, I. G., Pt., F, 119th Pennsylvania, age 33.	May 10, 1864.	Shot fracture of left humerus, with lesion of soft parts.	May 11, 1864.	Amputated at the shoulder, by Surg. Ph. Leidy, 119th Penn.	Disch'd Sept. 21, 1864; pensioned. Committed suicide December 14, 1867.
210	Mattison, C. S., Pt., I, 76th New York.	July 1, 1863.	Shot wound of right arm, the humerus shattered.	July 3, 1863.	Amputated by flap method, by Surgeon G. W. Metcalfe, 76th New York.	Disch'd Oct. 31, 1863; pensioned.



No.	NAME, AGE, AND MILITARY DESCRIPTION.	DATE OF INJURY.	NATURE OF INJURY.	DATE OF OPERATION.	OPERATION AND OPERATOR.	RESULT AND REMARKS.
211	McAnally, J. T., Corp'l, E, 6th U. S. Infantry, age 34.	Dec. 14, 1862.	Shot fracture of right humerus.	Dec. 15, 1862.	Amputation at the shoulder by the oval method.	Disch'd May 1, 1863; pensioned.
212	McCarty, C., Corp'l, E, 14th Maine, age 24.	July 3, 1863.	Left humerus fractured at the upper third.	July 4, 1863.	Amputation at the shoulder by double flaps.	Disch'd Oct. 23, 1863; pensioned.
213	McCauley, J., Serg't, A, 25th Indiana.	Feb. 13, 1862.	Shot fracture of right humerus.	Feb. 15, 1862.	Amputation at the shoulder by Lisfranc's method.	Disch'd Oct. 8, 1862; pensioned.
214	McClaskey, A. J., Pt., K, 1st Iowa Cavalry, age 27.	Dec. 8, 1863.	Shot fracture of upper third of left humerus.	Dec. 8, 1863.	Amputated at the shoulder, by Ass't Surg. J. J. Sanders, 1st Iowa Cavalry.	Disch'd May 30, 1864; pensioned.
215	McClintoc, J. H., Pt., F, 23d South Carolina, age 20.	June 16, 1864.	Gunshot fracture of left arm in upper third.	June 16, 1864.	Amputation at the arm.	Furloughed July 28, 1864.
216	McDonald, D. C., Pt., H, 51st New York, age 21.	Sept. 30, 1864.	Wound of left shoulder joint, with fracture of the head of humerus.	Oct. 1, 1864.	Antero-posterior flap amputation at the shoulder, by a Confederate surgeon.	Disch'd Feb. 8, 1865; pensioned.
217	McElhanev, V. J., Pt., B, 2d New York Mounted Rifles, age 20.	Mar. 31, 1865.	Shot fracture of middle third of left arm; two balls found in arm.	Mar. 31, 1865.	Amputated by the flap method, by Surg. R. T. Paine, 2d N. York Mounted Rifles.	Disch'd Aug. 21, 1865; pensioned.
218	McElyan, J., Pt., A, 11th Massachusetts.	July 21, 1861.	Shot wound of right arm, with lesions of bone and vessels.	July 23, 1861.	Amputated, by Dr. Swift, of New York.	Disch'd Jan. 17, 1862; pensioned.
219	McGuire, P., Pt., D, 103d Ohio, age 18.	May 14, 1864.	Shell fracture of the right humerus.	May 14, 1864.	Flap amput'd at the shoulder.	Disch'd Jan. 14, 1865; pensioned.
220	Melntosh, J. D., Pt., A, 120th Illinois.	Mar. 30, 1863.	Shot wound of arm near shoulder joint, with fracture.	Mar. 30, 1863.	Amputated, by Surgeon P. K. Guild and Ass't Surgeon S. Brownell, 120th Illinois.	Disch'd Aug. 15, 1863; pensioned.
221	McKenna, J., Serg't, F, 12th New York Cavalry.	July 20, 1863.	Shot wound of left shoulder, involving bone and artery.	July 20, 1863.	Amputated, by Surg. A. Potter, 5th Rhode Island Artillery.	Disch'd Feb. 2, 1864; pensioned.
222	McKenzie, S. C., Pt., H, 82d New York.	Dec. 12, 1862.	Shell wound of right wrist and shoulder.	Dec. 13, 1862.	Amputation at the shoulder.	Disch'd Feb. 4, 1863; pensioned.
223	McLaughlin, A., Pt., F, 57th Indiana.	Dec. 31, 1862.	Shell wound of upper third of left arm; humerus fractured, muscles lacerated.	Jan. 1, 1863.	Amputation at the shoulder, by Surgeon E. B. Glick, 40th Indiana.	Disch'd Mar. 17, 1863. Entered V. R. C. Discharged Sept. 19, 1864; pensioned.
224	Meagher, T., Pt., C, 1st Massachusetts.	June 25, 1862.	Shot wound of right arm, with fracture of humerus.	June 26, 1862.	Amputation at the shoulder by transfexion.	Disch'd April 9, 1863; pensioned.
225	Mears, G. W., Serg't, A, 6th Pennsylvania Reserves, age 20.	Nov. 27, 1863.	Shot fracture of head and neck of left humerus, outer third of left clavicle, and acromial process of scapula.	Nov. 28, 1863.	Arm amputated at shoulder and fragments of clavicle and scapula removed, by Surg. C. Bower, 6th Penn. Reserves.	Mustered out October 20, 1864; pensioned. <i>Spec.</i> 2531, A. M. M.
226	Melvin, J., Serg't, F, 61st New York, age 22.	June 22, 1864.	Shot fracture of right arm in upper third.	June 22, 1864.	Amputated at the shoulder, by Surg. J. W. Wishart, 140th Pa.	Disch'd May 20, 1865; pensioned.
227	Menzel, C. T., Serg't, B, 39th New York.	June 8, 1862.	Wounds of the right arm by two conoidal balls; much shattering.	June 10, 1862.	Amputated at the shoulder, by Surg. P. Wolf, 39th New York.	Disch'd July 4, 1862; pensioned. Shoulder very tender.
228	Merceer, J. J., Pt., F, 30th North Carolina, age 25.	July 2, 1863.	Shot wound of left arm, ball lodging in the shoulder joint; upper third of humerus extensively comminuted.	July 2, 1863.	Amputation at the shoulder by antero-posterior flaps.	Transferred, for exchange, Nov. 12, 1863.
229	Metcalf, C. L., Corp'l, I, 1st Maine Heavy Artillery, age 20.	June 18, 1864.	Shot fracture of the head of right humerus; considerable hemorrhage.	June 18, 1864.	Flap amputation at shoulder; lateral and internal flaps.	Disch'd Mar. 22, 1865; pensioned.
230	Miles, R., Corp'l, H, 148th Pennsylvania.	May 3, 1863.	Gunshot wound of right arm, with comminution.	May 3, 1863.	Amputated at the shoulder, by Surg. G. L. Potter, 145th Pa.	Disch'd July 15, 1863; pensioned.
231	Miller, A. B., Pt., A, 8th Michigan, age 36.	June 17, 1864.	Shot wound through the upper third of right humerus.	June 17, 1864.	Amputated at the shoulder, by Surg. W. B. Fox, 8th Mich.	Slight hemorrhages. Disch'd Sept. 14, 1864; pensioned.
232	Miller, M., Pt., H, 8th Tennessee Cavalry.	Nov. 11, 1864.	Shot wound of right arm by minié ball.	Nov. 11, 1864.	Amputated at shoulder joint, by Ass't Surg. C. Wheeler, 8th Tennessee Cavalry.	Disch'd Sept. 11, 1865; pensioned.
233	Mills, J., Serg't, D, 8th Vermont, age 21.	Sept. 19, 1864.	Shot wound of left wrist and shoulder; head of humerus comminuted; ball lodged.	Sept. 20, 1864.	Amputated, by Ass't Surg. B. A. Fordyce, 160th New York, by antero-posterior flap method; missile removed from over the second rib.	Several abscesses formed. Mustered out June 25, 1865; pensioned.
234	Mitchell, J., Pt., E, 76th New York, age 27.	May 5, 1864.	Comminuted shot fracture of upper third of left humerus; shoulder joint implicated.	May 6, 1864.	Amputated by the flap method, by Surg. Stratch, C. S. A.	Gangrene; stump healed. Oct. 15, 1864. Discharged July 19, 1865; pensioned.
235	Mohl, W., Pt., A, 7th New Jersey.	May 3, 1863.	Shot wound of right arm, the bone and artery injured.	May 3, 1863.	Amputation at the shoulder by the oval method.	Disch'd Sept. 12, 1863; pensioned.
236	Monaghan, T., Pt., B, 48th New York, age 26.	June 2, 1864.	Comp'd comminuted fracture of right humerus by a canister shot.	June 2, 1864.	Amputated by single anterior flap method, by Surg. J. L. Mulford, 48th New York.	Disch'd July 25, 1865; pensioned.
237	Mond, August, Pt., I, 8th Illinois.	Feb. 15, 1862.	Shot wound in right shoulder joint.	Feb. 16, 1862.	Amputation at the shoulder by Lisfranc's method.	Disch'd Aug. 17, 1862; pensioned.
238	Montgomery, D. C., Corp'l, H, 3d Georgia, age 25.	July 2, 1863.	Shot fracture of upper third of left humerus.	July 3, 1863.	Amputation at the shoulder by double flaps.	Transferred to Provost Marshal, for exchange, Sept. 1, 1863.
239	Morrison, P. A., Pt., A, 121st Pennsylvania.	Dec. 13, 1862.	Shot wound of left shoulder, involving bone and vessels.	Dec. 13, 1862.	Amputated at the shoulder, by Surg. J. A. Ranney, 121st Pa.	Disch'd April 22, 1863; pensioned.
240	Murray, L., Pt., B, 5th New York, age 29.	Aug. 18, 1864.	Right forearm carried away by solid shot.	Aug. 19, 1864.	Amputated at the shoulder, by Surg. A. A. White, 8th Md.	Disch'd Jan. 20, 1865; pensioned.
241	Nans, A. F., Pt., H, 118th Ohio, age 22.	Aug. 6, 1864.	Shell fracture of head and portion of shaft of left humerus; deltoid nearly torn away.	Aug. 7, 1864.	Amputated, by Surgeon J. W. Lawton, U. S. V.	Disch'd Mar. 28, 1865; pensioned.
242	Nelson, B. R., Corp'l, I, 122d Ohio, age 34.	Mar. 25, 1865.	Shot fracture of upper third of right humerus.	Mar. 25, 1865.	Amput'd at shoulder, by Surg. W. M. Houston, 122d Ohio.	Disch'd June 9, 1865; pensioned.
243	Nichols, C. A., Pt., E, 118th Pennsylvania.	Sept. 20, 1862.	Shot wound of right arm, with fracture of humerus.	Sept. 22, 1862.	Amputated at the shoulder, by Surg. J. Thomas, 118th Penn.	Disch'd Feb. 17, 1863; pensioned.
244	Nichols, J. W., Pt., D, 2d Vermont, age 22.	May 5, 1864.	Shot wounds of left arm and right thigh.	May 7, 1864.	Amputated at the shoulder, by Surg. E. M. Curtis, 6th Vt.	Disch'd May 12, 1865; pensioned.
245	Norris, G. C., Serg't, I, 61st Georgia, age 29.	July 3, 1863.	Shot fracture of left humerus in upper third.	July 3, 1863.	Amputation at the shoulder by double flaps.	Sent to Provost Marshal, for exchange, Sept. 16, 1863.
246	Noyes, A. M., Pt., C, 1st Massachusetts Heavy Artillery, age 30.	June 22, 1864.	Shell fracture of left humerus; soft parts extensively lacerated.	June 22, 1864.	Amputated at the shoulder, by Dr. Leicester, of New York.	Disch'd Sept. 23, 1864; pensioned.
247	Nutter, J., Pt., K, 123d Ohio.	June 13, 1863.	Shot wound of left arm; comminuted fracture.	June 13, 1863.	Amputated at the shoulder, by a Confederate Surgeon.	Disch'd Oct. 26, 1863; pensioned.
248	Oakley, P. W., Lieut., K, 7th Wisconsin.	Aug. 23, 1862.	Upper third of right arm badly shattered.	Aug. 23, 1862.	Amputated at the shoulder, by Surgeons J. McNulty and P. Penno, U. S. V.	Resigned September 29, 1862; pensioned.

NO.	NAME, AGE, AND MILITARY DESCRIPTION.	DATE OF INJURY.	NATURE OF INJURY.	DATE OF OPERATION.	OPERATION AND OPERATOR.	RESULT AND REMARKS.
249	O'Donnell, P., Pt., A, 104th Illinois.	July 20, 1864.	Fracture of neck of right humerus, with injury of artery.	July 20, 1864.	Amputated at the shoulder, by a Confederate surgeon.	Disch'd June 6, 1865; pensioned. Died July 17, 1870.
250	Osbourn, F. A., Pt., I, 20th Indiana.	June 25, 1862.	Shot wound in left arm; the humerus shattered.	June 25, 1862.	Amputated at the shoulder, by Surg. M. Gunn, 5th Michigan.	Disch'd Aug. 13, 1862; pensioned.
251	Ott, N., Pt., H, 208th Pennsylvania, age 28.	April 2, 1865.	Shot fracture of upper third of left humerus.	April 2, 1865.	Amputation at the shoulder by Lisfranc's method.	Disch'd June 30, 1865; pensioned.
252	Owens, D. L., Pt., B, 38th Virginia, age 24.	July 3, 1863.	Gunshot wound of right arm; fracture of humerus.	July 3, 1863.	Amputation at the shoulder by transfixion.	Paroled August 22, 1861.
253	Page, I., Pt., E, 26th Mich., age 33.	Aug. 16, 1864.	Shot wound of left arm; humerus comminuted.	Aug. 16, 1864.	Amputated at the shoulder by antero-posterior flap method, by Surg. J. W. Wishart, 140th Pennsylvania.	Disch'd Jan. 23, 1865; pensioned.
254	Pancost, J., Pt., H, 4th New Jersey.	Sept. 14, 1862.	Shot fracture of the upper third of right arm; shoulder joint involved.	Sept. 15, 1862.	Amputated by anterior flap method, by Surgeon L. W. Oakley, 2d New Jersey.	Disch'd Dec. 23, 1862; pensioned.
255	Parke, S. B., Pt., L, 6th Alabama, age 22.	May 3, 1863.	Shot fracture of upper third of humerus.	May 3, 1863.	Flap amputation at shoulder by Malgaigne's method.	Gangrene. Furloughed August 26, 1863.
256	Parker, W. B., Pt., I, 20th Massachusetts, age 21.	July 3, 1863.	Fracture of left humerus by conoidal ball.	July 4, 1863.	Amputation at the shoulder by the oval method.	Disch'd Jun. 6, 1864; re-enlisted June 20, 1867; disch'd April 1, 1869; died March 20, 1870.
257	Peck, A., Pt., H, 13th Wisconsin, age 24.	Jan. 16, 1865.	Wound through left shoulder joint, comminuting head of the humerus.	Jan. 17, 1865.	Amputated by the antero-posterior flap method, by Surg. J. Evans, 13th Wisconsin.	Disch'd April 30, 1865; pensioned.
258	Pellet, J. C., Serg't. E, 11th Vermont, age 40.	Aug. 21, 1864.	Shot fracture of right arm in upper third.	Aug. 21, 1864.	Amputated by the antero-posterior flap method, by Surg. C. B. Park, 11th Vermont.	Disch'd Dec. 28, 1864; pensioned.
259	Pentonay, M., Pt., G, 20th Massachusetts.	Dec. 11, 1862.	Shot fracture of right arm and injury of bloodvessels.	Dec. 13, 1862.	Amputated at the shoulder, by Surg. N. Hayward, 20th Mass.	Disch'd April 9, 1863; pensioned.
260	Pickering, W., Corporal, G, 84th Pennsylvania, age 29.	Aug. 15, 1864.	Shot wound of left arm; head of humerus shattered.	Aug. 16, 1864.	Flap amputation at the shoulder joint.	Disch'd Dec. 6, 1864; pensioned.
261	Pines, F. M., Serg't, F, 1st Alabama, age 32.	Nov. 30, 1864.	Shot injury near shoulder . . . .	Dec. 1, 1864.	Amputation at the shoulder by the oval flap method.	Sent to Provost Marshal March 27, 1865.
262	Piper, J. W., Pt., A, 104th New York.	Dec. 13, 1862.	Shot wound of left shoulder by a large projectile.	Dec. 13, 1862.	Amputation at the shoulder by Larrey's method.	Disch'd Feb. 9, 1863; pensioned.
263	Plyler, E., Pt., I, 148th Pennsylvania, age 29.	July 2, 1863.	Comp'd comminuted fracture of left humerus.	July 3, 1863.	Amputation at the shoulder by double flap.	Disch'd Oct. 23, 1863; pensioned.
264	Powers, N., Pt., C, 11th New York Artillery, age 45.	June 14, 1865.	Shot wound of right shoulder; lesions of bone and artery.	Feb. 14, 1865.	Amputated at the shoulder, by Surg. W. B. Fox, 8th Mich.	Disch'd May 29, 1865; pensioned.
265	Powers, P. S., Pt., B, 3d Confederate Regiment, age 36.	April 29, 1862.	Comminution of head and neck and upper portion of shaft of right humerus; much laceration and hæmorrhage.	April 29, 1862.	Amputation at the shoulder by antero-posterior flaps.	Sent to Camp Chase, Ohio, Sept. 14, 1862, for exchange.
266	Preston, W. E., Pt., — Virginia Artillery, age 23.	May 12, 1864.	Shot fracture of left humerus near surgical neck.	May 12, 1864.	Flap amputation at shoulder. . .	Sent to Old Capitol Prison June 30, 1864.
267	Putnam, J. C., Corp'l, H, 20th Massachusetts.	Oct. 21, 1861.	Shot fracture of right humerus; laceration of soft parts.	Oct. 21, 1861.	Amputated at the shoulder, by Surg. N. Hayward, 20th Mass.	Disch'd Sept. 8, 1863; pensioned.
268	Quattlebaum, W., Pt., A, 57th Alabama, age 35.	July 20, 1864.	Shot fracture of right humerus.	July 21, 1864.	Amputation at the shoulder by antero-posterior flap method.	Sent to Provost Marshal Nov. 15, 1865.
269	Rafferty, P., Pt., H, 73d New York, age 25.	Sept. 17, 1864.	Comminuted shot fracture of right humerus; wound of face.	Sept. 18, 1864.	Flap amputation at the shoulder, by Surg. J. S. Jamison, 6th New York.	Disch'd Nov. 15, 1865; pensioned. <i>Spec.</i> 4114, A. M. M.
270	Raugh, J. J., Pt., C, 53d Pennsylvania, age 19.	July 2, 1863.	Shaft of left humerus fractured; copious hæmorrhage; brachial probably wounded.	July 4, 1863.	Amputated, by Surgeon C. S. Wood, 6th New York, July 12th; ball extracted from thoracic wall below axilla.	Vet. Res. Corps, May 12, 1864. Disch'd October 17, 1864; pensioned.
271	Reed, J. H., Pt., B, 32d Maine, age 29.	July 30, 1864.	Shot comminution of head of right humerus.	July 30, 1864.	Amputated at the shoulder by the oval skin-flap method; five ligatures.	Disch'd Oct. 30, 1864; pensioned.
272	Reed, S. L., Pt., F, 25th Massachusetts, age 20.	June 15, 1864.	Shell wound of left arm, with laceration of vessels.	June 15, 1864.	Amputated, by Surgeon J. M. Rice, 25th Massachusetts.	Disch'd Nov. 17, 1864; pensioned.
273	Richardson, S. D., Pt., B, 26th North Carolina.	July 1, 1863.	Shot wound of right arm; artery and bone injured.	July 3, 1863.	Amputation at the shoulder by transfixion.	Furloughed October 5, 1863.
274	Rinehart, F., Pt., C, 2d Penn. Heavy Artillery, age 44.	June 17, 1864.	Shot fracture of upper third of left arm.	June 19, 1864.	Amputated at the shoulder, by Surgeon D. Seaverns, U. S. V.	Disch'd Feb. 2, 1865; pensioned.
275	Robbins, C. T., Pt., D, 13th Massachusetts, age 23.	Aug. 27, 1862.	Ball entered the upper part of left arm anteriorly, emerging in front of the middle of the inferior border of left scapula.	Aug. 27, 1862.	Amputated at shoulder by the antero-posterior flap method.	Disch'd Oct. 3, 1862; pensioned.
276	Robertson, J. H., Pt., H, 2d Michigan.	May 31, 1862.	Shot wound of right arm near the shoulder.	June 1, 1862.	Amputated at the shoulder, by Surgeon Z. E. Bliss, 3d Mich.	Disch'd Oct. 21, 1862; pensioned.
277	Rowlison, A. C., Pt., K, 22d Indiana, age 21.	Oct. 8, 1862.	Shot fracture of upper third of left humerus.	Oct. 8, 1862.	Amputation at the shoulder by Dupuytren's method.	Disch'd Dec. 18, 1862; pensioned. Died March 14, 1868, of pulmonary consumption, caused by the amputation.
278	Ruckstool, J. I., Pt., D, 95th Pennsylvania, age 19.	May 12, 1864.	Shot fracture of the left arm near the shoulder joint.	May 12, 1864.	Amputated by the flap method, by Surg. E. B. P. Kelley, 95th Pennsylvania.	To Veteran Reserve Corps July 3, 1864. Discharged July 17, 1865; pensioned.
279	Russell, L., Pt., 81st New York, age 19.	Aug. 1, 1863.	Ball crushed the entire upper third of the left humerus into the joint and tore nerves and bloodvessels.	Aug. 1, 1863.	Amputated, by Surg. W. H. Rice, 81st New York.	Disch'd Oct. 13, 1863; pensioned. Died April 15, 1868.
280	Ryan, T., Pt., D, 67th Pennsylvania, age 48.	Mar. 25, 1865.	Shot fracture of right shoulder; laceration of soft parts.	Mar. 25, 1865.	Amputation at the shoulder by the oval method.	Disch'd May 26, 1867; pensioned.
281	Salmon, W., Pt., A, 23d Indiana, age 19.	Mar. 19, 1865.	Shot wound of upper third of left arm.	Mar. 19, 1865.	Amputation at the shoulder by double flaps.	Disch'd June 12, 1865; pensioned.
282	Samoiel, L., Pt., G, 48th Illinois.	July 28, 1864.	Missile fractured left humerus and severed brachial artery.	July 29, 1864.	Amputated at the shoulder, by Surg. W. Lomax, 12th Ind.	Mustered out August 15, 1865; pensioned.
283	*Sampson, W. C., Pt., 44th Georgia.	Sept. 17, 1862.	Comminuted fracture of head of right humerus.	Sept. 17, 1862.	Flap amputation at shoulder. . .	Doing well October 1, 1862.
284	Sanborn, C. B., Pt., M, 1st New Hampshire Cavalry.	Sept. 14, 1863.	Shell fracture of right humerus, joint involved.	Sept. 14, 1863.	Amputated at the shoulder by the circular method.	Disch'd Dec. 5, 1864; pensioned.
285	Saul, F., Corp'l, C, 14th N.Y. Heavy Artillery, age 29.	July 27, 1864.	Shot wound of head and neck of left humerus.	July 27, 1864.	Amputated at the shoulder, by Surg. T. F. Oakes, 5th Mass.	Disch'd Dec. 20, 1864; pensioned.

\* FISCHER (G. J.), *Report of Fifty-seven Cases of Amputation in the Hospitals near Sharpsburg, Md., after the battle of Antietam, September 17, 1862, in Am. Jour. Med. Sci., 1863, Vol. XLV, N. S., p. 48.*



No.	NAME, AGE, AND MILITARY DESCRIPTION.	DATE OF INJURY.	NATURE OF INJURY.	DATE OF OPERATION.	OPERATION AND OPERATOR.	RESULT AND REMARKS.
286	Savage, J., Sergeant-Major, 61th New York, age 28.	July 2, 1863.	Shot fracture of right humerus near the shoulder joint.	July 2, 1863.	Amputation at the shoulder by antero-posterior flap method.	Disch'd Jan. 19, 1864; pensioned.
287	Schafer, G., Pt., H, 123d Ohio, age 21.	Sept. 3, 1864.	Shot fracture of upper third and head of left humerus.	Sept. 5, 1864.	Amputated at the shoulder, by Ass't Surg. N. B. Brisbane, 123d Ohio.	Disch'd Dec. 31, 1864; pensioned.
288	Schmidt, J., Pt., B, 5th Pennsylvania.	Dec. 20, 1861.	Shot fracture of right humerus in the upper third.	Dec. 21, 1861.	Amputation at the shoulder.	Disch'd Nov. 25, 1862; pensioned.
289	Schreiner, D., Pt., C, 25th Wisconsin, age 22.	Aug. 10, 1864.	Shell fracture of head of left humerus.	Aug. 10, 1864.	Flap amputation at shoulder.	Disch'd June 11, 1865; pensioned.
290	Schwigert, C., Pt., H, 42d Illinois.	May 9, 1862.	Shot fracture of right humerus in the upper third.	May 9, 1862.	Amputated at the shoulder, by Surg. T. D. Fitch, 42d Illinois.	Disch'd Dec. 20, 1862; pensioned.
291	Searle, F. K., Pt., B, 7th Michigan.	May 31, 1862.	Shot wound of right arm, with fracture, and injury of blood-vessels.	June 2, 1862.	Amputated at the shoulder by the circular method, by Surg. A. N. Dougherty, U. S. V.	Disch'd July 18, 1862; pensioned.
292	Seeman, A., Serg't, B, 7th New York, age 34.	Mar. 31, 1865.	Shot fracture of left humerus at upper third.	April 2, 1865.	Amputation at the shoulder.	Disch'd July 20, 1865; pensioned.
293	Severn, E. L., Lieut., K, 96th Pennsylvania, age 27.	May 10, 1864.	Shot wound of right arm and bones of clavicle.	May 10, 1864.	Amputation at the shoulder, with excision of four inches of clavicle and removal of injured portion of scapula, by Surg. D. W. Bland, 96th Penn.	Disch'd Aug. 17, 1864; pensioned.
294	Sewell, C. H., Pt., G, 1st Florida, age 29.	Dec. 16, 1864.	Left arm carried away by cannon shot.	Dec. 16, 1864.	Amputation at the shoulder.	Sent to Provost Marshal Feb. 24, 1865.
295	Shaughnessy, T., Pt., D, 14th New York Heavy Artillery, age 28.	June 29, 1864.	Shell fracture of upper third of left humerus; shoulder joint involved; contusion of left side of chest.	June 29, 1864.	Amputation at shoulder by the antero-posterior flap method.	Disch'd April 1, 1865; pensioned.
296	Shear, N. T., Serg't, H, 3d Arkansas, age 34.	July 3, 1863.	Right arm torn away by shell just below head of humerus.	July 4, 1863.	Amputated at the shoulder, by Surg. J. M. Hayes, C. S. A.	Sent to City Point, for exchange, November 12, 1863.
297	Shelton, W., Serg't, H, 12th Virginia, age 24.	Aug. 19, 1864.	Fragment of shell struck the right nipple and passed into the shoulder joint; head of humerus fractured.	Aug. 19, 1864.	Amputation at the shoulder by the oval method.	Sloughing. Aug. 27th, all symptoms favorable.
298	Shields, J. H., Pt., H, 6th Maryland, age 40.	May 9, 1864.	Shot wound of left arm.	May 10, 1864.	Amputation at the shoulder by transfexion.	Disch'd Feb. 6, 1865; pensioned.
299	Shull, A., Pt., A, 41st Ohio.	Nov. 25, 1863.	Fracture of left humerus by grapeshot; much laceration.	Nov. 25, 1863.	Amputated at the shoulder, by Surg. J. L. Teed, U. S. V.	Disch'd June 10, 1864; pensioned.
300	Shulz, W. G., Serg't, D, 43d New York, age 19.	Mar. 25, 1865.	Shell comminution of shaft of left humerus.	Mar. 25, 1865.	Amputation at the shoulder by the flap method.	Disch'd July 6, 1865; pensioned.
301	Slattery, M., Pt., C, 33d New York.	Sept. 17, 1862.	Shot wound of left arm; the humerus shattered.	Sept. 18, 1862.	Amputation at the shoulder by double flaps.	Disch'd Jan. 6, 1863; pensioned.
302	Smith, B. R., Pt., G, 56th Pennsylvania.	April 29, 1863.	Shot wound of left shoulder; fracture of humerus.	April 29, 1863.	Amputated at the shoulder, by Surgeon G. W. New, 7th Indiana.	Disch'd Sept. 12, 1863; pensioned.
303	Smith, J., Pt., A, 28th Pennsylvania, age 29.	Nov. 27, 1863.	Shot wound of right arm, with injury of vessels and bone.	Nov. 27, 1863.	Amputation at the shoulder by Larrey's method.	Disch'd May 14, 1864; pensioned.
304	Smith, J. A., Pt., A, 5th Maryland, age 18.	April 2, 1865.	Shot fracture of left humerus just below shoulder.	April 3, 1865.	Amputated at the shoulder, by a Confederate surgeon.	Discharged November 16, 1865.
305	Smith, J. L., Pt., B, 157th Pennsylvania, age 33.	June 28, 1864.	Compound fracture of upper third of right humerus.	June 28, 1864.	Amputated at the shoulder by the flap method.	Disch'd May 19, 1865; pensioned.
306	Smith, T. R., Pt., H, 3d Iowa.	Oct. 5, 1862.	Wound of right arm by canister shot.	Oct. 6, 1862.	Amputation at the shoulder by Lisfranc's method.	Disch'd June 14, 1863; pensioned.
307	Smith, W., Pt., E, 27th Massachusetts, age 22.	Mar. 8, 1865.	Shot fracture of the upper third of the right humerus.	Mar. 9, 1865.	Amputated at the shoulder, by Dr. Cox, C. S. A.	Disch'd Aug. 2, 1865; pensioned.
308	Snadden, J. A., Pt., B, 84th Pennsylvania, age 26.	May 6, 1864.	Shot fracture of left arm by conoidal ball.	May 6, 1864.	Amputated at the shoulder by the flap method.	Disch'd Dec. 29, 1864; pensioned.
309	Sponcer, B. F., Colonel, 83d Indiana, age 48.	June 27, 1864.	Shot wound of left humerus; ball passed through shoulder joint.	June 28, 1864.	Amputated at the shoulder, by Asst. Surg. C. B. Richards, 30th Ohio.	Disch'd April 28, 1865; pensioned.
310	Stephens, W. H., Pt., D, 13th Penn. Cavalry, age 24.	May 28, 1864.	Left arm almost torn off by a cannon ball.	May 28, 1864.	Amputation at the shoulder by oval incisions.	Disch'd Dec. 24, 1864; pensioned.
311	Stevens, G. F., Pt., B, 17th New Hampshire, age 19.	July 18, 1863.	Shot wound of left arm; ball passed through surgical neck of humerus.	July 18, 1863.	Amputated at the shoulder, by Surg. S. A. Greene, 24th Massachusetts.	Sloughing. Discharged Dec. 29, 1863; pensioned.
312	Stiles, R., Pt., B, 195th Pennsylvania.	April 2, 1865.	Shot fracture of right arm.	April 2, 1865.	Amputated at the shoulder, by Surg. P. S. Ainsworth, U. S. V.	Disch'd June 19, 1865; pensioned. Stump very sensitive.
313	Stokell, G. L., Pt., B, 32d Massachusetts.	May 5, 1864.	Shot wound of right arm.	May 7, 1864.	Flap amputation at shoulder, by a Confederate surgeon.	Disch'd Mar. 20, 1865; pensioned.
314	Stokes, J. D., Lieut., F, 146th Pennsylvania.	July 2, 1863.	Shot fracture of head and neck of right humerus.	July 4, 1863.	Amputated by the flap method, by Surgeon J. W. Wishart, 140th Pennsylvania.	Disch'd Jan. 15, 1864; pensioned. Neurotoma of axillary plexus removed. Died Sept. 17, 1864.
315	Stone, R. J., Pt., D, 23d Tennessee, age 26.	Dec. 16, 1864.	Shell wound of right arm, and lesions of bone and artery.	Dec. 16, 1864.	Amputation at the shoulder by the oval flap method.	Sent to Provost Marshal March 1, 1865.
316	Stautenburg, H. E., Serg't, E, 40th New York, age 24.	Sept. 10, 1864.	Shot fracture of the upper third of the right arm; soft parts lacerated.	Sept. 11, 1864.	Amputated at the shoulder, by Surg. H. F. Lyster, 5th Mich.	Mustered out Nov. 29, 1864; pensioned. Spec. 4107, A. M. M.
317	Stutsman, A. H., Pt., C, 1st Iowa Cavalry, age 25.	Aug. 27, 1863.	Comminuted shot fracture of left humerus; shoulder joint opened.	Aug. 29, 1863.	Amputated by Lisfranc's operation, by Surgeon Joseph C. Lymph.	Disch'd Jan. 19, 1864; pensioned.
318	Sullivan, J., Pt., I, 6th New Hampshire, age 23.	Sept. 30, 1864.	Fracture of right shoulder by a cannon ball.	Sept. 30, 1864.	Amputated by the flap method, by Surgeon W. Ingalls, 53th Massachusetts.	Disch'd June 7, 1865; pensioned.
319	Summers, D., Pt., A, 15th West Virginia, age 45.	July 17, 1864.	Fracture of upper third of right humerus.	July 18, 1864.	Amputated at the shoulder by the antero-posterior oval flap method.	Disch'd Mar. 4, 1865; pensioned.
320	Sunderland, J., Pt., E, 48th Pennsylvania.	Dec. 13, 1862.	Shell wound of right arm.	Dec. 13, 1862.	Amputation at the shoulder by double flaps.	Disch'd April 11, 1863; pensioned.
321	Sutphin, F., Pt., C, 24th Virginia, age 19.	May 16, 1864.	Fracture of upper third of left humerus; flesh wound of left leg.	May 15, 1864.	Amputated at the shoulder, by Surg. W. V. Harrison, C. S. A.	Retired February 3, 1865.
322	Swenson, J., Corp'l, D, 52d Illinois.	Oct. 4, 1862.	Shot wound of left arm; the humerus shattered.	Oct. 4, 1862.	Amputated at the left shoulder joint, by Surg. J. Andrews, 3d Michigan Cavalry.	Mustered out July 6, 1865; pensioned.
323	Taggart, J. S., Corp'l, E, 33d New York, age 19.	May 4, 1863.	Shot fracture of left humerus; laceration of soft parts.	May 4, 1863.	Amputation at the shoulder by the oval method.	Disch'd June 1, 1863; pensioned.

No.	NAME, AGE, AND MILITARY DESCRIPTION.	DATE OF INJURY.	NATURE OF INJURY.	DATE OF OPERATION.	OPERATION AND OPERATOR.	RESULT AND REMARKS.
324	Taylor, T., Pt., B, 58th Illinois, age 18.	May 18, 1864.	Shot fracture of left humerus near the shoulder joint.	May 19, 1864.	Amputated at the shoulder, by Surg. H. M. Crawford, 58th Illinois.	Mustered out April 1, 1866; pensioned.
325	Thing, E., Corp'l, K, 116th Maine, age 22.	Aug. 18, 1864.	Shot fracture of left humerus at surgical neck.	Aug. 18, 1864.	Amputation at the shoulder.	Disch'd Mar. 2, 1865; pensioned.
326	Thomas, J. W., Pt., K, 21st Alabama, age 42.	April 8, 1865.	Shell wound of left arm, with injury of bone and artery.	April 8, 1865.	Amputation at the shoulder.	Paroled June 28, 1865.
327	Thrane, T., Corp'l, K, 2d New York.	Aug. 27, 1862.	Shot fracture of left humerus in the upper third.	Aug. 27, 1862.	Amputated at the shoulder, by Surg. L. McLean, 2d N. York.	Disch'd Oct. 27, 1862; pensioned.
328	Trimball, L. A., Corp'l, G, 8th Arkansas, age 23.	Dec. 15, 1864.	Shot wound of left arm, with injury of bone and vessels.	Dec. 17, 1864.	Amputation at the shoulder.	Sent to Provost Marshal Feb. 24, 1865.
329	Up, C. C., Pt., B, 76th Pennsylvania, age 21.	July 11, 1863.	Shot fracture of left humerus in upper third.	July 13, 1863.	Amputated, by Surg. R. A. Kinloch, C. S. A.	Disch'd Jan. 7, 1864; pensioned.
330	Underwood, O., Pt., K, 43d Ohio.	Feb. 3, 1865.	Shot fracture of left arm, high up; laceration of soft parts.	Feb. 3, 1865.	Amputated at the shoulder, by Surg. F. M. Rose, 43d Ohio.	Disch'd June 17, 1865; pensioned.
331	—, —, Pt., 7th Michigan.	Dec. 13, 1862.	Extensive comminution of right humerus and fracture of the scapula and clavicle; parts lacerated.	Dec. 13, 1862.	Amputated at shoulder joint, with removal of portions of scapula and clavicle, by Surg. C. S. Wood, 6th New York.	Favorable
332	Vail, E., Pt., I, 159th New York.	May 24, 1863.	Shot wound of left arm, with injury of vessels and bone.	May 24, 1863.	Amputated at shoulder joint, by Surg. C. Robertson, 159th New York.	Disch'd July 29, 1863; pensioned.
333	Valence, C., Pt., E, 1st Pennsylvania Rifle Reserves.	June 26, 1862.	Shot wound of left arm, the humerus shattered.	June 27, 1862.	Amputation at the shoulder.	Disch'd Sept. 6, 1862; pensioned. Died June 24, 1870.
334	Vanderson, H. V., Pt., A, 11th U. S. Infantry.	June 27, 1862.	Shot wound of left arm, with injury of bone and artery.	June 28, 1862.	Amputation at the shoulder.	Disch'd Aug. 29, 1862; pensioned.
335	Vanhew, J., Pt., G, 149th Pennsylvania, age 21.	May 8, 1864.	Comminuted fracture of right arm.	May 8, 1864.	Amputated, by Surg. W. Humphreys, 149th Pennsylvania.	Disch'd Oct. 22, 1864; pensioned. Spec. 111, A. M. M.
336	Van Rialta, D., Pt., I, 25th Michigan, age 19.	Aug. 26, 1864.	Fracture of upper third of right humerus; head of bone split; missile penetrated the cheek, chipping malar bone.	Aug. 26, 1864.	Amputated, by Surgeon A. M. Wilder, U. S. V.; fragments of bone removed from face.	Disch'd April 12, 1865; pensioned.
337	Van Tassel, H., Pt., I, 95th New York.	July 1, 1863.	Shot wound in left shoulder.	July 1, 1863.	Amputated at the shoulder, by Surg. G. W. Metcalf, 76th N. Y.	To Veteran Reserve Corps Sept. 9, 1863.
338	Wager, S., Pt., B, 1st U. S. Artillery, age 21.	June 3, 1864.	Fracture of right humerus, high up, by a large projectile.	June 3, 1864.	Amputated at the shoulder by the flap method.	June 10, 1864, secondary hæmorrhage; circumflex ligated. Discharged Mar. 16, 1865; pensioned. Died Dec. 31, 1868, of consumption, resulting from amputation.
339	Wagner, A., Pt., E, 45th New York.	July 1, 1863.	Shot fracture of right humerus; soft parts near the shoulder carried away; arm held by skin of inner surface.	July 1, 1863.	Flap amputation at shoulder.	Disch'd Jan. 9, 1864; pensioned.
340	Wait, R. R., Pt., H, 49th New York.	May 12, 1864.	Shot fracture of left humerus by cannon ball.	May 12, 1864.	Amputation at the shoulder by transfexion.	Disch'd April 7, 1865; pensioned.
341	Walker, G. W., Pt., M, 6th Alabama, age 26.	July 1, 1863.	Comp'd comminuted fracture of right humerus.	July 1, 1863.	Amputation at the shoulder.	Transferred, for exchange, Sept. 25, 1863.
342	Waltz, C. K., Pt., C, 140th Pennsylvania.	July 2, 1863.	Shot fracture of neck and shaft of right humerus.	July 3, 1863.	Flap amputation at shoulder, by Surgeon J. W. Wishart, 140th Pennsylvania.	Disch'd Dec. 19, 1863; pensioned.
343	Warner, G. W., Pt., B, 20th Connecticut, age 32.	July 3, 1863.	Shell wounds of both arms; one fragment severed right arm from body, another fractured bones of left forearm, lacerating soft parts.	July 3, 1863.	Amputation at right shoulder joint and of left arm at lower third of humerus.	Disch'd Oct. 17, 1863; pensioned.
344	Watkins, D., Pt., E, 14th North Carolina, age 38.	July 1, 1863.	Comminution of right humerus and laceration of soft parts by shell.	July 1, 1863.	Amputation at the shoulder by the oval method.	Paroled September 25, 1863.
345	Webb, J. T., Pt., A, 114th Illinois.	May 20, 1863.	Fracture of right humerus in the upper third.	May 20, 1863.	Amputated at the shoulder, by Surg. M. W. Fisk, 11th Mo.	Disch'd July 20, 1863; pensioned.
346	Wegman, G., Pt., I, 6th New Jersey.	May 5, 1862.	Shot wound of right arm, with injury of vessels and bone.	May 6, 1862.	Flap amputation at shoulder, by Asst. Surg. J. H. Pooley, U. S. A.	Disch'd Aug. 29, 1862; pensioned.
347	Weight, W., Pt., D, 5th New Jersey.	June 1, 1862.	Shot wound of right arm, the humerus shattered.	June 1, 1862.	Amputation at the shoulder by double flaps.	Disch'd July, 1862; pensioned.
348	Wesley, S., Landsman, Gun-boat Maclinaw, age 23.	Feb. 14, 1865.	Shot fracture of right humerus.	Feb. 14, 1865.	Amputated at the shoulder, by a naval surgeon.	Sent to Marine Hospital in January, 1867; pensioned.
349	Westmeier, H., Pt., I, 70th Ohio, age 20.	Aug. 18, 1864.	Shot comminution of surgical neck of right humerus; shoulder joint opened.	Aug. 19, 1864.	Amputated at the shoulder, by Asst. Surg. D. Halderman, 46th Ohio.	Disch'd Jan. 2, 1865; pensioned.
350	Whitham, R., Pt., C, 15th New Jersey.	May 3, 1863.	Shot wound of right arm.	May 3, 1863.	Amputation at the shoulder.	Disch'd Sept. 25, 1863; pensioned.
351	Widdicombe, B. F., Corp'l, H, 82d Pennsylvania, age 20.	June 3, 1864.	Severe shot wound of the left shoulder joint.	June 3, 1864.	Amputation at the shoulder by Larrey's method.	Disch'd Sept. 13, 1864; pensioned.
352	Wild, E. A., Colonel, 35th Massachusetts.	Sept. 14, 1862.	Loss of left arm by a round shot.	Sept. 16, 1862.	Amputated at the shoulder, by Dr. Rogers of New York.	Promoted to Brigadier General April 25, 1863. Mustered out January 15, 1866; pensioned. Discharged April 5, 1865.
353	Wilkinson, P., Pt., I, 81st Pennsylvania.	June 4, 1864.	Shot wound of right shoulder, the humerus shattered.	June 4, 1864.	Lateral flap amputation, by Surg. J. W. Wishart, 140th Pennsylvania.	Amputation at the shoulder.
354	Williams, J., Pt., A, 14th Tennessee, age 24.	July 2, 1863.	Shot fracture of upper third of right humerus.	July 4, 1863.	Amputation at the shoulder.	Sept. 4, 1863, sloughing. Paroled November 12, 1863.
355	Wimberly, R. C., Pt., A, 3d Georgia, age 22.	July 1, 1863.	Shot wound through the right shoulder joint.	July 3, 1863.	Amputation at the shoulder by lateral flaps.	To Provost Marshal, for exchange, September 3, 1863.
356	Winchold, W., Pt., E, 17th Pennsylvania Cavalry, age 21.	June 21, 1864.	Comp'd comminuted fracture of right humerus, involving shoulder joint.	June 21, 1864.	Antero-posterior flap amputation at the shoulder.	Disch'd Mar. 9, 1865; pensioned.
357	Wirts, C., Pt., F, 30th Missouri.	May 20, 1863.	Shot wound of right arm.	May 20, 1863.	Amputation at the shoulder.	Disch'd Sept. 2, 1863; pensioned.
358	Wise, A., Pt., K, 7th Maryland, age 32.	Aug. 18, 1864.	Shot wound of left shoulder, with lesion of bone and vessels.	Aug. 18, 1864.	Flap amputation at shoulder, by Surg. A. A. White, 8th Maryland.	Disch'd Feb. 5, 1865; pensioned.
359	Wispert, G., Serg't, C, 1st New Jersey Cavalry, age 23.	May 12, 1864.	Right arm carried away by a six-pound shot, which struck midway between elbow and shoulder.	May 12, 1864.	Amputated at the shoulder, by Surg. W. W. L. Phillips, 1st New Jersey Cavalry.	Returned to duty, to be mustered out, August 31, 1864; pensioned.



NO.	NAME, AGE, AND MILITARY DESCRIPTION.	DATE OF INJURY.	NATURE OF INJURY.	DATE OF OPERATION.	OPERATION AND OPERATOR.	RESULT AND REMARKS.
360	Wood, B. S., Corp'l, C, 1st Maine Cavalry, age 31.	April 9, 1865.	Severe shot fracture of the left arm, extending nearly to the shoulder.	April 9, 1865.	Amputated at the shoulder, by Surg. G. W. Colby, 1st Maine Cavalry.	Disch'd Aug. 12, 1865; pensioned.
361	Woods, C., Pt., K, 16th Massachusetts, age 19.	May 9, 1864.	Shot comminuted fracture of upper third of right arm.	May 9, 1864.	Antero-posterior flap amputation at the shoulder, by Surg. C. C. Jewett, 16th Mass.	Disch'd Nov. 19, 1864; pensioned. <i>Spec. 123, A. M. M.</i>
362	Wright, L., Pt., H, 10th Iowa, age 21.	Nov. 25, 1863.	Fracture of left humerus in the upper third.	Nov. 25, 1863.	Amputated, by Surg. L. J. Ham, 48th Indiana.	Mustered out September 28, 1864; pensioned.
363	Yeatter, L., Pt., G, 143d Pennsylvania, age 32.	May 5, 1864.	Shot wound of left arm at upper third, with injury of vessels and bone.	May 6, 1864.	Posterior flap amputation at the shoulder, by Surgeon G. W. New, 7th Indiana.	Disch'd May 15, 1865; pensioned.
364	Young, G. G., Pt., A, 7th South Carolina Cavalry.	May 30, 1864.	Shot fracture of upper third of humerus.	May 31, 1864.	Amputated at the shoulder, by Surg. C. B. Gibson, C. S. A.	Transferred June 11, 1864.
365	Young, I. J., Pt., H, 63d Indiana, age 23.	May 14, 1864.	Ball entered near the head of left humerus, passed through joint and down the side to the sixth rib, whence it was extracted.	May 15, 1864.	Lateral flap amputation at the shoulder.	Gangrene. Discharged Nov. 30, 1864; pensioned.
366	Zahrli, J., Pt., G, 97th Illinois, age 28.	May 16, 1864.	Round shot passed through the middle third of the left arm; humerus shattered.	May 16, 1863.	Amputation at the shoulder by irregular flaps.	Disch'd Feb. 3, 1864; pensioned.
367	Zimmers, H., Serg't, A, 140th Pennsylvania, age 32.	July 2, 1863.	Comminuted fracture of the left humerus.	July 3, 1863.	Amputated at the shoulder, by Surg. J. W. Wishart, 140th Pennsylvania.	Disch'd June 15, 1865; pensioned.
368	Zubler, R., Corp'l, A, 134th New York, age 21.	July 1, 1863.	Comminuted shot fracture of surgical neck of left humerus; joint opened; escape of synovia.	July 2, 1863.	Double flap amputation at the shoulder.	Disch'd May 18, 1864; pensioned.

The side injured was specified in three hundred and fifty-seven of the cases here tabulated; in eleven instances this point was overlooked. One hundred and eighty-one operations were on the left, and one hundred and seventy-six on the right side. Seven patients were returned to modified duty in the second battalion of the Veteran Reserve Corps; three hundred and three were discharged and pensioned; thirty-seven were paroled or exchanged. Twenty-one of the pensioners have died since their discharge, at periods remote from the date of operation,—one from a railroad accident, one from suicide, eight from marasmus due, probably, to the mutilation, and eleven from various diseases unconnected with the injury. The Museum possesses twenty-two specimens of shot fractures of the upper extremity of the humerus, successfully treated by primary amputation at the shoulder.<sup>1</sup> Seven of them have been figured on preceding pages. Moreover, the primary appearances of shot comminutions of the upper portion of the bone are largely illustrated by wood-cuts intercalated among the abstracts of cases of excisions at the shoulder.

§ *Unsuccessful Operations.*—One hundred and seventeen primary amputations at the shoulder resulted fatally. The side implicated was specified in ninety-three instances, the right limb having been removed in forty-five, and the left in forty-eight operations. Three of the cases were complicated by other capital operations, one by amputation of the thigh, another by amputation of the leg, and a third by the removal of three-fourths of the scapula. In fourteen other cases serious wounds in other parts of the body contributed toward the

<sup>1</sup> GUTHRIE (G. J.) has devoted a chapter of fifty pages (*A Treatise on Gunshot Wounds, etc.*, 3d ed., 1827, pp. 420-470) to this operation. It filled with valuable practical remarks well worthy of the attention of the military surgeon. A few passages are here quoted: "The dread formerly entertained of this operation was very great, even by men of the best abilities: \* \* \* It can never, however, again be considered formidable, except under bad management, and from extreme ignorance. The distinction between the necessity of the operation, and the possibility of avoiding it, requires in many cases the exercise of the nicest judgment, and a due consideration of attending circumstances; for there is no part of military surgery, in which an operation can be performed with more advantage at the instant; or delayed for a few days, with a view of gaining information, with more prejudice; inasmuch as the necessary incisions are made, in the first instance, in parts disposed to take on healthy actions, and in the best possible state for undergoing surgical operations; the constitution of the patient being also at that moment generally good, and able to sustain the demands upon it under untoward circumstances; or of supporting, without future injury, the restraint and control requisite for the successful accomplishment of the cure. The difference between cutting in sound and diseased parts is justly appreciated by every surgeon, both as to his personal convenience and ease in operating, as well as to the future healing of the wound; and the advantage here is particularly great, as, from the contiguity of the wound to the chest and the principal organs of life, it is advisable to avoid any excess of action; and experience has demonstrated, that the evil to be apprehended from the equilibrium of the circulation being destroyed is infinitely less than it would be at a subsequent period of three or four weeks, after high suppurative action has been going on. It cannot be too strongly impressed on the mind, that the necessary examinations should take place, and the operation be performed in those cases demanding it, as soon after the injury as possible, consistent with the state of the patient; and the surgeon should not satisfy himself with the idea of being able to accomplish it as safely, or as successfully, when suppuration has been established, and when perhaps he may have better assistance at hand; a kind of self-deceit that is occasionally permitted, but which cannot be too much reprobated."

gravity of the situation. In eighteen instances the limb was nearly or completely torn away by cannon shot. The subjects of the operations were one hundred and one Union and sixteen Confederate soldiers. Two cases in the series furnished specimens to the Museum. Brief abstracts of these are appended:

CASE 1600.—Private J. K——, Co. G, 155th New York, was wounded at North Anna, Virginia, May 18, 1864. He was treated in a Second Corps hospital at Fredericksburg. Surgeon D. H. Houston, 2d Delaware, reported: "Fracture of left arm. Amputation at the shoulder joint, by Surgeon J. W. Wishart, 140th Pennsylvania. Arm severed by a cannon ball." The patient died May 21st. The specimen represented by the wood-cut (FIG. 488) was contributed by Surgeon W. O'Meagher, 69th New York, and is thus described in the 1866 Catalogue, p. 92: "The upper half of the left humerus, amputated at the shoulder joint after fracture in the middle third by a round shot. A fissure three inches in length exists in the upper and outer portion of the bone, without communicating with the seat of fracture." The fissure in the upper part, not extending to the point at which the bone was shattered by the round shot, is very curious and interesting, occurring unquestionably at the time of accident, and not in the transportation or preparation of the specimen.

In robust, fleshy subjects it is sometimes exceedingly difficult to determine whether the fissures from a shot comminution of the upper third of the humerus extend within the capsule. Specimen 1082 of the Surgical Series of the Museum is a good illustration. It is represented at page 30 of the preliminary surgical report (Circular 6, 1865, FIG. 32, and Catalogue of 1866, p. 91, FIG. 44). Before the removal of the limb it was examined by several experienced and accomplished surgeons, who consented to the exarticulation in the belief that the fissures penetrated the joint. On examination, the fracture was found to reach only to about two inches below the lower border of the tuberosities. In such cases, it is far better to commence the amputation with a view to dividing the humerus in its continuity. Should fissures be found to extend to the joint, it is easy to extend the incisions upward and effect exarticulation.

CASE 1601.—Private C. J——, Co. C, 12th Massachusetts, aged 26 years, was wounded at Jericho Ford, May 23, 1864, by a conoidal musket ball, and was admitted to a Fifth Corps field hospital. Surgeon C. J. Nordquist, 83d New York, noted: "Gunshot fracture of the right humerus; disarticulation at the shoulder joint." The patient was sent to Washington and entered Emory Hospital. Surgeon N. R. Moseley, U. S. V., recorded: "Admitted May 29th, from the field. Gunshot fracture of the right humerus. Amputation at the shoulder joint, May 24, 1864, on the field, by Surgeon J. W. Rawlings, 88th Pennsylvania. Died June 10, 1864." The specimen represented by the adjoining cut (FIG. 489) was contributed by the operator. It consists of "the right humerus, shattered in the upper third of the shaft, without displacement of fragments." (See *Cat. Surg. Sect.*, 1866, p. 91.) This and the foregoing specimen, 2323, are the only examples the Museum possesses of shot comminutions of the upper part of the humerus followed by primary unsuccessful amputation. In specimen 4149 the fissures extend, on the posterior parts, quite to the anatomical neck, without crossing, however, the line of the epiphysis.

In nine of the fatal cases consecutive ligation of the axillary or of the subclavian was required, a large proportion of cases of bleeding from these great trunks, tied primarily in healthy subjects. The mortality here recorded is greater than that observed by Larrey, who asserted that he had saved ninety in a hundred patients amputated at the shoulder for shot injury, but compared with the general averages<sup>1</sup> it is a favorable exhibit.



FIG. 488.—Upper half of left humerus, from which the lower half was torn by round shot. Spec. 2323.



FIG. 489.—Shot fracture of the upper extremity of the right humerus." Spec. 4149.

<sup>1</sup> SMITH (S.), in a careful paper in the *New York Journal of Medicine*, 1853, N. S., Vol. X, page 9, in treating of amputation at the large joints has given a good historical review, with statistics, of amputations at the shoulder. He states that the earliest instance of the performance of the operation in this country was by Dr. JOHN WARREN, in 1781 (*Boston Med. and Surg. Jour.*, Vol. XX, p. 210), at a military hospital in Boston. He doubts the assertion of Dr. S. W. WILLIAMS (*Med. Biography*, 1845, and *New York Jour. of Med.*, 1852), that Dr. JOSIAH GOODRICE, of Hadley, practised the operation yet earlier. He ascribes three exarticulations for injury to Dr. AMASA TROWBRIDGE, the first in 1809, and two to Dr. WILLIAM GIBSON, the earliest in 1812. Dr. S. SMITH collects seventy-one cases of exarticulation at the shoulder, with thirty-four deaths, a fatality of 47.9 per cent. GUTHRIE (*On Gunshot Wounds*, 3d ed., 1827, p. 469) gives the results of nineteen exarticulations at the shoulder, performed primarily on the field, from June 21st to December 24th, in the six divisions of the army of the Duke of Wellington, engaged at Vittoria, Balboa, and the siege of St. Sebastian. There was but one fatal case in nineteen amputations. Of nineteen similar ulterior operations, practised in general hospitals on wounded from the same engagements, but four were successful. BROMFIELD (*Chirurgical Observations*, 1873, Vol. I, p. 209) describes his uniform success in several cases of shoulder joint amputations, although he "had but little encouragement to do it at first from those who had seen it performed in the army, when the shoulder had been greatly injured by gunshot, and amputation at the joint was the only chance of preserving life; for, though the operations were seemingly well performed, and everything went on, to all appearance, well for near three weeks, yet, I am told, the patients all died."



TABLE XLIV.

*Summary of One Hundred and Seventeen Fatal Cases of Primary Amputation at the Shoulder for Shot Injury.*

No.	NAME, AGE, AND MILITARY DESCRIPTION.	DATE OF INJURY.	NATURE OF INJURY.	DATE OF OPERATION.	OPERATION AND OPERATOR.	RESULT AND REMARKS.
1	Ames, A. G., Serg't, D, 31st Maine, age 25.	May 30, 1864.	Shot fracture of right humerus at upper third.	May 30, 1864.	Arm amputated at the shoulder joint; external and internal flaps.	Died June 24, 1864, of pyæmia.
2	Andrews, M., Pl., E, 17th Vermont, age 19.	May 12, 1864.	Shot fracture of right humerus extending into shoulder joint.	May 14, 1864.	Amputation of arm at shoulder joint, by Surgeon J. Harris, 7th Rhode Island.	July 27th, hæmorrhage; subclavian artery ligated. Died July 28, 1864, from hæmorrhage.
3	Ash, D. B., Pt., B, 19th Massachusetts.	June 25, 1862.	Wound of right arm by musket ball, implicating bloodvessels and bone.	June 25, 1862.	Amputation of arm at shoulder joint, by Surgeon J. T. Dyer, 13th Massachusetts.	Died July 25, 1862.
4	Austin, A. Y., Captain, F, 23d Ohio, age 27.	Sept. 3, 1864.	Shot fracture of the neck of the right humerus.	Sept. 4, 1864.	Amputation of arm at shoulder joint, by A. A. Surgeon J. Younglove.	Died September 5, 1864.
5	Austin, W. S., Pl., D, 27th Michigan, age 43.	July 30, 1864.	Right arm carried away by a twenty-four pound solid shot.	July 30, 1864.	Removal of arm at shoulder joint, by Surg. W. B. Fox, 8th Michigan. Triangular external flaps with apex upward.	Died September 1, 1864, from exhaustion.
6	Baldwin, R. W., Pt., C, 21st Wisconsin.	Oct. 8, 1862.	Shot fracture of the upper portion of the left humerus.	Oct. 8, 1862.	Amputation of arm at shoulder joint.	Died October 30, 1862.
7	Barry, R., Corporal, F, 1st New Jersey.	May 6, 1864.	Comp'd comminuted shot fracture of — humerus.	May 6, 1864.	Amputation of arm at shoulder joint.	Died May 19, 1864.
8	Bates, J., Pl., A, 75th Ohio.	Aug. 22, 1862.	Ball perforated right shoulder and severely lacerated the soft parts, grooving the articular surfaces.	Aug. 22, 1862.	Amputation of arm at shoulder joint.	Patient sank rapidly. Died Aug. 29, 1862.
9	Bessimer, W., Pt., D, 137th New York.	July 3, 1863.	Fracture of left arm in upper third.	July 3, 1863.	Amputated at the shoulder by Larrey's method.	Not a pensioner; not on mortuary lists.
10	Bly, J., Lieutenant, M, 5th New York Cavalry, age 45.	May 8, 1864.	Shot wound of left arm; the upper extremity of humerus shattered.	May 8, 1864.	Amputation of left arm at the shoulder joint.	Died May 17, 1864.
11	Boneau, P., Corp'l, G, 80th Indiana, age 22.	Dec. 10, 1864.	Shot perforation of the right shoulder; head and upper extremity of shaft of humerus and scapula comminuted and shoulder joint opened.	Dec. 10, 1864.	Arm amputated at shoulder joint by oval flap method; also excision of entire lower three-quarters of scapula by extending the incision for anterior flap along spine of scapula, by A. A. Surgeon M. L. Herr.	Patient did not rally from the shock of the operation. Died December 11, 1864, from exhaustion.
12	Boyer, A., Pt., K, 19th Maine, age 22.	June 22, 1864.	Shot wound of left arm, with comminuted fracture of the shoulder joint.	June 22, 1864.	Amputation of arm at shoulder joint by Larrey's method, by Surgeon N. Hayward, 20th Massachusetts.	Died July 20, 1864, of pyæmia.
13	Brookway, O. P., Capt., A, 5th Colored Troops, age 28.	June 19, 1864.	Shot fracture of the right arm near the shoulder; head and shaft of humerus extensively comminuted.	June 21, 1864.	Amputation of arm at shoulder joint by lateral flap method, by Surg. D. G. Rush, 101st Pennsylvania.	Died June 22, 1864, from exhaustion.
14	Campbell, J., Pt., B, 1st Delaware.	May 3, 1863.	Gunshot wound of the left arm; fracture of humerus, high up.	May 5, 1863.	Amputation of arm at shoulder joint.	Died May 7, 1863.
15	Carr, L., Serg't., F, 16th West Virginia, age 26.	April 2, 1865.	Comminuted fracture of the left humerus by shell fragment.	April 2, 1865.	Arm amputated at shoulder joint, by Surgeon P. S. Ainsworth, U. S. V.	Died April 21, 1865, from exhaustion.
16	Church, F., Pt., I, 57th New York, age 20.	June 16, 1864.	Shot fracture of the left arm in upper third.	June 17, 1864.	Arm amputated at shoulder joint by lateral flaps, by Surg. G. L. Potter, 145th Penn.	Died July 15, 1864, of pyæmia.
17	Clark, C. W., Serg't, A, 67th New York, age 25.	May 6, 1864.	Shot fracture of right shoulder joint.	May 6, 1864.	Amputation of arm at shoulder.	Furloughed June 9, 1864. Died at his home in Brooklyn, while on furlough, July 21, 1864.
18	Compton, J. A., Pt., K, 3d South Carolina.	.....	Shot wound of the left arm; compound fracture.	.....	Primary amputation of the arm at the shoulder joint.	Erysipelas. Died May 22, 1864, of pyæmia.
19	Constock, G., Pt., F, 111th Pennsylvania.	May 3, 1863.	Left arm blown off by shot.	May 3, 1863.	Amputation of the arm at the shoulder joint.	Died May 5, 1863.
20	Conant, A. E., Pt., K, 8th Maine, age 22.	May 20, 1864.	Shot wound of the left arm, the head of humerus fractured.	May 20, 1864.	Amputation of the arm at the shoulder joint.	May 24th and 25th, hæmorrhage. May 26th, ligation of subclavian artery, by A. A. Surg. T. Siebold. Died May 29, 1864, from exhaustion.
21	Conner, A., Pt., C, 3d Batt., 18th Infantry.	Dec. 31, 1862.	Shot wound of the left arm, the humerus shattered.	Dec. 31, 1862.	Amputation of arm at shoulder joint.	Died January 10, 1863.
22	Copeland, F., Lieutenant, H, 2d North Carolina Cavalry.	.....	Shot wound of — arm, with fracture of humerus near joint.	.....	Primary amputation of arm at shoulder joint.	Died December 6, 1863.
23	Corrie, J. S., Serg't, A, 11th Missouri, age 25.	May 22, 1863.	Shot fracture of left humerus in its upper third.	May 22, 1863.	Amputation of arm at shoulder joint, by Surg. M. W. Fisk, 11th Missouri.	Hæmorrhage. June 7th, axillary artery ligated; 8th, branches of acromial thoracic artery ligated. Died June 9, 1863, from effects of hæmorrhage.
24	Cotrell, J., Pt., A, 43d New York, age 32.	July 3, 1863.	Shot fracture of the left arm near the shoulder joint.	July 3, 1863.	Amputation of arm at shoulder joint.	Died August 13, 1863, of rheumatism of the heart.
25	Cramer, J., Pt., A, 187th New York.	Oct. 27, 1864.	Shot wound of the left shoulder, with fracture.	Oct. 27, 1864.	Amputation of arm at shoulder joint.	Died October 29, 1864.
26	Crawley, M., Pt., Young's Virginia Battery, age 19.	Aug. 21, 1864.	Shot fracture of left humerus near the articulation.	Aug. 22, 1864.	Amputation of arm at shoulder joint.	Hæmorrhage Sept. 1st and 2d. Died Sept. 3, 1864.
27	Crittend, E., Pt., F, 11th Penn'a Reserves, age 22.	May 8, 1864.	Left arm shattered by shell fragment.	May 8, 1864.	Amputation of arm at shoulder joint by anterior flap method.	Typhoid symptoms. Died May 28, 1864.
28	Crotty, J. B., Pt., D, 108th New York.	Dec. 13, 1862.	Shell wound of the right arm, with fracture of the humerus.	Dec. 13, 1862.	Amputation of arm at shoulder joint.	Died December 21, 1862.
29	Davis, J. L., Pl., 2d South Carolina, age 30.	Sept. 17, 1862.	Comminuted fracture of neck and shaft of left humerus by a conoidal ball.	Sept. 18, 1862.	Flap amputation of arm at the shoulder joint.	Died Sept. 25, 1862, of pyæmia. <sup>1</sup>

<sup>1</sup> FISHER (G. J.), *Report of Fifty-seven Cases of Amputation, in the Hospitals near Sharpsburg, Md., after the Battle of Antietam, September 17, 1862, in Am. Jour. Med. Sci., N. S., 1863, Vol. XLV, p. 48.*

NO.	NAME, AGE, AND MILITARY DESCRIPTION.	DATE OF INJURY.	NATURE OF INJURY.	DATE OF OPERATION.	OPERATION AND OPERATOR.	RESULT AND REMARKS.
30	Dennis, A., Pt., C, 24th New York Cavalry.	Aug. 19, 1864.	Comminuted fracture of left shoulder by fragment of shell; laceration of soft parts.	Aug. 19, 1864.	Amputation at shoulder joint, by Surg. W. C. Shurlock, 51st Pennsylvania.	Died August 21, 1864.
31	Dorolph, C., Pt., K, 93d Pennsylvania, age 20.	June 3, 1864.	Shot fracture of neck of right humerus.	June 3, 1864.	Amputation of arm at shoulder joint.	Died June 12, 1864.
32	Dyer, H. P., Color Sergeant, 21st Maine.	May 27, 1863.	Shot perforations of the head of the right humerus, the right arm, the right hand, and the upper lip.	May 28, 1863.	Amputation of arm at shoulder joint, by Surg. G. E. Brickett, 21st Maine.	Died Aug. 19, 1863, from diarrhœa.
33	Ely, A. S., Lieut., F, 20th Pennsylvania Cavalry.	April 6, 1863.	Shot wound of the left arm, the humerus shattered high up.	April 6, 1863.	Amputation of arm at shoulder joint.	Died April 6, 1863.
34	Enig, J., Pt., C, 166th Pennsylvania.	April 15, 1863.	Comminuted shot fracture of the right humerus.	April 15, 1863.	Amputation of the arm at the shoulder joint by oval incision.	Died April 17, 1863.
35	Emerson, N., Serg't, K, 25th New York.	May 27, 1862.	Shot wound of — arm, with fracture of the humerus and injury of vessels.	May 27, 1862.	Amputation of arm at shoulder joint by Lisfranc's method.	Died June, 1862.
36	French, C. R., Pt., K, 1st Artillery, age 19.	July 6, 1863.	Musket ball fractured the left shoulder joint.	July 6, 1863.	Arm amputated at the shoulder joint by the oval method.	Died July 14, 1863, of gangrene.
37	Gibson, W., Pt., C, 9th Alabama Cavalry.	June 24, 1864.	Musket ball fractured upper third of left humerus, passed through axillary space and upper lobe of left lung, and lodged.	June 24, 1864.	Amputation of the arm at the shoulder joint by transfexion.	Died June 27, 1864.
38	Goodel, J. V., Pt., C, 8th Vermont, age 21.	Oct. 19, 1864.	Shot wound of the middle third of the right arm, with longitudinal splintering.	Oct. 20, 1864.	Amputation at the shoulder joint by the oval method.	Died November 28, 1864.
39	Graves, H., Pt., C, 6th Alabama.	July 3, 1863.	Shot fracture of the right arm in upper third.	July 4, 1863.	Arm amputated at the shoulder joint, by Surg. G. B. Leecompte, 1st Maryland, U. S.	Died July 26, 1863.
40	Greek, E., Pt., I, 34th New York.	Sept. 17, 1862.	Shot wound of shoulder joint, with fracture of the humerus.	Sept. 17, 1862.	Removal of arm at the shoulder joint by double flaps.	Died October 7, 1862.
41	Green, J. W., Pt., D, 2d Ohio.	Oct. 8, 1862.	Shot fracture of arm near the shoulder.	Oct. 8, 1862.	Amputation of the arm at the shoulder joint.	Died November 6, 1862.
42	Gregg, J. H., Capt., I, 137th New York.	July 2, 1863.	Gunshot wound of left shoulder and breast.	July 3, 1863.	Amputation of left arm at the shoulder joint, by Surg. A. K. Fifield, 29th Ohio.	Died July 3, 1863, eight hours after operation.
43	Gruff, H., Pt., A., 60th Indiana.	July 10, 1863.	Shot fracture of the scapula and neck and shaft of humerus.	July 10, 1863.	Amputation of the arm at the shoulder joint by transfexion.	Died September 15, 1864.
44	Hall, J., Pt., G, 3d Iowa....	April 7, 1862.	Shot wound involving left lung and upper third of the left humerus.	April 7, 1862.	Amputation of the arm at the shoulder joint by double flaps.	Died April 23, 1862, from exhaustion.
45	Hannan, J., Adjutant, 96th Pennsylvania, age 48.	June 1, 1864.	Shot fracture of the head of right humerus.	June 1, 1864.	Arm amputated at the shoulder joint; antero-posterior flaps.	Died July 7, 1864, from exhaustion.
46	Hathaway, O. P., Pt., I, 7th Rhode Island, age 43.	June 17, 1864.	Shot wounds of the right arm and shoulder.	June 17, 1864.	Arm amput'd at shoulder joint; internal and external flaps.	Died June 24, 1864, from exhaustion.
47	Haybecker, J. W., Pt., F, 143d Pennsylvania, age 33.	June 3, 1864.	Shot fracture of the right humerus, involving the entire shaft.	June 3, 1864.	Arm amputated at the shoulder joint, by Surg. F. C. Reamer, 143d Pennsylvania.	Died July 30, 1864.
48	Hoffman, J., Pt., E, 75th New York.	May 27, 1863.	Shot wound of the right arm, with fracture high up.	May 27, 1863.	Arm amputated at the shoulder joint.	Died May 31, 1863.
49	Hollingsworth, J., Pt., B, 3d New Jersey.	Sept. 14, 1862.	Compound fracture of the upper third of left humerus.	Sept. 14, 1862.	Removal of arm at the shoulder joint.	Died October 29, 1862.
50	Homer, J. P., Pt., A, 139th Pennsylvania.	May 12, 1864.	Shot fracture of right shoulder joint.	May 12, 1864.	Removal of arm at the shoulder joint.	Died June 25, 1864.
51	Hufflicker, E., Pt., I, 38th Mississippi, age 38.	May 15, 1864.	Shot comminution of the left humerus; laceration of soft parts.	May 15, 1864.	Amputation of the arm at the shoulder joint.	Died June 5, 1864, with cerebral symptoms. <sup>1</sup>
52	H——, D., Pt., D 6th Kentucky, age 24.	April 6, 1862.	Left arm carried away by cannon ball, leaving only the head and upper end of the bone.	April 6, 1862.	Amputation at shoulder joint, by Surgeon R. R. Stevenson, U. S. A. C. S.	Died July 16, 1862, of pyæmic fever. <sup>2</sup>
53	Johannes, C., Pt., C, 12th Massachusetts, age 26.	May 23, 1864.	Shot fracture of the head of the upper third of right humerus; no displacement of fragments.	May 24, 1864.	Amputation of the arm at the shoulder joint, by Surg. J. W. Rawlings, 88th Pennsylvania.	Died June 10, 1864. <i>Spec.</i> 4149.
54	Kearm, J., Pt., G, 155th New York.	May 18, 1864.	Shot fracture of left arm by a cannon ball.	May 18, 1864.	Arm amputated, by Surg. J. W. Wishart, 140th Penn.	Died May 21, 1864. <i>Spec.</i> 2323, A. M. M.
55	Kearnes, J., Serg't, G, 94th New York.	July 15, 1864.	Shot wound of the arm, with fracture of upper third of the humerus.	July 15, 1864.	Amputation of the arm at the shoulder joint by the oval method.	Died July 19, 1864.
56	Kenyon, J. R., Corp'l, M, 2d New York Artillery, age 43.	June 16, 1864.	Shot fracture of the head of left humerus.	June 17, 1864.	Amputation of the arm at the shoulder joint, by Surg. J. W. Wishart, 140th Pennsylvania.	Died July 4, 1864.
57	Kies, A., Pt., C, 12th New York Cavalry.	Mar. 10, 1865.	Compound shot fracture of the upper third of left humerus, and flesh wound of cheek by shell fragments.	Mar. 10, 1865.	Amputation of arm at shoulder joint by Scoutellen's method.	Died March 20, 1865, from exhaustion.
58	Kimberlin, M., Pt., I, 14th Kentucky.	June 4, 1864.	Comminuted fracture of right humerus by a conoidal ball.	June 4, 1864.	Amputation of arm at shoulder joint, by Surgeon E. Skippen, U. S. V.	Died June 18, 1864.
59	Lake, L. C., Pt., C, 21st Wisconsin.	Oct. 8, 1862.	Shot fracture of left humerus, high up.	Oct. 8, 1862.	Amputation of arm at shoulder joint by Larrey's plan.	Died November 4, 1862.
60	Langdon, G., Corp'l, D, 78th Pennsylvania, age 26.	Oct. 1, 1862.	Shot fracture of right humerus; bone badly shattered and soft parts greatly injured.	Oct. 2, 1862.	Arm amputated at the shoulder joint by transfexion.	Died October 10, 1862, of tetanus.
61	Lee, P., Serg't, D, 28th Kentucky, age 28.	Feb. 24, 1864.	Comminuted fracture of the upper third of left humerus, involving the shoulder joint, by a fragment of shell.	Feb. 26, 1864.	Arm amputated at the shoulder joint, by Surgeon F. Salter, U. S. V.	Died March 15, 1864, from exhaustion.
62	Loomis, W. D., Pt., B, 53d Georgia, age 22.	July 3, 1863.	Comp'd comminuted shot fracture of left shoulder, with perforation of left lung.	July 3, 1863.	Amputation of arm at shoulder, by Surg. J. J. Knott, P. A. C. S.; Larrey's oval method.	Died July 15, 1863.
63	McCarthy, C., Pt., K, 72d Pennsylvania.	July 3, 1863.	Shot wound of right shoulder, with lesion of bone.	July 3, 1863.	Arm amputated at the shoulder joint, by Surg. M. Rizer, 72d Pennsylvania.	Died July 12, 1863.

<sup>1</sup> O'KEEFE (D. C.), *Surgical Cases of Interest, treated at Institute Hospital, Atlanta, in Confed. States Med. and Surg. Jour.*, 1865, Vol. II, p. 29.  
<sup>2</sup> STEVENSON (R. R.), *On Primary and Secondary Amputations, in Gunshot Wounds, in The Canada Lancet* 1873, Vol. V, p. 7.



NO.	NAME, AGE, AND MILITARY DESCRIPTION.	DATE OF INJURY.	NATURE OF INJURY.	DATE OF OPERATION.	OPERATION AND OPERATOR.	RESULT AND REMARKS.
64	McCarthy, D., Pt., K, 122d New York.	July 3, 1863.	Shot wound of arm and fracture of the humerus.	July 3, 1863.	Amputation of arm at shoulder joint by the oval method.	Died July 6, 1863.
65	McCauslin, J., Pt., D, 72d Pennsylvania.	July 3, 1863.	Shot fracture of right humerus in upper third.	July 3, 1863.	Amputation of arm at shoulder joint, by Surg. M. Rizer, 72d Pennsylvania.	Died July 26, 1863.
66	McDaniels, J., Pt., D, 31st Indiana.	July 4, 1864.	Shot fracture of forearm and shoulder joint.	July 4, 1864.	Arm amputated at shoulder, by Surg. C. J. Walton, 21st Kentucky.	Died July 4, 1864.
67	McDowell, S., Pt., M, 11th Indiana, age 19.	Jan. 16, 1865.	Shot wound of shoulder. . . . .	Jan. 18, 1865.	Amputation of arm at shoulder joint by antero-posterior flaps: Surg. J. Evans, 13th Wis.	Died April 30, 1865.
68	Mulone, S., Pt., C, 41st New York, age 30.	Dec. 13, 1862.	Shot wound of left arm. . . . .	Dec. 13, 1862.	Arm amputated at the shoulder joint.	Died Jan. 2, 1863, from tetanus.
69	Marquis, W. H., Pt., E, 85th Pennsylvania, age 20.	Aug. 27, 1863.	Compound fracture of right arm and left leg by shell.	Aug. 27, 1863.	Amputation of right arm at the shoulder joint and amputation of left leg.	September 12th, hæmorrhage from brachial artery; axillary artery ligated on face of stump. Died September 12, 1863.
70	Measie, H., Pt., E, 160th New York.	Sept. 19, 1864.	Right arm nearly torn off by shell.	Sept. 19, 1864.	Amputation of the arm at the shoulder joint.	Died September 22, 1864.
71	Moore, A. J., Pt., G, 35th Georgia.	June 13, 1864.	Fracture of head of humerus by a conoidal ball.	June 13, 1864.	Amputation of arm at shoulder, by Surgeon Mont. C. S. A.	Died June 15, 1865.
72	Morgan, W., Pt., F, 126th New York, age 22.	July 2, 1863.	Compound shot fracture of the humerus.	July 3, 1863.	Arm amputated at the shoulder joint by double flap.	July 19th, hæmorrhage from axillary artery; ligation. Died July 19, 1863.
73	Mosby, T., Pt., F, 5th Alabama, age 21.	Oct. 19, 1864.	Shot wound of shoulder, with fracture.	Oct. 19, 1864.	Amputation of the arm at the shoulder.	Died Oct. 23, 1864, from shock and loss of blood.
74	Nickerson, J. T., Serg't, F, 4th Maryland.	Aug. 18, 1864.	Shot comminuted fracture of left humerus.	Aug. 19, 1864.	Flap amputation of arm at the shoulder joint.	Died September 13, 1864.
75	Noble, E. C., Pt., M, 1st Michigan Engineers.	Oct. 8, 1862.	Shot fracture of upper portion of humerus.	Oct. 8, 1862.	Amputation of the arm at the shoulder by oval incisions.	Died October 19, 1862.
76	Noble, J. C., Pt., B, 149th Pennsylvania.	May 3, 1863.	Shot wound of shoulder, with lesions of soft parts and fracture.	May 3, 1863.	Arm amputated at the shoulder by external and internal flaps.	Died May 4, 1863.
77	O'Brien, P., Corp'l, G, 29th Wisconsin.	April 9, 1864.	Shot wound of the right shoulder joint.	April 9, 1864.	Arm amputated at the shoulder.	Died April 18, 1864, from hæmorrhage.
78	Odell, J. S., Pt., D, 3rd Illinois, age 25.	June 2, 1864.	Head of the left humerus completely shattered by a conoidal ball.	June 2, 1864.	Amputation of arm at shoulder joint.	Died June 28, 1864, from gangrene.
79	Odell, C. M., Pt., I, 36th Wisconsin.	June 3, 1864.	Gunshot fracture of head and upper half of shaft of the humerus.	June 3, 1864.	Amputation at shoulder joint.	Died June 3, 1864, from chloroform, on operation table.
80	O'Hara, T., Pt., D, 63d New York.	Sept. 17, 1862.	Shot wound of right arm, with fracture of upper third of the humerus.	Sept. 17, 1862.	Amputation of arm at shoulder joint.	Hæmorrhage from axillary artery. Died Sept. 22, 1862.
81	Ordway, W. J., Serg't, A, 36th Illinois.	May 24, 1864.	Shot wound of right arm, with lesions of the bone and of the bloodvessels.	May 24, 1864.	Amputation at the shoulder, by Surgeons H. E. Hesse, 24th Wisconsin, and B. G. Pierce, 96th Illinois.	Died June 12, 1864.
82	Patton, J. W., Major, 145th Pennsylvania.	May 3, 1863.	Compound shot fracture of left humerus; neck comminuted and fissures extending down shaft to near the elbow.	May 4, 1863.	Amputation of arm at shoulder, by Surg. C. S. Wood, 6th New York.	Died May 15, 1863.
83	Phillips, J. M., Pt., H, 140th Pennsylvania, age 23.	July 2, 1863.	Comminution of upper third of left humerus by shell.	July 3, 1863.	Arm amputated at the shoulder joint.	Wound healed. Transferred Oct. 5, 1863. Died at Harrisburg, Dec. 17, 1863.
84	Pomeroy, E. C., Pt., B, 101st Ohio, age 21.	June 21, 1864.	Shot fracture of right arm in upper third.	June 21, 1864.	Amputation of arm at shoulder joint, by Surg. C. J. Walton, 21st Kentucky.	Died June 29, 1864, of pyæmia.
85	Prestidge, G. W., Pt., D, 44th Alabama, age 28.	June 2, 1864.	Compound comminuted shot fracture of humerus.	June 2, 1864.	Amputation of arm at shoulder joint: flaps made of deltoid muscle.	June 30th, almost entirely well. Died July 5, 1864.
86	Pullis, J., Pt., A, 1st New York Artillery, age 18.	June 5, 1864.	Shot wound of left arm, with fracture of upper third of the humerus.	June 5, 1864.	Flap amputation at shoulder joint, by a Confederate surgeon.	Died January 30, 1865.
87	Rand, W. J., Pt., K, 45th Massachusetts, age 25.	Dec. 14, 1862.	Shot fracture of left humerus near shoulder, and of lower third of right femur; solid shot.	Dec. 14, 1862.	Arm amputated at shoulder joint, and the thigh at middle third, by Surg. I. P. Galloupe, 17th Massachusetts. <sup>1</sup>	Wound at shoulder had healed, and stump of thigh nearly so, when intermittent fever set in followed by pyæmia. Died January 24, 1863.
88	Rankel, F., Corp'l, A, 77th Pennsylvania, age 46.	Dec. 16, 1864.	Shot wound of the right arm, with injury to the vessels and bone.	Dec. 16, 1864.	Amputation of arm at shoulder joint.	Died January 14, 1865.
89	Reed, A., Pt., B, 6th Massachusetts, age 18.	Jan. 30, 1863.	Right arm carried away from near shoulder joint by solid shot; profuse hæmorrhage.	Jan. 30, 1863.	Disarticulation at the shoulder joint, by Surg. G. C. Harlan, 11th Penn. Cav. Barely sufficient flap was obtainable to cover stump. Flaps sloughed. Feb. 6th, profuse hæmorrhage. Feb. 7th, subclavian artery ligated, by Ass't Surg. O. M. Humphrey, 6th Mass. <sup>2</sup>	Died, from exhaustion, February 27, 1863.
90	Richards, H. L., Pt., H, 58th Alabama.	May 15, 1864.	Gunshot fracture of upper third of left humerus.	May 15, 1864.	Amputation at shoulder, by Surg. W. R. Longshore, 147th Pennsylvania.	Died Sept. 20, 1864, of pyæmia.
91	Rutter, W., Pt., C, 1st Pennsylvania Rifles, age 24.	June 18, 1864.	Shot fracture of left arm. . . . .	June 18, 1864.	Lateral flap amputation at the shoulder joint.	Died July 25, 1864, from recurrent hæmorrhage.
92	Sawyer, D., Pt., D, 31st Maine, age 33.	July 30, 1864.	Shot comminuted fracture of head of left humerus.	July 30, 1864.	Amputation at shoulder joint by Lisfranc's method, by Surg. J. B. Mitchell, 31st Maine. Aug. 8-9th, axillary artery ligated, by Ass't Surg. W. F. Norris, H. S. A. Aug. 9th, axillary artery again tied, by Ass't Surg. W. Thomson, U. S. A.	Died August 9, 1864, five hours after last operation.

<sup>1</sup>GALLOUPE (I. P.), *Letter from New Berne, N. C.* in *Easton Med. and Surg. Jour.*, Vol. LXVIII, p. 205.<sup>2</sup>HUMPHREY (O. M.), *Remarks on Axillary and Subclavian Ligations, with Cases.* in *Am. Med. Times*, 1864, Vol. VIII, p. 161.

No.	NAME, AGE, AND MILITARY DESCRIPTION.	DATE OF INJURY.	NATURE OF INJURY.	DATE OF OPERATION.	OPERATION AND OPERATOR.	RESULT AND REMARKS.
93	Schley, E., Pt., K, 1st New Jersey Cavalry, age 23.	May 29, 1864.	Shell wound of the right arm, with lesions of bone and vessels near shoulder.	May 29, 1864.	Flap amputation at shoulder joint.	Died June 25, 1864, of pyæmia.
94	Sears, J., Serg't, I, 93d New York, age 32.	Aug. 16, 1864.	Fracture of the right arm; ball penetrated thorax.	Aug. 16, 1864.	Amputation of arm at shoulder.	Died August 21, 1864.
95	Shanks, J., Pt., K, 11th Kentucky.	Dec. 31, 1862.	Gunshot wound of arm, with injury of the bone and vessels.	Dec. 31, 1862.	Amputation of arm at shoulder joint.	Died January 5, 1863.
96	Shaw, T. C., Lieut., C, 2d Tennessee, age 20.	Dec. 16, 1864.	Shot fracture of head of the left humerus.	Dec. 18, 1864.	Antero-posterior flap amputation of arm at shoulder, by Ass't Surg. W. Trull, U. S. V.	Died December 24, 1864.
97	Sheridan, P., Pt., K, 6th N.Y. Heavy Artillery, age 25.	Oct. 19, 1864.	Shot wound of upper third of left arm.	Oct. 20, 1864.	Antero-posterior flap amputation at shoulder.	Died Oct. 27, 1864, from exhaustion.
98	Shill, C., Pt., G, 207th Pennsylvania, age 23.	April 2, 1865.	Shot fracture of right humerus; also shot wound of neck and fracture of lower jaw.	April 2, 1865.	Amputation of arm at shoulder.	Died April 6, 1865; autopsy revealed mortification extending into neck.
99	Slack, W. H., Pt., D, 11th Connecticut, age 41.	Mar. 14, 1862.	Left humerus comminuted by a grapeshot.	Mar. 14, 1862.	Amputation at shoulder joint, by Surg. G. Derby, 23d Mass.	Died March 22, 1862, of pyæmia.
100	Shuter, I. M., Lieut., D, 88th Indiana, age 42.	Mar. 19, 1865.	Shot fracture of upper third of right arm.	Mar. 19, 1865.	Amputation of arm at shoulder joint by Lisfranc's method.	Died April 26, 1865, of pyæmia.
101	Sweeney, H., Pt., A, 55th Pennsylvania, age 22.	June 18, 1864.	Shot fracture of upper third of left humerus.	June 19, 1864.	Flap amputation at shoulder joint, by Surg. G. T. Stevens, 77th New York.	Died February 19, 1865.
102	S——, C.....	Dec. 29, 1862.	Shot fracture of humerus in upper third.	Dec. 29, 1862.	Amputation of arm at shoulder joint.	Died four days after operation.
103	Tompkins, J., Pt., A, 77th Illinois.	Jan. 11, 1863.	Shot wound of the right shoulder, with injury of bone.	Jan. 11, 1863.	Amputation at shoulder joint, by Surg. J. B. Sparks, 19th Ky.	Died January 15, 1863.
104	Turner, W. J., Pt., K, 42d Georgia, age 37.	Dec. 16, 1864.	Shell fracture of the head and entire upper third of the right humerus.	Dec. 17, 1864.	Arm amputated at shoulder, by A. A. Surg. R. L. McClure.	Died January 2, 1865.
105	Valence, H., Pt., C, 23d Kentucky.	Dec. 29, 1862.	Shot wound of right shoulder through capsule of joint; humerus shattered for five inches.	Dec. 29, 1862.	Amputation of arm at shoulder joint.	Died January 5, 1863.
106	Van Gasbaek, —, Pt., 11th New York Battery, age 23.	June 6, 1864.	Shot fracture of upper part of left humerus.	June 6, 1864.	Amputation of arm at shoulder joint. June 18th hæmorrhage from axillary artery; ligation. June 23d, hæmorrhage recurred; artery religated.	Died of exhaustion June 23, 1864.
107	Wade, J. J., Corp'l, I, 40th Iowa.	Apr 11, 1864.	Gunshot fracture of humerus, extending into surgical neck.	April 10, 1864.	Amputation of arm at shoulder joint, by Surg. J. E. Lynch, 1st Missouri Cavalry.	Died April 15, 1864.
108	Whisnant, R. H., Pt., F, 17th South Carolina, age 39.	July 30, 1864.	Shot fracture of right arm, middle third, with laceration of soft tissues.	July 30, 1864.	Amputation of arm at shoulder joint, by Surgeon G. S. West, C. S. A.	Died August 1, 1864.
109	White, F. Q., Pt., E, 80th Indiana.	Oct. 8, 1862.	Shot fracture of arm in upper third.	Oct. 8, 1862.	Amputation at shoulder joint by transfexion.	Secondary hæmorrhage. Died November 6, 1862.
110	White, J. S., Pt., F, 140th Pennsylvania, age 22.	May 4, 1864.	Shell wound of head and neck of right humerus; severe flesh wound of left forearm.	May 4, 1864.	Amputation of arm at shoulder, by Surgeon J. W. Wishart, 140th Pennsylvania.	Secondary hæmorrhage. Died June 13, 1864.
111	Whiteman, W., Corp'l, K, 6th West Virginia.	Mar. 9, 1863.	Minié ball perforated the right arm near the shoulder joint, cutting brachial artery and basilic vein and splitting the humerus.	Mar. 10, 1863.	Amputation at shoulder joint by double flaps.	Died March 11, 1863, from exhaustion.
112	Wiesser, H. H., Corp'l, F, 27th Massachusetts, age 34.	June 15, 1864.	Upper third of left arm shattered by shell fragment.	June 15, 1864.	Amputation at shoulder joint. July 13th hæmorrhage; axillary artery ligated, by Ass't Surg. E. Curtis, U. S. A.; recurred Aug. 5th and 6th; subclavian ligated by same operator.	Died August 17, 1864, from exhaustion.
113	Woodward, E., Pt., I, 20th Massachusetts.	Dec. 13, 1862.	Shot wound of the shoulder, with lesions of bone and blood-vessels.	Dec. 13, 1862.	Amputation at the shoulder by antero-posterior flaps.	Died soon after the operation. See <i>Rec. Mass. Vols.</i> , 1861-5, Vol. II, p. 363.
114	Woolery, W., Pt., C, 71st Ohio, age 27.	Dec. 16, 1864.	Shot fracture of upper third of right humerus, extending into joint.	Dec. 17, 1864.	Antero-posterior flap amputation at shoulder, by A. A. Surgeon J. E. Link.	Died December 18, 1864, from exhaustion.
115	Worsham, D. E., Pt., D, 30th Georgia, age 19.	Dec. 16, 1864.	Comminuted shot fracture of the head and upper third of shaft of left humerus.	Dec. 18, 1864.	Amputation of arm at shoulder, by A. A. Surgeon R. L. McClure.	Died February 4, 1865.
116	Wright, W. W., Capt., F, 112th Illinois, age 44.	May 27, 1864.	Shot fracture of right humerus, upper third.	May 27, 1864.	Amputation of arm at shoulder; antero-posterior flaps; Surg. L. D. Griswold, 103d Ohio.	Died June 24, 1864, of pyæmia.
117	Young, J. C., Pt., A, 101st Indiana.	Mar. 20, 1863.	Shot wound of arm in upper third; bone shattered and vessels injured.	Mar. 20, 1863.	Amputation of arm at shoulder joint by the oval method.	Died May 2, 1863.

The causes of the fatal results in this series of one hundred and seventeen amputations are not particularly specified in more than half of the instances. Consecutive hæmorrhage is assigned as the cause of fatality in twelve cases, including nine in which large trunks were tied. The existence of pyæmia was verified by autopsy in thirteen cases, and suspected in seventeen other instances. Two patients succumbed to tetanus. Death in one case was ascribed to the effects of inhalation of chloroform. Gangrene, extending to the trunk, proved fatal in three cases. Cerebritis, cardiac disorder, and diarrhœa are each credited with a fatal result. Exhaustion from surgical fever or from protracted suppuration is most commonly referred to as the cause of death, and it is plain that a number of patients perished



from one or more of the various sources of insalubrity incident to over-crowded and badly policed field hospitals.

§ *Operations with Unknown Results.*—It was impracticable to ascertain the terminations of fourteen of the primary amputations at the shoulder joint for shot injury. Seven of these were practised on Union and seven on Confederate soldiers. The few facts collected regarding these cases are stated in the following table:

TABLE XLV.

*Summary of Fourteen Cases of Primary Amputation at the Shoulder for Shot Injury in which the Results are Unknown.*

No.	NAME, AGE, AND MILITARY DESCRIPTION.	DATE OF INJURY.	NATURE OF INJURY.	DATE OF OPERATION.	OPERATION AND OPERATOR.	REMARKS.
1	Batcher, W. H., Corp'l, B, 80th New York.	May 5, 1864.	Shot fracture of shoulder joint.	May 6, 1864.	Amputated at the shoulder by double flap.	Not a pensioner; not on mortuary lists.
2	Bensinger, J., Pt., F, 72d Ohio.	July 13, 1864.	Shot fracture of left arm .....	July 13, 1864.	Amputation of arm at shoulder joint.	.....
3	Bulls, A. S., Serg't, 12th Virginia Cavalry.	Jan. 11, 1865.	Wound of left arm and chest; humerus shattered.	Jan. 11, 1865.	Amputated at the shoulder by antero-posterior flaps.	Left at Beverly, W. Va., when evacuated, January 11, 1865.
4	Don, W., Lieut., E, 24th Virginia.	June 15, 1864.	Shot fracture of head of left humerus.	June 15, 1864.	Amputated at the shoulder by Lisfranc's method.	Transferred June 19, 1864.
5	Floyd, J. W., Pt., Grundy's Virginia Battery, age 23.	May 1, 1863.	Right arm carried away above elbow by shell.	May 1, 1863.	Amputated at the shoulder by the oval plan.	May 8, 1863, wound suppurating freely and looking healthy.
6	Harrison, J. H., Pt., I, 26th Georgia.	May 19, 1864.	Shot fracture of the right arm; severe laceration and splintering.	May 19, 1864.	Amputated at the shoulder by double flaps.	Sent to Richmond hospitals.
7	J——, J.....	Dec. 29, 1862.	Shot comminution of humerus.	Dec. 29, 1862.	Amputated at the shoulder. . .	"Did well."
8	Lewis, J. G., Pt., E, 44th Georgia.	May 11, 1864.	Shot fracture of right arm in upper third.	May 11, 1864.	Amputated at the shoulder by transfexion.	"Sent south by rail."
9	Lorick, W. G., Serg't, E, 42d Mississippi, age 26.	May 5, 1864.	Wound in upper third of arm, with injury of bone and vessels.	May 6, 1864.	Amputated at the shoulder by double flaps.	"Sent south by rail."
10	Mallard, C., Pt., 41st New York.	Oct. 19, 1864.	Shot wound of right shoulder; entire shaft of humerus comminuted; wound of knee.	Oct. 19, 1864.	Amputated, by Surg. G. F. Stevens, 77th New York.	Probably died in transit to base hospital.
11	Miller, J., Pt., 43d Colored Troops.	July 30, 1864.	Wounds of left shoulder and right hand by spherical case shot.	July 30, 1864.	Amputated at the shoulder, by Surg. F. M. Weld, 27th C. T.; also amputation of the right thumb.	Not a pensioner; not on mortuary lists.
12	Pagett, T. H., Pt., F, 28th Virginia.	May 16, 1864.	Shot fracture of surgical neck of humerus, with laceration of soft parts.	May 16, 1864.	Amputated at the shoulder, by Surg. E. J. Habersham, C. S. A.	June 17, 1864, not doing well.
13	V——, C.....	Dec. 29, 1862.	Shot fracture of humerus in upper third.	On field	Amputated at the shoulder by oval incision.	"Did well on fifth day."
14	Welsh, A., Pt., B, 152d New York.	May 12, 1864.	Shot fracture of left shoulder joint.	May 12, 1864.	Amputated, by Surg. M. Rizer, 72d Pennsylvania.	Not a pensioner; not on mortuary lists.

Four of the amputations were on the right and five on the left side; in five instances this point was not reported. Three cases were complicated by other severe injuries. No consecutive operations were reported in any of the series of primary amputations.

Even were all of these fourteen undetermined cases reckoned as fatal, which is a highly improbable conclusion, the mortality rate of the four hundred and ninety-nine primary amputations enumerated in the three preceding tables would not exceed the percentage of 26.2. The results of primary exarticulation at the shoulder joint for shot injury may, therefore, be regarded as eminently satisfactory.

**Intermediary Amputations at the Shoulder Joint.**—Operations practised from the third to the thirtieth day, inclusive, are comprised in this group. By this arrangement, it is probable that some cases that really belong to the series of primary operations are included; for it is well known that severe inflammatory symptoms are not frequently delayed much longer than forty-eight hours after the reception of injury. But data for determining this point in individual cases are not accessible to any extent, and it is necessary to draw an arbitrary line and to fix precise dates. One hundred and fifty-seven patients underwent exarticulation at the shoulder during the intermediary period: eighty-five recovered, and seventy-two, or 45.8 per cent., died.

§ *Successful Cases.*—Seventy-seven of the eighty-five successful intermediary amputations were practised on Union soldiers, seventy-six of whom were pensioned. Ten of these died subsequent to their discharge from service, at periods comparatively remote from the dates of injury, one from suicide, and nine from various diseases apparently without immediate connection with the mutilations to which they had been subjected. Eight of the operations were practised on Confederate soldiers, who were paroled or exchanged.

The following are examples of successful early intermediary amputations at the shoulder joint, for complications following fractures of the upper part of the humerus:

CASE 1602.—Corporal W. M. Nesbit, Co. D, 4th Vermont, aged 31 years, was wounded at Spottsylvania, May 12, 1864. He was admitted to a Sixth Corps field hospital on the same day. Surgeon S. J. Allen, 4th Vermont, diagnosed a "gunshot laceration of the upper part of the left arm." Amputation at the shoulder joint was performed on May 16th. He was transferred to Sickels Hospital, Alexandria, on the 27th. Surgeon T. Rush Spencer, U. S. V., recorded: "Gunshot wound. Amputation of left arm at shoulder joint." The patient was subsequently treated in hospitals at Brattleboro', Burlington, and Montpelier, Vermont. Surgeon Henry Janes, U. S. V., contributed the photograph represented by the cut (FIG. 490), accompanied by the following memoranda: "Admitted to Sloan Hospital, Montpelier, June 14, 1865. Was wounded by a rifle ball, which shattered the head of the humerus, in consequence of which the arm was amputated at the shoulder joint. The wound healed readily, except two small places, which discharged until the summer of 1865. No necrosed bone could be detected. He was discharged from the service July 29, 1865, with the stump healed, and in good health." This soldier was pensioned from the date of his discharge; his pension was paid him March 4, 1875. There is no evidence on file of the present condition of the shoulder. The pensioner received money compensation in lieu of an artificial limb.

In the next case, the mutilation produced such profound mental depression as to lead to the commission of suicide:

CASE 1603.—Private Henry F. Keyes, Co. E, 12th New Hampshire, aged 22 years, was wounded at Chancellorsville, May 3, 1863. He was sent to Washington, and entered Lincoln Hospital on the 6th. Acting Assistant Surgeon James N. Hyde, jr., reported: "Wounded by a ball, from an enemy forty or fifty yards distant, while he was kneeling on his right knee, in the act of firing his piece, his right hand grasping the breech. The ball entered the right arm in its upper third; passed through, comminuting the bone, and escaped at an opposite point posteriorly. May 7th: The patient was anaesthetized in the afternoon, and an examination was made of the wound with a view to operation. Many pieces of bone were removed, when an incision was made, and it was found that eight inches of the humerus was involved in the fracture. Amputation was performed immediately, by Surgeon G. S. Palmer, U. S. V., at the shoulder joint, by double antero-posterior flaps. May 8th: Water dressing and isinglass plaster; wound granulating finely; discharge healthy; no constitutional disturbance. June 13th: Wound cicatrizing nicely; granulations red; no pain; appetite good; sleeps well; respiration 20; pulse 88; bowels regular. June 23d: Water dressing and isinglass plaster; about all cicatrized; scar at the widest not more than four or five lines; very healthy appearance; appetite good; sleeps well; sits up all day." Assistant Surgeon H. Allen, U. S. A., contributed the specimen. It is described in the *Catalogue of the Surgical Section*, p. 92, as consisting of "the greater part of the right humerus, shattered at the junction of the upper thirds." The patient was discharged the service and pensioned, June 26, 1863. On July 24, 1865, the patient committed suicide by taking arsenic. His attending physician testifies: "Keyes was a young man in the prime of life, and feeling his future hopes and prospects clouded, he took his loss very much to heart; it continually preyed upon his mind, making him melancholic and disheartened, and while in this condition he took his own life."

CASE 1604.—Private Casper S——, Co. B, 7th New York, aged 30 years, was wounded at Weldon Railroad, August 24, 1864. He was admitted to a Second Corps field hospital. Surgeon W. Vosburg, 111th New York, diagnosed "Gunshot wound of the arm, slight." Simple dressings were used. The patient was shortly afterward sent to Washington, and entered Lincoln Hospital. Assistant Surgeon W. Lindsley, U. S. A., noted: "Admitted August 28th, with a gunshot wound, causing extensive comminuted fracture of the right humerus. September 1st: Amputation at the shoulder joint, by Assistant Surgeon J. C. McKee, U. S. A. Eight ligatures were used. The anæsthetic employed was a mixture of chloroform and ether. The condition of the soft parts was tolerably good; his constitution not very good." The specimen, represented by the cut (FIG. 491), was contributed by Acting Assistant Surgeon H. M. Dean. It consists of the upper half of the right humerus, shattered in the surgical neck, and amputated at the joint. A portion of the fracture extends to the epiphyseal line, which is not crossed. The patient was discharged the service and pensioned, March 30, 1865. His disability was rated total. He was paid June 4, 1874. This pensioner was provided with an artificial limb by G. R. Grenell & Co., March 22, 1866.

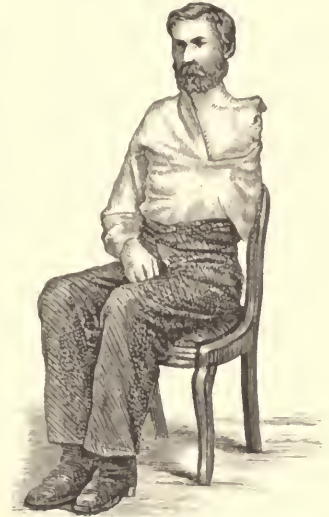

FIG. 490.—Centrix of an intermediary exarticulation of the left shoulder, a year after the operation.



FIG. 491.—Shot fracture implicating the neck of humerus. Spec. 3144.



TABLE XLVI.

Summary of Eighty-five Cases of Recovery after Intermediary Amputation at the Shoulder for Shot Injury.

NO.	NAME, AGE, AND MILITARY DESCRIPTION.	DATE OF INJURY.	NATURE OF INJURY.	DATE OF OPERATION.	OPERATION AND OPERATOR.	RESULT AND REMARKS.
1	Allen, J., Serg't, II, 2d Infantry, age 35.	May 10, 1864.	Shot fracture of left humerus two inches above the condyles; pieces of bone driven into muscles.	May 16, 1864.	Antero-posterior flap amputation at the shoulder joint, by Surg. E. Bentley, U. S. V.	Considerable hemorrhage. Discharged September 26, 1864; pensioned.
2	Belden, S., Pt., B, 5th Vermont.	June 29, 1862.	Right humerus shattered by a conoidal ball; hemorrhage.	July 2, 1862.	Amputated at the shoulder, by Surgeon W. P. Russell, 5th Vermont.	Disch'd Sept. 25, 1862; pensioned.
3	Berger, D., Serg't, I, 126th New York, age 26.	May 10, 1864.	Shot fracture of left arm in upper third.	May 14, 1864.	Flap amputation at shoulder joint, by a Confederate surgeon.	Disch'd Feb. 18, 1865; pensioned.
4	Blackman, G. H., Serg't, E, 93d New York, age 23.	May 6, 1864.	Shot wound of right arm, with fracture of humerus.	May 14, 1864.	Flap amputation, by Dr. G. A. Buck.	Disch'd June 29, 1865; pensioned.
5	Bond, G. J., Pt., A, 74th New York, age 21.	July 2, 1863.	Comminuted shot fracture of left humerus.	July 5, 1863.	Amputated at the shoulder, by Ass't Surgeon J. T. Calhoun, U. S. A.	Disch'd July 2, 1864; pensioned.
6	Bone, T., Corp'l, I, 35th Iowa, age 32.	July 14, 1864.	Fracture of neck of right humerus by a conoidal ball.	July 23, 1864.	Amputated at the shoulder, by Surg. J. G. Keenon, U. S. V.	Disch'd Feb. 7, 1865; pensioned.
7	Borchert, W., Pt., E, 4th Pennsylvania Reserves.	Aug. 30, 1862.	Shot wound through left shoulder joint; profuse suppuration; sloughing.	Sept. 9, 1862.	Amputated at shoulder joint by antero-posterior flaps.	Disch'd Dec. 6, 1862; pensioned.
8	Bowers, John L., Pt., C, 2d Wisconsin.	Aug. 30, 1862.	Shot wound of left shoulder, with injury of vessels and of bone.	Sept. 2, 1862.	Amputated at shoulder joint by transfexion.	Disch'd Oct. 10, 1862; pensioned.
9	Braswell, R. P., Pt., G, 15th Alabama, age 25.	Aug. 14, 1864.	Shot fracture of upper third of right arm; soft parts disorganized.	Aug. 19, 1864.	Flap amputation at the shoulder, by Act'g Ass't Surgeon H. B. White.	Sent to Military Prison January 12, 1865.
10	Brewer, D. Z., Pt., D, 115th New York, age 32.	Aug. 16, 1864.	Shot wound of right arm, with severe lesions of bone and soft parts.	Aug. 19, 1864.	Amputated at the shoulder, by a Confederate surgeon.	Disch'd May 18, 1865; pensioned.
11	Bryant, L. J., Pt., C, 3d Wisconsin, age 24.	May 3, 1863.	Comminuted shot fracture of left humerus, involving shoulder joint; sloughing.	May 8, 1863.	Amputated at the shoulder, by Surgeon H. E. Goodman, 28th Pennsylvania.	Disch'd Aug. 8, 1863; pensioned. <i>Spec. 1082, A. M. M.</i>
12	Buck, J., Pt., F, 2d Infantry, age 30.	June 27, 1862.	Compound fracture of anatomical neck of right humerus; fracture extended down shaft.	July 20, 1862.	Amputated at the shoulder by the oval method.	Disch'd Feb. 4, 1863; pensioned.
13	Cain, G. W., Pt., H, 140th Pennsylvania, age 19.	May 12, 1864.	Shot wound of right shoulder, with fracture of humerus.	May 20, 1864.	Amputated at the shoulder by Lisfranc's plan.	Disch'd Jan. 18, 1865; pensioned. Died March 17, 1871.
14	Cliggott, J., Pt., H, 99th Pennsylvania, age 20.	July 2, 1863.	Shot fracture of neck of left humerus, extending into the shoulder joint.	July 12, 1863.	Flap amputation, by Surgeon D. S. Hayes, 110th Pennsylvania.	To Vet. Res. Corps Jan. 27, 1864. Discharged June 30, 1864; pensioned. Died Dec. 25, 1871.
15	Coekefair, W., Pt., I, 9th New York Vols.	April 19, 1862.	Shot fracture of head of the left humerus; afterward hemorrhage.	May 18, 1862.	Amputated at the shoulder by Lisfranc's double flap method, by Dr. A. B. Mott.	Disch'd May 20, 1863; pensioned. Died March 26, 1872.
16	Cole, P., Pt., B, 102d New York.	Sept. 17, 1862.	Shot fracture of upper portion of left humerus, followed by gangrene.	Sept. 20, 1862.	Amputated, by Surgeon B. A. Vanderkleeft, U. S. V.	Disch'd Dec. 6, 1862; pensioned. "Wound occasionally breaks open and discharges pieces of bone."
17	Collins, T., Pt., E, 136th Pennsylvania.	Dec. 13, 1862.	Shot comminution of the right humerus near the upper third.	Dec. 25, 1862.	Amputated, by A. A. Surgeon S. L. Loomis.	Disch'd May 9, 1863; pensioned. Died in 1865. <i>Spec. 544, A. M. M.</i>
18	Cook, J. W., Pt., D, 11th Mississippi, age 24.	July 2, 1863.	Comminuted fracture of right humerus, high up.	July 6, 1863.	Amputated at the shoulder by double flaps.	Recovered; transferred September 1st, 1863.
19	Cooper, D. D., Pt., I, 37th Illinois, age 27.	April 9, 1863.	Comminuted fracture of left humerus; soft parts infiltrated with serum and blood from venous hemorrhage.	April 18, 1863.	Amputated, by Surg. A. McMahon, U. S. V.	Disch'd May 24, 1865; pensioned. Wound tender and frequently discharging in 1870.
20	Cronce, A., Pt., G, 15th New Jersey.	June 4, 1864.	Fracture of lower third of left humerus; soft parts lacerated; sloughing.	June 20, 1864.	Amputated, by A. A. Surgeon J. Butterbaugh.	Disch'd May 17, 1865; pensioned. <i>Spec. 2637, A. M. M.</i>
21	Decker, L., Pt., H, 76th Pennsylvania.	July 12, 1863.	Gunshot wound of right arm, with injury of nerves, bloodvessels, and bone.	July 16, 1863.	Amputated at shoulder by the double flap method.	To Vet. Res. Corps Jan. 20, 1864. Discharged October 27, 1864; pensioned.
22	Dempsey, J., Pt., D, 51st New York, age 41.	May 6, 1864.	Wound of the right arm near shoulder, with fracture of the humerus.	May 16, 1864.	Amputated at shoulder, by Dr. Comstock, of Harrisburg, Pa.	To Vet. Res. Corps Oct. 28, 1864. Disch'd Sept. 6, 1865; pensioned.
23	Donett, L. H., Serg't, B, 83d New York.	July 21, 1861.	Shot laceration of left arm, with fracture high up.	Aug. 11, 1861.	Amputated, by Surg. S. Logan, P. A. C. S.	Disch'd Nov. 12, 1861; pensioned.
24	Farris, L., Pt., F, 48th Ohio, age 18.	May 22, 1863.	Fracture of upper third of right humerus; arm swollen; abscess in the axilla burrowed beneath pectoral muscles.	June 14, 1863.	Amputated, by Surgeon J. G. Keenon, U. S. V.; diseased surface of glenoid cavity was gouged away.	Mustered out Oct. 17, 1863; pensioned. <i>Spec. 1701, A. M. M.</i>
25	Fegeley, M., Pt., K, 151st Pennsylvania.	July 1, 1863.	Wound of left arm, with longitudinal splintering of humerus.	July 9, 1863.	Amputated at the shoulder by Larrey's method.	Mustered out July 30, 1863; pensioned.
26	Flora, P., Pt., F, 7th Pennsylvania Reserves.	June 30, 1862.	Shot injury of right arm, high up, with great inflammatory swelling.	July 3, 1862.	Amputation at the shoulder by antero-posterior flaps.	Disch'd Oct. 4, 1862; pensioned.
27	Flory, J., Corp'l, G, 17th Penn'a Cavalry, age 24.	Mar. 1, 1864.	Fracture of the right humerus, extending into shoulder joint.	Mar. 5, 1864.	Flap amputation, by Surg. H. Johnson, 6th Michigan Cav'ry.	Disch'd July 27, 1865; pensioned.
28	Fuller, H. F., Pt., C, 3d South Carolina, age 24.	July 2, 1863.	Fracture of head and neck of right humerus; ball lodged in glenoid cavity.	July 5, 1863.	Flap amputation at shoulder.	September 16th, healed by first intention; paroled.
29	Glenn, J. B., Serg't, D, 18th Virginia, age 23.	July 3, 1863.	Extensive comminution of upper portion of left humerus; great laceration of soft parts.	July 11, 1863.	Amputated at the shoulder by the oval method.	August 2d, abscess in stump opened; paroled Aug. 22, 1863.
30	Hammous, R. T., Serg't, C, 2d West Virginia Cavalry.	April 1, 1865.	Wound of right shoulder, with lesion of bone and bloodvessels.	April 8, 1865.	Amputated, by Dr. W. D. Reynolds, of Lawrence, Mass.	Disch'd July 1, 1865; pensioned. Stump tender.

<sup>1</sup> The case is reported in detail by Dr. A. E. M. Purdy, in *Reports of Hospitals*, in *Am. Med. Times*, 1862, Vol. V, p. 132.

NO.	NAME, AGE, AND MILITARY DESCRIPTION.	DATE OF INJURY.	NATURE OF INJURY.	DATE OF OPERATION.	OPERATION AND OPERATOR.	RESULT AND REMARKS.
31	Hanson, W. L., Pt., I, 80th New York, age 28.	July 1, 1863.	Fracture of left humerus in the upper third; bleeding and sloughing.	July 7, 1863.	Amputated, by Surg. R. Loughran, 80th New York.	Disch'd Nov. 19, 1863; pensioned.
32	Harlow, J. R., Pt., B, 44th New York, age 21.	July 1, 1862.	Head and five inches of shaft of left humerus comminuted; ball lodged.	July 6, 1862.	Amputated by the Roux method, by Ass't Surg. J. S. Billings, U. S. A.; ball dropped out as the posterior incision was made.	Disch'd Sept. 1, 1862; pensioned. <i>Spec.</i> 3450, A. M. M.
33	Herring, J. M., Pt., K, 17th Mississippi, age 32.	June 1, 1864.	Comminuted fracture of head of — humerus, with gangrenous condition of arm.	June 4, 1864.	Antero-posterior flap amputation.	Furloughed July 20, 1864.
34	Henertz, J. B., Pt., D, 27th Iowa.	April 9, 1864.	Wounds through mouth and left shoulder; inferior left maxilla and head and neck of humerus fractured.	May 9, 1864.	Amputated at the shoulder by external and internal flaps.	Disch'd April 1, 1865, and pensioned. Died Dec. 15, 1871.
35	Hickman, T. N., Pt., E, 18th U. S. Infantry.	Dec. 31, 1862.	Wounded by several balls in right arm and forearm.	Jan. 3, 1863.	Amputated, by Surg. C. S. Muscog, 10th Ohio.	Disch'd Mar. 11, 1863; pensioned.
36	Hill, A. H., Pt., A, 3d Iowa Cavalry.	May 1, 1863.	One ball entered left elbow, splintering external condyle of the humerus; another ball passed through left shoulder.	May 4, 1863.	Flap operation, by Surgeon I. Castleberry, 1st Indiana Cavalry.	Disch'd July 15, 1863; pensioned. <i>Spec.</i> 1349, A. M. M.
37	Hoggatt, J. S., Pt., C, 6th Kansas Cavalry, age 34.	Aug. 3, 1864.	Comp'd comminuted fracture of the left humerus, extending nearly to head; also wounds of jaw and hip.	Aug. 6, 1864.	Antero-posterior flap operation, by Surgeon C. E. Swasey, U. S. A.	Several hæmorrhages; disch'd November 30, 1864; pensioned. Died November 4, 1866.
38	Howard, J. W., Pt., A, 31st Maine, age 38.	June 16, 1864.	Shot wound of left shoulder, the humerus shattered and soft parts lacerated.	June 20, 1864.	Amputated at the shoulder by the oval method.	Mustered out June 16, 1865; pensioned.
39	Irwin, S., Pt., Hampton's Penn'a Artillery, age 40.	Aug. 29, 1862.	Comminuted fracture of upper half of left humerus, with bleeding and sloughing.	Sept. 11, 1862.	Amputated, by Surg. I. Moses, U. S. V.	Disch'd Nov. 27, 1862; pensioned. Died Dec. 3, 1869. <i>Spec.</i> 2952, A. M. M.
40	Jones, C., Pt., D, 2d U. S. Colored Cavalry, age 35.	Mar. 9, 1864.	Shell fracture of upper third of left humerus; profuse suppuration of fetid pus.	Mar. 25, 1864.	Amputated by oval method, by Asst. Surg. J. H. Frantz, U. S. A.	Mustered out December 5, 1864; pensioned.
41	Jones, D. S., Pt., A, 30th Ohio.	Sept. 13, 1862.	Wound of right arm just below shoulder joint, followed by hæmorrhage.	Sept. 17, 1862.	Amputated at the shoulder by double flaps.	Disch'd Jan. 3, 1863; pensioned.
42	Jones, W. L., Pt., E, 2d Minnesota, age 29.	Sept. 19, 1863.	Right arm badly lacerated by shot.	Sept. 23, 1863.	Amputated, by Surg. O. Ayers, 2d Minnesota.	Mustered out October 10, 1864; pensioned.
43	Kastner, G., Pt., C, 116th Ohio.	June 5, 1864.	Shot wound of left arm, the humerus shattered.	June 27, 1864.	Amputated, by a Confederate surgeon.	Disch'd Mar. 7, 1865; pensioned.
44	Keys, H. F., Pt., E, 12th N. Hampshire, age 21.	May 3, 1863.	Ball shattered eight inches of right humerus.	May 7, 1863.	Antero-posterior flap amputation, by Surg. G. S. Palmer, U. S. V.	Disch'd June 25, 1863; pensioned. <i>Spec.</i> 119, A. M. M. Committed suicide July 24, 1865.
45	Kirby, George C., Pt., I, 61st Illinois.	April 6, 1862.	Shot wound of right arm near shoulder.	April 12, 1862.	Amputated at the shoulder by transfixion.	Disch'd Aug. 24, 1862; pensioned.
46	Kremer, P., Serg't, B, 32d Indiana.	Sept. 19, 1863.	Fracture of left humerus by a round ball.	Sept. 23, 1863.	Amputated, by a Confederate surgeon.	Disch'd April 28, 1864; pensioned. Stump occasionally painful.
47	Krome, E., Pt., K, 6th U. S. Infantry.	June 27, 1862.	Shot fracture of right arm near shoulder; consecutive hæmorrhage.	July 5, 1862.	Amputated at the shoulder, by Asst. Surg. C. P. Russell, U. S. A.	Disch'd Mar. 3, 1863; pensioned.
48	Lake, H., Pt., B, 1st New Jersey Cavalry, age 28.	May 5, 1864.	Shot through right humerus three inches below shoulder joint; severe hæmorrhage May 17th.	May 17, 1864.	Antero-posterior flap amputation at shoulder, by Surgeon B. G. Streeter, 4th New York Cavalry.	Disch'd Sept. 22, 1864; pensioned.
49	Lastofka, W., Pt., I, 26th Wisconsin, age 19.	May 2, 1863.	Ball passed through axilla, comminuted the right humerus near the surgical neck; arm painful.	May 15, 1863.	Flap amputation, by Surg. O. A. Judson, U. S. V.	May 23d, secondary hæmorrhage; recurred June 6th; stump opened and axillary artery re-ligated; disch'd Aug. 13, 1863; pensioned. <i>Spec.</i> 1243 and 1576, A. M. M.
50	Lyons, M., Sergeant, C, 9th Massachusetts.	July 1, 1862.	Fracture of the left humerus in upper third.	July 6, 1862.	Amputated, by Asst. Surg. H. L. Sheldon, U. S. A.	Disch'd Aug. 22, 1862; pensioned. Died July 17, 1863.
51	Main, H. A., Pt., E, 2d New York Cavalry.	Sept. 23, 1863.	Shot fracture of left humerus at surgical neck.	Sept. 28, 1863.	Flap amputation, by Dr. Black, C. S. A.	Mustered out August 13, 1864; pensioned.
52	McDonald, I. W., Pt., D, 15th Maine, age 29.	April 8, 1864.	Shot fracture of right humerus in upper third.	April 11, 1864.	Amputated at the shoulder by the oval method.	Disch'd May 22, 1864; pensioned.
53	McDonald, S., Pt., I, 16th New York.	Aug. 30, 1862.	Shot wound of left arm . . . . .	Sept. 9, 1862.	Amputated, by Asst. Surg. Geo. M. McGill, U. S. A.	Disch'd Dec. 16, 1862; pensioned.
54	McKenzie, D., Pt., B, 1st Michigan Cavalry.	Aug. 30, 1862.	Shot wound of left arm . . . . .	Sept. 2, 1862.	Amputated at the shoulder by Lisfranc's method.	Disch'd Nov. 3, 1862; pensioned.
55	McMahon, F. M., Pt., D, 78th Illinois, age 28.	Sept. 20, 1863.	Comminuted fracture of right arm near shoulder joint.	Sept. 21, 1863.	Amputated by flap method, by Asst. Surg. W. H. Matchett, 40th Ohio.	Disch'd June 10, 1864; pensioned.
56	Miles, J. H., Pt., G, 24th Virginia, age 23.	May 5, 1862.	Ball entered left arm four inches below shoulder joint; humerus extensively split and shattered.	May 26, 1862.	Oval amputation, by Asst. Surg. J. S. Billings, U. S. A.; five ligatures.	Discharged September 15, 1862. <i>Spec.</i> 1091, A. M. M.
57	Myers, J. C., Pt., D, 61st Pennsylvania, age 21.	June 1, 1862.	Fracture of head of right humerus; head excised June 1st, by Surgeon R. M. Tindle.	June 17, 1862.	Amputated, by Dr. Willard Parker.	Oct. 10, 1862, ball and several pieces of bone removed. Disch'd Dec. 3, 1862; pensioned.
58	Nesbitt, W. M., Corporal, D, 4th Vermont, age 31.	May 12, 1864.	Shot fracture of left humerus near shoulder joint.	May 16, 1864.	Amputated at the shoulder. . . . .	Disch'd July 29, 1865; pensioned.
59	Nichols, C., Pt., B, 121st New York.	May 3, 1863.	Comminuted shot fracture of left humerus.	May 6, 1863.	Amputated, by Ass't Surgeon D. M. Holl, 121st New York.	Disch'd Aug. 27, 1863; pensioned.
60	Richards, F. D., Pt., C, 35th Massachusetts, age 38.	Sept. 17, 1862.	Left humerus comminuted by a large projectile.	Sept. 27, 1862.	Amputated, by Asst. Surg. Geo. M. McGill, U. S. A.	Disch'd Mar. 4, 1865; pensioned.
61	Ripley, W. H., Pt., K, 70th New York.	Aug. 29, 1862.	Wound of left arm by ball and buckshot, followed by sloughing.	Sept. 7, 1862.	Amputated, by Acting Asst. Surg. W. B. Crane.	Disch'd Dec. 13, 1862; pensioned.
62	Robins, W. B., Pt., H, 5th New York Heavy Artillery, age 28.	Aug. 26, 1864.	Extensive shot comminution of right shoulder; wound gangrenous.	Aug. 29, 1864.	Amputated by double flap method, by Act'g Ass't Surg. J. R. Usher.	To Veteran Reserve Corps March 2, 1865; pensioned.
63	Rehm, C., Corp'l, F, 29th New York, age 24.	May 3, 1863.	Shot fracture of upper third of right humerus.	May 7, 1863.	Amputated, by Surgeon R. Thomain, 29th New York.	Mustered out June 22, 1863; pensioned. <i>Spec.</i> 1540, A. M. M.

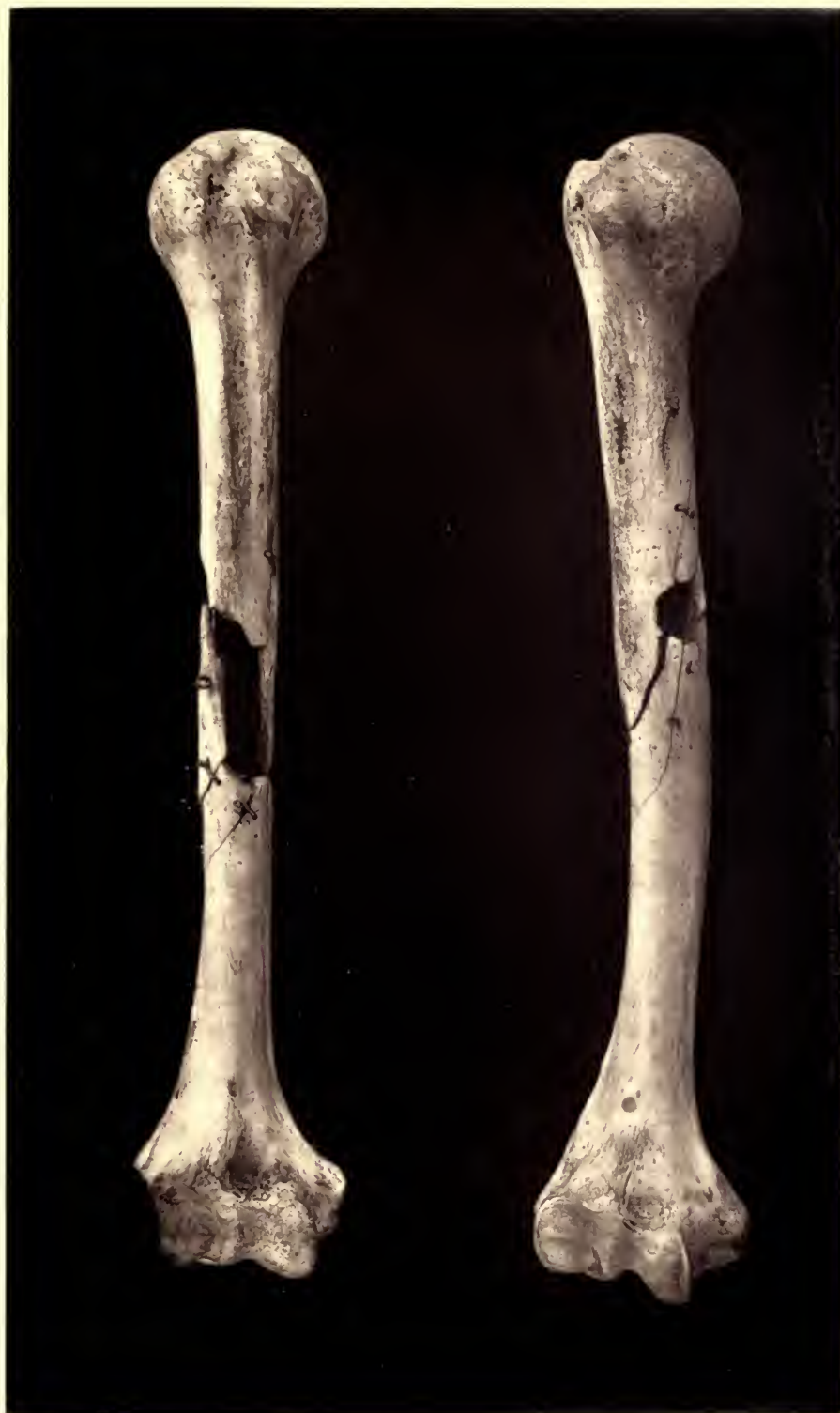<sup>1</sup> See CASE 81, TABLE XXIV, p. 531 *ante*, and *Am. Med. Times*, Aug. 16, 1862, Vol. V, p. 91.



No.	NAME, AGE, AND MILITARY DESCRIPTION.	DATE OF INJURY.	NATURE OF INJURY.	DATE OF OPERATION.	OPERATION AND OPERATOR.	RESULT AND REMARKS.
64	Roth, L. Pt., E, 12th Pennsylvania Reserves.	Sept. 14, 1862.	Shot comminution of upper portion of right humerus; profuse suppuration.	Oct. 2, 1862.	Flap amputation, by Surg. H. S. Hewitt, U. S. V.	Disch'd Dec. 15, 1862; pensioned. <i>Spec.</i> 441, A. M. M.
65	Schmidt, C., Pt., B, 7th New York Heavy Artillery, age 30.	Aug. 25, 1864.	Upper portion of right humerus shattered by large shot.	Sept. 1, 1864.	Amputated, by Asst. Surg. J. C. McKee, U. S. A.; eight ligatures.	Disch'd Mar. 30, 1865; pensioned. <i>Spec.</i> 3144, A. M. M.
66	Sewall, N. A., Pt., B, 100th Pennsylvania, age 25.	June 2, 1864.	Ball passed along the whole length of right arm, comminuted upper two thirds of humerus, and opened the elbow joint.	June 11, 1864.	Antero-posterior flap operation, by Asst. Surg. A. Ingram, U. S. A.; lower part of flaps left open and dry.	Mustered out August 31, 1864; pensioned. <i>Spec.</i> 2822, A. M. M. See left figure in PLATE XLVI, opposite p. 640.
67	Shaw, J. B., Pt., D, 65th Ohio.	Sept. 19, 1863.	Shot comminuted fracture of upper third of right humerus.	Sept. 22, 1863.	Amputated, by Surgeon A. McMahon, 64th Ohio.	Hæmorrhage Oct. 1st; Nov. 1st, stump healed. Disch'd April 16, 1864; pensioned.
68	Shepler, J., Pt., B, 108th New York, age 24.	June 3, 1864.	Comminuted fracture of right humerus; June 13, 1864, head and four inches of the shaft excised.	July 13, 1864.	Amputated by Larrey's method, by Asst. Surg. J. C. McKee, U. S. A.; ten ligatures.	Disch'd Feb. 6, 1865; pensioned. <i>Spec.</i> 550, A. M. M.
69	Showman, E. W., Pt., D, 113th Ohio, age 25.	Oct. 7, 1863.	Fracture of inferior costa of left scapula and neck of the left humerus.	Oct. 14, 1863.	Amputated by long lateral flap method, by Surgeon G. W. Hogeboom, U. S. V.	Gangrene. Discharged April 6, 1864; pensioned.
70	Sinex, C., Pt., A, 26th Pennsylvania, age 40.	July 2, 1863.	Fracture of upper third of the right humerus.	July 5, 1863.	Amputated, by Surg. C. C. Jewett, 16th Massachusetts.	Variola. Discharged August 24, 1864; pensioned.
71	Smith, J. A., Pt., A, 16th Wisconsin.	April 6, 1862.	Shot fracture of left humerus near shoulder.	April 9, 1862.	Amputated at the shoulder by double flaps.	Disch'd June 18, 1862; pensioned.
72	Spament, C. B. A., Corp'l, G, 5th Ohio, age 27.	May 3, 1863.	Shot fracture of left humerus.	May 6, 1863.	Amputated, by Surg. W. M. Nash, P. A. C. S.	Disch'd Aug. 21, 1863; pensioned.
73	Stewart, A. B., Pt., D, 121st Pennsylvania, age 23.	July 1, 1863.	Wound of left arm, involving bone and vessels, high up.	July 9, 1863.	Flap amputation at shoulder joint.	Large abscess between flaps; solution of the sulphate of zinc. Disch'd May 24, 1864; pensioned. Disch'd June 3, 1863; pensioned. Died November 6, 1871.
74	Striker, Philip, Pt., F, 31st New York.	June 27, 1862.	Wound of the right arm, with lesions of the bone and of the artery.	July 5, 1862.	Amputated at the shoulder by Larrey's method.	June 8th, secondary hæmorrhage. Disch'd Oct. 25, 1864; pensioned. <i>Spec.</i> 3385, A. M. M.
75	Taylor, J. J., Pt., K, 21st New York Cavalry, age 29.	May 22, 1864.	Shot fracture of right arm in upper third; wound gangrenous.	May 31, 1864.	Vertical flap amputation, by Surg. J. Hoone, 1st Bat. Home Brigade.	Disch'd Sept. 16, 1861; pensioned.
76	Vollman, John, Pt., G, 1st Ohio.	June 17, 1861.	Shot wound of right arm, the humerus shattered in upper third.	July 3, 1861.	Amputated at the shoulder by oval incisions.	Disch'd Oct. 25, 1864; pensioned. <i>Spec.</i> 3385, A. M. M.
77	Wade, S., Pt., A, 77th Pennsylvania, age 19.	Mar. 2, 1863.	Extensive fracture of upper portion of right humerus; March 30th, violent hæmorrhage.	Mar. 30, 1863.	Poupart's flap amputation, by Surg. B. A. Vanderkeiff, U. S. A.	Mustered out October 10, 1864; not a pensioner. <i>Spec.</i> 1044, A. M. M.
78	Welahan, M., Pt., C, 25th Virginia, age 21.	July 2, 1863.	Fracture of upper third of left humerus; profuse suppuration and sloughing.	July 6, 1863.	Exarticulation at shoulder by oval incisions.	Paroled November 12, 1863.
79	Welch, J., Pt., B, 6th Infantry, age 26.	Mar. 18, 1865.	Comminution of upper part of left humerus; axillary artery, vein, and nerves severed; March 20, 1865, five inches of shaft excised, by Asst. Surg. J. E. Semple, U. S. A.	Mar. 21, 1865.	Amputated at the shoulder by the same operator.	Disch'd July 3, 1865; pensioned.
80	Wendel, A., Corp'l, A., 22d Indiana.	Dec. 31, 1862.	Shot wound of left arm, with fracture and sloughing.	Jan. 12, 1863.	Amputated at the shoulder by Larrey's first method.	Disch'd April 27, 1863; pensioned.
81	White, J. M., Pt., Carter's Battery, age 28.	Sept. 14, 1863.	Fracture of left arm and shell wound of thigh.	Sept. 21, 1863.	Amputated, by Surg. Robertson, Carter's Battery, C. S. A.	Furloughed December 12, 1863.
82	Willott, H. B., Pt., E, 29th Wisconsin.	April 8, 1864.	Fracture of head and upper third of the right humerus; wound gangrenous.	April 18, 1864.	Antero-posterior flap operation, by Surg. P. Bacon, U. S. A.	Disch'd June 20, 1864; pensioned.
83	Winchell, J., Pt., D, 1st U. S. Sharpshooters.	June 27, 1862.	Wound of left arm, with injury of bone, nerves, and vessels.	July 1, 1862.	Amputated at the shoulder by external and internal flaps.	Disch'd Sept. 18, 1862; pensioned.
84	Zane, G. B., Serg't, A, 72d Pennsylvania, age 23.	Dec. 13, 1862.	Shell wound of left shoulder joint, shattering bone and injuring vessels.	Dec. 16, 1862.	Circular amputation, by Surg. M. Rizer, 72d Pennsylvania.	Disch'd May 2, 1864; pensioned.
85	Zuhorn, J., Pt., K, 93d Pennsylvania.	May 31, 1862.	Fracture of the left arm near shoulder.	June 21, 1862.	Amputated, by Acting Asst. Surg. W. K. Cleveland.	Disch'd Sept. 18, 1862; pensioned.

In these eighty-five amputations, the side implicated was specified in every case save one; the right limb was removed in forty, and the left in forty-four. Seventy-four patients were discharged, four went to modified duty in the second battalion of the Veteran Reserves, and seven were exchanged, furloughed, or paroled. Disarticulation was most frequently practised by making a large deltoid flap by transfixion, exarticulating, and then cutting a short internal flap; but the oval method was also frequently employed, and all the varieties of double flap procedures. The proportion of operations for wounds by large missiles was much less than among the primary operations. In many cases gangrene or hæmorrhage rendered operative interference imperative. Six of the patients had severe wounds coincident with those at the shoulder. One underwent consecutive ligation of the axillary artery; this was the patient who had previously submitted to excision at the shoulder. Two were cases in which four or five inches of the shaft of the humerus had been previously removed.

<sup>1</sup> See CASE 65, TABLE XXXIII, page 558 ante.



Ward phot.

Am. Photo-Relief Printing Co., Philada.

PLATE XLVI. SHOT COMMUNITIONS OF THE HUMERUS.

Nos. 2822 and 1234. SURGICAL SECTION.





§ *Unsuccessful Operations.*—The proportion of fatality in the intermediary amputations at the shoulder after shot injury was nearly twice as great as in the primary series. In seventeen instances, the disarticulations were subsequent to important primary or early intermediary operations. Thus, in eleven cases, the head or portions of the shaft of the humerus had been excised; prior amputations in the continuity had been practised in two of the cases; balls and fragments of bone had been extracted and arterial branches tied, in four cases. The three following examples illustrate fatal exarticulations at the shoulder at different periods of the intermediary stage:

CASE 1605.—Private P. P——, Co. E, 17th Wisconsin, aged 43 years, was wounded at Vicksburg, May 19, 1864. He was sent to Memphis on the hospital steamer R. C. Wood, and entered Gayoso Hospital June 1st. The pathological specimen represented (FIG. 492) was forwarded by the operator, Assistant Surgeon W. Watson, U. S. V., with the following history:

“Wounded by a conoidal ball, which fractured the left humerus at the surgical neck. When admitted the arm was swollen and livid; the general appearance of the patient was anemic and unpromising, but amputation was decided upon as affording the only chance of saving life. The arm was amputated at the shoulder joint June 3d. The patient gradually sank, and died June 7, 1864. The treatment consisted of concentrated nourishment and stimulants, freely given.” The specimen is thus described in the Catalogue of 1866, p. 114, by Assistant Surgeon A. A. Woodhull, U. S. A.: “The upper third of the left humerus amputated at the shoulder joint. The specimen shows a nearly transverse fracture of the surgical neck and a longitudinal fracture of the shaft for three inches, inflicted by a conoidal ball. Incipient caries is seen along the line of fracture.”

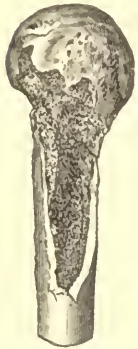

FIG. 492.—Upper third of humerus exarticulated at the left shoulder. Spec. 2082.

CASE 1606.—Private John B——, Co. C, 7th New York Heavy Artillery, aged 27 years, was wounded at Cold Harbor, June 3, 1864, and treated in a Second Corps field hospital. He was thence transferred to Washington, and admitted to Emory Hospital on June 8th. Surgeon N. R. Moseley, U. S. V., noted: “Gunshot wound of the right arm, the ball entering at the insertion of the deltoid, passing upward, and lodging in the shoulder joint. On June 16th, amputation at the shoulder was performed by antero-posterior flaps. At this time the wound was ecchymosed and oedematous, and the bones comminuted; constitutional condition unfavorable,

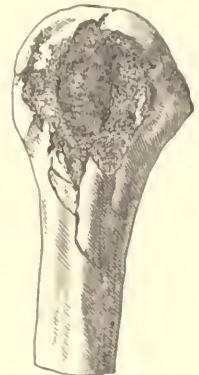

FIG. 493.—Conoidal ball impacted in the head of the right humerus. Spec. 2564.

with nervous prostration. The treatment consisted of stimulants internally, and local pressure on the femoral arteries to retain blood in the trunk. The patient continued to sink, and died of collapse six hours after the operation. The specimen (FIG. 493) consists of the upper fourth of the right humerus, disarticulated for fracture of the head by a conoidal ball, which destroyed the greater tuberosity and lodged. Several partial fractures extend through the head and neck.” Contributed by the operator, Surgeon N. R. Moseley, U. S. V.

CASE 1607.—Corporal E. K——, of the Band of the De Kalb Regiment (41st New York), was accidentally shot, by a comrade who was inspecting a pistol, July 23, 1861. He was conveyed to the E Street Infirmary, Washington. Surgeon

J. W. S. Gouley, U. S. A., operated, and contributed the specimen, represented by the cuts (FIGS. 494-5), with the following history: “Corporal K—— was sitting on his bed and leaning slightly forward, and his friend was sitting on the floor two feet in front of him, cleaning a pistol, which was accidentally discharged, the ball taking effect in his left shoulder. He was conveyed to the E Street Infirmary the day of the accident. The wound was carefully examined, and the ball found lodged in the head of the os brachii. Resection was proposed, but objected to by the surgeon in charge. Some days subsequent to the injury, and after due consultation with Surgeon R. Murray, Assistant Surgeons W. J. H. White, J. J. Milhan, U. S. A., and Acting Assistant Surgeon Butler, it was decided by the majority to amputate at the shoulder joint. With the assistance of these gentlemen the operation was performed. The patient sustained much loss of blood during the operation, and died a day and a half afterward, July 28, 1861. It is proper to state that prior to the operation the patient had exhibited symptoms of pyæmia. The specimen shows a conical ball embedded in the cancellated tissue of the bone, with two fissures, and also that it was a most favorable case for primary resection, for when he entered the hospital his condition was excellent.” The discussions to which this case gave rise are believed to have promoted the favorable consideration of the views of the advocates of excision in injuries of this character.

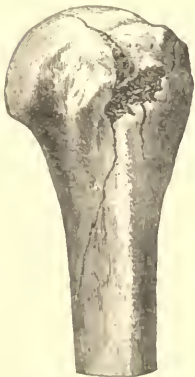

FIG. 494.—Pistol ball perforation of the head of the left humerus, which was exarticulated intermediately. Spec. 347.  $\frac{1}{2}$ .

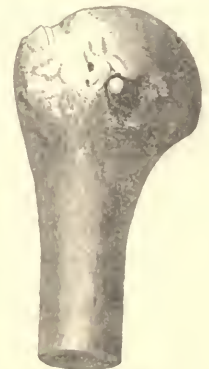

FIG. 495.—Posterior view of the same specimen, showing the apex of the ball, which has traversed the head of the humerus.

A tabular statement, including the above and sixty-nine other unsuccessful intermediary exarticulations at the shoulder, commences on the next page.



TABLE XLVII.

*Summary of Seventy-two Fatal Cases of Intermediary Amputation at the Shoulder for Shot Injury.*

NO.	NAME, AGE, AND MILITARY DESCRIPTION.	DATE OF INJURY.	NATURE OF INJURY.	DATE OF OPERATION.	OPERATION AND OPERATOR.	RESULT AND REMARKS.
1	Allen, F. A., Corp'l, G, 20th Massachusetts.	Sept. 17, 1862.	Shot fracture of the right arm; Sept. 17th, arm amputated at middle third; sloughing.	Oct. 12, 1862.	Re-amputated at the shoulder, by A. A. Surg. L. Fisher.	Pyæmia; death October 25, 1862. <i>Spec.</i> 267, A. M. M.
2	Andrews, C. N., Adjutant, 85th Illinois.	June 27, 1864.	Shot fracture of middle third of left humerus; June 27th, amputated at the junction of upper and middle thirds, by Surg. M. M. Hooton, 86th Illinois; gangrene.	July 19, 1864.	Re-amputated at the shoulder, by A. A. Surg. J. A. Hall.	Died July 23, 1864, from gangrene.
3	Bartley, J., Pt., C, 7th New York, age 27.	June 3, 1864.	Ball lodged in right shoulder joint; great nervous prostration.	June 16, 1864.	Antero-posterior flap exarticulation, by Surg. N. R. Moseley.	Died, six hours after operation, June 16, 1864. <i>Spec.</i> 2564, A. M. M.
4	Beekwith, G., Pt., E, 58th Pennsylvania, age 18.	June 30, 1864.	Shot fracture of right shoulder joint; necrosis; tissues lacerated.	July 26, 1864.	Amputation at the shoulder, by Ass't Surg. E. Curtis, U. S. A.	Died July 31, 1864.
5	Bell, I., Pt., B, 60th Ohio, age 19.	May 9, 1864.	Ball entered between left clavicle and trapezius, shattering scapula and lodged. Hemorrhages May 27th, 28th, 30th, and 31st.	May 31, 1864.	Amputation at the shoulder, by A. A. Surg. C. H. Osborne.	Died May 31, 1864; the autopsy showed extensive stellated fracture of scapula and division of enprascapula artery.
6	Bennett, —, Pt., Louisiana Regiment.	April 6, 1862.	Shot fracture of humerus, with laceration of soft parts.	April 16, 1862.	Amputated at the shoulder, by Ass't Surg. B. Howard, U. S. A.	Died April 17, 1862.
7	Bissell, W. R., Capt., A, 8th Virginia.	July 1-3, 1863.	Shot fracture of head of humerus; fissures extending nearly whole length of shaft.	A few days after July 7, 1863.	Amputated, by Surgeon C. S. Wood, 60th New York.	Died July 16, 1863.
8	Boone, W., Pt., G, 55th Pennsylvania.	Oct. 22, 1862.	Comminution of upper third of left humerus; Oct. 23d, fragments of bone removed.	Nov. 12, 1862.	Circular amputation, by A. A. Surg. T. T. Smiley.	No reaction; died November 12, 1862. <i>Spec.</i> 689, A. M. M.
9	Crompton, J. T., Serg't, I, 14th New Jersey, age 25.	July 9, 1864.	Comminuted fracture of right humerus; arm œdematous; pus burrowing.	July 22, 1864.	Amputated, by Ass't Surgeon R. F. Weir, U. S. A.	Died from shock, eight hours after operation, July 22, 1864.
10	Donaldson, T., Pt., E, 13th Ohio Cavalry, age 22.	Oct. 8, 1864.	Upper third of left humerus; bone necrosed for seven inches and head of bone completely destroyed; tissues disorganized.	Oct. 29, 1864.	Antero-posterior flap operation, by A. A. Surg. J. C. Morton.	Died Oct. 29, 1864, from effects of chloroform and shock. <i>Spec.</i> 3706, A. M. M.
11	Durif, E., Corp'l, B, 131st New York, age 37.	Sept. 19, 1864.	Head of left humerus comminuted; parts infiltrated with pus.	Sept. 27, 1864.	Flap amputation, by A. A. Surgeon J. R. Uhler.	Died October 4, 1864.
12	Elderkin, N., Pt., G, 18th Wisconsin.	May 22, 1863.	Compound fracture of upper third of left humerus.	June 1, 1863.	Amputated at the shoulder. . . .	Died June 5, 1863, from effect of excessive hæmorrhage during operation.
13	Fee, J. A., Capt., I, 48th New York, age 27.	June 28, 1864.	Wound of right shoulder; June 28th, excision of head of right humerus; profuse suppuration; secondary hæmorrhage.	July 13, 1864.	Amputation at the shoulder, by Surg. D. G. Rush, 101st Pennsylvania.	Died July 15, 1864.
14	Felton, C., Serg't, K, 122d New York, age 39.	June 3, 1864.	Wound of face and right arm; ball entered right shoulder, fractured humerus 1½ inches below head down to within 3 inches of elbow joint.	June 18, 1864.	Amputated, by A. A. Surgeon H. M. Dean.	Died June 23, 1864. <i>Spec.</i> 2573, A. M. M.
15	Ferros, J., Pt., I, 93d Indiana, age 20.	Sept. 11, 1864.	Wound through chest and right arm; humerus shattered at upper third.	Sept. 16, 1864.	Amputated, by A. A. Surgeon J. Brey.	Died Sept. 18, 1864. Autopsy showed fifth, sixth, and seventh ribs fractured, and fragments of bone driven into lung and liver.
16	Gallon, C., Corp'l, F, 96th Pennsylvania.	Nov. 7, 1863.	Shell fracture of right humerus to the anatomical neck; parts ecchymosed.	Nov. 12, 1863.	Amputated, by A. A. Surgeon W. M. Hudson.	Died November 20, 1863.
17	Gillies, P., Pt., H, 131st New York, age 25.	Oct. 19, 1864.	Comminution of head of left humerus; hæmorrhage from axillary amounting to twenty ounces.	Oct. 26, 1864.	Amputated, by Ass't Surgeon D. C. Peters, U. S. A.	Oct. 31st, hæmorrhage amounting to 32 ounces; axillary ligated on face of stump; hæmorrhage recurred; death Nov. 1, 1864.
18	Goudy, W., Pt., H, 26th Ohio.	Sept. 19, 1863.	Fracture of right radius and ulna; mortification extending high up in arm.	Sept. 25, 1863.	Amputation at the shoulder by double flaps.	Died.
19	Green, N. S., Pt., A, 53th Massachusetts.	May 6, 1864.	Wound of left shoulder joint; excision of head of humerus; hæmorrhage.	June 5, 1864.	Amputated, by Surgeon R. B. Boutecou, U. S. V.	Died June 7, 1864.
20	Hall, C., Serg't, F, 25th Massachusetts, age 28.	June 3, 1864.	Ball entered upper left arm, passed along the humerus, and lodged in elbow joint; gangrenous to near shoulder joint.	June 14, 1864.	Amputated, by Surgeon D. P. Smith, U. S. V.	Died June 14, 1864, from exhaustion.
21	Harrill, J. W., Serg't, B, 20th Alabama, age 25.	July 3, 1863.	Wound of right humerus; head excised, by Surgeon H. E. Goodman, 28th Pennsylvania.	July 12, 1863.	Amputation at the shoulder by the oval method.	July 19th, hæmorrhage from axillary; death July 21, 1863.
22	Harrison, G., Pt., G, 61st New York, age 23.	May 8, 1864.	Shot through right elbow; intense inflammation extending to the shoulder; pus diffused through arm.	May 19, 1864.	Amputated, by Surg. E. Bentley, U. S. V.	May 25th, symptoms of pyæmia; died June 4, 1864.
23	Hart, J., Pt., C, 50th New York, age 26.	June 22, 1864.	Fracture of the left scapula and shoulder joint.	June 29, 1864.	Double flap amputation, by A. A. Surg. T. F. Belton.	Sec'd'y hæmorrhage; transfusion of blood thro' incision on back of scapula; death July 7, 1864.
24	Hayes, J., Serg't, K, 7th Ohio.	April 2, 1862.	Comminuted fracture of humerus; much laceration.	April 18, 1862.	Amputated, by Ass't Surgeon B. Howard, U. S. A.	Died April 19, 1862.

<sup>1</sup> See CASE 13, TABLE XXV, p. 536 *ante*.

<sup>2</sup> See CASE 22, TABLE XXV, p. 536 *ante*.

<sup>3</sup> See CASE 27, TABLE XXV, p. 536 *ante*.

NO.	NAME, AGE, AND MILITARY DESCRIPTION.	DATE OF INJURY.	NATURE OF INJURY.	DATE OF OPERATION.	OPERATION AND OPERATOR.	RESULT AND REMARKS.
25	Herrick, M., Pt., D, 49th New York, age 21.	May 5, 1864.	Fracture of left humerus; same day three inches of shaft excised; secondary hæmorrhage May 29th; a large sac discovered over scapula containing about thirty ounces of blood.	May 26, 1864.	Amputated at the shoulder, by Ass't Surgeon W. Thomson, U. S. A.	Died one-half hour after the operation, May 26, 1864. <i>Spec.</i> 3595, A. M. M.
26	Higgins, C., C, 41st Mississippi.	Sept. 20, 1863.	Right arm shattered; hæmorrhage from sloughing of the brachial artery.	Sept. 28, 1863.	Amputation at the shoulder joint by lateral and internal flaps.	Died October 6, 1863, of pyæmia.
27	Hoffmann, W. H., Pt., C, 5th New Hampshire.	May 31, 1862.	Wound at upper third of left arm; secondary hæmorrhage.	June 10, 1862.	Amputated, by A. A. Surgeon J. Neill.	Died June 24, 1862, from secondary hæmorrhage.
28	Hoggard, J., Corp'l, E, 137th Illinois, age 20.	Aug. 21, 1861.	Shot fracture of upper third of right humerus; about one-half inch of each of the fractured ends was removed with the saw; hæmorrhage from the brachial artery; September 9th, hæmorrhage recurred.	Sept. 9, 1864.	Amputated, by A. A. Surgeon J. Brey. Sept. 11th, hæmorrhage from axillary artery to the amount of one pint and a half. Stump opened and artery again ligated at the same point.	Died Sept. 12, 1864, from effects of another hæmorrhage from axillary artery.
29	Holmes, D., Pt., I, 140th Illinois, age 35.	July 9, 1864.	Shot fracture of middle third of right humerus; parts gangrenous; hæmorrhage from the brachial artery, necessitating amputation.	July 17, 1864.	Amputated by Lisfranc's method, by A. A. Surgeon S. S. Jessup.	Died July 29, 1864.
30	Hornaday, D. B., Pt., C, 18th Indiana.	Oct. 19, 1864.	Shot wound of left arm; comminuted fracture of humerus, extending to joint; gangrene.	Oct. 23, 1864.	Amputated, by Ass't Surgeon B. Fordyce, 160th New York.	Died October 24, 1864, from exhaustion.
31	Irwin, D., Pt., K, 30th Ohio, age 23.	July 24, 1864.	Shot fracture of right humerus; August 7th, 8th, 9th, and 10th, hæmorrhages from posterior circumflex; arrested by compression on subclavian.	Aug. 10, 1864.	Amputated, by Surgeon J. B. Lewis, U. S. V.	Died Aug. 10, 1864, from effects of hæmorrhage and tetanus. <i>Spec.</i> 4263, A. M. M.
32	Kelsey, G., Pt., I, 4th New York Artillery, age 28.	June 18, 1864.	Severe shot wound of right arm; June 18, 1864, excision.	July 3, 1864.	Amputation at the shoulder joint by Lisfranc's method.	Died July 7, 1864, of pyæmia.
33	Kleinschmidt, E., Corp'l, 41st New York.	July —, 1861.	Small conoidal ball perforated the head of the left humerus, exposing its point in the anatomical neck opposite; symptoms of pyæmia.	July 26, 1861.	Amputated, by Ass't Surgeon J. W. S. Gouley, U. S. A.	Much loss of blood during the operation. Pyæmia supervened. Died July 28, 1861. <i>Spec.</i> 347, A. M. M.
34	Kuhlman, J., Pt., I, 121st Ohio, age 23.	June 27, 1864.	Shot fracture of right humerus; gangrene.	July 15, 1864.	Amputated, by A. A. Surgeon J. A. Hall.	Died July 18, 1864, of pyæmia.
35	Kuntz, J., Pt., D, 9th Wisconsin.	Sept. 29, 1862.	Shot wound of shoulder . . . . .	Oct. 4, 1862.	Amputation at shoulder joint by double flaps.	Died October 25, 1862, of pyæmia.
36	Lawson, G., Pt., A, 86th New York, age 35.	May 7, 1864.	Shot comminution of the upper third of left humerus; May —, 1864, excision of head and portion of shaft; hæmorrhage from axillary artery.	May 23, 1864.	Amputated at shoulder joint, by Surgeon R. B. Bontecou, U. S. V.	Died May 31, 1864.
37	Marquart, J., Pt., A, 17th Pennsylvania Cavalry, age 24.	June 21, 1864.	Shot wound of right forearm; June 25th, missile extracted; gangrene.	June 26, 1864.	Antero-posterior flap amputation at the shoulder joint, by Surg. O. A. Judson, U. S. V.	Died June 26, 1864, from effects of gangrene.
38	Mason, A. B., Corp'l, A, 4th Pennsylvania Reserves.	June 30, 1862.	Ball traversed surgical neck of left humerus, comminuting and splintering the bone into the shoulder joint; parts sloughing.	July 21, 1862.	Amputated by transfexion, by Surg. J. H. Brinton, U. S. V.	Died July 23, 1862. <i>Spec.</i> 571, A. M. M.
39	McCarthy, P., Pt., F, 57th Massachusetts, age 27.	June 17, 1864.	Shot wound through the right shoulder; upper portion of humerus fractured and axillary artery injured.	July 1, 1864.	Amputated, by A. A. Surgeon C. Everard.	July 2d, gangrene; died July 5, 1864, from exhaustion.
40	McColligan, M., Pt., C, 56th Massachusetts, age 18.	May 18, 1864.	Fracture of upper third of left humerus; gangrene; June 6th, symptoms of pyæmia; June 8th, hæmorrhage from brachial close to axilla; arrested by compression upon subclavian.	June 8, 1864.	Amputated, by Surgeon D. P. Smith, U. S. V.	Diarrhæa; died July 5, 1864, of pyæmia. <i>Specs.</i> 2917 and 3299, A. M. M.
41	McGough, J. H., Pt., I, 45th Georgia, age 23.	May 3, 1863.	Comminuted fracture of upper third of humerus; ball passing into thorax and lodging.	May 23, 1863.	Amputated at shoulder joint by oval incisions.	May 25th, severe chill. May 29, hæmorrhage; flaps opened and artery secured; died June 3, 1863.
42	McTeague, T., Pt., I, 86th New York, age 20.	May 14, 1864.	Shot wound of left arm; humerus comminuted about four inches from middle; pus burrowed around shoulder joint; symptoms of pyæmia.	June 5, 1864.	Flap amputation just above insertion of deltoid, and head of bone removed afterward, by Assistant Surgeon A. Ingram, U. S. A.	Died June 17, 1864, of pyæmia and shock. <i>Spec.</i> 2823, A. M. M.
43	Meeder, J., Pt., I, 1st Maine Heavy Artillery, age 25.	June 12, 1864.	Fracture of the right shoulder, opening joint and carrying away head of humerus.	June 20, 1864.	Amputated, by Ass't Surgeon J. S. Smith, U. S. A.	Gangrene; died July 1, 1864. <i>Spec.</i> 3078, A. M. M.
44	Moll, W., Pt., A, 14th U. S. Infantry.	Aug. 30, 1862.	Fracture of shaft of left humerus, extending into upper third.	Sept. 15, 1862.	Amputated, by Surgeon T. E. Mitchell, 1st Maryland.	Died Sept. 26, 1862. <i>Spec.</i> 829, A. M. M.
45	Morris, F. M., Pt., G, 18th Kentucky.	Sept. 19, 1863.	Fracture two inches above right elbow joint; gangrene.	Oct. 16, 1863.	Amputated, by Surgeon A. McMahon, 64th Ohio.	Died October 23, 1863.
46	Mowrey, H. B., Corp'l, B, 6th Pennsylvania Reserves, age 26.	Sept. 17, 1862.	Fracture of left humerus, ball lodging; Sept. 23d, ball extracted; Sept. 26th, hæmorrhage, caused by sloughing of brachial; gangrene.	Sept. 27, 1862.	Subclavian ligated in its third portion, and amputation performed, by Surg. A. B. Hasson, U. S. A.	Died Sept. 27, 1862, a few hours after the operation.
47	Mullen, B., Pt., D, 28th Massachusetts.	Aug. 30, 1862.	Fracture of left arm at middle third, ball lodging in axilla; remained on field for eight days.	Sept. 9, 1862.	Flap amputation, by A. Ass't Surgeon G. McCoy.	A large ecchymosed spot on sacrum and another over right scapula; both sloughing and discharging pus; died suddenly, Oct. 31, 1862, the wound entirely healed. <i>Spec.</i> 1226, A. M. M.
48	O'Dell, H., Pt., A, 1st Pennsylvania Rifles, age 36.	June 24, 1864.	Fracture of upper third of right humerus by a large projectile.	July 9, 1864.	Flap amputation, by A. A. Surgeon J. M. Flood.	Died July 9, 1864, from exhaustion, caused by hæmorrhage and operation.

<sup>1</sup> See CASE 41, TABLE XXXII. p. 571 ante.



No.	NAME, AGE, AND MILITARY DESCRIPTION.	DATE OF INJURY.	NATURE OF INJURY.	DATE OF OPERATION.	OPERATION AND OPERATOR.	RESULT AND REMARKS.
49	Oarish, P., Serg't, E, 32d Massachusetts, age 19.	May 30, 1864.	Fracture of left humerus at upper third; May 31st, excision to within two inches of the head, and axillary artery ligated close below clavicle; June 7th, hæmorrhage from axillary; two inches of the clavicle removed from over the artery and the vessel again ligated, by Asst. Surg. G. A. Mursiek, U. S. V.; gangrene.	June 8, 1864.	Amputated by the double flap plan, by Ass't Surgeon G. A. Mursiek, U. S. V.	Died June 8, 1864, from shock.
50	Paddock, B., Pt., E, 17th Wisconsin, age 43.	May 19, 1863.	Fracture of left humerus at surgical neck; diffuse suppuration, with sloughing.	June 3, 1863.	Amputated, by Ass't Surgeon W. Waters, U. S. V.	Died June 27, 1863, from exhaustion. <i>Spec.</i> 2082, A. M. M.
51	Peterson, P., Pt., 2d Battalion Missouri State Militia.	Aug. 11, 1862.	Shot wound of arm; ball struck styloid process of the radius, passed upward, carrying away olecranon process of ulna, and was cut out near insertion of deltoid; Sept. 1st, gangrene.	Sept. 2, 1862.	Amputated at shoulder joint by Larrey's first method.	Died September 4, 1862.
52	Regan, C., Pt., G, 37th New York.	May 5, 1862.	Fracture of head of left humerus and scapula.	May 31, 1862.	Amputated, by Surgeon A. B. Mott, U. S. V.	Died June 1, 1862, from hæmorrhage.
53	Rosa, J., Pt., K, 71st Ohio, age 30.	Dec. 16, 1861.	Fracture of upper third of left humerus; gangrene.	Dec. 31, 1861.	Amputated, by A. A. Surgeon M. N. Benjamin.	Died Feb. 5, 1865, of pyæmia.
54	Runkle, J. G., Corp'l, A, 15th New Jersey, age 19.	May 12, 1864.	Two shot wounds of left arm; one ball passed thro' shoulder, fracturing head and two inches of shaft of humerus, the other passed through forearm, splintering ulna at middle third.	June 1, 1864.	Amputated, by Surgeon D. W. Bliss, U. S. V.	Died June 7, 1864. <i>Spec.</i> 2395, A. M. M.
55	Saukey, M. A., Pt., I, 103d Pennsylvania, age 18.	Dec. 14, 1862.	Fracture of right humerus; Dec. 27th, excision of three and a half inches of middle third of humerus, by Surg. C. A. Cowgill, U. S. V.; January 8, 1863, hæmorrhage from brachial.	Jan. 8, 1863.	Amputated at shoulder joint, by Surgeon C. A. Cowgill, U. S. V.	Died, Jan. 8, 1863, from exhaustion. <i>Spec.</i> 1327, A. M. M.
56	Scroggs, J. J., Pt., D, 16th North Carolina, age 20.	July 3, 1863.	Fracture of left humerus, high up, with sloughing.	July 7, 1863.	Amputated at shoulder joint by the oval method.	Died July 22, 1863, of tetanus.
57	Smith, D., Pt., F, 13th New Hampshire, age 48.	June 2, 1864.	Fracture of the right humerus; comminution of the head and nearly the whole of the shaft; pus diffused through the muscular tissues.	June 13, 1864.	Amputated, by Surg. E. Bentley, U. S. V.	Died June 17, 1864, from exhaustion.
58	Smith, S. R., Pt., G, 207th Pennsylvania, age 34.	April 2, 1865.	Fracture of entire upper third of right humerus.	April 5, 1865.	Amputated, by Ass't Surg. W. Carroll, U. S. V.	Died April 7, 1865, from secondary hæmorrhage. <i>Spec.</i> 4162, A. M. M.
59	Smith, W., Pt., E, 40th Indiana, age 39.	Nov. 26, 1864.	Shot wound of left arm; erysipelas; gangrene.	Dec. 11, 1864.	Amputated, by A. A. Surgeon J. H. McIntyre.	Died Dec. 16, 1864, from exhaustion.
60	Spencer, J. A., Pt., K, 1st Maine.	Mar. 25, 1865.	Fracture of left humerus at upper third by two balls, one of which lodged; April 15th, hæmorrhage from brachial.	April 15, 1865.	Amputated, by Surgeon D. W. Bliss, U. S. V.	Died April 23, 1865. <i>Spec.</i> 4081, A. M. M.
61	Spies, M. S., Pt., K, 26th New York.	Sept. 17, 1862.	Fracture of right elbow joint; erysipelas; gangrene.	Oct. 3, 1862.	Amputated, by Ass't Surgeon R. P. Weir, U. S. A.	Died Oct. 12, 1862. <i>Spec.</i> 773, A. M. M.
62	Stengele, J., 1st Serg't, E, 14th U. S. Infantry, age 26.	June 18, 1864.	Fracture of upper third of left humerus, with injury to principal artery.	June 30, 1864.	Amputated, by Ass't Surgeon C. A. Hamilton, 70th N. York.	Died July 5, 1864, from secondary hæmorrhage.
63	Stokes, O., Pt., F, 100th New York, age 33.	Aug. 14, 1864.	Fracture of upper third of right humerus; bone comminuted to the articulation.	Aug. 27, 1864.	Lateral flap amputation, by A. A. Surg. R. O. Sidney.	Sept. 3d, secondary hæmorrhage from axillary; stump opened and artery ligated. Died Sept. 3, '64, from effects of hæmorrhage.
64	Sutliff, W. T., Pt., B, 137th New York, age 30.	July 2, 1863.	Fracture of right humerus, followed by suppuration and sloughing.	July 5, 1863.	Amputated, by Surgeon A. K. Fifield, 29th Ohio.	July 12th, secondary hæmorrhage. Died July 26, 1863.
65	Trafton, O., Pt., F, 32d Maine, age 32.	May 18, 1864.	Shot wound through left shoulder, fracturing head of humerus; wound sloughing; scapula exposed.	May 29, 1864.	Amputated, by Surgeon R. B. Bontecou, U. S. V.	Died May 29, 1864.
66	Vontaine, J. R., Serg't, A, 8th New York Cavalry.	June 13, 1864.	Comminuted fracture of lower part of upper third of right humerus; June 13th, excision of about four inches of shaft of humerus; June 30th and July 3d, hæmorrhages; wound gangrenous; a large slough removed; July 5th, hæmorrhages.	July 5, 1864.	Amputated at shoulder joint, by Dr. J. Boardman, Buffalo, N. York. (Sisters of Charity Hospital.)	Died July 5, 1864, six hours after operation.
67	Wallson, R., Pt., I, 13th North Carolina, age 17.	May 5, 1862.	Wound thro' right wrist joint, shattering styloid process of radius and ulna; gangrene.	May 28, 1862.	Amputated, by A. A. Surgeon B. A. Vanderkief.	June 6th, diarrhœa. Died June 9, 1862.
68	Weis, H., Pt., B, 48th New York, age 42.	Aug. 16, 1864.	Shell fracture of shaft of right humerus, extending to head; great laceration of soft tissues.	Aug. 21, 1864.	Amputated, by A. A. Surgeon W. L. Weller.	Died Aug. 31, 1864, from irritative fever.
69	Welch, B. R., Serg't, H, 1st District Columbia Cavalry, age 25.	Aug. 25, 1864.	Fracture of the left shoulder; Aug. 25th, excision of shoulder joint and upper portion of humerus; Sept. 6th and 15th, hæmorrhage from circumflex arteries.	Sept. 15, 1864.	Lateral flap amputation at the shoulder joint, by A. A. Surg. J. G. Morgan.	Sept. 24th, hæmorrhage from stump; flaps laid open and arteries ligated. Died October 11, 1864. <i>Spec.</i> 3675, A. M. M.
70	Whipple, P., Pt., K, 16th Wisconsin, age 27.	June 15, 1864.	Wound of right shoulder joint; hæmorrhage from axilla.	July 3, 1864.	Flap amputation, by Surgeon E. M. Powers, 7th Missouri.	Died Aug. 4, 1864, from hæmorrhage.
71	Wiggins, R., Pt., B, 119th Pennsylvania, age 40.	May 6, 1864.	Fracture of head of right humerus and articulating portion of scapula; gangrene.	May 14, 1864.	Amputated, by Surgeon A. F. Sheldon, U. S. V.	Died May 15, 1864.
72	White, T. A., Pt., E, 28th New Jersey.	Dec. 13, 1862.	Wound of left arm, with fracture, followed by sloughing.	Dec. 16, 1862.	Amputated at shoulder joint by the oval method.	Died January 10, 1863.

<sup>1</sup> See *American Med. Times*, 1862, Vol. V, p. 133.

<sup>2</sup> See CASE 76, TABLE XXXII, p. 572 *ante*.

In sixty-six of the seventy-two fatal intermediary amputations at the shoulder for the consequences of shot injury, the operations were equally divided between the two sides, thirty-three at the right and thirty-three at the left shoulder. Some modification of transfixion and double flap incisions was the most common operative method, although the oval and circular methods, the former particularly, were frequently practised. The remarks on the causes and extent of the injuries that led to the successful amputations apply to this series also; the wounds were, for the most part, from small projectiles. Tetanus supervened in two instances, gangrene in four; three patients succumbed to the shock of operation; in one case, chloroform was assigned as the cause of death. One patient had a mortal shot perforation of the lung and liver, and six others had important wounds in other regions.

**Secondary Amputations at the Shoulder Joint.**—In the sixty-six reported cases of amputations at the shoulder joint after shot injury, practised later than the thirtieth day from the reception of the injury, the mortality was 28.7 per cent. In nearly two-thirds of the cases the exarticulations were secondary not only as regarded date, but followed other unsuccessful capital operations.

§ *Successful Cases.*—Forty-seven, or 71.3 per cent., of these operations resulted favorably. Forty-four of the survivors were Union soldiers and were pensioned; three were Confederates, who were released on parole or exchanged. The operations were on the right side in twenty-six, on the left in twenty-one instances. Two of the pensioners died eight and eleven years, respectively, after their discharge. No less than twenty-three patients had previously undergone amputations lower down in the limb—a significant fact, corroborating the experience of military surgeons regarding the favorable results of re-amputations at the hip after amputations in the continuity of the thigh. Six of the patients had previously undergone excisions of the upper extremity of the humerus, one an excision of the shaft, one an excision of the upper part of the radius, and one a ligation of the subclavian artery. Four of the patients had received serious wounds in other portions of the body. At the date of exarticulation, the glenoid cavity was gouged out on account of caries in one instance, and in one case consecutive hæmorrhage necessitated secondary ligation of the axillary artery.

CASE 1608.—Private F. Lafayette, Co. G, 100th Illinois, aged 26 years, was wounded at Chickamauga, September 19, 1863, and after treatment in a Twenty-first Corps hospital was sent to Nashville, and, on November 7th, was admitted to Hospital No. 19. The Specimen (FIG. 496) was contributed by the operator, Surgeon J. W. Foye, U. S. V., with the following history: "Admitted with a gunshot fracture of the upper portion of the left humerus. When he first came under observation, the soft parts of the lower half of the arm were extensively involved in gangrenous disorganization. The forearm was much swollen and œdematous. The wound in the soft parts near the head of the humerus was also gangrenous, and the patient had lost much blood from hæmorrhage, caused by sloughing of the muscular branches of the brachial. The heart's action was frequent and feeble, and the surface of the body bathed in cold perspiration. Amputation being decided upon, the patient was stimulated, and the operation performed at the joint, December 13, 1863. He bore the operation well, convalesced without a bad symptom, and is now awaiting his discharge from service." The patient was discharged February 15, 1864, and pensioned. He was paid September 4, 1874. The specimen consists of "six inches of the shaft of the left humerus, showing a consolidated gunshot fracture, from an amputation at the shoulder joint for secondary hæmorrhage and gangrene. The union is excellent, although some necrosed fragments, sources of irritation, are yet imprisoned. The head of the humerus was improperly removed in mounting the specimen." (*Cat. Surg. Sect.*, 1866, p. 112.)



FIG. 496.—Ill united shot fracture of shaft of left humerus. *Spec.* 2175.

This group of forty-seven fortunate exarticulations might be subdivided into three sub-groups, viz.: Early secondary, or those practised within sixty days from the reception of injury (thirteen cases), usually on account of hæmorrhage, gangrene, or profuse suppuration,—later secondary amputations, or those performed from the end of the second to the end of the sixth month (fifteen cases), generally for hopeless disease of the humerus, some-



times with consecutive implication of the shoulder joint,—and ulterior amputations (nineteen cases), commonly performed long after the injury on account of chronic osteomyelitis, or for necrosis of the entire humerus. The following is a good example of the latter variety:

CASE 1609.—Private J. Potter, Co. II, 12th Illinois Cavalry, aged 45 years, was wounded at Cane River, April 27, 1864, and was treated in Barrack Hospital, New Orleans, from that date until January 31, 1865, when he was transferred to New York and entered De Camp Hospital. Assistant Surgeon Warren Webster, U. S. A., furnished the following special report:

"The patient was wounded while charging the enemy with his company. The projectile, a cylindro-conoidal ball, penetrated the posterior and inner surface of the arm at about the middle of the humerus, was flattened upon the bone, and passing downward and outward lodged in the soft parts near the elbow joint. He states that he did not dismount in consequence of the wound, nor throw away his carbine, but rode to Alexandria, a distance of ten miles, carrying the weapon on his wounded arm. On the following day he was transferred to hospital at New Orleans, where he arrived May 1, 1864. There he first received professional attention, and on the 9th of the month the ball was removed through an incision near the elbow. The surgeon, he says, informed him that the bone had not been fractured. The anterior part of the ball was deeply indented, seemingly by impingement upon the shaft of the humerus. The wound of entrance, from the man's statement, was of such small size and regular appearance as to render it probable that the ball was of its original shape when it entered the arm. After the extraction of the missile the limb rapidly inflamed, became greatly swollen between the elbow and shoulder, and was affected with deep-seated and almost unupportable pain. The constitutional disturbance appears also to have been correspondingly great. Local anodyne applications were employed, and morphia internally administered for several weeks. Six abscesses had appeared previously to November, 1864, some of which were opened by the knife and others allowed to break spontaneously. In that month Private Potter states that a deep incision, about three and a half inches long, was made longitudinally on the anterior aspect of the arm, apparently for the purpose of extracting necrosed bone, but the attempt was abandoned. Whenever the fistulous openings in the parts were allowed to close there was an access of deep-seated pain. The patient was transferred to De Camp Hospital in February, 1865. Upon his admission there he presented an appearance which led those who saw him to quite despair of his life. The long continuance of pain and exhausting discharges had brought him to the brink of the grave. For many months after his arrival at De Camp Hospital his hold upon existence was by the slenderest ties. By dint of most careful nursing and attention to diet, he was, however, so far improved in November as to render proper operative interference for the rescue of his life. At that time there were fourteen openings in the arm and shoulder, through which purulent matter discharged. Some of these openings did not communicate with bone, but with the axillary glands, which had taken on inflammatory and suppurative action. Through numerous cloacae in the encasing of new osseous deposit a vast amount of necrosed bone could be detected, which appeared to extend nearly from one articulation to the other. It having been determined, in view of all the circumstances of the case, to amputate at the shoulder joint, the operation was performed by Assistant Surgeon Warren Webster, U. S. A., November 10, 1865. A deltoid flap was raised and the knife made to sweep away as much as possible of the diseased gland tissue on the inner side of the bone. The patient rallied

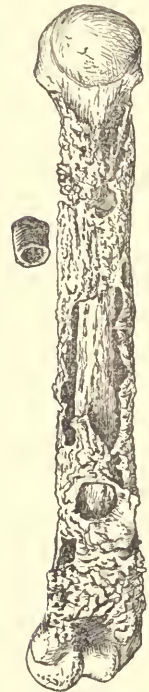

FIG. 497.—Necrosis of the humerus after shot injury. Spec. 2511.  $\frac{3}{4}$ .

with difficulty from the operation, but, gradually, improvement began, and, at this date, March 12, 1866, the shoulder is nearly healed, the patient has regained his health and strength, and is acting in the capacity of ward orderly in De Camp Hospital." The patient was discharged the service March 28, 1866, and pensioned. He was paid on September 4, 1874. The specimen (FIG. 497) consists of the right humerus, amputated at the shoulder joint after contusion by a conoidal ball, which is attached. The entire shaft is necrosed and surrounded by a partial involucrum. The specimen is interesting from the character of the injury, the extent of the disease, the duration of the case, and the result. It was contributed by the operator.

The next case illustrates one of the re-amputations that occurred in this category:

CASE 1610.—Private W. E. Crolins, Co. A, 72d Pennsylvania, aged 30 years, was wounded at Gettysburg, July 2, 1863, and was received into a Second Corps hospital. The following was recorded on Army Corps Register No. 93: "Compound comminuted fracture of right arm. Amputated by Surgeon M. Rizer, 72d Pennsylvania." On July 29th, the patient was admitted to Camp Letterman Hospital, where Acting Assistant Surgeon G. M. Ward reported that the improvement of the patient was uninterrupted from the date of his admission until September 3d, when he was transferred to Satterlee Hospital. Acting Assistant Surgeon Thomas G. Morton contributed the specimen (FIG. 498) and reported: "Wounded by a minié ball, which passed through the upper end of his arm. Amputation was performed twelve hours afterward, leaving about six inches of bone. The flap never entirely closed, and a probe could be passed up the medullary cavity to the head of the bone, the shaft of which was also necrosed and softened. January 8th, I re-amputated the arm at the shoulder and took away the entire bone, including its head. Considerable hæmorrhage took place, and some hæmorrhage secondarily, but not to any amount, brought on by an attack of vomiting. Silver sutures were used; the patient did well. On February 10, 1864, the patient was about, the wound almost entirely healed." The Catalogue of 1866, page 115, says: "The specimen, embracing the head and two inches of the shaft, exhibits a profound degree of necrosis as existing six months after the first operation, and requiring the second." This soldier was discharged and pensioned May 3, 1864, Surgeon I. I. Hayes certifying to "amputation of the right arm at the shoulder, following gunshot wound." The pensioner was paid June 4, 1874.

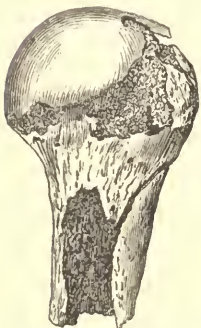


FIG. 498.—Upper portion of right humerus, carious, after amputation in the continuity for shot fracture. Spec. 2626.

TABLE XLVIII.

Summary of Forty-seven Cases of Successful Secondary Amputations at the Shoulder for Shot Injury.

No.	NAME, AGE, AND MILITARY DESCRIPTION.	DATE OF INJURY.	NATURE OF INJURY.	DATE OF OPERATION.	OPERATION AND OPERATOR.	RESULT AND REMARKS.
1	Alexander, C. H., Pt., B, 2d Maryland Artillery.	July 1, 1862.	Right forearm carried away by premature discharge of gun; July 1st, amputated at elbow joint, by Asst. Surg. J. S. O'Donnell, Purnell Legion; stump painful.	Oct. 9, 1862.	Amput'd by Larrey's method, by Act. Asst. Surg. J. A. Draper.	Disch'd Jan. 31, 1863; pensioned. <i>Spec.</i> 271, A. M. M.
2	Atley, W. ....	Aug. 15, 1864.	Fracture of the right humerus; amputated four inches below shoulder; hemorrhage eight days after operation.	Oct. -, 1865.	Head and remaining portion of shaft removed, by Dr. J. H. Erskine.	Recovered within a month.
3	Anderson, S. S., Pt., G, 27th Alabama, age 24.	Nov. 30, 1864.	Shell fracture of upper third of left humerus; gangrene.	Mar. 13, 1865.	Amputated, by Surg. Franklin, C. S. A.	May 23, 1865, recovered; sent to Provost Marshal May 31, 1865.
4	Beauchy, J. F., Pt., H, 39th Illinois, age 22.	June 2, 1864.	Shot fracture of lower third of left arm; June 2d, arm amputated at the middle third; necrosis.	Jan. 17, 1865.	Amputated, by Act. Asst. Surg. W. B. Metcavren.	Disch'd Mar. 15, 1865; pensioned.
5	Burger, S., Pt., A, 102d Illinois, age 30.	June 15, 1864.	Ball passed through head of right humerus; June 15th, excision of head and four inches of shaft of the humerus; June 21st, hemorrhage; discharged Dec. 17, 1864; pensioned.	June 20, 1867.	Amputated, by Dr. Madison Reese, formerly Surgeon 118th Illinois.	Still sore and running ulcer in 1870.
6	Burke, M., Serg't, K, 15th New York Artillery.	June 25, 1864.	Fracture of left ulna, elbow joint involved; July 4th, circular amputation at the upper third, by Act. Asst. Surg. H. M. Deau; parts erysipelatous; gangrene.	Mar. 29, 1865.	Head and remaining portion of shaft of humerus removed, by Acting Asst. Surg. W. H. Chambers.	Discharged November 30, 1865; pensioned.
7	Cockrum, M., Pt., C, 115th New York, age 35.	June 7, 1864.	Shot fracture of right elbow, opening joint; June 7, 1864, arm amputated near upper third, by Surg. J. M. Palmer, 3d New York, by lateral flap method; oedema.	Mar. 20, 1865.	Amputated at the shoulder and carious bone removed from glenoid cavity, by Surg. G. H. Hubbard, U. S. V.	Disch'd July 17, 1865; pensioned.
8	Craft, E., Pt., F, 126th New York, age 24.	July 2, 1863.	Left arm fractured; ball lodged; July 14th, the ball extracted; Aug. 12th, amputation at middle third; Aug. 23d, hemorrhage from brachial, arrested by actual cautery; Dec. 18, 1863, re-amputated at upper third; caries.	Dec. 22, 1863.	Head and remaining portion of shaft removed, by Act. Asst. Surg. E. Seyfforth.	Disch'd May 19, 1865; pensioned.
9	Crolins, W. E., Pt., A, 72d Pennsylvania, age 30.	July 2, 1863.	Shot fracture of middle third of right humerus; July 2d, amputated at upper third, by Surg. M. Rizer, 72d Penn.	Jan. 8, 1864.	Amputated at the shoulder, by Acting Asst. Surgeon T. G. Morton.	Disch'd May 3, 1864; pensioned. <i>Spec.</i> 2606, A. M. M.
10	Cufler, F. R., Pt., K, 72d Pennsylvania, age 17.	Sept. 17, 1862.	Six inches of right humerus shattered; inflammation of the medullary cavity.	Oct. 19, 1862.	Amput'd by Larrey's method, by Surg. H. S. Hewit, U. S. V.	Oct. 20th, hemorrhage from axilla; artery ligated; discharged Aug. 10, 1864; pensioned; died May 11, 1873.
11	Dahl, J., Pt., I, 6th Kentucky.	Sept. 20, 1863.	Fracture of lower third of left humerus; September 20, 1863, amputated near upper third; soft parts indurated and inflamed.	Mar. 9, 1864.	Amput'd by Lisfranc's method, by Asst. Surg. B. E. Fryer, U. S. A.	Disch'd Mar. 8, 1865; pensioned.
12	Dale, J. W., Serg't, B, 25th Illinois, age 22.	Sept. 20, 1863.	Wound of left elbow joint; Oct. 8, 1863, amputated at junction of middle and lower thirds; necrosis.	Jan. 16, 1864.	Flap amputation at shoulder.	Mustered out September 5, 1864; pensioned.
13	Davis, J. W., Serg't, F, 64th New York, age 23.	May 12, 1864.	Fracture of metacarpal bones of left hand; gangrene; May 30, 1864, circular amputation at middle third, by Surg. A. F. Sheldon, U. S. V.; disch'd May 10, 1865; pensioned.	April -, 1868.	Amputation at the shoulder for consecutive necrosis, by Surg. D. W. Bliss, U. S. V.	Recovered.
14	Dibble, A. H., Pt., F, 33d New York.	May 3, 1863.	Fracture of upper fifth of right humerus; May 4th, excision of head of humerus; gangrene.	July 22, 1863.	Amputated, by Dr. W. B. Alley, of Nunda, N. Y.	Gangrene controlled by bromine; discharged November 16, 1863; pensioned.
15	Dowd, P., Pt., K, 8th New Hampshire.	May 27, 1863.	Shot wound of left arm	July 31, 1863.	Circular amputation, Alanson's method.	Disch'd Sept. 2, 1863; served in Vet. Res. Corps, then pensioned.
16	Eldridge, J. C., Pt., H, 4th Tennessee Cavalry, age 20.	Feb. 15, 1865.	Fracture of left ulna, radius, and carpal bones; Mar. 5th, circular amputation at elbow joint, by Surg. D. Stahl, U. S. V.	June 28, 1865.	Amputation at the shoulder for gangrene, by Surg. D. Stahl, U. S. V.	Mustered out September 12, 1865; pensioned.
17	Frain, J. F., Pt., D, 1st Pennsylvania Cavalry, age 19.	June 3, 1864.	Fracture of the right humerus; June 3, 1864, lateral flap amputation at upper third, by Asst. Surg. L. E. Atkinson, 1st Pennsylvania Cavalry; Sept. 30th, stump exfoliating.	Oct. 21, 1864.	Dead stump and head of the humerus removed.	Disch'd April 1, 1865; pensioned.
18	Gilman, S. F., Pt., A, 5th Maine, age 30.	June 27, 1862.	Fracture of the right humerus; June 28th, excision of lower part of shaft, by Surg. G. E. Bracket, 5th Maine; necrosis.	Aug. 12, 1862.	Double flap amputation, by Act. Asst. Surg. H. B. Miles.	Disch'd Oct. 6, 1862; pensioned.

<sup>1</sup> See CASE 21, TABLE XXXI, p. 554 ante.

<sup>2</sup> See CASE 24, TABLE XXIV, p. 531 ante, and *Buffalo Med. and Surg. Journal*, 1863, Vol. III, p. 41.



No.	NAME, AGE, AND MILITARY DESCRIPTION.	DATE OF INJURY.	NATURE OF INJURY.	DATE OF OPERATION.	OPERATION AND OPERATOR.	RESULT AND REMARKS.
19	Graham, H. A., Corp'l, 11, 1st Pennsylvania Reserves.	May 10, 1864.	Fracture of right elbow joint; arm amputated at lower third, by Surg. D. W. Bliss, U. S. V.; discharged Oct. 8, 1864; pensioned; Sept., 1866, re-amputation of arm.	July -, 1869.	The remaining portion of humerus, including the head, removed, by Dr. W. H. Hess, of Nebraska City.	Did well after the operation.
20	Haney, J., Pt., C, 134th Pennsylvania.	Dec. 13, 1862.	Wound of left shoulder joint; pensioned.	June -, 1865.	Amputated at the shoulder for caries, by Dr. A. G. Walter, of Pittsburg, Pa.	In August, 1866, stump was still discharging.
21	Hearnsburger, A., Pt., G, 15th Georgia, age 24.	July 2, 1863.	Fracture of head and neck of left humerus; necrosis.	Oct. 28, 1863.	Lateral flap amput'n, by Act. Asst. Surg. James E. Steel.	Sent to Fort Delaware April 9, 1864.
22	Heim, Isaac, Corp'l, I, 53d Pennsylvania.	July 2, 1863.	Wound of right arm; necrosis.	Aug. 6, 1863.	Amputated, by Act. Asst. Surg. A. W. Colburn.	Disch'd July 29, 1864; pensioned.
23	Hunter, J. H., Corp'l, B, 12th New York.	June 27, 1862.	Wound of right elbow joint; July 7, 1862, amputated, by Act. Asst. Surg. A. Claude; discharged Sept. 6, 1862; pensioned.	April 30, 1863.	Amputated at the shoulder by flap method, by Surg. A. B. Mott, U. S. V.	Recovered. Died Aug. 11, 1871.
24	<sup>1</sup> Keeler, Wm., Pt., M, 8th New York Artillery.	June 23, 1864.	Fracture of upper third of right humerus; June 23, 1864, excision of head and part of shaft, by Surg. A. Churchill, 8th New York Artillery; disch'd February 25, 1865.	Oct. 1, 1866.	Amputated, by Dr. T. A. McArthur, of Soldiers' Home, Philadelphia.	Recovered; a pensioner.
25	<sup>2</sup> Kemmer, B., Pt., I, 2d Massachusetts, age 27.	Sept. 17, 1862.	Right humerus fractured; Nov. 20, 1862, head and part of shaft excised, by Surg. A. B. Hasson, U. S. A.; caries.	Feb. 10, 1863.	Amputated, by Surg. A. B. Hasson, U. S. A.	Disch'd April 23, 1863; pensioned.
26	Knapler, J. P., Lt., 5th Pennsylvania Cavalry, age 27.	May 8, 1864.	Wound of lower third of left arm by explosive ball; elbow joint opened; osteomyelitis.	June 24, 1864.	Amputated, by Act. Asst. Surg. E. De Witt.	Mustered out December 23, 1864; pensioned.
27	Lafayette, P., Pt., G, 100th Illinois, age 26.	Sept. 19, 1863.	Fracture of upper part of shaft of left humerus; hemorrhages from branches of brachial.	Dec. 13, 1863.	Amputated, by Surgeon J. W. Foye, U. S. V.	Disch'd Feb. 15, 1864; pensioned. Spec. 2175, A. M. M.
28	Lautz, J. A., Corp'l, C, 67th Ohio.	Mar. 24, 1862.	Right humerus fractured; osteitis and profuse suppuration.	April 28, 1862.	Amputated, by Surgeon A. D. Gall, 13th Indiana.	Disch'd June 3, 1862; pensioned.
29	May, D., Pt., D, 96th Ohio.	Jan. 11, 1863.	Fracture of left humerus at junction of middle and upper third; July 20, 1863, gangrene; July 26th, hemorrhage from brachial.	July 26, 1863.	Amputated, by Surgeon C. T. Alexander, U. S. A.	Disch'd Sept. 21, 1863; pensioned.
30	Mead, Jacob, Pt., I, 58th Indiana.	Dec. 31, 1862.	Wound of the left arm above elbow; January 1, 1863, arm amputated, by Asst. Surg. J. R. Adams, 58th Indiana.	Feb. 4, 1863.	Amputated at the shoulder, by Surg. A. Ewing, 13th Mich.	Disch'd Aug. 13, 1863; pensioned.
31	<sup>3</sup> Mesley, C. L., Pt., A, 18th Infantry, age 31.	July 4, 1864.	Shell wound of right shoulder and breast; July 4th, excision of shoulder joint.	Aug. 8, 1864.	Amputated at the shoulder, by Asst. Surg. Theo. McGraw, U. S. V.	Disch'd Dec. 31, 1864; pensioned.
32	Miller, W., Corp'l, II, 16th Ohio.	Dec. 28, 1862.	Wound of left arm; January 11, 1863, arm amputated, by Act. Asst. Surg. H. Hard.	Jan. 28, 1863.	Amputated at shoulder joint.	Disch'd April 14, 1863; pensioned.
33	Phelps, J. T., Pt., D, 24th Massachusetts, age 32.	Aug. 16, 1864.	Communion of neck of left scapula and head of left humerus; Sept. 20th, hemorrhage from axillary; subclavian ligated, by Act. Asst. Surg. J. C. Morton.	Sept. 26, 1864.	Amputated, by Act. Asst. Surg. J. E. Chesley; flap operation.	Disch'd Dec. 13, 1864; pensioned.
34	Poole, Theo. L., Lieut., II, 122d New York, age 25.	June 1, 1864.	Compound fracture of left arm, middle third.	Feb. 15, 1865.	Amputated, by Surgeon F. M. Everleth, 1st Maine.	Disch'd May 15, 1865; pensioned.
35	Potter, J., Pt., II, 12th Illinois Cavalry, age 45.	April 27, 1864.	Fracture of right humerus; entire humerus necrosed; fourteen fistulous orifices.	Nov. 10, 1865.	Amputated, by Asst. Surg. W. Webster, U. S. A. See CASE 1609, p. 646.	Disch'd Mar. 28, 1866; pensioned. Spec. 2511, A. M. M. FIG. 497.
36	Powers, P., Pt., C, 24th Massachusetts, age 22.	Aug. 16, 1864.	Wound of right arm; August 16th, amputated three inches below shoulder joint; necrosis.	April 13, 1865.	Amputated, by Act. Asst. Surg. F. C. Roper.	Disch'd June 17, 1865; pensioned.
37	Richards, B., Pt., G, 4th New Hampshire, age 29.	Feb. 21, 1865.	Wound of right elbow joint; February 21st, amputation at the middle third; March 27th, hemorrhage controlled by ligation; discharged June 11, 1865; pensioned.	1865.	Subsequently amputated at the shoulder joint.	Recovered.
38	<sup>4</sup> Rosa, J. W., Pt., I, 2d New York Artillery, age 24.	May 24, 1864.	Shell wound of right shoulder, humerus fractured; May 25th, head and part of shaft excised; discharged October 3, 1864; pensioned.	Dec. 27, 1865.	Amput'd, by Dr. H. S. Streeter, of Salisbury, New York.	A pensioner.
39	Sanders, J., Pt., II, 6th Illinois Cavalry, age 19.	May 12, 1863.	Fracture of head of right humerus and coracoid process.	July 10, 1863.	Amputated, by Surgeon J. G. Keenon, U. S. V.	Disch'd Oct. 9, 1863; pensioned. Spec. 1700, A. M. M.
40	Sias, G. W., Pt., G, 62d Pennsylvania.	June 27, 1862.	Fracture of upper third of left humerus; July 4th, circular amputation at upper third; discharged August 28, 1862; pensioned.	.....	Re-amputated at shoulder, by Dr. G. McCook, at Pittsburg.	A pensioner.
41	Smedley, F. L., Pt., II, 47th Pennsylvania, age 22.	Oct. 19, 1864.	Fracture of lower third of right arm, elbow joint involved; Oct. 19, amputation at middle third; discharged Dec. 28, 1864; pensioned.	Aug. 30, 1865.	Re-amputated, by Dr. J. H. Heinsling, of Newport, Pa.	Disch'd and pensioned. Applied for commutation in place of artificial limb, August, 1870. Spec. 2859, A. M. M.
42	Smiley, S. C., Corp'l, A, 33d Massachusetts.	May 15, 1864.	Fracture of clavicle and head of right humerus; parts infiltrated.	April 25, 1865.	Amputated, by Act. Asst. Surg. G. S. Stebbins; oral flap.	Disch'd July 8, 1865; pensioned.
43	Smith, W. W., Pt., C, 21st Wisconsin, age 29.	Sept. 19, 1863.	Left humerus at middle third; January 11, 1864, arm amputated; caries.	Feb. 13, 1865.	Remaining portion of humerus disarticulated, by Surg. H. Culbertson, U. S. V.	Disch'd July 19, 1865; pensioned.

<sup>1</sup> See CASE 106, TABLE XXXI, p. 558 ante.<sup>2</sup> See CASE 20, TABLE XXXV, p. 592 ante.<sup>3</sup> See CASE 71, TABLE XXIV, p. 533 ante.<sup>4</sup> See CASE 161, TABLE XXXI, p. 560 ante.

No.	NAME, AGE, AND MILITARY DESCRIPTION.	DATE OF INJURY.	NATURE OF INJURY.	DATE OF OPERATION.	OPERATION AND OPERATOR.	RESULT AND REMARKS.
44	Stearns, G., Pt., A, 31st Wisconsin, age 38.	Mar. 19, 1865.	Right arm, at junction of upper and middle third; April 26, 1865, amputated at the upper third; remaining bone found fractured.	April 25, 1865.	Amputated at the joint, by Asst. Surg. S. H. Orton, U. S. A.	Disch'd June 15, 1865; pensioned.
45	Steen, B. S., Serg't, C, 14th New York Militia.	Aug. 29, 1862.	Right elbow joint shattered; discharged Dec. 16, 1862; pensioned.	Mar. 23, 1864.	Amputated, by Dr. J. Johnson, of Brooklyn.	Wound healed.
46	Watson, Wm. D., Lieut., E, 71st Pennsylvania.	June 3, 1864.	Fracture of right radius; June 3, 1864, radius excised, by Surg. M. Rizer, 72d Penn.; mustered out July 2, 1864; pensioned.	July 23, 1864.	Amputated secondarily for secondary hemorrhage and gangrene.	Wound healed.
47	Yates, O. J., Pt., F, 11th Maine, age 37.	Aug. 16, 1864.	Fracture of metacarpals of left hand; gangrene; Sept. 15, 1864, arm amputated at lower third; discharged January 20, 1865; pensioned.	June 29, 1865.	Amputated at the joint, by Dr. W. T. Black, of Maine.	Healed.

§ *Unsuccessful Operations.*—Of the nineteen cases in this category, nine had been subjected to amputation, excision, or ligation of the principal trunk prior to the exarticulation. The right limb was removed in twelve of the seventeen instances in which this point is specified. Sixteen of the patients were Union, and three Confederate soldiers. Pyæmia was the commonest cause of death, being reported in six cases. One patient died from tetanus, and, in another, the fatal result was referred to "cardiac syncope from chloroform." Rupture of an axillary aneurism, general shock from operation, and pleurisy are each, in one instance, assigned as the cause of death. Exhaustion or surgical fever are made to account for the remaining fatal terminations. As an example of this group, a case in which a primary excision in the continuity, a secondary amputation, and finally an exarticulation were practised may be selected:

CASE 1611.—Private J. M——, Co. E, 22d Massachusetts, aged 38 years, was wounded at the Wilderness, May 5, 1864, and was taken to a Fifth Corps hospital. Surgeon W. R. De Witt, jr., U. S. V., noted: "Gunshot wound of right arm; exsection of upper part of shaft of humerus, May 6th." The patient was sent to Washington and entered Marewood Hospital. Surgeon R. B. Bontecou, U. S. V., reported: "On admission to this hospital, May 28, 1864, the patient was in poor health, suffering from abscesses in the arm, the wound suppurating freely. The patient did well until August 15th, when the parts became sloughy, with profuse sanious discharge; but by applications of astringent lotions the arm improved up to September 17th, when secondary hæmorrhage from the profunda occurred, amounting to about eight ounces. The artery could not be secured, and amputation was deemed necessary, and was performed by the surgeon in charge by bilateral flaps. The patient reacted promptly, and did tolerably well until September 19th, when hæmorrhage again occurred, this time from the anterior circumflex artery. The humerus was exarticulated and the bleeding vessel ligated. The stump, however, became gangrenous, and the patient sank from exhaustion, and died September 26, 1864. There were no pyæmic symptoms existing. Treatment, supporting throughout." The specimen (FIG. 499), contributed by the operator, consists of the right humerus, from which three inches of the shaft has been excised. The arm was subsequently amputated in the continuity, and disarticulation at the shoulder joint was finally performed. "The lower portion of the specimen, representing the condition nearly four and a half months after the injury, \* \* \* exhibits a copious deposit of spongy new bone, surrounding a nearly detached sequestrum of several inches. The shaft in the upper fragment is necrosed at the extremity, and the articular surface is eroded." (*Cat. Surg. Sect.*, 1866, p. 112.)



FIG. 499.—Humerus that has undergone excision of the shaft and exarticulation at the shoulder. *Spec.* 3331.

In the fatal, as in the successful secondary exarticulations, an unusual predominance of operations on the right side is observed. In seventeen unsuccessful amputations in which this point is specified, twelve were at the right shoulder. The fatality of the secondary exceeds that of the primary exarticulations by 4.6 per cent., and is 17.1 per cent. less than the intermediary amputations. It will be noticed that nearly all of the fatal secondary exarticulations were compulsory amputations, and consecutive to prior operative interference, the surgeons contesting the ground inch by inch. There were three instances



of previous amputation of the arm in the continuity. Two excisions in the continuity of the shaft of the humerus, one excision of the head and upper extremity of the shaft, two ligations of the brachial, and one of the anterior circumflex were practised prior to the exarticulations. In one case, the subclavian artery was tied after the amputation at the shoulder. Two patients had serious wounds in other regions of the body.

TABLE XLIX.

*Summary of Nineteen Fatal Cases of Secondary Amputation at the Shoulder for Shot Injury.*

NO.	NAME, AGE, AND MILITARY DESCRIPTION.	DATE OF INJURY.	NATURE OF INJURY.	DATE OF OPERATION.	OPERATION AND OPERATOR.	RESULT AND REMARKS.
1	Babbitt, A., Pt., D, 66th Indiana.	June 1, 1863.	Shot perforation of left wrist joint, followed by gangrene.	July 2, 1863.	Amputation of arm at shoulder joint, by Surg. J. G. Keenon, U. S. V.	Did not rally from shock of operation. Died July 4, 1863. <i>Spec.</i> 1705, A. M. M.
2	Battle, W. T., Lieut., D, 37th North Carolina, age 19.	July 2, 1863.	Comminuted fracture of left humerus at upper third by a conoidal ball. July 3d, excision of three inches of shaft of humerus.	Aug. 23, 1863.	Amputation of arm at shoulder joint.	Died August 23, 1863, three hours after operation.
3	Blakely, A., Pt., I, 3d Michigan Cavalry.	June 16, 1863.	Wound of left arm by buckshot. July 10th, hæmorrhage; brachial artery ligated, by Surg. B. A. Vanderkief, U. S. V. July 10th, amp. of arm at upper third, by A. A. Surg. A. Claude. Gangrene and hæmorrhage.	July 24, 1863.	Amputation of arm at shoulder joint, by Surg. B. A. Vanderkief, U. S. V.	Died July 26, 1863.
4	Brown, N. C., Pt., E, 59th Illinois, age 25.	Dec. 31, 1862.	Musket ball perforated arm near insertion of deltoid, causing compound comminuted fracture; caries.	Feb. 14, 1863.	Arm amputated at shoulder joint.	Died March 31, 1863, of diarrhœa.
5	Catis, J. R., Pt., E, 1st Tennessee.	July 3, 1863.	Shot wound of right arm by a conoidal ball; sloughing and hæmorrhage.	Aug. 8, 1863.	Amputation of arm at shoulder joint, by A. A. Surg. J. B. Draper.	Died September 25, 1863.
6	Charters, W. S., Pt., D, 145th Pennsylvania, age 18.	May 12, 1864.	Shot fracture of left arm. May 13th, excision of portion of humerus, by Ass't Surgeon B. Howard, U. S. A. Oct. 7th, amp. at upper third of arm on account of necrosis.	Oct. 7, 1864.	Disarticulation at the shoulder joint.	Died Oct. 21, 1864, of tetanus.
7	Doherty, P., Serg't, C., 173d New York, age 43.	April 9, 1864.	Compound comminuted shot fracture of upper third of right humerus.	July 7, 1864.	Amputation of arm at shoulder joint, by A. A. Surg. F. Hasenburger.	Died July 7, 1864, of cardiac syncope by chloroform.
8	Fagan, M., Pt., G, 72d New York, age 50.	May 5, 1862.	Shot wound through the right shoulder.	June 12, 1862.	Oval amputation at shoulder joint, by Dr. Willard Parker.	Died June 12, 1862, an hour after amputation.
9	Forrest, A. W., Pt., K, 141st Pennsylvania, age 21.	May 7, 1864.	Shot fracture of right humerus.	June 7, 1864.	Amputat'n at shoulder joint, by Surg. A. P. Sheldon, U. S. V.	Died June 29, 1864, of pyæmia.
10	Gallagher, C., Pt., C, 169th New York, age 32.	June 1, 1864.	Shot fracture of upper third of right humerus. June 6th, excision of two and a half inches of humerus.	Jan. 12, 1865.	Arm amputated at shoulder joint, by A. A. Surgeon H. Pearce.	Died March 3, 1865, from exhaustion. <i>Specs.</i> 383 and 3608, A. M. M.
11	Hoffman, A. J., Pt., E, 26th Iowa, age 53.	Jan. 11, 1863.	Comp'd shot fracture of right arm. March 12th, arm amputated at middle third.	May 10, 1863.	Amputation at shoulder joint.	Died June 3, 1863, of pyæmia.
12	Jackson, I. P., Corporal, E, 11th Florida.	July 30, 1864.	Shot wound of the right arm.	Sept. 7, 1864.	Amputation of arm at shoulder joint.	Died September 9, 1864.
13	Monohan, J., Corp'l, E, 22d Massachusetts, age 38.	May 6, 1864.	Shot fracture of middle third of right humerus. May 6th, excision of three inches of humerus. Sept. 17th, arm amp. at upper third, by Surg. R. B. Bontecou, U. S. V.	Sept. 19, 1864.	Amputation of arm at shoulder joint and ligation of anterior circumflex artery. See CASE 1611, p. 649.	Died September 26, 1864, from exhaustion. <i>Spec.</i> 3331, A. M. M. See FIG. 499.
14	Moore, W. K., Pt., E, 57th Massachusetts, age 23.	Oct. 8, 1864.	Shot fracture of right humerus. Oct. 8th, excision of portion of shaft of humerus.	Nov. 11, 1864.	Arm amputated at the shoulder joint, by A. A. Surgeon J. C. Morton. Nov. 21st, hæmorrhage from axillary artery; subclavian ligated, by Ass't Surg. C. Wagner, U. S. A.	Died November 27, 1864, from exhaustion.
15	Mullan, P., discharged soldier, age 30.	Jan. 29, 1862.	Shot wound of upper third of arm and thoracic parietes, with injury to humerus. Oct. 20th, hæmorrhage; ligation of brachial artery, by Drs. W. Parker and S. Smith.	Oct. 21, 1862.	Amputation by flap method, at shoulder joint, by Drs. W. Parker and S. Smith.	Died Nov. 5, 1862, of pleurisy.
16	Nason, H. J., Serg't, F, 28th Massachusetts.	May 16, 1864.	Shot wound of right arm; gangrene.	Aug. 9, 1864.	Amputat'n at shoulder joint, by A. A. Surg. T. B. Townsend.	Died August 12, 1864.
17	Orbin, J., Pt., F, 63d Pennsylvania, age 33.	June 16, 1864.	Shot fracture of left humerus, upper third; anterior portion of inferior maxilla carried away.	July 17, 1864.	Amputation of arm at shoulder joint, by Surg. R. B. Bontecou, U. S. V.	Died July 20, 1864. <i>Spec.</i> 3056, A. M. M.
18	Sanders, J., Pt., D, 89th Indiana, age 28.	July 14, 1864.	Musket ball splintered right humerus and lodged.	Aug. 15, 1864.	Amputation at shoulder joint, by A. A. Surg. J. Brey.	Died Sept. 22, 1864, of pyæmia.
19	Smith, J., Pt., K, 143d Pennsylvania, age 27.	May 5, 1864.	Shot fracture of upper third of right humerus. May 6th, excision of head and portion of shaft of humerus through a straight incision, by a Confederate surgeon.	Nov. 3, 1864.	Arm amputated at shoulder joint. Nov. 24th, profuse secondary hæmorrhage.	Died November 24, 1864, from the rupture of a large axillary aneurism.

<sup>1</sup> PECK (W. F.), *Amputation at the Shoulder Joint*, in *Am. Med. Times*, 1863, Vol. VI, p. 137.

**Amputations at the Shoulder, the Period of Operation doubtful.**—There were one hundred and thirty instances in which either the date of injury, or of operation, or both data were wanting, and which, therefore, could not be inserted in groups of exarticulations in the primary, intermediary, or secondary stages. The results as to fatality were ascertained in one hundred and nineteen of these cases.

§ *Successful Operations.*—Ninety-one cases in this category, or 76.5 per cent., terminated favorably. Eighty-eight of the patients were Confederate soldiers; three were Union soldiers, whose names are now on the Pension Roll:

TABLE L.

*Summary of Ninety-one Successful Cases after Amputation at the Shoulder for Shot Injury in which the Intervals between the Injuries and Operations were not ascertained.*

No.	NAME, AGE, AND MILITARY DESCRIPTION.	DATE OF INJURY.	NATURE OF INJURY.	DATE OF OPERATION.	OPERATION AND OPERATOR.	RESULT AND REMARKS.
1	<i>Auliff, P. C.</i> , Pt., C, 18th Virginia, age 18.	July 3, 1863.	Shot fracture of upper part of humerus.	July -, 1863.	Amputation of arm at shoulder joint.	Recovered; paroled Aug. 22, 1863.
2	<i>Allen, G.</i> , Pt., F, 4th Texas.	July -, 1863.	Shot wound of the shoulder.	July -, 1863.	Amputation of arm at shoulder joint.	Paroled August 24, 1863.
3	<i>Anderson, J. T. C.</i> , Pt., K, 4th Alabama.	July -, 1863.	Shot wound of the shoulder.	July -, 1863.	Amputation of arm at shoulder joint.	Doing well.
4	<i>Billingsley, J. M.</i> , Pt., A, 42d North Carolina.	July -, 1863.	Shot fracture of left humerus.	July -, 1863.	Amputation at shoulder joint.	Paroled September 23, 1863.
5	<i>Blackwell, R. B.</i> , Pt., H, 56th Virginia, age 28.	.....	Gunshot wound of left arm.	.....	Amputation at shoulder joint.	Retired from service Mar. 1, 1865.
6	<i>Blodsoe, F. M.</i> , Lieut., I, 11th Georgia, age 27.	July 3, 1863.	Shot wound of right shoulder.	.....	Amputation of arm at shoulder joint.	Furloughed June 27, 1864.
7	<i>Brown, M.</i> , Pt., K, 3d Alabama.	May 3, 1863.	Shot wound of right shoulder.	.....	Amputation at shoulder joint.	Furloughed June 12, 1863.
8	<i>Butler, W. A.</i> , Corporal, F, 61st Virginia, age 22.	Aug. 19, 1864.	Gunshot wound of right shoulder.	.....	Amputation at shoulder joint.	Retired March 16, 1865.
9	<i>Byrd, A.</i> , Pt., B, 50th Georgia.	May 3, 1863.	Gunshot wound of arm.	.....	Amputation of arm at shoulder joint.	Furloughed June 13, 1863.
10	<i>Byrnes, P.</i> , Sergeant, I, 6th Louisiana.	Sept. 17, 1862.	Shot wound of left shoulder.	.....	Amputation of arm at shoulder joint.	Furloughed February 9, 1864.
11	<i>Carter, R.</i> , Pt., C, 11th Georgia.	Aug. 25, 1864.	Shot wound of right shoulder.	.....	Amputation of arm at shoulder joint.	Furloughed October 28, 1864.
12	<i>Clark, C.</i> , Corporal, I, 8th Louisiana.	July -, 1863.	Shot wound of shoulder.	July -, 1863.	Amputation of arm at shoulder joint.	Transferred, for exchange, Aug. 24, 1863.
13	<i>Collins, T. L.</i> , Corporal, G, 61st Virginia, age 32.	Aug. 19, 1864.	Gunshot wound of left arm.	.....	Amputation of arm at shoulder joint.	Retired from service Jan. 23, 1865.
14	<i>Cor, J. W.</i> , Pt., K, 47th Virginia.	May 2, 1863.	Shot wound of right arm.	.....	Amputation of arm at shoulder joint.	Furloughed September 17, 1864.
15	<i>Crawford, M. P.</i> , Pt., G, 3th Mississippi, age 27.	.....	Shot wound of right shoulder.	.....	Amputation of arm at shoulder joint.	Retired from service Jan. 31, 1865.
16	<i>Crow, F. W.</i> , Sergeant, I, 6th Virginia.	May 3, 1863.	Shot wound of right shoulder.	.....	Amputation of arm at shoulder joint.	Discharged February 17, 1864.
17	<i>Dee, H.</i> , Pt., E, 7th South Carolina, age 38.	June 30, 1864.	Gunshot wound of upper third of left arm.	.....	Amputation of arm at shoulder joint.	Furloughed August 20, 1864.
18	<i>Eekles, J. A.</i> , Pt., G, 14th Ohio, age 20.	Sept. 19, 1863.	Shot fracture of left humerus.	.....	Amputation of arm at shoulder joint.	Disch'd Mar. 29, 1864; pensioned. Subsequently served in Co. A, 43d Infantry. Died June 6, 1870. Retired from service Mar. 18, 1865.
19	<i>Evans, C. A.</i> , Breathed's Battery, Steward's Horse Art.	Aug. 29, 1862.	Gunshot wound of right arm.	.....	Amputation of arm at shoulder joint.	Furloughed August 27, 1864.
20	<i>Fail, G. W.</i> , Pt., I, 17th S. Carolina, age 20.	July 30, 1864.	Gunshot fracture of right arm; also flesh wound of side.	.....	Amputation at shoulder joint, by Surgeon West, C. S. A.	.....
21	<i>Falvey, J. W.</i> , Pt., C, 18th Mississippi, age 22.	July -, 1863.	Shot fracture of left arm.	July -, 1863.	Amputation of arm at shoulder joint.	Transferred, for exchange, Sept. 10, 1863.
22	<i>Ferguson, J. J.</i> , Serg't, G, 2d Florida.	May 3, 1863.	Shot wound of left shoulder.	.....	Amputation of arm at shoulder joint.	Detained at hospital April, 1864.
23	<i>Fitzpatrick, E.</i> , Pt., G, 14th Louisiana.	July 2, 1863.	Shot wound of right shoulder.	.....	Amputation of arm at shoulder joint.	April 5, 1864, transferred to Eufala, Ala. Retired August 23, 1864.
24	<i>Flemming, W. B.</i> , 3d Maryland Artillery, age 27.	Oct. 3, 1861.	Gunshot wound of left arm and destruction of right eye.	.....	Amputation of arm at shoulder joint.	.....
25	<i>Ford, J.</i> , Pt., C, 4th Alabama.	July -, 1863.	Shot wound of shoulder.	July -, 1863.	Amputation at shoulder joint.	Paroled September 12, 1863.
26	<i>Fowler, T. M.</i> , Pt., G, 3d Virginia Cavalry.	.....	Shot wound of left shoulder.	.....	Amputation at shoulder joint.	Retired November 11, 1864.
27	<i>Gochnaur, P. S.</i> , Serg't, F, 8th Virginia, age 24.	Aug. 30, 1862.	Gunshot wounds of right arm and left leg.	.....	Arm amputated at shoulder joint and left fibula resected.	Retired from service Jan. 20, 1865.
28	<i>Goodson, T. R.</i> , Lieut., K, 26th Tennessee.	May 16, 1864.	Gunshot wound of left shoulder.	.....	Amputation of arm at shoulder joint.	Furloughed August 24, 1864.
29	<i>Gowans, H.</i> , Pt., E, 16th N. Carolina.	.....	Shot wound of left arm.	.....	Amputation of arm at shoulder joint.	Paroled September 12, 1863.
30	<i>Grew, H.</i> , Pt., I, 7th Louisiana.	May 4, 1863.	Shot wound of right arm.	.....	Amputation of arm at shoulder joint.	Transferred to Eufala, Ala., April 5, 1864.
31	<i>Ham, J.</i> , Pt., K, 26th South Carolina.	.....	Gunshot wound of right shoulder.	.....	Amputation of arm at shoulder joint.	Returned to duty Aug. 12, 1864.
32	<i>Hamrick, A. G.</i> , Pt., D, 55th North Carolina, age 30.	May 5, 1864.	Shot wound of left arm.	.....	Amputation of arm at shoulder joint.	Retired from service Feb. 21, 1865.
33	<i>Hanby, J. W.</i> , Pt., I, 3d S. Carolina.	July 3, 1863.	Comminuted shot fracture of right humerus.	July 3, 1863.	Amputation of arm at shoulder joint.	Paroled September 5, 1863.
34	<i>Harris, B. F.</i> , Pt., C, 23d North Carolina, age 23.	May 9, 1864.	Shot fracture of left humerus.	.....	Amputation of arm at shoulder joint.	Retired from service Feb. 17, 1865.



No.	NAME, AGE, AND MILITARY DESCRIPTION.	DATE OF INJURY.	NATURE OF INJURY.	DATE OF OPERATION.	OPERATION AND OPERATOR.	RESULT AND REMARKS.
35	<i>Hoyine, E. L.</i> , Corp'l, F, 46th Virginia, age 24.	July 1, 1863.	Shot wound of left arm . . . . .		Amputation at shoulder joint . . . . .	Retired from service Feb. 8, 1865.
36	<i>Heflin, L.</i> , Pt., A, 47th Virginia, age 26.	May 31, 1862.	Gunshot wound of left arm . . . . .		Amputation of arm at shoulder joint . . . . .	Retired from service Feb. 8, 1865.
37	<i>Hogg, A. P.</i> , Pt., C, 10th Alabama, age 26.	May 12, 1864.	Shot fracture of right humerus . . . . .		Amputation at shoulder joint . . . . .	Discharged January 4, 1865.
38	<i>Hussey, M.</i> , Serg't, C, 10th Louisiana.	July 2, 1863.	Shot wound of the right shoulder . . . . .		Amputation at shoulder joint . . . . .	Transferred to Eufala, Ala., April 5, 1864.
39	<i>James, S. F.</i> , Serg't, D, 33d North Carolina, age 31.	July -, 1863.	Shot fracture of head of right humerus . . . . .	July -, 1863.	Amputation at shoulder joint . . . . .	Transferred, for exchange, Sept. 1, 1863.
40	<i>Johnson, W. S.</i> , Pt., A, 9th Louisiana.	July 1, 1863.	Shot wound of right shoulder . . . . .		Amputation at shoulder joint . . . . .	Furloughed November 3, 1863.
41	<i>Jones, J.</i> , Pt., B, 12th North Carolina.	July -, 1863.	Shot wound of shoulder joint . . . . .	July -, 1863.	Amputation of arm at shoulder joint . . . . .	Transferred, for exchange, Sept. 5, 1863.
42	<i>Jordan, M.</i> , Pt., L, 6th Louisiana.	June 27, 1862.	Shot perforation of right arm . . . . .		Amputation of arm at shoulder joint . . . . .	Retired from service Oct. 22, 1864.
43	<i>Leavell, W. M.</i> , Pt., L, 1st South Carolina Rifles.	Dec. 11, 1862.	Gunshot wound of arm . . . . .		Amputation at shoulder joint . . . . .	Transferred to Columbia, S. C., May 22, 1863.
44	<i>Lema, J.</i> , Pt., E, 10th Louisiana.	July 3, 1863.	Shot fracture of humerus . . . . .		Amputation at shoulder joint . . . . .	Furloughed February 23, 1864.
45	<i>Logue, P.</i> , Pt., B, 27th Virginia, age 49.	June 9, 1862.	Gunshot wound of right arm . . . . .		Amputation of arm at shoulder joint . . . . .	Retired from service Feb. 20, 1865.
46	<i>Long, D. J.</i> , Pt., K, 19th Mississippi.	June 30, 1862.	Shot wound of shoulder . . . . .		Amputation of arm at shoulder joint . . . . .	Furloughed October 16, 1863.
47	<i>Loyle, M.</i> , Pt., K, 47th North Carolina.	July -, 1863.	Shot wound of left arm . . . . .		Amputation of arm at shoulder joint . . . . .	Paroled September 23, 1863.
48	<i>Magill, W. J.</i> , Colonel, 1st Georgia Regulars.	Sept. 17, 1862.	Gunshot wound of left arm . . . . .		Amputation of arm at shoulder joint . . . . .	Retired February 3, 1865.
49	<i>Martin, J. R.</i> , Pt., E, 3d South Carolina.	Sept. 17, 1862.	Shot fracture of left humerus; excision . . . . .		Amputation at shoulder joint . . . . .	Transferred December 3, 1862.
50	<i>Mayer, C.</i> , Pt., E, 12th Mississippi.	June 27, 1862.	Gunshot wound of right shoulder . . . . .		Amputation at shoulder joint . . . . .	Retired from service January 11, 1865.
51	<i>McCormick, J. C.</i> , Pt., I, 15th Alabama.		Gunshot wound of right shoulder . . . . .		Amputation of arm at shoulder joint . . . . .	Furloughed Nov. 27, 1863.
52	<i>McGovern, W.</i> , Sergeant, F, Phillip's Georgia Legion.	Dec. -, 1863.	Gunshot wound of right shoulder . . . . .		Amputation at shoulder joint . . . . .	Furloughed Sept. 23, 1864.
53	<i>McLean, G. A.</i> , Corporal, B, 12th Mississippi.	May 3, 1863.	Shot fracture of the right shoulder . . . . .		Amputation of arm at shoulder joint . . . . .	Furloughed June 18, 1863.
54	<i>McLean, J. M.</i> , Pt., M, 21st North Carolina, age 25.	July 1, 1863.	Gunshot wound of right arm . . . . .		Amputation of arm at shoulder joint . . . . .	Retired from service January 17, 1865.
55	<i>McLeod, Z. O.</i> , Pt., C, 26th Georgia, age 28.	July 9, 1864.	Gunshot wound of right arm . . . . .		Amputation of arm at shoulder joint . . . . .	Retired from service January 2, 1865.
56	<i>McPhaal, W. D.</i> , Pt., F, 13th Mississippi.	July -, 1863.	Gunshot wound of arm . . . . .		Amputation of arm at shoulder joint . . . . .	Paroled Sept. 5, 1863.
57	<i>Mooney, E. D.</i> , Pt., I, 56th North Carolina.		Gunshot wound of arm . . . . .		Amputation at shoulder joint . . . . .	Furloughed Sept. 14, 1864.
58	<i>Moorehouse, A. J.</i> , Pt., G, 24th Missouri, age 23.	April 9, 1864.	Shot fracture of left arm at the elbow joint; arm amputated at lower third, on field, by Surg. C. Winne, 77th Illinois.		Amputation of arm at shoulder joint, by Surgeon Winne . . . . .	Disch'd Jan. 18, 1865; pensioned.
59	<i>Morrell, R. F.</i> , Pt., K, 4th Texas.	July 2, 1863.	Shot wound of left shoulder . . . . .		Amputation at shoulder joint . . . . .	Furloughed Sept. 5, 1863.
60	<i>Palmer, R.</i> , I, 41st Virginia, age 29.		Shot fracture of left arm . . . . .		Amputation at shoulder joint . . . . .	Doing well.
61	<i>Parker, J.</i> , Pt., E, 60th N. Carolina, age 29.	July 12, 1863.	Wound of right arm by a cannon ball . . . . .		Amputation of arm at shoulder joint . . . . .	Retired from service Feb. 6, 1865.
62	<i>Pope, A. B.</i> , Sergeant, F, 5th Alabama.	July 1, 1863.	Shot fracture of right arm . . . . .	July -, 1863.	Amputation at shoulder joint . . . . .	Furloughed October 1, 1863.
63	<i>Pritchell, J. M.</i> , Pt., D, 41st Alabama.		Gunshot wound of shoulder . . . . .		Amputation at shoulder joint . . . . .	Furloughed December 23, 1864.
64	<i>Putnam, H. M.</i> , Pt., F, 6th Georgia.		Shot wound of right arm . . . . .		Amputation of arm at shoulder joint . . . . .	Furloughed December 19, 1862.
65	<i>Riner, D. W.</i> , Pt., G, 52d Virginia, age 36.	Oct. 19, 1864.	Gunshot wound of right arm . . . . .		Amputation of arm at shoulder joint . . . . .	Retired from service Feb. 10, 1865.
66	<i>Roberts, J.</i> , Pt., D, 16th Virginia.	May 16, 1864.	Shot wound of right shoulder . . . . .		Amputation of arm at shoulder joint . . . . .	Furloughed June 25, 1864.
67	<i>Royal, W. P.</i> , Pt., C, 23d Virginia, age 25.	Sept. 17, 1862.	Shot fracture of right humerus . . . . .		Amputation of arm at shoulder joint . . . . .	Retired from service Feb. 9, 1865.
68	<i>Ruff, J. S.</i> , Pt., G, 3d Alabama.	May 3, 1863.	Shot wound of shoulder . . . . .		Amputation of arm at shoulder joint . . . . .	Furloughed July 4, 1863.
69	<i>Ryan, D.</i> , Corp'l, I, 3d North Carolina Artillery, age 32.		Gunshot fracture of the right humerus . . . . .		Amputation of arm at shoulder joint . . . . .	Released June 29, 1865.
70	<i>Scott, A. A.</i> , Lieutenant, 6th Alabama.	Sept. 14, 1862.	Shot wound of right arm and thorax; comminuted fracture of humerus; hæmorrhage from axillary artery . . . . .	Sept. -, 1862.	Amputation of arm at shoulder joint, by Surg. E. D. Dailey, U. S. V. . . . .	Paroled and sent to his home.
71	<i>Seay, B. D.</i> , Pt., A, 14th Virginia, age 26.	July 3, 1863.	Shot wound of right arm . . . . .	July -, 1863.	Amputation of arm at shoulder joint . . . . .	Paroled Sept. 26, 1863.
72	<i>Seay, J. M.</i> , Corp'l, C, Holcomb's S. Carolina Legion.		Shot wound of right arm . . . . .		Amputation at shoulder joint . . . . .	Furloughed Dec. 11, 1864.
73	<i>Sharpton, P.</i> , Pt., G, 1st S. Carolina.	May 3, 1863.	Shot wound of right arm . . . . .		Amputation at shoulder joint . . . . .	Furloughed July 3, 1863.
74	<i>Shellman, W. F.</i> , Adjutant, 8th Georgia.	June 1, 1864.	Shot wound of right arm . . . . .	June -, 1864.	Amputation at shoulder joint . . . . .	Furloughed June 27, 1864.
75	<i>Smith, J. P.</i> , Pt., C, 56th Virginia, age 20.	April 3, 1865.	Fracture of left arm by a conoidal ball . . . . .		Amputation of arm at shoulder joint . . . . .	Transferred to Military Prison May 15, 1865.
76	<i>Smith, P.</i> , Pt., B, 45th North Carolina.	July -, 1863.	Shot fracture of right arm . . . . .	July -, 1863.	Amputation of arm at shoulder joint . . . . .	Paroled Sept. 5, 1863.
77	<i>Stanley, H.</i> , Pt., A, 28th N. Carolina, age 19.	April 2, 1865.	Shot fracture of left arm . . . . .	April -, 1865.	Amputation of arm at shoulder joint . . . . .	Transferred to Camp Distribution June 21, 1865.
78	<i>Stewart, C.</i> , Pt., E, 48th N. Carolina, age 36.	May 6, 1864.	Gunshot wound of right arm . . . . .		Amputation at shoulder joint . . . . .	Retired from service Dec. 29, 1864.
79	<i>Thomas, G. H.</i> , Pt., C, 14th Tennessee, age 29.		Shot wound of left arm . . . . .		Amputation of arm at shoulder joint . . . . .	Retired from service Feb'y 21, 1865.
80	<i>Thornhill, E. A.</i> , Pt., I, 16th Georgia, age 22.	May 3, 1863.	Gunshot wound of left arm . . . . .		Amputation of arm at shoulder joint . . . . .	Retired from service March 18, 1865.

NO.	NAME, AGE, AND MILITARY DESCRIPTION.	DATE OF INJURY.	NATURE OF INJURY.	DATE OF OPERATION.	OPERATION AND OPERATOR.	RESULT AND REMARKS.
81	<i>Timel, J.</i> , Pt., E, 3d Georgia.		Gunshot wound of right arm.		Amputation of arm at shoulder joint.	Furloughed Oct. 16, 1864.
82	<i>Tshear, N. T.</i> , Serg't, H, 3d Arkansas.		Gunshot wound of right shoulder.		Amputation of arm at shoulder joint.	Furloughed Jan. 20, 1864.
83	<i>Tucker, B. H.</i> , Sergeant, K, 50th Virginia, age 24.	July -, 1863.	Shot wound of right arm.	July -, 1863.	Amputation of arm at shoulder joint.	Paroled Sept. 25, 1863. Stump healed.
84	<i>Tucker, J. W.</i> , Pt., D, 59th Georgia.	Oct. 7, 1864.	Gunshot wound of left shoulder.	1864.	Amputation of arm at shoulder joint.	Furloughed Nov. 18, 1864.
85	<i>Unknown.</i>		Gunshot wound of arm.		Amputation of arm at shoulder joint.	Recovered.
86	<i>Unknown.</i>		Gunshot wound of arm.		Amputation of arm at shoulder joint.	Recovered.
87	<i>Vickers, F. M.</i> , Pt., G, 19th Virginia Cavalry, age 22.		Gunshot wound of right arm.		Amputation of arm at shoulder joint.	Retired from service Jan. 19, 1865.
88	<i>Wheaton, A. S.</i> , Corp'l, G, 104th New York, age 22.	Aug. 30, 1862.	Shot wound of left arm.		Amputation of arm at shoulder joint.	Disch'd Oct. 8, 1862; pensioned.
89	<i>Wheeler, C.</i> , Sergeant, F, 8th Georgia.	Dec. 10, 1864.	Gunshot wound of right arm.		Amputation at shoulder joint.	Discharged June 13, 1865.
90	<i>Willkousky, L.</i> , Pt., B, 9th Louisiana.	April 30, 1863.	Gunshot wound of arm.		Amputation at shoulder joint.	Furloughed June 7, 1863.
91	<i>Wyedmer, A.</i> , —, Dobaldsville Artillery.		Shot wound of arm.		Amputation at shoulder joint.	Transferred to Danville March 12, 1863.

Amputation was on the right side in forty-five, on the left in twenty-eight instances; in eighteen cases, this point was unnoticed. The method of operation was nowhere specified. In one case, an amputation above the elbow, and, in another, an excision of the upper extremity of the humerus, preceded the amputation at the shoulder. In one case, excision of a portion of the fibula was practised at the same time as the amputation. Eighty-five of the men were exchanged, paroled, released, or furloughed; two were discharged, and four were not accounted for. In one case, probably a primary one, the arm was torn off by a cannon shot; in the remainder the character of the projectile was not referred to, or else the wound was ascribed to a musket ball.

§ *Unsuccessful Operations.*—Twenty-eight cases, in the series of amputations at the shoulder for shot injury, in which the stage at which the operations were practised could not be determined with precision, resulted fatally:

TABLE LI.

*Summary of Twenty-eight Fatal Cases of Amputation at the Shoulder for Shot Injury, in which the Intervals between the Injuries and Operations were not ascertained.*

NO.	NAME, AGE, AND MILITARY DESCRIPTION.	DATE OF INJURY.	NATURE OF INJURY.	DATE OF OPERATION.	OPERATION AND OPERATOR.	RESULT AND REMARKS.
1	<i>Andrews, S.</i> , Pt., I, 57th N. Carolina.	1863.	Wound of right shoulder.	1863.	Amputated at the shoulder.	Died June 24, 1863.
2	<i>Baker, J.</i> , Sergeant, A, 61st New York.	May 8, 1864.	Shot fracture of right humerus.	May -, 1864.	Amputated at the shoulder, by Surg. J. W. Wishart, 140th Pennsylvania.	Died June 25, 1864.
3	<i>Bradley, J.</i> , Pt., A, 2d Connecticut Artillery.	June 2, 1864.	Wound of right arm and chest.	June -, 1864.	Amputated at the shoulder.	Died June 11, 1864.
4	<i>Chambers, B.</i> , Pt., D, 4th Alabama.	1862.	Shot fracture near shoulder.	1862.	Amputated at the shoulder.	Died September 18, 1862.
5	<i>Cheney</i> , —, 2d South Carolina, age 30.	Sept. 17, 1862.	Wound of right arm; constitutional syphilis; amputation of arm.	1862.	Re-amputation at the shoulder, by Surg. J. J. Knott, C. S. A.	Died.
6	<i>Cobb, S. S.</i> , Pt., B, 41st Alabama.	1865.	Wound of arm and fracture of right tibia.	1865.	Amputated at the shoulder.	Died February 4, 1865.
7	<i>Dillworth, L.</i> , Serg't, C, 61st Pennsylvania.	1862.	Wound of shoulder.	1862.	Amputated at the shoulder.	Died June 28, 1862, of pyæmia.
8	<i>Downey, A.</i> , Pt., I, 116th Pennsylvania.	Dec. 13, 1862.	Compound fracture of left humerus.	Dec. -, 1862.	Amputated at the shoulder.	Died January 6, 1863.
9	<i>Edwards, J. D.</i> , Pt., F, 44th North Carolina.	1864.	Shot wound near shoulder.	1864.	Amputated at the shoulder.	Died June 11, 1864.
10	<i>Everly, F. M.</i> , Pt., G, 17th Kentucky.	April 7, 1862.	Fracture of right humerus.	April -, 1862.	Amputated at the shoulder.	Died April 20, 1862, from sec'dry hæmorrhage from subclavian.
11	<i>Gaines, John P.</i> , Pt., D, 11th Kentucky.	Dec. 30, 1862.	Wounds of both legs and shoulder.	1862(?)	Amputated at the shoulder.	Died March 31, 1863.
12	<i>Goodrich, C. O.</i> , H, 12th Virginia.	1864.	Shot fracture of upper third of humerus.	1864.	Amputated at the shoulder.	Died November 21, 1864.
13	<i>Hornor</i> , —, Pt., I, 5th Texas.	July -, 1863.	Wound at shoulder joint.	July -, 1863.	Amputated at the shoulder.	Died July 17, 1863.



No.	NAME, AGE, AND MILITARY DESCRIPTION.	DATE OF INJURY.	NATURE OF INJURY.	DATE OF OPERATION.	OPERATION AND OPERATOR.	RESULT AND REMARKS.
14	Johnson, G. F., Pt., K, 4th Maine.	July -, 1863.	Wound of left arm.....	July -, 1863.	Amputated at the shoulder....	Died July 9, 1863.
15	Kinsey, B., Pt., D, 53d Pennsylvania.	1865.	Wound of left shoulder.....	1865.	Amputated at the shoulder....	Died April 17, 1865, from secondary hemorrhage.
16	Miller, J. A., Pt., B, 18th Georgia.	1863.	Wound of right shoulder.....	1863.	Amputated at the shoulder....	Died June 2, 1863.
17	Moor, C. H., Serg't, H, 61st Georgia.	1862.	Shot wound of shoulder joint..	1862.	Amputated at the shoulder....	Died July 3, 1862.
18	Padgett, T. H., Pt., F, 26th Virginia.	1864.	Shot fracture near shoulder....	1864.	Amputated at the shoulder....	Died June 29, 1864.
19	Ransom, B. H., F, 4th South Carolina.	1861.	Shot fracture of upper third of humerus.	1861.	Amputated at the shoulder....	Died August 2, 1861.
20	Sanderson, Geo., Serg't, K, 44th Indiana.	April 6, 1862.	Wound of left arm, high up...	1862.	Amputated at the shoulder....	Died May 14, 1862.
21	Shaw, C., Pt., E, 48th Alabama.	July -, 1863.	Wound of arm, with fracture..	July 3, 1863.	Amputated at the shoulder....	Died July 20, 1863.
22	Smith, G. D., Pt., E, 11th Pennsylvania.	Aug. 30, 1862.	Wound of arm, with fracture near shoulder.	1862.	Amputated at the shoulder....	Died September 11, 1862.
23	Smith, James, Pt., Naval Battery.	1865.	Shot fracture of upper third of os brachii.	1865.	Amputated at the shoulder....	Died April 18, 1865.
24	Toole, J., Pt., D, 14th Louisiana.	1862.	Shot wound, with fracture of humerus.	1862.	Amputated at the shoulder....	Died July 3, 1862.
25	Townsend, H. M., Corp'l, I, 9th Iowa.	Mar. 8, 1862.	Wound of right arm near the shoulder.	1862.	Amputated at the shoulder....	Died April 23, 1862.
26	Taten, J., Pt., B, 5th South Carolina Cavalry.	1864.	Wound of arm; fracture of left femur.	1864.	Amputated at the shoulder....	Died December 20, 1864.
27	Williams, J., Pt., D, 46th North Carolina.	1864.	Wound of arm and penetrating wound of thorax.	1864.	Amputated at the shoulder....	Died September 15, 1864.
28	Willford, T., Pt., G, 2d North Carolina.	July -, 1863.	Fracture of left humerus.....	July -, 1863.	Amputated at the shoulder....	Died August 5, 1863.

The side on which the amputation was practised was specified in only twelve (right 7, left 5) of the twenty-eight cases. In some instances the period of operation was implied, though not with precision.<sup>1</sup> One operation was a reamputation. Twelve of the patients were Union, and sixteen Confederate soldiers.

§ *Operations with Unknown Results.*—In eleven cases of shoulder joint amputations for shot injury, compiled from authentic but very scant memoranda, it was impracticable to ascertain the results as to recovery or fatality, or the exact dates of operation :

TABLE LII.

*Summary of Eleven Cases of Amputations at the Shoulder, in which neither the Results nor the Periods intervening between the Injuries and the Operations were ascertained.*

No.	NAME, AGE, AND MILITARY DESCRIPTION.	DATE OF INJURY.	NATURE OF INJURY.	DATE OF OPERATION.	OPERATION AND OPERATOR.	RESULT AND REMARKS.
1	Bruce, J. D., Major, 47th Virginia.	1863.	Shot wound of left arm.....	1863.	Amputated at the left shoulder.	It is hoped and requested that any one cognizant of the exact dates, or of the terminations of any of the cases in this category, will communicate the facts to the Surgeon General's Office.
2	Corriher, R. A., Pt., K, 57th North Carolina.	1863.	Shot fracture near shoulder....	1863.	Amputation at the shoulder....	
3	Deiss, G., Pt., G, 5th Alabama.	July -, 1863.	Shot fracture of upper third of humerus.	July -, 1863.	Amputation at the shoulder....	
4	Grogg, S. C., Pt., K, 49th North Carolina.	1863.	Shot wound of left arm.....	1863.	Amputated at the left shoulder.	
5	Murphy, Jno., Pt., B, 13th North Carolina Artillery.	1864.	Right arm torn off by shell fragment.	1864.	Amputated at the right shoulder.	
6	Norville, —, Pt., K, 4th Texas.	July -, 1863.	Wound of shoulder.....	July -, 1863.	Amputation at the shoulder....	
7	Pierson, J. A., Pt., B, 46th North Carolina.	Sept. 17, 1862.	Shot wound of right arm.....	1862.	Amputated at the right shoulder.	
8	Robinson, W. A., Pt., I, 4th Georgia, age 20.	May 2, 1863.	Shot fracture of the humerus, high up.	1863.	Amputation at the shoulder....	
9	Shook, J. A., Pt., B, 54th North Carolina.	1864.	Shot wound of right shoulder..	1864.	Amputated at the right shoulder.	
10	Sparks, Solomon, Pt., 25th Tennessee.	1863.	Shot wound of shoulder joint..	1863.	Amputation at the shoulder....	
11	Staton, Wm., Corp'l, C, 10th North Carolina Battery.	1864.	Shot fracture of left humerus..	1864.	Amputation at the shoulder....	

This series completes the reported cases of amputation at the shoulder for shot injury. All of these cases were taken from Confederate records. In the six instances in which

<sup>1</sup> CASES 3, 4, 8, 13, 14, 16, 17, 19, and 28 were probably primary exarticulations, and much the larger proportion of the cases appear to have been either primary or early intermediary operations. It is hardly possible to suppose circumstances that would warrant so considerable a number of exarticulations at the shoulder, in cases attended by probably mortal wounds elsewhere, as are here recorded: *E. g.*, in CASES 3 and 27, there were penetrating wounds of the thorax; in CASE 26, fracture of the femur; in CASE 11, wounds of both legs, etc.

the point was noticed, the operations were equally divided between the right and left sides. No complications, or prior or consecutive operations, are mentioned in the reports.

*Recapitulation.*—In the foregoing subsection, eight hundred and fifty-two exarticulations at the shoulder,<sup>1</sup> for shot injury, or for disease consequent on shot injuries, or the operations undertaken for their relief, have been enumerated. Four hundred and ninety-nine cases related to primary operations, one hundred and seventeen terminating fatally, the results in fourteen cases being unknown, and the remaining three hundred and sixty-eight resulting successfully,—a mortality rate for the determined cases of 24.1 per cent. Fifteen of the successful and two of the unsuccessful cases were detailed, with five cuts from photographs of recovered patients, and eight cuts representing the pathological specimens preserved. One hundred and fifty-seven cases of intermediary exarticulations were illustrated by details of three successful and three unsuccessful operations, with a wood-cut of a case of recovery, a plate and five cuts showing osteological specimens. The fatality in this series, in which the termination of all the cases was determined, was 45.8 per cent. Sixty-six secondary exarticulations were recorded, with details of one fatal and three successful operations, and wood-cuts of four specimens, and tabulations showing a mortality rate of 28.7 per cent. A fourth series, embracing one hundred and thirty cases, in which it was impracticable to determine precisely the interval between the injury and operation, included one hundred and nineteen in which the result as to fatality was known to be 23.5 per cent. The facts ascertained regarding these cases were presented in tabular form. The mean death-rate of the entire series of eight hundred and twenty-seven cases was 28.5 per cent. Adding fourteen cases, from the preceding Section, in which exarticulation at the shoulder was practised on account of lesions of the blood-vessels or the soft parts, this series of eight hundred and forty-one cases gives a ratio of mortality of 29.1. In seven hundred and sixty-six of these cases the side on which the operation had been practised was specified, and a slight predominance in number and fatality on the right side was indicated: in three hundred and ninety-one amputations at the right shoulder, the death-rate was 25.2 per cent.; in three hundred and seventy-five exarticulations on the left side, the mortality was 24.9 per cent.

<sup>1</sup> On exarticulation at the shoulder, the following authorities, besides those cited on page 613, may be consulted: PLATNER (J. Z.) (*Institutiones Chirurgiæ rat.*, Lipsiæ, 1758, § 251, p. 125) describes his method of operating; LE LAUMIER and POYET (*De methodis amputandi brachium ex articulo*, Paris, 1759) devote a thesis to the operative details; VAN GESCHER (*Verhandlung van het afzetting der dye in het gewricht*, Amsterdam, 1760) has a treatise on the ablation of the arm at the shoulder; BRASDOR (P.) treats of exarticulation at the shoulder in his essay *Sur les amputations dans les articules*, in the *Mém. de l'Acad. de Chir.*, 1774, T. V, p. 747; ALANSON (E.) describes his circular method, in his *Practical Observations on Amputation and the After-treatment*, London, 1782; HASELBERG (L. W.), in 1782, published, at Göttingen, a *Commentatio chirurgica, in qua novum humerum ex articulo extirpandi methodum* is contained; FLAJANI (G.) wrote *Osservazione pratiche sopra l'amputazione degli articoli*, Roma, in 1791; SEEBURG (D.), in 1795, published at Wittenberg an example of successful ablation of the arm at the shoulder: *Extirpatio ossis humeri exemplo frigie prabata*; MUR-SINNA (C. L.) printed in his journal, 1801, B. 1, S. 101, a paper *Von der Ablösung des Armes im Schultergelenke*; SCHREINER's dissertation, *Über die Amputation grosser Gliedmassen nach Schusswunden*, Leipzig, 1807, includes a section on amputations at the shoulder. Dissertations on the subject follow in rapid succession, as those by WALTHER (P. F.) (*Über die Amputationen in den Gelenken*, Landslut, 1810); KLOSS (G.) (*De amputatione humeri ex articulo*, Göttingen, 1809, Frankfurt, 1811); FRASER (W. W.) (*An Essay on the Shoulder Joint Operation*, London, 1813). To the systematic authors who treat of the subject, and are mentioned in the note on page 613 ante, may be added Sir CHARLES BELL (*System of Operative Surgery*, London, 1814, Vol. II, p. 39); LISFRANC and CHAMPESNE printed in Paris, 1815, a *Nouveau procédé opératoire pour l'amputation du bras dans l'articulation scapulo-humérale*, an expeditious method that has had a great vogue. Consult, further, MEUNIER (P.) (*Sur l'amputation du bras dans son articulation avec l'omoplate*, Paris, 1815); KLEIN (C.) (*Resultate der in den Kaiserlich Russischen Hospitälern im Württembergischen gemachten Ausschälungen aus dem Schultergelenk und dem Mittelfuss, sowie anderen ungewöhnlichen Amputationen*, Stuttgart, 1817); MANN (JAMES) (*Observations on Amputation at the Joints, in The Medical Repository*, 1822, Vol. VII, N. S., p. 14); MÜENZENTHALER (*Versuch über die Amputationen in den Gelenken*, Leipzig, 1822); HUBBARD (T.) (*On Amputation performed at the Joints, in The Medical Repository*, 1822, Vol. VII, N. S., p. 264); OBELTSCHEFFER (J. G.) (*Anatomisch-chirurgische Abhandlung von der Lösung des Oberarms aus dem Schultergelenke*, Würzburg, 1823); HUBBARD (*On Amputation at the Joint, in New York Med. Repository*, 1823, Vol. XXII, p. 264); MANN (*Observations on Amputation at the Joints, in New York Med. Repository*, 1823, Vol. XXII, p. 14); SCOUTETIEN (*La méthode avalaire, ou nouvelle méthode pour amputer dans les articulations*, Paris, 1827); JANVICKI (*De brachii extirpatione*, Vilna, 1828); CORNUAU (*Nouveau procédé opératoire pour pratiquer l'amputation dans l'articulation scapulo-humérale*, Paris, 1830); COOPER (S.) (*Dict. of Pract. Surg.*, 1838, Vol. I, p. 78, *Amputation at the Shoulder Joint*); DEWENEY (A.) (*Dans quels cas et comment pratique-t-on la désarticulation de l'épaule*, Paris, Thèse, 1838, No. 341); CONFOULANT (P. L. F.) (*Dans la désarticulation de l'épaule, à quelle méthode faut-il donner la préférence*, Paris, Thèse, 1838, No. 234); ELOIRE (J. P.) (*Essai d'un nouveau procédé pour la désarticulation scapulo-humérale*, Paris, Thèse, 1841, No. 289); SCHILLBACH (E. L.) (*De exarticulatione ossis humeri*, Jenæ, 1850); MCKINLEY (S. L.) (*Amputation at the Shoulder Joint, in New Orleans M. d. and Surg. Jour.*,



CONCLUDING OBSERVATIONS ON SHOT INJURIES AT THE SHOULDER.—In this Section, twenty-three hundred and twenty-eight of shot injuries of the shoulder joint, or of periarticular wounds necessitating operations at the articulation, have been somewhat fully discussed, and it seems proper, after adducing such a mass of evidence, to sum up the principal conclusions indicated by the facts, and to advert to the practical reflections on this subject of experienced military surgeons. The cases were analyzed under three heads: Those treated by expectant conservative measures, those in which excision was practised, and those in which recourse was had to ablation of the limb, and the facts will be reviewed in the same order.

In seventy-two instances, in which it was believed, from the escape of synovia and other symptoms, that shot penetration of the shoulder joint existed without injury of the osseous tissue, expectant treatment was pursued, and but six cases, or 8.33 per cent., terminated fatally, a result that assuredly justifies the repetition of such conservative attempts in all similar cases.

Of five hundred and five patients with shot wounds of the shoulder attended by fracture of some portion of the articulation, treated on the expectant plan, one hundred and thirty-nine, or 27.5 per cent., died. In many of these cases, free incisions were made into the joint, and detached fragments or exfoliations were removed, and occasionally carious surfaces were gouged away. With few exceptions, the cases appear to have been judiciously selected for the expectant plan, and, although the rate of mortality was greater than that of primary amputations at the shoulder, it was decidedly less than that of primary decapitations of the humerus. But it is, of course, to be taken into account, in instituting any comparison between the results of expectant and operative measures, that the cases treated in the early stage by expectation, in which compulsory ulterior operations are practised, and in which the ratio of fatality is disproportionately great, are subtracted from the former and added to the latter category. But it is absurd to attempt to decide this question purely from numerical data.<sup>1</sup> The importance of the arm is so great, and even a limited use of it is so valuable, that, as Guthrie declares,<sup>2</sup> it is justifiable to hazard much to save it when there is a tolerably fair prospect of success. Dr. Neudörfer, a very reliable writer,<sup>3</sup> with opinions formed from a vast personal experience, is another earnest advocate of expectant measures in this class of cases.

1853-54, Vol. X, p. 858); SMITH (S.) (*Amputation at the Large Joints: Statistics of Amputations at the Shoulder and Elbow Joints*, in *The New York Jour. of Med.*, 1853, Vol. X, N. S., p. 9); HODGES (R.) (*Amputation of the Shoulder Joint under the Influence of Chloroform, in a case of gunshot wound*, in *Assoc. Med. Jour.*, 1854, Vol. II, p. 1042); LARREY (II.) (*Observation d'amputation scapulo-humérale*, etc., Paris, 1857); LESÈRE (C.) (*Nouveau mode opérative pour l'amputation du bras dans l'articulation scapulo-humérale*, etc., Paris, 1831, Thèse No. 57); MALGAIGNE (J. F.) (*Manuel de Médecine opérat.*, Paris, 1861, *Amputation scapulo-humérale*, p. 313); MOON (W. P.) (*Amputation of Right Shoulder Joint (Incisions modified to suit case)*, in *Am. Jour. Med. Sci.*, January 1866, p. 143); ASHURST, jr. (JOHN) (*Observations in Clinical Surgery*, No. II, &c., Case III, *Necrosis of Humerus; Amputation at Shoulder Joint, Recovery*, in *Am. Jour. Med. Sci.*, January, 1868, p. 40); CHAMBAUD (J. G.) (*De la désarticulation scapulo-humérale (Modifications au procédé LARREY)*, Thèse à Paris, 1870, No. 62); BLACK (J. J.) (*Amputation at the Shoulder Joint for extensive Gunshot Wound of the Arm and Shoulder*, in *Phila. Med. Times*, 1874, p. 551).

<sup>1</sup> PONCET (F.) (*Contribution à la relation méd. de la guerre de 1870-71, Hôpital mil. de Strassbourg*, in *Montpellier Médical*, Dec., 1871—Mars, 1872) inquires: "Is it better to amputate or to attempt conservation? Truly we cannot comprehend why that question is propounded, or why it should be sought to solve it by commentary on statistics. Far better would it be to enquire what are the hygienic conditions, what the power of vital resistance of each patient. Each day these conditions vary with the overcrowding of the wards, with meteorological conditions, with the regimen of the patients, and the moral condition of those subjected to operations. Looking solely at the number of survivors and dead, and seeking, when remote from the facts, to establish by a comparative arithmetical computation the line of conduct of the surgeon, is, if we may be believed, to expose ourselves to conclusions that bear no truthful relation (*sans aucun rapport de vérité*) to the question. It suffices, to prove this, to take the purely numerical results laboriously and conscientiously collected by Dr. CHENU, and then to review under what conditions it has been sought to reduce rules for surgery. We beg those who would themselves, without prejudice, re-analyze this work, to take special account of the columns 'undetermined wounds or those without precise indications,' so often neglected in statistical works. They suffice, nevertheless, to change the proportions of the results."

<sup>2</sup> GUTHRIE (G. J.), *A Treatise on Gunshot Wounds*, London, 3d ed., 1827, p. 421.

<sup>3</sup> NEUDÖRFER (J.) (*Handbuch der Kriegschirurgie*, 1872, Zweite Hälfte, S. 1145) remarks: "One who performs immediate resection is not at all to be censured, but such a resection is not indicated, that is, indispensably, in a scientific point of view. We at least, and our followers, would, in such cases, prefer to extract the loose fragments, and to secure free admission of air to the capsule of the joint by means of insertion of an appropriate siphon."

Of one thousand and eighty-six patients subjected to excisions at the shoulder, completed histories are wanting in one hundred and thirty-five instances,—nine on the Union, and one hundred and twenty-six on the Confederate returns. The results of eight hundred and seventy-six<sup>1</sup> determined cases are analyzed in detail on page 599, and the results of the seventy-five completed cases from the Confederate reports are summed up on page 606. The operations are arranged in groups, comprising true excisions of the scapulo-humeral articulation, portions of the scapula or clavicle having been removed with the head of the humerus,—partial excisions of the head of the humerus,—decapitations of the humerus,—excisions of the head and part of the shaft of the humerus. The first group, of forty-two cases, is illustrated by the details of six instances, a plate and three wood-cuts of specimens, and three cuts of photographs of cases of recovery. Of the second group, of fourteen cases, two are related in detail, with two cuts of recovered patients, and two of pathological specimens. The numerous decapitations are subdivided into primary, intermediary, and secondary operations, and those of unknown date, and further separated into groups of successful and unsuccessful cases. They are illustrated by three plates and three wood-cuts of recovered patients, seven wood-cuts of specimens, and twenty-two detailed abstracts. The fourth group, comprising five hundred and seventeen cases, similarly divided as to stages of operation and results, is illustrated by twenty-seven pictures of patients after recovery, twenty-six cuts of pathological specimens, and narratives of sixty-six cases.

Of the nine hundred and fifty-one determined cases, three hundred and forty-eight terminated fatally, or 36.6 per cent. Recourse was had to amputation at the shoulder after only fourteen of the operations of excision. One hundred and forty-six operations on Confederate soldiers appear on the Union returns, and two hundred and one on the annexed TABLE XL, or three hundred and forty-seven cases. Of the seven hundred and thirty-nine Union soldiers subjected to this operation, four hundred and seventy-six survived. Of these, the names of three hundred and eighty are now (July, 1875) borne on the Pension Roll. It may be assumed that the medical examiners of the Pension Office, who have inspected these pensioners biennially, have usually represented the disabilities of the limbs in as grave a light as may be compatible with the facts observed, in order that the mutilated men may enjoy the largest rates of pension allowed by the laws.<sup>2</sup> The return "arm totally useless," is not infrequent in cases where the forearm and hand retain their functions in their integrity.<sup>3</sup> Dr. Thomas B. Hood, the medical referee of the Pension Commissioner, informs the writer that it is contemplated by the Bureau to institute an enquiry into the exact condition of the limbs that have undergone excisions. When this is done, precise statements on the subject will be practicable. After carefully analyzing the reports of the pension examiners, and comparing a large number of personal observations on pensioners visiting the Army Medical Museum, and special reports from numerous correspondents, I am convinced that the average extent of usefulness of the limb retained after excisions at the shoulder for injury is not overstated in the paragraph on that subject on page 611.

<sup>1</sup> It has been shown, on page 600, that the mortality of the eight hundred and seventy-six determined cases of excision on the Union reports was but 34.8 per cent. The rate is increased by the addition of the seventy-five completed cases from the Confederate return, with a high ratio of mortality, which would almost certainly have been reduced, could the results of the remainder of the cases in the series of two hundred and one have been ascertained.

<sup>2</sup> It is not, by any means, intended to imply that the duties of the Pension Examining Boards and of individual examiners are not faithfully performed, but the brief reports of disability total (or partial), of the first (or second, or third) grade, are unintelligible to any but those familiar with the complex system of pension laws, endlessly modified by successive enactments. Most of the pensioners were laboring men prior to enlistment, and, as the examiners invariably enquire into the avocations of applicants, a limb may be reported as "absolutely useless" for hard manual labor, when, for clerical or many mechanical tasks, it may be eminently useful.

<sup>3</sup> The reports of the pension examiners in this class of cases may be summarized as follows: "Slight," or "partial," or "impaired," use of arm, 146; useful, 4; entire loss of motion, 5; equal to loss of arm 31; equal to loss of hand, 24; useless, 131; disability not stated in 39 cases.



The amount of after-mobility in the limb appears to depend greatly upon the extent to which the nerve trunks and muscular attachments have been respected by the missile and by the knife, and upon the precautions taken in the after-treatment. Dr. O. Heyfelder divides the results as to mobility in recoveries from excision at the shoulder into four categories: *a*, The arm hangs powerless by the side, incapable of active movement, but susceptible of being moved by the sound arm. But the pendulous limb can raise considerable weights, and, when the elbow is supported, the functions of the forearm and hand may be perfect. These cases are not uncommon where a large portion of the shaft has been removed together with the head, and the muscles have atrophied through lesion of the nerves or from disease. The nerve-lesions appear to be irremediable; but much may be done, even at a late period, to relieve what Professor B. von Langenbeck terms "inactivity-paralysis."<sup>1</sup> The absence of mobility in the upper arm after operations extending to a large portion of the diaphysis, as has been proved by numerous examples.<sup>2</sup> The important precautions appear to be to divide the muscular insertions as near the bone as practicable, to guard against injury of the long head of the biceps, to support the elbow and bring the upper end of the diaphysis near the glenoid cavity, that the divided muscles and aponeuroses may become re-attached as high up as possible, and, lastly, to persevere in passive movements from the earliest moment at which they may be safely begun. Unless the nutrition of the limb is impaired by lesions of the vessels or nerves, by resolutely stimulating the muscular contractility by frictions and exercise, the patient regains control over the movements of the upper arm to a remarkable extent.<sup>3</sup> *b*, Dr. O. Heyfelder's<sup>4</sup> second category comprises those cases in which a new scapulo-humeral articulation is formed and the mobility and other functions of the arm are restored. A ginglymoid takes the place of an arthrodial joint, the action of the rotator and abductor muscles being greatly impaired or abolished, while the flexors and extensors acquire a compensatory power. This favorable result is happily the most frequent, and obtains, according to Dr. Heyfelder, in fully one-half of the survivors of excision at the shoulder. In the sense in which the term ginglymoid articulation is here used, I am satisfied that this statement, if applied to the survivors of excision at the shoulder in the American war, would not be exaggerated. A true new articulation with a synovial membrane and ligaments was rarely, if ever, formed; but in a larger proportion than one-half some control over the movements of the upper arm was retained, and often very perfect power of flexion, extension, and adduction. *c*, The third category comprises cases in which there is restricted mobility after the removal of the head with a very large extent of the shaft; and the fourth, *d*, includes the cases of absolute immobility, arising from paralysis from nerve injury, from prolonged disuse of the arm, or from bony ankylosis.

<sup>1</sup> LANGENBECK (B. v.), *Chir. Beobachtungen aus dem Kriege*, 1874, p. 143, observes: "By the preceding observations I believe to have proven that 'lame members' from resection of the head of the humerus are nothing but art products of a deficient after-treatment, owing especially to the indolence of the wounded, to the vicissitudes of war, and to the fact that, on account of the necessity of dispersing the wounded, the surgeon's supervision is frequently interrupted. The great difference between the inactivity-paralysis and mutilation of the nerves may be recognized by the fact that the former readily yields to proper stimulating and gymnastic treatment, while the latter, as a rule, cannot be cured in any way."

<sup>2</sup> In the case of Reardon, detailed on page 552 (CASE 1529), in which fully six inches of the humerus was removed, and a half-inch ring of bone subsequently exfoliated from the sawn extremity of the shaft, although there has been no regeneration of bone, entire control of the movements permitted by the ginglymoid articulation that has formed are practicable. The deltoid and biceps are as fully developed as on the opposite side. The pensioner can place his hand on the top of his head, and execute all the movements of the upper arm except abduction. Even when a still larger portion of the shaft or even the entire humerus was removed, a certain amount of mobility of the upper arm was attained by encasing it in an apparatus, a sort of exo-skeleton, as in the cases of Cleghorn, p. 568, Kegerries, p. 594, Wolff, p. 573, and Woods, p. 580.

<sup>3</sup> In the case of Lieutenant H. G. Jacobs (p. 553), the control of the movements of the arm was far greater in 1875, nearly twelve years after the operation, than ten years before. There was considerable power of abduction even, the arthrodial character of the articulation being preserved. There are many like instances that have come under my own observation.

<sup>4</sup> HEYFELDER (O.), *Lehrbuch der Resektionen*, Wien, 1863, *Nachbehandlung der Resection des Schultergelenkes*, S. 221

True bony ankylosis appears to have rarely resulted among the survivors of excision for injury that have been kept under observation. It is true that it is stated that this condition exists in twenty cases;<sup>1</sup> but, in most of these, the stiffness of the joint was apparently only partial, was, in fact, false or spurious ankylosis. This conforms to the experience of Dr. Esmarch in Schleswig-Holstein, and to observations after other wars,<sup>2</sup> and might be anticipated from the structure and latitude of movement permitted by the shoulder joint. True bony ankylosis after either disease or injury is of rare occurrence. There are but two examples in the Army Medical Museum,<sup>3</sup> and Dr. Hodges states that, in 1855, the museums in London and Paris possessed but four specimens illustrating such a condition. Dr. Albrecht Wagner declared, in 1853, that "ankylosis after resection of the shoulder joint has not been observed up to the present time."<sup>4</sup>

The reports justify the conclusion of Dr. Richard M. Hodges, that "comparatively rapid recovery follows excision for injury." Brigadier General E. B. Brown, U. S. V. (CASE 1495, page 522), used the forearm and hand freely three weeks after the operation, and guided his horse with the mutilated arm five weeks after a shot fracture of the head of the humerus with division of the long head of the biceps. There were many other instances in which officers and non-commissioned officers returned to duty, and privates to modified duty, within six months from the date of injury.<sup>5</sup>

Complete regeneration of the portion of bone excised was not observed in any instance, and partial regeneration to any appreciable extent was extremely rare. Subperiosteal excisions were seldom attempted, probably never after the systematic method adopted by Dr. Ollier<sup>6</sup> and Professor v. Langenbeck,<sup>7</sup> and such results as are reported by

<sup>1</sup> Namely: CASE 1499, p. 527, Hatfield; CASE 1497, p. 523, Hogan; CASE 1492, p. 521, Harvey; CASE 8, TABLE XXIII, p. 528, Jones; CASE 11, TABLE XXIII, p. 528, Robbins; CASE 14, TABLE XXIII, p. 528, Yeazell; CASE 55, TABLE XXIV, p. 532, Kidder; CASE 15, TABLE XXVI, p. 539, Pierson; CASE 11, TABLE XXVIII, p. 543, Turner; CASE 5, TABLE XXX, p. 547, Hayward; CASE 12, TABLE XXX, p. 547, Van Scooter; CASE 152, TABLE XXXI, p. 559, Regan; CASE 208, TABLE XXXI, p. 561, Yellot; CASE 7, TABLE XXXIII, p. 576, Biebford; CASE 20, TABLE XXXIII, p. 576, Coolman; CASE 67, TABLE XXXIII, Shockey; CASE 1575, p. 589, Lewis; CASE 12, TABLE XXXV, p. 591, Gahagan; CASE 13, TABLE XXXV, p. 591, Gravel; and CASE 13, TABLE XXXVII, p. 597, Scott.

<sup>2</sup> ESMARCH (F.) (*Ueber Resectionen nach Schusswunden*, Kiel, 1851, S. 43). LIEFFLER (F.) (*General-Bericht*, u. s. w., p. 291), in the Danish War of 1864, saw a solitary case, which he details, of ankylosis at the shoulder. SOCIN (A.) (*Kriegschir. Erf.*, 1872, S. 154) met with a single instance.

<sup>3</sup> The specimens in the Army Medical Museum are numbered 5287 and 5982, of Section I, and are from the cabinet of the late Professor WILLIAM GIBSON. DR. HODGES (*The Excision of Joints*, p. 25) makes his statement on the authority of Mr. HOLMES COOTE in the *Medico-Chirurgical Transactions*, 1855, Vol. XXXVIII, p. 95, and the same writer, in *The Lancet*, 1861, Vol. I, p. 381. The four specimens referred to by Mr. COOTE are: two in St. Bartholomew's Museum, Series H, Sub. B, Nos. 22 and 50, one in the Musée Dupuytren, No. 636, and one in the Richmond Hospital Museum, Dublin, mentioned by Professor R. W. SMITH (*Dublin Jour. Med. Sci.*, 1842, Vol. XXI, p. 295).

<sup>4</sup> WAGNER (A.), *Ueber den Heilungsprozess nach Resection und Exstirpation der Knochen*, Berlin, 1853, S. 9.

<sup>5</sup> E. g., Colonel *Dulaney*, p. 566; Lieutenant W. L. Horton, 24th Massachusetts, p. 577; Lieutenant Rand, p. 520; Lieutenant *Bigger*, p. 554; Sergeant Smyser, p. 539; Sergeant Fisher, p. 566; Private Black, p. 547; Private Mahon, p. 528; Private Grant, p. 566, etc. Of the four hundred and seventy-one Union soldiers who recovered after excision at the shoulder, one hundred and eleven, or nearly one-fourth, returned to modified duty.

<sup>6</sup> OLLIER (L.) (*Des résections des grands articulations*, Lyon, 1869, p. 15, and *Traité expérimental et clinique de la régénération des os et de la production artificielle du tissu osseux*, Paris, 1867, T. II, Chapter VIII, p. 187). Consult, also: RACORD for a case of regeneration of the entire humerus, in *Gazette Médicale de Paris*, 1842, p. 639; LARGHI (*Réssection sous-périostée de 87mm. de la diaphyse humérale pour une ostéite suppurée*, in *Gazette Hebdomadaire*, 1858, No. 50); WAGNER (A.) (*op. cit.*, S. 9); BORELLI (*Cenni storico-pathologici intorno alle resezione sottoperiostée*, Torino, 1858); GIRALDÈS (*Bulletin de la Société de Chirurgie de Paris*, Avril 15, 1863).

<sup>7</sup> LANGENBECK (B. V.) (*Chir. Beob. aus dem Kriege*, Berlin, 1874, S. 140) relates that: "Lieut. v. Röhl, 35th Infantry, was wounded at Mars la Tour, August 16, 1870, by a Chassepôt ball, which passed through the upper third of the right humerus. He was taken to the residence of Dr. Petebgrand, at Gorze. On August 26th, seven pieces of bone were removed through the wound of entrance. On Sept. 14th, pyæmic symptoms appeared. September 16th, the head of the bone and portions of the shaft were excised, with complete preservation of the muscles of the scapula in conjunction with the carefully separated periosteum. In October, 1870, the patient was transferred to Berlin, under charge of Dr. GRETHUYSON, who had assisted Dr. LANGENBECK in the treatment at Gorze. During the journey, it became necessary to make several incisions into the lower part of the arm to allow the escape of pus. Lieutenant v. Röhl was admitted to the "Königin Augusta" Hospital at Berlin, in charge of Professor Dr. SCHÜNBORN. It soon became evident that the elbow joint was involved. About the end of November, Dr. SCHÜNBORN resected the elbow joint, and at the same time extracted the remaining epiphysis of the humerus, which had become necrosed. Dr. LANGENBECK continues: "In the fall of 1871, I saw v. Röhl in Berlin. The entire upper arm bone is completely regenerated, and forms a really strong bony shaft. The elbow joint is so perfect in form and function that you are compelled to inspect the plainly visible resection-cicatrix to convince yourself that the elbow joint has really been removed. Hand and forearm are capable of all motions and functions. \* \* In November, 1871, v. Röhl, from a severe fall on the street, suffered a transverse fracture of the newly-formed humerus just above the elbow. I immediately applied a gypsum bandage, which remained five weeks. On its removal the fracture had completely united. Similar accidents recurred in the spring of 1872 three times, the new bone being fractured in a different place each time—in the middle, at the end of the upper third, and at the beginning of the upper third, just below the new head of the humerus. Recovery ensued, the gypsum bandage being applied as before. In consequence of the arm being fixed continually, until the spring of 1872, in gypsum bandages, its use had been entirely lost. \* \* On May 24, 1873, six weeks after the removal of the last gypsum bandage, a careful examination gave the following result: the entire right extremity



these surgeons, do not appear to have been achieved; nor was the scooping out of the diseased head of the humerus, the *évidement des os*, commended by M. Sédillot,<sup>1</sup> resorted to in any reported instance. It is true that in the accounts of a few of the operations it is stated that care was taken to preserve as much of the periosteum as possible; but these were almost all instances of early excisions, in which the methodical separation of the periosteum is a very different task from its removal when inflamed and thickened and ready to peel away on the application of a slight force. The reported instances of partial restoration of bone are enumerated below.<sup>2</sup>

There were a few examples among the early fatal cases of detailed reports of the necroscopic appearances, no attempts at reparation having been observed.<sup>3</sup> In the infrequent instances of deaths at remote periods after the operation, the valuable opportunities for ascertaining the conditions of the parts appear to have been neglected,<sup>4</sup> which is the more to be regretted as science possesses so few precise facts on this subject.<sup>5</sup>

I have nothing further to add to the remarks that have been made on the mode of performing excision at the shoulder for injury, save that there is a tendency toward unanimity in accepting the single straight anterior incision, commended by Professor v. Langenbeck, as the best procedure, and that the position of the shot openings need not be much regarded.<sup>6</sup>

The results of the treatment of shot injuries of the shoulder by amputation at the joint have been so recently recapitulated, on page 655, that it is unnecessary to review them here, except for purposes of statistical comparison with the results obtained on other occasions.

Of the twenty-three hundred and sixty-nine *determined cases* referred to in the preceding tables, five hundred and seventy-seven (577) were treated by expectancy, with a mortality of 25.1 per cent.; nine hundred and fifty-one (951) by excision, with a mortality of 36.6 per cent.; eight hundred and forty-one (841) by amputation, with a mortality of 29.1 per cent.,—in all, seven hundred and thirty eight cases terminating fatally, or 31.1 per

appears a little smaller, probably because it had participated little, since August, 1870, in the progressive development of the skeleton. Especially noticeable is the smallness of the right scapula in all dimensions as compared with the left scapula. Less observable is this backwardness in the growth of the rest of the extremity, and the right forearm and hand appear even more strongly developed than the left. The right upper arm from the end of the acromion to the external condyle is nearly four centimeters shorter than the left, and its muscular development is inferior; the new bone is a little thinner, and the places of the four fractures are observable. \* \* The active mobility of the arm forward and backward is quite extensive. Patient carries the hand to the mouth, uses it for eating, for buckling his cravat; carries it to the back, etc."

<sup>1</sup> SÉDILLOT (CH.), *De l'évidement sous-perosté des os*, 1860, 2<sup>m</sup>e éd., Paris, 1867, and *Traité de médecine opératoire*, Paris, 3<sup>m</sup>e éd., 1865, T. I, p. 474.

<sup>2</sup> In CASE 1503, p. 529, Surgeon J. J. KNOTT, P. A. C. S., enclosed a letter from the patient, stating that there "was a mere gristle attaching itself to the shoulder and to the end of the bone about five inches down the arm." In CASE 1534, p. 562, Surgeon G. C. HARLAN, 11th Pennsylvania Cavalry, reported that "two and a half inches of new bone have been formed," five years after the operation. In CASE 1575, p. 589, Surgeon R. B. BONTECOU, U. S. V., reported that "a new shaft had supplied the part of the bone removed," this a few months after the injury. In the case of D. Gravel (TABLE XXXV, No. 13), the Examining Board at Detroit reported, nine years after the operation, "the bone has been reproduced."

<sup>3</sup> In CASE 1584, p. 596, Professor JOSEPH LEIDY examined the shoulder of a man who died thirteen days after an excision of the upper extremity of the left humerus, for a shot injury received eleven months previously, and found "no restoration of bone." Assistant Surgeon J. S. BILLINGS, U. S. A., examined, five days after the operation, a fatal case of internedial excision at the right shoulder and discovered "no attempt at repair in the wound."

<sup>4</sup> Among the five hundred and fifty-one survivors of this operation, twenty-five pensioners are known to have died at periods remote from the operations; but no account of an autopsy having been made is recorded in any instance.

<sup>5</sup> Dr. A. WAGNER (*On the Process of Repair after Résection and Extirpation of Bones*, HOLMES'S *Trans. New Syd. Soc.*, 1859, p. 119) informs us that he was able to find (in the year 1853) but five "examples of dissection of the human body after resection of the head of the humerus. Three of these belong to TEXTOR and two to SYME. (HUMMEL, *Ueber die Resection im Oberarmgelenk*, Würzburg, 1832; TEXTOR (C.), *Neuer Chiron.*, Thl. I, Stek I. 3; TEXTOR (C.), *Ueber die Wiedererzeugung der Knochen nach Resection bei Menschen*, Würzburg, 1843, S. 11; SYME (J.), *Treatise on the Excision of Diseased Joints*, Edinburgh, 1831, pp. 51, 58; *Contributions to Practical Surgery*, Edinburgh, 1848, p. 97.) The patients had survived the operation six months, six, ten, eleven, and nineteen years, respectively. The usefulness of the arm had been very great in all of them. \* \* SYME found in both of his patients,—who had died, one six months, the other ten years, after the operation,—the head of the humerus rounded off and united by a firm ligamentous tissue to the shoulder blade. TEXTOR, however, gives expressly two cases, six and eleven years after the operation, of formation of bone, which in the first appeared as a bony styloid prominence, resembling the styloid process of the ulna, directed upward, and in the second covered the upper end of the humerus, in the form of an uneven tubercular mass, about half an inch long." In the latter case, and in that of a patient who died nineteen years after the operation, TEXTOR found a meniscus-shaped, moveable, fibro-cartilaginous formation between the upper extremity of the bone and the glenoid cavity. In one only of the five cases, a new articular capsule appeared to have formed.

<sup>6</sup> MAYER (L.) (*Kriegschir. Mittheilungen*, in *Deutsche Zeitschrift für Chir.*, 1873, B. III, S. 70) says: "I agree with Socin, that the surgeon should not allow himself to be induced, by the location of the wound openings, to modify the position and direction of the incision of LANGENBECK'S method."

cent.<sup>1</sup> Let us compare these results with those of other wars of the last half century, when excision as well as expectation and amputation became a common alternative:

TABLE LIII.

*Showing the Mode of Treatment and Results of Injuries involving the Shoulder Joint on the Occasions named and from Authorities quoted.*

ACTION, ETC.	MODE OF TREATMENT.									
	EXPECTANCY.			EXCISION.				EXARTICULATION.		
	Recovery.	Fatal.	Total.	Recovery.	Fatal.	Undetermined.	Total.	Recovery.	Fatal.	Total.
Revolution in Paris, 1830 (II. LARREY <sup>2</sup> )	1	.....	1	.....	.....	.....	.....	1	1	2
Revolution in Paris, 1830 (MÉNIÈRE)	2	3	5	.....	.....	.....	.....	2	1	3
Siege of Antwerp (II. LARREY)	.....	1	1	.....	.....	.....	.....	6	2	8
Revolution in Paris, 1830 and 1848 (ROUX)	.....	.....	.....	.....	.....	.....	.....	3	3	6
Revolution in Paris, 1848, (JOBERT DE LAMBALLE)	1	1	2	.....	.....	.....	.....	1	1	2
French in Algiers (BAUDENS)	.....	.....	.....	.....	.....	.....	.....	2	.....	2
Revolution in Paris, 1848 (BAUDENS)	.....	.....	.....	.....	.....	.....	.....	1	.....	1
Peninsular War (ALCOCK)	.....	.....	.....	.....	.....	.....	.....	15	3	18
From Civil Life (ALCOCK)	4	.....	4	.....	.....	.....	.....	1	4	5
Algiers and other occasions (BAUDENS <sup>3</sup> )	4	8	12	13	1	.....	14	.....	.....	.....
Austrians in Italy, 1848-49 (BECK)	.....	.....	.....	1	.....	.....	1	3	1	4
War in Sleswick-Holstein, 1848-51 (STROMEYER, ESMARCU)	3	5	8	12	7	.....	19	7	3	10
French in Algeria, 1854-56 (BERTHERAND)	.....	.....	.....	1	.....	.....	1	8	4	12
Crimean War, 1854-56, Russians (HUBBENET)	.....	.....	.....	2	11	7	20	10	70	80
Crimean War, 1854-56, French (CHENU)	.....	.....	.....	18	24	.....	42	85	137	222
Crimean War, 1854-56, British (MATTHEW)	.....	3	3	13	3	.....	16	30	15	45
Italian War, 1859-60, French (CHENU)	.....	.....	.....	10	9	.....	19	36	30	75
Italian War, 1859-60, Austrians (DEMME)	14	29	43	17	9	.....	26	12	9	21
New Zealand War, 1863-65 (MOUAT)	.....	.....	.....	9	.....	.....	9	.....	.....	.....
Danish War, 1864, (LEFFLER)	1	6	7	17	18	.....	35	4	6	10
Prussians in Six Weeks' War, 1866 (STROMEYER, BECK, BIEFEL, MAAS)	4	4	8	7	6	.....	13	8	5	13
Army of the United States (Circular 3)	.....	.....	.....	2	.....	.....	2	2	1	3
Franco-German War, 1870-71, Germans (II. FISCHER, SOGIN, BECK, BILLROTH, RUPPRECHT, SÜCKE, SCHÜLLER, G. FISCHER, LOSSEN, STEINBERG, MEYER, HOPMANN, <sup>4</sup> ESTERLEN, KIRCHNER, KOCH, SCHNIZINGER, STUMPF, MOSETIG, GRAAF).	37	7	44	78	48	.....	126	29	15	44
Franco-German War, 1870-71, French (PANAS, COUSIN, CHRISTIAN, PONCEI, HERRGOTT, GROS, F., TACHARD, SÉDILLOT, GRELLOIS, <sup>5</sup> CHIPAULT, VASLIN, McCORMACK, EVANS).	16	19	35	15	20	.....	35	20	27	47
	87	86	173	215	156	7	378	286	347	633

Of the aggregate of 1184<sup>6</sup> cases about one-seventh were treated by expectant measures, with a mortality of 49.7 per cent.; one third by excision, with a mortality of 42.0 per cent.; and over one-half by exarticulation, with a mortality of 54.8 per cent. The death rate of the whole number of determined cases is 50.0 per cent.

<sup>1</sup> A total of twenty-three hundred and twenty-eight cases of shot injury at the shoulder are spoken of at the commencement of this Section. The scapulo-humeral articulation was believed to be primarily implicated in fourteen hundred of these, and involved consecutively, either by disease or operation, or both, in nine hundred and twenty-eight. To the twenty-three hundred and twenty-eight cases were added two hundred and one Confederate cases of excision, and fourteen scapulo-humeral amputations for complications of flesh wounds (from Section I, p. 468), or a total of twenty-five hundred and twenty-nine cases (2,529). Of these, nine excisions, twenty-five amputations, and one hundred and twenty-six of the added Confederate cases, or one hundred and sixty cases, were undetermined, leaving twenty-three hundred and sixty-nine (2,369) determined cases for analysis.

<sup>2</sup> LARREY (II.) (*Relation chir. des événements de Juillet, 1830*, pp. 75 and 78); MÉNIÈRE (*L'Hotel-Dieu de Paris en Juillet et Aout, 1830*, Paris, 1830); LARREY (II.) (*Hist. chir. du siège d'Anvers*, in *Rec. de mém. de méd.*, 1833, T. XXXIV, pp. 284-377); ROUX (*Des plaies d'armes à feu. Communications faites à l'Acad. nat. de méd.*, par MM. les docteurs BAUDENS, ROUX, etc., Paris, 1849, pp. 37, 38); JOBERT (DE LAMBALLE) (*Plaies d'armes à feu. See Comm. faites à l'Acad.* par BAUDENS, ROUX, etc., 1849, pp. 151-155); BAUDENS (L.) (*Clinique des plaies d'armes à feu*, Paris, 1836, pp. 542, 545).

<sup>3</sup> Reference to this and the succeeding authorities will be found in connection with TABLE XLI, p. 607 ante.

<sup>4</sup> HOPMANN, *Aus Vercinslazarethen der Jahre 1807 und 1871*, in *Deutsche Zeitschrift für Chirurgie*, 1873, B. II, S. 555.

<sup>5</sup> GRELLOIS (E.), *Histoire méd. du Blocus de Metz*, 1872, pp. 348 and 353.

<sup>6</sup> It would be easy to swell this statement by citing cases from earlier authors, such as those adduced in notes on pages 608 and 613, but these are frequently returns of successful cases only, and it seems fairer to quote those statistics professing some claim to completeness.



The high rate of fatality exhibited in TABLE LIII is mainly due to the excessive losses presented in most of the French reports. Whether these lamentable results are traceable to unfavorable hygienic conditions in the French military hospitals, managed by intendants,—as M. Sédillot believes,—to inferior power of vital resistance in the French soldiery, or to persistence in depletory measures in the after-treatment of operations,—as some critics aver,—the fact is certain that there is a startling disparity between the results of major operations as reported by French surgeons and those reported by the surgeons of Great Britain, Germany, and the United States.

Although Hutin had set a good example in recording the remote results of injuries in the inmates of the *Hôtel des Invalides*, and D. J. Larrey and Dupuytren bestowed much attention on the ulterior effects of surgical mutilations, no systematic census of the condition of the survivors of the wounds and injuries of war has, until recently, been attempted. The English returns of the Crimean and Indian pensioners were fragmentary. In M. Chenu's Crimean and Italian narratives, the cases were dropped as soon as pensioned. Until I met Professor Hannover's work on the Danish invalids of the war of 1864, I thought that the initiative in this difficult task had been undertaken by this Office. The path opened by Professor Hannover has been further explored, and the appended table presents a limited number of facts on the subject collected by German and English authors:

TABLE LIV.

*Tabular Statement of One Hundred and Fifty Invalid Pensioners recovered from Shot Injuries implicating the Shoulder Joint, and treated either by Expectation, Excision, or Amputation.*

INSPECTORS OR REPORTERS.	TREATMENT.			TOTALS.
	EXPECTATION.	EXCISION.	AMPUTATION.	
Hannover <sup>1</sup> (Danish War).....		15	1	16
Mossakowski <sup>2</sup> (Franco-German War).....	17	6	5	28
Seggel <sup>3</sup> (Franco-German War).....		16	.....	16
Klewitz <sup>4</sup> (Franco-German War).....		6	.....	6
Kratz <sup>5</sup> (Franco-German War).....		33	.....	33
Berthold <sup>6</sup> (Franco-German War).....	11	5	1	17
Langenbeck <sup>7</sup> (Franco-German War).....	9	12	.....	21
Eilert <sup>8</sup> (Franco-German War).....		3	.....	3
Longmore <sup>9</sup> (Sepoy Mutiny, 1857-58).....		1	9	10
	37	97	16	150

It will be observed that the number of invalids surviving excision largely predominates over the combined numbers of those recovering after expectant treatment and amputation; and, when compared with the scanty records that have come down to us of the pension asylums in the early part of the century, this and the preceding table indicate a

<sup>1</sup> HANNOVER (A.), *Die Dänischen Invaliden aus dem Kriege*, 1864, in LANGENBECK'S *Arch. für Klin. Chir.*, B. XII, p. 386, 1870.

<sup>2</sup> MOSSAKOWSKI (P.), *Statistischer Bericht über 1415 französische Invaliden des deutsch-franz. Krieges*, 1870-71, in *Deutsche Zeitschr. für chir.*, 1872, B. I, p. 321.

<sup>3</sup> SEGCEL, *Resultate der während des Krieges von 1870-71 ausgeführten Gelenkresectionen*, in *Deutsche Militärärztl. Zeitschrift*, 1873, B. 2, S. 315.

<sup>4</sup> KLEWITZ, see SEGCEL, *ante*.

<sup>5</sup> KRATZ, *Resultate der während des letzten Feldzuges ausgeführten Gelenkresectionen*, in *Deutsche Militärärztl. Zeitschrift*, 1872, B. I, S. 399.

<sup>6</sup> BERTHOLD, *Statistik der durch den Feldzug 1870-71, invalide gewordenen Mannschaften des 10. Armee-corps*, in *Deutsche Militärärztl. Zeitschrift*, 1872, B. I, S. 469.

<sup>7</sup> LANGENBECK (B. V.), *Chirurgische Beobachtungen aus dem Kriege*, Berlin, 1874.

<sup>8</sup> EILERT, *Resultate der während des Krieges von 1870-71 ausgeführten Gelenkresectionen*, in *Deutsche Militärärztl. Zeitschrift*, 1873, B. 2, S. 536.

<sup>9</sup> LONGMORE (T.), *Resection of the Shoulder Joint*, in *Stat. San. and Med. Reports of the British Army Med. Dept.*, 1863, Vol. V, p. 562.

great diminution in the frequency of recourse to exarticulation for shot injuries of the shoulder. It has been claimed by Professors Hannover, v. Langenbeck,<sup>1</sup> and others, that the ulterior results are better after successful expectant treatment than after excisions at the shoulder. At page 505 *et seq.* many examples are adduced that lead some of our surgeons to share in this view. This may be conceded without detracting from the inestimable value of excisions at the shoulder,<sup>2</sup> which finds its application in cases in which expectant measures are utterly inadmissible.<sup>3</sup> Professor Hannover is undoubtedly in error in contending that remote amelioration after excisions for injury rarely or never occurs. I have under personal observation more than a score of pensioners in whom progressive improvement has continued for ten or twelve years after excision at the shoulder for shot fracture; and in several of them all the functions of the upper arm except abduction have become nearly perfect. Indeed, the testimony on this point is cumulative,<sup>4</sup> and will doubtless be fully put in evidence in an exhaustive treatise on the subject, now in preparation by Professor Gurlt, of the University of Berlin.<sup>5</sup>

A pamphlet on excisions, circulated during the war for the instruction of medical officers in the field,<sup>6</sup> contains the precept that "excisions of the larger joints should never be practised on the battle-field." I must utterly dissent from this dictum of the distinguished authors, and further demur to the assertion that "statistics show that secondary

<sup>1</sup> LANGENBECK (B. V.) (*Chirurgische Beobachtungen aus dem Kriege*, Berlin, 1874, S. 114) observes: "In regard to the value of the resection of the shoulder joint, as compared with the expectant mode of treatment, surgeons, who have examined invalid pensioners, generally arrive at the conclusion that better results are obtained by the conservative mode of treatment than by resection." HANNOVER (A.) (*Die Dänischen Invaliden aus dem Kriege*, 1864, Berlin, 1870, S. 35) remarks: "Among our men, we have never seen amelioration at a remote period [after excision]. Their condition either remained unchanged, or deteriorated in a high degree; so that the resected arm proved to the invalid a burthen and a hindrance. Whether this unfortunate result was due to the improper selection of subjects and modes of operation or to the after-treatment is difficult to decide. Evidently the conditions are different in shot wounds and in chronic disease." Dr. LOEFFLER, on the other hand, is a staunch advocate of the superior end-results of excisions (*Langenbeck's Archiv für Klinische Chirurgie*, 1871, B. XII, S. 319), and seeks to controvert Professor HANNOVER'S statements.

<sup>2</sup> LANGENBECK (B. V.) (*Chirurgische Beobachtungen aus dem Kriege*, Berlin, 1874, S. 156) sums up his conclusions regarding the comparative value and indications of treatment by expectation, excision, or amputation, in shot injuries at the shoulder, as follows: "1. All less severe shot injuries of the shoulder joint justify the attempt at expectant treatment, under the presumption that in many of these cases secondary resection will become necessary. 2. All extensive shot fractures of the shoulder joint indicate primary resection. 3. Crushing of the shoulder joint with laceration of the soft parts does not, of itself, indicate exarticulation, but secondary resection. 4. The aim of the conservative treatment is to avoid ankylosis, to restore mobility to the joint. 5. Ankylosis at the shoulder joint having supervened, the usefulness of the arm may be improved by secondary resection of the head of the humerus. 6. The formation of a new shoulder joint with voluntary motion will be most readily secured by subperiosteal resection. 7. After subperiosteal resection the most careful after-treatment is required to restore useful joints. 8. A gradually increasing deterioration, through increasing atrophy of muscles, does not occur after resection of the head of the humerus. The so-called *lähmungsartige Zustand* (lame-like condition) is nothing but paralysis from inaction. 9. The paralysis caused by want of exercise can be removed by appropriate treatment even a long time after resection, and the usefulness of the extremity may afterward be re-established." SCHÜLLER (M.) (*Kriegs-chir. Skizzen aus dem deutsch-französischen Kriege*, 1870-71, Hannover, 1871, S. 38) remarks: "In shot wounds of the shoulder joint generally resection is preferable to expectant treatment. By the removal of the voluminous head the suppurative process is considerably diminished, in the first place because the suppurating surface is contracted, and, in the second place, the patient escapes the tedious process of eliminating the necrosed fragments."

<sup>3</sup> BILLROTH (TH.) (*Chirurgische Briefe aus den Kriegslazarethen*, u. s. w., Berlin, 1872, S. 217) says: "We would undoubtedly be justified, from the end-results of the shoulder excision, to ponder the question whether this operation might not be more frequently avoided. For my own part, I have learned to value the life-saving results of this operation yet higher, and find that we cannot sufficiently thank the men who introduced this procedure into the surgery of war."

<sup>4</sup> Even Dr. NEUDÖRFER, who is an advocate of deferred or secondary excisions for injury, in a paper he has had the kindness to send me (*Die End-resultate der Gelenkresektionen*, extracted from the *Wiener Medizinische Presse*, 1871), concedes the amelioration of the functions of the arm after excisions at the shoulder. "What," he enquires, "are the results of favorably ending joint-suppurations under the expectant conservative treatment? The question may be in general answered that traumatic suppurative of the joint, as well as that from pathological causes, is only very rarely cured with complete motion of the joint. If, therefore, resection is indicated, it is justifiable in all cases where suppurative threatens the life of the patient; but the peril, the jeopardy to life must have begun, the suppurative of the joint in itself not necessarily imperilling life." This position will be regarded by many as untenable; but, on the point at issue, Dr. NEUDÖRFER, after citing a case of shoulder excision for shot injury, adds: "Yet to-day, ten years later, the result is the same as early after recovery, indeed the present condition is even better than then, as, at the last examination, I found that sensation in the parts to which the ulnar nerve is distributed was partially restored."

<sup>5</sup> Professor GURLT writes me, May 5, 1874: "I am occupied in making up the history and statistics of all the resections of joints that have been made for gunshot wounds since the wars at the end of the last century. My purpose is not only to elucidate some points in the history of these operations that have been partially forgotten, but principally to point out the ultimate results of these resections many years after their execution, a subject almost unexplored till now. Almost all the publications on this subject have been made up a short time subsequently, the results being recorded a year or two later than the operation, and when the restoration of the functions of the limb was incomplete. Thus it was that the publication of Professor Hannover, of Copenhagen, on the miserable state of the Danish invalids, excised by Prussian surgeons in the Dano-Prussian war of 1864, produced a painful impression, which was by no means lowered by the observations printed after the Franco-German war regarding the condition of the invalids who had undergone resection. Fortunately, we now know that the results have greatly improved after the limbs have been for some years in constant use. This I intend to prove by as many examples as possible, derived from all available sources. I have been enabled to collect information of the ultimate results and present condition of invalids with joint resections, in the Schleswig-Holstein campaigns (24-26 years ago), of the Dano-German war of 1864, and some others . . ."

<sup>6</sup> *A Report on the Subject of Excision of Joints for Traumatic Cause*, by Drs. HAYWARD, TOWNSEND, WARE, J. M. WARREN, CABOT, DALE, and HORTON, Cambridge, 1862.



excisions are more successful than primary in the proportion of 17 to 10," as unfounded on reliable data, and in flagrant contradiction with the real facts. I regard the recommendation of deferred operations as pernicious, and believe that, in the light of our present experience, it will never gain a foothold among military surgeons.

In regard to *partial* excisions of the head of the humerus, important evidence has been presented (p. 526-8) in confirmation of that precept of Baudens: *En principe il faut limiter la résection à la lésion et respecter le plus possible le tissu osseux.* The late Medical Director Hewit and Drs. Bontecou, B. Howard, Armsby, and W. Thomson especially advocated and exemplified the utility, under some circumstances, of partial excisions of the epiphysis.<sup>1</sup>

In 1862, excision at the shoulder was practised in the proportion of 2.3 in a thousand cases of shot injuries returned; in 1863, in 3.4 per thousand; in 1864, in 4.4 per thousand; in 1865, in 4. per thousand.

The facts that have been adduced in this Section appear fully to warrant the conclusions—1. That in slight shot injuries of the shoulder joint an expectant conservative treatment is justifiable.<sup>2</sup> 2. If a ball is impacted in the head of the bone, or if the epiphysis is much comminuted, unless there is injury to the blood-vessels and nerves, or very grave injury of the other soft parts, primary excision should be practised. 3. Concomitant fractures of the acromial end of the clavicle, or of the neck or processes of the scapula, or of the upper third of the shaft of the humerus, do not necessarily contraindicate excisions at the shoulder.<sup>3</sup> 4. Intermediary excisions should seldom or never be practised. If, in an attempt at expectant conservative treatment, intense suppurative inflammation arises, it should be combated by free incisions, drainage, emollient applications, etc., and every endeavor should be made to avoid inflicting another wound upon the inflamed medullary tissue, and to await the secondary stage, before undertaking operative interference.<sup>4</sup> 5. The after-treatment of securing comparative immobility and support of the limb and efficient drainage of the wound; and the ulterior after-treatment of judicious passive and active movements of the arm, are of essential importance in restoring the functions of the member. 6. Primary

<sup>1</sup> BAUDENS (O.) (*Comptes-rendus de l'Académie des Sciences*, Paris, Février 26, 1855, and *Recueil de Mem. de Méd. Mil.*, 2ème sér., T. XV, p. 180) says: "D'après ce principe il nous est arrivé de n'extraire que la moitié de la tête de l'humerus, ce qui n'avait jamais été fait encore, que nous sachions." HEWIT (H. S.) (*Appendix to Part I of Med. and Surg. Hist. of War of the Rebellion*, 1870, p. 312) remarks: "Partial excisions of the head of the humerus is a safe and successful operation. \* \* Scapular motion makes great compensation for ankylosis, and it is frequently better to accept this result, rather than to incur the risk to life of the more brilliant procedure of complete excision." See also PINKNEY (N.), *Am. Jour. Med. Sci.*, 1846, Vol. XII, p. 330.

<sup>2</sup> GEISSEL (R.) (*Kriegschirurgische Reminiscenzen von 1870 bis 1871*, in *Deutsche Zeitschrift für Chirurgie*, B. V, 1874-5, S. 36) remarks: "With VON LANGENBECK, I believe in accepting, as a practical rule, that all slight injuries of the shoulder joint \* \* justify the attempt at conservative surgery, with an anticipation of intermediary or secondary resection if necessary; but all extensive shot fractures indicate primary resection. If an expectative treatment has been resolved upon, under all circumstances an active mobile joint should be aimed at by early gymnastic exercise. Should, nevertheless, ankylosis supervene, the attempt may be made to obtain an active mobile joint by resection." Dr. GEISSEL relates the case of P. Dorweiber, wounded at Gravelotte, August 18, 1870; resection of head and three inches of diaphysis three days afterward. This man was examined four years afterward. No new bone-formation was found, but Dr. GEISSEL thinks the case confirms the opinion given by VON LANGENBECK, that results once achieved after resection of the joints will not be subsequently lost under judicious active after-treatment, and controverts the opinion of HANNOVER, of Copenhagen, that the end-results of joint resections deteriorate from year to year." The italics are by the editor.

<sup>3</sup> As this sheet is going to press, I have received an interesting monograph (*Die Resultate der Gelenkresektionen im Kriege*, Giessen, 1874) by Dr. E. BERGMANN, professor of surgery at Dorpat, and one of the surgeons of the great military hospitals at Carlsruhe and Mannheim during the war of 1870-71. He fully describes 15 intermediary and secondary excisions at the shoulder, with 12 recoveries. These and other successful resections are beautifully illustrated by Albertotype plates. Active mobility of the joint "in all directions" was achieved in one case, the patient declaring that he "could lift the arm upward to the top of the head, sideward to the top of the shoulder, and revolve the arm in a circle, without pain." In another case (Fall 23, S. 18, B. Geng, 6th Bavarian Infantry, wounded at FÉVAL, by shell, October 6, 1870), part of the scapula was removed on the third, and the head and part of shaft of humerus on the thirteenth day. "All the soft parts on the outer posterior arm, with a portion of the acromion and spine of scapula, were so completely torn away that the fractured acromial process and the fissured head of the humerus were plainly visible. Abscesses formed in the course of the treatment, \* \* and even gangrene supervened. Nevertheless, a result was obtained that leaves nothing to be desired. The muscles are splendidly restored, as is shown in Plates IX and X. \* \* Since Langenbeck, in 1866, saved, by resection, the arm of —, in a case where all the surrounding parts, with the exception of the large vessels and nerves and the triceps and latissimus muscles, were torn away, and even enabled the patient to re-enter the military service, to ride horseback, and carry the sword with the right (the resected) arm, this case is the most notable example that shot fracture of the shoulder joint with extensive laceration of the soft parts does not indicate primary amputation."

<sup>4</sup> In all three stages, statistics of large aggregates teach that the risk of excision at the shoulder is a little in excess of ablation of the limb at the joint. Thus, in our experience, the fatality of excisions was P, 31.06, I, 46.4, S, 29.3; of amputations, P, 24.1, I, 45.8, S, 28.7. M. CHENU (*Aperçu hist.*, etc., Paris, 1874, T. I, p. 492) reports 325 exarticulations at the shoulder with 207 deaths, or 63.69 per cent., and 819 excisions with 226 or 70.85 per cent.

exarticulation of the arm at the shoulder is imperative in cases of shot lesions of the upper extremity of the humerus attended by injury of the axillary vessels and nerves, or by very grave injuries of the other soft parts in the vicinity of the joint; and may also be demanded when fractures of the humerus involving the shoulder are conjoined with severe injuries lower down in the limb. Circumstances may also justify primary ablation of the arm when there is little injury to the soft parts and the epiphysis is untouched, if the humerus be so extensively shattered downward as to forbid excision, and fissures extend so near the joint that section of the bone in its continuity cannot be practised without danger of arthritis. Intermediary exarticulation at the shoulder may be required in cases of hæmorrhage, gangrene, or osteomyelitis; and secondary exarticulations for the same causes, and also for complete necrosis of the humerus.

---

#### SECTION IV.

#### INJURIES OF THE SHAFT OF THE HUMERUS.

It is proposed to consider in this place only injuries inflicted by weapons of war, and to relegate the instances of simple and compound fracture, produced by other causes, to the Chapter specially devoted to those subjects, in the *Third Surgical Volume*. As there were no reported instances of sword or bayonet injuries of the humerus, the Section will be wholly occupied by discussions of the reports of shot fractures of the shaft involving neither joint, and of the operations performed in the continuity of the upper arm. In a statistical point of view, the classification will often seem arbitrary, and the estimates cannot be otherwise than approximative. The summing up of the injuries and of the operations will not accord. It has been seen, in the last Section, that excisions and amputations at the shoulder joint were not infrequently practised for injuries attended by fractures strictly limited to the diaphyses. In this Section, many examples will appear of amputations through the shaft of the humerus for shot lesions of the elbow joint or of the forearm. This explanation is essential to a just appreciation of the discrepancies in the numerical statements of the shot fractures and operations involving the shaft of the humerus. Although much labor has been expended in the analysis of the cases of this group, their number and complexity is such, that precision in presentation could only be attained at the cost of long and tiresome iterations. At least eight thousand two hundred and forty-five cases are comprised in the category, the shot fractures of the shaft complicated by fractures of the shoulder or elbow joints being excluded. Of this large number, many were attended by flesh or penetrating wounds of the thorax, or by grave, and sometimes by multiple, injuries in other parts of the body. Through tabular statements, an effort is made to indicate the distribution of these instances of multiple injuries, which have been, or will be, referred to elsewhere. The Section is naturally divided into enquiries regarding the nature and extent of the fractures, the operations undertaken, and the complications of the injuries and operations, and will be subdivided into analyses of cases dealt with on the expectant conservative plan, of those treated by excision, and of those subjected to amputation. A general summary will be premised.



TABLE LV.

*Tabular Statement of Eighty-two Hundred and Forty-five Shot Fractures of the Shaft of the Humerus unattended by Primary Injury of the Shoulder or Elbow Joints.*

SUBDIVISIONS.	Cases.	Duty.	Discharged.	Undetermined.	Died.	Mortality of Determined Cases.
1. Treated by Expectation.....	3,005	1,055	1,454	45	451	15.2
2. Followed by Amputation at the Shoulder.....	606	64	370	21	151	25.8
3. Followed by Amputation of Upper Arm.....	3,685	430	2,223	259	773	22.5
4. Followed by Excision of Head and Portion of Shaft of Humerus....	245	28	141	4	72	29.8
5. Followed by Excision of Shaft of Humerus.....	632	87	353	28	164	27.1
6. Followed by Excision of Portion of Shaft, with the Elbow Joint....	8	3	4	0	1	12.5
7. Followed by Excision in the Shaft and Consecutive Amputation at the Shoulder.	15	0	4	0	11	73.3
8. Followed by Excision in the Shaft and Consecutive Amput'n of Arm.	49	3	30	0	16	32.6
Aggregates.....	8,245	1,670	4,579	357	1,639	20.7

The results of three hundred and fifty-seven of these cases could not be traced. Of the seventy-eight hundred and eighty-eight cases with ascertained results, above tabulated, it will be observed that little more than one-fifth terminated fatally; and if the cases complicated by grave injuries of the trunk or lower extremity were eliminated, the percentage of mortality would be yet further reduced. Two hundred and thirty-six cases furnished the Museum with pathological specimens.<sup>1</sup>

Two hundred and forty-five cases, in which excisions of the head or head and upper part of shaft of the humerus were excised, have already been examined, and also six hundred and twenty-one cases treated by scapulo-humeral amputation, leaving somewhat over seven thousand cases for consideration. These will be analyzed in the following order: Cases treated by 1st, expectant conservative measures; 2d, by excisions in the continuity; 3d, by amputations in the shaft.

**EXPECTANT CONSERVATIVE MEASURES.**—Three thousand and five cases of shot fractures limited to the shaft of the humerus, treated on the expectant conservative plan, are found on the returns. It is probable that many of the cases reported as excisions in the continuity really belong to the category now under consideration; but the indications of the reports have been followed in tabulating the cases. In forty-five instances, it was impracticable to trace the results. Of the remaining twenty-nine hundred and sixty-patients, nearly a third returned to modified duty; nearly half of the whole number were discharged; and somewhat over a seventh, or four hundred and fifty-one, died. The mortality rate is not large; but, obviously, the least severe cases were selected for treatment by expectant measures. The extent of the shot injuries, the varieties they presented in different portions of the shaft, the attendant and consequent complications, the details of treatment, and the causes of fatality will all claim attention.

**Shot Contusions and Partial Fractures of the Shaft of the Humerus treated by Expectation.**—According to the reports, injuries belonging to either of these groups, unless

<sup>1</sup> These are distributed as follows: Thirty-six specimens, 7 from cases of recovery and 29 from fatal cases treated on the expectant plan; 41 instances, 21 successful and 17 fatal, from amputations at the shoulder; 80 specimens from amputations of the arm, 51 successful, 29 fatal; 37 from excisions of head and part of shaft, 21 successful, 16 fatal; 30 specimens from excisions in the shaft, 19 recoveries, 11 *post-mortem* specimens; 1 specimen from a recovery after an excision of a portion of shaft with the elbow joint; 4 specimens from fatal cases of excisions in the shaft with anterior amputation at the shoulder; 7 specimens, 4 from successful and 3 from unsuccessful cases of excision in the shaft followed by amputation of the arm.

they resulted favorably and escaped recognition, were exceedingly rare. Unquestionably, opportunities of demonstrating such lesions after death, or after excision or amputation, were very infrequent. The Museum possesses but two examples in the humerus of those illustrations of the effects of shot contusion, characterized by a thin elliptical exfoliation or by a slight superficial caries, associated with signs in the cancellated tissue of suppurative osteomyelitis, of which instances are not uncommon in the femur, tibia, and cranial bones. It may be remarked also that Surgeon John A. Lidell, U. S. V., who made a special study of shot contusions of the long bones, and has published a valuable monograph<sup>1</sup> on the subject, does not adduce a single instance of contusion of the humerus. There are several specimens of missiles in the Museum slightly flattened by impact on the shaft of the humerus, from cases of recovery, where it was supposed that the humerus was contused or at most only partially fractured.<sup>2</sup> It is probable that some cases of necrosis after shot wounds of the upper arm, in which fractures were not discovered at the date of injury, were instances of grazing shots or contusions of the humerus. The following is an example:

CASE 1612.—Corporal A. M. A—, Co. B, 16th Michigan, aged 27 years, was wounded at Poplar Grove Church, September 30, 1861. From a Fifth Corps hospital he was admitted, on October 7th, to Harewood Hospital. Surgeon R. B. Bontecou, U. S. V., recorded: "Gunshot wound of left arm, upper third. Discharged from service March 6, 1865." Examiner J. Nichols, of Washington, D. C., on May 2, 1835, certified: "Gunshot wound of left humerus, with compound fracture; abscesses have formed; limb now greatly swollen and inflamed; flesh wound extensive and yet unhealed; gangrene attacked the wound, destroying a large portion of soft tissue." Dr. D. Stanton, of New Brighton, Pennsylvania, late surgeon U. S. V., on March 15, 1835, forwarded the specimen, represented in the annexed wood-cut (FIG. 500), to the Museum with the following history: "A minié ball passed through the upper third of the left arm and side, grazing the humerus. Hospital gangrene commenced in the wound on October 20th, at Harewood Hospital, which was arrested by the use of bromine, turpentine, &c., after having exposed four inches of the bone. The patient was admitted to the Massachusetts General Hospital, at Boston, in May, and a small scale of bone was removed by Drs. Bigelow and Clarke. He reported to me in Detroit, Michigan, in October, 1835. I made an incision four inches in length, enlarged the sinus in the new bone, broke off about an inch from the upper end of the sequestrum, when I was enabled to remove the remaining portion, three and a half inches in length. At last report (February 5th), the wound had almost healed and the arm was improving rapidly." The pensioner, in his application for increase, on July 9, 1836, states "that his arm is completely disabled, it being impossible to straighten his elbow, and that his shoulder joint is also stiff and he cannot use it." In another application, on October 3, 1871, he states: "The wound is now a running sore; four inches of bone were taken out soon after the reception of the wound, and last year a piece of bone was discharged." Drs. G. K. Johnson and S. R. Wooster, of the Examining Board at Grand Rapids, Michigan, January 3, 1872, certify: "Wounded by a musket ball in upper third of left arm, causing a flesh wound. Gangrene followed, with destruction of soft tissues and death of bone, three and a half inches of shaft of humerus being removed. There is now a slight union by the formation of new bone, with positive evidence of dead bone still remaining, the wound never having been entirely healed. The bone at the place of injury is covered only with skin for a space of three inches, which is adherent to the bone. No muscular or cellular tissue. There is increased disability because of the extent of death of bone, which still continues. Applicant can use his arm a little in feeding and dressing himself," &c. The same Board, with the addition of Drs. Z. E. Bliss and E. Boice, reported, September 12, 1873: "Ball entered upper third of left arm, injuring the bone, and, passing around, wounded back just below posterior border of left axilla. Gangrene followed, with destruction of soft tissues and death of bone. There is now complete continuity in shaft of humerus, with extensive adhesions of skin to bone, and loss of muscular tissue." The disability was rated total, and the pensioner was paid December 4, 1873.

Dr. R. B. Bontecou states that he has "observed *several* cases of death from pyæmia resulting from shot contusions of the humerus and the femur, and, in looking over a mass of manuscript, found a history of a case." Dr. Bontecou also contributed to the Museum the beautiful specimens (Nos. 6309, 6312) of shot contusion of the humerus represented



FIG. 500.—Cylindrical sequestrum from shaft of left humerus after necrosis from shot injury. Spec. 2434.

<sup>1</sup> LIDELL (J. A.), *On Contusion and Contused Wounds of Bone, with an Account of Thirteen Cases*, in the *Am. Jour. Med. Sci.*, 1865, Vol. L, p. 17.

<sup>2</sup> Namely: Spec. 4571, "a wafer-like fragment of a spherical ball extracted after flattening against the left humerus" (*Cat. Surg. Sect.*, 1866, p. 601); case of Pt. J. Stephens, 2d Massachusetts. He was wounded August 9, 1832, at Slaughter's Mountain, and died September 7, 1832, at Annapolis, of pyæmia. Spec. 4116, "a buckshot flattened against the humerus without fracture" (*Cat. Surg. Sect.*, 1863, p. 537); case of Pt. J. Pranel, 45th Pennsylvania, who recovered without complications. Spec. 4124 (see CASE 1514). Spec. 455, "a conoidal ball laterally flattened; the side next the bone is comparatively smooth, and retains a fragment of fascia or periosteum" (*Cat. Surg. Sect.*, 1863, p. 615); it was lodged in the middle of the arm without fracturing the humerus. Spec. 2751, "a conoidal ball with two portions smoothly cut off the body and base at an obtuse angle to each other" (*Cat. Surg. Sect.*, 1836, p. 616); Pt. C. C. Colo, 39th Massachusetts. This ball was found lying between the brachial and the middle of the right humerus, in contact with the bone, but no apparent fracture was detected.



in PLATE L, opposite. The specimens are from soldiers who died in Harewood Hospital, in 1864, from pyæmia, a few weeks after shot perforations of the right arm by musket balls, which must have grazed the humerus.<sup>1</sup>

We are indebted to the veteran Professor Louis Stromeyer for the first clear account of shot contusions of long bones.<sup>2</sup> Since this form of injury was described by him, it has received much attention from writers on military surgery.<sup>3</sup>

*Partial Shot Fractures.*—Specimens of partial fractures from small projectiles, though unusual, since such injuries are ordinarily reparable, are less infrequent in cabinets than illustrations of the effects of contusions. The Museum has a few examples :

CASE 1613.—Private Albert C—, Co. K, 6th Cavalry, aged 23 years, was wounded at Petersburg, April 1, 1863. On April 8th, he was admitted into Lincoln Hospital. Surgeon B. B. Wilson, U. S. V., reported: "The patient was a man of strong, plethoric habit, and in good condition; his mind was inclined to despondency. He had received a gunshot wound of the right shoulder, the ball entering in front of the joint, passing through, and was cut out posteriorly; the missile was a minié ball. Exploration with the finger discovered shattered fragments of bone, being either the head, or near the head, of the humerus. The soft parts were very much inflamed, and the whole arm was swollen; the discharge was healthy pus, slightly tinged with blood at first, but soon resumed its natural color and flowed freely. The arm was bandaged, and cold-water dressings were applied. At a consultation of surgeons to consider the propriety of resection, it was decided to wait for the inflammatory action to subside before operating. The patient continued to do well, the swelling subsiding, and the whole system becoming more comfortable until May 10th, when erysipelas set in and spread rapidly, going nearly to the median line both on the breast and back, and down the arm half way to the elbow. It was ushered in by a chill and accompanied by severe constitutional symptoms. Tincture of chloride of iron in doses of twenty drops was administered every two hours, and liniment of linseed-oil and lime-water applied locally. The inflammation ceased to spread twelve hours after the administration of the first dose of iron, and in a week the complications had disappeared. The discharge was suppressed during the attack. On April 29th, pyæmia was ushered in by a severe chill, followed by an exhausting sweat, the latter continuing with intermissions up to the time of the patient's death. One, two, or three of these chills occurred every day; the face and entire body became icteroid; there was pain in the right lung, with dyspnœa; the mind was dull, and the prostration was very great. The treatment consisted of the administration of quinine to the extent of forty grains per day, with capsicum and brandy freely, and beef essence. The diarrhœa and vomitings were treated with morphia. The patient died on the 4th of May. Autopsy eleven hours after death: Rigor mortis slightly marked; icteroid appearance of the whole body. There were small pyæmic abscesses at the apex of the right lung, which was also considerably collapsed by pressure of an effusion in the right pleural cavity, consisting of serum, fibrin, and pus intermixed. In the left pleural cavity four ounces of a similar effusion were found. In the middle lobe of the left lung were seventeen small pyæmic abscesses. The heart was normal, but contained fibrinous clots. The liver was honey-combed with pyæmic abscesses, one of which, in the superior portion of the right lobe, contained eight ounces of pus. The left kidney contained small abscesses in its substance, which opened into its pelvis when incised; there was a small abscess in the areolar tissue around the right kidney; the kidney was otherwise normal. The shoulder joint was not opened as had been anticipated, the ball having made a groove through the shaft of the humerus joint at the internal insertion of the capsular ligament, partially dividing that insertion and laying open the cancellated structure of the head. The joint was healthy, as was also the medullary canal of the humerus." The fractured portion of the humerus (FIG. 501) was contributed to the Army Medical Museum by Dr. Wilson.

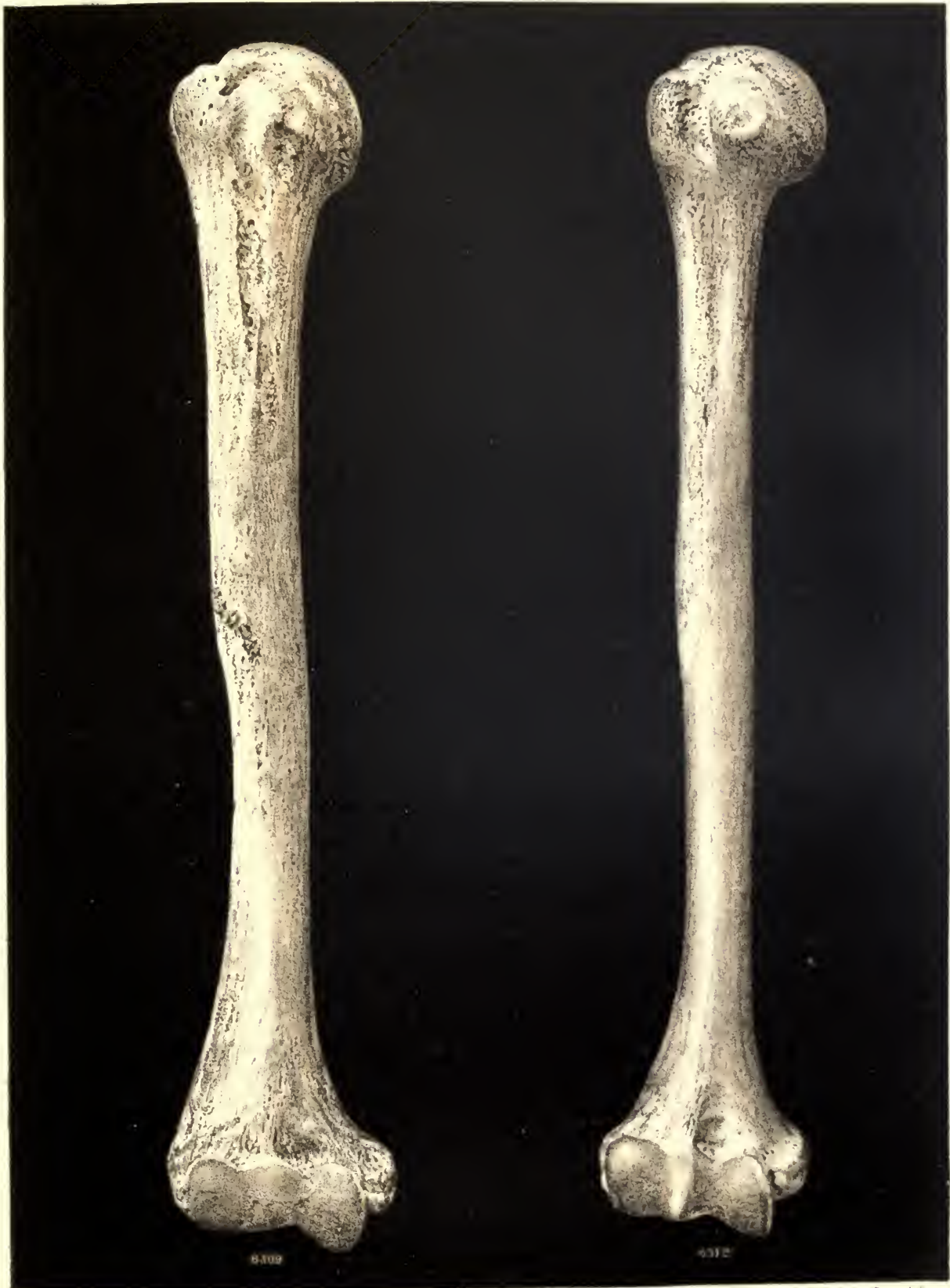

FIG. 501.—Upper extremity of the right humerus partially fractured by a musket ball. Spec. 3807.

<sup>1</sup> DR. BONTECOUR'S reported case was one of shot contusion of the femur, and will appear in the next Chapter; but his recollection of examples of contusions of the humerus resulting in fatal pyæmia is important. Of the case which furnished *Specimen* 6309, nothing more has been learned than is stated in the text: *Specimen* 6312 is from the case of Corporal N. J. E—, Co. II, 8th New York Artillery (CASE 5, TABLE XIV, p. 468). The fact of a bullet grazing the humerus was undiscovered when the case was classified as a flesh wound.

<sup>2</sup> STROMEYER (L.), *Ueber die bei Schusswunden Vorkommenden Knochen-Verletzungen*, Freiburg, 1850, S. 3: "Sie trifft den Knochen," u. s. v.; or, as Mr. S. F. Statham translates: "They strike the bone without breaking it, and flatten themselves against its surface; the bone struck becomes necrotic from the destruction of its periosteum. In crowded hospitals such injuries of the larger long bones cause suppuration of the medullary canal, which, extending itself, at last, by the passage of pus into the veins, gives a fatal termination. In the autopsy (the bone being sawn in its long axis) the marrow is found filled with pus from the wounded part upward, and the same morbid product in the neighboring large veins; as in the femoral vein after contusion of the femur. The spot struck by the ball is colorless and exsanguine; in its circumference appears the commencement of a line of demarcation. Contusions of this kind, which, up to the present time, have been little attended to in the long bones, are well known in the bones of the skull, where caused by a blow or fall; they have the same dangerous consequences if not properly treated, as suppuration occurs in the diploe and purulent inflammation in the sinus, with its usual results. Such contusions also occur in the cranial bones, if a bullet strikes at a right angle, of which I have seen many examples, where it could be determined, from the character of the wound in the soft parts, that the same had been so struck, without causing fracture or depression of the bone."

<sup>3</sup> BECK (B.) (*Chirurgie der Schussverletzungen*, Freiburg, 1872, p. 66) cites two cases of shot contusions of the humerus. In one case the wound healed without complication and without necrosis, but the arm was still emaciated and powerless at an examination ten months after the injury, invalidating the patient: in the other case, the missile passed through the upper third and contused the bone. The wound healed well, but free motion of the arm in the shoulder joint remained impaired and the bone remained thick up; the patient was also invalided. SOGIN (A.) (*Kriegschir. Erf.*, 1872, S. 106) tabulates three cases of contusion of the shaft of the humerus. Two were treated on wire splints. The patients recovered in 15, 49, and 82 days, respectively, with enlargement of the bone in every instance. In two cases, the functions of the arm and forearm remained normal; in the third case, extension of the wrist joint and the three last fingers became impossible.



Ward phot.

T. Sinclair & Son, Chromalith

PLATE L. SHOT CONTUSIONS OF THE SHAFT OF THE HUMERUS.

Fig. 1. Spec. 6309. Surgical Section.      Fig. 2. Spec. 6312. Surgical Section





Another case of partial shot fracture of the humerus was an interesting illustration of that rare occurrence, the lodgement of a ball in the medullary cavity of a long bone:

CASE 1614.—Corporal B. F. Knowlton, Co. I, 2d Wisconsin, aged 24 years, was wounded at South Mountain, September 14, 1862. He was conveyed to Frederick, and received into Hospital No. 1 three days after the injury. Acting Assistant Surgeon W. W. Keen, jr., contributed the specimen (*Cat. Surg. Sect.*, 1866, p. 600) with the following history: "The ball entered the left shoulder in the middle of a line drawn from the acromion to the anterior angle of the axilla, and entered the humerus, where it lodged. It was found impossible to extract the missile by forceps. On September 21st, it was decided to remove it. An incision was made three inches long, continuous with the wound and parallel to the fibres of the deltoid. The bone was found not to be fractured, but the ball had punched a hole in its anterior wall and had flattened out in the medullary cavity against the posterior wall. The insertion of the capsular ligament was involved, but there had been no tenderness of the joint nor escape of synovia, nor could the joint be discovered to be opened, and it was therefore decided not to resect. The opening in the bone was enlarged with the double-gouge forceps, and the ball was extracted. Half a grain of morphia was given immediately, and the wound was closed by sutures. No inflammation of the joint supervened. By October 14th, the wound had almost united, there having been but little and a healthy discharge. On November 12th, the wound had so nearly healed that the patient was able to be sent to his regiment for duty, having free though partly scapular motion of the arm." The specimen consists of a ball (FIG. 502) flattened to the diameter of an inch. After joining his command, the man was again wounded in the left ankle, at the battle of Fredericksburg, December 13, 1862. He was ultimately discharged from service, March 21, 1863, and pensioned. Examiner T. B. Smith, of Washington, D. C., April 1, 1863, certified: "Wound over outer malleolus, with injury to bone of left leg. Wound of left arm at shoulder joint, injury to bone; ball cut out of humerus. Neither wound healed." Disability, when first pensioned, rated total. Reduced to one-half on March 4, 1867. This pensioner was paid June 4, 1874.




FIG. 502.—Flattened ball extracted from anterior wall of the left humerus. *Spec.* 4424.

The student is referred to other instances in the foot note.<sup>1</sup>

*Complete Shot Fractures.*—The shot fractures of the diaphysis of the humerus treated on the expectant plan were very numerous, and furnished examples of every variety of comminution, of extraordinary longitudinal fissuring, of detachment of large fragments, of cases in which the bone was almost pulverized at the point of impact, and, rarely, of cases of slightly oblique or nearly transverse fracture without splintering from missiles moving at a low rate of velocity. Besides these primary conditions, the cases of this category sometimes exhibited in great variety the phenomena attendant on periostitis, osteitis, osteomyelitis, osteoporosis, caries and necrosis, and, occasionally, of non-union and pseudarthrosis. Some illustrations of shot fractures of the upper third of the shaft have been given in treating of excisions. A few examples of such fractures in different portions of the shaft will be detailed here:

CASE 1615.—Brigadier General Adams, C. S. A., was wounded at Chickamauga. Surgeon Israel Moses, U. S. V., in charge of the hospital at Murfreesboro', Tennessee, reports: "He was wounded and brought in a prisoner, on September 19th, having received a ball in the left arm about the middle third, fracturing the bone and lodging. There was a good deal of tumefaction and pain, he having been brought some fifteen miles without any medical aid. Having been put under chloroform, September 23d, for the purpose of exploring the extent of the injury so as to determine whether amputation should be performed, Surgeon Moses cut down and found the ball embedded among the fragments, all of which were removed, together with the pointed end of the upper fragment. The bone was split up and down extensively, but, as there appeared good periosteal attachment, it was decided to attempt to save the arm. About four weeks after the operation his arm was put up in splints of coaptation, and he was sent under flag of truce to the rebel lines at the earnest solicitation of General Bragg. He will without doubt have a good arm." The above officer was probably Brigadier General Wirt Adams, who was still in service January 14, 1865. The specimen (*Cat. Surg. Sect.*, 1866, p. 123) consists of "six fragments of bone, representing two inches in length, and a battered conoidal ball, removed from the middle third of the shaft of the left humerus." It was contributed by the operator, and is represented in the accompanying wood-cut (FIG. 503) of half of the natural size.



FIG. 503.—Fragments of shaft of humerus and battered conoidal ball. *Spec.* 2146.

It will be seen that, by many surgeons, the necessity for removal of even a large

<sup>1</sup> Specimen 2387 (*Cat. Surg. Sect.*, A. M. M., 1866, p. 123). "The upper third of the left humerus. From the inner portion of the shaft a triangle two and a half inches long by one inch broad at the base, which rests on the epiphyseal, has been fractured. A fissure of two and a half inches exists in the outer bicapital ridge independent of the fracture." In *MS. Register of Shot Wounds of Upper Extremity*, S. G. O., Vol. XXII, see cases of Pt. G. Loyd, 6th Indiana; Pt. J. Haskins, 1st Tennessee Artillery; Pt. A. Brown, 64th New York; Pt. F. Stayback, 16th Illinois. In Vol. VI (*Shot Fractures of the Humerus*), see cases of Pt. A. Lester, 134th New York; Pt. J. W. Collins, 29th Maine; Pt. J. G. Harvey, 39th New Jersey; Pt. J. R. Glongore, 2d Vermont; Pt. J. Hillen, 5th New York; Pt. D. Savage, 183d Pennsylvania; Capt. H. C. Smith, 6th Kentucky; Lieut. W. M. Begole, 2d Michigan; Pt. G. W. Benn, 103d Illinois.



number of detached fragments or primary sequestra was not regarded as a contra-indication of expectant conservative treatment. Shortening usually followed, but almost any deformity was thought tolerable could the functions of the hand be preserved.

The cases in which there was more or less trouble from consecutive exfoliations or extended necrosis were the rule rather than the exception, and cases complicated with wounds of the trunk were very common:

CASE 1616.—Sergeant-Major M. E. Haas, 4th Ohio, aged 20 years, was wounded at Morton's Ford, February 6, 1864, and sent to a Second Corps hospital the next day. Surgeon I. Scott, U. S. V., reported: "On admission, the patient was immediately placed under the influence of chloroform and the wound carefully examined, when it was found that the ball had gone directly through the upper third of the shaft of the right humerus, passing under the scapula, and was subsequently extracted from the lower edge of the left scapula. As the patient was young and had a vigorous constitution, it was decided to attempt the preservation of the limb, although there was considerable comminution of bone." This soldier was sent to St. Paul's Church Hospital, Alexandria, March 24, 1864, transferred to Ohio in April, discharged June 21, 1864, and pensioned. Examiner L. M. Whitney, of Ohio, reported, November 15, 1864: "A musket ball entered the right arm, striking the humerus about the centre of its long axis, shattering it, and, passing upward and inward, through the right shoulder, crossed the back to the inferior part of the scapula of the left side. \* \* Very partial use of left arm; the original wound is still open, and pus discharging, from disease of bone. Deafness also succeeded the receipt of this injury, and is now a decided disability." Examiner J. R. Rainey, of Illinois, reported, February 1, 1872, confirming the above, and adds: "Fracture of right scapula, resulting in contraction of the tendons and absorption of the deltoid muscle. Cannot rotate the arm, nor perform any labor requiring the use of the arm above, or on a level with, the shoulder. There is partial deafness in both ears. Disability one-half." This pensioner was paid September 4, 1873.

CASE 1617.—Private T. McC——, Co. A, 4th New York, aged 22 years, was wounded at Antietam, September 17, 1862. He was conveyed by railway to Baltimore, and received into Newton University Hospital. Surgeon C. W. Jones, U. S. V., contributed the specimen (FIG. 504, see *Cat. Surg. Sect.*, 1866, p. 132), with the following history by Acting Assistant T. H. Currey: "This man was admitted September 20th, with gunshot wound of left arm by a conoidal ball, causing compound comminuted fracture of the humerus; the point of entrance being four inches below the head of the humerus on the anterior side, and that of exit six inches below the head of the bone, on the posterior aspect. Previous to starting for this hospital, the wounded limb had been bound with splints and bandaged, for comfort and convenience of travel. These gave him a great deal of pain. When admitted into this hospital, the splints were removed and the arm rested upon a pillow covered with oiled silk. A continuous stream of cold water was then kept running upon the arm until the inflammation was controlled, the swelling abated, and suppuration commenced. Linseed poultices were then applied to promote suppuration. During the inflammatory stage saline cathartics were used to evacuate the bowels and counteract the constipating effect of the opium which was used at night to lessen pain and induce sleep. The poultices were continued for several days. Bandages were applied singly from the hand to the shoulder to prevent the pocketing of pus. The wound at the point of entrance healed kindly; the other continued to discharge pure healthy pus. On October 10th, the wound was carefully probed, when some loose particles of bone were detected, and also an extensive denuded surface of the bone. It was now determined to remove the diseased bone. Accordingly the patient was put under the influence of chloroform, and an incision, four inches long, was made hard down upon the anterior part of the bone, the loose pieces of bone removed, and the denuded portion dressed down smoothly with the chisel and scraper. After this a sponge tent was inserted and allowed to remain twenty-four hours, after which it was removed and a linen one used instead. The linseed poultices were again used, and, when granulation was fully established, the edges were approximated by adhesive



FIG. 504.—Ten small fragments removed at various times from a shot fracture of the left humerus. *Spec.* 1112.

strips and covered with cloth spread with resin ointment. The constitutional treatment during this stage was supporting, accompanied by generous diet. The wound continued to heal kindly until November 15th, when, at the point of exit, it presented the appearance of a small abscess. This was lanced and the probe introduced, when a small piece of bone was felt near the surface and removed by the ordinary dressing forceps, after which the wound healed rapidly. Again, on December 16th, the cicatrix at the point of entrance looked as if an abscess was pointing. This was promptly opened, and a foreign body found within. The forceps were introduced and a thin scale of lead removed. This had been scraped from the ball as it entered the bone, and was lost in the muscular structure of the arm. The wound then filled up rapidly and soon closed. On December 21, 1862, the patient was discharged and pensioned, his wounds being all healed and his arm increasing in strength and usefulness every day. Thus a valuable member of this poor man's body was saved after having been condemned to amputation by several respectable surgeons on the field. In connection with the fracture and its mode of cure this important fact was noticed: The bone was fractured in large and long splinters, extending from within one inch and a half of the condyles to within three inches of the head of the bone. These fragments united, and that so firmly too as to enable the patient to raise the arm from the side of the body by its own power; this, too, long before suppuration had ceased or the external wound had healed." The specimen consists of a shaving of lead and ten small necrosed fragments of bone, removed at various times from the shaft of the humerus. Examiner W. M. Chamberlain, of New York, May 13, 1863, certified: "The left humerus has been shattered and is now in a condition of necrosis. It is an inch or more shorter than its fellow. He has the marks of pulmonary consumption also." The disability was rated total for gunshot wound and phthisis. The man died on August 24, 1863. His attending physician, Dr. J. C. Acheson, of New York, testified "that up to the time of his death he was suffering with phthisis pulmonalis, aggravated by an unhealthy suppurating gunshot wound of the arm."

It was sometimes remarked that lateral shot perforations of the arm, with long fissuring of the humerus, were more troublesome than the fractures resulting from antero-posterior perforations; but this generalization needs confirmation:

CASE 1618.—Private *D. P. Morris*, 30th North Carolina, aged 46 years, was wounded at Gettysburg, July 1, 1863, and sent to Seminary Hospital. Surgeon A. B. Ward, 2d Wisconsin, reported: "Gunshot wound of arm." On July 25th, the patient was transferred to Camp Letterman, where Acting Assistant Surgeon J. Newcombe reported: "A ball entered the arm about four inches below the acromial process, on the outer side, and, passing upward and inward, lodged underneath the integument of the upper part of the anterior wall of the axilla, from which it was extracted. The humerus was considerably comminuted. There is now considerable discharge from both wounds." The general health of the patient was not good during the month, and the arm was swollen and painful up to August 18th; there was a general improvement in the condition of the patient recorded during the remainder of August, and the wounds were closed on the 13th August. He was reported as "about the same" on the 15th September, and he was transferred, for exchange, October 14, 1863.

The drain upon the system from protracted irritation and suppuration sometimes fatally impaired the health years after the reception of the injury:

CASE 1619.—Private A. Vanaken, 20th New York, aged 31 years, was wounded at Gettysburg, July 1, 1863. Surgeon A. B. Ward, 2d Wisconsin, reported, from Seminary Hospital, a shot wound of the left arm, and the patient's transfer, July 11, 1863, to Turner's Lane, when Acting Assistant Surgeon C. B. King recorded: "A compound fracture of the left humerus; the ball entered about three inches below the head of the bone and made its exit at a point directly back, comminuting the bone. An angular splint was applied. General health good. A number of pieces of bone can be felt. August 30, 1863: Wound granulating; small piece of bone removed. October 10, 1863: Wound closed, and bone united firmly, with good use of arm." Discharged November 30, 1863, and pensioned. Examiner E. Hall, of New York, reported, March 21, 1866: "The bone was badly shattered and still exfoliates; the arm and joint are quite stiff, and of little use. Disability total, and probably permanent." This pensioner died February 28, 1868.

Perfect union after extensive comminution was very tardy in taking place; but the reparative process was accelerated by the opportune removal of sources of irritation:

CASE 1620.—Corporal L. Schroeder, Co. E, 1st Artillery, aged 30 years, was wounded at White Oak Swamp, June 30, 1862, and, after a few days, fell into the enemy's hands. The case is first recorded in hospital at Camden Street, Baltimore, by Assistant Surgeon R. Bartholow, U. S. A., July 25, 1862: "Vulnus sclopeticum; transferred to New York, September 25, 1863." Acting Assistant Surgeon W. E. Townsend reported that this soldier was admitted to post hospital at Fort Independence shortly afterward, and discharged February 12, 1864, and pensioned, Dr. Townsend certifying that the right arm was useless from the effect of a gunshot wound. Examiner A. W. Dodge, of Baltimore, reported, September 9, 1869, that "a ball entered the anterior aspect of the right shoulder near the joint, and, passing obliquely downward, issued on the opposite side, three inches lower than the point of entrance, shattering the humerus. Large sequestra have been removed, and the arm is atrophied, and is too weak at this point to sustain any muscular exertion, such as is required for the performance of manual labor. Disability total." Examiners Owings, Jones, and Dodge reported, October 3, 1873: "Partial ankylosis of the right shoulder joint, and fracture of the upper part of humerus; cicatrix adherent to bone. Disability total." While this soldier was at the Camden Street Hospital, in 1862, Acting Assistant Surgeon Darr published an account of the case,<sup>1</sup> derived from the notes of Acting Assistant Surgeon E. G. Waters, who attended the patient. Dr. Waters transmitted a similar report to this Office. Apart from the details already given, this interesting paper notes that the man was wounded while in a stooping position, elevating his gun. The ball was extracted the same day, and the arm was placed in an apparatus. After ten days, this soldier was captured and taken to Richmond, thence paroled and sent to Baltimore, July 25, 1862. Several detached fragments of bone were soon afterward removed by dressing forceps. On August 24th, Dr. Waters states there was no disposition to union, and the man was taken to the operating room to undergo excision of the head of the humerus, but firmly refused to submit to the operation. Four weeks subsequently, union had unquestionably taken place, and on October 30, 1862, union was firm. The patient was sent northward convalescent, and his subsequent history, until the autumn of 1873, is related above.

CASE 1621.—Corporal J. L. Sheffery, 5th New York, aged 32 years, was wounded at Gaines's Mill, June 27, 1862, and taken prisoner. There is no mention of this case prior to the record made at Satterlee Hospital, where the patient was received July 30th. From this record it appears that there was "gunshot wound and a compound fracture of the left humerus at the middle third, and excision of fragments of the bone, through an incision in the outer side of the arm, prior to admission. When admitted, there was a superficial ulcer occupying a portion of the original incision. The wound rapidly cicatrized, but no bony union took place. When the arm was supported the patient was able to execute a variety of motions." This man was discharged September 11, 1862, and pensioned. Examiner J. S. Delavan, of Albany, reported, January 3, 1865: "Wounded above elbow, left arm; resection performed; taken prisoner; for want of care a false joint formed, rendering arm worse than useless. Disability total and permanent." Examiner H. Pierpont, of New Haven, reported, July 22, 1857: "Wound of upper third of left arm, resulting in excision of about two-thirds of the upper third of the humerus, and subsequent necrosis, and sloughing of the soft parts. At the present time the hand and arm are of no use whatever. The flexors of the hand and fingers are contracted, with flexion of the wrist to a right angle, and the fingers flexed, with loss of power to extend either fingers or wrist." This pensioner died in March, 1872.

<sup>1</sup> DARR (G. H.), *Conservative Treatment in Gunshot Fractures*; communicated to the "Army Medical and Surgical Society of Baltimore," February 19, 1863. *Am. Med. Times*, Vol. VI, p. 270.



In the four following examples of shot fractures of the shaft of the humerus treated on the expectant plan, forbearance from operative interference was carried to the farthest justifiable limits:

CASE 1622.—Private J. Rose, 54th New York, was wounded at Bull Run, August 29, 1862. Surgeon J. E. Summers, U. S. A., reported that he was received at the Baptist Church Hospital, Alexandria, on September 6th, with a "shot wound of the arm, and was transferred December 15th." He entered Ladies' Home Hospital, April 25, 1863, and was removed to Lovell Hospital, Portsmouth Grove, Rhode Island, July 23, 1863. Acting Assistant Surgeon H. B. Knowles reported: "A minie ball entered the posterior aspect of the left (right?) arm, passing directly through, and fracturing the humerus at the middle third. On admission, the arm was considerably inflamed and swollen, and on examination it was evident that sequestra existed." The condition of the patient having improved, an operation was done, August 8, 1863: "A linear incision was made down to the bone, on the posterior aspect of the arm, commencing about two and a half inches above the condyles of the humerus, and extending upward about four inches. Upon dissecting away the soft parts from the bone, several sinuses leading into and through the bone were exposed. An opening was made with the trephine and gouge, etc., sufficiently large, from which three sequestra, about two inches in length, were taken. Considerable caries of the humerus was found, which was also removed. After the hæmorrhage had ceased, the cavity was filled with dry lint, and cold-water applications continued." This soldier was transferred to the Veteran Reserve Corps, March 31, 1864, discharged April 16, 1864, and pensioned. Examiner C. Phelps, of New York, reported, October 13, 1868: "Gunshot fracture of the right humerus in the middle third, followed by extensive necrosis, and united. The temperature of the extremity is diminished and its muscular power enfeebled. The distal phalanx of the right middle finger has also been carried away by a shell." Examiner T. F. Smith, of New York, reported, November 7, 1863, substantially the same as above, adding: "The right arm is atrophied to a certain extent; the hand is cold and blue; he has no power in his right arm or hand." This pensioner was paid to December 4, 1872, and he has not since been heard from.

CASE 1623.—Private M. W. Cook, 6th New Hampshire, was wounded at Bull Run, August 29, 1862, and sent to Georgetown College Hospital, September 6, 1862. Assistant Surgeon J. M. Brown, U. S. A., reported: "Gunshot wound of shoulder; furlonged December 17, 1862." He was discharged, May 15, 1863, from Dover, New Hampshire, Acting Assistant Surgeon A. H. Robinson certifying that the injury was from a "musket shot, by which the left humerus was badly shattered; the arm rendered nearly useless." Examiner J. H. Wheeler reported, June 27, 1866, more facts than can be found elsewhere: "The ball entered on the anterior of the arm, eight and a half inches from the shoulder, and passed directly through, fracturing the humerus. A pasteboard splint was applied at Washington by Dr. Smith, of New York. Twenty-one pieces of bone and one of lead came away. A few pieces of bone worked down to the elbow and were cut out; the wound was eighteen months in healing. The arm is the full length. Is unable to fully straighten the arm, and cannot carry it behind, and with difficulty brings it to the head. The arm is smaller than the other. General health not so good as before injury." Examiner J. N. Buckman, of New Hampshire, reported, May 4, 1869: "A number of pieces of bone have been thrown off, and there is one and one-half inches shortening of arm. Patient suffers from increased pains extending from wound to left breast; the flexor muscles of the arm are contracted, so that he is unable to straighten it." Surgeon Wheeler, September 13, 1873, states that, "at present, patient suffers from weakness, an aching pain, numbness of the hand, and inability to move the arm perfectly."

CASE 1624.—Private H. Aust, 149th New York, aged 19 years, was wounded at Chancellorsville, May 3, 1863, and sent to a Twelfth Corps Hospital on the 17th. Surgeon H. E. Goodman, 25th Pennsylvania, reported "gunshot wound of right arm." The patient was sent to Douglas, and thence to Satterlee Hospital on June 17th. Medical Cadet N. M. Glaffelter recorded: "A ball entered at the exterior aspect of the arm, about two inches above the elbow joint, and, passing obliquely through the axis of the arm, fractured the humerus severely, and came out at the internal aspect, under and in front of the axilla. A large number of bone fragments were removed at different times." August 31, 1863, firm bony reunion is reported, with continued discharge from the wound, very slight motion in the elbow joint, and inability to close the hand completely. There is loss of motion in the shoulder joint, attributed chiefly to atrophy of the muscles, especially the deltoid. This soldier was discharged March 29, 1865, and pensioned. Examiner G. W. Cook, of New York, reported, September 22, 1863: "Wound of right arm about four inches above the elbow; now in a state of ulceration and necrosis. Atrophy of muscles, and ankylosis of elbow joint." Examiner B. F. Sherman, of Ogdensburg, reported, September 5, 1873: "Two or more constantly suppurating openings, and perfect ankylosis of elbow joint. Disability total." This pensioner was paid December 4, 1873.

CASE 1625.—Private J. M. Smart, 32d New York, was wounded at West Point, Virginia, May 7, 1862, and, two days after, sent to Hygeia Hospital, Fort Monroe, where Surgeon R. B. Bontecon, U. S. V., recorded "gunshot fracture of the left humerus." He was transferred, June 12th, on the transport Fulton, to New York, and entered Ladies' Home Hospital June 17, 1862. Surgeon A. B. Mott, U. S. V., reported: "Smart was in the act of stooping to aid his captain, who had just been shot, when a musket ball struck his left arm in front, one inch above the elbow joint, and, passing through the arm, splintered the humerus, but not completely fracturing it. He then threw off his jacket and fell back to the rear, and the arm was bound up with a handkerchief. The regiment being ordered to charge, he rejoined it, fell, and fractured the bone at the seat of the injury." He also, after this, fired ten rounds, and then got into a wagon and was carried to York River and down to Fort Monroe. Seven days after the reception of the wound the arm was put in splints. These were once renewed, and continued until July 5, 1862, when union of the shaft of bone was found to have taken place. The anterior wound meantime had closed. From the point of exit quite a large number of pieces of bone had come away. In the beginning of October, erysipelas attacked the wound. This soon yielded to treatment. The posterior wound healed in November, and, until the end of December, there was no discharge, and the patient had very good use of arm. At that time the anterior wound reopened, and suppuration continued until March 10, 1863. "The patient can use the arm pretty well; can flex the forearm to a right angle to the humerus, and can straighten it. There is considerable deformity, however, at the point of fracture, the arm being crooked, but this does not materially affect the use of the limb. April 2, 1863, the wound is now healed." This soldier was discharged June 11, 1863.

*Pseudarthrosis* was infrequent after shot fractures of the shaft of the humerus, although, after simple fractures, this diaphyses may be considered as almost the seat of predilection of that complication.<sup>1</sup> Six examples are recorded among the twenty-nine hundred cases treated by expectant measures, and a somewhat larger number among the excisions in the continuity. Two instances of the former category are detailed:<sup>2</sup>

CASE 1626.—Private J. Eggerstedt, Co. G, 2d United States Cavalry, aged 29 years, was wounded in the right arm, at Valverde, February 21, 1862. Dr. B. Norris, U. S. A., medical director of the troops engaged, reported on his list of casualties: "Gunshot fracture of humerus." The wounded man was conveyed to a hospital at Fort Craig, a distance of about five miles, where he was treated for a time. Subsequently he was transferred to the general hospital at Hot Springs, near Las Vegas, New Mexico, whence he was discharged on July 13, 1862, his term of service having previously expired. May 19, 1862, Assistant Surgeon B. Norris stated, in the certificate for pension, dated May 10, 1862, as follows: "A musket ball wound in right arm above elbow, fracturing the bone and permanently impairing the use of the arm." Examiner G. W. Mears, of Indianapolis, on October 3, 1862, certified: "Shot by a rifle ball passing through right arm near middle of humerus, having broken the bone, which never again united, leaving an artificial joint. In other respects, health good. \* \* In order to have a very imperfect use of his hand he is obliged to keep splints and a bandage upon his arm, &c." In another examination, for increase of pension, Dr. Mears reports the disability increased in consequence of "several efforts having been made to produce reunion of the fractured ends of the humerus without success, and the arm becoming somewhat painful." Examiner J. Phillips, of Washington, D. C., April 21, 1869, certified: "Ununited fracture of right arm. \* \* There is no discoverable defect of the system to account for his condition, &c." Examiner J. O. Stanton, on September 12, 1873, certified: "Ununited fracture. There is about two inches shortening of the limb, some atrophy of muscles of right forearm, and evident loss of strength. Can use the hand when the elbow is supported, and has then a good grasp of the hand, &c." The disability was rated total. Pensioner has been paid to June 4, 1865. This man visited the Army Medical Museum in the summer of 1867, when a photograph of him was taken. (*Surgical Series of Photographs*, No. 189, A. M. M.)

CASE 1627.—Private G. T. Abbott, Co. I, 4th Vermont, aged 21 years, was wounded at the Wilderness, May 5, 1864. From a field hospital he was received into Mount Pleasant Hospital on May 13th. Assistant Surgeon C. A. McCall, U. S. A., reported: "Gunshot wound of right arm. Transferred to Philadelphia, May 30th." Assistant Surgeon T. C. Brainerd, U. S. A., in charge of Broad and Cherry Streets Hospital, reported: "Gunshot fracture of right humerus. Water dressings and splints applied." On February 3, 1865, the wounded man was transferred to the Brattleboro' Hospital, Vermont, and on June 15th to Central Park, New York City. Acting Assistant Surgeon C. E. Phelps, from the latter hospital, reported: "Gunshot wound of right arm. A minié ball passed through middle third from within outward, producing oblique fracture of humerus. Missile cut out next day, in the field hospital. Fracture treated with right-angular splint. A month after reception of wound gangrene appeared, small in extent, but persistent. Result of injury, ligamentous union. On July 24th, an apparatus was furnished by Dr. E. D. Hudson, of New York, who reported: "Arm shortened one inch; some atrophy; false joint; fractured ends nearly in apposition; considerable enlargement about fractured part; functions of forearm good; arm useless." The patient was, on August 29th, admitted to Sloan Hospital, Montpelier, Vermont. Surgeon H. James, U. S. V., contributed a photograph of the patient (*Card Photos*, Vol. II, p. 113) with the following history: "Ball entered about the middle of arm on inner side, fracturing the humerus, and lodging under the skin on the posterior and outer side, where it was cut out. No bone was taken out with the ball, but a fragment, three-fourths by one-fourth of an inch, came out on the fourth day after the injury. Another fragment, one inch by one-fourth, and a small piece of the bullet, came away while he was at home on furlough, five months after the injury. No other pieces of bone have come away. No retentive apparatus was applied the first week after the injury. After that an angular curved splint was used for about two months, and afterward a pasteboard splint. About six weeks after the injury the wound became gangrenous, and nitric acid was freely used twice. Gangrene was arrested in about two weeks, and he began to improve very slowly, and was confined to the house about six weeks. The wound healed about the 1st of July, 1865, with a false joint. In the latter part of June, he was transferred to New York to be fitted with Hudson's retentive appa-

<sup>1</sup> Professor F. H. HAMILTON (*New Mode of Treatment of Delayed or Non-Union of a Fractured Humerus*, in *Buffalo Med. Jour.*, 1854, Vol. X, p. 142) remarks: "I have observed that non-union results more frequently after fracture of the shaft of the humerus than after fracture of the shaft of any other bone." This result is commonly ascribed to the difficulty of securing immobility in these fractures (NICANSE (E.), Article *Bras*, in *Dict. Encyc. des Sci. Méd.*, 1869, T. X, p. 520). Professor SÉDILLOT (*Du traitement des fractures des membres par armes à feu*, in *Arch. gén. de méd.*, Ser. VI, T. XVII, P. 1, p. 401) observes: "Pseudarthrosis, so common in ordinary fractures of the humerus, especially in those of its upper half, because of the difficulty of immobilization of the arm, are very rare after gunshot wounds, and an explanation is found in the extent and activity of the osteogenic process" in such grave injuries. NEUDÖRFER (J.) (*Handbuch der Kriegschirurgie*, 1872, B. II, S. 1179) remarks: "That in his own practice he has not met with a single case of pseudarthrosis after shot fracture. Only twice he had occasion to observe pseudarthrosis after shot fractures of the epiphysis of the humerus," and adds: "Pseudarthrosis, as a rule, is an evidence of a constitutional disease of the blood, which, by soldiers generally, and especially at the years in which they take the field, is rarely to be found. But retardation of the consolidation of shot fractures must not be called pseudarthrosis."

<sup>2</sup>The other four instances of pseudarthrosis after expectant treatment were: 1. Pt. J. Jackson, Co. B, 15th Wisconsin, aged 46, wounded at Chickamauga, September 19, 1863. Surgeon H. CULBERTSON, U. S. V., at Harvey Hospital, Wisconsin, July 12, 1864, notes: "Transverse fracture of right humerus below surgical neck; false joint at seat of fracture; external wound healed. Discharged September 20, 1864," and pensioned. The pension reports which extend to January 2, 1874, make no mention of the pseudarthrosis. 2. Pt. R. H. Miller, Co. A, 25th Ohio, wounded at McDowell, May 8, 1862. Surgeon L. G. MYERS, 25th Ohio, reported a "shot fracture of upper third of left humerus; general health good, but the fracture resulted in a false joint." 3. Sergeant J. D. Foulk, Co. A, 7th Iowa. Surgeon M. K. TAYLOR, U. S. V., noted: "Shot fracture of the lower third of the right humerus, resulting in a pseudarthrosis; discharged July 9, 1863." 4. Private J. W. Beaver, Co. G, 50th Indiana, aged 31, was wounded at Jenkins's Ferry, April 30, 1864, and taken prisoner; discharged May 30, 1865, and pensioned. Examiner J. Stillson, of Bedford, Indiana, reported, September 5, 1873: "He received a wound from an ounce ball which fractured the humerus in the lower third. The musculo-spiral nerve was severed; all its lower branches are paralyzed. Union has never taken place at the seat of fracture, but he has remaining a false joint with shortening of the humerus. The arm hangs as a useless appendage."



ratus, which he is now wearing. He can write with it, and do any kind of light work; without it the arm is nearly useless. Up to the time that the wound became gangrenous the patient was in good condition, and the wound seemed to do very well. After the gangrene the discharge was very profuse; a large abscess formed just above the wound, and the patient became much debilitated." He was discharged from service on September 25, 1855, and pensioned. Examiner G. S. Jones, of Boston, March 29, 1866, certified: "The wound was in the lower third of the right arm. The humerus has been fractured and now remains ununited, thereby rendering the forearm nearly powerless and useless." Examiner G. T. Gale, of Brattleboro', Vermont, September 12, 1867, certified: "The fracture was followed by gangrene, resulting in large loss of muscle and non-union of bone. Forearm hangs loosely by his side, almost entirely useless. Wounds are now closed, but open occasionally. Has very little control over motion of forearm and hand." Examiner H. S. Noble, of Chester, Vermont, reported, on September 4, 1873: "Nearly an inch of the bone is gone, and the upper and lower fragments are united by ligament. The arm is practically useless for purposes of manual labor, being entirely flail-like, and capable of being twisted upon itself nearly one and a half turns." The disability was rated total. The pensioner was paid March 4, 1875.

The old doctrine, that shôt fracture of the humerus with wound of the brachial artery imperatively indicates amputation, is still earnestly maintained by Dr. Lœffler, though called in question by M. Legouest and others.<sup>1</sup> Surgeon A. H. Hoff, U. S. V., warmly advocated attempts to save the limb under these conditions.

CASE 1628.—Private W. Lay, Co. F, 129th Pennsylvania, aged 21 years, was wounded at Fredericksburg, December 13, 1862, and admitted to the 3d division hospital, Fifth Army Corps, where Surgeon D. McKinney, 134th Pennsylvania, recorded: "Gunshot fracture of arm; bone adjusted." On December 17th, he was transferred to Mount Pleasant Hospital, at Washington. Assistant Surgeon C. A. McCall, U. S. A., reported: "Compound fracture of humerus, with wound of brachial artery, by conoidal ball. Hæmorrhage from the injured artery occurred on December 19th, 20th, and 21st, and was restrained by mechanical means and persulphate of iron. No ligation was performed, and no recurrence of hæmorrhage took place after the 21st." The patient was discharged from service on April 16, 1863, and pensioned. Examiner T. B. Smith, of Washington, D. C., April 17, 1863, certified: "Wound still discharging; partial ankylosis of left elbow joint; bone now united; health good; motions of shoulder and hand perfect; limb now useless." Examiner E. Swift, of Easton, Pennsylvania, certified, on April 13, 1864: "The arm can be flexed to a right angle with the humerus and extended to an angle of about forty-five degrees, &c." Examiner P. R. Palm, of Allentown, Pennsylvania, reported, on October 14, 1871: "There is considerable deformity of the limb, the arm being curved backward. The joint is somewhat stiff, and the arm cannot be straightened, &c." On September 4, 1873, the last examiner again reported: "Elbow joint partly ankylosed and deformed, &c." The disability was rated three-fourths. Pensioner has been paid to March 4, 1875.

I confess that the evidence in this and three other reported cases<sup>2</sup> appears to me insufficiently circumstantial and precise to decide affirmatively this controverted point.

To avoid iteration, further comments on expectant conservative treatment of shot fractures of the humerus will be reserved for the concluding pages of this Chapter.

<sup>1</sup> LÖFFLER (F.) (*General-Bericht*, u. s. w., 1867, S. 179) contends that amputation of the arm is necessary in all cases in which the fracture of the humerus is accompanied by lesion of the brachial artery, and censures LEGOUEST (*op. cit.*, p. 529, 1st ed., p. 680), who observes: "Nous pensons que dans ces cas l'amputation n'est pas toujours indispensable. Si l'artère brachiale est lésée au-dessous des tendons des muscles grand-rond et coraco-brachial, la grande artère collatérale externe et la grande artère nourricière de l'humerus restent intactes, rétablissement assez facilement et assez rapidement la circulation pour autoriser la conservation du membre. Si, au contraire, l'artère brachiale est ouverte au-dessous de l'origine de ces vaisseaux, il vaut mieux pratiquer l'amputation." Generalarzt LÖFFLER states: "That up to the present time, as far as I know, the literature of military surgery does not present a single case of preservation of the limb after injury of the brachial artery with shot fracture of the humerus," and adds: "Even LEGOUEST does not cite a case; his indication is more the result of *a priori* calculation, and has the fault, moreover, that it omits a consideration of the highest importance to this class of injuries, the relations of the brachial veins, which, at least in shot wounds, rarely remain uninjured when the artery has been struck. The mere contusion of the veins is sufficient to have considerable influence on the result of the injury." BILLROTH (TH.) (*Chirurg. Briefe aus den Kriegen Luzarthen*, u. s. w., Berlin, 1872, S. 223) remarks: "Whether shot fractures of the humerus, with injury of the brachial artery, always result in gangrene, I am not able to assert, as the two cases, in which gangrene of the arm supervened, were not carefully examined. That secondary ligation of the brachial for shot fracture of the humerus neither materially changes the circulation in the extremity nor obstructs consolidation, I have already stated."

<sup>2</sup> Surgeon IRA RUSSELL, U. S. V., reports, from notes of Surgeon B. O. REYNOLDS, 3d Wisconsin Cavalry, the case of: 1. Lieut. N. Cole, 20th Wisconsin, wounded at Prairie Grove, Arkansas, December 7, 1862: "Musket ball entered two and a half inches above right elbow joint, passed internally to the humerus, and made its exit posteriorly. Did well for seven days, when hæmorrhage occurred, and was restrained by the tourniquet. Two days afterward it again bled profusely, and I ligated the brachial artery three-quarters of an inch above its bifurcation, since which time the case has steadily improved." This officer was discharged and pensioned February 27, 1863. In 1868, Examiner L. D. MCINTOSH, of Sheboygan, reported: "Ball entered left arm, anteriorly, five inches below shoulder joint, and passed out opposite its entrance, severing the brachial artery and injuring the nerve. Secondary hæmorrhage supervening, the artery was ligated. The humerus was fractured. There is partial ankylosis of the elbow joint, etc." In 1873, Examiner HALL reports: "Arm considerably wasted, with numbness of ulnar border of forearm and hand." 2. Examiner O. MARTIN reports the case of Sergeant P. W. Briggs, 36th Massachusetts, wounded at Petersburg, June 17, 1864: "Ball hit an inch below coracoid process of right scapula, passed downward and outward, cutting off under side of neck of humerus, through the axilla, and out four inches below shoulder joint, on the back side of the arm. He was under my care for a long time, had gangrene and excessive hæmorrhage, and it was thought it would be necessary to amputate at the shoulder. Now (February 16, 1864) general health is good, shoulder stiff, bone diseased; no use of arm." 3. Pt. N. F. Huntley, Co. F, 5th Vermont, aged 33, was wounded at the Wilderness, May 5, 1864. Surgeon J. E. POMPHREY, 7th New York Heavy Artillery, reported: "Severe wound of arm, with lesion of the brachial artery. Medical Director A. N. DOUGHERTY." The patient was discharged and pensioned February 22, 1865. Examiner C. PORTER, of Rutland, certified, March 22, 1865: "Gunshot wound of the right arm on the inner side, about three inches above the elbow joint, ball passing obliquely upward and out midway between the elbow and shoulder, destroying the brachial artery and injuring the nerve." Dr. PORTER reported, in September, 1873: "A musket ball fractured the right humerus about three inches above the elbow joint."

EXCISIONS IN THE CONTINUITY OF THE HUMERUS FOR SHOT INJURY.—The cases returned under this head are very numerous, and probably many mere extractions of fragments have been improperly classified as excisions; but, making every allowance for erroneous returns, the number of formal operations is unprecedentedly large; the entire number of operations comprised in the series is six hundred and ninety-six.

**Primary Excisions of the Shaft of the Humerus.**—Our surgeons evidently did not share the opinion of European authorities regarding primary excisions in the continuity, since nearly two-thirds of the operations belong to the primary group.

§ *Cases of Recovery.*—Three hundred and twenty-six such cases are reported.

CASE 1629.—Private C. W. C——, Co. F, 39th Illinois, aged 22 years, was wounded at Weirbottom Church, June 17, 1864. He was removed to the field hospital of the Tenth Corps. Surgeon C. M. Clark, 39th Illinois, reported: "Private Carpenter was wounded by a conoidal ball, which entered the right arm near the insertion of the deltoid muscle, passing obliquely backward and downward, and was cut out at the inner surface of the arm two inches below the point of entrance. The ball had extensively fractured the body of the humerus. Chloroform was administered and six inches of the bone were taken away (leaving the periosteum) by a longitudinal incision. The bone removed included the portions taken from each end of the remaining humerus. The wound was dressed in the usual manner, and the man put to bed in the provisional hospital, where he remained under my care for the space of three weeks, the wound healing rapidly. He was then sent to Chesapeake Hospital, remaining a short time, and subsequently to hospital at Willet's Point, New York, whence he was discharged from service. Before leaving New York Dr. E. D. Hudson applied a supporting splint, which gave the arm its normal strength and use to a great extent. The case came under my observation again in April, 1867, at which time the man was following the occupation of 'expressman,' and stated that he could use the arm about as well as ever. On examination of the arm after removal of the splint, I found the space formerly occupied by bone to be filled with a dense rounded mass of cartilage with some ossific deposits. He stated that the arm was not as firm as formerly because of an accident that he met with while leaping a fence, at which time he fell, striking the elbow of the injured arm and disrupting the tissue, which had become sufficiently firm to allow the raising of the arm from the shoulder without the appearance of any false joint, but now, on raising the arm, there was some bending. It was, however, growing stronger, and he thought that he could soon dispense with the splint. He is at the present time, December, 1869, following the occupation of a gardener, and makes good use of the arm." Dr. E. D. Hudson, of New York, published the following memoranda of the case: "Five months after the operation he was sent from De Camp United States General Hospital to me for final treatment. His arm was shortened one inch. Nature had reproduced about one and a half inches, leaving a space of nearly two inches. Arm very flexile, uncontrollable, somewhat atrophied, and useless except to hold things when the forearm was extended. With sustaining apparatus applied as a representative shaft of bone, and auxiliary straps of rubber webbing, he was able to control his arm and forearm, flex his forearm, lift with the forearm flexed, and will do good service. The appliance was efficient, and his arm will recuperate to a high and gratifying degree of usefulness." Examiner J. P. Lynn, of Chicago, February 27, 1863, reported: "He was struck by a ball in front, just below the surgical neck of the humerus. It passed through, shattering the bone, four inches of which were excised. By an apparatus he wears he has a little use of the forearm." The Chicago Board, September 6, 1873, report: "Exsection of upper third of right humerus and anchylosis of what remains at shoulder joint. Loss of muscular structure of upper arm equal to loss of limb." This pensioner was paid March 4, 1874.



FIG. 505.—Apparatus in a case of excision of the shaft of the humerus. [After HUDSON.]

CASE 1630.—Lieutenant J. Egan, Co. C, 2d United States Cavalry, aged 27 years, was wounded at Cold Harbor, June 1, 1864. Assistant Surgeon J. W. Williams, U. S. A., reported: "A minie ball entered the upper third of the right arm, fracturing the humerus to the extent of three inches. Resection was performed and all the pieces of bone were removed, with the exception of a large piece on the internal aspect, which still preserved the length of the arm, and, from its intimate connection with the periosteum, was not likely to necrose. The operation was completed by smoothing the ends of the bone. Amputation was the preferable operation in this case, but the decided objection of the patient to losing his arm, and the situation of the internal fragment of bone decided the operation detailed above." The patient was transferred to Washington, and admitted into Stanton Hospital on June 4. Surgeon J. A. Lidell, U. S. V., reported: "Gunshot fracture of right humerus. Excision performed on field, of about two inches, by a straight incision through biceps muscle; ball extracted through place of entrance. Ice dressings and splints applied; tonics, stimulants, and saline cathartics prescribed." Surgeon B. B. Wilson, U. S. V., who was subsequently in charge of Stanton Hospital, performed an operation on March 14, 1865, in connection with which he reported the following: "Entire bony union of humerus. A cloaca, one inch in diameter, formed on the external edge of the biceps and on a level with and just below the insertion of the deltoid. Cut down on the external edge of the biceps, enlarged the cloaca with bone forceps to the extent of three inches, and removed the necrosed portion of the humerus, three inches long. Cold-water dressings applied." The patient was, on April 20th, transferred to Annapolis Hospital, whence he returned to his command for duty on May 25, 1865. In February, 1863, Lieutenant Egan was promoted captain.

HUDSON (E. D.), *Save the Arm. Remarks on Exsection, with Cases and Plates.* New York, 1865, p. 13.



TABLE LVI.

*Condensed Summary of Three Hundred and Twenty-six Cases of Successful Primary Excisions in the Shaft of the Humerus after Shot Injury.*

No.	NAME, AGE, AND MILITARY DESCRIPTION.	DATES.	OPERATIONS, OPERATOR, RESULT.	No.	NAME, AGE, AND MILITARY DESCRIPTION.	DATES.	OPERATIONS, OPERATOR, RESULT.
1	Abbott, J., Pt., I, 8th Alabama, age 23.	Oct. 27, '64.	Left: three inches middle third. February 28, 1865, union; entire recovery. Retired.	28	Bishop, A. J., Pt., A, 27th Ohio, age 25.	July 22, '64.	Left: four inches of upper third excised. Disch'd May 12, 1865; pensioned; arm useless.
2	Abbott, L. D., Corp'l, K, 38th Massachusetts.	Sept. 19, '64.	Right: Discharged June 30, 1865; not a pensioner.	29	Bixby, C. F., Pt., M, 2d Cavalry, age 19.	June 12, '64.	Left: five inches of middle third excised. Disch'd Jan. 12, 1865; pensioned.
3	Ainsworth, M. V. B., Serg't, I, 74th New York.	June 17, '64.	Right: three inches lower third. Disch'd May 17, 1865. Limb shortened two inches.	30	Blanchard, J., Pt., B, 10th Vermont, age 23.	Nov. 27, '63.	Left: two and a half inches of middle third excised. Discharged February 22, 1865.
4	Albright, F., Pt., B, 20th Michigan, age 28.	June 2, '64.	Right: four inches middle third; Surg. W. B. Fox, 8th Michigan. Discharged May 4, 1865.	31	Book, E., Pt., D, 57th Indiana, age 31.	Dec. 22, '64.	Left: three inches of upper third excised. Disch'd May 17, 1865.
5	Alberts, B., Pt., E, 10th New York Cavalry.	April 9, '65.	Right: two and a half inches middle third. Disch'd June 30, 1865. Arm shortened one inch and atrophied.	32	Bohmsack, H., Pt., F, 3d Mass. Cavalry, age 32.	May 9, '64.	Left: four inches of upper third; by Asst. Surg. C. H. Andrews, 128th New York. Disch'd Jan. 30, 1865; pensioned.
6	Allen, W. L., Pt., H, 1st Maine H. A., age 18.	June 4, '64.	Left: portion lower third. Discharged November 19, 1864.	33	Boice, A., Corp'l, B, 91st Ohio, age 21.	Aug. 24, '64.	Right: four inches of middle third; by Asst. Surg. J. B. Warwick, 91st Ohio. Discharged May 29, 1865; pensioned.
7	Amos, F., Lieut., H, 31st Iowa, age 34.	Aug. 24, '64.	Right: two inches of upper third; Surg. G. L. Carhart, 31st Iowa. Discharged February 2, 1865; good union.	34	Bolger, M. J., Pt., D, 10th Ohio.	Oct. 8, '62.	Left: three inches of middle third excised. Discharged March 17, 1863; re-enlisted; mustered out August 28, 1866; pensioned.
8	Andrew, H., Corporal, K, 116th Ohio, age 22.	June 1, '64.	Left: two and a half inches lower third. Disch'd Feb. 14, 1865.	35	Bostwick, E. M., Corp'l, H, 2d New York Cavalry, age 19.	April 1, '63.	Left: three inches of middle third; by Surg. S. F. Kingston, 2d New York Cavalry. Disch'd Nov. 24, 1865; pensioned. <i>Spec.</i> 2431.
9	Andrews, W. H., Pt., K, 13th Virginia.	July 3, '63.	Left: upper third. Nov. 12, 1863, sent to City Point for exchange.	36	Bratscher, G. W., Pt., D, 19th Colored Troops.	July 30, '64.	Left: two and a half inches of upper third; by Surg. J. S. Ross, 11th New Hampshire. Disch'd June 28, 1865; pensioned.
10	Ault, J., Pt., C, 101st Indiana, age 28.	Nov. 25, '63.	Left: two inches. Dec. 8th, arm amputated one and a half inches below shoulder joint, by Surg. C. Söllheim, 9th Ohio. Disch'd June 1, 1864.	37	Brelford, H. W., Serg't, H, 80th Ohio.	May 14, '63.	Left: lower third; by Surg. E. P. Buell, 80th Ohio. Disch'd Oct. 26, 1863; pensioned.
11	Bachelor, T. C., Lieut., I, 79th Indiana.	May 27, '64.	Left. Disch'd October 4, 1864. Artificial joint at upper third.	38	Bresler, H., Pt., E, 45th Pennsylvania, age 19.	Oct. 11, '63.	Left: four inches of upper third excised. Disch'd Sept. 14, 1864; pensioned.
12	Bagley, A., Pt., A, 19th Maine, age 36.	May 6, '64.	Right: three inches; by Surg. G. Chaddock, 7th Mich. Disch'd March 1, 1865; no union.	39	Brown, C. B., Pt., F, 3d New York, age 23.	Oct. 27, '64.	Right: three inches excised. Deserted April 28, 1865; not a pensioner.
13	Baker, J., Pt., I, 125th Ohio, age 18.	June 18, '64.	Left: middle third; by Surg. F. W. Lytle, 36th Illinois. Duty April 10, 1865.	40	Brown, F., Pt., G, 114th Illinois, age 21.	July 14, '64.	Right: middle third; by Acting Asst. Surg. W. D. Hall. Recovered; not a pensioner.
14	Baker, L. S., Brig. Gen., age 31.	Aug. 1, '63.	Right: three inches. Recovered.	41	Brown, G. D., Pt., A, 184th Penn., age 21.	Nov. 26, '64.	Left: three inches of lower half; by Surg. G. Chaddock, 7th Mich. Disch'd June 19, 1865; pensioned.
15	Baldwin, W., Pt., G, 8th Michigan.	Aug. 19, '64.	—: fragment at lower third. Discharged June 8, 1865. Ankylosis of joint.	42	Brown, J. R., Corp'l, A, 101st Illinois, age 20.	July 24, '64.	Right: two inches of middle third; by Surg. H. K. Spooner, 61st Ohio. Discharged June 22, 1865; pensioned; hand useless.
16	Ball, W. M., Pt., H, 22d Kentucky.	May 16, '63.	Right: upper third; by Surgeon B. F. Stevenson, 22d Kentucky. Duty November 28, 1863.	43	Bryan, L. V., Corp'l, E, 8th Kansas, age 30.	Dec. 16, '64.	Right: two and a half inches at middle third; false joint; arm useless. Disch'd April 18, 1865; pensioned.
17	Banks, J. H., Corp'l, E, 13th Maine, age 27.	May 18, '64.	Right: five inches middle third. July, 1866, amputation at junction of upper and middle third, by Dr. W. H. True, of Freeport, Maine.	44	Bunker, H. W., Lieut., H, 10th Iowa, age 23.	Nov. 25, '63.	Right: four inches of middle third; by Surg. R. J. Mohr, 10th Iowa. Mustered out Oct. 11, 1864; pensioned.
18	Barber, A. D., Pt., K, 10th Ohio, age 19.	Sept. 2, '64.	Right: two inches lower third; by Surg. D. C. Patterson, 124th Ohio. Disch'd June 5, 1865.	45	Burroughs, H., Corp'l, I, 1st U. S. Sharpshooters.	July 2, '63.	Right: excision at middle third; by Surg. H. F. Lyster, 5th Mich. Discharged June 7, 1864; not pensioned.
19	Barnett, W. B., Lieut., B, 97th Ohio, age 28.	June 22, '64.	Right: lower third; Surg. E. B. Glick, 40th Indiana; July 20th, amputation at upper third, by Act. Asst. Surg. L. E. Kelley. Resigned March 9, 1865; pensioned.	46	Burroughs, S. L., Capt., A, 2d New York Cavalry, age 26.	May 31, '64.	Left: middle third; by Surg. L. P. Woods, 5th New York Cav. Disch'd Sept. 10, 1864; pension'd.
20	Barnhizer, J. D., Pt., E, 7th Michigan, age 18.	May 12, '64.	Left: upper third; three inches; by Surg. G. Chaddock, 7th Mich. Discharged October 4, 1864; pensioned; arm useless.	47	Bush, J. A., Serg't, D, 154th New York, age 30.	July 2, '63.	Right: four inches of upper third; by Surg. H. Van Aernam, 154th New York. Discharged Jan. 30, 1865; pensioned.
21	Bausinger, C., B, 149th New York, age 20.	July 2, '63.	Right: upper fourth; four inches; by Surg. J. V. Kendall, 149th N. Y. Vols. To V. R. C. Oct. 16, 1864, pensioned.	48	Bymer, W. H., Pt., H, 5th New York, age 21.	June 27, '62.	Right: four inches of upper third; by A. A. Surg. J. Swinburne. Discharged May 25, 1863; arm useless.
22	Barnwell, B. T., Lieut. Confed. Navy, age 23.	Feb. 6, '65.	Left: middle third; two inches excised. Released June 29, 1865.	49	B——, J. B., C. S. A.	Sept. 25, '64.	Four inches of middle third; by Dr. A. Thompson, of Humboldt, Tenn.; "far better than no arm."
23	Bell, S. T., Pt., Co. K, 111th Penn., age 19.	July 3, '63.	Left: middle third; Surg. Geo. P. Oliver, 111th Penn. Mustered out February 27, 1865.	50	Camp, J., Pt., E, 12th Wisconsin, age 30.	July 21, '64.	Left: three inches of upper third; by Surgeon J. S. Reeves, 78th Ohio. Disch'd Sept. 20, 1865; pensioned.
24	Bett, G., Pt., K, 5th New Jersey, age 25.	May 5, '62.	Right: middle third; by Surg. C. W. Horner, U. S. V.; April 11, 1863, amputated at upper third. Disch'd Oct. 1, 1863.	51	Campbell, J. L., Pt., C, 9th New York Cavalry, age 26.	May 8, '64.	Left: four inches of upper half. Disch'd Jan. 30, 1865; pensioned.
25	Bennett, J., Pt., B, 23d Wisconsin, age 18.	May 22, '63.	Left: two inches of middle third; by Surg. J. W. Angell, 23d Wis. Discharged August 19, 1865.	52	Carroll, J. L., Pt., A, 7th Texas, age 27.	Nov. 29, '64.	Left: three inches of middle third; by Surg. J. R. Crain, 7th Texas. To Provost Marshal Jan. 7, 1865.
26	Berk, J. O., Pt., Co. A, 7th Connecticut, age 31.	Jan. 15, '65.	Right: two inches; by Surg. G. C. Jarvis, 7th Connecticut. Discharged July 6, 1865.				
27	Berrigan, E., Pt., I, 33d Massachusetts, age 40.	May 31, '64.	Left: three inches excised. Discharged Jan. 18, 1865; pensioned.				

NO.	NAME, AGE, AND MILITARY DESCRIPTION.	DATES.	OPERATIONS, OPERATOR, RESULT.	NO.	NAME, AGE, AND MILITARY DESCRIPTION.	DATES.	OPERATIONS, OPERATOR, RESULT.
53	Carpenter, C. W., Pt., F, 3rd Illinois, age 22.	June 17, '64.	Right; four inches of middle third; by Surg. C. M. Clark, 39th Ill. Discharged December 8, 1864.	80	Daw, J., Pt., K, 22d Michigan, age 24.	Sept. 20, '63.	Left; four inches middle third. Disch'd June 2, 1864; pensioned; false joint.
54	Carpenter, W. P., Pt., D, 101st Indiana, age 21.	June 27, '64.	Left; three inches; by Surg. C. N. Fowler, 105th Ohio. Disch'd June 12, 1865. Died May 18, 1870.	81	Dehp, E. J., Lieut., I, 5th Indiana Cavalry, age 23.	Dec. 14, '63.	Left; portion at upper third. Re-sigued Aug. 1, 1864; pensioned.
55	Carrer, A. R., Lieut., B, 50th N. Carolina, age 35.	May 13, '64.	Two inches of middle third. Furloughed July 29, 1864.	82	Demo, M., Pt., A, 14th New York Heavy Artillery, age 16.	July 30, '64.	Left; two and a half inches at middle third; by Surgeon T. F. Oakes, 50th Mass. Disch'd Nov. 9, 1864; pensioned.
56	Carroll, M., Corp'l, C, 6th Virginia.	May —, '64.	Four inches of middle third; by Surg. Kennedy, C. S. A.; doing well May 24, 1864.	83	Divine, W., Pt., F, 62d Pennsylvania, age 20.	May 5, '64.	Left; two inches; by Surg. J. Kerr, 62d Penn. Disch'd July 13, 1864; pensioned; arm useless.
57	Carter, H. W., Pt., D, 8th N. Y. Heavy Artillery.	June 3, '64.	Left; three inches of upper third; by Asst. Surg. F. P. Casey, 8th N. Y. Heavy Artillery. Disch'd June 13, 1865; pensioned.	84	Doner, J., Pt., C, 40th New York, age 21.	April 6, '65.	Left; one and a half inches upper third. Disch'd Dec. 4, 1865; pensioned.
58	Cary, M. L., Serg't, C, 1st Rhode Island Cavalry, age 25.	Sept. 14, '63.	Four and a half inches of upper half. Discharged December 24, 1863; pensioned.	85	Donchoo, H. M., Captain, B, 17th Pa. Cav., age 29.	April 1, '65.	Right; middle third. Duty May 10, 1865; pensioned.
59	Carver, B., Serg't, A, 142d New York, age 27.	Sept. 29, '64.	Right; two and a half inches; by Surg. D. McFalls, 142d N. York. Disch'd Jan. 4, 1865; pensioned.	86	Donnelly, J., Corp'l, D, 20th Mass.	May 18, '64.	Right; one inch middle third; by Surg. N. Hayward, 20th Mass. Disch'd June 9, 1865; doing well.
60	Childs, H. F., Pt., G, 95th Illinois, age 22.	June 17, '64.	Left; two inches of lower third; by Acting Ass't Surg. S. S. Jessop. July 23d, amputated at middle third, by A. A. Surg. R. W. Clark. Disch'd Jan. 26, 1865.	87	Dorsey, E., Pt., C, 1st Colored Troops, age 32.	Sept. 29, '64.	Left; three inches upper third. Disch'd April 1, 1865; pensioned.
61	Christin, G., Pt., C, 10th Pennsylvania Reserves, age 19.	May 8, '64.	Right; middle third; by Ass't Surg. B. Howard, U. S. A. Mustered out July 18, 1865; pensioned.	88	Drake, D. T., Pt., E, 100th Indiana, age 47.	Sept. 3, '64.	Right; three and a half inches at middle third; by Ass't Surg. D. Halderman, 46th Ohio. Disch'd Feb. 25, 1865; pensioned.
62	Churchill, W. S., Pt., C, 20th Connecticut, age 20.	July 20, '64.	Right; portion of the upper third. Disch'd June 30, 1865; pensioned.	89	Drake, J., Pt., B, 2d N. Y. Mounted Rifles, age 31.	June 1, '64.	Left; four inches of middle third. Disch'd Mar. 30, 1865; pensioned.
63	Clark, G. W., Lieut., I, 6th Iowa.	Aug. —, 1864.	Left; two and a half inches of middle third; by Surgeon J. H. Hutchinson, 15th Mich. Disch'd Dec. 24, 1864; not a pensioner.	90	Drake, R. P., Corp'l, K, 59th Illinois, age 22.	Dec. 16, '64.	Right; three inches middle third. Disch'd Sept. 14, 1865; loss of use of arm.
64	Clements, D., Pt., F, 11th Connecticut, age 22.	May 16, '64.	Right; one and a half inches of lower half. To V. R. C. April 23, 1865; not a pensioner.	91	Earle, F. W., Pt., G, 3d Arkansas, age 26.	Sept. 1, '64.	Left; portion of shaft at upper third; by Surg. Gold, C. S. A. Sent to prison at St. Louis.
65	Coffman, F., Pt., I, 20th Massachusetts, age 21.	April 26, '64.	Left; two and a half inches of middle third; by Ass't Surg. J. G. Perry, 20th Mass. Disch'd July 16, 1865; not a pensioner.	92	Egan, J., Lieut., C, 2d Cavalry, age 27.	June 1, '64.	Right; portion of upper third; by Ass't Surgeon J. W. Williams, U. S. A. Duty May 12, 1865.
66	Cole, A. V., Corp'l, G, 6th Michigan Cavalry, age 22.	May 28, '64.	Left; three inches of upper third. Disch'd July 6, 1865; pensioned.	93	Eislinger, F., Pt., A, 40th New Jersey, age 20.	April 2, '65.	Left; excision at middle third. Disch'd Sept. 7, 1865; not a pensioner.
67	Collins, N. B., Serg't, A, 11th New Hampshire, age 33.	May 12, '64.	Left; five inches of middle and lower third; by Surg. J. S. Ross, 11th New Hampshire. Disch'd July 3, 1865; pensioned; hand useful.	94	Ellis, L. S., Pt., G, 105th Illinois, age 22.	July 3, '64.	Right; excision at upper third. Disch'd June 7, 1865; pensioned.
68	Colwell, W., Pt., A, 146th New York, age 25.	May 1, '63.	Right; three inches upper third; by Ass't Surg. B. Howard, U. S. A. Disch'd July 4, 1863; pensioned; arm useless.	95	Engle, C. F., Serg't, K, 8d Ohio, age 23.	July 20, '64.	Right; four inches at junction of lower and middle thirds; by Surg. C. W. Myers, 8d Ohio. Disch'd Dec. 27, 1864; false ankylosis; pensioned.
69	Conklin, L. D., Pt., C, 137th New York, age 35.	Oct. 29, '63.	Left; two inches at middle third; by A. K. Field, Surg. 29th Ohio. Disch'd May 8, 1865; pensioned.	96	Ent, M. R., Serg't, B, 79th Ohio, age 19.	July 23, '64.	Right; three and a half inches upper third. Disch'd Feb. 17, 1865; pensioned; ankylosis of elbow joint.
70	Conway, M., Lieut., E, 173d New York.	June 14, 1863.	Right; three inches lower third. Disch'd October 18, 1865; arm useless.	97	Entler, D. M., Pt., B, 2d Virginia, age 28.	July 2, '63.	Left; three inches in lower third. Exchanged Sept. 22, 1863.
71	Cox, C., Serg't, G, 39th Illinois, age 27.	Oct. 27, '64.	Left; eight inches upper third; by Surg. C. M. Clark, 39th Illinois, and N. Y. Leet, 76th Penn'a. Disch'd June 8, 1865; pensioned; arm serviceable.	98	Evaus, A. H., Pt., C, 44th Illinois, age 39.	May 27, '64.	Right; one and a half inches at lower third; by Surgeon W. P. Pierce, 28th Illinois. Disch'd Feb. 15, 1865; pensioned; arm useless.
72	Cox, J., Pt., H, 26th Illinois, age 21.	Nov. 25, '63.	Right; four inches lower third. Disch'd July 8, 1864; pensioned.	99	Farrington, G. M., Lieut., H, 35th Mass., age 30.	Sept. 30, '64.	Left; four inches of upper third; by Surg. G. W. Snow, 35th Mass. Disch'd Jan. 13, 1865; pensioned; arm unfitted for manual labor.
73	Crandall, B., Pt., K, 81st New York, age 25.	July 2, '64.	Left; upper end of shaft turned out and sawed off square; by Surg. A. D. Palmer, 9th Maine. Disch'd April 1, 1865; pensioned.	100	Fernan, J. F., Corp'l, E, 63d Ohio.	Aug. 16, '63.	Left; four inches and twelve fragments of upper third. Disch'd October 29, 1863.
74	Crossman, S. H., Pt., D, 15th Michigan, age 18.	July 22, '64.	Left; two inches of shaft; by Surg. J. H. Hutchinson, 15th Michigan. Disch'd June 7, 1865; not a pensioner.	101	Finley, J. H., Pt., G, 2d Illinois Cavalry, age 19.	May 29, '64.	Right; four inches of middle third; by Surg. J. B. Cutts, 2d Illinois Cavalry. Disch'd Oct. 6, 1864; pensioned; arm useless.
75	Culbertson, S., Pt., M, 3d Penn. Cavalry, age 22.	Sept. 13, '63.	Left; three inches upper third. Mustered out August 24, 1864; pensioned.	102	Flemming, E., Pt., A, 152d New York, age 10.	Aug. 25, '64.	Right; portion of upper third. Discharged January 7, 1865.
76	Daily, R. H., Pt., G, 63d Pennsylvania, age 17.	May 8, '64.	Left; one inch upper third; subsequent excision, May 26th, of head and portion of upper third, by Surg. R. B. Bontecou, U. S. V.; cannot elevate arm or use shoulder in any way. <i>Phot.</i> Vol. 2, p. 9.	103	Flyna, H. J., Pt., M, 1st Vermont Cav'y, age 18.	Nov. 22, '64.	Left; two and a half inches of middle third. Disch'd Aug. 24, 1865; not a pensioner.
77	Davis, C., Pt., G, 1st N. York Dragoons, age 25.	May 31, '64.	Left; four inches of shaft, middle third. Discharged Jan. 5, 1865; pensioned. <i>Card Phot.</i> Vol. 2, p. 9.	104	Force, C. A., Pt., K, 60th New York, age 20.	July 25, '64.	Right; three inches middle third; by Surg. J. Reily, 33d New Jersey. Disch'd Aug. 31, 1865; arm amputated, by Dr. J. S. Greene, of Potsville, Iowa; pensioner. <i>Spec.</i> 1865.
78	Davis, J. R., Pt., B, 18th South Carolina, age 34.	Mar. 29, '65.	Right; three inches of shaft, middle third; by Ass't Surg. T. E. Nott, 18th S. Carolina. Sent to Fort Miffler May 9, 1865.	105	Foss, G. A., Serg't, A, 1st Wis. Cav., age 29.	May 24, '64.	Left; excision lower third. Mustered out Sept. 1, 1864; pensioned.
79	Davidson, H., Pt., B, 12th Mass.	Sept. 17, '62.	Left; two inches; by Brigade Surgeon A. L. Cox, U. S. V. Disch'd Jan. 11, 1863; pensioned. "arm in very bad condition."	106	Foster, J. M., Corp'l, F, 37th Mass., age 23.	April 6, '65.	Left; two inches at upper third. Disch'd Oct. 14, 1865; pensioned; arm powerless.
				107	Fowler, T. S., Lieut., D, 77th New York, age 23.	May 10, '64.	Left; three inches at junction of upper and middle thirds. Discharged Aug. 12, 1864; pensioned.
				108	Fox, J., Pt., B, 8th Vermont, age 21.	June 14, '63.	Left; two inches middle third. Disch'd Dec. 28, 1863. Died 1871.
				109	Frazier, L., Pt., C, 24th Texas, age 21.	Nov. 30, '64.	Left; excision of two inches of the shaft; by Dr. Lawrence. To Provost Marshal January 3, 1865.
				110	Frod, W. H., Pt., G, 70th Indiana, age 22.	May 15, '64.	Right resection at middle third; by Surg. J. Reily, 33d N. J. Discharged March 18, 1865.



No.	NAME, AGE, AND MILITARY DESCRIPTION.	DATES.	OPERATIONS, OPERATOR, RESULT.	No.	NAME, AGE, AND MILITARY DESCRIPTION.	DATES.	OPERATIONS, OPERATOR, RESULT.
111	Fulton, W. J., Serg't, II, 2d Penn. Reserves.	Sept. 17, 20, '62.	Left; four inches at middle third; by Surg. B. A. Vanderkief, U. S. V. Disch'd Dec. 20, 1862; pensioned; arm useless.	139	Heard, W., Pt., A, 40th Ill.	June 27, 27, '64.	Left; two inches at junction of the middle and lower thirds; by Surg. W. Graham, 40th Illinois. Discharged August 14, 1864.
112	Furber, F. B., Pt., II, 19th Maine, age 33.	May 6, 6, '64.	Right; three inches of lower third; by Surg. S. H. Plumb, 82d N. Y. Discharged May 15, 1865; disability three-fourths.	140	Heath, C. W., Pt., II, 6th Indiana, age 28.	May 27, 29, '64.	Excision of three inches at middle third; by Surg. H. B. Tuttle, 89th Illinois. Mustered out Sept. 22, 1864; no power to flex forearm.
113	Gallagher, W., Pt., K, 6th Iowa, age 25.	June 27, 27, '64.	Left; four inches of shaft; by Surg. J. H. Hutchinson, 15th Michigan. Amputation, by Surgeon M. K. Taylor, U. S. V. Disch'd July 26, 1865; pensioned.	141	Heek, H., Pt., I, 5th N. Y. Cavalry, age 29.	Oct. 19, 20, '64.	Left; excision of portion of shaft at middle third. Disch'd Jan. 10, 1865; not a pensioner.
114	Gardner, H., Serg't, I, 1st Rhode Island Cavalry, age 22.	Oct. 14, 17, '63.	Left; excision at upper third, by Surg. Edwin Bentley, U. S. V. Discharged February 16, 1864.	142	Hedrick, T. H., Capt., K, 13th Iowa, age 23.	July 22, 22, '64.	Right; two inches of upper third. Discharged Feb. 8, 1865; arm shortened two inches.
115	Gardner, S. A., Pt., B, 124th Ohio, age 22.	May 27, 30, '64.	Right; one and a half inches of upper third; by Surgeon D. C. Patterson, 124th Ohio. Disch'd March 27, 1865.	143	Heller, D., Pt., II, 51st Indiana, age 38.	Dec. 6, 6, '64.	Right; four inches at upper third. Disch'd May 24, 1865; pensioned; arm useless.
116	Gear, S., Corp'l, II, 49th Ohio, age 19.	Dec. 16, 16, '64.	Right; two and a half inches at middle third. Disch'd June 27, 1865; pensioned; died March 2, 1870.	144	Henry, N., Corp'l, F, 24th N. Y. Cavalry, age 31.	June 21, 21, '64.	Left; three inches of middle third. Discharged Jan. 30, 1865; false joint; good use of hand.
117	Gibbs, R. J., Pt., E., 6th Penn. Cav., age 21.	May 31, 31, '64.	Left; three inches at middle third. Duty Oct. 24, 1864; pensioned.	145	Hess, V., Serg't, A, 5th Ohio, age 22.	May 3, 3, '63.	Left; excision of most of surgical neck, by Surg. J. E. Herbst, U. S. V.; removal of half inch of bone and nearly whole circumference of humerus subsequently. Disch'd July 1, 1864. Spec. 1154
118	Giffard, O. F., Pt., I, 83d Penn., age 22.	June 27, 30, '62.	Left; resection two inches from shoulder, by A. A. Surg. J. Swinburne. Disch'd Jan. 16, 1863; "arm useless for labor."	146	Hetts, C., Pt., B, 7th Mich.	June 22, 22, '64.	Right; excision of lower third, by Surgeon G. Chaddock, 7th Michigan; amputation of arm July 29th. Discharged June 16, 1865; pensioned.
119	Giles, R. S., Serg't, K, 146th N. Y., age 23.	June 1, 1, '64.	Right; two inches of lower third; by Surg. T. M. Flandrau, 146th N. Y. Disch'd Jan. 9, 1865; arm amput'd four years after injury.	147	Hestand, I. H., Serg't, C, 23d Indiana.	May 1, 1, '63.	Right; resection at upper third. Discharged November 25, 1863.
120	Gilman, S. T., Pt., A, 5th Maine, age 30.	June 27, 28, '62.	Right; excision of lower third, by Surg. G. E. Brickett, 5th Maine. Amputation at shoulder joint, by A. A. Surg. B. B. Miles, Aug. 17th. Disch'd Oct. 6, 1862.	148	Hillman, A., Pt., I, 16th Penn. Cav., age 23.	April 22, 22, '64.	Right; excision at middle third. Disch'd Feb. 1, 1865; pension claim rejected.
121	Ginther, S., Pt., D, 88th Indiana, age 17.	May 13, 14, '64.	Left; one and a half inches at the lower and middle thirds. Discharged Feb. 21, 1865.	149	Hinspeter, J. G., Pt., C, 59th New York.	May 12, 12, '64.	Left; excision of middle third, by Surg. S. H. Plumb, 82d N. Y.; amputation of arm May 21, 1864. Mustered out August 27, 1864; pensioned; died Mar. 10, 1871.
122	Göebel, C. H., Captain, D, 73d Penn., age 23.	Nov. 25, 25, '63.	Left; three inches of middle third. Returned to duty; mustered out July 14, 1865.	150	Hintz, O., Pt., A, 1st Texas Cavalry, age 23.	June 6, 9, '64.	Right; four inches just below surgical neck; by Asst. Surg. A. E. Carothers. Disch'd Nov. 26, 1864; arm very useful.
123	Gordan, J. U., Pt., K, 55th Penn., age 17.	Mar. 31, 31, '65.	Left; five inches at middle third; by Surg. C. M. Clark, 39th Illinois. Disch'd July 22, 1865.	151	Hilton, F. I., Pt., M, 13th Penn. Cav., age 20.	May 30, 30, '64.	Right; one inch at lower third; amp. July 6th, upper third, by Surg. N. R. Moseley, U. S. V. Disch'd Sept. 21, 1864; pension'd; died Sept. 1, 1871. Spec. 2817.
124	Gore, J. M. L., Serg't, C, 13th Ohio Cav., age 28.	April 9, 9, '65.	Right; two inches at junction of middle with lower third; by Surg. F. LeMayne, 16th Penn. Cavalry. Disch'd May 31, 1865.	152	Hoadley, J. J., Pt., K, 14th Conn., age 29.	Mar. 25, 25, '65.	Left; four inches at upper third; by Surg. S. H. Plumb, 82d N. Y. Discharged August 4, 1865.
125	Gould, C. M., Corp'l, E, 61st Penn., age 27.	May 12, 12, '64.	Right; excision of portion at lower third. Disch'd Sept. 7, 1864.	153	Hoekings, J., Pt., M, 1st Mo. Engineers, age 48.	July 30, 30, '64.	Right; excision of portion at lower third. Mustered out February 6, 1865; not a pensioner.
126	Graham, C. E., Pt., G, 141st New York, age 22.	July 20, 21, '64.	Left; two and a half inches middle third, by Ass't Surg. M. T. Babcock, 141st N. Y. Disch'd July 15, 1865.	154	Hoagdon, T. F., Corp'l, B, 20th Maine, age 23.	May 5, 6, '64.	Right; five inches at upper third; by Surgeon J. Kerr, 62d Penn. Disch'd June 14, 1865.
127	Graham, J. M., Major, 7th Illinois Cav., age 38.	Dec. 16, 16, '64.	Right; four inches at upper third; by A. A. Surg. J. A. Hall; arm very useful. Disch'd Nov. 4, 1865.	155	Hoagman, J., Pt., E, 15th New Hampshire.	June 14, 14, '63.	Left; resection at middle third. Mustered out August 13, 1863.
128	Grant, A. H., Pt., K, 5th Iowa, age 21.	Nov. 25, 25, '63.	Left; excision of fractured portion at upper third, by Surg. E. J. Buck, 18th Wisconsin. Disch'd July 30, 1864.	156	Hally, L., Pt., E, 42d Ohio, age 20.	May 25, 25, '63.	Excision of four inches from middle and upper thirds, by Surg. B. F. Stevenson, 23d Kentucky. Returned to duty Jan. 24, 1864; perfect motion of joint.
129	Griffin, A., Pt., D, 62d Pennsylvania, age 25.	May 5, 6, '64.	Right; three and a half inches of shaft. Disch'd Feb. 25, 1865.	157	Holly, R. B., Pt., D, 39th Indiana, age 30.	July 19, 19, '63.	Left; two and a half inches at middle third. Discharged Oct. 14, 1863. Drowned Mar. 12, 1864.
130	Griffin, J., Pt., A, 3d N. York Artillery, age 19.	Mar. 10, 11, '65.	Left; two inches of fractured portion; amputation at middle third, by A. A. Surg. T. L. Van Norden. Disch'd Oct. 21, 1865.	158	Hoover, J., Pt., F, 2d Penn. Reserves, age 25.	Jan. 24, 24, '64.	Excision of one inch in middle third. Feb. 12th, amputation of arm. Disch'd July 14, 1864.
131	Griffith, R. C., Pt., C, 117th New York, age 23.	Sept. 29, 29, '64.	Left; two inches of upper third. Disch'd April 26, 1865.	159	Hopkins, E., Pt., H, 14th New York Heavy Artillery, age 18.	July 30, 30, '64.	Left; two and a half inches at middle third; by Surg. J. Oliver, 21st Mass. Disch'd Oct. 21, 1865.
132	Haley, E., Pt., A, 69th N. York, age 31.	June 16, 16, '64.	Right; portion of humerus excised, by Surgeon P. E. Hubon, 28th Mass. Disch'd Nov. 15, 1864.	160	Hopkins, G. F., Corp'l, H, 19th Maine, age 26.	May 6, 8, '64.	Right; four inches of lower portion of upper and upper portion of middle thirds; by Surg. G. Chaddock, 7th Mich. Disch'd Feb. 20, 1865; some atrophy.
133	Halsey, C. A., Pt., A, 36th Illinois, age 26.	May 26, 26, '64.	Left; three inches of middle third; by Surg. B. G. Pierce, 96th Illinois, and H. E. Hasse, 24th Wis. Returned to duty Sept. 22, 1864.	161	Horning, G., Pt., II, 8th Penn. Cav., age 23.	Oct. 12, 14, '63.	Left; one inch excised, by A. A. Surg. A. Hartsuff. Discharged Sept. 4, 1864.
134	Hann, H. H., Pt., E, 1st Maine Cav., age 19.	May 7, 1864.	Left; four inches at lower third. To V. R. C. April 13, 1865; pensioned; died Oct. 17, 1874.	162	Howard, D. D., Corp'l, B, 48th Miss., age 41.	July 3, 3, '63.	Left; four inches removed four inches from the shoulder. Furloughed Oct. 12, 1863.
135	Harding, T., Pt., K, 38th Wisconsin, age 25.	Mar. 4, 4, '65.	Right; one inch at upper third. Disch'd June 19, 1865. Phot.	163	Humphreys, T., Pt., D, 5th Michigan, age 23.	July 2, 2, '63.	Left; excision at upper third. Disch'd Oct. 1, 1864.
136	Harrison, W. H., Serg't, K, 28th Penn., age 23.	July 20, 20, '64.	Left; five inches in middle third. Disch'd Aug. 21, 1865; arm useless; died Sept. 17, 1866.	164	Hunter, J., Pt., A, 12th Wisconsin, age 45.	July 28, 29, '64.	Left; two inches at middle third; by Surg. H. McKernan, 17th Wisconsin. Discharged May 26, 1865; pensioned; arm partially useless for manual labor.
137	Hart, J. G., Pt., I, 20th Illinois, age 18.	May 12, 12, '63.	Left; two inches middle third; by Surg. A. H. Brundage, 32d Ohio. Disch'd Nov. 22, 1863; limb useless.	165	Hutchinson, S. A., Serg't, D, 93d Illinois, age 23.	Nov. 25, 1863.	Right; four inches of upper third. Disch'd Aug. 18, 1864; arm entirely useless. Died May 17, 1869.
138	Harvey, M., Pt., G, 9th Mich. Cav., age 44.	Sept. 13, 15, '64.	Right; three inches at middle third; by Surg. J. H. Rodgers, 104th Ohio. Disch'd Sept. 1, 1865; arm useless; died.				

No.	NAME, AGE, AND MILITARY DESCRIPTION.	DATES.	OPERATIONS, OPERATOR, RESULT.	No.	NAME, AGE, AND MILITARY DESCRIPTION.	DATES.	OPERATIONS, OPERATOR, RESULT.
166	Israel, J., Pt., B, 62d Penn., age 23.	July 2, '63.	Right: one and a half inches lower third. Disch'd July 13, 1861; union of parts firm.	196	Leonard, C. A., Pt., A, 20th Massachusetts.	July 3, '63.	Left: portion of the upper third. Discharged July 25, 1864, and pensioned; arm nearly useless.
167	Ives, A., Corp'l, K, 6th Penn. Reserves, age 19.	July 3, '63.	Left: four inches middle third; by Surg. C. Bower, 6th Penn. Reserves. To V. R. C. Nov. 19, 1863; ligamentous union.	197	Lernmond, F. H., Adjutant, 103d Illinois.	Mar. 21, '65.	Right: two inches lower third; by Surg. R. Morris, 103d Illinois. Disch'd June 21, 1865; use impaired.
168	J——, John A., C. S. A.	July 20, '64.	Six and a half inches upper third; by Dr. Roan. Arm serviceable.	198	Lillard, H. C., Pt., G, 45th N. Carolina, age 20.	Mar. 26, '63.	Left: three inches middle third; by Surgeon T. P. Oakes, 56th Mass. Released June 11, 1865; favorable.
169	J——, —, C. S. A. ....	May 15, '64.	Three inches lower third; arm of no service.	199	Linthurst, J. F., Pt., B, 12th Penn., age 24.	Sept. 17, '62.	Three inches middle third. Discharged April 7, 1863; no union.
170	John, Z. W., Pt., A, 7th Iowa, age 20.	Aug. 10, '64.	Right: five inches middle third; by Surg. W. R. Marsh, 2d Iowa. Disch'd Jan. 20, 1865; paralysis.	200	Locker, R. E., Serg't, G, 190th Penn., age 26.	Feb. 6, '65.	Right: three inches middle third; by Surg. H. Bendoll, 86th N. Y. Discharged October 13, 1865.
171	Johnson, W. S., Capt., M, 1st Arkansas Cavalry.	April 18, '63.	Right: four inches upper third; by Asst. Surg. J. E. Tefft, 1st Ark. Cav. To V. R. C. Sept. 30, 1863. Phot. Series, No. 353.	201	Love, C., Pt., A, 20th Maine, age 19.	July 2, '63.	Right: three inches middle third. Discharged March 21, 1865.
172	Jones, A., Pt., F, 112th New York, age 24.	June 1, '64.	Right: four inches upper third. Disch'd Oct. 21, 1865; did well. Spec. 289.	202	Luther, F. C., Pt., F, 1st N. Y. Dragoons, age 25.	Sept. 19, '64.	Right: two inches lower third. Discharged March 21, 1865.
173	Jones, H. T., Serg't, H, 6th Ill. Cav., age 22.	Aug. 13, '64.	Right: three inches upper third; by A. A. Surg. H. W. Coale, U. S. A. Disch'd April 7, 1865; arm powerless.	203	Lynch, C., Pt., G, 73d New York, age 20.	May 6, '64.	Right: at upper third; by Asst. Surgeon H. Howard, U. S. A. Discharged Nov. 9, 1864, and pensioned; partial ankylosis.
174	Jordan, S., Pt., M, 62d Pennsylvania, age 18.	May 13, '64.	Left: small portion lower third; by Surgeon J. Kerr, 62d Penn. Disch'd July 24, 1865; pensioned; bone ununited; false joint.	204	Mack, C. L., Pt., II, 89th New York, age 40.	April 2, '65.	Left: three inches at junction of upper with middle thirds. Discharged Nov. 25, 1865; satisfactory.
175	Judd, M., Pt., B, 13th Kentucky, age 22.	May 13, '64.	Right: five inches middle third; by Surg. J. W. Lawton, U. S. V. Discharged February 16, 1865.	205	Marsh, H. A., Pt., B, 32d Iowa, age 20.	May 18, '64.	Right: two inches of middle third; by Surgeon J. Roberts, U. S. V. Discharged April 20, 1865.
176	Kanouse, L. C., Lieut., D, 6th Michigan Cavalry.	Sept. 19, '61.	Left. Mustered out; recovered.	206	Marshall, D., Lieut., E, 3d N. Hampshire, age 24.	Jan. 15, '65.	Right: four inches at upper and middle thirds; by Asst. Surg. H. C. Merryweather, 6th U. S. C. T.; amputation July 4, 1865. Disch'd July 20, 1865; tender stump.
177	Keller, J., Pt., C, 1st Tex. Cavalry, age 40.	June 6, '64.	Left: three and a half inches at junction of the middle and lower thirds; by Asst. Surgeon A. E. Crothers, U. S. V. Discharged July 14, 1865; arm firmly united.	207	Mason, W. A., Pt., C, 2d Arkansas, age 24.	Nov. 30, Dec. 1, 1864.	Right: about three inches at middle third. To Provost Marshal March 23, 1865.
178	Kelley, J., Pt., G, 5th U. S. Cavalry, age 33.	Sept. 19, '64.	Right: four inches upper third; by Asst. Surg. W. S. Newton, 91st Ohio. Discharged April 17, 1865; no union.	208	Massey, W. T., Pt., I, 7th Illinois.	Oct. 5, '64.	Left: entire upper third; by Asst. Surg. G. W. Crossley, 57th Ill. Discharged Mar. 12, 1865; pensioned; nearly normal.
179	Keleher, S., Pt., K, 28th Kentucky, age 24.	June 27, '64.	Left: three inches upper third; by Surg. E. B. Glick, 40th Ind. Discharged May 27, 1865.	209	McCue, J. D., Pt., E, 8th Illinois, age 22.	April 9, '65.	Left: fractured portion upper third; by Surgeon J. B. Dieker, 47th Indiana. Disch'd June 5, 1865; pensioned; no union. Injured Oct., 1865; Dr. J. H. Stanway, late Asst. Surg. 102d Illinois, brought the bones together and applied friction to roughen the ends; union took place March 1, 1866; a good and useful limb.
180	Kellum, I., Pt., B, 97th Indiana, age 25.	July 16, '63.	Right: four inches upper third; by Surg. W. H. Leonard, 51st N. Y. Disch'd May 31, 1864; loss of use of forearm; pensioned; died July 12, 1874.	210	McDonald, A. D. J., Lieut., C, 108th N. Y., age 33.	July 2, '63.	Left: portions of middle and lower thirds; by Asst. Surgeon Fred. Wolf, 39th New York. Disch'd Nov. 21, 1863, and pensioned; arm useless; died Mar. 21, 1871.
181	Kemp, J., Lieut., G, 66th Indiana, age 35.	May 27, '64.	Left: four inches; by Surg. A. P. Marsh, 56th Ill. Disch'd Jan. 13, 1865; no union; arm useless.	211	McGarrity, J., Pt., F, 96th Pennsylvania.	June 27, '62.	Right: injured part of upper third; by A. A. Surg. J. Swinburne. Disch'd January 20, 1863.
182	Kibler, J. E., Pt., C, 76th Ohio, age 20.	May 14, '64.	Left: three inches lower third; by Surgeon G. L. Carhart, 31st Iowa. Disch'd Oct. 4, 1864; no bony union.	212	McIntyre, J., Pt., G, 2d Michigan, age 33.	Nov. 24, '63.	Right: upper third; by Surg. A. M. Wilder, U. S. V. Duty Mar. 23, 1864; amputated Mar., 1865.
183	Kilbourne, L., Pt., C, 8th Michigan, age 30.	May 12, '64.	Right: five inches middle third; by Surg. S. S. French, 20th Mich. Disch'd Nov. 14, 1864; arm useful.	213	McLaehlan, E., Pt., K, 89th Illinois, age 39.	June 25, '63.	Left: both ends in upper third. Discharged Mar. 30, 1864; ligamentous union.
184	King, L. A., 2d Lieut., F, 10th Kentucky, age 25.	Aug. 3, '64.	Left: two inches middle third; by Surg. W. H. Mullen, 12th Kentucky. Disch'd March 9, 1865.	214	McNaughton, P., Lieut., H, 151st N. Y., age 23.	July 9, '64.	Left: three inches middle third; by A. A. Surg. T. J. Dunatt, U. S. A. Disch'd Feb. 18, 1865; good condition.
185	Kline, L. E., Pt., C, 33d Missouri, age 21.	June 6, '64.	Right: two inches middle third. Disch'd Dec. 11, 1865; pensioned; arm useless; necrosis.	215	Meisner, C., Pt., B, 7th N. Y. Heavy Artillery, age 22.	May 12, '64.	Left: three inches middle third; by Asst. Surg. H. Howard, U. S. A. Disch'd June 6, 1865; union perfect; passive motion.
186	Klugh, J., Capt., I, 209th Pennsylvania, age 47.	Mar. 25, '65.	Right: two inches middle third; by Surg. W. G. Hunter, 211th Penn. Disch'd May 15, 1865.	216	Merrill, E. J., Capt., G, 17th Maine, age 37.	May 3, '63.	Left: five inches of upper third. Disch'd Dec. 15, 1863; condition good.
187	Knapp, A., Pt., B, 137th New York, age 25.	Oct. 28, '63.	Right: two inches lower third. Disch'd Dec. 3, 1864.	217	Metzler, G. M., Pt., H, 30th Iowa.	June 15, '64.	Right: by Surg. B. N. Bond, 27th Missouri. Furloughed July 30, 1864.
188	Lacy, H., Pt., I, 4th Georgia, age 21.	Sept. 19, '64.	Left: four inches; by Surgeon Young, 4th Georgia. To Fort Melleury Feb. 16, 1865; favorable.	218	Miller, J. H., Serg't, C, 36th Mass., age 32.	June 3, '64.	Left: four inches of lower third. Returned to duty Dec. 18, 1864; partial paralysis; forearm useful.
189	Lake, H., Pt., B, 1st New Jersey Cav., age 28.	May 5, '64.	Right: three inches upper third; amp. Disch'd Sept. 24, 1864.	219	Mills, A. R., Pt., E, 39th Iowa, age 35.	Oct. 5, '64.	Left: three inches middle third; by Asst. Surg. G. W. Crossley, 57th Illinois. Disch'd July 6, 1865; cartilaginous union; ankylosis.
190	Lanics, W. E., Pt., K, 3d North Carolina.	Sept. 19, '64.	Four inches. Deserted October 25, 1864.	220	Moffat, R., Serg't, K, 121st Pennsylvania, age 24.	July 15, '64.	Left: four inches upper third; by Surg. F. C. Renner, 143d Penn. Discharged June 29, 1865.
191	Laughran, P., Pt., C, 35th New Jersey, age 33.	Oct. 28, '63.	Right: at upper third. Disch'd Aug. 27, 1865; pensioned; arm useless for manual labor; died Feb. 15, 1870; cause unknown.	221	Montague, H. H., Serg't, F, 30th Mass., age 33.	June 3, '64.	Right: three inches upper third. Discharged May 19, 1865, and pensioned; non-union.
192	Lauson, G., Pt., A, 28th Massachusetts, age 38.	May 6, '64.	Right: five inches middle third. Disch'd April 1, 1865; pensioned.				
193	Leed, T. F., Pt., A, 99th Pennsylvania, age 23.	Dec. 13, '62.	Left: three inches. Discharged April 22, 1863; false joint; died Oct. 26, 1865.				
194	Leguey, J., Pt., G, 9th Maine, age 30.	Sept. 29, '64.	Left: four inches middle third. Discharged February 8, 1865, and pensioned; partial use of arm.				
195	Lemnell, J., Pt., I, 5th Wisconsin, age 40.	April 2, '65.	Left: two inches middle third; by Surg. G. D. Wilber, 5th Wis. Disch'd Oct. 16, 1865; interspace one inch.				



No.	NAME, AGE, AND MILITARY DESCRIPTION.	DATES.	OPERATIONS, OPERATOR, RESULT.	No.	NAME, AGE, AND MILITARY DESCRIPTION.	DATES.	OPERATIONS, OPERATOR, RESULT.
222	Moran, P. J., Serg't, I, 59th New York, age 26.	May 6, '64.	Right; two inches middle third; by Surg. S. H. Plumb, 82d New York. Disch'd June 12, 1865; non-union; died April 28, 1873.	247	Pettijohn, C., Pt., E, 50th Ohio.	May 31, '64.	Left; three inches lower third; by Surg. C. K. Crawford, 50th Ohio. Duty Aug. 25, 1864; not a pensioner.
223	Moran, T., Pt., F, 29th Pennsylvania, age 38.	May 25, '64.	Right; injured portion. Duty Aug. 1, 1864; rejected as pensioner.	248	Phillipsen, P., Pt., G, 26th Wisconsin, age 32.	July 29, '64.	Left; three and a half inches upper third. Discharged May 25, 1865; pensioned.
224	Morton, W. J., Serg't, II, 209th Penn., age 23.	Mar. 25, '65.	Right; three inches middle third; by Asst. Surg. J. A. Hayes, 11th N. H. Disch'd June 20, 1865; false joint.	249	Pickett, C., Pt., E, 20th Michigan, age 18.	June 18, '64.	Left; four inches middle third; by Surg. S. S. French, 20th Mich. Discharged June 10, 1865.
225	Moulton, E. C., Pt., D, 13th N. H., age 43.	Sept. 30, '64.	Right; three inches upper third. Disch'd Aug. 11, 1865; functions good. <i>Specs.</i> 4363.	250	Pineo, J. H., Serg't, K, 12th Maine.	June 19, '63.	Left; in upper third; by Surg. J. H. Thompson, 12th Maine. Discharged June 16, 1864; pensioned; necrosis.
226	Mullen, T., Corp'l, B, 61st Ohio.	June 1, '64.	Right; two inches. Disch'd Dec. 13, 1864; pensioned.	251	Piper, J., Pt., D, 73d Ill., age 37.	May 14, '64.	Left; two and a half inches upper third; by Surg. H. E. Hasse, 24th Wis. Disch'd Aug. 5, 1865, and pensioned; no use of arm.
227	Murphy, P. E., Lieut., E, 9th Mass., age 23.	May 5, '64.	Left; upper third; by Surg. D. F. Sullivan, 5th Mass.; amputated at upper third May 9th. Disch'd June 25, 1864, and pensioned; stump sound.	252	Porter, J., Pt., L, 1st New Jersey Cavalry, age 19.	May 28, '64.	Right; three inches upper third; by Surg. W. B. Reznar, 6th Ohio Cavalry. Duty April 25, 1865. Disch'd June 6, 1865; pensioned.
228	Myers, E. A., Capt., I, 72d Penn., age 34.	June 22, '64.	Left; two inches lower third; by Surg. G. Chaddock, 7th Mich. Mustered out Aug. 24, 1864, and pensioned; entirely disabled.	253	Porubsky, E., Pt., B, 46th New York, age 25.	April 2, '65.	Right; two inches upper third; by Surg. D. C. Roundy, 37th Wis. Disch'd Nov. 27, 1865, and pensioned; no union.
229	Myers, I., Pt., D, 100th Indiana, age 32.	May 13, '64.	Right; two inches at junction of middle and lower thirds; by Surg. W. Lomax, 12th Indiana; non-union; secondary excision Dec. 10, 1864. Disch'd June 17, 1865; ankylosed elbow; chronic ulceration.	254	Price, J., Pt., E, 139th New York, age 32.	July 5, '64.	Left; three inches upper third. Disch'd June 1, 1865; entirely disabled.
230	Myers, O. C., Capt., G, 2d Georgia, age 30.	Dec. 16, '64.	Right; two inches middle third. To Prov. Marshal June 14, 1865.	255	Quickel, J., Pt., E, 87th Pennsylvania, age 32.	Nov. 24, '64.	Three inches upper third; amputated Dec. 12, 1863. Disch'd February 15, 1864.
231	Myers, T., Pt., F, 124th Indiana, age 30.	Nov. 26, '64.	Right; two inches middle third. Disch'd May 15, 1865; unhealed.	256	Redding, G. W., Pt., L, 22d New York Cavalry, age 28.	Nov. 6, '64.	Left; three and a half inches middle third. Discharged June 12, 1865; false joint.
232	Naylor, Samuel, Pt., E, 78th Illinois, age 27.	July 19, '64.	Left; three inches middle third. Disch'd May 2, 1865; partial use.	257	Reid, T. E., Corp'l, C, 3d '64.	June 3, '64.	Left; three inches lower third; by Surg. J. A. Spencer, 69th N. Y. Disch'd Feb. 6, 1865; pensioned; arm flexile; necrosis. Died Jan. 27, 1871.
233	Nicholson, O., Pt., M, 3d Wisconsin Cav., age 18.	Oct. 20, '63.	Right; two inches upper third; by Asst. Surg. A. C. Van Duyn, U. S. V. To V. R. C. Aug. 2, 1864; useful arm.	258	Rice, B. F., Corp'l, I, 26th Illinois.	May 13, '64.	Right; three and a half inches upper third; by Surg. A. Goslin, 46th Illinois. Discharged July 20, 1865.
234	Nipper, R., Pt., E, 10th East Tenn. Cav., age 20.	Aug. 1, '64.	Right; two inches lower third; by Surg. L. C. Fouts, 2d Tenn. Mounted Infantry. Disch'd Mar. 21, 1865; pensioned; ankylosed elbow; arm of no use.	259	Riffles, D. J., Pt., B, 10th West Virginia, age 19.	Mar. 31, '65.	Left; three inches middle third; by Surg. C. M. Clark, 39th Ill. Duty July 26, 1865.
235	Nobles, W. M., Pt., K, 31st North Carolina, age 35.	May 31, 1864.	Right; four inches upper third. Furloughed Aug. 11, 1864. Reported by Surg. W. L. Baylor, P. A. C. S.	260	Riley, W. H., Pt., A, 59th Virginia, age 28.	June 17, '64.	Right; in lower third. Furloughed July 28, 1864.
236	Northrop, J., Pt., F, 103d Ohio, age 20.	Nov. 25, '63.	Right; fractured ends, upper third; by Surg. G. B. Cogswell, 29th Mass. Disch'd July 30, 1864; pensioned. Arm useless. Died March 4, 1872.	261	Roberts, B. F., Pt., I, 13th Penn., age 18.	Nov. 27, '63.	Left; two inches of lower third. Disch'd May 5, 1865; necrosis and ulceration.
237	Ostron, J. G., Pt., A, 3d Tenn. Cav., age 35.	May 24, '64.	Left; three inches upper third; by Surg. R. L. Stanford, U. S. V. Deserted Oct. 4, 1864.	262	Roberts, G. M., Pt., B, 13th Georgia, age 26.	Oct. 19, '64.	Left; in middle third. Transferred to Fort McHenry Jan. 5, 1865.
238	Ott, B., Pt., B, 26th Ohio, age 26.	May 10, '64.	Right; one and a half inches upper third; by Surg. J. Chapman, 123d N. York. Disch'd May 27, 1865; pensioned; partial union; loss of power. Died September 8, 1868.	263	Roberts, S. G., Lieut., B, 17th Mass., age 25.	April 9, '63.	Right; two inches middle third; by Surg. C. A. Cowgill, U. S. V. Disch'd August 3, 1864; perfect recovery.
239	Overmire, S., Pt., D, 14th Ohio.	Sept. 19, '63.	Left; two inches upper third. Duty Feb. 24, 1865; arm weak; necrosis still continues (April, 1873).	264	Robinson, D., Pt., D, 56th Massachusetts, age 35.	May 18, '64.	Left; three inches middle third; by Surg. T. F. Oakes, 55th Mass. To V. R. C. May 4, 1865; ligamentous union; useful arm.
240	Parker, C. W., Pt., F, 45th Pennsylvania, age 22.	May 6, '64.	Left; in upper third. To V. R. C. Jan. 18, 1865. Disch'd April 14, 1865; pensioned.	265	Robson, J., Pt., E, 32d-9th Massachusetts, age 26.	May 7, '64.	Right; in lower third. Disch'd June 23, 1865; loss of use of forearm.
241	Patchin, A. J., Pt., E, 20th Ohio, age 27.	July 27, '64.	Right; three inches upper third. Discharged February 27, 1865; favorable.	266	Robinson, J. Y., Pt., I, 8th Kansas, age 22.	July 21, '64.	Left; two inches upper third. Duty Jan. 18, 1865; osseous union.
242	Pease, I., Pt., D, 19th Maine, age 38.	Mar. 31, '65.	Right; three inches at junction of lower and middle thirds; by Surgeon D. W. Maul, 1st Delaware. Disch'd Aug. 24, 1865; no control of forearm; pensioned.	267	Rohle, G. A., Corp'l, II, 97th New York, age 33.	May 7, '64.	Left; portion in the upper third. Discharged September 11, 1865.
243	Pelton, Alfred, Serg't, I, 3d Michigan.	May 12, '64.	Right; in upper third; by Surg. H. P. Lyster, 5th Mich. Disch'd January 15, 1865.	268	Rosenthal, L., Pt., F, 69th New York, age 32.	June 16, '64.	Right; portion in middle third; by Surg. S. H. Plumb, 82d N. Y. Discharged March 29, 1865.
244	Perkins, J. S., Serg't, G, 14th Va. Cav., age 25.	July 9, '64.	Left; four inches middle third; by A. A. Surg. T. J. Dumott, U. S. A. Paroled Nov. 22, 1864; non-union. <i>Specs.</i> 3937, 1480.	269	Ross, G. M., Lieut., G, 77th New York.	Sept. 19, '64.	Right; upper third; by Surg. G. T. Stevens, 77th N. Y. Duty Nov. 4, 1864; perfect recovery; arm nearly as useful as the other.
245	Peters, F., Pt., L, 14th N. Y. Heavy Artillery, age 18.	Sept. 30, '64.	Right; two inches upper third. Discharged August 4, 1865; can use arm but little.	270	Rowley, E., Pt., I, 8th Iowa Cavalry, age 18.	May 13, '64.	Left; two inches middle third; by Surg. W. H. Finley, 8th Iowa Cavalry. Disch'd July 10, 1865.
246	Peters, J., Corp'l, C, 33d Missouri, age 34.	Dec. 16, '64.	Left; two and a half inches at junction of middle and lower thirds; by Surg. A. T. Bartlett, 33d Mo. Disch'd June 3, 1865; no use of arm.	271	Ruddock, W., Corp'l, C, 117th New York, age 21.	Oct. 27, '64.	Left; three and a half inches lower third; by Surg. H. W. Carpenter, 117th N. Y. Discharged May 4, 1865; useful arm.
				272	Russell, J. M., Pt., F, 12th Mississippi.	July 29, '64.	Left; four inches. Furloughed Sept. 10, 1864; suppuration when furloughed.
				273	Rutherford, C. E., Pt., A, 6th Illinois, age 31.	May 16, '64.	Right; three and a half inches middle third; by Surg. W. R. Marsh, 2d Iowa. Disch'd June 13, 1865; no bony union.
				274	Rykert, G. M., Corp'l, C, 154th N. York, age 22.	July 1, '63.	Right; four inches upper third. Disch'd Jan. 11, 1864; no control of arm.
				275	Saunders, J., Pt., B, 31st Maine, age 18.	May 12, '64.	Right; middle third; by Surg. L. W. Bliss, 51st N. York. Disch'd May 18, 1865.

No.	NAME, AGE, AND MILITARY DESCRIPTION.	DATES.	OPERATIONS, OPERATOR, RESULT.	No.	NAME, AGE, AND MILITARY DESCRIPTION.	DATES.	OPERATIONS, OPERATOR, RESULT.
276	Scanlon, J., Pt., A, 111th Ohio, age 21.	June 2, '64.	Left: five inches upper third; by Surg. C. W. McMillen, 1st Tenn. Disch'd Feb. 10, 1865.	302	Totten, C., Corp'l, E, 4th Iowa Cavalry, age 25.	Oct. 25, '64.	Right: two inches upper third. Disch'd June 1, 1865; arm entirely useless.
277	Scott, F., Serg't, B, 23d Wisconsin, age 27.	Nov. 3, '63.	Left: in upper third. Discharged March 10, 1864.	303	Toynont, W., Pt., E, 6th Michigan Cavalry.	Nov. 15, 1863.	Right: about three inches upper third. Disch'd Aug. 25, 1864; motion restricted.
278	Scott, J., Pt., E, 29th Colored Troops, age 27.	July 30, '64.	Left: two and a half inches upper third; by Surg. D. Mackay, 29th U. S. Colored Troops. Disch'd June 8, 1865; arm useless.	304	Van Brunt, A., Pt., C, 4th New York, age 22.	May 10, '64.	Left: three inches upper and middle thirds; by Surg. J. A. Hall, 4th N. Y. Discharged July 14, 1865; ligamentous union.
279	Shaffer, H., Pt., G, 12th Indiana, age 19.	May 13, '64.	Right: two and a half inches at junction of lower and middle thirds; by Surg. A. Goslin, 48th Illinois. Disch'd June 14, 1865.	305	VanVulkenburg, E. Corp'l, F, 109th N. Y., age 32.	May 12, '64.	Left: two inches middle third; by Surg. S. S. French, 20th Mich. Disch'd October 3, 1864; some mobility of elbow.
280	Shattuck, N., Pt., F, 5th Michigan, age 23.	Oct. 27, '61.	Right: portion of upper third. Disch'd Feb. 18, 1865.	306	Wall, G. W., Capt., C, 24th Mississippi, age 24.	April 6, '65.	Right: three inches middle third. To Fort McHenry May 9, 1865.
281	Shelley, J. J. L., Corp'l, K, 5th N. York, age 25.	June 27, '62.	Left: injured portion, middle third; by A. A. Surg. J. Swinburne, U. S. A. Disch'd Sept. 10, 1862; no bony union; arm useless.	307	Watkins, W. H., Serg't, E, 12th Miss. Cavalry, age 30.	Dec. 16, '64.	Right: five inches; by A. A. Surg. A. Rolls, U. S. A. Disch'd April 14, 1865; not a pensioner.
282	Shunway, D., Pt., K, 19th Illinois, age 21.	June 17, '64.	Right: one and a half inches. Discharged Nov. 24, 1865; ununited.	308	Watson, S., Pt., E, 184th Pennsylvania, age 24.	June 3, '64.	Right: at middle third; by Surg. M. Rizer, 72d Penn. Disch'd Feb. 20, 1865; motion recovered, strength not.
283	Sigler, J. W., Capt., I, 150th Penn., age 31.	May 10, '64.	Three inches lower third. Duty July, 1864; bone united; arm weak. Died Jan. 12, 1869.	309	Welch, J., Pt., H, 6th U. S. Infantry, age 26.	Mar. 18, '65.	Left: five inches upper third; by Act. Asst. Surg. J. E. Semple; amputation at the shoulder joint. Disch'd June 3, 1865; pensioned.
284	Smend, L. B., Pt., A, 9th New York Cav., age 35.	May 7, '64.	Right: two inches upper part of middle third; by Surg. B. G. Streeter, 4th N. Y. Cav. Disch'd Oct. 11, 1864; no bony union; arm of some use. <i>Phot.</i> , No. 2.	310	Wells, J., Pt., F, 19th U. S. Colored Troops.	July 30, '64.	Right: four inches middle third; by Surg. G. K. Potts, 23d U. S. C. T.; arm amputated August, 1864. Disch'd June 12, 1865.
285	Smith, A. H., Pt., A, 7th Indiana, age 26.	May 25, '64.	Right: three and a half inches upper third. Disch'd May 25, 1865.	311	Wentz, H., Pt., F, 112th New York, age 36.	Jan. 15, '65.	Right: three inches upper third; by Asst. Surg. F. B. Kimball, 3d New Hampshire. Disch'd Sept. 6, 1865.
286	Smith, H. T., Pt., C, 28th Georgia, age 20.	July 3, '63.	Left: six inches upper third; by Surg. W. J. Arrington, C. S. A. Exchanged Mar. 17, 1864; bone united; motion imperfect.	312	Westmoreland, J. E., Pt., I, 59th Virginia, age 25.	April 9, '65.	Left: three inches upper third; by Surg. Hopkins, C. S. A. To Fort McHenry May 9, 1865.
287	Smith, R. A., Pt., B, 67th New York, age 45.	June 27, '62.	Right: three inches lower third. Arm useless; amputated Feb. 22, 1863. Disch'd April 14, 1863.	313	Wheatley, T., K, 13th Georgia.	May 4, '65.	Two and a quarter inches lower third; recovering rapidly.
288	Sommers, J. B., Pt., I, 12th Wisconsin.	July 21, '64.	Right: one and a half inches lower third; by Surg. O. B. Ormsby, 45th Illinois. To V. R. C. April 24, 1865.	314	Wheeler, W. M., Pt., A, 6th Vermont, age 43.	May 5, '64.	Right: two inches upper third; by Surg. G. T. Stevens, 77th N. Y. Discharged May 6, 1865.
289	Spencer, J., Pt., G, 103d Ohio, age 23.	June 23, '64.	Left: four inches middle third; by Surg. C. W. McMillen, 1st Tenn. Disch'd April 27, 1865.	315	Wilson, J., Pt., D, 155th New York, age 36.	Mar. 29, '65.	Left: five inches upper and middle thirds. Discharged June 29, 1865; and pensioned; interspace two inches.
290	Stewart, J. F., Pt., B, 110th Penn., age 20.	May 6, '64.	In upper third. Disch'd June 28, 1865.	316	Winchell, S., Pt., I, 142d New York, age 30.	Jan. 15, '65.	Left: four inches middle third. Disch'd May 23, 1865; pensioned; arm useless; no bony union. Died September 5, 1871.
291	Stewart, W., Pt., C, 23d Indiana.	May 12, '63.	Right. Disch'd July 28, 1864.	317	Winslow, J., Pt., G, 16th Maine, age 19.	June 18, '64.	Left: one inch lower third. Discharged Jan. 2, 1865; no bony union.
292	Stiles, J. R., Pt., G, 148th New York, age 28.	June 18, '64.	Right: three inches upper third. Disch'd June 24, 1863; elbow ankylosed.	318	Wood, F. V., Pt., A, 14th Ohio, age 18.	June 2, '64.	Right: three inches middle third. Discharged January 23, 1865.
293	Stone, A. E., Pt., H, 115th New York, age 21.	Jan. 15, '65.	Left: portion in upper third; by Surg. G. C. Jarvis, 7th Conn. Discharged June 4, 1865.	319	Woodman, S. W., Pt., C, 2d Mass., age 24.	July 1, '63.	Left: two inches middle third. Disch'd April 19, 1864, and pensioned; can use hand and rotate forearm.
294	Stone, G. H., Serg't, A, 8th N. Y. H. A., age 21.	June 16, '64.	Left: three inches middle third. Disch'd Mar. 2, 1865; did well.	320	Woods, E. D., Corp'l, K, 25th Indiana, age 27.	Oct. 15, '64.	Right: four inches middle third; amputation. Disch'd May, 1865.
295	Stone, J., Pt., D, 92d New York, age 24.	June 1, '64.	Left: two inches of upper third. Disch'd Jan. 12, 1865; useful arm. Died Jan. 25, 1874, of pyæmia.	321	Young, B. F., Corp'l, A, 1st Maine Cav., age 27.	Oct. 27, '64.	Right: two inches upper third. Discharged June 10, 1865, and pensioned.
296	Strathdee, G., Pt., A, 100th Illinois, age 28.	Nov. 25, '63.	Left: one and a half inches middle third; amputated Feb. 9, 1864. Disch'd Feb. 5, 1865.	322	Young, E., Pt., D, 59th Illinois, age 20.	Dec. 16, '64.	Right: middle third. Discharged July 13, 1865.
297	Stout, F., Pt., C, 48th New York, age 18.	Feb. 21, '65.	Right: four inches middle third; by Surg. A. D. Palmer, 9th Me. Dis. June 6, 1865; not a pensioner.	323	Young, H., Pt., K, 20th Connecticut, age 29.	Mar. 19, '65.	Left: between upper and middle thirds. Disch'd Nov. 7, 1865; non-union; limb useless.
298	Tarbell, J., Pt., K, 6th New Hampshire, age 36.	June 28, '64.	Right: injured portion. Duty September 15, 1864.	324	Zerther, C., Pt., I, 63d Pennsylvania.	June 3, '64.	Left: injured portion. Duty July 20, 1864.
299	Tathwell, E. E., Pt., A, 96th Ohio, age 18.	Nov. 3, '63.	Right: about two inches lower third; by Asst. Surg. S. McClellan, 13th Conn. Disch'd March 10, 1864; favorable.	325	Zimmerman, C., Serg't, H, 6th Conn., age 30.	Aug. 14, '64.	Left: four inches of upper third; amputated August 21. Disch'd November 18, 1864.
300	Taylor, J. H., Pt., G, 8th Alabama, age 28.	June 23, '64.	Right: fractured ends in lower third; by Surgeon of 8th Alabama. Retired September, 1864; good motion of joint.	326	Zimmerman, S., Lieut., H, 81st N. Y., age 24.	June 3, '64.	Right: five inches upper third. Discharged September 21, 1864; no bony union.
301	Thompson, C. H., Pt., B, 38th Virginia.	Jan. 19, '65.	Left: four inches of lower third. Purloughed March 21, 1865.				

Of the foregoing list of three hundred and twenty-six operations, two hundred and twenty-six were practised on Union and thirty-one on Confederate soldiers. Two hundred and seventy-six of the men were discharged and pensioned, nineteen returned to duty, thirty-one were exchanged or paroled. Seventeen of the pensioners have died since their discharge—one by drowning, two from phthisis, one from general anasarca, one from pyæmia, and the rest from causes not stated. Unfortunately, no autopsy is recorded in any case. The injuries are reported to have been inflicted by shell-fragments in ten instances,



by grape or canister shot in two, and by small projectiles in three hundred and fourteen cases. The left arm was interested in one hundred and sixty-five, the right in one hundred and forty-seven, and this point was unnoticed in fourteen instances. In two hundred and ninety-four cases in which the seat of excision was precisely defined, the excised portion belonged chiefly to the upper third of the diaphysis in one hundred and twenty-two, to the middle third in one hundred and fourteen, and to the lower third in fifty-eight. The extent of bone excised is specified in two hundred and forty-nine instances, as enumerated in the foot-note.<sup>1</sup> Twenty-seven cases were complicated by other wounds; and, in one case, a leg was amputated, in another, an exsection of the ulnar nerve practised, and, in six, missiles extracted, at the time of excision. Later, exarticulations at the shoulder were thrice resorted to, and amputations of the arm were practised in twenty-four cases. In thirteen instances, consecutive operations for the removal of diseased bone were required:

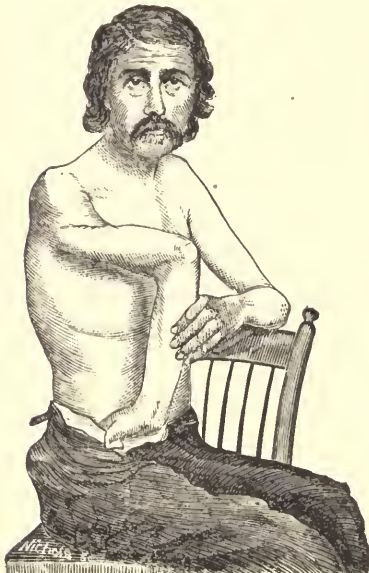

FIG. 506.—Dangling arm after excision in the continuity. [From a photograph.]

CASE 1631.—Private E. P——, Co. B, 46th New York, aged 25 years, was wounded at Petersburg, April 2, 1865. He was admitted into the field hospital of the Ninth Corps. Surgeon M. K. Hogan, U. S. V., recorded “a gunshot fracture of the right arm; resection of two inches of the humerus, by Surgeon D. C. Roundy, 37th Wisconsin.” On April 8th, he was transferred to Stanton Hospital, Washington. Surgeon B. B. Wilson, U. S. V., noted: “Compound comminuted fracture of the upper third of the right humerus.” On September 19th, he was transferred to Douglas Hospital, whence Assistant Surgeon W. F. Norris, U. S. A., reported: “Gunshot fracture of the right humerus, upper third, by a minie ball. Primary resection of four inches of the shaft of the right humerus. Incision three inches long on the external aspect; chloroform administered. Present condition: All closed except a fistulous opening which leads to the necrosed end of the upper portion of the lower fragment; no union; operation performed on the field; still under treatment.” On November 2d, he was transferred to Harewood, whence Surgeon R. B. Bontecou, U. S. V., forwarded a photograph of the patient, which is copied in the wood-cut (FIG. 506), and reported the wound as then healed, but with no bony union.” Pornbsky was discharged, on certificate of disability, November 27, 1865, and pensioned. Examiner J. H. Clark, of Newark, New Jersey, July 31, 1867, reported: “Has resection of the right humerus at the upper third of about three inches. The arm, forearm, and hand are of very little service; so little that his inability to perform manual labor is equivalent to the loss of the hand.” Examiner C. M. Chamberlain, New York, reported, February 10, 1868: “Six inches of the shaft of the humerus has been resected, and the bone has not been restored. The forearm dangles from the false joint and is atrophied, being of less use than if the injury had been the loss of the hand; disability total.” The pensioner has not been heard from since 1870.

CASE 1632.—Corporal S. Gear, Co. H, 49th Ohio, aged 19 years, was wounded at Nashville, December 16, 1864. He was admitted into the hospital of the 3d division, Fourth Army Corps, and on the following day was transferred to Hospital No. 1, Nashville. Surgeon B. B. Breed, U. S. V., reported: “Gunshot fracture of right humerus. Ball entered on anterior aspect of arm in middle third, passed through the humerus, and lodged in the tissues behind it. Resection was performed, on December 16th, of two and a half inches of shaft of humerus, middle third, through an incision three and a half inches long over anterior aspect of arm. Anæsthetic and operator unknown. Wound doing well. Water dressings used, and tonics and stimulants and nutritious diet administered. Patient transferred to Hospital No. 2 on December 22d.” Surgeon J. E. Herbst, U. S. V., in charge of the latter hospital, reported: “Gunshot fracture of right humerus. Hæmorrhage from posterior circumflex artery, to amount of ten ounces, occurred on December 26th, caused by gangrene of the wound. The bleeding was discovered early, and the artery was ligated by Acting Assistant Surgeon S. W. Blackwood. Constitutional condition of patient healthy, and improvement rapid.” The patient was discharged from service on June 27, 1865, and pensioned. In the certificate of disability for discharge Surgeon Herbst reports: “Gunshot fracture of right humerus, middle third, producing pseudarthrosis and extensive injury of nerves.” Examiner J. H. Hair, of Postoria, Ohio, July 15, 1865, certified: “Ball entered right arm, fracturing humerus, middle third. About three inches of said bone was resected (which wound is still discharging), from which he has lost fully three-fourths the use of right arm.” The disability was rated three-fourths. The pensioner died on March 2, 1870. The cause of his death is not known.

§ *Fatal Cases.*—One hundred and forty-five, or about one-third of the primary excisions in the continuity, terminated fatally.

<sup>1</sup> Viz: An inch in 7 seven cases; an inch and a half in 9 cases; two inches in 56 cases; two and a half inches in 19 cases; three inches in 71 cases; three and a half inches in 11 cases; four inches in 56 cases; four and a half inches in 1 case; five inches in 16 cases; six inches in 1 case (No. 286); six and a half inches in 1 case (No. 168); eight inches in 1 case (No. 71). In seventy-seven cases this point was not explicitly defined.

TABLE LVII.

Condensed Summary of One Hundred and Forty-five Fatal Primary Excisions of the Shaft of the Humerus for Shot Injury.

No.	NAME, AGE, AND MILITARY DESCRIPTION.	DATES.	OPERATIONS, OPERATOR, RESULT.	No.	NAME, AGE, AND MILITARY DESCRIPTION.	DATES.	OPERATIONS, OPERATOR, RESULT.
1	Arbuckle, R. A., Pt., A, 32d Ohio.	July 21, '64.	Right; two inches middle third; by Surg. A. C. Brundager, 32d Ohio. Died July 19, 1865, of dropsy.	35	Edgerly, H. F., Pt., H, 4th New Hampshire, age 26.	July 24, '64.	Left; three inches of upper third; by Surg. G. P. Gruby, 4th N. H. Died August 2, 1864, from exhaustion.
2	Barker, L., Pt., E, 4th Indiana Cavalry.	Jan. 16, '64.	Right; three inches upper third. Died April 26, 1864.	36	Finch, J., Pt., I, 3d Michigan.	May 12, '64.	Fractured portion upper third; by Surg. H. F. Lyster, 5th Mich. Died May 20, 1864.
3	Barnard, J. W., Pt., K, 11th Virginia, age 56.	July 2, '63.	Right. Died July 26, 1863, of pyæmia.	37	Freeman, W. S., Serg't, D, 16th Virginia, age 31.	July 30, '64.	Right; in lower third. Died Aug. 9, 1864, of erysipelas.
4	Bateholder, C. W., Corp'l, D, 13th N. Hampshire.	May 13, '64.	Right; at the middle third. Died July 2, 1864.	38	Gladding, J., Pt., I, 7th Rhode Island, age 20.	June 3, '64.	Right; two and a half inches middle third; by Surg. J. Harris, 7th R. I. Died July 3, 1864, of pyæmia.
5	Battle, W. L., Lieut., D, 37th N. Carolina, age 19.	July 2, '63.	Left: three inches upper third. Arm amputated Aug. 23, 1863; died three hours afterward.	39	Goff, J., Pt., D, 142d New York, age 28.	Oct. 29, '64.	Left; portion of shaft; by Surg. McFalls, 142d N. Y. Died Dec. 17, 1864, from exhaustion.
6	Beekleshymer, H., Pt., A, 103d Illinois.	July 22, '64.	Left; two inches middle third; by Surg. R. Morris, 103d Illinois. Died Aug. 23, 1864.	40	Harrington, L., Pt., G, 1st N. Carolina Cav., age 34.	April 2, '65.	Left; four inches. Died May 18, 1865, from exhaustion.
7	Bennet, A. S., Pt., C, 2d Ohio Cavalry, age 22.	June 1, '64.	Left; fractured portion. Died July 2, 1864.	41	Harrows, C., Pt., L, 3d New Jersey Cavalry.	Sept. 19, '64.	Right; portion of lower third; by Surg. R. Curran, 9th N. Y. Cav.; arm amputated Sept. 22, 1864. Died Sept. 29, 1864, from concealed hæmorrhage in back.
8	Black, J., Pt., H, 1st Pennsylvania Reserves.	July 2, '63.	Left; three inches. Died Aug. 15, 1863.	42	Hampton, J. K. P., Pt., 36th Tennessee, age 17.	Feb. 16, '62.	Left; three inches middle third; by Dr. Madden; amputation Mar. 25, 1862. Died March 29, 1862.
9	Boswell, B. M., Corp'l, E, 11th Illinois.	May 15, '61.	Left; at lower third; by Surg. A. C. Messenger, 57th Ohio. Died May 22, 1864.	43	Hamilton, B., Corp'l, C, 1st Maryland.	July 3, '63.	Right; by Surg. W. H. Tusford, 27th Ind. Died July 22, 1863.
10	Boynton, H. E., Pt., 1st Mass. Heavy Artillery, age 18.	May 19, '64.	Right; two inches middle third; by Surg. N. R. Moseley, U. S. V. Died June 22, 1864. Spec 2322.	44	Hanson, B., Pt., B, 5th New Hampshire.	June 16, '64.	In upper third; by Surgeon G. L. Potter, 145th Penn. Died June 27, 1864.
11	Brooke, J., Pt., I, 16th Connecticut, age 19.	Sept. 17, '62.	Left; six inches upper third; by Surg. N. Mayor, 16th Conn. Died Oct. 11, 1862.	45	Hartz, J., Pt., F, 23d Illinois.	July 7, '64.	Left; in lower third; by Asst. Surg. J. S. Taylor, 23d Illinois. Died July 15, 1864.
12	Buckley, J., Corp'l, G, 9th Mass., age 27.	May 12, '64.	Right; eight inches. Died May 28, 1864.	46	Henderson, S. S., Pt., F, 33d Maine, age 28.	June 5, '64.	Left; two inches. Died July 3, 1864.
13	Burke, J., Pt., H, 6th Penn. Cavalry, age 20.	May 8, '64.	Left; amputation June 4, 1864. Died June 5, 1864, of pyæmia. Spec. 3550.	47	Herdendorf, E. E., Pt., F, 130th New York.	May 15, '64.	Right. Died July 28, 1864.
14	Burruss, E. B., Pt., G, 2d South Carolina.	May 23, '64.	Middle third. Died July 12, 1864.	48	Horrick, M., Pt., D, 49th New York, age 21.	May 5, '64.	Left; three inches; nmp. at shoulder May 26, 1864. Died May 26, 1864, of asthenia. Spec 3555.
15	Butterfield, S. W., Corp'l, E, 11th Pennsylvania.	July 21, '64.	Right; in lower third. Died Sept. 5, 1864.	49	Hickey, T., Capt., A, 164th New York, age 25.	June 3, '64.	Right; four inches; by Surg. M. F. Regan, 164th N. Y.; arm amputated June 22, 1864. Died July 6, 1864, of pyæmia.
16	Byers, W. P., Serg't, A, 57th Indiana.	June 27, '64.	Right; by Surg. E. B. Glick, 40th Indiana. Died July 12, 1864.	50	Highman, R., Pt., K, 6th Penn. Cavalry.	Aug. 28, '64.	Left; injured portion. Died Sept. 2, 1864.
17	Campbell, G. W., Pt., K, 36th Wisconsin.	June 18, '64.	Left; in upper third; by Surgeon W. J. Burr, 42d N. Y. Died June 27, 1864.	51	Hinton, T., Pt., E, 6th Iowa.	Aug. 27, '64.	Left; two inches; by Surg. J. C. Hutchinson, 15th Mich. Died July 23, 1864.
18	Carman, G., Corp'l, E, 8th Illinois.	Prim'ry, '64.	Died June 8, 1864.	52	Hoggard, J., Corp'l, E, 137th Illinois, age 20.	Aug. 21, '64.	About half an inch of each end in upper third; amputated at shoulder joint Sept. 9, 1864. Died Sept. 12, 1864, from hæmorrhages. Right. Died May 14, 1864.
19	Charles, R., Pt., A, 19th Maine.	Feb. 5, '63.	Left; in upper third; by Surgeon S. H. Plumb, 83d N. Y. Died February 14, 1865.	53	Hooper, W. H., Lieut., D, 7th Maine.	May 5, '64.	Right. Died May 14, 1864.
20	Chapman, E., Pt., I-D, 75th New York, age 48.	June 14, '63.	Left; greater portion of the shaft. Died July 17, 1863, of pyæmia.	54	Hollis, H. S., Pt., H, 35th Massachusetts, age 26.	July 12, '63.	Two and a half inches lower third; by Surg. G. B. Cogswell. Died Aug. 7, 1863.
21	Charter, W. S., Pt., D, 145th Pennsylvania.	May 12, '64.	Left; portion in upper third; by Asst. Surg. B. Howard, U. S. A.; arm amputated October 7, 1864. Died Oct. 21, 1864, of tetanus.	55	Hoyt, C., Serg't, G, 10th New Hampshire, age 24.	May 14, '64.	Left. Died June 27, 1864.
22	Chestnut, J. W., Pt., D, 63d Alabama, age 18.	April 9, '63.	Left; by Surg. O. G. Hunt, 11th Ill. Died June 20, 1863, from exhaustion.	56	Houtz, I, Pt., K, 50th Pennsylvania.	June 3, '64.	Right; at middle third; by Surg. H. E. Smith, 27th Mich. Died June 12, 1864.
23	Childers, T. B., Pt., E, 38th Georgia.	Dec. 13, '64.	Died January 7, 1863, of pyæmia.	57	Huffman, H., Corp'l, H, 65th Ohio, age 20.	July 20, '64.	Left; upper third. Died August 1, 1864.
24	Coggins, J. B., Lieut., D, 50th North Carolina.	June 17, '64.	Left; one inch middle third. Died August 30, 1864.	58	Hull, D., Pt., C, 81st Indiana.	June 27, '64.	Upper third; by Surgeon C. J. Walton, 21st Kentucky. Died July 1, 1864.
25	Coker, W. C., Pt., A, 4th South Carolina Cavalry.	May 28, '64.	Left; two inches of lower third. Died June 19, 1864, from exhaustion.	59	Humphrey, E. D., Pt., C, 6th Tennessee, age 22.	June 16, '64.	Right; three inches middle third; by Surg. E. D. Moore, 13th Ky. Died July 6, 1864, of pyæmia.
26	Collins, J., Pt., B, 2d Michigan.	Nov. 29, '63.	Three and a half inches upper third; by Surg. A. M. Wilder, U. S. V. Died Nov. 29, 1863.	60	Hudson, J. E., Capt., D, 53d Illinois.	July 12, '63.	Right; by Surg. W. S. Edgar, 33d Ill. Died Aug. 6, 1863.
27	Cunningham, H. C., Pt., A, 35th Penn., age 19.	Mar. 25, '65.	Right; two inches middle third. Died July 11, 1865.	61	Ingalls, L., Pt., G, 17th Vermont, age 19.	May 6, '64.	Right; three inches; by Surg. J. T. Milbau, U. S. A. Died June 12, 1864.
28	Duiley, P., Pt., D, 56th Ohio, age 40.	Aug. 3, '64.	Left; two and a half inches middle third; by Surg. W. H. Mullens, 12th Kentucky. Died Nov. 9, 1864, from exhaustion.	62	Kelsey, G., Pt., I, 4th N. York Artillery.	June 18, '64.	Right; amputation at shoulder joint July 3, 1864. Died July 7, 1864, of pyæmia.
29	Davis, J. A., Corp'l, C, 32d U. S. Col'd Troops.	Nov. 30, '64.	Right; four inches upper third. Died Dec. 14, 1864. Spec 3701.	63	Kinsey, W. H., Serg't, H, 28th Illinois.	July 12, '63.	Left; upper third; by Surg. C. Curle, 41st Illinois. Died July 27, 1863.
30	Donaldson, W., Pt., I, 1st Virginia, age 32.	July 7, '64.	Left; portion of shaft. Died July 28, 1864.	64	Kletchaer, J., Pt., H, 2d Penn. Heavy Artillery, age 18.	July 5, '64.	Left; five inches middle third; by Surg. F. P. Oakes, 56th Mass.; arm amputated Aug. 9th. Died Aug. 11, 1864. Spec. 3667.
31	Dougherty, J., Pt., D, 54d Ohio.	June 27, '64.	Right; Lower third. Died July 12, 1864.				
32	Downs, T., Pt., G, 20th Indiana Cavalry.	June 4, '63.	Left; three inches; by Surg. I. Dees, U. S. A. Died July 6, 1863, of pyæmia. Spec. 1749.				
33	Drum, E., Pt., G, 97th Ohio.	June 22, '64.	Right; at middle third; by Surg. W. H. McFay, 26th Ohio. Died July 21, 1864, of pyæmia.				
34	Dudley, M. N., Pt., D, 106th Pennsylvania.	May 6, '64.	Left; portion of lower third; by Surg. W. J. Burr, 42d N. Y. Died May 20, 1864.				



No.	NAME, AGE, AND MILITARY DESCRIPTION.	DATES.	OPERATIONS, OPERATOR, RESULT.	No.	NAME, AGE, AND MILITARY DESCRIPTION.	DATES.	OPERATIONS, OPERATOR, RESULT.
65	Klahre, H. F., Corp'l, A, 184th Penn., age 22.	June 22, '64.	Right; one inch at upper third; by Surg. G. Chaddock, 7th Mich. Died July 23, 1864; hemorrhage. <i>Spec.</i> 3334.	101	Pritchard, W. H., Pt., F, 149th New York.	July 20, '64.	Left; four inches upper third; by Surg. J. V. Kendall, 149th N. Y. Died July 27, 1864.
66	Klitze, G., Pt., D, 19th Ohio.	June 20, '64.	Upper third. Died July 11, 1864.	102	Quinlan, J., Pt., B, 90th New York.	June 14, '63.	Left; portion of upper third; by Surg. C. Robertson, 150th N. Y. Died July 6, 1863.
67	Lampkin, H. T., Corp'l, K, 34th Virginia, age 28.	Aug. 5, '64.	Left; one and a half inches middle third. Died Sept. 5, 1864.	103	Ramsdell, G. A., Serg't, K, 20th Maine.	Oct. 1, '64.	Right; fractured portion of upper third. Died October 17, 1864.
68	Leaphart, T. E., Serg't, C, 15th South Carolina.	Sept. 19, '64.	Three inches middle third. Died Oct. 12, 1864, of pyæmia and dysentery.	104	Ralston, H., Pt., D, 8th Maryland, age 24.	May 12, '64.	Left; upper third. Died June 5, 1864.
69	Lewis, L. J., Pt., K, 1st Michigan Cav., age 27.	May 28, '64.	Right; three inches middle third. Died June 15, 1864, of pyæmia.	105	Remington, A. O., Corporal, H, 75th N. York.	June 14, '63.	Right; lower third. Died June 17, 1863.
70	Lillins, J., Drummer, F, 29th Mass., age 15.	June 19, '64.	Right. Died June 26, 1864.	106	Reeves, M., Pt., G, 9th New York Cavalry.	July 28, '64.	Left; of shaft. Died September 2, 1864.
71	Mall, W. A., Pt., E, 117th New York, age 19.	Oct. 27, '64.	Left; two-thirds of shaft. Died Oct. 31, 1864, from exhaustion.	107	Richard, W. H., Pt., I, 93d Illinois.	Nov. 25, '63.	Left; fractured portion; by Surg. E. J. Buck, 18th Wis. Died January 4, 1864.
72	Mapes, A. H., Serg't, C, 9th Illinois Cav., age 28.	Aug. 13, '64.	Right; one and a half inches; by A. A. Surg. B. W. Coale. Died Sept. 8, 1864, of typhoid fever.	108	Rich, G. H., Pt., B, 42d Massachusetts, age 21.	Aug. 3, '64.	Right; two inches upper third; by Surg. E. Bentley, U. S. V. Died Aug. 14, 1864, from hemorrhages.
73	Martin, J., Pt., B, 2d Pa. Artillery, age 30.	June 17, '64.	Left; three inches of upper third. Died July 5, 1864, from exhaustion.	109	Reach, J., Pt., A, 5th N. Jersey, age 16.	May 5, '64.	Left; two inches. Died June 25, 1864, of pyæmia.
74	McNabb, W. P., Pt., D, 62d Penn., age 31.	May 12, '64.	Left. Died June 8, 1864, of pyæmia.	110	Reese, J., Corp'l, K, 2d New York Cav., age 20.	Aug. 25, '64.	Left; three inches; by A. A. Surg. J. R. Fisher. Died Aug. 29, 1864, of typhoid fever.
75	McNulty, J. R., Pt., H, 1st N. Jersey Cav., age 32.	May 28, '64.	Right; middle third; arm amputated. Died June 9, 1864.	111	Roberts, J. H., Pt., I, 17th Maine, age 46.	May 14, '64.	Right; six inches upper third. Died Aug. 15, 1864, of asthenia. <i>Spec.</i> 3359.
76	Merrill, A. C., Pt., I, 1st Maine H. Art., age 30.	June 18, '64.	Right; portion of the shaft. Died July 5, 1864, from hemorrhage.	112	Rowley, A., Pt., H, 86th New York, age 19.	May 12, '64.	Right; six inches. Died May 30, 1864, from exhaustion.
77	Merrille, A., Pt., G, 5th Ohio.	July 3, '63.	Left; three inches middle third; by Surg. H. E. Goodman, 28th Penn.; arm amputated July 10, 1863. Died July 13, 1863, of pneumonia.	113	Rutherford, G., Pt., K, 76th Ohio.	Aug. 19, '64.	Right; three inches upper third; by Surg. A. Sabine, 76th Ohio. Died August 24, 1864.
78	Merchant, A. L., Pt., F, 17th Vermont, age 19.	June 17, 1864. On field.	Right; three inches upper third. Died July 12, 1864, from gangrene.	114	Scott, H. M., Corp'l, B, 100th Indiana.	May 14, '64.	Right; two and a half inches; by Surg. R. Morris, 103d Ill. Died June 6, 1864.
79	Miller, C. M., Pt., G, 105th Illinois.	May 25, '64.	Right; middle third; by Surg. I. M. Himes, 73d Ohio. Died June 18, 1864.	115	Scott, W. H., Capt., D, 1st Ohio Cav., age 25.	Aug. 20, '64.	Right; three inches; arm amputated Sept. 17, 1864. Died Sept. 27, 1864, from exhaustion.
80	Masher, G. H., Pt., H, 136th New York.	July 3, '63.	Left; fractured portion. Died August 1, 1863.	116	Shank, D., Pt., I, 44th Ohio.	Nov. 29, '63.	Right; middle third; by Surgeon G. A. Collamore, 100th Ohio. Died January 18, 1864.
81	Moat, C., Corp'l, E, 6th New York Cavalry.	Aug. 16, '64.	Died September 12, 1864.	117	Sharp, J., Pt., H, 100th New York.	June 1, '62.	Injured portion. Died June 9, 1862.
82	Monahan, J., Corp'l, E, 22d Mass., age 38.	May 5, '64.	Right; three inches middle third; arm amputated Sept. 17, 1864. Died September 26, 1864, from exhaustion. <i>Spec.</i> 3331.	118	Shickle, J., Corp'l, D, 52d Ohio.	June 27, '64.	Left. Died June 30, 1864.
83	Mooney, J., Pt., G, 11th U. S. Infantry.	May 12, '64.	Right; two inches lower third; arm amputated June 7, 1864. Died June 7, 1864.	119	Smith, I., Pt., G, 60th Ohio, age 19.	June 23, '64.	Left; lower portion; amputation July 11, 1864. Died July 13, 1864.
84	Moore, W. K., Pt., I, 57th Mass., age 23.	Oct. 8, '64.	Right; of shaft; amputated at shoulder joint Nov. 11, 1864. Died Nov. 27, 1864.	120	Smith, J. I., Pt., D, 1st Mass. Heavy Artillery.	June 23, '64.	Fractured portion. Died June 28, 1864.
85	Mulke, J., Pt., A, 7th New York, age 23.	Dec. 13, '62.	Left; of shaft. Died December 29, 1862, of traumatic tetanus.	121	Snyder, M., Pt., G, 69th Penn., age 19.	Oct. 27, '64.	Right; fractured portion at middle third; by Surg. S. H. Plumb, 82d N. Y. Died Nov. 5, 1864, from exhaustion.
86	Newton, J. M., Pt., C, 6th Indiana Cavalry.	July 14, '64.	Right; two and a half inches middle third; by Surg. S. K. Crawford, 50th Ohio. Died July 26, 1864.	122	Stover, W. L., Pt., D, 4th N. Y. Heavy Artillery, age 21.	May 19, '64.	Right; portion of shaft. Died June 13, 1864, of pyæmia.
87	Nelson, H., Pt., B, 31st U. S. C. Troops, age 27.	July 30, '64.	Right; middle third. Died Sept. 21, 1864.	123	Strickland, A. P., Pt., K, 24th N. Carolina, age 46.	Aug. 15, '64.	Left; three inches middle third. Died Sept. 19, 1864, from exhaustion.
88	Oliphaunt, D., Capt., B, 5th Mich. Cavalry, age 36.	May 28, '64.	Right; at upper third. Died June 28, 1864, from exhaustion.	124	Stropes, A. J., Pt., E, 53d Illinois.	July 12, '63.	Right; in upper third; by Surg. W. S. Edgar, 32d Illinois. Died Aug. 10, 1863, of pyæmia.
89	Ollis, L., Corp'l, K, 2d U. S. Cavalry.	Sept. 19, '64.	Left; three inches middle third. Died Oct. 13, 1864, of typhoid pneumonia.	125	Tarby, J., Pt., I, 82d U. S. Cav'd Troops, age 30.	April 5, '65.	Right; five inches; by Surg. H. Osborne, 51st U. S. C. T.; arm amputated April 12, 1865. Died April 19, 1865.
90	Ourish, P., Serg't, E, 32d Mass., age 19.	May 30, '64.	Left; upper third; amputation at shoulder joint June 8, 1864. Died June 8, 1864, from shock.	126	Templeman, J. W., Pt., E, 10th Mass., age 16.	May 5, '64.	Left; three inches. Died June 6, 1864, from exhaustion.
91	Owens, J., Pt., C, 1st Vermont Cavalry, age 24.	June 13, '64.	Left; fractured portion. Died July 21, 1864, of pyæmia.	127	Thomas, E., Pt., G, 31st Maine, age 19.	July 30, '64.	Left; in middle third; arm amputated. Died Aug. 13, 1864, from exhaustion. <i>Spec.</i> 2974.
92	Paddock, R., Pt., K, 81st New York, age 19.	Aug. 15, '64.	Right; fractured portion upper third. Died Sept. 3, 1864.	128	Tinkham, F. L., Pt., H, 33d Wisconsin.	April 24, '64.	Left; fractured portion and amputation of right arm. Died April 25, 1864.
93	Parliament, J., Pt., C, 13th New Jersey.	July 3, '63.	Right; portion of middle third; by Surg. J. A. Freeman, 13th N. J.; arm amputated July 18, 1863. Died July 28, 1863.	129	Vontaine, J. R., Commissary Serg't, A, 8th N. York Cavalry.	June 13, '64.	Right; fractured portion of upper third; amputation at shoulder joint July 5, 1864. Died July 5, 1864.
94	Parvis, H. S., Pt., D, 1st Delaware, age 26.	Aug. 25, '64.	Left; part of lower third. Died Jan. 31, 1865, of pyæmia. <i>Spec.</i> 3652.	130	Walker, J. W., Pt., K, 9th Maine, age 34.	Oct. 27, '64.	Left; portion of shaft; by Surg. Barlow, 62d Ohio. Died Dec. 5, 1864, from exhaustion.
95	Pensly, H., Pt., F, 58th Penn., age 21.	Sept. 30, '64.	Left; four inches upper third; by Asst. Surg. J. W. Gray, 98th N. Y. Died Oct. 9, 1864, from exhaustion.	131	Walker, W., Pt., C, 18th Georgia.	Nov. 25, '63.	Arm amputated by a Confederate surgeon, Dec. 10, 1863. Died December 11, 1863.
96	Pendar, F., Pt., G, 61st Penn., age 25.	May 5, '64.	Right; three inches. Died June 2, 1864.	132	Wentworth, M. R., Pt., F, 20th Maine.	June 3, '64.	Left; injured portion. Died June 8, 1864.
97	Perdue, C. R., Pt., B, 5th Virginia, age 44.	Sept. 3, '64.	Right; portion of shaft; by A. A. Surg. J. R. Uhler. Died Sept. 13, 1864.	133	Welch, W. C., Pt., E, 184th Penn., age 22.	June 22, '64.	Right; two inches middle third; by Surg. G. Chaddock, 7th Mich. Died July 5, 1864, of pyæmia.
98	Perkins, M., Serg't, B, 7th Michigan Cavalry.	May 28, '64.	Died May 30, 1864.	134	Webb, C. C., Capt., E, 13th Michigan.	Dec. 31, '62.	Middle third. Died February 14, 1863.
99	Pfister, H., Pt., I, 15th N. York Artillery, age 22.	May 6, '64.	Left; three inches of upper third. Died June 9, 1864, of pyæmia.	135	Whalen, M., Pt., I, 90th Illinois.	July 28, '64.	Right; by Surg. Halderman, 46th Ohio. Died Aug. 21, 1864.
100	Potts, J., Pt., A, 17th Penn. Cavalry.	June 1, '64.	Right. Died.				

No.	NAME, AGE, AND MILITARY DESCRIPTION.	DATES.	OPERATION, OPERATOR, RESULT.	No.	NAME, AGE, AND MILITARY DESCRIPTION.	DATES.	OPERATION, OPERATOR, RESULT.
136	Williams, T. G., P., 31st North Carolina, age 25.	May 16, '64.	Died June 13, 1864, of pyæmia.	141	Wilburn, G., Pl., G, 111th Illinois.	May 14, '64.	Upper third; by Surgeon S. O. Bonner, 47th Ohio. Died May 22, 1864, of erysipelas.
137	Williams, S., Pl., E, 140th Pennsylvania.	Oct. 14, '63.	Right. Died November 1, 1863, of pyæmia.	142	Woodbridge, W. O., Pl., C, 4th New Hampshire, age 35.	June 24, '64.	Two inches upper third; by Surg. D. Mackay, 30th U. S. C. T. Died July 13, 1864, of tetanus.
138	Wilson, W., Pl., K, 15th New Jersey, age 23.	Aug. 18, '64.	Left: three inches lower third; by Surg. H. Pearus, 175th N. Y. Died September 4, 1864.	143	Wyatt, A., Pl., H, 83d New York, age 26.	May 8, '64.	Left; two inches. Died June 3, 1864, of pyæmia.
139	Wilburn, I., Pl., A, 68th U. S. Colored Troops, age 30.	April 2, '65.	Left: portion of lower third; arm amputated April 13, 1865. Died April 28, 1865, from hectic fever.	144	Young, J., Pl., F, 13th Illinois.	Nov. 27, '64.	Right; in middle third; by Surg. S. C. Plummer, 13th Ill. Died Jan. 14, 1865.
140	Williams, J. J., Pl., K, 72d Indiana.	June 19, '64.	Left; in middle third; by Surg. A. T. Hudson, 26th Iowa. Died July 26, 1864.	145	Zonna, J., Pl., F, 44th Illinois, age 29.	Nov. 25, '63.	Left: injured portion lower third. Died December 6, 1863, from secondary hæmorrhage.

Some further details are appended of the cases numbered 38, 94, and 108, in the foregoing tabular statement.

CASE 1633.—Private H. S. P——, Co. D, 1st Delaware, aged 26 years, was wounded at the Weldon Railroad, August 25, 1864, and was sent to Washington, entering Lincoln Hospital August 25th. Assistant Surgeon J. C. McKee, U. S. A., reported: "Shot fracture of the left humerus, lower third, severe. Excision on the field." Acting Assistant Surgeon A. N. Sherman reported: "Gunshot fracture of left humerus. When the patient was admitted to Ward 14, about January 1st, he was much emaciated, with very irritable stomach. The discharge from the wound was of a dark sanious color, indicating extensive necrosis of bone; his general health would not admit of an operation. Pyæmia appeared to develop itself about fifteen days previous to death, which occurred January 31, 1865." Acting Assistant Surgeon H. M. Dean contributed the specimen (FIG. 507), and reported: "Post-mortem January 31, 1865, at 10 A. M.: Body very much emaciated; skin of a sallow color; height five feet five and a half inches; rigor mortis not very well marked; œsophagus, larynx, and trachea healthy; both lungs appeared normal; pericardium normal; heart contained a clot—very pale, otherwise appeared normal; liver very fatty; spleen appeared normal; both kidneys very pale; lining membrane of intestine very pale; right lung weighed nine ounces, left nine and a half ounces; spleen six ounces; heart nine ounces; right kidney six ounces, left six and a half ounces; liver eighty-eight ounces. The left humerus was found to be badly comminuted and necrosed in its middle third, and the tissues surrounding it were of a black color." The specimen, of which a wood-cut (FIG. 507) is annexed, consists of "the left humerus six months after fracture in the lower third. The entire shaft of the bone is occupied by a sequestrum. That in the lower fragment is heavy and nearly detached. The involucrum is wanting on the anterior surface, where it appears to have been absorbed after deposit. The new deposit on the upper fragment is irregular and sparse."

CASE 1634.—Private G. H. Rich, Co. B, 42d Massachusetts, aged 21 years, was, on August 3, 1864, accidentally shot while on guard duty at the Government docks in Alexandria. He was admitted into Old Hallowell Hospital. Surgeon E. Bentley, U. S. V., recorded: "Gunshot fracture of right humerus by minié ball. Patient was put under the influence of chloroform, and an incision having been made through the deltoid muscle, the fragments of the humerus were taken out and the ends of the bone saved off, removing altogether about two inches. Operator, Surgeon E. Bentley, U. S. V. Patient reacted and progressed well until August 13th, when, at 3 P. M., he was taken with a chill, and bleeding commenced immediately from the wound. The loss of blood amounted to sixteen ounces before it was arrested by pressure on the subclavian artery. The pulse after this was small and very indistinct at the wrist; stomach rejecting everything introduced. Patient continued to sink, and died at 4 P. M. on August 14, 1864."

CASE 1635.—Private J. N. Gladding, Co. F, 7th Rhode Island, aged 20 years, was wounded, at Bethesda Church, June 3, 1864. He was admitted into the 2d division hospital, Ninth Army Corps. Surgeon J. Harris, 7th Rhode Island, recorded: "Gunshot fracture of arm; resection; transferred to White House." On June 7th, the patient reached Washington, where he was admitted into Mount Pleasant Hospital. Assistant Surgeon C. A. McCall, U. S. A., reported: "Gunshot wound, causing comminuted fracture of middle third of right humerus. Resection of about two and a half inches of the shaft at middle third performed on day of injury, through an incision four inches long. Operator, Surgeon J. Harris, 7th Rhode Island. On admission the arm was much swollen and erysipelatous. Muriated tincture of iron was prescribed in doses of fifteen drops every four hours. By June 15th, erysipelas had disappeared and the wound was suppurating freely. On June 18th, pyæmia began to develop, of which the patient died, on July 3, 1864."

The excisions were practised on one hundred and thirty Union and fifteen Confederate soldiers. Of one hundred and twenty-seven operations, sixty-one were on the right and sixty-six on the left side, this point being unspecified in eighteen cases. Thirty-six excisions were mainly in the upper, thirty-four in the middle, and sixteen in the lower third; in fifty-nine cases, the extent and situation of excision could only be surmised. Fifteen of the patients had other serious wounds, one undergoing amputation of the right great toe.



FIG. 507.—Necrosis of left humerus after shot fracture of the lower third. Spec. 3652.



another amputation at the ankle by Syme's method, a third exarticulation of the opposite arm. Twenty-five were subjected to consecutive major operations, nine to exarticulations at the shoulder, fifteen to amputations of the arm, and one to excision in the fibula. Pyæmia was by far the most frequent cause of death, although there were twenty-two instances of consecutive hæmorrhage. Eleven pathological specimens are preserved.

§ *Primary Operations, in which the Results could not be definitely ascertained.*—Sixteen cases could not be traced to their termination; although there is reason to believe that a majority of them progressed favorably.

TABLE LVIII.

*Condensed Summary of Sixteen Cases of Primary Excisions in the Shaft of the Humerus after Shot Injury, in which the Results could not be determined.*

No.	NAME, AGE, AND MILITARY DESCRIPTION.	DATES.	OPERATIONS, OPERATOR, RESULT.	No.	NAME, AGE, AND MILITARY DESCRIPTION.	DATES.	OPERATIONS, OPERATOR, RESULT.
1	<i>Beahan, B. F.</i> , Pt., H, 33d Virginia, age 19.	May 3, '63.	Right; resection of three and a half inches of shaft.	9	<i>P——</i> , C. S. A. ....	May 28, '64.	Excision of two inches of middle third; cartilaginous union; limb not materially impaired.
2	<i>Byers, G.</i> , Pt., A, 6th Ky., age 21.	Sept. 20, '63.	Left; lower and upper third shattered; resection of one inch from end of each portion; October 1st, doing well.	10	<i>Rabb, J. W.</i> , Serg't, D, 9th Louisiana, age 19.	May 4, '63.	Fracture near surgical neck; partially resected.
3	<i>Cutbott, J. A.</i> , Pt., C, 9th Louisiana, age 25.	May 4, '63.	Two inches resected in lower third.	11	<i>Raben, J.</i> , Pt., E, 42d North Carolina.	May 21, '64.	Resection of entire lower third; July 1st, improving rapidly.
4	<i>Graham, W.</i> , Pt., D, 13th Georgia.	Sept. 21, '64.	Right; resection of upper third.	12	<i>Reffey, G.</i> , Pt., B, 40th Georgia.	Mar. —, 1865.	Excision of fractured portion of upper third; progress favorable.
5	<i>Wiggins, C.</i> , Pt., C, 41st Mississippi.	Sept. 20, '63.	Excision of middle third.	13	<i>Shannan, A. J.</i> , Pt., F, 35th North Carolina.	On field. April 20, '64.	Left; excision of three inches of middle third, by C. H. Ladd, C. S. A.; fair prospect of recovery.
6	<i>Huber, J.</i> , Pt., F, 2d U. S. Artillery.	Aug. 25, '64.	Right; excision of humerus, by Surgeon N. Gay, U. S. V.; not a pensioner.	14	<i>Sheppard, R. F.</i> , Pt., C, 4th Virginia.	May 3, '64.	Resection of four inches.
7	<i>McDonald, T. K.</i> , Pt., D, 60th Georgia.	May 4, '63.	Right; excision of two inches at surg. neck; Aug. 1st, gangrene in cicatrix; April 1, '64, nearly well.	15	<i>Watts, E. C.</i> , Pt., H, 8th North Carolina.	April 20, '64.	Right; one and a half inches of middle third; by C. H. Ladd, C. S. A.; doing well May 5th.
8	<i>Mc——, R.</i> , C. S. A. ....	July 28, '64.	Excision of four inches of upper third, by Asst. Surg. B. S. Barnes, 46th Tennessee.	16	<i>Wilkinson, J. A.</i> , Pt., K, 44th Tennessee, age 22.	May 16, '64.	Right; excision of part of upper third; doing well.

**Intermediary Excisions in the Shaft of the Humerus.**—Ninety-three excisions are comprised in this category, twenty-nine with fatal results.

§ *Recovery after Intermediary Excisions in the Shaft of the Humerus.*—The percentage of recovery in these operations was 68.9 per cent. A detailed example is given:<sup>1</sup>

CASE 1636.—Private T. K——, Co. C, 107th Pennsylvania, aged 17 years, was wounded at Antietam, September 17, 1862. Acting Assistant Surgeon J. Sweet reported, from Hospital No. 1, Frederick: "He was admitted, on September 25th, with compound shot fracture of the left humerus. Resection of two inches was performed on the following day; splints were applied to the arm. On December 6th, the patient had almost recovered and was ready to be discharged." Dr. Sweet contributed the specimen (FIG. 508), which consists of "several fragments, representing three and a half inches of the length and one-third of the circumference of the shaft of the humerus" (*Cat. Surg. Sect.*, 1866, p. 133). On April 18th, the patient was transferred and admitted to Broad and Cherry Streets Hospital, Philadelphia, and, on June 22d, to Turner's Lane Hospital. Assistant Surgeon C. H. Alden, U. S. A., noted: "Gunshot fracture of left arm, resection of humerus before admission." On August 12th, he was admitted to Haddington Hospital, where Acting Assistant Surgeon G. H. Mitchell noted: "Gunshot fracture of humerus, lower third." The patient was assigned to the Veteran Reserve Corps on May 3, 1864, and discharged from service October 26, 1864. Examiner C. H. Davis, of Timkhamnock, Pennsylvania, certifies, July 17, 1867: "The ball entered the outside of the arm and passed directly through, carrying a portion of the humerus. The operation of resection was performed, shortening the limb from two to three inches. There are extensive cicatrices on both sides of the arm and outer side; the integuments are calloused and adherent to the bone. The parts are very tender. He has no use of the forearm. He can produce very slight flexion of the elbow; no use of the muscles of the wrist or fingers." Examiner J. S. Crawford, of Williamsport, Pennsylvania, reported, September 6, 1873: "Caries followed the resection; the openings are now healed, but the cicatrices are tender and will open again. There is partial ankylosis of the elbow. The muscles of the arm are so injured and destroyed at the wound and by the suppuration that followed that they are entirely useless. His arm hangs at his side entirely useless, and is atrophied to a great extent. The arm is completely useless." The disability is rated total. He has been paid pension to March 4, 1875.



FIG. 508.—Excised fragments of humerus. *Spec.* 821.  $\frac{1}{2}$ .

<sup>1</sup> DR. WILLIAM GILFILLAN (*Transactions of the Medical Society of the State of New York*, 1866, p. 122) gives an interesting history, with a good plate, of the case enumerated as 25 in the TABLE.

TABLE LIX.

*Condensed Summary of Sixty-four Cases of Recovery after Intermediary Excisions of the Shaft of the Humerus for Shot Injury.*

No.	NAME, AGE, AND MILITARY DESCRIPTION.	DATES.	OPERATIONS, OPERATOR, RESULT.	No.	NAME, AGE, AND MILITARY DESCRIPTION.	DATES.	OPERATIONS, OPERATOR, RESULT.
1	Arnold, D. E., Pt., G, 72d New York.	May 5, 10, '62.	Right; three inches of middle third. Discharged May 14, 1863; pensioned.	22	Fausel, C., Corp'l, A, 50th Illinois, age 27.	April 6, 10, '62.	Left; four inches; by Surg. H. W. Kendall, 59th Ill. July, 1862, ends of bone sawn off. Disch'd Oct. 13, 1862; pensioned.
2	Baker, J., Pt., C, 6th Md., age 20.	Nov. 27, Dec. 1, 1863.	Right; three inches of middle third. Discharged April 29, 1864; pensioned.	23	Franz, W., Pt., F, 132d Penn., age 20.	Sept. 17, 27, '62.	Left; six inches of shaft of upper third; by Surg. G. Grant, U. S. V. Disch'd Dec. 12, 1862; pensioned. <i>Spec.</i> 814.
3	Balfe, J. E., Lieut. Col., 35th Indiana, age 25.	Dec. 9, 23, '62.	Left; three and a quarter inches upper third; considerable union of bone. Resigned April 11, 1864; pensioned.	24	George, J. N., Serg't, E, 73d Illinois, age 27.	Nov. 30, Dec. 10, 1864.	Right; three inches of upper third; by A. A. Surg. J. H. McIntyre. Disch'd June 6, 1865; pensioned. Died July 16, 1873, of erysipelas from injury to arm.
4	Bennet, J. D., Pt., B, 13th S. C., age 20.	April 2, 10, '65.	Left; two inches at middle third. Sent to Fort McHenry May 9, 1865.	25	Gleason, P., Pt., H, 5th New York, age 21.	Aug. 31, Sept. —, 1862.	Right; in lower third, by Surg. T. Crosby, U. S. V. Discharged Dec. 26, 1862. Elbow joint ankylosed; false joint; pensioned. Died July 6, 1873, of phthisis.
5	Bentley, C. M., Capt., H, 2d N. Y. Cav., age 27.	April 4, 16, '64.	Right; two inches of lower third; A. A. Surg. J. C. Lee; shortened two inches; bony union; little power in arm. Mustered out Nov. 8, '64; pension'd. died Sept. 3, '66.	26	Gleeson, J., Pt., G., 14th Infantry, age 28.	June 27, July 23, 1862.	Left; four inches; by Dr. Gillman. Disch'd Feb. 9, 1864; pensioned. Nine operations for removal of bone performed; free use of elbow joint and shoulder.
6	Black, J. C., Lieut. Col., 37th Illinois, age 24.	Dec. 7, 18, '62.	Left; excision of ends of bone in middle third, by Surgeon E. A. Clark, 37th Ill. Resigned Aug. 15, 1865; pensioned.	27	Glean, D. M., Corp'l, K, 1st Penn. Rifles, age 21.	Dec. 13, 17, '62.	Right; three and a half inches at middle third; amputation at upper third. V. R. C. Sept. 9, 1863; pensioned. <i>Spec.</i> 1066.
7	Bollinger, J., Pt., A, 1st Maryland.	July 3, 10, '61.	Left; excision of injured portion in middle third; perfect union of bone. Paroled.	28	Hall, J. H., Pt., A, 9th Maine, age 23.	Sept 29, Oct. 3, 1864.	Left; two inches middle third. Discharged June 17, 1865; pensioned.
8	Burke, J. L., Serg't, E, 165th N. Y., age 25.	April 9, 15, '64.	Right; two and a half inches of upper third; by A. A. Surg. J. C. Lee; continuity above condyle removed, by A. A. Surg. Ferguson. Discharged July 15, 1864; pensioned. Two false joints; elbow joint ankylosed; complex arm and forearm with apparatus.	29	Hance, T., Pt., F, 14th New Jersey, age 18.	May 30, June 6, 1864.	Right; removal of fragments and ends sawn off, by Surg. N. R. Moseley, U. S. V. Deserted Aug. 24, 1864; not pensioned. <i>Spec.</i> 2505.
9	Callender, J., Pt., A, 5th Colored Troops, age 32.	Sept. 29, Oct. 3, 1864.	Right; four and a half inches in upper third; by Asst. Surg. J. H. Frantz, U. S. A. Discharged June 22, 1865; pensioned. A. M. M. <i>Spec.</i> 2416.	30	Herman, A., Pt., C, 48th New York, age 42.	Feb. 20, Mar. 9, 1864.	Right; four inches of upper third; by A. A. Surg. J. T. Kennedy; partial union; bids fair to make a useful arm. Discharged Oct. 3, 1865; pensioned.
10	Chitty, H. E., Serg't, H, 10th Conn., age 32.	Dec. 14, 1862, Jan. 12, 1863.	Left; one and a quarter inches of middle third; by A. A. Surg. T. B. Upham. Duty March 27, 1863; resigned as lieutenant Sept. 20, 1864; pensioned.	31	Horton, E., Pt., I, 1st Wis., age 29.	May 26, June 9, 1864.	Left; by Asst. Surg. C. C. Byrne, U. S. A. Disch'd April 8, 1865, and pensioned.
11	Cleverton, J. S., Pt., B, 5th Ohio, age 22.	Nov. 27, Dec. 2, 1863.	Right; three and a half inches at junction of upper with middle thirds; false joint but useful limb. Discharged Feb. 25, 1865; pensioned.	32	Jarvis, W. D., Pt., D, 98th Ohio, age 23.	Oct. 8, 16, '62.	Left; upper third to surgical neck; by A. A. Surgeon A. S. Green. Disch'd Jan. 22, 1863; useful arm; pensioned. <i>Spec.</i> 340.
12	Chase, D. W., Pt., D, 35th Massachusetts, age 21.	June 3, 15, '64.	Left; three inches of shaft; by Surg. H. Palmer, U. S. V. Discharged June 22, '65; pensioned; arm amputated at upper third, by Dr. A. R. Gleason.	33	Johnston, D., Pt., F, 103d Penn., age 23.	Dec. 14, 1862, Jan. 13, 1863.	Right; two and a half inches lower third; no union; arm amputated. Discharged Nov. 25, 1863; pensioned.
13	Coleman, H., Musician, A, 5th Ohio, age 22.	Aug. 9, 13, '62.	Left; two and a half inches at middle third; by Surg. A. Ball, 5th Ohio. Discharged Nov. 13, 1862; pensioned.	34	Keeney, Alexander, Pt., F, 141st Penn., age 30.	July 2, 8, '63.	Left; three inches middle third; by A. A. Surg. H. Leeman. To V. R. C. Sept. 17, 1864; bone ununited; pensioned.
14	Collins, W. W., Corp'l, F, 1st Michigan.	Aug. 30, Sept. 21, 1862.	Left; two and a half inches at junction of lower and middle thirds. Disch'd March 11, 1863; pensioned. <i>Spec.</i> 145.	35	Kinsley, T., Pt., C, 107th Penn., age 17.	Sept. 17, 26, '62.	Left; two inches; by A. A. Surg. I. Sweet. To V. R. C. May 3, 1864; pensioned. <i>Spec.</i> 821.
15	Crist, J. M., Pt., H, 124th New York, age 20.	May 3, 10, '63.	Right; four and a half inches of shaft one and a half inches from elbow joint. Disch'd Oct. 18, 1863; pensioned.	36	Landgrove, J. M., Pt., A, 15th Wisconsin, age 18.	May 27, June 3, 1864.	Left; two and a half inches middle third; by Surg. S. B. Hawley, 35th Illinois. Disch'd Dec. 17, 1864; union. Not a pensioner.
16	Daggs, J. R., Pt., D, 24th Texas, age 20.	Sept. 29, Oct. 7, 1863.	Left; resection in lower third; gangrene, Oct. 29th. Nov. 30th, doing well.	37	Long, G. B., 2d Lieut., F, 11th Virginia, age 24.	July 3, 15, '63.	Right; three inches upper third; by A. A. Surg. B. F. Butcher. To Fort McHenry Nov. 12, 1863; recovered.
17	Davidson, E., Pt., F, 121st Ohio, age 15.	June 27, July 11, 1864.	Right; two inches of upper third; by A. A. Surg. J. W. Dighy. Disch'd Dec. 26, 1864; pensioned.	38	Loyd, M., Pt., F, 100th Pennsylvania, age 23.	Mar. 25, April 24, 1865.	Right; three inches upper third; by Surg. G. L. Pancoast, U. S. V. Discharged July 24, 1865; pensioned. <i>Spec.</i> 4292.
18	Deveraux, W. H., Pt., F, 9th N. Y. Cav., age 24.	June 21, 25, '64.	Right; three inches middle third; by O. A. Judson, U. S. V. Discharged June 23, '65; pensioned.	39	Maynard, H., Pt., C, 7th New Hampshire, age 31.	Feb. 20, Mar. 9, 1864.	Right; five inches lower third; by A. A. Surg. W. Balsler. Discharged September 7, 1864; pensioned. Arm nearly as strong as the other. Died March 15, 1872.
19	Dittman, R., Corp'l, E, 14th Infantry, age 29.	Aug. 18, 28, '64.	Right; four inches at upper and middle thirds, by A. A. Surg. W. C. Mulford; ends of bone firmly united. Disch'd Oct. 2, 1864; pensioned. <i>Spec.</i> 3554.	40	McAllister, J. A., Pt., I, 149th New York, age 24.	Nov. 24, Dec. 7, 1863.	Right; three inches middle third; by Surg. I. Moses, U. S. V. Discharged Jan. 26, 1865; pensioned; useful hands. <i>Spec.</i> 2143.
20	Dougherty, G. W., Pt., C, 77th Penn., age 17.	June 25, 29, '63.	Left; fragments removed and fractured ends sawn off, by Surg. I. Moses, U. S. V.; bony union. Duty Aug. 1, 1864; disch'd Oct. 11, 1864; pensioned. <i>Spec.</i> 1754.	41	McCully, A. S., Corp'l, C, 2d Penn. Reserves, age 20.	Dec. 13, 19, '62.	Right; four inches lower third; by Surg. E. Donnelly, 2d Penn. Reserves. To V. R. C. Feb. 24, 1864; pensioned; ankylosis.
21	Dunton, A. M., Pt., D, 124th Illinois, age 20.	June 26, 30, '63.	Left; two inches of upper third; by Surg. J. S. Reese, 63th Ohio. Disch'd Oct. 27, 1864; pensioned.	42	McCullough, D. G., Pt., A, 54th Penn., age 24.	May 15, 22, '64.	Left; two inches of shaft; by Surgeon J. B. Lewis, U. S. V. Discharged Jan. 31, 1865; pensioned; bone united.



No.	NAME, AGE, AND MILITARY DESCRIPTION.	DATES.	OPERATIONS, OPERATOR, RESULT.	No.	NAME, AGE, AND MILITARY DESCRIPTION.	DATES.	OPERATIONS, OPERATOR, RESULT.
43	McKeever, J. E., Serg't, G, 101st Ohio, age 22.	Oct. 8, 21, '62.	Right; four inches lower third; by A. A. Surgeon N. M. Elrod. Discharged Jan. 1, 1863; pensioned; useful firm. <i>Spec.</i> 331.	53	Swann, W. W., Pt., G, 17th Michigan, age 21.	Sept. 14, 27, '62.	Right; three inches lower third. Disch'd July 1, 1863; pensioned.
44	Miller, R. R., Corp'l, D, 4th Minnesota.	May 22, June 3, 1863.	Right; five inches middle third. Disch'd Oct. 22, 1863, and pensioned; arm amp. in Oct., 1865.	54	Swope, B., Pt., 1, 6th Michigan Artillery.	May 27, June 2, 1863.	Right; five inches upper third; by Ass't Surg. G. W. Avery, 9th Conn. Disch'd Sept. 7, 1863; pensioned; union firm.
45	Patton, G., Pt., I, 80th Indiana, age 23.	May 27, June 17, 1864.	Left; four inches upper and middle thirds; by Asst. Surg. C. C. Byrne, U. S. A. Disch'd Dec. 7, 1864, and pensioned.	55	Terwilliger, H., Pt., G, 46th Penn., age 20.	May 25, 29, '64.	Left; five inches middle third; by Surg. P. L. Bissel, 5th Conn. Disch'd Aug. 21, 1865; pensioned.
46	Peet, C. C., Corp'l, F, 121st New York.	May 3, 11, '63.	Right; five and a half inches from one-half inch below surgical neck to three inches above condyles. Disch'd Dec. 12, 1863, and pensioned.	56	Thompson, P. A., Pt., II, 16th U. S. Infantry.	Dec. 31, '62, Jan. —, '63.	Right; four inches upper third. Disch'd April 3, 1863, and pensioned.
47	Potter, N. F., Serg't, E, 149th New York, age 36.	Nov. 24, Dec. 7, 1863.	Right; three inches upper third; by Surgeon I. Moses, U. S. V. Disch'd July 22, 1864; pensioned; loss of use of arm. <i>Spec.</i> 2142.	57	Trott, S. T., Pt., K, 19th Maine, age 18.	Nov. 8, 18, '64.	Left; three inches upper third; by A. A. Surg. A. Ansell. Disch'd June 23, 1865, and pensioned.
48	Rechel, C., Pt., G, 34th Ohio, age 22.	July 24, 29, '64.	Right; fractured ends at junction of upper and middle thirds; by Surg. J. B. Lewis, U. S. V. Discharged Nov. 7, 1864; pensioned; bone ununited.	58	Walker, J., Pt., C, 25th Texas, age 24.	Nov. 30, '62, Jan. 1864.	Right; one and a half inches middle third; by A. A. Surg. L. Sinclair. To Provost Marshal May 6, 1865.
49	Smith, A., Pt., A, 9th N. Y. Heavy Artillery.	July 9, 17, '64.	Right; four inches middle third; by A. A. Surg. P. Middleton; arm amputated. Disch'd March 31, 1865, and pensioned.	59	Ward, W. M., Sergeant, Sharpshooter, 2d Mass.	July 2, 7, '63.	Right; three and a half inches middle third. Duty Dec. 15, 1863; pensioned; bone ununited.
50	Spray, J. C., Serg't, G, 71st Ohio, age 28.	Dec. 16, '64, Jan. 10, '65.	Right; two inches upper third; by Surg. J. H. Grove, U. S. V.; amputated. Disch'd May 16, 1865, and pensioned.	60	Warren, W. H., Corp'l, II, 20th Mass., age 22.	Sept. 17, Oct. 11, 1862.	Right; two inches middle third; arm amputated Oct. 19, 1862. Disch'd Jan. 10, 1863, and pensioned. <i>Spec.</i> 273.
51	Stahl, W., Pt., D, 150th Penn., age 26.	July 1, 20, '63.	Left; two large fragments at junction of middle and lower thirds; by A. A. Surg. W. V. Keating, Disch'd June 17, 1865; pensioned; union firm.	61	Wellington, B., Pt., C, 93d Penn., age 18.	Mar. 25, April 7, 1865.	Right; three inches upper third; by Surg. G. L. Hancock, U. S. V. Disch'd Aug. 1, 1865; not a pensioner.
52	Stevenson, J. V., Serg't, E, 96th Ohio, age 31.	April 8, 12, '64.	Left; three inches lower end of upper third. Disch'd July 31, 1865; pensioned; paralysis.	62	Whalen, W., Pt., F, 2d U. S. Cavalry, age 34.	Sept. 19, 23, '64.	Left; four inches upper third; by Ass't Surg. D. C. Beebe, 4th N. Y. Cav. Disch'd April 17, 1865; pensioned; bone ununited.
				63	Wiggin, A., Pt., A, 36th U. S. Colored Troops, age 40.	Sept. 29, Oct. 3, 1864.	Right; four inches upper third; by Ass't Surg. J. H. Frantz, U. S. A. Disch'd Dec. 14, 1865; pensioned; arm amputated. <i>Spec.</i> 3012.
				64	Wood, W., Pt., K, 10th New York Cav., age 29.	Dec. 10, 29, '64.	Left; four inches middle third; by A. A. Surg. A. Ausell. Disch'd June 16, 1865, and pensioned.

The operations were on fifty-nine Union and five Confederate soldiers. Eight amputations and nine other serious consecutive operations were practised. Thirty-five operations were on the right, and twenty-nine on the left arm. The operations in the middle and upper thirds were the most numerous.

§ *Intermediary Fatal Excisions.*—Twenty-nine, or 31.1 per cent., of the intermediary operations had a fatal result.

TABLE LX.

*Condensed Summary of Twenty-nine Fatal Intermediary Excisions of the Shaft of the Humerus for Shot Injury.*

No.	NAME, AGE, AND MILITARY DESCRIPTION.	DATES.	OPERATIONS, OPERATOR, RESULT.	No.	NAME, AGE, AND MILITARY DESCRIPTION.	DATES.	OPERATIONS, OPERATOR, RESULT.
1	Beaver, T., Pt., H, 2d Wisconsin, age 30.	Aug. 27, Sept. —, 1862.	Right; fragments from lower and middle thirds; by Ass't Surg. P. Adolphus, U. S. A. Died Sept. 17, 1862, of hæmorrhage.	9	Evans, A. R., Pt., A, 5th Michigan Cav., age 40.	July 2, 6, '63.	Right; two inches middle third. Died July 16, 1863, of pyæmia.
2	Berkey, E. H., Pt., C, 142d Penn., age 25.	Dec. 13, 19, '62.	Left; one and a half inches middle third. Died Jun. 15, 1863. <i>Spec.</i> 684.	10	Finleyson, A., Pt., K, 2d New York Cavalry.	April 7, 18, '64.	Right; three inches upper third; by A. A. Surgeon J. C. Lee, U. S. A. Died April 20, 1864, of pyæmia.
3	Brebl, H., Pt., A, 44th New York, age 45.	July 2, 7, '63.	Left. Died August 1, 1863, of pyæmia.	11	Fiselbrand, M., Pt., B, 149th N. Y., age 22.	May 3, 15, '63.	Right; three inches middle and lower thirds; by Surg. C. H. Lord, 103d N. Y. Died June 4, 1864, of pyæmia. <i>Spec.</i> 1150.
4	Carpenter, C. W., Corp'l, I, 95th Illinois, age 20.	June 10, July 2, 1864.	Right; four inches upper third; by A. A. Surg. C. H. Wade. Died July 10, 1864, of pyæmia.	12	Gallagher, C., Pt., C, 169th New York, age 32.	June 1, 6, '64.	Right; two inches upper third; disarticulation at shoulder joint. Died Mar. 3, 1865, of phthisis. <i>Specs.</i> 3638, 363.
5	Carrier, M. H., Serg't, E, 25th Connecticut.	May 27, June 8, 1863.	Right; fractured portion; by Surg. S. H. Plumb, 82d New York. Died June 15, 1863, from exhaustion; other wounds.	13	George, N., Pt., B, 47th Pennsylvania.	Oct. 22, 27, '63.	Right; four inches lower third; by A. A. Surg. T. T. Smiley. Died Nov. 13, 1862, of pyæmia.
6	Chandler, S., Pt., B, 9th U. S. C. T., age 30.	Sept. 29, Oct. 5, 1864.	Right; eight inches; by Assistant Surgeon D. R. Brown, U. S. V. Died Oct. 18, 1864, from exhaustion.	14	Geyer, H., Pt., A, 68th New York, age 23.	Aug. 29, Sept. 18, 1862.	Right; two pieces, each three-fourths of an inch in length, from junction of upper and middle thirds; by A. A. Surgeon J. O. French. Died October 18, 1862. <i>Spec.</i> 146.
7	Clements, W. T. C., Corp'l, C, 28th U. S. C. T., age 25.	June 23, July 1, 1864.	Left; five inches upper third; by Ass't Surg. S. B. Ward, U. S. V. Died July 4, 1864, of pyæmia.	15	Gray, J. C., Pt., D, 63d Penn., age 24.	May 3, 9, '63.	Left; 5½ inches middle third. Died May 21, 1863, of pyæmia.
8	Dudding, J. O., Pt., C, 28th Virginia, age 33.	July 3, 8, '63.	Right. Died Sept. 13, 1863, of tetanus.				

No.	NAME, AGE, AND MILITARY DESCRIPTION.	DATES.	OPERATIONS, OPERATOR, RESULT.	No.	NAME, AGE, AND MILITARY DESCRIPTION.	DATES.	OPERATIONS, OPERATOR, RESULT.
16	Hawkins, T. J., Pt., B. 2d U. S. Sharpshooters, age 29.	May 6, 15, '64.	Right; about four inches; by A. Surg. F. W. Kelly. Died June 1, 1864, from complications.	21	Sankey, M. A., Pt., I. 103d Penn., age 18.	Dec. 14, 27, '62.	Right; three and a half inches middle third; by Surgeon C. A. Congill, U. S. A.; disarticulation at shoulder joint Jan. 8, 1863. Died Jan. 8, 1863, of pyæmia. <i>Spec. 1327.</i>
17	Lansdown, A. K., Pt., II. 51st Illinois, age 21.	Nov. 30, Dec. 6, 1864.	Right; two inches upper third; by a Confederate surgeon. Died Jan. 4, 1865, of pneumonia.	25	Shaffer, A., Pt., B. 4th Iowa Cavalry, age 18.	Dec. 14, 1861, Jan. 7, 1862.	Left; lower third; by Ass't Surg. J. M. Study, U. S. V. Died Jan. 15, 1863, of typhoid fever.
18	Lee, J., Pt., I. 29th North Carolina, age 24.	April 8, 15, '65.	Left; four inches lower third; by Ass't Surg. E. McClintock, U. S. V. Died May 2, 1865, of typhoid pneumonia.	26	Shober, J., Pt., C, 14th New York, age 26.	July 1, 26, '62.	Left; one inch upper third; by A. Surg. D. Kennedy; four ins. of shaft at junction of middle and upper thirds removed Jan. 26, 1863. Died Feb'y 7, 1863, of chronic diarrhoea and pneumonia.
19	Merritt, E. F., Pt., F. 31th Illinois.	Jan. 1, 17, '63.	Right; arm amputated. Died Feb. 26, 18'63.	27	Simmons, T., Corp'l, A. 20th Connecticut.	July 3, 20, '61.	Right; by Surg. W. S. Heath, 2d Mass. Died July 21, 1863.
20	Minor, I. D., Pt., A, 5th Michigan, age 19.	May 5, 19, '62.	Right; three inches middle third; by Surg. ———, 5th Mich. Died July 11, 1862.	28	Sullivan, D., Pt., A 28th Massachusetts, age 20.	Mar. 25, April 4, 1865.	Right; four inches at middle third; by Ass't Surg. H. Allen, U. S. A. Died April 26, 1865, of pyæmia.
21	Nicholas, W., Pt., H. 40th Alabama, age 22.	June 13, 26, '64.	Left; two inches upper and middle thirds; by Ass't Surg. G. W. Burke, 46th Penn. Died Oct. 31, 1864.	29	Wilds, J. Q., Lieut. Col., 24th Iowa.	Oct. 19, Nov. 5, 1864.	Left; two inches middle third; by Ass't Surg. J. Homans, Jr., U. S. A. Died November 19, 1864, from exhaustion.
22	Oliver, H., Pt., F. 36th Ohio, age 18.	July 21, 30, '61.	Right; two and a half inches middle third; by A. Surg. J. H. Bartholf. Died Aug. 18, 1864, of pyæmia. <i>Spec. 3306.</i>				
23	Perkins, J. R., Pt., A, 121st New York.	May 3, 15, '63.	Right; three inches upper third; by A. A. Surg. A. E. Keyes. Died May 30, 1863, of pyæmia.				

Twenty-six Union and three Confederate soldiers are enumerated in this series. Nineteen of the operations were on the right, and ten on the left arm. The usual predominance of operations in the middle and upper thirds obtained. Pyæmia and hæmorrhage were the principal causes of death; one patient succumbed from tetanus. Eight cases furnished specimens to the Museum. There were six major consecutive operations, including two exarticulations at the shoulder. An account of one of them is subjoined:

CASE 1337.—Private C. Gallagher, Co. C, 169th New York, was wounded at Cold Harbor, June 1, 1864. Surgeon S. A. Richardson, 13th New Hampshire, reported, from the base hospital of the Eighteenth Corps: "Shot wound of right shoulder." On June 8th, he was transferred to the Methodist Church Hospital, Alexandria. Surgeon T. R. Spencer, U. S. V., reported: "Shot wound of right arm, upper third. Ball entered anterior margin of deltoid muscle, fracturing the humerus. Resection on field.

Transferred to Albany, September 27, 1864. Acting Assistant Surgeon O. H. Young reported: "Wounded June 1, 1861, by a ball passing through and fracturing the upper third of the humerus. On June 6th, in a hospital at White House Landing, exsection was performed, about two and a half inches of the humerus being removed, beginning about an inch below the surgical neck. A day or two afterward he was removed to the Methodist Church Hospital in Alexandria. He was admitted to this hospital September 27th. At this time he was anæmic, and had a constant and very troublesome cough. There were three sinuses in his arm, which discharged large quantities of pus. Exploration with the probe showed the entire shaft of the bone to be carious, and in some places necrosed. His appetite failed; he was restless and anxious, and his general health continued to fail until it became evident that he could not recover unless the arm were amputated. Accordingly, on January 12, 1865, the operation was performed by Acting Assistant Surgeon Henry Pearce. The head of the bone was carefully disarticulated, and, last of all, the inner flap was made. Scarcely any blood was lost, and the patient appeared quite as strong as he was before the operation. He continued to improve daily, and, on January 19th, was in excellent condition. The wound has apparently healed by the first intention, and his general health is better." Dr. Young also forwarded the specimen (FIG. 509), which consists of "the right humerus amputated at the shoulder joint for necrosis of the shaft after excision of two and a half inches of the upper third. The upper extremity is somewhat rounded, but spongy. A large sequestrum, around which there is an exceedingly imperfect and scanty involucrum, occupies nearly the entire shaft." (*Cat. Surg. Sect.*, 1863, p. 112.) Assistant Surgeon J. H. Armsby, U. S. V., subsequently reported that the wound seemed to do well after the operation, but the general health continued to fail. The symptoms of phthisis progressed rapidly until death, which occurred March 3, 1865." Dr. Armsby contributed a cast in the case (FIG. 510). "There is great emaciation, causing remarkable prominence of the anterior border and head of the scapula. The cicatrix is nearly linear, extending downward from the acromial process into the deep hollow underneath." (*Cat.*, *op. cit.*, p. 547.) This is one of many instances in which, could the end have been foreseen, primary exarticulation would have been regarded as the preferable and most truly conservative operation.



FIG. 509.—Necrosis of the humerus after excision for shot injury. *Sp. c. 3608.*



FIG. 510.—Cast from a case of exarticulation following a secondary excision of the shaft of the humerus. *Spec. 384.*



**Secondary Excisions in the Shaft of the Humerus.**—Forty-one examples were reported in this category, with a very low rate of mortality.

§ *Cases of Recovery.*—Thirty-six of the patients who underwent this operation recovered. A few detailed illustrations will precede the table:

CASE 1638.—Private P. Murray, Co. H, 70th New York, aged 20 years, was wounded at Williamsburg, May 5, 1862, and was admitted to Chesapeake Hospital, Fort Monroe, on the 9th. Here the patient states resection was performed by Surgeon R. B. Bontecou, U. S. V. He was sent north on the 22d, and was treated in the Twenty-second and Wood Streets Hospital, Philadelphia, until January, 1863, when he was transferred to Sixteenth and Filbert Streets Hospital. Acting Assistant Surgeon A. D. Hall made the following special report: "While not more than fifty yards from the enemy this man was struck by two minie bullets, which entered the outer side of the upper third of the left arm about three and a half inches apart, in a line parallel with the humerus; the upper one passed entirely through behind the bone, the other striking and comminuting the bone to such a degree as to render it a comminuted fracture, at the same time that it became arrested among the fragments, where it remained about two months, when it was removed, together with eight fragments of bone, the patient being at the time at Fort Monroe, to which place he was taken immediately after receiving his wounds. In the following July he was transferred to Philadelphia and taken to the Twenty-second and Wood Streets Hospital, where he remained under treatment until February 1, 1863, when he was brought to this house with a number of others. The wounds of entrance and exit of the upper ball, at this time, were healed entirely, while there were two orifices communicating with the carious cavity of the lower wound, one on the outer side, where the ball entered, the other on the inside, the result of an abscess; from these there was considerable discharge of pus. The wound was dressed with simple cerate, and the arm supported by a proper splint and roller. This treatment was continued, and the administration of tonics commenced. On exploration with a probe, it was found that there existed in the cavity of the lower wound considerable dead bone, which, upon consultation, it was decided to remove. Accordingly, on the 21st instant, at half past ten o'clock, the patient being in excellent condition, ether was given, and the operation commenced. An incision, about five inches in length, was made on the anterior and outer side of the arm in the line of the cicatrix; it was carried down to the bone and parallel with its axis. The fragments were found to be imperfectly united, as there was fibrous instead of bony union, and, as a consequence, motion existed to a certain extent between them. One piece of bone, three-fourths of an inch in length by half an inch in breadth, was removed. The hæmorrhage during operation was slight, about four ounces of blood being lost; when it was checked the wound was closed by means of pins, with points of interrupted suture intervening between them, and adhesive strips. The limb was placed upon a straight splint and bandaged, and cold water was kept applied over the whole arm by means of a saturated towel. In two hours after the commencement of the operation the patient was placed in bed, and was comfortable at seven o'clock in the evening, having been somewhat affected in the afternoon with sickness of the stomach from the effects of ether. The case is progressing favorably." In May, 1863, the patient was transferred to New York City, entering Ladies' Home Hospital, and was thence discharged the service and pensioned May 17, 1864. Surgeon A. B. Mott, U. S. V., certified to: "Ununited fracture of left humerus following exfoliation of bone from gunshot wound." Examiner G. S. Jones, of Boston, March 3, 1865, reported: "The wound was in the middle third of the left arm. In consequence of necrosis of the bone having taken place, the humerus is now ununited. Fistulous openings exist about the wounded parts, from which matter is discharging. The arm is now nearly powerless and useless." This man subsequently entered the Boston City Hospital. Dr. H. J. Bigelow reports the case in the *Boston Medical and Surgical Journal*, volume 76, page 332, as follows: "\* \* \* In November, 1865, he entered the hospital. The left humerus had a false joint at its middle. There was necrosed bone at the bottom of a couple of sinuses in the lower fragment. An incision was made over the fracture, the periosteum reflected, and the ends of the bone sawed off. In March, 1866, there was no union. March 31st, Dr. Bigelow again operated. The periosteum was detached from both fragments for a sufficient distance; about one and a half inches was sawed off from the lower, and one inch from the end of the upper fragment. The ends were drilled, silver wire inserted, and the fragments placed in apposition. The periosteum was then replaced and its edges united by sutures. April 28th, the arm had stiffened at the point of fracture. June 10th, he fell upon the arm and broke it. July 15th, he was discharged with an ununited fracture, to return when the arm looks and feels better. January 12, 1867, operation by Dr. Bigelow. Patient was etherized. An incision three inches long was made over the outer aspect of the arm and carried carefully down to the point of fracture. The two ends were found to be much roughened. Great difficulty was experienced in everting the ends of the now short fragments and in detaching the periosteum. The bone was finally separated from the periosteum for a sufficient distance, and a piece one inch long sawed from the upper, and one three-quarters of an inch long from the lower fragment. The lower fragment was two inches in diameter; the upper one was of normal size, but with fatty degeneration of the marrow. A hole was drilled through the sides of both fragments, a silver wire was inserted, the ends were placed in apposition and the wire twisted. The periosteum was replaced and its edges united by sutures. The external wound was partly closed by sutures. A folded towel was placed in the axilla to lift out the short upper fragment, and the arm secured to the side, the forearm across the chest. 13th: There is almost complete paralysis of the extensors of the fingers of the left hand. No nervous trunk was known to have been divided in the operation, and the paralysis is perhaps due to a compression of the nerve in very forcibly everting the shortened fragments. 21st: The arm was placed in an apparatus, which consists of a firm cap about the shoulder, secured by a strap around the chest; this is made firm by two steel bridges to a splint that invests the forearm like a coat sleeve. 27th: The arm remains in excellent position. The power of extension is returning to the fingers. February 3d, the wound is contracting by healthy granulation. 6th: Slight stiffening at point of fracture. 16th: Phosphate of lime ordered, ten grains, three times a day. March 4th, allowed to walk about. April 16th, the humerus is quite firm at the point of fracture. He flexes the forearm and raises the humerus from the side freely. 22d: Discharged, probably well, although sufficient time has not elapsed to determine the fact. As will be readily inferred, this humerus was materially shortened by these consecutive

operations—two before entering the hospital, and three subsequently by Dr. Bigelow. In fact, by measurement, it was *seven inches* shorter than its fellow, yet the biceps and triceps were fulfilling their functions, and the patient was regaining excellent motion. There can be no comparison in the value of an arm of this sort, however short, and an ununited humerus. In the first operation, and during the existence of undefined necrosis, the bony tissue of the lower fragment was of a reddish hue, and of a dense, brittle, and amorphous texture, sometimes to be observed in the denuded walls of the cavities of sequestra when chiseled. At the end of about a year, at the next operation, when the probe no longer detected dead bone, the operator was agreeably surprized to find that this tissue had given place to a comparatively healthy one, with cancellated interior." The fragments of bone removed at the two first operations of Dr. Bigelow, with one of the wires, are shown as specimen No. 1008 of the Warren Anatomical Museum, Harvard University. (See *Desc. Cat.*, Boston, 1870, p. 166.) The pensioner was paid June 14, 1874.

The next case was also an example of resection for pseudarthrosis following shot injury:

CASE 1639.—Lieutenant T. Michener, Co. A, 1st New Jersey Cavalry, aged 27 years, was wounded at the Wilderness, May 5, 1864. He remained at a cavalry corps field hospital for several days, and was thence conveyed to Seminary Hospital, Georgetown, on May 11th. Surgeon H. W. Duchet, U. S. V., reported: "Gunshot fracture of middle third of left humerus by a minié ball. Several days after admission the patient was furloughed. On July 2d, when returning to the hospital, the original wound had nearly healed, but the fracture was found ununited and the end of the bone rounded and covered with callus. Constitutional condition very good. On July 7th, chloroform was administered and one inch of the humerus excised. Favorable progress followed the operation. On September 23th, the patient again left the hospital on furlough." On October 22d, he was admitted to Division Hospital No. 1, Annapolis. Surgeon B. A. Vanderkeift, U. S. V., noted: "Resection of left humerus." Lieutenant Michener was discharged from service on December 2, 1864, and pensioned. Examiner W. Corson, of Norristown, Pennsylvania, April 12, 1865, certified: "The wound was received about the middle of the humerus, left arm; was resected about two months after injury, and is now remitted and firm, with shortening of not more than half to three-fourths of an inch." The Philadelphia Board, consisting of Drs. J. Collins, H. E. Goodman, and T. H. Sherwood, certify, on October 13, 1873: "Cicatrices adherent to bone and three inches long; arm weakened, curved, and muscles bulging." The disability was rated total. Pensioner has been paid to March 4, 1875.

Imperfect consolidation or non-union and pseudarthrosis, unusual after expectant treatment of shot fractures of the humerus, were not infrequent after excisions in the continuity.

The majority of the cases in this series, however, were of the nature of operations for necrosis, as in the following instance and in the abstract succeeding the tabular statement:

CASE 1640.—Sergeant J. W. Ross, Co. C, 93d New York, aged 25 years, was wounded at Petersburg, June 22, 1864. He was sent to Philadelphia, and entered Filbert Street Hospital. Assistant Surgeon S. J. Storrow, U. S. A., noted: "Gunshot fracture of the humerus, not involving the joint." The patient was transferred to McClellan Hospital April 28th, and subsequently entered Ira Harris Hospital, Albany. Assistant Surgeon J. H. Armsby, U. S. V., contributed the specimen (FIG. 511), with the following history: "Patient was wounded in the left arm, the ball injuring the humerus. Admitted July 20, 1865. The arm continued swollen and inflamed, and several fistulæ made their appearance. September 26, 1865: On exploring with the probe, they were found to lead to a large sequestrum, which was accordingly removed. A large incision was made, about five inches long, and the dead bone removed with the forceps. Ether was administered. Simple dressings applied." The specimen consists of four fragments of a sequestrum, four inches in length, from the left humerus, three months after gunshot fracture. About one-third of the circumference is involved (*Cat. Surg. Sect.*, 1866, p. 137). The patient was discharged November 30, 1865, and pensioned. Examiner E. W. Howard, October 3, 1866, certified: "Shot through the left arm near the shoulder, breaking the humerus, followed by extensive gangrene and sloughing of the muscles, leaving the entire arm utterly useless for any practical purpose, the remaining flesh having adhered firmly to the bone nearly the whole length of the arm." Examiner F. J. Bancroft, of Denver, Colorado, September 13, 1873, certified: "There is atrophy of the left arm, and it is entirely useless for manual labor." The disability was rated total. The pensioner was paid March 4, 1875.

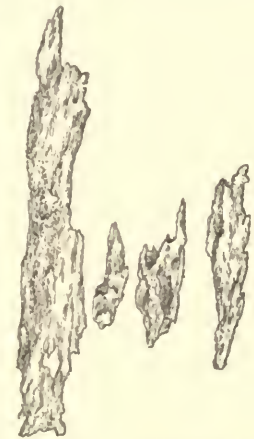

FIG. 511.—Necrosed sequestra from a humerus fractured by shot. Spec. 4016. †.

Of the thirty-six operations—thirty-one practised on Union and five on Confederate patients—fourteen were on the right and twenty on the left side, the point being unspecified in two cases. The middle third was chiefly implicated in fourteen, the upper in twelve, the lower in ten cases.<sup>1</sup> Twenty-five men were discharged, five paroled or exchanged, six returned to modified duty. Twenty-eight were placed on the pension list, two of whom have died. Troublesome gangrene appeared after three of the operations, and obstinate hæmorrhage in one.

<sup>1</sup>The extent of bone removed is specified, in 26 of the operations, as one inch in 4 cases, two inches in 9 cases, two and a half or three inches in 3 cases, three and a half inches in 3 cases, four inches in 6 cases, five inches in 1 case.



## TABLE LXI.

## Condensed Summary of Thirty-six Successful Secondary Excisions of the Shaft of the Humerus for Shot Injury.

No.	NAME, AGE, AND MILITARY DESCRIPTION.	DATES.	OPERATIONS, OPERATOR, RESULT.	No.	NAME, AGE, AND MILITARY DESCRIPTION.	DATES.	OPERATIONS, OPERATOR, RESULT.
1	Blough, P., Pt., G, 88th Indiana, age 28.	Feb. 23, Dec. 16, 1864.	Left; two inches lower third; by Surg. G. Grant, U. S. V. Disch'd March 20, 1865; pensioned; ankylosis.	20	Phillips, H. W., Pt., F, 1st Michigan Cavalry.	May 25, Dec. 6, 1862.	Right; fragments removed and ends of bone sawn off three and a half inches above external condyles, by Surg. W. M. Brood, U. S. V.; fracture united. Disch'd March 13, 1863; pensioned.
2	Boswice, P., Pt., D, 6th Wisconsin, age 21.	May 8, Dec. 6, 1864.	Right; four inches upper and middle thirds; by A. A. Surg. H. S. Streeter, U. S. A. Disch'd June 7, 1865; pensioned; bony union; ankylosis.	21	Pollock, G., Captain, E, 78th, Illinois, age 28.	Sept. 20, Oct. 22, 1863.	Right; about two inches of shaft; by Ass't Surg. W. W. Wytches, U. S. V. Duty April 19, 1864; resigned June 27, 1864; pensioned; arm useless.
3	Broughton, J., Pt., G, 6th Infantry, age 31.	May 2, Dec. 20, 1863.	Right; necrosed bone, lower third; by Ass't Surg. H. E. Brown, U. S. A. Disch'd March 29, 1864; pensioned.	22	Reeves, P. S., Serg't, G, 23d Kentucky, age 23.	May 27, July 5, 1864.	Right; two and a half inches of middle third; by Dr. A. McGraw. Duty Nov. 15, 1864; pensioned; complete bony union; arm of great service.
4	Claffey, H., Pt., C, 21st Massachusetts.	Mar. 14, April 15, 1862.	Left; three inches upper third; by Surg. W. H. Church, U. S. V. Duty July 10, 1862; pensioned; arm useful; atrophied.	23	Rifle, J., Pt., F, 16th West Virginia, age 25.	Nov. 6, Dec. 26, 1863.	Left; three and three-quarter inches lower third; by Surg. C. E. Denig, 28th Ohio; arm amp. Feb. 8th; healed. Disch'd Oct. 24, 1864; pensioned.
5	Darby, J., Pt., G, 96th Illinois, age 22.	Sept. 29, Nov. 26, 1863.	Left; two inches middle third; by A. A. Surg. M. L. Herr, U. S. A. To V. R. C. Aug. 26, 1864; progressed finely; pensioned.	24	Robbins, L. N., Pt., C, 9th New York Cavalry, age 27.	May 12, 1864, Jan. 27, 1865.	Left; two inches at middle third; by A. A. Surg. J. F. Thompson. Discharged May 31, 1865; pensioned.
6	Dusty, F., Pt., I, 31st Maine, age 16.	May 10, June 13, 1864.	Left; three and a half inches; by A. A. Surg. F. G. H. Bradford, U. S. A. Disch'd Jan. 14, 1865; pensioned. Died April 10, 1866.	25	Ross, J. W., Serg't, C, 33d New York, age 25.	June 22, 1864, Sept. 26, 1865.	Left; four inches of humerus; by Ass't Surg. J. H. Arnshy. Discharged Nov. 30, 1865; pensioned. <i>Spec.</i> 4016.
7	Ezekiel, I. D., Lieut., 10th West Virginia, age 22.	July 7, Aug. 22, 1864.	Right; four and a half ins. lower third; by Dr. W. H. Mussey. Disch'd Mar. 9, 1865; bony union; full use of arm; not a pensioner.	26	Sarbach, D., Pt., A, 107th Ohio, age 37.	July 1, Oct. 11, 1863.	Left; one and a half inches of humerus; by A. A. Surg. E. A. Korper. Disch'd April 18, 1865; pensioned.
8	Fisk, C. A., Pt., K, 11th Massachusetts, age 21.	July 2, —, '63.	Left; four inches upper third; by Dr. Hodges. Disch'd Mar. 15, 1864; necrosis; pensioner.	27	Shultz, E., Pt., D, 103d New York, age 30.	Dec. 18, Mar. 25, 1865.	Right; nearly one-half inch removed from each end; by Ass't Surg. S. H. Orton. Disch'd July 14, 1865; pensioned.
9	Floyed, E., Pt., I, 2d Georgia, age 30.	June 27, Dec. 17, 1862.	Dead bone to the extent of at least one-half the original; use of arm restored.	28	Snider, D., Pt., E, 74th Illinois, age 19.	May 17, 1865.	Left; two inches; by A. A. Surg. R. N. Isham. Disch'd June 12, 1865; pensioned.
10	Hill, M., Pt., B, 5th Louisiana.	Sept. 1, 1862, Aug. 20, 1863.	Left; diseased ends of bone in lower and middle thirds. Recovered.	29	Spinner, J., Corp'l, G, 28th Ohio, age 33.	Nov. 6, '63, Operat'n in 1864.	Left; excision of a large portion of middle third. Disch'd July 23, 1864; pensioned; can use hand well for light work.
11	Johnson, A., Pt., H, 7th New Jersey, age 21.	July 2, 1863, June 5, 1864.	Right; portion of humerus; by A. A. Surg. M. B. Richardson. Disch'd Oct. 7, 1864; pensioned; arm useless.	30	St. Clair, L., Pt., M, 2d Ohio Heavy Artillery, age 22.	April 10, June 20, 1865.	Left; ends of bone at middle third; by A. A. Surg. T. W. Baugh. Disch'd Sept. 30, 1865; pensioned. Died Dec. 12, 1865.
12	Kahlmeyer, W., Serg't, E, 8th N. York, age 40.	June 8, Aug. 19, 1862.	Right; nineteen fragments upper third; by A. A. Surg. S. D. Gross. Disch'd Jan. 28, 1863; pensioned.	31	Taylor, C. A., Pt., I, 4th Georgia, age 22.	May 10, Aug. —, 1864.	Left; excision of portion of upper third. Transferred to Old Capitol Prison Nov. 1, 1864.
13	Kanery, J., Pt., A, 9th Massachusetts, age 37.	July 1, 1862, Feb. —, 1863.	Left; two inches upper and middle thirds; by Dr. Hodges, Soldiers' Home, Boston. Disch'd Nov. 5, 1862; pensioned; no bony union.	32	Tucker, W. A., Pt., E, 49th Ohio, age 22.	April 15, July 14, 1864.	Right; three and a half inches at upper third. Veteran Reserves; not a pensioner.
14	Linn, C., Corp'l, H, 15th Ohio, age 31.	May 27, Sept. 4, 1864.	Right; one inch; by A. A. Surg. A. Buckingham. Disch'd March 17, 1865; pensioned; ankylosis.	33	Ward, J. H., Pt., C, 36th Illinois, age 25.	Sept. 20, 1863, Jan. 22, 1864.	Right; by A. A. Surgeon J. H. Coover; subsequent removal of extremities of both fragments; no bony union. Mustered out Sept. 13, 1864; pensioned.
15	Marrh, J. H., Lieutenant, Scott's Battery.	Sept. 19, Oct. 21, 1863.	Left; about four inches lower third. Recovered.	34	Wareham, H. H., Pt., A, 11th Penn'a Reserves, age 20.	June 30, Aug. 2, 1862.	Right; two inches middle shaft; by Surg. A. B. Hasson, U. S. A.; firm union. V. R. C. Aug. 30, 1863; not a pensioner. <i>Spec.</i> 434.
16	Mieheuer, T., Lieut., A, 1st New Jersey Cavalry, age 27.	May 5, July 1, 1864.	Left; one inch middle third; by Surg. H. W. Ducahot, U. S. V. Disch'd Nov. 2, 1864; pensioned.	35	Wittgenfeld, R., Pt., B, 10th Ohio, age 21.	Oct. 8, Dec. 10, 1862.	Left; two inches just below head; by Ass't Surg. B. H. Cheney. Disch'd Jan. 24, 1863; pensioned.
17	Miller, R., Pt., M, 3d R. Island Art'y, age 35.	Aug. 30, 1863, Feb. 25, 1864.	Left; portion of shaft; by A. A. Surg. J. W. Cushing, U. S. A. Disch'd Aug. 5, 1864; pensioned.	36	Woodward, J. W., Lieut., 1, 26th Penn., age 27.	May 3, 1863.	Right; at upper third; by Dr. Leavick. Transferred to V. R. C.; disch'd April 1, 1867; pensioned; ankylosis of shoulder joint and loss of power of whole limb.
18	Murray, P., Pt., H, 70th New York, age 22.	May 5, 1862, Feb. 21, 1861.	Left; necrosed portion of middle third. Disch'd May 17, 1864; pensioned.				
19	P——, late Confederate soldier.	May 3, 1863, Jan. 9, 1864.	Five inches upper third; by Dr. Schmidt; no bony union.				

CASE 1641.—Private H. H. Wareham, Co. A, 11th Pennsylvania Reserves, aged 20 years, was wounded in the right arm at White Oak Swamp, June 30, 1862. He was captured by the enemy and conveyed to Libby prison, at Richmond, at which place he remained until paroled and sent to Baltimore, where he entered Camden Street Hospital on July 25th. Surgeon A. B. Hasson, U. S. A., on August 2d, excised two inches of the middle third of the shaft of the humerus, and subsequently, on January 22, 1863, he removed eleven necrosed fragments, which he contributed to the Army Medical Museum (*Cat. Surg. Sect.*, 1866, p. 133, *Spec.* 434). On July 2d, the patient was transferred to Point Lookout Hospital, where Surgeon A. Heger, U. S. A., recorded: "Gunshot wound of right humerus." Subsequently the patient was transferred to Convalescent Camp at Alexandria, and on August 30, 1863, he was assigned to the Veteran Reserve Corps. He is not a pensioner. An account of this case was published by Acting Assistant Surgeon G. H. Dare, in the *American Medical Times*, Vol. VI, p. 208, 1863, as follows: "Private Wareham was wounded through the middle of the arm. He walked a mile to a field hospital, where his wound was bandaged.

On July 1st, he was captured by the Confederates and sent to Richmond, where he endured the usual hardships at the Libby prison until he was paroled and sent to Baltimore. He was admitted into the United States Army Hospital, Camden Street, Baltimore, July 25th. A musket ball had passed horizontally through the right arm from behind forward, fracturing the humerus in its middle third. Lateral splints were applied for the first time, and cold-water dressings. August 2d, union not having taken place, the fractured extremities were resected, about two inches of the bone being removed. The elbow was afterward well supported, but it was found impossible to keep the ends of the bone in immediate apposition—the finger for a long time could be passed between them. Notwithstanding this difficulty, within two months, union, at first of a cartilaginous or lymphatic nature, had taken place, and then osseous matter was gradually deposited. A fistulous orifice continued in front, and some dead bone being detected with the probe, the orifice was expanded January 22d, and several small sequestra, entirely detached, were removed. Osseous union was ascertained to be perfect. February 6th, there is still a trifling discharge from the anterior opening. The man can take off his cap without difficulty. Some stiffness of the muscles exists, which is rapidly passing away. There is every probability of his regaining almost perfect use of the limb."

There were in this series three instances of unsuccessful operations for pseudarthrosis, and one of consecutive amputation of the arm.

§ *Fatal Secondary Excisions.*—There were but five instances of fatal results after secondary excision of the shaft; one of them is detailed:

CASE 1642.—Corporal W. A. Armstrong, Co. B, 31st Maine, aged 23 years, was wounded at Petersburg, July 30, 1864, and was admitted into 2d division hospital, Ninth Army Corps. Surgeon J. Harris, 7th Rhode Island, noted: "Gunshot fracture of left arm; excision of humerus." On the second day after the reception of the injury the patient was transferred to City Point, and thence to Lovell Hospital, Portsmouth Grove. August 7th, Surgeon C. O'Leary, U. S. V., reported: "Gunshot fracture of left humerus, upper third. Patient furloughed November 30th, and readmitted on January 24th. At this time there was thorough cicatrization of the external wound; formation of false joint by re-absorption of callus; ligamentous union. On January 31st, resection of two inches of the upper third of the bone was performed, by Acting Assistant Surgeon E. Seyffarth, through a longitudinal incision four inches long. Anæsthetic: Chloroform and ether. Reaction prompt; considerable loss of venous blood attended the operation, but no arterial hæmorrhage. The arm was lightly bandaged, and the bones were brought in contact and secured by an elbow splint. Sutures were entirely dispensed with, as the edges of the wound were easily held in contact by the bandage and adhesive strips, the muscles having been somewhat relieved by a cross cut, about half an inch deep, in order to do away with the 'pockets' formed after pushing both ends of the bone together. During the first six days progress seemed favorable; but on the eighth day there was a severe chill, which was repeated every day or every other day; appetite failed; diarrhœa set in, and patient rapidly sank. On the ninth day several abscesses appeared on the inner surface of the arm. These, together with the wound, which had become partially reopened by the extreme tension caused by the swelling of the whole arm, were discharging an ichorous serum mixed with pus, and extremely offensive. The treatment consisted of cold-water applications in the beginning, and afterward of free use of solution of permanganate of potassa, stimulants as freely as could be borne, generous diet, muriated tincture of iron, &c. Death occurred on February 19, 1865. At the *post-mortem* examination of the shoulder and elbow joints, a small quantity of pus was found in the former, but no metastatic abscesses were discovered."

TABLE LXII.

*Condensed Summary of Five Fatal Secondary Excisions of the Shaft of the Humerus for Shot Injury.*

No.	NAME, AGE, AND MILITARY DESCRIPTION.	DATES.	OPERATIONS, OPERATOR, RESULT.	No.	NAME, AGE, AND MILITARY DESCRIPTION.	DATES.	OPERATIONS, OPERATOR, RESULT.
1	Armstrong, W. A., Corporal, B, 31st Maine, age 23.	July 30, 1864. Jan. 31, 1865.	Left; two inches upper third; by A. A. Surg. E. Seyffarth. Died Feb. 19, 1865, of pyæmia. It is stated that excision had been performed on the field.	4	Todd, W. H., Pt., F, 111th Illinois, age 22.	May 14, July 1, 1864.	Left; three inches middle third; by Ass't Surg. S. C. Ayres, U. S. V. Died Feb. 27, 1865, of pleuro-pneumonia.
2	Dunn, D., Pt., H, 37th North Carolina, age 23.	.....	One in. from each end of bone. Died July 28, '63, of pleuro-pneumonia.	5	Truitt, G. P., Pt., C, 110th Ohio, age 23.	June 9, July 21, 1864.	Left; portion of upper third; by Surg. G. S. Palmer, U. S. V. Died July 29, 1864.
3	Markel, J. D., Serg't, F, 56th Ohio.	May 16, June 24, 1863.	Left; upper third; by Ass't Surg. E. C. Strode, U. S. A. Died July 9, 1863, of pleuro-pneumonia.				

**Excisions in the Shaft of the Humerus at an Unknown Period after Shot Injury.**—

In seventy-five instances, the interval between the dates of injury and operation could not be ascertained.

§ *Cases of Recovery.*—Fifty-one operations were successful so far as the preservation of life was concerned, as indicated in the following table. The operations were practised on twenty-nine Confederate and twenty-two Union soldiers. Three of the latter resumed active duty, and nineteen were pensioned. In one case, consecutive exarticulation at the



shoulder was successfully practised. The operations were on the right arm in fourteen and on the left in twenty-nine, this point being left in doubt in eight cases. The excisions were made in the upper third in fifteen, the middle third in twelve, the lower in ten cases. In fourteen cases the seat of operation was not precisely specified:

TABLE LXIII.

*Condensed Summary of Fifty-one Successful Cases of Excision of the Shaft of the Humerus for Shot Injury, the Time between the Injury and Operation being unknown.*

No.	NAME, AGE, AND MILITARY DESCRIPTION.	DATES.	OPERATIONS, OPERATOR, RESULT.	No.	NAME, AGE, AND MILITARY DESCRIPTION.	DATES.	OPERATIONS, OPERATOR, RESULT.
1	Avery, S. H., Pt., C, 3d S. C. Battery, age 21.	Sept. 20, 1863.	Left; four inches; permanently disabled. Retired Jan. 31, 1865.	30	Martin, J. S., Serg't, K, 93d Illinois, age 33.	May 14, 1863.	Left; two and a half inches middle third; Veteran Reserves Mar. 2, 1864. Disch'd Mar. 30, 1865; pensioned.
2	B——, Confed. soldier.	Sept. 19, 1863.	Resection of two inches, one and a half inches above elbow joint, by Surgeon Crawford, C. S. A.; functions but little impaired.	31	McKeever, M., Pt., B, 23d Kentucky, age 35.	May 27, 1864.	Right; two inches at lower third and removal of fragments of bone from fractured scapula; V. R. C. March 10, 1865; shoul-der very weak; arm shorter. Mustered out August 29, 1866; pensioned.
3	Babcock, E., Pt., B, 26th New York.	Dec. 13, 1862.	Left; excision at the upper third. Disch'd Jan. 5, 1863; disability total; not a pensioner.	32	Mickey, T. E., Pt., I, 33d N. C., age 24.	May 3, 1863.	Left; four inches lower third. Retired January 28, 1864.
4	Boone, N. T., Pt., G, 57th Virginia, age 29.	July 3, 1863.	Left; five inches of middle third; recovered.	33	Miller, K. P., Pt., G, 7th N. C. Art'y, age 19.	Sept. 19, 1864.	Right; three inches at upper third. Transferred to Provost Marshal February 14, 1865.
5	Durnett, J. T., Lieut., K, 26th Mississippi.	Aug. 18, 1864.	Right; resection of three inches. Furloughed October 3, 1864.	34	Nusser, H., Pt., A, 49th Ohio, age 20.	Sept. 19, 1863.	Left; middle third. Discharged May 14, 1864; pensioned.
6	Butler, J., Pt., C, 2d Infantry.	July 21, 1861.	Left; excision of humerus; false joint formed. Disch'd April 24, 1862; pensioned.	35	Ogletree, W. D., Pt., K, 14th Alabama, age 19.	June 23, 1864.	Left; three inches at middle third; wound healing firmly, by granulation, July 31st. Furloughed August 31, 1864.
7	Carruth, A. D., Pt., F, 16th Mississippi, age 18.	May 12, 1864.	Right; three inches excised; no bony union; arm useless. Retired March 23, 1865.	36	Padgel, J. W., Pt., F, 13th Alabama, age 22.	May 6, 1864.	Left; one and a half inches; ligamentous union; wound did not heal. Retired Feb. 16, 1865; disability.
8	Clements, T. M., Serg't, A, 12th Georgia Battery, age 34.	June 2, 1864.	Left; excision of portion of shaft at upper third; false joint. Retired Jan. 30, 1865; arm almost useless.	37	Patton, J., Corp'l, E, 2d Pennsylvania Reserves.	Sept. 17, 1862.	Left; upper third. Disch'd Dec. 20, 1862, and pensioned.
9	Corsley, J. A., Pt., I, 6th Virginia, age 28.	June 28, 1864.	Left; excision three and a half inches. Retired Feb. 10, 1865; disability.	38	Paff, W. J., Pt., II, 19th Mississippi, age 18.	.....	Left; two and a half inches lower third; also right elbow joint fractured. Retired Jan. 27, 1865; partial ankylosis of elbow joint.
10	Cunningham, T., Pt., II, 11th Penn., age 21.	May 10, 1864.	Left; two inches of lower third. Disch'd July 31, 1865; necrosis of elbow joint; pensioned.	39	Powell, A. S., Pt., D, 6th N. C., age 30.	April 18, 1864.	Left; excision of portion of humerus. Retired December 30, 1864; disability.
11	Curtin, T., Serg't, I, 48th Massachusetts.	May 27, 1863.	Right; excision of two inches. Disch'd Sept. 2, 1863; pensioned; bone united; arm useless.	40	Powell, J. T., Pt., B, 5th N. C., age 22.	July 3, 1863.	Right; three inches at upper third. Exchanged March 17, 1864.
12	Doner, A. R., Pt., C, 77th Pennsylvania, age 21.	June 25, 1863.	Left; lower third. Disch'd Oct. 6, 1864; pensioned; partial ankylosis of elbow joint.	41	Powers, R., Corp'l, B, 45th Illinois, age 29.	April 6, 1862.	Left; resection at upper third; arm not much disabled; one and a half inches shortening. Veteran Reserves Nov. 25, 1863; not a pensioner.
13	Englis, J. T., Pt., G, 134th Pennsylvania, age 30.	Dec. 13, 1862.	Right; resection at middle third. Disch'd Mar. 24, 1863; pensioned.	42	Quinn, J., Pt., C, 83d Ohio, age 26.	Jan. 11, 1863.	Left; lower third. V. R. C. Nov. 11, 1863. Disch'd May 11, 1865; pensioned.
14	F——, O.W., 77th New York.	.....	Excision of three inches; false joint substituted; uses arm with great freedom.	43	Reed, A., Pt., B, 11th Missouri, age 19.	May 27, 1863.	Left; excision of upper third; not united; arm shortened about three inches; shoul-der joint ankylosed. Discharged August 5, 1863; pensioned.
15	Faulkner, D., Corp'l, B, 136th New York, age 24.	July 3, 1863.	Left; three inches of middle third. Disch'd Dec. 2, 1863; healed; pensioned; little or no use of arm; compelled to carry it in a sling.	44	S——, Capt., K, 31st Tennessee, C. S. A.	July 22, 1864.	Three inches of bone removed for fracture of the upper and middle thirds; cannot extend limb but can flex; arm healthy.
16	Fenstermacher, F., Pt., C, 50th Pennsylvania.	Sept. 17, '62.	Left; three inches of upper third. Disch'd Sept. 26, 1863; pensioned.	45	Shilling, J. J., Pt., B, 42d Virginia, age 25.	Sept. 19, 1864.	Excision of six inches three inches below shoul-der joint. Retired Jan. 20, 1865; disability; arm useless.
17	Fisher, C. Y., Capt., A, 18th Penn., age 32.	Nov. 27, 1863.	Right; two inches at lower third. Disch'd Sept. 17, 1864; pensioned.	46	Smith, J. N., Pt., G, 89th Illinois.	Sept. 19, 1863.	Right; three inches of upper third. Discharged June 6, 1864; pensioned; arm useless.
18	Gill, J. J. L., Lieut., F, 5th South Carolina.	May 7, 1864.	Resection of three inches. Furloughed July 14, 1864.	47	Stafford, J. S., Lieut., II, 7th North Carolina.	May 12, 1864.	Resection of two and a half inches. Furloughed May 30, 1864.
19	Hardy, T. S., Pt., D, 14th Alabama, age 24.	Operat'n Aug. 26, 1864.	Left; three and a half inches. Furloughed October 15, 1864.	48	Tolson, A. Pt., 1st Maryland Artillery.	May 3, 1863.	Right; excision of two inches of shaft. Duty October 30, 1863.
20	Harter, T. J., Pt., A, 41st Illinois, age 19.	April 6, 1862.	Right; middle of fractured portion united by shortening one and a half inches; cannot extend arm. Disch'd Dec. 5, 1862; pensioned.	49	Tucker, W. F., General.	May 14, 1864.	Left; three inches, to within three-fourths of an inch of anatomical neck; by Dr. J. S. Cain; healed promptly; no bony union; limb shortened three inches; can use forearm and hand when rested on a table or supported; is far preferable to no arm.
21	Haynie, J. B., Pt., A, 2d Georgia S. S., age 17.	Sept. 20, 1863.	Resection near elbow. Recovered, with false joint.	50	Usry, R. C., Pt., D, 10th Alabama, age 30.	June 6, 1864.	Left; four inches of middle third. Furloughed August 20, 1864.
22	Hood, J. M., Lieut., B, 1st Engineers, C. S. A.	May 1, 1864.	Resection of portion of left humerus. Furloughed Aug. 13, 1864.	51	Yeast, J. S., Pt., F, 6th Ohio, age 19.	Sept. 19, 1863.	Right; two inches of upper third; strong callus united the bone; arm shortened one inch. Disch'd June 21, 1864; pensioned.
23	Horne, C., Pt., II, 48th North Carolina, age 43.	Oct. 7, 1864.	Left; excision in middle third. Retired Feb. 10, 1865; permanent disability.				
24	Hunter, B. C., Pt., G, 2d Arkansas, age 21.	Nov. 30, 1864.	Left; about two inches of middle third. Sent to Provost Marshal March 7, 1865.				
25	Hunter W., Serg't, II, 13th Georgia, age 32.	May 12, 1864.	Right; one and a half inches. Retired February 9, 1865; partial paralysis; limb useless.				
26	Knight, D., Pt., D, 8th N. Y. Cav., age 26.	Nov. 2, 1862.	Right; resection. Disch'd July 14, 1864; pensioned.				
27	Koons, W., Pt., G, 132d Pennsylvania.	Sept. 17, 1862.	Left; excision of a portion. Discharged Dec. 6, 1862; pensioned.				
28	Logan, L. C., Corp'l, II, 21st N. C., age 22.	July 2, 1863.	Resection in the upper third. Recovered.				
29	Martin, J. R., Pt., E, 3d South Carolina.	Sept. 17, 1862.	Left; excision; amputation at the shoul-der joint. Dec. 1st, promised a speedy recovery.				

To complete the series of six hundred and ninety-six excisions in the continuity of the humerus after shot injury, there remain twenty-four cases, of which the histories are very imperfect. What has been ascertained is recapitulated in the two succeeding tables :

TABLE LXIV.

*Condensed Summary of Twelve Fatal Cases of Excision of the Shaft of the Humerus, in which the Time of Operation was not ascertained.*

NO.	NAME, AGE, AND MILITARY DESCRIPTION.	DATES.	OPERATIONS, OPERATOR, RESULT.	NO.	NAME, AGE, AND MILITARY DESCRIPTION.	DATES.	OPERATIONS, OPERATOR, RESULT.
1	Bowles, W., Pt., G, 57th Virginia.	.....	Left; excision of middle third. Died Sept. 30, 1863.	8	Sherwood, O., Pt., K, 132d Pennsylvania.	Sept. 17, 1862.	Excision of portion of humerus. Died Oct. 13, 1862.
2	Bunnell, D., Pt., H, 93d Illinois.	.....	Left; excision. Died September 13, 1863.	9	Squiers, H., Pt., F, 5th Ohio.	Sept. 17, 1862.	Right; excision of a portion of humerus. Died Nov. 5, 1862.
3	Garland, B. F., Pt., D, 11th Infantry.	May -, 1864.	Right; excision. Died June 3, '64.	10	Ward, H. B., Pt., A, 103d Ohio, age 19.	Oct. 15, 1863.	Left; about seven inches from surgical neck downward. Died Feb. 17, 1864, of small-pox.
4	Grissins, C., Pt., B, 11th Pennsylvania.	Mar. 31, 1865.	Right; excision of two inches at lower third. Died May 21, 1865, of erysipelas.	11	Wagner, C., Pt., F, 68th New York.	.....	Right; excision. Died October 15, 1862.
5	Joice, J. A., Pt., H, 42d Virginia.	.....	Excision of a portion of humerus. Died June 8, 1864, of pyæmia.	12	Westerman, G., Pt., F, 5th Ohio.	Sept. 17, 1862.	Left; excision of a portion. Died Oct. 27, 1862.
6	Moyer, M., Pt., G, 28th Pennsylvania.	Sept. 17, 1862.	Excision of a portion of humerus. Died Oct. 15, 1862.				
7	Seiler, W., Corp'l, A, 104th Ohio, age 19.	June 14, 1864.	Left; one and a half inches excised from middle third. Died Aug. 29, 1864.				

TABLE LXV.

*Condensed Summary of Twelve Cases of Excisions of the Humerus for Shot Injury, the Result and the Time between Injury and Operation being unknown.*

NO.	NAME, AGE, AND MILITARY DESCRIPTION.	DATES.	OPERATIONS, OPERATOR, RESULT.	NO.	NAME, AGE, AND MILITARY DESCRIPTION.	DATES.	OPERATIONS, OPERATOR, RESULT.
1	Beison, J. J., Corp'l, G, 27th Virginia, age 24.	May 3, 1863.	Three inches of shaft resected.	7	Hunt, B., Pt., K, 57th Virginia.	July 3, 1863.	Left; excision middle third.
2	Chastain, A. C., Pt., D, 2d South Carolina.	Sept. 30, 1864.	Left; excision.	8	King, T., Pt., B, 38th Georgia.	.....	Left; excision.
3	Craig, J., Pt., A, Orr's Rifles.	July 28, 1864.	Right; excision.	9	Land, S. L., Pt., C, 13th South Carolina.	Aug. 16, 1864.	Left; excision.
4	Gamble, J. A., Pt., F, 59th Georgia.	Nov 18, 1861.	Right; excision.	10	Murphy, J., Pt., F, 5th South Carolina.	Aug. 16, 1864.	Right; excision.
5	Harris, J., Pt., E, 21st Georgia.	July -, 1863.	Right; excision.	11	Snake, J. W., Pt., B, 30th Virginia, age 31.	Oct. 13, 1864.	Right; resection of upper third. January 1, 1865, not doing well.
6	Pennington, L., Corp'l, G, 46th Virginia, age 46.	June 2, 1864.	Left; two or three inches at lower part of upper third; progress favorable.	12	Welch, R. L., Corp'l, E, Palmetto Sharpshooters.	Oct. 7, 1864.	Right; excision.

*Concluding Observations on Excisions in the Continuity of the Humerus after Shot Injury.*—Excluding operations for necrosis, and, possibly, resections for pseudarthrosis, formal excisions in the continuity of the long bones, and especially in the humerus, were generally regarded prior to the war with disfavor by American surgeons.<sup>1</sup> They seem now to be less emphatically condemned. But I cannot discern that the experience of the war lends any support to the doctrine of the justifiability of operations of this nature, except in

<sup>1</sup> The opinions of American surgeons who have treated, since the war, of the merits of this operation, may be summarized as follows: Dr. J. ABTHURST, jr. (*The Principles and Practice of Surgery*, 1871, p. 167) declares: "Excision in the continuity of the humerus \* \* \* is more fatal than amputation of the corresponding parts; still the difference is not so great but that the operation may be regarded as justifiable in favorable cases." See also this author's remarks on *Surgical Cases*, in the *Am. Jour. Med. Sci.*, 1863, Vol. XLV, p. 342. Professor F. H. HAMILTON (*The Principles and Practice of Surgery*, 1872, p. 391) observes: "A few fortunate examples in which excisions of considerable portions of the shaft of the humeri have resulted in bony union do not authorize a well-grounded hope that it will generally occur, or a repetition of the practice, except as a last alternative." Dr. S. W. GROSS (*Military Surgery*, in *Am. Jour. Med. Sci.*, 1867, Vol. LIV, p. 475) regards formal resections of portions of the shafts of long bones "not only as unnecessary and dangerous, but also as prejudicial, from the fact of the union of the divided extremities being uncertain and imperfect." Professor S. D. GROSS (*A System of Surgery*, 5th ed., 1872, Vol. II, p. 1087) thinks "excision of the shaft of the humerus is sometimes required on account of gunshot injuries," and that the tabular statement prepared by his son, Dr. S. W. GROSS, "shows much more favorable results" than appeared from the Schleswig-Holstein and Crimean experience. Dr. G. H. STEVENS (*On Excisions in Cases of Gunshot Wounds*, in *Trans. of Med. Soc. of State of New York*, 1866, p. 138) gives a favorable case, and the opinion that "Excisions of the humeral shaft, although not often required, yet in some instances are advisable, and the cases were quite as promising as other resections." Dr. W. GIBBELLAS (*Ibid.*, p. 122. *Excision of the Shaft of the Humerus*) cites a partially successful case and advocates the operation as a secondary procedure. Surgeon D. G. BRINTON, U. S. V. (*Appendix to Part I of Med. and Surg. Hist. of the War of*



very exceptional cases. The numerical return, and the necessarily abbreviated summaries, may appear, at first glance, to represent the results in a favorable light; but a more precise analysis reveals most lamentable conclusions. The naked figures are as follows:

TABLE LXVI.

*Numerical Statement of Six Hundred and Ninety-six Cases of Excisions in the Shaft of the Humerus for Shot Injury.*

OPERATIONS.	Cases.	Recovery.	Fatal.	Result Unknown.	Mortality Rate of Determined Cases.
Primary.....	487	326	145	16	30.7
Intermediary.....	93	64	29	.....	31.1
Secondary.....	41	36	5	.....	12.1
Time of operation unknown.....	75	51	12	12	19.0
Aggregate of Excisions in Continuity.....	696	477	191	28	28.5

The mortality rate is nearly double that observed in the cases treated by expectant measures, and more than 12 per cent. higher than the fatality in a larger series of primary amputations in the upper third of the arm. Moreover, in the four hundred and seventy-seven cases of recovery, there were no less than ninety-nine instances in which "no bony union" was reported, and sixty-five others recorded as examples of "false-joint." There were also among the cases reported as "successful" thirty-seven instances of consecutive amputations of the arm. Recourse was had to ulterior exarticulation or amputation in sixty-four patients, of whom twenty-seven perished.

Such evidence warrants the assertion that early excisions in the continuity of the humerus after injury can seldom be justifiable, a conclusion at which European surgeons had already arrived from the experience of the Schleswig-Holstein and Danish wars,<sup>1</sup> and which has been confirmed by more recent observations.<sup>2</sup> The coaptation of the resected ends of the bone by silver wires was sometimes practised, with few illustrations of favorable

*the Rebellion*, p. 293) states that: "The astonishing success that attended resections of the humerus in its continuity, both here [Chattanooga] and after the battle of Gettysburg, convinces me that the objections urged against this operation are entirely unfounded." His argument in full may be found at the page indicated. AMERMAN (G. K.) (*Chicago Med. Jour.*, 1866, Vol. XXIII, p. 358) reports a primary excision of four inches of the middle of the shaft of the left humerus. The patient recovered in three months; but the arm refractured, and the author concludes that "the operation of excision in the continuity of the long bones is still of doubtful expediency." BILLINGS (J. S.) (*Appendix to Part I, Med. and Surg. Hist. of the Rebellion*, p. 146) remarks, after Gettysburg: "In no case of fracture of the long bones did I attempt any formal resection. \* \* \* From my experience in Cliffbourne Hospital, I am convinced that regular resections in such cases are worse than doing nothing at all."

<sup>1</sup> SCHWARTZ (H.) (*Beiträge zur Lehre von den Schusswunden*, Schleswig, 1854, S. 212) declared: "Resection in the continuity of the humerus is to be rejected." STROMEYER (L.) (*Maximen der Kriegschirurgie*, Hannover, 1855, S. 677) states: "Already, in the year 1849, extensive resections in the diaphyses were discontinued; and, in the campaign of 1850, even limited resections of the diaphyses were not undertaken, and the extraction of splinters was confined to the removal of such as were readily accessible and entirely loose. \* \* \* Far be it from me to contend," he adds, "that free incision in cases of shot fracture, and careful removal of all splinters and beveling of fragments, have no rational foundation, and may not lead to favorable results." DEMME (H.) (*Militär-chirurgische Studien*, 1861, S. 230) tabulates, from Italian hospitals, 7 cases of excisions in the shaft of the humerus, of which 4, or 57.1 per cent., were fatal, and concludes: "We must reject excision of the shaft of the humerus. The unfavorable result of the operation, as compared with resection of the shoulder joint, may be due partly to the greater extent of the operative interference, but especially to the opening of the medullary cavity." FISCHER (H.) (*Kriegschir. Erf.*, Erlangen, 1872, S. 145) says: "Even in case of necrosis of the fractured ends, we hesitated to institute operative interference, as in preceding wars our experience in regard to resection of the shaft of the humerus in the continuity had been exceedingly lamentable."

<sup>2</sup> KLEBS (E.) (*Beiträge zur Pathologischen Anatomie der Schusswunden*, Leipzig, 1872, S. 15) gives an autopsy in the case of Nötzel, wounded, near Strassbourg, September 4, 1870: "Shot fracture of the shaft of the humerus; resection of the ends of the bone; death October 14, 1870, \* \* \* large pus cavity, into which protrude the sawn ends of the shaft, denuded of periosteum and necrosed; the medullary cavity filled with exuberant granulations." Dr. KLEBS remarks: "It is true that it cannot be ascertained how far the loss of periosteum of the resected ends is due to the effect of ichorous pus, but, in view of the slight disposition toward callus-formation, the removal of larger but yet adherent bone-splinters must necessarily diminish the chances of a definite consolidation, and any aid toward the separation of the necrosed portions can hardly be expected; on the contrary, any interference before the consolidation might readily lead to fresh necrosis of the sawn ends." CHENU (J. C.) (*Aperçu hist., etc., pendant la Guerre de 1870-71*) tabulates 98 cases of excisions in the shaft of the humerus, of which 84, or 85.7 per cent., were fatal.

results. Examination of the details of many of the formal primary excisions in the shaft strengthens the impression that they were for the most part unnecessary and injurious.

**AMPUTATIONS OF THE ARM FOR SHOT INJURY.**—The records present fifty-four hundred and fifty-six cases of this nature. Fifty-four have already been particularized on page 469, as practised on account of flesh wounds or their complications. Three thousand six hundred and eighty-five were performed on account of shot fractures of the shaft of the humerus or their consequences, and seventeen hundred and seventeen amputations were done for the immediate or remote results of shot injuries of the elbow joint or of the forearm. The results as to fatality, the period at which the operations were done, and the point at which amputations<sup>1</sup> were practised are indicated, as far as known, in the following table:

TABLE LXVII.

*Summary of Five Thousand Four Hundred and Fifty-six Amputations of the Arm for Shot Injury.*

OPERATIONS.	CASES.				UPPER THIRD.			MIDDLE THIRD.			LOWER THIRD.			SEAT NOT RECORDED.		
	Recovery.	Death.	Result Undetermined.	Total.	Recovery.	Death.	Result Undetermined.	Recovery.	Death.	Result Undetermined.	Recovery.	Death.	Result Undetermined.	Recovery.	Death.	Result Undetermined.
Primary .....	2,657	602	.....	3,259	1,155	183	.....	1,019	143	.....	406	106	.....	77	170	.....
Intermediary .....	600	302	.....	902	239	108	.....	255	93	.....	94	67	.....	12	34	.....
Secondary .....	297	114	.....	411	127	46	.....	127	35	.....	37	24	.....	6	9	.....
Time between injury and operation not stated.	473	228	183	884	61	21	12	45	13	9	22	.....	2	345	194	160
Aggregates .....	4,027	1,246	183	5,456	1,582	358	12	1,446	284	9	559	197	2	440	407	160

It will be observed that the results as to fatality were ascertained in fifty-two hundred and seventy-three cases, twelve hundred and forty-six, or 23.6 per cent., terminating fatally. It has been seen (p. 655) that the fatality of the series of eight hundred and forty-one determined cases of amputation at the shoulder joint was in the proportion of 29.1 per cent. The results, therefore, conform to the general rule formulated by M. Legouest, that amputations in the continuity below a joint have less gravity than amputations through that joint,<sup>2</sup> and vindicate the precept of amputating always as far as possible from the trunk.

**PRIMARY AMPUTATIONS IN THE CONTINUITY.**—In three thousand two hundred and fifty-nine cases, or nearly three-fourths of those in which the precise period of operation was ascertained, the amputations were practised within the forty-eight hours succeeding the injury. Undoubtedly there are cases in which the invasion of inflammatory phenomena takes place earlier or is deferred much later than this period: but, in dealing with statistics of such magnitude, it is necessary to adopt some arbitrary limit, and in this work, in deal-

<sup>1</sup> The predominance of amputations for shot injury of the upper portion of the arm corresponds with what has been observed in other wars. Thus, M. CHENU (*Aperçu hist. stat. et clin. sur le service des ambulances et des hôpitaux*, 1874, p. 492) tabulating 2026 cases of amputations of the arm with 606 recoveries and 1420 deaths (a mortality rate of 70.09), is able to determine the locality of the operation in 327 of the 606 successful cases; namely: upper third, 170—middle third, 106—and lower third, 51.

<sup>2</sup> LEGOUEST (L.) (*Traité de Chirurgie d'Armée*, 2ème éd., 1872, p. 552) says: "On doit maintenir le précepte d'amputer le plus loin possible du tronc, et l'on peut dire d'une manière générale que l'amputation faite au-dessous d'une articulation est moins grave que l'amputation pratiquée dans cette articulation même, et que la désarticulation est moins grave que l'amputation dans la continuité pratiquée au-dessus d'elle."



ing with amputations of the extremities, those have been classified as primary that were practised in the interval of forty-eight hours subsequent to the reception of the injury. The results as to fatality are ascertained in all instances.

**1. Primary Amputations in the Upper Third of the Arm.**—Thirteen hundred and thirty-eight cases, including eleven hundred and fifty-five instances of recovery and one hundred and eighty-three fatal examples, are comprised in this subdivision, a percentage of mortality of 13.6.

§ *Successful Cases.*—A few illustrations of the nature and extent of the injuries for which amputations high in the arm were practised, may precede the tabular statement of the cases of recovery:

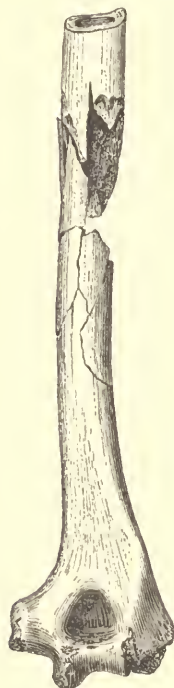

FIG. 512.—Shot fracture of shaft of right humerus. *Spec.* 1147.

CASE 1643.—Sergeant G. H. Johnson, Co. B, 56th Pennsylvania, aged 27 years, received a gunshot fracture of the right arm, at Fredericksburg, April 30, 1863. Having been admitted to the field hospital, 1st division, First Corps, the injured limb was amputated by Surgeon G. W. New, 7th Indiana, who contributed the specimen (FIG. 512), which consists of the right humerus, amputated in the upper third for complete comminution in the middle third by a conoidal ball. On May 26th, the patient was transferred to St. Aloysius Hospital, at Washington, and subsequently he entered the Mower Hospital, Philadelphia, whence he was discharged on July 20, 1863, by reason of "loss of right arm near shoulder," on certificate of disability by Surgeon J. Hopkinson, U. S. V. In a statement of artificial limbs, furnished by Mr. Lincoln, of Boston, the amputation is reported as having been performed by the "flap method;" and in his application for commutation, in 1870, the pensioner describes the stump as being two inches long from the shoulder, and as being "very well but tender." He was last paid on March 4, 1875.

CASE 1644.—Private J. P. Wenner, Co. B, 3d Pennsylvania Cavalry, aged 19 years, was wounded in the right arm, near Ellis's Ford, December 3, 1863. He was admitted to a Cavalry Corps Hospital, where amputation was performed but not recorded. He remained at the field hospital until February 1st, when he was transferred to Douglas Hospital at Washington. Assistant Surgeon W. Thomson, U. S. A., reported: "Primary amputation of right arm below the anatomical neck, performed on the field for gunshot fracture of the humerus. On February 9th, the wound was entirely healed by first intention. February 26th, after a severe chill, the posterior angle of the wound again opened spontaneously and showed symptoms of local inflammation, which had recently subsided. The patient was enjoying good health with the exception of a nervousness produced by local irritation, induced by the presence of a foreign body in the soft parts. March 19th, an extraction was made of a flattened bullet from its lodgement in the inferior flap, by an incision one inch in length internally of the cicatrice, by Acting Assistant Surgeon Carlos Carvallo. Poulices were applied, and the stump was incised March 26th, on account of erysipelatous redness, on which a spontaneous opening appeared at the internal angle of the wound." The patient was discharged on account of the expiration of his term of service, July 25, 1864, and pensioned. In his application for commutation for an artificial limb, in 1870, he described the stump as being "very sore," and stated that Surgeon W. B. Hezless, 3d Pennsylvania Cavalry, performed the amputation. This pensioner was last paid on March 4, 1875.

CASE 1645.—Private T. Carroll, Co. C, 58th Massachusetts, aged 23 years, was wounded at Spottsylvania, May 12, 1864. He was conveyed to the field hospital of the 2d division of the Ninth Corps. Surgeon James Harris, 7th Rhode Island,

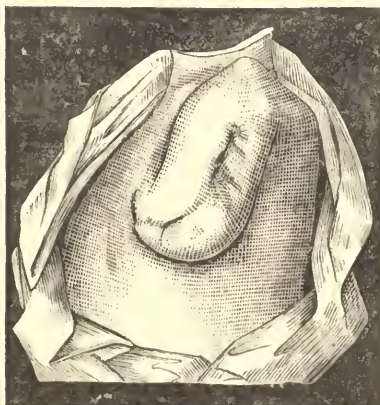

FIG. 513.—Cast of a stump seven months after a primary amputation at upper third of left arm. *Spec.* 1541.

reported a "shot wound near left shoulder; amputation a few hours after the injury, under chloroform, by Surgeon J. S. Ross, 11th New Hampshire, by the circular method, at the upper third. The humerus was found to be very much comminuted. The wound was brought together vertically by sutures." The case progressed favorably until May 26th, when the patient was transferred to Alexandria. Acting Assistant Surgeon A. McWilliams reported the admission of the patient at the general hospital at Alexandria, his progress without complications, and his transfer to Portsmouth Grove, Rhode Island. Here Surgeon L. A. Edwards, U. S. A., recorded his admission June 5, 1864, with "a large and unhealthy wound from a flap amputation at the upper third of the left arm, performed on the field on the day of injury. Stimulating applications, including bromine, were applied to the stump, and the patient slowly progressed toward recovery, and was sent to Central Park Hospital, New York, September 23, 1864, where he was supplied with an artificial limb, and discharged and pensioned January 1, 1875. While at Central Park, a plaster cast of the shoulder and stump was made, and a copy, from which the annexed wood-cut (FIG. 513) was prepared, was contributed to the Army Medical Museum by Acting Assistant Surgeon G. F. Shrady. (See *Cut. Surg. Sect.*, 1865, p. 546.) This pensioner was paid March 4, 1875.

Some of the primary amputations high up in the arm, in cases attended by comparatively little osseous splintering, were probably practised on account of real or apprehended lesions of the nerves, vessels, or other important soft parts:

CASE 1646.—Captain M. Runkle, Co. F, 56th Pennsylvania, age 36 years, was wounded in the right arm, at the Wilderness, May 6, 1864, and was operated upon at the field hospital, 4th division, Fifth Corps. Surgeon C. X. Chamberlain, U. S. V., noted: "Gunshot fracture of arm; amputation." Surgeon A. S. Coe, 147th New York, contributed the pathological specimen (FIG. 514), which consists of "a portion of the shaft of the humerus, nearly transversely fractured near the lowest third. From the posterior and inferior surface an irregular fragment, one by two inches, with the base at the line of fracture, has broken, but remains in position. Primary amputation has been performed at the junction of the upper thirds, three inches above the line of fracture, from which it appears the laceration of the soft parts must have been excessive." (*Cat. Surg. Sect.*, 1866, p. 123.) On May 19th, the patient reached Washington, where he obtained from Surgeon T. Antisell, U. S. V., a leave of absence for thirty days. On August 6th, he entered the Officers' Hospital, at Annapolis. Surgeon B. A. Vanderkief, U. S. V., reported: "Gunshot wound of right arm. Flap amputation at junction of upper and middle third performed on day after injury." Captain Runkle was discharged from service on August 12, 1864, and pensioned. He was paid on December 4, 1874. In his application for commutation for artificial limb, dated 1870, he stated the stump as being in a healthy condition; also that Surgeon G. W. Metcalf, 76th New York, performed the amputation.



FIG. 514.—Part of right humerus amputated for shot fracture. *Spec.* 2518.

A number of examples of painful stumps, from bulbous enlargement of the extremities of the divided nerves, are observed in this series:

CASE 1647.—Private J. Brien, Co. G, 97th New York, aged 36 years, was wounded in the right arm by grapeshot, at Antietam, September 17, 1862. On October 4th, he was received from a field hospital into Frederick Hospital No. 5, whence he was transferred to Patterson Park, Baltimore. On October 9th, Medical Cadet A. T. Piek furnished the following history: "The arm was amputated, on the battlefield, near the superior third of the humerus. The patient was suffering exceedingly, and on February 18, 1863, it was decided to open the stump, when a bulbous degeneration of the musculo-spiral nerve was discovered and removed by Surgeon S. D. Freeman, U. S. V. The patient now doing well." In the course of time, however, the tumor formed again, necessitating another operation for the removal of the enlarged bulbous extremity of the median nerve, which was performed by Surgeon Freeman, in September, 1863. Both of the specimens (*Cat. Surg. Sect.* 1866, p. 500, *Specs.* 1117 and 1790) were contributed to the Museum by the operator. The patient was subsequently transferred to the Veteran Reserve Corps, and on October 17, 1864, he was discharged from service and pensioned. In his application for commutation for an artificial limb, dated 1870, he describes the stump as being "in good condition." This pensioner was paid to June 4, 1875.

Laceration of the soft parts by large projectiles frequently demanded amputation high up, in cases in which the comminution of bone was limited to the lower portion of the shaft of the humerus:

CASE 1648.—Corporal T. W. Stocksleger, Co. H, 47th Pennsylvania, aged 21 years, was wounded at Pooatigo, October 22, 1862, and admitted into hospital at Hilton Head on the following day. Assistant Surgeon J. E. Semple, U. S. A., contributed the specimen represented in the wood-cut (FIG. 515), with the following history by Acting Assistant Surgeon T. T. Smiley: "Was wounded by a shot, which struck the anterior face of the left arm about two inches above the elbow joint, and passed obliquely upward and backward, coming out about two inches higher up than the point of entrance. The bone was extensively fractured, comminuted, and splintered, and it was therefore determined to amputate the limb. The operation was performed by the circular method, immediately above the highest point of the injury, and the patient is doing well." The specimen consists of the lower half of the left humerus, greatly comminuted at the lower third. The patient was discharged from service on December 15, 1862, and pensioned. He has been paid to March 4, 1875. In his application for commutation for artificial limb, dated 1870, the pensioner describes the stump of his left arm as "one and a half inches long from the shoulder, and in healthy condition."



FIG. 515.—Grapeshot comminution of the lower third of the left humerus. *Spec.* 688.

Eighty-nine of the eleven hundred and fifty-five amputations were practised on Confederate soldiers. There was the usual predominance of operations on the left extremity. This circumstance was specified in all but seventeen cases. Five hundred and fifty-five amputations were recorded on the right, and five hundred and eighty-three on the left side. Nine hundred and ninety-two patients were discharged, seventy-four returned to modified duty, and eighty-nine were paroled, exchanged, or furloughed, and subsequently unaccounted for. Two hundred and ninety-three amputations were by the circular, and five hundred and fifty-five by the flap or modified flap method. In three hundred and seven cases the mode of operation was not recorded.



TABLE LXVI. I.

*Condensed Summary of Eleven Hundred and Fifty-five Cases of Recovery after Primary Amputation in the Upper Third of the Shaft of the Humerus.*

No.	NAME, AGE, AND MILITARY DESCRIPTION.	DATES.	OPERATIONS, OPERATOR, RESULT.	No.	NAME, AGE, AND MILITARY DESCRIPTION.	DATES.	OPERATIONS, OPERATOR, RESULT.
1	Ackerman, T., Corp'l, B, 51st Penn., age 22.	July 30, '64.	Left; circular; by Surg. W. C. Shurlock, 51st Penn. Disch'd Mar. 17, 1865; pensioned.	36	B——, S., Pt., D, 11th Penn., age 31.	July 20, '64.	Left; circular. Disch'd April 2, 1865.
2	Adams, T. C., 1st Lieut., B, 121st N. Y., age 33.	May 12, '64.	Left; circular. Disch'd Oct. 17, 1864; pensioned.	37	Baker, J., Pt., G, 7th N. Y. Heavy Artillery.	May 30, '64.	Left; flap; by Surg. G. L. Potter, 145th Penn. Disch'd Sept. 15, 1865; pensioned. Spec. 2951.
3	Adams, J., Pt., A, 33th Mass., age 46.	May 8, '64.	Left; circular; by Surgeon Wm. Thorndike, 39th Mass. Disch'd Jan. 20, 1865; pensioned.	38	Baker, H., Pt., I, 12th Mass., age 30.	May 6, '64.	Left; lateral flap; by Surg. P. E. Hubon, 28th Mass. Discharged July 19, 1864; pensioned.
4	Ahlers, A., Lieut., C, 47th Ohio, age 28.	July 22, '61.	Left; by Surg. S. P. Bonner, 47th Ohio. Disch'd Jan. 25, 1865; pensioned.	39	Baker, G. W., Pt., G, 19th Wisconsin, age 31.	Aug. 7, '64.	Right; flap; by Asst. Surg. E. F. Dodge, 19th Wis. Disch'd Mar. 28, 1865; pensioned.
5	Ailiff, P. C., Pt., G, 28th Virginia.	July —, 1863.	Paroled August 22, 1863.	40	Baldwin, W. M., Capt., D, 14th N. Y. S. M., age 32.	May 10, '64.	Left; circular. Duty; pensioned.
6	Aisenhood, A., Pt., G, 4th Michigan.	May 5, '63.	Left; flap; by Asst. Surg. L. C. French, 4th Mich. Disch'd Sept. 29, 1863; pensioned.	41	Balde, F., Corp'l, D, 75th Pennsylvania.	July 1, '63.	Left; circular. Disch'd May 11, 1864; pensioned.
7	Aitken, J. S., Pt., D, 2d N. Y. Heavy Artillery, age 19.	June 3, '64.	Left; bilateral flap; by Surg. J. W. Wishart, 140th Penn. To V. R. C. May 2, 1865; pensioned.	42	Baleh, W. L., Pt., G, 19th Indiana, age 30.	June 25, '64.	Left; semi-circular and posterior flap; by Surg. J. Ebersole, 19th Ind. Disch'd Dec. 2, 1864; pens'd.
8	Aldrich, J. B., Pt., E, 4th Vermont, age 45.	May 5, '64.	Right; lateral flap; by Surg. D. M. Goodwin, 3d Vt. Disch'd August 17, 1865; pensioned.	43	Ball, J. A., Corp'l, D, 23d New York.	Sept. 17, '62.	Right; by Surgeon W. A. Madill, 23d N. Y. Disch'd Nov. 27, 1862; pensioned.
9	Allen, H. C., Pt., E, 1st Mass. Cav., age 19.	Sept. 14, '63.	Right; circular; by Surg. W. B. Hezlen, 3d Penn. Cav. Disch'd Nov. 8, 1863; pensioned.	44	Bandell, H. C., Pt., A, 38th Mass.	April 13, '63.	Left; circular; by Surgeon S. C. Hartwell, 38th Mass. Disch'd Aug. 4, 1863; pensioned.
10	Allen, F. M., Corp'l, A, 29th Maine, age 23.	Oct. 19, '64.	Left; circular; by Asst. Surg. B. Fordyce, 160th N. Y. Disch'd Mar. 6, 1865; pensioned.	45	Banks, R., Serg't, D, 6th Virginia, age 27.	July 30, '64.	Right; circular. Furloughed Sept. 27, 1864.
11	Allen, P., Pt., C, 5th Mich., age 40.	May 6, '64.	Left; by Surg. H. F. Lyster, 5th Michigan; pensioned.	46	Banc, J., Pt., I, 104th Ill., age 19.	Sept. 19, '63.	Right; flap; by Surg. R. F. Dyer, 104th Ill. Disch'd May 1, 1864.
12	Allen, T. B., Pt., E, 43d Missouri.	Oct. 15, '64.	Right. Discharged June 6, 1865; pensioned.	47	Barnes, T., Pt., Bowen's Battery, age 28.	Nov. 30, Dec. 1, 1864.	Left; circular. Transferred to Provost Marshal April 6, 1865.
13	Allen, J., Lieut., E, 5th Mich. Cav., age 25.	Sept. 19, '64.	Left; by Surg. A. K. St. Clair, 5th Mich. Cavalry. Disch'd April 5, 1865; pensioned.	48	Barnes, G., Pt., A, 143d Penn., age 30.	May 6, '64.	Left; circular. Disch'd July 20, 1864; pensioned.
14	Allgower, C. F., Pt., C, 6th New York.	April 17, '63.	Left. Discharged May 29, 1863; pensioned.	49	Barr, S. L., Serg't, B, 148th Penn., age 24.	Oct. 14, '63.	Circular. Disch'd July 10, 1864.
15	Amann, C., Pt., C, 41st New York, age 18.	July 2, '63.	Right; flap. Disch'd; pensioned.	50	Barber, C. H., Corp'l, G, 25th Conn.	June 14, '63.	Left; circular; by Surg. W. T. Provost, 159th N. Y. Duty Aug. 7, '63.
16	Ambler, J., Pt., F, 170th New York, age 29.	May 18, '64.	Right; flap; by Surgeon M. F. Reagan, 164th N. Y. Disch'd June 5, 1865.	51	Barber, G., Pt., D, 24th Indiana.	April 14, '64.	Flap; by Surg. A. W. Gray, 24th Indiana. Disch'd June 27, 1864.
17	Anderson, J., Pt., B, 10th Illinois, age 29.	May 27, '64.	Left; by Surg. H. R. Payne, 10th Illinois. Disch'd; pensioned.	52	Barnard, C., Pt., E, 6th Iowa.	May 27, '64.	Left; flap; by A. Surg. G. Morris, 56th Ill. Disch'd Sept. 26, 1864.
18	Anderson, G., Pt., C, 5th Conn.	Oct. 17, '63.	Right; flap; by A. Surg. J. E. Link, 21st Ill. Disch'd July 21, 1864.	53	Barriekman, R., Corp'l, B, 70th Ohio, age 21.	Dec. 13, '64.	Left; flap; by Surg. J. H. Hutchinson, 15th Mich. Discharged March 21, 1865.
19	Andrews, J., Pt., A, 43th Penn., age 30.	May 10, '64.	Left; antero-posterior flap. Discharged May 18, 1865; pensioned.	54	Barnes, E., Serg't, F, 46th Penn., age 21.	July 3, '63.	Right; by Surg. W. H. Twiford, 27th Indiana. Disch'd June 23, 1865; pensioned.
20	Anderson, P., Pt., I, 90th Penn., age 48.	May 10, '64.	Left; antero-posterior flap; by Surg. J. H. Beach, 24th Mich. Disch'd April 29, 1865; pensioned.	55	Barter, R., Pt., E, 3d Infantry.	Oct. 9, '61.	Right. Discharged Nov. 13, 1861; pensioned.
21	Anderson, A., Pt., I, 100th Ohio.	June 11, '64.	Left; circular; by Surgeon G. A. Collamore, 100th Ohio. Disch'd Feb. 17, 1865; pensioned.	56	Barnes, J., Pt., G, 76th New York.	Dec. 11, '62.	Right. Discharged Jan. 8, 1864; pensioned.
22	Annis, E. E., Serg't, G, 64th N. Y., age 31.	June 1, '62.	Right; flap. Discharged July 29, 1862.	57	Basom, G. E., Pt., G, 49th Ohio, age 33.	May 27, '64.	Left; flap; by Surg. C. J. Walton, 21st Kentucky. Disch'd Sept. 2, 1864; pensioned.
23	Anthon, F., Pt., F, 7th Indiana Cavalry, age 19.	Dec. 2, '64.	Left; circular; by A. A. Surg. J. A. Edmunson. Disch'd May 10, 1865; pensioned.	58	Bastain, M. D., Pt., B, 184th Penn.	June 22, '64.	Right; flap; by a Confederate surgeon. Disch'd Mar. 22, 1865.
24	Armstrong, J., Pt., G, 140th Pennsylvania.	May 3, '63.	Flap; by Surgeon J. W. Wishart, 140th Penn. Disch'd Aug. 10, 1863; pensioned.	59	Batchelor, J. M., Pt., G, 1st Me. H'y Art., age 47.	June 18, '64.	Left; double flap. Disch'd Oct. 18, 1864; pensioned.
25	Armstrong, W. A., Pt., G, 24th Mich., age 21.	July 1, '63.	Right. Disch'd Nov. 26, 1863.	60	Batty, H., Pt., B, 26th Pennsylvania.	May 3, '63.	Right. Discharged Aug. 4, 1863; pensioned.
26	Arnold, J., Pt., C, 17th U. S. C. T., age 19.	Dec. 16, '64.	Right; flap; by A. A. Surg. A. S. Giltner. Disch'd July 11, 1865; pensioned.	61	Baughner, J. A., Pt., F, 207th Penn., age 18.	April 2, '65.	Right; circular. Disch'd June 14, 1865; pensioned.
27	Auld, J. B., Pt., A, 5th Maine.	Nov. 7, '63.	Right; flap. Disch'd April 14, 1864; pensioned.	62	Beary, J. H., Pt., K, 5th U. S. Artillery, age 26.	July 3, '63.	Left; flap method. Disch'd May 26, 1864; pensioned.
28	Avery, Chas. E., Pt., A, 20th Maine.	May 5, '64.	Right; circular. Disch'd June 15, 1865; pensioned.	63	Beakes, A. W., Pt., E, 124th N. Y., age 19.	May 3, '63.	Left; flap; by Surg. J. H. Thompson, 124th N. Y. Disch'd Oct. 12, 1863; pensioned.
29	Aydt, J., Pt., A, 68th New York.	May 2, '63.	Left; flap; by Surg. L. Schultz, 68th N. Y. Disch'd July 17, 1863; pens'd.	64	Beasley, W. S., Pt., K, 41st Tenn., age 24.	Nov. 30, Dec. 1, 1864.	Left; antero-posterior flap. Provost Marshal Feb. 8, 1865.
30	Bael, L., Pt., K, 26th Penn., age 23.	May 15, '64.	Right; circular. Disch'd June 25, 1865.	65	Bean, A. B., Pt., A, 58th Massachusetts, age 34.	July 30, '64.	Left; flap; by Surg. A. A. Stocker, 58th Mass. Discharged Dec. 1, 1864; pensioned.
31	Bagley, C. R., Pt., E, 20th Connecticut.	May 3, '63.	Left. Disch'd August 11, 1865; pensioned.	66	Beaver, A. J., Serg't, C, 53d Penn., age 32.	Oct. 14, '63.	Right; circular; by Surg. W. W. Potter, 57th N. Y. V. R. C. Mar. 17, 1864; pensioned.
32	Bagaley, T., Capt., K, 63d Pennsylvania.	June 30, '62.	Right. Discharged Dec. 15, 1862; pensioned.	67	Beardsley, D., Pt., F, 20th Michigan, age 21.	July 30, '64.	Right; circular; by Surg. A. F. Whelan, 1st Mich. S. S. Disch'd Dec. 10, 1864; pensioned.
33	Bailey, H. C., Pt., G, Kane's Penn. Rifles.	June 6, '62.	Left. Discharged and pensioned.	68	Beason, J. J., Serg't, H, 1st Arkansas, age 29.	Nov. 30, '64.	Left; circular; by Surg. Young, 1st Ark. Transferred to Provost Marshal Jan. 3, 1865.
34	Baker, J., Pt., B, 68th Penn., age 38.	Nov. 27, '63.	By Surg. H. F. Lyster, 5th Mich. Discharged March 25, 1865; pensioned.	69	Beekman, C., Corp'l, K, 13th Illinois.	Nov. 27, '63.	Left; flap; by Surg. S. C. Plummer, 13th Ill. Disch'd Mar. 10, 1864; pensioned.
35	Baker, H. L., Pt., E, 2d Vermont, age 24.	May 6, '64.	Left; circular; by Surgeon W. J. Sawin, 2d Vermont. Discharged June 29, 1864; pensioned.	70	Beemer, L. O., Pt., F, 126th Ohio, age 22.	May 12, '64.	Left; antero-posterior flap; by Surgeon J. S. Ely, 126th Ohio. Disch'd Oct. 30, 1864; pensioned.

NO.	NAME, AGE, AND MILITARY DESCRIPTION.	DATES.	OPERATIONS, OPERATOR, RESULT.	NO.	NAME, AGE, AND MILITARY DESCRIPTION.	DATES.	OPERATIONS, OPERATOR, RESULT.
71	Behrens, J., 1st Serg't, I, 12th Missouri, age 34.	July 23, '64.	Left; flap; by Surg. M. W. Robbins, 4th Iowa. Disch'd Mar. 22, 1865; pensioned.	110	Bowen, W. H., Pt., C, 24th New York.	Aug. 29, '62.	Left; flap; by Surg. J. B. Murdoch, 24th N. Y. Disch'd Oct. 10, 1862; pensioned.
72	Belden, W. C., Serg't, B, 27th New York.	Sept. 14, '64.	Left; circular; by Asst. Surg. H. A. DuBois, U. S. A. Disch'd Jan. 5, 1864.	111	Bowman, G., Pt., B, 88th Pennsylvania.	Dec. 13, '62.	Right; flap. Disch'd April 10, 1863; pensioned.
73	Belony, J., Pt., K, 1st Maine Cav., age 16.	Aug. 16, '64.	Left; circular. Transferred to V. R. C. Jan. 17, 1865; pensioned.	112	Boynton, A. J., Pt., H, 13th Wisconsin, age 23.	Nov. 21, '64.	Left; flap; by Surg. J. Evans, 13th Wis. Disch'd April 8, 1865.
74	Bennett, Emerick, Corp'l, H, 142d N. Y., age 23.	Oct. 22, '64.	Left; lateral flap; by a Confed. surgeon. Disch'd Jan. 27, 1865.	113	Brandenberger, R., Pt., B, 122d Illinois, age 33.	July 20, '64.	Right; flap; by Surg. C. H. Lord, 102d N. Y. Disch'd March 24, 1865; pensioned.
75	Bender, R., Pt., E, 17th Penn. Cav., age 20.	May 30, '64.	Left; circular. Disch'd Dec. 10, 1864; pensioned.	114	Braley, H., Corp'l, B, 10th Michigan, age 22.	Sept. 1, '64.	Left; circular; by Surg. E. Batwell, 14th Michigan. Disch'd March 25, 1865; pensioned.
76	Benedict, M. A., 1st Lieut., F, 11th Michigan, age 23.	July 4, '64.	Right; circular; by Asst. Surg. N. I. Packard, 11th Mich. Duty Nov. 26, 1864.	115	Brenbarger, H., Pt., B, 110th Ohio, age 31.	Mar. 25, '65.	Right; ant.-post. flap; by Surg. R. R. McCandless, 110th Ohio. Discharged Aug. 10, 1865; pensioned.
77	Bennett, W. E., Pt., B, 5th Maryland, age 18.	Oct. 27, '64.	Left; circular; by Surg. O. W. Harrison, U. S. A. Disch'd Aug. 17, 1865; pensioned.	116	Brenan, J., Serg't, G, 3d Mass. Cav., age 27.	Sept. 19, '64.	Left; flap; by Surg. D. F. Leavitt, 3d Mass. Cav. Disch'd June 26, 1865; pensioned.
78	Benson, S. T., Serg't, F, 32d Iowa, age 24.	April 9, '64.	Left. Discharged Oct. 8, 1864.	117	Britton, J. B., Pt., C, 77th New York.	Sept. 19, '64.	Circular; by Surg. G. T. Stevens, 77th N. Y. Transferred to V. R. C. Jan. 28, 1865; pensioned.
79	Benton, J. F., Pt., E, 147th New York.	July 1, '63.	Left; by Surg. A. S. Coe, 147th N. Y. Disch'd Dec. 30, 1863; pensioned.	118	Bricknell, W., Pt., H, 19th Wisconsin, age 20.	June 27, '64.	Right; circular. Disch'd Feb. 7, 1865; pensioned.
80	Berger, C., Pt., 6th Wisconsin Battery.	May 19, '63.	Left. Disch'd Aug. 28, 1863; pensioned.	119	Britton, F. P., Pt., F, 14th N. Hamp., age 22.	Sept. 19, '64.	Right; flap. Disch'd July 8, '65.
81	Best, B. F., Lieut., E, 40th Illinois.	April 6, '62.	Left; by Asst. Surg. W. E. Turner, 40th Ill. Resig'd Sept. 6, 1862.	120	Briggs, G. Q., Pt., D, 73d New York.	Aug. 27, '62.	Right; flap; by Surg. J. M. Morrow, 2d N. Hampshire. Disch'd Oct. 21, 1862; pensioned.
82	Bigelow, D., Pt., F, 2d Michigan, age 28.	May 6, '64.	Left; antero-posterior flap; by Surg. E. J. Bonius, 2d Michigan. Disch'd Aug. 27, 1864; pensioned.	121	Brien, J., Pt., G, 97th N. York, age 25.	Sept. 17, '62.	Right; flap. Disch'd Oct. 17, 1864; pensioned. <i>Specs.</i> 1117 and 1790.
83	Billington, S. H., Pt., D, 8th Maine, age 31.	July 2, '64.	Right; flap. Discharged Nov. 24, 1864; pensioned.	122	Bridges, J., Pt., D, 12th Alabama, age 21.	July 1, '63.	Left. Paroled Sept. 25, 1863.
84	Binnaman, H., Pt., A, 26th Indiana.	Dec. 7, '62.	Right; flap; by Surgeon T. W. Flora, 26th Ind. Disch'd Mar. 7, 1863; pensioned.	123	Brink, S. H., Pt., C, 58th New York.	Dec. 13, '62.	Left. Disch'd; pensioned.
85	Bingham, B. F., Serg't, I, 122d N. Y., age 21.	Mar. 25, '65.	Left; flap; by Surg. E. A. Knapp, 122d N. Y. Disch'd June 23, 1865; pensioned.	124	Brown, T. S., Serg't, G, 103d Illinois, age 29.	Feb. 15, '65.	Right; by Surg. R. Morris, 103d Ill. Disch'd June 24, '65; pens'd.
86	Bird, S., Pt., C, 43d U. S. C. T., age 30.	July 30, '64.	Left; flap; by Surg. J. P. Princee, 30th Mass. Transferred to the insane asylum Dec. 20, 1865.	125	Brown, J., Pt., D, 179th New York, age 18.	June 17, '64.	Left; flap; by Asst. Surg. C. K. Winne, U. S. A. Disch'd June 22, 1864; pensioned.
87	Bissell, C. N., Pt., 1st Com. Light Battery, age 19.	May 14, '64.	Left; flap. Disch'd Oct. 26, 1864; pensioned.	126	Brown, A., Pt., G, 1st West Va. Artillery.	Aug. 26, '63.	Left; by Asst. Surg. C. K. Winne, U. S. A. Disch'd June 22, 1864; pensioned.
88	Blanchard, M., Serg't, C, 8th Ohio, age 21.	Nov. 27, '63.	Right; double flap. Disch'd April 12, 1864; pensioned.	127	Brown, J. D. R., Pt., H, 66th Indiana.	Aug. 30, '62.	Flap; by Surg. D. W. Voyles, 66th Indiana. Disch'd Dec. 29, 1862; pensioned.
89	Blanchard, Jos. B., Pt., F, 31th Illinois, age 27.	Mar. 16, '65.	Right; antero-posterior flap. Discharged July 12, 1865; pensioned.	128	Brown, J. F., Pt., C, 2d Mass., age 25.	July 3, '63.	Left; antero-posterior flap; by Surg. W. H. Heath, 2d Mass. Disch'd Oct. 7, 1863; pensioned.
90	Blue, W., Pt., C, 18th Ohio Cavalry, age 12.	June 9, '64.	Right; circular; by Asst. Surg. W. E. Seoby, 45th Ky. Disch'd Sept. 15, 1864; pensioned.	129	Brashears, Ira, Pt., B, 27th Indiana.	May 3, '63.	Right; flap; by Surg. Willis H. Twiford, 27th Indiana. Disch'd June 17, 1863; pensioned.
91	Blunt, G. A., Pt., B, 2d N. Y. Heavy Artillery.	June 3, '64.	Left; circular; by Surgeon J. C. Howe, 2d N. Y. Heavy Artillery. Disch'd Nov. 18, 1864; pensioned.	130	Brown, T., Pt., K, 10th Kentucky.	July 9, '64.	Right; flap; by Asst. Surg. J. T. Adair, 77th Pa. Duty Oct. 7, '64.
92	Boardman, E., Serg't, F, 121st N. Y., age 35.	May 10, '64.	Left; flap; by Surg. J. O. Slocum, 121st N. Y. Disch'd Dec. 16, 1864; pensioned.	131	Brown, J. A., Pt., D, 5th Maryland, age 30.	June 30, '64.	Left; flap; by Asst. Surg. C. H. Goldsborough, 5th Md. Mustered out Sept. 19, 1864; pensioned.
93	Bochner, G., Pt., H, 32d Ohio.	Sept. 15, '62.	Right; flap. Disch'd October 25, 1862.	132	Brown, J., Pt., A, 150th Penn., age 23.	Aug. 10, '64.	Right; flap. Disch'd Mar. 23, '65.
94	Bodine, W. F., Pt., I, 4th New Jersey.	June 27, '62.	Left. Disch'd Oct. 13, 1862, and pensioned.	133	Brown, E., Pt., F, 92d New York, age 20.	June 6, '64.	Left; flap; by Dr. Edmondson. Disch'd Jan. 9, 1865; pensioned.
95	Bolter, J. J., Pt., 40th Virginia, age 23.	Sept. 17, '62.	Left; flap; doing well.	134	Brooks, R., Pt., C, 150th Penn., age 22.	May 8, '64.	Left; flap; by Asst. Surg. J. T. Duffield, 7th Indiana. Disch'd Sept. 24, 1864; pensioned.
96	Bolenius, A. W., Capt., G, 50th Penn.	Aug. 27, '62.	Right; by Surgeon D. W. Bliss, U. S. V. Resigned April 18, 1863.	135	Broderick, J., Pt., E, 88th New York, age 36.	May 5, '64.	Left; flap; by Asst. Surg. G. R. B. Robinson, 71st Penn. Disch'd Oct. 21, 1865; pensioned.
97	Bond, W. A., Pt., E, 5th Maryland.	Sept. 17, '62.	Left; circular; by Surgeon John Houston, 81st Penn. Disch'd December 24, 1864.	136	Brogden, W., Pt., A, 23d U. S. C. Troops, age 16.	July 30, '61.	Right; circular; by Surg. J. S. Ross, 11th N. Hamp. Disch'd June 10, 1865.
98	Boob, L., Pt., A, 148th Pennsylvania, age 23.	Aug. 25, '64.	Left; circular; by Surgeon John Houston, 81st Penn. Disch'd December 24, 1864.	137	Brown, G. A., Pt., D, 11th Conn., age 20.	Mar. 14, '62.	Right; circular; by Surg. Geo. A. Otis, 27th Mass. Disch'd Nov. 10, 1862; pensioned.
99	Boosel, E., Pt., G, 149th Pennsylvania, age 18.	May 23, '64.	Left; flap. Disch'd July 18, 1865.	138	Brown, G. W., Corp'l, B, 157th Penn., age 24.	June 18, '64.	Left; circular; by Asst. Surg. J. T. Duffield, 7th Ind. Disch'd May 17, 1865; pensioned.
100	Borehard, E., Pt., B, 49th New York, age 20.	May 6, '64.	Left; flap. Disch'd April 6, 1865; pensioned.	139	Brown, J. B., Pt., D, 7th New Hampshire, age 17.	Oct. 1, '64.	Left; circular; by Asst. Surg. F. B. Kimball, 3d N. Hamp. Mustered out Dec. 22, 1864; pensioned.
101	Bostick, J. H., Corp'l, D, 47th Ohio.	May 22, '63.	Right; by Surgeon S. P. Bonner, 47th Ohio. Discharged July 31, 1863; pensioned.	140	Brown, S. P., Capt., A, 17th Vermont, age 23.	May 12, '64.	Left; circular; by Surg. P. O'M. Edson, 17th Vermont. Disch'd Aug. 22, 1864; pensioned.
102	Bovee, J., Corp'l, G, 12th Infantry, age 26.	June 18, '64.	Left. Discharged and pensioned.	141	Brown, L., Pt., E, 26th Michigan, age 27.	April 6, '65.	Left; circular; by Surg. M. H. Raymond, 26th Mich. Disch'd July 26, 1865; pensioned.
103	Bowers, M., Pt., E, 46th Pennsylvania, age 29.	May 15, '64.	Left; circular. Disch'd Feb. 3, 1865; pensioned.	142	Brandage, M., Lieut., I, 134th N. Y., age 24.	Sept. 17, '62.	Right. Disch'd March 27, 1863.
104	Boycen, J. W., Pt., A, 3d Virginia Cav., age 26.	May 11, '64.	Right; circular. June 16, 1864, stump healed.	143	Bruce, T. S., Corp'l, B, 1st Md. Cavalry, age 25.	July 26, '64.	Right; by Surg. A. A. White, 8th Md. Dis'd Feb. 25, 1865; pens'd.
105	Bowd, M., Pt., F, 48th New York.	July 18, '63.	Right; circular; by Surgeon H. Wirtz, U. S. A. Disch'd Nov. 29, 1863; pensioned.	144	Bryson, J. D., Pt., G, 11th Alabama.	May 5, '64.	Left; circular. Furloughed June 14, 1864.
106	Bowers, N. M., Pt., I, 5th Tennessee.	Sept. 14, '62.	Left; by Surg. G. W. McMillan, 5th Tennessee. Discharged; pensioned.	145	Buchanan, W. S., Serg't, A, 61st Pennsylvania.	July 12, '64.	Right; lateral flap; by Surgeon George T. Stevens, 77th N. Y. Disch'd Oct. 18, 1864; pensioned.
107	Bowles, J., Pt., F, 27th Ohio, age 37.	June 18, '64.	Left; antero-posterior flap. Duty Nov. 14, 1864; pensioned.	146	Buckley, W., Pt., C, 8th Wisconsin.	May 9, '62.	Left; by Surg. S. P. Thornhill, 8th Wis. Disch'd June 10, '62; pens'd.
108	Bowers, F. A., Pt., C, 25th Massachusetts.	July 14, '63.	Right; flap; by Asst. Surg. S. Flaagg, 25th Mass. Disch'd Oct. 13, 1863; pensioned.				
109	Bowman, F., Corp'l, C, 6th New Jersey.	July 3, '63.	Right; flap; by Surg. John Wilsey, 6th New Jersey. Disch'd Sept. 3, 1863; pensioned.				



No.	NAME, AGE, AND MILITARY DESCRIPTION.	DATES.	OPERATIONS, OPERATOR, RESULT.	No.	NAME, AGE, AND MILITARY DESCRIPTION.	DATES.	OPERATIONS, OPERATOR, RESULT.
147	Buhr, F., Pt., C, 37th Ohio, age 19.	July 7, '63.	Left; by Surg. S. P. Bonner, 47th Ohio. Dis'd June 8, 1864; pens'd.	186	Chase, J. F., Pt., 5th Maine Battery, age 20.	July 3, '63.	Right; flap; by Surg. G. W. New, 7th Ind. Disch'd Nov. 25, 1863; pensioned.
148	Bullard, G. W., Pt., C, 9th Minn., age 37.	Mar. 28, '65.	Left; by Asst. Surg. F. H. Milligan, 9th Minn. Disch'd May 17, 1865.	187	Chadwick, G., Pt., F, 28th Mass., age 19.	June 3, '64.	Left; flap; by Surg. G. L. Potter, 145th Penn. Disch'd Nov. 15, 1865; pensioned.
149	Bunker, E. A., Pt., E, 10th Iowa.	May 16, '63.	Right; flap. Discharged Sept. 3, 1863; pensioned.	188	Chadwick, C., Serg't. H, 1st Vermont Heavy Artillery, age 40.	June 1, '64.	Left; flap; by Surg. G. L. Potter, 145th Penn. Disch'd June 22, 1865; pensioned.
150	Burkley, B. F., Pt., D, 51st Ohio, age 16.	Dec. 16, '64.	Left; circular. Disch'd May 3, 1865; pensioned.	189	Chaffee, H. H., Serg't. E, 4th Vermont, age 24.	Oct. 19, '64.	Right; circular; by Surg. C. B. Park, jr., 11th Vermont. Disch'd July 31, 1865; pensioned.
151	Burbank, D. N., Corp'l, K, 111th N. Y., age 19.	July 3, '63.	Right; circular; by Surg. A. Ball, 5th Ohio. Disch'd Dec. 30, 1863; pensioned.	190	Church, L. E., Pt., I, 9th Ohio Cavalry, age 18.	June 1, '64.	Left. Discharged; pensioned.
152	Burbank, J. M., Pt., E, 5th Wisconsin, age 18.	April 2, '65.	Right; flap; by Surgeon Geo. D. Wilber, 5th Wis. Disch'd July 26, 1865; pensioned.	191	Claiborne, D., Serg't. D, 29th Missouri.	Dec. 29, '62.	Right. Disch'd Feb. 22, 1863.
153	Burke, J., Serg't. M, 1st Cavalry, age 32.	Sept. 28, '64.	Right; antero-posterior flap; by Surg. Ferguson, C. S. A. Discharged; pensioned.	192	Clapper, C. A., Pt., K, 12th New York.	May 27, '63.	Left. Returned to duty Aug. 13, 1863; pensioned.
154	Burrill, A., Pt., K, 88th Indiana, age 25.	July 29, '64.	Right; flap; by Surg. J. S. Gregg, 88th Ind. Disch'd May 24, 1865; pensioned.	193	Clark, H., Corp'l, G, 1st Maryland.	Aug. 18, '64.	Right. Discharged Feb. 8, 1865; pensioned.
155	Burt, A. S., Pt., C, 12th Massachusetts, age 28.	May 5, '64.	Right; antero-posterior flap. Discharged June 26, 1864; pensioned.	194	Clark, J. T., Pt., 24th Georgia, age 27.	Sept. 17, '62.	Left; antero-posterior flap; doing well.
156	Buriz, A., Pt., E, 5th New Jersey, age 33.	July 2, '63.	Left; flap; by Surg. H. F. Vanderveer, 5th N. J. V. R. Corps Dec. 11, 1863; pensioned.	195	Clark, W. R., Pt., K, 59th Ohio.	Dec. 31, '62.	Left; flap. Discharged Feb. 19, 1863; pensioned.
157	Burns, W., Pt., G, 40th New York.	June 1, '62.	Left. Disch'd Oct. 3, 1862, and pensioned.	196	Clark, N. M., Capt., E, 125th Illinois, age 38.	June 27, '64.	Right; flap; by Surgeon E. G. Donce, C. S. A. Disch'd Jan. 15, 1865; pensioned.
158	Butler, Z., Pt., E, 5th Colored Cavalry.	June 15, '64.	Left. Disch'd Nov. 8, 1864.	197	Clark, E. L., Pt., A, 60th New York, age 20.	Dec. 20, '64.	Right; antero-posterior flap; by Surg. J. V. Kendall, 14th N. Y. Disch'd July 19, 1865; pens'd.
159	Byerline, J. G., Pt., G, 1st Missouri Cavalry.	Jan. 1, '63.	Left; double flap; by Surgeon Joseph E. Lynch, 1st Mo. Cav. Disch'd Aug. 2, 1864; pensioned.	198	Cleveland, J. H., Serg't., B, 85th Illinois, age 28.	July 19, '64.	Right; circular. Disch'd May 5, 1865; pensioned.
160	Byrum, J. R., Pt., C, 12th North Carolina, age 19.	Sept. 19, '64.	Circular; by Surg. R. J. Hicks, 23d N. C. Discharged.	199	Clifton, W. B., Pt., K, 8th Indiana Cav., age 20.	Aug. 20, '64.	Left; circular; by a Confederate surgeon. Disch'd Mar. 30, 1865.
161	Byrum, C. E., Pt., D, 7th Illinois Cavalry, age 20.	Dec. 15, '64.	Right; flap. Disch'd June 22, 1865; pensioned.	200	Close, F., Pt., A, 55th Ohio, age 30.	May 15, '64.	Left; oval flap. Disch'd Oct. 15, 1864; pensioned.
162	Byrne, H., Pt., E, 9th New York.	April 9, '62.	Right; flap; by Surgeon G. H. Humphreys, 9th N. Y. Disch'd Sept. 30, 1862; pensioned.	201	Cloyd, S. J., Lieut., 12th Penn. Reserves.	Sept. 17, '62.	Right. Resigned Jan. 7, 1863; pensioned.
163	Cable, E. W., Corp'l, G, 99th Indiana.	July 28, '64.	Left; by Surg. D. Halderman, 46th Ohio. Disch'd Nov. 17, 1864; pensioned.	202	Cobb, E., Pt., D, 5th Maine, age 23.	May 10, '64.	Left; circular; by Surg. Francis G. Warren, 5th Maine. Disch'd July 27, 1864; pensioned.
164	Caffrey, T., Pt., G, 153th New York, age 33.	May 18, '64.	Right; circular; by Surg. J. W. Wishart, 140th Penn. Disch'd June 1, 1865; pensioned.	203	Cockran, M., Pt., C, 115th New York, age 35.	June 7, '64.	Right; flap; by Surg. J. M. Palmer, 3d N. Y.; amput. at shoulder joint Mar. 25, 1865. Disch'd July 17, 1865; pensioned.
165	Callahan, J., Pt., G, 17th Infantry, age 40.	May 6, '64.	Antero-posterior flap. Discharged August 6, 1864.	204	Cochrum, B., Pt., E, 7th Kentucky, age 19.	Sept. 26, '64.	Left; antero-posterior flap. Transferred to Provost Marshal Mar. 7, 1865.
166	Callahan, P., Pt., C, 11th Ohio.	Aug. 23, '61.	Left; Asst. Surg. H. Z. Gill, 11th Ohio. Disch'd April 25, 1862.	205	Coe, R. W., Pt., A, 2d Conn. Art., age 33.	June 1, '64.	Left; circular; by Surg. Henry Plumb, 2d Conn. Art. Disch'd April 25, 1865; pensioned.
167	Calvin, A. P., Pt., G, 111th New York, age 18.	June 22, '64.	Left; by Surg. J. W. Wishart, 140th Pa. Disch'd Jan. 19, 1865.	206	Coffin, J. D., Pt., D, 2d N. Y. Heavy Artillery, age 19.	Dec. 9, '64.	Left; antero-posterior flap; by Surg. Wm. Lyon, 191st Penn. Disch'd Mar. 30, 1865; pensioned.
168	Canon, W. S., Artificer, K, 1st New York Engineers.	Aug. 19, '63.	Left; flap; by Asst. Surgeon C. Mudge, 1st N. Y. Eng. Disch'd April 5, 1864; pensioned.	207	Cole, J., Pt., A, 14th New Jersey, age 21.	June 1, '64.	Right; circular; by Asst. Surg. T. A. Helvig, 57th Pa. Disch'd July 20, 1865; pensioned.
169	Capps, J. M., Pt., B, 28th Alabama, age 25.	Dec. 15, '64.	Right; lateral flap. Transferred to Provost Marshal Jan. 17, 1865.	208	Coles, T., Pt., E, 24th New York.	Aug. 30, '62.	Right; by Surg. J. B. Murdock, 24th N. Y. Disch'd Dec. 2, 1862; pensioned.
170	Carney, T., Pt., C, 32d C. T., age 32.	Dec. 7, '64.	Right; circular; by Surg. C. M. White, 32d C. Troops. Disch'd March 15, 1865.	209	Coleman, G. W., Pt., B, 142d Penn., age 28.	June 2, '64.	Right; by Asst. Surg. C. E. Humphreys, 142d Pa. Disch'd Nov. 20, 1864.
171	Carroll, T., Pt., C, 58th Massachusetts, age 26.	May 12, '64.	Left; circular; by Surgeon J. S. Ross, 11th N. H. Disch'd Jan. 1, 1865; pensioned. Spec. 1541.	210	Coleman, W. M., Corp'l, D, 17th Mich., age 20.	May 6, '64.	Left; bilateral flap; by Surg. J. D. Bevier, 17th Mich. Disch'd October 2, 1864; pensioned.
172	Carter, J. B., Pt., H, 13th Ohio Cav., age 36.	Sept. 30, '64.	Right; circular; by Surg. W. B. Fox, 8th Mich. Disch'd Feb. 24, '65.	211	Coltrou, C., Pt., D, 23th N. Y. Cavalry, age 19.	Aug. 3, '64.	Right; by Surg. W. C. Shurlock, 51st Penn. Discharged Feb. 12, 1865; pensioned.
173	Carter, J. L., 1st Lieut., 11th New York, age 24.	May 16, '64.	Right; flap; by Dr. Baxter, C. S. A. Resigned October 11, 1864.	212	Collins, W., Pt., E, 187th Penn., age 21.	June 18, '64.	Right; flap; by Surg. H. B. King, 21st Penn. Cav. Disch'd July 21, 1865; pensioned.
174	Carver, W., Pt., E, 14th Maine, age 19.	Oct. 19, '64.	Left; circular; by Asst. Surg. B. Fordyce, 160th N. Y. Disch'd July 8, 1865; pensioned.	213	Collins, P., Pt., E, 57th New York.	Sept. 17, '62.	Left; by Surg. G. B. Cogswell, 39th Mass. Disch'd Jan. 14, 1863; pensioned.
175	Cary, M., Pt., K, 23d Ill., age 50.	Sept. 19, '64.	Left; circular; by Asst. Surg. J. E. Barret, 23d Ohio. Disch'd Feb. 24, 1865; pensioned.	214	Comer, D., Pt., F, 28th Mass.	June 3, '64.	Left; by Surg. P. E. Hubon, 28th Mass. Disch'd Mar. 17, 1865; pensioned.
176	Carpenter, L. J., Pt., K, 149th Penn., age 21.	July 2, '63.	Left; circular. Disch'd Oct. 23, 1863; pensioned.	215	Connor, W. M., Corp'l, C, 6th Michigan.	May 27, '63.	Flap. Disch'd Dec. 22, 1863.
177	Carpenter, S., Pt., A, 124th Ohio, age 18.	May 27, '64.	Right; antero-post. flap; by Surg. D. C. Patterson, 124th Ohio. Disch'd Aug. 29, 1864; pens'd.	216	Connor, E., Pt., A, 12th Infantry, age 44.	May 5, '64.	Left; antero-posterior flap. Duty Jan. 19, 1865; pensioned.
178	Carr, B. L., Serg't. M, 1st N. H. Cav., age 24.	April 8, '65.	Right; antero-posterior flap. Discharged June 24, '65; pensioned.	217	Conley, R., Pt., B, 21st Mass., age 30.	Mar. 14, '62.	Left; circular; by Surg. Calvin Cutler, 21st Mass. Disch'd Sept. 25, 1862; pensioned.
179	Casey, J., Serg't. K, 42d New York.	July 3, '63.	Right; by Surg. H. Haywood, 20th Mass. Disch'd; pensioned.	218	Condo, S., Pt., C, 98th Ohio, age 27.	Mar. 19, '65.	Left; flap; by Surg. E. Batwell, 14th Mich. Disch'd June 13, 1865; pensioned.
180	Cassidy, P., Pt., G, 67th New York, age 19.	May 6, '64.	Left; flap. Disch'd Oct. 18, 1864; pensioned.	219	Conrad, L. D., Pt., C, 6th Iowa Cavalry.	April 14, '65.	Flap; by Surg. Jacob H. Camburn, 6th Iowa Cav. Disch'd July 28, 1865; pensioned.
181	Casford, D., Pt., A, 30th Ohio, age 33.	June 27, '64.	Left; flap; by Asst. Surg. Chas. B. Richards, 30th Ohio. Disch'd June 9, 1865.	220	Conger, J. H., Pt., A, 2d New Jersey, age 25.	May 5, '64.	Left; antero-posterior flap. Returned to duty Aug. 2, 1864.
182	Cassels, A., Pt., G, 56th Mass., age 21.	May 24, '64.	Right; duty Dec. 27, 1864.	221	Conant, S. G., Pt., A, 2d Vermont, age 25.	May 5, '64.	Left; lateral flap; by Surg. W. J. Sawin, 2d Vermont. Disch'd Dec. 29, 1864; pensioned.
183	Caulk, J., Pt., H, Purnell Legion, age 19.	Aug. 18, '64.	Right; flap; by Surgeon A. A. White, 8th Md. Disch'd April 29, 1865; pensioned.				
184	Cavins, J., Pt., H, 5th Cavalry, age 30.	Oct. 9, '64.	Right; duty Jan. 19, 1865.				
185	Chase, A. S., Pt., A, 19th Mass.	Dec. 13, '62.	Left; flap; by A. Surg. V. R. Stone, 19th Mass. Disch'd Feb. 28, 1863.				

No.	NAME, AGE, AND MILITARY DESCRIPTION.	DATES.	OPERATIONS, OPERATOR, RESULT.	No.	NAME, AGE, AND MILITARY DESCRIPTION.	DATES.	OPERATIONS, OPERATOR, RESULT.
222	Conger, W. Pt., A, 50th Illinois, age 22.	Oct. 5, '64.	Right; flap; by Surg. W. L. Leonard, 5th Ill. V. R. C. May 14, 1865.	260	Daiver, C., Pt., H, 10th Missouri, age 25.	Oct. 13, '64.	Right; flap. Returned to duty Jan. 20, 1865.
223	Cook, W. D., Pt., A, 5th Connecticut.	July 11, '63.	Left. Disch'd June 6, 1864; pensioned.	261	Danford, W. R., Pt., D, 23d Virginia.	July 3, '63.	Paroled August 23, 1863.
224	Cook, T., Pt., F, 1st Md., age 27.	Sept. 8, '64.	Left; flap; by Surg. A. A. White, 8th Md. Disch'd July 29, 1865; pensioned.	262	Darling, J., Pt., G, 20th Michigan, age 45.	June 3, '64.	Right; flap; by Surg. F. M. Lincoln, 35th Mass. Disch'd March 2, 1865; pensioned.
225	Cook, J. F., Pt., E, 52d North Carolina, age 25.	July 20, '64.	Right; antero-posterior flap; by Surg. Miller, C. S. A. Sent to Provost Marshal Nov. 1, 1864.	263	Davis, D. O., Corp'l, F, 5th N. H., age 34.	May 25, '65.	Left; flap; by Surg. W. Vosburg, 111th N. Y. Disch'd July 21, 1865; pensioned.
226	Cook, A. G., G, 56th Pennsylvania, age 20.	June 18, '64.	Left; flap; by Surg. J. C. Lyons, 56th Penn. Disch'd March 24, 1865; pensioned.	264	Davis, S., Pt., C, 5th Maine, age 22.	July 8, '61.	Right; flap; by Surg. C. Gray, 11th N. Y. Disch'd August 15, 1861; pensioned.
227	Cook, S., Pt., B, 54th Ohio.	April 7, '62.	Right Discharged; pensioned.	265	Davis, E. H., Capt., and Asst. Insp'r Gen., age 32.	Mar. 25, '65.	Right. Recovered.
228	Cooney, O., Pt., H, 12th Infantry, age 28.	May 6, '64.	Left; circular. Discharged May 12, 1865.	266	Davis, W., Pt., F, 8th N. Y. Cavalry, age 29.	Aug. 1, '63.	Left; by Surg. N. D. Ferguson, 8th N. Y. Cav. Disch'd October 14, 1863; pensioned.
229	Covey, W., Pt., 6th Ohio Battery.	Dec. 31, '62.	Right; by Surg. W. G. Bogue, 10th Ill. Disch'd Mar. 18, 1863; pensioned.	267	Davidson, J. P., Pt., K, 45th N. C., age 29.	June 2, '64.	Flap. Furloughed July 22, 1864.
230	Cornish, T., Pt., E, 30th U. T., age 39.	July 30, '64.	Right; flap. Discharged June 29, '65; pensioned.	268	Daywalt, T. A., Pt., A, 91st Ohio, age 34.	July 20, '64.	Left; flap; by Surg. J. B. Warwick, 91st Ohio. Disch'd Dec. 15, 1864; pensioned.
231	Cornish, G. G., 1st Lieut., H, 60th N. Y., age 30.	Dec. 20, '64.	Flap; by Surg. J. L. Dunn, 10th Penn. Disch'd April 29, 1865; pensioned.	269	Dean, G., Pt., E, 83d Pennsylvania.	June 27, '62.	Right; flap. Discharged Oct. 20, 1862.
232	Cordens, H., Pt., G, 18th Infantry, age 27.	Sept. 1, '64.	Circular; by A. A. Surg. J. G. Bingham. Duty Dec. 26, 1864; pensioned.	270	Dean, O. K., Pt., G, 109th New York, age 20.	Oct. 27, '64.	Right; flap; by Surgeon W. E. Johnson, 109th N. Y. Disch'd Jan. 20, 1865; pensioned.
233	Courier, L. D., Pt., H, 11th N. Hampshire, age 19.	Sept. 30, '64.	Right; circular; by Surg. J. E. Beatty, 2d Md. Disch'd May 13, 1865.	271	Dean, D. L., Serg't Mnj., 207th Penn., age 25.	April 2, '65.	Left; flap; by Surg. Washington Burg, 207th Penn. Disch'd June 23, 1865; pensioned.
234	Covett, A. M., Pt., E, 148th New York, age 23.	June 2, '64.	Left. Discharged; pensioned.	272	Dean, J. L., Pt., D, 19th Indiana.	Aug. 28, '62.	Right; by Surg. J. A. Ward, 2d Wis. Disch'd Nov. 18, 1862; pensioned.
235	Coyle, J., Pt., C, 198th Pennsylvania, age 20.	Mar. 29, '65.	Left; flap. Disch'd Aug. 2, 1865.	273	De Castro, Wm. E., Pt., D, 1st Mass., age 29.	May 12, '64.	Right; flap; by Surgeon E. A. Whiston, 1st Mass. Discharged May 24, 1864; pensioned.
236	Coyne, H., Corp'l, C, 3d New York, age 29.	July 8, '64.	Left; flap. Discharged July 18, 1865; pensioned.	274	Decker, M., Pt., E, 3d Missouri.	Jan. 11, '63.	Left; flap. Disch'd April 8, 1863; pensioned.
237	Crane, F., Pt., F, 83d Pennsylvania, age 19.	May 5, '64.	Right; by Surg. J. Avery, 21st Mich. Disch'd June 12, 1865; pensioned.	275	Decker, L., Corp'l, F, 67th Ohio, age 23.	April 2, '65.	Left; circular; by Surg. James Westfall, 67th Ohio. Disch'd July 8, 1865; pensioned.
238	Cranfield, B., Pt., F, 21st Michigan.	May 19, '65.	Right; circular; by Surg. G. T. Stevens, 77th N. Y. Disch'd June 16, 1865; pensioned.	276	De Diemer, L. N., Pt., E, 1st Wisconsin.	Oct. 8, '62.	Right; flap; by Asst. Surg. D. H. Davendorf, 1st Wis. Disch'd Nov. 1, 1862; pensioned.
239	Craven, M., Serg't, D, 105th Penn., age 21.	May 5, '64.	Left; antero-posterior flap. Discharged Nov. 5, 1862; pensioned.	277	De Hass, C., Pt., D, 49th Pennsylvania, age 43.	April 6, '65.	Left; circular. Disch'd June 22, 1865; pensioned.
240	Cresny, W. A., Pt., G, 7th Wisconsin, age 21.	Sept. 14, '62.	Right Disch'd July 18, 1862; pensioned.	278	Delameter, J., Pt., C, 20th Michigan, age 28.	May 5, '64.	Right; circular; by Surg. J. W. Wishart, 140th Penn. Disch'd Aug. 19, 1864; pensioned.
241	Crill, J., Pt., D, 56th New York.	May 31, '62.	Left. Disch'd March 19, 1863; pensioned.	279	Demmons, W. H., Pt., H, 31st Maine.	May 12, '64.	Left; flap; by Surg. T. F. Oakes, 56th Mass. Discharged Nov. 2, 1864; pensioned.
242	Croft, G., Pt., E, 33th Missouri.	Dec. 29, '62.	Right. Discharged Feb. 5, 1866; pensioned.	280	Denmark, C., Corp'l, D, 132d Pennsylvania.	Dec. 13, '62.	Left. Discharged.
243	Croft, S., Pt., G, 2d Penn. Heavy Art., age 27.	June 17, '64.	Right; by Surg. M. Rizer, 73d Pa; amp. at shoulder joint Jan. 8, '64. Disch'd May 3, 1864; pensioned. Spec. 2006.	281	Depue, H. J., Pt., F, 105th Illinois, age 18.	May 25, '64.	Left; flap; by Surg. A. W. Reagan, 70th Indiana. Disch'd Sept. 12, 1864; pensioned.
244	Crown, W. E., Pt., A, 72d Penn., age 30.	July 2, '63.	Left; flap; by Surg. M. M. Hooton, 86th Illinois. Disch'd Nov. 11, 1865; pensioned.	282	Derby, I. W., Corp'l, A, 2d New Hampshire.	July 21, '61.	Left; by Surg. G. H. Hubbard, 2d N. H. Discharged Sept. 17, 1861; pensioned.
245	Crownwell, J., Pt., I, 86th Illinois, age 19.	June 27, '64.	By Surg. G. T. Stevens, 77th N. Y.; afterward killed in action.	283	Derndinger, A., Corp'l, K, 5th New York.	Aug. 29, '62.	Right; by Surg. C. W. Hagen, 5th New York. Disch'd Nov. 1, 1862; pensioned.
246	Crosby, J. W., Major, 61st Penn., age 29.	July 12, '64.	Right; circular; by Surg. A. W. Whitney, 13th Mass. Disch'd Aug. 1, 1864; pensioned.	284	Dibble, J. T., Pt., H, 3d Michigan.	Feb. 3, '62.	Left; flap; by Surg. D. W. Bliss, U. S. V. Disch'd Mar. 5, 1862; pensioned.
247	Crosby, J. Q., Serg't, G, 13th Mass., age 32.	May 8, '64.	Right; flap; by Asst. Surg. H. C. Dean, 5th New York. Disch'd Jan. 19, 1863; pensioned.	285	Dickie, J. A., Serg't, E, 13th N. Carolina, age 21.	July 1, '63.	Furloughed Nov. 9, 1863.
248	Crossett, M. S., Pt., D, 57th New York.	Dec. 12, '62.	Left; antero-posterior flap. Discharged Jan. 27, 1865; pensioned.	286	Dickhart, J., Pt., F, 72d Penn.	Sept. 17, '62.	Right; by Surg. G. S. Palmer, U. S. V. Disch'd Dec. 15, 1862; pensioned.
249	Crothers, J., Pt., G, 6th Maryland, age 28.	May 5, '64.	Left; by Surg. Lee, 3d Alabama, C. S. A. Disch'd; pensioned.	287	Dingwell, J. H., Serg't, G, 8th New Jersey.	May 3, '63.	Left. Disch'd May 30, 1864; pensioned.
250	Crown, J., Serg't, C, 12th Infantry.	June 27, '62.	Right; antero-post. flap. Disch'd July 8, 1865. Spec. 4376.	288	D—, G. S., Corp'l, A, 1st Col'd Troops, age 18.	June 15, '64.	Left; flap; by Surg. J. R. Weist, 1st C. T. Disch'd Feb. 10, '65; pensioned. Died July 13, 1870. Spec. 96.
251	Cunliff, J. G., Pt., E, 51st New York, age 20.	Sept. 30, '64.	Left; flap. Disch'd August 22, 1862; pensioned.	289	Dodge, C. B., Pt., A, 5th Penn. Reserves.	Dec. 13, '62.	Left; flap; by Surg. C. Bower, 6th Pa. R. C. Disch'd Mar. 17, 1863; pensioned.
252	Curran, J., Pt., A, 57th Illinois.	Feb. 13, '62.	Right. Disch'd Sept. 18, 1862; pensioned.	290	Dolan, J., Pt., G, 5th N. Hampshire.	June 1, '62.	Right; flap; by Surg. L. M. Knight, 5th N. H. Disch'd July 25, '62.
253	Curtis, O. B., Pt., F, 5th New Hampshire.	June 1, '62.	Left; by Surg. J. S. Gale, 60th N. Y. Disch'd Nov. 24, 1862; pensioned.	291	Donnelly, J., Serg't, K, 191st Penn., age 23.	June 19, '64.	Left; lateral flaps. Disch'd Dec. 21, 1864; pensioned.
254	Curry, A., Pt., G, 60th New York.	Sept. 17, '62.	Left; circular; by Surg. G. A. Otis, 27th Mass. Disch'd July 29, 1862; pensioned.	292	Donnelly, C., Pt., E, 2d Louisiana.	May 27, '63.	Right; flap. Disch'd March 8, 1864; pensioned.
255	Cushman, J. E., Pt., D, 27th Mass.	Mar. 14, '62.	Left; re-amp. at shoulder joint, Mar. 9, 1864. Disch'd March 8, 1865; pensioned.	293	Doolioe, F. P., Pt., I, 90th Penn.	Aug. 29, '62.	Left; flap; by Surg. A. L. Cox, U. S. V. Disch'd Sept. 21, 1862; pensioned.
256	Dahl, J., Pt., I, 6th Ky.	Sept. 20, '63.	Right; circular; by Surg. Z. P. Hanson, 42d Ill. V. R. C. Feb. 3, 1865; pensioned.	294	Dooling, T., Pt., H, 155th New York, age 32.	June 15, '64.	Left; flap; by Surg. T. Wylie, 155th New York. Disch'd Feb. 18, 1865; pensioned.
257	Dailley, W., Pt., H, 125th Ohio, age 17.	June 27, '64.	Left; flap. Disch'd Aug. 5, 1863.	295	Datter, J., Pt., C, 143d Penn., age 29.	June 18, '64.	Left; flap; by Surg. J. C. Heamer, 143d Penn. Disch'd Dec. 9, 1864; pensioned.
258	Dailley, A., Pt., B, 162d New York, age 21.	May 27, '63.	Right; circular. Disch'd July 8, 1865.				
259	Dailley, J. F., Pt., I, 72d New York, age 31.	May 13, '64.					



No.	NAME, AGE, AND MILITARY DESCRIPTION.	DATES.	OPERATIONS, OPERATOR, RESULT.	No.	NAME, AGE, AND MILITARY DESCRIPTION.	DATES.	OPERATIONS, OPERATOR, RESULT.
296	Downs, C. L., Lieut., E, 2d Maine.	Dec. 13, '02.	Left; by Surg. C. S. Wood, 66th N. Y. Dis'd June 9, '63; pens'd.	335	Edwards, A. W., Corp'l, E, 37th Illinois.	Jan. 8, '63.	Right; flap. Disch'd March 27, 1862; pensioned.
297	Dow, R. P., Pt., D, 5th Ohio, age 21.	May 25, '64.	Left; flap. Disch'd Aug. 18, 1864.	336	Eggleston, R. J., Pt., D, 3d Virginia, age 23.	July 13, '64.	Left; flap. Furloughed August 19, 1864.
298	Dow, W., Pt., H, 7th Col'd Troops.	Aug. 17, '64.	Left; flap. Disch'd Feb. 10, 1865; pensioned.	337	Ellison, A. P., F, 16th Georgia.	Sept. —, 1862.	By Asst. Surg. H. A. DuBois, U. S. A. Paroled Oct. 15, 1862.
299	Dow, W. L., Pt., B, 13th Col'd Troops, age 21.	Dec. 16, '64.	Right; flap. Disch'd Aug. 8, 1865; pensioned.	338	Elliston, J., Pt., D, 5th Ky. M'd Inf., age 19.	July 19, '63.	Left; circular. Released August 14, 1863.
300	Drake, S. R., Corp'l, E, 47th Illinois.	May 23, '63.	Circular; by Asst. Surg. T. Babb, 47th Ill. Dis'd Oct. 9, '63; pens'd.	339	Ellis, O. A., Pt., A, 61st Penn., age 23.	May 5, '64.	Right; circular; by Surg. Wm. Buck, 6th Maine. Disch'd Feb. 7, 1865; pensioned.
301	Drain, V., Corp'l, I, 14th Col'd Troops, age 21.	Dec. 16, '64.	Right; antero-posterior flap; by Act. Asst. Surg. A. S. Giltner. Disch'd Aug. 8, 1865; pensioned.	340	Ellis, H. E., Pt., K, 1st Maine H'y Art., age 21.	June 18, '64.	Left; lateral flap. Disch'd May 5, 1865.
302	Drew, W., Corp'l, G, 96th Illinois, age 34.	June 20, '64.	Left; flap; by Surg. S. H. Kersey, 30th Illinois. Disch'd Oct. 27, 1864; pensioned.	341	Ellis, A., Pt., A, 74th Illinois, age 22.	July 4, '64.	Left; flap; by Surg. W. E. Hasse, 24th Wis. Disch'd Mar. 4, 1865; pensioned.
303	Duey, M., Pt., K, 97th Penn., age 21.	Jan. 15, '65.	Right; circular. Disch'd Oct. 21, 1865; pensioned.	342	Elliott, G. W., Pt., G, 5th Michigan, age 28.	Oct. 27, '64.	Left; flap; by Surg. H. F. Lyster, 5th Mich. Disch'd March 17, 1865; pensioned. Spec. 4118.
304	Duffy, T., Pt., C, 2d New Jersey.	Dec. 28, '64.	Right; flap. Discharged June 5, 1865; pensioned.	343	Elston, J., Pt., A, 57th Ohio, age 22.	July 22, '64.	Right; by Surgeon S. P. Bonner, 47th Ohio. Discharged April 17, 1865; pensioned.
305	Duffy, E., Pt., C, 95th Penn., age 22.	May 12, '64.	Right; antero-posterior flap; by Surg. E. B. P. Kelly, 95th Pa. Disch'd Oct. 3, 1864; pensioned.	344	Ely, D. H., Pt., F, 23d Iowa.	Sept. 19, '64.	Right; flap; by Surgeon J. C. Strader, 22d Iowa. Discharged May 2, 1865; pensioned.
306	Dunbar, E. M., Corp'l, I, 16th Vermont, age 22.	Sept. 19, '64.	Left; circular; by Surg. W. A. Barry, 98th Penn. Disch'd Aug. 15, 1865; pensioned.	345	Enterline, E., Pt., B, 116th Illinois.	Dec. 30, '62.	Left; flap; by Surg. G. S. Walker, 6th Missouri. Disch'd Mar. 16, 1863; pensioned.
307	Dunlap, I., Serg't, E, 6th Penn. Cav., age 26.	Aug. 29, '64.	Left; circular. Disch'd Dec. 18, 1864; pensioned. Spec. 3177.	346	Erdley, S., Pt., D, 150th Penn., age 26.	Oct. 27, '64.	Right; flap. Disch'd June 28, 1865; pensioned.
308	Dunkel, J., Pt., F, 86th Ohio.	Aug. 10, '62.	Right. Disch'd Sept. 25, 1862; pensioned.	347	Eskbridge, W. H., Pt., E, 12th N. C., age 24.	Sept. 23, '64.	Right; circular; by Surgeon A. Atkinson, C. S. A. Transferred to Fort McHenry Dec. 9, 1864.
309	Dunham, W. H., Pt., E, 14th New Jersey.	June 2, '64.	Right; flap; by Asst. Surg. T. A. Helwig, 87th Penn. Disch'd Sept. 20, 1864; pensioned.	348	Estell, E., Pt., B, 207th Pennsylvania.	April 2, '65.	Left; flap. Discharged July 12, 1865; pensioned.
310	Dunton, A. B., Corp'l, G, 50th Mass.	May 5, '64.	Left; flap; by Surg. Hunt, C. S. A. Disch'd April 1, 1865; pensioned.	349	Euscher, A., Pt., E, 49th N. Y., age 28.	Sept. 19, '64.	Right; flap; by Surg. G. T. Stevens, 77th N. Y. Disch'd July 15, 1865.
311	Duncan, R. R., 1st Lieut., B, 6th Virginia, age 32.	Oct. 9, '64.	Left; flap; by Confederate Surg. Ferguson. Transferred for exchange, January 10, 1865.	350	Evans, D., Pt., D., 51st Ohio, age 24.	June 23, '64.	Left; flap; by Surg. J. N. Beach, 40th Ohio. Disch'd Oct. 28, 1864; pensioned.
312	Dunce, L. P., 2d Lieut., E, 33d Indiana, age 21.	July 20, '61.	Left; flap; Surg. T. Hatchard, 22d Wisconsin. Resigned Dec. 17, 1864; pensioned.	351	Evans, L. C., Pt., I, 2d U. S. Infantry, age 20.	Aug. 21, '64.	Left; by skin flaps and circular section of muscles. Disch'd Oct. 23, 1864; pensioned. Spec. 416, plaster cast. A. B. b. 55.
313	Dunton, A. J., Pt., B, 5th Maine.	Sept. 2, '62.	Left; flap. Disch'd Nov. 1, 1862; pensioned.	352	Everman, J., Pt., D, 5th U. S. Col'd Cavalry.	Dec. 23, '64.	Left; flap; by Surg. James G. Hatchitt, U. S. V. Disch'd Mar. 29, 1865; pensioned.
314	Dunn, C., Corp'l, H, 5th Maine.	July 21, '62.	Left; flap; by Surg. B. F. Buxton, 5th Maine. Disch'd Nov. 12, 1861; pensioned.	353	Ewing, W., Pt., E, 119th Penn., age 40.	May 10, '64.	Left; flap; by Surg. P. Leidy, 119th Penn. Disch'd April 6, 1865; pensioned.
315	Dunn, G. W., Pt., K, 4th Iowa.	Dec. 29, '62.	Left. Disch'd Jan. 22, 1863.	354	Fahey, J., Pt., A, 111th New York.	Sept. 14, '62.	Right. Disch'd Aug. 18, 1863; pensioned.
316	Durstone, H. C., Pt., E, 4th Penn.	July 30, '64.	Left. Discharged Nov. 30, 1864; pensioned.	355	Falk, P., Pt., D, 7th N. York.	Dec. 13, '62.	Right; flap. Disch'd Feb. 27, 1863.
317	Durrah, F. H., Pt., F, 31st Penn., age 30.	May 31, 1862.	Right; circular. Disch'd Aug. 21, 1862; pensioned.	356	Fallon, T., Pt., H, 93d Illinois, age 26.	Nov. 25, '63.	Right; flap; by Ass't Surg. J. O. Skinner, 10th Iowa. Disch'd July 20, 1865; pensioned.
318	Durfee, E. O., Serg't, C, 24th Michigan, age 21.	July 1, '63.	Right; antero-posterior flap. Discharged Dec. 28, 1863; pens'd.	357	Farr, H. F., Pt., K, 16th Maine, age 27.	May 8, '64.	Left; antero-posterior flap. Discharged Dec. 15, 1864; pens'd.
319	Dykes, E. H., Pt., E, 8th Florida.	Feb. 5, '65.	Right; flap. Released June 28, 1865.	358	Farringer, J., Pt., C, 82d Penn., age 22.	June 1, '64.	Right; flap. Disch'd June 11, 1865.
320	Dyer, J., Pt., F, 2d West Virginia Cav., age 21.	Sept. 5, '64.	Left; flap; by Surg. T. Morton, 3d West Va. Cavalry. Disch'd March 4, 1865; pensioned.	359	Farrey, J., Pt., K, 2d New Jersey.	Sept. 15, '62.	Left; circular; by Surg. L. W. Oakley, 2d N. J. Disch'd Dec. 23, 1862; pensioned.
321	Earley, J., Pt., B, 10th New Hampshire.	June 3, '64.	Left; by Surg. H. N. Small, 10th N. H. Disch'd Dec. 2, '64; pens'd.	360	Feen, J., Corp'l, M., 5th N. Y. Cav., age 30.	May 18, '61.	Left; flap. Disch'd Aug. 2, 1865; pensioned.
322	Easterbrooks, A. J., Musician, I, 6th Penn. Reserves.	Aug. 30, '62.	Left; flap; by Surg. S. D. Freeman, 1st Penn. Rifles. Disch'd Sept. 9, 1862; pensioned.	361	Felrick, I. H., Pt., I, 49th Penn., age 28.	June 2, '64.	Right; double flap. Disch'd June 16, 1865; pensioned.
323	Eastman, C., Pt., K, 4th U. S. Artillery, age 21.	April 6, '65.	Circular; by Surg. J. H. Kimball, 31st Maine. Transferred to regimental headquarters July 1, '65.	362	Fenn, A. H., Capt., K, 2d Conn. H'vy Art.	Oct. 19, '64.	Left; flap; by Surg. H. Plumb, 2d Conn. H'vy Art. Mustered out Aug. 1865; pensioned.
324	Eastman, F. M., Corp'l, H, 102d Penn., age 21.	Oct. 19, '64.	Left; flap; by Surg. E. R. Umberger, 93d Penn. Disch'd June 25, 1865; pensioned.	363	Fenton, P. S., Corp'l, C, 116th Illinois, age 21.	June 3, '64.	Right; flap; by Surgeon Ira N. Barnes, 116th Illinois. Disch'd June 7, 1865; pensioned.
325	Eaton, W., Pt., 19th Ind. Battery, age 21.	May 15, '64.	Right; flap. Disch'd April 25, 1865; pensioned.	364	Ferus, M., Pt., K, 74th New York.	May 5, '62.	Left. Disch'd; pensioned.
326	Ebb, A., Pt., A, 30th U. S. Col'd Troops, age 19.	July 30, '64.	Left; circular. Disch'd Dec. 29, 1864; pensioned.	365	Fetterman, G., Pt., E, 5th Pa. Cav., age 30.	Oct. 13, '63.	Left. Disch'd April 23, 1865; pensioned.
327	Ebert, C., Pt., K, 1st N. York.	Aug. 29, '62.	Left; flap; by Asst. Surg. John Howe, 1st New York. Disch'd Sept. 26, 1862; pensioned.	366	Field, E., Corp'l, I, 27th Ohio, age 23.	June 21, '64.	Left; antero-posterior flap; by Surg. D. S. Young, 21st Ohio. Disch'd Nov. 29, 1864; pens'd.
328	Eckstein, J., Pt., F, 183d Penn., age 12.	May 12, '64.	Left; antero-posterior flap; by Surg. J. W. Wishart, 140th Pa. Disch'd July 10, 1865; pension'd.	367	Findley, J. D., Pt., K, 112th N. Y., age 28.	June 26, '64.	Left; flap; by Surg. C. E. Washburne, 112th N. York. Disch'd Sept. 11, 1865; pensioned.
329	Edelberle, R., Pt., H, 12th Penn. Reserves.	Sept. 17, '62.	Right. Disch'd Nov. 15, 1862.	368	Finneal, E., Pt., B, 5th Michigan.	Nov. 28, '63.	Right; by Surg. H. F. Lyster, 5th Mich. Disch'd July 15, '64.
330	Edgell, S. W., Corp'l, B, 15th Mass., age 33.	June 3, '64.	Right; flap; by Surgeon S. H. Plumb, 82d N. Y. Disch'd Dec. 2, 1864; pensioned.	369	Finnell, S., Pt., I, 69th N. Y., age 20.	June 16, '64.	Left; circular; by Surg. N. Hayward, 20th Mass. Disch'd Nov. 7, 1865; pensioned.
331	Edgeworth, R., Pt., D, 25th New York.	May 27, '62.	Right; flap. Disch'd Aug. 29, 1862; pensioned.	370	Pipps, W. P., Pt., K, 30th Illinois, age 19.	Aug. 12, '64.	Right; flap; by Surg. H. McKenna, 17th Wisconsin. Discharged Dec. 27, 1864; pens'd.
332	Edmundson, G. D., Pt., B, 13th Georgia, age 20.	July 9, '64.	Right; circular; by Surg. Green, 13th Georgia. Transferred Sept. 9, 1864, for exchange.	371	Fisher, C., Pt., H, 17th Wisconsin, age 27.	Mar. 8, '65.	Right; circular; by a Confederate surg. Disch'd May 31, '65; pens'd.
333	Edmonds, C. A., Capt., H, 17th Michigan.	Sept. 14, '62.	Right. Disch'd Jan. 31, 1863; pensioned.				
334	Edwards, J. W., Pt., F, 83d Col'd Troops.	Jan. 17, '65.	Left; by Surg. J. S. Redfield, 6th Kansas Cavalry. Disch'd June 1, 1865; pensioned.				

No.	NAME, AGE, AND MILITARY DESCRIPTION.	DATES.	OPERATIONS, OPERATOR, RESULT.	No.	NAME, AGE, AND MILITARY DESCRIPTION.	DATES.	OPERATIONS, OPERATOR, RESULT.
372	Fisher, J. H., Pt., F, 7th Indiana, age 25.	May 6, '64.	Left; by Surg. G. W. New, 7th Indiana. Duty Sept. 25, 1864; pensioned.	410	Gerhauser, J. L., Pt., D, 26th Wisconsin.	July 1, '63.	Right. Disch'd May 13, 1864; pensioned.
373	Fitzpatrick, M., Private, Wicken's Bat'y., C.S.A., age 48.	Aug. 31, Sept. 2, 1864.	Right; antero-posterior flap; by A. A. Surg. R. L. McClure, 7th Provost Marshal Jan. 31, 1865.	411	Gibson, L., cabin boy, Gumbout No. 10, age 25.	Jan. 12, '65.	Left; flap; by A. A. Surg. Geo. Harvey, Disch'd Mar. 7, '65; pens'd.
374	Flynn, M., Pt., E, 4th Delaware, age 48.	June 19, '64.	Right; antero-posterior flap; by A. Surg. C. B. Haynes, U. S. V., V. R. C. April 29, 1865.	412	Gibson, W. M., Pt., C, 34th Illinois.	Mar. 7, '62.	Right. Disch'd April 14, 1862; pensioned.
375	Fogle, A., Pt., K, 1st Pa. Rifles, age 19.	May 30, '64.	Right. Disch'd July 31, 1864; pensioned.	413	Giffard, A. A., Serg't, K, 119th Pa., age 46.	May 5, '61.	Left; by Surg. P. Leidy, 119th Pa. Disch'd Mar. 27, '65; pens'd.
376	Foley, D., Pt., C, 63d N. York.	Dec. 13, '62.	Right; flap; by Surg. L. Reynolds, 63d N. Y. Disch'd May 13, 1863; pensioned.	414	Gilbert, G. P., Corp'l, D, 4th Vermont, age 21.	April 2, '65.	Left; flap. Disch'd July 25, '65; pensioned.
377	Foley, J., Pt., H, 61st Pa., age 28.	Aug. 21, '64.	Right; circular; by Surg. G. T. Stevens, 77th N. Y. Duty Nov. 18, 1864, for muster out; pens'd.	415	Gill, J. C., Corp'l, D, 5th Kentucky.	April 7, '62.	Left. Disch'd Sept. 9, 1862; pensioned.
378	Forbes, G., Pt., H, 13th Iowa.	July 23, 1864.	Right; flap. Discharged Oct. 27, 1864.	416	Gilman, J. E., Pt., E, 12th Mass.	July 1, '63.	Right; circular. Disch'd Sept. 28, 1863; pensioned.
379	Ford, T., Landsman, U. S. Navy.	April 24, '62.	Left; by Dr. Lyons, U. S. Navy. Disch'd; pensioned.	417	Gissinger, G. B., Corp'l, G, 62d Pa., age 21.	May 5, '64.	Left; antero-posterior flap; by Surg. A. S. Coe, 147th N. York. Duty July 11, 1864; pensioned.
380	Fortinberry, W. G., Pt., H, 19th Ala., age 23.	Dec. 16, '64.	Left; lateral flap; by A. A. Surg. A. Rols, Pro. Mar. Feb. 28, '65.	418	Glesson, S., Pt., L, 5th Iowa Cav., age 28.	July 18, '64.	Left; flap; by Surg. Jones, C.S.A. Disch'd July 7, 1865; pensioned.
381	Foster, A. J., Pt., G, 7th Tennessee, age 27.	July 3, '63.	Right; paroled Aug. 22, 1863.	419	Glenn, W., Pt., E, 187th Pennsylvania.	June 18, '64.	Right; circular. Disch'd Nov. 10, 1864; pensioned.
382	Foster, J. F., Corp'l, F, 35th Mass.	Dec. 13, '62.	Right; flap; by Surg. J. P. Ho-sack, 51st Pa. Dis'd Mar. 12, '63.	420	Gibbden, W. H., Pt., A, 130th N. H., age 19.	June 15, '64.	Right. Disch'd; pensioned.
383	Foster, W. E., Lieut., D, 30th Illinois, age 25.	Aug. 28, '64.	Left; circular; by Surg. J. H. Boucher, U. S. V. Mustered out Feb. 2, 1865; pensioned.	421	Godfrey, A., Pt., D, 58th Pa., age 48.	June 3, '64.	Right; bilateral flap. Disch'd Nov. 11, 1864; pensioned.
384	Fox, T. B., Pt., H, 55th Ohio, age 19.	June 19, '64.	Circular; by Surg. I. N. Hines, 73d Ohio. Disch'd May 30, 1865; pensioned.	422	Godfrey, W., Pt., E, 169th N. Y., age 20.	July 30, '64.	Left; flap. Disch'd Sept. 19, 1865; pensioned. Spec. 3044.
385	Frain, J. P., Pt., D, 1st Pa. Cav., age 19.	June 3, '64.	Right; flap; by Ass't Surg. L. E. Atkinson, 1st Pa. Cav. Head and remaining shaft removed in fragments on Oct. 21, 1864. Discharged April 1, 1865; pens'd.	423	Goldworthy, T. M., Pt., C, 12th Wis., age 22.	July 21, '64.	Right; circular. Disch'd June 28, 1865; pensioned.
386	France, H., Pt., C, 5th Pa. Res. Corps.	Sept. 14, 1862.	Right; flap. Disch'd Nov. 12, 1862; pensioned.	424	Goller, H., Pt., D, 65th N. Y., age 36.	Oct. 19, '64.	Left; flap. Disch'd Nov. 7, 1865; pensioned.
387	Francey, F., Pt., B, 6th Wisconsin, age 44.	April 1, '65.	Left; circular. Disch'd July 10, 1865.	425	Goodwin, L., Pt., F, 8th Maine, age 18.	July 30, '64.	Left; flap. Disch'd June 24, 1865; pensioned.
388	Frey, A., Corp'l, 1, 97th Pa., age 36.	Jan. 15, '65.	Left; circular; by Surg. G. C. Jarvis, 7th Com. Disch'd May 2, 1865; pensioned.	426	Goodwin, A. K., Pt., I, 4th N. H., age 23.	May 16, '64.	Right. Disch'd Sept. 23, 1864; pensioned.
389	Frowwiler, L., Pt., B, 116th New York.	June 14, '63.	Left. Duty Aug. 21, 1863; pensioned.	427	Goodman, Wm. R., Pt., A, 1st Md. Lt. Artillery, age 19.	Dec. 13, '62.	Left; circular; by Surg. E. Shippen, U. S. V. Mustered out Aug. 8, 1866; pensioned.
390	Fry, G., Pt., H, 107th Pennsylvania, age 23.	June 3, '64.	Circular; by Surg. J. P. Hutchinson, 107th Penn. Disch'd May 20, 1865; pensioned.	428	Gordell, J. M., Pt., G, 147th N. Y., age 24.	June 3, '64.	Left; circular; by Surg. A. S. Coe, 147th N. Y. Disch'd Oct. 24, 1864; pensioned.
391	Fry, S., Pt., I, 148th Penn., age 30.	July 2, '63.	Right; antero-posterior skin flap; by Conf'd. Surg. Knox. Disch'd Nov. 21, 1863; pensioned.	429	Gordon, D., Pt., H, 4th Va. Cav., age 21.	April 6, '65.	Left; circular; by Surg. T. H. Squier, 89th N. Y. Released June 14, 1865.
392	Fuller, E., Corp'l, B, 6th N. Y. H'y Art., age 29.	June 1, '64.	Right; circular. Disch'd Oct. 22, 1864 and pensioned.	430	Gordon, Ira, Pt., F, 124th New York.	July 2, '63.	Left; flap. Disch'd Oct. 19, 1863; pensioned.
393	Fuller, J., Pt., F, 2d Vt.	May 4, '63.	Left; by Surg. W. J. Sawin, 2d Vt. Disch'd June 15, '63; pens'd.	431	Grabach, R., Pt., K, 2d New Jersey.	Sept. 18, '62.	Left; circular; by Surg. L. W. Oakley, 2d N. J. Disch'd Dec. 23, 1862; pensioned.
394	Fuller, W., Pt., C, 68th Ohio, age 24.	July 23, '64.	Right; circular. Disch'd June 27, 1865; pensioned.	432	Grace, E., Pt., D, 27th Indiana.	Sept. 17, '62.	Left; circular. Disch'd Dec. 6, 1862.
395	Fult, M., Pt., E, 66th New York.	Dec. 13, '62.	Left; flap. Disch'd Mar. 6, 1863; pensioned.	433	Grady, J. R., Pt., A, 23d North Carolina, age 33.	July 3, '63.	Left. Retired Jan. 23, 1865.
396	Furlong, P., Serg't, A, 7th Michigan.	Dec. 13, '62.	Right. Disch'd June 10, 1863; pensioned.	434	Graham, J., Pt., C, 107th Pennsylvania.	Dec. 13, '62.	Left. Disch'd Aug. 3, 1863.
397	Gall, G., Serg't, E, 29th New York.	Aug. 29, '62.	Left; flap; by Surg. C. Newhuss, 29th N. Y. Disch'd Nov. 14, '62.	435	Graham, J., Pt., F, 29th Pa., age 21.	June 15, '64.	Right; antero-posterior flap; by Surg. H. E. Goodman, U. S. V. Disch'd June 1, 1865; pensioned.
398	Gallagher, E., Pt., K, 42d New York, age 34.	Oct. 21, '61.	Right; flap; by Surg. J. D. Osborne, 42d N. Y. Disch'd Dec. 14, 1861; pensioned.	436	Granger, E. O., Serg't, F, 7th Ohio, age 30.	May 25, '64.	Right; by Surg. A. K. Fifeled, 29th Ohio. Disch'd Jan. 9, 1865.
399	Gallagher, L., Pt., A, 69th Ohio, age 18.	Sept. 1, '64.	Left; circular; by Surg. L. Shusser, 69th O. Dis'd Mar. 2, '66; pens'd.	437	Grant, G., Pt., G, 60th N. Y., age 22.	July 2, '63.	Left. Disch'd Dec. 9, 1863; pensioned.
400	Galvin, J., Pt., A, 136th New York, age 17.	Mar. 16, '65.	Left; flap. Disch'd July 31, 1865; pensioned.	438	Graves, W., Pt., 1st N. Y. Independent Bat., age 44.	Oct. 19, '64.	Right; circular. Disch'd July 4, 1865; pensioned.
401	Gaus, P., Serg't, C, 15th Infantry, age 27.	Sept. 1, '64.	Left. Duty October 27, 1864.	439	Gray, G. W., Pt., D, 37th Mass.	May 6, '64.	Left; flap. Disch'd Oct. 16, 1864; pensioned.
402	Gardiner, W. H., Pt., C, 91st N. Y., age 18.	Mar. 30, '65.	Right; flap; by Surg. A. S. Coe, 147th N. Y. Disch'd October 3, 1865; pensioned.	440	Greely, W. W., Pt., C, 3d Vermont, age 19.	May 4, '63.	Right; flap; by Surgeon D. M. Goodwin, 3d Vt. Disch'd Aug. 4, 1863; pensioned.
403	Gardner, N. B., Pt., K, 2d Michigan, age 23.	June 17, '64.	Left; flap; by Surg. E. J. Bonine, 2d Mich. Disch'd Nov. 28, 1864; pensioned.	441	Greene, H. P., Pt., F, 7th Wisconsin, age 16.	June 17, '64.	Left; flap; by Ass't Surg. J. T. Duffield, 7th Ind. Disch'd Dec. 6, 1864; pensioned. Spec. 1388.
404	Gardner, I. B., Capt., I, 14th Maine, age 21.	Sept. 19, '64.	Right. Duty Oct. 18, 1864; pensioned.	442	Greenfield, C. H., Pt., F, 9th N. Y. Heavy Art., age 29.	April 2, '65.	Left; antero-post flaps; by Surg. D. S. Chamberlin, 9th N. Y. H'y Art. Disch'd July 7, '65; pens'd.
405	Gardner, E. B., Pt., H, 35th Mass., age 31.	Sept. 17, '62.	Right. Disch'd March 4, 1863; pensioned.	443	Greenwalt, A., Pt., F, 63d Pennsylvania.	June 1, '62.	Right; by A. Surg. N. R. Gunn, 1st Mass. Disch'd Aug. 8, '62; pens'd.
406	Gandy, A., Corp'l, K, 46th Indiana.	May 1, 1863.	Right; double flap. Disch'd Aug. 8, 1863; pensioned.	444	Grogg, A., Pt., E, 4th Pa. Cav., age 24.	Aug. 16, '64.	Left; flap. V. R. C. Jan. 14, 1865; pensioned.
407	Gault, J. M., Pt., H, 13th Ohio, age 36.	Aug. 8, '64.	Left; circular; by Act. Staff Surg. C. B. Richards, U. S. A. Disch'd June 27, 1865; pensioned.	445	Grogg, D., Pt., F, 10th N. Y., age 34.	Sept. 28, '64.	Right; by antero-posterior flap; by Surg. G. Chaddock, 7th Mich. Disch'd July 12, 1865; pens'd.
408	Geiger, J. C., Serg't, E, 105th Pa., age 25.	July 2, '63.	Left; circular. Disch'd Oct. 7, '63.	446	Griffith, J. M., Corp'l, G, 191st Penn., age 27.	Feb. 6, '65.	Right; ant.-post. flap; by Surg. J. W. Wishart, 140th Penn. Disch'd May 5, 1865.
409	Gelray, J. W., Lieut., G, 2d Mass.	July 3, '63.	Right; by Surg. W. H. Heath, 2d Mass. M. O.; pensioned.	447	Grover, J., Serg't, F, 14th New Jersey, age 18.	April 12, '65.	Left; circular; by Surgeon J. S. Martin, 14th N. J. Discharged Sept. 12, 1865; pensioned.



No.	NAME, AGE, AND MILITARY DESCRIPTION.	DATES.	OPERATIONS, OPERATOR, RESULT.	No.	NAME, AGE, AND MILITARY DESCRIPTION.	DATES.	OPERATIONS, OPERATOR, RESULT.
451	Gumbert, J. H., Pt., G. 81st Penn.	Sept. 17, '62.	Right: flap. Discharged May 21, 1863; pensioned.	493	Henry, A. B., Pt., K, 2d West Virginia Cav.	May 19, '63.	Left: circular. Disch'd Sept. 20, 1863; pensioned.
452	Gunning, A. J., Pt., H, 35th Mass.	Dec. 13, '62.	Left. Discharged Feb. 20, 1863; pensioned.	494	Henry, P., Pt., H, 12th Iowa	July 13, '64.	Right: by Surg. J. H. Niglas, 6th Ill. Cav. Disch'd; pensioned.
453	Haag, S. C., Corp'l, G. 51st Ohio, age 23.	Sept. 2, '64.	Left: flap; by Surg. M. G. Sherman, 5th Ind. Disch'd Mar. 21, 1865; pensioned.	495	Herron, W., Pt., D. 9th Louisiana, age 32.	July 9, '61.	Right: circular; by Surg. C. H. Todd, C.S.A. Duty Sept. 19, '61.
454	Hains, W., Pt., H, 97th Ohio, age 21.	June 18, '64.	Left: flap; by Surg. E. B. Glick, 40th Ind. Disch'd Dec. 22, 1864.	496	Hernan, H. H., Pt., C. 37th Ohio, age 29.	May 22, '63.	Left: flap; by A. Surg. I. Ringle, 37th O. Dis'd Sept. 14, '63; pen'd.
455	Hall, W. K., Pt., 1, 4th Georgia, age 35.	April 2, '65.	Left: circular. Released June 14, 1865.	497	Hesson, J., Pt., C. 81st Pennsylvania, age 44.	Mar. 25, '65.	Left: double flap; by Surg. M. H. Raymond, 26th Mich. Disch'd June 20, 1865; pensioned.
456	Hall, H. S., Lieut.-Col., 4th C. T.	July 30, '64.	Right: cir.; by Surg. D. MacKay, 2d C. T. Disch'd Oct. 25, '65.	498	Hubbard, O. N., Pt., I. 16th New York, age 21.	May 3, '61.	Right: flap; by a Confed. surg. Disch'd July 7, 1863; pensioned.
457	Hall, B., Pt., D, 40th New York.	July 2, '63.	Right: flap; by Surg. Wm. Watson, 105th Penn. Disch'd Oct. 19, 1863; pensioned.	499	Hudson, R. W., Serg't, G. 4th Ind. Cav., age 26.	May 26, '64.	Left: circular; by Surgeon J. P. Taggart, 4th Ind. Cav. Disch'd June 29, 1865; pensioned.
458	Hall, H., Pt., H, 102th New York, age 21.	Sept. 17, '62.	Right: ant.-post. flap. Disch'd Oct. 11, 1862; pensioned.	500	Huddleson, W., Pt., B, 125th Illinois, age 18.	June 27, '64.	Right: flap. Discharged Oct. 29, 1864; pensioned.
459	Hall, N., Corp'l, D, 2d U. S. sharpshooters.	May 4, '63.	By Surg. J. S. Jamison, 86th N. Y. Disch'd Aug. 14, '63; pens'd.	501	Huff, R. D., Pt., K, 1st Michigan.	May 3, '63.	Right: circular; by Surgeon C. S. Wood, 66th N. Y. Disch'd Oct. 17, 1863; pensioned.
460	Hamilton, Z. C., Serg't, D, 1st California Cav.	July 13, '65.	Right: circular; by Surg. J. E. Kunkler, 1st Cal. Cav.; pens'd.	502	Hughes, S. T., Pt., K, 5th Tennessee.	May 14, '64.	Left: by Surg. L. D. Griswold, 103d Ohio. Disch'd Sept. 11, 1864; pensioned.
461	Hankinson, T. D., Corp'l, B, 3d N. Y., age 31.	July 12, '64.	Right: circular. Disch'd Oct. 26, 1864; pensioned.	503	Humphrey, A. J., Q. M. Serg't, I, 2d New York Mounted Rifles, age 22.	July 1, '64.	Left: circular; by Surgeon R. T. Payne, 2d N. Y. M. R. Disch'd October 3, 1865; pensioned.
462	Hannah, J., Pt., C, 45th New York.	May 3, '63.	Left: circular. Disch'd August 13, 1863.	504	Hunter, F. J., Pt., H, 148th Pennsylvania, age 23.	May 3, '63.	Right: by Surg. G. L. Potter, 145th Penn. Disch'd July 20, 1863; pensioned.
463	Harkins, A., Capt., B, 2d Minnesota.	Sept. 29, '63.	Left: flap; by A. Surg. O. Ayer, 2d Minn. Duty June 20, 1864.	505	Hunter, N., Pt., C, 2d N. Y. Heavy Artillery.	June 16, '64.	Left: flap; by Surg. J. W. Wishart, 140th Penn. Disch'd Oct. 11, 1864; pensioned.
464	Hartan, G., Pt., D, 106th Pennsylvania, age 38.	June 3, '64.	Right: circular; by Surgeon M. Rizer, 73d Penn. Disch'd July 18, 1865; pensioned.	506	Hunter, J. H., Pt., G, 6th Vermont, age 27.	May 6, '64.	Right: by Surg. N. Hayward, 20th Mass. Disch'd Mar. 10, '65; pens'd.
465	Harlow, G. R., Corp'l, E, 39th Mass., age 26.	Aug. 18, '64.	Right: circular; by Surg. Wm. Thorndike, 39th Mass. Disch'd March 17, 1865; pensioned.	507	Hunt, D., Corp'l, B, 7th W. Va., age 42.	Mar. 30, '65.	Right: ant.-post. flap; by Surg. A. Satterthwaite, 12th N. Jersey. Disch'd June 15, 1865.
466	Harn, C. E., 1st Lieut., I, 13th Mass., age 25.	May 8, '64.	Right: flap; by a Confed. surg. Disch'd Sept. 9, 1864; pensioned.	508	Hurst, P., Pt., C, 16th Ohio, age 24.	Dec. 29, '62.	Right: by A. Surg. B. S. Chase, 16th Ohio. Discharged Mar. 7, 1863.
467	Harrell, W., Pt., A, 10th Kentucky Cav., age 22.	June 12, '64.	Left: circular; by Surg. Miller, C. S. A. To Milit'y Pris. Aug. 16, '64.	509	Hutchins, L. W., Pt., C, 1st Georgia, age 26.	Dec. 1, '62.	Antero-posterior flaps. To Provost Marshal March 7, 1865.
468	Harrington, D. M., Serg't, G. 73d N. Y., age 37.	June 1, '64.	Left: ant.-post. flap; by Surgeon Fowler Prentice, 73d New York. Disch'd Mar. 22, 1865; pensioned.	510	Hicks, G. V., Pt., B, 3d Kentucky Cav., age 19.	Sept. 2, '64.	Right: flap; by Surg. R. M. Fairleigh, 3d Kentucky Cav. Disch'd May 16, 1865; pensioned.
469	Harrington, J. H., Pt., G, 107th N. Y., age 22.	May 25, '64.	Left: flap; by Asst. Surg. I. W. Kennedy, 123d N. Y. Disch'd April 14, 1865; pensioned.	511	Hiekey, M., Pt., E, 63d New York, age 38.	June 16, '64.	Left: flap; by Surg. P. E. Hubbon, 28th Mass. Disch'd Jan. 31, 1865; pensioned.
470	Harris, J., 1st Lieut., D, 2d Ky. Cav., age 25.	June 12, '64.	Right: flap; by Surg. Miller, C. S. A. To Milit'y Pris. Aug. 16, '64.	512	Higgs, J., Corp'l, H, 1st Mich. Light Art., age 24.	July 5, '64.	Circular. Disch'd March 13, 1865; pensioned.
471	Harris, H. L., Pt., F, 2d Vermont.	June 23, '62.	Right: by Surg. W. J. Sawin, 2d Vt. Disch'd Aug. 27, '64; pens'd.	513	Higson, W. H., Pt., H, 12th N. H., age 20.	Aug. 17, '64.	Left: flap. Disch'd Jan. 17, 1865.
472	Harshaw, H. B., 2d Lieut., E, 2d Wis., age 21.	May 8, '64.	Left: circular; by Surg. A. J. Ward, 2d Wis. Disch'd June 28, 1864; pensioned.	514	Hill, I. L., Corp'l, I, 30th Maine.	April 23, '64.	Right: flap; by Surg. J. M. Bates, 13th Me. Disch'd June 23, 1864; pensioned.
473	Hartnett, T., Pt., F, 30th Massachusetts.	Oct. 19, '64.	Right: circular; by Asst. Surg. S. H. Davis, 30th Mass. Disch'd April 1, 1865.	515	Hilton, W. G., Pt., C, 52d Ohio, age 35.	Mar. 16, '65.	Left: circular. Disch'd July 4, 1865; pensioned.
474	Hartman, J. P., Pt., I, 7th Illinois Cavalry.	Mar. 1, '62.	Right: Discharged July, 1862; pensioned.	516	Hillyer, I. C., Pt., D, 28th Illinois.	Oct. 5, '62.	Right: by Surg. W. P. West, 28th Ill. Disch'd Nov. 10, 1862; pens'd.
475	Hartwood, I. C., Serg't, C, 34th Virginia, age 32.	Oct. 27, '64.	Right: circular; by Surg. W. L. Baylor, C.S.A. Furl'd Dec. 13, '64.	517	Hines, J., Pt., E, 53d New York, age 23.	May 19, '64.	Left: circular; by Surg. A. Van Devere, 66th N. York. Disch'd October 19, 1864; pensioned.
476	Hastings, R. H., Pt., D, 35th Virginia.	May 10, '64.	Left: circular. Disch'd Mar. 17, 1865.	518	Hine, C. E., Pt., G, 8th Wisconsin.	Oct. 3, '62.	Right. Discharged Dec. 1, 1862; pensioned.
477	Hatcher, L., Pt., C, 57th Pennsylvania, age 40.	May 5, '64.	Left: circular. Disch'd June 1, 1865; pensioned.	519	Hipp, C., Major, 37th Ohio.	July 28, '64.	Left: flap; by Surg. A. C. Messenger, 57th Ohio. Duty Oct. 15, '64.
478	Haverly, J. F., Pt., C, 2d Massachusetts.	Aug. 9, '62.	Left: circular; by a Confed. surg. Disch'd Dec. 26, 1862; pensioned.	520	Hodgdon, J. F., Pt., I, 1st Mass. Heavy Artillery.	June 14, '63.	Right: circular; by A. Surg. M. P. Bowes, 12th Penn. Cav.; and left: circular; by A. Surg. T. C. Smith, 116th Ohio. Discharged Aug. 5, 1863; pensioned.
479	Hawkins, M. V., Serg't, E, 1st Tenn., age 22.	May 5, '64.	Right: flap. Furloughed June 21, 1864.	521	Hoel, C., Pt., D, 105th Pennsylvania, age 25.	May 10, '64.	Right: circular; by Surg. H. F. Lyster, 5th Mich. Disch'd Sept. 8, 1864; pensioned.
480	Hawkins, G., Pt., F, 2d Michigan.	Nov. 24, '63.	Right. Discharged Mar. 26, 1864; pensioned.	522	Hogarty, W. P., Pt., B, 4th U. S. Artillery.	Dec. 13, '62.	Left: flap. Disch'd Feb. 1, 1863; pensioned.
481	Hayes, P. T., Pt., A, 8th N. H., age 20.	Aug. 27, '64.	Right: flap; by A. A. Surg. A. H. Robinson. Discharged Dec. 1, 1864; pensioned.	523	Holschuh, W., Pt., F, 28th Ohio, age 22.	Sept. 17, '62.	Left: by A. Surg. A. Schonbein, 28th O. Disch'd June 9, '63; pens'd.
482	Haynes, J., Pt., F, 122d Illinois, age 20.	July 14, '64.	Right: flap. Discharged July 22, 1865; pensioned.	524	Honecker, J., Pt., D, 1st W. Va. Light Artillery.	June 6, '64.	Right: flap; by Surg. David Bagley, 1st W. Va. Disch'd June 14, 1865; pensioned.
483	Hayward, A. B., Serg't, A, 2d N. H., age 26.	June 3, '64.	Right: circular; by Surg. J. M. Merron, 2d N. H. Disch'd June 21, 1864; pensioned.	525	Homan, P., Pt., F, 75th Illinois.	Oct. 8, '62.	Right. Disch'd Jan. 12, 1863; pensioned.
484	Hay, J., Serg't, I, 57th Pennsylvania, age 24.	Nov. 27, '63.	Left: flap; by Sur. H. F. Lyster, 5th Mich. Disch'd Feb. 19, '64; pens'd.	526	Hood, J. D., Serg't, H, 16th S. C., age 34.	Nov. 30, '64.	Left: circular. To Provost Marshal March 28, 1865.
485	Healey, J., Pt., I, 65th New York.	July 2, '62.	Right: flap; by a Confed. surg. Discharged April 9, 1863.	527	Hoover, M., Pt., C, 64th Ohio, age 43.	Nov. 29, '64.	Right: circular. Disch'd Feb. 21, 1865.
486	Heaney, G. S., Pt., D, 1st New Jersey.	Sept. 14, '62.	Left: circular; by Surg. W. B. Little, 32d N. Y. Disch'd Mar. 6, 1863; pensioned.	528	Hook, L. T., Pt., G, 73d Pennsylvania.	Nov. 25, '63.	Discharged June 7, 1864.
487	Heathe, J., Pt., K, 7th U. S. C. T., age 30.	Sept. 29, '64.	Right: flap; by a Confed. surg. Discharged August 16, 1865.	529	Hoobler, J., Pt., F, 61st Pennsylvania.	June 1, '62.	Right. Discharged Aug. 4, 1862; pensioned.
488	Henderson, A. P., Pt., K, 11th N. H., age 19.	July 30, '64.	Left: flap. Disch'd October 26, 1864; pensioned.	530	Hopkins, R., Pt., M, 100th Pennsylvania.	Aug. 29, '62.	Right: flap. Disch'd October 18, 1862; pensioned.
489	Henderson, J., Pt., H, 57th Indiana, age 30.	May 27, '64.	Left: by Surg. E. B. Glick, 40th Ind. Disch'd Dec. 10, '64; pens'd.	531	Horner, H., Serg't, H, 70th New York.	June 1, '62.	Right: flap. Disch'd July 18, 1862.
490	Hendrick, T. C., Pt., A, 5th Vermont, age 27.	May 12, '64.	Right: oval flap; by Surg. A. H. Chessmore, 5th Vt. Discharged Sept. 15, 1864; pensioned.				
491	Henifer, T., Corp'l, D, 2d Delaware.	July 2, '63.	Left. Discharged Oct. 9, 1863; pensioned.				
492	Henry, W., Pt., H, 68th C. T., age 20.	April 2, '65.	Left: circular. Disch'd June 10, 1865.				

NO.	NAME, AGE, AND MILITARY DESCRIPTION.	DATES.	OPERATIONS, OPERATOR, RESULT.	NO.	NAME, AGE, AND MILITARY DESCRIPTION.	DATES.	OPERATIONS, OPERATOR, RESULT.
532	Horle, J., Pt., G, 3d New York Artillery.	April 4, '63.	Right. Discharged; pensioned.	572	Keeler, S., Pt., G, 10th Connecticut.	Aug. 7, '62.	Right; flap; by Surg. M. T. Newton, 14th Conn. Disch'd Dec. 10, 1862; pensioned.
533	Hosier, S. H., Pt., D, 112th New York, age 29.	Sept. 29, '64.	Right; flap. Discharged July 8, 1865; pensioned.	573	Keefe, A., Pt., F, 87th Pennsylvania, age 21.	June 3, '64.	Right; circular; by Surg. D. F. McKinney, 87th Penn. Disch'd Aug. 21, 1864; pensioned.
534	Hosler, W. N., Pt., I, 143d Pennsylvania, age 21.	May 10, '64.	Right; flap. Disch'd July 20, 1865; pensioned.	574	Kellogg, E. S., Pt., A, 20th New York, age 25.	June 18, '61.	Left; flap; by Surg. T. H. Squire, 83d N. York. Disch'd April 6, 1865; pensioned.
535	Hose, F., Pt., H, 13th Ohio.	Dec. 31, '61.	Left. Disch'd March 19, 1863; pensioned.	575	Keller, I., Pt., I, 23d I. S. C. T.	July 30, '64.	Left; flap; by Surg. F. M. Weld, 27th C. T. Disch'd June 23, '65.
536	Hover, S., Pt., D, 5th I. S. C. T., age 42.	June 18, '61.	Left; antero-posterior flaps. Discharged Dec. 15, 1864.	576	Kelly, L., Serg't, B, 2d R. I., age 20.	May 5, '61.	Right; flap; by Surg. G. W. Carr, 2d R. I. Dis'd June 7, '64; pens'd.
537	Howard, J. W., Pt., H, 14th New York Heavy Artillery, age 19.	June 17, '64.	Left; flap; by Surg. I. V. Mullen, 14th N. Y. H. A. Disch'd May 31, 1865; pensioned.	577	Kelley, A. J., Pt., D, 87th Pennsylvania, age 18.	May 16, '64.	Right; flap; by a Confed. Surg. Disch'd May 19, 1865; pensioned.
538	Howard, F., Pt., E, 11th Mass., age 23.	May 3, '63.	Left; lateral flaps. Discharged November 28, 1863.	578	Kelch, W., Pt., H, 9th Mich. Cav., age 20.	Oct. 1, '64.	Left; circular; by A. Surg. B. A. Stebbins, 14th Ky. Discharged June 17, 1865.
539	Howard, J. R., Pt., B, 7th Iowa.	Nov. 7, '61.	By Dr. Bateman. Disch'd June, 1863.	579	Kelly, J., Pt., C, 8th New Jersey, age 30.	May 5, '64.	Left; circular. Disch'd Aug. 22, 1865.
540	Hugonfrey, W., Pt., E, 87th Pennsylvania, age 21.	Oct. 19, '64.	Right; flap; by Surg. T. A. Helwig, 87th Penn. Disch'd July 21, 1865; pensioned.	580	Kellerman, E., Pt., F, 49th Pennsylvania, age 42.	April 6, '65.	Right; flap. Disch'd July 26, 1865; pensioned.
541	Ingraham, J. J., Pt., F, 33d Mo., age 33.	Dec. 16, '64.	Left; circular; by Surg. A. T. Bartlett, 33d Mo. Disch'd May 20, 1865; pensioned.	581	Kelley, T., Pt., F, 60th New York.	Sept. 17, '62.	Left. Discharged Dec. 13, 1862; pensioned.
542	Ingram, M. L., Pt., F, 2d S. Carolina, age 24.	July 2, '63.	Right. Exchanged Nov. 12, 1863.	582	Kenney, C. T., Pt., D, 130th N. Y., age 20.	Mar. 16, '65.	Left; circular; by Surg. E. Amsden, 130th N. Y. Disch'd Sept. 7, 1865; pensioned.
543	Ingram, W. A., Pt., G, 31st Illinois.	May 16, '63.	Right; by Surg. D. T. Whitnell, 31st Ill. Disch'd Aug. 13, 1863; pensioned.	583	Kenoyer, J., Pt., B, 31st Indiana.	Dec. 31, '61.	Right. Disch'd Mar. 25, 1863; pensioned.
544	Ives, H., Pt., A, 1st Penn. Artillery.	Nov. 14, '62.	Right. Discharged and pensioned.	584	Kern, J. D., Pt., H, 89th Illinois, age 32.	May 27, '64.	Left; circular; by Surgeon H. B. Tuttle, 89th Ill. Disch'd Mar. 27, 1865; pensioned.
545	Jackson, C. C., Pt., F, 183d Penn., age 19.	May 12, '61.	Right; circular; by Surg. W. C. Byington, 183d Penn. Disch'd Jan. 15, 1865; pensioned.	585	Kerfoot, W. F., Pt., B, 8th Virginia, age 19.	July 2, '63.	Right; by Surg. C. J. Bellows, 7th Ohio. Transfer'd Sept. 14, '63.
546	Jackson, P. R., Serg't, F, 7th Conn.	June 16, '62.	Left; flap; by Surg. M. Bellinger, C. S. A. Disch'd Oct. 19, 1862; pensioned.	586	Keynan, J., Pt., G, 49th Indiana.	June 1, '63.	Right; by Surg. B. F. Stevenson, 22d Ky. Disch'd Aug. 16, 1863; pensioned.
547	Jagger, S. G., Pt., C, 20th Conn., age 23.	July 20, '64.	Left; flap; by Asst. Surg. J. W. Perry, 20th Conn. Disch'd Feb. 4, 1865; pensioned.	587	Kibley, G. B., Pt., B, 3d Michigan, age 27.	May 31, '62.	Left; flap. Disch'd Nov. 20, 1862; pensioned.
548	Jaines, S. F., Serg't, D, 33d N. C., age 21.	July 3, '63.	Right; flap. Paroled Sept. 1, 1863.	588	Kille, T., Corp'l, B, 53d Ohio, age 21.	July 22, '64.	Left; flap; by Surg. S. P. Bonner, 47th Ohio. Disch'd May 27, 1865; pensioned.
549	Jeffrey, J., Pt., B, 5th Me., age 22.	May 9, '61.	Right; ant.-post. flap; by Surg. F. G. Warren, 5th Me. Disch'd July 27, 1864; pensioned.	589	Killian, W., Pt., A, 2d U. S. Artillery, age 25.	April 3, '63.	Right; circular. Disch'd Aug. 7, 1864; died April 20, 1871.
550	Jenkins, H., Pt., G, 123d Illinois.	Oct. 8, '62.	Left. Discharged Nov. 21, 1862; pensioned.	590	Kimball, C. M., Pt., 5th Maine Battery.	May 3, '63.	Right; flap. V. R. C. Nov. 21, 1863.
551	Jemey, G., Pt., F, 5th Vermont, age 45.	April 2, '65.	Right; flap. Discharged Sept. 11, 1865; pensioned.	591	King, J., Pt., K, 100th Pennsylvania, age 19.	Mar. 25, '65.	Left; circular; by Surg. W. C. Shurlock, 51st Penn. Disch'd June 15, 1865; pensioned.
552	Johnson, A., Pt., E, 67th New York.	May 12, '64.	Left; flap. Duty Sept. 24, 1864; pensioned.	592	Kinney, D., Pt., E, 123d Indiana, age 19.	Aug. 24, '64.	Left; circular; by Surg. John H. Rodgers, 104th Ohio. Disch'd August 25, 1865; pensioned.
553	Johnson, F., Corp'l, B, 142d N. Y., age 22.	July 4, '64.	Left; flap; by Surg. D. McFalls, 142d N. Y. Disch'd May 4, 1865; pensioned.	593	Kingly, F., Pt., B, 12th New Hampshire.	Dec. 23, '63.	Right; circ.; by A. A. Surg. W. L. Ward, Disch'd April 1, 1864.
554	Johnson, G. H., Serg't, B, 56th Pennsylvania.	April 30, '63.	Right; flap; by Surg. G. W. New, 7th Ind. Disch'd July 20, 1863; pensioned. Spec. 1147.	594	Kinder, I., Pt., F, 82d Ohio, age 26.	July 19, '64.	Left; by a Confed. Surg. Disch'd May 12, 1865; pensioned.
555	Johnson, J., Pt., F, 4th Maine, age 30.	May 2, '63.	Left; by A. Surg. G. H. Martin, 4th Me. Disch'd Oct. 6, 1863; pens'd.	595	Kirchner, C., Pt., H, 15th U. S. Infantry.	Aug. 7, '64.	Right. Duty October 21, 1864; pensioned.
556	Johnson, J., Pt., E, 6th Georgia, age 24.	Aug. 19, '64.	Left; flap. To prison Nov. 23, 1864.	596	Kitzmiller, J. A., Pt., B, 138th Penn., age 21.	May 12, '64.	Left; flap; by Surg. C. E. Cady, 138th Penn. Disch'd Sept. 20, 1864; pensioned.
557	Johnson, N., Pt., A, Purcell Legion, Md. Vols.	May 31, '62.	Left; flap; by Surg. H. F. Bowen, Purcell Legion. Disch'd July 17, 1862; pensioned.	597	Kittell, J. H., Pt., D, 3d Tennessee.	July 12, '63.	Right; flap; by Surg. D. F. Wright, P. A. C. S. Furl'd Sept. 1, '63.
558	Johnson, T. H., Pt., E, 39th Illinois, age 19.	May 16, '64.	Right. Discharged and pensioned.	598	Klechner, J., Pt., I, 53d Pennsylvania.	July 2, '63.	Left; double flap; by Surg. J. Y. Cantwell, 82d Ohio, and A. A. Surgeon A. D. Kibbee. Disch'd Dec. 14, 1863; pensioned.
559	Johnson, W. L., Pt., G, 12th N. H., age 34.	July 2, '63.	Right; flap; by Surg. H. B. Fowler, 12th N. H. Disch'd Aug. 9, 1864; pensioned.	599	Kline, D. W., Pt., B, 148th Pennsylvania, age 28.	June 22, '64.	Left; ant.-post. flap; by Surg. J. W. Wisbart, 140th Pa. Disch'd Oct. 25, 1864; pensioned.
560	Jones, A., Pt., G, 28th Illinois.	Oct. 5, '62.	Right; by Surg. J. G. Keonon, U. S. V. Discharged; pensioned.	600	Knapp, E., Serg't, H, 1st Wis. Cav., age 27.	April 14, '65.	Right; flap; by Surg. G. E. Ranney, 2d Mich. Cavalry. Disch'd Nov. 15, 1865; pensioned.
561	Jones, L. F., Pt., A, 12th N. H., age 23.	July 2, '63.	Left. Disch'd Dec. 9, 1863; pensioned.	601	Knapp, C. T., Pt., H, 45th Pennsylvania.	Sept. 17, '62.	Left. Discharged Dec. 27, 1862; pensioned.
562	Jones, Michael, Pt., F, 163d New York.	Dec. 13, '62.	Left; circular. Disch'd May 23, 1863.	602	Knights, W. M., Pt., G, 13th Alabama, age 28.	May 3, '63.	Transferred May 23, 1863.
563	Jones, R., Pt., I, 132d Pennsylvania.	Sept. 17, '62.	Left. Disch'd Dec. 4, 1862.	603	Koogler, J., Pt., F, 110th Ohio.	July 22, '64.	Left; circular; by Surgeon R. R. McCalliss, 110th Ohio. Disch'd February 7, 1865.
564	Jones, W. D., Corp'l, C, 3d N. Y. Heavy Artil'y, age 23.	Jan. 9, '65.	Left; circular; by Surgeon C. A. Cowgill, U. S. V. Disch'd Oct. 5, 1865; pens'd. A. M. M. Spec. 533.	604	Kornberger, R., Corp'l, C, 4th Missouri Cavalry.	July 10, '63.	Left; flap. Discharged March 28, 1864.
565	Jones, W. J., Pt., C, 16th Wisconsin.	Oct. 3, '62.	Right; circular; by A. Surg. I. A. Torrey, 16th Wis. Disch'd Nov. 4, 1862; pensioned.	605	Koster, J. S., Serg't, H, 21st Mass., age 22.	June 2, '61.	Right. Disch'd August 30, 1864; pensioned.
566	Jordan, R. H., Serg't, B, 33d Indiana, age 26.	June 22, '64.	Flap; by Surg. J. Bennett, 19th Mich. Disch'd Mar. 14, 1865.	606	Krull, H. L., Pt., H, 13th Infantry.	Jan. 11, '63.	Right; flap. Disch'd April 6, '63; pensioned.
567	Juddins, M. W., Pt., G, 15th Iowa, age 21.	April 6, '62.	Left; by Surg. S. B. Davis, 16th Iowa. Disch'd Aug. 15, '62; pens'd.	607	Kreig, P., Pt., C, 46th New York, age 28.	Aug. 21, '64.	Left; circular; by Surgeon W. B. Fox, 8th Mich. Disch'd April 27, 1865; pensioned.
568	Jukes, H., Serg't, L, 18th Pennsylvania, age 28.	June 30, July 1, 1863.	Left; flap; by Asst. Surg. Perin Gardner, 1st Va. Cav. Disch'd Jan. 8, 1864; pensioned.	608	Kretzer, J. H., Pt., I, 73d Ohio, age 16.	May 25, '64.	Left; flap; by Surg. J. M. Hines, 73d Ohio. Discharged Sept. 30, 1864; pensioned.
569	Kappenberg, F., Pt., E, 14th Connecticut.	Dec. 13, '62.	Right; flap; by Surg. P. G. Rockwell, 14th Conn. Disch'd June 25, 1863; pensioned.	609	Kruder, J., Pt., F, 82d Ohio, age 26.	July 19, '64.	Left; ant.-post. flaps; by A. Sur. G. G. Roy, C. S. A. Dis'd May 11, '65.
570	Kaufman, F., Pt., C, 2d New Jersey, age 32.	July 4, '63.	Left; flap; by Dr. Taylor, C. S. A. Disch'd Oct. 20, 1863; pensioned.	610	Kuhn, P., Pt., D, 6th Iowa, age 22.	April 6, '62.	Right. Disch'd Sept. 27, 1862; pensioned.
571	Keene, G., Pt., E, 1st Penn. Reserves.	June 26, '62.	Right; by Surg. L. W. Read, 1st Pa. Res. Dis'd Dec. 6, '62; pens'd.				



No.	NAME, AGE, AND MILITARY DESCRIPTION.	DATES.	OPERATIONS, OPERATOR, RESULT.	No.	NAME, AGE, AND MILITARY DESCRIPTION.	DATES.	OPERATIONS, OPERATOR, RESULT.
611	Kutzele, A., Pt., B, 9th Ohio.	Nov. 25, '63.	Left; by Surg. C. Soellheim, 9th Ohio. Discharged; pensioned.	650	Lyon, S., Pt., F, 165th New York.	May 27, '63.	Right; flap. Disch'd Sept. 1, '63.
612	Lacy, J. L., Pt., C, 2d Delaware, age 23.	June 5, '64.	Right; circular; by Surgeon A. Van Deyere, 60th N. Y. Duty July 18, 1864; pensioned.	651	Mack, J., Pt., B, 5th Pa. Cavalry, age 46.	Feb. 12, '65.	Left; flap. Disch'd Aug. 7, 1865; pensioned.
613	Ladd, J. O., Pt., I, 15th Massachusetts.	Sept. 17, '62.	Flap; by Asst. Surg. C. H. Richmond, 104th N. Y. Discharged Dec. 27, 1862; pensioned.	652	Madden, J., Serg't, G, 1st New Jersey.	May 3, '61.	Left; flap. Disch'd Sept. 21, 1863; pensioned.
614	Lambert, W., Corp'l, K, 13th New Jersey.	May 3, '63.	Left; flap. Disch'd Sept. 3, 1863; pensioned.	653	Madden, J. A., Capt., G, 79th Pennsylvania.	Mar. 19, '65.	Right; flap; by Surg. W. B. Gibson, 94th Ohio. Disch'd May 15, 1865; pensioned.
615	Landon, J. H., Pt., F, 142d N. Y., age 31.	Oct. 27, '61.	Right; flap; by Surg. G. C. Jarvis, 7th Conn. Disch'd Feb. 18, 1865; pensioned.	654	Maher, M., Corp'l, Ord. Detachment.	Sept. 19, '63.	Right; by Surg. E. H. Abadie, U. S. A. Disch'd Feb. 8, 1864; pensioned.
616	La Pine, A., Pt., I, 37th Mass., age 20.	May 12, '64.	Left; flap. Disch'd Jan. 4, 1865; pensioned.	655	Malley, A., Pt., F, 11th Vermont, age 25.	June 23, '64.	Left; flap. Disch'd Dec. 31, 1864; pensioned.
617	Larkin, J. M., Pt., C, 30th Illinois, age 21.	Oct. 13, '64.	Left; circular. Disch'd June 19, 1865.	656	Manley, T., Pt., B, 18th Illinois.	Feb. 14, '62.	Left; by Surg. H. W. Davis, 18th Illinois. Disch'd Sept. 20, '62; pens'd.
618	Law, J., Pt., I, 104th New York.	Aug. 19, '64.	Transferred to Soldiers' Home; healed.	657	Manning, E., Pt., E, 21st New York, age 24.	Sept. 17, '62.	Right; by Surg. C. H. Wilcox, 21st N. Y. Disch'd Oct. 31, '62; pensioned.
619	Law, R., Pt., E, 6th Wis.	April 29, '63.	Right; by Surg. E. Shippen, U. S. V. Disch'd June 22, 1863; pensioned.	658	Mariny, W. F., Corp'l, K, 125th Illinois, age 29.	June 27, '64.	Right; flap; by Surg. J. H. Phillips, U. S. V. Disch'd April 28, 1865; pensioned.
620	Leavens, G. G., Pt., I, 16th Maine.	Dec. 13, '62.	Right. Disch'd Feb. 29, 1863; pensioned.	659	Marsh, J. W., Pt., B, 32d North Carolina, age 18.	May 10, '64.	Left. To prison March 1, 1865.
621	Leech, E. A., Serg't, I, 106th Pennsylvania.	Oct. 28, '63.	Right; flap; by Surg. J. L. Dunn, 109th Penn. Disch'd March 17, 1864; pensioned.	660	Martin, L., Pt., E, 20th Colored Troops.	July 30, '64.	Right; flap; by Surg. D. MacKay, 20th C. T. Disch'd Dec. 6, 1865; pensioned.
622	Leech, W. H., Corp'l, E, 43th Ohio, age 23.	May 26, '64.	Right; flap. Disch'd October 26, 1864; pensioned.	661	M——, P., Pt., A, 5th N. Jersey, age 28.	May 10, '64.	Left; flap; by Surg. C. C. Jewett, 16th Mass. Discharged June 16, 1865; pensioned. Spec. 3227.
623	Leighow, J., Pt., A, 132d Pennsylvania.	Sept. 17, '62.	Left; by A. Surg. G. K. Thompson and G. W. Hoover, 132d Pa. Disch'd Oct. 28, 1862; pensioned.	662	Maftratt, M. A., Corp'l, C, 169th N. Y., age 24.	June 1, '64.	Circular. Disch'd July 27, 1865; pensioned.
624	Lendall, S., Pt., A, 12th Massachusetts.	May 12, '64.	Left. Discharged Nov. 28, 1864; pensioned.	663	Mason, J. B., 1st Lieut., A, 31st C. T., age 25.	July 30, '64.	Right; circular; by Surgeon D. MacKay, 29th C. T. Disch'd Dec. 12, 1864; pensioned.
625	Lennox, H., 1st Lieut., 2d U. S. Cavalry, age 29.	Aug. 10, '64.	Left; ant.-post. flap; by A. Surg. J. W. Williams, U. S. A. Duty Jan. 11, 1865; pensioned.	664	Massey, J. W., Pt., F, 72d Pennsylvania.	Dec. 13, '62.	Right; circular. Disch'd April 13, 1863; pensioned.
626	Leonard, E. M., Corp'l, A, 5th Michigan.	July 2, '63.	Left; by Surg. H. F. Lyster, 5th Mich. Disch'd Oct. 14, 1863; pensioned.	665	Mastin, S., Serg't, F, 72d Illinois, age 30.	Nov. 30, Dec. 1, 1864.	Right; flap; by Asst. Surg. C. C. Byrne, U. S. A. Disch'd April 1, 1865.
627	Leonard, T., Pt., K, 15th Kentucky.	Oct. 8, '62.	Left; flap. Disch'd Jan. 30, 1863; pensioned.	666	Maul, J. E., Pt., H, 66th New York.	Dec. 13, '62.	Left; by Surg. C. S. Wood, 66th N. Y. Disch'd Feb. 1863; pens'd.
628	Lewis, H., Serg't, B, 145th Pennsylvania.	July 3, '63.	Left; flap; by Surg. G. L. Potter, 145th Penn. Disch'd Dec. 18, 1863; pensioned.	667	Maurer, N., Pt., D, 188th Pennsylvania, age 38.	May 16, '64.	Left; flap. Disch'd April 27, '65; pensioned.
629	Lewis, J., Pt., H, 19th Colored Troops, age 29.	July 30, '64.	Left; circ.; by Surg. J. P. Prince, 36th Mass. Disch'd Jan. 16, '65.	668	Mayne, S. W., Pt., B, 1st Penn. Artillery.	Aug. 29, '62.	Right. Disch'd Nov. 10, 1862; pensioned.
630	Lieber, H., Lieut., B, 9th Illinois.	Feb. 15, '62.	Left. Disch'd March 4, 1863.	669	Mayo, R. E., Pt., A, 11th New Jersey.	July 2, '63.	Left; by Surgeon E. L. Welling, 11th N. J. Disch'd Oct. 31, 1863; pensioned.
631	Lindley, D. W., Corp'l, H, 36th Wis., age 29.	April 2, '65.	Left; by Surg. W. Ingalls, 59th Mass. Disch'd June 26, 1865; pensioned.	670	McBorney, A., Serg't, H, 4th Mo. Cav., age 28.	Oct. 25, '64.	Right. Disch'd April 26, 1865.
632	Lindsay, J., Serg't, C, 9th Col. red Troops.	Oct. 27, '64.	Right; by Surg. N. Y. Leit. 76th Penn. Disch'd June 7, 1865.	671	McCabe, J. W., Pt., K, 51st Ohio, age 21.	June 19, '64.	Left; ant.-post. flap. Discharged April 13, 1865; pens'd.
633	Loudsey, W. H., Capt., I, 26th Alabama, age 24.	Nov. 30, '64.	To Provost Marshal Feb. 8, 1865.	672	McCannah, J., Pt., K, 109th N. Y., age 27.	June 3, '64.	Right; bilateral flap; by Surg. A. F. Wholan, 1st Michigan S. S. Disch'd June 5, 1845; pensioned.
634	Livermore, W. B., Pt., F, 80th New York.	Sept. 17, '62.	Right; by Surgeon T. H. Squire, 89th N. Y. Discharged Oct. 19, 1862; pensioned.	673	McCarran, P., Pt., I, 3d Missouri S. M. Cav.	Aug. 2, '62.	Left. Discharged May 1, 1863; pensioned.
635	Livingstone, E., Pt., B, 3d South Carolina.	July 2, '63.	Right. Recovered.	674	McCarter, E., Pt., D, 59th Mass., age 23.	May 24, '64.	Left; flap; by Surg. W. C. Shurluck, 51st Penn. Disch'd Nov. 12, 1864; pensioned.
636	Loebbler, C., Capt., I, 1st Missouri Engineers.	Sept. —, '63.	Right. Disch'd Nov. 18, 1864; pensioned.	675	McClain, M. G., Pt., G, 76th Indiana, age 20.	May 15, '64.	Right; flap; by Surgeon A. W. Kegan, 76th Ind. Disch'd Aug. 19, 1864; pensioned.
637	Lochner, C., Pt., A, 183d Penn., age 21.	Aug. 16, '64.	Right; flap; by a Confed. surgeon. V. R. C. May 1, 1865; pens'd.	676	McClean, R. A., Corp'l, K, 116th Penn., age 20.	May 18, '64.	Left; circular; by Surgeon J. W. Wishart, 116th Penn. Disch'd June 27, 1865; pensioned.
638	Lombard, D. C., Pt., K, 15th Maine, age 23.	July 2, '63.	Right; flap; by Asst. Surg. J. S. Billings, U. S. A. Disch'd Oct. 23, 1863; pensioned.	677	McClure, E., Pt., K, 139th New York.	Nov. 15, '63.	Left; flap; by Surg. J. H. Thompson, 139th N. Y. Disch'd Jan. 13, 1864; pensioned.
639	Loomis, E. W., Pt., F, 2d Vermont.	June 29, '62.	Left; circular; by Surg. Wm. P. Russell, 5th Vt. Disch'd Sept. 16, 1862; pensioned.	678	McClurg, J. B., Pt., E, 26th Alabama, age 32.	May 3, 1863.	Circular. Transferred May 23, 1863. Favorable.
640	Lorch, H., Corp'l, K, 26th Wisconsin, age 19.	July 29, '64.	Right; flap; by Asst. Surg. S. Vander Vaart, 26th Wis. Disch'd July 2, 1865; pensioned.	679	McCollum, A., Pt., F, 8th N. Y. Heavy Artillery.	June 3, '64.	Left; flap; by Surg. D. W. Maul, 1st Del. Disch'd Oct. 10, 1864; pensioned.
641	Lounsbury, J. M., Pt., A, 143d New York.	July 11, '64.	Right. Discharged.	680	McCrudden, T., Pt., I, 88th Penn., age 17.	May 12, '64.	Left; flap. Disch'd July 13, 1865; pensioned.
642	Lovell, A., Pt., H, 40th Mass., age 37.	July 1, '64.	Left; flap. Disch'd Oct. 20, 1864; pensioned.	681	McClune, J., Pt., F, 28th Pennsylvania, age 41.	May 3, '63.	Left. Discharged Nov. 21, 1863; pensioned.
643	Lowell, D. K., Pt., E, 11th Maine, age 24.	May 18, '64.	Left; flap. Disch'd Feb. 21, 1865.	682	McDaniel, D. R., Pt., F, 30th Georgia.	Aug. 30, '62.	Left. Disch'd Oct. 15, 1862.
644	Lucas, S., Pt., M, 2d N. Y. Heavy Art., age 17.	June 18, '64.	Left; ant.-posterior flap; by Surg. J. W. Wishart, 140th Pa. Disch'd July 4, 1865; pensioned.	683	McDaniel, J. P., Pt., F, 6th South Carolina.	Sept. 30, '64.	Right; double flap; by A. Surg. W. F. Richardson, C. S. A.
645	Lukens, J. L., Pt., G, 116th Illinois, age 25.	June 27, '64.	Right; flap; by Act. Staff Surg. C. B. Richards. Disch'd June 17, 1865; pensioned.	684	McDonald, J., Pt., G, 85th Penn.	July 29, '62.	Right; by Surg. S. A. Greene, 24th Mass. Disch'd March 7, 1864; pensioned.
646	Lundy, J., Pt., I, 8th Ind., age 22.	Dec. 15, '64.	Right; flap; by Surg. M. G. Sherman, 9th Ind. Disch'd May 10, 1865; pensioned.	685	McFarland, D., Pt., A, 11th Maine, age 19.	June 2, '64.	Right; flap. Disch'd Dec. 2, '64; pensioned.
647	Lupient, G., Pt., G, 2d Wisconsin, age 24.	May 6, '64.	Right. Disch'd June 27, 1864; pensioned.	686	McGill, H., Pt., K, 34th Mass., age 41.	Mar. 31, '65.	Left; flap; by Asst. Surg. C. G. Allen, 34th Mass. Disch'd Aug. 12, 1865; pensioned.
648	Lyde, M., Pt., D, 97th Illinois.	May 23, '63.	Left; by Surg. W. D. Turner, 97th Ill. Disch'd Sept. 33, 1863; pensioned.	687	McGlinchy, J., Corporal, 9th Penn.	June 3, '64.	Left. Discharged.
649	Lyon, N. A., Pt., F, 6th Alabama, age 26.	July 1, '63.	Right. Paroled Aug. 22, 1863.	688	McGraw, T. H., Pt., A, 9th Maine, age 18.	July 21, '64.	Left; flap; by Surg. J. N. Palmer, 3d N. Y. Disch'd Sept. 27, 1864; pensioned.

No.	NAME, AGE, AND MILITARY DESCRIPTION.	DATES.	OPERATIONS, OPERATOR, RESULT.	No.	NAME, AGE, AND MILITARY DESCRIPTION.	DATES.	OPERATIONS, OPERATOR, RESULT.
689	McCreedy, P., Pt., D, 73d Penn.	Oct. 8, '62.	Right. Disch'd Dec. 31, 1862; pensioned.	731	Monroe, A., Pt., C, 123d New York, age 21.	Sept. 13, '64.	Left; flap. Discharged Feb. 16, 1865.
690	McHenry, J., Pt., C, 7d New Jersey.	May 6, '64.	Left; flap. To Vet. Res. Corps.	732	Monroe, A. C., Pt., H, 12th Mass., age 22.	July 1, '63.	Left; circular; by A. Surg. J. H. McGregor, 12th Mass. Disch'd October 17, 1863.
691	McIntire, J. J., Pt., C, 110th C. T., age 28.	Dec. 8, '64.	Left; antero-posterior flap. Discharged March 5, 1867.	733	Montgomery, E., Serg't, 1, 26th Pennsylvania.	July 2, '63.	Flap; by Surg. J. M. Morrow, 2d N. H. Disch'd Feb. 29, 1864; pensioned.
692	McKay, D., Pt., H, 6th Infantry.	Nov. 3, '62.	Right; circular; by Asst. Surg. B. Howard, F. S. A. To V. R. C. July 7, 1863.	734	Montgomery, R., Pt., — Georgia Art., age 42.	Dec. 13, '64.	Left; by Surg. J. H. Hutchinson, 15th Mich. To Provost Marshal March 20, 1865.
693	McKee, S., Sergeant, B, 20,th Pa., age 23.	April 2, '65.	Left; ant. posterior flap. Disch'd May 31, 1865; pensioned.	735	Moore, G., Pt., A., 63d New York, age 39.	June 19, '64.	Left; flap; by Surg. F. S. Grimes, 62d N. Y. Disch'd Feb. 29, 1865; pensioned.
694	McKeever, W., Pt., K, 6th Pa. Reserves.	Sept. 17, '62.	Left; by Surg. C. Bower, 6th Penn. Reserves.	736	Morgan, H. B., 2d Lieut. A., 1st Tenn, age 42.	Nov. 30, Dec. 1, '65.	By ant. post. flaps. To Provost Marshal Jan. 23, 1865.
695	McKenzie, D., Pt., K, 17th Indiana, age 24.	Oct. 28, '64.	Right; flap; by a Confed. surgeon. Disch'd Sept. 14, 1865; pens'd.	737	Morris, G., Pt., G, 5th Ohio, age 24.	May 3, '63.	Right; flap. Discharged Oct. 18, 1863.
696	McKinney, J., Pt., D, 5th Conn., age 40.	July 20, '64.	Right; by Surg. E. L. Bissell, 5th Conn. To V. R. C. Mar. 8, 1866; pensioned.	738	Morris, G., Pt., A, 82d Pennsylvania, age 46.	June 1, '64.	Right; circular. To V. R. C. Jan. 7, 1865; pensioned.
697	McLeod, C. O., Pt., C, 26th Georgia, aged 27.	July 9, '64.	Right; circular; by Surg. Velk, 26th Ga. Exchange Sept. 19, '64.	739	Morris, G. A., Pt., K, 6th Virginia.	May 6, '64.	Circular. Fair'd June 9, 1865.
698	McLoughlin, R., Pt., E, 14th N. Y. H. A., age 25.	June 27, '64.	Right. Disch'd Aug. 15, 1865.	740	Morris, H. C., Pt., C, 112th Illinois, age 20.	Nov. 17, '63.	Left; flap. Discharged July 2, 1864; pensioned.
699	McMannus, O., Pt., F, 25th New York.	Aug. 31, Sept. 2, '64.	Left. Discharged Feb. 1, 1863; pensioned.	741	Morrison, H. C., Pt., H, 72d Pennsylvania.	June 29, '62.	Left; circular; by Surg. —, 11th Ga. Disch'd Sept. 24, 1862.
700	McMullen, J., Pt., K, 111th Pa., age 19.	May 21, '65.	Right; circular. Disch'd June 1, 1865; pensioned.	742	Morrison, T., Pt., E, 108th New York, age 36.	Sept. 17, '62.	Right; flap; by A. Surg. T. Arner, 108th N. Y. Disch'd Nov. 28, 1864; pensioned. <i>Spec. 911.</i>
701	McMurray, M., Corp'l, K, 125th New York.	July 2, '63.	Left; by Surg. W. S. Cooper, 125th N. Y. Disch'd Dec. 11, '63; pens'd.	743	Morrow, R., Lieut., 1, 14th N. Y. H. Y. Art., age 42.	July 29, '64.	Left; circular. Disch'd Oct. 25, 1864; pensioned.
702	McNett, A. J., Lieut., Col., 111st New York.	July 20, '64.	Right; flap; by Surg. J. B. Chapman, 123d N. York. Duty Dec. 10, 1864; pensioned.	744	Morrow, W. H., Pt., G, 4th Ohio, age 24.	May 3, '63.	Left; by A. Surg. J. Y. Cantwell, 4th Ohio. Disch'd Sept. 1, 1863; pensioned.
703	McRobbie, J., Pt., P, 21st Massachusetts.	Sept. 1, '62.	Right; flap. Disch'd Nov. 1, 1862; pensioned.	745	Morrow, W. W., Pt., H, 200th Pennsylvania.	Mar. 25, '65.	Left; flap. Disch'd July 26, 1865; pensioned.
704	Mead, R. P., Pt., E, 33d Iowa, age 27.	April 9, '64.	Right. Duty July 20, 1864; pensioned.	746	Morse, R., Pt., D, 111th Penn., age 22.	June 14, '64.	Left; circular; by Surg. G. P. Oliver, 111th Penn. Discharged Sept. 30, 1864; pensioned.
705	Mears, C., Pt., H, 1st Mass., age 20.	May 19, '64.	Flap. Disch'd July 8, 1864; pensioned.	747	Morton, D., Pt., A, 81st New York, age 20.	Nov. 30, '61.	Flap; by Surg. W. H. Rice, 81st N. Y. Disch'd Aug. 5, 1864.
706	Mears, G., Pt., K, 63d Ohio.	Oct. 4, '62.	Left; by Surg. N. S. Gay, F. S. V. Disch'd Nov. 26, 1862; pens'd.	748	Mosher, H. A., Serg't, F, 10th Minnesota, age 29.	Dec. 16, '61.	Left; circular; by A. A. Surg. T. B. Mossinger. Disch'd April 17, 1865; pensioned.
707	Meddick, J., Pt., H, 15th New Jersey, age 19.	May 12, '64.	Right; flap. Disch'd July 8, 1865; pensioned.	749	Mowen, D. C., Pt., D, 123d Ohio.	May 15, '64.	Right; by Surg. O. Ferris, 123d Ohio. Disch'd Feb. 11, 1865; pensioned.
708	Mcenan, M., Serg't, E, 2d Delaware.	July 3, '63.	Right; circular; by Surg. C. S. Wood, 66th N. Y. Discharged April 18, 1864; pensioned.	750	Muldoon, W., Wagoner, E, 11th Mass., age 24.	July 30, '64.	Left; flap; by Surg. J. A. Douglas, 11th Mass. Duty Nov. 3, 1864; pensioned.
709	Melden, W. R., Pt., G, 19th Massachusetts.	June 25, '62.	Left; flap; by Surg. J. F. Dyer, 19th Mass. Disch'd August 20, 1862; pensioned.	751	Munger, A., Pt., B, 181th Penn., age 17.	June 10, '64.	Left; flap; by Surg. M. Rizer, 72d Penn. Disch'd Aug. 29, 1864.
710	Merrifield, D. M., Pt., F, 5th Mich. Cav., age 28.	July 4, '63.	Right; flap. Disch'd October 17, 1863; pensioned.	752	Munson, F. A., Capt., H, 10th Illinois, age 26.	July 18, '64.	Left; flap; by Surg. H. R. Payne, 10th Ill. Disch'd July 4, 1865; pensioned.
711	Messner, I. G., Pt., 1, 5th Maryland, age 24.	Oct. 27, '64.	Right; circular. Disch'd July 18, 1865; pensioned.	753	Murman, W., Pt., B, 23d Illinois.	Sept. 18, '61.	Flap; by Surg. W. D. Wynor, 23d Ill. Disch'd Oct. 8, 1861; pens'd.
712	Metz, A., Corp'l, E, 66th New York, age 31.	June 21, '64.	Left; flap; by Surg. W. J. McDermott, 66th N. Y. Disch'd Dec. 14, 1864; pensioned.	754	Murphy, E., Serg't, 1, 148th Penn., age 24.	July 2, '63.	Left; by Surg. C. S. Wood, 66th N. Y. Disch'd March 17, 1864; pensioned.
713	Meyers, R. C., Pt., C, 10th Michigan Cavalry.	Jan. —, 1864.	Left. Discharged and pensioned.	755	Murphy, J., Pt., 1, 14th N. H., age 24.	Oct. 29, '64.	Right; circular. Deserted Sept. 20, 1865.
714	Middlebrooks, W. J., Pt., D, 43d New York.	July 12, '64.	Left; flap; by Asst. Surg. V. V. Etting, 43d N. Y. Disch'd April 4, 1865; pensioned.	756	Murphy, J., Pt., C, 113th Ohio, age 21.	Aug. 7, '64.	Right; ant. post. flap; by Surg. N. Wilson, 113th Ohio. To V. R. C. Dec. 5, 1864; pensioned.
715	Miles, J., Serg't, B, 36th F. S. C. T., age 35.	Sept. 29, '64.	Left; circular. Disch'd Oct. 13, 1865; pensioned.	757	Murray, D. A., Serg't, D, 63d N. Y., age 40.	May 18, '64.	Left; by Surg. H. P. Lyster, 5th Michigan.
716	Miller, J. H., Pt., A, 169th New York, age 30.	June 30, '64.	Left; flap. Disch'd Nov. 18, 1864; pensioned.	758	Murray, M., Serg't, A, 116th Penn., age 28.	July 2, '64.	Right; flap. Discharged Dec. 15, 1863.
717	Miller, S., Serg't, G, 95th Penn., age 25.	May 12, '64.	Left; ant. post. flap; by Surg. E. B. Kelly, 95th Penn. Disch'd Sept. 14, 1864; pensioned.	759	Musselman, W., Pt., C, 12th Penn. Res.	Dec. 13, '62.	Right; flap. Discharged May 18, 1863; pensioned.
718	Miller, W. H., Corp'l, C, 83d New York, age 23.	July 1, '63.	Left; flap. Disch'd Oct. 7, 1863; pensioned.	760	Mustain, B., Pt., D, 33d Ohio, age 28.	July 5, '64.	Right; flap; by Act. Staff Surg. D. S. Griffith, F. S. A. To V. R. C. Nov. 26, 1864; pensioned.
719	Millerich, J., Pt., F, 58th Massachusetts.	July 30, '64.	Right; circular. Disch'd July 31, '64; pensioned.	761	Myers, G. W., Pt., E, 43d Wisconsin.	Oct. 15, '64.	Right; flap. Disch'd June 6, 1865; pensioned.
720	Mills, J. H., Pt., D, 20th N. C., age 38.	May 3, '63.	Left. Recovery.	762	Myrick, M. M., Corp'l, C, 4th Vermont, age 20.	May 5, '64.	Right; lateral flap; by Surg. D. M. Goodwin, 3d Vt. Disch'd Sept. 20, 1864; pensioned.
721	Mills, W. J., Pt., E, 7th Wisconsin, age 17.	May 10, '64.	Left; flap; by Surg. J. H. Beach, 24th Mich. Disch'd August 10, 1864; pensioned.	763	Myton, F. W., Pt., H, 148th Pennsylvania.	May 3, '63.	Flap; by Surg. F. Reynolds, 88th N. Y. Disch'd July 22, 1863; pensioned.
722	Mitchell, J. H., Pt., C, 9th C. T., age 23.	Sept. 23, '64.	Left; flap. Disch'd April 11, 1866.	764	Napier, J. A., Lieut., E, 28th Pennsylvania.	Dec. 13, '62.	Discharged March 21, 1863.
723	Mitchell, J. R., Pt., C, 30th Iowa, age 31.	Mar. 19, '63.	Left; circular; by Surgeon W. Graham, 40th Ill. Disch'd June 5, 1865; pensioned.	765	Neal, J., Pt., B, 33d C. T., age 29.	July 29, '64.	Left; flap. Disch'd May 29, 1865.
724	Mitchell, O. P., Cpt., F, 40th Mass., age 28.	May 17, '64.	Left. Discharged; pensioned.	766	Nearly, P., Pt., B, 53d Illinois.	July 12, '61.	Left; flap; by a Confed. surgeon. Disch'd May 5, 1864; pensioned.
725	Mitchell, R., Pt., F, 93d Ohio, age 19.	May 27, '64.	Left; flap; by Surg. D. C. Peterson, 124th Ohio. Disch'd Oct. 28, 1864; pensioned.	767	Negus, D., Pt., D, 4th R. I., age 21.	Sept. 17, '62.	Left; flap; by A. Surg. R. M. Har, 4th R. I. Disch'd April 23, 1863; pensioned.
726	Moeller, W., Serg't, I, 1st New York Artillery.	Aug. 29, '62.	Left; flap; by Surg. J. H. Beach, 24th Mich. Disch'd August 10, 1864; pensioned.	768	Neil, J. O., Pt., 1, 32d Massachusetts, age 27.	June 22, '64.	Right; ant. post. flap; by Surg. J. W. Hastings, 32d Mass. Discharged Nov. 12, 1864.
727	Moffatt, T. B., Capt., A, 45th Tenn., age 25.	Nov. 30, Dec. 1, '65.	Right; ant. post. flap. To Provost Marshal Jan. 3, 1865.	769	Neilson, G., Corp'l, H, 3d New Jersey, age 22.	May 12, '64.	Left; ant. post. flap. Disch'd Nov. 4, 1864; pensioned.
728	Moditt, A. J., Serg't, H, 3d W. Va. Cav., age 25.	Aug. 26, '63.	Right; circular; by Surg. L. L. Comstock, 7th W. Va. C. Disch'd Jan. 14, 1864; pensioned.				
729	Moist, W. H., Pt., A, 93d Ohio.	Nov. 25, '63.	Right. Discharged April 4, 1864; pensioned.				
730	Molann, —, Pt., 12th Mississippi.	May 3, '63.	By A. Surg. B. Howard, F. S. A.				



No.	NAME, AGE, AND MILITARY DESCRIPTION.	DATES.	OPERATIONS, OPERATOR, RESULT.	No.	NAME, AGE, AND MILITARY DESCRIPTION.	DATES.	OPERATIONS, OPERATOR, RESULT.
770	Nelligan, J., Pt., II, 28th Massachusetts.	Dec. 13, '62.	Flap. Discharged April 4, 1863.	808	Peckham, C. W., Pt., B, 25th Wisconsin.	May 31, '64.	Right; by Surg. H. K. Spooner, 61st Ohio. Discharged Sept. 21, 1864; pensioned.
771	Nelson, C. G., Pt., I, 4th Iowa.	May 19, '63.	Left; by Surg. M. W. Robbins, 4th Iowa. Disch'd Sept. 5, 1863; pensioned.	809	Pelton, P., Corp'l, K, 149th New York, age 25.	July 3, '63.	Right; flap. Disch'd Oct. 12, 1863; pensioned.
772	Nelson, R., Pt., II, 8th Maine, age 44.	Sept. 29, '64.	Right; circular. Disch'd May 28, 1865.	810	Penny, E. W., Capt., A, 130th Indiana, age 25.	Aug. 6, '64.	Right; by Surg. J. T. Woods, 90th Ohio. Disch'd Aug. 29, 1865; pensioned.
773	Nelson, T. I., Pt., G, 13th Kentucky.	April 7, '62.	Left; by Surg. C. D. Moore, 13th Ky. Disch'd Oct. 24, '62; pens'd.	811	Perkins, J., Pt., G, 8th Illinois, age 29.	April 9, '65.	Right; flap; by Surg. O. G. Hunt, 11th Ill. Disch'd May 3, 1866.
774	Nesbit, W., Pt., C, 9th Pennsylvania Reserves.	June 27, '62.	Left; circular. Disch'd Aug. 1, 1862. Died Aug. 15, 1864.	812	Perkins, M., Pt., II, 3d N. Y. Artillery, age 27.	July 30, '64.	Right; flap; by Surg. H. F. Lyster, 5th Mich. Disch'd Jan. 23, 1865; pensioned.
775	Nevel, J., Pt., F, 143d Newm. A. G., Serg't, G, 3d Michigan.	June 25, '64.	Left; double flap. Disch'd Mar. 23, 1865; pensioned.	813	Perrine, T. A., Serg't, G, 140th Pennsylvania.	May 3, '63.	Right; circular; by Surg. C. S. Wood, 60th N. Y. Disch'd Aug. 7, 1863; pensioned.
776	Newman, A. G., Serg't, G, 3d Michigan.	Aug. 29, '62.	Right. Discharged Dec. 8, 1862; pensioned.	814	Perry, W., Pt., F, 10th New York.	Dec. 13, '62.	Left; circular. To V. R. C. Sept. 23, 1863; pensioned.
777	Newton, W. R., 2d Lieut., G, 30th Wisconsin.	June 1, '64.	Left; flap. Disch'd Jan. 2, 1865.	815	Persing, R., Pt., II, 46th Pennsylvania, age 35.	June 15, '64.	Left; flap. Disch'd April 19, 1865; pensioned.
778	Ney, D. H., Pt., I, 21st Pennsylvania, age 19.	June 3, '64.	Right. Disch'd Aug. 18, 1864; pensioned.	816	Pestel, J., Capt., D, 15th Missouri, age 29.	Dec. 16, '64.	Left; flap; by Surg. D. S. Young, 21st Ohio. Disch'd May 15, 1865; pensioned.
779	Neyland, J. A., Pt., B, 145th Pennsylvania.	June 16, '64.	Left; circular; by Surg. G. L. Potter, 145th Penn. To V. R. C. Jan. 24, 1865; pensioned.	817	Peterson, J., Pt., K, 4th Louisiana, age 25.	Dec. 16, '64.	Right; circular. To Prov. Marshal April 2, 1865.
780	Noble, B. R., Corp'l, E, 5th Ohio, age 26.	May 1, '63.	Right. Disch'd June 9, 1863.	818	Phelps, B. L., Corp'l, I, 4th Michigan, age 20.	July 2, '63.	Left; flap. Disch'd Dec. 15, 1863.
781	Nolan, M., Pt., D, 85th Indiana, age 27.	Mar. 16, '65.	Left; flap. Discharged June 30, 1865; pensioned.	819	Phillbrick, C. W., Pt., F, 3d N. H., age 22.	May 15, '64.	Left; by Surg. A. J. H. Buzzell, 3d N. H. Disch'd; pensioned.
782	Numbers, T., Pt., C, 130th Pennsylvania.	Sept. 17, '62.	Left; circular; by Surg. P. Pincio, U. S. A. Disch'd Mar. 30, 1865; pensioned.	820	Phillips, A., Major, 77th Pennsylvania, age 27.	Sept. 3, '64.	Right; circular; by Surg. J. N. McCandless, 77th Penn. Disch'd May 8, 1865; pensioned.
783	O'Brien, E., Pt., II, 76th New York, age 22.	June 18, '64.	Right; flap; by Surg. G. W. Metcalf, 76th N. Y. Disch'd Dec. 23, 1865; pensioned. Spec. 565.	821	Phillips, F. L., Pt., A, 2d Wisconsin, age 24.	May 8, '64.	Right; by Surg. A. J. Ward, 2d Wis. Duty June 15, 1864.
784	O'Brien, P., Pt., 1st Mich. Light Artillery.	Oct. 4, '62.	Right; flap. Discharged Mar. 20, 1863; pensioned.	822	Phillips, G., Pt., K, 34th Virginia.	April 9, '65.	Left; flap; by Surg. J. Westfall, 6th Ohio. Paroled.
785	O'Donnell, J., Pt., M, 1st Mass. H'y Art., age 28.	Mar. 31, 1865.	Left; circular. Disch'd July 15, 1865; pensioned.	823	Pierce, H. M., Serg't, B, 10th Vermont, age 22.	Nov. 27, '63.	Left; circular; by Surg. A. Treganowan, 10th N. J. Disch'd Sept. 23, 1864; pensioned. Spec. 1657.
786	O'Neil, W. H., Pt., II, 19th Massachusetts.	June 13, '62.	Right; circular; by Surg. A. N. Dougherty, U. S. V. Disch'd March 14, 1863.	824	Piper, A. J., Corp'l, C, 7th Vermont, age 22.	Aug. 5, '62.	Right; by Surg. E. Blanchard, 7th Vt. Disch'd Sept. 13, '62; pens'd.
787	Orr, G. S., Capt., A, 77th New York.	Oct. 19, '64.	Left; by Surg. G. T. Stevens, 77th N. Y. Disch'd Dec. 13, 1864; pensioned.	825	Pipes, J. M., Capt., A, 140th Pennsylvania.	Aug. 25, '64.	Right; flap; by Surgeon J. W. Wishart, 140th Penn. Duty Dec. 9, 1864; pensioned.
788	Osborn, G., Pt., C, 10th W. Va., age 26.	Nov. 6, '63.	Right; antero-posterior flap; by A. Surg. J. R. Blair, 10th W. Va. Disch'd Nov. 14, 1864.	826	Pitman, E., Pt., B, 11th Missouri Cavalry.	July 1, '63.	Left; by Surg. Z. B. Pondrum, 2d Mo. Art. Disch'd Feb. 2, 1864; pensioned.
789	O'Shaughnessy, F., Pt., D, 5th Mich., age 38.	May 5, '64.	Right; circular. Disch'd Sept. 19, 1865.	827	Platt, F. M., Corp'l, G, 10th Connecticut.	Dec. 14, '62.	Right; by A. Surg. C. R. Hart, 10th Conn. Discharged Aug. 27, 1863; pensioned.
790	Oxenrider, J., Pt., B, 87th Pennsylvania, age 28.	Sept. 19, '64.	Left; flap; by Surg. G. T. Stevens, 77th N. Y. Disch'd Feb. 6, 1865; pensioned.	828	Ploof, J., Pt., E, 8th Michigan, age 19.	June 3, '64.	Left; circular; by Surg. W. B. Fox, 8th Mich. Disch'd Sept. 14, 1864; pensioned.
791	Page, G. A., Pt., D, 33d Massachusetts, age 21.	Oct. 29, '63.	Right; flap; by Surg. Wm. Gunkle, 73d Penn. Disch'd April 13, 1864; pensioned.	829	Plunket, T., Serg't, E, 21st Massachusetts.	Dec. 13, '63.	Right; flap. Disch'd March 9, 1864; pensioned.
792	Pallezette, G., Hospital Steward, 4th New York Cavalry.	Oct. 10, '63.	Right; flap; by Sur. B. G. Streeter, 4th N. Y. Cav. Disch'd April 1, 1865; pensioned.	830	Pomroy, C. R., Pt., I, 45th Illinois.	June 25, '63.	Left; circular; by Surg. J. R. Reeves, 78th Ohio. Disch'd Oct. 27, 1863; pensioned.
793	Palmer, H. W., Pt., II, 31st Maine, age 18.	May 12, '64.	Left; flap; by Surg. L. W. Bliss, 51st N. Y. Disch'd Dec. 2, 1864; pensioned.	831	Pontious, A. T., Serg't, B, 139th Pa., age 23.	June 19, '64.	Right; flap; by Surg. S. F. Chapin, 139th Pa. Disch'd July 25, 1865; pensioned.
794	Palmer, J., Pt., G, 10th Ala., age 20.	Mar. 13, '65.	Right; circular. Released July 17, 1865.	832	Poor, J., Pt., I, 41st New York, age 21.	July 2, '63.	Right; antero-posterior flaps. To V. R. C. Mar. 24, 1861; pens'd.
795	Palmer, R., Pt., C, 7th Kentucky.	May 20, '65.	Right; by A. Surg. W. R. Davidson, 7th Ky. Disch'd July 10, 1865; pensioned.	833	Poppa, J., Pt., D, 41st Illinois.	June 18, '63.	Left; by Surg. C. Carle, 41st Ill. V. R. C. Oct. 1, 1863; pensioned.
796	Pankey, J. W., Pt., II, 43d N. C., age 21.	Mar. 25, '65.	Left. Released June 14, 1865.	834	Porter, H. F., Lieut., K, 1st Me. Hvy Art., age 28.	June 18, '64.	Right; circular. Disch'd Dec. 14, 1864.
797	Parker, C. M., Pt., A, 46th Indiana.	May 16, '63.	Left; by Surg. H. Coleman, 46th Ind. Discharged July 20, 1863; pensioned.	835	Porter, L., Lieut., A, 68th Penn.	July 2, '64.	Left. To V. R. C. Nov. 21, 1863; pensioned.
798	Parker, J. H., Pt., K, 44th New York.	Dec. 13, '64.	Left; circular; by Surg. A. W. Whitney, 13th Mass. Disch'd June 15, 1863; pensioned.	836	Post, C. R., Pt., F, 173d New York.	April 23, '64.	Right; by Surg. G. Clary, 13th Conn. Disch'd June 23, 1864; pensioned.
799	Parkison, R., Pt., F, 168th Ohio, age 19.	June 10, '64.	Left; flap. Duty Aug. 23, 1864; pensioned.	837	Potry, A., Pt., F, 96th New York, age 18.	June 1, '64.	Left; circular. Discharged May 20, 1865; pensioned.
800	Patterson, J. M., Serg't, A, 110th Ohio, age 34.	May 6, '64.	Right; by a Confederate surgeon. Disch'd Mar. 14, 1865; pensioned.	838	Potter, A. J., Corp'l, B, 126th New York, age 20.	May 6, '64.	Left; by Surg. G. L. Potter, 145th Pa. Disch'd Jan. 14, '65; pens'd.
801	Patterson, S. D., Pt., 11th N. Y. Battery, age 20.	May 3, '63.	Right; flap; by Surg. M. F. Price, 1st Penn. Art. Disch'd Sept. 15, 1863; pensioned.	839	Potter, W., Pt., D, 63d Illinois, age 22.	July 4, '63.	Right; flap. Disch'd Oct. 26, 1863; pensioned.
802	Paul, H., Pt., D, 20th New York.	Sept. 17, '62.	Right; flap; by Surg. J. Hanson, 20th N. Y. Disch'd Dec. 18, 1862; pensioned.	840	Power, H. H., Serg't, A, 23d Va. Battery, age 25.	Sept. 19, '64.	Left; flap. To prison Oct. 23, 1864.
803	Paulley, F., Pt., I, 2d Missouri Light Artillery.	Jan. 11, '63.	Internal single flaps; by a Confed. surg. Disch'd April 24, 1863; pensioned.	841	Powers, P., Pt., C, 24th Mass., age 22.	Aug. 16, '64.	Right; re-amputation at shoulder joint April 3, 1865. Disch'd July 17, 1865; pensioned.
804	Payne, D. S. F., Pt., I, 5th Vermont.	June 29, '62.	Right; by Surg. W. R. Russell, 5th Vt. Disch'd Sept. 17, 1862; pensioned.	842	Preas, H. Y., Pt., I, 23d North Carolina, age 24.	May 3, '63.	Circular. Health impaired.
805	Payne, G. H., Pt., II, 104th Ohio, age 24.	May 21, '64.	Left; flap; by Surg. J. H. Rodgers, 104th Ohio. Discharged Dec. 2, 1864; pensioned.	843	Price, J. E., Pt., II, 1st Md. P. H. B., age 23.	July 3, '63.	Left; antero-posterior flap; by Surg. G. B. LeCompte, 1st Md. P. H. B. Disch'd Oct. 21, '63; pens'd.
806	Payne, J. W., Pt., K, 1st U. S. Cavalry.	Mar. 17, '63.	Circular. Disch'd July 7, 1863.	844	Price, M. L., Pt., 26th Mississippi.	Feb. 15, '62.	Right.
807	Peck, W. B., Serg't, E, 4th Rhode Island.	Sept. 17, '62.	Circular; by Surg. H. W. Rivers, 4th R. I. Disch'd Jan. 5, '63; pens'd.	845	Price, W. H., Pt., II, 1st Md. Home Brig., age 27.	July 3, '63.	Left; by Surg. G. B. LeCompte, 1st Md. P. H. B. Disch'd Oct. 21, 1863; pensioned.
				846	Price, W. P., Serg't, G, 11th Mass.	Aug. 5, '62.	Left; circular; by Asst. Surg. T. F. Oakes, 1st Mass. Discharged April 14, 1863; pensioned.

No.	NAME, AGE, AND MILITARY DESCRIPTION.	DATES.	OPERATIONS, OPERATOR, RESULT.	No.	NAME, AGE, AND MILITARY DESCRIPTION.	DATES.	OPERATIONS, OPERATOR, RESULT.
847	Pritchard, G. H., Pt., D, 11th New Hampshire.	June 16, 18, '64.	Left. Discharged Oct. 25, 1864; pensioned.	887	Rockefeller, H., Pt., F, 71st New York.	July 21, 21, '61.	Left; by A. Surg. F. Swift, 39th N. Y. Disch'd; pensioned.
848	Pruditt, C. H., Corp'l, F, 126th N. Y., age 23.	May 6, '64.	Left; flap; by Surg. J. W. Wisbart, 144th Pa. Duty Dec. 2, 1864; pensioned.	888	Rogers, D. W., Corp'l, K, 10th Vermont, age 27.	April 2, '65.	Left; by A. Surg. A. Clark, 10th Vt. Disch'd June 22, '63; pens'd.
849	Prun, A. Pt., A, 2d N. Y. Rifles, age 20.	July 15, '64.	Left; circular; by Surg. R. T. Payne, 2d N. Y. Disch'd July 6, 1865.	889	Rogers, W. A., Corp'l, C, 15th Ohio.	April 7, '62.	Right. Disch'd July 15, 1862; pensioned.
850	Puff, E. S., Pt., K, 124th New York.	May 3, 4, '63.	Right; circular; by Surg. J. H. Thompson, 124th N. Y. Disch'd Sept. 18, 1863; pensioned.	890	Rolston, J., Pt., G, 6th Infantry.	Dec. 14, 14, '62.	Left; flap. To V. R. C. Sept. 3, 1863; pensioned.
851	Pugh, J. H., Pt., B, 15th Virginia Cav., age 32.	May 11, '64.	Left; circular. Retired from service Feb. 23, 1865.	891	Root, J. P., Pt., L, 16th N. Y. H. A., age 20.	Dec. 9, 10, '64.	Ant. post. flaps; by A. A. Surg. W. P. Litch. Disch'd July 8, 1865.
852	Quinlan, D. Pt., G, 26th Mass., age 28.	Sept. 19, 19, '64.	Left; circular; by Surg. J. G. Bradt, 26th Mass. Disch'd Mar. 16, 1865; pensioned.	892	Rose, F., Pt., D, 57th N. Y., age 20.	Oct. 14, 15, '63.	Left; circular; by Surg. W. W. Potter, 57th N. Y. Disch'd Oct. 3, 1864; pensioned. Spec. 3104.
853	Quinn, T., Pt., B, 139th New York, age 25.	Sept. 29, 30, '64.	Left; circular; by Surg. A. Hurt, 139th N. York. Disch'd May 31, 1865; pensioned.	893	Rose, G. W., Pt., K, 56th Pennsylvania.	Nov. 2, 2, '62.	Left; circular; by Surgeon J. C. Lyons, 56th Pa. Disch'd March 26, 1863; pensioned.
854	Radgedell, J. F., Pt., I, 2d Georgia Cavalry.	May 17, 17, '64.	Left; circular; by Surg. A. Hurt, 139th N. York. Disch'd May 31, 1865; pensioned.	894	Ross, H., Pt., B, 79th Pennsylvania.	Dec. 12, 14, '62.	Right; circular.
855	Ragan, C. G., Pt., G, 1st Kentucky Cav., age 22.	June 12, 12, '64.	Left; circular; by Surg. Miller, C. S. A. To prison Aug. 16, '64.	895	Ross, H., Pt., B, 79th Pennsylvania.	Dec. 12, 14, '62.	Left; by A. Surg. F. G. Albright, 79th Penn. Disch'd Jan. 1, 1863; pensioned.
856	Raker, J. B., Pt., C, 21st N. Y. Cavalry.	July 19, 20, '64.	Left; flap; by Surg. B. S. Catlin, 21st N. Y. Cav. Duty Feb. 11, 1865; pensioned.	896	Rossman, N., Pt., E, 9th Iowa.	Mar. 7, '62.	Left; flap. Disch'd Sept. 5, 1863; pensioned.
857	Ralls, A., Pt., H, 44th Colored Troops.	Nov. 6, 7, '64.	Right; by a Confederate surgeon. Disch'd; pensioned.	897	Rothwell, B. J., Pt., C, 70th Ohio.	April 7, 7, '62.	Right; flap. Disch'd August 24, 1863; pensioned.
858	Raymond, H. H., Pt., E, 46th Pa., age 17.	July 20, 21, '64.	Right; flap; by Asst. Surg. G. W. Burke, 46th Penn. Disch'd June 24, 1865; pensioned.	898	Rover, A. D., Pt., B, 14th Virginia, age 28.	July 3, 4, '63.	Right. Exchanged Sept. 25, 1861.
859	Reader, J., Pt., D, 148th Pa., age 32.	June 3, 3, '64.	Left; circular. V. R. C. May 16, 1865.	899	Rowe, D., Pt., E, 9th Maine.	Nov. 7, 7, '63.	Right; double flap. Discharged February 16, 1864.
860	Reay, R. D., Pt., A, 14th Virginia.	July 2, 2, '63.	Paroled Sept. 27, 1863.	900	Zucker, E. W., Brig.-Gen. Forrest's C. Div., age 23.	Dec. 16, 17, '64.	Left; flap; by Surg. B. B. Breed, U. S. V. To Prov. Mar. Feb. 6, '65.
861	Reed, J. Pt., H, 97th Illinois.	May 22, 22, '63.	Left. V. R. C. Sept. 1, '63; pens'd.	901	Runkle, M. E., Capt., F, 56th Penn., age 37.	May 6, 7, '64.	Right; flap; by Surg. G. W. Metcalf, 76th N. Y. Disch'd Aug. 14, 1864; pensioned. Spec. 2518.
862	Reed, J., Pt., G, 116th N. Y., age 21.	May 16, 16, '61.	Left; circular; by Asst. Surg. J. H. Sullivan, 3d N. Y. Disch'd Jan. 20, 1865; pensioned.	902	Rupert, U. J., Pt., B, 139th Penn., age 27.	April 6, 6, '65.	Right; flap; by Asst. Surg. J. R. Patten, 139th Pa. Disch'd June 14, 1865; pensioned.
863	Reed, L. S., Pt., D, 1st Vt. Cavalry, age 24.	Aug. 26, '64.	Right; flap; by A. A. Surg. J. R. Usher. Disch'd June 26, 1865; pensioned.	903	Russell, J. A., Pt., A, 2d Mississippi, age 25.	Nov. 30, Dec. 2, 1864.	Right; circular. To Prov. Mar. January 3, 1865.
864	Reed, W. E. S., Pt., E, 123th Illinois, age 18.	July 23, 23, '64.	Right; antero-posterior flap. Discharged April 6, 1865; pens'd.	904	Russell, M., Capt., C, 60th Georgia, age 27.	Sept. 19, 20, '64.	Right; circular. To Point Lookout Nov. 23, 1864.
865	Reeves, I., Pt., D, 11th Missouri.	May 22, 22, '63.	Right. Disch'd Sept. 9, 1863; pensioned.	905	Rutherford, L. J., Pt., H, 23d Indiana, age 24.	May 17, 17, '64.	Right; ant. post. flap; by Surg. E. H. Payne, 10th Ill. Disch'd Sept. 25, 1864; pensioned.
866	Reeves, T., Serg't, G, 6th Ohio Cavalry.	May 28, 28, '64.	Left; flap; by Surg. W. B. Rezer, 6th Ohio Cavalry. Disch'd Jan. 5, 1865; pensioned.	906	Ryan, J., Pt., G, 91st New York.	June 14, 14, '63.	Left. Duty July 31, 1863; pensioned.
867	Reynolds, J. H., Pt., B, 1st Mass. Hvy Art., age 27.	June 22, 22, '64.	Left; flap. Duty Feb. 3, 1865; pensioned.	907	Rye, E., Pt., H, 2d Penn. Artillery, age 21.	Aug. 21, 21, '64.	Right; flap; by Surg. T. F. Oakes, 56th Mass. Disch'd July 8, 1865.
868	Rhodes, O. W., Pt., I, 11th Mass.	May 2, 2, '63.	Flap; by Surg. H. McLane. 2d N. Y. Disch'd July 1, '63; pens'd.	908	Sampier, W., Pt., K, 35th New York.	Sept. 17, 17, '62.	Left; circular; by Asst. Surg. S. French, 35th N. Y. Disch'd Mar. 6, 1863; pensioned.
869	Rhodes, B., Pt., F, 7th N. Y. Heavy Artillery.	June 3, 3, '64.	Left; by Surg. G. F. Stevens, 7th N. Y. Disch'd Aug. 13, '65; pens'd.	909	Sanderson, F. L., Pt., F, 53d Massachusetts.	June 14, 14, '63.	Right; flap. Discharged June 28, 1865; pensioned.
870	Richardson, W., Pt., F, 60th New York S. M.	June 3, 3, '64.	Right; circular; by a Confederate surg. Disch'd July 8, '65; pens'd.	910	Saner, A., Pt., I, 148th Penn., age 28.	May 29, 30, '64.	Left; internal flap; by Surg. P. E. Hubon, 28th Mass. Discharged Jan. 26, 1865; pensioned.
871	Ricker, A., Pt., B, 20th Maine, age 20.	Dec. 13, 13, '62.	Left; circular. Disch'd Mar. 19, 1863; pensioned.	911	Saners, M., Pt., A, 28th Illinois.	Oct. 5, 5, '62.	Right; flap. Disch'd March 28, 1863; pensioned.
872	Ricker, J. B., Pt., C, 21st New York Cav.	June 11, 11, '64.	Left; flap; by a Confed. surgeon. Duty Feb. 11, 1865.	912	Sapp, J. G., Corp'l, D, 25d Kentucky, age 20.	Sept. 19, 19, '63.	Right; flap. Disch'd July 25, 1864; pensioned.
873	Rickey, S., Serg't, D, 39th Indiana.	April 7, 7, '62.	Left; by Surg. C. B. Lake, 7th Iowa. Disch'd March 25, 1863; pensioned.	913	Savrage, P., Pt., C, 7th N. Y. H. A., age 40.	June 3, 3, '64.	Right; circular; by Surg. J. W. Wishart, 140th Penn. Disch'd Dec. 9, 1864; pensioned.
874	Riggs, H., Serg't, H, 1st Conn. Cnv., age 27.	June 30, 30, '64.	Right; flap. Disch'd Feb. 17, 1865; pensioned.	914	Sawyer, C. G., Pt., L, 31st Maine, age 33.	April 9, 2, '65.	Left; circular. Disch'd June 29, 1865; pensioned.
875	Ripley, E. H., Capt., C, 8th Conn.	Sept. 17, 17, '62.	Left; flap; by Surg. M. Storrs, 8th Conn. V. R. C. Oct. 7, '63; pens'd.	915	Sawyer, H. A., Pt., F, 14th Maine, age 30.	Sept. 19, 19, '64.	Left; flap; by a Confed. surgeon. Disch'd June 14, 1865.
876	Ripptoe, W., Corp'l, D, 25th Virginia.	July 1, 1, 1863.	Flap. Paroled August 24, 1863.	916	Schenk, W. A., Corp'l, B, 15th N. J., age 19.	Sept. 19, 19, '64.	Left; flap; by Surg. R. Sharp, 15th N. J. Disch'd Jan. 28, 1865; pensioned. Spec. 2179.
877	Ritz, J., Pt., H, 9th Ind., age 33.	April 7, 7, '62.	Right; circular; by Surg. M. G. Sherman, 9th Ind. Disch'd Aug. 17, 1862; pensioned.	917	Schlinker, G., Pt., B, 100th New York, age 22.	May 14, 14, '64.	Left; circular; by A. Surg. W. D. Murray, 100th N. Y. Disch'd Dec. 23, 1864; pensioned.
878	Rivet, T., Pt., A, 13th Louisiana, age 33.	Jan. 2, 3, '63.	Left. To Provost Marshal.	918	Schmalzriedt, C., Pt., H, 71st Penn., age 17.	May 12, 12, '64.	Left; circular; by Surg. M. Rizer, 72d Penn. Disch'd June 27, 1865; pensioned.
879	Robert, J. J., Pt., A, 4th Michigan.	May 5, 5, '64.	Left; flap; by Surg. J. Kerr, 62d Penn. Disch'd Mar. 1, '65; pens'd.	919	Schmidt, A., Pt., C, 3d Michigan.	Aug. 29, 29, '62.	Right. Disch'd October 11, 1862; pensioned.
880	Roberts, G. W., Pt., L, 24th N. Y. Cav., age 16.	June 25, 25, '64.	Right; flap; by Surg. J. H. Beach, 24th Mich. Disch'd Oct. 10, 1864; pensioned.	920	Schmidt, H., Pt., G, 57th Illinois.	Oct. 4, 4, '62.	Right; by a Confed. surg. Disch'd Dec. 18, 1863; pensioned.
881	Roberts, H., Pt., C, 7th Colored Troops.	June 24, 24, '64.	Flap. By A. Surg. N. S. Roberts, 21st C. T. Duty Aug. 5, '64; pen'd.	921	Schock, V., Pt., E, 32d Indiana.	Nov. 25, 25, '63.	Left. Discharged Sept. 7, 1864; pensioned.
882	Roberts, I. W., Pt., I, 6th Wisconsin, age 31.	May 5, 5, '64.	Left. Disch'd Oct. 4, 1864; pensioned.	922	Schoppelreich, C., Pt., F, 7th New York.	Dec. 12, 12, '62.	Right; by Surg. C. Gray, 7th N. Y. Disch'd April 15, 1863; pens'd.
883	Roberts, M., Pt., D, 18th Michigan, age 17.	Sept. 26, '64.	Right; circular; by Dr. Sarwell, of Athens, Ala. Disch'd Sept. 20, 1865; pensioned.	923	Schuman, R., Pt., B, 1st Michigan Light Artry, age 26.	Nov. 22, 22, '64.	Right; ant. post. flap; by Surg. A. T. Hudson, 26th Iowa. Disch'd April 13, 1865; pensioned.
884	Robinson, G. H., Pt., F, 123d N. Y., age 26.	July 20, 22, '64.	Right; flap; by Surg. J. Chapman, 123d N. Y. Disch'd June 15, 1865; pensioned.	924	Scott, A. G., Pt., E, 67th Penn., age 20.	Oct. 19, 19, '64.	Right; antero-posterior flap. Discharged Jan. 20, 1865.
885	Robinson, R., Pt., H, 9th Illinois Cav., age 27.	July 15, 15, '64.	Left; flap. Disch'd Oct. 8, 1864; pensioned.	925	Scott, A. P., Pt., B, 29th Va., age 31.	June 7, 7, '64.	Recovery.
886	Rohy, H., Serg't, A, 18th Ohio.	Jan. 2, 2, '63.	Right. Disch'd March 27, 1863; pensioned.	926	Scribner, F. M., Pt., E, 96th Ohio.	Jan. 11, 11, '63.	Right; by Surg. D. W. Henderson, 96th O. Disch'd Mar. 7, 1863.
				927	Scruggs, C., Pt., A, 44th Colored Troops, age 29.	Dec. 2, 2, '61.	Right flap. Duty Jan. 12, 1865.



No.	NAME, AGE, AND MILITARY DESCRIPTION.	DATES.	OPERATIONS, OPERATOR, RESULT.	No.	NAME, AGE, AND MILITARY DESCRIPTION.	DATES.	OPERATIONS, OPERATOR, RESULT.
928	Scruggs, M., Pt., C, 13th Colored Troops, age 20.	Dec. 15, 16, '64.	Right; flap; by A. A. Surg. A. S. Giltner. Disch'd Aug. 3, '65.	967	Smith, O. W., Pt., D, 8th New Hampshire.	May 27, 27, '61.	Right. Disch'd August 17, 1863; pensioned.
929	Seabrook, J. B., Lieut., 1, 38th Alabama.	Nov. 25, '63.	Right; by Surg. G. L. Carhart, 31st Iowa. Pro. Mar. Feb. 19, '64.	968	Smith, R., Serg't, 1, 76th Pennsylvania, age 24.	July 30, '64.	Left; circular. Duty Nov. 11, 1864; for muster out.
930	Seamans, W., Pt., K, 126th N. York, age 22.	May 6, '64.	Left; by Surg. G. L. Potter, 145th Penn.; pensioned.	969	Smith, S. P., Capt., II, 115th N. Y., age 34.	Aug. 16, '64.	Left; flap. Disch'd Jan. 14, 1865.
931	Segar, J., Pt., M., 15th N. Y. Artillery.	May 10, 10, '64.	Left; circular. Disch'd April 6, 1865; pensioned.	970	Smith, W., Pt., G, 48th Missouri, age 26.	Oct. 1, '64.	Left; circular; by Surg. W. A. Gibson, 48th Mo. Disch'd Mar. 20, 1865.
932	Sehn, P., Pt., C, 14th N. York.	Dec. 13, '62.	Left; circular. Disch'd Mar. 12, 1863; pensioned.	971	Smith, W. T., Pt., A, 47th Alabama, age 21.	June 14, '64.	Right; circular. Furl'd July 28, 1864.
933	Seward, W. L., Serg't, B, 14th Infantry.	July 2, 3, '63.	Left; circular; by A. Surgs. W. R. Ramsey and W. H. Forwood, 17, S. A. Disch'd June 1, '64; pens'd.	972	Smysler, M. P., Pt., 1, 149th Penn., age 34.	May 5, '64.	Right; by Surg. W. T. Humphrey, 149th Penn. To V. R. C. Oct. 20, 1864; pensioned.
934	Sharp, H., Pt., II, 16th New York.	June 27, '62.	Left. Discharged Sept. 23, 1862; pensioned.	973	Sneade, S., Pt., E, 91st New York.	June 14, '63.	Right; flap; by Surg. W. Y. Probst, 159th N. Y. Disch'd Sept. 20, 1863; pensioned.
935	Shaw, A., Pt., II, 91st New York, age 18.	Mar. 31, April 1, 1865.	Left; circular; by Asst. Surg. J. L. Morris, 150th Pa. Disch'd Aug. 12, '65; pens'd. Spec. 3490.	974	Snedeker, A., Pt., 7th Co. 1st N. Y. Sharpshooters.	July 17, '64.	Left; circular; by Surgeon D. E. Wolfe, 3d Del. Disch'd Nov. 3, 1865; pensioned.
936	Shoely, M., Serg't, 15th New York Ind. Battery.	Aug. 21, 21, '64.	Right; antero-posterior flap. Discharged Oct. 29, 1864; pens'd.	975	Snooks, H., Pt., G, 115th N. Y., age 34.	May 7, '64.	Disch'd Aug. 20, 1864; pensioned.
937	Sheldon, E. B., Pt., E, 19th Maine, age 23.	July 2, 4, '63.	Right; flap; by Surg. A. J. Billings, 19th Maine. Disch'd Oct. 23, 1863; pensioned.	976	Somers, J., Pt., II, 21st N. C., age 22.	Oct. 19, '64.	Right. Sent to prison October 27, 1864.
938	Shelton, P. K., Pt., D, 35th Kentucky.	Mar. 26, 27, '64.	Lat. flap; by A. A. Surg. O. F. Schellett. Disch'd Dec. 21, 1864.	977	Southworth, C., Pt., D, 149th N. Y., age 32.	June 11, '64.	Right; ant.-post. flap; by Surg. J. V. Kendall, 149th N. Y. Disch'd July 6, 1865; pensioned.
939	Shepard, L., Pt., F, 10th Vermont, age 22.	Sept. 19, '64.	Left; circular; by Surg. W. A. Barry, 8th Pa. Disch'd Mar. 18, 1865; pensioned.	978	Spaulding, C. F., Serg't, F, 9th N. Y. S. M.	Dec. 13, '62.	Right; flap; by Surg. A. W. Whitney, 13th Mass. Disch'd Jan. 30, 1863; pensioned.
940	Shirland, W., Pt., 1, 1st Me. Hvy Art., age 18.	June 18, 18, '64.	Right; antero-posterior flap. Discharged Dec. 15, 1864; pens'd.	979	Specht, D. S., Pt., F, 148th Pennsylvania, age 21.	May 12, 12, '64.	Right; circular. Disch'd Oct. 4, 1864; pensioned.
941	Shoemaker, H. P., Pt., F, 101st Illinois.	Oct. 16, 16, '63.	Left. Discharged Jan. 12, 1864; pensioned.	980	Speelman, J., Corp'l, F, 65th Ohio.	Sept. 19, '63.	Right; flap; by Surg. E. M. Seeley, 21st Ill. Disch'd Feb. 3, 1864.
942	Sigler, W. D., Corp'l, G, 30th Iowa.	May 22, 23, '63.	Left; flap; by Surg. W. N. Robbins, 4th Iowa. Disch'd June 27, 1863; pensioned.	981	Spencer, W. F., Corp'l, F, 1st Mich. Cav., age 28.	Mar. 31, April 1, 1865.	Right; flap. Disch'd June 23, 1865.
943	Simms, J., Pt., F, 88th Penn.	Aug. 29, 30, '62.	Left. Discharged Oct. 10, 1862; pensioned.	982	Spofford, F., Serg't-Maj., 8th Conn., age 29.	Sept. 17, '62.	Left; flap; by Surg. M. Storrs, 8th Conn. Disch'd Sept. 20, 1864; pensioned.
944	Simms, S. A., Pt., G, 11th Infantry.	May 3, 3, '63.	Right; flap; by Asst. Surg. B. Howard, 1, S. A. Disch'd Nov. 4, 1863; pensioned.	983	Springer, M., Pt., F, 149th Pennsylvania, age 28.	Mar. 10, 10, '64.	Left; flap; by Surg. W. F. Humphrey, 149th Penn. Discharged Aug. 7, 1864; pensioned.
945	Simpson, T., Serg't, E, 103d Illinois.	Mar. 16, 16, '65.	Left; circular; by Surg. William Hamilton, 103d Ill. Discharged June 9, 1865; died Dec. 30, 1866.	984	Sprouse, D., Pt., D, 56th Pennsylvania, age 24.	June 18, 18, '64.	Right; flap; by Surg. J. C. Lyons, 56th Penn. Disch'd May 20, 1865; pensioned.
946	Simpson, W. H., Pt., H, 21st Mass., age 22.	July 30, 30, '64.	Left; circular; by Surg. G. W. Snow, 35th Mass. Disch'd Oct. 17, 1864; pensioned.	985	Squires, H., Pt., F, 117th N. Y., age 19.	June 23, '64.	Right; flap. Discharged Nov. 16, 1864; pensioned.
947	Singer, A., Serg't, B, 6th Col'd Troops, age 33.	June 15, 15, '64.	Left; antero-posterior flap. Discharged June 10, 1865; pension'd.	986	Stallord, J., Pt., D, 170th N. Y., age 37.	June 16, '64.	Right; flap; by Surg. F. Douglass, 170th N. Y. Discharged June 2, 1865; pensioned.
948	Singletary, G., Pt., C, 29th Georgia, age 24.	June 15, '64.	Left. To Provost Marshal Oct. 21, 1864.	987	Stafford, Joseph, Pt., D, 14th Connecticut.	Sept. 17, 17, '62.	Left; flap; by Surg. G. King, 29th Mass. Disch'd Dec. 26, 1862; pensioned.
949	Skiles, J. W., Capt., C, 23d Ohio.	Sept. 14, 15, '62.	Left; flap; by Surg. J. T. Webb, 23d Ohio. Disch'd July 3, 1865; pensioned.	988	Stansby, J., Pt., D, 129th Illinois, age 33.	July 20, 21, '64.	Right; flap. Disch'd June 18, 1865; pensioned.
950	Skipton, W., Pt., F, 92d Ohio, age 30.	Aug. 4, 4, '64.	Left. Discharged Mar. 21, 1865; pensioned.	989	Stall, J. M., Pt., F, 39th Mass., age 42.	May 8, '64.	Right; flap; by Surg. W. Thornecke, 39th Mass. Disch'd Dec. 13, '64.
951	Slaughter, J. D., Pt., F, 24th New York.	Aug. 29, 29, '62.	Left; ant.-post. flap; by Surg. J. B. Murdoch, 24th N. Y. Disch'd Nov. 6, 1862; pensioned.	990	Stannard, D. W., Pt., A, 97th N. Y., age 28.	June 13, 13, '64.	Right; circular; by Surg. W. B. Chambers, 97th N. Y. Duty October 8, 1864; pensioned.
952	Sleeper, B. C., Pt., B, 1st Maine Cavalry, age 20.	June 24, 25, '64.	Right; circular; by A. Surg. H. Stevens, 1st Me. Cav. Disch'd Dec. 5, 1864.	991	Stannard, G. J., Brigadier General U. S. V.	Sept. 29, 29, '64.	Right. Disch'd Aug. 24, 1865.
953	Sliippy, I. D., 11th Penn., age 16.	June 13, 13, '64.	Right; circular; by Surg. J. W. Anawalt, 11th Penn. Disch'd Nov. 5, 1864; pensioned.	992	Stansburg, J. W., Serg't, K, 110th Ohio, age 31.	Sept. 19, '64.	Left; circular; by Surgeon T. A. Helwig, 87th Penn. Disch'd Nov. 21, 1864; pensioned.
954	Smith, A. A., Pt., K, 121st Ohio.	Oct. 8, 8, '62.	Left. Discharged Dec. 27, 1862; pensioned.	993	Starkey, C., Bugler, E, 4th Mo. S. M. Cav.	Aug. 28, 28, '64.	Right; flap. Disch'd October 29, 1864; pensioned.
955	Smith, A., Pt., C, 116th Pennsylvania.	Dec. 13, 13, '62.	Right; flap; by Asst. Surg. P. A. Boyle, 116th Penn. Discharged Nov. 12, 1863; pensioned.	994	Starr, T. H., Pt., 1, 87th New York, age 37.	Oct. 27, '64.	Right; circular. Disch'd Jan. 7, 1865; pensioned.
956	Smith, A. C., Corp'l, A, 111th Illinois, age 31.	July 22, 23, '64.	Right; flap; by Dr. Grey, C. S. A. Disch'd June 22, 1865.	995	Starrett, E., Pt., E, 31st Indiana, age 22.	June 21, 21, '64.	Left; ant.-post. flap; by Surg. J. P. Woods, 99th Ohio. Discharged Feb. 24, 1865; pensioned.
957	Smith, B. F., Pt., M, 2d Cavalry, age 21.	June 12, 12, '64.	Right; circular; by Surg. B. G. Streeter, 4th N. Y. Cav. Duty Dec. 5, 1864; pensioned.	996	Staudt, V., Pt., D, 9th Pa. Reserves.	June 27, 28, '62.	Left; by a Confederate surgeon. Disch'd Sept. 1, 1862; pensioned.
958	Smith, C. A., Pt., F, 3d New Jersey Cavalry.	Aug. 19, '64.	Left; circular; by Surg. H. Fearn, 175th N. Y. Disch'd March 17, 1865; pensioned.	997	Steele, J., Pt., K, 16th Michigan.	June 21, '63.	Right; flap; by Surg. T. J. Dunnett, 1st Md. Cav. Disch'd Aug. 16, 1863; pensioned.
959	Smith, D. T., Capt., F, 100th Indiana.	Nov. 25, 27, '63.	Left; by Surg. R. L. von Harlingen, 70th Ohio. Resigned July 28, 1864; pensioned.	998	Steinke, W., Pt., M, 8th Illinois Cav., age 30.	July 8, 8, '61.	Left; flap; by Surg. T. W. Stull, 8th Ill. Cav. Disch'd April 3, 1865; pensioned.
960	Smith, F., Serg't, E, 73d Pennsylvania, age 21.	June 16, 16, '64.	Left; circular; by Surg. J. Reilly, 3d N. J. Disch'd Nov. 28, 1864.	999	Sterman, G., Pt., D, 12th N. Hampshire, age 30.	June 3, 3, '64.	Right; circular; by Asst. Surg. O. P. Rice, 9th Me. Disch'd May 17, 1865; pensioned.
961	Smith, G. F., Corp'l, B, 31st Mass., age 26.	May 26, '63.	Right; flap; by Surg. S. C. Hartwell, 38th Mass. Disch'd Sept. 17, 1864; pensioned.	1000	Stevens, J. B., Lieut.-Col., 53d Ohio.	May 3, 3, '63.	Left. Resigned.
962	Smith, J. H., Pt., II, 5th Penn. Cav., age 28.	Oct. 7, 7, '64.	Right; flap. Disch'd June 9, 1865.	1001	Stevens, M. B., Pt., H, 8th Illinois Cav., age 24.	July 8, 8, '63.	Left; flap. Disch'd Oct. 5, 1863.
963	Smith, J. L., Pt., D, 17th Connecticut, age 18.	May 16, '64.	Right; flap. Disch'd Nov. 29, 1864; pensioned.	1002	Stewart, J. E., Pt., A, 50th Virginia, age 24.	May 8, '64.	Right; circular. Furloughed July 28, 1864.
964	Smith, J. M. W., Pt., F, 80th Illinois, age 18.	June 22, '61.	Left; flap; by Surg. M. M. Hooton, 80th Ill. Disch'd Oct. 29, 1864.	1003	Stewart, J. W., Pt., G, 83d Pa., age 19.	April 6, '65.	Left; flap; by Surg. J. R. Richardson, 83d Pa. Disch'd July 20, 1865; pensioned.
965	Smith, J. P., E, 22d Ga., age 30.	July 3, '63.	Right; circular. Sent to Cay Point for exchange Nov. 12, 1863.	1004	Stieglennier, W. H., Sgt., A, 8th N. Y. Cav.	June 9, 9, '63.	Left; flap; Surg. N. D. Ferguson, 8th N. Y. C. Disch'd Aug. 13, 1863; pensioned. Spec. 1221.
966	Smith, M., Pt., G, 1st Pennsylvania Reserves.	June 30, July 2, 1862.	Right; flap. Disch'd June 9, 1865.				

NO.	NAME, AGE, AND MILITARY DESCRIPTION.	DATES.	OPERATIONS, OPERATOR, RESULT.	NO.	NAME, AGE, AND MILITARY DESCRIPTION.	DATES.	OPERATIONS, OPERATOR, RESULT.
1005	Stiemer, L. D., Pl., B, 23d Pa., age 24.	Nov. 30, 1863. On field.	Left; circular; by Surg. W. C. Bolter, 23d Pa. Disch'd May 7, 1864; pensioned.	1042	Tierney, J., Pl., B, 25th N. Y. Cav., age 35.	July 11, 12, '64.	Right; flap; by A. A. Surg. W. H. Randolph. Disch'd Mar. 21, 1865; pensioned.
1006	Stiles, B., Pl., A, 14th Conn., age 21.	May 12, '64.	Right; circular; by Surg. F. A. Dudley, 14th Conn. Disch'd June 18, 1865; pensioned.	1043	Tierney, J., Pl., F, 2d N. Y. Cav., age 20.	April 23, 23, '64.	Left; flap. Disch'd May 16, 1865; pensioned. <i>Spec.</i> 1485.
1007	Stocker, J. H., Pl., I, 6th Ohio, age 37.	Dec. 31, 1862. Jan. 2, 1863.	Right; circular. Disch'd Nov. 27, 1863.	1044	Tilson, G. M., Capt., K, 161st N. Y.	April 8, 10, '64.	Right. Disch'd Sept. 14, 1864; pensioned.
1008	Stocksleger, P. W., Corporal, H, 47th Pa.	Oct. 22, 24, '62.	Left; circular; by A. A. Surg. T. T. Smiley. Disch'd Dec. 23, 1862; pensioned. <i>Spec.</i> 688.	1045	Tolin, M., Pl., C, 6th Ohio Cav., age 22.	July 2, 2, '63.	Right; circular. Disch'd Jan. 5, 1864; pensioned.
1009	Stone, A., Pl., A, 23d Mass., age 23.	May 9, 9, '64.	Right; circular; by Surg. J. M. Rice, 25th Mass. Disch'd Aug. 25, 1864; pensioned.	1046	Torrence, S., Pl., H, 140th Penn., age 20.	May 12, 13, '64.	Right; circular; by Surg. J. W. Wishart, 140th Penn. Disch'd Jan. 12, 1865; pensioned.
1010	Stone, W., Pl., G, 49th Ohio, age 25.	Nov. 25, 25, '63.	Right; flap. Disch'd Sept. 13, 1864.	1047	Tracy, A., Corp'l, F, 1st Maine H. A., age 19.	July 18, 19, '64.	Right; circular; by Surg. H. F. Lyster, 5th Mich. Disch'd Dec. 19, 1864; pensioned.
1011	Stonking, J., Pl., F, 64th Ill., age 17.	June 27, 27, '64.	Right; circular; by Surg. J. T. Stewart, 64th Ill. Disch'd Dec. 17, 1864.	1048	Trevor, B., Pl., D, 55th Ohio, age 22.	Mar. 19, 19, '65.	Right; flap. Discharged June 15, 1865; pensioned.
1012	Straight, J. W., Pl., A, 33d Illinois.	Aug. 4, 4, '62.	Left; flap; by Surg. G. Rex, 33d Ill. Disch'd Sept. 8, 1862; pens'd.	1049	Trimbale, H. G., Serg't, C, 3d Ky., age 21.	June 2, 2, '64.	Left; circular; by Surg. J. B. Burris, 3d Ky. Duty Sept. 30, 1864; pensioned.
1013	Strayer, G. G., Pl., G, 4d Ohio, age 21.	May 1, 1, '63.	Left; double flap; by Surg. J. Pomorie, 43d Ohio. Disch'd Oct. 15, 1863; pensioned.	1050	Trumbull, W. C., Pl., C, 161st Pennsylvania.	July 1, 1, '63.	Left; flap. Disch'd August 27, 1863.
1014	Sullivan, A., Pl., G, 161st New York, age 29.	July 13, 13, '63.	Left; flap. Disch'd April 18, 1864.	1051	Therk, J. G., Lieut., 3d N. J. Battery, age 35.	Mar. 25, 25, '65.	Right; by Surg. W. C. Shurlock, 51st Penn. Discharged July 28, 1865; pensioned.
1015	Summerville, J., Pl., D, 135th Penn.	July 12, 12, '64.	Left; circular; by Surg. S. P. Chapin, 135th Pa. Discharged Jan. 10, 1865.	1052	Turner, E. S., Lieut., D, 121st New York.	July 2, 3, '63.	Left; by Asst. Surg. J. N. Miller, 120th N. Y. Disch'd Jan. 10, 1864; pensioned.
1016	Sutherland, S., Serg't, 5th Ohio Battery, age 31.	April 6, 6, '62.	Right; flap. Disch'd Nov. 1, 1862.	1053	Turner, M., Corp'l, A, 78th Ohio, age 22.	Mar. 21, 22, '65.	Flap. Discharged Aug. 5, 1865; pensioned.
1017	Swain, H. W., Serg't, I, 69th Indiana.	Aug. 30, 30, '62.	Left; by Asst. Surg. W. B. Witt, 69th Ind. Disch'd April 1, 1863; pensioned.	1054	Tuttle, E., Pl., G, 10th Vermont.	Sept. 17, 17, '62.	Left. Disch'd June 27, 1865.
1018	Swaney, D., Pl., F, 121st Penn., age 18.	July 2, 2, '63.	Left; antero-posterior flap; by Surg. W. Buck, 6th Me. Disch'd Nov. 30, 1863; pensioned.	1055	Tyler, P., Serg't, A, 126th New York, age 30.	May 5, 5, '64.	Right; circular; by Surg. J. W. Wishart, 140th Penn. Disch'd Dec. 24, 1864; pensioned.
1019	Swartwout, W. M., Lieut., G, 69th N. Y., age 28.	Aug. 13, 13, '64.	Left. Discharged Dec. 31, 1864; pensioned.	1056	Tyson, J. F., Pl., B, 95th Penn., age 23.	May 3, 3, '63.	Right; flap. Disch'd Sept. 18, 1863.
1020	Swartz, H. S., Pl., F, 53d Pa., age 16.	Sept. 29, 29, '61.	Left; circular. Discharged Jan. 26, 1865; pensioned.	1057	Ulmer, D., Pl., G, 13th Penn. Cav., age 24.	June 2, 2, '64.	Right; circular. Disch'd Dec. 6, 1864; died October 28, 1866.
1021	Swaney, C. P., K, 27th Iowa, age 24.	July 15, 15, '64.	Right; flap; by Surg. J. E. Sanborn, 27th Iowa. Disch'd June 4, 1865; pensioned.	1058	Utz, S., Pl., 13th N. Y. Battery, age 26.	July 12, 12, '64.	Right; circ.; by Surg. J. L. Dunn, 105th Penn. Disch'd May 17, '65.
1022	Tallmadge, H. R., Pl., K, 7th N. Y. H. A., age 24.	May 30, 31, '64.	Right. Disch'd October 24, 1864; pensioned.	1059	Uppograd, J., Pl., I, 211th Pennsylvania, age 26.	April 2, 2, '65.	Left; circular; by Surg. M. F. Bowes, 205th Penn. Disch'd June 30, 1865; pensioned.
1023	Taylor, G. W., Serg't, H, 9th N. J., age 25.	June 3, 3, '64.	Right; circular; by Surg. A. W. Woodhall, 9th N. J. Disch'd Aug. 23, 1864.	1060	Vail, A., Pl., F, 61st N. Y.	July 2, 2, '63.	Right. Disch'd Oct. 23, 1863; pensioned.
1024	Taylor, J., Lieut., H, 70th Ohio.	April 6, 7, '62.	Right. Discharged Nov. 1, 1862; pensioned.	1061	Valave, J., Pl., A, 1st Michigan.	June 27, 28, '62.	Left; flap. Disch'd Aug. 18, 1863; pensioned.
1025	Taylor, J. M., Pl., M, 11th Penn. Cav., age 21.	Aug. 25, 25, '64.	Right; flap; by Surgeon J. W. Wishart, 140th Penn. Disch'd Dec. 20, 1864; pensioned.	1062	Valentine, D., Pl., E, 9th New Jersey.	Dec. 14, 14, '62.	Left; by Surg. G. A. Otis, 27th Mass. Disch'd Jan. 14, '64; pens'd.
1026	Taylor, J. P., Pl., I, 141st Pennsylvania, age 32.	May 3, 3, '63.	Right. Disch'd August 7, 1863; pensioned.	1063	Van Brimmer, C., Pl., I, 3d Ohio.	Oct. 8, 8, '62.	Right. Discharged Mar. 28, 1863; pensioned.
1027	Taylor, W. B., Pl., E, 1st Tennessee, age 35.	Oct. 1, 1, '64.	Flap. Furloughed Nov. 25, 1864.	1064	Van Baskirk, M., Corp'l, A, 109th N. Y., age 29.	April 2, 2, '65.	Left; flap; by Surg. W. E. Johnson, 109th N. Y. Disch'd July 20, 1865; pensioned.
1028	Temperman, M. L., Pl., D, 61st N. Y., age 43.	June 17, 17, '64.	Left; flap; by Surg. J. W. Wishart, 140th Penn. To V. R. C. Feb. 4, 1865; pensioned.	1065	Vance, J. W., Pl., G, 4th West Virginia.	Nov. 25, 25, '63.	Left; flap; by Surg. S. P. Bonner, 47th Ohio. Disch'd Jan. 17, '65; pensioned.
1029	Thatcher, W., Corp'l, C, 16th Penn. Cav., age 21.	July 28, 28, '64.	Left; flap. Disch'd June 15, 1865.	1066	Van Etnan, D., Pl., I, 15th New Jersey.	June 1, 1, '64.	Right; circular; by A. Surg. C. E. Hall, 15th N. J. Disch'd Aug. 22, 1864; pensioned.
1030	Thomas, J. R., Pl., H, 1st Penn. Res., age 25.	Sept. 14, 16, '62.	Right; ant.-post. flaps; by Surg. L. W. Read, 1st Penn. Disch'd Dec. 10, 1863.	1067	Van Horn, C. A., Serg't, K, 1st Mo. Lt. Art.	Oct. 4, 4, '62.	Left; by A. Surg. E. L. Peckham, 1st Mo. Lt. Art. Disch'd and pens'd.
1031	Thomas, S., Pl., K, 12th Louisiana, age 20.	Nov. 30, Dec. 2, 1864.	Right; circular; by Surg. Fields, 12th La. Pro. Mar. Jan. 17, 1865.	1068	Vanlucven, A. G., Pl., A, 11th Penn., age 21.	May 3, 3, '63.	Left; by Surg. W. H. Twiford, 27th Ind. Disch'd Sept. 7, 1863; pensioned.
1032	Thomas, W. A., Pl., I, 30th C. T.	July 30, 31, '64.	Left; circular; by Surg. G. R. Potts, 23d U. S. C. T. Disch'd June 8, 1865.	1069	Vanglin, H. S., Pl., A, 8th N. Y. Heavy Art.	June 3, 4, '64.	Right; flap; by Asst. Surg. C. H. Pezz, 8th N. Y. Hvy Art. Disch'd Nov. 23, 1864; pensioned.
1033	Thompson, C., Pl., E, 91st Pennsylvania, age 20.	Oct. 28, 28, '64.	Right; flap; by Surg. W. G. Kier, 91st Penn. Disch'd Feb. 13, 1865; pensioned.	1070	Vaughn, M. S., Pl., M, 7th N. Y. Hvy Art., age 26.	June 11, 12, '64.	Flap. Discharged April 24, 1865; pensioned.
1034	Thompson, G. W., Pl., H, 15th Mass., age 17.	June 30, '62.	Left; by A. Confed. surg. Disch'd Mar. 21, 1861; pensioned.	1071	Vining, J., Pl., B, 4th Ohio Batt'n, age 27.	Aug. 26, 26, '64.	Right. Discharged Dec. 19, 1864; pensioned.
1035	Thompson, H., Pl., I, 6th Mich. Cav., age 24.	July 14, 14, '63.	Right; flap. Disch'd July 7, 1865; pensioned.	1072	Vinn, J., Pl., D, 148th New York, age 24.	June 3, 3, '64.	Left; by Asst. Surg. B. A. Clements, 148th N. Y. Disch'd Feb. 27, 1863.
1036	Thompson, J., Pl., K, 94th N. Y., age 31.	Mar. 31, April 1, 1865.	Left; circ.; by Surg. J. F. Dyer, 19th Mass. Disch'd April 8, 1863.	1073	Voight, H., Serg't, A, 54th New York.	Aug. 29, 30, '62.	Right; flap. Discharged May 21, 1864.
1037	Thompson, J. T., Pl., G, 133d Penn., age 17.	June 18, 18, '64.	Right; circular. Disch'd April 6, 1865; pensioned.	1074	Vreeland, C., Pl., D, 28th Penn.	Nov. 27, 27, '63.	Right; flap. Disch'd Jan. 15, '65; pensioned.
1038	Thompson, O., Pl., E, 9th N. Y. Heavy Artillery.	June 2, 2, '61.	Right; circular. Disch'd April 28, 1865; pensioned.	1075	Wade, B., Pl., G, 45th Colored Troops, age 27.	Oct. 13, 13, '64.	Right. Disch'd Aug. 25, 1863.
1039	Thompson, W., Pl., D, 1st Kentucky.	Oct. 23, 23, '61.	Left; circular; by Surg. S. G. Menzies, 1st Ky. Disch'd April 18, 1862; pensioned.	1076	Wahly, H., Serg't, H, 116th New York.	May 27, 27, '63.	Right. Disch'd Aug. 25, 1863.
1040	Thorn, E. W., Pl., F, 17th Maine, age 40.	May 12, 12, '64.	Left; circ.; by Sur. H. F. Lyster, 5th Mich. Disch'd Nov. 15, 1864.	1077	Walt, G. A., Pl., K, 123d New York, age 23.	May 11, 11, '64.	Right; circular. Disch'd May 20, 1865; pensioned.
1041	Tobbits, J. I., Pl., C, 19th Massachusetts.	June 27, 27, '62.	Right; by Surg. J. F. Dyer, 19th Mass. Disch'd July 19, 1862; pensioned.	1078	Waldron, J., Pl., C, 187th Pa., age 20.	June 18, 19, '64.	Left; circular. Discharged Jan. 5, 1865; pensioned.
				1079	Walker, B. J., Pl., H, 53d Virginia, age 19.	July 3, 3, '63.	Right; by Surg. C. S. Wood, 66th N. Y. Paroled Sept. 25, 1861.
				1080	Walker, G. O., Serg't, D, 2d Michigan.	July 11, 11, '64.	Right; flap; by Surg. E. J. Bonine, 3d Mich. Disch'd Sept. 10, 1863; pensioned.
				1081	Walker, H. D., Serg't, K, 110th Ohio, age 38.	Mar. 25, 25, '65.	Left; flap; by Surg. W. A. Child, 16th Va. Discharged June 28, 1865; pensioned.



No.	NAME, AGE, AND MILITARY DESCRIPTION.	DATES.	OPERATIONS, OPERATOR, RESULT.	No.	NAME, AGE, AND MILITARY DESCRIPTION.	DATES.	OPERATIONS, OPERATOR, RESULT.
1082	Walker, W. J., Corp'l, A, 31st Illinois.	Nov. 7, '61.	Right; by A. A. Surg. W. R. Burke. Disch'd Dec. 27, 1861; pens'd.	1119	White, J. D., Pt., C, 1st Mich. Cav., age 29.	Aug. 16, '61.	Right; flap. Disch'd July 16, 1865; pensioned.
1083	Wallace, I. M., Pt., F, 2d New Hampshire.	Aug. 29, '62.	Right; flap. Disch'd Oct. 17, '62.	1120	Whitehurst, W. C., Pt., C, 16th Va., age 22.	May 12, '64.	Circular.
1084	Walls, J., Pt., B, 182d Pa., age 23.	June 1, '64.	Right; circular; by Surgeon P. E. Hubon, 28th Mass. Disch'd Oct. 21, 1864; pensioned.	1121	Whiting, L. J., 2d Lieut., 1st R. I. Cavalry.	July 1, '62.	Left; flap; by Surg. Chas. O'Leary, U. S. V. Disch'd Dec. 21, 1863.
1085	Walter, C., Pt., C, 118th Pa., age 30.	May 6, '61.	Left; flap. Disch'd Sept. 20, 1864.	1122	Wilecox, C., Pt., K, 6th Wisconsin.	July 1, '63.	Right; Discharged Jan. 7, 1864; pensioned.
1086	Walter, J. W., Pt., I, 95th Pa., age 20.	May 12, '64.	Left; ant. posterior flap; by Surg. E. B. P. Kelly, 95th Pa. Disch'd Sept. 7, 1865; pensioned.	1123	Wiler, H., Corp'l, H, 8th New York Cavalry.	Sept. 14, '63.	Right; by Surg. A. Hard, 8th Ill. Cav. Discharged Mar. 17, 1864; pensioned.
1087	Walters, T., Pt., E, 48th New York, age 23.	July 30, '64.	Right; circular; by Surg. G. P. Greely, 4th New Hampshire. Disch'd June 24, 1865.	1124	Wilkinson, J., Pt., I, 20th Mass., age 32.	June 3, '64.	Left; circular; by Surg. N. Hayward, 20th Mass. Disch'd Oct. 11, 1864; pensioned.
1088	Ward, M., Pt., D, 105th Ohio, age 21.	Mar. 3, '65.	Right. Disch'd June 26, 1865; pensioned.	1125	Will, L. G., Corp'l, H, 3rd Missouri, age 26.	June 6, '64.	Right; by Surg. A. T. Bartlett, 33d Mo. Transferred to V. R. C. Oct. 23, 1864.
1089	Warner, C. E., Lieut.-Col., 30th Wisconsin, age 28.	Aug. 14, '64.	Left; by Surg. N. Hayward, 20th Massachusetts. Mustered out July 12, 1865.	1126	Willard, C. S., Pt., A, 30th Illinois, age 28.	April 2, '65.	Right; circular; by Surg. C. M. Clark, 30th Ill. Disch'd Aug. 18, 1865; pensioned.
1090	Warren, Jr., W., Pt., F, 24th Indiana.	May 16, '63.	Right; flap; by Surg. R. B. Jessup, 24th Ind. Disch'd Oct. 23, 1863; pensioned.	1127	Williams, B., Serg't, K, 60th Illinois, age 25.	Aug. 11, '64.	Right; flap; by Surg. J. Pogue, 60th Ill. Disch'd May 9, 1865; pensioned.
1091	Waterman, R., Pt., H, 62d New York, age 45.	Oct. 19, '64.	Right; flap; by Asst. Surg. J. M. Dickson, 33d Pa. Disch'd July 27, 1865; pensioned.	1128	Williams, J., Serg't, A, 48th C. T., age 36.	April 2, '65.	Left; ant. posterior flaps. Disch'd May 20, 1865; pensioned.
1092	Watson, W., Pt., I, 6th Colored Troops.	June 15, '64.	Left. Discharged Dec. 1, 1864; pensioned.	1129	Wilmarth, B. S., Serg't, D, 6th New York.	Dec. 12, '64.	Right; circular. Disch'd April 14, '65.
1093	Wears, R., Pt., F, 7th W. Va., age 22.	Dec. 13, '62.	Left; by Surg. J. Scott, 7th West Virginia. Disch'd Jan. 4, 1864; pensioned.	1130	Wilmott, N. S., Serg't, A, 27th Conn.	Dec. 13, '64.	Right; circular; by Surg. C. S. Wood, 60th N. Y. Disch'd Mar. 11, 1863; pensioned.
1094	Weaver, C. A., Pt., B, 12d N. Y., age 19.	July 12, '61.	Right; ant. post. flap; by Surg. E. A. Knapp, 12d N. Y. Disch'd Jan. 19, 1865; pensioned.	1131	Wilson, J. B., Pt., A, 7th Wisconsin, age 39.	May 23, '64.	Right; flap; by Surg. J. H. Beach, 23rd Mich. Disch'd March 29, 1865; pensioned.
1095	Weaver, G. M., Pt., K, 185th New York.	Mar. 29, '65.	Right; flap. Disch'd Aug. 11, 1865; pensioned.	1132	Wilson, J. F., Pt., K, 18th Missouri.	April 6, '62.	Left. Discharged; pensioned.
1096	Webb, T. C., Pt., H, 8th Indiana.	Mar. 7, '62.	Left; by Surg. J. K. Bigelow, 8th Ind. Mustered out and pens'd.	1133	Wilson, J. W., 2d Lieut., H, 5th Ind., age 25.	May 27, '64.	Right; flap; by Surg. E. B. Glick, 40th Ind. Disch'd Dec. 21, 1864; pensioned.
1097	Wehber, B., Pt., C, 2d N. Y. Mounted Rifles, age 19.	Mar. 31, '65.	Right; by Surg. R. T. Paine, 2d N. Y. Mounted Rifles. Disch'd July 13, 1865; pensioned.	1134	Winchester, R. A., Pt., D, 11th Penn.	Sept. 17, '64.	Right. Disch'd Dec. 22, 1862; pensioned.
1098	Weeks, C., Corp'l, H, 23d Cold Troops, age 27.	Sept. 30, '64.	Right; flap. Disch'd March 23, 1865; pensioned.	1135	Wirth, J., Corp'l, H, 6th Wisconsin.	Aug. 28, '62.	Right. Disch'd October 23, 1862; pensioned.
1099	Weinstock, E., Pt., E, 7th New York, age 26.	Dec. 13, '62.	Left; flap; by Surg. Chas. Gray, 7th N. Y. Must'd out Apr. 23, '63. Re-enlisted in V. R. C.	1136	Wolfe, M., Pt., A, 50th Penn., age 26.	May 9, '64.	Left; circular; by Surg. W. C. Shurlock, 51st Penn. Disch'd July 6, 1864; pensioned.
1100	Welch, L., Pt., A, 131st New York, age 52.	Sept. 19, '64.	Left; antero-post. flap; by Asst. Surg. J. G. Thompson, 77th N. Y. Disch'd May 20, 1865; pens'd.	1137	Wollert, A., Pt., I, 108th New York.	May 1, '63.	Right; flap. Disch'd July 24, 1863; pensioned.
1101	Welch, T., Pt., C, 40th Indiana.	Nov. 25, '63.	Right; by Surg. E. B. Glick, 40th Ind. Disch'd Feb. 4, 1864; pens'd.	1138	Wood, C. H., Pt., D, #53d Pennsylvania, age 19.	Mar. 31, '65.	Left; circular. Disch'd July 5, 1865; pensioned.
1102	Weller, J., Pt., I, 1st N. Y. Artillery.	July 3, '63.	Right; circular; by Surg. E. W. Thurm, U. S. V. Transferred to V. R. C.; pensioned.	1139	W——, H., Pt., H, 1st Mass. H. A., age 23.	Oct. 1, '64.	Right; flap; by Surg. O. Evarts, 20th Ind. Disch'd April 3, 1865; pensioned. Spec. 4123.
1103	Wells, A., Pt., E, 9th N. Y. S. M., age 21.	May 6, '64.	Left; circular. Disch'd Oct. 5, 1864.	1140	Wood, R., Pt., B, 10th Infantry, age 40.	May 24, '64.	Right; flap; by Surg. R. T. Paine, 2d N. Y. M. R. Disch'd July 12, 1865; pensioned. Spec. 4352.
1104	Wells, B. W., Pt., B, 76th New York.	Aug. 29, '62.	Left. Discharged Oct. 8, 1862; pensioned.	1141	Woods, J., Pt., C, 7th Missouri.	May 22, '63.	Right; flap. Discharged Sept. 9, 1863.
1105	Wells, S. R., Corp'l, G, 33d Illinois, age 25.	May 22, '63.	Right; flap. Disch'd Sept. 6, 1864.	1142	Woody, A., Pt., E, 14th Pennsylvania Cavalry.	Aug. 25, '63.	Right; by Surg. W. B. Wynne, 14th Penn. Cav. Disch'd Jan. 26, 1864; pensioned.
1106	Wells, W. H. H., Corp'l, D, 13th Mich., age 24.	Mar. 19, '65.	Right; circular. Disch'd June 12, 1865; pensioned.	1143	Woolsey, G. W., Pt., G, 1st Tenn., age 23.	Nov. 30, Dec. 1, 1864.	Left; circular; by Surg. J. R. Buist, 10th Penn. Transferred to Provost Marshal January 23, 1865.
1107	Wenk, J., Pt., K, 60th New York.	Dec. 11, '62.	Right; flap; by Surg. C. S. Wood, 60th N. Y. Disch'd Feb. 23, 1863; pensioned.	1144	Woolley, G. A., Pt., F, 1st U. S. S. S., age 22.	July 3, '63.	Right; flap. Discharged Jan. 11, 1864; pensioned.
1108	Werner, J. P., Pt., B, 3d Penn. Cav., age 19.	Dec. 3, '63.	Right; superior and inferior flaps; by Surg. W. B. Hezless, 3d Pa. C. Disch'd July 25, 1864; pens'd.	1145	Woodford, T., Pt., D, 7th Colored Troops, age 22.	Sept. 29, '61.	Left; ant. post. flap. Discharged April 17, 1865; pensioned.
1109	Werts, S., Pt., D, 124th Ohio, age 24.	May 27, '64.	Left; circular; by Surg. W. Patterson, 124th Ohio. Discharged Feb. 17, 1865.	1146	Wright, G., Pt., I, 2d Conn. Hvy Art., age 26.	Oct. 19, 20, '64.	Right; flap; by Surg. H. Plumb, 2d Connecticut Heavy Artillery. Discharged January 20, 1865; pensioned.
1110	Wetzell, M., Serg't, I, 35th Illinois, age 22.	April 2, '65.	Right; circular; by Surg. Wm. S. Walsh, 15th West Va. Disch'd June 17, 1865; pensioned.	1147	Wright, P. M., Pt., A, 71st Indiana.	Aug. 30, '62.	Right. Disch'd Nov. 21, 1862; pensioned.
1111	Wheeler, C., Lieut., D, 10th Massachusetts.	July 1, '62.	Left; by Surg. C. N. Chamberlain, 10th Mass. Resigned Dec. 20, 1862; pensioned.	1148	Wright, J. N., Pt., I, 98th New York.	June 1, '64.	Right. Disch'd Aug. 22, 1864.
1112	Wheeler, D. C., Pt., G, 22d New York.	Aug. 26, '62.	Right. Discharged; pensioned.	1149	Wyman, H. F., Pt., A, 3d Vermont, age 24.	May 12, '64.	Left; double flap; by Surg. D. M. Goodwin, 3d Vt. Discharged Oct. 31, 1864; pensioned.
1113	Wheeler, J. G., Pt., I, 101st New York.	July 1, '62.	Right; by Surgeon T. Cunningham, 101st N. Y. Disch'd Aug. 26, 1862; pensioned.	1150	Yokes, W., Pt., C, 29th Ohio, age 32.	May 8, '61.	Right; antero-posterior flap; by Asst. Surg. C. C. Byrne, U. S. A. (Excision of radius May 8th.) Disch'd Sept. 1, 1864; pensioned.
1114	Whims, J., Pt., H, 140th Pennsylvania, age 24.	May 12, '64.	Right; lateral flap; by Surg. J. W. Wishart, 140th Pa. Disch'd Dec. 14, 1864; pensioned.	1151	Yonles, A., Pt., H, 45th Illinois.	April 6, '62.	Right. Disch'd July 12, 1862; pensioned.
1115	Whims, J. K., Pt., H, 140th Pa., age 27.	Dec. 9, '64.	Left; flap; by Surg. J. W. Wishart, 140th Penn. Disch'd May 20, 1865; pensioned.	1152	Young, A. H., Pt., A, 6th Wisconsin.	Sept. 17, '62.	Left; (also amputation of right forearm;) by Surg. J. McNulty, U. S. V. Discharged Nov. 16, 1863; pensioned.
1116	Whitaker, A. C., Pt., B, 2d N. C. Batt'n, age 20.	July 1, '63.	Left; circular. Furloughed Oct. 5, 1863.	1153	Young, H., Pt., C, 1st Maine Cavalry.	June 19, '63.	Right. Discharged Nov. 17, 1863; pensioned.
1117	White, H. K., Pt., A, 6th Maine, age 21.	June 1, '64.	Left; flap; by Surg. Wm. Buck, 6th Maine. Disch'd Aug. 15, 1864; pensioned.	1154	Young, W. S., Pt., A, 11th Kentucky.	June 3, '63.	Right. Discharged; pensioned.
1118	White, J., Pt., B, 42d N. York, age 22.	Sept. 17, '62.	Right; circular. Disch'd Dec. 5, 1862. Subsequently served in Veteran Reserve Corps.	1155	Zwango, J., Pt., B, 7th N. Y. Hvy Art., age 32.	June 3, '64.	Right; circular; by Surg. G. L. Potter, 143th Pa. Disch'd Sept. 27, 1864.

The series includes one case of primary amputations of both arms in the upper thirds; a similar fatal case will be noticed hereafter.

CASE 1519.—Private J. F. Hodgdon, Co. I, 11th Massachusetts, aged 21 years, received a severe injury of both arms by the premature discharge of a cannon at Winchester, June 11, 1833. He remained for some weeks at Winchester, where both his arms were amputated on the day of injury. On July 29th, he reached Harper's Ferry Hospital, and on the following day he entered Jarvis Hospital, at Baltimore. Assistant Surgeon D. C. Peters, U. S. A., noted: "Amputation of both arms." On August 27th, the patient was transferred to Mason Hospital, at Boston, whence he was discharged on September 10, 1833, and pensioned. In February, 1871, an account of this case was communicated by Dr. T. C. Smith, of Middleport, Ohio, late Surgeon 116th Ohio, as follows: "During the engagement at Winchester, June 11, 1833, Private Hodgdon had both arms torn off to the elbow by the premature discharge of a gun, which also caused the lower halves of the humeri to be fractured in several places, and the surrounding flesh to be fearfully burnt and torn into shreds. The tongue, eyes, face, neck, and anterior part of the chest were all frightfully burned, and powder driven into the flesh. Over nearly all this surface the skin was destroyed. At first he was left for dead; but signs of animation soon became manifest, and he was then carried to my regimental hospital, where stimulants and cold water were freely used, and reaction was soon established. He was a very large, robust, and powerfully muscled man. Assistant Surgeon M. F. Bowes, 12th Pennsylvania Cavalry, at first had him in charge. After reaction became established he was chloroformed, and Dr. Bowes amputated the right arm and I the left at the same time, both near the shoulder joints. There was very slight loss of blood. Stimulants were used freely, and he reacted rapidly from the effects of the chloroform and the operation. The accident occurred at one o'clock P. M., and the operations were completed and the stumps dressed by six o'clock P. M. At seven o'clock P. M., when we were driven from our position too rapidly to save anything, I had him carried to a distant house. Being among the captured medical officers, I obtained a pass and permission to search for him on the 16th. I found him as I had left him, under the shade of a large tree, the residents having supplied a little food and plenty of water. I then had him, with others, conveyed to the hospital in Winchester, where, with careful nursing, good feeding, and tonics, he made a rapid recovery. One year later, I learned from a reliable source that he was well, and had an apparatus fixed by which he was enabled to peddle about the vicinity for a livelihood. Dr. Bowes kindly assisted me at various times with the case." In a statement of artificial arms furnished by Mr. Lincoln, of Boston, in February, 1854, both amputations are described as having been performed by the "circular method." The pensioner died on June 30, 1871, eight years after the operation. The immediate cause of his death is not known.

There were also practised, simultaneously with the arm amputations, in five instances, amputations of the opposite forearm,—in one, an amputation through the wrist joint,—in two, amputations in the thigh,—and amputations of the leg, great toe, and thumb, each in one case. Altogether there were fifty-seven cases in which serious wounds had been received elsewhere than in the mutilated arm.

Among the recoveries were also numerous instances in which the patients survived consecutive operations. Thus, five underwent secondary amputation at the shoulder joint,<sup>1</sup> and have already been enumerated in TABLE XLVIII. There were two successful ulterior thigh amputations,—one for shot fracture, one for compound fracture from a railroad accident. There were several important ligations. In eight cases osteomyelitis resulted favorably, with the elimination or extraction of long tubular sequestra. The following is one of these examples:

CASE 1650.—Private R. Wood, Co. D, 20th U. S. Infantry, aged 40 years, was wounded at North Anna, May 24, 1864, and received into the field hospital, 1st division, Ninth Corps. Surgeon M. K. Hogan, U. S. V., recorded: "Right forearm blown off; upper arm amputated." On May 29th, the wounded man reached Mt. Pleasant Hospital, at Washington. Assistant Surgeon C. A. McCall, U. S. A., reported: "Gun-shot wound of right arm. Flap amputation at upper third performed, on the field, by Surgeon R. T. Paine, 2d New York Mounted Rifles. Progress favorable." The patient was transferred, on August 26th, to Fort Columbus, New York Harbor, where he subsequently entered the Post Hospital. On March 25, 1865, Assistant Surgeon P. S. Conner, U. S. A., removed the specimen, which he contributed to the Museum, and which is represented in the annexed wood-cut (FIG. 516), consisting of a sequestrum four inches long, removed from the face of the stump. The patient was discharged from service on July 12, 1865, and pensioned. He has not been heard from since September 4, 1863.



FIG. 516.—Cylindrical sequestrum after amputation of right arm for shot injury. *Spec.* 4352.

There were twenty instances of grave secondary hæmorrhage among the successful primary amputations at the upper third, seven requiring ligature of main arterial trunks, several others treated by torsion or ligature of the circumflex or other branches of the axillary, and several controlled by pressure and styptics.

<sup>1</sup>Cases of Cochran, Collins, Dahl, Frain, and Powers, pp. 647-8.



There were, in this series, three instances of consecutive ligation of the *subclavian*. One of these is here detailed; and the others will be again noticed in the section on ligations, in the future Chapter on Hæmorrhage:

CASE 1651.—Private E. S. Kellogg, Co. A, 89th New York, aged 21 years, was wounded at Petersburg, June 18, 1864. Two days afterward he was received into hospital at Fort Monroe, whence Assistant Surgeon E. McClellan, U. S. A., reported: "Amputation of left arm at upper third." On July 6th, the patient entered the Christian Street Hospital, at Philadelphia. Acting Assistant Surgeon R. J. Levis reported: "Gunshot wound of left arm. Amputation by flap method was performed the day after the injury. The stump commenced to slough badly, involving the main artery, causing recurring hæmorrhage for several hours on July 25th, and necessitating ligation of the axillary artery. This was performed at the second portion of the vessel by Acting Assistant Surgeon G. B. Boyd, ether being used, and prompt reaction following. The stump became healthy in appearance, and the patient did well until August 8th, when hæmorrhage occurred from the point of ligation. Acting Assistant Surgeon R. J. Levis then ligated the subclavian artery over the first rib. Ether was again used at this operation, and reaction was very slow. No further hæmorrhage took place until August 15th, when another attack was controlled by plug, iron, pressure, etc." On September 30th, the patient was transferred to South Street Hospital, whence he was discharged on April 6, 1865, and pensioned. In his application for commutation of artificial limb he stated that Surgeon T. H. Squire, 89th New York, performed the amputation upon his arm. Examiner W. W. Potter, Washington, D. C., March 6, 1871, certified: "Physical condition not good. Has sustained amputation at the middle third of the left arm. Secondary hæmorrhage occurred, and it became necessary to ligate the axillary artery; the ligature sloughed and the subclavian was tied. This operation only succeeded in saving his life through the indefatigable attentions of an assistant, who compressed the artery for six weeks." Examiner J. G. Orton, of Binghamton, New York, subsequently reported: "Has much pain in parts, vertigo, and loss of blood from mouth upon any exertion; he is unable to do anything by manual labor for his support." The pensioner was paid June 4, 1875.

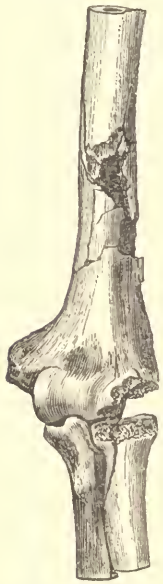

FIG. 517.—Double shot fractures of the humerus and radius. *Spec.* 3227.

There were also, among the successful upper-third amputations, four instances of successful ligation of the *brachial* for consecutive bleeding.<sup>1</sup>

*Gangrene* proved a serious complication in fifteen cases.<sup>2</sup> The following is an example, illustrating, in addition, double shot perforations of the shaft and elbow joint:

CASE 1652.—Private P. Martin, Co. A, 5th New Jersey, aged 27 years, was wounded in the left arm, at Spottsylvania, May 10, 1864. The injured limb was amputated at a field hospital, on the following day, by Surgeon C. C. Jewett, 16th Mass. The specimen (FIG. 517) was contributed to the Museum by the operator, and consists of "the lower half of the right humerus and the upper portions of the bones of the forearm; the inferior portion of the outer condyle and the anterior face of the head of the radius are fractured, and the humerus is comminuted at the junction of the lower thirds. The injuries appear to have been inflicted by separate missiles, probably fragments of shell." (*Cat. Surg. Sect.*, 1866, p. 147.) On May 14th, the patient reached King Street Hospital, Alexandria, where Surgeon E. Bentley, U. S. V., recorded the following details of the case: "Amputation of left arm at upper third, performed on the field. May 16th, parts of flap gangrenous. May 18th, line of demarcation forming. May 23d, portion sloughed off. May 29th, doing well; has severe pain at times. Opiates and water dressings used. June 10th, doing well. June 28th, last ligature came away." On June 29th, the patient was transferred to Philadelphia, where he was treated at Christian Street and Broad and Cherry Streets Hospitals. Subsequently he entered Ward Hospital, Newark, and lastly, on April 4, 1865, he was admitted to Central Park Hospital, New York City. Surgeon J. J. Milhan, U. S. A., reported: "Gunshot wound of left elbow joint. Flap amputation at junction of upper and middle thirds. Chloroform used. Wound healed on admission." The patient was discharged on June 16, 1865, and pensioned. He was paid June 4, 1875. In his application for commutation for an artificial limb, in 1870, the pensioner says "the stump remains very painful."

In the eleven hundred and fifty-five recoveries from primary amputation at the upper third of the arm for shot injury above noticed, the wounds were inflicted by large projectiles in about one case in nine.<sup>3</sup> In fifty-seven cases, the wound of the arm was complicated by grave injury in some other region. Pathological specimens from twenty-six of the cases, and photographs of twenty-three, are deposited in the Museum.<sup>4</sup> Among the survivors of this operation, the number of deaths after discharge is remarkably small.<sup>5</sup>

<sup>1</sup>Cases of Boynton (112), Goodwin (426), McGraw (688), and Philbrick (819).

<sup>2</sup>Cases of Aydt (23), Basom (57), Bissell (87), Boynton (112), Findley (367), A. K. Goodwin (426), Jordan (566), Jukes (568), Kellogg (574), Knapp (600), Mason (663), Neal (765), Shelton (938), Warren (1090), and Wyman (1149).

<sup>3</sup>The reports specify the causes of injury as follows: By large solid cannon shot, 15; by shell fragments, 91; by grape, canister, or shrapnel, 17; by bursting of cannon, 2; by premature explosion of cannon, 4; by mine explosion, 1; by musket, carbine, pistol, or other small projectiles, 1025.

<sup>4</sup>Six of the specimens are figured with the text. The numbers of the specimens are noted in the table. The photographs illustrate cases 8, 188, 235, 249, 306, 348, 414, 422, 442, 450, 507, 509, 526, 551, 564, 660, 785, 869, 892, 935, 1099, 1118, 1138.

<sup>5</sup>Only eight deaths have come to the knowledge of this Office, among the survivors of primary amputation at the upper third for shot injury. Major J. W. Crosby, 61st Pennsylvania (Case 216), was killed in action April 2, 1865.

*Fatal Cases.*—Of the thirteen hundred and thirty-eight primary amputations in the upper third of the arm after shot injury, one hundred and eighty-three had fatal terminations. A few instances are detailed:

CASE 1653.—Private *J. P.*—, Co. A, 12th Georgia, aged 19 years, was wounded at Monocacy, July 10, 1864, and was conveyed to Frederick. Assistant Surgeon R. F. Weir reported his admission to the general hospital on the same day with a bad shot comminution of the left humerus. He was in poor health, suffering from the effects of chronic diarrhœa. After the administration of restoratives and a period of rest under supporting treatment, on July 12th Acting Assistant Surgeon T. E. Mitchell amputated the arm at the upper third by double flaps. "The diarrhœa was very troublesome, though every effort was made to relieve him by the use of tonics, astringents, and stimulants. The stump commenced sloughing soon after the amputation, and continued to do so for nearly two weeks, until the bone protruded about two inches. In the early part of August there was some amelioration in the diarrhœa, but he had a distressing cough, and chills daily, from August 12th to 15th, evidently due, as the sequel proved, to pyæmic infection. He had cod-liver oil, milk punch, and other stimulants, but steadily grew worse, and died August 21, 1864. At the autopsy, made twelve hours after death, the right lung was found to abound with metastatic abscesses, and in the left there was diffused tuberculous deposit." Dr. Mitchell presented to the Army Medical Museum the preparation of the shattered humerus represented by the annexed wood-cut (FIG. 518). It is a good example of the longitudinal fissuring frequently inflicted in this region by conoidal balls.

A successful case of amputation of both arms in the upper thirds has been cited on page 715; in a similar case, death resulted two months after the operation:

CASE 1654.—Private *W. Bawn*, Co. G, 16th Maine, aged 26 years, was wounded at Fredericksburg, December 13, 1862. He was admitted into the hospital of the 2d division, First Corps. Assistant Surgeon H. Allen, U. S. A., reported: "Patient was wounded by a shell in the right arm and by a minié ball in the left arm. Both arms were amputated on the field, December 14th, at the junction of the upper and middle thirds. He was much exposed until December 23d, when admitted to Lincoln Hospital. He was then doing well, with the stumps nearly healed, had good appetite and spirits, and sat up all day. He remained so for two weeks, and then suddenly, without any apparent cause, had a slight chill and began to decline. Ordered tonics, with wine and cordial stimulants. He remained about the same, with but little change. January 20th, has had slight rigors, being restless and delirious at times, with all the symptoms of irritative fever. Fluctuations were discovered over the nates, and two abscesses being opened discharged freely. Tongue dry and brown. Mineral acids and tonics ordered freely, with nourishing diet, beef tea, milk punch, etc. Not much improved; abscesses continue discharging; pus burrowing beneath the gluteal muscles; profuse perspiration day and night, with slight rigors at times, and occasional troublesome delirium. Continued stimulants and supporting treatment. Sinuses laid open as soon as discovered. Patient passed stools involuntarily. The integument over the sacrum and gluteal regions looked badly, and the sloughing in a few days assumed a gangrenous character. Fermenting poultices applied. February 10th, perspiration not so profuse; no rigors; delirium ceased. In a few days the integument over the entire sacrum and part of the gluteal region had sloughed away; the surface, though still discharging, was much improved, also the constitutional symptoms. There was no disposition, however, to granulate and heal. Mineral tonics were continued freely, and good diet. The ulcers again become gangrenous, perspiration profuse, delirium set in, and the patient sank rapidly. He died on February 22, 1863. The *post-mortem* examination was made forty hours after death. The subject was five feet eight inches tall, and was at this time emaciated and moderately rigid. The brain weighed forty-eight ounces, was light colored and firm. The right lung weighed fourteen ounces, the left lung eleven and one-quarter ounces. The whole of the right lung and the second lobe of the left lung were in a state of incipient tubercular degeneration. Two masses of diseased lobules (consolidated) were found in the lower part of the second portion of the left lung. The melanic matter upon the first lobe of the same lung was ribbed. The bronchi were slightly congested in this case, and the bronchial glands were black. The heart weighed ten and one-quarter ounces; the external adipose tissue was abundant. The substance of the organ was firm and of a pale color; the valves were slightly thickened and opaque. About the junction of two of the segments of the aortic valve was a hard cartilaginous mass, lifting the valves from the side of the aorta and encroaching upon its calibre. In the place of the corpus arantii of the opposite valve was another mass whose section was cartilaginous and translucent, and which broke on pressure, discharging a clear gelatinous matter. The mesenteric glands were much enlarged. The mesocolic were large and black. Two ounces of a light-yellow bile was taken from the gall bladder. The liver weighed seventy-three ounces, and measured eleven and one-quarter by seven and a half by three and three-quarters inches. It was of a pinkish-brown color and firm consistence. It was mottled externally yellow and crimson with white stellar spots. The acini were distinct on a cut surface, but not on the torn. The spleen weighed ten and a half ounces, and measured six and a half by four and a half inches. Its color was light red and its consistence firm. Its trabiculæ were marked. The pancreas measured eight by one and one-quarter and five and three-quarters inches, and weighed three and one-quarter ounces. It was of firm consistence and natural color. The supra-renal capsules together weighed three-eighths of an ounce. They were large and of a burnt-ochre color. Each kidney weighed six and a half ounces, and measured four and a half by two and a half inches. They were of a light reddish slate color and firm consistence. The cortical lines were distinct. One or two small cysts were found in the anterior part of the right kidney. The fundus of the stomach was congested, and the mucous membrane was slightly soft in the duodenum. It was of a slate color and pitted near the pylorus. Throughout the small and large intestine the mucous lining was of a slate color, varied by bile, stained in the middle third of the jejunum. The first third of the ilium was purple, the second stained with bile, and the third



FIG. 518.—Comminution of the left humerus by a musket ball. Spec. 3952.



dark again, where also it was soft. In the ascending colon it was of a grayish green color. The valvulae were marked throughout the intestine except in a patch of about six inches in the lower half of the ilium. The ilium was congested in its upper third. Tubercles were irregularly scattered in the lower third of the ilium from the smooth patch to the valve. In the large intestine, at the hepatic flexure, were two small ulcers with dark bases. Others with jagged edges were irregularly scattered through the large intestine, but principally grouped along the longitudinal bands. Some of these were one-quarter of an inch in diameter. In the rectum were marked and covered with false membrane, under which was a great number of small ulcers. The intestines weighed fifty-three ounces. A very large bed-sore was found over the sacrum, leaving the spinous and transverse processes exposed. The ulceration extended to the posterior spines of the ilium. This sent two great wings down under the skin and fascia, which had opened over either trochanter major. Ulcers of the right hip and the main sore; another small and separated ulcer was found just above the first mentioned. With exception of the last, the openings were surrounded by black and discolored edges which looked as if gangrene would soon supervene."



FIG. 519.—Segment of shaft of right humerus shattered by a conoidal ball, which is attached. Spec. 4142.

Seventy-six patients succumbed within three weeks after operation.

CASE 1655.—Corporal G. H. G——, Co. K, 90th Pennsylvania, was wounded at Petersburg, June 19, 1864, in an assault of the Fifth Corps. He was taken to the field hospital of his division, the third, and Surgeon L. W. Read, U. S. V., reported a "shot wound of the back and arm, necessitating amputation of the latter a little below the surgical neck. The patient was sent to City Point on the following day." Surgeon W. L. Faxon, 32d Massachusetts, reported the patient's arrival at the depot hospital, and recorded the operator's name as Surgeon Joseph H. Hayes, 70th Pennsylvania. The progress of the case is not described. The patient died July 1, 1864. Surgeon Hayes contributed the specimen (FIG. 519) of the comminuted portion of the right humerus, with the missile that inflicted the injury attached. The comminution extends for six inches, and presents a fair example of the effects of the impact of a minié ball upon the compact tissue of the humerus when impinging at a comparatively moderate velocity.

The one hundred and eighty-three unsuccessful amputations at the upper third of the arm were practised on one hundred and eighty-two patients, of whom twenty-three were Confederates. The limb implicated was specified in one hundred and seventy cases, the operations on the *right* side being the most numerous (91 right, 79 left). Twenty-three cases were complicated by serious wounds in other regions, and in twenty-three other simultaneous or consecutive operations were practised.<sup>1</sup> Four patients died with tetanus and one with variola; but pyæmia or septicæmia were the most frequent causes of death.<sup>2</sup>

TABLE LXIX.

Condensed Summary of One Hundred and Eighty-three Unsuccessful Cases of Primary Amputation in the Upper Third of the Shaft of the Humerus.

NO.	NAME, AGE, AND MILITARY DESCRIPTION.	DATES.	OPERATIONS, OPERATOR, RESULT.	NO.	NAME, AGE, AND MILITARY DESCRIPTION.	DATES.	OPERATIONS, OPERATOR, RESULT.
1	Adams, J. C., Pt., K, 126th N. Y., age 26.	June 18, '64.	Left; flap. Died July 26, 1864.	10	Bailey, D., Pt., C, 11th Penn., age 35.	June 2, '64.	Left; circular. Died July 7, 1864, pyæmia.
2	Alsbrook, H. H., Serg't, A, 19th Ga., age 23.	May 16, '64.	Circular. Died June 13, 1864, pyæmia.	11	Bailey, I. K., I, 5th Cav., age 21.	June 9, '63.	Right; (also removal of portion of tibia.) Died June 15, '63, pyæmia.
3	Anders, W. M., Pt., C, 12th Georgia.	Mar. 25, '65.	Left; by A. Surg. E. M. Smyser, 48th Penn. Died Mar. 27, 1865.	12	Baker, N. I., Pt., E, 12th N. H., age 18.	May 3, '63.	Left; tetanus; re-amp. May 16, '63, died May 19, 1863, tetanus.
4	Andrews, C. N., Adj't, 85th Illinois, age 21.	June 27, '64.	Left; by Surg. M. M. Hooten, 86th Ill.; re-amputation shoulder joint. Died July 23, 1864, gangrene.	13	Baldwin, H. M., Lieut., M, 5th Artillery.	Oct. 19, '64.	Left; flap; by Surg. H. Plumb, 2d Conn. Art.; hemorrhage. (Pen. w'd thorax.) Died Nov. 9, toxæmia.
5	Armour, J. A., Lieut., F, 80th Illinois.	June 1, '64.	By Surg. S. H. Kersey, 36th Ind. Died June 11, 1864.	14	Barker, J. H., Corp'l, E, 142d Penn., age 25.	May 12, '64.	Left; ant.-post. flaps; hemor.; lig. of brachial. Died June 1, 1864.
6	Austin, D. M., Pt., I, 60th Virginia.	Sept. 19, '64.	Circular. Died October 3, 1864, pyæmia.	15	Barton, J. H., Pt., K, 11th Conn., age 25.	June 18, '64.	Right; flap. Died Aug. 8, 1864, pyæmia.
7	B——, A.....	Feb. 16, '63.	Died Feb. 24, 1862, exhaustion.	16	Bates, N. S., Pt., I, 19th Georgia, age 23.	Aug. 19, '64.	Right; ant.-post. flap; by Sur. A. A. White, 8th Md. Died Sept. 9, '64.
8	Babeock, A. J., Serg't, H, 2d Mass.	July 3, '63.	Left; flap. Died August 6, 1863.	17	Bawn, W., Pt., G, 16th Maine, age 26.	Dec. 13, '62.	Both; junction of upper and middle thirds. Died Feb. 22, 1863.
9	Bacon, C., Private, D, 4th Colored Troops.	Feb. 14, '65.	Right; circular; by A. Surg. H. C. Merryweather, 5th C.T. Died February 21, 1865.	18	Beales, J. E., Pt., II, 148th Penn., age 19.	July 3, '63.	Left; gangrene; hemorrhage. Died Aug. 8, 1863, exhaustion.

<sup>1</sup> Unsuccessful excision in the forearm was essayed in one case; in another, the fingers of the opposite limb were amputated, and an attempt to excise the injured portion of the humerus was abandoned. The opposite forearm, in one case, the opposite arm in two cases, were removed at the time of the amputations here enumerated. Other simultaneous or subsequent operations included: 1 amputation of the thigh, 1 amputation of the leg, an excision of several inches of the tibia, a re-amputation at the shoulder, 2 re-amputations in the continuity, 4 ligations of the brachial, 2 ligations of the axillary, 2 ligations of the subclavian. The fatal double amputation in the case of Bawn is counted twice.

<sup>2</sup> The causes of death are recorded as: Pyæmia, 42 cases; exhaustion from suppurative or surgical fever, 25; erysipelas, 2; debility, 3; anemia, 2; emaciation, 1; amputation of thigh, 1; tuberculosis, 2; small-pox, 1; typhoid fever, 2; pneumonia, 7; hydrothorax, 1; secondary hemorrhage, 9; gangrene, 6; chronic diarrhoea, 6; tetanus, 4. In 68 cases the cause of death was not specified.

No.	NAME, AGE, AND MILITARY DESCRIPTION.	DATES.	OPERATIONS, OPERATOR, RESULT.	No.	NAME, AGE, AND MILITARY DESCRIPTION.	DATES.	OPERATIONS, OPERATOR, RESULT.
20	Beard, G. G., Pt., G, 9th Maine.	Oct. 27, '64.	Right; by Surg. D. McFalls, 143d New York. Died Nov. 20, 1864, exhaustion.	61	Furson, S., Pt., H, 1st Virginia, age 36.	July 3, '64.	Left; (also fracture of leg.) Died Aug. 29, 1864, pyæmia.
21	Beamen, J., Pt., D, 11th Conn., age 35.	Mar. 14, '64.	Left; circ.; by Surg. G. Derby, 23d Mass. Died April 11, '64, pyæmia.	62	Fitzpatrick, J. P., Pt., G, 52d New York, age 37.	May 18, '64.	Left; ant.-post. flap; by A. Surg. J. T. Duffield, 7th Ind.; hæmorrhage; ligation of brachial. Died June 4, 1864, pyæmia.
22	Bessey, J., Pt., K, 3d N. Y. Artillery, age 20.	June 30, '64.	Right. Died July 23, 1864, tetanus.	63	Follar, S. G., Serg't, G, 2d Ohio Cavalry, age 23.	May 7, '64.	Right; circular. Died June 2, '64.
23	Blake, E., Pt., Cavalry's Battery.	July 2, '63.	Circular. Died August 18, 1863.	64	Foster, J. B., Pt., G, 83d New York, age 39.	May 6, '64.	Right; flap; hæmorrhage. Died June 17, '64, typhoid pneumonin.
24	Bowe, C., Capt., K, 6th Ohio Cavalry.	Oct. 14, '63.	Right; flap; by Surg. W. B. Reznor, 6th Ohio Cavalry. Died Nov. 4, 1863.	65	Foster, W., Pt., I, 5th N. Jersey, age 25.	June 16, '64.	Left; flap. Died July 7, 1864.
25	Bowers, H. W., Pt., D, 87th Penn.	Sept. 19, '64.	Right. Died Oct. 28, 1864.	66	Fratic, W. J., Serg't, F, 25th S. C., age 32.	Aug. 21, '64.	Left; flap. Died Sept. 11, 1864.
26	Boy, J., Pt., A, 89th Ohio, age 20.	Mar. 21, '65.	Right. Died April 6, 1865, exhaustion.	67	Frank C., Pt., D, 4th N. York Cavalry, age 20.	June 21, '64.	Right; flap; hæmorrhage. Died July 16, 1863, pyæmia.
27	Brackett, J., Corp'l, H, 44th N. Y., age 25.	July 2, '63.	Right; circular; hæmorrhage. Died July 5, 1863, exhaustion.	68	Freese, L. P., Pt., C, 138th Pa., age 29.	June 3, '64.	Right; flap; (also wound of lung.) Died July 28, 1864, debility.
28	Brandenburg, H. S., Pt., H, 1st N. Y. Cavalry.	May 15, '64.	Left. Died.	69	Fry, J. C., Pt., B, 60th Ohio.	May 26, '64.	Right; by Surg. W. C. Shurlock, 51st Pa. Died June 2, 1864.
29	Brennan, F., Lieut., H, 97th N. Y.	May 6, '64.	Right; flap. Died May 7, 1864.	70	Fryer, J. F., Corp'l, A, 53d Penn., age 34.	June 3, '64.	Right; circular; by Surg. G. L. Potter, 145th Pa.; hæmorrhage; lig. Died June 15, 1864, pyæmia.
30	Briner, J., Pt., D, 16th Indiana.	Aug. 30, '62.	Died Sept. 30, 1862, pyæmia.	71	Galbert, W. C., Corp'l, I, 32d Mass.	May 12, '64.	Right; flap; (also wound of nates.) Died July 15, 1864.
31	Burt, A., Pt., I, 72d Ind.	May 27, '64.	Left. Died June 25, 1864.	72	Gardner, J. H., Corp'l, K, 90th Penn.	June 19, '64.	Right. Died July 1, 1864. Spec. 4142.
32	C——, W. H., Pt., D, 12th Georgia, age 19.	July 9, '64.	Right; circular; by A. A. Surg. T. E. Mitchell. Died July 22, 1864, pyæmia. Spec. 3820.	73	Gardson, H., Pt., Young's Battery, age 21.	Sept. 3, '64.	Left. Died Sept. 16, 1864.
33	C——, N. W., Pt., E, 7th N. Y. H. A., age 16.	June 18, '64.	Left; ant.-post. flap. Died July 20, 1864. (Excision of bone of forearm.) Spec. 488.	74	Graback, H., Pt., F, 8th Ohio, age 21.	May 5, '64.	Right; circular; by Surg. D. W. Maul, 1st Del. Died June 7, 1864, exhaustion.
34	Caffey, H. P., Pt., H, 3d Alabama, age 26.	July 3, '63.	Right; circular; by Surg. J. M. Hayes, C. S. A. Died Sept. 13, 1863, exhaustion.	75	Graham, W., Pt., K, 67th Penn.	May 5, '64.	Left. Died May 20, 1864.
35	Cain, J. W., Pt., E, 20th Illinois.	April 6, '62.	Erysipelatous-inflammation. Died April 16, 1862.	76	Gusset, S., Pt., F, 8th N. C., age 38.	Sept. 29, '64.	Right; (also wound of left arm.) Died Oct. 11, 1864, exhaustion.
36	Canan, M., Pt., C, 11th Penn., age 20.	May 8, '64.	Right; circular; by A. Surg. W. F. Osborne, 11th Penn. Died May 27, 1864, pyæmia.	77	Hardendorf, R., Pt., E, 105th N. Y., age 21.	July 30, '64.	Right; ant.-post. flap; by Surg. W. C. Shurlock, 51st Pa.; hæmorrhage. Died Sept. 3, '64, pyæmia.
37	Cannan, A., Pt., C, 183d Penn., age 40.	Aug. 16, '64.	Right; flap; by Surg. Williams. C. S. A. Died April 14, 1865, consumption.	78	Hardy, J. H., Pt., K, 60th Ohio.	July 17, '64.	Right; bi-lateral flap; diarrhoea. Died June 21, 1864.
38	Clark, R., Pt., D, 13th C. T., age 18.	Dec. 16, '64.	Both; flap; right at upper and left at middle third; by A. A. Surg. J. S. Giltner. Died Dec. 19, '64.	79	Henniken, J., Corp'l, G, 26th Illinois.	Aug. 17, '64.	Right; by Surg. J. C. Hutchinson, 15th Mich. Died Aug. 30, 1864.
39	Cole, C., Pt., A, 26th Mich.	June 3, '64.	Right; by Surg. J. W. Wishart, 140th Penn. Died July 6, 1864.	80	Hensley, J., Serg't, I, 74th Illinois.	May 15, '64.	Right. Died June 16, 1864.
40	Cooper, H., Corp'l, G, 97th Ohio.	June 22, '64.	Left; by Surg. E. B. Glick, 40th Ind. Died July 12, 1864.	81	Heringen, O., Capt., F, 7th N. Y., age 39.	Dec. 13, '62.	Right; flap. Died Jan. 30, 1863, pyæmia.
41	Corwin, J. H., Pt., M, 15th N. Y. H. A., age 25.	May 6, '64.	Right; flap. Died June 21, 1864, typhoid fever.	82	Hesser, M., Pt., G, 52d New York, age 29.	June 17, '64.	Right; circ.; by Surg. G. L. Potter, 145th Pa. Died July 2, 1864, gangrene.
42	Curran, F., Pt., D, 102d Penn., age 34.	May 5, '64.	Left; oval flap; erysipelas. Died June 1, 1864, pyæmia.	83	Hicks, H., Pt., B, 7th Michigan.	Sept. 19, '64.	Left; oval skin flaps. Died Oct. 16, 1864, pyæmia.
43	Curran, T., Pt., H, 69th N. Y., age 20.	Sept. 16, '62.	Left. Died Oct. 17, 1862, pyæmia.	84	Holland, H., Pt., K, 13th Colored Troops, age 21.	Dec. 10, '64.	Right; flap; by A. A. Surg. J. S. Giltner. Died Dec. 27, '64, gang. c.
44	Dale, E. H., Pt., K, 14th N. H.	Sept. 19, '64.	Left; circular. Died Nov. 23, '64.	85	Hubert, E. B., Serg't, K, 1st Me. Cav., age 26.	Dec. 10, '64.	Right. Died Jan. 5, 1865, fever of a low typhoid type.
45	Dapple, M., Pt., E, 159th N. Y.	Sept. 19, '64.	Right. Died.	86	Humphrey, L., Pt., E, 4th Kentucky Cav., age 25.	June 26, '63.	Died July 21, 1863, pyæmia.
46	Davis, H. J., Pt., G, 3d N. C., age 41.	June 21, '64.	Left; lateral flap; by Surg. J. W. Wishart, 140th Pa.; hæmorrh'ge. Died July 6, 1864.	87	Ibler, W. S., Music'n, D, 15th Ohio, age 22.	May 27, '64.	Right; flap; hæmorrhage. Died Sept. 16, 1864.
47	Dart, C. C., Pt., A, 187th Pa., age 36.	June 16, '64.	Right; flap. Died July 24, 1864, debility.	88	Jackson, T. J., Lieuten't General.	May 3, '63.	Left; (brachial severed, also fracture of hand and contus. of side.) Died May 10, 1863.
48	Dean, W. H., Pt., D, 49th Ohio, age 21.	May 27, '64.	Right; circular. Died June 28, 1864, typhoid pneumonia.	89	Johns, E. F., Pt., E, 57th Indiana.	May 27, '64.	Left; by Surg. E. B. Glick, 40th Ind. Died July 1, 1864.
49	Demorest, L., Pt., K, 179th New York, age 33.	April 2, '65.	Right; circular; by Surg. J. C. Rutherford, 17th Vt. Died April 20, 1865, exhaustion.	90	Johnson, D. F., Pt., D, 75th Indiana, age 21.	Sept. 19, '63.	Right. Died Oct. 20, 1863, exhaustion and pyæmia.
50	Dennis, J. N., Pt., I, 153d Pa., age 43.	July 1, '63.	Left; flap. Died July 19, 1863, effects of hæmorrhage.	91	Johnson, J., Corp'l, F, 21st New York.	Aug. 30, '62.	Left; ant.-post. flap; by A. A. Surg. G. E. Fallen. Died Sept. 12, 1862, tetanus. Spec. 312.
51	Diagman, A. M., Pt., D, 4th Mich. Cav., age 20.	June 20, '64.	Left; circular. Died Mar. 5, 1865, small-pox.	92	Jones, T., Pt., C, 40th Mass., age 40.	May 16, '64.	Right. Died March 18, 1865, pneumonia.
52	Downing, S., Pt., C, 9th Illinois Cav.	July 14, '64.	Right; flap; gangrene; hæmorrhage; ligation of subclavian. Died Aug. 30, 1864. Spec. 2568.	93	Joslin, E., Pt., B, 3d Rhode Island, age 35.	Sept. 16, '64.	Left; ant.-post. flap; by A. A. Surg. W. Balsler. Died Oct. 10, 1864, pyæmia.
53	Dudley, G. M., Serg't, K, 7th N. H., age 22.	Aug. 16, '64.	Left; circular. Died Sept. 24, 1864, pyæmia.	94	Jullivett, M., Pt., D, 98th New York, age 19.	Sept. 29, '64.	Left; by Surg. J. A. Bigelow, 8th Conn. (Amp. leg.) Died Oct. 9, 1864, exhaustion.
54	Dutton, L. J., Pt., A, 5th Virginia, age 22.	May 8, '64.	Left; circular; pneumonia. Died June 11, 1864.	95	Keating, P., Serg't, H, 10th Minn.	April 3, '65.	Left; by Asst. Surg. F. H. Milligan, 10th Minn. Died April 19, '65.
55	Dyer, A. O., Pt., G, 21st Mass.	Nov. 24, '63.	Right; by Surg. A. M. Wilder, U. S. V. Died Dec. 6, 1863.	96	Keim, C. W., Serg't, E, 68th Penn.	July 3, '63.	Left. Died July 12, 1863.
56	Ellis, L. E., Pt., L, 1st Mich. Cav., age 28.	May 6, '64.	Right; lateral flap; by Asst. Surg. W. S. Willis, 1st N. J. Cavalry. Died Jan. 9, 1865, pyæmia.	97	Kœnig, J., Pt., E, 17th Missouri.	May 14, '64.	Right; flap; by Surg. B. N. Bond, 27th Mo. Died May 18, 1864.
57	Emerich, H., Pt., B, 20th New York.	Sept. 17, '62.	Right. Died Oct. 23, 1862.	98	Laine, T. G., Capt., G, 4th Georgia, age 30.	July 1, '63.	Left; circular. Died April 25, 1863, diarrhoea. Spec. 3821.
58	Emerson, J. S., Pt., C, 1st Maine Heavy Art., age 21.	June 18, '64.	Left; circular; (wounds of chest, thigh, penis, etc.) Died June 30, 1864, exhaustion.	99	Lary, L. H., Pt., Harris's Battery, age 35.	May 26, '64.	Circular. Died June 10, 1864, pyæmia.
59	Fairchild, J. M., Pt., G, 10th N. Y. Cav., age 27.	June 11, '64.	Right; circular. Died July 17, 1864.	100	Lee, I. B., Pt., H, 125th New York, age 21.	May 12, '64.	Left; circular; by Surg. J. W. Wishart, 140th Pa. Died June 12, 1864, pyæmia.
60	Fales, J. A., Corp'l, K, 3d Vermont, age 32.	May 5, '64.	Right; ant.-post. flap; by Surg. H. F. Lyster, 5th Mich. Died July 6, 1864, exhaustion.	101	LeFevre, A., Pt., F, 5th Minn., age 18.	Dec. 16, '64.	Left; antero-posterior flap. Died Jan. 7, 1865.
				102	Lewis, G., Pt., I, 12th Colored Troops, age 28.	Dec. 14, '64.	Right; flap; by A. A. Surg. J. S. Giltner. Died Dec. 24, 1864, pyæmia.



No.	NAME, AGE, AND MILITARY DESCRIPTION.	DATES.	OPERATIONS, OPERATOR, RESULT.	No.	NAME, AGE, AND MILITARY DESCRIPTION.	DATES.	OPERATIONS, OPERATOR, RESULT.
103	Lewis, M. C., K, 96th New York.	Sept. 29, '64.	Left; by Surg. T. H. Squires, 89th N. Y. (Prostrated with hæmorrhage.) Died one hour after operation.	141	Roop, B., Corp'l, K, 21st Mich., age 23.	Mar. 22, '65.	Right. Died April 24, 1865.
104	Lincoln, S. F., Adj't, 126th New York, age 26.	June 16, '64.	Left; circular; by Surg. J. W. Wishart, 140th Pa. Died July 9, 1864.	142	Rosen, J., Pt., D, 51st Pa.	Aug. 21, '64.	Left. Died August 24, 1864.
105	Logan, R. J., Serg't, D, 110th Illinois, age 28.	Mar. 18, '65.	Left; circular. Died April 25, 1865, pyæmia.	143	Rosenberg, A., Pt., H, 7th New York, age 39.	Mar. 31, '65.	Right; flap. Died April 13, '65, exhaustion.
106	Love, J., Serg't, A, 15th Iowa, age 26.	Mar. 21, '65.	Right; flap; by Surg. T. P. Bond, 32d Ohio. Died July 20, 1865, chronic diarrhœa and wound.	144	Ross, J. W., Farrier, E, 1st Maine Cavalry.	April 6, '65.	Right. Died April 17, 1865.
107	Maekin, P., Pt., A, 69th New York, age 30.	June 1, '62.	Left; flap; hæmorrhage. Died July 6, 1862.	145	Rudisil, S., Corp'l, I, 50th Pennsylvania, age 35.	June 3, '64.	Left; circular; by Surg. W. B. Fox, 8th Mich. Died July 12, 1864, pyæmia.
108	McArnold, J., Pt., I, 26th Pennsylvania.	June 18, '64.	Left; (also severe contusion of thorax.) Died June 19, 1864.	146	Sadler, J. C., Pt., C, 19th Virginia.	May 12, '64.	Flap; by A. Surg. Brocknridge, C. S. A. Died May 13, 1864.
109	McDonald, G., Corp'l, D, 4th Virginia Cavalry.	April 1, '65.	Right. Died April 21, 1865.	147	Sayers, B. F., Pt., C, 114th Ill., age 34.	Feb. 15, '65.	Right; circular; by A. Surg. W. M. Dooram, I. S. V. Died Feb. 26, 1865, tetanus.
110	McDowell, W., Pt., L, 27th Michigan.	July 19, '64.	Right; by Surg. W. B. Fox, 8th Mich. Died July 24, 1864, exhaustion.	148	Shanock, H. S., Pt., E, 90th Ohio.	Sept. 19, '63.	Right. Died October 25, 1863, pyæmia.
111	McGinniss, J., Pt., A, 23d Pennsylvania, age 22.	June 1, '64.	Right; circular; by Surg. E. B. P. Kelly, 95th Pa. Died June 28, 1864, exhaustion.	149	Shenp, J. M., Corp'l, A, 199th Pa., age 25.	April 2, '65.	Left; by Surg. T. H. Squire, 89th N. Y. Died May 4, 1865, effusion in chest.
112	McNulty, J. R., Pt., H, 1st N. J. Cav., age 28.	May 28, '64.	Right; circular; by Surg. E. B. P. Kelly, 95th Pa. Died June 9, 1864, gangrene.	150	Shuman, J. F., Pt., K, 4th Maine, age 22.	July 2, '65.	Right. Died July 15, 1865, hæmorrhage.
113	Mesick, G. P., Pt., K, 10th Michigan.	Sept. 1, '64.	Right. Died Sept. 20, 1864.	151	Simont, W., Pt., F, 1st N. J., age 26.	May 3, '64.	Left; lateral flap. Died July 22, 1864, gangrene.
114	Middaugh, J., Pt., C, 109th N. Y., age 26.	June 17, '64.	Left; circular. Died June 27, '64, double pneumonia.	152	Smith, A. C., Pt., D, 118th Pennsylvania.	Dec. 13, '62.	Right. Died Jan. 4, '63, pyæmia.
115	Miller, A., Serg't, I, 9th Iowa.	May 12, '63.	Left; flap; by Surgeon E. J. McGoorisk, 9th Iowa. Died July 10, 1863.	153	Smith, J. G., Serg't, G, 12th Mass., age 37.	May 10, '62.	Left; circular. Died June 7, '64, pyæmia.
116	Miller, C. A., Corp'l, F, 27th Massachusetts.	June 15, '64.	Left. Died July 19, 1864, exhaustion.	154	Smith, P., Pt., G, 24th Wisconsin, age 19.	May 17, '64.	Right; circular. Died Sept. 2, 1864, at home.
117	Mockre, J. W., Pt., B, 51st New York, age 37.	May 18, '64.	Right; flap. Died Sept. 11, 1864, diarrhœa and exhaustion.	155	Stanhope, W., Pt., A, 9th Maine, age 27.	July 18, '63.	Right; circular. Died August 28, 1863, pyæmia.
118	Morgan, W. B., Pt., F, 17th Conn., age 24.	July 3, '63.	Left; flap; hæmorrhage. July 20, 1863, axillary; gangrene. Aug. 3, re-ligation. Died Aug. 16, '63.	156	Stevens, E., Pt., E, 23d Mass., age 37.	Dec. 14, '62.	Right. Died January 19, 1863, pyæmia.
119	Morris, H. C., Corp'l, K, 39th New York, age 19.	May 18, '64.	Right; circular; (also wounds of left arm and chest.) Died May 30, 1864, exhaustion.	157	Stratton, A., Pt., D, 11th Maine, age 26.	Aug. 14, '64.	Left. Died Aug. 15, 1864, hæmorrhage.
120	Nelson, P. M., Pt., C, 150th Pennsylvania.	May 6, '64.	Died August 13, 1863.	158	Strickland, J., Pt., I, 116th Illinois, age 27.	Sept. 1, '64.	Right; circular; by A. S. Surg. C. B. Richards. Died Jan. 10, 1865, pneumonia.
121	Newman, A., Pt., C, 140th Pennsylvania.	July 3, '63.	Right; circular. Died May 31, '64.	159	Sullivan, J. C., Corp'l, F, 90th Illinois.	Sept. 1, '64.	Right; by Surg. W. Lomax, 12th Ind. Died September 19, 1864.
122	Nichols, W. J., Corp'l, D, 37th Mass., age 22.	May 6, '64.	By Surg. C. S. Wood, 66th N. Y. (Also amp. thigh.) Died July 19, 1863.	160	Sweeney, J., Color Serg't, 30th Ohio.	June 27, '64.	Left; by A. Surg. C. B. Richards, 30th Ohio. Died July 7, 1864.
123	Nickinson, A., Pt., G, 52d North Carolina.	July 3, '63.	Left; circular; by Surgeon D. W. Manll, 1st Delaware. Died June 23, 1864.	161	Taylor, T. B., Pt., B, 38th Kentucky.	Sept. 18, '62.	Left. Died September 29, 1862, pyæmia.
124	Noecker, I. B., Serg't, C, 149th Pa., age 22.	May 12, '64.	Right; circular. Died August 4, '64, pyæmia.	162	Taylor, T. H., Pt., G, 118th N. Y., age 16.	Aug. 9, '64.	Flap. Died September 13, 1864, pyæmia.
125	O'Hara, M., Pt., E, 8th Conn., age 22.	June 1, '64.	Left; flap; by Surg. W. A. Gray, 60th Illinois; hæmorrhage. Died August 23, 1864, anæmia.	163	Thomas, W. S., Pt., K, 14th Ind., age 17.	May 11, '64.	Right; oval flap. Died June 3, 1864, pleuro-pneumonia.
126	Palmer, C. H., Pt., A, 10th Mich., age 23.	May 30, '64.	Right. Died.	164	Thomen, M. K., Serg't, D, 90th Ohio, age 32.	Dec. 16, '64.	Right; antero-posterior flap. Died Dec. 31, 1864, erysipelas.
127	Palmer, H., Pt., E, 146th New York.	May 5, '64.	Left; flap; by Surg. J. S. Taylor, 23d Illinois. Died Aug. 24, 1865, diarrhœa.	165	Thompson, S. C., Pt., D, 1st Conn. H. Art., age 18.	June 27, '64.	Right; circular. Died Aug. 23, 1864, debility.
128	Pangborn, A., Pt., K, 62d Ohio, age 33.	April 6, '65.	Right. Died Oct. 1, 1864.	166	Trate, N., Pt., I, 188th Pennsylvania, age 22.	June 2, '64.	Right; circular. Died Aug. 26, 1864, chronic diarrhœa.
129	Park, F. H., Capt., B, 4th Pa. Cav., age 24.	Aug. 23, '64.	Left; circular; by Asst. Surg. B. Howard, U. S. A.; hæmorrhages; subclavian ligated. Died July 18, 1863, exhaustion. Spec. 2607.	167	Tripp, W. H., Pt., C, 8th Iowa, age 20.	Aug. 21, '64.	Left; circular; by Asst. Surg. E. C. Strode, U. S. A. Died Sept. 4, 1864.
130	Peterson, S. R., Pt., D, 14th Infantry, age 27.	May 3, '63.	Right. Died Feb. 7, 1863.	168	Van Alstine, J., Pt., I, 140th New York.	Feb. 6, '65.	Right; by Surg. A. A. White, 8th Md. Died March 13, 1864.
131	Peyton, T. W., Capt., A, Austin's Battalion S. S.	Dec. 31, '62, Jan. 1, '63.	Right. Died April 13, 1865, exhaustion.	169	Vandenburgh, H. L., H, 1st New York Cav.	May 15, '64.	Left. Died Sept. 28, 1864.
132	Phillips, W. L., Pt., F, 5th Wisconsin, age 20.	April 2, '65.	Right. Died June 10, 1864.	170	Vanswalenburg, G. P., Pt., K, 2d Michigan.	June 3, '61.	Right; by Surg. S. S. French, 20th Mich. Died June 12, 1861.
133	Pierce, G. W., Pt., E, 149th N. Y.	May 15, '64.	Right. Died Oct. 1, 1864.	171	Varnam, B., Pt., E, 142d New York, age 22.	Oct. 27, '64.	Right; by Surg. G. C. Jarvis, 7th Conn. Died Nov. 29, 1864, exhaustion.
134	Pinson, J., Pt., G, 12th Georgia, age 19.	July 10, '64.	Left; circular; by Asst. Surg. B. Howard, U. S. A.; hæmorrhages; subclavian ligated. Died July 18, 1863, exhaustion. Spec. 2607.	172	Walker, P., Pt., I, 104th New York, age 40.	June 18, '64.	Right; muscular flaps; (also amp. left forearm.) Died July 9, 1864, exhaustion.
135	Powell, J., Pt., F, 76th Pa., age 29.	July 30, '64.	Right. Died Feb. 7, 1863.	173	Welsh, E., Pt., C, 90th Illinois.	Aug. 3, '64.	Right; flap; by Surg. R. Morris, 103d Illinois. Died August 11, 1864.
136	Powers, J. G., Serg't, C, 57th Mass.	July 30, '64.	Right. Died April 13, 1865, exhaustion.	174	Westcott, D. L., Pt., C, 121th New York.	May 3, '63.	Left; (also wound of left side.) Died May 24, 1863.
137	Reagles, L., Pt., A, 64th New York, age 20.	Oct. 14, '63.	Right. Died June 10, 1864.	175	White, A., Pt., F, 140th Pa., age 23.	May 10, '64.	Left; circular; by Surg. J. W. Wishart, 140th Pa. Died June 13, 1864, pyæmia.
138	Reynold, W., Lieut., H, 12th Georgia, age 24.	July 12, '64.	Right; circular; by A. A. Surg. T. E. Mitchell. Died Aug. 21, 1864, pyæmia. Spec. 3952.	176	White, G. A., Pt., H, 2d Vermont.	May 5, '64.	Right. Died May 28, 1864.
139	Rheinhardt, M., Pt., F, 85th Pa.	May 31, '62.	Left; flap. Died Aug. 28, 1864, exhaustion.	177	Whitton, D. T., Pt., C, 5th Maine, age 24.	May 10, '64.	Right; antero-posterior flap. Died June 14, 1864, exhaustion.
140	Rouch, M., Pt., D, 9th Mass., age 23.	May 12, '64.	Left; circular; (also wounds of ribs and sternum. Vide M. & S. H. W., Vol. II, pt. 1, p. 535.) Died Aug. 16, 1864.	178	Wise, M., Pt., K, 9th Mich., age 37.	Nov. 10, '64.	Right; circular; by Surg. J. H. Phillips, U. S. V. Died Dec. 6, 1864, pyæmia.
			Left; circular; by Surg. D. E. Kelsey, 64th N. Y. Died Oct. 29, 1863, hæmorrhage.	179	Wixon, D., Pt., 1st Mich. H. Art., age 29.	June 16, '64.	Left; flap; erysipelas; gangrene. Died Aug. 11, 1864, exhaustion.
			Flap. Died July 9, 1862, pyæmia.	180	Woodward, J. D., Pt., C, 48th Mississippi.	May 13, '64.	Right; (also wound of both legs.) Died May 13, 1864.
			Left; antero-posterior flap. Died June 20, 1864, pyæmia.	181	Wolf, W., Pt., B, 13th Ohio Cav., age 25.	July 27, '64.	Left; flap. Died Aug. 14, 1864, gangrene.
				182	Yoricks, D., Corp'l, F, 3d New Jersey, age 29.	May 8, '64.	Left; circular. Died June 2, 1864, exhaustion.
				183	Zirphes, S., Pt., I, 51st Indiana, age 30.	Dec. 16, '64.	Left; circular. Died Jan. 1, 1865.

**2. Primary Amputations in the Middle Third of the Arm.**—There were eleven hundred and sixty-two of these operations. The results as to fatality having been ascertained in all of them, give a mortality rate of 12.3 per cent., or slightly less than in the amputations in the upper third.

§ *Successful Cases.*—Of amputations in the middle third of the arm for shot injuries involving the lower part of the humerus or the elbow joint, a thousand and nineteen had favorable results.

CASE 1656.—Private J. W. McLeod, 3d Maine Battery, aged 23 years, was wounded before Petersburg, September 11, 1864, by a minié ball, which produced compound fracture of the right elbow joint. He was received into the field hospital, 3d division, Second Corps, where the arm was amputated by Surgeon J. S. Jamison, 86th New York. The specimen (FIG. 520) was contributed to the Museum by the operator, and consists of the lowest third of the humerus. The bullet perforated the bone from the front, just above the condyles, producing two complete fractures downward through the trochlea, besides several in other directions, and much loss of substance from the posterior part of the bone. The wounded man was transferred to the Depot Hospital at City Point, and thence, on October 1st, to hospital at Alexandria. Surgeon E. Bentley, U. S. V., reported: "Antero-posterior flap amputation of right arm at middle third, performed on the field. Tonics and stimulants freely administered. Progress favorable." The patient was discharged from service on May 12, 1865, and pensioned. In his application for commutation, 1870, he stated that the stump was in a "healthy condition." The pensioner died on October 13, 1872. The immediate cause of his death has not been ascertained.

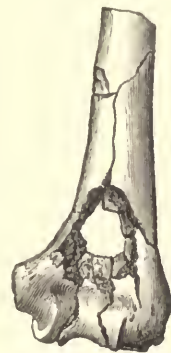

FIG. 520.—Shot perforation of lowest third of the right humerus. Spec. 4109.

TABLE LXX.

*Condensed Summary of One Thousand and Nineteen Cases of Recovery after Primary Amputation in the Middle Third of the Shaft of the Humerus.*

No.	NAME, AGE, AND MILITARY DESCRIPTION.	DATES.	OPERATIONS, OPERATOR, RESULT.	No.	NAME, AGE, AND MILITARY DESCRIPTION.	DATES.	OPERATIONS, OPERATOR, RESULT.
1	Abbe, A. W., Pt., K, 9th Iowa.	May 22, '63.	Right; flap; by Surg. E. J. MeGoorisk, 9th Iowa. Disch'd July 16, 1863; pensioned.	19	Arnold, E. C., Pt., II, 15th Massachusetts.	Oct. 21, '61.	Right; flap; by Surg. J. N. Bates, 15th Mass. Discharged April 14, 1862; pensioned.
2	Abbott, L., Serg't, B, 73d Ohio, age 33.	July 20, '64.	Left; flap; by Surg. J. W. Hastings, 33d Mass.; necrosis: removal of bone June 27, 1865. Discharged Nov. 16, 1865; pens'd.	20	Arnold, J., Pt., C, 41st New York.	Feb. 9, '64.	Right. Discharged; pensioned.
3	Abrams, J. S., Corp'l, II, 10th N. Jersey, age 22.	Oct. 19, '64.	Left; flap; by Surg. O. R. Freeman, 10th N. J. Disch'd June 28, 1865; pensioned.	21	Aston, J. D., Pt., C, 23d Ohio.	June 18, '64.	Left; flap; by Surg. McKee. Discharged Dec. 12, '64; pensioned.
4	Ackernicht, J. F., Pt., I, 99th Pa., age 26.	May 15, '64.	Right; flap. Disch'd Dec. 4, 1864.	22	Atwater, S. C., Pt., I, 40th Ohio, age 22.	Dec. 15, '64.	Left; circular; Discharged March 15, 1865.
5	Adams, C. O., Pt., G, 57th Mass., age 18.	May 6, '64.	Right; flap; by Surg. D. W. Maul, 1st Del. Disch'd Jan. 14, 1865; pensioned.	23	Aubrey, H. C., Serg't, I, 145th Pa., age 22.	June 3, '64.	Right; by Surg. G. L. Potter, 145th Pa. Discharged Sept. 13, 1864; pensioned.
6	Adams, G. G., Pt., II, 10th Georgia, age 17.	Sept. 17, '62.	Left; flap. Paroled Oct. 16, 1862.	24	Austin, W. G., Pt., K, 4th N. C., age 20.	Oct. 28, '64.	Right; circular. Furloughed Dec. 15, 1864.
7	Adlington, J. S., Pt., I, 12th Mass.	Sept. 17, '62.	Left; circular; by Asst. Surg. J. T. Duffield, 7th Ind. Disch'd Nov. 11, 1862; pensioned.	25	Averitt, W. H., Pt., K, 5th Florida, age 21.	July 3, '63.	Left. Disch'd Nov. 17, 1863.
8	Albee, H., Pt., A, 34th Mass., age 31.	Mar. 31, '65.	Right; circular; by A. Surg. J. J. Allen, 34th Mass. Disch'd July 18, 1865; pensioned.	26	Avery, J. A., Serg't, K, 37th Wis., age 32.	June 18, '64.	Left. Furloughed Oct. 31, 1864.
9	Alfred, S., Serg't, E, 68th Ind., age 45.	Aug. 15, '64.	Right; circular; by Surg. C. Spinzig, 2d Mo. Disch'd Jan. 26, 1865; pensioned.	27	Avery, L. K., Pt., C, 6th Pa. Reserves.	Sept. 14, '62.	Left; flap. Discharged Feb. 3, 1863; pensioned.
10	Allen, D., Pt., A, 1st Cavalry.	June 28, '62.	Right; by Surg. Young, P. A. C. S. Disch'd Oct. 26, 1862; pensioned.	28	Ayres, A. M., Pt., C, 132d Pa., age 21.	Sept. 17, '62.	Left. Disch'd; pensioned.
11	Allen, M. V., Pt., C, 6th Iowa.	Nov. 25, '63.	Left; by Surg. W. S. Lombard, 6th Iowa. Disch'd Jan. 28, 1864; pensioned.	29	Badger, W., Pt., I, 6th Col'd Troops, age 47.	Sept. 29, '64.	Left. Discharged April 14, 1865; pensioned.
12	Allen, W., Pt., F, 116th Ohio, age 25.	July 18, '64.	Right; flap; by Surg. T. J. Shannon, 116th Ohio. Disch'd Feb. 14, 1865; pensioned.	30	Bailey, J. E., Corp'l, D, 11th Maine, age 30.	June 2, '64.	Left; by Surg. N. F. Blunt, 11th Me. Disch'd; pensioned.
13	Allison, J. M., Corp'l, I, 111th Illinois.	May 14, '64.	Right; by Surg. J. N. Barnes, 110th Ill. Disch'd June 7, 1865; pensioned.	31	Baker, T. R., Corp'l, K, 2d Ohio Cav.	May 31, '64.	Left. Disch'd Jan. 26, 1865; gangrene; pensioned.
14	Amonett, J. P., Pt., II, 50th Illinois, age 19.	April 6, '62.	Right. Discharged Sept. 22, 1862; pensioned.	32	Balcolm, E. H., Pt., E, 61st N. Y., age 39.	May 12, '64.	Right; by Surg. J. W. Wishart, 140th Pa. Furloughed.
15	Andrews, J., Pt., K, 42d Ohio.	May 1, '63.	Right; circular; by Surg. J. Pomerene, 42d Ohio. Disch'd July 23, 1863; pensioned.	33	Banghart, L., Pt., G, 52d Ohio, age 24.	July 9, '64.	Right; circular; by Surg. H. M. Duff, 52d Ohio. Disch'd Feb., 1865; pensioned.
16	Annis, D. M., Pt., F, 11th N. H., age 37.	May 16, '64.	Left; circ.; by Surg. W. B. Pax, 8th Mich. Disch'd; pensioned.	34	Barber, D., Pt., I, 33d New York.	May 4, '64.	Left; by Surg. J. Haussen, 20th N. Y. Disch'd; pensioned.
17	Anthony, E., Pt., D, 1st Conn. H. Art., age 27.	April 2, '65.	Right; flap. Discharged June 24, 1865.	35	Barber, R. J., Serg't, D, 43d Ala., age 26.	Mar. 25, '65.	Right. Transferred to prison May 10, 1865.
18	Archer, C., Corp'l, II, 7th N. C., age 24.	June 22, '64.	Left; flap.	36	Barber, R. M., Pt., B, 148th N. Y., age 17.	June 15, '64.	Right; flap. V. R. C. April 8, 1865; pensioned.
				37	Baringer, J. H., Pt., D, 100th Ohio, age 22.	Aug. 5, '64.	Right; circular; by Surg. J. H. Rodgers, 104th Ohio. Disch'd May 18, 1865; pensioned.
				38	Barlow, A., Pt., C, 14th Michigan, age 21.	Sept. 1, '64.	Right; flap; by Surg. E. Batwell, 14th Mich. Discharged June 22, 1865; pensioned.
				39	Barlow, I. H., Pt., B, 6th N. Y. Cav., age 39.	Sept. 4, '64.	Left; flap. Discharged Jan. 23, 1865; pensioned.



No.	NAME, AGE, AND MILITARY DESCRIPTION.	DATES.	OPERATIONS, OPERATOR, RESULT.	No.	NAME, AGE, AND MILITARY DESCRIPTION.	DATES.	OPERATIONS, OPERATOR, RESULT.
40	Barnes, J. A., Pt., B, 91st New York.	Dec. 13, '62.	Right. Disch'd April 24, 1863; pensioned.	78	Bridgeman, G. M., Pt., I, 128th Indiana, age 18.	Mar. 10, '65.	Right; circular. Disch'd June 27, 1865; pensioned.
41	Barnes, J. A., Pt., C, 60th Ohio, age 40.	Sept. 30, Oct. 1, 1864.	Right; circular; by Surg. W. C. Shurlock, 51st Pa. Discharged May 13, 1865; pensioned.	79	Bright, W. H., Corp'l, C, 22d Wis., age 22.	July 20, '64.	Right; flap; by Surg. T. Hatchard, 23d Wis. Disch'd April 25, 1865; pensioned.
42	Barrett, W., Pt., A, 104th Illinois, age 22.	May 16, 17, '64.	Right; circ.; by Surg. J. S. Gregg, 85th Ind.; gangrene. Discharged Feb. 27, 1865; pensioned.	80	Brieggs, L. A., Serg't, K, 27th Mich., age 30.	May 12, '64.	Left; by Surg. H. E. Smith, 27th Mich. Disch'd Oct. 3, 1864.
43	Barrow, J., Pt., A, 4th Ohio, age 39.	Aug. 25, 27, '64.	Left; double flap. Discharged April 9, 1865; pensioned.	81	Brighton, C., Pt., E, 10th New Jersey, age 23.	May 13, '64.	Right; circular. Discharged Jan. 14, 1865; pensioned.
44	Barnes, P., Pt., D, 39th Massachusetts.	July 7, 8, '64.	Right; flap; by Surg. E. G. Chase, 104th N. Y. Discharged Oct. 28, 1864; pensioned. Spec. 4127.	82	Britton, W. G., Serg't, D, 5th Ala., age 22.	Sept. 19, '64.	Right; flap; by Surgs. Duvall and F. B. Wilkinson, C. S. A.
45	Bartlett, L., Pt., II, 93d New York, age 25.	Aug. 15, 15, '64.	Left; flap; by Surg. H. F. Lyster, 5th Mich. Disch'd Jan. 8, 1865; pensioned.	83	Broadfoot, J., Pt., F, 137th New York.	July 2, '64.	Right; flap; by Surg. A. Hall, 5th Ohio. Disch'd Dec. 30, 1863.
46	Bastin, T., Pt., B, 21st Kentucky, age 47.	Sept. 2, 3, '64.	Left; flap; by Asst. Surg. W. H. Matchett, 40th Ohio; gangrene. Disch'd Mar. 22, '65; pensioned.	84	Broderrick, W. H., Pt., I, 3d Maryland.	May 3, '63.	Right; (also fingers of left hand amputated) Disch'd Aug. 30, 1863.
47	Beauchy, J. F., Pt., H, 39th Ill., age 22.	June 2, 2, '64.	Left; necrosis. Jan. 17, 1865, amp. at shoulder joint. Discharged March 15, 1865; pensioned.	85	Bromberger, C., Pt., G, 15th N. Y. H. Art., age 36.	Mar. 31, '64.	Right; flap. Discharged July 1, 1865; pensioned.
48	Beals, W. L., Pt., G, 29th Mass., age 18.	Sept. 23, 23, '64.	Left; circular; gangrene. Disch'd June 23, 1865; pensioned.	86	Brooks, I. B., Corp'l, B, 39th C. Troops, age 23.	July 30, '64.	Right; circular; by A. Surg. A. T. Bryant, 30th Mass. Disch'd June 10, 1865.
49	Beamer, T. D., Serg't, H, 110th Penn., age 30.	May 6, 6, '64.	Right; flap; by Surg. D. S. Hays, 110th Penn. Disch'd Sept. 20, 1864; pensioned.	87	Brooks, J. M., Serg't, K, 23d Miss., age 28.	Dec. 15, '64.	Left; circular. To Provost Marshal Feb. 8, 1865.
50	Bean, G. L., Pt., A, 48th Illinois.	April 6, 7, '62.	Right; by Surg. W. S. Edgar, 33d Ill. Disch'd Aug. 15, '65; pens'd.	88	Brosnan, J., Pt., E, 164th New York, age 18.	June 17, '64.	Left; flap; by Surg. M. F. Regan, 164th N. Y. Discharged Feb. 7, 1865; pensioned.
51	Beard, L., Pt., F, 40th Ohio, age 24.	May 28, 28, '64.	Right; flap; by A. Surg. W. H. Matchett, 40th Ohio. V. R. C. Dec. 31, 1864; pensioned.	89	Brown, A. H., Pt., G, 13th Iowa, age 24.	July 20, '64.	Left; flap. Discharged March 10, 1865; pensioned.
52	Beeman, L., Pt., H, 5th Wisconsin, age 21.	April 2, 3, '65.	Right; circular. Disch'd July 17, 1865.	90	Brown, A., Pt., B, 1st N. H. Cavalry, age 18.	June 23, '64.	Left; circular. Duty July 14, 1865; pensioned.
53	Been, J., Pt., E, 81st Ind., age 28.	Dec. 15, 15, '64.	Left; circular; by Surg. T. M. Cook, 101st Ohio. Disch'd May 4, 1865; pensioned.	91	Brown, C., Pt., F, 156th Ohio, age 20.	June 23, '64.	Left; flap; by A. Surg. F. Grube, U. S. V. Disch'd Aug. 3, 1864; pensioned.
54	Beers, C. F., Pt., F, 185th New York, age 19.	Mar. 22, 29, '65.	Left; flap. Disch'd May 21, 1865; pensioned.	92	Brown, C., Pt., I, 13th W. Va., age 17.	Oct. 19, '64.	Left; circular; by Surg. C. H. Andrus, 176th N. Y. Discharged June 8, 1865; pensioned.
55	Beisley, W. H., Serg't, K, 18th Mich., age 20.	Sept. 24, 26, '64.	Left; flap. Mustered out Nov. 9, 1864; pensioned.	93	Brown, C., Pt., C, 30th Indiana, age 21.	Dec. 16, '64.	Left; circular. Muster'd out Nov. 25, 1865.
56	Bennett, D., Serg't, A, 1st Md. Cav., age 24.	Aug. 18, 18, '64.	Left; flap. Disch'd Feb. 2, 1865.	94	Brown, H. C., Serg't, H, 87th Indiana.	Aug. 4, '64.	Left; flap; by Surg. C. E. Triplett, 87th Ind. Discharged Jan. 18, 1865; pensioned.
57	Benson, J., Pt., A, 151st New York, age 24.	Nov. 27, 27, '63.	Right; flap. Disch'd Feb. 13, 1864; pensioned.	95	Brown, H. M., Pt., L, 1st Vt. Art., age 27.	July 10, '64.	Left; circular. Discharged May 30, 1865; pensioned.
58	Berniger, C., Corp'l, C, 5th Wis., age 24.	Feb. 7, '65.	Right; circular. Disch'd May 16, 1865; pensioned.	96	Brown, J. G., Pt., H, 162d Pennsylvania.	May 31, '62.	Left; circular. Discharged July 29, 1862.
59	Berthanne, J. B., Corp'l, A, 10th Vt., age 23.	Sept. 19, 21, '64.	Right; circular; by Surg. T. A. Helwig, 87th Pa. Disch'd Aug. 12, 1865; pensioned.	97	Brown, R., Pt., B, 48th Pennsylvania.	Dec. 13, '62.	Right; by A. Surg. J. M. Morrison, 48th Pa. Discharged Feb. 12, 1865; pensioned.
60	Bickford, W., Pt., B, 50th New York.	Dec. 11, '62.	Left; circular. Discharged Feb. 11, 1863; pensioned.	98	Brown, T. J., Corp'l, K, 55th Mass., age 20.	July 2, '64.	Right; ant.-post. flap. Disch'd June 5, 1865; pensioned.
61	Biehl, E., Pt., D, 9th New Jersey, age 21.	Aug. 11, '64.	Right; flap. Discharged Sept. 7, 1865; pensioned.	99	Brown, W., Pt., I, 14th Connecticut, age 28.	Feb. 6, '64.	Right. Discharged May 31, 1864; pensioned. Spec. 2038.
62	Bishop, R., Pt., C, 43d New York, age 22.	April 28, '62.	Right; flap; by Surg. M. Case, 43d N. Y. Discharged Dec. 11, 1862; pensioned.	100	Brown, W. B., 1st Lt., C, 174th Ohio, age 43.	Mar. 10, '65.	Left; circ.; by Surg. P. W. Morrison, 174th O. Disch'd; pens'd.
63	Blackford, S., Lieut., 60th Ohio.	Oct. 27, '64.	Left; by A. A. Surg. A. T. Fitch. Disch'd April 17, '65; pensioned.	101	Brownlee, J. A., Pt., E, 13th Georgia.	Sept. 19, '64.	Circular. Recovered Oct. 25, '64.
64	Blackledge, L., Pt., II, 48th Ill., age 18.	July 20, '64.	Right; flap; gangrene. Disch'd April 12, 1865; pensioned.	102	Brownson, F., Corp'l, H, 1st C. T., age 26.	Jan. 15, '64.	Right; circular. Disch'd Nov. 21, 1864; pensioned.
65	Blanchard, W. H., II, Sgt., K, 12th Iowa, age 27.	July 14, '64.	Left; circular; by Surg. S. W. Huff, 12th Iowa. Disch'd Jan. 26, 1865.	103	Brunette, D., Pt., F, 12th Wisconsin, age 26.	July 21, '64.	Left; flap; by Surg. J. S. Reeves, 78th Ohio. Discharged July 11, 1865; pensioned.
66	Bleeker, C. H., Corp'l, F, 140th N. Y., age 22.	Sept. 30, '64.	Left; flap. Discharged July 15, 1865; pensioned.	104	Bueklin, H., Pt., F, 2d Rhode Island.	June 25, '62.	Right; flap; by Asst. Surg. G. Jewett, 10th Mass. Discharged July 29, 1863; pensioned.
67	Bleiter, C., Pt., C, 9th Ohio, age 41.	Sept. 20, '63.	Flap. Disch'd May 26, 1864.	105	Bunk, J. W., Serg't, A, 5th North Carolina.	Oct. 19, '64.	Left. Recovered.
68	Boice, D., Pt., D, 39th New Jersey, age 18.	April 2, 2, '65.	Right; circular; by Surg. G. R. Sullivan, 39th N. J. Discharged Aug. 16, 1865; pensioned.	106	Burke, M., Corp'l, F, 2d Infantry.	Jan. 29, '62.	Left; by Surg. of 3d Ala. Disch'd Aug. 27, 1862; pensioned.
69	Bolds, A., Pt., H, 51st Indiana, age 30.	Dec. 9, '64.	Left; circular. Discharged May 13, 1865; pensioned.	107	Barrows, B. L., Pt., II, 55th Mass., age 22.	July 2, '64.	Left; by Surg. W. S. Brown, 55th Mass. Disch'd May 11, '65; pens'd.
70	Bonnell, D. V., Lieut., D, 93d Ohio, age 24.	Dec. 16, '64.	Left; circular; by Surg. J. M. Weaver, 93d Ohio. Resigned April 3, 1865; pensioned.	108	Butcher, W., Lt., A, 163d New York.	Dec. 13, '62.	Right. Discharged Jan. 20, 1863; pensioned. Died May 21, 1867.
71	Book, H., Corp'l, E, 100th Pennsylvania.	Aug. 29, '62.	Left; by Surg. H. Ludington, 100th Pa. Discharged Nov. 18, 1862; pensioned.	109	Cadwallader, A. D., Lt., B, 85th Ill., age 18.	July 19, '64.	Right; flap; by Surg. H. K. Payne, 10th Ill.; re-amp. Aug. 25, 1864. Disch'd April 10, '65; pensioned.
72	Boppel, M., Pt., E, 153d New York.	Sept. 19, '64.	Right; circular. Disch'd Nov. 28, 1864; pensioned. Spec. 2720.	110	Cadwell, G. P., Pt., A, 4th Ohio, age 25.	Aug. 25, '64.	Left; circ.; by Surg. J. F. Dyer, 19th Mass. Discharged Dec. 12, 1864; pensioned.
73	Fosworth, M. L., Pt., H, 6th Mich. Heavy Art.	May 27, '63.	Left; by Asst. Surg. J. W. Mison, 6th Mich. Disch'd Aug. 7, 1863; pensioned.	111	Cady, R. M., Pt., C, 18th Infantry, age 42.	July 4, '64.	Left; flap. Mustered out March 24, 1865; pensioned.
74	Bouron, L. E., Serg't, D, 98th N. Y., age 22.	Sept. 29, '64.	Right; flap; by Surg. J. J. Van Kesselaer, 98th N. Y. Disch'd Jan. 13, 1865; pensioned.	112	Cairns, W., Serg't, B, 1st N. J. Artillery.	June 17, '62.	Left; flap; by Surg. H. McLane, 2d New York. Pensioned.
75	Boyle, R. C., Serg't, 6th New York S. C., age 23.	May 18, '64.	Left; ant.-post. flaps. Duty Aug. 10, 1864.	113	Cameron, A., Serg't, G, 16th Michigan.	July 2, '63.	Right; by Surg. R. A. Everett, 16th Mich. Discharged Oct. 28, 1863; pensioned.
76	Bradford, L., Serg't, E, 16th Maine, age 23.	Feb. 6, '65.	Circular; by Surg. W. W. Eaton, 16th Maine. Disch'd July 23, 1865; pensioned.	114	Cameron, J., Musician, E, 48th Pennsylvania.	Aug. 29, '62.	Left; flap; by Surg. C. F. Reber, 48th Pa. Disch'd Feb. 5, 1863; pensioned.
77	Brady, J., Pt., A, 73d New York, age 22.	May 5, '62.	Left; flap; by Surg. F. Prentice and A. Surg. F. Ridgway, 73d N. Y.; gangrene; necrosis; sequestrum removed. Disch'd; pens'd.	115	Campbell, A., Pt., D, 2d Maine, age 21.	Dec. 13, '62.	Left; flap; by A. Surg. R. Millar, 4th R. I. Discharged Nov. 11, 1863; pensioned.
				116	Campbell, A. M., Corp'l, M, 10th Mich. Cav., age 21.	June 16, '64.	Left; circular; by A. Surg. W. D. Scott, 10th Mich. Cav. Disch'd June 6, 1865; pensioned.
				117	Campbell, B., Pt., I, 4th R. I., age 19.	Sept. 17, '62.	Flap; by Surg. H. W. Rivers and Asst. Surg. R. Millar, 4th R. I. Disch'd Nov. 27, 1862; pens'd.

No.	NAME, AGE, AND MILITARY DESCRIPTION.	DATES.	OPERATIONS, OPERATOR, RESULT.	No.	NAME, AGE, AND MILITARY DESCRIPTION.	DATES.	OPERATIONS, OPERATOR, RESULT.
118	Campbell, E. D., Pt., E, 30th Georgia, age 30.	Nov. 30, '61.	Right; lateral flap; To Provost Marshal Jan. 3, 1865.	159	Cole, A. W., Serg't, C, 11th Maine, age 31.	Aug. 14, '61.	Left; by Asst. Surgeon W. W. Royal, 11th Maine. Disch'd Oct. 27, 1864; pensioned.
119	Campbell, H., Pt., B, 4th Colored Troops.	June 15, '64.	Left. Discharged Nov. 10, 1864.	160	Cole, W., Pt., F, 13th Arkansas, age 23.	Nov. 30, Dec. 1, 1864.	Left; circ.; by Surg. McFadden, C. S. A. To Provost Marshal Jan. 3, 1865.
120	Campbell, J., Corp'l, G, 107th Pa., age 23.	June 18, '64.	Flap; by Surg. J. F. Hutchinson, 107th Pa. Pensioned.	161	Coleman, G. W., Pt., D, 5th Wisconsin.	April 6, '65.	Right; circular. Disch'd June 17, 1865.
121	Canfield, W. A., Serg't, F, 9th N. H., age 22.	June 21, '64.	Left; circular. Disch'd May 30, 1865; pensioned.	162	Coleman, P. W., Pt., I, 8th Michigan.	June 16, '62.	Left; flap; by Surg. J. C. Wilson, 8th Mich. Disch'd Oct. 21, 1862; pensioned.
122	Cann, J., Pt., B, 129th Illinois, age 27.	July 20, '64.	Right; flap. Discharged Feb. 25, 1865; pensioned.	163	Collard, E., Pt., B, 5th Michigan, age 45.	Oct. 28, '64.	Right. Disch'd Dec. 25, 1864; pensioned.
123	Capner, H., Pt., B, 23d New Jersey.	Dec. 13, '62.	Right. Discharged Feb. 22, 1863; pensioned.	164	Colley, J., Corp'l, E, 3d Mississippi, age 27.	Dec. 1, 1861.	Right; circular. To Provost Marshal Jan. 23, 1865.
124	Carey, W. H., Pt., A, 1st Maryland.	May 8, '64.	Right; circular. Disch'd May 18, 1865; pensioned.	165	Colson, C., Pt., B, 165th New York.	May 27, '61.	Left; circular; by Surg. E. F. Sanger, U. S. V. Disch'd Aug. 29, 1863; pensioned.
125	Cargon, S., Pt., G, 146th New York.	May 5, '64.	Right; flap. Discharged Jan. 20, 1865; pensioned.	166	Colston, E., Corp'l, K, 2d Va. Cav., age 21.	April 2, '65.	Right. To prison May 4, 1865.
126	Carothers, W., Pt., G, 21st Illinois.	Nov. 25, '63.	Right; flap. To V. R. C. April 29, 1864.	167	Comer, G. H., Pt., C, 13th New Jersey.	May 3, '63.	Right; flap; by Surg. W. H. Twiford, 27th Ind. Disch'd Aug. 18, 1863; pensioned.
127	Carpenter, A. G., Pt., K, 21st Illinois, age 26.	June 19, '64.	Right; by Surg. C. J. Walton, 21st Ky. Discharged; pensioned.	168	Compton, W., Pt., G, 25th Ohio, age 19.	Feb. 6, '65.	Right; flap; by Surg. W. Walton, 25th Ohio. Discharged May 17, 1865; pensioned.
128	Carpenter, G. B., Pt., B, 4th R. I., age 18.	July 30, '64.	Right; flap; by A. Surg. R. Miller, 4th R. I. Disch'd Oct. 15, 1864; pensioned.	169	Compton, W., Serg't, B, Marion Mo. Bat'y.	July 4, '61.	Left; by Dr. E. Duffield. Disbanded Sept. 5, 1861; pens'd.
129	Carroll, H., Pt., E, 145th Pennsylvania.	June 16, '64.	Right; circular; by Surg. G. L. Potter, 145th Pa. Disch'd Dec. 9, 1864; pensioned.	170	Conaway, M. M., Pt., D, 3d Del., age 25.	June 18, '64.	Left; circular; by A. Surg. C. B. Haynes, U. S. V. Disch'd; pens'd.
130	Cashin, T., Pt., K, 101st Illinois, age 26.	July 29, '64.	Right; ant.-post. flap. Discharged Dec. 20, 1864; pensioned.	171	Conover, J. B., Corp'l, D, 83d Ill., age 20.	July 19, '64.	Right; lateral flap. Discharged Feb. 8, 1865; pensioned.
131	Cassidy, L., Corp'l, B, 10th Ill. Cavalry.	Dec. 7, '62.	Left; flap. Discharged Dec. 22, 1862; pensioned.	172	Conway, P., Pt., H, 12th Connecticut.	May 28, '64.	Right; flap. Discharged Jan. 26, 1864; pensioned.
132	Caswell, G. W., Serg't, K, 11th N. H., age 44.	July 30, '64.	Left; circular. Disch'd May 15, 1865; pensioned.	173	Cook, B. F., Pt., B, 4th Mo. S. M. Cav.	Oct. 23, '64.	Right; flap. Disch'd March 1, 1865; pensioned.
133	Cavanaugh, N., Pt., D, 155th N. Y., age 45.	June 3, '64.	Right; bilateral flap; by Surg. F. Wylie, 155th N. Y. Discharged March 31, 1865; pensioned.	174	Cook, E. R., Pt., E, 9th Vermont, age 18.	Sept. 29, '64.	Left; circular. Disch'd June 19, 1865; pensioned.
134	Cavanaugh, T. J., Serg't, E, 133th N. Y., age 45.	June 12, '64.	Right; ant.-post. flap. Disch'd Oct. 27, 1864; pensioned.	175	Cook, O., Pt., F, 18th Connecticut, age 22.	July 18, '64.	Left; flap; by Surg. L. Holbrook, 18th Conn. Discharged July 27, 1865; pensioned.
135	Cazeau, L., Pt., B, 113th Illinois.	May 28, '63.	Right; circular. Disch'd Nov. 18, 1863; pensioned.	176	Cook, S., Corp'l, 1st New York Chasseurs.	July 1, '62.	Left; circular. Disch'd Aug. 11, 1862; pensioned.
136	Cecil, H. P., Pt., B, 3d Iowa, age 19.	July 22, '64.	Right; flap. Discharged June 22, 1865.	177	Corey, J. H., Pt., I, 60th New York, age 19.	July 24, '64.	Left; circ.; by Surg. J. V. Kendall, 149th N. Y. Disch'd May 25, 1865; pensioned.
137	Chadbourne, J. W., Pt., F, 16th Maine, age 23.	Aug. 18, '64.	Right; circular. Disch'd June 16, 1865; pensioned.	178	Corey, J. W., Pt., I, 33d New York, age 20.	May 4, '63.	Left; flap; by Surg. Pope, C. S. A. Duty Aug. 13, '63; pens'd.
138	Chamberlain, S. S., Pt., D, 8th Mich., age 21.	May 6, '64.	Right; ant.-post. flap; by Surg. W. B. Fox, 8th Mich. Disch'd Sept. 22, 1864; pensioned.	179	Conch, H. L., Capt., K, 3d N. Y., age 40.	May 16, '64.	Left; circular. Discharged Dec. 15, 1864.
139	Champion, D. P., Pt., A, 183d Pa., age 18.	April 28, '64.	Left; ant.-post. flap. Discharged Dec. 28, 1864; pensioned.	180	Courts, J., Pt., I, 21st Mass., age 48.	July 30, '64.	Right; flap; by Surg. T. F. Oakes, 56th Mass. Disch'd Sept. 30, 1864.
140	Chandler, H., Serg't, D, 8th Indiana, age 32.	May 14, '64.	Right. Discharged Oct. 4, 1864; pensioned.	181	Coveng, W., Pt., D, 33d Massachusetts.	July 2, '63.	Left; flap; by Asst. Surg. G. Rebay, 45th N. Y. Disch'd Dec. 24, 1863; pensioned.
141	Chappel, P., Pt., D, 23d N. C., age 22.	Sept. 19, '64.	Right; circular; by Surg. G. L. Miller, C. S. A. To Provost Marshal Feb. 11, 1865.	182	Cowan, D. S., Pt., B, 4th N. C., age 28.	Sept. 19, '64.	Left; circular. To Fort McHenry Jun. 16, 1865.
142	Chase, D., Pt., I, 1st Corps D'Afrique.	May 27, '63.	Right; by Surg. J. B. G. Baxter, U. S. V. Duty Aug. 13, 1863; pensioned.	183	Cox, J., Pt., K, 33d New Jersey, age 28.	May 8, '64.	Right; flap; by Surg. A. K. Pi-field, 29th Ohio. Disch'd May 8, 1865; pensioned.
143	Church, G., Pt., G, 17th New York, age 40.	Aug. 30, Sept. 1, 1864.	Left; flap; by Surg. E. Batwell, 14th Mich. Discharged Dec. 30, 1864; pensioned.	184	Cox, J. R., Pt., G, 7th Indiana.	Aug. 28, '62.	Left; flap. Disch'd Oct. 30, 1862; pensioned.
144	Churcher, J. H., Pt., I, 2d Iowa, age 23.	Feb. 15, '62.	Left; flap; by Surg. W. R. Marsh, 2d Iowa. Discharged June 1, 1862; pensioned.	185	Craig, A. P., Pt., A, 1st Louisiana, age 27.	Sept. 19, '64.	Right; circular; by A. Surg. Dorsey, 1st Md. Cav., C. S. A. Retired Feb. 27, 1865.
145	Clark, D., Pt., E, 6th Maine, age 20.	April 6, '62.	Left; flap; by Asst. Surg. A. H. Smith, U. S. A. Disch'd April 6, 1863; pensioned.	186	Crawford, G. H., Serg't, D, 6th Md., age 24.	Oct. 19, '64.	Left; flap. Duty March 3, 1865; pensioned.
146	Clark, F. E., Corp'l, C, 86th N. Y., age 22.	May 9, '64.	Right; circular; by Surg. J. W. Wishart, 140th Pa. Discharged Dec. 2, 1864; pensioned.	187	Crawford, J., Serg't, I, 18th Pa. Cav., age 42.	Sept. 19, '64.	Left; circular. Disch'd Jan. 6, 1865; pensioned.
147	Clark, J., Pt., A, 1st Ill. Light Artillery.	Aug. 3, '64.	Left; by Surg. S. P. Bonner, 47th Ohio. Disch'd Oct. 11, 1864.	188	Crebaugh, H., Pt., B, 80th Illinois, age 36.	Mar. 10, '64.	Left; circ.; by Surg. J. E. Herbst, U. S. V. Disch'd Aug. 26, '64.
148	Clarke, W. H., Pt., I, 7th New York, age 21.	June 3, '64.	Right; flap; by Asst. Surg. W. Childs, 5th N. H. Disch'd June 8, 1865; pensioned.	189	Crist, C. B., Pt., G, 138th Pennsylvania, age 23.	May 6, '64.	Right; flap. Discharged Dec. 8, 1864; pensioned.
149	Clarkson, L., Pt., K, 23d Illinois, age 21.	July 10, '64.	Left; flap; by Surg. J. S. Taylor, 23d Ill. Disch'd Feb. 24, 1865; pensioned.	190	Crosby, J. F., 1st Lt., D, 6th N. Y. H. A., age 26.	May 19, '64.	Left; lateral flap. Disch'd June 23, 1865; pensioned.
150	Clary, R., Corp'l, D, 125th Illinois, age 36.	June 27, '64.	Right; ant.-post. flap; by Surg. C. H. Mills, 125th Ill. Disch'd Jan. 27, 1865.	191	Crouse, H., Pt., D, 149th New York.	July 20, '64.	Left; circular; by Surgeon J. V. Kendall, 149th N. Y. Disch'd May 12, 1865.
151	Clegg, T., Serg't, E, 11th Ohio, age 42.	May 14, '61.	Left; circular. Disch'd Aug. 5, 1864; pensioned.	192	Crosby, J. W., Pt., K, 5th New Hampshire.	Dec. 13, '62.	Right. Discharged July 24, 1864; pensioned.
152	Cleveland, W. H., Pt., A, 1st Maine Cav., age 29.	July 18, '64.	Right; flap; by Asst. Surg. A. U'tter, 1st R. I. Cav. Disch'd Oct. 14, 1864; pensioned.	193	Crout, T. J., Serg't, F, 3d Pa. Cav., age 24.	Nov. 27, '63.	Left; circular; by Surgeon W. B. Hezless, 3d Pa. Cav. Disch'd May 9, 1864; pensioned.
153	Cloud, A., Pt., H, 22d Iowa, age 41.	May 22, '63.	Left; circular. Disch'd Sept. 19, 1863; pensioned.	194	Crowell, P. J., Pt., D, 5th Vermont, age 26.	June 5, '64.	Left; circular. Discharged Feb. 13, 1864; pensioned.
154	Coehran, J. M., Pt., E, 188th Penn., age 18.	May 16, '64.	Left. Discharged Dec. 3, 1864; pensioned.	195	Crummey, D., Pt., I, 27th Connecticut.	Dec. 14, '62.	Left; flap; by Asst. Surg. T. M. Hills, 27th Conn. Disch'd Feb. 13, 1863; pensioned.
155	Coffield, W., Pt., I, 1st Missouri Cavalry.	May 11, '62.	Right; circular. Disch'd Sept. 11, 1862.	196	Crozier, O., Pt., G, 111th Pennsylvania, age 28.	May 27, '64.	Right; circular; by Surg. G. P. Oliver, 111th Pa. Disch'd Oct. 24, 1864; pensioned.
156	Cogswell, E. S., Pt., F, 53d Penn., age 39.	Mar. 31, April 1, Dec. 13, '62.	Left; circular. Disch'd July 10, 1865; pensioned.	197	Cullison, J., Pt., M, 22d Pa. Cav., age 27.	Oct. 19, '64.	Left; flap; by Surg. B. R. Taylor, 13th N. Y. Cav. Discharged March 27, 1865; pensioned.
157	Colby, M., Pt., D, 4th Vermont.	Dec. 13, '62.	Left. Discharged April 14, 1863; pensioned.				
158	Cole, I., Pt., B, 123d Ohio, age 22.	June 13, '63.	Right. Disch'd October 3, 1864; pensioned.				



No.	NAME, AGE, AND MILITARY DESCRIPTION.	DATES.	OPERATIONS, OPERATOR, RESULT.	No.	NAME, AGE, AND MILITARY DESCRIPTION.	DATES.	OPERATIONS, OPERATOR, RESULT.
198	Cunningham, G. W., Sgt., B, 125th Ill., age 26.	June 27, '64.	Left; flap; by Surg. C. H. Mills, 125th Ill. Disch'd Dec. 10, '64; pensioned.	237	Eastline, W., Serg't, B, 24th S. C., age 19.	Nov. 30, Dec. 1, 1864.	Right; ant.-post. flap. To Provost Marshal Jan. 7, 1865.
199	Cunningham, W., Pt., I, 12th Ky. Cav., age 38.	Mar. 27, '65.	Left; flap; by Surg. R. H. Tipton, 90th Ohio. Disch'd July 19, '65; pensioned.	238	Eaton, C. A., Serg't, E, 79th Ind., age 29.	Sept. 2, 3, '64.	Right; circular; by Surg. D. C. Patterson, 124th Ohio. Disch'd Feb. 3, 1865; pensioned.
200	Currier, H. E., Pt., G, 11th N. H., age 19.	May 14, '64.	Left; circular; by Surgeon J. S. Ross, 11th N. H. Disch'd Nov. 17, 1864; pensioned.	239	Eaton, R. P., Serg't, G, 32d Maine, age 18.	July 30, 31, '64.	Left; flap. Discharged Dec. 5, 1864; pensioned.
201	Cutting, G. L., Pt., G, 26th Mass., age 26.	Sept. 19, 20, '64.	Right; flap; by A. Surg. T. Buck, 1st Conn. Disch'd Feb. 22, '65; pensioned.	240	Edgar, L. G., Corp'l, I, 191st Pa., age 24.	Mar. 31, 31, '65.	Left; flap; by Surg. A. A. White, 8th Md. Disch'd July 4, 1865; pensioned.
202	Daley, J. A., Pt., B, 67th New York.	Dec. 13, '62.	Right. Discharged Feb. 5, 1863; pensioned.	241	Edgerton, S. W., 2d Lt., H, 30th C. T.	July 30, 30, '64.	Right; circ.; by Surg. D. Mackay, 29th C. T. Discharged March 31, 1865; pensioned.
203	Darnell, S. H., Corp'l, G, 14th Tenn., age 21.	May 6, '64.	Left; circular. Retired March 21, 1865.	242	Edmonds, J. Q., Serg't, K, 5th Maine, age 28.	May 12, '64.	Left; by Surg. F. G. Warren, 5th Me. Disch'd May 1, 1865; pens'd.
204	Davis, C. A., Serg't, C, 11th Maine, age 20.	April 9, '65.	Right; ant.-post. flap; by Surg. C. P. Blunt, 11th Me. Disch'd June 26, 1865; pensioned.	243	Edmonds, W., Corp'l, C, 4th W. Va., age 20.	July 18, 19, '64.	Left; flap; by A. Surg. J. Reagles, 62d N. Y.; pensioned.
205	Davis, J. G., Pt., G, Hampton's Legion.	Sept. 29, 30, '61.	Right; circular; by A. Surg. W. F. Richardson, C. S. A.	244	Edwards, E., Pt., A, 49th Ohio, age 21.	May 27, 29, '64.	Left; flap. Disch'd Oct. 25, 1864; pensioned.
206	Davis, J. M., Serg't, E, 5th N. H.	May 3, '63.	Left; flap; by Surg. J. H. Buckman, 5th N. H. Disch'd Nov. 18, 1863; pensioned.	245	Edward, O. J., Pt., D, 114th N. Y., age 18.	Sept. 19, 19, '64.	Left; circular; by Asst. Surg. J. Humans, jr., U. S. A. Disch'd Nov. 27, 1864; pens'd. <i>Spec.</i> 362.
207	Davison, J., Pt., D, 82d Illinois, age 41.	July 23, '64.	Left; flap. Discharged Jan. 6, 1865.	246	Egolf, J., Capt., I, 125th N. Y., age 34.	Aug. 25, 26, '64.	Right. Discharged pensioned.
208	De Boe, J., Pt., C, 22d N. Y. Hy Art., age 19.	Aug. 4, '64.	Right; circular; by Surg. G. T. Stevens, 77th N. Y. Discharged Dec. 28, 1864.	247	Einwehler, W., Pt., K, 183d Pa., age 47.	May 12, 13, '64.	Left; flap. Disch'd Mar. 20, 1865; pensioned.
209	Dewalt, W., Pt., A, 155th Pennsylvania, age 23.	Oct. 27, '64.	Left; circular. Disch'd June 3, 1865; pensioned.	248	Elliott, J., Pt., D, 111th Illinois, age 33.	Dec. 13, 13, '64.	Left; circular; by A. Staff Surg. C. B. Richards. Disch'd June 15, 1865; pensioned.
210	Deviner, F., Pt., A, 155th Pennsylvania, age 29.	Mar. 25, '65.	Left; ant.-post. flap. Discharged July 8, 1865.	249	Ellis, T. S., Corp'l, F, 30th Tennessee.	Sept. 19, 21, '63.	Left; by Surgs. Wright and Henderson, C. S. A. Recovered.
211	Dillinger, J. D., Corp'l, G, 31st Illinois.	May 22, 22, '63.	Flap; by Surg. D. T. Whitnell, 31st Ill. Disch'd Aug. 12, 1863; pensioned.	250	Ellithrop, P. D., Serg't, B, 2d N. Y. M. R., age 24.	June 17, '64.	Left; circular. Disch'd Jan. 20, 1865; pensioned.
212	Dillon, R., Capt., B, 115th Pennsylvania.	May 3, '63.	Flap; by Surg. F. Reynolds, 88th N. Y. V. R. C. Oct. 5, '63; pens'd.	251	Englehart, F. A., II, 16th New York.	Sept. 14, 15, '62.	Right. Disch'd Nov. 19, 1862; pensioned.
213	Dipple, C. A., Pt., I, 37th Wisconsin, age 32.	June 17, '64.	Right; circular. Disch'd Dec. 8, 1864; pensioned.	252	Enright, J., Pt., I, 98th New York, age 32.	June 1, 2, '64.	Right; circular. Disch'd Aug. 22, 1864; pensioned.
214	Disney, J., Pt., I, 26th Iowa, age 19.	May 13, '64.	Left; flap; by Surg. A. Sabin, 76th Ohio. Disch'd Dec. 12, '64; pensioned.	253	Estell, E., Pt., I, 3d N. J., age 18.	Aug. 25, 26, '64.	Left; circular. Disch'd June 28, 1865; pensioned.
215	Divine, R. M., Corp'l, L, 1st Pa., age 21.	May 28, 28, '64.	Left; circular. Disch'd Dec. 11, 1864; pensioned.	254	Estess, E. A. J., Serg't, D, 7th Wisconsin.	Aug. 26, 26, '62.	Right. Disch'd Oct. 22, 1862; pensioned.
216	Dobbins, S. S., Pt., C, 125th Illinois, age 24.	Sept. 1, '64.	Left; flap; by Surg. E. Batwell, 14th Mich. Discharged Feb. 21, 1865; pensioned.	255	Evans, J. M., Pt., C, 33d Illinois.	May 22, 22, '63.	Right; flap; by Surg. G. P. Rex, 33d Ill. Disch'd Aug. 12, 1863; pensioned.
217	Dolan, B., Pt., G, 69th New York, age 32.	June 3, '64.	Right; circ.; by Surg. W. O'Meargher, 69th N. Y. Disch'd April 3, 1865; pensioned.	256	Facequire, J. W., Pt., C, 83d Indiana.	May 22, 22, '61.	Left. Disch'd Sept., 1863; pensioned.
218	Dolan, J., Serg't, K, 58th Illinois, age 38.	April 9, '64.	Left; circ.; by Surg. H. M. Crawford, 58th Ill. Disch'd; pens'd.	257	Fair, E., Pt., A, 64th N. Y., age 20.	April 7, 6, 1865.	Right; flap. Disch'd Nov. 25, 1865.
219	Donovan, J., Pt., F, 15th Massachusetts.	Sept. 17, 17, '62.	Right; circular. Disch'd Apr 13, 1864; pensioned.	258	Falardan, F., Pt., K, 7th Conn., age 23.	Oct. 13, 13, '64.	Right; flap. Disch'd June 29, 1865.
220	Donovan, J., Pt., A, 9th Mass., age 18.	July 1, '62.	Left; flap; by Surg. W. O'Meargher, 69th N. Y. Disch'd Sept. 30, 1862; pensioned.	259	Falls, J. O., Pt., D, 14th N. C., age 25.	July 3, 3, '63.	Right. Exchanged.
221	Dowd, H. D., Pt., G, 8th Pa. Reserves.	Aug. 28, 28, '62.	Left; flap; by Surg. W. S. King, U. S. A. Disch'd Oct. 18, 1862; pensioned.	260	Farr, E. W., Capt., G, 2d New Hampshire.	May 5, 5, '62.	Right; flap; by Surg. J. M. Merrou, 2d N. H. Disch'd Oct. 5, 1862; pensioned.
222	Doyle, P., Pt., A, 35th Massachusetts.	Aug. 12, 12, '64.	Left; circular. Discharged June 27, 1865.	261	Farrell, M., Pt., U. S. Art. Detachment, W. Point.	July 4, 4, '63.	Left; flap; by Surg. E. H. Abadie, U. S. A., and Asst. Surg. H. L. Sheldon, U. S. A. Discharged Aug. 18, 1863; pensioned.
223	Duessler, J. J., Pt., A, 55th Ohio.	May 2, '63.	Right. Discharged Aug. 4, 1863; pensioned.	262	Faulkner, F., Pt., I, 117th Illinois, age 27.	Dec. 15, 15, '64.	Right; ant.-post. flap; by Surg. M. Wiley, 117th Ill. Mustered out Aug. 5, 1865.
224	Dugan, D., Pt., C, 105th Pennsylvania, age 24.	Aug. 16, '64.	Right; flap. Discharged Feb. 26, 1865; pensioned.	263	Fauls, J., Pt., K, 13th Conn., age 18.	Sept. 19, 20, '64.	Right; flap; by Surg. G. Clary, 13th Conn. Discharged Jan. 6, 1865; pensioned.
225	Dunn, D., Pt., K, 11th Pennsylvania, age 34.	Feb. 6, '65.	Right; flap. Disch'd July 13, 1865; pensioned.	264	Favreau, J., Serg't, B, 146th N. Y., age 25.	May 5, 5, '64.	Left; circular; by Surg. T. M. Flandrau, 146th N. Y. Disch'd Sept. 10, 1864; pensioned.
226	Dunn, J., Pt., H, 5th New York, age 20.	June 10, '61.	Right; flap. Disch'd Aug. 14, 1861.	265	Fellows, D. T., Corp'l, C, 2d N. Y. Mtd. Rifles.	July 18, 18, '64.	Right; circular; by Surg. J. D. Mitchell, 31st Me. Discharged Dec. 27, 1864; pensioned.
227	Dupau, L., Serg't, I, 98th Pennsylvania, age 38.	May 18, 18, '64.	Antero-posterior flap. Discharged Dec. 17, 1864; pensioned.	266	Ferguson, U. L., Serg't, K, 58th N. Y.	Sept. 17, 19, '62.	Left. Discharged; pensioned.
228	Durr, A. J., Pt., H, 72d Illinois, age 19.	April 1, '65.	Right; flap; by Surg. E. Powell, 72d Ill. Disch'd May 25, 1865; pensioned.	267	Finneal, S., Pt., K, 5th Mich., age 23.	Nov. 27, 28, '63.	Right; flap; by Surg. H. F. Lytster, 5th Mich. Discharged July 15, 1864; pensioned.
229	Dusenbery, H., Pt., D, 30th Ohio, age 35.	Nov. 25, 25, '63.	Left; lateral flap; by Surg. J. M. Woodworth, 1st Ill. Lt Art. Disch'd July 27, 1864; pens'd.	268	Fitch, S. N., Corp'l, C, 6th Vermont, age 22.	May 5, 5, '64.	Flap; by Surg. E. Phillips, 6th Vt. Disch'd Oct. 26, '64; pens'd.
230	Dutton, I. R., Pt., G, 49th New York, age 22.	May 12, '64.	Right; ant.-post. flap. Disch'd Sept. 3, 1864; pensioned.	269	Fisher, J., Pt., F, 1st Mich. Sharpshooters, age 18.	June 17, 18, '64.	Left. Discharged Dec. 29, 1864.
231	Dwinelle, J. W., Corp'l, G, 21st Mass.	Dec. 13, '62.	Left; circular; by Surg. C. Cutter, 21st Mass. Discharged Jan. 1, 1863; pensioned.	270	Fitzpatrick, J. M., Serg't, A, 2d Ohio, age 20.	Sept. 19, 20, '63.	Left; flap; by Surg. B. F. Miller, 2d Ohio. Disch'd Jan. 20, 1864.
232	Dykes, J., Pt., C, 35th Missouri.	July 4, '63.	Right. Disch'd Sept. 10, 1863; pensioned.	271	Fitzpatrick, R., Pt., B, 115th Pa., age 47.	July 2, 3, '63.	Right; flap; by Surg. E. Ewing, 115th Pa. Discharged Dec. 13, 1864; pensioned.
233	Dyke, L. J., Serg't Maj., 11th Pa., age 22.	July 20, 20, '64.	Left; flap; by Surg. A. K. Fifield, 29th Ohio. Duty April 13, '65; pensioned.	272	Fletcher, J. A., Pt., I, 45th Pa., age 26.	May 6, 7, '64.	Right; circular; by Surg. W. F. Humphrey, 14th Pa. Disch'd Jan. 19, 1865; pensioned.
234	Eakes, A., Pt., K, 55th North Carolina.	July 2, '63.	Left. Exchanged Nov. 12, 1863.	273	Flynn, J., Pt., F, 16th Mass., age 20.	June 25, 25, '62.	Right; flap. Discharged Oct. 22, 1862; pensioned.
235	Earing, A., Pt., G, 3d New York, age 26.	May 14, '64.	Left. Discharged July 16, 1865; pensioned. <i>Spec.</i> 3090.	274	Folwell, T., Pt., I, 198th Pennsylvania, age 21.	Mar. 31, 31, '65.	Left; circular. Discharged Sept. 19, 1865; pensioned.
236	Easterbrook, A. B., Pt., H, 142d N. Y., age 29.	Oct. 27, 28, '64.	Left; flap; by Surg. G. C. Jarvis, 7th Conn. Discharged Jan. 8, 1865; pensioned.	275	Foreman, S., Pt., A, 43d C. T., age 48.	July 30, Aug. 1, 1864.	Left; circ.; by Surg. D. Mackay, 29th C. T. Disch'd Apr 17, '65.

NO.	NAME, AGE, AND MILITARY DESCRIPTION.	DATES.	OPERATIONS, OPERATOR, RESULT.	NO.	NAME, AGE, AND MILITARY DESCRIPTION.	DATES.	OPERATIONS, OPERATOR, RESULT.
276	Foss, B. M., Serg't, I, 1st Me. H'y Art., age 31.	June 18, '64.	Right; flap. Discharged Nov. 9, 1864; pensioned.	317	Graves, E. L., Pt., II, 3d Michigan.	May 31, '62.	Right; flap. Discharged Aug. 13, 1862.
277	Foster, W. S., Corp'l, I, 70th N. Y., age 31.	May 6, '64.	Left; circular. Discharged Oct. 20, 1864.	318	Gray, W. M., Pt., F, 12th Kansas.	April 30, '64.	Left; by Surg. C. R. Stuecklager, 12th Kans. Discharged May 25, 1864; pensioned.
278	Fraiser, J., Corp'l, H, 55th Illinois, age 19.	June 27, '64.	Left; by Surg. I. N. Barnes, 116th Ill. Disch'd Nov. 16, 1864.	319	Grotzman, J. N., Pt., E, 52d N. Y., age 27.	May 12, '64.	Right; flap; by Surg. M. O. Froelick, 52d N. Y. Disch'd Aug. 7, 1865.
279	Frazier, J., Pt., G, 116th Ohio, age 19.	Oct. 13, '64.	Right; flap; by Surg. T. J. Shannon, 116th Ohio. Discharged June 10, 1865; pensioned.	320	Grier, F., Pt., B, 12th Tenn., age 22.	Nov. 30, '62.	Right; ant.-post. flap. To Provost Marshal Jan. 7, 1865.
280	Frazier, R., Pt., C, 18th Connecticut.	June 15, '63.	Left; by Surg. T. C. Smith, 116th Ohio. Disch'd Dec. 14, 1863; pensioned.	321	Griffith, E. T., Pt., F, 13th Alabama.	July 3, '63.	Left. Exchanged Mar. 3, 1864.
281	Frazier, J. Q., Pt., K, 5th Pa., age 22.	June 1, '64.	Right; lateral flap. Discharged Nov. 28, 1864; pensioned.	322	Griffith, F. J., Pt., F, 6th Colored Troops, age 20.	Sept. 29, '64.	Right; flap. Discharged July 26, 1865; pensioned.
282	Fry, G., Pt., D, 2d New Hampshire, age 22.	June 3, '64.	Circular. Disch'd June 2, 1865; pensioned.	323	Griswold, G. B., Pt., H, 5th Mich. Cav., age 20.	Sept. 19, '64.	Right; flap; by Surg. A. K. St. Clair, 5th Mich. Cav. Disch'd May 30, 1865; pensioned.
283	Freeman, C. W., Pt., I, 75th Ill., age 22.	July 4, '64.	Left; flap; by Surg. C. J. Walton, 21st Ky. Disch'd Feb. 11, 1865.	324	Groff, J., Pt., K, 85th Penn., age 21.	June 17, '61.	Left; flap. Discharged Oct. 21, 1864; pensioned.
284	Freeman, N., Serg't, D, 2d N. H., age 24.	June 3, '64.	Left; flap; by Surg. J. M. Meron, 2d N. H. Discharged Oct. 21, 1864; pensioned.	325	Gross, D., Pt., H, 6th N. Y. Cav., age 31.	Sept. 19, '64.	Right; flap. Disch'd June 16, 1865; pensioned.
285	Friend, F., Serg't, B, 35th Mass., age 23.	Oct. 3, '64.	Left; circ.; by Surg. G. W. Snow, 35th Mass. Disch'd Mar. 17, '65.	326	Grove, J. H., Pt., C, 34th Indiana.	May 16, '63.	Left; circular; by Surg. D. W. Taylor, 34th Ind. Disch'd Sept. 29, 1863; pensioned.
286	Frier, A., Corp'l, M, 6th N. Y. Cavalry.	Aug. 15, '62.	Right. Discharged Oct. 9, 1862; pensioned.	327	Grove, W. S., Pt., I, 5th Virginia.	Mar. 25, '65.	To prison June 11, 1865.
287	Freshman, G. W., Pt., F, 6th Ohio.	July 2, '62.	Right; flap; by Surg. L. Shusser, 6th Ohio. Disch'd Sept. 11, '62.	328	Gruber, E. H., Pt., G, 151st Pennsylvania.	July 2, '63.	Left; flap. Mustered out July 28, 1863.
288	Fritte, H. M., Pt., M, 9th N. Y. H'y Art., age 33.	Oct. 19, '64.	Left; ant.-post. flap; by A. Surg. B. Fordyce, 160th N. Y. Disch'd Aug. 7, 1865; pensioned.	329	Gunderman, C., Pt., C, 126th N. Y.	Sept. 13, '62.	Left. Discharged Dec. 4, 1862; pensioned.
289	Funderburk, W. F., Pt., E, 114th Illinois.	June 10, '64.	Left; flap; by a Confederate surg. Disch'd April 1, 1866.	330	Gunn, D. K., Pt., A, 21st Michigan, age 25.	Mar. 19, '65.	Left; circular. Disch'd June 12, 1865; pensioned.
290	Galley, P., Pt., C, 65th New York, age 19.	May 6, '64.	Left; antero-posterior flap; pensioned.	331	Gwinne, N. M., Pt., H, 13th Ohio Cav., age 15.	July 30, '64.	Left; flap; by Surg. A. A. White, 8th Md. Disch'd Jan. 1, 1865; pensioned.
291	Gallentine, J., Pt., I, 63d Pennsylvania.	May 3, '63.	Left; flap. To V. R. C. Oct. 7, 1863; pensioned.	332	Haas, W. H., Pt., A, 10th N. Y. H'y Art., age 26.	July 3, '64.	Right; flap. Disch'd October 22, 1864; pensioned.
292	Gampert, Chas., Pt., A, 7th N. Y., age 32.	April 2, '65.	Left; circular. Discharged Aug. 17, 1865.	333	Haag, J., Pt., C, 20th New York.	June 30, '62.	Right; by Asst. Surg. C. Heiland, 20th N. Y. Discharged Dec. 16, 1862; pensioned.
293	Gantz, J. S., Corp'l, M, 4th Iowa Cav., age 29.	Mar. 31, '65.	Flap; by Asst. Surg. T. J. Maxwell, 3d Iowa Cavalry. Disch'd July 29, 1865; pensioned.	334	Hable, P., Pt., K, 59th Illinois, age 35.	July 4, '64.	Left; by Surg. C. J. Walton, 21st Kentucky; pensioned.
294	Gerhart, D. H., Pt., B, 5th Pa., age 16.	May 31, '61.	Left; circular. Disch'd Dec. 28, 1864; pensioned.	335	Hadley, L. D., Pt., B, 25th Massachusetts.	Mar. 14, '62.	Right; flap; by Surg. G. A. Otis, 27th Mass. Disch'd Nov. 11, '62.
295	Garrity, M., Pt., I, 7th N. Y. H. A., age 25.	June 16, '64.	Left; circular; by Surg. J. E. Pomret, 7th N. Y. Heavy Art. Disch'd Feb. 13, 1865; pensioned.	336	Haight, L., Pt., G, 34th New York.	May 31, '61.	Left; by Surg. S. N. Sherman, 34th N. Y. Disch'd Aug. 20, 1862; pensioned.
296	Garry, T., Pt., I, 95th N. York, age 44.	May 5, '64.	Left; circular. Disch'd June 18, 1864.	337	Hale, J., Pt., I, 87th Pa.	June 3, '64.	Left; circular; by Surg. D. P. McKinney, 87th Pa. Disch'd Sept. 17, 1864; pensioned.
297	Gash, G. H., Corp'l, K, 91st Penn., age 28.	June 18, '64.	Left; circular. Disch'd Mar. 16, 1865; pensioned.	338	Haley, J. H., Pt., D, 6th Missouri Cav.	July 5, '62.	Left; by Asst. Surg. J. K. Bigelow, 6th Mo. Cav. Disch'd Aug. 2, 1862; pensioned.
298	Gaskin, B., Pt., D, 14th N. J., age 36.	June 1, '64.	Left; flap. Disch'd Dec. 30, 1864; pensioned.	339	Hall, E. F., Pt., B, 3d N. Hampshire, age 40.	Aug. 16, '64.	Left; ant.-post. flap. Discharged Oct. 28, 1864; pensioned.
299	German, D., Pt., F, 100th Indiana.	Nov. 25, '63.	Left. Discharged June 8, 1865; pensioned.	340	Hall, G. T., Corp'l, E, 6th Wisconsin, age 35.	Sept. 14, '62.	Left; flap. Disch'd Mar. 1, 1864.
300	Getchell, E., Pt., C, 3d Maine, age 29.	May 5, '64.	Left; flap. Disch'd Dec. 13, 1864; pensioned.	341	Hambliu, O., Pt., E, 2d Mich. Cav., age 22.	Oct. 30, '64.	Left; circular. Duty May, 1865; pensioned.
301	Gibbs, W., Serg't, F, 32d Virginia, age 25.	Sept. 17, '62.	Right; circular. Disch'd Dec. 17, 1862.	342	Hamilton, A. B., Corp'l, A, 31st Illinois.	Feb. 15, '62.	Right. Disch'd July 23, 1862; pensioned.
302	Gibson, W. S., Pt., C, 4th Iowa, age 19.	May 26, '64.	Left; circ.; by Surg. B. N. Bond, 27th Mo. Disch'd Feb. 21, 1865.	343	Hamilton, J. T., Pt., I, 112th N. Y., age 34.	Jan. 15, '65.	Left; circular; by Surgeon J. W. Mitchell, 4th C. T. Discharged May 16, 1865; pensioned.
303	Giddings, A. A., Pt., C, 44th N. Y., age 17.	May 5, '64.	Left; circular; by Surg. M. W. Townsend, 44th N. Y. Disch'd May 15, 1865; pensioned.	344	Hammersly, T., Pt., I, 81st N. Y., age 20.	June 3, '64.	Left; flap. Disch'd Feb. 16, 1865; pensioned.
304	Gilchrist, W. H., Pt., K, 53d Penn., age 20.	May 10, '64.	Left; circular; by Surg. G. L. Potter, 145th Penn. Disch'd Oct. 24, 1864; pensioned.	345	Hammond, C. W., Pt., D, 10th Maine.	May 25, '62.	Left. Discharged Aug. 20, 1862; pensioned.
305	Gilmore, J., Pt., A, 1st W. Virginia Cavalry.	July 18, '63.	Right; flap. To V. R. C. pensioned.	346	Hanbury, G. W., Lieut., I, 102d Pa., age 26.	Sept. 19, '64.	Right. Discharged Nov. 21, 1864; pensioned.
306	Gilroy, J., Pt., A, 33d New Jersey, age 38.	May 28, '64.	Left; flap; by Surg. J. Reiley, 33d N. J. Disch'd May 15, '65; pens'd.	347	Hanchett, S. F., Serg't, L, 15th N. Y. Cav., age 24.	April 1, '65.	Left; flap; by Surg. G. V. Skiff, 15th N. Y. Cav. Disch'd June 28, 1865; pensioned.
307	Gleason, A., Pt., K, 39th Mass., age 19.	June 18, '64.	Left; circ.; by Surg. W. Thordike, 39th Mass. Disch'd May 16, 1865; pensioned.	348	Hancy, J., Pt., G, 5th N. Y. H'y Art., age 28.	Sept. 19, '64.	Left; circular. Disch'd Mar. 27, 1865; pensioned.
308	Goff, L. S., Pt., E, 17th Maine, age 21.	May 5, '64.	Right; ant.-post. flap; by Surg. C. Bower, 6th Pa. Res. Disch'd Dec. 2, 1864; pensioned.	349	Handy, A. S., Pt., E, 5th N. H., age 33.	June 3, '64.	Left; flap. Disch'd June 15, 1865; pensioned.
309	Goodbread, J. C., Pt., C, 14th Tenn., age 20.	Nov. 30, '62.	Antero-posterior flap. To Provost Marshal Jan. 31, 1865.	350	Handy, C., Pt., G, 7th Col'd Troops.	24 hours after inj. Aug. 29, '62.	Right. Discharged May 27, 1865; pensioned.
310	Goodman, T. A., Lieut., K, 24th Georgia.	Sept. '62.	Paroled Oct. 18, '62. Almost well.	351	Hannluser, J., Pt., G, 29th New York.	Aug. 29, '62.	Left. Discharged Dec. 5, 1862; pensioned.
311	Goodnow, E. J., Pt., A, 14th N. H., age 28.	Sept. 19, '64.	Left; flap; by Surg. W. H. Thayer, 14th N. H. Disch'd Feb. 8, 1865; pensioned.	352	Hardacre, W. B., Serg't, C, 71st Ohio, age 24.	Dec. 16, '64.	Left; flap. Discharged May 11, 1865.
312	Googery, A. M., Pt., D, 11th Me., age 28.	Aug. 16, '64.	Left; circular. Discharged Nov. 19, 1864.	353	Hardieks, W. H., Pt., D, 59th Mass.	June 16, '64.	Left; flap; by Asst. Surg. E. W. Norton, 59th Mass. Discharged Aug. 26, 1864; pensioned.
313	Gould, D. W., Pt., G, 2d New Hampshire.	May 5, '62.	Left. Discharged Dec. 11, 1862; pensioned.	354	H——, F. H., Pt., B, 7th Pa. Res., age 46.	May 10, '64.	Left; flap; by A. Surg. Cowles, U. S. A. Disch'd Jan. 18, 1865; pensioned. Spec. 2732.
314	Granger, H. F., Pt., F, 19th Mich., age 23.	July 20, '64.	Right; flap; by Asst. Surg. G. M. Frowbridge, 19th Mich. Disch'd May 11, 1865; pensioned.	355	Harmer, E., Corp'l, F, 110th Pa., age 21.	May 6, '64.	Left; lateral flap; by Surg. G. E. Ewing, 115th Pa. Disch'd Dec. 28, 1864; pensioned.
315	Grant, C. H., Corp'l, C, 43d N. Y., age 19.	Mar. 27, '65.	Right; ant.-post. flap; by Surg. G. T. Stevens, 77th N. Y. Disch'd Oct. 4, 1865; pens'd. Spec. 3223.	356	Harriss, R. H., Pt., K, 97th Ohio.	June 22, '64.	Left; flap; by Surg. Z. P. Hanson, 42d Ill. Disch'd Oct. 28, 1864.
316	Grant, I., Serg't, C, 60th N. C., age 30.	May 21, '64.	Right; flap. Furloughed June 10, 1864.	357	Harrison, T., Pt., E, 111th Pennsylvania, age 23.	Oct. 29, '63.	Left; flap. Discharged June 1, 1865; pensioned.



No.	NAME, AGE, AND MILITARY DESCRIPTION.	DATES.	OPERATIONS, OPERATOR, RESULT.	No.	NAME, AGE, AND MILITARY DESCRIPTION.	DATES.	OPERATIONS, OPERATOR, RESULT.
358	Harrison, J., Corp'l, G, 20th Mass., age 27.	Sept. 19, '64.	Left; circular; by Surg. J. G. Bradd, 26th Mass. Disch'd Feb. 28, 1865; pensioned.	396	Holloway, S., Pt., B, 23d Colored Troops.	July 30, Aug. 1, 1864.	Left; circ.; by Surg. J. H. Ross, 11th N. H. Disch'd Jan. 9, '65.
359	Harrington, W., Pt., G, 40th Indiana.	June 27, '64.	Right; by Surg. E. B. Glick, 40th Ind. Disch'd Oct. 24, '64; pens'd.	397	Homan, W., Pt., E, 6th N. Y. H'y Art., age 24.	May 12, 13, '64.	Right. Discharged; pensioned.
360	Harris, A., Pt., K, 47th Colored Troops.	Feb. 3, '64.	Right; circular; by Surg. N. N. Horton, 47th Colored Troops. Disch'd Sept. 11, '64; pensioned.	398	Hooks, C. E., Pt., H, 7th Conn.	June 16, '62.	Flap; by Surg. F. Bacon, 7th Conn. Disch'd Jan. 8, '63; pens'd.
361	Hartman, J., Corp'l, C, 70th New York, age 22.	May 31, '64.	Left; flap; by Surg. J. Ash, 70th N. Y. Disch'd Oct. 26, '64; pens'd.	399	Hotehkiss, P. D., Pt., E, 8th Conn., age 23.	May 7, '64.	Left; circular. Disch'd Oct. 10, 1864; pensioned.
362	Hartman, J., Pt., B, 142d Pennsylvania.	Dec. 13, '62.	Left. Disch'd March 15, 1863; pensioned.	400	Hosetter, J. C., Pt., A, 7th W. Va., age 22.	June 4, '64.	Right; flap; by Surg. I. Scott, 7th W. Va. Disch'd Sept. 30, '64; pens'd.
363	Hartwell, J. W., Corp'l, F, 31st Illinois.	July 21, '64.	Left; flap; by Surg. O. B. Ormsby, 45th Illinois. Disch'd March 6, 1865; pensioned.	401	House, J. W., Pt., H, 38th Indiana, age 20.	July 20, 20, '64.	Left; flap. Discharged May 10, 1865; pensioned.
364	Harwood, A., Pt., G, 2d Michigan.	July 11, '63.	Left; circ.; by Surg. E. J. Bonine, 2d Mich. Disch'd Sept. 30, 1863; pensioned.	402	Howard, O. O., Brig. Gen'l, U. S. V., age 34.	June 1, '62.	Right; flap; by Surg. G. S. Palmer, U. S. V. Duty Aug. 1, '62.
365	Harvey, L., Pt., F, 39th Illinois, age 35.	Aug. 16, '64.	Right; circular; by Surg. C. M. Clark, 39th Ill. Discharged Oct. 18, 1864.	403	Howe, J. F., Pt., D, 61st Pennsylvania, age 22.	May 7, 7, '64.	Right; flap. Disch'd; pensioned.
366	Haskell, S. F., Serg't, C, 17th Maine, age 25.	June 16, '64.	Right; ant.-post. flap; by Surg. N. A. Harsam, 17th Me. Disch'd Dec. 16, 1864; pensioned.	404	Hubbard, J., Pt., B, 29th Pennsylvania, age 31.	May 15, '64.	Right; flap; by Surg. J. A. Wolfe, 29th Pa. Re-amp. Aug. 10, '64. Disch'd July 4, 1865; pensioned.
367	Hasley, W. N., Pt., I, 143d Pa., age 21.	May 10, '64.	Right; circular; by Surg. F. M. Aug. 23, 1865; pensioned.	405	Huber, J., Capt., F, 52d N. Y., age 41.	June 16, 17, '64.	Right; by Surg. G. L. Patter, 143d Pa. Duty Oct. 25, 1864.
368	Hassett, L., Pt., D, 5th Maine, age 28.	May 12, '64.	Right; circular; by Surg. F. M. Aug. 23, 1865; pensioned.	406	Hughes, W., Corp'l, B, 1st N. J., age 32.	June 3, '64.	Right; circular; by Asst. Surg. L. D. Miller, 1st N. J. Disch'd; pensioned.
369	Hayes, T., Serg't, A, 28th Col'd Troops, age 44.	July 30, Aug. 1, 1864.	Right; circular; by Surg. T. H. Squire, 8th N. Y. Disch'd Oct. 13, 1865; pensioned.	407	Hull, F., Pt., B, 124th Ohio, age 21.	May 27, '64.	Right; by Surg. D. C. Patterson, 124th Ohio. Discharged Sept. 5, 1864; pensioned.
370	Heady, H., Pt., F, 85th New York, age 26.	April 2, '65.	Right; circular; by Surg. T. H. Squire, 8th N. Y. Disch'd Oct. 13, 1865; pensioned.	408	Hull, J., Pt., K, 11th Ohio.	Sept. 14, 15, '62.	Left; circular. Discharged Oct. 16, 1862.
371	Heasley, D. F., Pt., H, 130th Pa.	Dec. 13, '62.	Right. Duty May 18, 1863; pensioned.	409	Hull, S. T., Corp'l, K, 73d Ohio, age 44.	May 30, 30, '64.	Right; circular. To V. R. C. Dec. 5, 1864; pensioned.
372	Heeker, H. L., Pt., A, 7th Pa. Reserves.	June 27, '62.	Right; flap. Discharged Sept. 13, 1862.	410	Hummell, J., Pt., I, 27th Pennsylvania, age 52.	July 1, '63.	Left. Discharged Oct. 23, 1863; pensioned.
373	Hecht, H., Pt., H, 76th Illinois, age 24.	April 9, 1865, 10 hrs aff'r.	Left; flap; by Surg. W. A. Babcock, 76th Ill. Discharged July 22, 1865; pensioned.	411	Hunt, J., Pt., E, 4th Rhode Island.	Sept. 17, '62.	Right; flap; by Asst. Surg. R. Miller, 4th R. I. Disch'd April 14, 1863; pensioned.
374	Henderson, A. H., Corp'l, I, 1st N. Y. Cav.	Aug. 22, '64.	Right; circular. Disch'd March 22, 1865; pensioned.	412	Hunter, J. W., Pt., I, 19th Massachusetts.	Dec. 13, '62.	Left; circular. Disch'd Jan. 9, 1863.
375	Hendrick, C., Pt., A, 29th Ohio, age 18.	July 3, '63.	Right; ant.-post. flap; by Surg. A. K. Fifield, 29th Ohio. Disch'd Oct. 17, 1863; pensioned.	413	Hurst, J., Pt., A, 34th Mass., age 41.	Sept. 22, '64.	Right; circular; by Surg. R. R. Clark, 34th Mass. Disch'd July 30, 1865; pensioned.
376	Henry, J., Pt., B, 13th Illinois.	Dec. 29, '62.	Right; flap. Disch'd May 23, '64; pensioned.	414	Husbands, C. D., Pt., G, 12th N. J., age 32.	July 2, '63.	Left; flap; by Surg. A. Satterthwaite, 12th N. J. Disch'd Oct. 18, 1863; pensioned.
377	Hesford, Z., Pt., F, 8th Indiana.	Mar. 7, '62.	Left; by Hospital Steward J. K. Bigelow. Disch'd; pensioned.	415	Huston, W., Pt., B, 81st Pennsylvania, age 24.	Dec. 13, '62.	Left. Discharged June 7, 1864; pensioned.
378	Hess, J., Pt., K, 66th N. Y., age 24.	May 12, '64.	Left; circular; by Surg. C. S. Wood, U. S. V. Duty Dec. 2, 1864; pensioned.	416	Hutchinson, F., Pt., G, 137th N. Y., age 18.	July 20, '64.	Right; circular; by Surg. J. A. Wolfe, 23th Pa. Disch'd Dec. 27, 1864; pensioned.
379	Hibler, J., Pt., F, 180th Ohio, age 30.	Nov. 18, '64.	Right; circular; by A. Surg. S. Hart, U. S. A. Disch'd March 21, 1865.	417	Hutzleman, M., Pt., B, 107th Ohio, age 34.	July 3, 4, '63.	Right; flap; by Surg. J. V. Cantwell, 82d Ohio (Also excision of metacarpal bone, left hand.) Disch'd Jan. 29, 1864; pens'd.
380	Higgins, J., Pt., G, 65th New York.	May 31, June 1, 1862.	Right; flap. Discharged Feb. 16, 1863; pensioned.	418	Hyde, E., Pt., K, 2d Michigan.	July 11, '63.	Left; circular; by Surg. J. P. Prince, 30th Mass. Disch'd Sept. 25, 1863.
381	Hill, G. D., Lieut., 1st Mich. Cav., age 25.	April 9, '65.	Left. Discharged Nov. 7, 1865.	419	Hynemann, H. A., Lieut., B, 50th Pa., age 48.	May 6, 7, '64.	Left; flap; by Asst. Surg. W. P. Book, 50th Pa. Disch'd Sept. 5, 1864.
382	Hill, J., Pt., I, 123d Indiana, age 19.	June 29, '64.	Circular; by Surg. J. W. Lawton, U. S. V. Disch'd Mar. 9, '65.	420	Imboden, G., Pt., A, 93d Pennsylvania, age 26.	Oct. 19, '64.	Left; circular; by Surg. E. R. Umberger, 93d Pa. Disch'd June 8, 1865; pensioned.
383	Hill, L., Pt., G, 19th Colored Troops, age 40.	July 30, '64.	Right; circular; by Surg. Geo. J. Potts, 23d C. T. Disch'd Jan. 9, 1865; pensioned.	421	Inskep, A., Pt., H, 7th Ohio.	Aug. 9, '62.	Right. Disch'd Oct. 18, 1862; pensioned.
384	Hindman, J. S., Pt., E, 140th Penn., age 24.	June 19, '64.	Right; circular; by Surg. J. W. Wishart, 140th Pa. Disch'd Apr. 1 20, 1865; pensioned.	422	Irish, M. F., Pt., F, 121st New York, age 18.	June 1, '64.	Left; circular. Disch'd Aug. 27, 1864; pensioned.
385	Hinds, D., Pt., A, 3d Michigan, age 28.	Aug. 29, '62.	Right; flap. Disch'd Nov. 12, 1862; pensioned.	423	Ireland, B., Pt., G, 1st Pa. Rifles.	June 7, 9, '62.	Left; by Surg. S. D. Freeman, 1st Pa. Rifles. Disch'd Dec. 5, 1862; pensioned.
386	Hinkley, L. D., Lieut., K, 10th Wisconsin.	Nov. 19, '64.	Left; by Surg. Le Grand, C. S. A. Discharged; pensioned.	424	Irwin, F. J., Serg't, K, 140th N. Y., age 20.	Aug. 19, 20, '64.	Right; circ; by Surg. T. M. Flan-deau, 146th N. Y. Discharged April 3, 1865; pensioned.
387	Hirsch, G. E., Pt., E, 5th Wisconsin, age 18.	April 6, '65.	Left; flap. Disch'd June 30, '65.	425	Irwin, W. F., Corp'l, E, 56th Mass., age 28.	May 31, '64.	Right; flap; by Surg. T. F. Oakes, 56th Mass. Discharged Nov. 14, 1864; pensioned.
388	Hiscock, A. S., Serg't, G, 20th Maine, age 28.	July 2, '64.	Right. Disch'd Jan. 19, 1864; pensioned.	426	Jackman, O. F., Pt., A, 7th Ohio, age 22.	May 1, 2, '63.	Right; flap; by Surg. A. K. Field, 29th Ohio. Disch'd Nov. 20, 1863; pensioned.
389	Hoag, J. M., Lieut., B, 4th Col. Troops, age 21.	Sept. 29, '64.	Left; by Surg. J. W. Mitchell, 4th C. T. Duty May 10, 1865; pensioned.	427	Jackson, C. A., Pt., 39th Illinois, age 18.	Aug. 16, '64.	Left; circ.; by Surg. C. M. Clark, 39th Ill. Disch'd Nov. 7, 1864.
390	Hodges, W. B., Pt., B, 7th Mo. Cav., age 20.	April 17, '64.	Right; flap; by Surg. I. Casselberry, 1st Ind. Cav. Disch'd Dec. 27, 1864; pensioned.	428	Jackson, M., Pt., H, 9th N. Y. Cav., age 19.	June 12, '64.	Right; circular. Disch'd Feb. 11, 1865; pensioned.
391	Hogan, J. H., Pt., E, 105th New York.	Sept. 17, '62.	Right; flap; by A. Surg. D. A. Chamberlain, 105th N. Y. Discharged Oct. 31, '62; pensioned.	429	Jarrett, J. F., Pt., B, 40th Illinois.	April 7, '62.	Right; flap. Discharged Aug. 22, 1862; pensioned.
392	Hogan, M., Pt., F, 8th Indiana.	Mar. 7, '62.	Left; flap; by Surg. B. J. Newland, 23d Ind. Discharged May 13, 1863; pensioned.	430	Jarvey, J., Pt., L, 7th Mich. Cav., age 18.	Sept. 19, '64.	Right; circ.; by Surg. N. S. Richardson, 13th Ohio Cav. Disch'd March 30, 1865; pensioned.
393	Hogan, P., Pt., D, 3d N. Hampshire, age 20.	Sept. 29, '64.	Left; bilateral flap. Disch'd July 12, 1865; pensioned.	431	Jefferson, G., Serg't, A, 31st Col'd Troops.	July 30, 30, '64.	Right; flap; by Surg. G. J. Potts, 23d C. T. Discharged Jan. 14, 1865; pensioned.
394	Holcomb, A. H., Serg't, A, 141st Illinois.	Aug. 29, '64.	Left; by Surg. H. A. Buck, 141st Ill. Disch'd Oct. 10, '64; pens'd.	432	Jeffries, G. W., Color Sgt., 11, 29th Pa., age 25.	June 15, '64.	Left; flap; by Surg. J. L. Dunn, 109th Pa. Must'd out July 17, '65.
395	Hollenbach, J., Pt., I, 81st Pa., age 33.	May 12, '64.	Right; flap; by Surg. J. W. Wishart, 140th Pa. Discharged Jan. 11, 1865; pensioned.	433	Johnson, G. L., Sgt. Maj., 142d New York.	Feb. 9, '64.	Right; flap; by Surg. D. McFall, 142d N. Y. Disch'd June 7, '65; pensioned.

NO.	NAME, AGE, AND MILITARY DESCRIPTION.	DATES.	OPERATIONS, OPERATOR, RESULT.	NO.	NAME, AGE, AND MILITARY DESCRIPTION.	DATES.	OPERATIONS, OPERATOR, RESULT.
434	Johnson, H. C., Pt., I, 69th Ohio, age 19.	Sept. 1, '64.	Right; circ. by Surg. L. Slusser, 69th Ohio. Disch'd May 11, '65.	475	Kimerling, C., Pt., F, 100th New York.	July 18, '63.	Left; double flap. Disch'd Jan. 15, 1864.
435	Johnson, J., Pt., K, 153d Pennsylvania.	July 1, '63.	Left; flap. Discharged July 24, 1863; pensioned.	476	Kincaid, W. H., Pt., E, 11th Maine, age 18.	Aug. 14, '64.	Right; flap. Disch'd Oct. 2, 1865; pensioned.
436	Johnson, J. A., Pt., A, 22d Col'd Troops, age 23.	June 15, '64.	Left; ant.-post. flap. Discharged Dec. 1, 1864; pensioned.	477	Kinderman, H., Corp'l, F, 10th Illinois, age 30.	June 22, '64.	Right; circular; by Surg. H. R. Payne, 10th Illinois. Disch'd Dec. 15, 1864.
437	Johnson, J. H., Pt., F, 60th Indiana.	Aug. 30, '62.	Right; by Surg. N. Field, 66th Ind. Disch'd Dec. 1, '62; pens'd.	478	King, G. H., Pt., C, 49th New York, age 25.	May 6, '64.	Right; ant.-post. flap. Disch'd Oct. 17, 1864; pensioned.
438	Johnson, J. R., Pt., F, 63d Pennsylvania.	July 25, '62.	Left; flap. Disch'd Aug. 8, '62.	479	Kingsbury, E., Lieut., E, 39th Illinois.	May 16, '64.	Left; by Surg. C. M. Clark, 39th Illinois. Disch'd; pensioned.
439	Johnson, S., Pt., I, 46th Indiana.	May 16, '63.	Right; by Surg. H. Coleman, 46th Ind. Disch'd Sept. 30, 1863; pensioned.	480	Kiplinger, L. H., Corp'l, C, 42d Ohio.	May 1, '63.	Right; flap; by Surg. J. Pomeroy, 42d Ohio. Disch'd July 15, 1863; pensioned.
440	Johnson, S. H., Pt., D, 145th Pennsylvania.	Dec. 13, '62.	Right; flap. Discharged Jan. 8, 1863; pensioned.	481	Kircher, H., Capt., E, 12th Missouri.	Nov. 27, '63.	Right; by Surg. J. Spiegelhalter, 12th Mo. (Also amp. of thigh.) Mustered out Nov. 14, 1864, and pensioned.
441	Johnson, W., Pt., D, 6th Ohio Cav., age 20.	Sept. 30, Oct. 1, '64.	Right; flap; by Surg. W. B. Reznor, 6th Ohio Cav. Disch'd July 8, 1865; pensioned.	482	Kirk, J. G., Pt., II, 26th Mich., age 19.	May 10, '64.	Right; lateral flap; by Surg. W. Vosburg, 111th, N. Y. Disch'd June 30, 1865.
442	Johnson, E. M., Serg't, A, 155th Penn., age 37.	May 5, '64.	Left; flap. Duty Jan. 18, 1865; pensioned.	483	Kirkendall, A., Serg't, E, 25th Ohio, age 17.	Dec. 9, '64.	Right; flap; by Surg. A. B. Monahan, 63d Ohio. Disch'd June 15, 1865; pensioned.
443	Jones, C. A., Pt., G, 5th Alabama.	April 2, '65.	Right; by Surg. W. V. White, 57th Mass. Released June 14, 1865.	484	Kitch, P. C., Pt., D, 60th Illinois, age 25.	May 9, '64.	Right; ant.-post. flap; by Surg. W. M. Gray, 60th Ill. Disch'd Jan. 28, 1865; pensioned.
444	Jones, D., Pt., E, 11th Vermont.	Sept. 19, '64.	Right; flap; by Surg. C. B. Park, 11th Vt. Disch'd Oct. 3, 1865; pensioned.	485	Kistler, J., Pt., F, 132d Pennsylvania.	Dec. 13, '62.	Left; circular. Discharged July 23, 1863.
445	Jones, L., Pt., K, 77th Pennsylvania, age 28.	Aug. 4, '64.	Left; flap; by Surg. J. H. Kersey, 36th Ind. Disch'd June 14, 1865; pensioned.	486	Kleckner, I. F., Pt., B, 46th Illinois.	April 6, '62.	Left; flap. Disch'd June 14, '62; pensioned.
446	Jones, W. W., 2d Lieut., A, 2d Wisconsin.	Sept. 17, '62.	Right; circular; by Surg. A. J. Ward, 2d Wis. Resigned Nov. 5, 1863; pensioned.	487	Klink, F., Government employe, age 34.	July 24, '64.	Right; circular; by Surg. W. H. Thorn, U. S. V. Disch'd Oct. 13, 1864.
447	Jordan, J. M., Capt., F, 12th Penn. Cav., age 25.	Dec. 16, '64.	Left; circular; by A. A. Surg. J. A. Hall. Duty Mar. 31, 1865.	488	Knaggs, W. J., Pt., A, 4th Michigan.	July 1, '62.	Left; flap; by Surg. J. P. Prince, 34th Mass. Disch'd Dec. 28, '62; pensioned.
448	Kalb, E., Pt., C, 11th Penn. Res.	May 30, 1864.	Left; circular; by Surgeon W. Lyons, 11th Pa. Res. Disch'd Aug. 7, 1865; pensioned.	489	Kneeland, J. H., Pt., D, 15th Mass., age 25.	Sept 17, '62.	Flap. Discharged Dec. 13, 1862; pensioned.
449	Kalb, G., Pt., G, 11th Wisconsin.	May 22, '63.	Right; flap. Disch'd Dec. 5, 1863.	490	Koegle, J., Pt., F, 3d Pa. Battery, age 52.	Oct. 16, '63.	Left; circular; by A. A. Surg. J. S. Hill. Disch'd Mar. 20, 1864; pensioned.
450	Kannon, T., Pt., G, 14th Mich., age 20.	Aug. 7, '64.	Right; circular. Disch'd July 13, 1865.	491	Koontz, G. W., Pt., K, 70th Indiana, age 19.	May 15, '64.	Left; by Surg. J. G. McPheeters, 33d Ind. Disch'd; pensioned.
451	Karker, G. F., Pt., E, 61st New York, age 27.	May 8, '64.	Right; flap; by Surg. J. W. Wisbart, 140th Pa. Disch'd March 10, 1865; pensioned.	492	Kraft, C., Pt., I, 14th Connecticut.	May 3, '63.	Right; flap. Discharged Aug. 23, 1863; pensioned.
452	Kauffman, C., Pt., E, 68th New York.	July 1, '63.	Right; by Surg. L. Schultz, 68th N. Y. To V. R. C.; pensioned.	493	Kramer, M., Major, 2d Missouri.	Nov. 25, '63.	Left; by Surg. A. McMahon, U. S. V. Dis'd Dec. 24, '63; pens'd.
453	Keek, W., Pt., C, 106th New York, age 20.	June 2, '64.	Left; flap. Discharged Aug. 24, 1864; pensioned.	494	Krause, H., Corp'l, E, 14th Infantry.	Aug. 30, Sept. 1, 1862.	Left; by Surg. H. Bryant, U. S. V. Disch'd Nov. 1, '62; pens'd.
454	Keene, J. M., Serg't, G, 6th Arkansas, age 24.	Nov. 30, '64.	Right; ant.-post. flap. To Provost Marshal Jan. 23, 1865.	495	Kyle, J. H., Corp'l, II, 94th Ohio, age 24.	Mar. 19, '65.	Right; circular. Disch'd June 22, 1865; pensioned.
455	Keeper, H., Pt., K, 85th Penn., age 21.	Aug. 16, '64.	Left; flap. Disch'd April 6, 1865; pensioned.	496	Lafan, R., Pt., F, 69th New York.	Sept. 17, '62.	Right; by Asst. Surg. H. Pinckney, 9th N. Y. S. M. Duty Mar. 28, 1863; pensioned.
456	Keboe, T., Pt., E, 20th Mass., age 20.	May 13, '64.	Left; double flap. Discharged August 31, 1864.	497	Lamb, C., Pt., I, 3d Cl'd Troops, age 24.	Oct. 2, '63.	Antero-posterior flap. Discharged May 10, 1864. Spec. 3783.
457	Kelbourne, C., Pt., G, 11th Iowa, age 26.	July 22, '64.	Right; ant.-post. flap. Disch'd Jan. 23, 1865; pensioned.	498	Lammers, J., Pt., I, 39th N. Y., age 20.	Oct. 27, '64.	Left; circ.; by Surg. C. S. Hoyt, 39th N. Y. Disch'd May 8, 1865; pensioned.
458	Kelley, E. W., Pt., K, 50th Va., age 22.	July 3, '63.	Left; by Surg. A. Bull, 5th Ohio. Retired March 17, 1865.	499	Lancaster, D. H., Serg't, C, 85th Penn.	May 28, '62.	Left; by Asst. Surg. J. C. Lewis, 85th Pa. Disch'd Mar. 6, 1863; pensioned.
459	Kelley, J. E., Pt., E, 20th North Carolina.	Sept. 19, '64.	Right; circular; by Surg. J. M. G. McGuire, C. S. A. Transferred October 27, 1864.	500	Langley, J. N., Pt., B, 54th Mass., age 25.	Feb. 8, '64.	Right; flap; by Surg. S. Kurtz, 85th Pa. Disch'd June 21, 1864.
460	Kelley, I. F., Pt., B, 6th Wisconsin.	Nov. 27, '63.	Left; flap; by Surg. J. Ebersole, 19th Ind. Discharged April 2, 1864; pensioned.	501	Lanning, R. C., Serg't, I, 15th Massachusetts.	Dec. 13, '62.	Flap. Discharged Mar. 12, 1863; pensioned.
461	Kelly, C. Q., Pt., C, 11th New Jersey.	May 3, '63.	Left; circular. To V. R. C. Oct. 29, 1863; pensioned.	502	Larry, M., Pt., I, 35th Colored Troops, age 18.	Feb. 20, '64.	Left. Disch'd July 17, 1864.
462	Kelly, J., Pt., C, 24th Indiana.	June 20, '63.	Left; circular. Discharged July 30, 1864.	503	Larson, J. F. S., Pt., G, 40th N. Y., age 21.	April 6, '65.	Right; flap. Discharged Nov. 25, 1865; pensioned.
463	Kelly, J., Pt., K, 125th Illinois, age 23.	Sept. 1, '64.	Right; flap; by Surg. C. H. Mills, 125th Ill. Disch'd Mar. 24, 1865.	504	LaRue, G., Corp'l, I, 6th Ohio, age 27.	Sept. 19, '63.	Right; flap; by Surg. A. H. Stephens, 6th Ohio. Disch'd Jan. 29, 1864; pensioned.
464	Kelly, P., Pt., G, 6th Conn., age 28.	Jan. 15, '65.	Left; ant.-post. flap; by Surg. F. B. Kimball, 3d N. H. Disch'd July 25, 1865; pensioned.	505	Latton, E., Corp'l, D, 179th New York, age 22.	July 30, '64.	Right; flap; by Surg. W. V. White, 57th Mass. Disch'd Dec. 4, '64; pensioned.
465	Kelly, Thos., Pt., H, 39th N. Y., age 18.	May 12, '64.	Right; circular; by Surg. Wm. Vosburgh, 111th N. Y. Disch'd Nov. 3, '64; pens'd. Spec. 2959.	506	Latonrette, H. S., Capt., G, 85th Illinois, age 40.	June 27, '64.	Right; by Surg. M. M. Hooton, 86th Ill. Duty Nov. 7, '64; pen'd.
466	Kent, S., Pt., H, 1st Mich. Cavalry, age 20.	Sept. 19, '64.	Right; flap. Discharged June 12, 1865; pensioned.	507	Lauster, G. W., Lieut., K, 121st Pa.	April 1, '65.	Left. Disch'd June 2, 1865.
467	Kennally, E., Pt., A, 90th Illinois, age 23.	Nov. 25, 1863.	Right; flap; by Surg. H. Strang, 90th Ill. Disch'd May 12, 1865.	508	Law, T., Corp'l, II, 126th New York.	Feb. 6, '64.	Right; circular; by Surg. W. W. Potter, 57th N. Y. V. R. C. Aug. 31, 1864; pensioned. Spec. 2037.
468	Kennedy, M. R., Serg't, D, 17th Ky., age 21.	May 27, '64.	Right; circular. Mustered out Jan. 19, 1865; pensioned.	509	Lay, J. D., Pt., A, Cox's Battalion, 1st Mo. S. M.	Dec. 9, '61.	Flap; by Drs. W. H. Folsbee and G. A. Brosius. Disch'd Feb. 20, 1862; pensioned.
469	Kenyon, C. E., Pt., F, 63d New York, age 22.	June 3, '64.	Right; circular. Duty Oct. 22, 1864; pensioned.	510	Layton, N., Pt., C, 95th Penn., age 25.	May 12, '64.	Ant.-posterior flap; by Surg. E. B. P. Kelly, 95th Pa. Disch'd Oct. 5, 1864; pensioned.
470	Kerns, A., Pt., A, 100th Pa., age 23.	June 17, '64.	Left; flap. Disch'd June 20, '65; pensioned.	511	LeBaron, F. S., Pt., K, 20th Mich., age 24.	May 9, '64.	Left; flap; by Surg. S. S. French, 20th Mich. Disch'd Dec. 6, 1864.
471	Kibler, J., Pt., I, 4th N. York.	Dec. 13, '62.	Left. Discharged April 4, 1863; pensioned.	512	Lefevre, D. T., Pt., G, 149th Penn., age 25.	May 8, '64.	Left; flap; by Asst. Surg. E. M. White, 37th Mass. Disch'd Dec. 3, 1864; pensioned.
472	Kimball, A. J., Pt., F, 85th Pa., age 21.	Aug. 15, '64.	Right; by Surg. C. M. Clark, 39th Illinois. Disch'd Nov. 5, 1864; pensioned.				
473	Kimball, G. W., Pt., B, 6th Vermont.	May 4, '63.	Right; flap; by Surg. C. M. Chandler, 6th Vt. Disch'd Oct. 23, 1863; pensioned.				
474	Kimball, O., Pt., A, 1st Mich. S. S., age 20.	May 9, '64.	Right; flap; by Surg. A. T. Whelan, 1st Mich. S. S. Disch'd Dec. 27, 1864; pensioned.				



No.	NAME, AGE, AND MILITARY DESCRIPTION.	DATES.	OPERATIONS, OPERATOR, RESULT.	No.	NAME, AGE, AND MILITARY DESCRIPTION.	DATES.	OPERATIONS, OPERATOR, RESULT.
513	Legg, J. W., Pt., K, 14th Va. Cav., age 26.	July 9, '64.	Right; circular: by A. A. Surg. T. J. Dunett. Transferred Aug. 11, 1864. <i>Spec.</i> 3950.	550	Mandeville, A. C., Pt., C, 87th Indiana, age 35.	Aug. 4, '64.	Left; circular: by Surg. C. E. Triplett, 87th Ind. Discharged March 24, 1865; pensioned.
514	Lehman, C. E., Serg't, A, 26th Mich., age 33.	April 7, '65.	Right; circular: by Surg. M. H. Raymond, 26th Mich. Re-amp. June 14, 1865. Disch'd Aug. 13, 1865; pensioned.	551	Manger, C., Corp'l, B, 15th N. York Art., age 32.	Aug. 21, '64.	Right; flap. Discharged Jan. 3, 1865; pensioned.
515	Lend, N. P., Pt., F, 56th New York.	May 31, '62.	Right. Discharged July 15, 1862; pensioned.	552	Mandley, C. H., Pt., A, 1st Michigan.	July 2, '63.	Left; flap. Discharged Oct. 1, 1863; pensioned.
516	LeRoy, F., Pt., B, 81st New York.	June 3, '64.	Left; by Surg. W. H. Rice, 81st N. Y. Disch'd Oct. 17, '64; pens'd.	553	Manly, E. S., Pt., H, 20th Michigan, age 18.	Oct. 10, '63.	Left; flap. Discharged May 31, 1864; pensioned.
517	Lester, P., Lieut., B, 16th Indiana.	Jan. 11, '63.	Right; by Asst. Surg. J. D. Gateh, 16th Ind. Resig'd June 10, 1864; pensioned.	554	Mansur, Z., Corp'l, K, 10th Vermont, age 21.	Sept. 19, '64.	Right; circular: by Surg. R. Barr, 67th Pa. Disch'd Aug. 31, 1865; pensioned.
518	Lewis, D., Serg't, I, 61st Alabama, age 29.	Sept. 19, '64.	Right; circular: by A. Surg. Me Garrity, C. S. A. Paroled June 28, 1865.	555	Mantner, M., Pt., K, 3d Missouri.	May 21, '63.	Left; circular. Discharged Oct. 15, 1863.
519	Lewis, G. W., Capt., B, 124th Ohio, age 28.	Dec. 16, '64.	Left; circular: by Surg. D. C. Patterson, 124th Ohio. Duty April 21, 1865; pensioned.	556	March, L., Pt., K, 38th Illinois, age 22.	Aug. 16, '64.	Left; circular. Discharged Nov. 19, 1864.
520	Lewis, J. R., Col., 5th Vt., age 29.	May 5, '64.	Left; flap. Duty Sept. 12, 1864.	557	Marke, C., Pt., D, 131st Pennsylvania.	Dec. 13, '62.	Right; circular. Discharged May 13, '62.
521	Lewis, W., Pt., K, 48th New York, age 24.	July 30, '64.	Left; flap; by Surg. J. L. Mulford, 48th N. Y. Discharged Feb. 2, 1865; pensioned.	558	Marshall, J., Pt., G, 73d Ohio.	July 2, '63.	Left; flap; by Surg. J. N. Heimes, 73d Ohio. To V. R. C. Oct. 31, 1863; pensioned.
522	Libbert, C., Pt., A, 7th Indiana.	June 1, '64.	Left; by Surg. G. W. New, 7th Ind. Disch'd Sept. 20, '64; pens'd.	559	Martin, J. P., Pt., C, 28th Virginia, age 21.	Aug. 25, '64.	Left; circular. Retired Jan. 27, 1865.
523	Linehan, D., Serg't, C, 28th Mass., age 29.	Aug. 25, '64.	Left; circular: by Surg. Brown, C. S. A. Disch'd May 9, 1865; pensioned.	560	Martin, R., Pt., G, 11th Illinois.	Feb. 15, '62.	Left. Discharged Nov. 18, 1862; pensioned.
524	Lingle, S. B., Pt., C, 5th Pa. Reserves.	June 26, '62.	Right; circular. Disch'd April 14, 1863; pensioned.	561	Martin, W., Pt., C, 7th Illinois Cavalry.	June 10, '64.	Left; by Surg. Cowan, C. S. A. Disch'd July 22, 1865; pens'd.
525	Little, B. F., Capt., E, 57th N. C., age 32.	July 3, '63.	Left; circular. Exchanged Mar. 4, 1864.	562	Martin, W., Corp'l, D, 2d Penn. H. A., age 23.	July 22, '64.	Left; circular: by Surg. W. V. White, 5th Mass. Disch'd Dec. 17, 1864; pensioned.
526	Livingston, J. H., Pt., E, 7th N. Y. Art., age 21.	June 3, '64.	Left; circular. Discharged June 3, 1865; pensioned.	563	Martindell, I. R., Pt., A, 150th Penn., age 26.	July 1, '63.	Left; flap. Disch'd Feb. 17, 1864.
527	Lloyd, T., Pt., I, 32d Col. Troops.	Nov. 30, '64.	Right; flap; by A. A. Surg. J. F. Pratt. Disch'd April 14, 1865; pensioned.	564	Mason, J. M., Pt., G, 19th Massachusetts.	June 30, '62.	Right; flap. Disch'd Aug. 20, '62.
528	Lockhart, T., Pt., H, 7th Ind., age 18.	June 2, '64.	Flap; by Asst. Surg. J. T. Duffield, 7th Ind. Disch'd Sept. 20, 1864; pensioned.	565	Mathews, E., Pt., F, 30th C. T., age 22.	July 30, '64.	Left; circular: by Surg. T. M. Weld, 27th U. T. Disch'd Feb. 10, 1865; pensioned.
529	Loflus, N., Pt., G, 7th Mass., age 43.	June 3, '64.	Left; circular: by Surg. W. H. Lincoln, 7th Mass. Discharged April 24, 1865; pensioned.	566	Mathiol, J., Pt., E, 211th Pennsylvania, age 33.	April 2, '65.	Right; circular: by Surg. W. G. Hunter, 211th Pa. Discharged July 26, 1865; pensioned.
530	Loomis, G., Corp'l, G, 150th Pa., age 23.	May 10, '64.	Right; flap; by Surg. H. Strauss, 150th Pa. Discharged April 3, 1865; pensioned.	567	Mauds, C., Pt., K, 11th Conn., age 30.	June 3, '64.	Right; flap. To V. R. C. Sept. 17, 1864; pensioned.
531	Loomis, G. C., Serg't, H, 12th Illinois, age 23.	Oct. 5, '61.	Right; circular: by Surg. J. R. Zearing, 57th Ill. Discharged May 2, 1865; pensioned.	568	May, F., Pt., G, 148th Pa., age 36.	Mar. 31, '65.	Right; circular. Disch'd June 20, 1865; pensioned.
532	Lowe, F., Corp'l, —, 6th New Jersey, age 23.	May 6, '64.	Left; circular: by Surg. G. L. Potter, 143th Pa. V. R. C. Mar. 2, 1865; pensioned.	569	May, L. J., Pt., E, 12th Georgia, age 38.	July 9, '64.	Left; circ.; by Surg. C. H. Todd, C. S. A. Exchanged Sept. 19, 1864.
533	Lovegrove, J., Pt., K, 56th Pennsylvania, age 24.	Aug. 18, '64.	Left; flap; by Surg. G. W. Metcalf, 76th N. Y. Disch'd Dec. 7, 1864; pensioned.	570	May, R., Pt., A, 23d Iowa.	May 17, '63.	Right. Discharged July 23, 1863; pensioned.
534	Lovely, C., Pt., F, 11th Vermont, age 38.	June 1, '64.	Left; double flap; (also amp. of thigh.) Discharged Feb. 6, 1865; pensioned.	571	Mayberry, C., Pt., E, 100th Pennsylvania, age 19.	June 17, '64.	Right; circular. Discharged Jan. 29, 1865; pensioned.
535	Lowell, D. R., Pt., G, 121st N. Y., age 20.	April 6, '65.	Right; ant.-post. flap. Disch'd June 21, 1865; pensioned.	572	Mayo, J. S., Pt., K, 25th Massachusetts.	Mar. 14, '62.	Left; circ.; by Surg. G. Derby, 25d Mass. Disch'd Aug. 5, '62; pens'd.
536	Lowman, G. W., Pt., B, 11th Pa. Reserves.	Oct. 14, '63.	Right; circ.; by Surg. J. S. De Bienville, 11th Pa. Res. Discharged Feb. 20, '64; pensioned.	573	McCart, P., Pt., F, 120th Illinois, age 30.	May 15, '64.	Right. Discharged; pensioned.
537	Ludford, J. A., Corp'l, K, 2d Conn. H. A., age 17.	June 1, '64.	Right; circular. Discharged Feb. 25, 1865.	574	McCarty, P., Pt., A, 43d New York, age 18.	June 3, '64.	Left; circular: by Surg. G. T. Stevens, 77th N. Y. To V. R. C. May 10, 1865; pensioned.
538	Luscomb, A. C., Pt., H, 1st Mass. H. A., age 24.	June 22, '64.	Left; circular. Discharged Dec. 19, 1864.	575	McCary, J., Pt., K, 5th Vermont, age 24.	May 5, '64.	Left; flap; by Surg. D. M. Goodwin, 3d Vt. Discharged Aug. 25, 1864; pensioned.
539	Lutz, D., Pt., I, 2d Iowa Cavalry.	July 1, '62.	Right; flap; by Surg. G. H. Noyes, 2d Iowa Cav. Disch'd Sept. 5, 1862; pensioned.	576	McCastin, N., Pt., G, 1st U. S. Sh'pshooters, age 39.	June 18, '64.	Left. Discharged Sept. 6, 1864; pensioned.
540	Lutz, G., Pt., A, 147th Pennsylvania, age 28.	June 15, '64.	Right; circular: by Surg. J. L. Dunn, 109th Pa. Disch'd July 13, 1865; pensioned.	577	McCauley, L. J., Lieut., C, 7th Pa. Res. Corps.	June 30, '62.	Right; by Surg. M. S. Kittinger, 100th N. Y. Duty Oct. 7, 1862; pensioned.
541	Lyman, E. W., Serg't, I, 75th Illinois.	Oct. 8, '62.	Left; flap. Discharged March 3, 1863.	578	McDonald, G., Pt., B, 79th Ohio, age 22.	May 15, '64.	Left; flap; by Surg. H. H. Langdon, 79th Ohio. Discharged Jan. 12, 1865; pensioned.
542	Magnuson, I., Pt., E, 20th Indiana, age 35.	May 3, '63.	Right; flap. Discharged March 14, 1864; pensioned.	579	McElroy, W., Pt., B, 13th Indiana, age 20.	July 30, '64.	Left; ant.-post. flap; by Surg. W. B. Fox, 8th Mich. Discharged Jan. 11, 1865; pensioned.
543	Maher, F. S., Serg't, C, 103d New York, age 22.	May 15, '64.	Right; circular: by Surg. J. V. Kendall, 149th N. Y. Disch'd Sept. 13, 1865; pensioned.	580	McClellan, J., Serg't, H, 21st Pa. Cav., age 20.	June 3, '64.	Left; ant.-post. flap; by Surg. H. B. King, 21st Pa. Cav. Disch'd Dec. 22, 1864; pensioned.
544	Mahler, J. H., Pt., F, 2d Colorado Cavalry.	Mar. 12, '65.	Left; by Asst. Surg. A. A. Smith, 1st Col. Cav. Disch'd; pens'd.	581	McClelland, T. A., Pt., Chi. B'd of Trade But., age 21.	July 22, '64.	Left; flap. Discharged Oct. 13, 1864.
545	Mahoney, D., Pt., I, 61st Pennsylvania.	May 31, '62.	Left; flap. Discharged Aug. 21, 1862; pensioned.	582	McConahey, J., Pt., I, 102d Pa., age 21.	June 2, '64.	Right; antero-posterior flap. Discharged Oct. 20, 1864.
546	Mahoney, J., Pt., K, 2d Mass. Cav., age 29.	Aug. 5, '63.	Right; circular. Discharged Nov. 12, 1863.	583	McConnell, J., Pt., I, 93d Pennsylvania.	Sept. 22, '64.	Right; flap; by Surg. E. R. Umberger, 93d Pa. Duty Nov. 26, 1864; pensioned.
547	Mallory, P., Pt., C, 83d Pennsylvania, age 19.	Feb. 6, '65.	Right; by Surg. J. B. Burchfield, 83d Pa. Disch'd June 25, 1865; pensioned.	584	McCord, W. B., Pt., B, 8th Iowa Cav., age 18.	Sept. 5, '64.	Right; circular. Disch'd April 19, 1865.
548	Malone, W., Pt., D, 51st N. Carolina, age 23.	June 17, '64.	Right; circular. Furloughed Aug. 26, 1864.	585	McCoy, C., Pt., G, 11th Pennsylvania.	Sept. 17, '62.	Right; flap; by Surg. Wm. A. Madill, 23d N. Y. Disch'd Feb. 28, 1863; pensioned.
549	Manchester, J. S., Serg't-Major, 7th R. Island.	Dec. 13, '62.	Right. Appointed Lieut.; resigned July 26, 1864.	586	McCoy, J., Pt., D, 20th Indiana, age 25.	July 2, '63.	Right; by Surg. O. Eyarts, 20th Ind. Disch'd Oct. 22, '63; pens'd.
				587	McCumber, G., Pt., E, 90th New York, age 30.	Oct. 19, '64.	Left; circular: by Asst. Surg. J. Homans, U. S. A. Disch'd Aug. 30, 1865; pensioned.
				588	McGinley, J., Corp'l, B, 12th New York.	July 1, '62.	Right; double flap. Discharged Aug. 26, 1862; pensioned.
				589	McGuire, D., Pt., I, 185th New York, age 34.	Mar. 29, '65.	Right; circular. Discharged May 25, 1865; pensioned.

NO.	NAME, AGE, AND MILITARY DESCRIPTION.	DATES.	OPERATIONS, OPERATOR, RESULT.	NO.	NAME, AGE, AND MILITARY DESCRIPTION.	DATES.	OPERATIONS, OPERATOR, RESULT.
590	McKio, J. A., Pt., F, 3d Mass. Cavalry, age 19.	April 8, '64.	Left: by Surg. M. P. McFarland, 56th Ohio. Re-amp. April, 1864. Disch'd Sept. 30, 1864; pens'd.	628	Morse, G., Pt., I, 141st Pennsylvania.	Oct. 13, '63.	Right: flap; by Surg. W. Church, 141st Pa. Discharged Dec. 20, 1863; pensioned.
591	McKinley, T., Pt., K, 73d Ohio.	Aug. 30, '62.	Left: Discharged Dec. 16, 1862, pensioned.	629	Mosin, O., Pt., F, 57th New York.	July 1, '62.	Left: circular. Discharged Aug. 5, 1862; pensioned.
592	McKim, C., Pt., H, 82d Pennsylvania, age 18.	June 1, '64.	Left: circular. Discharged Feb. 2, '64.	630	Mountain, T. V., Serg't, K, 47th N. Y., age 23.	Feb. 21, '65.	Left: lateral flap; by Surg. A. D. Palmer, 9th Me. Discharged June 2, 1865; pensioned.
593	McLardy, A., Pt., B, 90th Pennsylvania.	Sept. 17, '62.	Right: flap. Discharged Nov. 25, 1862; pensioned.	631	Mueller, P., Pt., K, 36th Missouri, age 19.	May 19, '64.	Right: by Surg. C. G. Strother, 31st Mo. Disch'd Feb. 27, '64.
594	McLaughlin, D., Pt., F, 155th New York, age 20.	June 16, '64.	Left: circular; by Surg. D. W. Maull, 1st Del. Discharged July 26, 1865; pensioned.	632	Mulberry, J., Pt., D, 143th Pa., age 40.	May 7, '64.	Right: flap. Discharged May 20, 1865.
595	McLeod, J., Pt., 3d Maine Battery, age 23.	Sept. 11, '64.	Right: flap; by Surg. J. S. Jamison, 86th N. Y. Discharged May 10, 1865; pensioned. <i>Spec.</i> 4109.	633	Mulholland, H., Pt., H, 97th Pa., age 28.	June 6, '64.	Left: circ.; by Surg. J. R. Everhart, 97th Pa. Discharged Mar. 22, 1865; pensioned.
596	McLeod, W., Pt., G, 104th New York.	Aug. 30, '62.	Right: by Surg. J. E. McDonald, 79th N. Y. Discharged Nov. 4, 1862; pensioned.	634	Müller, G., Pt., C, 4th Missouri Cav.	July 5, '62.	Left: circular; by Surg. H. W. Nichols, 4th Mo. Disch'd Sept. 11, 1862; pensioned.
597	McMahon, W., Pt., K, 53d Illinois.	Oct. 5, '62.	Left Discharged March 31, 1863; pensioned.	635	Munee, P., Pt., F, 14th N. Y. H'y Art., age 39.	May 5, '64.	By modification of Tenle's method. Disch'd Oct. 26, 1864; pensioned.
598	McMann, D., Pt., B, 11th Connecticut, age 22.	July 1, '64.	Left: circular. Discharged Oct. 21, 1865.	636	Munson, C. N., 1st Lieut., E, 106th N. Y., age 24.	July 1, '64.	Left: flap. Discharged Dec. 19, 1864; pensioned.
599	McManus, B., Pt., I, 33d New Jersey, age 30.	June 16, '64.	Left: circular; by Surg. J. Reily, 33d N. J. Duty Jan. 26, 1865; pensioned.	637	Murphy, R., Pt., C, 15th Indiana.	Nov. 25, '63.	Left. Discharged April 30, 1864.
600	McMannus, J., Pt., A, 69th New York, age 33.	May 18, '64.	Right: circular. Discharged Oct. 15, 1864; pensioned.	638	Myers, B., Pt., D, 57th New York.	Sept. 17, '62.	Right: flap. Discharged Dec. 13, 1862; pensioned.
601	McNally, J., Pt., B, 1st New York Artillery.	May 2, '63.	Left: flap. Duty April 23, 1864; pensioned.	639	Myers, A. H., Pt., G, 49th Pennsylvania, age 34.	May 10, '64.	Right: circular; by Surg. Graham, C. S. A. Discharged May 3, 1865; pensioned.
602	McQuinn, E., Pt., D, 32d Mass., age 25.	Sept. 30, '64.	Left: circular. Discharged April 30, '64.	640	Nash, G., Pt., D, 24th Indiana.	May 16, '63.	Left: by Surg. R. B. Nash, 24th Ind. Dis'd Aug. 19, '63; pens'd.
603	McWhorter, A. H., Corp'l, F, 123d N. Y., age 25.	July 20, '64.	Right: flap; by Surg. J. Chapman, 123d N. Y. Disch'd June 18, 1865; pensioned.	641	Newman, M. N., Pt., F, 53d Va., age 47.	July 3, '63.	Left: flap; by Asst. Surg. W. F. Richardson, C. S. A. Paroled Sept. 25, 1863.
604	Meacham, H. H., Pt., E, 32d Mass., age 39.	June 22, '64.	Right: flap. Discharged Aug. 26, 1864; pensioned.	642	Newton, G. F., Pt., C, 61st Virginia, age 22.	July 2, '63.	Left: circular. Transferred for exchange Nov. 12, 1863.
605	Meek, A. W., Corp'l, A, 21st Indiana.	May 27, '63.	Right: flap. Discharged Sept. 29, 1863; pensioned.	643	Nichols, C. W., Pt., I, 21st Conn., age 24.	June 3, '64.	Left: circular. Discharged May 9, 1865; pensioned.
606	Melocho, S., Pt., F, 1st Louisiana Cav., age 18.	Jan. 16, '65.	Right: circular; by A. A. Surg. J. P. Musgrave. Disch'd May 25, 1865; pensioned.	644	Nichols, J., Pt., K, 5th N. Hampshire.	June 30, '62.	Right. To V. R. C. July 1, 1863; pensioned.
607	Melvin, W. T., Pt., B, 15th Indiana.	Dec. 31, '63.	Left: by A. Surg. G. W. Hewit, 34th Ill. Discharged March 9, 1863; pensioned.	645	Nichols, T. G., Pt., F, 15th Georgia.	Sept. 29, '64.	Left: circular; by Asst. Surg. W. P. Richardson, C. S. A.
608	Menear, C. W., Pt., C, 3d West Virginia.	Aug. 26, '63.	Right: flap; by Surg. E. C. Thomas, 3d W. Va. Discharged Jan. 20, 1864; pensioned.	646	Nicks, N., Pt., G, 12th Louisiana, age 27.	Nov. 30, '64.	Right: ant.-post. flap. To Provost Marshal Jan. 14, 1865.
609	Menz, J., Pt., G, 1st Mo. Heavy Art., age 23.	Feb. 22, '65.	Right: circular; by Asst. Surg. J. M. Brown, U. S. A. Disch'd June 28, 1865; pensioned.	647	Nicols, S. M., Pt., B, 13th Mich., age 43.	Mar. 20, '65.	Left: flap; by Asst. Surg. F. Pratt, 13th Mich. Dis'd July 17, 1865.
610	Merriek, R., Pt., D, 10th Michigan, age 41.	Aug. 7, '64.	Right: circular. Disch'd June 17, 1865.	648	Nierman, C. A., Pt., F, 5th Ohio Cavalry.	Oct. 5, '62.	Right: flap; by Asst. Surg. G. Sprague, 5th Ohio Cav. Disch'd Jan. 19, 1863; pensioned.
611	Metzgar, A. T., Corp'l, G, 14th N. J., age 23.	June 1, '64.	Left: circ.; by Surg. J. S. Martin, 14th N. J. Discharged Dec. 30, 1864; pensioned.	649	Nitzschke, L. F., Hospital Steward, 1st Tenn.	same day	Right: by A. Surg. E. M. Norwood, 1st Tenn. Disch'd May 25, 1864; pensioned.
612	Meyer, J., Corp'l, F, 12th Missouri.	May 22, '63.	Left: antero-posterior flap; by A. Surg. J. S. Spiegelhalter, 12th Mo. Disch'd April 19, 1864.	650	Noah, W., Pt., D, 21st Michigan, age 34.	Mar. 19, '65.	Right: circular. Discharged July 18, 1865; pensioned.
613	Miller, C., Pt., K, 36th Wisconsin.	June 17, '64.	Right: ant.-post. flap. Disch'd Dec. 9, 1864; pensioned.	651	Noble, H., Pt., G, 29th Maine, age 32.	Oct. 19, '64.	Right: flap. Discharged Sept. 7, 1865; pensioned.
614	Miller, E., 1st Lieut., I, 38th New York.	May 5, '62.	Left: circ.; by Surg. G. L. Pancost, U. S. V. Discharged Jan. 29, 1863; pensioned.	652	Nolan, J., Pt., I, 19th Wisconsin.	Oct. 27, '64.	Right: by Surg. Gibbs, C. S. A. Disch'd May 16, 1865; pensioned.
615	Miller, T. C., Corp'l, 1st Virginia Art.	Sept. 29, '64.	Right: circular; by Surg. of Powhatan Art. Retired Feb. 6, '65.	653	Nolte, H., Pt., C, 56th Ohio.	May 16, '63.	Right: by Surg. W. N. King, 56th Ohio. Discharged Sept. 2, 1863; pensioned.
616	Miller, W. R., 2d Lieut., P, 56th Penn.	May 8, '64.	Left: flap; by Asst. Surg. C. L. Duffell, 51st Pa. Disch'd July 29, 1864; pensioned.	654	Norrross, D. A., Pt., E, 18th Ind., age 22.	Oct. 19, '64.	Left: circular. Discharged Aug. 1, 1865; pensioned.
617	Millett, A. C., Serg't, C, 23d Mass., age 22.	Mar. 14, '62.	Right: circ.; by Brigade Surgeon J. H. Thompson. Disch'd April 21, 1863; pensioned.	655	Nordurth, J. H., Corp'l, I, 9th Ind., age 22.	Dec. 15, '64.	Left: flap. Discharged May 10, 1865; pensioned.
618	Milliman, J. C., Pt., E, 46th N. Y., age 18.	Sept. 30, '64.	Left: circular; by Surg. W. C. Shurlock, 51st Pa. Discharged Dec. 8, 1864; pensioned.	656	Norton, P. A., Serg't, D, 76th N. Y., age 27.	Aug. 21, '64.	Left: flap; by Surg. G. W. Metcalf, 76th N. Y. Discharged Dec. 23, 1864.
619	Mitchell, J., Pt., E, 145th Pennsylvania, age 43.	Dec. 13, '62.	Right: circular. Discharged April 15, 1863.	657	Northwood, J., Pt., C, 16th Michigan.	June 27, '62.	Right: flap. Discharged Aug. 30, 1862; pensioned.
620	Montgomery, G., Pt., B, 103d Illinois, age 18.	Nov. 25, '63.	Right: flap; by Surg. R. L. Von Harlinger, 70th Ohio. Disch'd Dec. 20, 1864; pensioned.	658	Nutton, H., Pt., I, 14th Iowa, age 22.	April 9, '64.	Left: circular; by Surg. H. M. Crawford, 58th Ill. Duty Nov. 9, 1864; pensioned.
621	Montgomery, W. C., Corp., B, 70th Ohio, age 24.	Nov. 27, '61.	Right: flap; by Surg. A. Sabine, 70th Ohio. Disch'd Nov. 15, 1864; pens'd.	659	Oberwetter, H., Pt., A, 36th Wisconsin, age 43.	May 27, '64.	Left: circular; by Surg. C. Miller, 36th Wis. Discharged June 17, 1865; pensioned.
622	Moody, J., Corp'l, D, 24th Mich., age 23.	May 25, '64.	Right: flap; by Surg. J. H. Beach, 24th Mich. Discharged Aug. 25, 1865; pensioned.	660	O'Donald, F., Pt., C, 8th New Jersey, age 23.	May 20, '64.	Left: circular. Discharged June 25, 1865.
623	Moore, J. M., Serg't, H, 102d N. Y., age 23.	July 20, '64.	Left: flap; by Surg. J. Riley, 33d N. J. Re-amputated July, 1865. Disch'd Nov. 25, '65; pensioned. <i>Spec.</i> 2522.	661	O'Hara, M., Pt., F, 63d New York, age 22.	May 8, '64.	Left: flap. Discharged Sept. 11, 1865; pensioned.
624	Moren, J., Pt., K, 9th Maine, age 32.	Aug. 16, '63.	Left: circular. Discharged May 3, 1864; pensioned.	662	Oliver, E., Pt., 7th Ohio Battery.	Oct. 5, '62.	Right. Discharged; pensioned.
625	Morgan, P., Pt., F, 15th N. J., age 25.	May 1, '63.	Left: circular. Discharged Oct. 26, 1863; pensioned.	663	O'Neil, M., Pt., G, 17th New York Cavalry.	Mar. 16, '65.	Left: circular; by Surg. E. Batwell, 14th Mich. Discharged June 17, 1865; pensioned.
626	Morgan, P., Pt., F, 14th Ky. Mounted Inf., age 19.	Sept. 27, '64.	Right: flap. Discharged July 27, 1865.	664	O'Neil, R., Pt., K, 6th Vermont.	June 6, '63.	Flap; by Surg. C. M. Chandler, 6th Vt. To V. R. C. Jan. 8, 1864; pensioned.
627	Morgan, T., Pt., A, 7th Iowa, age 19.	Nov. 7, '61.	Left: by A. A. Surg. W. R. Burke, Disch'd Dec. 21, 1861; pens'd.	665	O'Neil, W., Pt., G, 120th New York, age 30.	Oct. 2, '64.	Right: circular; by Surg. F. D. Morris, 35th Ohio. Discharged Mar. 28, 1865; pensioned.
				666	Orell, J., Pt., I, 188th Penn., age 32.	June 3, '64.	Left: flap. Discharged Dec. 23, 1864; pensioned.
				667	Orr, H. C., Pt., H, 136th New York.	July 3, '63.	Right. Discharged Dec. 15, 1863; pensioned.



No.	NAME, AGE, AND MILITARY DESCRIPTION.	DATES.	OPERATIONS, OPERATOR, RESULT.	No.	NAME, AGE, AND MILITARY DESCRIPTION.	DATES.	OPERATIONS, OPERATOR, RESULT.
668	Orvis, S. E., Pt., F, 5th Wisconsin, age 30.	May 5, '64.	Left; circular: by Surg. C. E. Crane, 5th Wis. Disch'd June 24, 1864; pensioned.	708	Plank, M., Pt., D, 53d Pa., age 32.	June 16, '64.	Left; ant.-post. flap; by Surg. G. L. Potter, 145th Pa. Discharged Jan. 10, 1865; pensioned.
669	Outcalt, T., Pt., K, 17th Ohio.	Jan. 1, '63.	Right; flap; by Surg. J. B. Cutts, 2d Ill. Cav. Discharged April 27, 1863; pensioned.	709	Plunkett, A. E., Serg't, I, 82d Ohio.	July 1, '63.	Left; by Surg. J. Y. Cantwell, 82d Ohio. Discharged Feb. 7, 1864; pensioned.
670	Pace, S. T., Pt., I, 60th Illinois.	Sept. 1, '64.	Right; by Surg. W. C. Pace, 110th Ill. Disch'd Feb. 17, '65; pens'd.	710	Plunkett, P., Serg't, K, 35th Ind., age 35.	June 21, '64.	Right; flap; by Surg. H. G. Averdick, 35th Indiana. Discharged March 17, 1865; pensioned.
671	Page, L. H., Pt., C, 3d Vermont, age 27.	May 5, '64.	Left; flap; by Surg. D. M. Goodwin, 3d Vt. Discharged July 9, 1864; pensioned.	711	Potts, W., Pt., K, 52d Ohio, age 22.	June 27, '64.	Right; flap; by Surg. H. M. Duff, 52d Ohio. Discharged Feb. 6, 1865; pensioned.
672	Palmer, D. S., Pt., G, 14th New Jersey, age 18.	June 1, '64.	Circular: by Surg. J. S. Martin, 14th N. J. Discharged June 30, 1865; pensioned.	712	Premo, P., Pt., H, 98th New York, age 35.	June 1, '64.	Right; circular. Discharged Dec. 22, 1864; pensioned.
673	Palmer, M. E., Pt., B, 15th Conn., age 23.	Mar. 8, '65.	Left; ant.-posterior flap; by Surg. Cox, C. S. A. Discharged July 27, 1865; pensioned.	713	Pringle, G., Pt., B, 44th Indiana.	April 6, '62.	Right. Discharged; pensioned.
674	Parin, J., Pt., H, 76th N. York, age 27.	May 9, '64.	Left; circular: by Surg. G. T. Stevens, 77th N. Y. Discharged Sept. 16, 1864.	714	Pritchard, T., Pt., D, 79th Pennsylvania.	Oct. 8, '62.	Right; by A. Surg. D. B. Devendorf, 1st Wis. Discharged Jan. 2, 1863; pensioned.
675	Parker, D. H., Pt., G, 79th Ohio, age 21.	July 20, '64.	Right; flap; by Surg. H. H. Langden, 79th Ohio. Disch'd Nov. 1, 1864; pensioned.	715	Proud, F. P., Pt., I, 57th New York.	Dec. 27, '61.	Left; circular: by Surg. G. Leach, 57th N. Y. Discharged July 18, 1862; pensioned.
676	Parker, J. H., Pt., K, 44th New York.	Dec. 13, '62.	Left; circular. Discharged June 15, 1863; pensioned.	716	Purinton, E. P., Pt., B, 9th N. H., age 31.	Sept. 17, '62.	Left; by Surg. W. A. Webster, 9th N. H. Discharged; pensioned.
677	Parlow, W. H., Pt., F, 121st New York.	Oct. 19, '64.	Right; flap. Discharged June 9, 1865; pensioned.	717	Putnam, S. B., Pt., D, 10th N. H., age 30.	June 3, '64.	Circular: by Surg. H. N. Small, 10th N. H. Discharged June 27, 1865; pensioned.
678	Parmenter, C., Pt., E, 94th New York, age 21.	June 2, '64.	Left; flap; by Surg. M. Bellinger, C. S. A. Disch'd Feb. 8, 1865; pensioned.	718	Raby, C. E., Pt., K, 97th Pa., age 19.	May 20, '64.	Left; flap. Discharged Aug. 20, 1864; pensioned.
679	Parmenter, C., Pt., I, 122d New York, age 37.	Oct. 19, '64.	Right; circular: by Surg. G. T. Stevens, 77th N. Y. Disch'd Mar. 19, 1865; pensioned.	719	Randall, C. H., Serg't, C, 18th Mich., age 24.	Sept. 24, '64.	Left. Duty Dec. 2, 1864.
680	Parrish, W. G., Pt., C, 14th Virginia, age 31.	July 2, '63.	Right. Exchanged Nov. 12, 1863.	720	Randolph, A., Pt., K, 22d Colored Troops, age 25.	Aug. 18, '64.	Left; flap. Discharged May 26, 1865; pensioned.
681	Parsons, T. F., Corp'l, D, 5th Maine.	May 11, '64.	Circular: by Surg. F. G. Warren, 5th Me. Duty Sept. 10, 1864; pensioned.	721	Ransom, H. S., Capt., I, 118th New York.	May 16, '64.	Right. Discharged Nov. 2, 1864; pensioned.
682	Patterson, J. B., Pt., H, 111th Illinois.	May 27, '64.	Left; flap; by Act. Staff Surg. H. W. Nichols. Disch'd Nov. 23, 1864; pensioned.	722	Raphall, A., Lieut., and A. D. C, 40th N. York.	July 2, '63.	Right; by Surg. H. B. Fowler, 12th N. H. Discharged Aug. 18, 1864; pensioned.
683	Patterson, J. N., Pt., B, 49th Penn., age 30.	May 10, '64.	Right; flap. Discharged July 10, 1865; pensioned.	723	Rathburn, D. S., Pt., B, 5th Minn., age 21.	Dec. 16, '64.	Right; flap; by Surg. V. B. Kennedy, 5th Minn. Discharged June 30, 1865; pensioned.
684	Paul, A., Pt., G, 87th Pennsylvania, age 23.	April 2, '65.	Left; circ: by Surg. W. A. Childs, 10th Vt. Disch'd June 28, 1865.	724	Reed, A. H., Serg't, K, 2d Minnesota.	Nov. 25, '63.	Right; flap. Discharged July 11, 1865.
685	Paver, H., Pt., B, 82d Ohio.	Aug. 29, '62.	Left; by A. Surg. A. W. Munson, 82d O. Dis'd Oct. 18, '63; pens'd.	725	Reed, C., Serg't, H, 12th Infantry, age 32.	June 25, '65.	Left; ant.-post. flap. Duty Nov. 25, 1864; pensioned.
686	Payne, E. W., Pt., A, 34th Illinois.	Sept. 1, '64.	Right; flap; by Surg. E. Batwell, 14th Mich. Discharged April 3, 1865; pensioned.	726	Reed, C. C., Corp'l, I, 14th New Jersey.	Sept. 19, '64.	Right; flap; by Surg. J. S. Martin, 14th N. J. Discharged Apr 13, 1865; pensioned.
687	Peabody, J., Pt., B, 23d Ohio, age 21.	May 9, '64.	Left; flap; by Surg. N. F. Graham, 12th O. Dis'd Mar. 30, '65; pens'd.	727	Reed, S. E., Pt., H, 91st New York, age 38.	Mar. 31, '65.	Left; circular. Discharged July 4, 1865; pensioned.
688	Peck, G., Pt., I, 10th N. Y. Cavalry.	June 19, '63.	Right; circular. To V. R. C. Oct. 23, 1863; pensioned.	728	Reeder, D., Corp'l, H, 47th Penn.	Oct. 22, '62.	Left; circular; by A. Surg. J. E. Semple, U. S. A. Discharged Dec. 15, 1862; pens'd. Spec. 730.
689	Peck, H., Pt., E, 1st Ohio Light Artillery.	Feb. 5, '62.	Flap; by Surg. C. S. Muscroft, 10th O. Disch'd June 18, 1862; pen'd.	729	Reese, J. J., Pt., F, 48th Penn., age 28.	May 12, '64.	Left. Discharged Aug. 29, 1864; pensioned.
690	Peiffer, J. M., Pt., A, 211th Pa., age 40.	April 2, '65.	Right; circular; by Surg. W. G. Hunter, 211th Pa. Disch'd July 4, 1865; pens'd. Re-amputation.	730	Remington, R., Pt., E, 3d N. Y. Artillery, age 22.	July 1, '64.	Right. Discharged October 19, 1864; pensioned.
691	Pels, A., Pt., C, 47th Ohio, age 27.	July 22, '64.	Left; flap; by Surg. S. P. Bonner, 47th Ohio. Discharged Nov. 29, 1864; pensioned.	731	Retan, H. C., Pt., G, 16th Michigan.	June 27, '62.	Right. Discharged December 19, 1862; pensioned.
692	Pence, W. F., Pt., I, 23d North Carolina, age 25.	July 3, '63.	Left; circular. Paroled Sept. 23, 1863.	732	Rex, J., Pt., F, 88th Ill., age 21.	May 26, '64.	Right; ant.-post. flap; by Surg. W. P. Pierce, 88th Ill. Disch'd Jan. 19, 1865; pensioned.
693	Pendegrast, J., Corp'l, F, 24th Mass., age 27.	June 17, '64.	Right; flap. Duty Nov. 22, 1864; pensioned.	733	Reynolds, W. P., Corp'l, E, 88th Penn.	July 1, '63.	Right; flap. Discharged Nov. 19, 1863; pensioned.
694	Penley, W. H., Pt., A, 8th Maine, age 24.	June 18, '64.	Left; flap; by Surg. G. T. Stevens, 77th N. Y. Discharged Dec. 15, 1864; pensioned.	734	Rhine, J. W., Corp'l, I, 34th Indiana.	May 26, '62.	Right; by Surg. J. S. White, 34th Ind. Discharged Aug. 9, 1862; pensioned.
695	Perkins, S., Pt., F, 6th Ohio.	Sept. 19, '63.	Left; circular. Duty June 17, 1864.	735	Rice, G. W., Serg't, G, 119th Penn., age 22.	May 11, '64.	Left; lat. flap; by Surg. P. Leidy, 119th Pa. To V. R. C. Oct. 29, 1864; pensioned.
696	Perry, E. A., Serg't-Maj., 14th Infantry, age 25.	June 27, '64.	Right; circular: by Surg. C. J. Nordquist, 83d N. Y. Discharged April 3, 1865; pensioned.	736	Richards, H., Pt., H, 1st Maryland Cav., age 24.	Aug. 16, '64.	Right. Discharged October 26, 1864; pensioned.
697	Perry, F. E., Corp'l, E, 30th Mass., age 20.	Aug. 11, '64.	Right; flap; by Surg. J. E. Beatty, 2d Md. Dis'd Mar. 4, '65; pens'd.	737	Richards, R., Pt., G, 4th N. H., age 29.	Feb. 21, '65.	Right; circular. Discharged June 11, 1865; pensioned. Re-amputation at shoulder joint.
698	Pflaum, A., Pt., H, 28th Iowa, age 26.	May 16, '63.	Left; flap; by Surg. J. W. H. Vest, 28th Iowa. Dis'd Aug. 10, 1863.	738	Richards, T. J., Serg't, C, 9th N. H.	Sept. 17, '62.	Right; flap. Discharged Nov. 28, 1862; pensioned.
699	Phelps, W. I., Pt., D, 24th Mass., age 44.	Aug. 16, '64.	Right; circular. Duty Sept. 27, 1864; pensioned.	739	Richardson, L., Lieut., C, 4th Vermont.	May 6, '63.	Right. Disch'd Sept. 6, 1864.
700	Phillips, J., Pt., I, 5th Artillery, age 21.	May 12, '64.	Right. Discharged; pensioned.	740	Ridenour, J. F., Pt., F, 81st Ohio, age 23.	May 14, '64.	Left; flap; by Surg. W. C. Jacobs, 81st Ohio. Disch'd Dec. 2, 1864; pensioned.
701	Phinney, A. E., Pt., H, 32d Iowa, age 21.	April 9, '64.	Left; flap. Discharged Oct. 27, 1864; pensioned.	741	Ridout, W. S., Pt., G, 5th Iowa.	May 16, '63.	Right. Discharged September 29, 1863; pensioned.
702	Phipps, D., Pt., H, 126th N. Y., age 40.	July 2, '63.	Left; circular. Discharged Dec. 23, 1863; pensioned.	742	Riocker, E., Pt., E, 2d Conn. Art., age 28.	June 1, '64.	Right; circ: by Surg. H. Plumb, 2d Conn. Art. Discharged April 3, 1865; pensioned.
703	Pierce, W., Corp'l, E, 149th Penn., age 19.	July 2, '63.	Left; flap. Discharged Jan. 7, 1864.	743	Rigdon, H. J., Pt., E, 85th Penn., age 23.	Aug. 22, '62.	Left; flap; by Surg. S. A. Green, 24th Mass. Disch'd Oct. 28, '64.
704	Pickelheimer, W. D., Pt., K, 34th Ohio, age 38.	June 18, '64.	Right; flap. Discharged Sept. 26, 1864; pensioned.	744	Ripley, J., Pt., G, 153d Pennsylvania.	May 2, '63.	Right. Duty June 26, 1863; pensioned.
705	Pickett, L. W., Pt., E, 2d Michigan Cav.	June 7, '63.	Left. Discharged Aug. 9, 1863; pensioned.	745	Rippen, Wm., Pt., F, 12th Illinois, age 18.	Oct. 5, '64.	Left; by Surg. J. R. Zearing, 57th Ill. Disch'd Mar. 16, '65; pens'd.
706	Pillsbury, T., Serg't, B, 4th Maine, age 23.	May 6, '64.	Right; circular. Discharged July 19, 1864; pensioned.	746	Robbins, S. J., Pt., A, 108th N. Y., age 20.	June 3, '64.	Right; circular: by Surg. D. W. Maul, 1st Del. Disch'd Sept. 20, 1864; pensioned.
707	Pinkney, J. W., Pt., B, 27th C. T., age 17.	June 15, '64.	Left; flap. Discharged Jan. 19, 1865; pensioned.				

No.	NAME, AGE, AND MILITARY DESCRIPTION.	DATES.	OPERATIONS, OPERATOR, RESULT.	No.	NAME, AGE, AND MILITARY DESCRIPTION.	DATES.	OPERATIONS, OPERATOR, RESULT.
747	Roberts, J., Corp'l, E, 67th N. Y., age 25.	May 6, '64.	Left; flap. Discharged Oct. 18, 1864; pensioned.	786	Schweis, A., Pt., G, 19th Infantry.	Sept. 20, '63.	Left. Disch'd Mar. 10, 1864; pensioned.
748	Roberts, C. R., Pt., G, 3d Penn. Heavy Artillery.	May 23, '65.	Left; by Act. Staff Surg. W. H. Palmcr. Discharged July 29, 1865; pensioned.	787	Scott, D. M., Serg't, E, 52d Ohio, age 23.	Mar. 19, '65.	Right; flap; by Surg. E. Batwell, 14th Mich. Discharged June 30, 1865; pensioned.
749	Robertson, J. A., 1st Lt., I, 45th Ala., age 32.	Nov. 30, Dec. 1, 1864.	Left; circular; by Surg. Wing, 7th Tex. To Prov. Mar. Jan. 3, '65.	788	Scouton, I. J., Pt., K, 146th N. Y., age 22.	May 5, '64.	Left; antero-post. flap; by Surg. T. M. Flandrau, 14th N. York. Disch'd Mar. 28, 1865; pensioned.
750	Robertson, S., Pt., A, 149th Penn., age 22.	May 5, '64.	Left; flap. Discharged June 28, 1865.	789	Seoville, M. L., Pt., F, 7th Ohio, age 18.	May 25, '64.	Right; circular; by Surg. A. K. Field, 29th Ohio. Disch'd July 13, 1864; pensioned.
751	Robinson, G. N., Pt., F, 147th N. Y., age 30.	April 1, '65.	Left; ant.-post. flap; by Surg. A. S. Coe, 147th N. Y. Discharged July 12, 1865; pensioned.	790	Scully, C., Pt., D, 1st N. York.	Aug. 29, '62.	Right. Discharged; pensioned.
752	Robinson, J. B., Pt., A, 123d N. Y., age 20.	June 1, '64.	Left; circular. Discharged Feb. 29, 1865; pensioned.	791	Seegmiller, G., Pt., 1st Co. S. S., 27th Mich., age 28.	May 12, '64.	Right; circular; by Surg. W. B. Fox, 8th Mich. Disch'd Aug. 22, 1864; pensioned.
753	Robinson, J. H., Pt., D, 34th Ill., age 18.	May 14, '64.	Left; flap. Discharged Dec. 26, 1864; pensioned.	792	Selbing, L., Pt., B, 3d Me.	May 3, '63.	Left; flap; by Surg. F. Hildreth, 3d Me. Dis'd Nov. 4, '63; pens'd.
754	Robinson, O., Pt., E, 7th Vermont.	July 4, '62.	Flap; by Surg. B. H. Comings, 13th Conn. Discharged Oct. 21, 1862; pensioned.	793	Sonneff, J., Pt., D, 34th Illinois, age 29.	Mar. 19, '65.	Right; circular; by Surg. E. Batwell, 14th Mich. Disch'd June 12, 1865; pensioned.
755	Rodgers, J., Pt., H, 5th U. S. Cav., age 24.	Aug. 25, '64.	Right. Duty Jan. 19, 1865; pensioned.	794	Sergent, W., Pt., E, 53d Penn., age 18.	June 1, '62.	Left; circular; also amp. right arm July 13, 1862. Disch'd Nov. 19, 1864; pensioned.
756	Rodgers, W. P., Corp'l, H, 7th Md., age 21.	May 8, '64.	Left; circular. Discharged May 5, 1865.	795	Seyfert, J., Pt., B, 88th Pennsylvania.	June 17, '64.	Left; flap; by Surg. J. W. Rawlins, 88th Penn. Disch'd Dec. 9, 1864; pensioned.
757	Roer, S. E., Pt., B, 44th New York, age 30.	Sept. 30, '64.	Right; circular. Disch'd Sept. 8, 1865.	796	Sewall, A. R., Pt., I, 5th Michigan.	May 5, '62.	Left; flap; by Surg. D. W. Bliss, U. S. V. Disch'd June 20, 1862; pensioned.
758	Roedel, J., Lieut., C, 28th Ohio.	June 5, '64.	Right; by Surg. C. E. Demig, 28th Ohio. Disch'd July 23, 1864; pensioned.	797	Shaw, I., Pt., H, 5th New Hampshire.	Sept. 17, '62.	Right. Discharged Dec. 18, 1862; pensioned.
759	Rogers, W. H., Corp'l, K, 30th Massachusetts.	Aug. 5, '62.	Left; circular; by Surg. S. K. Towle, 30th Mass. Disch'd Oct. 6, 1862; pensioned.	798	Shannon, J., Pt., E, 158th New York, age 29.	April 2, '65.	Left; ant.-post. flap; by Surg. N. M. Carter, 100th N. Y.
760	Rook, G., Pt., M, 1st Ohio Artillery, age 28.	Sept. 3, '64.	Left; circular; by A. Surg. W. H. Matchett, 40th Ohio. Disch'd August 7, 1865.	799	Shannon, W. G., Pt., G, 12th Ill., age 38.	Oct. 5, '64.	Left; circ. by Surg. P. W. Wood, 30th Iowa. Disch'd June 25, 1865; pensioned.
761	Root, H. L., Serg't, F, 109th N. Y., age 35.	July 30, '64.	Right; flap; by Surg. A. F. Whelan, 1st Mich. S. S. Disch'd Nov. 3, 1864; pensioned. <i>Spec. 1361.</i>	800	Sharp, G. W., Pt., B, 95th Penn., age 19.	April 2, '65.	Right; flap; by Surg. C. C. MeLaughlin, 95th Penn. Disch'd Oct. 20, 1865; pensioned.
762	Rosengrant, C., Pt., C, 107th Penn., age 18.	June 19, '64.	Right; flap; by Surg. J. F. Hutchinson, 107th Penn. Disch'd Feb. 10, 1865; pensioned.	801	Shelafoo, N., Pt., H, 2d Minnesota, age 22.	June 18, '64.	Right; circ.; by Surg. E. D. Morris, 35th Ohio. Disch'd Oct. 24, '64.
763	Rothgeb, J., Serg't, K, 12th Missouri, age 21.	Dec. 15, '64.	Left; circular; by A. A. Surg. T. B. Nossinger. Disch'd April 27, 1865; pensioned.	802	Shell, T., Pt., F, 21st New York, age 23.	Aug. 30, '61.	Right; flap; by Surg. C. L. Wilson, 31, '62.
764	Rowe, C. E., Pt., G, 40th New York, age 22.	May 12, '64.	Right; flap; by Surg. Powell, C. S. A. Disch'd; pensioned.	803	Sherman, J., Pt., A, 2d N. Y. M. R., age 26.	June 1, '64.	Left; circular; by Surg. R. T. Payne, 2d N. Y. M. R. Disch'd May 17, 1865; pensioned.
765	Rowe, L., Pt., F, 20th Maine.	Sept. 17, '62.	Left. Discharged Feb. 26, 1863; pensioned.	804	Sherrell, T., Pt., C, 81st Penn., age 23.	May 10, '64.	Left; circ.; by Surg. J. W. Wishart, 140th Penn. Disch'd July 28, 1865; pensioned.
766	Royce, J. B., Corp'l, I, 7th Vermont, age 18.	Sept. 10, '63.	Left; by Surg. R. Morris, 91st N. Y. Disch'd Dec. 4, '63; pens'd.	805	Sheneman, H., Pt., I, 62d Ohio, age 37.	Aug. 16, '64.	Left; flap. Disch'd Nov. 14, 1864.
767	Rudisell, H. P., Lieut., A, 12th N. C., age 25.	Sept. 19, '64.	Left; circ.; by Surg. J. W. Lawson, C. S. A. To prison Oct. 25, 1864.	806	Shippee, S. C., Pt., D, 3d Rhode Island Artillery.	July 10, '63.	Right; by A. Surg. H. S. Lumsion, 3d R. I. Art.; (also amp. of left forearm.) Disch'd Oct. 19, 1863; pensioned.
768	Rue, A. L., Corp'l, H, 14th N. J., age 30.	Sept. 19, '64.	Right; flap. Discharged Feb. 8, 1865; pensioned.	807	Shoells, A., Pt., H, 61st Penn., age 21.	May 6, '64.	Right; flap. Disch'd Oct. 28, 1864.
769	Russ, G. F., Serg't, B, 110th Ohio, age 24.	April 2, '65.	Right; circular. Discharged July 21, 1865; pensioned.	808	Shuek, J., Pt., G, 1st Md. Cav., age 28.	Oct. 13, '64.	Right; flap; by Surg. M. S. Kittinger, 100th N. Y. Disch'd July 6, 1865; pensioned.
770	Russell, L. W., Pt., C, 2d Michigan, age 19.	Oct. 8, '64.	Left; circ.; by Surg. E. J. Bonine, 2d Mich. Disch'd Jan. 1, 1865; pensioned.	809	Shultz, F., Pt., G, 5th N. Y. Artillery, age 42.	Aug. 21, '64.	Left; circular. Discharged June 26, 1865.
771	Russel, H. A., Pt., E, 39th New Jersey, age 38.	April 2, '65.	Left; circ.; by Surg. G. R. Sullivan, 39th N. J.; pensioned.	810	Shumway, H., Pt., H, 46th Ohio.	Nov. 25, '63.	Left; circ.; by Surg. R. L. Von Harlinger, 70th Ohio. Disch'd May 17, 1864; pensioned.
772	Safford, J. M., Pt., E, 8th Maine, age 26.	Oct. 27, '64.	Right; flap. Discharged June 29, '64; pensioned.	811	Sims, J. B., Pt., I, 11th Mississippi.	July 3, '63.	Right; circular. Recovered.
773	Salisbury, R. S., Pt., C, 23d Wisconsin.	May 15, '64.	Right; by Surg. J. Bennett, 19th Mich. Dis'd Aug. 18, '64; pens'd.	812	Sims, J. S., Pt., G, 1st N. C. Cav., age 25.	April 19, '65.	Right; circular. Released June 10, 1865.
774	Salter, M. B., Pt., E, 4th Ala., age 23.	July 2, '63.	Right; circular; by Asst. Surg. E. Brennehan, U. S. A. To Pro. Marshal Sept. 25, '63. <i>Spec. 1591.</i>	813	Slade, H., Pt., B, 110th Ohio, age 38.	May 12, '64.	Left; flap. Disch'd June 20, 1865.
775	Sawyer, E. F., Serg't, A, 18th Infantry.	July 30, '64.	Right; flap. Furloughed Sept. 19, 1864.	814	Slason, J. C., Pt., C, 11th Vermont.	April 2, '65.	Right; flap; by Surg. C. B. Park, 1st Vt. H. A. Disch'd June 12, 1865; pensioned.
776	Sawyer, H. S., Pt., I, 45th Pa., age 24.	June 3, '64.	Left; circular; by Surg. T. Christ, 45th Pa. Disch'd Dec. 7, 1864; pensioned.	815	Slater, J. F., Serg't, A, 26th Mass., age 29.	Sept. 19, '64.	Right; flap; by Surg. J. G. Bradt, 26th Mass. Discharged Feb. 23, 1865; pensioned.
777	Saxton, R. B., Pt., D, 62d New York.	Dec. 13, '62.	Left; flap; by Asst. Surg. W. W. Bidlake, 62d N. York. Disch'd Aug. 14, 1864; pensioned.	816	Slavin, T., Pt., D, 93d Penn., age 22.	Mar. 25, '65.	Right; flap. Discharged June 5, 1865.
778	Sayles, I. A., Pt., G, 157th N. Y., age 20.	Dec. 3, '64.	Right; flap; by Surg. H. C. Hendrick, 157th N. Y. Disch'd May 24, 1865; pensioned.	817	Sleeth, S. D., Serg't, D, 54th Penn.	June 18, '64.	Right; by A. Surg. W. W. Lamb, 8th N. J. Disch'd Dec. 19, 1864.
779	Seanton, D., Pt., D, 20th Mass., age 24.	May 6, '64.	Left; circular; Discharged Jan. 31, 1865; pensioned.	818	Sledge, J. W., Pt., K, 13th Georgia.	Sept. 22, '64.	Left. Exchanged Oct. 12, 1864.
780	Searbough, J., Pt., H, 105th Pa., age 30.	Aug. 16, '64.	Right; circular; by Surg. H. F. Lyster, 5th Mich. Pensioned.	819	Sliver, I. N., Corp'l, D, 47th Ohio, age 22.	Dec. 13, '64.	Left; circular; by Surg. J. H. Hutchinson, 15th Mich. Disch'd June 13, 1865; pensioned.
781	Schied, C., Pt., C, 1st Mo. Light Artillery.	April 6, '62.	Flap; by Asst. Surg. W. D. Turner, 1st Ill. Lt. Art. Discharged Oct. 18, 1862; pensioned.	820	Slocum, J. E., Pt., G, 14th New Jersey.	June 1, '64.	Left; flap. Disch'd Dec. 28, 1864; pensioned.
782	Schmidberger, J., Pt., A, 29th N. Y., age 22.	Aug. 29, '62.	Right; flap. Discharged Jan. 3, 1863. Died from abscess of liver, caused by amp. of arm. Jan. 2, 1870.	821	Smaltz, C., Pt., C, 91st Pennsylvania, age 32.	Oct. 27, '64.	Left; flap; by Surg. W. G. Keir, 91st Pa. Disch'd April 11, 1865; pensioned.
783	Schmidt, J., Pt., E, 2d Mo. Artillery.	Sept. 11, '62.	Left; flap; by Asst. Surg. T. W. Johnson, 1st Wis. Cav. Disch'd Jan. 10, 1863; pensioned.	822	Smodley, F. J., Pt., H, 47th Penn., age 22.	Oct. 19, '64.	Right; circ.; by A. Surg. J. Homans, U. S. A. Disch'd Dec. 28, 1864; pensioned. Amp. at shoulder joint Aug. 30, '65. <i>Spec. 2850.</i>
784	Schneider, C. F., Serg't, A, 1st Mo. Light Art.	Aug. 10, '61.	Left; by Brig. Surg. E. C. Franklin. Disch'd; pensioned.				
785	Scholan, W., Pt., K, 43d New York, age 21.	May 10, '64.	Right; circular. Furloughed July 15, 1864.				



No.	NAME, AGE, AND MILITARY DESCRIPTION.	DATES.	OPERATIONS, OPERATOR, RESULT.	No.	NAME, AGE, AND MILITARY DESCRIPTION.	DATES.	OPERATIONS, OPERATOR, RESULT.
823	Smith, A. B., Pt., A, 13th Iowa, age 19.	April 6, '62.	Flap. Discharged Aug. 6, 1862; pensioned.	861	Stoddard, L., Pt., K, 12th New Hampshire, age 38.	May 2, '62.	Right. Discharged Oct. 30, 1863; pensioned.
824	Smith, A. C., Corp'l, G, 32d Illinois.	Sept. 25, '62.	Left; by Surg. W. S. Edgar, 32d Ill. Dis'd May 6, 1864; pens'd.	862	Stone, B. F., Corp'l, K, 10th Missouri.	Oct. 4, '62.	Right; circular; by Asst. Surg. H. H. Meredith, 10th Mo. Discharged Jan. 23, 1863; pens'd.
825	Smith, E. F., Pt., E, 8th N. Y. H. Art., age 23.	June 3, '64.	Right; by Surg. S. H. Plumb, 82d N. Y. Re-amp. at upper third July 10, 1864. Discharged May 31, 1865; pensioned. <i>Spec.</i> 2875.	863	Stone, H. S., Pt., F, 112th Illinois, age 28.	Nov. 30, Dec. 1, 1864.	Right; circ.; by A. A. Surg. E. L. Jones. Dis'd Mar. 6, '65; pens'd.
826	Smith, F. W., Pt., F, 38th Alabama, age 21.	Nov. 30, Dec. 1, 1864.	Left; lateral flap. To Provost Marshal Jan. 3, 1865.	864	Stoner, P. Q., Serg't, G, 2d Iowa, age 25.	Feb. 15, '62.	Right; flap; by Surg. W. R. Marsh, 2d Iowa. Disch'd Aug. 11, 1862; pensioned.
827	Smith, G. H., Pt., G, 59th Massachusetts.	May 24, '64.	Left; by Surg. W. Ingalls, 59th Mass. Disch'd Nov. 12, 1864; pensioned.	865	Storer, G., Pt., C, 36th Virginia, age 21.	Sept. 19, '64.	Left; circular; by Surg. J. M. G. McGuire, C. S. A. To Pro. Marshal Feb. 11, 1865.
828	Smith, H. G., Pt., A, 1st Miss. Mar. Brig., age 20.	May 25, '64.	Circular; by Surg. J. Roberts, U. S. V. Disch'd June 24, 1864; pensioned.	866	Stover, M. W., Pt., K, 22d Iowa.	May 22, '63.	Right; flap; by Surg. W. H. White, 22d Iowa. To V. R. C. Sept. 1, 1863; pensioned.
829	Smith, J. A., Pt., B, 41st Illinois.	Jan. 3, '62.	Flap; by Surg. W. P. Cady, 12th Ill. Dis'd April 21, '62; pens'd.	867	Stratton, A., Pt., G, 147th New York, age 17.	June 18, '64.	Right and left; flap; by Surg. A. S. Coe, 147th N. Y. Disch'd Oct. 3, 1864; pens'd. Died June 13, 1874.
830	Smith, M., Pt., I, 12th Rhode Island.	Dec. 13, '62.	Left; circular. Discharged April 22, 1863; pensioned.	868	Stratton, W. H., Pt., E, 13th Mich., age 20.	Mar. 19, '65.	Right; lateral flap; by Surg. E. Batwell, 14th Mich. Disch'd April 17, 1865.
831	Smith, R. L., Corp'l, D, 4th Del., age 23.	June 18, '64.	Left; flap; by Surg. G. W. Metcalf, 76th N. Y. Dis'd Jan. 9, '65; pen'd.	870	Strayer, A. F., Pt., B, 188th Pa., age 18.	Sept. 29, '64.	Right; flap. Disch'd May 29, 1865; pensioned.
832	Smith, T., Pt., 1, 8th Mississippi, age 24.	Nov. 30, Dec. 1, 1864.	Circular. To Provost Marshal Feb. 8, 1865.	871	Strickland, F., Pt., I, 154th N. Y., age 33.	July 1, '63.	Right; by A. Surg. J. H. Wilson, 73d Pa. Disch'd Oct. 6, '63; pens'd.
833	Smith, W., Pt., B, 24th Michigan.	July 1, '63.	Left; circular; by Surgeon J. H. Beach, 24th Mich. Disch'd Nov. 27, 1863; pensioned.	872	Strickler, H., Serg't, K, 12th Pennsylvania.	Dec. 13, '62.	Left; flap; by Surg. W. Nugent, 126th Pa. Disch'd April 27, '63; pensioned.
834	Smith, W., Pt., C, 115th New York, age 44.	Jan. 15, '65.	Right; circular; by Surg. J. W. Mitchell, 4th C. Troops. Disch'd June 12, 1865; pensioned.	873	Strapp, J., Pt., B, 106th New York, age 21.	Sept. 19, '64.	Right; circular. To V. R. C. Mar. 3, 1865; pensioned.
835	Smith, W. A., Pt., D, 2d U. S. Sharpshooters.	June 19, '64.	Left; flap; by Surg. W. B. Reynolds, 2d U. S. S. S. Discharged Dec. 16, 1864; pensioned.	874	Strong, H. F., Pt., I, 12th Wisconsin, age 26.	Aug. 31, '64.	Right; circular; by Surg. J. S. Reeves, 78th Ohio. Disch'd April 7, 1865; pensioned.
836	Sneath, A., Pt., F, 118th Pa., age 24.	May 8, '64.	Right; circular. Disch'd Sept. 16, 1864; pensioned.	875	Strope, N., Pt., H, 57th Pennsylvania, age 18.	May 5, '64.	Right; circular. Duty Sept. 5, 1864.
837	Snider, L. A., Pt., K, 33d Ohio.	Sept. 20, '63.	Right; circular. Disch'd Jan. 7, 1864; pensioned.	876	Strout, N. A., Pt., E, 9th Maine, age 27.	May 18, '64.	Left; circular; by Surg. A. D. Palmer, 9th Me. Disch'd Jan. 26, 1865; pensioned.
838	Snow, F. H., Pt., F, 1st Maine H'y Art., age 25.	June 18, '64.	Left; flap. Disch'd Jan. 17, 1865; pensioned.	877	Sullivan, W., Pt., M, 3d Iowa Cav., age 18.	July 14, '64.	Left; circular; by Surg. J. E. Sanborn, 27th Iowa. Disch'd Nov. 8, 1864.
839	Snyder, W. H., Pt., E, 110th Penn.	May 3, '63.	Right; flap. Discharged Sept. 21, 1863; pensioned.	878	Sultzbaueh, H., Pt., B, 6th Pa. Reserves, age 16.	May 10, '64.	Right; flap; by Surg. B. Kohrer, 10th Pa. Res. Disch'd Dec. 17, 1864; pensioned.
840	Southard, S. C., Pt., E, 12th New Jersey.	July 2, '63.	Right; by Surg. A. Satterthwaite, 14th N. J. To V. R. C. Sept. 9, 1863; pensioned.	879	Summerlin, A. I., Serg't, G, 55th N. C., age 25.	July 1, '63.	Left; re-amp. near shoulder Aug. 9, 1863. Furloughed Nov. 12, 1863.
841	Sowaal, L., Pt., B, 133d New York, age 38.	June 14, '63.	Left; circular. Disch'd Sept. 29, 1863; pensioned.	880	Sutherland, R. J., Lt., B, 109th Penn., age 27.	May 3, '63.	Right. Disch'd Aug. 24, 1863; pensioned. Died Feb. 21, 1870.
842	Speicher, J., Pt., C, 149th Penn., age 25.	Aug. 1, '64.	Right; flap; by Surg. J. Thomas, 118th Pa. Discharged Feb. 23, 1865; pensioned.	881	Suzor, G., Pt., C, 1st Mich., age 48.	June 27, '64.	Left; circular; by Surg. W. Fulkner, 1st Mich. Disch'd May 13, 1865; pensioned.
843	Spelder, J. D., Pt., F, 14th Mich., age 25.	Mar. 20, '65.	Left; circular; by Surg. E. Batwell, 14th Mich. Disch'd June 15, 1865; pensioned.	882	Swank, G. W., Pt., F, 49th Ohio, age 22.	May 27, '64.	Right; flap. Disch'd Sept. 21, 1864; pensioned.
844	Spetzagle, G., Pt., F, 95th N. Y., age 31.	May 6, '61.	Right; flap. To V. R. C. Oct. 29, 1864; pensioned.	883	Swift, W. R., Pt., E, 23d Mass., age 25.	Dec. 16, '62.	Right; flap. Disch'd Aug. 11, 1863; pensioned.
845	Stacey, B., Pt., A, 29th Illinois.	Mar. 29, '65.	Left; by Surg. J. L. Dieken, 47th Ind. Disch'd Nov. 6, '65; pen'd.	884	Sweet, D., Corp'l, A, 12th Georgia, age 20.	June 2, '64.	Right; circular. Furloughed July 22, 1864.
846	Stage, J. F., Pt., H, 9th New York.	April 19, '62.	Right; by Surg. G. H. Humphreys, 9th N. Y. Disch'd Sept. 30, 1862; pensioned.	885	Sykes, H. E., Serg't, A, 5th N. C., age 29.	Mar. 25, '65.	Right; circular. Released June 14, 1865.
847	Starkey, C., Pt., C, 20th Connecticut, age 35.	July 20, '64.	Right; ant.-post. flap. Disch'd Feb. 4, 1865; pensioned.	886	Sykes, H. W., Pt., C, 37th Mass., age 23.	June 3, '64.	Right; circular; by Surg. C. F. Crehore, 37th Mass. Disch'd June 17, 1865; pensioned.
848	Starr, S. H., Major, 6th Cavalry.	July 2, '63.	Right. Duty Nov. 12, 1863.	887	Tanner, A., Pt., I, 66th Ohio, age 21.	June 19, '64.	Left; circ.; by Surg. G. P. Oliver, 111th Pa. Disch'd Jan. 7, 1865; pensioned.
849	Staten, E. E., Pt., H, 53d Indiana, age 18.	Oct. 5, '62.	Left; flap; by Surg. R. C. Slaughter, 83d Ind. Discharged Nov. 23, 1862; pensioned.	888	Tapp, L., Corp'l, K, 13th Tennessee Cav.	Dec. 11, '64.	Right; by Surg. J. W. Brady, 8th Tenn. Disch'd and pensioned.
850	Stearns, W. E., Corp'l, D, 97th Indiana, age 25.	Sept. 4, '64.	Right; flap; by Surg. W. Lomax, 12th Ind. Discharged June 12, 1865; pensioned.	889	Tate, J., Pt., D, 16th Connecticut.	Sept. 17, '62.	Left; by Surg. M. Storrs, 8th Conn. Disch'd Mar. 18, 1863; pensioned.
851	Steele, C., Corp'l, F, 8th New Jersey, age 22.	April 2, '65.	Right; flap; by Asst. Surg. W. W. Lamb, 8th N. J. Disch'd July 27, 1865.	890	Taylor, C. E., Pt., I, 82d New York, age 32.	May 10, '64.	Left; double skin flaps; by Surg. S. H. Plumb, 82d N. Y. Disch'd May 21, 1865; pensioned.
852	Stehfest, H., Corp'l, A, 24th Michigan, age 27.	Feb. 6, '65.	Left; circ.; by Surg. J. H. Beach, 24th Mich. Disch'd June 15, 1865; pensioned.	891	Taylor, E., Pt., I, 28th Tenn., age 31.	Nov. 30, Dec. 1, 1864.	Left; ant.-post. flap. To Provost Marshal Jan. 23, 1865.
853	Stephenson, G. H., Lieut., D, 27th Ind., age 29.	May 15, '64.	Right; circular; by Surg. W. H. Heath, 2d Mass. Duty Aug. 1, '64.	892	Taylor, P., Pt., G, 31st Illinois.	Aug. 15, '64.	Right; flap; by Surg. H. McKennan, 17th Wis. Disch'd July 25, 1865; pensioned.
854	Stevens, C. E., Pt., K, 37th Wisconsin, age 20.	July 30, '64.	Left; flap; by Surg. W. B. Fox, 8th Mich. Discharged Sept. 15, 1864; pensioned.	893	Thomas, F., Lieut., I, 1st Mass., age 28.	June 25, '62.	Left; flap; by Surg. J. J. McGoran, 71st N. Y. Duty Sept. 2, 1862.
855	Stevens, U. S., Corp'l, D, 109th N. Y., age 23.	July 30, '64.	Right; circular; by Surg. A. F. Whelan, 1st Mich. S. S. Discharged Feb. 2, 1865; pens'd.	894	Thomas, J., Pt., A, 57th Indiana, age 19.	June 23, '64.	Right; flap; by Surg. W. B. McGuyron, 26th O. Disch'd Dec. 13, 1864; pensioned.
856	Stevens, W. H., Pt., D, 44th Illinois.	Oct. 8, '62.	Left. Discharged; pensioned.	895	Thomas, J. H., Pt., B, 23d C. T., age 18.	July 30, '64.	Left; flap; by Surg. G. J. Potts, 23d C. T. Disch'd May 29, 1865.
857	Stevens, W. O., Pt., H, 80th New York, age 18.	May 10, '64.	Left; flap. Disch'd Sept. 20, 1864.	896	Thomas, J. N., Pt., D, 122d Illinois.	Dec. 31, '62.	Right; by Surg. Cowan, C. S. A. Disch'd April 3, 1863; pens'd.
858	Stevenson, F., Pt., B, 152d Penn., age 29.	May 12, '64.	Right; flap; by Surg. M. Rizer, 72d Pa. Disch'd Jan. 8, 1865.	897	Thomas, L., Pt., E, 60th Illinois.	June 19, '64.	Left. Discharged Jan. 25, 1865.
859	Stieckles, C., Pt., I, 91st New York, age 29.	May 25, '63.	Flap; by A. Surg. J. T. Myers, 91st N. Y. Disch'd Aug. 19, '63.	898	Thomas, L. L., Pt., A, 5th Alabama, age 38.	May '64.	Right; circular. Recovered.
860	Stine, F., Pt., E, 93d Ohio, age 21.	Dec. 16, '64.	Left; flap; by Surg. J. M. Weaver, 93d Ohio. Disch'd May 30, '65; pensioned.	899	Thomas, N., Pt., C, 110th Ohio, age 28.	June 2, '64.	Left; flap. Discharged Sept. 28, 1864.

No.	NAME, AGE, AND MILITARY DESCRIPTION.	DATES.	OPERATIONS, OPERATOR, RESULT.	No.	NAME, AGE, AND MILITARY DESCRIPTION.	DATES.	OPERATIONS, OPERATOR, RESULT.
900	Thompson, J., Pt., B, 66th New York, age 50.	May 6, '64.	Left; circular. Discharged Mar. 22, 1865; pensioned.	939	Wangelin, H., Col., 12th Missouri.	Nov. 27, '63.	Right; by Surg. J. Spiegelhalter, 12th Mo. Discharged; pens'd.
901	Thompson, J. F., Pt., K, 79th Ohio, age 31.	Mar. 16, '65.	Right; circular; by Surg. H. H. Langdon, 79th Ohio. Disch'd Mar. 30, 1865; pensioned.	940	Ward, M., Pt., B, 14th N. Y. S. M., age 31.	May 10, '64.	Left; flap. Discharged July 18, 1864; pensioned.
902	Thompson, L. J., Pt., G, 53d Penn., age 17.	May 12, '64.	Right; ant.-post. flap; by Surg. J. W. Wishart, 140th Pa. Disch'd Jan. 6, 1865; pensioned.	941	Warner, D. B., Lieut. Col., 113th Ohio, age 32.	June 27, '64.	Left; flap; by Surg. R. H. Payne, 10th Ill. Duty Nov. 19, 1864.
903	Thompson, W. S., Pt., C, 46th Pennsylvania.	Aug. 9, '62.	Right; circular. Disch'd Feb. 1, 1863; pensioned.	942	Warner, H., Pt., B, 51st Pennsylvania, age 37.	June 3, '64.	Left; circ.; by Surg. W. B. Fox, 8th Mich. Disch'd Mar. 15, '65; pensioned.
904	Thornton, M. L., Pt., E, 31st Georgia, age 22.	Oct. 19, '64.	Right; by Surg. G. G. Button, 31st Ga. Pro. Mar. April 8, 1865.	943	Warner, H. E., Pt., E, 23d Wisconsin, age 25.	May 15, '64.	Left; flap; by Surg. T. Natchard, 23d Wis. Discharged March 7, 1865; pensioned.
905	Thorp, G., Pt., G, 60th Ohio, age 21.	Aug. 19, '64.	Left; re-amp. upper third Sept. 27, 1864. Disch'd Dec. 9, 1864; pensioned.	944	Warner, J. B., Corp'l, G, 12th Indiana, age 19.	Mar. 10, '65.	Left; flap. Disch'd May 29, '65; pensioned.
906	Thrall, J. E., Pt., K, 47th Illinois.	Oct. 3, '62.	Right; by Surg. G. L. Lucas, 47th Ill. Disch'd Nov. 5, '62; pens'd.	945	Washburn, A., Pt., H, 19th Maine, age 23.	July 2, '63.	Right; flap; by Surg. S. H. Plumb, 8th N. Y. Discharged Oct. 23, 1863; pensioned.
907	Thumma, F., Corp'l, F, 20th Pa., age 42.	April 2, '65.	Right; flap; by Surg. M. F. Bowes, 209th Pa. Disch'd Aug. 12, 1865; pensioned.	946	Wasser, L., Pt., A, 44th Illinois, age 19.	Dec. 16, '64.	Right; by Surg. H. E. Hasse, 24th Wis. Disch'd Sept. 15, '65.
908	Tinker, A. G., Pt., C, 4th New Hampshire.	Dec. 11, '63.	Left; by Surg. G. P. Greely, 4th N. H. Disch'd Feb. 14, '64; pens'd.	947	Watson, A. J., Pt., H, 134th New York.	July 1, '63.	Right; circular. Disch'd May 9, 1864.
909	Tinkler, J., Serg't, G, 18th Infantry.	Nov. 25, '63.	Left; by A. Surg. E. J. Darken, U. S. A. Disch'd Dec. 22, 1864; pensioned.	948	Watson, C. C., Corp'l, D, 3d Iowa, age 18.	Oct. 5, '62.	Right; by Surg. B. F. Keables, 3d Ia. Disch'd Nov. 18, '62; pens'd.
910	Tompkins, E. B., Pt., F, 89th New York.	April 19, '63.	Right; circular; by Surg. T. H. Squire, 89th N. Y. Disch'd May 20, 1863; pensioned.	949	Watson, T. J., Serg't, I, 20th Ohio, age 23.	July 21, '64.	Right; circular; by Surg. Danco, 8th Tenn., C. S. A. Discharged July 21, 1865; pensioned.
911	Toms, H., Corp'l, G, 22d Iowa, age 23.	Sept. 19, '64.	Left; flap; by Surg. J. W. H. Vest, 25th Iowa. Disch'd Jan. 31, 1865; pensioned.	950	Webb, G. A., Pt., C, 5th Michigan.	Dec. 13, '62.	Left; flap. Discharged March 18, 1863; pensioned.
912	Topping, H. B., Pt., F, 137th New York, age 18.	June 16, '64.	Right; circ.; by Surg. E. Hutchinsson, 137th N. Y. Disch'd May 25, 1865; pensioned. Spec. 4322.	951	Weber, H., Pt., E, 31st New York.	May 7, '62.	Right. Discharged July 21, 1862; pensioned.
913	Towling, J., Pt., F, 3d Mass. Cav., age 45.	May 18, '64.	Left; circ.; by Surg. C. H. Andrus, 176th N. Y. Disch'd Nov. 1, 1864; pensioned.	952	Webster, G. W., Pt., K, 44th New York.	Aug. 30, '62.	Left; by Surg. W. Frothingham, 44th N. Y. Disch'd Oct. 10, 1862; pensioned.
914	Travers, J., Corp'l, K, 115th N. Y., age 21.	July 30, '64.	Right; circular. Disch'd Oct. 28, 1865; pensioned.	953	Weed, A. L., Pt., B, 16th Illinois, age 24.	Mar. 20, '65.	Left; flap; by Surg. H. R. Payne, 10th Ill. Disch'd June 25, 1865; pensioned.
915	Travis, J., Pt., D, 5th C. T., age 30.	June 15, '64.	Right; circular; by Surg. J. W. Mitchell, 4th C. T. Disch'd Feb. 10, 1865; pensioned.	954	Weeks, J. T., Pt., G, 3d Colored Troops, age 20.	Nov. 14, '63.	Left; antero-posterior flap; by Surg. S. W. Gross, U. S. A. (Also amp. of thigh.) Disch'd July 26, 1865; pensioned.
916	Troth, J. H., Pt., G, 12th New Jersey, age 23.	May 12, '64.	Left; circular. Disch'd Mar. 24, 1865; pensioned.	955	Weisheit, I., Pt., I, 87th Pennsylvania.	June 13, '63.	Left. Discharged Feb. 15, 1864; pensioned.
917	Tucker, J. L., Pt., I, 119th Illinois, age 32.	July 4, '64.	Right; ant.-post. flap; by Surg. D. G. Brinton, U. S. V. Disch'd Oct. 1, 1864; pensioned.	956	Weiss, C., Servant to General Howard.	July 3, '63.	Left; circular. Discharged Oct. 30, 1863.
918	Turner, J., Serg't, G, 49th Ohio, age 22.	May 27, '64.	Right; circ.; by Surg. H. B. Tuttle, 89th Ill. Disch'd Oct. 29, 1864; pensioned.	957	Welch, E. P., Pt., E, 57th New York, age 20.	June 16, '64.	Left; flap; by Surg. W. W. Potter, 57th N. Y. Disch'd Sept. 9, '64; pensioned.
919	Tuttle, J. F., Pt., B, 32d N. C., age 20.	July 1, '63.	Left; circular. Paroled Sept. 25, 1863.	958	Welling, L. H., Pt., J, 7th Wisconsin, age 21.	Aug. 28, '62.	Right; circular. Disch'd Oct. 10, 1862.
920	Tuttle, A. B., Corp'l, F, 15th N. Y. Cav., age 23.	April 8, '65.	Right; ant.-post. flap; by A. Surg. J. C. Wall, 15th N. Y. C. Disch'd June 20, 1865; pensioned.	959	Wells, H. E., Pt., H, 19th Illinois.	Dec. 29, '62.	Left; flap; by Surg. R. G. Pogue, 19th Ill. Disch'd Feb. 9, 1863; pensioned.
921	Tyler, G. E., Serg't, I, 23d Ohio.	Sept. 14, '62.	Right. Discharged Nov. 8, 1862; pensioned.	960	Wells, W. B., Pt., L, 67th N. C., age 19.	Mar. 8, '65.	Right; circular. Duty May 1, 1865.
922	Taylor, R. W., Lieut., K, 1st U. S. S. S., age 23.	Aug. 16, '64.	Left; ant.-post. flap; by Surg. G. M. Brennan, 1st U. S. S. S. Duty Oct. 25, 1864; pensioned.	961	Welsh, T., Pt., L, 102d Pennsylvania, age 26.	June 18, '64.	Right; circular; by Surg. M. J. Morrison, 102d Pa. Disch'd Feb. 10, 1865; pensioned.
923	Ulrick, F., Pt., E, 35th Mass., age 33.	April 2, '65.	Left; flap. Discharged June 1, 1865.	962	Wempler, A. F., Corp'l, F, 50th Virginia.	July 1, '63.	Left; flap. Paroled Sept. 5, 1863.
924	Umphrey, J., Pt., E, 49th Georgia, age 21.	May 3, '63.	Recovery.	963	Wescott, D. C., Pt., B, 111th N. Y., age 21.	Mar. 31, '65.	Right; flap; by A. Surg. W. Aiken, 121st N. Y. Disch'd July 27, 1865; pensioned.
925	Van Felt, J. W., Pt., C, 1st N. C. Cav., age 25.	Mar. 31, '65.	Left. Paroled June 29, 1865.	964	West, M. C., Pt., H, 2d Maine Cav., age 46.	July 18, '64.	Left; by Surg. G. W. Martin, 2d Me. Cav. Disch'd Aug. 17, 1864; pensioned.
926	Vane, W. S., Pt., G, 4th Delaware, age 25.	June 18, '64.	Right; circ.; by Surg. D. S. Hopkins, 4th Del. Disch'd July 20, '65.	965	West, J., Pt., F, 31st Ill., age 33.	July 21, '63.	Left; circular. Duty Dec. 7, 1864; pensioned.
927	Vanderryt, B., Pt., I, 25th Wisconsin.	July 22, '64.	Left. Discharged April 29, 1865; pensioned.	966	Wessells, H., Pt., D, 16th Connecticut.	Sept. 17, '62.	Right; by Surg. Brown, 12th S. C. Disch'd Jan. 8, 1863; pensioned.
928	Vaughn, J., Pt., C, 71st New York, age 27.	May 11, '64.	Left; flap. Disch'd July 8, 1864; pensioned.	967	Wetzlan, G., Lt., H, 17th Missouri.	Sept. 1, '64.	Right; by Surg. A. Savine, 76th Ohio. Disch'd; pensioned.
929	Viall, N. A., Corp'l, E, 15th Massachusetts.	Oct. 21, '61.	Left; flap; by Surg. Gilmore, C. S. A. Disch'd Nov. 8, '62; pens'd.	968	Wheeler, W., Pt., B, 100th New York.	Aug. 27, '63.	Left; flap. Discharged Nov. 16, 1863.
930	Victor, F., Pt., F, 11th Penn. Res., age 17.	May 5, '64.	Right; flap; by Surg. W. Lyons, 11th Pa. Res. Duty Sept. 15, 1864; pensioned.	969	Wheelless, A. W., Pt., I, 43d N. C., age 29.	Mar. 25, '65.	Right; circular; by A. Surg. E. R. Roche, 35th Mass. Released June 14, 1865.
931	Vroman, N., Corp'l, C, 60th New York, age 22.	June 15, '64.	Right; flap; by Surg. H. B. Whiton, 60th N. Y. Disch'd Feb. 13, 1865; pensioned.	970	White, F. F., Pt., B, 11th Maine, age 20.	Mar. 30, '65.	Right; circular; by Surg. C. M. Clark, 39th Ill. Disch'd July 20, 1865; pensioned.
932	Wade, J. W., Pt., K, 5th Vermont.	Dec. 13, '62.	Left. Discharged Feb. 15, 1863; pensioned.	971	White, F. L., Pt., K, 107th New York, age 31.	May 25, '64.	Left; flap. Disch'd Feb. 7, 1865; pensioned.
933	Wakenshaw, W., Capt., H, 5th Michigan, age 34.	May 6, '64.	Right; flap; by Surg. H. F. Lyster, 5th Mich. To V. R. C. Nov. 6, 1864.	972	White, J., Serg't, G, 42d Illinois, age 21.	May 14, '64.	Left; flap. Disch'd Feb. 4, 1865; pensioned.
934	Walch, P., Pt., G, 3d Wisconsin, age 20.	May 25, '63.	Right; flap. Discharged Jan. 23, 1865; pensioned.	973	White, J. W., Pt., A, 14th Penn. Cav., age 19.	Dec. 4, '64.	Left; flap; by Surg. W. A. Barry, 98th Pa. Disch'd Feb. 25, 1865; pensioned.
935	Walker, S., Serg't, A, 1st Mo. Light Art.	May 16, '63.	Left; flap; by Surg. R. B. Jessup, 24th Ind. Discharged Oct. 13, 1863; pensioned.	974	Whittemore, E. F., Corp'l, H, 32d Mass., age 22.	May 12, '64.	Right; circular. Disch'd June 3, 1865.
936	Wallace, T., Corp'l, K, 116th Pennsylvania.	Dec. 13, '62.	Right. Discharged Mar. 24, 1863; pensioned.	975	Wickware, C., Corp'l, I, 6th Vermont, age 23.	May 5, '64.	Left; flap; by Surg. E. Phillips, 6th Vt. Disch'd Aug. 11, 1864; pensioned.
937	Walton, W., Pt., H, 71st Pennsylvania.	June 29, '62.	Left. Discharged Aug. 22, 1862; pensioned.	976	Widell, W., Pt., K, 5th Penn. Cav., age 35.	Oct. 7, '64.	Right; flap. Discharged May 15, 1865; pensioned.
938	Walter, C., Pt., F, 59th Virginia, age 25.	July 18, '64.	Circular. Furloughed Oct. 19, 1864.	977	Wiesterberg, F., Pt., A, 2d Michigan.	July 21, '61.	Left; circular; by Surg. H. F. Lyster, 5th Mich. Disch'd Aug. 22, 1861; pensioned.



No.	NAME, AGE, AND MILITARY DESCRIPTION.	DATES.	OPERATIONS, OPERATOR, RESULT.	No.	NAME, AGE, AND MILITARY DESCRIPTION.	DATES.	OPERATIONS, OPERATOR, RESULT.
978	Wilbur, T. T., Pt., II, 40th Mass., age 19.	June 24, '64.	Left; circular. Disch'd June 23, 1865.	998	Wingert, J., Pt., F, 143d New York, age 26.	July 20, '64.	Left; flap. Discharged June 1, 1865; pensioned.
979	Wilcher, J. P., Pt., I, 10th Kentucky.	Sept. 1, '64.	Left; flap; by Surg. C. H. Fowler, 105th Ohio. Disch'd Dec. 6, 1864.	999	Winkler, A., Pt., C, 1st Maryland Cav., age 22.	Oct. 13, '64.	Right; circular. Disch'd July 6, 1865; pensioned.
980	Wilcox, J. P., Pt., A, 49th Tennessee, age 19.	Nov. 30, Dec. 1, 1864.	Left; ant.-post. flap; by Surg. Jackson, C. S. A. Duty Jan. 23, '65.	1000	Winn, J. J., Q. M., U. S. Navy, Steamer Oneida.	April 22, '62.	Left; by Surg. J. Y. Taylor, U. S. N. Pensioned.
981	Wilds, C. B., Pt., B, 146th N. Y., age 23.	May 5, '64.	Left; circular; by Surg. T. M. Flaudrau, 146th N. Y. Disch'd July 27, 1864; pensioned.	1001	Winn, W., Pt., F, 95th New York, age 40.	June 24, '64.	Left; ant.-post. flap. Discharged May 31, 1865; pensioned.
982	Wilkins, O., Pt., II, 16th Mississippi, age 18.	April 2, '65.	Left; by Surg. T. H. Squire, 89th N. Y. Paroled June 25, 1865.	1002	Winslow, I. B., Serg't, A, 6th Conn., age 31.	Aug. 16, '64.	Right. Discharged Nov. 15, 1864.
983	Wilkinson, F. L., Pt., C, 53d Virginia, age 24.	April 20, '63.	Right. Disch'd February 10, 1864.	1003	Wise, A. J., Pt., A, 46th Penn.	May 25, '62.	Left; by Brig. Surg. T. Antisell. Discharged; pensioned.
984	Willett, T. B., Pt., D, 10th Kentucky, age 60.	Sept. 1, '64.	Left; lateral flap; by Surg. J. E. Fowler, 17th Ohio. Disch'd Dec. 6, 1864; pensioned.	1004	Witherton, J. C., Pt., Ala. Battalion, age 23.	May 16, '64.	Left; circular. Furloughed June 9, 1864.
985	Williams, A. J., Pt., B, 22d New York.	Sept. 14, '62.	Right. Disch'd Nov. 18, '62; pens'd.	1005	Wauderby, G. W., Pt., B, 97th Pennsylvania.	June 10, '62.	Left; by Surg. J. R. Everhart, 97th Pa. Disch'd July 31, 1862; pensioned.
986	Williams, A. R., Pt., K, 208th Pa., age 31.	April 2, '65.	Right; circular. Disch'd June 8, 1865; pensioned.	1006	Wood, C., Pt., G, 10th Connecticut, age 20.	Oct. 7, '64.	Left; flap. Disch'd Mar. 18, 1865; pensioned.
987	Williams, E. E., Serg't, E, 50th Va., age 27.	July 3, '63.	Left. Paroled August 22, 1863.	1007	Wood, S., Pt., C, 33d Ohio, age 23.	Aug. 9, '64.	Left; flap. Duty Jan. 17, 1865; pensioned.
988	Williams, J. H., Pt., I, 2d Ohio Cav.	Sept. 30, '62.	Left; circular; by Surgeon J. S. Redfield, 6th Kansas Cavalry. Disch'd Jan. 27, 1863; pens'd.	1008	Wood, W. H., Corp'l, I, 1st Ohio Light Artillery.	July 23, '61.	Right. Disch'd Dec. 11, 1863; pensioned.
989	Williams, T. L., Lieut., E, 59th Alabama, age 25.	June 18, '64.	Right; circular. To prison Sept. 28, 1864.	1009	Woodbury, U. A., Serg't, H, 2d Vermont.	July 21, '61.	Right; by Surg. N. H. Ballou, 2d Vt. Disch'd; pensioned.
990	Willison, S., Pt., H, 59th New York, age 25.	Sept. 17, '62.	Left; flap. Disch'd Nov. 5, 1862.	1010	Woodhouse, F., Pt., K, 50th N. Y., age 42.	July 3, '64.	Right; by A. A. Surg. M. A. Hanly. Discharged October 12, 1863.
991	Wilson, J. B., Pt., E, 11th Connecticut, age 24.	Aug. 2, '64.	Left; eirc.; by A. Surg. W. R. Benson, 8th Maine. Discharged June 17, 1865; pensioned.	1011	Woodward, J., Pt., C, 93d Ohio, age 30.	June 23, '64.	Left; flap; by Asst. Surg. A. M. Morrison, 23d Ky. Disch'd Dec. 2, 1864; pensioned.
992	Wilson, I. H., Serg't, G, 77th New York, age 22.	Sept. 19, '64.	Left; flap; by Asst. Surg. W. G. Bryant, 123d Ohio. Discharged Nov. 27, 1864; pensioned.	1012	Worden, C. H., Corp'l, B, 2d Ohio Cav., age 24.	May 9, '64.	Left; eirc.; by Surg. J. T. Smith, 2d Ohio Cav. Disch'd Mar. 20, 1865; pensioned.
993	Wilson, T., Pt., C, 32d Colored Troops, age 40.	Dec. 7, '64.	Left; circular; by Surg. C. M. White, 32d C. T. Discharged March 15, 1865; pensioned.	1013	World, J., Pt., D, 44th Virginia, age 20.	April 6, '65.	Left; ant.-post flap. Released July 5, 1865.
994	Wilson, W., Pt., A, 13th Ohio.	Dec. 31, '62.	Right; circular; by Surg. W. H. W. Hinds, 12th Mass. Disch'd August 20, 1864; pensioned.	1014	Worley, D. T., Pt., D, 8th Ind. Cav., age 23.	Mar. 16, '65.	Left; ant.-post flap. By A. Surg. M. C. Connett, 8th Ind. Cav. Disch'd Sept. 1, 1865; pens'd.
995	Wilton, G. F., Pt., G, 12th Mass., age 30.	May 5, '64.	Right; circular; by Surg. W. H. W. Hinds, 12th Mass. Disch'd August 20, 1864; pensioned.	1015	Wright, J. H., Pt., II, 29th Ohio, age 35.	May 8, '64.	Right; by Surg. A. K. Field, 29th Ohio. Disch'd; pensioned.
996	Wilton, W. F., Pt., K, 30th Illinois.	May 16, '63.	Right; by A. Surg. W. Feland, 30th Illinois. Discharged Aug. 19, 1863; pensioned.	1016	Wright, J. E. P., Pt., G, 2d Vermont, age 27.	May 12, '64.	Left; circular; by Surg. A. H. Chessmore, 5th Vt. Disch'd Aug. 22, 1864; pensioned.
997	Windsor, T. A., Pt., E, 40th Indiana, aged 22.	Dec. 16, '64.	Right; flap; by Asst. Surg. J. C. Thorpe, U. S. V. Discharged July 22, 1865; pensioned.	1017	Wright, M., Pt., I, 31st Colored Troops.	July 30, '64.	Left; flap. Disch'd Jan. 12, 1865.
				1018	Wright, S. A., Pt., F, 1st U. S. S. S., age 27.	May 5, '64.	Left; flap; by Surg. H. P. Lyster, 5th Mich. Disch'd Sept. 12, '64; pensioned.
				1019	Young, J. W., Pt., D, 30th Indiana, age 21.	June 19, '64.	Left; flap; by Surg. S. H. Kersey, 30th Ind. Disch'd Mar. 3, 1865; pensioned.

The foregoing series of a thousand and nineteen successful primary amputations at the middle of the arm were practised on a thousand and eighteen patients, of whom seventy-six were Confederates. The wounds were inflicted by solid cannon shot in fourteen cases; by shell fragments, in seventy-nine; by grape or canister, in twelve; by premature explosion of cannon, in twelve; by small projectiles, in nine hundred and one cases. Twenty-eight patients were seriously wounded in other regions. In one case, an excision of the upper extremity of the radius was essayed, but abandoned for amputation. Three amputations of the thigh,<sup>1</sup> one of the leg, one of the opposite arm, one of the forearm, and two of the fingers of the opposite hand, were operations practised simultaneously with the arm amputations. Subsequently there were practised: re-amputations in the upper third, in nine instances; excartulation at the shoulder, in three cases; secondary amputation of the opposite arm, in one case; three operations of neurotomy; a ligation of the axillary, and two of the brachial artery.<sup>2</sup> Sixty-six of the patients returned to modified duty, eight hundred and eighty-nine were discharged for disability, forty-seven were exchanged or paroled, eight were furloughed from Confederate hospitals; the final disposition of eight

<sup>1</sup> Surgeon S. W. GROSS, U. S. V. (*Cases of Synchronous Amputation of the Left Thigh at its Upper Third, and of the left Arm*, in *Am. Med. Times*, 1864, Vol. VIII, p. 122) gives a detailed account of one of these double amputations (CASE of Weeks, No. 954).

<sup>2</sup> Dr. G. J. FISHER (*Report of Fifty-seven Cases of Amputations in the Hospitals near Sharpsburg, after the Battle of Antietam*, in *Am. Jour. Med. Sci.*, 1863, Vol. XLV, p. 49. See CASES 6 and 301); Surgeon JAMES BRYAN, U. S. V. (*Seventeen Amputations from the Armies of the Southwest*, in *Am. Med. Times*, 1863, Vol. VII, p. 287. See CASE 135); Medical Cadet D. C. LLOYD, U. S. A. (*Report of Cases of Hospital Gangrene, at Memphis*, in *Am. Med. Times*, 1863, Vol. VII, p. 267. See CASE 153); and Surgeon J. H. THOMPSON, U. S. V. (*Report of the Wounded at the Battle of New Berne*, in *Am. Med. Times*, 1862, Vol. V, p. 7. CASE 335), have published observations on successful amputations of the arm at the middle third for shot injury.

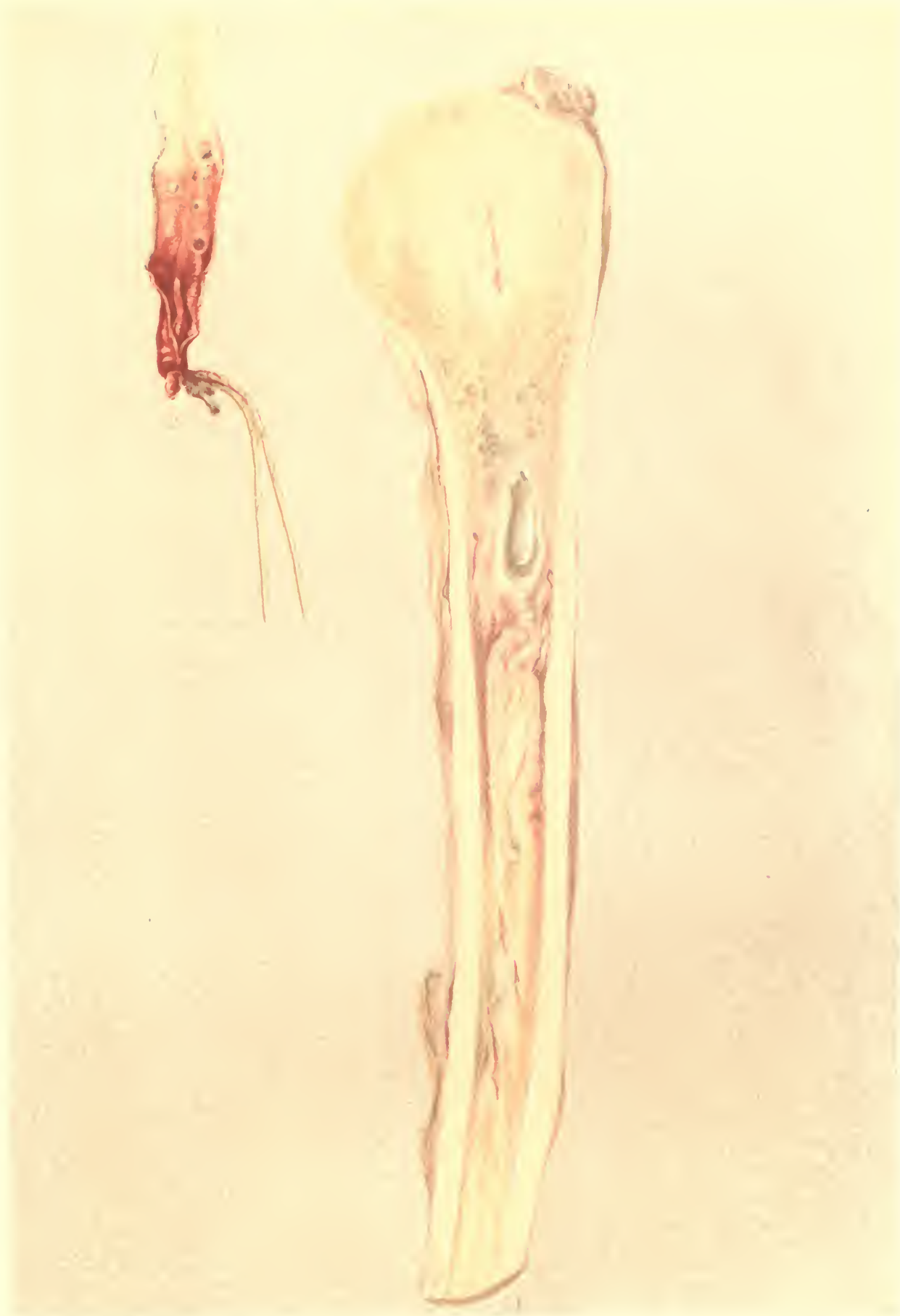

PLATE XXII. 1, OSTEOMYELITIS OF HUMERUS. 2, LIGATION OF POPLITEAL





TABLE LXXI.

Condensed Summary of One Hundred and Forty-three Unsuccessful Cases of Primary Amputation in the Middle Third of the Shaft of the Humerus.

No.	NAME, AGE, AND MILITARY DESCRIPTION.	DATES.	OPERATIONS, OPERATOR, RESULT.	No.	NAME, AGE, AND MILITARY DESCRIPTION.	DATES.	OPERATIONS, OPERATOR, RESULT.
1	Allen, C. W., Pt., C, 1st Maine H. A., age 23.	June 18, '64.	Left; double flap; by Surg. J. S. Jamison, 86th N. Y. Died July 22, '64, pyæmia. <i>Specs.</i> 2886, 3134.	37	Cole, R., Pt., II, 40th Ohio.	June 1, '64.	Left; by Surg. S. H. Kersey, 36th Indiana. Died June 30, 1864.
2	Allen, F. A., Corp'l, G, 20th Massachusetts.	Sept. 17, '62.	Right; re-amp. at shoulder joint Oct. 12. Died Oct. 25, 1862, pyæmia. <i>Spec.</i> 267.	38	Collins, D. F., Pt., G, 155th N. Y., age 20.	June 3, '61.	Left. Died July 7, 1864, typhoid fever.
3	Armitinger, C., Pt., K, 36th Wisconsin.	June 3, '64.	Right; circ.; by Surg. C. Miller, 36th Wis. Died June 22, 1864, pyæmia.	39	Collins, W., Capt., G, 5th N. Hampshire, age 35.	April 5, '65.	Right; flap. Died April 29, 1865, pyæmia.
4	Atkinson, M., 1st Serg't, G, 1st N. J., age 27.	May 3, '64.	Right; flap. Died May 25, 1863, pyæmia.	40	Consuegra, J., Pt., D, 2d New York, age 20.	May 20, '64.	Left; circular. Died May 31, 1864, exhaustion.
5	Baldwin, G. E., Pt., B, 14th N. Y. S. M., age 22.	May 8, '64.	Right; circular; by A. Surg. J. T. Duffield, 7th Ind. Died June 13, 1864, typhoid fever.	41	Cornick, J. M., Pt., A, 90th N. Y.	Mar. 30, '65.	Died.
6	Barnett, W. H., Pt., B, 15th New Jersey.	June 1, '64.	Right; flap; by A. Surg. G. R. Sullivan, 15th N. J. Died July 15, 1864, pyæmia.	42	Davis, C. H., Pt., E, 27th Mass., age 32.	June 18, '64.	Right; by Surg. G. T. Stevens, 77th N. Y. Died July 2, '64, pyæmia.
7	Barr, S. A., Pt., I, 110th Ohio, age 20.	July 9, '64.	Right; circular. Died Aug. 12, 1864, pyæmia.	43	Dorse, P. H., Pt., II, 100th Illinois.	June 14, '64.	Left; by Surg. E. B. Glick, 40th Indiana. Died August 13, 1864.
8	Barrow, W. H., Pt., A, 66th N. C., age 18.	Mar. 10, '65.	Left; circular; by A. Surg. R. G. Harrison, 120th Ind. Died April 3, 1865, typhoid fever.	44	Dudley, S., Pt., E, 36th Indiana.	Sept. 19, '61.	Left. Died January 6, 1864.
9	Bartholomew, N. G., Capt., E, 76th New York.	May 5, '64.	Right; circular. Died Aug. 12, 1864, pyæmia.	45	Echelberry, P., Pt., F, 47th Ohio, age 21.	Dec. 13, '64.	Right; circ.; by Surg. S. P. Bonner, 47th Ohio. Died Jan. 11, 1865, pyæmia.
10	Baryan, L., Pt., A, 75th New York.	Sept. 19, '64.	Left. Died Sept. 19, 1864.	46	Ferris, G. W., Corp'l, A, 36th Wisconsin, age 34.	May 27, '64.	Left; circ.; by Surg. N. Hayward, 20th Mass.; (amp. right forearm June 12.) Died June 17, 1864, pyæmia.
11	Bell, E., Pt., G, 62d Ohio, age 30.	April 9, '65.	Right; by Surg. C. M. Clark, 39th Ill. Died May 31, 1865, phthisis pulmonalis.	47	Fitzgerald, P., Pt., C, 4th Artillery, age 25.	April 9, '65.	Right; ant.-post. flap. Died June 19, 1865, typhoid fever.
12	Berry, C., Pt., E, 70th Indiana.	June 16, '64.	Left. Died June 30, 1864.	48	Gate, R., Corp'l, B, 25th Texas, age 25.	Nov. 30, '64.	Right; circular. Died April 28, 1865, chronic diarrhœa.
13	Black, J. W., Pt., I, 40th Tennessee, age 21.	Dec. 15, '64.	Left. Died December 22, 1864.	49	Giedner, T., Corp'l, G, 34th Illinois.	May 14, '64.	Right; circular. Died June 22, 1864, pyæmia.
14	Bowker, J., Adj't, 179th New York, age 24.	Sept. 30, '64.	Left; flap; by Surg. T. M. Flandran, 146th N. Y. Died Oct. 26, 1864.	50	Glitzam, C., Pt., E, 77th Pennsylvania.	June 27, '64.	Right; by Surg. S. H. Kersey, 36th Ind. Died July 1, 1864.
15	Braunau, I. M., Corp'l, B, 95th Pa.	Dec. 12, '62.	Died December 14, 1862.	51	Goodhart, J. F., Pt., F, 88th Penn., age 29.	May 10, '64.	Left; circular. Died June 5, '64, hæmorrhage.
16	Brigham, J. S., Pt., K, 17th Maine, age 19.	June 1, '64.	Right; ant.-post. flap. Died July 25, 1864, exhaustion.	52	Graybill, S., Corp'l, C, 41st Ohio, age 21.	May 27, '64.	Left; circular. Died June 15, 1864, chronic diarrhœa.
17	Burton, L., Pt., B, 43d Colored Troops.	July 17, '64.	Left; circ.; by Surg. J. P. Prince, 36th Mass. Died Aug. 5, 1864.	53	Grover, M., Pt., I, 2d Vermont, age 28.	May 19, '64.	Left; circular. Died June 19, '64, "from wound and fever."
18	Butler, F., Pt., F, 8th Maine, age 25.	July 7, '64.	Left; lateral flap. Died July 5, 1864.	54	Halsey, A., Corp'l, K, 7th New Jersey.	June 16, '64.	Left. Died June 21, 1864.
19	Caboon, S., Pt., A, 58th Mass., age 22.	May 6, '64.	Right. Died July 25, 1864.	55	Halstead, C., Pt., A, 1st N. Y. Cav., age 28.	June 1, '64.	Circular; by Surg. B. F. Kaealand, 19th N. Y. C. Died July 2, 1864.
20	Calvin, W. H., Pt., D, 91st Indiana, age 25.	Nov. 30, '64.	Left; ant.-post. flaps; by A. Surg. J. Tolerton, 129th Ind. Died Feb. 13, 1865, chronic diarrhœa.	56	Haltzee, F., Pt., F, 16th N. Y. Artillery, age 21.	Sept. 1, '64.	Right and left; by Surg. M. S. Kittinger, 100th N. Y. Died Oct. 9, 1864, exhaustion.
21	Canfield, J., Pt., I, 5th Michigan, age 20.	May 6, '64.	Right; flap; by Surg. H. F. Lyster, 5th Mich. Died June 9, '64, typhoid fever.	57	Harrington, G. M., Pt., A, 12th Infantry.	Oct. 1, '64.	Right; by Surg. A. A. White, 8th Md. Died Dec. 28, 1864.
22	Carlow, W. H., Pt., G, 121st N. Y., age 23.	Oct. 19, '64.	Right. Died November 8, 1864; pyæmia.	58	Hathaway, L., Pt., M, 2d Iowa Cavalry.	Dec. 15, '64.	Right; circular. Died Dec. 23, 1864, inflammation of lung.
23	Carpenter, O. F., Pt., B, 25th Mass., age 20.	June 3, '64.	Right; circular. Died June 16, 1864, pyæmia.	59	Healey, M., Pt., F, 1st Mass., age 25.	June 10, '63.	Left; oval flap; by A. Surg. F. B. Kimball, 7th N. H. Died Feb. 13, 1865, exhaustion.
24	Carroll, M., Corp., K, 81st Pennsylvania, age 22.	June 4, '64.	Right; ant.-post. flaps; by Surg. J. W. Wishart, 140th Pa.; (also exc. head left humerus.) Died June 14, 1864, exhaustion.	60	Hemphill, R. W., Serg't, II, 203d Penn., age 36.	Jan. 15, '65.	Left; flap. Died June 18, 1864, pyæmia.
25	Chapman, O. C., Pt., E, 2d Michigan, age 47.	June 17, '64.	Left; circular. Died July 22, '64.	61	Holden, J., Pt., E, 2d Arkansas, age 22.	May 14, '64.	Left. Furloughed, and died at home.
26	Clark, C. T., Pt., I, 111th Illinois, age 49.	Aug. 31, '64.	Right; flap; by Surg. I. N. Barnes, 116 Ill. Died March 26, 1865, pneumonic.	62	Hunter, C., Serg't, F, 10th New York, age 28.	May 6, '64.	Left. Died July 2, 1864, debility.
27	Clark, J., Pt., B, 99th Pennsylvania.	Dec. 13, '62.	Right. Died January 14, 1863.	63	Jackson, A. T., 1st Lt., F, 1st Michigan Cavalry.	Sept. 19, '64.	Left; circ.; by Surg. S. R. Wooster, 1st Mich. C. Died Nov. 2, 1864, typhoid fever.
28	Clark, J., Corp., K, 14th N. Y. H y Art., age 17.	May 8, '64.	Left; double flap. Died June 1, 1864, typhoid fever.	64	Jay, B. H., Serg't-Maj., 38th Ohio.	Nov. 25, '63.	Left. Died Dec. 21, 1863.
29	Clark, R., Pt., D, 13th Colored Troops, age 18.	Dec. 16, '64.	Left; flap; by A. A. Surg. I. S. Giltner; (amp. right arm, upper third.) Died Dec. 19, 1864.	65	Jewell, W. B., Pt., B, 21st Kentucky.	Jan. 2, '63.	Left; by Surg. C. J. Walton, 21st Ky.; (also wound of neck and face.) Died Jan. 8, 1863.
30	Clarke, O. G., Pt., B, 10th Vermont, age 20.	May 12, '64.	Right; circular. Died July 28, 1864.	66	Johnson, S. H., Pt., D, 19th Maine, age 30.	May 6, '64.	Right; circular; by Surg. W. J. Burr, 42d N. Y. Died July 22, 1864, debility.
31	Cline, E., Pt., E, 12th N. Carolina.	Sept. 19, '64.	Right; circular; by Surg. G. L. Miller, C. S. A. Died Oct. 14, '64, pyæmia.	67	Kingsbury, E. B., Capt., I, 125th Ill., age 27.	July 5, '64.	Right; flap. Died Aug. 19, 1864.
32	Coachman, E. F., Serg't, A, Hampton Legion.	May 31, '64.	Flap; by Surg. G. Grant, U. S. V. Died August 6, 1862.	68	Knight, J., Pt., K, 16th Penn. Cav., age 32.	Aug. 16, '64.	Left; circular. Died Sept. 19, 1864, pyæmia.
33	Cochran, R. A., Corp., F, 102d Pa., age 28.	May 15, '64.	Left; flap. Died May 27, 1864, anemia.	69	Knowles, W. F., Pt., G, 50th Penn., age 27.	May 12, '64.	Right; by Surg. A. F. Whelan, 1st Mich. S. S. Died July 13, 1864, exhaustion.
34	Cock, A., Pt., H, 42d Tennessee, age 31.	Dec. 16, '64.	Right; circular. Died January 7, 1865.	70	Koblen, G., Pt., E, 40th New York, age 29.	May 6, '64.	Left. Diarrhœa, erysipelas, and hæmorrhage. Died June 20, '64. <i>Spec.</i> 2687.
35	Coffett, A. C., Pt., C, 71st Ohio, age 32.	Dec. 17, '64.	Right; circular; by A. A. Surg. K. McNeilly. Died Dec. 31, '64.	71	Kruesen, W. E., Pt., E, 2d N. Y. H. A., age 29.	Mar. 31, '65.	Left; flap; hæmorrhage. Died Dec. 25, '63, pyæmia. <i>Spec.</i> 1987.
36	Colby, G. H., Corp., D, 1st N. H. Cav.	April 9, '64.	Right; circular. Died April 30, 1864.	72	Lake, J. F., Corp'l, A, 14th New Jersey, age 44.	Nov. 27, '63.	Right; circular. Died Jan. 3, '63, pyæmia.
				73	Ledwidge, F., Pt., D, 69th New York, age 23.	Dec. 13, '62.	Right; by Surg. S. K. Crawford, 50th Ohio. Died Aug. 24, 1864.
				74	Leginby, J. Pt., F, 107th Illinois, age 19.	Aug. 5, '64.	



No.	NAME, AGE, AND MILITARY DESCRIPTION.	DATES.	OPERATIONS, OPERATOR, RESULT.	No.	NAME, AGE, AND MILITARY DESCRIPTION.	DATES.	OPERATIONS, OPERATOR, RESULT.
76	Lutz, A., Pt., H, 64th Ohio, age 29.	June 27, '64.	Right; circular. Died Sept. 9, 1864, chronic diarrhoea.	112	Shake, W. J., Serg't, E, 13th Kentucky, age 29.	July 20, '64.	Right; circular. Died August 29, 1864, pyæmia.
77	Mapes, P., Pt., K, 2d Mich., age 52.	June 1, '64.	Left. Died June 11, 1864.	113	Shivers, W. D., Pt., E, 1st S. C. Cavalry, age 21.	May 4, '63.	Left. Died Aug. 14, '63, pyæmia.
78	Marlnee, J. D., Pt., B, 13th Indiana, age 43.	June 24, '64.	Right. Died July 6, 1864, tetanus.	114	Sigourney, F., Pt., G, 14th N. Y. H. A., age 17.	June 16, '64.	Right; circular. Died July 19, 1864.
79	Martin, P. J., Pt., B, 28th N. Y., age 21.	Sept. 29, '64.	Right; flap. Died Nov. 30, 1864, exhaustion and pneumonia.	115	Silver, M., Pt., F, 10th Connecticut.	April 2, '65.	Left; flap; by Surg. H. C. Levensaler, 8th Me. Died during operation; effects of chloroform.
80	McClellan, E., Pt., D, 6th Maine, age 30.	May 10, '64.	Left; circular; hæmorrhage; re-amp, June 17. Died Aug. 13, 1864, exhaustion.	116	Sims, T., Pt., C, 39th Colored Troops, age 25.	Aug. 15, '64.	Left; circular. Died Sept. 8, 1864, phthisis.
81	McCobb, G. B., Pt., F, 31st Maine, age 16.	May 6, '64.	Right; ant.-post. flap. Died Aug. 6, '64.	117	Smith, J. M., Pt., 39th Alabama.	Sept. 19, '64.	Died. Stump became erysipelalous.
82	McKeavy, W., Pt., F, 63d New York, age 27.	May 13, '64.	Right. Died July 3, 1864.	118	Smith, S. J., Pt., B, 170th New York, age 37.	May 24, '64.	Left; circ.; by Surg. W. J. Burr, 42d N. Y. Died June 20, 1864, exhaustion and pyæmia.
83	McMillan, J. B., Pt., E, 183d Penn., age 48.	June 4, '64.	Left; double flap. Died June 27, '64.	119	Speer, H., Lieut., II, 78th Ohio, age 21.	July 20, '64.	Left; circ.; by Surg. J. S. Reeves, 78th Ohio. Died Aug. 29, 1864.
84	McMillen, S., Lt., K, 53d Ohio.	July 22, '64.	Right; by Surg. I. N. Barnes, 110th Ill. Died Aug. 3, 1864.	120	Stanford, V. B., Pt., A, 1st Ohio Light Artillery.	May 15, '64.	Right; by Surg. E. B. Gilick, 40th Ind.; (amp. left hand.) Died June 4, 1864.
85	Mesimer, E., Pt., G, 149th Pennsylvania, age 26.	May 27, '64.	Right; circular. Died July 18, 1864.	121	Staufer, D. G., Pt., B, 84th Pennsylvania.	Dec. 13, '62.	Died January 8, 1863.
86	Miller, J., Pt., F, 90th Pennsylvania.	Aug. 19, '64.	Died Aug. 23, 1864.	122	Steele, L. W., Pt., I, 1st Conn. Artillery, age 22.	June 30, '64.	Left. Died July 14, 1864.
87	Moore, W. L., Pt., K, 97th Pennsylvania.	May 20, '64.	Right. Died June 17, 1864.	123	Stemang, C., Pt., F, 8th N. J., age 36.	May 5, '64.	Left. Died July 8, 1864, pyæmia.
88	Morford, J. W., Serg't, D, 2d Md. E. S., age 24.	Sept. 3, '64.	Left; flap. Died Sept. 30, 1864.	124	Storers, J., Pt., II, 203d Pennsylvania, age 23.	Jan. 15, '65.	Left; circ.; by A.-Surg. F. B. Kimball, 3d N. H. Died Feb. 22, 1865, exhaustion.
89	Mosier, L. M., Pt., C, 37th Massachusetts, age 24.	May 24, '64.	Left; circular; by Surg. C. F. Crehore, 37th Mass. Died June 19, 1864, pyæmia.	125	Sullivan, B., Pt., I, 3d Missouri.	July 28, '64.	Left; by Surg. A. Sabine, 76th Ohio. Died Aug. 26, 1864.
90	Nichols, J., Pt., I, 141st Penn., age 30.	May 3, '62.	Right. Died May 19, 1863, of tetanus.	126	Sweitzer, S., Pt., B, 3d Kentucky, age 25.	June 1, '64.	Right; flap; by Surg. J. B. Burns, 3d Ky. Died June 23, 1864, pyæmia.
91	Nowland, W., Pt., II, 16th New York.	Sept. 14, '62.	Right; flap; by A. Surg. II. A. DuBois, U. S. A.; (also wound of left lung.) Died Sept. 17, 1862.	127	Taylor, F., Pt., A, 1st N. C. A. (colored), age 27.	Mar. 12, '65.	Right; circular. Died May 29, 1865, exhaustion.
92	Ordway, E., Pt., F, 3d Vermont, age 21.	May 12, '64.	Right. Died June 12, 1864, pyæmia.	128	Temple, T. B., Pt., A, 8th N. C., age 29.	June 14, '64.	Left; flap; erysipelas. Died July 31, 1864, exhaustion.
93	Osborne, L. F., Pt., I, 1st Conn. Hvy Art.	June 23, '64.	Right. Died July 26, 1864.	129	Troy, P., Corp'l, G, 2d Conn., age 26.	Sept. 19, '64.	Right; circular; by Surg. W. A. Barry, 9th Pa. Died Oct. 19, 1864, secondary hæmorrhage.
94	P——, G. R., Pt., F, 3d Maine, age 21.	May 31, '62.	Left; hæmorrhage. Died Aug. 5, '62. <i>Specs.</i> 4338, 4339, and 1827.	130	Wachter, J., Pt., E, 52d New York.	June 2, '62.	Left; circular. Died June 10, 1862, gangrene.
95	Pinney, A. H., Capt., II, 27th Colored Troops.	July 30, '64.	Right; circular; by Surg. G. J. Potts, 23d C. T.; (also amp. leg.) Died August 8, 1864.	131	Wagner, O., 1st Lieut. Topographical Engineers.	April 17, '62.	Left; circ.; by Surg. O. A. Judson, U. S. V. Died April 21, 1862.
96	Pratt, G. H., Pt., G, 38th Massachusetts.	Sept. 19, '64.	Left. Died October 23, 1864.	132	Walbridge, D. S., Lt., A, 11th Vermont, age 31.	June 4, '64.	Right; ant.-post. flap; by Surg. C. B. Parks, 11th Vt.; hæmorrhage. Died June 19, 1864, exhaustion.
97	Putnam, C. O. M., Corp., H, 12th New Jersey.	May 5, '64.	Right. Died May 24, 1864.	133	Ward, E. E., Pt., F, 6th Mich. Cav., age 27.	April 1, '65.	Left. Died April 27, 1865, pneumonia.
98	Reynolds, J., Corp., A, 164th N. Y., age 34.	June 3, '64.	Right. Died July 1, 1864, pyæmia.	134	Wendorf, F., Pt., B, 26th Wisconsin, age 29.	June 22, '64.	Left; ant.-post. flap. Died July 26, 1864, enteric fever.
99	Richards, L. K., Pt., E, 33d Massachusetts.	May 25, '64.	Right; by Surg. J. W. Hastings, 33d Mass. Died June 21, 1864.	135	Westfall, C. M., Pt., D, 24th Iowa.	Sept. 19, '64.	Right; circular. Died October 14, 1864, gangrene.
100	Riddle, J. S., Capt., C, 127th Illinois.	May 19, '63.	Left. Died July 22, 1863.	136	Whitehead, H., Corp., I, 191st Penn., age 24.	Feb. 4, '65.	Right; circular; by Surg. W. Lyons, 191st Penn. Died March 1, 1865, pyæmia.
101	Rief, C., Pt., D, 2d Missouri, aged 25.	Nov. 25, '63.	Right. Died January 10, 1864.	137	Wilder, H., Pt., G, 117th Illinois, age 32.	Dec. 16, '64.	Left; flap; by Surg. M. Wiley, 117th Ill. Died Jan. 15, 1865, typhoid fever.
102	Rowland, J. G., Serg't, K, 111th Illinois, age 35.	Aug. 6, '64.	Left; by Surg. C. S. Friuk, U. S. V. Died August 24, 1864.	138	Williams, A. H., Pt., D, 97th N. Y., age 17.	May 10, '64.	Left; circular. Died May 23, 1864.
103	Rumey, J., Pt., 18th Indiana Battery, age 24.	Dec. 29, '63.	Left; flap; by Surg. O. M. Robins, 9th Pa. Cav. Died July 2, 1864, chronic diarrhoea.	139	Williams, P., Pt., G, 113th Ohio, age 35.	June 27, '64.	Right; circular; by Surg. S. H. Kersey, 36th Ind. Died Sept. 11, 1864, acute bronchitis.
104	Russell, N. H., Pt., B, 31st Colored Troops.	July 30, '64.	Right; circ.; by Surg. D. Mackay, 29th C. T. Died Sept. 20, 1864.	140	Wills, J. H., Pt., H, 23d Col'd Troops, age 21.	July 30, '64.	Right; flap; by Surg. G. J. Potts, 23d C. T. Died May 9, 1865, inflammation of pleura.
105	Sampler, B., Pt., A, 1st Delaware.	July 3, '63.	Right; by Surg. C. S. Wood, 60th N. Y. Died August 1, 1863.	141	Woods, J. G., Pt., E, 59th Mass., age 45.	June 3, '64.	Left. Died June 29, 1864, pyæmia.
106	Schimer, E., Pt., K, 151st Pennsylvania, age 21.	July 1, '63.	Double flap. Died July 26, 1863.	142	Wolverton, J. D., Pt., D, 11th Ohio.	Nov. 10, '61.	Right. Died December 25, 1861, pyæmia.
107	Schofield, C., Pt., A, 1st Mass. Hvy Art., age 26.	June 16, '64.	Right; circular. Died Sept. 6, 1864, chronic diarrhoea.	143	Yeatman, R., Pt., D, 40th Virginia, age 25.	Aug. 27, '64.	Right; circular; by Asst. Surg. W. P. Richardson, C. S. A. Died September 27, 1864.
108	Schmucker, G. W., Pt., C, 31th Illinois.	May 14, '64.	Right. Died June 27, 1864.				
109	Scott, J. N., Confederate prisoner, age 42.	June 23, '64.	Left. Died August 17, 1864, exhaustion.				
110	Scott, P. H., Pt., E, 121st New York, age 32.	Oct. 19, '64.	Left; circular. Died December 14, 1864, typhoid pneumonia.				
111	Shadeek, W., Corp., C, 156th New York.	Sept. 19, '64.	Right; circular. Died October 22, 1864, gangrene.				

The operations were practised on one hundred and thirty-two Union and eleven Confederate soldiers. Seventy amputations were on the right and sixty-four on the left side, this particular being unnoticed in the nine remaining instances. Fourteen of the patients had serious wounds in other regions, and seven underwent synchronous operations of magnitude—two having the opposite arm amputated, one the opposite shoulder excised, another losing a hand, another a leg, a sixth the greater part of the hand, and the seventh having splinters of the trochanter gouged away. There were two re-amputations, and other consecutive major operations were performed in several cases.







Stauch, pins

HOSPITAL CANCRENE OF AN ARM STUMP

J. B. Baer, M.D.

**3. Primary Amputations in the Lower Third of the Arm.**—Contrary to the rule that has come to be regarded almost as axiomatic,—that the gravity of amputations of the extremities steadily augments in proportion as the incisions approach the trunk,—the mortality rate of amputations in the lower third greatly exceeded that of amputations in the middle and upper thirds. Although the number of operations was less than half as in either of the other regions, yet a series of five hundred and twelve cases would appear sufficient to afford a fair average of results. An analysis of the operations will suggest some explanation of this anomalous fact, even if failing fully to account for it.

§ *Successful Cases.*—Four hundred and six amputations in the lower third of the arm for the effects of shot injuries of the forearm or elbow joint had favorable results.

PLATE XV, opposite, is from a water-color drawing of a gangrenous stump of a paroled soldier, who had undergone primary amputation at the lower third of the arm. The drawing was prepared at Annapolis, by Mr. Stauch, in August, 1863.

CASE 1662.—Private Milton E. Wallen, aged 41 years, was enrolled at Albany, July 27, 1861, in Co. C, 1st Kentucky Cavalry. The muster-out roll of his regiment refers to his being captured near Lawrenceville, Georgia, in August, 1864, and released at Goldsboro', in February, 1865. There has been much discussion regarding the identification of this man with the paroled prisoner who answered to this name and military description. Surgeon B. A. Vanderkief, U. S. V., reports that: "Private Milton Wallen, Co. A, 1st Kentucky Cavalry, was admitted to the general hospital August 3, 1863. He states that he was taken prisoner on Cumberland River, June 1, 1863, and while in prison at Richmond was shot by one of the guards with a minié ball, which entered the upper third of the right forearm posteriorly, fracturing the bones and implicating the elbow joint, and that amputation was performed, on the same day, above the elbow. When admitted the patient was feeble, but, on the whole, doing well. On August 20th, the stump commenced to take on unhealthy action, and by the 24th the entire stump was attacked by hospital gangrene, the flaps being rapidly disorganized and the bone protruding. The treatment was limited to the strictest attention to hygienic measures, with an allowance of an abundance of the invigorating salt air from the bay." At this period a sketch in color of the gangrenous stump (PLATE XV) was prepared by Hospital Steward Stauch, sent from Washington with that object. "For a few days afterward the stump was dressed with charcoal and yeast poultices, and a generous diet and an ample allowance of ale and other stimulants was allowed. By August 30, 1863, the sloughing process was entirely arrested, and from this date the patient steadily improved. In October he was furloughed from the hospital, and was reported as having deserted on furlough, April 5, 1864." In 1873, he made application for a pension, stating that "he was captured at Rowena, on the Cumberland River, May 26, 1863, and carried to Atlanta, Georgia, then from there to Richmond, and placed in Castle Thunder, and while there was shot by the guards, July 4, 1863." The affidavits of two former company comrades were filed, stating that they knew that this man was captured near Camp Nelson, on the Cumberland River, while attached to Colonel Haskins's command, at Albany, Kentucky.

CASE 1663.—Private C. Canty, 1st Massachusetts Heavy Artillery, aged 21 years, received a gunshot fracture of the left elbow before Petersburg, June 18, 1864. Amputation was performed at the hospital of the 3d division, Second Corps, by Surgeon G. M. Brennan, 1st United States Sharpshooters. June 29th, the patient reached the First Division Hospital, at Alexandria, whence Surgeon C. Page, U. S. A., reported: "Amputation of left arm at lower third; operation performed on the field, apparently by circular method. Doing well. Treatment: Tonics and stimulants." On November 28, 1864, the patient was discharged from service and pensioned. In his application for commutation, 1870, he described the stump as being "healthy but extremely tender." The pensioner was paid on June 4, 1875. The specimen (FIG. 523) was received from the Army of the Potomac, and consists of the "bones of the left elbow after primary amputation at the lowest third of the arm, showing the olecranon badly fractured, the outer condyle carried away, and the head of the radius clipped."—*Cat. Surg. Sect.*, 1866, p. 147.

CASE 1664.—Corporal F. R. Leach, Co. D, 1st Maine Heavy Artillery, aged 23 years, received a shot fracture of the right elbow at Petersburg, September 9, 1864, for which amputation was performed by Surgeon J. S. Jamison, 86th New York, at the field station of the 3d division, Second Corps. The specimen (FIG. 524) was forwarded to the Museum by the operator, and consists of "the bones of the right elbow, amputated in the lower third of the humerus for a perforating fracture directly over the joint. The bullet entered from before, clipped the conoidal process of the ulna, carried away the central portion of the trochlea, shattered the olecranon, and caused a vertical fracture of the humerus, which terminated in a transverse one two inches above the condyle. The forearm was probably partly flexed at the time of the injury." (*Cat. Surg. Sect.*, 1866, p. 164.) Two days after the injury, the wounded man was transferred to the Second Corps dépôt hospital at City Point, and, October 1st, he was admitted to the First Division Hospital, Alexandria. Surgeon E. Bentley, U. S. V., reported: "Amputation at lower third of right humerus by flap operation, performed at a field hospital. Chloroform used. Wound healing. Stump looks well. Patient furloughed on November 1st." He was discharged May 5, 1865, and pensioned. The pensioner was paid June 4, 1875.

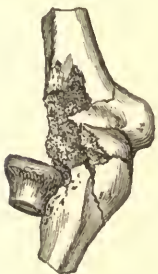

FIG. 523.—Shot fracture of the left elbow. *Spec.* 3023.

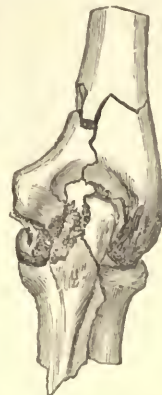

FIG. 524.—Posterior view of a shot fracture of the right elbow. *Spec.* 4168.



In eight instances in this series, amputation was practised because of wounds inflicted by solid cannon shot, and in twenty-six instances, for comminutions by shell fragments; but fracture at or near the elbow by musket balls was the predominating form of injury:

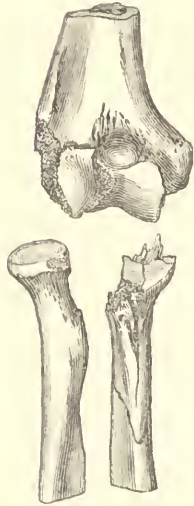

FIG. 525.—Shot comminution of the articular extremities of the bones of right elbow. *Spec.* 3219.

CASE 1665.—Captain B. B. Brown, Co. I, 1st New Jersey, aged 37 years, was wounded at Spottsylvania, May 12, 1864, by a minié ball, which struck upon the internal portion of the right elbow joint, passing transversely through, fracturing and comminuting the superior two and a half inches of the ulna, grazing the articular surface of the radius, and comminuting the external trochlea of the humerus. The shot was received in the act of charging, from a distance of about fifty yards. Amputation was performed the same day, at the field hospital, 1st division, Sixth Corps, by Surgeon L. W. Oakley, 2d New Jersey, who contributed the specimen (FIG. 525), consisting of “the bones of the right elbow, amputated at the lowest third of the arm.” The patient entered the Seminary Hospital, Georgetown, May 25th, where Surgeon H. W. Ducachet, U. S. V., recorded: “Circular amputation at lower third.” The stump healed kindly, but about two months after the injury was received the Captain was accidentally thrown from a wagon, causing protrusion of the humerus through the integuments. After this, however, the stump again healed kindly. Captain Brown was mustered out of service on June 23, 1864, but was subsequently appointed an officer of the 10th regiment, Veteran Reserve Corps, and ultimately discharged on July 23, 1867, and pensioned. Examiner B. A. Watson, of Jersey City, November 9, 1867, certified: “Arm amputated at junction of upper third with middle. The stump is very sensitive, so much so that an artificial limb cannot be worn.” The pensioner was paid June 4, 1875.

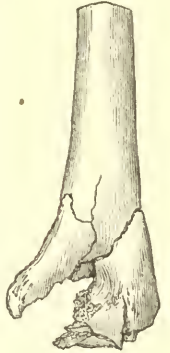


FIG. 526.—Shot comminution of the lower portion of the left humerus. *Spec.* 2917.

CASE 1666.—Private W. Acker, Co. I, 148th Pennsylvania, aged 21 years, received a shot fracture of the right arm at Cold Harbor, June 3, 1864. Amputation at the lower third was performed at a field hospital of the 1st division of the Second Corps, by Surgeon D. E. Kelsey, 64th New York, who contributed the specimen (FIG. 526), which consists of “the lower portion of the humerus, showing double oblique fracture just above the condyles, the inner articular surface having been carried away by a conoidal ball.” (*Cat. Surg. Sect.*, 1866, p. 147.) The patient was admitted to Lincoln Hospital on June 11th, and was transferred to Broad and Cherry Streets Hospital, Philadelphia, about four months afterward. On January 6, 1865, he was discharged from service and pensioned. The pensioner was paid on March 4, 1875.

CASE 1667.—Private E. McKnight, Co. D, 2d Massachusetts Cavalry, aged 30, was wounded at Opequan Creek, September 13, 1864, and conveyed to hospital at Sandy Hook. Acting Staff Surgeon N. F. Graham reported: “Gunshot wound of left elbow joint by minié ball, producing much comminution of the joint and shafts of the bones. Double flap amputation at lower third of humerus was performed, on September 14th, by Acting Assistant Surgeon J. R. Uhler. Chloroform used. The patient was debilitated from loss of blood before the operation. Analeptic treatment and simple dressings were employed. Patient transferred on September 17th.” Assistant Surgeon R. F. Weir, U. S. A., reported his admission into Frederick Hospital, and transfer therefrom to New York on December 20th, with the remark that necrosis was going on at the date of transfer. On December 21st, the patient was admitted to Central Park Hospital, New York City, whence Surgeon J. J. Milhau, U. S. A., reported, March 28, 1865, “that the stump was much swollen and inflamed, an abscess having formed three inches above the end, discharging freely, and that an incision was made through the end of the stump and four inches of dead bone removed by Acting Assistant Surgeon F. G. H. Bradford.” The specimen, represented by the figure in the lower left hand part of PLATE XLVII, was contributed by the operator, and consists of the tubular sequestrum. Acting Assistant Surgeon G. F. Shradly contributed a cast of the stump (FIG. 527), which shows the skin to have been divided into bilateral flaps and the cicatrix deeply depressed in the centre, but apparently firm. (See *Cat. Surg. Sect.*, 1866, p. 543.) The patient was discharged from DeCamp Hospital on September 11, 1865, and pensioned. In his application for commutation, in 1870, he described the stump as being “sound and healthy.” He was paid March 4, 1875.

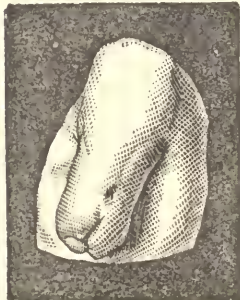


FIG. 527.—Cast of stump of left arm. *Spec.* 1403.

The primary successful amputations at the lower third were practised on three hundred and sixty Union, and forty-six Confederate soldiers. With three exceptions, the limb removed was specified in the four hundred and six amputations, showing a slight predominance of operations on the *right* side, or 212, against 191 amputations of the left arm. The circular method was followed in one hundred and twenty-eight, and the flap method in two hundred operations, this point being unmentioned in seventy-eight cases. Twenty-nine patients were returned to modified duty, three hundred and thirty-seven were discharged, and, for the most part, pensioned and supplied with artificial limbs, twenty-seven were exchanged or paroled, and thirteen remained unaccounted for, on furlough or other absence.

## TABLE LXXII.

*Condensed Summary of Four Hundred and Six Cases of Recovery after Primary Amputation in the Lower Third of the Shaft of the Humerus.*

NO.	NAME, AGE, AND MILITARY DESCRIPTION.	DATES.	OPERATIONS, OPERATOR, RESULT.	NO.	NAME, AGE, AND MILITARY DESCRIPTION.	DATES.	OPERATIONS, OPERATOR, RESULT.
1	Aber, D., Pt., D, 111th Pennsylvania.	Sept 17, '62.	Right; flap. Discharged December 27, 1862.	40	Brown, J. R., Serg't, D, 11th Penn., age 21.	June 18, '64.	Right; flap. Duty Nov. 24, 1864; pensioned.
2	Acher, M., Pt., G, 32d Ohio, age 25.	Aug. 21, '64.	Right; flap; by Surg. A. H. Brundage, 23d Ohio. Disch'd May 15, 1865; pensioned.	41	Brown, J. S., Corp'l, A, 70th Indiana, age 25.	May 15, '64.	Right; flap; by Surg. A. W. Reagan, 70th Ind. Disch'd Mar. 10, 1865; pensioned.
3	Acker, W., Pt., B, 148th Pennsylvania.	June 3, '64.	Right; by Surg. D. E. Kelsey, 64th N. Y. Dis'd Jan. 6, '65. <i>Spec.</i> 2847.	42	Brown, R. W., Corp'l, I, 61st Alabama, age 31.	Sept. 22, '64.	Right; flap; by Surg. Williams, 6th Ala. To Pro. Mar. April 1, '65.
4	Adams, S. H., Serg't, B, 26th Alabama, age 32.	July 1, '63.	Left; circular. Paroled September 25, 1863.	43	Buchanan, R., Pt., F, 1st Colored Troops, age 22.	June 15, '64.	Left; circular. Discharged Feb. 15, '64; pensioned.
5	Adcock, S., Pt., E, 136th Illinois, age 27.	May 22, '63.	Left; by Surg. L. K. Wilcox, 130th Ill. Dis'd Jan. 22, '64; pen'd.	44	Bush, B., Pt., H, 97th Ohio, age 24.	May 29, '64.	Right; flap; by Surg. E. B. Glick, 46th Ind. Disch'd May 31, 1865; pensioned.
6	Adkins, E., Pt., D, 112th Illinois, age 38.	Nov. 18, '63.	Right. Discharged April 21, 1864; pensioned.	45	Butler, G. B., Lieut., 3d Infantry.	July 4, '63.	Right. Ordered before a Retiring Board Nov. 3, 1863.
7	Adriance, J. A., Pt., D, 91st New York.	April 1, '65.	Right; by Surg. R. Morris, 91st N. Y. Dis'd July 31, '65; pen's'd.	46	Byrd, C., Corp'l, I, 33d Alabama, age 21.	Nov. 30, '64.	Right; flap. To Provost Marshal March 1, 1865.
8	Aldridge, H. W., Pt., D, 22d Kentucky, age 23.	May 5, '64.	Left; by Surg. V. H. Coffman, 34th Iowa. Dis'd July 25, '64; pen'd.	47	Byres, R. G., Serg't, G, 25d Virginia, age 24.	Mar. 25, '65.	Left; circular. Paroled June 18, 1865.
9	Alexander, W., Pt., C, 11th Wisconsin, age 20.	April 9, '65.	Right; flap. Discharged August 22, 1865.	48	Byrne, J., Pt., F, 123d New York, age 18.	July 20, '64.	Left; circular. Disch'd Jan. 19, 1865; pensioned.
10	Allston, T., Pt., D, 31st Colored Troops.	July 30, '64.	Right; circular; by Surg. G. J. Potts, 23d C. T. Dis'd Mar. 23, '65.	49	Calhoun, C. L., Corp'l, K, 118th Penn., age 35.	Mar. 29, '65.	Right; circular. Disch'd July 6, 1865; pensioned.
11	Antery, U., Pt., M, 6th Alabama, age 25.	July 1, '63.	Left. Paroled Sept. 23, 1863.	50	Call, G., Pt., D, 6th New York Cavalry, age 22.	July 28, '64.	Right; flap. Discharged June 18, 1865; pensioned.
12	Arbuckle, J. N., Pt., F, 123d Indiana, age 21.	Aug. 17, '64.	Left; flap; by Surg. W. P. Welborn, 80th Indiana. Disch'd May 9, 1865; pensioned.	51	Campbell, D., Serg't, K, 130th Penn., age 21.	Sept. 19, '64.	Left; flap; by Surg. S. F. Chapin, 139th Pa. Disch'd Mar. 16, '65; pensioned.
13	Arnold, D. S., Pt., G, 119th Pa., age 37.	May 12, '64.	Left; flap; by Surg. P. Leidy, 119th Pa. Dis'd Mar. 31, '65; pen's'd.	52	Camper, N., Pt., I, 4th Colored Troops, age 35.	June 15, '64.	Right; flap; by Surg. J. W. Mitchell, 4th C. T. Disch'd Mar. 20, '65.
14	Arnold, I. N., Pt., E, 69th Ohio, age 24.	Aug. 11, '64.	Left; circ.; by Surg. L. Slusser, 69th O. Dis'd Apr. 10, '65; pen'd.	53	Canfield, T. B., Pt., A, 1st Ill. Light. Art., age 21.	July 22, '64.	Right; circular. Disch'd Feb. 6, 1865; pensioned.
15	Ashmore, J., Pt., E, 5th New Jersey.	July 1, '62.	Right. Discharged September 7, 1864; pensioned.	54	Canty, C., Pt., L, 1st Mass. Artillery, age 21.	June 18, '64.	Left; circular; by Surg. G. M. Brennan, 1st U. S. S. S. Disch'd Nov. 23, '64; pen's'd. <i>Spec.</i> 3023.
16	Aspinwall, J., Pt., H, 12th Wisconsin, age 21.	Mar. 21, '65.	Right; flap. Discharged July 4, 1865.	55	Carey, J., Pt., B, 101st Indiana, age 24.	July 20, '64.	Left; circ.; by Surg. C. N. Fowler, 105th O. Disch'd Mar. 9, 1865; pensioned.
17	Ayres, B. F., Pt., A, 48th Indiana.	May 16, '63.	Left; flap; by Surg. L. J. Ham, 48th Ind. Dis'd Aug. 7, 1863; pen'd.	56	Carles, G. W., Pt., G, 21st Ohio.	Aug. 8, '63.	Right; by Surg. D. S. Young, 21st Ohio. Disch'd; pensioned.
18	Baker, P., Pt., B, 1st Louisiana.	May 27, '63.	Right; flap. Discharged June 25, 1864; pensioned.	57	Cassiday, P., Pt., E, 59th Massachusetts, age 23.	Sept. 30, '64.	Left; circ.; by Surg. W. C. Shurluck, 51st Pa. Disch'd Feb. 20, '65.
19	Balcom, W. J., Pt., F, 20th North Carolina.	July 1, '61.	Left. Duty Sept. 25, 1863.	58	Cather, W., Pt., E, 32d Illinois.	April 7, '62.	Right. Discharged Aug. 30, 1862.
20	Barau, C., Pt., F, 11th Vermont, age 21.	Aug. 21, '64.	Left; flap; by Surg. C. B. Park, 11th Vt. Dis'd Dec. 23, '64; pen'd.	59	Cayford, J., Pt., H, 19th Maine, age 35.	May 18, '64.	Left; flap; by Surg. N. Hayward, 20th Mass. Disch'd Oct. 31, '64; pensioned.
21	Barker, H., Pt., M, 8th N. Y. Artillery.	June 16, '64.	Right; circular; by Surg. A. Satterthwaite, 12th N. Y. Disch'd Oct. 11, 1864; pensioned.	60	Chapman, W., Pt., D, 45th Illinois.	June 26, '63.	Left; circ.; by Surg. E. L. Hill, 20th Ohio. Disch'd Aug. 9, '63; pensioned.
22	Barnes, J. J., Pt., E, 83d Penn., age 21.	June 3, '64.	Right; flap. Disch'd June 21, 1865.	61	Chappell, J., Pt., D, 53d Indiana, age 46.	June 27, '64.	Right. Disch'd June 8, 1865.
23	Barser, J., Pt., A, 38th Virginia, age 24.	Dec. 23, '64.	Circular. Healed.	62	Charmolle, C., Pt., B, 146th N. Y., age 34.	July 18, '64.	Right; flap; by Surg. T. M. Flandran, 146th N. Y. Disch'd April 26, 1865; pensioned.
24	Bayles, J., Pt., E, 5th Colored Troops, age 17.	Feb. 20, '65.	Right; circular; by Surg. M. Tucker, 3th C. T. Dis'd May 26, '65.	63	Chidester, J. W., Corp'l, H, 3d Va. Mounted Inf.	Aug. 26, '63.	Left; circular; by Surg. W. B. Wynne, 14th Pa. Cav. Disch'd March 1, 1864; pensioned.
25	Beek, J. A., Pt., 15th Co., 2d Battalion V. R. C., age 19.	Nov. 26, '64.	Left; ant.-post. flap; by Surg. J. R. Ludlow, U. S. V. Disch'd Aug. 25, 1865; pensioned.	64	Clark, H. M., Pt., D, 18th Michigan, age 27.	Oct. 28, '64.	Right; flap; by Surg. J. Evans, 15th Wis. Disch'd Mar. 24, 1865; pensioned.
26	Bell, G. H., Pt., H, 1st Mass. H'y Art., age 32.	May 19, '64.	Right; flap. Disch'd July 8, 1864; pensioned.	65	Clegg, J., Pt., I, 147th New York, age 35.	Feb. 6, '65.	Left. Disch'd March 11, 1865.
27	Belleville, L., Pt., H, 52d Massachusetts.	June 17, '63.	Right; by Surg. C. Robertson, 153th N. Y. Disch'd Aug. 14, 1863; pensioned.	66	Coburn, R., Pt., H, 83d Pennsylvania, age 18.	May 8, '64.	Left; double flap. Disch'd Aug. 23, 1864; pensioned.
28	Bishop, G. W., Pt., F, 6th Kentucky, age 23.	May 27, '64.	Right; flap. Duty Jan. 4, 1865; pensioned.	67	Cochrane, W. S., Pt., K, 11th Penn., age 42.	Feb. 6, '65.	Left; antero-post. flap. Disch'd June 16, 1865; pensioned.
29	Bissell, G. E., Capt., K, 5th Wisconsin, age 25.	May 6, '64.	Left; ant.-post. flap; by A. Surg. J. W. Davis, 5th Wis. Disch'd July 30, 1864; pensioned.	68	Coffman, S., Pt., E, 8th Mich., age 28.	May 5, '64.	Left; antero-post. flap. Disch'd August 11, 1864; pensioned.
30	Botts, J., Serg't, D, 15th Missouri, age 26.	May 14, '61.	Right; ant.-post. flap; by Surg. H. E. Hasse, 24th Wis. Disch'd Dec. 30, 1864; pensioned.	69	Colbridge, S. C., Serg't, G, 115th N. Y., age 22.	Sept. 29, '64.	Right; flap; by Surg. C. Macfarlane, 115th N. Y. Disch'd July 20, 1865. <i>Spec.</i> 2854.
31	Bowdish, L., Pt., B, 7th Mich., age 23.	May 6, '64.	Right; flap. Disch'd Aug. 24, '64; pensioned.	70	Combs, J. R., Pt., D, 127th Illinois.	July 28, '64.	Right; flap. Discharged June 3, 1865.
32	Brandt, D., Pt., I, 17th Penn. Cav., age 20.	Sept. 19, '64.	Right; flap. Disch'd Nov. 30, '64; pensioned.	71	Coner, C. W. H., Pt., I, 3d Mass. Cav., age 21.	Oct. 19, '64.	Right; flap. Disch'd July 4, 1865; pensioned.
33	Branby, T. S., Pt., K, 11th Ohio, age 30.	Feb. 25, '64.	Right; flap. Discharged April 12, 1864; pensioned.	72	Conner, C., Pt., B, 14th Ohio, age 27.	July 21, '64.	Left; flap. Disch'd June 27, '65.
34	Brantley, B. C., Serg't, B, 13th Georgia, age 20.	Sept. 19, '64.	Left; circ.; by A. Surg. Dorsey, 1st Md. C. Pro. Mar. Feb. 11, '65.	73	Connor, W., Pt., I, 6th N. Y. H. A., age 49.	June 22, '64.	Left; flap; by Surg. C. H. Porter, 6th N. Y. H. A. Disch'd May 17, 1865; pensioned.
35	Bremmer, J. A., Pt., G, 21st Wisconsin, age 21.	May 30, '64.	Right; flap; by Surg. J. R. Goodwin, 37th Ind. Disch'd May 31, 1865; pensioned.	74	Conway, J., Serg't, F, 164th N. Y., age 30.	May 18, '64.	Right; by Surg. J. W. Wishart, 140th Pa. Disch'd Dec. 29, '64; pensioned.
36	Brocket, J., Pt., A, 38th Col'd Troops, age 47.	Sept. 29, '64.	Left; circular. Discharged April 10, 1865; pensioned.	75	Cook, J. H., 1st Serg't, G, 16th Indiana.	May 20, '63.	Left; circular; by Surg. G. F. Chittenden, 16th Ind. Disch'd October 23, 1865; pensioned.
37	Brown, B. B., Capt., I, 1st New Jersey, age 37.	May 12, '64.	Right; circular; by Surg. L. W. Oakley, 2d N. J. To V. R. C.; pensioned. <i>Spec.</i> 3219.	76	Cook, W. L., Corp'l, B, 94th New York.	Aug. 30, '62.	Right; flap; by Surg. R. A. Everett, 16th Mich. Disch'd Sept. 13, '62; pensioned.
38	Brown, H. L., Corp'l, D, 24th Conn., age 21.	Oct. 27, '64.	Right; flap; by Surg. G. C. Jarvis, 7th Conn. Disch'd Mar. 8, 1865; pensioned.				
39	Brown, J. F., Pt., C, 10th Kentucky, age 26.	July 21, '64.	Left; flap. Duty Nov. 22, 1864; pensioned.				



No.	NAME, AGE, AND MILITARY DESCRIPTION.	DATES.	OPERATIONS, OPERATOR, RESULT.	No.	NAME, AGE, AND MILITARY DESCRIPTION.	DATES.	OPERATIONS, OPERATOR, RESULT.
77	Cooper, I., Capt., K, 99th Illinois.	May 17, '63.	Left; by Surg. J. H. Ledlie, 99th Ill. Discharged; pensioned.	114	Fike, S., Pt., K, 23d Ohio, age 28.	June 9, '64.	Left; double flap; by Surg. N. P. Graham, 12th Ohio; pensioned.
78	Correll, D., Pt., F, 26th Iowa.	Jan. 11, '63.	Right; flap. Disch'd April 4, '63; pensioned.	115	Fisher, G. B., 1st Serg't, A, 143d Pa., age 20.	June 28, '64.	Right; flap; by Surg. F. C. Reamer, 143d Pa. Dis'd Dec. 25, 1861; pensioned.
79	Craigier, G. W., Pt., F, 23d Virginia.	Sept. 19, '64.	Left; circular. To prison Oct. 25, 1864.	116	Flynn, M., Pt., 5th Mass. Battery, age 20.	April 2, '65.	Right; circ.; by Surg. W. Ingalls, 50th Mass. Discharged June 15, 1865; pensioned.
80	Crandall, R., Corp'l, F, 73d Indiana.	April 30, '63.	Right; by Surg. S. F. Myers, 73d Ind. Disch'd July 28, '63; pens'd.	117	Foggerty, M., Pt., G, 14th Mich., age 20.	Sept. 1, '64.	Right; flap; by Surg. E. Batwell, 14th Mich. Disch'd May 31, '65.
81	Cullen, J., Pt., E, 170th New York.	May 24, '64.	Left; flap; by Surg. N. Hayward, 20th Mass. To V. R. C. Jan. 6, 1865; pensioned.	118	Foley, J., Pt., B, 96th New York, age 41.	July 30, '64.	Left; circular. Discharged Dec. 27, 1864.
82	Cutler, G. H., Pt., E, 133d New York, age 20.	Oct. 15, '63.	Right; flap; by A. Surg. A. C. Walker, 133d N. Y. Disch'd April 6, 1864.	119	Foote, G. E., Pt., F, 147th New York, age 21.	May 12, '64.	Left; ant.-post. flap. Disch'd Nov. 25, '64; pens'd. Re-amp. Oct. '60.
83	Dake, F. E., 1st Serg't, F, 130th Penn.	May 3, '63.	Right; circular; by Surg. S. H. Plumb, 82d N. Y. Disch'd July 13, 1863; pensioned.	120	Forsyth, H. N., Pt., G, 30th Wisconsin, age 28.	Aug. 25, '64.	Left; circular. Discharged Oct. 20, 1865.
84	Davis, G. P., Capt., E, 52d Penn.	May 31, '62.	Right; by Surg. W. S. Woods, 52d Pa. Resigned Nov. 7, 1863; pensioned.	121	Foster, G. W., Pt., M, 72d Pennsylvania.	Sept. 17, '62.	Right; circular. Discharged Nov. 14, 1852; pensioned.
85	Davis, J. W., Pt., K, 9th V. R. C., age 24.	July 11, '64.	Right; flap. Discharged Nov. 4, 1864; pensioned.	122	French, G. H., Lieut., H, 12th Massachusetts.	July 1, '63.	Left. Resigned October 28, 1863; pensioned.
86	Davis, T., Pt., H, 141st Pennsylvania, age 18.	May 12, '64.	Left; ant.-post. flap; by Surg. H. F. Lyster, 5th Mich. Disch'd December 23, 1864; pensioned.	123	Fretter, T. O., Pt., H, 103d Ohio, age 23.	May 14, '64.	Right; flap; by A. Surg. G. R. Harrison, 120th Ind. Re-amp. July 13. Dis'd Oct. 22, '64; pen'd.
87	Day, L., Pt., B, 101st Indiana.	July 20, '64.	Left; by Surg. C. M. Fowler. Disch'd Mar. 4, 1865; pensioned.	124	Friday, W. T., 3d Lt., B, 16th S. C., age 28.	Nov. 30, Dec. 1, 1861.	Left; circular. To Pro. Marshal January 7, 1865.
88	Degen, C. H., Pt., D, 111th New York, age 43.	May 6, '64.	Left; circ.; by Surg. G. L. Potter, 145th Pa. Disch'd Jan. 20, 1865; pensioned.	125	Fuller, H. D., Pt., F, 28th Iowa, age 16.	Oct. 19, '64.	Left; flap; by Surg. J. W. H. Vest, 28th Iowa. Disch'd June 21, '65; pensioned. Spec. 4226.
89	Denton, J., Pt., K, 12th N. C., age 17.	July 9, '61.	Right; circ.; by Surg. R. J. Hicks, 23d N. C. Exch'd Sept. 23, '64.	126	Furrow, C., Corp'l, K, 21st Mass., age 21.	Sept. 30, Oct. 1, '64.	Right; circular. Discharged Dec. 20, 1864; pensioned.
90	De Peyster, R. V., Pt., H, 44th Mass., age 36.	Nov. 2, '62.	Left; circ.; by Surg. G. A. Otis, 27th Mass. Disch'd June 18, '63.	127	Geller, J., Serg't, F, 138th Pennsylvania, age 37.	Oct. 19, '61.	Right; flap; by Surg. C. E. Cady, 138th Pa. Disch'd Mar. 4, 1865.
91	Dickson, W., Pt., F, 2d N. Y. Mounted Rifles.	July 30, '64.	Right; flap; by Surg. R. T. Payne, 2d N. Y. M. R. Disch'd Jan. 12, 1865; pensioned.	128	George, J. A., Pt., A, 80th Ohio.	May 14, '63.	Left; flap; by Surg. E. P. Buell, 80th O. Duty Sept. 10, '63; pen'd.
92	Dinsmore, J. M., Corp'l, B, 105th Penn., age 22.	Aug. 16, '64.	Right; flap; by Asst. Surg. A. C. Vaughn, 105th Pa. Mus'd out Oct. 30, 1865; pensioned.	129	Gibson, F. W., Pt., C, 2d Louisiana.	May 27, '63.	Right; flap. Discharged Jan. 30, 1864; commissioned.
93	Dobyns, T., Corp'l, E, 10th Mass., age 44.	June 3, '64.	Right; flap. Disch'd Nov. 12, '64; pensioned.	130	Githens, J., Corp'l, E, 33d Missouri.	July 14, '64.	Left; flap; by Surg. A. T. Bartlett, 33d Mo. Disch'd June 12, 1865; pensioned.
94	Dodge, E., Pt., G, 1st Maine H'y Art., age 21.	June 18, '65.	Right; circular. Disch'd May 4, 1865.	131	Glazier, N. N., Lt., A, 1st Vermont H. A., age 25.	May 18, '64.	Left; flap; by Surg. C. B. Park, 1st Vt. Art. Disch'd Sept. 6, 1864; pensioned.
95	Downing, P., Pt., C, 36th Colored Troops, age 43.	Sept. 29, '64.	Right; flap. Discharged Feb. 19, 1865; pensioned.	132	Goodwin, C. C., Pt., B, 2d Vermont, age 27.	May 19, '64.	Left; circular; by Surg. D. M. Goodwin, 3d Vt. Disch'd Sept. 24, 1864; pensioned.
96	Dudley, J. T., Serg't, G, 32d N. C., age 23.	July 1, '63.	Left. Transferred Sept. 13, 1863.	133	Grammer, J., Pt., C, 60th Illinois, age 21.	Mar. 13, '65.	Right; flap. Disch'd July 5, 1865; pensioned.
97	Duples, E., Pt., F, 3d New Hampshire.	Aug. 28, '63.	Right; circular; by Surg. A. J. H. Buzzell, 3d N. H. Discharged Oct. 10, 1863; pensioned.	134	Green, R. W., Pt., F, 136th New York, age 21.	Aug. 18, '64.	Left; flap; by A. Surg. E. Amundson, 136th N. Y. Disch'd Mar. 7, 1865; pensioned.
98	DuShane, T. W., Pt., K, 100th Penn., age 24.	Mar. 25, '65.	Right; flap; by Surg. W. C. Shurlock, 51st Pa. Disch'd July 4, '65.	135	Green, W. D., Pt., H, 125th New York, age 22.	May 12, '64.	Left; flap; by Surg. W. S. Cooper, 125th N. Y. Disch'd Mar. 30, '65.
99	Earl, J., Pt., D, 51st Pennsylvania, age 25.	Sept. 17, '62.	Right; by Surg. C. L. Duffell, 51st Pa. Arm re-amp. Feb. 7, 1863. Dis'd March 17, '63; pensioned.	136	Griffin, J., Pt., G, 67th Ohio, age 38.	May 10, '64.	Right; flap; by Surg. J. Westfall, 67th O. Disch'd May 17, 1865; pensioned.
100	Eaton, R., Pt., E, 83d Pennsylvania, age 21.	Oct. 27, '64.	Left; flap; by Surg. J. P. Burchfield, 83d Pa. Disch'd June 28, 1865; pensioned.	137	Gunter, W. W., Pt., G, 16th N. C., age 30.	July 3, '63.	Left. Retired January 4, 1865.
101	Eberlee, W. B., Pt., L, 20th Pa. Cav., age 20.	April 1, '65.	Right; ant.-post. flap; by Surg. W. R. Smith, 5th Mich. Cav. Discharged June 8, 1865; pensioned.	138	Guppy, A., Serg't, 1, 1st Maine H'y Art., age 23.	June 19, '64.	Right; flap. Disch'd Feb. 13, '65; pensioned.
102	Edwards, W. G., Corp., B, 14th Miss., age 20.	Nov. 29, Dec. 1, 1864.	Left. To Provost Marshal March 7, 1865.	139	Hammer, H., Capt., K, 55th Pennsylvania, age 22.	April 2, '65.	Left; by Surg. H. B. Fowler, 12th N. H. Disch'd Aug. 30, 1865.
103	Emmerson, P., Pt., C, 57th Colored Troops.	Nov. 7, '64.	Left; circ.; by A. A. Surg. M. Bloek. Dis'd Mar. 25, '65; pen'd.	140	Hancock, J., Serg't, H, 23rd Mass., age 23.	June 17, '64.	Left; circular. Discharged Aug. 25, 1864; pensioned.
104	Erickson, C., Pt., A, 5th Wisconsin, age 29.	April 6, '65.	Right; ant.-post. flap. Disch'd June 26, 1865; pensioned.	141	Harkins, M., Pt., A, 62d New York, age 21.	June 19, '64.	Right; flap; by A. Surg. F. S. Grimes, 62d N. Y. Disch'd Sept. 1, 1864; pensioned.
105	Irwin, W. T., Pt., F, 21st Indiana.	Dec. 26, '63.	Right; circular; by Asst. Surg. E. McClintock, 175th N. Y. Discharged Mar. 23, '65; pensioned.	142	Harper, S. J., Serg't, K, 11th Mississippi, age 24.	July 3, '63.	Right; circular. Recovered.
106	Ell, J. C., Pt., F, 5th Virginia, age 19.	June 9, '64.	Right; circular; by Surg. W. A. Brown, 149th Ohio. Exchanged Sept. 19, 1864.	143	Harris, C., Pt., D, 2d Michigan, age 25.	Nov. 24, '63.	Left; flap; by Surg. J. P. Prince, 30th Mass. Disch'd Feb. 9, 1865; pensioned.
107	Farrell, T., Pt., K, 3d New Hampshire.	May 12, '64.	Right; circular; by Surg. A. J. H. Buzzell, 3d N. H. Discharged Sept. 3, 1864; pensioned.	144	Harris, R., Pt., B, 6th Alabama, age 25.	July 13, '64.	Right; circ.; by Surg. Wetherly. To Prison November 23, 1864.
108	Faulk, P. K., Corp., F, 11th Pa., age 25.	May 6, '64.	Right; flap; by Surg. J. S. Jamison, 86th N. Y. Disch'd Nov. 4, 1864; pensioned.	145	Hatch, E. M., Pt., A, 4th Maine, age 28.	May 6, '64.	Right; flap; by Surg. G. L. Potter, 145th Pa. Disch'd July 19, 1864; pensioned.
109	Fee, P., Pt., F, 20th Massachusetts, age 19.	July 3, '63.	Right; flap; by Surg. N. Hayward, 20th Mass. Discharged April 8, 1864; pensioned.	146	Hayes, P., Pt., A, 6th Mass. Cavalry.	April 8, '64.	Right. Discharged Dec. 10, 1864; pensioned.
110	Fell, E., Pt., C, 2d Penn. Heavy Art., age 21.	June 10, '64.	Left; circ.; by Surg. T. F. Oakes, 56th Mass. Discharged Jan. 30, 1865; pensioned.	147	Haymaker, W. H., Pt., E, 2d Virginia.	Sept. 29, '64.	Right; circular; by A. Surg. W. F. Richardson, C. S. A. Furloughed October 8, 1864.
111	Ferguson, W., Corp., C, 5th Mich., age 20.	June 16, '64.	Left; flap; by Surg. H. F. Lyster, 5th Mich. Discharged April 5, 1865; pensioned.	148	Hayes, W., Pt., E, 50th Massachusetts, age 18.	May 6, '64.	Left; flap. Duty June 4, 1863; pensioned.
112	Fertig, T. S., Pt., C, 45th Pennsylvania, age 26.	June 3, '64.	Right; ant.-post. flap; by Surg. T. S. Christ, 45th Pa. Discharged June 23, 1865; pensioned.	149	Hendricks, J. W., Pt., A, 33d New York.	May 5, '63.	Left; circular; by Surg. M. M. Houston, 86th Ill. Disch'd Feb. 18, 1865; pensioned.
113	Fieser, H., 1st Serg't, C, 27th Michigan, age 26.	June 25, '64.	Left; ant.-post. flap; by Surg. W. B. Fox, 8th Mich. Discharged May 6, 1865; pensioned.	150	Hendy, F. T., Serg't, I, 113th Ohio, age 22.	Sept. 1, '64.	Right; circular. Discharged Dec. 28, 1864; pensioned.
				151	Herwig, J., Pt., I, 15th New York Art., age 31.	May 5, '64.	Right; circular. Discharged Dec. 28, 1864; pensioned.
				152	Hesser, H. R., Pt., A, 7th Iowa.	Nov. 7, '61.	Left. Discharged Dec. 21, 1861; pensioned.
				153	Hicks, S. B., Pt., F, 4th Vermont, age 20.	May 5, '64.	Left; lateral flap; by Surg. D. M. Goodwin, 3d Vt. Disch'd June 8, 1865; pensioned.

No.	NAME, AGE, AND MILITARY DESCRIPTION.	DATES.	OPERATIONS, OPERATOR, RESULT.	No.	NAME, AGE, AND MILITARY DESCRIPTION.	DATES.	OPERATIONS, OPERATOR, RESULT.
154	Hill, W., Serg't, A, 70th Colored Troops, age 29.	April 4, '63.	Right; flap; by Surg. N. N. Horton, 47th C. T. Disch'd July 22, 1865; pensioned.	196	Kuebler, M., Pt., E, 178th N. Y., age 27.	Apr. 9, '65.	Right; antero-posterior flap. Discharged June 24, 1865.
155	Hinton, G., Serg't, B, 38th Wisconsin.	April 2, '65.	Right; by Surg. H. L. Butterfield, 38th Wis. Disch'd May 18, '65; pensioned.	197	Lafferty, A., Pt., D, 8th Ohio Cav., age 28.	Sept. 4, '64.	Left; circ.; by Surg. T. Morton, 3d Va. C. Disch'd Jan. 10, '65.
156	Hixson, J., Pt., D, 149th New York, age 21.	June 27, '64.	Right; flap. Re-amp. July 11. Disch'd July 14, '65; pensioned.	198	La Fontaine, C. C., Pt., P, 100th Ohio, age 28.	Nov. 30, '64.	Right; ant-post. flap. Disch'd May 13, 1865; pensioned.
157	Hoffman, R., Pt., B, 95th New York, age 19.	Aug. 21, '64.	Right; flap; by Surg. A. S. Coe, 147th N. Y. Disch'd Oct. 17, '65; pensioned.	199	Lambert, M., Pt., H, 8th Florida, age 18.	July 1, '63.	Left. Paroled August 22, 1863.
158	Hogan, C., Pt., E, 40th New Jersey.	April 2, '65.	Left; circular. Discharged July 21, 1865; pensioned.	200	Laplant, C., Pt., D, 1st Vt. H. Art., age 22.	Oct. 19, '64.	Left; flap; by Asst. Surg. E. O. Porter, 1st Vt. H. A. Disch'd Aug. 12, 1865; pensioned.
159	Hogencamp, J., Pt., C, 176th New York.	June 3, '63.	Right; by Surg. A. J. Willetts, 176th N. Y. Duty Sept. 15, 1863; pensioned.	201	Larkins, J., Serg't, H, 9th N. Y. S. M., age 28.	June 1, '64.	Left; circular. Disch'd May 21, 1865.
160	Holder, J., Pt., D, 80th Ohio.	May 14, '63.	Right; flap. Disch'd August 21, 1863; pensioned.	202	Lash, J. J., Serg't, F, 13th Michigan.	Mar. 19, '65.	Left; flap. Disch'd June 25, '65.
161	Holt, A., Pt., A, 1st Me. Heavy Art., age 22.	May 19, '64.	Left; flap. Disch'd Jan. 13, '65; pensioned.	203	Lawson, H., Pt., B, 32d Massachusetts.	Apr. 2, '65.	Left; flap. Discharged Sept. 1, 1865; pensioned.
162	Holton, W. C., Pt., K, 10th Texas, age 25.	Dec. 16, '64.	Left; circular. To Pro. Marshal January 17, 1865.	204	Lawton, W. M., Pt., I, 2d S. C., age 26.	July 2, '63.	Right. Paroled Sept. 25, 1863.
163	Hoover, J. W., Pt., G, 21st Penn. Cav., age 18.	Sept. 30, '64.	Right; flap. To V. R. C. March 23, 1865; pensioned.	205	Leach, F. R., Corp'l, D, 1st Me. H. Art., age 23.	Sept. 9, '64.	Right; flap; by Surg. J. S. Jamison, 86th New York. Disch'd May 5, 1865. Spec. 4108.
164	Hora, F. I., Pt., D, 40th Missouri, age 20.	Mar. 28, '65.	Right; circular. Disch'd Aug. 18, 1865.	206	Leroy, S., Pt., I, 26th Indiana.	Dec. 7, '62.	Left. Discharged Feb. 13, 1863; pensioned.
165	Horney, J., Pt., H, 18th U. S. Infantry.	Sept. 20, '62.	Left; circular. Disch'd Feb. 10, 1864.	207	Leverenz, A., Pt., K, 12th Ill. Cav., age 38.	Nov. 18, '64.	Left; circular; by A. Surg. C. E. Wentworth, 12th Ill. Cav. Discharged Oct. 21, 1865.
166	Horton, C. N., Pt., H, 7th Vermont, age 18.	Oct. 19, '64.	Left; circular; by Surg. E. Phillips, 6th Vt. Disch'd May 5, '65; pensioned.	208	Lewis, J. L., Corp'l, C, 7th Virginia, age 19.	May 18, '64.	Left. Discharged Nov. 3, 1864.
167	Hose, I., Pt., F, 97th New York, age 27.	July 3, '63.	Left; by Surg. A. Ball, 5th Ohio. Disch'd Sept. 28, 1863; pens'd.	209	Lilly, W., Corp'l, I, 11th Vermont, age 37.	June 3, '64.	Left; flap; by Surg. D. M. Goodwin, 3d Vt. Disch'd June 15, 1865; pensioned.
168	Howard, J. B., Serg't, K, 14th Texas, age 21.	Dec. 16, '64.	Left; flap; by Surg. R. L. McClure. To Pro. Mar. 7, '65.	210	Littleton, T., Pt., A, 20th South Carolina, age 40.	Oct. 19, '64.	Right; circular; by Dr. Miller. To Pro. Mar. April 1, 1865.
169	Hubbell, F., Pt., E, 121st New York.	Dec. 14, '62.	Right. Discharged January 29, 1863; pensioned.	211	Lobaugh, E., Pt., K, 184th Penn., age 39.	Oct. 18, '64.	Right; ant-post. flap; by Surg. W. B. Britton, 184th Penn. Disch'd May 20, 1865; pensioned.
170	Huber, J. P., Corp'l, K, 51st Pa., age 34.	May 6, '64.	Right. Disch'd March 19, 1865; pensioned.	212	Looman, G., Corp., E, 100th N. Y., age 20.	Aug. 19, '63.	Left; by Surg. M. S. Kittinger, 100th N. Y. Re-amp. upper third Aug. 28, '63. Dis'd Oct. 6, '64; pen. Right. Discharged March 1, 1865; pensioned.
171	Hudson, G., Pt., D, 29th Colored Troops, age 21.	July 30, '64.	Right; circ.; by Surg. F. M. Weld, 2th C. T. Re-amp. upper third Jan. 30, '65. Dis'd Mar. 17, '65.	213	Loomis, D. P., Lieut., A, 5th Vermont, age 23.	Sept. 19, '64.	Right. Discharged March 1, 1865; pensioned.
172	Hunt, N. E., Pt., C, 45th Georgia.	Oct. 19, '64.	Right. Exchanged.	214	Lott, A. H., Pt., D, 123d Ohio, age 18.	Mar. 31, '65.	Right; flap; by Surg. G. DeLandre, 158th N. Y. Dis'd July 25, 1865; pensioned.
173	Hunt, W. A., Pt., E, 4th Iowa.	Nov. 25, '63.	Right; by Surg. M. W. Robbins, 4th Iowa. Dis'd May, '64; pen'd.	215	Lotz, J., Pt., B, 1st Infantry.	June 25, '63.	Right. Discharged; pensioned.
174	Hurch, J., Pt., K, 1st Maryland Cav., age 38.	April 2, '65.	Right; ant-post. flap. Disch'd June 21, 1865; pensioned.	216	Lovejoy, W. W., Pt., J, 1st New England Cav.	Sept. 14, '63.	Right. Discharged February 2, 1863; pensioned.
175	Ireland, R., Pt., C, 69th Ohio, age 25.	Sept. 1, '64.	Right; circular. Disch'd June 15, 1865.	217	Lucia, H. J., Lieut., H, 17th Vermont, age 22.	Sept. 30, '64.	Left; circular. Duty March 18, 1865; pensioned.
176	Jackson, P., Corp., K, 30th Ohio.	Sept. 14, '62.	Right; circular. Discharged Nov. 3, 1862; pensioned.	218	Ludwick, E. A., Major, 112th N. Y., age 27.	Oct. 1, '64.	Right. Discharged June 13, 1865.
177	James, S. L., Serg't, H, 2d Ind. Cav., age 28.	April 16, '65.	Left; flap; by Asst. Surg. H. D. Garrison, 4th Indiana Cav. Discharged June 25, '65; pensioned.	219	Lumbkin, S. R., Pt., E, 16th Miss., age 22.	Sept. 29, '64.	Left; circular. To prison Sept. 5, 1864.
178	Johnson, E., Pt., K, 5th Vermont, age 28.	April 2, '65.	Right. Discharged July 6, 1865; pensioned.	220	Luna, W. L., Pt., F, 2d Mississippi, age 34.	July 1, '63.	Right; circular.
179	Johnson, J., Pt., F, 97th Ohio, age 41.	July 21, '64.	Left; flap; by Surg. E. B. Glick, 40th Indiana. To V. R. C. Dec. 5, 1864; pensioned.	221	Lynch, T., Pt., F, 31st Illinois, age 19.	July 22, '64.	Left; flap. Discharged May 31, 1865.
180	Johnson, R. W., Corp., B, 14th W. Va., age 40.	Aug. 26, '64.	Left; flap. Discharged March 4, 1865.	222	Lyons, J., Serg't, G, 120th New York, age 23.	Mar. 31, '65.	Left; antero-posterior flap. Discharged July 12, '65; pensioned.
181	Jones, J., Lieut., D, 13th Virginia, age 44.	Sept. 19, '64.	Right; circular; by Surg. A. Atkinson, C. S. A.	223	Mackey, W. M., Pt., C, 14th Illinois.	June 23, '63.	Right; by Surg. B. F. Stephenson, 14th Ill. Dis'd July 27, '63; pen'd.
182	Jones, T., Pt., C, 2d New Hampshire, age 19.	Aug. 26, '64.	Right; flap. Discharged Feb. 28, 1865; pensioned.	224	Malarkey, G., Pt., F, 100th Pa., age 36.	June 29, '64.	Left; circular. Discharged Dec. 16, 1864; pensioned.
183	Jordan, W. J., Pt., C, 61st Georgia, age 31.	July 9, '64.	Left; circular; by Dr. Schley. For exchange Sept. 19, 1864.	225	Malone, W., Pt., K, 1st N. Y. Eng., age 36.	Aug. 24, '63.	Left; flap; by Surg. S. Green 24th Mass. Discharged Nov. 3, 1864; pensioned. Spec. 357.
184	Kates, E., Pt., I, 14th Kentucky Cavalry.	July 30, '64.	Left; flap; by Surg. C. E. Swasey, U. S. V. Dis'd Apr. 25, '65.	226	Manamee, J., Pt., K, 97th Pennsylvania, age 19.	July 18, '64.	Right; flap; by Surg. J. R. Everhart, 97th Penn. Discharged June 18, 1865; pensioned.
185	Keagan, E., Pt., A, 1st U. S. Artillery, age 20.	Oct. 9, '61.	Right; flap. Discharged Nov. 30, 1861; pensioned.	227	Marks, M., Pt., C, 46th Illinois.	April 6, '62.	Right. Discharged June 19, 1862; pensioned.
186	Kelley, J., Pt., H, 14th N. Y. H. A., age 45.	May 18, '64.	Right; circular; by Surg. T. F. Onkes, 56th Mass. Discharged March 16, 1865; pensioned.	228	Martin, H. M., Pt., C, 4th Georgia, age 27.	Sept. 19, '64.	Right; circ.; by Surg. Young, C. S. A. To Pro. Mar. Feb. 11, '65.
187	Kenney, M., Pt., H, 10th Missouri, age 25.	Nov. 25, '63.	Left; circular. Discharged June 17, 1864; pensioned.	229	Matter, J., Pt., B, 21st Ohio, age 34.	July 20, '64.	Left; circular; by Surg. D. S. Young, 21st Ohio. Discharged Feb. 18, 1865; pensioned.
188	Kernan, J., Pt., A, 2d Penn. Reserves.	June 26, '62.	Left; circular. Discharged Oct. 14, 1862.	230	Mayfield, J. W., Pt., D, 78th Illinois.	Sept. 20, '63.	Right; by Surg. O. Q. Herriek, 34th Ill. Dis'd Nov. 2, '63; pen'd.
189	Kerr, J., Private, G, 6th Vermont.	Sept. 17, '62.	Right; by Surg. C. M. Chandler, 6th Vt. Disch'd Nov. 29, '62; pensioned.	231	Mayo, P., Pt., I, 81st Illinois, age 41.	April 6, '65.	Left; flap; by Surg. L. Dyer, 81st Ill. Disch'd Aug. 5, 1865; pensioned. Died May 6, 1867.
190	Kersnitz, H., Pt., B, 93d Pennsylvania, age 20.	Mar. 25, '65.	Right. Discharged June 24, 1865.	232	McCabe, J., Pt., B, 60th Pennsylvania.	Sept. 17, '62.	Right; circular. Disch'd Dec. 19, 1862.
191	Kilpatrick, W. H., 1st Lieut., D, 1st Colored Troops.	June 15, '64.	Left; flap; by A. Surg. H. W. Willoughby, 1st C. T. Duty April 13, 1865.	233	McCoy, F. M., Pt., F, 69th Ohio, age 26.	Mar. 19, '65.	Left; circular. Discharged June 16, 1865.
192	Kinney, E., Pt., F, 123d New York, age 24.	July 20, '64.	Right; circ. Re-amp. middle third Aug. 6. Dis'd June 18, '65; pen'd.	234	McCullough, G. R., Serg't, I, 20th Pa. Cav., age 29.	Apr. 5, '65.	Right; circ.; by Surg. P. Gardner, 1st W. Va. C. Disch'd June 27, 1865; pensioned.
193	Kinsty, J., Pt., A, Parcell's Battery, age 23.	Dec. 13, '62.	Right; circular.	235	McCullough, J. S., Pt., G, 76th Illinois.	Apr. 9, '65.	Left; flap; by Surg. W. A. Babcock, 76th Ill. Disch'd July 6, 1865; pensioned.
194	Kline, C., Serg't, D, 115th New York, age 24.	Sept. 29, '64.	Right; flap; by Surg. C. Macfarlane, 115th New York. Duty May 13, 1865; pensioned.	236	McElrath, W. B., Pt., E, 48th Penn., age 18.	Sept. 11, '64.	Right; circ.; by Surg. W. R. D. Blackwood, 48th Penn. Disch'd Feb. 6, 1865; pensioned.
195	Kremis, H., Pt., G, 145th Pennsylvania, age 21.	June 16, '64.	Left; flap; by Surg. G. L. Potter, 145th Pa. Disch'd June 16, '65.				



No.	NAME, AGE, AND MILITARY DESCRIPTION.	DATES.	OPERATIONS, OPERATOR, RESULT.	No.	NAME, AGE, AND MILITARY DESCRIPTION.	DATES.	OPERATIONS, OPERATOR, RESULT.
237	McFarland, M., Corp'l, B, 24th Texas.	Nov. 18, '63.	Right; double flap. To Provost Marshal Jan. 27, 1864.	276	Osborne, S. J., Corp'l, M, 5th Mich. Cav., age 24.	Oct. 19, '64.	Right; flap; by Surg. A. K. St. Clair, 5th Mich. Cav. Disch'd April 27, '65; pensioned.
238	McGovern, F., Pt., E, 18th New York, age 32.	Aug. 25, '64.	Right; circular; by Surg. J. A. Spencer, 182d N. Y. Disch'd Dec. 19, 1864; pensioned.	277	Oswalt, J. L., Pt., F, 5th Ohio, age 19.	Feb. 12, '65.	Left; circular; by Surg. J. L. Dunn, 109th Penn. Discharged June 23, 1865; pensioned.
239	McKelvy, A., Pt., G, 13th Michigan.	Mar. 9, '65.	Right; flap; by Surg. F. Pratt, 13th Mich. Discharged July 23, 1865; pensioned.	278	Owens, J. F., Pt., F, 60th Illinois, age 22.	May 7, '64.	Right. June 2, '64, re-amp. middle third. Mustered out July 31, 1865; pensioned.
240	McKnight, E., Pt., D, 2d Mass. Cav., age 30.	Sept. 13, '64.	Left; double flap; by A. A. Surg. J. R. Fhler. Disch'd Sept. 11, 1865. <i>Specs.</i> 1403 and 4333.	279	Parker, A. J., Pt., G, 2d Massachusetts.	Aug. 9, '62.	Right; circular; by Surg. A. W. Whitney, 13th Mass. Disch'd Oct. 20, 1862; pensioned.
241	McNaughton, C., Pt., K, 77th New York, age 19.	May 3, '63.	Left; flap. Discharged Aug. 5, 1863.	280	Patrick, S., Capt., H, 5th Illinois, age 25.	July 4, '61.	Left; flap; by Surg. S. H. Kersoy, 36th Ind. Resigned March 8, 1865; pensioned.
242	McNeil, J. M., Pt., K, 52d North Carolina.	Oct. 19, '64.	Left; circular; by A. Surg. Covat, 53d N. C. To prison Jan. 5, '65.	281	Perret, A., Pt., F, 13th Connecticut.	May 24, '63.	Left; flap; by Surg. C. A. Robertson, 150th N. Y. To V. R. C. Feb. 18, 1864; pensioned.
243	McPeak, E. E., Pt., A, 86th Illinois, age 21.	July 27, '64.	Left; circular. Discharged May 19, 1865.	282	Perry, W., Capt., I, 16th Virginia Cav., age 32.	July 6, '63.	Right. For exchange September 5, 1863.
244	McQuiston, A. J., Serg't, I, 10th Pa. R., age 25.	May 9, '64.	Left; flap; by Surg. B. Rohrer, 10th Pa. Res. Disch'd July 27, 1864; pensioned.	283	Pettit, O. W., Pt., K, 148th Penn., age 27.	May 30, '64.	Right; circ.; by Surg. J. W. Wisbart, 140th Pa. Disch'd April 6, 1865.
245	McTaggart, C. P., Lieut., H, 3d Michigan, age 26.	May 31, June 1, 1862.	Left; flap; by Surg. D. W. Bliss, U.S.V. (Prim'y exc. clb. joint.) re-amp. Sept. 7, 1863. To V. R. C. Dec. 15, '64; pens'd. <i>Spec.</i> 1741.	284	Pineard, J. B., Pt., D, 122d Illinois, age 22.	April 9, 1865. On field.	Right; flap. Discharged July 15, 1865.
246	Medford, A. F., Pt., E, 40th Ohio, age 23.	Aug. 25, '64.	Right; flap; by Asst. Surg. W. H. Matchett, 40th Ohio. Disch'd March 21, 1865; pensioned.	285	Plankey, J., Pt., C, 91st N. Y., age 20.	Mar. 31, Apr. 1, 1865.	Left; flap; by Surg. R. Morris, 91st N. Y. Disch'd June 19, '65; pensioned.
247	Methven, J. F., Pt., L, 2d Pa. Hvy Art., age 39.	July 30, '64.	Right; circular; by Surg. G. W. Snow, 35th Mass. Discharged July 27, 1865; pensioned.	286	Polley, E. B., Pt., C, 54th Indiana, age 32.	Dec. 29, '62.	Left; circular. Discharged Mar. 26, 1863.
248	Mickel, J., Pt., I, 26th Michigan, age 33.	Jan. 8, '65.	Left; circular. Discharged Feb. 26, 1865.	287	Pratt, E. A., Capt., G, 8th Colored Troops.	Oct. 13, '64.	Left. Discharged Jan. 19, 1865; pensioned.
249	Miles, J., Pt., B, 12th Wisconsin, age 21.	July 21, '64.	Left; circular; by Surg. E. M. Rodgers, 12th Wisconsin. Discharged Mar. 28, '65; pensioned.	288	Price, I., Corp'l, F, 15th W. Va., age 34.	Oct. 13, '64.	Right; by Surg. W. S. Walsh, 15th W. Va. (Left forearm amp.) Disch'd June 9, '65; pensioned.
250	Miller, R. H., Pt., H, 2d Vermont, age 30.	May 19, '64.	Right; circular. Discharged Aug. 21, 1864; pensioned.	289	Pugh, C. L., Pt., G, 46th Ohio, age 17.	Aug. 3, '64.	Left; flap; by Surg. D. Halderman, 46th Ohio. Disch'd April 24, 1865; pensioned.
251	Mitchell, J. W., Pt., K, 37th Indiana.	Dec. 31, Jan. 1, 1863.	Right; flap. Disch'd March 22, 1863; pensioned.	290	Quick, C. H., Pt., F, 120th N. Y., age 19.	Mar. 25, '65.	Right; ant.-post. flap. Disch'd June 5, 1865; pensioned.
252	Modix, D., Pt., I, 106th New York, age 32.	June 1, '64.	Right; circular. Disch'd Sept. 26, 1864; pensioned.	291	Ramsdell, J. V., Pt., K, 32d Massachusetts.	Sept. 17, '62.	Right; flap; by Surg. Z. B. Adams, 32d Mass. Disch'd Nov. 25, 1863; pensioned.
253	Molder, E. A., Pt., I, 43d Georgia, age 22.	Nov. 30, '64.	Left; flap. To Provost Marshal Feb. 3, 1865.	292	Randall, C. W., Corp'l, F, 5th Vermont, age 28.	May 5, '64.	Right; circular; by Surg. A. H. Chessmore, 5th Vt. Discharged Aug. 19, 1864; pensioned.
254	Mouroe, A. H., Pt., E, 122d New York, age 18.	Sept. 13, '64.	Left. Discharged Feb. 16, 1865.	293	Randall, G. W., Pt., H, 6th Maine.	June 27, '62.	Right; by Surg. M. Case, 43d N. Y. Disch'd Aug. 29, '62; pens'd. 1865; pensioned.
255	Moore, P., Pt., B, 6th Colored Troops, age 18.	Feb. 11, '65.	Left; flap; by Surg. M. Tucker, 39th Col'd Troops. Disch'd Sept. 23, 1865.	294	Randolph, A. J., Corp., D, 10th N. J., age 22.	Aug. 17, '64.	Right; flap. Discharged April 6, 1865; pensioned.
256	Moore, W. M., Corp., E, 190th Penn., age 23.	Aug. 19, '64.	Right; circular. Discharged June 28, 1865; pensioned.	295	Reeder, J. P., Pt., D, 148th New York, age 31.	June 3, '61.	Left; circular. Discharged Feb. 8, 1865.
257	Moorehouse, A. J., Pt., G, 24th Missouri, age 23.	April 9, '64.	Left; by Surg. C. Winne, 77th Ill. Re-amp. at shoulder joint. Discharged June 18, 1865; pens'd.	296	Reid, W. J., Pt., —, 2d North Carolina.	July 28, '62.	Left; circ.; by Surg. G. Derby, 22d Mass. Recovery Oct. 8, 1862.
258	Morris, F., Pt., B, 2d Maryland.	April 2, '65.	Right; by Surg. J. A. Hayes, 11th N. H. Disch'd July 21, '65.	297	Reynolds, J. W., Serg't, G, 49th Ohio, age 29.	Dec. 16, '64.	Right; circular; by Surg. W. H. Park, 49th O. Dis'd May 29, '65.
259	Morton, M. F., Pt., E, 7th Texas, age 25.	Nov. 30, '64.	Left; flap. To Provost Marshal Jan. 3, 1865.	298	Richmond, I. G., 2d Lt., B, 33d Miss., age 29.	Nov. 30, '64.	Right; circular. To Provost Marshal January 21, 1865.
260	Mosely, J. M., 1st Co. Powhattan Bat., age 22.	Sept. 29, '64.	Left; circ.; by Surg. Mathews, C. S. A. Retired.	299	Ricks, D., Pt., D, 50th Colored Troops, age 39.	April 1, '65.	Left; circular; by Asst. Surg. D. Seofield, 47th Colored Troops. Disch'd June 18, 1865; pensioned.
261	Mulverhill, T., Pt., H, 98th N. Y., age 21.	Sept. 29, '64.	Left; flap; by Surg. J. J. Van Reusselaer, 98th N. Y. Disch'd Jan. 16, 1865; pensioned.	300	Riley, C., Pt., C, 10th Indiana, age 43.	Aug. 1, '64.	Right; flap. Mustered out May 25, 1865; pensioned.
262	Murphy, E., Pt., D, 55th Pennsylvania, age 20.	Sept. 29, '64.	Right; flap. Discharged January 13, 1865.	301	Roberts, C. H., Pt., H, 27th Col. Tr'ps, age 17.	Feb. 11, '65.	Left; flap. Discharged May 26, 1865; pensioned.
263	Murray, J., Pt., D, 1st New Jersey, age 29.	May 12, '64.	Right; flap; by Surg. L. W. Oakley, 2d New Jersey. Disch'd July 8, 1865; pensioned.	302	Roberts, J., Pt., D, 1st Colored Troops, age 25.	Sept. 30, '64.	Right; flap. Discharged July 8, 1865; pensioned.
264	Myers, D., Pt., C, 8th New York Cav., age 28.	June 13, '64.	Left; ant.-post. flap. Discharged June 19, 1865; pensioned.	303	Rockwood, H. S., Pt., D, 106th N. Y., age 20.	Sept. 19, '64.	Right; flap. Discharged Feb. 18, 1865; pensioned.
265	Nagle, S. S., Pt., G, 95th Penn., age 44.	May 12, '64.	Left; flap. Discharged Mar. 18, 1865.	304	Roddy, M., Pt., A, 17th Vermont, age 19.	May 13, '64.	Right; flap; by Surg. P. O. Edson, 17th Vt. Disch'd Nov. 25, 1865.
266	Neal, W. T., Pt., D, 4th N. J., age 21.	Sept. 19, '64.	Right; circular; by Surg. O. R. Freeman, 10th N. J. Disch'd July 6, 1865; pensioned.	305	Rodenbough, T. F., Capt., D, 2d U. S. Cav., age 26.	Sept. 19, '64.	Right; circular. Healed.
267	Newman, R., Pt., I, 83d New York, age 43.	May 6, '64.	Left; flap. Trans. to V. R. C. Jan. 17, 1865.	306	Roe, G., Pt., F, 71st Pennsylvania.	Sept. 17, '62.	Left; flap. Discharged May 19, 1863.
268	Newton, R. S., Pt., A, 76th Pa., age 24.	Aug. 16, '64.	Right; flap. Discharged Dec. 11, 1865; pensioned.	307	Roipbaugh, B., Pt., C, 157th New York.	July 1, '63.	Right; flap. Discharged April 13, 1864; pensioned.
269	Nicholson, W., Pt., A, 63d New York.	Nov. 7, '64.	Left; flap; by Surg. Williams, C. S. A. Duty Jan. 28, '65; pen'd.	308	Roof, S. E., Capt., 20th South Carolina.	Oct. 19, '64.	Right. To Fort Mifflin Dec. 9, 1864.
270	Niles, J. D., Corp'l, D, 3d Vermont, age 25.	May 10, '64.	Right; flap; by Surg. D. M. Goodwin, 3d Vt. Disch'd; pensioned.	309	Ross, G. D., Serg't, G, 21st Wisconsin, age 21.	Aug. 7, '64.	Right; by Surg. J. T. Reeve, 21st Wis. Disch'd Sept. 1, '65; pens'd.
271	O'Brien, M., Pt., 17th N. Y. Independent Battery, age 30.	Aug. 21, '64.	Right; circular; by Asst. Surg. C. F. Haynes, U. S. V. Disch'd Oct. 29, 1864; pensioned.	310	Rosser, G. G., Pt., E, 6th Virginia Cavalry.	May 11, '64.	Left. Recovery.
272	O'Connell, M., Pt., H, 164th New York, age 29.	Nov. 25, '64.	Left; flap. Discharged Aug. 11, 1865. <i>Spec.</i> 4321.	311	Rubins, E. H., Pt., G, 144th Ohio, age 27.	July 9, '61.	Right; flap; by A. A. Surg. J. H. Bartholf, Duty Aug. 30, '64; pen.
273	O'Donnell, F., Pt., C, 8th New Jersey, age 25.	May 6, '64.	Left; circular. Discharged June 26, 1865.	312	Russell, A. M., Pt., 12th Wis. Battery, age 21.	Dec. 15, '64.	Right; flap; by Surg. B. N. Bond, 27th Mo. Disch'd Mar. 30, '65.
274	Oliver, P., Pt., B, 108th New York, age 20.	May 10, '64.	Left; flap; by Surg. N. Hayward, 20th Miss. Disch'd Nov. 3, 1864; pensioned.	313	Sails, S., Pt., K, 61st Ohio, age 21.	Aug. 1, '64.	Right; flap. Discharged June 26, 1865.
275	O'Seale, J., Pt., C, 10th New York, age 17.	June 7, '64.	Left; flap; by Surg. W. A. Smith, 47th N. Y. Discharged Feb. 11, 1865; pensioned.	314	Saunborn, T. T., Serg't, I, 17th Vt., age 41.	Sept. 30, Oct. 1, 1864.	Right; flap; by Asst. Surg. L. H. Cooper, 17th Mich. Discharged Aug. 25, 1865; pensioned.
				315	Sanders, J. M., Pt., E, 60th Illinois, age 19.	Jan. 25, '65.	Right; circular; by A. Surg. G. H. Baker, 21st Mich. Disch'd Oct. 23, 1865; pensioned.

No.	NAME, AGE, AND MILITARY DESCRIPTION.	DATES.	OPERATIONS, OPERATOR, RESULT.	No.	NAME, AGE, AND MILITARY DESCRIPTION.	DATES.	OPERATIONS, OPERATOR, RESULT.
316	Sanner, A., Pt., A, 62d Pennsylvania, age 35.	May 17, '64.	Right; flap. Discharged July 7, 1865; pensioned.	359	Thorman, G. W., Pt., K, 24th S. C., age 31.	Nov. 30, '64.	Left; circular. To Provost Marshal Jan. 21, 1865.
317	Santee, James, Serg't, F, 31st Colored Troops.	July 30, '64.	Right; circular; by Surg. G. J. Potts, 23d C. Troops. Disch'd.	360	Timmerman, R. C., Corp., I, 81st N. Y., age 24.	June 3, '64.	Left; flap. Discharged Oct. 26, 1864; pensioned.
318	Sargeant, C. J., Serg't, C, 1st Me. H. Art., age 16.	April 6, '65.	Right; lateral flap. Discharged June 6, 1865; pensioned.	361	Toleson, J., Serg't, A, 70th N. Y., age 29.	July 3, '63.	Left; circular. Discharged June 20, 1864; pensioned.
319	Scheil, J. F., Pt., E, 46th New York.	July 16, '63.	Left; flap; by Surg. G. R. Cogswell, 29th Mass. Dis'd Dec. 3, '63.	362	Tours, J. M., Corp'l, I, 70th N. Y., age 24.	May 12, '64.	Right; circular. Discharged July 8, 1864; pensioned.
320	Schervier, B., Pt., I, 19th Ohio, age 18.	May 27, '64.	Right; circular. Furlough'd July 3, 1864.	363	Trail, P., Pt., E, 23d Virginia, age 21.	May 30, '64.	Left; by Surg. H. F. Lyster, 5th Michigan. Recovery.
321	Seeley, J. W., Pt., II, 7th Michigan, age 23.	May 12, '64.	Left; flap; by Surg. F. A. Dudley, 14th Conn. Disch'd Sept. 29, '64.	364	Truheart, G. W., Pt., F, 67th N. Y., age 20.	May 12, '64.	Right; flap; by Surg. L. W. Oakley, 2d New Jersey. Discharged May 30, 1865; pensioned.
322	Shaw, W. B., Pt., B, 19th Maine, age 25.	May 12, '64.	Right; flap; by Surg. N. Hayward, 29th Mass. Disch'd Mar. 25, 1865; pensioned.	365	Turner, L., Pt., D, 10th Kansas, age 28.	Dec. 15, '64.	Left; antero-posterior flap; by A. Surg. W. B. Trull, U. S. V. Discharged June 26, 1865.
323	Shelby, J. C., Capt., K, 30th Ohio.	Nov. 25, '63.	Right; recovered. Died Sept. 14, 1864, of wound of thigh.	366	Turney, W. F., Capt., II, 41st Illinois.	July 12, '63.	Right; by Surg. C. Carle, 41st Ill. Disch'd Aug. 20, 1864; pens'd.
324	Sherlock, M., Pt., II, 203d Pennsylvania, age 40.	Jan. 15, '65.	Left; circular. Discharged July 11, 1865; pensioned.	367	Van Camp, I. Pt., I, 80th Indiana, age 21.	Aug. 14, '64.	Left; flap. Discharged Oct. 6, 1864; pensioned.
325	Sherman, S., Pt., F, 2d W. Va. Cav., age 23.	Sept. 5, '64.	Left; circular; by Surg. T. Morton, 2d W. Va. Cav. Duty Jan. 4, 1865; pensioned.	368	Van Corr, W. N., Pt., G, 17th Vermont, age 21.	June 3, '64.	Right; flap; by Surg. P. O'M. Lidsen, 17th Vt. Disch'd April 6, 1865; pensioned.
326	Shouse, J. H., Corp'l, II, 51st Indiana, age 21.	Dec. 16, '64.	Left; circular. Discharged May 22, 1865; pensioned.	369	Van Dusen, D. C., Pt., K, 42d Ohio.	May 20, '63.	Right; flap. Discharged Sept. 25, 1863; pensioned.
327	Slacker, J., Pt., II, 62d Pennsylvania.	July 1, '62.	Right; circular. Disch'd Aug. 6, 1862; pensioned.	370	Veal, E., Pt., D, 57th Indiana, age 23.	May 27, '64.	Right; flap; by Surg. E. B. Glick, 40th Ind. Disch'd Dec. 10, 1864.
328	Smith, P., Pt., I, 7th N. York.	Dec. 13, '62.	Left; circular; by Surg. T. Morton, 2d W. Va. Cav. Duty Jan. 4, 1865; pensioned.	371	Vesper, O. R., Pt., F, 3d Vermont, age 21.	May 5, '64.	Right; flap; by Surg. D. M. Goodwin, 3d Vermont. Discharged June 25, 1864; pensioned.
329	Smith, A., Pt., K, 54th Ohio, age 23.	June 18, '63.	Right; flap; by Asst. Surg. J. C. G. Happersett, U. S. A. Disch'd March 6, 1864; pensioned.	372	Wadsworth, F., Pt., D, 7th Maine, age 25.	May 12, '64.	Right; flap; by Surg. F. M. Eveleth, 7th Maine. Discharged June 22, 1865; pensioned.
330	Smith, A. J., Serg't, D, 164th N. Y., age 22.	May 18, '64.	Right; flap; by Surg. M. F. Regan, 164th N. Y. Discharged Sept. 23, 1865; pensioned.	373	Wager, H. N., Pt., II, 188th N. Y., age 19.	Feb. 7, '65.	Left; antero-posterior flap; by Surg. O. S. Paine, 188th N. Y. Disch'd July 25, '65; pensioned.
331	Smith, G., Pt., C, 1st Wisconsin, age 25.	July 4, '64.	Left; flap. Discharged July 4, 1865; pensioned.	374	Wakefield, J. P., Pt., E, 11th Pennsylvania.	May 5, '64.	Left; Discharged May 22, 1865.
332	Smith, H., Pt., E, 11th Vermont, age 19.	Sept. 13, '64.	Left; flap; by Surg. C. B. Park, 11th Vt. Leg amp. Discharged Sept. 14, 1865; pensioned.	375	Wallam, M., Pt., A, Ky. Cavalry.	June 14, '63.	Right. Furloughed Oct., 1863. Recovered.
333	Smith, J., Pt., A, 12th N. Y. Cavalry, age 24.	Mar. 8, '65.	Left; flap. Disch'd June 8, 1865.	376	Walser, E., Pt., I, 48th N. Y., age 49.	Jan. 15, '65.	Right; circular. Discharged Oct. 3, 1865.
334	Snooks, I., Pt., C, 7th Iowa.	Oct. 22, '62.	Left; flap; by Surg. C. B. Lake, 7th Ia. Disch'd Dec. 12, 1862; pens'd.	377	Warner, G. W., Pt., B, 20th Conn., age 32.	July 3, '63.	Left; flap; right arm amput'd at shoulder joint. Disch'd Oct. 17, 1863; pensioned.
335	Snow, A. P., Pt., E, 58th Mass., age 17.	June 7, '64.	Left; circular. Discharged July 15, 1864; pensioned.	378	Watts, R. J., Pt., K, 37th Georgia, age 18.	Nov. 30, Dec. 2, 1864.	Right; ant. post. flap. To Provost Marshal Jan. 17, 1865.
336	Somers, I. E., Pt., D, 5th Maine, age 24.	May 10, '64.	Left; flap; by Surg. F. G. Warren, 5th Me. Mustered out July 27, 1864; pensioned.	379	Webster, B. G., Pt., F, 20th Mich., age 23.	Mar. 25, '65.	Left; circ.; by Surg. W. C. Shurlock, 51st Pa. Disch'd Oct. 2, 1865; pensioned.
337	Sopher, J., Pt., A, 8th Ohio.	Sept. 17, '62.	Left; Discharged Jan. 12, 1864; pensioned.	380	Weiland, N., Pt., I, 32d Wisconsin, age 22.	Mar. 21, '65.	Right; flap. Disch'd Jan. 22, 1865; pensioned.
338	Spaulding, J. A., Corp'l, F, 3d Vt., age 21.	June 2, '64.	Left; flap; by Surg. D. M. Goodwin, 3d Vt. Discharged May 6, 1865; pensioned.	381	West, H. W., Pt., E, 6th Mich. Hvy Art.	Jan. 21, '65.	Right. Discharged Mar. 9, 1865; pensioned.
339	Spear, S. R., Pt., A, 81th Illinois.	Dec. 31, '62.	Left; by Surg. C. J. Walton, 21st Ky. Dis'd Feb. 26, '63; pens'd.	382	Westfall, S., Pt., C, 9th N. Y. Hvy Art., age 19.	Oct. 19, '64.	Right; circular. Disch'd Aug. 13, 1865; pensioned. Spec. 1363.
340	Sperry, J., Pt., I, 51st New York.	Sept. 17, '62.	Right. Discharged Oct. 19, 1862; pensioned.	383	Wheeler, G., Corp'l, A, 16th Illinois, age 24.	Mar. 16, '65.	Left; by A. Surg. A. L. Ritchey, 16th Ill. Duty June 16, 1865.
341	Stapleton, S. S., Pt., II, 48th N. Y., age 28.	July 22, '64.	Left; flap; by A. Surg. C. Devenorf, 48th N. Y. Dis'd Jan. 20, '65.	384	Wicks, M. B., Pt., G, 130th N. York, age 30.	June 2, '64.	Left; flap. Discharged Dec. 19, 1864; pensioned.
342	Starts, J., Pt., B, 12th Iowa.	April 6, '62.	Left; circular. Discharged Jan. 26, 1863.	385	Wilbur, J. B., Pt., II, 112th Penn., age 24.	June 18, '64.	Left; flap; by Surg. G. T. Stevens, 77th N. Y. Disch'd Dec. 23, 1864; pensioned.
343	Stevens, M. S., Pt., F, 11th W. Va., age 24.	Mar. 31, '65.	Right; by Surg. C. M. Clark, 39th Ill. Discharged June 24, 1865.	386	Wilburn, J. P., Corp'l, M, 2d Mass. Cav., age 28.	Sept. 28, '64.	Left; circular. Disch'd Mar. 29, 1865; pensioned.
344	Stevens, T., 1st Lieut., G, 91st Ind., age 38.	July 29, '64.	Left; flap; by Surg. E. Shippin, U. S. V. Disch'd Mar. 10, 1865.	387	Wilkins, J., Pt., E, 53d Illinois.	July 12, '63.	Right; by Surg. W. S. Edgar, 32d Ill. Disch'd; pensioned.
345	Stocking, J. S., Lieut., A, 100th Pennsylvania.	Oct. 23, '64.	Left; by Surg. W. E. Johnson, 109th New York. Discharged Jan. 10, 1865; pensioned.	388	Williams, C., Pt., K, 5th New Jersey.	Oct. 15, '63.	Left; circular; by Surg. H. F. Vandervoer, 5th N. J. Disch'd Mar. 10, 1864; pensioned. Spec. 2242.
346	Swett, W. H., Pt., II, 17th Maine, age 32.	June 16, '64.	Right; ant. post. flap. Disch'd Dec. 6, 1864; pensioned.	389	Williams, J., Pt., M, 8th Illinois Cav., age 43.	July 1, '63.	Left. Discharged Oct. 27, 1863; pensioned.
347	Sympton, W. C., Pt., D, 15th Kentucky.	Aug. 28, '62.	Right; by Surg. R. Logan, 15th Ky. Disch'd Feb. 6, '63; pens'd.	390	Williams, R., Pt., E, 97th New York, age 24.	June 2, '64.	Right; circular; by Surg. W. P. Chambers, 97th N. Y. Disch'd Nov. 18, 1864; pensioned.
348	Taney, P., Pt., A, 73d N. Y., age 21.	May 10, '64.	Left; circ.; by Surg. F. Prentice, 73d N. Y. Disch'd May 29, '65.	391	Williams, T., Pt., A, 142d N. Y., age 24.	Jan. 14, '65.	Left; circ.; by Surg. A. J. H. Buzzell, 3d N. H. Disch'd Aug. 30, 1865; pensioned.
349	Taylor, S. J., Pt., E, 30th Ala., age 21.	Dec. 16, '64.	Right; flap; by A. A. Surg. E. Woodruff. To Pr. Mar. Apr. '65.	392	Wilson, D. D., Pt., D, 3d Delaware, age 21.	June 3, '64.	Right; circ.; by Surg. J. Ebersole, 19th Ind. Disch'd April 19, 1865; pensioned.
350	Taylor, N., Pt., D, 1st Massachusetts.	May 5, '62.	Left; circular. Discharged Oct. 29, 1862; pensioned.	393	Wilson, J. L., Pt., D, 34th Iowa, age 22.	Aug. 23, '64.	Right; flap; by Surg. V. H. Coffman, 34th Iowa. Disch'd Oct. 23, 1864; pensioned.
351	Thacker, J. F., Pt., A, 23d Virginia, age 48.	Sept. 19, '64.	Right; circular. To Ft. McHenry January 5, 1865.	394	Wilson, W. C., Pt., I, 5th Kansas Cavalry.	June 1, '64.	Left; flap; by Surg. C. E. Swasey, U. S. V. Disch'd Sept. 18, 1864; pensioned.
352	Thomas, J. M., Pt., II, 24th Ala., age 35.	Dec. 15, '64.	Left; antero-posterior flap. To Provost Marshal Jan. 23, 1865.	395	Wingate, W., Pt., II, 6th Pennsylvania Reserves.	Dec. 13, '62.	Right; circular. Discharged Feb. 12, '63; pensioned.
353	Thomas, W., Pt., D, 4th Col. Troops, age 22.	June 15, '64.	Left; flap. Discharged Feb. 10, 1865; pensioned.	396	Wood, A., Pt., A, 118th Pennsylvania, age 20.	Sept. 30, Oct. 2, '64.	Left; circular. Disch'd July 28, 1865.
354	Thomas, W. H., Serg't, I, 5th Colored Troops.	Feb. 19, '65.	Right; circular; by Asst. Surg. H. C. Merryweather, 5th Col. Tr'ys. Disch'd July 25, 1865; pensioned.	397	Wood, G. T., Pt., F, 67th New York, age 31.	May 5, '64.	Left; flap. Discharged July 15, 1864; pensioned.
355	Thompson, A., Corp'l, II, 122d N. Y., age 20.	June 1, '64.	Right; flap. Discharged Oct. 7, 1864; pensioned.	398	Wood, J. V., Pt., C, 96th Ohio.	Nov. 3, '63.	Right; flap; by Surg. J. F. Hess, 96th Ohio. Disch'd Jan. 16, '64.
356	Thompson, E., Pt., M, 24th N. Y. Cav., age 26.	Mar. 31, '65.	Right; flap. Discharged Dec. 12, 1865. Spec. 325.				
357	Thompson, J. M., Capt., A, 49th Penn., age 26.	Sept. 19, '64.	Right; circular; by Surg. P. Leidy, 119th Pa. Discharged Jan. 13, 1865; pensioned.				
358	Thompson, N., Pt., A, 121st Penn., age 24.	July 1, '63.	Left; lateral flap. Discharged June 1, 1864; pensioned.				



No.	NAME, AGE, AND MILITARY DESCRIPTION.	DATES.	OPERATIONS, OPERATOR, RESULT.	No.	NAME, AGE, AND MILITARY DESCRIPTION.	DATES.	OPERATIONS, OPERATOR, RESULT.
399	Wolfe, G., Pt., E, 3d Kentucky Cavalry, age 39.	Sept. 30, '64.	Right; circular; by Surg. R. M. Fairleigh, 3d Ky. Cav. Disch'd June 26, 1865; pensioned.	403	Young, R., Pt., I, 27th Michigan, age 26.	May 6, '64.	Left. Disch'd Sept. 20, 1864; pensioned.
400	Wright, J., Pt., E, 30th Indiana, age 30.	Dec. 16, '64.	Left; circular. Disch'd April 4, 1865; pensioned.	404	Zeigler, H., Pt., G, 138th Pennsylvania, age 23.	Oct. 19, '64.	Left; circular; by Asst. Surg. G. Steiner, 151st N. Y. Disch'd April 15, 1865; pensioned.
401	Wright, W., 1st Lieut. and Adj't., 146th N. Y.	May 5, '64.	Left; flap. Disch'd Sept. 28, '64.	405	Zeller, E. R., Pt., E, 36th Illinois, age 24.	Nov. 25, '63.	Right; flap; by Surg. H. E. Hasse, 24th Wis. Discharged July 28, 1864; pensioned.
402	Young, E., Pt., I, 8th Kentucky.	Sept. 20, '63.	Right; flap; by Surg. H. Herriek, 17th Ohio. Discharged April 6, 1864.	406	Zug, J. T., Lieut., H, 7th Pennsylvania Reserves.	Dec. 13, '62.	Right. Discharged June 12, '63; pensioned.

One of the operations succeeded an unsatisfactory excision at the elbow. Thirteen of the patients had received severe injuries in other regions, and several underwent simultaneous operations in other parts. Thus, one had the opposite limb amputated at the shoulder, two at the upper third of the arm, one lost a leg, and another submitted to Chopart's operation. There were practised consecutively, on the limbs already mutilated, an exarticulation at the shoulder, three re-amputations at the upper third, six re-amputations in the middle third, an amputation of a leg, six operations on necrosed stumps, a ball extraction, a ligation of the axillary, and a ligation of a minor artery. Consecutive hæmorrhage of a serious nature occurred in seven cases, including that in which a ligature was placed on the axillary. Gangrene supervened in ten cases, and grave erysipelatos inflammation in four cases.

§ *Fatal Cases.*—Of the five hundred and twelve primary amputations at the lower third of the arm for shot injury, one hundred and six or 20.7 per cent. had fatal results. The unsuccessful operations were practised on one hundred and one Union and five Confederate soldiers. Fifty-seven were on the right and forty-eight on the left side, and in one case this particular was not recorded. The proportion of injuries from large projectiles was not excessive. Two patients were mutilated by solid cannon shot, five by shell fragments, and one by the premature explosion of a cannon, but ninety-eight were wounded by small missiles. Eleven patients had serious wounds in other regions than the upper arm, and two of these underwent simultaneous amputations—one of the remaining forearm, the other at mid thigh. A large proportion of the deaths were referred to pyæmia or septicæmic infection. Consecutive operations were practised in six instances. There were two re-amputations of the arm higher up, an amputation of the opposite arm at upper third, a removal of a sequestrum, a removal of a ball and of enlarged ends of nerves, and a ligation of the brachial artery. There were nine cases of hospital gangrene, and four of phlegmonous erysipelas. Consecutive hæmorrhage occurred twice only, including the case in which the brachial was tied. Specimens from nine of the cases are preserved in the Museum. The following is an example:

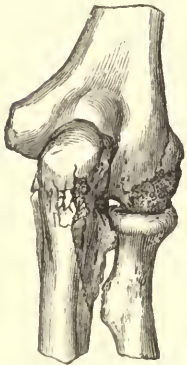

FIG. 528.—Shot Fracture of the olecranon and outer condyles of the right elbow. Spec. 3088.

CASE 1668.—Private S. W. Williams, Co. F, 2d United States Sharpshooters, aged 35 years, was wounded by a minie ball in the right elbow, at Petersburg, June 16, 1864, and was amputated on the field, by Dr. A. Garcelon, of Maine, by the circular method. The specimen (FIG. 528) was contributed by the operator, and consists of "the fractured bones of the right elbow. A ball appears to have passed obliquely from rear to front, breaking the posterior surface of the olecranon and chipping the outer condyle. A partial fracture extends above the articulation in the humerus and for the length of the specimen in the ulna. After being received into the hospital of the 3d division of the Second Corps, and transferred thence to the depot hospital at City Point, the patient was, on June 28th, admitted to Armory Square Hospital, at Washington. Surgeon D. W. Bliss, U. S. V., reported: "Amputation at the lower third of the arm was performed, before admission, on account of gunshot fracture. Erysipelas exists at the wound. Simple dressings, stimulants, and nourishing diet were prescribed. The patient died August 4, 1864."

TABLE LXXIII.

Condensed Summary of One Hundred and Six Unsuccessful Cases of Primary Amputation in the Lower Third of the Shaft of the Humerus.

No.	NAME, AGE, AND MILITARY DESCRIPTION.	DATES.	OPERATIONS, OPERATOR, RESULT.	No.	NAME, AGE, AND MILITARY DESCRIPTION.	DATES.	OPERATIONS, OPERATOR, RESULT.
1	Adair, H., Pt., G, 70th Indiana, age 26.	June 16, '64.	Left; double flap; by Surg. J. W. Hastings, 70th Ind. Died July 20, 1864, traumatic erysipelas.	38	H—, J., Pt., K, 109th New York, age 23.	June 17, '64.	Right; circular. Died July 19, '64, pyemia. <i>Spec.</i> 4741.
2	Alexander, P., Pt., F, 11th Wisconsin, age 21.	April 9, '65.	Right; flap. Died May 6, 1865, in typhoid condition.	39	Hovser, M., Pt., C, 30th Colored Troops.	Feb. 11, '65.	Left; circ.; by Surg. L. Barnes, 6th Colored Troops. Died April 9, 1865, chronic dysentery.
3	Andrews, C. B., Pt., C, 21st Conn., age 19.	May 16, '64.	Left. Died June 18, 1864.	40	Jackson, H., Pt., E, 4th Colored Troops.	Sept. 20, '64.	Left; (also amp. thigh.) Died Oct. 11, 1864, exhaustion.
4	Andrews, G., Pt., E, 54th Ohio.	Aug. 24, '64.	Left; by Surg. A. C. Messenger, 57th Ohio. Died Sept. 24, 1864.	41	Jackson, S., Pt., G, 58th Mass., age 45.	June 1, '64.	Right; circular. Died July 4, 1864, exhaustion.
5	Avery, C., Serg't, K, 36th Mass., age 28.	June 3, '64.	Right; lateral flap. Died June 30, 1864, pyemia.	42	Jerauld, W. F., Lieut., C, 97th Indiana.	July 13, '63.	Left. Died July 31, 1863.
6	Baldwin, L., Serg't, E, 6th Connecticut.	Aug. 16, '64.	Right. Died Sept. 8, 1864, pyemia.	43	Johnson, J. J., Pt., B, 83d Indiana.	June 27, '64.	Right; by Surg. A. C. Messenger, 57th Ohio. Died June 27, 1864.
7	Baskin, A., Pt., E, 78th Colored Troops.	Dec. 15, '64.	Left; flap. Died Dec. 23, 1864, pyemia.	44	King, J., Pt., C, 185th New York, age 32.	Mar. 29, '65.	Right; circular. Died May 19, 1865, pyemia.
8	Blanchard, N. A. D., Pt., K, 61st C. T., age 20.	Oct. 10, '64.	Left; circ. by Surg. S. J. Quimby, 61st Col'd Troops. Died Feb. 3, 1865, consumption.	45	King, J., Pt., D, 141st Penn., age 20.	May 6, '64.	Right; by Surg. H. F. Lyster, 5th Mich. Died June 3, 1864.
9	Broek, J., Pt., G, 97th Indiana.	July 13, '63.	Left; by Surg. A. Goslin, 48th Ill. Died Sept 1, 1863, acute dysentery.	46	Kinnau, L. J., Pt., D, 179th New York, age 41.	July 17, '64.	Right. Died June 25, 1864.
10	Call, L., Corp'l, F, 33d Ohio, age 28.	July 20, '64.	Right; re-amp.; gangrene. Died Nov. 17, 1864, chronic diarrhoea.	47	Lafferty, G. W., Pt., K, 53d Penn., age 25.	May 12, '64.	Left. Died June 11, 1864.
11	Campbell, P., Pt., D, 10th N. H., age 37.	May 14, '64.	Right. Died June 4, 1864, typhoid fever.	48	LaF—, G., Pt., E, 26th New York.	Dec. 13, '62.	Right; flap; (also wound of knee joint.) Died Jan. 14, 1863, pyemia. <i>Spec.</i> 718.
12	Carleton, H. D., Pt., F, 37th Wisconsin, age 24.	June 17, '64.	Right; circular. Died Aug. 22, 1864, exhaustion.	49	Libby, J. W., Pt., I, 20th Maine.	Oct. 1, '64.	Left. Died Nov. 8, 1864.
13	Christy, S., Pt., F, 188th Penn., age 17.	Sept. 29, '64.	Left. Died Nov. 14, 1864, pyemia.	50	Long, J. C., Corp'l, G, 145th Pennsylvania.	July 7, '64.	Right; by Surg. G. L. Potter, 145th Pa. Died July 2, '64, pyemia.
14	C—, H., Pt., A, 8th N. J., age 25.	June 16, '64.	Left; by Surg. W. Watson, 105th Pa. Died July 19, 1864, exhaustion. <i>Spec.</i> 3093.	51	Major, W. N., Pt., 11th South Carolina.	May 13, '64.	Right; (also wound of side.) Died May 14, 1864.
15	Calwell, A. N., Pt., E, 1st R. I. Artillery.	Nov. 7, '63.	Left; also amp. right forearm; by A. Surg. H. G. Taylor, 8th N. J. Died one hour after operation.	52	McDermott, J., Pt., H, 71st New York.	June 17, '64.	Left; ant.-post. flap. Died July 21, 1864, exhaustion.
16	Cook, T., Pt., K, 1st New Jersey.	May 10, '64.	Right. Died May 25, 1864.	53	McGonigal, A. M., Pt., I, 126th Pennsylvania.	Dec. 13, '62.	Right. Died Dec. 31, 1862.
17	Cooper, H. F., Pt., M, 14th N. Y. H. A., age 34.	May 12, '64.	Left; bilateral flaps. Died June 9, 1864, typhoid fever.	54	McHenry, W., Corp'l, B, 123d Ind., age 39.	June 27, '64.	Right; by Surg. C. D. Moore, 13th Ky. Died July 20, 1864.
18	Cottrell, A. H., Pt., F, 4th Minnesota.	Oct. 5, '64.	Left; by Surg. E. J. Bueck, 18th Wisconsin. Died Oct. 19, 1864.	55	McLane, J., Pt., H, 155th New York.	May 18, '64.	Right; by Surg. M. Rizer, 72d Pa. Died May 23, 1864.
19	Cox, P., Pt., G, 66th Ohio, age 42.	May 29, '64.	Right; circular; by Surg. J. W. Brock, 66th Ohio. Died Sept. 21, 1865, chronic diarrhoea.	56	McKinley, W. D., Pt., D, 84th Indiana.	Jan. 27, '64.	Right; by Surg. C. J. Walton, 21st Ky. Died July 11, 1864.
20	Coyne, J., Pt., I, 170th New York.	June 16, '64.	Left. Died June 20, 1864.	57	Merchison, J., Pt., I, 27th Georgia.	June 1, '64.	Right; irregular flaps; by Surg. Matthews, C. S. A. Gangrene; re-amp.; erysipelas. Died June 25, 1864.
21	Cronan, J., Pt., E, 10th Louisiana, age 27.	May 12, '64.	Right; circ.; hæmorrhage June 1; lig. brachial. Died June 2, '64.	58	Merrick, T. L., Corp'l, E, 51st Penn.	June 17, '64.	Right; by Surg. W. C. Shurlock, 51st Pa. Died June 20, 1864.
22	Crumbie, P., Serg't, G, 123d N. Y., age 19.	May 25, '64.	Right; circ.; by A. Surg. L. W. Kennedy, 123d New York. Died Oct. 19, 1864.	59	Miller, A. J., Pt., G, 93d Pennsylvania.	Oct. 19, '64.	Right; circular. Died November 16, 1864, peritonitis.
23	Cullins, D. P., Pt., C, 155th N. Y., age 20.	June 3, '64.	Left; circ.; by Surg. F. Wylie, 155th N. Y. Died July 7, 1864, pyemia.	60	Miller, J., Pt., I, 4th Michigan.	June 27, '64.	Right; flap. Died July 19, 1862; post-mortem.
24	Daily, J., Pt., Olynech's Georgia Art., age 42.	Dec. 13, '64.	Right; by Surg. J. A. Lair, 53d Ohio. Died Feb. 11, 1865.	61	Miller, P., Pt., D, 8th Col. Troops, age 21.	Sept. 29, '64.	Left; circular. Died November 27, 1864, exhaustion.
25	Davenport, A., Pt., C, 170th New York.	May 24, '64.	Left; by Surg. M. F. Regan, 164th N. Y. Died June 18, '64, pyemia.	62	Miller, P., Pt., A, 13th W. Virginia.	Sept. 4, '64.	Left; by A. A. Surg. J. R. Uhler. Died Sept. 12, 1864, erysipelas.
26	Davis, J. K. P., Pt., E, 37th Mass., age 19.	June 11, '64.	Right. Died July 29, 1864, irritative fever.	63	Minor, H., Pt., E, 49th Missouri, age 23.	April 4, '65.	Right; by Surg. E. Powell, 72d Ill. Died April 13, 1865.
27	Etter, S., Corp'l, K, 1st Missouri S. M. Cav.	Oct. 13, '63.	Right. Died November 2, 1863.	64	Mooney, J., Pt., E, 147th Pennsylvania.	July 20, '64.	Right. Died August 11, 1864.
28	Ewell, K., Serg't, L, 8th N. Y. H. A., age 23.	Oct. 27, '64.	Right; circular; by Surgeon A. Churchhill, 8th N. Y. H'y Art. Died Jan. 2, 1865, pyemia.	65	Moulton, S. J., Pt., C, 17th Vermont, age 19.	June 3, '64.	Left. Died June 25, 1864.
29	F—, T., 16th Pa. Cav., age 24.	Sept. 9, '64.	Right; flap; by A. A. Surg. J. F. Thompson; (wound of thigh and testicles.) Died Oct. 16, 1864, exhaustion. <i>Spec.</i> 3210.	66	Newton, C., Corp'l, E, 5th New York Cav.	Sept. 19, '64.	Right. Died October 19, 1864, pyemia.
30	Flinn, F., Corp'l, G, 46th Ohio.	Sept. 1, '64.	Left; by Surg. R. Morris, 103d Ill. Died Sept. 2, 1864.	67	Nickerson, R., Pt., E, 19th Maine.	July 3, '63.	Right. Died July 21, 1863.
31	Flynn, J., Pt., E, 17th Conn.	July 1, '63.	Left. Died July 14, 1863.	68	Patrick, J. W., Pt., I, 27th Indiana, age 22.	May 28, '64.	Left; circular. Died July 8, 1864, variola.
32	Gillaspie, A., Pt., I, 2d Penn. Art.	June 17, '64.	Right; Died July 23, 1864.	69	P—, N. R., Pt., F, 5th W. Virginia, age 23.	Sept. 3, '64.	Left; lateral flap; by A. A. Surg. J. Younglove. Died Sept. 16, '64, doublepleurisy. <i>Spec.</i> 3468.
33	Gough, J., Pt., H, 118th New York, age 46.	May 16, '64.	Left. Died June 27, 1864.	70	Pierson, W. T., Pt., G, 6th Maryland.	Oct. 19, '64.	Left; flap; hæmorrhage. Died Nov. 8, 1864, pyemia.
34	Gowran, J., Pt., G, 59th New York, age 22.	July 27, '64.	Left; circular; by Surg. D. W. Maull, 1st Del. Gangrene; removal nerve and necrosed bone. Died Dec. 7, 1865, typhoid fever.	71	Potter, H. C., Corp'l, H, 2d N. Y. H'y Art., age 20.	June 6, '64.	Left; circular; by Surg. G. L. Potter, 145th Penn. Died Aug. 2, 1864, gangrene.
35	Hartzel, S., Pt., A, 184th Penn., age 22.	June 23, '64.	Left; by Surg. G. F. Winslow, U. S. N.; (also penetrating wound of chest.) Died June 30, 1864. <i>Spec.</i> 3008.	72	Pullam, T., Pt., H, 50th Ohio, age 23.	Aug. 3, '64.	Left; by Surg. S. K. Crawford, 50th Ohio. Died Oct. 12, 1864, consumption.
36	Harvey, G. B., 1st Lieut., E, 10th Tenn. C., age 29.	Dec. 4, '64.	Right; circular; by Surg. J. E. Herbst, U. S. V. Died Jan. 2, 1865, pyemia.	73	Quinn, A., Serg't, H, 183d Penn., age 30.	June 10, '64.	Left; circular. Died July 12, '64, exhaustion.
37	Hedglin, J. W., Pt., B, 184th Penn., age 22.	June 3, '64.	Right; by Surg. G. Chaddock, 7th Mich. Died July 1, '64, debility.	74	Renka, A., Pt., C, 26th Wisconsin.	May 16, '64.	Right; by Surg. W. P. Hobbs, 85th Ind. Died June 2, 1864.
				75	Renn, J., Pt., G, 69th New York, age 42.	June 3, '64.	Right; by Surg. J. A. Spencer, 69th N. Y. Died June 15, 1864.
				76	Riley, C. H., Pt., C, 61st New York, age 28.	June 3, '64.	Right; ant.-post. flap; by Surg. C. T. Stevens, 77th N. Y. Died June 29, 1864, typhoid fever.
				77	Robinson, P., Pt., F, 203d Pennsylvania.	Jan. 15, '65.	Right; circular; by Surg. G. C. Jarvis, 7th Conn. Died Feb. 23, 1865, gangrene.



No.	NAME, AGE, AND MILITARY DESCRIPTION.	DATES.	OPERATIONS, OPERATOR, RESULT.	No.	NAME, AGE, AND MILITARY DESCRIPTION.	DATES.	OPERATIONS, OPERATOR, RESULT.
78	Russell, D., Pt., F., 13th Colored Troops, age 30.	April 1, '65.	Left; flap: by A. A. Surg. H. C. Hill. Died Apr. 7, '65, prostration.	92	Tinklepaugh, S., Pt., G., 49th Penn., age 28.	May 5, '64.	Right; circular. Died August 21, 1864.
79	Ruth, J., Pt., II, 6th Arkansas, age 32.	Nov. 30, Dec. 1, 1864.	Right; flap; amp. of left arm Jan. 2, 1865, exhaustion.	93	T——, P. II., Pt., K., 34th Indiana, age 27.	June 27, '63.	Left. Died June 29, 1863. <i>Spec.</i> 1637.
80	Sawyer, H., Pt., D, 8th Kansas, age 18.	Dec. 15, '64.	Left; circular. Died Feb. 2, 1865, pyæmia.	94	Vasconsellos, M., Pt., C., 23d Mass., age 19.	Mar. 14, '62.	Right; circular: by A. Surg. S. E. Stone, 23d Mass. Died April 12, 1862, pyæmia.
81	Schellie, G., Pt., E, 11th Missouri, age 24.	Dec. 16, 17, '64.	Right; circular: by A. Surg. W. B. Trull, U.S.V. Gang.; erysip. Died Dec. 30, '64, irritable fever.	95	Wakeman, M., Pt., II, 5th Michigan.	June 16, '64.	Left: by Surg. H. F. Lyster, 5th Mich. Died April 25, 1865.
82	Shouldise, H., Pt., I, 81st Indiana, age 19.	July 4, '64.	Left; circ.: by Surg. J. D. Brumley, U.S.V. Died Aug. 1, 1861, chronic diarrhoea.	96	Walters, W., Pt., II, 2d New York II'vy Art.	June 16, '64.	Left; circ.: by Surg. J. W. Wishart, 140th Penn. Died July 21, 1864.
83	Smith, H. C., Corp'l, E, 8th Michigan, age 29.	June 10, '63.	Left; circular. Died July 31, '64, pyæmia.	97	Webb, H., Pt., C, 186th New York, age 18.	April 2, '65.	Right; circular: by A. Surg. J. H. Kimball, 32d Maine. Died May 1, 1865, pyæmia.
84	Smith, J., Farrier, B, 3d Michigan Cav., age 28.	June 10, '63.	Left; circular: by A. Staff Surg. J. Roberts. (Also w'd side: severe hæmorrhage.) Died June 23, 1865, pleurisy.	98	Welch, J., Pt., D, 69th New York.	May 31, '64.	Right. Died July 11, 1864.
85	South, W., Corp'l, A, 145th Pennsylvania.	May 10, '64.	Right; circular: by Surg. J. W. Wishart, 140th Penn. Died May 23, 1864.	99	West, J. O., Pt., I, 31st Maine.	May 12, '64.	By A. Surg. A. G. Sprague, 7th R. I. Died May 23, 1864.
86	S——, J., Lieut., C, 88th New York.	May 5, '64.	Left; by Surg. W. O. Meagher, 69th N. Y. Died May 8, 1864. <i>Spec.</i> 3116.	100	White, A., Corp'l, F, 140th Penn., age 23.	May 10, '64.	Left; circ.: by Surg. J. W. Wishart, 140th Penn. Died June 13, 1864, pyæmia.
87	Stang, C., Corp'l, D, 24th New Jersey.	Dec. 13, '62.	Left; (also wound of both legs.) Died December 20, 1862.	101	Williams, S. W., Pt., F, 2d U. S. S. S., age 35.	June 16, '64.	Right; by Dr. A. Garcelon. Died August 1, 1864. <i>Spec.</i> 3088.
88	Stropper, S., Pt., II, 30th Mass., age 29.	Oct. 19, '64.	Right; ant.-post. flaps. Died Dec. 4, 1864, pneumonia.	102	Willoughby, J. R., Pt., 37th Wis., age 21.	July 6, '64.	Left; flap: by Surg. W. B. Fox, 8th Mich. Died Sept. 12, 1864, debility.
89	Tarbox, C. M., Pt., E, 100th N. York, age 40.	June 16, '64.	Left; circular. Died June 29, '64, exhaustion.	103	Wymer, H., Corp'l, F, 57th Penn., age 23.	June 16, '64.	Left. Died July 12, 1864, exhaustion.
90	Taylor, J., Pt., K, 7th Rhode Island, age 37.	June 6, '64.	Right. Died July 6, 1864, irritable fever.	104	Yanson, H., Pt., F, 91st New York, age 25.	April 2, '65.	Right; ant.-post. flaps. Died May 6, 1864, exhaustion.
91	Thambray, J. A., Pt., II, 1st N. Y. Art., age 30.	Sept. 30, Oct. 1, '64.	Right; flap. Died November 2, 1864, exhaustion.	105	Young, J. T., Pt., I, 38th Ohio, age 19.	June 21, '64.	Right; circ.: by Surg. J. Hallen, 38th Ohio. Died July 30, 1864, gangrene.
				106	Young, J. W., Pt., C, 55th Ohio, age 18.	Mar. 19, '65.	Left; circular. Died April 16, '65, typhoid fever.

CASE 1669.—Private G. L——, Co. E, 26th New York, was wounded at Fredericksburg, December 13, 1862, and entered Lincoln Hospital on the 24th. Surgeon H. Bryant, U. S. V., contributed the specimen, consisting of the soft tissues of the stump of the right arm, amputated in the lowest third (*Cat. Surg. Sect.*, 1866, p. 502, *Spec.* 718), and recorded the following history: "He received three wounds. Two of these were gunshot wounds of the right arm, and one of them an injury of the right knee joint. The upper wound of the arm was caused by a musket ball perforating the biceps. Another ball entered the arm lower down, fractured the lower part of the humerus and penetrated the elbow joint. In consequence of this latter wound the arm was amputated at its lower third on December 13th. The stump was very painful and was much swollen at first. After application of cold dressings the swelling, tenderness, and pain began to subside, but left the soft parts having a gangrenous appearance. Fomentations were then applied, after which the stump improved rapidly and continued to do well. The treatment thus far was stimulating and sedative. On the 2d of January, there began to be symptoms of arthritis affecting the knee joint. The wound near this joint had emitted a copious and constant discharge. Cold-water dressings were applied for one or two days, when an alterative treatment was substituted. On the 5th, the patient had a high fever and night sweating. Tonics were now added to the treatment. The swelling and pain of the knee joint now began to subside; but on the 9th, symptoms of pyæmia were noticed. The stimulants were doubled and nourishment was freely administered. Nausea, accompanied at night by profuse sweating, soon supervened, and the patient continued to sink until January 14th, when he died. The autopsy was performed twenty-seven hours after death. There was but slight muscular rigidity at the time. The lower extremity was first examined. The limb was swollen and infiltrated with serum. Upon laying open the knee joint and the muscles of the thigh, the extensor muscles were found to be dissected up to the hip joint by a large collection of fibrinous, flaky, and tenacious pus of a gray color, which emitted an offensive odor of sulphuretted hydrogen. The abscesses thus laid open communicated with the knee joint, and extended posteriorly, behind the tibia, under the deep fascia, down the leg. In the knee joint was found extensive erosion of the cartilage upon the articular surfaces of the femur and tibia, especially of the former, the internal condyle of which was partly denuded. An oval island of cartilage was left upon its extremity, the denudation being especially at the borders. The internal articular facet of the tibia was also more affected than the external. A dark deposit was found upon the synovial membrane, which extended above the patella, and also over the crucial ligaments, thus appearing upon the whole synovial membrane. The thorax was next examined. The lungs presented a mottled, black, and reticulated appearance. Melanic matter was found in the parenchyma. The black spots were distinguishable by their feeling from the other portions of the lung. This melanic deposit was found in all parts of the lung, but especially posteriorly. The bronchial glands were enlarged and were as black as ink. In the abdomen the liver was large and finely mottled. The gall bladder was light colored. The spleen had a very light color, was enlarged and rather hard. Both kidneys were large and pale. The intestines were full of gas, the colon being especially distended."

#### 4. Primary Amputations of the Arm, without Indication of the Seat of Incision.—

Two hundred and forty-seven cases of primary amputation of the upper arm were reported, in which the precise seat of operation was not specified. Although there is no reason to question their authenticity, their defectiveness in detail detracts from their statistical value, and, in proportion to their number, impairs the exactness of conclusions deducible from

the preceding series. When, however, it is considered that the total number of primary amputations of the arm under consideration is three thousand two hundred and fifty-nine, and that the results as to fatality are ascertained in all, it will be admitted that the uncertainty as to the precise seat of seven per cent. of the operations does not greatly vitiate the conclusions.

§ *Successful Cases.*—Only seventy-seven of the cases of primary amputations of the arm for shot injury thus briefly recorded resulted in recovery. These seventy-seven operations were practised on sixty-four Union and thirteen Confederate soldiers. The injuries were caused by shell fragments in three instances; in the remainder, by small projectiles. In nine instances, the limb implicated was not specified; in sixty-eight, the operations were equally divided between the right and left sides. Eight of the patients returned to modified duty, nine were exchanged or paroled, one was sent to a lunatic asylum, fifty-two were discharged, and seven are not accounted for. Three patients received serious wounds in other regions of the body. Eight survived re-amputations, in one instance at the shoulder joint. One underwent an amputation of the opposite arm. Few details of these cases are reported save those recorded in the tabular statement.

TABLE LXXIV.

*Condensed Summary of Seventy-Seven Cases of Recoveries after Primary Amputation of the Arm, the Point of Ablation Unspecified.*

No.	NAME, AGE, AND MILITARY DESCRIPTION.	DATES.	OPERATIONS, OPERATOR, RESULT.	No.	NAME, AGE, AND MILITARY DESCRIPTION.	DATES.	OPERATIONS, OPERATOR, RESULT.
1	Ackerly, N. S., Pt., K, 48th New York.	July 18, '63.	Left. Discharged Nov. 16, 1863.	24	Edwards, R. D., Private, Blunt's Battery.	April 1, '65.	Right. Recovered.
2	Adams, M., Civilian.	May 17, '64.	Left. Recovered.	25	Fairehild, L., Col., 2d Wisconsin.	July 1, '63.	Left. Recovery; union by first intention.
3	Alsen, H., Pt., I, 8th Wisconsin.	May 22, '63.	Right; by Surg. M. W. Fish, 11th Missouri. Discharged.	26	Fernald, C. O., Pt., B, 4th Maine, age 21.	July 21, '61.	Right; by Surg. S. C. Hawkins, 4th Me. Aug. 1, 1861, re-amp. Disch'd Oct. 27, '61; pensioned.
4	Anderson, J. B., Pt., F, 17th Michigan.	Nov. 23, '63.	Right; by Surg. G. B. Cogswell, 25th Mass. Recovered.	27	Franklin, W. F., Pt., C, 14th Indiana.	Dec. 13, '62.	Right. Discharged May 7, 1863.
5	Bantwell, J. O., Pt., A, 59th Georgia, age 25.	July 2, '63.	Right. Exchanged Oct. 3, 1863.	28	Frazer, A. H., Lt., F, 51st Illinois.	Nov. 5, '62.	Right. Resigned Aug. 6, 1864.
6	Banty, N. I., Pt., G, 61st Virginia, age 22.	June 6, '64.	Right. Sent to prison August 11, 1864.	29	Fuller, W., Serg't, I, 20th New York S. M.	July 2, '63.	Left. Duty Sept. 11, 1863.
7	Batchelor, S. K., Corp'l, K, 7th Md., age 35.	June 19, '64.	Left; by Surg. A. A. White, 8th Md. July 8, '64, re-amp. Discharged Dec. 26, '64; pensioned.	30	Galland, M., Pt., G, 11th Alabama, age 19.	July 3, '63.	Left. To Provost Marshal Sept. 10, 1863.
8	Beamer, A., Pt., G, 125th Pennsylvania.	Sept. 17, '62.	Right. Discharged Dec. 8, 1862.	31	Gelbart, T., Pt., B, 20th New York.	Sept. 17, '62.	Left. Disch'd May 5, 1863; pensioned. Sept. 9, 1863, re-amp.
9	Beck, L., Corp'l, A, 3d Missouri.	Dec. 25, '61.	Right. Discharged; pensioned.	32	Gould, A. E., Pt., A, 14th Illinois.	May 19, '63.	Right; by Surg. H. Z. Gill, U. S. V. Discharged Sept. 3, 1863.
10	Bixler, J. A., Pt., C, 5th U. S. Artillery.	Sept. 17, '62.	Left. Discharged Dec. 5, 1862; pensioned; re-amputated.	33	Gatshall, H., Pt., D, 48th Pennsylvania.	Aug. 30, '62.	Right. Discharged Oct. 9, 1862; pensioned.
11	Borden, J. E., Pt., 1, 7th Wisconsin, age 36.	May 5, '64.	Right. Disch'd December 27, 1864.	34	Gray, O. B., Lieut., E, 120th New York.	July 2, '63.	Right. To V. R. C. Oct. 9, 1863.
12	Bradshaw, J. A.	May 17, '64.	Right. Sent to Provost Marshal Sept. 11, 1864.	35	Gregory, J. M., Lieut., H, 2d Connecticut Art.	Oct. 19, '63.	Right; by Surgeon H. Plumb, 2d Conn. Art. Disch'd Jan. 10, '65.
13	Burgart, T., Pt., D, 18th Mississippi.	May 3, '63.	Left. June 25, 1863, exchanged.	36	Griswold, L. S., Pt., D, 14th Connecticut.	Sept. 17, '62.	Left; by Surg. H. Jones, 3d Vt.; re-amp. Disch'd Jan. 24, '63; pen'd.
14	Caldwell, S., Pt., D, 88th Pennsylvania.	Sept. 17, '64.	Left; hemorrhage. Disch'd April 23, 1865. Died Jan. 17, 1866.	37	Hall, J. D., Pt., G, 10th Alabama, age 21.	July 2, '63.	Left. Exchanged May 1, 1864.
15	Campion, P., Serg't, K, 20th Massachusetts.	Dec. 13, '62.	Right. Discharged January 8, 1864.	38	Harbison, W., Pt., K, 27th Indiana, age 23.	May 3, '63.	Left. Discharged Dec. 2, 1863.
16	Clark, R., Serg't, G, 83d Indiana.	May 19, '63.	Left. Discharged August 27, '63.	39	Hatcher, R., Pt., F, 24th Alabama.	Sept. 19, '63.	Right. Recovered.
17	Cobb, H. L., Pt., D, 14th Tenn.	Dec. 13, '62.	Right. Sent to prison February 13, 1863.	40	Henson, H. H., Pt., E, 19th Col. T., age 22.	Dec. 16, '64.	Right. Discharged April 14, 1865.
18	Coffin, T., Freedman, age 35.	Mar. -, '64.	Left; gangrene; (also frac. right hand; hemorrhage; amp. right arm.) Discharged July 19, 1864.	41	Hoover, W. H., Pt., F, 11th New Jersey.	May 3, '63.	Left. To V. R. C. Feb. 4, 1864.
19	Converse, L., Lieut., 2d New Hampshire.	July 2, '63.	Right. Mustered out Aug., 1865.	42	Hoppy, E., Pt., D, 2d Artillery.	July 21, '61.	Left. July 31, 1861, re-amp. Disch'd Feb. 24, 1862; pensioned.
20	Conway, L. N., Pt., B, 11th Iowa.	July 22, '64.	Left. Discharged; pensioned.	43	Hughes, I., Pt., E, 19th Indiana.	July 1, '63.	Right. Discharged Sept. 28, 1863.
21	Coulter, W. B., Captain, 53d Pennsylvania.	Dec. 13, '62.	Right. Resigned April 8, 1864.	44	Hughes, J., Pt., B, 18th Massachusetts.	May 3, '63.	Right. Disch'd March 4, 1864.
22	Dawson, M., Pt., B, 9th Alabama, age 23.	July 3, '63.	Left. Sent to Provost Marshal September 1, 1863.	45	Hunting, B., Corp'l, C, 3d Iowa, age 37.	Sept. 17, '61.	Left; by A. Surg. D. M. Cool, 3d Iowa. Disch'd Nov. 7, '61; pens'd.
23	Dooley, J. H., Capt., F, 40th Indiana.	Nov. 25, '63.	Right; by Surg. A. W. Heise, 100th Ill. Disch'd Feb. 10, 1864; pensioned.	46	Jeffries, W., Pt., F, 49th Colored Troops.	June 7, '63.	Right. Discharged July 23, 1863.
				47	Jones, T. M., Pt., G, 22d Illinois.	Nov. 7, '61.	Left. Discharged Jan. 1, 1863.



No.	NAME, AGE, AND MILITARY DESCRIPTION.	DATES.	OPERATIONS, OPERATOR, RESULT.	No.	NAME, AGE, AND MILITARY DESCRIPTION.	DATES.	OPERATIONS, OPERATOR, RESULT.
48	Julian, P., Lieut., B, 54th Indiana.	July 12, '63.	Left. Duty August 10, 1863.	62	Phillipe, A., Pt., A, 72d New York.	May 5, '62.	Discharged March 17, 1863.
49	Junge, A., Pt., H, 28th Wisconsin, age 30.	Mar. 31, Ap. 1, '65	Right; by Surg. C. Winne. 77th Ill. Discharged June 20, 1865.	63	Priece, J., Pt., E, 50th Ill.	April 6, '62.	Recovered.
50	Kereheval, E. R., Lieut., 6th Indiana Cavalry.	Aug. 29, '62.	Left. Resigned February 17, '63.	64	Porter, S. A., Capt., B, 104th Illinois.	Sept. 19, '63.	Left. Resigned August 25, 1864.
51	Lenix, C., Pt., 26th Pennsylvania.	July 3, '63.	Right. Discharged August 24, 1864.	65	Readington, H., Pt., G, 7th Indiana.	Mar. 23, '62.	Left. Discharged June 18, 1863.
52	Leonard, T. H., Pt., C, 24th Alabama.	Sept. 19, '63.	Recovery.	66	Rollins, O., Pt., G, 10th Missouri.	Oct. 4, '62.	Discharged May 16, 1863.
53	Marks, E., Pt., B, 17th Wisconsin.	May 16, '63.	Left. Discharged August 8, '63; pensioned.	67	Seward, S. H., Lieut., H, 14th Conn.	May 6, '64.	Left; by Surg. T. A. Dudley, 14th Conn. Disch'd July 29, '64; pen. Right. Discharged; pensioned.
54	Martineau, A., Pt., A, 118th New York.	Oct. 27, '64.	Left; by Surg. W. V. Harrison, C. S. A. Re-amp. Dec. 9, '64. Disch'd May 10, '65; pensioned.	68	Simmons, J. Y., Pt., K, Missouri Home Guards.	Aug. 6, '61.	
55	Mead, J., Pt., I, 58th Indiana.	Dec. 31, 1862, Jan. 1, 1863.	Left; by Surg. J. R. Adams, 58th Ind. Amp. at shoul. joint Feb. 4, 1863. Disch'd August 13, '63; pensioned.	69	Small, W. F., Pt., A, 100th New York.	May 31, '62.	Discharged July 10, 1862.
56	Meyer, H., Corp'l, H, 58th New York.	Aug. 28, '62.	Duty. October 14, 1862.	70	Smalley, I. R., Serg't, K, 104th New York.	Dec. 12, '62.	Discharged February 16, 1863.
57	Nugent, A. A., Pt., I, 21st Wisconsin, age 16.	Mar. 19, '65.	Right; by Surg. J. T. Reeves, 21st Wis. Disch'd May 16, 1865; pensioned.	71	Tilley, W., Pt., G, 9th Maine.	July 18, '61.	Left. Discharged Oct. 14, 1863.
58	Orlanzo, P., Pt., E, 3d Artillery, age 28.	May 20, '64.	Right; erysipelas. To St. Elizabeth January 20, 1865.	72	Tilton, W. L., Pt., K, 149th N. Y., age 28.	June 27, '61.	Right; by A. Surg. H. E. Goodman, U. S. V.
59	Paden, J., Pt., E, 16th Ohio.	Jan. 19, '61.	Right. Discharged August 18, 1861; pensioned.	73	Van Horn, W., Pt., I, 89th Illinois.	Nov. 25, '63.	Left. Discharged August, 1865.
60	Pate, C. A., Pt., C, 24th Alabama.	Sept. 19, '63.	Recovery. Union by first intention.	74	Wilcox, J., Pt., C, 3d Wisconsin.	Aug. 9, '62.	Discharged November 17, 1862.
61	Pelton, W., Pt., E, 7th Ohio.	Nov. 27, '63.	Left. Discharged January 22, 1864.	75	Wise, J. F., Pt., H, 20th South Carolina.	Oct. 19, '64.	Left. Exchanged.
				76	Woolbridge, W. R., Corporal, G, 29th Iowa.	April 2, '64.	Left. Discharged June 21, 1865.
				77	Wright, A., Pt., C, 76th Ohio.	Jan. 11, '63.	Right. Discharged April 17, '63; pensioned.

*Fatal Cases.*—One hundred and seventy cases of the series of two hundred and forty-seven primary amputations for shot injury of the upper arm, but without more explicit indication of the seat of operation, had fatal terminations—a percentage of mortality of 68.9. The right limb was involved in sixty-six, the left in fifty-eight, of the hundred and twenty-four cases in which this point was noted. The operations were practised on one hundred and sixty-five patients, of whom twelve were Confederates. Five patients submitted to synchronous amputations of both arms. In nine cases, the injuries were inflicted by shell fragments; in two, by the premature explosion of cannon; in one hundred and fifty-four, by small projectiles. Four patients underwent simultaneous amputations of the thigh, and four of the leg, and one an excision in the shaft of the opposite humerus. Two patients submitted to re-amputation higher up, and one to a resection of the protruding end of the humerus. One patient was drowned, two died of tetanus, five from the effects of consecutive hæmorrhage, three from gangrene, and twelve from pyæmia. In the large majority of cases, there was no indication of the proximate cause of death.

TABLE LXXV.

*Condensed Summary of One Hundred and Seventy Fatal Primary Amputations of the Arm, the Point of Ablation Unspecified.*

No.	NAME, AGE, AND MILITARY DESCRIPTION.	DATES.	OPERATIONS, OPERATOR, RESULT.	No.	NAME, AGE, AND MILITARY DESCRIPTION.	DATES.	OPERATIONS, OPERATOR, RESULT.
1	Allen, A., Pt., E, 109th New York, age 19.	June 17, '64.	Died June 26, 1864, chronic diarrhœa.	8	Arms, A. J., Pt., H, 71st New York.	July 2, '61.	Right; (also amputation of thigh.) Died July 3, 1863.
2	Allen, C., Pt., E, 9th Indiana.	Dec. 13, '61.	Died February 13, 1862.	9	Arnold, O. W., Corp'l, K, 105th Ohio.	Sept. 19, '63.	Right. Died November 9, 1863.
3	Allen, R., Corp'l, A, 13th Ohio.	Nov. 25, '63.	Right. Died Dec. 20, 1863.	10	Atkinson, J. C., Pt., I, 28th Pennsylvania.	July 20, '61.	Left. Died Sept. 27, 1864.
4	Alleywood, R., Pt., E, 5th Michigan.	July 3, '63.	Right. Died July 27, 1863.	11	Babbett, C. F., Lieut., A, 141st New York.	July 20, '64.	Right. Died July 21, 1864.
5	Anderson, W. T., Corp'l, C, Cutts' Georgia Art.	Prim'ry.	Died December 10, 1863.	12	Bakling, D., Pt., F, 1st Tennessee.	Oct. 8, '62.	Died October 22, 1862.
6	Anguish, H., Pt., I, 157th New York.	July 1, '63.	Right. Died July 26, 1863, pyæmia.	13	Barkel, P., Corp'l, A, 77th Indiana.	Dec. 16, '64.	Died January 14, 1865.
7	Anthony, N. M., Pt., G, 21st Mississippi.	Prim'ry.	Left. Died December 15, 1862.	14	Bear, A., Pt., G, 29th Iowa.	April 2, '64.	By Surg. A. Shaw, 29th Iowa. Died June 19, 1864.

No.	NAME, AGE, AND MILITARY DESCRIPTION.	DATES.	OPERATIONS, OPERATOR, RESULT.	No.	NAME, AGE, AND MILITARY DESCRIPTION.	DATES.	OPERATIONS, OPERATOR, RESULT.
15	Benbow, W., Pt., A, 39th Indiana.	Sept. 20, '63.	Left. Died September 29, 1863, tetanus.	61	Geyer, C. G., Pt., J, 2d Illinois Art., age 28.	Aug. 21, '64.	Left. Died Sept. 18, '64, pyæmia.
16	Benson, H., Pt., F, 9th Maine.	May 20, '64.	Right. Died June 1, 1864, gangrene.	62	Gibbs, S. E., Serg't, F, 2d Conn. Artillery.	June 1, '64.	Left. Died June 2, 1864.
17	Berry, G. H., Corp'l, B, 16th Maine.	Dec. 13, '62.	Right. Died January 2, 1863, pyæmia.	63	Giles, C., Serg't, B, 17th Infantry.	July 3, '63.	Left. Died July 16, 1863, gangrene.
18	Bissinott, J. S., Pt., B, 11th Infantry.	Aug. 18, '64.	Left; by Surg. A. A. White, 8th Maryland. Died Aug. 29, 1864.	64	Gillin, J., Pt., F, 44th N. Y., age 28.	May 23, '64.	Left; by Surg. M. W. Townsend, 44th N. Y.; hæmorrhage; re-amputation June 3. Died June 26, 1864, gangrene.
19	Blandikou, C., Pt., A, 9th Wisconsin.	April 4, '64.	Right; by A. Surg. W. L. Nieholson, 29th Ia. Died April 6, '64.	65	Goodruff, G. S., Pt., G, 8th Vermont.	Oct. 19, '64.	Died October 20, 1864.
20	Bonner, J., Pt., G, 63d Colored Troops.	June 7, '63.	Left. Died June 24, 1863.	66	Grossman, W., Pt., C, 11th Pa. Reserves, age 23.	May 8, '64.	Right; by Surg. W. Lyons, 11th Pa.; (amp. leg.) Died Aug. 3, '64.
21	Bowden, F., Pt., K, 16th Maine.	July 2, '63.	Right. Died July 20, 1863.	67	Grouse, J., Pt., I, 52d Ohio, age 46.	Sept. 1, '64.	Left. Drowned Dec. 28, 1864.
22	Boyles, D. J., Pt., D, 1st Maryland.	June 9, '63.	Left; (also wound of hip.) Died July 3, 1863.	68	Groves, J. H., Corp'l, II, 58th Indiana.	Dec. 31, '62.	Left. Died January 16, 1863.
23	Boyle, J., Pt., I, 19th Massachusetts.	Dec. 13, '62.	Right; by Surg. J. F. Dyer, 19th Mass. Died January 2, 1863.	69	Hardy, J. H., Pt., 60th Ohio.	June 17, '64.	Right. Died June 21, 1864.
24	Burgess, F. M., Lieut., H, 14th Kentucky.	July, 1864.	Left. Died August 10, 1864.	70	Harlin, M. M., Pt., G, 70th Indiana.	Prim'ry, April 6, '62.	(Wound of face and arm.) Died July 9, 1864.
25	Burse, H. H., Pt., E, 11th Maine.	July 26, '64.	Died July 26, 1864.	71	Harlington, W., Pt., B, 55th Illinois.	April 6, '62.	Died May 11, 1862.
26	Byrnes, D. L., Pt., D, 11th Michigan.	Dec. 31, '62.	Left. Died January 2, 1863.	72	Haynes, J. F., Pt., G, 1st Me. H'vy Art.	June 20, '61.	(Wound of both legs and thorax.) Died June 22, 1864.
27	Canty, J., Pt., 5th Mass. Battery, age 36.	July 3, '63.	Right; hæmorrhage. Died July 7, 1863.	73	Heger, A., Corp'l, D, 7th New York.	Mar. 31, '65.	Died April 1, 1865.
28	Carter, G. W., Corp'l, A, 70th Ind., age 19.	May 15, '64.	Right; by Surg. A. W. Reagan, 70th Ind. Died July 16, 1864, consumption.	74	Heistand, M., Pt., A, 49th Ohio.	Sept. 19, '63.	Left. Died Dec. 30, 1863.
29	Cash, F. W., Pt., F, 15th New Jersey.	May 3, '63.	Died May 15, 1863.	75	Higgins, J., Pt., A, 1st Rhode Island Art.	July 3, '63.	By Surg. J. F. Dyer, 19th Mass. Died July 8, 1863.
30	Castner, J. C., Pt., H, 1st Ohio.	Nov. 25, '63.	Died December 23, 1863.	76	Hillman, T., Pt., G, 27th Indiana.	May 3, '63.	Right. Died May, 1863.
31	Cero, C., Pt., D, 20th Massachusetts.	Dec. 13, '62.	Left. Died December 31, 1862.	77	Holbrook, H., Lieut., M, 3d Rhode Island Art.	Aug. 19, '63.	Died Aug. 21, 1863.
32	Chapman, F., Pt., K, 76th New York.	July 3, '63.	Right. Died July 8, 1863.	78	Holenback, A., Pt., K, 149th New York.	May 3, '63.	Right. Died June 12, 1863.
33	Chase, D. P., Capt., A, 2d U. S. S. S.	May 3, '63.	Right. Died May 8, 1863.	79	Holley, J., Pt., C, 83d Ohio.	Jan. 11, '63.	Right; by Surg. J. B. Sparks, 19th Ky. Died Feb. 9, 1863.
34	Clendenning, C. W., S'g't, K, 143d Penn.	May 6, '64.	Left. Died June 1, '64, pyæmia.	80	Holman, J. H., Pt., A, 12th Wisconsin.	July 22, '62.	Left; by Surg. H. McKennan, 17th Wis. Died Sept. 17, 1864.
35	Cole, E. I., Pt., C, 140th Penn., age 29.	July 3, '63.	Left. Died Aug. 2, '63, pyæmia.	81	Holmes, G. W., Lieut., C, 113th Ohio.	Sept. 19, '63.	Left. Died Oct. 10, 1863.
36	Colvin, S. D., Lieut., F, 36th Indiana.	Sept. 19, '63.	Left. Died October 9, 1863.	82	Howe, H. L., Serg't, F, 89th New York.	Sept. 30, '64.	Died Sept. 30, 1864.
37	Conklin, C., Pt., C, 25th Mass., age 22.	Feb. 8, '62.	Died February 13, 1862.	83	Habelier, E. W., Pt., I, 72d Pennsylvania.	Dec. 13, '63.	Left. Died Jan. 4, 1863.
38	Coulson, G. H., Pt., E, 78th Ohio.	July 22, '64.	Left; by Surg. J. S. Reeves, 78th Ohio. Died August 4, 1864.	84	Hulbert, J. H., Corp'l, D, 4th Vermont.	May 5, '64.	Left. Died May, 1864.
39	Cramer, S., Pt., B, 142d Pennsylvania.	July 1, '63.	Left; (also amputation of thigh.) Died July 9, 1863.	85	Hunkerfillar, W. R., Pt., B, 19th Alabama.	Sept. 19, '63.	Tetanic symptoms. Died Oct. 17, 1863.
40	Crownshield, L. C., Pt., G, 142d N. Y.	Dec. 25, '64.	Left; (also amputation of leg.) Died January 11, 1865.	86	Jaynes, N., Pt., E, 11th West Virginia.	Oct. 19, '64.	Died Oct. 19, 1864.
41	DeFries, F. F., Corp'l, G, 114th Illinois.	Dec. 15, '64.	Right; (also wound of head and leg.) Died December 16, 1864.	87	Jenning, W., Pt., A, 22d Michigan.	Sept. 19, '63.	Right. Died of wounds.
42	Degarmo, C., Pt., I, 12th Wisconsin.	July 22, '64.	Right; by Surg. E. M. Reeves, 12th Wis. Died Sept. 20, 1864.	88	Jigler, D., Pt., H, 53d Indiana.	Oct. 5, '62.	(Wound of arm and leg.) Died. '62.
43	Deuziger, N., Pt., H, 7th New York.	Dec. 13, '62.	Right. Died January 18, 1863.	89	Kerney, D., Pt., D, 2d Missouri.	Sept. 19, '63.	Right. Died Nov. 29, 1863.
44	Dickinson, E. J., Pt., H, 23d Mass., age 23.	May 16, '64.	Left. Died June 17, '64, pyæmia.	90	Laehine, L., Pt., D, 1st New York Art.	June 18, '64.	Right and left; (other injuries.) Died June 20, 1864.
45	Dille, L., Pt., D, 140th Pennsylvania.	July 3, '63.	By Surg. C. S. Wood, 66th N. Y.; (wound of thigh, scrotum, and penis.) Died July 19, 1863.	91	Larew, J., Corp'l, C, 83d Ohio.	Jan. 11, '63.	Left; by Surg. J. W. F. Gerrish, 67th Ind. Died Feb. 4, 1863.
46	Dirlan, H. S., Lieut., G, 41st Ohio.	Nov. 25, '63.	Right. Died December 18, 1863.	92	Leach, L. N., Pt., E, 2d U. S. S. S.	May 5, '64.	Left. Died May 12, 1864.
47	Dixon, W. C., Pt., B, 78th Illinois.	June 27, '64.	Right. Died August 1, 1864.	93	Leonard, P., Pt., A, 13th Ohio.	Dec. 31, '62.	Left. Died March 1, 1863, pyæmia.
48	Dorson, J., Pt., H, 76th New York.	July 1, '63.	Left. Died.	94	Limberger, W., Serg't, D, 11th Indiana.	May 16, '63.	Died May, 1863.
49	Dowd, F., Pt., F, 12th Connecticut.	Mar. 27, '63.	Died April 3, 1863.	95	Long, C., Pt., F, 3d Infantry.	July 3, '63.	Left; (also wound of leg.) Died July 24, 1863.
50	Durbin, J., Serg't, K, 49th Ohio.	June 18, '61.	Right. Died July 12, 1864.	96	Lynch, P., Serg't, E, 100th New York.	July 18, '63.	Right. Died August 15, 1863.
51	Durkee, H., Pt., H, 21st Ohio.	Aug. 10, '64.	Right; (also wound of side.) Died August 20, 1864.	97	Martin, J., Pt., B, 124th Ohio.	May 26, '64.	Died May, 1864.
52	Ebringhaus, E., Pt., A, 54th New York.	Feb. 10, '65.	Left. Died March 7, '65, typhoid fever.	98	Martin, J., Pt., F, 102d New York.	Aug. 9, '62.	Died August 27, 1862.
53	Feeman, L., Corp'l, H, 16th Ohio.	July 12, '64.	Left. Died August 4, 1864.	99	Martin, J. B., Corp., C, 14th Virginia.	July 3, '63.	Right. Died July 10, 1863.
54	Fiske, R., Pt., B, 124th Illinois, age 34.	Mar. 30, '65.	By A. Surg. C. A. Bueher, 72d Ill.; (also wound of leg.) Died April 21, 1865.	100	Maux, L., A, 15th New York Heavy Artillery.	Aug. 18, '64.	By Surg. A. A. White, 8th Maryland. Died August 22, 1864.
55	Freeman, J., Rebel prisoner, age 21.	June 17, '64.	Left; (also wound of lung.) Died June 21, 1864, exhaustion.	101	McClosky, A., D, 20th Kentucky.	April 6, '62.	Right. Died April 28, 1862, pyæmia.
56	Fruit, E., Serg't, K, 41st Illinois.	July 11, '63.	Left; by Surg. J. L. Dieken, 47th Indiana. Died July, 1863.	102	McConnell, G., Pt., I, 14th New York.	July 3, '63.	Left; (also wound of chest.) Died July 8, 1863.
57	Fultex, F., C, 11th Connecticut, age 46.	May 16, '64.	Right. Died June 18, '64, pyæmia.	103	McCorms, W. J., Pt., G, 6th Indiana.	May 15, '64.	Right. Died May 21, 1864.
58	Gabert, W., Pt., A, 60th Indiana.	Jan. 11, '63.	Left; by Surg. J. W. F. Gerrish, 67th Ind.; (also wound of leg.) Died January 29, 1863.	104	Mellugh, O., Pt., D, 37th New York.	Dec. 13, '62.	Both. Died.
59	Gault, A., Serg't, F, 4th Ohio, ago 22.	May 27, '64.	Left. Died Aug. 19, '64, pyæmia.	105	McNally, P., Major, 2d West Virginia.	Aug. '63.	Left; (also wound of chest.) Died September 22, 1863.
60	Genung, S., Pt., G, 13th Illinois.	Dec. 29, '62.	Died April 1, 1863.	106	McNeal, E., Pt., K, 52d Ohio.	July 20, '64.	Left. Died August 21, 1864.
				107	Mears, J., Pt., K, 63d Ohio.	Oct. 3, '62.	Left. Died October 4, 1862.



No.	NAME, AGE, AND MILITARY DESCRIPTION.	DATES.	OPERATIONS, OPERATOR, RESULT.	No.	NAME, AGE, AND MILITARY DESCRIPTION.	DATES.	OPERATIONS, OPERATOR, RESULT.
110	Messeroe, G. G., Pt., G., 127th New York.	Dec. 9, '64.	Left. Died December 18, 1864.	140	Smith, J., Pt., II, 104th Illinois.	Sept. 19, '63.	Right. Died Oct. 9, 1863.
111	Moore, D., Corp'l, C, 9th Georgia.	May 5, '64.	Died May 7, 1864.	141	Snyder, G., Pt., I, 1st Delaware.	Dec. 13, '62.	(Wound of arm and chest.) Died Dec. 13, 1862.
112	Morehouse, G. G., Serg't, I, 14th Illinois.	Oct. 5, '62.	Right. Died November 2, 1862.	142	Soper, A., Pt., E, 30th Illinois.	July 22, '64.	Left. Died August 8, 1864.
113	Morrell, R., Pt., E, 108th New York.	Sept. 17, '62.	Died October 4, 1862.	143	Speetes, J., Pt., II, 35th Ohio.	Sept. 19, '63.	Right. Died Oct. 15, 1863.
114	Nichols, J., Pt., K, 90th New York.	May 27, '63.	Right; by Surg. C. Robertson, 159th N. Y. Died July 12, 1863.	144	Standish, G. W., Pt., K, 4th Massachusetts.	June 14, '63.	Right. Died June 29, 1863, diarrhoea.
115	Oehsle, S., Pt., E, 58th Illinois.	Oct. 3, '62.	Right. Died October 24, 1862.	145	Steinmaker, F., Serg't Maj., 59th New York.	July 3, '63.	Left. Died July 12, 1863.
116	Peer, J. O., Pt., II, 22d Michigan.	Sept. 19, '63.	Right. Died October 15, 1863.	146	Stetson, S. N., Pt., B, 32d Maine.	May 31, '64.	Right. Died June 22, 1864.
117	Permea, H., Pt., I, 14th Alabama.	July 3, '63.	Left. Died July 12, 1863.	147	Stevens, A. P., Lieut., F, 17th Michigan.	Nov. 16, '63.	Right. Died December 11, 1863.
118	Phillips, P., Pt., D, 99th Pennsylvania, age 24.	May 9, '64.	Left. Died May 22, 1864.	148	Stouffer, F., Pt., F, 18th Infantry.	Dec. 31, '62.	Left. Died January 10, 1863.
119	Pierce, J. M., Pt., F, 145th Pennsylvania.	May 3, '63.	Right; (also wound of lung:) by Surg. F. Reynolds, 88th New York. Died June 14, 1863.	149	Stowe, J., Pt., F, 57th North Carolina.	Sept. 29, '64.	Right. Died December 6, 1863.
120	Pierce, T. J., Pt., B, 12th New Hampshire.	May 3, '63.	Right. Died June 20, 1863.	150	Stein, J., Pt., F, 55th Pennsylvania.	Sept. 29, '64.	Right. Died October 2, 1864.
121	Pierson, D. W., Rebel prisoner, age 39.	June 24, '64.	Right. Died June 27, 1864, exhaustion.	151	Tanner, T. B., Pt., D, 3d Rhode Island Art.	July 10, '63.	Both; secondary hæmorrhage. Died August 9, 1863.
122	Pool, J., Pt., B, 16th Ga.	July, 1863.	(Wound of arm and leg.) Died July 6, 1863.	152	Thorn, T. J., Lieut., D, 16th N. C., age 30.	July 3, '63.	Right; (also amp. at thigh.) Died July 30, 1863, pyæmia.
123	Proppf, J., Pt., D, 10th Missouri.	July 4, '63.	Left; erysipelas and hæmorrhage. Died Aug. 6, 1863.	154	Tincher, J., Pt., C, 57th Indiana.	Dec. 16, '64.	Right. Died January 2, 1865.
124	Ralston, J., Lieut., B, 64th Indiana.	Dec. 29, '62.	Died Jan. 12, 1863.	155	Tinekham, T. L., Pt., II, 33d Wisconsin.	April 24, '64.	Right; (also excision left humerus.) Died April 25, 1864.
125	Ray, S., Serg't, D, 84th Illinois.	Sept. 2, '64.	Also amputation of leg. Died Sept. 6, 1864.	156	Tousley, L. M., Pt., C, 15th Mass., age 27.	Sept. 17, '62.	Left. Died September 29, 1862.
126	Rhinhart, A. J., Pt., A, 18th Penn. Cav.	Sept. 19, '64.	Left. Died Oct. 16, 1865.	157	Tricee, J. H., Pt., B, 56th Pennsylvania.	May 6, '64.	Died May 6, 1864.
127	Richardson, G. W., Pt., B, 9th Tennessee.	Oct. 8, '62.	Died Oct. 8, 1862.	158	Vannatta, L., Pt., A, 23d Wisconsin.	Jan. 11, '63.	Both; by Surg. J. W. F. Gerrish, 67th Ind. Died March 6, 1863.
128	Riggs, A., Pt., E, 60th Illinois.	Sept. 1, '64.	Right. Died Sept. 8, 1864.	160	Wadley, A. H., Pt., G, 31st Maine.	May 18, '64.	Right; by Surg. W. R. D. Blackwood, 48th Pa. Died July 2, 1864, exhaustion.
129	Roller, J., Pt., C, 11th Illinois.	May 22, '63.	Right. Died July 28, 1863.	161	Wait, M. C., Pt., D, 39th Illinois, age 21.	June 23, '64.	Right. Died July 2, 1864, exhaustion.
130	Rubio, C., Pt., I, 97th N. York.	June 2, '64.	Died October 25, 1864.	162	Walters, A. P., Pt., C, 150th Penn.	May 5, '64.	Died August 25, 1864.
131	Ruppball, H., Pt., A, 39th Illinois, age 20.	May 20, '64.	Right. Died June 18, 1864, exhaustion.	163	Weleh, W., Pt., G, 88th New York.	Sept. 17, '62.	Right. Died October 16, 1862.
132	Savage, G., Pt., A, 2d Ct. Artillery.	June 1, '64.	Both. Died June 4, 1864.	164	Wheeler, G. M., Pt., E, 6th Indiana.	Nov. 25, '63.	Right. Died December 16, 1863.
133	Savage, P., Pt., I, 4th Artillery.	Sept. 19, '63.	Right. Died Oct. 9, 1863.	165	Williams, J. W., Pt., F, 8th Iowa.	April 6, '62.	Died May 6, 1862.
134	Schroeder, C. J., Pt., D, 51st New York.	Dec. 13, '62.	Died Dec. 30, 1862.	166	Wilson, I. N., Pt., K, 16th Maine.	Dec. 13, '62.	Right. Died January 6, 1863.
135	Seagar, J. G., Pt., I, 11th Missouri.	Sept. 19, '62.	Left; (also wound of abdomen.) Died Sept. 21, 1862.	167	Wilson, J., Pt., 21st New York Battery.	Mar. 27, '65.	Left; (also amp. thigh.) Died March 27, 1865.
136	Shaffer, J., Pt., D, 18th Infantry.	July 3, '64.	Right; (also wound of side.) Died July 16, 1864.	168	Wood, J. H., Pt., B, 4th New Jersey, age 21.	May 6, '64.	Right; hæmorrhage; re-amputation May 28, 1864. Died June 1, 1864, pyæmia.
137	Smiller, E., Pt., D, 41st Ohio.	Nov. 25, '63.	Died Nov. 25, 1863.	169	Wood, O., Pt., F, 86th Indiana.	Nov. 25, '63.	Left. Died December 26, 1863.
138	Smith, H., Corp'l, F, 2d New Hampshire.	May 5, '62.	Died June 7, 1862.	170	Yoethas, A., Pt., II, 148th Pennsylvania.	May 2, '63.	Left. Died June 9, 1863.

Over four-fifths of the patients enumerated in the foregoing statement perished within thirty days from the reception of the injury.<sup>1</sup> But few found their way to general hospitals, which partly accounts for the paucity of reported details. The surgical statistician has often occasion to observe a predominance of fatal cases in series imperfectly recorded.

This group completes the tabulation of the three thousand two hundred and fifty-nine reported primary amputations for shot injury of the arm in the continuity, with a fatality of six hundred and two cases, or 18.4 per cent.

INTERMEDIARY AMPUTATIONS IN THE CONTINUITY.—In nine hundred and two of the series of fifty-four hundred and fifty-six cases of amputation of the arm for the effects of shot injury, or in about one-fifth of the forty-five hundred and seventy-two cases in which the precise date of amputation was ascertained, the operations were practised during the interval from the third to the thirtieth day, inclusive, from the date of the reception of the injury. The mortality rate was 33.4 per cent., or 15 per cent. greater than after primary amputation in the same region.

<sup>1</sup> Of the 165 patients represented in the foregoing statement of 170 operations, 43 died in the first, 22 in the second, 31 in the third, 22 in the fourth week from the dates of operation.

**1. Intermediary Amputations in the Upper Third of the Arm.**—Three hundred and forty-seven cases are classified in this category, with a mortality rate of 31.1 per cent.

§ *Successful Cases.*—Two hundred and thirty-nine cases of intermediary amputation at the upper third of the arm recovered. The operations were practised on two hundred and thirty-one Union and eight Confederate soldiers. Nearly a tenth of the amputations succeeded excisions, ligations, or amputations lower down in the limb. In some instances operative intervention was demanded by uncontrollable hæmorrhage or by rapidly spreading gangrene. In other cases constitutional disturbance was so grave that delay was adjudged more hazardous than interference. Often the reasons for regarding intermediary amputation as advisable or compulsory were not reported, as in the following case:

CASE 1670.—Private C. Dunn, Co. L, 5th Michigan Cavalry, aged 27 years, was wounded at Newtown, November 12, 1864. He was received into the hospital of the 1st division, Cavalry Corps, where Assistant Surgeon C. I. Wilson, U. S. A., recorded: "Shot fracture of right humerus. Splints and bandages applied. Arm amputated on November 20th, by muscular flap method, at surgical neck of humerus, by Assistant Surgeon H. B. Noble, 2d Ohio Cavalry. General condition of patient bad; reaction slow. Treatment: Simple dressings and stimulants. January 14, 1865, patient recovered and sent to General Hospital." He was afterward treated at McKim's Mansion, Baltimore, and lastly at Broad and Cherry Streets Hospital, Philadelphia. On April 23, 1865, the patient was discharged from service and pensioned. Examiner H. O. Hitchcock, of Kalamazoo, Michigan, May 20, 1866, reported: "Wound entirely healed, but occasionally reopens and discharges for a time. Health perfect, except now and then, in damp weather and on the approach of a storm, some neuralgia about the stump. Has not used an artificial arm because of difficulty of attaching it to his body." The pensioner was shot at Kalamazoo, by some unknown person, on the 16th day of May, 1869, and died the same day. The pension examiner contributed a photograph of this pensioner, which is copied in the wood-cut (FIG. 529).

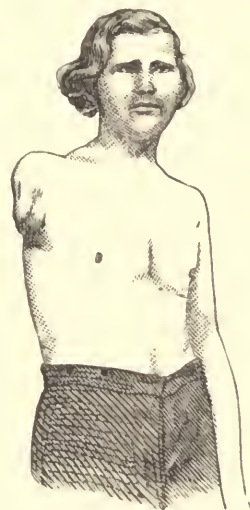


FIG. 529.—Stump after an intermediary amputation at the upper third of the arm.

Several amputations were in cases in which primary excisions of the diaphysis were likely to terminate disastrously. In the following, amputation was resorted to when an attempt at intermediary excision in the shaft proved abortive:

CASE 1671.—Private W. Johnson, Co. E, 7th Rhode Island, aged 24 years, was wounded in the right arm, at Fredericksburg, December 13, 1862, and entered the Patent Office Hospital, at Washington, four days afterward. Acting Assistant Surgeon H. Stone contributed the specimen (FIG. 530), with the following description: "This case might be somewhat instructive as an illustration of the extent to which a musket ball may break up the shafts of the long bones in passing through them, and also of the necessity of a thorough exploration of such fractures before undertaking any method of conservative treatment. The case is that of W. Johnson, admitted to this hospital, for gunshot fracture of the right humerus, on December 17th. When admitted, extreme œdematous effusion, with extensive vesication of the arm and forearm, existed, caused by binding of splints to the arm by cords, without the usual roller having been first applied to the forearm and upward. The cords and splints were immediately removed, and for twenty-four hours the arm was treated for the removal of the œdema by the application of stimulating liniments, bandages, and by elevated position of the extremity. At the end of that period the swelling had been sufficiently reduced to admit of an examination of the fracture and the performance of such operation as might be indicated. The ball had entered the arm anteriorly, at the upper portion of the middle third, and, passing diagonally downward through the humerus, came out posteriorly, two inches above the elbow joint. Upon passing the finger into the anterior wound loose fragments of bone were found, which indicated that probably two inches of the shaft had been so broken up as to require resection, which was decided upon. The wound was laid open upward, and the shattered end of the upper portion of the humerus removed by the saw. Upon cutting downward to prepare for the removal of the jagged end of the lower portion, the shaft was found to have been split down in three splinters and completely broken off close to the condyles. Upon this discovery the resection was abandoned and amputation decided upon, and performed by the bilateral flap operation at the point, or a little above, of the insertion of the anterior portion of the deltoid muscle. The section of the humerus, preserved among the fragments of the specimen, it was decided to remove, so that sound flaps could be obtained above the lacerated and inflamed parts about the fracture. Cold-water dressings were applied to the stump for eight or ten days, afterward cerate and lint. The flaps healed by first intention. On January 15, 1863, Johnson received his discharge from service, and left the hospital." The specimen consists of the two lower thirds of the right humerus, shattered for six inches by a conoidal ball. A portion of the battered missile is attached. In a section of the upper extremity of the specimen the attempt at excision is shown. In his application for commutation, 1870, the pensioner reported the stump as healed, and stated that Surgeon J. D. Robinson, U. S. V., performed the amputation. He was paid June 4, 1875.

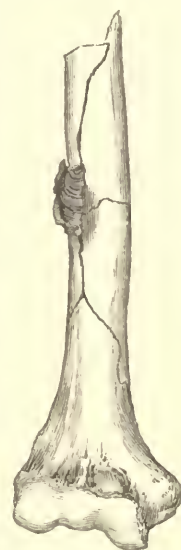

FIG. 530.—Shot fissures of right humerus.—intermediary amputation. Spec. 486.



The period of convalescence was usually more protracted after intermediary than after primary amputations. In some cases, however, the stumps promptly healed. More vessels needed to be tied, as a rule, than in primary operations. In the following case an exorbitant number of ligatures were required:

CASE 1672.—Corporal W. A. Emerson, Co. H, 16th Massachusetts, aged 25 years, was wounded at White Oak Swamp, June 30, 1862, and admitted to Ascension Church Hospital, at Washington, four days afterward. Acting Assistant Surgeon W. W. Keen, jr., forwarded the specimen (FIG. 531), with the following history of the case: "The patient, previous to his enlistment a watchmaker, and in excellent health, was wounded in the right arm four and a half inches below the shoulder joint; the ball entering on the antero-internal surface, making its exit on the postero-external surface, passing directly through the humerus and making a comminuted fracture. He entered the hospital July 4th with nothing save a cold-water dressing; there were maggots in the wound; these were destroyed by dilute Labarraque's solution, and the arm was dressed on an internal angular splint in hopes of union. July 5th, some fragments of bone were extracted; the pus was of a dark grumous character; several large pieces of bone were left, as they were adherent by periosteum and might unite. July 8th, other pieces of bone were removed; the discharge is still unhealthy and sanious; the health of the man is much impaired, and he has a small bed-sore on his hip, but his mind is so cheerful that he bears up under suffering and danger with remarkable fortitude. I placed him on quinine and sulphate of iron, each two grains, four times a day, with milk punch and beef tea, and as immediate union was not to be hoped for, the arm was laid straight on a padded splint, and half a grain of sulphate of morphia was administered each night, inducing good sleep. July 19th, the suppuration still continued of the same character, and pieces of bone were still extracted every two or three days. There being no hope now of saving the arm, the man's health failing daily, Surgeon R. H. Coolidge, U. S. A., Medical Inspector, amputated in the surgical neck of the humerus by internal and external flaps, with but little hæmorrhage, the subclavian artery being compressed. The wound was united by silver wire and adhesive strips, and cold-water dressings employed—ten ligatures having been applied. Half a grain of morphia was immediately administered. July 20th, slept well; wound uniting by first intention; appetite good; a little suppuration in the track of the ligatures. July 23d, has slept well; the wound mostly united save a little of the edges, which were everted by the cutting out of the wires; seven of the ligatures came away with ease; dressings the same. July 28th, removed the adhesive plasters and applied others, as the first were loose; two other ligatures came away; wound doing admirably; dressed with resin cerate. August 3d, the remaining ligature came away; continued dressings. Sulphate of iron and sulphate of quinine, with milk punch, broths, and some little meat, was now allowed." The specimen consists of a portion of the shaft of the humerus, much comminuted at the junction of the upper thirds. Slight osseous deposit has occurred on a few of the fragments, but there is no attempt at union. A fragment of bullet is attached. The patient was discharged from service September 8, 1862, on certificate, by Surgeon J. C. Dorr, U. S. V., in charge of Ascension Church Hospital. In his application for commutation, 1870, the pensioner reported the stump as being in a "healthy condition." He was paid on June 4, 1875.



FIG. 531.—Shot comminution of shaft of right humerus, amputated intermediately. *Spec. 26.*

Diseased conditions of stumps were more frequent than after primary amputations, and there were several instances of necrosis of the protruding extremity of the humerus.

CASE 1673.—Private W. Lambert, Co. C, 148th Pennsylvania, aged 21 years, was wounded in the left arm, at Chancellorsville, May 3, 1863, and was operated upon at a Second Corps Hospital. Surgeon A. Heger, U. S. A., in charge of the Point Lookout Hospital, contributed the specimen (FIG. 532), with the following history of the case, by Acting Assistant Surgeon T. Siebold: "The patient was wounded on May 3d, and amputation by circular method was performed on May 11th, at the junction of the upper and middle thirds. He arrived here on June 14th, from Aquia Creek Hospital. July 10th, the stump had opened again and was, in the whole circumference, gangrenous, of the soft pulpous variety; bone of humerus protruding three-fourths of an inch. General condition of the patient better than would naturally be expected. Ordered the stump to be syringed every hour with diluted solution of chlorinated soda, and picked lint and dressings to be wet with the same. July 21st, the wound has improved nicely; the gangrenous action was stopped on the second day, and, on the third day, red, fresh granulations were to be seen all over. Extracted to-day a loose piece of humerus, which is a fine specimen of the destructive action of osteomyelitis. One-third of an inch long the entire bone became necrosed, and nearly two inches more at the longest point, and one inch more at the shortest, only the inner portion, the outer or cortical portion remaining intact. Only a few drops of blood followed the extraction. In place of the marrow there were already healthy granulations. The same treatment was continued, only the solution weaker and at longer intervals, gradually coming down to two or three times a day. August 21st, the wound has closed entirely, only a little proud flesh, as large as a pea, protruding yet, which was touched with nitrate of silver." The specimen consists of a delicate tubular sequestrum, nearly two inches in length, removed from the stump of the left humerus ten weeks after amputation. The patient was discharged on September 24, 1863, but re-entered the service on May 12, 1865, as captain of the 124th United States Colored Troops. He was ultimately mustered out on October 24, 1865, and pensioned. He died on March 29, 1868. The cause of his death is not known.



FIG. 532.—Sequestrum from an amputation of the left arm. *Spec. 1866.*

Thirty-three of the cases reported in the succeeding table furnished specimens for the Army Medical Museum.

## TABLE LXXVI.

Condensed Summary of Two Hundred and Thirty-Nine Cases of Recovery after Intermediary Amputation in the Upper Third of the Shaft of the Humerus.

NO.	NAME, AGE, AND MILITARY DESCRIPTION.	DATES.	OPERATIONS, OPERATOR, RESULT.	NO.	NAME, AGE, AND MILITARY DESCRIPTION.	DATES.	OPERATIONS, OPERATOR, RESULT.
1	Akers, G. W., Pt., C, 40th Illinois.	April 6, 19, '62.	Right; by A. Surg. D. Stahl, 10th Ill. Dis'd April 13, '63; pens'd.	39	Clancy, P., Pt., G, 67th New York, age 32.	May 6, 15, '64.	Left; ant. post. flap. Discharged Dec. 8, 1864; pensioned.
2	Albritton, W., Pt., E, 13th Tennessee Cav., age 24.	April 12, 15, '64.	Right; flap; by Asst. Surg. J. C. G. Happersett, U. S. A. Disch'd July 22, 1864; pensioned.	40	Clark, P., Pt., I, 97th Penn., age 24.	Aug. 16, Sept. 15, 1864.	Right; ant. post. flap; by A. A. Surg. E. B. Woolston. Must'd out Oct. 30, 1865. <i>Spec.</i> 3717.
3	Allender, J. B., Pt., A, 121st Penn., age 29.	May 8, 24, '64.	Left; by Surg. D. W. Bliss, U. S. V.; (exc. of elbow joint May 8, '64.) Disch'd Sept. 5, 1864; pens'd.	41	Clemens, R. B., Pt., Coonin's Art., age 24.	April 6, 15, '63.	Left; circular; by Surg. G. R. Sullivan, 39th New Jersey. Exchanged May 9, 1865.
4	Allison, J. M., Pt., M, 1st Artillery, age 23.	May 16, June 15, 1864.	Left; flap; by A. A. Surg. W. P. Moon. Disch'd Sept. 16, 1864; pensioned. <i>Spec.</i> 3612.	42	Comstock, A., Pt., I, 89th Illinois, age 30.	July 3, 24, '64.	Right; circular. Discharged May 30, 1865.
5	Anderson, W. F., Pt., Knapp's Penn. Battery.	Sept. 17, 26, '62.	Circular; by Asst. Surg. C. A. McCall, U. S. A. Disch'd Nov. 24, 1862; pensioned. <i>Spec.</i> 168.	43	Cooper, S., Pt., G, 82d Ohio.	July 1, 5, '63.	Left. Discharged December 23, 1863; pensioned.
6	Arnold, P., Pt., B, 30th Indiana, age 21.	Sept. 1, 19, '64.	Left, circ.; by A. Surg. T. A. McGraw, U. S. V. Disch'd Sept. 29, 1864; pensioned.	44	Cornick, F., Pt., K, 36th Col. Troops, age 22.	Sept. 29, Oct. 19, 1864.	Right; flap; by A. A. Surg. C. C. Fla. Disch'd March 27, 1860; pensioned. <i>Spec.</i> 3402.
7	Armstrong, G., Pt., I, 143d Penn., age 19.	July 1, 7, '63.	Left; circular. Discharged Jan. 7, 1864; pensioned.	45	Craig, R. L., Pt., B, 2d Ind. Cav., age 24.	April 2, 10, '63.	Left; circ.; by Surg. J. B. Larkins, 17th Ind. Disch'd Oct. 25, 1865; pensioned.
8	Arthur, F. W., Pt., F, 57th Virginia, age 32.	July 2, 7, '63.	Left. Paroled Sept. 25, 1863.	46	Crampton, W. H., Pt., A, 28th New York.	Aug. 9, 21, '62.	Right; double flap; by Surg. J. E. Summers, U. S. A. Disch'd Sept. 24, '62; pens'd. <i>Spec.</i> 45.
9	Ault, J., Pt., C, 101st Indiana, age 28.	Nov. 25, Dec. 8, 1863.	Left; by Surg. C. Soellheim, 9th O.; (exc. humerus Nov. 25, '63.) Disch'd June 4, '64; pensioned.	47	Creutz, A., Pt., A, 82d Illinois.	July 20, 29, '64.	Left; circular. Disch'd Feb. 24, 1865; pensioned.
10	Bailey, J. S., Corp'l, F, 1st U. S. S. S.	May 4, J. 3, '63.	Left; circular. Discharged Aug. 26, 1863.	48	Crumbo, C., Pt., A, 13th Indiana.	July 11, Aug. 5, '61.	Left; by A. Surg. E. S. Duuster, U. S. A. Dis'd Dec. 10, '61; pens'd.
11	Barnett, C. M., Pt., F, 3d New Jersey Cavalry.	Aug. 21, Se. 11, '64.	Right; by A. A. Surg. M. Rizer. Disch'd Jan. 9, 1865; pensioned.	49	Dale, J. W., Serg't, B, 25th Illinois, age 22.	Sept. 20, Oct. 8, '63.	Left; flap; (re-amp. shoulder joint Jan. 16.) Dis'd Sep. 5, '64, post'd.
12	Barnett, S. L., Pt., K, 130th Pennsylvania.	Sept. 17, 27, '62.	Left; circ.; by Surg. H. Palmer, U. S. V. Dis'd Jan. 16, '63; pens'd.	50	Davis, A., Serg't, C, 142d Pennsylvania.	July 1, 9, '63.	Left; flap; by Asst. Surg. A. B. Haines, 19th Ind. Disch'd Dec. 18, 1863; pensioned.
13	Barnett, W. B., Lieut., B, 97th Ohio, age 28.	June 22, July 20, 1864.	Right; circ.; by A. A. Surg. L. E. Keeley. Duty Dec. 14, '64; pensioned. (Par. exc. June 22, '64.)	51	Davis, J. A., Pt., A, 9th West Virginia.	May 9, 16, '64.	Left; by Surg. J. Morris, 9th W. Va. Dis'd July 20, 1864; pen'd.
14	Baronouski, F., Pt., K, 46th Pennsylvania.	Sept. 14, 17, '62.	Left; flap. Disch'd Dec. 15, 1862; pensioned.	52	Day, J., Pt., F, 1st Mass. H. Art., age 30.	Oct. 1, 18, '64.	Right; flap; by A. A. Surg. G. A. Chesley. Dis'd Mar. 23, '65; pen'd.
15	Battin, T., Corp'l, C, 25th Ohio.	May 2, 14, '63.	Right. Discharged Sept. 17, 1863; pensioned.	53	Dempsey, E., Pt., C, 4th Kentucky Cav.	July 10, 13, '62.	Right; by Surg. C. Smith, 9th Mich. (also fract. left humerus.) Disch'd Jan. 1, 1863; pensioned.
16	Beck, S. E., Lieut., B, 53d N. C., age 50.	July 3, 10, '63.	Left. Exchanged March 3, 1864.	54	Dennerlee, L., Pt., B, 16th Infantry.	Sept. 19, 27, '63.	Left; flap. Discharged Jan. 27, 1864; pensioned.
17	Beers, W., Corp'l, C, 15th New Jersey, age 30.	May 3, 28, '63.	Right; flap; by Surg. R. Sharpe, 10th N. J. Dis'd Nov. 20, '63; pen.	55	Denning, W. B., Pt., F, 93d Ohio.	Nov. 25, 28, '63.	Right; by Surg. J. L. Teed, U. S. V. Disch'd Feb. 26, '64; pens'd.
18	Belton, A., Pt., H, 10th Kentucky.	Sept. 20, 23, '63.	Left. Discharged Dec. 11, 1863; pensioned.	56	Deweese, S., Pt., D, 33d Iowa, age 18.	April 30, May 17, '64.	Flap. Disch'd March 21, 1865.
19	Berger, P., Pt., F, 11th Mass., age 28.	May 6, 16, '64.	Left; flap. Disch'd Oct. 5, 1865; pensioned.	57	Dillon, G., Pt., D, 125th Illinois.	June 2, 21, '64.	Right; circ.; by A. A. Surg. M. I. Franklin. Disch'd Jan. 27, '65; pensioned.
20	Billman, W., Pt., G, 87th Indiana.	Sept. 19, Oct. 1, '63.	Discharged December 8, 1863; pensioned.	58	Dobson, J., Pt., A, 39th Illinois, age 40.	May 20, 24, '64.	Right; circ.; by Asst. Surg. H. C. Roberts, U. S. V. Disch'd Nov. 3, 1864; pensioned.
21	Blair, B. X., Capt., I, 149th Penn.	July 1, 4, '63.	Left; by Asst. Surg. W. G. Hunter, 149th Penn. Discharged Feb. 5, 1864; pensioned.	59	Doyle, F., Capt., G, 84th New York.	Aug. 29, Sep. 4, '62.	Circ.; by Surg. E. Bentley, U. S. V. Disch'd Oct. 28, 1862.
22	Blair, C. W., Landsman, I. S. Gunboat Tama.	April 3, 15, '64.	Left; flap. To Naval Hospital May 15, 1864.	60	Duffy, H., Lieut., D, 155th New York, age 46.	June 3, 21, '64.	Left; circ.; by Surg. D. W. Bliss, U. S. V.; (hemorrhage; lig. brachial June 13.) Disch'd Oct. 11, 1864; pensioned.
23	Blaiddell, W., Pt., F, 78th New York, age 22.	June 17, 20, '64.	Left; circ.; by Surg. G. P. Oliver, 111th Pa. Disch'd Oct. 28, 1865; pensioned.	61	Dunlap, A. P., Pt., D, 21st New York.	Aug. 30, Se. 15, '62.	Right; by Surg. D. W. Bliss, U. S. V. Disch'd Oct. 22, '62; pen'd.
24	Bowlin, J. S., Pt., C, 84th Illinois.	Sept. 20, Oct. 6, 1863.	Right; by Surg. A. H. Stephens, 6th Ohio. Discharged February 22, 1864; pensioned.	62	Dunlap, E., Pt., C, 1st Maryland, age 21.	May 8, 22, '64.	Left; Discharged Feb. 1, 1865; pensioned.
25	Bramhall, E. H., Serg't, D, 24th Wisconsin.	Sept. 20, 25, '63.	Right; circular. Discharged Feb. 18, 1864; pensioned.	63	Dunn, C., Pt., L, 5th Mich. Cav., age 27.	Nov. 12, 20, '64.	Right; flap; by A. Surg. H. B. Noble, 2d O. Cav. Dis'd Apr. 21, '65.
26	Brebner, J., Pt., H, 1st Michigan Cavalry.	Aug. 4, 13, '62.	Left. Discharged March 24, 1863; pensioned.	64	Elliott, J. F., Pt., I, 8th Indiana.	May 22, 27, '63.	Right; flap; by Surg. J. K. Bigelow, 8th Ind. Disch'd Nov. 28, 1863; pensioned.
27	Bresnahan, J., Pt., A, 27th Indiana.	May 3, 9, '63.	Right; by A. Surg. H. Allen, U. S. A. Disch'd Mar. 15, '64; pens'd.	65	Emerson, W. A., Pt., H, 16th Mass., age 25.	June 30, July 19, 1862.	Lat. flap; by Surg. R. H. Coolidge, U. S. A. Disch'd Sept. 9, 1862. <i>Spec.</i> 26.
28	Brodrie, J., Pt., K, 9th Illinois.	Feb. 10, 27, '62.	Right; flap. Discharged May 26, 1862; pensioned.	66	Evans, J. M., Pt., D, 82d Penn., age 36.	June 1, 16, '64.	Right; circ.; by A. A. Surg. C. Ewen. Dis'd Nov. 10, '64; pen'd.
29	Brown, W., Serg't, I, 66th N. Y., age 38.	July 2, 6, '63.	Right; circular; by Surg. L. W. Oakley, 2d N. J. To V. R. C. May 3, '64; pens'd. <i>Spec.</i> 1466.	67	Farnum, E. P., Pt., B, 132d Pennsylvania.	Sept. 17, 26, '62.	Right; circ.; by Surg. G. Grant, U. S. V. Dis'd Dec. 20, '62; pensioned. Died Aug. 14, 1871.
30	Burke, M., Serg't, K, 15th N. Y. Art., age 28.	June 25, July 4, 1864.	Left; circ.; by A. A. Surg. H. M. Dean; (excis'n head of humerus March 29, 1865.)	68	Farrell, J., Pt., B, 10th New York Cav., age 22.	July 31, Aug. 24, '64.	Left; flap; by A. A. Surg. E. A. Page. Disch'd Jun. 3, '65; pen'd.
31	Caldwell, F. B., Pt., A, 17th Infantry, age 20.	Oct. 1, '64.	Left; flap; by Surg. D. W. Bliss, U. S. V. Disch'd Ap. 17, '65; pen'd.	69	Farrell, J., Serg't, I, 15th N. Y. Engineers.	Dec. 11, 26, '62.	Left; by Surg. D. W. Bliss, U. S. V. Duty June 16, 1863; pens'd.
32	Call, G., Pt., C, 3d Iowa.	July 12, 15, '63.	Left. Discharged; pensioned.	70	Farrell, W. A., Pt., F, 36th New York.	July 12, '62.	Left; flap; by A. A. Surg. J. R. Uhlher. Dis'd Aug. 19, '62; pens'd.
33	Cameron, D., Captain, G, 22d New York.	Aug. 30, Sept. 13, 1862.	Right; by A. Surg. J. B. Brinton, U. S. A.; (see'r'y hemorrhage.) Disch'd June 19, '63. <i>Spec.</i> 318.	71	Finlay, J., Pt., C, 3d Mass. Battery, age 23.	Aug. 18, Sept. 1, 1864.	Right; circ.; by A. A. Surg. J. P. Agnew; (prim'y amp. forearm.) Recov'd Nov. 26, '64; pensioned.
34	Campbell, G. W., Pt., C, 7th Mo. S. M. Cav.	Oct. 28, No. 12, '62.	Right. Discharged March 7, '63; pensioned.	72	Finney, P., Pt., A, 7th Wisconsin.	Aug. 28, Se. 25, '62.	Right; by A. A. Surg. J. L. Smith. Disch'd Nov. 19, '62; pensioned.
35	Carr, J. L., Pt., D, 116th Penn., age 18.	June 16, July 6, '64.	Left; by A. A. Surg. W. W. Valk. To V. R. C. Mar. 3, '65; pens'd.	73	Flahirn, L., Pt., B, 7th N. Hampshire, age 34.	Feb. 20, Mar. 17, 1864.	Left; circ.; by A. A. Surg. J. P. Kennedy. Discharged June 27, 1864; pensioned. <i>Spec.</i> 2808.
36	Carson, G. P., Pt., B, 130th N. Y., age 30.	Sept. 23, Oct. 10, '64.	Left; flap; by A. Surg. C. H. Alden, U. S. A. Disch'd May 17, '65.	74	Fox, W. H., Pt., H, 7th Ohio, age 22.	May 3, 14, '63.	Right; ant. post. flap; by Surg. H. Bryant, U. S. V. Disch'd Nov. 20, 1863; pensioned. <i>Spec.</i> 1106.
37	Chandler, G. B., Lieut., D, 10th Michigan.	June 27, July 2, '62.	Left. To V. R. C. Aug. 11, '63.				
38	Chrisman, E., Pt., E, 11th Iowa, age 25.	April 6, 23, '62.	Left; flap; by Dr. J. H. Turner. Disch'd Dec. 2, 1862; pens'd.				



No.	NAME, AGE, AND MILITARY DESCRIPTION.	DATES.	OPERATIONS, OPERATOR, RESULT.	No.	NAME, AGE, AND MILITARY DESCRIPTION.	DATES.	OPERATIONS, OPERATOR, RESULT.
75	Freyer, J., Pt., 1, 3d New Jersey Cavalry, age 43.	Aug. 20, Se. 15, '64.	Left; flap. Discharged Oct. 21, 1865; pensioned.	116	Kent, O. D., Pt., H, 157th New York, age 19.	July 1, 18, '63.	Left; flap; by A. A. Surg. A. D. Kibbee. Discharged December 28, 1863; pensioned.
76	Frost, D., Pt., B, 8th Michigan, age 24.	May 6, 27, '64.	Left; circular; by Asst. Surg. A. DeClancy, U. S. V. Discharged Sept. 12, 1864; pensioned.	117	Keyes, P., Pt., I, 25th Wisconsin, age 22.	July 22, 25, '64.	Right; flap. Discharged June 30, 1865; pensioned.
77	Furnish, J., Pt., F, 34th Indiana, age 25.	Jan. 7, Feb. 5, '64.	Left; circular; by A. A. Surg. F. Hassenberg. Disch'd Mar. 10, '64.	118	Kinsey, M. H., Pt., G, 6th Wisconsin.	Aug. 28, 1865; pensioned.	Right. Discharged November 27, 1862; pensioned.
78	Gardiner, G. R., Corp'l, C, 48th New York.	July 18, 21, '63.	Right; flap. Discharged November 14, 1863.	119	Kraus, E. F., Pt., D, 50th Pennsylvania, age 18.	May 6, 12, '64.	Left. Discharged December 11, 1864; pensioned.
79	Gaskell, E. C., Lieut., C, 36th C. T., age 20.	Sept. 29, Oct. 3, '64.	Left; flap; by A. A. Surg. W. F. Litch. Duty April 8, '65; pens'd.	120	Lambert, W., Pt., C, 148th Penn., age 21.	May 3, 11, '63.	Left; circ. Disch'd Sept. 21, 1863. Spec. 1806. Died March 29, '68.
80	Gaunt, T. M., Pt., E, 22d Indiana.	Dec. 31, '62, Jan. 4, '63.	Right; flap. Discharged Sept. 10, 1863.	121	Langan, A., Pt., G, 14th Infantry, age 22.	July 2, 6, '61.	Left; flap. Discharged June 22, 1865; pensioned.
81	Gibson, D. C., Pt., I, 31st Virginia, age 24.	July 20, 26, '64.	Left; circ.; by Surg. J. B. Lewis, U. S. V. Pro. Mar 1 Nov. 1, 1864.	122	Lason, H. P., Pt., P, 76th New York.	Aug. 29, Sep. 3, '62.	Left; flap; by Surg. D. W. Bliss, U. S. V. Disch'd Oct. 9, '62; pens'd.
82	Gibson, R. H., Corp'l, F, 21st Michigan, age 22.	Sept. 20, Oct. 1, '63.	Left; by A. A. Surg. H. M. Lilly. Disch'd April 6, '64; pensioned.	123	Lee, B. F., Serg't, I, 8th Illinois Cavalry.	July 11, 29, '64.	Left; circ.; by Surg. A. Hard, 8th Ill. Cav. Dis'd July 17, '65; pen'd.
83	Gildersleeve, J., Pt., G, 79th New York.	July 21, Aug. 11, '61.	Right; flap; by Asst. Surg. A. McArthur, 79th N. Y. Dis'd; pens'd.	124	Lee, D., Private, B, 13th Michigan.	Sept. 20, Oct. 15, '63.	Left. Discharged Dec. 24, '63; pens'd.
84	Gorton, F., Pt., A, 1st Penn. Rifles.	June 30, July 10, '62.	Right; flap; by A. A. Surg. T. B. Castle. Dis'd Oct. 1, '62; pens'd.	125	Livers, J. A., Pt., C, 104th Illinois.	Dec. 7, 11, '62.	Left; circular; by A. Surg. J. A. Freeman, 104th Ill. Discharged January 27, 1863; pensioned.
85	Green, S. H., Pt., E, 2d U. S. S. S., age 28.	Oct. 27, Nov. 14, '64.	Right; circular. Disch'd July 16, 1865; pensioned.	126	Long, C. D., Pt., II, 8th Michigan.	April 16, May 14, 1862.	Left; flap; by A. Surg. C. A. McCull, U. S. A. Discharged June 23, 1862; pensioned.
86	Gregg, W., Pt., I, 2d Conn. Art., age 23.	June 1, 12, '64.	Right; by Surg. D. W. Bliss, U. S. V. Dis'd Aug. 21, '64; pens'd.	127	Lorentz, W., Pt., I, 25th N. Y. Cav., age 18.	Oct. 9, Nov. 30, 1865; pensioned.	Right; flap. Discharged June 16, 1865; pensioned.
87	Guerrin, J. E., Pt., C, 113th Illinois.	June 10, 14, '64.	Left; flap; by A. A. Surg. R. W. Conde; hemorrhage. Discharged Sept. 9, 1864; pensioned.	128	Lutz, S. D., Pt. F, 40th Indiana, age 26.	Dec. 5, '64.	Right; ant.-post. flap; by Ass't Surg. J. Tolerton, 129th Indiana. Disch'd April 7, 1865; pens'd.
88	Hanese, J., Pt., E, 16th Michigan, age 19.	July 30, Aug. 22, 1864.	Right; circ.; by A. A. Surg. A. N. Brockway. Discharged Sept. 14, 1865; pensioned.	129	Lynch, J., Pt., C, 7th Maryland.	May 8, 11, '64.	Left; circular. Discharged April 12, 1865; pensioned.
89	Harper, W., Lieut., A, 43d Indiana.	April 30, May 3, '64.	Left; by Surg. Swindell, C. S. A. Disch'd June 14, 1865; pens'd.	130	Manley, J. P., Corp'l, D, 38th Indiana.	Dec. 31, '62, Jan. 15, '63.	Left; by Surg. J. Y. Finley, 2d Ky. Cav. Disch'd April 14, '63; pensioned.
90	Harris, J., Pt., B, 72d Pennsylvania.	June 29, July 13, 1862.	Left; by A. Surg. T. H. Heisby, U. S. A. Disch'd Sept. 13, 1862; pensioned.	131	Marey, L., Pt., G, 4th Michigan, age 22.	May 9, 19, '64.	Left; ant.-post. flap; by Surg. E. Bentley, U. S. V. Discharged Sept. 12, 1864; pensioned.
91	Hart, H., Pt., A, 16th Infantry.	Aug. 17, 23, '64.	Right; flap; by A. A. Surg. T. Thompson. Discharged May 15, 1865; pensioned.	132	Martin, W. S., Pt., K, 29th Iowa.	April 30, May 4, 1864.	Left; circ.; by Surg. W. L. Nicholson, 29th Iowa. Disch'd Sept. 19, 1864.
92	Hartnett, D., Pt., I, 185th New York, age 22.	Mar. 29, April 4, '63.	Left; circ.; by A. Surg. H. Allen, U. S. A. Disch'd July 3, 1865; pensioned. Spec. 154.	133	May, C., Private, E, 82d Illinois.	May 3, 31, '63.	Left; circular; by A. A. Surg. W. D. Wolhaupter. Disch'd Sept. 9, 1863; pensioned.
93	Hartwell, F. E., Pt., C, 10th Mass., age 21.	May 5, 10, '64.	Left; flap; by Surg. D. W. Bliss, U. S. V. Dis'd July 20, '64; pen'd.	134	Maybury, C. E., Pt., C, 1st Maine Cav., age 17.	Oct. 27, 30, '64.	Right; circular; by Surg. W. Upjohn, 7th Mich. Cav. Disch'd August 12, 1865; pensioned.
94	Haynes, E. C., Lieut., D, 6th Iowa, age 23.	Aug. 22, Sep. 2, '64.	Right; circ.; by Surg. J. A. Gore, 17th Ill.; (prim'y exc.) hemorrhage. Disch'd July 21, 1865; pensioned. Spec. 3484.	135	McCann, P., Pt., G, 145th Pennsylvania, age 26.	Dec. 31, '62, Jan. 1, '63.	Left; circ.; by A. Surg. C. Wagner, U. S. A. To V. R. C. May 12, 1864; pens'd. Specs. 653, 931.
95	Hecker, F. L., Pt., K, 5th N. Y. Cav., age 29.	May 6, 14, '64.	Right; ant.-post. flap; by Surg. D. W. Bliss, U. S. V. Disch'd Nov. 17, 1864; pensioned. Spec. 2264.	136	McDonald, J., Pt., G, 81st Illinois.	Dec. 31, '62, Jan. 27, '63.	Left; by Surg. F. Seymour, U. S. V. Disch'd Mar. 12, '63; pens'd.
96	Holbeg, J. S., Pt., E, 1st Maryland, age 19.	July 3, 8, '63.	Right. Paroled Sept. 25, 1863.	137	McElhaney, J., Pt., E, 5th Maryland.	Sept. 17, 21, '62.	Left; by Surg. W. H. Norris, 5th Md. Dis'd Dec. 24, '62; pens'd.
97	Holsel, H., Pt., I, 54th Pennsylvania, age 37.	May 15, 20, '64.	Right; circ. Disch'd Feb. 20, 1865; pensioned.	138	McGeehan, T., Pt., D, 155th N. Y., age 24.	May 30, J'e 10, '64.	Left; by A. A. Surg. J. H. Thompson. Dis'd Feb. 4, '65; pens'd.
98	Hill, L. O., Pt., H, 9th Maine.	July 10, 15, '63.	Left; circ.; by Surg. L. Hill, 9th Me. Dis'd Nov. 25, '63; pens'd.	139	McNamee, E., Pt., I, 30th New York.	Aug. 29, Se. 12, '62.	Left; by Surg. D. P. Smith, U. S. V. Dis'd Mar. 25, '63; pens'd.
99	Hinkley, O., Pt., F, 22d Maine, age 32.	May 11, 14, '64.	Right; ant.-post. flap. Disch'd Dec. 3, 1864; pensioned.	140	Mezner, C. G., Pt. F, 1st Wis. Cav., age 24.	April 14, May 5, '65.	Left; flap. Discharged Sept. 18, 1865; pensioned.
100	Hinspeter, J. G., Pt., C, 53th New York, age 47.	May 12, 21, '64.	Left; double flap; (prim'y exc.) Disch'd Aug. 27, '64; pensioned. Died March 10, 1871.	141	Miller, G. H., Pt., B, 11th Maine, age 21.	Aug. 16, 23, '64.	Right; circ.; by A. A. Surg. S. J. Holley. Dis'd May 17, '65; pens'd.
101	Hipsman, V., Pt., B, 151st Pennsylvania.	July 1, 8, '63.	Right; by Surg. R. Loughran, 80th N. Y. Duty Sept. 3, 1863; pensioned.	142	Miller, G. W., Pt. F, 3d New Hampshire.	June 16, July 7, '62.	Left; by A. Surg. J. Bell, U. S. A. Disch'd Sept. 9, 1862; pensioned.
102	Hoover, J., Pt., F, 2d Pa. Reserves, age 25.	Jan. 24, Feb. 12, '64.	Left; flap; by Surg. D. W. Bliss, U. S. V.; (prim'y exc.) Disch'd July 14, 1864; pensioned.	143	Miller, W. B., Pt., A, 8th Michigan, age 15.	Aug. 30, Sep. 8, '62.	Right. To V. R. C. October 27, 1864.
103	Horton, W. H., Lieut., 1st U. S. S. S.	May 5, 10, '63.	Left; by Dr. Hammill. To V. R. C. Sept. 14, 1863; pensioned.	144	Moody, J. C., Corp'l, B, 1st N. H. Cav., age 32.	May 30, J'e 15, '64.	Left; flap; by Surg. D. W. Bliss, U. S. V. Disch'd June 3, '65; pens'd.
104	Howe, J., Pt., B, 18th Illinois.	Feb. 14, 28, '62.	Right; flap. Discharged Sept. 18, 1862.	145	Moon, R., Pt., C, 79th Ohio, age 27.	May 27, June 17, 1864.	Left; circular; by A. Surg. J. D. Johnson, U. S. V. Discharged Sept. 29, 1864; pensioned.
105	Humphrey, J. W., Pt., E, 15th Mass., age 18.	Oct. 5, 21, '62.	Left; circ. Discharged January 16, 1863; pensioned.	146	Mooney, J., Pt., F, 69th New York, age 21.	Aug. 25, 29, '64.	Left; by Surg. W. O. Meagher, 69th New York. To V. R. C. March 3, 1865; pensioned.
106	Huron, E., Pt., A, 53d Indiana.	Oct. 5, 9, '62.	Right; flap. Discharged Nov. 14, 1862; pensioned.	147	Morand, J. B., Pt. F, 6th Maryland, age 33.	May 6, 12, '64.	Left. Discharged Feb. 4, 1865.
107	Ingersoll, A. J., Pt., H, 14th Ohio, age 23.	Sept. 19, 23, '63.	Left; circ. Discharged October 1, 1864.	148	Morgan, H., Pt., G, 31st Illinois.	Feb. 15, 22, '62.	Right; by Surg. E. C. Franklin, U. S. V. Dis'd May 31, '62; pens'd.
108	Irish, A., Pt., H, 106th New York, age 23.	May 12, 17, '64.	Right; flap; (prim'y exc.) gangrene. Disch'd June 3, '65; pen'd.	149	Morgan, P. C., Pt., E, 2d New Hampshire.	Aug. 29, Sep. 7, '62.	Right; by A. A. Surg. B. B. Miles. Disch'd Nov. 8, 1862; pensioned.
109	Jewett, J. A., Pt., F, 24th Indiana.	May 2, '62, June 29, '62.	Left; by A. A. Surg. T. B. Harvey. Disch'd Jan. 5, 1863; pensioned.	150	Morse, C. M., Pt., A, 11th Connecticut.	June 2, 27, '64.	Right; flap. Discharged October 12, 1864.
110	Johnson, R., Pt., C, 5th Vermont.	June 29, July 3, '62.	Right. Disch'd April 14, 1863; pensioned.	151	Murphy, E., Pt., F, 7th Maine.	Sept. 16, Oct. 6, '62.	Left; circ.; by Surg. A. Ball, 5th Ohio. Disch'd Nov. 7, '63; pens'd.
111	Johnson, W., Pt., E, 7th Rhode Island.	Dec. 13, 18, '62.	Right; bi-lat. flap; by Surg. J. D. Robison, U. S. V. Disch'd Dec. 16, 1863; pensioned. Spec. 486.	152	Murphy, J., Pt., H, 14th Michigan, age 28.	Sept. 17, 24, '63.	Left; circ.; by A. A. Surg. C. C. Shoyer. Dis'd July 25, '63; pen'd.
112	Jones, E. J. B., Pt., F, 10th Kansas.	Dec. 7, 10, '62.	Left; by Surg. J. W. Scott, 10th Kan. Dis'd Feb. 18, '63; pens'd.	153	Murphy, P. E., Lieut., E, 9th Mass., age 23.	May 5, 9, '64.	Left; flap; (primary excision). Disch'd June 21, '64; pensioned.
113	Jones, T., Pt., D, 48th N. Y., age 24.	July 18, 24, '63.	Right; flap; by Surg. D. Merritt, 55th Pa. Disch'd Oct. 14, 1863; pensioned. Spec. 4187.	154	Murrin, B., Pt., D, 1st Rhode Island Cav.	Mar. 17, 22, '63.	Left; by Surg. W. H. Wilbur, 1st R. I. C. Dis'd Nov. 6, '63; pens'd.
114	Keene, J., Serg't, II, 2d Minnesota.	Sept. 20, 24, '63.	Left. Discharged January 23, 1864; pensioned.	155	Nelson, J., Pt., H, 17th Infantry.	Aug. 30, Sept. 22, 1862.	Right; flap; by A. Surg. A. E. Keyes. Discharged April 9, '63; pensioned. Spec. 909.
115	Kelly, W., Serg't, B, 10th Infantry, age 31.	May 12, 17, '64.	Left; oval flap. Duty February 18, 1865; pensioned.	156	Norton, B. N., Corp'l, F, 5th Maine, age 19.	Nov. 7, 17, '63.	Left; double-skin flap; by A. A. Surg. W. M. Hudson. Disch'd May 9, 1864; pensioned.

No.	NAME, AGE, AND MILITARY DESCRIPTION.	DATES.	OPERATIONS, OPERATOR, RESULT.	No.	NAME, AGE, AND MILITARY DESCRIPTION.	DATES.	OPERATIONS, OPERATOR, RESULT.
157	Noyes, E., Corp'l, C, 11th Maine, age 21.	Aug. 16, Sept. 10, 1864.	Right; antero-posterior flap; by A. A. Surg. E. B. Woolston. Disch'd Jan. 27, 1865; pens'd.	199	Smith, J. A., Pt., B, 1st Missouri Cavalry.	Feb. 17, 27, '62.	Right; flap; by Surg. J. I. Lynch. 1st Mo. C. Dis'd Dec. 22, '62; pens'd.
158	Otto, M., Pt., K, 1st Michigan S. S.	May 12, 30, '64.	Right; flap. Discharged August 28, 1864; pensioned.	200	Smith, J. B., Pt., A, 8th New Jersey.	May 5, 29, '62.	Right; flap; by A. Asst. Surg. J. Neill. Dis'd July 21, '62; pens'd.
159	Page, C. H., Pt., F, 3d Vermont, age 34.	Apr. 16, 19, '62.	Right; flap; by Surg. H. Jones, 3d Vt. Disch'd Feb. 28, '63; pens'd.	201	Smith, J. M., Pt., E, 12th Connecticut, age 47.	Sept. 19, Oct. 6, '64.	Left; circular; by A. A. Surg. J. M. Boissod. Dis'd April 21, '65.
160	Pancost, G. W., Pt., F, 83d New York.	Sept. 17, Oct. 10, 1862.	Left; circ.; muscle and skin flaps; by A. Surg. R. F. Weir, U. S. A. (exc. Sept. 18, necrosis). Dis'd Dec. 19, '62; pens'd. <i>Spec.</i> 772.	202	Spaulling, S., Pt., F, 100th Illinois, age 21.	Aug. 5, 11, '64.	Left; circular; by A. Surg. E. B. Glick, 100th Ind. Dis'd Jan. 2, '65.
161	Perrine, H., Pt., F, 20th Michigan, age 22.	July 1, 21, '64.	Left; circ.; by A. A. Surg. J. K. Lineweaver. Discharged April 14, 1865; pensioned.	203	Sprague, C., Pt., A, 4th Art., age 28.	July 3, 7, '63.	Left; by Surg. C. S. Wood, 66th N. Y. Disch'd Oct. 12, '63; pens'd.
162	Perry, J. H., Pt., H, 29th Mass., age 20.	Sept. 17, Oct. 3, 1862.	Right; circ.; by A. A. Surg. W. S. Adams; gangrene. Disch'd Dec. 19, 1862; <i>Spec.</i> 820.	204	Stager, J., Corp'l, E, 95th Pennsylvania.	May 2, 9, '61.	Left; flap; by A. Surg. W. Thomson. Disch'd Sept. 9, 1863; pens'd.
163	Peter, J., Pt., I, 65th Ohio, age 44.	Nov. 30, Dec. 4, '64.	Right; flap; by Dr. Rauey. Discharged May 31, 1865.	205	Stover, N. W., Pt., D, 5th Maine.	June 27, 30, '62.	Right; ant.-post. flap; by Surg. G. E. Brickett, 21st Maine. Discharged Sept. 2, 1862; pens'd.
164	Peterman, H. C., Pt., H, 6th Indiana.	Sept. 20, Oct. 17, '63.	Left; flap; by Dr. J. A. Romayne. Disch'd Feb. 13, '65; pensioned.	206	Sullivan, J., Pt., E, 15th Mass., age 19.	Sept. 17, 23, '62.	Left; flap. Discharged December 18, 1862; pensioned.
165	Peters, H., Pt., D, 4th Artillery, age 22.	Jan. 30, Feb. 16, '63.	Left; flap; (amp. at elbow) Jan. 30, '63. Disch'd July 28, '63.	207	Sweeney, J., Pt., D, 69th New York.	June 1, 4, '62.	Right; flap. Discharged August 22, 1862; pensioned.
166	Phillips, M., Serg'l, E, 35th Col. T., age 24.	May 16, 22, '64.	Left; flap; by Dr. Yandell. C. S. A. Disch'd July 28, '65; pens'd.	208	Thayer, L., Serg'l, H, 1st Ohio Cav.	Aug. 25, Sept. 3, '64.	Left; flap. Duty January 28, 1865.
167	Pinkerton, J., Corp'l, E, 12th New Jersey.	May 3, 10, '63.	Right; flap. To V. R. C. February 4, 1864.	209	Theobald, V., Corp'l, D, 44th Ill., age 29.	June 27, July 3, 1864.	Right; circular; by A. Surg. C. C. Byrne, U. S. A. Disch'd March 14, 1865; pensioned.
168	Pipes, R., Pt., D, 23d Indiana.	May 16, 19, '63.	Right; circular. Discharged August 12, 1863; pensioned.	210	Thomas, G. W., Pt., D, 24th Mass., age 20.	Aug. 16, 27, '64.	Right; flap; by Asst. Surg. J. H. Franz, U. S. A. Disch'd May 31, '65; pens'd.
169	Powers, J. K., Pt., H, 9th Indiana.	April 7, 23, '62.	Right; flap; by Dr. J. M. Kitchen. Disch'd June 13, '62; pensioned.	211	Thomas, R., Pt., B, 14th New York.	July 1, 26, '62.	Right; circ.; by A. A. Surg. C. P. Russell. Disch'd April 29, '63.
170	Price, B. F., Pt., M, 9th Illinois Cav.	June 10, 13, '64.	Left; flap; by Surg. G. B. Christie, 9th Ill. Cav. Disch'd August 5, 1865; pensioned.	212	Timme, E., Pt., C, 1st Wisconsin, age 22.	Sept. 19, 23, '63.	Left; circ.; by Surg. P. J. A. Cleary, U. S. V. Pens'd May 6, 1864.
171	Quikel, J., Pt., E, 87th Penn., age 32.	Nov. 27, Dec. 12, 1863.	Left; circ.; by A. A. Surg. C. P. Bigelow (prim. exc.) Disch'd February 15, 1864; pensioned.	213	Tobin, T., Pt., A, 23d Penn., age 24.	June 23, July 9, '64.	Left; flap; by Surg. A. H. Thurston, U. S. V. Disch'd May 14, 1865; pensioned.
172	Quitterfield, A., Pt., B, 125th N. Y., age 19.	July 2, 13, '63.	Left; by Surg. W. C. Cooper, 125th N. Y. Disch'd Jan. 4, '63; pens'd.	214	Trask, J. R., Pt., D, 21st Ohio, age 31.	Mar. 24, 28, '65.	Left; by Surgs. Pearson & Wilson. C. S. A. Duty May 5, '65; pens'd.
173	Resides, W. S., Pt., G, 51st Penn., age 32.	Dec. 13, 16, '62.	Left; by A. Surg. C. G. Lee, U. S. A. Disch'd Nov. 9, 1864; pens'd.	215	Tarpin, L. R., Lieut., G, 34th Va., age 35.	April 6, 13, '65.	Right; circ.; by A. Surg. W. Carroll, U. S. V. Released June 6, 1865. <i>Spec.</i> 4166.
174	Richardson, J., Pt., F, 46th Penn.	Aug. 9, 16, '62.	Right; by Surg. A. M. Helmer, 28th N. Y. Disch'd Nov. 17, '62; pensioned.	216	Tuttle, J. G., Pt., D, 52d N. C., age 23.	July 3, 15, '63.	Right; circular. Furloughed October 5, 1863.
175	Richtentaylor, R., Pt., G, 18th New York.	July 1, 15, '62.	Right. Discharged September 1, 1862; pensioned.	217	Twombly, J., Pt., D, 12th N. H.	May 3, 17, '63.	Left; by Surg. H. F. Lyster, 5th Mich. Disch'd Oct. 24, '63; pens'd.
176	Riley, J. O., Pt., B, 23d Illinois, age 23.	July 23, 28, '64.	Left; circ.; by Dr. T. E. Mitchell. Disch'd April 3, 1865. <i>Spec.</i> 3927.	218	Vancelle, T., Pt., D, 3d Vt., age 21.	April 16, 25, '62.	Left; by Surg. R. B. Bontecou, U. S. V. (fig. axillary April 23, '62.) Disch'd Jan. 13, 1863; pens'd.
177	Riley, W. T., G, 51st New York.	Sept. 17, Oct. 14, '62.	Left; Discharged December 6, 1862; pensioned.	219	Van Steinburgh, B., Pt., A, 24th Iowa.	May 16, 30, '61.	Right. Discharged March 29, 1864; pensioned.
178	Robertson, M. E., Pt., B, 2d N. C. Mt'd Infantry.	Dec. 15, 26, '63.	Right; flap; by Drs. J. A. Reagen and J. Wallen. Disch'd August 16, 1865; pensioned.	220	Vantine, A. C., Corp'l, B, 123d Ohio, age 23.	Sept. 22, Oct. 12, '64.	Right; flap; by A. A. Surg. F. Etter; hemorrhage Oct. 16, '64. Disch'd Feb. 21, '65; pens'd.
179	Robinson, C. A., Pt., E, 11th N. Y. Cav.	Mar. 14, 21, '65.	Right; lateral flap; by Surg. T. N. Burke, U. S. V. Disch'd July 3, 1865; pensioned.	221	Veistel, C., Pt., C, 119th New York, age 20.	May 2, 10, '63.	Left; flap. Discharged Sept. 5, 1865; pensioned.
180	Robinson, J. A., Corp'l, F, 96th Illinois, age 27.	Sept. 19, 27, '63.	Right; circ.; by A. A. Surg. J. Romayne. Dis'd Mar. 16, '64; pens'd.	222	Vignos, A., Captain, H, 107th Ohio.	July 1, 4, '63.	Right; circ.; by A. Surg. E. M. Wilson, 25th O. Dis'd Sept. 30, '64; pen'd.
181	Rockwood, S. A., Corp'l, F, 25th Mass., age 26.	May 9, 15, '64.	Ward. Dis'd Oct. 20, '64; pens'd.	223	Walrod, H., Pt., B, 55th Illinois.	April 6, 12, '62.	Right; flap. Discharged June 25, 1862; pensioned.
182	Rose, H. W., Pt., G, 4th Iowa, age 26.	Mar. 7, 28, '62.	Left; by Surg. W. Robinson, 4th Iowa. Dis'd Oct. 13, '62; pens'd.	224	Walter, H. C., Pt., D, 23d Ohio.	May 9, 13, '64.	Left. Discharged March 22, '65; pensioned.
183	Rost, L. T., Pt., D, 39th Illinois, age 34.	Aug. 16, Se. 15, '64.	Right; circular; by A. A. Surg. E. B. Woolston. Dis'd Jan. 7, '65.	225	Watson, L., Corp'l, G, 87th Pennsylvania.	June 17, '64.	Right; by Dr. H. P. P. Veates. Discharged February 8, 1865.
184	Roth, W., Pt., F, 3d Missouri, age 19.	July 5, 19, '61.	Right; flap; by Surg. F. Haussler, 3d Mo. Dis'd Sept. 3, '61; pen'd.	226	Weeks, M., Pt., G, 3d Ohio Cav., age 23.	April 2, 6, '65.	Left; circ.; by Surg. W. W. Bickett, 3d O. C. Dis'd Aug. 16, '65; pen'd.
185	Rowland, W., Pt., F, 37th Indiana.	Dec. 31, '62.	Left; by Surg. W. Anderson, 37th Ind. Disch'd April 1, '63; pens'd.	227	Welch, M., Pt., D, 51st New York, age 21.	Sept. 30, Oct. 15, 1864.	Right; by Asst. Surg. W. S. Tremaine, U. S. V. Disch'd July 24, 1865; pensioned.
186	Russell, J. C., Pt., H, 11th Massachusetts.	Nov. 27, Dec. 5, '63.	Right; flap; by Surg. C. Page, U. S. A. Disch'd May 20, '64; pens'd.	228	Weston, J. D., Pt., I, 84th New York.	July 1, 10, '63.	Left; by Surg. J. W. Rawlins, 88th Pa. Disch'd Oct. 25, '63; pens'd.
187	Scales, G., Pt., B, 44th Col'd Troops, age 22.	Nov. 29, Dec. 2, '64.	Right; flap; by a Confed'l Surg. Duty Jan. 11, 1865; pensioned.	229	Whalen, T., Pt., D, 68th New York, age 63.	June 5, 16, '64.	Left; ant.-post. flap; by Surg. A. F. Sheldon, U. S. V.; (exc. ulna June 12) recovered Nov. 22, '64. Died May 29, '65, cancer of liver.
188	Schurig, C., Lieut., H, 84th New York.	May 8, 12, '64.	Right; by Dr. Hyland. Disch'd July, 1864; pens'd. <i>Spec.</i> 2263.	230	White, A. K., Capt., F, 21st South Carolina.	July 10, 15, '63.	Left; circular. Exchanged July 31, 1863.
189	Sears, W. H., Corp'l, A, 2d Vermont, age 21.	May 5, 9, '64.	Left; by Surg. W. J. Sawin, 2d Vt. Disch'd June 29, '64; pens'd.	231	White, M., Pt., E, 88th Colored Troops.	Feb. 20, Mar. 10, 1865.	Left; ant.-post. flap; by Surg. F. E. Piquette, 86th C. T. Disch'd May 28, 1865.
190	Seibert, J., Pt., G, 95th Illinois, age 38.	April 2, 12, '65.	Left; circ.; by Surg. J. Buckee, U. S. V. Dis'd June 23, '65; pens'd.	232	Whytal, J., Pt., C, 5th New York.	Aug. 30, Sep. 4, '62.	Right. Discharged Dec. 7, 1862; pensioned.
191	Seigrist, A., Pt., C, 14th N. Y. H. A., age 28.	June 2, 13, '64.	Left; circular. Discharged July 16, 1865; pensioned. <i>Spec.</i> 4860.	233	Wiley, F. A., Pt., A, 4th Cavalry, age 25.	Aug. 20, Sept. 13, 1864.	Right; circ.; by Asst. Surg. T. A. McGraw, U. S. V.; hæm'ge Sept. 13. Dis'd May 23, '65; pensioned.
192	Shurtliff, A. T., Pt., D, 1st Rhode Island.	July 21, 24, '61.	Right; flap. Discharged October 30, 1861; pensioned.	234	Willard, J. S., Pt., M, 2d Iowa Cav., age 18.	Aug. 5, 16, '64.	Left; flap; by A. A. Surg. J. Z. Hall. Disch'd Jan. 27, '65; pensioned.
193	Sias, G. W., Pt., G, 63d Pennsylvania.	June 27, July 4, '62.	Left; circ. Disch'd Aug. 28, 1862; pens'd. Re-nmp. shoulder joint.	235	Williamson, H. C., Corp'l, D, 90th Ohio, age 21.	Dec. 16, '64, Jan. 9, '65.	Right; ant.-post. flap; by A. A. Surg. A. Rolls. Dis'd June 12, '65.
194	Sickafosse, M., Corp'l, E, 44th Indiana.	April 6, May 4, '62.	Left. Discharged May 19, 1862; pensioned.	236	Woods, E. D., Corp'l, K, 25th Indiana, age 27.	Oct. 15, Nov. 4, 1864.	Right; circ.; by Surg. E. P. Buell, 80th Ohio; (excision October 16.) Disch'd May 8, 1865; pensioned.
195	Sims, E., Pt., F, 21th Michigan, age 19.	July 1, 12, '63.	Left; flap. Discharged Nov. 7, 1863; pensioned.	237	Werthin, E., Pt., H, 27th Illinois.	Dec. 31, '62, Jan. 28, '63.	Right; by a Confederate Surgeon. Disch'd May 19, 1863; pens'd.
196	Skinner, H. A., Pt., K, 83d Pennsylvania.	June 27, July 5, '62.	Left; by Surg. W. Faulkner, 83d Pa. Disch'd Dec. 17, '62; pens'd.	238	Zafost, M., Pt., I, 155th Pennsylvania.	Sept. 30, Oct. 28, '64.	Left; circ.; by A. A. Surg. H. M. Dean. Dis'd July 20, '65; pen'd.
197	Slack, G., Lt., C, 26th Ohio, age 22.	Sept. 19, 26, '63.	Right; flap; by Surg. W. B. McGavran, 26th Ohio. Discharged July 1, 1864; pensioned.	239	Zimmerman, C., Serg't, H, 6th Conn., age 30.	Aug. 14, 21, '64.	Left; flap; by A. A. Surg. W. Hletts; (excision Aug. 14.) Discharged November 18, 1864; pensioned.
198	Smith, A., Pt., A, 9th N. Y. H. Art., age 28.	July 9, 19, '64.	Right; circular; by Dr. P. Middleton; (exc. hum. July 17, 1864.) Discharged Mar. 31, '65; pens'd.				



Of this series of two hundred and thirty-nine recoveries after intermediary amputation at the upper third of the arm, one hundred and thirty-two were operations on the left, and one hundred and seven on the right extremity. Thirteen patients were returned to modified duty, three paroled, one furloughed, four exchanged, and two hundred and eighteen discharged, and, with few exceptions, pensioned. The injuries were inflicted by large projectiles in fifteen cases. In twenty-one instances, antecedent operations had been practised: Excisions in the continuity of the humerus, in nine cases; at the elbow joint, in two cases; in the continuity of the radius or ulna, in two cases; ligation of the brachial or axillary, in two cases; removal of large fragments of bone, in three cases; amputation at the elbow, in one case. In six instances, consecutive operations were performed: Exarticulation at the shoulder in three cases, ligations of minor arteries in two cases, extraction of ball from latissimus dorsi in one case. Secondary hæmorrhage occurred in sixteen cases, gangrene in twelve cases, and erysipelas in seven cases. The operations are described as practised by flap methods in ninety-five cases, by circular or oval incisions in seventy cases. Four of the pensioners are reported to have died, after discharge, from phthisis, cancer, or other affections unconnected with the operations. Most of the pensioners have been heard from at the expiration of ten years, through applications for the renewal of artificial limbs or commutation thereof.

§ *Fatal Cases.*—One hundred and eight cases of intermediary amputations at the upper third of the arm for the effects of shot injury resulted fatally. The operations were practised on ninety-eight Union and ten Confederate soldiers,—for lesions due to wounds inflicted by cannon balls in three instances, to the premature explosion of a cannon in one case, and to injuries from small projectiles in one hundred and four instances. The cases were complicated by injuries in other regions in ten instances, and in twenty-four instances<sup>1</sup> there had been antecedent operations. Two of the cases were further complicated by synchronous operations elsewhere,—a Pirogoff amputation, and a partial excision of the lower maxilla. One patient submitted to a secondary re-amputation at the joint; another to a re-amputation very close to the joint, and ligation of the subclavian; and another to ligation of the subclavian. The axillary was tied consecutively in one case, the brachial in two, and the superior profunda in two. The operations were practised on the right arm in fifty-nine, on the left in forty-three cases—this point being unnoted in six. In eighty-three cases in which the mode of operation was mentioned, circular incision was employed in thirty-eight, and the flap in forty-five. Although secondary hæmorrhage and gangrene contributed largely to the fatality, the mortality appears to have been mainly due to pyæmia and other forms of septic infections.<sup>2</sup>

The formidable extent to which the cases of this series were complicated by gangrene and secondary hæmorrhage is very impressive. These conditions are recorded as the proximate causes of death in seventeen cases; but they supervened in many other cases in which the immediate causes of fatality was described in other terms. Thus, there were eighteen cases in which gangrene occurred, and no less than forty-four complicated by consecutive hæmorrhage. Five cases were characterized also by the invasion of erysipelas.

<sup>1</sup> In seven cases there had been antecedent excisions in the shaft of the humerus; in five, of the elbow joint; in two, amputations of the forearm; in three cases, amputations of several fingers or portions of the metacarpus; in six (including one of the cases of excisions in the shaft of the humerus), ligations of the brachial; in two, removal of bone fragments and ball.

<sup>2</sup> The proximate causes of death were reported in ninety-one of the hundred and eight cases, as follows: Shock of operation, 1; tetanus, 2; chronic diarrhoea or dysentery, 6; gastro-enteritis, 1; secondary hæmorrhage, 12; gangrene, 5; erysipelas, 2; pyæmia, 31; ichoræmia, 1; surgical fever, 1; typhoid fever, 4; fever, with jaundice, 1; anasarca, 1; exhaustion, 15; pneumonia, 5; phthisis, 2; hectic fever, 1.

The clinical histories of many of the fatal cases of intermediary amputations of the arm were accompanied by reports of autopsies.<sup>1</sup>

A considerable proportion of the fatal intermediary amputations, a group of cases that were usually treated in general hospitals, supplied the Museum with pathological preparations, consisting for the most part of portions of the shattered humeral diaphyses, exhibiting comminutions in great variety and in various stages of reparation or disorganization.

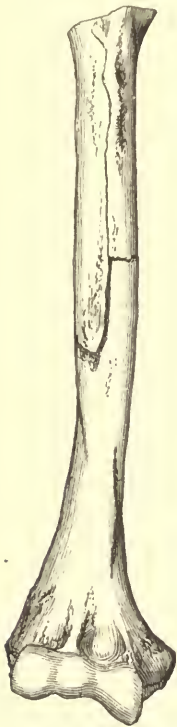


FIG. 533.—Longitudinal shot fissuring of right humerus. Spec. 160.

CASE 1674.—Private L. F. Spragg, Co. H, 100th Pennsylvania, was wounded in the right arm, at Chantilly, September 1, 1862. Assistant Surgeon W. Webster, U. S. A., forwarded the specimen (FIG. 533), with the following history by Medical Cadet S. F. Kingston: "The patient was brought to Douglas Hospital on September 8th. The ball entered about two inches below the head of the humerus on the outside, passed downward and inward, fracturing the bone, and passed out just above the inner condyle of the humerus. His wound appeared to get along finely, up to the 20th of September, when it began to bleed from the brachial artery, at which time Dr. Webster, in charge of the hospital, found it necessary to amputate. But, owing to the amount of blood lost (sixty ounces) and the great degree of nervous prostration, the patient survived the operation but a short time." The specimen consists of "the right humerus, amputated at the surgical neck. In the middle third a transverse-oblique fracture connects with a longitudinal fissure of three and a half inches on the external surface of the upper portion of the shaft. There is no attempt at repair, and but a minute trace of necrosis at what appears to be the point of impingement on the posterior surface of the bone."—(*Cat. Surg. Sec.*, 1866, p. 129.)

Specimens of injured bones in this series, which are twenty-six in number, sometimes exhibit slight attempts at reparation, but are more generally characterized by the effects of destructive inflammatory action and often by extended caries and necrosis.

CASE 1675.—Private A. Duchene, Co. A, 11th Indiana, age 23 years, was wounded at Champion Hills, May 16, 1863. He was treated at a field hospital until June 10th, when he was received on board of the hospital steamer City of Memphis for transfer to General Hospital. Assistant Surgeon H. M. Sprague, U. S. A., forwarded the specimen (FIG. 534), consisting of the shaft of the right humerus, amputated in the upper third by circular method, on June 12th, by Acting Assistant Surgeon L. Darling. The specimen shows a badly comminuted fracture in the middle third, with a trivial amount of callus deposited upon the fragments, the borders of which are necrosed. Two days after the operation the patient reached the Washington Hospital, at Memphis, where he died on July 5, 1863.



FIG. 534.—Shot comminution of right humerus four weeks after injury Spec. 1634.

TABLE LXXVII.

Summary of One Hundred and Eight Fatal Cases of Intermediary Amputations in the Upper Third of the Shaft of the Humerus.

No.	NAME, AGE, AND MILITARY DESCRIPTION.	DATES.	OPERATIONS, OPERATOR, RESULT.	No.	NAME, AGE, AND MILITARY DESCRIPTION.	DATES.	OPERATIONS, OPERATOR, RESULT.
1	Allen, C. M., Pt., K, 109th N. Y., age 25.	April 2, 18, '65.	Left; ant.-post. flap; by A. A. Surg. T. H. Getchell. Died Ap. 21, '65.	7	Briekell, E., Pt., A, 7th Mich. Cav., age 19.	July 2, 6, '63.	Right; flap; hæmorrhage—ligation. Died August 10, 1863, pyæmia.
2	Archer, H., Pt., H, 14th N. Y. S. M., age 23.	May 8, 13, '64.	Right; ant.-post. flap; by Surg. A. F. Sheldon, U. S. V. Died May 30, 1864, pneumonia.	8	Burke, J., Pt., H, 6th Penn. Cav., age 20.	May 8, June 4, 1864.	Left; by A. Surg. W. F. Norris, U. S. A.; (exe. May 9; hæm. May 27.) Died June 5, '64, pyæmia. Spec. 3550.
3	Bain, J. W., Pt., Shanks' Cavalry, age 23.	Oct. 23, 31, '64.	Right; flap; by Surg. G. W. Hoegboom, U. S. V. Died November 6, 1864, typhoid fever.	9	Burnett, B., Pt., B, 89th Ohio.	Sept. 19, 29, '63.	Right; circ.; by A. Surg. C. F. Haynes, U. S. V. Died Oct. 10, 1863, traumatic pneumonia.
4	Barton, J., Pt., A, 2d Rhode Island, age 18.	Sept. 19, 27, '64.	Right; flap; by A. A. Surg. E. A. Page. Died Sept. 27, '64, ex'h'n.	10	Burnham, T., Corp'l, K, 42d New York.	May 10, 20, '64.	Left; by Surg. W. J. Brown, 42d N. Y. Died June 4, '64, pyæmia.
5	Blakely, A., Pt., I, 3d Michigan Cav.	June 16, July 10, 1863.	Left; by A. A. Surg. A. Claude; hæm.; gang.; re-amp. sh. joint July 24. Died July 26, 1863.	11	Burton, L. G., Pt., F, 14th Cona., age 50.	May 6, 27, '64.	Right; circ.; by Dr. Nelson. Died June 18, '64. Spec. 2473.
6	Bowers, C., Pt., A, 8th N. Y. H. A., age 19.	July 9, 19, '64.	Right; flap; by Surg. G. S. Palmer, U. S. V. Died July 26, '64, exhaustion.	12	Chambler, J. L., Pt., B, 36th Alabama, age 19.	April 8, 14, '65.	Left; ant.-posterior flap; by A. A. Surg. H. B. Cole. Died June 13, 1865, chronic diarrhœa.

<sup>1</sup> I am compelled by want of space to omit the interesting reports of autopsies in many cases of this series, made by Acting Assistant Surgeons M. Baldwin, O. P. Sweet, J. Prieto, J. S. Wents, S. B. Harris, D. McDill, S. O. French, S. P. Bigelow, and Assistant Surgeon S. H. Orton, U. S. A. They contain many valuable descriptions of the local conditions and remote visceral complications observed, and merit careful study in the light of the accompanying detailed clinical histories. I hope to revert to them in the Chapter on Pyæmia, in the *Third Surgical Volume*; but, in the meantime, the student must be referred to the manuscript files of this Office.



No.	NAME, AGE, AND MILITARY DESCRIPTION.	DATES.	OPERATIONS, OPERATOR, RESULT.	No.	NAME, AGE, AND MILITARY DESCRIPTION.	DATES.	OPERATIONS, OPERATOR, RESULT.
13	Clapsaddle, G., Pt., G, 84th Indiana, age 24.	Sept. 20, '65.	Right. Died October 21, 1863, pyæmia.	49	Loce, J. E., Capt., A, 5th Texas, age 29.	July 2, '63.	Right: circ.; by A. Surg. E. D. Lrenneman, U. S. A.; (re-amp. August 15; hæmorrhage.) Died Aug. 22, '63, exhaust n. <i>Spec.</i> 1522.
14	Cline, C. R., Pt., D, 7th West Virginia, age 21.	June 1, '64.	Right: flap; by A. A. Surg. H. D. Vosburg. Died June 25, 1864, exhaustion.	50	Magagan, G., Pt., G, 61st Ohio, age 17.	July 20, Aug. 11, 1864.	Right: ant.-post. flap; by A. A. Surg. L. E. Tracy. Died Sept. 20, 1864, pyæmia.
15	Cole, A., Pt., D, 18th Massachusetts, age 35.	Dec. 13, '62, Jan. 11, '63.	Left: flap; by A. A. Surg. J. W. Digby. Died Jan. 16, '63, dropsy.	51	Marshall, H., Pt., E, 1st Mich. Cav., age 20.	May 28, June 24, 1864.	Right: flap; by A. A. Surg. S. B. Harris. ( hæmorrhage.) Died July 11, '64, pyæmia. <i>Spec.</i> 1877.
16	Cook, G. A., Pt., G, 65th Pennsylvania.	May 31, June 28, 1862.	Right: circular; by A. A. Surg. D. W. Cheever. Died July 4, 1862, pyæmia. <i>Spec.</i> 16.	52	Marshall, T., Pt., F, 96th Penn., age 20.	May 10, June 6, 1864.	Left: flap; by A. A. Surg. M. P. Price. Died June 22, 1864, abscess (metastatic) in lung.
17	Cook, J., Pt., D, 1st Me. Heavy Art., age 39.	June 17, July 7, '64.	Left: ant.-posterior flap; by A. A. Surg. W. W. Valk. Died July 16, 1864, pyæmia.	53	McDermott, P., Serg't, D, 81st Penn., age 25.	Dec. 13, Dec., '62.	Left: flap; by A. A. Surg. G. A. Chesley. Died July 8, 1864, typhoid fever.
18	Cramer, S., Pt., E, 45th Pennsylvania, age 32.	June 3, '64.	Right: circular; by A. A. Surg. B. B. Miles. Died July 6, 1864.	54	McNeil, W. R., Pt., D, 40th Pennsylvania.	Aug. 30, Sept., '62.	Left. Died October 26, 1862.
19	Cronkrite, L., Pt., E, 86th Indiana, age 22.	June 27, Jul. 12, '64.	Left: circ.; by A. A. Surg. P. C. Leber. Died Aug. 8, '64, pyæmia.	55	Merveille, A., Pt., G, 5th Ohio.	July 3, 10, '63.	Right: by Surg. H. E. Goodman, 28th Pa.; (exc.) July 4; gangrene.) Died July 13, 1863, pneumonia.
20	Deiter, L., Pt., E, 9th Michigan.	May 23, June 6, 1865.	Left: ant.-posterior flap; by A. A. Surg. J. D. Skeer. Died June 14, 1865, irritative fever.	56	Monroe, M. V., Pt., E, 18th Indiana, age 24.	Sept. 19, Oct. 3, 1864.	Right: flap; by A. A. Surg. W. P. Moon. Died October 14, 1864, exhaustion. <i>Spec.</i> 3113.
21	Delaney, M., Pt., G, 27th North Carolina.	May 5, 15, '64.	Right: circular; hæmorrhage. Died May 29, 1864, pyæmia.	57	Moore, M., Pt., A, 68th Cold Troops, age 30.	July 15, 24, '64.	Right: flap; by A. A. Surg. J. Prieto; gang. Died July 28, '64.
22	Duchene, A., Pt., A, 11th Indiana, age 23.	May 16, June 12, 1863.	Right: circular; by A. A. Surg. L. Darling. Died July 5, 1863. <i>Spec.</i> 1634.	58	Morgan, W. P., Pt., A, 16th Kentucky, age 19.	Nov. 30, Dec. 13, 1864.	Left: circ.; by A. A. Surg. E. H. Oney; gangrene. Died Dec. 23, 1864, pyæmia.
23	Elliott, W. H., Pt., A, 100th Penn., age 18.	Oct. 28, Nov. 4, '63.	Left: circular. Died November 15, 1863, ichoræmia.	59	Munford, A. M., Corp'l, A, 80th Indiana.	May 14, June 7, 1864.	Right: circ.; by Asst. Surg. B. E. Fryer, U. S. A. Died June 10, 1864, chronic dysentery.
24	Faulkner, S., Pt., F, 63d New York, age 30.	April 8, '64.	Right: flap. Died July 12, 1864, pyæmia.	60	Musgrove, W. H., Pt., K, 43th Ohio.	Dec. 17, '62, Jan. 17, '63.	Left. Died February 3, 1863, wound and rheumatism.
25	Fish, C., Pt., A, 15th Maine, age 26.	April 8, 15, '61.	Right: circ.; by Surgs. B. Wilson, U. S. V., and M. D. Benedict, 75th N. Y. Died May 18, '64, pneum.	61	Nelson, R., Pt., H, 11th New Jersey, age 18.	July 1, 23, '64.	By A. A. Surg. F. D. Weiss, 23, '64. Died August 31, 1864, pyæmia.
26	Forster, C. A., Pt., C, 11th Vt. age 22.	July 1, 8, '64.	Circ.; by A. A. Surg. F. D. Weiss. Died July 28, 1864, pyæmia.	62	Newell, E. F., Pt., E, 31st Georgia, age 27.	May 5, 18, '64.	Right: lateral flap. Died May 28, 1864, pyæmia.
27	Fowler, W. W., Corp'l, F, 67th N. Y., age 23.	May 6, 10, '64.	Right; by Surg. G. T. Stevens, 77th N. Y.; gangrene. Died June 7, 1864, typhoid fever.	63	O'Donnell, M., Pt., Ayres' Battery, age 22.	April 16, 21, '62.	By Surg. R. B. Bontecou, U. S. V. Died April 30, 1862, tetanus.
28	Frank, J., Pt., K, 33d Indiana, age 22.	May 25, June 17, 1864.	Left: flap; by Asst. Surg. C. C. Byrne, U. S. A.; gangrene. Died June 21, 1864, pyæmia.	64	Palmer, U., Pt., B, 4th Artillery.	July 1, 12, '63.	Left: ( hæmorrhages—ligation.) Died July 21, 1863.
29	Fulton, G. E., Pt., C, 4th Vt., age 26.	July 7, 20, '64.	Left: circ.; by A. A. Surg. A. N. Brookway; (exc. July 7; hæm.) Died Feb. 6, '65, ch. diarrhœa.	65	Pow, E. B., Pt., B, 3d New Jersey, age 24.	May 5, 20, '64.	Right: ant.-post. skin flap; by A. Surg. A. Delaney, U. S. V. Died May 20, 1864, shock.
30	Gabele, E. R., Pt., I, 3d Michigan.	June 1, 12, '62.	Right: flap; by A. A. Surg. J. D. Draper, 100th. Died June 24, '62.	66	Phillips, H., Pt., A, 14th Conn., age 36.	Aug. 13, Sept. 10, 1864.	Right: flap; by A. A. Surg. W. H. Ensign; (exc. Aug. 14.) Died Oct. 24, 1864, ex. h. <i>Spec.</i> 3248.
31	Gleason, M., Pt., A, 1st Michigan, age 22.	June 18, 29, '64.	Right: circ.; by A. A. Surg. W. Badger. Died June 29, 1864, hæmorrhage.	67	Pugh, E. D., Pt., B, 2d N. Y. Art., age 40.	May 30, June 12, '64.	Left; by A. Surg. H. M. Sprague, U. S. A. Died June 12, '64, tetanus.
32	Gregory, J., Pt., D, 6th Virginia, age 28.	July 30, Aug. 15, '64.	Right: circ.; by Surg. J. P. Smith, C. S. A. hæm. Died Aug. 24, '64.	68	Pursell, L. B., Pt., 24th Ga. Troops, age 20.	Sept. 17, 23, '62.	Left: circular. Died September 23, 1862, pyæmia.
33	Guthrie, F., Pt., K, 27th Mass., age 26.	June 3, 9, '64.	Right: flap; by Surg. D. P. Smith, U. S. V.; (exc. el. joint June 3; hæmorrhage.) Died July 6, '64, pyæmia. <i>Spec.</i> 2915.	69	Randall, P. F., Pt., D, 58th Mass., age 27.	May 12, 30, '64.	Circular; by A. A. Surg. J. S. Wentz. Died June 7, '64, pyæmia.
34	Harris, J. D., Pt., K, 33d Mass., age 26.	Oct. 30, Nov. 13, 1863.	Left: circ.; by A. A. Surg. D. Merrill. Died November 28, 1863, pyæmia. <i>Spec.</i> 1927.	70	Rea, J. K., Pt., H, 102d Penn., age 17.	May 5, 17, '64.	Left: flap; by Surg. C. Page, U. S. A. (gang.; hæm.; lig. brach.) Died Dec. 1, '64, phth. and diar.
35	Haxton, T., Pt., H, 86th New York.	Aug. 30, Sept., '62.	Right. Died September 24, '62, typhoid fever.	71	Reese, W., Pt., B, 115th Illinois.	Sept. 20, 27, '63.	Left: lat. flap; gang.; erysipelas. Died Oct. 12, 1863, gangrene and hæmorrhage.
36	Hendrix, W. A., Pt., G, 33d Ohio, age 19.	July 21, Aug. 3, '64.	Left: by A. A. Surg. J. A. Hall. Died August 18, '64, pneumonia.	72	Reynolds, H., Pt., H, 5th New York, age 32.	Aug. 8, Sept. 17, 1864.	Right: circ.; by A. A. Surg. J. R. Agnew; (amp. forearm Aug. 21; necrosis hæm.) Died Oct. 10, '64.
37	Hemiker, C., Pt., H, 12th Infantry, age 23.	June 1, 21, '64.	Left: circ.; by A. A. Surg. A. W. K. Andrews; (amp. finger June 1.) Died June 23, '64, gangrene.	73	Richards, J. H., Pt., H, 1st Me. Cav., age 34.	June 24, July 15, 1864.	Right: ant.-post. flap; by A. Surg. T. Artaud, U. S. V. Died July 15, 1864, pyæmia. <i>Spec.</i> 3323.
38	Hollis, P. A., Pt., H, 20th Kentucky, age 20.	Aug. 26, Se. 23, '64.	Left: circ.; by A. A. Surg. C. S. Merrill. Died Sept. 26, '64, pyæmia.	74	Rieker, B., Pt., G, 6th Vermont, age 45.	May 5, 16, '64.	Left: ant.-post. flap; by Surg. E. Bentley, U. S. V. Died May 22, 1864, gangrene.
39	Hoof, F. A., Corp'l, F, 40th Mass., age 39.	June 3, 26, '64.	Left: by A. A. Surg. A. V. Cherbonnier; (amp. of forearm June 16; erysipelas hæmorrhage.) Died June 27, 1864.	75	Ripley, R., Pt., I, 7th Vermont, age 18.	Sept. 10, 14, '63.	Right: (amp. finger Sept. 10; gangrene.) Died Sept. 20, '63.
40	Jess, W., Pt., F, 125th Illinois, age 21.	June 27, July 24, 1864.	Left: circ.; by Surg. S. E. Fuller, U. S. V. Died August 31, 1864, chronic diarrhœa.	76	Sanford, C. D., Pt., L, 4th N. Y. H. A., age 18.	May 19, 28, '64.	Right: circ.; by A. A. Surg. O. P. Sweet. Died June 2, '64, gastroenteritis.
41	Johnson, J. J., Corp'l, K, 48th New York, age 26.	June 3, 27, '64.	Left: ant.-posterior flap; by A. A. Surg. J. A. Bates; (exc. June 22; gangrene; hæm. ge.) Died June 29, '64, exhaustion. <i>Spec.</i> 3042.	77	Schoncekles, F., Pt., G, 2d Delaware.	Dec. 13, 19, '62.	Right: by Surgs. C. S. Wood, 66th N. Y., and C. Gray, 7th N. Y.; (amp. foot Dec. 19.) Died.
42	Kane, J. F., Pt., D, 27th Georgia.	June 1, 16, '64.	Left: circ.; by Surg. C. B. Gibson, C. S. A. Died June 16, 1864, hæmorrhage.	78	Scott, W. H., Capt., D, 1st Ohio Cav., age 25.	Aug. 20, Sept. 17, 1864.	Right: circ.; by A. A. Surg. P. L. Rice; (excision; hæmorrhages.) Died Sept. 27, '64, exhaustion.
43	Keefer, J., Pt., G, 14th Virginia, age 47.	May 10, 27, '64.	Right: flap. Died June 24, 1864. Complicated by wound of lung.	79	Shew, A., Pt., A, 72d Penn., age 19.	Dec. 13, '62, Jan. 1, 1863.	Right: double flap; by A. A. Surg. J. W. Digby. Died Jan. 8, '63. <i>Spec.</i> 927.
44	Kenedy, J., Pt., C, 47th Indiana.	April 7, 17, '64.	Right: circ.; by Asst. Surg. S. H. Orton, U. S. A.; (icterus from contus. of liver.) Died April 27, '64.	80	Sinclair, F., Pt., B, 8th Maine, age 26.	May 20, June 11, 1864.	Right: double flap; by A. A. Surg. M. Baldwin. Died July 1, '64, pyæmia.
45	Kreiman, J., Pt., A, 10th Infantry, age 40.	Sept. 30, Oct. 14, 1864.	Left: flap; by Surg. G. S. Palmer, U. S. V. Died November 27, 1864, exhaustion.	81	Slater, J., Pt., G, 5th Cav., age 46.	May 6, J'e 5, '64.	Right: circ.; by A. A. Surg. J. Newcombe. Died June 15, '64, ex. h. u.
46	Lambkin, R. A., Pt., I, 2d Michigan Cavalry.	Mar. 5, 26, '63.	Right. Died March 29, 1863.	82	Spellman, F., Serg't, G, 5th New York.	Aug. 30, Sep. 4, '62.	By A. Surg. B. Howard, U. S. A.; (exc. of jaw.) Died Sept. 9, '62.
47	Lambur, J., Pt., B, 183d Ohio, age 16.	Nov. 30, Dec. 4, 1864.	Left: flap; by A. A. Surg. S. T. Williams. Died Dec. 8, 1864, pyæmia.	83	Spragg, L., Pt., H, 100th Pennsylvania.	Sept. 1, 20, '62.	Right: by A. Surg. W. Webster, U. S. A. Died Sept. 20, 1862, hæmorrhage. <i>Spec.</i> 160.
48	L'Amée, A. B., Pt., G, 51st New York, age 21.	Mar. 14, 21, '62.	Right: circular; by Surg. G. A. Otis, 27th Mass.; (dig. subclav.) Died April 15, 1862, pyæmia.	84	Stetson, S. M., Pt., B, 32d Maine, age 19.	May 31, June 4, 1864.	Right: circ.; by Surg. T. F. Oakes, 56th Mass.; ( hæm.; lig. axillary.) Died June 22, 1864.

No.	NAME, AGE, AND MILITARY DESCRIPTION.	DATES.	OPERATIONS, OPERATOR, RESULT.	No.	NAME, AGE, AND MILITARY DESCRIPTION.	DATES.	OPERATIONS, OPERATOR, RESULT.
85	Strange, J., Pt., II, 63d New York, age 60.	May 3, June 3, 1864.	Right; circ.; by A. A. Surg. H. M. Dean. Died June 10, 1864, exhaustion. <i>Spec.</i> 2426.	96	Waldo, A., Corp'l, I, 35th Massachusetts, age 30.	May 19, 25, '64.	By Surg. D. W. Bliss, U. S. V. Died June 7, 1864.
86	Sutherland, W. S., Corp'l, D, 6th Maine, age 26.	May 3, 11, '63.	Right; flap. Died May 19, 1863, hæmorrhage. <i>Specs.</i> 1079, 1254.	97	Walker, W., Pt., C, 18th Georgia.	Nov. 25, Dec. 10, '63.	(Excision November 25; hæmorrhages.) Died Dec. 11, 1863.
87	Tarby, J., Ft., I, 83d Cold Troops, age 36.	April 5, 12, '65.	Right; ant.-post. flap; by Asst. Surg. E. McClintock, U. S. V.; (exc. April 5.) Died April 20, '65.	98	Wallace, S. H., Pt., B, 3d Arkansas.	July 2, 10, '63.	Left; gangrene in foot extended to abdomen. Died Aug. 20, 1863.
88	Thayer, J., Pt., C, 10th Massachusetts, age 21.	May 3, 26, '63.	Left; circ.; by A. A. Surg. J. P. Wyer; (exc. elb. joint May 18; hæmorrhage.) Died May 27, '63, pyæmia. <i>Spec.</i> 1178.	99	Walters, L., Pt., F, 46th New York, age 40.	June 17, July 15, 1864.	Right; circular; by Surg. R. B. Bontecon, U. S. V. Died July 21, 1864, pyæmia.
89	Thomas, E., Pt., G, 31st Maine, age 19.	July 30, Aug. 7, 1864.	Left; flap; by Surg. A. F. Sheldon, U. S. V. Died August 13, 1864, exhaustion. <i>Spec.</i> 2974.	100	Whaley, W., Serg't, H, 142d Penn., age 30.	July 1, 14, '63.	Right; flap; by A. A. Surg. G. H. Dare; hæmorrhage. Died July 21, 1863, pyæmia.
90	Tucker, A. J., Pt., F, 7th Indiana, age 18.	July 22, Aug. 1, 1864.	Right; circ.; by A. A. Surg. T. H. Van Tegen. Died Sept. 24, 1864, exhaustion. <i>Spec.</i> 4725.	101	Wilburn, I., Pt., A, 68th Col'd Troops, age 30.	April 2, 13, '65.	Left; circ.; by Surg. F. E. Piquette, 80th C. T.; (exc. April 3.) Died April 28, 1865, hectic fever.
91	Van Curen, J., Serg't, II, 21st Iowa.	May 1, 31, '63.	Left; doub. flap; by A. A. Surg. H. H. Littlefield. Died June 18, 1863.	102	Williams, G., Pt., E, 32d Alabama, age 33.	Dec. 31, '62, Jan. 8, '63.	Right. Died January 24, 1863, erysipelas in face.
92	Vincent, C., Pt., D, 122d Ohio, age 19.	Nov. 27, Dec. 27, 1863.	Left; ant.-posterior flap; by A. A. Surg. C. P. Bigelow. Died January 6, 1864, sec'y hæmorrhage.	103	Williamson, J., Corp'l, F, 11th Illinois, age 26.	Dec. 13, '64, Jan. 7, '65.	Right; flap; by A. A. Surg. H. Leaman. Died Feb. 1, '65, pyæmia.
93	Wagguer, D. T., Pt., II, 21st Penn., age 19.	Dec. 12, '62.	Right; circular; by A. A. Surg. J. Stearns. Died Dec. 25, 1862.	104	Woods, J., Pt., C, 85th Pennsylvania, age 23.	Sept. 2, 9, '63.	Left; flap; (hæmorrhage from profunda)-ligation. Died September 17, 1863, exhaustion.
94	Wagner, C., Pt., F, 68th New York.	Aug. 30, Se. 24, '62.	Right; by Surg. O. A. Johnson, U. S. V. Died Oct. 15, '62. <i>Spec.</i> 219.	105	Wright, D., Pt., G, 9th Colored Troops, age 35.	Aug. 16, 28, '64.	Right; flap; by A. A. Surg. W. B. White. Died Sept. 4, 1864.
95	Waldo, P. H., Serg't, B, 1st Mass. Heavy Art'y, age 28.	May 19, June 2, 1864.	Left; circ.; by A. A. Surg. S. O. French. Died June 23, 1864, exhaustion; pleurisy. <i>Spec.</i> 2929.	106	Yates, M., Pt., A, 6th West Virginia, age 23.	May 16, '62.	Right. Died May 23, 1862, pyæmia.
				107	Young, P., Pt., A, 19th Kentucky.	May 1, 29, '63.	Left; lateral flap; diarrhœa. Died July 11, 1863.
				108	Young, W., Pt., K, 68th Colored Troops, age 29.	April 9, 13, '65.	Left; circular. Died May 2, 1865, diarrhœa.

**2. Intermediary Amputations in the Middle Third of the Arm.**—Three hundred and forty-eight cases, with a ratio of fatality of 26.7 per cent., were referred to this group. The operations were practised on three hundred and twenty-nine Union and nineteen Confederate soldiers.

§ *Successful Cases.*—Of two hundred and fifty-five patients who recovered from intermediary amputations of the arm in the middle third for lesions consequent on shot injury, twenty-one returned to modified duty, one was sent to an asylum for the insane, fifteen were exchanged or paroled, and two hundred and eighteen were discharged, a large proportion being pensioned. The operations were on the right arm in one hundred and fifteen, and on the left in one hundred and thirty-nine cases, this point being unnoticed in one instance. A few detailed illustrations will be given:

CASE 1676.—*D. O'Herron*, a seaman of the Confederate gunboat *Ponchartrain*, aged 26 years, was wounded in the left arm, at Arkansas Post, January 10, 1863. He was admitted into the City Hospital, St. Louis. Surgeon J. T. Hodgen, U. S. V., reported: "The patient, of healthy sanguine constitution, was admitted on January 22d, having been wounded by a fragment of shell striking the left arm at the lower part of the middle third, causing a very large flesh wound and fracturing the humerus for several inches, also causing a deep flesh wound in the left side. Amputation was performed on the day of admission. January 26th, patient feverish, tongue dry, suppuration weak and watery. A mixture of nitre, gum arabic, tincture of opium, and water was prescribed in doses of a tablespoonful hourly, and warm fomentations (wine and chamomile tea) were applied to the arm; patient kept on low diet. January 29th, wound healthy; suppuration good; appetite fair; bowels regular. The prescription was continued every two hours, simple dressings applied every morning, and nourishing diet and wine were ordered. March 1st, doing well; wound nearly healed. Patient says he still feels a 'buzzing' in the stump. March 27th, patient sent to military prison." The specimen (FIG. 535) was contributed by the operator, Surgeon Hodgen, and consists of "the lower half of the left humerus, with a nearly transverse fracture in the lowest third, complicated by several deep but short fissures."—(*Cat. Surg. Sect.*, 1866, p. 128.)

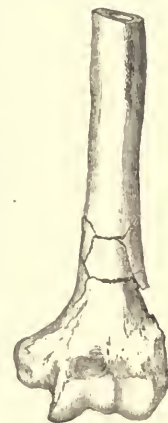

FIG. 535.—Shell fracture low down in humerus. *Spec.* 1017.

CASE 1677.—Lieutenant *B. Anderson*, Co. D, 38th Alabama, aged 39 years, was wounded at Mission Ridge, November 25, 1833. He was admitted into Hospital No. 4, at Chattanooga, and was sent, on January 25th, to the General Field Hospital, where Assistant Surgeon R. Bartholow, U. S. A., recorded: "Gunshot wound of left arm; amputation. Patient transferred on February 26th." On the following day the patient was received into Hospital No. 1, at Nashville, where Acting Assistant Surgeon G. P. Hachenberg reported: "The patient was wounded by a conoidal ball, which produced a partial fracture of the lower third of the humerus. On December 12th, secondary hæmorrhage took place, and the following day the arm was amputated at the junction of the middle and lower thirds. On February 27th, when admitted, the patient was a good deal emaciated and exhausted, laboring under a free purulent discharge from the stump. His appetite was fair and he improved in strength. On March 25th, it was noticed that the end of the bone of the stump was more prominent than usual and appeared to be detached.



On March 27th, a large sequestrum of necrosed bone was removed from the stump by simply seizing hold of it and extracting it." Surgeon C. W. Hornor, U. S. V., reported the man transferred to the Provost Marshal April 26, 1864. The specimen is represented by the figure in the lower right-hand part of PLATE XLVII, opposite, and consists of a sequestrum, five inches in length, from the stump of the left humerus three and a half months after amputation.

CASE 1678.—Private N. Wenning, Co. A, 125th Ohio, aged 38 years, was wounded at Resaca, May 14, 1864, and entered the Chattanooga General Hospital three days afterward, when Surgeon F. Salter, U. S. V., recorded: "Gunshot fracture of arm." On May 19th, the wounded man reached Hospital No. 1, at Nashville, whence Surgeon R. L. Stanford, U. S. V., reported: "The ball entered the external aspect of the left arm about two inches above the elbow joint, making its exit at the opposite side, producing a comminuted fracture of the humerus. When admitted, the soft parts around the elbow were much lacerated and contused, the arm much swollen, and the hand œdematous. The patient's general health was good. The soft parts were so much contused as to render resection unjustifiable, and in consequence of the comminuted condition



FIG. 536.—Shot fissuring of humerus. Spec. 3363.

of the bone, amputation was decided upon, and performed by circular method at the middle third, on May 21st, by Acting Assistant Surgeon M. L. Herr. The stump healed kindly." The patient was transferred to the Clay Hospital, Louisville, on July 11th, and subsequently to Camp Dennison, whence he was discharged on January 26, 1865, and pensioned. In his application for commutation he reported the condition of the stump as "healed over and perfectly well." The specimen (FIG. 536) consists of "the lower half of the left humerus, amputated for an ordinary gunshot fracture of the lowest third."

CASE 1679.—Private P. Farley, Co. K, 23d New Jersey, aged 18 years, was wounded in the right arm, at Salem Heights, May 3, 1863, and entered Mount Pleasant Hospital, Washington, on May 8th. Assistant Surgeon C. A. McCall, U. S. A., performed amputation on May 18th, at the lower portion of the middle third, and contributed the specimen (Fig. 537), consisting of "the lower half of the right humerus, showing comminution over the condyles, involving the joint. The shaft is destroyed; the articular surface carious." On June 19th, the patient was transferred to Mower Hospital, Philadelphia, whence he was discharged on July 23, 1863, his term of service having expired. An artificial arm was furnished, five years afterward, by D. W. Kolbé, of Philadelphia, who reported the stump as being perfectly healed and the amputation as having been performed by flap method. The pensioner was paid June, 1875.

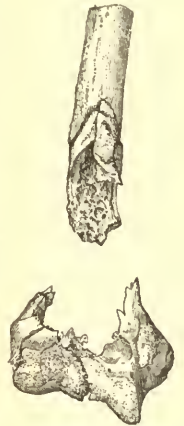

FIG. 537.—Comminution above condyles. Spec. 1179.

In several of the intermediary amputations at the middle third, where specimens of the shattered humerus or elbow joint are preserved, the lesions would, in the judgment of many surgeons, have justified primary amputation. The reasons that were thought to forbid delay until the inflammatory stage had passed, are rarely set forth:

CASE 1680.—Private G. Halsey, Co. D, 26th New York, aged 19 years, was wounded in the right arm, at Bull Run, August 30, 1862. On September 1st, he was admitted to Mount Pleasant Hospital, Washington. Medical Cadet E. Cones reported: "The patient, a remarkably strong, well developed, and healthy man, was admitted on September 1st. Amputation was performed on September 6th, by circular method, at the middle third, by Assistant Surgeon C. A. McCall, U. S. A. Not a single untoward symptom, locally or constitutionally, occurred, and the stump was completely healed in about three weeks." The specimen (Fig 538) consists of "the lower half of the right humerus, completely shattered for four and a half inches. The upper portion of the bones of the forearm are attached." The patient was discharged from service on November 24, 1862, and pensioned. In his application for commutation for an artificial arm, dated 1870, he stated that the "stump had very much perished away." The pensioner was paid on June 4, 1875.

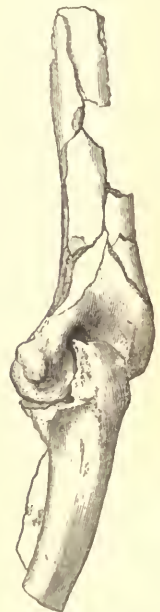

FIG. 538.—Shot shattering of humerus. Spec. 163.

CASE 1681.—Private J. Otterbacher, Co. B, 55th Ohio, aged 17 years, was wounded at Chancellorsville, May 2, 1863. He was taken to the field hospital of the 2d division of the Eleventh Corps, where Surgeon W. H. Thorn, U. S. V., recorded: "Gunshot wound of arm." On May 25th, the patient was transferred to the Mansion House Hospital, at Alexandria. Assistant Surgeon J. B. Bellanger, U. S. V., reported: "A conoidal ball entered the posterior part of the elbow and passed out in front, fracturing and comminuting the joint badly. At the time of admission the parts were so infiltrated and swollen, and the pus so dark and fœtid, that upon consultation amputation was determined upon, and performed by the circular method, at the middle third. This boy's system was in a bad condition at the time, and the result is yet uncertain." The patient was discharged from service on August 24, 1863, and pensioned. In his application for commutation for an artificial limb, in 1870, he described the stump as being in a "sound condition," and stated that he believed "Surgeon C. Page, U. S. A., performed the amputation." The pensioner was paid on June 4, 1875. The specimen (FIG. 539) consists of "the lower half of the right humerus and upper portion of the bones of the forearm, after amputation. The ball entered the olecranon fossa, destroying the trochlea, and tearing up the coronoid process and anterior portion of the olecranon. The remainder of the articular surface, not involved in the comminution, is carious."—(*Cat. Surg. Sect.*, 1836, p. 170.) It was forwarded to the Museum by Surgeon Charles Page, U. S. A.

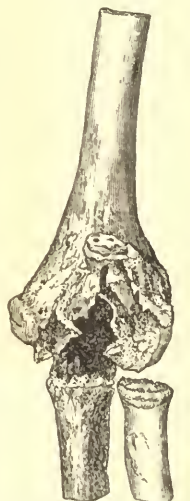

FIG. 539.—Lesions after shot perforation of elbow. Spec. 1205.



Ward phot.

Am. Photo-Relief Printing Co., Philada.

PLATE XLVII. TUBULAR SEQUESTRA FROM AMPUTATIONS  
OF THE HUMERUS.

Nos. 142, 1266, 4333, and 2209. SURGICAL SECTION.





TABLE LXXVIII.

Condensed Summary of Two Hundred and Fifty-Five Cases of Recovery after Intermediary Amputations in the Middle Third of the Shaft of the Humerus.

No.	NAME, AGE, AND MILITARY DESCRIPTION.	DATES.	OPERATIONS, OPERATOR, RESULT.	No.	NAME, AGE, AND MILITARY DESCRIPTION.	DATES.	OPERATIONS, OPERATOR, RESULT.
1	Adkins, J. L., Corp'l, H, 6th Iowa.	June 27, July 3, 1864.	Right; circ.; by Surg. A. Geslin, 48th Ill. Discharged April 29, 1865; pensioned. <i>Spec.</i> 3481.	37	Carroll, V., Serg't, E, 25th Ohio.	July 1, 7, '63.	Left; flap. To V. R. C. Oct. 31, 1863; pensioned.
2	Agnew, W. G., Pt., B, 3d Iowa, age 22.	April 7, 18, '62.	Right; flap. Discharged July 3, 1862; pensioned.	38	Casaday, A. C., Corp'l, C, 62d Pennsylvania.	July 2, 6, '63.	Left. Discharged Sept. 28, 1863; pensioned.
3	Allen, H. B., Pt., B, 117th N. Y., age 19.	Sept. 30, Oct. 16, 1864.	Left; circular; by A. Surg. D. R. Brower, U. S. V. Discharged May 16, 1865; pensioned.	39	Chandler, W., Pt., D, 8th Col'd T., age 31.	Feb. 20, M'h 14, '64.	Left; flap. Discharged Dec. 26, 1864.
4	Anderson, B., Lieut., D, 38th Alabama.	Nov. 25, Dec. 12, '63.	Left; hemorrhage. To Provost Marshal April 26, '64. <i>Spec.</i> 2309.	40	Chappell, H., Pt., G, 18th Indiana.	Mar. 8, Apr. 3, '62.	Right; by Surg. W. C. Otterson, U. S. V. Discharged; pens d.
5	Anderson, J., Pt., B, 161st N. Y., age 18.	April 8, 16, '64.	Right; flap; by A. A. Surg. I. C. Lec. Discharged May 17, 1864.	41	Chipman, C. S., Pt., A, 22d Wisconsin.	Mar. 4, 28, '63.	Left; by Surg. F. Scymour, U. S. V. Dis'd June 25, '64; pensioned.
6	Arnold, T., Corp'l, I, 32d Maine, age 21.	July 30, Aug. 7, 1864.	Right; circular; by Surg. A. F. Sheldon, U. S. V. Discharged March 6, '65; pens d. <i>Spec.</i> 2974.	42	Christie, T., Pt., B, 69th Pennsylvania, age 24.	Dec. 13, 20, '62.	Left; (neuro.; re-amp. May 17, '64.) Must'd out Dec. 30, '64; pens d.
7	Atherton, R. L., Corp'l, G, 10th Mass.	May 31, J'e 15, '62.	Left; circular. Discharged July 8, 1862; pensioned.	43	Clark, H., Pt., E, 23d Illinois, age 17.	July 24, 30, '64.	Left; flap; by A. A. Surg. M. M. Townsend, Discharged Oct. 27, 1864; pensioned. <i>Spec.</i> 4262.
8	Battle, L., Lt., F, 2d Col'd Cav., age 23.	Mar. 9, 23, '64.	Left; flap. Discharged Decem-ber 15, 1864.	44	Claney, P., Pt., E, 4th New Jersey, age 19.	May 12, June 3, 1864.	Left; skin flaps and circ. sec. of muscles; by Surg. Z. E. Bliss, U. S. V.; (excision radius May 12.) Disch'd Aug. 30, '64; pensioned.
9	Bates, A., Pt., C, 1st Mass. H. A., age 39.	May 19, J'e 16, '64.	Right; circ.; by A. A. Surg. C. W. Carrier. Dis'd Sept. 23, '61; pen'd.	45	Coates, C., Pt., C, 125th Ohio, age 18.	June 27, July 2, '64.	Right; circular. Discharged Feb. 9, 1865; pensioned.
10	Beasley, S., Lt., F, 111th Col'd Troops, age 25.	Oct. 1, 8, '64.	Right; by Surg. W. Spencer, 10th T. Enn. C. Dis. Nov. 5, '65; pen'd.	46	Cook, J. A., Pt., B, 54th Pennsylvania, age 29.	June 18, July 3, '64.	Left; circ.; by Surg. L. R. Stone, U. S. V. Dis'd Aug. 18, '64; pen'd.
11	Beals, B. P., Serg't, A, 3th Maine.	April 8, 19, '64.	Right; circular; by A. Surg. S. H. Orton, U. S. A. Discharged June 16, 1864; pensioned.	47	Coon, J. K. P., Pt., B, 10th W. Va., age 18.	Sept. 19, 24, '64.	Left; flap. Discharged June 9, 1865.
12	Bechtel, M. S., Serg't, G, 14th Infantry.	July 3, 19, '63.	Right; circular; by Surg. T. A. Means, C. S. A. Discharged Nov. 23, 1863; pensioned.	48	Copley, J. G., Capt., E, 86th New York, age 25.	May 6, 23, '64.	Left; circ.; by A. Surg. J. C. McKee, U. S. A.; (also frac. left leg; exc. ulna May 6; humer's.) Dis'd Sept. 19, '64; pens d. <i>Spec.</i> 2325.
13	Benrens, E., Pt., D, 7th N. Y. H. A., age 31.	Mar. 31, Apr. 11, 1865.	Left; circ.; by A. Surg. A. Delaney, U. S. V.; (exc. radius April 1.) Disch'd Aug. 2, '65; pensioned. <i>Spec.</i> 4053. Died Oct. 9, 1871.	49	Criley, E. B., Corp'l, H, 32d Iowa, age 24.	April 9, 12, '64.	Right; flap. Discharged Nov. 28, 1864; pensioned.
14	Berger, J., Pt., H, 2d Minn., age 20.	July 9, 23, '64.	Left; circ.; by Surg. C. Spinzig, 2d Mo.; (also wound right hand.) Discharged June 17, 1865.	50	Cromwell, G. W., Pt., K, 73d Penn., age 24.	Sept. 17, 21, '62.	Left; by Surg. M. Rizer, 72d Pa. Disch'd Nov. 16, '62; pensioned.
15	Best, J., Pt., F, 7th Ind. Cav., age 20.	Feb. 22, 26, '65.	Left; flap; by A. Surg. J. M. Study, U. S. V. Disch'd May 7, '65.	51	Crossley, S., Capt., H, 91st Ohio, age 40.	July 20, Aug. 15, 1864.	Right; ant.-post. flap; by A. A. Surg. C. H. Ohr. Disch'd Dec. 23, '64; pensioned. <i>Spec.</i> 4245.
16	Birch, G. W., Pt., A, 26th Iowa, age 41.	Oct. 1, 17, '64.	Right; ant.-post. flap; by Surg. A. T. Hudson, 26th Iowa. Discharged January 7, 1865.	52	Cummings, W. J., Pt., F, 14th N. H., age 24.	Sept. 19, 24, '64.	Left; flap; by Asst. Surg. W. V. Cowan, 34th O.; (rom' increased bone.) Dis'd Apr. 20, '65; pens d.
17	Blanchfield, J., Pt., A, 61st Ill., age 40.	Sept. 27, Oct. 8, 1864.	Right; flap; by A. A. Surg. W. Sturgis; gangrene. Discharged January 8, 1865; pensioned.	53	Dana, J. J., Corp'l, H, 20th Michigan, age 30.	May 12, 17, '64.	Right; circular; by Asst. Surg. J. C. McKee, U. S. A. Discharged Feb. 12, '65; pens d. <i>Spec.</i> 2727.
18	Blotner, J., Pt., E, 40th Ohio, age 39.	Sept. 20, 23, '63.	Right; flap; by Surg. J. N. Beach, 46th O. Dis'd Feb. 13, '64; pen'd.	54	Darrah, H. C., Pt., I, 1st Iowa, age 19.	Aug. 10, 13, '61.	Left; flap; by Surg. E. C. Franklin, 5th Mo. Disch'd Aug. 20, 1861; pensioned.
19	Bolin, N. C., Pt., A, 1st Ohio Cav., age 32.	April 18, 26, '65.	Left; circ.; hem. Dis'd Sept. 12, 1865; pens d.; (re-amp. Oct. 9, '65.)	55	Davis, J. W., Serg't, F, 6th New York, age 23.	May 12, 30, '64.	Left; circ.; by Surg. A. F. Sheldon, U. S. V.; gangrene. Dis'd May 10, '65; pens d. (Re-amp. April, 1868, shoulder joint for necrosis.)
20	Bordner, H., Pt., G, 21st Ohio, age 22.	Sept. 19, 24, '63.	Right; circular. Disch'd Decem-ber 23, 1863.	56	Day, A. J., Pt., E, 31st Indiana, age 21.	Dec. 15, 26, '64.	Right; flap; by Asst. Surg. W. H. Trull, U. S. V.; (removal necrosed bone.) M. out Dec. 8, '65; pens d.
21	Breen, J. H., Corp'l, A, 20th Maine, age 20.	May 5, 25, '64.	Left; circular; by Surg. Miner, P. A. C. S. Disch'd July 25, '65.	57	Day, H. H., Pt., D, 96th New York, age 24.	Oct. 27, Nov. 14, 1864.	Right; circular; (amp. at wrist joint Nov. 9, '64; hemorrhage.) Disch'd July 25, '65; pensioned.
22	Briggs, T. H., Corp'l, A, 4th R. I., age 24.	Sept. 17, Oct. 5, '62.	Right; by Surg. B. Van Heust, U. S. V. Disch'd May 5, '63; pens d.	58	Denton, J. B., Lieut., A, 1st Ga., age 24.	Nov. 20, Dec. 4, '61.	Left; circ.; by Surg. Roberts, 1st Ga. To Pro. Mar. Jan. 7, 1865.
23	Brown, G., Pt., H, 16th Mich., age 24.	June 30, July 27, 1864.	Left; circ.; by A. A. Surg. J. O. French; (amp. Aug. 7, 1864; gangrene.) Disch'd Mar. 9, '65.	59	Detweiler, J. W., Pt., C, 51st Pennsylvania.	Dec. 13, '62, Ja. 10, '63.	Left; by Surg. D. W. Bliss, U. S. V. Disch'd April 6, '63; pens d.
24	Brown, H. C., Pt., C, 45th N. C., age 19.	July 1, 5, '65.	Left. Paroled Sept. 23, 1863.	60	Dougall, W. H., Pt., E, 6th Connecticut.	July 19, Aug. 2, 1863.	Right; circ.; by A. Surg. W. Webster, U. S. A. Disch'd Nov. 16, 1863; pensioned.
25	Bryant, G. D., Pt., D, 161st New York.	April 18, 20, '64.	Right; circ.; by A. Surg. S. H. Orton, U. S. A. Disch'd August 27, 1864; pensioned.	61	Dougherty, T. H., Pt., H, 38th Indiana.	July 20, 27, '64.	Left; ant.-post. flap; by Surg. W. H. Thorne, U. S. V.; gangrene. Disch'd Nov. 25, 1864; pens d.
26	Buek, D., Pt., K, 84th Pennsylvania.	Aug. 29, Sep. 2, '62.	Left. Discharged October 20, '62; pensioned.	62	Dowling, C., Pt., K, 6th New Jersey.	May 5, 8, '62.	Right; flap; by Asst. Surg. Wm. Smith, 105th Pennsylvania. Discharged July 15, 1862; pens d.
27	Burhard, F., Corp'l, K, 35th Ohio, age 23.	Sept. 19, 23, '63.	Left; flap. Discharged June 9, 1864; pensioned.	63	Duncan, J. C., Pt., C, 11th Iowa.	April 6, 14, '62.	Right. Discharged September 15, 1862; pensioned.
28	Burke, J. R., Pt., C, 73d Illinois.	Sept. 20, 23, '63.	Left; flap. Discharged June 9, 1864; pensioned.	64	Durant, N., Captain, I, 113th Ohio, age 32.	June 27, July 7, '64.	Left; by A. A. Surg. J. A. Hall. Furloughed Aug. 31, '64; pens d.
29	Burns, W., Serg't, K, 34th New York.	June 30, J'y 14, '62.	Left; by A. A. Surg. D. N. Rankin. Duty Jan. 12, 1863; pens d.	65	Dwyer, M., Pt., C, 160th N. Y., age 28.	Sept. 19, Oct. 15, 1864.	Right; circ.; by A. A. Surg. E. R. Ould; (exc. elbow; hem. Sept. 30.) Disch'd July 6, 1865; pens d. <i>Spec.</i> 1958.
30	Butler, F. A., Pt., A, 100th Illinois, age 19.	Sept. 20, 24, '63.	Left; circ.; by Surg. A. J. Mullen, 35th Ind. Dis'd Apr. 6, '64; pens d.	66	Eastman, E. H., Pt., B, 15th Illinois.	April 6, 9, '63.	Left; flap. Disch'd July 1, 1863; pensioned.
31	Butler, P., Pt., E, 2d N. H. Cavalry, age 23.	April 8, 12, '64.	Left; circular. Discharged July 7, 1864; pensioned.	67	Edwards, J., Corp'l, H, 97th Col. Troops.	Dec. 17, 23, '64.	Right. Discharged March 17, '65; pensioned.
32	Butler, T. J., Pt., G, 45th Penn., age 20.	May 6, 20, '64.	Right; circular. Discharged Oct. 1, 1864; pensioned.	68	Edwards, M., Pt., H, 120th N. Y., age 21.	Mar. 24, April 8, 1865.	Left; ant.-post. flap; by A. Surg. J. H. Arnsby, U. S. V. Disch'd July 3, 1865.
33	Butler, L., Pt., H, 10th Michigan, age 20.	June 21, July 11, 1864.	Right; flap; by A. Surg. W. B. Trull, U. S. V. Discharged Nov. 14, 1864; pensioned.	69	Emlan, M. J., Pt., H, 3d Michigan.	May 31, J'e 14, '62.	Left. To V. R. C. Discharged June 8, 1863; pensioned.
34	Butts, H. S., Pt., A, 116th New York.	May 27, J'e 13, '63.	Left; by Surg. P. Pineo, U. S. A. Discharged; pensioned.	70	Engle, J. E., Corp'l, I, 97th Penn., age 21.	May 20, June 15, 1864.	Left; circ.; by A. Surg. E. McClellan, U. S. A. Discharged August 17, 1864; pensioned.
35	Carter, G., Pt., H, 100th Col'd Troops, age 24.	Dec. 15, 18, '64.	Left; flap; by A. A. Surg. J. S. Giltner. Dis'd Aug. 3, '65; pens d.				
36	Carr, S. H., Pt., C, 90th Ohio, age 21.	June 20, July 13, 1864.	Left; flap; by Surg. J. C. Swartzwelder, U. S. V.; (gang.; hemor-rhages; lig. brachial.) Disch'd Sept. 23, 1864; pensioned.				



No.	NAME, AGE, AND MILITARY DESCRIPTION.	DATES.	OPERATIONS, OPERATOR, RESULT.	No.	NAME, AGE, AND MILITARY DESCRIPTION.	DATES.	OPERATIONS, OPERATOR, RESULT.
71	England, W. W., Lieut., E. 25th N. C., age 21.	April 1, '65.	Left; flap. Sent to prison.	109	Hautkee, C. Pt., B. 7th Wisconsin, age 22.	July 1, '63.	Left; by Surg. A. J. Ward, 2d Wisconsin. To Vet. Res. Corps Dec. 12, 1863; pensioned.
72	Ernfied, J. S., Serg't, P. 2d Ohio.	Oct. 8, '62.	Right; flap. Discharged January 7, 1863; pensioned.	110	Hawkins, A. P., Lieut., E. 8th N. Y. H. A., age 20.	Aug. 25, Sept. 1, 1864.	Left; flap; by Surg. N. R. Moseley, U. S. V.; (exc. cib. Aug. 26; Sept. 10, hæmorrhage—lig. brachial.) Dis'd Jan. 25, '65; pens d. Spec. 2010.
73	Estes, G., Pt., I, 8th New Hampshire.	May 27, June 10, 1863.	Left; by A. Surg. W. S. Webster, 156th N. Y. Discharged Nov. 4, 1863; pensioned.	111	Hayes, A. L., Pt., K, 20th New York, age 22.	July 3, 29, '63.	Right; flap; by A. A. Surg. F. H. Getchell. Discharged Aug. 27, 1864; pensioned.
74	Evans, J. G., Serg't, D, 1st N. C., age 24.	July 1, 26, '63.	Right; by A. Asst. Surg. G. M. Paulin. Paroled Nov. 12, '63. Spec. 3921.	112	Hazzard, J. D., Lieut., D, 79th Pennsylvania.	Oct. 8, Nov. 5, 1862.	Left; by Surg. J. G. Hatchitt, U. S. V.; hæmorrhage. Discharged September, 1865; pensioned.
75	Farley, P., Pt., K, 23d N. J., age 18.	May 3, 18, '63.	Right; flap; by A. Surg. C. A. McCall, U. S. A. Mustered out July 23, '63; pens d. Spec. 1179.	113	Healey, T., Pt., D, 14th N. Y. S. M., age 22.	July 1, 5, '63.	Right; circular; by Surg. J. M. Farley, 14th N. Y. S. M. Disch'd April 9, '64; pens d. Spec. 215.
76	Ferns, J., Pt., II, 73d Penn., age 31.	May 2, 16, '63.	Left; flap; by Surg. R. Thomaine, 29th N. Y.; (re-amp. Apr. 28, '64.) Disch'd July 15, '64. Died Nov. 11, '64, heart disease. Spec. 2742.	114	Henderson, J., Pt., E, 25th Ohio, age 30.	Nov. 30, Dec. 13, '64.	Right; ant. post. flap; by A. A. Surg. W. B. Buler. Dis'd June 9, '65.
77	Filler, H., Pt., II, 36th Pennsylvania.	Aug. 30, Sept. 4, 1862.	Left; flap; by Surg. J. E. Summers, U. S. A. Disch'd Nov. 3, 1862; pensioned.	115	Hester, J. C., Pt., C, 13th Indiana.	Sept. 14, '62.	Right. Discharged November 29, 1862; pensioned.
78	Fitzgerald, T., Pt., D, 18th Infantry.	Sept. 19, Oct. 10, '63.	Right; flap; by A. A. Surg. E. Kramer. Dis'd Jan. 5, '64; pen'd.	116	Hild, J., Corp'l, K, 1st Michigan.	July 2, '62.	Right; ant. post. flap; by A. A. Surg. D. N. Rankin. (July 28, hæmorrhage.) Dis'd Dec. 16, '62. To Insane Asylum. Spec. 20.
79	Fuederle, P., Pt., E, 52d New York, age 44.	Dec. 13, 20, '62.	Right; circ.; by A. Surg. C. Wagner, U. S. A. Discharged July 8, '63; pensioned. Spec. 921.	117	Hinton, T. J., Corp'l, B, 3eth Wisconsin.	April 2, '65.	Right; flap; by Surg. D. P. Smith, U. S. V. Dis'd May 18, '65; pens d.
80	Ford, P., Pt., G, 18th Ohio.	Dec. 31, '62, Jan. 3, '63.	Left; circ.; by A. A. Surg. E. H. Oncy. Dis'd April 10, '65; pen'd.	118	Heard, J., Pt., I, 7th Rhode Island, age 21.	June 3, 22, '64.	Right; flap; by A. A. Surg. R. W. Mansfield; (re-amp. Dec. 20.) Disch'd April 3, '65; pensioned.
81	Fox, H., Corp'l, K, 50th Ohio, age 23.	Nov. 30, Dec. 3, '64.	Left; by Surgeon C. O'Neil, 9th Wis. Disch'd May 15, '65; pens d.	119	Hobbs, J., Pt., I, 96th Pennsylvania.	June 27, 30, '62.	Right; flap. Discharged August, 1862; pensioned.
82	Frantz, C., Capt., G, 9th Wisconsin.	April 30, May 10, '64.	Left; by A. A. Surg. W. E. Allen. Disch'd July 22, '63; pens d.	120	Hooper, J. A., Pt., 10th Mass. Battery.	Oct. 14, Nov. 1, 1863.	Left; circular; by Surg. N. R. Moseley, U. S. V.; hæmorrhage. Discharged Feb. 17, 1864.
83	Frazier, L., Pt., B, 13th Indiana.	Dec. 21, '62.	Right; by Surg. C. E. Denig, 28th O. Disch'd Feb. 4, '63; pens d.	121	Hoye, P., Pt., G, 2d Missouri Art., age 30.	Aug. 21, Sept. 16, 1864.	Circular; by A. A. Surg. W. M. Downan (amp. forearm Aug. 21; hæmorrhages; gangrene; ligat. stump.) Dis'd Dec. 17, '64; pens d.
84	French, A., Pt., B, 1st Ohio Artillery.	Dec. 31, '62, Jan. 10, '63.	Left; flap. Discharged February 21, 1863; pensioned.	122	Hunter, J., Pt., C, 73d New York, age 33.	July 2, 18, '63.	Left; circular; by Asst. Surg. P. Fitch, 10th New Jersey. Discharged Oct. 5, 1863; pensioned.
85	Gannon, J., Pt., K, 5th Connecticut.	Aug. 9, 13, '62.	Left; ant. posterior flap; by Asst. Surg. G. W. Champ, 139th Ind. Disch'd March 13, 1865; pens d.	123	Hunt, S., Pt., II, 28th New York.	Aug. 9, 12, '62.	Right; flap; by A. A. Surg. W. F. Price. Disch'd Oct. 5, '64; pens d.
86	Garner, J., Pt., II, 28th Kentucky, age 24.	July 20, Aug. 12, 1864.	Left; flap; by A. A. Surg. B. Peering. Disch'd Sept. 15, '63; pen'd.	124	Hunter, G., Pt., L, 14th N. Y. H. A., age 40.	May 12, J'e 10, '63.	Left; flap. Discharged July 4, 1862; pensioned.
87	Garing, J., Pt., F, 10th Iowa, age 25.	May 16, J'e 12, '63.	Right; by Dr. Ellsworth. Disch'd November 17, 1863; pensioned.	125	Hutchinson, B., Pt., K, 6th Iowa.	April 6, 10, '62.	Left; circular. Discharged May 9, 1863; pensioned. Spec. 984.
88	Gaylord, R. S., Lieut., G, 70th New York.	July 24, '63.	Left; antero-posterior flap; by Surg. Keller, C. S. A.	126	Hutton, J., Pt., II, 131st Pennsylvania.	Dec. 13, 19, '62.	Right; circular; by Dr. Johnson. Disch'd June 21, '62; pensioned.
89	Gelt, S. Pt., E, Morgan's 1st Battalion, age 20.	June 10, 17, '64.	Right. Discharged September 3, 1862; pensioned.	127	Huxley, E. B., Serg't, K, 45th Illinois.	April 6, May 6, '62.	Right; circular; by Surg. J. B. Lewis, U. S. V.; hæmorrhage. Disch'd June 23, '65; pensioned.
90	Gibson, W. B., Pt., B, 10th Pennsylvania.	May 9, 26, '64.	Right; by Surg. N. R. Moseley, U. S. V.; (amp. fingers May 15; erysipelas.) Discharged June 27, 1864; pensioned. Spec. 2358.	128	Jarvis, A., Pt., G, 10th West Va., age 45.	Oct. 13, 28, '64.	Right; circ.; by A. A. Surg. J. A. Hall. Dis'd Jan. 13, '65; pens d.
92	Gilbert, J., Pt., C, 42d New York, age 21.	July 3, 11, '63.	Left; circ.; by A. A. Surg. W. W. Keen, jr. To Vet. Res. Corps September 11, 1863; pensioned.	129	Jeffries, W. C., Capt., B, 5th Ind. C., age 42.	July 24, 28, '64.	Left; double flap; by A. A. Surg. H. K. Neff. Discharged July 30, 1864; pensioned. Spec. 946.
93	Gilbert, C., Pt., II, 28th Massachusetts, age 32.	July 1, 10, '63.	Right. Discharged January 29, 1864; pensioned.	130	Johnson, G., Serg't, K, 35th Col'd Troops.	Feb. 20, Mar. 14, 1864.	Left; flap; (exc. elbow May 12; hæmorrhage.) Discharged Jan. 18, 1865; pensioned.
94	Glasner, P., Pt., B, 83d Pennsylvania, age 19.	July 2, 7, '63.	Right. Discharged March 28, '63; pensioned.	131	Johnce, H., Pt., G, 62d Penn., age 22.	May 12, Jun. 4, '64.	Right; flap; by Surg. J. L. Woodcut, 68th Ind.; (also wound left hand.) Dis'd June 20, '64; pens d.
95	Glening, D. T., Pt., B, 28th New Jersey.	Dec. 13, 28, '62.	Left; by A. A. Surg's J. L. Stewart and D. J. Brown. Discharged November 22, 1864; pensioned.	132	Jones, S. B., Pt., D, 68th Indiana, age 20.	Sept. 19, 24, '63.	Left; flap; by Surg. J. W. Poye, U. S. V. Dis'd Dec. 24, '64; pens d.
96	Goodex, E., Pt., C, 88th Pennsylvania.	June 21, 25, '64.	Left; circ.; by Asst. Surg. B. E. Fryer, U. S. A.; (hæmorrhage; lig. radial July 20.) Discharged May 2, 1865.	133	Jones, C. G., Pt., II, 33d New Jersey, age 24.	Oct. 5, 17, '63.	Left; circular; by A. A. Surg. C. P. Bigelow; hæmorrhage. Discharged August 11, 1865.
97	Gracy, A., Pt., E, 52d Ohio, age 40.	July 1, 22, '64.	Right. Discharged February 9, 1863; pensioned.	134	Keegan, B. C., Pt., K, 2d Conn. Art., age 47.	June 1, 8, '64.	Left; flap; by Surg. T. Antisell, U. S. V. Dis'd Sept. 18, '63; pens d.
98	Gray, L. J., Pt., B, 20th Wisconsin.	Dec. 7, 11, '62.	Left; flap; by Med. Insp. P. Pineo, U. S. A. Disch'd Jan. 27, 1865; pensioned.	135	Kelley, A., Pt., I, 5th Wisconsin, age 24.	May 4, 10, '63.	Right; circular; by A. Surg. S. H. Orton, U. S. A. Dis'd June 16, '64.
99	Green, J., Pt., C, 7th Col'd Troops, age 22.	Sept. 29, Oct. 4, '64.	Left; circ.; by A. A. Surg. T. L. Van Norden; (exc. huñerus Mar. 11.) M. out Aug. 17, 1865; pen'd.	136	Kellai, F., Pt., E, 6th Mass. Cavalry.	June 15, '64.	Left; circ.; (amp. fingers June 18, '64.) M. out Feb. 5, '66; pens d.
100	Griffin, J., Pt., A, 3d N. Y. Artillery, age 19.	Mar. 10, 23, '65.	Right; ant. post. flap; by A. A. Surg. F. A. Seymour; gangrene. Disch'd July 29, '65; pensioned.	137	Kennedy, W., Pt., L, 2d Penn. Art., age 24.	June 16, July 4, '64.	Left; long post. skin flap; short ant. flap and circ. sec. of muse.; by A. A. Surg. J. Ashhurst, jr.; abscesses. Dis'd July 17, '65; pen'd.
101	Grin, G. W., Pt. I, 57th Indiana, age 23.	Nov. 30, Dec. 20, 1864.	Right; flap. Discharged June 16, 1865; pensioned.	138	Laehbrooke, C., Pt., D, 1st Mich. S. S., age 32.	May 6, June 1, 1864.	Left. To prison Dec. 18, 1863.
102	Gross, D., Pt., II, 6th N. Y. Cavalry, age 31.	Sept. 19, 22, '64.	Right. Discharged December 20, 1863.	139	Lamont, D. H., Pt., K, 27th N. C., age 19.	Oct. 14, 21, '63.	Left; flap; by Surg. D. H. Warren, 8th Iowa C. Dis'd June 14, '65.
103	Hake, S., Pt., I, 105th Ohio.	Sept. 20, 27, '63.	Left; circ.; by A. A. Surg. J. B. Wells. Dis'd Sept. 16, '65; pen'd.	140	Lantz, N., Serg't, H, 8th Iowa Cav., age 30.	July 29, Aug. 15, '64.	Right; circ.; by A. A. Surg. W. K. Cleveland; (rem. necro'd bone.) Disch'd Sept. 18, '62. Spec. 975.
104	Halsiger, J. H., Pt., F, 9th New Jersey.	July 13, Aug. 9, '64.	Right; circ.; by Asst. Surg. C. A. McCall, U. S. A. Disch'd Nov. 24, 1862; pensioned. Spec. 163.	141	Leaur, T., Pt., K, 85th New York.	Nov. 7, 26, '61.	Right; flap. Discharged September 26, 1862; pensioned.
105	Halsey, G., Pt., D, 24th New York.	Aug. 30, Sept. 6, 1862.	Right; flap; by Surg. V. H. Coffman, 3th Iowa. Disch'd August 8, 1865; pensioned.	142	Leary, J. D., Corp'l, G, 2d Illinois.	Nov. 7, 26, '61.	Right; flap; by Surg. J. B. Lewis, U. S. V. Disch'd Dec. 19, 1862. Spec. 864.
106	Hamilton, M. D., Serg't, G, 17th Ind., age 22.	April 1, 28, '65.	Left; flap; gangrenous. Disch'd February 18, 1865; pensioned.	143	Lehman, J. A., Pt., G, 1st Pa. Reserves.	Sept. 17, Oct. 4, 1862.	Left; lateral flaps; by Surg. A. C. Van Duyn, U. S. V.; (pyæmic; gangrenous.) Discharged February 11, 1865; pensioned.
107	Hartman, L., Pt., B, 21st Ohio, age 22.	July 20, 29, '64.	Left; flap. Discharged March 3, 1865; pensioned.	144	Lewark, J. H., Pt., E, Merrill's Mo. Horse, age 26.	Nov. 2, 1864.	

NO.	NAME, AGE, AND MILITARY DESCRIPTION.	DATES.	OPERATIONS, OPERATOR, RESULT.	NO.	NAME, AGE, AND MILITARY DESCRIPTION.	DATES.	OPERATIONS, OPERATOR, RESULT.
145	Lindenwood, J. L., Pt., H, 58th Va., age 19.	Sept. 19, '61.	Left; by Surgeon J. M. McGuire, C. S. A.	182	Murphy, T., Pt., B, 26th Mass., age 21.	Sept. 19, '61.	Right; circ.; by Surg. J. G. Braudt, 26th Mass. Disch'd September 9, 1865; pensioned.
146	Lipscomb, T., Corp'l, G, 5th Michigan.	July 2, '63.	Right; by A. A. Surg. E. B. Thompson. Disch'd Oct. 19, '63; pens'd.	183	Nelson, J. B., Pt., B, 33d N. C., age 28.	May 3, '63.	Right; (exc. left radius May 11.) Retired January 25, 1865.
147	Liste, J. N., Corp'l, K, 12d Ohio, age 28.	Sept. 19, '64.	Flap; by Surg. E. D. Buckman, 98th Pa. Dis'd Feb. 14, '65; pens'd.	184	Newton, S., Pt., I, 102d Penn., age 29.	May 5, '64.	Left; lateral flap; by Surg. G. T. Stevens, 77th N. Y. Discharged November 3, 1864; pensioned.
148	Logue, J., Pt., K, 116th Pennsylvania.	Dec. 13, '62.	Left; circ.; by A. A. Surg. W. Eddy. To V. R. C. March 24, 1864; pensioned. Spec. 494.	185	O'Brien, J., Pt., D, 90th Illinois, age 22.	Nov. 25, Dec. 13, 1863.	Left; circ.; by Surg. H. Strong, 90th Illinois. Disch'd Sept. 6, 1865; pensioned.
149	Looney, M., Pt., B, 18th New York.	July 2, '62.	By A. A. Surg. T. B. Castle. Discharged Sept. 14, 1862.	186	O'Herron, D., Seaman, C. S. Navy, age 26.	Jan. 10, '63.	Left; also wound of side. Duty March 27, 1863. Spec. 1017.
150	Londmilk, W., Pt., B, 114th Illinois.	June 10, '64.	Left; flap; by Surg. F. L. Parker, P. A. C. S. Disch'd July 12, '65; pen. Right. Discharged July 27, '65.	187	O'Riley, J., Pt., II, 1st Vt. Cav., age 41.	July 3, '63.	Left; circular. Duty August 22, '63; pensioned. Spec. 4251.
151	Loughy, M., Serg't, F, 5th Penn., age 31.	Sept. 29, Oct. 6, '64.	Left; circular; by Dr. O. D. Ford. Disch'd Jan. 28, '65; pens'd.	188	Ostrander, H., Pt., F, 1st California.	Aug. 10, '62.	Right; by A. A. Surg. W. A. Kittridge; (cryst.) Dis'd; pens'd.
152	Lyon, P., Pt., B, 2d U. S. S. N., age 21.	July 11, '64.	Left; by A. A. Surg. J. A. Hall. Discharged; pensioned.	189	Otterbacher, J., Pt., B, 55th Ohio, age 17.	May 3, '63.	Left; circ.; by A. A. Surg. C. Page, U. S. A. Disch'd August 27, 1863; pensioned. Spec. 1205.
153	Lytle, R. P., Capt., B, 27th Ill., age 27.	July 8, '64.	Right; by Surg. A. H. Van Nostand, 4th Wis. C.; (amp. hand June 17.) Dis'd Sep. 30, '63; pen. Right; circ.; by A. A. Surg. W. S. Hendrie; (hgm.; lig.) Disch'd; pensioned. Spec. 1588.	190	Owens, D., Corp'l, E, 178th Ohio, age 38.	Dec. 14, '61.	Left; circ.; by Surg. S. D. Turney, U. S. V. Dis'd May 30, '65; pen'd.
154	Mabbett, A. L., Capt., I, 24th Conn.	July 8, 1863.	Right; circ.; by A. A. Surg. W. S. Hendrie; (hgm.; lig.) Disch'd; pensioned. Spec. 1588.	191	Parshall, A., Pt., I, 8th Michigan, age 18.	Sept. 14, '62.	Right; by Surg. C. W. Jones, U. S. V.; (hamorrhage.) Disch'd Dec. 6, '62; pensioned.
155	Martin, T. A., Pt., G, 91st N. Y., age 22.	Mar. 31, April 18, 1865.	Right. Discharged October 26, 1863.	192	Parkhurst, J. P., Serg't, D, 86th Ill., age 24.	June 27, July 4, 1864.	Right; circ.; by A. Surg. G. G. Ray, C. S. A. Discharged Feb. 28, 1865; pensioned.
156	Martin, G. W., Lieut., B, 25th Ohio, age 24.	July 1, '63.	Left; by A. A. Surg. J. A. Draper. Exchanged March 3, '64.	193	Pierce, A. W., Pt., II, 12th W. Va., age 27.	June 5, '64.	Right; flap; by Asst. Surg. Wm. Grumbine, 20th Penn. Cavalry. Disch'd August 4, 1865; pens'd.
157	Marrison, R. B., Pt., II, 11th Mississippi.	July 27, '63.	Left; by A. A. Surg. J. J. Bell; (exc. elbow July 22; gangrene.) Disch'd Feb. 23, 1865; pens'd.	194	Pinyerd, A., Pt., D, 65th Ohio, age 20.	Jan. 1, '63.	Right; flap; by Surg. G. Coatsworth, 23d Ill. Dis'd July 2, '62; pen'd.
158	Martin, J. W., Pt., F, 2nd Ky., age 22.	Aug. 3, 1864.	Left; by A. A. Surg. J. J. Bell; (exc. elbow July 22; gangrene.) Disch'd Feb. 23, 1865; pens'd.	195	Passon, H. A., Pt., G, 45th Illinois.	April 6, '62.	Right; circ.; by Surg. J. C. Lovv, C. S. A. Dis'd Oct. 18, '61; pen'd.
159	Marsh, B. F., Corp'l, F, 18th Conn.	June 15, 19, '63.	Left; circular; by A. A. Surg. W. Cleary. Disch'd Aug. 13, '63; pen. Left, ant. post. flap; by A. A. Surg. W. Balsler. Disch'd June 21, '65.	196	Pratt, R. M., Pt., E, 2d Vermont.	July 21, '61.	Left; skin flaps; by A. A. Surg. H. D. Vosburg. Disch'd Dec. 24, 1864; pensioned.
160	Masters, J., Corp'l, C, 25th Ohio, age 24.	Nov. 30, Dec. 13, '64.	Left; circular; by A. A. Surg. E. Vogle. Disch'd May 27, '65; pen. Right; circ.; by A. A. Surg. J. A. Edmonson. Disch'd April 29, 1865; pensioned.	197	Pratt, H., Pt., B, 36th Wisconsin, age 16.	June 17, '64.	Left; circ.; by A. Surg. John Homann, U. S. A. Discharged Dec. 21, 1864; pensioned.
161	Mathews, J. H., Pt., F, 20th Pennsylvania.	Nov. 6, '64.	Right; circ.; by A. A. Surg. M. N. Benjamin. Dis'd Nov. 9, '64.	198	Price, J., Pt., A, 47th Penn., age 29.	Oct. 19, '64.	Right. Duty June 16, 1865; pensioned.
162	Mattoon, W., Pt., E, 6th Illinois Cav., age 19.	July 22, Aug. 9, 1864.	Left; flap; by A. A. Surg. C. W. Stinson; exc. humerus Jan. 6, 1865. Dis'd June 17, '65; pen'd.	199	Quilty, M., Serg't, II, 28th Mass., age 24.	May 12, '64.	Right; circular. Discharged Feb. 20, 1865; pensioned.
163	Mayes, T. A., Serg't, E, 25th Illinois, age 26.	June 22, Sept. 18, '64.	Left; by A. A. Surg. C. W. Stinson; exc. humerus Jan. 6, 1865. Dis'd June 17, '65; pen'd.	200	Reed, S., Pt., K, 40th N. York.	June 22, July 21, '64.	Left; flap; by Surg. W. B. Fox, 8th Mich.; (amp. fingers August 4.) Discharged Oct. 21, 1864.
164	McAndrews, W., Pt., K, 23d Illinois, age 32.	Oct. 19, 1864.	Left; circ.; by Asst. Surg. C. A. McCall. U. S. A. Disch'd July 27, 1863; pensioned.	201	Reed, C. A., Pt., B, 51st Penn., age 22.	Aug. 4, '64.	Left. Discharged February 1, 1864; pensioned.
165	McDermott, M., Pt., F, 29th Penn., age 26.	May 15, J'e 10, '64.	Left; circ.; by A. A. Surg. H. H. Bank. To Vet. Res. Corps May 1, 1865.	202	Resh, B., Pt., A, 107th Ohio, age 25.	July 1, '63.	Right; (also wound of hand.) Discharged Oct. 26, 1864; pens'd.
166	McGinnes, H., F, 21st Massachusetts.	Aug. 31, Sep. 4, '62.	Left; circ.; by A. A. Surg. D. W. Bliss, U. S. V. Discharged August 2, 1865; pensioned.	203	Reynolds, J., Corp'l, G, 108th N. Y., age 37.	May 10, '64.	Right; flap. Discharged June 9, 1865; pensioned.
167	McLeer, J., Serg't, C, 8th New York.	Aug. 29, Sept. 2, 1862.	Right. Sent to Fort McHenry February 10, 1865.	204	Reynolds, S., Corp'l, G, 6th N. Y. H. A., age 21.	May 30, J'e 2, '64.	Right; by Surg. N. Hayward, 20th Mass. V. R. C. Sept. 8, '63; pens'd.
168	Meehan, P., Pt., I, 2d New York Art., age 28.	May 18, 29, '64.	Left; circ.; by Asst. Surg. W. F. Norris, U. S. A.; (May 21, hamorrhage.) removal of sequestrum. Discharged October 8, 1864.	205	Riddle, W. R., Serg't, I, 20th Mass.	Oct. 21, '61.	Right; circular; gangrene. Discharged Jan. 7, 1865; pens'd.
169	Meeks, J. C., Serg't, A, 21st Georgia, age 22.	July 16, 19, '64.	Right; circular. Sent to prison May 26, 1865.	206	Ringer, W. G., Pt., C, 84th Ill., age 26.	July 20, Aug. 18, '64.	Right; circ.; by Surg. A. McManhon, U. S. V. Disch'd; pens'd.
170	Mendenhall, J., Pt., C, 19th Indiana, age 19.	May 5, 21, '64.	Left; flap. Discharged June 14, 1865; pensioned.	207	Roesch, L., Pt., C, 15th Missouri, age 35.	Nov. 25, '63.	Left; flap; by Dr. Brown, C. S. A. Disch'd March 7, 1865; pens'd.
171	Merritt, M., Pt., I, 36th N. C., age 23.	Jan. 15, '65.	Left; circ.; by A. A. Surg. H. M. Dean; (May 15, 1865, removal necrosed bone.) Disch'd May 27, 1865; pensioned.	208	Rose, A., Pt., K, 98th New York.	May 15, '64.	Left; circ.; by A. A. Surgeon D. Brekes. Dis'd Jan. 20, '65; pen'd.
172	Metz, M., Mus'n, A, 88th Pennsylvania, age 21.	June 21, Jul. 5, '64.	Right; circ.; by A. A. Surg. H. M. Dean; (May 15, 1865, removal necrosed bone.) Disch'd May 27, 1865; pensioned.	209	Ross, J., Pt., G, 142d N. Y., age 20.	Sept. 29, Oct. 8, '64.	Left; ant. post. flap; by A. A. Surg. J. H. McIntyre. Disch'd June 9, 1865; pensioned.
173	Miller, J., Pt., F, 2d Vermont, age 19.	May 10, June 6, 1864.	Right; circ.; by A. A. Surg. R. W. W. Carroll. V. R. C. Jan. 17, '65.	210	Rowe, J., Corp'l, A, 77th Penn., age 23.	Nov. 30, Dec. 12, 1864.	Right; circular; by Surg. E. L. Bissell, 5th Conn. Discharged Sept. 11, 1864; pensioned.
174	Miles, M., Pt., F, 2d N. Y. Cavalry, age 18.	April 8, 19, '64.	Right; flap; by Surg. A. P. McConnell, 22d Michigan. Disch'd December 18, 1863; pensioned.	211	Sabine, R. H., Pt., F, 107th N. Y., age 52.	May 25, '64.	Right; flap; by Surg. J. T. Reeve, 21st Wis. Dis. May 26, '64; pen'd.
175	Mitchell, P. L., Corp'l, A, 23d Mich., age 30.	Sept. 19, 24, '63.	Left; flap; by Asst. Surg. T. A. McGraw, U. S. V. Duty January 20, 1865.	212	Salmons, J. D., Lieut., E, 3d Ky., age 26.	Sept. 20, '63.	Left; ant. post. flap; by A. Surg. A. H. Hunt, 12th Ohio Cavalry. Disch'd Oct. 22, '64; pensioned.
176	Moore, J., Lieut., E, 11th Penn., age 26.	July 20, Aug. 14, 1864.	Right; double skin flap; by A. A. Surg. J. Neill; hamorrhage. Disch'd Sept. 19, '62; pensioned. Spec. 223.	213	Sawmiller, G. W., Pt., G, 12th Ohio C., age 18.	July 9, '64.	Left; flap. To V. R. C. Disch'd Sept. 22, 1863; pensioned.
177	Morton, C., Pt., G, 2d Michigan, age 19.	May 5, June 3, 1862.	Right; circular; by A. A. Surg. E. D. Ringer, U. S. A.; (May 21, hamorrhage.) removal of sequestrum. Discharged October 8, 1864.	214	Schmidt, F., Corp'l, D, 103d New York.	May 7, '63.	Left; circular; by A. Surg. E. H. Nims, 1st Vt. C. Dis'd Mar. 31, '65.
178	Morse, J., Serg't, I, 131st New York, age 28.	Sept. 19, '64.	Right; flap; by Surg. D. F. Leavitt, 3d Mass C. Dis. May 19, '65.	215	Scheich, I. W., Pt., A, 18th Pa. Cav., age 21.	July 1, '63.	Right; by Surg. J. A. Armstrong, 75th Pa. Dis'd Jan. 5, '64; pens'd.
179	Morgan, T. I., Corp'l, E, 39th Iowa, age 25.	Oct. 5, '64.	Right; flap; by Surg. J. Pogue, 60th Ill.; (also w'd left shoulder.) Disch'd June 14, 1865; pens'd.	216	Schneider, C., Pt., II, 82d Ill., age 40.	July 1, '63.	Left; flap; by Surg. Abernether, C. S. A. Dis'd Aug. 2, '65; pens'd.
180	Moulton, J., Pt., D, 1st Maine Cav., age 26.	Aug. 16, 28, '64.	Left; circ.; by A. A. Surg. L. K. Baldwin; (exc. elbow joint Aug. 16; hamorrhage.) re amp Mar. 14, '65. Disch'd August 29, '65; pensioned. Died of lung disease Dec. 20, 1869. Spec. 3649.	217	Schoepf, J., Pt., F, 17th Ohio, age 20.	Mar. 3, '65.	Right; by Surg. G. P. Christy, 9th Ill. Cavalry; (gangrene.) Dis'd April 14, 1864; pensioned.
181	Murphy, T., Pt., I, 60th New York, age 19.	June 15, Jul. 2, '64.	Left; flap; by A. A. Surg. S. L. Merrill. Disch'd May 19, 1865; pensioned.	218	Scott, R. A., Serg't, E, 9th Illinois Cavalry.	Dec. 3, '63.	Left; flap; by Surg. W. Watson, 105th Pa. Disch'd May 10, 1865; pensioned.
				219	Scott, W., Serg't, K, 141st Pa., age 34.	Oct. 27, No. 1, '64.	Right; circular; by Surg. S. E. Fuller, U. S. V. Duty Oct. 12, 1864; pensioned. Spec. 3354.
				220	Seiter, G., Pt., E, 23d Kentucky.	May 27, June 15, 1864.	Right. Disch'd October 23, 1863; pensioned.
				221	Shaw, J. W., Pt., I, 142d Penn., age 23.	July 1, '63.	



NO.	NAME, AGE, AND MILITARY DESCRIPTION.	DATES.	OPERATIONS, OPERATOR, RESULT.	NO.	NAME, AGE, AND MILITARY DESCRIPTION.	DATES.	OPERATIONS, OPERATOR, RESULT.
222	Sberman, D. J., Pt., I, 17th New York, age 23.	Aug. 31, Sept. 5, 1862.	Right; ant.-post. flap; by A. Surg. G. M. McGill, U. S. A. Disch'd Oct. 14, '62. Re-enlisted in V. R. C.	239	Ulmer, D., Pt., M., 4th Penn. Cav., age 36.	Mar. 31, April 21, 1865.	Left; skin flaps, circ., of muscles; by A. A. Surg. H. Craft (April 14, part of olecranon removed—crystallus) necrosed bone rem'd. Disch'd Sept. 3, '65; pens'd. 192.
223	Sherman, F. A., Corp'l, 11, 4th Maine, age 23.	May 5, 29, '64.	Left; circ.; by A. A. Surg. F. G. H. Bradford; (exc. ulna May 5; erysipelas.) Discharged March 7, '65; pensioned. <i>Spec.</i> 2503.	240	Van Sickle, A. M., Pt., A, 22d Ohio.	Sept. 14, 19, '62.	Right. Discharged Dec. 14, 1862; pensioned.
224	Shreekgost, H., Pt., C, 105th Pa., age 22.	May 3, 27, '63.	Right. Discharged Dec. 25, '63; pensioned. <i>Spec.</i> 1174.	241	Voorhees, W. S., Pt., K, 12th Ohio.	May 19, June 9, 1863.	Right; flap; by Surg. N. T. Graham, 12th Ohio. Disch'd Sept. 1, 1863; pensioned.
225	Sigley, D., Pt., B, 85th Illinois, age 25.	July 20, 27, '64.	Right; ant.-post. flap; by Surg. Mattow, C. S. A. Discharged Aug. 2, 1865; pensioned.	242	Vosburg, J. B., Pt., E, 45th Penn., age 19.	May 6, June 1, 1864.	Left; circ.; by A. A. Surg. W. C. Minor; (May 6, amp'n fingers.) Disch'd March 16, 1865; pens'd.
226	Smith, B., Pt., I, 54th Col'd Troops, age 41.	July 18, Aug. 1, '63.	Right; flap; by Surg. Mord, P. A. C. S. Dis'd Aug. 16, '63; pens'd.	243	Wareham, R. A., Corp'l, 1, 6th Wisconsin.	Aug. 28, Se. 8, '62.	Left; by Surg. H. Bryant, U. S. V. Disch'd Dec. 21, 1862; pens'd.
227	Smith, J. W., Corp'l, E, 39th Iowa, age 25.	Oct. 5, 31, '64.	Right; circular; by Asst. Surg. G. W. Crossley, 57th Illinois. Disch'd May 24, '65; pensioned.	244	Winning, W., Pt., A, 125th Ohio, age 36.	May 14, 21, '64.	Left; circ.; by A. A. Surg. M. L. Herr. Disch'd January 26, 1862; pensioned. <i>Spec.</i> 3363.
228	Smith, J. M., Pt., E, 10th N. J., age 32.	Oct. 19, 24, '64.	Right; circular; by Surg. C. H. Andrus, 176th New York. Discharged May 16, '65; pensioned.	245	Wells, J., Pt., F, 19th C. T., age 21.	July 30, Aug. '64.	Right; flap; (July 30, exc. humerus.) Dis'd June 10, '65; pen'd.
229	Smith, C., Pt., K, 1st Tenn. Cav., age 29.	Nov. 8, 19, '64.	Left; circular; by Surg. W. Spencer, 10th Tenn. Cav. To V. R. C. April 5, 1865; pensioned.	246	Welch, D., Pt., A, 8th Iowa, age 21.	April 6, 28, '62.	Right; flap; by A. A. Surg. J. C. Hughes. Disch'd June 25, 1862; pensioned.
230	Spoehel, R., Pt., C, 6th Conn., age 44.	May 18, 24, '64.	Left; flap; by Dr. J. E. Garretson, Phila. Dis'd Mar. 29, '65; pens'd.	247	West, W. C., Pt., B, 96th N. Y., age 26.	Oct. 27, Nov. 10, 1864.	Left; circ.; by Surg. V. W. Harrison, C. S. A. Disch'd June 13, 1865; pensioned.
231	Stark, A., Serg't, D, 68th New York.	July 1, 15, '63.	Right; flap; by A. Surg. D. C. Peters, U. S. A. (July 1, excision ulna.) To V. R. C. Jan. 5, 1864. Disch'd Aug. 6, '64; pensioned.	248	Wharton, W. C., Pt., G, 10th Ala., age 21.	July 2, 7, '63.	Right; hæmorrage; (re-amp. Aug. 8, '63.) Fort McHenry Mar. 2, '64.
232	Stanley, C. E., Pt., B, 33d New Jersey.	June 27, July 3, '64.	Left. Discharged; pensioned.	249	Whiting, J. E., Pt., D, 46th Illinois.	April 6, 10, '62.	Left. Discharged July 18, 1862; pensioned.
233	Stevens, J. P., Pt., F, 1st Delaware.	May 12, 18, '64.	Left; flap; by Dr. G. Buck, of N. Y. Disch'd Oct. 23, '64; pens'd.	250	Wilson, J. H., Pt., F, 54th Mass., age 20.	Feb. 10, 24, '65.	Flap; by A. Surg. N. S. Roberts, 21st C. T.; gangrene; also loss of eyes. Dis. Aug. 20, '65; pen'd.
234	Stillwell, D. D., Serg't, B, 13th New York.	Aug. 30, Se. 15, '63.	Right; by A. A. Surg. W. Eddy. Disch'd Dec. 17, 1862; pens'd.	251	Winslow, E., Pt., K, 2d Maine Cavalry.	De. 27, '64.	Left; by Surg. G. W. Martin, 2d Me. Cav. Dis. Mar. 1, '65; pen'd.
235	Totten, J. M., Serg't, C, 20th Indiana, age 33.	June 15, July 8, 1864.	Right; circular; by Surg. E. M. Powers, 7th Missouri. Disch'd Sept. 13, 1864; pensioned.	252	Woodring, D., Pt., H, 148th Pennsylvania.	May 3, 11, '63.	Left; by Surg. C. Gray, 7th N. Y. Disch'd August 20, 1863; pen'd.
236	Townsend, J., Pt., H, 14th Infantry.	Aug. 30, Se. 5, '62.	Right; flap; by Surg. H. Bryant, U. S. V. Disch'd Oct. 30, 1862; pensioned.	253	Young, S., Pt., C, 10th Minnesota, age 24.	July 14, 21, '64.	Left; flap; by Asst. Surg. J. C. G. Happersett, U. S. A. Disch'd September 28, 1864; pensioned.
237	Tuttle, D., Pt., I, 83d Pennsylvania.	Sept. 1, 13, '62.	Left. Discharged February 9, 1863; pensioned.	254	Young, J., Serg't, A, 170th N. Y., age 20.	Aug. 25, 31, '64.	Left; double flap; hæmorrhage. Disch'd May 27, 1865; pens'd.
238	Underwood, W. E., E, 30th Tennessee.	Sept. 20, Oct. 18, '63.	Left; by Surg. P. F. Eve, C. S. A.; hæmorrhage. Doing well.	255	Zettler, J., Pt., C, 24th Wisconsin, age 19.	June 27, Jul. 27, '64.	Right; circular; by Surg. A. Zipperlen, 108th Ohio. Discharged August 2, 1865; pensioned.

Of the successful intermediary amputations at the middle third above enumerated, eighty-six were practised by the circular method, one hundred and nine by flap methods, generally by transfixion and antero-posterior flaps, though four instances are mentioned of Teale's operation, and many in which lateral flaps were formed. The plan of reflecting skin flaps and dividing the muscles circularly, and that of forming a single flap accommodated to the injuries of the soft parts, were resorted to in a number of cases. The wounds were inflicted by shell fragments, grapeshot, or the premature explosion of cannon in fifteen cases. In twenty-six instances antecedent operations had been performed.<sup>1</sup> Consecutive operations, including eight re-amputations, were resorted to in sixteen cases.<sup>2</sup> Thirty of the cases were complicated by serious hæmorrhage, twenty-seven by sloughing, and twelve by gangrene.

Besides the six examples illustrated by drawings of specimens that precede the tabular statement, there were twenty-seven other cases of this series represented in the Army Medical Museum by pathological specimens, that are described by Dr. Woodhull in the sixth and seventh sections of the Catalogue of 1866, of the Surgical Section of the Museum. The numbers of the preparations are recorded in the Table.

§ *Fatal Cases.*—Intermediary amputation at the middle third of the arm resulted fatally in ninety-three cases. Sixteen amputations were subsequent to excisions lower

<sup>1</sup>As follows: Amputation of forearm, with consecutive ligation of the ulnar artery, in 1 case; disarticulation at the wrist in 2 cases; of fingers and portions of hand in 5 cases; excisions in shaft of humerus in 2 cases; excision of elbow joint in 7 cases; excision in radius or ulna in 3 cases; removal of fragments of olecranon in 1 case; extraction of ball through incision in 1; ligations of brachial in 2, of ulna in 1, of radial in 1.

<sup>2</sup>Thus: One patient underwent exarticulation at the shoulder; four, re-amputations at the upper third; three, re-amputations at the junction of the upper and middle thirds; six, removals of sequestra from protruding humerus; one, extirpation of bulbous extremities of nerves; one, a ligation of the brachial artery.

down in the limb, two to amputations lower down, and one to an ineffective ligation of the radial. Seven of the patients had received serious wounds in other parts of the body; in one case ulterior amputation of the opposite arm at the lower third was required. The fatal results were ascribed to the shock of operation in one case, to tetanus in three cases, to secondary hæmorrhage in seven, to pulmonary complications in six; in far the larger proportion of cases to purulent absorption or septic infection.<sup>1</sup> The amputations were on the right side in fifty cases, on the left in forty-one, not specified in tow cases.

CASE 1682.—Private J. V——, Co. C, 13th New York, age 21 years, was wounded in the right arm, at Bull Run, August 30, 1862. He was conveyed to the Episcopal Church Hospital, at Centreville, where Acting Assistant Surgeon W. W. Keen, jr., amputated the limb, at the middle third, on September 7th. The specimen (FIGS. 540, 541) was forwarded to the Museum by the operator, and consists of the lower half of the right humerus "perforated, with much comminution at the junction of the lower thirds."—(*Cat. Surg. Sect.*, 1866, p. 129.) On September 9th, the patient was sent to Fairfax Seminary Hospital, whence Surgeon D. P. Smith, U. S. V., reported: "Tetanus supervened two days after the patient's admission. The treatment consisted in the administration of extract of cannabis indica and of morphia. Death occurred on September 19, 1862."



FIG. 540.—Shot perforation of lower half of right humerus. Spec. 73.

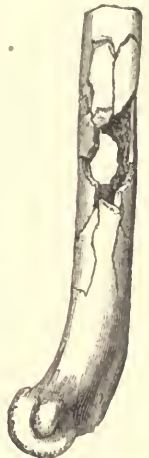

FIG. 541.—Another view of the same specimen.

CASE 1683.—Private A. D——, Co. E, 8th New York Artillery, aged 23 years, was wounded at Cold Harbor, June 3, 1864. Surgeon J. F. Dyer, 19th Massachusetts, reported his admission to the field hospital of the 2d division, Second Corps, with "Gunshot wound of the left arm." On June 8th, the patient entered Emory Hospital, Washington. Surgeon N. R. Mosceley, U. S. V., contributed the specimen (FIG. 542) to the Museum, with the following minutes of the case, furnished by Acting Assistant Surgeon E. B. Harris: "Gunshot wound of arm and shoulder. One ball entered three inches above the bend of the elbow, passed through the humerus and out at the opposite point posteriorly, fracturing the bone into the elbow joint. The other ball entered one inch below the acromion, and, passing down and out, made its exit at the inferior angle of the scapula. The parts, from four inches below and eight inches above the wound in the arm, were greatly swollen and tumefied, with slight

erysipelatous inflammation, and sinuses extending above and below the wound for four inches. The patient was much exhausted from loss of blood and exposure on the field and in transit, with loss of appetite, diarrhœa, a quick and hurried pulse, disturbed sleep, and general instability of the system. June 9th, placed the patient in an easy position with slight extension of the parts, made a free incision adjoining the wound of entrance, and had a copious discharge of coagulated blood and pus. Ice-water dressings were applied to keep the parts cool day and night. The wound of the shoulder was injected with cold water, removing coagula and a piece of the coat of the patient, probably worn at the time of the injury. This treatment was continued up to June 15th, when the tumefaction of the arm had subsided, and extension was applied, with slight counter-extension, and treating as compound fracture, with the hope of obtaining union with ankylosis. June 16th, the wound of the arm continues to discharge a thin sanious matter, and the wound of the shoulder is discharging a more healthy pus. Appetite improving, and patient resting well at night with the use of anodynes. Cold applications were continued to the limb, and the wound cleansed night and morning with injections of water and solution of gum acacia. Stimulants of milk punch were given, with chicken broth and essence of beef daily. June 17th, diarrhœa checked; pulse and appetite better; patient slightly improving. June 18th, patient attacked with chills, continuing for some two hours, followed by fever, continuing during the day, with profuse sweating at night. The treatment was continued with the addition of the following: Sulphate of quinine twenty grains, aromatic sulphuric acid a drachm and a half, and brandy four ounces, given in doses of a table-spoonful every two hours during day and up to the patient's time of going to sleep. Anodyne was given at night. June 19th, patient restless during the previous night; appetite slight; uneasiness of the system. Discharge from wound of shoulder of a dark pitchy character with blood, and from the arm of a sanious character, with increased swelling and lividness of the parts. Continued the tonic mixture during the day with punch and oyster broth, and the dressing with cold water; anodynes at night. Called Dr. Risny as counsel, and concluded to remove the arm. June 20th, patient rested quietly during the night. At ten A. M. the arm was removed at the upper part of the middle third, the patient bearing the operation well. The flaps were left open for six hours, after which they were closed with sutures and supported by straps. Stimulants were given with nourishment during the day, and anodynes at night. The discharge from the shoulder continued of a dark offensive character. The patient was attacked with rigors, slight deliriousness, nausea and vomiting during the day, refusing to take food and commencing to sink. June 21st and 22d, patient continued to sink, remaining unconscious until death supervened, on June 23, 1864." The specimen consists of "the lower half of the left humerus, amputated for comminution of the lower third, with a fracture extending through the trochlea. The borders of the fracture are necrosed, and on the posterior surface of the shaft there has been some periosteal deposit."—(*Cat. Surg. Sect.*, 1866, p. 168.)

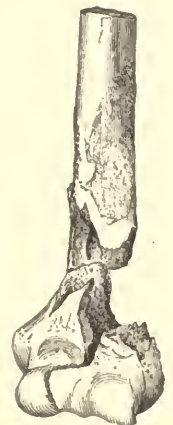

FIG. 542.—Shot comminution of lower part of left humerus. Spec. 2536.

<sup>1</sup>The proximate causes of death are noted on the returns as: Shock of operation in 1 case; tetanus in 3 cases; secondary hæmorrhage in 7; gangrene in 2; pyæmia in 44; typhoid, pleuro-pneumonia, or other pulmonary complications in 6; irritative fever and exhaustion in 21; typhoid fever in 2; diphtheritic infection of wound in 1; diarrhœa and dysentery in 6.



## TABLE LXXIX.

Condensed Summary of Ninety-three Unsuccessful Cases of Intermediary Amputation in the Middle Third of the Shaft of the Humerus.

No.	NAME, AGE, AND MILITARY DESCRIPTION.	DATES.	OPERATIONS, OPERATOR, RESULT.	No.	NAME, AGE, AND MILITARY DESCRIPTION.	DATES.	OPERATIONS, OPERATOR, RESULT.
1	Adams, S., Pt., I, 119th Penn., age 23.	April 2, '65.	Left; (excision of elbow April 10.) Died April 20, 1865, pyæmia.	34	Hoover, J. W., Pt., I, 36th Ohio, age 21.	Sept. 14, '62.	Right; circ.; by A. A. Surg. W. W. Keen, Jr. Died October 6, 1862, pyæmia. <i>Spec.</i> 802.
2	Akhurst, J. S., Pt., C, 39th Ill., age 21.	May 20, '64.	Left; circ.; by A. A. Surg. J. E. Garrettson. Died May 28, '64, exh. Right; circular. Died July 7, '64.	35	Hughes, H., Pt., E, 21st Kentucky, age 21.	June 22, July 5, 1864.	Right; flap; by A. A. Surg. J. J. O'Reilly; (exc. elbow June 22.) Died July 6, 1864, pyæmia.
3	Aldrich, W., Pt., I, 2d Rhode Island.	June 3, '64.	Left; circ.; by A. A. Surg. M. J. Grier; (hæm.; also w'd abdm'n.) Died June 17, '64, diar. <i>Spec.</i> 780.	36	Hughes, F., Capt., E, 37th Indiana, age 27.	June 22, July 13, 1864.	Right; circ.; by A. A. Surg. J. H. Greene; (July 9, exc. abm; gangrene.) Died July 28, '64, pyæmia.
4	Ames, W. H., Pt., C, 4th Maine, age 24.	May 11, '64.	Right; flap; by Surg. J. E. Herbst, U. S. V.; (amp. left arm July 19.) Died July 21, 1864, pyæmia.	37	Kells, T., Pt., B, 106th New York, age 34.	Sept. 21, Oct. 5, 1864.	Left; lat. flap; by A. A. Surg. B. B. Miles; (hæm; age; neuris'm.) Died October 15, 1864, pyæmia. <i>Spec.</i> 3435.
5	Bacon, B. W., Capt., G, 74th Ill., age 40.	June 27, July 14, 1864.	Left; circ.; (hæm.;) necrosis. Died June 8, '64, pyæmia. <i>Spec.</i> 3532.	38	Kirk, J., Pt., I, 121st Ohio, age 23.	June 28, Jul. 15, '64.	Right; circ.; by Surg. S. E. Fuller, U. S. V. Died July 21, '64, diarrh.
6	Baddorf, P., Pt., G, 96th Penn., age 18.	May 10, '64.	Right; circ.; by A. A. Surg. A. J. Smith; (hæm.) Died Sept. 11, '64, pyæmia.	39	Krake, A., Corp'l, A, 27th Mich., age 31.	May 6, '64.	Left. Died June 14, 1864, fever and shock.
7	Barr, W. H., Corp'l, B, 62d Ohio, age 24.	Aug. 16, Sept. 8, 1864.	Right; circular. Died August 8, 1864.	40	Kretger, P., Pt., F, 7th Pa. Cav., age 40.	Dec. 8, '64.	Left; ant.-post. flap; by Asst. Surg. B. E. Fryer, U. S. A.; erysipelas. Died Jan. 2, 1865, pyæmia.
8	Benjamin, A., Pt., I, 53d N. C., age 23.	July 12, '64.	Left; circ.; by A. A. Surg. R. N. Atwood. Died June 6, '64, gang.	41	Krise, D. O., Pt., A, 1st Pa. Rifles, age 26.	June 17, July 10, 1864.	Left; circ.; by A. A. Surg. John Ransom; necrosis. Died August 3, 1864, pyæmia.
9	Brewer, J. R., Pt., E, 140th Pa., age 26.	May 8, '64.	Right; circ.; by A. A. Surg. H. E. Paine; (erysip.; Nov. 1, amp. forearm; hæm.) Died Nov. 27, 1863, pyæmia.	42	Lambert, T., Pt., E, 72d Pa., aged 30.	July 3, '63.	Right. Died August 17, 1863, pyæmia.
10	Brown, I., Pt., F, 5th N. Y. Cav., age 30.	Oct. 17, Nov. 9, 1863.	Left; circ.; by A. A. Surg. A. Ansell. Died October 21, 1864.	43	Lamphier, J. G., Pt., D, 31st Maine, age 28.	May 12, J'e 6, '64.	Right; circ.; by A. A. Surg. C. W. Carrier. Died June 20, '64, pyæmia.
11	Burt, S., Private, H, 1st Mich. S. S., age 20.	Sept. 30, Oct. 13, '64.	Right; flap; by A. A. Surg. T. H. Stillwell. Died Nov. 21, 1863, pyæmia. <i>Specs.</i> 1841 and 1842.	44	Leonard, H., Pt., H, 2d N. J. Cav., age 21.	June 10, '64.	Right; circ.; by A. A. Surg. J. N. Sharp; (hæm; age; gangrene.) Died June 28, '64, pneumonia.
12	Bush, A. P., Pt., F, 1st Mass. Cav., age 29.	Oct. 14, '63.	Left; double flap; by A. A. Surg. B. B. Miles. Died July 18, '62, pyæmia.	45	Lock, W., Pt., 1st Delaware.	Sept. 17, '62.	Right; by Surg. H. S. Hewitt, U. S. V. Died Oct. 16, 1862, irritative fever. <i>Spec.</i> 361.
13	Camp, L. B., Pt., F, 5th Penn. Reserves.	June 30, July 10, 1862.	Left; flap; by A. A. Surg. F. P. Geisdorf; hæmorrhages. Died Oct. 28, 1864, exhaustion.	46	Lutes, C., Pt., D, 23d Mich., age 23.	Dec. 3, '64.	Left; ant.-posterior flap; by A. A. Surg. M. L. Herr; (Dec. 7, exc. radius; hæmorrhage; gangrene.) Died December 23, 1864.
14	Carr, G., Corp'l, F, 36th Col. T., age 45.	Sept. 29, Oct. 23, 1864.	Circular; by Surg. S. E. Fuller, U. S. V.; (gangrene.) Died August 7, 1864, diarrhoea.	47	Marsh, G. J., Pt., G, 11 Pa. Res., age 23.	Dec. 13, '62.	Right; circular; by Surg. J. S. Delienneville. 11th Penn. Res. Died Jan. 1, 1863, pyæmia.
15	Clark, T. B., Pt., G, 17th Ohio, age 26.	May 27, June 10, 1864.	Right; circ.; by A. Surg. T. A. McGraw, U. S. V.; (also w'd leg; hæmorrhage; gangrene.) Died Sept. 7, 1864, exhaustion.	48	McCormick, W. J., Corp., D, 5th Mich. C., age 24.	Mar. 31, Ap. 21, '65.	Right; circ.; by A. A. Surg. M. F. Price. Died May 1, '65, typh' fever.
16	Darwood, H., Pt., I, 15th Infantry, age 17.	Aug. 5, Sept. 8, 1864.	Right; circ.; by A. A. Surg. A. N. Brookway; (June 18, exc. radius.) Died Sept. 13, 1864, pyæmia.	49	McCauley, J., Pt., L, 10th N. Y. C., age 29.	April 19, 1865.	Left; circular; by A. A. Surg. A. H. Haven. Died May 1, 1865, pyæmia. <i>Spec.</i> 182.
17	Davis, J., Pt., E, 143d Penn., age 24.	June 18, 29, '64.	Left. Died June 23, 1864. <i>Spec.</i> 2566.	50	McGovlin, M., Pt., II, 86th New York, age 28.	Oct. 27, Nov. 4, '64.	Right; circ.; by A. Surg. H. Allen, U. S. A. Died Dec. 1, '64, pyæmia.
18	Deitz, A., Pt., E, 8th N. Y. H. A., age 23.	June 3, '64.	Right; circ.; by A. A. Surg. J. Case. Died June 29, '64, pyæmia.	51	McLaughlin, B., Pt., Andrew's Mass. Sharpshooters, age 25.	May 30, June 17, 1864.	Right; circular; by A. A. Surg. E. P. Fitch; (exc. elbow May 30; gang.) Died June 21, '64, pyæmia.
19	Dekruif, J. P., Pt., B, 16th Mich., age 28.	May 10, J'e 1, '64.	Left; (hæm.) Died August 1, 1864, pyæmia and hæmorrhage.	52	Merriek, T., Serg't, F, 102d Illinois, age 25.	Oct. 20, Nov. 6, 1864.	Left; circ.; by A. A. Surg. P. L. Rice; (hæmorrhage; rad. lig. w'd hip.) Died Nov. 15, '64, exhaust'n.
20	Emory, C. E., Lieut., F, 12th N. H., age 34.	June 1, '64.	Right; circ.; by Surg. R. B. Bonteeon, U. S. V.; (thumb amp. J'e 18; gang.) Died Jul. 21, '64, ex'h'n.	53	Millhollen, H., Pt., E, 51st Illinois, age 19.	Nov. 29, Dec. 3, '64.	Right; circ.; by A. A. Surg. S. L. Merrill. Died Dec. 24, '64, diar.
21	Ferguson, D. D., Pt., K, 2d Pennsylvania H'vy Artillery, age 23.	July 16, 1864.	Right; circ.; by A. A. Surg. E. Seyfarth. Died June 13, '64, hæm.	54	Mooney, J., Pt., G, 11th Infantry, age 23.	May 12, June 7, 1864.	Right; (exc. humerus May 12; hæmorrhages.) Died 15 minutes after operation.
22	Finn, J., Serg't, B, 22d Mass., age 23.	May 23, J'e 9, '64.	Right; double flap; by A. Surg. W. Thomson, U. S. A.; (exc. elb. Nov. 8; erysipelas; hæmorrhage.) Died Nov. 30, 1863, pyæmia.	55	Morse, W. H., Pt., C, 1st Maryland, age 32.	Aug. 18, Sep. 6, '64.	Right; circ.; by A. Surg. H. Allen, U. S. A. Died Sep. 9, '64, pyæmia.
23	Fitzgerald, W., Pt., B, 1st U. S. S. S., age 19.	Nov. 7, 12, '63.	Left; circ.; hæmorrhages. Died July 30, 1864, hæmorrhage.	56	Munson, C., Pt., K, 2d New York State Mil.	May 4, 31, '62.	Circular. Died June 29, 1862.
24	Glines, J., Corp'l, C, 17th Vermont, age 38.	June 18, Jul. 1, '64.	Left. Died Oct. 5, 1862, tetanus. <i>Spec.</i> 381.	57	Noyes, C. A., Pt., D, 21st Wisconsin, age 23.	May 14, June 3, 1864.	Right; circular; by A. A. Surg. H. C. May. Died Aug. 12, 1864, pyæmia. <i>Spec.</i> 370.
25	Grant, G., Corp'l, B, 31st Maine, age 20.	May 12, 19, '64.	Right; oval skin flap; by Surg. R. Curran, 9th N. Y. Cav.; (wound of back; Sept. 20, excis. humerus.) Died Sept. 29, '64, hæmorrhage, of wound in back.	58	O'Brien, J., Pt., B, 1st Pa. Rifles, age 24.	May 8, June 3, 1864.	Right; skin flaps; cir. cut of mus.; by Surg. Z. E. Bliss, U. S. A.; (erysip.) Died June 4, '64, pyæmia.
26	Grant, W., Pt., B, 59th New York, age 38.	Sept. 17, '62.	Left; ant.-post. flap; by A. A. Surg. H. Craft; erysipelas. Died July 12, 1864, pyæmia.	59	Orin, D., Pt., H, 51st Ohio, age 23.	July 4, 26, '64.	Right; circular; by A. A. Surg. S. T. Williams; (gang'e.) Died Sept. 15, 1864, chronic diarrhoea.
27	Harrowes, C., Pt., L, 3d New Jersey Cavalry.	Sept. 19, 22, '64.	Left; circ.; hæmorrhages. Died July 30, 1864, hæmorrhage.	60	Perry, A. D., Serg't, E, 2d Mich., age 28.	June 1, 28, '64.	Left; circ.; by A. A. Surg. P. C. Porter; (June 1, exc. radius; gang. caries.) Died July 17, '64, pyæmia.
28	Harper, P. W., Pt., A, 10th West Va., age 22.	Oct. 9, Nov. 8, 1864.	Right; flap; by A. A. Surg. B. B. Miles; (hæmorrhages.) Died Nov. 18, 1864, pyæmia.	61	Porter, J. T., Pt., C, 6th Maryland, age 28.	May 6, 12, '64.	Right; by Asst. Surg. J. C. McKee, U. S. A. Died June 8, '64, pyæmia. <i>Spec.</i> 124.
29	Hayberry, G., D, 51st Pennsylvania, age 32.	Sept. 17, 28, '62.	Left; lateral flap; by Surg. H. A. Martin, U. S. V.; hæmorrhage. Died March 28, 1863, pyæmia.	62	Powell, J., Corp'l, K, 10th Ohio, age 23.	Dec. 15, 27, '64.	Left; circ.; by A. A. Surg. J. F. Rolls; (hæm's.) Died Jan. 15, '65.
30	Hickox, T. C., Pt., K, 6th N. Y. Art., age 33.	Oct. 19, Nov. 1, 1864.	Left; ant.-post. flap; by A. A. Surg. H. Craft; erysipelas. Died July 12, 1864, pyæmia.	63	Rader, J., Pt., F, 6th Wisconsin, age 27.	July 1, 24, '63.	Left; circ.; by A. A. Surg. B. N. Downs; (hæmorrhages.) Died August 24, 1863.
31	Hiles, J., Pt., I, 1st Neb., age 20.	Feb. 27, Mar. 3, 1863.	Left; ant.-post. flap; by A. A. Surg. H. Craft; erysipelas. Died July 12, 1864, pyæmia.	64	Reed, T. A., Serg't, D, 51st Ohio, age 32.	Dec. 16, 20, '64.	Left; ant.-post. flap; by A. Surg. W. B. Trull, U. S. V.; (Dec. 16, exc. el. jt.) Died Jan. 15, '65, pyæmia.
32	Hinkley, B. F., Pt., A, 1st Mich. S. S., age 30.	May 9, '64.	Left; circ.; by A. A. Surg. J. A. Hall; (exc. elbow June 24; gangrene.) Died July 27, '64, pyæmia.	65	Robinson, W., Pt., B, 2d Penn. Art., age 19.	June 17, July 13, 1864.	Left; ant.-post. flap; by Surg. R. B. Bonteeon, U. S. V.; (July 3d, exc. el. jt.; July 12, hæm.) Died July 15, '64, ex'h'n. <i>Spec.</i> 3030.

No.	NAME, AGE, AND MILITARY DESCRIPTION.	DATES.	OPERATIONS, OPERATOR, RESULT.	No.	NAME, AGE, AND MILITARY DESCRIPTION.	DATES.	OPERATIONS, OPERATOR, RESULT.
66	Rosa, W. H., Pt., H, 20th N.Y.S.M., age 21.	Aug. 30, Sept. 10, 1862.	Right; circ.; by A. Surg. C. A. McCull, U. S. A. Died September 28, 1862, pyæmia. <i>Spec.</i> 165.	80	Varter, J., Pt., C, 13th N. Y.	Aug. 30, Sept. 7, 1862.	Right; by A. A. Surg. W. W. Keen, jr. Died Sept. 17, 1862, tetanus. <i>Spec.</i> 73.
67	Ryal, J., Pt., A, 43d Col'd Troops, age 19.	July 30, Aug. 22, 1864.	Left; circ.; by A. A. Surg. W. W. Shapley; (July 31st, excision ulna) hamor. Died August 29, 1864, exhaustion. <i>Spec.</i> 3666.	81	Watson, S. H., Pt., E, 5th Texas, age 21.	July 2, 15, '64.	Right. Died Sept. 13, 1863, exhaustion. <i>Spec.</i> 1937.
68	Samson, C., Pt., C, 7th Col'd Troops, age 20.	Aug. 11, 18, '64.	Right; flap; by A. A. Surg. H. B. White. Died August 22, 1864, inflammation of lung.	82	Webb, H., Pt., I, 45th North Carolina.	Oct. 19, 23, '64.	By Surg. G. L. Miller, C. S. A.; erysipelas. Died Nov. 8, 1864, hemorrhage; pyæmia.
69	Sammis, C. A., Serg't, E, 127th N. Y., age 21.	Nov. 30, Dec. 12, '64.	Right; flap; by A. A. Surg. Wm. Balsler. Died Dec. 22, '64, pyæmia.	83	White, H. M., Pt., A, 2d Wisconsin, age 19.	May 8, June 1, 1864.	Left; flap; by Surg. A. F. Sheldon, U. S. V.; June 20, gang. Died June 29, 1864, exhaustion.
70	Shepperd, D. G., Corp'l, I, 6th Connecticut.	Oct. 22, 26, '62.	Left; circular; (trae. jaws.) Died Oct. 28, '62; exhaust'n. <i>Spec.</i> 690.	84	Wicker, W. B., Pt., 15th Virginia, age 21.	Sept. 17, 22, '62.	Circular. Died Sept. 25, 1862, pyæmia.
71	Shults, J., Pt., D, 93d Penn., age 30.	May 12, June 9, 1864.	Left; circular; by A. A. Surg. L. Wells; (hemorrh's.) Died June 10, 1864, from shock. <i>Spec.</i> 2936.	85	Willis, A., Pt., K, 8th Col. Troops, age 37.	Feb. 20, Mar. 7, 1864.	Left; double skin flaps; by A. A. Surg. C. T. Reber. Died Mar. 16, '64, typ. pneum. <i>Spec.</i> 2722.
72	Smith, R. L., Serg't, B, 17th Infantry.	July 3, 19, '63.	Circular; by A. A. Surg. B. B. Miles; July 25, hemorrhage. Died July 26, 1863, pyæmia.	86	Williams, J., Corp'l, A, 1st Michigan Cavalry, age 27.	June 12, July 7, 1864.	Right; circ.; by A. A. Surg. H. Craft; (erysipelas.) Died July 29, 1864, pyæmia.
73	Smith, D., Pt., A, 57th Pennsylvania, age 36.	May 6, 20, '64.	Right; circular; by Asst. Surg. J. C. McKee, U. S. A. Died June 14, 1864, pyæmia.	87	Wilson, G. A., Pt., I, 5th Michigan.	May 5, 21, '62.	Right; flap; by A. A. Surgeon J. Neill; hemorrhages. Died June 24, 1862, pyæmia. <i>Spec.</i> 222.
74	Stadler, N., Corp'l, E, 21th Penn., age 25.	April 2, 24, '65.	Right; flap; by A. Surg. T. G. Mackenzie, U.S.A. Died June 2, 1865, exhaustion.	88	Winship, D., Pt., F, 5th N. H., age 19.	Sept. 17, Oct. 13, 1862.	Right; by A. Surg. J. A. Bigelow, 8th Conn. (Sept. 18, exc. cl. jt.) Died Nov. 12, '62, typ. pneum.
75	Tasker, R., Corp'l, D, 4th Michigan, age 25.	May 5, 25, '64.	Right; circ.; by A. A. Surg. D. P. Wolhaupter. Died June 6, '64.	89	Wise, I., Pt., D, 2d N. Y. Cav., age 31.	Nov. 12, 21, '64.	Right; anterior flap; by A. A. Surg. W. P. Moon. Died Dec. 3, '64, pyæmia. <i>Spec.</i> 2556.
76	Tracy, H., Corp'l, A, 3d Iowa, age 32.	April 7, May 5, 1862.	Left; flap; by A. A. Surg. J. A. Murphy; (gangrene.) Died May 13, 1862, pyæmia.	90	Woodruff, F. B., Pt., K, 147th N. Y., age 22.	May 11, 31, '64.	Left; skin flaps and circular section of muscles; by A. A. Surg. W. G. Small. Died June 2, '64.
77	Tyler, E. H., Pt., D, 11th Conn., age 45.	May 16, 22, '64.	Left; flap; by A. A. Surg. J. E. Garretson; hemorrhage; lig. brachial. Died July 14, 1864.	91	Wordley, J., Pt., K, 151st N. Y., age 25.	July 9, 14, '64.	Right; circ.; by A. A. Surg. J. H. Bartholf. Died July 19, 1864, pleuro-pneumonia.
78	Urwiler, C. A., Serg't, C, 67th Pennsylvania.	May 5, 13, '64.	Left; single post-flap; by A. Surg. W. G. Bryant, 12d O.; May 28, ham. Died May 30, '64, typ. fev.	92	Wyman, B., Pt., K, 8th Michigan.	May 31, June 29, 1862.	Right; circ.; by A. A. Surg. W. K. Cleveland. Died July 7, 1862, exhaustion.
79	Van Nevil, W., Corp'l, E, 8th Michigan.	June 18, 22, '64.	Right; by A. Surg. M. J. Asch, U. S. A.; (ex. ulna.) Died July 7, 1864, diphtheria. <i>Spec.</i> 2885.	93	Zipperer, D., Corp'l, B, 15th New York Heavy Artillery, age 23.	June 18, July 2, 1864.	Left; circ.; by A. A. Surg. A. Ansell; July 9, ham. Died July 26, 1864, pyæmia. <i>Spec.</i> 2632.

In a considerable proportion of the cases in the two preceding tables of intermediary amputations at the middle third of the arm the ages are noted; but an analysis of these cases fails to indicate any very marked influence of age on the mortality.<sup>1</sup>

**3. Intermediary Amputations at the Lower Third of the Arm.**—One hundred and sixty-one intermediary amputations at the lower third of the arm were practised on one hundred and forty-nine Union and twelve Confederate soldiers. The limb implicated was not specified in three cases; in eighty-one the right, and in seventy-seven the left, extremity was sacrificed. The mortality rate was 41.6 per cent.

§ *Successful Cases.*—Ninety-four patients recovered after intermediary amputations at the lower third of the arm. Five returned to modified duty, seven were exchanged or paroled, and eighty-two were discharged, and, with few exceptions, pensioned.

CASE 1634.—Lieutenant G. F. Quinn, Co. K, 155th New York, aged 33 years, was wounded at Ream's Station, August 25, 1864, and admitted to the field hospital of the 2d division, Second Corps, where Surgeon N. Hayward, 20th Massachusetts, noted: "Shot fracture of right forearm." Surgeon D. W. Bliss, U. S. V., contributed the specimen (FIG. 543), and reported the following history of the case: "The patient was wounded by a shrapnel shot, which entered the anterior aspect of the right arm, passed through the supinator longus muscle about two inches below the elbow joint. The arm was very much swollen, with a great deal of inflammation. Cold-water dressings, nourishing diet, tonics, and stimulants constituted the treatment until September 7th, when the arm was amputated, by flap method, by the Surgeon in charge. September 8th, patient doing well. December 1st, patient furloughed." The specimen consists of "the bones of the right elbow after amputation in the lowest third of the humerus for fracture of the outer condyle by an iron canister shot, which is attached. In the humerus there are two sections, the lower being an inch and a quarter below the final one."—(*Cat. Surg. Sect.*, 1833, p. 164.) The round iron shot weighs three hundred and twenty-two grains. The patient was mustered out of service on February 27, 1865, and pensioned. It appears that the stump subsequently became diseased, and that the pensioner submitted to secondary re-amputation; for, in his application for commutation for an artificial arm, he stated that a "second amputation was performed by Dr. Stone, at Boston;" also that the remaining stump of his injured

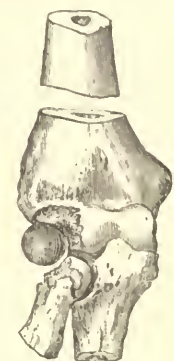

FIG. 543.—Perforation of elbow by shrapnel. *Spec.* 3208.

<sup>1</sup>The data are probably insufficient to warrant any very decided conclusions. The ages were recorded in two hundred and thirty-seven instances: 158 recoveries and 79 deaths. The mean of the ages of the patients who recovered was 22 years and 6 months; of those who died, 26 years and 6 months. Among the recoveries 31 patients were under 23; 65 from 20 to 25; 26 from 25 to 30; 23 from 30 to 43; 13 over 40. Those who died were: under 20, 12; 20 to 25, 30; 25 to 30, 15; 30 to 45, 18; over 40, 4,—the two series presenting an approach to uniformity in the ratios.



arm is "three inches long and tender." Examiner G. S. Jones, of Boston, March 21, 1865, certified: "The right arm has been amputated in its upper third. Disability total and permanent." The pensioner was paid on June 4, 1875.

CASE 1685.—Private W. M. Harris, Co. D, 130th Illinois, aged 24 years, was wounded in the right arm, at the siege of Vicksburg, June 25, 1863, and was sent from a Thirteenth Corps hospital on a transport steamer, and transferred to the Adams Hospital at Memphis on July 11th. Surgeon J. G. Kenon, U. S. V., contributed the specimen (FIG. 544), with the following memorandum of the case: "The wound was caused by a shell. A fortnight subsequently, on the patient's admission to this hospital, the limb being in a gangrenous condition, it was thought expedient to remove it. Acting Assistant Surgeon J. Thompson amputated at the lower third of the humerus on July 12th. The patient will get well." The specimen consists of the lower extremity of the right humerus, amputated in the lower third for gangrene following fracture of the outer condyle. The hospital case-book states that, in this case, there was extensive laceration of the soft parts, and that the injury was much more severe than would be suspected from an examination of the bone. The patient was discharged from service November 9, 1863, and pensioned. He was paid June 4, 1875.

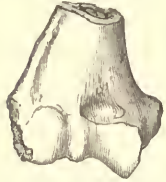

FIG. 544.—Fracture of outer condyle by shell. Spec. 1707.  $\frac{2}{3}$

CASE 1686.—Private W. Bennett, Co. I, 138th Pennsylvania, aged 31 years, was wounded at the Wilderness, May 6, 1864. He was received into hospital of the 3d division, Sixth Corps, where Surgeon R. Barr, 67th Pennsylvania, noted: "Compound fracture of right radius; spicula removed." On May 20th, the patient entered Mount Pleasant Hospital, Washington, and, on the following day, he was transferred to Philadelphia. Acting Assistant Surgeon R. J. Lewis reported his admission to Christian Street Hospital with flap amputation of right arm, followed by favorable results. On September 30th, the patient was transferred to South Street, and subsequently to Broad Street Hospital, whence Acting Assistant Surgeon J. Tyson contributed the specimen (FIG. 545), and Assistant Surgeon T. C. Brainerd, U. S. A., reported the following history: "The patient was admitted on November 23d, from furlough, with amputation of the right arm at lower third, performed on May 16th, after gunshot fracture of the right radius, received May 6th. When he returned from furlough it was evident that much dead bone was still present in the stump, as detected by the probe, while the lower three inches appeared somewhat thickened, hard, and 'honey-combed.' On December 3d, it was concluded to cut down upon the bone and remove such part as would appear necrosed. Ether being administered, the operation was performed by Acting Assistant Surgeon J. Tyson, by an incision along the middle line of the outer half of the stump, carried up four inches on outside of arm to avoid the brachial artery. The bone being bared, presented the peculiarly riddled and broken-down appearance characteristic of dead bone, many points being so soft that they were easily broken by pressure between the fingers. About three inches of bone were removed by chain-saw. The extremity of the remaining

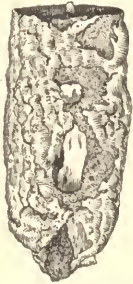

FIG. 545.—Sequestrum and osteoporosed involucrum resected from stump of right humerus. Spec. 4195.  $\frac{1}{2}$

portion being still soft, about one and a half inches additional was removed by bone forceps in small fragments. It was noticed that the inner side of the humerus became hard and healthy before the outside, upon which the disease extended higher. The bone was taken off, however, high enough up to cover, as is thought, all diseased portion. None of the flap was removed, so that after the operation it extended some four inches below the extremity of the humerus. No arterial vessels of any size were opened, and therefore no ligatures were required. The incision was closed with lead wire, dry dressings applied and continued for two days, when they were substituted by lead water and laudanum. December 9th, edges of incision nicely approximated at upper portion, while healthy discharge escapes at the end of the stump. December 14th, the entire incision is at this date cicatrized except about an inch at the upper portion. December 31st, patient is walking about as usual, goes out on pass, and is in excellent health. But two small points are uncicatrized. January 4th, cicatrization is complete, and the stump presents a most gratifying result. The patient was discharged the service January 28, 1865, at which time the stump was entirely healed, and an artificial limb had been fitted." The specimen comprises three inches from the stump of the right humerus nearly seven months after amputation, and consists of a large but spongy involucrum, removed by the chain-saw. In his application for commutation for an artificial arm, dated 1870, the pensioner reported the stump as being in a "healthy condition." He was paid on June 4, 1875.

CASE 1687.—Private P. Harvey, Co. F, 2d Infantry, aged 25 years, was wounded in the left forearm, at Fredericksburg, December 13, 1862, and was sent to Point Lookout Hospital on December 16th. Assistant Surgeon C. Wagner, U. S. A., decided that an attempt to save the shattered limb would be hopeless, and amputated at the lower third of the humerus on December 21st, sending a preparation of the bones of the forearm to the Museum (*Cat. Surg. Sect.*, 1833, p. 184, Spec. 923), with the following history of the case, compiled by Medical Cadet I. S. Lombard: "The patient was shot through the forearm by a minie ball, which, entering on the flexor side a little above the carpal articulation, passed through the radius, fracturing it extensively. When admitted there was considerable swelling of the hand and forearm, which increased after admission, extending to the elbow. On December 18th, two days after the patient's arrival, hæmorrhage from the radial artery took place, and was with difficulty checked by the application of compresses. The arm continued to swell and also began to assume a gangrenous appearance, and, as the patient's strength was evidently giving way, amputation was performed at the lower third of the humerus, December 21st, by Assistant Surgeon C. Wagner, U. S. A. After the operation the man gradually improved, and was discharged cured about the middle of February. The circular method was adopted in the amputation." The specimen consists of the left radius and ulna, showing the radius shattered in the lowest fourth, with longitudinal splintering half way up the shaft, the posterior surface of the bone bearing traces of the corrosive effect of the topical application. Assistant Surgeon W. Thomson, U. S. A., reported the patient's admission to Douglas Hospital February 23d, and his progress, as follows: "The stump was swollen and tender, and on examination an exfoliation was discovered, and removed on March 27th. The discharge ceased very soon, and the patient was discharged from service on March 24, 1863, with a good stump." The necrosed fragment extracted was contributed by Dr. Thomson to the Museum, and is represented in the upper right-hand figure of PLATE XLVII. It consists of a tubular sequestrum two inches in length. (*Cat. Surg. Sect.*, 1866, p. 137, Spec. 1233.) The pensioner re-enlisted in the general service May 16, 1863, and was placed on duty in the Adjutant General's Office, where he is still serving. He reports the stump as being in good condition. His pension was paid June 4, 1875.

TABLE LXXX.

Condensed Summary of Ninety-four Cases of Recovery after Intermediary Amputation in the Lower Third of the Shaft of the Humerus.

No.	NAME, AGE, AND MILITARY DESCRIPTION.	DATES.	OPERATIONS, OPERATOR, RESULT.	No.	NAME, AGE, AND MILITARY DESCRIPTION.	DATES.	OPERATIONS, OPERATOR, RESULT.
1	Austia, J. P., Pt., K, 121st N. Y., age 27.	May 3, '63.	Left. Discharged December 30, 1863; pensioned.	35	Gunthar, G., Pt., B, 7th New York, age 25.	May 18, '64.	Right; skin flaps and circ. see of muscle; by A. A. Surg. C. B. Me-Question. Dis'd July 18, '65; pen'd.
2	Barker, A., Pt., I, 7th Rhode Island.	Dec. 13, '62.	Right; flap. Disch'd Feb. 4, '63; pensioned. Re-amp. May 18, '64.	36	Harper, S., Pt., A, 1st Michigan S. S., age 20.	May 12, '64.	Right; by Surg. W. C. Shurlock, 51st Pa.; (amp. forearm May 12.) Disch'd Jan. 13, 1865; pens'd.
3	Bennett, W., Pt., I, 138th Penn., age 31.	May 6, '64.	Right; flap; (exc. dead bone Dec. 3d.) Disch'd Jan. 28, 1865; pensioned. <i>Spec.</i> 4195.	37	Harris, W., Pt., D, 130th Illinois, age 34.	June 25, July 12, 1863.	Right; by A. A. Surg. J. Thompson. Disch'd Dec. 12, '63. <i>Spec.</i> 1707.
4	Berry, P., Corp'l, G, 23d Illinois, age 27.	June 21, '61.	Left: ant.-post. flap; by A. A. Surg. W. B. Crain; (hæmorrhage; lig. brachial July 1.) Disch'd Dec. 5, 1864; pensioned.	38	Harvey, P., Pt., 2d Infantry, age 35.	Dec. 13, '62.	Circ.; by A. Surg. C. Wagner, U. S. A.; hæm. Disch'd May 28, 1863; pens'd. <i>Specs.</i> 923, 1266.
5	Besse, W. H., Pt., 11, 20th Maine, age 25.	May 5, '61.	Left: flap; necrosis. Discharged Aug. 25, 1865; pensioned. Re-amp. Sept. 23, 1865.	39	Haynes, W., Pt., A, 123d N. Y., age 18.	Nov. 7, '63.	Left; flap; by Surg. R. B. Bontecou, U. S. V. Disch'd April 6, 1864; pensioned.
6	Black, J. F., Pt., 11, 37th Tennessee, age 21.	Dec. 16, '64.	Right; ant.-post. flap; by A. A. Surg. E. Woodruff. To Prov. Marshal March 7, 1865.	40	Hillebrand, H., Serg't, E, 12th Penn. Cavalry, age 21.	July 24, '64.	Right; flap; by A. Surg. C. W. Stinson, 23d Ill. To V. R. C. March 3, 1865; pensioned.
7	Bolle, H., Pt., F, 54th New York.	Aug. 29, Sept. 4, 1862.	Left; by a civilian surg.; re-amp. Sept. 6, 1862. Disch'd Dec. 12, 1862; pensioned.	41	Hinds, N., Pt., D, 3d Vermont, age 25.	May 5, '64.	Right; circ.; by A. A. Surg. W. B. Casey. Disch'd Feb. 22, 1865; pensioned. <i>Spec.</i> 2356.
8	Brown, C., Pt., E, 4th Artillery.	Dec. 13, '62, Jan. 12, '63.	Right; necrosis; caries. Disch'd Feb. 17, '63; pens'd. <i>Spec.</i> 651.	42	Humphrey, N., Pt., E, 98th Ohio.	Oct. 8, '62.	Left; circular; by A. A. Surg. J. Sloan. Disch'd Nov. 23, 1862.
9	Brue, L., Pt., E, 80th Colored Troops, age 23.	April 2, '65.	Left: ant.-post. flap; by Surg. F. E. Piquette, 85th C. T. Disch'd August 17, 1865; pensioned.	43	Husley, H. B., Pt., J, 140th New York, age 25.	Feb. 6, '65.	Left; circ.; by A. A. Surg. W. W. Bidlack; (exc. Feb. 6; hæmorrhage.) Disch'd July 24, 1865; pens'd.
10	Bunt, W. H., Pt., B, 141st Pennsylvania.	May 3, '63.	Right; also wound of leg. Disch'd August 13, 1863; pensioned.	44	Jones, T., Pt., E, 51st Illinois.	Sept. 20, Oct. 8, 1863.	Right; circ.; by A. Surg. J. E. Link, 21st Ill. Disch'd Mar. 28, 1864; pens'd; arm re-amp. in '65. Flap; by A. A. Surg. B. B. Miles. Discharged Sept. 2, 1862.
11	Bards, W., Pt., G, 83d Pennsylvania, age 24.	Sept. 19, '64.	Left; circ.; by Asst. Surg. W. G. Bryant, 122d Ohio. Disch'd July 10, 1865; pensioned.	45	Kent, C., Pt., D, 81st Pennsylvania.	July 21, '62.	Left; circ.; by A. A. Surg. C. W. Fisher; (gang; bone removed Dec. 23, '64.) Disch'd July 31, 1865.
12	Burns, W. J., Pt., B, 90th Illinois.	Nov. 25, Dec. 18, '63.	Left; by Surg. H. Strong, 90th Illinois. Disch'd June 6, 1865.	46	Knittel, A., Pt., F, 9th Illinois Cav., age 37.	Nov. 24, '64.	Right; flap; by Surg. D. W. Bliss, U. S. V. Disch'd Mar. 21, 1865.
13	Caldwell, I. W., Pt., K, 83d Indiana, age 33.	May 29, June 27, 1864.	Right; ant.-post. flap; by A. A. Surg. W. B. Marsh. Disch'd January 30, 1865; pensioned.	47	Lenz, C., Pt., E, 1st Conn. Cav., age 19.	July 25, Aug. 17, '64.	Right; flap; by Surg. D. W. Bliss, U. S. V. Disch'd Dec. 21, '64; pen'd.
14	Campbell, J., Pt., A, 62d Penn., age 25.	July 1, '62.	Right; (exc. clb. 17 July 14; hæmorrhage July 21.) Dis'd Aug. 23, 1864; pens'd. Re-amp. 1870. Died June 4, 1873. <i>Spec.</i> 15.	48	Lippincott, I. E., Corp'l, B, 45th Penn., age 26.	Aug. 21, Sept. 8, 1864.	Right; circ.; by A. A. Surg. J. Dickson; (exc. ulna Aug. 21; hæm.) Dis'd Mar. 19, '65; pens'd.
15	Cantrell, E. R., Pt., A, 143d N. Y., age 33.	July 20, Aug. 10, 1864.	Right; flap; by Asst. Surg. S. C. Ayres, U. S. V. Disch'd June 25, 1865; pensioned.	49	Luse, J. B., Pt., C, 125th Ohio, age 22.	July 18, Aug. 2, 1864.	Right; circ.; by A. A. Surg. H. S. Kilbourne; (exc. radius July 23; hæm's.) Dis'd Apr. 11, '65; pen'd.
16	Carkhuff, D., Pt., H, 145th Penn., age 25.	May 3, '63.	Left; circular. Disch'd August 24, 1863; pensioned.	50	Malone, W. D., Pt., G, 28th Massachusetts.	June 16, '62.	Right; circular. Discharged December 24, 1864.
17	Carns, R. M., Pt., B, 57th Penn., age 21.	July 2, '63.	Right; flap. Disch'd October 23, 1864.	51	Mason, W. J., Pt., C, 34th Massachusetts.	Dec. 13, '62.	Right; circ.; (exc. Dec. 15.) Dis'd April 8, 1863; pensioned.
18	Chaffey, W., Pt., D, 1st Mass., age 18.	Aug. 29, Sept. 12, 1862.	Right; circ.; by Surg. D. W. Bliss, U. S. V.; (see y hæmorrhage.) Disch'd Nov. 22, 1862; pens'd.	52	Mayo, J., Pt., D, 14th New Hamp., age 42.	Oct. 19, Nov. 15, 1864.	Right; circular; by A. A. Surg. W. Staveland; (exc. elbow Nov. 5; necro.) Dis'd May 2, '65; pens'd.
19	Clemens, W. C., Pt., C, 14th Alabama, age 20.	July 1, '63.	Left; re-amp. July 14. Paroled September 25, 1863.	53	Meyer, J. H., Capt., G, 11th New Jersey.	May 3, June 2, 1863.	Left; flap; exc. radius May 14; hæmorrhages. Disch'd Nov. 12, '63; pensioned. <i>Specs.</i> 1189, 1190.
20	Coffin, T., Freedman, age 35.	Mar. —, April 6, 1864.	Right; circ.; by A. A. Surg. B. E. Dodson; (also amp. of left arm; hæmorrhage; gangrene.) Discharged July 19, 1864.	54	McCloud, R. A., Serg't, B, 26th S. C., age 20.	Aug. 21, Sept. 1, '64.	Right; circular; by A. A. Surg. W. P. Moon. Exch'd Oct. 27, '64.
21	Cook, B. C., Serg't, H, 5th Michigan, age 25.	July 2, '63.	Right; (exc. radius July 2.) Dis'd October 7, 1863; pensioned.	55	McConnell, J. P., Pt., E, 9th Ind. Cav., age 19.	May 5, '64.	Right; flap; by Surg. W. Brownell, 2d Mich. C. Dis'd May 14, 1865.
22	Crockett, J. M., Pt., A, 4th Alabama, age 22.	Nov. 27, Dec. 26, '63.	Left; (gangrene; hæmorrhage.) Furloughed; doing well.	56	Miller, M., Pt., B, 123d Ohio, age 20.	June 15, July 4, '64.	Left; by A. A. Surg. E. G. Walters. Disch'd Oct. 5, '64; pens'd.
23	Curtis, A. A., Serg't, K, 39th Wisconsin, age 36.	Aug. 5, '64.	Left; circular; by A. A. Surg. J. Ransom. Dis'd Oct. 11, '64; pen'd.	57	Mitchell, C. K., Pt., D, 18th Infantry, age 32.	Aug. 7, '64.	Right; circ.; by Surg. S. S. Bond, 84th Ind. Dis'd May 10, '65; pen'd.
24	Danford, H., Pt., C, 14th N. Y. H. A., age 37.	June 16, '64.	Left; lateral flap. Disch'd Feb. 8, 1865; pensioned.	58	Mohr, C., Corp'l, E, 2d New Jersey, age 31.	May 6, '64.	Right; circ.; by Surg. S. S. Sheldon, U. S. V. Dis'd Dec. 13, '64; pens'd.
25	Davis, R. W., Pt., D, 4th West Virginia.	June 13, July 9, '63.	Left; by A. Surg. W. B. Brown, 50th Ind. Disch'd; pensioned.	59	Morey, S. P., Corp'l, B, 82d Ohio, age 31.	July 20, '64.	Left; flap; by Surg. C. W. Myers, 83d O. Dis'd Oct. 27, '64; pens'd.
26	Debolt, M. Pt., B, 174th Ohio, age 24.	Mar. 10, '65.	Right; (excision radius Mar. 10.) Disch'd July 19, 1865; pens'd.	60	Neal, J. W., Lieut., I, 39th Illinois, age 22.	Nov. 30, '65.	Left; circ.; by Surg. H. B. Fowler, 12th N. H. Duty Jan. 13, '65; pens'd.
27	Denar, C., Pt., A, 49th Illinois.	Feb. 15, '62.	Left; flap. Discharged January 23, 1863; pensioned.	61	Nelgen, J., Pt., D, 32d Ind., age 19.	Nov. 25, Dec. 8, '64.	Right; circ.; (hæmorrhage Dec. 1, 2, 7.) Disch'd July 5, 1865.
28	Field, H., Pt., D, 160th New York, age 44.	April 9, '64.	Right; circ.; by A. Surg. D. H. Armstrong, 160th N. Y.; hæm.; gangrene. Disch'd Oct. 8, 1864; pensioned.	62	O'Hara, C. W., Serg't, I, 18th Ala., age 19.	Nov. 30, Dec. 27, '64.	Left; circ.; by A. A. Surg. L. Sinclair. To Pro. Mar' Mar. 18, '65.
29	Gill, M., Teamster, age 26.	Oct. 29, No. 20, '64.	Left; circ.; by A. A. Surg. G. L. Stockell. Disch'd Feb. 27, '65.	63	Olson, S., Corp'l, K, 10th Iowa, age 22.	May 16, June 14, 1863.	Right; circ.; by Surg. W. Watson, U. S. V.; re-amp July, 1863. Disch'd Nov. 6, '63; pensioned.
30	Graham, H. A., Corp'l, H, 1st Pennsylvania Reserves, age 21.	May 10, '64.	Right; by Surg. D. W. Bliss, U. S. V. Disch'd Oct. 8, 1864; pens'd; arm re-amp. Sept. 18, 1866; exc. head of humerus and part of scapula July, 1869.	64	Page, E., Pt., I, 2d Michigan Cavalry.	Sept. 19, '62.	Circular; by A. A. Surg. J. Sloan. Discharged October 28, 1862.
31	Griffee, S. I., Serg't, C, 3d Penn., age 30.	June 30, July 20, '62.	Left. Discharged Nov. 18, 1862; pensioned.	65	Pansley, A., Pt., F, 5th West Virginia, age 21.	June 18, '64.	Right; circular. Discharged February 14, 1865; pensioned.
32	Griffin, E. B., Corp'l, D, 1st Colorado Cav.	Mar. 28, Ap. 12, '62.	Left. Discharge 1 July 13, 1862; pensioned.	66	Patriek, J. C., Pt., K, 30th New York.	Aug. 29, Sept. 3, '62.	Flap; by Surg. D. W. Bliss, U. S. V. Disch'd Oct. 9, '62; pensioned.
33	Gross, T., Pt., A, 30th Illinois.	Nov. 7, '61.	Left; circular. Discharged Jan. 1, 1862; pensioned.	67	Pense, B. P., Pt., D, 5th New York.	Aug. 20, Sept. 3, 1861.	Right; necrosis; re-amp. upper third May, 1863. Duty July 17, 1861; pensioned. <i>Spec.</i> 1201.
34	Grubbs, D., Pt., B, 63d Pennsylvania.	July 2, '63.	Right; flap. To V. R. C. Dec. 1, 1863.	68	Quinn, G. F., Lieut., K, 155th N. Y., age 33.	Aug. 25, Sept. 7, 1861.	Right; flap; by Surg. D. W. Bliss, U. S. V. Dis'd Jan. 18, '65; pens'd. Re-amp. upper third. <i>Spec.</i> 3208.
				69	Quisfield, K., Serg't, G, 76th Colored Troops.	April 8, '65.	Right; flap; by Surg. F. L. Piquette, 80th Col'd Troops. Discharged June 10, 1865.



No.	NAME, AGE, AND MILITARY DESCRIPTION.	DATES.	OPERATIONS, OPERATOR, RESULT.	No.	NAME, AGE, AND MILITARY DESCRIPTION.	DATES.	OPERATIONS, OPERATOR, RESULT.
70	Redding, V., Pt., B. 97th Indiana.	July 16, 30, '63.	Left; flap. Discharged October 2, 1863; pensioned.	83	Vance, L., Serg't, H, 61st New York.	July 1, 7, '62.	Left; flap. Discharged August 20, 1862; pensioned.
71	Rhodes, B. R., Pt., H, 33d Alabama, age 18.	Nov. 30, Dec. 29, 1864.	Right; ant.-post flap; by A. A. Surg. J. R. Holmes. To Provost Marshal Jan. 15, 1865.	84	Wallace, J., Pt., I, 1st W. Virginia, age 19.	June 18, Jul. 14, '64.	Right; flap; by Surg. L. R. Stone, U. S. V. Duty Sept. 7, 1864.
72	Rivers, J., Pt., E, 4th Col'd Troops, age 35.	Mar. 30, April 5, 1865.	Lateral flap; by Surg. W. O. McDonald, U. S. V. Discharged Dec. 28, 1865. <i>Spec.</i> 413e.	85	Weidner, W. A., Corp'l, B, 37th Ind., age 20.	July 21, 29, '64.	Right; circ.; by A. A. Surg. W. Stemmerman. Discharged Oct. 25, 1864; pensioned.
73	Ross, C., Corp'l, G, 88th Illinois, age 35.	June 27, July 5, 1864.	Right; circ.; by Surg. J. E. Herbst, U. S. V.; gangrene. Discharged Feb. 4, 1865; pensioned.	86	Welpley, J. H., Pt., K, 1st Mo. L't Art., age 24.	Aug. 10, —, '61.	Left; by Asst. Surg. S. K. Melcher, 5th Mo. (amp. forearm Aug. 10.) Discharged April 25, 1864; pensioned. Died July 16, 1868.
74	Ross, J., Pt., I, 6th Conn., age 23.	June 16, 29, '64.	Right; circ.; by Asst. Surg. D. R. Brown, U. S. V.; (exc. June 16.) Disch'd Dec. 24, 1864; pens'd.	87	Wilbur, J. A., Pt., I, 18th Connecticut, age 22.	June 5, 8, '64.	Left; flap; by Surg. L. Holbrook, 18th Conn. Disch'd Mar. 8, 1865; pensioned.
75	Ross, T. A., Pt., C, 10th Tennessee, age 29.	Sept. 26, Oct. 10, '64.	Left; ant.-post. flap; by A. A. Surg. S. M. Olden. Disch'd Mar. 24, '65.	88	Wilfong, S. T., Serg't, A, 12th S. C., age 19.	May 3, 18, '63.	Right; ant.-post. flap; by A. A. Surg. H. M. Dean; (exc. radius May 11; hemorrhage.) Exch'd June 25, 1863.
76	Schafer, H., Pt., I, 68th New York.	Aug. 29, Se. 9, '62.	Left; by Asst. Surg. G. M. McGill, U. S. A. Dis'd Dec. 24, '62; pen'd.	89	Wills, O., Pt., B, 149th New York, age 20.	May 15, Je 11, '64.	Left; flap; by A. A. Surg. J. M. Bligh. Dis'd Dec. 2, '64; pens'd.
77	Staples, J., Pt., F, 13th Maine.	April 9, May 1, '64.	Right; flap. Discharged July 25, 1864.	90	Wood, F., Pt., H, 13th Colored Troops.	June 23, 27, '64.	Left; flap; by A. A. Surg. J. Romaine. Dis'd Aug. 7, '64; pens'd.
78	Stephens, J. M., Serg't, I, 2d Kentucky Cav.	Nov. 28, Dec. 2, '64.	Right; flap. Discharged July 26, 1865; pensioned.	91	Wright, J. T., Serg't, E, 16th Mass., age 32.	May 6, 21, '64.	Right; circ.; by A. A. Surg. C. F. Trautman. Disch'd Oct. 25, '64.
79	Sullivan, E., Serg't, B, 12th Infantry, age 27.	May 5, 14, '64.	Right; circ.; by Surg. O. A. Judson, U. S. V. Duty Sept. 19, 1864.	92	Wunseh, E., Pt., G, 29th New York.	May 3, 8, '61.	Left. Disch'd August 14, 1863; pensioned.
80	Sutherland, W. H., Pt., D, 49th Ohio, age 23.	May 27, 30, '64.	Left; flap; by Surg. R. W. Thrift, 49th Ohio. Discharged Feb. 6, 1865; pensioned.	93	Yates, O. J., Pt., F, 11th Maine, age 37.	Aug. 16, Sept 15, 1861.	Left; circ.; by A. A. Surg. E. P. Fish; (gangrene.) Disch'd Jan. 20, 1865; pensioned. Amp. at shoulder joint June 29, 1865.
81	Taylor, J. M., Serg't, C, 94th Illinois, age 24.	May 9, 27, '64.	Left; circ.; by Surg. W. H. Thorn, U. S. V. Dis'd Mar. 18, '65; pen'd.	94	Zink, T., Pt., H, 45th New York, age 24.	July 2, 15, '63.	Left; circ.; by Asst. Surg. H. S. Schell, U. S. A. Dis'd Nov. 21, '63.
82	Thompson, E. N., Pt., H, 10th Penn. Res.	June 30, July 27, 1862.	Left; flap; by A. A. Surg. C. P. Russel. Disch'd Sept. 25, 1862; pensioned.				

§ *Fatal Cases.*—Sixty-seven patients died after intermediary amputations at the lower third of the arm.<sup>1</sup> Circular and flap incisions were employed in about equal proportions.<sup>2</sup> Fifteen patients had undergone serious operations already,<sup>3</sup> and four suffered from wounds in other regions. In one of the last group the opposite forearm was amputated simultaneously with the amputation at the lower third.



FIG. 546.—Shot fissure of lower extremity of right humerus. *Spec.* 322.

CASE 1688.—Private C. H. Warren, Co. F, 20th New York State Militia, aged 30 years, was wounded at Ball Run, August 30, 1862, and admitted to the Methodist Church Hospital, at Alexandria, on September 2d. Surgeon J. E. Summers, U. S. A., contributed the specimen (FIG. 546) with the following report: "The patient was shot through the right elbow, the ball entering posteriorly, shattering the olecranon process and producing fracture of the internal condyle of the humerus. The arm was amputated, on September 5th, by Acting Assistant Surgeon A. Delaney. Death occurred, from pyæmia, on September 27, 1862." The specimen consists of the lowest third of the right humerus, amputated for oblique fracture near the inner condyle, with loss of the posterior portion of the trochlea.

CASE 1689.—Private J. H. —, Co. A, 140th New York, aged 28 years, was wounded at Gettysburg, July 2, 1863, and admitted to the field hospital of the 2d division, Fifth Corps, where Assistant Surgeon C. Wagner, U. S. A., recorded: "Gunshot wound of left forearm. Patient transferred to General Hospital on July 13th." Acting Assistant Surgeon C. H. Jones reported: "The patient was admitted to Jarvis Hospital, Baltimore, on July 14th, having been wounded by a minie ball which passed through the left wrist joint, producing a compound comminuted fracture of the radius and ulna. A high degree of suppurating inflammation came on, extending to the elbow joint, and rendering amputation necessary on the 28th. The stump looked healthy, and he seemed to improve up to the 20th of August, when he suddenly became affected with the symptoms denoting pyæmia, from which he died on August 24, 1863. Autopsy twenty-four hours after death: Pus found in both lungs, with adhesion of left lung to costal pleura. Right lobe of liver softened, and several large abscesses found in the posterior portion; one of them, when opened, contained about four ounces of pus. A large abscess was also found under the sheath of the rectus muscle near the pubis." The specimens were contributed to the Museum by Assistant Surgeon C. Wagner, U. S. A., in charge of the hospital. The first one consists of a ligamentous preparation of the left hand, wrist, and lower portion of the bones of the forearm, which were fractured at their articulation with each other and with the carpus, opening the joint. The *post-mortem* specimen consists of the stump of the left humerus, showing the extremity necrosed and superficial caries extending over the lower half of the shaft. There was no deposit of callus. (*Spec.* 1711.) In addition, a small portion of liver was contributed, in the upper margin of which is an irregular abscess about the size of a hen's egg.—(*Cat. Surg. Sect.*, p. 495, *Spec.* 2937.)

<sup>1</sup>The proximate causes of death are recorded: Tetanus in 3 cases, secondary hæmorrhage in 14, gangrene in 12, pyæmia in 25, pneumonia in 4, ichoremia in 1, anemia and debility in 2, typhoid fever in 2, cardiac disease in 1, chagrin from disappointment in promotion in 1, and diarrhoea in 2 cases.

<sup>2</sup>It is noted that the circular method was adopted in 24 cases; the flap method in 22,—antero-posterior flaps being made more frequently than lateral flaps. In 21 cases the mode of operation was not described.

<sup>3</sup>Thus: One had the opposite arm amputated at middle third, another, a portion of the hand. Three had submitted to excisions of the elbow joint; three to excision of the ulna, one of whom had also been amputated at the middle third of the forearm, and four to excision of the radius. In one the fractured portion of condyle had been extracted; in one the ulnar artery, and in another the radial artery, had been tied.

## TABLE LXXXI.

Condensed Summary of Sixty-Seven Unsuccessful Cases of Intermediary Amputations in the Lower Third of the Shaft of the Humerus.

No.	NAME, AGE, AND MILITARY DESCRIPTION.	DATES.	OPERATIONS, OPERATOR, RESULT.	No.	NAME, AGE, AND MILITARY DESCRIPTION.	DATES.	OPERATIONS, OPERATOR, RESULT.
1	Bacon, B. W., Capt., G. 74th Illinois, age 40.	June 27, July 19, 1864.	Left: flap; by A. A. Surg. J. H. Green; (gangrene; also amp. right arm, middle third, July 14.) Died July 21, 1864, pyæmia.	34	Klein, R., Pt., E, 111th Penn., age 36.	June 21, 28, '64.	Right: circ.; by A. A. Surg. M. J. Franklin; July 3, gang. Died July 3, 1864, ichoræmia.
2	Beal, B. W., Pt., A. 20th Mass., age 24.	May 6, 15, '64.	Left: ant.-post. flap; by Surg. R. B. Bontecou, U. S. V. Died May 28, 1864, exhaustion.	35	Knapp, J. L., Pt., E, 112th N. Y., age 18.	June 3, July 1, '64.	Right: flap; by Surg. H. Palmer, U. S. V. Died July 3, 1864, exhaustion.
3	Bell, G. L., Serg't, E, 10th Conn., age 34.	Dec. 15, 27, '62.	Right: flap; (ulna ligated.) Died Mar. 11, 1863, from disappointment.	36	Knoek, A., Sergeant, B, 84th Ill., age 36.	June 27, July 24, 1864.	Left: circ.; by Surg. R. L. Stanford, U. S. V.; (gang. hæm.; lig. radialis.) Died October 11, 1864, diarrhæa, exhaustion.
4	Beveridge, R., Pt., D, 62d Virginia.	Oct. 29, Nov. 7, '64.	Right: flap; by A. A. Surg. J. Younglove. Died Oct. 5, 1864.	37	Kulthan, H., Serg't, I, 1st New Jersey Cav., age 27.	May 28, June 11, 1864.	Right: circ.; by A. A. Surg. O. W. Peck; (May 28, excision radius; hæm.) Died June 19, '64, pyæmia.
5	Brand, D., Pt., K, 14th New Jersey, age 29.	Sept. 19, 26, '64.	Left: flap; by A. A. Surg. C. H. Osborn; ( hæmorrhages; right forearm amputated.) Died July 14, 1863.	38	La Fond, P., Pt., F, 20th Wis., age 24.	April 2, 6, '65.	Left: by Surg. E. Powell, 73d Ill. Died April 24, 1865, pyæmia.
6	Burns, T. R., Pt., G, 50th Mass., age 38.	May 6, 14, '64.	Left: by A. A. Surg. C. H. Osborn; ( hæmorrhages; right forearm amputated.) Died July 14, 1863.	39	Lintner, J. I., Pt., B, 115th New York, age 24.	July 5, 29, '64.	Left: flap; by A. A. Surg. H. M. Sprague, U. S. A.; (July 29, hæm.) Died August 1, 1864, exhaustion.
7	Chatfield, J., Pt., E, 6th Ohio Cav., age 32.	July 14, 1863.	Right: circ.; by Surg. C. H. Todd, U. S. A. Died Aug. 2, '64, pneum.	40	Mathews, A., Pt., C, 35th Ind., age 20.	June 19, July 17, 1864.	Left: circ.; by Surg. R. R. Taylor, U. S. V.; (June 19, excision ulna.) Died August 29, 1864, pyæmia.
8	Chisolm, O., Corp'l, E, 5th Louisiana.	July 9, 18, '64.	Right: circ.; by A. A. Surg. A. N. Brockway. Died July 31, 1864, pyæmia.	41	Mayo, J., Pt., D, 10th Vermont, age 20.	Oct. 19, Nov. 10, '64.	Right: circ.; by A. A. Surg. J. Neff. Died Nov. 27, 1864, pyæmia.
9	Clark, J. W., Adj't, 1st Maine H. A., age 28.	June 18, July 7, 1864.	Right: by A. A. Surg. T. F. Belton. Died September 8, 1864.	42	Morris, J., Pt., E, 57th Indiana.	June 27, July 26, 1864.	Right: circ.; by A. A. Surg. B. E. Fryer, U. S. A. Died July 27, 1864, pyæmia.
10	Condon, P., Serg't, F, 60th Penn., age 24.	Aug. 25, Sep. 4, '64.	Flap; by A. A. Surg. G. McCoy; ( hæmorrhages.) Died July 11, 1863. Specs. 1386 and 1387.	43	Morain, M., Pt., F, 3d Vermont, age 28.	May 6, 23, '64.	Right: (amp. finger May 6; erysip.) Died June 24, 1864, pyæmia.
11	Conrad, A., Pt., C, 8th Illinois Cav., age 27.	June 21, July 9, 1863.	Left: flap; by A. Surg. W. Carroll, U. S. V. Died May 10, 1865, pyæmia. Spec. 4165.	44	Nash, J. L., Pt., B, 9th New York Heavy Artillery, age 25.	July 9, 21, '64.	Left: circ.; by A. A. Surg. B. H. McCleery; Aug. 2, hæm.; lig. brachial. Died Aug. 7, 1864.
12	Crumph, G. L., Pt., Crutcherfield's Art., age 25.	April 6, 13, '65.	Left: (also wounds of back; hæm.; ex. ulna Aug. 21.) Aug. 25. Died Sept. 5, 1862, pyæmia.	45	Noel, P., Pt., I, 28th Iowa, age 29.	May 16, 26, '63.	Right: gangrenous. Died July 20, 1863.
13	Daniels, W. A., Pt., E, 2d Massachusetts.	Aug. 9, 25, '62.	Left: circ.; by A. Surg. H. Allen, U. S. A.; erysipelas. Died June 26, 1864. Spec. 2315.	46	Oglethorpe, B. F., Pt., I, 13th Georgia, age 36.	July 10, Aug. 6, '64.	Right: circ.; by Surg. A. Chapel, U. S. V. Died Aug. 23, 1864, exhaustion.
14	Ducklin, W., Pt., G, 82d New York, age 54.	May 18, June 3, 1864.	Right: flap; by A. A. Surg. C. H. Weaver; (gangrenous.) Died Oct. 9, 1864, debility.	47	Otis, I. L., Pt., D, 83d Penn., age 25.	June 27, July 9, '62.	Right: by Surg. R. H. Coolidge, U. S. A. Died Aug. 10, '62, pyæmia.
15	Fleagle, J. B., Pt., II, 140th Pennsylvania.	Aug. 14, Sept. 7, 1864.	Left: circ.; by A. Surg. S. H. Orton, U. S. A.; (excision elbow April 8.) Died May 14, 1864.	48	Paine, W., Pt., K, 67th Ohio, age 24.	May 18, '64.	Left: circ.; by A. A. Surg. J. S. Hill. Died July 5, 1864, typhoid fever.
16	Green, W. H., Lieut. Col., 173d New York.	April 8, May 6, 1864.	Left: lat. flap; by A. A. Surg. F. P. Maury; (June 3, ex. radius; gangrenous; hæmorrh'e.) Died June 19, 1864, heart disease.	49	Peck, D. R., Pt., E, 13th Connecticut.	Mar. 21, Ap. 10, '63.	Right: by A. Surg. J. S. Tolson, 161st N. Y. Died April 15, 1863.
17	Griswold, H., Pt., II, 154th N. Y., age 37.	June 3, 11, '64.	Left: circ.; by A. A. Surg. R. L. McClure. Died Aug. 14, 1864, exhaustion.	50	Pendergrast, P., Pt., A, 2d Maryland, age 50.	Aug. 13, 16, '64.	Right: flap; by A. A. Surg. W. B. Craun. Died Sept. 1, '64, pyæmia.
18	Gross, J., Corp'l, H, 55th Alabama, age 20.	July 20, Aug. 10, 1864.	Left: flap; by A. A. Surg. W. F. Leitch. Died August 28, 1864.	51	Pinney, J., Capt., K, 86th N. Y., age 28.	May 10, 15, '64.	Left: skin flaps and circ. sec. muscles; by Surg. H. W. Ducaehet, U. S. V.; (gang.) Died Aug. 10, '64.
19	Haeggle, F., Pt., A, 2d Penn., age 40.	Aug. 18, 27, '64.	Right: flap; by Surg. Z. E. Bliss, U. S. V. Died Nov. 20, '64, pyæmia.	52	Pierce, A., Pt., II, 8th Maine, age 23.	June 3, 20, '64.	Right: ant.-post. flap; by A. Surg. W. Webster, U. S. A. Died June 27, 1864, pyæmia.
20	Halderman, P. H., Pt., B, 47th Penn., age 22.	Oct. 19, Nov. 5, '64.	Left: caries; necrosis. Died Aug. 24, 1863, pyæmia. Specs. 2907, 1711, and 1614.	53	Rhode, C. B., Pt., C, 25th Iowa.	Jan. 11, Feb. 1, '63.	Left: by A. A. Surg. T. T. Smiley; gangrene. Died Feb. 25, 1863.
21	Healey, J., Pt., A, 140th New York.	July 2, 28, '63.	Right: circ.; by A. A. Surg. S. H. Orton, U. S. A. Died May 15, '64.	54	Rose, W. E., Pt., G, 143d N. Y., age 23.	May 15, 24, '64.	Left: circ. Died June 12, 1864, diarrhæa.
22	Heald, P. T., Corp'l, A, 19th Maine, age 23.	July 2, 28, '63.	Right: flap; by A. Surg. J. C. McKee, U. S. A. Died May 18, '64, tetanus. Spec. 2329.	55	Sander, T., Pt., E, 23d Cold Troops, age 20.	July 30, Aug. 16, '64.	Right. Died.
23	Hefflinger, H., Pt., G, 24th Iowa.	April 8, 29, '64.	Left: flap; by Surg. D. W. Bliss, U. S. V.; (gangrene.) Died June 12, 1864. Spec. 2357.	56	Schwartz, W., Pt., I, 29th Illinois, age 30.	Mar. 30, April 24, 1865.	Right: ant.-post. flap; by Surg. J. J. B. Baxter, U. S. V. (Mar. 30, excis. radius.) Died May 4, '65, typhoid pneumonia.
24	Hemmlinger, F., Pt., G, 18d Penn., age 50.	May 6, 18, '64.	Right: circ.; by A. A. Surg. S. H. Orton, U. S. A. Died May 15, '64.	57	Skellinger, P., Serg't, F, 15th N. J., age 23.	May 8, 15, '64.	Left: ant.-post. flap; by Surg. A. F. Sheldon, U. S. V.; gangrene. Died May 27, 1864, exhaustion.
25	Hill, W., Pt., C, 2d U. S. Infantry, age 26.	May 9, 23, '64.	Left: flap; by Surg. D. W. Bliss, U. S. V.; (gangrene.) Died June 12, 1864. Spec. 2357.	58	Soper, W. F., Pt., C, 17th Maine, age 26.	April 6, 14, '65.	Right: circular; by A. A. Surg. W. H. Lathrop. Died May 7, 1865.
26	Hoffard, M., Pt., G, 104th Pennsylvania.	May 31, J'e 13, '62.	Left: by A. A. Surg. T. B. Castle. Died July 1, 1862, pyæmia.	59	Stene, J. H., Serg't, K, 7th Maine, age 24.	May 11, 21, '64.	Right: circ.; (May 11, ex. radius.) Died June 16, '64, pyæmia.
27	Hoshier, J., Pt., K, 37th Wis., age 28.	Aug. 19, 30, '64.	Left: circ.; by A. A. Surg. A. N. Brockway; (gangrene.) Died September 3, 1864, pyæmia.	60	Stoneburner, J., Pt., K, 33d Ohio, age 30.	May 15, 25, '64.	Left: circular; by A. Surg. R. McNeill, 19th Ohio. Died May 31, 1864, pyæmia. Spec. 3365.
28	Hunley, J., Pt., II, 80th Indiana, age 35.	Nov. 29, Dec. 16, 1864.	Left: circ.; by Surg. H. B. Stearns, U. S. V.; (erysipelas.) Died Jan. 11, 1865, anæmia.	61	Thackery, T. J., Pt., A, 95th Ohio, age 27.	May 23, 31, '63.	Right: (May 23, humerus removed; hæm'e.) Died June 27, '63, typh'd fever and hæmorrh'e. Spec. 2092.
29	Hunt, C., Pt., H, 57th Indiana, age 22.	June 22, July 19, 1864.	Right: by A. A. Surg. S. H. Olden; (exc. ulna; gang.; forearm amp. July 15.) Died July 21, '64, ex. h.	62	Thomas, E. L., Pt., F, 144th N. Y., age 24.	Nov. 20, Dec. 13, 1864.	Right: flap; by A. Surg. C. T. Reber, U. S. V.; (Dec. 13, hæmorrhage.) Died Jan. 1, 1865.
30	Jones, C. W., Corp'l, I, 102th New York.	Dec. 13, 22, '62.	Left: by Surg. E. Bentley, U. S. V. Died Dec. 28, '62, hæm. Spec. 615.	63	Warren, C., Pt., F, 20th New York, age 30.	Aug. 30, Sept. 5, 1862.	Left: by A. A. Surg. A. Delaney. Died Sept. 27, 1862, pyæmia. Spec. 322.
31	Kennedy, J., Pt., K, 170th N. Y., age 32.	Aug. 15, Sept. 9, 1864.	Right: circ.; by A. A. Surg. A. A. Smith; (Aug. 15, excision elbow joint; hæmorrhage.) Died Sept. 24, 1864, pyæmia. Spec. 3651.	64	Widner, N., Pt., D, 10th New York, age 19.	Aug. 23, Sep. 4, '64.	Flap; by A. Surg. J. C. McKee, U. S. A. Died Sep. 19, '64, pyæmia.
32	Killips, R. C., Serg't, I, 21st Wis., age 24.	Aug. 7, 28, '64.	Right: circ.; by A. A. Surg. C. S. Merrill; (Aug. 28, hæm.) Died Sept. 1, '64, erysipelas, pyæmia.	65	Willis, B. Pt., E, 50th Ohio, age 39.	Nov. 30, Dec. 26, 1864.	Right: circular; by Surg. J. F. Randolph, U. S. A.; (gangrene; erysipelas.) Died Feb. 11, 1865.
33	Kirtz, G. W., Pt., B, 61st Ohio, age 19.	July 29, Aug. 9, 1864.	Right: flap; by A. Surg. B. E. Fryer, U. S. A. Died August 10, 1864, typhoid fever.	66	Wing, L. D., Pt., F, 121st N. Y., age 31.	May 10, June 3, 1864.	Right: circ.; by A. A. Surg. H. B. Knowles; (May 10, excis. ulna.) Died June 20, 1864, pyæmia.
				67	Young, R. B., Pt., K, 102d Penn., age 42.	May 5, 17, '64.	Right: by A. A. Surg. F. G. H. Bradford. Died May 20, 1864, tetanus. Spec. 4706.



#### 4. Intermediary Amputation of the Arm without Indication of the Seat of Incision.—

Forty-six of the reported cases of intermediary amputation come under this head. These operations were practised on thirty-nine Union and seven Confederate soldiers, of whom four were exchanged or paroled, eight were discharged and pensioned, and thirty-four died, a predominance of unsuccessful cases appearing, as usual, in series of imperfectly recorded observations.

§ *Successful Cases.*—The twelve successful cases of intermediary amputations of the arm in which the exact seat of ablation was unspecified were uncomplicated by wounds in other regions or by antecedent operations. Six of the operations were on the right, and five on the left arm, and in one case this point was not mentioned.

TABLE LXXXII.

*Condensed Summary of Twelve Cases of Recovery after Intermediary Amputations of the Arm, the Point of Ablation Unspecified.*

No.	NAME, AGE, AND MILITARY DESCRIPTION.	DATES.	OPERATIONS, OPERATOR, RESULT.	No.	NAME, AGE, AND MILITARY DESCRIPTION.	DATES.	OPERATIONS, OPERATOR, RESULT.
1	Babb, S., Pt., C, 7th Mo. Cavalry, age 25.	Aug. 16, Sep. 1, '62.	Right. Discharged Jan. 27, 1863.	7	Messer, J., Pt., E, 37th Alabama.	Nov. 25, Dec. 12, '63.	Left; gangrene. Exch'd February 14, 1864.
2	Bachelor, H. H., Pt., I, 30th N. C., age 24.	May 3, '63.	Recovered.	8	Miller, H., Corp'l, II, 16th Ohio.	Dec. 28, '62, Jan. 11, 1863.	Left; by A. A. Surg. H. Hard (amp. shoulder joint Jan. 29, '63.) Disch'd April 14, 1863; pens'd.
3	Bletcher, J. F., Serg't, B, 14th Tenn., age 21.	July 3, 10, '63.	Right. To Provost Marshal Sept. 1, 1863.	9	Nash, A. P., Pt., C, 12th Massachusetts.	Aug. 30, Sept. 6, 1862.	Right; (re-amputat'd Oct. 18, '62.) Discharged Dec. 19, 1862; pensioned.
4	Hunter, J. H., Corp'l, B, 12th New York.	June 27, July 7, 1862.	Right; by A. A. Surg. A. Claude. Disch'd Sept. 6, 1862; pens'd. Amp. shoul. joint April 30, 1863. Died Aug. 11, 1871.	10	Palmer, B. D., Serg't, C, 3d Kansas Cavalry.	July 2, 12, '63.	Right; by Surg. W. Wakefield, 9th Kansas Cav.; (arm re-amp.) Disch'd April 18, 1863; pens'd.
5	Kelley, J., I, 10th Tenn.	Sept. 19, Oct. 2, '63.	Right; by Surg. P. F. Eve, C. S. A.; (hæmorrhage.) Doing well.	11	Svensen, J. E., Pt., I, 1st New York, age 30.	June 30, July, '62.	Left; (re-amp. Aug., 1862.) Disch'd Jan. 29, 1863; pensioned.
6	Lunbeck, I. J. K., Pt., D, 12th Indiana.	Aug. 30, Sept. 4, 1862.	Left; by Dr. O'Farrell. Disch'd Feb. 19, 1863; pensioned. (Arm re-amp. January, 1865.)	12	Vandemark, J., Pt., A, 143d Penn., age 45.	July 1, 11, '63.	Left. Discharged Dec. 9, 1863.

Six of the patients underwent re-amputation,—two at the shoulder joint, and four high up in the continuity. Two survived attacks of gangrene and secondary hæmorrhage.

§ *Fatal Cases.*—Of the patients of the series of thirty-four unsuccessful intermediary amputations of the arm without specification of the precise seat of incision, five had been subjected to antecedent operations,—to excision of the shaft of the ulna in one case, of the elbow joint in one, and of the shaft of the humerus in three cases; three had received serious though not mortal wounds in other regions.

TABLE LXXXIII.

*Condensed Summary of Thirty-four Unsuccessful Cases of Intermediary Amputations of the Arm, the Point of Ablation Unspecified.*

No.	NAME, AGE, AND MILITARY DESCRIPTION.	DATES.	OPERATIONS, OPERATOR, RESULT.	No.	NAME, AGE, AND MILITARY DESCRIPTION.	DATES.	OPERATIONS, OPERATOR, RESULT.
1	Brown, W., Capt., I, 147th Pennsylvania.	Dec. 13, 18, '62.	Died December 24, 1862.	9	Grier, T., I, 2d Delaware.	July 3, 19, '63.	Right. Died July 22, 1863, pyæmia.
2	Buehart, R., Pt., B, 151st Pennsylvania, age 30.	July 1, 8, '63.	Left. Died July 26, 1863, pyæmia.	10	Harrison, J., Pt., K, 71st Indiana.	Aug. 20, Sept. 21, '62.	Left; (hæmorrhages.) Died Sept. 30, 1862, hæmorrhages.
3	Coleman, W. H., Serg't, F, 95th Pa., age 27.	May 2, 6, '63.	Died May 31, 1863, typhoid fever.	11	Heston, P. D., Corp'l, G, 62d Ohio, age 21.	July 18, 24, '63.	Left. Died August 20, 1863, pyæmia.
4	Culp, J., Pt., E, 95th Pennsylvania, age 29.	May 2, 6, '63.	Left. Died May 30, 1863, pyæmia.	12	Hickey, T., Capt., A, 164th N. Y., age 25.	June 3, 22, '64.	Right; by Surg. D. W. Bliss, U. S. V.; (June 3, ex. hum.; June 18, hæm.) Died July 6, '64, pyæmia.
5	Donnelly, E., Pt., C, 51st N. Y., age 29.	Sept. 17, Oct. 6, '62.	Right. Died November 7, 1862, pyæmia.	13	Hubbell, R., Pt., I, 11th Mass., age 23.	Aug. 20, Sept. 16, 1862.	Left; by A. A. Surg. S. D. Gross; (hæmorrhage.) Died Sept. 29, 1862; hæmorrhage. <i>Spec.</i> 2769.
6	Dyas, J. W., Pt., K, 51st Indiana.	De. 31, '62, Ja. 22, '63.	Left; (hæmorrhages and diarrhœa.) Died February 1, 1863.	14	Jacobs, C. W., Corp'l, B, 105th New York.	Dec. 13, 22, '62.	Left; by Surg. E. Bentley, U. S. V.; hæm. age. Died Dec. 28, '62.
7	Faller, F., Pt., D, 12th Missouri, age 25.	May 22, Jun. 5, '63.	Right. Died June 20, 1863, pyæmia.	15	Jones, I. Pt., A, 143d Penn., age 28.	July 1, 15, '63.	Right; July 17, lig. of brachial; pyæmia. Died July 18, '63, hæm.
8	Gordon, J. W., Pt., G, 34th New York.	June 1, 11, '62.	By A. A. Surg. T. G. Morton. Died June 22, 1862, pyæmia.				

No.	NAME, AGE, AND MILITARY DESCRIPTION.	DATES.	OPERATIONS, OPERATOR, RESULT.	No.	NAME, AGE, AND MILITARY DESCRIPTION.	DATES.	OPERATIONS, OPERATOR, RESULT.
16	Lockard, J., Pt., D, 53d Ohio.	June 27, July 4, 1864.	Left; by A. Surg. D. J. Swartz, 100th Ind.: (June 27, excis. ulna; gangrene.) July 5, hæmorrhage gangrenous. Died July 6, 1864.	25	Petree, G., Pt., C, 33d N. C., age 41.	July 2, 7, '63.	Right; also pen. wound of side. Died July 26, 1863, tetanus.
17	Lehre, G., Pt., D, 142d Penn., age 25.	July 1, 9, '63.	Right; also wound of back. Died July 31, 1863, pyæmia.	26	Rhodes, M., Pt., II, 13th Penn. Cav., age 48.	Aug. 11, 16, '64.	By Dr. Gibbs: also fracture of clavicle. Died Aug. 29, 1864.
18	Marsh, E. D., Pt., B, 18th Louisiana.	April 7, 10, '62.	Right; acute diarrhœa. Died May 10, 1862.	27	Rider, J. S., Pt., II, 24th Michigan.	July 1, 6, '63.	Left. Died July 18, 1863.
19	Martin, E., Pt., I, 2d Vermont.	Dec. 13, 29, '62.	Left. Died Jan. 10, 1863, pyæmia.	28	Rockwood, C. A., Pt., G, 15th Mass., age 21.	May 12, 16, '64.	Right. Died May 30, 1864.
20	Margold, L., Pt., G, 33d New Jersey.	Nov. 25, Dec. 22, '63.	Left. Died January 1, 1864, pyæmia.	29	Shaw, L. E., Pt., D, 12th Ill. Cav., age 26.	July 1, 9, '63.	Right. Died July 24, 1863, pyæmia.
21	Miller, H. A., 41st N. Y., age 20.	July 2, 20, '63.	Right. Died August 4, 1863, tetanus.	30	Smith, L., Pt., G, 60th Ohio, age 19.	June 23, Jul. 11, '64.	Left; June 23, excision of humerus. Died July 13, 1864.
22	Miller, E., I, 46th N. Y., age 27.	Sept. 17, 26, '62.	Right. Died October 21, 1862, pyæmia.	31	Strober, L., Pt., A, 107th Ohio, age 30.	July 3, 16, '63.	Left. Died August 4, 1863, pyæmia.
23	Nora, F., Pt., I, 26th Wisconsin, age 23.	May 2, 6, '63.	Right. Died May 28, 1863, exhaustion.	32	Turner, E., Pt., D, 30th Col. Troops, age 18.	July 30, Aug. 16, '64.	Right. Died Sept. 23, 1864.
24	Parliament, J., Pt., C, 13th New Jersey.	July 3, 18, '63.	Right; by Surg. H. E. Goodman, 28th Pa.: (excision July 4; hæm. July 16.) Died July 28, 1863.	33	White, H. P., Pt., G, 57th Virginia.	July 3, - '63.	(Primary excision of elbow joint.) Died July 27, 1863.
				34	Wilmoth, S., Pt., C, 67th New York.	May 27, Jun. 6, '62.	By A. A. Surg. M. Stovell. Died June 21, 1862, pyæmia.

Eight of the above cases were complicated by secondary hæmorrhage, seventeen succumbed to pyæmia, two died from tetanus, two from diarrhœa. In one case the brachial artery was unavailingly ligated. No autopsies were reported.<sup>1</sup>

The eight preceding tables enumerate nine hundred and two intermediary amputations of the arm with a mortality of 33.4 per cent.<sup>2</sup>

SECONDARY AMPUTATIONS IN THE CONTINUITY.—In four hundred and eleven, or about one-eleventh of the forty-five hundred and seventy-two cases of amputation of the arm in which the date of operation was precisely ascertained, the amputations were practised subsequent to the thirtieth day from the reception of the injury. The ratio of mortality was 27.7 per cent.—5.7 per cent. less than in the series of intermediary amputations, 9.3 per cent. greater than in the series of primary amputations of the arm in the continuity.

**1. Secondary Amputations in the Upper Third of the Arm.**—One hundred and seventy-three of the secondary amputations of the arm involved the upper third, and resulted in a fatality of 26.6 per cent. The operations were practised on one hundred and sixty-seven Union and six Confederate soldiers. In one hundred and twenty-two cases in which the mode of operation was specified, the circular method was adopted in sixty-six, the oval in ten, the flap in forty-six.

§ *Successful Cases.*—One hundred and twenty-seven of the secondary amputations at the upper third of the arm resulted favorably. The right extremity was interested in sixty-eight, the left in fifty-eight cases, this point being unnoted in one case. Twelve of the patients returned to modified duty, two were exchanged, and one hundred and thirteen discharged. In five cases the lesions were consequent on injuries inflicted by cannon shot, in one on injuries from the premature discharge of a cannon; in one hundred and twenty-one cases the antecedent injuries were believed to be produced by small projectiles. Forty-four of the patients had already undergone major operations, viz: Amputation of the opposite arm at the middle third in one case, of opposite forearm in one, of the same arm

<sup>1</sup> One case (No. 13), an instance of intermediary amputation for a shot comminution of the left ulna, with consecutive bleeding from the ulnar and interosseous arteries, supplied the Museum with *Specimen 2769*.—(*Cat. Surg. Sect.*, 1866, p. 189.)

<sup>2</sup> Observations on intermediary amputations of the arm for the effects of shot injury have been published: By Medical Cadet E. COUES, U. S. A. (*Med. and Surg. Reporter*, 1863, Vol. IX, p. 230); by Dr. G. H. FISHER (*Report of Amputations near Sharpsburg*, in *Am. Jour. Med. Sci.*, Vol. XLV, p. 49); by Surgeon J. H. THOMPSON, U. S. V. (*Am. Med. Times*, 1862, Vol. V, p. 7); by Surgeon J. BRYAN, U. S. V. (*Am. Med. Times*, 1863, Vol. VII, pp. 4 and 287); by Surgeon A. B. MOTT, U. S. V. (*Cases in Military Surgery*, in *Am. Med. Monthly*, 1862, Vol. XVIII, p. 348,—1 fatal and 2 successful cases); by Surgeon P. F. EVE, P. A. C. S. (*Surg. Memoirs by the U. S. Sanitary Commission*, 1870, Vol. I, p. 210); by Dr. A. E. M. PURDY (*Severe Case of Gunshot Wound*, in *Am. Med. Times*, 1862, Vol. V, p. 35); by Dr. W. H. HESS (*Chicago Med. Journal*, 1870, Vol. XXVII, p. 207); by Acting Assistant Surgeon T. T. SMILEY (*Gunshot Wounds from Arkansas Post*, in *Boston Med. and Surg. Jour.*, 1863, Vol. LXIX, p. 154); by Surgeon N. HAYWARD, 20th Massachusetts (*Army Surgery on the Battlefield*, in *Boston Med. and Surg. Jour.*, 1862, Vol. LXV, p. 396).



at elbow joint in one, of the forearm of the same side in one, of excisions of the humerus of the same side in eighteen cases, of excisions of the elbow joint in thirteen cases, of excisions in the shafts of the bones of the forearm in five cases, of ligations of the brachial artery in two cases, of complex operations for neurotomy and extraction of balls and bone fragments in two cases. Five of the patients survived, moreover, operations subsequent to the secondary amputations of the arm, viz: Exarticulation at the shoulder in one case, resection of the protruding shaft of humerus in one, ligation of the axillary artery in one, and of the brachial artery in two cases. The course of convalescence was interrupted in nineteen cases by sloughing, in six cases by gangrene, and there were nine examples of copious but controllable consecutive bleeding. In one instance, grave symptoms of tetanus were temporarily manifested.



FIG. 547.—Lesions following an excision in the humerus from shot injury. *Sp.* 3209.

CASE 1690.—Private S. J. Call, Co. D, 32d Massachusetts, age 35 years, was wounded at Spottsylvania, May 12, 1864. Surgeon W. R. De Witt, U. S. V., recorded at the field hospital of the 1st division, Fifth Corps: "Right arm fractured by bullet." Assistant Surgeon P. C. Davis, U. S. A., in charge of Judiciary Square Hospital at Washington, contributed the specimen (FIG. 547), with the following description of the case: "Gunshot wound of the lower third of the right humerus; a compound fracture. On September 8th, amputation at the upper third of the humerus was performed in this hospital by Acting Assistant Surgeon J. H. Thompson. A flap operation was chosen. Ether and chloroform were the anesthetics used. The condition of the injured parts showed that an excision of the lower extremity of the humerus with the condyles had been performed upon the field, May 13th. A sequestrum several inches in length was found embedded in the callus, and a portion of the shaft of the humerus necrosed. The soft parts were much inflamed and in an unhealthy condition. The constitutional state of the patient was moderately good. The treatment consisted of stimulants. September 30th, patient rapidly improving." The specimen consists of the upper extremity of the bones of the right forearm and the lower two-thirds of the humerus. The radius and ulna do not appear to have been directly injured, but are carious and partly absorbed, and have united at their adjoining borders. A loose sequestrum of six inches lies within a partial involucrum of spongy bone, the osseous deposit extending nearly to the point of amputation. The patient was discharged from service on January 5, 1865, and pensioned. In his application for commutation, dated 1870, he stated that the condition of the stump was "healthy." He was paid on June 4, 1875.

CASE 1691.—Private J. Siler, Co. E, 35th Illinois, aged 22 years, was wounded at Chickamanga, September 19, 1863, in the casualty list of which battle his injury was described by Surgeon G. Perin, U. S. A., Medical Director of the Army of the Cumberland, as follows: "Both arms wounded; left fractured." With a number of others the wounded man fell into the hands of the enemy, where he remained until October 6th, when he was received into Hospital No. 2, at Chattanooga. Assistant Surgeon J. C. Norton, U. S. V., in charge of the hospital, reported: "Compound fracture of left humerus, lower third. Treated with felt splints and cold-water dressings. The splints could not be well adapted on account of extensive laceration of the soft parts, which presented large fungous granulations. In consequence the bones united at an angle. A large callus is thrown out, however, and the deformity will not be great. There is partial ankylosis of the elbow joint. Patient was sent to Stevenson, Ala., on November

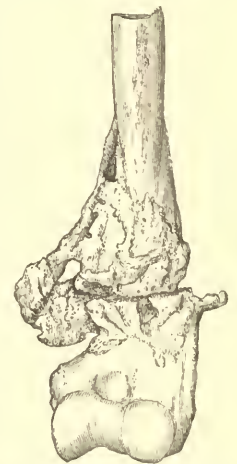

FIG. 548.—Lower part of humerus amputated two months after shot comminution. *Spec.* 1917.

7th, in good condition." On November 11th, the patient reached Hospital No. 1, at Nashville, whence Acting Assistant Surgeon P. Peter furnished the following history: "When admitted, his wound, a compound comminuted fracture of the left humerus, produced by a ball, had not been dressed for forty-eight hours, and consequently was offensive, somewhat inflamed and irritated, and discharging pus freely. The tissues immediately around the fracture presented an uncomely appearance, being bulged out all around, and superabundant granulations at the external openings, of which there were three or four distinct ones. On examination with a probe I detected several fragments of bone, two or three of which, as large as a grain of Indian corn, I removed with the small forceps without enlarging the openings. The patient was stout and his general health good. I applied simple water dressings, and gave him full diet. November 19th, patient has been doing moderately well till to-day, having rested well all the time; appetite kept good and bowels regular. To-day the tongue is coated with a white fur; appetite poor and bowels constipated; patient generally restless. Arm inflamed and swollen, with small blisters about the fracture. Checks flushed, and pulse 90. Prescribed castor oil  $\zeta$ ss, also a mixture of spirit. nitre and spirit. mindereii  $\bar{a}$   $\zeta$ ss, tart. antim. gr. 1, in doses of a teaspoonful every two hours, and half diet. November 20th, patient has not rested much; the wound and surrounding tissues are covered with large blisters, of puffy condition and of a gangrenous appearance; pus fetid; tongue still coated; appetite poor; pulse 100, and patient weak at times. On consultation with Surgeon C. W. Hornor, U. S. V., in charge of the hospital, in the afternoon, it was deemed advisable to amputate the arm immediately. Accordingly at 4 P. M. the patient was put under the influence of an anæsthetic, which he bore well, and I performed the circular amputation at the upper third of the humerus,

being the most distal point at which sound tissue could be had. The patient bore the operation well, and, after he was thoroughly from under the influence of the anæsthetic, he rested quietly and slept very well through the night. November 21st, tongue still a little coated. Pulse about 100, but patient rests well and his appetite improved; stump looks well, and but little inflamed. Treatment: Simple water dressings, and wine  $\bar{5}$ i every three hours, with nourishing diet. November 22d, patient rested well through the night and is cheerful this morning. The wound or stump is a little more inflamed, and has slight appearance of erysipelas. Appetite moderate; pulse 112, soft and full. Prescribed tinct. iron gtts. xx, and quinine gr. iss, every three hours, and applied glycerine locally. November 23d, patient rested well through the night and is cheerful this morning; appetite good; tongue cleaning off; less appearance of erysipelas; wound beginning to suppurate; pus a little fetid; pulse 112. Treatment continued, with the addition of chlor. sodæ. November 24th, patient rests well; tongue clean; appetite good; less feverish; pulse 100; wound suppurating freely. I removed half the stitches and applied a poultice of flaxseed and charcoal. Continued iron and wine and good diet. November 25th, patient rested well through the night; appetite good; wound suppurating freely; pus fetid; good deal of tenderness about the shoulder joint on handling the parts; pulse 90; excretions regular. The general health of the patient is good." The specimen (FIG. 548) was contributed to the Museum by the operator, and consists of "the lower half of the left humerus, showing a nearly transverse fracture in the lowest third, with a splinter of nearly two and a half inches broken off the inner border of the upper fragment. A considerable effusion of callus has partially united the fragments, with some displacement to the upper portion, but no union of the broken shaft has occurred." On April 1, 1864, the patient was transferred to hospital at Louisville, subsequently to Madison, and lastly to Camp Chase, where he was discharged from service on August 30, 1864, and pensioned. Examiner R. T. Higgins, of Vandalia, January 6, 1875, certified: "The left arm is amputated about two and a half inches below the shoulder joint. The cicatrix of the wound of the right forearm is very tender. Development of arm very good, but seems weak in grasping. Cannot carry any weight any distance in hand or on arm, etc." The pensioner was paid on June 4, 1875.

TABLE LXXXIV.

*Condensed Summary of One Hundred and Twenty-seven Cases of Recovery after Secondary Amputations in the Upper Third of the Shaft of the Humerus.*

NO.	NAME, AGE, AND MILITARY DESCRIPTION.	DATES.	OPERATIONS, OPERATOR, RESULT.	NO.	NAME, AGE, AND MILITARY DESCRIPTION.	DATES.	OPERATIONS, OPERATOR, RESULT.
1	Allen, R., Pt., G, 37th Indiana.	Dec. 31, '62	Right; by Surg. R. G. Bogue, 19th Ill. Disch'd Mar. 15, '63; pens'd.	22	Coleman, C. T., Corp'l, B, 75th New York, age 23.	June 14, Aug. 7, 1863.	Right; flap; by A. Surg. W. S. Webster, 156th N.Y.; (exc. June 15, '63.) Disch'd Apr. 7, '64; pens'd.
2	Banks, J. H., Corp'l, E, 13th Maine, age 27.	July 8, 1866.	Right; flap; by Dr. W. H. True; (excis. humerus May 21, 1864.) Disch'd Oct. 19, 1864; pens'd.	23	Coleman, H., Emp. Q.M. Dept., age 24.	Mar. 16, Ap. 16, '65	Right; circ. Transferred June 5, 1865.
3	Beebe, S. M., Pt., H, 4th Michigan Cavalry.	De. 15, '62	Right. Discharged Sept. 3, '63; pensioned.	24	Collins, A., Pt., K, 14th Kentucky.	June 22, 1864, Mar., '65.	Left; by Drs. H. S. Sivetnam, E. R. Turner, and J. Roland; (excision June 22, 1864.) Discharged January 31, 1865; pensioned.
4	Belt, G., Pt., K, 5th New Jersey, age 25.	May 5, '62	Right; flap; by A. Surg. C. R. Greenleaf, U.S.A. and A.A. Surg. C. R. Maclean; (excis. humerus May 6.) Disch'd Oct. 1, '63; pens'd.	25	Conner, J., Pt., F, 3d Delaware, age 15.	Feb. 2, May 26, 1863.	Left; by Surg. D. E. Wolfe and A. Surg. J. M. Houston, 3d Del.; (amp. right forearm Feb. 2.) Discharged Nov. 12, 1863; pensioned.
5	Berry, H., Government employe, age 57.	Nov. 5, '64	Right; circ.; by Surg. J. Perkins, U.S.V.; (gang.) Disch'd May 9, '65.	26	Cotton, A., Pt., F, 22d Massachusetts, age 25.	June 27, Au. 16, '62	Left; circ.; by Surg. A. B. Mott, U.S.V. Disch'd Nov. 1, '62; pens'd.
6	Best, L., Private, A, 83d Pennsylvania.	Aug. 30, Sept. 30, 1862.	Left; by A. A. Surgs. C. C. Tower and C. B. Fry. Disch'd March 30, 1863; pensioned.	27	Crites, W. M., Corp'l, B, 10th W. Va., age 26.	July 24, Au. 24, '64	Right; circ.; by a Confed'e surg. Disch'd Aug. 9, 1865; pensioned.
7	Bicknell, J. T., Serg't, K, 23d Mass., age 44.	June 27, Sep. 3, '62	Right; flap; by Med. Cadet F. A. Keffer, V.R.C. Aug. 20, '63; pen'd.	28	Dark, A. M., Pt., C, 1st New Jersey.	May 3, June 26, 1861.	Right; by A. A. Surg. D. P. Wolhaupter. Discharged August 10, 1863; pensioned. Spec. 1312.
8	Bird, W. A., Pt., G, 68th Indiana, age 32.	Aug. 14, Sept. 15, 1864.	Left; circ.; by A. A. Surg. A. Rollard; (hæm.; lig. of brachial.) Disch'd Nov. 26, 1864; pens'd.	29	Davis, T., Pt., C, 30th Iowa, age 21.	July 2, Aug. 8, 1864.	Right; ant.-post. flap; by A. A. Surg. J. C. Thorpe. Discharged March 20, 1865; pensioned.
9	Birge, W. C., Pt., G, 37th Massachusetts.	June 6, Au. 13, '64	Left; (amp. of forearm June 19; gang.) Disch'd Feb. 28, '65; pen'd.	30	Davis, W. S., Pt., C, 32d Maine.	May 12, Au. 11, '64	Right; flap; by Dr. E. White. Disch'd Nov. 29, 1864; pensioned.
10	Bishop, H., Pt., K, 22d Michigan, age 21.	Sept. 20, Oct. 26, '63	Left; circ.; by A. A. Surg. W. K. Mairty. Disch'd June 30, '65; pen'd.	31	Dennis, J., Pt., D, 3d New Jersey.	May 8, July 3, '64	Left; by Dr. T. Iverson. Discharged June 27, '64; pensioned.
11	Bower, W. H., Serg't, L, 1st New York Light Artillery.	Aug. 21, 1862.	Left; (amp. elbow) Aug. 21, '62.) Disch'd Nov. 10, '62. Re-enlisted, and disch'd Aug. 2, '71; pens'd.	32	Dilley, L. L., Pt., D, 22d Illinois, age 23.	Jan. 20, Feb. 23, 1864.	Circular; by A. Surg. J. E. Link, 21st Ill.; (gangrene.) Discharged July 7, 1864; pensioned.
12	Bowman, J., Serg't, B, 54th Penn., age 29.	June 21, July 27, 1864.	Right; circ.; by Surg. W. S. Welsh, 15th W. Va. Disch'd Oct. 27, '64; pensioned.	33	Doyle, P., Pt., D, 69th New York.	Sept. 17, Dec. 4, 1862.	Right; flap; by Surg. H. S. Hewit, U.S.V.; (excision October 2, and again Dec. 4.) Discharged Feb. 5, '63; pens'd. Specs. 458, 807.
13	Bozier, H., Pt., K, 91st Penn., age 18.	June 19, July 21, 1864.	Right; flap; by Surg. N. R. Mosely, U. S. V. Disch'd May 27, 1865; pensioned. Spec. 2893.	34	Erdman, C. W., Serg't Maj., 121st O., age 22.	De. 24, '63, Mar. 9, '64	Left; flap; by Dr. C. B. Cliff. Disch'd Apr. 23, 1864; pensioned.
14	Brown, J. W., Pt., B, 97th Ohio, age 20.	May 26, July 10, 1864.	Left; circ.; by Surg. S. E. Fuller, U. S. V.; (excis. May 26, 1864.) Disch'd Jan. 10, 1865; pens'd.	35	Fehls, G., Pt., G, 12th Missouri.	July 17, Au. 20, '63	Discharged August 7, 1864; pensioned.
15	Brown, T., Pt., C, 1st Mass. H. A., age 50.	Feb. 21, '64, Feb. 12, '67	Left; circ.; by Dr. I. P. Galloupe. Disch'd July 3, 1865; pens'd.	36	Finkbone, J., Pt., B, 124th Ind., age 45.	June 2, Aug. 1, 1864.	Right; circ.; by Dr. W. H. Twiford; (excision June 3.) Disch'd May 8, 1865; pensioned.
16	Bumgardner, M., Serg't, B, 9th Iowa.	May 22, Oct. 2, 1863.	Right; circ.; by A. Surg. H. R. Tilton, U. S. A.; (hæm.; gang.) Disch'd Dec. 3, 1863; pens'd.	37	Force, C. A., Pt., K, 60th New York, age 20.	Jul. 25, '64, 1870.	Right; by Dr. J. S. Green; (excision July 25, 1864.) Discharged Aug. 31, '65; pens'd. Spec. 1805.
17	Burns, J. R., Corp'l, C, 74th New York.	May 5, J'e 5, '62	Right; by Surg. A. B. Mott, U. S. V. Discharged; pensioned.	38	Fries, A., Corp'l, E, 100th Illinois, age 26.	Sept. 19, Oct. 31, 1863.	Right; circ.; by Surg. A. McMahon, 64th Ohio; hæmorrhage. Disch'd April 18, 1864; pens'd.
18	Call, S. J., Pt., D, 32d Mass., age 35.	May 12, Sept. 8, 1864.	Flap; by A. A. Surg. J. H. Thompson; (exc. May 13; necro.) Disch'd Jan. 5, 1865; pens'd. Spec. 3209.	39	Frohne, C., Pt., B, 32d Indiana, age 35.	May 27, July 27, 1864.	Left; flap; by A. A. Surgeon E. G. White; (hæmorrhage.) Disch'd January 28, 1865; pensioned.
19	Chamberlain, J. A., S'g'l, D, 6th Maine, age 28.	May 11, June 22, 1864.	Left; circ.; by A. A. Surg. C. Carvallo. Disch'd Dec. 28, 1864; pensioned. Spec. 3567.	40	Fulmore, J. C., Pt., I, 21st Iowa.	May 22, J'e 25, '63, J'e 27, '64	Right. Discharged August 25, 1863.
20	Chapman, E. T., Corp'l, B, 58th Mass.	Au. 15, '64	Left; circ.; by Dr. J. H. Hodges. Disch'd April 11, 1865; pens'd.	41	Gullagher, W., Pt., K, 6th Iowa, age 25.	J'e 27, '64, April 8, 1865.	Left; flap; by Surg. M. K. Taylor, U. S. V.; (excis. June 27; gang.) Disch'd July 26, 1865; pens'd.
21	Chase, D. W., Pt., D, 36th Mass., age 21.	J'e 3, '64, Nov. 8, 1866.	Left; by Dr. A. R. Gleason; (exc. humerus June 18, 1864.) Disch'd June 22, 1865; pensioned.				



No.	NAME, AGE, AND MILITARY DESCRIPTION.	DATES.	OPERATIONS, OPERATOR, RESULT.	No.	NAME, AGE, AND MILITARY DESCRIPTION.	DATES.	OPERATIONS, OPERATOR, RESULT.
42	Gentzsch, E., Serg't Major, 36th Pa., age 30.	My 18, '64 Dec. 21, 1868.	Left; circular; necrosis. Disch'd June 19, 1865; pensioned. Removal of necrosed bone.	77	McIntyre, J., Pt., G, 2d Michigan.	No. 24, '63 Mar. 4, 1865.	Right; by Dr. W. W. Anderson; (excis. Nov. 24, 1863.) Disch'd June 8, 1864; pensioned.
43	Glenn, D. M., Pt., K, 1st Pa. Rifles, age 26.	Dec. 13, 1862, April 20, 1863.	Right; flap; by Surg. H. Bryant, U.S.V.; (excis. Dec. 17, '62, followed by gangrenous ulcerations.) To V. R. C. Sept. 9, '63. Spec. 1066.	78	McLain, J., Pt., F, 16th Infantry.	Jan. 1, 1863.	Right. To Veteran Reserve Corps October 29, 1863.
44	Greenman, J., Pt., I, 4th Wisconsin.	May 27, July 1, '63	Right; Discharged; pensioned.	79	McQuade, D., Pt., B, 90th Ohio, age 27.	May 14, July 1, '64.	Left; circ.; (excis. May 14, 1864.) Disch'd March 17, 1865; pens'd.
45	Harsh, G. H., Pt., A, 7th W. Va., age 34.	May 12, June 23, 1864.	Right; circ.; by A. Surg. A. Ingram, U. S. A. Duty Aug. 20, 1864; pensioned.	80	Miller, J. W., Pt., D, 39th Ohio, age 37.	July 24, Au. 29, '64	Right; by Surg. J. C. Denice, 27th Ohio, Disch'd June 26, 1865; pensioned.
46	Heath, B. F., Pt., A, 6th Connecticut.	May 20, 1864, Mar. 22, 1865.	Left; flap; by A. A. Surg. T. B. Townsend. Bone-sawn off at surgical neck March 26, 1865. Discharged May 23, 1865; pens'd.	81	Miller, R. R., Corp'l, D, 4th Minnesota.	My '62, '63 Oct. —, 1864.	Right; by Dr. J. H. Murphy; (excis. June, 1863.) Disch'd October 22, 1863; pensioned.
47	Hess, B. E., Lieut., D, 3d Michigan.	Au. 29, '63 Mar., '63	Left; by Dr. H. H. Palmer; (also wound of lung.) Disch'd May 20, 1863; pensioned.	82	Mitchener, B., Serg't, E, 4th Delaware, age 39.	June 22, July 23, 1864.	Right; circular; by A. A. Surg. J. Newcombe. Disch'd March 18, 1865; pensioned.
48	Hetts, C., Pt., B, 7th Michigan, age 18.	June 22, July 29, 1864.	Circular; by A. A. Surg. L. E. Nordman; (excis. June 22, '64.) Disch'd June 16, '65; pensioned.	83	Mulville, M., Pt., A, 10th Wisconsin, age 20.	Sept. 20, Oct. 30, '63.	Left; by Surg. W. M. Wright, 79th Pa. Disch'd June 24, '64; pens'd.
49	Hilton, A. L., Pt., H, 1st Maine Cav., age 23.	Sept. 29, Nov. 3, 1864.	Flap; by A. A. Surg. J. P. Thompson. Discharged June 8, 1865; pensioned. Spec. 3383.	84	Murray, J. M., Serg't, E, 23d Illinois.	No. 25, '63 Ap. 2, '64.	Left; by Surg. J. E. Herbst, U.S.V. Discharged and pensioned.
50	Hilton, F. J., Pt., M, 13th Pa. Cav., age 20.	May 30, July 6, 1864.	Right; circular; by Surg. N. R. Moseley, U.S.V.; (excision May 30.) Discharged Sept. 24, 1864; pensioned. Spec. 2817.	85	Myers, T. D., Pt., D, 11th Ohio, age 20.	May 14, July 10, 1864.	Right; circ.; by A. A. Surg. John Sloan; (gangrene.) Discharged Dec. 14, 1864; pensioned.
51	Henson, J., Capt., D, 33d Ohio.	Sept. 20, Oct. 23, '63.	Left; circular; by A. Surg. T. B. Hamilton. Duty Jan. 23, 1864.	86	Morton, W., Pt., K, 123d New York.	July 3, Au. 3, '63.	Left; by A. A. Surg. G. H. Dare. Disch'd Oct. 17, 1865; pens'd.
52	Hodges, F., —, A, 3d Michigan.	May 31, Jul. 17, '62	Left; by A. A. Surg. C. G. Page. Disch'd Aug. 23, '62; pensioned.	87	Pearson, J., Pt., C, 32d Missouri.	Dec. 4, '62, Jan. 4, '63.	Left; by A. A. Surg. W. S. Dyer. Disch'd March 4, 1863; pens'd.
53	Holland, J., Pt., C, 137th New York, age 38.	July 2, Aug. 8, 1863.	Right; (excision ulna July 2; mortification ensued.) Disch'd Oct. 19, 1863; pensioned.	88	Perry, J. M., Pt., D, 40th Mass., age 40.	June 18, Jul. 21, '64	Circular; by A. A. Surg. W. P. Moon. Disch'd Dec. 12, '63; pens'd.
54	Hollister, O. H., Corp'l, I, 10th Pa. Reserves.	June 27, Aug. 9, 1862.	Left; circular; by A. A. Surg. J. O. French; (excision July 21.) Disch'd Sept. 12, '62; pensioned.	89	Perry, O. H., Pt., C, 97th Illinois, age 33.	April 9, 1865.	Right; by A. A. Surg. W. P. Johnson. Discharged October 18, 1865; pensioned.
55	Hoover, S., Pt., B, 21st Illinois.	Sept. 19, Nov. 12, 1863.	Right; ant-post. flap; by A. Surg. C. F. Haynes, U. S. V. Discharged March 9, '64; pensioned.	90	Place, J. W., Pt., D, 13th N. H., age 19.	Second y. June 15, Jul. 23, '64	Right; flap. To Vet. Res. Corps December 20, 1864; pensioned.
56	Houghland, J., Pt., K, 59th Indiana.	May 22, J'e 29, '63.	Right; by Dr. Leslie. Discharged Sept. 2, 1863; pensioned.	91	Powell, E., Pt., E, 15th Mississippi, age 32.	No. 30, '64 1865.	Left; ant-posterior flap; by Surg. Voorhies, C. S. A. Transferred March 31, 1865.
57	Huber, J., Pt., B, 51st New York, age 31.	May 5, J'e 11, '64.	Right; circ.; by Surg. A. F. Shelton, U.S.V. Disch'd Apr. 9, '65.	92	Quinn, J. W., Corp'l, E, 18th Ohio.	Jan. 2, Feb. 13, 1863.	Right; by Surg. W. P. Johnson. 18th Ohio. Discharged March 31, 1863; pensioned.
58	Johnston, D., Pt., F, 103d Penn., age 21.	Dec. 14, '62 Jan. 30, 1863.	Right; by Surg. C. Haddock, 8th Mass. (excision Jan. 13.) Discharged Nov. 25, '63; pensioned.	93	Rackliff, B. R., Pt., I, 7th Minnesota.	July 14, Se. 17, '64.	Left; by a Confederate surgeon. Discharged and pensioned.
59	Jordi, C., Pt., A, 16th Michigan, age 39.	June 27, July 29, 1862.	Right; circ.; (excision.) Disch'd Sept. 5, '63; pensioned. Spec. 433. Died Jan. 6, 1869, hem. from lungs.	94	Raser, T., Pt., I, 9th Ill. Cavalry.	July 12, Au. 26, '64	Right; by a Confederate surgeon. Disch'd Feb. 13, 1865; pens'd.
60	Kelly, J., Pt., G, 5th Cavalry, age 40.	Se. 19, '64 Jan. —, 1866.	Right; by Dr. Lewis; (excis. Sept. 20, 1864; also wound of thorax.) lig. of axillary. Disch'd April 17, 1865; pensioned.	95	Reardon, J., Pt., K, 21st Wisconsin, age 21.	May 14, July 10, 1864.	Left; ant-post. flap; by A. Surg. T. A. McGraw, U.S.V.; (excis. May 14.) Disch'd June 11, '65; pens'd.
61	King, G. W., Pt., K, 26th Illinois.	Au. 14, '64 Ap. —, '65	Right; by Surg. J. R. Ludlow, U. S. V. Dis'd Aug. 16, '65; pens'd.	96	Rhoades, S., Pt., I, 56th Indiana.	Sept. 19, Nov. 9, 1863.	Left; ext. single flap; by Surg. B. Woodward, 23d Ill.; (excis. Sept. 20.) Disch'd March 15, 1864; pensioned. Spec. 2076.
62	Kissinger, A. L., Pt., B, 18th Infantry, age 21.	Aug. 7, Se. 15, '64.	Left; flap; by A. A. Surg. J. C. Thorpe. Duty Aug. 24, 1865; pensioned.	97	Rice, J. H., Pt., A, 20th Connecticut, age 22.	Mar. 19, May 7, '65	Right; circ.; by A. A. Surg. J. L. Sanders. Disch'd Oct. 18, '65; pens'd.
63	Laken, D., Pt., D, 18th Infantry.	De. 31, '62 Feb. 11, 1863.	Right; flap; by Surg. W. P. Johnson, 18th Ohio. Disch'd March 18, 1863; pensioned.	98	Richmond, M. L., Pt., G, 12th Illinois.	April 6, My 31, '62	Left; circular; by Dr. Marshall. Disch'd Aug. 8, 1862; pens'd.
64	Lamphear, G. N., Pt., B, 16th Conn., age 19.	April 20, May 22, 1864.	Left; circ.; by Surg. E. B. Haywood, C. S. A. Disch'd Feb. 28, 1865; pensioned.	99	Rifle, J., Pt., F, 10th W. Va., age 25.	No. 6, '63 Feb. 8, 1864.	Left; ant-post. flap; by Surg. C. E. Denig, 28th Ohio; (excis. Dec. 26, 1863; gangrene.) Disch'd Oct. 21, 1864; pensioned.
65	Langdon, W. H., Corp'l, F, 12th Illinois.	Oct. 3, No. 19, '62.	Right. Discharged Jan. 2, 1863; pensioned. Spec. 1032.	100	Rockey, W. H., Pt., 1st Ohio, age 22.	June 27, Au. 17, '64	Left; circ.; by Surg. J. R. Ludlow, U.S.V. Duty Oct. 3, '64; pens'd.
66	Lauer, P., Serg't, A, 82d Illinois, age 44.	May 25, Jul. 2, '64.	Left; circ.; by Surg. J. K. Rogers, U.S.V. Dis'd June 9, '65; pens'd.	101	Rowley, J. R., Corp'l, F, 65th Ohio, age 20.	Sept. 19, Nov. 26, 1861.	Right; circ.; by A. A. Surg. W. H. Matlack; (excis. Nov. 12.) Disch'd June 7, '64; pens'd. Spec. 2408.
67	Legrange, J., Pt., H, 103d N. Y., age 39.	Sept. 17, Oct. 23, 1862.	Right; circ.; by A. A. Surg. A. A. Hines. Disch'd Nov. 26, 1862; pensioned. Spec. 401.	102	Schelger, L., Serg't, I, 28th Ohio.	June 5, Jul. 28, '64	Right; circ.; by a Confed. surg. Duty Oct. 26, 1864; pensioned.
68	Lewis, R., Pt., G, 83d Indiana.	De. 28, '62 Feb. 8, 1863.	Left; by Asst. Surg. C. T. Alexander, U. S. A. Discharged March 24, 1863; pensioned.	103	Scott, J., Pt., E, 29th Col. Troops, age 27.	Jul. 30, '64 Dec. 3, 1866.	Left; by Dr. E. Andrews; (excis. July 30, 1864.) Discharged June 8, 1865; pensioned.
69	Linnaberry, O. H., Pt., G, 45th Ohio.	Nov. 18, De. 23, '63	Right; flap. Discharged April 27, 1864.	104	Sebring, C., Pt., F, 48th Indiana.	Se. 19, '62 May —, 1863.	Left; by Drs. Grimes and Badger; (also wound of right forearm, scalp, and thigh.) Discharged April 8, 1863; pensioned.
70	Lombard, H., Pt., F, 40th Mass., age 31.	May 16, Se. 2, '64.	Left; circ.; by A. A. Surg. W. C. Feyer. Dis'd Jan. 12, '65; pens'd.	105	Sergeant, W., Pt., E, 53d Penn., age 18.	June 1, Aug. 1, 1862.	Right; circ.; (also amp. left arm, middle third.) Disch'd Nov. 19, 1864; pensioned.
71	Long, D. B., Serg't, H, 1st Ohio, age 36.	July 29, Se. 17, '64.	Right; flap; by A. Surg. T. A. Me- Craw, U.S.V. Duty April 17, '65.	106	Silber, J., Pt., E, 38th Illinois, age 20.	Sept. 19, No. 29, '63.	Left; by A. A. Surg. P. Peter. Disch'd Aug. 31, 1864; pens'd. Spec. 1917.
72	Marks, J. C., Pt., D, 14th Penn., age 28.	May 10, Oct. 19, 1864.	Right; flap; by Surg. J. A. Liddell, U.S.V.; (lin. median nerve exc. Oct. 6, '64.) Disch'd May 27, '65.	107	Smith, J. H. B., Capt., B, 139th N. Y., age 29.	J'e 24, '64, Mar. 15, 1866.	Right; flap; by Dr. J. Farley; (excis. June 21, 1864.) Disch'd January 4, 1865; pensioned.
73	Marshall, D., Lieut., A, 3d N. H., age 24.	Jan. 15, July 4, 1865.	Right; by A. Surg. G. W. Minter, 3d N. H.; (excis. Jan. 15.) Disch'd July 20, 1865; pensioned.	108	Smith, W. A., Pt., D, 17th Michigan, age 29.	No. 16, '63, Ja. 17, '64.	Right; circ.; by Surg. A. Nash, 9th Mich. Cav. Disch'd July 11, '64.
74	Martin, J., Pt., E, 91st New York.	May 27, Jul. 14, '63	Left. To Vet. Res. Corps August 10, 1863; pensioned.	109	Smith, W. W., Pt., C, 21st Wisconsin, age 29.	Se. 19, '63, Jan. 11, 1864.	Left; by A. A. Surg. C. F. Haynes; (remainder became carious and was removed Feb'y 13, 1865.) Disch'd July 19, 1865; pens'd.
75	Martin, J. T., Pt., K, 6th Virginia, age 21.	July 30, Oct. 5, '64.	Right; flap; by A. Surg. S. H. Orton, U.S.A. To prison May 9, '65.	110	Snell, W. L., Corp'l, D, 6th Vermont, age 21.	May 6, June 12, 1864.	Right; double flap; by Drs. Patch, Richmond, and Bugbee. Dis'd May 18, 1865; pensioned.
76	McGrath, W., Corp'l, D, 90th New York, age 30.	June 16, Oct. 8, 1864.	Right; circ.; by Asst. Surg. Wm. St. G. Elliott, U. S. V. Disch'd May 20, 1865; pensioned.	111	Speeie, G., Pt., B, 53d Illinois.	July 13, Au. 13, '63	Left; circular. Discharged April 23, 1864; pensioned.
				112	Spray, J. C., Serg't, G, 71st Ohio, age 22.	De. 16, '64 Jan. 22, 1865.	Right; circ.; by Surg. J. H. Grove, U.S.V.; (excis. Jan. 10, '65; ham.) Disch'd May 16, 1865; pens'd.

No.	NAME, AGE, AND MILITARY DESCRIPTION.	DATES.	OPERATIONS, OPERATOR, RESULT.	No.	NAME, AGE, AND MILITARY DESCRIPTION.	DATES.	OPERATIONS, OPERATOR, RESULT.
113	Strathdee, G. P., Pt., A, 100th Illinois, age 28.	No. 25, '63 Feb. 9, 1864.	Left; ant.-post. flap; by Surg. W. C. Offerson, U. S. V.; (exc. Nov. 27, '63.) Disch'd Feb. 6, '65; pens'd.	121	Weaver, S. B., Pt., K, 45th Penn., age 19.	May 6, July 25, 1864.	Right; circ.; by Surg. A. F. Sheldon, U. S. V.; (excision May 24; gangrene.) Disch'd February 28, 1866; pens'd. <i>Spec.</i> 2889.
114	Swopes, R., Pt., K, 111th Cold Troops, age 18.	Sept. 27, No. 15, '64 May 31,	Circular; by A. A. Surg. J. S. Giltner. Disch'd Aug. 14, 1865.	122	White, J. F., Pt., K, 23d Indiana.	April 7, May 16, '62	Left; by A. A. Surg. J. Sloan. Disch'd July 8, 1862; pens'd.
115	Tanner, L. G., Serg't, K, 100th New York.	May 31, An. 29, '62 June 18,	Left; circ.; by A. A. Surg. B. B. Miles. Disch'd Oct. 3, '62; pens'd.	123	Whitehouse, A. D., Pt., D, 8th N. Y. S. M.	July 21, Se. 21, '61.	Right; by Dr. B. Burnell, C. S. A. Disch'd; pens'd. Subsequent operation.
116	Tolman, M., Pt., G, 1st Maine Heavy Art.	June 18, An. 2, '64 June 27, Nov. 7, 1864.	Right; circ.; by Dr. J. B. Walker. Disch'd June 14, 1865; pens'd.	124	Widrig, T., Pt., E, 199th Penn., age 24.	April 7, May 18, '65	Right. Disch'd August 25, 1865; pensioned.
117	Tolman, E. T., Pt., F, 55th Illinois, age 20.	June 27, Nov. 7, 1864.	Right; circ.; by A. A. Surg. D. H. Bell; (excis. June 28; necrosis.) Disch'd April 15, 1865; pens'd.	125	Wiggin, A., Pt., A, 36th Cold Troops, age 40.	Sept. 29, April 7, 1866.	Left; by Dr. W. T. Forbes; (exc. Oct. 3, 1864.) Disch'd Dec. 14, 1865; pensioned. <i>Spec.</i> 3012.
118	Underwood, R., Pt., L, 6th Ohio Cavalry.	May 31, '63 July 16, '67.	Right; flap; by Dr. C. McDermot. Disch'd July 21, 1865; pens'd.	126	Wood, A., Pt., I, 22d Michigan.	Sept. 19, Oct. 23, 1863.	Left; ant.-post. flap; by A. Surg. C. F. Haynes, U. S. V.; hemorrhage. Disch'd March 13, 1864; pensioned.
119	Warren, C. F., Pt., H, 15th Indiana, age 20.	No. 25, '63 Feb 10, '64.	Left. Discharged December 17, 1864.	127	Wood, J., Corp'l, D, 27th Mass., age 31.	May 16, An. 4, '64.	Left; circular; by a Confed. surg. Disch'd June 20, 1865; pens'd.
120	Warren, W. H., Corp'l, H, 20th Mass.	Sept. 17, Oct. 19, 1862.	Right; oval skin flaps and circular sect. of muscles; by A. A. Surg. J. Ashhurst; (exc. Oct. 11; hem.) Discharged Jan. 11, 1863; pens'd. <i>Spec.</i> 273.				

Specimens from nineteen of the foregoing cases of successful secondary amputations in the upper third of the shaft of the humerus are preserved in the Museum.<sup>1</sup>

§ *Fatal Cases.*—There were forty-six fatal cases in the series of secondary amputations of the arm at the upper third,—twenty-one on the right, twenty-four on the left, and one in which this point was not ascertained. Eleven of the patients had already submitted to grave operations,—one to amputation of the opposite arm, three to excisions of the shaft of the humerus, five to excisions of the elbow joint of the arm finally amputated, one to an extirpation of a portion of the ulnar nerve, and one to a ligation of the brachial.

CASE 1692.—Private H. Wilson, Co. G, 27th Ohio, was wounded at Corinth, October 4, 1862. The injury was described on the casualty list of the 2d Division of the Army of the Mississippi, by Surgeon I. L. Crane, 62d Ohio, as: "Wound of arm; serious." Assistant Surgeon J. P. Wright, U. S. A., contributed the specimen (FIG. 549), with the following history: "A conoidal ball entered the right elbow joint between the internal condyle and the olecranon process. The missile was extracted three months after the reception of the injury, from the outer surface of the arm, midway between the elbow and the shoulder. This man was transferred from Corinth to the general hospital at Jackson, on December 13th. On January 29th, the arm was attacked with severe erysipelatos inflammation, upon the subsidence of which—February 6th—the limb was amputated a little below the surgical neck. The man survived the operation eleven days, and sank with colliquative diarrhœa." The specimen consists of "the lower half of the right humerus and upper portion of the bones of the forearm. \* \* The head of the radius has nearly disappeared under absorption following fracture. The ulnar processes are not distinguishable, but several splinters are irregularly attached by callus to the extremity of that bone. The lower extremity of the humerus was comminuted; fragments covered with foliaceous callus are partially attached in irregular positions, and the extremity of the main body of the shaft is carious."—(*Cat. Surg. Sect.*, 1866, p. 173.) In setting up the preparation a section, several inches in length, of the upper portion of the diaphysis has been removed.

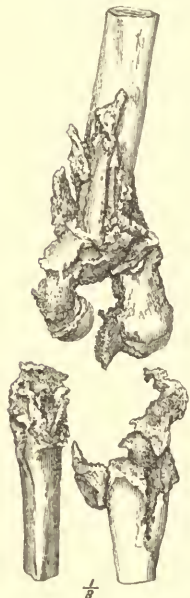

FIG. 549.—Anterior consequences of a shot perforation of the right elbow. *Spec.* 969.

CASE 1693.—Private J. Kramer, Co. D, 72d New York, aged 20 years, was wounded at Williamsburg, May 5, 1862. Brigade Surgeon D. W. Bliss reported the injury on the casualty list as a "Wound of the left arm." On May 9th, the man was admitted to Hygeia Hospital, Fort Monroe, and, on October 2d, he entered Chester Hospital. It was decided that the condition of the limb necessitated amputation, which was performed at the upper third, by Acting Assistant Surgeon J. A. Draper, on February 16, 1863. Death resulted on February 25, 1863, from pyæmia. The specimen (FIG. 550) was contributed by the operator, and consists of "the lower thirds of the left humerus, amputated forty-one weeks after fracture, at their junction. The shaft is fairly consolidated, with slight deformity, but the interior, in which is lodged a battered bullet, is carious."—(*Cat. Surg. Sect.*, 1866, p. 131.)

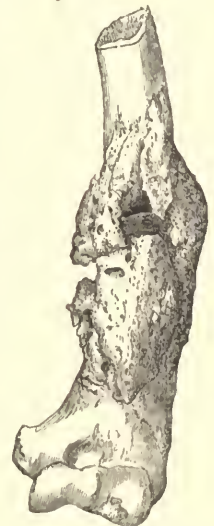

FIG. 550.—Ball impacted in humerus, ten months after injury. *Spec.* 2063.

<sup>1</sup>Two are shown in FIGS. 547, 548. One (No. 1805) is a plaster cast of a flail-like dangling arm. Two (Nos. 1066 and 1032) are wet preparations of much interest, showing the remote alterations after excision and after comminution in the shaft. Fourteen show various morbid processes in bone after injury. The numbers of the specimens are recorded in the Table.



One of the patients submitted to re-amputation at the shoulder joint, and five to ligations—of the axillary in one case, of the brachial in three, and of a smaller trunk, probably the superior profunda, in one. Four patients had received serious wounds in other parts of the body, less grave, however, than the injuries of the arm. One patient perished from tetanus, three succumbed to colliquative diarrhœa, the majority to surgical fever and pyæmia.<sup>1</sup> Nine of the cases were complicated by intercurrent hæmorrhage, five by the invasion of erysipelas, and nine by gangrene.

CASE 1694.—Sergeant H. Herpst, Co. H, 119th Pennsylvania, aged 25 years, was wounded at the Wilderness, May 5, 1864, and admitted to the field hospital of the 1st division, Sixth Corps, where Surgeon R. Sharpe, 15th New Jersey, noted: "Fracture of lower third of humerus by minié ball." Surgeon G. L. Pancoast, U. S. V., in charge of Findlay Hospital, Washington, where the patient was admitted on May 11th, contributed the specimen (FIG. 551), with the following report: "Gunshot wound of the right arm, ball entering near elbow and having its exit on the inner side of the arm, about two inches below the axillary space, fracturing the humerus. The parts having become unhealthy and sloughing, amputation was performed, on June 7th, by flap method, at the upper third of the humerus, by Acting Assistant Surgeon D. P. Wollhaupter. Chloroform was given as an anæsthetic. Progress was unfavorable. The artery sloughed off, necessitating ligation of the axillary, which was practised by Acting Assistant Surgeon J. C. Nelson on June 13th. The treatment consisted of tonics, stimulants, and nutritious diet. Death occurred on June 15, 1864." The specimen consists of "the lower two-thirds of the right humerus, with a nearly transverse fracture in the lowest third. There was no comminution, but both extremities are necrosed, without attempt at repair."—(*Cat. Surg. Sect.*, 1866, p. 129.) There is no mention of an autopsy.

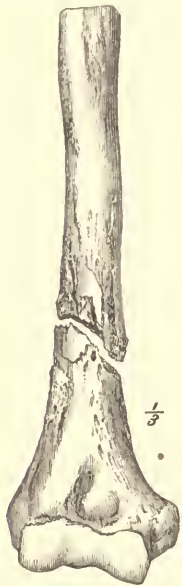

FIG. 551.—Necrosis after slightly oblique shot fracture of the humerus. *Spec.* 2463.

CASE 1695.—Private A. Bradford, Co. B, 28th Alabama, aged 22 years, was wounded at Mission Ridge, November 24, 1863, and was treated in hospital at Chattanooga, for gunshot fracture of the right arm, until February 15, 1864, when he was transferred to Hospital No. 1, Nashville. Surgeon Caleb W. Hornor, U. S. V., reported: "Admitted to the prison ward February 16th. When admitted, he was suffering from profuse purulent discharge from the arm; appetite poor; tongue coated. On examination of the wound several spiculae were found, and no union had taken place. February 25th, Acting Assistant Surgeon T. G. Hickman performed a flap amputation near the shoulder joint. Patient did not bear the operation well, but rallied in the course of twenty-four hours. February 28th, symptoms of pneumonia set in, and the patient continued very restless, and died on the morning of the 2d of March. The treatment had consisted of simple dressings to the stump, with anodynes and stimulants internally, and supporting and easily assimilable diet. Examination twelve hours after death: External appearance, moderate emaciation. On examination of the stump the tissues were found gangrenous, and a sinus was found to extend over the head of the humerus, but not communicating with the glenoid cavity. Nearly the whole of the left lung was in the stage of gray hepatization. The lower lobe of the right lung was deeply engorged. The heart contained large light yellow clots. There was fatty infiltration of the liver, which weighed three pounds and six ounces.

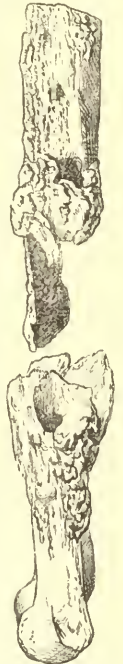

FIG. 552.—Humerus amputated three months after shot fracture. *Spec.* 2490.

The spleen was soft and pulpy, and weighed five ounces. Kidneys healthy; the right weighed four and a half, and the left five ounces." The specimen (FIG. 552) exhibits "an ununited fracture of the lowest third of the right humerus, amputated three months after injury. The specimen shows small fragments of bone thinly coated with callus and attached to the extremities. The middle third of the shaft is necrosed."—(*Cat. Surg. Sect.*, 1866, p. 131.) It was contributed to the Museum by Acting Assistant Surgeon G. P. Hachenberg.

*Remarks.*—As indicated in the TABLE, the cases of fatal primary amputation of the upper third of the arm furnished the Museum with twenty pathological specimens. Four are figured in the immediately preceding wood-cuts, and one on page 649 *ante* (FIG. 499). Of the fifteen remaining specimens, three (*Specs.* 4033, 4056, and 4095) are wet preparations, from the case of Knox (No. 24 of the TABLE), and are, respectively, an excised neuroma of the median nerve, a dissection of the median and ulnar nerves with slight fusiform enlargements, and the soft tissues removed *post-mortem* from the stump of the upper arm, showing nearly complete union, with a beautiful linear cicatrix and a bulbous enlargement of the nerves just behind the cicatrix. Two (*Specs.* 2638, 2667) are from the case of Crooker (No. 11), and consists of the comminuted and necrosed lower portion of the humerus, and of its upper portion rarefied and eroded by periostitis and osteomyelitis. *Spec.* 1928 is the fractured and carious metacarpus and carpus from the case of Tucker (No. 41); *Spec.* 2776 is the fractured ulna and diseased radius from the case of Barkhuff (No. 4); *Specs.* 1215 and 3756 show different stages of diseased stumps, from the cases of Shaw and Brint (Nos. 37 and 8)—one with a tubular sequestrum and involucrum densely studded with osteophytes, the other with an incipient annular exfoliation. *Spec.* 3667 is the fissured and necrosed lower thirds of the humerus, amputated on account of secondary hæmorrhage, in the case of Kleckner (No. 23); *Specs.* 2767, 2784, 2950, 3610, and 2836, from the cases of Fleckinger, Riggles, Logan, Perry, and Austin, are fine examples of mingled reparative and destructive processes succeeding shot fracture at the shoulder joint. The last exemplifies a firm bony ankylosis. Including the case of Bradford (CASE 1695), minutes of autopsies are preserved in seven

<sup>1</sup> The immediate causes of death are noted as: Tetanus, 1; diarrhœa and dysentery, 3; gangrene, 1; tubercular phthisis, 1; pneumonia, 4; pyæmia, 19; irritative fever and exhaustion, 17.

instances: In the case of Ackerman (No. 2 of the TABLE), Dr. Grant reports that "the necropsy revealed pus in the shoulder joint, two large metastatic foci in the liver, and one in the lower lobe of the right lung." In Brint's case (No. 8, *Spec.* 3756), Dr. A. C. May records: "Abscesses from face of stump to axillary space; the medullary tissue of the humerus was broken down and softened; the posterior portions of both lungs were studded with light grayish nodules; the posterior portions showed red hepatization; the supra renal capsules and spleen were much softened and disorganized." In the case of Cole (No. 10), Dr. J. W. Cushing observes: "Three-fourths of an ounce of purulent exudation of the left shoulder joint. The other joints were healthy, and the pulmonary parenchyma and pleural cavities normal." In Crooker's case (No. 11, *Specs.* 2638 and 2667), Dr. H. M. Dean noted: "At *post-mortem* examination the right shoulder joint was found filled with pus; the upper extremity of the humerus denuded of periosteum. The tissues of the stump were infiltrated with pus, but the veins leading from the parts showed no evidence of disease." In the case of Satterfield (No. 36), Dr. B. B. Miles reported that "the autopsy revealed a few minute abscesses in the right lung; the liver was softened but presented no purulent foci." In Tucker's case (No. 41, *Spec.* 1928), Dr. W. H. Matlock found, on *post-mortem* examination, "the arachnoid cavity distended with serum. Both lungs were congested at the bases and contained a few hard isolated tubercles in the upper lobes. Heart healthy. Parts of the surface of the liver were mottled with light yellow spots which resembled, when incised, incipient abscesses; the viscera weighed four pounds. The kidneys were much elongated. The shoulder, knee, and ankle joints contained viscid ill-conditioned pus."

TABLE LXXXV.

*Condensed Summary of Forty-six Unsuccessful Cases of Secondary Amputations in the Upper Third of the Arm.*

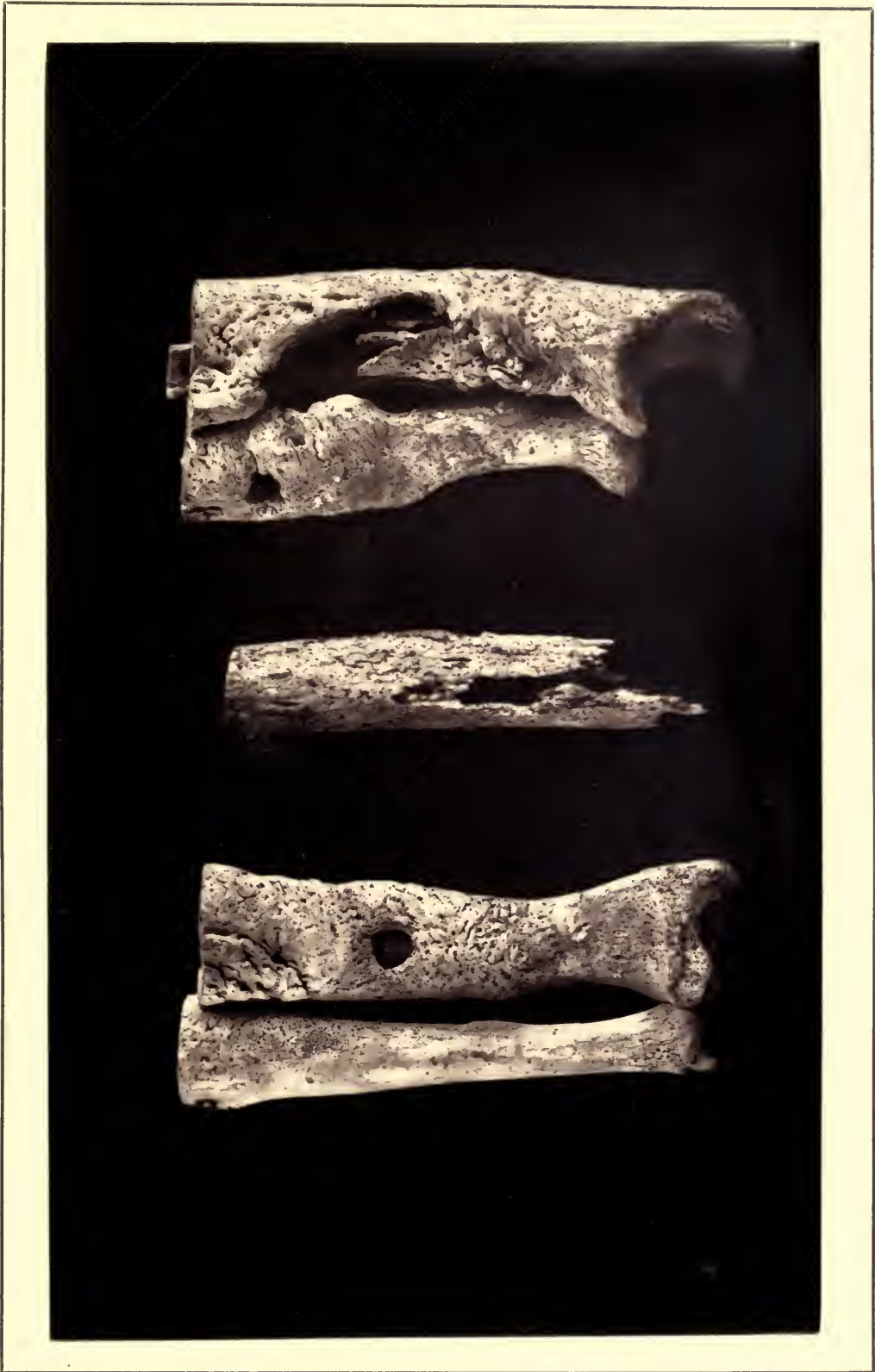NO.	NAME, AGE, AND MILITARY DESCRIPTION.	DATES.	OPERATIONS, OPERATOR, RESULT.	NO.	NAME, AGE, AND MILITARY DESCRIPTION.	DATES.	OPERATIONS, OPERATOR, RESULT.
1	Abbott, G. J., Serg't, G, 45th Ohio, age 21.	July 21, Oct. 25, 1864.	Left; circ.; by A. A. Surg. J. B. McPherson; (excision July 21; gang.) Died Nov. 7, '64, pyæmia.	24	Knox, B. E., Pt. A, 1st Delaware Cavalry, age 27.	Feb. 15, April 10, 1865.	Right; flap; by Surg. D. W. Bliss, U. S. V.; (also w'd of thigh.) Died Apr. 28, '65, pyæmia. <i>Specs.</i> 4008, 4036, 4095.
2	Ackerman, M., Pt., G, 15th Infantry, age 24.	July 3, An. 4, '64.	Left; flap; by A. A. Surg. J. Grant. Died Aug. 10, 1864, pyæmia.	25	Kramer, J., Pt. D, 72d New York, age 22.	May 5, '62, Feb. 16, 1863.	Left; by A. A. Surg. J. A. Draper. Died Feb. 23, '63, pyæmia. <i>Spec.</i> 2069.
3	Austin, C., Pt., B, 1st Penn. Rifles, age 23.	May 7, July 12, 1864.	Left; circ.; by A. A. Surg. J. Morris; (exc. May 7; erysip.) Died July 28, '64, ex. n. <i>Spec.</i> 2836.	26	Logan, J. M., Corp'l, A, 8th Md., age 29.	May 8, An. 6, '61.	Left; circ.; by A. A. Surg. J. Morris. Died Aug. 6, '64. <i>Spec.</i> 2950.
4	Barkhuuff, J. H., Pt., H, 134th N. V., age 17.	July 3, Se. 15, '63.	Right; (hæmorrhage.) Died Sept. 23, '63, pyæmia. <i>Spec.</i> 2776.	27	Molloy, J., Pt., A, 58th Penn., age 28.	May 21, July 6, '63.	Right; by Surg. I. F. Galloupe. 17th Mass. Died Jul. 14, '63, pyæmia.
5	Basley, G. W., Pt., I, 1st Massachusetts Heavy Artillery, age 38.	June 22, Aug. 5, 1864.	Right; by A. A. Surg. W. C. Flowers; (gang; hæmorrhage.) Died Aug. 5, 1864, no reaction.	28	Monahan, J., Corp'l, E, 22d Mass., age 38.	July 6, '63, Sept. 17, 1864.	Right; flap; by Surg. R. B. Bontecon, U. S. V.; (exc. May 6; hæm.) hæm. Sept. 19; amp. sh. ft.; gang. Died Sept. 26, 1864. <i>Specs.</i> 3331.
6	Bell, W. A., Pt., C, 17th Ohio, age 22.	Sept. 19, Oct. 22, 1861.	Left; flap; by A. A. Surg. J. H. Greene; hæmorrhage. Died Nov. 7, 1863, pneumonia.	29	Perry, J. N., Pt., I, 7th Mass., age 22.	May 5, July 12, 1864.	Right; oval flap; by A. A. Surg. J. H. Janar; pyæmia. Died July 24, '64, exhaustion. <i>Spec.</i> 3610.
7	Bradford, A., Pt., B, 28th Alabama, age 22.	No. 25, '63, Feb. 25, 1864.	Right; flap; by A. A. Surg. T. G. Triekman. Died March 2, 1864, pneumonia. <i>Spec.</i> 2190.	30	Piser, T., Pt., D, 125th New York, age 21.	May 12, J'e 22, '64.	Right; flap; by Surg. Chas. Page, U. S. A. Died July 2, 1864, dysentery.
8	Brint, J., Corp'l, F, 14th Ohio, age 27.	Aug. 5, Sept. 23, 1864.	Right; circ.; by A. A. Surg. J. H. McIntyre; (hæm.; liga. brachial; gangrene;) necrosis. Died Oct. 12, '64, pyæmia. <i>Spec.</i> 3756.	31	Price, W. T., Corp'l, D, 10th Kentucky.	Se. 19, '63, Second V.	Right. Died Dec. 3, '63, diarrhoea, erysipelas, and pleuritis.
9	Christy, T., Pt., G, 25th Illinois, age 25.	June 21, Aug. 11, 1864.	Right; flap; by A. A. Surg. F. B. Mossinger. Died Sept. 26, '64, irritative fever.	32	Pyne, E. L., Lieut., K, 50th Ohio, age 35.	Feb. 15, '64, Feb. 6, 1865.	Right; circ.; by A. Surg. W. B. Trull, U. S. V.; (necrosis.) Died Feb. 6, 1865, tetanus.
10	Cole, J., Private, H, 7th Michigan.	July 3, Se. 12, '63.	Left; circ.; by A. A. Surg. J. W. Cushing. Died Oct. 10, '63, pyæmia.	33	Riggle, M. A., Pt., F, 2d Pennsylvania Reserves, age 21.	July 2, Aug. 5, 1863.	Right; circ.; by A. A. Surg. J. A. Buchanan. Died Aug. 19, 1863, pyæmia. <i>Spec.</i> 2784.
11	Crooker, J. L., Pt., L, 1st Maine Heavy Artillery, age 17.	May 19, June 23, 1864.	Right; lat. flaps; by A. A. Surg. H. M. Dean; (necrosis.) Died June 21, '64, pyæmia. <i>Specs.</i> 2638, 2667.	34	Rowland, J., Serg't, H, 124th N. Y., age 26.	May 3, J'e 21, '63.	Left; flap; (exc. May 13; pyæmia; hæm.) Died June 22, 1863.
12	Cusick, M. J., Pt., F, 20th Pennsylvania, age 24.	May 25, Aug. 2, 1864.	Left; by A. A. Surg. J. M. Brown; (excis. May 25.) Died August 8, 1864, exhaustion.	35	Ruth, J., Pt., H, 6th Arkansas, age 33.	No. 30, '64, Jan. 2, 1865.	Left; ant.-posterior flap; by Surg. Cooper, C. S. A.; (amp. of right arm Dec. 1;) gangrene. Died March 26, 1865, exhaustion.
13	Davison, S., Pt., K, 40th Missouri, age 28.	Nov. 14, Dec. 14, '64.	Left; by Surg. J. K. Rogers, U. S. V.; (gang.) Died Jan. 3, '65, pyæmia.	36	Satterfield, E., Pt., F, 12th W. Va., age 40.	April 2, July 31, 1865.	Left; circ.; by Surg. H. L. W. Burritt, U. S. V.; (erysipelas;) hæm.; Died Aug. 7, 1865, pyæmia.
14	Dabord, L., Pt., B, 12th Kentucky, age 28.	No. 30, '64, Jan. 16, 1865.	Right; flap; by A. A. Surg. C. L. Randall; (gangrene.) Died Feb. 5, 1865, tubercular phthisis.	37	Shaw, T. M., Pt., H, 10th Alabama, age 24.	July 3, Aug. 4, '63.	Left; by A. A. Surg. H. H. Sutton. Died March 1, 1865, <i>Spec.</i> 1215.
15	Disbrow, F., Pt., B, 9th New Jersey.	Feb. 8, M'h 11, '62.	Left; hæmorrhage. Died March 18, 1862, pyæmia.	38	Smith, D. S., Pt., 14th Ind. Bat., age 21.	Mar. 27, June 13, 1865.	Right; circular; by Asst. Surg. A. Hartsuff, U. S. A.; (phleg. erysipelas.) Died June 15, 1865, exhaustion.
16	Easley, J. W., Lieut., C, 55th Alabama, age 35.	July 13, Oct. 17, 1864.	Left; circ.; by A. A. Surg. C. H. Fisher; (necrosis.) Died Nov. 7, 1864, exhaustion.	39	Steele, J. M., Lieut., F, 44th Missouri, age 37.	Nov. 30, Dec. 31, '64.	Left; flap; by A. A. Surg. J. A. Hall. Died Feb. 7, '65, pyæmia.
17	Ewell, H., Pt., I, 10th Mass. H. A., age 20.	Aug. 24, No. 10, '64.	Left; circ.; by A. A. Surg. I. P. Arthur. Died Nov. 21, '64, pyæmia.	40	Sullivan, J., Pt., I, 8th Maine, age 53.	June 3, Au. 15, '64.	Left; by A. A. Surg. G. L. Brickett; (necrosis.) Died Sept. 3, 1864.
18	Fleckinger, T. P., Pt., I, 81st Pennsylvania, age 23.	July 2, Aug. 2, 1863.	Right; lat. flaps; by A. A. Surg. J. McClellan. Died August 13, 1863, typhoid fever. <i>Spec.</i> 2767.	41	Tucker, H. S., Corp'l, D, 23d Kentucky, age 20.	Sept. 19, Nov. 17, 1863.	Left; circ.; by A. A. Surg. W. H. Matlock; (gang e.) Died Nov. 28, 1863, pyæmia. <i>Spec.</i> 1928.
19	Hampton, J. K. P., Pt., 30th Tennessee.	Feb. 16, M'h 25, '62.	Left; circ.; by Dr. Briggs; (excis. Feb. 18, '62.) Died March 29, '62.	42	Washburn, M. S., Pt., A, 45th Indiana.	Sept. 19, Oct. 20, '62.	Left. Died November 2, 1862, pneumonia.
20	Haviland, W., Pt., C, 92d Illinois.	Sept. 19, Oct. 27, 1863.	Circ.; by A. Surg. C. F. Haynes, U. S. V. Died Nov. 6, '63, traumatic pneumonia.	43	Williams, W., Corp'l, K, 6th Cold T., age 25.	Sept. 29, Dec. 24, '64.	Left; flap; by A. A. Surg. A. M. Paine. Died January 19, 1865, typhoid fever.
21	Herrst, H., Serg't, H, 119th Penn., age 25.	May 5, June 7, 1864.	Right; flap; by A. A. Surg. D. P. Wolfhapter; hæm.; lig. axil'ry. Died June 15, 1864, exhaustion.	44	Wilson, H., Pt., G, 27th Ohio.	Oct. 4, '62, Feb. 6, '63.	Left; (erysipelas.) Died Feb. 17, '63, colliquidant diarr. <i>Spec.</i> 209.
22	Inglidsby, J., Pt., G, 23d Illinois.	Nov. 20, '61, 1862.	Left; by Surg. W. D. Winer, 23d Ill.; (Sept. 20, excis. exostosis; erysipelas.) Died Aug. 7, 1863.	45	Wooden, W., Pt., D, 11th Louisiana.	April 6, M'y 12, '62.	Right; circ.; by A. A. Surg. E. De Witt; (gangrene.) Died August 23, 1864, pyæmia.
23	Kleckner, J., Pt., H, 2d Penn. Art., age 18.	July 5, Aug. 9, 1864.	Right; flap; by A. A. Surg. C. M. Bellows; (exc. July 5; hæm. Aug. 9.) Died Aug. 11, '64. <i>Spec.</i> 3667.	46	Worden, H., Pt., I, 6th N. Y. H. A., age 35.	July 5, 1864.	



**2. Secondary Amputation at the Middle Third of the Arm.**—The one hundred and sixty-two secondary amputations at the middle third of the arm furnished one hundred and twenty-seven recoveries, or as many as the somewhat larger series of secondary amputations in the upper third, but only thirty-five deaths, a mortality rate of 21.6, or 5 per cent. less than in the upper third amputations. Eleven of the one hundred and sixty-two operations were practised on Confederate soldiers. The modes of operation are returned as—circular, sixty-five; flap, sixty-four; oval, three; not stated, thirty.

§ *Successful Cases.*—Of one hundred and twenty-seven successful secondary amputations of the arm at the middle third, seventy-eight were practised on the left and forty-nine on the right extremity. The injuries in six cases had been inflicted by large projectiles. Seven patients were returned to modified duty, seven were exchanged or paroled, and one hundred and thirteen discharged, and, with rare exceptions, pensioned. Seven of the pensioners have died from causes but remotely connected with their injuries. Five of the patients had received wounds elsewhere than in the arm. Forty-four had undergone antecedent operations, viz: Ablation at the elbow, one; amputation of the forearm, twelve; amputation of portions of the hand, two; primary excision in shaft of humerus, three; excision of elbow joint, nine; excision in ulna, seven; in radius, three; in radius and ulna, one; partial excision of carpus, three; removal of portion of radial nerve, one; ligation of brachial artery, one; ligation of radial artery, one. Twelve of the patients survived ulterior operations—one a re-amputation of the shoulder joint, one a re-amputation of the upper third and subsequent enucleation of the head of the humerus, two others re-amputation in the upper third, seven resections of the protruding humerus or extraction of the sequestra, and one ligation of the brachial artery. Many patients eventually recovered after being placed in jeopardy by the gravest complications: In one case there were symptoms of tetanus; in eighteen, consecutive bleeding; in twenty, serious sloughing; in fourteen, erysipelas,—several of these complications sometimes appearing in the same patient.

CASE 1696.—Sergeant N. Strain, Co. C, 9th Regiment Veteran Reserve Corps, aged 28 years, was wounded at Fort Stevens, July 11, 1864, and sent to Mount Pleasant Hospital. Assistant Surgeon C. A. McCall, U. S. A., reported: "Gunshot wound of left forearm, middle third; ball entered outer side, making its exit near inner condyle of humerus. Hæmorrhage occurred on July 23d, and August 3d and 12th, from the posterior interosseous artery. Thirty-four ounces was the probable amount of blood lost. The first hæmorrhage was arrested by compression, the second and third by the introduction of a finger into the wound." Acting Assistant Surgeon C. E. C. Darby, who performed the amputation, reported, February 20, 1865: "The patient was admitted from Fort Stevens, having been wounded through the left upper extremity. Erysipelas supervened shortly after admission, and was controlled by the usual means. On the fifth or sixth day after admission, profuse hæmorrhage took place from the posterior wound, which was checked by compressing the brachial artery. The patient himself states that he had hospital gangrene in the limb, but as the surgeons in attendance in his ward have been frequently changed since his admission it is impossible to obtain a continuous record of the case. On February 10th the limb presented the following appearance: The skin was tense, shiny, and of a dark red color, the arm much swollen and its surface irregular, with profuse suppuration from three large sloughing surfaces at different points. On examination with the probe sinuses were found running in various directions, but no dead bone could be detected. The pulsations of the radial artery were observable at the wrist. The general health of the patient was good. He was of a cheerful, contented disposition, with good appetite, and regular in every respect, though somewhat debilitated from suppuration and confinement. On February 15th, as the arm still continued to suppurate, it was decided to amputate the limb, which was done at eleven o'clock A. M. on that day. A circular amputation was performed at the junction of the middle and lower thirds of the arm. The anæsthetic used was a mixture of chloroform one-third, to ether two-thirds. Some little difficulty was experienced in ligating the bleeding vessels, these being much enlarged from previous inflammation. Thirteen ligatures were applied. The patient reacted finely, and has progressed favorably to date. Suppuration was freely established four days after the amputation, and it was found necessary to remove one suture to give exit to pus. The diet of the patient is nourishing, consisting of mutton chops, ham, potatoes, milk, bread, butter, corn-starch, etc. He also takes a moderate amount of whiskey, from six to eight ounces each day." Pathological preparations, represented in PLATE XLVIII, opposite, were contributed to the Museum by Assistant Surgeon H. Allen, U. S. A. One of them consists of "the bones of the left forearm after amputation at the junction of the lower thirds of the humerus, showing apparent contusion of both bones in their upper thirds, and necrosis of the entire shaft of the radius and of nearly the whole of the ulna, surrounded by extensive



Ward phot.

Am. Photo-Relief Printing Co., Philada.

PLATE XLVIII. INVOLUCRA OF BONES OF THE FOREARM AND SEQUESTRUM FROM HUMERUS.

Nos. 3686 and 3727. SURGICAL SECTION.





involucra." In addition to the history by the operator, Dr. Allen furnished the following note: "This case was reported to have been a flesh wound. There is no evidence to the contrary, though the amount of osseous change which has taken place in the radius and ulna would lead to the inference that the ball, if not absolutely fracturing either bone, had at least grazed one or both. In addition to the facts given by Dr. Darby, it may be said the phalangeal, wrists, and elbow joints were ankylosed, pronation and supination destroyed, the member painful, burdensome, and useless. Upon examining the fleshy parts of the forearm after amputation, it was found that the sub-integumental layer was of a yellowish-white color and of dense consistence. The muscles were almost colorless and unelastic, the section of their fibres resembling the transverse section of an onion. Upon opening the elbow joint partial true ankylosis was demonstrated. The greater sigmoid cavity of the ulna and the outer two-thirds of the articular face of the head of the radius were covered with firm plastic growth adherent to the contiguous surface of the humerus. This new tissue was of a pearly lustre on the outer layer, subnded by the presence of streaks of blood, while the deeper seated portions were of a dark purplish red color. It was very vascular, and presented numerous tortuous vessels of small calibre through its substance. The cartilage of the joint presented no abnormal appearance to the naked eye, but a section of that portion covering the radius presented unequivocal evidence of degenerative change in the cartilage cells when examined with the one-fifth objective." Another operation was performed at a subsequent date, when a heavy tubular sequestrum, four and a half inches in length, was removed from the stump. This specimen was also contributed by Dr. Allen, and is represented in PLATE XLVIII, between the two preparations of the bones of the forearm. On May 22d, the patient was transferred to Chester Hospital, whence he was discharged on July 27, 1855, and pensioned. In his application for commutation, dated 1870, he described the stump as being in "bad condition, as merely covered by integument, and as too tender to wear an artificial arm." Examiner D. W. Shindel, of Sunbury, Pennsylvania, on September 2, 1874, certified that "amputation was performed between the elbow and shoulder joints," and that there is a "poor stump," etc. The pensioner was paid June 4, 1875.

CASE 1697.—Private *S. B. Christienberry*, Co. C, 37th North Carolina, aged 33 years, was wounded in the right arm, at Gettysburg, July 3, 1863, and entered Chester Hospital on July 18th. Acting Assistant Surgeon G. Martin forwarded the following description of the case: "A conoidal ball caused a fracture of the olecranon process. Extensive destruction of the soft parts ensued, and the arm was amputated September 8th, with a favorable result; patient convalescing." The specimen consists of the upper halves of the bones of the right forearm, and the humerus amputated at the junction of the lower thirds. A considerable splinter of the posterior portion of the ulna is attached, by callus, out of position. The upper portion of the ulna and head of radius are necrosed, as well as the articular surface of the humerus, of which a portion has been absorbed. The shaft of each bone shows a slight coating of new osseous matter. On October 4th, the patient was transferred to the Point Lookout Hospital, whence he was sent to City Point for exchange on March 17, 1864. Acting Assistant Surgeon W. W. Bidlack reported that when the patient left the hospital "the stump, though nearly well, had not quite healed." The specimen is represented in the adjacent wood-cut (FIG. 553).

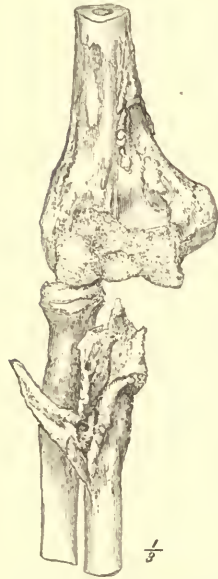

FIG. 553.—Disorganization of elbow joint, after shot fracture of the olecranon. *Spec. 2063.*

CASE 1398.—Private *W. Leiblein*, Co. C, 20th Massachusetts, aged 32 years, was wounded at Fredericksburg, December 11, 1862. He was admitted to the field hospital of the 2d division, Second Corps, where Surgeon G. S. Palmer, U. S. V., recorded: "Fracture of arm; resection of upper third of ulna and radius." On December 25th, the wounded man reached Washington, where he was admitted to Armory Square Hospital. In the following April he was transferred to McDougall Hospital, New York, where the arm was amputated. Assistant Surgeon R. Bartholow, U. S. A., in charge of the latter hospital, forwarded the specimen (FIG. 554) consisting of the bones of the right elbow, from which the olecranon and the lowest two inches of the humerus have been excised; subsequently amputated in the middle third of the arm. The bones of the forearm are ankylosed, and the extremity of the humerus presents an irregular deposit of callus. Acting Assistant Surgeon W.

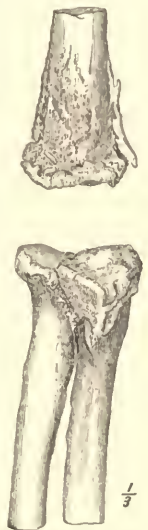

FIG. 554.—Bones of right elbow, amputated after excision for shot injury. *Spec. 1064.*

F. Cornick reported the patient's admission to Lovell Hospital, Portsmouth Grove, R. I., on November 4th, by reason of "amputation of right arm, performed before admission, May 16, 1863;" also that "Surgeon N. Hayward, 20th Massachusetts, performed the operation of excision." The patient was finally discharged from Central Park Hospital, New York City, on August 1, 1864, and pensioned. In the previous month he was furnished with an artificial arm by Mr. Lincoln, of Boston, who, in his statement, reported that the amputation was performed by flap method. In the man's application for pension it is mentioned that "Assistant Surgeon R. Bartholow, U. S. A., performed the amputation." This pensioner died on May 23, 1872.

CASE 1699.—Private *S. C. Stewart*, Co. F, 2d Maine, aged 44 years, was wounded at Bull Run, July 21, 1861, and admitted to the E street Infirmary, at Washington, on the following day. Assistant Surgeon J. W. S. Gourley, U. S. A., contributed the specimen with the following minutes of the case: "The patient was shot in the left elbow, the ball having been extracted previous to his admission. The missile entered at the external and posterior part of the elbow. On the day subsequent to his admission erysipelas set in, and was followed by very profuse suppuration and burrowing of pus nearly midway up the arm. Free incisions were made for the escape of pus, and the arm kept still, with a hope of performing a secondary resection of the elbow, which had been objected to when the patient was first seen. But about one month after the injury he had become so feeble, and his condition was such, that longer delay would have been fatal, and amputation at the middle third was resorted to as the only means of preserving his life. From that moment his condition improved, and the bed-sores which he had healed, he having meanwhile been placed on a water-bed kindly furnished by Dr. T. Foster Jenkins, of the Sanitary Commis-



sion. The patient was discharged from hospital, cured, on September 21st." On October 2, 1861, the patient was discharged from service and pensioned. On December 21, 1864, an artificial arm was furnished by Mr. Lincoln, of Boston, who described the case as a "circular amputation at the middle of the arm," and the stump, as "healed." This pensioner died on January 23, 1869. The specimen (FIG. 555) consists of the lower half of the left humerus, from which the outer condyle has been carried away, and a large fragment of the shaft split off and afterward partially reunited.

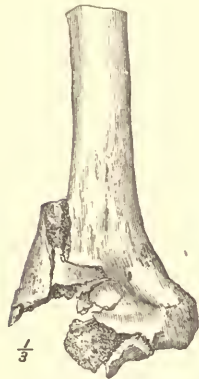

FIG. 555.—Results of shot fracture of outer condyle of left humerus. *Spec.* 350.

CASE 1700.—Private J. T. Crawford, Co. K, 51st New York, aged 17 years, was wounded in the left arm, at Manassas, August 30, 1862, and entered Judiciary Square Hospital at Washington. Surgeon C. Page, U. S. A., reported: "Gunshot wound through left elbow joint, ball entering nearly over and somewhat toward the outer edge of the coronoid process of the ulna and emerging behind the olecranon. The wound was explored on September 16th, when entire comminution of the joint was discovered. The arm was amputated at the middle third of the humerus, on October 7th, by Acting Assistant Surgeon F. H. Brown. Ether was used." The specimen (FIG. 556) was contributed by the operator, and consists of "the lowest third of the left humerus and upper halves of the bones of the forearm. \* \* A nearly longitudinal fracture has split off the lower and outer four inches of the humerus; the tip of the olecranon is fractured, and the articular surfaces of the three bones are carious. A large fragment of the shaft has reunited with displacement. The epiphyseal lines are well shown."—(*Cat. Surg. Sect.*, 1866, p. 166.) On March 28th, the patient was transferred to Ladies' Home, New York City, whence he was transferred to the Veteran Reserve Corps on September 14, 1863. He was ultimately discharged on November 28, 1865, and pensioned. An artificial arm was

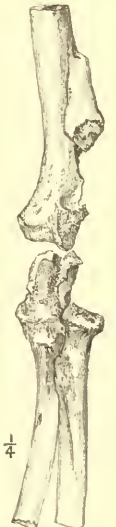

FIG. 556.—Shot comminution of the left elbow. *Spec.* 133.

furnished in May, 1864, by Mr. Lincoln, of Boston, who reported that the amputation was performed by flap method. In his application for commutation, in 1870, the pensioner reported that two operations were performed, subsequent to the amputation, by Surgeon A. B. Mott, U. S. V., and Acting Assistant Surgeon G. M. Smith, at the Ladies' Home Hospital, and described "the remaining stump of the arm as being four inches long from the shoulder, and in good condition." This pensioner was paid June 4, 1875.

TABLE LXXXVI.

Condensed Summary of One Hundred and Twenty-Seven Cases of Recovery after Secondary Amputation in the Middle Third of the Shaft of the Humerus.

No.	NAME, AGE, AND MILITARY DESCRIPTION.	DATES.	OPERATIONS, OPERATOR, RESULT.	No.	NAME, AGE, AND MILITARY DESCRIPTION.	DATES.	OPERATIONS, OPERATOR, RESULT.
1	Allen, J. B., Serg't, B, 30th Ohio.	May 22, '62; '63	Left. Discharged Aug. 7, 1863; pensioned.	16	Brundage, E. A., Pt., F, 11th Michigan Cav.	Oct. 2, Nov. 27, 1864.	Right; circular; by A. A. Surg. G. W. McMillan. Discharged March 20, 1865; pensioned.
2	Averill, J., Corp'l, K, 154th New York.	Oct. 27, Dec. 23, '62	Right. Discharged February 25, 1863; pensioned. <i>Spec.</i> 667.	17	Batt, E., Pt., G, 30th Indiana.	Dec. 31, '62; Mar. 14, 1863.	Left; flap; by A. A. Surgs. J. W. Knight and J. M. Pillsbury. Disch'd Aug. 17, '63; pensioned.
3	Babeock, D. A., Serg't, C, 6th N. Y. C., age 24.	Aug. 16, Oct. 9, 1864.	Left; circ.; by A. A. Surg. J. Neff; (exc. el. joint Aug. 17.) Disch'd Dec. 7, '64; pens'd. <i>Spec.</i> 3418.	18	Calloway, J., Pt., D, 50th Virginia, age 41.	July 9, Aug. 10, 1864.	Left; circ.; by A. A. Surg. A. Kessler; (July 9, excision of ulna.) For exchange Sept. 19, 1864.
4	Baker, A. D., Pt., A, 1st Pa. Rifles, age 20.	Sept. 14, Oct. 18, 1862.	Left; lateral flap; by A. A. Surg. W. W. Keen. Disch'd Nov. 27, '62; pens'd. Re-amp. 1869. <i>Spec.</i> 760.	19	Carter, R. E., Pt., E, 7th Mo. S. M., age 23.	Oct. 23, Dec. 3, '64	Left; circ.; by A. A. Surg. G. H. Hood. Duty March 23, 1865.
5	Bartlett, R. F., Serg't, D, 96th Ohio, age 23.	Nov. 3, Dec. 13, '63	Left; circ.; by A. Surg. S. H. Orton, U. S. A. Dis'd Jan. 25, '64; pens'd	20	Carnauck, A., Pt., 63d Indiana, age 35.	May 14, Jul. 13, '64	Right; flap. Discharged August 30, 1865.
6	Beck, G., Pt., B, 35th Ill., age 20.	May 27, Aug. 17, 1864.	Right; circ.; by A. A. Surg. L. B. McNabb; (amp. forearm May 28; gangrene.) Mustered out Sept. 27, 1864; pensioned.	21	Cary, G. W., Pt., A, 87th Illinois.	April 8, May 15, 1864.	Right; flap; by Surg. W. S. Webster, 95th C. T.; (exc. wrist April 8, '64.) Dis'd June 16, '64; pens'd
7	Bennett, J., Pt., G, 118th N. Y., age 24.	May 16, '64; '64	Left; circular. Discharged Dec. 26, 1864; pensioned.	22	Chambers, B., Pt., I, 5th Tenn., age 17.	May 14, Aug. 10, 1864.	Right; flap; by A. Surg. W. B. Trull, U. S. V.; (gangrenous.) Discharged June 14, 1865.
8	Berry, P., Pt., A, 31st Maine, age 21.	May 12, July 12, 1864.	Left; flap; by Surg. N. R. Moseley, U. S. V.; (amp. forearm May 14; erysip.; necrosis.) Disch'd Sept. 28, '64; pensioned. <i>Spec.</i> 2873.	23	Childs, H. F., Pt., G, 95th Illinois.	June 17, July 23, 1864.	Left; lat. flap; by A. A. Surg. R. W. Carle; (exc. humerus June 18.) Disch'd Jan. 26, '65; pens'd
9	Bierce, P., Pt., A, 1st Ohio Art., age 20.	Nov. 13, Dec. 25, 1863.	Left; flap; by Surg. G. H. Bame, 115th Ill.; (Nov. 13, leg amp.) Disch'd Aug. 29, '64; pensioned.	24	Christenberry, S. B., Pt., C, 37th N. C.	July 3, Sep. 8, '63	Right. Exchanged Mar. 17, 1864. <i>Spec.</i> 2063.
10	Bix, D., Pt., I, 78th New York, age 35.	May 3, Sept. 23, 1863.	Left; double flap; by A. A. Surg. R. A. Cleenan; (May 11, amp. finger; gangrene.) Disch'd Dec. 19, 1863; pensioned. <i>Spec.</i> 2741.	25	Clancy, M., Pt., D, 9th Mass., age 26.	July 1, Aug. 14, 1862.	Left; flap; by A. A. Surg. E. M. Robertson. Disch'd Nov. 27, '62. Died Dec. 13, 1864, ch. diarrhoea.
11	Boughan, J. M., Pt., C, 54th Ohio.	May 18, '63; '63	Left; flap; by Surg. E. McDonnell, U. S. V. Dis'd Nov. 1, '63; pens'd	26	Cole, T. W., Serg't, D, 74th Illinois, age 26.	May 14, Oct. 23, 1864.	Right; circ.; by Dr. C. H. Richings; (May 14, exc. elb. joint.) Dis'd 1864.
12	Bowers, J. W., Pt., D, 1st Maryland, age 36.	June 1, July 8, 1864.	Left; flap; by A. A. Surg. A. MeLethie; (gang.; hæm'c.) amp. sh. j't Mar. 22. Disch'd July 3, '65; pensioned. Died July 21, 1868.	27	Connelly, M., Pt., D, 65d N. Y., age 23.	June 3, 12, '64.	Left; circ.; by A. A. Surg. J. P. Arthur; (exc. ulna June 3), June 1865, removal of bone. Disch'd October 5, 1865; pensioned.
13	Brady, H., Pt., G, 6th Wisconsin.	Sept. 17, Dec. 18, 1862.	Left by A. A. Surg. L. Heard. Discharged January 15, 1863; pensioned. Re-amp. Sept., 1864.	28	Coolkey, J. W., Pt., G, 44th Georgia, age 22.	July 1, Sep. 2, '62	Left; circ.; by Surg. W. A. Thom, P. A. C. S. Disch'd Oct. 11, '62.
14	Brandon, J. J., Pt., H, 41st Miss., age 26.	No. 20, '64; Feb. 7, '65	Right; circ.; by Surg. B. B. Breed, U. S. V. To Pro. Mar. May 6, '65.	29	Coons, O. C., Pt., H, 65th New York, age 24.	May 5, Sept. 16, 1864.	Right; circular; by A. A. Surg. H. Craft; (gangrene.) Mar. 27, '65, sequestrum removed. Disch'd May 27, 1865. <i>Spec.</i> 1990.
15	Brown, R. N., Pt., G, 22d Massachusetts.	May 16, Sept. 19, 1864.	Right; circ.; by A. A. Surg. T. B. Townsend; (June 9, amp. forearm.) Disch'd Feb. 7, '65; pens'd	30	Cost, G. T., Corp'l, C, 49th Ohio.	De. 31, '62; Fe. 16, '63.	Right; circ.; by Surg. J. F. Weeks, 51st Ill. Disch'd April 4, 1863; pensioned.

No.	NAME, AGE, AND MILITARY DESCRIPTION.	DATES.	OPERATIONS, OPERATOR, RESULT.	No.	NAME, AGE, AND MILITARY DESCRIPTION.	DATES.	OPERATIONS, OPERATOR, RESULT.
31	Craft, E., Pt., F, 126th New York, age 24.	July 2, Aug. 12, 1863.	Left; circular; by A. A. Surg. E. Seyffarth; ham., necrosis; Dec. 18, re-amp., caries; Dec. 22, exc. head humerus. Disch'd May 19, 1865; pensioned.	58	Hastings, C. W., Pt., E, 2d U. S. S., age 21.	May 2, July 4, 1861.	Right; flap; by Surg. D. P. Smith, U. S. V.; (also w/ flap; June 23, exc. bones hand; ham.; brachial lig'd.) Disch'd Oct. 9, '63; pens'd.
32	Crawford, J. T., Pt., K, 51st New York.	Aug. 30, Oct. 7, 1862.	Left; flap; by A. A. Surg. F. Brown; two subseq. opera's. To V. R. C. Sept. 24, '63; pensioner. <i>Spec.</i> 132.	59	Hatch, S., Pt., F, 20th Maine, age 24.	May 5, Aug. 8, '61	Right; flap; by Dr. Benson. Discharged Feb. 8, 1865; pens'd.
33	Crone, L. E., Corp'l, E, 23d Massachusetts.	June 27, Au. 4, '62	Left; flap; by A. A. Surg. J. H. Lyman. Disch'd Sept. 3, '62; pens'd.	60	Hawkins, L. H., Pt., C, 77th N. Y., age 26.	May 6, Aug. 6, 1864.	Left; circ.; by A. A. Surg. J. Neff; (gangrenous.) Disch'd Feb. 14, 1865; pens'd. <i>Spec.</i> 317.
34	Crymble, S., Pt., E, 72th New York.	July 16, Jul. 28, '62	Left; flap; by A. A. Surg. Sands. Disch'd Oct. 4, 1862; pensioned.	61	Herman, C., Pt., E, 1st Massachusetts.	Jan. 30, '62, after discharge.	Right; circ.; (June 30, amp. el. jt.) Disch'd Sept. 6, 1862; pens'd.
35	Cutting, H., Corp'l, C, 6th Iowa, age 23.	July 18, '63.	Left; by A. A. Surg. A. Sterling; (exc. elb. joint July 16.) Disch'd July 18, 1864; pensioned.	62	Herron, J. T., Pt., D, 9th Penn. Reserves.	Dec. 20, '61	Left; by Surg. E. Shippen, 1st Pa. L. A. Disch'd May 21, '62; pens'd.
36	Davis, S., Pt., B, 6th Conn., age 26.	June 17, Jul. 26, '64	Left; flap; by A. A. Surg. T. H. Bishop. Dis'd April 13, '65; pen'd.	63	Heintz, M., Pt., K, 13th Illinois.	Dec. 29, '62	Left; flap. Discharged Mar. 30, 1863; pensioned.
37	Davis, D., Pt., G, 1st Maine H. A., age 19.	July 24, July 24, 1864.	Left; flap; by A. A. Surg. G. E. Brickett; (gangrene.) Disch'd Sept. 13, 1865; pensioned.	64	Holbrook, J. M., Capt., F, 27th Iowa.	April 9, May 25, '64	Left; circ.; by A. Surg. S. H.orton, U. S. A. M'd out Aug. 8, '65.
38	Davis, D. C., Pt., I, 11th N. H., age 30.	May 18, Jul. 28, '64	Left; flap; (exc. radius May 18.) Disch'd Jan. 31, 1865; pens'd.	65	Hooker, W. H., Serg't, H, 142d N. V., age 39.	June 29, Aug. 15, 1864.	Right; ant. post. flap; by A. Surg. H. M. Sprague, U. S. A. Disch'd Oct. 5, 1864; pensioned.
39	Delong, J., Pt., A, 7th Missouri, age 41.	Dec. 5, '64, Jan. 26, 1865.	Right; circ.; by A. Surg. C. B. Merrill, U. S. A.; (gangrene; crysipelas before and after amp'n.) Disch'd Oct. 9, 1865; pensioned.	66	Hosack, J., Corp'l, A, 142d Pa., age 26.	May 5, July 2, 1864.	Left; flap; by A. A. Surg. C. B. King; (gangrene; hæmorrhages.) Discharged July 27, 1865.
40	Dixon, J., Corp'l, F, 8th N. Y. H. A., age 22.	Jan. 29, '64, Ja. 20, '65.	Flap; by A. A. Surg. M. A. M. Smith. Disch'd June 24, 1865.	67	Irving, A. F., Pt., B, 159th New York.	May 28, Oct. 23, 1863.	Left; circ.; by Surg. A. B. Mott, U. S. V.; (June 18, amp. forearm; gang.) Disch'd Jan. 17, '64; pen'd.
41	Doney, D., Pt., H., 28th Mass., age 44.	May 5, June 11, 1864.	Right; flap; by A. A. Surg. W. P. Moon; (crsypelas; necrosis.) Disch'd Jan. 11, 1865; pens'd.	68	Jenkins, J., Pt., I, 4th N. Y. Prov. Cav.	Mar. 11, October, 1865.	Left; by Surg. C. M. Clark, 39th Ill.; (Mar., 1865, portion of ulna removed.) Disch'd Dec. 5, '65.
42	Dukes, G., Pt., B, 97th Pennsylvania.	Aug. 4, Sept. 20, 1864.	Left; flap; by A. Surg. C. Wagner, U. S. A.; (amp. forearm Aug. 28, '64.) Disch'd Jan. 20, '65; pen'd. Died Mar. 14, '67, hæm. from lung.	69	Jessop, M., Pt., D, 14th Iowa.	Apr. 6, '62	Left; by Drs. Swates and Schreiner. Disch'd Sept. 13, '63; pens'd.
43	Dunbar, G. H., Serg't, C, 19th Maine, age 26.	July 3, Aug. 15, 1863.	Right; flap; Mar. 24, 1864, bone removed; crysipelas. Disch'd February 6, 1865.	70	Kelly, C., Pt., E, 35th Iowa.	April 9, May 17, 1864.	Left; ant. post. flap; by Surg. J. G. Keenon, U. S. V. Disch'd June 1, 1865; pensioned.
44	Ellis, D., Pt., A, 12th N. H., age 34.	May 4, June 16, 1863.	Right; by A. A. Surg. E. Coues; ham.; lig. of brachial. Disch'd August 29, 1863; pensioned.	71	Kent, J., Pt., D, 30th Illinois, age 23.	July 22, Aug. 24, 1864.	Left; flap; by A. Surg. N. S. Hill, 121st Ohio; (July 22, excision.) Disch'd May 15, '65; pensioned.
45	Ellis, I. N., Pt., C, 103d Ill., age 25.	Mar. 21, May 16, 1865.	Left; circ.; by A. Surg. W. Webster, U. S. A.; (Mar. 21, exc. el. jt.) Disch'd June 29, '65; pens'd.	72	Larke, H., Pt., G, 8th Pa. Reserves, age 18.	Dec. 13, '62	Left; flap; by A. Surg. J. W. Pettinas, 67th Pa.; (gang.) Disch'd June 1, '63; pens'd. <i>Spec.</i> 945.
46	Eva, J. H., Pt., K, 106th Pa., age 42.	July 3, Oct. 28, 1863.	Left; flap; by A. A. Surg. T. G. Morton; (July 5, amp. forearm; necrosis;) crysip. Disch'd Sept. 26, 1864; pens'd. <i>Spec.</i> 2752.	73	Leinbach, T., Pt., E, 9th Mich. Cav.	Se. 22, '63, Dec., '63.	Right; flap; by A. A. Surg. F. M. Lincoln. Dis'd Jul. 27, '64; pen'd.
47	Everett, C. W., Serg't, H, 49th Ohio.	De. 31, '62	Left; flap; by A. Surg. L. Russell, 8th Ky.; (Jan. 6, exc. at elbow.) Disch'd Apr. 16, '63; pens'd.	74	Leiblein, W., Pt., C, 20th Mass., age 33.	Dec. 11, 1862, May 16, 1863.	Right; flap; by A. Surg. R. Bartholow, U. S. A.; (Dec. 11, excis. el. jt.) Disch'd Aug. 1, '64; pen'd. Died May 23, 1872. <i>Spec.</i> 1664.
48	Frederick, J. G., Pt., E, 103d Ill., age 27.	Nov. 25, 1863.	Left; circ.; by Med. Cadet C. H. Fisher; (Nov. 25, exc. radius and ulna; necrosis.) Disch'd Feb. 18, 1865; pensioned. <i>Spec.</i> 2206.	75	Lewis, H., Serg't, A, 2d Wisconsin.	Aug. 28, Nov. 10, 1862.	Left; circ.; (Aug. 30, amp. forearm; caries of elbow.) Pens'd Nov. 21, '64. <i>Spec.</i> 368.
49	Frederick, J. S., Serg't, D, 1st Wisconsin Cavalry, age 24.	April 16, May 18, 1865.	Left; flap; by Surg. G. E. Ranney, 2d Mich. Cav. Disch'd Nov. 15, 1865; pensioned.	76	Long, D., Pt., L, 72d Indiana.	June 24, Oct. 25, 1863.	Right; circ.; (June 24, exc. elbow joint; hæm.; gang.) Disch'd Feb. 24, 1864. <i>Spec.</i> 2129, 1750.
50	Garland, N., Pt., C, 1st Maine Heavy Art.	May 19, July 29, 1864.	Right; circ.; by Drs. Parker and Harding. Discharged Dec. 3, 1864; pensioned.	77	Lynch, J., Pt., H, 55th Illinois.	May 22, Jul. 21, '63	Right; by A. A. Surg. R. McGowan. Disch'd Oct. 6, '63; pens'd.
51	Gaston, S. S., Pt., K, 100th Penn.	Aug. 29, Nov. 11, 1862.	Left; circ.; (Sept. 26, exc. radius; crysipelas.) Disch'd Jan. 27, '63; pensioned. <i>Spec.</i> 1868.	78	McAdams, W., Pt., G, 28th C. T., age 15.	May 16, July 4, '64	Left; circular. Duly November 21, 1864.
52	Giles, R. S., Serg't, K, 146th N. Y., age 23.	June 1, 1864, 1868.	Right; by Drs. James and Walcott; (June 1, '64, exc. humerus; anchylosis.) Disch'd Jan. 9, '65; pensioned.	79	McCarty, F., Pt., 10th Wisconsin Battery, age 27.	Nov. 9, 1864.	Right; ant. post. flap; by A. Surg. B. E. Fryer, U. S. A.; (hiem.) Mustered out in 1865; pensioned.
53	Green, N. H., Pt., D, 6th Michigan Cavalry.	Sept. 14, Nov. 17, 1863.	Left; circ.; by A. A. Surg. W. F. Peck; (Sept. 15, exc. ulna; gang.; Nov. 3, amp. forearm; hæmorrhage.) Disch'd Mar. 25, '64; pens'd.	80	McClintock, J. H., Corp., H, 24th South Carolina, age 21.	No. 30, '64	Left; ant. post. flap; by Surg. G. E. Cooper, U. S. A. To Provost Marshal March 1, 1865.
54	Green, J. J., Pt., B, 18th Massachusetts.	Aug. 30, Oct. 2, '62	Left; by A. Surg. G. M. McGill, U. S. A. Disch'd Nov. 26, '62; pens'd.	81	McCarny, J., Pt., E, 60th Georgia.	Aug. 27, Se. 30, '62.	Right; flap; Disch'd Nov. 14, 1862.
55	Griest, O. E., Pt., B, 104th Ill., age 21.	May 14, J'e 26, '64.	Left; antero-posterior flap. Discharged March 8, '65; pens'd.	82	McFadden, L. L., Pt., E, 79th Indiana.	May 10, Jul. 13, '64	Left; by A. A. Surg. C. K. Hendee. Disch'd March 7, 1865; pens'd.
56	Hagey, W., Pt., E, 57th Penn., age 16.	May 10, July 7, 1864.	Right; flap; by A. Surg. H. M. Sprague, U. S. A.; (hæm.; also w'd of abdomen.) Disch'd April 19, 1865; pensioned.	83	McFalls, A., Private, C, 157th Penn., age 21.	Jan. 3, '64, Feb. 27, 1865.	Left; flap; by A. A. Surg. M. Rizer; (June 15, amp. forearm.) Disch'd Aug. 2, 1865; pens'd.
57	Hancock, S., Pt., I, 1st Maine Heavy Art., age 38.	May 19, Aug. 10, 1864.	Right; circ.; by A. A. Surg. G. E. Brickett; (erysip.) Disch'd Jan. 1, 1865.	84	McGinness, J., Pt., H, 9th New York.	Sept. 17, Nov. 25, 1862.	Right; flap; by A. A. Surg. L. Fisher; (necrosis.) Disch'd June 17, '63; pens'd. <i>Spec.</i> 892.
				85	McKenny, W. W., Corp., F, 134th N. Y., age 21.	May 8, June 9, 1864.	Right; ant. post. flaps; by Dr. A. D. White; (May Feb. excision of radius.) Pens'd Feb. 9, 1865.
				86	Miller, H., Pt., I, 2d Md., age 26.	June 20, July 20, 1864.	Left; circ.; by A. A. Surg. B. D. Miles; (necrosis.) Disch'd Dec. 14, 1864; pensioned.
				87	Millet, A. F., Pt., A, 17th Mich., age 27.	Mar. 31, May 5, 1865.	Left; circular; by A. A. Surg. H. Craft; (erysip.; gang.) June 24, sequestrum removed. Disch'd July 26, '65; pens'd. <i>Spec.</i> 142.

<sup>1</sup> This case is identical with CASE 35, on page 470, in TABLE XLV, of *Amputation in the Upper Arm for Complications of Shot Injury unattended by Fracture*. It is again inserted here because some of the reports intimate that there was contusion of bone as well as of the soft parts. Assistant Surgeon H. ALLEN, U. S. A., reports from Mt. Pleasant Hospital, April 2d, that nearly two-thirds of the integument on the outer and anterior parts of the forearm had been destroyed by pblegmonous crysipelas, and that about May 1st hospital gangrene supervened and made rapid progress above the bend of the elbow, destroying integument and muscles, exposing the brachial, and destroying the continuity of the radial, recurrent from which copious bleeding took place. After amputation the wound took on bad action and was treated by applications of bromine and creosote. Necrosis of the humerus ensued, and on July 2d a tubular sequestrum three and a half inches in the extreme length was extracted, and contributed to the Museum by Dr. ALLEN as *Specimen* 142. It is represented by the upper left-hand figure in PLATE XLVII, opposite page 762. The patient was discharged and pensioned, July 26, 1865. Examiner C. Rynd certified, on May 7, 1873: "The cicatrix is still tender, and will necessitate another amputation, which I have advised. There is about five inches of the upper end of the humerus remaining, which is painful and comparatively useless to him, &c." The pensioner was paid on June 4, 1875.



No.	NAME, AGE, AND MILITARY DESCRIPTION.	DATES.	OPERATIONS, OPERATOR, RESULT.	No.	NAME, AGE, AND MILITARY DESCRIPTION.	DATES.	OPERATIONS, OPERATOR, RESULT.
88	Miner, J. M., Pt., D, 6th Wisconsin.	Aug. 26, '62	Right; circular. Discharged Dec. 1, 1862.	109	Smith, O. D., Corp'l, E, 30th Ohio, age 29.	June 27, Aug. 16, 1864.	Left; ant.-post. flaps; by Professor Hamilton; (June 27, ex. of three inches of ulna; gangrenous.) Disch'd April 17, '65; pensioned.
89	Murphy, R., Pt., F, 81st Penn., age 35.	Dec. 13, '62 Jan. 13, 1863.	Left; flap; by A. A. Surgeon J. Stearns; necro. V. R. C. Dec. 31, '63. M'd out J'e 29, '66. Spec. 996.	110	Snyder, C. H., Corp'l, C, 150th Penn., age 28.	July 3, Aug. 5, 1863.	Right; flap; by A. A. Surg. D. Hamilton; (also w'd of thorax.) Disch'd Feb. 13, 1864; pens'd.
90	Murphy, T., Pt., I, 88th New York, age 21.	Dec. 13, '62 Jan. 24, 1863.	Right; by Surg. W. Clendenin, U. S. V. To V. R. C. Aug. 23, 1863. Discharged; pensioned.	111	Southwick, H. K., Pt., 1, 3d Wisconsin, age 25.	May 15, June 15, 1864.	Left; circ.; by A. Surgeon M. C. Woodworth, U. S. V. Disch'd March 24, 1865; pensioned.
91	Naskow, C., Pt., I, 98th New York.	May 31, July 4, '62	Left; circular. Discharged; pensioned.	112	Stewart, S. C., Pt., I, 2d Maine.	July 21, Aug. 28, 1861.	Left; circular; by Surg. J. W. S. Gouley, U. S. A.; (erysip.) Dis'd Sept. 21, 1861; pensioned. Died Jan. 3, 1869. Spec. 350.
92	Nelson, P., Corp'l, K, 135th Pa., age 19.	May 5, June 11, 1864.	Left; circ.; by A. A. Surg. D. P. Wellhauper. Disch'd July 27, 1865; pens'd. Spec. 2586.	113	Stewart, J. A., Pt., A, 61st Penn., age 25.	May 12, June 27, 1864.	Left; ant.-post. flap; by Surg. D. W. Bliss, U. S. V.; (May 12, rem'l bones of hand; erysip.; also amp. finger, right hand.) Discharged March 16, 1863; pensioned.
93	Newcomb, W. J., Corp'l, K, 1st Michigan.	Aug. 30, 1862, April 3, 1863.	Left; flap; by Surg. T. R. Crosby, U. S. V.; (Sept. 3, '62, amp. forearm; necrosis.) Disch'd June 9, '63; pens'd. Specs. 1175, 1176.	114	Strain, N., Serg't, C, 9th V. R. C., age 28.	July 11, 1864. Feb. 15, 1865.	Left; circ.; by A. A. Surg. C. E. C. Darby; (haem.; erysip.; gang.) Disch'd July 27, 1865; pens'd. Specs. 3785, 3727.
94	Noonan, J., Pt., C, 81st New York.	July 1, 1864.	Left; flap; by A. A. Surg. H. B. White; (haem.; lig. radial July 15.) Discharged Feb. 11, 1865.	115	Sullivan, J. O., Pt., II, 73d New York.	May 5, J'e 5, '62.	Left; circ. To V. R. C. Disch'd July 26, '64. Died Oct. 11, 1866.
95	O'Dryan, M., Pt., 169th New York, age 24.	June 30, Aug. 2, 1864.	Right; by Dr. Sinclair; (May 10, 1864, exc. ulna.) Disch'd Aug. 24, 1864; pensioned.	116	Taylor, D., Pt., II, 75th New York.	May 27, Jul. 14, '63	Right. Discharged Aug. 25, '63; pensioned.
96	Patterson, J. A., Pt., G, 11th Pennsylvania Reserves, age 41.	My 10, '64 Oct. 15, 1866.	Right; by Dr. Sinclair; (May 10, 1864, exc. ulna.) Disch'd Aug. 24, 1864; pensioned.	117	Till, W. A., Pt., A, 23d Ohio.	Sept. 17, Oct. 24, '62	Right; flap; by A. A. Surg. E. Pulling. Disch'd Dec. 11, 1862; pensioned.
97	Pepper, E., Pt., 18th U. S. Infantry, age 35.	Dec. 31, 1862, Feb. 12, 1863.	Right; ant.-post. flap; by Surg. J. Shady, 2d Tenn.; (haem's; brachial lig. Jan. 10; necrosis.) Discharged April 21, 1863; pens'd.	118	Travers, W. H., Pt., K, 128th New York, age 24.	Sept. 19, Dec. 6, 1864.	Left; circ.; by A. A. Surg. M. B. McCausland. Disch'd Feb. 3, '65; pensioned. Specs. 1575, 3913.
98	Peterson, J., Serg't, F, 5th Kentucky.	June 24, Sept. 17, 1863.	Right; circular; by A. Surg. J. K. Baudrey, U. S. V. Discharged Nov. 27, 1863; pensioned.	119	Turrell, J. D., II, 1st Michigan Cav.	Aug. 29, Oct. 2, 1862.	Right; flap; by A. A. Surg. A. E. Keyes. Disch'd Dec. 5, 1862; pensioned. Spec. 907.
99	Peterson, P., Pt., I, 5th Wisconsin, age 48.	April 6, May 14, 1865.	Left; ant.-post. flap; by A. A. Surg. B. B. Miles; (caries.) Disch'd June 19, 1865.	120	Vanhorn, C., Pt., II, 16th Michigan.	Aug. 30, Oct. 21, 1862.	Left; circ.; by A. A. Surg. C. A. McCall, U. S. A.; (caries.) Discharged Feb. 23, 1863; pens'd. Spec. 331.
100	Ramey, J., Corp'l, A, 70th Ohio.	April 6, M Y 8, '62.	Left; by A. A. Surg. J. C. Hughes. Disch'd Aug. 8, 1862; pensioned.	121	Vickers, J., Pt., B, 4th Ohio, age 44.	Aug. 25, Oct. 12, 1864.	Left; circ.; by A. A. Surg. T. F. Belton; (gangrene.) Discharged May 6, 1865; pens'd. Spec. 412.
101	Reiley, P., Serg't, F, 96th Pennsylvania.	May 10, 1864.	Right; circ.; by Dr. G. L. Pancoast; (June 10, '64, amp. forearm.) Disch'd April 12, '65; pensioned.	122	Wagoner, J., Pt., B, 11th Pa. Res., age 19.	June 30, Sept. 14, 1862.	Left; by A. A. Surg. E. G. Waters; (Aug. 20, excision of ulna; necrosis.) Disch'd Nov. 29, 1862; pensioned. Spec. 427.
102	Rose, J., Pt., B, 6th Tenn. Mt. Inf., age 28.	Mar. 24, April 25, 1865.	Right; circ.; by A. A. Surg. J. W. Taylor; (gangrene; March 31, amp. forearm.) Disch'd June 20, 1865; pensioned.	123	Weleh, J. O., Pt., D, 9th Maine.	May 20, J'e 30, '64.	Left; by Dr. Leavitt. Disch'd Dec. 16, 1864; pensioned.
103	Schwartz, N., Pt., F, 5th Michigan.	May 3, July 2, '63	Right. Discharged November 11, 1863; pensioned.	124	Whitely, W. B., Pt., II, 35th Mo., age 25.	No. 30, '64, Jan. 2, 1865.	Left; ant.-posterior flap; by Surg. Brist, C. S. A. To Provost Marshal April 2, 1865.
104	Scott, N. W., Pt., F, 23d Miss., age 24.	No. 30, '61 Jan. 23, '65	Left; circ.; by A. A. Surg. R. McNulty. To P. Mar. Mar. 7, 1865.	125	Wilson, T. R., Pt., M, 3d Ill. Cav., age 32.	Aug. 25, Oct. 23, 1863.	Left; flap; by A. A. Surg. H. K. Hendee. Duty Feb. 25, 1864. Mustered out October 29, 1864.
105	Sharp, J. A., Pt., A, 3d New Jersey.	June 27, Sept. 22, 1862.	Right; double flap; by A. A. Surg. J. Neill. (June 27, exc. elb.) Dis'd Jan. 5, '63; pens'd. Spec. 225.	126	Yeldon, A., Pt., A, 28th Mass., age 22.	Mar. 25, Ap. 28, '65	Right; flap; by A. A. Surg. T. E. Marsh. Discharged Sept. 22, 1865.
106	Simonson, F., Pt., B, N. Y. H. A., age 19.	July 18, Jul. 22, '64	Right; circ.; by A. A. Surg. W. C. Fryer; (gang.) Dis'd June 15, '65.	127	Young, E. F., Pt., D, 59th Ill., age 20.	De. 16, '64 Mar. 31, 1867.	Right; by Dr. J. Pogen; (excis. humerus Dec. 17.) Discharged July 12, 1865; pensioned.
107	Sipel, P., Serg't, 2d U. S. Infantry.	July 3, Aug. 15, 1863.	Left; skin flaps and circ. sec'n of muscle; by Surg. C. W. Jones, U. S. V.; Nov. 23, necrosed bone removed; hemorrhage. To duty July 30, 1864; pensioned.				
108	Smith, A. J., Pt., F, 49th Tenn., age 23.	Nov. 30, Feb. 11, 1865.	Left; oval flap; by Surg. J. H. Brinton, U. S. V.; (carious.) Released April 13, 1865.				

§ *Fatal Cases.*—Thirty-five fatal secondary amputations of the arm at the middle third were practised—on the right side in eighteen, and on the left in seventeen instances. Twelve of the patients were in an unfavorable condition, having undergone previous operations, viz: Amputation of the forearm in two instances, of the hand in one, excision of the elbow joint in two, excision in the radius and ulna in five cases, ligation of the subclavian in one case, and of the brachial artery in one. Subsequently to amputation at midarm a tubular sequestrum five inches long was extracted in one case, and in another exarticulation at the shoulder was practised. In the course of the treatment there were eleven instances of consecutive bleeding, one of erysipelas, four of gangrene, and eleven of pyæmia.

CASE 1701.—Lieutenant J. S. DeCamp, Co. C, 14th New York Cavalry, aged 24 years, was wounded near Alexandria, La., April 27, 1864, and entered St. James Hospital, New Orleans, on May 2d. Assistant Surgeon P. S. Conner, U. S. A., reported: "Gunshot wound of right elbow. The parts about the joint became much swollen and the suppuration profuse. On June 6th, circular amputation at the middle third of the humerus was performed by Assistant Surgeon P. S. Conner, U. S. A. Chloroform was used. The patient's constitutional condition was fair at the time of the operation, and better than it had been during the preceding two weeks. Upon examination of the amputated arm, it was found the ball had split off into the condyle of the humerus and opened the joint. The case progressed very favorably. June 29th, patient is walking about and has good appetite. He was transferred on July 10th." Surgeon A. Hammer, U. S. V., reported his admission to the Marine Hospital, St. Louis,

on July 17th, and his condition as follows: "Stump in a high degree of inflammation and suppuration; patient quite feeble, and unable to sleep from pain in wound. On July 18th, a counter-opening was made near the shoulder joint, and about thirty-six ounces of pus were evacuated. Dressings with Labarraque's solution were applied, and quinine, morphia, and stimulants were given. The patient died, of phlegmonous inflammation of the stump and axilla, on July 26, 1864."

CASE 1702.—Private G. S. Hicks, Co. A, 12th New York, aged 40 years, was wounded at Bull Run, August 30, 1862, and admitted to Mount Pleasant Hospital, Washington, on the following day. Assistant Surgeon C. A. McCall, U. S. A., contributed the specimen (FIG. 557), with the following notes of the case: "Compound comminuted fracture of right ulna; operation on October 2d; death on October 8, 1862. The treatment was cold-water dressings to the parts, with tonics and stimulants constitutionally, it being attempted to save the limb. But extensive inflammation set in, with profuse discharge, rendering amputation necessary. Teale's operation was performed. The patient, whose strength had been greatly reduced by the profuse suppuration, began to fail rapidly, and died, six days after the operation, of pyæmia." The specimen consists of "the upper halves of the bones of the right forearm and the lowest third of the humerus; the ulna was shattered throughout the upper third of the shaft and the fragments necrosed."—(*Cat. Surg. Sect.*, 1866, p. 189.)

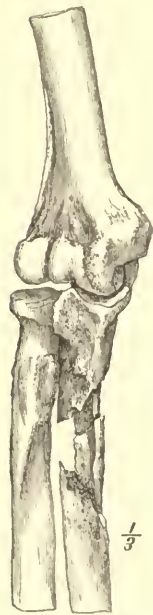

FIG. 557.—Shot comminution of ulna, after amputation. *Spec.* 166.

CASE 1703.—Corporal J. B. Rogers, Co. K, 57th Massachusetts, aged 30 years, was wounded at Petersburg, June 17, 1864, and admitted to the field hospital of the 1st division, Ninth Corps. Surgeon M. K. Hogan, U. S. V., noted: "Wound of left hand by minie ball; amputation of second finger, and removal of last two fingers with excision of last two metacarpal bones." On June 24th, the patient entered Emory Hospital at Washington, where the arm was amputated on July 19th. Acting Assistant Surgeon E. B. Harris forwarded the pathological specimen (FIG. 558), consisting of "the lower extremities of the bones of the forearm, the scaphoid, semilunar, cuneiform, trapezium, trapezoid, and the first two metacarpals, showing the bones entering the articulation to be carious." The remainder of the bones of the hand had been removed on the field. The following description of the case was transmitted with the specimen: "From the effects of disease of the soft parts it was found best to remove the limb at the middle third of the arm. Death resulted on the morning of July 26, 1864." The stump of the amputated limb was also contributed to the Museum (*Cat. Surg. Sect.*, 1866, p. 136, *Spec.* 2894) by Dr. Harris, who described the *post-mortem* appearances as follows: "No union of flaps save a slight degree of granulation at the bottom of the wound; soft parts around the bone remaining healthy, with an appearance of general inactivity of the muscular tissues; the medullary substance of a dark grumous character and showing evidence of disease."

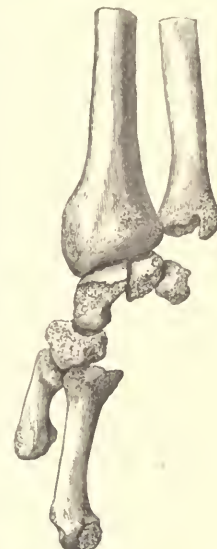

FIG. 558.—Necrosis after shot perforation of the carpus. *Spec.* 2852.

*Remarks.*—Nine of the cases of the above group are represented in the Museum by pathological preparations. Two are figured above (FIGS. 556, 557). *Spec.* 2894 belongs to CASE 1701, and is the upper half of the humerus, showing the effects of osteitis. *Spec.* 443 is a necrosed stump of the humerus a month after amputation. *Specs.* 2810 and 3497 are preparations of the bones of the forearm, showing extensive excisions in the shafts of the radius and ulna. *Spec.* 64 is a beautiful preparation of the upper portions of the left ulna and radius seven months after amputation—the extremities greatly developed by osteoporosis. *Spec.* 399 represents a shot fracture above the condyles without much comminution. *Spec.* 3103, carries after shot fracture of the upper thirds of the left radius and ulna. In the case of Thompson (No. 33 of the Table), Dr. S. Teats reports that "numerous metastatic foci in the lungs were found at the autopsy."

TABLE LXXXVII.

Condensed Summary of Thirty-five Unsuccessful Cases of Secondary Amputations in the Middle Third of the Arm.

NO.	NAME, AGE, AND MILITARY DESCRIPTION.	DATES.	OPERATIONS, OPERATOR, RESULT.	NO.	NAME, AGE, AND MILITARY DESCRIPTION.	DATES.	OPERATIONS, OPERATOR, RESULT.
1	Allen, C. W., Corp'l, K, 8th Conn., age 21.	May 16, June 27, 1864.	Right; ant.-post. flap; by A. Surg. B. R. Brown, U. S. V. Died July 7, 1864, exhaustion.	8	Eastwood, J. H., Pt., D, 24th N. Y. Cav., age 45.	June 18, Aug. 17, 1864.	Left; circ.; by A. A. Surg. J. H. Thompson. Died Aug. 22, 1864, exhaustion. <i>Spec.</i> 3103.
2	Andrews, G., Serg't, F, 69th Ohio, age 25.	Sept. 1, Oct. 17, '64.	Right; circular; (ulna necrosed.) Died November 12, 1864.	9	Eddy, E. S., Pt., K, 95th Pennsylvania.	June 27, Jul. 30, '62	Right; (necrosis.) Died August 1, 1862. <i>Spec.</i> 399.
3	Borden, J. W., Pt., D, 31st Maine, age 25.	June 18, Aug. 1, 1864.	Right; circ.; by A. A. Surg. B. F. Butcher; (gangrene.) Died Aug. 2, 1864, exhaustion.	10	Findall, C. H., Pt., D, 3d Delaware, age 23.	June 18, Sept. 1, 1864.	Left; circ.; by A. A. Surg. A. N. Brookway. Died September 21, 1864, pyæmia.
4	Bose, W., Pt., H, 17th N. Y., age 27.	Sept. 1, Nov. 6, '64	Right; circular; by A. A. Surg. L. Sinclair. Died Dec. 6, '64, pyæmia.	11	Fitzgerald, M., Pt., B, 14th N. Y., age 20.	May 16, June 16, 1864.	Left; circ.; by Surg. A. P. Frick, 103d Pa.; (June 11, hæm.) Died June 19, '64, hæm'ge and shock.
5	Boyd, R., Pt., K, 47th N. Y., age 20.	Oct. 7, Dec. 7, '64	Right; circ.; by A. A. Surg. S. D. Farrell. Died Dec. 19, '64, pyæmia.	12	Foley, M., Pt., D, 42d Indiana, age 44.	May 15, July 1, '64	Left. Died July 18, '64, chronic diarrhœa.
6	De Camp, J. S., Lieut., C, 14th N. Y. Cav.	April 28, June 6, 1864.	Right; circular; by A. Surg. P. S. Conner, U. S. A. Died July 26, 1864, phlegmonous inflammation.	13	Greenough, F., Pt., C, 7th N. H., age 18.	Jan. 3, '65.	Right; (hæm.; necrosis.) Disch'd Sept. 11, '65. Died Sept. 22, '65.
7	Dickinson, N. S., Pt., C, 25th Mass., age 27.	June 3, July 21, 1864.	Left; circ.; by A. A. Surg. T. H. Snow; (July 2, exc. elb. joint; July 31, gangrene. Died Aug. 7, 1864; exhaustion.	14	Harrison, D., Pt., D, 94th Ohio, age 34.	May 14, June 24, 1864.	Right; ant.-posterior flap; by A. A. Surg. H. C. May; (June 17, lig. radial and exc. radius; June 24, hæm.) Died July 2, '64. <i>Spec.</i> 3497.



No.	NAME, AGE, AND MILITARY DESCRIPTION.	DATES.	OPERATIONS, OPERATOR, RESULT.	No.	NAME, AGE, AND MILITARY DESCRIPTION.	DATES.	OPERATIONS, OPERATOR, RESULT.
15	Heatherly, J., Pt., E, 11th W. Va., age 35.	Oct. 28, 1864, Jan. 4, 1865.	Left; circular; by A. Surg. W. A. Banks, U. S. V.; (Oct. 29, excis. radius and ulna; hæmorrhgs; lig. brach.) Died Jan. 24, '65, pyæm.	25	Miller, G., Pt., I, 93d Ohio, age 27.	June 5, Jul. 12, '64	Right; circ.; by Surg. S. E. Fuller, U. S. V. Died Jul. 28, '64, ch. dar.
16	Henry, A., Pt., I, 143d N. Y., age 31.	Aug. 25, Sept. 25, 1864.	Right; flap; by Surg. A. Chapel, U. S. V.; (Aug. 25, amp. forearm.) Died Oct. 9, 1864, exhaustion.	26	Neill, T., Pt., D, 16th Miss., age 38.	Au. 21, '64	Left; circ.; by A. A. Surg. N. A. Robbins; (Aug. 22, amp. forearm.) Died Apr. 18, '65, pyæm. <i>Spec. 64.</i>
17	Hicks, G. S., Pt., A, 13th N. Y., age 40.	Aug. 30, Oct. 2, 1862.	Right; rectangular flaps; by A. Surg. C. A. McCall, U. S. A. Died Oct. 8, 1862, pyæmia. <i>Spec. 166.</i>	27	Phillips, J., Pt., E, 3d Md. Cav., age 26.	April 12, 1865, Mar. 4, May 27, 1864.	Left; circ.; by A. A. Surg. R. W. W. Carroll; (March 4, excis. radius; hæmorrhages.) Died May 16, 1865, exhaustion.
18	Hobbs, J. M., Pt., K, 32d Texas.	Mar. 28, April 29, 1865.	Left; circ.; by Surg. C. H. Mastin, C. S. A.; July 10, sequestrum removed. Died Aug. 3, '65, pyæm.	28	Richardson O. B., Serg't, E, 32d Maine, age 21.	June 3, July 15, 1864.	Right; by Dr. E. Russell; (hæmorrhage; July 5, lig. brachial.) Died from exhaustion.
19	Hoffman, A. J., Pt., E, 26th Iowa, age 55.	Jan. 11, Mar. 12, 1863.	Right; erysipelas; necrosis; May 10, amp. at shoulder joint. Died June 3, 1863, pyæmia.	29	Rogers, J. B., Corp'l, K, 57th Mass., age 30.	June 17, Jul. 19, '64	Left; (June 17, partial amp. hand.) Died July 26, 1864. <i>Specs. 2852, 2894.</i>
20	Howell, E., Pt., II, 9th Iowa Cav., age 20.	Sept. 6, Nov. 15, 1864.	Left; double flap; by A. Surg. L. Lyeon, 54th Ill.; (Nov. 15, hæm.) Died Dec. 14, 1864, exhaustion.	30	Sawtell, W., Pt., F, 25th Mass., age 33.	May 14, J'e 19, '64.	Left; circ.; by A. A. Surg. J. Money-penny. Died July 26, 1864, exhaustion.
21	Isherwood, J., Pt., E, 4th Delaware, age 60.	June 18, Aug. 21, 1864.	Right; circ.; by A. A. Surg. J. A. McArthur. Died Oct. 1, 1864, inflammation of the brain.	31	Smith, A. H., Pt., F, 25th Iowa, age 30.	Jan. 11, M'h 12, '63	Right; (sec. hæm.; lig. subelav.) hæm. Died April 14, 1863, exhaustion.
22	Jones, W., Pt., G, 77th Penn., age 32.	Aug. 5, Nov. 14, 1864.	Left; circ.; by A. A. Surg. L. Sinclair; (Sept. 10, excis. radius.) Died January 7, 1865.	32	Smith, J., Pt., B, 24th Ill., age 34.	Sept. 20, Oct. 28, '63	Left; flap. Died October 29, '63.
23	Kelley, J., Pt., G, 95th New York, age 19.	May 10, June 13, 1864.	Left; flap; by A. A. Surg. E. De Witt; (June 13, hæmorrhage.) Died June 19, 1864, pyæmia.	33	Thompson, A., Pt., A, 100th Penn., age 19.	Sept. 14, Oct. 16, 1862.	Right; circ.; by A. A. Surg. S. Teats; Oct. 17, hæmorrhage. Died Nov. 1, 1862, pyæmia.
24	McCready, J. S., Capt., II, 126th Ohio, age 35.	May 10, July 6, 1864.	Left; flap; by Surg. N. R. Moseley; (hæm's; May 20, lig. radial; ulna excised; hæmorr's and necrosis.) Died Sept. 7, 1864. <i>Spec. 2810.</i>	34	Van Dyke, J., Pt., K, 107th N. Y., age 24.	July 3, Aug. 24, 1863.	Right; circ.; by A. A. Surg. E. Martin; (July 4, exc. ulna.) Died Sept. 12, '63, hæc. fever. <i>Spec. 443.</i>
				35	Wyatt, L. D., Pt., I, 24th Missouri.	April 9, May 16, 1864.	Left; ant.-post. flap; by A. A. Surg. S. S. Jessop. Died June 2, 1864, pyæmia.

**3. Secondary Amputations of the Arm at the Lower Third.**—There were sixty-one operations in this group with a fatality of 39.3. Two of the patients were Confederates. Twenty-five of the patients had undergone antecedent operations.

§ *Successful Cases.*—There were thirty-seven recoveries after secondary amputations at the lower third,—the left limb was involved in twenty-four, and the right in thirteen instances. One of the patients suffered also from a serious flesh wound of the thigh, and eighteen had already submitted to operative interference.<sup>1</sup> There were no ulterior operations except torsion, or deligation of small arteries on the face of some of the stumps. Nine cases were complicated by consecutive bleeding, ten by sloughing, and five by erysipelas.

CASE 1704.—Private Isaac Martz, Co. B, 184th Pennsylvania, aged 39 years, was wounded at Cold Harbor, June 3, 1864. A conoidal ball shattered the middle phalanx of the right middle finger, which was disarticulated at the second joint at a Second Corps hospital. Surgeon T. R. Spencer, U. S. V., reported the patient's admission to an Alexandria hospital on June 7th, and his transfer to Pennsylvania a few days subsequently. Acting Assistant Surgeon J. G. F. Strowbridge recorded the patient's admission to the hospital at Chester, Pennsylvania, on June 12th, with diffuse suppuration of the palm of the hand following an amputation of the middle finger, with much sloughing of the connective tissue and tendons. The metacarpals had become carious, and on June 30th amputation of the lower third of the forearm by circular incision was performed by Dr. Strowbridge. The external appearances of the parts removed are shown in the wood-cut (FIG. 559), drawn from the wet preparation contributed by the operator. Dr. Strowbridge adds that the case progressed favorably for a month, but this report is not confirmed by the subsequent history of the case. Acting Assistant Surgeon G. S. Stein reported, when he took charge the succeeding month, that "the whole stump was in a diseased state, and the radius and ulna necrosed in their entire extent." Excessive swelling, with purulent infiltration of the soft parts of the forearm, was not relieved by incisions and fomentations, and it was finally decided to re-amputate the limb in the continuity of the upper arm. The amputation at the lower third of the arm by circular incision was performed April 4, 1865, by Dr. Stein. The parts removed were contributed to the Museum, and present a striking illustration of the results of destructive osteomyelitis after amputation.

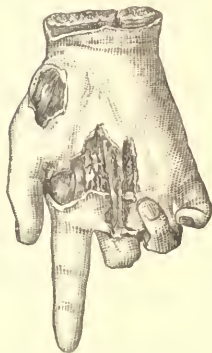

FIG. 559.—Hand disorganized after amputation of the middle finger for shot fracture. *Spec. 551.*

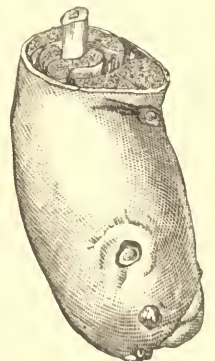
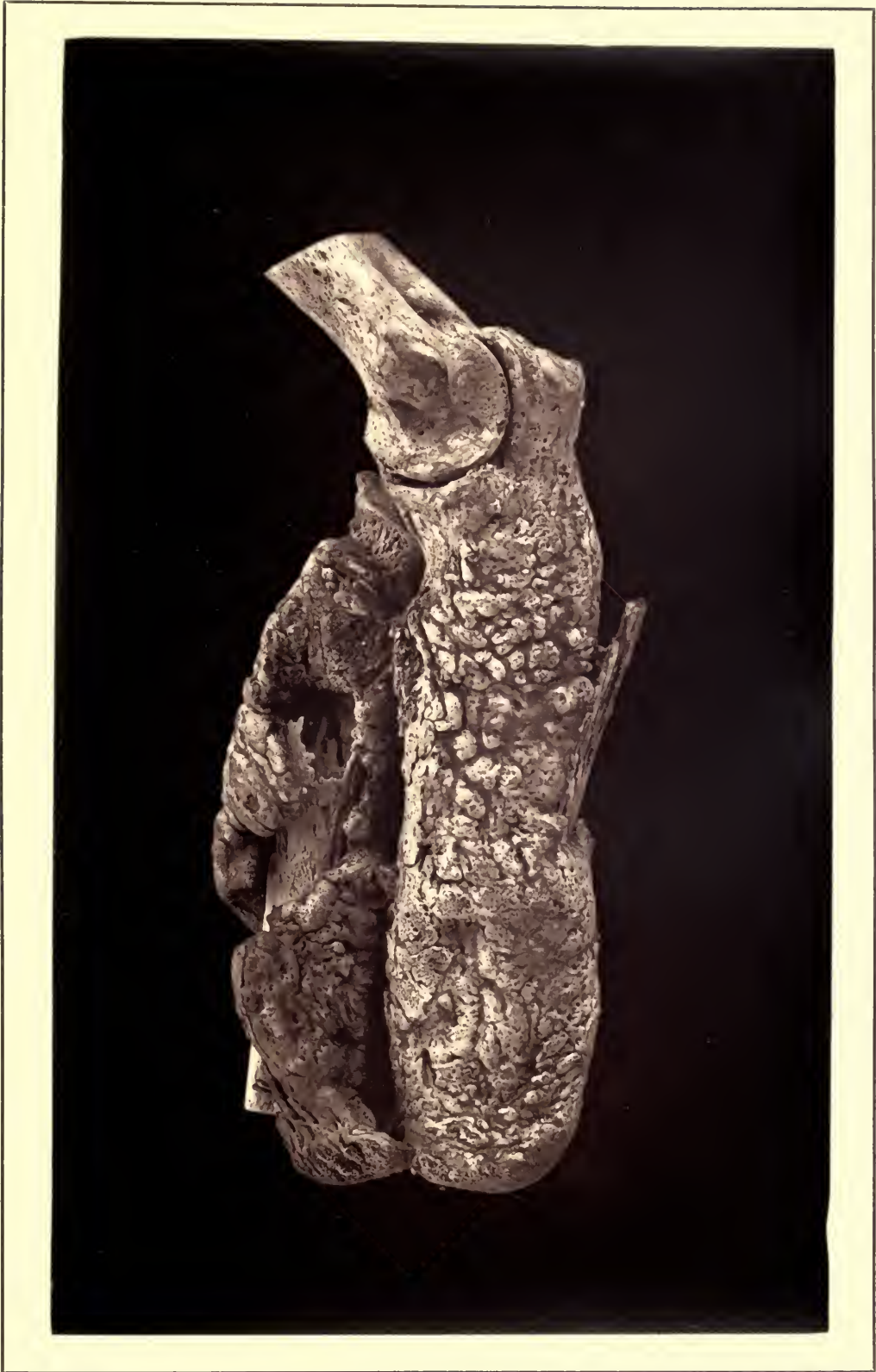

FIG. 560.—Stump of forearm, from a re-amputation for osteomyelitis. *Spec. 2672.*

The soft tissues of the stump of the forearm, represented in the wood cut (FIG. 560), are preserved as a wet preparation. The bones are represented in PLATE XLIV, opposite. What remained of the shafts of the radius and ulna has perished and is sur-

<sup>1</sup>As follows: Five had undergone amputation of the forearm; four, amputations of fingers or portions of hand; excision of the elbow joint had been practised in 2 cases; excision in the shaft of the humerus in 1 case; excision in the radius or ulna in 4 cases; ligation of the brachial artery in 2 cases.



Ward phot.

Am. Photo-Relief Printing Co., Philada.

PLATE XLIV. NECROSIS OF THE RIGHT RADIUS AND ULNA.

No. 4170. SURGICAL SECTION.





rounded by huge involucra. There is a slight erosion of the cartilages of the head of the radius, but not much other evidence of disease of the structures of the joint. This soldier was discharged from service June 26, 1865, and pensioned. He was paid September 4, 1875.

CASE 1705.—Sergeant C. J. G——, Co. D, 16th New York, age 21 years, was wounded at South Mountain, September 14, 1862. He was sent from a Sixth Corps field station to the hospital at Burkettsville, where Surgeon Henry Jones, 3d Vermont, reported that "a musket ball had entered just behind the head of the left radius, and, passing downward and forward, emerged near the middle of the forearm, having comminuted the ulna for two inches beyond the joint. It was determined to save the limb if possible; but the patient became so weak from the profuse discharge, and the arm remaining too much swollen to admit of resection, and a large abscess having formed about the joint, it became necessary to amputate the arm, which was done on November 14, 1862, and the patient was a few days afterward sent to Frederick." Assistant Surgeon T. G. MacKenzie, U. S. A., reported his admission to Camp B hospital, his favorable convalescence, and his discharge from service March 5, 1863. The pathological specimen, represented in the adjacent wood-cut (FIG. 561), was contributed to the Museum by the operator, Dr. Jones. Gardiner was pensioned, and supplied with an artificial limb by Mr. Lincoln. This pensioner was in good health in June, 1875.

CASE 1706.—Charles R——, a substitute, aged 20 years, was wounded at Philadelphia, October 17, 1863. While attempting to escape, he was fired upon by the sentinel. He was removed to the Broad and Cherry Streets Hospital, whence Acting Assistant Surgeon W. V. Keating reported: "The ball entered on the inner side of the left forearm at the upper third, passed obliquely across and slightly downward, and came out on the radial side in the middle third, fracturing the radius in its course and injuring the radial artery. The wound was a severe one and the radius was greatly comminuted. The patient was apparently in very good condition, though his system was probably somewhat reduced from too free indulgence in alcoholic stimulants; pulse and secretions normal. Acting Assistant Surgeon A. Hewson made an incision two inches long and ligated the brachial artery at its middle third; about twelve ounces of blood was lost. The patient did well for a day or two, when considerable constitutional disturbance became manifest, and, by October 21st, the wound produced by the ball had sloughed extensively. October 31st, a slight oozing hemorrhage occurred at wound of ligation, which was controlled by the tourniquet. The sloughing ceased about November 7th, and the wound commenced granulating and healed very rapidly, the constitutional condition of the patient at the same time improving greatly. By December 6th the wound had nearly granulated over, but there was still some discharge from the point of exit of the ball. His system generally was in pretty good condition. The wound, however, again took on unhealthy action, necrosis set in, and on January 7, 1864, amputation of the left arm, at the lower third, was performed by Acting Assistant Surgeon E. Livezey." The patient recovered, and was discharged from service November 28, 1864.

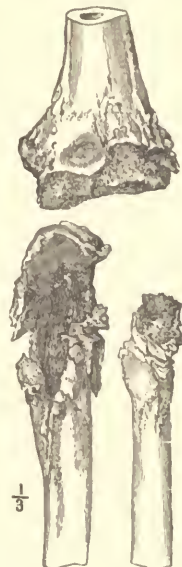

FIG. 561.—Shot comminution of upper ends of ulna and radius. Spec. 775.

TABLE LXXXVIII.

Condensed Summary of Thirty-seven Cases of Recovery after Secondary Amputation in the Lower Third of the Arm.

NO.	NAME, AGE, AND MILITARY DESCRIPTION.	DATES.	OPERATIONS, OPERATOR, RESULT.	NO.	NAME, AGE, AND MILITARY DESCRIPTION.	DATES.	OPERATIONS, OPERATOR, RESULT.
1	Allard, P., Pt., F, 17th Vermont, age 43.	May 18, Jul. 30, '64	Right; (exc. May 18; gang.; hæm.) Disch'd Dec. 21, 1864; pens'd.	13	Gannon, J., Pt., D, 126th Ohio, age 42.	Sept. 22, Nov. 7, 1864	Left; flap; by A. A. Surg. C. W. Stinson; (exc. Sept. 22.) Disch'd June 23, 1865; pensioned.
2	Ashford, J., Pt., B, 17th Kentucky, age 22.	June 18, Oct. 1, 1864.	Right; circ.; by Surg. J. R. Ludlow, U.S.V.; (exc. June 18.) Discharged Mar. 25, 1865; pens'd.	14	Gardiner, C. J., Pt., D, 16th N. Y., age 21.	Sept. 14, Nov. 14, 1862.	Left; circ.; by Surg. H. Jones, 3d Vermont. Discharged March 5, 1863; pensioned. Spec. 775.
3	Burns, W. W., Pt., E, 91st Penn., age 28.	June 18, Sept. 30, 1864.	Right; circ.; by A. A. Surg. G. P. Sargent; (amp. finger June 18; amp. forearm Aug. 1.) Disch'd July 31, 1865; pensioned.	15	Glancey, F., Pt., G, 12th New Hampshire, age 21.	June 29, Aug. 18, 1864.	Left; by A. A. Surg. T. W. Leibold; (amp. forearm June 29; hæm.) Dis'd Dec. 29, '64; pens'd.
4	Butler, J., Pt., C, 22d Iowa.	May 22, June 29, 1863.	Right; (amp. finger May 22; phlegmonous erysipelas.) Died Sept. 9, '65, typhoid fever. Spec. 1708.	16	Hackett, G., Lieut., A, 10th N. Y., age 20.	May 6, July 9, 1864.	Right; by A. A. Surg. J. W. Folie; (exc. May 6, '64; gang.) Disch'd May 26, 1865; pens'd.
5	Centre, S., Pt., B, 3d Vermont, age 28.	June 3, July 25, 1864.	Right; circ.; by A. A. Surg. W. R. Stavelly; (erysip.; necro.) Disch'd Feb. 2, '65; pens'd. Spec. 3616.	17	Hendricks, S. J., Pt., A, 183d Penn., age 19.	May 7, Aug. 25, 1864.	Left; circ.; by A. A. Surg. S. A. Cummins; (amp. finger May 7.) Pens'd Dec. 12, 1864; Spec. 3617.
6	Clark, G. D., Pt., K, 140th N. Y., age 23.	May 5, Sept. 16, 1864.	Left; flap; by A. A. Surg. D. F. Elton; (erysip.; necro.) Disch'd Apr. 10, '65; pens'd. Spec. 3623.	18	Hutton, W. McL., Pt., H, 147th Illinois, age 32.	April 3, May 4, 1865.	Left; circ.; by A. A. Surg. S. A. Baxter; (gangrene.) Discharged Nov. 23, 1865; pensioned.
7	Coehran, G. R., Pt., G, 8th N. Y. P. A.	June 22, Au. 20, '64	Left; flap; by A. A. Surg. S. Smith. Disch'd Jan. 20, 1865; pens'd.	19	Johnson, J., Corp'l, F, 82d Col. Troops, age 30.	April 2, J'e 1, '65.	Right; flap; by A. A. Surg. J. C. Richards. Disch'd; pensioned.
8	Cosior, J. A., Private, D, 125th N. Y., age 30.	May 10, J'e 23, '61.	Left; circ.; by Dr. Thorn. Discharged Feb. 1, 1865; pens'd.	20	Jolly, J., Pt., E, 63d Penn., age 27.	Oct. 1, Dec. 19, 1864.	Left; flap; by A. A. Surg. E. B. Harris; (amp. forearm Oct. 1, '64; erysip.; gang.; symp. pyæmia.) Disch'd June 1, 1865; pensioned. Died Jan. 18, 1868.
9	Crisman, W., Pt., B, 24th Iowa.	April 8, May 13, 1864.	Left; double flap; by Surg. F. Bacon, U. S. V. Dis'd June 10, '64; pensioned.	21	Killan, C., Corp'l, H, 2d Michigan.	May 31, July 3, 1862.	Right; by A. A. Surg. T. B. Castle; (ex. June 1, '62, symp. pyæ.) Disch'd Aug. 15, 1862; pens'd.
10	Cullen, R. J., Serg't, F, 9th New Hampshire, age 22.	May 12, July 14, 1864.	Right; circ.; by A. A. Surg. G. E. Brickett; (gang.) Disch'd June 5, 1865; pensioned.	22	Martz, I., Corporal, B, 184th Penn., age 39.	J'e 5, '64, April 9, 1865.	Right; circ.; by A. A. Surg. G. S. Stein; (amp. finger June 5, and forearm June 26; hæm.; necro.) Disch'd June 26, 1865; pens'd. Spec. 551. 2672. 4170.
11	Fauccell, W. F., Pt., E, 13th North Carolina, age 22.	July 1, Se. 23, '63.	Left. Exchanged March 17, '64. Spec. 2073.				
12	Fritsche, W., Serg't, M, 12th Pa. Cav., age 24.	Mar. 21, May 11, 1865.	Left; circ.; by Surg. I. B. Lewis, U. S. V.; (hæm's; lig. brachial.) Disch'd June 27, 1865; pens'd.				



No.	NAME, AGE, AND MILITARY DESCRIPTION.	DATES.	OPERATIONS, OPERATOR, RESULT.	No.	NAME, AGE, AND MILITARY DESCRIPTION.	DATES.	OPERATIONS, OPERATOR, RESULT.
23	Mathews, B. W., Serg't, E, 47th North Carolina, age 28.	July 3, Oct. 25, 1863.	Left; circ.; by A. A. Surg. J. E. Steele; (erysip.; amp. forearm Aug. 30; erysipelas; necrosis.) To prison April 19, 1864.	30	Rease, C., Substitute for conscript, age 20.	Oct. 17, '63, Jan. 7, 1864.	Left; flap; by A. A. Surg. E. Livezey; (haem.; lig. brachial; necrosis.) Disch'd Nov. 28, 1864.
24	McCabe, J., Pt., F, 69th New York, age 40.	June 22, 1864, July 11, 1865.	Left; circ.; by A. Surg. S. H. Orton, U. S. A.; (exc. June 22, '64.) Disch'd Oct. 14, '65; pensioned.	31	Renville, N., Pt., K, 76th Illinois, age 17.	July 7, An. 24, '64.	Left; circ.; by Surg. J. Powell, 73d Ill. Disch'd Oct. 12, '64; pens'd.
25	McDaniel, S., Pt., F, 140th Penn., age 29.	May 12, June 27, 1864.	Right; circ.; by A. A. Surg. J. S. Newcombe. Disch'd Dec. 6, '64; pensioned.	32	Rosa, F., Pt., G, 24th Iowa.	May 16, An. 15, '63.	Right; circular; (amp. forearm May 16; gangrene.) Dis'd Sept. 16, 1863; pensioned.
26	Miller, J., Pt., D, 48th Penn., age 40.	May 12, June 15, 1864.	Left; circ.; by A. Surg. W. Webster, U. S. A. Disch'd March 15, 1865; pensioned.	33	Schmidt, G., Corp'l, E, 64th New York, age 31.	June 3, Aug. 30, 1864.	Left; circ.; by A. A. Surg. J. H. Thompson; (necrosis.) Disch'd Jan. 19, 1865. Spec. 3180.
27	Murphy, J., Pt., H, 162d New York, age 24.	Apr. 9, '64, Aug. 1, 1865.	Circ.; by A. Surg. S. H. Orton, U. S. A.; (necrosis;) gangrene. Discharged Nov. 7, 1865; pens'd.	34	Settell, R., Sergeant, E, 10th Michigan, age 26.	Feb. 25, June 14, 1864.	Left; circ.; by A. A. Surg. T. H. Hammond; (necrosis.) Disch'd May 12, 1865; pensioned.
28	Parsons, C., Corp'l, H, 32d Colored Troops, age 35.	Feb. 9, Mar. 21, 1865.	Circ.; by A. Surg. W. R. Way, U. S. V.; (hæmorrhage.) Disch'd June 5, 1865; pensioned.	35	Smith, R. A., Pt., B, 67th New York, age 45.	Feb. 27, '62, Feb. 22, 1863.	Right; double flap; by A. A. Surg. E. A. Smith; (excision June 27.) Disch'd April 14, 1863; pens'd.
29	Rapp, A. G., Serg't, H, 135th Pennsylvania.	Nov. 8, 1863, Second y.	Left; flap; by A. Surg. H. Allen, U. S. A.; (amp. forearm Nov. 8; gang.) Dis'd Apr. 12, '64; pens'd.	36	Sullivan, P., Pt., E, 11th Mass., age 40.	June 16, Sept. 19, 1864.	Left; ant.-post. flap; by A. A. Surg. A. C. Cobb; (necrosis.) Disch'd Mar. 16, '65; pens'd. Spec. 3329.
				37	Tennant, C., Pt., B, Pur-nell Legion, age 20.	Aug. 29, Sept. 24, 1864.	Left; flap; by A. A. Surg. B. B. Miles; (haem.; gang.) Disch'd April 28, 1865; pensioned.

Ten pathological specimens were preserved for the Museum from eight of the thirty-seven successful secondary amputations.<sup>1</sup>

§ *Fatal Cases.*—The twenty-four fatal secondary amputations of the arm at the lower third were equally divided between the two extremities. Thirteen were practised by the circular and eleven by flap methods. Seven patients had undergone previous operations.<sup>2</sup> Death was ascribed to pernicious fever in one case, to diarrhœa in four, to diphtheria in one, to exhaustion from profuse suppuration in seven, and to pyæmia in eleven cases. Four cases were complicated by secondary hæmorrhage, eight by gangrene, and three by erysipelas.

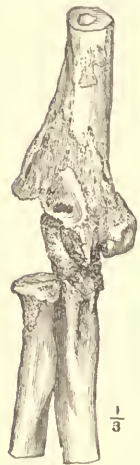

FIG. 562.—Lesion after shot fracture of the elbow. Spec. 2104.

CASE 1707.—Private A. J. Daniels, Co. F, 25th Illinois, was wounded at Mission Ridge, November 25, 1863, and admitted to the field hospital of the 1st division, Twentieth Corps. Surgeon L. D. Waterman, 39th Indiana, recorded: "Wound of arm; severe." On December 1st, the wounded man entered the general field hospital at Chattanooga, whence Acting Assistant Surgeon R. Bartholow, U. S. A., contributed the specimen (FIG. 562), with the following statement of the case: "Private Daniels was wounded while in the act of firing, the ball striking the inner condyle of the humerus and emerging two inches above. The wound became sloughy and unhealthy, the limb œdematous, and general health impaired. The arm was amputated, at the lower third, on January 17th. The patient died on January 26, 1864, with symptoms of pyæmia." The specimen consists of the right elbow, the outer condyle and greater portion of the trochlea being shot away, and the olecranon; the fractured extremity and the head of the radius carious and partially absorbed.

CASE 1708.—Private W. W. Hutton, Co. D, 16th New York, aged 23 years, was wounded in the left arm at South Mountain, September 14, 1862, and entered Hospital D, at Burkittsville, on October 1st. Surgeon H. Jones, 3d Vermont, contributed the specimen (FIG. 563), with the following report: "The ball entered the hollow of the elbow and passed through the joints, slightly fracturing the external condyle of the humerus. Considerable sloughing of the soft parts followed, and the patient became much exhausted by the discharge and an obstinate diarrhœa. On November 14th, amputation was performed at the lower third, it having been decided upon as giving the patient the best chance of life.

The operation had been delayed for several days on account of an erysipelatous inflammation of the arm. The patient died of exhaustion two hours after the operation." The specimen consists of the bones of the left elbow, showing the articular surfaces to be destroyed by caries.—(*Cat. Surg. Sect.*, 1863, p. 161.)

There were no autopsies referred to in this series; but twelve pathological specimens were preserved,<sup>3</sup> two of which are figured above. Several of the others, enumerated in the succeeding tabular statement, are well worthy of examination.

<sup>1</sup> Three are shown in FIGS. 559, 560, 561, and one in PLATE XLIV. The six others illustrate various alterations of the bones of the forearm after injury, and may be referred to in the Catalogue through the number in the Table.

<sup>2</sup> As follows: Amputation in forearm of same side in 1 case; disarticulation at wrist in 1; excision in radius in 1; amputations of portions of hand in 2; incision for extraction of ball in 1; ligation of interosseous artery in 1 case.

<sup>3</sup> Besides the two preparations figured in the text (FIGS. 562, 563) are two of destructive caries of the elbow, five of various alterations in the bones of the forearm, and three of lesions of the carpal and metacarpal bones.

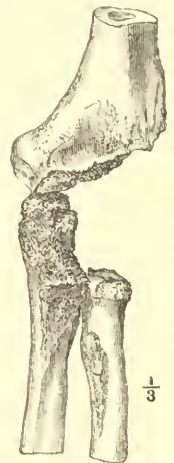

FIG. 563.—Caries after shot wound of elbow. Spec. 786.

TABLE LXXXIX.

Condensed Summary of Twenty-Four Unsuccessful Cases of Secondary Amputations in the Lower Third of the Arm.

NO.	NAME, AGE, AND MILITARY DESCRIPTION.	DATES.	OPERATIONS, OPERATOR, RESULT.	NO.	NAME, AGE, AND MILITARY DESCRIPTION.	DATES.	OPERATIONS, OPERATOR, RESULT.
1	Alltop, G. N., Pt., B, 7th West Virginia, age 22.	No. 27, '63 Jan. 5, 1864.	Left; flap; by Surg. S. N. Sherman, U.S.V.; (hem.; necrosis, erysip.) Died Jan. 21, 1864, pyæmia.	14	Knox, F. M., Pt., D, 99th Penn., age 26.	May 5, Aug. 31, 1864.	Left; circ.; by A. A. Surg. E. C. Hullard. Died Sept. 16, 1864, exhaustion. <i>Spec.</i> 3627.
2	Racon, C., Pt., 1st Conn. Battery, age 24.	May 16, July 4, '64	Left; circ.; by A. A. Surg. E. P. Fitch. Died July 10, '64, pyæmia.	15	Lake, J. S., Serg't, H, 97th Ohio, age 40.	June 22, July 27, 1864.	Right; circular; by Surg. R. L. Stanford, U. S. V.; (gangrene;) pyæmia. Died Aug. 27, 1864, exhaustion.
3	Bennett, G. A., Pt., I, 8th Ohio, age 20.	June 2, July 6, 1864.	Left; lateral flap; by Surg. N. R. Mosely, U.S.V. Died July 11, 1864, pyæmia. <i>Spec.</i> 2815.	16	Lehman, C. A., Pt., F, 74th New York.	July 2, Aug. 2, '63	Left. Died August 10, 1863, pyæmia. <i>Spec.</i> 2790.
4	Bessee, G. W., Pt., K, 56th Mass., age 19.	May 12, June 28, 1864.	Right; circ.; by A. A. Surg. P. G. H. Bradford; (erysipelas.) Died July 2, 1864, exhaustion.	17	Mackey, S., Pt., A, 10th Penn. Reserves.	June 28, Aug. 21, '62	Right. Died September 30, 1862, pyæmia.
5	Bowman, J., Pt., K, 20th Indiana, age 25.	July 2, Sept. 5, 1863.	Left; by A. A. Surg. T. G. Morton; (hæmorrhage.) Died Dec. 6, '63, dipth'a; gang. <i>Spec.</i> 2753.	18	O'Connell, J., Corp'l, D, 63d N. Y., age 41.	June 3, July 11, 1864.	Left; circ., by A. A. Surg. R. A. Cleemann; (hæmorrhage.) Died July 16, 1864, exhaustion.
6	Button, D., Pt., H, 149th New York, age 35.	May 25, July 21, 1864.	Right; flap; by A. A. Surg. L. B. Yates; (amp. forearm June 12; gang.) Died Aug. 16, '64, ch. diar. Right; flap. Died July 21, 1864.	19	Powell, W., Pt., H, 65th Indiana, age 28.	March 7, Apr. 14, 1864.	Right; circular; by Surg. G. Grant, U.S.V.; (gangrene.) Died Aug. 25, 1864, chronic diarrhœa.
7	Carroll, M., Pt., G, 10th Connecticut, age 20.	May 13, June 23, '64.	Right; double flap; by A. A. Surg. E. Seyflarth; (gangrene.) Died June 17, 1864, pyæmia.	20	Smith, G., Pt., G, 21st Penn. Cav., age 20.	June 22, Sept. 17, 1864.	Left; circ.; by A. A. Surg. J. T. Lanning; (amp. finger June 22; forearm July 9.) Died Oct. 7, '64, bilious intermittent fever.
8	Colby, H., Pt., K, 2d Conn. H. A., age 23.	May 12, June 14, 1864.	Right; flap; by A. A. Surg. S. Smith; (exc. May 8, hæmorrh.; gangrene.) Died Sept. 23, 1864.	21	Springer, J., Pt., B, 35th Iowa, age 22.	April 9, June 23, 1864.	Left; circ.; by A. A. Surg. F. Haesburg. Died July 26, 1864, exhaustion; chronic diarrhœa.
9	Conrad, H., Pt., H, 10th N. Y. Cav., age 44.	May 7, Sept. 10, 1864.	Left. Died January 26, 1864, pyæmia. <i>Spec.</i> 2104.	22	Thompson, J. C., Pt., B, 17th Pa. Cav., age 43.	June 12, Sept. 20, 1864.	Left; circ., by A. A. Surg. M. K. Knorr; (gangrene; disarticulation of wrist July 15.) Died Oct. 17, 1864, pyæmia. <i>Spec.</i> 3674.
10	Daniels, A. J., Pt., F, 25th Illinois.	No. 25, '63 Jan. 17, '64.	Right; circular; by A. Surg. J. J. Woodward, U. S. A. Died Dec. 22, 1862, phthisis. <i>Spec.</i> 332.	23	Thorneroft, D., Serg't, I, 20th Conn., age 27.	July 20, Aug. 25, 1864.	Right; flap; by A. Surg. B. E. Fryer, U.S.A. Died February 11, 1865, pyæmia.
11	Gillespie, J. R., Pt., F, 27th Indiana, age 33.	Sept. 17, Nov. 13, 1862.	Left; (erysipelas.) Died Nov. 15, 1862, exhaustion. <i>Spec.</i> 766.	24	Wallace, A., Pt., B, 1st Mich. S. S., age 23.	May 12, June 14, 1864.	Right; circ.; by A. A. Surg. G. Beebe; (necrosis;) signs of pyæmia. Died February 23, 1865.
12	Hutton, W. W., —, D, 16th New York, age 21.	Sept. 14, No. 14, '62 Jan. 23, '64	Right; circ.; by A. A. Surg. G. Beebe; (necrosis;) signs of pyæmia. Died February 23, 1865.				

4. Secondary Amputations of the Arm without Indication of the Seat of Incision.—

Fifteen cases of secondary amputation of the upper third of the upper arm were reported in which the precise seat of operation was not specified. Six were successful, and nine terminated fatally, a mortality rate of 60 per cent. All of the patients were Union soldiers. The operations were practised on the right side in nine cases, on the left in five, not reported in one. There had been antecedent excisions in the shaft of the humerus in one case, of the bones of the elbow joint in two cases, and in the radius in two cases. The deaths are referred to secondary hæmorrhage, exhaustion, and pyæmia—the larger proportion to the latter cause. The successful and fatal cases are enumerated together.

CASE 1709.—Private J. Sehe, Co. C, 165th New York, aged 40 years, was wounded at Port Hudson, May 27, 1863, and admitted to the field hospital of the 2d division, Nineteenth Corps, where Surgeon E. F. Sanger, U. S. V., recorded: "Gunshot wound of right arm, lower third." Two days afterward he entered University Hospital, at New Orleans. Assistant Surgeon P. S. Conner, U. S. A., forwarded the specimen (FIG. 564), with the following report: "The ball passed through the arm nearly transversely, just above the elbow. The lower portion of the humerus was found much comminuted, the fracture extending into the elbow joint. On June 9th, the fractured portion of the humerus, together with the articulating extremities of the radius and ulna, were removed. Case doing well." The specimen consists of the excised parts, three inches of the lower extremity of the humerus, and the upper extremities of the radius and ulna. The arm was subsequently amputated. On October 19, 1863, the patient was discharged from service by reason of "amputation of right arm." This pensioner was last paid on March 4, 1870, since which date he has not been heard from.

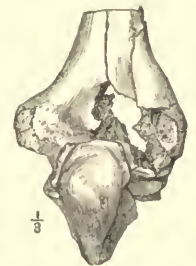

FIG. 564.—Excised elbow, comminuted by shot. *Spec.* 1309.

The case is interesting as illustrating the result of an attempt at conservative excision when the fissures from an antero-posterior perforation of the condyloid portion of the humerus obviously extended far up the shaft. The fifteen cases of this group are enumerated in the table on the next page. The reports were very imperfect, and there were no records of autopsies accompanying the nine fatal cases.



TABLE XC.

*Condensed Summary of Fifteen Cases of Secondary Amputations of the Arm, the Point of Ablation Unspecified.*

No.	NAME, AGE, AND MILITARY DESCRIPTION.	DATES.	OPERATIONS, OPERATOR, RESULT.	No.	NAME, AGE, AND MILITARY DESCRIPTION.	DATES.	OPERATIONS, OPERATOR, RESULT.
1	Baldwin, J. F., Pt., C, 126th Ohio, age 34.	May 6, Jun. 6, '64.	Left; by Dr. J. D. Wortman. Discharged Jan. 8, 1863; pens'd.	9	Haller, M., Pt., C, 6th Connecticut.	Jul. 19, '63	Left. Died August 29, 1863, pyæmia.
2	Hawley, E., Pt., A, 14th Wisconsin.	June 15, Au. 31, '63	Right. Discharged October 2, 1863.	10	Hutton, J. C., Pt., E, 10th Missouri.	Second y. No. 25, '63, Second y.	Right. Died.
3	McEvoy, J., Pt., D, 7th Missouri.	May 12, J'e 30, '63.	Right; gangrene. Disch'd Sept. 11, 1863.	11	Jones, M. E., Corp'l, F, 94th New York.	Sept. 17, Dec. 19, 1862.	Right: (exc. part of radius Oct. 15; caries.) Died December 30, '62. <i>Spec.</i> 487.
4	Mullen, H., Pt., E, 36th Illinois.	Dec. 30, '62, M'h 12, '63	Left; hæmorrhage; ligation brachial. Disch'd June 27, 1863.	12	Merritt, E. F., Pt., F, 34th Illinois.	Jan. 1, Feb. -, 1863.	Right: (excision shaft of humerus Jan. 17.) Died Feb. 26, 1863, exhaustion.
5	Sche, J., Pt., C, 165th New York, age 40.	M'y 27, '63	Right; (exc. elb. June 9.) Disch'd Oct. 19, '63; pens'd. <i>Spec.</i> 1309.	13	Milton, J., Serg't, H, 25th Ohio.	July 1, Aug. 8, '63	Right: (hæmorrhage.) Died Aug. 9, 1863, hæmorrhage.
6	Tanner, M., Pt., G, 11th Michigan.	Dec. 31, '62, Se. 24, '63.	Right. Discharged Mar. 25, '64.	14	Reider, G., Corp'l, D, 73d Penn., age 21.	Au. 30, '62, Feb., '63.	Died March 12, 1863.
7	Anthoine, J., Serg't, D, 13th Illinois.	No. 27, '63, Jan. 1, '64.	Right; (exc. part of radius Nov. 27; gang.) Died Jan. 2, '64, pyæmia. (Excision of elbow May 27, 1864.)	15	Wright, W., Private, C, 100th Penn.	June 3, Jul. 9, '64.	Left; by A. A. Surg. B. Leaman. Died Dec. 20, 1864.

This group completes the record of the secondary amputations of the arm,<sup>1</sup> and also of all that portion of the entire series of amputations of the arm in the continuity for shot injury in which the period of operation was determined, an aggregate of forty-five hundred and seventy-two operations. We have yet to consider those cases of arm amputations in which the date of injury or of operation was uncertain.

AMPUTATIONS IN THE CONTINUITY OF THE ARM, OF UNCERTAIN DATE.—Eight hundred and eighty-four cases of amputation of the arm for shot injury are placed in this category, as the intervals between the injuries and operations are unknown, one or other of the dates having been omitted in the reports. The cases are subdivided into four groups, according as the ablations were practised in the upper, middle, or lower thirds, or at an unspecified portion of the upper arm. These groups, in turn, are each separated into series of successful, unsuccessful, and undetermined cases.

In one hundred and eighty-three cases, after diligent investigation, the results as to fatality could not be ascertained. In the series of seven hundred and one determined cases there were two hundred and twenty-eight deaths, a mortality rate of 32.5 per cent. Supposing the mortality of the one hundred and eighty-three undetermined to have been the same as that of the determined cases, or about one-third, the death-rate of the aggregate ratio of mortality would, of course, be unchanged. If two-thirds of the undetermined cases proved fatal, the death-rate would be 36.3 per cent. Assuming that *all* the undetermined cases resulted fatally, the ratio of mortality of the aggregate of eight hundred and eighty-four cases would be 46.4 per cent.<sup>1</sup>

**1. Amputations in the Upper Third of the Arm, of Uncertain Date.**—Ninety-four amputations in the upper third of the arm, in which either the date of injury, or, more commonly, the date of operation, or, occasionally, both dates, were omitted in the reports, are included in this series. The operations were practised on twenty-three Union and seventy-one Confederate soldiers. In eighty-two cases, in which the results were ascertained, the mortality rate was 25.6 per cent.

<sup>1</sup>Observations on secondary amputations of the arm during the war, for the effects of shot injury, have been published: By Act'g Ass't Surgeon W. H. BUTLER (*Am. Med. Times*, 1863, Vol. VII, p. 159); by Surgeon A. B. MOTT, U. S. V. (*Am. Med. Monthly*, 1862, Vol. XVIII, p. 351); by Dr. J. ASHBURST, Jr. (*Am. Jour. Med. Sci.*, 1863, Vol. XLV, p. 344); by Surgeon J. BRYAN, U. S. V. (*Boston Med. and Surg. Jour.*, 1863, Vol. LXXVII, p. 374, and *Am. Med. Times*, 1863, Vol. VII, p. 288); by Act'g Ass't Surgeon W. P. MOON (*Am. Jour. Med. Sci.*, 1862, Vol. LV, p. 58); by Ass't Surgeon J. W. PITTSOS, 67th Pennsylvania (*Am. Jour. Med. Sci.*, 1863, Vol. XLVI, p. 51); by Med. Cadet E. COUES, U. S. A. (*Med. and Surg. Reporter*, 1863, Vol. IX, p. 430, three cases); by Surgeon J. SHRAWY, Jr. (*Am. Med. Times*, 1863, Vol. VI, p. 173).

§ *Successful Cases.*—Sixty-one amputations in the upper third, resulting successfully, were—on the right side in thirty-three, on the left in twenty-six, unspecified in two cases. The methods of operating are not recorded. Six of the patients returned to modified duty; the remainder were exchanged, paroled, or released. In two cases the limb was torn off by cannon shot; the other cases are simply described as gunshot fractures. There were no recorded antecedent or synchronous operations. In one instance, an enucleation of the head and remaining portions of the shaft of the humerus was secondarily practised.

TABLE XCI.

*Condensed Summary of Sixty-one Successful Cases of Amputation in the Upper Third of the Humerus, of Uncertain Date.*

No.	NAME, AGE, AND MILITARY DESCRIPTION.	DATES.	OPERATIONS, OPERATOR, RESULT.	No.	NAME, AGE, AND MILITARY DESCRIPTION.	DATES.	OPERATIONS, OPERATOR, RESULT.
1	Akin, C. E., Pt., E., 13th Virginia, age 27.	Sept. 14, 1862.	Left. Retired March 15, 1865.	32	Norton, W. E., Pt., F., 13th Georgia, age 24.	—	Left. Discharged.
2	Alley, W., C. S. A.	Aug. 15, 1864.	Right; October, 1865, excision of head of humerus. Right. Discharged.	33	Nott, A. M., Pt., F., 25th Michigan.	—	Right. Discharged September 4, 1863.
3	Anderson, L., Serg't, F., 10th Virginia, age 21.	—	Left. Retired.	34	Owen, I., Pt., C., 6th Alabama, age 23.	May 12, 1864.	Left. Discharged.
4	Apple, F. J., Corp'l, A., 56th Virginia, age 25.	June 17, 1864.	Left. Retired.	35	Palmer, E. L., Serg't, A., 9th Ala., age 23.	May 3, 1863.	Right. Discharged.
5	Ayres, T. B., Pt., C., 20th Alabama, age 38.	June 27, 1864.	Right. Discharged.	36	Parker, J. H., Pt., D., 58th Virginia, age 28.	May 12, 1864.	Left. Discharged.
6	Bowdon, —, Pt., A., 53d Georgia, age 25.	May 5, 1864.	Right; by Surg. J. J. Knott, P. A. C. S.	37	Paston, C. H., Lieut., A., 18th Virginia.	May 14, 1864.	Right. Furloughed June 2, 1864.
7	Carrer, A. J., Corp'l, F., 45th Tennessee, age 23.	Aug. 31, 1864.	Left. Discharged.	38	Peck, W. H., Pt., A., 36th Virginia.	June 5, 1864.	Left. Discharged.
8	Case, T. D., Serg't, D., 30th North Carolina.	July 15, 1864.	Right. Discharged.	39	Philbrick, J., Pt., C., 2d Illinois Cavalry.	Aug. 16, 1862.	Right. Discharged Oct. 23, 1862; pensioned.
9	Chapman, H., Pt., A., 48th North Carolina.	Sept. 17, 1862.	Left. Discharged.	40	Phillips, W. F., Pt., F., 37th Georgia, age 26.	June 19, 1864.	Right. Discharged.
10	Chapman, J., Corp'l, F., 23d Georgia.	July 30, 1861.	Left. Discharged.	41	Pinkhard, R. G., Pt., B., 6th Missouri, age 25.	June 27, 1864.	Right. Retired March 4, 1865.
11	Clay, S. M., Pt., F., 9th Virginia.	July, 1863.	Left. Paroled Sept. 25, 1863.	42	Patillo, J. L., Serg't, D., 60th N. C., age 35.	Nov. 25, 1863.	Right; (also wound of lung.) Discharged.
12	Culler, J. C., Pt., A., 30th Virginia, age 20.	Oct. 19, 1864.	Right. Discharged.	43	Salloway, R. P., Serg't, 1st South Carolina.	May 5, 1864.	Right. Discharged.
13	Eldridge, J. F., Pt., C., 13th Mississippi.	Sept. 24, 1863.	Left. Retired Feb. 1, 1865.	44	Steed, W. J., Serg't, A., 63d Georgia, age 32.	June 27, 1864.	Left; (also wound of lung.) Discharged.
14	Gartick, C. W., Serg't, B., 4th Va., age 23.	July 3, 1863.	Left. To prison Jan. 15, 1864.	45	Talbot, J. B., Pt., H., 4th Alabama, age 24.	Aug. 30, 1862.	Right. Furloughed October 4, 1862.
15	Gear, R. M., Pt., F., 12th Georgia.	Sept. 19, 1864.	Left. To Provost Marshal Feb. 11, 1865.	46	Thompson, W. G., Pt., D., 32d Miss., age 21.	July 21, 1864.	Right. Discharged.
16	Gillespie, J., Capt., E., 12th Wisconsin.	July 21, 1864.	Left; (also wound involving spine.) Discharged June 7, 1865.	47	Thomas, J. W., Corp'l, H., 43d N. C., age 23.	Aug. 25, 1864.	Right. Exchanged October 27, 1864.
17	Grubb, A., Pt., A., 54th N. C., age 18.	Sept. 24, 1864.	Left. Discharged.	48	Tombs, W. F., Pt., E., 16th Miss., age 20.	July 2, 1863.	Left. To Provost Marshal October 6, 1863.
18	Guest, J., Pt., F., 53d Georgia, age 21.	May 5, 1864.	Right; by Surg. J. J. Knott, P. A. C. S. Died 1867, cancer of penis.	49	Upshur, A. G., Pt., B., 13th Georgia, age 22.	Sept. 17, 1862.	Right. Discharged.
19	Guilliam, J. T., Pt., I., 4th Ky., age 28.	May 14, 1864.	Right. Discharged.	50	Waggoner, F. M., Pt., A., 23d Tennessee, age 24.	June 22, 1864.	Right. Discharged.
20	Hardin, J., Corp'l, D., 15th Texas, age 25.	Sept. 1, 1864.	Right. Discharged.	51	Warbington, A. J., Pt., C., 41st Miss., age 29.	Aug. 31, 1864.	Right. Discharged.
21	Harland, —, Pt., A., 53d Georgia, age 18.	Sept. 17, 1862.	Left; by Surg. J. J. Knott, P. A. C. S.	52	Waver, J. R., Pt., D., 13th Mississippi.	July 2, 1863.	Right. Retired Dec. 27, 1864.
22	Harris, J. M., Capt., D., 3d S. C., age 30.	—	Right. To prison Aug. 10, 1863.	53	Welchel, R. F., Pt., D., 28th Georgia, age 21.	Sept. 17, 1862.	Left. Discharged.
23	Helms, J. T., Serg't, A., 24th Virginia, age 20.	May 16, 1864.	Right. Discharged.	54	Whittaker, W., Lieut., E., 37th North Carolina, age 27.	July —, 1863.	Right. To prison April 10, 1864.
24	Johnson, J. L., Capt., B., 24th Georgia.	Aug. 16, 1864.	Left. Furloughed Sept. 22, '64.	55	Williamson, W. H., Maj., 7th Tennessee.	July 1, 1863.	To prison September 23, 1863.
25	Jones, W. J., Pt., B., 40th Alabama, age 24.	June 4, 1863.	Left. Discharged.	56	Wilson, W. E., Pt., D., 2d Louisiana.	July 1, 1862.	Left. Retired Dec. 19, 1864.
26	Lassiter, R. W., Pt., A., 63d Georgia, age 41.	July 22, 1864.	Left. Discharged.	57	Williams, J. H., Pt., I., 25th North Carolina.	April 2, 1865.	Right. To prison May 15, 1865.
27	Law, G. W., Lieut. Col., 3d Missouri.	May, 1863.	Left. Discharged.	58	Wise, E. B., Serg't, F., 11th Pa. Reserves.	July 1, 1863.	Right. To Vet. Res. Corps Dec. 1, 1863.
28	Litaker, J. A., Serg't, K., 57th N. C., age 31.	Dec. 13, 1863.	Right. Discharged.	59	Woods, J. H., Serg't, C., 10th Ala., age 27.	May 6, 1864.	Right. Retired January 5, 1865.
29	Londenlager, T. D., Pt., Johnston's Battery.	May 30, 1864.	To Provost Marshal April 21, 1865.	60	Yates, B. F., Pt., K., 20th North Carolina.	July 1, 1863.	Right. Retired January 27, 1865.
30	Lyon, J. L., Pt., H., 11th Mississippi, age 17.	July 3, 1863.	Left. Exchanged March 3, 1864.	61	Zachary, A. F., Capt., F., 61st Alabama.	May 12, 1864.	Left. Furloughed June 2, 1864.
31	Minor, E. C., Serg't, F., 3d Va. Cav., age 20.	Sept. 22, 1864.	Right. Discharged.				

§ *Fatal Cases.*—There were twenty-one amputations of the arm at the upper third, of undetermined date, that resulted fatally. There were nine on the left and nine on the right side, and in three cases this point was unnoticed. No antecedent operations were



recorded. The proximate causes of death were referred to in very few instances. In one case, the subclavian artery was consecutively ligated.

TABLE XCII.

*Condensed Summary of Twenty-one Fatal Cases of Amputations at the Upper Third of the Humerus, of Uncertain Date.*

No.	NAME, AGE, AND MILITARY DESCRIPTION.	DATES.	OPERATIONS, OPERATOR, RESULT.	No.	NAME, AGE, AND MILITARY DESCRIPTION.	DATES.	OPERATIONS, OPERATOR, RESULT.
1	Allston, T. B., Major, 1st South Carolina.	—	Right. Died June 19, 1864.	12	Kline, H., Serg't, A, 8th Michigan, age 32.	June 17, 1864.	Left. Died July 12, 1864, asthenia.
2	Averitt, W. E., Pt., 11, 14th Tennessee.	Aug. 9, 1862.	Hæmorrhage: ligat'n subclavian. Died June 26, 1863.	13	Marsh, J., Pt., I, 98th Ohio.	Oct. 8, 1862.	Left. Died November 12, 1862.
3	Bragg, A. C., Pt., 2d Ohio Battery.	—	Right. Died May 15, 1863, gangrene.	14	Moore, H., Pt., E, 4th Colored Troops.	Feb. 11, 1865.	Right. Died March 7, 1865.
4	Chase, N., Pt., 1, 4th Maine.	July —, 1863.	Left. Died July 21, 1863.	15	Mott, G. D., Pt., D, 58th Pennsylvania, age 20.	July 4, 1864.	Left. Died August 9, 1864, gangrene.
5	Ewing, H., Pt., H, 140th Pennsylvania.	July —, 1863.	Left. Died July 23, 1863.	16	Newman, T., Pt., B, 4th Alabama.	—	Left. Died September 29, 1862.
6	Gailes, G. A., Pt., D, 55th Virginia, age 32.	April 2, 1865.	Right. Died May 29, 1865, exhaustion.	17	Richards, I., Pt., E, 82d Ohio.	July —, 1863.	(Also fracture of head.) Died July, 1863.
7	Green, E. T., Pt., B, 14th Virginia.	July —, 1863.	Right. Died August 15, 1863.	18	Smith, J. B., Lieut., B, 53d Illinois.	July 11, 1863.	Right. Died April 11, 1864.
8	Harsh, J., Pt., I, 98th Ohio.	Oct. 8, 1862.	Died November 12, 1862.	19	Strachan, D., 1st Lieut., B, 63d Pennsylvania, age 23.	—	Left. Died June 6, 1864.
9	Hassner, J., Corp'l, A, 37th Ohio.	May 16, 1862.	Left. Died June 8, 1862, erysipelas.	20	Waldman, J. D., Pt., B, 16th Mississippi.	—	Right. Died June 3, 1863.
10	Jeffries, S. S., Pt., C, 54th Indiana.	Dec. 29, 1862.	Right. Died January 29, 1863.	21	Young, M. M., Capt., K, 17th Maine.	July —, 1863.	Left. Died August 13, 1863.
11	Kirkley, D. M., Corp'l, G, 2d South Carolina.	Sept. 17, 1862.	Right. Died December 7, 1862. <i>Spec.</i> 1103.				

*Undetermined Cases.*—The final result of twelve operations could not be ascertained.

TABLE XCIII.

*Condensed Summary of Twelve Cases of Amputations at the Upper Third of the Humerus, of Uncertain Date and Undetermined Result.*

No.	NAME, AGE, AND MILITARY DESCRIPTION.	DATES.	OPERATIONS, OPERATOR, RESULT.	No.	NAME, AGE, AND MILITARY DESCRIPTION.	DATES.	OPERATIONS, OPERATOR, RESULT.
1	Bell, G. J., Saddler, M, 15th N. Y. Cavalry.	—	Left.	7	Goodson, J. E., Serg't, A, 8th S. C.	July 29, 1864.	Right.
2	Burrell, B., Pt., I, 3d South Carolina.	July 29, 1864.	Left.	8	Green, W., Pt., 11, 14th South Carolina.	July 28, 1864.	Left.
3	Civit, R. A., Private.	Dec. 13, 1862.	Right.	9	Jordan, H. E., Corp'l, C, 21st Georgia.	Aug. 21, 1862.	Left.
4	Finley, R., Pt., E, 28th Georgia.	—	Left.	10	Moorfield, H., Pt., G, 53d North Carolina.	Mar. —, 1865.	Right; (erysipelatos inflammation April 2.)
5	Fry, M., Private, B, 4th Ohio.	May 18, 1864.	Right.	11	Steinmacker, W., Serg't-Major, 7th Michigan.	July 3, 1863.	Left.
6	Gladden, J., —, D, 6th Kansas Cavalry.	—	Left.	12	Thompson, L. H., Serg't, H, 22d Georgia.	July —, 1863.	Left.

The reports of the ninety-four cases of amputations in the upper third, of uncertain date, were not accompanied by pathological specimens, except in a single instance.<sup>1</sup>

**2. Amputations in the Middle Third of the Arm, of Uncertain Date.**—In this group sixty-seven cases are recorded, of which forty-five were successful and thirteen fatal, while in nine instances the result is unknown. The operations were practised on fifteen Union and fifty-two Confederate soldiers. The amputations were on the left side in thirty-four, on the right in twenty-nine, not reported in four.

§ *Successful Cases.*—Of the forty-five patients who recovered, four returned to modified duty, four were discharged, twenty-nine were paroled or exchanged, and eight were furloughed from Confederate hospitals.

<sup>1</sup> Specimen 1103, from Case 11 of TABLE XCII, is "the stump of the right humerus, amputated two inches below the tuberosities. The extremity is necrosed; periosteal thickenings occupy the most of the shaft, but without positive reparation."

TABLE XCIV.

*Condensed Summary of Forty-five Cases of Recovery after Amputations in the Middle Third of the Shaft of the Humerus, of Uncertain Date.*

NO.	NAME, AGE, AND MILITARY DESCRIPTION.	DATES.	OPERATIONS, OPERATOR, RESULT.	NO.	NAME, AGE, AND MILITARY DESCRIPTION.	DATES.	OPERATIONS, OPERATOR, RESULTS.
1	Abercrombie, J. T., Lt., E, 27th Georgia.	—	Right. Furloughed October 6, 1864.	21	Hunter, L., Pt., C, 105th Penn., age 18.	—	Right. Discharged December 2, 1863.
2	Albright, J., Pt., H, 10th Va. Cav., age 18.	April 3, 1865.	Right. Discharged June 23, '65.	25	James, R., Lieut., C, 51st North Carolina.	June 1, 1864.	Right. Furloughed June 11, '64.
3	Allen, W. N., Q. M. Sgt., 43d Georgia, age 23.	May 28, 1863.	Right. Retired January 30, '65.	26	Lettice, M., Pt., B, 10th Georgia.	July 2, 1863.	Left. Retired December 31, '64.
4	Amg, T., Private, C, 8th Louisiana.	July, 1863.	Right; (also wound of thigh.) Retired May 9, 1864.	27	Lackman, J. N., Pt., C, 3d North Carolina Artillery, age 36.	—	Right. Paroled June 28, 1865.
5	Anderson, C. M., Pt., E, 6th N. C., age 23.	July 1, 1862.	Left. Discharged.	28	Lyell, J. W., Lieut. Colonel, 47th Virginia.	Aug. 18, 1864.	Left. Furloughed August 29, 1864.
6	Ball, S., Pt., H, 25th S. C., age 22.	—	Left. Paroled June 28, 1865.	29	Madden, P., Pt., E, 9th Louisiana.	May 25, 1862.	Right. Retired September 12, 1864.
7	Benton, W. H., Pt., F, 1st Miss. Art., age 22.	April 9, 1865.	Left. Paroled May 16, 1865.	30	Murmon, J., Pt., G, 42d Mississippi.	July, 1863.	Right. Paroled November 12, 1863.
8	Bond, J., Pt., B, 52d Ohio.	—	Left. Discharged September 1, 1864.	31	McCarthy, T., Serg't, F, 2d Virginia, age 25.	May 5, 1864.	Right. Discharged.
9	Bradley, D. F., Lieut., A, 2d Florida.	May 6, 1864.	Left. Furloughed July 7, 1864.	32	McGowan, E., Pt., K, 22d Mass.	Sept. 17, 1862.	Right. Discharged December 29, 1862; pensioned.
10	Branch, A. H., Serg't, D, 6th Virginia.	—	Left. Retired October 25, 1864.	33	Miceli, H., Pt., B, 14th Louisiana.	May 5, 1862.	Left. Discharged October 27, 1863.
11	Brown, W. W. L., Pt., E, 2d Louisiana.	Nov. 27, 1863.	Right. Discharged January 29, 1864.	34	Nash, T., Pt., B, 7th North Carolina.	—	Discharged October 25, 1862.
12	Byrd, R., Serg't, D, 25th North Carolina.	—	Left. Discharged September 29, 1862.	35	Patterson, J. R., Lieut., K, 25th N. C.	July 30, 1864.	Left. Furloughed September 8, 1864.
13	Connally, J., Col., 55th North Carolina.	July 1, 1863.	Left; (also wound of ilium.) Exchanged March 3, 1864.	36	Simms, G., Pt., D, 61st Alabama, age 19.	July 12, 1864.	To prison September 24, 1864.
14	Darden, J. M., Lieut., B, 13th Georgia.	May 12, 1864.	Right. Furloughed June 30, '64.	37	Slaughter, H. J., Lieut., I, 61st Alabama.	July 18, 1864.	Left. Furloughed August 29, 1864.
15	Diall, B., Pt., G, 9th Illinois.	—	Left. Discharged July 10, 1864.	38	Stewart, J., Pt., K, 183d Penn., age 45.	May 26, 1864.	Right; by A. A. Surg. G. H. Mitchell. Disch'd June 14, '65; pensioned.
16	Dudley, R. S., Pt., C, 4th Virginia.	July, 1863.	Left. Paroled September 5, '63.	39	Tingit, J. R., Pt., H, 24th N. C., age 30.	Sept. 17, 1862.	Right. Discharged.
17	Dusebury, J., Pt., D, 51st Ohio.	Dec. 31, 1862.	Right. Discharged March 23, 1863.	40	Tucker, W. A., Pt., A, 23d N. C., age 26.	May 3, 1863.	Right. Retired February 21, '65.
18	Eubanks, F. M., Pt., H, 19th Georgia, age 23.	June 26, 1862.	Left. Discharged.	41	Tyson, T. P., Corp'l, I, 33d N. C., age 28.	July 11, 1864.	Left. To prison September 28, 1864.
19	Falls, J. O., Pt., D, 14th North Carolina.	July 3, 1863.	Right. Transferred October 6, 1863.	42	Walden, —, Pt., F, 53d Georgia, age 30.	1863.	Left; by Surgeon J. J. Knott, P. A. C. S.
20	Freeman, I., Pt., D, 12th South Carolina.	Aug. 16, 1864.	Right. To prison December 6, 1864.	43	Watson, C. R., Pt., A, 18th Virginia, age 25.	Mar. 31, 1865.	Left. Discharged June 29, 1865.
21	Green, J., Pt., 6th Cavalry, age 30.	—	Left. Duty October 1, 1864.	44	West, J., Pt., A, 53th Virginia, age 42.	June 2, 1864.	Left. Discharged.
22	Hardy, J. P., Serg't, D, 13th Miss., age 22.	Nov. 30, 1864.	Left. Retired March 7, 1865.	45	Woodall, F. J., Pt., H, 18th Georgia, age 30.	Aug. 30, 1862.	Left. Furloughed October 4, '62.
23	Hels, D., Pt., A, 14th Kansas Cavalry.	—	Left. Discharged June 30, 1864.				

§ *Fatal Cases.*—In thirteen fatal amputations in the middle third of the arm, in which the interval between the injury and operation was not recorded, the details are very scanty. One patient succumbed to secondary hæmorrhage, and two died from diarrhœa or dysentery. The causes of death in the remaining cases are not reported.

TABLE XCV.

*Condensed Summary of Thirteen Cases of Unsuccessful Amputations in the Middle Third of the Shaft of the Humerus, of Uncertain Date.*

NO.	NAME, AGE, AND MILITARY DESCRIPTION.	DATES.	OPERATIONS, OPERATOR, RESULT.	NO.	NAME, AGE, AND MILITARY DESCRIPTION.	DATES.	OPERATIONS, OPERATOR, RESULT.
1	Adams, J., Serg't, C, 2d Missouri.	Sept. 19, 1863.	Right. Died Oct. 17, 1863.	8	Legell, J., Pt., D, 12th Alabama.	Mar., '65.	Right. Died.
2	Bond, H. C., Pt., B, 28th Virginia, age 32.	Mar. 31, 1865.	Right. Died July 9, 1865, dysentery.	9	Lester, W., Pt., F, 69th Indiana.	—	Right. Died June 5, 1863, chronic diarrhœa.
3	Coble, J., Pt., F, 3d N. Carolina Art., age 25.	—	Right. Died Feb. 16, 1865.	10	McGinnis, H., Pt., E, 27th Ohio, age 29.	July 22, 1864.	Right. Died Nov. 17, 1864.
4	Evans, J. H., Serg't, A, 52d Georgia, age 32.	1864.	Left. Died June 23, 1864, secondary hæmorrhage.	11	Parker, W. M., Pt., C, 28th Illinois.	April-Gor 7, 1862.	Died May 2, 1862.
5	Gurnsey, G. H., Pt., E, 17th Conn., age 33.	—	Right. Died Aug 9, 1862.	12	Scaright, G. W. B., Pt., D, 18th Infantry.	—	Left. Died Oct. 13, 1863.
6	Hatfield, G. W., Pt., E, P. S. S.	—	(Also flesh wound of thorax.) Died July 21, 1862.	13	Stems, G. W., Pt., G, 24th New York Cav., age 27.	June 17, 1864.	Left. Died July 23, 1864.
7	Johnson, D. F., Pt., F, 3d N. C. Art., age 41.	—	Right. Died Feb. 28, 1865.				



The death-rate as computed from the fifty-eight determined cases of this series of amputations at the middle third is, therefore, 22.4 per cent. The nine undetermined cases of this group are tabulated below.

§ *Undetermined Cases.*—In nine cases of amputation at the middle third neither the period of operation nor result were recorded. All the facts that are known are recited in the table.

TABLE XCVI.

*Condensed Summary of Nine Cases of Amputations in the Middle Third of the Shaft of the Humerus, of Uncertain Date and Uncertain Result.*

No.	NAME, AGE, AND MILITARY DESCRIPTION.	DATES.	OPERATIONS, OPERATOR, RESULT.	No.	NAME, AGE, AND MILITARY DESCRIPTION.	DATES.	OPERATIONS, OPERATOR, RESULT.
1	<i>Fry, J. P.</i> , Pt., B, 42d N. C., age 28.	Sept. 1, 1861.	Left; by Surg. Kimble.	6	<i>Melton, B. W.</i> , Pt., H, 11th Georgia.	Aug. 16, 1864.	Left.
2	<i>Gilbert, W. T.</i> , Pt., I, 18th S. C.	Nov. 5, 1864.	Left.	7	<i>Myers, G. E.</i> , Lieut. Col., 10th Mississippi.	Aug. 31, 1864.	Left.
3	<i>Harris, W. B.</i> , H, 2d Mississippi, age 30.	July 12, 1862.	Left.	8	<i>Partain, J. M.</i> , Pt., D, Phillips' Ga. Legion.	May 6, 1864.	Right.
4	<i>Jennings, R. H.</i> , Lieut., G, 3d S. C.	July 28, 1864.	Left.	9	<i>Thrift, W. D.</i> , Pt., B, 40th Virginia, age 38.	Aug. 18, 1864.	Right.
5	<i>Lynn, T. H.</i> , Pt., F, 5th South Carolina.	Oct. 29, 1863.	Left.				

**3. Amputations in the Lower Third of the Arm, of Uncertain Date.**—Twenty-four amputations of the arm belong to this group, the interval between the injury and operation being unknown. Twenty-two patients recovered; in two cases the result is not reported. The operations were practised on five Union and nineteen Confederate soldiers,—on the left side in twelve, on the right in nine, not reported in three. Four patients returned to modified duty, four were paroled, and fourteen discharged; in two cases the result remained undetermined. The cases appear to have been uncomplicated by other injuries or operations. There were no fatal examples in this group,<sup>1</sup> and the successful and undetermined cases will be included in one tabular statement.

TABLE XCVII.

*Condensed Summary of Twenty-four Cases of Amputations in the Lower Third of the Shaft of the Humerus, of Uncertain Date.*

No.	NAME, AGE, AND MILITARY DESCRIPTION.	DATES.	OPERATIONS, OPERATOR, RESULT.	No.	NAME, AGE, AND MILITARY DESCRIPTION.	DATES.	OPERATIONS, OPERATOR, RESULT.
1	<i>Autney, W. J.</i> , Lieut., A, 14th Alabama.	—	Discharged October 17, 1862.	13	<i>Jennings, J. C.</i> , Pt., C, 24th Va., age 29.	May 16, 1864.	Right. Discharged.
2	<i>Check, R. P.</i> , Pt., G, 12th Georgia, age 18.	Mar. 31, 1865.	Left. Released June 29, 1865.	14	<i>King, A. A.</i> , Lieut., A, 3d S. C. Battery.	—	Right. To prison December 5, 1863.
3	<i>Dudley, J.</i> , Pt., B, 7th Texas, age 21.	July 22, 1861.	Left; (wound of jaw.) Duty January 30, 1865.	15	<i>Mathews, D.</i> , Pt., C, 1st N. C. Art., age 20.	—	Paroled June 28, 1865.
4	<i>Elliott, B. S.</i> , Lieut., F, 53d Georgia, age 26.	—	Right. To prison September 3, 1863.	16	<i>McIver, D. R. W.</i> , Serg't, 21st N. C., age 33.	—	Left. To Provost Marshal May 31, 1865.
5	<i>Gamble, J. M.</i> , Serg't, B, 6th Alabama.	—	Right. Discharged June 23, 1863.	17	O'Connor, P., Pt., K, 31st New York.	—	Right. Discharged August 25, 1863.
6	<i>Gillion, J.</i> , Pt., A, 10th Louisiana.	July 2, 1863.	Left. Duty March 15, 1864.	18	<i>Patterson, J. F.</i> , Pt., G, 40th Georgia.	Sept. 19, 1864.	Right. Retired Feb. 27, 1865.
7	Graves, W., Pt., M, 4th Col'd Art., age 20.	Mar. 2, 1865.	Left. Discharged February 26, 1866.	19	<i>Randolph, J. B.</i> , Pt., C, 26th Miss., age 38.	Feb. 28, 1864.	Right. Discharged.
8	<i>Gutierrez, J.</i> , Pt., F, 10th Louisiana.	May 18, 1862.	Left. Discharged September 22, 1863.	20	<i>Rawpey, S. D.</i> , Pt., F, 31st S. C., age 18.	Oct. 19, 1864.	Left. To Provost Marshal Feb. 11, 1865.
9	<i>Hockett, J.</i> , Pt., D, 29th Alabama, age 25.	—	Left; gangrenous. Discharged.	21	<i>Savage, S.</i> , Pt., A, 38th N. C., age 27.	April 2, 1865.	Left. Discharged July 9, 1865.
10	Higgins, A. T., Pt., K, 99th Pa., age 19.	April 6, 1865.	Left. Disch'd August 15, 1865.	22	Sexton, G. W., Pt., D, 140th Pennsylvania.	May 3, 1863.	Right. Discharged August 28, 1863.
11	<i>Holloway, W. L.</i> , Pt., A, 13th Virginia.	—	Left. Retired December 8, 1864.	23	<i>May, L. J.</i> , Pt., E, 12th Georgia.	July 9, 1864.	Left.
12	Horner, N., Pt., B, 2d Colored Troops.	—	Right; by A. A. Surg. N. J. Pettijohn. Dis'd Nov. 5, '63. Spec. 1675.	24	<i>Tipton, J. J.</i> , Confederate prisoner.	—	By Surg. T. J. Bluthardt, 23d Missouri.

<sup>1</sup>That is, reported as fatal. Of CASE 12, TABLE XCVII, which furnished specimen 1675, no trace can be found at the Pension Office. The specimen represents a shot comminution of the bones of the right forearm, probably from a primary or early intermediary amputation at the junction of the lower and middle thirds of the humerus.

**4. Amputations in the Continuity of the Arm, of Uncertain Date, without Indication of the Seat of Incision.**—There were six hundred and ninety-nine amputations in the upper arm, in which not only the interval between the injury and operation, but the precise seat of operation, were unrecorded. In about a fourth of these cases the result as to fatality was also unknown. The determined cases give a death-rate of 35.9 per cent. The operations were practised on two hundred and twenty-five Union and four hundred and seventy-four Confederate soldiers.

§ *Successful Cases.*—Three hundred and forty-five amputations in the continuity of the upper arm, in which the precise point of incision and the date of operation are alike undetermined, resulted successfully. Twenty-eight of the patients returned to modified duty, one hundred and twenty were exchanged or paroled, and one hundred and ninety-seven were discharged. The operations were practised on the right side in one hundred and eleven, on the left in one hundred and fifty-eight, not recorded in seventy-six. Eleven patients received wounds in some other region than the arm. In one case there was a synchronous amputation of the leg. One patient survived an ulterior disarticulation at the shoulder.

TABLE XCVIII.

*Condensed Summary of Three Hundred and Forty-Five Cases of Recovery after Amputations in the Arm, of Uncertain Date, without Indication of the Seat of Incision.*

NO.	NAME, AGE, AND MILITARY DESCRIPTION.	DATES.	OPERATIONS, OPERATOR, RESULT.	NO.	NAME, AGE, AND MILITARY DESCRIPTION.	DATES.	OPERATIONS, OPERATOR, RESULT.
1	Abbey, J., Pt., K, 74th New York.	July 1, 1863.	Left. Discharged March 2, 1864.	28	Branch, W. H. II., Pt., A, Phillips' Legion.	—	Discharged October 15, 1862.
2	Adams, C., Pt., A, 37th North Carolina.	—	Left. Paroled July 10, 1862.	29	Bremer, G., Pt., H, 32d Ohio.	—	Right. Discharged October 25, 1863.
3	Adcock, J. C., Pt., G, 26th North Carolina.	July, 1863.	Left. Paroled Sept. 12, 1863.	30	Briggs, C., Corp'l, A, 26th Louisiana.	Sept. 26, 1863.	Right. Recovery.
4	Allen, J. W., Pt., H, 18th Georgia.	July, 1863.	Paroled August 22, 1863.	31	Brimer, C., Pt., I, 3d Ohio.	Oct. 8, 1862.	Transferred October 31, 1862.
5	Allen, J., Pt., G, 5th Texas.	—	Discharged October 16, 1862.	32	Brock, A. G., Serg't, E, 18th Mississippi.	—	Discharged October 30, 1861.
6	Allen, J. H., Pt., B, 2d Mississippi.	—	Left. Discharged July 18, 1862.	33	Brown, G. S., Pt., B, 5th Virginia.	—	Left. Discharged August 2, '62.
7	Amy, T., Private, C, 8th Louisiana.	—	Retired May 9, 1864.	34	Brown, H. P., Corp'l, F, 6th Virginia.	—	Left. Discharged September 13, 1864.
8	Anderson, W. J., Pt., I, 19th Alabama.	Dec. 31, 1862.	Exchanged February 25, 1863.	35	Brown, E., Pt., G, 27th N. C., age 42.	Oct. 14, 1863.	Right. Discharged.
9	Andrews, W. B., —, C, 16th Louisiana.	Dec. 31, 1862.	Left. To Provost Marshal.	36	Brown, P. W., Pt., I, 15th Virginia.	Sept., 1862.	Left; (also amp. of leg.)
10	Anderson, R. J., Serg't, A, 20th Georgia.	—	Right. Paroled Aug. 24, 1863.	37	Bryant, G. W., F, 11th Georgia.	July 2, 1863.	Left. Paroled September 5, 1863.
11	Atkinson, W., Pt., C, 5th Florida.	July 3, 1863.	Left. Paroled Sept. 25, 1863.	38	Bryce, J., Pt., A, 49th Massachusetts.	May 27, 1863.	Right. Discharged August 12, 1863.
12	Baber, S., Pt., K, 19th Virginia.	—	Left. Discharged Nov. 4, 1862.	39	Buchanan, J., Pt., A, 6th Virginia.	—	Right. Discharged March 24, '63.
13	Bailey, J. B., Pt., B, 44th Georgia.	July 2, 1863.	Left. Paroled Sept. 23, 1863.	40	Bulger, H. B., Pt., D, 11th S. C., age 30.	May 16, 1864.	Right. Discharged.
14	Baley, S. G., Pt., E, 26th Alabama.	July 2, 1863.	Left. Paroled October 31, 1863.	41	Burnett, S. J., Lieut., A, 33d Missouri.	July 4, 1863.	Right. Duty September 24, 1863.
15	Balter, A. D., Pt., A, 1st Penn. Res. Corps.	—	Left. Discharged November 25, 1862.	42	Burkheart, J. F., Pt., I, 42d North Carolina.	—	Discharged October 6, 1862.
16	Bateman, J. M., Pt., E, 24th Virginia.	—	Discharged October 21, 1862.	43	Butler, J. T., Lieut., 11, Polks' Regiment.	—	Left. Discharged.
17	Baugh, W. A., Serg't, A, 18th Va., age 27.	July 3, 1863.	Left. Paroled August 22, 1863.	44	Callen, E. D., Serg't, F, 13th New Jersey.	—	Left. Discharged November 25, 1862.
18	Beck, T. F., Corp'l, G, 30th Ohio.	Sept. 17, 1862.	Left. Discharged November 20, 1862; pensioned.	45	Caplinger, D., Pt., A, 15th W. Va., age 40.	Mar. 31, 1865.	Left; (gangrene.) Discharged August 7, 1865.
19	Bennett, W., Pt., A, 29th Virginia.	—	Retired September 18, 1864.	46	Carriek, R. M., Pt., F, 10th Missouri.	—	Right. Discharged September 29, 1863.
20	Bennett, A. E., Lieut., K, 81st Penn.	May 3, 1863.	Left. To Veteran Reserve Corps October 12, 1863.	47	Carlisle, B. F., Pt., K, 27th Georgia.	—	Left. Furloughed April 7, 1865.
21	Bennett, J. J., Pt., A, 4th N. Carolina, age 31.	May 3, 1863.	Right. Discharged.	48	Cassell, S. M., Pt., H, 2d South Carolina.	Sept. 30, 1864.	Left. Furloughed November 4, 1864.
22	Bergen, J., Pt., B, 23d Indiana.	Oct. 8, 1862.	Right. Discharged December 26, 1862.	49	Castrops, G. W., Corp'l, D, 20th Missouri.	—	Right. Discharged August 20, 1863.
23	Black, I. N., Pt., D, 8th Illinois.	Oct. 8, 1862.	Left. Discharged Jan. 4, 1863.	50	Cathey, W., Corp'l, E, 11th North Carolina.	July 2, 1863.	Left. Exchanged September 23, 1863.
24	Blakeslie, G. A., Pt., H, 2d Kentucky.	April 7, 1862.	Left. Discharged December 6, 1862.	51	Chambers, H. W., Pt., I, 4th Ark., age 22.	April 4, 1864.	Right. Discharged June 16, 1865.
25	Bohannon, J. D., Pt., G, 8th Georgia.	July, 1863.	Left. Paroled September 23, '63.	52	Childs, W. S., Pt., D, 15th Conn., age 43.	Mar. 8, 1865.	Discharged in 1865.
26	Booth, A. J., Pt., H, 22d Iowa.	May 22, 1863.	Recovered.	53	Clark, J. E., Corp'l, F, 8th Louisiana.	July, 1863.	Paroled September 5, 1863.
27	Borrell, M., Pt., F, 1st Arkansas, age 29.	April 12, 1864.	Right. Duty May 12, 1864.	54	Clauson, W., Pt., A, 62d Pennsylvania.	June 27, 1862.	Left. Discharged September 20, 1862.



No.	NAME, AGE, AND MILITARY DESCRIPTION.	DATES.	OPERATIONS, OPERATOR, RESULT.	No.	NAME, AGE, AND MILITARY DESCRIPTION.	DATES.	OPERATIONS, OPERATOR, RESULT.
55	Clouse, W. C., Lieut., D, 6th Alabama.	Sept. 17, 1862.	By Surgeon Parks, 5th Alabama.	103	Farthing, R. H., Pt., E, 37th N. C., age 23.	June 27, 1862.	Right. Discharged.
56	Cole, J. F., Pt., I, 14th Alabama.		Discharged January 12, 1862.	104	Felked, D. C., Pt., K, 5th Florida.	July, 1863.	Left. Paroled Nov. 12, 1863.
57	Conley, J. W., Pt., I, 36th Va., age 23.		Left. Discharged.	105	Ferrill, J. A., Pt., B, 1st Tennessee.		Left. Retired Nov. 23, 1864.
58	Corbett, M., Pt., E, 2d Georgia.	July, 1863.	Right. Paroled September 12, 1863.	106	Finka, H., Serg't, G, 31st Missouri, age 31.	Nov. 27, 1863.	Left. To Veteran Reserve Corps October 8, 1864.
59	Cottrell, A. F., Pt., D, 97th N. Y.		Left. Discharged November 25, 1862.	107	Fleming, E., —, I, 20th Georgia.	July, 1863.	Paroled August 22, 1863.
60	Crister, J. J., Pt., E, 22d Georgia.		Discharged October 8, 1862.	108	Flynn, J., Pt., B, 18th Mississippi.	July 2, 1863.	Right. Retired July 12, 1864.
61	Crist, R. A., Pt., I, 58th Virginia.		Right. Discharged December, 28, 1863.	109	Forson, W. G., Pt., H, 9th Florida, age 42.	June 3, 1864.	Right. Discharged.
62	Cruey, W. G. W., Pt., K, 45th Va., age 24.	May 9, 1864.	Left. Discharged.	110	Foster, A. W., Pt., E, 3d Alabama.		Right. To Provost Marshal April 21, 1865.
63	Crussell, M. B., Pt., G, 19th Tennessee.	Dec. 31, 1862.	Right. Exchanged February 25, 1863.	111	Frazier, J. S., Pt., I, 14th Louisiana.		Right. Discharged September 17, 1862.
64	Curtis, W., Pt., F, 26th North Carolina.		Left. Paroled September 5, 1863.	112	Frederick, J., Pt., F, 13th Mississippi.	July, 1861.	Paroled September 4, 1863.
65	Cuttell, D. F. O., Pt., A, 24th Iowa.	May 16, 1863.	Left. Discharged November 5, 1863.	113	Fry, J., Pt., A, 25th Virginia Battery.		Left. Retired September 5, '64.
66	Cutler, D. M., Pt., I, 2d Indiana.	Oct. 8, 1862.	Discharged January 2, 1863.	114	Gardner, T. R., Pt., E, 12th South Carolina.		Left. Paroled September 12, '63.
67	Daniel, F. J., Pt., I, 7th Georgia.		Right. Discharged October 23, 1861.	115	Geddy, J., Pt., A, 23d North Carolina.	July, 1863.	Left. Paroled September 23, '63.
68	Dao, A., Pt., 41st New York.	Oct. 19, 1864.	Right. Deserted October 31, '65.	116	Gibson, J., Pt., D, 19th Arkansas.		Right. Duty March 27, 1863.
69	Darby, C. C., Pt., K, 34th Indiana.		Left. Discharged July 6, 1863.	117	Gilbert, R. T., Serg't, D, 18th Georgia.	July, 1863.	Paroled November 12, 1863.
70	Darey, S. J., —, G, 15th Texas.	Dec. 31, 1862.	Right. To Provost Marshal.	118	Gill, J., Pt., I, 111th Pennsylvania.	Sept. 17, 1862.	Left. Discharged December 6, 1862.
71	Davis, G. J., Pt., H, Holeomb's Legion.	Sept. 30, 1864.	Right. Furloughed November 4, 1864.	119	Glynn, J., Pt., E, 7th Louisiana.	July, 1863.	(Also wound of leg.) Paroled August 24, 1863.
72	Davis, W., Pt., K, 7th Virginia.	July, 1863.	Right. Paroled Sept. 5, 1863.	120	Godfrey, E. P., Corp'l, D, Cobb's Legion.		Left. Discharged November 30, 1862.
73	Davis, F. M., Pt., I, 17th Mississippi.	July, 1863.	Left. Paroled August 24, 1863.	121	Gomes, A. T., Pt., G, 52d Virginia.	July, 1863.	Paroled August 24, 1863.
74	Davis, H. L., Pt., B, 8th Georgia.		Right. Recovery.	122	Goodwin, T. J., Pt., I, 4th Virginia.	July 2, 1863.	Right. Paroled August 22, 1863.
75	Davis, J. S., Pt., H, 8th Iowa, age 29.	April 9, 1862.	Left; (also wound of right hand.) Discharged August 15, 1862.	123	Goodwin, S. H., Pt., H, 45th Georgia.	July, 1863.	Left. Paroled September 23, 1863.
76	Davis, J. M., Pt., K, 3d West Virginia.	Sept. 17, 1862.	Right. Discharged November 26, 1862.	124	Gough, H. N., G, 33d Ohio.		Left. Discharged October 21, '63.
77	Davis, T. R., Pt., F, 33d Georgia, age 32.		Left. Discharged.	125	Grayson, G. W., Lieut., A, 7th Tennessee.	May 3, 1863.	Left. Duty February 23, 1865.
78	Davis, G. P., Pt., C, 55th North Carolina.	July, 1863.	Left. Paroled September 5, 1863.	126	Graff, C. D., Pt., B, 61st New York.		Left. Discharged November 25, 1862.
79	Davis, W. W., Pt., K, 7th Georgia.		Left. Discharged September 9, 1861.	127	Graeson, J. A., Pt., K, 21st Georgia.		Discharged October 8, 1862.
80	Davis, J. H., Pt., A, 6th N. C., age 21.	May 4, 1864.	Right. Discharged.	128	Grigsby, J. M., Pt., E, 17th Iowa, age 21.		Right. Discharged June 25, '62.
81	Davis, J. T., Pt., B, 8th Tennessee Cavalry.		Left. Recovered.	129	Hagflner, J., Pt., I, 11th North Carolina.	July, 1863.	Left. Paroled September 5, 1863.
82	Decker, A. F., Pt., A, 4th Florida.	Dec. 31, 1862.	Right. Exchanged February 25, 1863.	130	Harrow, S. W., Pt., D, 4th Georgia.	July, 1863.	Left. Paroled November 12, 1863.
83	De Long, C., Pt., A, 8th Michigan.	April 16, 1862.	Left; (also wound of hip.) Discharged June 23, 1862.	131	Harrell, D., Pt., G, 36th N. C. Art., age 25.		Left. To Provost Marshal April 8, 1865.
84	Dent, J. F., Corp'l, I, 55th North Carolina.	July, 1863.	Left. Paroled September 12, '63.	132	Harmon, J., Pt., H, 11th Virginia.		Left. Discharged January 31, '65.
85	Denton, J., Pt., K, 12th North Carolina, age 19.	July 9, 1864.	Right. Discharged.	133	Harreman, J. B., Pt., D, 20th N. C.	July, 1863.	Left. Paroled September 12, '63.
86	Dice, G., Pt., G, 5th Florida.		Right. Recovered.	134	Harvelk, J. D., Pt., G, 13th Mississippi.		Right. Paroled Sept. 5, 1863.
87	Dickerson, F. S., Serg't, K, 50th Va., age 25.	June 2, 1861.	Right. Discharged.	135	Harris, F. C., Serg't, H, 11th North Carolina.	July, 1863.	Paroled September 5, 1863.
88	Dickinson, J. T., Pt., H, 47th Virginia, age 19.	Aug. 19, 1864.	Left. Furloughed Oct. 18, 1864.	136	Hall, J. R., Serg't, A, 40th Virginia.		Left. Retired Sept. 2, 1864.
89	Dorn, F. F., Serg't, D, 33d North Carolina.	July 2, 1863.	Right. Exchanged Sept. 28, 1863.	137	Hall, J. O., Pt., B, 38th Virginia.		Right. Discharged September 22, 1862.
90	Dorr, C. P., Lieut., E, 6th Maine.	May 10, 1864.	Right. Discharged August 15, 1864.	138	Hanks, T. W., Serg't, G, 4th Iowa Cav., age 29.	Oct. 11, 1862.	Right; (also wound of abdomen.) Discharged November 20, 1862.
91	Doromany, A. S., Pt., I, 2d Florida.	July, 1863.	Right. Paroled August 22, 1863.	139	Higbee, F., Pt., B, 64th New York.		Left. Discharged November 29, 1862.
92	Dowdy, L. S., Pt., D, 21st Virginia.	July, 1863.	Paroled August 24, 1863.	140	Hill, J. M. P., Corp'l, C, 4th Texas.		Right. Furloughed January 8, 1863.
93	Drake, F. E., Serg't, F, 139th Pennsylvania.		Right. Discharged July 13, 1863.	141	Hindman, D. J., Serg't, A, 7th Georgia.		Discharged October 10, 1862.
94	Durham, J. L., Corp'l, I, 13th Mississippi.	July, 1863.	Right. Paroled August 24, 1863.	142	Hughes, M. D., Pt., E, 4th Georgia, age 21.	May 5, 1864.	Right. Discharged.
95	Eblis, M., Pt., H, 44th Tennessee.	Dec. 31, 1862.	Right. Exchanged February 25, 1863.	143	Holler, W. L., Pt., K, 7th North Carolina.		Right. Discharged November 4, 1862.
96	Edward, J. W., Pt., F, 89d U. T., age 33.	Jan. 1, 1865.	Left. Discharged June 1, 1865.	144	Holliday, F. W. M., Maj., 33d Virginia.		Furloughed October 17, 1862.
97	Edwards, J., Pt., G, 59th Illinois.	Oct. 8, 1862.	Left. Discharged Dec. 24, 1862.	145	Hollock, J., Pt., C, 17th Mississippi.	July, 1863.	Left. Paroled September 12, '63.
98	Egbert, J. D., Pt., A, 107th New York.		Left. Discharged Jan. 8, 1863.	146	Honk, W. L., Pt., K, 26th North Carolina.	July, 1863.	Right. Paroled August 24, 1863.
99	Eggidy, C., Pt., C, 22d Indiana.	Oct. 8, 1862.	Left. Discharged March 6, 1863.	147	Howard, P., Pt., C, 4th Va. Heavy Artillery.		Left. Discharged January 15, 1864.
100	Ellis, L. W., Pt., C, 11th Georgia.	July, 1863.	Left. Paroled August 24, 1863.	148	Howard, S. W., Pt., E, 2d U. S. Sharpshooters.		Left. Discharged November 25, 1862.
101	Eskridge, R. C., Pt., C, 55th North Carolina.	July, 1863.	Right. Paroled Sept. 5, 1863.	149	Howard, P. C., Serg't, G, 12th N. C.	May 19, 1864.	Left. Furloughed.
102	Elters, H., Pt., G, 49th North Carolina, age 39.	Oct. 19, 1864.	Left. Discharged.	150	Howell, T. A., Pt., B, 5th N. C., age 37.	July 1, 1863.	Left. Retired January 20, 1865.

No.	NAME, AGE, AND MILITARY DESCRIPTION.	DATES.	OPERATIONS, OPERATOR, RESULT.	No.	NAME, AGE, AND MILITARY DESCRIPTION.	DATES.	OPERATIONS, OPERATOR, RESULT.
151	Hurst, J. L., Pt., B, Orr's S. C. Rifles.	—	Discharged October 10, 1862.	200	Maples, N., Corp'l, E, 81st Illinois.	—	Discharged April 14, 1863.
152	Hutchinson, J. W., Lieut. and Ensign, 25th N. C.	Aug. 21, 1864.	Right. Discharged.	201	Martin, T., Pt., B, 8th Indiana.	—	Right. To V. R. C. December 14, 1863.
153	Jackson, T., Serg't, K, 54th North Carolina.	Sept. 29, 1864.	Right. Discharged.	202	Martin, W. M., Pt., G, 19th Virginia.	—	Left. Retired September 25, '64.
154	James, T. C., Adj't, 3d North Carolina.	May 5, 1864.	Right. Furloughed May 24, '64.	203	Marlow, J. M., Pt., B, 55th North Carolina.	—	Left. Paroled September 12, '63.
155	Jennings, T. K., Serg't, 1, 13th Mississippi.	July, 1863.	Right. Paroled August 24, 1863.	204	Massey, R., Pt., C, 6th North Carolina.	July, 1863.	Left. Paroled September 5, '63.
156	Jeter, J. E., Pt., B, 2d Va.	—	Discharged October 1, 1862.	205	Mason, W., Pt., F, 3d Penn. Cav.	—	Left. Discharged December 1, 1862.
157	Johnson, C. V., Pt., G, 20th Ohio.	—	Right. Discharged December 6, 1863.	206	Maxson, A. M., Serg't, D, 15th Indiana.	Dec. 31, 1862.	Right. Discharged; pensioned.
158	Johnson, F., Pt., B, 9th Georgia.	—	Discharged October 8, 1862.	207	May, W. B., Pt., A, 48th N. C., age 31.	Dec. 13, 1862.	Right. Discharged.
159	Johnson, L. D., Pt., H, 15th Alabama.	—	Right. Discharged July 14, 1862.	208	Maynold, C. A., Pt., D, 8th Texas, age 21.	April 9, 1864.	Left. Discharged.
160	Jones, R. M., Pt., E, 4th Texas.	—	Discharged October 21, 1862.	209	McAllister, J. H., Pt., K, 57th Virginia.	July, 1863.	Paroled August 22, 1863.
161	Jones, J. C., Pt., C, 11th Virginia, age 28.	July 3, 1863.	Left. Paroled August 22, 1864.	210	McBride, J. H., Pt., 18th Prov. Militia.	Sept. 17, 1862.	Discharged October 6, 1862.
162	Jones, S. F., Corp'l, M, 6th Alabama.	Sept. 17, 1862.	Right. Discharged December 19, 1862.	211	McCauley, J., Pt., B, 159th New York.	May 20, 1863.	By Surg. Wilson, C. S. A. Discharged July 23, 1863.
163	Jones, R. M., Pt., K, 20th New York.	—	Right. Discharged January 27, 1863.	212	McCaughy, E., Pt., E, 1st Louisiana.	July, 1863.	Paroled September 23, 1863.
164	Jones, T. C., Pt., Carter's Virginia Battery.	July, 1863.	Left. Paroled Sept. 5, 1863.	213	McCriston, J., Pt., A, 54th N. C., age 23.	Oct. 19, 1864.	Left. Discharged.
165	Jowees, J., Pt., A, 31st Georgia.	July 3, 1863.	Left. Paroled August 22, 1863.	214	McDonald, A. J., Pt., H, 45th Georgia.	July, 1863.	Left. Paroled August 24, 1863.
166	Joyner, D. E., Pt., B, 26th South Carolina.	—	Right. Furloughed January 21, 1865.	215	McGinnis, J., Pt., H, 6th Alabama, age 31.	—	Right. Duty.
167	Kelley, C. M., Pt., G, 42d Illinois, age 21.	Dec. 31, 1862.	Right; (also wound of left arm.) Disch'd September 14, 1863.	216	McKeever, J. E., Serg't, 4, 10th Ohio.	Oct. 8, 1862.	Right. Disch'd January 1, 1863; pensioned.
168	Kelly, J. C., Serg't, A, 16th Iowa, age 19.	April 6, 1863.	Right. Discharged August 26, 1863.	217	McKee, J. B., Pt., A, 11th Mississippi, age 22.	July, 1863.	Left. Paroled August 22, 1863.
169	Kellin, W., Pt., A, 2d Artillery.	—	Duty September 26, 1863.	218	McMahon, J., Pt., 5th Virginia.	July 29, 1861.	Discharged October 14, 1861.
170	Keys, J., Corp'l, E, 1st Georgia.	—	Discharged October 10, 1862.	219	McMurray, W. L., Lieut., B, 20th Tennessee.	—	Left. Paroled June 9, 1865.
171	King, R. N., Serg't, G, 21st Virginia.	—	Right. Retired October 6, 1864.	220	Meade, H., Capt., D, 38th Virginia.	July, 1863.	Right. Paroled August 24, 1863.
172	Kirkland, S., Serg't, I, 4th Alabama, age 22.	July 25, 1864.	Right. Discharged.	221	Meek, J. M., Pt., E, 5th Virginia.	July, 1863.	Left. Paroled September 5, 1863.
173	Klockner, A., Pt., E, 48th Pennsylvania.	—	Left. Discharged April 11, 1863.	222	Melton, E. F., Pt., H, 25th S. C., age 17.	Feb. 10, 1864.	Left. Discharged.
174	Knight, J. B., Corp'l, G, 41st Illinois.	1863.	Right. Discharged September 21, 1863.	223	Merriman, W. F., E, 7th Ohio.	—	Left. Disch'd August 2, 1862.
175	Knorr, A. E., Corp'l, G, 17th Mississippi.	July, 1863.	Right. Paroled Sept. 5, 1863.	224	Miller, J., Pt., K, 5th N. C., age 33.	June 1, 1864.	Left. Discharged.
176	Laffey, P., Pt., C, 10th Louisiana.	July, 1863.	Left. Discharged December 28, 1864.	225	Miller, J., Pt., 1, 43d N. C., age 58.	July 9, 1864.	Right. Discharged.
177	Lambden, S., Corp'l, A, 8th Kentucky.	—	Discharged February 7, 1863.	226	Miller, F. B., Lieut., C, 8th Alabama.	July, 1863.	Left. To prison August 22, 1863.
178	Lancasters, J. W., —, G, 51st Ohio.	Dec. 31, 1862.	Left. Discharged February 10, 1863.	227	Mills, J., Pt., E, 55th N. C., age 22.	—	Right. Discharged.
179	Lang, J. T., Pt., D, Phil- lips' Ga. Leg'n, age 19.	Oct. 9, 1863.	Left. Discharged.	228	Mills, F. M., Pt., I, 1st N. C. Cav., age 24.	Oct. 27, 1864.	Right. Discharged.
180	Langley, E. T., Pt., M, 22d North Carolina.	—	Discharged July 30, 1862.	229	Minicke, J. W., Pt., F, 7th South Carolina.	—	Right. Discharged November 10, 1862.
181	Langir, A. N. V.	—	Duty.	230	Mitchell, J., Pt., E, 145th Pennsylvania.	—	Left. Discharged April 16, 1863.
182	Lasher, E., Pt., B, 97th New York.	—	Left. Discharged November 25, 1862.	231	Moat, W. W., Pt., A, 48th Georgia.	—	Discharged October 13, 1862.
183	Leary, J., Pt., H, 1st Missouri.	—	Left. Discharged July 31, 1862.	232	Monk, J. W., Serg't, A, 5th North Carolina.	Oct. 19, 1864.	Left. Discharged.
184	Lee, S. P., Major, 3d Maine.	—	Right. To V. R. C. November 12, 1863.	233	Moore, J. T., Pt., C, 10th Alabama, age 27.	July, 1863.	Right. To Provost Marshal Sep- tember 10, 1863.
185	Letchanth, R., Pt., I, 9th Louisiana.	July 2, 1863.	Paroled September 5, 1863.	234	Moore, J. A., Pt., F, 11th Mississippi.	—	Right. Discharged June 29, 1864.
186	Lima, J., Pt., E, 10th Louisiana.	July, 1863.	Paroled September 12, 1863.	235	Mott, R., Pt., F, 1st Min- nesota.	—	Left. Discharged April 14, 1863.
187	Lipscombe, I. L., Pt., C, 18th Virginia.	July, 1863.	Paroled August 22, 1863.	236	Mulligan, L. S., Serg't, G, 4th N. C., age 26.	May 3, 1863.	Left; (also wound of right shoulder and thigh.) Discharged.
188	Littler, R. M., Capt., B, 2d Iowa, age 30.	April 6, 1862.	Left. To V. R. C. August 5, '63.	237	Murphy, D. S., Pt., I, 17th Virginia.	July 18, 1863.	Discharged February, 1865.
189	Little, C. E., Pt., I, 59th Georgia.	—	Left. Duty April 8, 1864.	238	Neil, G., Musician, 11th North Carolina.	—	Left. Furloughed Oct. 7, 1863.
190	Lloyd, J., Pt., C, 13th Mississippi.	July, 1863.	Paroled September 5, 1863.	239	Nicholas, J. M., Pt., G, 16th Georgia.	July, 1863.	Paroled August 22, 1863.
191	Logart, W. A., Serg't, H, 11th Alabama.	July, 1863.	Left. Transferred October 15, 1863.	240	Norton, P., Pt., G, 28th Maine, age 20.	June 28, 1863.	Left. Duty September 30, 1863.
192	Logan, J. M., Pt., D, 33d Ohio.	Dec. 31, 1862.	Left. Duty April 1, 1863.	241	O'Brien, P., Pt., H, 18th Louisiana.	—	Left. Discharged September 19, 1863.
193	Long, G. T., Pt., G, 5th Texas.	—	Discharged October 17, 1862.	242	Orr, W., Pt., Capt. Tann- er's Ind. Co.	—	Left. Discharged March 2, 1865.
194	Loudon, J. W., Serg't, B, 11th N. C.	Feb. 5, 1865.	Left. Furloughed.	243	Overcash, O. C., Pt., I, 7th N. Carolina, age 30.	April 25, 1864.	Left. Discharged.
195	Lowe, J. H., Pt., F, 5th Virginia.	—	Left. Discharged March 27, 1863.	244	Pate, G. B., Corp'l, A, 3d North Carolina.	May 3, 1863.	Left. Discharged.
196	Lyall, W., Corp'l, A, 34th N. C., age 22.	—	Right. Discharged.	245	Payne, Q. A., Pt., G, 25th Virginia.	—	Left. Discharged July 14, 1862.
197	Lyon, J., Pt., B, 23d Iowa.	—	Left. To V. R. C. March 4, 1864.	246	Pendleton, G., Pt., C, 41st Illinois.	—	Right. Discharged August 12, 1862.
198	Macon, T. H., Pt., A, 12th Alabama.	July, 1863.	Left. Paroled September 5, 1863.	247	Perry, W., Pt., F, 8th Louisiana.	—	Paroled October 27, 1863.
199	Manning, J., Pt., B, 16th N. C., age 26.	June 15, 1864.	Left. Discharged.				



No.	NAME, AGE, AND MILITARY DESCRIPTION.	DATES.	OPERATIONS, OPERATOR, RESULT.	No.	NAME, AGE, AND MILITARY DESCRIPTION.	DATES.	OPERATIONS, OPERATOR, RESULT.
248	<i>Pettit, L. H.</i> , Pt., E, 11th Mississippi.	—	Right. Paroled August 22, 1863.	297	<i>Thomason, H. C.</i> , Pt., H, 11th Georgia.	July, 1863.	Right. Paroled August 24, 1863.
249	<i>Phillips, B. A.</i> , Pt., F, 28th N. C., age 22.	—	Right. Retired January 11, 1865.	298	<i>Thompson, W. L.</i> , Pt., L, 8th Illinois Cav.	—	Left. Discharged February 18, 1863.
250	<i>Pierson, W.</i> , Pt., K, 44th Alabama.	—	Left. Discharged November 21, 1862.	299	<i>Thompson, C. M.</i> , Pt., I, 14th N. C., age 20.	May 12, 1864.	Right. Discharged.
251	<i>Pierce, J. W.</i> , Pt., F, 7th Georgia.	—	Discharged October 21, 1863.	300	<i>Tieman, L. B.</i> , Lt., D, 21st Mississippi.	July, 1863.	(Also wound of leg.) Paroled September 25, 1863.
252	<i>Piper, P.</i> , Pt., P, 71st Pa.	—	Left. Deserted August 24, 1863.	301	<i>Travers, R. D.</i> , Pt., E, 57th N. C.	—	Discharged February 26, 1863.
253	<i>Pixley, J.</i> , Pt., A, 18th Michigan.	—	Left. Discharged April 7, 1863.	302	<i>Tromler, W.</i> , Pt., K, 116th N. Y., age 37.	April 23, 1864.	Left. Duty August 21, 1864.
254	<i>Plunket, J.</i> , Pt., A, 25th Missouri.	June 8, 1863.	Left. Discharged July 30, 1863. Rejected as pensioner.	303	<i>Truller, W. M.</i> , Pt., C, Phillips' Georgia Legion, age 29.	May 10, 1864.	Left; (also loss of right finger.) Discharged.
255	<i>Preusch, G.</i> , Serg't, D, 5th Louisiana.	—	Right. Retired October 22, 1864.	304	<i>Unbarger, J. B.</i> , Pt., D, 4th Virginia, age 31.	July, 1863.	Left. Duty January 2, 1865.
256	<i>Putnam, O. W.</i> , Lieut., E, 18th Georgia.	July, 1863.	To prison August 23, 1863.	305	<i>Underhill, J. D.</i> , Pt., H, 31st N. C., age 19.	May 14, 1864.	Left. Discharged.
257	<i>Quaresima, F. W.</i> , Serg't, E, 8th Georgia.	—	Discharged February 17, 1863.	306	Unknown, alias "Company I."	May 5, 1864.	Gangrene; re-amputation near the shoulder May 10, 1864.
258	<i>Quisenberry, W. B.</i> , Pt., H, 36th Virginia.	—	Left. Discharged January, 1865.	307	<i>Wagner, A. E.</i> , Pt., D, 16th Mississippi.	May 12, 1864.	Left. Discharged.
259	<i>Reed, J. D.</i> , Lieut., D, 25th Texas Cavalry.	—	Right. To prison March 27, 1863.	308	<i>Walker, J.</i> , Pt., H, 76th New York.	May 8, 1864.	Discharged.
260	<i>Reid, J.</i> , Capt., H, 72d Illinois.	—	Right. Resigned February 15, 1864.	309	<i>Walker, W. T.</i> , Pt., H, 6th North Carolina.	May 31, 1862.	Right. Retired February 14, 1865.
261	<i>Reynolds, J. R.</i> , Pt., K, 15th Ga., age 32.	July 3, 1863.	Left. Paroled August 22, 1863.	310	<i>Walker, B. D.</i> , Pt., F, 75th Illinois.	Oct. 8, 1863.	Right. Discharged January 12, 1863.
262	<i>Rhea, G. W. A.</i> , Corp'l, D, 17th Mississippi.	—	Left. Paroled August 24, 1863.	311	<i>Wall, A. J.</i> , Pt., B, 17th Georgia.	July, 1863.	Paroled September 5, 1863.
263	<i>Ritjgs, C. C.</i> , Serg't, A, 28th N. C., age 25.	Sept. 30, 1864.	Left. Discharged.	312	<i>Waller, A.</i> , Pt., K, 5th Florida.	July 2, 1863.	Left. Discharged November 11, 1863.
264	<i>Robinett, H.</i> , Lieut., 1st Virginia Cavalry.	July, 1863.	Left. Discharged October 28, '63.	313	<i>Walls, H.</i> , Pt., C, 140th Penn., age 42.	July, 1863.	Right. Discharged December 19, 1863.
265	<i>Robert, W. H.</i> , Pt., H, 4th Georgia.	—	Exchanged July 30, 1862.	314	<i>Warner, A. W.</i> , Lieut., H, 2d Virginia.	July, 1863.	(Also flesh wound of thigh.) Paroled October 21, 1863.
266	<i>Robertson, J.</i> , Pt., I, 5th North Carolina.	July 2, 1863.	Paroled September 12, 1863.	315	<i>Warren, J. W.</i> , Pt., C, 61st Virginia.	Aug. 21, 1863.	Right. Duty April, 1864.
267	<i>Robertson, R.</i> , Pt., F, 5th South Carolina.	—	Discharged October 17, 1862.	316	<i>Warren, R.</i> , Pt., E, 23d Virginia.	—	Right. Discharged November 3, 1862.
268	<i>Robinson, J.</i> , Pt., F, 31st North Carolina.	—	Left. Furloughed March 27, '65.	317	<i>Ward, A. C.</i> , Pt., B, 20th Alabama.	—	Left. To prison September 15, 1863.
269	<i>Robinson, J.</i> , Pt., D, 38th Virginia.	July, 1863.	Paroled September 5, 1863.	318	<i>Wartick, F. T.</i> , Corp'l, C, 55th N. C., age 19.	May 5, 1864.	Left. Discharged.
270	<i>Rodgers, F. L.</i> , Lieut., B, 15th N. C.	Oct. 14, 1863.	Left. Furloughed November 19, 1863.	319	<i>Watts, W. D.</i> , Serg't, Rheff's Battery.	July 2, 1863.	(Also wound of neck.) Paroled September 6, 1863.
271	<i>Rogerson, E. G.</i> , Serg't, C, 2d Florida.	—	Right. To prison October 17, '63.	320	<i>Webber, G. E.</i> , Private, Branch's Artillery.	Sept. 17, 1862.	Right. Discharged February 18, 1863.
272	<i>Roling, D. H.</i> , Corp'l, E, 23d North Carolina.	July, 1863.	Left. Paroled September 5, 1863.	321	<i>Weldon, W.</i> , Pt., G, 19th Massachusetts.	—	Left. Discharged August 20, 1862.
273	<i>Rook, J.</i> , Pt., L, 1st Texas.	Sept. 17, 1862.	Furloughed December 3, 1862.	322	<i>Welch, R. J.</i> , Pt., H, 26th South Carolina.	Nov. 17, 1864.	Left. Furloughed December 26, 1864.
274	<i>Rue, J. I.</i> , Pt., K, 59th Illinois.	Oct. 8, 1862.	Left. Discharged December 27, 1862.	323	<i>Wheeler, J. R.</i> , Pt., F, 45th Va., age 25.	June 1, 1864.	Left. Discharged.
275	<i>Ruffle, J.</i> , Pt., A, 73d Illinois.	Dec. 31, 1862.	Right. Discharged January 25, 1863.	324	<i>Wheeler, J.</i> , Pt., K, 45th North Carolina.	July, 1863.	Paroled August 24, 1863.
276	<i>Rush, D. H.</i> , Pt., Hampton's Legion.	—	Left. Discharged October 14, 1861.	325	<i>White, J. C.</i> , Pt., E, 5th Alabama.	—	Left. Furloughed January 29, 1863.
277	<i>Sandlin, A.</i> , Pt., H, 26th Alabama.	July 1, 1863.	Left. Paroled October 22, 1863.	326	<i>White, J. W.</i> , Pt., D, 5th New Jersey.	—	Right. Discharged September 13, 1862.
278	<i>Saxton, J.</i> , Pt., H, 2d North Carolina.	—	Right. Paroled Sept. 12, 1863.	327	<i>Whitton, W. J.</i> , Pt., B, 4th N. C. Cav., age 37.	Oct. 11, 1863.	Right. Discharged.
279	<i>Scott, G. W.</i> , Pt., E, 31st N. C., age 19.	—	Left. Discharged.	328	<i>Williamson, W. H.</i> , Major, 7th Tennessee.	July 2, 1863.	Right. To prison September 23, 1863.
280	<i>Sherrill, J. A.</i> , Pt., G, 52d N. C.	Oct. 1, 1864.	Left. Discharged.	329	<i>Williamson, J.</i> , Pt., G, 60th Georgia.	—	Discharged December 20, 1862.
281	<i>Shivers, J. B.</i> , Pt., K, 11th Alabama.	—	Discharged August 13, 1862.	330	<i>Williams, G. W.</i> , Pt., B, 49th Virginia.	July, 1863.	Left. Paroled August 24, 1863.
282	<i>Shields, P.</i> , Pt., C, 63d Va.	—	Left. Duty Sept. 25, 1863.	331	<i>Williams, H.</i> , Pt., E, 35th Georgia.	—	Right. Paroled Sept. 5, 1863.
283	<i>Simpson, G. W.</i> , Pt., K, 6th N. C.	July 1, 1863.	Left. Discharged.	332	<i>Williams, W. J.</i> , Pt., D, 38th Georgia.	—	Discharged October 17, 1862.
284	<i>Smith, G. W.</i> , Pt., K, 21st Georgia.	—	Right. Discharged July 14, 1862.	333	<i>Wiley, S.</i> , Pt., K, 18th Ga.	—	Discharged August 27, 1862.
285	<i>Smith, W. F.</i> , Serg't, I, 5th N. C.	July, 1863.	Right. Paroled Sept. 5, 1863.	334	<i>Wilson, D. T.</i> , Pt., E, 20th North Carolina.	—	Right. Discharged November 3, 1862.
286	<i>Smith, C.</i> , Pt., D, 74th Colored Troops.	—	Discharged March 29, 1863.	335	<i>Winters, G. L.</i> , Lieut., H, 154th New York.	July, 1863.	Left. Discharged December 29, 1863.
287	<i>Smith, C.</i> , Pt., G, 22d North Carolina.	—	Left. Discharged September 23, 1863.	336	<i>Winston, E. M.</i> , Pt., F, 4th Alabama.	—	Right. Discharged November 11, 1862.
288	<i>Snook, J. A.</i> , Lieut., G, 12th N. C. Battery.	—	Left. To Provost Marshal April 28, 1865.	337	<i>Wise, G. W.</i> , Pt., F, 6th Virginia.	—	Right. Retired November 3, 1864.
289	<i>Somersel, J. S.</i> , Pt., G, 20th N. C.	July, 1863.	Left. Paroled Sept. 12, 1863.	338	<i>Wise, R.</i> , Pt., F, 31st Va.	—	Discharged October 24, 1864.
290	<i>Stacy, T. F.</i> , Pt., G, 16th N. C., age 35.	Aug. 26, 1862.	Left. Discharged.	339	<i>Wise, G.</i> , Pt., H, 6th Va.	—	Left. Discharged Feb. 9, 1865.
291	<i>Stacey, H. H.</i> , Pt., A, 64th N. Y.	—	Left. Discharged December 1, 1862.	340	<i>Womac, R. R.</i> , Pt., H, 7th Tennessee, age 23.	July 3, 1863.	Right. Paroled August 22, 1863.
292	<i>Stevens, O. H. P.</i> , Lieut., C, 42d Mississippi.	May 5, 1864.	Left. Discharged.	341	<i>Wright, W.</i> , Pt., D, 5th New Jersey.	June 1, 1862.	Right. Discharged July 28, 1862.
293	<i>Sullivan, J.</i> , Pt., F, 14th Wisconsin.	—	Left. Discharged April 19, 1864.	342	<i>Yorkman, J. W.</i> , Pt., H, 11th Alabama, age 30.	Feb. 6, 1865.	Right. Released June 21, 1865.
294	<i>Swainright, J. W.</i> , Cp'l, K, 115th Illinois.	Sept. 19, 1863.	Right. Disch'd March 18, 1864.	343	<i>Young, C. P.</i> , Corp'l, F, 5th Virginia, age 33.	July, 1863.	Left. Paroled August 22, 1863.
295	<i>Tanner, E. S.</i> , Pt., A, 10th Georgia.	—	Discharged July 25, 1862.	344	<i>Zang, P.</i> , Teamster, K, 47th Ohio.	—	Duty January 15, 1863.
296	<i>Teal, M. H. L.</i> , Pt., K, 42d Virginia.	—	Discharged February 10, 1863.	345	<i>Zeigler, L.</i> , Corp'l, H, 5th Virginia.	July 20, 1864.	Right. Discharged.

§ *Fatal Cases.*—One hundred and ninety-four amputations of the arm of uncertain seat and date resulted fatally. Of these, seventy operations were on the right, fifty-eight on the left side, not recorded, sixty-six. The causes of death are recorded in a small proportion of the cases.<sup>1</sup> One patient had undergone previously an excision of the elbow; one submitted to a synchronous amputation of the thigh; one succumbed after a subsequent exarticulation at the shoulder.

TABLE XCIX.

*Condensed Summary of One Hundred and Ninety-Four Fatal Cases of Amputations in the Arm, of Uncertain Date and Seat.*

No.	NAME, AGE, AND MILITARY DESCRIPTION.	DATES.	OPERATIONS, OPERATOR, RESULT.	No.	NAME, AGE, AND MILITARY DESCRIPTION.	DATES.	OPERATIONS, OPERATOR, RESULT.
1	Agnew, T. W., Pt., A, 25th Illinois.	Dec. 29, 1862.	Right. Died February 6, 1863.	36	Dawson, J., Pt., C, 21st Iowa.	May 22, 1863.	Right. Died June 25, 1863.
2	Anderson, C. O. C., Pt., H, 21st Iowa.	—	Died June 14, 1863.	37	Doctenberg, J., Pt., I, 6th Kentucky.	Nov. 25, 1863.	Left. Died December 25, 1863.
3	Alloway, W. H., Pt., B, 21st Iowa.	May 17, 1863.	Right. Died June 8, 1863.	38	Dorsey, J. W., Corp'l, 11, 53d Georgia.	—	Died November 29, 1863.
4	Aston, T. C., Pt., C, 37th Virginia.	—	Died July 22, 1863.	39	Drew, R. B., Corp'l, F, 1st N. J., age 40.	May 10, 1864.	Right. Died May 31, 1864.
5	Aylward, R., Pt., E, 5th Michigan.	July, 1863.	Right. Died July 27, 1863.	40	Edge, S. C., Pt., D, 8th Georgia.	July, 1863.	Right. Died July 21, 1863.
6	Baker, H., Pt., G, 42d Indiana.	August, 1864.	Left. Died August 12, 1864.	41	Ellis, J., Pt., G, 12th Illinois Cavalry.	July, 1863.	Right. Died August 19, 1863.
7	Beeckhart, R., Pt., E, 151st Pennsylvania.	July, 1864.	Left. Died July 26, 1863.	42	Emmerson, T. R., Lieut., C, 20th N. C.	July, 1863.	Left. Died August 11, 1863.
8	Bennett, J., Pt., B, 27th Connecticut.	Dec. 13, 1862.	Left. Died December 25, 1862.	43	Estes, J. M., Pt., B, 43th Illinois.	1862.	Secondary hæmorrhage. Died May 9, 1862, pyæmia.
9	Beckham —, Pt., G, 3d Alabama.	—	Right. Died July 9, 1863.	44	Farmer, B., —, G, 37th North Carolina.	July, 1863.	Died July 26, 1863.
10	Belleng, G., Pt., D, 98th Pennsylvania, age 23.	July 1, 1862.	Left. Died July 29, 1862.	45	Farnon, J., Pt., C, 8th Alabama.	—	Right; (wound of hips and privates.) Died June 18, 1862.
11	Benson, J. W., Pt., B, 45th North Carolina.	July, 1863.	Left. Died July 25, 1863.	46	Fastenegger, J., Pt., B, 14th N. Y., age 46.	May 15, 1864.	Left. Died July 2, 1864, pyæmia.
12	Bodman, P., Pt., E, 17th Wisconsin.	—	Left. Died June 7, 1863.	47	Fraecker, J., Pt., 100th New York.	—	Right. Died November 25, 1864.
13	Border, J., Pt., D, 60th Illinois.	July 4, 1864.	Right. Died August 2, 1864.	48	Fuller, T., Pt., F, 7th Louisiana.	—	Died August 23, 1861.
14	Bollings, J., Pt., D, 93d Illinois, age 20.	May 22, 1863.	Left; gangrene. Died July 9, 1863.	49	Gettes, E., Pt., H, 12th South Carolina.	—	Right. Died June 2, 1864.
15	Brooks, J., Pt., H, 42d North Carolina.	—	Died February 15, 1863.	50	Gough, T., Pt., F, 38th Colored Troops.	Sept. 29, 1864.	Right; (also wound of lung.) Died October 13, 1864.
16	Brown, J., Pt., K, 77th Illinois.	May 16, 1863.	Left. Died July 18, 1863.	51	Gravet, G. A., Lieut., K, 1st Michigan Sharpshooters, age 24.	June 17, 1864.	Left. Died June 30, 1864.
17	Bullis, A. W., Pt., F, 52d North Carolina, age 22.	July, 1863.	Right. Died August 3, 1863.	52	Hagerty, J., Pt., G, 9th Massachusetts.	—	Died September 5, 1862.
18	Burke, J. R., Pt., F, 11th Virginia.	—	Right. Died June 7, 1864.	53	Hatfield, S. A., Pt., B, 118th Ohio.	—	Left. Died June 20, 1864.
19	Burris, C. F., Pt., B, 39th Indiana.	—	Died February 2, 1863.	54	Hall, W. R., Pt., C, 35th Illinois.	Mar. 7, 1862.	Right. Died April 22, 1862.
20	Burton, J., Pt., I, 40th New York.	May 3, 1863.	Right. Died May 26, 1863.	55	Hank, H., Pt., I, 4th Iowa.	Mar. 7, 1862.	Died April 17, 1862.
21	Calhoun, C. W., Pt., E, 5th Florida.	—	Right. Died June 6, 1864.	56	Harden, M. S., Pt., G, 79th Indiana.	—	Right. Died February 18, 1863.
22	Calhoun, W., Pt., E, 11th South Carolina.	—	(Wound of thigh.) Died October 1, 1862.	57	Hart, H. C., Pt., I, 28th Illinois.	1863.	Left. Died August 1, 1863.
23	Cantrell, C. M., Pt., E, 13th South Carolina.	—	Died June 27, 1864.	58	Hartong, R., Pt., D, 100th Illinois.	Sept. 19, 1863.	Left. Died October 29, 1863, icterus.
24	Carr, J., Pt., K, 59th New York.	Sept. 17, 1862.	Right. Died November 16, 1862.	59	Haste, A., Corp'l, B, 32d Wisconsin, age 22.	—	Left. Died August 22, 1864.
25	Carroll, D. L., Pt., D, 5th Alabama.	—	Right. Died May 14, 1863.	60	Hatcher, V., Pt., A, 12th Virginia.	—	Died September 25, 1862.
26	Cason, J. D., Pt., I, 6th Virginia.	—	Died May 27, 1864.	61	Healy, M., Corp'l, F, 1st Mass., age 25.	June 10, 1863.	Left. Died July 7, 1863, pyæmia.
27	Cheney, —, 2d South Carolina, age 30.	Sept. 17, 1862.	Right; re-amputation of shoulder joint. Died.	62	Hernon, E. J., Pt., F, 19th Virginia.	July, 1863.	Right; (also wound of lung.) Died July 10, 1863.
28	Coffey, I. G., Pt., F, 26th North Carolina.	July, 1863.	Left. Died August 24, 1863.	63	Hickman, H., Pt., K, 3d N. C. Artillery.	—	Right. Died February 7, 1865.
29	Collins, A., —, A, 118th New York.	—	Right. Died June 9, 1864.	64	Hill, L. G., Pt., E, 11th Indiana.	May 16, 1863.	Left. Died July 3, 1863.
30	Cook, J. S., Pt., E, 11th Indiana.	—	Left. Died June 17, 1863, diarrhoea and exhaustion.	65	Hilloek, B., Pt., G, 72d New York, age 31.	May 31, 1862.	Left. Died June 25, 1862.
31	Coon, A. D., Pt., D, 7th Wisconsin.	Aug. 30, 1862.	Left. Died October 12, 1862.	66	Hough, J., Pt., E, 9th Georgia.	July, 1864.	Left. Died September 9, 1863.
32	Cornwell, M., Pt., G, 24th Indiana.	May 16, 1863.	Died July 24, 1863.	67	Howard, J. S., Pt., C, 51st Ohio, age 18.	—	Right. Died July 19, 1864, exhaustion.
33	Cowan, W., Pt., D, 6th South Carolina.	—	Left. Died October 11, 1862, pyæmia.	68	Hoyt, G., Pt., C, 32d Illinois.	April 6, 1862.	Left. Died April 27, '62, pyæmia.
34	Cronan, J., Pt., K, 77th Illinois.	—	Left. Died July 8, 1863, phthisis pulmonalis.	69	Humphreys, W., Carpenter's Artillery.	July, 1863.	Died September 11, 1863.
35	Curtis, W. C., Serg't, I, 43d North Carolina.	—	Died July 6, 1863.	70	Hunter, W. F., Pt., B, 27th North Carolina.	—	Right. Died November 9, 1863.

<sup>1</sup> Death is referred to tetanus in 2 cases, to secondary hæmorrhage in 2, to diphtheria in 1, to pyæmia in 12, to erysipelas with gangrene in 3, to diarrhoea and exhaustion in 4, to icterus in 1, to typhoid fever in 1, to phthisis in 1. The cause was not specified in 167 cases.



No.	NAME, AGE, AND MILITARY DESCRIPTION.	DATES.	OPERATIONS, OPERATOR, RESULT.	No.	NAME, AGE, AND MILITARY DESCRIPTION.	DATES.	OPERATIONS, OPERATOR, RESULT.
71	Hussey, M., Serg't, C, 2d Louisiana.	July, 1863.	Died September 18, 1863.	119	Nichols, J. A., Pt., B, —, Virginia.	July, 1863.	Right. Died September 21, 1863.
72	Huver, R., Pt., G, 1st Missouri.	Aug. 10, 1861.	Died August 26, 1861.	120	Oar, J. M., Pt., A, 18th Mississippi.	—	Died November 18, 1861.
73	Ingraham, J., Pt., K, 15th Alabama.	—	Left. Died August 13, 1863.	121	Onell, J., Pt., G, 7th Michigan.	Sept. 17, 1862.	Right. Died October 10, 1862.
74	Jay, B. F., Pt., A, 1st Louisiana, age 18.	April 24, 1864.	Right; also w'd neck; (exc. Apr. 28; erysip.) Died May 29, 1864.	122	Parker, J. J., Pt., D, 24th Mississippi.	Oct. 8, 1862.	Died October 19, 1862, tetanus.
75	Jenkins, B., Pt., I, 34th Iowa.	—	Right. Died August 28, 1863.	123	Penny, F., Pt., F, 12th Georgia.	July, 1863.	Right. Died July 23, 1863.
76	Johnson, J. Q., Pt., G, 56th North Carolina.	—	Left. Died May 6, 1865.	124	Peterson, A. H., Pt., H, 33d Alabama.	Oct. 8, 1862.	Died October 26, 1862.
77	Jones, E. P., Pt., E, 1st Missouri.	Aug. 10, 1861.	(Also wound of spine.) Died August 18, 1861.	125	Phillips, T. H., Private, Richardson's Battalion, Hughes' Battery.	—	Left. Died June 14, 1864.
78	Jones, T., Pt., C, 1st Kansas.	Aug. 10, 1861.	Died August 18, 1861.	126	Pickett, J. W., Pt., G, 13th Alabama.	July, 1863.	Left. Died July 28, 1863.
79	Judd, D. B., Serg't, C, 8th Kentucky.	—	Right. Died November 2, 1863.	127	Proctor, T. D., Pt., A, 45th North Carolina.	July, 1863.	Died August 16, 1863, pyæmia.
80	Keller, J., Pt., C, 11th Illinois.	—	Right. Died June 21, 1863, typhoid fever.	128	Pugh, E., Pt., D, 50th Virginia.	—	Died August 8, 1863.
81	Kindrick, W. R., Serg't, B, 13th S. C.	—	Left. Died September 23, 1862.	129	Quarrels, J., Pt., H, 2d South Carolina.	—	Died July 23, 1862, diphtheria.
82	King, W. A., —, E, 8th Georgia.	—	Died August 31, 1861.	130	Rawls, W. S., Pt., D, 11th Mississippi.	—	Died January 14, 1863.
83	Kizer, W. A., Pt., G, 21st North Carolina.	July, 1863.	Died July 16, 1863.	131	Raymond S., Pt., B, 21st Wisconsin.	Oct. 8, 1862.	Right. Died November 18, 1862.
84	Largent, J., Pt., H, 22d Iowa.	June 10, 1863.	Died June 24, 1863.	132	Reed, C. W., G, 8th Va.	July, 1863.	Died July 17, 1863.
85	Larkin, A., Pt., D, 53d Illinois.	—	Left. Died August 12, 1863.	133	Reed, F., Pt., A, 53d Ill.	July 12, 1863.	Left; (also amputation of thigh.) Died August 12, 1863.
86	Lauson, J., Pt., D, 42d Mississippi.	July, 1863.	Right. Died August 29, 1863.	134	Reinohl, A., Pt., F, 1st Kansas.	Aug. 10, 1861.	Right. Died September 22, 1861, secondary hemorrhage.
87	Lemons, T. H., Pt., H, 12th Alabama.	—	Died November 10, 1862.	135	Robinson, D. P., Corp'l, K, 4th Indiana.	May 16, 1863.	Right. Died July 20, 1863.
88	Lockridge, W. L., Pt., D, 7th S. C.	—	Died June 11, 1864, pyæmia.	136	Robinson, J., Pt., B, 45th North Carolina.	July, 1863.	Left. Died August 4, 1863.
89	Lofell, W. H., Pt., C, 28th Virginia.	—	Died October 14, 1862.	137	Roney, F., Pt., F, 14th Infantry.	July, 1863.	Left. Died August 2, 1863.
90	Long, W. A., Pt., D, 14th North Carolina.	—	Died July —, —.	138	Sanderson, G., Pt., K, 44th Indiana.	April 6, 1862.	Left. Died May 14, 1862, pyæmia.
91	Louger, E., Corp'l, F, 3d R. I. Cav., age 26.	April 20, 1864.	Right. Died May 26, 1864.	139	Schoen, D., Lieut., 10th Kansas.	Dec. 7, 1862.	Died December 19, 1862.
92	Lower, S. P., Serg't, F, 3d Alabama.	July 1, 1863.	Left. Died July 29, 1863.	140	Schoepp, J., Pt., E, 21st Iowa.	May 22, 1863.	Left. Died June 27, 1863.
93	Maloon, W. G., Pt., I, 12th New York.	May 3, 1863.	Died June 16, 1863.	141	Scholl, H., Pt., C, 24th Connecticut.	June 17, 1863.	Left. Died July 13, 1863.
94	Markwalder, J., Pt., C, 41st Ohio.	Nov. 25, 1863.	Left. Died December 25, 1863.	142	Scott, J. F., Serg't, A, Phillips' Legion.	July, 1863.	Died July 6, 1863.
95	Martin, F. H., Pt., E, 1st R. I. Art.	July, 1863.	Right; (also wound of side and back.) Died July 24, 1863.	143	Scroggs, D. D., Pt., G, 38th Virginia.	July, 1863.	Died July 10, 1863.
96	Martin, L., Pt., D, 61st North Carolina.	—	Died October 22, 1864.	144	Seruton, D. K., 2d Lt., G, 3d N. H.	June 16, 1862.	Died August 8, 1862.
97	March, L. S., Lieut., K, 97th Pennsylvania.	—	Right. Died August 13, 1864, exhaustion.	145	Sever, A., Pt., I, 2d N. York Mounted Rifles, age 20.	June 1, 1864.	Right. Died June 14, 1864.
98	Masson, D. G., Pt., D, 33d Missouri.	—	Right. Died May 5, 1864.	146	Sexton, C. T., Pt., K, 5th S. C. Cavalry.	—	Right. Died June 21, 1864.
99	McCarty, A. J., Pt., B, 28th Virginia.	—	Died October 2, 1862.	147	Simeely, W. A., Pt., D, 115th Illinois.	Sept. 19, 1863.	Left. Died October 11, 1863.
100	McChine, jr., H., Pt., A, 6th Connecticut.	July 18, 1863.	Left; (also wound of chest.) Died July 27, 1863.	148	Smith, C. F., Pt., I, 4th Michigan Cavalry.	—	Right. Died February 1, 1863.
101	McCullough, J. T., Sergeant, A, 3d Georgia.	July, 1863.	Right. Died July 27, 1863.	149	Smith, D., —, D, 28th N. C., age 19.	July 3, 1863.	Left. Died August 21, 1863, pyæmia.
102	McDonald, J. M., Pt., D, 56th New York.	—	Left. Died June 25, 1862.	150	Smith, F. L., Pt., I, 19th Mass., age 25.	—	Died August 5, 1862, pyæmia and diarrhœa.
103	McPerson, A. C., Pt., K, 7th Georgia.	—	Died October 12, 1862.	151	Smith, F. W. C., Pt., C, —	—	Left. Died June 26, 1864.
104	McGinnis, P., Pt., Ried's Virginia Battalion.	—	Right. Died June 29, 1864.	152	Smith, J. A., Capt., K, 47th New York.	—	Died May 9, 1864.
105	McMakin, J., —, A, 13th Mississippi.	July, 1863.	Died August 3, 1863.	153	Smith, P., Pt., C, 64th New York.	—	Left; (also wound of hip.) Died July 9, 1862.
106	McQuinty, P., Pt., I, 1st Reserve Artillery.	—	Right. Died September 5, 1863.	154	Smith, T., Pt., H, 31st Georgia.	July, 1863.	Left. Died July 7, 1863.
107	McSwain, W. D., Pt., H, 28th North Carolina.	—	Died October 30, 1864.	155	Snell, C., Pt., F, 147th New York.	July 2, 1863.	Died July, 1863.
108	McVay, D., Lieut., A, 76th Pennsylvania.	July 30, 1864.	Right. Died September 12, 1864, erysipelas.	156	Snow, A., Pt., G, 15th Massachusetts.	—	Died October 18, 1862.
109	Meret, L. R., Pt., C, 2d South Carolina.	July, 1863.	Died July 9, 1863, tetanus.	157	Stalcup, W., Pt., K, 15th Iowa.	—	Right. Died August 13, 1864.
110	Messer, B. H., Pt., D, 17th Georgia.	—	Died September 26, 1862.	158	Stevenson, J., Corp'l, D, 38th Wisconsin, age 37.	June 16, 1864.	Right. Died June 25, 1864, exhaustion.
111	Meyer, S., Pt., A, 2d Kentucky.	April 7, 1862.	Died of pyæmia.	159	Stith, W. W., Lieut., K, 18th Virginia.	—	Right. Died in 1864.
112	Mitchell, C. T., Pt., 19th Indiana Battery.	Oct. 8, 1862.	Secondary hæmorrhage. Died October 13, 1862.	160	Stroud, G. W., Pt., G, 11th Wisconsin.	—	Left. Died August 11, 1863.
113	Mitchell, W. L., Pt., D, 11th Georgia, age 21.	July 1, 1863.	Left. Died August 7, 1863.	161	Swanson, J., Pt., D, 42d Mississippi.	July, 1863.	Right. Died August 29, 1863.
114	Moffat, W., Pt., H, 53d Pennsylvania.	—	Right. Died August 2, 1862.	162	Taylor, J. S., Corp'l, G, 23d South Carolina.	—	Died September 28, 1862.
115	Merel, G. W., Corp'l, G, 53d Illinois.	—	Right. Died August 23, 1863.	163	Taylor, J. Y., Corp'l, C, 96th Illinois.	Sept. 19, 1863.	Right. Died November 24, 1863.
116	Munsey, G., Pt., B, 12th New Hampshire.	July 2, 1863.	Left. Died August 1, 1863.	164	Thomas, J. A., Pt., C, 27th South Carolina.	—	Left. Died June 9, 1864.
117	Murchison, J., Serg't, E, 32d Georgia.	—	Right. Died June 25, 1864.	165	Thomason, S. J., Pt., Corbett's Georgia Battery.	—	Left. Died August 8, 1864.
118	Mustin, J. G., Pt., C, 38th Tennessee.	Oct. 8, 1862.	Died October 25, 1862.				

No.	NAME, AGE, AND MILITARY DESCRIPTION.	DATES.	OPERATIONS, OPERATOR, RESULT.	No.	NAME, AGE, AND MILITARY DESCRIPTION.	DATES.	OPERATIONS, OPERATOR, RESULT.
166	Thompson, O., Pt., B, 1st Minnesota.	July, 1863.	Left. Died August 8, 1863.	180	Walker, G. C., Corp'l, B, 4th Virginia Cavalry.	—	(Wound of side.) Died June 21, 1862.
167	Tibbetts, I., Pt., K, 3d New Hampshire.	July 12, 1863.	Right. Died September 17, 1863.	181	Wallace, W. G., Lieut., C, 5th Texas.	—	Died June 27, 1862.
168	Till, J., Pt., F, 1st Missouri.	Aug. 10, 1861.	Died August 23, 1861.	182	Watson, J. T., Corp'l, B, 11th Georgia.	July, 1863.	Right. Died July 14, 1863.
169	Tittsworth, C., Pt., H, 12th Illinois.	—	Right. Died June 23, 1863.	183	Weakly, J., Pt., D, 20th Michigan, age 20.	—	Left. Died June 6, 1864.
170	Toole, M., Corp'l, I, 3d Iowa.	—	Right. Died August 13, 1863.	184	Webber, H. S., Pt., B, 3d Maine.	May 27, 1862.	Died June 30, 1862.
171	Trotter, P. E., Pt., G, 7th New York.	—	Right. Died July 25, 1862.	185	Wells, D. L., Pt., H, 24th Virginia.	—	Died September 26, 1862.
172	Truesdell, M., Corp'l, H, 65th New York.	—	Right. Died August 2, 1862.	186	Wentz, F., Pt., I, 41st New York.	—	Right. Died July 12, 1863.
173	Turk, J. G., Serg't, D, 4th Georgia.	—	Right. Died May 26, 1864.	187	Whaley, A., Pt., Saint Mary's Cannoniers.	April 24, 1862.	Died.
174	Turner, G., Pt., A, 116th Pennsylvania.	July 3, 1863.	Right. Died August 16, 1863.	188	White, P. F., Pt., E, 14th Vermont.	—	Right. Died August 5, 1863.
175	Twedde, J., Pt., F, 14th New York.	July, 1862.	Right; by Assistant Surgeon T. H. Helsby, U. S. A. Died Oct. 6, 1862.	189	Williams, G. F., Pt., G, 1st South Carolina.	—	Died September 24, 1862.
176	Tyree, T. H., Pt., A, 49th Virginia.	—	Right. Died January 8, 1863.	190	Williams, M. L., Pt., D, 2d Georgia Battalion.	—	Died June 10, 1863.
177	Van Kusen, J., Serg't, H, 2d Iowa.	—	Left. Died June 18, '63, pyæmia.	191	Williams, S. P., Pt., K, 6d Ohio, age 23.	—	Left. Died September 3, 1864.
178	Wade, J. J., Corp'l, I, 40th Iowa.	April, 1864.	Right. Died April 15, 1864.	192	Williams, S., Pt., C, 25th Ohio.	May 8, 1862.	Left. Died May 31, 1862.
179	Wahous, J. P., 2d Lieut., D, 28th Virginia.	July, 1863.	Left. Died July 31, 1863.	193	Wilson, A., Pt., E, 157th New York.	July 2, 1863.	(Also wound of breast.) Died July, 1863.
				194	Young, J. A., Capt., G, 8th Georgia.	July, 1863.	Right. Died July 10, 1863.

§ *Undetermined Cases.*—In one hundred and sixty amputations of the arm in which the precise date and seat of operation are unrecorded, the result also is unknown. These operations were practised on twenty-five Union and one hundred and thirty-five Confederate soldiers,—on the right side in sixty, on the left in seventy-two, not recorded in twenty-eight.

TABLE C.

*Condensed Summary of One Hundred and Sixty Cases of Amputations in the Arm, in which the Precise Date and Seat of Operation and the Result are Unknown.*

No.	NAME, AGE, AND MILITARY DESCRIPTION.	DATES.	OPERATIONS, OPERATOR, RESULT.	No.	NAME, AGE, AND MILITARY DESCRIPTION.	DATES.	OPERATIONS, OPERATOR, RESULT.
1	Allen, J. C., Pt., C, 11th Georgia.	July 6, 1864.	Right; (wound of side.)	20	Brondham, J. C., 25th South Carolina.	May 14, 1864.	Right.
2	Alston, T. P., Major, 1st South Carolina.	—	Right.	21	Bruce, A., Pt., D, 14th Georgia.	June 27, 1862.	Left.
3	Ashley, J. T., Pt., E, 20th South Carolina.	July 26, 1864.	Right.	22	Bryan, A. F., Serg't, I, 1st South Carolina.	—	Right.
4	Atkins, W. C., Pt., H, 2d South Carolina.	—	Right.	23	Bryan, J. B., Serg't, H, 27th Georgia.	—	Right.
5	Atley, H. V., Pt., D, 48th Georgia.	—	Left.	24	Burgess, J., Pt., C, 51st Georgia.	—	Left.
6	Avant, B. F., Pt., B, 27th Georgia.	—	Left.	25	Calhoun, J. W., Pt., E, 28th Georgia.	—	Right.
7	Baker, T. M., Lieut., D, 43d North Carolina.	—	—	26	Cardy, J., Pt., B, 44th Colored Troops.	Decem., 1864.	—
8	Bancom, L. R., Pt., C, 10th North Carolina.	—	Right.	27	Carlton, N., Serg't, E, 14th N. Y. S. M.	July 1, 1863.	Left.
9	Barefield, J. M., Pt., B, 12th Georgia.	—	Left.	28	Casey, T., Pt., D, 7th Louisiana.	Sept. 17, 1862.	Right.
10	Bartly, W. J., Pt., G, 3d Georgia.	Aug. 21, 1864.	Right.	29	Clayton, S. W., Palmetto Sharpshooters.	June 23, 1864.	Left.
11	Bateman, J. M., Serg't, E, 9th Georgia.	—	Right.	30	Cole, J. H., Pt., D, 22d Virginia.	—	Left.
12	Bath, A., Serg't, K, 3d New Jersey Cavalry.	April 1, 1865.	Left.	31	Cole, R., Pt., H, 1st S. Carolina.	—	Right.
13	Bell, J. A., Serg't, F, 5th South Carolina.	Oct. 7, 1864.	Left.	32	Connally, J. R., Pt., I, 50th Georgia.	July, 1863.	—
14	Benton, J. T., Pt., H, 147th New York.	July 1, 1863.	—	33	Crantrell, C. M., Pt., C, 13th South Carolina.	—	Left.
15	Boggs, W. H., Serg't, C, 24th Georgia.	July, 1863.	—	34	Crawford, E. G., Pt., F, 7th North Carolina.	—	Left.
16	Booth, S., Lieut., D, 58th Virginia.	—	Left.	35	Cross, C. C., Pt., F, 24th Georgia.	—	Left.
17	Booser, C. P., Pt., C, 3d South Carolina.	Nov. 18, 1863.	Left.	36	Dailey, A., Pt., F, 1st South Carolina.	—	Left.
18	Bowen, J. D., Pt., G, 42d Mississippi.	—	Right.	37	Dalrymple, J. R., Pt., B, 3d South Carolina.	Nov. 18, 1863.	Left.
19	Boyer, W., Pt., K, 25th Virginia.	—	Left.	38	Davidson, E. J., Pt., A, 49th Georgia.	Sept. 21, 1864.	Left.



No.	NAME, AGE, AND MILITARY DESCRIPTION.	DATES.	OPERATIONS, OPERATOR, RESULT.	No.	NAME, AGE, AND MILITARY DESCRIPTION.	DATES.	OPERATIONS, OPERATOR, RESULT.
39	Davis, C. F., Serg't, A, 49th Georgia.	—	Left.	88	Jolly, H., Pt., C, 5th South Carolina.	Oct. 7, 1864.	Left.
40	Davis, H. L., Pt., B, 8th Georgia.	—	Right.	89	Joyner, J., Pt., G, 8th North Carolina.	—	Right.
41	Davis, L., Pt., F, 16th Georgia.	—	Left.	90	Kelly, P., Pt., E, 6th Louisiana.	—	—
42	Dowdy, A. B., Pt., C, 35th North Carolina.	Sept. 17, 1862.	Left. Transferred November 8, 1862.	91	King, A., Pt., A, 27th North Carolina.	Sept. 17, 1862.	Right. Transferred October 16, 1862.
43	Duval, T. S., Kentucky Home Guard.	July 17, 1862.	—	92	Kuer, J., Pt., D, 28th South Carolina.	—	Left.
44	Ernest, —, Pt., A, 12th Alabama.	July, 1863.	Right. Transferred July 20, 1863.	93	Lamkin, A. H., Pt., I, 20th South Carolina.	—	Left.
45	Fitz, E., Pt., F, 11th South Carolina.	—	Right.	94	Lanier, J. F., Pt., H, 7th Georgia Cavalry.	—	Left.
46	Fleming, G. H., Corp'l, C, 41st N. C.	—	—	95	Lavadria, T., Pt., 2d New Mexico.	Feb. 21, 1862.	—
47	Fleming, J. W., Pt., C, Cobb's Legion.	—	Right.	96	Lawrence, J. R., Lieut., I, 1st Louisiana.	—	Right.
48	Floyd, S. H., Corp'l, E, 50th Georgia.	—	Left.	97	Leaphart, S. L., Capt., A, 2d South Carolina.	July, 1863.	—
49	Fogle, W. A., Pt., E, 5th South Carolina.	—	Right.	98	Lucas, B. S., Corp'l, A, 7th Georgia.	—	Left.
50	Folsom, J. W., Corp'l, B, 20th Georgia.	—	Right.	99	Lyon, T. H., Pt., H, 49th Virginia.	Dec. 13, 1862.	—
51	Fouts, J. S., Pt., G, 43d North Carolina.	—	Left.	100	Maddox, W. C., Corp'l, I, 2d South Carolina.	—	Right.
52	Friman, F., Pt., 5th New York.	Aug. 30, 1862.	Right.	101	Manning, R., Pt., G, 8th Georgia.	—	Right.
53	Furnace, M., Pt., K, 73d New York.	May 5, 1862.	Left.	102	Marco, J. J., Pt., F, 22d South Carolina.	—	Left.
54	Futrell, B. G., Pt., B, 1st North Carolina.	—	Right.	103	Marshall, D. P., Pt., G, 15th Georgia.	Oct. 7, 1864.	Right.
55	Gevicot, W. H., Pt., K, 5th Florida.	July, 1863.	Left.	104	Martin, J. T., Pt., F, 2d New York Cavalry.	1865.	—
56	Gillispie, P., Pt., A, 9th Louisiana, age 29.	Aug. 30, 1862.	Left.	105	McCrotty, J., Corp'l, A, 24th N. C. Cavalry.	March, 1865.	Left.
57	Glass, G. W., Pt., I, 89th Indiana.	April 9, 1865.	Left.	106	McDaniel, D. R., Pt., F, 35th Georgia.	—	—
58	Gonnel, R., Pt., E, 32d North Carolina.	July, 1863.	(Also wound of leg.)	107	McKaa, H. H., Serg't, E, 21st North Carolina.	—	Right.
59	Grice, J. G., Pt., K, 31st Georgia.	—	Left.	108	McMath, N. T., Pt., F, 23th Georgia.	—	Left.
60	Gulledge, W. D., Pt., C, 40th North Carolina.	—	Right.	109	McNair, W. C., Lieut., G, 8th Georgia.	—	Left.
61	Hall, R. M., Pt., F, 17th Mississippi.	July, 1863.	Left.	110	Meade, R., Pt., F, 2d Virginia.	July 21, 1861.	—
62	Hamlin, J., Pt., F, 170th New York.	May 18, 1864.	—	111	Miller, J. P., Pt., F, 30th North Carolina.	July, 1863.	Left.
63	Hannold, G. W., Pt., E, 24th New Jersey.	Decem., 1862.	—	112	Moore, J. L., —, A, 52d North Carolina.	July, 1863.	—
64	Harbin, J. F., Pt., C, 4th North Carolina.	—	Right.	113	Moore, R. L., Pt., D, 27th South Carolina.	—	Right.
65	Harden, J. O., Pt., F, 6th South Carolina.	Sept. 30, 1864.	Right.	114	Morgan, R., Pt., G, 1st Kansas Col. Troops.	May 25, 1864.	—
66	Harris, B. F., Pt., F, Palmetto S. S.	—	Right.	115	Murray, T., Pt., F, 14th Infantry.	July 3, 1863.	Left; (wound of leg.)
67	Hasell, H., Laborer, 15th Army Corps.	June 9, 1863.	Left; by Surg. C. G. Strother, 31st Missouri.	116	Neaville, W. A., Pt., G, 42d Mississippi.	—	Left.
68	Henderson, J. J., Pt., H, 19th Virginia.	—	Right.	117	Neighbors, G., Lieut., F, 10th Louisiana.	July 2, 1863.	Transferred July 18, 1863.
69	Hessleburg, J., Pt., B, 6th Louisiana.	—	Right.	118	Newton, D. J., Serg't, F, 27th Georgia.	—	Left.
70	Hetrick, W. H., Pt., G, 1st Pa. Artillery.	July, 1863.	Right; by Asst. Surg. W. Aiken, 125th New York.	119	Norton, J. J., Major, Orr's Rifles.	Dec. 13, 1862.	Left.
71	Hill, N., Pt., A, 3d S. C.	July '63.	—	120	Nures, J. A., Pt., E, Cobb's Legion.	July, 1863.	—
72	Hine, L., Pt., 13th New York.	Aug. 30, 1862.	Right; by Asst. Surg. B. Howard, U. S. A.	121	O'Brien, A. P., Serg't, I, 1st South Carolina.	May 12, 1864.	Right.
73	Hodge, J. B., Pt., H, 5th South Carolina.	July 27, 1864.	Left.	122	Oliver, —, Capt., I, 18th Virginia.	July, 1863.	Transferred July 25, 1863.
74	Hodnett, A., Corp'l, C, 1st Mississippi.	—	Left.	123	Ord, A., Pt., K, 61st Ohio.	—	Right.
75	Hokel, J. W., Pt., H, 1st Georgia Cavalry.	—	Right.	124	Oughts, T., Pt., K, 14th South Carolina.	—	Left.
76	Holloway, R. B., Pt., G, 9th Georgia.	July, 1863.	Left.	125	Parker, G. S., Pt., E, 14th Alabama.	July, 1863.	Left.
77	Hornbeck, H., Pt., K, 43d North Carolina.	June 2.	Left.	126	Pearson, R. R., Pt., C, 2d South Carolina.	July, 1863.	—
78	Howard, B., Pt., I, 40th New York.	July, 1863.	Right.	127	Plunkett, Y., Pt., A, 64th Georgia.	July 30, 1864.	Left.
79	Hunburg, R. C., Corp'l, A, 3d Georgia.	July, 1863.	Right.	128	Pope, J., F, 20th North Carolina.	Sept. 17, 1862.	Right. Transferred to hospital.
80	Hurbsburg, J., Pt., B, 6th Louisiana.	March, 1865.	Right.	129	Ray, A. W., Pt., A, 4th Georgia.	—	Left.
81	Ivy, W. S., Pt., B, 8th Georgia.	July, 1861.	—	130	Ray, J. M., Pt., B, 49th Georgia.	Sept. 15, 1864.	Right.
82	Jackson, N., Pt., E, 8th South Carolina.	July 28, 1864.	Right.	131	Ring, M., Pt., I, 4th Maine.	July, 1863.	Left.
83	Jennings, —, Pt., C, 44th New York.	May, 1864.	—	132	Robinson, W. P., Pt., Orr's Rifles.	—	Left.
84	Joel, J., Pt., E, 1st S. C.	—	Left.	133	Rogers, J., Pt., I, 14th Tennessee.	July, 1863.	Left.
85	Johnson, D., Pt., K, 19th Mississippi.	—	Left.	134	Ruth, A., Serg't, K, 3d New Jersey Cavalry.	April 1, 1865.	—
86	Johnson, J. W., Pt., H, 6th Georgia.	July 30, 1864.	Right.	135	Rutherford, B. H., Pt., F, 23d Georgia.	—	Right.
87	Johnson, N. G., Pt., B, 18th Georgia.	—	Right.				

No.	NAME, AGE, AND MILITARY DESCRIPTION.	DATES.	OPERATIONS, OPERATOR, RESULT.	No.	NAME, AGE, AND MILITARY DESCRIPTION.	DATES.	OPERATIONS, OPERATOR, RESULT.
136	<i>Sansona, J.</i> , Pt., D, 42d Mississippi.	July, 1863.	Right.	149	<i>Walters, E. P.</i> , Serg't, E, 35th N. C.	—	Right. Transferred January 1, 1865.
137	<i>Sawyer, D.</i> , Pt., F, Palmetto S. S.	—	Right.	150	<i>Wallon, J. T.</i> , Lieut., I, 28th Georgia.	—	Left.
138	<i>Seef, S.</i> , Pt., D, 7th S. C.	—	Right.	151	<i>Watson, F. M.</i> , Pt., G, 7th Georgia.	—	Left.
139	<i>Snelling, W. A.</i> , Pt., A., 4th Georgia.	—	Right.	152	<i>Watt, W. T.</i> , Pt., E, 49th North Carolina.	—	Left.
140	<i>Spencer, S. H.</i> , Pt., A, 4th S. C. Cav.	—	Left.	153	<i>Watts, F. J.</i> , Pt., G, 1st Texas.	Sept. 17, 1862.	Right. Transferred October 25, 1862.
141	<i>Stagg, R. A.</i> , Pt., E, 27th South Carolina.	—	Right.	154	<i>Weathers, G. A.</i> , Pt., H, 52d North Carolina.	July, 1863.	Transferred July 28, 1863.
142	<i>Steptoe, W.</i> , Pt., D, 59th South Carolina.	—	Left.	155	<i>Wheeler, J. L.</i> , Lieut., C, 50th Georgia.	—	Left.
143	Thompson, J. H., Serg't, H, 86th Illinois.	June 27, 1864.	Left; (flesh wound of right arm.)	156	<i>Williams, D. R.</i> , Pt., F, 53d Virginia.	July, 1863.	(Also wound of leg.) Transferred July 25, 1863.
144	Thurston, R. B., Pt., E, 14th N. Y. S. M.	July 1, 1863.	Right.	157	<i>Williams, P. H.</i> , Pt., D, 10th Virginia.	April 8, 1865.	Right; by A. Surg. J. H. Kimball, 33d Maine.
145	<i>Tindall, J.</i> , Pt., A, 26th South Carolina.	—	Left.	158	<i>Williams, T. L.</i> , Pt., D, 6th Georgia.	—	Left.
146	<i>Tolbert, T. J.</i> , Pt., E, 12th South Carolina.	—	Right.	159	Wooldridge, W. R., Cp'l, G, 29th Iowa.	April 2, 1864.	Left. Captured.
147	Tolson, J., Serg't, A, 70th New York.	July 2, 1863.	Left.	160	<i>Young, H.</i> , Pt., F, 13th South Carolina.	—	Left.
148	<i>Vaddigan, E.</i> , Pt., C, 27th South Carolina.	—	Left.				

RECAPITULATION.—Fifty-four hundred and fifty-six cases of amputations of the upper arm in the continuity, on account of shot injury, have been enumerated in the thirty-three preceding tabular statements. In TABLE LXVII, on page 697, the reader will find these cases numerically classified, according to the date, seat, and results of the operations, the figures having been verified by careful scrutiny of the individual cases, as proven by the concise alphabetical record devoted to each group. A series of analogous facts of such unusual magnitude will commend itself to the statistical student; yet some readers may not care to analyze the numerical array, preferring a digest of the conclusions it presents.

The results of the amputations were ascertained in fifty-two hundred and seven-three cases, and present a mean fatality of 23.6 per cent. The proportion in which the group of one hundred and eighty-three undetermined cases detracts from the precision of the conclusions is less than three per cent. Assuming that *all* the undecided cases terminated fatally, the ratio of mortality of the aggregate of fifty-four hundred and fifty-six cases would be 26.1 per cent., or, on the more probable supposition that not more than one-half or two-thirds of them were fatal, the death-rates would be respectively 24.5 or 25.1 per cent. When we come to compare these results with those of the same operation in other wars, it will be apparent that the variable quantity introduced by the group of undetermined cases is comparatively insignificant.

The date of operation was learned in forty-five hundred and seventy-two cases, with results as to fatality determined in all. There were thirty-two hundred and fifty-nine primary operations, practised within forty-eight hours from the date of the injury, with six hundred and two deaths, or 18.4 per cent. Nine hundred and two intermediary amputations, practised from the third to the thirtieth day inclusive, present three hundred and two deaths, or 33.4 per cent. Four hundred and eleven secondary amputations, practised subsequent to the thirtieth day, were followed by one hundred and fourteen deaths, or 27.7 per cent.

The seat of operation, or rather the point of section in the arm, was reported in forty-four hundred and forty-nine cases. In the upper third, nineteen hundred and fifty-two amputations—primary, intermediary, secondary, and of undetermined date—had a mortality rate of 18.+ per cent.<sup>1</sup> In the middle third, seventeen hundred and thirty-nine amputations

<sup>1</sup> Of the 1,952 amputations at the upper third, 358 are known to have terminated fatally, and the results of 12 cases are undetermined. If the latter are reckoned fatal, the death-rate will be 18.9 per cent. If the mortality rate is computed from the determined cases only, it is 18.4 per cent.



of the four groups present a death-rate of rather more than 16 per cent.<sup>1</sup> In the lower third, seven hundred and fifty-eight amputations had a death-rate of 26.+ per cent.<sup>2</sup> The excessive proportion of fatal results in the amputations at the lower third, already adverted to on page 739, will be hereafter discussed. Of the series of fifty-four hundred and fifty-six amputations in the continuity, the right limb was involved in twenty-five hundred and nineteen, and the left in twenty-six hundred and thirty-two; hence it is highly probable that the left extremity was most frequently interested, although the three hundred and five cases, in which this point could not be ascertained, forbid exact conclusions on the subject. Nothing, however, invalidates the remarkable fact that the determined operations on the left side, while the most numerous, had a less proportionate fatality than those on the right. This accords with the conclusion established on page 610, in regard to excisions at the shoulder, in which, it will be recollected, the operation on the left side furnished a slightly larger proportion of favorable results.<sup>3</sup>

The influence of age on the result of amputations of the arm for injury may be inferred from the issue of about three-fifths of the cases in which the ages were recorded, as shown in the following Table, which exhibits the mortality rate of four hundred and twelve patients under twenty years of age, as 18.4 per cent.; of eleven hundred and sixty-eight patients of twenty to twenty-four years, inclusive, as 19.6 per cent.; of six hundred and eighty-two patients of twenty-five to twenty-nine years, inclusive, at 23.8 per cent.; of three hundred and sixty patients of thirty to thirty-four years, at 21.4 per cent.; of two hundred and thirteen patients of thirty-five to thirty-nine years, at 27.3 per cent.; of two hundred and thirty-three patients over forty years, at 24.9 per cent.

TABLE CI.

*Statement of the Ages of Three Thousand and Sixty-eight Patients who submitted to Amputation of the Arm for Shot Injury.*

AMPUTATIONS OF ARM.		Under 20.		20-1-2-3-4.		25-6-7-8-9.			30-1-2-3-4.			35-6-7-8-9.			40 and over.		Age unknown.		
		Recovery.	Fatal.	Recovery.	Fatal.	Recovery.	Fatal.	Unknown.	Recovery.	Fatal.	Unknown.	Recovery.	Fatal.	Unknown.	Recovery.	Fatal.	Recovery.	Fatal.	Unknown.
Primary.	Upper third.....	104	12	271	43	171	32	92	11	37	15	41	5	430	65				
	Middle third.....	105	8	269	33	142	30	77	12	44	7	54	6	328	45				
	Lower third.....	38	9	126	19	61	14	29	7	22	4	22	8	108	45				
	Unknown.....	1	2	6	9	4	4	2	2	4	2	2	2	62	149				
Intermed'y.	Upper third.....	16	20	52	24	27	16	17	9	5	6	9	8	113	25				
	Middle third.....	26	8	74	34	26	18	17	11	9	4	15	5	88	13				
	Lower third.....	9	3	26	17	13	15	8	7	8	7	2	6	28	12				
	Unknown.....	2	2	5	1	9	1	1	2	1	2	1	2	7	14				
Secondary.	Upper third.....	8	3	27	15	17	10	9	1	8	6	8	2	50	9				
	Middle third.....	9	4	31	6	17	6	4	7	7	3	7	5	52	4				
	Lower third.....	2	1	10	11	6	3	4	1	2	1	6	4	7	3				
	Unknown.....			2				1				1		4	7				
Uncertain.	Upper third.....	3		17	2	12		4	2	1		1		23	17	12			
	Middle third.....	3		6		4	3	4	3	1		2	1	25	6	6			
	Lower third.....	4		2		4		1						10		2			
	Unknown.....	8	4	20	9	13	2	14	2	5	3	6	2	279	172	159			
		336	76	939	229	518	162	282	77	154	58	175	58	1,623	586	179			

<sup>1</sup> Of the 1,739 amputations at the middle third, 284 were fatal and 9 undetermined cases; the death-rate varies from 16.4 to 16.8 per cent., according as the undetermined cases are estimated.

<sup>2</sup> The 758 amputations at the lower third present 197 fatal cases and 2 undetermined, leaving a margin of variation from 26.06 to 26.2 per cent. of fatality.

<sup>3</sup> Of the 1,246 determined fatal amputations in the arm, 584 belonged to the series of 2,519 amputations on the right side, and 506 to the series of 2,632 amputations on the left side, while 156 cases could not be referred. Thus the more numerous amputations on the left side were less fatal in the proportion of about 4 per cent.

The tables furnish some data toward estimating the influence of season and of climate on the results of injuries and operations; but it will be well to reserve deductions on these subjects until analyses can be made from larger aggregates. It may be observed, in passing, that little difference is exhibited in this series, in the mortality in the amputations practised among troops campaigning in the Eastern or Atlantic region, and those in the Western armies, serving in the "Middle region" of the Medical Returns.<sup>1</sup>

The five thousand four hundred and fifty-six amputations were practised on five thousand four hundred and forty-eight patients, the discrepancies in numbers being due to the cases of double amputation, as will be more fully explained hereafter. Of the five thousand four hundred and forty-eight patients, four thousand four hundred and eighty-one were Union and nine hundred and sixty-seven Confederate soldiers. The latter escaped with a rather smaller mortality rate than the former, the determined cases giving a fatality of 21.9 per cent., instead of the 23.6 death-rate of the aggregate.

#### CONCLUDING OBSERVATIONS ON SHOT INJURIES OF THE UPPER ARM.—

Notwithstanding the extent of space they occupy, I have thought it expedient to introduce a large number of instances and illustrations of shot fractures of the shaft of the humerus and of the lesions consequent thereon, and to put on record all the individual cases, without exception, of amputations in the continuity of the bone, whether practised for direct injury of its diaphysis, or for lesions implicating the elbow or distal portions of the limb. A numerical statement of the amputations might have been accepted as accurate; but the record of the details of each case not only permits their classification and comparison as to the influence on the results of age, of length of service, of season and climate, of the mode of operating, of the complications, and of other conditions; but also furnishes facilities to those who would sum up and put together these facts from new points of view, or subject the printed record to a more exhaustive analysis, or study particular cases from the manuscript files; besides affording opportunity for the recognition and correction of erroneous or duplicated entries. By collating the data in this Section with the observations on flesh wounds in the first part of the Chapter, and with many of the cases of excision and amputation at the shoulder in the third Section, the reader has access to a body of statistical facts on shot injuries of the upper arm of extraordinary extent. While, however, the exposition of details has been so extended, little has been said of those features of the subject less amenable to statistical arrangement, and it remains to make some remarks of a more general nature on the treatment and progress of such cases of injury when managed by expectation, excision, or amputation.

It will be remembered that, on page 666, the results of nearly three thousand shot fractures of the shaft of the humerus treated on the expectant conservative plan were found highly consolatory, so far as loss of life was concerned, hardly a seventh of the patients having succumbed. But there was excluded from this aggregate a large number of cases treated conservatively at the outset, but ultimately subject to intermediary or secondary excisions or amputations, with a high rate of mortality. Were these facts added, it is probable that the expectant method would exhibit a greater fatality than primary amputations. Yet such is the inestimable value of the upper extremity to the patient's comfort and welfare, that surgeons will never hesitate to incur a very considerable hazard to life, and the certainty of protracted inconvenience and suffering, provided there be a favorable

<sup>1</sup> In 5,039 cases the localities at which the operations were practised are known. 3,455 patients belonged to Eastern armies, of whom 802 died, or 23.2 per cent. 1,584 belonged to Western armies, and of these patients 372 died, or 23.4 per cent., a trivial difference.



prospect of ultimately preserving a useful hand. Accordingly, ever since primary amputations began to be practised methodically and with comparative safety—that is, since the latter part of the seventeenth century—there have not been wanting distinguished advocates of conservative measures in very severe shot comminutions of the shaft of the humerus,<sup>1</sup> and teachers of military surgery have limited more and more the conditions under which amputation may be warrantable, until, in our day, accepted authorities teach, with Guthrie, that, “an upper extremity should not be amputated for almost any accident that can happen to it from musket shot,” or, with M. Legouest, that shot comminution of the humerus, even attended by laceration of the brachial artery, does not render amputation

<sup>1</sup> JOSEPH DU CHESNE (1544-1609), a physician of Henry IV, and best known as a chemist and follower of PARACELSUS, and, under his pseudonym of Quercetanus, was one of the earliest writers to advocate conservative measures in dealing with shot fractures of the arm. In his *Sclopetarius, sive de curandis vulneribus, quae sclopetarum et similium tormentorum ictibus accidunt*, Lyon, 1576, he deprecates the readiness of surgeons in such cases “to cut off, to put asunder, as I may say to play the butcher,” and declares that a just appreciation of the injury forbiddeth that it [the wound] be hid and rowled so fast, as is used in simple fractures, in that it requireth to be dressed off, that the filth and extremitates whiche nature expelleth may have issue, and, for that cause, some use straightwayes *stones* (as they thearne them) if it may easily be put in the wound \* \* \* and some use only tentes, and if need require, they also amplifie and enlarge the orifice thereof, and likewise the lower parts, whereby all filth and baggage may issue out the better.” (*The Sclopetarie of JOSEPHUS QUERCETANUS, or his Booke containing the cure of wounds received by Shot or Gunne or such like Engines of Warre*, Published into English by JOHN HESTER, London, 1590, p. 57.) BELLOSTE (*Le Chirurgien de l'Hôpital*, 1696, et 3ème éd., 1716, Chapt. xxii. p. 183, and English ed., 1706, Chap. xxi, p. 146), a very prudent surgeon, and a devoted disciple of MAGATUS, in the excellent little work in which he narrates his experience in the Italian campaigns of his time, details a case of badly comminuted shot fracture of the upper part of the left humerus, treated so successfully, on the expectant plan, that the patient, “the grenadier *Bellehumeur* of the Navarre regiment, wounded in 1693, and treated in hospital at Briançon, returned to the ranks in forty days.” He also narrates (*op. cit.*, 3ème éd., p. 199) the case of M. de la Roque, Colonel of the Montferrat regiment, whose humerus was shattered by a ball at Mondevis. He was treated by BELLOSTE, at Turin, on a strictly expectant plan, being allowed to go about with his arm in a sling. His convalescence was but once interrupted, when a consultation of surgeons decided to inject the sinuses with stimulating lotions, and afterward to stuff them with lint. This excited great inflammation; but, expectant measures being resumed, the case again progressed favorably, and resulted in an excellent recovery. The famous HENRY FRANÇOIS LE DRAN, although he introduced into surgery the operation of exarticulation at the shoulder, was averse to resorting lightly to this or other amputations. Throughout his *Traité sur les Playes d'armes à feu* his strong leaning toward conservative measures is manifested. In his *Observations de Chirurgie*, 1731, T. I, p. 332, he devotes a chapter to the case of M. de Therade, whose left humerus was shattered between the insertions of the great pectoral and the deltoid, by a musket ball, at the siege of Gironne, in 1710, and condemns the tents, and incisions, and tractions on adherent fragments, and other meddling practises just instituted, and relates how rapidly the case progressed toward recovery, when simple dressings and a sling were substituted, by his direction. RAVATON, whose works on military surgery abound in carefully detailed cases, relates no less than five successful examples of shot comminutions of the humerus treated on the expectant plan. In his *Chirurgie d'Armée*, 1708, p. 274, etc., he mentions first the case of a soldier of the Guiso regiment, wounded during Marshal Broglie's retreat from Bavaria, the shaft of the right humerus being shattered by a ball. Exarticulation at the shoulder was proposed, but RAVATON'S advice prevailed, and the patient recovered under conservative measures, with a shortened arm, and was sent to the springs of Bourbonne. Secondly, Webert, of the Marek regiment, was wounded February 11, 1757, his left humerus being shattered. RAVATON introduced his finger, and found so much comminution, that he was inclined to amputate, but, as the patient was but 22 years old and of vigorous constitution, he concluded to remove nine large and many small fragments by slightly enlarging the wound, and then laid the arm on a concave tin splint padded with felt, supported on a pillow, and had the satisfaction on the sixty-ninth day of good union of the bone and motions of the arm, though with considerable shortening. Vavineour, marine, 22 years old, had his right arm fractured by a cannon ball, on the frigate *Formidable*, November 20, 1759. He was treated on the conservative plan, and RAVATON met him two years subsequently, with good use of his arm and ability to write, play the violin, etc. Fourth, Lebourié, a sailor, 20 years old, had his arm fractured at the same battle by grapeshot, the forearm and metacarpus being also shattered. He left hospital eleven months afterwards, cured. Lastly, Vaché, a sailor, aged 22 years, had the lower part of the right humerus shattered, by a cannon ball in the same action, on the *Formidable*, and recovered in four months, after numerous exfoliations. RAVATON adds that he knows of a “prodigious number” of facts testifying to the extent to which wounds with great loss of substance may favorably unite in young subjects. PIERRE JOSEPH BOUCHER, in the first part of his celebrated dissertation, *Sur des Playes d'Armes à feu, compliquées de fracture, aux articulations des extrémités, ou au voisinage de ces articulations* (in *Mém. de l'Acad. de Chir.*, 1753, T. II, pp. 292 and 301), relates two cases of successful conservative treatment of shot comminutions of the humerus: A case in which one of the King's bodyguard had the lower portion of the shaft of the humerus shattered, and recovery ensued without amputation, at the hospital of St. Sauveur; and the case of a soldier wounded at Ramilles, the upper portion of the shaft of the humerus being shattered by a ball. The chief surgeon of the army declared that the limb must come off; but, by the advice of M. POLLET, an assistant of the famous J. L. PETIT, the limb was preserved, and the patient made a good recovery at the hospital at Lisle. As might be expected, examples of successful conservative treatment of shot comminutions of the humerus are accumulated in the writings of the fanatical opponent of amputation, J. U. BILGUER. In his *Chirurgische Wahrnehmungen*, Berlin, 1763, Sn 466-482, he details nine cases of shot fractures of the shaft of the humerus treated by extraction of loose fragments and retentive apparatus, all resulting favorably (Cases 35, 36, 60, 64, 69, 74, 92, 101, 108). Surgeon Major BOURIENNE relates (ROUX'S *Journal de Méd. Chir. et Pharm.*, Paris, 1774, p. 170) a very interesting case of shot fracture of the upper portion of the shaft of the right humerus in the person of J. May, wounded May 15, 1765, a Corsican soldier, 26 years old, who made a good recovery, although the bone was shattered into many fragments. BOURIENNE observes that although such an extent of injury usually decides the need to amputate, such a success proves “que c'est toujours une tentative louable que de travailler à la conservation des membres,” and argues that amputations should be avoided in similar cases, although: “on a vu, dans ce siècle, le plus grands praticiens d'une opinion contraire sur cette matiere.” II. ST. JOHN NEALE, in his *Chirurgical Institutes drawn from Practice in Gunshot Wounds*, 2d ed., London, 1805, p. 230, relates the case of Captain Van Nagel, of the Donop Hessian regiment, wounded at the storming of the Redbank fort, on the Delaware, near Philadelphia, October 23, 1777. A grapeshot entered the biceps five inches above the elbow, and running obliquely upward shattered the bone and emerged through the triceps. The orifices of the wound were “very largely dilated,” and the patient was copiously bled by Surgeon STEIGLITZ. After taking four and a half pounds of Peruvian bark, this officer recovered with a shattered but useful arm, in thirteen weeks, exfoliations weighing one ounce and two drachms having been eliminated. The distinguished J. L. SCHMUCKER (*Vermischte Chir. Schriften*, Berlin, 1872, B. III, S. 84) cites the case of a boy, aged 11 years, shot on June 9, 1777, through the arm. The shot was fired at a distance of less than six paces, and the gun was loaded with bird shot and a small ball: five inches of bone were carried away, and the soft parts were terribly lacerated. The boy recovered, with free use of the arm and fingers. CHEVALIER (T.) (*A Treatise on Gunshot Wounds*, 1804, p. 114) relates the case of G. W.—, with shot splintering of the right os brachii, October 2, 1799, with recovery after extraction of a loose portion of the bone. In five months the wound was perfectly healed. “The arm was two inches shorter than the other; but he retained the use of the shoulder joint, limited only by the state of the muscles and the rigidity remaining after so much inflammation.” LARREY gives many examples of the conservative treatment of shot fractures of the shaft of the humerus in his *Mémoires et Campagnes* and in the *Clinique Chirurgicale*, and, from his time forward, in place of general allusions, such instances are frequently detailed.

"indispensable." In the class of injuries under consideration, Professor Pirogoff<sup>1</sup> repeats, in effect, the famous declaration of Velpeau: "the older I grow the less I amputate." Professor Esmarch relates how conservative measures were resorted to in constantly increasing proportion in each of the successive Schleswig-Holstein campaigns. Drs. Matthew<sup>2</sup> and Williamson state that the British surgeons in the Crimea and India had recourse to primary amputation of the arm only under "the most desperate circumstances."<sup>3</sup> Drs. Schwartz, Lohmeyer, and Rupprecht, and Professors Sédillot and Legouest bear equally emphatic testimony regarding the principles and practice of contemporary French and German military surgeons, on this point.<sup>4</sup> Drs. Gherini and Demme inform us that similar

<sup>1</sup> PIROGOFF (V.) (*Grundzüge der Allgemeinen Kriegs-Chirurgie*, 1864, S. 777), speaking of shot fractures of the diaphyses of the humerus, observes: "The large majority of them are susceptible of a conservative treatment." And elsewhere: "The amputation in the humerus figured in a very subordinate rôle with us in the Crimea." Nevertheless, he adds: "Yet I believe that we were too free with this operation, as a primary amputation in the middle third of the humerus for shot fractures. That operation I would like to banish entirely from the practice of war surgery, and would say that only in comminuted, and very complicated fractures of the forearm, night amputation in the lower third of the humerus still be considered as indicated."

<sup>2</sup> Staff Surgeon T. P. MATTHEW, the historian of the surgery of the British Army in the Crimea (*Med. and Surg. History of the British Army which served in Turkey and the Crimea during the War against Russia*, 1858, Vol. II, p. 359), after remarking that "complete compound gunshot fractures of the long bones were the accidents by which amputation was, in the great majority of cases, necessitated," and that the percentage of recoveries in shot fractures of the humerus, without resort to amputation, either primary or consecutive, was 26.6, continues as follows: "With regard to the humerus, unless very extensive longitudinal splintering of the bone had taken place, or there had been very large destruction of soft parts, no amount of comminution appeared to warrant amputation. In many instances, the comminuted portions were cleared away and the jagged ends smoothed by the saw or cutting pliers; as much as three inches in length of the entire thickness of the shaft of the bone has been thus taken away, and the patient recovered with a useful arm. Some of the patients, indeed, where smaller portions only had been removed, were able to return to duty. Thus, three private soldiers and a sergeant of the 97th Regiment each received a compound fracture of the humerus on the 8th of September, at the assault on the Redan (three of which were said to have been received in the body of the work); three were from musket bullets which had perforated the arm, and one from a grapeshot, which had been removed through the wound. In all, some fragments of bone were taken away. The last-named returned to his duty, well, on the 25th of November, and the three former were sent to England in January, as there was little prospect of their services being required in the Crimea, all nearly fit to resume duty, and only requiring time." Dr. G. H. B. MACLEOD says (*Notes on the Surgery of the War in the Crimea*, 1858, p. 304): "The injury, indeed, would need to be very extensive before we would think of performing amputation at an early period in gunshot wounds of the arm; as, unless the vessels are destroyed, there are many most dreadful and hopeless-looking accidents from which the arm will recover; and, besides, secondary amputations are so successful and resections so often sufficient to fulfil the necessary indications, that primary amputation is never performed in the upper extremity except under the most desperate circumstances."

<sup>3</sup> In recording the condition of the invalided British soldiers who returned from the Mutiny in India of 1858, Staff Surgeon G. WILLIAMSON, M. D. (*Military Surgery*, 1863, pp. xxv, 127, 222), after remarking that: "In compound fractures of the upper extremities primary amputation is never resorted to except in very severe and hopeless cases of gunshot wounds," relates some particulars of twenty-three invalids after shot fracture of the humerus. These comprised one case of ununited fracture at the middle third, two of ankylosis of the shoulder, and several complicated by exfoliations and abscesses. Six returned to modified duty. Dr. WILLIAMSON is of opinion that shot fractures of the humerus "are generally of such a severe character as ultimately to incapacitate the patient for the duties of a soldier." \* \* "Great muscular contraction and rigidity of the tendons and ligaments is usually the result," and if the fracture is near the head or condyles, the neighboring joint is very liable to become ankylosed. Dr. C. A. GORDON (*Experiences of an Army Surgeon in India*, 1872, p. 27) details the treatment of two of the cases mentioned by Dr. WILLIAMSON—two officers, who recovered after shot comminution of the shaft of the humerus, with loss of power and sensation. In his *Lessons on Hygiene and Surgery from the Franco-Prussian War*, London, 1873, p. 143, Dr. GORDON reverts to this subject.

<sup>4</sup> Thus, ESMARCH (F.) (*Ueber Resectionen nach Schusswunden*, Kiel, 1851, S. 26), treating of the war in Schleswig-Holstein, narrates: "Bei sehr beträchtlichen Zerschmetterungen," u. s. w., or, as Mr. STATHAM translates: "In very considerable comminution of the shaft of the humerus, amputation was not infrequently performed in the two first campaigns. In 9 cases, preservation was attempted by removal of the splinters and resection of the ends of the fragments: 4 of these patients died, and of the remaining 5 many retained very defective limbs. In 7 similar cases in 1849, consolidation was essayed, without resection, by immediate removal of the loosened splinters in 3 cases, and, after the occurrence of suppuration, in the 4 others. The result was beyond expectation, as but 1 of the three first proved fatal, and in the last 4 the recovery was complete and comparatively rapid. In 1850, therefore, in such cases, we followed the same (last-mentioned) practice, and with surprising consequences. Of 25 cases, but 4 died; in the remainder a complete cure followed, although in many the humerus had been shattered by canister shot. In all these cases the fractures fully consolidated, and, in many, the usefulness of the arm was almost entirely restored." SCHWARTZ (*Beiträge zur Lehre von den Schusswunden*, Schleswig, 1854, S. 212), writing of the same campaigns, declares that: "In clean transverse fractures [of the humerus] primary amputation is always to be rejected, even where the brachial artery has been injured; it is only when the vessels and nerves are simultaneously lacerated that amputation remains the sole alternative." \* \* "In cases of slight splintering in the upper, middle, or lower thirds, primary amputation is not to be performed." \* \* "All cases of extensive splintering in the upper or lower thirds should be primarily amputated, or, for the former injury, exarticulated; but, in cases of comminuted fracture of the middle third, primary amputation should be rarely practised. We have seen cases of this kind recover, and recover exceedingly well." \* \* "Resection in the continuity of the humerus is to be rejected." LOHMEYER (C. F.) (*Die Schusswunden und ihre Behandlung*, Göttingen, 1859, S. 187) observes: "Even cases of crushing of the diaphysis of the humerus, as a rule, result favorably without operative interference, even when they are very extensive," and details a case in which sixty pieces of bone were removed and the patient recovered with shortening of about two inches. RUPPRECHT (L.) (*Militärärztliche Erfahrungen*, 1871, S. 65) is another advocate of expectant conservative measures. He tabulates 134 cases of shot fractures of the humerus, from Massy, Langensalza, etc., of which 42 proved fatal; eighty were amputated with 29 deaths, and 54 were treated expectantly with 13 deaths. He concludes that: "In the aggregate, about one-third of the cases of this sort of injury proved fatal." He subsequently discriminates by the remark: "Of those operated upon, one-third died as a rule, while of those treated on the conservative expectant plan, one-fourth, at the most, perished." M. SÉDILLOT (*De traitement des fractures des membres par armes de guerre*, in *Arch. gén. de méd.*, 1871, VI sér., T. 17, Vol. 1, p. 400) remarks of shot fractures of the arm: "La conservation doit être le but principal du chirurgien, et nos observations prouvent qu'elle peut être fréquemment suivie de succès. Nous y avons eu recours sur des malades auxquels l'amputation avait été conseillé, et nous avons eu la satisfaction de sauver des membres, qui allaient être sacrifiés. Sans doute, l'amputation réussit plus sûrement et plus promptement; mais les usages de la main sont d'une si grande utilité qu'on peut abandonner quelques chances de vie devant l'avantage de les conserver, dans tous les cas où les pertes de substance ne sont pas trop considérables et où les nerfs et les vaisseaux n'ont pas été totalement divisés." M. LEGOUEST (*Chirurgien d'armée*, 2ème éd., 1872, p. 529) remarks, on amputation of the arm for shot injury: "Lorsque les vaisseaux et les nerfs sont intacts, l'amputation n'est indiquée que si les parties molles sont compromises dans une grande étendue, ou si l'humérus est fracturé avec éclats ou esquilles considérables, dont l'extraction doit entraîner une perte de substance dans la continuité de l'os qui ne permettrait pas d'espérer la consolidation des fragments."



views prevail among the Italian medical officers.<sup>1</sup> The Confederate surgeons who have published their views on the subject, generally advocated conservatism in dealing with shot fractures of the humerus, except in most aggravated cases. The compilers of the Confederate Surgical Manual embody their recommendations on this point in the words of Professor Longmore.<sup>2</sup> Dr. Warren and Dr. Chisolm, in their treatises on military surgery,<sup>3</sup> advise attempts to save the limb, even when fracture of the humerus is complicated by division of the brachial artery. Indeed, among recent writers of any authority, Mr. Cole, who served with the auxiliary forces of the British Army in the Punjab in 1848-49, and Dr. Appia, of Geneva, are almost solitary advocates of primary amputations for ordinary comminutions of the shaft of the humerus by musket balls.<sup>4</sup> It is true, however, that the teachings of many of the authorities admit a great latitude of interpretation, and, while commending an expectant conservative policy, recognize exceptions that may be readily more numerous than cases conforming to the rule. Many authors adopt the phraseology of Dupuytren and sanction an expectant conservative treatment except in "very extensive comminutions."<sup>5</sup> Now, in a large proportion of fractures of the shaft of the humerus by musket ball, the bone is shattered to an extent that would be reckoned a *very extensive comminution* if it had occurred in civil practice or was produced by any other form of violence,<sup>6</sup> and it is certain that, at all events in the earlier periods of the late civil war, such splintering of the bone, uncomplicated by lesions of the blood-vessels or nerves, or extended lacerations of the soft parts, or implication of the articulations, was very frequently regarded as a sufficient cause for primary amputation. After deducting from the thirty-two hundred and fifty-nine cases of primary amputations all those that were practised for lacerations of the upper arm, elbow, or forearm, by cannon shot, and all attended by injury to the vessels and nerves, or by unusual destruction of the soft parts, there still

<sup>1</sup> GHERINI (A.), *Vade Mecum per le Ferite d'Arma da Fuoco*, Milano, 1866, p. 132; and DEMME (H.), *Mil.-Chir. Studien*, Würzburg, 1861, B. II. S. 237, who states that: "The Italian War of 1850 has again confirmed the experience, that even extensive comminuted fractures of the shaft of the humerus do not in themselves demand amputation. But it is a fact not to be denied that, notwithstanding this experience, many amputations and exarticulations performed in the Italian hospitals might have been left undone."

<sup>2</sup> *A Manual of Military Surgery, prepared for the Use of the Confederate States Army*, by order of the SURGEON-GENERAL, Richmond, 1863, p. 65. It is understood that Drs. A. TALLEY, ST. GEORGE PEACHY, A. E. PETICOLAS, J. DUNN, and H. F. CAMPBELL were the compilers of this manual. The passage quoted from Professor LONGMORE'S well-known dissertation on *Gunshot Wounds* is as follows: "Unless the bone be extremely injured by a massive projectile, or longitudinal comminution exist to a great extent, especially if also involving a joint, or the state of the patient's health be very unfavorable, attempts should always be made to preserve the upper extremity after a gunshot wound," which is the language used by Deputy Inspector-General T. LONGMORE in his dissertation on *Gunshot Wounds*, in HOLMES'S *System of Surgery*, London, 1861, Vol. II, p. 75.

<sup>3</sup> WARREN (E.), *An Epitome of Mil. Surgery*, 1863, p. 372, and CHISOLM (J. J.), *A Manual of Military Surgery*, 1863, p. 386.

<sup>4</sup> COLE (J. J.) (*Military Surgery, or Experience of Field Practice in India during the Years 1848-49* [War in the Punjab], 1852, p. 154) observes, of gunshot wounds of the upper arm: "In a very large proportion of cases, loss of limb is the inevitable consequence when the humerus is broken by a musket bullet. In every instance now before us [in the Punjab], the bones were comminuted—smashed, and although the soft parts were little torn, the arteries and nerves untouched, still in all it was absolutely necessary to amputate. If you do not cut off the arm, long-continued suppuration will cut off the patient." APPIA (P. L.) (*The Ambulance Surgeon, or Practical Observations on Gunshot Wounds*, English translation, edited by Messrs. NUNN and EDWARDS, Edinburgh, 1862, p. 163): "Fracture of the humerus at its middle is always a serious wound, and one which calls for amputation whenever the splinters are very numerous and the laceration of the skin very extensive." Dr. G. H. B. MACLEOD (*Notes on the Surgery of the War in the Crimea*, London, 1858, p. 304) asserts that PIROGOFF "was so displeased with the results of his attempts to cure fractures of the upper extremity in the Caucasus, that he was disposed to submit them all to amputation." This statement is not consistent with the passage from Professor PIROGOFF'S *Grundzüge, u. s. w.*, quoted on the preceding page, and I find no warrant for it in the *Reminiscenzen aus dem Kriege im Kaukasus* of the celebrated Russian surgeon.

<sup>5</sup> DUPUYTREN left the question of amputation for shot fractures of the shaft of the humerus to be determined by the extent of comminution: "The shattering of the bones of limbs by a ball," he says (*Leçons Orales de clin. chir.*, 2ème éd., 1839, T. V, p. 300), "is one of the most frequent conditions requiring amputation, even when this is the sole complication. When a ball has broken the principal bone of a limb into splinters, it is very difficult to determine in what cases amputation should be practised. Here the foresight of the skilled surgeon is often at a loss. If the disorders are mediocre; if the splinters are not too numerous, of which it is easy to be assured by the finger after enlarging the ball track; if the soft parts are not too much damaged, an attempt may be made to save the limb, after making suitable incisions to prevent inflammation from constriction, and to extract splinters, etc. The patient is placed in a complicated fracture apparatus, and dressed once or twice daily, according to the abundance of the suppuration; the strictest cleanliness is observed, and the patient is often cured, principally in those cases in which the upper extremity is involved and the patient is endowed with a good constitution." In very young subjects, DUPUYTREN thinks it justifiable to trust to expectant measures in shot fractures of great severity.

<sup>6</sup> The specimens represented in FIGURES 512, 514, 515, 518, 519, 520, 523, although by no means selected for the purpose of showing the extent of longitudinal fissuring produced by musket balls, were all examples of shot comminutions for which primary amputations were practised, and very fairly illustrate the ordinary amount of splintering observed in such accidents. In the very numerous specimens of comminutions of the diaphysis of the humerus by musket balls, preserved in the Army Medical Museum, in which the missile has struck the compact tissue of the middle region of the shaft, the bone is usually found with from two to five large fragments, and a half dozen, or often many more, small fragments, and the fissures seldom extend for less than three or four inches, and often interest six or eight inches of the shaft.

remains a very large group, in which the limb was sacrificed solely because of the extensive comminution of the shaft. Such operations were sometimes criticised as unnecessary;<sup>1</sup> but it is consolatory to reflect that they were probably attended with the saving of life at least, since they were usually practised under conditions which precluded the adoption of suitable conservative measures in the absence of hospital facilities or of easy transportation. The surgeons, doubtless, sometimes yielded to what John Bell called "an argument of necessity as well as of choice, and limbs that in happier circumstances might have been preserved, had often, in a flying army or a dangerous campaign, to be cut off;" since "it is less dreadful to be dragged along with a neat amputated stump, than with a swollen and fractured limb, where the arteries are in constant danger from the splintered bones."

When it was determined that a shot fracture of the humerus should be treated on the expectant plan, after foreign bodies had been removed, the limb was commonly put up in splints. There was great variety in the primary dressings. Many, perhaps the majority of surgeons, were averse to the use of complex apparatus,<sup>2</sup> and dreaded the effects of constricting bandages. Some employed the modes of dressing recommended by Medical Inspector Hamilton, U. S. A., an accepted authority on the treatment of fractures.<sup>3</sup> Others, after

<sup>1</sup> Surgeon C. H. RAWSON, writing in regard to the wounded from the battle of Wilson's Creek (*Am. Med. Times*, 1862, Vol. IV, p. 11), says: "I was shown several cases of compound comminuted fracture of the leg and arm, in all of which the bones had united and some healed up permanently, but with every prospect of final recovery, \* \* \* considering the number of cases, the serious character of the injuries, and the results in all that I saw, I can but come to one conclusion, that very many limbs are removed that might be saved."

<sup>2</sup> HENNEN (J.) (*Principles of Military Surgery*, 3d ed., 1829, p. 117) teaches that: "In compound fractures of the humerus and forearm, complex machinery is not called for. With ordinary splints and a leather sling, furnished with a strap to go round the neck and support the limb, we are able to manage extremely well. When fever, or some other untoward circumstance, does not forbid it, I always encourage patients with these injuries to keep out of bed as much as possible; the weight of the forearm assists considerably in keeping fractures of the humerus in a proper state of coaptation, while the flexing at the elbow often prevents sinuses from running down under the integuments and among the muscles of the forearm, which sometimes occurs when the patient lies long in the horizontal position, and especially if the forearm is *spread out in a line with the humerus*, as I have more than once seen. \* \* \* Once in the day, at least, a compound fracture should be *regularly* and formally dressed. On these occasions, all depositions of matter should be carefully pressed out (?), splinters felt for and removed, and clean strips of bandage applied in lieu of those soiled or destroyed by the suppuration. To prevent the soaking of the bedding, a piece of coarse cloth or oiled silk should be placed permanently under the whole limb, and occasionally renewed; and, to obviate the ill effects of the matter stagnating in the wound, the lightest scraped lint should be laid on it. In some cases I have effectually obviated this stagnation, when the position of the wound did not favor the flow of matter, by placing a soft sponge over the limb, which absorbed the pus as soon as it was formed, and by drawing a woollen thread through it, and connecting it with a proper dish below, it has performed the part of a syphon. During the employment of these surgical means the bowels should be kept in a natural state by saline laxatives."

<sup>3</sup> HAMILTON (F. H.) (*A Treatise on Military Surgery*, 1865, p. 392) describes his dressing for shot fracture of the shaft of the humerus as follows: "If the shaft is involved in the fracture at any point above the base of the condyles, the fragments will require some support. It would be well, indeed, if splints could be applied firmly, as in simple fractures, but such is not usually the fact; and the truth is, that in general too much has been attempted; the bandages have been applied too tightly and perseveringly, and sometimes at the sacrifice of the limb. We employ usually, in these cases, a single splint, made of felt, leather, or gutta-percha, long enough to extend over the top of the shoulder on the one hand, and to the lower part of the elbow joint on the other, and broad enough to encircle one-third of the circumference of the arm; by moulding or otherwise fitting the upper part of the splint over the top of the shoulder, it will be prevented from being displaced downward (FIG. 565). Before being applied, the concave surface should be padded with cotton or tow, and covered with a piece of cotton cloth stitched along the back of the splint. This splint should be secured in place by a few light turns of a roller, and never applied so tightly as to endanger congestion of the limb below, or to render necessary the application of a roller to the hand and forearm. If this cannot be borne, or if it is found inconvenient from the position and size of the wounds, the limb must be simply laid upon a properly shaped and sufficiently firm pillow, the application of splints being reserved to a later day." In his instructive *Practical Treatise on Fractures and Dislocations*, 3d ed., 1866, p. 231, Professor HAMILTON gives substantially the same directions for the dressing of fractures of the upper portion of the humerus, adding that a "sling may then be applied as recommended by Sir ASTLEY COOPER, or the arm may be permitted to hang perpendicularly beside the body." After rejecting the axillary pad and clavicular bandage of COOPER as complicated and likely to expose the brachial plexus to painful if not injurious pressure, Professor HAMILTON comments favorably on the "very complete shoulder and arm splint of WELCH (FIG. 565, No. 1) as a substitute for the felt or gutta-percha splints he prefers, cites the pertinent observations of MALGAIGNE (*Traité des Fractures*, etc., 1847, T. 1, p. 531) and W. J. WALKER (*Essay on the Treatment of Compound and Complicated Fractures*, Boston, 1845), refers to the crutch splint of Mr. LONSDALE (*A Pract. Treatise on Fractures*, 1838, p. 174) and leather splint of Mr. ERICHSEN as contrivances likely to prove occasionally useful, and refers to his own memoir in the *Buffalo Medical Jour.*, 1851, in proof of the advantages of extension in the straight position in some cases of delayed union of oblique fractures of the humerus. In another work, Professor HAMILTON (*Principles and Practice of Surgery*, 1872, p. 273) regards fractures of the shaft of the humerus near the elbow joint as much more difficult of management than higher up. We take the liberty of citing his description and illustration (FIG. 566) of the mode of dressing such fractures: "The forearm should be placed at a right angle with the humerus and maintained in this position by a right-angled splint. After a thorough trial of angular splints made of movable joints, of wood, pasteboard, and various other kinds of apparatus, I am convinced that a thick piece of gutta-percha, moulded to the back and side of the arm, elbow, and forearm, will give the most satisfaction. When it can be obtained, no angular splint of hard felt, previously moulded upon a model, will answer nearly as well. Soie leather, if used, must be cut at right angles and applied to each side of the limb, since it cannot be made to double smoothly over the elbow upon its posterior aspect when bent at a right angle; but splints applied to the sides of the limb are not managed so easily as when applied to the back; and they are particularly inconvenient when laid upon the front, where most of the swelling usually takes place."



FIG. 565.—Splints for shot fractures of the shaft of the humerus. 1, Welch's; 2, Hamilton's. [After HAMILTON.]

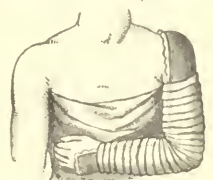


FIG. 566.—Dressing for fractures near the elbow joint. [After HAMILTON.]



the usual primary care of the wound by the removal of foreign bodies, the suppression of hæmorrhage, etc., steadied the upper arm by short splints of pasteboard, and put the forearm in a sling. Not a few bandaged the extremity from the fingers to the shoulder,

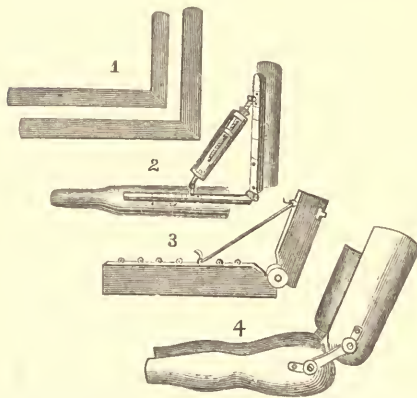


FIG. 567.—No. 1. Physick's splint; No. 2. Rose's splint; No. 3. Kirkbride's splint; No. 4. Welch's splint.<sup>1</sup>

<sup>1</sup>The drawing represents PHYSICK's angular splint for the arm as usually figured. As described by DONSEY (*Elements of Surgery*, 1818, Vol. I, p. 150), the arms are united at a much more obtuse angle. DR. KIRKBRIDE's splint was originally proposed for compound fractures of the elbow, and figured in the *American Journal of the Medical Sciences*, 1835, Vol. XVI, p. 315.

<sup>2</sup>HAMILTON (F. H.) (*A Treatise on Military Surgery and Hygiene*, New York, 1865, p. 504) remarks: "At Fredericksburg, in May last, while the battles of the 'Wilderness' were in progress, we saw several of these excisions of the head of the humerus which had been made upon the field, to most of which were applied long arm-splints, and sometimes right-angled splints extending along the forearm as well as arm, and secured in position by rollers. These dressings were all loose, saturated with pus, and generally covered with maggots; while at the same time they were of no possible use."

<sup>3</sup>DR. JOSEPH H. VEDDER, of Flushing, Long Island, has published (*Am. Med. Times*, 1862, Vol. IV, p. 254) a *New Apparatus for the Treatment of Fractures of the Long Bones*. He proposes to make extension and counter-extension in fractures of the arm either by an external lateral splint (FIG. 568), which is secured at the shoulder by an axillary padded strap, and to the lower part of the arm by adhesive strips, or else by an internal splint (FIG. 569) with an axillary crutch for counter-extension, both provided with circular turns of adhesive plaster to prevent lateral displacement. The extension is made in each case by attaching a cord connected with the loops of extending adhesive strips to a somewhat complicated "extension ratchet pulley" (FIG. 570), which is described in detail in a preceding number of the same medical journal (*Am. Med. Times*, 1862, Vol. IV, p. 24). Moved by a key, it regulates the degree of extension with as much precision as is permitted by the conditions under which counter-extension is made. The pulley is of brass, an inch in diameter, and a fourth of an inch in thickness, its circumference ratcheted at one edge and supplied with a groove at the other. A cat-gut cord, which is attached to the extension loop of adhesive plaster, is wound around the groove and tightened by means of an ordinary clock-key applied to the square head of the pivot (FIG. 570). A catch and spring fix the pulley in any desired position. The forearm is supported by a sling. This ingenious contrivance appears to have been very little used.

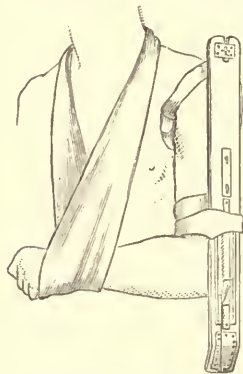


FIG. 568.—Bracket extension splint. [After VEDDER.]

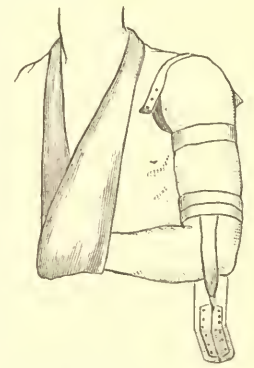


FIG. 569.—Internal arm splint. [After VEDDER.]

<sup>4</sup>Surgeon FOSTER SWIFT, 8th New York Militia, has described (*Am. Med. Times*, 1862, Vol. IV, p. 255) an extemporaneous field splint for fractures of the humerus: "After the battle of Bull Run, on the 21st July, 1861, we were left with four or five cases of fractured arms, with no appliances for their treatment, and with the prospect of their transportation over a rough road in rough wagons to Manassas, and from thence to Richmond. Without splints and without any light material to make them of, I am indebted to Dr. HOGES, of one of the Mississippi regiments in the rebel army, for the following simple contrivance, which afforded great relief to our wounded men in their jolting journey. Two strips of adhesive plaster were cut two feet in length and three inches in width, one of which was carried over the upper fragment to the point of fracture, leaving a loop above; the other was carried in a similar manner over the lower fragment, forming a loop below. A piece of board about one foot longer than the fractured limb, with a V-shaped piece removed from each end, was then applied to the arm. The lower loop was tied by a bandage to the lower V, and the upper loop to the upper V. The fragments were thus separated, and the limb could be secured to the splint by a simple turn of the bandage above and below the point of fracture, thus leaving the orifice of the entrance and exit of the ball open." \* \* \* "When the surgeon is unable to provide himself with boards, he may extemporize a retentive splint from tree branches, by binding together two of suitable length and size so that a fork will be left (FIG. 571) on either end, over which the bandage attached to the loops may be tied. An axillary strap and the necessary pads must be made of such material as may be at hand." A similar expedient has been suggested by Professor ESMARCH, in a print on his half-handkerchief for ready battle-field dressings.

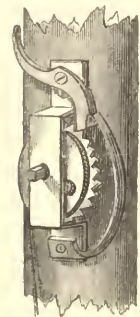


FIG. 570.—Extension pulley. [After VEDDER.]

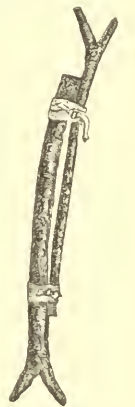

FIG. 571.—Arm splint of branches. [After F. SWIFT.]

<sup>5</sup>Originally proposed by Dr. JOSIAH CROSBY, of Manchester, New Hampshire, in 1849, for the treatment of fractures of the leg (*New Mode of Extension in Fractures*, in *Am. Jour. Med. Sci.*, 1854, Vol. XXVII, p. 76), and said to have been first mentioned in print in MUSSEY's report on Surgery, in the third volume of the *Transactions of the American Medical Association*, 1850. Priority for this important surgical improvement has been claimed for Dr. WALLACE, of Philadelphia (J. H. BINTON, in note to Am. ed. of FRICHSEN'S *Surgery*), for Professor GROSS (P. W. SARGENT, in note to MILLER'S *Surgery*), and for Dr. SWIFT, of Easton (*North American Med. Chir. Rev.*, Vol. IV, p. 584)

and attempted to secure immobility of the injured limb by the application of one of the forms of external and internal angular splints which were supplied with most of the regimental hospital chests (FIG. 567). The ill effects of such constriction of the arm after shot comminutions and operations for excisions of the humerus were severely criticised by the medical inspectors.<sup>2</sup> Several plans were devised for extension and counter-extension in shot comminutions of the humerus. Dr. Vedder proposed two splints with this object,<sup>3</sup> and Surgeon F. Swift suggested a dressing that could be improvised for the same purpose.<sup>4</sup> The New England plan,<sup>5</sup> of using adhesive plaster for securing the extending loops, was regarded with much favor. The ingenious method practised by Dr. G. C. Harlan for maintaining immobility

after shot fractures of the upper part of the humerus or after excisions of that portion of the bone has been already noticed.<sup>1</sup> Dr. Swinburne has recommended a method for extension in fractures of the humerus by means of adhesive strips,<sup>5</sup> connected either with an external splint extending above the shoulder, or an internal splint with an axillary crutch. Dr. Clark has advised, in fractures near the head, extension by means of a weight<sup>2</sup> (FIG. 572). Many surgeons agreed with Professor Stromeyer,<sup>3</sup> that immobility was best secured in these fractures by securing the arm to the thorax, interposing a triangular cushion, as figured and described on page 517. This admirable appliance permits the arm to be kept at rest without materially interfering with the circulation and evoking the fatal facility for gangrene observed in these cases. Dr. Stromeyer assured Dr. MacCormac that he considered this arm-cushion "the most valuable appliance he had invented during his life." Where hospital facilities were immediately available, the injured arm was sometimes simply laid upon a pillow without splints or bandages, and treated by irrigation<sup>4</sup> or the application of ice-bags; but the surgeons were generally restricted to water dressings and evaporating lotions, means for



FIG. 572.—Extension method for fractures high up of the humerus. [After CLARKE.]

<sup>1</sup> DR. HARLAN'S two forms of apparatus are described on page 509 *ante*, FIG. 388, and on page 562, FIG. 431. His apparatus was roughly made at the field forge of the 11th Pennsylvania Cavalry. An apparatus, on the same principle, for fractures of the radius, permitting the variable adjustment of the bracket, was devised by the late HENRY S. HEWIT, and a handsome model is deposited in the Army Medical Museum, and numbered 6359 in the Surgical Series. Surgeon-General BARNES has remarked that this dressing of shot comminutions of the upper part of the humerus, which he examined at the hospitals at Suffolk, Virginia, answered the indications more perfectly than any of the great variety of appliances he had occasion to observe during his extended tour of inspection as Acting Medical Inspector General.

<sup>2</sup> CLARK (E. A.) (*Method of Treating Fractures of the Humerus*, in *A Report on the Progress of Surg.*, St. Louis, 1871, p. 77): "The appliance consists merely of two strips of adhesive plaster about three inches in width, applied to the internal and external surface of the arm as high as the upper part of the middle third of the humerus. These strips are bound to the arm by a roller bandage, and at their lower end, beneath the point of the elbow, are attached to a cord, to which a sand-bag is attached weighing, ordinarily, from three to four pounds."

<sup>3</sup> STROMEYER (L.) (*Erfahrungen über Schusswunden im Jahre*, 1866, Hannover, 1867, S. 47) remarks: "For shot fractures of the diaphysis of the humerus, there is only one suitable mode of bandaging, in which the thorax forms the splint; but that a uniform bed be formed, a pillow must be inserted between the arm and the thorax." \* \* \* Any splint affixed to the humerus itself is always dangerous in the first weeks, and it cannot be firmly adjusted without circular pressure, and impedes the discharge of secretion." In his *Maximen* (1855, S. 696), the same great teacher says of fractures of the shaft of the humerus: "These shot fractures, in their treatment, require more perseverance on the part of the wounded than art on the part of the surgeon," and cautions against treating the fractured arm in an extended position on a splint, remarking that "every motion of the body displaces the upper fragment, while the lower remains on the splint, favoring the production of a false joint."

<sup>4</sup> WAHREN (E.) (*Epitome of Pract. Surg. for Field and Hospital*, Richmond, 1863, p. 373) advises, in compound shot fractures of the shaft of the humerus, that: "The patient should be put to bed and the injured limb supported on a pillow, the forearm being kept at an obtuse angle with the arm, the elbow on a level with the shoulder, and the hand a little higher than the elbow. No bandage should be applied, but support may be given, either by wire splints, permitting irrigation, or two lateral wooden splints. The patient must be kept perfectly quiet, so that the upper fragment may not be disturbed by any movement of the trunk. When the swelling has subsided and the inflammation has been subdued, the starch bandage may be used with advantage."

<sup>5</sup> DR. JOHN SWINBURNE (*Treatment of Fractures of Long Bones by Simple Extension*, Albany, 1861, p. 33) proposes to treat all fractures of the shaft of the humerus by extension and counter-extension. He describes his method as consisting in the use of a thin lath or board (FIG. 573) surmounted by a crutch piece, which supports a heavily padded axillary belt (1) secured by tapes (2 2). For convenience in packing, the splint may be folded by the hinge (3). At its lower end some holes are bored (4). The crutch is fitted accurately into the axilla (FIG. 574) and the tapes (3) are carried around and fastened over the shoulder (7). "This crutch apparatus extends from the axilla along the inside of the humerus to about six or eight inches below the elbow. Strips of adhesive plaster (2) are placed longitudinally about the lower end of the humerus so as to form a loop, through which is passed a cord, and thence through a hole in the lower end of the instrument (1) six or eight inches below the elbow; by tightening this cord, extension is made to the normal length of the bone, when it will be seen (FIG. 574) that the arm appears as natural as its fellow. All that now remains is to surround the arm and splint with an occasional strip of adhesive plaster to steady the limb at the seat of fracture. The object of connecting the elbow to the apparatus at so great a distance, is that the angle of extension shall not be too obtuse, otherwise it would draw against the splint." Dr. SWINBURNE sometimes places the splint externally and lets it extend above the shoulder (FIG. 575), so as to make counter-extension more in the axis of the limb. "The splint does not go below the elbow, but is fastened to it by adhesive plaster (2) after full extension is made." The axillary belt is passed through holes in the splint (4). Strips of adhesive plaster (2 2) are placed circularly at intervals "to prevent any kind of lateral motion in the parts." The arm thus dressed is kept in a sling (FIG. 576). "These forms of apparatus," the author says, "have succeeded most admirably, and are well adapted to the treatment of fractures occurring in any portion of the humerus, from the surgical neck down to within two inches of the elbow joint."

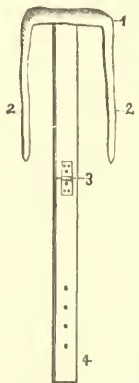


FIG. 573.—Crutch arm splint.

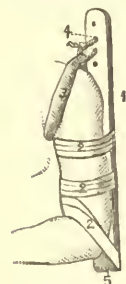


FIG. 575.—SWINBURNE'S external arm splint.

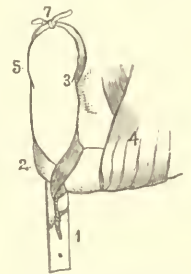


FIG. 574.—Crutch apparatus applied to the right arm. [After SWINBURNE.]

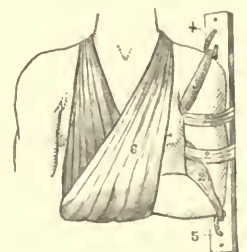


FIG. 576.—Arm splints applied with sling. [After SWINBURNE.]



the persistent and methodical application of cold being rarely available in the field.<sup>1</sup> Ice was plentifully supplied to the hospital department; but was consumed in iced drinks rather than in iced lotions.<sup>2</sup> Although recommended in the medical periodicals of the time,<sup>3</sup> plaster of Paris or gypsum bandages, latterly most favorably appreciated by many European military surgeons,<sup>4</sup> were rarely or never, during the war, employed by the American surgeons as a primary dressing in shot fractures of the humerus or other long bones. The use of starch and dextrine and plaster dressings in fractures had not been encouraged by surgical teachers in this country, and plaster was not issued with the hospital supplies. The removal of all detached splinters of bone was almost universally regarded as an essential preliminary to attempts at conservative treatment, although there was some difference of opinion as to propriety of disturbing large fragments that remained partially adherent. This subject is discussed by Assistant Surgeon Billings, U. S. A., in a report in the *Appendix to the First Part* of this work, with conclusions adverse to interference with

<sup>1</sup> The great advantage of the continuous application of cold after comminuted fractures is generally conceded. Unhappily, the opportunity of availing of this important adjuvant is rarely presented on the battle-field. STROMEYER (L.) (*Über die bei Schusswunden vorkommenden Knochen-Verletzungen*, Freiburg, i, B. 1850, S. 16, and STATHAM's translation, London, 1856, p. 10) says: "Cold applications are next in importance to abstraction of blood as an antiphlogistic means. Unfortunately, in the campaign of 1849, we had no ice at our disposal; but in Freiburg, in 1848, at the time of the revolution, I had opportunity to assure myself of the great value of its application. In this form cold can be applied in the gentlest and least annoying manner. In the absence of ice, the application of cold water must sometimes take its place without nearly equalling it in value." ESMARCH (P.) (*Über Resektionen nach Schusswunden*, 1851, S. 20, and STATHAM's translation, London, 1856, p. 52) observes: "In very many cases, however, the serous infiltration subsides by the mere application of cold, that is to say, when ice is procurable. In the year 1850, after the battle of Idstedt, we had in Schleswig plenty of ice at our disposal, so as to be able to employ it in all cases of comminution of bone, and indeed we found the most excellent results from it." In the Franco-German war, FISCHER (H.) (*Kriegschirurgische Erfahrungen*, 1872, S. 35) remarks: "Of ice we seldom made use, as we either had none or were only scantily supplied. \* \* The wounds were generally syringed with a solution of lime water, generally used cold. It hardly needs special mention, that wounds were cleansed by irrigation only, and that sponges were entirely banished."

<sup>2</sup> Ice was bountifully furnished to the general and post hospitals; but it was often impossible to have it accessible at the field station. The returns of the Chief Medical Purveyor show that nearly fifty thousand tons of ice (48,861 tons) were issued during the war by the purveying department, "in addition to vast quantities purchased from the hospital funds by the general and regimental hospitals throughout the country." The purveyors issued to hospitals at the rate of a pound daily to each patient. To this supply was added an occasional sloop or schooner load of ice sent to the hospitals by benevolent societies, and widely noticed in the newspapers. The utility of ice dressings in shot fractures of the long bones and in periarticular wounds has been strenuously insisted on by BAUDENS (*Des plaies d'armes à feu, Comm. à l'Acad. de Méd.*, 1849, p. 212), who remarks: "Je ne connais rien de plus énergique et de plus souverain que la méthode des réfrigérants et de la glace, avec ou sans addition de sel marin, selon qu'il convient d'obtenir un degré plus ou moins prononcé de froid." Dr. H. FISCHER, from experience in the Silesian, or Six Weeks War, also advocates topical applications of ice (*Lehrbuch der allgemeinen Kriegschirurgie*, Erlangen, 1868, S. 350): "The most energetic form of the application of cold is that of ice. It is best applied in bags of vulcanized caoutchouc, as hog bladders are never water-tight and rot readily. Caoutchouc, as a poor conductor of heat, admits of a longer application of cold. \* \* But it is necessary to place the ice-bag over a compress, and not immediately over the injured part. The ice was therefore extensively used in the late campaigns, and benefited the patients exceedingly in the first days,—pain diminished, sleep and better spirits supervened, \* \* but it has its disadvantages, \* \* and in times of war it is frequently difficult to supply ice in sufficient quantities. The present excellent means of transportation and the co-operation of all civilized nations for the relief of the wounded, facilitates the supply of ice. During the Bohemian War (1866), at a time when our supplies had dwindled down, large quantities of ice were sent us from North America. \* \* It is difficult to preserve ice in actual warfare. MIDDLEBORFF recommends to raise a shady place in an open field about a foot, and dig a ditch around it. The ice is then to be placed upon thick layers of leaves, straw, or moss, and to be thickly covered with the same. For the transportation of small quantities, MIDDLEBORFF had ice-boxes lined with zinc, made small enough to be placed on any farmer's wagon." There are, however, military surgeons of great experience who do not rate highly the utility of ice applications. It is true that they do not state how far they have made trial of them. M. LEGUEST (*Traité de Chir. d'Armée*, Paris, 1872, p. 177, etc.) does not think favorably either of topical applications of ice or by irrigation, and Dr. NEUDÖRFER (*Handbuch der Kriegschirurgie*, Leipzig, 1872) asserts that such treatment will cause tetanus, neuralgia, and rheumatic affections!

<sup>3</sup> Dr. ISIDOR GLÜCK, "Chief Surgeon to the Hungarian Hussars," published in the *American Medical Monthly*, 1855, p. 419, in a course of military surgery, a lecture on *Conservative Treatment of Fractures*, in which he described in detail the application of gypsum bandages in shot comminutions of the humerus, and insisted on their utility as a battle-field dressing. This lecture was reprinted in the *American Medical Times*, 1862, Vol. IV, p. 295, but the valuable suggestions it inculcates apparently attracted little attention. Professor F. H. HAMILTON states (*A Pract. Treatise on Fractures, etc.*, 3d ed., 1866, p. 89): "For the use of the surgeons in the U. S. Army, the Sanitary Commission furnished the plaster in tin cans hermetically sealed, but at a period too late to enable us to give it a fair trial in field practice. It is my impression, however, that this material is not well suited to the service of campaigns in this country, and that the opinions of foreign army surgeons as to its value must be taken with some allowance." After many inquiries, I cannot learn that any of these hermetically sealed cans of plaster found their way to the army surgeons.

<sup>4</sup> LOSSEN (H.) (*Kriegschirurgische Erf.*, n. s. w., *Deutsche Zeitschr. für Chirurgie*, 1873, B. II, S. 54) remarks, of the treatment of shot fractures of the shaft of the humerus, that: "with a few exceptions the gypsum bandage was given the preference over all bandages," and gives the drawing of a splint, to which, if necessary, an extension apparatus can readily be supplied. He continues: "VOLKMANN'S wire suspension splint for the upper extremity, after the pattern of SMITH'S suspension splint, often did excellent service. It was used as well to suspend fractures encased in gypsum bandages, as also to keep at rest fractures of the humerus already consolidated but yet suppurating freely. For treating the wound exposed, this simple splint, readily prepared out of telegraph wire, was very useful." BILLROTH (Th.) (*Chir. Briefe*, u. s. w., 1872, S. 223) admits that he has seen the gypsum bandage excellently applied by Dr. LOSSEN, but adds: "I have never succeeded very well in applying the gypsum bandage firmly to the shoulder, that the patient was not greatly inconvenienced." NEUDÖRFER (J.) (*Handbuch*, u. s. w., 1872, B. II, S. 1178) writes: "Regarding the gypsum bandage, I will only say this much: For the purpose of transportation no bandage can compete with the gypsum bandage, a fact that need not be dwelt on; but also for the treatment of those who remain in the hospitals, the application of the gypsum bandages is very beneficial, since they possess, as already mentioned, antiphlogistic properties, and as they are the best means of combating progressive inflammation and the burrowing of pus. That the gypsum bandage yet finds so many opponents among surgeons proceeds from the fact that they do not know how to use the plaster properly, and cannot entirely control the bandage. Did they understand how to use the gypsum as an elastic splint-like bandage, elinging to the limb, without support; and, further, to retain the integrity of the edges at the fenestra, preventing the ingress of pus into the bandage, there would remain not a single objection to the gypsum bandage."

fragments adherent to periosteum.<sup>1</sup> The necessity of thoroughly exploring the ball track with the finger, and, if necessary, of enlarging the entrance or exit orifices to facilitate such explorations, as well as the extraction of foreign matters, was generally recognized and acted on.<sup>2</sup> Some surgeons removed fragments with great freedom, whether the periosteal attachments were retained or not.<sup>3</sup> When this was done, it became necessary to remove the pointed extremities of the upper and lower portions of the broken shaft, and the case was transferred from the category of expectant conservative treatment<sup>4</sup> to that of conservation with excision. Before treating further of this series, it is convenient to refer to two varieties of shot injury of the humerus, which, without being extremely infrequent, are by no means common; I refer to the fractures without breach of surface of the soft parts, and to the contusions and partial fractures.

*Simple Shot Fractures.*—It is my impression that shot fractures of the long bones without injury of the soft parts, are more infrequent than visceral ruptures without external wounds. Medical Inspector Hamilton, however, speaks of bones of a limb broken by solid shot and the integuments not torn as not uncommon,<sup>5</sup> and Professor S. D. Gross met with a case,<sup>6</sup> which he mentions in the last edition of his classical systematic treatise, and this, and four other examples probably referable to this group, are found on the returns.

CASES 1710-14.—Sergeant Thomas Jefferson, Co. I, 1st Artillery (Rickett's Battery), was struck at the first battle of Bull Run, July 21, 1861, "by a twelve-pound shot, which fractured the humerus at three different points but did not even bruise the skin." (GROSS.) He was admitted to the Circle Hospital, at Washington, July 22d. Surgeon Levi H. Holden, U. S. A., reported that he had a shot contusion of the arm and was treated in quarters. On October 30, 1861, he was readmitted with fracture of the humerus, and was treated in hospital until January 20, 1862, and then furloughed for one month. He was readmitted February 7, 1862, and returned to duty, well, February 11, 1862. This completes the hospital record in the case, which is undoubtedly that referred to by Professor Gross. The sergeant re-enlisted July 29, 1864, in Battery A, 1st Artillery, and, on July 3, 1867, was promoted and detailed ordnance sergeant. On August 18, 1867, he was mustered out, and appointed Superintendent of the National Cemetery at Annapolis, and died, of typhoid fever, on May 17, 1868.—Second, Private John Wallace, Co. B, 10th Massachusetts, aged 26 years, is reported by Acting Assistant Surgeon E. E. Andrews as having entered Lincoln Hospital June 13, 1863, with a "gunshot fracture of the middle portion of the left humerus. Wounded at Chancellorsville,

<sup>1</sup> BILLINGS (J. S.), *Report on the Treatment of Diseases and Injuries, in the Army of the Potomac, during 1864, in Appendix to Part I, Med. and Surg. Hist. of the War, 1870, p. 201.* In "Directions to Army Surgeons on the Field of Battle, adopted by the U. S. Sanitary Commission, and printed, for the use of U. S. A. Surgeons," as Document No. 14, the rule is laid down on page 4 that: "In a case of gunshot fracture of the upper arm, in which the bone is much splintered, incisions are to be made for the removal of all the broken pieces which it is feasible to take away." This paper, of which two editions were widely circulated, may have influenced the judgment of some surgeons. The rules laid down were ascribed to GUTHRIE, and, with sundry intercalations, are taken from his writings. The illustrious veteran is styled "Surgeon General to the British Forces during the Crimean War." It is true that he took the keenest interest in the doings of the British medical staff in the Crimea, but he had then long since retired, full of years and honors. He died at the age of 75, May 1, 1856.

<sup>2</sup> SIR CHARLES BELL (*A System of Operative Surgery, 2d ed., 1814, Vol. II, p. 476*) early laid down the correct practice: "A question arises, whether there be any better mode of averting evil consequences than by amputating the limb? In my opinion the practice is obviously this: make a deep and long incision down to the fractured bone, pick away the loose pieces; let those which are long and adhering to the membrane remain till thrown off by the supuration; dress the wound with lint dipt in oil, so that the lips of the incision do not contract nor the matter and slough be in the slightest degree retained; lay the limb on a wooden or tin splint, and apply wet cloths to the whole extremity. That the cure will be slow must be a necessary consequence, but the evils already enumerated will be avoided, and instead of years of suffering, or the loss of the arm, the patient will preserve a useful member."

<sup>3</sup> Surgeon D. P. SMITH, in *Remarks on the Wounded after the Engagements at Mill Spring (Am. Med. Times, 1862, Vol. IV, p. 332)*, gives the following observations: "In two instances I removed a large amount of fragments from the shaft of the humerus, in each instance equal to at least two and a half inches of the entire shaft. In each of these cases it was the finger alone, introduced as a probe, that conveyed any adequate idea of the extreme comminution of the bone. Indeed, in military surgery it is, in almost every instance, folly to place any reliance upon or attempt to gain accurate information with an ordinary probe. In these cases, too, the *dispersive* effects of the minié ball were clearly shown, for, not only were fragments of bone driven into all the surrounding tissues, but in one case, where the ball impinged just below the insertion of the deltoid and passed entirely through from the front, I found by my finger a fragment driven into the elbow joint from between the coronoid process of the ulna and the articulating facet of the humerus. About two months after these operations, I heard that the arms had become rigid and were being used. I mention their having become rigid because I thought there was much danger of false joint, inasmuch as the excisions had occurred at the favorite place for that complication."

<sup>4</sup> LÖFFLER (P.) (*General-Bericht, u. s. w., 1867, p. 176*) lays down the following rules for the treatment of shot fractures of the shaft of the humerus, as deduced from the experience of Prussian surgeons in the Schleswig-Holstein campaigns of 1848-50: 1. All shot fractures of the shaft of the humerus by small shot and grape or canister shot unattended by injury to the brachial artery admit of conservative treatment. 2. Primary amputation is necessary if the brachial artery is injured. 3. Resection in the continuity as a means of conservative treatment is to be rejected. 4. Primary removal of splinters is to be limited to fragments completely separated and easily accessible. 5. A vigorous persevering antiphlogistic treatment, including particularly local treatment with ice, is beneficial and necessary, in the cases treated on the expectant conservative plan. 6. The early application of firm retentive bandages is unnecessary and injurious.

<sup>5</sup> HAMILTON (F. H.), *A Treatise on Military Surgery and Hygiene, 1865, p. 194.*

<sup>6</sup> GROSS (S. D.) (*A System of Surgery, 5th ed., 1872, Vol. II, p. 1011*). The case to which Professor GROSS refers has been identified, and the details that can be gleaned are given in the abstract above.



May 3, 1833, in action, by a piece of shell, producing contusion and a simple transverse fracture of the left humerus. Union has taken place." It is endorsed on the descriptive list that this man was transferred to McClellan Hospital, at Nicetown, June 23d, and had no treatment, but was detailed as a ward nurse, and, on September 4th, on duty with the hospital guard, and, on October 26, 1833, returned to duty with his regiment. It will be seen that the authenticity of the fracture of the humerus depends on the accuracy of the diagnosis of Dr. Andrews, who found the fracture united forty-one days after the alleged injury. Nothing is found of the case on the field reports, and the soldier's name is not on the Pension Roll.—Third, Private Orson Barrington, Co. B, 25th Wisconsin, aged 24 years, was wounded at Resacca, Georgia, May 14, 1864. He was sent to Nashville, where Surgeon W. H. Thorn, U. S. V., reported a "gunshot fracture of the humerus from a piece of shell." The patient was transferred to Madison, Wisconsin, August 2, 1864, where Surgeon H. Culbertson, U. S. V., reported a "shell fracture of the middle third of the right humerus, with contusion of the soft parts of the middle of the arm." The soldier was furloughed September 2d; readmitted September 29th, with "impaired motion of the arm," and returned to duty April 4, 1865. There is no pension record in the case.—The other two cases are included in the tables on excisions in the shaft of the humerus: One, the case of Lieutenant L. C. Kanouse, is CASE 176 of TABLE LVI, and is entered at page 679 *ante*. This officer received a shot contusion of the left humerus at Winchester, September 19, 1864. Assistant Surgeon C. I. Wilson, U. S. A., reported that there was a primary excision performed on account of a fracture of the humerus. The patient recovered and was mustered out. His name is not on the Pension Roll.—The fifth case, which has been entered in TABLE LXI, p. 692, as CASE 27, is of real value. It is that of Private Eli Schultz, Co. D, 102d New York, aged 30 years, who was wounded at Savannah, December 18, 1864. He was admitted to the 2d division, Twentieth Corps, field hospital, where Surgeon E. Hutchinson, 137th New York, reported: "Contusion of right breast and shell wound of right humerus, with simple fracture. The limb was put up with splints and simple dressings." The patient was transferred January 16, 1865, and admitted to McDougall Hospital, Fort Snivelyer, January 29, 1865. Assistant Surgeon Samuel H. Orton, U. S. A., reports: "Simple fracture of the right humerus by a shell fragment. No external wound was made. Ligamentous union has taken place and there remains a pseudarthrosis. The constitutional condition is fair. On March 25, 1865, a straight incision was made three inches in length, on the exterior aspect of the arm over the seat of fracture, cutting down to and around the fractured ends of the bone. The ends of the bone being turned out, nearly half an inch of each was removed by bone-cutting forceps. The ends of the bone were then brought in apposition, the wound closed by sutures and adhesive straps, and immobility of the arm was carefully maintained. On March 31st, the incision was closing; there was moderate discharge of pus, and the bone was in good condition, but there was apparently no attempt at union." This soldier was discharged July 14, 1865, for "fracture of right arm (simple), ununited for five months, but now quite firm after operation, etc." He was pensioned. Examining Surgeon A. H. Crittenden, of Bath, N. Y., certified, May 10, 1866: "Fracture of right arm midway between elbow and shoulder, resulting in non-union. The arm in consequence is a useless appendage. It has been operated upon two or three times, but without relief." Examiner H. L. Robbins, of Lincoln, Nebraska, certified, September 6, 1873: "\* \* no osseous union of humerus, muscles much atrophied, and the elbow, wrist, and finger joints almost completely ankylosed from long-continued inability to use the arm. The arm is wholly useless for purposes of manual labor, and is suspended loosely from the upper third of the humerus by the atrophied 'rope-like' muscles of the middle third." The pensioner was last paid March 4, 1875.

The comparative rarity of pseudarthrosis after compound shot fractures has been adverted to on page 673. It is curious to observe that two of the five examples of simple shot fractures of the humerus were characterized by non-union. In one of these rare instances recorded in the German *Ephemerides*<sup>1</sup> also, a false joint occurred.

Paillard, in his narrative of the surgical events at the siege of the citadel of Antwerp, in 1832, gives many interesting details of the effects of contusion by spent projectiles, and mentions a case of luxation of the head of the humerus, without apparent external injury, from the impact of a cannon ball.<sup>2</sup>

<sup>1</sup> ROMBERG (J. W.) (*Eph. med. phys. ger. nat. cur.*, Dec. III, Norimberge, Francofurti, et Lipsiæ, 1706, Obs. CLXXV, p. 208) relates that during the siege of London, in 1686, a soldier of the Legion of the Hanseatic town Lübeck had his arm fractured (*raram fracturam*) transversely, three fingers below the head of the humerus, just above the insertion of the deltoid, by a large bomb fragment (pyrobolum). Although there was extensive contusion, pain, loss of motion, and curving of arm and other symptoms, there was no wound. The "legitimate treatment" of application of splenwort and splints was employed, and, after a few weeks, the patient suffered no pain; there was no deformity of the member, or suspicious color of the external cutis, or any external indication of fracture, aside from the loss of motion, which prevented the abduction of the arm. "Cum vero in calli generationem investigarem, primo tactu nolum nullus apparuit, sed et manu membro transversim imposita, illud in quacunq[ue] partem circa dietum fracture locum absque omni strepitu vel molestia blando et facile inflecti poterat, extremitatibus ossis fracti nondum firmatis, sed cartilagine superinductis et munitis, ita ut naturam novam articulationem ex dieta fractura efformasse dixeris." LAVATON (*Chirurgie d'Armée*, 1768, p. 283) records a case of fracture of the right humerus by a cannon ball, "sans former des plaies," in a marine of the frigate Formidable. The case is alluded to in the note to p. 808 *ante*. STROMMEYER (L.) (*Mazimen der Kriegsheilkunst*, Hannover, 1855, S. 165) refers to simple fractures of bones from shot, and cites the case of a young man, in 1853, whose humerus was fractured in this manner, with only slight lesion of the soft parts. LEGOUËST (*Traité de chirurgie d'armée*, Paris, 1872, p. 466) remarks: "Les premières (fractures simples), sans être rares, ne sont cependant pas communes," and adds "SAUREL a rapporté quelques exemples de ces dernières (SAUREL, *Des fractures des membres par armes à feu*, Montpellier, 1858—according to DEMME, at p. 69, ten cases in 300). DEMME (*Mit. chir. Studien*, Würzburg, 1861, S. 69) observes: "Simple fractures, similar to the usual subcutaneous fractures, or complicated by wounds of the soft parts, occurred more frequently than is generally supposed. Generally they were caused by 'Contusions Schüsse' of larger projectiles, sometimes also by small projectiles," and adds that, in 1852, PAILLARD observed a simple fracture of the humerus from a spent cannon ball. The latter statement is erroneous; it was a luxation that PAILLARD observed.

<sup>2</sup> PAILLARD (A.) (*Relation Chirurgicale du Siège de la Citadelle d'Anvers*, Paris, 1833, p. 24) remarks: "J'ai vu à l'hôpital militaire d'Anvers, un soldat qui avait reçu un coup de boulet mort à la partie externe et supérieure du bras. Il n'y avait rien d'apparent à la peau, mais une luxation de l'humerus s'était faite. Je ne puis donner d'autres détails sur ce blessé dont j'ai égaré l'observation. Je le regrette, car je l'avais prise avec soin, et ses détails étaient intéressants."

*Shot Contusions of the Humerus.*—In the subsection commencing on page 666, shot contusions of the humerus are discussed. The views on this obscure subject<sup>1</sup> of Surgeons Lidell and Bontecou, and of Drs. Stromeyer, Beck, and Socin, are cited, and three reported examples that terminated favorably, and three that had a fatal result, are adduced. Pathological specimens from two of the latter are reproduced in PLATE L. I fear that the infrequency of such lesions, which have received slight attention until late years, was overstated. On careful scanning of the reports, sixteen additional instances are found that appear to belong to this group, and references to such cases in foreign campaigns have become more numerous since attention has been drawn to this subject.<sup>2</sup>

CASES 1715-1730.—1. Lt. W. M. Begole, Co. H, 23d Michigan, was wounded at Lost Mountain, June 16, 1864. Surgeon E. Shippen, U. S. V., Medical Director of the Twenty-third Corps, reported from the field a "severe gunshot wound of the left shoulder." At the Officers' Hospital, at Chattanooga, Surgeon L. D. Harlow, U. S. V., reported: " \* \* The ball grazed the humerus and emerged near the axilla. Hæmorrhage occurred, August 30th, from the superior thoracic, with loss of twelve ounces of blood. The bleeding was arrested by compression and application of solution of persulphate of iron. Hæmorrhage recurred, and death resulted October 15, 1864."—2. Pt. A. Brown, Co. D, 64th New York, aged 26 years, was wounded at Hatcher's Run, March 25, 1865, by a minié ball. Surgeon T. R. Crosby, U. S. V., reported that: "The ball entered the middle of the arm anteriorly, passed upward and backward, and lodged and flattened against the humerus. It was extracted from beneath the deltoid by an incision along its posterior border." The patient recovered, and was discharged from Columbian Hospital May 2, 1865.—3. Pt. J. W. Collings, Co. A, 29th Maine, aged 40 years, was wounded at Cedar Creek, October 19, 1864. Surgeon L. P. Wagner, 114th New York, reported, from the field hospital of the Nineteenth Corps, a "flesh wound of the left arm; simple dressings applied." Surgeon S. J. W. Mintzer, U. S. V., reported the patient's admission into York Hospital, and discharge May 5, 1865, "on account of a gunshot wound of the left arm, with injury to the humerus, resulting in atrophy." Examiner E. Russell reported, May 4, 1866: "The wound is still suppurating; the arm is atrophied, and there is partial ankylosis of the elbow joint."—4. Pt. O. Crippen, Co. G, 41st Ohio, was struck, at Chickamauga, September 19, 1863, in the left arm by a bullet. Surgeon G. Perin, U. S. A., reported a "contusion of the humerus." The patient was treated in Nashville Hospital No. 1, and is recorded by Surgeon C. W. Hornor, U. S. V., as furloughed, re-admitted, and returned to duty January 27, 1864.—5. Pt. H. T. Fleenor, Co. C, 30th Iowa, was wounded at Resaca, May 15, 1864. Surgeon F. Salter, U. S. V., reported, from the general hospital at Chattanooga, "gunshot flesh wound of the left arm." On June 2d the patient was admitted into Hospital No. 2, Nashville. Surgeon J. E. Herbst, U. S. V., reported: "Shot contusion of humerus of left arm." This soldier was returned to duty August 9, 1864. He is not a pensioner.—6. Pt. J. R. Glogre, Co. H, 2d Vermont, was wounded at the Wilderness, May 5, 1864. Surgeon S. J. Allen, 4th Vermont, reported, from a Sixth Corps hospital, that a "conoidal ball, entering near the point of the shoulder, grazed the humerus, and was extracted from the muscles near the lower angle of the scapula." This soldier was treated at Columbian, Summit House, and Baxter Hospitals, and was discharged February 22, 1865, and pensioned. Examiner H. H. Atwater reported, July 18, 1865, that "small portions of the humerus have exfoliated. There are three openings still discharging."—7. Pt. P. Graves, Co. G, 5th Missouri Militia Cavalry, aged 28 years, is reported by Surgeon W. Dickenson, U. S. V., to have received, accidentally, August 25, 1863, "a conoidal ball wound of the left arm at the upper third, with injury of the periosteum of the humerus," and to have been returned to duty December 7, 1863.—8. Pt. J. G. Harvey, Co. G, 39th New Jersey, aged 19 years, was wounded at Petersburg, April 19, 1865. Asst. Surgeon H. Allen, U. S. A., reports from Mount Pleasant Hospital that "a conoidal musket ball had grazed the lower third of the left humerus, the shaft of the bone being denuded of periosteum and somewhat roughened, but not fractured." This soldier was mustered out June 28, 1865. His name does not appear upon the Pension Roll.—9. Pt. J. Haskins, Co. B, 1st Tennessee Artillery, aged 20 years, was wounded April 12, 1864, at Fort Pillow. Surgeon H. Wardner, U. S. V., reported a "gunshot perforation of the upper third of the left arm, with injury of the humerus, but not a clear fracture." The patient recovered, and was returned to duty June 22, 1864; he is not a pensioner.—10. Serg't S. M. Karnes, Co. H, 18th Infantry, aged 24 years, received, at Allatoona, May 27, 1864, a wound of the right arm. Surgeon S. Marks, 10th Wisconsin, reports a "contusion of the humerus." Surgeon B. B. Breed, U. S. V., reports the patient's reception at No. 1 Hospital, Nashville, with a "gunshot wound of the upper third of the right arm, with contusion of the humerus; recovery, and return to duty November 21, 1864;" not a pensioner.—11. Pt. R. H. Leavell, Co. E, 36th Indiana, aged 22 years, was wounded at Dallas, May 27, 1864. Surgeon J. D. Brumley, U. S. V., reported that he entered a Fourth Corps hospital with a "shot perforation of the right arm." The patient was sent to Cumberland Hospital,

<sup>1</sup> Professor L. STROMEYER (*Maximen der Kriegsheilkunst*, Hannover, 1855, S. 155) recognizes two classes of contusions of bone, one with, the other without an open wound, and considers the former far more serious than the latter. "It occurred regularly, that the wounds with so-called grazing of the bone healed much slower, inflamed more severely, suppurated more freely [than perforations of the soft parts], even if, from the direction of the ball, it was to be supposed that the accident was slight." He cites the case of a soldier shot at Colditz, in 1849, through the exterior soft parts of the left upper arm. The injury, from the beginning, appeared very slight, and even later caused little difficulty, but would not heal. "I saw the patient in September, 1850. The entire humerus was covered with a firm excrecence; some fistula, which suppurated only a little, led to a sequestrum that had not yet become loose. The patient was weak and thin, and greatly inclined to diarrhoea, which increased, and death occurred 14 weeks afterward. In the lungs were crude tubercles; in the eson no ulcers. Nearly the entire diaphysis of the humerus had become necrosed from a slight contusion, with an open wound."

<sup>2</sup> CHIPAULT (A.) (*Fractures par armes à feu*, 1872, pp. 2, 3) records three instances of recovery after shot contusion of the humerus, an injury he designates as "*éraïllement*" (fretting, fraying): Tranceof, 8th Chasseurs, age 20; the left arm was perforated at the insertion of the deltoid by a musket ball, which touched the humerus. There was intense inflammation, and several small exfoliations. After free incisions a good recovery ensued. Doussy, 4th Marines, aged 23, and Aubonnet, 27th marching regiment, received shot contusions of the humerus, the latter from a shell fragment. Both recovered after copious suppuration, treated by free incision. M. CHIPAULT (*l. c.*, p. 9) gives particulars of six comminuted fractures of the shaft of the humerus treated by expectation, five patients recovering, and the one who succumbed having in addition a shot penetration of the anterior mediastinum.



thence to Totten Hospital, whence Surgeon A. C. Swartzwelder, U. S. V., reported that "a ball passed through the middle third of the right arm, touching the humerus." Thence transferred to Evansville and to Indianapolis, this soldier was mustered out September 11, 1864, and pensioned. Examiner R. Bosworth reported, September 14, 1872, that: "The cicatrix of wound, through which the ball passed, is contracted, and the muscles contiguous to each other adherent. Forearm numb."—12. Pt. A. Lester, Co. H, 134th New York, aged 19 years, was wounded at Gettysburg, July 1, 1863. Surgeon Henry Palmer, U. S. V., reported from York Hospital: "Musket ball penetrated directly below the coracoid process, right side, passed the brachial artery outwardly, impinged against the humerus at the anatomical neck, and, seemingly, glided around the head of the bone without penetrating the joint. Two or three small chips of bone were removed since admission. Has good and free use of the arm except in outward extension. Can scarcely raise it to a right angle with the body; wound of exit still open." This soldier was discharged from Central Park Hospital June 24, 1864, and pensioned. Examiner J. G. Orton, of Binghamton, reported, January 15, 1838: "The action of the joint is very imperfect. The bone is undoubtedly necrosed to some extent." The pensioner died August 18, 1874. Dr. D. S. Burr states that at date of death the wounds were "open and discharging both outwardly and inwardly."—13. Pt. G. Loyd, Co. F, 6th Indiana, aged 27 years, was wounded at Chickamauga, September 20, 1863. Surgeon G. Perin, U. S. V., reported, from a Twentieth Corps hospital, a "shot contusion of the left arm." Assistant Surgeon W. C. Daniels, U. S. V., reported the patient's admission into Hospital No. 2, Evansville, with a "gunshot wound of the middle third of the right arm; the ball entered anteriorly and lodged on the humerus, whence it was extracted. Gangrene supervened but was readily arrested." This soldier was mustered out September 22, 1864, and pensioned. Examiner A. L. Lowell reported, July 25, 1868: "The arm is full, strong, and efficient."—14. Pt. D. Savage, Co. D, 183d Pennsylvania, aged 29 years, was wounded at Hatcher's Run, February 6, 1865. Surgeon W. R. Dewitt, jr., reported, from a Fifth Corps hospital, "gunshot flesh wound of the right shoulder," and the patient's transfer to Baltimore. Surgeon Z. E. Bliss, U. S. V., reported, from Camden Street Hospital: "\* \* \* Ball entered the right axillary space, having passed obliquely through, grazing the humerus, and making its exit in the front four inches below the shoulder joint." Furloughed April 25, 1865, to report to be mustered out of service.—15. Capt. H. C. Schmidt, Co. C, 6th Kentucky, aged 27 years, received at Chickamauga, September 19, 1864, a shot wound of the right arm. Surgeon J. E. Herbst, U. S. V., reported that the ball slightly grazed the humerus. The captain was furloughed September 26, 1863, and returned to duty January 19, 1864.—16. Pt. F. Schmeberg, Co. F, 16th Illinois Cavalry, aged 17 years, was wounded at Atlanta, August 7, 1864. He was treated in several hospitals, the case being registered as a gunshot wound of the elbow. Surgeon B. Cloak, U. S. V., at the Cumberland Hospital, gives the fullest account of the case, and records the diagnosis as a "wound of the right arm, with implication of the humerus." This soldier was discharged August 7, 1865.

Viewing these cases in connection with the six examples of shot contusions of the humerus previously cited, it must be inferred that while necrosis following ecchymosis, or osteitis, suppurative and gangrenous osteomyelitis, and purulent infection, and such direful results, vividly portrayed by Drs. Lidell and Gibbons,<sup>1</sup> occasionally follow such injuries, yet the great majority of shot contusions of the humerus<sup>2</sup> that have been observed have either terminated favorably, or in limited exfoliation, as Dufouart long since declared<sup>3</sup> regarding shot contusions of bone in general; and that there is every probability that many such injuries recover without recognition. In the grave cases, when dull, deep-seated pain announces mischief beneath the periosteum, an incision should be made down to the bone, to relieve tension and permit further exploration. If signs of medullary abscess are discovered, it has been recommended to penetrate the compact tissue of the bone with the trephine.<sup>4</sup> Dr. Lidell insists upon the value, in acute osteitis from contusion, of topical abstraction of blood, and of ice-dressings followed by hot fomentation.

<sup>1</sup> GIBBONS (II.) (*Contused Wounds of Bone*, in *Pacific Med. and Surg. Jour.*, 1866, Vol. VIII, p. 285) remarks: "In the severest of these injuries, in the shafts of long bones, not only is the periosteum, nourishing the external table, destroyed, but the endosteum is separated from its attachment, or otherwise injured, and the entire thickness of bone is deprived of the means of nutrition. The medulla also receives a severe concussion, causing extensive inflammation and subsequent gangrene, which may extend several inches above and below. Whether removal of this gangrenous product, always intensely fetid, could be advantageously accomplished, as by trephining, remains to be proved."

<sup>2</sup> FISCHER (II.) (*Lehrbuch der Allgemeinen Kriegs-Chirurgie*, Erlangen, 1868, S. 50) observes: "A perforation of the cutis and muscles is not necessary in cases of contusion of the bone. If there is a blind shot channel of the soft parts, the missile either remains lodged before the bone, or is deflected and escapes in a changed direction and form. In consequence of the contusion, the periosteum, at the injured locality, is either denuded and undermined with blood, or extensively torn from the bone and sugillated. \* \* \* As a constant result of contusion of the bone are found circumscribed demolition of the brittle cancellated tissue, and some extravasations of blood in the medullary cavities of the long bones." Elsewhere, in the same work, Dr. FISCHER says: "As soon as a contusion of bone is followed by dull pain and enlargement of the bone, deep incisions should be made, that penetrate through the periosteum to the affected locality. The then generally already existing, or soon to be developed, necrosis of the contused bone is to be carefully watched, and the sequestra, as soon as detached, are to be extracted, to prevent burrowing of pus and inflammation."

<sup>3</sup> PIERRE DUFOUART (*Analyse des Blessures d'Armes à Feu et de leur Traitement*, Paris, an X (1801), p. 26) devotes several pages to shot contusion and slight lacerations of substance of bone ("entamures et écornures"), and gives a tolerably good account, and one of the earliest, of the appearances of contused bone. He sums up with the reflection: "Il est consolant d'avertir ici que la contusion des os et la déchirure du périoste donnent rarement de pareilles alarmes: je les ai vu nombre de fois suivre, dans leur guérison la voie douce et prompte des plaies les plus simples."

<sup>4</sup> Dr. WALTER F. ATLEE (*Am. Jour. Med. Sci.*, 1865, Vol. I., p. 119) remarks: "The injuries of bones, caused by balls, are those of all others whose final result has most grievously disappointed all our calculations. \* \* \* We have again and again seen a stout fellow sink when one of the long bones had been touched so slightly as merely to carry off a small piece of periosteum. When this happened to the femur, death *always* followed. \* \* \* Should such cases again fall under our care, we shall proceed to trepan the bone at the seat of injury."

*Excisions in the Continuity.*—On page 676 were summed up facts proving that, in formal extended excisions in the shaft of the humerus, the mortality was excessive, and the results in the cases of recovery for the most part deplorable, a third of the number suffering from pseudarthrosis, and nearly a sixth having recourse to ulterior amputations. While the wisdom of removal after shot fractures of the shaft of the humerus of all detached splinters is fully conceded, the assertions of Drs. Loeffler and Schwartz, that formal primary excisions in the continuity shall be absolutely rejected, is not too emphatic.

The plan of wiring together the fractured extremities of the humerus<sup>1</sup> was advocated and practised, in one instance, by Surgeon W. H. Church, U. S. V.,<sup>2</sup> and subsequently, in three instances, by Assistant Surgeon B. Howard, U. S. A.<sup>3</sup> Dr. Church's patient recovered; but it was not believed by the surgeons who observed the case, that the operative interference promoted the cure. Dr. Howard insisted on this expedient<sup>4</sup> as a primary

<sup>1</sup>Although M. BÉRENGER-FÉRAUD has undertaken to ascribe the invention of sutures of bone to HIPPOCRATES, it has been satisfactorily shown by M. LETENNEUR, of Nantes, in a note to the *Société de Chirurgie*, in 1870, that "ξενύρνατ, τοὺς ὀδόντας" of HIPPOCRATES (*Oeuvres complètes par É. LITTRÉ*, Paris, 1844, T. IV, p. 148) signifies "to attach the teeth together," and that HIPPOCRATES referred to tying the teeth together in fractures of the lower jaw, and not to wiring together the fragments of the maxilla, a position sustained by LITTRÉ and by M. MARTIN, another learned hellenist. As to the historical question, it seems to be agreed that suture of bone is a modern invention. GEORGE W. NORRIS (*On the Occurrence of Non Union after Fractures; its Causes and Treatment*, in *Am. Jour. Med. Sci.*, 1842, Vol. III, p. 51, reprinted in *Contributions to Practical Surgery*, 1873, p. 9) thought it was first practised by ICART (*Jour. de Méd., Chir., et Phar. de Roux*, 1775, T. XLIV, p. 170). In a fracture of the humerus by a cart wheel, ICART cut down and secured the ends of the bone by iron wire. The patient died on the twelfth day, and ICART was bitterly criticised by PUJOL (*l. c.*, Vol. XLV, p. 167). The practice was revived in July, 1826, by J. K. RODGERS, of New York (Dr. JOHN S. HEARD's remarkable *Report on Cases of Ununited Fracture, treated at the New York Hospital*, in *New York Jour. of Med.*, 1833, Vol. I, p. 351, details the case of Geo. Westerfield, aged 15, with a pseudarthrosis of the right humerus two inches above the elbow. Dr. RODGERS resected the ends of the bone, and united them by silver wire, and the patient regained perfect motion of the arm, with two inches shortening), and it is stated by Dr. HEARD that it was successfully repeated by MOTT and CHEESEMAN. In 1838, it was again successfully practised by FLAUBERT, of Ronen. (His pupil, LALOY, relates the case—an ununited fracture of the middle third of the left humerus, in a girl of 21 years—in his thesis *De la suture des os appliquée aux résections et aux fractures avec plaie*, Paris, 1839, p. 11.) In 1850, VILPEAU is said to have practised this operation unsuccessfully in a pseudarthrosis (*Gazette des Hôp.*, 1850, p. 233); and LATGIER repeated the operation on a pseudarthrosis of the right humerus, in a man of 40, in 1855.—(*Comptes Rend. de l'Acad. de Sci.*, 1855, T. XL, p. 935.) In 1859, SANBORN (E. K.) (*The Silver Wire in Ununited Fracture, with a Case*, in *Am. Jour. Med. Sci.*, 1860, N. S., Vol. XXXIX, p. 339) operated successfully on a patient of 33, with an ununited fracture of the lower third of the right humerus of three years' standing, which had been vainly treated by the seton and other expedients. E. S. COOPER and BRAINARD practised similar operations in pseudarthrosis of the femur in 1859-60. In 1865, M. DEMARQUAY (*Bull. gén. de thérap.*, T. LXXI, p. 557) operated on a woman of 20, with pseudarthrosis of the humerus, by wiring together the broken extremities; and in 1872, M. DOLBEAU succeeded in curing a pseudarthrosis of the left humerus, of four years' standing, in a woman of 40, by resecting the extremities of the ununited lower third of the shaft and bringing them into apposition by wire sutures.—(*Bull. gén. de thérap. med. et chir.*, T. LXXXIX, 1875, p. 1.) M. BÉRENGER-FÉRAUD (*De la suture des os*, in *Gaz. hebdom. de méd. et de chir.*, 1867, T. IV, p. 611) and M. PIÉL (*Essai sur les pseudarthroses*, Thèse, Paris, 1867, No. 6) have collected numerous other instances of the sutures of bones, principally of the lower maxilla and femur.

<sup>2</sup>Dr. CHURCH's patient was Private H. Claffey, 21st Massachusetts, who was operated on at New Berne, April 15, 1862, a month after the reception of the injury, by Dr. CHURCH, assisted by Surgeon G. DERRY, 23d Massachusetts, and the writer of these lines. The particulars of the excision are recorded in TABLE LXI, p. 692, CASE 4. This man recovered and is still living, with a comparatively useful limb. Examiner B. S. SHAW, of Boston, reported, April 25, 1863: "He now has ankylosis of the shoulder without the slightest motion. There is shortening of the arm with great deformity." The Worcester Examining Board (Drs. MARTIN, CLARK, and WOOD) reported, September 4, 1863: "bone three inches shortened, shoulder joint stiff, sore, and painful; disability rated total."

<sup>3</sup>The operations for suture of bone after shot fracture of the humerus reported as practised by Assistant Surgeon HOWARD, U. S. A., occurred after the battles of the Wilderness and Spotsylvania, in May, 1864. The first case was that of Sergeant G. Chrispin, 10th Pennsylvania Reserves, and is reported in TABLE LVI, on p. 677, as CASE 1. He was treated in Carver and Chester hospitals, and was discharged and pensioned July 18, 1865. Examiner S. G. Snowden, of Franklin, Pennsylvania, reported of this pensioner, January 31, 1870: "Gunshot fracture of right humerus at upper third. Excision of a portion of humerus, followed by complete atrophy of the deltoid muscle. The biceps is also partially atrophied. The cicatrix is large, depressed, and tender." Examiner W. S. WELSH, of Franklin, reported, September 14, 1873: "The ball carried away the belly of the deltoid muscle, leaving an adherent cicatrix two and a half inches in length and two inches in width. There was considerable destruction of bone. The arm is three-fourths of an inch shorter from the shoulder to the elbow than the left, and much atrophied." This pensioner was paid December 4, 1874. The next case was that of Private Charter, reported at page 683 *ante*, in TABLE LVII, as CASE 21. This patient submitted to consecutive amputation at the shoulder (see TABLE XLIX, CASE 6, p. 650), and died, from tetanus, October 21, 1864. The third case was that of Private Meisner, recorded on page 679 as CASE 215 of TABLE LVI, and fully detailed in Dr. HOWARD's paper on *The Application of Sutures to Bone in Recent Gun-Shot Fractures*, in the *Medico-Chirurgical Transactions*, London, 1865, Vol. XXX, p. 247. This man was discharged June 16, 1865, and pensioned. Examiner H. L. HODGE, of Philadelphia, certified at that date: "Resection in the shaft of the humerus has been made on account of gunshot wound. The wound is not yet healed, and the arm is still useless." On September 12, 1873, the Dayton, Ohio, Examining Board (Drs. JEWITT, BECK, and DUNLAP) certified: "A very deep sear, adherent to humerus, in upper third of left arm, in front; sear between two and three inches long. A deep and much longer sear posteriorly. The pensioner states that there has been resection of two inches of the humerus; bony union. Cannot raise arm to horizontal line. Hand in pronation, and he cannot supinate; has very little strength in hand." The pensioner was paid March 4, 1875.

<sup>4</sup>Assistant Surgeon BILLINGS, U. S. A., has expressed (*Appendix to Part I, Med. and Surg. Hist. of the War*, 1870, p. 240) the disapprobation with which Dr. HOWARD's operations for primary suture in gunshot fractures of the humerus were regarded by the medical officers of the Army of the Potomac. On December 23, 1863, Dr. HOWARD sent to the Surgeon General a memoir, which is printed in full below, describing his proposed operation. He published (*Am. Jour. Med. Sci.*, 1865, Vol. LXIX, p. 351) *A Description of a New Bone Drill* (with eight woodcuts), and the same year a paper, already referred to, in the *Medico-Chirurgical Transactions*, of London, and publicity was given to the plan through many other channels. This officer laid before the profession, in rapid succession, propositions for "hermetically sealing" chest wounds, for ligating the intercostal artery with inclusion of the rib, for a new form of ambulance wagon, and for a new method of ligating vessels in the continuity (the latter proposition was adjudged a prize by the *Am. Med. Association, Essay on the Treatment of Aneurism*. See *Transactions*, 1870, Vol. XXI, p. 499). It may be said that each of these plans were based on ideas of value within limited spheres of application, although devoid of originality, and were urged with such unreasonable pertinacity that they were fruitful in notoriety rather than usefulness. I have sacrificed much space (*First Surg.* Vol., pp. 497-514) to a demonstration that the



operation "specially adapted for the field." His operations were regarded, I think most justly, with general disfavor by the experienced field surgeons of the Army of the Potomac.

recorded facts disproved Dr. HOWARD'S assertions regarding treatment of wounds of the hum. It would be easy, but tedious and profitless, to refute the claims advanced for the other alleged improvements, and to show that they caused mischief before their worthlessness became apparent. The communication to the Surgeon General is appended as a document bearing on the surgical annals of the war:

"PRIMARY RESECTIONS AND THE USE OF METALLIC SUTURES IN GUNSHOT FRACTURES OF THE SHAFT OF THE HUMERUS.—Conservative surgery, which alone can inscribe living records in the archives of our profession, is the absorbing consideration with every surgeon feeling as he does that he never achieves a triumph but when he saves. Too much pains cannot be taken, especially to preserve the upper extremities; for while an artificial leg of great utility and beauty may be readily obtained, nothing really useful can be substituted for a natural arm; the amputation of the smallest portion is an irreparable loss. *Conservatism* is one thing, *conservation* is another. The tendency to the former having its origin more or less in feeling, has often acquired an impetus which has carried us beyond the latter. We have attempted too much to *keep* what we could not *save*; the result too often being not only the loss of the part we attempted to save, but of the entire limb, or ending perhaps in the death of the patient. In the official consolidated statement of gunshot wounds for September, October, November, and December, 1862, compiled by Surgeon BRINTON, U. S. V., and to which alone I shall here refer for statistics, we find that of two hundred and twenty-eight excisions performed on the upper extremities, all but thirty-three were secondary operations. Now, if the remaining one hundred and ninety-five were at all any proper subjects for resection, most of them were probably never in such a favorable physical condition for the operation as immediately after the reception of the wound, for fighting men generally are healthy men. Moreover, it is interesting to enquire what percentage this one hundred and ninety-five formed of the whole number who were originally proper subjects for primary resection, but who in consequence of intercurrent diseases, superadded as a result of delay, were subsequently obliged to submit to amputation, or perhaps to a fate still worse. For we find that while there were but one hundred and twenty-six primary, there were four hundred and one secondary amputations. Of these we can hardly suppose that more than a small part could have been considered subjects for amputation at all, when first wounded. The unsuccessful attempt to save the rest by other means, resulting in submission to the same operation subsequently, and under much more unfavorable circumstances, is one of those facts which have supplied a forcible argument for extensive primary amputations. In gunshot fractures of the humerus, every field surgeon knows that there are usually but two questions uniformly presented for consultation: "Shall we amputate?" or, "Shall we put it up in splints and leave it just as it is?" Between these distant points opinion is ever vibrating. Many who ventured to adopt the latter course a year ago have since found that their *conservatism* resulted in so little *conservation* that they have swung straight back across the intervening chasm to the simple plan of treatment by amputation. In the following remarks I shall endeavor to compare faithfully the different plans of treatment usually adopted, to let it appear that in some cases both extremes are variably improper, and that in many others both are equally and positively wrong. I shall try to show that by a new application of an old principle a happy medium, however, is found, in which the dangers attending both extremes are measurably diminished. From the authority above quoted we find that this treatment has been followed in more than thirty-three per cent. of gunshot fractures of the humerus with a mortality of more than 24 per cent. This does not appear very conservative, and is perhaps a more serious result than is generally apprehended. This method of treatment, then, gives us certain loss of arm with 24 per cent. risk of life. Suppose the operating surgeon, on examination of the case on its arrival at a field hospital, finds an ordinary gunshot fracture of the humerus, with comminution of from two to four inches, and orders it to be put up in splints (an operation which is usually performed more carelessly than any other on the field); an assistant applies them as well as he is able with the limited means at his command, trying to put up the limb firmly, and making pressure which is likely to become increasingly painful. The patient is transported overland say from twenty to fifty miles in ambulance or railroad car. At every motion of the vehicle the sharp comminuted fragments are moving upon each other and lacerating the soft parts in which they are contained like gravel in a bag; the vessels and nerves are continually exposed to injury from them, while the danger is increased every time a change of surgeons or arrival at a different hospital becomes the occasion of a removal of the dressings and a re-examination of the wound. Meanwhile the parts become inflamed and painful and profuse suppuration occurs. Nature has now to do the work first of *police*, second of *repair*. The primary fragments of bone or these wholly detached begin gradually to extrude themselves week after week; still later the secondary are endeavoring to find their way outward month after month—the larger pieces macerating, softening, and disintegrating, preparatory to final exit. The parts are a centre of constant irritation; the peculiar deformative pus resulting from inflammation of the deep-seated tissues tends to burrow in every direction; the fractured ends of the shaft are bathed in it, and instead of preparing to unite are becoming liable to fall into a state of necrosis; the open mouths of the veins of the bone are constantly exposed in the same manner, and phlebitis, pyæmia, gangrene or other intercurrent diseases may occur. Non-union may renew the original question of amputation, or death may ensue from constitutional depression. The case may, however, go on toward recovery. The tertiary sequestra of Dupuytren, consisting of detached fragments of bone which have become embedded in callus, are yet, and while they remain must ever continue, foreign bodies—so that after apparent recovery they may be reserved as causes of more serious trouble for ten or twenty years afterward—so says Dupuytren. The best result this treatment usually furnishes, then, is a painful, slow and tedious recovery, with shortening corresponding to the extent of original comminution; subsequent deformity of bone, induration, and atony of soft parts, and general changes of structure remaining for a longer or shorter period. Let us take a view of the same patient treated by this method: The seat of fracture has been cut down upon; all spicule of bone have been removed, the ends of the divided shaft have been made smooth by the saw; the lips of the wound have been brought together with sutures or adhesive straps, and the arm has been put up in the best possible manner which can be obtained by splints and bandages. The chief causes of irritation are now all removed and the patient is in a greatly improved condition. But coaptation is not secured and cannot be maintained. The patient is put into an ambulance wagon; the bandage becomes loosened, the splints displaced. The ends of the bone are all the time apart, all the time in motion. Every time the patient rises the weight of the forearm drags the ends of the bone still further asunder, and this weight is thus sustained by the soft parts between the divided ends of the bone. Though in a much better condition than where the fragments are allowed to remain, there is motion enough to set up considerable inflammation, and the space formerly occupied by three or four inches of bone has become a convenient pouch for the collection of pus, while a large amount of new material has to be formed. The best result which can be usually anticipated is a false joint with an arm like a flail. The impossibility of approximating the ends of the bones has made this treatment very unpopular in the field. Notwithstanding, I have often adopted it in preference to the two other methods previously mentioned. The treatment which I propose as being specially adapted for the field is, to make a straight incision down to the seat of fracture and proceed as in the usual manner for resection, taking special care to remove all spicule of bone and other foreign bodies. Turn out the fractured ends of the bone and saw them off smoothly, and with a view to accurate mutual adaptation, at the same time using the different styles of fracture to such advantage as to secure the most perfect apposition with the least shortening. Unite the two ends with sutures of annealed iron wire secured firmly by twisting, taking care to leave no kink in the uniting loop which may be afterward straightened out by the weight of the forearm, loosening the suture and allowing of motion. With a sharp scalpel shave away any dead mass about the track of the ball, reducing it, as nearly as may be, to a simple incised wound. Everything of the nature of a foreign body having been removed, and the wound being now perfectly clean, bring the edges together with sutures. Side splints may now be applied, or, by preference, one of pasteboard, or any flexible material in addition, bent at a right angle so as in common with the sling which is afterward applied to receive the weight of the forearm. A retentive bandage is the only further dressing required. Treatment by irrigation may be kept up by the patient from his cauteen, as his feelings may indicate. The patient is now secure against every emergency incident to transportation. He may be jolted on the road to any extent, the dressings may become displaced, or the splints even may be removed, but the ends of the bone remain in perfect apposition and at rest. So secure is the fastening, that, after the application of the sutures on the subject, I have allowed the arm to drop, and appended to the wrist a weight of fifty-six pounds without producing displacement. The chief causes of inflammation and suppuration are now entirely removed, and the necessary dressings are so light that any tendency to it is the more readily controlled by the freedom with which cold applications can be made. The soft parts being crowded up around the approximated ends of the bone, no interspace is left for the admission of air or collection of pus. Nature has simply to address herself to the work of repair to restore union; and the utility of the limb promises to return promptly, without that delay after union is secured which is the result of those structural changes which occur where the continued causes of irritation and inflammation have not been removed. The shortening need not be greater than in any other treatment,

It has been fully shown that primary excisions in the shaft of the humerus for shot injury are inadvisable, and this particular form of excision, involving a tedious operative procedure, is singularly ill adapted to field practice. That it may be advantageously employed in certain cases of pseudarthrosis of the humerus, is rendered probable by the results published by M. Ollier and Professor H. J. Bigelow. Dr. O. Heyfelder (*Lehrbuch der Resectionen*, 1863, S. 226) professes to give twenty-seven cases of excision in the shaft of the humerus for shot injury, with eleven deaths; but several of his examples of recovery are

as, by proper management, a fracture extending four inches may sometimes be so sawn as to create a shortening of but two inches when united. *The amount of bone which may be removed* must vary in different cases, and be always left to the discretion of the surgeon. On the subject, where the advantage of contractility of the muscles is absent, I have, on a very muscular subject, had some puckering of the outer wound after removing three inches. I have, however, repeatedly removed four and four and a half inches without any inconvenience from the protrusion of muscle on closing the wound. In any case, it is safe to proceed with all the steps of the operation as if preparatory to uniting the ends of the bone. If the approximation cannot be completed without making it difficult, or impossible, to close the outer wound, it may, if preferred, be left open; or the ends of the bone may be left apart. The best thing possible will have been done so far, and the best of the ordinary modes of treatment may now be pursued. Should there be but a slight superabundance of muscle, it is a small consideration; nature will soon dispose of what she does not want by absorption. *Compression of the artery* might be apprehended from the crowding up of the muscles on the approximation of the ends of the bone; but we must remember that the pressure is made directly in the axis of the limb and muscular fibres rather than transversely; that the artery is exceedingly elastic, gliding in its sheath, and always ready to contract. We have never heard of any bad results to circulation by simple shortening from fracture, where not only muscle is similarly crowded, but where no portion of bone has been removed to increase the room for it. The danger to the vessels from compression is certainly

much less than that from splique of bone where they are allowed to remain. *Respecting the wire as a foreign body*, nothing need be said, its similar use in other cases being universally approved and adopted. If desired, the patient, having arrived at general hospital, and the bones become knit, the wire can readily be removed; or it may be left to work its way out unaided, which it will do without any serious discomfort to the patient. In order to facilitate this method of treatment and make it easily practicable in the field, where it is of most importance, I have invented a bone drill, which works very rapidly, and is much simpler and cheaper than anything else of the kind in use. Its chief advantage, however, is, that its portability is such that it can be crowded into almost any field-case without any compartment having been specially provided for it. It can be used sometimes more conveniently than a more elaborate instrument, and is in all cases as expeditious and efficient. As seen in FIG. 578, the instrument consists of a stock and movable drill. The stock is about three and a half inches long, the drill about an inch and a half or two inches. The drill is inserted into the shaft of the stock and secured by a little spring-catch. The steel shaft of the stock into which the drill is inserted is provided with a wheel with a hollow groove, and it revolves on its axis by means of a little pivot wheel let into the handle. FIG. 577 is simply a straight strip of thin steel with a hole in one end and a notch in the other. A knot is made in one end of a piece of catgut; the other is passed through the hole and made fast to the notch at the other end, constituting a bow. The string of the bow is passed around the wheel-shaped part of the stock, and revolution may be produced at any velocity required. The stock is the only part for which a special compartment might be desired in a field case. The drills, of which there are four varieties, when not in use are packed inside the handle, which is made hollow for that purpose. The bow can be laid open or alongside the saw. FIG. 578 shows an exploring drill, which I have invented for the subcutaneous examinations of bony tumors, etc., their character being ascertained by submitting the successive contents of the hollow drill to the microscope, etc.; also a caries drill, likewise a concavo drill, which for some purposes works more freely than any other. The drill attached is the only one needed in the field. For other than field purposes, Tiemann, of New York, affixes a handle to the bow, and otherwise makes the instrument in different degrees of elegance. The manner in which I prefer to apply the sutures is shown in FIG. 577. By using two sutures thus, and passing them as nearly as possible through opposite sides of the same bone, great firmness is secured, and if left to come away of themselves by ulceration, both of them together

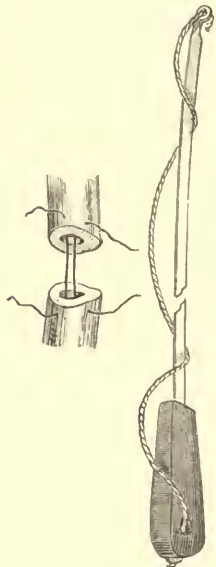


FIG. 577.—Apparatus for suture of bone. From a drawing by Dr. B. HOWARD.

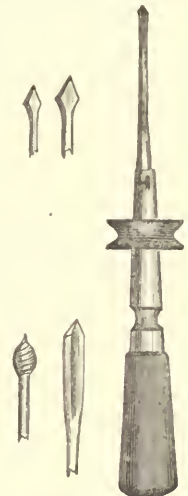


FIG. 578.—Bone drill, from a drawing by Dr. HOWARD. Spec. 4680.

accomplish it in less than half the time in which it could be done by one wire, which should be passed through the opposite cortical portions of each end of both fragments. Also, if desired, they can be withdrawn with greater facility. *The apparent advantages of the treatment proposed over amputation* are: Greater probability of ultimately saving the limb, diminished shock, and less risk of life. *It is better than simple application of splints*, because the irritation, peculiar suppuration, the injurious pressure of tight splints, disintegration of detached fragments, necrosis of the fractured ends of the bone, exposure to phlebitis, pyæmia, and danger from 'tertiary sequestra,' with their various attendant risks, are all avoided, or the probability of their occurrence is greatly diminished. *It is better than simple resection*, because non-coaptation, the intervening space for admission of air and collection of pus, motion of the ends of the bone, and probability of false joint, are avoided. In addition to these negative advantages, there are more or less the positive ones, of sound medulla, sound bone, healthy periosteum, each respectively in apposition and at rest. We have a healthy patient who has not to submit to a tedious constitutional drain before the reparative process can be rendered possible; but one who, having little to do, has surplus strength adequate to the task, and everything tends toward a *prompt recovery*. This plan of treatment is applicable mainly to the humerus. It should be performed in all cases where amputation would otherwise be resorted to on account of the degree of the comminution of the bone. If applied with discretion, it may appear that *amputation of the arm, either primary or secondary, need be of but rare occurrence*, except where rendered necessary by injury of vessels or extensive destruction of soft parts. I would not restrict its application to the humerus alone; there may be cases of fracture of the femur where it is just as applicable. In such cases amputation is at once excluded from consideration. Should there be an inclination to preserve the limb as it is, it would be difficult to show what harm could be done by removing entirely detached fragments, by reducing the rough fractured ends of the bone to a smooth surface, or, in view of transportation, what evil could result from securing the smooth surfaces in perfect apposition, and certain rest, wherever practicable. Is it not rather apparent that, under these circumstances, we may fairly expect, according to the theory of Virchow, that the medulla and the apposed periosteal surfaces will, alone, almost entirely effect a complete repair; thus preventing the demand upon the soft parts for that superabundant mass of provisional callus which, under other circumstances, is thrown out, and so much of which subsequently remains, embarrassing the proper action of the parts, until removed by a slow process of absorption? The principles are plain and unvarying; their application can be governed only by circumstances, and directed by the judgment of the surgeon in each particular case. The time necessary to perform this operation is greater than for amputation. Presuming, however, that the surgeon's own humerus is the one in question, according to the golden rule of every conscientious man, and the consideration of a little more or less of time or trouble would not be entertained for a moment; that plan of treatment



either unauthentic or duplicated; yet, even on such data, he concludes that resection in the continuity of the humerus should only be practised for the removal of protruding ends of the bone, hindering its reposition; otherwise shot fractures of the diaphysis of the humerus should be severely let alone,—“möglichst sich selbst überlassen.”

Among the varieties of dressing employed after excisions in the shaft, the felt or adaptable porous splints, devised by Dr. David Ahl, gave much satisfaction.<sup>1</sup> It was practicable to use them with fenestrated openings and with water lotions, and some surgeons thought that they realized the advantages without the disadvantages of the gypsum dressings.

In addition to the plans for making extension after excisions of the shaft of the humerus mentioned on pages 509, 562, 812, 813 *ante*, was one proposed in 1869, by Dr. H. A. Martin, of Boston, which, though unlikely to come into general use, may prove serviceable under certain circumstances.<sup>2</sup>




FIG. 579.—Dr. H. A. Martin's splint for excisions and fractures of the shaft of the humerus. *Spec.* 5574.

*Amputations in the Continuity.*—It has been shown that the mean mortality after amputation in the continuity of the arm in the War was 23.6 per cent., a larger death-rate than that presented by Norris, Hayward, Buel, and Stone,<sup>3</sup> for the results of this operation, for disease or injury, in American civil hospital practice; but comparing very favorably with any authentic statements that have been published regarding the surgery of other wars. This appears clearly on consulting the figures in TABLE CIV, on page 826. There are several points to which it is important to revert.

I think that it may safely be assumed, from the evidence adduced, that amputation at the upper third of the arm is less dangerous than exarticulation at the shoulder, and should always be preferred to the latter operation when the alternative is presented. This is one of

alone would be adopted which was considered absolutely best for the patient. The operation, however, need not be a long one, if plenty of room be allowed to clear out the fragments of bone. By far the most tedious part, and one which I have labored to overcome, is made easy by the use of the little drill described. Though unable to cite field experience in this plan of operation, I have, with ease, drilled the four holes in the femur and completed the process of wiring on the subject in about five minutes. For such little additional trouble we are certainly well rewarded. The tedious resections which I have performed on the field, some of which were done under fire, have given me more subsequent satisfaction than the amputations after many battles, all put together. The treatment and transportation of gunshot fractures is one of the most important and interesting subjects which has occupied the attention of military surgeons during the present war. The chief questions being: First, how to avoid the consequences arising mainly from the presence of detached fragments and spiculae of bone? Second, how to prevent the present fearful exaggeration of those consequences by unavoidable transportation? By removing the cause of the former, and by maintaining perfect apposition and rest during the latter, in the manner described, I think these desiderata are obtained, and, when practicable, will furnish better results than any other treatment previously adopted or recommended.

ANNAPOLIS, MD., December 18, 1863.

(Signed)

B. HOWARD, Assistant Surgeon, U. S. A."

<sup>1</sup> AHL (D.), *Surgeons' Splints and Improved Adaptable Apparatus*, New York, 1866, pp. 16. *Adaptable Porous Splints, with Directions for their Employment*, Newville, 1875. Surgeon-General U. A. FINLEY ordered a thousand sets of these splints for army use, and more than a thousand additional sets were subsequently procured by the purveyors.

<sup>2</sup> Professor F. H. HAMILTON, in the 5th edition of his *Practical Treatise on Fractures and Dislocations*, 1875, p. 250, figures and describes this apparatus, and says: "In my opinion, and in the opinion of nearly all practical surgeons who have written upon this subject, it is impossible, by these or any other similar contrivances, to make extension in fractures of the humerus. \* \* The adhesive plasters must inevitably fail to retain their places even when a moderate amount of traction is continually made upon them." The apparatus of Dr. H. A. MARTIN, Lieutenant Colonel, and formerly Surgeon U. S. V., was submitted to the Surgeon General in May, 1869, and referred to a board of medical officers (Assistant Surgeons WOODWARD, CURTIS, and OTIS), which reported as follows: " \* \* The advantages claimed for the apparatus are that it provides a firm point of resistance for extension without injurious pressure anywhere, avoids the necessity of irksome removal and repetition of dressings, and furnishes means of preserving an unchangeably proper relation between the elbow and shoulder, thus precluding overlapping or angular deformity. The board were of the opinion that the shoulder cap secured by adhesive strips across the chest and back, provided a satisfactory mode of counter-extension; that the apparatus, like other bracketed splints, afforded a ready means of access to the wound in compound fractures or excisions, and that it secured immobility of the arm, if not absolutely, at least to a satisfactory degree, and in a convenient manner. Though not convinced that extension is frequently required in fractures of the humerus, the board considered this apparatus an excellent means of effecting this purpose when requisite. It furnishes, moreover, a convenient means of supporting the arm and forearm after excisions of the humerus. \* \* With these exceptions, the appliance was regarded by the board as an ingenious one, which might be made quite useful in a limited number of cases."

<sup>3</sup> NORRIS (G. W.), *Stat. Account of the Cases of Amputation at the Pennsylvania Hosp.*, in *Am. Jour. Med. Sci.*, 1831, Vol. XXII, p. 363. HAYWARD (G.), *Stat. of Amputation of Large Limbs at Mass. Gen. Hosp.*, in *Am. Jour. Med. Sci.*, 1840, Vol. XXVI, p. 64, and in *Surgical Reports*, Boston, 1855, p. 142. BUEL (H. W.), *Stat. of Amp. in the New York Hosp.*, in *Am. Jour. Med. Sci.*, 1848, Vol. XVI, p. 33. STONE (J. O.), *Ampul. and Comp. Fract., with Stat.*, in *New York Jour. of Med.*, 1849, Vol. III, p. 297. The number of cases of amputations is not large, but they are most conscientiously recorded and analyzed.

the few instances in which a favorite dictum of the celebrated Larrey has been reversed by the experience of modern military surgeons.<sup>1</sup> Experience does not justify the assertion that



FIG. 580.—Stump after amputation at the surgical neck. TABLE LXVIII, CASE 509.

there is great liability of consecutive arthritis after section of the humerus at the surgical neck. The rounded form of the shoulder is preserved by leaving the head and even the smallest portion of the shaft of the bone; and it is quite remarkable how serviceable even the shortest stump may become. Many pensioners thus mutilated can hold in the axilla a cane, umbrella, or a small parcel, and leave the sound limb free for use. Moreover, by such a stump the adaptation of an artificial limb is greatly facilitated. A comparison of the annexed figures (Figs. 580, 581), drawn from patients at Harewood Hospital,




FIG. 581.—Another example of amputation near the shoulder. [From a photograph.]

with those of the subjects of exarticulation at the shoulder, on pages 616, 618, etc., illustrate the advantages of the operation in the continuity. The uniformity with which amputations at the lower third of the arm afford less favorable results than ablations higher in the continuity, and than exarticulations at the shoulder even, is another point deserving of attention. This exaggerated fatality in the amputations in the aggregate series reported in this Section is not fortuitous; for it obtains not only in the several groups of primary, intermediary, and secondary operations, as shown in the TABLE CII, following, but also in the only other statistical summaries, by Professors Günther and Warren, as cited in TABLE CIII, in which the question has been examined from this point of view. This curious result has been noticed on pages 739 and 806.

<sup>1</sup>LARREY (D. J.) (*Mémoires de Chirurgie Militaire et Campagnes*, 1812, T. III, p. 400) says: "Lorsqu'elles [les blessures du bras] s'étendent très-haut au lieu de conserver un très-court moignon formé avec l'extrémité supérieure du membre, il vaut mieux l'extirper à l'articulation; car, lorsqu'on ne peut pas faire la section de l'humérus, tout au moins au niveau de l'attache tendineuse du deltoïde, le moignon est rétracté vers le creux de l'aisselle, par le pectoral et le grand dorsal. La ligature des vaisseaux qu'il faut porter profondément dans le creux de l'aisselle, irrite le plexus brachial, et augmente cette rétraction, qui ne peut se faire sans douleur ni tiraillement extrêmement incommodes à l'invalidé. Souvent cette cause amène le tétanos: le moignon reste toujours engorgé, et l'humérus finit par s'ankyloser avec l'omoplate, en sorte que cette portion du bras est tout-à-fait inutile à l'individu et l'expose à des accidents. J'ai vu plusieurs soldats et officiers de toutes classes regretter de n'avoir pas été amputés à l'article." GUTHRIE (*Treatise on Gunshot Wounds*, 3d ed., 1827, p. 508, and *Commentaries, etc.*, 5th ed., 1855, p. 113) emphatically dissents from this opinion of LARREY, and earnestly recommends that the humerus shall be sawn a half inch or inch below the insertion of the deltoid. This exaggeration he justified by alleging that union was more prompt after disarticulations than after amputations in the continuity of the upper third; secondly, that the loose cellular tissue uniting the deltoid to the humerus was prone to conduct inflammation to the shoulder joint; and thirdly, that phlebitis was common in amputations high up in the continuity,—all these assertions being founded on altogether insufficient proof. Many of the French military surgeons adhered to the precept of LARREY. Thus, for example, BÉGIN (L. J.) (*Nouv. Elém. de Chir. et de Méd. Opér.*, 1838, T. III, p. 937) declares: "Si la section devait porter au col chirurgical de l'humérus on devrait opérer plutôt dans l'articulation." On the other hand, Dr. HARALD SCHWARTZ (*Beiträge zur Lehre von den Schusswunden*, 1854, S. 215), treating of amputations high in the arm, in the Schleswig-Holstein war, remarks: "We preferred amputation high up, often only an inch below the head of the humerus, to exarticulation at the shoulder, partly because we considered it less fatal, partly because it preserved the rounded form of the shoulder. We never observed necrosis of the humerus when it was divided so near the shoulder." PIROGOFF (N.) (*Grundzüge der Allgemeinen Kriegschir.*, 1864, S. 800) teaches: "In shot fractures of the upper third of the diaphysis of the humerus—even where they extend to the extreme end of the upper epiphysis, but leave the head and capsule uninjured—I prefer the amputation close to the limits of the joint capsule to exarticulation. This amputation has, regarding the healing of the wound and the infiltration of pus, given equal and even better results than amputation through the joint (the ratio of mortality in both operations fluctuates between 25 and 35 per cent.), and, as regards the secondary bleeding and deformity, the results of the high amputation are much more favorable. I have, as yet, lost not a single patient from secondary hemorrhage after this operation, but have seen several perish from this cause after exarticulation." BECK (B.) (*Chir. der Schussverletzungen*, 1872, S. 789) asserts: "This method (the circular) made it possible to operate close to the shoulder joint wherever the lesion of bone will yet permit an amputation through the surgical neck; in such cases I prefer the high amputation to disarticulation, as being less dangerous on the one hand and more apt to give a serviceable stump on the other."



TABLE CII.

*Tabular Statement showing the Percentages of Mortality of the Various Subdivisions of the Fifty-four Hundred and Fifty-six Amputations of the Arm for Shot Injury.*

OPERATIONS.		CASES.	RECOVERIES.	DEATHS.	RESULT UN-DETERMINED.	PERCENTAGE OF MORTALITY.
PRIMARY	Upper third	1,338	1,155	183		13.6
	Middle third	1,162	1,019	143		12.3
	Lower third	512	406	106		20.7
	Location not recorded	247	77	170		68.8
INTERMEDIARY	Upper third	347	239	108		31.1
	Middle third	348	255	93		26.7
	Lower third	161	94	67		41.6
	Location not recorded	46	12	34		73.9
SECONDARY	Upper third	173	127	46		26.6
	Middle third	162	127	35		21.6
	Lower third	51	37	24		39.3
	Location not recorded	15	6	9		60.0
DATE NOT KNOWN	Upper third	94	61	21	12	25.6
	Middle third	67	45	13	9	22.4
	Lower third	24	42		2	0.0
	Location not recorded	699	345	194	160	35.9
Aggregates		5,456	4,027	1,246	183	23.6

TABLE CIII.

*Showing the Relative Percentage of Mortality of Amputations in the Upper, Middle, and Lower Thirds of the Upper Arm for Shot Injury.*

UPPER ARM.	GÜNTHER. <sup>1</sup>				UPPER ARM.	WARREN. <sup>2</sup>			
	Cases.	Recoveries.	Deaths.	Percentage of Mortality.		Cases.	Recoveries.	Deaths.	Percentage of Mortality.
Upper third	25	21	4	0.0	Upper third	48	21	1	31.2
Middle third	1	1		0.0	Middle third	126	46	11	26.1
Lower third	4	2	2	50.0	Lower third	18	9	4	33.3
Aggregates	30	24	2	7.6	Aggregates	192	76	16	28.1

I at first ascribed this excessive fatality of amputations at the lower third of the arm<sup>3</sup> to the fact that the slighter injuries of the elbow were treated by expectation or excision.

<sup>1</sup> GÜNTHER (G. B.), *Lehre von den Blutigen Operationen*, Leipzig, 1859, B. III, Abschnitt XII, S. 101.

<sup>2</sup> WARREN (W.), *An Epitome of Practical Surgery for Field and Hospital*, Richmond, 1863, p. 397.

<sup>3</sup> There were 1952 amputations in the upper third of the arm (exclusive of 866 exarticulations at the shoulder). 1739 amputations at the middle third, and only 758 amputations at the lower third. There were 626 cases of excisions at the elbow; and although the resulting mortality was 23.7, it might be argued, with a *petitio principii*, it is true, that had these cases been submitted to amputation at the lower third, the mean fatality of this operation would have been reduced below the death-rate of amputations higher up. I have unavailingly made many sections of prepared and recent humeri—longitudinally, obliquely, and transversely—with a view of discovering some anatomical explanation of the greater fatality of amputations at the lower third. It has been suggested that section of bone below the entrance of the nutritious artery is more liable to be followed by osteitis and osteomyelitis; but such is not the rule in other long bones. The section in amputations at the lower third is made through the smallest periphery of the bone, and where its structure is least compact, and reparation might, *a priori*, be expected to be most rapid. I think that the cause is to be sought in the structural arrangement of the soft parts rather than in the bone. Professors WARREN and GÜNTHER statistically proved the fact that amputations augment in fatality as the trunk is approached, appears to be here invalid, without noticing the importance of the conclusion. Professor SÉDILLOT, however, in his important memoir (*Du traitement des fractures des membres par armes de guerre*, in *Gaz. méd. de Strasbourg*, and *Arch. gén. de méd.*, 1871, Ser. 4, T. XVII, 1, pp. 49, 382) speaks of the subject as "deserving the most serious consideration." I did not receive this masterly paper until I had long devoted much serious though unsuccessful study to the question. M. SÉDILLOT terms the insertion of the deltoid (*creux deltoïdienne*) the place of election in arm amputations, and asserts that he has ascertained incontestably that those amputated at that point "ont guéri plus promptement et en plus grand nombre." "Here," he says, "the circumference of the limb is less, and the wound less extensive, the fasciuli of the biceps, triceps, and brachialis augment in size as the elbow is approached, and in amputating lower down inflammatory engorgements of the stump, deep abscesses, and osteitis are common, although rarely seen in amputations in the upper thirds. Three-fourths of the survivors are found among these amputated at the insertion of the deltoid, and though we made numerous amputations in the lower third, we found few invalids with this mutilation." I think the eminent professor is in error regarding the circumference of the arm. In fifty measurements of the arm of men employed in the War Department, I found the mean circumference of the deltoid depression = 9.9 inches,

while the graver cases were reserved for amputation; whereas, in the upper thirds, the gravest cases were treated by disarticulation at the shoulder, and the mortality of amputa-

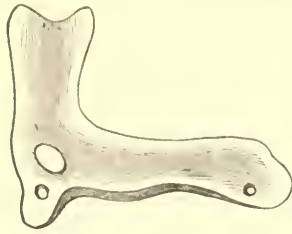


FIG. 582.—Lossen's extension splint.

tions in the continuity was proportionally reduced. But this explanation, and the further suggestion that the greater anatomical complexity of the tissues divided near the elbow admit a greater risk of sep-

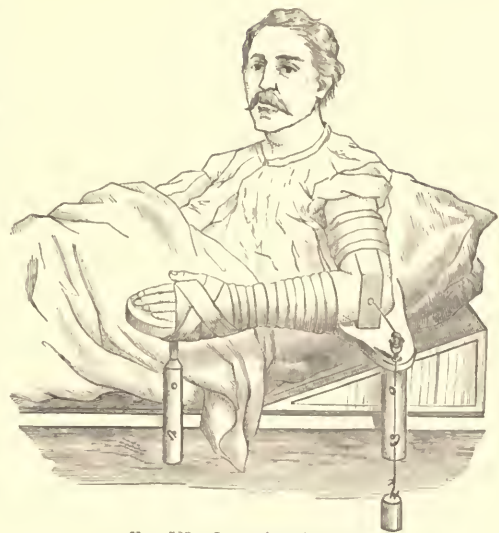

FIG. 583.—Lossen's splint applied.

ticæmic infection and consecutive hæmorrhage, are alike inadequate. Nor is the difficulty solved by an analysis of the causes of death in the individual cases of the several groups. The various immediate causes of fatality were in very nearly the same proportion in the lower as in the upper thirds. The question merits, and will doubtless receive, further investigation.

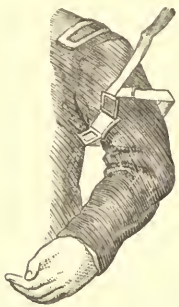


FIG. 584.—Tourniquet of Lee and Lambert applied to the brachial artery.

There is room, in the space allotted to this Section, for a mere allusion to a remarkable instance of simple united shot fracture of the humerus,<sup>1</sup>—to an apparatus for extension<sup>2</sup> of shot fracture of the shaft (FIGS. 582, 583), with the remark that fractures of this bone requiring much extension are exceptional,—and to the fact of the frequent use of the tourniquet in shot wounds of the arm from dread of primary hæmorrhage. Besides the ordinary field tourniquets issued by the Army Medical Department, the more complex compressors devised by Drs. Lambert and A. B. Mott<sup>3</sup> were supplied to some of the troops. Some further observations on amputations of the arm,<sup>4</sup> bearing more especially on diseases of arm-stumps, must be reserved.

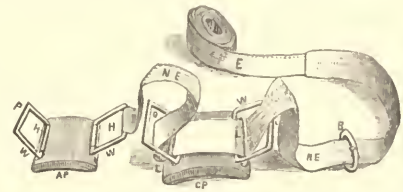


FIG. 585.—Lee and Lambert's tourniquet. AP, arterial pad; CP, counteracting pad; E, elastic band; W W W W, wire wings hinged at H H; B, buckle. *Spec.* 2292(3).

over the most prominent part of the middle of the flexed arm = 9.7 inches, and at the point of section in amputations near the elbow = 8.7 inches. It seems more probable that the disposition of the aponeuroses, and of the veins and absorbents, may account for the greater liability to inflammatory engorgements in the section in the lower third. I have carefully analysed the causes of death in the three groups, and do not find a greater proportionate frequency of secondary hæmorrhage in the lower third amputations, and no marked predominance in the complications of gangrene, osteomyelitis, and pyæmia.

<sup>1</sup> In treating of simple shot fracture of the humerus, on p. 815, I omitted to mention a specimen in the museum of the New York Hospital, *Spec.* I, 103, of a united oblique fracture of the humerus, taken from a soldier wounded in the Mexican war, September, 1847. Dr. J. O. STONE, the donor, states that a cannon ball passed between the patient's arm and thorax, and broke the humerus without abrading the skin. Union took place, but there was complete paralysis, and the limb was successfully exarticulated at the shoulder, at the patient's request (*RAY'S Cat. Path. Cab. N. Y. Hosp.*, 1860, p. 69).

<sup>2</sup> Professor H. LÖSSEN, of Heidelberg (*Kriegschir. Erf.*, in *Deutsche Zeitschrift für Chir.*, 1873, B. II, S. 56), describes this appliance as used advantageously in the hospitals at Manheim and Karlsruhe during the late Franco-German War, a judgment corroborated by Professor BILLROTH. The application of the lightly padded wooden angular splint is sufficiently explained by the drawing.

<sup>3</sup> The description of Dr. MOTT's tourniquet is contained in a paper by his distinguished father, VALENTINE MOTT, *On Hæmorrhage from Wounds*, New York, 1863. It was favorably considered by Surgeon-General HAMMOND, and placed in the Duntun field panniers. Dr. T. S. LAMBERT, of Peckskill, proposed the tourniquet illustrated in the wood-cuts (FIGS. 584, 585), in *A Description of the newly-invented elastic Tourniquet for the use of Armies*, etc., New York, 1862. This instrument, according to the editor of the *American Medical Times*, 1862, Vol. V, p. 40, was officially issued to Maine, Connecticut, and New Hampshire troops, and it was actually urged that every soldier should carry one. The remarks made at p. 39 of *Circular 6*, S. G. O., 1865, are fully justified by further investigation. Serious primary hæmorrhage from shot wounds of the extremities is exceedingly rare.

<sup>4</sup> The first detailed instance of an amputation in the continuity of the arm for shot injury that I am able to find on record, is related by VALLERIOLA (*Observationum medicinalium Libri sex*, Lugduni, 1206, p. 301): On September 17, 1562, in a battle between the Huguenots and Papists, near the Cistercian city (Cîteaux), a servant man received a wound from a brass blunderbuss, between the ulna and humerus, and his arm fell into a gangrene. Receiving no succor from the surgeon of the army, he went to Areleta (Arles), where VALLERIOLA saw him, with the arm sphacelated "cum fore-re mirabili, ingredine, mollitie, frigiditate summa," and called a council of surgeons, and, "acting on the precept that GALEN gives from THUCYDIDES, that where there is but one way of salvation the most dangerous and doubtful remedies may be used," it was resolved to cut the limb, "and the man Jacobus recovered in a month, and we returned thanks to God."



I will conclude this Section by a comparative numerical statement of the results of shot fractures of the arm under different modes of treatment on sundry occasions:

TABLE CIV.

*Showing the Mode of Treatment and Results of Shot Fractures involving the Shaft of the Humerus on the Occasions named and from the Authorities quoted.*

ACTION, ETC.	MODE OF TREATMENT.					
	EXPECTANT.		EXCISION.		AMPUTATION.	
	Recovery.	Death.	Recovery.	Death.	Recovery.	Death.
Battle of New Orleans, 1815 (GUTHRIE) <sup>1</sup> .....					9	1
Battle of Waterloo, 1815 (GUTHRIE) <sup>2</sup> .....					55	17
Revolution in Paris, 1830 (MÉNIÈRE, <sup>3</sup> LARREY, <sup>4</sup> ROUX <sup>5</sup> ).....	2	2			12	5
Siege of Antwerp, 1832 (LARREY <sup>6</sup> ).....					9	2
Spanish Peninsular War, 1836 (ALCOCK <sup>7</sup> ).....	7	2			13	9
Paris Hospitals, 1836-'42 (MALGAIGNE <sup>8</sup> ).....					12	17
French in Algiers, (BAUDENS <sup>9</sup> ).....	1		3			
Revolution in Paris, 1848 (ROUX, JOBERT, HUGUIER, BAUDENS <sup>10</sup> ).....					5	7
Revolution in Baden, 1849 (BECK <sup>11</sup> ).....					3	2
War in Sleswick-Holstein, 1848-'50 (STROMEYER <sup>12</sup> ).....	24	5	5	4	35	19
French in Algiers, 1854-'56 (BERTHERAND <sup>13</sup> ).....			1		23	13
Crimean War, 1854-'56, Russian (HUBBENET <sup>14</sup> ).....					187	439
Crimean War, 1854-'56, French (CHENU <sup>15</sup> ).....			3	1	510	638
Crimean War, 1854-'56, British (MATTHEW <sup>16</sup> ).....					130	33
British in India, 1858 (GORDON <sup>17</sup> ).....	2					
Italian War, 1859-60 (DEMME <sup>18</sup> ).....	261	39	3	4	169	71
Italian War, 1859-60 (CHENU <sup>19</sup> ).....	166	59	1		139	175
American War of the Rebellion, 1861-2, Confederates (CHISOLM <sup>20</sup> ).....					339	95
New Zealand War, 1863-'65 (MOUAT <sup>21</sup> ).....					3	1
Danish War, 1864 (LÆFFLER <sup>22</sup> ).....	42	11	2	3	14	17
Prussians, 1866 (K. FISCHER, <sup>23</sup> STROMEYER, <sup>24</sup> BECK, <sup>25</sup> MAAS <sup>26</sup> ).....	8	1			34	7
Army of the United States, 1865-'70, ( <i>Circular</i> 3 <sup>27</sup> ).....	4		7		19	5
Franco-German War, 1870-71, Germans (BECK, <sup>28</sup> BILLROTH, <sup>29</sup> FISCHER, G., <sup>30</sup> FISCHER, II., <sup>31</sup> GRAF, <sup>32</sup> HEYFELDER, <sup>33</sup> KOCH, <sup>34</sup> KIRCHER, <sup>35</sup> LOSSEN, <sup>36</sup> LÜCKE, <sup>37</sup> MOSEITIG, <sup>38</sup> OTT, <sup>39</sup> RUPPRECHT, <sup>40</sup> SCHÜLLER, <sup>41</sup> SOCIN, <sup>42</sup> STEIN- BERG, <sup>43</sup> STOLL, <sup>44</sup> VOGT <sup>45</sup> ).....	138	18	10		114	66
Franco-German War, 1870-71, German (McCORMAC <sup>46</sup> ).....					11	9
Franco-German War, 1870-71, French (CHENU <sup>47</sup> ).....			14	84	606	1,420
Aggregate.....	655	137	49	96	2,451	3,068

<sup>1</sup> GUTHRIE (G. J.), *A Treatise on Gunshot Wounds*, London, 3d ed., 1827, p. 308. <sup>2</sup> *Ib.* Commentaries, etc., London, 6th ed., 1855, p. 158. <sup>3</sup> MÉNIÈRE (P.), *L'Hotel-Dieu de Paris en Juillet et Aout, 1830*, Paris, 1830, pp. 314, 323. <sup>4</sup> LARREY (II.), *Relation-chir. des événements de Juillet, 1830*, Paris, 1831, p. 87. <sup>5</sup> ROUX, *Des plaies d'armes a feu, etc., par MM. les Docteurs BAUDENS, etc.*, Paris, 1849. <sup>6</sup> LARREY (II.), *Hist. Chir. du siège de la citadelle d'Anvers, 1833*, p. 285. <sup>7</sup> ALCOCK (R.), *Notes on the Med. Hist. and Stat. of the British Legion in Spain, London, 1838*, p. 54. <sup>8</sup> MALGAIGNE (*Des plaies d'armes a feu, etc., par MM. les Docteurs BAUDENS, etc.*, Paris, 1849, p. 42. <sup>9</sup> BAUDENS (M. L.), *Chir. des plaies d'armes a feu*, Paris, 1836, p. 466, etc. <sup>10</sup> ROUX, JOBERT, HUGUIER, BAUDENS, *Des plaies d'armes a feu, etc., par MM. les Docteurs, etc.*, Paris, 1849. <sup>11</sup> BECK (B.), *Die Schuss-Wunden*, Heide elberg, 1850, p. 346. <sup>12</sup> STROMEYER (L.), *Maximen*, u. s. w., Hannover, 1855, p. 756. <sup>13</sup> BERTHERAND (A.), *Campagnes de Kabylie*, Paris, 1862, pp. 220-315. <sup>14</sup> HUBBENET (C. V.), *Die Sanitäts-Verhältnisse der Russischen Verwundeten, 1854-1856*, Berlin, 1871, p. 182. <sup>15</sup> CHENU (J. C.), *Campagne d'Orient*, Paris, 1865, pp. 249, 677. <sup>16</sup> MATTHEW (*loc. cit.*, Vol. I, p. 338, etc.). <sup>17</sup> GORDON (C. A.), *Experiences of an Army Surgeon in India*, London, 1872, p. 27. <sup>18</sup> DEMME (II.), *Militär-Chirurgische Studien*, Würzburg, 1861, pp. 228, 230. <sup>19</sup> CHENU (J. C.), *Campagne d'Italie*, Paris, 1869, T. I, p. 580. <sup>20</sup> CHISOLM (J. J.), *A Manual of Military Surgery*, Columbia, 1864, p. 361. <sup>21</sup> MOUAT (*loc. cit.*) p. 476. <sup>22</sup> LÆFFLER (F.), *General-Bericht*, u. s. w., Berlin, 1867, pp. 175, 301. <sup>23</sup> FISCHER (K.), *Militärärztliche Skizzen aus Süddeutschland und Böhmen*, Aarau, 1867, p. 69. <sup>24</sup> STROMEYER (L.), *Erfahrungen über Schusswunden im Jahre 1866*, Hannover, 1867, pp. 16, 17. <sup>25</sup> BECK (B.), *Kriegs-Chirurgische Erfahrungen während des Feldzuges, etc.*, Freiburg I. Br. 1867, p. 330. <sup>26</sup> MAAS (II.), *Kriegschirurgische Beiträge aus dem Jahre 1866*, Breslau, 1870, p. 73. <sup>27</sup> *Circular* No. 3, S. G. O., Washington, 1871, pp. 61, 180, 223. <sup>28</sup> BECK (B.), *Chir. der Schussverletzungen*, Freiburg I. Br. 1872, p. 648. <sup>29</sup> BILLROTH (Th.), *Chir. Briefe*, u. s. w., 1872, S. 222. <sup>30</sup> FISCHER (G.), *Dorf Floing*, u. s. w., in *Deutsche Zeitschrift für Chir.*, B. I, p. 187. <sup>31</sup> FISCHER (II.), *Kriegs-Chir. Erfahrungen*, 1872, p. 213. <sup>32</sup> GRAF (E.), *Die Königl. Reservelazareth zu Düsseldorf während des Krieges, 1870-71*, Elberfeld, 1872. <sup>33</sup> HEYFELDER (O.), *Bericht über meine Wirksamkeit am Rhein und in Frankreich während des deutsch-französischen Krieges*, Petersburger med. Zeitschr., 1871, No. 1. <sup>34</sup> KOCH (W.), *Notizen über Schussverletzungen*, in LANGENBECK'S Arch., B. XIII, 1872, S. 544. <sup>35</sup> KIRCHNER (C.), *Aerztl. Bericht über das Königlich Preussische Feldlazareth im Palast zu Versailles*, Erlangen, 1872. <sup>36</sup> LOSSEN (I.), *Kriegschir. Erf.*, u. s. w., in *Deutsche Zeitschrift für Chir.*, 1873, B. II, S. 53. <sup>37</sup> LÜCKE (A.), *Kriegschirurgische Fragen und Bemerkungen*, Bern, 1871, p. 103. <sup>38</sup> MOSEITIG (V.), *Erinnerungen aus dem deutsch-französischen Kriege*, in *Der Militärarzt*, 1872. <sup>39</sup> OTT, OESTERLEN und ROMBERG, *Kriegschir. Mittheilungen*, u. s. w., Stuttgart, 1871. <sup>40</sup> RUPPRECHT (L.), *Militärärztliche Erfahrungen*, u. s. w., Würzburg, 1871, p. 68. <sup>41</sup> SCHÜLLER (M.), *Kriegschirurgische Skizzen*, Hannover, 1871, p. 12. <sup>42</sup> SOCIN (A.), *Kriegschirurg. Erfahrungen*, 1872, p. 119. <sup>43</sup> STEINBERG, *Die Kriegslazareth und Baracken von Berlin*, Berlin, 1872, p. 148. <sup>44</sup> STOLL, *Bericht aus dem Königlich Württembergischen 4 Feld hospital, von 1870-71*, in *Deutsche Mil. Zeitschrift*, 1874, B. III, S. 192. <sup>45</sup> VOGT (P.), *Beitrag zur Lehre von der primären Behandlung der Schussverletzungen*, in *Deutsche Klinik*, 8, 1872. <sup>46</sup> McCORMAC (W.), *Notes and Recollections*, London, 1871, pp. 130, 131. <sup>47</sup> CHENU (J. C.), *Aperçu Hist. Stat. et Clin. pendant la Guerre de 1870-1871*, Paris, 1874, p. 492.

## SECTION V.

## WOUNDS AND INJURIES OF THE ELBOW JOINT.

Reserving for future consideration the reported cases of sprains, contusions, simple and compound luxations and fractures resulting from other causes than shot injury, there remain, for present consideration, a few instances of bayonet and sabre wounds of the elbow joint,<sup>1</sup> many examples of shot injury, and a considerable number of operations involving the articulation. As usual, in treating of war injuries of the extremities the shot fractures will form the main subject of discussion, and, after glancing briefly at the punctured and incised wounds, and the periarticular shot wounds, the shot fractures will be examined in detail, according to their treatment by expectation, excision, or amputation, the materials for the history of the last category having been, to a large extent, collated in the preceding Section. A small group of exarticulations at the elbow, or amputations in the contiguity for injuries of the forearm, will also be comprised in this Section.

**PUNCTURED AND INCISED WOUNDS.**—The few reported examples of such injuries were received in action, and were inflicted by the sword or bayonet.

**Bayonet Wounds of the Elbow.**—Three cases were reported as stabs penetrating the elbow joint; but it appears almost incredible that in either of them the articulation could have been really opened with such slight inflammatory reaction:

**CASES 1731–1733.**—Surgeon H. Wardner, U. S. V., reports that Sergeant G. Salz, Co. B, 9th Illinois, “received a severe bayonet wound directly over the external condyloid ridge, at Corinth, Mississippi, October 3, 1862. The wounded man was sent to Mound City Hospital on the following day. Simple cerate dressing was applied, and the wound healed kindly; the sergeant was returned to duty December 29, 1862.—Surgeon Isaac Scott, 9th West Virginia, reports that “Private C. Upson, Co. C, 14th Connecticut, received a bayonet wound of the elbow, at Chancellorsville, May 3, 1863. He was treated at regimental hospital near Potomac Creek, and also at the Second Corps general hospital.” Surgeon F. A. Dudley, 14th Connecticut, reported that the patient returned to duty three days afterward. The Adjutant-General of Connecticut reports (*Report of 1865*) that the soldier subsequently died in the Andersonville prison.—Later information respecting the case of Private Welcome David (recorded as CASE 1230, on p. 436 of this volume, and erroneously entered “D. Welcome”) indicates, if the nature of the injury is correctly reported, a very remarkable recovery. It will be remembered that the case was regarded as a flesh wound, with lesion of the brachial artery, which was successfully secured by double ligatures. The captain of the company, however, testifies that “the bayonet ran through the elbow joint.” Examiner Joseph Robbins, of Quincy, Illinois, certifies that there was “a bayonet wound of the right elbow joint. The bayonet penetrated the joint and passed between the radius and ulna, causing partial dislocation of the head of the radius, which still exists. There is partial ankylosis of the elbow, and the arm cannot be fully extended; pronation and supination are impossible, and the muscles of the arm and forearm are atrophied.” Examiner J. W. Trader, of Sedalia, certifies, February 21, 1873: “The joint was injured, but no stiffness or ankylosis exists. There is some tenderness, owing no doubt to implication of the nerve. The brachial artery and median nerve were wounded.” On January 15, 1874, this same Examiner reported that “rotation of the arm is perfect, and the joint free and mobile. Some muscular weakness.” This soldier was pensioned and paid to March 4, 1875.

<sup>1</sup> Elbow: Anglo-Saxon, *Elboga*; German, *Elbogen*; Ital., *Gomito*; Fr., *Coude*; Sp., *El codo*. The region of the elbow is situated at the angular union of the arm with the forearm, and contains the humero-cubital articulation, and the tissues near it. (*J. Hart, in Cyclop. of Anat. and Phys.*, 1839, Vol. 11, p. 62): “It may be arbitrarily defined as limited above by a circular line a finger’s breadth above the inner condyle, and inferiorly, by a similar line, two fingers’ breadth, below that process. Its greatest extent is in the transverse direction, and it forms an angle salient posteriorly, and retiring in front, which cannot be effaced even in the utmost extension of the forearm.” *Ἐγκών*, a bend, or *ἀγκάλη*, the bend of the elbow, were the terms used in referring to this region by the Greeks.



**Sabre Wounds of the Elbow.**—Six instances are reported under this rubric.<sup>1</sup> It is possible that the joint may have been directly implicated in two of the cases; but the meagre evidence renders it most probable they were all six periarticular wounds. Three of the six patients were pensioned:

CASES 1734–1739.—Surgeon B. A. Vanderkief reported that “Private P. A. Carlin, Co. F, 1st New York Mounted Rifles, was wounded at a skirmish at Scott’s Mills, May 17, 1863, by a sabre thrust in the left arm, the point of the weapon entering below and within the olecranon process; entered Annapolis Hospital May 25th, and was returned to duty June 13, 1863.” This soldier was discharged August 31, 1864, to re-enlist as a veteran, and deserted August 17, 1865, at Charlottesville. He applied for a pension, and the Brooklyn Examining Board (McCullum, Leighton, and Atwood) recommended his claim, May 6, 1874, stating that he had “received a sabre thrust on the left elbow joint. The cicatrix is an inch and a half long and over the external condyle. Prolonged exertion of the joint is attended with pain.” The claim was disallowed until the charge of desertion was disproved.—Private G. Townsend, Co. A, 6th Michigan Cavalry, aged 28 years, is recorded on the casualty lists from Gettysburg, by Assistant Surgeon E. J. Marsh, U. S. A., as having received, July 2, 1863, a sabre cut on the forehead and a severe wound in the left elbow. He was sent to Satterlee Hospital, registered as a case of “sabre wound of the frontal region and left elbow,” and returned to duty September 23, 1863. He was discharged June 21, 1865, and applied for pension. Examiner W. E. Dockey, of Michigan, certifies, April 21, 1875, that the cicatrix from the sabre wound of the head, “extending upward in a straight line about an inch above the left orbit, occasions no inconvenience. The wound of the left elbow was received in an effort to ward off a blow aimed at the head, the sabre striking across and about half an inch above the external condyle, injuring the nerve in its passage around the condyle. The cicatrix is about three-fourths of an inch long by one quarter of an inch in breadth, tender, but not firm. There is no difference in the size of the arm. There is loss of sensation on the ulnar side of forearm and hand, both on the dorsal and palmar aspects. There is no loss of motion. He claims to suffer from cold.”—Surgeon W. W. Bowlby, 3d New Jersey Cavalry, reports that Private D. W. Cherrington, Co. C, 2d West Virginia Cavalry, “received, at Five Forks, April 1, 1865, a sabre wound of the right elbow.” Assistant Surgeon C. A. McCall, U. S. A., reported this soldier’s admission to the depot hospital of the Cavalry Corps April 3d, and return to duty April 27, 1865. Not a pensioner.—Private A. Hager, Co. C, 105th Pennsylvania, was wounded and captured at the engagement on the Weldon Railroad, October 27, 1864. Surgeon E. H. Smith, P. A. C. S., recorded his admission into Chimborazo (Confederate) Hospital, Richmond, November 3, 1864, and return to quarters, January 11, 1865. He was exchanged, and discharged from service May 29, 1865. Not a pensioner.—Private A. Dubriell, Co. K, 1st New York, was wounded at Antietam, September 17, 1862. Surgeon J. H. Robinson, U. S. V., reported his admission to the Patent Office Hospital, December 24, 1862, “with ankylosis of the right elbow, resulting from a sabre cut,” and the soldier’s discharge from service January 15, 1863. Not a pensioner.—The case of Private J. T. Reed, Co. C, 1st Vermont Cavalry, has already been detailed on page 21 of the *First Surgical Volume*, and it remains only to add the report of Examiner J. Nichols, of Washington, who certifies, December 28, 1861: “Severe sabre cut across the left elbow joint, fracturing the olecranon process, and inflicting a serious flesh wound and severing tendons of forearm. The elbow joint is ankylosed and entirely useless. Also received a severe cut on the head, fracturing the right parietal bone and depressing the inner table. Several pieces of bone have been removed, and dizziness and pain, almost always present, has resulted.” The subsequent examiners report substantially the same. The pensioner was paid September 4, 1875.

Punctured and incised wounds of the elbow may usually be treated hopefully on the

<sup>1</sup> Sabre wounds of the joints are so infrequent that the following examples are of interest: BILGUER (J. U.) (*Chirurgische Wahrnehmungen*, \* \* \*), who has collected many surgical cases reported by various surgeons at the Prussian field hospitals during the Seven Years’ War, 1756–1763, details five cases of sword wounds of the elbow joint. CASE 14 (p. 426): Hussar Kollmar, of von Lau’s Escaudron; sabre wound through the olecranon into the articulation, June 2, 1762; fever, vomiting, copious suppurative; sinus; free incision, removal of numerous fragments of the posterior surface of the humerus; recovery in six months. Reported by Chief Surgeon BRAUN.—CASE 15 (p. 439): Lieut. von Prittwitz, sword wound through elbow joint; olecranon nearly split; joint opened; June 15, 1762, suppurative; free incision; removal of splinters; recovery in three months; ankylosis of elbow joint; partial ankylosis of shoulder joint, which gradually disappeared. Reported by Staff-Surgeon HENRIEL.—CASE 16 (p. 431): Uhlan Weitgewitsch; sabre wound of elbow, extending obliquely across the joint; olecranon nearly cut away; wound gaping; recovery in five months, with complete ankylosis of joint. Reported by Surgeon HORLACHER.—CASE 17 (p. 435): Corporal von Fangerow, of Foreade’s regiment, at the battle of Hoch-Kirchen, October 14, 1758, while protecting his head with his uplifted arm against the attacks of a cuirassier, received a sword wound of the right elbow, which nearly severed the forearm; deep incisions, removal of many bone splinters; healthy suppurative established; recovery in five months. Reported by Staff-Surgeon BEYER.—CASE 18 (p. 440): A captured French dragoon, Birron, had been cut across the right elbow at the battle of Rossbach, November 5, 1757; the wound had been sewed up; Staff-Surgeon BEYER cut the sutures, enlarged the wound, and removed splinters; recovery in a short time, with tolerable use of the elbow. RAVATON (*Chirurgie d’Armée*, Paris, 1768, p. 613, OBS. XXV) gives the case of a dragoon of the Beauremont regiment, whose left olecranon was severed by a sword cut and hung by a flap of skin. The parts were replaced, and maintained in apposition by compresses dipped in balsamic emulsions, and frequently wetted by vulnerary lotions. The limb was kept at an obtuse angle on an anterior splint. The patient recovered, with moderate stiffness of the elbow. RAVATON remarks that the regeneration of the integuments of the elbow is very slow, the aponeurosis and ligaments opposing almost insurmountable obstacles to reunion, and, in the latter stages, a whitish gelatinous discharge appearing that is arrested only with great difficulty. Irritating dressings are likely to induce caries of the condyles of the humerus, etc. LARREY (D. J.) (*Mém. de chir. mil. et camp.*, Paris, 1812, T. II, p. 257) observes: “Toutes les fois que’une articulation ginglymoïde est ouverte et altérée profondément par la cause vulnérante, il importe d’examiner avec soin cette blessure, pour résoudre la question de savoir s’il n’est pas plus avantageux (comme je le pense) de couper le membre, que de laisser le malade livré à un danger certain,” and on page 256 cites the case of Gabriel Sauvages, a chasseur, who received a sabre cut in the left elbow, dividing the articulating portion deeply and extensively. It had been attempted to bring the lips of the wound into exact apposition; inflammation had already set in, and in twenty-four hours gangrene supervened. M. LARREY amputated the arm, and the patient left the hospital in forty days, perfectly cured. In the case of d’Aout, a captain of mamlukes, the skin, the olecranon, a part of the articulating surface of the humerus, the contiguous ligaments, and some branches of the recurrent arteries were divided. M. LARREY observes: “Malgré la gravité de la plaie, je conçus l’espoir de conserver le bras, je ne voulus point la réunir par première intention, l’expérience m’ayant appris que les réunions trop exactes pour les plaies des articulations sont plus pernicieuses qu’utiles, a raison de la pression très-forte que les bandages unissants exercent sur les parties irrégulièrement coupées ou déchirées. L’inflammation se déclare, marche avec l’appareil qui l’accompagne, et il est difficile d’en prévoir les suites.” The captain recovered with the principal motions of the arm preserved.

expectant conservative plan, reserving the remedy of secondary excision until rendered imperative by inflammatory disorganization of the joint; but temporization sometimes involves grave and even fatal consequences.<sup>1</sup>

SHOT WOUNDS.—Instances were reported of periarticular shot wounds, with consecutive involvement of the joint, and of shot penetrations of the articulation without fracture. Illustrations of these injuries will be met in studying the expectant and operative treatment of shot injuries of the elbow. At present, our attention will be particularly directed to the recorded examples of shot wounds involving primarily the bones composing the humero-cubital articulation. These are classified in the subjoined table:

TABLE CV.

*Tabular Statement of Two Thousand Six Hundred and Seventy-eight Shot Fractures of the Bones of the Elbow Joint.*

MODE OF TREATMENT.	CASES.	DUTY.	DIS-CHARGED.	UNDE-TERMINED.	DIED.	MORTALITY OF DETERMINED CASES.
1. Treated by Expectation.....	938	285	543	14	96	10.3
2. Followed by Excision of the Elbow Joint.....	529	80	318	16	115	22.4
3. Followed by Excision of the Elbow Joint and subsequent Amputation of the Arm.....	64	4	35	.....	25	39.0
4. Followed by Amputation at the Elbow Joint.....	6	.....	5	.....	1	16.6
5. Followed by Amputation of the Arm.....	1,124	109	738	5	272	24.3
6. Followed by Amputation at the Shoulder.....	17	.....	13	.....	4	23.5
Aggregates.....	2,678	478	1,652	35	513	19.4

Thus, of the twenty-six hundred and seventy-eight instances of shot fractures interesting one or more of the bones of the elbow, nine hundred and thirty-eight were treated throughout on the expectant conservative plan, five hundred and ninety-three by excision, and eleven hundred and forty-seven by amputation. The class embraces injuries of great variety,—comminutions or perforations of the shaft of the humerus, with fissures extending into the joint; fractures of the ulna or of the radius, or of both, communicating with the joint; penetrations of the joint by small missiles with slight lesion of one or more of the articular surfaces and lodgement of the missile; grazing shots implicating one or other of the processes; perforations in all directions with more or less destruction of tissue; and comminutions by large projectiles; and each of these varieties was further complicated by

MALLE (P) (*Clin. chir. de l'hôpital mil. d'instruction de Strasbourg*, Paris, 1838, p. 620) informs us that "a soldier of the 1st Artillery received, on February 15, 1835, in the bent elbow joint, a sabre cut, which detached the olecranon. The wound was exceedingly painful. M. BÉGIN secured the arm in a nearly extended position; whenever the bandage was removed, the arm was flexed a little farther. The soldier recovered in fifty days; the movements of the arm were preserved. MACLEOD (G. H. B.) (*Notes on the Surgery of the War in the Crimea*, 1858, p. 327) reports: "A dragoon was cut across the elbow of his sword arm by a Russian horseman, at the heavy cavalry charge at Balaclava (October 25, 1854). The olecranon was completely detached and the joint opened. The wound was immediately closed, the arm placed in an extended position, and cold employed to allay inflammation. Little more was done, and the divided surfaces quickly adhered, and an arm remained which, although not so free in its motions at that joint as it was formerly, was yet most useful."

<sup>1</sup> MICHELEIS (*Nachrichten aus New York*, in RICHTER'S *Chir. Bibliothek*, Göttingen, 1782, B. VI, p. 727): A soldier ran a large nail into the elbow joint; little blood but a great deal of yellow fluid escaped; enormous swelling ensued; counter-openings were made at the hand, when a large quantity of pus escaped; small pieces of loose carious bone were removed from the elbow joint by enlarging the wound. The patient recovered in seven weeks, with nearly complete ankylosis of the joint. LANGENBECK (B. V.) (*Chirurgische Beobachtungen aus dem Kriege*, 1874, p. 158): A carpenter, 54 years of age, received, on February 22, 1857, in the streets of Berlin, a punctured wound of the left elbow joint, which bled very freely. When admitted to the clinic, blood and synovia escaped. The arm was secured at right angle and ice applied. February 27, the arm was swollen and gangrene developed at the wound; March 6, resection of elbow joint; March 9 to 16, healthy suppuration and granulation; March 30, pyæmic chills; April 11, death. Autopsy: Pyæmic foci in the lungs and in the connective tissue of the anterior wall of the bladder; pus in the left shoulder joint. The resected humerus necrosed for two and a half inches, the medulla infiltrated with ichorous sanies. HERRMANN (A. G.) (*Compendium der Kriegs-Chirurgie*, Wien, 1870, S. 255): "Punctured and incised wounds of the elbow joint may be treated on the expectant-conservative plan, or by secondary resection when extensive suppuration of joint supervenes."



the extent of injury to the synovial membrane, the cartilages, ligaments, vessels, nerves, and other soft parts with which they were attended. In the discussion of this series of shot wounds of the elbow under the three heads of cases treated by expectation, excision, and amputation, there will be occasion to refer to each of these different forms of injury.

**Shot Wounds of the Elbow treated on the Expectant Plan.**—There were nine hundred and thirty-eight cases of shot injury of the elbow treated throughout on the expectant plan,<sup>1</sup> at least two hundred and fifty treated by temporization with ulterior recourse to intermediary or secondary excision, and a large number, undetermined with strict exactness, by consecutive amputation. Several examples of the first group will be cited, commencing with such as recovered with conservation of the functions of the joint:

CASE 1740.—First Lieutenant E. A. Ellsworth, Co. D, 11th Infantry, aged 24 years, was wounded at Bethesda Church, June 1, 1864. Two days afterward he reached the Fifth Corps Hospital at White House, and, on June 7th, he entered Harewood Hospital, Washington. Surgeon D. W. Bliss, U. S. V., reported: "Gunshot wound of right arm. Patient transferred to private residence on June 13th." The missile, represented in the annexed cut (FIG. 586), is a small triangular fragment of a shell weighing two hundred and five grains troy; remarkable for having furnished lustre to a porcelain bulb though of cast iron. It was contributed to the Museum by Assistant Surgeon J. S. Smith, U. S. A., who reported: "The missile struck the ulna of the right arm about one and a half inches from the elbow joint, fracturing the bone transversely at the point of contact and rending it into long splinters in its length. The presence of the missile was revealed by the Nélaton probe about midway of the ulna, between the long spiculæ." In a report of observations by Assistant Surgeon J. S. Billings, U. S. A., to the Medical Director of the Army of the Potomac, mention is made of this case as follows: "Lieutenant Ellsworth was wounded by a minié ball, which passed through the upper and outer portion of the right ulna, the fracture extending into the elbow joint. The smaller fragments and spiculæ were removed by Assistant Surgeon J. S. Smith, U. S. A., and two large and firmly attached fragments, one joined to the upper, the other to the lower fractured end, were left *in situ*. Simple cold-water dressings were applied. This officer went to Washington, and was treated by Surgeon B. Norris, U. S. A. Two months afterward the wound had almost entirely healed, motion was good in the joint, although somewhat limited, and the deformity of the arm was slight. Only three small spiculæ of bone came away." Lieutenant Ellsworth resigned his commission on December 18, 1866, and was pensioned. Examiner W. W. Potter, April 19, 1869, certified: "Fracture of right ulna near elbow joint, caused by a shell. \* \* \* The head of the radius appears displaced and the limb is deformed. The muscles are atrophied; extension cannot be completely made; pronation and supination are imperfect; strength of limb destroyed for any purpose of labor." The pensioner was paid on March 4, 1875.

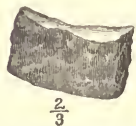

FIG. 586.—Shell fragment extracted from a wound of the elbow. *Spec.* 4280.

CASE 1741.—Brigadier-General John W. Geary, U. S. V., was wounded at the engagement at Cedar Mountain, August 9, 1862. He was struck in the evening in the left foot, and afterward received a more severe wound in the left elbow, "but remained on the field until nine o'clock, when he was compelled to retire from exhaustion produced by pain and loss of blood." (BATES, in *Hist. of Penna. Vols.*, 1869, Vol. I, p. 427.) His wounds were dressed at the field hospital of the 2d division, Second Corps, established by Surgeon A. Ball, 5th Ohio, and he was sent to Culpeper and thence to Washington. He was attended in quarters by Surgeons M. Clymer, B. A. Vanderkief, U. S. V., and Dr. David Ahl. It was found that a conoidal musket ball had shattered the left olecranon and outer condyle, and had flattened itself against the latter. There had been considerable bleeding, and the joint was already swollen and tender. The battered projectile and some bone splinters were extracted, and the limb was put up in a felt trough or angular splint, a large fenestrum being cut out opposite the wound, and kept at rest at an angle of 130°. There was very considerable inflammatory reaction and copious suppuration; but the inflammation was kept within bounds and there was little destructive action in the tissues about the joint. At the end of five weeks, it was practicable to commence passive motion, cautiously, and by September 25th the General was able to rejoin the army, "with his arm still in a bandage" (BATES, *op. cit.*, p. 428), and took command of the 2d division, Twelfth Corps. He was again wounded at Chancellorsville; but served to the end of the war with very tolerable motion of the elbow. He was subsequently elected Governor of Pennsylvania, and died February 9, 1873, aged 53 years.

<sup>1</sup> PARÉ (*Œuvres Complètes*, éd. MALGAIGNE, 1840, T. II, p. 168, IX Livre, Chap. XIV) relates two instances of shot wounds of the elbow that recovered without operative interference—that of the Comte de Mansfelt and that of Bassompierre, colonel of horse, both wounded at the battle of Moncontour, 1569. PARÉ observes that neither of these noble lords was able to flex or extend the arm after recovery, and that in the case of Comte de Mansfelt more than sixty pieces of bone were removed during the cure. Such examples are very rare in the early records. RICHARD WISEMAN, Sergeant Surgeon to Charles II, seems to have regarded amputation as indispensable in shot fractures of the elbow. He tells us (*Several Chirurgical Treatises*, London, 1676, p. 420) that a Scottish soldier was brought to him at the battle of Worcester, shot with a musket bullet into the elbow joint, which fractured not only the ends of the radius and ulna, but likewise that of the *adjutorium*. WISEMAN proposed to cut off the arm, and encouraged the soldier to endure it. "In answer thereto, he only cried: 'Give me drink and I will die!' They did give him drink, and he made good his promise, and died soon after; yet had no other wound than that." The urgent thirst and speedy dissolution suggest that he perished from hæmorrhage. MUNNIX (*Praxis Chirurgica*, Amsterdam, 1715, p. 324, Lib. II, Cap. XXIII), though he gives no case, refers to the liability of ankylosis after wounds of the elbow: "Sin Cubiti articulo inflitctum sit vulnus, brachium nequè extensum servandum, nequè inflexum nimis; illa enim figura contractionem sanato vulnere, solet impedire; hæc liberam extensionem; quocirca mediâ collocandum figurâ, quæ anulum obtusum refert." BORDENAVE (*Mém. de l'Acad. de Chir.*, 1753, T. II, p. 523) relates the case of an Irish soldier, wounded at Ypres by a ball which carried away the aponeurosis of the extensors of the forearm, the olecranon, and a portion of the external condyles. After violent inflammation and exfoliation, the patient recovered in three months, under the care of PLANQUE. BOUCHER (*Obs. sur. des playes d'armes à feu*, in *Mém. de l'Acad. de Chir.*, 1753, pp. 292, 302) records four cases of shot fracture of the elbow resulting favorably, after Fontenoi and other engagements of that period.

Another instance of recovery after shot fracture of the head of the radius, the ulna, and outer condyle of the humerus, with good motion of the elbow, has been published by Acting Assistant Surgeon F. H. Brown.<sup>1</sup> Mr. E. N. B. Smith, of Buffalo, has also printed, in July, 1864, an account<sup>2</sup> of a shot comminution of the olecranon and epitrochlea in a soldier wounded at the Wilderness in the previous May, who was rapidly recovering with "the motions of the joint retained in a remarkable degree;" but the report of the pension examiners does not confirm the favorable prognosis of mobility of the elbow. Eight other instances are found on the records of recovery after shot penetration of the elbow without much loss of motion; but whenever it has been practicable to trace the ulterior histories of these discharged men it appeared that they had stiff or diseased joints. Assistant Surgeon D. C. Peters, U. S. A., states<sup>3</sup> that he treated twelve cases of shot injury of the elbow joint on the expectant conservative plan, with extraordinary success; but the examples I have given are all that have come to my knowledge of recovery with motion. On the other hand, the recoveries with ankylosis in a favorable position are numerous.

CASE 1742.—Lieutenant-Colonel Isaac J. Wistar, 71st Pennsylvania, was wounded at Ball's Bluff, October 21, 1861. In his *History of Pennsylvania Volunteers*, 1870, Vol. III, page 790, Mr. Samuel P. Bates reports that: "Lieutenant-Colonel Wistar was twice severely wounded, but kept his place until he was completely disabled by a third wound." The first two injuries were shot flesh wounds of the thigh and of the neck, the third a shot fracture of the right elbow. The case is referred to by Surgeon A. B. Crosby, U. S. V. (*Appendix to First Part Med. and Surg. Hist. of the War*, p. 11), in his report of the wounded at Ball's Bluff, and by Surgeon J. A. Lidell, in the same volume of documents, p. 13. There was little inflammatory reaction for a fortnight, but grave trouble ensued. However, the patient recovered with an ankylosed joint, and, in August, 1862, returned to duty as colonel. At Antietam he received a shot perforation of the left arm, near the elbow, but not implicating the bone. (See Bates, *l. c.*, p. 794.) Promoted to be brigadier-general, November 29, 1862, this officer served until honorably mustered out, September 15, 1864. In November, 1875, Dr. George C. Harlan, of Philadelphia, had the kindness to make the following notes of the injury to the right elbow: "The ball seems to have shattered the external condyle of the right humerus and the head of the radius, and to have chipped the olecranon in passing out. There was no resection, but the wound was opened about three weeks after the injury and some pieces of bone were extracted. *Present condition*: The wounds of entrance and of exit are united by a broad cicatrix. The elbow is firmly ankylosed at a right angle. The forearm is well developed. The hand is in excellent position and its functions are perfect except that slight limitation of flexion interferes with the handling of small objects. The 'other elbow' is in good condition, never having received any injury, but there is an adherent cicatrix on the inner side of the arm, at about its middle, and some numbness of the little, ring, and middle fingers of the left hand. There was occasional pain in the right elbow for two years, after which it became constant, and was at times very intense. There were no signs of inflammatory action in the joint—the pain was of a neuralgic character, and extended over the whole arm and forearm. This lasted about two years, when it gradually subsided, and, of late, the General has suffered only occasionally and slightly." This officer's name is borne on the Pension List as last paid June 4, 1875.

<sup>1</sup> BROWN (F. H.) (*Cases illustrating conservative surgery*, in *Boston Med. and Surgical Journal*, 1864, Vol. LXX, p. 9): "Ball entered outer and dorsal aspect of right arm three inches below olecranon; the ball there split, one portion passing up through the outer condyle of the humerus and lower part of the shaft of the bone, and thence out on the outer and posterior aspect of the arm, three inches below the elbow; the second portion passed through the radius and ulna at a right angle to the axes of the bones, and lodged. This portion was removed by incision at a subsequent period. In addition, the humerus was fractured transversely, just above the exit wound of the first portion of the ball, either by a fall or by concussion. In this case, there was fracture of the humerus, comminution of the lower end of the same bone, injury to the joint, comminuted fracture of the radius and ulna, and two ball tracks of perhaps six and ten inches, respectively." The arm was put up in felt splints, and the fractures united well. The report concludes: "At the earliest possible day flexion and extension and pronation and supination were induced. When last heard from, three and a half months after the injury, he had entirely recovered, the only trouble being that, in extending the arm, it lacked an inch or two of being straight. This soldier was transferred to Buttonwood, to Mower, and to Convalescent Hospital, and mustered out with his regiment June 18, 1863. Not an applicant for pension.

<sup>2</sup> SMITH (E. N. B.) (*Buffalo Med. and Surg. Jour.*, 1864, Vol. III, p. 460): Private J. Brunner, Co. B, 49th New York, aged 39 years, was wounded at the Wilderness, May 5, 1864, and was sent to Emory Hospital, at Washington, May 11th, and was furloughed May 16th. He went to Buffalo, and Mr. SMITH states that Dr. MINER laid open the wound, and found that the ball had entered the forearm about an inch and a half below the olecranon, and had broken off the process and shattered the ulna for three inches below the point of entrance, and fractured the inner condyle of the humerus, not touching the radius. The ball and pieces of bone were removed, and the wound cleansed and drawn together. This patient was readmitted to Emory Hospital, September 10th, and discharged December 3, 1864, "for paralysis of left arm and ankylosis of left elbow, caused by gunshot wound." Examiner Tormis, of Buffalo, certified, September 17, 1866: "Ball entered left elbow near olecranon, passed into joint, and was removed by incision; exfoliation ensued, and the elbow joint is now completely ankylosed in nearly an extended position." The Buffalo Examining Board reported, September 4, 1873: "Loss of pronation and supination of hand; flexion and extension almost lost; unable to extend and flex fingers." The pensioner was paid June 4, 1875.

<sup>3</sup> PETERS (D. C.) (*Gunshot Wounds of Joints*, in *Am. Med. Times*, 1863, Vol. VII, p. 156) tabulates six cases of shot injury of the right and six of the left elbow, treated at Jarvis Hospital from June 20, 1862, to October 1, 1863. Of the twelve patients, one was cured and returned to duty, seven were transferred to other hospitals, three were remaining under treatment, and one had died. Dr. PETERS observes: "The gunshot wounds of the elbow joint enumerated in the table, we treated by resting the limb bent at a right angle on a grooved tin splint which had been previously well padded with tow. They were retained in this position by loose bandages; the wounds were kept clean, and the patient, as soon as able, was made to exercise in the open air, and attention was paid to passive motion. The diet of these patients must be generous, and malt liquors are to be ordered them to support their strength. The diet of a soldier in the field is substantial, but it is not sufficiently mixed to be healthy—that is, he does not have the opportunity to obtain his customary amount of vegetables; and it has been found in general hospitals, where the men are supplied with these articles, that their condition is much improved, and, indeed, in most chronic complaints a most wonderful change is worked under their use."



A number of examples of the results of expectant measures after shot penetration of the elbow joint will be detailed, and, for comparison, some results will be cited of analogous cases<sup>1</sup> in other campaigns,<sup>2</sup> both remote and recent.<sup>3</sup>

CASE 1743.—Private E. T. Parker, Co. E, 2d New Hampshire, aged 21 years, was wounded at Gettysburg, July 2, 1863, and admitted to the field hospital of the 2d division, Third Corps, where Surgeon C. K. Irwin, 72d New York, recorded: "Wound of right arm and left thigh." On July 13th, the wounded man entered West's Buildings Hospital, Baltimore, and on November 2d he was transferred to Baxter Hospital, Burlington. Surgeon G. Rex, U. S. V., and Assistant Surgeon S. W.



FIG. 587.—Anchylolysis after shot fracture of the olecranon and outer condyle. [From a photograph.]

Thayer, U. S. V., reported "the favorable progress of a gunshot wound of right arm." This soldier was transferred to the Veteran Reserve Corps March 8, 1864, and discharged from service June 9, 1864. He subsequently re-enlisted, and was placed on duty as messenger at the Army Medical Museum, where he is still employed in the clerical force of the Surgeon General's Office. According to his statement, he was wounded in both thighs and in the scalp, in addition to receiving a gunshot fracture of the right elbow, the ball entering the joint below the external condyle of the humerus, passing through the ulna, and emerging about one inch from the end of the olecranon. About October 1, 1863, twenty-nine fragments of bone were removed, varying from one-fourth to one and a half inches in length, the two largest being nearly one-quarter of an inch wide. A photograph was taken of the pensioner at the Museum in 1871, and is represented in the annexed cut (FIG. 587.) This pensioner was examined April 17, 1862, by Dr. J. O. Stanton, who certified: "Gunshot wound of right elbow; the ulna and radius seem to have been fractured. The forearm is partially flexed and the elbow joint ankylosed; is unable to rotate the forearm; slight atrophy; circulation poor in forearm and hand," etc. A plaster cast of the injured elbow in this case was taken and contributed to the Museum, about three years after the reception of the injury, by Hospital Stewart E. F. Schafhirt, U. S. A. It shows the joint in a semi-flexed position, with an irregular transverse cicatrix extending across the dorsal surface just below the articulation. (*Cat. Surg. Sect.*, 1866, p. 537, *Spec.* 4026.) In January, 1876, this case was examined by the writer. The cicatrix over the olecranon and external condyle was rather more conspicuous than represented in the cut. The joint was very firmly ankylosed, the forearm in pronation; the power of supination was entirely gone. There had been no traces of inflammation about the joint or of neuralgic pain for several years. The muscles of the forearm were well developed, and the functions of the hand perfect, the pensioner writing well.

Other cases were complicated with protracted suppuration and extended caries:

CASE 1744.—Private T. Hayes, 1st Kansas, aged 41 years, was wounded at Wilson's Creek, August 10, 1861, and sent to St. Louis on the 19th. Surgeon S. M. Horton, U. S. A., reported, September 17, 1862: "The wound was by a conical ball, which entered the outer and anterior side of upper portion of forearm three inches below the elbow joint, and escaped through the inner and posterior portion of the lower end of the arm one inch above the joint, fracturing the upper end of the radius, and fracturing and breaking off the internal condyle of the humerus. Violent inflammation set in soon after infliction of the wound. The soft parts have healed several times, but abscesses formed again and again around and near the joint. \* \* \* Several pieces of bone have been extracted, and now, after the lapse of thirteen months, the man is confined to his bed with a painful, diseased arm. The upper half of the surface of the forearm is erysipelatous, and pus of an unhealthy character exudes from openings near the joint every fourteen to twenty days." This soldier was discharged February 12, 1863, and pensioned. Examiner Cumminsky reported, July 27, 1866: "Anchylolysis of right elbow joint, with forearm at a right angle, and partial paralysis of the fingers, rendering them useless in any kind of manual labor. Caries of the humerus and upper part of radius and ulna." Examiner Corson reported, September 29, 1873: "There has been disease of the humerus nearly to the shoulder joint, with discharge of bone. Arm is atrophied, with two inches shortening; hand and fingers distorted."

<sup>1</sup> BILGUER (J. U.) (*Chirurgische Wahrnehmungen*, Berlin, 1763, S. 407-482) details fourteen cases of recovery after shot fractures of the bones of the elbow joint, treated on the expectant conservative plan; but in one instance only (*Wahrnehmung* VI, S. 408) is it reported that some motion of the elbow joint remained. THOMPSON (J.) (*Report of Obs. after Waterloo*, 1816, p. 156) refers to several cases of shot wounds of the elbow joint in which recovery would probably take place by anchylolysis, and to one in which the ball was lodged in the joint without much inflammation. PERCY and LARREY appear to have been very skeptical as to the propriety of treating shot injuries of the elbow without operative interference. HENKEN and ALCOCK are silent on the subject. GUTHRIE (G. J.) (*A Treatise on Gunshot Wounds*, 2d ed., 1827, p. 521) recommends excision in cases of shot fractures of the bones of the elbow joint; but where the head of the radius or ulna alone is injured, it "will not require so severe an operation; the pieces of bone should be removed, and the efforts of nature carefully awaited."

<sup>2</sup> I find but few references to shot wounds of the elbow joint in the meagre surgical annals of the American Revolution and the War of 1812. NEALE (H. S. J.) (*Chirurgical Institutes*, London, 1865, p. 224) relates the case of Major Ferguson, wounded at Brandywine by a musket ball, which carried away the olecranon of the right elbow. This officer recovered after three months, and resumed active service, with a stiff joint. Dr. AMASA TROWBRIDGE, who was surgeon of the 21st U. S. Infantry during the engagements on the northern frontier in 1812, relates (*Lecture on Gunshot Wounds, at Willoughby University, in Boston Med. and Surg. Jour.*, 1838, Vol. XVIII, p. 342) that "Col. Aspínwall, at the battle of Chippewa, received a gunshot wound near the elbow joint. The ball pierced the capsules and condyles of the humerus, and yet he appeared to be but little affected by it. He remained on the field until the battle was ended, then immediately suffered amputation of his arm without much pain or disturbance."

<sup>3</sup> In the Schleswig-Holstein campaigns of 1848-'50, STROMAYER (L.) (*Maximen*, S. 756) tabulates three cases of shot fractures of the elbow recovering without operative interference, with stiff joints. In the Dano-Prussian War of 1864, Dr. LÖFFLER (*General-Bericht über den Gesundheitsdienst im Feldzuge gegen Dänemark*, 1864, S. 229) informs us that of forty-seven cases of shot fracture of the elbow, four were treated by amputation, forty by resection, and three by expectation. Of the latter group, two cases resulted fatally. Twelve of the resected and two of the amputated cases were fatal

The next case furnishes an example of fair recovery after shot fracture of the olecranon, the joint, though stiff, remaining exempt from disease:

CASE 1745.—Private A. Brown, Co. K, 13th New Jersey, aged 19 years, was wounded at Gettysburg, July 3, 1863, and admitted to the Twelfth Corps Hospital. Surgeon H. E. Goodman, 28th Pennsylvania, noted: "Gunshot wound of right elbow." On July 11th, the patient entered Mower Hospital, Philadelphia, where Surgeon J. Hopkinson, U. S. V., recorded the following history: "He was injured by a rifle ball in the right elbow joint, directly over the olecranon, causing a transverse wound extending down to the bone. On admission, the arm was painful and swollen; ordered poultice of linseed meal. July 13th, ordered cold-water dressings. July 21st, wound looking much the same; arm a good deal inflamed and painful; has a good deal of fever. Ordered sulphate of magnesia an ounce; also a prescription of liquor ammoniæ acetatis four ounces, and spiritus ætheris nitrici two ounces, given in tablespoonfuls every two hours. July 24th, discontinued fever mixture; the arm is kept enveloped in lint saturated with lead water and laudanum. July 27th, wound suppurating freely; inflammation much reduced; patient is on extra diet. The same treatment was continued to August 8th; wound healthy. August 9th, warm-water dressings applied; an abscess forming above the elbow. August 10th, abscess opened and a great quantity of pus discharged; emollient poultice applied. Patient anæmic; is on extra diet, with a bottle of porter per day and tonics, a prescription of sulphate of quinine eight grains, and pills of carbonate of iron twenty-four grains, with sufficient extract of gentian to make twelve pills, being given in doses of one pill every three hours; also an anodyne at bedtime. August 11th, improving; same treatment continued. August 12th, stimulating poultice applied to wound, and a solution of plumbi subacetatis mixed with tincture opii, to surrounding parts to obviate the inflammation; anodyne at bedtime. August 13th, 14th, and 15th, doing very well; treatment continued. August 16th and 17th, wound looks well; patient has diarrhœa; a dose of one-half ounce of castor oil and ten drops of tincture of opium prescribed. August 18th, 19th, and 20th, diarrhœa checked; wound in excellent condition; discharge much decreased; patient on extra diet. August 21st, a superficial abscess formed on elbow, was opened, and discharged a thin sanious pus; general health good. August 22d and 23d, continued treatment; doing well. August 24th to 31st, cold-water dressings applied; patient doing well, and still on extra diet, with a bottle of porter daily and tincture of sesquichloride of iron twenty drops thrice daily. September 1st, opened a small abscess, which discharged thin sanious pus; applied flaxseed poultice. September 2d to 10th, general treatment continued; doing well. September 11th to 18th, continued treatment. I think this patient will have a stiff joint. The wound is nearly healed; it is still a little tender upon pressure, and there is little or no motion. September 19th to October 7th, doing well; treatment continued. October 8th to 12th, the elbow joint is injured, but there is no complete ankylosis; the wound is nearly healed. October 13th to 20th, doing well; a small piece of bone came away; the wound looks better since, and is now doing very well. October 23d, doing well; wound nearly healed; dressed with simple cerate. October 27th to November 1st, doing well; treatment continued." On January 10, 1864, the patient was assigned to the Veteran Reserve Corps, to which organization he belonged until March 1, 1869, when he was transferred to the general service. Examiner J. O. Stanton, June 6, 1872, certified: "Gunshot wound of right arm at elbow joint, injuring the olecranon process. The elbow joint is partially flexed and ankylosed, and there is slight atrophy and some loss of power in the forearm." This pensioner has been on duty as messenger in the Surgeon General's Office since September 5, 1865, and is at present serving in that capacity. At the Army Medical Museum, a photograph of him, represented in the annexed cut (FIG. 588), was taken in 1875. The elbow then permitted no flexion or extension, but movements in pronation and supination were perfect, and the functions of the forearm and hand were unimpaired, and the joint was free from any inflammatory action.



FIG. 588.—Elbow ankylosed after shot injury. [From a photograph.]

In the next case, the ulna was more extensively fractured, and the functions of the forearm and hand were less perfectly restored:

CASE 1746.—Corporal W. Marshall, Co. F, 1st Pennsylvania Reserves, was wounded at South Mountain, September 14, 1862, and sent to Washington. After treatment in Ryland Chapel, he was admitted, December 5th, to Stanton Hospital. Surgeon J. A. Lidell, U. S. V., reported: "The patient received a gunshot wound of the left elbow joint. The forearm was partially bent upon the arm at the time of injury. The bullet entered the outside of the joint close to the ulna, and passed directly inward, splitting the ulna, passing through the articulation, and escaping on the inner side of the joint; thence continuing its course inward and grazing the antero-lateral part of his body. For about six weeks after he was hurt the wound at the elbow pained him a great deal, and discharged copiously. The joint has never swelled to a marked degree. No large bone splinters have been discharged. Some bone in the form of grit, as the patient calls it, has been discharged, but the quantity has not been large; he has been treated for the most part with the water dressing. The wound is now nearly closed; discharge trifling. Ankylosis has occurred; all motion of joint lost, including pronation and supination. There is now no pain, and but little soreness; the forearm is permanently flexed on the arm at an obtuse angle of about 120°. He has good motion of the fingers, hand, and wrist; the amount of atrophy is small. Discharged from the service on surgeon's certificate of disability. January 13, 1863, condition improving; excellent prospect of preserving a useful limb." Examiner P. R. Palm, of Allentown, Pennsylvania, May 4, 1872, certifies: "The joint is completely ankylosed, and the arm partly bent and considerably atrophied. Complains of want of strength in the limb, and cannot well grasp objects; says he has much pain in the whole arm." And May 6, 1874: "There is ankylosis of the joints of the left hand, partly." This pensioner was paid December 4, 1874.



In the following case, the elbow joint was opened by a ball, with but slight injury to the articular surfaces of the bones composing the elbow:

CASE 1747.—Private A. Parkess, Co. I, 16th Connecticut, aged 22 years, was wounded at Antietam, September 17, 1862, and was sent to Baltimore and entered Camden Street Hospital. Acting Assistant Surgeon E. G. Waters made the following special report: "Admitted September 25, 1862. Examination showed that a musket ball had entered the posterior aspect of the left forearm five inches below the elbow, passed upward and outward, emerging over the outer condyle of the humerus. The wounds were treated with water dressing. October 5th, it being evident that the elbow joint had been opened by the bullet, or so severely contused that violent inflammation had been set up, and fluctuation being apparent, the wound over the outer condyle was freely opened; a quantity of pus issued, and the finger passed into the cavity of the articulation. The extremity of the humerus was found already roughened through the ulceration or absorption of cartilage. Constitutional irritation was met by general treatment, and the wound dressed with aqueous infusion of opium. The forearm was maintained at a right angle and ankylosis secured in this position. A superficial abscess of the joint was subsequently opened. This youth, while under treatment for the above injury, had a mild attack of gastric fever, and subsequently of scarlet fever. During this last attack he was a good deal plagued with retention of urine, the catheter being daily required for his relief for a week or more. February 26th, cured and discharged the service, using his hand and arm at the time with great facility." Examiner S. G. Ridley, of Vernon, Connecticut, July 27, 1870, finds: "Perfect ankylosis of the left elbow joint; the forearm related to the arm at an angle of about 110°." \* \* "Unable to use the arm any in manual labor; the entire arm about two-thirds the size of the other arm; cannot reach any part of the head with any part of the hand when the head is erect, so he cannot use it in feeding himself." The Hartford Board (Drs. Brownell, Jarvis, and Fuller) reported, September 16, 1873: "Ball struck near the outer condyle and passed down to the middle of the forearm, and came out over the radius. Complete ankylosis at about a right angle. Forearm pronated and incapable of rotation." This pensioner was paid December 4, 1874.

The limb was often preserved when the articular surfaces were very badly fractured,<sup>1</sup> as in the following case, in which the humerus, radius, and ulna were involved:

CASE 1748.—Corporal O. G. Hess, Co. C, 8th Illinois Cavalry, was wounded at Beverly Ford, June 9, 1863, and was sent to St. Paul's Church Hospital, at Alexandria. Assistant Surgeon A. W. Tryon, 100th New York, reported: "Admitted June 11, 1863. Ball entered over the middle point of the upper aspect of the elbow joint, and, passing upward and backward, made its exit on the outer surface of the arm an inch above the joint, fracturing the humerus. General health good; bowels constipated. A mild cathartic was given, and the wound was constantly irrigated with ice water. June 20th, some fever; pulse 118; tongue a little coated. June 30th, arm is but little swollen; some small pieces of bone discharged; appetite good; pulse 92; bowels constipated. Compound cathartic pill given, cold-water dressings to wound, and one glass of porter daily. July 10th, arm is improving finely. July 15th, has an attack of diarrhoea; pulse 98; arm looks well; discharge is small. Astringents given. July 20th, diarrhoea checked; appetite good; is able to sit up, and can move the joint. July 24th, is able to walk about; upper opening of the wound entirely healed; discharge slight; pulse 84. July 26th, was up in the morning, feeling unusually well; at five in the afternoon was taken with a chill. July 27th, erysipelas appeared on the right arm—the swelling is considerable, redness extending six inches above and below the elbow; pulse 118; tongue coated light brown. During the day the pulse rose to 130; the redness and swelling extended to the body and down to the wrist. Iron, quinine, and stimulants given; discontinued stimulants at about three P. M., and gave spirits of mildererous and nitric ether, and, locally, lead and opium wash. July 28th, feels the quinine considerably; pulse 120; swelling and redness not much increased; tongue not much coated, red at the edge, and moist. July 29th, redness and swelling has crossed the line of nitrate of silver and extended upon the neck and on the sides; it is somewhat lessened where it first appeared; pulse 116; tongue but little coated, quite red; has severe headache. Tonics and stimulants, quinine in small doses at long intervals; lead and opium wash locally. July 30th, feels better; pulse 107; swelling extending on hand and down back; redness fading along the whole arm. 31st, diminished the stimulant; fingers much swollen; redness and swelling has reached to the hip. August 1st, swelling and redness still extending over the body; has disappeared in the arm; pulse 120 and feeble; tongue still coated; bowels loose. Quinine, iron, and brandy ordered. 2d, redness and swelling extending over abdomen and down on the hips; pulse 112 and a little stronger; tongue moist. 3d, redness and swelling has not extended; pulse 90 and full. 5th, redness disappearing over most of his body, but still extending on the outer margin of its course; pulse 100, a little quicker; tongue quite clean. 6th, redness almost entirely disappeared. 8th, all symptoms of erysipelas have disappeared; the wound discharges some; appetite good. 11th, is able to be up and walk about; but little dressing. 20th, wound has not quite healed up; elbow joint is quite stiff, though he has some motion; uses his arm considerably; appetite good; all medicine discontinued; simple dressing and exercise employed. The patient continued much the same until October 1st, at which time the arm was quite stiff; the patient could not put his hand to his mouth, but could touch his forehead, and could not rotate the hand; he was detailed on duty as mounted orderly at headquarters. He was discharged April 29, 1864, and pensioned." Examiner R. A. Wells, Jefferson City, October 29, 1866, reported: "Wounded by a ball which entered the right arm near the external condyle of the elbow joint, and, passing directly through the joint in a somewhat diagonal direction, escaped about an inch above the internal condyle, evidently fracturing badly the heads of both radius and ulna, \* \* complete ankylosis of said joint; arm bent at nearly a right angle; the entire arm has wasted away to a considerable degree." Examiner A. H. Coffee, of Carthage, September 13, 1869, reported: "Complete ankylosis; atrophy of muscles of arm;" and in September, 1873: "Rotation of arm destroyed." This pensioner was paid December 4, 1874.

<sup>1</sup> COLE (J. J.) (*Military Surgery*, 1852, p. 155), although a determined advocate of primary amputation for shot wounds of the elbow, relates that: "In Major Edwards's second battle with the Sikhs, one of his best officers was badly wounded in the right elbow joint. I saw him a few days after, when suppuration was profuse. The articulating extremities of the humerus, radius, and ulna were all exposed to view—the latter two broken. The patient would not bear of amputation, or even of extraction of detached portions of bone, but left camp in disgust of the European doctor. He recovered, with a useless arm. (See Major EDWARDS'S '*Year in the Punjab*.')"

The various appliances employed in the treatment of shot fractures and excisions at the elbow will be more fully noticed in the sequel; but it is convenient meanwhile to intercalate in the text figures of some of the forms of apparatus employed. FIG. 589

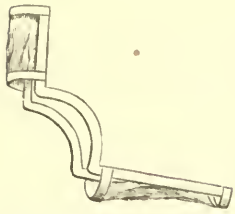


FIG. 589.—Bauer's wire elbow splint.

represents Dr. L. Bauer's wire splint,<sup>1</sup> and FIG. 590 Professor Esmarch's suspension splint.<sup>2</sup> References to cases of shot fracture of the elbow treated on the expectant plan in foreign countries are continued in the foot notes,<sup>3</sup> and other

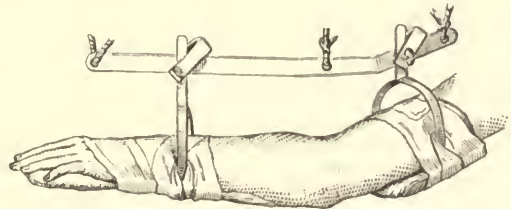


FIG. 590.—Esmarch's elbow splint. [After OCHWADT.]

instances from the large number returned from the American war, are adduced in the text, selection being made of such as exemplify the repair of different varieties of injury, or illustrate the divers complications which impeded recovery:

CASE 1749.—Private J. A. Erwin, 8th Battery, 2d Indiana Artillery, was wounded at Chickamauga, September 19, 1863, and was treated in Hospital No. 8, Nashville, for "gunshot wound of the left elbow joint, with fracture." On December 13th he was furloughed, and January 5, 1864, admitted to the hospital at Evansville, Indiana. Acting Assistant Surgeon J. A. Janson reported: "The ball passed through the elbow joint in an oblique direction from the bend of the elbow, back toward the edge of the olecranon. January 12th, the joint is ankylosed; the wound is gangrenous; application of bromine to wound, and stimulants often. The general health of the patient is feeble. January 25th, the wound is healing kindly, but the constitutional disturbance is still marked. Suppuration growing less, and granulation going on under the sloughing surface. February 20th, the wound is improving, and the general health is good. March 2d, patient put on light duty; the joint is completely ankylosed. April 12th, discharged on surgeon's certificate of disability." Examiner B. I. Day, April 13, 1864, certified: "Ball entered elbow through anterior aspect; joint ankylosed; wound discharging, and hand quite useless for the present." Examiner S. E. Mumford, September 4, 1873, certified: "The ball entered at the external condyle, fracturing the lower end of the left humerus. Considerable bone is missing; the joint is perfectly stiff; the forearm is flexed at an obtuse angle." This pensioner was paid December 4, 1874.

Few cases of this group were reported with detailed histories, and the abstracts of recoveries with ankylosis from shot injuries of the elbow have been compiled, with few

<sup>1</sup> BAUER (L.) (*Contributions to Surgery, in St. Louis Med. and Surg. Jour.*, 1870, Vol. VII, p. 193). Professor BAUER presumes this splint "to be preferable to the plaster of Paris bandage, from the fact that it is equally effective in immobilizing the elbow, and leaves the wound more approachable to wet applications without lacking in firmness."

<sup>2</sup> As figured by Oberstabsarzt OCHWADT (*Kriegschir. Erf.*, 1865, S. 235, and TAF. II), and described as a flat iron rod suspended above the arm and parallel with its axis. The limb reposes on dish-shaped padded splints, one for the upper and one for the forearm, which are hung from the rod by movable stirrups.

<sup>3</sup> The annals of the French Revolution of 1830 furnish some examples of the successful expectant treatment of shot injuries of the elbow. Thus: MENIÈRE (P.) (*L'Hotel-Dieu de Paris en Juillet*, 1830, p. 321) records the case of "Grenier, a plumber, aged 28, whose left elbow was shattered by a ball July 29, and who was in a fair way to recover September 16th." JOBERT (A. J.) (*Plaies d'armes à feu*, Paris, 1833, p. 356) details two instances of shot fracture of the right elbow among the insurgents of July, 1830. Both patients recovered under expectant measures, with stiff joints. To these may be added a case referred to about the same period by MALLE (*Clinique Chirurgicale de Strasbourg*, 1838, p. 624): An officer of the 26th regiment received, March 10, 1830, in a duel, a pistol ball perforation through the right elbow joint. With local depletion and cold irrigation, he recovered with a stiff arm. The late M. BAUDENS (*Clinique des Plaies d'Armes à Feu*, Paris, 1836, p. 444) sets forth that: "Lorsque la balle n'a pas atteint les cartilages inter-articulaires, et qu'elle a borné son action à la perforation d'un condyle avec déchirure partielle des ligaments, sa lésion est moins grave que dans le cas contraire; car dans cette hypothèse il n'y a pas de corps étrangers entre les surfaces de l'articulation, et s'il est vrai que des fentes se prolongent souvent jusque dans celle-ci quand un condyle a été nettement perforé par une balle, cette blessure n'en est pas moins susceptible de guérison. Or, on conçoit que ces considérations ne se rapportent qu'aux articulations par ginglymes, parce qu'en effet la tête des os qui constituent des énarthrozes, quand elles viennent à être atteintes par des balles, laissent toujours des débris osseux dans la capsule articulaire; et si le projectile sort au-dessous de cette capsule, on n'a plus affaire qu'à une solution de continuité du corps des os. D'où il résulte que toute plaie d'articulation par énarthrose avec brisure des têtes articulaires exigent l'amputation ou la résection, tandis que celle par ginglyme est guérissable sans opération chirurgicale, lorsque les surfaces articulaires n'ont pas été en contact immédiat avec le plomb. Aussi n'ai-je jamais vu guérir les fractures de la tête du fémur et de l'humérus, tandis que la guérison a presque toujours été obtenue après les plaies de l'articulation huméro-cubitale, radio-cubitale, tibio-tarsienne, et même tibio-fémorale, celle-ci toutefois beaucoup plus difficilement que les trois autres; ces vérités ressortiront de l'examen des faits exposés ci-dessous." He then adduces four instances from the Algerian campaigns (1831-1836) who recovered from shot fractures implicating the elbow, under expectant treatment, viz: E——, 13th regiment, aged 25 years, musket ball in joint; recovery in three months after extraction of ball and bone fragments. H——, 17th regiment, wounded at Tafia, the ball breaking the olecranon and passing down the forearm; recovery in three months with ankylosis. D——, 47th regiment, and T——, 17th regiment, with fractures of the olecranon and epicondyle or epitrochlea on the same occasion; recovered in three months with stiff joints. The four cases were treated by free incisions, removal of primary splinters, cold applications to the joint, and the extraction of secondary sequestra. In the discussion at the Paris Academy, in August, 1848 (*Comm. sur des plaies d'armes à feu*, par MM. AMUSSAT, BLANDIN, etc., 1849, p. 152), it appears that most of the shot wounds of the elbow in the late insurrection had been treated by excision or amputation; but two cases were reported from Hotel Dieu of recovery with incomplete ankylosis. BERTHIERAND (A.) (*Campagnes de Kabylie, Histoire Médico-Chirurgicale des Expéditions de 1854-6-7*, Paris, 1862, pp. 127 and 162) details two examples of expectant treatment of shot fractures of the elbow: H——, 1st Zouaves, received a shot comminution of the right olecranon and trochlear extremity of the humerus, and recovered in three months; there was incomplete ankylosis, some flexion, but imperfect extension. Capt. L——, of the Chasseurs, with shot splintering of the articular extremity of the ulna, recovered in five months, with ankylosis, but good use of the hand.



exceptions, from brief hospital entries and pension memoranda. If not presented with the vividness of a connected narrative by a single hand, the examples gain, perhaps, in authentic value, from the corroborative evidence<sup>1</sup> accumulated from several sources.<sup>2</sup> The next case is another example of the complication of hospital gangrene.<sup>3</sup>

CASE 1750.—Private J. Mattie, Co. K, 1st New York Artillery, was wounded at Chancellorsville, May 2, 1863, and was sent to Aquia Creek Hospital. On June 14th, he was transferred to Douglas Hospital, Washington, and on October 29, 1863, to St. Joseph's Hospital, New York. Acting Assistant Surgeon G. T. Shradly reports that: "The conical ball entered the left elbow joint on the anterior face, and was extracted on June 11th from the posterior part of the joint, together with several fragments of bone. Patient states that erysipelas set in in the latter part of July and terminated in gangrene. The treatment of the latter consisted in the application of nitric acid for the first week; but it did not seem to benefit the case, and bromine was next used, applied once a day for four days, when the gangrene was arrested. Constitutional treatment consisted of milk punch and a good nourishing diet. One piece of bone has been thrown out of the wound of entrance since the operation. This piece came out about October 1st. The wound is still discharging a little. The joint is ankylosed at nearly right angles." Discharged November 12, 1863, because of "anelylosis of the left elbow joint," and pensioned, and paid December 4, 1874.

CASES 1751-1753.—Private W. C. Duckett, Co. K, 4th Infantry, wounded at Petersburg, June 15, 1864, was sent to Annapolis by a transport steamer June 20th. Acting Assistant Surgeon C. W. Neff reported: "A fracture of the right elbow by a musket ball, which had entered the posterior portion of the forearm and passed through the joint. Oakum dressings were used, and full diet." This soldier was discharged April 16, 1865, and pensioned. Examiner Owens reported, March, 1866: "Partial loss of motion at joint; is unable to flex the fingers and thumb of the right hand." Examiner J. O. Stanton reported, in September, 1873: Cicatrices sound; slight atrophy of muscles; some loss of motion in thumb and index. Was pensioned December 4, 1874.—Serg't B. D. Savage, Co. F, 3d Maine, aged 22 years, was wounded at the Wilderness, May 5, 1864. Surgeon D. Everts, 20th Indiana, recorded: "Shot fracture of right elbow." The patient was treated at Campbell Hospital, Washington; discharged June 28, 1864, and pensioned. Examiner C. W. Snow, of Maine, reported, June 30, 1864: "A minié ball entered the right forearm, upper third, coming out above the joint, and fracturing the humerus; arm perfectly useless." Examiner A. Lambert, of Massachusetts, March 1, 1865, recommended a reduction of pension, stating: "The arm is improving rapidly, and the applicant is beginning to earn a respectable livelihood." Examiner G. A. Wilbur, of Maine, reported, March 5, 1865: "Shot wound of ulna, five inches below olecranon, to just above the right external condyle, shattering the lower end of the humerus. The arm cannot be extended exactly straight; otherwise perfect." Examiner Snow again reported, September 4, 1873: "Motion of elbow joint impaired; arm atrophied and painful; disability one-half." This pensioner was paid June 4, 1874.—Pt. F. Hintzpetter, 22d Illinois, aged 30 years, was wounded at Belmont, Missouri, November 7, 1861, and sent to Mound City Hospital on November 13th. Surgeon E. C. Franklin, U. S. V., reported: "Shot wound of right arm, fracture of humerus into elbow joint; recovered with partial ankylosis; arm bent at 45°; can use it well." This soldier was sent to duty January 27, 1862, and was discharged the service March 5, 1862, and pensioned. Assistant Surgeon W. W. Bailey, 22d Illinois, reported: "Ankylosis of right elbow joint, produced by shot wound; disability total." This pensioner was paid June 4, 1874.

In the three foregoing cases recovery took place with incomplete ankylosis, although

<sup>1</sup> WILLIAMSON (G.) (*Military Surgery*, 1863, p. 168) relates that four soldiers returned from the Indian Mutiny of 1858, invalidated on account of shot fractures of the elbow, treated on the expectant plan. "In these elbow joint cases there can be no doubt of the direct penetration of the joint, with comminution of bone, resulting in ankylosis. In three of them the ulnar nerve was injured. In these instances the olecranon was fractured, and in one case the external condyle; the joint was ankylosed in all of them. In three of them the forearm was at an obtuse angle. In the fourth case the arm was quite straight and the elbow joint ankylosed, rendering the arm very useless; but in this case the humerus had also been fractured, making it very difficult to treat; even now the limb is much more useful than any artificial arm which he could have been supplied with. In none of them had resection been performed, and it becomes a question whether these patients would have had a more useful arm had the joint been excised so as to allow of free motion of the joint. If it were possible to induce patients to use the arm at an earlier period of the treatment, they might preserve some motion of the joint." The pensioners were: 1. Pt. Arthurs, 32d regiment, aged 33 years, wounded at Lucknow, September 27, 1857; musket ball entered the external condyle and passed out at the inner side of the olecranon. The arm was ankylosed in a bent position. No sensation in little finger and outer half of ring. 2. Pt. Wardleworth, aged 34 years, wounded at Lucknow; musket ball fracture of olecranon; abscess of joint; ankylosis. 3. Pt. Marshall, 52d regiment, aged 27 years; wounded at Delhi, September 14, 1857; pistol ball perforation of left elbow. Ankylosis in bent position; anesthesia on ulnar side. 4. Pt. Dunne, 61st regiment, aged 33 years, wounded at Delhi; musket ball fracture of shaft of humerus, with perforation of joint and fracture of ulna. Elbow ankylosed with limb in extension; an inch and a half shortening.

<sup>2</sup> M. CHENU (*Campagne d'Italie en 1859-60*, Paris, 1869, p. 602) tabulates 162 shot wounds of the elbow with 17 deaths, and enumerates 58 cases of pensioners with more or less complete ankylosis, many suffering also with various degrees of muscular atrophy and paralysis. In the same work, Dr. CUVELLIER, chief surgeon of the French military hospital San Ambrogio, at Milan, observes: "Les blessures graves de la région huméro-cubitale, les fractures comminutives compliquées de lésions s'étendant jusqu'à l'articulation, sont de celles qui ont retiré le plus d'avantages de la temporisation. A moins de désordres tellement étendus que l'amputation fût exigible sur le champ de bataille, il nous fut permis pour cette région d'attendre plus longtemps qu'on ne le pense en général." On the German side, Dr. DEMME (*Studien*, 1860, B. II, S. 232) observes that: "The extended practice of the conservative expectant treatment of shot comminutions of the elbow joint in Italy has proven that the hopes of success are less than in injuries of the shoulder joint, but that, nevertheless, frequent cures are accomplished in this manner," and cites six cases of this class, the patients having all recovered with ankylosis; and, on p. 235, tabulates 81 cases of fractures of the elbow joint treated on the conservative expectant plan, with 52 deaths, or 64.2 per cent. And again, on page 235, adds: "The active conservative treatment (resection) found few advocates in 1869 in Italy. The majority of the Italian and French surgeons choose between the expectant conservative treatment and amputation, a fact incomprehensible in the face of the results of latest campaigns. The only two resections of the elbow that I call to mind were performed by my friend Neudörfer, at the hospital San Spirito in Verona, and had favorable results."

<sup>3</sup> The results published of the conservative treatment of shot injuries of the elbow in the Silesian or Bohemian or Six Weeks' War of 1866, are very satisfactory. Thus, Oberstabsarzt R. BIEFEL (*Im Reservelazareth. Kriegschür. Aphorismen* von 1866, in LANGENBECK'S *Archiv.*, 1869, B. XI, S. 432) records eleven cases of shot wounds of the elbow joint conservatively treated with success. One case recovered with complete motion, nine with limited motion, and one case resulted in complete ankylosis. The Swiss ambulance-surgeon K. FISCHER (*Militärärztliche Skizzen, aus Süddeutschland und Böhmen*, Aarau, 1867, S. 69) tabulates twelve cases of shot fractures of the elbow from the Bohemian battles treated conservatively, of which nine recovered and three died. He refers to thirteen cases of the same nature treated conservatively in South Germany, but is ignorant of their termination.

the evidence seems to show that they were instances of penetration of the joint, with lesion of some portion of the articular surfaces.<sup>1</sup> In the following cases, also of penetrating wound with fracture, recovery ensued with imperfect motion at the joint:

CASES 1754-1756.—Corp<sup>t</sup> J. Hare, Co. G, 21st Massachusetts, aged 21 years, was wounded at Chantilly, September 1, 1862. On September 5th, Acting Assistant Surgeon John Neill reported, from Philadelphia, a "fracture of the right elbow joint by a conoidal ball. The limb was placed in an internal rectangular splint, with cold-water dressings, and afterward stimulating poultices. Spicula of bone were removed. By November 1st the injury was repaired, with *considerable motion of the joint.*" This soldier was discharged January 16, 1863, and pensioned. Examiner Jewett, of Fitchburg, reported, September 6, 1864: "A ball entered the inner surface of the right forearm, and fractured the head of the radius and external condyle of humerus. Spicula of bone make their way to the surface from time to time. There is chronic inflammation of the joint and of the ulnar nerve. Imperfect and partial extension of the forearm is practicable." In 1869, Examiner A. Miller noted: "This wound has produced great pain and atony of the muscles." The Fitchburg Board reported, May, 1873: "There is *partial* ankylosis of the joint, and disease of the radial nerve, with constant pain. General appearance, worn and pale, the result of the wound. The pensioner is unable to do any manual labor." Paid September 4, 1875.—Pt. C. N. Summerlin, Co. II, 74th Indiana, aged 28 years, was shot in the left elbow at Chickamauga, September 19, 1863, and sent to Louisville, and thence to Madison, and treated by immobilizing the arm on a splint, with simple dressings. He was discharged March 24, 1864, Surgeon G. Grant, U. S. V., reporting: "With little motion at elbow; a gunshot fracture of the left external condyle has caused ankylosis. There is also a subluxation at the right elbow." Examiner Rerick, of La Grange, certified, April 4, 1868: "Wounded in left arm and elbow. The wound is now healed, but the elbow is ankylosed and the forearm cannot be fully straightened. Was injured by a railroad accident in the right elbow." Pensioner paid June 4, 1875.—Pt. H. McGuire, Co. D, 6th Vermont, aged 23 years, was wounded at Funkstown, Maryland, July 10, 1863, and sent to Hammond Hospital, with a shot fracture of the left elbow. Surgeon E. E. Phelps, U. S. V., reports that the patient was admitted to the hospital at Brattleboro', August 10, 1863, with a shot fracture of the humerus involving the elbow joint, and transferred to the Veteran Reserve Corps, February 17, 1864, with the fracture united and motion of the arm incomplete." This soldier was discharged October 1, 1864, and pensioned. Examiner Skimmer, of Barton, Vermont, reported, in 1864: "Ball entered left elbow near the junction of the radius with the external condyle, and is now lodged in the arm, causing partial stiffness of the joint. The arm is lame; the wound is now healing." Examiner Woodruff, of Joliet, Illinois, certifies, September 6, 1873: "Shot entered left elbow, and was never removed; motion of joint greatly impaired." Pensioner paid September 4, 1875.

In some cases of recovery from arthritis following shot wounds in the region of the elbow, it is exceedingly difficult to determine whether the primary lesion directly implicated the ends of the bones, or even whether the capsule was penetrated. The two following instances appear to have been strictly periarticular wounds:

CASES 1757-1758.—Private W. Galbreath, Co. K, 6th Indiana, aged 35 years, received at Chickamauga, September 19, 1863, a shot wound of the left elbow. He was sent to Cumberland Hospital, and thence to Madison, Indiana. Acting Assistant Surgeon D. W. Flora reported, November 17, 1863: "The ball entered the forearm on the anterior surface while the elbow was flexed, and came out in the lower third of the arm, the wounds of entrance and exit being about four inches apart. The elbow is permanently flexed, and in view of the extensive suppuration in the vicinity of the joint, its structures are no doubt implicated. December 16th, inflammation has been pretty severe, and several abscesses have formed. Tincture of iodine applied once a day. February 4th, wound entirely healed; elbow permanently flexed; transferred to Invalid Corps March 23, 1864, and discharged October 10, 1864, and pensioned. Examiner Collins, of Madison, September 25, 1868, certified: "Minié ball entered exterior face of upper third of left forearm, and passed upward to near the shoulder joint, where it was extracted. The left arm is greatly disabled." Dr. Collins made substantially the same report in 1873, and recommended a reduction of pension, and the disability was rated one-fourth, at which estimate the pensioner was paid December 4, 1874.—Pt. E. F. Stevens, Co. A, 1st Maine Cavalry, was wounded at Shepherdstown, July 16, 1863, and sent to Camden Street Hospital, Baltimore, on July 19th. Acting Assistant Surgeon E. G. Waters noted: "A minié ball entered the posterior aspect of the left arm just above the olecranon, passed downward and outward, and emerged on the outer aspect of the forearm, below the outer condyle of the humerus, crossing the elbow joint in its passage, and probably getting within its capsule." The patient was discharged June 26, 1865, and pensioned. Examiner J. C. Weston, of Bangor, May 18, 1866, reported: "The motions of the elbow joint are impaired. Can only extend his left arm half way between a right angle and a straight line, and can only flex it to a right angle. There is atrophy of arm and forearm. They measure in circumference nearly an inch less than the other. Cannot as well lift, chop, etc., with it. Complains of an occasional rheumatic pain in the joint, and a creaking noise can be heard on motion." The Bangor Board, Drs. Jones and Sanger, August 3, 1874, reported: "The forearm was at a right angle with the humerus, which was raised in front of his body when wounded." Paid December 4, 1874.

In a great proportion, however, of this series of eight hundred and twenty-eight cases of recovery after shot wounds at the elbow treated on the expectant plan, the evidence of penetration of the joint and injury of the articulating extremities of one or more of the

<sup>1</sup> BECK (B.) (*Chir. der Schussverletzungen*, 1872, S. 588) details two cases of shot injury of the elbow joint without injury to the bone: B—, of the 1st Baden grenadiers, received a shot wound of the elbow which opened the joint: bone not injured; synovia escaped; recovery in five weeks. From the fact that the man did not apply for a pension, Dr. Beck presumes that the usefulness of the arm was only slightly impaired. W—, 2d Baden regiment, received a similar wound; synovia escaped. Patient recovered, with partial ankylosis.



bones was incontestable, and the ordinary result was more or less complete ankylosis, often associated with muscular atrophy, and not infrequently with paralysis and neuralgic affections.<sup>1</sup> When the outer condyle and head of radius escaped, motion in pronation and supination was sometimes retained, although ankylosis of the humero-cubital joint forbade all movement of flexion and extension:

CASES 1759-1761.—Private G. Best, Co. I, 186th New York, aged 39 years, was wounded at Fort Hell, Virginia, April 2, 1865, and sent to Harewood Hospital, Washington. Surgeon R. B. Bontecou, U. S. V., noted: "Patient was admitted April 5th, with a shot wound of the left elbow joint. Erysipelas supervened; but with the liberal use of tincture of sesquichloride of iron and supporting treatment the patient recovered and was doing well, the parts nearly healed, on July 20th, when transferred to Lincoln Hospital. This soldier was discharged August 3, 1865, for "ankylosis of the left elbow in consequence of a minie ball passing through the joint." Examiner Johnson, of Watertown, New York, September 22, 1873, reported: "Shot wound of the left forearm at upper fourth, complicating the elbow joint, producing complete ankylosis; the forearm flexed at right angles with the humerus; circulation and strength impaired." This pensioner was paid December 4, 1874.—Pt. E. W. Law, Co. A, 1st Massachusetts, aged 21 years, was wounded at Oak Grove, June 25, 1862, and sent to St. Elizabeth Hospital, Washington; returned to his regiment at Fort Worth, Virginia, and subsequently discharged and pensioned. Surgeon F. LeB. Monroe, 1st Massachusetts, certified on his discharge papers: "Ankylosis of the right elbow joint, the result of shot wound. There is immobility of the joint, probably permanent, with loss of the power of supination." Examiner G. S. Jones, of Boston, recorded, October 14, 1862: "Ankylosis of right elbow joint. The arm has been left in a straight and pronated position, and its usefulness destroyed. It is the result of a shot wound of the elbow joint, and his disability is increased in consequence of neglect in its management." Examiners Fry, Treadwell, and Chase, of Boston, reported, August 9, 1871: "A ball entered the right arm at the insertion of the biceps, and escaped from between the olecranon and the inner condyle, its course being directly through the joint, which latter is ankylosed in a slightly flexed position. The ulnar nerve was divided, and connections have never been re-established. That part of the hand dependent upon the ulna for nervous power is paralyzed, and the flexor power of the radial side of the hand is so much weakened as to destroy the usefulness of the member." This pensioner was paid June 4, 1874.—Private J. A. Dingman, Co. G, 134th New York, was wounded while shooting at a mark at Thoroughfare Gap, November 5, 1862, and sent to Satterlee Hospital, Philadelphia, December 12, 1862. Acting Assistant Surgeon J. Berryman reported that: "The ball entered the anterior aspect of the left arm at the flexure of the elbow, and passed into the articulation, where it still remains. At present there is nearly complete ankylosis of the joint, and a discharge from the wound very like synovial fluid. The patient's general health is feeble. The limb was put in an angular splint, with cold-water dressings. The patient was ordered quinine and iron and extra diet." The patient had a series of chills, with pulmonary complications, which excited apprehensions of the invasion of pyæmia. Abscesses formed about the joint, and were freely incised, and quinine was administered, and the part poulticed. On December 16th he was etherized and a flattened pistol ball was removed. On January 28, 1863, he was discharged. Examiner Dockstader, of Sharon, reports that: "He has a crooked arm and stiff elbow, with no use of the fingers; he cannot get his hand to his mouth." As the wound was accidental no pension was allowed.

<sup>1</sup> From the Franco-German war of 1870-71 we have many references to the expectant treatment of shot fractures of the elbow, from both French and German sources. Professor ALBERT SCHNIZINGER, of Freiburg (*Das Reserve-Lazareth im Kriege, 1870 und 1871*, S. 64) states that there were received at the hospital at Schwetzingen eight cases of shot fracture of the elbow, of which one was treated by resection and seven by expectation. All recovered, and of the seven treated expectantly, two retained motion of the joint, while five had ankylosis in favorably flexed positions. Professor LÜCKE, of Bern (*Kriegschirurgische Fragen und Bemerkungen*, 1871, S. 41), records seventeen examples of shot fracture of the elbow, of which two were treated by amputation, eleven by excision, and four by expectation. Of the latter group, three recovered with ankylosis, and one submitted to consecutive exarticulation at the shoulder. Professor LÜCKE declares that to him "it is indubitable that a large proportion of shot injuries of the elbow joint may be successfully treated conservatively, that is without any operation whatever." Dr. LUDWIG MAYER, of Munich (*Kriegschir. Mittheilungen aus den Jahren 1870-71*, in *Deutsche Zeitschrift für Chirurgie*, Leipzig, 1873, B. III, S. 50), records a case of recovery after shot fracture of the elbow. MACCORMAC (W.) (*Notes and Recollections, etc.*, 1871, pp. 94-106) records fifteen cases of penetrating shot wounds of the elbow, and remarks: "In the great majority resection was performed at once, as all secondary operations do so very badly. In a few cases of elbow wounds, for one reason or another, expectant surgery received a trial." He then details two such cases,—of Vivien and Soitel, of the 89th French infantry, who recovered very satisfactorily after Sedan. PONCET (P.) (*Contribution à la relation méd. de la guerre de 1870-71. Hôpital milit. de Strasbourg*, in *Montpellier Médicale*, 1872) records a case of recovery, with ankylosis, of shot fracture of the elbow, healed without operative interference. SÉDILLOT (*Du traitement des fractures des membres par armes de guerre*, in *Arch. gén. de méd.*, 1871, IV sér., T. XVII, p. 409) relates eight cases of conservative treatment of shot wounds of the elbow joint with seven recoveries. CHRISTIAN (J.) (*Relation sur les plaies de guerre observées à l'ambulance de Bitschwiller, 1870-71*, in *Gaz. méd. de Strasbourg*, 1872, No. 23, p. 279) cites five cases of shot wounds of the elbow joint treated on the expectant conservative plan. All recovered; but one died of variola afterward. RAËIS (E.) (*Deux cas remarquables de blessure par armes de guerre observés à l'ambulance internationale de Pfaffenhofen*, in *Gaz. méd. de Strasbourg*, 1872, No. 3, p. 26) gives an interesting case of successful treatment on the expectant conservative plan of a shot injury of the elbow joint. COUSIN (A.) (*Hist. chir. de l'ambulance de l'école des ponts et chaussées, in L'Union méd.*, 1872, T. XIII, p. 126) notes two cases of shot wounds of the elbow joint treated expectantly, favorably in one case, and with a fatal result in the other. GROSS (F.) (*Notice sur l'hôpital civil pendant le siège et le bombardement de Strasbourg*, in *Gaz. méd. de Strasbourg*, 1871, No. 12, p. 133, CASE 20) adduces an instance of complicated fracture of the elbow successfully treated on the expectant conservative plan. CHUPAULT (A.) (*Fraet. par armes à feu*, 1872, p. 35) records a shot comminution of the right olecranon, with suppurative arthritis, extraction of fragments, and copious suppuration, but recovery with some movement of the joint. He gives (p. 128, Obs. XC) another case, in which expectation was persevered in for many weeks after a musket ball perforation of the right elbow, the recourse was ultimately had, and successfully, to resection. SOGIN (A.) (*Kriegschir. Erf.*, 1872, S. 158) mentions two instances of shot fracture of the elbow successfully treated without operative interference. GOLTDAMMER (*Bericht über die Thätigkeit des Reserve-Lazareths des Berliner Hilfsvereines, etc.*, in *Berlin Klin. Wochenschrift*, 1871, SS. 139-149) records two cases of shot wounds of the elbow joint successfully treated by the conservative plan. STOLL (*Bericht aus dem Königlich Württembergischen 4 Feldspital von 1870-71*, in *Deutsche Mil.-ärztl. Zeitschrift*, 1874, B. III, S. 193) remarks: "Of eleven shot injuries of the elbow joint (seven from small projectiles, four from shell) three were conservatively treated,—one proved fatal; the result in the other two cases is unknown." STUMPF (L.) (*Bericht über das Kriegsspital des St. Georg-Ritter-Ordens zu Neuberghausen, in Bayerisches Ärztl. Intelligenzblatt*, 1872) records three cases of conservative expectant treatment of wounds of the elbow joint; two recovered with ankylosis, one proved fatal from tetanus. BECK (B.) (*Chir. der Schussverletzungen*, n. s. w., 1872, S. 588) records 41 cases of shot wounds of the elbow, of which 15 were treated by expectation, without a single fatal result; 9 by intermediary or secondary amputation, with 5 deaths; and 17 by excision, with 2 deaths.

We have seen, on page 674, that, although conservation of the limb has been advocated in cases of shot fracture of the humerus complicated by wound of the brachial artery, our late war experience is not known to have furnished an example of a successful essay in this direction; and, indeed, according to Guthrie and Löffler,<sup>1</sup> the annals of military surgery afford no instance of such an achievement.<sup>2</sup> The following successful operation, by Dr. A. V. Cherbonnier (now Medical Storekeeper, U. S. A.), gives, however, irrefragable evidence that, in shot fracture of the condyles of the humerus with lesion of the *radial*, it is possible to tie the vessel and to preserve the limb:

CASE 1762.—Private J. H. Scritchfield, Co. B, 20th Indiana, aged 21 years, was wounded in the left elbow at Spottsylvania, May 12, 1864, and sent to the hospital of the 3d division, Second Corps, where Surgeon D. Evarts, 20th Indiana, recorded: "Gunshot wound of arm." The wounded man was transferred, May 18th, to Patterson Park Hospital, Baltimore. Surgeon T. Sim, U. S. V., reported: "A minie ball entered above the left olecranon process, making exit near the bend of the elbow. Hæmorrhage occurred, on May 24th, to the amount of six ounces, and was controlled by pressure and persulphate of iron. Hæmorrhage recurred May 31st, to the same amount, and was controlled by the same means. A third hæmorrhage occurred on June 7th, when the probable loss of blood amounted to sixteen ounces. The probable source of bleeding was the radial artery. On the last occasion, the brachial artery was ligated at the lower third by Acting Assistant Surgeon Cherbonnier, the patient at the time of the operation being very feeble and pale. There was no recurrence of hæmorrhage; the patient rallied and recovered. There was partial ankylosis of the joint. He was transferred, July 20th, to La Fayette, Indiana, and mustered out July 29, 1864, and pensioned. Examiner Clippinger, of Indianapolis, Indiana, July 30, 1864, certified: "Has been shot through the left elbow; the brachial artery has been tied. The wound is still suppurating. There is inability to use the forearm and it remains flexed." Examiner S. Roberts, of Manhattan, Kansas, reported February 10, 1869, and September 6, 1873: "The applicant was wounded in the left elbow, the ball passing from behind forward, fracturing the lower portion of the humerus and wounding the radial artery in its upper third, making necessary the ligation of the brachial artery in its lower third, thereby hindering the circulation and preventing the proper nourishment of the arm and hand. He has partial ankylosis of the elbow joint, having neither perfect flexion nor extension of the forearm. . . . The limb is somewhat atrophied." This pensioner was paid September 4, 1875.

The two following cases of shot wounds at the elbow complicated by hæmorrhage and successfully treated by ligation of the brachial, are reported; but it appears probable that they were both examples of periarticular wounds; at least, there is no direct testimony that the extremities of either the humerus or bones of the forearm were fractured. On page

<sup>1</sup> LÖFFLER (F.) (*General-Bericht*, u. s. w., 1867, B. I, S. 231) details the case of J. Fries, 9th Danish Infantry, wounded April 18, 1864. The missile passed through the olecranon and comminuted the epiphysis of the humerus at the inside of the arm. Tourniquet applied to control the bleeding. April 20th, resection. Death, April 22, 1864. At the autopsy the ulnar artery was torn high up, and the brachial artery was obstructed at the point of division by a thrombus. Dr. LÖFFLER concludes: "The co-injury of the brachial artery itself, in cases of shot fractures of the elbow joint, is sufficient cause for immediate amputation, and the practice of 1864 does not show a single case in which, with this complication, life and limb were preserved." Case 157 (Fries, above cited) renews the admonition, to consider this point before attempting conservation or resection, even if bleeding should not remind you thereof at the moment.

<sup>2</sup> That compound fracture of the humerus, or femur, complicated by wounds of the main arteries of the limb, demand amputation, had come to be one of the commonplace precepts of practical surgery, and is still taught in the best modern surgical text-books; thus ASHURST (J., jr.) (*The Principles and Practice of Surgery*, 1871, p. 164) emphasizes: "Especially do wounds of the main arteries and nerves of a limb, in conjunction with fracture, demand amputation." But there have always been surgeons who have urged that, on account of the freedom of anastomosis, etc., the danger was much less in the upper extremity. LE DRAN (1675-1770) was one of the earliest writers to intimate that injury of the brachial, in shot wounds of the arm, does not necessitate amputation. Although he could not be accused of timidity, yet, as SPRENGEL tells us; he was very reluctant to sacrifice limbs. In his *Traité ou Reflexions tirées de la Pratique sur les Playes d'armes à feu*, 1737, p. 107, he teaches that when a ball passes in the vicinity of the brachial artery, the surgeon should be watchfully on his guard, placing about the limb a loose tourniquet for use in case of accident; if hæmorrhage supervenes, he must make an incision and place a ligature on the vessel: "Si c'est le tronc de l'artérie, il ne faut pas moins en faire la ligature, quitte à faire après, l'amputation du membre si l'on s'aperçoit que, faute de nourriture, il soit menacé de gangrene." GUTHRIE (G. J.) (*A Treatise on Gunshot Wounds*, 3d ed., 1827, p. 516) says: "If the artery be wounded with an extensive fracture, the operation is then imperious; but if it be wounded with merely a splintering of the bone, without complete solution of its continuity, or even if it [the bone] be broken short across, with little or no splintering, the vessel should be secured above and below and the event carefully watched. *I have no case in support of the opinion*; it is therefore more theoretical than practical; but I think it a case well deserving trial." M. LEGUEST (*Chirurgie d'armée*, 1863, p. 689) believes that if, in shot fracture of the shaft of the humerus, the brachial artery is divided below the origins of the external circumflex and nutritious arteries, conservation may be attempted. His opinions, and those of Professor BILLROTH and Dr. HOFFE, and the opposing views of Herr LÖFFLER, are cited at length on page 674 *ante*. I believe that Dr. LÖFFLER's assertion, that surgical literature has not presented an example of recovery from shot fracture of the humerus with division of the brachial, remains uncontradicted. VELPEAU, it is well known, gives a remarkable case (*Nouv. élém. de méd. opérat.*, 2<sup>me</sup> éd., 1839, T. II, p. 568) from CHAMPION, of a boy of seven, with compound fracture of the lower part of the left humerus, with injury of the artery and nerve, in whom HERRIOT divided and ligated the brachial, resected and reduced the humerus, and preserved the arm (see BLACKMAN'S MOTT'S VELPEAU, 1856, Vol. II, p. 289). But this was not a shot fracture, and the injury was very low down. CHUSOLI (J. F.) (*A Manual of Military Surgery*, 3d ed., 1864, p. 386) affirms: "Should the main vessel be injured, in connection with the fractured bone [humerus], we have not sufficient cause to sacrifice the limb; but, ligating the artery at its bleeding mouths, we treat the fracture as if this complication had not existed. Owing to the free anastomosis of the blood-vessels of the arm, mortification is not to be feared when a ligature is applied even to the brachial; a circuitous route soon supplies the needed nourishment to the parts beyond. Should the nerves as well as the artery be wounded, or the principal nerves be divided with the bone, then the limb, even when saved, would be a useless paralyzed extremity, and its immediate removal will save the patient a long, tedious, and painful convalescence." Dr. E. WARREN (*An Epitome of Pract. Surg. for Field and Hospital*, Richmond, 1863, p. 373) coincides in these opinions.



843 will be found abstracts of two fatal cases (1770, 1771) illustrating this complication, and completing the information it has been practicable to collect on this interesting topic.

CASE 1763.—Private *G. McClinty*, Co. F, 7th South Carolina Cavalry, aged 17 years, was wounded at Weldon Railroad, August 21, 1864. On the following day he was admitted to the depot hospital of the Fifth Corps, at City Point, where Surgeon *W. L. Faxon*, 32d Massachusetts, recorded: "Wound of right elbow." From City Point the patient was sent to Whitehall Hospital, near Bristol, and thence he was transferred to West's Buildings Hospital, Baltimore, on September 10th. Surgeon *A. Chapel*, U. S. V., in charge of the latter, reported: "Gunshot wound of right elbow joint. The wound became gangrenous and involved the lower part of the brachial artery, producing hæmorrhage, on September 20th, to the amount of thirty-two ounces. The artery was tied in two places above the line of the sloughing parts. Tonics and stimulants were used, and the patient did well, no hæmorrhage recurring. He was transferred to Point Lookout, for exchange, on October 17, 1864."

CASE 1764.—Private *R. Graham*, Co. B, 81st Pennsylvania, aged 43 years, was wounded at Malvern Hill, July 1, 1862, and entered Broad and Cherry Streets Hospital, Philadelphia, on July 31st. Acting Assistant Surgeon *J. Neill* contributed the following history: "Gunshot wound of left elbow joint. A round ball entered in front on the radial side of the forearm about two inches below the joint, and, passing obliquely inward and upward, made its exit on the inner side of the arm, about three inches above the internal condyle of the humerus, afterward producing a slight wound of the chest. No fracture detected. The radial artery was wounded, and profuse hæmorrhage followed, amounting to syncope. The patient remained insensible on the field until next morning, when he was removed to Savage Station. The arm was kept quiet, and cold water was applied to the parts. On the eighth day after the injury he suffered from a severe attack of secondary hæmorrhage, and a surgeon tied the brachial artery in its lower third. Violent inflammation of the elbow joint followed; an abscess formed on the front of the forearm and a large slough was thrown off. The ligature came away on the 8th day after the operation. At the time of admission the patient was very much broken down in health, the joint and forearm being still very much inflamed and discharging a large amount of unhealthy pus. He was ordered a good diet, with stimulants and tonics. A stimulating poultice was applied, and the arm kept at perfect rest on a rectangular splint. Under the treatment he improved rapidly and the parts healed, leaving a large cicatrix on the front of the forearm extending almost to the joints, and giving rise to a contraction of the tissues, resembling that of a burn. He stated that about two weeks after the artery was tied he was seized with severe pain in the forearm and hand, and trembling of the whole limb, which has continued to the present time. November 1st, is now able to walk about the ward, and will probably have a useful limb." The patient was discharged December 9, 1862, and applied for pension.

The twenty-five preceding abstracts of cases of shot wounds at the elbow successfully treated by expectation,<sup>1</sup> fairly represent those of the series most fully reported. I regret that a lack of clerical assistance has forbidden the search, in the files of the Pension Bureau, of the ulterior histories<sup>2</sup> of a larger number of cases. At a future day, it may be possible to supply this hiatus. As far as the investigation has gone, the results as to the average usefulness of the limb after conservative expectant treatment is not flattering.<sup>3</sup> Of the eight hundred and twenty-eight patients of the series who recovered, two hundred and eighty-five returned to modified duty, or were paroled or exchanged, and five hundred and forty-three were discharged. Among the survivors there were many examples of chronic arthritis, with caries and persistent fistulæ and exfoliations; many instances of paralysis and paresis, with shrunken and wasted limbs and contracted and powerless hands. The known instances of recovery with preservation of the functions of the joint were very few; and those with ankylosis in a favorable position, with freedom from disease about the joint and good use of the forearm and hand, were not numerous.

<sup>1</sup> MATTHEW (T. P.) (*Med. and Surg. Hist. of Brit. Army in Crimea, etc.*, 1858, Vol. II, p. 361) informs us that of 34 cases of shot injury of the elbow, reported after April 1, 1865 (4 officers and 30 men), 18 were treated by expectation, of whom 4 submitted to secondary excision, 2 to conservative amputation, 4 died without operation, and 4 underwent primary amputation. Of 16 submitted to primary excision, 3 died. *M. CHENU* (*Rap. sur la Campagne d'Orient*, 1865, p. 262) records 320 "*Blessures de l'articulation humero-cubitale*," under the heads of fractures, 57; undetermined wounds, 97; wounds, 123; luxations, 4; and contusions, 33. At page 504, *M. CHENU* mentions four cases of excision of the elbow joint resulting fatally. It is impracticable to learn from his tabulations how many cases of shot wounds of the elbow treated by expectation recovered. The names of 70 pensioners are given, of whom 2 had suffered luxations, 1 a bayonet wound, and 67 either "fractures, wounds, or undetermined wounds of the elbow," cases that were probably, for the most part, shot injuries of the elbow; and it is added that 130 cases of these groups were discharged cured, or transferred, and that 79 died. It is impossible to draw precise conclusions from these statistics, or the yet more imperfect and confused reports of the surgical experience of the Russians in the Crimea.

<sup>2</sup> HANNOVER (A.) (*Die Fänischen Invaliden aus dem Kriege 1864*, Berlin, 1870, S. 23): "Of 54 invalids after injury of the elbow joint, 26 have complete and incurable ankylosis, a few suffer from atrophy or loss of power of forearm, or liming or incurvation of some of the fingers, especially of the last two fingers. In the rest the power of extension is generally mere circumscribed than the power of flexion, and pronation and supination is in various degrees impeded or painful at passive motion."

<sup>3</sup> MOSSAKOWSKY (P.) (*Statistischer Bericht über 1415 Französische Invaliden des deutsch-französischen Krieges 1870-71*, in *Deutsche Zeitschrift für Chir.*, 1872, B. 1, S. 236) observes: "Not less than thirty-eight penetrating elbow joint wounds were conservatively treated, and on the whole with not very pleasing results. Only in ten the wounds had healed; in the rest they yet suppurated freely, principally in consequence of bone sequestration within the joint—conditions that undoubtedly have finally led to serious consequences. . . . In all cases the motion of the joint was destroyed. In twenty cases the arm was ankylosed at nearly a right angle, in six at near 135°, and in twelve at nearly straight arm."

§ *Fatal Cases.*—We may turn now to the fatal cases, which are not uninteresting or uninteresting for the clinicians, and are most important for the pathologists. Setting aside fourteen instances in which the result was not ascertained, there remain ninety-six treated by expectation that terminated fatally. Several are illustrated in the Museum:

CASE 1765.—Private W. K——, Co. E, 32d Indiana, aged 36 years, was wounded at Missionary Ridge, November 25, 1863. He was admitted to the field hospital of the third division, Fourth Corps, where Surgeon W. W. Blair, 5th Indiana, recorded: "Wound of the left elbow." On December 3d the patient entered Hospital No. 1, at Nashville, where Surgeon C. W. Hornor, U. S. V., reported: "Gmshot fracture of left arm by minie ball. Treatment, simple water dressings and supporting diet. Death from exhaustion, on December 24, 1863. *Post-mortem* forty hours after death: On examination of the wound it was found that the missile had entered on the inner side of the elbow joint, passed backward, and fractured the olecranon process of the ulna. The tissues were very dark and fetid immediately around the wound. Slight pleuritic adhesion was found in the right side of the thorax, and small hard tubercles in the apex of each lung, the lower lobe of each lung being highly congested. The heart apparently was healthy and weighed fifteen ounces; the liver was fatty and weighed five pounds and six ounces; the spleen ten ounces and healthy. Both kidneys were fatty and somewhat elongated, and weighed nine ounces each." The specimen (FIG. 591) was contributed by Acting Assistant Surgeon P. Peter, and consists of the bones of the left elbow, showing the ulnar articulating surfaces to be carious, and a slight plate of necrosed bone adhering in the upper part of the coronoid fossa.

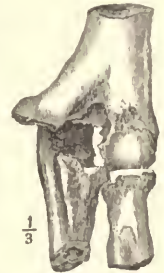

FIG. 591.—Caries a month after shot penetration of left elbow. Spec. 2189.

CASE 1766.—Private A. B——, Co. C, 38th Georgia, was wounded at Gettysburg, July 1, 1863, and admitted into hospital at Frederiek on the 6th. Acting Assistant Surgeon W. S. Adams reported as follows: "Wounded by a conoidal ball, which entered on the posterior and outer surface of the arm one inch and a half above the olecranon process, passing out anteriorly near the flexure, grooving its way through the bone immediately above the external condyle, the fracture communicating with the joint. The patient was a man of delicate frame, medium size, and was much worn down by the fatigue of marching and exposure. Water dressings were applied to the wound, and the patient was ordered nonrishing diet. July 18th: There has been for several days considerable œdema of the limb and redness about the joint. On consultation, it was decided to make a resection of a portion of the injured part. Ether having been given for fifteen or twenty minutes without producing anæsthesia, a small amount of chloroform was added to the sponge, and, as near as I can guess, from one and a half to two ounces were poured on it, and then placed closely over the mouth and nose. In the course of from thirty to forty seconds stertorous breathing was produced, whereupon the surgeon in charge proceeded to operate, commencing his incision two inches above the olecranon and extending it downward one inch and a half below the joint, cutting down to the bone at the first incision. About this time, I noticed that the pulsation of the brachial artery was rapidly running down, and on observing the respiration and seeing no movements of the chest or abdomen, remarked that it had ceased, and immediately instructed one of the attending surgeons to examine the patient's tongue, and finding it had not fallen back, proposed that Marshall Hall's ready method should be instituted, which was done instantly, and kept up for half a minute, when the surgeon in charge, observing that there was no respiratory effort, immediately proceeded to open the larynx, and, after artificial respiration, by means of compressing and relaxing the chest and abdominal walls for about two minutes, natural breathing was re-established and a pulsation of the radial artery was felt. There was scarcely any hæmorrhage from the incision, and none, perhaps, entered the trachea; the edges of the wound were drawn together by adhesive straps. It not being thought proper to proceed with the operation, the patient was returned to his ward, and stimulants were ordered to be given freely, with generous diet. July 19th: Patient rested finely last night, and took broth very freely this morning for breakfast; pulse 130 and feeble; respiration quite easy. July 20th: He had a chill last night, and has but little appetite this morning; no evidence of bronchial trouble; skin disposed to be dry. July 24th: He has had a chill each day since last note, and considerable cough; auscultation affords well-marked evidence of capillary bronchitis throughout the whole extent of the left lung. Only a few râles can be heard in the right lung; the tongue is much coated and brown, appetite very poor; wound of the elbow little disposed to suppurate; no granulations are being thrown out. 25th: Cough more troublesome; the patient is much depressed in spirits, and refuses all manner of nourishment; the pulmonary trouble is increasing. Four o'clock P. M., slight hæmorrhage has taken place from the incision over the olecranon; no bleeding vessel can be discovered; it seems to be a general oozing from all the parts. Seven o'clock P. M., hæmorrhage of the same character has again occurred to the extent of three or four ounces; applied Monsel's solution freely to the parts, and ordered water dressings. 27th: Slight bleeding again this morning; respiration 40 to the minute; pulse very feeble and quick. The patient has been taking beef-tea and whiskey in the way of clyster for the last two days. 28th: The patient died this morning at ten o'clock. Autopsy six hours after death: On opening the chest I found two small abscesses, each containing about one ounce of pus, situated just beneath the pleura costalis on either side of the sternum, and about one inch and a half below the clavicle; capillary bronchitis well marked throughout the whole extent of the left lung; no pleuritic adhesions; right lung somewhat engorged, several small abscesses in the upper lobe. The mucous membrane of the smaller bronchii was only slightly congested, but otherwise healthy. I removed the larynx, together with several small rings of the trachea; the openings through the cricothyroid membrane shows the seat of operation." The specimen of the lower third of the right humerus (FIG. 592) was contributed to the Army Medical Museum by Assistant Surgeon R. F. Weir, U. S. A. The outer border is chipped just above the condyle, opening the joint. Superficial necrosis of the adjacent bone and the development of numerous foramina are observable.

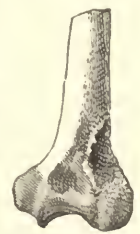

FIG. 592.—Lower third of right humerus fractured by a conoidal ball. Spec. 3901.

Pyæmic infection, illustrated in the foregoing case, was reported as the cause of death in sixteen instances. The next most frequent cause of fatality was hospital gangrene,



alone or accompanied by consecutive hæmorrhage, complications that are exemplified in the two succeeding abstracts:

CASE 1767.—Corporal J. H——, Co. H, 68th Pennsylvania, age 21 years, was wounded at Gettysburg, July 3, 1863, and sent to Satterlee Hospital, Philadelphia, July 10th. Acting Assistant Surgeon W. C. Dixon states that “a buckshot struck the ulnar side of the right forearm two inches below the elbow, producing a slight flesh wound. The patient had chronic diarrhœa; the wound presented a very unhealthy appearance, and on the 23d began to slough, and acid nitrate of mercury was applied. On August 13th and 14th, profuse hæmorrhage took place from a recurrent branch of the ulna and was arrested by torsion. The sloughing continued until the structures of the elbow joint were destroyed. On September 7th pyæmia appeared, and terminated fatally September 14, 1863. Amputation had been proposed on August 20th, but the condition of the patient would not warrant an operation.” This case furnished the Museum with specimen 2782 (*Cat. Surg. Sect.*, 1866, p. 152). “The entire articular surfaces are carious.”

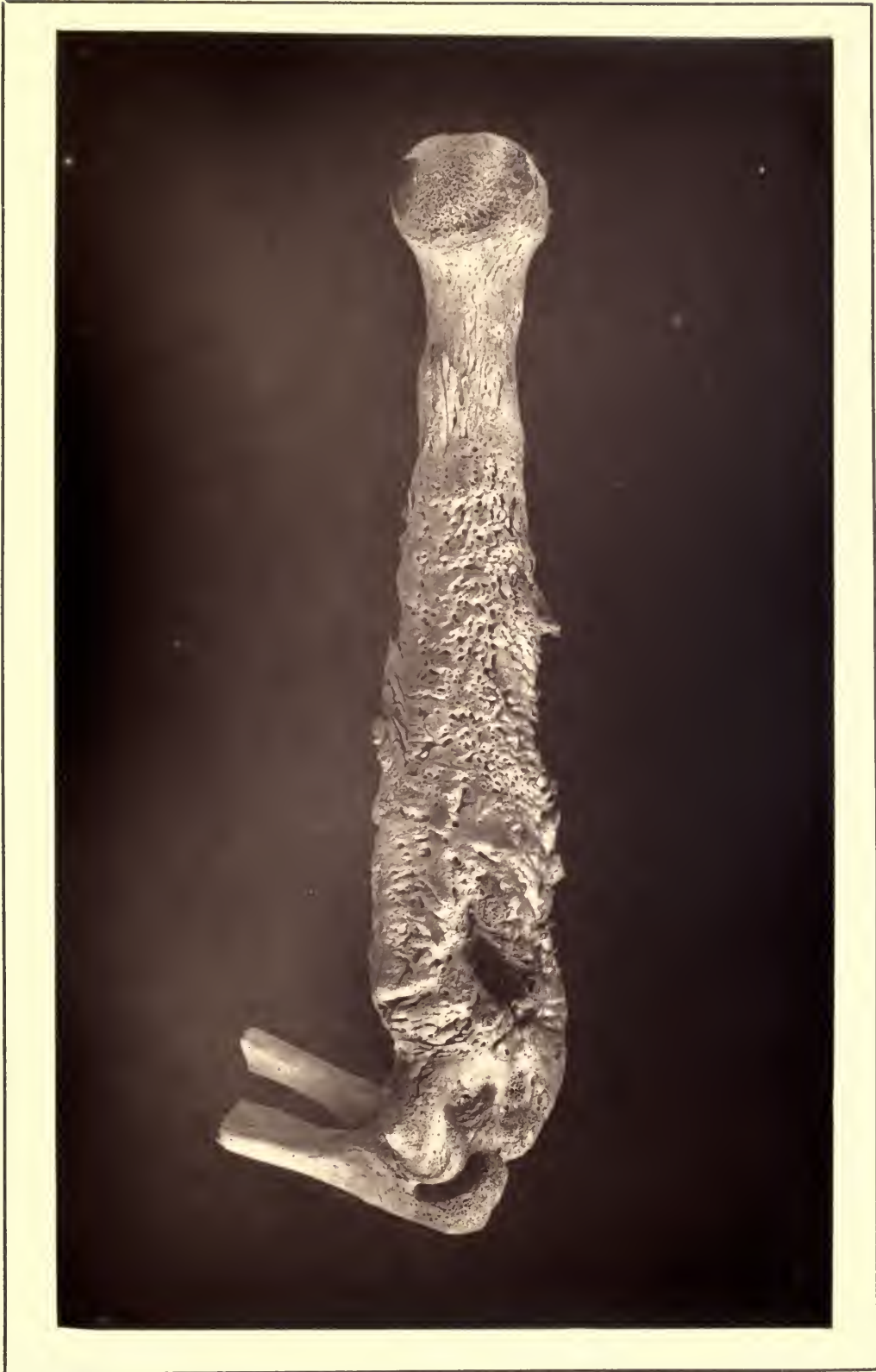CASE 1768.—Sergeant J. Whittaker, Co. E, 33d Iowa, was wounded at Helena, July 4, 1863. On the 7th he was admitted into Jackson Hospital, Memphis, and, on the 30th, was transferred to Presbyterian Church Hospital. Acting Assistant Surgeon C. H. Cleveland noted as follows: “The patient, a man of nervous, bilious temperament, with light hair and eyes, was admitted with gangrene of the right elbow, having been wounded by a ball which had entered just above the outer condyle of the humerus, emerging three inches posterior to the entrance, fracturing the condyle in its course. The patient says he has suffered but little from it since the injury; his appetite has been good, but he has slept but little since that time; simple local dressings have been used. The patient’s arm now presents a large ulcer on both the external and internal condyles, while the outer condyle is now protruding through the wound but resists attempts at its removal; it is still connected with the joint below, and drawn downward half an inch from the line of fracture; the patient’s condition is good. A solution of sulphate of zinc was applied and tonics given internally. August 3d: Wound healthy and perfectly clean; zinc lotion continued. 5th: Appetite good, pulse firm, bowels regular; cannot sleep; application, tonics and stimulants continued. 6th: Wound granulating; bone still firmly attached to the joint; treatment the same. 8th: Found the same appearance; discontinued the medicine, but still gave milk punch. 10th: Slept poorly; bowels regular; appetite good; wound continues improving. 15th: Patient the same, wound improving slowly. 17th: Gangrene has been arrested for some days past under the use of bromine; this morning it has reappeared at one or two points; bromine reapplied. 20th: Gangrene still extending at one or two points; condyle detaching itself in small fragments. 25th: Patient sleeps well; wound scarcely changed in appearance; compound solution of bromine applied. 31st: Wound entirely clean, with the exception of the cavity over the outer condyle, which still retains a little factor; bromine was injected with a glass syringe. September 4th: Patient slept poorly; appetite small; he has had diarrhœa for the last few days; this morning he had a spell of vomiting; stomach irritable; no unfavorable change in the wound; simple dressings. 12th: Patient passed a restless night; the diarrhœa is but slightly checked; pulse quick, feeble, and irregular; tongue slightly coated; patient complains of soreness of the throat, which slightly troubles him upon swallowing; little appetite; seems to be failing fast; the arm has assumed a dark hue and a dry, shrivelled appearance. 16th: Patient very low; saccharine odor of the breath; hippocratic expression of countenance; pulse imperceptible; he died at 10 o’clock from pyæmia.”

Granular degeneration of the kidney supervening after protracted suppuration, a complication that has attracted interest of late, is illustrated by the next case:

CASE 1769.—Private Bernard W——, Co. I, 37th New York, aged 22 years, was wounded at Williamsburg, May 5, 1862, and after treatment on the field was sent to Philadelphia, and entered Wood Street Hospital June 12. On December 6, 1862, Assistant Surgeon C. W. Hornor, U. S. V., reported: “Admitted with gunshot wound of the right elbow, with compound fracture of the lower extremity of the humerus, involving the joint; several large spiculæ of bone were removed. Still under treatment, with inflammation threatening the loss of the arm.” On March 12, 1863, the patient was transferred to McClellan Hospital, Nicetown. Acting Assistant Surgeon C. H. Boardman noted: “Nothing but simple dressings were applied while he was under my care. There was at all times a profuse purulent discharge from the various orifices, through which small sequestra frequently came away. During the spring and summer his general condition was much improved under the use of tonics, stimulants, and nourishing diet. A few weeks before his death my attention was attracted by an œdematous condition of his feet and legs, which on one or two subsequent occasions became general, affecting the whole surface. This was corrected readily at first by diuretics. An examination of his urine proved it to be highly albuminous. From this time he became steadily worse, and about ten days or two weeks before he died was attacked with uncontrollable diarrhœa and vomiting, accompanied with extreme prostration. All available remedies were tried, some with a little temporary success, more with none. These symptoms all became partially alleviated shortly before death, which ensued August 20, 1863. I had almost forgotten to add that, at the autopsy, the kidneys presented the characteristic lesions of Bright’s disease.” The case is mentioned and the specimen figured in the preliminary surgical report in *Circular 6*, S. G. O., 1865, p. 30, and in the Museum catalogue of 1866, *Surg. Sect.*, p. 151. An anterior view of the specimen is given in the annexed wood-cut (FIG. 593), and a lateral view is presented in PLATE XIX, opposite, which is copied from Photograph No. 42 of the Surgical Series of the Museum. The specimen consists of “the right humerus and the upper thirds of the bones of the forearm, fifteen and a half months after shot injury; fracture of the humerus immediately above and involving the joint was followed by inflammation and resulted in ankylosis. New bone has formed to double the volume of the shaft at its lower extremity, and extending to the surgical neck. Through a number of cloacæ a very heavy sequestrum, occupying six inches of the shaft, is seen. The head of the bone is spongy, and a large part of the articular surface has been destroyed by ulceration. Donor: Dr. C. H. Boardman.



FIG. 593.—Anchyl-  
osis and necrosis  
after shot wound of  
elbow. Spec. 2749.



Ward phot.

Am. Photo-Relief Printing Co., Philada.

PLATE XIX. NECROSIS OF THE HUMERUS AFTER SHOT INJURY.

No. 2749. SURGICAL SECTION.





Of shot fracture at the elbow complicated by injury of a main arterial trunk, but successfully treated conservatively, an instance has been adduced on page 839, together with two cases of periarticular wounds with lesion of the artery. It is hardly necessary to observe that, in order to reasonably hope for such happy results, the wounded vessel must be ligated above and below the seat of injury. In the two following cases, in which this complication was presented, a single ligature was ineffectually placed on the bleeding vessel:

CASE 1770.—Private W. E.—, Co. E, 9th Wisconsin, was wounded by a musket ball in the elbow, at Newtonia, Missouri, September 30, 1832. He was admitted to hospital at Sarcoux, and transferred thence to Fort Scott. Surgeon H. Buckmaster, U. S. V., reported, from the latter hospital: "He was shot through the elbow joint, the missile splintering the articular extremities of the bones and wounding the ulnar artery. Profuse hæmorrhage followed at intervals while he was on the way to this hospital, and, arriving here, the brachial artery was ligated just above the elbow; but the patient died of loss of blood within twenty-four hours,—October, 1832.

CASE 1771.—Private A. H.—, Co. C, 140th New York, was wounded at Gettysburg, July 2, 1863, and admitted to the field hospital of the 2d division, Fifth Corps. Assistant Surgeon C. Wagner, U. S. A., noted: "Gunshot compound fracture of right elbow joint. Patient transferred to Philadelphia on July 9th." On the following day he entered Satterlee Hospital, whence Acting Assistant Surgeon W. F. Atlee contributed the specimen (FIG. 594), with the following minutes of the case: "Wound in elbow joint, the ball passing through the bone, breaking off the inner condyle and the posterior extremity of the olecranon. Applied angular splints and water dressings. July 17th, some pieces of bone removed. July 26th, some hæmorrhage. July 27th, simple cerate dressings. August 2d, considerable hæmorrhage; took up an artery. August 3d, cold-water dressings. August 4th, hæmorrhage arrested by ligature. August 8th, simple cerate and syrup wash for dressings. August 14th, slight hæmorrhage; bones removed. August 16th, slight hæmorrhage. August 17th, small pieces of the olecranon came off with the dressing, some synovia running from the wound. Wound looking well, with a prospect of healing up. August 18th, patient died." The specimen shows the bones of the right elbow seven weeks after the injury, all the adjoining osseous tissue being carious and much absorbed.



FIG. 594.—Right elbow seven weeks after shot perforation. Spec. 2787.

The next case exemplifies the frequent complication of fatal pyæmia, in the course of an expectant treatment of a shot perforation of the elbow, and may be compared with CASE 1766.

CASE 1772.—Private G. S. R.—, Co. G, 3d Maine, was wounded at Fredericksburg, December 13, 1862. Surgeon J. M. Cummings, 114th Pennsylvania, reported that he was admitted into a Third Corps hospital for a "gunshot wound of the left arm," and December 23d transferred to Lincoln Hospital, Washington. Surgeon Henry Bryant, U. S. V., reported: "External condyle of the left humerus carried away; preservation was attempted. Died January 13, 1863. Autopsy six hours after death: The lungs and heart were found normal. A metastatic abscess occurred in the liver, on the inferior surface of the lobus major, of one quarter of an inch in diameter. In the spleen numerous small metastatic abscesses were found; some inflammatory congestion of the lower part of the ilium was observed. The left elbow joint was destroyed; the ulna was dead for more than four inches below the articulation, and was completely surrounded by sinuses, so that the bone might have been removed by slight traction

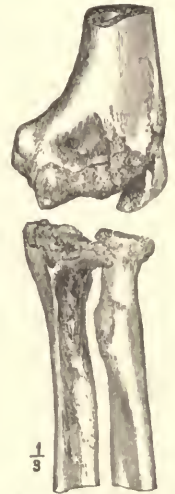

FIG. 595.—Effects of shot fracture of the left elbow. Spec. 678.

from its muscular envelope; the olecranon process was separated. All the articular cartilage was gone, except a little upon the head of the radius. The synovial membrane was, of course, destroyed; the sinuses were full of sanious fluid; the radius did not appear to be dead below the synovial membrane; the humerus was dead for three inches above the articulation." The specimen (FIG. 595), contributed by Dr. Bryant, consists of the bones of the left elbow. The external condyle has been split off and the olecranon destroyed as if by the oblique passage of a bullet. The fractured articular extremities are necrosed.

There were seven instances of shot wounds of the elbow fatally complicated by tetanus; of which five have been enumerated under the head of amputations of the arm,<sup>1</sup> while two were treated throughout on the expectant plan:

CASES 1773-1774.—Private J. W. McConnell, Co. M, 100th Pennsylvania, aged 24 years, was wounded May 13, 1864, by a conoidal ball, which shattered the right elbow. He was sent to Harewood Hospital on May 26th. Surgeon R. B. Bontecou, U. S. V., reports that, on the following day, "violent tetanic spasms occurred, the attack assuming no particular form. The treatment was antispasmodic, anodyne, and supporting. The spasms continued uninterruptedly, and death ensued June 1, 1864. The ulnar nerve was found, at the autopsy, pierced by a sharp splinter of bone, and was lacerated by the ball."—Corporal R. Morrison, Co. I, 55th Massachusetts, was wounded at Honey Hill, South Carolina, November 30, 1864. Surgeon J. Trenor, U. S. V., reported his admission, on December 2d, at Beaufort, with a "shot wound of the outer condyle of right humerus and upper third of ulna by a conical musket ball. Trismus supervened, and terminated fatally December 7, 1864."

<sup>1</sup> As follows: CASE 90 (Nichols), TABLE LXXI, p. 738; CASE 15 (Benbow), TABLE LXXV, p. 751; CASE 85 (Hunkerfillar), *Ibid.*; CASE 63 (O'Donnell), TABLE LXXVII, p. 760; CASE 19 (Haeggle), TABLE LXXXI, p. 773.



Many illustrations of the immediate or remote effects of shot injury of the elbow, besides those here adduced,<sup>1</sup> have been presented in the preceding Section,<sup>2</sup> and many others will appear in the succeeding observations on excisions at the elbow. Examples of projectiles lodged in the elbow joint have been mentioned on pages 769, 830, and 837. The following is one of the most remarkable of those in the Museum.<sup>3</sup>

CASE 1775.—Private A. Hoffman, Co. I, 86th Indiana, aged 26 years, was wounded at Missionary Ridge, November 25, 1863. He was sent from a Fourth Corps hospital, December 3d, to Hospital No. 1, at Nashville, whence Acting Assistant Surgeon M. L. Herr contributed the specimen (FIG. 596), with the following history: "The patient was admitted from Chattanooga, suffering from a severe gunshot wound of the left elbow joint. The missile, a conical musket ball, entered the forearm immediately below the joint and passed upward and outward, fracturing the external condyle of the humerus. On admission, the arm was much inflamed and tumefied, the discharge profuse, dark colored, and exceedingly fetid; pulse at 90, tongue coated, and appetite impaired. Tonics, stimulants, and nutritious diet were freely used, and cold-water dressings locally. December 12th, discharge from wound the same as on admission. A severe chill occurred to-day. There is much pain, wakefulness, and entire loss of appetite; also icteroid skin. Two grains of sulphate of quinine and three grains of Dover's powder were given every three hours. December 14th, respiration labored; pain in region of liver; great thirst; sordes; skin very yellow; pulse feeble and 120 per minute; respiration 30. Death from pyæmia, on December 16, 1864."



FIG. 596.—Ball lodged in outer condyle of left humerus. Spec. 2192.

A *post-mortem* examination was held twenty-three hours after death, and is described as follows: "External appearance a deep icteric hue. On examining the wound the articulations corresponding to the external condyle were found to be denuded. The tissue immediately in contact with the wound was very dark, of a gangrenous appearance, and filled with dark, fetid, and purulent matter. On opening the thorax the lungs were found covered with heavy deposits of lymph. The lower lobe of each lung contained several superficial abscesses, also several small circumscribed and hard masses of a light red color. The heart weighed thirteen ounces, and was apparently healthy in texture, except the mitral valves, which were thickened. The liver contained several dark diffused patches, which were soft and interspersed throughout the organ. The gall bladder contained no bile. The liver weighed five pounds and eight ounces; the spleen soft, and weighing one pound and eight ounces. The left kidney weighed eight and a half ounces, was soft in texture, and the pyramids obscure. The right kidney weighed seven and a half ounces and was healthy." The specimen consists of the bones of the left elbow, showing a severe fracture from a conoidal ball which, battered, is lodged in the outer condyle. The outer condyle is destroyed, and a perpendicular fracture extends upward two inches. There is no mention of any attempt to remove the ball.

It is well to terminate this subsection with at least a brief review of the cases unsuccessfully treated on the expectant conservative plan, lest a superficial survey of figures alone should mislead,<sup>4</sup> and cause that plan to be unduly appreciated. The reader must not lose sight of the fact that, besides the nine hundred and thirty-eight cases of shot injury of the elbow treated expectantly and comprised in this series, there were at least five hundred and forty-three cases of shot wounds of the elbow, and probably many more,<sup>5</sup> that were treated expectantly at the outset; but were ultimately submitted to intermediary or secondary excision or amputation, with fatal results in two hundred and fifty-seven cases, or 47.3 per cent.

<sup>1</sup> In the Museum of St. George's Hospital, London, there are two illustrations of the results of conservative expectant treatment of shot wounds of the elbow: Spec. 106, Series I, is from W. W.—, aged 22 years, and shows a shot comminution of the external condyle and adjacent portion of the shaft of the humerus, and fracture of the ulna. Amputation was practised four weeks after the injury, and death from pyæmia resulted à fortnight afterward, January 4, 1830. Spec. 216, of the same series, is from George R.—, aged 51 years, a soldier of the Peninsular war, who was wounded in the elbow, in 1810. He had suffered for 22 years from attacks of inflammation of the joint with abscesses. His arm was amputated in September, 1832, and he was discharged cured a month after. A musket ball was found lodged in the cancellous structure of the lower end of the humerus, which was considerably enlarged, as were the upper extremities of the radius and ulna. The articular lamella of each of the bones was extensively destroyed. The ball lay uncovered at the bottom of the olecranon fossa (OGLE and HOLMES, *Cat. of Path. Museum of St. George's Hospital*, 1866, pp. 35, 65).

<sup>2</sup> Viz: Among the records of amputations of the arm, pp. 716-791, eighteen instances, represented by wood-cuts numbered: FIGS. 517, 523, 524, 525, 526, 528, 537, 539, 542, 543, 544, 546, 549, 553, 561, 562, 561, 564.

<sup>3</sup> Descriptions of the following may be consulted in the Catalogue of the Surgical Section, p. 146 *et seq.*: Specs. 1578, 2265, 2732, and 4264.

<sup>4</sup> LANGENBECK (B. v.) (*Chirurgische Beobachtungen aus dem Kriege*, Berlin, 1874, S. 165) details a number of cases of shot wounds of the elbow joint, and carefully compares the results of expectant conservative treatment with those of resection, and concludes: "The number of cases of recovery with ankylosis after conservative expectant treatment of shot wounds of the elbow joint, is pretty large. . . . The fact that, among the patients treated on the expectant conservative plan and recovered with limited motion or ankylosis, the usefulness of the hand and fingers is sooner restored, will not astonish us when we consider that these were the cases of slighter injury, and that the wounded arm was treated in a more or less flexed position allowing motion of the hand and fingers, while the more severely injured limbs, treated by resection, were generally fastened upon splints with the wrist joint extended and hand and fingers, as a rule, immovably secured for 4 to 8 weeks. . . . If, therefore, on a superficial examination or by consideration of figures solely, the scales appear to weigh in favor of the expectant conservative treatment, we will still find, on a more careful examination, that the end-results of elbow resection are not so bad."

<sup>5</sup> There were 197 intermediary and 54 secondary excisions with 74 deaths, and 292 intermediary and secondary amputations with 183 deaths. There were more consecutive amputations, but these are particularized as cases in which expectant treatment was undertaken.

**EXCISIONS AT THE ELBOW JOINT FOR SHOT INJURY.**—At the outbreak of the War, resection of the elbow joint for the effects of shot injury had been practised in this country but once, and then without success;<sup>1</sup> but the surgeons were familiar with Dr. Esmarch's account of the brilliant series of achievements by which Professors Langenbeck and Stromeyer and their disciples had established this resource as an unquestioned advance in military surgery, and the operation had been done with remarkable success in civil practice, for disease or injury, in thirty cases or more. It was performed, during the War, in a large number of cases, but compared with excision at the shoulder was relatively a less frequent substitute for amputation, and its results, as a conservative measure, must be esteemed, on the whole, less brilliant than those of decapitation of the humerus. The cases are classified in the following table:

TABLE CVI.

*Numerical Statement of Six Hundred and Twenty-six Cases of Complete or Partial Excisions of the Bones of the Elbow Joint for Shot Injury.*

OPERATIONS.	TOTAL CASES.	RECOVERIES.	FATAL CASES.	RESULT UNKNOWN.	MORTALITY RATE, DETERMINED CASES.
PRIMARY .....	322	250	68	4	21.3
INTERMEDIARY .....	197	127	69	1	35.2
SECONDARY .....	54	49	5	.....	9.2
TIME OF OPERATION UNKNOWN.	53	44	4	5	8.3
Aggregates .....	626	470	146	10	23.7

It will be observed that the ratio of mortality slightly exceeds the mean fatality of the amputations in the upper arm, practised during the War.<sup>2</sup>

**1. Primary Excisions at the Elbow.**—There are included in this category the instances reported during the war of formal excision of the ends of either or of all the bones of the elbow. Forty-seven cases treated by extraction merely of splintered detached fragments have been considered in the preceding subsection. A classification dividing the partial from the complete resections of the joint, while preserving the distribution into primary,

<sup>1</sup> Dr. H. H. TOLAND, of San Francisco (*Pacific Med. and Surg. Jour.*, 1858, Vol. I, p. 70), relates an excision at the elbow, in 1856, for caries of two years' standing, following shot fracture, in the case of P. McMahon, aged 40; amputation was resorted to, and the patient died from "phthisis" in 1857.

<sup>2</sup> HUGELSHOFER (A.), of Basel (*Ueber die Endresultate der Ellbogengelenkresection*, in *Deutsche Zeitschrift für Chir.*, 1873, B. III, S. 1), after citing statistics from Professors ESMARCH, SCHOLZ, SALTZMANN, O. HEYFELDER, DOUTRELEPONT, and others regarding the relative percentage of fatality of elbow joint resection and of amputation of the arm, remarks: "Finally, I will refer to a compilation of 315 cases of resections of the elbow performed during the North American War [*Circular No. 6*], with a mortality of 21.67 per cent. in cases of resection of the elbow, compared with 21.24 per cent. in amputations of the arm. These are the only published comparative statistics of elbow joint resections with amputations of the upper arm, in which the latter give a more favorable percentage of fatality than the former. To explain this, the reporter adds the following remark: 'It may be ascribed partly to the fact that the returns for the earlier part of the war include quite a large proportion of partial excisions, which are far more hazardous than complete removal of the articular surfaces.' . . ." In the preliminary report in *Circular No. 6*, I remarked that the conclusions resulting from the returns then examined, representing excisions at the elbow as more dangerous than amputations of the upper arm, "were altogether opposed to the Schleswig-Holstein and Crimean experiences, and will doubtless be modified when the statistics are completed." This anticipation was not realized. The statistics, so far as it has been possible to complete them, corroborate the conclusions expressed in *Circular No. 6*. From the tabular statements on pp. 824 and 845 of this volume, it may be seen that a strict analysis of nearly double the number of cases adduced in the preliminary report (with so small proportion of undetermined instances that there is little room for error) represent the excisions at the elbow, in the aggregate, as slightly more dangerous than amputations of the upper arm: 5,273 amputations, with 1,246 deaths, giving a death-rate of 23.6 per cent.; and 616 excisions, with 146 deaths, a mortality of 23.7 per cent. The difference is very slight, it is true, but is in favor of the amputations. Dr. HUGELSHOFER (although the statistics of excisions at the elbow and amputations of the arm for traumatic, as well as non-traumatic causes, cited by him, show a percentage in favor of excision over amputation) deplors his inability to separate in his returns the traumatic from the non-traumatic cases, and appears to doubt the correctness of the results regarding the non-traumatic cases at least, when he remarks: "*A priori*, it seems not improbable that in such cases the amputation of the arm, in which a far more radical removal of all diseased tissues occurs and a far more simple wound is caused, allows a more favorable *quoad vitam* prognosis than the resection of the joint, which occasioned a much more complicated wound, requiring a greater period for healing. . . . As I am not able to prove this assertion by statistical data, I only give it as my subjective view, and far be it from me to proclaim it general truth."



intermediary, and secondary excisions, and those of uncertain date, would be inconveniently complex. The results of four of the three hundred and twenty-two operations are not ascertained. Sixty-eight of the remaining cases, or 21.3 per cent., terminated fatally, a mortality rate higher than that presented by primary amputations of the arm in the same campaigns, or by the expectant conservative treatment; but it would be unwise to conclude from such data that primary excision at the elbow for shot injury was not, under certain circumstances, a most salutary and advisable operation. That such was the conviction of the surgeons of largest experience in the field is proven by the increasing frequency with which the operation was resorted to during the progress of the war.<sup>1</sup>

§ *Recoveries after Primary Excisions at the Elbow.*—Of the two hundred and fifty cases included in this group, there were many that could be only termed successful in the sense that life was preserved. Twenty-seven of the patients ultimately submitted to amputation, and their histories have been alluded to in the preceding Section. Others required operative interference for caries or necrosis or for neuralgic affections. Others suffered from paralysis and muscular atrophy. Of a hundred and ninety-six pensioners, thirteen, at least, have died since their discharge, in most cases from causes more or less indirectly due to their mutilation. Yet a fair proportion of the survivors retain a tolerable control over the functions of the forearm and hand, a smaller number have very serviceable limbs, and, in a very few, the usefulness of the limb is hardly at all impaired. A number of instances of complete and of partial successful primary excisions at the elbow will be narrated, as comparatively few of those of the late war have been published:<sup>2</sup>

CASE 1776.—Private *W. S. Droughom*, Co. C, 60th Georgia, aged 18 years, was wounded at Monocacy, July 9, 1864, and was taken to hospital at Frederick. Acting Assistant Surgeon J. H. Coover reported: "Admitted July 10th. Was wounded by a minié ball, which entered the outer side of the elbow joint, fracturing the head of the ulna and inner condyle of the humerus, thus making its exit on the inner side of the elbow. Exsection of the elbow joint was practised on the day of injury by Surgeon *W. L. Graves*, C. S. A., by a simple straight incision; the limb was subsequently placed in a tin splint, and, according to the patient, cold-water dressings were used. The patient came under my care August 4th, when I found the arm in a tin splint, with the wound nearly healed, and cold-water dressings applied. I placed the arm in an angular splint so as to allow of passive motion. The wound healed nicely and gave the patient no pain or discomfort whatever. July 28th, the arm nearly healed, and passive motion was made every fair day, so that the arm can now be brought to the patient's mouth and extended almost entirely straight, when transferred to Dr. Mitchell's barracks, August 28, 1864." Acting Assistant Surgeon *T. E. Mitchell* noted: "August 29th, the patient came under my care, when I found his arm in an angular anterior splint with hinge joint; considerable motion in the joint; wound healed. September 15th, splint removed; patient able to write, though unable to raise the hand to the mouth without assistance. November 7th, at this date patient was transferred to Baltimore. The result of the case was most satisfactory. Patient has almost perfect use of the limb; pronation and supination are normal; flexion and extension are promptly performed; extreme flexion is somewhat interfered with; he cannot touch his shoulder with his thumb on the injured side as he does on the other side. The arm apparently has not been deformed in the least by the injury." The patient was transferred to Fort McHenry for exchange.



FIG. 597.—Rear view of excised right elbow. *Spec.* 3949.

The specimens figured in the adjacent wood-cuts were contributed by Assistant Surgeon *R. F. Weir*, U. S. A. The pathological specimen (FIG. 597) consists

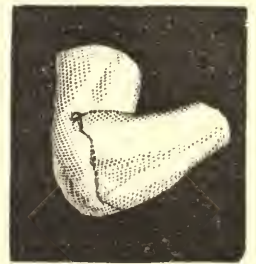

FIG. 598.—Cast of right elbow after excision. *Spec.* 3238.

of the head of the radius, the ulna sawn at the coronoid process, and two-thirds of an inch of the lower extremity of the humerus excised from the right elbow for a fracture of the olecranon and inner condyle. The specimen (FIG. 598) is a cast of the limb after recovery, and represents the arm well flexed in pronation, without deformity.—*Cat. Surg. Sect.*, 1866, p. 536.

<sup>1</sup> In the year 1861, but a single primary excision at the elbow for shot injury was reported (TABLE CVIII, No. 28); in 1862, there were 16 cases; in 1863, 66 cases; in 1864, 219 cases; in the early part of 1865, when the war concluded, 20 cases.

<sup>2</sup> Accounts of successful primary excisions at the elbow for shot injury, during the civil war, have been published by Dr. F. FORMENTO, in his somewhat rare *Notes and Observations on Army Surgery*, New Orleans, 1863, p. 51 (Case of *Lt. Myatt*, TABLE CVII, No. 161, p. 856);—by Surgeon *W. O'MEAGHER*, 37th New York, in *Notes on the Casualties at Fredericksburg* (*Am. Med. Times*, 1863, Vol. VI, p. 179), referring to the case of General *C. F. Campbell* (*l. c.*, No. 33, p. 852);—by Surgeon *CARLYLE TERRY*, P. A. C. S., (*Confed. States Med. and Surg. Jour.*, 1864, Vol. I, p. 76), referring to the case of Sergeant *New* (*l. c.*, No. 166, p. 856);—by Surgeon *G. T. STEVENS* (*Trans. Med. Soc. of New York*, 1866, p. 138), detailing and illustrating the case of Sergeant *Merriam* (*l. c.*, No. 145, p. 855);—by Surgeon *J. J. KNOTT*, P. A. C. S., (*Report of Cases of Gunshot Wound of the Elbow Joint with partial or total Excision*, in *Atlanta Med. and Surg. Jour.*, 1867, Vol. VII, p. 218), detailing three primary (*l. c.*, Nos. 7, 113, 169) and several resections of uncertain date. It is quite probable that other primary excisions of this joint for shot injury during the campaigns in question may have been published, although they have escaped my notice.

Primary excisions at the elbow were more frequently practised for shot injuries involving the articular extremity of the humerus without lesion of the ulna or radius:

**CASE 1777.**—Private J. Murtagh, Co. B, 69th New York, aged 30 years, was wounded at Fredericksburg, December 13, 1862. Surgeon D. W. Bliss, U. S. V., reported the following history and contributed the specimen (FIG. 599): "The patient is a native of Ireland, of sanguine temperament, robust figure, strong constitution, has always enjoyed good health, and has been in the service four months. He was wounded at 1 P. M., while in the act of firing, the ball taking effect in the right arm. He laid on the field until dark, and then walked more than a mile, into Fredericksburg, where he remained until the next morning. He was carried in an ambulance wagon to Alexandria, where his arm was bandaged and he was placed on board of a transport for Washington. December 14th, he was admitted to the Armory Square Hospital in the night, and no examination was attempted. December 15th, the general condition of the patient is good. Examination showed that the ball entered a little above the external condyle and emerged a little below the internal, causing a compound comminuted fracture of the humerus. The operation of resection was decided upon, and performed at 2 P. M. An S incision was made, commencing two inches above the elbow and extending the same distance below. The bone was found most terribly shattered. Both the condyles were removed, and the bone, as far as denuded of periosteum, taken off with the chain saw. In all, about three inches of the lower end of the humerus was removed, and numerous spiculae of bone were taken out. The ulna and radius were uninjured, as were also the attachments of the extensors and flexors of the arm. The incision was closed by sutures, the wound where the ball made its exit being deemed a sufficient opening for the discharge of the pus which may be formed. December 16th, the patient has stood the operation well and appears comfortable." On May 12th, the patient was transferred to De Camp Hospital, David's Island, New York Harbor, whence Acting Assistant Surgeon J. W. Dickie reported the following result in the case: "The wound was healed when admitted. There is a space of about one inch between the bones of the upper and lower arms. The motion of the wrist and fingers is not affected. With this exception the arm is useless, as there is no motion, except passive, of the elbow joint. The tissues around the joint are tender." On June 25th, the patient was transferred to the Veteran Reserve Corps at Fort Schuyler, and on April 29, 1864, he was discharged from service and pensioned. In September, 1865, the pensioner was supplied with an apparatus by Dr. E. D. Hudson, of New York City, who described the injured arm as being "shortened one and a half inches." Examiner B. A. Watson, of Jersey City, December 11, 1873, certified: "Gunshot wound of right elbow, followed by excision. The arm hangs powerless at his side. This disability is equal to the loss of a limb for all purposes of manual labor, is total, third grade, and permanent." This pensioner was paid June 4, 1875.

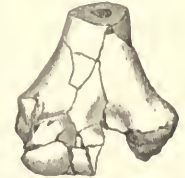

FIG. 599.—Lower extremity of right humerus excised for shot injury. Spec. 2234.  $\frac{1}{4}$

**CASE 1778.**—Private J. H. Cruver, Co. B, 95th Illinois, aged 22 years, was wounded at Chickamunga, September 19, 1863, and admitted to the field hospital of the 1st division, Reserve Corps, where Surgeon W. Varian, U. S. V., recorded: "Fracture of arm." Two days after the battle the wounded man reached Hospital No. 3, Chattanooga. Surgeon I. Moses, U. S. V., reported: "Wound through right elbow joint, the ball entering outside, opposite the external condyle of the humerus, passing out below and two inches inside of the head of the ulna, completely breaking up both condyles and the olecranon process. September 19th, Surgeon I. Moses removed both condyles and the olecranon process, the coronoid being left. Not a bad symptom occurred during his recovery, which was rapid. He was removed to Murfreesboro' with a good arm, and went on furlough with a very useful hand." The specimen, represented in the annexed cut (FIG. 600), was contributed by the operator, and embraces two inches of the lower extremity of the humerus and a portion of the olecranon. On May 7, 1864, the patient entered the Marine Hospital at Chicago, where a subsequent operation was performed by Acting Assistant Surgeon R. H. Isham, who reported the condition of the injured limb as follows: "Ankylosis of arm, nearly straight, with enlargement of bones; bone carious; fistulous openings; much suppuration, pain, and emaciation. Constitutional condition of patient very fair, but suffering from irritation of the diseased joint. On March 5, 1865, exsection of the elbow joint was re-performed. Uninterrupted good progress followed." The patient was subsequently transferred to Camp Douglass, and lastly to Camp Butler, where he was discharged, September 4, 1865, and pensioned. Drs. W. C. Lyman, E. O. F. Rohr, and F. A. Emmons, of the Chicago Examining Board, September 10, 1873, certified: "Resection of right elbow joint, with complete ankylosis in a flexed position; arm shortened two inches." The pensioner was paid June 4, 1875.

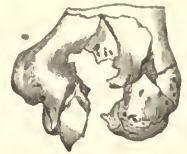

FIG. 600.—Excised lower extremity of right humerus and portion of olecranon. Spec. 2144.

**CASE 1779.**—Private U. Howes, Co. E, 1st Massachusetts, age 22 years, was wounded by a shell, at Spottsylvania, May 18, 1864, the missile causing a fracture of the left humerus, involving the elbow joint. He was admitted to the field hospital of the 3d division of the Second Corps, where Surgeon C. K. Irwin, 72d New York, performed excision. On May 25th the patient entered the 2d division hospital, Alexandria, and on July 7th he was transferred to Judiciary Square, Washington. Surgeon T. R. Spencer, U. S. V., in charge of the former, and Assistant Surgeon A. Ingram, U. S. A., in charge of the latter hospital, reported: "Gunshot wound of left arm." The specimen (FIG. 601) was contributed by the operator, and consists of two inches of the lower extremity of the humerus. The appearance simulating periosteal disturbance is due to the mode of preparation. The patient left the hospital for his home on August 5, 1864, his term of service having expired on May 25, 1864, from which date he was pensioned. Examiner H. Clark, of Worcester, Mass., September 15, 1864, certified: "I find the left arm rendered useless by an injury to the heads of the bones forming the elbow joint. The condyles of the humerus are wanting, leaving a loose joint, with scarcely any voluntary motion of the forearm. Disability total and chiefly permanent." Examiner E. Barton, of Orange, Mass., reported, on September 1, 1873: "A fragment of shell struck the arm, fracturing and lacerating the elbow severely; the bones of the forearm are drawn up, shortening the arm some three inches and abridging the use of the arm very much. Disability total." The pensioner was paid June 4, 1875. Compare *Catalogue of the Surgical Section, Army Medical Museum*, 1863, p. 115.

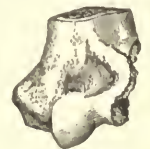


FIG. 601.—Excised lower extremity of left humerus. Spec. 3234.



In the two hundred and fifty operations, the precise extent of excision was recorded in one hundred and ninety-four cases, of which sixty-one belong to the group represented by the three preceding abstracts, in which the lower extremity of the humerus alone was removed. In twenty-two operations, illustrated by the next two abstracts, the upper extremity of the radius only was resected; and in thirty-seven instances, of which CASE 1782 affords an example, the olecranon alone, or with the coronoid process or a portion of the shaft of the ulna, was excised:

CASE 1780.—Brigadier-General Max Weber, U. S. V., aged 38 years, received a shot perforation of the right elbow at Antietam, September 17, 1862. Excision of the joint was practised on the field by Assistant Surgeon Charles Heiland, 20th New York, the regiment of which General Weber was formerly colonel. The patient was treated at a Sixth Corps hospital until December 20th, when he was transferred to Washington. Surgeon Thomas Antisell, U. S. V., attending volunteer officers, reported that there was necrosis of the bones. The patient was furloughed for sixty days. After some small exfoliations the wound healed, and this officer resigned May 13, 1865, and was pensioned. Examiner James Neill, of New York, reported, September 6, 1865, that: "A bullet wound through the right elbow has resulted in complete ankylosis of the joint at an angle of 45°. The limb is paralyzed, and the hand cold and useless." Examiner T. Franklin Smith reported, November 26, 1873: "Ball entered at the right outer condyle of the humerus, and emerged at the inner surface of the forearm, about midway, carrying away about three inches of the radius. There is complete ankylosis of the elbow joint at a right angle, rendering the patient incapable of feeding himself." Dr. Heiland contributed to the Museum a photograph of the fragment of the radius removed, as represented in the wood-cut (FIG. 602).



FIG. 602.—Head of right radius from an excision for shot injury.

CASE 1781.—Colonel S. S. Carroll, 8th Ohio, was wounded at Spottsylvania, May 12, 1864. Surgeon J. L. Brenton, of the regiment, recorded the injury as follows: "Gunshot wound of left arm; resection of radius." The patient entered the field hospital of the 2d division, Second Corps, where Surgeon J. F. Dyer, 19th Massachusetts, recorded: "Wound of left elbow; cold-water dressings." In a report to the Medical Director of the Army of the Potomac, dated November 4, 1864, Surgeon A. N. Dougherty, U. S. V., Medical Director Second Corps, makes mention of this case as follows: "Colonel Carroll was wounded by a minié ball, which traversed the left elbow. He was brought to the hospital near Alsop's Mills, where I saw him. Before any examination of the injury (which was of course made under chloroform) he insisted that an effort should be made to save the arm, and I assented. The head of the radius was comminuted and the anterior surface of the ulna, including, as I thought, the coronoid process, was broken. I enlarged the wound with the scalpel; with the chain saw I removed the head of the radius, and with the forceps I picked out whatever loose spiculae of bone presented themselves; then having the wounds patulous, I put up the arm in a hollow obtuse angle splint. After a very exhausting operation, and irritative fever lasting all summer, and accompanied by bed-sores and great emaciation, he is, as I learn by recent advices, recovering slowly but satisfactorily. The wounds are still uncatrized, and there is complete ankylosis of the joint. He was confined to bed almost three months since he left; since that time he has gained greatly in strength and weight." Colonel Carroll was promoted Brigadier General, U. S. V., on June 14, 1864, and mustered out June 15, 1866. Subsequently he was appointed Lieutenant Colonel of the 21st Infantry, and on June 9, 1869, he was retired from active service with the rank of Major General. Surgeon B. Norris, U. S. A., was requested to report the result in this case, and had the kindness to furnish the following memorandum: "I have read the narrative of the case of Major-General S. S. Carroll, U. S. Army, retired, and can only add that he was under my care, at his mother's house in Washington, D. C., two or three months after the operation of resection of the head of the radius was performed on the field by Surgeon Dougherty. Erysipelas supervened and extended up the arm and over the shoulder, and for two years after he suffered pain and occasionally abscesses, and particles of necrosed bone were discharged. I meet him frequently in the city and at his house in Montgomery county, Maryland. The elbow joint is completely ankylosed. He has use of the wrist joint and of the hand and fingers unimpaired. He can hold the fork firmly in carving at table, and says the arm is invaluable."



FIG. 603.—Excised olecranon. Spec. 1378.

CASE 1782.—Corporal J. Moynahan, Co. G, 91st Pennsylvania, was wounded in the right elbow joint, by a minié ball, at Gettysburg, July 3, 1863. He was admitted to the field hospital of the 2d division, Fifth Corps, where Assistant Surgeon B. Howard, U. S. A., on July 5th, performed resection by a single straight incision. The excised parts, represented in the annexed cut (FIG. 603), were contributed to the Museum by the operator, and embraces the olecranon process and a spicula of the shaft, one inch long. A vertical fissure extends nearly through the process. On July 10th the patient entered Ward Hospital, Newark, where Surgeon G. Taylor, U. S. A., recorded his injury as: "Wound of right elbow," and his transfer to the Veteran Reserve Corps, February 4, 1864, by reason of "ankylosis of right elbow." He is not a pensioner. He must have retained a tolerably useful arm, since he was transferred from Co. 136, of the 2d battalion of the Veteran Reserves, to the 1st battalion, in which the more efficient men were employed, by a Board organized by Special Order 28, War Department, Provost Marshal General's Office, May 24, 1864.

The three foregoing operations resulted in complete ankylosis of the elbow. The pension returns indicate that this result was observed in at least eighty-three cases, and partial ankylosis in seventeen cases of this series; and that these terminations were more frequent after the partial than after the complete excisions of the joint. After the

extended excisions of the articular ends of the bones, the opposite inconvenience of a flail-like limb was more common.

CASE 1783.—Lieutenant E. D. Hall, Co. C, 8th Connecticut, aged 29 years, was wounded at Drury's Bluff, May 14, 1864. Excision of the elbow joint was performed on the field, and after treatment in hospitals at Fort Monroe and Annapolis the patient was discharged and pensioned October 5, 1864. The operator, Surgeon M. Storrs, 8th Connecticut, contributed the pathological specimen, with the following history: "Wounded May 14, 1864, by a musket ball, which passed through the outer condyle of the left humerus. I performed the operation a few hours afterward, on the field. A straight incision was made outside the olecranon in the track of the wound; through this the lower end of the humerus in many fragments was extracted. The bones of the forearm, nerves, and blood-vessels were uninjured. These were untouched in the operation; only the condyles and lower end of the humerus were removed, as shown by the specimen, which consists of some twenty pieces glued together. The patient was sent from the field to the general hospital at Fort Monroe, where he made a fine recovery. He has a loose swinging joint, which he ascribes to the treatment—to the extension used, which did not allow the bones to come together. The arm is now (March, 1866) perfectly well; strong to lift; able to carry a pail of water, but rotation of the hand is impaired. The patient is well satisfied with the result as it now is, but by a little mechanical help in the way of a suitable enveloping case for the joint he will have a very strong and useful limb." The specimen (FIG. 604) consists of "three inches of the lower extremity of the left humerus, comminuted by perforation from behind forward above the outer condyle, and excised."—(*Cat. Surg. Sect.* 1866, p. 145.) In March, 1865, Examiner J. Nichols, of Washington, reported: "Gunshot wound of left elbow, with removal of the joint by operation. False point of motion exists; entire loss of use of arm. I doubt its ever being restored for service." On April 27, 1874, Mr. Hall visited the Army Medical Museum, and the photograph represented by the wood-cut (FIG. 605) was then taken. See also photograph No.

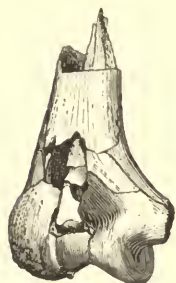

FIG. 604.—Excised lower extremity of left humerus, after shot comminution. *Spec.* 1421.



FIG. 605.—Appearance of elbow ten years after excision for shot perforation. [From a photograph.]

350, Surgical Series. In a letter of May 14, 1874, Mr. Hall, then general agent of an insurance company of Meriden, Connecticut, gave the following description of his injury: "I was wounded May 14, 1864, at Drury's Bluff, and had resection of the elbow joint performed by Surgeon Melancthon Storrs, on the field. I was sent to the Chesapeake Hospital, and was there seventy days, when I had leave of twenty days, and on my way back to my regiment was sent to Annapolis Hospital, and there condemned by an Examining Board as unserviceable, and told that I better have my arm cut off, as it would never be of any use to me. I had a case of sheet-iron made and wore it for the first year. I had it well lined with fur. At the end of one year I could go without the case, and my arm did not hurt me much unless I took a misstep and jarred it. I began to get a little use of my fingers, which were very stiff for the first year. For the first three years, the arm pained me most of the time, and used to bother me a good deal of nights; but I find it quite useful now, and I think it paid to run the risk of saving it."

CASE 1784.—Lieutenant A. D. Campbell, Co. F, 45th Pennsylvania, aged 23 years, was wounded at Petersburg, July 30, 1864, and admitted to the field hospital, 2d division, Ninth Corps. Surgeon J. Harris, 7th Rhode Island, recorded: "Gunshot fracture of elbow joint; resection of elbow joint." The patient was transferred to the Depot Hospital at City Point, and thence, on August 25th, to hospital at Alexandria. Surgeon E. Bentley, U. S. V., reported: "Resection of right elbow joint, removing about two inches of humerus and about two inches of radius and ulna. The operation was performed previous to admission, by an incision four inches in length on the posterior aspect of the arm. Patient furloughed October 19, 1864." Acting Assistant Surgeon J. H. Longenecker reported his admission to the Officers' Hospital, Annapolis, November 30th, and described the injury as follows: "A minié ball entered outer side of joint, passed upward and lodged in the inner side of upper third of arm. The wound of resection is healed. There are several abscesses forming, and the arm is inflamed and painful. Flaxseed poultices and afterward dry dressings were applied. The patient continued to improve. He was discharged from service December 12, 1864." Examiner J. Nichols, of Washington, D. C., certified, December 13, 1864: "Wound yet unhealed; ball still remains in wound. Amputation may yet have to be resorted to. Arm useless; prognosis doubtful." In December, 1863, the pensioner was furnished with an apparatus (FIG. 606) by Dr. E. D. Hudson, of New York, who described "the injured limb as being shortened four inches," and stated that "the missile was still embedded under the pectoral muscle." Examiner J. T. Bundy, of Deposit, N. Y., reported, September 4, 1873: "Has a limited use of hand while resting upon a fixed basis, otherwise the arm is useless and rather an encumbrance, frequently becoming inflamed from irritation by spiculae of bone, which are discharged by ulceration." This pensioner was paid on June 4, 1875.

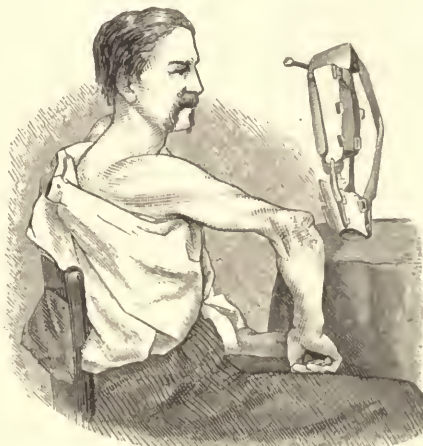

FIG. 606.—Incomplete recovery after excision at the elbow. [From a photograph.]



Few primary excisions at the elbow for shot injury resulted more favorably than that illustrated in the left-hand figure of PLATE LIII, and the result is the more remarkable when the extent to which the shaft of the humerus was necessarily removed is considered:

CASE 1785.—Captain W. G. Tracy, A. A. D. C., was wounded at Chancellorsville, May 2, 1863, receiving a postero-anterior musket-ball perforation of the inferior extremity of the right humerus. On May 5th, Surgeon H. E. Goodman, 28th Pennsylvania, assisted by Surgeon R. W. Pease, 10th New York Cavalry, excised the joint, removing four and a half inches of the lower extremity of the right humerus. The large portion of the humerus removed, of which two views are presented in the annexed wood-cuts (FIGS. 607, 608), was presented to the Army Medical Museum by the operator. The amount of comminution is very extensive. The operation appears from the cicatrix to have been practised through an H-shaped incision. The nerves have escaped injury, and the muscles have regained attachments advantageously to a remarkable degree. A letter from Captain Tracy, received through the courtesy of Surgeon-General James E. Pomfret, of New York, and dated April 2, 1866, mentions these facts, and that "the bones of the forearm were not touched," and continues: "I returned to the army August 15th, the wound being perfectly healed, the bones remaining disunited, and I continued to serve on the staff of General Slocum until the close of the war. My arm has become about three inches shorter. The muscles have never withered away, and sensation is perfect in the limb. I can write as well as ever [with great elegance, it may be remarked, in passing], but experience some difficulty in raising my arm." Captain Tracy, having served gallantly through the war, resigned at its conclusion, and was discharged October 13, 1865, and pensioned. The reports of the Pension Examining Board at Syracuse for November, 1865, and September, 1875, recapitulate the facts above recorded. In



FIG. 607.—Lower fourth of right humerus excised for shot injury. Spec. 1155.



FIG. 608.—Posterior view of the same specimen.

October, 1875, Captain Tracy was in good health, and the usefulness of his mutilated limb had in no wise deteriorated. At this time he had the kindness to have made two photographs of the injured limb, which are bound with the contributed surgical photographs of the Army Medical Museum, one of them being copied in the left-hand figure of PLATE LIII, opposite.

Another instance, in which an excellent result followed a primary excision of nearly the lower third of the humerus, is presented by the following case:

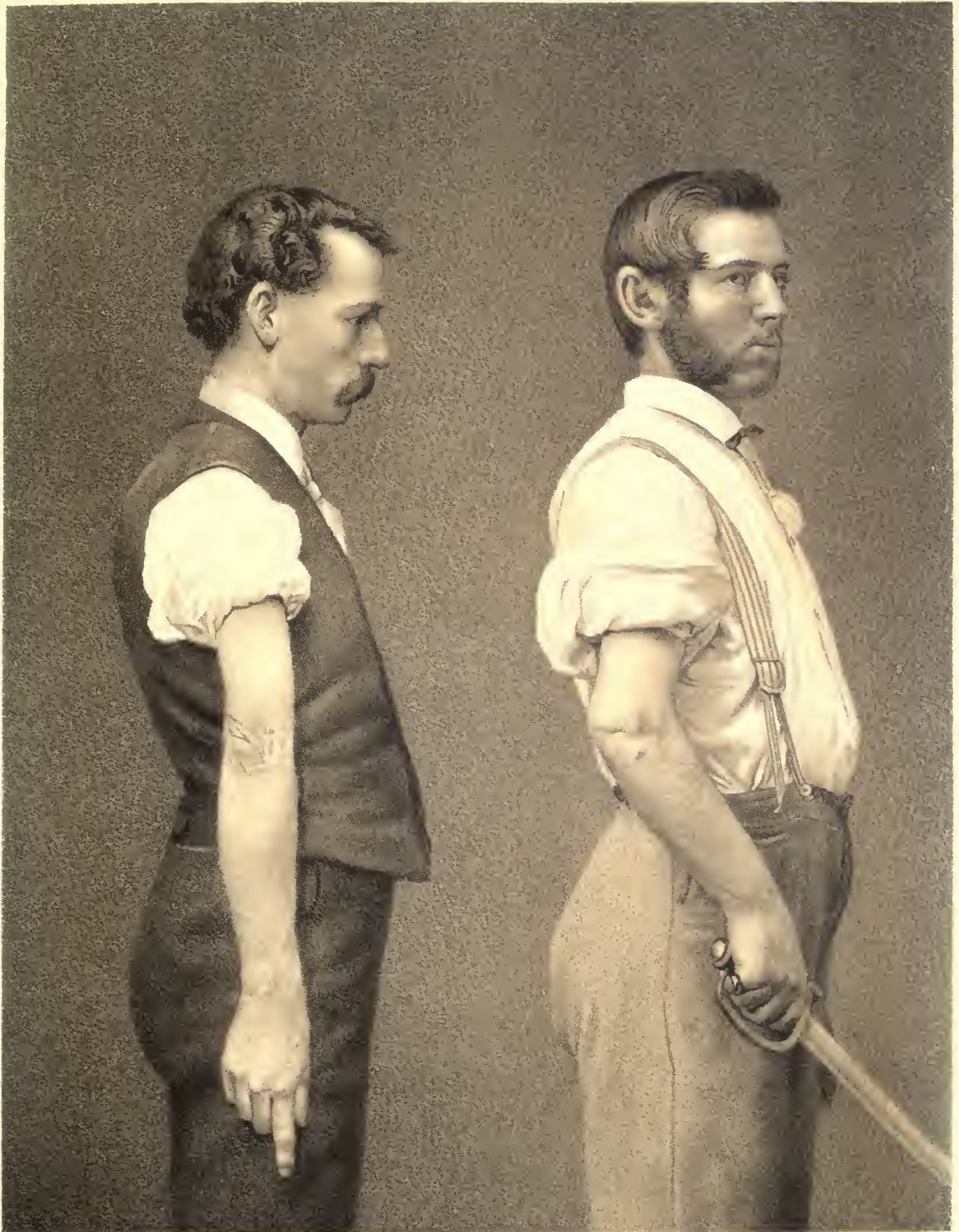CASE 1786.—Sergeant C. H. Lovell, Co. D, 14th New York Heavy Artillery, aged 24 years, was wounded at Cold Harbor, June 2, 1864, and taken to the 1st division, Ninth Corps, hospital. Surgeon M. K. Hogan, U. S. V., reported "a gunshot wound of the right arm with fracture of the condyles of the humerus, and that the patient was operated upon, by excision of the elbow, twenty hours after being wounded. On the 9th he was transferred to Lincoln Hospital, Washington, and thence to Philadelphia, entering Mower Hospital July 22d. Surgeon Joseph Hopkinson, U. S. V., recorded the operation as follows: "Gunshot fracture of lower third of right humerus. Excision of four inches of right humerus, commencing at a point one inch above the condyles, by a straight incision four and a half inches in length, over and in the line of the humerus. The patient was in good condition at the time of operation." On September 6, 1864, the patient was discharged and pensioned, his disability being rated one-half. Examiner J. B. Graves, of Corning, New York, September 8, 1864, reported: "Gunshot wound of right arm. Resection of humerus just above the elbow joint, three inches in extent." On June 29, 1865, he reported: "Pieces of bone are working out, and the wound discharging pus continually. Every attempt to use the arm inflames it and lays him up." On January 16, 1866, Dr. E. D. Hudson furnished the patient with a prothetic apparatus, which, from the outset, proved highly useful. At that time the arm was shortened nearly four inches, and slightly atrophied. There was no use of the forearm, but the functions of the hand were normal. When the apparatus was applied, however, the patient was able to lift his forearm and to carry at right angles from the body, and to raise a chair at an angle of 45 degrees. Dr. Hudson contributed the photograph of the pensioner, taken at this time, to the Museum. A reduced copy of it is represented in the adjacent wood-cut (FIG. 609). On October 22, 1866, Examiner J. B. Graves, who reports the patient to be suffering from caries of the lower end of the humerus, with a continuous discharge and pain, rates his disability total and permanent. A communication from Dr. H. C. May, late Assistant Surgeon of Volunteers, dated March 18, 1868, states that this man has been employed for two years as a fireman in a factory at Corning, New York, and is able to do any work at arm's length, like pitching wood, shoveling coal, etc. The Elmira board, consisting of Drs. H. S. Chubbuck, H. C. May, and George Dean, September 5, 1873, reported: ". . . Circulation of arm good, and arm well nourished; disability total." This pensioner was paid to March 4, 1874.



FIG. 609.—Results nineteen months after primary excision.

It would be interesting to narrate other cases in detail, and many of the series are represented in the Museum by specimens of the excised parts, or by photographs of the appearances after recovery; but the eleven foregoing abstracts exemplify the principal varieties of the successful primary excisions at the elbow; and it is imperative to compress further references to the group into the subjoined tabular statement.





Bell & Ward phot.

Fig. 1.

T. Sinclair & Son lith Phila.

Fig. 2.

PLATE LIII. RESULTS AT EXCISIONS OF THE ELBOW JOINT FOR SHOT INJURY.

Fig. 1. Case of Capt. Tracy. - 1735 p. 850

Fig. 2. Case of Pt Riley. - 1797 p. 869





TABLE CVII.

*Summary of Two Hundred and Fifty Cases of Recovery after Primary Excision at the Elbow Joint for Shot Injury.*

NO.	NAME, AGE, AND MILITARY DESCRIPTION.	DATE OF INJURY.	NATURE OF INJURY.	DATE OF OPERATION.	OPERATION AND OPERATOR.	RESULT AND REMARKS.
1	Achor, J. M., Pt., C, 14th Indiana, age 20.	May 12, 1864.	Shot fracture of right elbow . . .	May 12, 1864.	Olecranon process excised, by Surg. G. W. McCune, 14th Indiana.	Disch'd Nov. 19, 1864; pensioned. Complete ankylosis and paralysis of arm.
2	Allen, C. F., Pt., G, 24th Mich., age 20.	June 3, 1864.	Disintegration of joint by musket ball; excessive hemorrhage.	June 3, 1864.	Three inches of humerus and radius, through longitudinal incision.	Gangrene. Mustered out May 17, 1865; pensioned. Arm shortened three inches and useless.
3	Allender, J. B., Corp'l, A, 121st Pennsylvania, age 22.	May 8, 1864.	Fracture of upper third of left radius by minie ball.	May 8, 1864.	Excision of elbow joint. . . . .	Arm amputated May 24. Disch'd Sept. 5, 1864; pensioned.
4	Anthony, J. H., Pt., K, 123d New York, age 27.	April 2, 1865.	Wound of right elbow joint by conoidal ball.	April 2, 1865.	Lower two and a half inches of right humerus, by Surg. W. Vosburg, 111th New York.	Disch'd July 6, 1865; pensioned. No union; forearm worthless.
5	Babbitt, O. L., Pt., G, 33d New Jersey, age 23.	May 27, 1864.	Shot fracture of right elbow joint; erysipelas.	May 27, 1864.	Two inches of humerus, through incision three inches long, by Surg. J. L. Dunn, 109th Pa.	Disch'd May 26, 1865; pensioned. Ankylosis; arm useless.
6	Babcock, D. A., Serg't, C, 6th New York Cav., age 24.	Aug. 16, 1864.	Left external condyle and head of radius almost entirely destroyed by gunshot.	Aug. 17, 1864.	Excision. . . . .	Necrosis; total disorganization of joint; Oct. 9, 1864, amputation. Disch'd Dec. 6, 1864; pensioned. Spec. 3418.
7	Bailey, J. T., Lieut., H, 51st Georgia, age 25.	Oct. 19, 1864.	Fracture of both condyles of left humerus, involving joint.	Oct. 20, 1864.	Excision of condyles and olecranon process, through longitudinal incision, by Surg. J. J. Knott, 53d Georgia.	Recovered in December with a useful limb.
8	Barber, J., Pt., H, 11th New Jersey, age 20.	May 10, 1864.	Compound comminuted fracture of right elbow by conoidal ball.	May 11, 1864.	Condyles of humerus and olecranon process; three ins. of bone, thro' crucial flap incision.	Disch'd Oct. 20, 1864; pensioned. Total loss of use of arm.
9	Barton, J., Pt., F, 1st D. C. Cavalry, age 21.	Aug. 25, 1864.	Right elbow joint fractured by conoidal ball.	Aug. 25, 1864.	Excision of joint. . . . .	Disch'd April 13, 1865; not a pensioner.
10	Beach, O., Pt., B, 1st Michigan, age 21.	June 1, 1864.	Gunshot fracture of right elbow joint, opening it.	June 2, 1864.	Olecranon process and lower end of humerus.	Disch'd Aug. 10, 1864; pensioned. Complete ankylosis; muscular atrophy.
11	Beal, W., Pt., I, 88th Illinois, age 26.	May 17, 1864.	Wound of left elbow joint by conoidal ball.	May 18, 1864.	Excision of four inches of ulna and head of radius.	Disch'd July 19, 1865; pensioned. Total loss of use at right angle; arm atrophied.
12	Beaumont, T., Pt., M, 9th New York Cavalry, age 20.	Aug. 23, 1864.	Conoidal ball entered elbow, passed through internal condyle, fracturing lower third of left humerus.	Aug. 26, 1864.	Two inches of humerus, condyles, and entire ulna, thro' linear incision, by Surg. R. Curran, 9th New York Cav.	Disch'd June 19, 1865; pensioned. Arm shortened two and a half inches, atrophied, and useless.
13	Behrens, E., Pt., D, 7th New York Heavy Artillery.	Mar. 31, 1865.	Fracture of left forearm, involving elbow joint.	April 1, 1865.	Excision of two inches upper extremity of radius, by Surg. P. E. Hubon, 28th Mass.	Arm amputated April 11, 1865, for hemorrhage. Disch'd Aug. 2, 1865; pensioned. Died Oct. 9, 1871. Spec. 4053.
14	Belcher, M. H., Pt., H, 60th Virginia, age 26.	Sept. 19, 1864.	Conoidal ball fractured bones forming articulation of right elbow joint.	Sept. 22, 1864.	Heads of ulna and radius and condyles of humerus, by Surg. G. L. Miller, C. S. A.	Sent to Provost Marshal April 1, 1865.
15	Bell, A. H., Corp'l, K, 8th Georgia, age 21.	Oct. 7, 1864.	Wound of right elbow joint. . . .	Oct. 8, 1864.	Excision of portion of humerus and ulna.	Furloughed November 10, 1864.
16	Benner, H. H., 2d Lieut., B, 45th Pennsylvania, age 36.	June 17, 1864.	Wound of right elbow joint by musket ball.	June 17, 1864.	Portions of condyles of humerus, by Surg. T. S. Christ, 45th Pennsylvania.	Disch'd Dec. 5, 1864; pensioned. Joint completely ankylosed.
17	Bentley, J. J., Pt., D, 13th Georgia, age 27.	July 9, 1864.	Conoidal ball fractured condyles of right humerus and upper end of ulna.	July 11, 1864.	Two inches humerus and one and a half inches ulna, including olecranon, by Asst. Surg. R. F. Weir, U. S. A.	Sent to Provost Marshal February 11, 1865.
18	Bereaw, S. W., Pt., G, 64th Ohio, age 27.	Nov. 29, 1864.	Fracture of left elbow joint. . . .	Nov. 29, 1864.	Excision of external condyles of humerus.	Disch'd April 17, 1865; pensioned. Ankylosis, with paralysis of forearm.
19	Bolee, J., Pt., C, 8th Louisiana, age 29.	Aug. 29, 1864.	Wound of left elbow joint by conoidal ball.	Aug. 29, 1864.	Excision, by Surgeon J. N. K. Monmonier, 8th Louisiana.	To Provost Marshal February 15, 1865.
20	Borne, H., Pt., I, 139th Pennsylvania, age 22.	May 3, 1863.	Fracture of left elbow joint. . . .	Primary	Excision of olecranon process. .	V. R. C. Feb. 5, 1864; pens'd. Complete ankylosis at right angle.
21	Bowers, J. T., Pt., H, 8th Indiana, age 27.	Oct. 19, 1864.	Shot comminution of left ulna, joint opened.	Oct. 19, 1864.	Five inches of ulna excised through straight incision six inches long.	Disch'd June 20, 1865; pensioned. Complete ankylosis; muscular atrophy; arm at times useless.
22	Bradley, C., Serg't, I, 12th Kentucky Cavalry, age 30.	Dec. 14, 1863.	Shot fracture of lower end of right humerus.	Dec. 15, 1863.	External condyles of humerus, through longitudinal incision, by Surg. J. F. Kembley, 11th Kentucky Mounted Infantry.	Erysipelas. Disch'd May 16, '65; pens'd. Complete ankylosis; partial loss of motion of hand.
23	Brooks, W. H., Pt., B, 134th New York, age 35.	Nov. 25, 1863.	Fracture of right elbow joint by conoidal ball.	Nov. 25, 1863.	Upper portion of radius excised.	Disch'd April 2, 1864; pensioned. Ankylosis; arm nearly useless. Died October 11, 1868.
24	Bronk, D. W., Pt., D, 16th Infantry, age 25.	May 28, 1864.	Compound comminuted fracture of left elbow joint by conoidal ball.	May 28, 1864.	Excision of lower end of humerus and olecranon process of ulna through linear incision.	Disch'd Oct. 14, 1865; pensioned. No union; limb perfectly useless.
25	Brown, E., Pt., F, 31st Ohio, age 18.	May 14, 1864.	Olecranon process of left ulna fractured by conoidal ball.	May 15, 1864.	Olecranon excised, and ball removed, by Surg. E. S. Chappel, 31st Ohio.	Disch'd July 20, 1865; pens'd. Full use of joint.
26	Brown, J. W., Pt., B, 97th Ohio.	May 26, 1864.	Conoidal ball fractured left elbow joint.	May 23, 1864.	Upper third of radius and outer condyle of humerus, by Surg. E. B. Glick, 40th Indiana.	July 10th, arm amputated at upper third. Disch'd January 10, 1865; pensioned.
27	Brown, T., Pt., C, 14th New York Artillery, age 30.	July 30, 1864.	Wound of left elbow by conoidal ball; (also fracture of eighth rib.)	July 30, 1864.	Excision of elbow joint. . . . .	Mustered out October 11, 1865; pensioned. Motion of joint good; cannot grasp small objects.
28	Buchanan, T. J. T., Serg't, A, 7th Wisconsin, age 20.	May 5, 1864.	Fracture of right elbow joint by conoidal ball; ulna involved.	May 7, 1864.	Upper third of ulna removed. .	Discharged February 11, 1865; pens'd. Ankylosis; no rotation.
29	Buck, A., Lieutenant, E, 8th New Jersey.	May 3, 1863.	Comminuted fracture of head of left radius by conoidal ball.	May 3, 1863.	Head, neck, and two inches of radius, by Surg. C. S. Wood, 66th New York.	Mustered out October 6, 1864. Not a pensioner.



No.	NAME, AGE, AND MILITARY DESCRIPTION.	DATE OF INJURY.	NATURE OF INJURY.	DATE OF OPERATION.	OPERATION AND OPERATOR.	RESULT AND REMARKS.
30	Buckley, T., Pt., C, 32d Massachusetts.	June 6, 1864.	Conoidal ball wound of left elbow joint.	June 6, 1864.	Removal of lower extremity of humerus.	Discharged June 26, 1865. Not a pensioner.
31	Call, S. J., Pt., D, 33d Massachusetts, age 33.	May 12, 1864.	Shot fracture of lower third of humerus, extending into elbow joint.	May 13, 1864.	Lower extremity of humerus, including condyles, excised.	Septemur 8th amp.; sequestrum found embedded in callus; necrosis. Discharged January 5, 1865; pensioned. <i>Spec.</i> 3209.
32	Campbell, A. D., 2d Lieutenant, F, 45th Pennsylvania, age 23.	July 30, 1864.	Fracture of right elbow joint by conoidal ball; parts much lacerated.	July 30, 1864.	Two inches humerus, same of radius and ulna, thro' incision four inches in length.	Disch'd December 12, 1864; pensioned. No bony union; muscles absorbed; arm rather an encumbrance.
33	Campbell, C. T., Brigadier General, U. S. V., age 38.	Dec. 13, 1862.	Fracture of right elbow joint; (also wounds through body, leg, and groin.)	Dec. 13, 1862.	Resection of elbow joint, four inches of ulna, and other bones.	Discharged January 16, 1866; pensioned. Arm almost useless.
34	Carroll, S. S., Colonel, 8th Ohio.	May 12, 1864.	Shot wound of the left elbow, conoidal ball comminuting head of radius and anterior surface of ulna.	Primary	Excision of head of radius and removal of loose spicula with forceps, by Surg. A. N. Dougherty, U. S. V.	Promoted Brig. General May 12, 1864; mustered out July 13, 1864. Complete ankylosis.
35	Canala, J., Pt., I, 107th New York, age 36.	May 3, 1863.	Fracture of right forearm by a fragment of shell.	May 3, 1863.	Four inches of ulna and olecranon process, by A. Surgeon C. H. Lord, 103d New York.	Disch'd October 8, 1863; pens'd. Ankylosis; arm useless for labor. <i>Spec.</i> 1151.
36	Cash, W., Pt., D., 40th Virginia, age 23.	Sept. 30, 1864.	Conoidal ball entered three inches below left elbow joint, passed through articular surface of ulna and humerus.	Oct. 1, 1864.	Excision of joint through single straight six-inch incision along posterior aspect.	October 30, 1864, good prospect of speedy recovery.
37	Chawing, W. B., Serg't, B, 8th Tennessee, age 22.	Nov. 30, 1864.	Shot wound of left ulna at elbow joint.	Dec. 1, 1864.	Excision	Transferred to Provost Marshal March 7, 1865.
38	Christinn, F., Pt., B, 12th Ohio Cavalry, age 22.	Jan. 24, 1864	Fracture of left elbow joint by conoidal ball.	Jan. 24, 1864.	Removal of four inches of radius and ulna.	Disch'd June 4, 1865; pensioned. Complete ankylosis; atrophy.
39	Churchill, A., Corp'l, M, 8th Illinois Cavalry, age 21.	June 9, 1863.	Articular surface of right elbow joint comminuted by carbine ball, which entered below joint and was removed three inches above.	June 10, 1863.	Lower portion condyles of humerus, olecranon process, and head of radius, thro' straight incision, by Surgeon A. Hard, 8th Illinois Cavalry.	Slight hemorrhage and erysipelas. Disch'd Sept. 28, 1863; pensioned. Good use of forearm and hand.
40	Cigler, H., Pt., C, 68th Ohio, age 29.	July 22, 1864.	Fracture of left elbow by minic ball.	July 25, 1864.	Excision of elbow joint.	Discharged June 26, 1865; pensioned. Ankylosis; cicatrix interfering with motion.
41	Clifford, R., Pt., C, 2d Rhode Island, age 19.	April 6, 1865.	Compound fracture of left elbow by conoidal ball.	April 6, 1865.	Resection of portion of humerus through T incision.	Disch'd June 11, 1865; pensioned. Ankylosis; atrophy; necrosis.
42	Cline, C. R., Pt., D, 24th Kentucky, age 21.	June 20, 1864.	Shot fracture of left elbow joint.	June 20, 1864.	Excision of olecranon process.	Disch'd Jan. 30, 1865; pensioned. Complete ankylosis; can use fingers and hand, but arm weak.
43	Cohler, J., Corp'l, G, 140th New York, age 24.	Feb. 5, 1865.	Fracture of right elbow joint by conoidal ball.	Primary	Partial excision of elbow joint.	Disch'd Aug. 12, 1865; pensioned. No bony union; arm useless.
44	Cole, L. B., 2d Lieut., D, 88th Illinois, age 25.	Nov. 22, 1863.	Fracture of heads of left radius and ulna.	Dec. 1, 1863.	Heads and four inches of shafts of radius and ulna; longitudinal incision over olecranon and down ulna.	Resigned May 4, 1864; pensioned. Some atrophy; shortened two and a half inches; entirely flexible. Died Oct. 26, 1866.
45	Cole, T. W., Serg't, D, 74th Illinois, age 26.	May 14, 1864.	Fracture of right elbow joint by conoidal ball.	May 14, 1864.	Elbow joint, by Surg's W. P. Pierce, 88th Illinois, and H. E. Hasse, 24th Wisconsin.	October 23, 1864, arm amputated. Discharged June 19, 1865; pensioned.
46	Collins, A., Pt., K, 14th Kentucky, age 25.	June 22, 1864.	Left elbow joint fractured by a conoidal ball.	June 22, 1864.	Excision, by Surgeon C. D. Moore, 13th Kentucky.	Arm amputated. Mustered out Jan. 31, 1865; pensioned.
47	Connor, J., Pt., G, 163d New York, age 43.	June 14, 1863.	Wound of right forearm just below elbow by conoidal ball.	Primary	Three inches of ulna, including olecranon, and three-fourths inch of head of radius.	Disch'd Dec. 26, 1863; pensioned. Partial rotation; double inguinal hernia. Died Oct. 13, 1865.
48	Copeland, J. P., Serg't, I, 8th Georgia, age 27.	Oct. 7, 1864.	Compound fracture of left elbow joint.	Oct. 8, 1864.	Excision of a portion of humerus, radius, and ulna.	Retired March 3, 1865.
49	Copley, J. J., Capt., E, 86th New York, age 25.	May 6, 1864.	Fracture of left forearm, upper third of ulna, by a conoidal ball; also fracture of left leg.	May 7, 1864.	Excision of upper fourths of ulna and radius.	May 22, hemorrhages; ulnar ligated; May 23, hemorrhage recurred; May 25, arm amputated. Discharged September 27, 1864; pensioned. <i>Spec.</i> 2325.
50	Costello, J., Pt., E, 164th New York, age 18.	Nov. 25, 1864.	Wound of left elbow by canister shot.	Nov. 26, 1864.	Resection of three inches lower end of humerus through linear incision, by—Bayard, U. S. A.	Disch'd June 29, 1865; pensioned. Exfoliation; forearm and hand useless.
51	Couser, W. P., Pt., C, 4th Tennessee, age 25.	May 28, 1864.	Compound fracture, opening left elbow joint.	May 28, 1864.	End of ulna and two inches of humerus, through a V-shaped incision.	Retired Jan. 2, 1865. No union; arm only an encumbrance.
52	Crawford, R. R., 2d Lieut., I, 7th Infantry.	July 2, 1863.	Bones of left elbow comminuted by conoidal ball.	July 2, 1863.	Bones of joint, through an H incision, by Asst Surg. J. S. Billings, U. S. A.	Furloughed October 1, 1863; not a pensioner.
53	Crozier, J., Corp'l, M, 7th Michigan Cavalry, age 20.	June 12, 1864.	Conoidal ball fractured left humerus at elbow joint.	June 12, 1864.	Entire articular surface of humerus excised.	August 22, piece of bone and ball removed. Disch'd June 8, 1865; pens'd. Arm hangs useless.
54	Cruver, J. H., Pt., B, 96th Illinois, age 20.	Sept. 19, 1863.	Shot fracture of condyles of right humerus and olecranon process of ulna.	Sept. 19, 1863.	Two inches of lower extremity of humerus and portion of olecranon, by Surg. I. Moses, U. S. V.; March 3, 1865, re-excision of elbow joint, by A. A. Surg. R. N. Isham.	Disch'd September 4, 1865; pensioned. Complete ankylosis; arm useless. <i>Spec.</i> 2444.
55	Curran, J., Pt., I, 14th Wisconsin, age 27.	May 22, 1863.	Right elbow joint fractured by shell.	May, 1863, on field.	Olecranon and two inches of end of humerus, through a single straight incision.	Erysipelas. Disch'd October 9, 1865; pensioned. Firm ankylosis.
56	Cutting, H. P., Corp'l, C, 6th Iowa, age 23.	July 16, 1863.	Compound comminuted fracture of left elbow joint by conoidal ball.	July 16, 1863.	Two and a half inches of radius and ulna and three of humerus, by Surg. W. H. Leonard, 51st New York.	Arm amputated at middle third. Disch'd July 18, 1864; pens'd.
57	Daniels, D., Pt., A, 8th Missouri, age 29.	May 17, 1862.	Ball passed through right elbow joint.	May 18, 1862.	Resection of joint, by Surg. E. Andrews, 1st Illinois Artillery.	Disch'd Sept. 29, 1862; pens'd. No bony union; no control over movements of forearm.
58	Darling, J. J., Pt., E, 31st Ohio, age 19.	May 14, 1864.	Wound of left elbow by a conoidal ball.	May 16, 1864.	Excision of elbow through five-inch incision.	Disch'd Jan. 3, 1865; pensioned. Perfect ankylosis; little use of hand.
59	Davis, C. S., Corp'l, D, 32d Massachusetts, age 19.	May 12, 1864.	Conoidal ball through right elbow; ent'd thorax; removed from right lumbar region.	May 12, 1864.	Excision of elbow joint, by A. Surgeon S. W. Fletcher, 32d Massachusetts.	Disch'd April 22, 1865; pens'd. Firm ankylosis at a right angle.

No.	NAME, AGE, AND MILITARY DESCRIPTION.	DATE OF INJURY.	NATURE OF INJURY.	DATE OF OPERATION.	OPERATION AND OPERATOR.	RESULT AND REMARKS.
60	Dennick, J., Pt., K, 91st New York, age 20.	April 1, 1865.	Shot fracture of head of right ulna.	April 1, 1865.	Head and two inches of shaft of ulna excised.	Disch'd July 15, 1865; pensioned. Arm entirely useless for labor.
61	Dixon, W., Corp'l, K, 143d Pennsylvania, age 22.	May 5, 1864.	Internal condyle of right humerus fractured, and joint opened by a conoidal ball.	May 5, 1864.	Excision May 18; several fragments internal condyle removed through straight incision, by Surgeon Z. E. Bliss, U. S. V.	Hemorrhage. Disch'd July 20, 1865; pens'd. Anchylosis; carries frequently opens, discharging spicule.
62	Donnell, S. P., Pt., H, 11th Missouri, age 20.	May 22, 1863.	Fracture of left elbow joint by conoidal ball.	May 22, 1863.	Excision of elbow joint, by Surg. M. W. Fish, 11th Missouri.	Union by fibrous tissue. Disch'd Oct. 11, 1863; pensioned. Arm useless; false joint.
63	Dranghon, N. T., Pt., G, 60th Georgia, age 18.	July 9, 1864.	Fracture of right elbow by conoidal ball; condyles of humerus and head of radius involved.	July 10, 1864.	Two-thirds of an inch of end of humerus, head of radius, and one and a half inches of ulna, by Dr. Graves, C. S. A.	Good use of forearm and hand. Transferred November 19, 1864. <i>Specs.</i> 3238, 3949.
64	Dudley, A. H., Pt., A, 9th New York Heavy Artillery, age 32.	June 1, 1864.	Head of right radius and olecranon process fractured by conoidal ball.	June 1, 1864.	External condyle of humerus, head of radius, and ulna, thro' straight four-inch incision.	Disch'd Nov. 28, 1864; pensioned. Partial anchylosis; arm atrophied and of little use.
65	Durgin, J. P., 1st Serg't, F, 3d Maine, age 39.	May 12, 1864.	Compound comminuted fracture of left elbow joint by conoidal ball.	May 12, 1864.	Elbow joint, through T incision, by Surg. T. Hildreth, 3d Maine.	Disch'd May 4, 1865; pensioned. Complete anchylosis.
66	Durgin, N. S., Serg't, A, 5th New Hampshire.	April 7, 1865.	Fracture of left elbow joint by conoidal ball.	April 7, 1865.	Elbow joint excised, by Surg. W. Vosburg, 11th New York.	Disch'd July 19, 1865; pens'd. Ligamentous union; arm and hand completely useless.
67	Dyer, J. O., Pt., D, 18th Mississippi.	Sept. 18, 1862.	Wound of right elbow joint, involving ulna.	Sept. 18, 1862.	Excision of part of ulna . . . . .	Disch'd December 19, 1862.
68	Ellis, I. N., Pt., C, 103d Illinois, age 23.	Mar. 21, 1865.	Left radius and ulna fractured at upper third by conoidal ball.	Mar. 21, 1865.	Two inches of articular ends of radius and ulna, by Surg. D. Halderman, 46th Ohio.	May 16th, arm amputated. Discharged June 29, 1865; pens'd.
69	England, J., Serg't, K, 16th Pennsylvania Cavalry, age 26.	Aug. 23, 1864.	Fracture of left elbow joint by conoidal ball.	Aug. 23, 1864.	Excision . . . . .	Disch'd Dec. 31, 1864; pens'd. Anchylosis; great atrophy of arm; useless for labor.
70	Ernst, J. C., Corp'l, G, 65th Ohio, age 22.	Nov. 25, 1863.	Head of right radius fractured by conoidal ball; joint involved.	Nov. 25, 1863.	Head of radius excised . . . . .	Disch'd Aug. 18, 1864; pens'd. Anchylosis; forearm flexed at right angle; rotation not lost.
71	Fæmger, J. C., 2d Lieut., C, 3d Michigan.	Nov. 30, 1863.	Shot fracture of internal condyle of left humerus.	Dec. 1, 1863.	Excision of condyle, by Surg. H. F. Lyster, 5th Michigan.	Disch'd May 28, 1864; pensioned. Complete anchylosis; rotation destroyed.
72	Farrell, M., Pt., F, 6th New Hampshire, age 22.	July 2, 1864.	Fracture of elbow joint by shell.	July 2, 1864.	Excision of olecranon process of ulna.	Disch'd Oct. 17, 1865; pens'd. Complete bony anchylosis at right angle.
73	Foote, G. W., Corp'l, E, 55th Ohio, age 21.	May 3, 1863.	Right humerus injured by a musket ball.	May 3, 1863.	External condyle of humerus removed.	Disch'd July 9, 1863; pensioned. Limb almost useless.
74	Funk, M., Private, C, 148th Pennsylvania, age 24.	May 3, 1863.	Wound of right elbow joint by a musket ball.	Primary	Articulating portion of humerus removed.	Disch'd Oct. 12, 1864; pensioned. Total anchylosis; great deformity and atrophy of arm.
75	Gannon, J., Pt., D, 126th Ohio.	Sept. 22, 1864.	External condyle of left humerus fractured by conoidal ball.	Sept. 22, 1864.	Excision of fractured condyle	November 7, 1864, amputation of arm. Disch'd June 23, 1865; pensioned.
76	Gardner, W. W., Private, A, 136th New York, age 20.	Mar. 19, 1865.	Fracture of right humerus by conoidal ball; elbow joint involved.	Mar. 19, 1865.	Two inches of humerus excised.	Disch'd June 26, 1865; pens'd. No bony union; arm useless.
77	Garvin, J. F., Pt., F, 1st Michigan Cavalry, age 21.	June 12, 1864.	Conoidal ball fractured condyle of left humerus.	June 12, 1864.	Three inches of lower end of humerus, through straight incision, by Surg. A. R. St. Clair, 5th Michigan Cavalry.	Disch'd June 12, 1865; pensioned. False movable joint; little power of rotation.
78	Gillespie, F. B., Pt., F, 80th Indiana, age 19.	May 14, 1864.	Fracture of head of right ulna by conoidal ball.	May 15, 1864.	Four inches of proximal extremity of bone, through straight incision, by A. Surg. S. K. Crawford, 50th Ohio.	Disch'd March 4, 1865; pens'd. Complete anchylosis of joint.
79	Goan, J., Pt., C, 37th Tennessee, age 25.	Nov. 30, 1864.	Elbow joint fractured by a conoidal ball.	Dec. 1, 1864.	Joint excised through straight incision.	To Provost Marshal January 17, 1865.
80	Good, W., Pt., I, 99th Illinois, age 21.	May 21, 1863.	Ball entered three inches below right elbow and emerged at the joint.	May 21, 1863.	Excision of three inches of upper end of radius.	Complete anchylosis. Disch'd Feb. 3, 1864; pensioned. Fistulous openings; discharge of bone; arm useless.
81	Goolsby, W. E., Lieut., L, 21st North Carolina, age 19.	July 1, 1863.	Compound comminuted fracture of left elbow joint.	July 2, 1863.	Excision of joint . . . . .	Recovered. Transferred December 5, 1863.
83	Gordon, J. I., Corp'l, A, 139th Pennsylvania, age 19.	May 5, 1864.	Left elbow joint fractured by conoidal ball.	May 5, 1864.	Excision of entire joint, by Surgeon G. T. Stevens, 77th New York.	Disch'd Dec. 20, 1864; pensioned. Forearm revolves on arm like a flail; arm entirely useless.
83	Graham, A. S., Corp'l, F, 120th New York, age 24.	Nov. 7, 1864.	Wound of left elbow; lower end of humerus fractured by conoidal ball.	Nov. 8, 1864.	Three inches of lower third of humerus excised, by Surgeon H. F. Lyster, 5th Michigan.	Disch'd June 27, 1865; pensioned. Perfect anchylosis; forearm at a right angle.
84	Green, G. C., Serg't, F, 32d Massachusetts, age 21.	May 30, 1864.	Fracture of right elbow joint by conoidal ball.	May 31, 1864.	Excision of three and a half inches of humerus.	Disch'd Oct. 16, 1865; pensioned. Arm useless. <i>Specs.</i> 4381.
85	Graves, H., Pt., H, 105th Pennsylvania.	May 31, 1862.	Shot comminuted fracture of right elbow joint, involving end of humerus; (also flesh wound of thigh.)	May 31, 1862.	Olecranon process gnawed off with forceps even with end of radius; lower end of humerus turned out and removed with ordinary saw.	Discharged March 26, 1863; pensioned. Artificial joint; arm useless.
86	Gyles, E. S., Pt., G, 179th New York.	July 30, 1864.	Gunshot fracture of upper third of left radius.	July 30, 1864.	Excision of three inches of radius, by Surg. W. V. White, 57th Massachusetts.	Disch'd Feb. 27, 1865; pensioned. Complete anchylosis; atrophy.
87	Hall, E. D., 2d Lieutenant, C, 8th Connecticut.	May 14, 1864.	Comminution of left humerus by conoidal ball.	May 14, 1864.	Three inches of lower end of humerus removed, by Surg. M. Storrs, 8th Connecticut.	Disch'd Oct. 4, 1864; pensioned. False point of motion; use of arm lost. <i>Specs.</i> 1421.
88	Hammerly, M., Pt., B, 12th Illinois, age 29.	July 22, 1864.	Wound of right elbow . . . . .	July 22, 1864.	Excision, by Surg. J. Zeiring, 57th Illinois.	Mustered out Sept. 14, 1864; pensioned. Rotary motion nearly destroyed.
89	Hannan, J., Serg't, G, 11th Kentucky Cavalry, age 19.	June 29, 1864.	Compound comminuted fracture at upper third of left radius by conoidal ball; joint involved.	Primary	Excision of head and four inches of radius, by Surg. C. W. McMillan, 1st Tennessee.	Good use of elbow, though partially anchylosed. To V. R. C. March 10, 1865; pensioned. Great atrophy of forearm.
90	Hanrahan, J., Pt., K, 90th Illinois, age 37.	July 22, 1864.	Right elbow joint fractured by conoidal ball.	July 22, 1864.	Excision of joint with two inches of humerus, by Surg. J. A. Hutchinson, 15th Michigan.	Disch'd June 10, 1865; pensioned. Anchylosis with atrophy; limb entirely useless.



NO.	NAME, AGE, AND MILITARY DESCRIPTION.	DATE OF INJURY.	NATURE OF INJURY.	DATE OF OPERATION.	OPERATION AND OPERATOR.	RESULT AND REMARKS.
91	Harding, H. J., Corp'l, C, 8th New York Heavy Artillery, age 24.	June 3, 1864.	Shot wound through right elbow joint; ulna fractured.	June 3, 1864.	Five inches upper end of ulna excised through five-inch incision.	Disch'd July 12, 1865. False joint, motion free, rotation lost; hand and forearm useless for labor.
92	Hartings, J., Pt., B, 33d New Jersey.	May 25, 1864.	Right elbow joint severely fractured by a round bullet.	May 25, 1864.	Excision, by Surg. J. Riley, 23d New Jersey.	Duty November 23, 1864. Not a pensioner.
93	Hartwick, M. S., Corp'l, D, 55th Ohio, age 24.	Mar. 19, 1865.	Outer condyle of right humerus shattered by a conoidal ball.	Mar. 19, 1865.	Portion of outer condyle of humerus excised.	Disch'd July 25, 1865; pens'd. Bony ankylosis at angle of 45°.
94	Hathaway, G. W., Pt., D, 40th Massachusetts, age 23.	June 1, 1864.	Fracture of left elbow joint by a conoidal ball.	June 2, 1864.	Elbow joint, through four-inch incision on posterior aspect.	Disch'd Oct. 15, 1864; pensioned. Perfect ankylosis; arm almost useless.
95	Hawkins, A. P., Lieut., E, 2th New York Heavy Artillery, age 20.	Aug. 25, 1864.	Gunshot fracture of lower third of left humerus.	Aug. 26, 1864.	Condyles and one inch of humerus removed through three-inch incision, by Surgeon G. Chaddock, 7th Michigan.	September 1, 1864, amputation of arm; hemorrhage; brachial ligated. Disch'd Jan. 25, 1865; pensioned. <i>Spec.</i> 2010.
96	Haynes, E. C., Lieut., D, 6th Iowa, age 21.	Aug. 22, 1864.	Ball passed through right elbow joint.	Aug. 22, 1864.	Excision of portion of shaft of humerus, by Surg. A. Goslin, 48th Illinois.	Erysipelas; hemorrhage; arm amputated Sept. 2, hemorrhage recurred. Disch'd July 22, 1865; pensioned. <i>Spec.</i> 3484.
97	Hays, W. L., Pt., I, 44th Alabama, age 30.	Oct. 7, 1864.	Compound comminuted fracture of left elbow.	Oct. 7, 1864.	Three inches of bone from elbow joint, through a longitudinal incision.	Disch'd January 11, 1865. Entirely recovered, without union.
98	Heaton, H., Corp'l, F, 148th Pennsylvania, age 35.	Mar. 31, 1865.	Left olecranon fractured and elbow joint opened by conoidal ball.	Mar. 31, 1865.	Olecranon excised through straight incision.	Disch'd Sept. 29, 1865; pens'd. Complete ankylosis; atrophy; 1872, ulcer discharging.
99	Hinman, G. C., Corp'l, B, 188th Pennsylvania, age 20.	May 14, 1864.	Rifle ball passed from point of elbow down between bones, fracturing ulna.	May 14, 1864.	Excision of two inches of ulna, including the head.	Disch'd Oct. 8, 1864; pensioned. Complete ankylosis; limb useless.
100	Hopkins, G. B., Pt., A, 3d Vermont, age 23.	May 5, 1864.	Bones of right elbow comminuted by conoidal ball.	May 5, 1864.	Partial excision of elbow joint.	Mustered out May 13, 1865; pensioned. Flexion and extension lost; arm useless.
101	Horton, E., Pt., I, 71st Pennsylvania, age 25.	June 4, 1864.	Shell fracture of condyles of right humerus.	June 5, 1864.	Three inches of humerus, including condyles, by Surg. M. Rizer, 73d Pennsylvania.	Disch'd Nov. 29, 1864; pens'd. Arm of but little use for manual labor.
102	Howes, L., Pt., E, 1st Massachusetts.	May 18, 1864.	Fracture of elbow joint; outer condyle of left humerus shattered by a shell.	May 18, 1864.	Two inches end of humerus, by Surg. C. K. Irwine, 73d New York.	Left hospital Aug. 5, 1864; pensioned. Arm shortened three inches, abridging its use. <i>Spec.</i> 3234.
103	Hubbard, T. J., Sergeant, C, 8th Connecticut, age 30.	May 7, 1864.	Right elbow fractured by conoidal ball passing through it.	May 7, 1864.	Inferior articular extremity of humerus excised through straight incision.	Disch'd July 11, 1865; pens'd. Ankylosis; forearm flexed; 1873, occasional discharge of pieces of bone; atrophied.
104	Hubner, F., Pt., B, 26th Wisconsin, age 26.	May 26, 1864.	Comp'd comminuted fracture condyles of humerus by conoidal ball.	May 26, 1864.	Excision of left elbow through six-inch incision.	Disch'd July 20, 1865; pensioned. Joint nearly ankylosed; rotation lost.
105	Hudson, C. W., Pt., C, 140th New York, age 22.	May 6, 1864.	Conoidal ball entered olecranon process and fractured the left elbow joint.	May 7, 1864.	One and a half inches end of humerus, two inches radius and ulna, through four-inch linear incision.	Disch'd May 7, 1865; pensioned. False joint; limb useless; will never be restored for labor.
106	Hunt, P., Pt., I, 74th Ohio, age 35.	April 4, 1864.	Shot fracture of upper end of right ulna.	April 5, 1864.	Excision of six inches upper portion of ulna, by A. Surg. A. J. Gilson, 6th Connecticut.	Erysipelas. Disch'd September 17, 1864; pensioned. Permanent ankylosis; cannot flex fingers; forearm atrophied.
107	Ingersoll, G., Pt., E, 47th Illinois.	May 22, 1863.	Fracture of right elbow joint by a shell.	May 22, 1863.	Two and a half inches end of humerus, and olecranon process, by Surgeon H. Z. Gill, U. S. V.	Disch'd Nov. 25, 1863; pensioned. Can do manual labor not requiring elevation of arm.
108	Jackson, J. L., Pt., A, 72d Ohio.	June 8, 1863.	Fracture of olecranon and condyles of left humerus by conoidal ball.	June 8, 1863.	Excision of condyles and olecranon, by Surg. J. B. Rice, 72d Ohio.	Soft joint. Duty Nov. 23, 1863. Disch'd May 31, 1864; pensioned. Separation between bones, two inches; forearm hangs dangling.
109	Johne, H., Pt., G, 62d Pennsylvania, age 22.	May 12, 1864.	Compound fracture of left elbow joint by a conoidal ball.	May 12, 1864.	Head and portion of shaft of ulna removed.	Hemorrhage; arm amputated June 4, 1864. Disch'd January 18, 1865; pensioned.
110	Johnson, G. W., Pt., L, 1st Virginia.	July 2, 1863.	Right elbow joint wounded by a conoidal ball.	July 3, 1863.	Resection of right elbow joint.	To City Point November 12, 1864, for exchange.
111	Johnson, J. A., Pt., B, 2d N. Y. M. I., age 23.	June 3, 1864.	Comminuted fracture of heads of left radius and ulna and condyles of humerus.	June 4, 1864.	Excision of joint.....	Disch'd July 14, 1865; pensioned. Complete ankylosis; periostitis and osteitis; arm worse than useless.
112	Johnston, J. E., Pt., B, 122d Ohio, age 19.	June 3, 1864.	Shot fracture of the right forearm.	June 3, 1864.	Head of radius excised through incision six inches long.	Disch'd Mar. 17, 1865; pensioned. Permanent ankylosis; arm of little use.
113	Jones, C. H., Serg't, A, 24th Massachusetts, age 26.	Oct. 7, 1864.	Right elbow joint fractured by a conoidal ball.	Oct. 7, 1864.	One and a half inches end of humerus.	Disch'd Jan. 29, 1866; pensioned. Necrosis of humerus; arm useless.
114	Jones, J. A., Pt., B, 53d Georgia, age 18.	Nov. 29, 1863.	Fracture of radius and both condyles of left humerus; also wound three inches below shoulder joint.	Nov. 29, 1863.	Both condyles of humerus, olecranon process, and three inches radius, through longitudinal incision, by Surg. J. J. Knott, 53d Georgia.	Useful limb; ulna extending beyond radius formed a new olecranon process; no impairment of functions.
115	Jones, J. A. II., Pt., B, 1st Palmetto Sharpshooters.	Oct. 27, 1864.	Wound of right elbow joint.....	Oct. 27, 1864.	Excision of joint.....	Furloughed. Recovered.
116	Kelley, W., 1st Lieut., D, 59th New York, age 27.	June 22, 1864.	Fracture of left elbow joint ..	June 22, 1864.	Excision of elbow joint, by Surg. N. Hayward, 20th Massachusetts.	Disch'd Oct. 22, 1864; pensioned. No union; atrophied; no control over forearm; can use hand when arm is supported.
117	Kerr, W. J., Pt., H, 11th Alabama, age 22.	Aug. 16, 1864.	Upper third left radius and ulna fractured by conoidal ball.	Aug. 16, 1864.	Both bones at elbow joint, three inches removed.	Did well. Retired January 2, 1865.
118	Kieffer, T. T., Pt., M, 14th New York Heavy Artillery, age 16.	June 18, 1864.	Fracture right elbow joint by conoidal ball; (also wound through body.)	June 18, 1864.	Head and upper third of radius excised.	Disch'd May 27, 1865; pensioned. Complete ankylosis; cough hectic. Died in May, 1866.
119	King, C. B., Pt., B, 25th Virginia, age 25.	July 3, 1863.	Conoidal ball entered right elbow joint, injuring articular surfaces.	July 3, 1863.	Complete excision of elbow joint; removal of ball.	Gangrene; little motion at elbow. Sent to City Point for exchange March 3, 1864.

NO.	NAME, AGE, AND MILITARY DESCRIPTION.	DATE OF INJURY.	NATURE OF INJURY.	DATE OF OPERATION.	OPERATION AND OPERATOR.	RESULT AND REMARKS.
120	King, W., Pt., B, 15th Michigan, age 20.	July 22, 1864.	Left humerus, radius, and ulna fractured at elbow.	July 22, 1864.	Three inches of ulna, end of radius smoothed, by Surg. J. H. Hutchinson, 15th Mich.	Disch'd Sept. 21, 1865; pensioned. Ankylosis and deformity; forearm and hand atrophied; useless for labor.
121	Lane, W. M., Pt., D, 9th New York Cavalry, age 22.	Aug. 25, 1864.	Conoidal ball penetrated right elbow joint, emerging at internal condyle.	Aug. 26, 1864.	Excision of upper portion of ulna through a straight incision.	Disch'd June 15, 1865; pens'd. Ankylosis; arm flexed and entirely useless.
122	Langdon, L., Pt., G, 17th Vermont, age 29.	May 6, 1864.	Fracture of right elbow joint by conoidal ball.	May 6, 1864.	Excision of three inches of shaft and condyles of humerus through linear incision.	Arm shortened nearly two inches. To V. R. C. December 14, 1864; pensioned. Died.
123	Leiblin, W., Pt., C, 20th Massachusetts.	Dec. 11, 1862.	Right elbow joint fractured by conoidal ball.	Dec. 11, 1862.	Lower two inches of humerus and olecranon process excised, by Surg. N. Hayward, 20th Massachusetts.	Arm amputated May 16, 1863. Disch'd August, 1864; pens'd. Died May 23, 1872. <i>Specs.</i> 1664.
124	Linsley, J., Private, G, 19th Michigan, age 20.	July 20, 1864.	Compound comminuted fracture of left humerus, involving elbow joint.	July 20, 1864.	Excision of three inches lower end of humerus through five-inch incision.	Erysipelas. Disch'd July 22, 1865; pensioned. Arm entirely useless.
125	Long, D., Pt., D, 72d Indiana.	June 27, 1863.	Gunshot wound of right elbow, comminuting head of ulna; soft parts much lacerated.	June 28, 1863.	Twenty-one fragments—one-third shaft of ulna, also olecranon process, thro' a straight incision, by Surg. I. Moses, U. S. V.	Hæmorrhage, gangrene. Amputation October 26, 1863. Disch'd February 24, 1864; pensioned. <i>Specs.</i> 1750, 2129.
126	Lovell, C. H., Serg't, D, 14th New York Heavy Artillery, age 23.	June 2, 1864.	Compound comminuted fracture of lower third of right humerus by a conoidal ball.	June 3, 1864.	Excision of four inches of articulating extremity of humerus through a linear incision.	Disch'd Sept. 6, 1864; pensioned. Extension and flexion of limb and grip of hand perfect; can do any work at arm's length.
127	Lucas, W. R., Pt., A, 10th Missouri.	May 14, 1863.	Shot fracture of left elbow joint	May 14, 1863.	Excision of entire lower end of humerus, including condyles and portion of ulna.	Disch'd Nov. 20, 1863; pens'd. Limbs shortened over four inches; forearm hangs powerless.
128	Lyman, W., Serg't, A, 22d Massachusetts, age 33.	June 3, 1864.	Compound comminuted fracture of right ulna by a bullet.	June 6, 1864.	Upper portion of ulna excised through straight incision.	Disch'd Oct. 17, 1864; pensioned. Limb powerless; 1873, false ankylosis.
129	Lynch, C., Pt., H, 20th Massachusetts, age 22.	Aug. 14, 1864.	Shell wound of left elbow joint	Aug. 14, 1864.	Excision of joint through incision four inches long.	Furloughed September 16, 1864. Not a pensioner.
130	Mahon, J. J., Corp'l, G, 69th New York, age 30.	June 3, 1864.	Wound of left elbow joint, fracture of ulna by conoidal ball; articular surface of humerus destroyed by pins; (also w'nd of chest.)	June 5, 1864.	End of humerus above condyles, and ulna one inch below its articular facet, excised through linear incision, by A. A. Surg. E. DeWitt.	Disch'd June 8, 1865; pensioned. Joint weak and requires support; arm useless for manual labor.
131	Martin, J. W., Pt., F, 21st Kentucky.	July 22, 1864.	Shot fracture of left elbow.	July 22, 1864.	Excision, by Surg. C. J. Walton, 21st Kentucky.	Gangrene; August 3, 1864, arm amputated. Disch'd Feb. 23, 1865; pensioned.
132	Mashev, J., Lieut., E, 1st Louisiana, age 23.	July 3, 1863.	Articular processes left elbow destroyed by conoidal ball.	July 4, 1863.	Resection of left elbow joint.	Recovery. Transferred for exchange March 21, 1864.
133	Mason, N., Pt., F, 29th Massachusetts, age 19.	June 17, 1864.	Fracture of shaft and condyles of left humerus by conoidal ball; joint involved.	June 19, 1864.	Two inches shaft and condyles of humerus, through straight incision.	Necrosis; arm shortened three inches. Disch'd Jan. 16, 1866; pensioned. An ulcer covers half of arm; emaciation; arm useless. Died Oct. 24, 1866.
134	May, J. N., Pt., B, 6th Florida, aged 20.	May 31, 1864.	Fracture of right elbow joint.	May 31, 1864.	Excision of four inches of extremity of humerus.	Convalescent from measles. Furloughed July 28, 1864.
135	McBride, B., Serg't, I, 10th Georgia, age 32.	May 3, 1863.	Compound fracture right radius, extending to elbow joint.	May 4, 1863.	Fractured portions through a longitudinal incision.	July 6, erysipelas. Furloughed August 12, 1863.
136	McCowen, A., Pt., Carpenter's Va. Battery, age 24.	Nov. 30, 1863.	Extensive fracture of right elbow joint by conoidal ball.	Nov. 30, 1863.	One and an eighth inches of humerus, three of ulna, and two and a half of radius.	February 28, 1864, doing well. Recovered.
137	McGrath, J., Pt., C, 109th Pennsylvania, age 20.	May 3, 1863.	Left elbow joint fractured by a conoidal ball.	May 3, 1863.	Lower portion external condyle of humerus, by Surg. James L. Dunn, 109th Penn.	To V. R. C. January 11, 1864; pensioned. Complete ankylosis; in good position.
138	McGuire, J., Pt., C, 26th Massachusetts, age 18.	Sept. 19, 1864.	Shot fracture of left humerus and upper portion of ulna, involving joint; (also right radius and ulna fractured at middle third, and wound of jaw.)	Sept. 19, 1864.	Both condyles, and articular surface of ulna—left arm—through incision four inches, by Surg. C. H. Andrus, 176th New York.	Can raise hand to head. Disch'd June 5, 1865; pensioned. Ankylosis of both joints; limbs powerless and useless.
139	McIntyre, Jr., T., Sergeant, B, 36th Mass., age 47.	Sept. 19, 1864.	Comminuted fracture of left ulna and internal condyle of humerus.	Sept. 20, 1864.	Four inches of ulna and internal condyle of humerus, by Surg. H. Fearn, 175th N. Y.	Discharged March 11, 1865; pensioned. Forearm and hand are powerless and useless.
140	McMainus, P., Pt., I, 20th Massachusetts.	Oct. 27, 1864.	Left humerus fractured by a conoidal ball; joint opened.	Oct. 27, 1864.	Inner condyle of humerus, by Surg. S. H. Plumb, 82d N. Y.	To V. R. C. August 3, 1865. Not a pensioner.
141	McPherson, A., Corp'l, C, 4th Ohio, age 22.	May 24, 1864.	Shell fracture of left elbow joint.	May 24, 1864.	Excision of elbow joint.	Duty October 7, 1864.
142	McTaggart, C. P., Lieut., K, 3d Michigan.	May 31, 1862.	Comminuted fracture of left elbow joint by a conoidal ball.	May 31, 1862.	Excision of elbow joint.	June 1, 1862, arm amputated; Sept. 7, 1863, re-amputation. Mustered out Sept. 24, 1866; pensioned. Appointed Lieutenant March 1, 1867. <i>Specs.</i> 1741.
143	Mead, G. C., Pt., C, 10th Vermont, age 22.	June 3, 1864.	Fracture of left radius at elbow by a conoidal ball.	June 3, 1864.	Upper part of radius excised.	Disch'd June 12, 1865; pensioned. Ankylosis at right angle; some use of hand.
144	Melody, H., Pt., B, 109th New York, age 47.	May 5, 1864.	Right humerus fractured by a conoidal ball; joint involved.	May 6, 1864.	Partial excision of elbow joint.	Disch'd June 5, 1865; pensioned. Complete ankylosis at right angle; atrophy.
145	Merriam, I. B., Serg't, I, 122d New York, age 23.	Sept. 19, 1864.	Outer condyle of right humerus shattered by a piece of shell.	Sept. 19, 1864.	Partial resection of elbow joint, all shattered portions of bone removed, by Surg. G. T. Stevens, 77th New York. A second piece of shell afterward found and removed.	Free use of elbow one month after injury. Disch'd July 1, 1865; pensioned. Sept. 1866, entire ankylosis of elbow joint at right angle; no rotation; atrophy of whole limb; has use of fingers.
146	Meyer, W., Pt., C, 7th Maryland, age 30.	Oct. 8, 1864.	Fracture of right forearm and humerus, involving elbow joint.	Oct. 8, 1864.	Excision of two inches of radius, including head, by Surg. A. A. White, 8th Maryland.	Disch'd June 26, 1865; pensioned. Sequæstrum three inches long removed in 1866; ankylosis; arm atrophied and useless.
147	Miller, C., Serg't, H, 15th New York Heavy Artillery, age 25.	Feb. 6, 1865.	Fracture of left ulna.	Feb. 6, 1865.	Resection upper third of ulna at elbow joint, by Surg. A. A. White, 8th Maryland.	Disch'd July 17, 1865; pensioned. Joint completely ankylosed at nearly right angle; rotation lost.



No.	NAME, AGE, AND MILITARY DESCRIPTION.	DATE OF INJURY.	NATURE OF INJURY.	DATE OF OPERATION.	OPERATION AND OPERATOR.	RESULT AND REMARKS.
148	Miracle, T., Pt., E, 7th Indiana Cavalry, age 17.	Oct. 20, 1864.	Shot fracture of olecranon process of left ulna by conoidal ball.	Oct. 21, 1864.	Olecranon process, thro' semi-circular incision, by A. Surg. S. S. Jessop, U. S. V.	Favorable. To Veteran Reserve Corps May 11, 1865.
149	Mitchell, J., Lieut., B, 4th Artillery.	Mar. 29, 1865.	Gunshot fracture of olecranon process of ulna and head of radius by conoidal ball.	Mar. 30, 1865.	Two and a half inches olecranon process, articular end of radius, through longitudinal incision, by Surg. W. S. Thompson, U. S. V.	Duty October 24, 1865. Died November 13, 1869, while still in the service.
150	Mix, D. N., Serg't, F, 8th Connecticut, age 38.	June 3, 1864.	Fracture of right forearm at upper third by an explosive ball.	June 3, 1864.	Excision of elbow joint. . . . .	Disch'd Jan. 16, 1865; pensioned. March, 1865, portion of missile removed; excitation: cannot feed himself with hand.
151	Monaghan, J., Corp'l, G, 91st Pennsylvania.	July 2, 1863.	Fracture of right elbow by a conoidal ball; olecranon fissured vertically.	July 4, 1863.	Olecranon and portion of ulna, through straight incision, by A. Surg. B. Howard, U. S. A.	To Veteran Reserve Corps February 4, 1864; not a pensioner. <i>Spec.</i> 1378.
152	Monroe, A. R., Corp'l, B, 11th Infantry, age 24.	May 12, 1864.	Gunshot wound of left elbow joint by a conoidal ball; (also wound of lung, and one on right side of spine.)	May 13, 1864.	Condyloid extremity left humerus, and olecranon process of ulna, through incision five inches long.	Gangrene. Disch'd Dec. 27, 1864; pensioned. Forearm dangles by loose attachment; muscles atrophied; arm useless.
153	Mooney, N., Corp'l, E, 25th Massachusetts, age 20.	June 3, 1864.	Comminution of left elbow joint by a conoidal ball.	June 6, 1864.	Excision of heads of radius and ulna and condyles of humerus through straight incision.	Motion and power of entire extremity retained. Disch'd Oct. 19, 1864; pensioned. Pension Examiner reports forearm useless; free use of fingers.
154	Moore, W. E., Pt., G, 66th Indiana, age 20.	Aug. 11, 1864.	Wound of left arm. . . . .	Aug. 11, 1864.	Condyles and portion of humerus, four and a half inches in all, by Surg. J. Pogue, 66th Illinois.	Disch'd June 18, 1865; pensioned. Forearm entirely useless.
155	Morey, F. A., 1st Lieut., D, 125th New York, age 23.	May 31, 1864.	Wound of left elbow joint by ball.	May 31, 1864.	Excision of external condyle of humerus, by Surg. W. S. Cooper, 125th New York.	Disch'd Jan. 4, 1865; pensioned. Ankylosis at right angle; arm emaciated; unable to move wrist joint.
156	Moseley, G. W., Serg't, K, 9th Tennessee, age 24.	Nov. 30, 1864.	Shot fracture of right ulna one inch below elbow joint by a conoidal ball.	Dec. 1, 1864.	Two and a half inches end of ulna, through five-inch incision, by Surg. Owens, 9th Tenn.	To Provost Marshal February 24, 1865.
157	Moulton, J., Pt., D, 1st Maine Cavalry, age 25.	Aug. 16, 1864.	Gunshot fracture of left elbow joint.	Aug. 16, 1864.	Condyloid extremity of humerus and olecranon process excised through an incision six inches long at back of elbow.	Hæmorrhage; amp. arm, middle third, Aug. 28; re-amp. upper third March 14, 1865. Disch'd Aug. 29, 1865; pensioned. Died December 20, 1869, of lung disease. <i>Spec.</i> 3649.
158	Mueller, G. H., Pt., F, 11th New Jersey, age 26.	Mar. 31, 1865.	Fracture of right elbow joint by fragments of shell.	Apr 1, 1865.	Excision of upper part of radius through six-inch incision.	Disch'd Sept. 18, 1865; pensioned. Complete ankylosis at obtuse angle; arm useless for labor.
159	Murphy, J., Corp'l, D, 139th New York, age 21.	June 2, 1864.	Conoidal ball entered anteriorly one inch above right elbow, making its exit through olecranon process.	June 2, 1864.	Excision of three and a half inches of humerus, radius and ulna.	Ankylosis; false joint; atrophy; forearm useless. Disch'd June 28, 1865; pensioned.
160	Murtaugh, J., Pt., D, 69th New York, age 30.	Dec. 13, 1862.	Comminution of lower end of right humerus; ball passed through condyles.	Dec. 15, 1862.	Two inches end of humerus, both condyles, and spicula removed thro' an S-shaped incision, by Surgeon D. W. Bliss, U. S. V.	Passive motion at elbow; motion of wrist and fingers unaffected. To V. R. C. Jan. 25, 1863; pensioned. Arm useless for labor. <i>Spec.</i> 2224.
161	Myatt, H. B., Lieut., K, 14th Louisiana, age 26.	June 28, 1862.	Compound comminuted fracture of both condyles of left humerus and olecranon process of ulna by a shell; also wound of inguinal region.	June 28, 1862.	The olecranon sawn off at its base, and humerus resected two inches above the condyles through crucial incision, by Surg. P. Formento, jr.	Furloughed October 29, 1862; re-joined his regiment. Can use his left arm with as much facility as the other.
162	New, A., Serg't, I, 24th Alabama, age 20.	Sept. 19, 1863.	Gunshot wound of elbow joint.	Sept. 19, 1863.	Excision of elbow joint thro' an H-shaped incision.	Favorable; recovered.
163	O'Donnell, M., Pt., H, 8th Pennsylvania Cavalry, age 21.	Aug. 23, 1864.	Fracture of left elbow by a conoidal ball.	Aug. 23, 1864.	Excision of elbow, including about six inches of bone.	Disch'd Feb. 23, 1865. In 1870 Pen. Exam. reports wound unhealed, limb shortened six inches. In 1873 four inches shortening; false joint; necrosis; discharging ulcers.
164	Ohland, F., Pt., H, 2d Michigan, age 20.	Nov. 24, 1863.	Compound fracture of right elbow joint by a conoidal ball.	Nov. 24, 1863.	Excision of right elbow joint, by Surg. G. B. Cogswell, 29th Massachusetts.	Disch'd June 8, 1864; pensioned. Arm hangs by the ligaments, and muscles useless.
165	Oliver, W. M., Pt., B, 174th Ohio, age 18.	Dec. 4, 1864.	Fracture of left radius and ulna by a conoidal ball, involving elbow joint.	Dec. 5, 1864.	Articular ends of radius and ulna, with three inches of shaft, through a T-shaped incision, by Surg. S. D. Turney, U. S. V.	Mustered out May 30, 1865; pensioned. Joint firmly ankylosed; forearm at an obtuse angle; atrophy; loss of use and strength of arm.
166	Owen, C. J., Pt., F, 66th Illinois, age 17.	May 28, 1864.	Conoidal ball passed laterally through right elbow joint, comminuting the bones.	On field.	Excision of lower end of humerus and upper ends of radius and ulna.	Artificial joint; muscles atrophied. Disch'd July 7, 1865. In 1867 arm dangles uselessly at side.
167	Palmer, V., Pt., G, 14th New Jersey, age 50.	Nov. 27, 1863.	Fracture of left elbow joint by a conoidal ball.	Nov. 27, 1863.	Condyles and lower third of humerus, through an incision four inches long, by Surg. J. S. Martin, 14th New Jersey.	No bony union. Disch'd June 11, 1865; pensioned. Arm useless for labor.
168	Pancost, G. W., Pt., F, 83d New York, age 29.	Sept. 17, 1862.	Fracture of upper third of left radius.	Sept. 18, 1862.	Excision of head and one inch of shaft of radius, by A. Surg. H. Pinkney, 83d New York.	End of radius necrosed, surface of joint carious; amputation of arm Oct. 10, 1862. Disch'd Dec. 23, 1862; pensioned. <i>Spec.</i> 772.
169	Parlee, A. C., Pt., E, 53d Georgia, age 33.	May 3, 1863.	Fracture of right elbow joint, injuring olecranon.	May 4, 1863.	Both condyles of humerus, with olecranon process of ulna and head of radius, thro' incision nine inches long, by Surg. J. J. Knott, 53d Ga.	Recovered, with a useful limb.
170	Paul, A., Pt., B, 111th Illinois, age 26.	July 22, 1864.	Fracture of condyle of right humerus by a conoidal ball.	July 22, 1864.	Excision of condyle, by Surg. J. C. Morgan, 29th Missouri.	Disch'd June 6, 1865; pensioned. Ankylosis; joint at right angle; arm atrophied.
171	Paulman, C., Pt., B, 115th Pennsylvania, age 38.	May 6, 1864.	Fracture of left elbow joint. . . . .	May 6, 1864.	Excision of elbow joint with four inches of radius and ulna.	Disch'd March 4, 1865; pensioned. Forearm hangs by soft parts, and totally useless. Died Mar. 6, '68.

No.	NAME, AGE, AND MILITARY DESCRIPTION.	DATE OF INJURY.	NATURE OF INJURY.	DATE OF OPERATION.	OPERATION AND OPERATOR.	RESULT AND REMARKS.
172	Pease, A. N., Pt., C, 3d South Carolina, age 23.	July 3, 1863.	Articulating surfaces left elbow joint fractured by a conoidal ball.	July 4, 1863.	Lower end of humerus, and upper end of radius and ulna, through longitudinal incision.	Slight motion of joint. For exchange September 28, 1863.
173	Peck, D., Corp'l, E, 9th New York Cavalry, age 22.	May 5, 1864.	Wound of left elbow by a conoidal ball.	May 5, 1864.	Excision of left elbow joint through an incision five inches long.	Disch'd Aug. 31, 1864; pensioned. Complete ankylosis; arm semiflexed; motor of fingers not much impaired.
174	Pendergast, R., Serg't, A, 2d Massachusetts, age 27.	Dec. 20, 1864.	Conoidal ball passed through right elbow, comminuting lower third of humerus.	Dec. 20, 1864.	Two and a half inches end of humerus, through linear incision over internal condyle, by Surg. P. S. Arndt, 31st Wis.	Duty, June 15, 1865; pensioned. No joint; no use of forearm; worse than useless.
175	Peterson, A. S., Pt., B, 2d Massachusetts, age 30.	Mar. 16, 1865.	Compound comminuted fracture of left elbow by a conoidal ball.	Mar. 16, 1865.	Resection of two and a half inches lower end of humerus through T incision, by Surg. H. Z. Gill, U. S. V.	Passive motion; movement 90°. Disc'd July 26, 1865; pensioned. Arm shortened two inches and forearm hangs by flesh; useless.
176	Phipps, E. P., 1st Lieut., A, 12th New Jersey, age 21.	May 12, 1864.	Shot fracture of left elbow by a conoidal ball.	May 12, 1864.	Excision of elbow joint, external condyle of humerus, and ends of radius and ulna.	Disch'd Sept. 20, 1864; pensioned. Complete ankylosis; forearm semiflexed; impaired.
177	Pollock, A. J., Corp'l, F, 12d Ohio, aged 29.	June 1, 1864.	Wound of right elbow, fracturing external condyle, by a minie ball.	June 1, 1864.	Excision of elbow joint, external condyle.	Disch'd Feb. 8, 1865; pensioned. Complete ankylosis; atrophy of arm and hand. Died Dec. 31, 1869, of consumption.
178	Poole, J. M., Capt., E, 1st South Carolina.	May 24, 1864.	Ball passed through elbow joint.	May 25, 1864.	Complete resection of elbow joint through an H incision.	Furloughed July 23, 1864.
179	Poor, L., Serg't, A, 23d Massachusetts, age 27.	Mar. 8, 1865.	Wound through right elbow joint.	Mar. 8, 1865.	Excision of joint.	Disch'd June 8, 1865; pensioned. Arm at right angle; strong and useful; cannot put hand to mouth; writes easily.
180	Primrose, W., Pt., F, 8th Colored Troops, age 22.	Oct. 12, 1864.	Fracture of left elbow joint by a conoidal ball.	Oct. 12, 1864.	Excision of elbow joint.	Discharged April 14, 1865; pensioned. Arm useless.
181	Pringle, J. Pt., F, 11th W. Virginia, age 33.	Oct. 19, 1864.	Comminuted shot fracture of right elbow joint.	Oct. 20, 1864.	Excision of head of radius and internal condyle of humerus through straight incision over olecranon, by Surg. C. H. Andrus, 176th New York.	Motion of joint quite limited. Disch'd May 27, 1865; pens'd. No bony union; cannot raise arm, the muscles having no fixed point of attachment.
182	Pullin, R. H., Pt., E, 31st Virginia, age 35.	May 16, 1864.	Ball entered anterior aspect of left elbow joint and passed directly thro', crushing head of ulna.	May 17, 1864.	Excision of head and two inches of shaft of ulna.	Furloughed July 25, 1864.
183	Ratekin, J., Pt., B, 68th Indiana, age 23.	Sept. 19, 1863.	Gunshot fracture of lower end of right humerus; elbow joint opened.	Sept. 20, 1863.	Fractured portion of humerus excised and ball extracted.	Disch'd November 29, 1864; pensioned. No union; forearm hangs pendant and useless.
184	Reardon, J., Pt., K, 21st Wisconsin.	May 14, 1864.	Fracture of left elbow joint by conoidal ball.	May 14, 1864.	Excision of elbow joint.	Amputation of arm July 10, 1864. Disch'd June 11, 1865; pens'd.
185	Reynolds, J. F., Pt., I, 13th Indiana Cavalry, age 18.	Dec. 14, 1864.	Fracture of inner condyle of right humerus and upper end of ulna by a conoidal ball.	Dec. 15, 1864.	Head and three and a half inches of right ulna, and condyle of humerus, through T-shaped incision, by Surg. C. H. Bill, 5th Tennessee Cav.	Ankylosis. Mustered out Sept. 30, 1865; pensioned. Angle of flexion 30°; hand and arm weak and nearly useless.
186	Reynolds, O., Pt., B, 137th New York.	Nov. 24, 1863.	Gunshot fracture of left elbow joint.	Nov. 24, 1863.	Excision of left elbow joint, by Surg. C. J. Bellows, 7th Ohio.	Disch'd July 3, 1865; pensioned. Ankylosis at an angle of 45°; the entire limb is atrophied, and useless for labor.
187	Rhoads, S., Pt., I, 58th Indiana, age 32.	Sept. 19, 1863.	Shot comminuted fracture of end of left ulna and humerus; patient weakened by diarrhoea and erysipelas.	Sept. 20, 1863.	Excision of comminuted portion of ulna.	Amputation of left arm at surgical neck Nov. 3, 1863. Disch'd March 15, 1864; pens'd. Spec. 2076.
188	Richardson, E. E., Corp'l, H, 80th Indiana, age 28.	May 14, 1864.	Comminuted fracture of left elbow joint by a conoidal ball; also fracture of ilium.	May 15, 1864.	Three inches of lower end of humerus, by Surgeon C. S. Frink, U. S. V.	Disch'd April 14, 1865; pens'd. Hand and arm almost entirely useless.
189	Roekwood, N. P., 1st Lieut., D, 14th Connecticut, age 32.	May 6, 1864.	Fracture of left radius and ulna.	May 6, 1864.	Excision of head of radius, by Surgeon F. A. Dudley, 14th Connecticut.	Disch'd Nov. 30, 1864; pens'd. Ankylosis; arm at a little more than a right angle; powerless.
190	Roe, W. M., Pt., I, 143d New York, age 38.	July 20, 1864.	Shot wound of right elbow joint, fracturing olecranon process of ulna.	July 24, 1864.	Excision of one and a half inches of ulna, by Surgeon D. Mathews, 143d New York.	Duty June 27, 1865; pensioned. Complete ankylosis; muscles atrophied; arm useless for labor.
191	Rogers, H. C., Lieut.-Col., 8th Minnesota, age 31.	Dec. 7, 1864.	Shot fracture of right ulna extending into elbow joint.	Dec. 8, 1864.	Head and two and a half inches of shaft of ulna, through a T-shaped incision, by Surg. S. D. Turney, U. S. V.	Disch'd May 15, 1865; pens'd. Complete ankylosis and loss of use of arm. Died May 8, 1871.
192	Ruddell, J. L., Pt., A, 15th Texas, age 21.	Sept. 1, 1864.	Wound of right elbow joint.	Sept. 1, 1864.	Five inches upper end of ulna excised.	Gangrene. Retired February 18, 1865.
193	Ryan, M., Pt., G, 1st Massachusetts Cavalry, age 24.	May 5, 1864.	Compound comminuted fracture of left humerus by a conoidal ball.	May 5, 1864.	Three and a half inches of condyles and shaft of humerus, through a linear incision over external condyle, by Surg. W. B. Reznor, 6th Ohio Cav., and A. Wood, 1st Mass. Cav.	Disch'd Oct. 26, 1864. In 1865, was able to draw forearm to shoulder; has a useful arm. In 1873, loss of motion in the joint; useless for labor; pensioned.
194	Seace, W. B., Pt., E, 96th Illinois, age 18.	May 9, 1864.	Compound shot fracture of right elbow joint.	May 9, 1864.	Partial excision, by Surg. C. J. Walton, 21st Kentucky.	Disch'd March 8, 1865; pens'd. Partial ankylosis of joint; cannot extend arm beyond right angle; atrophied.
195	Shackford, N., Capt., E, 12th New Hampshire.	June 3, 1864.	Fracture of humerus; destruction of elbow joint by musket ball; piece of shell knocked off three spinous processes.	June 3, 1864.	Resection of left elbow.	Disch'd June 21, 1865; pens'd. Whole arm useless; (previous wounds of head, forearm, thigh, and scapula.)
196	Sharp, J. A., Pt., A, 3d New Jersey, age 25.	June 27, 1862.	Compound fracture of right elbow joint by a musket ball.	June 27, 1862.	Upper third of ulna and lower fourth of humerus, by A. A. Surg. J. Swinburne.	Amputation of arm September 24, 1862. Discharged Dec. 3, 1862; pensioned. Spec. 225.
197	Shattuck, A. S., Serg't, F, 5th Michigan, age 24.	May 6, 1864.	Fracture of right elbow joint by a conoidal ball.	May 6, 1864.	Excision of right elbow joint and two inches of shaft of humerus.	Disch'd Sept. 28, 1864; pensioned. Forearm movable in any direction; arm shortened and smaller; nearly useless.
198	Sheppard, N., Corporal, B, 146th New York, age 21.	May 5, 1864.	Fracture of condyles of right humerus by a conoidal ball.	May 7, 1864.	Excision of elbow joint by an incision on posterior aspect four inches long.	Disch'd Oct. 6, 1864; pensioned. Perfect ankylosis at right angle; hand useless for labor.



No.	NAME, AGE, AND MILITARY DESCRIPTION.	DATE OF INJURY.	NATURE OF INJURY.	DATE OF OPERATION.	OPERATION AND OPERATOR.	RESULT AND REMARKS.
199	<i>Simmons, D. S.,</i> Pt., I, 4th North Carolina, age 33.	May 3, 1863.	Wound of left elbow joint by a round ball.	May 3, 1863.	Resection of left elbow joint.	Was nearly well when exchanged, June 25, 1863.
200	<i>Simpson, T. L.,</i> Lieut., 11, 17th Ohio, age 28.	Nov. 25, 1863.	Fracture of lower end of left humerus, involving elbow joint.	Nov. 26, 1863.	Excision of about two inches lower portion of humerus, including condyles.	Disch'd July 8, 1864; pensioned; No bony union; signs of necrosis; considerable use of arm.
201	<i>Smith, D. G.,</i> Pt., D, 12th Indiana, age 24.	May 26, 1864.	Fracture of right elbow joint by a conoidal ball.	May 26, 1864.	Excision of entire elbow joint, by Surg. D. Halderman, 46th Ohio.	Discharged June 29, 1865; pensioned. Artificial joint; arm and hand worse than useless.
202	<i>Smith, E. J.,</i> Pt., I, 7th Georgia, age 24.	July 25, 1864.	Fracture of right elbow joint.	July 25, 1864.	Excision of elbow joint.	On August 31, 1864, was in hospital "doing well."
203	<i>Smith, G. W.,</i> Serg't, K, 139th New York, age 36.	Sept. 29, 1864.	Comp'd comminuted fracture of right elbow joint by a minie ball; radius and ulna not involved.	Sept. 29, 1864.	Three inches of condyle and continuity of humerus, through a linear incision.	Disch'd April 18, 1865; three-fourths of an inch shortening; pensioned. Anchylosis; forearm and hand atrophied and useless.
204	<i>Smith, I. D.,</i> Pt., E, 6th Louisiana, age 23.	July 3, 1863.	Shot fracture of left elbow joint.	July, 1863.	Excision of elbow joint.	Flexion and extension of arm about 45°; no rotation. Paroled Sept. 25, 1863.
205	<i>Smith, J. A. B.,</i> Captain, B, 139th New York, age 29.	June 24, 1864.	Compound fracture of right elbow joint by a conoidal ball.	June 24, 1864.	Excision of joint.	Disch'd Jan. 4, 1865; pensioned. Amputation of arm at upper third March 15, 1866.
206	<i>Smith, P.,</i> Corp'l, C, 25th Indiana, age 41.	Dec. 11, 1864.	Wound of left elbow joint.	Dec. 11, 1864.	Resection of joint.	Discharged March 20, 1865.
207	<i>Speidel, J.,</i> Lieut.-Colonel, 6th Connecticut, age 37.	Oct. 22, 1862.	Articular surfaces of right humerus, radius, and ulna fractured by a canister shot.	Oct. 24, 1862.	Entire right elbow joint and portion of shaft of humerus, through an H incision, by Surg. F. L. Dibble; 6th Conn.	Useful arm. Discharged July 11, 1864; pensioned. Wound opens; amputation will be necessary eventually.
208	<i>Stahl, L.,</i> Serg't, E, 4th Alabama, age 23.	July 28, 1864.	Injury of elbow joint by shell.	July 28, 1864.	Excision of elbow joint.	Did well. Furloughed September 17, 1864.
209	<i>Stanton, C. T.,</i> Captain, E, 21st Connecticut, age 24.	May 16, 1864.	Ball entered below elbow joint, passed upward, and emerged at joint, fracturing external condyle of right humerus.	May 16, 1864.	External condyle of humerus excised through the wound enlarged.	Gangrene; anchylosis of joint; rotation preserved. Discharged September 14, 1864; pensioned.
210	<i>Stanway, D.,</i> Captain, G, 1st Michigan, age 27.	May 5, 1864.	Compound comminuted fracture of end of left humerus by a conoidal ball.	May 5, 1864.	Two inches lower end of humerus, through straight incision, by Surg. W. Holbrook, 18th Massachusetts.	Duty Aug. 29, 1864; pensioned. Loose joint; has no use of hand and forearm.
211	<i>Stark, A.,</i> Serg't, D, 68th New York, age 23.	July 1, 1863.	Compound fracture of right elbow joint.	July 1, 1863.	Excision of upper part of ulna.	Amputation of arm July 15, 1863. To V. R. C. Jan. 5, '64; pens'd.
212	<i>Stephens, F. M.,</i> Pt., D, 26th Tennessee, age 26.	June 22, 1864.	Compound comminuted fracture of right elbow joint.	June 23, 1864.	Internal condyle of humerus, two inches of ulna, and head of radius.	Retired January, 1865. False joint; arm powerless.
213	<i>Stephenson, J.,</i> Pt., C, 6th Texas, age 45.	Nov. 30, 1864.	Wound of right elbow joint by a conoidal ball.	Nov. 30, 1864.	Excision of elbow joint.	To Provost Marshal January 17, 1865.
214	<i>Stewart, T.,</i> Pt., B, 57th Pennsylvania, age 19.	May 5, 1864.	Wound of right elbow joint by a conoidal ball.	May 5, 1864.	Excision of two inches upper end of radius.	Disch'd Nov. 4, 1864; pensioned. Anchylosis at an angle of 45°; arm and hand useless.
215	<i>Story, W.,</i> Pt., G, 10th Georgia Battery, age 29.	June 22, 1864.	Compound comminuted fracture of superior end of right ulna, ball lodging on inner condyle of humerus.	June 23, 1864.	Two inches head and end of ulna, through a straight incision four inches long.	Furloughed July 28, 1864.
216	<i>Summers, W. H.,</i> Serg't, D, 42d Ohio, age 29.	May 19, 1863.	Compound comminuted fracture of right elbow; ball struck olecranon and passed through condyles of humerus.	May 19, 1863.	Condyles of humerus and upper end of ulna excised, by Surg. J. Pomrene, 42d Ohio.	Free motion at elbow joint and some at fingers. Duty Aug. 20, 1863; pens'd. In 1866, Pen. Ex. reports arm no account for labor.
217	<i>Taylor, J. T.,</i> G, 168th New York, age 20.	Sept. 17, 1862.	Comminuted fracture of upper third of left ulna by conoidal ball.	Sept., 1862.	Three and a half inches of extremity of ulna, by Surg. G. Grant, U. S. V.	Disch'd Jan. 13, 1863; pensioned. Forearm at right angle; able to do light work.
218	<i>Teal, M. W.,</i> Pt., K, 26th North Carolina, age 31.	July 3, 1863.	Minié ball carried away portions of radius and external condyle of humerus.	July, 1863.	Excision of elbow joint.	Disch'd November 12, 1863.
219	<i>Thieme, C.,</i> Pt., A, 26th Wisconsin, age 23.	Mar. 19, 1865.	Fracture of right elbow by a conoidal ball; (also wound of neck.)	Mar. 19, 1865.	Excision of joint.	Disch'd June 28, 1865; pensioned. Anchylosis at an obtuse angle; atrophy; pronation lost.
220	<i>Thomas, H.,</i> Pt., K, 81st New York, age 21.	June 1, 1864.	Fracture of right elbow joint by a conoidal ball.	June 2, 1864.	Excision of elbow joint.	Gangrene. Disch'd December 14, 1864. Not a pensioner.
221	<i>Thomas, W.,</i> Pt., L, 13th Pennsylvania Cavalry, age 29.	Mar. 9, 1864.	Fracture of lower third of left humerus by a pistol ball.	March, 1864.	Excision of external condyle of humerus.	Anchylosis. Disch'd April 13, 1865; pens'd. Forearm flexed and pronated; wound discharges pieces of diseased bone.
222	<i>Thuring, C. G.,</i> Serg't, C, 1st Maine Cavalry, age 31.	June 19, 1863.	Fracture of condyles of left humerus by a rifle ball.	June 19, 1863.	Excision of condyles of humerus.	Disch'd Nov. 24, 1863; pensioned. Heads of radius and ulna project posteriorly; wound discharging.
223	<i>Titus, C. B.,</i> Corp'l, G, 31st Maine, age 20.	July 30, 1864.	Ball through right elbow, carrying away internal condyle of humerus, lodging in back.	July 30, 1864.	Excision of elbow joint.	Disch'd May 11, 1865; pensioned. Anchylosis of joint; arm useless for manual labor.
224	<i>Titus, S. N.,</i> Major, 11th Pennsylvania Cavalry, age 36.	Oct. 7, 1864.	Minié ball; gunshot fracture of lower part of right humerus, involving elbow joint.	Oct. 7, 1864.	Excision of two or three inches lower end of humerus, by a Confederate surgeon.	Partial anchylosis. Disch'd Mar. 11, 1865; pens'd. Forearm and hand paralyzed; limb useless.
225	<i>Tolbert, C.,</i> Pt., C, 48th Illinois.	July 21, 1864.	Wound of left elbow joint.	July 21, 1864.	Resection, by Surg. R. Morris, 103d Illinois.	Disch'd March 22, 1865. Anchylosis; pensioned. Atrophy; no strength in arm.
226	<i>Totman, E. T.,</i> Pt., F, 55th Illinois, age 20.	June 27, 1864.	Fracture of right elbow joint by a conoidal ball.	June 28, 1864.	Excision of elbow joint, by Surg. A. C. Messenger, 57th Ohio.	Gangrene; arm amp. Nov. 7, '64. Disch'd April 28, 1865; pens'd.
227	<i>Tracy, A. W.,</i> 1st Lieut., F, 11th Penna., age 27.	May 25, 1864.	Fracture of left humerus by grapeshot; (also w'd of side.)	May 25, 1864.	Excision of internal condyle.	Disch'd May 15, 1865; pensioned. Loss of power and motion in arm.
228	<i>Tracy, W. G.,</i> Cpt., and Asst. Aide-de-Camp, General Slocum's Staff, age 20.	May 2, 1863.	Fracture of right elbow by conoidal ball, the humerus being comminuted two inches above condyles; two fissures extend into joint.	May 5, 1863.	Four and a half inches lower end of humerus, including condyles, by Surgeon H. E. Goodman, 28th Pennsylvania.	Useful arm; flexion of forearm fixed; perfect motion at wrist. Duty Aug. 15, 1863; pensioned. No bony union. Spec. 1155.
229	<i>Tredco, J.,</i> Pt., H, 109th New York, age 18.	May 12, 1864.	Fracture of left ulna and radius by a conoidal ball.	May 12, 1864.	Excision of head and upper third of radius, by Surg. W. C. Shurlock, 51st Penn.	Disch'd April 4, 1865; pensioned. Rotation lost; anchylosis; arm entirely useless.
230	<i>Tredway, S.,</i> Pt., D, 3d Maryland, age 18.	June 1, 1864.	Fracture of right elbow by conoidal ball.	June 1, 1864.	Excision of elbow.	Disch'd May 6, 1865; pensioned. No bony union; arm only an enueurance.

No.	NAME, AGE, AND MILITARY DESCRIPTION.	DATE OF INJURY.	NATURE OF INJURY.	DATE OF OPERATION.	OPERATION AND OPERATOR.	RESULT AND REMARKS.
231	Turner, G. W., Pt., D, 51st Ohio, age 44.	Dec. 16, 1864.	Fracture of right elbow by a shell; humerus comminuted.	Dec. 16, 1864.	Excision of two inches lower end of humerus through six-inch incision.	Disch'd July 10, 1865; pensioned. Unable to flex forearm without aid; cannot grasp or hold.
232	Vauheuren, J. F., Corp'l, F, 86th New York, age 22.	May 12, 1864.	Fracture of right humerus and ulna by a conoidal ball.	May 12, 1864.	Excision of lower third of humerus and three inches of upper end of ulna, by Surg. H. P. Lyster, 5th Michigan.	To V. R. C.; pens'd. Cannot extend arm beyond semi-flexion; cartilaginous union; cannot supinate hand.
233	Wagner, J., Serg't, G, 119th Pennsylvania, age 23.	May 3, 1863.	Fracture of left humerus at elbow joint.	May 6, 1863.	Excision of lower end of humerus, by Dr. Todd, P. A. C. S.	Disch'd Oct. 30, 1863; pensioned. No union; arm atrophied and useless.
234	Walker, W. A., 1st Lieut., C, 146th New York, age 21.	May 5, 1864.	Ball passed through right elbow joint; also wound of back of head and left forearm.	May 5, 1864.	Excision of inner condyle of humerus and head of ulna through a straight incision on posterior aspect.	To V. R. C. Sept. 20, 1864; pensioned. Little power in arm; flexion and extension well performed; rotation lost.
235	Wall, J., Corp'l, D, 169th New York, age 19.	June 1, 1864.	Shot fracture of left elbow; missile passed through joint.	June 1, 1864.	End of humerus excised.	Disch'd July 7, 1865; pensioned. Complete ankylosis at an angle of 60°; partial paralysis of muscles; arm useless.
236	Watson, R., Pt., K, 8th Connecticut, age 32.	Aug. 18, 1864.	Gunshot wound of left elbow joint; (wounded in left groin Sept. 17, 1862.)	Aug. 18, 1864.	Excision of heads of ulna and radius through an incision four inches long.	No bony union; arm powerless. Disch'd July 31, 1865; pens'd. Arm short, five inches; useless. Died June 27, 1869, of pyæmia.
237	Weber, M., Brigadier-General, U. S. V.	Sept. 17, 1862.	Gunshot fracture of head of right radius.	Sept. 17, 1862.	Excision of three inches of right radius, including head, by Surg. C. Heiland, 20th New York.	Removal of necrosed bone. Re-signed May 13, 1865; pensioned. Complete ankylosis at an angle of 15°.
238	Weigle, J., Pt., I, 76th Pennsylvania, age 23.	Jan. 15, 1865.	Wound through right elbow joint by a conoidal ball.	Jan. 16, 1865.	About two inches of ulna, thro' straight incision, by Surg. G. C. Jarvis, 7th Connecticut.	Disch'd June 9, 1865; pensioned. Ankylosis of joint; total loss of use of arm.
239	Whelan, P., Pt., C, 18th Mississippi, age 32.	July 2, 1863.	Gunshot wound of elbow joint	July 3, 1863.	Excision of two inches of upper end of ulna.	Ankylosis of elbow joint. Furloughed October 5, 1863.
240	Wheeler, D., Pt., B, 2d Infantry, age 39.	July 2, 1863.	Fracture of left ulna, extending into joint, and dislocation of upper end of radius by conoidal ball.	July 3, 1863.	Excision of upper three inches of left ulna.	To V. R. C. May 3, 1864; pens'd. Disease of joint; rotation destroyed; flexion and extension of hand good.
241	Wileox, H. O., Quartermaster-Sergeant, A, 1st Michigan Cavalry, age 27.	May 27, 1864.	Fracture right elbow and opening of joint by conoidal ball; (also wound of side.)	May 27, 1864.	Excision of external condyle of humerus through a semicircular incision.	Disch'd June 9, 1865; pensioned. Complete ankylosis of joint and atrophy of arm and hand.
242	Wileox, P. H., Corp'l, K, 50th Pennsylvania, age 40.	June 3, 1864.	Shell fracture of upper third left radius.	June 3, 1864.	Three inches of end of radius, straight incision, by Surg. A. F. Whelan, 1st Mich. S. S.	Disch'd Dec. 14, 1864; pensioned. Rotation lost; no motion of fingers; limb almost useless.
243	Williams, D., Pt., G, 26th Ohio, age 19.	May 29, 1864.	Fracture of left elbow by a conoidal ball.	May 29, 1864.	Excision of neck of radius, by Surg. W. B. McGavran, 26th Ohio.	Disch'd June 13, 1865; osseous ankylosis elbow joint; pens'd. Atrophy of muscles of forearm.
244	Williams, H. C., Pt., D, 13th Georgia, age 32.	July 2, 1863.	Fracture of right elbow joint by a conoidal ball.	July 3, 1863.	Excision of right elbow joint.	Transferred to City Point for exchange Nov. 12, 1864.
245	Wingood, J. H., Corp'l, D, 32d Massachusetts, age 19.	May 12, 1864.	Right ulna fractured at upper end by conical ball.	May 12, 1864.	Excision of upper end of ulna.	Disch'd Apr. 27, 1865; pensioned. Erysipelas; gangrene; atrophy; flexion and extension two-thirds; rotation of hand one-third.
246	Wood, J. V., Pt., I, 1st Maine Cavalry, age 18.	Oct. 27, 1864.	Fracture of internal condyle of left humerus by conoidal ball.	Oct. 27, 1864.	Excision of internal condyle.	Disch'd May 20, 1865. Complete ankylosis elbow joint; pens'd. Arm useless.
247	Wooster, U. T., Pt., G, 89th New York, age 22.	Aug. 21, 1864.	Gunshot wound of right elbow	Aug. 21, 1864.	Excision of olecranon process of ulna.	Disch'd Nov. 14, 1864; pensioned. Complete ankylosis of joint; hand of no use.
248	Wunderlen, F., Pt., G, 49th New York, age 29.	May 12, 1864.	Wound of right elbow joint by a conoidal ball.	May, 1864.	A portion of condyles of humerus and heads of ulna and radius, through straight incision over posterior part of joint.	Disch'd Jan. 3, 1865; pensioned. Ankylosis at right angle; rotation destroyed; atrophied; olecranon process drawn upward.
249	Yokes, W., Pt., C, 29th Ohio, age 32.	May 8, 1864.	Head and shaft of right ulna fractured by a conoidal ball.	May 8, 1864.	Three inches of radius, through two straight incisions, by Surgeon A. K. Fifield, 29th Ohio.	Amputation of arm May 10, 1864. Discharged September 1, 1864; pensioned.
250	Zeller, J., Sergeant, C, 100th Illinois, age 26.	Sept. 19, 1863.	External condyle of left humerus comminuted; internal condyle detached, with its condyloid ridge.	Sept. 19, 1863.	Joint laid open by transverse and longitudinal incisions and fragments of the internal condyle, with sharp point of the shaft, cut off by chain saw, by Surg. H. E. Huse, 24th Wis.	Union between condyle and humerus; arm useful. Disch'd Aug. 25, 1864; pensioned. Forearm swings freely on arm; has no power over it.

The foregoing two hundred and fifty operations were practised on forty-one Confederate and two hundred and nine Union soldiers, of whom one hundred and ninety-four were discharged and pensioned, twenty-one were returned to modified duty, and thirty-five were exchanged, paroled, or furloughed. One hundred and twenty-four operations were on the right, and one hundred and twenty-two on the left side, and four were without record on this point. In eighteen cases the injuries were inflicted by shell fragments or large projectiles; in the remainder, as far as known, by small missiles. A single straight longitudinal incision was the most common method of operating, and was employed in at least sixty-six cases. **H**-shaped, crucial, **T**-shaped, **S**-shaped, and **U**-shaped incisions were each adopted, in a half dozen or more cases. In a large proportion, the mode of operating was not detailed. The missile lodged and was removed in nine instances. Eighteen of the patients



had wounds of more or less severity in other regions. Eleven cases were complicated by consecutive hæmorrhage, necessitating ligation of the brachial in two cases, of the ulnar in one, and of smaller branches in two. In nine cases, the wounds became affected by erysipelas, and in ten by gangrene.<sup>1</sup>

Disease in the continuity of the resected bones sometimes followed; resulting not infrequently in small exfoliations, and occasionally in extended necrosis. Not a few of the twenty-seven consecutive amputations were practised on account of necrosis of the shaft of the humerus, and in several instances large sequestra were extracted at a late date. In the following instance the ulna became necrosed and was extirpated:

CASE 1787.—Private T. C. Beaumont, Co. M, 9th New York Cavalry, aged 20 years, was wounded at Shepherdstown, August 25, 1864, and was taken to a field hospital, where resection of the left elbow joint was performed by Surgeon R. Curran,

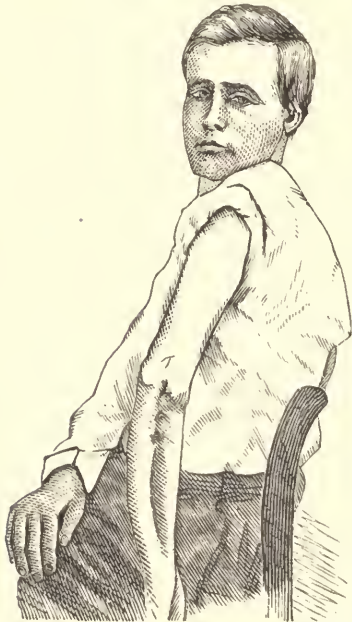

FIG. 610.—Appearance of an excision at the left elbow for shot injury, followed by extirpation of the ulna for caries.

9th New York, through a linear dorsal incision, two inches of the lower extremity of the humerus and the olecranon and coronoid processes being excised thirteen hours after the reception of the injury. On the following day, the patient was sent to Baltimore and entered the Camden Street Hospital. Surgeon Z. E. Bliss, U. S. V., noted: "Ball entered the inner side of the left elbow and passed through the internal condyle. Excision of the elbow joint August 26th." On September 27th, this patient was transferred to hospital in Philadelphia, and thence to New York, where he was treated in Ladies' Home and McDougall hospitals, and was finally discharged June 19, 1865, and pensioned. Assistant Surgeon S. H. Orton, U. S. A., certified on his discharge papers: "Excision of the left elbow joint; arm useless." The pensioner was fitted with an apparatus by E. D. Hudson, M. D., of New York, who reported that a subsequent operation having become necessary, the entire ulna had been resected. Dr. Hudson also contributed the photograph represented by the wood-cut (FIG. 610), showing the result of the latter operation, and stated that "the functions of the hand are unimpaired, but there is no command of the forearm; the head of the radius is drawn up, the flexors of the forearm atrophied; there is slight pronation and supination, and the wrist joint is normal. On the application of an apparatus, two years after a second excision [to be mentioned presently], the extremity of the humerus afforded a good *point d'appui*, and the action of the appliance is encouraging. Although the muscles are debilitated through disuse, persevering practice will secure the man a good arm. This is the second case of excision of the entire ulna practised in this country; the first was by Dr. Carnochan." Examiner E. Bradley, of New York City, July 25, 1866, reported: "Gunshot wound of left forearm, involving loss of the entire ulna by resection, with condyles of os brachii. The limb is atrophied, weak, and of no use to him. Operation was performed ten weeks ago [May 2, 1866], by Assistant Surgeon J. T. Calhoun, U. S. A., and the wound has fully healed; disability total and permanent." This pensioner was paid March 4, 1874.

Summing up the results of these two hundred and fifty operations of primary excision at the elbow, we find that thirteen patients ultimately succumbed to causes more or less directly connected with the mutilation; that twenty-seven submitted to consecutive amputation; that one hundred, for the most part of the younger patients, recovered with false or true ankylosis, often retaining, however, very useful limbs, with complete preservation of the functions of the hand. Among the remaining hundred and ten, who recovered with active or passive motion at the joint, some examples are presented of wasted and painful limbs; but the majority had fairly useful arms, and, in a few instances, the usefulness of the member was but slightly impaired. As a rule, the total excisions resulted more favorably than the partial excisions,<sup>2</sup> furnishing comparatively fewer instances of consecutive complications, and, in short, a larger proportion of useful limbs.

<sup>1</sup>In addition to the illustrations of the results of primary excision of the elbow joint that have accompanied the detailed cases of this series, photographs of subjects who had undergone this operation were contributed to the Army Medical Museum in the cases of Anthony, 125th New York, CASE 4 (*Contrib. Surg. Phot.*, A. M. M., Vol. VII, p. 55); Jones, 53d Georgia, CASE 114 (*Ibid.*, Vol. II, p. 15); McGuire, 26th Massachusetts, CASE 138 (*ib.*, Vol. XIII, p. 7); Summers, 43d Ohio, CASE 216 (*ib.*, Vol. III, p. 30).

<sup>2</sup>It was mentioned on page 848 that in the 250 primary excisions resulting favorably, 61 were resections of the lower extremity of the humerus alone, 22 of the upper extremity of the radius only, and 37 of the upper extremity of the ulna. In the 130 remaining cases, the parts removed were unspecified in 56, the articular extremities of all the bones were resected in 31, the condyles and upper extremity of the ulna in 27, the condyles and head of radius in 2, and the upper extremities of the ulna and radius without resection of the humerus in 11.

§ *Fatal Cases of Primary Excision at the Elbow.*—Among the sixty-eight cases of excision at the elbow that terminated fatally, the extent of the parts removed was in nearly the same proportion as in the recoveries, so far as this point was specified.<sup>1</sup> The deaths resulted largely from exhaustion from protracted suppuration, surgical fever, or pyæmia.<sup>2</sup> The two following are abstracts of cases terminating fatally from pyæmia or tetanus:

CASE 1788.—Private C. E. Hyatt, Co. A, 14th Connecticut, was wounded at Morton's Ford, February 6, 1864, and admitted to the field hospital of the 3d division, Second Corps. Surgeon F. A. Dudley, 14th Connecticut, in charge, who operated in this case, reported: "Gunshot wound of left elbow joint by minié ball. Excision was performed on February 8th. Pyæmic symptoms set in on February 23d, and death ensued on February 28, 1864." It was impracticable to make an autopsy. The specimen, represented in the annexed cut (FIG. 611), consists of two inches of the lower extremity of the left humerus and two inches of the shaft and processes of the ulna. It was contributed by Surgeon J. Dwinelle, 106th Pennsylvania.

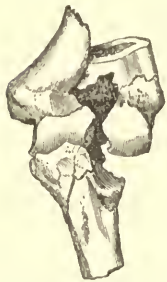

FIG. 611.—The lower extremity of the left humerus and portion of the ulna excised for shot injury. *Spec.* 2040.

CASE 1789.—Major B. S. Stanhope, 6th Ohio Cavalry, was wounded in the right elbow at Aldie Gap, June 17, 1863, and entered the field hospital of the 2d division, Cavalry Corps. Assistant Surgeon G. M. McGill, U. S. A., who performed excision, furnished the following account of the case: "He was wounded in the right upper extremity by a carbine ball. Entrance two inches above the tip of the olecranon in semiflexion; course inward, downward, and forward, breaking the humerus—without extensive shock of the bone or comminution—passing down anteriorly, partially denuding the radius; exit in the anterior inferior third of the forearm. Primary resection was performed six hours after the injury. Patient is about 26 years, short, and has an abundance of adipose tissue." The specimen, represented in the annexed cut (FIG. 612), consists of three inches of the lower extremity



FIG. 612.—Three inches of the lower extremity of the right humerus excised for shot injury. *Spec.* 1289.

of the right humerus, which was nearly transversely fractured, with some comminution, two inches above the articulation. It was contributed by the operator. On the day following the injury the patient reached Prince Street Hospital, at Alexandria, whence Surgeon J. R. Spencer, U. S. V., reported the following result: "This patient had been transported sixteen miles in an ambulance wagon and the same distance by cars, after the operation, before entering this hospital. The weather was warm and damp. The musculo-spiral and ulnar nerves were injured. Tetanus in the form of acute opisthotonos set in on June 23d. The treatment consisted of stimulants, tonics, and narcotics. Death occurred on June 25, 1863."

Sixteen of the patients died after submitting to consecutive amputation.

CASE 1790.—Private J. Kimmely, Co. F, 170th New York, aged 32 years, was wounded at Deep Bottom, August 15, 1864. He was admitted to the field hospital of the 2d division, Second Corps, where Surgeon J. F. Dyer, 19th Massachusetts, noted: "Fracture of elbow joint. Resection of head of ulna by Surgeon F. Douglass, 170th New York." On August 20th, the patient entered Sutterlee Hospital, whence Acting Assistant Surgeon A. A. Smith contributed the specimen (FIG. 613) with the following report: "The patient was admitted from a field hospital at City Point with a gunshot fracture of the upper third of the right ulna, a minié ball entering one inch below the elbow joint, embedding itself between the radius and ulna, fracturing the ulna, and destroying the articulating surface of the radius. The ball was removed by an incision posteriorly, and about two inches of the ulna was resected on the field. When admitted, the whole arm and forearm was œdematous and the wound quite unhealthy, with the radius protruding some two inches through the incision. Etherized the patient and replaced the radius, then applied an anterior angular splint, afterward dressing the wound with cold water. Tonics and stimulants, with a nutritious diet, were administered, under which treatment he improved slightly, his general health being much impaired previously. September 9th, at 9 A. M. had a hæmorrhage, supposed to be from the radial and interosseous arteries, losing some five or six ounces of blood. A consultation was held, and it was decided to amputate the arm at the middle of the lower third, which was done by Acting Assistant Surgeon A. A. Smith by the circular operation. September 15th, removed two of the ligatures. September 17th, removed the others. Up to this time there has been very little change in his condition. September 19th, had a hæmorrhage from the stump, losing some four ounces of blood, which was arrested by compression. September 20th and 21st, had a severe chill. September 22d, slight chill, all of which was followed by slight fever and profuse cold clammy perspiration. Is slightly delirious, and complains of pain on pressure in the right hypochondriac region. In addition to tonics and stimulants, gave him bisulphate of soda, ten grains every two hours, in an infusion of quassia. From the first chill on September 20th he rapidly sank, and died at 7 A. M. on September 24th, 1864." The specimen consists of the bones of the right elbow after excision of the upper portion of the ulna. A partially detached sequestrum exists in the upper extremity of the ulna, around which is a very slight involucrum. Some spongy bone has been thrown out at the radial tuberosity. The articular surface of the radius is eroded, and the extremity of the humerus is carious.

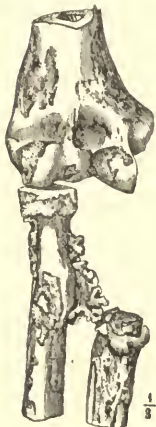

FIG. 613.—The bones of the right elbow after excision of the upper three inches of the ulna. *Spec.* 3651.

<sup>1</sup> They may be classified according to the parts excised as follows: Removal of ends of all the bones, 4; excision of condyles of the humerus and upper part of ulna, 7; condyles of humerus, with or without a part of its shaft, 14; olecranon only, 5; olecranon, with upper part of ulna, 10; head of radius and upper part of ulna, 1; parts not specified, 27.

<sup>2</sup> The causes of death are returned as variola, 1; tetanus, 1; erysipelas and gangrene, 6; secondary hæmorrhage, 9; exhaustion, 10; pyæmia, 22; pneumonia, 4; chronic diarrhoea, 2; gastritis, 1; typhoid and intermittent fevers, 2; general paralysis, 1; unknown, 9. The soldier who succumbed to general paralysis had nearly recovered with an ankylosed joint; he went in bathing, when he had a seizure that eventuated in progressive ataxia.



In some of the cases returned as resections at the elbow, as in the two following, the operations consisted in little more than the removal of detached fragments of bone. Such cases impressively illustrate the disadvantages of partial excisions, with limited division of the articular capsule, whereby, as Professor Esmarch observes,<sup>1</sup> that feature of the operation which deprives the wound of its danger, the extensive severing of the ligamentous apparatus of the joint, is omitted:

CASE 1791.—Private J. Allen, Co. G, 9th New York Cavalry, was wounded in an engagement at the Rapidan River, September 14, 1863. Surgeon W. H. Rulison, 9th New York Cavalry, recorded his admission at the field hospital of the 1st division, Cavalry Corps, with: "Gunshot fracture of left arm." On the following day the wounded man entered Armory Square Hospital at Washington, where Surgeon D. W. Bliss, U. S. V., in charge, performed excision at the elbow joint. The details of the case he reported as follows: "The patient was wounded by a pistol bullet entering immediately over the external condyle of the left humerus, fracturing the condyle, passing downward, and opening the elbow joint. He was admitted to the hospital on September 15th, and a portion of the condyle removed by the chain saw, and several loose fragments taken out, the incision through the muscles being of an S-shape; patient under ether. The ball remains in the arm. After the operation cold water was applied continuously, and opiates given when necessary to relieve pain. The whole arm became greatly swollen the

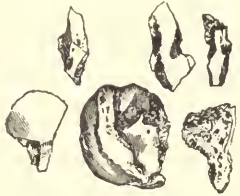


FIG. 614.—Fragments of the outer condyle and portion of the left humerus removed for shot injury. Spec. 1729.

ensuing day, yet not very painful; tongue moist; pulse full and regular; appetite tolerably good; wound secreting healthy pus. He was, however, unable to void his urine, which was drawn off by the catheter—an operation which had to be frequently repeated during his illness. On the 18th, cold water as an application to the arm was omitted as it appeared to increase the pain, and warm-water dressing was substituted. The latter was also discontinued for a like reason, and from that time onward the limb was kept wet with a lotion composed of acetate of lead one drachm, pulverized opium half a drachm, and water one pint, and the wound itself with a solution of permanganate of potassa one-half drachm in one pint of water. From the 16th his symptoms became more unfavorable, having daily two and sometimes three rigors, followed by increased heat of body and profuse sweats. On the 26th, wound secreting a greenish and very offensive pus; pulse frequent and sometimes intermittent; skin dry; conjunctiva yellow; tongue dry with brown fur in centre; no appetite; urine of dark amber color; bowels constipated. The bowels were opened by podophyllum half a grain, and extract of colocynth eight grains. Sulphate of quinine was given daily, as it had been from the commencement of the rigors, and opium also to relieve pain; sweet spirit of nitre and spirit of mindererus in proper doses when the skin was hot and dry. Milk punch and beef essence were freely administered, and every proper article of diet which he imagined he could eat, such as chicken, chicken broth, &c., was procured and given to him. Free incisions were made from time to time to evacuate pus, which unavoidably found its way beneath the muscles of the arm. On the 30th hæmorrhage occurred, which was, however, readily controlled by pressure. He continued to sink hourly, and died at 10½ o'clock A. M., October 1, 1863." The specimen, represented in the annexed cut (FIG. 614), consists of six fragments, embracing the outer condyle and the adjoining portion of the left humerus. It was contributed by the operator.

CASE 1792.—Sergeant B. McBride, Co. H, 88th New York, aged 25 years, was wounded at the Wilderness, May 5, 1864, and admitted to the field hospital of the 1st division, Second Corps. Surgeon J. E. Pomfret, 7th New York Artillery, recorded: "Wound of right elbow joint; fracture of bones. Resection by Surgeon P. E. Hubon, 28th Massachusetts." Assistant Surgeon W. Thomson, U. S. A., contributed the specimen (FIG. 615), and reported the result of the case as follows: "The patient was admitted to Douglas Hospital, Washington, on May 11th, with comminuted fracture of the elbow joint, produced by a conoidal ball. He died on June 13, 1864, of pyæmia, having had chills, profuse perspiration, and icterus for several days previous. At the autopsy fourteen ounces of dirty-yellow serum was removed from the pleural cavities, and numerous pyæmic patches were found in the posterior portion of both lungs. The liver and spleen were both softened, but contained no yellow patches." The specimen consists of the bones of the right elbow, from which the outer condyle and the head of the radius are missing. The articular surfaces are carious. (*Cat. Surg. Sect.*, 1866, p. 150.) Evidences of periosteal inflammation with thin osteophytic depositions extend along the parts of each of the bones contiguous to the fracture. The operation must have been limited to the extraction of the fragments of the outer condyle and of the head of the radius.

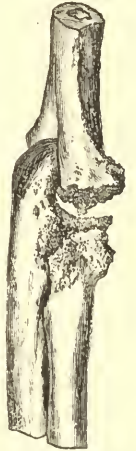

FIG. 615.—Shot perforation of the right elbow. Spec. 3556.

Five of the patients had wounds in other regions, but of little gravity, except in one case, in which the patient was subjected to a partial amputation of the foot by Chopart's method. Twenty-six of the operations were on the right and thirty-five on the left side; in seven cases this point was not reported. Nine of the patients were Confederate, and fifty-nine Union soldiers. The method of Langenbeck was most frequently adopted. Next in frequency were the methods by H-shaped and curvilinear incisions.

<sup>1</sup> ESMARCH (E.) (*Über Resectionen nach Schusswunden*, Kiel, 1851, S. 78) remarks that "man sich auch nicht damit begnügen soll, in Fällen, wo die Knochen nur in geringer Ausdehnung verletzt sind, eine partielle resection der getroffenen Knochentheile vorzunehmen, ohne die Gelenkkapsel in ihrer ganzen Ausdehnung zu durchschneiden, denn gerade diese ausgiebige Zerschneidung des ligamentösen Gelenk-apparates halte ich bei Resectionen für dasjenige Moment, welches der Verwundung ihre Gefährlichkeit benimmt; je weniger man aber von den Gelenk-enden der Knochen entfernt, desto grösser ist die Wahrscheinlichkeit der Ankylosierung."

TABLE CVIII.

Summary of Sixty-eight Fatal Cases after Primary Excision of Elbow Joint for Shot Injury.

NO.	NAME, AGE, AND MILITARY DESCRIPTION.	DATE OF INJURY.	NATURE OF INJURY.	DATE OF OPERATION.	OPERATION AND OPERATOR.	RESULT AND REMARKS.
1	Abbott, G., Pt., G, 45th Ohio, age 21.	July 21, 1864.	Shot fracture of internal condyle of left humerus.	July 21, 1864.	Excision of internal condyle...	Hæmorrhage; arm amputated; pyæmia. Died Nov. 7, 1864.
2	Abe, H., Pt., A, 91st Indiana.	July 1, 1864.	Fracture of right elbow joint by conoidal ball.	July 1, 1864.	Excision, by Surg. J. W. Lawton, U. S. V.	Died July 27, 1864.
3	Allen, J., Pt., G, 9th New York Cavalry, age 28.	Sept. 14, 1863.	Pistol ball fractured the external condyle of left humerus and opened joint.	Sept. 15, 1863.	Portion external condyle thro' S incision, spicula removed, by Surg. D. W. Bliss, U. S. V.	Hæmorrhage. Died October 1, 1863, of pyæmia. Spec. 1729.
4	Austin, C., Pt., B, 42d Pennsylvania, age 23.	May 7, 1864.	Wound through left elbow; articular ends of the bones composing joint comminuted by conoidal ball.	May 7, 1864.	One inch of articular end of ulna excised and ball extracted, by Surgeon C. Bower, 6th Pennsylvania Reserves.	July 1st, anchylosis; erysipelas; abscesses. Arm amp. July 12th. Died July 28, 1864, from exhaustion. Spec. 2836.
5	Bair, S., Sergeant, I, 7th Indiana.	May 23, 1864.	Fracture of right elbow joint.	May 23, 1864.	Humerus and ulna, by Surg. C. Chamberlain, U. S. V.	Died June 26, 1864, of pyæmia.
6	Blackwell, P., Corp'l, G, 7th New York Heavy Art.	June 16, 1864.	Shot fracture of arm	June 16, 1864.	Excision elbow joint, by Surg. P. E. Hubon, 28th Mass.	Died June 23, 1864.
7	Bolles, J., Pt., H, 107th Illinois.	May 27, 1864.	Compound comminuted fracture of middle third of right ulna by conoidal ball.	May 28, 1864.	Excision of seven inches disarticulating ulna at elbow joint, by Surg. E. Shippen, U. S. V.	Died June 19, 1864.
8	Bugby, N., Corp'l, A, 65th Illinois.	June 15, 1864.	Fracture of left olecranon and external condyle of humerus.	June 15, 1864.	Excision of olecranon and external condyle.	Died June 24, 1864.
9	Carr, F. W., Sergeant, C, 16th N. Y. H. A., age 28.	Oct. 7, 1864.	Fracture of right arm by conoidal ball.	Oct. 7, 1864.	Excision of right elbow joint.	Died October 30, 1864, from exhaustion.
10	Cusic, N. B., Pt., F, 29th Pennsylvania, age 24.	May 25, 1864.	Head of left ulna comminuted by conoidal ball.	May 25, 1864.	Three inches of ulna excised.	Arm amputated. Died August 4, 1864, from exhaustion.
11	Darrow, H. C., Pt., G, 77th New York, age 24.	May 18, 1864.	Left elbow joint laid open by ball; also wound of foot; amp. at middle tarsal articulation.	May 18, 1864.	Elbow joint, through incision four inches long over olecranon process of ulna.	Gangrene; hæmorrhage on June 13th; humerus necrosed. Died June 23, 1864, from gangrene.
12	Dickson, B. F., Sergeant, B, 7th Louisiana, age 26.	July 2, 1863.	Wound of left elbow by conoidal ball.	July 3, 1863.	Removal of two inches of lower end of humerus.	Sloughing Aug. 12th; intermittent fever; constant vomiting. Died October 6, 1863.
13	Dornmoyer, L., Pt., E, 17th Penn. Cav., age 35.	May 31, 1864.	Shot fracture of condyles of left humerus.	May 31, 1864.	Excision of condyles of humerus.	Pyæmia. Died July 2, 1864.
14	Edwards, T. J., Pt., H, 55th Indiana, age 25.	May 28, 1864.	Shot fracture of forearm	May 28, 1864.	Excision of head of ulna, by Surg. E. B. Glick, 40th Ind.	Died June 22, 1864.
15	Elliott, J., Pt., B, 104th New York.	June 2, 1864.	Shot wound of arm; also wound of left side.	June 2, 1864.	Excision of elbow joint, by Surg. M. Rizer, 72d Pa.	Died June 12, 1864.
16	Ellinberger, A. C., Pt., B, 59th New York.	July 2, 1863.	Fracture of left elbow joint	July 2, 1863.	Excision of joint	Died July 30, 1863.
17	Fand, W. H., Pt., C, 7th Virginia Cavalry, age 37.	June 14, 1864.	Comminuted fracture of olecranon process by conoidal ball.	June 14, 1864.	Olecranon process, through vertical incision over joint.	Died July 4, 1864, of erysipelas.
18	Fitzgerald, W., Pt., B, 1st U. S. Sharpshooters, age 19.	Nov. 7, 1863.	Shot fracture of the right humerus near elbow joint; arm erysipelatous.	Nov. 7, 1863.	Two inches of humerus, by Surg. H. F. Lyster, 5th Mich.	Erysipelatous; hæmorrhage Nov. 12. Died November 29, 1863, of pyæmia.
19	Fulton, G. E., Pt., C, 4th Vermont, age 26.	July 7, 1864.	Wound of left elbow joint	July 7, 1864.	Excision of portion of olecranon process.	Amputation of upper third; July 8, hæmorrhage; ligation. Died Feb. 6, 1865, of chronic diarrhæa.
20	Green, W. N., Lieut.-Col., 173d New York.	April 8, 1864.	Wound of left elbow	April 8, 1864.	Excision of head of ulna	Arm amputated May 6th. Died May 14, 1864, of gastritis.
21	Grove, W. C., Pt., E, 11th Pennsylvania, age 22.	June 23, 1864.	Fracture of right elbow by conoidal ball.	June 23, 1864.	External condyle of humerus excised.	Died July 26, 1864.
22	Gutheriet, F., Pt., K, 27th Massachusetts, age 26.	June 3, 1864.	Wound of right elbow joint by conoidal ball.	June 3, 1864.	Excision of joint	Hæmorrhage; arm amp. Died July 6, '64; pyæmia. Spec. 2915.
23	Haltiwanger, G. J., Pt., C, 20th South Carolina, age 21.	Oct. 19, 1864.	Comminution of elbow joint	Oct. 19, 1864.	Excision	Died September 1, 1864.
24	Hodsdon, D. C., Capt., H, 9th Indiana, age 24.	June 24, 1864.	Fracture of left radius, penetrating elbow joint.	June 21, 1864.	Excision	Gangrene; erysipelas; amputated. Died July 27, 1864, of pyæmia.
25	Hough, M., Pt., D, 14th U. S. Infantry, age 18.	June 1, 1864.	Fracture of lower third of left humerus by conoidal ball.	June 2, 1864.	Excision of elbow joint through incision six inches long.	Anchylosis of elbow; gangrene. Died September 11, 1864, of general paralysis.
26	Hughes, H., Pt., E, 21st Kentucky, age 24.	June 22, 1864.	Fracture of right elbow joint	June 22, 1864.	Excision of joint, by Surg. J. D. Brumley, U. S. V.	Arm amputated at middle third. Died July 6, 1864, of pyæmia.
27	Hyatt, C. E., Pt., A, 14th Connecticut.	Feb. 6, 1864.	Condyles of left humerus and superior articulating extremity of ulna comminuted by conoidal ball.	Feb. 8, 1864.	Two inches of lower extremity of humerus and two inches of upper end of ulna, by Surg. F. A. Dudley, 14th Conn.	Died February 28, 1864, of pyæmia. Spec. 2040.
28	Ingolsby, J., Pt., G, 23d Illinois.	Sept. 20, 1861.	Wound of left elbow joint	Sept. 20, 1861.	Resection of joint	Erysipelas; Nov. 1, amp. of arm. Disch'd Feb. 20, 1863. Wound never healed. Died Aug 7, 1863.
29	Jacobs, W. H., Pt., E, 8th New York Heavy Art.	June 3, 1864.	Fracture of right elbow joint, destroying olecranon, by conoidal ball.	June 3, 1864.	Excision of portion of ulna, by Surg. D. W. Maull, 1st Delaware.	Hæmorrhage from brachial artery. Died June 23, 1864.
30	Kenedy, W. J., Pt., G, 55th Illinois, age 31.	May 22, 1863.	Wound of left arm	May 22, 1863.	Excision of elbow joint, removing one and a half inches end of ulna.	Pyæmia. Died June 23, 1863, of typhoid fever.
31	Kennelly, J., Pt., K, 170th New York, age 32.	Aug. 15, 1864.	Fracture of upper third of right ulna, articular surface of radius destroyed, by conoidal ball.	Aug. 15, 1864.	Upper three inches of ulna, by Surg. F. Douglas, 170th N. York.	Caries of end of humerus; hæm. Arm amputated September 4th; hæmorrhage. Died September 24, 1864, of pyæmia. Spec. 3651.
32	Kessler, J. E., Pt., K, 20th Ohio.	July 22, 1864.	Fracture of right elbow joint	July 22, 1864.	Excision	Died September 13, 1864.
33	Krats, A., Pt., B, 73d Pennsylvania.	May 15, 1864.	Fracture of left elbow joint	May 15, 1864.	Excision, by Surg. J. L. Dunn, 100th Pennsylvania.	Died June 21, 1864.
34	Lang, W., Pt., H, 61st Ga., age 33.	May 8, 1864.	Wound of left elbow joint	May 8, 1864.	Excision, through straight incision.	Pleurisy. Died May 16, 1864, symptoms of pyæmia.
35	Lee, T., Pt., C, 6th Cavalry.	Feb. 9, 1863.	Fracture of right elbow	Feb. 9, 1863.	Excision	Died June 23, 1863.
36	Lewis, J., Corp'l, B, 136th New York.	June 23, 1864.	Fracture of left elbow joint	June 23, 1864.	Internal condyle of humerus by Surg. B. L. Hovey, 136th N. Y.	Died July 10, 1864, of pyæmia.
37	Littleton, A. C., Pt., A, 20th South Carolina.	Oct. 19, 1864.	Shot wound of elbow joint, splitting off internal condyle of humerus.	Oct. 21, 1864.	Heads of radius and ulna and three inches of humerus, by Dr. J. M. G. McGuire, C. S. A.	Died Nov. 17, 1864, of double pneumonia.



No.	NAME, AGE, AND MILITARY DESCRIPTION.	DATE OF INJURY.	NATURE OF INJURY.	DATE OF OPERATION.	OPERATION AND OPERATOR.	RESULT AND REMARKS.
38	McBride, B., Pt., A, 88th New York, age 25.	May 5, 1864.	Outer condyle and head of radius, right elbow, fractured by ball.	May 5, 1864.	Portion of outer condyle of humerus and head of radius, by Surg. P. E. Hubon, 28th Mass.	Pyæmia. Died June 13, 1864. <i>Spec.</i> 3556.
39	McLaughlin, B., Pt., 20th Massachusetts.	May 30, 1864.	Wound of right elbow joint, fracture of olecranon process of ulna, by conoidal ball.	May 30, 1864.	Excision of pieces of bone, by Surg. N. Hayward, 20th Massachusetts.	Gangrene; joint opened. Arm amputated June 16th. Died June 23, 1864, of pyæmia. Pain intense. Died July 7, 1863. <i>Spec.</i> 1751.
40	Meyer, G., Pt., A, 32d Indiana.	June 25, 1863.	Fracture of left elbow joint; minic ball split the humerus and fractured olecranon.	June 28, 1863.	Excision of fifteen fragments, representing extremities of all bones forming elbow joint.	Resection of elbow. Died August 7, 1864.
41	Miller, G., Pt., F, 31st Colored Troops, age 35.	Aug. 1, 1864.	Fracture of left elbow joint.	Aug. 1, 1864.	Excision of condyles and two inches of shaft.	Died July 8, 1864, from exhaustion.
42	Noel, J., Pt., B, 19th Virginia, age 35.	June 3, 1864.	Fracture of the left humerus through condyles.	June 3, 1864.	Excision of both condyles of humerus.	Died July 22, 1863, of pneumonia.
43	Parey, H. C., Pt., B, 3d Indiana Cavalry.	July 1, 1863.	Fracture of left elbow joint.	July 1, 1863.	Condyles of humerus excised, by Surg. G. Chaddeock, 7th Michigan.	Arm amputated Sept. 10. Died Oct. 24, 1864, from exhaustion and debility. <i>Spec.</i> 3248.
44	Phillips, H., Pt., A, 14th Connecticut, age 36.	Aug. 13, 1864.	Shot fracture of lower portion of right humerus and olecranon process of ulna.	Aug. 14, 1864.	Excision of elbow.	Died Feb. 24, 1863, of variola.
45	Potts, M., Captain, D, 8th Missouri.	Jan. 11, 1863.	Wound of left elbow.	Jan. 11, 1863.	Excision of radius and ulna, by Surg. D. W. Maull, 1st Delaware.	Condyles of humerus removed May 24. Died June 11, 1864, of pneumonia.
46	Prettyman, C., Corp'l, E, 1st Delaware, age 20.	May 7, 1864.	Shot wound of left elbow, ulna and radius fractured.	May 7, 1864.	Partial excision of elbow joint, removing portion of ulna.	Died July 4, 1863.
47	Query, J. R., Pt., E, 2d Pennsylvania.	July 2, 1863.	Wound of left arm and leg.	July, 1863.	Excision of left elbow joint.	Amputation of left arm at middle third. Died January 15, 1865, of pyæmia.
48	Reed, T. A., Serg't, D, 51st Ohio, age 32.	Dec. 16, 1864.	Fracture of ulna, involving joint, by conoidal ball.	Dec. 16, 1864.	Excision of portion of ulna by a vertical incision.	Died December 20, 1863.
49	Reidel, P., Pt., A, 2d Missouri, age 30.	Nov. 25, 1863.	Shell fracture of external condyle of left humerus.	Nov. 27, 1863.	Excision of elbow.	Died June 16, 1864, from exhaustion.
50	Randenbush, F., Pt., E, 55th Pennsylvania, age 20.	June 3, 1864.	Fracture of right elbow by conoidal ball.	June, 1864.	Excision of elbow joint.	Pyæmia. Died June 13, 1864.
51	Slover, W. L., Pt., D, 4th New York, age 21.	May 19, 1864.	Wound of right arm.	May 21, 1864.	Excision.	Died June 6, 1864.
52	Smith, A., Pt., F, 21st Wisconsin.	May 27, 1864.	Shot fracture of left elbow joint.	May 27, 1864.	Excision, by Surg. J. D. Brun-ley, U. S. V.	Died July 9, 1864, from exhaustion.
53	Springer, W., Pt., B, 90th Ohio, age 21.	June 21, 1864.	Carbine ball fractured right humerus, denuded radius, joint opened, musculo-spiral and ulna nerves injured.	June 17, 1863.	Three inches of end of humerus and olecranon process of ulna through an H incision, by Surg. G. A. McGill, U. S. A.	Died June 25, 1863, from tetanus. <i>Spec.</i> 1282.
54	Stanhope, B. C., Major, 6th Ohio Cavalry, age 26.	June 17, 1863.	Fracture of right elbow by conoidal ball.	June 3, 1864.	Excision of end of humerus, by Surg. M. Rizer, 73d Penn.	Died May 5, 1865, of pyæmia.
55	Steel, J., Pt., B, 16th New York.	June 3, 1864.	Fracture of left elbow joint by conoidal ball.	April 2, 1865.	Olecranon process, by Surg. G. L. Carhart, 11st Iowa.	Died June 13, 1864.
56	Sullivan, D. J., Pt., C, 58th Massachusetts, age 26.	April 2, 1865.	Compound fracture of left ulna by conoidal ball.	Dec. 29, 1862.	Excision of left elbow joint, by Surg. G. S. Walker, 6th Mo.	Died February 21, 1863, from exhaustion.
57	Sykes, J. J., Pt., A, 2d Arkansas.	May 14, 1864.	Compound fracture of left elbow, and wound of neck.	May 5, 1862.	Excision of joint.	Died May 26, 1862, of pyæmia.
58	Sculler, F. M., Corp'l, G, 6th Missouri.	Dec. 29, 1862.	Wound of elbow joint.	June 20, 1864.	Excision of extremity of ulna and end of humerus, by Surg. J. T. Woods, 99th Ohio.	Died July 19, 1864, of pyæmia.
59	Sharp, W. J., Corp'l, H, 73d New York.	May 5, 1862.	Shot wound of right elbow joint.	May 30, 1864.	Excision of portion of ulna by a vertical incision.	Died July 4, 1864, of erysipelas.
60	Shleep, J., Pt., B, 51st Ohio, age 32.	June 20, 1864.	Comminuted fracture of olecranon process of left ulna.	April 2, 1865.	Excision of left elbow joint, by Surg. L. W. Bliss, 51st N. Y.	Died April 16, 1865, of phlegmonous erysipelas.
61	Simpson, W. D., Pt., E, 52d Virginia, age 23.	May 30, 1864.	Fracture of left elbow joint by conoidal ball.	Nov. 25, 1863.	Excision of right elbow joint.	Died December 27, 1863.
62	Taylor, E., Pt., I, 7th Rhode Island, age 19.	April 2, 1865.	Shot fracture of left elbow joint.	June 18, 1864.	Three inches of extremity of humerus and olecranon.	Gangrene. Died July 20, 1864.
63	Tueker, W. A., Pt., K, 56th Illinois.	Nov. 25, 1863.	Fracture of condyles of left humerus and portion of ulna.	June 1, 1864.	Condyles of humerus, also conoidal process of ulna.	Died October 6, 1864, from chronic diarrhæa.
64	Whitehead, O., Pt., D, 66th North Carolina, age 34.	June 1, 1864.	Wound of right elbow joint by conoidal ball.	Sept. 18, 1862.	Excision, by Surg. M. Storrs, 8th Connecticut.	Arm amputated. Died November 12, 1862.
65	Williams, H., Pt., B, 36th Wisconsin, age 29.	Sept. 17, 1862.	Shell fracture of right elbow joint.	May 11, 1864.	Two inches of upper end of ulna.	Arm amputated June 2d. Died June 30, 1864, of pyæmia.
66	Winship, D., Pt., F, 9th New Hampshire, age 19.	May 10, 1864.	Fracture of right elbow joint by conoidal ball.	Dec. 16, 1863.	Excision of lower end of humerus and removal of condyles, by Surg. H. G. Keeler.	Died January 14, 1864, of pyæmia.
67	Wing, F. D., Pt., F, 121st New York, age 31.	May 10, 1864.	Condyles of right humerus broken off by conoidal ball; spiculæ removed.			
68	Wood, C. C., Pt., B, 2d Ohio Heavy Artillery.	Dec. 15, 1863.				

TABLE CIX.

Summary of Four Cases of Primary Excisions of the Bones of the Elbow Joint with Undetermined Result.

No.	NAME, AGE, AND MILITARY DESCRIPTION.	DATE OF INJURY.	NATURE OF INJURY.	DATE OF OPERATION.	OPERATION AND OPERATOR.	REMARKS.
1	Honeycut, W. M., Pt., H, 16th Georgia, age 24.	Nov. 29, 1863.	Wound of right elbow joint.	Nov. 29, 1863.	Excision of elbow joint.	
2	Low, A. B., Pt., A, 31st Georgia.	Mar. 25, 1865.	Fracture of right elbow joint by conoidal ball.	Mar. 25, 1865.	Excision of olecranon process.	
3	Niekerson, J. H., Pt., K, 4th Maine.	May 6, 1864.	Fracture of right elbow joint.	May 6, 1864.	Excision of elbow joint, by Surg. D. W. Maull, 1st Del.	
4	Williams, C. D., G, 2d South Carolina, age 28.	Dec. 13, 1864.	Wound of left elbow joint.	Dec. 13, 1864.	Excision.	

**2. Intermediary Excisions at the Elbow.**—The hundred and ninety-seven reported cases of this group (the result having been determined in every instance but one) presented a mortality rate of 35.2, or nearly fourteen per cent. greater than in the series of primary excisions, and nearly two per cent. greater than in the series of *intermediary amputations* in the continuity of the arm. Somewhat more than a fourth of the operations were complete excisions,—in the strict sense the articular ends of the humerus, radius, and ulna having been resected. These fared better than the cases of partial excision.<sup>1</sup> The limb interested is unspecified in eight cases; in ninety-one instances excision was at the right, and in ninety-eight at the left elbow, with less favorable results in the operations on the left side. In nineteen cases, recourse was ultimately had to amputation, with eight deaths.

§ *Recoveries after Intermediary Excisions at the Elbow.*—The survivors of this operation were four Confederate and one hundred and twenty three Union soldiers. Apart from three cases in which the point is not specified, the excisions were practised in equal number on the two limbs, sixty-two on each. Thirteen patients returned to modified duty, three were exchanged or furloughed, three recovered whose final disposition is unrecorded, and one hundred and eight were discharged and pensioned. Eight of the pensioners have died since their discharge, three from causes unconnected with their injury. Three of the survivors had received serious wounds in other regions. In all but four cases the injuries were believed to have been inflicted by musket or carbine balls. Complications will be noticed in connection with some of the detailed abstracts of cases, or in the summary in TABLE CX.

CASE 1793.—Private F. A. Warner, Co. C, 7th Ohio, aged 26 years, was wounded at Winchester, March 23, 1862. Surgeon W. A. King, U. S. A., Medical Director, reported, on the casualty list: "Compound fracture of elbow." Assistant Surgeon R. F. Weir, U. S. A., in charge of Frederick Hospital No. 1, contributed the following minutes of the case: "The man was shot in the left elbow while in the act of loading his gun. He was carried to the hospital at Winchester, and thence sent to Frederick on April 5th. He stated that considerable swelling and pain had ensued, but had diminished within a week previous to his entrance here, a free discharge of matter taking place from the wound. On examination the ball (spherical) was found to have entered just over and to the outside of the articulation of the radius with the humerus, and to have made its exit above and external to the inner condyle. The wound of entrance had enlarged to the size of a half dollar from sloughing, which, however, had ceased. The parts about the joint were much swollen, painful, and tender on pressure, which caused escape of pus mingled with synovial fluid. The wound was examined digitally by Dr. Dunott, who reported communication with the articulation. But moderate constitutional disturbance was present. Patient is a man of robust constitution, though of somewhat irritable temperament. April 6th, I saw him this morning for the first time, and as the previous introduction of the finger by the attending surgeon had caused much pain and increased the swelling of the parts, contented myself with an examination by the probe, revealing quite extensive fracture of the radius and humerus. Exit of matter was quite free through the anterior opening. Advised resection, but the patient refused his consent to the operation. In view of his otherwise good condition ordered the arm to be placed in a guttered tin splint at an angle of about 110°, and water poultice to be applied to the joint. April 15th, since last date patient has fallen off rapidly, especially within the past two or three days, though suffering but moderate pain. The joint has become more swollen, and burrowing of matter on the posterior aspect of the arm has supervened. The discharge from the anterior opening has deteriorated in quality, becoming more sanious. He has also had some slight diarrhœa with tendency to dryness of tongue; hectic at night; pulse 118 and irritable. He was more strongly urged to submit to the operation, to which, by the advice of his brother and family physician, he finally consented. April 16th, the diarrhœa was readily checked by opiates and careful regulation of diet with judicious administrations of stimulants, and this morning his general condition has much improved; pulse 108 and less irritable and fuller; has fever. An abscess one and a half inches above the original wound of entrance opened spontaneously this morning above the olecranon. At 11 o'clock A. M., the patient being etherized, in presence of Drs. Pinkney, Chittenden, Heany, Goldsborough, and Dumott, the Hospital Staff, I proceeded to excise the joint by a longitudinal incision six inches long through the opening of the abscess, having the inner margin of the olecranon process for its centre. The ulnar nerve was carefully dissected from the internal condyle and turned back, and confided to an assistant. The posterior internal and exterior lateral ligaments were successively divided and the joint forced open by extensive flexure of the limb. It was then seen that the ball had struck the anterior margin of the head of the radius, clipping off a small portion, and traversed the middle of the external portion of the extremity of the humerus, splitting off the external condyle and articulating surface corresponding to the head of the radius. The ends of the bone were separated anteriorly and laterally by the knife

<sup>1</sup> The parts removed were specified in 179 of the 197 cases of intermediary excisions. The articular extremities of all the bones of the elbow were excised in 46; the ends of the humerus and ulna in 29; the ends of the humerus and radius in 7; the condyles in 33; the upper extremities of the ulna and radius in 17; of the ulna, alone, in 39; of the radius in 8; in 18 cases the parts removed were not specified.



kept constantly close to the bony parts, and then protruded through the incision and sawn off by an ordinary short amputating saw; the radius and ulna being removed on a line a little below the articulating surface of the radius, and the humerus just above the condyles, only such an amount being taken away as was sufficient to comprise the fractured parts. The unfractured portion of the joint was found with the cartilage softened and eroded, and spongy granulations springing from its surface. The abscess extended to a little below the middle of the arm. But little hæmorrhage was present, and only two small arteries required ligation. Some difficulty was experienced in dividing the internal ligaments, and after the restricted portion had been divided by a blunt-pointed bistoury, which, by slipping, cut my left index finger used as a guide, it was thought by some of the assistants that the nerve had been severed. Whether the bundle divided was the nerve was not then ascertained. The upper and lower thirds of the wound were closed by silver interrupted sutures, the middle portion, involving the opening of the abscess, being left open for drainage. The arm was then placed on a well-padded splint, covered with oiled silk, at an angle of 140°, and cold-water dressings were applied. The patient suffered but slightly from the operation, and within two hours reaction was firmly established. Twenty minims of Magendie's solution of sulphate of morphia was given to allay pain. April 17th, patient passed a quiet night; pulse 120, quick, and somewhat weak; skin a little dry and warm. Ordered brandy half an ounce every four hours, and a prescription of spirit of mildererus three ounces and a half, sweet spirit of nitre half an ounce, and tincture opii two drachms, given in half-ounce doses every three hours. The arm is much swollen. The place left open for drainage has become closed from tumefaction, and the gaping edges are bathed in purulent lymph. The secretion finds ready exit through the original wound over the external condyle, which presents, however, a sloughy appearance consequent upon the contusion unavoidable during the operation. Tension on the sutures is present. In the afternoon one suture was removed, and adhesions to the extent of one and a half inches broken up by a probe, giving free exit to matter. Having obtained ice with some difficulty, it was placed in a bladder and applied to the elbow. The patient's appetite is fair and he takes a good allowance of beef tea. He complains of numbness in little and ring fingers, having had, he states, sensation in them prior to the operation. The unavoidable inference is that the nerve was injured. April 18th, passed a very comfortable night, and this morning the pulse is 100 and fuller; skin moist and appetite very good. Takes solid food and one bottle of ale daily. The ice application has been very grateful to him, and the swelling has perceptibly subsided. The discharge is assuming a more natural appearance and is less bloody. Treatment continued. April 20th, continues to improve. His general condition is very good; pulse 92 and of good force. The swelling of the limb is rapidly diminishing, the discharge is becoming more laudable, and the gaping edges of the wound are commencing to clean off and granulations to appear. Takes good diet and one bottle of ale per diem. Continued the ice applications. April 25th, the swelling has entirely subsided. The surface of the wound cleaned off, also the original wound, and they are now covered with healthy granulations. The discharge is moderate and laudable; no burrowing. Has continued the local applications of ice to the present time. Ordered arm to be dressed with balsam of Peru. General condition much improved; appetite good; pulse 80. Takes good diet, and a prescription of sulphate of quinine one grain, sulphate of




FIG. 616.—Portions of left humerus, ulna, and radius excised for shot injury. *Spec.* 838.

iron two grains, and extract of gentian sufficient quantity. May 1st, the splints having become displaced by the movements of the body, and the patient having complained of pain over site of external condyle, the arm for the first time since the operation was carefully and clearly lifted from the splint, examined, cleaned, and replaced on a new and broader splint, bent at a more acute angle—about 120°. The old splint on being removed was found to be too narrow, the lower lip of the wound projecting over the edge, thereby becoming œdematous. Evidences of cicatrization are showing themselves. The under surface of the limb was perfectly sound. No pain was complained of consequent upon bending the arm in the new splint. Has considerable motion of both little and ring fingers, and thinks he has some sensation in the latter. There is no constitutional trouble whatever. The limb is dressed with Scultetus's bandage, balsam Peru being applied to the wound. Treatment continued. May 11th, since last date the arm has been progressing very favorably. No disturbance followed the change of splint. The wound is nearly filled with healthy granulations and cicatrization is advancing. Some collection of pus occurred a few days since over site of external condyle, due to the adhesions of the granulations of the main wound.

These were broken down by a probe and free vent established. Wound dressed with Hays's lotion and many-tailed bandages. General condition excellent. May 23d, for the last five or six days the arm has been raised daily from the splint and passive motion to a slight extent resorted to, not causing any pain to the patient. The wounds are closing up rapidly. The opening noticed at last date closed up rapidly in spite of tents, and a small abscess formed at upper portion of cicatrix of incision and discharged *sua sponte*, completely draining the granulations. General and local condition admirable. Wounded arm rests on a pillow. June 23d, since last note patient has steadily improved. Is now up and about, carrying the arm in a sling at an angle of about 40°. Passive motion is daily resorted to and well borne. One or two small scales of bone have cast off. The wounds remaining are of small size, and rapidly closing. General condition excellent. July 2d, at his own request the patient has been discharged from service to-day. The arm has been doing admirably, and but two small ulcers are now seen, one at the seat of the original wound and the other at site of the operation. No dead bone is felt. Flexure and extension are almost perfect, though some obstructions from muscular adhesions are found in pronation and supination. Patient was ordered to continue passive motion. On August 1, 1862, he wrote to me that his arm is doing very well, that the ulcers had healed, strength in arm was increasing, and motion of articulation very perfect; also that sensation in the little finger was still absent, though motion exists." The specimen (FIG. 616) consists of the excised parts, the articular surfaces of which are carious. It was contributed by the operator. Examiner H. Pierpoint, of New Haven, Connecticut, certified April 27, 1863: "Was wounded through the left elbow joint, resulting in resection of the joint, but has an arm reflecting much credit upon the operating surgeon." Examiner C. H. Rawson, of Des Moines, Iowa, January 1, 1873, certified: "Excision, &c. The limb is two and a half inches shorter than the right; it is one inch smaller below the joint and two and a half inches less around the humerus. Can flex forearm and carry it to the head, but has no power of extension. Can rotate forearm on arm. Circulation in the limb is good except slight tendency in two lesser fingers to coldness," &c. The disability was rated total, third grade. The pensioner was paid June 4, 1875.

CASE 1794.—Private *J. Harris*, Co. D, 2d North Carolina Cavalry, aged 40 years, was wounded at Gettysburg, July 3, 1863, and admitted to Frederick Hospital three days afterward. Acting Assistant Surgeon J. C. Shimer reported the following minutes of the case: "A minié ball entered the right arm posteriorly about two inches above the elbow, passing through the joint, and emerging on the ulnar side about four inches below the joint, fracturing and comminuting the ulna. The patient's general health at the time of admission was somewhat depraved and suffering greatly from the wound. Cold-water applications were used for the arm, stimulants administered internally, with generous diet, and opiates given to produce rest and sleep. July 15th, eight small fragments of bone were extracted from the forearm and two small spiculae from the wound of exit. The patient's general health remains about the same; appetite but little improved. He takes three ounces of whiskey and twelve grains of sulphate of quinine daily, and sulphate of morphia in the evening. Arm still painful and is becoming somewhat swollen. July 20th, bowels a little constipated; ordered a dose of sulphate of magnesia in the evening. Arm not quite so painful; a healthy suppurative process going on; wound injected daily with a diluted solution of chlorinated soda to counteract impure smell. July 25th, arm put into an Ahl felt splint, fitting nicely; walks about, and does not suffer much pain; swelling somewhat subsided; is able to flex fingers as well as elbow to a slight extent; has a cough, for which expectorants were ordered. July 29th, condition of arm much worse; it is becoming enlarged and very painful. To-day the joint was resected. The operation consisted of the removal of about three inches of the humerus and one-fourth of an inch of ulna (olecranon process). Applications of powdered ice to the arm were used; stimulants and beef tea administered. July 31st, patient doing well; suffers no pain; wound discharging freely; pulse 96; appetite moderate; slight diarrhœa, for which opium is given. Patient takes generous diet; has some cough and expectorates yellowish thickish sputa. Ordered mild stimulating expectoratives. August 1st, swelling somewhat subsided; less tenderness; appetite improving; rests comfortably. August 3d, has had chills two evenings in succession, followed by fever. Ordered sulphate of quinine, three grains every four hours; discontinued iron. Diarrhœa about the same; twenty drops of tincture opii given after each stool. Pulse 100; still has cough; arm looking well; œdema gradually subsiding; rests well; had five passages in the evening. August 4th, had three passages last night, no chills; pulse 102; wound dressed with balsam; arm looking well. August 6th, tongue cleaning off; pulse 100 and rather feeble; had three passages during the night; arm looks well; patient improving. August 7th, patient a little delirious; tongue looking better; pulse 98; coughs a great deal and expectorates freely; appetite still very poor; diarrhœa about the same; dressing of arm continued; complains of pain in chest; some dulness on percussion. August 9th, patient seems to be sinking; pulse 124 and very feeble; still complains of a great deal of oppression in chest; diarrhœa worse. Ordered tincture opii forty-five drops, and starch water, to be given per rectum twice daily. He also complains of great thirst; ordered plenty of broken ice. August 10th, no marked change, the wound looking well. Swelling very nearly subsided and the arm looks natural in size. August 13th, pulse 100; diarrhœa worse again. Discontinued the use of injections and ordered pulverized opium, one grain every hour. August 14th, diarrhœa decidedly better. Discontinued the free use of opium and gave it moderately. Patient improving; seems to be more cheerful; appetite a little improved. August 15th, complains of considerable pulmonary trouble; diarrhœa completely checked. Applied blister over seat of pain. August 17th, appetite still improving. Placed arm in an angular splint, bound fast to the limb to enable him to sit up in bed; discontinued the use of powdered ice to arm, as the inflammation and swelling has entirely subsided. Wound cicatrizing nicely; flexes the fingers slightly; loss of sensation in little and ring fingers; still some œdema of hand. The arm is brought to an angle between an obtuse and a right angle. August 27th, passive motion of arm practised daily. Is able to walk about the ward and has better relish for food. Patient doing well. September 2d, is not so well to-day; an abscess formed below the joint; considerable inflammation. Ordered patient to be put to bed and applied ice. Wound of exit discharging freely; slight diarrhœa, for which he is taking stimulants and tonics. September 16th, still indications of phthisis. Has a dry cough, night sweats, and swelling of the extremities; appetite good; arm looking well. September 23d, for a few days past has complained of incontinence of urine. Ordered fluid extract of buchu and sweet spirit of nitre half a drachm each, every two hours. Also complains of great pain in lumbar region; ordered blister to be applied. October 1st, patient experiencing relief; doing well with the exception of neuralgic pain in hand and ulnar side of arm; takes a moderate amount of whiskey daily, with generous diet. The wounds have healed and the splints are removed. There is a good deal of motion of the joint; patient can flex his wrist slightly. October 30th, pain in arm and hand becoming more intense, relieved by applications of opium and belladonna plasters, tincture iodine, chloroform, tincture opii, etc. Symptoms of pulmonary trouble disappeared. November 2d, patient still experiencing much pain in arm and hand; otherwise doing well; he receives a pint of porter daily. November 30th, pain in arm subsided, but increased in hand. Treatment continued. December 10th, suffers excruciating pain in hand; anodynes freely administered to deaden sensibilities, and opiates and lotions externally. Wound of entrance again discharging; necrosed bone found on probing. January 25th, extracted small fragments of bone from opening near hand, followed by some relief from pain. Treatment: poultice externally and opium pills internally. April 29th, treatment continued; slight improvement in motion of arm and slight abatement of neuralgic pain; otherwise the patient remains the same. May 5th, transferred to hospital in Baltimore." Assistant Surgeon R. F. Weir, U. S. A., who performed the resection in this case, contributed the specimen (FIG. 617), consisting of the excised upper half of the olecranon and three inches of the lower extremity of the right humerus. A complete fracture was produced by the missile from the point struck, just above the inner condyle, through the trochlea. A space at the point of impact about the calibre of the bullet is necrosed, between which some periosteal inflammation has occurred. A cast of the injured elbow, made after the removal of the bony articulation, was contributed by Dr. Shimer, showing the arm in a semi-flexed position, that amount of motion being attainable in it. (*Cat. Surg. Sect.*, 1866, p. 536, *Spec.* 2570.) On May 9th the patient entered the post hospital at Fort McHenry, whence Surgeon J. H. Currey, U. S. V., reported his transfer to the post prison on July 21, 1864, and his subsequent removal to Point Lookout, "the wound having healed, but the bones not united."

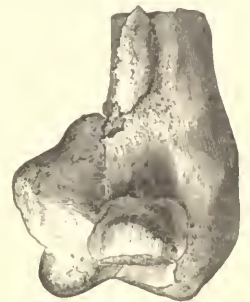

FIG. 617.—The tip of the olecranon and three inches of the humerus excised for shot injury. *Spec.* 3912.



Attention has been repeatedly directed to the fact that the records of the Pension Bureau represent the results of wounds and mutilations in the least favorable light, the certificates of the examiners being generally drawn so as to secure for the pensioner the largest allowance he may be entitled to receive under the provisions of the law. This is especially true in regard to the results of the excisions of joints, many men being returned as more or less unfit to follow their callings, although they have fairly useful limbs. Professor B. v. Langenbeck<sup>1</sup> has commented on the misleading effects of this cause in Germany, whereby misapprehension has arisen respecting the results of excisions in military practice, and a somewhat embittered controversy, in which Professors Hannover, Loeffler, and Neudorfer engaged.<sup>2</sup>

CASE 1795.—Private C. H. Gove, Co. I, 145th New York, aged 18 years, was wounded at Chancellorsville, May 3, 1863, by a minié ball, which entered the anterior aspect of the forearm above the middle, and made its exit through the olecranon process. On May 8th, resection of the olecranon process (and probably of the articular extremities of the humerus, radius, and ulna, as the interspace between the ends of the bones was very considerable) was performed on the field by a Confederate surgeon; and an angular splint was applied, with cold-water dressings. Gove was a prisoner for thirteen days after he was wounded; but in June was sent to Washington, was treated at Mount Pleasant Hospital, and thence transferred to Satterlee Hospital, Philadelphia, where he was received June 21st. Acting Assistant Surgeon T. G. Morton reported that "the wound was then sloughing; the use of the splint and cerate dressing was continued for about three weeks, when the splint was removed. The wound nearly healed, leaving the joint with its movement impaired and the arm semi-flexed," and the patient was discharged the service November 21, 1863, and pensioned. Mr. Gove visited the Army Medical Museum February 3, 1873, and a photograph, represented by the cut (FIG. 618), was then taken. A memorandum made at the time states that there was good use of the hand and very fair use of the forearm. Examiner H. L. Dodge, of Boston, reported, November 24, 1863: "There is great separation between the bones of the arm and the forearm." Examiner G. S. Jones reported, October 6, 1863: "The forearm is powerless and useless." The last examination of the pensioner was made under Surgeon Thomas Franklin Smith, of New York, September 17, 1873, who reported: "Complete resection of the right elbow joint. The hand hangs to the side, and for purposes of manual labor the disability is equal to the loss of the arm." Pensioner was paid March 4, 1874.



FIG. 618.—Results of a primary excision at the elbow for shot injury.

CASE 1793.—Private J. H. Stark, Co. M, 7th Indiana Cavalry, age 22 years, was wounded in the left arm, while on scout near Memphis, October 22, 1864, and underwent excision of the elbow joint at the Adams Hospital. Assistant Surgeon J. M. Study, U. S. V., who performed the operation, furnished the following report: "The ball (conical) entering the left arm one inch above the olecranon process, detaching the condyles from the shaft of the humerus and separating them from each other at the same time, passed forward through the joint and lodged under the integument on the anterior aspect of the forearm, midway.

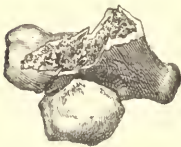


FIG. 619.—The olecranon and two inches of the lower extremity of the left humerus excised for shot injury. Spec. 3506.

The entire forearm became much swollen, and the parts adjacent to the elbow joint tense and livid. October 31st, a deep incision was made, four inches in length, from a point one inch above the entrance of the ball downward, the forearm forcibly flexed, and the articular surface of the upper extremity of the radius and the olecranon process of the ulna sawn through, the fractured end of the shaft of the humerus sawn off squarely, the wound cleansed, and its margin brought together by four stitches, the arm in nearly a straight position placed upon a pillow, and cold applications directed. Chloroform was used; hæmorrhage was slight. The patient did remarkably well. December 31st, the patient is going about the ward, and able to rotate and flex the forearm." The specimen, represented in the annexed cut (FIG. 619), and consisting of the olecranon and two inches of the lower extremity of the left humerus, was contributed by the operator. The patient was discharged from service May 13, 1865, and pensioned. Examiner J. G. Hendrick, of Madison, Indiana, November 8, 1865, reported: "The ball entering posterior face of

the humerus, between the condyles, passed through the elbow joint, and was cut out in the upper third of the forearm. An inch and a half of the lower end of the humerus was resected, making a false joint, and leaving the forearm and hand entirely useless." Examiner W. A. Collins certified, September 17, 1873: "Gunshot wound, excision, etc., greatly impairing the use of the arm, the muscles of the arm being almost completely lost at this time by atrophy. Disability third grade and permanent." The pensioner was paid June 4, 1875.

<sup>1</sup> In his address at the third session of the Second Congress of the German Surgical Society, at Berlin, April 18, 1873: *Über die Endresultate der Gelenkresektionen im Kriege*, in LANGENBECK'S *Archiv. für Klinische Chirurgie*, B. XVI, 1874, and since republished in his *Chirurgische Beobachtungen aus dem Kriege*, Berlin, 1874. In Europe, as in this country, the difficulty lies in framing laws that shall definitively adjudge relief to different classes of invalids in equitable proportion, according to their degree of disability. The points of view of the practical surgeon and of the pension examiner are, of necessity, different. The operator is rejoiced where his patient recovers with a limb useful for many purposes. The pension examiner, acting under strict instructions, returns the same limb as useless, in the sense that it is of no service to the pensioner's particular vocation.

<sup>2</sup> Prof. DOUTRELOUP and Dr. HUGELSIOFFER subsequently discussed the matter in a more judicial spirit.

While, as a rule, the performance of excisions of the elbow joint for injury during the inflammatory stage is greatly to be deprecated, it cannot be denied, that such operations have achieved felicitous results. The two following examples prove this:

CASE 1797.—Private W. T. Riley, Co. D, 86th New York, aged 21 years, was accidentally wounded by a comrade, near Mine Run, November 26, 1863, and was admitted into Mansion House Hospital, Alexandria, on the same day, having bled quite largely on the way. Acting Assistant Surgeon C. W. Kœchling noted as follows: "The ball entered the right arm a little above the internal condyle of the humerus, fracturing it, and emerging through the olecranon process. When admitted, the whole arm was greatly inflamed and swollen; several pieces of bone were extracted and cold-water dressings applied. December 19th, patient was in good condition for an operation, and resection of the elbow joint was performed by Surgeon Charles Page, U. S. A. The patient was put under the influence of chloroform, and an incision three inches long was made over the exterior surface of the arm, and another of the same length over the olecranon process of the ulna; the transverse section was then made, and the flaps dissected back, and two and a half inches of the inferior extremity of the humerus, one inch of the upper extremity of the ulna, and a small portion of the head of the radius were removed. Very little hæmorrhage occurred. The wound was dressed with cold-water dressings. December 20th, the patient rested well during the night; he complains of a little pain in the arm; pulse 100; appetite poor. December 21st, renewed dressing; appearance of wound very good; discharge healthy." The case progressed most favorably, and in May, 1864, Riley went to his home on furlough with a useful arm, and on October 21, 1864, was discharged the service. In 1865, he re-enlisted in Co. K, 5th regiment, First Corps, with the approval of Lieutenant Colonel Dougherty, Medical Director of the Corps. "The man went through the manual before me," Surgeon Dougherty writes, "and stated his readiness to do all the duties of a soldier. He wished it

recorded that he was competent and prepared, in order that during the term of his service he might be held to full duty. The degree of motion was perhaps one-third of the normal amount." In July, 1865, Riley visited the Army Medical Museum, and a photograph was taken, which is copied in the right-hand figure of PLATE LIII, opposite page 850, and in the wood-cut (FIG. 621). The specimen (FIG. 620) consists of "two and a half inches from the lower extremity of the right humerus excised. One inch of the upper extremity of the ulna and a small portion of the head of the radius were removed at the same time, but have not been preserved. Two incomplete longitudinal fractures, one on each surface of the shaft, arise from the lower border. The trochlea is destroyed, the outer condyle shattered, and the inner condyle separated by an oblique fracture. Superficial necrosis exists over much of the specimen, the remainder showing reparative periosteal disturbance. Contributed by Acting Assistant Surgeon C. W. Kœchling." (See *Cat. Surg. Sect.*, 1866, p. 158.) Examiner C. M. Crandall, of Belfast, New York, reported, December 28, 1866: "The arm is much more shortened; the flexor muscles of the forearm more contracted, so that the arm is fixed at near a right angle and is subject to suppuration near the elbow." Examiner J. W. Graham, of Utah Territory, October 9, 1873, reported: "Resection was performed with but partial success; disability total." [!] This pensioner was paid March 4, 1873.

CASE 1798.—Corporal J. Patne, Co. C, 39th New York, age 20 years, was wounded at the Wilderness, May 6, 1864. The ball was extracted on the field and the wound dressed in a Second Corps hospital. He was sent to Washington on May 13th was admitted to Finley Hospital, where he was operated on by Surgeon G. L. Pancoast, U. S. V., who reported: "Gunshot fracture of elbow joint, fracturing the olecranon process and condyles of the humerus. On May 25th the patient was chloroformed, and the humerus one inch above the condyles, and the heads of the radius and ulna were removed. At the time of operation the joint was much swollen and painful; there was great discharge of pus, and of small pieces of bone occasionally; the olecranon was movable. His constitutional condition was not very good. Cold-water dressings were used, and the wound healed kindly by healthy granulations." The specimen, shown in the wood-cut (FIG. 622), was contributed by the operator. It consists of three inches of the lower extremity of the left humerus excised. The specimen shows a complete oblique fracture in the lowest part of the shaft, complicated with a perpendicular one directly through the trochlea, of which the central portion is missing. On the posterior upper border of the transverse fracture is a moderate collection of callus. The olecranon was fractured but was not preserved with the specimen. The patient remained in Finley Hospital until July 13, 1865, when he was transferred to New York and entered De Camp Hospital, whence he was discharged the service November 7, 1865, and pensioned. On November 16th the patient was fitted with an apparatus by Dr. E. D. Hudson, who reported that the limb was shortened two and three-fourths inches, with an interspace of one and a quarter inches. On December 25, 1865, the photograph of the patient, represented in the cut (FIG. 623), was taken, and was contributed to the Army Medical Museum by Assistant Surgeon Warren Webster, U. S. A. The wound was at that time completely healed, and the pensioner enjoyed valuable use of his arm and hand. Examiner T. F. Smith, of New York, January 30, 1866, reported: "Bullet shot of right elbow, with resection of the elbow joint; the forearm hangs like a flail, so that he has no use of it. The pensioner was last paid March 4, 1870, since which time he has not been heard from by the Pension Bureau.

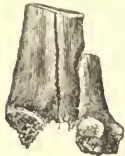

FIG. 620.—Caries of lower extremity right humerus after shot fracture.



FIG. 621.—Appearance two years after a complete excision of right elbow joint.

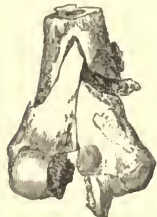

FIG. 622.—Posterior view of the lower extremity of a right humerus excised for shot injury.

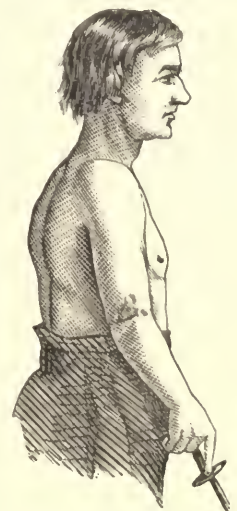


FIG. 623.—Appearance of patient twenty-one months after an excision of right elbow.



Sixty-two, or nearly one-half of the one hundred and twenty-seven patients who recovered after intermediary excisions at the elbow, are reported to have complete ankylosis at the elbow,—such a large proportion that it seems probable that the term may have been applied, in some cases, where the joint permitted only very limited motion. A number of examples of this termination will be detailed:

CASE 1799.—Private F. A. Dixon, Co. A, 1st Maryland regiment, Potomac Home Brigade, aged 18 years, was wounded in the left arm at Winchester, July 24, 1864. Three days afterward he was admitted to Frederick Hospital, where he was operated upon by Assistant Surgeon R. F. Weir, U. S. A., who reported as follows: “Gunshot wound, fracturing inner condyle of left humerus. July 29th, excision of elbow joint. Patient did pretty well. The wound of incision had cicatrized by October 15th. Used an angular tin splint for a month; arm resting on pillows the rest of the time. A few fragments of necrosed bone were removed. November 20th, patient has very little flexion at elbow, and some rotation. January 20th, Motion continues the same. There is an opening and a sinus leading to dead bone, not yet loose. Patient’s health is good.” He was discharged from service on June 17, 1865, by reason of “ankylosis of left elbow joint, resulting from the injury.” The specimen (FIG. 624) consists of the olecranon and one and a half inches of the lower extremity of the humerus. It was contributed by the operator. Examiner G. W. Wayson, of Baltimore, December 15, 1865, certified: “The ball entered above the elbow, shattered that joint, and passed out near the wrist joint, entirely disabling the arm and ankylosing the joint; the wound has not healed.” Examiner W. H. Baltzell, of Frederick, September 29, 1873, describes the wound, and says: “The arm is ankylosed in a semi-flexed position, and two sinuses communicate with exfoliating bone. The fingers and thumb are distorted and ankylosed in the position of extension. The pensioner was paid June 4, 1875.

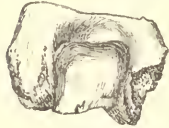

FIG. 624.—Excised condyles of the left humerus and the olecranon. *Spec.* 3948.  $\frac{3}{4}$

CASE 1800.—Private J. D. Douglass, Co. G, 63d Pennsylvania, aged 19 years, was wounded at Fredericksburg, December 13, 1862, and admitted to the field hospital of the 1st division, Third Corps, where Surgeon J. M. Cummings, 114th Pennsylvania, recorded: “Compound fracture of left humerus.” Assistant Surgeon C. Wagner, U. S. A., in charge of the Point Lookout Hospital, contributed the specimen (*Cat. Surg. Sect.*, 1866, p. 157, *Spec.* 925), which is illustrated in PLATE LI, FIG. 5, with the following description of the case: “The patient was wounded by a minié ball, which entered on the external aspect of the left forearm about over the neck of the radius, and made its exit just above the inner condyle, shattering, in its course, the radius at its neck, and breaking off portions of the coronoid process, internal aspect of the olecranon, and the trochlea. The patient was admitted on December 16th, and, on January 12th, resection of the injured bones was performed by Assistant Surgeon W. H. Gardner, U. S. A. The joint having been exposed by the quadrilateral flap operation of Moreau, the radius was sawed off just below its tuberosity. The upper extremity of the ulna and the articular surface of the humerus were also removed. After the operation the limb was laid on a cushion with the forearm pronated and slightly flexed. When last seen, on March 6th, the movements of the joint were tolerably free, extension full, flexion about five degrees above a right angle, slight pronation and supination, and the movements increasing almost daily.”<sup>1</sup> The specimen consists of one-fourth inch of the articular extremity of the humerus, and nearly two inches of the radius and ulna divided just below the coronoid process. It is disorganized by caries. In April, 1863, the patient was transferred to the Pittsburg Hospital, whence he was discharged December 26, 1863, and pensioned. Examiner O. Ayer, of LeSueur, Minnesota, December 19, 1863, certified; “Ankylosis of left elbow joint. In the humerus, some four inches from the lower extremity, there is a false joint, the result of an ununited fracture which occurred in 1864 (since his discharge from service). The muscles of the arm and forearm are much diminished in size, and the arm is of but little use.” Examiner S. Willey, of St. Paul, Minnesota, certified, November 26, 1839: “No use of hand or arm; complete ankylosis of elbow; muscles of arm, forearm, and hand attenuated and flabby, so as to have lost all muscular outlines; muscles of left shoulder all emaciated, and much pain of a neuralgic character in shoulder, arm, and hand. Disability permanent and equivalent to loss of hand.” The pensioner was paid September 4, 1875.

CASE 1801.—Private J. L. Mortimer, Co. C, 67th Pennsylvania, aged 40 years, was wounded at Petersburg, March 25, 1865, and was treated in the depot hospital at City Point, thence transferred to Washington, and admitted to Mount Pleasant Hospital on April 2d. Assistant Surgeon H. Allen, U. S. A., the operator, noted: “Admitted with gunshot wound of the right upper extremity, compound comminuted fracture, involving elbow joint; ball entered at the outer side of the bend of the elbow and emerged one inch internal to and above the olecranon, fracturing the external condyle. On April 5, 1865, the patient was anesthetized by equal parts of ether and chloroform and an incision was made from the outer border of the bend of the elbow, posteriorly, to the inner border. The articular surface was removed by the saw; of the ulna and radius by gouging with forceps. Four ligatures were applied to small branches. There was considerable oozing from the bone. At the time of operation the forearm and hand were edematous, the swelling extending above the elbow; the wounds had an unhealthy appearance and an unhealthy pus exuded from them; the general health was good. The after-treatment consisted of simple cold-water dressings, and afterward lead and opium wash; tonics, stimulants, and nourishing diet. The wound healed rapidly, and the patient was transferred to Philadelphia.” He was admitted to Mower Hospital May 18, 1865, and thence discharged the service, with ankylosis of the elbow, June 29, 1865, and pensioned. The specimen (FIG. 625), consisting of the articular extremity of the right humerus sawn just above the condyles and excised for fracture of the external condyle, was contributed by the operator. In September, 1873, Examiner W. J. Mullin, of Shellsbury, reported: “The arm is wasted and badly deformed; disability total.” Pensioner was paid March 4, 1874.



FIG. 625.—Excised condyles of humerus, shattered by shot. *Spec.* 72.  $\frac{3}{4}$

In many avocations, ankylosis at the elbow at a favorable angle, if associated with control of the functions of the hand, is a less serious disability than a loose, flail-like

<sup>1</sup> Compare reports of this case in *Am. Jour. Med. Sci.*, 1863, Vol. XLVI, p. 38, and *Boston Med. and Surg. Jour.*, 1863, Vol. LXVIII, p. 251.

connection between the arm and forearm. The latter condition, it is true, can be remedied to a certain extent by mechanical contrivances; but the stiff joint is the least of the two evils. It gains this distinction, however, only on condition that the ankylosis is effected in a good position of semiflexion, without extreme forced pronation or supination.<sup>1</sup>

CASE 1802.—Captain Richard N. Doyle, Co. H, 8th Michigan, aged 34 years, was wounded at James Island, June 16, 1862, and was admitted to hospital at Hilton Head on June 20th. On June 23d he was sent on a hospital steamer to De Camp Hospital, New York Harbor. Surgeon S. D. Gross, U. S. V., made the following special report: "The patient was wounded by a conoidal ball, which produced a comminuted fracture of the left elbow joint. He was admitted into the general hospital at David's Island, New York Harbor, on June 27th, and on the 1st of July Acting Assistant Surgeon W. K. Cleveland resected the joint, making a single straight incision. The articular surfaces of the humerus, ulna, and radius were removed, and were badly shattered. The case progressed badly, abscesses being of frequent occurrence about the joint, and at the latter part of September a large abscess, extending to the axilla, was opened and discharged a pint and a half of pus. At the present time, February 14, 1863, there is bony ankylosis of the joint, and dead bone can be detected with the probe. As far as regards motion of the joint the operation is a failure." On March 26, 1863, the patient was returned to duty, serving with his regiment until April 22, 1864, when he was admitted to No. 1, Annapolis; again returned to duty June 11, 1864. He was promoted Major August 20, 1864; Brevet Lieutenant Colonel April 2, 1865; and was mustered out July 30, 1865, and pensioned. The photograph, represented by the cut (FIG. 626), was forwarded to the Army Medical Museum by Examiner E. R. Ellis, of Grand Rapids, Michigan, April 24, 1863. In addition to the foregoing history, Dr. Ellis states: "About December 1, 1862, an operation was performed for the removal of portions of necrosed bone; quite a large fragment was removed. And again on the last of May, 1863, Surgeon Goldsmith, of Louisville, Kentucky, removed a portion five inches long and nearly three-quarters of an inch in diameter. On April 16, 1864, several smaller pieces of bone were removed at Annapolis. The enclosed photograph gives a good representation of the limb. It is seen to be somewhat smaller and shorter than its fellow. The dark lines on the inner surface are cicatrices where abscesses have been opened. There are five or six smaller ones on other parts of the arm, not shown. There is ankylosis of the elbow, of course, and the rotary motion of the forearm is lost. Altogether the limb is somewhat serviceable, and quite valuable in preserving the symmetry of the body." This pensioner was paid December 4, 1873.

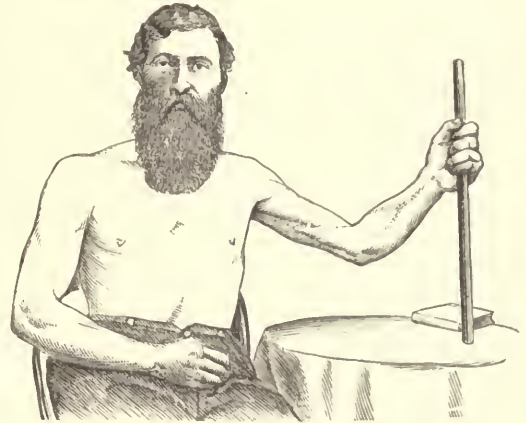

FIG. 626.—Appearance after an early intermediary excision of the left elbow for shot injury, four years after the operation.

CASE 1803.—Private J. Graisbury, Co. D, 6th New Jersey, aged 24 years, was wounded in the right elbow joint at Bull Run, August 29, 1862, and entered the College Hospital, Georgetown, on September 5th. Assistant Surgeon B. A. Clements, U. S. A., who operated in this case, reported the following history: "The patient was wounded by a minie ball at a distance of seventy-five yards, which fractured the olecranon process of the ulna. He did not suffer much. The operation of excision was performed three weeks after the injury. Both condyles of the humerus, the head of the radius, and all of the ulna above the coronoid process were removed. On January 1, 1863, one small piece of bone was discharged. The wound then immediately closed, leaving complete ankylosis. The bone was removed by a T incision. There was typhoid fever at the expiration of one month after the operation. Health now good; limb is strong; sensation in hand perfect; motion of hand almost perfect; slight stiffness of joints. He has the use of the hand and fingers, but the usefulness of the whole hand is materially impaired. Perfect ankylosis of the elbow has taken place in the extended position of the forearm. This is the result of an accident,—the forearm was nearly at right angles with the arm, when he stepped into a hole while walking, the hand and forearm falling heavily to the extended position, where it has ever since remained." The excised parts, represented in the annexed cut (FIG. 627), the articular surfaces being carious, were contributed to the Museum by the operator. On February 2d the patient was transferred to Stanton Hospital, Washington, whence he was discharged February 18, 1863, and pensioned. Drs. H. E. Goodman, J. Collins, and T. H. Sherwood, of the Philadelphia Examining Board, December 6, 1873, certified: . . . "Joint ankylosed in a straight position, arm atrophied, and hand almost useless; not equivalent to loss of hand." The pensioner was paid June 4, 1875.



FIG. 627.—The lower end of the right humerus and portion of the radius and ulna excised for shot injury. *Spec.* 327.

<sup>1</sup> LANGENBECK (B. v.) (*Chir. Beobachtungen aus dem Kriege*, Berlin, 1874, p. 183): "It is now the question, whether we should strive to cause ankylosis after resection of the elbow, or a movable joint. According to my view, this question cannot yet be finally decided, as we do not know whether every dangle-joint can be changed into an active mobile joint by appropriate treatment at the proper time. That an ankylosed joint is far preferable to a dangle-joint, as in cases Nos. 35 and 36 [two instances of loose-joint—*Schlotterverbindung*—reported by Herr v. LANGENBECK], cannot be disputed. But should it be possible to achieve, after resection of the elbow joint, as favorable results as, for instance, in cases Nos. 25, 29, and 34 [cases in which dangle-joints were converted into useful limbs by appropriate after-treatment], a movable limb would be preferable. If LÖFFLER (*l. c.*, p. 270) contends that we should appreciate more highly the cure of excision of the elbow joint with ankylosis, and that under certain circumstances, this result must be considered as one to be desired, I agree with him fully, but only on the express condition that the ankylosis sought for shall nearly approach a rectangular one."



The next case illustrates the group of seventeen successful excisions of the articular ends of the ulna and radius, without removal of any portion of the humerus:

CASE 1804.—Private J. Hastings, Co. K, 19th Indiana, aged 21 years, was wounded at South Mountain, September 14, 1862, and entered Hospital No. 1, Frederick, on the 18th. Acting Assistant Surgeon W. W. Keen, jr., described the injury as follows: "The ball entered the posterior part of the left forearm four inches below the elbow joint (the arm being flexed at the time), passed through the elbow joint, and made its exit one and a half inches above. On the battle-field, the surgeon opened the arm at the joint and removed several pieces of bone, varying in size from two inches in length to small fragments." Acting Assistant Surgeon J. H. Bartholf, who excised the elbow joint, furnished the following detailed history: "Wound in elbow joint; upper extremity of the ulna badly shattered. September 25th, general condition not good. Free suppuration. September 28th, operation: one linear incision was made from the tip of the olecranon to four inches along the line of the ulna; the head of the ulna was disarticulated without difficulty, and the olecranon and coronoid processes and one inch of the shaft to the point of the fracture were removed, and also two inches of the radius, it being found injured one and a half inches from its upper extremity. Several fragments of the ulna were removed, and the upper extremities of the lower fragments of both bones sawn off. The loss of blood was trifling. The patient's condition after the operation was good. Loss of continuity in ulna five inches, and of radius one-half inch. October 3d, patient doing well; wound free from accumulation of pus. October 4th, good symptoms continue. October 10th, placed arm in an angular wire splint, which secures immobility of elbow joint and permits the patient to leave his bed and go out-doors. October 14th, patient doing well; goes around the barrack and out-doors. October 18th, granulations are looking healthy and have entirely filled up the cavity; discharge has nearly ceased. There is one and a half inches shortening, the sound arm being fifteen inches from the epicondyle to the distal end of the metacarpal bone of the index finger, the injured limb thirteen and a half inches. October 19th, discharge ceased; cicatrization nearly complete; shortening two inches. November 6th, sloughing to a small extent has taken place in the granulating surface; amount of granulating surface left is small. The splint was removed, but patient has no muscular control of motion in joint. Callus is believed to have been thrown out in the track of the removed bone; splints reapplied. November 10th, nitric acid had been applied to the wound on the 6th and 9th inst., but the character of the wound is still sloughy; appetite and general condition pretty good. November 16th, through the continued application of nitric acid the sloughing has been arrested, and the wound appears quite healthy. December 8th, wound not entirely healed. Patient has slight motion in fingers, and, when the splint was removed, could bend the wrist. Union at the elbow is not yet very firm. Passive motion is now in use and may improve the joint. December 16th, symptoms of gangrene appeared in the wound to-day; strong nitric acid applied. General condition excellent. December 18th, gangrene disappeared. January 15th, arm slowly progressing—still in splint. Has pretty good motion in fingers, but cannot pronate or supinate the hand. January 23d, wire splint removed to-day, when it was found that the shoulder joint was rather stiff from being so long confined. Moved the elbow, and found the fingers described an arc of about four inches. Ordered splint to be removed entirely and employed passive motion. January 29th, arm improving under passive motion; can almost bring his hand to his mouth; condition excellent. February 1st, has some diarrhœa. Ordered castor oil and tincture of opium. February 2d, arm improving. General condition pretty good. Diarrhœa not yet stopped. February 6th, diarrhœa stopped; motion in arm good; patient able to bring it to his mouth." The specimen (FIG. 628) consists of the olecranon and coronoid processes and two and a half inches of the shaft of the left ulna, and the head and one inch of the shaft of the radius. The shaft of the ulna is completely comminuted, and that of the radius has several partial fractures. It was contributed by the operator. The patient was discharged from service February 7, 1863, and pensioned. Examiner W. Freeman, of Pennville, Indiana, September 21, 1873, certified: "The ball entered on ulnar side of arm and came out above condyle of humerus. The joint has been resected. There is very little motion at the resected-point, and the arm is flexed nearly at a right angle; the biceps and triceps muscles are very much atrophied. The disability is equivalent to the loss of an arm and is permanent." This pensioner was paid December 14, 1874.

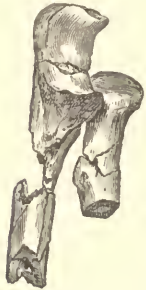
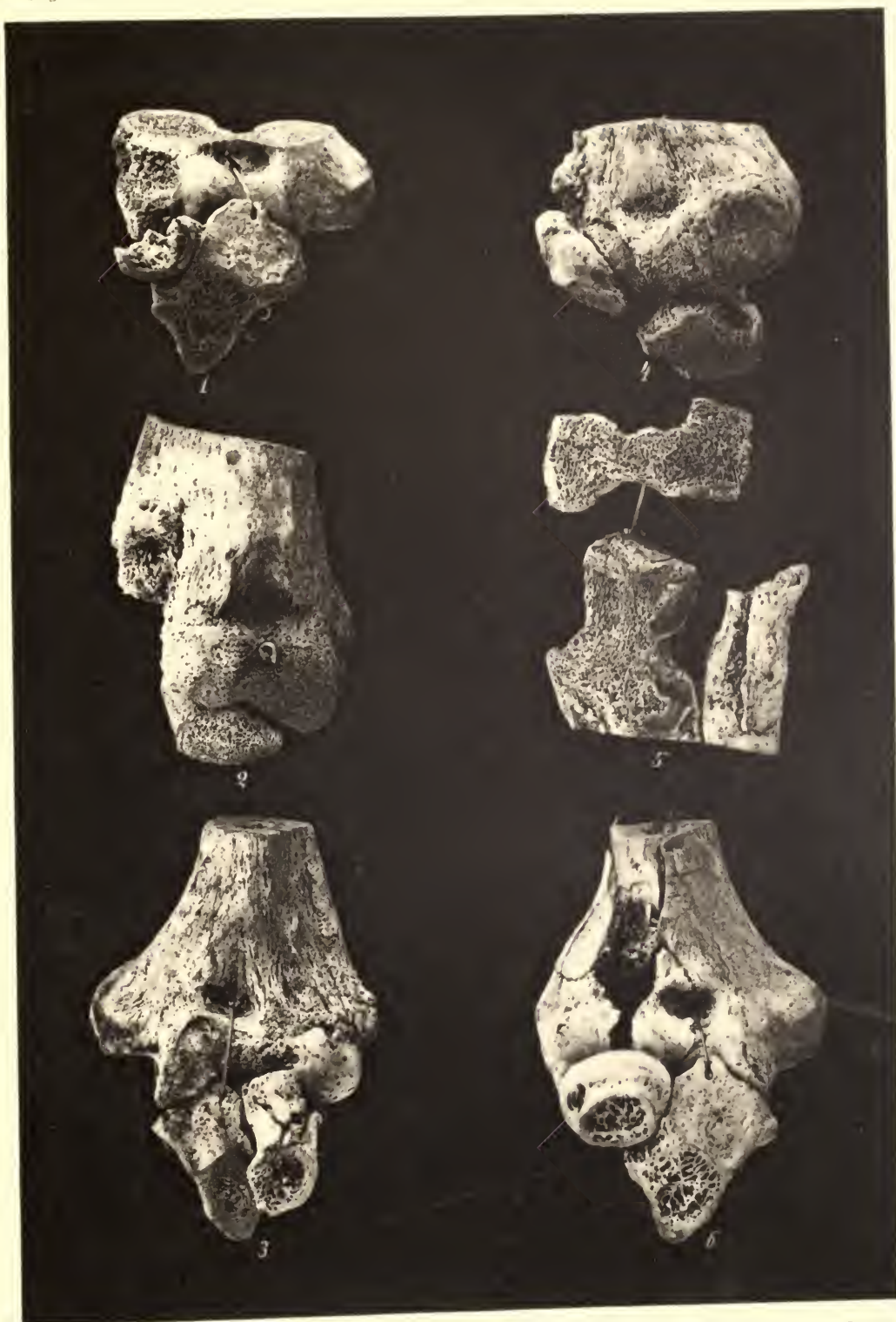
FIG. 628.—The olecranon and coronoid processes and portions of the ulna and radius excised. *Spec. 749.*

Eleven of the survivors of this series submitted to ulterior amputation:

CASE 1805.—Private J. Campbell, Co. A, 62d Pennsylvania, aged 25 years, was wounded at Malvern Hill, July 1, 1862, and entered Judiciary Square Hospital, Washington, three days afterward. Acting Assistant Surgeon D. W. Cheever contributed the specimen [*Cat. Surg. Sect.*, 1866, p. 153, *Spec. 15*, shown in PLATE LI, FIG. 1, opposite], with the following history: "The ball entered the right arm at the outer condyle of the humerus, and emerged on the inner side, near the bend of the elbow, and apparently in front of the coronoid process. July 13th, the arm has become extensively swollen, red, and painful; both wounds are suppurating; constitutional state fair. Explored under ether and found the outer condyle smashed up, and also the head of the radius. The injury had probably extended into the ginglymoid articulation also; at any rate the joint is open and liable to suppurative action extending itself from the injured trochlear surface. July 14th, the elbow joint was excised by an H incision. The radius was found to be split below the tubercle and was removed to that extent. The flaps were brought together with stitches and adhesive straps, the arm supported by an inside felt splint and a cold compress applied. July 17th, arm swollen; discharge of good pus; constitutional state fair; granulations exuberant. July 19th, capillary bleeding from wound, checked by ice; stimulants diminished. July 20th, doing well again. July 21st, copious bleeding from inner wound. Arm amputated." The specimen consists of the excised bones of the elbow, the line of section in the humerus being just above the condyles, in the ulna just below the coronoid process, and in the radius just below the head; only a portion of the latter is preserved. The patient was discharged from service August 29, 1862, and pensioned. Examiner G. McCook, of Pittsburgh, Pennsylvania, certified: "Amputation of right arm above elbow joint." In his application for commutation, dated 1870, the pensioner stated that "Dr. George L. McCook performed a second operation," and described "the length of the remaining stump as two inches from the shoulder joint and its condition as not very good." This pensioner died on June 4, 1873.



*Heliotype.*

*James R. Osgood & Co., Boston.*

PLATE II. BONES OF ELBOW, EXCISED FOR SHOT INJURY.

SURGICAL SECTION, ARMY MEDICAL MUSEUM.

Fig. 1. Specimen 15.  
" 2. " 1365. \*  
" 3. " 3476.

Fig. 4. Specimen 998.  
" 5. " 925.  
" 6. " 1309.





No instance appears on the returns in which excision was attempted in shot fractures of the elbow complicated by injury of the brachial, radial, or ulnar arteries. In the preceding subsection, however, at page 839, an instance is adduced, in which such a lesion was successfully dealt with by ligation of the radial and conservative expectant treatment of the fracture, while two fatal cases of the same sort appear on page 843. Since the war, a marvellous observation of shot comminution of the elbow, with laceration of the brachial, ulnar, radial, and interosseous arteries, ulnar and median nerves, and median vein, has been published by Dr. T. Curtis Smith, of Middleport, Ohio.<sup>1</sup> If the diagnosis be accepted as incontestable, the result of this case would refute the view heretofore generally entertained, that such lesions render amputation imperative.

As has been stated, eleven, or 8.6 per cent., of the one hundred and twenty-seven patients submitted to consecutive amputation,—demanded in three cases by consecutive hæmorrhage, as in an instance cited on the preceding page; in two cases for spreading gangrene; and, in six cases, for necrosis of the extremities of the bones contiguous to the excised parts. The following is an example of the last group:

CASE 1806.—Private P. D——, Co. D, 69th New York, aged 29 years, was wounded at Antietam, September 17, 1862. He was admitted to the field hospital of the 1st division, Second Corps, where Surgeon J. H. Taylor, U. S. V., recorded: "Wound of right arm." On September 24th, the patient entered Hospital No. 5, Frederick, where Surgeon H. S. Hewit, U. S. V., excised the elbow joint and subsequently amputated the arm. The following account of the case was furnished by the operator: "A conoidal ball fractured the elbow joint. Resection was performed on October 2d. The after-treatment consisted of yeast poultice and applications of tincture of iodine to the arm. December 4th, no perceptible improvement. Resection was again resorted to in hopes of saving the arm, but the damage was found to be so great that it was decided to amputate the arm near the shoulder. (See CASE 33, TABLE LXXXIV, p. 777 *ante*.) The stump was dressed with strips of muslin saturated with cold water, and compress and roller used. December 6th, patient comfortable. December 28th, stump looks well; health good; patient complains of pain in back; ordered belladonna plaster. December 29th, transferred to Hospital No. 6." The specimen, represented in the annexed cut (FIG. 629), consists of the excised portion, and embraces two inches of the lower extremity of the humerus and the olecranon. The upper portion of the bones of the forearm and the greater portion of the shaft of the humerus, amputated in the upper third, are also preserved in the Army Medical Museum, and numbered 807 of the *Surg. Sect.* The extremities of the radius and ulna are carious and show no attempt at reparation. The humerus is necrosed to the line of section. Both specimens were contributed by the operator. The patient was discharged from service on February 5, 1863, and pensioned. He subsequently joined the Veteran Reserve Corps, and was ultimately discharged December 9, 1864. He was last paid June 4, 1875.

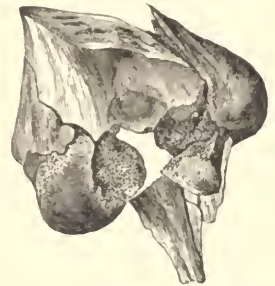

FIG. 629.—Lower extremity of the right humerus and the olecranon excised for shot fracture. *Spec. 458.*

Another instance<sup>2</sup> is detailed on page 791, and illustrated by FIGURE 6 of PLATE LI. Of the cases in which the arm was preserved with a high degree of usefulness, there are mentioned, in the succeeding tabular statement, at least six examples (numbered 9, 16, 65, 73, 91, 101) in addition to the instances above cited, of recovery with almost perfect control of the movements of the elbow and of the functions of the forearm and hand.<sup>3</sup>

<sup>1</sup> SMITH (T. CURTIS), *Case of Resection of the Elbow after Complete Destruction of the Principal Artery, Veins, and Nerves*, in *Cincinnati Lancet and Observer*, 1871, Vol. XIV, p. 65. Thomas Lloyd, aged 22, wounded by small shot, October 6, 1870, the muzzle of the fowling-piece being but four inches from the inner border of the left elbow. The ulna was shattered, the trochlear surface of the humerus laid bare, the humero-radial articulation torn apart, and a portion of the head broken off, the soft tissues dreadfully lacerated; wadding, shot, and bone splinters were driven into the tissues in all directions, the ulnar nerve evidently divided, the brachial artery torn off at its bifurcation, and enough of the radial and ulnar arteries were missing to include the origin of the recurrent and interosseous; the median nerve and vein were also divided. On October 7th, with the assistance of Dr. A. C. Barlow, of Pomerooy, Dr. Smith resected the joint, removing the ulna two inches below the olecranon, and the articular ends of the humerus and radius, with splinters and devitalized portions of muscular tissue. The wound healed without any drawback save an exfoliation from the ulna. On December 28, 1870, the man was in "excellent general health, with free use of shoulder joint, partial and improving use of wrist joint, with ability to flex and extend the thumb and fingers, and little atrophy of the muscles of the forearm . . . the limb so completely saved as to be of great utility to its possessor!"

<sup>2</sup> The case of Pt. Sche, an intermediary excision at the elbow, by Assistant Surgeon P. S. Conner, U. S. A., detailed as CASE 1709, on p. 791, and included in the summaries of TABLE XC, No. 5, and TABLE CIX, No. 104, p. 878.

<sup>3</sup> My note-books furnish the following references to published abstracts of cases of intermediary excisions at the elbow for the effects of shot injury practised during the civil war: STEARNS (J., JR.), *A few cases of Excision of Elbow*, etc., in *Boston Med. and Surg. Jour.*, 1863, Vol. LXVIII, p. 251 *et seq.* GILFILLAN (W.), *Excision of the Elbow Joint*, etc., in *Trans. of Med. Soc. of New York*, 1866, p. 125. GROSS (S. W.), *Interesting Cases of Gunshot Wounds*, in *Am. Med. Times*, 1864, Vol. VIII, p. 137. WAGNER (C.), *Reports of Cases of Resection*, in *Am. Jour. of Med. Sci.*, 1863, Vol. XLVI, p. 37. LESTER (E.), *Reports of Cases at Mill Creek Hospital*, in *Am. Med. Times*, Vol. V, p. 48. COUES (E.), *Report of some cases of Resection*, in *Med. and Surg. Reporter*, 1863, Vol. IX, p. 229.



TABLE CX.

*Summary of One Hundred and Twenty-seven Cases of Recovery after Intermediary Excisions of the Bones at the Elbow, for Shot Injury.*

NO.	NAME, AGE, AND MILITARY DESCRIPTION.	DATE OF INJURY.	NATURE OF INJURY.	DATE OF OPERATION.	OPERATION AND OPERATOR.	RESULT AND REMARKS.
1	Albin, J. E., Pt., C, 12th New York, age 24.	July 1, 1862.	Wound of forearm by conoidal ball.	July 9, 1862.	Partial excision of elbow joint.	Complete ankylosis of elbow; not a pensioner.
2	Andreas, G., Pt., B, 39th New York, age 43.	Oct. 14, 1863.	Compound comminuted fracture of left radius and upper third of ulna by conoidal ball.	Oct. 18, 1863.	Excision of head of radius and upper third of ulna, by Surg. E. Bentley, U. S. V.	Disch'd April 19, 1864; not a pensioner. Complete recovery except partial ankylosis.
3	Barlow, A. R., Corp'l, G, 157th New York, age 23.	Dec. 6, 1864.	Fracture of olecranon process of left ulna by conoidal ball.	Dec. 13, 1864.	Olecranon and one inch of shaft of ulna, by A. A. Surg. W. Balser.	Carries of ulna; complete ankylosis of elbow joint. Disch'd June 12, 1865; pensioned.
4	Binnings, J. R., Pt., K, 97th New York, age 22.	May 6, 1864.	Wound of left elbow joint by a conoidal ball.	May 27, 1864.	Excision of four inches of ulna, by Asst. Surg. A. Delaney, U. S. V.	Duty Nov. 23, 1864; pensioned. Complete ankylosis; persistent neuralgia.
5	Bivans, R., Pt., E, 115th Illinois, age 20.	Sept. 20, 1863.	Wound through right elbow, fracturing ulna and inner condyle of humerus, by conoidal ball.	Sept. 26, 1863.	Portion of right ulna and inner condyle of humerus excised, by Surg. W. Varian, U. S. V.	Inflammation of lung with formation of abscesses; paracentesis. Disch'd March 23, 1865; pensioned. Ankylosis of elbow.
6	Bixler, B. R., Pt., F, 80th Indiana, age 23.	Oct. 8, 1862.	Right elbow joint opened, and upper end of ulna commin'd, by a conoidal ball.	October, 1862.	Head and two inches of radius, and two and a half inches of ulna, L-shaped incision, by A. A. Surg. J. Sloan.	Disch'd Jan. 6, 1863; pensioned. Complete ankylosis; arm semiflexed. <i>Spec.</i> 341.
7	Bosz, J., Pt., D, 187th New York, age 33.	Oct. 27, 1864.	Shot compound comminuted fracture of upper third of left ulna and olecranon process.	Nov. 3, 1864.	Three inches of ulna and olecranon, by Surg. O. A. Judson, U. S. V.	Disch'd May 19, 1865; pensioned. No bony union; forearm dangles in every direction.
8	Bragg, L., Pt., H, 3d Maine, age 28.	May 10, 1864.	Conoidal ball entered left elbow joint, fracturing lower part of humerus.	May 28, 1864.	Excision of left elbow joint, by Surg. R. B. Bontecou, U. S. V.	Disch'd July 27, 1865; pensioned. Humerus shortened four inches; arm useless.
9	Brewer, W. H., Pt., C, 73d Indiana, age 28.	Mar. 21, 1865.	Left humerus comminuted just above condyles by shot; elbow involved.	Mar. 25, 1865.	Excision of condyles of humerus, by Surg. S. D. Turney, U. S. V.	Full motion of hand; no motion in joint. Disch'd June 18, 1865. Almost entirely recovered.
10	Brooks, W., Corp'l, H, 68th Pennsylvania, age 21.	May 3, 1863.	Buckshot lodged in olecranon process of right ulna.	May 13, 1863.	Excision of olecranon process, by Surg. O. A. Judson, U. S. V.	Partial ankylosis of joint. Discharged August 13, 1863; pensioned. <i>Spec.</i> 1214.
11	Brown, J., Pt., K, 93d Pennsylvania, age 47.	May 3, 1863.	Comminuted fracture of right elbow, injuring the ulna.	May 10, 1863.	Excision of upper third of ulna.	Disch'd Feb. 5, 1864; pensioned. Ankylosis of elbow joint at an angle of 120°; no rotation of radius.
12	Buley, J., Pt., G, 2d Vermont, age 20.	May 5, 1864.	Fracture of inner condyle of right humerus and olecranon process of ulna by a conoidal ball.	May 25, 1864.	Two inches of humerus and upper part of olecranon, by A. A. Surg. F. G. Bradford.	Arm ankylosed, shortened one and three-fourths inches, atrophied, and flexed; good use of hand. Disch'd Aug. 21, 1864; pensioned. <i>Spec.</i> 2502.
13	Burns, J., Serg't, K, 19th Massachusetts, age 23.	May 12, 1864.	Fracture of upper part of right ulna and dislocation of radius by a conoidal ball; parts unhealthy.	May 21, 1864.	One and a half inches of radius of ulna, by A. A. Surg. G. H. Dare.	To V. R. C. May 6, 1865; pens'd. Ankylosis of joint; no rotation of forearm; caries of both bones; large fistula. Died July 11, 1871.
14	Cameron, T., Pt., K, 59th New York, age 48.	Sept. 17, 1862.	Conoidal ball comminuted the inner condyle of left humerus and olecranon process.	Oct. 4, 1862.	Excision of inner condyle and olecranon process, by Surg. H. S. Hewit, U. S. V.	Ankylosis of elbow; forearm at right angle. Disch'd July 18, 1865; pensioned.
15	Campbell, J., Pt., A, 62d Pennsylvania, age 25.	July 1, 1862.	Fracture of right elbow, radius split below tubercle, and outer condyle of humerus shattered.	July 14, 1862.	H-shaped incision.	Copious hemorrhage July 21, arm amputated. Disch'd Aug. 29, 1862; pens'd. Re-amputation. Died June 4, 1873. <i>Spec.</i> 15.
16	Church, J. W., Pt., B, 48th Virginia, age 18.	July 1, 1863.	Musket ball chipped off a small portion of articular cartilage of humerus and comminuted radius and ulna.	July 11, 1863.	Excision of three-fourths of an inch of end of humerus, one of radius, and two of ulna, by A. Surg. R. F. Weir, U. S. A.	Motion of elbow; by steadying humerus hand can be moved in an arc of fourteen inches. Escaped May 2, 1864. <i>Spec.</i> 2918.
17	Clark, G., Pt., H, 5th Vermont, age 35.	June 29, 1862.	Right elbow joint opened and the olecranon process of ulna comminuted by a ball.	July 17, 1862.	Head of radius and entire articular surfaces of humerus and ulna, through an H-shaped incision, by A. A. Surg. S. Teats.	Imperfect false joint; two and a half inches shortening; cannot raise anything except perpendicularly. Disch'd Dec. 26, 1862; pensioned. <i>Spec.</i> 1005.
18	Clarke, J., Pt., H, 50th Illinois, age 32.	Mar. 21, 1865.	Fracture of right elbow joint by a conoidal ball.	Mar. 31, 1865.	Resection of olecranon and three inches of shaft of ulna, by Surg. W. R. Marse, 2d Iowa.	Disch'd Aug. 1, 1865; pensioned. Complete ankylosis of joint; a little better than no arm.
19	Cook, J., Capt., F, 91st New York, age 62.	May 27, 1863.	Comminuted fracture of right humerus at lower third by a musket ball.	May 31, 1863.	Excision of two and a half inches of lower third of humerus, involving joint.	No union. Disch'd June 22, 1864; pensioned. Forearm a useless appendage. <i>Spec.</i> 2630.
20	Costello, M., Pt., B, 10th Ohio.	Oct. 8, 1862.	Comminuted fracture of upper third of left ulna.	Intermediary	Olecranon process and about two inches shaft of ulna, thro' straight incision, by A. A. Surg. M. N. Elrod.	Disch'd Jan. 9, 1863; pensioned. Complete ankylosis; forearm and hand atrophied; partial digital paralysis. <i>Spec.</i> 337.
21	Curtis, L. H., Pt., E, 1st Michigan Engineers, age 21.	Aug. 17, 1864.	Fracture of left radius by a conical ball.	Aug. 28, 1864.	Excision of head of radius.	Disch'd Feb. 7, 1865; pensioned. Perfect ankylosis; arm nearly useless.
22	Davis, J. W., Pt., B, 36th Illinois, age 23.	Dec. 31, 1862.	Musket ball struck olecranon process of right ulna, comminuting the bones of elbow and opening the joint.	Jan. 12, 1863.	Excision of ends of humerus, radius, and ulna, by A. A. Surg. M. H. Lyman.	Disch'd April 18, 1863; pens'd. Joint stiff; forearm shortened four inches; arm useless.
23	Davis, J. W., Pt., H, 3d Georgia, age 26.	Feb. 6, 1865.	Fracture at upper third of right ulna by a conoidal ball.	Feb. 10, 1865.	Two and a half inches end of ulna, by Asst. Surg. W. L. Baylor, C. S. A.	In April, 1865, was "nearly well."
24	Davis, T., Pt., D, 62d Pennsylvania, age 35.	May 5, 1864.	Fracture of head of left ulna by a copper explosive ball, which penetrated the joint.	May 25, 1864.	Excision of heads of ulna and radius, by Surg. G. L. Pancoast, U. S. V.	Disch'd July 13, 1864; pens'd. Complete ankylosis at right angle; forearm wasted, useless.
25	Dillman, H. C., Pt., F, 48th Pennsylvania, age 20.	June 3, 1864.	Elbow joint opened and bones fractured by a conoidal ball.	June 26, 1864.	Left elbow excised through a three-inch incision, by Surg. H. Palmer, U. S. V.	Disch'd May 15, 1865; pensioned. Complete ankylosis of joint; grasping power perfect.

No.	NAME, AGE, AND MILITARY DESCRIPTION.	DATE OF INJURY.	NATURE OF INJURY.	DATE OF OPERATION.	OPERATION AND OPERATOR.	RESULT AND REMARKS.
26	Dixon, P. A., Pt., A, 1st Potomac Home Brigade (Maryland), age 18.	July 24, 1864.	Fracture of inner condyle of left humerus by conoidal ball; (also wound of shoulder and ear.)	July 29, 1864.	One and a half inches of left humerus and olecranon process of ulna, thro' a straight incision, by Asst. Surg. R. F. Weir, U. S. A.	Necrosed bone removed. Disch'd June 17, 1865; pensioned. Anchylosis of elbow and wrist joints; two sinuses communicating with exfoliating bone. <i>Specs.</i> 3948.
27	Dorran, D., Pt., C, 14th New York Cavalry, age 23.	Feb. 26, 1864.	Conoidal ball entered posteriorly just above the left elbow joint, and emerged at middle of forearm anteriorly.	March 5, 1864.	Excision of bones composing joint, about four inches of bones of forearm, by Surg. C. P. Sanger, U. S. V.	Disch'd May 3, 1864; pensioned. June, wound still open, discharging splenful of bone; arm useless.
28	Douglass, J. D., Pt., G, 63d Pennsylvania, age 19.	Dec. 13, 1862.	Minié ball shattered the neck of left radius, parts of coronoid, olecranon, and trochlea.	Jan. 12, 1863.	Excision of extremities of ulna, radius, and humerus, by Asst. Surg. W. H. Gardner, U. S. A.	Disch'd Dec. 26, 1863; pensioned. Arm and hand useless; anchylosis of elbow; atrophy of hand, arm, and shoulder. <i>Specs.</i> 925.
29	Doyle, P., Pt., D, 69th New York.	Sept. 17, 1862.	Fracture of right elbow joint by a conoidal ball.	Oct. 2, 1862.	Excision of two inches of lower extremity of humerus and olecranon, by Surg. H. S. Hewit, U. S. V.	Arm amputated at upper third December 4, 1862. To Veteran Reserve Corps Dec. 29, 1862; pensioned. <i>Specs.</i> 458 and 807.
30	Doyle, R. N., Capt., H, 8th Michigan.	June 16, 1862.	Articulating surfaces of left elbow joint shattered by conical ball.	July 1, 1862.	Articulating surfaces of humerus, radius, and ulna, through straight incision, by A. A. Surg. W. K. Cleveland.	Bony anchylosis of joint; fragments of necrosed bone removed. Discharged July 30, 1865; pensioned.
31	Durivage, E., Pt., A, 1st Vermont Cavalry, age 20.	June 15, 1864.	Lower end of right humerus and head of radius fractured by conoidal ball.	June 21, 1864.	Excision of end of humerus and head of radius, by A. A. Surg. S. Colossian.	Disch'd April 3, 1865; pensioned. Partial anchylosis; artificial joint; arm useless.
32	Dwyer, M., Pt., C, 160th Pennsylvania, age 28.	Sept. 19, 1864.	Fracture of right olecranon process and dislocation upward of radius.	Sept. 30, 1864.	External condyle of humerus and olecranon process by A. A. Surg. J. C. Schumer.	Arm amputated at middle third October 15, 1864. Disch'd July 6, 1865; pensioned. <i>Specs.</i> 1852.
33	Edwards, O., Pt., A, 69th Indiana, age 24.	Aug. 30, 1862.	Fracture of left elbow joint by conoidal ball.	Sept. 20, 1862.	Excision of heads of radius and ulna.	Disch'd June 17, 1863; pensioned. Complete anchylosis; forearm semi-flexed; wrist bent; necrosis of radius; nearly useless. Arm amputated Feb. 6, Disch'd April 14, 1863; pensioned.
34	Everett, C. W., Serg't, H, 49th Ohio, age 18.	Dec. 31, 1862.	Fracture of head of left radius and extremity of ulna by conoidal ball.	Jan. 6, 1863.	Fractured portions of radius and ulna excised.	Favorable anchylosis. Disch'd Dec. 12, 1864; pensioned. Complete anchylosis.
35	Fisher, A., Pt., G, 55th Pennsylvania, age 21.	May 13, 1864.	Round musket ball entered three inches below right elbow, passed through joint.	May 27, 1864.	Joints of humerus, olecranon, and radius, by A. A. Surg. W. W. Bidlack.	Bone ununited. Disch'd Aug. 12, 1863; pensioned. Tolerable use of arm.
36	Fisher, N., Pt., H, 6th Infantry.	May 3, 1863.	Gunshot fracture of elbow of right arm.	May 31, 1863.	Excision, by Asst. Surg. B. Howard, U. S. A.	Permanent anchylosis. Disch'd December 19, 1863. Power of rotation lost; atrophy.
37	Fox, A. B., Pt., G, 157th New York, age 20.	May 2, 1863.	Gunshot fracture of right elbow.	May 17, 1863.	Excision of olecranon process of ulna.	Anchylosis; forearm at right angle with arm; pronation limited; fingers stiff. Disch'd March 6, 1864; pensioned; atrophy.
38	Frye, D. M., Pt., D, 12th Massachusetts, age 18.	Sept. 17, 1862.	Compound comminuted fracture of left ulna, ball emerging at elbow joint.	Sept. 23, 1862.	Excision of two and a half inches of upper third of ulna at elbow joint.	Erysipelas inflammation; amputation of arm at middle third Nov. 11, 1862. Disch'd Jan. 27, 1863; pensioned. <i>Specs.</i> 1868.
39	Gaston, S. S., Pt., K, 100th Pennsylvania.	Aug. 29, 1862.	Fracture of upper third of left radius with incomplete fracture of its head.	Sept. 26, 1862.	Excision of two and a half inches upper third of radius, including head, by A. A. Surg. W. F. Atlee.	Anchylosis of elbow joint. Discharged Nov. 21, 1863; pensioned.
40	Gove, C. H., Pt., I, 145th New York, age 17.	May 3, 1863.	Ball entered posterior aspect of forearm above its middle and exit through olecranon.	May 8, 1863.	Excision of right olecranon process.	Disch'd Aug. 29, 1862; pens'd. Forearm a dead weight; hand atrop'd, paralysed; carious bone. Died Aug. 3, 1866, of cholera.
41	Grady, M., Pt., D, 37th New York, age 20.	May 5, 1862.	Compound comminuted fracture of left elbow.	May 17, 1862.	Olecranon, and ends of radius and humerus, by Surg. R. B. Bontecou, U. S. V.	Pieces of dead bone came away; typhoid fever. Disch'd Feb. 18, 1863. Joint ankylosed; slight flexion in fingers. <i>Specs.</i> 327.
42	Graisberry, J., Pt., D, 6th New Jersey, age 24.	Aug. 29, 1862.	Conoidal ball comminuted olecranon process of right ulna; articular surfaces carious.	Sept. 20, 1862.	Condyles of humerus, head of radius, and end of ulna, thro' a T-shaped incision, by Asst. Surg. B. A. Clements, U. S. A.	Disch'd April 9, 1865; pensioned. Complete anchylosis; arm atrophied to shoulder.
43	Green, E. C., Corp'l, C, 44th New York, age 20.	May 5, 1864.	Gunshot fracture of left elbow joint; olecranon process comminuted.	May 20, 1864.	Partial excision of elbow joint, removing fragments, by A. A. Surg. J. Neil.	Ankylosed. Arm somewhat atrophied, flexed, and weakened. Duty May 7, 1863. Disch'd May 13; pens'd. Anchylosis of joint at right angles. <i>Specs.</i> 639.
44	Griffin, C. J., Corp'l, B, 82d New York, age 22.	Sept. 17, 1862.	Gunshot fracture of olecranon process of left ulna.	Oct. 13, 1862.	Resection of upper third of left ulna.	Useful arm. Disch'd March 30, 1863; pens'd. Anchylosis of joint at right angles; the arm is an encumbrance from elbow down.
45	Haber, C., Pt., C, 123d Pennsylvania, age 19.	Dec. 13, 1862.	Gunshot fracture of head of right radius and external condyle of humerus.	Dec. 29, 1862.	Head of radius and external condyle of humerus, by Surg. O. A. Judson, U. S. V.	Necrosis; removal of fragments; motion of joint limited. For exchange May 5, 1864. <i>Specs.</i> 2570 and 3912.
46	Haines, R. H., Pt., 4th Indiana Battery, age 21.	Dec. 31, 1862.	Shot fracture of upper end of right ulna; a piece driven into elbow joint.	Jan. 25, 1863.	Olecranon process and three inches end of shaft of ulna excised thro' straight incision, by Surg. A. Ewing, 13th Mich.	Disch'd Feb. 7, 1863; pensioned. Joint ankylosed at nearly right angle; two-inch shortening; muscles atrophied; arm useless. <i>Specs.</i> 749.
47	Harris, J., Pt., D, 2d North Carolina, age 36.	July 3, 1863.	External condyle of right humerus fractured by conoidal ball.	July 29, 1863.	Excision of upper half of olecranon and three inches end of humerus through straight incision, by Asst. Surg. R. F. Weir, U. S. A.	Slight motion of elbow joint. Duty Sept. 7, 1863. Disch'd Nov. 20; pens'd. Complete anchylosis; atrophy; hand numb. Deserted July 28, 1861. Claim for pension pending.
48	Hastings, J., Pt., K, 19th Indiana, age 21.	Sept. 17, 1862.	Gunshot wound of left elbow joint, badly shattering upper end of ulna.	Sept. 28, 1862.	Olecranon and coronoid processes, two and a half inches of ulna, head and one inch of radius, thro' a linear incision, by A. A. Surg. J. H. Burtholf.	Disch'd April 1, 1865; pensioned. No bony union; arm useless.
49	Haverly, C. R., Pt., K, 10th Missouri, age 33.	May 14, 1863.	Elbow joint opened, and external condyle of left humerus and head of ulna fractured, by a conoidal ball.	June 10, 1863.	External condyle and upper part of ulna excised thro' an H-shaped incision, by Surg. B. A. Vanderkief, U. S. V.	
50	Heinbach, W. B., Pt., G, 116th Pennsylvania, age 19.	May 12, 1864.	Wound of right elbow by conoidal ball.	May 20, 1864.	Head and four inches of shaft of ulna, by Asst. Surg. J. C. McKee, U. S. A.	
51	Henson, B., Pt., K, 23d Colored Troops, age 24.	June 15, 1864.	Condyles of left humerus and upper ends of radius and ulna injured by shell.	July 9, 1864.	Excision of elbow joint thro' semi-lunar incision, by Asst. Surg. J. H. Frantz, U. S. A.	



No.	NAME, AGE, AND MILITARY DESCRIPTION.	DATE OF INJURY.	NATURE OF INJURY.	DATE OF OPERATION.	OPERATION AND OPERATOR.	RESULT AND REMARKS.
52	Heritage, W. H., Pt., I, 13th Pennsylvania, age 21.	June 1, 1864.	Wound of left elbow joint by conoidal ball; exterior condyle of humerus detached; necrosis.	June 21, 1864.	Excision of external condyle of humerus through vertical incision, by A. A. Surg. W. B. Corbit.	To V. R. C. Jan. 18, 1865; pens'd. Joint ankylosed at an angle of 45°; grasp good; muscles well developed; rotation impossible.
53	Hertzog, J. F., Pt., K, 47th Pennsylvania, age 29.	Oct. 22, 1862.	Ball entered the outer condyle and emerged just above the inner condyle of right humerus.	Oct. 26, 1862.	Excision of three inches lower end of humerus and articular ends of radius and ulna thro' an H-shaped incision, by Surg. R. B. Bontecou, U. S. V.	Good motion in elbow; arm shortened three and a half inches. Disch'd February 24, 1863; pensioned. The arm "hangs dangling by his side and is useless." <i>Spec.</i> 2023.
54	Hilsdon, E., Pt., D, 155th Pennsylvania, age 26.	May 10, 1864.	Compound fracture of upper part of right radius, involving elbow joint, by a conoidal ball.	May 15, 1864.	Excision of three inches upper part of radius, by Surg. C. Page, U. S. A.	Anchylolysis of elbow joint and partial loss of use of arm. Discharged May 21, '65; pensioned.
55	Hinchman, J., Pt., E, 12th New Jersey, age 22.	May 3, 1863.	Fracture of head of about two inches of shaft of left ulna by conoidal ball, which lodged in arm and was extracted on the field.	May 25, 1863.	Excision of three inches upper end of ulna, including olecranon, through a straight incision.	Partial use. Disch'd October 22, 1863; pensioned. Anchylolysis at angle of 35°; loss of pronation and supination; arm useless for manual labor. <i>Spec.</i> 1200.
56	Hobart, J., Pt., F, 112th New York, age 21.	June 1, 1864.	Shot fracture of condyles and lower four inches of left humerus, extending into joint.	June 9, 1864.	The olecranon, part of coronoid process, upper three inches of radius, and condyles of humerus excised, by Surg. D. P. Smith, U. S. V.	Disch'd Nov. 16, 1864; pensioned. Anchylolysis at nearly a right angle. March, 1867, bones became diseased; discharge continuous. <i>Spec.</i> 3298.
57	Hoffnagle, M. H., Pt., G, 153d New York, age 22.	Nov. 7, 1864.	Fracture of right humerus, involving elbow joint, by a conoidal ball.	Nov. 22, 1864.	Two inches of humerus and olecranon process of ulna by straight incision, by Asst. Surg. R. F. Weir, U. S. A.	Disch'd May 16, 1865; pensioned. Partial flexion and extension but no rotation; muscles atrophied; almost constant discharge kept up by necrosed bone.
58	Holbert, M. T., Pt., B, 124th New York, age 27.	May 3, 1863.	Fracture of condyles of right humerus by musket ball.	May 9, 1863.	Excision of lower four inches of humerus through linear incision, by Surg. T. Antisell, U. S. V.	Disch'd Oct. 18, 1863; pens'd. No bony union; complete mobility of joint; full use of hand with forearm supported.
59	Hollister, O. H., Corp'l, I, 16th Penn. Reserves.	June 27, 1862.	Wound of left elbow joint. . . .	July 21, 1862.	Excision of joint, by A. A. Surg. J. O. French.	Amputation of arm. Disch'd Sept. 12, 1862; pensioned.
60	Hotchkiss, D. H., Pt., G, 45th Pennsylvania, age 21.	May 5, 1864.	Ball entered left forearm one inch from joint, fracturing both radius and ulna.	May 25, 1864.	Ends of humerus, radius, and ulna excised, by Surg. R. B. Bontecou, U. S. V.	Disch'd Sept. 5, 1865; pensioned. Complete anchylolysis; limb straight.
61	Howe, E., Pt., A, 6th Vermont, age 21.	May 5, 1864.	Wound of right elbow, compound comminuted fracture of ulna, by a conoidal ball.	May 23, 1864.	Excision of two and three-fourths inches of upper extremity of ulna, by A. A. Surg. H. A. Armstrong.	Disch'd Jan. 15, 1865; pensioned. Partial flexion and extension but no rotation; muscles atrophied; almost constant discharge kept up by necrosed bone.
62	Johnson, F., Pt., H, 118th New York, age 22.	Oct. 27, 1864.	Fracture of external condyle of right humerus and opening of joint by conoidal ball.	Nov. 26, 1864.	Both condyles of humerus and olecranon process of ulna excised, by A. A. Surg. C. C. Ela.	Disch'd May 27, 1865; pensioned. With exception of pronation and supination the motions of arm are nearly perfect.
63	Johnston, D., Serg't, K, 6th Ohio Cavalry, age 24.	May 9, 1864.	Wound of left arm, implicating elbow joint, by a musket ball.	June 8, 1864.	One and a half inches of radius and ulna excised through longitudinal incision, by A. A. Surg. T. Liebold.	To V. R. C. April 12, '65. Disch'd Aug. 24; pens'd. Complete anchylolysis; forearm in nearly extended position; atrophy.
64	Jordo, C., Pt., A, 16th Michigan, age 33.	June 27, 1862.	Fracture of inner condyle of left humerus, involving elbow joint.	July, 1862.	Excision of inner condyle of humerus.	Sloughing; hæm.; amp. July 29, 1862. Disch'd Sept. 7, 1863; pens'd. Died Jan. 6, 1869, of hæm'g from lungs. <i>Spec.</i> 433.
65	Kelly, M., Capt., C, 182d New York.	Jan. 20, 1863.	Fracture of olecranon process of ulna, opening elbow joint, by a piece of shell.	Feb. 14, 1863.	Olecranon, articular surface of humerus, and radius, L incision, by Dr. Gillilan.	All motions of elbow complete. Disch'd March 24, 1865. Not a pensioner.
66	Killian, C., Corp'l, H, 2d Michigan, age 18.	May 31, 1862.	Gunshot fracture of olecranon process of right ulna, involving elbow joint.	June 4, 1862.	Excision of olecranon process of ulna.	June 14, symptoms of pyæmia; amp. of arm July 3, 1862. Discharged August 16, 1862; pensioned.
67	Laird, H. S., Pt., I, 136th Pennsylvania, age 20.	Dec. 13, 1862.	Compound comminuted fracture of right ulna three inches below external condyle of humerus.	Intermediary	Excision of upper portion of ulna, by Asst. Surg. G. M. McGill, U. S. A.	Disch'd May 29, 1863; pensioned. Extension and flexion good; Nov. 1871, joint enlarged, ankylosed, out of place and crooked.
68	Leonard, J., Pt., E, 95th New York, age 22.	May 5, 1864.	Fracture of right radius by a conoidal ball entering just below elbow and lodging in limb.	May 20, 1864.	Excision of head and two and a half inches of radius thro' straight incision, by Surgeon Maynard, U. S. A.	Disch'd May 12, 1865; pensioned. Anchylolysis; cannot raise hand to his mouth; motion at joint about four degrees; muscles atrophied.
69	Lewis, G. W., Musician, 2d Brigade, 3d Division, 10th Army Corps, age 17.	July 23, 1864.	Gunshot fracture of right olecranon process of ulna by a conoidal ball.	Aug. 1, 1864.	Olecranon and necrosed portion articular surface of ulna, by A. A. Surg. W. L. Welles.	Disch'd October 29, 1864. Not a pensioner.
70	Lindsey, W., Pt., M, 62d Pennsylvania, age 23.	May 8, 1864.	Olecranon comminuted and condyles of right humerus split by a conoidal ball.	May 19, 1864.	Partial excision, removing fragments, by A. A. Surg. B. B. Miles.	Gangrene; partial anchylolysis. Disch'd Dec. 23, 1864; pens'd. Forearm extended; atrophy.
71	Longsmith, H., Pt., I, 125th Ohio, age 24.	Nov. 23, 1863.	Ball struck shaft of left ulna, fracturing upper end into sigmoid notch.	Nov. 29, 1863.	Resection of two inches of ulna with coronoid and olecranon processes.	Disch'd Aug. 5, 1864; pensioned. Paralysis of forearm; muscles atrophied.
72	Mathias, A. C., Corp'l, K, 65th Ohio, age 20.	May 14, 1864.	Shot wound of right elbow. . . .	May 20, 1864.	Excision of four inches of humerus through four-inch incision, by A. Surg. C. C. Byrne, U. S. A.	Disch'd Feb. 6, 1865; pensioned. Artificial joint; ulceration of ends of humerus and ulna; constant use of a sling to support the forearm.
73	Mattix, J., Pt., D, 64th Ohio, age 22.	Sept. 19, 1863.	Fracture of both condyles of right humerus by a conoidal ball, which lodged against the eighth rib.	October, 1863.	Internal condyle of humerus sawn off; four days later the external condyle, by Surg. A. McMahon, 64th Ohio.	Disch'd May 5, 1864; pensioned. Has a good arm.
74	Mayo, J., Pt., D, 14th New Hampshire, age 42.	Oct. 19, 1864.	Right elbow joint opened and olecranon process of ulna fractured by a conoidal ball.	Nov. 5, 1864.	Excision of olecranon process of ulna thro' straight incision, by A. A. Surg. W. Staveley.	Arm subsequently amputated at lower third. Disch'd May 2, 1865; pensioned.
75	McCauley, R. W., Pt., H, 56th Virginia, age 30.	July 3, 1863.	Gunshot wound of left elbow by a conoidal ball.	July 13, 1863.	Resection of elbow joint. . . . .	Transferred April 25, 1864, to Fort Monroe for exchange.
76	McInturf, E., Serg't, I, 62d Ohio, age 27.	Aug. 16, 1864.	Fracture of olecranon process of ulna and external condyle of left humerus by a conoidal ball.	Sept. 1, 1864.	External condyle of humerus, one-half inch of radius and ulna, thro' a five-inch incision, by A. A. Surg. A. J. Smith.	Anchylolysis of joint. Discharged May 23, 1865; pensioned. Arm atrophied; is unable to close the fingers.

NO.	NAME, AGE, AND MILITARY DESCRIPTION.	DATE OF INJURY.	NATURE OF INJURY.	DATE OF OPERATION.	OPERATION AND OPERATOR.	RESULT AND REMARKS.
77	McMurphy, H., Pt., C, 5th New Hampshire, age 28.	Dec. 13, 1862.	Minié ball entered posterior aspect of left ulna two inches below the extremity of olecranon, shattering the bone, breaking off the upper end, and involving the joint.	Dec. 18, 1862.	Excision of head of radius, olecranon and coronoid processes, and portions of condyles of humerus, Mercru's method, H incision, by A. A. Surg. J. Stenrus.	Disch'd Sept. 3, '63; pens'd. Arm could be extended and flexed by passive motion. In 1869 Pension Examiner reports "complete ankylosis; atrophy forearm; almost useless." Spec. 930.
78	Mead, J. M., Pt., D, 17th Michigan, age 19.	May 12, 1864.	Fracture of left elbow, and joint opened, by a conoidal ball.	May 16, 1864.	Excision of condyles and one inch of shaft of humerus, also two inches of radius, by A. A. Surg. F. W. Kelly.	Duty July 12, 1864; pensioned. Complete ankylosis; forearm at an angle of 60° with arm; no rotation.
79	Mendenhall, I., Corp'l, 5th Indiana Battery.	Oct. 8, 1862.	Right humerus fractured within elbow joint by a musket ball.	October, 1862.	Two inches of end of humerus, through an L-shaped incision, by A. A. Surg. J. Sloan.	Favorable. Discharged Dec. 15, 1862.
80	Meyer, J., Pt., A, 1st Battalion, 12th Infantry.	Aug. 29, 1862.	Gunshot fracture of external condyle of right humerus and the head of radius.	Sept. 7, 1862.	Portion of external condyle of humerus and head and one-half inch of shaft of radius, through an S-shaped incision, by Surg. D. W. Bliss, U. S. V.	Favorable. Discharged Nov. 15, 1862. Spec. 181.
81	Miller, D., Pt., A, 1st Maryland, age 18.	Feb. 6, 1865.	Fracture of right elbow by a conoidal ball.	Feb. 15, 1865.	Upper ends of radius and ulna removed, by Asst. Surg. J. Vansant, U. S. A.	Spiculae of dead bone removed. Disch'd Oct. 7, 1865; pensioned. Joint ankylosed; limb atrophied and shortened.
82	Moore, G., Pt., B, 106th Pennsylvania.	July 3, 1863.	Shot fracture of left elbow joint.	July 12, 1863.	Excision of ends of humerus, radius, and ulna.	Duty June 22, 1864; pensioned. Pulse joint; atrophy of muscles; use of hand, one-half.
83	Moore, J., Pt., C, 45th Pennsylvania, age 20.	June 3, 1864.	Compound comminuted fracture of right external epicondyle by a conoidal ball.	June 9, 1864.	Removal of fragments of epicondyle by lifting up truck of wound, by Asst. Surg. H. Allen, U. S. A.	Disch'd Jan. 11, 1865; pensioned. Complete ankylosis of joint; arm fixed at an obtuse angle, with hand between pronation and supination.
84	Mortimore, J. L., Pt., C, 67th Pennsylvania, age 40.	Mar. 25, 1865.	Fracture of left humerus and radius.	April 5, 1865.	Excision, by Asst. Surg. H. Allen, U. S. A.	Disch'd June 29, 1865; pens'd. Spec. 72. See CASE 1801, p. 870.
85	Moser, P., Pt., F, 47th Pennsylvania.	Oct. 22, 1862.	Fracture of head of radius and both condyles of left humerus by a musket ball.	Nov. 1, 1862.	Excision of condyles of humerus and head of radius, by A. Surg. J. E. Semple, U. S. A.	Disch'd February 24, 1863. Not a pensioner.
86	Newman, G. R., Pt., K, 61st Pennsylvania, age 34.	May 6, 1864.	Fracture of upper end of left radius and ulna and lower end of humerus; joint opened.	May 15, 1864.	Condyles of humerus, two inches of ulna, and a portion of radius, by A. A. Surg. F. W. Kelly.	Progress favorable. Disch'd Nov. 25, 1864. Not a pensioner.
87	O'Keefe, T., Serg't, F, 82d New York.	July 3, 1863.	Gunshot fracture of right ulna, opening elbow joint; olecranon destroyed.	July 29, 1863.	End of ulna and one and a half inches of radius, by A. A. Surg. I. H. B. McClellan.	Disch'd April 15, 1864, for promotion. Not a pensioner. Spec. 2900.
88	O'Neil, Jr., E., Pt., D, 10th Ohio, age 18.	Oct. 8, 1862.	Gunshot wound of right elbow joint.	October, 1862.	Excision of condyles of humerus and portion of shaft, three inches in all, through straight incision, by A. A. Surg. J. Sloan.	Disch'd Jan. 6, 1863; pensioned. Artificial joint excellent; forearm reduced in length; action of elbow joint, forearm, and hand good, except rotation. Spec. 351.
89	Osgood, O. S., Corp'l, C, 15th Massachusetts, age 22.	Sept. 17, 1862.	Coronoid and olecranon processes of ulna destroyed and radius of left arm dislocated by a conoidal ball; condyles of humerus and head of radius diseased.	Oct. 15, 1862.	Condyles of humerus and articular ends of radius and ulna excised through a T-shaped incision, by Asst. Surg. J. H. Bill, U. S. A.	Elbow stiff, deformed; rotary motion nearly lost; fingers nearly numb. Disch'd Dec. 30, 1862; pens'd. Complete ankylosis of joint; forearm one-third flexed and turned inward.
90	Pattue, J., Corp'l, C, 39th New York, age 20.	May 5, 1864.	Fracture of olecranon and condyles of right humerus.	May 25, 1864.	Complete excision, by Surg. G. L. Hancock, U. S. V.	Disch'd Nov. 7, 1865; pensioned. Spec. 2478. See CASE 1798, p. 869.
91	Peaslee, J. O., Pt., G, 121st New York.	July 10, 1863.	Gunshot wound of left elbow by a conoidal ball; joint opened and bones shattered.	July 18, 1863.	Articular ends of humerus, radius, and ulna removed through a straight incision four inches long, by Asst. Surg. W. H. Gardner, U. S. A.	Able to raise hand to mouth. To V. R. C. June 28, 1864; pens'd. Good use of forearm and hand. Died Dec. 15, 1866, of phthisis pulmonalis.
92	Phelps, F. S., Pt., D, 36th Illinois, age 24.	Sept. 19, 1863.	Gunshot fracture of head of left ulna and external condyle of humerus by a conoidal ball.	Oct. 2, 1863.	Excision (articular surfaces of humerus not removed), by Surgeon Dodd, of Wisconsin.	End of humerus exfoliated; spicula removed. Disch'd Nov. 6, 1864; pens'd. Forearm danglies; muscles atrophied.
93	Plimpton, O. B., Pt., G, 39th Illinois, age 25.	Aug. 8, 1864.	Gunshot wound of left elbow joint.	Aug. 31, 1864.	Inner condyle of humerus and olecranon process of ulna removed, by A. Surg. C. Wagner, U. S. A.	Disch'd Nov. 21, 1864; pensioned. Ankylosis of joint; forearm atrophied; arm nearly useless. Died October 11, 1866.
94	Ream, J. A., Pt., I, 31th Ohio, age 21.	July 18, 1863.	Gunshot fracture of left humerus at lower third, involving elbow joint, by a ball.	Aug. 10, 1863.	Excision of lower end of humerus, by a Confederate surgeon.	Duty May 16, 1864; pensioned. Ligamentous union; atrophy; loss of strength and motion.
95	Riley, P., Pt., E, 44th New York, age 34.	May 8, 1864.	Gunshot wound of left elbow joint by a conoidal ball.	May 15, 1864.	Olecranon process of ulna, through straight incision, by Surg. A. P. Sheldon, U. S. V.	Disch'd Oct. 11, 1864; pensioned. Complete bony ankylosis of joint.
96	Riley, W. T., Pt., D, 86th New York, age 21.	Nov. 26, 1863.	Shot perforation of right elbow.	Dec. 19, 1863.	H-shaped incision, by Surg. C. Page, U. S. A.	Disch'd Oct. 21, 1864; pensioned. Spec. 3026. See CASE 1797, p. 869.
97	Ripley, L. G., Pt., B, 10th Vermont, age 20.	Nov. 27, 1863.	Left elbow joint opened and inner condyle fractured by a conoidal ball.	Dec. 6, 1863.	Excision of left elbow joint, olecranon and articulating surface, and one inch of shaft of humerus, through an H incision, by Surg. D. P. Smith, U. S. V.	Arm shortened one inch; ankylosis nearly at right angle; liable to ulceration; useless for manual labor. To V. R. C. Feb. 20, 1865; pensioned.
98	Rittinghouse, Z., Pt., K, 51st Illinois, age 18.	Nov. 30, 1864.	Fracture of upper third of right radius and ulna by a conoidal ball; joint opened.	Dec. 29, 1864.	Two and a half inches of end of ulna and head of radius, through straight incision, by A. A. Surg. C. H. Fisher.	Disch'd May 25, 1865. Re-enlisted Mar. 25, 1867. Disch'd 1869; pensioned. Ankylosis; wound never healed.
99	Rodenbarger, D., Pt., E, 46th Pennsylvania, age 29.	May 2, 1863.	Ball entered outer side forearm one inch below head of left radius, and emerged at inner side of arm, two inches above, comminuting joint.	May 10, 1863.	Removal of lower four inches of humerus and upper six inches of ulna, by A. A. Surg. W. A. Harvey.	Motions of forearm imperfect. Disch'd Oct. 2, 1863; pensioned. Arm danglies by side; is useless.
100	Sands, W. P., Serg't, C, 5th Ohio, age 21.	Mar. 22, 1862.	Wound of right elbow joint by a rifle ball.	Mar. 27, 1862.	Portions of humerus, radius, and ulna, by Surg. A. D. Gall, 13th Indiana.	Disch'd June 3, 1862; pensioned. Permanent semiflexion of forearm.



No.	NAME, AGE, AND MILITARY DESCRIPTION.	DATE OF INJURY.	NATURE OF INJURY.	DATE OF OPERATION.	OPERATION AND OPERATOR.	RESULT AND REMARKS.
101	Schneider, M., Pt., I, 23d Ohio, age 24.	Sept. 16, 1862.	Wound through left elbow joint by a musket ball; olecranon shattered.	Oct. 8, 1862.	Olecranon entirely removed through a longitudinal incision, by Surg. S. D. Gross, U. S. V.	Recovered with useful arm, all the motions being excellent. Discharged December 15, 1862; not a pensioner.
102	Schroeder, L., Serg't, E, 12th Missouri, age 28.	Nov. 27, 1863.	Gunshot fracture of lower end of right humerus and heads of radius and ulna.	Dec. 11, 1863.	Excision of elbow joint . . . . .	Disch'd Nov. 5, 1864; pensioned. Ankylosis of joint; arm drawn toward body at an angle of about 30°; arm and hand useless.
103	Sedille, E. D., Pt., I, 7th Infantry, age 21.	July 2, 1863.	Gunshot fracture of right radius and ulna, involving the elbow joint.	July 12, 1863.	Excision of three inches of upper end of radius.	Complete ankylosis of joint. Disch'd October 10, 1863; pensioned. A large cicatrix on anterior surface of forearm impairs use of member.
104	Sche, J., Pt., C, 165th New York, age 40.	May 27, 1863.	Ball passed nearly transversely thro' right arm just above the elbow, comminuting humerus and involving elbow joint.	June 9, 1863.	Excision of lower three inches of humerus and articulating extremities of radius and ulna.	Secondary amputation of arm. Disch'd October 19, 1863; pensioned. <i>Spec.</i> 1309.
105	Skelton, T., Pt., A, 149th Pennsylvania, age 30.	May 6, 1864.	Conoidal ball entered at outer side of right arm, fracturing external condyle of humerus and upper end of ulna.	May 29, 1864.	Removal of two and a quarter inches of end of humerus, by A. A. Surg. P. G. H. Bradford.	Disch'd Sept. 9, 1865; pensioned. Arm and hand atrophied; nearly whole extent of humerus carious; will require amputation at shoulder joint to save life. Died May 25, 1867. <i>Spec.</i> 2501.
106	Smith, L., Pt., B, 70th New York.	May 5, 1862.	Fracture of elbow joint by ball.	May 12, 1862.	Excision of entire joint, by Surg. R. B. Bontecon, U. S. V.	To Veteran Reserve Corps July 11, 1863; not a pensioner.
107	Smith, R., Pt., B, 105th Pennsylvania, age 38.	April 6, 1865.	Shot wound through left elbow joint by a conoidal ball; joint badly shattered.	April 24, 1865.	Excision of condyles of humerus and upper part of ulna thro' two parallel incisions, one anterior, one posterior, by Surg. B. A. Vanderkief, U. S. V.	Gangrene. Disch'd Oct. 2, 1865; pensioned. Deformity; motion to 74°; ring and little fingers paralyzed; rotation lost. <i>Spec.</i> 102.
108	Smith, W. V., Capt., G, 7th Colored Troops, age 24.	Sept. 27, 1864.	Fracture of external condyle of right humerus by a conoidal ball. Also wound of left shoulder.	Oct. 23, 1864.	Excision of four inches of end of humerus, including condyles, by Surg. D. G. Rush, 101st Pennsylvania.	Very useful arm. Mustered out October 13, 1866; pensioned. Forearm atrophied. <i>Spec.</i> 3803.
109	Squires, S., Pt., B, 59th New York.	Sept. 17, 1862.	Round ball wound of right elbow joint, removing triangular piece of ulna, including lesser sigmoid cavity and one-third of head of radius.	Oct. 6, 1862.	Head and one inch of radius and portion of olecranon, thro' a T-shaped incision, by Asst. Surg. E. D. Breneman, U. S. A.	Disch'd Dec. 22, 1862; not a pensioner. <i>Spec.</i> 884.
110	Stacy, C., Pt., C, 1st Massachusetts Heavy Artillery, age 27.	June 19, 1864.	Compound comminuted fracture of olecranon process and upper third of left ulna by a conoidal ball.	July 1, 1864.	Two inches of ulna and olecranon, through straight incision over outer part of arm, by A. A. Surg. R. E. Price.	Favorable. Duty January 17, 1865, for muster out.
111	Stanley, T. F., Serg't, 14th Indiana Battery, age 24.	Mar. 31, 1865.	Comminuted fracture of lower end of left humerus by a conoidal ball.	April 23, 1865.	Excision of extremity of humerus and olecranon process of ulna, by Surg. J. Boeckee, U. S. V.	Erysipelas. Disch'd June 20, 1865; pens'd. No joint; three inches intervene between arm and forearm; latter dangling and spinning on its axis.
112	Stark, J. H., Pt., M, 7th Indiana Cavalry, age 22.	Oct. 22, 1864.	Shot through elbow . . . . .	Oct. 31, 1864.	Excision, by Asst. Surg. J. M. Study, U. S. V.	Disch'd May 13, 1865; pensioned. <i>Spec.</i> 3606. See CASE 1796, p. 868.
113	Stephens, J. H., Pt., F, 10th Indiana, age 19.	Sept. 19, 1863.	Wound of left elbow; olecranon process fractured by conoidal ball.	Sept. 26, 1863.	Excision of olecranon through straight incision.	Disch'd Sept. 19, 1864; pens'd. Complete ankylosis of joint; limb atrophied; useless.
114	Stickleman, H., Pt., K, 40th Ohio, age 19.	Sept. 20, 1863.	Gunshot fracture of inner condyle of left humerus and head of ulna; elbow erysipelatous.	Oct. 14, 1863.	Head and three inches of shaft of ulna, and portion of condyle of humerus, through straight incision, by Asst. Surg. J. E. Link, 21st Illinois.	Joint ankylosed. Disch'd Dec. 7, 1864; pensioned. Forearm at right angle; muscles atrophied.
115	Thompson, F., Pt., K, 51st Illinois.	Sept. 20, 1863.	Gunshot wound of right elbow, the ball entering below head of radius and emerging above external condyle of humerus.	Oct. 3, 1863.	The articular ends of the humerus, radius, and ulna removed through a T-shaped incision, by A. A. Surg. P. Feldbausch.	Perfect use of fingers; mobility in elbow 30°. Must'd out Jan. 13, 1865; pens'd. Arm can be extended to right angle, and flexed a little; used for eating, but not for ordinary labor; atrophied.
116	Thompson, J. W., Pt., C, 23d Pennsylvania, age 25.	June 1, 1864.	Compound comminuted fracture of left humerus, involving elbow joint, by a conoidal ball.	June 12, 1864.	Three inches lower third of humerus, including condyles, through five-inch incision, by A. A. Surg. P. Wilson.	Duty Aug. 5, 1864. Discharged Sept. 8, 1864; pensioned. Forearm hangs helpless by the side; muscles atrophied.
117	Toner, M., Pt., C, 69th Pennsylvania, age 26.	July 3, 1863.	Shot fracture of inner condyle of right humerus and olecranon process of ulna; humerus superficially necrosed.	July 21, 1863.	Three inches lower end of humerus removed, by A. Surg. C. R. Greenleaf, U. S. A.	Disch'd Sept. 26, 1864; pens'd. Ligamentous union only, leaving a useless extremity. <i>Spec.</i> 2578.
118	Tracy, T., Pt., C, 2d Infantry, age 25.	Aug. 29, 1862.	Conoidal ball passed through left elbow joint, breaking it up completely.	Sept. 12, 1862.	Excision of joint thro' a large H-shaped incision.	Disch'd Jan. 23, 1863. Small pieces of bone came away; arm wasted; joint ankylosed; pensioned. Pronation and supination lost; forearm flexed at an angle of 90°. Re-enlisted.
119	Valentine, W. H., Serg't, B, 5th Colored Troops, age 23.	Sept. 29, 1864.	Comminuted fracture of lower end of right humerus by a conoidal ball; bone split into joint.	Oct. 5, 1864.	Excision of lower third of right humerus, by A. A. Surg. T. Hopkins.	Disch'd June 21, 1865; pens'd. Complete atrophy; paralysis; no bony union; arm entirely useless.
120	Vanderhoof, G., Pt., F, 83d Pennsylvania, age 44.	May 8, 1864.	Fracture of lower four inches of right humerus by conoidal ball.	May 26, 1864.	Fractured bone excised, by Surg. D. P. Smith, U. S. V.	Disch'd Oct. 3, 1864; pensioned. Ankylosis almost complete; great deformity.
121	Walker, A., Pt., E, 41st New York, age 38.	May 2, 1863.	Fracture of right elbow joint by a conoidal ball.	May 14, 1863.	Excision of external condyle of humerus, by A. A. Surg. P. G. H. Bradford.	Disch'd Sept. 8, '63. To V. R. C.; pensioned. Complete ankylosis at an obtuse angle; arm useless for manual labor.
122	Warner, F. A., Pt., C, 7th Ohio, age 26.	Mar. 23, 1862.	Spherical ball chipped off left radius and external condyle.	April 16, 1862.	Complete excision, by Asst. Surg. R. F. Weir, U. S. A.	Disch'd July 2, 1862; pensioned. <i>Spec.</i> 838. See CASE 1793, p. 865.
123	Weaver, S. B., Pt., K, 45th Pennsylvania, age 18.	May 6, 1864.	Upper part of ulna and both condyles of right humerus fractured by a musket ball.	May 24, 1864.	Three inches upper end of ulna and part of condyles of humerus excised, by Surg. A. F. Sheldon, U. S. V.	Right arm amputated at upper third, for gangrene, July 25, '64. Mustered out July 17, 1865; pensioned. <i>Spec.</i> 2889.

NO.	NAME, AGE, AND MILITARY DESCRIPTION.	DATE OF INJURY.	NATURE OF INJURY.	DATE OF OPERATION.	OPERATION AND OPERATOR.	RESULT AND REMARKS.
124	Welliver, J., Pt., B., 131st Pennsylvania, age 22.	Dec. 13, 1862.	Minié ball entered posterior aspect left arm, shattered olecranon, and lodged in front of inner condyle of humerus; slight comminution of articular surface of humerus.	Jan. 10, 1863.	Head of radius, ulna just below coronoid, and articular surface of humerus, thro' a longitudinal incision, by A. A. Surg. T. Liebold.	Pronation and supination to full extent. Disch'd April 10, 1863; pensioned. Bones united; motions of forearm imperfect.
125	Wells, E. L., Corp'l, I, 17th Vermont, age 17.	Sept. 30, 1864.	Fracture of left radius, ulna, and humerus at elbow joint by conoidal ball.	Oct. 7, 1864.	Excision of external condyle of humerus through straight incision, by A. A. Surg. O. P. Sweet.	An ulcer covering elbow and extending half way up arm. January, 1865, forearm ankylosed at right angles. Disch'd Aug. 11, 1865; pensioned.
126	Winterstein, J., Pt., I, 15th New York Heavy Artillery, age 21.	Mar. 31, 1865.	Fracture of condyles of right humerus and olecranon process of ulna by conoidal ball.	April 22, 1865.	Excision of condyles and one inch of shaft of humerus, and also olecranon process of ulna, by Surg. G. L. Pancoast, U. S. V.	Disch'd Nov. 29, 1865; pensioned. Ankylosis of joint at an angle of 45°; arm shrunk and entirely useless. Spec. 4289.
127	Young, T. M., Pt., I, 83d Pennsylvania, age 29.	July 1, 1862.	Ball passed laterally through left elbow joint, shattering both articulating surfaces.	July 6, 1862.	Excision of a portion of lower end of left humerus and upper ends of radius and ulna, by Asst. Surg. J. S. Billings, U. S. A.	Disch'd Sept. 2, 1862. Flexion of forearm one-sixth; rotation at elbow one-third; strong grasp; can bring hand to neck. In 1873, has to carry arm in sling; no great use.

§ *Fatal Cases of Intermediary Excision at the Elbow.*—This group comprises sixty-nine cases, a fatality of 35.2 per cent. The operations were practised upon four Confederate and sixty-five Union soldiers. Twenty-nine were on the right, and thirty-six on the left side; not reported, four. The extent of the excisions is indicated in the foot note.<sup>1</sup> The mortality was due to much the same proximate causes as in the series of fatal primary cases; but the proportions were different, instances of septicæmic infection and of consecutive hæmorrhage being relatively more frequent.<sup>2</sup> Eight of the patients had serious though not mortal wounds in other regions. Eight succumbed after submitting to consecutive amputation; the following is one of these cases:

CASE 1807.—Corporal J. J. Johnson, Co. K, 48th New York, aged 26 years, was wounded at Cold Harbor June 3, 1864. He was sent to Washington, and entered Harewood Hospital. The pathological specimen (*Spec.* 3042, A. M. M.) was forwarded by the operator, Surgeon R. B. Bontecou, U. S. V., with the following minutes of the case: "Admitted June 7th, suffering from gunshot wound of the left elbow joint, the ball passing through and injuring the extremities of the humerus and radius. At the time of operation the parts were somewhat swollen; the constitutional state of the patient was not very good. Resected elbow joint, removing about half an inch of humerus, June 23, 1864. Patient did well for two days after the operation, but the parts became gangrenous and sloughing. Secondary hæmorrhage occurred on the 25th and 27th of June, the patient losing about five ounces of arterial blood each time. Amputation of the left arm, upper third, antero-posterior flap, by Acting Assistant Surgeon J. A. Bates, June 27, 1864. The patient did not improve after amputation, but rapidly sank. Died June 27, 1864, from exhaustion." The specimen consists of two and a half inches of the extremities of the left humerus, the head of the radius, and the coracoid and olecranon processes of the ulna, excised for disorganization of the elbow following gunshot. The tips of the olecranon and outer condyle were fractured by a ball passing transversely, and ulceration destroyed the articular surfaces.

In twenty instances the excised portions of bone were preserved:

CASE 1808.—Corporal D. J. Davis, Co. E, 20th U. S. Sharpshooters, aged 24 years, was wounded at the Wilderness, May 6, 1864, and after treatment in a Second Corps hospital was sent to Washington, and there admitted to Finley Hospital on March 28th. Surgeon G. L. Pancoast, U. S. V., reported: "A conoidal ball entered the forearm two inches below the olecranon process of the ulna, passed upward, and emerged two inches above the external condyle of the humerus, right side. The parts were much swollen, with great suppuration about the joint. On June 3d, the patient was chloroformed and one and a half inches of the lower extremity of the right humerus and an inch of each of the bones of the forearm were removed. At the time of operation the general condition of the patient was good. Diarrhœa set in after the operation." On June 20th, hæmorrhage occurred from the brachial, and resulted in death, June 22, 1864. The operator, Acting Assistant Surgeon R. Westerling, contributed the specimen (*FIG. 630*). It consists of one and a half inches of the lower extremity of the humerus and half an inch of each of the bones of the forearm excised from the right elbow. The olecranon and a small fragment of the trochlea were torn off by a conoidal ball. The articular surfaces are carious.



FIG. 630.—Excised portion right elbow for caries after shot wound. *Spec.* 2483.

In the foregoing case and in CASE 1811, the fatal event was due to consecutive hæmor-

<sup>1</sup> The articular extremities of the three bones (with more or less of their diaphyses in some cases) were excised in 13 cases; the ends of the humerus and ulna, in 9 cases; the ends of the humerus and radius, in 2 cases; the end of the humerus only, in 13 cases; the ends of the ulna and radius, in 5 cases; the upper end of the ulna alone, in 12 cases; the head of the radius, in 3 cases; excised parts unspecified, in 12 cases.

<sup>2</sup> The causes of death were returned as follows: pyæmia, 25 cases; erysipelas, 3; gangrene, 5; exhaustion, 12; typhoid fever, 1; secondary hæmorrhage, 12; serous apoplexy, 1; tetanus, 1; chronic diarrhœa, 2; not stated, 7.



rhage; the other four detailed cases were attended probably by purulent absorption, as revealed in an instance in which an autopsy was made, by metastatic foci in the lungs:

CASE 1809.—Corporal P. Long, Co. D, 3d New Hampshire, aged 25 years, was wounded at Bermuda Hundred, June 17, 1864, and was received from a Tenth Corps hospital into Hampton Hospital, Fort Monroe, and on the 19th was transferred to Mower Hospital, Philadelphia. Acting Assistant Surgeon J. B. Lapsley contributed the following history: "Admitted June 21, 1864, with wound of the elbow joint and fracture of the olecranon process of the ulna by a conoidal ball. Parts very much inflamed and painful at time of admission; dressed with lead water and laudanum. July 6th, forearm and hand very much swollen. Acting Assistant Surgeon W. P. Moon saw the case, gave chloroform, and examined the joint thoroughly, finding a slight fracture of the olecranon. The joint being seriously involved, the ends of all the bones being denuded, a free incision was made to relieve the inflamed parts. Acting Assistant Surgeon T. G. Morton saw the case and recommended excision, which was performed July 12th, by Dr. Moon. About an inch of the radius, one and a half inches of the ulna, the external condyle, and a portion of the internal were removed. A pasteboard splint was applied to the front of the arm, dry dressings to the wound, stimulants and nourishing diet. July 14th, patient has pain in the chest and cough. July 19th, wound doing well; patient very feeble; coughing hard. July 30th, large abscess opened on left buttock, discharging a great amount of pus. August 3, 1864, patient died at four and a half o'clock A. M. from exhaustion, the wound remaining healthy." The specimen is thus described in the Museum Catalogue: "The lower extremity of the right humerus, one inch of the radius, and one and a half inches of the ulna excised for

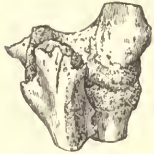

FIG. 631.—Excised bones of right elbow joint.—Spec. 3615.

fracture of the olecranon. The articular surfaces are all carious. The line of section in the humerus is very oblique." Acting Assistant Surgeon J. B. Lapsley contributed to the Museum the excised parts of the articulation, which are represented in the accompanying wood-cut (FIG. 631).

CASE 1810.—Private J. S. West, Co. A, 5th Maryland, was wounded at Antietam, September 17, 1862, a musket ball passing from before backward through the right elbow, destroying the olecranon and trochlear portion of the humerus. He was treated at the field hospitals for four days, and then was sent to Hospital No. 5, Frederick. Surgeon H. S. Hewitt, U. S. V., operated a fortnight after the reception of the injury, making a total excision of the articular ends of the three bones through an H-shaped incision, and contributed the specimen (FIG. 632), with the following history: "Admitted September 22d, with compound comminuted fracture of the right elbow by a minie ball. Operation, excision of joint and two inches of the humerus, on October 3d. October 12th, up to this time the patient is doing well. October 14th, irritative fever set in, and the patient is reported as sinking rapidly. Died October 20th, at one o'clock A. M." The specimen consists of the head of the radius, extremity of the ulna, and two inches of the extremity of the humerus excised from the right elbow for direct perforation by a conoidal ball. The coronoid process has been carried away, and a portion of the inner condyle as well, and a vertical fissure separates the latter from the lower end of the humerus. The articular cartilages have been everywhere destroyed by ulceration, and the subjacent bones are rough and worn.

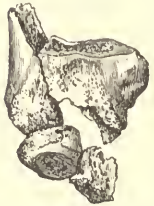

FIG. 632.—Excised elbow. Spec. 435.

CASE 1811.—Private C. Zimmer, Co. M, 7th New York Heavy Artillery, aged 20 years, was wounded in the right elbow at Cold Harbor, June 3, 1864, and was sent from a hospital of the 1st division, Second Corps, to Washington, and admitted to Finley Hospital on June 8th. Surgeon G. L. Pancoast, U. S. V., who excised the joint, contributed the specimen (FIG. 633), and reported the following account of the operation: "The ball entered the anterior surface of the joint and passed directly through it, carrying away the coronoid process and adjacent parts of the ulna. Resection was performed on June 16th, under chloroform, the injured parts at the time being in good condition, not much swollen, and not suppurating. The patient's pulse was good, but intermittent fever set in after the operation. Cold-water dressings were applied. The progress of the case was unsatisfactory, and the patient suffered much pain. Hæmorrhage from the brachial artery, to the amount of twenty ounces, occurred on June 24th. Death resulted, from the effects of hæmorrhage, on June 24, 1864." The specimen consists of the head and one inch of the shaft of the radius, the tip of the olecranon, and two inches of the lower extremity of the humerus. The articular surfaces are denuded and eroded, patches of the encrusting cartilage remaining here and there. The tip of the olecranon remains in the fossa and does not show in the cut.

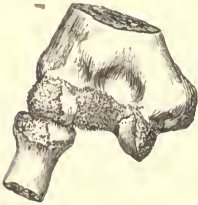

FIG. 633.—Excised portion of the right elbow joint. Spec. 2582.

CASE 1812.—Private J. K. Moyer, Co. H, 138th Pennsylvania, aged 25 years, was wounded at the Wilderness, May 7, 1864, and admitted to Carver Hospital, Washington, four days afterward. Surgeon O. A. Judson, U. S. V., reported: "The ball entered the left elbow joint from without inward, fracturing the lower third of the humerus; the ulna and radius were not involved. At date of admission, the constitutional state of the patient was good, and there was no emaciation; the injured parts were in tolerable condition, and not greatly swollen, nor complicated with œdema of forearm or hand. May 13th, the patient being anæsthetized, a T-shaped incision was made over the elbow joint, extending up the arm, and the condyles and about two inches of the lower third of the shaft of the humerus were removed by Assistant Surgeon H. Allen, U. S. A. Water dressings were used and a posterior rectangular splint applied. May 23d, the patient continued to improve slowly up to this date. The wound has secreted a large amount of pus, which has reduced the patient somewhat. To-day he had a severe chill, followed by other pyæmic symptoms; appetite capricious; obstinate vomiting. Ordered spiritus vini gallici ten ounces, to be taken during twenty-four hours. May 30th, the symptoms last noted have continued and gradually increased in severity. Chills at regular intervals. Has a decided icteric tinge. Prescribed two quinine pills, to be taken every three hours. The stimulant and tonic treatment has been continued. The patient died this evening—May 30, 1864." The specimen, represented in the annexed cut (FIG. 634), is the excised portion of the lower extremity of the humerus. It was contributed by the operator.

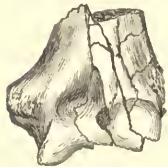

FIG. 634.—Lower extremity of left humerus excised for shot injury. Spec. 2293.

Details of the morbid appearances found after death are recorded in but few of the cases of this series. In the preceding instances, the appearances of the excised portions of bone throw some light on the pathological conditions under which the operations were practised:

CASE 1813.—Private C. Wesley, Co. G, 4th New York Heavy Artillery, aged 18, was wounded at Petersburg, June 18, 1864. He was admitted to the Artillery Brigade Hospital, Second Corps, where Surgeon H. C. Tompkins, 4th New York Artillery, recorded: "Wound of elbow by bullet; simple dressings." On June 22d, the wounded man entered Carver Hospital, Washington, where excision at the injured joint was performed by Surgeon O. A. Judson, U. S. V., who reported the following history of the case: "The patient, of good constitution, was admitted suffering from a gunshot wound of the right elbow joint, the ball entering at the olecranon process, passing downward and outward, and making its exit on the radial side of the forearm, about two inches below the point of entrance, producing compound comminuted fracture of the olecranon process and head of radius. June 24th, the parts appeared considerably swollen and intensely painful, the patient somewhat emaciated and anæmic. He was taken to the operating room and etherized, when about four inches of the ulna including the olecranon, and three inches of the radius including its head, were excised by making a T-shaped incision over the elbow joint. June 25th, patient comfortable; appetite very poor. Ordered stimulants and generous diet. June 30th, wound secretes a small quantity of laudable pus; simple dressings used. July 1st, severe chill, lasting three hours. Wound rapidly filling up with healthy granulations. Appetite continues poor. Ordered sulphate of quinine with tincture of iron. July 3d, slight chill; no febrile reaction. Has slight cough. July 7th, no more chills. Ordered Fowler's solution and syrup of iodide of iron with stimulants. July 10th, opened a diffused abscess surrounding the elbow joint; profuse discharge of dark sanious pus; almost entire loss of appetite. Stimulating applications were made to the wound. July 14th, patient complains of severe pain in left side; dulness is found on percussion in lower lobe of each lung; cough continues; expectorates a thick mucus mixed with pus. Treatment continued. July 15th, pulse 90; acute pain in left side and small of back. July 16th, extremities cold; pulse small and easily compressed. Stimulants ordered in sufficient quantities. July 17th, no pulse at wrist; involuntary watery discharges from bowels; mental aberration. Death at three o'clock A. M., on July 19, 1864. Autopsy seven hours after death: Parts *in situ* appeared normal. Posterior portion of right lung found bound down by old adhesions, posterior portion of left lung by recent adhesions; right lung slightly congested. In the lower portion of the upper lobe of the left lung an abscess was found about the size of a large walnut, containing a dark fœtid pus; the upper lobe above this point contained innumerable small abscesses, also containing pus. A few abscesses were found in the upper portion of the lower lobe, the remaining portion being congested. The right side of the heart contained a large fibrinous clot and about a half ounce of pericardial fluid of pinkish color. The liver was enlarged, congested, and pale; serous membrane easily removed. The spleen was three and a half by six inches and dark; the kidneys pale; pyramidal bodies not distinctly defined; ascending colon congested. The axillary artery contained a small washed clot. A large amount of pus was found in the cancellated structure of the lower portion of the humerus and upper portion of the radius. No pus was found in the vessels of the arm." The specimen, represented in the annexed cut (FIG. 635), exhibits the excised portions of the radius and ulna. It was contributed by the operator.



FIG. 635.—Excised portion of right ulna and radius.—Spec. 2378.

TABLE CXI.

Summary of Sixty-nine Unsuccessful Cases of Intermediary Excision of the Elbow Joint for Shot Injury.

NO.	NAME, AGE, AND MILITARY DESCRIPTION.	DATE OF INJURY.	NATURE OF INJURY.	DATE OF OPERATION.	OPERATION AND OPERATOR.	RESULT AND REMARKS.
1	Adams, A., Pt., D, 109th New York, age 18.	May 12, 1864.	Comminuted fracture of lower third of right humerus by conoidal ball; joint much swollen.	May 21, 1864.	Three and a half inches of humerus, including condyles, thro' crucial incision, by Asst. Surg. J. C. McKee, U. S. A.	Erysipelas; treatment supportive. Died June 9, 1864, of pyæmia.
2	Adams, S., Pt., I, 119th Pennsylvania, age 23.	April 2, 1865.	Fracture of left humerus, extending into elbow joint, by a conoidal ball.	April 10, 1865.	Excision of two inches of lower portion of humerus.	April 12, amputation at middle third. Died April 20, 1865, of pyæmia.
3	Barrier, W. L., Pt., F, 3d North Carolina Cavalry.	May 6, 1864.	Shot fracture of inner condyle of humerus and olecranon process of ulna.	May 13, 1864.	Trochlea surface of humerus, also olecranon, through H incision, by Surg. C. B. Gibson, C. S. A.	Died May 17, 1864.
4	Black, L., Pt., K, 61st New York, age 24.	May 18, 1864.	Shot fracture of head of radius and external condyle of humerus.	May 31, 1864.	Excision of right elbow joint, by A. A. Surg. D. P. Wulpharter.	Died June 27, 1864.
5	Blaney, J. S., Musician, I, 1st Artillery, age 19.	May 19, 1864.	Fracture of lower third of left humerus by conoidal ball.	June 8, 1864.	Two and a half inches of humerus and olecranon process of ulna, six-inch straight incision, by Surg. J. A. Lidell, U. S. V.	Died June 15, 1864, of phlegmonous erysipelas.
6	Brown, M. M., Corp'l, G, 17th Kentucky.	Sept. 20, 1863.	Shot wound of left elbow joint, olecranon and coronoid processes carious.	October, 1863.	Excision of olecranon process with portion of ulna, by Surg. I. Moses, U. S. V.	Died December 12, 1863. Spec. 2147.
7	Brown, W. H., Corp'l, I, 72d Pennsylvania.	Dec. 13, 1862.	Comminuted fracture of left humerus two inches above condyles, also trochlea and olecranon process.	December, 1862.	Excision of two inches of extremity of humerus and olecranon process.	Died December 26, 1862. Spec. 594.



NO.	NAME, AGE, AND MILITARY DESCRIPTION.	DATE OF INJURY.	NATURE OF INJURY.	DATE OF OPERATION.	OPERATION AND OPERATOR.	RESULT AND REMARKS.
8	Brunner, W., Pt., I, 49th Pennsylvania, age 20.	May 10, 1864.	Compound fracture of olecranon by conoidal ball.	May 31, 1864.	Excision of right elbow joint, by Surg. H. Palmer, U. S. V.	Died September 9, 1864, of typhoid fever.
9	Butterfield, W. W., Pt., F, 25th Mass., age 19.	June 3, 1864.	Gunshot fracture of left ulna.	June 13, 1864.	Three inches upper part ulna, by Surg. A. P. Sheldon, U. S. V.	Died June 17, 1864, from exhaustion.
10	Case, W. H., Corp'l, I, 15th New Jersey, age 24.	May 11, 1864.	Shot fracture of bones of left elbow joint.	May 23, 1864.	Head of radius and articular surfaces of humerus and ulna by T method, by A. A. Surg. P. C. Gilbert.	Died June 3, 1864, of pyæmia.
11	Chandler, S. T., Pt., C, 6th South Carolina.	June 1, 1862.	Conoidal ball entered external condyle of left humerus and emerged at third rib, below clavicle.	June 12, 1862.	Articulating end of humerus and olecranon process, by Surgeon R. B. Bontecon, U. S. V.; cross incision.	Secondary hæmorrhage occurred. Died June 21, 1862.
12	Chase, H. H., Corp'l, D, 26th Maine, age 31.	April 14, 1863.	Elbow joint opened and four inches of upper portion of right radius fractured by conoidal ball, which lodged.	April 20, 1863.	Head of radius and five inches of shaft, with the ball, by Asst. Surg. P. S. Conner, U. S. A.	Died August 3, 1863, of wound and diarrhoea. <i>Spec.</i> 1308.
13	Clay, H., Pt., I, 76th New York, age 20.	May 5, 1864.	Fracture of right elbow joint by conoidal ball.	May 21, 1864.	Ext. condyle of humerus and olecranon process, straight incision, by Asst. Surg. C. A. McCall, U. S. A.	Died June 9, 1864, of asthenia.
14	Clayton, G. P., Pt., B, 71st Indiana.	Aug. 30, 1862.	Gunshot fracture of the elbow joint.	Sept. 19, 1862.	Excision of head of radius and portion of ulna.	Died October 6, 1862.
15	Colgrove, S. H., Corp'l, F, 48th New York, age 33.	Feb. 20, 1864.	Shot fracture of right elbow joint by conoidal ball.	Mar. 3, 1864.	Four inches of ulna and one of radius removed, by Act. Asst. Surg. W. Balsler.	Died March 16, 1864.
16	Conkling, G. W., Serg't, M, 2d Illinois Cavalry.	Jan. 25, 1864.	Shot fracture of outer condyle of right humerus.	Feb. 14, 1864.	Outer condyle and splinter of shaft of humerus, through vertical incision, by Act. Asst. Surg. S. S. Jessop.	Erysipelas supervened. Died March 5, 1864, comatose.
17	Core, T., Capt., A, 148th Pennsylvania, age 27.	May 6, 1864.	Wound of right elbow joint by conoidal ball.	May 15, 1864.	Excision of head of radius, by A. A. Surg. J. O. Stanton.	Died May 21, 1864, of pyæmia.
18	Davis, D. I., Corp'l, E, 2d U. S. Sharpshooters, age 23.	May 6, 1864.	Conoidal ball fractured right elbow.	June 3, 1864.	Excision, by Act. Asst. Surg. R. Westerling. See CASE 1808, p. 879.	Died from hæmorrhage from brachial artery, June 22, 1864. <i>Spec.</i> 2483.
19	Davis, G. E., Bugler, F, 2d New York Cavalry, age 23.	June 16, 1863.	Shot wound of left elbow joint; ball in contact with humerus.	June 21, 1863.	Excision of elbow joint, three incisions, by Surg. E. Bentley, U. S. V.	Died June 22, 1863.
20	Day, I. W., Pt., B, 128th Indiana, age 18.	March 8, 1865.	Fracture of left arm by conoidal ball; elbow implicated.	April 5, 1865.	Excision of elb. joint through L incision, by Asst. Surg. W. Webster, U. S. A.	Died May 9, 1865, of pyæmia.
21	Diekerson, N. S., Pt., C, 25th Massachusetts, age 27.	June 3, 1864.	Ball entered anteriorly above outer condyle of left humerus, emerged two inches below inner condyle, fracturing bone; two pieces removed on field.	July 2, 1864.	Excision of elbow joint, by A. A. Surg. T. H. Snow.	Gangrene; July 21, amputation of arm at middle third. Died August 7, 1864, from exhaustion.
22	Essex, A., Pt., G, 11th U. S. Infantry, age 26.	May 12, 1864.	Ball passed through the joint; head of radius and ulna protruded from the wound.	May 31, 1864.	Heads of radius and ulna, condyles of humerus, with portion of shaft, by Surg. R. B. Bontecon, U. S. V.	Died July 6, 1864, from exhaustion.
23	Eustis, W., Pt., C, 7th Wisconsin, age 23.	May 5, 1864.	Ball passed thro' elbow joint.	May 27, 1864.	Resection of joint and three inches of humerus.	Arm amputated. Died July, '64.
24	Evans, W., Pt., B, 9th Colored Troops, age 41.	Sept. 29, 1864.	Comminuted fracture of lower third of left humerus.	Oct. 5, 1864.	Five inches of end of humerus, by A. A. Surg. T. Hopkins.	Died October 12, 1864, from exhaustion.
25	Fuller, W. H., Pt., I, 8th New York Heavy Artillery, age 24.	June 3, 1864.	Fracture of right elbow joint by conoidal ball; also wound of hip and thigh.	June 13, 1864.	Three inches of radius and ulna and inner end of humerus, by A. Surg. A. Delaney, U. S. V.	Died July 8, 1864.
26	Garvin, T., Serg't, H, 51st New York, age 46.	May 6, 1864.	Comminuted fracture external condyle of left humerus, opening elbow joint.	May 26, 1864.	Condyle removed thro' straight incision, by Surg. O. A. Judson, U. S. V.	Died September 18, 1864, of pyæmia. <i>Spec.</i> 3271.
27	Golden, O., Pt., D, 16th Massachusetts.	Aug. 30, 1862.	Shot fracture of elbow joint.	Sept. 4, 1862.	Excision, by Asst. Surg. B. Howard, U. S. A.	Died October 4, 1862.
28	Goodman, J., Pt., E, 26th Ohio.	Sept. 20, 1863.	Shot frac. of left elbow, carrying away portion of olecranon.	Sept. 26, 1863.	Excision of olecranon process.	Also flesh wound of thigh. Died Nov. 22, 1863. <i>Spec.</i> 2135.
29	Goodwin, E., Pt., E, 21st Massachusetts.	Sept. 1, 1862.	Upper part of left ulna comminuted.	Sept. 11, 1862.	Four inches of upper extremity of left ulna.	Died Oct. 30, 1862, from wound.
30	Graham, P., Corp'l, K, 26th Ohio.	Sept. 19, 1863.	Fracture of right elbow, left radius, and right foot.	Sept. 25, 1863.	Excision of right elbow, and removal of portion of left radius two inches above the wrist.	Also Chopart's operation on foot. Died October 8, 1863.
31	Gaisler, F., Pt., B, 74th Pennsylvania.	Aug. 28, 1862.	Fracture of olecranon process - left ulna and comminution of internal condyle of humerus by a musket ball.	Sept. 12, 1862.	Excision of elbow joint, by A. Surg. C. A. McCall, U. S. A.	Died September 30, 1862, of pyæmia.
32	Hammack, J. C., Pt., H, 4th Virginia, age 32.	May 19, 1863.	Wound of right elbow, right leg, and abdominal muscles.	June 7, 1863.	Excision of elbow joint.	Died June 13, 1863, of pyæmia.
33	Hillman, G., Pt., F, 6th Ohio.	Dec. 31, 1862.	Comminution right olecranon process, external condyle of humerus, and head of radius.	Jan. 9, 1863.	Excision of olecranon, part of outer condyle, and head of radius.	Died January 20, 1863.
34	Hodge, G. H., Pt., D, 57th Massachusetts, age 23.	May 6, 1864.	Comminution of condyles of humerus and heads of radius and ulna.	May 29, 1864.	Complete excision of right elbow joint, by A. A. Surg. F. G. H. Bradford.	Died June 4, 1864, from exhaustion.
35	Hungerford, G., Pt., B, 1st Colored Troops, age 49.	Oct. 27, 1864.	Right olecranon process fractured and joint opened by conoidal ball.	Oct. 31, 1864.	Excision of olecranon and removal of ball, by A. A. Surg. C. C. Ela.	Died December 18, 1864, from exhaustion.
36	Hunt, A., Pt., G, 72d New York.	Dec. 13, 1862.	Comminuted fracture of left ulna, middle third, by a conoidal ball.	Jan. 11, 1863.	Head and half of shaft of ulna, through four-inch incision, by A. Surg. C. Wagner, U. S. A.	Died January 23, 1863, of pyæmia.
37	Jackson, W. M., Pt., D, 1st Michigan Sharpshooters, age 17.	May 6, 1864.	Fracture of outer condyle of left humerus, involving ulna, by conoidal ball.	May 26, 1864.	Condyles of humerus, olecranon, and articular surface of radius removed, by Surg. D. P. Smith, U. S. V.	Died June 3, 1864. <i>Spec.</i> 3306.
38	Jay, B. F., Pt., A, 1st Louisiana, age 18.	April 24, 1864.	Musket ball fractured right ulna and end of humerus.	April 28, 1864.	Two inches of humerus and the broken fragments of the ulna, by Surg. E. P. Sanger, U. S. V.	April 29, erysipelas; amputation of arm. Died May 29, 1864.
39	Johnson, J. L., Corp'l, K, 48th New York, age 26.	June 3, 1864.	Ends of left humerus, radius, and ulna injured.	June 22, 1864.	Excision, by Surg. R. B. Bontecon, U. S. V. See CASE 1807, p. 879.	Secondary hæmorrhage and gangrene; arm amp. June 27, 1864. Died June 29, 1864. <i>Spec.</i> 3042.

No.	NAME, AGE, AND MILITARY DESCRIPTION.	DATE OF INJURY.	NATURE OF INJURY.	DATE OF OPERATION.	OPERATION AND OPERATOR.	REMARKS.
40	Long, P., Corp'l, D, 3d New Hampshire, age 38.	June 16, 1864.	Fracture of right olecranon.	July 12, 1864.	Excision, by A. A. Surg. W. P. Moon. See CASE 1814, p. 880.	Died August 3, 1864, from exhaustion. <i>Spec.</i> 3615.
41	Lyon, L. E., Serg't, F, 4th New York, age 22.	Feb. 20, 1864.	Fracture of right humerus, extending into elbow joint, by round musket ball.	Mar. 12, 1864.	Four and a half inches of lower portion of humerus, including condyles, excised by A. Surg. W. R. Ramsey, U. S. A.	Died June 5, 1864.
42	Madigan, T., Serg't, A, 2d Infantry.	June 27, 1862.	Ball passed through olecranon process and lodged behind it, involving joint.	July 5, 1862.	Removal of olecranon process, by Surg. R. B. Bontecou, U. S. V.	Died August 5, 1862, from exhaustion and tetanus.
43	Massie, H., Pt., II, 9th West Virginia, age 19.	July 20, 1864.	Fracture of condyles of right humerus, involving elbow joint, by conoidal ball.	July 28, 1864.	Excision of two inches of lower extremity of humerus thro' incision along radial border of arm, by Surg. J. B. Lewis, U. S. V.	Died August 20, 1864, of pyæmia. <i>Spec.</i> 4261.
44	McEvoy, W., Lieut., I, 6th U. S. Colored Troops, age 22.	Sept. 29, 1864.	Condyles of left humerus fractured by conoidal ball.	Oct. 8, 1864.	Condyles of humerus and portion of shaft, olecranon process, and two inches of radius and ulna, by A. A. Surg. W. P. Litch.	Died Nov. 9, 1864, of pyæmia.
45	McKinney, J., Pt., C, 184th Pennsylvania, age 40.	June 3, 1864.	Ball lodged between head of radius and olecranon process of ulna.	June 20, 1864.	External condyles of right humerus and head of radius, by Surg. G. L. Pancoast, U. S. V.	Died July 5, 1864.
46	Minsberger, J., Pt., I, 90th Pennsylvania, age 40.	May 6, 1864.	Gunshot fracture of left humerus, implicating elbow joint.	May 18, 1864.	Two and a half inches of humerus, including condyles and olecranon, straight incision, by Asst. Surg. G. A. Murglok, U. S. V.	Died suddenly, July 28, 1864, of serous apoplexy. <i>Specs.</i> 2912, 2913.
47	Mitchell, J. W., Pt., II, 17th Maine, age 33.	April 6, 1865.	Fracture of right ulna by conoidal ball, joint involved.	April 20, 1865.	Extremity of ulna just below coronoid process, through V incision, by Surg. B. A. Vanderkief, U. S. V.	Died May 27, 1865, of pyæmia. <i>Spec.</i> 4102.
48	Moyer, J. K., Pt., II, 38th Pennsylvania, age 25.	May 7, 1864.	Shot wound left elbow, lower third of humerus fractured.	May 13, 1864.	Exc. by Asst. Surg. H. Allen, U. S. A. See CASE 1812, p. 880.	Died May 30, 1864, of pyæmia. <i>Spec.</i> 2293.
49	O'Conner, T., Pt., K, 81st Indiana.	Sept. 19, 1863.	Shot fracture head of left ulna, opening into elbow joint.	Sept. 30, 1863.	Excision of portion of ulna.	Died Oct. 27, 1863, of pyæmia.
50	Randall, H. B., Pt., C, 14th Ohio.	Sept. 20, 1863.	Conoidal wound right elbow joint; shaft of humerus fractured just above condyles.	Oct. 10, 1863.	Two and a half inches of lower extremity of right humerus, by Surg. I. Moses, U. S. V.	Died Oct. 26, 1863. <i>Spec.</i> 2141.
51	Robinson, W., Pt., B, 2d Penn. Artillery, age 19.	June 17, 1864.	External condyle of humerus fractured by conoidal ball.	July 3, 1864.	Head of radius and two inches of lower end of humerus, by Surg. R. B. Bontecou, U. S. V.	Arm amputated July 13, 1864. Died July 15, 1864, from exhaustion. <i>Spec.</i> 3039.
52	Rowland, J., Serg't, II, 124th New York, age 26.	May 3, 1863.	Wound of left elbow joint.	May 13, 1863.	Excision of articulating surface of ulna.	Amputation at junction of upper with middle third. Died June 22, 1863.
53	Ryder, A., Pt., II, 58th Massachusetts, age 23.	June 3, 1864.	Shot wound communicating with left elbow joint, injuring head of radius.	June 14, 1864.	Excision of left elbow joint, by Surg. R. B. Bontecou, U. S. V.	Died June 24, 1864, from exhaustion following chronic diarrhoea.
54	Shaffer, M. E., Pt., C, 54th Pennsylvania, age 22.	May 15, 1864.	Fracture of condyles of left humerus by musket ball.	May 24, 1864.	Greater portion of external condyle and fragments, thro' enlarged wound, by Surg. J. B. Lewis, U. S. V.	Died June 11, 1864.
55	Simkins, J. A., Pt., F, 7th Wisconsin.	Sept. 17, 1862.	Comminuted fracture of radius and ulna, joint implicated; conoidal ball.	Oct. 6, 1862.	Excision of injured bone.	Died October 8, 1862.
56	Smith, F. M., Corp'l, A, 7th Illinois Cavalry, age 21.	Dec. 17, 1864.	Wound of left elbow by conoidal ball.	Dec. 30, 1864.	Resection of elbow joint.	Died January 14, 1865.
57	Sperry, O. M., Pt., A, 16th Illinois, age 21.	May 14, 1864.	Fracture of olecranon and flesh wound of left arm by conoidal ball.	May 20, 1864.	One and a half inches of ulna excised through straight incision, by Asst. Surg. C. C. Byrne, U. S. A.	Died May 31, 1864, of wound.
58	Stowell, J. T., Pt., C, 5th U. S. Colored Troops, age 30.	Sept. 26, 1864.	Shot wound through right elbow joint by conoidal ball.	Oct. 20, 1864.	Excision of right elbow joint through T incision, by A. A. Surg. P. P. Geisdorf.	Died November 28, 1864, from exhaustion.
59	Sutherland, E. C., Lieut., F, 20th Indiana, age 26.	May 6, 1864.	Wound of right arm, lower third, by conoidal ball.	May 16, 1864.	Outer condyle of right humerus, by A. A. Surg. J. O. Stanton.	Died May 26, 1864, from exhaustion.
60	Thayer, J., Pt., C, 10th Massachusetts, age 21.	May 3, 1863.	Slight fracture of superior extremity of ulna; joint opened.	May 18, 1863.	Three inches extremity of humerus and coracoid and olecranon processes, thro' straight incision, by Asst. Surg. C. A. McCall, U. S. A.	Died of pyæmia, May 27, 1863. <i>Spec.</i> 1178.
61	Tinney, S., Ohio State Militia, age 40.	July 14, 1863.	Wound of left ulna, elbow, and left hip.	Aug. 5, 1863.	Excision of olecranon and two inches of ulna.	Died August 23, 1863, of pyæmia.
62	Venable, J., Pt., C, 12th New Jersey, age 29.	May 3, 1863.	Wound of left elbow joint.	May 16, 1863.	Excision of two inches of ulna and three of humerus.	Died June 16, 1863, of pyæmia.
63	Wesley, C., Pt., G, 4th New York II. Artillery, age 18.	June 18, 1864.	Fracture of ulna and head of radius.	June 24, 1864.	Excision, by Surg. O. A. Judson, U. S. V. See CASE 1813, p. 881.	Died July 19, 1864, of pyæmia. <i>Spec.</i> 2278.
64	West, J. S., Pt., A, 5th Maryland.	Sept. 17, 1862.	Conoidal ball passed through right elbow joint.	Oct. 2, 1862.	Excised, by Surg. H. S. Hewitt, U. S. V. See CASE 1810, p. 880.	Died October 20, 1862. <i>Spec.</i> 435.
65	Wheeler, Z., Pt., F, 63d New York, age 43.	June 2, 1864.	Fracture of upper extremity of left ulna, opening joint; number of fragments removed.	June 13, 1864.	Two and a half inches of ulna, head and one-half inch of radius, by A. A. Surg. R. Westering.	Died July 5, 1864. <i>Spec.</i> 2588.
66	Whitinger, R. G., Pt., G, 16th Mississippi, age 17.	April 2, 1865.	Comminution of lower third left humerus by a conoidal ball, joint implicated.	April 7, 1865.	Lower third of humerus, including condyles, by A. Surg. W. D. Wolverton, U. S. A.	Died April 26, 1865, from exhaustion following operation.
67	Wilber, J., Pt., E, 72d New York, age 23.	May 4, 1862.	Fractured condyles of right humerus, ball lodging in elbow joint.	May 16, 1862.	Excision of entire joint, by Surg. R. B. Bontecou, U. S. V.	Died June 4, 1862, of pyæmia.
68	Youngs, T., Pt., A, 5th Colored Troops, age 29.	Sept. 29, 1864.	Head of right radius fractured and joint opened by conoidal ball.	Oct. 25, 1864.	Excision of head and one-half inch of neck of radius, by A. A. Surg. O. Warner.	Pyæmia supervened. Died Dec. 5, 1864.
69	Zimmer, C., Pt., M, 7th New York II. Artillery, age 20.	June 3, 1864.	Gunshot wound through right elbow joint.	June 16, 1864.	Exc. by Surg. G. L. Pancoast, U. S. V. See CASE 1811, p. 880.	Died June 25, 1864, of hæmorrhage. <i>Spec.</i> 2582.



§ *Excision with Undetermined Result.*—Of the one hundred and ninety-seven intermediary excisions at the elbow, the result remains undetermined in one instance:

CASE 1814.—Private J. Walker, 5th New York (Duryea's Zouaves), is reported by Assistant Surgeon B. Howard, U. S. A., to have been "wounded at the second battle of Bull Run, August 30, 1862," and to have undergone "resection of the elbow joint on the field on September 4, 1862." It is impracticable to terminate this case. The name does not appear on the regimental returns, or on the registers of any of the field or base hospitals at Alexandria or Washington; neither is it found on the lists of deaths and discharges, nor on lists of applications for pension, nor on reports of the Adjutant General of New York.

The mode of operating was noted in less than half the cases; but the method by a single straight incision appears to have been most commonly adopted:<sup>1</sup>

**3. Secondary Excisions at the Elbow.**—Fifty-four operations, grouped in this category, were practised thirty days or more subsequent to the reception of shot injury. But five cases, or 9.2 per cent., terminated fatally, the ulterior histories of all having been traced.<sup>2</sup> Such evidence appears to show conclusively that excision at the elbow for the effects of shot injury may be done after the inflammatory phenomena have subsided, with as little jeopardy to life as excisions for disease entail, and consequently with far less risk than primary excisions for injury involve. But such secondary excisions can only be practised on those patients who have survived the dangers of the inflammatory stage. In this group, the proportion of complete excisions was relatively greater than in the primary and intermediary series.<sup>3</sup>

§ *Recoveries after Secondary Excisions at the Elbow.*—The forty-nine operations of this group were practised on forty-four Union and five Confederate soldiers,—on the right in twenty-two, and on the left elbow in twenty-seven. Four patients returned to modified duty, four were exchanged, and forty-one were discharged and pensioned. Two of the patients recovered after consecutive amputation in the upper third of the arm, and two after ulterior operations for necrosis of the resected bone-ends.

CASE 1815.—Private R. Brocklehurst, Co. A, 116th Pennsylvania, aged 21 years, was wounded at Chancellorsville, May 3, 1863, and admitted to Harewood Hospital, Washington, on the following day. Surgeon R. B. Bontecou, U. S. V., noted: "Gunshot wound of arm." Surgeon J. Hopkinson, U. S. V., reported the patient's admission to Mower Hospital May 10th, with the following description of the injury and operation: "Gunshot wound of left elbow, shattering internal condyle and olecranon process. Resection was performed, by a straight incision, on July 11th, by Acting Assistant Surgeon C. R. McLean. The treatment consisted of stimulants and anodynes, and cold-water dressings. On July 29th, the splints were removed and the arm placed on a pillow. September 2d, wound healing rapidly. December, 1863, wound nearly well." The specimen, represented in the annexed wood-cut (FIG. 636), shows the excised bones of the elbow, consisting of the head of the radius, the olecranon and coronoid processes, and one inch of the shaft of the ulna and two inches of the extremity of the humerus, all the structures being changed by caries and partially absorbed. It was contributed by the operator. The patient was assigned to the Veteran Reserve Corps May 12, 1864, and mustered out of service June 15, 1865, and pensioned. In September following, he was furnished with an apparatus by D. W. Kolbé, of Philadelphia, which he wore, however, only about one month, finding it "too heavy and chafing his arm," as he states in his application for commutation. Examiner W. Jewell, of Philadelphia, certified, September 18, 1866: "The ball passed through the left elbow joint. A resection was performed, but it has left the arm below the elbow entirely useless. The arm hangs from the elbow like a wet rag." The Philadelphia Examining Board, consisting of Drs. H. E. Goodman, T. H. Sherwood, and J. Collins, reported, September 4, 1873: "Condyles and articulating surface of humerus having been removed, the joint is limber and hangs useless." The pensioner was paid June 4, 1875.

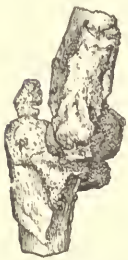

FIG. 636.—Bones of left elbow excised for caries 10 weeks after shot fracture. *Spec.* 2593.

Of the three following early secondary resections, the first and third were practised

<sup>1</sup> The method was specified in 83 instances as: Straight incision, 55; crucial, 2; T-shaped, in 6; *Liston's* A-shaped, in 2; *Moreau's* H-shaped, 10;  $\perp$  incision, in 4; V-shaped incision in 1; S-shaped, or otherwise curvilinear, in 3.

<sup>2</sup> This conclusion is significant, since, as may be seen by consulting TABLE CVI, on page 845, there were few reported instances of excision at the elbow that were not traced to their termination. Of ten such instances, five are known to have been primary or intermediary operations. It is improbable that the five remaining cases were all secondary operations, and improbable that they all resulted fatally, and the probability of the coincidence of the two improbabilities is almost infinitesimally small. But assuming that the five were all secondary fatal excisions, this group would consist of 59 cases with 10 deaths, or 16.9 per cent., 4.6 per cent. less than the mortality of primary excisions. A strong presumption of the greater safety of secondary excisions is therefore presented.

<sup>3</sup> The extent of the excision was specified in every instance but one. The joint ends of the three bones were reported removed in 23 cases (certainly in 7 cases in which the point is directly adverted to, and probably in 16 others entered as "complete excisions of the joint" or by equivalent expressions);—the articular extremities of the humerus and ulna, in 12 cases;—the humerus alone, in 9 cases;—the upper ends of the radius and ulna, in 1 case;—the upper end of the ulna alone, in 4 cases;—the upper extremity of the radius alone, in 4 cases.

for disorganization of the joint following fracture, the second for destructive arthritis from periarticular wound; the third was remarkable for the characteristic burning pain consequent on lesion of the ulnar nerve, periodically affecting the otherwise useful limb.

CASE 1816.—Private Mathias Rogers, Co. A, 38th Colored Troops, aged 22 years, was wounded at Deep Bottom, September 29, 1864, and was sent to Portsmouth, and admitted to Balfour Hospital on the following day. Assistant Surgeon J. H. Frantz, U. S. A., noted: "Compound comminuted gunshot fracture of the internal condyle of the right humerus, opening the elbow joint; ulna and radius fractured. On November 4th, ether was administered, and Acting Assistant Surgeon Oswald Warner excised the elbow joint, making a T incision. At the time of operation the patient was much enfeebled from the effects of the wound and long-continued discharge. The arm was slightly swollen; the wound appeared healthy and was discharging freely; the articular cartilages were destroyed by suppuration. After the operation the symptoms were at first unfavorable, but afterward he steadily improved. Stimulants, tonics, anodynes, nutriment, and simple dressing constituted the after-treatment." In March, 1865, he was transferred to Grant Hospital, New York, and thence discharged the service April 1, 1865, and pensioned. Surgeon W. H. Thurston, U. S. V., states, in a certificate for discharge: "Resection of olecranon process, right elbow, the result of a gunshot wound." Examiner James Phillips, of Washington, reported, September 16, 1865: "Partial resection of right elbow joint. He cannot pronate or supinate the forearm; ankylosis nearly complete." The disability was rated at total. The pensioner died April 13, 1868; cause of death unknown to the Pension Bureau. The specimen (FIG. 637) consists of the olecranon and coracoid processes, and the articular extremity of the excised humerus just above the condyles, from the right elbow. The articulation is entirely destroyed by suppuration. Contributed by Assistant Surgeon J. H. Frantz, U. S. A.

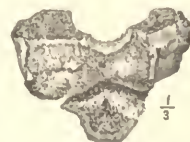

FIG. 637.—Right elbow excised secondarily. Spec. 1050.

CASE 1817.—Corporal F. Ott, Co. E, 93d Pennsylvania, aged 35 years, was wounded March 25, 1865, in an assault on Fort Steadman, in the lines about Petersburg. Surgeon S. F. Chapin, 139th Pennsylvania, reported his admission to the hospital of the 2d division of the Sixth Corps, with "a slight gunshot wound of the right arm by a minie ball." The patient was transferred to the Sixth Corps depot hospital at City Point, where Assistant Surgeon J. S. Ely, U. S. V., reported: "A gunshot flesh-wound of the right forearm." The patient was sent, March 27, 1865, on the hospital transport "State of Maine" to Washington, and entered Finley Hospital, March 29th. The wound, as reported by Acting Assistant Surgeon C. J. Polk, who has published an account of the case,<sup>1</sup> was regarded as trivial for more than a week. Pyæmic symptoms supervened. It was discovered that the joint was affected with suppurative inflammation, and on May 6, 1865, Surgeon G. L. Pancoast, U. S. V., excised the joint, "removing an inch of the humerus and the half of the head of the radius, and the olecranon process of the ulna." The preparation (FIG. 638) was presented to the Museum by Dr. Pancoast (*Cat. Surg. Sect.*, 1865, p. 154). There has been no fracture of the articular extremities, but ulceration and destruction of the cartilages evidently existed. There is a transverse section of the humerus above the trochlea, half an inch from the point at which the bone was ultimately sawn. The case progressed favorably, and the patient was discharged August 1, 1865, and pensioned. Examiner M. D. Benedict, of Washington, reported, at that date: "He had compound comminuted fracture (!) of the right elbow joint: the entire joint was removed by excision; limb entirely useless for labor." Examiner W. B. Lowman, of Johnstown, Pennsylvania, reported, September 6, 1873: "Resection of right elbow joint; the limb is two inches shorter than its fellow; the arm is but of little use; he cannot grasp anything with his hand. Address, Scalp Level, Cambria County, Pennsylvania."

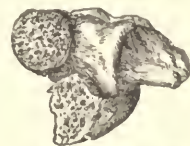

FIG. 638.—Excised bones of right elbow. Spec. 4287.

CASE 1818.—Private G. L. Essick, Co. K, 7th Pennsylvania Reserves, aged 19 years, was wounded at Antietam, September 17, 1862, and entered Hospital No. 3, Frederick, on October 1st, where he underwent excision of the elbow joint. Assistant Surgeon J. H. Bill, U. S. A., who performed the operation, transmitted the following report of the case: "Gunshot wound of right elbow joint. I saw the case on the 3d of October. The patient was not in a good state of health. The olecranon was destroyed in part, the internal condyle wounded, and the ulnar nerve divided. The indication here was for constitutional treatment and then a resection. On the 29th of October, the patient's condition being much improved, a resection of the joint was made, a T-shaped incision being employed. The condyles of the humerus and the olecranon process were removed. The insertion of the brachialis anticus was preserved. None of the radius was removed. No hæmorrhage occurred. The sensation in the outer fingers, as before the operation, is deficient. Limb placed on a pillow, five wire sutures used, and cold-water dressings. November 10th, wound united in part; suture removed and limb placed on an angular splint of 90°. Will do well. December 1st, wound nearly healed; sensation in outer fingers greatly improved; patient's health and strength completely restored; limb will be serviceable." The excised parts, including the coronoid process, were contributed to the Museum by the operator, and are represented in the annexed wood-cut (FIG. 639). They are carious, and the line of section in the ulna is exceedingly oblique. On January 24th, the patient was transferred to Hospital No. 1, whence he was discharged April 4, 1863, and pensioned. Examiner T. B. Reed, of Philadelphia, September 13, 1865, certified: "Gunshot wound of right elbow joint; resection of upper third of ulna. Use and power of arm a good deal impaired." The Philadelphia Examining Board, consisting of Drs. H. F. Goodman, J. Collins, and T. H. Sherwood, reported, May 27, 1874: "Ball struck behind internal condyle of humerus, passing through and out in front. Result, fracture of condyle, with loss of the ends of the bones, producing considerable deformity, leaving the joint partially ankylosed. Cannot extend beyond angle of forty-five degrees [135°?]. Rotation seriously impaired. Disability rated three-fourths. Ball re-entered abdomen three inches above crest of right ilium, and out one inch to left of median line, above umbilicus. Complains of burning sensation in track of wound in bad weather. Does not cause him any serious trouble otherwise. Disability rated one-fourth." The pensioner was paid June 4, 1875.

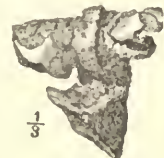

FIG. 639.—Bones of right elbow excised for caries and shot injury. Spec. 842.

<sup>1</sup> POLK (C. J.), *Rare Cases in Surgery*, in *The [Philadelphia] Medical and Surgical Reporter*, 1874, Vol. XXXI, p. 44. The operation by Dr. PANCOAST is the second case reported.



### Imperfect recoveries with partial mobility are detailed in the next three abstracts:

**CASE 1819.**—Corporal W. R. Corey, Co. H, 4th Rhode Island, aged 23 years, was wounded at Poplar Grove Church, September 30, 1864. He was treated in a Ninth Corps hospital and at City Point; thence he was sent to New Jersey, and admitted into Beverly Hospital on October 15th. Assistant Surgeon C. Wagner, U. S. A., the operator, noted: "Gunshot wound of the left arm, injuring the upper part of the ulna. On December 11, 1864, three inches of the upper third of the ulna were resected, under chloroform.




FIG. 640.—Results of an excision of the upper extremity of the left ulna. (From an aquarelle by BAUMGRAS.)

At the time of operation the parts were in a sloughing condition, and the head of the bone was exposed and necrosed. The general health of the patient was favorable, and he did well under a treatment of cold-water dressings." The patient was transferred to Whitehall Hospital, Bristol, April 6, 1865, and discharged from service June 7, 1865, and pensioned. The drawing from which the cut (FIG. 640) is taken was executed by Mr. Baumgras, Hospital Steward, U. S. A. The pathological specimen (FIG. 641), contributed to the Museum by the operator, consists of the coronoid and olecranon processes and two and a half inches of the shaft of the left ulna excised after gangrene had attacked a shot flesh wound of the forearm. The bone appears to have been slightly contused about midway on the posterior surface. There has been a slight osseous deposit on the posterior portion of the shaft. The tip of the olecranon is carious. Examiner C. McKnight, of Providence, July 21, 1865, reported the arm as entirely useless below the elbow; and, on June 30, 1866, reported, "the wound still continues open and the patient has entirely lost the use of the arm; disability is rated total and permanent." This pensioner is reported to have died June 11, 1869.

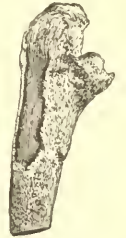

FIG. 641.—Upper part of left ulna excised following gunshot contusion. *Spec.* 3713.

**CASE 1820.**—Private W. Dempsey, Co. C, 36th Colored Troops, aged 20 years, was wounded at Deep Bottom, September 29, 1864, and admitted to the field hospital of the 3d division, Eighteenth Corps, where Surgeon J. W. Mitchell, 4th Colored Troops, recorded: "Gunshot wound of arm." Assistant Surgeon J. H. Frantz, U. S. A., reported the patient's admission to Balfour Hospital, Portsmouth, October 5th, and contributed the specimen (shown in FIG. 2, PLATE LI, *Spec.* 1365), with the following account of the operation: "Severe penetrating gunshot wound of right elbow; joint opened; considerable comminution and laceration. November 3d, slight swelling of parts; copious discharge. Patient much debilitated from the effects of the wound. Exarticulation of two and a half inches of lower portion of humerus and removal of olecranon process through a T-shaped incision, by Acting Assistant Surgeon C. C. Ela. Sulphuric ether was used. The treatment consisted of stimulants, nutriment, and simple dressings. The patient steadily improved." He was discharged from service June 1, 1865, by reason of "partial ankylosis of the elbow joint and the limb being nearly powerless." The specimen consists of the excised parts of the elbow joint. The outer condyle and the adjacent part of the humerus is wanting, and the articular surface is carious. Examiner J. Williamson, of Portsmouth, Virginia, May 24, 1866, certified: "Total stiffening of right elbow joint and loss of use of right arm," etc. Examiner S. B. Kinney, March 2, 1874, certified: " \* \* Arm in a semi-flexed position, with very slight motion at the false joint, rendering it of no more use than an artificial one would be. \* \* The pensioner is also suffering from disease of the hip joint with caries of the head of the femur." The pensioner was paid June 4, 1875.

**CASE 1821.**—Private A. M. McAtee, Co. F, 23d Ohio, aged 20 years, was wounded in the left elbow, at Antietam, September 17, 1862. Five days afterward he was admitted to Mount Pleasant Hospital, Washington, where Assistant Surgeon C. A. McCall, U. S. A., excised the injured joint on October 21st. The patient recovered, and was discharged from service, December 30, 1862, and pensioned. The specimen, represented in the wood-cut (FIG. 642), was contributed by the operator, and consists of two inches of the extremity of the humerus, and the ulna removed just below the coronoid process, the olecranon being fractured, and a vertical fracture extending through the middle of the trochlea. The articular surface is partly eroded. An account of this case was published by Dr. McCall in the *Medical and Surgical Reporter*, Vol. IX, 1862-63, p. 231, as follows: "Gunshot wound of elbow joint, causing compound comminuted fracture of olecranon, of condyle of humerus, and of the shaft of the latter bone for some distance above the articular head. About half the lower third of the humerus was removed, together with the olecranon and articular head of the ulna. The radius was left intact. The arm was put upon a straight splint, with simple absorbent dressings to parts. Tonics and stimulants. The straight splint was exchanged for an angular pasteboard one about November 1st, the forearm being semi-flexed upon the arm.

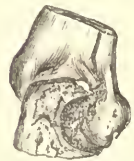

FIG. 642.—Bones of left elbow excised for shot fracture. *Spec.* 343.

No untoward symptoms occurred; the wound healed well, and ceased discharging the first week in December. At this date all pain and most of the swelling had disappeared. The fingers could be moved slightly, but the arm had no power to support itself without the splint. The mobility of the joint was considerable: the arm could be moved, without causing pain or inconvenience, from a nearly straight to a semi-flexed condition." Examiner W. D. Scartt, of Bellefontaine, Ohio, certified, on the following respective dates: April 4, 1863: "The ball seems to have passed longitudinally through the joint, thereby destroying the joint and rendering the arm useless." February 16, 1864: "The wound has healed entire, but the forearm hangs just as an appendage and is an encumbrance, of no use to him." November 11, 1866: "The injury is fully equal to the loss of the forearm." September 4, 1873: "The muscles are all shrunken, and the entire arm is more of an encumbrance than otherwise." The pensioner was paid September 4, 1875.

<sup>1</sup>WAGNER (C.), *Reports of Interesting Surgical Operations at Beverly, New Jersey.* 1865, p. 4.

There were examples, among the recoveries after secondary excisions, in which the functions of the forearm and hand are reported to have been most satisfactorily preserved, as in those numbered, 3, 5, 21, 28 of the succeeding TABLE CXII; but in most of the instances recorded in detail, control of the movements of the limb was but limited:

CASE 1822.—Private J. M. Tarbell, Co. E, 2d U. S. Sharpshooters, aged 21 years, was wounded at the Wilderness, May 6, 1864, and was admitted into a field hospital of the Second Corps, and thence sent to Washington, and received into Harewood Hospital on the 26th. Surgeon R. B. Bontecou, U. S. V., noted: "Gunshot wound of the right arm, severely injuring the elbow joint. On admission, the parts were considerably swollen and inflamed, and the constitutional state of the patient was very poor. The arm was kept quiet, and cold applications with general constitutional treatment employed until June 18th, when an operation was deemed necessary, which was performed, on that day, by Surgeon R. B. Bontecou, U. S. V., who resected the elbow joint. The patient improved in health after the operation, and, at this date, December 26, 1864, the wound has entirely healed and the patient is about to be discharged from service. He has no ability to flex the right arm, which is about two inches shorter than the left, but in other respects useful. Splints, simple dressings, and supporting treatment." The photograph from which the cut (FIG. 644) is taken, together with the specimen (FIG. 643), was contributed by the operator. The specimen consists of two fragments of carious bone, representing the condyles of the humerus, the olecranon, and head of the radius, excised from the right elbow. Tarbell was discharged from service December 31, 1864, and pensioned. Examiner C. L. Allen, of Vermont, reported, August 3, 1873: "A portion of the lower extremity of the humerus was removed by excision. The right humerus is two and one-half inches shorter than the left. The right arm and forearm measure, respectively, one and a quarter, and one and a half inches less than the left in circumference. There is complete loss of rotation of the hand except from the shoulder joint. The forearm can be extended, but can

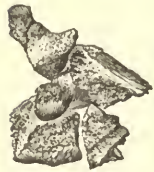

FIG. 643.—Excised portions of the right elbow joint after caries from shot injury. *Spec. 3602.*

be flexed only to an angle of about one hundred and ten degrees; there is fair use of the hand. The forearm is evidently not strong, especially in pushing. The hand cannot be brought near enough to the head to be of any use in eating. Disability total." This pensioner was paid March 4, 1874.

CASE 1823.—Sergeant M. B. Soule, Co. E, 16th Maine, aged 25 years, was wounded at Gettysburg, July 1, 1863, and admitted to the field hospital of the 2d division. First Corps. Surgeon C. J. Nordquist, 83d New York, noted: "Gunshot wound of right arm." On September 5th, the patient reached Baltimore, whence Assistant Surgeon D. C. Peters, U. S. A., in charge of Jarvis Hospital, contributed the specimen (FIG. 645), with the following history: "He was badly wounded in the right elbow joint. Upon examination it was found that a minié ball had entered just above the head of the radius and passed directly through the humerus, between the condyles. The joint was in a high state of inflammation, extending up and down the arm. About the latter part of September the wound was attacked with gangrene, which was soon overcome by the local application of permanganate of potassa. October 29th, patient feverish; secretions large; skin moist; appetite good; rest not disturbed; desirous of having the limb sawed. Excision of the entire elbow joint, by cross-incision, was performed by Acting Assistant Surgeon F. Hinkle. The head of the radius and the condyles of the humerus were removed, ether being used as the anæsthetic. The patient reacted promptly. The limb was placed in an angular tin splint. December 3d, patient is in fine spirits; parts entirely healed; arm looks natural; a false joint is forming. December 29th, patient is well, and can raise the forearm fully one inch without any assistance. The case has been entirely successful." The specimen consists of three and a half inches of the lower extremity of the humerus. It was sawn through one and a half inches below the point of the final excision. The extremity is carious, but the outer condyle, which was split off, has imperfectly united to the shaft. The patient was transferred to De Camp Hospital, New York, April 24th, and subsequently to Cony Hospital, Augusta, where he was discharged from service June 24, 1864, and pensioned. Examiner N. R. Boutelle, of Waterville, Maine, September 28, 1864, certified: "Wound still discharging;" and again, in October, 1866: "Has now no use of arm and next to none of forearm." In a supplementary letter, dated February 4, 1867, he stated: "About three inches of the lower third of the right humerus has been removed, including a portion of the condyles. A false joint and also false ankylosis now exist. The forearm can only be flexed to a right angle and only extended one-third. The power of rotating the forearm and hand is lost. The forearm is also distorted," etc. Examiner R. D. Barber, of Worthington, Minnesota, reported, September 6, 1873, that: "The resection shortened the arm about four inches, and ligamentous union only has resulted." The pensioner was paid September 4, 1875.

That the ulterior usefulness of limbs after excision at the elbow depends greatly upon



FIG. 644.—Appearance after a secondary excision of the elbow for shot injury. [From a photograph.]

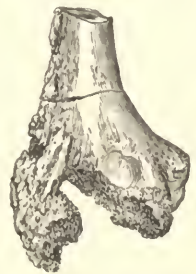

FIG. 645.—Condyles of right humerus excised for caries after shot fracture. *Spec. 1995.*



judicious after-treatment, is a proposition made as obvious by the cases of the secondary group as by those of the primary and intermediary series. Various expedients were adopted in order to secure, in the early period after the operation, immobility of the limb and simultaneously access to the wound for facility of dressing, and, later, to make passive movements conveniently.

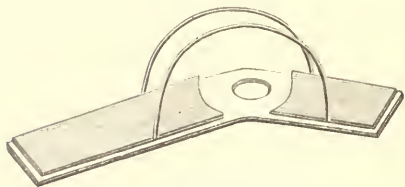


FIG. 646.—ESMARCH'S elbow splint. [Reduced from STROMEYER'S drawing.]

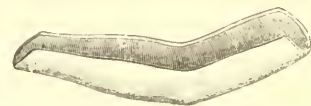


FIG. 647.—AHL'S felt elbow splint. [From specimen in A. M. M.]

The felt splint of Dr. Ahl<sup>1</sup> (FIG. 647), in which fenestra of any size might be cut, and which permitted water or ice dressings to be used, was found very useful, as in CASE 1794. Dr. Stromeyer's excellent double bracketed splint<sup>2</sup> (FIG. 646) was unknown at the time.

CASE 1824.—Private M. Lewis, Co. A, 133d Pennsylvania, aged 19 years, was wounded at Fredericksburg, December 13, 1862, and admitted to Point Lookout Hospital three days afterward. Assistant Surgeon C. Wagner, U. S. A., forwarded the specimen (*Cat. Surg. Sect.*, 1866, p. 161, *Spec.* 998), with the following description of the injury and operation of the case: "He was wounded by a minié ball in the posterior aspect of the left arm, just over the olecranon. The inner portion of the olecranon was shattered, and the inner condyle with a portion of the trochlea broken off. The ball lodged among the muscles on the anterior aspect of the forearm, about over the head of the radius, and was cut out on December 25th. When the patient arrived his general condition was good. It continued so after his admission. There was considerable swelling of the elbow and forearm, which alternately subsided and increased every few days up to the time of the operation. January 15th, chloroform having been administered, the articulation was exposed by the quadrilateral flap-operation of Moreau, and the olecranon sawed off at the base of the coronoid process. The detached inner condyle, which was thrown forward and inward, was next removed, the ulnar nerve being found intact. The lower extremity of the humerus was then sawed off just above the condyle. The flap was laid back and the edges of the wound brought together and detained by eight sutures. The operation was performed by Acting Assistant Surgeon T. H. Allison. January 21st, strips of adhesive plaster were applied in order to bring the edges of the wound into closer apposition, an opening being left for the escape of pus. After the operation the arm was supported by a cushion, the forearm being pronated and slightly flexed. The case did well, and when last seen the wound had healed. The joint has motion as follows: extension very nearly perfect; flexion about ten degrees with elbow at right angle, and about half the full extent of pronation and supination; movement increasing daily."<sup>3</sup> The specimen (shown in FIGURE 4 of PLATE LI) consists of the excised bones of the elbow, the joint being carious, and a little indifferent callus being shown near the inner condyle. The patient was discharged March 13, 1863, and pensioned. Examiner J. Lowman certified, April 11, 1863: "Ball passed through elbow, which required excision of the joint, leaving ankylosis." Examiner W. B. Lowman, of Johnstown, August 5, 1871, reports that: "The first time he was examined for pension his arm was not altogether healed, but he could use it better than now. He could extend it farther; now he cannot fully extend the arm, or rotate the hand or arm. He cannot push from him, but can raise or lift anything," etc. Substantially the same report was made in 1873. The disability was rated three-fourths. The pensioner was paid June 4, 1875.

CASE 1825.—Private G. Thompson, Co. E, 15th New Jersey, aged 21 years, was wounded at the Wilderness, May 5, 1864. Surgeon E. F. Taylor, 1st New Jersey, recorded his admission to the field hospital of the 1st division, Sixth Corps, with "gunshot fracture of left elbow." On May 11th, the patient entered Finley Hospital, Washington, where he was operated on by Surgeon G. L. Pancoast, U. S. V., who reported as follows: "The ball entered on the posterior surface of the arm near the internal condyle, and passed through the elbow joint, fracturing the olecranon process and the upper end of the ulna. June 7th, parts much swollen and inflamed; constitutional state of patient good. Resection of the elbow joint was performed, chloroform being used as the anæsthetic. Favorable progress followed. The treatment consisted of water dressings, tonics, and stimulants. The patient rapidly recovered." The specimen, represented in the annexed cut (FIG. 648), shows the excised parts, consisting of nearly two inches from the lower extremity of the humerus, the head of the radius, and the upper portion of the ulna cut half an inch below the coronoid process. The articular surfaces are eroded. It was contributed by the operator. The patient was discharged February 21, 1865, and pensioned. Examiner J. Nichols, of Washington, D. C., February 23, 1865, certified: "Gunshot fracture of left elbow joint, with resection. Not yet entirely healed. Limb shortened about two inches," etc. Examiner C. Hodge, jr., certifies, March 4, 1867: "The joint is entirely cut out and the arm thereby rendered entirely useless for manual labor." Drs. J. B. Coleman, C. Hodge, jr., and W. W. L. Phillips, of the Trenton Board, reported, September 8, 1873: "Ball destroyed the elbow joint, from which bones were removed, and there remains a false joint." The pensioner was paid September 4, 1875.

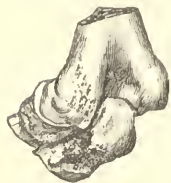

FIG. 648.—Bones of left elbow excised for shot injury. *Spec.* 2465.

<sup>1</sup> AHL (D.), *Adaptable Porous Splints, with Directions for their employment in Fractures and other Surgical Lesions*, Newville, Jan., 1875, p. 10.

<sup>2</sup> STROMEYER (L.), *Erfahrungen über Schusswunden im Jahre 1866*, Hannover, 1867, S. 50. A modification of the obtuse-angled splint used by Professor STROMEYER, suggested by Professor ESMARCH in a visit to the former at Langensalza, which Dr. STROMEYER says "should be generally known," and Dr. H. FISCHER (*Lehrbuch der Allg. Kriegs-Chir.*, 1868, S. 234) considers "most convenient to the surgeon and comfortable to the patient, either in the expectant treatment or with after treatment of resections."

<sup>3</sup> See published accounts of this case by Dr. JOHN STEARNS, jr. (*Boston Med. and Surg. Jour.*, 1863, Vol. LXVIII, p. 252), and by Dr. C. WAGNER (*in Am. Jour. Med. Sci.*, 1863, Vol. XLVI, p. 39).

TABLE CXII.

Summary of Forty-nine Cases of Recovery after Secondary Excision of the Bones at the Elbow for Shot Injury.

No.	NAME, AGE, AND MILITARY DESCRIPTION.	DATE OF INJURY.	NATURE OF INJURY.	DATE OF OPERATION.	OPERATION AND OPERATOR.	RESULT AND REMARKS.
1	Anstee, E., Pt., E, 61st Pennsylvania, age 34.	May 31, 1862.	Caries following shot fracture of bones of right elbow joint.	Aug. 12, 1862.	Complete excision of articular surfaces of humerus, radius, and ulna, by A. A. Surg. J. E. Steele.	Disch'd Nov. 28, 1862; pensioned. Ankylosis; arm atrophied; rotation absent.
2	Arant, A. J., Pt., 5th Alabama, age 26.	Sept. 19, 1864.	Fracture of inner condyle of right humerus.	Oct. 20, 1864.	Three inches of humerus, thro' straight incision.	Retired January 6, 1865.
3	Bowe, T., Serg't, F., 6th Louisiana, age 26.	Sept. 17, 1862.	Shot wound, with fracture of right elbow.	Mar. 13, 1863.	Olecranon, articular surface of ulna, and inferior end of humerus.	Furloughed June 15, '63. Nearly entire use of arm and hand.
4	Brooklehurst, R., Pt., A, 116th Pennsylvania, age 21.	May 3, 1863.	Fracture of left epitrochlea and olecranon.	July 11, 1863.	Excision, by Dr. C. R. McCuan. See CASE 1815, p. 884.	Disch'd June 15, 1865; pensioned. Spec. 2533.
5	Burgess, C., Pt., D, 33d Colored Troops, age 37.	Dec. 7, 1864.	Fracture of left ulna into elbow joint by conoidal ball.	Jan. 29, 1865.	Excision of joint, five inches of bone, thro' straight incision, by Dr. F. E. Martindale.	Disch'd May 22, 1865; pensioned. No ankylosis of joint; quite good use of hand.
6	Cooper, W., Pt., A, 82d Ohio, age 28.	July 1, 1863.	Comminuted fracture of left joint by conoidal ball.	Aug. 22, 1863.	Five inches of humerus and upper extremity of radius and ulna, straight incision twelve inches long, by Surg. S. D. Freeman, U. S. V.	Spicule of bone came away; arm useless. Disch'd April 23, 1864; pensioned.
7	Corey, W. R., Corp'l, II, 4th Rhode Island, age 23.	Sept. 30, 1864.	Shell flesh wound of left forearm; bones exposed and necrosed.	Dec. 11, 1864.	Excision, by Asst. Surg. C. Wagner, U. S. A. See CASE 1819, p. 886.	Disch'd June 7, 1865; pensioned. Arm useless. Died June 11, 1869. Spec. 3713.
8	Criggen, P. O., Pt., C, 3d New York, age 24.	May 14, 1864.	Shot wound of left elbow joint. Iron ball, from sharpnel shot, extracted June 1st.	June 20, 1864.	Condyles of humerus and point of ulna excised thro' straight incision, by A. A. Surg. T. Liebold.	Transferred for muster out May 10, 1865; not a pensioner.
9	Davis, R. M., Corp'l, F, 5th Minnesota, age 34.	Aug. 23, 1864.	Shot fracture of head of right radius by musket ball.	Oct. 23, 1864.	Excision of head of radius. . . .	Disch'd June 24, 1865; pensioned. Rotation destroyed.
10	Dempsey, W., Pt., C, 36th Colored Troops, age 20.	Sept. 29, 1864.	Right elbow joint opened by conoidal ball.	Nov. 3, 1864.	Excision, by A. A. Surg. C. C. Ela. See CASE 1820, p. 886.	Disch'd June 1, 1865; pensioned. Spec. 1365.
11	Esstick, G. L., Pt., K, 7th Pennsylvania Reserves, age 20.	Sept. 17, 1862.	Fracture and caries of right elbow, and division of ulnar nerve, by musket ball.	Oct. 29, 1862.	Excision, by Asst. Surg. J. H. Hill, U. S. A. See CASE 1818, p. 885.	Serviceable limb. Disch'd April 4, 1863; pensioned. Partial ankylosis. Spec. 842.
12	Green, A., Pt., E, 98th Ohio, age 34.	Oct. 8, 1862.	Wound of left elbow joint. . . .	Nov. 10, 1862.	Excision of upper third of ulna.	Pyæmia. Disch'd Jan. 1, 1863; pensioned. Ankylosis; muscular atrophy.
13	Haley, T., Corp'l, F, 84th New York, age 22.	May 8, 1864.	Fracture of left olecranon by conoidal ball; erysipelas.	June 20, 1864.	Articular ends of humerus, radius, and ulna, thro' Liston's incision, by Surg. B. A. Clements, U. S. A.	Joint ankylosed. Disch'd Jan. 26, 1865; pensioned. Atrophy of muscles; loss of rotation.
14	Hathaway, E., Corp'l, H, 3d Wisconsin Cavalry, age 31.	Oct. 9, 1863.	Heads of left ulna and radius fractured; piece of bone removed October 9; pyæmia, erysipelas, necrosis.	Jan. 27, 1864.	Excision of lower end of humerus and upper extremities of radius and ulna, by Surg. H. Culbertson, U. S. V.	False joint formed. Disch'd Feb. 8, 1865; pensioned. Forearm hangs useless, and shortened about four inches.
15	Henby, J. K., Pt., F, 51st Indiana, age 22.	Aug. 14, 1864.	Fracture of right humerus, involving elbow joint, by conoidal ball; hæm's from brachial.	Sept. 16, 1864.	Excision, by Act. Asst. Surg. A. Robillard.	Partial ankylosis. Disch'd April 25, 1865; pensioned. Has some motion of joint; fingers closed.
16	Keller, M. Van B., Pt., D, 1st Pennsylvania Reserves, age 21.	June 30, 1862.	Ball passed laterally through right elbow joint; arm œdematous; joint full of pus. July 28, 1862, incision thro' to back of joint, uniting wounds of entrance and exit; detached fragments removed.	Sept. 1, 1862.	Incision four inches, crossing previous one; one and a half inches of humerus, radius, and ulna removed by chain saw and bone forceps, by A. A. Surg. J. H. Packard.	Disch'd February 20, 1863; pensioned. Arm and hand useless; can be moved in any direction without resistance. Dr. Packard mentions ( <i>Handbook of Op. Sur.</i> , 1870, p. 167) the reception of letters written by this patient.
17	Kerr, J. G., Pt., C, 91st Pennsylvania, age 25.	May 23, 1864.	Compound comminuted fracture of right elbow by conoidal ball.	July 2, 1864.	Both condyles of humerus and entire upper third of ulna by linear incision, by Surg. J. I. Hayes, U. S. V.	Disch'd July 24, 1865. Periosteal formation of bone; union of radius and ulna; ankylosis; no radial motion; pensioner. Limb nearly useless.
18	Kidd, W. R., Serg't, E, 12th Pennsylvania.	Aug. 29, 1862.	Musket ball through left elbow and into body above crest of ilium.	Oct. 2, 1862.	Two and a half inches of humerus and olecranon removed.	Disch'd Dec. 15, 1862; pensioned. Ball lodged in lumbar muscles; health good; arm useless.
19	Kluff, L., Pt., D, 2d New Jersey, age 46.	Aug. 27, 1862.	Compound comminuted fracture of right humerus at lower third by conoidal ball.	April 27, 1863.	Excision of four inches of condyles and continuity of humerus' through linear incision, by Drs. Ristley and Welter.	Discharged March 16, 1861; pensioned. Arm shortened three and one half inches. False ankylosis.
20	Lewis, M., Pt., A, 133d Pennsylvania, age 19.	Dec. 13, 1862.	Epitrochlea and olecranon shattered; musket ball lodged.	Jan. 15, 1863.	Excision, by A. A. Surg. T. H. Allison. See CASE 1824, p. 888.	Extension nearly perfect; rotation half. Disch'd Mar. 13, 1863; pensioned. Spec. 998.
21	Love, J. S., Pt., K, 13th North Carolina.	July 3, 1863.	Shot wound through left elbow.	Feb. 11, 1864.	Olecranon and one inch of radius and ulna, by A. A. Surg. T. Liebold.	Healed, with motion of joint. Exchanged March, 1864.
22	Lyon, J., Corp'l, E, 30th Iowa, age 27.	Oct. 21, 1863.	External condyle of left humerus fractured, triceps muscle injured, by buckshot; wound supposed to involve left lung.	1864.	Excision, by A. A. Surg. T. G. Bernays.	Ankylosis. Disch'd February 5, 1864. Died April 5, 1865, of hæmorrhage from lungs.
23	Matthison, E. M., Pt., E, 55th New York, age 34.	May 31, 1862.	Great tumefaction after musket ball comminution of right elbow.	July 6, 1862.	Articulating ends of bones of elbow, thro' straight incision, by A. A. Surg. I. Dieker.	Good use of elbow. Discharged Feb. 10, 1863; pensioned. Partial ankylosis; arm useless.
24	McAtee, A., Pt., F, 23d Ohio, age 20.	Sept. 17, 1862.	Shot fracture of trochlea and olecranon.	Oct. 21, 1862.	Excision, by A. Surg. C. A. McCall, U. S. A. See CASE 1821, p. 886.	Disch'd December 30, 1862; pensioned. Spec. 343.
25	McFarland, H., Pt., B, 155th Pennsylvania, age 40.	Oct. 27, 1864.	Disorganization following shot wound of left elbow by conoidal ball.	1865.	Excision of upper part of ulna, by Asst. Surg. G. H. Rugg, 104th New York.	Disch'd July 7, 1865; pensioned. Arm useless. Died October 22, 1867, of pneumonia.
26	Mikesell, D. D., Pt., D, 9th Kansas Cavalry.	May 28, 1863.	Caries of condyles of right humerus following perforation by conoidal ball.	July 3, 1863.	Articulating surfaces of humerus, radius, and olecranon, through V incision, by A. A. Surg. J. Thorne.	Complete union, with ankylosis. Discharged December 10, 1863; pensioned. Arm flexed across chest.



No.	NAME, AGE, AND MILITARY DESCRIPTION.	DATE OF INJURY.	NATURE OF INJURY.	DATE OF OPERATION.	OPERATION AND OPERATOR.	RESULT AND REMARKS.
27	Mixon, W., Pt., C, 2d Infantry.	June 27, 1862.	Condyles of left humerus shattered by conoidal ball.	Aug. 1, 1862.	Lower end of humerus excised.	Disch'd Nov. 8, 1862; pensioned. Arm entirely useless.
28	O'Brien, —, Pt., Texas regiment.		Disease following fracture of condyles of left humerus by pistol ball.	June, '62, six weeks after.	Six and one-quarter inches of humerus, including condyles, through T incision, by Asst. Surg. J. H. Bill, U. S. A.	Complete recovery. Returned to Provost Marshal.
29	O'Brien, M., Corp'l, A, 143d Pennsylvania, age 20.	July 1, 1863.	Conoidal ball through right elbow joint; fracture of external condyle of humerus.	August, 1863.	Excision, by A. A. Surg. F. Hinkle.	No use in joint. Disch'd Feb. 1, 1864; pensioned. Ankylosis; firm union.
30	Ott, F., Pt., E, 93d Pennsylvania, age 27.	Mar. 25, 1865.	Disorganization of right elbow from shot fracture.	May 6, 1865.	Excision, by Surg. G. L. Pancoast, U. S. V. See CASE 1817, p. 885.	Disch'd Aug. 1, 1865; pensioned. Spec. 4287.
31	Pernell, I., Pt., K, 6th Colored Troops, age 21.	Sept. 29, 1864.	Ankylosis after shot fracture of head of left radius.	Sept. 15, 1865.	Head of radius excised thro' straight incision, by Acting Asst. Surgeon E. B. Lyon.	Discharged September 20, 1865; pensioned. Thirteen pieces of bone discharged at intervals; complete ankylosis.
32	Perry, O. H., Pt., C, 97th Illinois, age 33.	April 9, 1865.	Shot fracture of condyles of right humerus and olecranon; also wound of chest.	June 12, 1865.	Excision of inch of humerus, olecranon, and head of radius, by Asst. Surgeon A. Hartsuff, U. S. A.	Disch'd Oct. 18, 1865; pensioned. Entire loss of use of arm; amputated near shoulder for disease of bone.
33	Pilgrim, F., Pt., D, 8th New York Cavalry, age 22.	April 11, 1865.	Suppuration, caries, and erysipelas after fracture of right elbow by a conoidal ball.	May 15, 1865.	Ends of humerus, radius, and ulna excised, by Surgeon R. B. Bontecou, U. S. V.	Gangrene. Disch'd Nov. 6, 1865; pensioned. Whole upper extremity atrophied; arm useless; joint is ligamentous.
34	Ports, J. W., Pt., C, 148th Pennsylvania, age 31.	May 10, 1864.	Fracture of lower extremity of left humerus, involving elbow joint, by conoidal ball.	June 25, 1864.	Condyles, with three inches of shaft of humerus, by Asst. Surg. P. C. Davis, U. S. A.	Aug. 31, two small sequestræ removed. Disch'd Feb. 14, 1865; pensioned. Arm entirely useless. Spec. 3182.
35	Powell, O. N., Pt., C, 105th Pennsylvania, age 21.	June 30, 1862.	Disease following shot wound of left elbow joint.	Sept. 24, 1862.	One and one-half inches humerus, two inches ulna, and one inch of radius.	Able to put hand to mouth. Discharged Dec. 26, 1862; pens'd. Atrophy of entire arm.
36	Redpath, S. J., Serg't, A, 82d New York, age 26.	July 3, 1863.	Shell fracture of right radius, upper third; wound closed by sutures.	Aug. 12, 1863.	Two inches of radius, including head, removed, by Acting Asst. Surg. J. H. McLellan.	Necrosed bone and piece of shell removed Nov. 2d; joint ankylosed. Disch'd June 25, 1864; pensioned. Arm useless.
37	Reynaud, C., Pt., H, 2d Kentucky Cavalry, age 28.	May 4, 1864.	Ball ent'd near right olecranon process, passing nearly thro'.	June 13, 1864.	Excision of three inches of upper portion of ulna.	Joint ankylosed. Discharged June 13, 1865; pensioned.
38	Rodgers, E., Serg't, A, 5th Artillery, age 23.	June 9, 1864.	Comminuted fracture of lower end of left humerus by musket ball.	Aug. 8, 1864.	Two and a half inches of humerus, including condyles, through straight incision, by A. Surg. A. Ingram, U. S. A.	To regimental headquarters November 4, 1864. Not a pensioner.
36	Rogers, M., Pt., A., 38th Colored Troops, age 22.	Sept. 29, 1864.	Destructive suppuration of elbow after shot fracture.	Nov. 4, 1864.	Excision, by A. A. Surg. O. Warner. See CASE 1816, p. 885.	Disch'd April 1, 1865; pensioned. Spec. 1050.
40	Rowley, J. R., Corp'l, F, 65th Ohio, age 20.	Sept. 19, 1863.	Compound comminuted fracture of right elbow by conoidal ball.	Nov. 12, 1863.	Four inches of end of humerus, with coronoid and olecranon, by A. A. Surg. W. H. Matlock.	Arm amputated three inches below shoulder November 26th. Disch'd June 6, 1864; pens'd. Specs. 1929, 2208.
41	Soule, M. B., Serg't, E, 16th Maine, age 24.	July 1, 1863.	Gangrene following round musket ball perforation of elbow.	Oct. 29, 1863.	Excision, by A. A. Surg. F. Hinkle. See CASE 1823, p. 887.	Disch'd June 4, 1864; pensioned. Arm wholly useless; false joint and false ankylosis. Spec. 1995.
42	Tarbell, J. M., Pt., E, 2d U. S. Sharpshooters, age 21.	May 6, 1864.	Caries following shot injury of right elbow joint.	June 18, 1864.	Excision, by Surg. R. B. Bontecou, U. S. V. See CASE 1822, p. 887.	Disch'd December 31, 1864; pensioned. Spec. 3602.
43	Taylor, B., Pt., D, 20th New York, age 25.	Aug. 30, 1862.	Conoidal ball penetrated left elbow; the inner condyle being broken off slipped upward and ankylosed.	Jan. 22, 1863.	Excision of entire joint, by Surg. I. Moses, U. S. V.	Disch'd June 4, 1863; pensioned. Entire loss of voluntary motion; false joint. Spec. 734.
44	Thomasson, S. G., Pt., H, 24th Virginia, age 35.	May 16, 1864.	Conoidal ball fractured inner condyle of left humerus, extending to joint; small spicule removed every few days.	June 24, 1864.	Four inches humerus, one and a half inches of ulna, and head of radius, through a vertical incision.	Furloughed July 28, 1864; doing well.
45	Thompson, G., Pt., E, 15th New Jersey, age 21.	May 5, 1864.	Destructive arthritis after shot fracture.	June 7, 1864.	Excision, by Surg. Pancoast, U. S. V. See CASE 1825, p. 888.	Disch'd February 21, 1865; pensioned. Spec. 2465.
46	Watkins, T., Pt., E, 8th Iowa Cavalry.	Nov., 1863.	Pistol shot fracture of left elbow joint.	Dec., 1863.	Excision of the elbow.	Disch'd convalescent Jan. 23, '64. Died from measles Mar. 10, '64.
47	Williams, G., Serg't, K, 14th New York Cavalry, age 39.	Mar. 12, 1865.	Disorganization consequent on fracture of left external condyle by conoidal ball.	April 18, 1865.	Olecranon and debris of condyle of humerus, thro' three-inch incision, by Surg. A. McMahon, U. S. V.	Disch'd May 10, 1865; pensioned. Complete ankylosis at an angle of 120°; no motion.
48	Weymer, M., Pt., D, 18th New York, age 26.	June 27, 1862.	Rifle ball passed directly thro' joint; caries of articular surfaces.	July 28, 1862.	Complete excision of left elbow joint, by Act. Asst. Surg. J. Brookes.	Necrosed bone came away; gangrene; permanent ankylosis. Disch'd May 28, 1863; pens'd. Arm partially paralyzed.
49	Whitten, W., Pt., H, 121st Ohio, age 22.	Sept. 20, 1863.	Complete ankylosis; dense mass of callus surrounding joint after a shot fracture of the left elbow.	April 2, 1864.	Two inches of bone from each extremity being sawn thro' at site of original joint, thro' Moreau's incision, by Donald Maclean, M. D.	Erysipelas; motion of forearm, except slight difficulty in supination, perfect. Disch'd Oct. 8, 1864; Pension Examiner reports arm useless.

§ *Fatal Secondary Excisions at the Elbow.*—The proportion of fatal terminations in the series of secondary excisions at the elbow was small; and appears the more remarkable when it is considered that in one or two instances death resulted less from the local mutilations than from the constitutional conditions. The five operations of this group were on the right elbow in one, and on the left in four instances; four were complete or nearly complete, and one a partial excision; all the patients were Union soldiers; one died after submitting to consecutive amputation for gangrene. Abstracts of two of the cases,

which are represented in the Museum by pathological specimens, are subjoined; the second is the only one of the fatal cases accompanied by a necroscopical record:

CASE 1826.—Private A. R. Davis, Co. F, 102d Pennsylvania, aged 28 years, was wounded at the Wilderness, May 5, 1864. Surgeon S. F. Chapin, 139th Pennsylvania, recorded his admission to the field hospital of the 2d division, Sixth Corps, with "a gunshot wound of left arm." The patient was sent to Washington, whence Surgeon G. L. Pancoast, U. S. V., in charge of Finley Hospital, performed excision of the elbow joint, and described the operation as follows: "The patient was admitted May 13th, with gunshot fracture of left elbow joint, the ball entering the anterior part, passing directly upward and backward. The joint was opened, the parts became much swollen, and ankylosis was taking place rapidly. June 17th, excision was performed, under chloroform, by an incision about five inches in length, a portion of the ends of the radius, ulna, and humerus being taken out. June 30th, patient has been doing very well. Water dressings were applied, and afterward emollient poultice. Death took place on August 22, 1864. The immediate cause of death was diarrhoea. The excised bones of the joint, represented in the annexed cut (FIG. 649), were contributed to the Museum by the operator, and embrace the head and one inch of the shaft of the radius, six fragments representing two inches of the extremity of the humerus, and the upper part of the ulna. The specimen has slight osteophytic deposits upon it, and the articular surfaces are more or less carious.

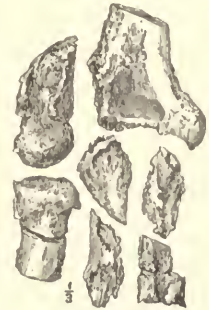

FIG. 649.—Excised part of elbow. Spec. 2583.

CASE 1827.—Private A. N. Perkins, Co. K, 2d Connecticut Heavy Artillery, aged 35 years, was wounded at Cold Harbor, June 1, 1864, and admitted to the field hospital of the 1st division, Sixth Corps, where Surgeon R. Sharpe, 15th New Jersey, noted: "A gunshot wound of the left elbow." On June 7th, the wounded man entered Lincoln Hospital, Washington, and four days afterward he was transferred to Patterson Park Hospital, Baltimore, where he underwent excision of the elbow joint. Acting Assistant Surgeon G. W. Fay, who performed the operation, furnished the minutes of the case as follows: "The ball entered near the external condyle of the humerus and lodged in the joint. The missile was removed soon after admission. June 30th, patient suffers very much from great swelling and inflammation of arm, and has a bed-sore over the sacrum. Made an incision in the arm near the elbow, which discharged about a pint of pus. Applied bread and milk poultice, and prescribed tincture of muriate of iron, fifteen drops three times a day. July 16th, the swelling and inflammation is so much diminished as to admit of an operation. Administered chloroform, and excised from lower part of humerus two and a half inches, and from the radius and ulna each one and a half inches. Made a vertical incision about seven inches long. August 1, patient suffers much from bed-sore, which is more weakening than the wound itself. The incision is nearly healed. Patient has stealthily procured and eaten unripe pears, causing pain and vomiting followed by diarrhoea. August 3d, had two chills to-day, one in the forenoon and the other past noon. Prescribed two grains of sulphate of quinine thrice daily. August 9th, chills are arrested; there is now pain in right side of chest, with a cough. Prescribed a mixture with squills. August 11th, pain in right breast continues; dullness on percussion over right lung; pulse rapid; cough. Expectoates a thick tough mucus. Ordered a prescription of sulphate of morphia two grains, diluted hydrocyanic acid ten drops, syrup of squills one-half ounce, and mucilage of gum arabic two ounces, to be given in teaspoonfuls every four hours. August 12th, patient very feeble; former symptoms continue; alternate cold sweats and paroxysms of fever; administered stimulants. August 13th, patient died. Autopsy: On opening the chest, the right pleural cavity was found to contain about thirty-four ounces of yellowish serum. The lower lobe of the right lung was congested, and a large ulcer near its apex had discharged pus into the thoracic cavity. There was also a small ulcer at the apex of the left lung. The examination of the arm at the seat of operation disclosed that the lower end of the humerus had become deprived of periosteum, subsequent to the operation, for a space of about one and a half inches. This part had become encased with an osseous substance, which completely protected it from the soft parts. In other respects all parts adjacent to the operation had healed favorably." The excised bones of the elbow joint were contributed to the Museum by the operator, and show (FIG. 3, PLATE LI, *opposite* p. 872) the articular surfaces to be destroyed by suppuration. The line of section in the shafts of the bones of the forearm are very oblique. The outer condyle and head of radius had been fractured and were removed. In the specimen the olecranon has been divided.—*Cat. Surg. Sect.*, 1866, p. 156, Spec. 3466.

### TABLE CXIII.

#### *Summary of Five Fatal Cases of Secondary Excision at the Elbow for Shot Injury.*

NO.	NAME, AGE, AND MILITARY DESCRIPTION.	DATE OF INJURY.	NATURE OF INJURY.	DATE OF OPERATION.	OPERATION AND OPERATOR.	RESULT AND REMARKS.
1	Davis, A. R., Pl., F, 102d Pennsylvania, age 28.	May 5, 1864.	Shot wound through left elbow.	June 17, 1864.	Excision, by Surg. G. L. Pancoast, U. S. V. See CASE 1826, p. 891.	Died August 21, 1864. Spec. 2583.
2	Jones, W., Pl., G, 77th Pennsylvania, age 32.	Aug. 5, 1864.	Fracture upper third left radius, joint involved, by conoidal ball.	Sept. 10, 1864.	Excision of four inches upper end of radius thro' straight incision, by Surg. S. H. Kersey, 36th Indiana.	Gangrene. November 14, 1864, arm amputated. Died January 7, 1865, of chronic diarrhoea.
3	McReynolds, P. W., Pl., G, 57th Indiana, age 20.	June 23, 1864.	Shot wound of left elbow joint; joint opened; chronic dysentery.	July 29, 1864.	One and a half inches humerus, two inches ulna, three-fourths inch radius, by Asst. Surg. B. E. Fryer, U. S. A.	Died August 22, 1864, of chronic dysentery.
4	Perkins, A. N., Pl., K, 2d Conn. H. A., age 35.	June 1, 1864.	Canister shot wound of left elbow.	July 16, 1864.	Excision, by A. A. Surg. G. W. Fay. See CASE 1827, and FIG. 3, PLATE LI.	Died August 13, 1864. Spec. 3466.
5	Vanwarner, J., Pl., A, 7th New York H. A., age 24.	Oct. 30, 1864.	Shot wound of right elbow joint.	Dec. 16, 1864.	Ends of humerus and ulna removed by crucial incision, by Surg. G. L. Pancoast, U. S. V.	Died January 10, 1865, of pneumonia.



In the group of fifty-four secondary excisions at the elbow, as well as in the primary and intermediary series, Langenbeck's method,<sup>1</sup> by a single vertical incision, appears to have been the favorite mode of operating.

**4. Excisions at the Elbow of Uncertain Date.**—Fifty-three cases of resection at the elbow for shot injury were reported, in which either the dates of injury or of operation, or both, were unspecified, or that the interval between the two could not be computed. The terminations of five of the cases were not ascertained. Of the remaining forty-eight patients, five died, or 8.3 per cent., an exception to the ordinary rule that lists of operations imperfectly reported present a mortality rate higher than the average. From a fatal case, probably an early intermediary operation, a specimen was contributed:

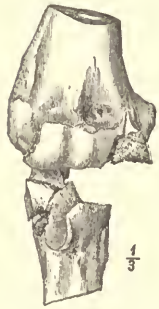

FIG. 650.—Excised elbow. Spec. 202.

CASE 1828.—Private R. Phipps, Co. E, 30th Pennsylvania, aged 21 years, was wounded in the right elbow at Bull Run, August 30, 1862. He was admitted to Ascension Hospital, Washington, where the joint was excised. Surgeon J. C. Dorr, U. S. V., who performed the operation, reported that the patient died from "the effects of a gunshot wound of the arm" on September 20, 1862. The specimen, represented in the annexed wood-cut (FIG. 650), consists of two inches of the lower extremity of the humerus and the upper extremity of the ulna. The olecranon is badly fractured, a part of the trochlea is broken, and the articular surface of the greater sigmoid cavity and of the trochlea are deeply eroded; the outer condyle is intact, and shows but slight traces of disease. In the cut the extremity of the ulna is placed too far over on the radial side.

The forty-four recoveries, five undetermined, and four fatal cases are tabulated together. Twenty-seven operations, including the four fatal cases, were on the right side, nineteen on the left; in seven cases, this point is not noted. Thirty-one of the patients were Union, and twenty-two Confederate soldiers.

TABLE CXIV.

*Summary of Fifty-three Cases of Excision at the Elbow Joint, of Uncertain Date, for Shot Injury.*

NO.	NAME, AGE, AND MILITARY DESCRIPTION.	DATE OF INJURY.	NATURE OF INJURY.	DATE OF OPERATION.	OPERATION AND OPERATOR.	RESULT AND REMARKS.
1	Adams, B. C., Lieut., G, 4th Pennsylvania Cavalry.	Oct. 12, 1863.	Shot fracture of right elbow . . .	—	Excision of four or five inches of humerus.	Discharged March 16, 1864; pensioned. Arm useless.
2	Adams, J., Pt., K, 155th Pennsylvania, age 21.	May 5, 1864.	Wound of right elbow joint by conoidal ball.	1864.	Partial excision of right elbow joint.	Discharged November 2, 1864; pensioned. Arm atrophied; partial ankylosis of joint.
3	Andrews, T., Serg't, A, 53d Georgia.	July 3, 1863.	Shot fracture of both condyles right humerus, olecranon process ulna, and head of radius.	1863.	Condyles of humerus, olecranon and head of radius, by Surg. J. J. Knott, 53d Ga.	Recovered with a useful limb. Died of typhoid fever and dysentery.
4	Bacon, M. A., Corp'l, K, 102d New York.	Sept. 17, 1862.	Wound of right arm, fracturing bone.	—	Excision of joint . . . . .	Disch'd March 3, 1863; pensioned. Ankylosis of joint.
5	Baker, J., Pt., C, 102d New York.	Sept. 17, 1862.	Shot fracture of left elbow . . . .	1862.	Excision of joint . . . . .	Discharged December 20, 1862; pensioned. Bony ankylosis.
6	Beauchamp, J. T., Serg't, D, 3d Georgia S. S., age 19.	Nov. 19, 1863.	Wound of right elbow joint . . .	—	Excision of joint . . . . .	Retired February 10, 1865.
7	Boehm, P., Lieut., 15th New York Cavalry, age 20.	April 1, 1865.	Wound of right elbow joint . . .	1865.	Excision of joint . . . . .	Wound healed; good prospect of useful arm. Not a pensioner.
8	Bracken, R., Lieut., B, 2d Louisiana.	—	Wound of elbow . . . . .	—	Excision of joint . . . . .	Transferred July 18, 1863.
9	Bradford, R. J. K. P., Pt., B, 2d Wisconsin.	July, 1863.	Wound of left elbow joint . . . .	1863.	Resection . . . . .	Discharged November 27, 1863; not a pensioner.
10	Brown, G., Captain D, 20th New York State Militia.	Aug. 30, 1862.	Shot fracture of right ulna by musket ball.	—	Excision of four inches of ulna, including articulation, by Surgeon O. A. Judson, U. S. V.	To V. R. C. Dec. 21, '63. Re-enlisted, and was discharged in 1869. Ankylosis of elbow and wrist joints; hand useless.
11	Coleman, J., Pt., G, 54th Massachusetts, age 23.	July 18, 1863.	Wound of right elbow joint by fragment of shell.	—	Excision of portion of humerus.	Disch'd May 13, 1864; pensioned. Limb dangles by his side.
12	Collier, E., Lieut., B, 5th Texas.	—	Wound of left elbow . . . . .	—	Excision of left elbow joint . . .	Retired November 27, 1864.
13	Courforth, C., Pt., I, 1st Pennsylvania Rifles.	Dec. 13, 1862.	Gunshot wound through left elbow joint by a conoidal ball.	—	Excision of portion of joint . . .	Disch'd June 3, 1863; pensioned. Ankylosis of joint; total loss of use of hand.
14	Crother, J. J., Pt., B, Orr's Rifles.	1864.	Wound of right arm . . . . .	1864.	Excision of elbow . . . . .	Died May 25, 1864.
15	Dickson, L., Pt., F, 6th Colored Troops, age 27.	Sept. 29, 1864.	Fracture of right arm by conoidal ball.	—	Excision of lower end of humerus.	Discharged April 28, 1865; pensioned. No union; forearm hangs loosely at side.

<sup>1</sup> In 25 of the secondary excisions in which the mode of operating was specified, the method by a straight vertical incision was adopted in 15,—MORREAU'S H-shaped incision in 2,—a crucial incision in 3,—LISTER'S H-shaped incision in 1,—a T-shaped incision in 2,—V or U-shaped incisions in 2.

No.	NAME, AGE, AND MILITARY DESCRIPTION.	DATE OF INJURY.	NATURE OF INJURY.	DATE OF OPERATION.	OPERATION AND OPERATOR.	RESULT AND REMARKS.
16	<i>Diemberger, G.</i> , Pt., F, 1st Maryland, age 23.		Gunshot wound through left elbow joint.		Excision of joint.....	Union; ankylosis of joint. Fell and produced a second fracture. Transferred January 15, 1864.
17	<i>Doyle, J.</i> , Pt., I, 10th Ohio, age 28.	Oct. 8, 1862.	Fracture right humerus at lower third, involving elbow joint.		A great portion of external condyle removed.	Discharged May 2, 1863; pensioned. Joint ankylosed; grasp of hand much enfeebled.
18	<i>Everhart, J.</i> , Pt., C, 1st Tennessee Cavalry, age 41.	July 29, 1864.	Fracture of lower third of right humerus.		Partial; removing distal extremity of humerus.	Retired Feb. 10, 1865, on certificate of permanent disability.
19	<i>Fical, H.</i> , Corp'l, F, 97th New York.	Aug. 29, 1862.	Wound through right elbow and of abdomen by same ball.	1862.	Excision of joint.....	Disch'd Dec. 21, 1862; pensioned. Arm reduced in size; complete ankylosis at right angle.
20	<i>Gaffaly, L.</i> , Pt., D, 62d New York, age 18.	May 2, 1863.	Compound fracture of left ulna, separating olecranon process, by a conoidal ball.		Excision of one inch and a half of upper portion of ulna.	Disch'd Feb. 25, 1864; pensioned. Firm ankylosis at right angle; osseous tissues in carious condition (1867).
21	<i>George, J. D.</i> , Pt., C, 36th Virginia, age 18.	June 5, 1864.	Conoidal ball through left elbow joint, almost separating outer condyle of humerus from shaft.	1864.	Two and a half inches extremity of left humerus.	Erysipelas. Retired December 3, 1864. Loss of use of arm.
22	<i>Gorman, J. O.</i> , Pt., E, 19th Michigan, age 30.	Mar. 5, 1863.	Fracture of left radius and ulna.	1863.	Six inches upper end of radius and five and a half of ulna, one and a half inches from joint.	Disch'd July 22, 1863; pensioned. Arm shortened five inches; perfectly useless and in the way.
23	<i>Grinnell, W.</i> , Lieut., I, 104th Ohio, age 24.	Nov. 29, 1863.	Wound of left elbow joint by conoidal ball.		Portion of radius and condyle of humerus, thro' T incision.	Disch'd June 3, 1864; pensioned. Arm useless; completely ankylosed.
24	<i>Gunter, E.</i> , Pt., F, Palmetto Sharpshooters.	Sept. 30, 1864.	Wound of left elbow joint....		Excision of joint.....	Furloughed October 28, 1864.
25	<i>Hammock, S. L.</i> , Pt., A, 3d Georgia Cavalry.	July 21, 1864.	Wound of right elbow joint...		Excision of joint.....	Retired March 7, 1865. Arm powerless.
26	<i>Hand, A. J.</i> , Pt., D, 19th Georgia.		Shot wound of left elbow.....		Excision of elbow.....	
27	<i>Helms, G. M.</i> , Lieut., A, 24th Virginia.	1864.	Wound of left elbow.....	May 16, 1864.	Excision.....	
28	<i>Hendricks, —</i> , Pt., C, 53d Georgia, age 17.	1864.	Fracture of right elbow joint..		Both condyles and olecranon, through longitudinal incision, by Surg. J. J. Knott, 53d Ga.	Recovered with a useful limb.
29	<i>Hoffman, J.</i> , Corp'l, G, 119th New York, age 36.	July 1, 1863.	Wound of right elbow joint....		Both condyles of humerus and olecranon process of ulna.	Disch'd Feb. 17, 1864. Jan. 29, 1873, complete ankylosis; arm useless.
30	<i>Hoops, G. W.</i> , Pt., E, 98th Ohio.	July 19, 1864.	Wound of left elbow joint, fracturing inner condyle.		Excision of inner condyle.....	Disch'd July 3, 1865; pensioned. Partial ankylosis of joint; arm weakened.
31	<i>Hoover, W. G.</i> , Pt., G, 14th Ohio.	Nov. 25, 1863.	Shot fracture of right elbow joint.	1863.	Excision of elbow joint.....	Died March 9, 1864.
32	<i>Houston, J.</i> , Pt., F, 55th Pennsylvania, age 29.	June 15, 1864.	Wound of right elbow joint by a shell.		Two and a half inches of humerus and one and a half of ulna, through straight incision.	Disch'd March 16, 1865; pens'd. Arm hangs powerless.
33	<i>Higgins, C. P.</i> , Pt., C, 13th South Carolina.	Aug. 16, 1864.	Wound of elbow joint.....		Excision of joint.....	
34	<i>Jones, E. P.</i> , Serg't, D, 3d South Carolina Battery.	July 28, 1864.	Wound of right elbow joint...		Excision of ulna at elbow joint.	
35	<i>Kauffman, J. K.</i> , Pt., E, 21st Ohio.	Sept. 19, 1863.	Carries after shot wound of right elbow joint.	1863.	Lower third of humerus, involving elbow joint.	Died from hepatitis October 27, 1863.
36	<i>Leutz, F.</i> , Pt., B, 8th Georgia.	Aug. 21, 1864.	Wound of elbow.....		Excision of elbow.....	Discharged December 30, 1861.
37	<i>Long, J.</i> , Pt., F, 11th North Carolina, age 27.	Aug. 21, 1864.	Wound of elbow joint.....		Excision of joint.....	Retired February 21, 1865. Ankylosis.
38	<i>Major, D. K.</i> , Pt., I, Orr's Rifles.	May 5, 1864.	Wound of right elbow.....		Excision.....	
39	<i>Maguire, J. A.</i> , 1st U. S. Mounted Rifles.	Oct. 3, 1862.	Fracture of ulna, involving elbow joint.		Excision of three inches of ulna.	Forearm flexed on arm; joint completely ankylosed. Discharged; not a pensioner.
40	<i>Miller, C. H.</i> , Pt., L, 1st Pennsylvania Cavalry.		Wound of left elbow joint....		Resection of joint.....	Disch'd May 14, 1865; not a pensioner.
41	<i>Negele, W.</i> , Pt., H, 55th Ohio, age 27.	Aug. 30, 1862.	Fracture of head of left radius.		Excision of two or three inches of radius, including head.	Disch'd Jan. 27, 1863; pensioned. Permanent ankylosis; partially flexed.
42	<i>O'Gready, J.</i> , Pt., B, 2d Louisiana.		Wound of elbow.....		Excision of joint.....	Transferred July 18, 1863.
43	<i>Piper, A.</i> , Serg't, B, 53d Georgia.	June 1, 1864.	Fracture, opening right elbow joint.		Excision, with removal of olecranon, through longitudinal incision, by Surg. J. J. Knott, 53d Georgia.	Complete ankylosis of elbow.
44	<i>Phipps, R.</i> , Pt., E, 30th Pennsylvania.	Aug. 30, 1862.	Shot fracture of right elbow...	Sept., 1862.	Excision, by Surg. J. C. Dorr, U.S.V. See CASE 1828, p. 892.	Died September 20, 1862. <i>Spec.</i> 202.
45	<i>Reynolds, A. J.</i> , Pt., K, 19th Kentucky, age 49.		Fracture of left elbow.....		Excision of entire elbow joint.	Disch'd Oct. 11, 1863; pensioned. Arm useless. Died Dec. 27, '71.
46	<i>Shauf, H.</i> , Corp'l, K, 42d Ohio, age 22.	May 22, 1863.	Fracture of right elbow by grapeshot.		Excision of entire elbow joint.	Disch'd Nov. 7, 1864; pensioned. Complete ankylosis and atrophy.
47	<i>Sinerson, S. E.</i> , Pt., A, 54th North Carolina, age 18.	May 10, 1864.	Wound of left elbow joint....	1864.	Excision of joint.....	Discharged December 30, 1864.
48	<i>Stringfield, —</i> , Pt., A, 4th Texas.				Excision of elbow joint.....	Transferred September 25, 1863.
49	Unknown, 1st Serg't,— Pennsylvania, age 25.	May 3, 1863.	Fracture of both condyles of left humerus by a musket ball.	1863.	Both condyles, olecranon process, and head of radius, thro' longitudinal incision, by Surg. J. J. Knott, 53d Georgia.	Fair prospect of recovery with a useful limb.
50	<i>Weitershausen, C. R.</i> , Pt., B, 9th Pa. Reserves, age 21.	June 30, 1862.	Wound of right forearm and elbow joint by musket ball.	1862.	Three inches of bones forming joint excised.	Disch'd Sept. 27, 1862; pensioned. Arm hangs useless.
51	<i>Weller, W. J.</i> , Pt., E, 76th Ohio, age 20.	May 16, 1863.	Left elbow joint crushed by ball.	1863.	Resection of almost entire joint, by Surg. E. L. Hill, 20th Ohio.	Disch'd Oct. 16, 1863; pensioned. Power of arm greatly impaired.
52	<i>Weston, C. J.</i> , Pt., I, 7th Infantry, age 19.	July 2, 1863.	Fracture of right elbow by minie ball; also wound of left knee Dec. 13, 1862.	1863.	Excision of portion of elbow..	Discharged July 9, 1864. Use of arm permanently impaired.
53	<i>Wilkins, N.</i> , Pt., D, 99th Illinois, age 22.	May 17, 1863.	Fracture of right elbow joint..		Excision of entire joint.....	Disch'd Oct. 13, 1863; pensioned. Some use of fingers if arm is assisted.



Further facts regarding the fifty-three excisions at the elbow of uncertain date are summed up in the foot-note.<sup>1</sup>

RECAPITULATION.—In the eight preceding tabular statements, six hundred and twenty-six cases of excisions at the elbow on account of the immediate or remote effects of shot injury have been enumerated and the result recorded except in ten instances. Among the six hundred and sixteen cases, there were one hundred and forty-two deaths, or a mortality of 23.7 per cent., or one-tenth of one per centum greater than the fatality of the series of amputations in the upper arm. The extent of the resections in the several groups is set forth in the subjoined table, which indicates very clearly that, upon an average, the more complete excisions were the least hazardous to life:

TABLE CXV.

*Statement of the Parts Excised in Six Hundred and Twenty-six Instances of Excisions at the Elbow for Shot Injury.*

PARTS RESECTED.	CASES.			PRIMARY.			INTERMEDIARY.			SECONDARY.		UNCERTAIN DATE.			FATALITY OF DE-TERMINED CASES.
	Recovery.	Fatality.	Unknown.	Recovery.	Fatality.	Unknown.	Recovery.	Fatality.	Unknown.	Recovery.	Fatality.	Recovery.	Fatality.	Unknown.	
1. Articular Ends of Humerus, Ulna, and Radius.....	93	21	.....	34	4	.....	33	13	.....	20	3	6	1	.....	18.4
2. Articular Ends of Humerus and Ulna.....	61	16	.....	27	7	.....	20	9	.....	11	.....	3	.....	.....	20.7
3. Ends of Humerus and Radius.....	8	2	.....	2	.....	.....	5	2	.....	.....	.....	1	.....	.....	40.0
4. Lower Extremity of Humerus.....	97	29	.....	61	14	.....	20	13	.....	9	1	7	1	.....	23.0
5. Articular Extremities of Ulna and Radius.....	25	6	.....	11	1	.....	12	5	.....	1	.....	1	.....	.....	19.3
6. Upper Extremity of Ulna.....	72	27	2	37	15	1	27	12	.....	4	.....	4	.....	1	27.2
7. Upper Extremity of Radius.....	31	4	.....	22	.....	.....	5	3	.....	3	1	1	.....	.....	11.4
8. Parts not specified with precision.....	83	41	8	56	27	3	5	12	1	1	.....	21	2	4	33.0
Totals.....	470	146	10	250	68	4	127	69	1	49	5	44	4	5	
Aggregates.....	626			322			197			54		53			

The increasing relative frequency with which the operation was resorted to as the war progressed, has been adverted to on page 846, in treating of the primary excisions. TABLE CXVI shows that this remark applies to each of the groups, and that the results were perhaps less favorable toward the close.

TABLE CXVI.

*Period of the War at which the Excisions at the Elbow were practised, with the Results.*

EXCISIONS.	CASES.	1861.			1862.			1863.			1864.			1865.		
		Recovery.	Fatality.	Unknown.	Recovery.	Fatality.	Unknown.	Recovery.	Fatality.	Unknown.	Recovery.	Fatality.	Unknown.	Recovery.	Fatality.	Unknown.
Primary.....	322	.....	1	13	3	.....	51	14	1	169	42	2	17	2	1	
Intermediary.....	197	.....	.....	34	10	1	38	13	.....	47	42	.....	8	4	.....	
Secondary.....	54	.....	.....	12	.....	.....	12	.....	.....	19	5	.....	6	.....	.....	
Uncertain date.....	53	1	.....	9	1	.....	19	2	.....	13	1	5	2	.....	.....	
Aggregates.....	626	1	1	68	14	1	120	29	1	248	96	7	33	6	1	

<sup>1</sup> Of the 34 patients who recovered 30 were discharged, and 22 of these were pensioned; 5 returned to modified duty, and 9 were exchanged or furloughed. Three patients (CASES 3, 6, and 28, of TABLE CXIV) are reported to have recovered with useful arms, 7 with partial mobility, 15 with complete ankylosis, 2 with partial ankylosis, 6 with useless arms, and the results in 11 cases are not specified. The method of operating was specified in 6 instances only.—straight incision in 5, and T-shaped in 1.

The period of the year in which the operation was practised was ascertained in over eleven-twelfths of the cases. It appears from the figures in the following table that more than half of the operations were done in the warm months of May, June, and July, with a death-rate of 27.4 per cent., or rather higher than the average.

TABLE CXVII.

*Results of Five Hundred and Seventy-three Excisions at the Elbow according to the Season at which the Operations were practised.*

MONTHS.	CASES.	PRIMARY.			INTERMEDIARY.			SECONDARY.		UNCERTAIN DATE.		
		Recovery.	Fatality.	Unknown.	Recovery.	Fatality.	Unknown.	Recovery.	Fatality.	Recovery.	Fatality.	Unknown.
January .....	13	2	1	.....	5	2	.....	3	.....	.....	.....	.....
February .....	8	2	1	.....	3	1	.....	1	.....	.....	.....	.....
March .....	17	9	.....	1	4	2	.....	1	.....	.....	.....	.....
April .....	24	7	3	.....	5	6	.....	3	.....	.....	.....	.....
May .....	159	82	19	1	33	21	.....	2	.....	.....	.....	1
June .....	96	42	21	.....	10	13	.....	9	1	.....	.....	.....
July .....	71	32	8	.....	18	5	.....	6	2	.....	.....	.....
August .....	30	15	3	.....	4	1	1	6	.....	.....	.....	.....
September .....	42	15	3	.....	11	8	.....	3	1	.....	1	.....
October .....	54	16	3	.....	20	8	.....	7	.....	.....	.....	.....
November .....	27	13	3	1	6	.....	.....	4	.....	.....	.....	.....
December .....	32	15	3	1	8	2	.....	2	1	.....	.....	.....
Season unspecified .....	53	.....	.....	.....	.....	.....	.....	2	.....	44	3	4
Totals .....	626	250	68	4	127	69	1	49	5	41	4	5

In three-fourths of the cases the ages of the patients were recorded, and the results apparently indicate that the operation was borne better by the younger men of military age; but in the one hundred and thirty-one cases in which the age was undetermined the death-rate is sufficiently high to counterbalance this proportion in favor of the younger men, provided it be assumed that a majority of the undetermined class belonged to the groups of patients under thirty years. Without such assumption the figures are consistent with the doctrine that surgical interference is more hazardous to life as age advances.

TABLE CXVIII.

*Statement of the Results of Four Hundred and Ninety-five Excisions at the Elbow for Shot Injury, according to the Ages of the Patients.*

EXCISIONS AT ELBOW.	CASES.	Under 20.		20-24.			25-29.			30-34.		35-39.		40 and over.		Unknown.			
		Recovery.	Fatality.	Recovery.	Fatality.	Unknown.	Recovery.	Fatality.	Unknown.	Recovery.	Fatality.	Recovery.	Fatality.	Recovery.	Fatality.	Recovery.	Fatality.	Unknown.	
Primary .....	322	30	4	90	13	1	48	10	1	25	8	16	5	8	.....	31	28	2	
Intermediary .....	197	17	10	54	19	.....	20	9	.....	6	5	6	2	8	6	16	18	1	
Secondary .....	54	1	.....	20	2	.....	10	1	.....	7	1	3	1	2	.....	6	.....	.....	
Uncertain date .....	53	6	.....	9	.....	.....	6	.....	.....	1	.....	1	.....	3	.....	18	4	5	
Aggregates .....	626	54	14	173	34	1	84	20	1	39	14	26	8	21	6	73	50	8	
Ratios .....		379   2 cases with 68 deaths equal 17.9 per cent.									114 cases with 28 deaths equal 24.5 per cent.								



EXCISIONS AT THE ELBOW IN THE CONFEDERATE SERVICE.—I am under a large debt of obligation, in which every student of the subject will share, to Dr. Howell L. Thomas, of Richmond, Virginia,<sup>1</sup> for the use of the register of cases of resection compiled by him from the records of the military hospitals and files of the Surgeon General's Office, in Richmond. This register comprises memoranda of one hundred and eighty-four operations of excision at the elbow. Forty-six of these were found to be identical with cases included in the preceding tables.<sup>2</sup> A summary of the facts ascertained regarding the remaining one hundred and thirty-eight cases is presented in the succeeding tabular statement.<sup>3</sup> Detailed abstracts of a few cases are subjoined, examples being selected of the seven varieties of the operation usually recognized, viz: the resection of the joint ends of the three bones,—of the ends of the humerus and ulna,—of the humerus and radius,—of the articular extremity of the humerus alone,—of the ends of the ulna and radius,—of the ulna alone,—and of the radius alone. The joint ends of the three bones were excised in the first case:

CASE 1829.—“Private *G. W. Collins*, Co. B, 40th Georgia, aged 23 years, was wounded November 25, 1863, the ball entering two inches below the elbow joint, passing upward and forward, fracturing the articular ends of the bones forming the elbow joint, and making its final exit through the pectoral muscles. The injury resulted in ankylosis. On March 14, 1864, Surgeon *J. C. Logan*, of Cassville, Georgia, made an **H**-shaped incision on the posterior aspect of the elbow and sawed off the articulating ends of the humerus, ulna, and radius. On April 1st the patient was doing quite well; the wound was still suppurating freely; there was considerable motion in the joint, with healthy granulations at the wound.”

In the two following cases, the humero-cubital and humero-radial articulations, respectively, were resected:

CASE 1830.—“Private *C. H. Perry*, Co. D, 11th Georgia, aged 17 years, was wounded July 2, 1863, the ball entering half an inch above the angle of the elbow and emerging an inch below the angle on the inner side of the external condyle. Surgeon *J. L. Cabell* reported that a resection of the elbow was made on July 20th, by a longitudinal incision extending two inches above and below the point of the elbow, a few lines to the outer side of the ulnar nerve, and a transverse cut crossing to the external condyle, making a **T**-shaped incision. Three-fourths of an inch of the inferior articular extremity of the humerus, the olecranon process, and the head of the ulna were removed. The operation was followed by considerable fever, which passed off on the fourth day. The arm was first placed upon a wire splint, and on July 23d was supported on a pillow until August 1st. Cold applications were continuously employed, and ice for several days. Early in August he could move and raise the arm without pain. The flaps of the transverse incision had retracted from a quarter to a third of an inch only, and those of the longitudinal cut from a half to three-fourths of an inch, the interspaces being filled by healthy granulations. In August, the record states: ‘Arm has continued to improve with the exception of an accidental injury. The transverse incision has cicatrized except at its external angle, and the vertical incision for half its length. The patient can flex the forearm on the arm so as to bring the hand to his mouth, and can make partial pronation and supination.’”

CASE 1831.—Private *S. M. Taylor*, Co. I, 2d Louisiana, aged 24 years, formerly a farmer, was wounded at Sharpsburg, July 2, 1863, in the left elbow. Surgeon *W. C. N. Randolph* reported from Lynchburg that: “The ball entered the posterior portion of the elbow, passed obliquely forward and outward, fractured the external condyle, and opened the joint. The patient did well until August 8th, when disorganized synovial fluid was discharged from the anterior orifice and serous effusions commenced in the tissues covering the joint, which increased daily, until the joint was three times its natural size. On August 12, 1863, resection was performed by Moreau's method, removing two and a half inches of the inferior articular extremity of the humerus, a portion of the head of the radius, and incrusting cartilage of the articular surface of the ulna and radius, the cartilage being removed by the rongeur. The soft parts were then brought together with silver sutures; the arm was bent at an obtuse angle and placed on a pillow, and the wound was treated by continuous irrigation for four days. By this time the serous effusion and swelling had in a great measure subsided and the general condition of the patient was good. He steadily improved, and recovered with limited motion of the joint.”

<sup>1</sup> The painstaking and conscientious statistician whose very important contribution to the history of excisions at the shoulder for shot injury was presented (at pp. 660-667) in the Third Section of this Chapter.

<sup>2</sup> The patients having either been treated in Union hospitals, or entered on records delivered to the United States at the conclusion of the War.

<sup>3</sup> These results have the greater value since little can be learned from other sources of the results of excisions of the elbow by the Confederate military surgeons. In an extract from an official Report of the Sickness and Mortality in the Armies of the Confederate States for 1863 (*Confederate States Med. and Surg. Jour.*, Oct., 1864, Vol. I, p. 155), Surgeon *F. Sorrel*, C. S. A., inspector of hospitals, presents a table said to “exhibit the general results of . . . resections thus far collected and carefully prepared from reports throughout the Confederacy.” This table includes 54 excisions at the elbow, the result as to fatality determined in each instance. Of 25 primary excisions, 3 were unsuccessful; of 29 secondary excisions, 6 were unsuccessful. Seven patients recovered with useful joints. Surgeon General *L. Warren*, of North Carolina, published (*Epitome of Pract. Surg.*, 1863, p. 299) a “Consolidated Table of Capital Operations performed in and around Richmond from June 1st to August 1, 1862,” which comprises 6 excisions at the elbow—3 fatal primary cases; 2 intermediary cases, of which 1 recovered; 3 secondary cases, of which 1 recovered. *Chisolm (J. J.) (A Manual of Mil. Surg.*, 3d ed., Columbia, 1864, p. 377) gives a consolidated table of resections, collated from records in the Surgeon General's office at Richmond, from June 1, 1862, to February 1, 1864, by Surgeon *H. Baer*, P. A. C. S., which includes 54 excisions at the elbow, and in every particular, except the period said to be covered by the return, appears to be identical with that of Inspector *Sorrel*. In a *Report on Wounds of Large Joints*, made to the Confed-

Of ninety-two operations in which the parts removed are specified, fifteen were complete excisions in the strict anatomical sense, the articular extremities of the three bones having been removed. In nine, the humero-cubital joint ends were removed; in one, the humero-radial; in eight, the upper ends of the ulna and radius; in twenty-one, the upper extremity of the ulna alone; and in nine, the head of the radius. Forty-six other operations, reported as excisions of the elbow joint, or by equivalent terms, comprise, doubtless, a fair proportion of complete excisions. The three foregoing cases illustrate the first three groups, the four following abstracts exemplify the more partial excisions:

CASE 1832.—“Private *H. L. Ballow*, Co. A, 16th Alabama, aged 25 years, was wounded on September 20, 1863, receiving a ball in the lower end of the humerus. On October 6th, the fractured lower extremity of the humerus was excised by Surgeon S. E. Chaillé, P. A. C. S. The patient did well, and was furloughed December 22, 1863.”

CASE 1833.—“*A. H. Traylor*, Co. D, 5th Texas, aged 21 years, was wounded September 21, 1863, and reported by Surgeon Charles E. Michell, of Marietta, as having received a gunshot wound of the right arm, with a portion of the elbow joint excised. The head of the radius and articular portion of the ulna were removed on the day of the injury, the operation being done on the field, by longitudinal incision. November 30, 1863, the patient is doing well, and the incision is nearly healed.”

CASE 1834.—“Private *D. Herren*, Co. F, 48th Mississippi, aged 23 years, was wounded May 12, 1864, *vulnus sclopticum* of right elbow joint, with fracture of the coronoid process of the ulna. Surgeon A. G. Lane performed a resection of the articular extremity of the ulna soon after the injury. On June 30th, the patient was doing well; on July 20, 1864, he was furloughed, the incision having nearly healed.”

CASE 1835.—“Lieutenant *A. S. Erwin*, of Phillips's Legion, received a shot wound near the elbow September 20, 1863, at the battle of Chickamauga. Surgeon W. F. Westmoreland, P. A. C. S., performed resection of the head of the radius, on the field, the day of the injury. On Oct. 11th, the patient had an attack of hemorrhage, which was suppressed; he made a good recovery.”

The result as to fatality, determined in one hundred of the hundred and thirty-eight cases of this series as 19 per cent., is far more favorable than that indicated by the returns already discussed, a result to be anticipated in view of the circumstances under which the cases of this series were collected.<sup>1</sup> The ratios in which the various methods of operating and the several periods for operation were selected, approximate closely to the corresponding proportions in the Union returns. There was, also, apparently the same uniformity in the methods of after-treatment. There is frequent mention in the abstracts of placing the limb after operation upon “a well-padded angular splint,” or upon “a tin trough splint” (possibly Bond's splint,<sup>2</sup> FIG. 651), and of “keeping the arm flexed at an obtuse angle of 130° or 140°.” The use of cold irrigation or of ice-bags is so often alluded to that it is probable that this resource was employed more generally, in this class of cases, than in the Union hospitals. The importance of early passive motion, commenced as soon as suppuration is diminished and before cicatrization is complete, is referred to by several reporters. Repeated declarations are met with in favor of complete resections in preference to removal of the parts only of the articulation injured; although this rule, seemingly accepted in theory, was often disregarded in practice. The most important recorded facts of each of the one hundred and thirty-eight cases are condensed in the succeeding tabular statement.

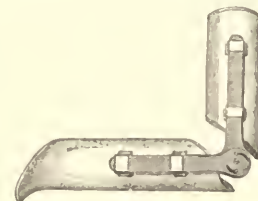


FIG. 651.—Bond's elbow splint.

*erate States Association of Navy and Army Surgeons*, and published in the *Southern Medical and Surgical Journal* for 1866, Vol. XXI, p. 293. Dr. J. B. READ, of Savannah, publishes a list of resections of the elbow from the files of the Confederate Surgeon General's office, making the whole number 45 cases: 22 primary with 3 deaths, and 23 secondary with 6 deaths. This is obviously an erroneous version of Dr. SORRELL's table, the 9 fatal cases being deducted from the successful series instead of being added to them. Dr. READ misinterprets his 22 primary operations with 3 deaths as giving a death-rate of 35, instead of 13.6 per cent., and the 23 secondary operations with 6 deaths as having a mortality ratio of 20, instead of 26.6 per cent. The *Manual of Military Surgery, prepared for the use of the Confederate States Army by order of the Surgeon General*, Richmond, 1863, gives instructions for performing the operation, from M. CHASSAIGNAC and Professor PIRRIE, and recognizes partial excisions as proper when only a portion of the joint is injured; but does not refer to any observed results.

<sup>1</sup> Many mutilated soldiers assembled at Richmond either to await the action of retiring boards, to procure apparatus, or to seek for employment; hence observations on amputations and resections at that centre are liable to show a larger proportion of recoveries than the just average.

<sup>2</sup> BOND (H.), *Description of a new Splint for Dressing Diseases and Injuries of the Elbow Joint*, in *Am. Jour. Med. Sci.*, 1857, Vol. XXXIV, p. 344. This splint is manufactured by Genrig, 109 South Eighth street, Philadelphia.



## TABLE CXIX.

Summary of One Hundred and Thirty-eight Cases of Excisions at the Elbow after Shot Injury, practised in the Confederate Army.

No.	NAME, AGE, AND MILITARY DESCRIPTION.	DATES.	OPERATIONS, OPERATOR, RESULT.	No.	NAME, AGE, AND MILITARY DESCRIPTION.	DATES.	OPERATIONS, OPERATOR, RESULT.
1	Allen, J. H., Pt. G, 34th Alabama, age 31.	July 28, '64.	Right; joint through V incision.	40	Gregory, J. F., Pt., B. 39th N. C., age 27.	Dec. 31, 1862.	Head of ulna and part of inner condyle of humerus, by Surg. R. Battey, P. A. C. S. February 13, arm amputated.
2	Allen, O., Pt., G, 14th Alabama.	May 3, '63.	Fractured portion. July 15, tumefaction and suppuration diminishing. Resection of elbow joint.	41	Griffin, W., Pt., C, 32d Georgia.	June 22, '64.	Excision of elbow joint.
3	Buggott, R., Pt., H, 20th North Carolina.	May 19, '64.	Left; joint through T incision. Died June 19, 1864.	42	Griffin, W. J., Serg't, C, 2d Georgia.	Aug. 3, '64.	Right; external condyle of humerus; gangrene.
4	Bulford, G. W., Pt., H, 5th Alabama, age 23.	May 5, '64.	Left; joint through T incision. Died June 19, 1864.	43	Gidding, F. G., Pt., H, 10th Alabama, age 21.	May 12, '64.	Excision of elbow joint. Aug. 23, wound healed with fair motion.
5	Bullow, H. L., Pt., A, 16th Alabama, age 21. See CASE 1832, p. 895.	Sept. 28, Oct. 6, '63.	Excision of fractured end of humerus. Furloughed Dec. 22, '63.	44	Günger, H. H., Corp'l, B, 1st South Carolina, age 24.	May 6, 1864.	Left; head of radius and ulna, through straight incision. Aug. 6, good motion in joint.
6	Bell, D. F., Pt., B, 12th Virginia Cavalry.	June 9, Jul. 19, '63.	Left; three inches lower end of humerus. Furl'd Nov. 9, 1863. Excision of elbow joint. Died of pyæmia.	45	Haney, J. L., Serg't, C, 9th Tennessee.	Sept. 20, Oct. 14, '63.	Excision of humerus just above condyles. Mar. 1, '64, doing well.
7	Breadle, G. S.	July 1, '64.	Left; condyles and olecranon process.	46	Hardwick, J. A., Pt., K, 44th Alabama, age 27.	Sept. 20, Oct. 19, '63.	Excision of elbow joint; (gangrene.) Furloughed Nov. 26, doing well.
8	Brook, M. E., Lieut., B, 1st Florida Cavalry.	July 1, '64.	Excision of elbow joint.	47	Harper, E. G., Pt., I, 32d Tennessee, age 22.	June 22, '64.	Condyles of humerus, three inches of ulna, and two inches of radius, through T incision.
9	Butler, J. T., Pt., K, 36th Georgia, age 18.	July 21, '64.	Right; articulating extremities of bones through U incision. Recovered promptly.	48	Hartman, J. F., Pt., C, 21st Mississippi, age 30.	Aug. 9, Second'y	Three inches of ulna and articular surfaces of radius and humerus. Recovery, useful joint.
10	Cabill, W. H., Pt., F, 7th Virginia Cavalry.	Mar. 19, 1863.	Excision of right elbow joint. Sent to hospital.	49	Herron, D., Pt., F, 48th Mississippi, age 28.	May 12, 1864.	Excision of ulna at elbow joint. July 30, furl'd; nearly healed. See CASE 1834, p. 895.
11	Caig, N., Pt., G, 55th Alabama, age 21.	July 20, '64.	Right; portions of humerus, radius, and ulna. Furl'd June 17, '63.	50	Herener, H., Pt., G, 31st Virginia, age 24.	May 31, '64.	Excision of joint through straight incision. Recovery.
12	Caldwell, J. W., Pt., E, 44th Georgia, age 19.	May 3, '63.	Left; joint excised thro' straight incision. Furl'd July 29, 1864.	51	Hickerson, J., Pt., B, 2d Arkansas.	July 22, '64.	Right; condyles of humerus. Furloughed Oct. 6, 1864.
13	Cannon, T. J., Pt., G, 53d Georgia.	May 6, '64.	Left; joint excised thro' straight incision. Furl'd July 29, 1864.	52	Hill, J. T., Pt., A, 16th Georgia, age 21.	May 25, 1864.	Left; through T incision. Died July 8, 1864.
14	Carper, J., Pt., C, 36th Virginia, age 19.	June 7, '64.	Right; portions of humerus, radius, and olecranon. Furl'd Sept. 5, 1864. Considerable motion.	53	Hill, W., Pt., H, 18th Georgia, age 19.	Oct. 19, 1864.	Left; excision of humerus at elbow joint. Jan. 1, '65, unfavorable.
15	Caskie, J. D., Pt., D, 1st South Carolina, age 40.	May 6, 1864.	Excisions of heads of radius and ulna. June 21, doing well.	54	Hook, J. A., Pt., I, 28th Alabama, age 19.	Sept. 20, '63.	Excision of elbow joint.
16	Caster, J. W., Capt., E, 3d Alabama.	Sept. 19, Oct. 4, '64.	Left; outer condyle of humerus. Died October 12, 1864.	55	Hopper, E. G., Serg't, I, 32d Tennessee, age 22.	May 22, '64.	Left; excision of joint. Aug. 1, '64, not doing well.
17	Chenault, D. P., Pt., K, 11th Georgia, age 32.	May 30, 1864.	Left; inner condyle of humerus. Furloughed July 31, 1863.	56	Boyle, J. C., Pt., A, 14th Alabama.	May 3, '63.	Excision of elbow joint. Furloughed July 24, 1863.
18	Clements, J. T., Serg't, E, 46th Georgia.	June 20, 1864.	Excision of head of radius.	57	Hobson, J. H., Pt., I, 9th Va. Cav., age 22.	Oct. 14, '63.	Left; excision of joint. Furloughed January 26, 1864.
19	Cockrell, R. H., Pt., J, 6th Virginia, age 28.	May 12, '64.	Excision of two and a half inches of ulna, including olecranon.	58	Hoff, J., Pt., G, 45th Georgia, age 18.	May 5, '64.	Left; through T-shaped incision. Recovery with fair motion.
20	Collins, G. W., Pt., B, 40th Georgia, age 28. See CASE 1829, p. 894.	Mar. 14, 1864.	Excision of articulating surfaces of bones of elbow thro' H incision. April 1, doing well.	59	Hulse, J. T., Serg't, K, 6th Arkansas, age 26.	July 21, '64.	Right; excision of joint. Aug. 31, doing well.
21	Conroy, M., Pt., E, 15th Louisiana, age 36.	Aug. 30, '63.	Excision of joint. Recovered.	60	Hard, P., Sergeant-Major.	Sept. 19, Oct. 12, '63.	Right; lower end of humerus and olecranon. Nov. 30, doing well.
22	Cooper, J. D., Pt., D, 1st South Carolina, age 37.	May 6, '64.	Right; through H-shaped incision; typhoid fever. June 30, still under treatment.	61	Hart, J. L., Pt., B, 3d Georgia, age 26.	June 5, '64.	Excision of elbow joint. Furloughed August 3, 1864.
23	Coughman, D. T., Pt., F, 15th South Carolina.	July 2, Aug. 21, 1863.	Left; olecranon process, head of radius, and one inch of lower articular end of humerus. Recovered; very fair use of limb.	62	Ingram, F., Pt., C, 49th Georgia, age 21.	May 6, '64.	Excision of elbow joint. Recovery.
24	Credille, J. M., Lt., F, 4th Georgia.	Nov. 22, '64.	Left; head of ulna and internal condyle of humerus.	63	Jenkins, E. Pt., K, 1st Virginia Cav., age 22.	May 14, '64.	Left; excision of portions of bone. Died August 24, 1864.
25	Davis, A. T., Corp'l, H, 1st South Carolina, age 22.	May 5, 1864.	Olecranon, head and three inches of ulna, and one-half inch of head of radius. July 31, joint anky'd.	64	Johnson, D. J., Pt., E, 1st Alabama, age 44.	Sept. 19, Oct. 2, 1863.	Right; four and a half inches ulna, olecranon, and small portion outer condyle. Oct. 31, nearly healed.
26	Davis, J. J., Serg't, G, 47th Tennessee, age 35.	July 26, '64.	Right; excision of joint. Died August 14, 1864.	65	Jones, O., Pt., E, 3d Florida, age 45.	Sept. 20, Oct. 19, 1863.	Four inches of humerus, including articular extremity; hectic. Died October 26, 1863.
27	Dunlop, L. D., Pt., E, 19th South Carolina, age 20.	Aug. 31, '64.	Left; condyles of humerus, head of radius, and olecranon, through H incision.	66	Keen, W. L., Pt., F, 31st Georgia, age 27.	May 6, '64.	Resection of joint. Recovered. Furloughed July, 1864.
28	Ellis, A., Lieut.-Col., 34th N. C., age 36.	Sept. 19, '64.	Excision of elbow joint.	67	Lawton, B. T., Lieut., E, 11th S. C., age 32.	June 24, '64.	Right; excision. Aug. 1, doing well.
29	Elmore, F. S., Pt., K, 46th Virginia, age 17.	June 17, '64.	Right; excision of joint.	68	Lawyer, A., Pt., A, 11th Virginia Cavalry.	May 8, 1864.	Head and one-fourth inch of shaft of radius.
30	Erwin, A. S., Lieut., Phillips' Legion. See CASE 1835, p. 895.	Sept. 20, '63.	Excision of head of radius. Oct. 11, hemorrhage; recovered.	69	Leatherwood, W. H., Pt., K, 2d Arkansas.	Nov. 24, Dec. 8, 1863.	Epitrochlea and all fragments of bone excised. Dec. 31, almost healed.
31	Forster, W. M., Corp'l, D, Palmetto S. S.	May 6, '64.	Left; excision of joint. June 23, doing well.	70	Leonard, G., Pt., B, 63d Virginia, age 37.	Sept. 20, Oct. 5, 1863.	Four inches shaft of ulna, olecranon, and condyle, linear incision. Nov. 1, doing well.
32	Foster, G. W., Pt., I, 4th Texas, age 27.	Oct. 7, '64.	Right; excision of joint. Furloughed November 20, 1864.	71	Leonard, J., Pt., D, 5th Confederate, age 24.	June 24, 1864.	Right; part of ulna, including olecranon.
33	Frezier, S. W., Pt., G, 2d Mississippi, age 28.	July 3, '63.	Left; two inches of head of ulna. Recovered.	72	Little, E. P., Pt., I, 10th Alabama, age 21.	May 6, '64.	Right; excision of joint. Aug. 13, nearly well.
34	Freeman, W. J., Serg't, D, 16th Va., age 31.	July 30, 1864.	Right; elbow joint and one inch of humerus. Died Aug. 29, 1864.	73	Martin, G. W., Serg't, C, 19th Ala., age 48.	Sept. 20, Oct. 2, '63.	Olecranon and one inch of shaft, and spicula. Nov. 1, sloughing.
35	Friday, J. C., Pt., C, 4th Alabama.	May 6, '64.	Left; condyle and three inches of ulna.	74	Marwell, A. J., Pt., I, 9th Texas.	Dec. 31, '62.	Two and a half inches of ulna. March 4, doing well.
36	Ferguson, W. C., Pt., I, 19th Arkansas, age 29.	July 2, 1864.	Right; ulna and inner half of humerus, thro' H-shaped incision.	75	McCully, G., Capt., A, 54th Tennessee.	July 22, Aug. 23, '64.	Right; excision of elbow joint. Furloughed October 18, 1864.
37	Gasque, W. B., Pt., A, 21st S. C., age 21.	Aug. 21, 1864.	Right; excision of elbow joint. Doing well.	76	McGee, J. W., Pt., A, Hampton's L'n, age 19.	Aug. 30, Sept. 1, '62.	Excision of elbow joint. Died September 7, 1862.
38	Gawett, W. E., Pt., E, 20th Mississippi, age 18.	July 23, '61.	Right; excision of joint. August 31, doing well.	77	McGhee, M. M., Lieut., 2d Arkansas, age 27.	May 8, 11, '64.	Left; excision of olecranon process. Returned to duty.
39	Greenlaw, H. C., Pt., F, 5th Arkansas, age 20.	Sept. 19, '64.	Right; head of radius and ulna.	78	McLeland, R. C., Capt., D, 20th Mississippi.	July 2, '64.	Excision of external condyle.





uncertainty introduced by the twenty-nine undetermined cases, detracts from the significance of the results of this series.<sup>1</sup> Thirty-four of these excisions were intermediary, of which thirty with known results include five fatal cases only, a death-rate of 16.6 per cent., a remarkably favorable exhibit for such operations practised during the inflammatory period.<sup>2</sup> The group of eleven secondary operations includes three deaths, giving the exceptionally high mortality ratio for excisions at the elbow at this period of 27.2.<sup>3</sup> Nineteen operations of uncertain date comprise five in which the result is unknown, ten recoveries, and four fatal cases, a percentage of mortality in the determined cases of 28.5.<sup>4</sup> The operation appears to have grown in favor as experience was acquired, three-fifths of the cases bearing the date 1864. Dr. Thomas specifies the limb interested in seventy-four instances; these operations were on the right side in forty, on the left in thirty-four cases.<sup>5</sup>

TABLE CXX.

*Dates and Results of One Hundred and Thirty-eight Confederate Cases of Excision at the Elbow for Shot Injury.*

YEAR.	CASES.	PRIMARY.			INTERMEDIARY.			SECONDARY.			UNCERTAIN DATE.		
		Recovery.	Fatality.	Unknown.	Recovery.	Fatality.	Unknown.	Recovery.	Fatality.	Unknown.	Recovery.	Fatality.	Unknown.
1861 .....	1												1
1862 .....	3		1	2									
1863 .....	42	7		3	19	3	2	3	1		3		1
1864 .....	89	31	6	24	6	2	2	4	1		7	3	3
1865 .....													
Not stated .....	3							1	1			1	
Total .....	138	38	7	29	25	5	4	8	3	0	10	4	5
Aggregates .....	138	74			34			11			19		

Surgeons H. McGuire and J. B. Read, P. A. C. S., have published *ex professo* their views on shot wounds of the larger joints. The former refers briefly to excisions at the elbow;<sup>6</sup> the latter is more explicit,<sup>7</sup> and reviews the indications, operative method, after-treatment, and results of resections of this joint, fortifying his positions by citations from Drs. Stromeyer and Macleod.

<sup>1</sup> Of the 38 recoveries after primary excision, 2 were excisions of the three joint ends, 2 of the end of the humerus, 2 of the end of the ulna and radius, 5 of the upper end of the ulna alone, 2 of the head of the radius; in 25 cases the parts excised are not specified. In the 7 fatal primary excisions, it is known that 1 was a humero-cubital excision, 1 a removal of the upper end of the radius and ulna, and 1 of the upper end of the ulna. Of the 29 cases with unknown results, 3 were complete excisions, 3 humero-cubital, 2 of end of humerus, 1 of joint ends of radius and ulna, 3 of ulna, and 2 of radius.

<sup>2</sup> Of the 25 cases of recovery after intermediary excision, 3 were complete excisions, 4 of the humero-cubital articulation, 3 resections of the articular extremity of the humerus, 1 of the ends of the ulna and radius, 8 of the upper end of the ulna alone, and 2 of the head of the radius. The extent of excision was noted in 2 of the 5 fatal cases, which were resections of the condyle of the humerus. In the 4 cases undetermined as to fatality, the condyles of the humerus were excised in 2, the upper extremity of the ulna in 1, the upper extremity of the radius in 1.

<sup>3</sup> Of the 8 cases of recovery, 4 were complete excisions, 1 humero-radial, 1 of the end of the humerus, 1 of the end of the ulna, and 1 unspecified. The parts removed in the 3 fatal cases are not recorded.

<sup>4</sup> The 10 cases of recovery include 2 total excisions, 2 of the end of the humerus, 3 of the end of the ulna and radius, 1 of the head of the radius, and 1 of the end of the ulna. The end of the humerus was excised in 1 of the 4 fatal cases; in 3 the parts excised are not specified. Of the 5 cases with undetermined result, 1 was total, 1 humero-cubital, 1 of end of humerus, 1 of end of ulna, and 1 of end of radius.

<sup>5</sup> Of the 40 excisions at the right elbow, 4 resulted fatally; of the 34 at the left elbow, 6 were fatal,—the excisions at the left elbow, according to this imperfect return, giving less favorable results than those on the right side.

<sup>6</sup> Dr. H. MCGUIRE, in a *Lecture on Gunshot Wounds of the Joints* (*Richmond Med. Jour.*, 1855, Vol. I, p. 147), after remarking that "gunshot wounds of the larger joints almost invariably demand operative interference," adverts cursorily to shot lesions of the elbow, observing that: "In excision at the elbow, the arm is especially useful when you can save the insertion of the biceps and brachialis muscles."

<sup>7</sup> READ (J. B.) (*Report on Wounds of Large Joints*, in *Southern Med. and Surg. Jour.*, 1866, Vol. XXIII, p. 203) declares that the operation should "always be primary . . . intermediary operations are inadmissible." Complete excision, by the removal of all the articular facets, is enjoined, and the simple straight incision is pronounced the simplest and best method. The limb must be kept flexed at an angle of 130° or 140°, the most favorable position should ankylosis ensue.

EXCISIONS AT THE ELBOW IN OTHER CAMPAIGNS.—It is of interest to compare the results here detailed of this comparatively modern operation, introduced into military surgery only of late years, with the results observed in other campaigns.

TABLE CXXI.

*Showing the Results of Cases of Shot Fracture of the Elbow treated by Excision on the Occasions named and from the Authorities quoted.*

ACTION, ETC.	TOTAL.	RECOVERY.	DEATHS.	RESULT UNKNOWN.	PERCENTAGE OF FATALITY.
Revolution in Paris, 1848 (BAUDENS <sup>1</sup> )	2	1	1		50.0
War in Sleswick-Holstein, 1848-'50 (ESMARCH <sup>2</sup> )	40	34	6		15.0
Crimean War, Russian (HUBBENET <sup>3</sup> )	25	7	9	9	56.2
Crimean War, French (CHENU <sup>4</sup> )	4		4		100.0
Crimean War, British (MATTHEW <sup>5</sup> )	20	17	3		15.0
Italian War, 1850-60 (DEMME, <sup>6</sup> RODOLFI <sup>7</sup> )	3	3			0.0
New Zealand War, 1863-'65 (MOUAT <sup>8</sup> )	1	1			0.0
Danish War, 1864 (LÖFFLER <sup>9</sup> )	43	30	13		30.2
Six Weeks' War, 1866 (BECK, <sup>10</sup> STROMEYER, <sup>11</sup> K. FISCHER, <sup>12</sup> MAAS, <sup>13</sup> HASCHKE, <sup>14</sup> BEREND <sup>15</sup> )	53	43	10		18.8
Campaign in Dalmatia, 1869 (RIEDEL and EBNER <sup>16</sup> )	2	2			0.0
Franco-German War, 1870-71 (BARTHELMESS and MERKEL, <sup>17</sup> BECK, <sup>18</sup> BERGMANN, <sup>19</sup> BILLROTH, <sup>20</sup> G. FISCHER, <sup>21</sup> H. FISCHER, <sup>22</sup> GOLTDAMMER, <sup>23</sup> GRAF, <sup>24</sup> HERRGOTT, <sup>25</sup> KIRCHNER, <sup>26</sup> KOCH, <sup>27</sup> LANGENBECK, <sup>28</sup> LOSSEN, <sup>29</sup> LÜCKE, <sup>30</sup> MAC'ORMAC, <sup>31</sup> MAYER, <sup>32</sup> OTT, <sup>33</sup> RUPPRECHT, <sup>34</sup> SCHLEFFER, <sup>35</sup> SCHINZINGER, <sup>36</sup> SCHÜLLER, <sup>37</sup> SOCIN, <sup>38</sup> STEINBERG, <sup>39</sup> STOLL, <sup>40</sup> )	183	135	48		26.2
Franco-German War, 1870-71, French (CHENU <sup>41</sup> )	212	48	164		77.3
Aggregates	588	321	258	9	44.5

By lumping these figures with those derived from the American war-experience, a large total of excisions at the elbow for shot injury would be obtained,\* and one could emulate those statisticians who rejoice in piling up large numerical aggregates, regardless of the varied circumstances under which they were accumulated, and without criticism of their

<sup>1</sup> BAUDENS, *Des plaies d'armes a feu*, 1849, p. 237. In the days in July, 1848, in Paris, BAUDENS successfully excised, at Val de Grace, the condyles of the humerus for shot fracture in the case of Villiard, and performed the same operation in the case of Jacquemin, another garde-mobile, who succumbed from purulent absorption. Professor ESMARCH overlooked these two instances when he asserted (*Über Resectionen*, u. s. w., S. 72) that this operation was not practised in the disorders of 1848-49, in Paris, Italy, Baden, and Hungary. <sup>2</sup> ESMARCH (F.) (*Über Resectionen nach Schusswunden*, Kiel, 1851) gives the most complete record, but many of the cases are alluded to in the writings of LANGENBECK and STROMEYER. <sup>3</sup> HUBBENET (C. v.), *Die Sanitätserhältnisse der Russischen Verwundeten*, 1854-56, Berlin, 1871, p. 182. <sup>4</sup> CHENU (J. C.), *Campagne d'Orient*, Paris, 1865, p. 504. <sup>5</sup> MATTHEW (*loc. cit.*, Vol. II, p. 365). <sup>6</sup> DEMME (H.), *Militär-chir. Studien*, Würzburg, 1861, p. 235. <sup>7</sup> RODOLFI (R.), *Palla di fugile penetrata nel gomito sinistro con frattura del grande olecrano-anchilosi; guarigione*, in *Gaz. med. de Lomb.*, Milano, 1859, IV, ser. 4, p. 378. <sup>8</sup> MOUAT, *The New Zealand War*, in *Brit. Army Med. Rep.* for 1865, p. 520. <sup>9</sup> LÖFFLER (F.), *General-Bericht*, u. s. w., Berlin, 1867, p. 302. <sup>10</sup> BECK (B.), *Kriegschir. Erfahr.*, 1867, p. 348. <sup>11</sup> STROMEYER (L.), *Erfahrungen über Schusswunden*, Hannover, 1867, p. 16. <sup>12</sup> FISCHER (K.), *Militärärztliche Skizzen*, 1867, p. 69. <sup>13</sup> MAAS, *Kriegschir. Beiträge*, Breslau, 1870, p. 73. <sup>14</sup> HASCHKE, *Allgemeine Wiener Med. Zeitung*, 1867, B. XII, p. 82. <sup>15</sup> BEREND (H. W.), in *Wiener Med. Presse*, 1867, B. VIII, p. 263. <sup>16</sup> RIEDEL and EBNER, *Aus dem Truppspital in Cattaro*, in *Wiener Med. Wochenschrift*, 1870, S. 155. <sup>17</sup> BARTHELMESS and MERKEL, in *Bayer. Ärtl. Intelligenzblatt*, 1871, No. 22. <sup>18</sup> BECK (B.), *Chir. der Schussverletzungen*, 1872, p. 588, und Anhang; 22 cases (3 fatal). <sup>19</sup> BERGMANN (E.), *Die Resultate der Gelenkresectionen in Kriege*, 1874, p. 3; 9 cases (2 fatal). <sup>20</sup> BILLROTH (Th.), *Chir. Briefe*, u. s. w., 1872; S. 225, 2 cases. <sup>21</sup> FISCHER (G.), *Dorf Floing*, u. s. w., in *Deutsche Zeitschrift für Chir.*, B. I, p. 187; 9 cases (4 fatal). <sup>22</sup> FISCHER (H.), *Kriegschir. Erf.*, 1872; p. 213, 17 cases (3 fatal). <sup>23</sup> GOLTDAMMER, *Bericht*, in *Berl. Klin. Wochenschrift*, 1871, S. 129; 2 cases. <sup>24</sup> GRAF (E.), *Die Königl. Reservelazareth zu Düsseldorf*, Elberfeld, 1872; 3 cases (1 fatal). <sup>25</sup> HERRGOTT (see BECK, *Chir. der Schussverletz.*, 1872, p. 909); 6 cases (1 fatal). <sup>26</sup> KIRCHNER (C.), *Ärztlicher Bericht über das K. P. Feldlazareth im Palast zu Versailles*, Erlangen, 1872; 9 cases (5 fatal). <sup>27</sup> KOCH (W.), *Notizen über Schussverletzungen*, in LANGENBECK'S *Archiv*, B. XIII, 1872, p. 575; 8 cases (2 fatal). <sup>28</sup> LANGENBECK (H. v.), *Chir. Beobachtungen aus dem Kriege*, Berlin, 1874, p. 158; 10 cases (1 fatal). <sup>29</sup> LOSSEN (L.), *Kriegschir. Erf.*, u. s. w., in *Deutsche Zeitschrift für Chir.*, 1873, B. II, p. 57; 6 cases (2 fatal). <sup>30</sup> LÜCKE (A.), *Kriegschir. Fragen u. Bemerk.*, Bern, 1871, S. 41; 11 cases (4 fatal). <sup>31</sup> MAC'ORMAC, *l. c.*, 1871, p. 130; 11 cases (6 fatal). <sup>32</sup> MAYER (L.), *Kriegschir. Mittheil. aus den Jahren 1870-71*, in *Deutsche Zeitschrift für Chir.*, 1873, B. III, p. 50; 1 case. <sup>33</sup> OTT, *Kriegschir. Mittheilungen*, u. s. w., Stuttgart, 1871; 1 case (fatal). <sup>34</sup> RUPPRECHT (L.), *Mil.-ärztl. Erf.*, u. s. w., Würzburg, 1871, p. 63; 3 cases. <sup>35</sup> SCHÄFFER (Th.), *Chir. Studien*, in LANGENBECK'S *Archiv*, B. 13, 1872, p. 101; 2 cases. <sup>36</sup> SCHINZINGER (A.), *Das Reserve Lazareth Solwetzingen*, Freiburg, 1871; 3 cases. <sup>37</sup> SCHÜLLER (M.), *Kriegschir. Skizzen*, Hannover, 1871, p. 12; 3 cases (2 fatal). <sup>38</sup> SOCIN (A.), *Kriegschir. Erf.*, 1872, p. 153. 10 cases (1 fatal). <sup>39</sup> STEINBERG, *Die Kriegs Lazarethe und Baracken von Berlin*, 1872, p. 148; 27 cases (7 fatal). <sup>40</sup> STOLL, *Bericht*, u. s. w., in *Deutsche Mil. Zeitschrift*, 1874, B. III, p. 193, 2 cases (1 fatal). <sup>41</sup> CHENU (J. C.), *Aperçu Hist. Stat. et Clin. pendant la guerre de 1870-71*, Paris, 1874, p. 492.

\* It would be possible to swell this list by a few isolated excisions at the elbow for shot injury, as, for example, the successful amputation of the ulna for shot fracture by GOERKE, in 1793; MOREAU'S two complete excisions for caries following shot wounds, in 1794; Dr. H. H. TOLAND'S unsuccessful excision for caries after shot fracture, at San Francisco, in 1856; a humero-ulnar excision by Assistant Surgeon H. A. DUBOIS, U. S. A. (*Circular* 3, S. G. O., 1871, p. 225); and a late successful complete excision by Dr. C. HIEBER (LANGENBECK'S *Archiv*, 1867, B. VIII, S. 101). An omnivorous collector might add the four cases in my view apocryphal ascribed by Dr. O. HAYFELDER and others to LARREY and to PERCY.



relative authenticity and value; such are perverters of the legitimate uses of the numerical methods, who purvey for not over-fastidious systematic writers those "largest collections of facts of this nature with which we are acquainted" appended to their descriptions of special injuries,—who, with cool effrontery, profess to decide, from their heterogeneous integrations, within a small decimal whether in any given circumstance amputation, resection, or temporization should be selected. In American civil practice,<sup>1</sup> excision at the elbow has

<sup>1</sup> In the United States, Dr. JOHN C. WARREN is believed to have first practised excision of the elbow, October 16, 1834 (*Records of Mass. Gen. Hosp.*, quoted by R. HODGES, *op. cit.*, p. 46). The result was fatal (VELPEAU, *Nouv. Élém. de Méf. Opérat.*, Paris, 2ème éd., 1829, T. II, p. 699). June 5, 1835, Dr. T. HARRIS, U. S. N., repeated the operation successfully in the case of Mrs. Plunkett, aged 26 years, with caries of the left elbow following a fall (*A Case of Excision of the Elbow Joint*, in *Am. Jour. Med. Sci.*, 1836, Vol. XIX, p. 341). Dr. GORDON BUCK (*New York Jour. of Med. and Surg.*, 1841, Vol. IV, p. 330) successfully excised the right elbow in 1841, for suppurative arthritis, in a seaman, J. Wharton, aged 26 years. He also successfully removed, October 29, 1842, the olecranon, for anchylosis, in the case of J. McCormick, aged 28 years (*Am. Jour. Med. Sci.*, 1843, Vol. V, p. 297); and again excised the elbow successfully, for caries, in the case of B. Foley, aged 25 years (*N. Y. Jour. of Med. and Surg.*, 1846, Vol. VII, p. 38). Dr. JOSEPH PANCOAST, in 1842 (*Med. Examiner*, 1842, Vol. I, p. 609), operated successfully for caries. An operation by Dr. W. J. WALKER, of Charlestown, is described in Dr. J. B. S. JACKSON'S *Dise. Cut. of the Anatomical Museum of the Boston Soc. for Med. Improvement*, Boston, 1847, p. 41, *Spec.* 181: a very interesting and successful case of removal of two inches of the lower extremity of the right humerus for injury, in the case of a drover, aged 53 years, in August, 1845. Dr. H. J. BIGELOW (*Am. Jour. Med. Sci.*, 1849, Vol. XVII, p. 29) exhibited, August 14, 1848, at a meeting of the Boston Society for Medical Improvement, the bones of an elbow removed for serofulous caries two days previously. Dr. J. O. STONE (*New York Jour. of Med. and Surg.*, 1851, Vol. VI, p. 300) successfully removed the condyles of the humerus, in the case of Mary Lally, aged 26 years, with a compound fracture, in November, 1850. CAMPBELL (H. F.) (*Surgical Cases*, in *Southern Medical and Surgical Journal*, 1851, N. S., Vol. VII, p. 387) relates a case of compound fracture of the olecranon with luxation of the radius, in a negro of 60, beaten with a cudgel, who recovered with good motion of the joint. Dr. S. SMITH (*A Case of Excision of the Elbow Joint*, in *American Medical Gazette*, 1855, Vol. VI, p. 338) records a successful excision of the elbow for caries, in the case of M. Mullino, aged 18. Professor H. H. SMITH (*New York Journal of Medicine*, 1855, Vol. XIV, p. 310) successfully excised the elbow for caries in 1854, in the case of a lad of 16. The following surgeons have also practised excisions of the elbow joint: POST (A. C.) (*Caries of Elbow Joint, Excision*, in *New York Jour. of Med.*, 1856, Vol. I, p. 209) successfully excised the elbow for caries in a lad of 14, and in May, 1866 (*Med. and Surg. Rep.*, 1866, Vol. XIV, p. 411), presented to the New York Academy of Medicine a young lady whose elbow he had successfully excised ten years previously for caries following injury. BELLAMY (C. E.) (*Am. Jour. Med. Sci.*, 1856, Vol. XXXII, p. 375), Cath. S.—, aged 28; caries, successful. BLACKMAN (G. C.) (*Western Lancet*, 1856, Vol. XVII, p. 725), Catherine Greary, aged 24; caries, successful. KIMBALL (G.) (*Excision of the Elbow Joint in a case of lacerated Wound of the Articulation*, in *Boston Med. and Surg. Jour.*, 1856, Vol. LIII, p. 513), W. F.—, aged 24; successful. HITCHCOCK (A.) (*Excision of Elbow Joint*, in *Boston Med. and Surg. Jour.*, 1857, Vol. LV, p. 12), H. Lawrence, aged 47, railway accident; successful. BIGELOW (H. J.) (*Excision of the Elbow Joint*, in *Boston Med. and Surg. Jour.*, 1857, Vol. LV, p. 122), two cases, males; caries, successes. AYRES (D.), a successful *Case of Excision of the Elbow Joint*, in a child of twenty months, in 1857 (*Am. Med. Gaz.*, 1858, Vol. IX, p. 267). BAUER (L.) reported a case of *Perfect Ankylosis of Elbow Joint, Resection of entire Joint with a view of establishing a movable Articulation; Remarks on the value of that operation* (*Am. Med. Gazette*, 1858, IX, p. 718). BRAINARD (D.) (*Resection of two and a half inches of the lower end of the os humeri, the same extent of the upper end of the radius, and nearly all of the ulna; Recovery with a useful member*, in *Chic. Med. Jour.*, 1858, I. N. S., p. 435). TOLAND (H. H.) relates (*Pacific Med. and Surg. Jour.*, San Francisco, 1858, I, p. 70) the case of P. McMahon, aged 40, who received, June 4, 1854, a shot wound of the right elbow, which resulted in caries, for which excision was performed in 1856. The operation was unsuccessful, and amputation was resorted to November 5, 1856. The patient died of phthisis in November, 1857. This secondary excision at the elbow is apparently the first instance in which the operation was practised for shot injury in this country. FRIER (J. W.) (*Resection of the Elbow Joint and Ulna; Recovery with useful member*, in *Chic. Med. Jour.*, 1858, I. N. S., p. 632). Dr. D. H. AGNEW (*Med. and Surg. Rep.*, 1859, Vol. II, p. 18) successfully excised the elbow joint for caries in a colored boy, aged 15. SMITH (S.) (*Excision of Elbow*, in *New York Jour. of Med.*, 1859, Vol. VIII, p. 258), Catherine Kearns, aged 36; injury by fall, recovery. Also reported in *Am. Med. Times*, 1860, Vol. I, p. 213. WOOD (J. R.) (*Am. Med. Times*, 1860, Vol. I, p. 212) has recorded five cases of excision of the elbow for serofulous caries: Thompson, age 10, in April, 1852, recovery with motion; Hughes, aged 14, June, 1856, rapid recovery with free motion; Rudd, aged 18, November, 1859, recovery with motion; Curry, aged 23, November, 1859, recovery with fistula; Jones, aged 40, in 1859, recovery after amputation. WHALEY (*Excision of the Elbow Joint*), case of R. Cahl, a lad of 11; caries, success (reported by Dr. G. A. OSBRANDEN). HUSTEDT (N. C.) records, in the *Trans. of the Med. Soc. of New York*, 1862, p. 327, the history of a girl of 14, with *Caries of Elbow Joint; Excision, with Recovery of Useful Arm*. BARTON (E.) (*Resection of the Elbow Joint*, in *Boston Med. and Surg. Jour.*, 1863, Vol. LXXVII, p. 32), R. French, aged 61, injured by a circular saw; recovery with motion. WARREN (J. MASON) (*Surgical Observations*, etc., 1867, p. 410), removal of external condyle of humerus for compound fracture from a railway accident, in a man of 24 years, November 27, 1864. RANKIN (J. D.) (*Resection of the Elbow Joint*, in *Galeston Med. Jour.*, 1867, Vol. II, p. 874), compound dislocation, in case of W. Payne, a lad of 6; intermediary excision, recovery with motion. HODGINS (R. M.) (*Excision of Elbow Joint for Deformity*, in a girl of 14, in *Boston Med. and Surg. Jour.*, 1867-8, Vol. LXXVII, p. 315). ASHHURST (J., jr.) (*Resection of Elbow*, in *Am. Jour. Med. Sci.*, 1868, Vol. LV, p. 42), a man of 58 years; caries, fatal. TODD (S. J.) (*Compound Fracture of Ulna; Resection of Elbow Joint*; case of U. S., a mulatto of 35; wound, primary excision, recovery with motion; *Am. Jour. Med. Sci.*, 1868, Vol. LV, p. 122). DUBOIS (H. A.), successful humero-cubital excision three days after shot injury in a soldier, aged 26, June 7, 1857 (*Circular 3, S. G. O.*, 1871, p. 225). ROPES (F. C.) (*Compound Comminuted Fracture into Elbow, Resection*; Italian barkeeper, aged 34; primary excision, recovery after consecutive amputation; *Boston Med. and Surg. Jour.*, 1869, Vol. II, p. 41). THAXTER (*Excision of Elbow*, reported by G. B. SHATTUCK, in *Boston Med. and Surg. Jour.*, 1869, Vol. II, p. 377), D. D. T.—, aged 47, injured by saw; consecutive amputation, recovery. BAUER (L.) (*Total Excision of Elbow Joint*, in *St. Louis Med. and Surg. Jour.*, 1870, Vol. VII, p. 193), F. H.—, a man of 39; caries, successful. ASHHURST (J., jr.) (*Excision of the Elbow*; man of 25; caries, death from meningitis; in *Am. Jour. Med. Sci.*, 1870, Vol. LX, p. 148). HILLER (F.) (*Resection of Elbow Joint*; in case of W. Hunter, aged 24; caries after injury, recovery with motion; in U. S. (Homoeopathic) *Med. and Surg. Jour.*, 1870, Vol. V, p. 164). DAWSON (W. W.) (*Excision of the Elbow*, in a negro man with syphilitic disorganization of the joint; recovery with motion; in *The Clinic* (Cincinnati), 1873, Vol. III, p. 283). HOMANS (J.) (*Excision of Elbow*, in a man of 250 pounds, who fell from a roof; death from laceration of the liver and kidney; in *Boston Med. and Surg. Jour.*, 1871, Vol. VII, p. 247). RICHARDSON (*Clinic. Med. Times*, 1873, p. 338) relates a successful primary excision of condyles and olecranon in a man of 54, with compound fracture. BIGGAR (H. F.), *Excision of Elbow*, two cases: Mrs. S., aged 30, caries; J. S., aged 39, caries after dislocation; recoveries with motion; in *Ohio Med. and Surg. Rep.*, 1874, Vol. VIII, p. 94 (reported by Dr. H. C. FROST). BRIDGON (C. K.) (*Resection of Elbow Joint*, in a lad of 10, in the *Medical Record*, 1873, Vol. VIII, p. 319). LOGAN (S.) (*Resection of the Elbow Joint*, W. F., negro laborer of 23; syphilitic caries, excision, recovery with ankylosis; in *New Orleans Med. and Surg. Jour.*, 1875, Vol. III, p. 171). ASHHURST (J., jr.) (*Excision at the Elbow*, in *Proceedings of College of Physicians of Philadelphia*, in *Philadelphia Med. Times*, 1875, Vol. V, p. 539) records eight cases in which he had excised the elbow,—two have been cited above; the third case, of J. K., a girl of 7, with arthritis from injury, recovered with partial ankylosis; the fourth case, J. C., an Englishman of 51, compound dislocation with fracture, death from delirium tremens; the fifth case, arthritis from injury, R. A., a lad of 10, recovery with motion; the sixth case, G. P., a lad of 4, recovery with motion, death a year and a half subsequently from constitutional disease; seventh case, J. S., a lad of 6, syphilitic caries death from intracranial syphilis; eighth case, C. K., a boy of 6, with ankylosis and arthritis, recovery with motion. The foregoing references include 58 excisions at the elbow with 6 deaths, or 10.3 per cent., but several of the deaths were from causes foreign to the operation.

proved so safe as to almost confirm Syme's famous declaration<sup>1</sup> that "carious joints may be cut into with the same impunity as ordinary abscesses, and cut out with no more danger than what attends amputation, or rather not so much, since the balance of action will be less disturbed, *cæteris paribus*, when the limb is allowed to remain. In military practice, in this country, however, a brilliant success can hardly be claimed for the operation. Although the point is open to argument, I fear that the substitution of this resection for amputation effected no saving of life.<sup>2</sup> The operation would appear to have given more favorable results in the hands of the Confederate surgeons than were observed in the Union armies, judging merely by the reported terminated cases; but the incompleteness of these returns precludes the possibility of any exact estimate of the aggregate results really obtained by the Confederate surgeons. From the best accounts that can be had, it is almost certain that neither in the northern nor southern armies was there achieved any near approximation to the success, either in the proportion of lives or of useful limbs preserved in excisions at the elbow,<sup>3</sup> that rewarded the German surgeons in Schleswig-Holstein in 1848-50. But the excisions in those campaigns marked a new epoch in military conservative surgery. The operations were done, and the after-treatment conducted, either person-

<sup>1</sup> SYME (J.) (*Three Cases in which the Elbow Joint was successfully excised, etc.*, *Edin. Med. and Surg. Jour.*, 1829, Vol. XXXI, p. 261). Other remarks by this eminent teacher are contained in his *Treatise on the Excision of Diseased Joints*, Edinb., 1831, Chapt. V, and in his *Principles of Surgery*, 1842, and *Observations on Clinical Surgery*, 1861, p. 51.

<sup>2</sup> It may be asserted, on the one hand, that the mortality of the aggregate of excisions at the elbow in the Union armies was slightly greater than the mean mortality of all the amputations in the continuity of the upper arm. Secondly, that the mortality of *primary amputations* in the upper and middle thirds of the upper arm for shot injury did not exceed 13.6 per cent. (see TABLE CII, p. 824); whereas the series of either complete or partial primary excisions at the elbow for the same cause was more than 21 per cent. (see TABLE CVI, p. 847). On the other hand, it may be urged that the amputations in the arm for shot injury of the elbow joint had a fatality of 24.3 per cent. (see TABLE CV, p. 829), and that the experience of the American War on this question is opposed to the conclusions arrived at by most enlightened and sagacious observers in several European campaigns.

<sup>3</sup> M. DEXTRÉ in his article *coule* (in the *Nouveau Dictionnaire de Médecine et de Chirurgie pratique*, Paris, 1863, T. IX, p. 808) ascribes to BOUCHER, of Lisle, the merit of first treating shot comminution of the elbow conservatively by extracting all large splinters. BOUCHER's interesting cases in the *Memoirs of the French Academy of Surgery* (1753, T. II, p. 292) are cited in the foot-note to p. 830 *ante*. WAUCHER (*Diss. chir. de articulis extirpandis*, Gröningen, 1810, p. 17), and after him O. HEYFELDER, and others ascribe the same practice to J. V. BELGUER in the Seven Years' War (1756-63). It is true that BELGUER (*Chir. Wahrnehmungen*, Berlin, 1763, SS. 407-483), in three of his fourteen cases of shot injury of the elbow treated conservatively with success (already cited in the foot-note to p. 832 *ante*), mentions an instance, case 4 (p. 407), in which the olecranon was carried away by a cannon ball; case 6 (p. 408), in which "detached fragments were removed from the tissues by the knife;" and case 25 (p. 452), in which 26 necrosed fragments exfoliated; but expressly mentions in regard to case 6, the only one in which there was any operative interference, that "the sharp points were covered with dry dressings, but not removed." GÖRKE, in 1793, excised the head and part of the shaft of the ulna in the case of a soldier wounded in the elbow joint by a cannon ball. The soldier refused to have the arm amputated. The wound healed in five months. The arm was shortened and ankylosed (JUSST's *Theo-prakt. Handbuch der Chir.*, Berlin, 1831, B. V, S. 631). This is the earliest reference I find to this case, which is the first example of a formal excision at the elbow for shot injury, and is cited a year later by JÉGER in his chronological conspectus of resections (Erlangen, 1832), and later by TOROLD (*De Art. Cubiti Resect.*, Berlin, 1855), and others. MOREAU (*père*), in 1794, twice successfully excised the elbow for caries following shot injury. In the first case (Obs. VIII), the joint ends of the three bones were removed; in the second (Obs. IX), the condyles of the humerus and head of the radius were excised (see P. F. MOREAU's *Essai sur l'emploi de la resection des os*, 1816). Dr. HODGES asserts (*op. cit.*, p. 47) that Baron LARREY urged this excision on his surgeons, a recommendation that cannot be found in the writings of the master, who has little to say of any injuries of the elbow except sabre wounds, and most distinctly advocates amputations at the elbow when the joint is wounded. (His strong language on this point is quoted in the foot-note on p. 828.) The misapprehension is probably due to a passage in PERCY's article on *Resections* (*Diet. des Sci. Méd.*, 1820, T. XLVII, p. 549), in which he states that it was the old chieftain of military surgery who first suggested to his colleagues to have recourse to resections, and emboldened his co-operators, who still . . . "from timidity, routine, or indifference," often amputated under his very eyes. I think PERCY is here referring to LARREY's advice regarding shot injuries of the shoulder. In his essay of 1803, enlarged in 1815, and translated into English and German, MOREAU states that: "In the armies, resection at the elbow has been practised by Baron PERCY, whose procedures, on account of the variety of shot injuries, must vary according to the loss of substance," VELPEAU and many others have attributed to PERCY one or more excisions at the elbow on the authority of this statement, and Dr. O. HEYFELDER (*Lehrbuch der Resect.*, Wien, 1863, S. 247) goes so far as to particularize three successful excisions for shot injury. His French editor, M. BOECKEL, seems to recognize that some authority for this audacious statement is requisite, and cites (*Traité de Resect.*, 1863, p. 190) the article *Resection*, by PERCY and LAURENT, in the forty-seventh volume of the *Dictionnaire des Sciences Médicales*, where it is stated, in commenting on MOREAU's resections at the elbow, that: "The armies witnessed a multitude of similar or analogous operations, practised with almost constant success on soldiers with the elbow comminuted by large projectiles or disorganized by balls," but not a single concrete case is given; and PERCY would assuredly have adduced an example if he had operated for shot injury, for he soon after relates a case in which he ["l'un de nous"] excised the elbow for a comminuted fracture. The only authentic instances of excision at the elbow for shot injury in the last century were the resection of the upper part of the ulna by GÖRKE, in 1793, and the two excisions for caries following shot injury, by MOREAU, the elder, in 1794. In the present century, although the operation was strongly advocated by GUTHRIE (*Treatise on Gunshot Wounds*, 3d ed., 1827, p. 251), no attempt at excision at the elbow for shot injury appears to have been made until April, 1836, when BAUDENS, in the case of a recruit whose left olecranon was shattered by a ball in an engagement in Algeria, united, by an incision an inch and a half long, the entrance and exit wounds "afin d'en extraire toutes les pièces d'os mobiles et de resequer à l'aide de la scie les angles aigus qui couronnaient la tête du enubitus, en sorte que son apophyse disparût en totalité" (*Clin. des Plaies d'Armes à Feu*, 1836, p. 452, Ob. VI). Notwithstanding the success with which excision at the elbow for disease had been practised by SYME, it was not until 1848 that the operation was fairly introduced in military surgery. Professor ESMARCK's memorable tabular statement (*Ueber Resectionen nach Schusswunden*, 1851, p. 137) shows that the operation was done twice in that year by Professor B. v. LANGENBECK; in 1849, by Dr. STROMFeyer on seven occasions, on four occasions by Dr. ESMARCK, on four by Dr. SCHWARTZ, twice by Dr. GÖZE, and once by Drs. B. v. LANGENBECK, NIESE, HANSON, MARCUS, and DOHRN. In 1850, the operation was repeated twice by Dr. STROMFeyer, twice by Dr. SCHWARTZ, four times by Dr. DOHRN, twice by Dr. BARTELS, twice by Dr. HERRICH, and by Drs. NIESE, GÖZE, and KUNCKEL, each in one case.



ally or under the immediate direction of masters of the art, upon patients who were not exposed to the perils of transportation. In the Crimean War the excisions at the elbow practised by the British surgeons had equally gratifying results; but the Russians had little success with the operation, and the French, none. In the Danish War, of 1864, the German surgeons were much less successful in their resections of this joint. In the late Franco-German war, the average results obtained by the German surgeons are not discour-

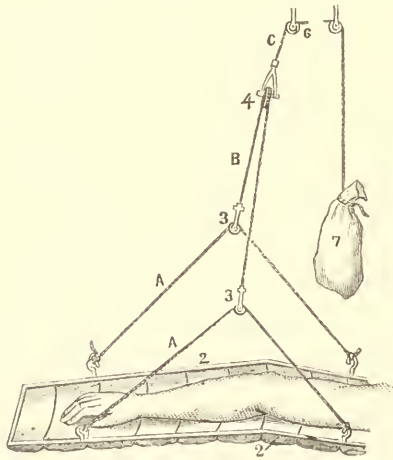


FIG. 652.—HODGEN'S wire suspension splint.<sup>4</sup>

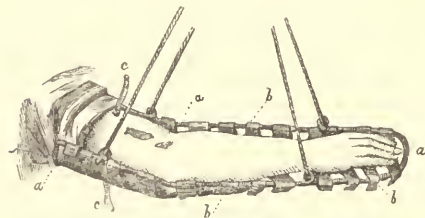


FIG. 652 (bis).—VOLKMAN'S wire splint.<sup>5</sup>

aging, when the circumstances of the campaigns are considered. But the results which M. Chenu reports from the French armies are simply appalling, and, if taken alone, would fully justify Professor Sédillot's recent declaration, that resections at the elbow should be altogether rejected in the present state of war surgery.<sup>1</sup> It is impossible to call in question the accuracy of the returns of M. Chenu, the eminent surgical historiographer and statistician of the last three great wars in which France has engaged. The terrible fatality his last volumes present, is everywhere corroborated by the fragmentary reports that have been published.<sup>2</sup> There is no other explanation to be given of such deplorable and inexcusable loss of life than that offered by Professor Sédillot, which is quoted in the foot-note. The organiza-

tion of the French medical staff in the late war was such that the surgeons were powerless to give directions in their own department, or to secure the comforts essential for the welfare of their wounded, since they were subordinated to a stolid body of line officers ignorant of their necessities. This miserable system, which it is sought to enforce in our own Navy, and which not a few would like to introduce into our Army, brought about results so obviously disgraceful and horrible,<sup>3</sup> that it has been radically reformed by the French republican government.

#### CONCLUDING OBSERVATIONS ON EXCISIONS AT THE ELBOW.—The period of election

<sup>1</sup> SÉDILLOT (*Du traitement des fractures des membres par armes de guerre*, in *Gaz. méd. de Strasbourg*, 1870, and *Arch. gén. de méd.*, 1871, VI<sup>e</sup> série, T. XVII, p. 98 et p. 411): "Nous avons exposé les motifs qui nous avaient fait rejeter cette opération dans les conditions actuelles de la chirurgie de guerre, et nous ne les rappellerons pas." The "motifs" elsewhere explained are: "Triste à avouer? Les chirurgiens n'ont pu encore, malgré toutes leur réclamations et l'évidence des désastres auxquels on les condamne, placer leur blessés dans des conditions salubres, et l'encombrement et les endémies infectieuses paralysent leurs efforts et les privent d'une des plus belles ressources de leur art."

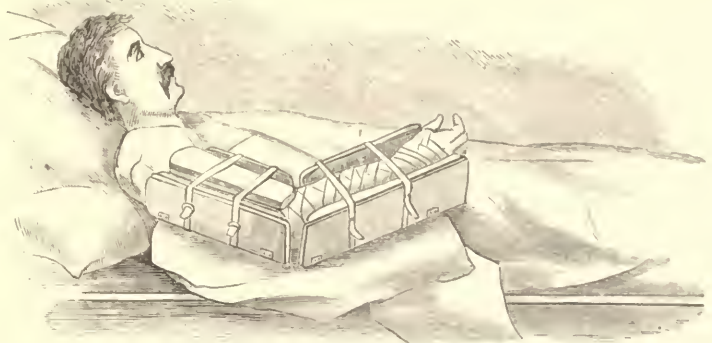
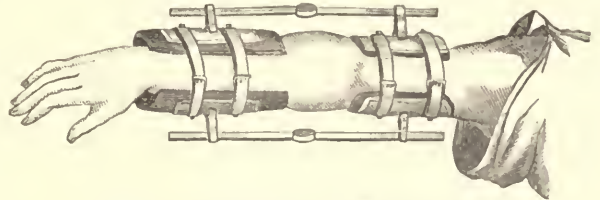
<sup>2</sup> PONCET (V.) (*Contrib. à la Relat. Méd. de la Guerre, de 1870-71*, in *Montpellier Médicale*, Mars, 1872) records 3 cases of excision at the elbow for shot injury of which 2 were fatal. TACHARD (E.) (*Réflexion pour servir à l'Hist. de la Chir. en Campagne*, in *Gaz. des Hôp.*, 1871, p. 231) tabulates 5 resections at the elbow, 3 fatal. MACCORMAC (W.) (*Notes, etc., op. cit.*, 1871, p. 30) tabulates 11 excisions at the elbow, 4 primary with 1 death, 7 secondary with 5 deaths. DESPRÈS (A.) (*Rapport de la Septième Ambulance*, 1871, p. 58) records 4 resections at the elbow with 2 deaths. ARNAUD (in GRELLOIS. *Blocus du Metz*, 1872, p. 353) gives a fatal excision of the elbow. COUSIN (*Ambul. de la Presse Française, Service de M. DEMARQUAY, l'Union Méd.*, 1872, p. 126) relates a fatal case of complete excision. FELTZ and GROLLEMUND (*Rel. Clin. sur les Ambul. Haguenau*, in *Gaz. Méd. de Strasbourg*, 1872, p. 224) and M. SÉDILLOT (*Arch. Gén. de Méd.*, 1871, T. XVII, p. 411) relate single fatal instances. BRIGHAM (C. P.) (*Quelques Obs. Chir.*, Paris, 1872, p. 40) also gives an unsuccessful complete excision. M. A. CHIPPAULT (*Fractures par Armes à feu*, 1872, pp. 128, 138) narrates, at length, 2 successful complete excisions at the elbow joint.

<sup>3</sup> These expressions are not exaggerated. In the unimpeachable testimony of Professor SÉDILLOT, even stronger language is employed. In accounting for the frightful mortality of the wounded at Haguenau, he says: "Supposez, comme ne l'ont que trop prouvé les lamentables statistiques du Dr. Chenu, dont les travaux ont été couronnés par l'Académie des sciences, que les blessés soient laissés sans eau potable, sans aliments convenablement choisis et préparés, sans médicaments, sans moyens de pansements, au milieu d'une telle puanteur qu'on était obligé, pour la masquer, de brûler du bois vert dans les salles,—et vous comprendrez les effroyables mortalités qui ont eu lieu."

<sup>4</sup> HODGEN (J. T.), *St. Louis Med. and Surg. Jour.*, 1867, Vol. IV, p. 500. *An Apparatus for Suspending the Superior Extremities in case of Extensive Injuries about the Wrist, Forearm, and Elbow.* 1 1, movable hooks on the wire frame 2 2, to which cords, A A, passing through pulleys, 3 3, are attached; 4, pulley for cord B; 5 and 6, pulleys for cord C; 7, sand-bag.

<sup>5</sup> The cut is copied from SOGIN (*Kriegschir. Erf.*, 1872, S. 120), who calls this the "American splint." a, iron wire frame; b, webbing strips; c, drainage tube. Dr. LOSSEN (*Deutsche Zeitschrift für Chir.*, 1873, B. 11, S. 57) declares that SOGIN erroneously terms this splint "American," since it was devised by Professor VOLKMAN. It is obviously derived from Professor N. R. SMITH'S wire splint for the lower extremity.

for excisions at the elbow for shot injuries has been hitherto regarded as an unsettled question.<sup>1</sup> I believe that the evidence, when fully analyzed, will demonstrate that this resection conforms to the general rule in shot fractures of the limbs, that primary operations are preferable whenever it is certain that recourse must eventually be had to operative interference.<sup>2</sup> We have seen<sup>3</sup> that Medical Director Tripler regarded this as the best rule. It is to be regretted that a committee of surgeons of high standing, but without much experience in this particular branch of surgery, distributed through the armies a document recommending an opposite line of conduct, and essayed to strengthen their position by what we cannot but regard as an undoubtedly unintentional misinterpretation of the experience of the Schleswig-Holstein surgeons.<sup>4</sup> A great cause of misapprehension on the subject is the confounding of the intermediary and secondary operations. It is undoubted that of those patients who have sufficient power of vital resistance to pass through the stage of inflammation and suppuration a larger proportion will survive severe surgical operations than would recover

FIG. 653.—BUTCHER'S dressing for excision at the elbow.<sup>5</sup>FIG. 654.—HEATH'S splint for excision at the elbow.<sup>6</sup>

<sup>1</sup> BILLROTH (TH.) (*Chir. Briefe aus den Kriegs-Lazarethen*, u. s. w., Berlin, 1872, S. 224): "According to present experience regarding the end-results after elbow resection, we cannot implicitly endorse the primary resection. The statistics accessible at present, it is true, are *quoad vitam* in favor of primary resection as compared with secondary: but the numbers appear to me too small to arrive at a definite conclusion; and would we place any great value on such limited statistics, we would be compelled, from the facts known to us at present, to pronounce in favor of non-operative treatment."

<sup>2</sup> Facts rather than authorities are of weight in determining this question: but it is of interest to observe that the majority of surgeons of much experience with this operation are in favor of early interference, and insist that if excision is not practised immediately it shall be delayed until after the inflammatory phenomena have entirely disappeared. J. P. HEYFELDER, for instance (*Über Resektionen und Amputationen*, Breslau und Bonn, 1854, S. 150), treating of excision at the elbow, remarks: "Regarding the time for the performance of this resection, it will be seen that, as in amputations after shot wounds, a favorable result of the operation is so much more to be expected the earlier the resection is performed, whereas, when inflammation has already appeared, it is preferable to delay the operation until the inflammation has been subdued, which may be accomplished by the application of ice."

<sup>3</sup> APPENDIX to PART I, *Med. and Surg. Hist. of the Rebellion*, p. 60. In a note to General Orders No. 30, of October 3, 1861, promulgated from General McCLELLAN'S headquarters, it is stated that: "The Medical Director desires that excision of the shoulder and elbow joints shall be resorted to, in preference to amputation, in all cases offering a reasonable hope of success."

<sup>4</sup> *Report of a Committee of the Associate Members of the Sanitary Commission on the Subject of Excision of Joints for Traumatic Cause*, Cambridge, 1862, signed by Drs. HOWARD, TOWNSEND, WARE, J. MASON WARREN, CABOT, DALE, and HODGES. The general statements are made that: "The fact cannot be concealed that excisions, hardly excepting even those of the humerus and of the elbow, are operations not likely to succeed in the hospitals of an army under any circumstances," and that "excisions of large joints are never to be practised on the battle-field." The committee then lays down rules for the excisions of the several joints, uniformly advocating delayed operations, a precept already advocated by the reporter, Dr. HODGES (in his well-known Boylston prize essay *On the Excision of Joints*, Boston, 1861), whose conviction in favor of secondary excisions had been established, he says, before he "learned that the experience of the Schleswig-Holstein surgeons had led them to a similar conclusion." Now nothing can be clearer than that the experience of the Schleswig-Holstein surgeons led to a directly opposite conclusion. Dr. ESMARCH says of excisions at the elbow (*Über Resektionen*, 1851, S. 89): "As regards the space of time between the reception of the injury and the operation, a similar relation exists as in resection of the shoulder joint, and indeed as in amputation of the larger limbs," previously stated, S. 49, thus: "It is advisable to resect early, if possible directly after the reception of the injury, or within the first twenty-four hours." Professor ESMARCH is avowedly expressing not only his own opinions, but those of the Prussian chief-surgeon B. von LANGENBECK, and the Hannoverian chief-surgeon LOUIS STROMEYER. In the passage quoted from STROMEYER'S work (*Ueber die bei Schusswunden vorkommenden Knochenverletzungen*, Freiburg, 1850, S. 29) that, "as regards the result, it is of no consequence whether the operation has been performed in the first forty-eight hours or after the full development of suppuration," the professor is undoubtedly speaking as to the result in relation to the mobility and usefulness of the limb, for the whole tenor of the context is in advocacy of early interference and in opposition to expectant measures. That such was Dr. STROMEYER'S later conviction is well known, for in speaking of the less favorable results of the elbow excisions at Langensalza (*Erfahr. über Schusswunden*, in *Jahre*, 1866, S. 48), he ascribes as the cause the larger proportion of delayed operations. Professor LANGENBECK did not publish directly his opinion on this point; but it was well known through his disciples. Dr. HARALD SCHWARTZ says (*Beiträge zur Lehre von den Schusswunden*, Schleswig, 1851, S. 219): "Regarding the time of operations, primary operations, within the first twenty-four hours, are decidedly preferable;" and MAAS (*Kriegschir. Erf.*, Breslau, 1870, S. 82) says: "The operation is always to be practised as early as possible."

<sup>5</sup> BUTCHER (R. G.), *Essays and Reports on Operative and Conservative Surgery*, 1865, Pl. XV, and page 147.

<sup>6</sup> HEATH (C.) (*The Lancet*, 1857, Vol. II, p. 546, and *Manual of Minor Surgery*, 4th ed., 1870, p. 227). Four padded iron plates are connected by hinged steel rods.



from the same operations practised when they were in robust health; but it is known that a large number perish before inflammation abates; and the real question is, whether life is exposed to greater jeopardy by immediate interference or by delay.

The extent to which the bones should be removed in attempts to save the limb by resection is another grave question, on which it may be hoped the observations here accumulated may throw some light. The doctrine that complete resections give more

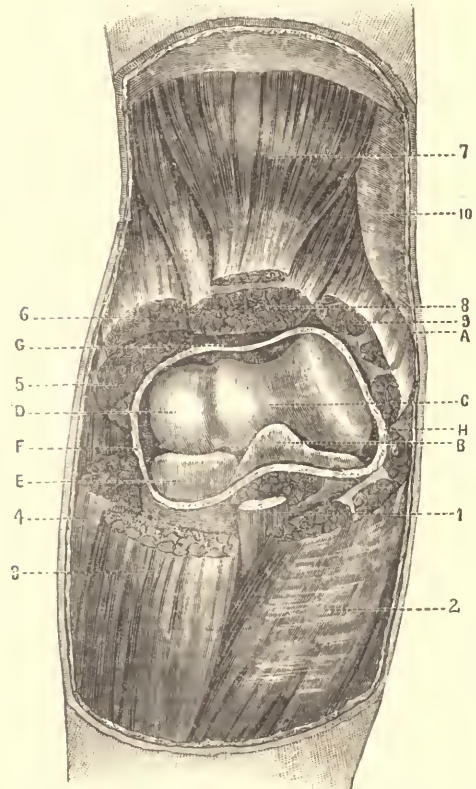


FIG. 655.—Surgical anatomy of the elbow. [After B. ANGER.] Right extremity. A—epitrochlea. B—coronoid process. C—trochlea. D—outer condyle. E—head of radius. F—external ligaments. G—anterior edge of capsular ligament. H—internal ligament. 1—tendon of biceps. 2—pronator radii teres, palmaris longus, flexor carpi, etc. 3—supinator longus. 4—extensor carpi radialis longior. 5—section of the extensor radialis. 6—section of the long supinator. 7—biceps. 8—brachialis antiens. 9—section of pronator teres. 10—deep aponeurotic sheath.

favorable results both in preserving life and utility of limb is generally conceded, and is confirmed by the experience here recorded. The view of Baudens, that excision should only be practised when one of the joint ends is injured, is entirely abandoned. There can be little doubt that removal of the head of the radius, for example, or of one of the condyles, or the upper extremity of the ulna, is much more

liable to be followed by ankylosis or by destructive inflammation than the excision of the entire joint. But it is not a settled question whether, when the joint is exposed, and the ligamentous attachments have been freely divided, and the injury is found confined to the lower end of the humerus, it is safer to saw off the uninjured extremities of the radius and ulna, or whether, if the joint ends of the bones of the forearm alone are comminuted, it may be necessary to remove the condyles of the humerus. In excision

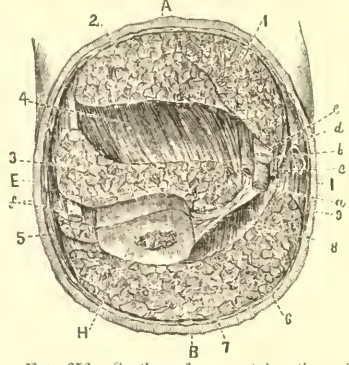


FIG. 656.—Section of arm at junction of lower and middle thirds. [After B. ANGER.] A—anterior part of the preparation. I—internal. E—external. B—base or posterior part. H—section of humerus. 1—internal portion of biceps. 2—external portion. 3—section of brachialis antiens. 4—anterior fibres of brachialis. 5—section of supinator longus. 6—transverse section of triceps. 7—tendinous fibres of triceps. 8—anterior fibres of inner portion of triceps. 9—internal intermuscular septum. a—brachial artery. b and c—venae comitatis. d—basilic vein. e—median nerve. f—anterior branch of radial nerve.

for white swelling, Syme has shown that it is wisest to remove all the articular extremities, for the cartilages and subjacent porous bone are already diseased. But in operations for

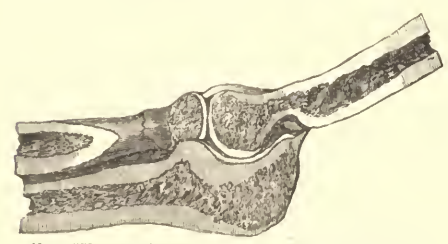

FIG. 657.—Section showing the relations of the bones of the elbow in the median line. [After ANGER.]

injury, it would seem *a priori* that there was not the same object in inflicting additional injury by a section of healthy bone, and the deduction seems to be sustained by facts, excellent results having been obtained when the joint ends of either the upper or forearm have been removed after complete exposure of the joint, and the uninjured portions of the articulation have been unmolested. The method of operating most frequently

<sup>1</sup> The section gives an excellent idea of the relations of the elbow joint. It is a reduction from a drawing by M. BICE for Dr. B. ANGER'S admirable *Traité iconographique des maladies chirurgicales*, p. 148, FIG. 35. It was obtained, Dr. ANGER informs us, from a preparation injected with hyposulphite of soda, and then mummified; it represents the bones only of the elbow joint, divided antero-posteriorly and vertically, nearly in the median line.

adopted by both Confederate and Union surgeons appears to have been by a single longitudinal incision parallel with the radial border of the ulnar nerve, extending a convenient distance above and below the olecranon, as originally proposed

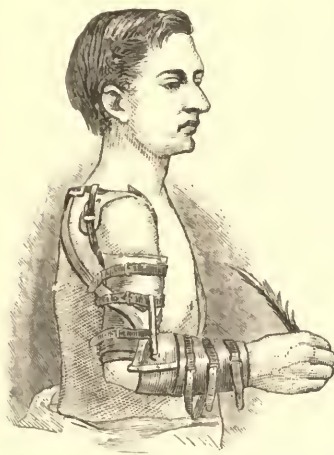


FIG. 658.—Apparatus commended by B. v. LANGENBECK.<sup>3</sup>

by Park, and commended by Langenbeck, Gross, and Ashhurst.<sup>1</sup> Not a few, however, preferred the methods of Moreau or Liston, or crucial or lunated incisions. The  $\nabla$ -shaped incision of Liston undoubtedly affords an easy mode of exposing the joint, and nothing can be more lucid and satisfactory than Dr. Esmarch's description of the operation by this method,<sup>2</sup> which he and Dr. Stromeyer prefer; but I can bear the same testimony as Dr. Lücke, who declared, after observing a large number of elbow

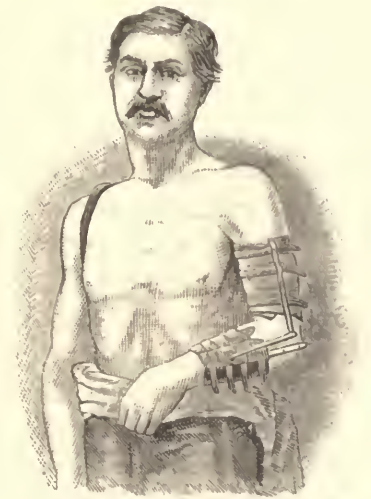

FIG. 658 (bis).—Another view of the same apparatus. [After LÖFFLER.<sup>4</sup>]

joint resections, that he had seen none in which the parts could not be readily removed through a single straight incision. The immediate after-dressing was regarded as of not less essential importance than the later after-treatment. Various ingenious appliances for suspending or supporting the limb in a favorable position, and affording at the same time facilities for dressing, devised by Drs. Hodgen, Bauer, Bond, Ahl, and others, have been figured on preceding pages. Perhaps nothing so perfectly meets the indication as the Stromeyer-Esmarch bracketed splint, shown on page 888. When a loose dangling limb results, some support is required by an artificial apparatus. That of Dr. E. D. Hudson, figured in PLATE LIV in connection with the portrait of the patient for whom it was devised, and of another who used it with advantage to assist his "dangle-joint,"<sup>6</sup> is similar in principle, and perhaps less complicated and cumbrous than those employed by the European surgeons, and figured by Loeffler (Fig. 658), by Dr. von Langenbeck, and by Dr. Socin (Fig. 659). The advantages derived from such apparatus are but limited.

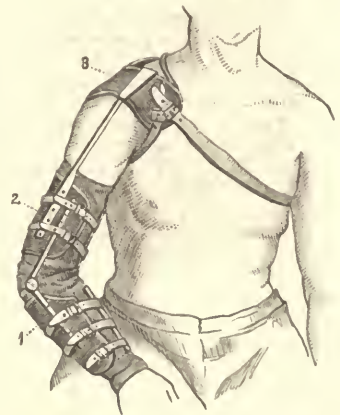


FIG. 659.—SOCIN'S apparatus for supporting the limb after excision at the elbow.<sup>5</sup>

<sup>1</sup> PARK (H.), *An account of a new Method of treating diseases of the Joints of the Knee and Elbow*, London, 1783, p. 45. This is unquestionably the mode of operating recommended by Prof. LANGENBECK (see LÜCKE, *Beiträge zur Lehre von den Resectionen*, in *Archiv für Klin. Chir.*, 1862, B. III, S. 358), although Dr. KYRIAKOS (*De articuli hum. et cubiti resectione*, Berlin, 1854, p. 14) minutely describes his preceptor's method as requiring a second transverse incision, as corresponding in fact with the  $\nabla$ -shaped method commonly described as LISTON'S plan. GROSS (S. D.), *A System of Surgery*, 5th ed., 1872, T. II, p. 1086. ASHURST (J., jr.), *Princ. and Pract. of Surgery*, 1871, p. 600.

<sup>2</sup> ESMARCH (F.), *Über Resectionen nach Schusswunden*, 1851, S. 82, and STATHAM'S translation, 1856, p. 82.

<sup>3</sup> LANGENBECK (*Chirurgische Beobachtungen aus dem Kriege*, 1874, Taf. IV).

<sup>4</sup> LÖFFLER (F.) (*General-Bericht*, u. s. w., 1867, p. 257).

<sup>5</sup> SOCIN (A.) (*Kriegschirurgische Erfahrungen*, 1872, p. 161).

<sup>6</sup> LÖFFLER (F.) (*General Bericht über den Gesundheitsdienst im Feldzuge gegen Dänemark*, 1864, Berlin, 1867, S. 269) remarks: "Therefore it will be seen that of 28 recoveries after resection of the elbow joint in the campaign of 1864, 20, or 71 per cent., resulted in dangle-joints. Dangle-joints without supporting apparatus are of little use, even if the hand and fingers are capable of voluntary motion. The supporting apparatus, at least as now constructed, does not, as a rule, materially increase the usefulness of the limb, and frequently it cannot be worn at all, as it should be worn to be useful. . . . Nevertheless the possessor of a dangle-arm rejoices that he has not lost the member by amputation, and has so much the more reason for it, as the artificial substitute for losses on the upper extremity serve us little more than ornamental appendages. But the surgeon, to-day, must consider the question from another point. He must compare the recoveries with ankylosis and recoveries with a loose dangling limb." Further on (*op. cit.*, p. 272) he observes: "There is not a single case of complete ankylosis after resection of this joint in the campaign of 1861,—a happy exhibit if it were not overshadowed by 71 per cent. of cases of dangle-joint (although no one operated or aimed to operate otherwise than subperiosteally). It is true, we find now



There was a numerical predominance of injuries and operations on the left side,<sup>1</sup> slight, but too decided to be likely to be counterbalanced by any determination of the few cases in which the side interested was unspecified. The excisions at the left elbow had less favorable results in the proportion of 4 per cent.

I regret that the information collected respecting the end-results of the cases of elbow excisions is often so vague, and even contradictory, as not to be susceptible of expression in a condensed shape, and also that there is not space to record all the definite facts that have been obtained. In a considerable number of cases, however, the condition of the pensioners many years subsequent to operation has been recorded, and sometimes illustrated by copies of photographs. I hope to revert to this subject, and to submit ample details in the *Third Surgical Volume*. PLATE XLV, opposite, illustrates the later history of two deferred excisions,<sup>2</sup> resulting in loose flail-like joints, which were to some extent benefited by Dr. Hudson's apparatus.

In the course of this Section, many of the more important writings on the subject have been referred to. Some of the special monographs are enumerated below.<sup>3</sup>

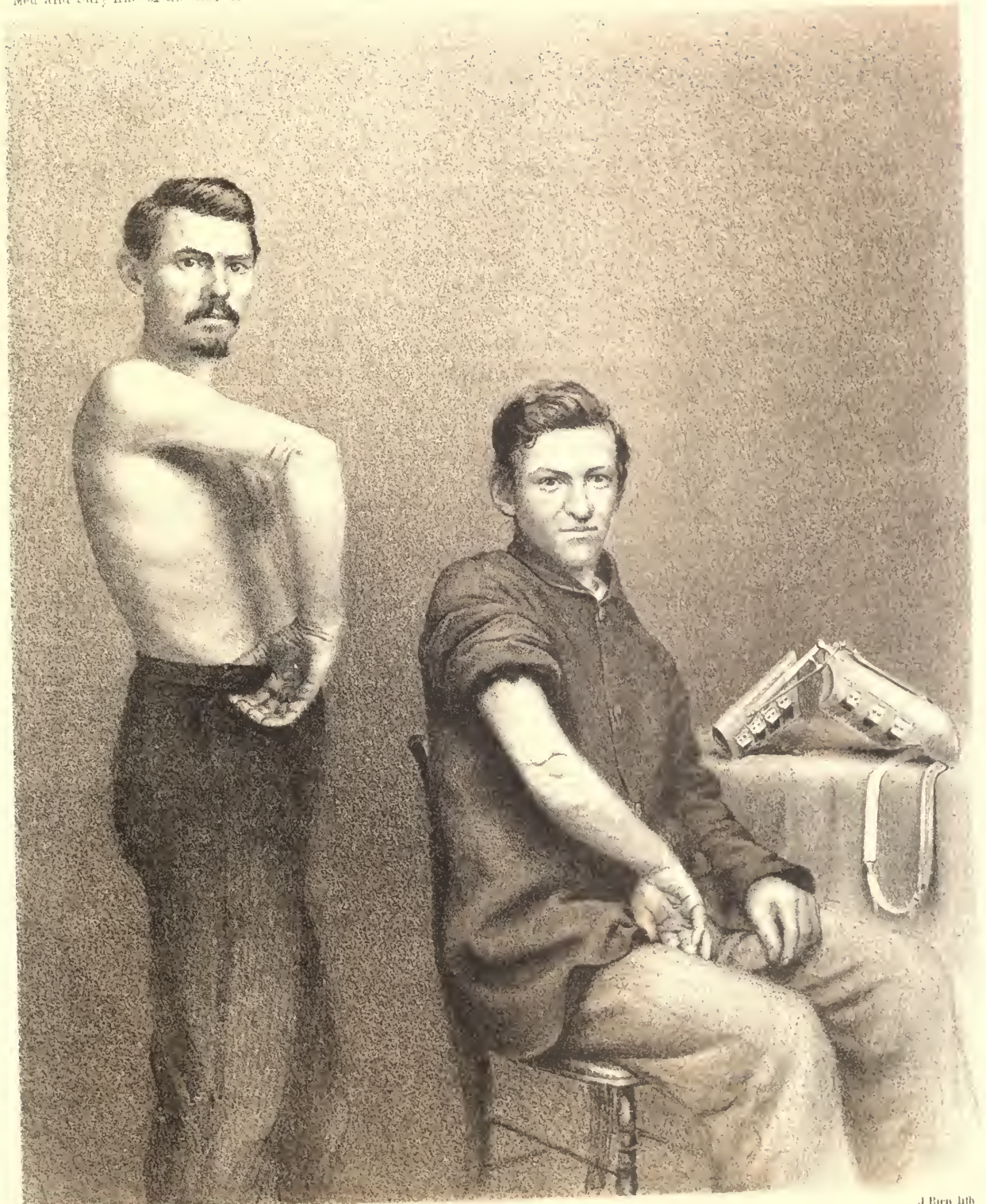
and then, among the cases of recovery, thickening of the sawn ends, even osteophytic after-formations of normal protuberances; but nowhere is a prolongation of the sawn end by new bone-formation in the axis demonstrated, while cases of shortening by necrosis of the ends of the bones are not wanting."

<sup>1</sup> The series of 623 excisions at the elbow comprises 470 recoveries,—229 operations practised on the right, and 238 on the left elbow; not specified, 13; and 146 fatal operations,—60 on the right, and 75 on the left, with 11 unspecified cases; also 10 excisions with unknown results,—5 on the right, 3 on the left side, and 2 unspecified. It will be observed that of 600 cases in which the side involved was known, 294 were excisions at the right, and 306 at the left elbow; of 289 of the former with known results, 60 or 20.7 per cent. were fatal; of 303 excisions at the left elbow with known results, 75 or 24.7 per cent. were fatal. Compare Note 5 on page 900.

<sup>2</sup> The left-hand standing figure in PLATE LIV represents the appearances of the limb in the case of Private J. F. Hertzog, 47th Pennsylvania (CASE 53, of TABLE CX, p. 876), from a photograph taken three years after a complete intermediary excision at the right elbow for shot comminution, by R. B. BONTECOU, U. S. V., and contributed to the Museum by Dr. E. D. HUDSON. Dr. HUDSON has given a full account of the case, with wood-cut illustrations, in his pamphlet *Save the Arm*, New York, 1864, p. 6. It was an example of "dangle-joint," he says, for which he originated his first apparatus for excision at the elbow. With the aid of this appliance (which is figured in the plate) the pensioner could flex and extend the forearm, holding a ten-pound dumb-bell. The functions of the hand were good when the pensioner was paid in 1874, twelve years after the operation. The second, or sitting figure, is from a photograph of Private Martin V. B. Keller, 1st Pennsylvania Reserves (CASE No. 16, TABLE CXII, p. 889), taken three years after a complete secondary excision of the elbow joint for caries following shot perforation, by Dr. JOHN H. PACKARD. This was another example of "dangle-joint," in which the apparatus supplied by Dr. E. D. HUDSON, who contributed the photograph, proved of some service. Dr. PACKARD received, in 1870, letters from this pensioner, who, in June, 1875, was in good health.

<sup>3</sup> Besides the general treatises on excision or resection of joints, of which many have been cited, the student can refer to the following special papers on elbow-joint resection: THORE (A. M.) (*De la résection du coude, et d'un nouveau procédé pour la pratiquer*, Thèse, Paris, 1843) collects 82 cases of excision of the elbow: 14 for injury—12 recoveries and 2 doubtful; 68 for disease—48 recoveries and 20 fatal; and adds 3 cases operated on by himself, of which 1 proved fatal. NICKELS (G. J.), *Ueber die Resection im Ellenbogen-Gelenke*, Würzburg, 1837. BIER (II.), *De articuli humero-cubitalis resectione*, Bonnae, 1839. KYRIAKOS (P. G.), *De articuli humeri et cubiti resectione*, Diss. Berolini, 1854. KUPFER (O. R.), *Diss. inaug., casus duos resectionis partii humeri cubitalis sistens*, Jenae, 1855. TOBOLD (A.), *De articuli cubiti resectione*, Berolini, 1855. *Ueber die Resection des Ellenbogengelenkes*, Würzburg, 1856. MICHAUX, *Sur la resection du coude*, in *Bull. de l'Acad. Roy. de Méd. Belg.*, Bruxelles, 1856-7. BURGGRAEVE, *Plaie pénétrante de l'articulation du coude.—Arthrite traumatique. Guérison*, in *Bull. Soc. de Méd. de Gand*, 1857, T. XXIV, p. 140. BAUCHET, *Lésions traumatiques du coude*, in *Gaz. hebdomadaire de méd.*, Paris, 1858, T. V, p. 213. HEFFELDER (J. F.), *Resection des Ellenbogengelenkes*, in *Deutsche Klinik*, 1862, B. XIV, p. 9, *ibid.*, 1860, T. XII, pp. 292 and 301. BAAS (J. H.), *Die Resection im Ellenbogengelenke*, Giessen, 1860. KELLER (II.), *De articuli cubitalis resectione*, Berolini, 1861. PHILLIPS (G.), *De articuli cubitalis resectione*, Bonnae, 1861. DÜRER (P.), *Beitrag zur Resection des Ellenbogengelenkes*, Tübingen, 1861. LÜCKE (A.), *Zur Resection im Ellenbogengelenk*, in *Archiv für Klin. Chir.*, III, 1862, S. 352. DIESTERWEG (A. C. G. E.), *De resectione articuli cubiti*, Berolini, 1863. BARTH (C. T.), *Ueber die Resection des Ellenbogengelenkes*, Leipzig, 1863. MÜLLER, *De resectione articuli cubiti*, Berolini, 1864. BAKKER (P.), *Over resectie van het elleboogsgewricht*, Nieuwediep, 1864. DOUTRELEPONT, *Beitrag zu der Resection des Ellenbogengelenkes* (20 Fälle), in *Arch. für Klin. Chir.*, Berlin, 1865, VI, pp. 86-116. PAINETVIN (M.), *De la résection du coude*, Thèse, Paris, 1865. HAESCHKE (C. T.), *Ueber die Resection des Ellenbogengelenkes nach Schussverletzungen*, Leipzig, 1865. GIESKER (B.), *Über die Resection des Ellenbogen-Gelenkes*, Zürich, 1865. LÖWENTHAL (A.), *De resectionibus cubiti partialibus et totalibus*, Regimontii, 1866. TARDIEU (V.), *De la résection du coude et d'un nouveau procédé opératoire*, Montpellier Thèse, 1866. HELMBOLD (H. O.), *Drei Fälle doppelseitiger Ellbogengelenk-resectionen*, Jena, 1866. MARDUEL (L.), *De la résection sous-capsulo-périostée de l'articulation du coude*, Thèse à Paris, 1867. KOLBE (G. H.), *Über Resection des Ellenbogengelenkes*, Berlin, 1869. WILLIÈME, *Fracture comminutive de l'extrémité inférieure de l'humérus avec large plaie pénétrante de l'articulation du coude; résection sous-périostée immédiate d'une grande portion de la diaphyse humérale*, in *Bull. de l'Acad. de Méd. de Belg.*, T. III, 3<sup>e</sup> sér., p. 848. WIECZORECK (R.), *Zur Resection des Ellenbogengelenkes*, Breslau, 1869. MAUNDER (C. F.), *On primary Excision of the Elbow-joint*, in *Lancet*, 1869, Vol. I, p. 6. DELOUEY (E. S.), *Considérations générales sur la résection traumatique du coude*, Paris, 1870. STRENGER (E. R.), *Etwas über Ellenbogen-Gelenk-Resectionen*, Leipzig, 1870. SALTZMAN (F.), *Om Resektion i Armbagsleden*, Helsingfors, 1871. NEUDÜRFER, *Die Endresultate der Gelenk-Resectionen*, in *Wiener Med. Presse*, 1871. AUGÉ (A.), *De la résection du coude*, Paris, 1872. OLLIER, *Résection du coude*, in *Lyon médical*, 1872, p. 464. WEITHE (E.), *Beitrag zur Resection des Ellenbogengelenkes*, Greifswald, 1872. MURON (A.), *De la résection primitive du coude dans le cas de plaie par armes à feu*, in *Gaz. méd.*, Paris, 1872, T. XXVII, p. 238. COUSIN (A.), *Note pour servir à l'histoire de la résection du coude en temps de guerre*, in *L'Union Méd.*, Paris, 1873. PONCET (A.), *Nouvelles observations de résections sous-périostées du coude, démontrant la régénération des extrémités osseuses, la reconstitution d'une articulation solide et l'activité de l'extension par les contractions du triceps*, in *Gaz. des Hôp.*, 1873, p. 1018. ERTEL, *Ueber die Contusion des Ellenbogengelenkes bei Soldaten*, in *Deutsche Militärärztl. Zeitschr.*, Berlin, 1873, B. II, S. 33. MAYER (L.), *Zur Frage der partiellen Resectionen der Gelenke*, in *Deutsche Zeitschrift für Chirurgie*, 1873, B. III, S. 444. HUGELSHOFER (A.), *Ueber die Endresultate der Ellbogengelenkresection*, in *Deutsche Zeitschrift für Chir.*, 1873, B. III, p. 1. FOLLET, *Des indications et des résultats de la résection du coude*, in *Bull. méd. du Nord*, Lille, 1874, T. XIV, p. 37. D'ARLEUX (J. P. M.), *Considérations sur la résection du coude et particulièrement sur la pratique de cette résection en Angleterre*, Paris, 1874. GIRARD, *Zur Frage der Endresultate nach der Ellbogengelenkresection*, in *Deutsche Zeitschrift für Chirurgie*, Leipzig, 1874, B. IV, S. 246. ASHURST (J. J.), *On the Operative and Conservative Surgery of the Larger Joints: I, Excision of the Elbow*, Philadelphia, 1875.





Hirschinger phot.

J. Bier lith.

PLATE LIV.— RESULTS OF RESECTIONS AT THE ELBOW FOR SHOT INJURY

Fig 1. Case of Private J.F. Hertzog  
(See page 876)

Fig 2 Case of M.V. B. Keller  
(See page 889)





**AMPUTATIONS AT THE ELBOW JOINT.**—Forty examples of this operation are found on the returns, and the results were very satisfactory, since the ratio of mortality was far less than in amputations in the continuity of the upper arm.<sup>1</sup> Of thirty-nine determined cases, but three, or 7.6 per cent., terminated fatally, although five patients recovered only after submitting to re-amputation—three in the continuity of the upper arm, two by disarticulation at the shoulder.

Amputation at the elbow was first practised in this country July 4, 1821, by a military surgeon,—Surgeon James Mann, U.S.A.,—the operation being the fourth of the kind recorded in surgical annals.<sup>2</sup>

As indicated in TABLE CV, amputation at the elbow has been seldom practised for shot injuries directly interesting the joint; but more commonly for grave mutilations of the forearm, in which the only alternatives were disarticulation or amputation in the upper arm. In six only, of the forty cases, were the bones of the elbow fractured.

There are two accidents of war in which this operation<sup>3</sup> is often especially indicated, viz.: when a portion of the forearm is carried away by a large projectile, or when the forearm of an artilleryman is pulpified by the premature explosion of his gun while he is ramming the cartridge. In these cases, even if the limb is dismembered a little above the wrist, there are often such deep-seated lacerations that it is desirable to get above the tendinous and muscular insertions in removing the limb. Twelve of the forty disarticulations of this series were necessitated by one or the other of these forms of injury.

<sup>1</sup> At the date of publication of Circular No. 6, S. G. O., 1863, but *nineteen* amputations at the elbow had been found on the returns. These presented a gratifying uniformity of success (Circ. 6, p. 46). Twenty-one other authentic examples of the operation were subsequently reported, besides cases described as "amputations at the elbow," that proved, on investigation, to have been in reality amputations in the continuity, in the lower third of the humerus.

<sup>2</sup> Probably few readers of this work will fail to recall the terms in which Professor GROSS (*A System of Surgery*, 5th ed., 1872, Vol. II, p. 1110) adverts to this operation, expressing surprise that until recently it was performed so seldom, in view of "what an admirable stump it leaves, what little risk it involves, and how promptly the parts usually heal."

<sup>3</sup> The bibliography of this operation has been studied in an inaugural dissertation by ERNST F. L. THOMAS, of Gotha, (*Ueber die Exarticulation des Vorderarmes*, Würzburg, 1861), and in an extended monograph by Professor C. W. F. UHDE, of Brunswick (*Die Abnahme des Vorderarms in dem Gelenke Braunschweig*, 1865). The first recorded amputation at the elbow was by AMBROISE PARÉ, in 1536 (it is recorded in the Paris edition of 1575, in Chapter XXX of the *Livre des Contusions*, p. 413; *Histoire memorable d'une mortification advenue à un soldat, auquel le bras fut coupé à la jointure du coude*; in GUILLEMEAU's edition of 1582, at Chap. XXV, p. 379; in the Latin Frankfort edition of 1594, at Chapter XXV, p. 373; in UFFENBACH's *Thesaurus*, of 1610, Lib. XI, Cap. XXV, p. 379; in JOHNSON's English translation of 1634, Lib. XII, Chap. XXV, p. 463; in the Lyon edition of 1652, at Chap. XXXVII, p. 309; in MALGAIGNE's edition of 1840, in the XXVIII Chapter of the tenth book, T. II, p. 233), in a case of a soldier at Turin, whose left forearm became gangrenous after a lacerated wound by harquebuse ball. PARÉ recalls the precept of HIPPOCRATES, in the fourth section of his book *Περὶ ἀρθρῶν* (*Œuvres d'Hippocrate*, éd. LITTRÉ, T. IV, p. 285), in favor of amputations at the joints in gangrene, and describes the rapid recovery of the patient, despite an inter-current attack of tetanic spasms. MATTHIAS GOTTFRIED PURMANN (*Funffzig sonder- und wunderbahre Schuss-Wunden-Curen*, Franckfurt und Leipzig, 1721, S. 3, and *Chirurgia Curiosa*, Frankf. und Leipzig, 1699, p. 651,—the allusion omitted in COWPER's English translation of PURMANN, London, 1706, p. 211) relates, with disapprobation, an unsuccessful amputation at the left elbow joint, performed in 1671, by CHRISTIAN RAMPHUN, surgeon of the Götz regiment of foot, in the case of a musketeer, Christian Andersohn, wounded at Castle Türkshausen, by a falconet-shot. Great inflammation ensued, and cramps and convulsions on the third, and death on the fifth day. Although in his *Essai sur les Amputations dans les Articcles* (*Mém. de l'Acad. de Chir.*, 1774, T. V, p. 747), which still remains the basis of all modern dissertations on the subject, BRASOR had described and commended exarticulations at the elbow, the operation remained in desuetude for nearly a century and a half, when it was revived, in 1819, by CAJETAN TEXTOR (*Der Neue Chiron*, Sulzbach, 1823, B. 1, S. 126; see also, for a description of the mode of operation, SCOUTETTEN's oval method being commended, TEXTOR's *Grundzüge der Chirurg. Operationen*, Th. I, S. 420), in the case of a laceration, from blasting, of the left forearm of H. Keller, aged 41 years, who made a good recovery. In 1822, Dr. JAMES MANN (the distinguished author of *Medical Sketches of the Campaigns of 1812-14*, Dedham, 1816) printed, in the seventh volume of the *Medical Repository*, a paper entitled *Observations on Amputations at the Joints*, which appears to have attracted less attention than it merited in this country, although it has been much cited by European surgeons. It is an excellent argument in favor of amputations in the contiguity, showing a great familiarity with the literature of the subject, and embracing an account of a successful primary amputation at the elbow, in the case of an artillery soldier at Fort Independence, whose right forearm was carried away July 4, 1821, by the premature discharge of a cannon. Ignorant of MANN's important paper (since he was "not aware that the operation had been attempted at the elbow joint since it was performed by AMBROISE PERÉ"), Dr. J. KEARNEY ROGERS (*New York Med. and Phys. Jour.*, 1828, Vol. VII, p. 85) reports a successful amputation at the right elbow joint by antero-posterior flaps, in the case of a negro of 35 years, with a laceration of the forearm from the discharge of a musket at near range. Although Baron D. J. LARREY at first disapproved of amputations at the elbow, observing (*Mém. de Chir. Mil.*): "Nous ne parlerons de l'extirpation de l'avant-bras à son articulation avec le bras, parce qu'elle ne peut être utile au sujet qui serait dans le cas de la subir et qu'elle serait rarement suivie de succès" yet he subsequently (*Clin. Chir.*, 1836, T. V, p. 202) cited the recovery of Sergeant-major Labuerrasse, whose right forearm was torn off at the elbow, in 1793, by a cannon ball, remarking, "ce succès prouve que l'on peut, dans quelques cas, pratiquer l'amputation du membre thoracique dans l'articulation huméro-cubitale." DUPUYTREN (*Leçons orales de clin. chir.*, 2ème ed., 1839, T. II, p. 343) warmly advocated amputations at the elbow, and the editors of SABATIER-DUPUYTREN (*De la Méd. Op.*, 1832, T. IV, p. 653), MM. SANSON and BEGIN, speak as if the master frequently practised the operation ("Sept ou huit fois avec succès"), although none of the individual cases are recorded. DUPUYTREN proposed a well-known anterior flap operation and the division of the olecranon by the saw, in place of BRASOR's more complex procedure. LISTON also (*Practical Surgery*, 3d ed., 1840, p. 366) declared that the operation might be performed with advantage, and that he had done it "more than once on the living body, and should be disposed to repeat it in favorable cases." V. WALTHER, according to ZANDERS (*Die Ablösung der Glieder in den Gelenken*, Düsseldorf, 1831), and JAEGER (*Hand-*



**Primary Disarticulations.**—Twenty-eight of the forty disarticulations at the elbow were primary—operations with but one fatal result,—in a patient who submitted to a simultaneous amputation of the left leg. Sixteen of the primary disarticulations were at the right, and twelve, including the fatal case, at the left elbow.

CASE 1836.—Private C. McDavitt, Co. K, 19th Massachusetts, aged 23 years, was wounded at Fredericksburg, December 13, 1852. Assistant Surgeon V. R. Stone, of the regiment, recorded: "Gunshot fracture of arm; amputated. Transferred to General Hospital." Surgeon H. Bryant, U. S. V., recorded the man's admission to Lincoln Hospital, Washington, December 23d, with "amputation in consequence of compound comminuted fracture of both bones of right forearm by minié ball, and slight flesh wound of left leg." The patient was subsequently transferred to Lovell Hospital, Portsmouth Grove, whence he was discharged May 28, 1853, and pensioned. Examiner B. T. Shaw, of Boston, June 4, 1853, certified: "Was wounded by a ball which caused a compound comminuted fracture of his right forearm, which required amputation at the elbow joint. He was also wounded by a minié ball in the calf of the left leg at the same time, badly injuring the muscles and tendons, so that he is lame." In March, 1864, the pensioner was furnished with an artificial limb by M. Lincoln, of Boston, who described the amputation as having been performed by the "circular method (though very uncertain)." Dr. B. B. Breed, of Lynn, Mass., late surgeon U. S. V., in answer to a request of the Surgeon General, U. S. A., communicated, July 19, 1855: "I have examined the case of C. McDavitt, late private, Co. K, 19th Massachusetts. McDavitt is a man of good intelligence, and after his discharge from the 19th received a commission in the 4th Massachusetts Heavy Artillery. His arm was amputated for gunshot fracture of the forearm at the elbow joint. The arm is very thin, and bears marks of numerous cicatrices where collections of pus have been opened. The skin is drawn rather tightly over the condyles, and is thin and tender. He thinks the stump would have been much sounder if the amputation had been performed two inches higher. His principal objection to the operation is, however, that in fitting an artificial limb the maker was obliged to make the joint two inches below the extremity of the stump, thus making an awkward and useless limb. He has only worn it for a few days, and states that it is as good as so much cord-wood, and no better." It proved a great encumbrance, and not of the slightest benefit. The operation was performed by Surgeon N. Hayward, 20th Massachusetts," etc. In a communication dated July 21, 1853, the pensioner stated that "his arm was amputated on the day following the injury," and that "the stump healed up about four months after his discharge from service, and had given no trouble since." The pensioner was paid September 4, 1875.

*wörterbuch der gesammten Chirurgie*, Leipzig, 1836, B. I, S. 363-368), and LANGSTAFFE, according to UHDE (*l. c.*, S. 64), practised this operation for disease. BAUDESS (*Clinique des plaies d'armes à feu*, 1836, p. 579) insisted on the utility or the operation in military surgery, and reported a successful case, 1—, 15th Carbineers, together with some instructive criticisms on the methods of operating. Baron PIROGOFF advocated the operation (*Zeitschrift für die gesammten Medicin von OPPENHEIM*, Hamburg, 1842, S. 567, and *Rapport mé. d'un Voyage au Caucase*, St. Petersburg, 1849, pp. 175-182), and reported three cases, with one death. In the revolution in Paris, in 1848, MALGAIGNE especially, and JOBERT, defended this amputation, and each of them practised it in two instances of shot wounds (MALGAIGNE, *Gaz. Méd.*, 1848, Nos. 32-35, and *Méd. Op.*, 7ème ed., 1861, p. 311; JOBERT, *Gaz. Méd.*, 1848, No. 37). BAUDESS also (*Plaies d'armes à feu, Discussion à l'Académie de Méd.*, 1849, p. 223) reports a fatal disarticulation at the elbow, of June 23, 1848, the case being complicated by a penetrating shot wound of the chest, for which reason, doubtless, it has been rejected by Dr. UHDE. Dr. STEINER, a Baden regimental surgeon, in 1849 (B. BECK, *Die Schusswunden im Kriege 1848-49*, Heidelberg, p. 328), Dr. H. SCHWARTZ (*Beiträge zur Lehre von den Schusswunden*, Schleswig, 1854, S. 222) in 1841, and M. E. SOULÉ (*Gaz. des Hôp.*, 1851, p. 114) in 1850, each successfully disarticulated at the elbow in cases of shot injury; and Dr. PERENGER, of Coburg (UHDE, *l. c.*, p. 6), had a successful case in 1855. This brings us to the extraordinary series of exarticulations at the elbow ascribed to M. SALLERON during six months' service in the Crimean War. Professor UHDE (*l. c.*, S. 64) and M. LEGUEST (*Chir. d'Armée*, 1863, p. 723) state that M. SALLERON had twenty-six disarticulations at the elbow with five deaths. In M. SALLERON'S own report (*Des Amp. Prim. et des Amp. Conséc.*, dans *Recueil de Mém. de Méd. de Chir. et de Phar. Mil.*, 1858, T. XXI, p. 281, et T. XXII, p. 240), however, only twenty cases are tabulated—three primary and sixteen consecutive amputations for shot injury, with three deaths among the deferred operations, and, in addition, one fatal case of amputation at the elbow for compound fracture. M. SALLERON does not claim to have practised all of these operations in person; but describes them as treated at Dolma-Bagtelé Hospital, at Constantinople. It is known that M. LEGUEST (*Chir. d'Armée*, 1863, p. 724, et 2ème éd., 1872, p. 557, and letter of M. LEGUEST, Nov. 8, 1863, in UHDE, *l. c.*, p. 61) had one successful disarticulation at the elbow for shot injury, that M. MAUPIN (*Souvenir d'Orient, Amp. prim. et consé. faites en Orient*, 1857, p. 17, et *Rec. de Mém. de Méd. de Chir. et de Phar. Mil.*, 1857, 2ème série, T. XIX, p. 292) had two such successes, and that M. MAILLEFER also practised the operation. Indeed, M. CHENU (*Rapport, etc., Camp. d'Orient*, 1865, p. 291) details by name the cases of twenty-six (26) French Crimean pensioners who had undergone disarticulation at the elbow, and mentions a twenty-seventh case of recovery, the patient being discharged cured. But, in his tabular statement, M. CHENU gives the formidable offset of fifty-two (52) deaths (p. 289), instead of twenty-one deaths as recorded by M. LEGUEST; but it seems impossible to arrive at a precise estimate of the total number of the operations and their results, unless the statements of the official reporter, M. CHENU, be accepted,—*i. e.*, seventy-nine operations with fifty-two deaths, or a mortality rate of 65.8 per cent. M. SALLERON, after the Italian War of 1859, is said (UHDE, *l. c.*, p. 66) to have had three amputations at the elbow, with one death. Signor PARAVICINI had one successful and one fatal case in the same campaign (PARAVICINI, *L'Ospitale militare a Santa Maria di Lorcio*, etc., Milano, 1860, p. 27); and DEMME (*Studien*, u. s. w., 1861, S. 237, Dritter Fall) records another successful case, in a soldier wounded at Solferino. In his *Campagne de Kabylie*, 1854-6-7, Paris, 1862, p. 317, M. A. BERTHERAND tabulates two amputations at the elbow, one resulting fatally. CHENU (*Camp. d'Italie, op. cit.*, 1869, T. II, p. 609) tabulates six cases of disarticulation at the elbow for shot injury, with five deaths; two of the cases just cited from SALLERON are probably included in this return. UHDE (C. W. F.) (*Die Abnahme des Vorderarms in dem Gelenke*, Braunschweig, 1865, S. 51) records a primary successful exarticulation at the elbow in the case of Severdt, aged 24 years, wounded by machinery, August 28, 1852, and, in the following year (*l. c.*, S. 56), the same surgeon reports an unsuccessful operation in the case of a woman of 34 years, injured by machinery, October 12, 1861. M. MARTENOZ, of Lyons, communicates to Dr. UHDE (*l. c.*, S. 56) a successful secondary exarticulation at the elbow, June 14, 1863, for compound fracture three months previously. BECK (B.) (*Chir. der Schussverletzungen*, 1872, S. 143) records a successful intermediary amputation at the elbow for comminution of the radius followed by uncontrollable hæmorrhage. HORWITZ (P. J.) (*Annual Rep. of the Chief of the Bureau of Medicine and Surgery of the United States Navy*, for 1863) records two successful amputations at the elbow practised by naval medical officers during the Rebellion. SOCIN (A.) (*Kriegs-chir. Erfahr.*, 1872, S. 153) records two successful exarticulations at the elbow at the hospital at Carlsruhe. Dr. J. C. CHENU, in his *Aperçu Hist. Stat. et Clin. pendant la guerre 1870-71*, Paris, 1874, T. I, p. 492, tabulates an extraordinary number of 133 disarticulations at the elbow for the effects of shot injury, with 101 deaths, or the excessive death-rate of 75.9 per cent. Probably the cases referred to in the following authors are included in M. CHENU'S appalling return: TACHARD (E.) (*Reflexions servir à l'histoire de la chir. en campagne, Gaz. des Hôp.*, 1871) enumerates five cases of amputation at the elbow, with three deaths. MAC'ORMAC (W.) (*Notes, etc., op. cit.*, p. 95) records two secondary fatal elbow amputations at Asfeld, in October and November, 1870. M. LEPAT (in *Grellois, Hist. Méd. de Blocus de Metz*, 1872, p. 348) mentions two successful amputations at the elbow, at the ambulance de l'esplanade. M. ARNAUD (*Ibid.*, p. 353) records two successful exarticulations at the elbow at the engineer barracks.

In several instances, there were complaints that the stumps formed by disarticulation at the elbow were ill-suited for the adaptation of an artificial limb:

**CASE 1837.**—Sergeant S. C. Clobridge, Co. G, 115th New York, aged 22 years, was wounded in the right forearm at Chapin's Farm, September 29, 1864. He was admitted to the field hospital of the 2d division, Tenth Corps, where amputation at the elbow joint was performed. On the following day he was admitted to the base hospital at Point of Rocks, where Surgeon H. P. Porter, 10th Connecticut, noted: "Gunshot wound of arm. Patient transferred to General Hospital October 26th." Assistant Surgeon E. McClellan, U. S. A., reported his admission to the Fort Monroe Hospital on October 27th, with "amputation of right arm," and his departure from the hospital "on furlough January 27th." Three months afterward the patient entered Ira Harris Hospital, Albany, whence Assistant Surgeon J. H. Armsby, U. S. V., contributed the cast represented in the annexed wood-cut (FIG. 660). On July 18, 1865, the patient was discharged from service and pensioned. Several weeks afterward he was furnished with an artificial limb by the National Leg and Arm Company, of New York. In a communication dated Albany, New York, August 10, 1866, the pensioner recounted the facts of his case as follows: "I was wounded by a piece of a shell, the larger part of my right forearm being completely carried away, resulting in the amputation of my arm at the elbow (unjointed). I was immediately taken to the field hospital, about one mile distant, where Surgeon C. Macfarlane, of my regiment, performed the operation of amputation. The operation was circular, and said by many to be a good one. I was then sent to City Point, where my arm was treated by different surgeons whose names I am not acquainted with; the attention I received there was the very best. The dressing consisted of oakum and cold water. After about two weeks treatment at this hospital I was sent to Fortress Monroe, where—I am very sorry to say—I received poor care from both doctors and nurses. I was soon attacked with gangrene, which had the awful effect always following that disease. They then used a wash termed disinfectant, which soon checked the disease, but not until about one-half inch of the entire end of the stump had sloughed off, leaving my arm in a much worse state than when first amputated. Creasote was then used freely by one doctor, while another banded with cold water; the latter process I liked the best. They soon, however, commenced to use simple syrup, which was the principal dressing used till my arm healed. It was about the middle of February, 1865, when I received a furlough to visit my home at Saratoga. On my arrival home I found that my arm was much worse than when I started from Fort Monroe, being on the road so long without dressing it. The proud flesh showed itself, for which the doctor applied caustic. But my arm not seeming to do well at all, I effected a transfer to Albany, where I received treatment at the Ira Harris U. S. A. General Hospital. \* \* \* My arm is now healed, but very tender from the effects of the gangrene. \* \* \* For this reason my artificial arm is of no possible use to me. I have now had it about one year, but have not worn it more than a dozen times at the most." Drs. Ferguson, Smith, and Hogan, of the New York City Examining Board, December 9, 1874, certified: "The right arm has been amputated through the elbow joint." This pensioner was paid September 4, 1875.



FIG. 660.—Cast of stump of right arm after amputation at the elbow. Spec. 2854.

**CASE 1838.**—Private J. Caseman, Co. D, 25th Kentucky, aged 32 years, received a gunshot wound of the left forearm at Nashville, October 3, 1863. He was admitted to Hospital No. 8, whence Acting Assistant Surgeon O. J. Vincent contributed the following detailed history: "He was shot by a drunken guard at the barracks, and was immediately brought to this hospital for treatment. There had been considerable hemorrhage. The wound was through the upper third of the forearm, the radius being shot through, cutting it off, and the ulna shot through; the radial and interosseous arteries wounded. Amputation was decided upon. Administered tincture of opium a drachm and whiskey two ounces. After the patient had rallied, chloroform was given, and amputation at the elbow performed by Acting Assistant Surgeon T. J. Karber, as follows: Anterior flap taken from forearm; internal condyle and portion of outer condyle sawed off, leaving the olecranon with the triceps attached; vessels well secured after the posterior flap was made; flaps adjusted and secured by sutures. The patient bore the operation well, was placed in bed, given tincture opii one-half drachm and spirits two ounces, and permitted to rest. October 4th, patient rested well through the night; has some fever this morning; tongue coated; gastric irritation with vomiting; pulse accelerated; arm somewhat swollen; pain slight; bowels constipated. 5th, constipation continues, also the gastric irritation; tongue furred; headache; thirst; fever. Gave an enema of salt and water. 6th, gastric irritation continues, also fever and furred tongue; suppuration commenced. Gave enema of salt and water. Slight evacuation of bowels took place. Gave two ounces of sulphate of magnesia and dressed arm with cold water. 7th, full evacuation of bowels has taken place; patient feels better; symptoms of excitement subsiding; suppuration continues with considerable fetor; some sloughing at corresponding point with the inner condyle. Used a wash with chlorinated solution of soda and continued the dressing. 8th, fever subsiding; suppuration increasing and fetid. Continued the dressing. No changes were made in the treatment, the wound doing well up to October 21st, when the ligatures came away, and the wound was dressed with adhesive straps. 27th, patient somewhat restless; hardness and soreness near the point of the inner condyle. 28th, patient has had a severe chill; erythema on posterior portion of arm; fever; nausea; headache; furred tongue; rapid pulse and thirst. Gave pills of mercury eight grains. 29th, patient has had another severe chill. Dressed the arm with cloths saturated with a mixture consisting of camphor water one pint, tincture opii one ounce, and glycerine two drachms. 30th, gave sulphate of magnesia two ounces. Patient has evacuation of bowels. Erythema extends to back; arm is better. 31st, erythema extends still farther and to opposite side of back. Continued dressing, and gave sulphate of quinine twelve grains per diem. Wound improving. November 1st, case convalescing; patient feels comfortable. 18th, patient has been improving gradually up to the present date." Surgeon W. C. Otterson, U. S. V., in charge of the hospital, reported that the patient left "on furlough January 25, 1864." He entered the Marine Hospital, Cincinnati, February 6th, and was discharged from service May 18, 1864, and pensioned. In his application for commutation for an artificial limb he described the stump as having "shrunk away very considerably." The pensioner died September 23, 1874.



The next case illustrates the group in which disarticulation at the elbow is required, in artillerymen using the rammer, by disorganization of the forearm from the premature explosion of a cannon. The patient submitted to secondary disarticulation at the shoulder:

CASE 1839.—Private C. H. Alexander, Battery B, Maryland Light Artillery, aged 35 years, was wounded at Malvern Hill, July 1, 1862. Acting Assistant Surgeon J. A. Draper furnished the following history from Chester Hospital: "While loading one of the guns it accidentally went off, carrying away the greater portion of his right forearm. The remaining portion of the shattered bones were taken off by an amputation at the elbow joint, in which the operator removed the olecranon process but left the condyles intact. The next morning the patient was taken prisoner and removed to Richmond, where he remained three weeks. He was admitted to this hospital on the 29th of July. According to the patient's statement, he had no power whatever over the arm since receiving the injury, and the stump had been exceedingly painful since the operation. When admitted, the stump was in a swollen and exceedingly painful condition, with a discharge sometimes of a sanious and sometimes of a serous character. After a long and careful course of treatment by Acting Assistant Surgeon L. Fassitt, the stump healed and became reduced to its natural size, but the patient gained no power over the limb. Dr. Fassitt having gone away, the patient came under my care about the 1st day of October. I found the stump still very painful, so much so that the patient could sleep only when under the influence of morphia. The deltoid muscle was greatly atrophied, the capsular ligament completely relaxed, and the stump, so far as motion was concerned, hung dead by the patient's side. On consultation with the surgeons attached to the hospital it was thought proper to amputate at the shoulder joint. The operation was performed by the oval flaps of Larrey, on the 9th of October. The flaps were closed in the ordinary manner, and dressed with a wash containing acetate of lead and opium. The patient has steadily recovered without an untoward symptom. On dissecting the stump the radial nerve was found bulbous from the lower end to above the middle of the arm, and the ulnar nerve pressed against the inner condyle by the adherent skin." The specimen, represented in the adjacent wood-cut (FIG. 661), was contributed by the operator; and the lower half of the humerus only is preserved, the extremity being somewhat eroded, while on the posterior surface of the outer condyle there is a thin deposit of callus. The patient was discharged from service January 31, 1863, and pensioned. He was paid September 4, 1875. I have ascertained that Assistant Surgeon J. S. O'Donnell, Purnell's Maryland Legion, was the operator at the first amputation. [Compare the entry of this case, in TABLE XLVIII, Case 1, p. 647.]

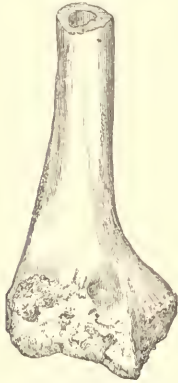

FIG. 661.—Lower half of right humerus after disarticulation at the elbow. *Spec 271.*

Among the primary disarticulations there were three other examples of re-amputations; these were in the continuity, one intermediary and two secondary—one at the middle and two at the upper thirds.<sup>1</sup>

**Intermediary Disarticulations.**—Five patients submitted to early intermediary disarticulation at the elbow; two were amputated on the third, one on the fifth, one on the seventeenth, and one on the twenty-first day from the date of injury. All recovered; but, in the following instance, only after submitting to secondary amputation at the shoulder joint. Four were discharged and pensioned; the fifth, Bush, was a deserter when wounded.

CASE 1840.—Private J. C. Eldridge, Co. II, 4th Tennessee Cavalry, aged 20 years, was wounded in the left forearm and hand by the accidental discharge of his pistol, while disembarking with his regiment from a steamer at Memphis, February 16, 1865. He was admitted to the Washington Hospital, where he was operated on by Surgeon D. Stahl, U. S. V., who made the following report: "The ball entered at the posterior surface of the forearm, lower third, and emerged at the upper end of the metacarpal bone of the thumb, causing compound fracture of the ulna, radius, and carpal bones, the ulna being very badly shattered and split up. March 5th, constitutional condition of patient very debilitated and showing typhoid symptoms; pulse 130, small and weak; tongue dry; the wound discharging an offensive sanious fluid. Amputation at the elbow joint was performed by circular operation. Hardly any hæmorrhage occurred. Chloroform was used, and three ligatures were applied. The patient reacted promptly. The treatment consisted of punch and porter and cod-liver oil. The wound was dressed with permanganate salts." On May 15th, the patient was transferred to the Gayoso Hospital, where he was mustered out of service September 12, 1865. In his application for pension he stated that, owing to gangrene having set in, the arm was re-amputated by the same operator—Surgeon Stahl—at the shoulder joint, on June 28, 1865. Drs. T. H. Roddy and C. H. Smith, of Hamilton county, Tennessee, December 22, 1866, certified that they carefully examined Eldridge and found that he had suffered "amputation at the left shoulder joint." The pensioner was paid September 4, 1875.

Four of the intermediary disarticulations were on the left, and one on the right side. In one of the intermediary cases (CASE 6, TABLE XXII) symptoms of tetanus supervened, which were relieved, by Acting Assistant Surgeon Bowen, by division of the median nerve, which had been included in the ligation of the brachial. An interesting abstract of this case has been published.<sup>2</sup>

<sup>1</sup> Viz: CASE 29, p. 914, of Pt. H. Peters, 4th Artillery; compare CASE 165, TABLE LXXVI, p. 757;—CASE 6, of Serg't W. H. Bower, 1st New York Artillery; compare CASE 11, TABLE LXXXIV, p. 777;—CASE 18, of Pt. C. Herman, 1st Massachusetts; compare CASE 61, TABLE LXXXVI, p. 785.

<sup>2</sup> BUTLER (W. H.), *Remarks on Tetanus, with Histories of Nine Cases*, in *Am. Med. Times*, 1863, Vol. VII, p. 150.

**Secondary Disarticulations.**—There were two secondary disarticulations at the elbow. One (CASE 4, TABLE CXXII) a fatal case, reported without details. The other, narrated below, was a re-amputation on account of gangrene, with protrusion of the ends of the ulna and radius, after an intermediary amputation in the forearm, which failed to arrest the progress of gangrene following a shot wound of the fingers. A sound stump resulted from the disarticulation at the elbow. The two secondary operations were of the right elbow.

CASE 1541.—Private M. Burroughs, Co. A, 148th New York, aged 18 years, was wounded at Cold Harbor, June 2, 1864. Assistant Surgeon C. A. McCall, U. S. A., reported his admission to Mount Pleasant Hospital, Washington, June 6th, with "Gunshot wound of right hand." On June 10th, the patient entered McDougall Hospital, New York, where Acting Assistant Surgeon F. H. Hamilton, jr., recorded the following history: "He was wounded by a rifle ball entering the hand on the palmar surface, passing obliquely through, and making its exit on the dorsum. The metacarpal bones of the little and ring fingers were broken and badly comminuted. The wound looked well until the 15th of June, when it was attacked with hospital gangrene. On the first examination of the condition of the wound sloughing had produced an ulcer two inches in diameter, and the hand and forearm were much inflamed. Pure nitric acid was applied twice, which nearly arrested the disease. On June 27th, the patient was seen by Assistant Surgeon H. M. Sprague, U. S. A., in charge, and amputation being advised, it was performed by him the same day. The operation was by double flaps at the lower third of the forearm. The constitutional state of the patient at the time of the operation was in good condition and not much reduced. The stump looked well until about the 2d of July, when it was discovered that gangrene was present and the sutures had given away. The stump was laid open and the bones bare, and pure nitric acid applied, which stayed the progress somewhat. July 16th, since the last application of nitric acid—on July 2d—two applications have been made of bromine one part to three parts alcohol. The bones are now protruding one inch and the gangrene is nearly arrested. The general state of the patient is not very much prostrated, considering the nature of the wound and its result. He is receiving generous diet, with tonics and stimulants." Re-amputation was subsequently performed at the elbow joint, the precise date of which operation has not been ascertained. The patient was discharged from service August 26, 1864, by reason of "loss of right forearm, amputated at the elbow joint." In the following year he was furnished with an artificial forearm by J. M. Grenell & Co., of New York, who in their surgical statement described the case as a "flap amputation at the elbow joint." In his application for commutation the pensioner stated that he wore the artificial limb only a few times; that it was heavy and made the stump sore, etc.; also that the stump was then—in 1870—in a sound condition. Assistant Surgeon Sprague, the operator at the first amputation in this case, is also alleged by the pensioner as having performed the subsequent disarticulation at the elbow joint. The pensioner was paid September 4, 1875.

**Disarticulations of Uncertain Date.**—In five of the amputations at the elbow, the period intervening between the date of injury and operation could not be ascertained. Two of the disarticulations were on the right and two on the left side. In the fifth case, this point was not noted. One case, a shot comminution of the ulna, proved fatal.

RECAPITULATION.—Of forty patients who submitted to disarticulation at the elbow for shot injury, thirty-six recovered, three died, and the ultimate history of one case could not be traced. Eighteen operations were on the left, twenty-one on the right side, and one undetermined. Circular and flap incisions were employed in about equal proportion in the instances in which the method of operation was mentioned. Thirty-six of the patients were Union, and four Confederate soldiers. The forty cases of the four groups appear below:

TABLE CXXII.

*Summary of Forty Cases of Amputation at the Elbow Joint for Shot Injury.*

NO.	NAME, AGE, AND MILITARY DESCRIPTION.	DATE OF INJURY.	NATURE OF INJURY.	DATE OF OPERATION.	OPERATION AND OPERATOR.	REMARKS.
1	Adams, I. R., Pt., D, 11th Michigan, age 18.	Sept. 20, 1863.	Grapeshot wound of right forearm; tissues disorganized.	Sept. 23, 1863.	Circular amputation	Discharged November 1, 1863; pensioned.
2	Adams, L., Pt., A, 20th New York, age 21.	April 2, 1865.	Compound comminuted fracture of right forearm, involving elbow joint, by shell.	April 2, 1865.	Flap amputation; extensive slough; much constitutional prostration.	Discharged August 30, 1865; pensioned. Healthy stump.
3	Alexander, C. H., Pt., Battery B, Maryland Light Artillery, age 35.	July 1, 1862.	Right forearm carried away. Compare CASE 1, TABLE XLVIII, p. 647.	July 1, 1862.	Amputation, by Asst. Surg. J. S. O'Donnell. See CASE 1830, p. 912.	Oct. 9, re-amputation at shoulder joint. Discharged Jan. 31, 1863; pensioned. A. M. M., Spec. 271.
4	Allen, N. P., Pt., II, 22d Illinois.	Dec. 31, 1862.	Fracture of right radius and ulna.	March, 1863.	Amputation at elbow.	Died March 16, 1863.
5	Ballman, A., Corp'l, C, 52d New York, age 38.	May 18, 1864.	Shot wound of left forearm, involving elbow joint.	May 18, 1864.	Amputation, by Surg. M. Froehlich, 53d New York.	Purloughed July 7, 1864. Not a pensioner.
6	Bower, W. H., Serg't, L, 1st New York Light Artillery, age 35.	Aug. 21, 1862.	Shell fract. of left forearm. See CASE 11, TABLE LXXXIV, p. 777.	Aug. 21, 1862.	Flap amputation.	Stump healed. Disch'd Nov 10, 1862; pens'd. Re-amputation.



No.	NAME, AGE, AND MILITARY DESCRIPTION.	DATE OF INJURY.	NATURE OF INJURY.	DATE OF OPERATION.	OPERATION AND OPERATOR.	RESULT AND REMARKS.
7	Boutright, J., Pt., G. 2d Louisiana.	1862.	Shot wound of left forearm....	1862.	Amputation at left elbow.....	Furloughed October 8, 1862.
8	Burgin, J., Pt., B, 23d Indiana, age 35.	Oct. 8, 1862.	Shot wound of right forearm..	Oct. 10, 1862.	Amputation, by Surgeon G. W. Phillips, 75th Illinois.	Discharged Dec. 28, 1862; pensioned. Stump healthy.
9	Barroughs, M. Pt., A, 148th New York, age 18.	June 2, 1864.	Comminuted fracture of metacarpal bones.	June 27, 1864.	Amputated by Asst. Surg. H. M. Sprague, U. S. A. See CASE 1841, p. 913.	Discharged August 26, 1864; pensioned.
10	Bush, E., Pt., A, 104th New York, age 24.	Nov. 23, 1863.	Ball entered between the radius and ulna at left wrist; intense pain and swelling; colliquative diarrhœa.	Dec. 14, 1863.	Antero-posterior flap operation, by Surg. E. Bentley, U. S. V.	Discharged April 20, 1864. Rejected as a pensioner.
11	Caseman, J., Pt., D, 23d Kentucky, age 32.	Oct. 3, 1863.	Fracture of left radius and ulna.	Oct. 3, 1863.	Amput'd, by A. A. Surg. T. O. Karber, See CASE 1837, p. 911.	Discharged May 18, 1864; pensioned. Died Sept. 23, 1874.
12	Clobridge, S. C., Serg't, G, 115th New York, age 18.	Sept. 29, 1864.	Portion of right forearm carried away by a shell.	Sept. 29, 1864.	Amputation, by Surg. C. Macfarlane, 115th New York.	Discharged July 18, 1865; pensioned. CASE 1838, p. 911.
13	Burke, J. H., Capt., A, 146th New York, age 26.	May 1, 1863.	Fract. of both bones left forearm and divis'n of ulnar and radial arteries: also w'd of abdomen.	May 2, 1863.	Circular amputation, by Dr. Todd, 52d Georgia, and Dr. Watts, of North Carolina.	Discharged May 17, 1864; pensioned.
14	Eldridge, J. C., Pt., H, 4th Tennessee Cav., age 20.	Feb. 16, 1865.	Shot fræc. left ulna, radius, and carpal bones by pistol ball.	Mar. 5, 1865.	Circular amputation, by Surg. D. Stahl, U. S. V.	Discharged September 12, 1865. pensioned.
15	Gallagher, P., Pt., I, 1st Infantry.	June 15, 1863.	Shell wound of left forearm ..	June 15, 1863.	Amputation, by A. Surg. J. W. Van Brunt, 103d Illinois.	Discharged August 27, 1863; pensioned. Sound stump.
16	Gates, A., Pt., I, 97th New York, age 35.	May 10, 1864.	Shot wound of left hand; metacarpal bones badly comminuted. May 10, amp. fourth finger; hand and lower third of forearm gangrenous; arm œdematous to shoulder.	May 15, 1864.	Amputation, by Surgeon E. Bentley, U. S. V., by circular flaps; five ligatures applied.	Discharged September 2, 1864; pensioned. Healthy stump.
17	Gould, G. W., Pt., I, 8th New York H. A., age 21.	June 16, 1861.	Shot fracture of left forearm, involving elbow joint.	June 16, 1861.	Ant.-post. flap amputation, by Surg. M. F. Regan, 164th N. Y.	Disch'd Oct. 22, 1861; pensioned. Stump very tender (1870).
18	Herman, C., Pt., E, 1st Massachusetts, age 44.	June 30, 1862.	Shot wound of right forearm..	June 30, 1862.	Amputation at elbow joint. See CASE 61, TABLE LXXXVI, p. 785.	Discharged Sept. 5, 1862; pensioned. Re-amputated in middle third: good stump.
19	Hinkle, R., Corp'l, F, 67th Ohio, age 24.	Oct. 13, 1864.	Shot fracture of right forearm	Oct. 13, 1864.	Amputation, by Surg. J. Westfall, 67th Ohio.	Discharged April 8, 1865; pensioned. Good stump.
20	Johnson, W. C., Pt., B, 4th Delaware, age 50.	Feb. 28, 1863.	Shot wound of right wrist, passing toward elbow.	Feb. 28, 1863.	Amputation, by Surg. D. S. Hopkins, 4th Delaware.	Discharged May 17, 1863; pensioned. Stump healed.
21	Kress, W. B., Pt., H, 75th Indiana, age 30.	June 18, 1864.	Shot fracture, involving right elbow joint.	June 18, 1864.	Amputation, by Surgeon C. S. Arthur, 75th Indiana.	Disch'd Nov. 29, 1864; pensioned. Stump perfectly sound.
22	Kurtz, M., Pt., I, 53d Pennsylvania, aged 20.	May 12, 1864.	Fracture of right ulna, implicating elbow joint.	May, 1864.	Amputation at elbow joint....	Died June 3, 1864, from exhaustion.
23	McAuliffe, J., Pt., I, Cobb's Legion.	1864.	Shot wound.....	1864.	Amputation at right elbow joint.	Furloughed November 18, 1864.
24	McDavitt, C., Pt., K, 19th Massachusetts, age 25.	Dec. 13, 1862.	Shot compound comminuted fracture of both bones of right forearm; also flesh wound of left leg.	Dec. 14, 1862.	Circular amputation, by Surg. N. Hayward, 20th Massachusetts. See CASE 1836, p. 910.	Disch'd May 28, 1863; pensioned. Stump healed but tender; lameness of left leg.
25	Montgomery, T., Lieut., A, 170th New York, age 28.	May 18, 1864.	Wound of left forearm by a cannon ball. (Wound of neck, July 1, 1861.)	May 18, 1864.	Amputation.....	Discharged October 18, 1864; pensioned. Stump healed.
26	Moore, H. G., Pt., K, 148th Pennsylvania, age 33.	June 3, 1864.	Comminution of bones of right forearm by shell and laceration of soft tissues.	June 3, 1864.	Flap amputation, by Surgeon G. L. Potter, 145th Pennsylvania.	Discharged June 1, 1865; pensioned. Sound stump.
27	Murphy, J., Serg't, E, 47th New York, age 23.	Aug. 16, 1864.	Shell wound of middle third of left forearm, fracturing bones to elbow joint; joint opened.	Aug. 16, 1864.	Amput'n at elbow joint and condyles of humerus removed, by Surg. J. R. Everhart, 97th Pa.	Disch'd July 7, 1865; pensioned. Stump very tender (1870).
28	Newman, E., Pt., A, 8th N. Y. Heavy Art., age 19.	June 3, 1864.	Shell wound of right forearm.	June 4, 1864.	Amputation by circular incisions, by Surg. C. H. Pegge, 8th New York Heavy Art.	Disch'd Jan. 28, 1865; pensioned. Stump sore and tender (1870).
29	Peters, H., Pt., D, 4th Art., age 22.	Jan. 30, 1863.	Shell wound of left forearm ..	Jan. 30, 1863.	Flap amputation at elbow joint. Sloughing. See CASE 165, TABLE LXXXVI, p. 757.	Feb. 16, re-amp. in upper third by flap. Disch'd July 28, 1863; pensioned; stump healed.
30	Pulleu, F., Pt., A, 109th Colored Troops, age 21.	Dec. 5, 1864.	Shot fracture of left wrist and forearm.	Dec. 8, 1864.	Amputation.....	Discharged April 14, 1865; pensioned. Good stump.
31	Rowan, S. W., Corp'l, A, 2d South Carolina.	1862.	Shot wound.....	1862.	Amputation at left elbow joint.	Furloughed December 19, 1862.
32	Selley, G., Pt., B, 117th New York, age 48.	Jan. 15, 1865.	Shot fracture of upper third of left forearm.	Jan. 15, 1865.	Circular amputation, by Surg. G. C. Jarvis, 7th Connecticut.	Disch'd Aug. 2, 1865; pensioned. Died July 27, 1869.
33	Scorton, S. J., Pt., H, 2d North Carolina Battery.	July, 1863.	Wound.....	1863.	Amputation at elbow joint...	.....
34	Spaulding, E. A., Pt., K, 8th N. Y. Heavy Art., age 17.	June 3, 1864.	Fracture of right forearm by minié ball.	June 3, 1864.	Flap amputation, by Surg. M. Rizer, 72d Pennsylvania.	Discharged October 3, 1864; pensioned. Sound stump.
35	Stoltz, B., Lieut., A, 15th New York Art., age 28.	Mar. 31, 1865.	Shot fracture of left forearm..	Mar. 31, 1865.	Circular amputation, by Surg. T. M. Flaudrau, 146th N. Y.	Discharged July 8, 1865; pensioned.
36	Stone, E. J., Pt., H, 1st New York Artillery, age 25.	June 18, 1864.	Right forearm blown off by explosion of gun.	June 18, 1864.	Amputation, by Asst. Surg. C. F. Haynes, U. S. V., by the oval flap method.	Discharged Aug. 26, 1864; pensioned. Healthy stump.
37	Sullivan, J., Pt., A, 30th Michigan.	April 10, 1865.	Right forearm blown off by premature discharge of cannon.	April 10, 1865.	Amputation, by Surg. J. Willett, 30th Michigan.	Discharged June 30, 1865; pensioned. Healthy stump.
38	Truair, A. N., Pt., M, 8th N. Y. Heavy Art., age 43.	June 3, 1864.	Compound comminuted fracture of right radius and ulna.	June 3, 1864.	Flap amputation, with removal of internal condyle of humerus, by Asst. Surgeon C. H. Pegge, 8th New York H. A.	Discharged December 6, 1864; pensioned. Sound stump.
39	Vivlamore, P., Pt., M, 6th N. Y. Artillery, age 23.	July 12, 1864.	Right ulna shattered, radial artery lacerated, and extensive laceration of soft parts.	July 12, 1864.	Amputated by the lateral flap method, by Surg. C. H. Porter, 6th N. Y. Artillery.	Disch'd Mar. 18, 1865; pensioned. Stump sound but tender.
40	Wimpfler, S., Pt., C, 9th Ohio.	Nov. 25, 1863.	Shot wounds of left forearm and foot.	Nov. 25, 1863.	Amputation at elbow joint, and leg at lower third.	Died December 9, 1863.

The Chief of the Bureau of Medicine and Surgery of the United States Navy has published<sup>1</sup> two cases of disarticulation at the elbow practised with success by naval medical

<sup>1</sup>HORWITZ (P. J.). *Annual Report of the Chief of the Bureau of Medicine and Surgery of the United States Navy for 1866*, embracing a statement of the casualties in the Navy from 1866 to 1866.

officers during the War; but without further particulars. Medical Inspector F. Sorrell, C. S. A., reported<sup>1</sup> seven cases of disarticulation at the elbow for shot injury practised in the hospitals of the Confederate Army of Northern Virginia at the close of 1863, with two fatal results. There were four primary operations with one death, and three secondary operations with one death. The recorded experience of the War on this point from all sources, therefore, sums up forty-nine cases, with five deaths and one undetermined result.

CONCLUDING OBSERVATIONS ON INJURIES OF THE ELBOW.—Of the third mode of treatment of shot injuries at the elbow,—by amputation in the continuity of the arm,—which was adopted in nearly one half of the cases we have reviewed, since the subject has been fully discussed in Section IV of this Chapter, I will not revert further than to point out that the fatality of the amputations practised for injury of the elbow joint was slightly greater than the mortality rate of amputations done for injuries of the upper arm or forearm, as there were two hundred and seventy-two deaths in eleven hundred and nineteen determined cases. Doubtless the constitutional reaction is much graver when a large joint is penetrated than when the injury is confined to the continuity. Moreover, a large proportion of the amputations for elbow joint injuries are practised at the lower third of the arm, where, as we have seen, amputations give undeniably less favorable results than at the upper third,—a curious fact, partly explicable, perhaps, by the anatomical complexity of the tissues divided in the section just above the elbow, as shown in M. Anger's cut, FIGURE 656, on page 906.

Comparing the three methods of dealing with shot injuries of the elbow, by expectation, excision, and amputation, we observe that many surgeons accept the rule presented on the high authority of Professor Esmarch,<sup>2</sup> that "in all injuries of this kind it is the duty of the surgeon to assist nature by an operation." But facts adduced in the first part of this Section prove that there are many exceptions to this rule; and while, on page 844, the reader has been warned not to exaggerate the favorable results which statistical returns assign to the expectant plan, it would appear that in numerous instances it is nevertheless justifiable to adopt that plan, a view to which several surgeons of the widest experience on the subject now incline.<sup>3</sup> Indeed the present danger would seem to be that the early brilliant successes obtained by excision may cause that mode of treatment to be overrated,

<sup>1</sup> SORRELL (F.) (*Report on Gunshot Wounds, in Confed. States Med. and Surg. Jour.*, 1864, Vol. I, p. 153). Surgeon J. J. CHISOLM, P. A. C. S., gives the same report (*Manual of Mil. Surg.*, 3d ed., 1864, p. 361) as including the cases reported from all of the Confederate armies to February 1, 1864.

<sup>2</sup> ESMARCH (F.) (*Ueber Resectionen nach Schusswunden*, Kiel, 1851, S. 77) says: "Halten wir es für die Pflicht des Wundarztes, bei allen Verwundungen dieser Art der Natur durch eine Operation zu Hülfe zu kommen." And Dr. STROMEYER's precept is equally unqualified: "In all cases where I recognized a [shot] injury of the bones of the elbow joint, I did not hesitate to allow the resection of the joint to be performed" (*Über die bei Schusswunden vorkommenden Knochen-Verletzungen*, Freiburg, 1850, S. 36), and further on (S. 38): "Je mehr Resectionen des Ellenbogengelenks ich selbst machte, oder unter meiner Aufsicht machen liess, desto weniger konnte ich mich dazu entschliessen, Zerschmetterungen des Ellenbogengelenks durch Kugeln der Natur zu überlassen, wie GUTHRIE dies zuweilen gethan zu haben scheint." And MAAS (H.) (*Kriegschir. Beiträge aus dem Jahre 1866*, Breslau, 1870, S. 82) insists that "Shot fractures of the elbow joint without exception demand the resection of the joint." Professor ALBERT LÜCKE, of Bern, also (*Kriegschir. Fragen und Bemerk.*, 1871, S. 44) seems disposed to reject expectant conservative treatment altogether. He puts the question thus: "What can be accomplished by expectant treatment? What by excision at the elbow joint? Under the former method, the healing process is undoubtedly very slow. This might unconditionally be submitted to, if better end-results were obtained. But in the most favorable cases we only achieve a stiff joint with the limb in a favorable position, by this treatment; and the more the bone is comminuted, the greater the extent of callus formation, and the function of the joint is destroyed. Excision, opportunely practised, preserves the functional mobility of the joint, promotes quick healing, and lessens the danger from consecutive bleeding and suppuration. There are cases of ankylosis after elbow resection, it is true; but they are infrequent. There are also those bugbears, the dangle-joints, so sedulously held up to ridicule by the opponents of excision. But, in my experience, these never occur *except* from great carelessness in the after-treatment, as in the instance of the Danes, resected in 1864, by the Prussian surgeons. I consider the point, already adverted to by OLLIER of employing early ferulization of the muscles very important."

<sup>3</sup> LANGENBECK (B. v.) (*Chirurgische Beobachtungen aus dem Kriege*, Berlin, 1874, S. 163) remarks that: "The numerous cases of the last wars indicate that there must be many shot injuries of the elbow joint where resection can be avoided, and it is to be deplored that we generally do not soon enough learn the nature of the injury in such cases." REPPECHT (L.) (*Militärärztl. Erfahrungen*, Würzburg, 1871, S. 68) observes: "It is easy, after a complete shot comminution of the elbow joint, to decide on amputation in the continuity, or, if the splintering does not extend too far, to resort to primary resection (which I prefer to delayed operations, whether complete or partial excision be contemplated); nevertheless, it is to be deplored that the advantages of resection should ever be so enthusiastically regarded, and the dangers of inflammatory reaction of these injuries viewed with such exaggerated apprehension, as to lead to the danger that the expectant conservative treatment of such injuries should be liable to exist only in name."



and the resources of expectation and amputation to be undervalued. That excision should *always* be preferred to amputation in shot injuries of the elbow cannot be conceded. Apart from the graver lacerations by large projectiles, which render amputation imperative, there are many cases in which longitudinal fissuring of the shaft of the humerus, or lesions of the vessels and nerves; render immediate amputation advisable; for the cases in which it is alleged that excision has succeeded after ligation of the brachial are not sufficiently numerous or explicit to be accepted as precedents; and there is not a reasonable prospect of success by resection when the bones are crushed for some distance from the joint, or when the circulation and innervation are seriously disturbed and would be further impaired by the necessary interference with the collaterals in the course of the incisions for resection. Some surgeons, on the erroneous assumption that the extent of the lesions always corresponds with the magnitude of the projectiles inflicting them, would make the nature of the missile the criterion in deciding between excision and amputation.<sup>1</sup> While it is desirable to be as sparing as possible in the resection of the joint ends, and to respect the muscular attachments as much as practicable, and partial excisions<sup>2</sup> may possibly be sometimes justifiable, as a rule they are inadvisable, and, at all events, should not be practised without that free division of the ligamentous attachments of the joints, which mainly deprives the wound of its danger. That primary excisions are preferable to deferred operations, is as well established as the superiority of primary amputations.<sup>3</sup> The general rules for the management of shot injuries of the elbow I have sought to formulate below.<sup>4</sup>

<sup>1</sup> DR. ANTONIO RESTELLI (*Note ed Osservazioni cliniche di chirurgia militare*, in *Ann. univers. di Medicina*, 1849, Vol. CXXX, Fasc. 389, p. 241) appears to assume that, while all shot injuries of the elbow joint require operative interference, excision will suffice for injuries from musket balls, while wounds from grapeshot, shell-fragments, etc., demand amputation: "Le fratture comminutive delle estremità articolari del cubito, se da sola palla da fucile, talvolta richieggono la sola rezezione, e se vi sono complicazioni o la ferita sia da mitraglia, pezzo di bomba, ecc., si deve eseguire l'amputazione."

<sup>2</sup> SCHÜLLER (M.) (*Kriegschir. Skizzen aus dem Deutsch-Franz. Kriege*, Hannover, 1871, S. 46), after relating a partial excision at the elbow for shot injury, practised on the advice of his colleagues, adds: "I believe that facts fully justify me in the opinion that such incomplete resections are inadvisable. They lead almost uniformly to ankylosis, generally after tedious suppuration, maintained by the partially removed synovial membrane of the ridges and recesses of the joint. The peril of partial resection is probably due more to this fact than to an improperly flexed position during the after-treatment, as STROMEYER contends. In my case, at least, death ensued, although I allowed the arm to remain on the STROMEYER-ESMARCH splint in a slightly flexed position. The important feature as to prognosis in the partial resections appears to me—*where and how much* was resected? Whether sufficient drainage of the wound-secretions was possible, and especially whether extensive fissures and contusions exist." Professor S. D. GROSS states (*System*, *op. cit.*, 5th ed., 1862, Vol. II, p. 1087) that "STROMEYER and ESMARCH have conclusively shown, contrary to the opinion generally received, that partial excisions are followed by better results as regards the mobility of the joint than total operations." The professor will thank us for calling attention to this oversight. Dr. ESMARCH enforces a precisely opposite view. His language is quoted in full in the note on page 862 *ante*. He declares that "where the bones are only injured to a small extent, we ought not to be content with a partial resection of the wounded parts," etc. Dr. STROMEYER (*Ueber die bei Schusswunden*, 1850, S. 38) advises very sparing interference with the uninjured parts; but by no means advocates partial excisions, or admits that they "are followed by better results as regards the mobility of the joint than total operations." It is true that, after Laugansalza, Dr. STROMEYER (*Erfahr. über Schusswunden*, 1867, S. 49) argues that with proper after-treatment good results may be had after incomplete excisions, as of the olecranon process alone. BAUDENS (*Mém. sur les plaies d'armes à feu*, in *Gaz. des. Hôp.*, 1849, T. 1, Ser. 3, p. 38) observes: "Les fractures des extrémités articulaires du coude sont à la fois des cas de résection ou d'amputation, selon la gravité de la lésion. Je pense que, si la résection peut être limitée à l'extrémité articulaire de l'un des trois os du coude, il n'y a pas à hésiter à y recourir. Des deux militaires auxquels j'ai réséqué l'extrémité articulaire inférieure de l'humerus, l'un est mort un mois après l'opération, l'autre est radicalement guéri."

<sup>3</sup> NEUDÖRFER (J.) (*Die Endresultate der Gelenkresektionen*, in *Wiener Med. Presse*, 1871) asserts that: "In all joint injuries where the suppuration is attended with danger to life, resection is fully justifiable, even where the operation amounts to a very perilous interference and no complete cure can be anticipated. But to justify interference the danger, the hazard, to life must have actually begun. Suppuration in itself does not constitute inevitable danger to life. . . . In this view, primary resection cannot be advised, as at the outset after the injury no sign of danger to life is apparent. Favorable statistical statements of mortality of primary resection, according to my view, can never be used as an argument in favor of that operation." Which is much like arguing that a wounded artery should not be tied until the patient is in delirium, or that a fire in a house should not be extinguished until the conflagration has made some headway.

<sup>4</sup> The practical conclusions that appear to me deducible from the foregoing investigations are: 1. That in shot wounds in young healthy subjects, attended with slight injury of the articular extremities of the bones of the elbow, such as fractures of the olecranon, of the outer condyle, or of the trochlea, without much splintering and without lesion of important vessels or nerves, it is justifiable, in many instances, to attempt an expectant conservative treatment, keeping the injured extremity in entire rest, after removing any detached fragments or foreign bodies, in a semi-prone and very slightly flexed position, employing ice or other cold applications. If the inflammatory action becomes intense, the wound should be freely enlarged and the joint cavity fully laid open, and easy escape provided for the altered wound secretions by position and drainage-tubes. The strength should be sustained by a tonic regimen, and when the inflammatory stage has completely abated, and not before, if healing is slow, secondary excision or amputation may be hopefully resorted to. Unless all the favorable conditions mentioned are present at the outset, it would be safer to resort to primary excision or to amputation. 2. In grave shot comminutions with lesion of the principal vessels or nerves, amputation should be practised immediately after the reception of the injury. 3. In severe shot fracture without extensive lesions of the soft parts, the joint should be freely exposed by a longitudinal posterior incision, and the full extent of the fracture ascertained. Unless there is extraordinary fissuring, the injured joint ends should then be sawn off as close to the limits of injury as possible, save that the bones of the forearm should be shortened to the same level. If the splintering extends very far, or if there is reason to believe that the humeral vessels are injured though not wounded, the incisions should be so modified as to convert the operation into an amputation.

## SECTION VI.

## WOUNDS AND OPERATIONS IN THE FOREARM.

In conformity with the plan pursued in the previous sections of this Chapter, our discussion of the returns of wounds of the forearm<sup>1</sup> will be restricted to those inflicted by the weapons of war or by the procedures of the surgeon. A summary of the numerous examples of burns, frost-bites, simple and compound fractures produced by other causes than shot, and other cases grouped as miscellaneous injuries, will be relegated to chapters in the Third Surgical Volume. The forearm is much exposed in action. Besides the great number of instances in which it is wounded independently, we have seen, in Chapters V and VI, how projectiles striking the chest or abdomen implicate also the forearm. It is, perhaps, more liable to sword wounds than any other region, especially when raised to protect the head or upper parts of the person. Serrier,<sup>2</sup> whose synoptical table on the relative frequency of shot wounds in the different regions of the body, derived from an analysis of seven hundred and eighty-four cases, is often quoted as authoritative, places the wounds of the forearm tenth in his list. From an analysis of returns<sup>3</sup> from the Union armies of over one hundred thousand cases of shot wounds in which the seat of injury in all wounded men brought from the field is carefully noted, it may be safely inferred that the proportion of wounds of the forearm is probably between four and five per cent. of the whole number received in action that are not immediately mortal.

TABLE CXXIII.

*Partial Numerical Statement of Gunshot Wounds of the Forearm in the Field or Primary Hospitals in various Campaigns during the last year of the Rebellion, 1864-65.*

CAMPAIGNS.  NAMES OR DATES.	FLESH WOUNDS.		FRACTURES.		MISSILE.		TOTAL WOUNDED.	PERCENTAGE OF WOUNDS OF FORE-ARM.
	Cases.	Deaths.	Cases.	Deaths.	Large projec- tiles, cannon shot, shell, and bomb frag- ments, grape, and canister.	Small projec- tiles, musket, carbine, rifle, pistol balls, and small mis- siles from shrapnel and canister		
Army of the Potomac from May 4th to August 31, 1864.....	1,375	.....	564	1	131	1,802	38,944	4.97
Campaign to Atlanta from May 4th to September 8, 1864.....	841	.....	476	2	52	1,178	23,308	5.65
Gen. George H. Thomas's Army from Oct. 25th to Dec. 31, 1864.....	95	.....	46	.....	4	137	3,610	3.90
Gen. W. T. Sherman's Army through the Carolinas in 1865.....	53	.....	25	.....	2	76	1,533	5.08
From Fort Fisher to Goldsborough, N. C., 1865.....	24	.....	15	.....	2	37	1,075	3.62
Siege of Mobile from March 26th to April 9, 1865.....	40	.....	30	.....	24	42	2,111	3.31
Army of the James from May 4, 1864, to April 9, 1865.....	353	.....	184	.....	69	455	16,120	2.33
Shenandoah Valley from May 4th to August 20, 1864.....	17	1	20	.....	7	29	2,196	1.68
Shenandoah Valley from August 21st to December 30, 1864.....	209	.....	97	.....	25	278	7,542	4.05
Army of the Potomac from Sept. 1, 1864, to April 9, 1865.....	177	.....	108	.....	17	267	9,101	3.13
Aggregates.....	3,184	1	1,565	3	333	4,301	105,540	4.49

<sup>1</sup> Forearm, the part of the upper extremity between the elbow and wrist. *Gr.*, ΠΙΧΥΣ; *Latin*, antibrachium, cubitus; *Fr.*, avant-bras; *Ger.*, Vorderarm. *Unterarm*; *Ital.*, antibraccio; *Danish*, Underarmen.

<sup>2</sup> SERRIER (L.) (*Traité de la Nature, des Complications, et du Traitement des Plaies d'Armes à Feu*, Paris, 1844, p. 31). The 784 cases derived from the works of H. LAKREY, JOBERT, LAROCHE, DUPUYTREN, BAUDENS, and others, were distributed thus: Leg, 100 cases; thigh, 97; face, 61; arm, 69; hand, 57; chest, 53; abdomen, 52; shoulder, 42; cranium, 37; forearm, 36; knee, 35; foot, 29; elbow, 23; hip, 22; neck, 22; genito-urinary organs, 18; ankle joint, 15; shoulder joint, 13; hip joint, 6; spinal column, 4; wrist joint, 2.

<sup>3</sup> The blank form for a *Classified Return of Wounds and Injuries Received in Action*, of the Army Medical Department, is printed on p. XV of the Introduction to the First Surgical Volume. In the last year of the War it was filled up with commendable fidelity. It does not comprise the seats of injury in those killed in battle.



**PUNCTURED AND INCISED WOUNDS.**—The cases found on the returns, of stabs and cuts implicating the soft tissues of the forearm, have been noticed at page 432 *et seq.* in the first Section of this Chapter; a few instances of sabre cuts involving the bones remain.

**Sabre Wounds.**—Seven instances were reported of sword cuts dividing one or both bones of the forearm. Two of them, associated with sabre cuts of the skull, have been already detailed.<sup>1</sup> Evidently the forearm, especially its ulnar border, is most exposed to

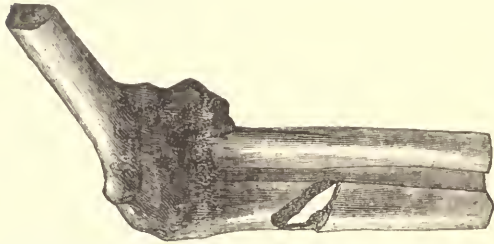


FIG. 662.—Division of the ulna by a sabre cut. [From a specimen at the Museum of Val-de-Grace, figured by M. LEGOUEST.]

sword cuts when raised to protect the head. Of the other five cases it is curious to observe that two recovered with pseudarthrosis, corroborating the old observation that sections of bone by cutting weapons<sup>2</sup> are slow to consolidate. LaMotte cited several instances of this,<sup>3</sup> and M. Legouest has observed two examples, one of which is represented in the annexed wood-cut (FIG. 662). Another instance of non-union after the division of the

bones of the left arm at the lower third by a sabre, was preserved in Hutin's collection at the *Hôtel des Invalides*, in which both the ulna and radius<sup>4</sup> were divided.

**CASE 1842.**—Private R. R. Knapp, Co. E, 6th Cavalry, aged 23 years, received a sabre cut over the right wrist and a pistol ball in the left thigh, at Funkstown, July 7, 1863. He was captured, and his wounds were dressed by Surgeon Jackson, of the Confederate army. On August 8th, he was paroled and admitted to the hospital at Annapolis. Acting Assistant Surgeon S. J. Radcliffe reported: "A sabre wound of the right forearm one and a half inches above the articulation of the ulna, cleaving the bone through, which resulted in loss of use of the little and ring fingers." The patient was discharged at St. Mary's Hospital, Detroit, September 13, 1864, on account of "shot wound penetrating the left knee joint, resulting in permanent ankylosis; also, because of sabre wound of right forearm, producing fracture of the ulna, resulting in false joint." Examiner J. S. Hildreth, of Chicago, reported, October 30, 1867: "The bony parts have not united; the action of the hand is unimpaired thereby, but the use of the wrist is, to a certain extent, impaired." On Sept. 5, 1873, the Chicago Board certified that "the ulna fracture remains ununited." The disability for the fracture of the ulna is rated three-fourths. This pensioner was paid June 4, 1875.

**CASE 1843.**—Moses Spangler, company and regiment not reported, was wounded in October, 1862. He was admitted to the hospital at Quincy, Illinois, February 15, 1863, with a fracture of the ulna. Surgeon R. Nichols, U. S. A., reported that Spangler stated "that his arm was fractured by a blow from a rebel sword; no union when admitted; general health good. On March 1, 1863, a starch bandage was applied, with benefit. The patient was laboring under hypertrophy of the heart. A full diet and elixir calisaya" were prescribed. He was returned to duty May 25, 1863. No pension record.

<sup>1</sup> Cases of Sergeant T. Connolly and A. Shurey, related in Section I, Chapter I, of the *First Surgical Volume*, pp. 5 and 22.

<sup>2</sup> M. LEGOUEST justly remarks (*Chir. d'Armée*, 2<sup>ème</sup> éd., 1872, p. 460): "Ces lésions sont plutôt des plaies des os que de véritables fractures."

<sup>3</sup> LAMOTTE (GUILLAUME MAUQUEST) (*l. c.*, 2<sup>e</sup> éd., 1732, T. IV, Obs. 383, 384, 385, pp. 303-315) taught by these examples that while it would be thought *a priori* that a cut bone would unite more readily than a broken bone, the reverse was true, and his explanation was that the clean section permitted the fragments to ride upon each other readily, while the asperities and irregularities of the broken bone, fitting into each other, were more conducive to immobility: "J'avois crû qu'un os coupé auroit été infiniment plus aisé à guérir, que lorsqu'il est rompu, parce qu'étant coupé les extrémités de l'os se rapprochent plus facilement, et qu'étant plus unies, la matière du callus fait mieux son esset que quand l'os est fracturé, l'inégalité des extrémités paroissant s'opposer à l'union; mais l'expérience m'a fait connoître que ces extrémités si unies se dérangent au moindre mouvement, et frottent l'une contre l'autre; en sorte que ce callus ne se forme que très-difficilement, par la peine qu'il y a à les tenir en repos, quelque attention que j'eusse à le faire, et le blessé à y contribuer, parce qu'il ne faut qu'une toux un peu forte, ou un étouernement, pour tout dérangier; au lieu qu'un os fracturé ne peut être sous inégalité, et ces inégalités étant une fois bien réduites, elles s'enclâssent et s'emboîtent si exactement les unes dans les autres, que la matière du callus s'y conserve plus aisément, et a plus de facilité à en faire la réunion que quand il est coupé."

<sup>4</sup> In that delightful work, *The Life and Opinions of General Sir Chas. James Napier, G. C. B.*, by Lieut. General Sir W. NAPIER, in Volume IV: Sir Charles is reported as saying: "Hunter (General), who is here, told me a curious thing: Showing me a large sword, which cut off his arm at Bruthpoo, when leading the assault, he said that on the rampart a giant, in complete armor, whirling this sword, met him. Hunter held his sword up in defense, but, to use his own words, the giant sent it with a *whirr* into the air. Hunter then held up the scabbard, but the blow went through it and his arm just below the elbow, leaving merely a *bit of skin uncut*. He fell sitting, and held his severed arm in his right hand, while an officer tied a sash above the wound to stop the hemorrhage; then a surgeon came up, put the *two ends together* and tied them, *and they united*." If this narrative has a flavor of the marvellous, it is easy to cite other examples of union of long bones after complete division by sabre cuts. Instances from RAVATON, BÉGIN, and others are cited in the foot-note on page 828. An interesting case, in which the shaft of the humerus was severed, is adduced by J. L. SCHMUCKER (*Vermischte Chir. Schriften*, Berlin, 1785, B. 1, S. 315), from a report by regimental surgeon HOFFMAN: A huzzar of the regiment, Möring, aged 30 years, received a sabre cut across the arm four fingers' width above the condyles, severing the humerus entirely. The ends of bone were placed in apposition, the severed muscles fastened by sutures and secured by splints, and the huzzar recovered perfectly in ten months. A still more remarkable example is communicated by Surgeon J. STEVENSON, of the Madras army, in Sir GEORGE BALLINGALL'S *Cases illustrative of Military Surgery*, in *Edinburg Med. and Surg. Jour.*, 1837, Vol. XLVII, p. 334: On August 29, 1823, Abdoo Braheem, Jemadar of the Nabob of Masulipatam, received a sabre cut, dividing the belly of the biceps and the shaft of the humerus. The attendants described the stream of blood as profuse and projecting many feet. A turban twisted about the limb with great tightness had completely arrested the hemorrhage. There was no pulse at the wrist. On the third day the pulse was barely perceptible and tremulous. On the thirteenth day the pulse was stronger, at 68, while in the sound arm it was at 82. The wound was cicatrized on the twenty sixth day, and, on the forty-fifth, the bone was firmly united. The arm proved of little use to him.

In the next case, it is impracticable to determine to what extent consolidation took place:

CASE 1844.—Second Lieutenant T. S. Bonney, Co. A, 129th Indiana, received a sabre wound of the left forearm at Atlanta, August 20, 1861. On November 1, 1861, he was admitted to the Officers' Hospital at Chattanooga, where Surgeon R. M. S. Jackson, U. S. V., noted: "A sabre wound of left forearm, fracturing both bones near the middle." The patient was furloughed November 5th, and discharged from the service December 24, 1861. Not a pensioner.

It is not intended to imply that pseudarthrosis, after complete division of the bones of the forearm by cutting weapons, is the rule, but simply to point out that the frequency of the complication under such circumstances is remarkable and deserving of attention.

A primary and secondary amputation of the forearm, after division of the bones by sabre cuts, are reported:

CASE 1845.—Private William Billows, Co. C, 3d New York Cavalry, aged 30 years, received a sword wound of the left forearm in a cavalry charge near Trenton, North Carolina, May 15, 1862. Surgeon D. F. Galloupe, 18th Massachusetts, states that "the radius and ulna, with nearly all the soft parts, were completely severed by one stroke of the weapon, which was an unusually heavy one, roughly finished at a manufactory in New Orleans." Dr. Galloupe amputated the forearm near the wrist by the circular method, within ten minutes after the casualty occurred. The patient was then taken to New Berne, where he was placed in the hospital of his regiment. The entire wound healed by the first intention; no pus appeared, except in the track of the ligature, and complete recovery took place in eight days after the operation. Not a pensioner.

CASE 1846.—Private Corwin Davis, Co. I, 93d Indiana, stated, in his application for commutation for an artificial limb, that he was wounded at Gainesville, July 27, 1865, by a sabre cut in the left forearm. Two months after the reception of the injury his forearm was amputated five inches below the elbow by Surgeon Agnew, 6th Illinois Cavalry, at the regimental hospital. The stump is sound. This soldier was discharged November 10, 1865, and pensioned.

The comparative rarity of the reception of severe sabre wounds in action in recent wars<sup>1</sup> invests these examples with interest. The sabre cuts implicating the soft parts only of the upper extremity are noticed on page 435 *ante*. It was impracticable to discriminate from the returns the proportion implicating respectively the arm and forearm.

**SHOT WOUNDS OF THE FOREARM.**—The facts of most importance found on the returns regarding shot wounds of the soft parts of the forearm and the varieties of operative interference called for by such injuries, have been detailed at page 438 *et seq.*, in the 1st Section of this Chapter. Before discussing the shot fractures of the forearm, some examples of contusion and incomplete fracture will be noticed.

CONTUSIONS AND PARTIAL FRACTURES.—Ten cases of shot contusion, and thirty-two of partial fracture of one or both of the bones of the forearm, are reported.

§ *Shot Contusions of the Radius and Ulna.*—The ten cases of shot contusions of bones of the forearm were all of the second class, *i. e.* attended by penetrating wounds. One, followed by excision at the elbow (CASE 1819), is detailed on page 886; another (CASE 1410), treated by intermediary amputation unsuccessfully, is narrated on page 472. Eight are briefly noted here:

CASE 1847.—Private Mathias Weiser, Co. C, 6th Connecticut, aged 33 years, was wounded at Fort Wagner, July 18, 1863, and was sent from Morris Island to Hospital No. 1, at Beaufort, July 19, 1863. Assistant Surgeon C. E. Goddard, U. S. A., reported that the "patient was wounded by a musket ball in the upper third of the left forearm; the ball was removed October 25, 1863. There was some necrosis and exfoliation from the radius." This soldier was furloughed February 7, 1864, and discharged from the service, at Knight Hospital, New Haven, September 7, 1864. Not a pensioner. The ball (FIG. 663), a conoidal bullet, is split from the apex into the body, with the halves separated and rounded and the base somewhat roughened. It was sent to the Museum by Dr. Goddard, and weighs 515 grains Troy.

CASE 1848.—Second Lieutenant Michael Houser, Co. C, 57th Pennsylvania, was wounded at Gettysburg, July 3, 1863. He was sent to Philadelphia, and admitted to the Officers' Hospital July 5, 1863, where Acting Assistant Surgeon Wm. Canine noted a "shot wound of the right forearm; a minié ball struck outer edge of radius about three inches from its upper extremity, passed obliquely across and outward, and made its exit about three inches below; bone not much injured, no bad symptoms, and on August 17th the wound had nearly healed." The patient was returned to duty September 3, 1873.

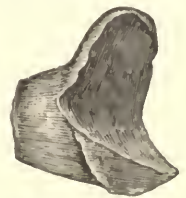

FIG. 663.—Bullet split on radius.—*Spec.* 4569. 1-1

<sup>1</sup> BECK (B.) (*Kriegschir. Erfahr. während des Feldzuges*, 1866, S. 286) observed a case of nearly complete division of the ulna by a sabre cut. The injury of the bone was very severe, and, aside from periostitis, extensive cellulitis with pus formation supervened, necessitating incisions. After several fragments had exfoliated, recovery took place at the end of ten weeks without impairment of usefulness of the limb.



Professor Nott, of Mobile, has published an interesting case of shot contusion of the ulna,<sup>1</sup> remarking that his experience leads him "to believe that contusion is often quite as bad or worse than gunshot fracture."

CASE 1849.—Private D. C. Thatcher, Co. I, 12th New York, was wounded at Fredericksburg, December 13, 1862, and was admitted to Lincoln Hospital, Washington, December 26, 1862. Surgeon Henry Bryant, U. S. A., noted "*vulnus sclopetarium* of left forearm, the ball grazing the bone." This soldier was returned to duty May 7, 1863. Not a pensioner.

CASE 1850.—Private John Cook, Co. A, 37th North Carolina, received a gunshot wound of the right forearm at Ream's Station. The radius was partially fractured and the posterior interosseous nerve injured; extensive sloughing of the muscles of the back part of the forearm and slight exfoliation of bone ensued. The patient was retired February 8, 1865.

CASE 1851.—Private John T. McCartney, Co. E, 14th Pennsylvania Cavalry, aged 22 years, was wounded at Winchester September 19, 1864, and was sent to the Cavalry Corps Hospital, at Winchester, the next day. Surgeon L. P. Wagner, 114th New York, noted: "Gunshot wound of right forearm, a minié ball contusing the ulna a few inches below the olecranon process. Patient's health good; swelling of the arm very severe, with tendency to œdema; improving rapidly." The patient was transferred to the hospital at Frederick City, December 14, 1864, where Assistant Surgeon Helsby, U. S. A., noted that the "patient was nearly well on admission." Returned to duty March 30, 1865, with "good use of arm. flexion and extension improving daily." Examiner J. A. McLane, of Morgantown, West Virginia, certified, April 24, 1866, that the elbow joint was "nearly completely ankylosed and the arm somewhat atrophied." The Wheeling Board reported, September 6, 1872: "Complete ankylosis of elbow joint, and inability to bring the hand to the head or face; arm atrophied." Examiner L. L. Comstock, of Charleston, West Virginia, certified, April 7, 1875, that the "joint is ankylosed at an angle of forty degrees." This pensioner was paid September 4, 1875.

CASE 1852.—Private Allan M. Blanchard, Co. D, 12th Ohio, was wounded at Corinth, October 4, 1862, and discharged May 23, 1863, on account of necrosis. In January, 1867, he was examined, for re-enlistment in the army, by Acting Assistant Surgeon E. M. Powers, who reported a "gunshot wound of the left forearm, injuring the radius and necrosis of the radius, which continued to discharge until five months ago, since which time there has been no discharge; soft parts still red and puckered." This man is a pensioner, but the papers in the case were in use when application was made for information.

CASE 1853.—Private George M. Jacob, Co. D, 8th Maryland, aged 39 years, was wounded at Spotsylvania, May 8, 1864, by a conical ball. He was admitted to the hospital at Fairfax Seminary, May 12, 1864, where Acting Assistant Surgeon H. Allen noted: "Gunshot wound of right wrist, grazing bones of forearm." The patient was furloughed June 17, 1864, and discharged the service, on certificate of disability, July 13, 1864. On January 8, 1866, examiner Thomas Owings, of Baltimore, certified that the "ball fractured the radius near the wrist joint; a considerable portion of bone was lost. The wound has now closed, but several sharp spiculæ of bone are embedded in the callus, their ends protruding in such a way as to interfere with the proper action of the muscles; the right hand is consequently almost useless." This pensioner was paid September 4, 1875.



FIG. 664.—Osteitis from shot contusion of the ulna. Spec. 2017.

CASE 1854.—Private Charles McFadden, Co. B, 40th Ohio, was wounded at Lookout Mountain, November 24, 1863, and was sent from the field hospital, 1st division, Fourth Corps, to the hospital at Tullahoma, November 30, 1863, where Surgeon Benjamin Woodward, 22d Illinois, furnished the following history, viz: "Gunshot flesh wound through left forearm; the wound did well in all respects till the 15th of December, when from some unknown cause it suddenly took on unhealthy action and the arm swelled badly; lead lotion prescribed. December 20th, to this time there has been evidence of periosteal inflammation, elbow joint involved; rigors; high fever; whole arm œdematous; laid open arm in three places, giving exit to large quantities of sanious serum. 24th, pulse 140, small; tongue dry; bronchial respiration; moist rales; evident signs of pneumonia of both lungs. 25th, evidences of pyæmia prominent; put on stimulants, iron and quinine. 26th, arm to shoulder greatly swollen; inflammation extending over shoulder; arm laid open above elbow; no pus, but great quantities of sanious serum. 27th, breathing diaphragmatic; brain oppressed; pus in sputa. Died this P. M. Autopsy twenty hours after death; present, Surgeon W. C. Bennett, U. S. V., and Assistant Surgeon H. Pierce, 150th New York: From the putrid condition of the body no examination was made excepting the thorax; heart normal; twelve ounces of straw-colored fluid in the pericardium; emboli in ventricles, pulmonary artery, and innominate; fibrinous concretions adherent to the columnæ carneæ; lungs full of small abscesses; all of the bronchi contained pus; blood in cava descendens, under the microscope, showed very numerous oil globules; mucous coat of all the large bronchi injected and inflamed; arm removed four inches below the head of humerus, pus flowed from upper part; removed head of bone, glenoid cavity full of pus. *Dissection of bone*: Head of humerus showed in some parts destruction of articular cartilage, as did the edges of glenoid cavity; periosteum of ulna all gone; the greater part of radial periosteum dissected up by pus; all the ligaments and cartilage of elbow destroyed, also all the attachments of muscles. A well-marked prominent case of pyæmia." The specimen was sent to the Museum by Surgeon B. Woodward, and is described (*Cat. Surg. Sect.*, 1866, p. 151) as the bones of the left forearm, showing a necrosed condition of the middle third of the radius and erosion of the articular surfaces of the elbow, after pyæmia, following a flesh wound (and probably contusion of the ulna) of the forearm; it is copied in the annexed wood-cut (FIG. 664).

<sup>1</sup> NOTT (J. C.) (*Contributions to Bone and Nerve Surgery*, 1866, p. 65): Case of General Gracie, wounded at Bean's Station, Tennessee, afterward killed at Petersburg. A musket ball struck the forearm posteriorly two inches below the elbow, grazed the ulna, passed deeply and transversely through the deep flexors, and came out in front of the radius. The field surgeon could detect no lesion of bone. Twenty days after the injury the limb was much swollen and the little and ring fingers were paralyzed; and Dr. NOTT inferred that there had been a contusion of bone and that suppuration and exfoliation were imminent. Abscesses formed, and, at the end of six weeks, two exfoliations were removed, and rapid recovery ensued.

§ *Partial Shot Fractures of the Bones of the Forearm.*—Thirty-two instances were reported in which the bones of the forearm were grooved or chipped, or partially fractured, by small projectiles. The injuries involved the ulna in twelve cases, the radius in fifteen, both bones in one; in four cases the precise seat of the lesion was not specified. The left forearm was implicated in twenty cases, the right in ten, and in two cases this point was not noticed. Twenty-eight cases, of which two resulted fatally, were treated by expectation; in four, amputation in the upper arm was resorted to, unsuccessfully in two instances.<sup>1</sup> Brief memoranda of three of the recoveries and of the two fatal cases, treated by expectation, are subjoined:

CASES 1855–1857.—1. Major H. J. Covell, 6th Colored Troops, wounded in the right forearm, at New Market Heights, September 29, 1864, was sent to Fort Monroe, and thence to Seminary Hospital, Georgetown, and furloughed November 4th. On December 27th, he entered the Annapolis Hospital, and Hospital Surgeon B. A. Vanderkeift, U. S. V., reported: "The ball entered the posterior aspect of the middle third of the right forearm, passing between the ulna and radius, slightly fracturing the radius, and emerged opposite; the wound has healed, requiring no further treatment." Returned to duty January 2, 1865, and discharged April 25, 1865, and pensioned, Assistant Surgeon W. S. Codman, 107th Colored Troops, certifying that the wound produced "such adhesions of the muscles as to render the use of the arm and hand very imperfect." In September, 1873, Examiner W. M. Eames, of Ashtabula, certified that "the ball injured the ulnar nerve, so that the ring and little fingers are now numb, and the tendons of the thumb so adherent in the cleft that the power of grasping small objects is quite imperfect." This pensioner was paid September 4, 1875.—2. Pt. S. Ralph, Co. E, 13th New York, was wounded at Bull Run, August 29, 1862. On September 3d, he entered Filbert Street Hospital, Philadelphia, where Acting Assistant Surgeon R. J. Dunglison noted: "Gunshot wound of left forearm through the interosseous space; the ball passed through the posterior portion of the arm and emerged on the opposite side. The patient states that a small portion of bone was removed on the field, but there is nothing in the history or progress of the case to induce a belief that it was more than a mere splinter, without actual fracture. A compress has been placed in the interosseous space to prevent the accumulation of pus, and the forearm has been placed in a straight arm splint. October 1st, case progressing favorably." Transferred April 22, 1863, to Turner's Lane, and mustered out May 13, 1863. On September 30, 1863, he applied for a pension, but has not since been heard from at the Pension Office.—3. Pt. P. Ginglesperger, Co. H, 54th Pennsylvania, was wounded at New Market Heights, May 15, 1864, and sent to the hospital at Cumberland on May 18th. Acting Assistant Surgeon I. D. Skilling noted: "Gunshot wound of the left forearm by a musket ball, which entered the ulnar side three inches above the wrist joint, and passed upward and outward to its exit five inches above, cutting a small sliver from the external border of ulna; fragments of bone came out by ulceration; the patient was treated with cold-water dressings and simple cerate; afterward with resin cerate and poultices; the wound healed favorably, and he was returned to duty, cured, July 13, 1864." This soldier was again wounded in the left wrist at Winchester, September 19, 1864. He was discharged from service on account of the latter wound, September 16, 1855, and pensioned, his claim being based entirely upon the wound of September 19th; that of May 15th seems, however, to be alluded to by Examiner J. Lowman, of Johnstown, who certifies, November 20, 1866, that "one ball entered the left arm posteriorly, disabling the extensor muscles slightly; another ball entered the same arm anteriorly, one inch above the wrist joint, severing the muscles and nerves and leaving all the fingers crippled." Pensioner was paid September 4, 1875.

Pyæmia and tetanus, respectively, were the causes of death in the two fatal cases:

CASES 1858–1859.—1. Pt. J. Fuller, Co. H, 7th Illinois Cavalry, aged 24 years, was wounded, in General Forrest's raid on Memphis, August 21, 1864, and sent to Gayoso Hospital, from a provisional hospital at Fort Pickering, on August 23d. Surgeon F. Noel Burke, U. S. V., reported: "Gunshot wound of left forearm by a conical ball; partial fracture of the ulna. Gangrene appeared September 9th, and was cured by bromine. On October 4th pyæmia developed, and resulted fatally October 11, 1864. About seven days before death the patient took, twice daily, violent paroxysms very much like those of intermittent fever, which were broken by quinine and arsenic. At the time of his death the wounds were nearly healed. *Post-mortem* appearances: Metastatic abscesses in apex of left lung, and in liver, of the size of a hen's egg each; pns remarkably cream-like; spleen three times the ordinary size; a large and firm thrombus in right ventricle."—2. Pt. L. Conerty, Co. B, 203d Pennsylvania, aged 18 years, was wounded at Fort Fisher, January 15, 1865, and was sent from a Twenty-fourth Corps field hospital to Hampton Hospital, Fort Monroe, where Assistant Surgeon Ely McClellan, U. S. A., noted: "Admitted June 19, 1855; gunshot wound of left forearm, middle third, with partial fracture of ulna, by a minié ball; simple dressings." The patient died January 23, 1865, of traumatic tetanus.

Two of the ten cases of contusion, and four of the thirty-two cases of partial fracture, resulted fatally; which seems to show that these lesions, when situated in the ulna and radius, have far less gravity than when they affect the humerus or femur.

**Shot Fractures of the Forearm.**—The details and results of over five thousand shot fractures of one or both of the bones of the forearm have been satisfactorily ascertained.

<sup>1</sup> As follows: Case of Private Sullivan (TABLE LXXXVIII, No. 36, p. 790, *Spec.* 3329); Case of Corporal J. Dixon (TABLE XLV, No. 35, p. 470, and TABLE LXXXVI, No. 40, p. 785, and *Am. Jour. Med. Sci.*, 1868, Vol. LV, p. 581); these two patients recovered and were pensioned. The two fatal cases are noted as: Private J. C. Thompson (TABLE LXXXIX, No. 22, p. 791, *Spec.* 3674); Private J. W. Dyas (TABLE LXXXIII, No. 6, p. 774).



The results as to fatality have been determined in 98.6 per cent. of the cases—in all but 78. The classification of cases according to their treatment by temporization, excision, or amputation, is also very complete, and the ratio of results under the different methods of treatment are the more valuable since there are so few undetermined instances.

TABLE CXXIV.

*Descriptive Numerical Statement of the Nature and Treatment of Five Thousand One Hundred and Ninety-four Shot Fractures of the Bones of the Forearm.*

MODE OF TREATMENT.	CASES.	BONES OF FOREARM INJURED.																MORTALITY OF DETERMINED CASES.
		RADIUS.				ULNA.				RADIUS AND ULNA.				NOT SPECIFIED.				
		Discharged.	Duty.	Died.	Result un-known.	Discharged.	Duty.	Died.	Result un-known.	Discharged.	Duty.	Died.	Result un-known.	Discharged.	Duty.	Died.	Result un-known.	
Treated by Expectation.....	2,970	504	445	50	10	490	490	59	5	196	103	24	.....	240	284	58	12	6.4
Followed by—																		
Excision of Bones of the Forearm.....	910	243	71	32	7	288	121	39	13	52	14	4	1	16	3	6	.....	9.1
Excision of Bones of Forearm, and Amp. of Forearm.....	22	5	1	3	.....	3	.....	1	.....	6	.....	2	.....	1	.....	.....	.....	27.2
Exc. in Forearm—Amp. in Forearm—Amp. in Arm.....	2	1	.....	.....	.....	.....	.....	.....	.....	.....	.....	1	.....	.....	.....	.....	.....	50.0
Excision in Forearm—Amputation in Upper Arm.....	51	12	1	11	.....	9	1	9	.....	6	.....	1	.....	1	.....	.....	.....	41.1
Excision in Forearm—Amputation at Shoulder Joint.....	1	1	.....	.....	.....	.....	.....	.....	.....	.....	.....	.....	.....	.....	.....	.....	.....	0.0
Amputation in the Forearm.....	875	9	.....	8	.....	8	2	5	.....	528	70	76	2	61	4	9	23	11.5
Amputation in Forearm—Amputation in Upper Arm.....	11	.....	.....	.....	.....	.....	.....	.....	.....	6	.....	2	.....	2	.....	1	.....	27.2
Excision at the Elbow Joint.....	31	8	1	.....	.....	7	2	5	.....	4	.....	.....	.....	3	.....	.....	1	16.6
Excision at Elbow Joint—Amputation in Upper Arm.....	2	.....	.....	.....	.....	.....	.....	.....	.....	2	.....	.....	.....	.....	.....	.....	.....	0.0
Amputation at the Elbow Joint.....	24	.....	.....	.....	.....	1	.....	.....	.....	9	.....	.....	.....	12	.....	2	.....	8.3
Amputation at Elbow Joint—Amputation in Upper Arm.....	3	.....	.....	.....	.....	.....	.....	.....	.....	1	.....	.....	.....	2	.....	.....	.....	0.0
Amputation at Elbow Joint—Amp. at Shoulder Joint.....	1	.....	.....	.....	.....	.....	.....	.....	.....	1	.....	.....	.....	.....	.....	.....	.....	0.0
Amputation in the Upper Arm.....	287	21	2	11	.....	18	2	8	.....	67	9	31	.....	85	9	22	2	25.3
Exarticulation at the Shoulder Joint.....	4	.....	.....	.....	.....	.....	.....	.....	.....	2	.....	1	.....	.....	.....	1	.....	50.0
Total.....	5,194	804	521	115	17	824	618	126	18	950	196	142	3	423	300	99	38	9.4
Aggregates.....		1,457				1,586				1,291				860				

It will be observed that of the forty-three hundred and thirty-four cases in which the seat of injury was precisely specified, the ulna alone was most frequently implicated; next the radius (in a third, within a near fraction, of the cases); and last in frequency were the cases in which both bones were involved.

**SHOT FRACTURES OF THE FOREARM TREATED BY EXPECTATION.—**

Nearly three-fifths of all the reported cases were treated without operative interference. The average result was satisfactory, but one hundred and ninety-one deaths occurring in twenty-nine hundred and forty-three determined cases,—a mortality rate of 6.4 per cent.

**1. FRACTURES INVOLVING BOTH BONES OF THE FOREARM.**—The ulna and radius were both interested in twelve hundred and ninety-one instances, or less than a third of the forty-three hundred and thirty-four cases in which the precise seat of injury was specified. As might be inferred *a priori*, this group includes fewer examples of cases treated on the expectant plan than either of the series of fractures involving a single bone, and comprises the large majority of cases treated by amputation.

§ *Recoveries under Expectant Treatment.*—Of three hundred and twenty-three cases of shot fractures of both bones of the forearm treated on the expectant plan, two hundred

and ninety-nine terminated favorably. One hundred and three of the patients returned to full or modified duty; one hundred and ninety-six were discharged.

CASE 1860.—Private B. Koehly, Co. K, 2d Missouri, aged 40 years, was wounded and captured at Chickamauga, September 20, 1863. On October 29th, he entered the First Division Hospital, Annapolis, whence Acting Assistant Surgeon E. C. Malloch reported: "This man was taken prisoner when wounded and carried to Richmond, where he remained three weeks, and was then exchanged and brought to this hospital. He was wounded by a bullet passing through the middle of the right forearm, fracturing the ulna. At the time of admission his general health was good and the wound was perfectly healthy—the wound of entrance quite small, but that of exit very large, with ragged edges. Water dressings were applied to the wound, and the arm was kept in position by means of a splint to the anterior surface of the forearm. November 5th, doing well; six small pieces of bone have come away since he was wounded. 10th, wound looks healthy; patient complains of no pain. 30th, up to this date not an unfavorable symptom has appeared. December 19th, two small pieces of bone could be seen and were easily removed by forceps. 20th, removed another piece of bone and a small piece of lead. 21st, complains of pain in the arm and general uneasiness. 22d, wound does not look healthy; secretion of pus more abundant and rather fetid. Ordered a mixture of solution of permanganate of potassa two ounces, and water five ounces, to be used locally. 23d, to-day the wound presents a decidedly sloughing appearance, the edges undermined and inflamed, and the whole surface covered with a superficial slough. General appearance of patient changed, face anxious, tongue slightly furred; no appetite; bowels costive; pulse more quick than usual. Ordered the patient to a separate ward, and the arm to be treated with poultices composed of yeast and charcoal, the former lotion being used only as a wash. Prescribed whiskey six ounces, and beef tea *ad libitum*. 24th, the wound, formerly two inches in diameter, has extended half an inch the last two days. 25th, unhealthy action still proceeds; extension of slough quite visible. Complains of very severe pain in arm, which was alleviated by the local application of solution of morphia one grain to an ounce of water. Is unable to sleep, and takes one-third of a grain of morphia at bed-time. The poultices, &c., were continued as before. 26th, general condition unchanged; the wound measures three inches long and two and a half wide. Last night had a slight hemorrhage, when a slight local application of solution of persulphate of iron was used. Bowels still being costive, three compound cathartic pills were given. 27th, no change; cannot sleep at night. Ordered the following draught at bed-time: Sulphate of morphia half a grain, chloroform eight drops, spirits one ounce, simple syrup four drachms, and water an ounce and a half. 29th, condition as formerly; slept well last night; bowels regular; local applications continued. 31st, appearance unchanged; boundary line of wound several lines more in extent. January 5th, a very perceptible change has taken place; the sloughing process has entirely stopped, except at the upper angle. Ordered the poultices to be discontinued and the parts washed twice daily with alcohol. The wound now measures four inches and a half in its largest diameter, three inches wide, and one and a half inches deep. The extremity of the lower fragment of the broken bone is visible. 8th, feels very much improved; the whole wound appears healthy; complains of very little pain except during dressing; appetite very much improved; can rest well at night. At this date the case, by order of the surgeon in charge, was placed under treatment of Acting Assistant Surgeon H. Loewenthal." On April 9th, the patient was returned to duty at Camp Parole. Subsequently he rejoined his regiment in the field, whence he was discharged July 18, 1864. Examiner E. A. Clark, of St. Louis, February 12, 1867, certified: "Gunshot wound in right arm, fracturing the radius and ulna at their middle. The fracture has united, but the union has taken place conjointly between the two bones, preventing the movements of pronation and supination of the forearm. The ulna at the point of fracture is still in a state of necrosis. There has also been extensive sloughing of the soft parts, so that the extensor tendons of the forearm have become so contracted as to prevent flexion of the fingers," etc. The St. Louis Board reported, September 16, 1873: "There is now atrophy of the forearm, deformity, and almost total loss of grasping power." The pensioner was paid September 4, 1875.

CASE 1861.—Corporal A. Burlingame, Co. D, 64th New York, aged 22 years, was wounded at Fair Oaks, June 1, 1862. Surgeon G. W. Barr, of the regiment, recorded: "Gunshot wound of arm." On June 6th, the wounded man entered Wood Street Hospital, Philadelphia, whence Acting Assistant Surgeon C. B. Voight reported: "He had been wounded in the left forearm by an explosive missile of the size of a musket or rifle ball. It penetrated the limb at the middle, on its front surface, and detonated within with the collision against the ulna. Four or five inches of this bone was blown away by the explosion of the embedded projectile in part, or was subsequently detached and removed in fragments of various sizes. The muscular and other soft textures on the front of the arm participated in the disruption and dissipation of substance and structure. The radius was denuded to some degree but escaped without fracture. The wound also opened freely on the back of the arm. There was, of course, considerable loss of substance. Profuse suppuration kept up for six weeks continuously, but gradually abated, and under careful bandaging, and dressing of charpie imbued with simple cerate in the interior of the wound, with tonics to sustain the powers of the system, the patient was discharged at the end of two months in good general health, the excavation being more than one-half diminished and filled in with healthy florid granulations, promising obliteration within further reasonable space of time. He was a person of muscular and full-sized frame." The patient was discharged, at his own request, July 29, 1862, and pensioned. Examiner F. Findlay, of Franklinville, New York, March 23, 1874, certifies: "A scar about four and a half inches long occupies the middle of the back of the left forearm and indicates the entrance of the ball. It emerged in front of the ulna. It grazed the radius and broke the ulna in its middle third. The upper fragment overlaps the lower; the lower is consolidated with the radius. The entire arm is atrophied; flexion and extension abridged at the elbow; pronation and supination entirely destroyed; the skin is adherent to the back and middle of radius and ulna, the muscles being destroyed; flexion and extension of fingers very imperfect or irregular," etc. This pensioner was paid September 4, 1875.

In the two foregoing instances (in which splinters were removed), and in most cases of fracture of both bones with much comminution, union resulted with various degrees of deformity, and usually with serious impairment of the rotatory movements of the forearm,



especially of supination. Permanent pseudarthrosis was reported in but two of the three hundred and twenty-three cases,<sup>1</sup>—in the radius in one case, in both bones in one:

CASE 1862.—Private W. E. Bunting, Co. C, 68th Pennsylvania, aged 19 years, was wounded at Gettysburg, July 2, 1863, and admitted to the field hospital of the 1st division, Third Corps, where Surgeon J. W. Lyman, 57th Pennsylvania, recorded: "Compound comminuted fracture of right forearm by conoidal ball; simple dressings applied." On July 9th, the wounded man entered Satterlee Hospital, Philadelphia, whence Acting Assistant Surgeon J. H. Hutchinson reported: "Gunshot wound of right forearm. Both bones appear to have been fractured, but were united with some deformity at the time of his admission into my ward, on September 17th. While under treatment in one of the other wards, it was at one time doubtful whether it would be possible to save the arm. There is slight caries of the ulna, but it is not considered advisable to interfere. General health excellent. October 1st, no change. November 10th, arm continues in very much the same condition. November 23d, all the motions of the hand are preserved, while those of the forearm are gone. December 8th, doing well. 31st, patient transferred to the Veteran Reserve Corps." He was discharged from service, October 20, 1864, by reason of "permanent ankylosis of elbow joint following the wound." Examiner T. B. Reed, of Philadelphia, September 22, 1865, certified: " \* \* \* Caries and discharge. Use and power of arm much impaired." The Philadelphia Board, consisting of Drs. T. H. Sherwood, J. Collins, and H. E. Goodman, September 24, 1873, certified: " \* \* \* Arm and forearm atrophied. Now healed, but breaks out." At a subsequent examination, May 20, 1874, they reported: "Some deformity in ulna, it being bent outward. There is no appreciable shortening. Cicatrices adherent and tender; motion of hand and fingers good." The pensioner was paid September 4, 1875.

CASE 1863.—Private M. Harrington, Co. K, 5th Cavalry, aged 20 years, was shot by a guard while trying to escape from the guard-house in camp at Washington, November 17, 1865. On the following day he was admitted to Harewood Hospital, whence Surgeon R. B. Bontecou, U. S. V., reported: "Compound comminuted gunshot fracture of radius and ulna, a minié ball entering externally, about the junction of middle and lower thirds, passing through in an upward direction, and emerging on inner side, at middle third. Numerous pieces of bone were removed at different times, and on December 2d one-half of the ball was taken away. The treatment was supporting and the wound did well. Patient transferred to post hospital May 1, 1866." Assistant Surgeon W. Thomson, U. S. A., reported the soldier's admission to the latter hospital with "gunshot fracture of both bones of left forearm," and his return to his company for duty August 6, 1866. This man is not a pensioner.

§ *Fatal Cases of Shot Fracture of the Ulna and Radius.*—Twenty-four, or 7.4 per cent. of the whole number of cases reported, resulted fatally. The following is an example:<sup>2</sup>

CASE 1864.—Private D. O'Leary, Co. K, 15th New Jersey, aged 29 years, was wounded at Chancellorsville, May 3, 1863. Five days afterward he was admitted to Douglas Hospital, Washington, where he was attended by Assistant Surgeon C. C. Lee, U. S. A., who made the following report of the case: "A conoidal ball entered the middle third of the right forearm,

comminuted the radius and ulna, and, passing up the arm to the elbow, was arrested at the bifurcation of the brachial artery, upon which it was found lying when admitted to this hospital. The patient was in a state of collapse, with dry tongue and fluttering pulse; the right arm was immensely swollen, and from the elbow to the chest was of a dark-red mottled color, somewhat resembling diffused erysipelas; the hand and lower third of the forearm were cold, puffy, and œdematous, but not discolored to the same extent. No pulse was perceptible at the wrist. A wineglass of brandy, with small quantities of morphia, was given every three hours. On the day after his admission, the erysipelatous redness had spread from the arm to the chest and down the right side as far as the ilium; and on the anterior surface of both thighs, along the lines of the lymphatics, a similar discoloration was observed. It also began to assume a darker color, more closely resembling the eruption of scurvy than the light-red hue of erysipelas. A wineglass of milk-punch and of beef essence was administered on this day every alternate hour. May 10th, egg-nog was substituted for the milk-punch. The patient, in spite of all the stimulants he could take, was beginning to sink. In addition to his prostration, singultus and vomiting came on, for which two drops of creasote was given in emulsion every hour. He sank exhausted, on May 11th, the third day after entering the hospital. He had no fever from the first, and complained of very little pain when the arm or chest was handled. At an autopsy, made ten hours after death, the bones of the forearm were found extensively comminuted, as already stated, and the bullet, which was much bent and distorted, was compressing the bifurcation of the brachial artery and the accompanying veins. This pressure was undoubtedly the cause of the œdematous and semi-gangrenous condition of the hand, but it offered no clue to the remarkable change of color of the skin. The latter was mainly due to extravasated blood in the subcutaneous tissue, which was tough and brawny; no phlebitis could be detected, and all the viscera were sound." Assistant Surgeon W. Thomson, U. S. A., in charge of the hospital, who contributed the specimen (FIG. 665), remarked, in addition to the above: "There was no evidence of pyæmia or phlebitis, and indeed nothing to account for the singular and very extensive discoloration of the skin. The most remarkable fact was this livid hue of so great an extent of the surface, not erysipelatous, entirely unaffected by pressure and hence petechial in its character, and resembling an effusion into or beneath the skin of the coloring matter of the blood." The specimen consists of the upper half of the

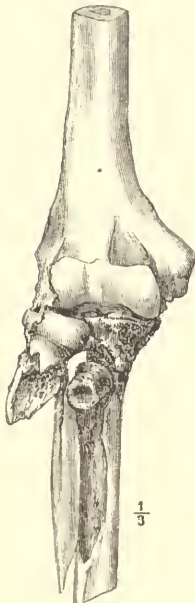

FIG. 665.—Ulna and radius comminuted by a conoidal ball. Spec. 1252.

right ulna and superior extremity of the radius, and the lowest third of the humerus, with the battered ball lodging in the ulna just below the coronoid process. The ulna presents a longitudinal fracture extending along the entire length of the specimen.

<sup>1</sup>Cases of Pt. H. Kanber, Co. L, 5th Pennsylvania Cavalry, and Pt. J. N. Beesup, Co. B, 114th Illinois, both with shot fractures of the right ulna and radius, and reported by Drs. G. McCook and B. A. Vanderkief, the first with pseudarthrosis of the radius, the last with non-union of both bones.

<sup>2</sup>Two other examples of the appearances after shot fracture of both bones of the forearm are shown in FIG. 628, on p. 872, and FIG. 635, on p. 881.

**2. FRACTURES OF THE ULNA TREATED BY EXPECTATION.**—The results of a thousand and forty-four cases of shot fracture of the shaft of the ulna, treated on the expectant plan, were determined, except in five cases. There were fifty-nine deaths, a mortality rate of 5.6 per cent.

§ *Successful Cases.*—Some instances will be detailed from the series of nine hundred and eighty recoveries from this injury. Four hundred and ninety of the patients were returned to modified duty, and four hundred and ninety were discharged.

CASE 1865.—Private A. E. Wilcox, Co. K, 6th Connecticut, aged 31 years, was wounded at Pocotaligo, October 22, 1862. Two days afterward he was admitted to Hospital No. 1, Beaufort, where Surgeon R. B. Bontecou, U. S. V., noted as follows: "Gunshot wound of right forearm. The wound was inflicted by a portion of a shell, which passed across the outer aspect of the forearm three inches below the extremity of the olecranon, and fractured the ulna without comminution. Considerable tumefaction of the whole arm induced me to relieve the tension of the fascia by the knife, and lay the arm on a simple straight splint, applied to the palmar side, and an ice-bag over a thin poultice to the wound. November 15th, considerable discharge, and a rough portion of bone discovered by the sound. General health disturbed by chills, which, I think, are independent of the wound. Quinine, in ten-grain doses, stopped these. December 1st, patient walks about and requires little attention. Discharge from arm trifling. December 28th, the bone has become firmly united; he is carrying his arm in a sling without the splint, and will soon be able to go to his regiment. February 15th, sent to his company." On April 25th, this man was admitted to Hospital No. 2, Beaufort, whence he was discharged from service May 11, 1863, on account of "loss of use of right arm." Examiner H. Pierpont, of New Haven, August 4, 1863, certified: "Was wounded by a piece of shell in the right arm, about three inches below the elbow joint, crushing the ulna. The bones are not yet firmly united. The extensors of the fingers and hand are contracted so as to prevent the shutting of it." Drs. G. C. Jarvis and H. S. Fuller, of the Hartford Examining Board, certified, September 8, 1873: " \* \* \* No motion of the forearm. The hand can only be partly closed on account of adhesion of muscles and skin to the bones." The pensioner was paid June 4, 1875.

The utility of free incisions to relieve the strangulations from inflammatory engorgement or intermuscular extravasation, so common in seton wounds of the forearm, is well exemplified in this case, a sound practice derided by many misinterpreters of John Hunter.

CASE 1866.—Sergeant P. Hogan, Co. L, 3d U. S. Artillery, was wounded at the battle of Gaines's Mill, June 27, 1862, and sent to one of the hospital transport steamers on James River. He was admitted to the Union Chapel Hospital, Washington, July 7, 1862, where Acting Assistant Surgeon W. H. Butler recorded: "Gunshot wound of left arm. Patient transferred to Douglas Hospital July 28th." Assistant Surgeon W. Webster, U. S. A., in charge of the hospital, contributed the specimen (FIG. 666), and reported that the patient was discharged from service November 13, 1862, by reason of "gunshot wound." The specimen is described in the *Catalogue of the Surgical Section*, 1866, p. 601, as "a flattened, distorted round ball perforated by a fragment of bone from the forearm, which it embraces, necrosed." It is a curious specimen, in which the metal, softened by impact, has embraced and carried off what appears to be a fragment of the upper part of the shaft of the ulna, seven-eighths of an inch in length and three-eighths in thickness. The ball, with the enclosed bone fragment, weighs three hundred and seventy grains Troy. This man was a pensioner. He died November 19, 1873. The papers in the case which might afford additional particulars were in use at the Pension Office and could not be consulted.



FIG. 666.—A distorted ball enveloping a fragment of the ulna. *Spec.* 4182.

CASE 1867.—Corporal H. W. Hurd, Co. B, 7th New Hampshire, aged 29 years, was wounded at Fort Wagner, July 18, 1863. On the following day he was admitted to Hospital No. 4, Beaufort, where Assistant Surgeon J. Trenor, jr., U. S. V., recorded: "A minie ball entered the right forearm just outside the radial artery and half an inch from wrist joint, passed upward, fracturing the ulna at the junction of the middle with the upper third, and passed out two and a half inches below the elbow joint posteriorly. The point of exit was marked by a protuberance the size and shape of half a hen's egg, and composed of a muscular mass. The shock to the nervous system was great; pulse feeble; surface natural; sensation and circulation perfect in hand and over surface; a good deal of tumefaction. Patient complains of pain, and has not slept since the reception of the wound. Applied cold-water dressings. The radius acts as a splint to the ulna. July 20th, passed a poor night; arm less hot but painful; discharge increasing, rather too fluid in character, and inclined to be sanious. Continued the dressings, and gave one ounce of spiritus frumenti. July 21st, passed a better night, and slept well for three hours; arm little if at all painful when kept quiet; discharge pretty free; pulse 88, strong and natural; bowels have moved, and patient feels comfortable every way. Continued dressings, and gave one ounce of spiritus frumenti three times a day. July 23d, slept well; appetite still fickle; arm much cooler and less swollen. Continued treatment. July 23d, passed a good night; skin natural; arm comfortable; pulse 86; appetite improving; everything going on well. July 31st, inflammation has mostly subsided; patient doing extremely well. August 1st, a long strip of linen appeared at the lower opening and was removed; the protuberant mass at the upper opening decreasing in size." The patient was subsequently transferred to Lovell Hospital, Portsmouth Grove, R. I., where he was discharged from service December 30, 1863, by reason of "gunshot fracture, etc., with entire loss of motion of right hand." Examiner B. S. Warren, of Concord, N. H., January 19, 1864, certified: "A ball struck the front of his right wrist over the lower extremity of the radius, and, passing upward and backward, issued from the back of the forearm about two and a half inches below the olecranon, fracturing the ulna and injuring the ulnar and radial nerves, thereby paralyzing the hand, which is purplish, the fingers being flexed, and he having no power to extend them. He can make only partial rotation of the forearm." Other examiners report substantially the same at subsequent dates. The pensioner was paid September 1, 1875.



It is deemed an unprofitable task to attempt to determine the proportion of cases in which the shot fractures of the ulna and of the radius treated by expectation interested the right or left extremity; partly because the number of instances in which this point is unspecified in the records is so great that the approximate result would be almost worthless, and partly because the facts respecting the fractures of the forearm thus treated are gleaned from such a large variety of returns that the labor of reviewing them would be inordinate for the object in view, and indeed impracticable with the limited time and clerical assistance at my disposal.

Eighteen of the cases of recovery from shot fracture of the ulna treated by expectation were complicated by consecutive hæmorrhage. In three of the cases, recourse was had to ligation of the brachial on the method of Anel:<sup>1</sup>

CASE 1838.—Corporal A. D. May, Co. II, 33d Indiana, aged 22 years, was wounded at Resacca, May 15, 1864. He was admitted to the field hospital of the 3d division, Twentieth Corps, where Surgeon W. Grinstead, U. S. V., recorded: "Gunshot compound fracture of right forearm; fragments removed by Assistant Surgeon J. S. McPheeters, 25th Indiana." On May 21st, the wounded man entered the General Field Hospital at Bridgeport, whence Assistant Surgeon H. T. Legler, U. S. V., reported as follows: "Wounded in right forearm by a musket ball, fracturing the ulna in the middle extensively. Hæmorrhage occurred on May 24th, 25th, 26th, and 27th from the ulnar or interosseous artery; patient anæmic in consequence of the loss of blood—amounting to thirty-four ounces; wound looking well and suppurating. On May 27th, ligation of the brachial artery in its continuity was performed at the elbow by the reporter. Chloroform was the anæsthetic used, and the patient reacted promptly. The treatment consisted of water dressings, stimulants, and nourishing diet. The new circulation was well established on the third day after the operation; the ligature came off on the eleventh day. Patient furloughed August 27th." At the expiration of his furlough the patient reported at Indianapolis, where he was discharged from service March 17, 1865, and pensioned. Examiner G. W. Mears certified, April 4, 1865: "Ball entered on inner side of middle third of forearm, and ranging outwardly, fracturing in its course the ulna badly, escaped on outside, a little lower down. The wound is not quite healed; the rotary motion of arm uninjured, as is also the motion of hand and wrist, but all the fingers are somewhat stiff, considerably impairing their usefulness." A Board, consisting of Drs. Newcomer, Mears, and J. K. Bigelow, certified, September 10, 1873, that "the injury has left the forearm distorted, and with adhesive and tender cicatrices." The pensioner was paid September 4, 1875.

Five of the eighteen cases of secondary hæmorrhage were successfully treated by tying the ulnar artery.<sup>2</sup> In three instances, at least, distal and proximal ligatures were applied at the seat of the injury:

CASE 1869.—Private W. H. Harrison, Co. M, 1st Artillery, aged 22 years, was wounded at Olustee, February 20, 1864, and admitted to Hospital No. 2, Beaufort, three days afterward. Surgeon C. L. Allen, U. S. V., reported: "Gunshot fracture of left ulna. Ball entered on the outside of the forearm three inches above the wrist, and made its exit on the inside, four inches above the wrist. Ulna fractured without much comminution. March 1st, hæmorrhage occurred from the distal extremity of the ulnar artery to the amount of about forty ounces. The wound was enlarged above and below, and, upon a director, the artery was ligated both above and below the seat of injury, by the reporter. Chloroform was safely employed. The patient had been attacked with diarrhœa from the moment of receiving the wound; bowels regular before. The diarrhœa was not easily checked by remedies, and had passed into dysentery a few days before the hæmorrhage occurred. Simple dressings were used. The wound granulated quickly; the upper ligature came away March 8th, the lower one on the 10th. By March 31st, callus was distinct around the fractured point; patient doing well. Result: recovery." The patient was furloughed April 13th, readmitted to hospital during the following month, and returned to his command for duty July 12, 1864. He is not a pensioner.

Four of the eighteen cases of consecutive hæmorrhage associated with fracture of the ulna were treated by ligation of the radial.<sup>3</sup>

<sup>1</sup> Besides the instance detailed in the text, there can be studied, in the manuscript records: 1. The case of G. L. B. McMillan, Co. C, 40th Ohio, aged 21 years, shot fracture of right ulna, Chickamauga, December 20, 1863; gangrene, hæmorrhage, ligation of brachial; recovery. 2. The case of W. Henderson, Co. E, 115th Pennsylvania, left ulna comminuted in lower third, Gettysburg, July 2, 1863; sent to Cuyler Hospital, Germantown—sloughing; August 8th, uncontrollable hæmorrhage from ulnar artery, ligation of brachial by Dr. J. ASHURST, jr.; recovery.

<sup>2</sup> Besides the detailed case of Harrison were: 1. Case of Pt. M. Ford, Co. G, 51st New York, left ulna fractured, Antietam, September 17, 1862; hæmorrhage, ulna ligated at both ends, at Newark, October 2, 1862; recovery. 2. Pt. L. H. Price, Co. G, 86th New York, ulna fractured, Manassas, August 30, 1862; September 15th, ligation; recovery. 3. Lieut. J. B. Kripps, Co. E, 2d Pennsylvania Artillery, left ulna fractured, Chapin's Farm, September 29, 1864; October 8th, hæmorrhage, ligation of ulnar artery, both ends tied. 4. Pt. W. H. Fox, Co. F, 15th Wisconsin, aged 18 years, left ulna fractured, Atlanta, August 20, 1864; consecutive hæmorrhage, ligation, recovery, by Dr. HILL.

<sup>3</sup> 1. Pt. O. Donnell, Co. C, 3d Pennsylvania Artillery, aged 20 years, left ulna fractured, Gettysburg, July 3, 1863; hæmorrhage July 21st, ligation of proximal end of radial; slight recurrent hæmorrhage, from distal end; recovery. 2. Pt. G. M. Rose, Co. G, 6th Cavalry, ulna fractured, Bealton's Station, March 9, 1864; hæmorrhage April 7th, proximate end of artery ligated in wound by Acting Assistant Surgeon D. P. WOLHAUPTER; duty July 12, 1864. 3. Pt. P. Vankirk, Co. A, 26th Pennsylvania, left ulna fractured, Gettysburg, July 2, 1863; July 22d, hæmorrhage from radial, one end of artery tied in wound; duty May 3, 1864. 4. Pt. C. Lamper, Co. F, 82d Pennsylvania, aged 21 years, left ulna fractured, Cold Harbor, June 1, 1864, sloughing, hæmorrhage; July 27th, radial ligated in wound by Acting Assistant Surgeon W. F. ATLEE; discharged May 17, 1865.

§ *Fatal Cases.*—Fifty-nine, or 5.6 per cent. of the thousand and thirty-nine determined cases of shot fracture of the ulna, treated by expectation, belong to this subdivision. Pyæmia and gangrene were the principal fatal complications.

CASE 1870.—Private H. A. Fellows, Co. C, 12th New Hampshire, aged 18 years, was wounded at Gettysburg, July 3, 1863, and admitted to Satterlee Hospital two days afterward. Surgeon I. I. Hayes, U. S. V., recorded: "Wound of right forearm. July 6th, erysipelas. 7th, the arm is very much swollen and red. It is possible that there is a fracture of one of the bones of the forearm, but in its present condition it is impossible to discover it.

Gave twenty drops of tincture of chloride of iron every three hours, and applied mucilage to the arm, which is simply laid upon a pillow; low diet. 8th, is very much better; the erysipelas appears to have been arrested by tincture of iodine. 9th, improving; low diet continued. 10th, on examination to-day, it appears that the ulna is decidedly broken. 11th to 20th, patient doing well; low diet continued; cold-water dressings used. He died, of exhaustion from hæmorrhage and diarrhœa, on August 20, 1863." Acting Assistant Surgeon J. Leidy, who contributed the specimen (FIG. 667), made the following report of the *post-mortem* examination: "Body vigorous in appearance, but exceedingly pale, apparently the result of frequent hæmorrhage. The wound was extremely gangrenous and its course filled with a large recent coagulum of blood from hæmorrhage. Organs of chest healthy. Spleen full size, curiously mottled; in section pale, comparatively bloodless, and occupied by a great multitude, apparently, of malpighian bodies. Mucous membrane of the small intestines, more especially the ileum, moderately inflamed; the solitary glands large, white, and conspicuous; mucous membrane of the cæcum moderately inflamed. No disease of the brain existed, but like all the organs it was exceedingly pale and bloodless." The specimen shows the bones of the forearm, the middle third of the ulna having been shattered, with comminution and loss of substance for three inches. The lower extremity has a small deposit of callus, but the upper fragment is necrosed.



FIG. 667.—Bones of right forearm: ulna shattered at middle third. Spec. 1874.

CASE 1871.—Private N. Harris, Co. I, 24th Michigan, aged 23 years, was wounded at Gettysburg, July 3, 1863. Acting Assistant Surgeon A. L. Eakin reported his admission to Satterlee Hospital, Philadelphia, July 9th, and the progress and result of the case as follows: "Patient had a compound fracture of the right ulna, and also a like wound of the metacarpal bones of the left hand. Splints were applied to the right arm and flaxseed dressings to left hand. About July 23d, diarrhœa set in, which was somewhat checked during the following week. Cough came on also; a prescription of syrup of squills two and a half ounces, paregoric an ounce, and solution of sulphate of morphia half an ounce, was ordered in doses of a teaspoonful when needed, and tannic acid two grains, together with half a grain of pulverized opium, was administered four times daily. Beef tea and milk-punch were ordered, and cold-water dressing was applied to the hand. On the 24th, the feces were passed involuntarily, and so continued for several days. There was also a slight hæmorrhage from the wound in the hand, checked by cold applications. From the 24th, though the diarrhœa was somewhat checked, he continued to fail, and about the 28th, pneumonia of the left lung, complicated with pleurisy, attacked him; prescribed tartar emetic one grain, calomel sixteen grains, and nitrate of potassa one and a half drachms, to be divided into sixteen powders, and administered one every three hours; also, sulphate of quinine two grains, and carbonate of ammonia one and a half grains, four times daily. During the attack of diarrhœa there was also an injection given of fifty drops of tincture of opii three times a day. The patient died August 5, 1863." Acting Assistant Surgeon J. Leidy contributed the specimen, represented in the adjacent wood-cut (FIG. 668), and the following report of the *post-mortem* examination: "The parts in the track of the ball, extending some distance above and below, and including all the tissues, were gangrenous, black, semifluid, and putrid. The external wounds had not enlarged to any important degree from the gangrene. The wound of the hand was also in a similar gangrenous condition. Excepting recent pleuro-pneumonia of the lower lobe of the left lung, extending to the upper lobe, the organs of the chest and abdomen appeared healthy." The specimen consists of the left ulna, obliquely fractured in the lower third with some comminution, the extremities of the bone being necrosed.



FIG. 668.—Left ulna, obliquely fractured in lower third. Spec. 1876.

3. **SHOT FRACTURES OF THE RADIUS TREATED BY EXPECTATION.**—Of a thousand and nine cases, the results are unascertained in ten. The proportion of deaths are slightly less than in the preceding group, the proportion of grave disabilities somewhat greater.

§ *Successful Cases.*—Of the nine hundred and forty-nine patients who recovered, four hundred and forty-five returned to modified duty, and five hundred and four were discharged.

§ *Successful Cases.*—Of the nine hundred and forty-nine patients who recovered, four hundred and forty-five returned to modified duty, and five hundred and four were discharged.

CASE 1872.—Private A. Clough, Co. C, 31st Maine, aged 18 years, was wounded at Cold Harbor, June 3, 1864, and admitted to the 2d division hospital, Ninth Corps, where Surgeon J. Harris, 7th Rhode Island, recorded: "Wound of right arm." On June 7th, the wounded man entered Harewood Hospital, Washington, whence Surgeon R. B. Bontecou, U. S. V., reported: "Compound fracture of right radius, lower third. Secondary hæmorrhage occurred on June 8th, to the amount of about twenty-four ounces; radial artery ligated above and below the wound. Hæmorrhage did not recur; patient doing well." On July 21st, he was transferred to DeCamp Hospital, New York, and subsequently to Cory Hospital, Augusta, where he was assigned to the Veteran Reserve Corps, February 18, 1865. The man was ultimately discharged from service August 30, 1865, and pensioned. Examiner J. G. Bell, of Augusta, Maine, May 25, 1866, certified: "Ball passed through the forearm five inches above the wrist, causing compound comminuted fracture of the radius, and removing a large part of diameter of the bone for a space of two inches in length. Muscles attached to bone; use of hand much impaired." The pensioner was paid March 4, 1867.



The foregoing and following cases were complicated by secondary hæmorrhage and successfully treated by ligation of the radial, and there were six others of the same description.<sup>1</sup> There were eighteen instances of secondary hæmorrhage; five treated by compression, eight by ligation of the radial, and five by ligation of the brachial.<sup>2</sup>

CASE 1873.—Captain H. S. Harding, Co. A, 122d Ohio, aged 42 years, was wounded at Cold Harbor, June 3, 1864, and admitted to the field hospital of the 2d division, Sixth Corps. Surgeon R. Barr, 67th Pennsylvania, noted: "Gunshot fracture of left radius by shell; ligation of radial artery." Surgeon A. F. Sheldon, U. S. V., reported the patient's admission to Campbell Hospital, Washington, June 11th, with "gunshot fracture of left forearm," and his departure "on furlough, August 30th." This officer was mustered out of service October 29, 1864, and pensioned. Examiner Hildreth, of Zanesville, April 30, 1865, certified: "The missile passed through the lower third of the forearm, fracturing both bones. The wound was followed by erysipelas, etc. His fingers are partially stiffened, but they are gradually improving," etc. The Zanesville Examining Board reported, September 5, 1873: "\* \* \* The fracture of the radius was superficial, that of the ulna was complete; the flexor tendons wounded, also the internal cutaneous nerve. The skin is numb on the inner side of the forearm, and there is adhesion of tendons at seat of wound to skin and fascia. Hence he can only flex the fingers to one-half, the adhesions limiting the further flexion of them, and from this cause the power of the forearm and hand is impaired." The pensioner was paid Sept. 4, 1875.

Hospital gangrene, as illustrated in Plate XVI opposite, occurred occasionally in the cases of this group, but less frequently than in shot wounds on the ulnar side:

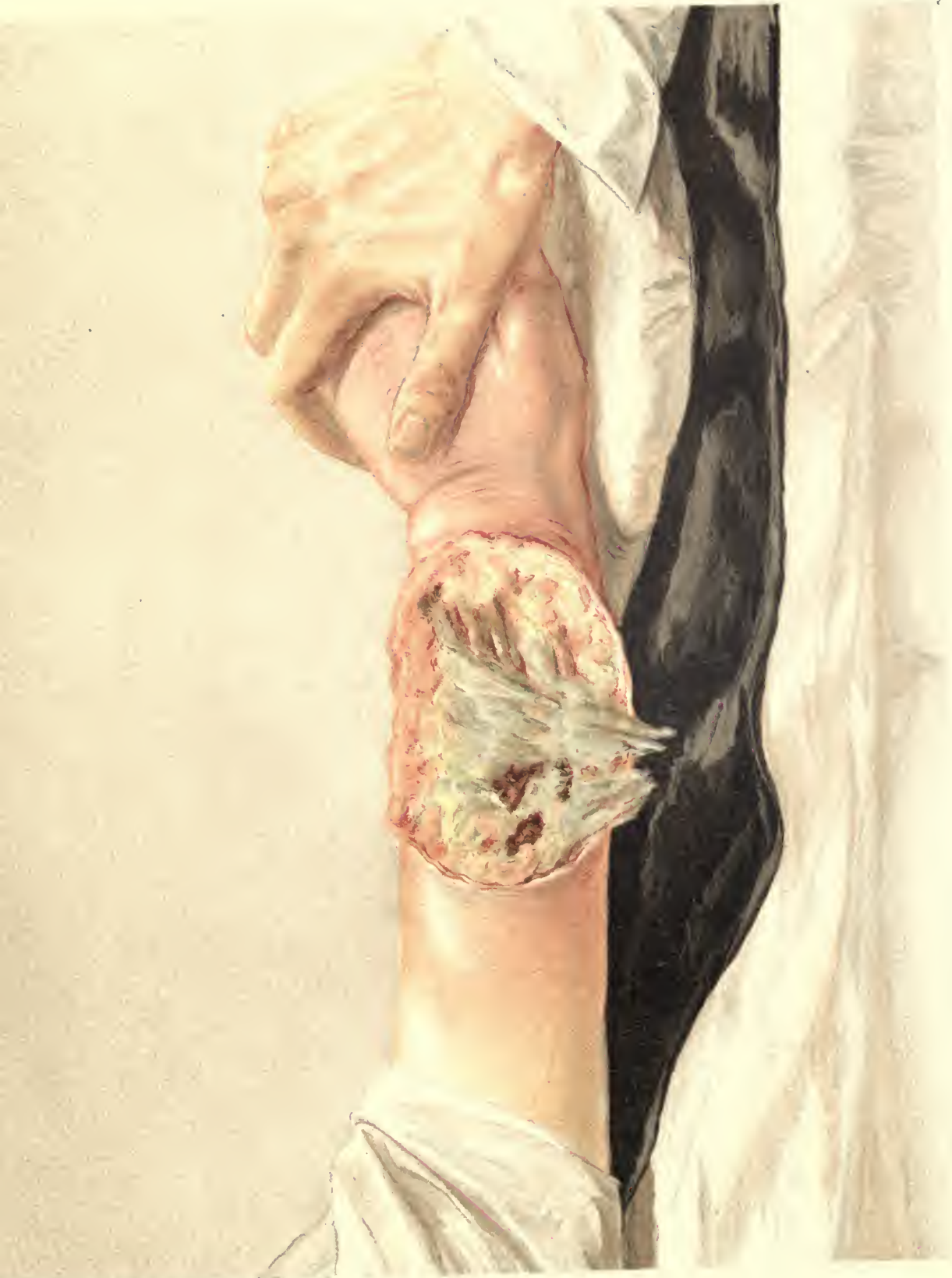CASE 1874.—Private C. F. Keables, Co. C, 18th Connecticut, aged 24 years, was wounded at Winchester, June 14, 1863, and was taken prisoner. He is reported at Annapolis, August 3, 1863, from Richmond. Surgeon B. A. Vanderkeift, U. S. V., reported: "Gunshot wound of left forearm." Acting Assistant Surgeon C. Hayes reported: "Ball entered outer portion of left forearm at lower third, passing through and slightly fracturing the radius. When admitted was doing well. August 12th, outer wound commenced to slough; slight chill, followed by fever. 13th, slough increasing rapidly. 14th, wound still sloughing at lower side; along the upper edge it looks better. 15th, slough is separating from the upper side. 16th, slough is almost entirely separated; wound throwing off healthy granulations. 18th, wound is now clean and healthy; is about four inches long, three wide, and one quarter of an inch deep." This soldier was furloughed December 22, 1863; transferred to Veteran Reserve Corps May 8, 1864; discharged August 17, 1865, and pensioned. Examiner A. W. Nelson, of New London, Connecticut, April 2, 1867, reported: "Wound healed; cicatrix two inches above left wrist, back of forearm; cicatrix two and a half inches square adherent to radius; lost several pieces of bone before healing of wound—two pieces an inch long; mummified ball came out at the inner and ulnar side of forearm five inches above the wrist; pronation of forearm perfect; supination somewhat impaired; wrist movement very slight; joint nearly ankylosed; fingers of the left hand can only be extended to an angle of 150 degrees; movements of thumb much impaired; cicatrix tender." A drawing of the wound in its gangrenous condition was made by Hospital Steward E. Stanch, and is shown in the chromo-lithograph, PLATE XVI.

Other complications were erysipelas and exfoliation of necrosed fragments:

CASE 1875.—Private C. Sibolt, Co. C, 11th Massachusetts, aged 28 years, was wounded at the Wilderness, May 6, 1864. Surgeon A. O. Judson, U. S. V., reported his admission to Carver Hospital, Washington, May 26th, with "gunshot fracture of right radius," and his transfer to Philadelphia on May 31st. Acting Assistant Surgeon H. M. Bellows reported, from Broad and Cherry Streets Hospital: "This patient was first admitted to this hospital, June 1st, with a compound gunshot fracture of right radius by a bullet, which entered the upper third of the radial side of the forearm, and, passing posteriorly upward and slightly outward, came out on the upper posterior part of the forearm, about one inch below the external condyle of the humerus. July 10th, several pieces of bone have come away from the wound. August 25th, patient transferred to Turner's Lane Hospital." Acting Assistant Surgeon C. Carter, from the latter hospital, reported: "Forearm fixed in a pronated position; wrist and fingers extended, but not fully, with little power of motion; large amount of callus at seat of wound, with apparent deformity; orifice two inches below flexure of elbow, over upper part of radius, discharging pus; dead bone felt with probe. August 28th, active and passive movements resorted to. September 6th, removed dead bone, a piece the size of a small finger nail, November 1st, wound still discharging; has gained slight motion in fingers, wrist, and supination. Continued active and passive motion." The patient was discharged December 12, 1864, and pensioned. Examiner Howell, of Aurora, June 4, 1873, certified: "\* \* \* Rotary motion is entirely destroyed; necrosis of radius at point of exit of ball; arm swollen and painful; muscles of forearm and hand weak and partially paralyzed; hand entirely useless for manual labor." On July 7, 1875, he again reported: "Constant discharge of ichorous purulent matter, with occasional spiculæ of bone. Supination and pronation destroyed; atrophy of muscles of forearm and hand, rendering forearm and hand totally useless," etc. The pensioner was paid June 4, 1875.

<sup>1</sup> Pt. J. M. Hall, Co. E, 20th Illinois, right radius, Shiloh, April 6, 1862, radial artery ligated; discharged August 6, 1862. Pt. A. Hakes, Co. A, 32d New York, right radius, Antietam, September 17, 1862; hæmorrhage October 9th, radial artery ligated in upper extremity only; duty February 13, 1863. Serg't O. P. Babcock, Co. H, 207th Pennsylvania, left radius, Petersburg, April 2, 1865; hæmorrhage April 12th, proximal and distal ends of recurrent branch of radial artery ligated; discharged June 2, 1865. Pt. W. A. Hannabaugh, Co. A, 26th Pennsylvania, left radius, Gettysburg, July 3, 1863; hæmorrhage July 19th, one end of radial artery tied in wound; discharged February 9, 1864. Pt. C. H. Cottrell, Co. I, 7th New Jersey, left radius, Spotsylvania, May 10, 1864; hæmorrhage, radial ligated; duty October 17, 1864. Pt. S. Smith, Co. H, 74th Ohio, left radius, Lookout Mountain, October 2, 1863; sloughing and hæmorrhage May 24th, ligation of superior extremity of radial; duty November 20, 1863.

<sup>2</sup> Pt. M. Porman, Co. F, 2d New Jersey Cavalry, aged 23 years, right radius, Bolivar, Tennessee, May 2, 1864; gangrene, hæmorrhage, brachial ligated June 21st; discharged September 25, 1864. Pt. T. J. Smith, Co. A, 6th Iowa, aged 22 years, Shiloh, April 6, 1862; hæmorrhage April 24th, ligation of brachial artery; discharged March 19, 1863. Pt. H. Letterman, Co. K, 67th Pennsylvania, aged 36 years, left radius, Cold Harbor, June 3, 1864; hæmorrhage July 13th, from radial artery, brachial tied; discharged March 1, 1865. Pt. C. C. Powers, Co. A, 40th Iowa, left radius, accident, June 13, 1865; hæmorrhage June 17, 1865, ligation of brachial; recovered. Pt. M. H. Hardy, General Service, radius, accident, 1862, brachial ligated; discharged February 26, 1863.



HOSPITAL GANGRENE





In numerous cases, there was extended necrosis of the diaphysis; in some instances long cylindrical sequestra being eliminated:

CASE 1876.—Corporal I. H. Rawlins, Co. E, 76th Pennsylvania, aged 20 years, was wounded at Pocatigo, October 22, 1862. Surgeon R. B. Bontecou, U. S. V., in charge of Hospital No. 1, Beaufort, noted: "He was admitted, October 24th, with gunshot wound of right forearm, a portion of shell having entered far enough to break the radius two inches above the wrist, and not tearing the coat. The fracture was a simple one, and the wound slight. A straight splint to the palmar aspect of the forearm was applied, and lint with cerate to the wound. December 1st, the patient has required very little attention, the injury of the arm not disturbing his general health nor creating much local disturbance. He has been dressed and about the ward nearly all the while since his admission. December 20th, arm sound; bone a little enlarged by callus, but the patient is considered well, and sent to-day to his regiment." Surgeon M. A. Withers, 6th Connecticut, recorded this man's admission and treatment for nearly three weeks at the regimental hospital during the following month—January, 1863. On November 28, 1864, Corporal Rawlins was mustered out of service and pensioned. Examiner J. Phillips, of Washington, D. C., May 16, 1867, certified: " \* \* Fracture of radius; the tendons of the extensor muscles injured: the strength of the arm and hand somewhat impaired." Examiner D. S. Hays, of Hollidaysburg, Pa., certified, March 12, 1872: " \* \* The original wound has recently reopened, caused by exfoliation of bone, and presents an unhealthy, dark, inflamed appearance, surrounded by a large purple areola. There is considerable suffering, and the applicant is unable to use the arm to any extent. A partially detached spicula can be felt." An Examining Board, consisting of Drs. Hays and G. W. Smith, certified, September 4, 1873: " \* \* Necrosis of bone and loss of pronation and supination," etc. The same Board reported, July 1, 1874, that they found "the cicatrix red and somewhat tender; some enlargement of joint; pronation and supination somewhat impaired though tolerably good; wrist not as strong as natural, and functionally impaired. The wound reopened some months ago, but is now well. There is no evidence of its reopening." This pensioner was paid September 4, 1875.

CASE 1877.—Private R. Hotz, Co. I, 183d Pennsylvania, aged 29 years, was wounded at Cold Harbor, June 3, 1864, and admitted to the field hospital of the 1st division, Second Corps, where Surgeon W. S. Cooper, 125th New York, noted: "Gunshot wound of arm." On June 7th, the wounded man entered Harewood Hospital, Washington, and several days afterward he was transferred to Philadelphia. Surgeon L. Taylor, U. S. A., in charge of McClellan Hospital, made the following detailed report of the case: "He was wounded by a minié ball, which entered on the lower part of the posterior surface of the left forearm and came out immediately opposite the orifice of entrance, fracturing the radius, through which it passed. The patient was admitted to this hospital on June 13th, the lower wound being in a sloughing condition. It ceased sloughing by June 20th, and did well until July 1st, when the opening began again to increase in size. On July 28th, an abscess, pointing half way up the forearm, was opened: a probe introduced detected the presence of necrosed bone. The wound caused by the entrance of the ball had healed entirely about this time, while that of exit continued sloughing at intervals until September 1st, when it began to present a healthy appearance. It was now evident that a large portion of the radius was entirely necrosed. On September 3d, an incision was made from the cicatrized wound of entrance to near the elbow, on the posterior surface of the forearm, passing through the opening previously made, July 28th; the muscles were partly cut and partly torn apart, when a portion of the radius, six inches long, was found nearly loose, and was removed without any trouble. It was partly surrounded by callus. The wound was closed with sutures and adhesive plaster, and has since done well. The operation was performed by Acting Assistant Surgeon W. L. Wells. October 30th, the patient has some motion of the little finger, and there is prospect of the hand becoming useful to a slight degree." The sequestrum was contributed to the Museum by the operator, and is represented in the annexed wood-cut (FIG. 669). Its middle third occupies the totality of the bone, about one-third of the circumference being wanting at the extremities. There is an osseous deposit upon the middle of the specimen. The patient was discharged from service February 1, 1865, and pensioned.



FIG. 669.—Sequestrum from left radius. *Spec.* 3672.

CASE 1878.—Private J. C. Roberts, Co. C, 26th New York, aged 18 years, was wounded in the left forearm at Antietam, September 17, 1862. Three days afterward he was admitted to Newton University Hospital, Baltimore, whence Surgeon C. W. Jones, U. S. V., furnished the following history: "He was wounded by a minié ball, which passed through the forearm, fracturing the radius. The ball entered the middle of the forearm upon its anterior aspect, and passed out about two inches below the elbow, on the posterior side. The wounds were dressed with cold water and lint. On the first, second, and third days of October, secondary hæmorrhages occurred, which were restrained by temporary compression of the brachial artery and the injection of solution of persulphate of iron. The probable loss of blood amounted to sixteen ounces, and the probable source of the hæmorrhage was the interosseous artery. On October 4th, an abscess being opened on the posterior aspect of the middle of the forearm, Surgeon C. W. Jones, U. S. V., removed four large fragments of the radius varying from one to two inches in length. A sponge tent was then inserted and allowed to remain until the next morning, when a poultice was applied to soften and favor its removal, which was afterward accomplished. The dressing of cold water and lint was then resumed, and was followed by rapid improvement in the condition of the patient. At this time—November 8th—the arm is nearly well." The removed fragments were contributed to the Museum by the operator (*Cat. Surg. Sect.*, 1866, p. 191, *Spec.* 407). The patient was discharged from service December 18, 1862, by reason of "partial ankylosis of the elbow joint and atrophy of hand, resulting from the wound." Examiner H. B. Day, of Utica, New York, January 10, 1863, certified: "Gunshot wound in left arm, shattering the radius. Pieces of bone have been taken from the wound. \* \* \* Wound still suppurating; forearm perfectly useless." The Utica Examining Board, consisting of Drs. H. B. Day and S. B. Coventry, certified, November 27, 1863: "The wrist joint is distorted from loss of portions of the radius and laceration of the flexors of the wrist and fingers." Examiner G. W. Avery, of Norwich, reported, September 4, 1873: "The act of pronating and supinating the forearm is much impeded." The pensioner was paid September 4, 1875.



There were no less than one hundred and forty-seven instances among the recoveries, in which considerable fragments were removed or necrosed sequestra were extracted.

CASE 1879.—Private J. V. Davis, Co. C, 76th Pennsylvania, aged 18 years, was wounded at Pocatigo, October 22, 1862, and admitted to Hospital No. 1, Beaufort, two days afterward. Surgeon R. B. Boutecon, U. S. V., recorded: "Gunshot wound of left forearm, the ball entering the outside at the middle of the radius, and, passing obliquely through that bone near the elbow joint, emerged in front of the inner condyle, at the flexure; then again entered the arm two inches above that point, and, after passing under the integuments about one inch, emerged at the inner side of the arm just above the inner condyle, making four wounds. The radius was somewhat comminuted and the short upper extremity drawn upward and inward by the biceps. I kept the arm well flexed, and by compresses and splints corrected this displacement somewhat. The swelling and inflammation that followed was slight. November 15th, fluctuation at the middle of the forearm anteriorly led me to lay open the fascia to some extent, and with the finger and forceps removed some sequestra which had become detached. December 1st, splint still worn, and yesterday another sequestrum removed, after dilating the wound with sponge-tent twenty-four hours. December 29th, patient has union of radius and has been without a splint ten days; will be sent to his regiment soon. His health has not been affected since the wounding. The upper fragment could not be kept in line, and I perceive the union will be weak. February 6th, patient sent to his regiment." He was discharged from his regiment March 3, 1863, and pensioned. Examiner D. S. Hays, of Hollidaysburg, Pennsylvania, certified: "The ball penetrated the arm about the middle and emerged near the bend of the elbow, comminuting the radius, a considerable portion of which was evidently removed in its continuity. The bones are forced together at the interosseous space, with vicious union and resulting partial destruction of pronation and supination. There is considerable deformity, and incurable loss of complete use of the limb," &c. Drs. A. S. Dunlop and J. S. Beck, of the Dayton National Military Asylum Board, July, 1871, reported: "\* \* \* There is necrosis of both bones of forearm. Partial ankylosis of elbow joint. Rotation is but imperfect. There is an unreduced dislocation of the ulna at the wrist joint, leaving great deformity," &c. Examiner W. M. Wright, of the Hampton Military Asylum, September 5, 1873, certified: "\* \* \* The injury has produced extensive adhesions and lesion of most of the muscles of the forearm, especially of the flexor longus pollicis, pronator quadratus, supinator radii longus, extensor carpi radialis longior, and other important muscles connected with the movements of the arm and hand." The pensioner was paid September 4, 1875.

§ *Fatal Cases of Shot Fracture of the Radius treated by Expectation.*—There were fifty deaths among the thousand and nine cases of this category. In five, pyæmia was reported as the proximate fatal cause. The following is one of these cases:

CASE 1880.—Private S. McCan, Co. F, 1st Cavalry, aged 23 years, was wounded in the right forearm, at Funkstown, July 8, 1863, and entered Frederick Hospital one week afterward. Acting Assistant Surgeon W. S. Adams contributed the specimen (FIG. 670) with the following history: "A fragment of shell produced a compound comminuted fracture of the right ulna. The fragments had been removed prior to admission, and the wound was granulating nicely. His general condition was fair; appetite good. Ordered simple dressings and generous diet. August 2d, patient has been doing well up to yesterday, walking about the hospital grounds at will. At about 5 P. M. he was attacked with chilliness and went to bed, and this morning I found him with considerable fever, skin hot and dry, pulse 100, tongue somewhat furred, face flushed, slight headache, and total loss of appetite. 3d, patient slightly delirious; pulse 120; slight diarrhœa; complains of tenderness over the right iliac region, and a gurgling sound is produced on pressure. Ordered stimulants, astringents, and tonics. 4th, diarrhœa no better; tympanitis well marked; tongue dry and brown. Treatment continued. 6th, delirium still continues; tongue cracked; the wound discharges less freely and this morning presents a sloughy appearance; pulse 130. Continued the treatment and applied acid lotion to wound. 6 P. M., slight hæmorrhage has just taken place; no bleeding vessel can be found; it seems to be a general oozing from the granulations. 7th, several well-marked rose spots are observed in the epigastric region; diarrhœa still exists; sordes on the teeth. Ordered stimulants to be increased, and a wineglassful of milk-punch every hour. 9th, rose spots quite numerous this forenoon. Patient is evidently growing worse. At 6 P. M. he had a severe chill. 10th, patient evidently sinking. He died at mid-day. *Section cadaveris* eight hours after death: rigor mortis complete. On opening the chest, found left pleural cavity containing about a pint of yellow sero-purulent fluid; lungs heavily coated with broken-down lymph; substance of lungs highly engorged—left lung highly congested, but containing no abscesses; right lung literally filled with small circumscribed abscesses. Weight of lungs one pound and nine ounces each. Liver weighed five pounds and two ounces, and contained three abscesses, holding about two ounces of pus each. Heart healthy and weighing seven ounces. Spleen weighed ten ounces and hyperæmic; kidneys six ounces and much congested. The carpus was found filled with pus, and the ulna stripped of periosteum for the space of three inches above the point of the injury and down to the wrist joint." The specimen consists of the bones of the forearm, and shows comminution of the ulna in the lowest third. The lower extremity is necrosed, which condition extends superficially up two-thirds of the shaft.



FIG. 670.—Shell fracture of right ulna and radius. Spec. 3889.

In six cases,<sup>1</sup> secondary hæmorrhage induced the fatal result. An example is given in CASE 1883, on the opposite page. Two patients succumbed from tetanus, one from gangrene, and in two instances, which are detailed on the next page, severe erysipelatous inflammation

<sup>1</sup> One, Pt. W. H. Croyle, Co. H, 55th Pa., died after ligation of the ulna. Lamareaux (CASE 1883, p. 931) and Serg't Pieffer, Co. I, 5th Mich., fracture of radius, Petersburg, September 3, 1864, died after ligations of the radial. Three patients treated by styptics and pressure succumbed: Pts. G. Tunbgin, 20th Indiana; J. W. Jones, 1st Mass. Art.; J. Quick, 25th South Carolina.

preceded the fatal issue. The majority of the patients died from exhaustion from protracted suppuration, or from intercurrent affections arising during their treatment in hospitals.

CASE 1881.—Private M. Poquett, Co. A, 33d New York, aged 30 years, was wounded at Chancellorsville, May 3, 1863. Surgeon D. E. Dickerson, of the regiment, recorded the injury as "Gunshot fracture of right forearm," and the man's transfer to General Hospital May 7th. On the following day the patient entered Douglas Hospital, Washington, whence Assistant Surgeon W. Thomson furnished the following history: "He was struck by a bullet, which passed through his right arm, fracturing the radius, and then caused a flesh wound over the ninth rib. At time of admission had diffused erysipelas extending to the shoulder, which yielded to local use of tincture of iodine, etc. There was copious discharge from the arm. On the 19th, the erysipelas recurred, and was successfully treated by one-drop doses of bromine internally. His general condition, however, was improving, and on the 21st he suffered from dyspnoea and pain in the chest. This increased rapidly, and was supposed to be due to acute capillary bronchitis. He finally died, on June 22, 1863. Autopsy: There were adhesions in the right pleural cavity, with serum in both pleural cavities. The mucous membrane lining the bronchial tubes was strongly injected; both lungs seemed to be much congested, sinking in water, but with no hepatization. A fracture of the radius, surrounded by a fibrous investment and in a fair way to be united, was found, which is now forwarded." The specimen is represented in the adjacent wood-cut (FIG. 671), and shows a few necrosed splinters entangled in the callus that was thrown out.



FIG. 671.—Right radius fractured in middle third. *Spec.* 1341.

CASE 1882.—Private D. Scott, Co. A, 1st Kansas Colored Troops, was wounded on April 10, 1864, and entered the Little Rock Hospital May 4th. Assistant Surgeon R. M. Lackey, U. S. V., recorded: "Gunshot wound of forearm. Patient returned to duty May 9th; readmitted with same wound September 11th, and returned to duty November 24th; readmitted with erysipelas December 2d, and died April 2, 1865." An account of this case was reported to Surgeon J. R. Smith, U. S. A., Medical Director of the Department of Arkansas, by Acting Assistant Surgeon H. S. Hannen, as follows: "The patient was wounded at Poison Springs, while with a foraging party, by a minié ball, which made its entrance at the lower third of the right forearm, fracturing the radius, and passing downward to the carpus produced a dislocation of the ulnar portion of the carpus, where it made its exit. Nothing had been done for the patient's arm previous to his admission to this hospital. About one week after his admission a reduction was attempted, but the case having been neglected so long the parts could not be reduced, and a bandage was applied and the wound dressed with simple cerate.



FIG. 672.—Lower portions of radius and ulna, the former partly repaired after shot fracture. *Spec.* 4.

The patient's general condition, when he came under treatment, was good, and continued so until March 26th, when he was seized with an attack of erysipelas which affected his face and neck severely. The usual remedies were resorted to but proved unsuccessful, and he died April 2, 1865. I would remark that the patient had recovered sufficiently to be able to assist at the work in the kitchen, and could use his arm quite well except that he could not supinate or pronate, and there was some stiffness of the carpus and a dislocation of the extremity of the ulna, the arm presenting a very crooked appearance. I made an examination of his arm and wrist and had the carpal bones prepared, but having become detached from the radius and ulna they were lost. Thinking the remaining portion of the preparation would be of interest, I beg leave to present them with the foregoing history, which is all I can learn. \* \* \* The specimen, represented in the annexed wood-cut (FIG. 672), was forwarded to the Museum by Surgeon Smith. The radius has been shattered for two inches; a fair osseous deposit has occurred, but actual union has obtained only for a volume of one-fourth the normal size.

CASE 1883.—Corporal A. Lamareaux, Co. E, 124th New York, aged 20 years, was wounded near Hatcher's Run, April 1, 1865, and admitted to the field hospital of the 3d division, Second Corps, where Surgeon O. Everts, 20th Indiana, recorded: "Gunshot wound of left arm." On April 5th, the man entered Douglas Hospital, Washington, whence Assistant Surgeon W. F. Norris, U. S. A., contributed the specimen (FIG. 673), together with the following description of the injury and operations which he performed: "Gunshot fracture of left radius. The ball was found to have entered the forearm from behind, fracturing the radius near its head, and lodging above the elbow joint in the arm. When admitted, the general condition of the patient was unfavorable, being feverish and without appetite; pulse 110. He stated that there was profuse hemorrhage at the time of the injury. The parts were not healthy looking, the arm somewhat swollen and hot, and the hand œdematous. On April 6th the bullet was extracted, two counter-openings being made. On April 9th, secondary hæmorrhage occurred to the amount of six ounces, which ceased spontaneously. Another hæmorrhage occurred on the 13th, and two attacks took place on the 14th, the last two being very slight. The parts were still much swollen and painful, discharge profuse, tongue dry, and countenance pale. Patient has considerable pain in chest, and dyspnoea, but no cough, and is rapidly losing strength. On April 15th there was hæmorrhage, amounting to three ounces, at 8 A. M., which ceased upon slight compression of the brachial, but recurred at 12 M. to the amount of eight ounces, when the brachial artery was ligated in its continuity. The areolar tissue was found filled with clots of blood. The patient was almost moribund, and the operation was only a temporary measure, and was performed to render the patient comfortable, without expectation of saving life. He died of exhaustion, at 2 A. M. the following day, April 16, 1865. The autopsy, twelve hours after death, showed that the radius had been fractured just below the head, also that the radial artery had been severed by the bullet, and that the elbow joint had become secondarily involved. Incipient pneumonia existed in the posterior lobes of both lungs. The other organs were healthy. The specimen consists of the upper halves of the bones of the forearm."



FIG. 673.—Shot fracture of radius. *Spec.* 4186.



§ *Complications.*—Among the twenty-nine hundred and seventy cases of shot fractures of the bones of the forearm treated on the expectant plan, the graver complications were comparatively infrequent. *Pyæmia* supervened in twenty-seven cases, all terminating fatally. One of these (CASE 1880) is detailed on page 930. One case of recovery from *tetanus*, and four fatal cases are reported.<sup>1</sup> There were fifty-seven instances of serious *secondary hæmorrhage*. Forty-four of the patients recovered, the hæmorrhage having been controlled by compression in sixteen cases, and by ligature in twenty-eight cases. Thirteen patients died, nine after treatment by compression and styptics, and four after ligation. In eight instances the brachial was tied at a distance from the wound. In five cases the ulna was ligated. In fourteen cases the radial was tied, distal as well as proximal ligatures being mentioned in two cases. In the remaining case, the interosseous was the vessel secured. *Splinters* were extracted in one hundred and fifty-eight cases.

§ *Treatment.*—The expectant conservative treatment of shot fractures of the ulna and radius was very simple, and, where one bone only was interested, and the injury was uncomplicated, very satisfactory. The limb was laid in semi-pronation on a wide padded splint, supported by a sling. A few

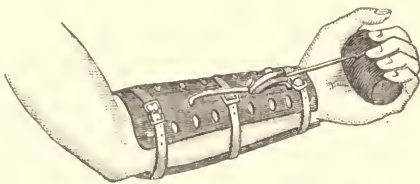


FIG. 674.—Hewit's splint for fractures near the wrist.

loose turns of roller at the upper and lower ends served to secure the splint and to remind the patient not to move the arm, and were so disposed as to permit the application of cold lotions to the wound. In short, the wise

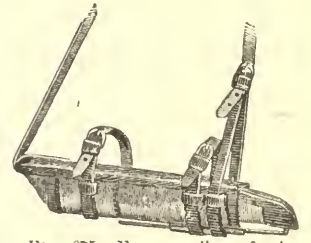


FIG. 675.—Forearm sling of wire gauze. Spec. 6359, A. M. M.

counsel of Dr. Stromeyer appears to have been generally followed.<sup>2</sup> Attempts to keep the bones separated by graduated compresses and all tight circular bandaging were found harmful.<sup>3</sup> The various special splints for fractures of the lower part of the radius (to which an ingenious addition was made<sup>4</sup> by the lamented Medical Director H. S. Hewit, FIG. 674) were found inapplicable in shot fractures. Often a wire trough (FIG. 675), or Ahl's felt forearm splint, could be used advantageously, and Medical Inspector Hamilton (*Mil. Surg.*, 1865, p. 395) commended more accurately adjusted apparatus when the inflammatory phenomena had abated.

<sup>1</sup> Viz: Pt. J. E. Peters, 26th Indiana, fracture of ulna and radius; Pt. P. Loughan, 26th Pennsylvania, and Pt. C. C. Hill, 2d Michigan, with fractures of radius; and Pt. M. White, 111th New York, unspecified shot fracture in forearm.

<sup>2</sup> STROMEYER (*L.*) (*Maximen*, u. s. w., 1853, S. 703) remarks: "Whatever the injury of the bones of the forearm may be, there is only one proper mode of bandaging, and this consists in the elevated position on a splint, on which there is room for the hand; forearm and hand resting on the volar side. The injured arm must be slightly secured by two broad bandages, which only serve to remind the patient that he must not move his arm. On this splint the arm remains until the healing process is sufficiently advanced to allow the substitution of a sling trough, with which the patient may walk about. . . . I would warn against all attempts to secure the position of the fragments by tight bandaging." The celebrated professor strongly advises against the supine position, as recommended by MALGAIGNE, LONSDALE, SOUTH, NÉLATON, etc.

<sup>3</sup> Several methods of treating fractures of the forearm were proposed that suggest a surprising lack of appreciation of the indications in such cases on the part of their inventors. One (FIG. 676), devised by Dr. J. H. VEDDER (*Am. Med. Times*, 1862, Vol. IV, p. 255), is intended to permit the use of an "extension ratchet pulley" in fractures of the forearm, which seldom has need of extension.

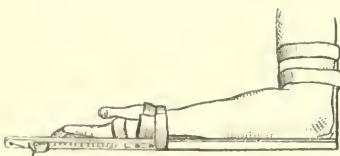


FIG. 676.—Forearm extension splint.

The other (FIG. 677) is commended by Surgeon POSTER SWIFT, 8th New York Militia, who states (*Am. Med. Times*, 1862, Vol. IV, p. 256) that after the battle of Bull Run he was "left with four or five cases of fractured arms, with no appliances for their treatment, and with the prospect of their transportation over a rough road, in rough wagons, to Manassas, and thence to Richmond, without splints and without any light material to make them of," and improvised

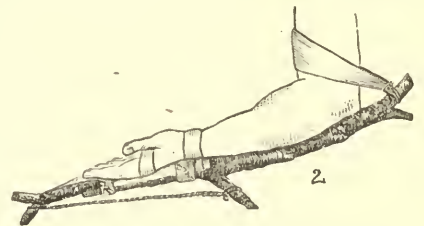


FIG. 677.—Improvised splint.

for the forearm cases a splint such as is shown in the cut. It is somewhat difficult to accept Dr. SWIFT'S assurance, quoted on page 812, NOTE 4, that such appliances "afforded great relief to our wounded men in their jolting journey."

<sup>4</sup> HEWIT (H. S.), A new splint for fractures of the forearm (*Medical Record*, 1873, Vol. VIII, p. 165).

**EXCISIONS IN THE CONTINUITY OF THE BONES OF THE FOREARM FOR SHOT INJURY.**—Formal excisions of the shaft of the ulna, or radius, or of both bones<sup>1</sup> were frequently practised, especially as primary operations. If the results were unsatisfactory as regards the average amount of functional utility preserved in the hand, they showed unquestionably a considerably less fatality than was observed in cases treated by amputation in the forearm. The excisions were usually limited to the removal of a few inches of the shaft of one of the bones. The diaphysis of the ulna alone was interested in four hundred and ninety-six, or more than half of the determined cases; the radius alone was resected in four hundred and thirteen cases; portions of the shafts of both bones were excised in fifty-nine, or about 6 per cent. of the cases. In eighteen instances the precise parts excised are unspecified. In the tabular statements the operations have been separated into primary, intermediary, secondary, and subdivided into successful and fatal groups. There would be too great complexity in arranging the tables according to the parts interested; but this division is observed partially in the illustrative cases and comments. The following table gives an outline of the results of the several groups:

TABLE CXXV.

*Numerical Statement of Nine Hundred and Eighty-six Cases of Excisions in the Forearm for Shot Injury.*

OPERATIONS.	TOTAL CASES.	RECOVERIES.	FATAL CASES.	RESULT UNKNOWN.	MORTALITY RATE, DETERMINED CASES.
PRIMARY.....	665	589	71	5	10.7
INTERMEDIARY.....	149	120	29	.....	19.4
SECONDARY.....	40	36	4	.....	10.0
TIME OF OPERATION UNKNOWN.	132	111	5	16	4.3
Aggregates.....	986	856	109	21	11.2

The uniformity of the death-rate in the several series indicates that the stage at which the excisions were done had far less influence on the gravity of the operations than is observed in operations of greater magnitude. Recourse was had to consecutive amputations in seventy-six cases; a much smaller proportion than obtained in the series of excisions in the shaft of the humerus.

**PRIMARY EXCISIONS IN THE SHAFT OF THE ULNA, OF THE RADIUS, OR OF BOTH BONES.** There were five hundred and eighty-nine recoveries, and seventy-one deaths, in the series of six hundred and sixty-five primary excisions, the results remaining undetermined in five instances. The excisions involved the ulna in three hundred and twenty-one cases, the radius in two hundred and ninety-one, both bones in forty cases, and the seat of excision was unspecified in thirteen instances. The operations were performed on six hundred and twenty-one Union and forty-four Confederate soldiers.

**Recoveries after Primary Excision in the Forearm.**—Some examples of the excisions

<sup>1</sup> Excision in the shafts of these bones for shot injury has not, until recently, been regarded as an accepted resource of surgery, and its value is still *sub judice*. BILGWER, in the Seven Years' War, 1756-63, would appear to have been the earliest to perform an operation to which this name might be applied. BAUDENS, in the Algerian campaigns, stoutly advocated the excisions in the continuity of these and other long bones; and LANGESHECK and his followers practised operations of this sort in Sleswick-Holstein. The historical relations of each of the special operations will be noticed more in detail further on.



in the shafts of both bones, of the ulna alone, and of the radius, will precede the general tabular enumeration, presenting details of the principal varieties of the several operations.

**EXCISIONS IN SHAFTS OF ULNA AND RADIUS.**—Of the forty primary excisions of this nature,<sup>1</sup> thirty-four were successful in the *quoad vitam* sense; but many of the patients recovered with useless limbs, and several only after submitting to amputation. Not a single really good result is noted among the twenty-two patients who retained their limbs.

CASE 1884.—Private J. G. Frederick, Co. E, 103d Illinois, aged 26 years, was wounded at Mission Ridge, November 25, 1863, and admitted to the field hospital of the 4th division, Fifteenth Corps. Surgeon W. W. Bridge, 46th Ohio, recorded: "Gunshot wound of left forearm; resection of radius and ulna. Patient sent to general hospital December 20th." Assistant Surgeon R. Bartholow, U. S. A., reported the man's admission to the general field hospital, Chattanooga, with "gunshot fracture of left forearm," and his transfer to Nashville January 30th. On the following day the patient was admitted to Hospital No. 1, Nashville, whence Surgeon R. L. Stanford made the following report of the case: "The ball entered three inches below the elbow joint, producing a compound comminuted fracture of the ulna and the radius. Resection was performed the same day, three inches of both bones being removed. When admitted, the arm was loosely confined in a sling. No union had taken place. The wound was discharging freely, both by the original opening and also by the counter-opening above. Brought the bones in apposition and applied splints. March 23d, suppuration is still going on, and no union is taking place. Chloroform being administered, the wound was examined and the ends of the bones found to be necrosed. The arm was then amputated above the elbow, by the circular method, by Medical Cadet C. H. Fisher. The treatment after the operation consisted of simple dressings, stimulants, and good supporting diet." (Compare Case 48, TABLE LXXXVI, p. 785.) The amputated bones of the forearm were contributed to the Museum by the operator, and are represented in the cut (FIG. 678). The extremities of the bones are carious. On October 15th, the patient was transferred to Joe Holt Hospital, Jeffersonville, whence he was discharged February 14, 1865, and pensioned. In his application for commutation, dated 1870, the pensioner described "the condition of the stump as sound and strong." He was paid September 4, 1875.



FIG. 678.—Left ulna and radius resected in the continuity for shot fracture, and subsequently removed by amputation of the arm. *Spec.* 2206.

CASE 1885.—Corporal M. Huntley, Co. A, 2d Massachusetts, aged 24 years, was wounded at Gettysburg, July 3, 1863, receiving a comminuted fracture of both bones of the right forearm from a musket ball. Resection of several inches of the lower portion of the shafts of the ulna and radius was practised on the field soon after the injury, by the regimental surgeon, Dr. W. H. Heath. The patient was sent to York, Pennsylvania, on July 18th. Surgeon H. Palmer, U. S. V., reported that: "A minié ball entered the radial border of the right forearm at the junction of the upper and middle thirds, passed outward and downward, and emerged at the lower third of the ulnar border, comminuting both bones. Four inches of the continuity of each bone was excised the same day, and the limb was placed on a flat splint with cold-water compresses. This soldier was discharged March 28, 1864, and pensioned. The discharge certificate stated that there was no bony union, and that the functions of the hand were nearly destroyed." Examiner G. S. Jones, August 29, 1866, recited the preceding facts, and stated that "the forearm and hand are powerless and useless." Examiner N. Allen of Lowell, reported, September 3, 1873: "Huntley's disability remains without change. It consists of a false joint near the right wrist; \* \* \* the hand is sustained by the muscles and ligaments—swinging this way and that, so that the hand and the whole arm are of but little use, in some respects worse than no hand or arm; but, by applying support and bandages, the hand is kept in its place, making a better appearance than good use."

The operations were on the right side in eighteen, the left in fourteen, and unspecified in two of the thirty-four recoveries—on the right in one, and the left in five fatal cases.

**EXCISIONS IN SHAFT OF ULNA.**—Two hundred and ninety patients recovered after excisions in the continuity of the ulna; a hundred and fifty-two of the operations were on the right, a hundred and thirty-two on the left side, and were unspecified in six cases.

<sup>1</sup> DR. O. HEYFELDER and others assert that BILGUER, SAINTE-HILAIRE, and FRICKE were among the earliest to resect simultaneously portions of the shafts of both bones of the forearm. The fact is that BILGUER (J. U.) (*Chirurgische Wahrnehmungen*, Berlin, 1763, S. 479, Case 99) relates the case of: "An hussar, Christoph Kasbad, of the regiment Dingelstädt, whose forearm bones were so badly fractured that it became necessary to remove, with the trepan, one of the largest pieces." The patient recovered with good use of the forearm. M. de SAINTE-HILAIRE (*Considerations sur les os de l'avant bras*, Paris, 1814, p. 10) records that in a case of compound fracture, or rather of epiphyseal separation of the lower ends of the bones of the forearm, he found it necessary to resect the protruding ends of the ulna and radius before they could be reduced. FRICKE (J. C. B.) (*Annalen der chirurgischen Abtheilung des allgemeinen Krankenhauses in Hamburg*, 1828, p. 289, copied in *Hamburger Zeitschrift*, B. III, S. 458) excised, in 1826, the middle portions of the radius and ulna for pseudarthrosis following fracture from a fall: two inches of each bone were removed. To these may be added a successful case communicated, in 1829, to the Academy of Medicine of Paris, by HUBLIER, chief surgeon to the Hotel-Dieu, of Provins. The forearm of a woman of 33 years was crushed under the wheel of a heavy carriage, and the displaced bones of the forearm perforated the soft parts, the ulna protruding fully an inch and a half. After eleven days the fractured portions of the radius and ulna were resected, "with entire success." MM. ROUX, RIBES, and HERVEZ DE CHÉGOIN made a flattering report on the operation (*Arch. gén. de Méd.*, 1829, T. XX, p. 291). According to RIED (F.) (*Die Resektionen*, Nürnberg, 1860, S. 349), HOLSCHER also, in 1830, resected the continuity of the bones of the forearm successfully in a case of pseudarthrosis. In KIRKBRIDE'S *Clinical Reports* (*Am. Jour. Med. Sci.*, 1835, Vol. XVII, p. 40) a case is recorded of ununited fracture of both bones of the left forearm, in a shoemaker, aged 24 years, treated unsuccessfully by seton and caustic, when Dr. THOMAS HARRIS, U. S. N., April 24, 1833, turned out and excised the ends of the radius and ulna, after which both bones united. There may also be compared the interesting cases of shot comminution of the bones of the forearm in which BORDENAVE (*Obs. sur les Plaies d'armes à feu*, in *Mém. de l'Acad. de Chir.*, 1753, T. II, p. 529) removed large fragments of both bones without formal resection. VELPEAU cites these cases as resections in his article on excisions in the forearm (*Méd. Op.*, 1839, T. II, p. 563).

CASE 1886.—Private T. Christie, Co. A, 131st New York, aged 44 years, was wounded at Port Hudson, May 27, 1863, and admitted to the field hospital of the 1st division, Nineteenth Corps, where Surgeon M. D. Benedict, 75th New York, noted: "Gunshot wound of arm and side." Surgeon A. L. Van Nostrand, 4th Wisconsin Cavalry, recorded the wounded man's admission to hospital at Baton Rouge, May 31st, with "grapeshot wound through lumbar region." Surgeon B. A. Clements, U. S. A., in charge of Central Park Hospital, New York City, reported as follows: "The patient was admitted January 14, 1864, being transferred here from the Theatre Hospital, Baton Rouge. He stated that the ball struck the left arm while hanging by the side, fracturing the ulna at the junction of the middle with the lower third. It entered the left side about one inch above the crest of the ilium and four inches from the centre of the spinal column, passing backward and a little downward, and escaping just to the right of the median line of the back. The spinous processes were not fractured. For two months had hæmaturia; diarrhoea three days after the injury. Four hours after the reception of the injury resection of five inches of the ulna was performed. On admission all the wounds had healed; flexion and extension good; partial ankylosis of wrist; rotation very fair. Can grasp very well with the index finger and thumb, with very little power in the other fingers. General condition good. Complains of tenderness and pain of left side and back, in region of wound. Discharged from service April 16, 1864." A cast of the wounded forearm, made ten months after the date of the injury, was contributed to the Museum by Assistant Surgeon J. W. S. Gouley, U. S. A., and is represented in the adjacent wood-cut (FIG. 679). A cicatrix nearly two inches long by one-fourth inch deep marks where fragments have been removed, and where it is probable union has not occurred. The muscular portion of the lower half of the forearm is atrophied. The New York Examining Board certified, January 17, 1872: "Resection of four inches of left ulna without reproduction of bone; pronation and supination almost destroyed; very little muscular power in the hand. The forearm and hand are useless for the purposes of manual labor." The pensioner was paid September 4, 1875.<sup>1</sup>



FIG. 679.—Appearance after an excision in the shaft of the left ulna for shot fracture. [From a cast in the Museum.] Spec. 2386.

CASE 1887.—Private C. O'Neill, Co. F, 10th New York, aged 35 years, was wounded at Spottsylvania, May 10, 1864, and admitted to the field hospital of the 2d division, Second Corps, where Surgeon J. F. Dyer, 19th Massachusetts, noted: "Gunshot fracture of right forearm; excision of ulna by Surgeon M. Rizer, 72d Pennsylvania." Surgeon C. Page, U. S. A., reported the wounded man's admission to Wolf Street Hospital, Alexandria, with "gunshot fracture of the right upper extremity." On June 4th, the patient entered Central Park Hospital, New York City, whence Acting Assistant Surgeon S. Teats reported the following history: "Wounded by a musket ball, which struck the forearm on the ulnar aspect, about the middle, fractured that bone, and passed through the arm without fracturing the radius. He received two other gunshot wounds at the same time, one on the internal aspect of the left arm two inches above the elbow joint, the other two inches below the elbow, on the internal aspect of the forearm. Resection of the ulna was performed May 11th, under chloroform, three inches at least of the bone being removed by a straight incision. The parts were drawn together by sutures, after which water dressings were used. On admission, the flesh wounds were healed and the fractured arm nearly so; patient debilitated and pale from loss of blood. June 10th, improving. July 1st, mental derangement; wound doing well. 9th, had improved in his mental condition so much that he was allowed to walk about the hospital. While walking on a porch of the hospital he suddenly jumped off, and fractured his right tibia and fibula at the middle, both bones very obliquely broken without the skin being ruptured. Much ecchymosis and swelling soon followed. Extension was applied and cold water used. 15th, swelling very much diminished; bandage and lateral splints applied. Mental condition, partially deranged but not violent. Put on a plaster apparatus. October 19th, removed the plaster apparatus, the bones being well united." The patient was discharged from service August 11, 1865, and pensioned. A cast of the injured forearm (FIG. 680) was made in New York three months after the reception of the injury, and contributed by Acting Assistant Surgeon G. F. Shrady. This pensioner died in 1866.



FIG. 680.—Appearance after an extensive excision in the shaft of right ulna. [From a plaster cast.] Spec. 4365.

<sup>1</sup> The history of excisions in the shaft of the ulna is sketched in brief by VELPEAU (*Nouv. élém. de Méd. Opér.*, 1839, T. II, p. 648), whose researches have been accepted by subsequent writers with scanty acknowledgment. We will avail of such of his references as we have verified, and make some additions. He tells us that SCULIETUS (*Armamentarium chirurgicum XLIII tabulis exornatum*, Gallie, Lyon, 1675, Tab. XXVIII, p. 83) excised a long invaginated sequestrum of the ulna. CASPAR PETZOLD (*Obs. med. chir. select.*, Breslau, 1715, p. 128) relates that AMBRUSTUS extracted thirty fragments of the ulna from a student suffering spino ventosa of that bone. A successful resection or rasping of the ulna for caries is ascribed to ROLANDUS, on the authority of BONETUS (*Scpulchretum*, T. IV, p. 116). L. CHAMPION relates (*Traité de la resection des os cariés dans leur continuité, ou hors des articulations*, Paris, 1815) that "M. DUPUYTREN m'a fait part du cas d'un militaire qui avait perdu une portion assez considérable de toute l'épaisseur du corps du cubitus, sans qu'il se soit opéré de changement dans la forme du bras." WITHUSEN (*Acta nor. Soc. med.*, Havnia, V. III) in 1819 successfully resected a portion of the shaft of the ulna for exostosis. ROBERT B. BUTT, of Portsmouth, Virginia (*Phila. Jour. of Med. and Phys. Sci.*, 1825, Vol. 1, p. 115), excised (in 1821 or '22) a large involucrum embracing a sequestrum consisting of nearly the whole shaft of the left ulna, in the case of a stout healthy young man of 25, and printed a good illustration of the pathological specimen. The result was so satisfactory that, two or three years after, the man could do the most laborious manual labor, and had as much strength in the mutilated limb as most people have in a sound one. LUIGI CITTADINI (*Osservazioni chirurgiche, Frattura non consolidata degli ossi dell' antibraccio curata colla resecuzione dei frammenti*, in *Annali Universali de Medicina da A. OMODEI*, Milano, 1826, Vol. XXXVII, p. 412) relates the case of D. Caneschi, a farmer. Both bones of the forearm were fractured in the lower third from a blow with a cane, October 12, 1819. The bones united; the man resumed his avocation too early and the bones separated again, causing a falso joint. Resection of both ends of the fractured ulna in January, 1820—patient refused resection of radius. Both bones reunited. MALAGODI (LUIGI) (*Sulla resecuzione dell' Ulna*, in *Bullettino delle Scienze mediche*, Bologna, 1834, Vol. 10, p. 266) relates that, on June 29, 1831, he removed nearly the entire diseased shaft of the left ulna, in the case of Barbarini di Mondolfo, aged 20 years. The patient, a laborer, recovered with the full use of his hand, and was able to resume his ordinary avocation. BAUDENS, who became such an advocate of excisions in the continuity of the long bones, relates (*Gaz. med.*, 1838, p. 15) a successful excision of four inches of the ulna for shot injury at the siege of Constantine. RIED (F.) (*Die Resectionen der Knochen*, 1860, S. 347) states that CAJEFAN TEXTOR (in 2 cases) and ROTHMUND successfully excised portions of the shaft of the ulna about this period in cases of compound fracture. MURVILLE (*Annales de la Chir.*, 1842, T. IV, p. 181) records a successful excision of the shaft of the ulna comminuted by shot.



The extent of the shaft removed varied from one to six inches or more,<sup>1</sup> comprising, in one instance, the entire diaphysis:

CASE 1888.—Private A. Hyland, Co. B, 2d New York Provisional Cavalry, aged 16 years, was wounded at Smithfield, August 29, 1864, and admitted to the field hospital of the 1st division, Cavalry Corps. Assistant Surgeon C. I. Wilson, U. S. A., noted: "Gunshot fracture of left forearm; patient sent to general hospital." Acting Staff Surgeon N. F. Graham reported the man's admission to hospital at Sandy Hook with "gunshot wound of left forearm." On September 10th he was transferred to Division Hospital No. 1, Annapolis, and on October 24th he entered Central Park Hospital, New York City, whence Acting Assistant Surgeon J. K. Merritt reported: "The patient was wounded by a minié ball, which entered the left forearm at its inner aspect, about two or two and a half inches below the elbow, and passed transversely outward.




FIG. 681.—Cicatrix after excision in the shaft of the left ulna. [From a cast.] *Spec.* 4390.

The ulna was fractured into a number of fragments in its middle third. On the second day after the injury an operation was performed, which resulted in the removal of about four inches of the ulna—according to the statement of the patient. On admission the forearm was considerably swollen, but the incision of the operation was nearly healed, excepting three small openings evidently communicating with necrosed bone. Wound dressed with balsam Peru and forearm supported in pasteboard sling. November 27th, removed a fragment of necrosed bone, being a portion of the excised end of the ulna. Wound dressed with balsam of Peru." A cast of the injured forearm was made about a year after the operation, and contributed by Acting Assistant Surgeon G. F. Shady (FIG. 681). The patient was temporarily assigned to the Veteran Reserve Corps August 23, 1865, and discharged November 4, 1865, and pensioned, and furnished with an apparatus by Dr. E. D. Hudson. Examiner A. L. Lowell, March 10, 1866, certified: " \* \* \* There is no evidence of injury to important vessels or nerves. Three inches of the ulna have been resected. The shaft of the radius is the only bony support left to the hand. Brachial and muscles of forearm diminished in size, firmness, and efficiency. Temperature of injured arm lower than normal." Examiner P. Treadwell, of New York, Dec. 14, 1869, certified: " \* \* \* The limb is distorted and shorter than its fellow." Examiner T. P. Smith reported, Sept. 8, 1873: "There has been no reproduction of bone, and for purposes of manual labor the arm is useless." The pensioner was paid Sept. 4, 1875.

CASE 1889.—Musician G. W. Leeti, Co. H, 2d Pennsylvania Veteran Reserves, aged 21 years, was wounded at Petersburg, June 17, 1864, and admitted to the field hospital of the 3d division, Fifth Corps. Surgeon L. W. Read, U. S. V., noted: "Gunshot wound of forearm, severe. Excision of two inches of ulna, by Surgeon W. Lyons, 11th Pennsylvania." The wounded man entered DeCamp Hospital, New York, June 25th, and was subsequently admitted to Satterlee, and lastly to Filbert Street Hospital, Philadelphia, January 17, 1865. Surgeon T. B. Reed, U. S. V., in charge of the latter, recorded:

"Gunshot fracture of left ulna by minié ball. Excision of bone before admission. Large open wound in forearm; much attenuated; no use of fingers; arm partially ankylosed at elbow joint. Patient has also pustular eruption in arm and body." The excised parts, consisting of seven small fragments of the ulna, were contributed to the Museum by the operator, and are represented in the annexed cut (FIG. 682).

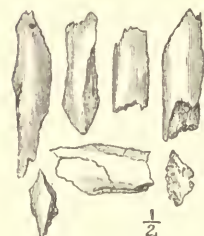

FIG. 682.—Fragments of ulna removed after shot fracture. *Spec.* 4144.

The patient was discharged from service April 24, 1865, and pensioned. Examiner J. H. Oliver, of Philadelphia, December 10, 1867, certified: "It appears that a minié ball entered the anterior surface of the left forearm at the junction of the upper and middle third, passed upward, and made its exit from the posterior inner surface, near the olecranon process, extensively comminuting the ulna, three inches of which has been resected. The adjacent soft parts of the inner side of the forearm have also been carried away by ulceration and otherwise, leaving an extensive though healthy cicatrix. The elbow joint is but slightly affected, but from just below that joint the limb, including the hand, is entirely useless. The ring and index fingers are flexed upon the palm and motionless. The other fingers are not entirely without motion, but the power is so much diminished that the pensioner cannot hold a handkerchief with them." The Philadelphia Examining Board reported, September 8, 1873: " \* \* \* Tender puckered cicatrix. Numbness of all parts supplied by ulnar nerve. Atrophy, etc." The pensioner was paid September 4, 1875.

In one curious case, excision was practised in the continuity of the ulna of one limb, and of the radius of the other:

CASE 1890.—Private J. Nugent, Co. F, 49th New York, aged 24 years, was wounded at Spottsylvania, May 10, 1864, and admitted to the field hospital of the 2d division, Sixth Corps. Surgeon S. J. Allen, 4th Vermont, noted: "Gunshot fracture of radius of right forearm and ulna of left forearm. Resection." Surgeon E. Bentley, U. S. V., reported the wounded man's admission to Third Division Hospital, Alexandria, May 24th, with "gunshot fracture of both forearms," and his transfer to the First Division Hospital October 7th. Assistant Surgeon T. G. Mackenzie, U. S. A., reported that the patient was discharged from the latter hospital February 7, 1865, by reason of "resection of both forearms following gunshot wounds." Examiner O. M. Stockwell, of Port Huron, Michigan, December 15, 1865, certified: "Such were the wounds that exsection of a portion of the radius of the right, and ulna of the left, forearm was required. The right is greatly pronated, and no power is left of flexure of the fingers, while the left is of little use except in very light work." On April 6, 1867, he stated: "The exsection was not successful, as the ends of the bones were not brought in position or retained there; consequently both are not only much shortened, but twisted or pronated, so as to weaken them very much, and also to make them very inconvenient even in feeding himself." The same examiner subsequently reported that "the disability is almost equivalent to the loss of both hands." The pensioner died November 28, 1872. The immediate cause of death has not been ascertained.

<sup>1</sup> The extent of the shaft removed is unspecified in 59 of the 290 cases. In 3 cases it is reported that 1 inch of the continuity was excised; in 63 cases, an inch and a half or 2 inches; in 88 cases, 2½ or 3 inches; in 47 cases, 3½ or 4 inches; in 10 cases, 5 inches; in 9 cases, 6 inches; in 1 case, the lower half; in 4 cases, the lower third; in 3, the middle third; in 2, the upper third; in 1, the whole diaphysis.

In the cases specially reported as favorable, the pension reports or other ulterior histories almost invariably disappoint the anticipations the first record awakened:

CASE 1891.—Corporal F. M. Gay, Co. F, 12th New Hampshire, age 22 years, was wounded at Cold Harbor, June 3, 1864, and was admitted to Harewood Hospital, Washington, on the 7th. Surgeon R. B. Bontecou, U. S. V., contributed the photograph of the patient, represented by the adjacent wood-cut (FIG. 683), and reported: "Gunshot wound of the left forearm, the ball entering the middle third posteriorly and making its exit anteriorly, fracturing the ulna in its course. June 3, 1864, resection of the ulna of the right side, middle third, three inches of the shaft removed; anæsthetic unknown. Operation performed on the field; operator unknown. Patient states that he was in good health at the time of the operation. Progress was favorable; treatment, simple dressing and supporting diet. Furloughed July 23, 1864." The patient was discharged the service December 3, 1864. In January, 1865, the patient was an applicant for pension, and stated that in addition to the above wound he was continually suffering from a severe form of chronic diarrhœa. In May, 1865, his agent withdrew the claim on account of the death of the soldier, but did not give the date of or cause of death.



FIG. 683.—Appearance after primary excision in the shaft of the left ulna for shot injury. [From a photograph.]

CASE 1892.—Private J. N. Hawkins, Co. F, 40th Illinois, aged 21 years, was wounded at Atlanta, July 28, 1864, and was admitted to a Fifteenth Corps field hospital. Surgeon J. M. Woodworth, 1st Illinois Light Artillery, noted: "Resection of ulna for gunshot wound of the left elbow joint, July 29th. Operator, W. Graham, Surgeon, 40th Illinois." The patient was transferred to the General Field Hospital, at Marietta, on August 9th, and was furloughed on August 12th. The patient was admitted to hospital at Quincy, Illinois, November 17th. Surgeon D. G. Brinton, U. S. V., noted: "Excision of one and a half inches of the ulna." Acting Assistant Surgeon D. C. Owen recorded: "Gunshot wound by minié ball entering the dorsal surface of the wrist one inch above the joint, fracturing the ulna severely. A section of ulna one and a half inches long was removed, by operation by Surgeon Graham, twenty-four hours after reception of the wound. At this date the wound is healed. The hand is almost useless; no treatment; full diet. November 28th, no improvement. December 15th, no improvement; on duty in the ward. January 1, 1865, still on duty in the ward. 24th, discharged from service." Examiner J. Robbins, of Quincy, January 25, 1865, reported: "Ball passed through the forearm about two and a half inches above the wrist joint, shattering the ulna, of which about four inches were removed. Wrist ankylosed. Ring and little fingers of left hand forcibly flexed upon the palm; the other fingers and thumb have slight motion; little strength; hand practically useless." The reports of subsequent examinations are substantially the same as the foregoing. The pensioner was paid June 4, 1874.

**EXCISIONS IN THE SHAFT OF THE RADIUS.**—Of four hundred and thirteen excisions in the continuity of the radius,<sup>1</sup> two hundred and fifty-six were cases of recovery after primary operations—one hundred and thirty-four on the left, one hundred and fourteen on the right side, and eight unspecified:

CASE 1893.—Private W. K. Gardiner, Co. D, 43d New York, age 42 years, was wounded at the Wilderness, May 6, 1864, and entered Finley Hospital, Washington, on May 17th. Surgeon G. L. Pancoast, U. S. V., reported: "Gunshot wound of left upper extremity." On July 14th the patient was admitted to Ira Harris Hospital, Albany, whence Assistant Surgeon J. H. Armsby, U. S. V., contributed a cast of the injured limb (FIG. 684), with the following description of the wound: "Gunshot fracture of left radius by minié ball. Excision of portion of the radius was performed on the day of the injury, chloroform being administered; patient in good constitutional condition at the time of operation." The cast was made six months after the date of the operation, and shows a broad oblique cicatrix extending over the dorsal surface, the line at the point of the injury being depressed and union probably not having occurred. The patient was mustered out of service June 16, 1865, and pensioned. Examiner W. H. Craig, of Albany, April 12, 1869, certified: "Ball passed through left forearm near the middle, causing a compound fracture of the radius. The bone is crooked and distorted, causing numbness, weakness, and impaired use of arm and hand." The Albany Board, consisting of Drs. Craig, C. H. Porter, and W. H. Bailey, reported, December 2, 1874: " \* \* Several pieces of bone were removed, causing some deformity of the arm. Three cicatrices remain which are tender. The rotary motion of the arm and hand are weakened." The same Board again reported, January 5, 1876: " \* \* The bone was shattered and portions were removed. The cicatrices are tender and the arm is greatly weakened. Within the last six months there has been an ulcer near the wound of exit, owing to the presence of necrosed bone," etc. The pensioner was paid September 4, 1875.

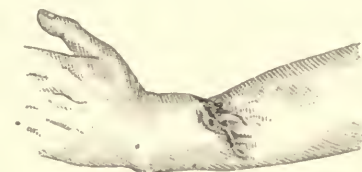


FIG. 684.—Distortion of left forearm after removal of fragments of radius comminuted by shot. [From a cast.] Spec. 2671.

<sup>1</sup> L. CHAMPEON (*Traité de la Resection des osariés dans leur continuité ou hors des articulations*, Thèse de Paris, 1815, No. 11, p. 57) relates the case of a young peasant in whom the lower third of the radius, becoming necrosed and nearly detached, was cut away by strong pincers by the youth's father. VÉLÉBEAU states (*Méd. Op.*, 1836, T. II, p. 650) that a portion of the shaft of the radius affected by necrosis was successfully excised by a chain saw by Dr. FLAMING, a Hollander (*Dissert. inaug.*, etc., Utrecht, June, 1834,—a paper to which Leannet refers. Dr. HEYFELDER, *Lehrbuch der Resectionen*, 1863, S. 257, refers to this operator as FLEMING. REID, *Die Resectionen*, 1860, S. 349, by an obvious misprint, styles him HANSEN; and O. HEYFELDER,



The next two abstracts detail the most favorable reported examples of this excision:

CASE 1894.—Corporal P. P. Whitehouse, Co. C, 6th New Hampshire, aged 20 years, was wounded at Spottsylvania, May 12, 1864, and admitted to the field hospital of the 2d division, Ninth Corps, where Surgeon J. Harris, 7th Rhode Island, recorded: "Fracture of forearm; resection by Surgeon J. S. Ross, 11th New Hampshire." On May 24th, the wounded man entered Mount Pleasant Hospital, Washington, whence Assistant Surgeon C. A. McCall, U. S. A., reported his convalescence

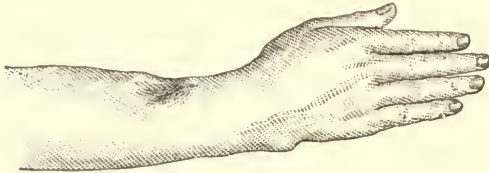


FIG. 685.—Forearm after excision in the lower third of the radius for shot injury. [From a plaster cast.] *Spec. 4378.*

from a resection of the lower third of the radius for shot fracture. The patient was subsequently treated at the Haddington and South Street Hospitals, Philadelphia, and at Webster Hospital, Manchester. Lastly, he was transferred to Central Park Hospital, New York City, where, on July 10, 1865, he was furnished with an apparatus, designed to promote the mobility of the hand, by Dr. E. D. Hudson. Surgeon J. J. Milhan, U. S. A., reported that the patient was discharged from service August 15, 1865, by reason of "excision of two inches of the right radius on account of a gunshot wound." A cast (FIG. 685) in this case was contributed by Acting Assistant Surgeon G. F. Shrady. Examiner W. G. Perry certified, March 20, 1866: "The ball lodged in the radius about three inches above its lower end; it was removed and nearly two inches of the bone was taken out. The hand is drawn toward the radial side. The head of the ulna is thrown out; the fingers are stiff, and the hand at present is of no use to him as regards labor." At subsequent examinations Dr. Perry reports substantially the same, and in September, 1873, he adds: "There is no improvement in the disability." This pensioner was paid September 4, 1875.

CASE 1895.—Colonel W. H. Penrose, 15th New Jersey, received a wound of the forearm at Cedar Creek, October 19, 1864, and was operated on in a Sixth Corps Hospital by Surgeon J. D. Osborne, 4th New Jersey, who made the following special report: "The Colonel was wounded by a minie ball fired at a distance of twenty yards. The ball passed through the right forearm as it was raised above his head, from before backward, entering on the radial aspect about two inches below the elbow, and making its exit at a point nearly opposite, about one inch below the elbow, fracturing the radius to the extent of three inches and a half, badly comminuting the bone, and driving the fragments into the surrounding tissues. The radial nerve was divided, but the radial artery was uninjured. Eight hours afterward, chloroform was administered, and the wound on the radial aspect was extended to about four inches; the ends of the bone were sawn off by a chain saw and the ends carefully smoothed. The space between the ends of the bone was then about four and a half inches. The wound was then nearly closed by a number of silk sutures, the arm placed in temporary splints, and the next morning the patient was sent to the rear. The subsequent history is described from the Colonel's own statement. No unfavorable results followed, nor was he confined

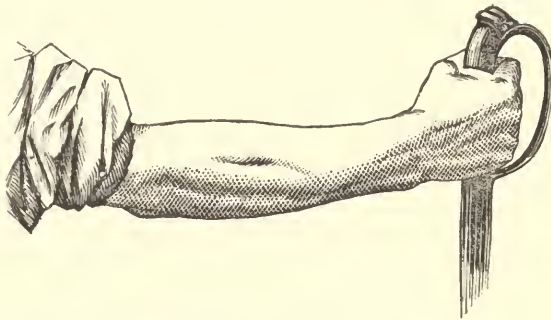


FIG. 686.—Appearance after an excision of the upper portion of the radius for shot injury. [From a photograph.]

within doors a day. The wound soon healed, but was subsequently opened three times, and each time a small fragment of bone, that had escaped detection at the time of the operation, was removed. He rejoined his brigade for duty in February, 1865, a little more than four months after the injury, and participated in the final movements of the Army of the Potomac in the spring. The wound was permanently healed by May 1st." The photograph, represented by the annexed wood-cut (FIG. 686), forwarded by Dr. Osborne in 1868, shows the condition of the limb at that time: "Arm very slightly bent inward; union, partly bony and partly cartilaginous, is complete between the fractured extremities of the bone. All motions of the arm are retained except rotation, which is lost; the motions of the hand and fingers are retained, except a very slight impairment of the power and motion of the thumb and index finger; ankylosis has taken place in the last joint of the latter; he is perfectly enabled to use both

these latter in all movements, such as holding pen, writing, handling knife and fork, etc." Colonel Penrose was promoted Brigadier General of Volunteers July 1, 1865, and was mustered out January 15, 1866, resuming his rank as Captain 3d Infantry, and was found not incapacitated for active duty, by a Retiring Board in 1870, and is still (March, 1876) in service. quoting from RIED and LISFRANC, converts the observation into two distinct cases), in the case of a soldier who was operated on in 1826, and died in 1832. Dissection showed that a fibro-cartilaginous tissue had replaced the portion of bone removed. (*Compare LISFRANC, Précis. de Méd. Opér.*, 1846, T. II, p. 568.) The first excision of the shaft of the radius for shot injury is recorded by Dr. P. FAHNESTOCK, of Pittsburg (*Am. Jour. Med. Sci.*, 1840, Vol. XXVI, p. 91): V. Wyant, aged 23 years, October 14, 1836, received a comminuted fracture of both bones of the forearm about the middle. The ulna formed a ligamentous union, but the ends of the radius remained widely separated. July 25, 1837, Dr. FAHNESTOCK cut down upon the radius, and, dissecting aside the interposed muscular fasciculi, sawed off an inch and a quarter from the end of the lower fragment and three quarters of an inch from the upper fragment with Hey's saw. Fifty-six days afterward the radius had formed firm bony union; subsequently a seton was passed between the ends of the ulna, and ossific union took place. At the assault on Constantine, October 13, 1837, BAUDENS successfully performed a primary excision of three and a half inches of the middle of the shaft of the radius (*Relat. del Exped. de Constantine, in Revue de Paris*, Avril 1, 1838); on the same occasion, this surgeon performed five other excisions in the continuity of long bones, in the ulna, humerus, or clavicle. RKLITSKY, chief surgeon of the Morskoy hospital, St. Petersburg, in 1837, removed with the osteotome the entire diaphysis of the radius, leaving the joint ends only, with perfect success; regeneration of bone took place, and in three months the wound had healed, the patient retaining the use of his arm. (See RIVIÈRE, *Observations de resections pratiques dans la continuité des os longs par le docteur RKLITSKY, etc.*, in *Gaz. Méd.*, 1840, T. XI, p. 213.) NOOBT (*Das Ostratom*, München, 1838, S. 64) states that HEINE, at the hospital at Kronstadt, in 1837, excised a portion of the diaphysis of the radius, 5" 4" in length: the result of the operation is not recorded. J. K. RODGERS, in 1838, removed, with bone pliers, the fractured ends of the radius for pseudarthrosis, in a German, C. Grill, aged 26 years, and united the ends of the bone by silver wire. In 1842, Surgeon C. S. TRIPLETT, U. S. A. (*Case of Ununited Fracture of the Forearm, of four years' standing, successfully treated*, in *Maryland Med. and Surg. Jour.*, Vol. III, p. 1), in the case of Lt. F——, 5th Infantry, with pseudarthrosis in

Of recoveries after excisions in the radius or ulna with extreme deformity, of which, unfortunately, a large number are represented in the Museum, the following is an instance:

CASE 1893.—Private J. R. Collett, Co. B, 7th Kentucky, aged 18 years, was wounded and captured at Richmond, August 30, 1862. Having been paroled by the enemy immediately after the battle, he remained in hospital at Richmond for about two months, and was then allowed to proceed to his home, where he was treated for a time by a private physician. He subsequently rejoined his regiment, and was discharged from service March 16, 1864, because of "the effects of a gunshot wound which entirely destroyed the use of his left hand, his right arm also being injured."

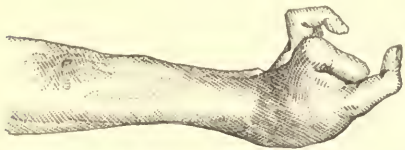

FIG. 687.—Deformity resulting from shot injuries of left hand and forearm treated by excision of a large segment of the shaft of the radius. [From a cast in the Museum.] Spec. 5004.

July 21, 1865, certified: "A part of an exploded shell struck the left hand in the palm and passed back and up, severing and fracturing the metacarpal bones of the middle and ring fingers, and fracturing both the radius and ulna up to the upper end of the middle third. The right elbow joint is partially ankylosed from the wound by the fragment of shell and his gun striking it, and cannot be flexed. The hand is not only useless, but it is in the way, and will have to be amputated." Examiner W. W. Potter, of Washington, D. C., reported, May 14, 1869: "Has received a gunshot wound of the left forearm, fracturing the radius and ulna through the shafts, a large number of pieces having been removed. The carpus has sustained extensive injury and a portion appears to have been

removed. The extensor tendons are contracted, completely and permanently extending that portion of the hand remaining. The second and third fingers were carried away at the time of the injury, and the thumb with the first and fourth fingers are flexed, thus leaving a deformed and shapeless hand. The other injury was a fracture between the condyles of the right humerus. The olecranon process of the ulna has forced itself upward into the fracture. Union taking place in this condition leaves the joint partially ankylosed; flexion cannot be carried to a right angle, nor extension completely performed." The pensioner has been for some years employed at the Treasury Department. In March, 1868, he visited the Museum, where a cast of his left arm (FIG. 687) was obtained. According to the pensioner, Surgeon W. Berry, 7th Kentucky, excised the greater portion of the shaft of the radius on the third day after the injury. The pensioner was paid September 4, 1875.

TABLE CXXVI.

Summary of Five Hundred and Eighty-nine Cases of Recovery after Primary Excision of Bones of the Forearm for Shot Injury.

No.	NAME, AGE, AND MILITARY DESCRIPTION.	DATES.	OPERATIONS, OPERATOR, RESULT.	No.	NAME, AGE, AND MILITARY DESCRIPTION.	DATES.	OPERATIONS, OPERATOR, RESULT.
1	Ablett, J. W., Pt., I, 7th N. Y. H. A., age 21.	June 3, '64.	Two, left ulna, upper; by Surg. A. Van Devere, 66th N.Y. Dis'd June 15, 1865; pens'd; partial paralysis.	9	Allvord, J., Serg't, G, 96th Penn., age 27.	May 10, '64.	Three, lower, left ulna; by Surg. D. W. Bland, 96th Penn. Dis. Jan. 9, '65; pens'd; adherent etc.
2	Ackerman, J., Pt., K, 27th Indiana, age 22.	May 25, '64.	Three and a half, left ulna, mid. third. Duty Dec. 15, '64; pens'd. Died Jan. 23, 1869.	10	Anaker, A., Pt., B, 40th Indiana, age 20.	May 27, '64.	Left radius, middle; by Surg. E. B. Glick, 40th Indiana. Disch'd January 25, 1865.
3	Adams, T., Pt., 198th Pennsylvania, age 34.	April 1, '65.	Two, left radius, middle. Disch'd Sept. 7, 1865.	11	Anderson, J., Pt., F, 9th New Hampshire.	May—, '61.	Three and a half, left ulna. Disch'd October 20, 1864.
4	Agin, W., Pt., G, 1st Cavalry, age 20.	July 18, '64.	Three, left ulna. Duty Jan. 20, 1865; pens'd; large cicatrix.	12	Applebee, C., Pt., D, 11th Vermont, age 18.	Oct. 19, '64.	Two and a half, upper, left ulna. Disch'd May 19, 1865; pens'd; semi-flexed and ankylosed.
5	Albright, J., Pt., II, 100th Ill., age 27.	Sept. 19, '63.	Two, right radius, lower; by Surg. A. M. McMahon, 61th G. Disch'd June 11, '64; pens'd; ankylosed wrist.	13	Appleton, B., Pt., K, 128th Indiana, age 44.	Nov. 25, '61.	Five, upper, right ulna. Disch'd May 30, 1865; pens'd; use of arm impaired.
6	Allard, P., Pt., F, 17th Vermont, age 39.	May 18, '64.	Right ulna, middle; by Surg. P. O. M. Edson, 17th Vt. gang., ham. July 30th, amp. arm. Disch'd Dec. 21, 1864; pens'd.	14	Arnold, J. M., Pt., E., 111th Illinois, age 24.	Mar. 10, '65.	Portion of middle, left radius. Discharged Aug. 29, '65; pens'd; use of hand lost.
7	Allman, J., Serg't, E, 26th Wis., age 26.	June 1, '64.	Six, left ulna, upper. Disch'd Apr. 20, '65; pens'd; ankylosed elbow; use of hand impaired.	15	Ashford, J. M., Pt., B, 17th Kentucky, age 22.	June 18, '61.	Right ulna and radius. Oct. 1, amp. Disch'd Mar. 25, 1865.
8	Alverson, J. K., Pt., M, 7th N. Y. H. A., age 19.	June 3, '64.	Three, middle, right ulna; by Surg. A. Van Devere, 66th N.Y. Disch'd May 23, 1865; pens'd; arm useless.	16	Babbitt, J. C., Lieut., K, 13th C. T., age 23.	Dec. 16, '64.	Two, lower, right rad. Disch'd Jan. 10, '66; pens'd. 1873, necrosis; has never healed.
				17	Bachman, S., Pt., A, 7th Wisconsin, age 31.	May 6, '64.	Two, upper, left ulna. June 3, necrosed bone excised. Disch'd May 6, 1865; pensioned; fingers contracted and useless.

the left forearm resulting from a neglected fracture, effected ossific union in the ulna by position and pressure; but failing to bring about union in the radius, with the advice and assistance of Surgeon Z. PITCHER, U. S. A., exposed the ends of the radius and sawed off each extremity with the trophine, April 18, 1842. By May 31st, there was bony union of the radius, and, on June 21, 1842, the officer returned to duty with a slightly shortened but very useful limb. (Compare also *Boston Med. and Surg. Jour.*, 1842, Vol. XXVII, p. 129.) According to F. RIED (*Die Resectionen der Knochen*, Nürnberg, 1860, S. 347), Dr. ZÄHNER, some time between 1840 and 1850, resected a half inch of the diaphysis of the radius for ununited fracture, in Dr. JÄGER'S clinic, and the patient recovered with considerable deformity. LOBE (II.) (*Doppelte Fractur des Radius. Nekrose des Mittelstückes. Heilung durch Resection*, in *Deutsche Klinik*, 1853, B. V, S. 102) resected, with good results, three inches of the radius in a woman, aged 28 years, for disease. Professor v. BRUNS, in 1856 (in WERNER, *Bericht über die, auf der von BRUNS'schen Klinik zu Tübingen vorgekommenen Resectionen*, u. s. w., in *Deutsche Klinik*, 1858, S. 89), excised three inches of the shaft of the radius for disease; the patient recovered with displacement of the hand toward radial side at an angle of 130°. Professor J. M. CARNOCHAN (*Excision of the Entire Radius*, in *Am. Jour. Med. Sci.*, 1878, Vol. XXXV, p. 383), in the case of D. Kne, an Irish laborer, aged 20 years, with great inflammatory enlargement of the radius following a blow, extirpated the entire bone, preserving to a remarkable degree the functions of the wrist and hand. The same surgeon (*Excision of the Lower Four-fifths of the Radius*, in *Am. Jour. Med. Sci.*, 1858, Vol. XXXVI, p. 89), in the case of Catharine Wilson, aged 31 years, removed the greater portion of the radius, greatly altered and hypertrophied by rheumatic otitis, April 7, 1857, with end-results equally satisfactory.



No.	NAME, AGE, AND MILITARY DESCRIPTION.	DATES.	OPERATIONS, OPERATOR, RESULT.	No.	NAME, AGE, AND MILITARY DESCRIPTION.	DATES.	OPERATIONS, OPERATOR, RESULT.
18	Bacon, H. B., Pt., K, 8th N. Y. H. A., age 34.	June 3, 4, '64.	Three, lower, left radius; gang. Disch'd April 3, 1865; pens'd;	47	Bradley, J. W., Pt., D, 18th Ohio, age 19.	Dec. 15, 15, '64.	One and a half, radius, lower, and lig. ant. interes.; by A. A. Surg. S. W. Blackwood. Dis'd June 16, '65; pens'd; anehyl. wrist; fingers hooked; hand to one side.
19	Bailey, B. F., Serg't, E, 25th Wisconsin, age 22.	July 23, 24, '64.	Four, right radius; by Surg. W. A. Gott, 25th Wis. Duty April 22, 1865; pens'd; dislocation ulna.	48	Bradley, P., Pt., D, 8th Penn. Cav., age 19.	April 5, 5, '65.	Portion lower, left ulna. Disch'd June 29, '65; pensioned; use of hand; loss of power in arm.
20	Baker, C. J., Pt., K, 80th New York, age 20.	Dec. 1, 1, '61.	Lower half of shaft left ulna. Discharged June 23, '62; pens'd; re-enlist. Aug. 30, '64; use impaired.	49	Brandon, A., Lieut., II, 12th Illinois.	Aug. 8, 8, '64.	Three, left ulna; by Surg. J. Pogue, 66th Ill. Disch'd July 18, 1865; pensioned; head of radius dislocated; anchylosis of elbow.
21	Baker, C. W., Corp'l, K, 118th N. Y., age 22.	May 16, 16, '64.	Upper, right ulna; by Surg. H. N. Small, 10th N. H.; (wound hip.) Disch'd Feb. 27, 1865; pens'd; anchylosis forearm at 90°.	50	Brewster, H. M., Lieut., I, 57th New York.	Dec. 11, 11, '62.	Six, right ulna. V.R.C. Aug. 10, 1863; pens'd; anchylosis; almost complete loss of use.
22	Baker, J. N., Pt., F, 17th Indiana, age 25.	June 24, 27, '63.	Four, middle, right radius. Discharged June 8, '64; pens'd; fingers stiff; forearm deformed.	51	Briggs, C. L., Corp'l, B, 132d Penn., age 19.	May 3, 5, '63.	Five, right radius. Disch'd May 24, 1863; pensioned; distortion; no power in hand or forearm.
23	Barnett, J. L., Serg't, B, 7th W. Va., age 25.	Oct. 27, 28, '64.	Three, upper, right ulna; by Surg. I. Scott, 7th W. Va. Duty May 4, 1865; pens'd; forearm useless; imperfect use of hand.	52	Briggs, M. M., Pt., C, 102d Ill., age 22.	May 25, 26, '64.	Two, upper, right rad.; by Surg. W. Hamilton, 102d Ill. Disch'd April 27, '65; pens'd; disloc. carpal end of ulna.
24	Barney, J. L., Corp'l, K, 6th Wisconsin, age 21.	May 5, 5, '63.	Middle and part of upper and lower third, right ulna. Disch'd Nov. 1, 1864; pens'd; forearm flexed; no rotation or extension.	53	Briggs, S. S., Pt., II, 105th Penn., age 27.	Aug. 16, 16, '64.	Six, middle, right ulna. Disch'd June 20, '65; pens'd; anchylosis elbow and finger joints.
25	Bartlett, T. H., Pt., II, 52th Mass., age 30.	July 30, 30, '64.	Portion of lower and middle, right ulna. Disch'd Feb. 9, '65; pens'd; no union; wrist anchylosed.	54	Brinton, J. B., Lieut., G, 9th Ind., age 25.	Sept. 2, 2, '64.	Three, middle, left radius; by A. Surg. W. H. Matchett, 40th O. Disch'd Dec. 19, '64; pens'd; part anchylosed elbow; little and ring fingers flexed.
26	Barto, W. H., Pt., D, 107th N. Y., age 26.	May 26, 26, '64.	Middle, left ulna; by A. Surg. L. W. Kennedy, 123d N. Y. Disch'd June 10, 1865; pens'd; partial anchylosis elbow; part. paral.	55	Broughton, G., Pt., F, 144th N. Y., age 18.	Nov. 30, Dec. 3, 1864.	Five, lower, left ulna; by A. A. Surg. W. Balser. Disch'd June 12, '65; pens'd; hand useless.
27	Barton, P., Pt., A, 19th Mass., age 17.	May 19, 19, '64.	Two, lower, left radius; by Surg. T. Jones, 8th Penn. Res.; (amp. right forearm.) Disch'd Oct. 26, 1864; pens'd; ulna dislocated.	56	Brown, —, Private . . . . .	Dec. 13, '62.	Three, right ulna; by Surg. W. O. Meagher, 69th N. Y. Keeney.
28	Battles, W., Corp'l, A, 102d C. T., age 33.	Dec. 9, 10, '64.	Middle, left radius. Disch'd Mar. 20, '65; pens'd; arm disabled.	57	Brown, B., Pt., A, 27th C. T., age 23.	July 30, 30, '64.	Three, lower, left radius. Disch'd Feb. 11, 1865; pens'd; hand at right angle; attached to ulna by false joint.
29	Batten, J. R., Pt., A, 112th Illinois, age 26.	Aug. 6, 6, '64.	Two, lower, left ulna; by Surg. G. A. Collamore, 100th Ohio. Discharged May 12, 1865; pens'd; partial use of elbow and hand.	58	Brown, D. B., Serg't, D, 3d New Jersey, age 30.	May 3, 5, '63.	Five, upper, right ulna; by Surg. Todd, C. S. A.; necro. bone removed. Duty Aug. '63; pens'd; partial pronation and supination.
30	Bauer, M., Pt., A, 2d Michigan, age 21.	June 17, 17, '64.	Three, middle, right radius. To V. R. C. Feb. 25, '65; pens'd; deformed and seriously impaired.	59	Brown, F., Corp'l, II, 19th Maine, age 32.	Oct. 12, 12, '64.	Middle, left radius and ulna; by Surg. S. H. Plumb, 23d N. Y. Disch'd June 12, '65; usefull arm. Died April 4, '74.
31	Beech, S. R., Pt., E, 83d Penn., age 17.	May 5, 5, '64.	Three and a half, left ulna. Disch'd Jan. 12, '65; pens'd; slight use of thumb and index finger.	60	Brown, G. B., Corp'l, A, 95th Penn., age 43.	May 12, 12, '64.	Four, upper, left ulna; by Surg. E. B. Kelly, 95th Pa. Disch'd June 9, '65; pens'd; fingers flexed backward.
32	Beale, E. C., Corp'l, E, 2d N. Y. A., age 27.	July 30, 30, '64.	Three, middle, left ulna. Disch'd May 27, 1865; pens'd; much impaired. Died Jan. 9, '71.	61	Brown, J. E., Serg't, K, 13th Miss., age 27.	July 2, 4, '61.	Two and a half, lower, left radius; gang. Oct. 17, 1863, recovered.
33	Belknap, H. A., Serg't, A, 56th Penn., age 52.	June 19, 19, '64.	Three, middle, left ulna; by Surg. G. W. New, 7th Ind. Disch'd Nov. 11, 1864; pens'd; no union; elbow joint impaired.	62	Brown, O., Pt., C, 16th Michigan, age 19.	May 30, Je. 1, '64.	Two, upper, left rad. Dis'd Nov. 16, '64; pens'd; fingers contr'd.
34	Bennett, H. M., Corp'l, B, 39th Mass., age 21.	May 10, 10, '64.	Four, middle, left radius. Disch'd Jan. 7, 1865; pensioned; atrophied and entirely useless.	63	Brown, S. A., Serg't, F, 110th Ohio, age 22.	June 5, 7, '64.	Four, middle, left radius. Disch'd May 19, 1865; pens'd; anehyl. elbow and dislocated wrist.
35	Birdsall, A. J., Corp'l, E, 2d N. Y. H. A., age 27.	Aug. 14, 15, '64.	Three, lower, pt ulna; by Surg. J. W. Buckman, 5th N. H. Dis'd Oct. 1, 1864; pensioned; anchylosed wrist; nearly useless.	64	Brown, T. F., Capt., D, 51st Illinois, age 29.	June 27, 27, '64.	Three, middle, left radius; by Surg. T. L. Magee, 31st Ill. Mar. 17, resec. part. both bones. Disch'd May 15, 1865; pens'd. April, '66, excis. portion radius; limb wholly disabled.
36	Bird, C., Pt., K, 103d C. T., age 21.	Dec. 9, 9, '64.	Two and a half, lower, left ulna. Disch'd April 7, '65; pensioned. Died May 5, '66, consumption.	65	Brown, V. T., Pt., E, 21st S. C., age 28.	May 16, 16, '64.	Middle, radius. June 18, '64, fur-loughed; nearly healed.
37	Bitner, F., Pt., D, 87th Pennsylvania, age 18.	Sept. 19, 19, '64.	Portion right radius. Dis'd June 14, '65; pens'd; great deformity wrist; finger's stiff. Died May 5, '67.	66	Bryant, D. M., Pt., C, 5th Cavalry, age 20.	July 21, 21, '63.	Right radius, middle (frac. ulna). Disch'd Dec. 2, '64; pens'd; part. anehyl. wrist; much deformity.
38	Black, J. A., Capt., B, 56th Pa., age 36.	May 23, 23, '64.	One and a half, upper, left ulna; hæmorrhage. Disch'd July 1, '65; pens'd; elbow anchylosed.	67	Bumberger, S., Pt., G, 145th Pennsylvania.	June 16, 16, '64.	Right ulna; by Surg. J. W. Wishart, 140th Pa. Duty Nov. 1, 1864. Not a pensioner.
39	Bland, S., Serg't, C, 55th Virginia, aged 30.	Aug. 19, 19, '64.	Upper third, right radius. Sept. 30, recovered.	68	Bunch, J. W., Pt., A, 20th Ind., age 19.	May 12, 12, '64.	Two, lower, right radius. Disch'd Sept. 7, 1864; pens'd; use of arm much impaired.
40	Budgett, P. D., Capt., E, 10th Vt., age 36.	June 2, 3, '64.	Four, middle, left ulna; by Surg. T. A. Helwig, 87th Pa. Disch'd Nov. 25, '64; pens'd; no union; fingers extended—stiff.	69	Burdick, M. W., Pt., E, 16th Wis., age 18.	July 21, 21, '64.	Two and a half, middle, left ulna; by Surg. H. McKenna, 17th Wis. Duty May 18, '65; pens'd; no union; anchylosed elbow.
41	Bonbright, D., Corp'l, E, 11th Pa., age 17.	May 8, 11, '64.	Middle, left radius. Duty Nov. 8, '64; pensioned; dislocation ulna; hand at right angle.	70	Burgett, J. F., Serg't, I, 16th Pa., age 28.	May 28, 28, '64.	Portion right radius, upper. Discharged Feb. 9, 1865; pens'd; grasp impaired.
42	Bosworth, G. A., Serg't, D, 14th New York H. Art., age 27.	July 30, 30, '64.	One and a half, middle, right rad.; by Surg. G. W. Snow, 35th Mass. Duty Jan. 19, 1865; (necrosis); pensioned; styloid process ulna displaced; anchylosed wrist.	71	Burrett, I. N., Capt., K, 56th Pa., age 25.	May 6, 6, '64.	Two, upper, left ulna. Disch'd Nov. 21, 1864; pens'd; no rotation; anchylosed elbow.
43	Booze, C., Pt., H, 118th Illinois, aged 17.	Sept. 15, 15, '64.	Three and a half, lower, left rad. Dis'd Oct. 1, '65; pens'd; wrist't distorted; hand almost useless.	72	Barrows, J. H., Pt., K, 111th Illinois.	May 14, 14, '64.	Left ulna; by Surg. S. P. Bonner, 47th Ohio. Duty July 8, 1864.
44	Bowlick, J., Pt., E, 14th South Carolina.	June 22, 22, '64.	Por. left ulna; by Surg. G. Chad-dock, 7th Mich. Prison Oct. 4, '64.	73	Burlingame, R. G., Pt., A, 20th Mich., age 25.	June 2, 2, '64.	Four, middle, left ulna; by Surg. S. S. French, 20th Mich.; erysip.; gang. Disch'd Dec. 5, '64; pens'd; Aug. '68, disease in elbow joint.
45	Bowyer, E., Lieut. Col., 11th Mo., age 44.	Dec. 16, 16, '64.	Two, middle, left ulna; by Surg. J. E. Murta, 8th Wis. Duty Mar. 1, '65; pens'd; necrosis; partial paralysis limb.	74	Burt, D., Pt., K, 10th Vermont, age 19.	Sept. 19, 22, '64.	Three, middle, right ulna; by A. Surg. W. G. Bryant, 123d Ohio. Duty April 25, 1865; suicide December 31, 1874.
46	Bower, R. T., Pt., C, 49th Ohio, age 34.	May 27, 30, '64.	One and a half, lower, right ulna. Disch'd Nov. 17, '64; pensioned; permanently weak and imperf't.				

No.	NAME, AGE, AND MILITARY DESCRIPTION.	DATES.	OPERATIONS, OPERATOR, RESULT.	No.	NAME, AGE, AND MILITARY DESCRIPTION.	DATES.	OPERATIONS, OPERATOR, RESULT.
75	Burton, J. P., Pt., D, 66th Indiana, age 23.	May 27, '64.	Five, upper, left radius. Disch'd Jan. 10, '65; pens'd; no rotation.	103	Cline, M., Pt., D, 110th Illinois, age 38.	Aug. 7, '64.	Three, lower, right radius. Disch'd Jan. 20, 1865; pens'd; such, w'st joint; ulna disloc.; fingers stiff.
76	Buzzell, F. A., Serg't, I, 4th N. H., age 26.	July 19, '64.	Four, lower, right ulna; gang. Disch'd Feb. 18, 1865; pens'd; no rotation.	104	Clouts, A., Pt., F, 32d Missouri, age 21.	May 26, '64.	Right ulna; by Surg. H. N. Bond, 25th Mo. Dnty Aug. 29, '64, amp. thigh; pens'd; limb impaired.
77	Byers, L. F., Serg't Maj., 6th Maryland, age 28.	Oct. 19, '64.	Four, lower, left radius; by Surg. C. H. Andrus, 176th N. Y.; nec. Disch'd June 23, '65; pens'd; anchy. wrist; 1873, amp. forearm.	105	Coe, J. L., Serg't, G, 38th New York.	Dec. 13, '62.	Two, lower, right ulna; by Surg. J. Howe, 1st N. Y.; no bony union. Disch'd March 14, 1863; pens'd.
78	Callahan, A. N., Pt., B, 6th Iowa, age 21.	Sept. 2, '64.	Two and a half, lower, left ulna; by Surg. W. Loumax, 12th Ind. Duty April 7, 1865; pensioned; united with deformity.	106	Coffee, H. A., Lieut., E, 11th Florida, age 40.	Aug. 21, '64.	Three, upper, third, radius; Dec. 1, doing well.
79	Callahan, D., Pt., A, 5th C. S. Infantry, age 24.	Nov. 30, '64.	Three, middle, right ulna. To Provost Marshal Jan. 17, 1865.	107	Collin, W., Corp'l, D, 95th Pa., age 33.	Sept. 24, '64.	Upper third, left ulna. Disch'd July 15, '65; pens'd; cicatrix adherent.
80	Campbell, E. L., Lieut.-Col., 15th N. J., age 31.	Oct. 19, '64.	Six, lower, left ulna; by Surg. R. Sharp, 15th N. J. Disch'd July 9, 1865; pens'd; limited motion.	108	Collin, Z., Serg't, F, 19th Indiana, age 22.	June 3, '64.	Three, middle, right ulna; by Surg. J. Ebersole, 19th Indiana. Disch'd July 28, '64; pens'd; elbow anchy.; both bones disloc. Portion middle, left ulna (flesh wound log). Disch'd May 3, '65; pens'd; contr. tendons of hand.
81	Campbell, M., Pt., K, 13th Conn., age 21.	Sept. 19, '64.	Three, lower, left radius; by Surg. C. H. Andrus, 176th N. Y. Disch'd Jan. 20, '65; pens'd; hand inverted; ulna very prominent.	109	Cole, C., Pt., E, 14th New Jersey, age 28.	May 13, '64.	Two, middle, left ulna. Disch'd Aug. 7, 1865; pens'd; atrophy; motion impaired.
82	Campbell, W. H., Lieut., C, 4th Iowa, age 28.	May 29, '64.	Three, middle, right radius; by Surg. G. L. Carhart, 31st Iowa. Disch'd July 24, '65; pens'd; no union; dislocation ulna.	110	Cole, S. B., Serg't, F, 10th Conn., age 29.	Oct. 7, '64.	Portion upper, right radius; Aug. 7, amp. arm. Disch'd Apr. 7, '64.
83	Campbell, H. W., Pt., A, 10th N. Y., age 48.	Nov. 11, '64.	Four, left ulna; by Surg. I. Scott, 7th W. Va. Disch'd Mar. 10, '65; pensioned; limb impaired. Died February 22, 1875.	111	Coleman, J. W., Pt., A, 142d Pa., age 19.	May 5, '64.	Three, left ulna (fracture radius). Disch'd Sept. 21, 1864; pens'd; paralysis of hand.
84	Cappell, F., Pt., E, 4th New Jersey, age 40.	Oct. 19, '64.	Four, upper, left radius; by Surg. B. A. Watson, 4th N. J. Disch'd Oct. 17, 1865; pens'd; carp. end of ulna dislocated.	112	Collett, J. R., Pt., B, 7th Kentucky, age 18.	Aug. 30, Sept. 2, 1862.	Greater part left radius; amp. portion hand; by Surg. W. B. Berry, 7th Ky.; (other wounds.) Dis'd Mar. 17, '64; pens'd; hand deformed, shapeless. Spec. 5004.
85	Carbrey, J. T., Pt., G, 1st Mass., age 21.	Dec. 14, '62.	Four, lower, left radius; by Asst. Surg. T. P. Oakes, 1st Mass. Disch'd Jan. 22, '63; pens'd; use of arm restricted. Re-enlisted.	113	Collins, J. P., Corp'l, A, 15th N. J., age 24.	June 7, '64.	Two, upper, right radius; by Surg. R. Sharp, 15th N. J. Disch'd May 30, '65; pens'd; limb imp'd.
86	Carroll, J., Pt., C, 10th Vermont, age 20.	Oct. 19, '64.	Two, middle, left radius (wound of hip). Disch'd May. 5, 1865; pensioned. Disloc. carp. end of ulna; partial ankylosis elbow.	114	Colloway, J., Pt., D, 50th Virginia, age 40.	July 9, '64.	Two, upper, left ulna; Aug. 10, amputation of arm. Exchanged September 13, 1864.
87	Carroll, T., Corp'l, 4th West Virginia.	July 11, '63.	Four, lower, right radius and lig. radial; by Surg. S. P. Bonner, 47th Ohio. To V. R. C. Nov. 27, 1863; pensioned; hand inverted; great deformity.	115	Cordon, I., Pt., B, 9th N. Y. H. A., age 31.	June 2, '64.	Lower, four, fragments, and frac. ends left ulna; by Surg. G. T. Stevens, 77th N. Y. Disch'd Apr. 15, '65; pens'd; motion lost.
88	Carson, J., Pt., K, 99th Pennsylvania, age 30.	May 12, '64.	Portion of middle, left ulna. To V. R. C. Jan. 18, 1865; pens'd. Died December 2, 1867.	116	Connelly, J., Pt., G, 4th N. Y. Art., age 30.	June 18, '64.	Left ulna, middle. Disch'd June 26, 1865; pens'd; deformity of hand; amputation of fingers.
89	Case, W. W., Lieut., C, 10th Minnesota.	Dec. 16, '64.	Three, upper, right radius. Dis'd Aug. 19, 1865; pensioned; hand inverted; no power.	117	Connelly, M., Pt., D, 63d New York.	June 3, '64.	Portion left ulna; by Surg. W. O. Meagher, 63th N. Y.; July 12, amp. arm; necrosis; two ins. humerus rem'd. Dis'd Oct. 21, '65.
90	Caton, S., Pt., B, 78th Ohio, age 27.	May 16, '63.	Middle, left radius; by Surg. A. H. Brundage, 32d Ohio. Disch'd Oct. 23, 1863; pens'd; partial anchy. wrist, elbow, and fingers.	118	Conway, J. G., Pt., I, 62d Pa., age 18.	May 12, '64.	Four, left ulna. Disch'd May 13, 1865; pensioned; rotation lost.
91	Caufman, J. A., Corp'l, A, 200th Pa., age 24.	Mar. 25, '65.	Two, lower, left radius and ulna. Disch'd June 16, '65; pensioned. radius united; useful arm.	119	Cook, A., Pt., H., 42d Pennsylvania.	Dec. 13, '62.	Two inches, lower third, ulna. Discharged.
92	Chambers, J., Pt., F, 27th Michigan, age 19.	Apr. 22, '65.	Three, middle, left ulna. Disch'd Aug. 31, 1865; pensioned; somewhat disabled.	120	Cook, B. C., Serg't, H, 5th Mich., age 25.	July 2, '63.	One and a half, right radius; by Surg. H. F. Lyster, 5th Mich. July 19, amputation arm. Discharged October 7, 1863.
93	Chandler, E. S., Pt., F, 9th N. H., age 29.	May 25, '64.	Three, upper, right radius. Dis'd April 20, '66; pensioned; caries; condition bad.	121	Courtwright, D. C., Pt., C, 15th Ohio, age 24.	May 27, '64.	One and a half, right radius; by A. A. Surg. J. W. Dighty. Discharged Jan. 13, 1865; pensioned; anchy.; slight grasping power.
94	Chase, R., Pt., C, 22d Massachusetts, age 29.	June 3, '64.	Four, upper, right ulna; by Surg. I. H. Stearns, 22d Mass.; gang. Disch'd Nov. 3, 1864; pensioned; rotation lost.	122	Cowdon, W., Serg't, B, 6th Iowa.	May 28, '64.	Two, right radius; by Surg. A. Goslin, 48th Ill. Disch'd April 5, 1865; pens'd; little use of limb.
95	Chatterton, B. W., Pt., C, 24th New York Cav., age 32.	June 12, '64.	Two, middle, left ulna; by Surg. W. B. Fox, 8th Mich. Disch'd Dec. 3, 1864; pensioned. Died May 24, 1869, phthisis.	123	Cox, J. W., Pt., E, 26th Virginia, age 24.	June 25, '64.	Upper, right radius (nerve inj'd). Retired Jan. 24, 1865; partial paralysis.
96	Christie, T., Pt., A, 131st New York, age 45.	May 27, '63.	Five, lower half, left ulna. Dis'd April 16, '64; pensioned; flexion and extension good; partial ankylosis of wrist. Spec. 2386.	124	Coyne, P., Pt., H, 69th New York, age 33.	June 16, '64.	Two and a half, middle, left radius; by Surg. M. F. Regan, 164th N. Y. Discharged June 1, 1865.
97	Clancy, P., Pt., E, 4th New Jersey, age 19.	May 12, '64.	Two, middle, left radius (ulna grazed, crys.); June 3, amp. arm. Disch'd Aug. 30, '64; pens'd.	125	Cranshaw, S., Pt., C, 70th N. Y., age 45.	May 31, '64.	Portion, lower, left radius and ulna (ulnar wounded); gang'e. June 18, hem. lig. ulnar; amp. forearm. Disch'd Sept. 13, 1865.
98	Clark, G. W., Pt., Smith's Virginia Bat., age 46.	April 5, '65.	Three, upper, right radius. Released June 14, 1865.	126	Cramer, A. S., Serg't, H, 55th Ohio, age 29.	June 21, '64.	Three, lower, right radius; by Surg. I. N. Hines, 73d Ohio. Disch'd Feb. 14, '65; pensioned; atrophy; fingers stiff.
99	Clark, J., Pt., D, 9th New Jersey, age 21.	June 22, '64.	Gangrene; three, middle, left ulna; frag. removed. Disch'd Aug. 23, 1865; claim pending.	127	Croft, W. M., Pt., B, 190th Pa., age 29.	June 21, '64.	Three, middle, right radius; by Surg. J. J. Comfort, 1st Penn. Disch'd Feb. 25, '65; pensioned; hand turned inward, powerless.
100	Clark, L., Lieut., 2d Infantry, age 19.	Aug. 19, '64.	Portion of middle of right radius and ulna; by Surg. L. W. Rend, U. S. V. Retired Feb. 28, 1865.	128	Crattenden, W. J., Pt., K, 210th Pa., age 26.	Mar. 31, '65.	One and a half, middle, left, both bones. Dis'd June 21, '65; pen'd; can do trifling amount of labor.
101	Clark, T. B., Pt., E, 66th Illinois, age 33.	July 22, '64.	Three, lower, right radius and ulna; by Surg. W. C. Jacobs, 81st Ohio. Disch'd June 6, '65; pens'd; hand and fingers powerless.	129	Culin, D., Pt., H, 72d Pa., age 46.	May 6, '64.	Three, middle, right ulna (fract. radius); by Surg. M. Rizer, 72d Pa. Duty Oct. 27, '64; pens'd; ankylosed wrist and fingers.
102	Clark, W. H., Pt., K, 51st N. Y., age 20.	May 18, '64.	Left ulna (wound of hip); by Surg. W. B. Fox, 8th Michigan. Not a pensioner.	130	Cullen, S. W., Pt., K, 107th Pa., age 27.	Dec. 13, '62.	Greater portion of right radius. Disch'd June 25, '63; pensioned; hand entirely useless.
				131	Cunningham, W., Capt., I, 90th Illinois, age 34.	Nov. 25, '63.	Entire shaft left ulna. Disch'd July 11, 1864; pensioned; arm and hand useless.



No.	NAME, AGE, AND MILITARY DESCRIPTION.	DATES.	OPERATIONS, OPERATOR, RESULT.	No.	NAME, AGE, AND MILITARY DESCRIPTION.	DATES.	OPERATIONS, OPERATOR, RESULT.
133	Dain, J. M., Serg't, C, 36th Wisconsin, age 30.	Dec. 8, '64.	One inch, middle, left ulna; by Surg. W. E. Johnson, 109th N. Y. Discharged June 9, 1865; limb materially impaired.	164	Ermen, J., Pt., A, 111th Pa., age 21.	June 11, '64.	Two, upper, left ulna; by Surg. G. P. Oliver, 111th Pa. Disc'd May 30, '65; pen., part, anch. elb.
134	Dale, J. M., Pt., B, 31st Missouri, age 25.	June 12, '64.	Right ulna; by Surg. B. N. Bond, 27th Missouri. Disc'd April, 26, 1865. Not a pensioner.	165	Estes, J., Pt., E, 73d Indiana, age 22.	Oct. 28, '64.	Five, right radius; by Surg. G. R. Baldwin, 18th Mich. Discharged March 27, 1865.
135	Darrah, G., Pt., G, 97th New York, age 23.	May 10, '64.	Two, middle, left ulna. To V. R. C. Dec. 27, 1864; pensioned; elbow crooked and stiff.	166	Everhart, W. M., Lieut.-Col., 16th Pa. Cavalry, age 23.	April 6, '65.	Three, lower, left ulna. Disc'd July 24, 1865; pensioned; ligamentous union; bones distorted.
136	Darst, J., Serg't, C, 80th Ohio, age 43.	Nov. 25, '63.	Five, upper half, left radius; by Surg. E. J. Buck, 18th Wis. Disc'd Feb. 14, '65; pensioned; fingers immovable; rotation lost.	167	Farrar, L., Pt., K, 19th Maine, age 21.	June 1, '64.	Five, middle, right ulna; by Surg. D. W. Maull, 1st Arn. Disc'd Apr. 23, '65; pens'd; arm weak'd.
137	Davis, D. C., Pt., I, 11th N. H., age 36.	May 18, '64.	Lower, left radius; by Surg. J. Harris, 7th R. I. July 28, amp. arm. Disc'd Jan. 31, '65; pens'd; Portion right ulna. Nov. 1, '63, doing well.	168	Fenton, C. H., Pt., G, 162d N. Y., age 21.	June 22, '64.	One-half, middle, left ulna; by Surg. G. Chaddock, 7th Mich. To V. R. C. March 28, '65; pens'd; Died June 24, '66, ch. diarrhœa.
138	Davis, J. T., Pt., McIntosh's Bat., age 24.	Oct. 14, '63.	Three, right rad. Mar. 31, amp. arm. Disc'd July 19, '65; pens'd.	169	Finkbone, J., Pt., C, 124th Indiana, age 45.	June 2, '64.	Right radius and ulna. Aug. 1, amp. arm. Disc'd May 5, '65.
139	Debolt, M., Pt., B, 174th Ohio, age 23.	Mar. 10, '63.	Four, middle, left rad; by Surg. G. C. Jarvis, 7th Conn. Disc'd June 30, '65; partially ankylosed elbow.	170	Fisher, R. E., Lieut., K, 5th Ohio, age 40.	July 3, '63.	Upper, left radius; by Surg. A. Ball, 5th Ohio. Duty Dec. 3, '63; pens'd; hand turned inward.
140	Decker, P. T., D, 112th New York, age 36.	Jan. 15, '65.	Two and three-fourths, middle, r't radius; by Surg. G. T. Stevens, 77th New York; rotation lost. Duty July 5, 1864.	171	Fitzpatrick, J. G., C, 27th Georgia, age 25.	Feb. 21, '64.	Two and a half, middle, left ulna. Disc'd June 10, 1865; pens'd; limb useless.
141	Dedrick, G. F., Pt., B, 61st Penn., age 19.	Nov. 5, '63.	Two, lower, left ulna; by Surg. M. Rizer, 73d Pa.; (other wounds.) Duty Aug. 20, 1864; pens'd; ankylosed wrist.	172	Fitzsimons, J., Pt., M, 2d Conn. H. A., age 19.	Oct. 19, '64.	Upper, left radius (fr. ulna); gang. Disc'd Nov. 10, '64; pens'd; motions of elbow and flexor and extensor muscles destroyed.
142	DeLacy, W., Lieut.-Col., 164th N. Y., age 35.	May 18, '64.	Two and a half, upper, left ulna. To V. R. C. Jan. 22, '64; pens'd; bone ununited; slight impairm't.	173	Flynn, P., Pt., 21st Ohio Light Artillery, age 18.	June 2, '64.	Four, upper, left ulna; flexion and supination lost. To V. R. C. Mar. 2, 1865; pens'd.
143	Denny, F., Corp'l, K, 82d New York, age 27.	May 2, '63.	Three, middle, r't rad.; by Surg. D. L. Heath, 23d Mich. Disc'd Sept. 28, '64; pens'd; crooked and weak; of but little use.	174	Fogle, J. E., Pt., F, 7th Maryland, age 20.	June 1, '64.	Three, upper, right radius (fract. ulna); by Surg. A. Sabine, 76th Ohio. Disc'd Sept. 17, '64; pen'd; no rotation.
144	Dibble, H. B., Pt., II, 23d Michigan, age 24.	May 14, '61.	One and a half, lower, right rad.; lig. radial; by Surg. A. K. Fifield, 29th Ohio. Disc'd Nov. 3, 1864. Not a pensioner.	175	Foster, F. W., Lieut., G, 9th Iowa, age 24.	May 13, '64.	Three, middle, right radius; by Surg. S. K. Crawford, 50th Ohio. Disc'd Mar. 29, '65; pens'd; disloc. carpal end ulna; no motion hand.
145	Diefenbach, H., Lieut., I, 111th Penn., age 30.	July 20, '64.	One and a half, upper, left radius (fr. ulna). Duty Oct. 18, '61; pen.; wrist def'med; no bony union.	176	Fraze, W., Pt., A, 27th Kentucky, age 21.	June 26, '64.	Three, right radius, portion ulna; by Surg. A. K. Fifield, 29th Ohio. Disc'd Oct. 25, 1864; pens'd; ankylosed wrist; ulna projects.
146	Dilley, J. B., Pt., A, 33d Ohio, age 20.	July 21, '61.	Two, upper, left rad. Dis'd Jan. 8, '64; pens'd; partial rotation.	177	Frisbie, W. F., Pt., A, 29th Ohio, age 31.	May 27, '64.	Three, upper, left, both bones; necrosis; amp. arm Mar. 23, 1864. Disc'd Feb. 18, '65. Spec. 2406.
147	Ditson, M. S., Corp'l, K, 2d Mass., age 24.	July 2, '63.	Middle, left ulna. Disc'd Nov. 30, 1864; pens'd; false joint; prehension gone.	178	Fry, R., Pt., E, 7th Maryland, age 27.	June 1, '64.	Two and a half, middle, right ulna; by Surg. G. T. Stevens, 77th N. Y. Disc'd Dec. 19, '64; pensioned; useless.
148	Dinsmore, J. N., Pt., B, 8th Maine, age 28.	May 20, '64.	Four, upper, left ulna. Disc'd Feb. 24, 1865; pens'd; impaired use of hand.	179	Fuller, A. M., Lieut., K, 10th Vermont, age 28.	Oct. 19, '64.	Two, lower, left radius. Disc'd April 3, 1865; pens'd; wrist turned; little grasp.
149	Dodge, G. F., Pt., C, 6th Vermont, age 34.	Sept. 19, '64.	Two, middle, left radius; by Surg. W. H. Mullens, 12th Ky. Disc'd April 3, '65; pens'd; carpal end of ulna luxated.	180	Fuller, L., Pt., I, 66th New York, age 19.	May 12, '64.	Three, lower, left radius; by Surg. C. M. Clark, 39th Illinois; hæm. Disc'd Aug. 7, 1865; pens'd; dislocation wrist; no bony union.
150	Dole, M. V., Pt., I, 104th Ohio, age 26.	Aug. 6, '64.	Left radius. Deserted Nov. 1, '64.	181	Gaddis, J. F., Pt., K, 39th Illinois, age 19.	Aug. 16, '64.	Lower, right radius; by Surg. H. McKenna, 17th Wis. Disc'd July 4, '65; pens'd; hand flexed.
151	Donaldson, J. H., Pt., C, 5th Ohio, age 19.	May 27, '64.	Two, middle, left radius; hæmor. Dis'd Mar. 11, '65; pen'd; wrist joint anhyt.; fingers contracted.	182	Gamble, D. C., Capt., E, 66th Illinois, age 27.	May 30, '64.	Three, upper, left ulna. Disc'd July 7, '65; pens'd; lig. union.
152	Donovan, M., Pt., C, 155th Penn., age 47.	May 5, '64.	Four, middle, right ulna; by Surg. B. Rohrer, 8th Pa. Res. Disc'd Feb. 10, 1865; pens'd; limb weak and cold.	183	Gardiner, W. H., Pt., D, 43d N. Y., age 42.	May 6, '64.	Portion lower, left radius. Disc'd June 16, 1865; pens'd; impaired use. Spec. 2761.
153	Donze, J., Pt., A, 8th Pa. Res., age 22.	May 8, '64.	Large portion left radius; by Surg. C. B. Purks, 1st Vt. H. A. Discharged Dec. 20, '64; pensioned; disloc. ulna; imperfect rotation.	184	Gardner, L. L., Serg't, C, 11th Maine, age 27.	April 10, '65.	Two, right ulna; by Surg. H. C. Levensaler, 8th Maine. Disc'd July 15, '65; pens'd; very weak.
154	Drown, O., Pt., A, 11th Vermont, age 27.	June 22, '64.	Three, middle, left ulna. Disc'd June 5, 1865; pens'd; fingers stiff.	185	Garcy, A. J., Capt., I, 12th Mass., age 30.	May 8, '64.	Four, upper, left ulna. Duty July 6, '64; pensioned; partial dislocation radius; elbow distorted.
155	Drahmer, N., Corp'l, D, 188th N. Y., age 32.	April 1, '65.	Middle third of ulna. Recovered.	186	Garner, R. E., Pt., B, 21st Georgia.	Aug. 28, '60.	Four, middle, ulna. Good use of arm.
156	Duke, R. H., Pt., G, 47th Alabama.	July 2, '63.	Three, lower, right radius; by Surg. T. F. Oakes, 56th Mass. Discharged July 19, 1865; pensioned; wrist distorted.	187	Gavrick, D., Pt., A, 149th Pa., age 22.	June 1, '64.	Three, middle, right radius. Dis'd Dec. 14, '64; pens'd; disloc. wrist; flexion and extension impaired.
157	Eaton, J., Corp'l, II, 4th N. H., age 25.	July 30, '64.	Three inches of radius. Exch'd September 5, 1863.	188	Gaston, J. H., Pt., A, 97th Indiana, age 20.	June 27, '64.	Two, upper, right, both bones; by Surg. R. Morris, 103d Ill. Dis'd May 10, '65; part, anhyt. elbow; no bony union; limb only ornamental.
158	Eaúy W. P., Ft., F, 5th North Carolina.	July 3, '63.	Four, lower, right ulna; by Surg. J. W. Lawton, U. S. V.; gang. Dis'd Ap. 27, '65; pen.; good use.	189	Geiler, A., Pt., C, 72d Pennsylvania, age 32.	July 5, '63.	Lower, right ulna. By Surg. M. Rizer, 73d Pa. Dis'd Aug. 37, '64.
159	Edgington, R. H., Pt., F, 6th E. Tenn., age 23.	June 16, '64.	Four, low, half, right ulna. Dis'd Jan. 24, '65; pens'd; wrist anhy.	190	Geelan, B., Pt., G, 49th New York, age 21.	May 12, '64.	Three, lower, left ulna; by Surg. J. A. Hall, 49th N. Y. Disc'd July 25, '65; pensioned; useless.
160	Ellis, J. B., Pt., D, 20th Ohio.	May 9, '64.	Right radius and ulna, middle. Discharged May 30, 1865.	191	Geroe, W., Pt., G, 51st New York, age 22.	June 30, '61.	Part upper, right ulna. Disc'd May 30, '65; pens'd; ankylosed elb. Burned to death Dec. 29, '65.
161	Elsler, J., Pt., D, 3d N. Jersey, age 21.	Nov. 22, '64.	Left radius mid. V. R. C. May 11, 1865; pens'd; greatly impaired.	192	Gibson, S. O., Corp'l, D, 11th N. H., age 23.	June 16, '64.	Four, right radius and one inch of ulna; by Surg. J. W. Wishart, 140th Pa.; gang.; necrosis; amp. forearm. Disc'd June 2, 1865.
162	Emmons, J. A., Pt., II, 5th Minn., age 28.	Dec. 15, '64.	One and a half, lower, left rad.; by Surg. W. A. Gott, 25th Wis.; hæm.; lig. radial. Disc'd July 20, '65; pensioned; hand disloc. inward; bones ununited.				
163	Engle, G. D., Pt., 28th Mich., age 20.	March 10, '65.					

NO.	NAME, AGE, AND MILITARY DESCRIPTION.	DATES.	OPERATIONS, OPERATOR, RESULT.	NO.	NAME, AGE, AND MILITARY DESCRIPTION.	DATES.	OPERATIONS, OPERATOR, RESULT.
195	Gilbert, H. E., Pt., F., 12th Mass., age 31.	May 10, 11, '61.	Four, middle, right ulna; erysipelas. Disch'd Sept. 26, '61; pensioned; forearm badly deformed and atrophied; no rotation.	225	Harbo, J. W., Pt., A, 2d Mississippi, age 21.	May 6, '64.	Two, upper, radius. Furloughed June 22, 1864.
196	Gilley, C. B., Pt., G, 1st Maine Heavy Art'y, age 23.	June 23, 23, '64.	Three, middle, left radius; by Surg. H. F. Lyster, 5th Mich. Disch'd Feb. 20, '65; pensioned; ankyl. wrist; limb soft, atroph'd.	226	Harris, P. W. H., Serg't, E, 40th N. Y., age 30.	June 18, '64.	Two, middle, right ulna (radius frac.); by Asst. Surg. O. J. Evans, 40th N. Y. Disch'd Mar. 14, '65; pens'd; no power to grasp.
197	Gilligan, T., Pt., H, 56th Pennsylvania, age 21.	May 12, 12, '61.	Four, lower, left radius. Disch'd May 16, 1865; pensioned; hand tremulous and useless.	227	Harrod, M. S., Pt., D, 45th Ohio, age 22.	June 15, 15, '64.	Two, middle, left ulna; by Surg. S. K. Crawford, 50th Ohio. Discharged May 9, '65; pensioned; limb weak, of but little use.
198	Gingerick, W., Pt., B, 64th Illinois, age 22.	Aug. 10, 11, '64.	Three, upper, left radius. To V. R. C. May 9, 1865; pensioned; no rotation; arm weak.	228	Hartfield, J. A., Pt., H, 17th Mississippi, age 21.	May 3, '63.	Five, lower, left radius. Furl'd June 11, 1863; improving.
199	Goodall, R. S., Serg't, F, 5th N. H., age 23.	April 7, 7, '65.	Two and a half, lower, right radius. Disch'd Sept. 12, '65; pensioned; Nov., 1865, open sore from dead bone. Died June 11, 1866.	229	Hartley, M. P., Corp'l, I, 27th Illinois, age 25.	June 18, 18, '64.	Four, upper, right ulna; by Surg. S. J. Young, 79th Ill. Duty Feb. 8, 1865; pensioned; ankylosed elbow; limb impaired.
200	Gorman, T., Corp'l, E, 183d Pa., age 25.	May 10, 10, '64.	Four, upper, left ulna. Disch'd June 13, 1865; pensioned; ankylosed elbow; hand paralyzed.	230	Harvey, W. F., Pt., G, 41st Penn., age 19.	May 6, '64.	Three, middle, right ulna. Duty Nov. 26, 1864; pens'd; limb deformed and weak.
201	Grace, A. J., Pt., K, 17th Maine, age 19.	May 12, 12, '64.	Two and a half, upper, right ulna (fract. radius). Disch'd Jan. 2, 1865; pens'd; cartilag. union.	231	Hawkins, J. N., Pt., F., 40th Ill., age 21.	July 28, 29, '64.	One and a half, lower, left ulna; by Surg. W. Graham, 40th Ill. Dis. Jan. 24, 1865; pens'd; ankyl. wrist; hand practically useless.
202	Graham, W., Corp'l, D, 66th Illinois, age 21.	June 27, 27, '64.	Three, lower, right radius. Dis'd Feb. 6, '65; pensioned; ankylosed wrist; fingers contracted.	232	Haynes, J. A., Pt., I, 11th New Hampshire.	July 12, 12, '63.	Two and a half, lower, left, both bones. Disch'd Nov. 17, '63; pensioned; ligamentous union; hand almost useless.
203	Gravell, L., Pt., I, 34th Mass., age 28.	June 18, 18, '64.	Three, lower, left radius. Disch'd March 14, '65; pensioned; ulna dislocated; hand useless.	233	Hayes, A., Pt., I, 3d Michigan, age 30.	May 12, 13, '64.	Two, middle, right radius (ulna fractured); by Surg. H. F. Lyster, 5th Mich. Disch'd June 6, '65; pens'd; ulna dislocated; no flexion of fingers.
204	Grayburn, R. W., Serg't, G, 5th Ky., age 22.	Nov. 25, 25, '63.	Four, lower, right rad.; by Surg. O. Chamberlain, 8th Kan. Duty Aug. 3, '64; pens'd; hand inverted; ulna dislocated.	234	Healy, J., Pt., K, 155th New York.	June 3, '64.	Right forearm; by Surg. M. Rizer, 72d Pa. Disch'd May 18, '65. Not a pensioner.
205	Grayson, A., Serg't, F, 50th C. T., age 47.	April 5, 5, '65.	Four, upper, right radius. Disch'd June 1, 1865; partial loss use of arm. Not a pensioner.	235	Heath, L. J., Pt., E, 1st Maine Cav., age 36.	Mar. 31, 31, '65.	Middle, left rad. and ulna. Disch'd June 1, 1865; pens'd; fractured ends loose in muscles.
206	Green, N., Pt., D, 6th Michigan Cavalry.	Sept. 14, 15, '63.	Two, lower, left rad.; gang; Nov. 3, amp. forearm; haem; Nov. 17, amp. arm. Dis'd March 24, 1864.	236	Heckler, J., Corp'l, D, 14th Ohio, age 22.	Sept. 1, '64.	Two, lower, right ulna; Sept. 8, accidental frac. rad. at middle. Duty June 21, '65; pens'd; part. paral. middle and ring fingers.
207	Greenfield, J. M., Pt., F, 7th Michigan, age 21.	May 31, 31, '64.	Lower, left ulna; by Surg. S. H. Plumb, 82d N. Y. Disch'd Dec. 13, '64; pensioned; rotation fair; moderate motion in hand.	237	Henderson, G., Pt., C, 124d Ohio, age 19.	May 6, 6, '64.	Four, lower, left radius. Disch'd Apr. 3, '65; pens'd; wrist joint enlarged and tender.
208	Griesenger, G. W., Sergeant, K, 111th Ohio, age 27.	June 28, 28, '64.	Three, lower, right ulna; by Surg. J. W. Lawton, U. S. V. Disch'd Jan. 24, '65; pensioned; ankyl. wrist; no flex. or exten. fingers.	238	Henry, W., Pt., A, 68th New York, age 31.	May 31, 31, '64.	Lower, left radius and ulna; by Surg. P. E. Hubon, 28th Mass.; gang; amp. forearm. Dis. July 27, 1865.
209	Groff, J. H., Serg't, H, 12th N. J., age 27.	May 3, '63.	One and a half, lower, left radius. Duty July 30, 1864; pensioned; dislocation ulna.	239	Herrard, F., Pt., A, 6th Kansas Cavalry.	April 2, 3, '63.	Over one inch rad. and ulna; co-aptation of bones. Disch'd Oct. 8, '64; complete union; rotation nearly complete. Not a pensioner.
210	Guild, P. M., Serg't, K, 57th Pa., age 30.	May 4, '63.	Four, upper, right rad.; by Surg. H. F. Lyster, 5th Mich. Disch'd Sept. 21, '61; pensioned; no rotation; little flexion.	240	Hersey, P., Pt., B, 1st Mass. H. A., age 29.	June 16, 17, '64.	Two and a half, middle, right ulna. Disch'd Dec. 19, '64; pens'd; no bony union; grasp impaired.
211	Gwin, C. A., Pt., B, 129th Illinois.	May 15, 15, '64.	Middle, right radius (fract. ulna); Oct. 18, two ins. radius rem'd. Disch'd June 6, '65; pensioned.	241	Hickman, E., Pt., C, 27th Illinois, age 22.	June 27, 27, '64.	Four, lower, left rad. Disch'd Oct. 29, '64; pens'd; hand pronated; fingers semi-flexed. Drowned July 10, 1873.
212	Gwinne, A. D., Lieut.-Col., 38th Tennessee.	July 22, 23, '64.	Portion of ulna. Transferred.	242	Hickman, W. W., Corp'l, 11, 1st Del., age 22.	June 18, 18, '64.	Right ulna, upper; by Surg. D. W. Mauld, 1st Del. To V. R. C. Jan. 28, '65; pens'd; rotation impaired.
213	Hack, J. W., Lieut., E, 9th Virginia.	July 2, '61.	Portion of ulna. To prison Aug. 1, 1863.	243	Hicks, J. C., Pt., E, 190th Pennsylvania, age 26.	May 8, 8, '64.	Portion upper, left ulna. To V. R. C. Mar. 7, '65; pens'd; ankyl. elbow; atrophy.
214	Hackett, G. H., Lieut., A, 10th N. Y., age 20.	May 6, 6, '64.	Four, right ulna; amp. arm for gangrene. Disch'd May 26, '65.	244	High, L., Lieut., K, 64th Ohio.	June 18, 18, '64.	Upper, right ulna. Disch'd Apr. 4, '65; pens'd; rotation impaired.
215	Hadley, B., Pt., F, 179th New York, age 19.	Feb. 7, '65.	Portion left ulna; by Surg. L. W. Bliss, 51st N. Y. Disch'd June 10, 1865. Not a pensioner.	245	Hill, J. R., Pt., 4th New York Battery.	July 3, '63.	Por. left ulna; (wound of right thigh.) To V. R. C. Sept. 23, '61. Not a pensioner.
216	Hagan, W. J., Pt., I, 33d Wis., age 19.	March 21, 21, '65.	Three, lower, left ulna; by Surg. A. B. Monohan, 63d O. Dis. July 10, '65; pen'd; hand alm. useless.	246	Hinchey, T., Pt., D, 6th N. Y. H. A., age 24.	May 20, 20, '64.	Middle, left radius. Disch'd Jan. 26, 1865; pens'd; distortion of wrist; fingers partly ankyl.
217	Hageman, A. W., Pt., D, 103d Ill., age 23.	Nov. 25, 26, '63.	Two, middle, right ulna; by Asst. Surg. S. S. Buck, 103d Ill. Dis'd Oct. 28, '64; pensioned; lig. union; ankyel. elb.; arm nearly ext'd.	247	Hodges, B., Pt., G, 5th Connecticut, age 22.	July 20, 22, '64.	Two, middle, right ulna; Aug. 15, erysipelas; gang. Oct. 20, amp. forearm. Disch'd Feb., 1865.
218	Hall, M., Pt., F, 87th Penn., age 19.	April 2, 2, '65.	Portion left radius, middle (ulna fractured). Disch'd June 17, '65; pen'd; hand inward; fngs. flex'd.	248	Hogan, M., Pt., D, 3d Maryland, age 31.	Dec. 24, 24, '64.	Two, middle, right ulna; by Surg. W. E. Johnson, 109th New York. Disch'd Aug. 7, '65; pensioned; third and fourth fingers contract'd.
219	Hainline, J. L., Serg't, A, 16th Illinois, age 26.	Mar. 19, 19, '65.	Two, lower, left ulna. Duty June 16, '65; pens'd; imperfect use of hand.	249	Hoguet, F., Lieut., E, 110th Pa., age 24.	July 2, 2, '63.	Three, middle, right radius; (w'nd hip.) Disch'd Sept. 3, '64; pens'd; ankylosis wrist; hand atrophied.
220	Hamilton, J. H., Pt., G, 18th Miss., age 26.	May 3, '63.	Four, right ulna, upper; by Surg. T. B. Williams, 121st Ohio. Discharged Sept. 28, 1864; pens'd; fngs. contracted; forearm atroph'd.	250	Holbrook, C. D., Corp'l, D, 37th Massachusetts, age 32.	May 18, 18, '64.	Two, upper half, right ulna (radius fract.); by Surg. C. Page, U. S. A. Disch'd Nov. 28, 1864. Partial motion of fingers.
221	Hammel, W., Pt., F, 121st Ohio, age 22.	June 27, 27, '64.	Three, right ulna, upper; by Surg. T. B. Williams, 121st Ohio. Discharged Sept. 28, 1864; pens'd; fngs. contracted; forearm atroph'd.	251	Holland, R. H., Pt., E, 6th Virginia.	July 30, 30, '64.	Middle, left ulna; by Surg. T. F. Oakes, 56th Mass. Recovered.
222	Hammond, R. P., Pt., E, 110th Ohio, age 30.	April 2, 2, '65.	Three and a half, middle, left ulna; by Surg. R. R. McCandless 110th Ohio. Disch'd June 19, '65; pen'd; can't close fngs.; elb. impaired.	252	Holliday, L., Pt., I, 2d Minnesota, age 23.	June 18, 18, '64.	Two, middle, left radius; ball extracted; by Surg. H. Herriek, 17th Ohio. Disch'd May 6, '65; pensioned; ankylosed wrist.
223	Hamlin, J. M., Lieut., H, 36th Ohio, age 25.	June 11, 11, '64.	Five, middle, ulna; by Surg. J. W. Whitford, 36th Ohio. Duty Oct. 18, 1864.				
224	Harley, A., Pt., E, 2d Penn. H. A., age 19.	July 30, 30, '64.	Four and a half, upper, left, both bones. Disch'd May 16, '65; pensioned; disloc. elb.; hand useless.				



No.	NAME, AGE, AND MILITARY DESCRIPTION.	DATES.	OPERATIONS, OPERATOR, RESULT.	No.	NAME, AGE, AND MILITARY DESCRIPTION.	DATES.	OPERATIONS, OPERATOR, RESULT.
253	Hollinger, S., Pt., A, 43d C. T., age 17.	July 30, '64.	Three, left ulna; by Surg. J. S. Ross, 11th N. H. Disch'd Feb. 20, 1865. Not a pensioner.	282	Jennings, W. H., Pt., G, 43d Ohio, age 27.	Feb. 3, '65.	Portion of right radius; by Surg. F. M. Rose, 43d Ohio. Disch'd July 20, '65; pens'd; disloc. ulna.
254	Holman, J. H., Capt., F, 2d Pa. H. A., age 26.	July 30, '64.	Middle, right radius; by Surg. T. F. Oakes, 56th Mass. Duty Dec. 28, '64; pens'd; cannot grasp tightly; no deform'y except scars.	283	Jerue, G., Pt., I, 5th Iowa Cav., age 35.	Nov. 25, '63.	Left ulna (radius fractured); by A. Surg. W. H. Burrow, 5th Iowa. Disch'd June 27, '65; pen'd; uses a supporter constantly.
255	Horner, G. W., Pt., G, 2d Pa. H. A., age 19.	June 17, '64.	Four, middle, left ulna. Disch'd Aug. 29, 1865; pensioned. Died Aug. 20, 1871, phthisis.	284	Johnson, A., Pt., H, 1st Illinois Artillery, age 35.	July 22, '64.	Middle, right ulna; by Surg. S. P. Bonner, 47th Ohio. Disch'd June 19, 1865; pensioned; partial ankylosis of elbow.
256	Horner, L. W., Pt., A, 11th New York.	May 5, '64.	Lower, radius; by Surg. G. L. Potter, 145th Pa. Disch'd July 20, 1865. Not a pensioner.	285	Johnson, B. S., Pt., F, 141st N. Y., age 42.	May 15, '64.	One and a half, middle, right radius (fract. ulna); by Surg. A. K. Fitch, 29th Ohio. Disch'd June 24, 1865; pens'd; false joint; ulna dislocated.
257	Hotham, W. H., Pt., F, 11th Pa., age 30.	Mar. 31, '65.	Two, lower, right radius (fracture scapula). Disch'd Aug. 28, '65; pen'd; fingers extend; hand bent.	286	Johnson, R. D., Serg't, I, 50th Va., age 25.	July 30, '64.	Two inches, lower third, left radius.
258	Houck, B. F., Pt., C, 1st Ohio S. S., age 24.	Aug. 3, '64.	Lower, left radius. Disch'd May 26, 1865; pensioned; hand bent; fingers stiff; paralysis.	287	Johnston, J., Pt., E, 60th Ohio, age 35.	June 24, '64.	Middle, right radius; by Surg. C. E. Ames, 60th Ohio, Duty Mar. 11, 1865. Not a pensioner.
259	Hough, R. W., Corp'l, A, Independ. Virginia Rangers, age 21.	April 6, '65.	One, middle, left radius; by A. A. Surg. S. T. Breck. Discharged June 5, 1865.	288	Jones, J., Pt., F, 115th Illinois.	Sept. 19, '63.	Three, lower, radius. Disch'd June 11, '65; pens'd; ulna dislocated at wrist; hand bent.
260	Houghten, A. C., Capt., A, 2d Ohio Cavalry, age 22.	April 1, '65.	Two and a half, upper, left ulna; by Surg. R. Curran, 9th N. Y. C. Disch'd May 15, 1865; pens'd; atrophied and useless.	289	Jones, R., Pt., C, 43d Colored Troops, age 19.	Oct. 27, '64.	Left ulna; by A. Surg. M. Tucker, 39th C. T. Disch'd June 8, 1865; claim pending.
261	Howie, S., Pt., I, 186th New York, age 35.	April 2, '65.	Two, middle, left ulna; by Asst. Surg. J. H. Kimball, 32d Maine. Disch'd June 12, 1865; pens'd; no bony union or rotation.	290	Justin, F., Pt., H, 31st Maine.	June 3, '64.	Left forearm; June 9, amp. forearm. Disch'd Jan. 5, 1865.
262	Howk, A., Pt., H, 2d Ohio Cavalry, age 22.	June 21, '64.	Three, middle, left ulna. Disch'd Mar. 18, 1865; pens'd; elbow ankylosed; fingers flexed.	291	Kautz, L., Pt., H, 1st Pennsylvania Rifles, age 32.	May 6, '64.	Two, lower, right ulna; (May 20, amp. left forearm.) Disch'd June 1, 1865; rotation and muscular functions lost.
263	Hoy, M., Lieut., K, 10th Minn., age 28.	Dec. 16, '64.	Three, middle, right radius. Dis'd Apr. 13, 1865; pens'd; rotation lost; deformity.	292	Keith, E. R., Pt., K, 149th N. Y., age 23.	June 16, '64.	Two and a half, lower, left ulna; by Surg. J. N. Kendall, 149th N. Y. June 29, gang. Dis. May 17, '65; pen'd; limb ulna. useless.
264	Hubbard, W. L., Serg't, D, 3d N. Y., age 28.	Jan. 15, '65.	Portion lower, right radius. Dis'd June 17, 1865; pens'd; rotation lost; ulna dislocated.	293	Kelley, J., Pt., F, 2d Cavalry, age 28.	June 11, '64.	Portion upper, right radius; part I ankylosis elbow. Disch'd Dec. 13, '64; pensioned; rotation lost.
265	Hubbard, W. F., Pt., D, 149th N. Y., age 18.	July 2, '63.	Three, middle, right radius. Dis. June 8, 1865; pens'd; hand turned half around.	294	Kent, D. H., Capt., 4th Delaware, age 28.	Feb. 5, '65.	Three, upper, right ulna; by Surg. J. F. Bendoll, 86th N. Y. Disch'd May 10, 1865; pensioned; use greatly impaired.
266	Hudson, C., Pt., I, 21st Connecticut, age 25.	June 16, '64.	Three, upper, right ulna. Disch'd April 26, 1865; pens'd; ankylosed elbow; atrophy.	295	Kent, J., Pt., D, 30th Illinois, age 23.	July 22, '64.	Left ulna; Aug. 24, amp. arm. Disch'd May 15, '65; pensioned.
267	Huffman, J., Pt., F, 85th Pennsylvania, age 22.	Oct. 13, '64.	Portion of lower half, right ulna; muscles of forearm removed. Duty Apr. 22, 1865; pens'd; use of limb impaired.	296	Kernberger, F., Pt., K, 56th Mass., age 18.	June 27, '64.	Three, middle, right radius. Discharged Dec. 8, '64; pensioned; no union; hand almost useless.
268	Hughes, J., Pt., C, 157th Pennsylvania, age 41.	Aug. 18, '64.	Middle, left ulna. Disch'd Dec. 5, 1864; pens'd; elbow ankyl.; arm impaired.	297	Kieffer, J., Pt., F, 73d New York.	Sept. 25, '64.	Right ulna. Discharged June 10, 1865. Not a pensioner.
269	Hull, C., Pt., L, 2d Mass. Cav., age 30.	July 31, '63.	Two, lower, right radius. Disch'd February 19, 1864.	298	Kiernan, M., Pt., F, 2d Rhode Island, age 19.	May 6, '64.	Two, middle, left radius. To V. R. C. Nov. 30, '64; pensioned; rotation nearly lost; impaired use.
270	Hull, L. C., Pt., A, 107th Illinois, age 28.	May 27, '64.	Four, lower, left radius; by Surg. J. W. Lawton, U. S. V. Disch'd Jan. 8, 1865; pens'd; ulna dislocated; cannot close hand.	299	Kirkhaven, A., Pt., F, 1st Md. Cav., age 27.	Aug. 16, '64.	Three, lower, left radius. Disch'd Dec. 31, '64; pensioned; carpal end of ulna protrudes; distortion.
271	Hunt, W. L., Corp'l, F, 79th Ohio, age 20.	June 22, '64.	Portion lower, radius. Disch'd Dec. 3, 1864; pens'd; ligamentous union; hand entirely useless.	300	Kitson, A., Pt., E, 148th New York, age 36.	Mar. 30, April 1, 1865.	Three, lower, left ulna; fracture radius. Dis'd July 22, '65; pen'd; hand and forearm nearly useless.
272	Huntley, M., Corp'l, A, 2d Mass., age 25.	July 3, '63.	Entire lower, right, both bones; by Surg. W. H. Heath, 2d Mass. Disch'd Mar. 28, '64; no union; motion of wrist and hand fair.	301	Klaus, F., Pt., C, 17th Missouri, age 25.	Nov. 27, '61.	Two, left radius, upper. Disch'd May 14, '64; pen.; part anch. elb.
273	Hurd, C. W., Pt., D, 1st New York Light Artillery, age 23.	May 23, '64.	Two, right ulna, upper. Disch'd Dec. 17, '64; pens'd; impaired use of forearm and hand; imperfect flexion of fingers.	302	Kromes, G., Pt., E, 96th Pennsylvania, age 21.	May 10, '64.	Two, lower, left radius. Disch'd July 20, 1865; pensioned; deformity at wrist; arm useless.
274	Husky, A., Pt., E, 9th Iowa, age 21.	June 27, '64.	Portion, left radius; by Surg. B. N. Bond, 27th Mo. To V. R. C. May 14, 1865. Not a pensioner.	303	Lahr, P., Pt., M, 7th Michigan Cavalry.	Oct. 1, '63.	Three, middle, ulna. Discharged July 12, 1865; pensioned; non-union; head of radius dislocated.
275	Hutchinson, A. H., Pt., K, 5th Maine, age 23.	May 6, '64.	Three, lower, right radius. Dis'd Dec. 2, 1864; pens'd; hand turned inw.; ulna thrown forward.	304	Landon, J., Pt., B, 32d Massachusetts, age 27.	Feb. 6, '65.	One, middle, left ulna. Disch'd July 17, '65; pensioned; ankyl. and disloc. elbow; hand deform.
276	Hutchinson, J. A., Pt., H, 2d West Virginia Cavalry, age 26.	Sept. 22, '64.	Upper, right ulna. Disch'd June 7, 1865; pens'd; no rotation; ankylosis elbow.	305	Langford, J. W., Pt., F, 15th Alabama.	May 6, '64.	Three, lower third, radius; erysipelas. Recovered.
277	Hutchinson, T., Pt., F, 71st N. Y., age 29.	Nov. 2, '62.	Portion lower, radius (ulna disarticulated at wrist); ham.; Mar. 15, amp. forearm. Disch'd Jan. 20, 1863.	306	Lane, G., Pt., K, 4th Iowa, age 26.	May 27, '64.	Three, lower, right radius; by Surg. N. W. Robbins, 4th Ia. Disch'd March 8, 1865; pensioned; wrist joint ankylosed; hand flexed.
278	Hyland, A., Serg't, B, 2d N. Y. Tro. Cav., age 16.	Aug. 29, '64.	Four, upper, left ulna; nec. bone. Disch'd Nov. 4, '65; no reproduction; elbow intact. Spec. 4360.	307	Lanc, R. R., Pt., G, 32d Missouri, age 29.	July 28, '64.	Two, lower, left ulna; by Surg. A. T. Hudson, 26th Iowa. Disch'd Nov. 30, '64; pensioned; fingers contracted; partial paral. arm.
279	Hsley, H., Pt., I, 140th New York, age 35.	Feb. 6, '65.	Middle, left radius; by Surg. T. M. Flaudran, 146th N. Y.; gang.; hæm.; Feb. 25, amp. arm. Discharged July 24, 1865.	308	Lanham, S. M., Pt., D, 8th Kansas, age 16.	July 24, '64.	Right radius, middle (fract. ulna); gangrene. Duty April 19, '65; pensioned; fingers impaired.
280	Irish, A. J., Pt., H, 106th New York, age 12.	May 12, '64.	Middle, right radius; May 17, amp. arm; gang. Disch'd June 3, 1865; pensioned.	309	Larwood, J. J., Pt., C, 8th New York H. Art., age 18.	June 3, '64.	Two, lower, left radius (ulna fractured). Disch'd May 31, 1865; pensioned; hand dislocated; fingers extended.
281	Jackson, I., Corp'l, G, 124th Illinois, age 24.	May 16, '63.	Two, lower, right radius; by Surg. E. J. Buck, 18th Wis. Disch'd Nov. 9, 1863; pensioned; hand at a right angle; ulna disloc.	310	Lathrop, J. R., Pt., C, 15th Iowa, age 19.	July 22, '64.	Three, left radius and ulna; by Surg. W. H. Gibbon, 15th Iowa. Disch'd June 14, '65; pen'd; hand can be partly closed; arm crook'd.
				311	Leavitt, D. W., Pt., C, 32d Missouri, age 30.	May 12, '64.	Three, lower, right ulna; by Surg. J. S. Ross, 11th N. H. To V. R. C. Feb. 22, 1865; pensioned; useful for light labor.

NO.	NAME, AGE, AND MILITARY DESCRIPTION.	DATES.	OPERATIONS, OPERATOR, RESULT.	NO.	NAME, AGE, AND MILITARY DESCRIPTION.	DATES.	OPERATIONS, OPERATOR, RESULT.
312	Leach, R. M., Pt., F., 12th Mass., age 29.	May 5, '64.	Four, middle, right ulna. Disch'd June 24, 1865; ankylosis elbow; grasp impaired.	341	Martin, R. A., Pt., C., 7th W. Va., age 21.	June 18, '64.	Four, upper, right ulna; by Surg. I. Scott, 7th W. Va. Disch'd Dec. 20, 1864; pens'd; ankylosis of elbow; pronation lost.
313	Leoti, G. W., Mus'n, H., 191st Pa., age 21.	June 17, '64.	Excision; by Surg. W. Lyons, 11th Pa. Res. Disch'd April 24, 1865. Spec. 414. See CASE 1889.	342	Mason, W. J., Pt., C., 34th Massachusetts.	Dec. 13, '62.	Right forearm; Jan. 1, '63, amp. arm. Disch'd April 8, 1863.
314	Le Targe, V., Pt., I., 28th Mass., age 32.	May 6, 7, '64.	Two and a half, lower, left ulna; by Surg. P. E. Hubon, 28th Mass. Disch'd July 21, '65; pensioned; anechl. wrist; impaired power.	343	Masters, T. W., Pt., K., 61st Pennsylvania, age 25.	May 12, '64.	Two, lower, right ulna. Disch'd April 29, 1865; pens'd; rotation lost; use of fingers impaired.
315	Leomon, A., Capt., B., 6th Ohio, age 21.	Nov. 25, '63.	Right radius, lower. Disch'd July 17, '65; pens'd; paralysis of hand. Died Sept. 5, 1867, jaundice.	344	Maurer, E., Pt., K., 46th Pennsylvania, age 26.	June 27, '64.	Three, middle, left radius. Disch'd Oct. 25, '64; pens'd; ulna dislocated; no bony union.
316	Leuhart, E., Corp'l, D., 45th Pa., age 24.	May 12, '64.	Two, upper, left ulna; by Surg. J. Harris, 7th R. I. Discharged Dec. 20, 1864; pens'd; anechl. elbow; fingers do not flex.	345	Maxfield, A. D., Pt., F., 14th Michigan, age 22.	June 30, '64.	Two, lower, right radius. Disch'd May 23, 1865; pens'd; hand distorted and useless.
317	Livingston, L., Pt., A., 103d Illinois, age 28.	June 27, '64.	Two, lower, right radius and ulna. Disch'd Jan. 8, 1865; pensioned; no bony union; hand powerless.	346	Maxwell, G. R., Capt., E., 1st Michigan Cavalry, age 22.	May 28, '64.	Three, upper, left radius; by Surg. S. R. Wooster, Michigan Cavalry. Disch'd August 4, 1865. Not a pensioner.
318	Lewis, E. E., Lieut. Col., 110th Pa., age 25.	June 16, '64.	Six, left radius. Disch'd Jan. 11, 1865; pens'd; wrist deformed; styloid process prom't; necrosis.	347	McCabe, J., Pt., F., 69th N. Y. S. M., age 49.	June 22, '64.	Lower, left ulna; by Surg. F. Douglass, 170th N. Y.; July 11, amp. arm. Disch'd Oct. 14, '65. Died Dec. 27, 1867.
319	Light, L., Pt., A., 149th New York, age 21.	June 15, '64.	Three and a half, middle, left ulna. To V. R. C. Sept. 8, '61; pens'd; paralysis and atrophy ulnar side; vicious and adherent cicatrix.	348	McCabe, W., Serg't, K., 46th Ohio, age 28.	July 13, '63.	Four, lower, left ulna; by Surg. W. Lomax, 12th Ind. Disch'd Oct. 10, '63; pens'd; loss of rotation, flex., and extens. of hand. Part of right ulna. Disch'd Jan. 24, '65; pens'd; part, anch. wrist; complete loss of power of limb.
320	Lindsey, S. W., Pt., K., 47th Alabama, age 25.	Oct. 7, '64.	Four and a half, middle, right ulna; hem. rha.; lig. ulnar. Retired Jan. 7, '65; limb impaired.	349	McCaffry, M., Serg't, I., 2d Massachusetts, age 21.	May 15, '64.	Six, middle, right ulna; by Surg. T. J. Maxwell, 3d Iowa Cav. Disch'd Sept. 1, '65; pens'd; eib. enlarged and stiff; three internal fingers constantly flexed.
321	Lippincott, J. P., Corp'l, B., 95th Pennsylvania, age 26.	Aug. 21, '64.	Three, middle, right ulna; hem. from traumatic aneurism; amp. arm. Disch'd March 19, 1865.	350	McCallum, J. K. P., Corp'l, E., 3d Iowa Cavalry, age 20.	Aug. 8, '64.	Four, upper, half, right ulna; by Surg. R. Curran, 9th N. Y. Cav. Disch'd May 20, 1865; pens'd; useless for ordinary labor.
322	Listy, J., Pt., K., 5th Wisconsin, age 22.	April 2, '65.	Three, middle, right radius. Dis'd July 12, 1865; pensioned; hand drawn inward; ulna dislocated.	351	McCaskey, J. K., Lieut., I., 27th Indiana, age 28.	July 3, '63.	Three ins. right rad., four ins. ulna, upper; by Surg. W. H. Twiford, 27th Ind. Disch'd May 20, '64; pens'd; false joint.
323	Little, J. H., Serg't, I., 32d Maine, age 32.	June 4, '64.	Three, lower, right ulna; by A. Surg. J. A. McArthur; lig. brachial. June 14. Duty Jan. 26, 1865; pensioned; ankylosis eib.; fingers permanently ext'd.	352	McColloff, J., Pt., B., 2d Illinois Cavalry, age 29.	Aug. 11, '64.	Four, left radius, middle; by A. Surg. D. C. Jones, 2d Ill. Cav.; hem. from ulna—ligated. Duty Nov. 25, 1864. Not a pensioner.
324	Locker, C. B., Serg't, D., 8th New York H. Art., age 25.	June 3, '64.	Two lower, right radius; by Surg. C. H. Pegg, 8th N. Y. H. A. Dis. Oct. 6, '64; no union; dislocation of ulna.	353	McCormick, T., Serg't, 1st Cavalry, age 29.	June 1, '64.	Four, middle, left radius. Duty April 6, '65; pens'd; deformity; ankylosis of wrist.
325	Louder, J., Pt., E., 123d Ohio, age 30.	Mar. 31, '65.	Two, right radius and ulna (ext. ball near elbow); by Surg. F. S. Ainsworth, U. S. V. Disch'd July 10, '65; pens'd; elbow joint ankylosed.	354	McCullough, W. S., Lieut., F., 3d Indiana, age 24.	July 20, '64.	Three, lower, right ulna. Promoted; mustered out; pensioned; use very much impaired.
326	Long, G. H., Lieut., H., 29th Massachusetts.	June 3, '64.	Three, middle, right ulna; no rotation; limb deformed and useless. Disch'd Oct. 11, '64; pens'd.	355	McDonald, J., Pt., C., 14th New York Heavy Artillery.	July 3, '64.	Two and a half, middle, left rad.; by Surg. T. F. Oakes, 56th Mass. Discharged June 8, 1865. Not a pensioner.
327	Long, J., Pt., K., 45th Penn., age 22.	June 3, '64.	Four, left radius and ulna; by A. Surg. W. S. Yundt, 45th Pa. Disch'd Dec. 5, '64; pens'd; wrist disloc.; no bony union.	356	McGay, F., Corp'l, F., 12th New Hampshire.	June 3, '64.	Three, middle, left ulna. Disch'd December 31, 1864; useful arm. Not a pensioner.
328	Long, J. H., Capt., K., 68th Ohio, age 25.	July 22, '64.	Three and a half, lower, left ulna; by Surg. H. McKean, 17th Wis.; erysip. Dis'd Nov. 8, '64; pen'd; false joint; fingers cont'd.	357	McGroarty, S. J., Col., 61st Ohio.	July 15, '64.	Left ulna (other wounds). Must'd out July 24, 1865; pens'd; amp. several times. Died January 2, 1870, wound of lung.
329	Long, S., Serg't, F., 55th Illinois, age 23.	July 28, '64.	Three, middle, right rad. Disch'd Mar. 23, '65; pens'd; disloc. carp. end ulna; cannot flex fingers.	358	McIntyre, W., Pt., M., 62d Pa., age 40.	June 3, '64.	Four, middle, right radius. To V. R. C. Jan. 18, 1865; pensioned; anechl. eib.; atrophy; adherent cicatrix; no grasping power.
330	Loper, D., Pt., F., 25th Wis., age 55.	July 22, '64.	Portion upper, left radius. Dis'd Apr. 13, '65; pens'd; impaired; can perform manual labor.	359	McKinney, W. W., Corp'l, C., 134th New York.	May 8, '64.	Lower, right radius; by Surg. W. H. Hong, 134th N. Y. June 9, amp. arm. Disch'd Feb. 9, 1865.
331	Lovejoy, I. A., Pt., A., 33d Mass., age 24.	May 25, '64.	Two, upper, left rad. Dis'd June 8, '65; pens'd; no rotation; abscess disch'd dead bone (1870).	360	McLaughlin, F., Pt., B., 2d Maryland.	July 30, '64.	Right ulna. Duty May 31, 1865. Not a pensioner.
332	Maher, J., Serg't, K., 20th Massachusetts.	June 16, '64.	Upper, right ulna; by Surg. P. E. Hubon, 28th Mass. Disch'd June 30, '65. Not a pensioner.	361	McMannus, G. W., Serg't, E., 70th Ohio, age 23.	Dec. 13, '64.	Two, right radius. Disch'd May 22, 1865; pensioned; hand bent inward, useless; ulna displaced.
333	Mahon, B., Pt., G., 39th New Jersey, age 18.	Dec. 2, '64.	Portion right ulna. To V. R. C. Jan. 27, 1865.	362	McNulty, R., Pt., E., 4th Iowa, age 25.	June 14, '64.	Four, middle, left radius; by Surg. B. N. Bond, 27th Mo.; gangrene. Disch'd Jan. 2, 1865; pensioned; hand drawn inward; ulna disloc.
334	Manger, H., Corp'l, E., 22d N. Y. Cavalry.	Sept. 19, '64.	Four, middle, left ulna. Duty Feb. 9, 1865; pens'd; no bony union; limb almost useless.	363	McParland, H., Serg't, F., 15th Massachusetts, age 30.	June 23, '64.	Two, right ulna; by Surg. S. Hayward, 20th Mass. Disch'd May 22, 1865; pens'd; rotation lost; hand almost powerless.
335	Mansfield, J., Pt., F., 4th Vermont, age 20.	Aug. 21, '64.	Two, lower, left radius. Disch'd July 24, '65; pens'd; hand dislocated; imperfect grasp.	364	McQuade, D., Pt., B., 90th Ohio, age 27.	May 14, '64.	Left forearm; by Surg. D. J. Griffith, 2d Ky. July 1, amp. arm. Disch'd March 17, 1865.
336	Marranville, M. P., Corp'l, B., 2d Vermont, age 23.	Apr. 2, '65.	Three, lower, left rad.; by Surg. R. T. Paine, 2d N. Y. M. R. Disch'd June 27, 1865; pens'd; disloc. hand; grasp impaired.	365	Medberry, A. S., Pt., B., 1st Rhode Island Cav.	Aug. 2, '63.	Four, right radius. Disch'd Mar. 16, '64; pens'd; great deformity.
337	Mardon, E. S., Pt., B., 13th N. H., age 23.	July 4, '64.	Five, left ulna. Furlough Oct. 4, 1862, wound entirely healed.	366	Megarey, O., Pt., D., 4th New York, age 21.	May 5, '64.	Upper, left ulna. Disch'd June 28, 1864; pens'd; rotation lost.
338	Marsh, S. N., Serg't, G., 2d N. Y. M. R., age 30.	June 17, '64.	Two, lower half, left ulna; rotation unimpaired. To V. R. C. Feb. 1867, claim suspended.	367	Miles, W. J., Pt., F., 23d Kentucky, age 30.	Dec. 16, '64.	Six, left ulna. Discharged.
339	Martin, J., Pt., C., 17th Infantry, age 22.	May 8, '64.		368	Miller, C., Serg't, C., 15th New Jersey, age 26.	Sept. 21, '64.	Three, upper, left ulna; by Surg. O. R. Freeman, 10th N. J. To V. R. C. March 31, 1865.



No.	NAME, AGE, AND MILITARY DESCRIPTION.	DATES.	OPERATIONS, OPERATOR, RESULT.	No.	NAME, AGE, AND MILITARY DESCRIPTION.	DATES.	OPERATIONS, OPERATOR, RESULT.
370	Miller, D. J., Serg't, K, 6th Wisconsin, age 29.	Feb. 6, '65.	One, right radius (ulna fractured). Disch'd May 30, 1865; pensioned; carpal end of ulna dislocated; deformity.	400	Parsons, D., Pt., H, 44th Illinois, age 31.	Dec. 16, '64.	Two, lower, left radius. Disch'd May 11, '65; pens'd; hand at right angle, powerless; ulna disloc.
371	Miller, J., Pt., D, 184th Pennsylvania, age 21.	June 23, '64.	Middle, right ulna; by Surg. G. Chaddock, 7th Mich. To V. R. C. Jan. 23, 1865. Not a pensioner.	401	Patterson, J. A., Pt., G, 11th Pennsylvania Reserves, age 41.	May 10, '64.	Four, right ulna; by Surg. W. Lyons, 11th Pa. Reserves. Discharged Aug. 22, 1864; pens'd; Oct. 15, 1866, amputation arm.
372	Miller, J. B., Pt., B, 113th Ohio.	June 27, '64.	Three, lower, left radius; by Surg. A. Wilson, 113th Ohio. Disch'd May 11, '65; pensioned; deformity; ankylosis of wrist.	402	Patterson, S., Corp'l, B, 4th Wisconsin Cavalry, age 33.	Aug. 23, '64.	One and a half, lower, left ulna; by Asst. Surg. A. D. Carothers, 1. S. V. Duty Sept. 27, 1864; pensioned; no union.
373	Mitchell, J. H., Capt., B, 81st Pa., age 23.	Aug. 24, '64.	One and a half, lower, left ulna; by Surg. J. W. Wishart, 146th Pennsylvania. Disch'd June 29, 1865; pens'd; useless f. r. labor.	403	Peet, C. W., Lieut., G, 2d New York Heavy Artillery.	June 16, '64.	Two, middle, right ulna; by Surg. J. W. Wishart, 146th Pa. Disch'd Nov. 17, '64; pens'd; Eg. union; paralysis. Died Dec. 30, 1858.
374	Montgomery, R., Pt., Clynch's Battery, age 42.	Dec. 13, '62.	Three, right ulna, and amp. left arm; by Surg. J. H. Hutchins, 15th Mich. To Provost Marshal March 2, 1865.	404	Pennington, W. H., Sergeant, I, 13d Indiana, age 32.	Dec. 16, '64.	Left ulna, lower (radius fract.). Disch'd May 24, '65; pens'd; fingers flexed; hand almost useless.
375	Moore, G., Pt., L, 14th Tennessee, age 31.	Dec. 13, '62.	Portion middle, left ulna. March 1, 1833, convalescent.	405	Perrin, W. H., Colonel, 15th New Jersey.	Oct. 19, '64.	Four and a half, upper, right radius. Duty Feb. 27, '65; motions retained, except rotation. Not a pensioner.
376	Moran, R. T., Pt., B, 2d Maryland.	June 3, '64.	Three, upper, left ulna. Disch'd November 4, 1864.	406	Perry, G. H., Corp'l, F, 24th N. Y. Cav., age 23.	June 2, '64.	Upper third, left forearm. Discharged March 10, 1865.
377	Mum, W. M., Serg't, H, 105th Illinois, age 24.	Feb. 2, '65.	Portion of left radius; hamor., amp. forearm. Disch'd May 5, 1865; pens'd. Died Jan. 26, '72.	407	Phelan, S. S., Pt., G, 1st Connecticut Heavy Artillery, age 41.	July 24, '64.	Two, lower, left radius; hamor., Aug. 9, amp. forearm. Disch'd April 7, 1865.
378	Morrill, E. C., Pt., I, 3d Vermont, age 31.	April 21, '64.	Three, upper, right ulna. Oct. 1, frag. removed. To V. R. C. Nov. 25, 1864; pens'd; partial flexion of fingers; arm of little use.	408	Philipi, J., Pt., B, 76th Ohio, age 30.	Aug. 23, '64.	Four, lower, right ulna; by Surg. A. Sabine, 76th Ohio. Disch'd May 24, '65; pens'd; ankylos. elb. Two, right ulna; by Surg. H. P. Lyster, 7th Michigan. To V. R. C. Jan. 17, 1865.
379	Morse, A. J., Pt., B, 14th Michigan, age 27.	July 5, '64.	Three, upper, right ulna (fract. of radius); by Surg. D. Batwell, 14th Mich. Disch'd July 19, '65; pens'd; ankylosed elbow; little use.	409	Pickens, F., Pt., C, 106th New York.	Nov. 30, '63.	Four, middle, left ulna; by Surg. A. A. Stocker, 5th Mass. Discharged Mar. 27, '65; great deformity. Not a pensioner.
380	Moss, A. H., Pt., H, 20th Kentucky.	June 18, '64.	Two, lower, left ulna; by Surg. J. W. Lawton, 1. S. V. Duty December 10, 1864.	410	Pierce, C. F., Pt., G, 58th Mass., age 22.	June 9, '64.	Right, one and a half of ulna and one of radius. Duty Sept. 5, '64; pens'd; 1873, inflamed and suppurating, prob. from dead bone.
381	Mote, H. T., Serg't, D, 21st Georgia.	Aug. 28, '62.	Right, middle, three ulna, three and a half radius. Recovered.	411	Pifer, G. W., Pt., F, 2d Kentucky Cavalry, age 27.	Sept. 20, '63.	Right radius, upper. Disch'd June 21, '65; pens'd; no rotation; use of hand much impaired.
382	Myers, B. V. C., Pt., G, 125th N. Y., age 19.	June 23, '64.	Portion upper half, left ulna; by Surg. A. Van Devere, 60th N. Y. Disch'd May 29, 1865; pensioned;ropy union; nearly useless.	412	Patt, J. H., Serg't, A, 25th Connecticut, age 22.	Mar. 19, '65.	Three, lower, right ulna; by Surg. J. Reilly 33d N. J. Discharged July, 1865.
383	Myers, M. E., Pt., A, 21st Pa. Cavalry.	June 23, '64.	Three, middle, left ulna; by Surg. G. Chaddock, 7th Mich. Discharged March 6, 1865.	413	Porter, J., Pt., I, 111th Pennsylvania, age 30.	June 21, '64.	Two, lower, right radius. Disch'd Dec. 23, 1864; pensioned; hand bent inward.
384	Nace, W. M., Pt., D, 60th Ohio, age 21.	May 9, '64.	Two, lower third, left ulna. To V. R. C. Oct. 3, '64; pensioned.	414	Pest, C. P., Serg't, A, 25th Pennsylvania, age 25.	May 10, '64.	Four, upper half, left radius; by Surg. J. W. Lawton, U. S. V. Disch'd Mar. 29, '65; pens'd; lux. ulna; hand extremely supinated.
385	Neilson, C. J., Pt., G, 3d Wisconsin, age 25.	July 29, '64.	Two and a half, middle, right rad. Duty Dec. 2, '64; pens'd; disloc. ulna; cont. tendons; hand useless.	415	Potter, W. M. N., Corp'l, D, 13d Indiana, age 20.	June 27, '64.	At middle, left ulna. Disch'd June 28, 1865; pens'd; extreme atrophy forearm and hand; fingers contracted on palm.
386	Nelson, L., Serg't, E, 38th Wis., age 42.	Sept. 30, '64.	Two, lower, right rad.; by Surg. W. C. Shurluck, 51st Pa. Discharged Feb. 20, '65; pensioned; deformity; hand useless.	416	Powers, L., Pt., B, 1st New York Dragoons, age 22.	Aug. 11, '64.	Three, right ulna, lower (left ulna fract.). Disch'd May 23, '65; pensioned; no rotation; ulceration, caused by fractured end.
387	Nix, P. C., Pt., E, 44th Alabama, age 29.	May 6, '64.	Three, middle third, radius. Recovered.	417	Price, N., Pt., H, 97th Ohio, age 23.	Nov. 30, Dec. 2, 1864.	Right ulna; by Surg. J. A. Spencer, 6th N. Y. Disch'd Mar. 21, '65; pensioned; partial ankylosis elbow; fingers flexed.
388	North, E. D., Serg't, A, 60th New York.	Nov. 24, '63.	Two, upper, right ulna; by Surg. J. V. Kendall, 14th N. Y.; gang; crysip. Dis. July 25, '64; pens'd; no bony union; part. ankylos. elb.	418	Purcell, J., Pt., A, 6th New York, age 40.	June 16, '64.	Three, middle, right ulna; by Surg. S. H. Plumb, 83d N. Y. Duty Nov. 24, '64; pens'd; elb. ankylos. elbow; fingers flexed.
389	Norton, S. M., Serg't, K, 16th Conn., age 31.	Apr. 20, '64.	Four, upper, right radius and ulna; by Surg. N. Myers, 16th Conn. Discharged May 12, 1865; pensioned; no bony union.	419	Quick, A. A., Pt., L, 7th N. Y. H. A., age 30.	June 3, '64.	Three, upper, radius and ulna; by Surg. W. Saunders, C. S. A.; arm somewhat impaired.
390	Nugent, J., Pt., F, 49th New York, age 35.	May 10, '64.	Portion right radius and left ulna. Disch'd Feb. 7, '65; pensioned; right hand pronated; no flexion of fingers; left of little use for light work. Died Nov. 28, 1872.	420	R——, Colonel, . . . . .	Aug. 16, '64.	Three, middle, right ulna; by Surg. J. W. Lawton, U. S. V. June 7, amp. forearm. Disch'd July 22, '65.
391	Odell, I., Pt., H, 45th Pennsylvania, age 20.	June 3, '64.	Left forearm; amp. forearm for sloughing. Disch'd Jan. 22, '65.	421	Randall, J. M., Pt., G, 20th Ky., age 22.	June 15, '64.	Three, lower, left ulna; by Surg. F. M. Weld, 27th C. T. Disch'd Nov. 8, '65; pens'd; cicatrix adherent; fingers perm'd flexed.
392	Oliphant, H. H., Capt., G, 16th Pa. Cavalry.	April 6, '65.	Upper third, right ulna. Disch'd June 29, 1865. Not a pensioner.	422	Ray, W., Pt., C, 25th C. T., age 18.	July 30, '64.	Two, upper, left radius; by Surg. H. E. Goodman, 28th Penn. (median nerve inj.). To V. R. C. Mar. 21, '64; arm weakened; severe pain. Pens'n of imp'd July (1875).
393	Olley, R. H., Pt., G, 15th Virginia, age 29.	Oct. 30, '63.	Five, upper half, right ulna. Recovered.	423	Redd, W. H., Pt., F, 2th Pa., age 23.	July 3, '63.	Two, middle, left ulna; by Surg. T. V. R. C. Dec. 21, '64; pens'd; Portion left radius. Disch'd June 9, 1865. Not a pensioner.
394	O'Neil, C., Pt., F, 16th New York, age 35.	May 10, '64.	Three, mid., right ulna; by Surg. M. Rizer, 72d Pa. Dis. Aug. 11, '65; pens'd. Spec. 4265. Died in 1866.	424	Reed, H. H., Pt., G, 123d N. Y., age 19.	May 18, '64.	Lower, left ulna (wound left arm). To V. R. C. March 24, '65; pens'd; no rotation; little strength.
395	Osborn, C., Corp'l, G, 29th Maine, age 31.	July 2, '63.	Three, upper, left radius. Discharged Jan. 6, 1864; pensioned; hand withered and partially stiff.	425	Reed, N., Pt., E, 9th New Jersey, age 18.	Aug. 23, '64.	Three, middle, left radius; by A. A. Surg. W. B. Trull, Disch'd May 18, 1865; pensioned; stiffness of wrist.
396	Osborne, D. D., Pt., B, 18th Pa., age 38.	Sept. 27, '64.	Portion upper, left radius; by Surg. G. Chaddock, 7th Mich. Discharged May 16, '65; pensioned; ankylos. elb.; atrophy; deformity.	426	Reed, P. R., Pt., C, 106th N. Y., age 25.	June 3, '64.	
397	Ossman, A., Pt., A, 56th Pennsylvania, age 24.	May 12, '64.	Four, left ulna; by Surg. W. C. Shurluck, 51st Pa. Discharged Feb. 27, '65; pensioned; caries and necr. sis; elbow ankylosed.	427	Reed, T. A., Pt., D, 45th Ohio, age 20.	Aug. 21, '64.	
398	Parker, J. H., Pt., I, 36th C. T., age 28.	July 30, '64.	Two, lower, left radius; by Surg. F. M. Weld, 27th C. T. Disch'd June 26, 1865; pensioned.				
399	Parker, L., Pt., 85th New York, age 36.	Mar. 8, '65.	Two, middle, right ulna. Disch'd June 4, 1865; no union; motion at elbow limited.				

No.	NAME, AGE, AND MILITARY DESCRIPTION.	DATES.	OPERATIONS, OPERATOR, RESULT.	No.	NAME, AGE, AND MILITARY DESCRIPTION.	DATES.	OPERATIONS, OPERATOR, RESULT.
428	Reigle, D., Pt., E. 78th New York, age 31.	July 2, '63.	Two and a half, right radius; by Surg. A. K. Field, 29th Ohio. To V. R. C. Oct. 13, 1863. Dis'd Jan. 31, 1866; pensioned; rotation lost; wrist joint displaced.	456	Selmal, G., Pt., H. 26th Wis., age 23.	Mar. 16, '65.	Portion upper, right ulna (injury to astragalus). Discharged Oct. 21, '65; pens'd; motion impaired.
429	Reese, J., Pt., K. 101st Ohio, age 25.	May 19, '64.	One and a half, lower, left radius; by Surg. C. J. Wilton, 21st Ky. To V. R. C. Dec. 17, '64; pens'd; no bony union; dislocation ulna.	457	Schmetzer, C., Pt., A. 2d Ohio Cav., age 51.	June 4, '64.	Two and a half, middle, right rad. Disch'd May 16, '65; pens'd; hand turned in; fingers stiff.
430	Reton, W. S., Pt., A. 170th N. Y., age 42.	May 25, '64.	Two, right radius. To V. R. C. March 3, '65; pensioned; hand turned backward; ulna projects.	458	Scott, J., Pt., A. 7th Maine, age 18.	June 3, '64.	Two and a half, lower, left rad.; by Surg. G. P. Stevens, 77th N. Y. Disch'd Feb. 16, '65; hand bent inward and use-less.
431	Rice, Z. M., Pt., A. 60th Ohio, age 30.	May 11, '64.	Three, lower half, left ulna. Discharged Feb. 3, '65; pensioned; ligament, union; use impaired.	459	Scott, J., Pt., D. 145th Penn., age 19.	July 2, '63.	Three, middle, left radius. Dis'd Jan. 7, 1864; pens'd; carpal and ulna dislocated; hand useless.
432	Rich, T., Pt., A. 8th Wisconsin, age 32.	Dec. 15, '64.	Portion lower, right radius; by Surg. J. E. Murta, 8th Wis. Discharged March 22, 1865; pensioned; entirely useless.	460	Scott, R., Pt., E. 28th Penn., age 19.	June 18, '64.	Two, middle, left rad. (ulna fract.); by Surg. J. L. Dunn, 105th Pa. Duty Feb. 21, '65; pens'd; partial false joint; deformity.
433	Richards, E. P., Capt., D. 56th N. V., age 25.	June 4, '64.	Portion, middle, right ulna; by Surg. S. H. Plumb, 82d N. Y. Disch'd Nov. 2, 1864; pensioned; no rotation; numbness of hand.	461	Sexton, C. W., Serg't, 1. 2d N. V. Cav.	June 19, '63.	Middle, right rad. (w'd of shoulder). To V. R. C. Oct. 25, '63; pens'd; hand dislocated.
434	Richardson, C. A., Corp'l, K. 23d Mich., age 21.	June 9, '64.	Two and a half, middle, left rad.; by Surg. D. L. Heath, 23d Mich. Disch'd April 18, '65; pensioned; no union; dislocation of wrist.	462	Shaw, J. J., Pt., G. 16th Wis., age 41.	Aug. 13, '64.	Two, middle, right ulna. Disch'd May 30, 1865; pens'd; loss of supination; imp. flexion of arm.
435	Rienby, R. W., Capt., A. 2d Mich., age 31.	June 25, '64.	Two, lower, left radius. Disch'd Dec. 14, '64; pens' mod. ulna displaced; hand numb and useless.	463	Shearer, W. D., Corp'l, B. 55th Penn., age 23.	May 15, '64.	Right radius and ulna. Dis'd Feb. 27, '65; pens'd; of little use. Died May 1, 1872.
436	Rickey, J. M., Pt., F. 53d Ohio, age 21.	May 29, '64.	Two and a half, lower, right rad. Disch'd May 30, '65; pensioned; hand dislocated inward; limb entirely useless.	464	Sheldon, H., Pt., D. 7th Iowa, age 18.	Aug. 30, '64.	Upper, left radius; by Surg. J. Togue, 60th Ill. To V. R. C. Not a pensioner.
437	Riley, B. S., Pt., B. 23d Pennsylvania, age 21.	Sept. 19, '64.	Lower, right ulna. Disch'd May 16, 1865. Not a pensioner.	465	Shemelia, P., Pt., I. 4th New Jersey, age 26.	May 12, '64.	Two, middle, right radius. To V. R. C. May 17, '65; claim for pension rejected; no disability.
438	Riser, B. W., Pt., H. 1st Maryland Cav., age 23.	Aug. 16, '64.	Portion, lower, left radius (wound right arm). Disch'd Dec. 8, '64; pens' mod.; no rotat'n; use fair.	466	Shellbarger, W., Capt., A. 110th Ohio, age 23.	April 2, '63.	Three, lower, left ulna. Duty May 25, 1865; pensioned; loss of use of hand.
439	Roach, J., Pt., H. 15th Massachusetts, age 29.	May 5, '64.	Three, upper, left ulna. Disch'd June 15, 1865; pensioned; head of radius dislocated.	467	Sherrill, L., Pt., K. 1st Massachusetts Artillery, age 25.	Dec. 13, '62.	Four, right ulna, upper. Disch'd Feb. 11, '63; pens'd; radius dislocated; atrophy and weakness.
440	Roberts, J., Corp'l, F. 145d Pa., age 38.	June 18, '64.	Three, lower, left ulna. Disch'd Jan. 15, 1865; pensioned; anechyl. elbow; use impaired.	468	Shilson, C., Pt., C. 16th Minnesota, age 28.	Mar. 31, '65.	Two, lower, left ulna; by A. Surg. T. H. Mulligan, 16th Minn. Discharged June 28, 1865; pens'd; rotation at wrist impaired.
441	Rockwell, S. G., Pt., K. 94th New York Heavy Artillery, age 26.	May 12, '64.	Five, middle, left radius. Disch'd Jan. 16, '65; pens'd; anechyl. wrist; cannot flex or extend fingers.	469	Shoemaker, J., Pt., D. 1st New York Artillery.	May 5, '64.	Five, upper, right radius; by Surg. W. S. Thompson, U. S. V. Duty Aug. 19, 1864; pens'd; (1873) exfoliating; fingers contracted.
442	Road, E., Pt., M. 3d Wis., age 21.	May 3, '63.	Upper, left radius; by Surg. W. H. Twiford, 57th Indiana. Duty Mar. 21, 1864; pensioned; can flex and partially rotate arm.	470	Sigman, H. M., Pt., D. 26th Pennsylvania, age 27.	May 23, '64.	Two and a half, right ulna; by Surg. H. P. Lyster, 5th Mich. Disch'd July 1, 1865; pens'd; no bony union.
443	Rooney, J., Pt., C. 3d Pennsylvania Heavy Artillery, age 20.	Nov. 8, '64.	Two, lower, left radius; Nov. 26, amp. Trepan. Disch'd August 26, 1865.	471	Silvius L., Corp'l, B. 143d Pennsylvania, age 35.	June 2, '64.	Three, middle, left radius. Discharged Jan. 26, '65; pens'd; dislocated ulna; distortion; useless.
444	Ross, J., Pt., I. 6th Connecticut, age 23.	June 16, '64.	Right ulna; erysipelas. June 29, amputation arm. Discharged December 29, 1864; pens' mod.	472	Simmons, C., Pt., C. 32d Indiana, age 21.	May 27, '64.	Four, upper, right radius. Disch'd Nov. 23, 1864; pens'd; atrophy.
445	Rudes, G. T., Pt., I. 2d N. Y. H. A., age 25.	May 19, '64.	One and a half, middle, left rad. To V. R. C. Oct. 19, '64; pens'd.	473	Shovin, P. S., Col., 100th Ohio, age 49.	Aug. 6, '64.	Two, lower, left ulna; by Surg. G. A. Collamore, 100th Ohio. Discharged Nov. 30, 1864; pensioned; anechyl. of wrist.
446	Ruge, H., Serg't, B. 3d Missouri, age 28.	Nov. 27, '63.	Four, upper, left radius; by Surg. E. J. McGoorisk, 3th Iowa. Disch'd Sept. 3, '64; pensioned; atrophy; anechyl. wrist; no grasp.	474	Sloan, P., Pt., B. 169th New York, age 29.	July 4, 1864.	Six, lower, right radius. Disch'd May 29, '65; pens'd; limb greatly deformed and entirely useless.
447	Rulison, C. E., Corp'l, F. 2d Mich., age 34.	Nov. 29, '63.	Three, left radius; by Surg. G. B. Cogswell, 29th Mass. Duty April 5, '64; pens'd; rotation lost.	475	Smith, C., Pt., F. 29th Colored Troops, age 17.	August, 1864.	Two, lower, right radius. Disch'd Jan. 7, 1865. Not a pensioner.
448	Ryan, P., Pt., B. 23d Illinois, age 41.	July 24, '64.	Middle, left ulna (wound of left shoulder) Disch'd June 12, '65; pens'd; useless for manual labor.	476	Smith, C. P., Pt., K. 55th Ohio, age 19.	Aug. 5, '64.	Four, upper, left radius (ulna fractured). Disch'd Feb. 4, '65; pens'd; disloc. and anechyl. of wrist.
449	S——, E. L., Lieut., D. 9th Alabama.	Primary.	Left, radius and ulna; by Surg. H. A. Minor, 9th Ala. No bony union; use fair; has broken arm at seat of resection.	477	Smith, G., Pt., A. 157th Pennsylvania.	October, 1864.	One, left radius; by Surg. T. M. Flaudrau, 146th N. Y. Disch'd
450	Samson, H. J., Pt., K. 2d N. Y. H. A., age 18.	June 16, '64.	Portion upper half, left radius (ulna fract.); by Surg. P. E. Hubon, 28th Mass. July 22d, fragments and ends of rad. rem. Disch'd June 20, '65; pens'd; rad. and ulna anechyl. osed.	478	Smith, J., Pt., E. 29th Massachusetts, age 23.	May 31, '64.	Two and a half, upper, left radius; by Surg. N. Hayward, 20th Mass. Duty Jan. 31, 1865; pensioned; atrophy.
451	Sanbrook, G. T., Pt., K. 93d N. Y., age 26.	May 6, '64.	Four, middle, right rad.; by Surg. J. J. Comert, 1st Penn. Disch'd Feb. 16, '65; pens'd; distortion of wrist; no grasp in hand.	479	Smith, J., Pt., 4th Ohio.	May 10, '64.	Two, ulna; by Surg. G. W. McCune, 14th Indiana. Recovery.
452	Sattezahn, J., Pt., H. 5th Penn., age 32.	May 6, '64.	One-half inch, middle right ulna. Discharged.	480	Smith, J., Serg't, K. 26th Illinois, age 27.	Mar. 19, '65.	Two, lower, left ulna; by Surg. A. Sabine, 76th Ohio. Disch'd July 29, 1865; pensioned; partial ligamentous union.
453	Saur, L., Pt., G. 6th Mich. Cav., age 19.	May 28, '64.	Four, middle, right rad. Disch'd Feb. 7, 1865; pens'd; palm turned backward and outward.	481	Smith, J., Pt., I. 14th Michigan, age 26.	July 5, '64.	Two, upper, right ulna; gangrene. Discharged May 17, 1865; pensioned; fingers rigid and stiff.
454	Sayer, A. C., Serg't, G. 93d Ohio, age 32.	Dec. 16, '64.	Two, upper, right ulna; by Surg. J. M. Weaver, 93d Ohio. Dec. 25th, ham.; gang. Dis'd May 30, '65; part anechyl. elbow; pens'd.	482	Smith, J. C., Pt., B. 1st Pa. Rifles, age 19.	May 30, '64.	Two, right radius, lower. Disch'd June 11, 1864; pensioned; hand at right angle; disabled.
455	Scanlin, J., Serg't, H. 5th Wis., age 27.	May 12, '64.	Three, lower, right ulna (wound of chest). Disch'd June 26, '65; pens'd; loss of use of hand.	483	Smith, M. B., Pt., F. 16th Maine, age 18.	Aug. 18, '64.	Lower, right radius; by Surg. W. Thorndike, 3th Mass. Disch'd Feb. 27, '65; pens'd; disloc. ulna.
				484	Smith, N., Pt., A. 151st New York, age 21.	Oct. 19, '61.	Four, upper, right ulna; by Surg. J. R. Cotes, 151st N. Y. To V. R. C. May 8, 1865; pensioned; fingers flexed; adhesion muscles.
				485	Smith, O. D., Corp'l, E. 30th Ohio, age 20.	June 27, '64.	Three, lower, left ulna; by Asst. Surg. C. B. Richards, 34th O. gangrene; Aug. 16th, amp. arm. Disch'd April 17, 1865.



NO.	NAME, AGE, AND MILITARY DESCRIPTION.	DATES.	OPERATIONS, OPERATOR, RESULT.	NO.	NAME, AGE, AND MILITARY DESCRIPTION.	DATES.	OPERATIONS, OPERATOR, RESULT.
486	Smith, S. R., Lieut., H. 33d N. Y., age 37.	May 8, '64.	Three, lower, left radius; by Surg. J. Reily, 33d N. Y. Duty Oct. 24, 1864; pens'd; hand useless.	517	Sweeney, T., Pt., C. 111th New York, age 36.	Mar. 31, Apr. 1, 1865.	Two, lower, left rad. Disch'd July 26, 1865; pens'd; little use of arm, none of hand.
487	Smock, S. J., Serg't, A. 70th Indiana, age 31.	July 20, 20, '64.	Three, upper half, left ulna. Discharged Oct. 31, '64; pensioned; ginglymoid motion elbow slight; imperfect use of fingers.	518	Sweeney, W., Pt., C. 48th Penn.	July 7, '64.	Portion of ulna. Court-martialed and discharged.
488	Sneider, J. N., Serg't, E. 14th Indiana.	May 3, '63.	Upper, right ulna. Disch'd June 16, '64; pens'd; Feb. '74, no new bone; necrosis; open ulcer.	519	Swards, J. W., Serg't, H. 26th Iowa, age 48.	Mar. 20, 20, '65.	Left rad.; lig. artery. Disch'd June 6, '65; wrist fl. weakened.
489	Snook, F. M., Pt., G. 14th Ohio, age 18.	Sept. 1, '64.	Two, lower, right ulna; gangrene. Discharged June 15, 1865; pensioned; equal to loss of hand.	520	Talbot, W. H., Pt., L. 1st Maine H. A.	May 20, 20, '64.	Two and a half, right ulna; by Surg. H. F. Lyster, 5th Mich. Disch'd March 20, 1865; pens'd; muscular power of arm nearly destroyed.
490	Snyder, W., Serg't, D. 15th Indiana, age 30.	Nov. 25, 27, '63.	Three, middle, left ulna; by Surg. A. M. McMahon, U. S. V. Dis'd May 7, 1864; pensioned; little motion in elbow.	521	Tate, W., Pt., B. 11th Ill., age 21.	Dec. 13, 13, '64.	Two and a half, middle, right ulna; by Act. Staff Surg. C. B. Richards. Disch'd June 6, 1865; pens'd; good serviceable arm.
491	Sourbeer, J., Pt., B. 45th Pa., age 24.	June 3, '64.	Four, lower, left radius. Disch'd April 17, '65; pensioned; wrist and fingers ankylosed.	522	Tennant, G., Pt., D. 2d Maryland.	Oct. 1, 1, '64.	Left ulna; by Surg. J. E. Beatty, 2d Md. Disch'd July 17, 1865; pens'd; adherent cicatrices.
492	Sparks, T. B., Serg't, G. 29th Missouri.	Feb. 15, '65.	Four, right ulna; by Surg. A. Sabine, 70th Ohio. Duty May 5, 1865. Not a pensioner.	523	Thomas, J. H., Pt., D. 31st Maine, age 25.	July 2, 2, '64.	Middle, right radius. Duty Nov. 17, 1864; pens'd; limited rotation; partly ankylosed.
493	Spare, G. A., Pt., G. 1st Pa. Res., age 31.	May 30, 30, '64.	Portion lower, left ulna. Disch'd June 13, '64; pensioned; adherent cicatrix; hand impaired.	524	Thomen, A., Pt., D. 35th N. Y., age 32.	Apr. 16, 16, '63.	Five, middle, left radius in thirty-six fragments. Disch'd Aug. 5, '63; pens'd; ulna projects.
494	Sparling, J. S., Pt., I. 20th Ohio, age 20.	July 22, 22, '64.	Four, lower, right radius. Disch'd Mar. 24, 1865; pensioned; hand paralyzed and turned inward.	525	Thompson, J., Serg't, I. 61st Penn., age 21.	Sept. 19, 19, '64.	Three, middle, r't ulna; by Surg. G. T. Stevens, 7th N. Y. Dis'd June 13, '65; pens'd; ext. fingers.
495	Spector, S., Pt., B. 57th Pennsylvania.	May 12, 12, '64.	Middle, right radius; by Surg. H. F. Lyster, 5th Mich. Not a pensioner.	526	Till, H., Pt., D. 28th Penn., age 27.	Nov. 27, 27, '63.	Portion, left radius. Disch'd September, 1861.
496	Speicher, J., Pt., C. 149th Pennsylvania, age 25.	Aug. 1, '64.	Upper, right radius; gangrene; amputation arm Aug. 4th. Discharged Feb. 23, '65; pensioned.	527	Tindall, W. W., Serg't, H. 116th Ill.	July 22, 22, '64.	Right radius, middle; by Surg. S. P. Bonner, 37th Ohio. Disch'd Dec. 19, 1864; pens'd; hand turned inward and paralyzed. Died Apr. 29, 1872, tuberculosis.
497	Spencer, C., Pt., G. 23d Indiana.	May 12, 12, '63.	Three, middle, radius. Disch'd Nov. 30, 1863; pensioned; anethyl. of fingers and wrist joint.	528	Tirrell, C. B., Lieut., A. 1st Minn., age 27.	June 18, 18, '64.	Four, upper half, left radius and ulna; by Surg. S. H. Plumb, 82d N. Y.; part. anethyl. elbow. Disch'd Dec. 19, 1864. Not a pensioner.
498	Spencer, N. B., Pt., C. 13th Ohio Cav., age 30.	Sept. 30, Oct. 1, 1864.	Two, middle, left radius. Disch'd May 27, 1865; pensioned; disloc. of ulna; free motion of fingers.	529	Titus, E., Capt., I. 6th New York Cavalry, age 24.	Sept. 19, 19, '64.	Two, middle, right ulna. Disch'd Jan. 16, '65; pens'd; some anethyl. elb.; thumb and forefinger paral.
499	Spofford, G. S., Pt., I. 1st Vermont Cavalry, age 21.	July 13, 14, '63.	Three, lower half, left radius. To V. R. C. Mar. 30, 1864; pens'd; dislocation of wrist; no rotation.	530	Tompkins, D., Pt., E. 1st N. Y. Drag., age 19.	May 30, 31, '64.	Two, left ulna. Disch'd Nov. 18, 1864. Not a pensioner.
500	Sprague, A., Pt., H. 57th Mass., age 34.	June 26, 26, '64.	Three, upper, right ulna. Disch'd July 22, 1865; pensioned; no power in hand or forearm.	531	Tower, M., Pt., C. 1st Massachusetts Heavy Artillery, age 18.	May 18, 20, '64.	Three, left ulna; by Surg. H. F. Lyster, 5th Mich. Disch'd Nov. 20, 1864; pensioned; flexion and extension of hand imperfect.
501	Staines, A., Serg't, I. 33d Maine, age 32.	June 6, '64.	Middle, right radius. Discharged Feb. 9, 1865; pensioned; hand almost useless.	532	Tridteman, J., Pt., H. 12th Missouri, age 21.	July 15, 15, '64.	Two and a half, upper, left radius; by Surg. B. N. Bond, 27th Mo. Duty Jan. 27, '65. Not a pens'r.
502	Stebbins, P., Pt., K. 122d N. Y., age 23.	Sept. 19, 19, '64.	Six, lower, right ulna; by Surg. G. T. Stevens, 77th New York. Disch'd June 1, 1865; pensioned; atrophied and useless.	533	Trisket, L., Pt., A. 129th Illinois, age 19.	Aug. 6, 7, '64.	Three, upper, left ulna; by Surg. L. A. Brewer, 11th Ohio; gangrene. Duty Dec. 14, '64; pens'd; adherent cicatrix; no rotation.
503	Stepp, W. T., Pt., H. 13th Indiana, age 22.	June 1, '64.	Portion lower, left radius; by Surg. D. Merritt, 55th Pa. Dis'd Sept. 5, 1865; pensioned; wrist very crooked, fingers partly stiff.	534	Trowville, P., Pt., K. 11th Vermont, age 20.	Oct. 19, 19, '64.	Three, upper, right ulna (radius grazed). Dis'd Feb. 6, '65; pens'd; anethyl. elbow; no bony union.
504	Stetson, O., Pt., B. 33d Maine, age 18.	June 1, '64.	Three, left radius. Disch'd June 3, '65; pensioned; anethyl. of wrist; ulna projects; re-enlisted.	535	Trover, J. C., Pt., D. 109th Pa., age 19.	June 15, 15, '64.	Three, middle, right radius; by Surg. J. L. Dunn, 109th Pa. Discharged April 17, 1865; pens'd; partial dislocation of ulna; little motion of wrist; no rotation.
505	Stevens, W., Serg't, D. 11th N. H., age 22.	July 30, 30, '64.	Two, lower, right ulna. Disch'd June 5, 1865; pensioned; partial exten'n and good flex'n of fingers.	536	Turner, E. N., Lieut., C. 1st Texas, age 32.	Oct. 7, 7, '64.	Lower radius. Recovered and furloughed November 2, 1864.
506	Stevenson, G. W., Pt., H. 78th Ohio.	July 22, 22, '64.	Right ulna, lower. Disch'd July 11, 1865; pensioned; partial ankylosis wrist; general atrophy.	537	Twyman, N., Capt., E. 13th Kentucky.	July 22, 22, '64.	One and a half, lower, right ulna; by Surg. J. W. Lawton. Disch'd Jan. 12, 1865; pens'd; no grasp.
507	Stevenson, J., Pt., K. 8th Pa. Cav., age 44.	May 5, '64.	Three, middle, left ulna. To V. R. C. Jan. 7, '65. Not a pensioner.	538	Tyrril, E., Pt., E. 21st Massachusetts, age 18.	Nov. 24, 24, '63.	Three, right radius; by Surg. A. M. Wilder, U. S. V. (hall extr'd). Duty January 14, 1864. Not a pensioner.
508	Stokes, J., Pt., C. 78th Ohio.	July 22, 22, '64.	Lower, left ulna (fract. of radius); by Surg. H. McKenna, 17th Wis. Disch'd Mar. 15, '65; pens'd; anethyl. wrist; fingers contracted.	539	Urtel, F., Pt., H. 151st New York, age 36.	May 18, 18, '64.	Two, lower, left ulna. Disch'd Jan. 8, '65; pens'd; hand at right angle; fingers stiff.
509	Stoner, E. C., Serg't, G. 22d C. T., age 30.	Sept. 29, 1864.	Four, lower, left radius. Duty Jan. 12, '65; pens'd; anethyl. and dislocation of ulna at wrist.	540	Van Campen, C., Pt., I. 89th Illinois, age 20.	May 27, 28, '64.	One and a half, middle, right ulna; by Surg. H. B. Tuttle, 89th Ill. Discharged June 3, 1865; pensioned; no rotation.
510	Stortz, W., Pt., C. 11th Conn., age 26.	June 18, 18, '64.	Three, right ulna; by Surg. G. T. Stevens, 77th N. Y. To V. R. C. April 25, 1865. Not a pensioner.	541	Van Horn, J., Pt., K. 151st New York.	June 3, 3, '64.	Middle third, right ulna. Disch'd October 1, 1864.
511	Stouch, G. W. H., Serg't Maj., 11th Infantry.	July 2, '63.	One and a half, lower, left radius. Duty Jan. 6, '64. Not a pensioner.	542	Vincent, N. H., Capt., D. 86th New York, age 24.	May 10, 10, '64.	Two, middle, left ulna; by Surg. J. S. Jamison, 86th N. Y. Duty Aug. 25, '64; pens'd; no reproduc'n.
512	Strout, J. A., Corp'l, I. 31st Maine, age 38.	April 2, 2, '65.	Two, middle, left radius; erysip. Disch'd June 23, 1865; pens'd; hand turned inward; fingers ext'd.	543	Volk, F. T., Lieut., C. 63th New York, age 21.	May 10, 12, '64.	Lower, left radius. Disch'd July 17, 1865; pens'd; no reproduction; hand dislocated inward.
513	Stumbaugh, J., Corp'l, K. 128th Ind., age 46.	June 15, 15, '64.	Four, middle, right rad.; by Surg. J. H. Rodgers, 104th Ohio. Duty Sept. 18, '64; pens'd; hand useless.	544	Wainmann, C., Pt., I. 2d New York Heavy Artillery, age 18.	June 3, 3, '64.	Three, lower, left radius; caries. Disch'd April 3, '65; pens'd; wrist distorted; hand nearly useless.
514	Sullivan, J., Pt., F. 23d Ill., age 35.	July 7, '64.	Portion, left ulna; by Surg. S. H. Plumb, 82d N. Y.; pens'd; rotation impaired.	545	Waldeck, R., Pt., H. 15th New York Heavy Artillery, age 20.	Mar. 31, 31, '65.	Lower, left radius; by Surg. T. M. Flandrau, 146th N. Y. Disch'd Aug. 1, '65; pens'd; hand drawn sideways; carpus articulating with ulna alone; rotation good.
516	Swanton, J., Corp'l, A. 145th Penn., age 22.	June 16, '64.	Three, lower, right rad.; by Surg. G. L. Potter, 145th Penn. To V. R. C. Mar. 2, '65; pens'd; hand disloc. and hangs useless.				

No.	NAME, AGE, AND MILITARY DESCRIPTION.	DATES.	OPERATIONS, OPERATOR, RESULT.	No.	NAME, AGE, AND MILITARY DESCRIPTION.	DATES.	OPERATIONS, OPERATOR, RESULT.
546	Waldron, W. A., Pt., H, 26th Mass., age 21.	Sept. 19, '64.	Two, middle, left radius; by A. Surg. C. S. Mann, 31st Mass. Disch'd Jan. 28, '65; pensioned; hand dislocated; useless.	568	Wilford, J., Pt., A, 12th Ohio, age 25.	May 27, '64.	Left ulna, lower; amputation right thumb, middle, and index fingers. Disch'd Dec. 7, 1864; ankylosis wrist joint.
547	Walker, S. E., Serg't, D, 2d Virginia, age 35.	May 9, '63.	Resection. Transferred to General Hospital; doing well.	569	Williams, J., Pt., 1, 97th Indiana, age 34.	June 27, '64.	Two, lower, left ulna; by Surg. D. Halderman, 40th Ohio. Disch'd Mar. 3, '65; pens d.
548	Walker, W. H., Pt., P, 6th Pa. Res., age 27.	May 12, '64.	Six, right ulna; by Surg. C. Bowser, 6th Pa. Res. Duty Oct. 21, '64; pensioned; quite useless.	570	Williams, J., Pt., 1, 92d Ohio, age 22.	June 19, '64.	Three, upper, left radius. Disch'd June 2, '65; pens'd; deformity and immobility of wrist.
549	Wantland, F., Pt., B, 18th Indiana, age 22.	May 22, '63.	One and three-fourths, middle, right radius and ulna; by Surg. J. K. Bigelow, 8th Ind. Disch'd Oct. 15, 1863; pensioned; good use of forearm and hand.	571	Williams, J. N., Pt., D, 5th Conn., age 20.	July 20, '64.	Two, middle, left rad. To V. R. C. Dec. 21, '64; pens'd; hand dislocated; limb of little use.
550	Ward, W. H., —, G, 41th N. C., age 30.	Oct. 1, '64.	Upper third, right radius.	572	Williams, W., Pt., A, 91st Indiana, age 30.	July 29, '64.	Two and a half, lower, left ulna; by Surg. S. K. Crawford, 50th O. Disch'd March 19, 1865; pens'd; fingers semiflexed. Died Dec. 21, 1870.
551	Watson, H. G., Pt., I, 48th Illinois, age 23.	Dec. 13, '64.	Five, left ulna. Disch'd Mar. 30, '65; pens d. large ugly tend. scar.	573	Williams, J. P., Pt., K, 1st Maine.	Oct. 19, '64.	Six, right radius; by Surg. G. T. Stevens, 77th N. Y. Duty Jan. 21, '65; pens'd; wrist dislocated; hand at obtuse angle.
552	Warren, G. A., Pt., G, 23rd Wisconsin.	Dec. 12, '64.	Two, upper, left radius. Disch'd May 25, 1865; pensioned; hand pronated; no rotation.	574	Wilson, E., Pt., A, 4th New Jersey, age 23.	May 5, '64.	Two, lower, left ulna. Duty Dec. 2, 1864. Not a pensioner.
553	Watson, W. D., Lieut., E, 71st Pa., age 27.	June 3, '64.	Portion right radius; by Surg. M. Rizer, 73d Pa. Disch'd July 2, '64; pensioned. July 23d, gang. hæm. amp. shoulder joint.	575	Wilson, G. C., Pt., G, 14th N. J., age 23.	June 1, '64.	Four, middle, left ulna; gang. Disch'd Feb. 11, '65; pens'd; motions imperfect and weak.
554	Weaver, W., Pt., I, 11th Pennsylvania, age 27.	May 5, '64.	Lower, left radius. Disch'd Apr. 10, '65; ulna dislocated at 90°; partial dexion thumb and finger.	576	Wilson, J. P., Lt., F, 33th New York, age 18.	June 6, '64.	Three, middle, right ulna. Disch'd Oct. 7, 1864; pens d; rotation destroyed.
555	Weekly, F. M., Pt., C, 7th W. Va., age 17.	May 10, '64.	Four, upper, right ulna; by Surg. M. Rizer, 73d Pa. (wound left forearm); motion of elbow unimpair'd; rotation gone. Disch'd June 7, 1865; pensioned.	577	Wilson, J. P., Serg't, C, 100th Penn., age 22.	Oct. 2, '64.	Two, right radius; by Surg. W. C. Shurlock, 51st Penn. Disch'd Mar. 20, 1865; pens'd; hand supine and subluxated.
556	Welchance, L., Pt., K, 4th Ohio, age 21.	May 12, '64.	One lower, right radius; by Surg. I. Scott, 7th W. Va. Disch'd June 21, '64; pensioned; disloc. ulna; not entirely useless.	578	Wilson, S., Pt., B, 23d C. T., age 26.	July 30, '64.	Three, lower, left ulna; by Surg. J. S. Ross, 11th N. H. Disch'd Mar. 21, 1865; pens'd; no use of hand; no rotation.
557	Wells, G., Pt., B, 60th New York, age 23.	June 17, '64.	Two, lower, right ulna; by Surg. J. L. Dunn, 100th Pa. Duty Nov. 24, 1864; pensioned; bone ununited; arm crooked.	579	Wimble, J., Pt., D, 2d N. Y. H. A., age 25.	May 18, '64.	Four, right ulna. Duty Sept. 24, 1864; pens'd; radius dislocated at elbow.
558	West, A., Pt., G, 107th Illinois, age 24.	July 29, '64.	Three, lower, left ulna; by Surg. J. W. Lawton, 1, S. V. Duty Nov. 26, 1864; pensioned; open sore, discharging bone (1873).	580	Wingood, J. H., Corp'l, 1, 33d Mass., age 25.	May 13, '64.	Upper, right ulna. Discharged April 28, 1865; ankyl. elbow and permanent extension of the fingers.
559	West, E., Pt., G, 99th Illinois, age 18.	May 21, '63.	Two, middle, radius and ulna. Disch'd Feb. 3, '64; pensioned; hand luxat'd; fingers extended.	581	Widick, A. J., Serg't, B, 116th Ill., age 24.	July 28, '64.	Middle, left radius; by Surg. I. N. Barnes, 116th Ill. Disch'd June 7, '65; pens d.
560	Wetro, H., Pt., D, 26th Ohio, age 22.	May 29, '64.	Two, middle, right ulna; by Surg. W. B. McTavran, 24th Ohio. Disch'd Feb. 14, '65; pens d; ankyl. wrist; no flexion or exten. hand.	582	Wiseman, E., Pt., E, 130th Indiana, age 20.	July 22, '64.	Three, middle, right radius; by Surg. A. M. Wilder, 11, S. V. Disch'd July 19, '65; pens'd; disloc. carpal end of ulna.
561	Weydemeyer, P. R., Sergeant, F, 1st Michigan Cavalry, age 25.	Sept. 19, '64.	Upper, radius and ulna. Disch'd July 14, 1865; pensioned; ankylosis and deformity.	583	Wolverton, A. C., Corp'l, H, 137th N. Y.	Nov. 24, '63.	Middle, right radius; gangrene. Not a pensioner.
562	Wheeler, H. H., Lieut., E, 10th Mich., age 26.	Sept. 1, '64.	Two, lower, left ulna. Duty Nov. 10, '64; pensioned; ankylosis elbow and all joints of hand.	584	Wood, G. W., Pt., C, 9th N. Y. H. A., age 49.	June 2, '64.	Three, lower half, right rad. Dis'd Mar. 17, '65; pens'd; ankyl. wrist and finger joints; disloc. wrist.
563	Whitcraft, E. P., Corp'l, A, 10th N. J., age 28.	June 4, '64.	Four, middle, left radius; by A. Surg. B. Thomas, 10th New Jersey. Disch'd Feb. 16, 1865.	585	Woodcock, H. B., Pt., C, 140th N. Y., age 24.	May 5, '64.	Middle, right radius and ulna; by Surg. E. Donnelly, 2d Pa. Res. May 17, hæm. amp. forearm. Disch'd Oct. 12, '65.
564	White, J., Pt., G, 5th New Jersey.	May 31, '64.	Two, left ulna. To V. R. C. Jan. 19, 1865; pensioned; part ankyl. elb.; flex. finger's with little force.	586	Wright, E. H., Pt., A, 2d Pa. H. A., age 21.	June 17, '64.	Three, lower, left radius. Disch'd Mar. 17, '65; pens'd; hand powerless.
565	Whitehouse, P. P., Pt., 6th N. H., age 21.	May 12, '64.	Two and three-fourths, lower, right radius; by Surg. J. S. Ross, 11th N. H. Disch'd August 13, 1865; pensioned; head of ulna thrown out. Spec. 4378.	587	Wyman, H., Pt., K, 26th Mich., age 28.	May 12, '64.	Three, lower, right ulna; by Surg. J. W. Wishart, 140th Penn., gangrene. Disch'd May 15, '65; pens'd; rotation much impaired.
566	Whitfield, W. C., Pt., I, 149th Pa., age 37.	June 19, '64.	Three, lower, right radius. To V. R. C. Jan. 16, '65; pensioned; dis. wrist joint; great deformity.	588	Young, A., Corp'l, I, 32d Wis., age 32.	Feb. 2, '65.	Portion of left ulna; by Surg. A. B. Monahan, 63d Ohio (wound in side). Disch'd Nov. 10, '65; pensioned; disloc. wrist.
567	Whitaker, W., Corp'l, K, 18th Wis., age 24.	Oct. 5, '64.	Four, upper, left ulna; by Surg. E. J. Buck, 18th Wis. Disch'd June 16, '65; pens'd; ankyl. elbow; general atrophy.	589	Zeis, J., Pt., I, 20th Massachusetts, age 27.	May 19, '64.	Two, lower, right ulna; by Surg. N. Hayward, 2th Mass. Deserted Oct. 20, '64. Not pens d.

The foregoing five hundred and eighty-nine primary excisions were practised on five hundred and fifty-three Union and thirty-six Confederate soldiers. The operations were on the right extremity in two hundred and sixty-six cases, on the left in three hundred and five, unspecified in eighteen cases. The extent of removal of bone in these excisions is set forth in the foot-notes, according as the excisions interested both the bones,<sup>1</sup> or only the

<sup>1</sup> In the 34 cases of recovery after excision of the shafts of both bones of the forearm, the extent of bone removed was not definitely stated in 13 cases. In 3 cases it was reported that the greater portions of the lower, the middle, and the upper third, respectively, was removed; in 1, that an inch and a half of the ulna and an inch of the radius were excised; in 1, that an inch and three-quarters of both bones was resected, in 4, 2 inches of both; in 5, 3 inches of both; in 5, between 3 and 4 inches of both; in 2, almost 4½ inches of both.



ulna,<sup>1</sup> or the radius<sup>2</sup> alone, or belonged to the group in which the bone implicated was unspecified.<sup>3</sup> The excisions interested all portions of the diaphysis; but the number of cases in which the operations were midway in the shafts largely predominated. One hundred and forty-seven patients returned to modified duty, thirty-six were exchanged or paroled, and four hundred and six discharged. The names of four hundred and seventy-nine were placed on the Pension List, of whom twenty-five have since died. There were thirty-eight consecutive amputations of limbs on which excision had been practised.

**Fatal Cases after Primary Excision in the Forearm.**—Seventy-one, or 10.7 per cent., of the six hundred and sixty determined cases of excisions in the forearm were fatal:

CASE 1897.—Private *Francis M. Hardy*, Co. B, 30th North Carolina, aged 22 years, was wounded near Fort Stevens, July 12, 1864, captured, and admitted to Lincoln Hospital, from the Defences of Washington, on the 14th. Assistant Surgeon W. Lindsay, U. S. A., reported: "Gunshot wound; a minie ball entering and shattering left ulna, lower third, passing through and entering right radius, middle third, shattering that bone and lodging." Acting Assistant Surgeon F. L. Leavitt described the case as follows: "Patient was wounded while lying behind the corner of a frame dwelling house, and in the act of firing, by a minie ball, which he states first passed through the angle of the house. Resection of both injured bones was performed on the field the same day, by Surgeon G. W. Briggs, 30th North Carolina, the arm placed on straight splints, and in this condition the patient was received in the hospital, suffering a good deal from the tightness of the bandages, the parts swelling considerably. Applied a loose water dressing merely sufficient to keep the bones in position. Signs of abscess at edge of right biceps; the exploring needle revealed pus, and the probe the presence of a foreign body which I removed, and it proved to be the bullet very much battered and irregular. 28th, doing well on iron and quinine. 29th, erysipelatous condition of left forearm; right upper extremity looks healthy. August 2d, left forearm entirely healed; right heals slowly. 8th, gangrene started in the wound of incision where the ball was extracted. 11th, arrested by bromine and stimulating poultices. 12th, patient delirious and very feverish; much prostrated and emaciated from the effects of the diarrhœa; gangrene again commenced and attacked the left forearm; bromine used with no success; brachial artery exposed for the space of two inches in right arm; a tourniquet was placed high up in the axilla ready for use if required. 13th, secondary hæmorrhage occurred this morning, about eight o'clock, from the right brachial artery, but was promptly checked and the artery tied. Afternoon, secondary hæmorrhage took place about two o'clock, in the other arm, from one of the muscular branches of the radial artery; the persulphate of iron arrested the bleeding. Evening, brachial artery sloughed through at point of ligation and a severe hæmorrhage followed; the blood being in a defibrinated condition all efforts at forming a clot failed. 17th, hæmorrhage from left ulnar artery occurred this morning, but was arrested by pressure; patient very much weakened; comatose. Died." Dr. Leavitt does not mention a hæmorrhage from the brachial, and the ligation of that artery, in his report of the case to the Surgeon General. In an account published in the *Medical and Surgical Reporter*, Vol. XIII, for 1865-6, p. 299, he states that the patient died on the 14th. At two o'clock on the afternoon of the 17th, Acting Assistant Surgeon H. M. Dean made an autopsy, and furnished the following notes: "Body considerably emaciated; *rigor mortis* well marked; height, five feet six inches. He has three sores which have evidently been the seat of phagedœna, viz: one on the inner surface of the left forearm; one on the outer aspect of the right forearm; and one on inner aspect of right arm just above the elbow; the former was in a state of gangrene. The lower half of the left ulna and a portion of the middle third of the right radius had been resected, the brachial artery stretched across the ulcer in the right arm having been entirely isolated from the

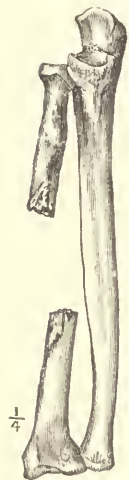

FIG. 688.—Bones of right forearm with mid. third of radius excised. Spec. 3085.

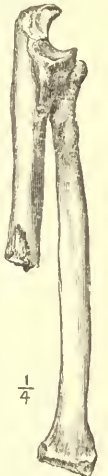

FIG. 689.—Bones of left forearm with lower half of ulna excised. Spec. 3086.

surrounding tissues for a distance of two and a half inches. Lower lobe of right lung in a state of gray hepatization, with the exception of the upper portion of its free margin; posterior portion of the upper lobe also in the third stage of pneumonia, the rest of the right lung was normal; posterior portion of lower lobe of left lung in a state of gray hepatization, the rest of the lung was normal; right lung weighed twenty-three ounces, left thirteen ounces; pericardium normal; spleen normal, weight nine and a half ounces; left lobe of liver somewhat longer than usual; the right lobe was in the shape of a sugar loaf; parenchyma normal, weight fifty-seven and one-half ounces; brain healthy, weight fifty-one and one-half ounces." The specimens, represented in the accompanying wood-cuts, were forwarded to the Museum by Dr. Dean. The first (FIG. 688) consists of the bones of the right forearm with the middle third of the radius excised; no reparative action exists at the extremities. The second (FIG. 689) consists of the bones of the left forearm from which the lower half of the ulna has been excised; the extremity of the bone shows a slight ring of necrosis and no attempt whatever at repair.

<sup>1</sup> The extent of bone excised from the shaft of the ulna is unspecified in 58 of the 290 cases: in 3, 1 inch was removed; in 63, from  $1\frac{1}{2}$  to 2 inches; in 88, from  $2\frac{1}{2}$  to 3 inches; in 47, from  $3\frac{1}{2}$  to 4 inches; in 19, from  $4\frac{1}{2}$  to 6 inches; in 1, the greater portion of the lower half of the shaft; in 4, the greater portion of the lower third; in 4, the greater portion of the middle third; in 2, much of the upper third; in 1, the greater part of the diaphysis.

<sup>2</sup> In the 256 excisions in the shaft of the radius the amount of bone removed was reported in 206 cases: in 4, an inch was excised; in 64,  $1\frac{1}{2}$  or 2 inches; in 73, from  $2\frac{1}{2}$  to 3 inches; in 32,  $3\frac{1}{2}$  to 4 inches; in 13,  $4\frac{1}{2}$  to 6 inches; in 7, the greater portion of the lower third; in 8, the greater portion of the middle third; in 4, the greater portion of the upper third; in 1, nearly the entire diaphysis.

<sup>3</sup> In the 9 instances in which the bone implicated was not specified, the excision was in the lower third in 1, in the upper third in 1, and its seat was not specified in 7 cases.

Many of these excisions in the continuity of the forearm were followed by amputation:

CASE 1898.—Private J. Contraman, Co. G, 142d Pennsylvania, aged 20, was wounded at Spottsylvania, May 11, 1864, and admitted to Fairfax Hospital, from a Fifth Corps field hospital, on the 16th. Surgeon D. P. Smith, U. S. V., noted: "Gunshot fracture of left forearm by a minié ball. Excision of three inches of radius performed on the field." On May 18th, the parts being in a gangrenous condition, Surgeon Smith amputated the forearm at the upper third. The patient was extremely irritable. The treatment consisted in the application of simple dressings, followed by a solution of bromine. Death resulted, on May 27, 1864, from pyæmia following the amputation. The specimen, represented in the accompanying wood-cut (Fig. 690), was forwarded to the Museum by Dr. Smith. It consists of the lower two-thirds of the bones of the left forearm from which three inches of the radius were excised primarily. The age of the patient was probably overestimated.



FIG. 690.—Excision in radius. Spec. 3297.

CASE 1899.—Private H. Conrad, Co. H, 10th New York Cavalry, aged 44 years, was wounded at the Wilderness, May 7, 1864, and sent from a Sixth Corps field hospital to Douglas Hospital, Washington. On July 18th, he was transferred to the hospital at Blackwell's Island. Acting Assistant Surgeon Stephen Smith reported: "Admitted July 20, 1864; gunshot fracture of lower extremity of radius with resection of two inches; wound sloughy. Severe secondary hæmorrhage September 9th. September 10th, amputation two inches above elbow joint; flaps of skin and circular section of muscles; at time of operation hand and forearm tensely swollen and infiltrated; hand gangrenous; patient weak from loss of blood; very much dejected and indifferent; refused food and stimulants. Wound looked well for two weeks. General and great emaciation ensued, with disintegration of the margin of the flaps. Result: death from inanition, September 23, 1864. The autopsy revealed no morbid appearances except great emaciation."

CASE 1900.—Private James Ryal, Co. H, 43d Colored Troops, aged 19 years, was wounded at Petersburg, July 30, 1864, by a minié ball, which fractured the left ulna. Surgeon James P. Prince, 36th Massachusetts, excised an inch and three-fourths of the left ulna at a Ninth Corps field hospital, and on August 18th the patient was admitted to Summit House Hospital, Philadelphia, from City Point. Surgeon J. H. Taylor, U. S. V., reported: "August 19, 1864, extensive sloughing of wound, exposing elbow joint; patient in very feeble health; has some pleurisy in left side. 23d, elbow joint still exposed; slough extending along up the arm. Acting Assistant Surgeon W. W. Shapley amputated the arm at middle third of humerus by the circular operation; chloroform used; general health of the patient bad; appetite very poor. The treatment consisted of simple dressings to the wound, tonics and stimulants; extra diet, milk-punch, and beef tea freely given. 24th, patient somewhat better, still very weak. 25th, stump looks tolerably well. 26th, stump sloughing at under part. 27th, patient seems somewhat better; appetite improving. 28th, secondary hæmorrhage occurred from profunda artery, consequent upon extensive sloughing; patient lost about thirty ounces of blood; the artery was not ligated; local treatment, permanganate of potassa to sloughing wound; general treatment, tonics, stimulating expectorants, and counter-irritants; patient very much debilitated throughout. Died August 29, 1864, of exhaustion from secondary hæmorrhage." The specimen (Fig. 691) was sent to the Museum by Dr. Shapley. An inch and three-fourths has been excised from the middle third of the ulna; its extremities are necrosed, as well as the adjoining surface of the radius. Beyond the necrosis are slight friable osteophytic deposits.



FIG. 691.—Excision in ulna. Spec. 3666.

CASE 1901.—Private John Vandyke, Co. K, 107th New York, aged 21 years, was wounded at Gettysburg, July 3, 1863, and admitted to a Twelfth Corps field hospital, where Surgeon H. E. Goodman, 28th Pennsylvania, noted: "Compound fracture of right radius and ulna by a minié ball. Resection of two and a half inches of ulna, middle third, by Surgeon W. H. Twiford, 27th Indiana, July 4th." On July 23d, the patient was transferred to Letterman Hospital, Gettysburg, where Acting Assistant Surgeon Edwin Martin described the case as follows: "Gunshot wound of right forearm. Ball passed through forearm directly over the ulna, about three inches below the elbow. On examination, it was found that the ulna was fractured and the radius slightly grazed. The patient was put on medium diet, cold-water dressings were applied to the wound, and quinine and iron administered internally. When brought to this hospital he was in good condition, but in a few days it became apparent that his strength would fail before the discharge would subside. Stimulants, however, were persistently given until this date (August 24th), when it was decided to amputate, which operation I performed by the circular method, at the middle third of the arm, as the inflammation had extended to that distance." The patient died of hectic fever September 12, 1863. There is a specimen in the Museum from this case (No. 443), a stump of the humerus, with annular necrosis.

TABLE CXXVII.

Condensed Summary of Seventy-one Fatal Primary Excisions of the Bones of the Forearm.

No.	NAME, AGE, AND MILITARY DESCRIPTION.	DATES.	OPERATIONS, OPERATOR, RESULT.	No.	NAME, AGE, AND MILITARY DESCRIPTION.	DATES.	OPERATIONS, OPERATOR, RESULT.
1	Anderson, R., Pt., G, 30th Colored Troops.	July 30, 31, '64.	Three, lower, right radius (also amp. fingers), by Surg. D. Mackay, 20th C.T. Died Aug. 19, '64.	3	Beale, J., Corp'l, H, 53d Ohio.	June 27, '64.	Two and a half, radius and ulna: by Surg. A. C. Messenger, 57th O. Died July 25, 1864, congestion of lungs.
2	Anthonie, J., Serg't, D, 13th Illinois.	Nov. 27, '63.	Portion of right radius. Jan. 1, 1864, amputation of arm. Died Jan. 2, 1864, pyæmia.	4	Bente, W., Pt., N, 198th Pennsylvania, age 28.	Mar. 29, '65.	Excision gangrene hæmorrhage. Died April 8, 1865, exhaustion.



No.	NAME, AGE, AND MILITARY DESCRIPTION.	DATES.	OPERATIONS, OPERATOR, RESULT.	No.	NAME, AGE, AND MILITARY DESCRIPTION.	DATES.	OPERATIONS, OPERATOR, RESULT.
5	Bishop, E., Pt., A, 1st Connecticut Cav.	Nov. 12, '64.	Two, lower, left radius; by Surg. N. D. Ferguson, 8th N. Y. Cav. Died Dec. 9, 1864, pyæmia.	37	Mathews, A., Pt., C, 33d Indiana, age 20.	June 19, '64.	Two and a half, lower, left ulna; by Surg. J. Bennet, 15th Mich.; gangrene. July 17, amp. arm. Died Aug. 29, 1864, pyæmia.
6	Bullard, I. B., Corp'l, II, 57th Mass., age 27.	May 24, '64.	Upper, left radius. Died May 30, 1864.	38	McAllister, H. V., Pt., D, 148th Pa., age 21.	June 4, '64.	Three, middle, left radius. Died August 11, 1864.
7	Burton, L. C., Pt., D, 78th Illinois, age 22.	May 9, '64.	Three, middle, left ulna; by A. A. Surg. S. M. Olden. Died June 26, '64, colliquative diarrhœa.	39	McGrew, M., Pt., H, 6th Kentucky.	May 14, '64.	Portion of left ulna. Died July 13, 1864.
8	Carrol, M., Pt., E, 164th New York, age 37.	June 16, '64.	Portion of left radius; by Surg. M. F. Regan, 164th N. Y. (also wound thigh). Died July 17, '64.	40	Montgomery, T. A., Pt., I, 207th Pa., age 35.	April 2, '65.	Right ulna, middle. Died April 22, 1865.
9	Chesly, W. H., Pt., F, 120th N. Y., age 18.	Nov. 25, '64.	Portion lower, ulna. Died Feb. 16, 1865, exhaustion.	41	Mulford, W. D., Pt., D, 6th Ohio.	Nov. 25, '63.	Right radius, lower. Died December 15, 1863.
10	Conrad, H., Pt., H, 10th N. Y. Cav., age 44.	May 7, '64.	See CASE 1899.	42	Newman, C., Pt., K, 3d Missouri.	Aug. 14, '64.	Three, right radius; by Surg. A. Sabine, 70th Ohio. Died Aug. 20, 1864.
11	Cornelius, J. M., Pt., K, 4th Pa. Cav., age 23.	March 28, '65.	Three, middle, left radius; by Surg. D. W. Maul, 1st Del. Died July 15, 1865, acute dysentery. See CASE 1898.	43	Ogden, O., Pt., K, 5th Mich. Cav., age 21.	Sept. 24, '64.	Portion of left ulna. Died Feb. 23, 1865, small-pox.
12	Contraman, J., Pt., G, 143d Pa., age 29.	May 11, '64.		44	Perry, A. D., Serg't, E, 2d Michigan, age 28.	June 1, '64.	Three, upper, left radius; by Surg. S. S. French, 30th Mich.; gang. Amputation arm June 28. Died July 17, 1864, pyæmia.
13	Crimmer, S., Corp'l, I, 53d Pa., age 19.	March 31, '65.	Two and a half, lower, right radius; by Surg. P. E. Hub. n. 28th Mass. May 5, amp. forearm. Died May 23, 1865, pyæmia.	45	Phillips, A., Pt., L, 16th Pa. Cavalry, age 18.	May 8, '64.	Right ulna, middle. Died May 31, 1864, pyæmia.
14	Davis, J., Pt., E, 143d Pennsylvania, age 24.	June 18, '65.	Portion radius. June 24th, amp. arm. Died Sept. 13, '65, pyæmia.	46	Phillips, J., Pt., D, 3d Md. Cav., age 26.	Mar. 4, '64.	Two, lower, left radius; hæmorrhœas. May 27, amp. of arm. Died same day, exhaustion.
15	Dawson, R. F., Capt., I, 65th Pennsylvania, age 24.	Jan. 15, '65.	Left ulna, middle; by Surg. G. C. Jarvis, 7th Connecticut. Died February 1, 1865, exhaustion.	47	Pope, G. W., Lieut., F, 20th Mass., age 35.	June 17, '64.	Two, lower, radius and ulna; by Surg. H. Luddington, 100th Pa. Died August 5, 1864.
16	Dumas, J. C., Pt., H, 10th New York.	May 12, '64.	Lower, right radius; ball passed into pelvic cavity. Died May 22, 1864.	48	Preston, S., Pt., E, 63d New York, age 23.	June 3, '64.	Portion of bone; by Surg. P. E. Hubon, 28th Mass. (also penetrating wound of side). Died June 14, 1864.
17	Durant, J. M., Pt., E, 11th Vermont, age 26.	June 1, '64.	Right ulna, upper; by A. Surg. C. B. Park, 11th Vt. (also wound of knee). Died July 31, 1864, typhoid fever.	49	Ransom, J. W., Pt., A, 1th Virginia, age 58.	Aug. 19, '61.	Two, middle, right ulna. Died Nov. 28, '61, carbuncle on neck.
18	Ewen, J. S., Pt., I, Pennsylvania Heavy Artillery.	July 30, '64.	Three, middle, right radius; by Surg. W. V. White, 57th Mass. Died Aug. 19, '64, hæmorrhage.	50	Robinson, J. B., Corp'l, G, 53d N. C., age 24.	July 2, '63.	Three, middle, left radius; by Surg. J. S. Dunn, 10th Pa. (also fract. scapula). Died Sept. 9, '63.
19	Felzer, J., Pt., G, 33d New Jersey.	May 25, '64.	Portion, left ulna; by Surg. J. Healy, 33d N. J. Died May 25, 1864.	51	Robinson, J., Serg't, H, 48th Illinois.	May 26, '64.	Three, right radius (also amp. thigh); by Surg. A. Goslin, 48th Illinois. Died June 1, 1864.
20	Frink, G. W., Serg't, H, 14th New York Heavy Artillery.	July 30, '64.	Two and a half, lower, left radius; by Surg. J. Oliver, 21st Mass. Died August 7, 1864.	52	Rock, J. J., Pt., F, 45th Pennsylvania, age 23.	May 14, '64.	Three, lower, left ulna; by Surg. T. Christ, 45th Pennsylvania. Died June 9, 1864, pyæmia. See CASE 1900.
21	Garboden, W. H., Lieut., B, 3rd Indiana.	Sept. 19, '63.	Left forearm. Died October 28, 1863.	53	Ryal, J., Pt., A, 43d C. T., age 19.	July 30, '64.	Three, right radius. Died Feb. 22, 1864, tetanus.
22	Griswold, H., Pt., K, 151st New York, age 31.	June 3, '64.	Two-thirds, radius; June 11, left arm amputated. Died June 19, 1864, heart disease.	54	Salling, J., Pt., F, 3d East Tenn., age 24.	Feb. 12, '64.	One and a half, radius and ulna; by Surg. T. M. Flaudrau, 10th New York. Died Oct. 4, 1864.
23	Grover, J., Pt., D, 79th Illinois, age 54.	June 22, '64.	Portion lower, left rad.; by Surg. S. J. Young, 79th Ill.; gangrene. July 19, three, lower end; by A. A. Surg. D. J. Griffith; hæm.; July 24, amputation forearm. Died July 30, 1864. See CASE 1897.	55	Simonds, B., Pt., C, 146th New York.	Sept. 3, '64.	Portion lower, right ulna. Died Sept. 16, 1864, diarrhœa.
24	Hardy, F. M., Pt., B, 30th N. C., age 22.	July 12, '64.	Lower, right ulna; by Surg. H. McKeenan, 17th Wis. Died September 26, 1864.	56	Stevenson, S., Pt., D, 53d Ohio.	Aug. 31, '64.	Four, lower, right radius; by Surg. P. M. Eveleth, 7th Maine; amp. arm; pyæmia. Died June 16, 1864, asthenia.
25	Harrison, J., Corp'l, A, 31st Illinois.	July 22, '64.	Left radius and ulna, upper; by A. Surg. W. A. Banks, U. S. V.; lig. brachial; hæm. Jan., arm amputated. Died Jan. 24, 1865, pyæmia.	57	Stone, J. H., Serg't, K, 7th Maine, age 24.	May 11, '64.	Lower half of right radius; by Surg. A. G. Hunt, 11th Illinois. April 24, arm amp. Died May 4, 1865, typhoid pneumonia.
26	Heatherby, J., Pt., E, 11th West Virginia, age 35.	Oct. 28, '64.	Two and a quarter, right ulna; Nov. 6, amp. thigh. Died Nov. 6, 1864, pyæmia.	58	Swartz, W., Pt., I, 29th Illinois, age 39.	Mar. 30, '65.	Two, lower, left ulna; by Surg. J. F. Kimbly, 11th Ky. Died Aug. 4, '64, chronic ricinism.
27	Henderson, N. W., Pt., E, 123d Ohio.	Sept. 19, '64.	Portion right ulna; by Surg. E. B. Glick, 30th Ind.; gang. July 15, amp. forearm; July 19, arm amputated. Died July 21, 1864, exhaustion.	59	Thomas, J. M., Corp'l, C, 123th Indiana.	June 14, '64.	Portion of left ulna. Died March 9, 1865, double pneumonia.
28	Holter, R. J., Pt., F, 50th Ohio.	June 4, '64.	Left radius and ulna. Died June, 1864.	60	Tunnel, I., Pt., K, 32d C. T., age 22.	Feb. 10, '65.	Portion lower, right radius; by Surg. A. Goslin, 7th R. I. Died June 6, 1864, tetanus.
29	Howe, A. W., Pt., K, 57th Massachusetts.	July 30, '64.	Two and a half, left radius; by Surg. G. W. Snow, 35th Mass. Died Aug. 8, 1864, hæmorrhage.	61	Tyler, D. S., Pt., H, — N. H., age 29.	May 11, '64.	Portion middle, right ulna; by Surg. J. V. Kendall, 149th N. V. Died July 21, 1864.
30	Hunt, C., Pt., H, 57th Indiana, age 22.	June 22, '64.	Portion right ulna; by Surg. E. B. Glick, 30th Ind.; gang. July 15, amp. forearm; July 19, arm amputated. Died July 21, 1864, exhaustion.	62	Vancomer, E., Pt., H, 149th New York.	July 20, '64.	Excision. Died January 7, 1863.
31	Kelley, J. D., Serg't, B, 29th C. T., age 33.	Oct. 4, '64.	Portion left ulna; by Surg. M. S. Kittenger, 100th N. Y. Died Oct. 31, 1864, acute pleurisy.	63	Van Dean, A. F., Pt., I, 116th Pennsylvania.	Dec. 13, '62.	Portion lower, ulna. Discharged Nov. 19, '61. Amp. forearm Mar., 1864. Died November 23, 1866, effects of gangrene. See CASE 1901.
32	Kelly, D., Corp'l, H, 6th Wisconsin, age 32.	May 10, '64.	Three, right radius; hæmorrhage. May 23, amp. forearm. Died June 23, 1864, pyæmia.	64	Vandermark, N., Pt., G, 5th New York, age 25.	June 11, '61.	Portion of right radius (also amp. thigh). Died June 24, 1861.
33	Kuhns, R., Pt., C, 11th Pennsylvania, age 50.	May 10, '61.	Left radius, lower. Died Aug. 23, 1864, diarrhœa.	65	Van Dyke, J., Pt., K, 107th N. Y., age 21.	May 25, '64.	Portion lower, right radius; by Staff Surg. C. B. Richards, U. S. A. Died June 27, 1864.
34	Kulthan, H., Serg't, L, N. J. Cav., age 27.	May 28, '64.	Two, right radius; hæmorrhage. June 11, arm amputated. Died June 19, 1864, pyæmia.	66	Van Vliet, J. M., Pt., H, 107th New York.	June 27, '64.	Portion left ulna. May 14, amp. forearm. Died May 15, 1864, tetanus.
35	Lockard, J., Pt., D, 53d Ohio.	June 27, '64.	Lower two-thirds of left ulna; by Surg. L. P. Bonner, 47th Ohio; gangrene. July 4, amp. arm; hæmorrhage. Died July 6, '64.	67	Welber, P., Serg't, E, 57th Ohio, age 22.	Sept. 27, '64.	Portion of middle, left ulna; by Surg. S. P. Bonna, 47th Ohio. Died August 10, 1864.
36	Manning, P., Pt., D, 20th Massachusetts.	July 3, '63.	Right and left radii, middle; by Surg. N. Hayward, 20th Mass. Died July 12, 1863.	68	Woodruff, R., Capt., C, 31st Colored Troops.	July 30, '64.	Two, left ulna; by Surg. F. M. Weld, 27th C. T. Died Aug. 11, 1864, tetanus.
				69	Woodward, E. P., Pt., I, 53d Pennsylvania.	Dec. 13, '62.	Radius (also tibia). Died January 6, 1863.

§ *Primary Excisions in the Forearm with undetermined Results.*—Five cases of this group complete the record of six hundred and sixty-five primary excisions in the forearm:

CASES 1902-1906.—Pt. *I. Hadley*, B, 7th Louisiana, age 35 years, wounded May 13, 1864; compound comminuted fracture of left ulna; May 13th, resection of four inches of shaft.—Pt. *E. W. Honeycut*, C, 13th Mississippi, age 28 years; wounded July 3, 1863; fracture of ulna; resection of three inches of shaft same day.—Pt. *P. R. Lanier*, D, 4th Georgia, age 21 years; wounded May 2, 1863; fracture of ulna; resection of five inches of shaft May 3d.—Sergeant *L. Lesser*, A, 4th Georgia, age 27 years; wounded May 2, 1863; compound comminuted fracture of radius; May 3d, four inches of its shaft were resected.—Pt. *R. J. Smoot*, A, 53d Virginia; wounded May 23, 1864; fracture of ulna; resection of a portion of shaft same day.

**Intermediary Excisions in the Bones of the Forearm.**—There were one hundred and forty-nine cases reported in this group, with a mortality of 19.4 per cent., or nearly double that of the primary operations.

§ *Recoveries after Intermediary Excisions.*—In nine cases these excisions involved both bones, in sixty-four the ulna,<sup>1</sup> in forty-seven the radius.<sup>2</sup> Examples of each group precede the tabular statement:

CASE 1907.—Private *W. D. Boyce*, Co. 1, 124th New York, age 37 years, was wounded before Petersburg October 27, 1864. On the following day he was admitted to the Depot Hospital of the Second Corps, at City Point, where Surgeon *G. B. Parker*, U. S. V., recorded: "Gunshot wound of right arm. Surgeon *O. A. Judson*, U. S. V., reported

the wounded man's admission to Carver Hospital, Washington, October 30th, and described the injury and operation, which he performed, as follows: "Gunshot wound of right forearm, a conoidal ball entering the posterior and middle portion, producing a compound comminuted fracture of the middle third of the shaft of the ulna, and lodging in the wound. At date of admission the wounded parts were greatly swollen and slightly œdematous. The constitutional state, however, was tolerably good, but he seemed somewhat exhausted, and was suffering from anorexia. On November 1st, the patient was anesthetized and the wound thoroughly examined, when it was thought proper that excision should be performed. Six inches of the middle portion of the shaft of the ulna was removed by a straight incision and the missile was extracted. The patient rallied promptly from the shock of the operation and continued to improve without any unfavorable complication, the wound filling rapidly with healthy granulations. Simple dressings were applied, and tonics and nourishing diet were administered. December 31st, the wound is healing rapidly. The above treatment has been continued; patient has had no unfavorable symptom. March 31st, the wound has entirely healed with loss of rotatory motion of forearm, otherwise the arm being very useful." The specimen, consisting of the excised portion of the ulna, and represented in the adjacent wood-cut (FIG. 692), was contributed to the Museum by the operator. The patient was discharged from service April 13, 1865, and pensioned. Examiner *J. Nichols*, of Washington, D. C., April 20, 1855, certified: " \* \* Great deformity. Limb entirely useless for even light labor. It is an impediment to labor," etc. Examiner *J. H. Helmer*, of Lockport, N. Y., certified, August 29, 1865: " \* \* Elbow dislocated. He cannot close his hand," etc. The Lockport Examining Board, consisting of Drs. Helmer and *S. T. Clark*, reported, October 11, 1873: " \* \* Dislocation of elbow still unreduced. \* \* Pronation and supination is destroyed. The arm is useless, as perfectly so as if amputated at the elbow joint." The pensioner was paid September 4, 1875. A photograph, taken about the time of his discharge, and recently obtained from the Pension Bureau, is copied in the annexed cut (FIG. 693).



FIG. 692.—Six inches of right ulna excised for shot fracture.—Spec. 4245.

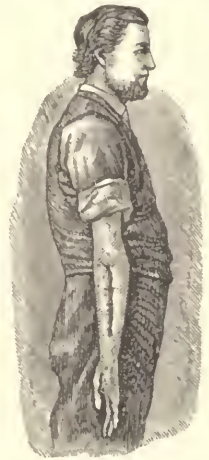

FIG. 693.—Cicatrix six months after an excision in the shaft of the ulna.

Among the intermediary excisions in the shaft of the ulna were many such examples as the foregoing of removal of very considerable portions of the diaphysis.

<sup>1</sup> In addition to the instances cited of excisions in the shaft of the ulna enumerated on page 935, the following may be added: *WARMPATH* (RUSE, J. N.) (*Handbuch der Chir.*, 1831, B. VI, S. 544), in 1827, excised part of the ulna, in a girl of 19 years, for ununited fracture. *ADELMANN* (GEORG) (*Erfahrungen und Bemerkungen über Resection der Knochen*, in *Prager Vierteljahrsschrift*, 1868, Jahrg. XV, B. III, S. 43) resected, at Dorpat, August 9, 1841, an inch and a half of the diaphysis of a diseased ulna, in the case of Emma V——, aged 20 years, a good recovery followed. *BLANDIN* (*Gaz. Med.*, 1843, T. XI, p. 51) presented, at the meeting of the Paris Academy of Medicine, January 17, 1843, a portion of the ulna, an inch and a half long, that he had excised eight months previously. *PITHA* (*Ueber die Operative Behandlung der Necrose*, in *Allg. Wiener Med. Presse*, 1863, No. 11, S. 81) excised a large portion of a diseased ulna, in 1845, at the clinic at Prague, in a farmer, aged 26 years; a good result ensued. *MEYZ* (*Resect. eines 3 Zoll langen Stückes des unteren Endes der Ulna*, in *Deutsche Klinik*, 1851, B. III, S. 410) resected three inches of the lower end of the ulna in the case of an operative in a factory, in 1850, for injury from machinery; good results. Dr. *ROBERTI*, whose elaborate articles on this subject constitute the most important contribution to the literature of excisions of the ulna that has been made (*Eine Reihe Resectionen an der Ulna ausgeführt*, in *Deutsche Klinik*, 1855, B. VII, S. 144, etc.), cites no less than nine examples of excision of the ulna for disease, viz: *H. Neebe*, aged 12 years, 1845; *M. Prugold*, aged 14 years, 1849; *D. Garthe*, aged 2½ years, 1848; *K. Menninger*, aged 14½ years, 1848; *M. Sartorius*, aged 18 years, 1852; *S. Saffonvontu*, aged 15 years, 1852; *M. Füssbender*, aged 13 years, 1853; *J. Conrad*, aged 14 years, 1853; *L. Wahl*, aged 45 years, 1848. Each of the cases are described in detail, and in nearly all the pathological preparations are handsomely engraved. *WUTZER* (*O. WEBER Die Knochengeschwülste*, in *Anat. und Prakt. Beziehung*, Bonn, 1856, B. I, S. 155) excised, for exostosis, the middle portion of the ulna, in a man aged 19 years. There was no new formation of bone three years after the operation, but a solid fibrous connection. *GARNEY* (A. S.), *Case of resection and excision in a fracture of the ulna*, in *Transactions of Med. Assoc. State of Alabama*, 1871, p. 148.

<sup>2</sup> A large number of examples of excisions in the continuity of the radius are cited in the foot note commencing on page 937. Twenty six examples of excisions of the lower extremity of the bone for shot injury will be detailed in the next Section, under the head of excisions at the wrist.



CASE 1908.—Corporal J. Lefevre, Co. H, 28th Pennsylvania, aged 28 years, was wounded in the right forearm at Antietam, September 17, 1862. Six days afterward he was admitted to Hospital No. 1, Frederick, where he underwent excision. Acting Assistant Surgeon W. W. Keen, jr., who performed the operation, described the case as follows: "The ball entered the ulnar side of the forearm posteriorly, about two and a half inches above the carpal extremity, fractured the ulna, emerged, and immediately re-entered at the bend of the elbow, and made its exit at the middle of the arm posteriorly. The ulna was much comminuted, the radius and humerus were uninjured, and the bicipital fascia was exposed at the elbow, neither the radial nor ulnar pulse being perceptible. On September 28th, five and a half inches were resected in the continuity of the bone, leaving a large amount of periosteum. October 14th, the wound is granulating and cicatrizing. Motion at the elbow is quite good, that of the fingers improving; pronation and supination to some extent, and improving under passive motion. General condition better. November 3d, wound all united but not cicatrized. Has had two chills at the interval of a week, but they have yielded to quinine and sulphuric acid. Good diet and moderate amount of stimulants have been given. Motion is better. 16th, doing well; no more chills; line of incision almost healed. Passive motion is not quite so effective as I could desire, but it is improving. Flexion and extension of the elbow is good, also pronation and supination, but flexion and extension of the fingers is poor. Patient is awaiting his discharge." The specimen, represented in the annexed cut (FIG. 694), consists of the excised portion of the ulna. It was contributed by the operator. The patient was discharged from service January 15, 1863, and pensioned. Examiner G. McCook, of Pittsburg, Pennsylvania, January 30, 1863, certified: "A bullet entered at the outer part of the right wrist and passed upward to near the middle of the humerus. It destroyed five inches or more of the ulna and has permanently injured or ruined the median nerve and its main branches. The hand is useless." The Pittsburg Examining Board, consisting of Drs. A. G. McCandless, J. W. Wishart, and W. J. Gilmore, September 20, 1873, certified: "The forearm is wasted, the hand cold and blue; pronation and supination is lost." The pensioner was paid September 4, 1875.



FIG. 694.—Five and a half inches of the right ulna. *Spec.* 823.

The next case is one of the nine recoveries<sup>1</sup> after excisions of both bones:<sup>2</sup>

CASE 1909.—Private J. B. Cooper, Co. D, 122d Ohio, aged 28 years, was wounded at Cold Harbor, May 31, 1864, and admitted to the field hospital of the 3d division, Sixth Corps, where Surgeon R. Barr, 67th Pennsylvania, noted: "Gunsnot fracture of right forearm; simple dressings applied." On June 4th, the wounded man entered Emory Hospital, and was transferred to Patterson Park Hospital. Surgeon T. Sim, U. S. V., reported: "Gunsnot comminuted fracture of radius and ulna at middle third. The bones were very much shattered, and the parts very much swollen by the accumulation of matter; health of patient very good. On June 17th, A. V. Cherbonnier extracted all the loose fragments and resected both ends of both bones, removing altogether three inches, the extent of the incision being four inches. Chloroform was used. The patient's progress was favorable. The arm was placed upon a simple splint and dressed altogether with dry oakum, water only being used in washing the wound with castile soap twice a-day. On July 22d, the patient was transferred to Ohio by order of the Secretary of War. At the date of transfer, he was able to lift the arm from the splint, and, although recovery was not complete, a most favorable result was promised." He entered Seminary Hospital, Columbus, and was discharged from service September 30, 1864. Examiner E. A. Kratz, June 15, 1874, certified: "Ball entered four inches below elbow, outer side, fracturing radius and ulna. Bony union at seat of injury. Arm is permanently pronated and deflected downward; the thumb is behind; radius and also ulna one inch shorter than natural; arm somewhat atrophied; cicatrix adherent to bones; moderately good use of wrist and hand. Complains that sensation is destroyed." This pensioner was paid September 4, 1875.

The next case was complicated by consecutive hæmorrhage and ended in amputation:



FIG. 695.—Four inches of right radius and pieces of lead. *Spec.* 1089.

CASE 1910.—Sergeant S. T. Wilfong, Co. A, 12th North Carolina, aged 19 years, was wounded at Chancellorsville, May 3, 1863, and entered Lincoln Hospital, Washington, one week afterward. Acting Assistant Surgeon H. M. Dean reported: "Compound comminuted fracture of right radius in its middle third by a minie ball. May 11th, resected some four inches of the shaft of the radius. In the operation the interosseous artery was wounded high up, and, owing to the close proximity of the elbow joint, could not be got at to tie. The forceps was therefore left on it to control the hæmorrhage, which it did very effectually. 15th, a large abscess has formed, which, although opened freely, is connected by a sinus from the wrist to the elbow. 17th, had hæmorrhage from the wound about noon; forceps still in the wound. 18th, had hæmorrhage at four o'clock P. M., and again at five and a half o'clock P. M., which was very persistent. Amputation of the arm in the lower third was agreed upon, and performed the same afternoon, by antero-posterior skin flaps, by Surgeon H. Bryant, U. S. V. 19th, patient is feeling quite comfortable. 21st, still continues to do well; appetite very good. 26th, has had no bad symptoms since the operation. June 1st, still continues to recover." The excised portion of the radius is represented in the adjacent wood-cut (FIG. 695), two flattened pieces of lead, as though a distorted ball and a buckshot, being mounted with the specimen. The specimen was contributed by Assistant Surgeon H. Allen, U. S. A. Surgeon G. S. Palmer, U. S. V., recorded that "the patient was transferred to the Old Capitol Prison June 25, 1863."

<sup>1</sup> Five of the operations were on the right, and four on the left forearm. Considerable portions of the shafts were removed: in 2 instances, 3 or 3½ inches of both bones; in 2, at least 5 inches of the ulna and somewhat less of the radius; in 4 cases, about 2½ inches of both bones.

<sup>2</sup> In addition to the examples of excisions in the shafts of both bones of the forearm cited on page 934, the following may be consulted: A. INGLIS (*Observations on the Cure of those Unnatural Articulations which are sometimes the consequence of Fractures in the Extremities*, in *The Edinburgh Med. and Surg. Jour.*, 1805, Vol. 1, p. 419), in 1802, resected the ends of both bones of the forearm for fracture, in the case of Margaret Adie, age 20; the patient was discharged in about 2 months, perfectly cured. G. W. NORRIS (*Med. Examiner*, 1840, Vol. III, p. 205), in the case of G. D——, a lad of 12, with fracture with protrusion of the left ulna and radius, all other efforts at reduction proving unavailing, removed the extremities of both bones by LISTON'S pliers. Firm osseous union without deformity resulted. G. MAY recorded (*London Med. Gaz.*, 1846, N. S., Vol. III, p. 487) a case of pseudarthrosis affecting both bones of the forearm, successfully treated by resecting the ends of the bones.

The next case, remarkable for resulting favorably after a ligation of the brachial, is followed by an example of synostosis of the ulna with the radius, and that in turn by a case of pseudarthrosis in the radius:

CASE 1911.—Private R. Rees, Co. A, 105th Ohio, aged 30 years, was wounded at Perryville, Kentucky, October 8, 1862, and admitted to Hospital No. 4, where Assistant Surgeon G. W. Carr, 129th Ohio, noted: "Gunshot wound of elbow." Acting Assistant Surgeon M. N. Elrod reported: "The patient was admitted to Hospital No. 4, New Albany, October 20th, for hemorrhage from gunshot wound of right forearm, the ball entering near the inner condyle of the humerus and passing out near the middle of the forearm, causing compound fracture of the ulna. When the hemorrhage occurred he was just convalescing from measles. The wound had a healthy appearance, and there was but slight swelling. On October 22d, hemorrhage occurred to an alarming extent, and, after many fruitless attempts to find its source, the brachial artery was ligated with only temporary relief. It was then determined to try excising the shattered fragment of the ulna, which was done by Surgeon W. Varian, U. S. V., making an incision parallel with the bone and removing three inches of the shaft including the fragments. The wound did well from this, except slight erysipelas, without any further hemorrhage." The excised part of the ulna was contributed to the Museum by the operator, and is represented in the cut (FIG. 695). By several fractures the specimen is divided longitudinally into three fragments, which are necrosed on the borders of the lines of solution, but over their greater surface present friable deposits. The patient was discharged from service January 6, 1863, and pensioned. Examiner E. Mygatt, of Youngstown, Ohio, June 4, 1867, certified: "Anchylolysis of right elbow joint, in consequence," etc. Examiner C. S. Leonard, of Ravenna, Ohio, reported, June 4, 1869: " \* \* \* Arm decidedly atrophied; wrist joint ankylosed; hand and arm useless. Disability equal to loss of hand." The pensioner was paid June 4, 1875.



FIG. 695.—Three inches of right ulna excised. Spec. 338.

CASE 1912.—Private S. Painter, Co. K, 122d Ohio, aged 33 years, was wounded at Spotsylvania, May 12, 1864, and admitted to the field hospital of the 3d division, Sixth Corps, where Surgeon R. Barr, 67th Pennsylvania, recorded: "Gunshot wound of right forearm." On May 21st, the wounded man entered Finley Hospital, Washington. Surgeon G. L. Hancock, U. S. V., reported: "Gunshot fracture of ulna, the ball entering the outer side of the forearm at the middle third. The missile was extracted by a surgeon on the field. On May 24th, an operation was performed, consisting of excision of the fractured ends by chain saw and the removal of the spicule. The wound healed by healthy granulations." The specimen, represented in the cut (FIG. 697), consists of the excised part of the ulna, amounting to one and a half inches. It was contributed by the operator. On February 4, 1865, the patient was discharged from service and pensioned. Examiner J. Nichols, of Washington, D. C., certified, February 11, 1865: "Removal of four inches of shaft. Pronation and supination lost. Loss of use of wrist joint by ankylosis. Loss of use of all the fingers by reason of injury to extensor tendons—the fingers all remaining permanently extended. Limb quite useless and will never be restored." Examiner H. Culbertson, of Zanesville, Ohio, certified, January 13, 1870: " \* \* \* A portion of the flexor and extensor muscles, etc., on external aspect, are destroyed, producing contraction as well as partial atrophy. \* \* \* The elbow joint is normal. The motion of the wrist joint is unimpaired. The upper end of the lower fragment of the ulna is united to the radius by bony union. The function of rotation is obliterated," etc. Substantially the same was reported at an examination in September, 1873. The pensioner was paid September 4, 1875.



FIG. 697.—Inch and a half of right ulna. Spec. 2489.

CASE 1913.—Private W. B. Bradford, Co. I, 29th Maine, aged 20 years, was wounded at the Wilderness, May 5, 1864, and admitted to the field hospital of the 1st division, Fifth Corps, where Surgeon W. R. DeWitt, jr., U. S. V., noted: "Gunshot wound of arm." Surgeon O. A. Judson, U. S. V., in charge of Carver Hospital, Washington, furnished the specimen (FIG. 698) and the following history: "The missile, a conoidal ball (probably), entered the middle of the right forearm on the radial side, passing transversely through, and produced a compound comminuted fracture of the middle third of the radius. The general condition of the patient at date of admission—May 11th—appeared good. Simple dressings were applied, and a pint of ale was ordered during every twenty-four hours. May 20th, patient anesthetized and about three inches of radius removed, by Acting Assistant Surgeon W. C. Clark, making a straight incision, and removing sequestra and the serrated ends of the bone with the chain saw. The incision was then filled with charpie and cold-water dressings applied. 25th, wound filling rapidly with healthy granulations. Appetite good. Treatment continued. June 1st, patient about the same; the wound secretes a large quantity of laudable pus; simple cerate dressings used. 12th, pus burrowing about forearm to slight extent; free incisions were made. July 18th, has continued to improve. Wound now nearly healed. Patient was furloughed to-day. September 16th, patient returned from furlough." The specimen consists of eleven fragments, comprising the excised portion, from the middle of the radius. The patient was discharged from service March 2, 1865, and pensioned. Examiner J. Nichols, of Washington, D. C., March 7, 1865, certified: " \* \* \* No union has yet taken place; movable false joint exists, rendering hand and limb nearly useless for labor." Examiner C. N. Germaine, of Rockland, Me., September 5, 1867, certified: " \* \* \* The usual action required by an effort to use any implement, etc., produces severe pain in the affected limb. Besides this, the arm is almost entirely deprived of its rotary power. His arm is useful so far as regards any duty which does not require dexterity or strength. The arm is now in a worse condition than formerly, in consequence, I presume, of necrosis of one of the excised ends of the radius *in situ*, which more effectually destroys the power and comfort of the limb," etc. In September, 1873, the same examiner reported: "The wrist joint is partially ankylosed, pronation and supination of his arm injured, and his arm much reduced in power. Manual labor of an hour or less completely exhausts his arm." The pensioner was paid September 4, 1875.

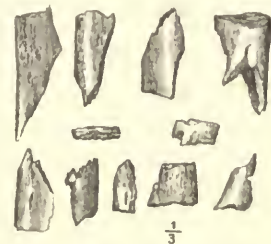

FIG. 698.—Eleven fragments of right radius removed by excision. Spec. 2297.



Among the hundred and twenty recoveries after intermediary excisions in the forearm, were eleven instances of secondary hæmorrhage, three consecutive amputations in the forearm, and six in the upper arm:

CASE 1914.—Captain J. H. Meyer, Co. G, 11th New Jersey, aged 34 years, was wounded at Chancellorsville, May 3, 1863. Assistant Surgeon G. Ribble, of the regiment, recorded the injury as "wound of arm, severe." On May 9th, the patient reached Washington, where he was treated by Surgeon C. L. Allen, U. S. V., who contributed the two specimens with the following report: "The ball entered externally near the middle of the left forearm, producing a comminuted fracture of the radius, and making its exit from the inner surface through the flexor muscle. The wound of exit was large and ragged. He had obtained a leave of absence, and as I saw him incidentally, he requested me to dress his wound before starting for his home. On examination, I found many fragments of bone lying irregularly in the wound, and recommended him to remain and have them removed. May 14th, being well etherized, the wound of exit was enlarged upward and downward and about twenty fragments of bone of different sizes were removed. The oblique points of the upper and lower portions of the radius were excised by the chain saw. The space left measured about two and a half inches. No vessel required ligating, and very little blood was lost. The

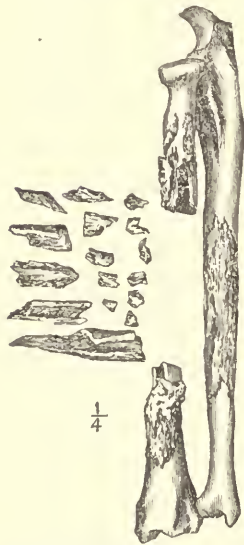


FIG. 699.—Bones of right forearm. Three and a half inches of radius excised. *Spec.* 1189.

fresh-cut extensions of the wound were approximated and secured by pins, two above and one below the original wound. 20th, he has suffered no pain since the operation, from which he was scarcely free a moment before. There is considerable swelling of the whole forearm; no union under the pins, and they were to-day removed. 25th, forearm considerably swollen, and œdematous around the elbow. About three o'clock P. M. some hæmorrhage occurred, which soon ceased. 28th, about five o'clock P. M. hæmorrhage commenced profusely, a steady stream of arterial blood, of the size of a crow's quill, pouring forth from the larger wound, some blood flowing also from the smaller wound (that of the entrance). The nurse (a woman) compressed the brachial artery with her fingers until a Lieutenant, who happened to be in the house, applied a Lambert's tourniquet. The loss of blood was estimated at from fifteen to twenty ounces. The tourniquet was continued on the arm, but loosened so as to allow of distinct pulsation of the radial artery at the wrist without recurrence of hæmorrhage. 31st, the bowels having become somewhat constipated, he took, this morning, some sulphate of magnesia. The tourniquet has been continued sufficiently tight to diminish the force of the pulse, but not so as to stop it. About five o'clock P. M., while having the first evacuation from the bowels in answer to this morning's laxative, there was a hæmorrhage of one or two ounces, readily checked by tightening the tourniquet. His pulse was 96 per minute, and has been between 90 and 100 constantly since the first hæmorrhage. June 1st, slight hæmorrhage at five o'clock P. M., and again at ten o'clock P. M.; pulse 96. 2d, since May 31st the bowels have been quite loose, and during the night he was up quite frequently to defecate. At half-past two o'clock this morning hæmorrhage again commenced, not profusely but persistently, and could not be controlled by tightening the tourniquet, which now, although very tightly applied, did not stop pulsation at the wrist. The brachial artery was held for a considerable time by the hand; pulse 120. He has suffered much pain, and had full doses of tincture of opium during the night. At ten o'clock A. M., amputation of the arm in its lower third was performed by Surgeon W. Moss, U. S. V. The operation was by double flap of skin, the muscles being cut

circularly. He was etherized readily and no unpleasant symptom was manifested. The brachial artery was held by the hand, and there was no hæmorrhage other than venous from the part removed. The brachial artery and three branches were ligated. The wound was left open and exposed to the air until four o'clock P. M., when the flaps were nicely coapted and held by strips of ichthyocolla plaster simply. 7th, the stump has nearly all healed by first intention, there being only slight dripping from the inner angle of the wound, where the free ends are brought out. He has been somewhat restless part of the time and has taken tincture of opium. He has also taken compound tincture of cinchona with the addition, during the last two days, of a few drops of tincture cantharides. 8th, during the night has been very restless, and occasionally delirious. All medicines were omitted, and he was soothed by being held by the hand gently and quietly spoken to. 13th, he has steadily continued to improve, taking no medicine except occasionally a dose of tincture of opium to check the diarrhœa, which has persisted but has not been severe. 18th, gaining finely. The ligature of the brachial artery and two of the others have come away to-day. 19th, the last ligature came away; discharge small in quantity but slightly bloody. 22d, he is feeling very well; got a leave of absence for thirty days, and started for his home." The specimen, represented in the cut (FIG. 699), consists of the bones of the forearm, and shows a space of excision of several inches in the radius. The excised extremities are necrosed, and periosteal disturbance is observable in the ulna opposite the seat of injury. The majority of the excised fragments are mounted with the specimen. The other specimen consists of a wet preparation of the soft tissues of the elbow, showing a false aneurism of the common interosseous, the injury, which is seated near the bifurcation, being due to a fragment of bone which is still embedded in the part. (*Cat. Surg. Sect.*, 1865, p. 456, *Spec.* 1190.) Captain Meyer was mustered out November 12, 1863, and entered the Veteran Reserve Corps several weeks afterward. He was discharged from service March 24, 1866, and pensioned. In his application for commutation, in 1870, he reported the stump as in good condition. The pensioner was paid September 4, 1875.

The extremity involved,<sup>1</sup> the dates of injury and of operation, the name of the operator, the complications, and the immediate and remote results are noted as far as practicable in the subjoined numerical statement.

<sup>1</sup>Of the 64 excisions in the shaft of the ulna, 31 were on the right, and 33 on the left side. Of the 47 excisions in the radius, 18 were on the right, 27 on the left, and 2 unspecified. Of the 9 cases of excision in the shafts of both ulna and radius, 5 were on the right side, and 4 on the left.

TABLE CXXVIII.

Summary of One Hundred and Twenty Cases of Recovery after Intermediary Excisions in the Bones at the Forearm for Shot Injury.

No.	NAME, AGE, AND MILITARY DESCRIPTION.	DATES.	OPERATIONS, OPERATOR, RESULT.	No.	NAME, AGE, AND MILITARY DESCRIPTION.	DATES.	OPERATIONS, OPERATOR, RESULT.
1	Ayers, C. D., Pt., 1, 6th Ohio Cav., age 18.	May 7, 13, '64.	Three, lower, left radius: by A. Surg. O. P. Swoet. Duty Nov. 22, 1864; pensioned.	26	Fink, H., Pt., B, 26th Wisconsin, age 23.	May 2, 16, '63.	One and a half, middle, right radius; by Surg. N. Hayward, 29th Mass.; gang.; spic. remov'd. To V. R. C. Mar. 10, '64; pens'd; disloc. hand; cannot close fingers.
2	Barry, T., Pt., K, 8th N. Y. H. A., age 25.	May 19, June 1, 1864.	Portion right ulna; by A. A. Surg. F. G. H. Bradford; crysp. Duty Nov. 25, '64; pens'd; crit. union.	27	Fitchett, C., Pt., A, 11th Pennsylvania Cavalry, age 18.	Aug. 26, Sept. 17, 1864.	Five and a half, upper, right ulna; by A. A. Surg. W. P. Moon (necrosis). Disch'd Jan. 20, 1865. Not a pensioner.
3	Barter, P., Pt., D, 31st Maine, age 53.	Aug. 16, Sept. 12, 1861.	Three, middle, left ulna; by A. Surg. C. Wagner, U. S. A.; necro. To V. R. C. May 11, '65; partial anchy. elb.; hand half disabled.	28	Flint, I. B., Pt., K, 1st Massachusetts Artillery, age 21.	May 18, 28, '64.	One, middle, right radius; by A. A. Surg. L. K. Baldwin; hemo.; lig. radial. Duty Feb. 16, 1865; pensioned; necrosis; deformity. Died February 18, 1868.
4	Bouras, T., Pt., H, 5th Mich. Cav., age 18.	June 9, July 4, 1864.	One and a half, middle, left ulna; by A. A. Surg. P. C. Porter. Dis. July 5, 1865; no bony union.	29	Flora, J. C., Pt., C, 4th Michigan, age 32.	July 2, 25, '63.	Four, middle, right ulna; by Surg. H. Palmer, U. S. V. Disch'd June 29, 1864; pensioned; ankylosis of elbow; general atrophy.
5	Bowton, C. F., Pt., I, 3d Michigan, age 22.	May 5, 11, '64.	Lower, right ulna; by A. A. Surg. S. Graham. Disch'd June 19, '64; pens'd; ligamentous union. See CASE 1907, p. 934. Spec. 4235.	30	Frank, E., Pt., H, 78th Pennsylvania, age 22.	Dec. 31, '62.	Four, upper, ulna. Disch'd May 1, 1863; pensioned; no rotation; hand cold and useless.
6	Boyce, W. D., Pt., I, 12th N. Y., age 37.	Oct. 27, Nov. 1, '64.	Three, right radius, middle. Discharged March 2, '65; pensioned; useful limb. Spec. 2297. See CASE 1913, p. 955.	31	French, L. W., Pt., M, 1st Maine Heavy Artillery, age 31.	May 19, 29, '64.	Two, lower, left radius; by A. A. Surg. W. C. Mulford (w'd right arm). Disch'd Dec. 3, '64; pen'd; hand paralyzed and cold.
7	Bradford, W. B., Pt., I, 20th Maine, age 34.	May 5, 20, '64.	Three, upper, left radius. Duty Sept. 2, 1863; arm partially stiff. Not a pensioner.	32	Fulton, A., Pt., A, 93d New York, age 24.	May 6, 14, '64.	Three, lower, left radius; by A. A. Surg. J. O. French. Disch'd Dec. 15, '64; pens'd; disloc. carp. end of ulna; hand useless.
8	Bran, J. G., Pt., G, 30th Maine, age 29.	Sept. 30, Oct. 12, 1864.	Lower, right ulna; by A. A. Surg. J. M. McCalla. Disch'd Aug. 5, '64; pensioned; arm impaired.	23	Greer, J. B., Pt., K, 41st Mississippi, age 26.	Dec. 31, '63.	Three, lower, radius. To prison March 20, 1863.
9	Brohl, M., Corp'l, A, 5th Michigan, age 23.	May 3, 11, '63.	Three, lower, left ulna; by A. A. Surg. J. C. Thorpe. Duty Mar. 14, 1865. Not a pensioner.	34	Griffith, J., Pt., M, 102d Penn., age 35.	May 5, 21, '64.	Middle, left ulna; by Surg. N. R. Moseley, U. S. V. Disch'd Sept. 3, '64; pens'd; almost useless. Spec. 2330.
10	Brooks, J. B., Lieut., I, 4th Vermont, age 24.	May 6, 17, '64.	Four, middle, left ulna; by A. A. Surg. A. D. White (rad. fract.); Disch'd June 14, '65; pen'd; 1866, rad. united, curved outward; no rotation; imperfect grasp.	35	Hahn, F., Pt., C, 20th Massachusetts, age 19.	July 1, 5, '61.	Portion of middle, right radius. Duty Nov. 16, 1863.
11	Brown, C., Pt., E, 42d Illinois, age 20.	Nov. 30, Dec. 6, 1864.	Two, middle, left radius. To V. R. C. May 12, 1864; pensioned; crysp. sub-luxated and no motion of wrist or fingers.	36	Harratty, J., Pt., D, 69th N. Y., age 27.	July 29, Aug. 3, 1861.	Two and a half, lower, left rad. Disch'd Feb. 13, '64; pens'd; atrophy arm and shoulder.
12	Brown, J., Pt., B, 52d Ohio, age 23.	May 11, June 1, 1864.	Fragments and upper thirds radius and ulna; by Surg. E. Swift, U. S. A.; June 18, amputation fore-arm. Disch'd Nov. 16, 1863.	37	Hayes, D. P., Pt., I, 19th Mass., age 19.	June 30, July 10, 1862.	Four, right ulna. Disch'd Sept. 17, '62; pens'd; forearm greatly impaired; fingers contracted.
13	Brown, M. A., Pt., B, 148th Pa., age 28.	July 2, 11, '63.	Two, middle, left radius; by A. Surg. C. Bacon, U. S. A. Disch'd Dec. 24, 1862; pensioned; great distortion of forearm.	38	Herbst, W., Pt., E, 59th Penn., age 19.	May 6, 14, '64.	Two, middle, left ulna; by A. Surg. H. Allen, U. S. A.; crysipelas. Disch'd Jan. 22, 1865.
14	Cambe, S., Pt., A, 40th Indiana, age 23.	Dec. 31, 1862, Jan. 18, 1863.	Three, left ulna; by A. Surg. C. Hill, 102d N. Y. Disch'd Dec. 30, '63. In 1870, amp. fore-arm; pensioner. Spec. 1152.	39	Hill, T. A., Pt., D, 120th New York, age 30.	Oct. 27, No. 4, '64.	One and a half, upper, left radius; by A. Surg. H. Allen, U. S. A. Disch'd Feb. 20, 1865.
15	Carney, J., Pt., B, 2d Massachusetts.	Sept. 17, Oct. 1, 1862.	Two, middle, right ulna; by Asst. Surg. S. A. Storrow, U. S. A. Disch'd July 24, '62. Re-enlisted Dec. 5, '67; pens'd; rotation fair.	40	Hodges, J. J., Lieut., C, 9th Louisiana, age 24.	July 9, 27, '64.	Lower, right ulna; by Surg. Todd, C. S. A.
16	Casey, M., Pt., D, 36th New York.	June 25, 30, '62.	Five of ulna, two and a half of radius, left, middle; by Surg. H. S. Hewit, U. S. V.; gang.; Feb. 28, rotation limited. Disch'd Mar. 13, 1863; pensioned.	41	Holland, J., Pt., A, 137th New York, age 34.	July 2, 21, '63.	Three, middle, right ulna; by Surg. J. A. Wolfe, 29th Penn.; Aug. 8th amp. arm. Disch'd Oct. 19, 1863; pensioned.
17	Cheney, D. J., Pt., A, 2d Massachusetts, age 39.	May 2, 7, '63.	Four, upper, right ulna; by A. A. Surg. W. P. Moon; Sept. 28, extoliation removed. To V. R. C. Feb. 6, '65; pens'd; shaft of ulna gone; moderate use. Spec. 3614. See CASE 1909, p. 959.	42	Irwin, R. B., Pt., A, 51st Ohio, age 27.	Dec. 16, 24, '64.	Four, right ulna, by A. A. Surg. A. Rollis. Disch'd June 2, 1865; pens'd; anchy. and paralysis.
18	Clark, W. H., Pt., D, 1st Delaware, age 25.	Sept. 17, 21, '62.	Three, lower, right radius. Discharged Feb. 28, 1865.	43	Jackson, S., Corp'l, D, 21st Ohio.	July 9, 15, '64.	Three, lower, right radius. Discharged Feb. 28, 1865.
19	Colb, D. B., Serg't, H, 118th Pa., age 20.	July 1, 22, '64.	Four and a half, middle, left ulna, with fragments; by Surg. J. L. Van Alstyne, 3d N. Y. C.; amp. arm Sept., '65. Disch'd Dec. 5, 1865; pensioned.	44	Jenkins, J., Pt., C, 3d N. Y. Cav.	Mar. 14, April 3, 1865.	Four and a half, middle, left ulna, with fragments; by Surg. J. L. Van Alstyne, 3d N. Y. C.; amp. arm Sept., '65. Disch'd Dec. 5, 1865; pensioned.
20	Cooper, J. B., Pt., D, 122d Ohio, age 28.	May 31, June 17, '64.	Four, lower, left ulna, with fragments; by Surg. O. A. Judson, U. S. V. Disch'd June 29, '65; pens'd; bony union; no rotation.	45	Johnson, W. D., Pt., K, 100th Penn., age 43.	June 2, 10, '64.	Four, lower, left ulna, with fragments; by Surg. O. A. Judson, U. S. V. Disch'd June 29, '65; pens'd; bony union; no rotation.
21	Crosby, E. S., Pt., K, 1st Maine Heavy Artillery, age 23.	June 18, 26, '64.	One and a half, lower, left radius. Disch'd Nov. 10, 1863; pen'd; ulna disloc.; wrist anchy.	46	Jones, C. P., Corp'l, D, 5th Wisconsin, age 26.	May 3, 11, '63.	One and a half, lower, left radius. Disch'd Nov. 10, 1863; pen'd; ulna disloc.; wrist anchy.
22	Dean, C. H., Pt., H, 2d Massachusetts Cavalry, age 21.	Aug. 24, Sept. 12, 1861.	Lower, left ulna. Disch'd Sept. 16, '62. Not a pensioner.	47	Jones, W. F., Corp'l, E, 12th Infantry.	June 27, July 19, '62.	Lower, left ulna. Disch'd Sept. 16, '62. Not a pensioner.
23	Denneston, J. F., Lieut., E, 70th New York, age 21.	May 5, 19, '62.	Six, upper, right ulna. Disch'd Oct. 1, '63.	48	Jordan, G., Pt., C, 17th Ohio, age 20.	Sept. 20, Oct. 1, '63.	Six, upper, right ulna. Disch'd May 6, '64; pens'd; arm useless.
24	Enos, J. H., Pt., B, 35th New York, age 32.	Aug. 30, Sept. 10, 1862.	Three, right ulna; by A. A. Surg. P. Hall. To V. R. C. Dec. 4, 1864; pens'd; wrist distorted; no bony union; atrophy.	49	Kent, E. B., Pt., A, 6th Vermont, age 21.	May 6, 16, '64.	Three, right ulna; by A. A. Surg. P. Hall. To V. R. C. Dec. 4, 1864; pens'd; wrist distorted; no bony union; atrophy.
25	Evans, G. G., Serg't, K, 44th Alabama, age 26.	July 6, 31, '64.	One and a half, right, rad. Duty. Died Oct. 21, '64, acute dysentery.	50	Kelly, J. W., Pt., H, 6th Kentucky, age 19.	Sept. 19, Oct. 1, '63.	One and a half, right, rad. Duty. Died Oct. 21, '64, acute dysentery.
			Six, right ulna; by Surg. J. Bryan, U. S. V. Disch'd Nov. 11, '62; pens'd; elbow dislocated; wrist stiff; some use of hand.	51	Killian, W. M., Pt., H, 11th Alabama.	July 2, 8, '61.	Three, upper, ulna. Furloughed August 26, 1863.
			Five, right ulna and portion of radius. Ret'd Mar. 1, '65; complete anchy. elb.; loss of use of hand.	52	Keinig, W., Pt., E, 119th N. Y., age 25.	Dec. 2, 9, '62.	Half inch from end, upper, right ulna; by Surg. A. Wynkoop, U. S. V. Discharged April 3, '63; pensioned; atrophy and deformity. Died August 18, 1874.



No.	NAME, AGE, AND MILITARY DESCRIPTION.	DATES.	OPERATIONS, OPERATOR, RESULT.	No.	NAME, AGE, AND MILITARY DESCRIPTION.	DATES.	OPERATIONS, OPERATOR, RESULT.
53	Lang, W., Pt., K, 1st Maine Cav., age 25.	June 24, July 15, 1864.	Middle, left ulna, and fractured ends; by A. Surg. T. Artand, U. S. V. Disch'd Feb. 24, '65; pensioned; no bony union; atrophy.	82	Rhein, G., Pt., K, 1st Wisconsin, age 32.	May 28, June 3, 1864.	Two, lower, right ulna; by A. A. Surg. G. E. Stubbs; gangrene. Disch'd Nov. 20, 1864; pens'd; fingers almost immovable.
54	Leasure, J. G., Pt., D, 138th Pa., age 22.	June 2, 13, '64.	Four, lower, left radius; by A. A. Surg. W. E. Sparrow. Disch'd February 10, 1865; pensioned; ankylosis; deformity; useless. See CASE 1908, p. 954. <i>Spec.</i> 823.	83	Rheads, H. C., Pt., C, 138th Pa., age 24.	June 3, 15, '64.	Three, left radius; by A. A. Surg. D. G. Caldwell, To V. R. C. Jan. 18, 1865; pens'd; carpal end ulna luxated; grasp impaired.
55	Lefevre, J., Corp'l, H, 48th Pa., age 28.	Sept. 17, 18, '62.	Three, lower, left ulna; by Surg. W. Varian, U. S. V. Disch'd Dec. 4, 1862; pensioned; partial ankylosis elbow; use impaired.	84	Robbins, R. B., Major, 4th Michigan Cavalry, age 31.	May 18, June 1, 1864.	Three, lower, left ulna; by Surg. J. E. Herbst, U. S. V. Duty Oct. 20, 1864; pens'd; paralysis; partial loss of use of hand.
56	Little, J. C., Pt., G, 21st Wisconsin, age 19.	Oct. 8, 20, '62.	Five, middle, left radius. Disch'd May 22, 1863; pens'd; no bony union; ankyl. elb.; hand useless.	85	Roberts, A. N., Pt., L, 7th New York Heavy Artillery, age 27.	June 3, 9, '64.	Three, middle, left ulna; by Surg. J. S. Wentz. Disch'd Nov. 19, 1864; pensioned; no bony union; limb impaired.
57	Lucas, C., Corp'l, C, 16th New York, age 22.	May 3, 11, '63.	Three and one-fourth, middle, left, both bones; by A. Surg. A. V. Cherbonnier. Disch'd Mar. 27, 1865; pensioned; limb deformed.	86	Root, E. C., Lieut., D, 2d New York Artillery, age 29.	May 19, 29, '64.	Two and a half, upper, left radius; by A. A. Surg. J. O. Stanton; ham; lig. and re-lig. brach'd. Dismissed January 25, 1865.
58	Lupton, H. R., Serg't, B, 126th Ohio, age 27.	July 9, 27, '64.	Three and a half, upper, right radius; by A. A. Surg. H. S. Kilbourne; August 2, amp. arm. Disch'd April 11, '65; pensioned.	87	Ryan, J., Pt., K, 45th Pennsylvania, age 22.	Sept. 17, 24, '62.	Two and a half, middle, left radius; by Surg. H. S. Hewit, U. S. V. Dis'd Dec. 19, '62; pens'd; imp'd.
59	Luse, J. B., Pt., C, 125th Ohio, age 22.	July 18, 23, '64.	Three and a half, lower half, left radius; by A. A. Surg. W. E. Sparrow. Disch'd Feb. 10, '65; pensioned; ulna displaced; hand badly deformed.	88	Sage, J. W., Pt., F, 75th Indiana, age 22.	Sept. 19, Oct. 19, 1863.	One, lower and middle, left ulna. Disch'd June 20, 1865; pens'd; no rotation; hand weak.
60	Mack, E., Pt., D, 138th Pennsylvania, age 25.	June 2, 13, '64.	Three, lower, left ulna; by A. A. Surg. P. Wilson. Disch'd Sept. 2, '64; pen'd; lig. union; no grasp.	89	Schmidt, E., Pt., C, 28th Kentucky.	June 11, 18, '64.	Upper, left ulna; by Surg. E. B. Glick, 46th Ind. To V. R. C. Dec. 27, 1864. Not a pensioner.
61	Masland, J. W., Serg't, F, 23d Pa., age 23.	June 1, 10, '64.	Two and a half, lower, right rad.; by A. A. Surg. S. Coloosidian. Disch'd March 4, '65; pensioned; ankylosis; deformity of wrist.	90	Scott, J. D., Serg't, D, Cobb's Legion, age 27.	Oct. 11, Nov. 3, 1863.	Loose fragments and ends of bone of right ulna, near wrist. Prolonged November 22, 1863.
62	Matthewson, A., Pt., A, 2d Pa. Heavy Artil'y, age 50.	June 16, 23, '64.	Two and a half, lower, right ulna; by A. A. Surg. C. C. Ela. Discharged June 26, '65; pensioned; no rotation; adherent cicatrix.	91	Scott, T. E., Pt., K, 19th Maine, age 26.	July 2, 6, '63.	Portions lower, right radius and ulna. Disch'd Mar. 23, '65; pen'd; no rotation; cannot flex fingers.
63	Matthews, W. E., Serg't, C, 4th C. T., age 28.	Sept. 29, Oct. 19, 1864.	Two and a half, lower, right ulna; by A. Surg. T. Artand, U. S. V. Mustered out Nov. 6, 1864; pensioned; limb useless.	92	Shannon, A. J., Pt., F, 55th Ohio, age 25.	May 15, June 13, 1864.	Three, upper, left ulna. Disch'd Oct. 29, '64; pens'd; partial flexion forearm; fingers contracted.
64	Maurly, L., Corp'l, E, 2d Pennsylvania Cavalry, age 21.	June 24, 1864.	Two and a half, lower, right radius; by A. Surg. T. Artand, U. S. V. Disch'd Sept. 17, 1863.	93	Sheridan, A. A., Pt., E, 13th Illinois, age 29.	Nov. 27, Dec. 3, 1863.	Portion, left radius (ulna fract.); gang. Disch'd June 18, '64; pens'd; dis. car. end ulna; hand pow'less.
65	McCartney, R., Pt., K, 124th N. Y., age 41.	May 3, 11, '63.	Two, middle, left radius; by A. A. Surg. W. E. Clark. Disch'd Apr. 13, '65; flex. and rota. imp'd. See CASE 1914, p. 956. <i>Specs.</i> 1189 and 1190.	94	Short, W. S., Pt., G, 114th New York, age 19.	Sept. 21, Oct. 18, 1864.	Three, upper, left radius; by A. A. Surg. W. P. Moon. Disch'd Mar. 4, '65; pens'd; disloc. ulna; forearm much deformed.
66	McCoy, H. J., Lieut., K, 33d N. C., age 29.	May 3, 13, '63.	Four, upper, left ulna. Furloughed Sept. 17, 1863.	95	Shumway, W., Pt., K, 8th Michigan, age 20.	May 6, 13, '64.	Three, middle, right rad.; by Surg. W. B. Fox, 8th Mich.; gangrene. Disch'd Aug. 25, '65; pensioned; ankylosis of elbow; carpal end of ulna displaced.
67	McNealy, J., Pt., C, 93d New York, age 21.	May 5, 11, '64.	Three, upper, left ulna; by A. A. Surg. W. H. Truce. Drowned November 11, 1864.	96	Smith, G. P., Serg't, C, 68th Pennsylvania, age 38.	May 3, 15, '63.	Four, upper, right ulna; fragments removed. Disch'd Mar. 8, 1864; fingers semiflexed.
68	Meyer, J. H., Capt., G, 11th New Jersey, age 23.	May 3, 14, '63.	Two, lower, right ulna. Disch'd Sept. 5, 1864; pensioned; no rotation; cannot flex fingers.	97	Speidel, C., Serg't, E, 74th Pennsylvania, age 29.	May 21, June 6, 1864.	Two-thirds lower, left radius; by A. A. Surg. W. Baker. Disch'd Aug. 22, '64; pensioned; ankylosis of wrist; hand turned inward and paralyzed.
69	Mills, N. J., Serg't-Maj., 1st Me. H. A., age 20.	June 18, 30, '64.	Three, upper, left ulna; by A. Surg. H. Allen, U. S. A. Disch'd Mar. 21, '65; pens'd; ankyl. elb.; wrist swollen; limb useless.	98	Stevens, D. W., Corp'l, G, 122th N. Y., age 21.	May 5, 31, '64.	One and a half, lower, left radius; by A. A. Surg. P. C. Price; erysip. Disch'd Jan. 16, '65; ankyl. wrist; flex. fingers imp'rt.
70	Milner, W., Lieut., K, 1st New Jersey, age 23.	June 3, 1864.	Four, middle, left ulna; by Surg. G. L. Ponceast, U. S. V. Disch'd Aug. 3, '65; pens'd; paral.; atrophy. Died Feb. 18, '67. <i>Spec.</i> 4285.	99	Stevens, E. O., Serg't, B, 165th N. Y., age 23.	April 7, 19, '64.	Two, right radius; by Surg. F. Tacon, U. S. V. Duty Sept. 16, '61; pens'd; ulna disloc. at wrist.
71	Morian, S., Pt., C, 8th New Jersey, age 25.	Oct. 27, Nov. 4, 1864.	Three and a half, upper, left ulna; by Surg. J. C. Derr, U. S. A. Dis. Sept. 12, '62; hand nearly useless.	100	Stewart, J., Serg't, C, 12th Iowa, age 27.	July 14, 22, '64.	Two, middle, left radius; by A. A. Surg. R. W. Coale. Disch'd May 20, '65; pens'd; entire loss of use of limb; great deformity.
72	Morony, J., Pt., C, 94th New York, age 43.	Mar. 31, April 14, 1865.	Three, lower, right radius; by A. Surg. W. S. Ely, U. S. V. Dis. Feb. 6, 1865; pensioned; ankylosis wrist; fingers extended.	101	Sunrington, T. C., Pt., H, 8th La., age 30.	July 9, 13, '64.	Portion radius; by A. A. Surg. G. L. Goldborough. Exchanged September 19, 1864.
73	Morris, J., Pt., I, 9th Massachusetts, age 26.	July 1, 8, '62.	Four, lower half, left radius (fracture humerus; amp. right arm). Retired January 25, 1865.	102	Sweeney, H., Pt., E, 121st N. Y., age 18.	May 3, 10, '63.	Two and a half, lower, right ulna (fract. radius); necrosed radius removed. Disch'd Nov. 2, '63; pens'd; ankyl. wrist; fingers cold and stiff.
74	Murdock, J. C., Serg't, C, 123d Ohio, age 36.	July 9, 13, '64.	Half inch and frag's lower, right ulna (radius fract.). Duty Sept. 20, '62; pen'd. Died Dec. 20, '70. See CASE 1912, p. 955. <i>Spec.</i> 2480.	103	Sylvia, J., Corp'l, D, 21st Ohio, age 37.	July 9, 14, '64.	Two and a half, upper, right rad.; by A. A. Surg. G. E. Stubbs. Disch'd Feb. 28, '65; pens'd; hand ankyl. right angle; paral.
75	Nelson, J. B., Pt., B, 33d North Carolina, age 28.	May 3, 11, '63.	Portion lower, left ulna; by A. Surg. H. Allen, U. S. A. Disch'd Feb. 27, 1865; necrosis both bones; open sore; no rotation.	104	Taft, D. W., Pt., I, 95th N. Y., age 20.	Mar. 31, April 12, 1865.	Two and a half, lower, right rad.; by Surg. G. L. Ponceast, U. S. A.; hamor.; amp. forearm. Disch'd July 22, 1865. <i>Spec.</i> 4284.
76	Noonan, J., Serg't, G, 14th Infantry, age 30.	June 27, July 15, 1862.	Necrosed portion and spicula lower, left ulna. Disch'd Dec. 13, '62; pens'd; anky. fingers and wrist.	105	Tuck, C. H., Pt., F, 17th Maine, age 22.	May 6, 12, '64.	Three, lower, right radius; by A. A. Surg. J. O. French. Disch'd Dec. 29, 1864.
77	Painter, S., Pt., K, 123d Ohio, age 33.	May 12, 24, '64.	Five, lower right radius; by Surg. D. Merriat, 53th Pa. Disch'd Dec. 11, '63; pens'd; arm deform.; hand almost useless. <i>Spec.</i> 1890. See CASE 1911, p. 955. <i>Spec.</i> 338.	106	Voltz, G., Pt., B, 1st Conn. Cav., age 26.	April 6, 22, '65.	Two, middle, right ulna; by Surg. G. L. Ponceast, U. S. V. Disch'd July 28, '65; pens'd; no bony union. <i>Spec.</i> 4286.
78	Quinn, F., Pt., H, 124th New York, aged 25.	Oct. 27, Nov. 3, 1864.		107	Walker, W. H., Serg't, D, 7th Wis., age 32.	Mar. 31, April 12, 1865.	One and a half, middle, left rad.; by Surg. G. L. Ponceast, U. S. V. Disch'd July 31, '65; pens'd; ankylosed at 45°. <i>Spec.</i> 4283.
79	Raymond, W., Pt., D, 8th Ohio, age 29.	Sept. 17, Oct. 9, 1862.					
80	Rayner, J. B., Pt., E, 48th N. Y., age 18.	July 18, Aug. 14, 1863.					
81	Rees, R., Pt., A, 105th Ohio, age 29.	Oct. 8, 22, '62.					

No.	NAME, AGE, AND MILITARY DESCRIPTION.	DATES.	OPERATIONS, OPERATOR, RESULT.	No.	NAME, AGE, AND MILITARY DESCRIPTION.	DATES.	OPERATIONS, OPERATOR, RESULT.
108	Watkins, A. J., Pl., B, 101st Penn., age 32.	May 31, June 24, 1862.	Four, lower, left ulna. Disch'd July 7, '62; pens'd; useless for heavy work.	115	Walfang, S. T., Serg't, A 14th N. C., age 19.	May 3, 11, '61.	See CASE 1910, p. 954. Exch'd June 25, '61. Spec. 1489.
109	Warner, D., Pl., A., 157th Pa., age 26.	June 18, 27, '64.	Four, lower, right radius. Disch'd July 27, '65; pens'd; no rotation—hand drawn inw'd, much imp'd.	116	Walter, S. C., Pl., A., 28th Tenn., age 24.	Feb. 12, 25, '65.	Three, lower, right radius and ulna; by A. A. Surg. W. J. Holmes. To Provost Marshal May 6, 1865.
110	Warren, J. H., Serg't, A, 4th C. T., age 25.	Sept. 29, Oct. 25, 1864.	Four and a half, middle, right ulna; by A. A. Surg. O. Warner. Disch'd April 1, '65; pen'd; hand nearly useless.	117	Wilse, M. H., Pl., G, 1st Sharpsh'rs, age 25.	May 3, 9, '63.	Three and a half, upper, r't ulna; by Surg. T. Antsell, U. S. V. May 26, '63; brachial; Sept. 20, neuro, rad. rem'd. Disch'd Jun. 11, 1864; pens'd; limited ankylosis wrist, cannot flex fingers.
111	Weber, W., Pl., B, 114th Penn., age 34.	May 3, 10, '63.	Three, upper, left ulna. To V. R. C. Sept. 9, 1863; pens'd; atrophy; radius subluxated.	118	Witt, E., Pl., A, 187th N. Y., age 43.	Oct. 27, Nov. 18, 1864.	Three, lower, left radius. Disch'd May 26, '65; pens'd; ankyl. wrist at 159; utterly useless.
112	Weidner, M., Pl., B, 93d Penn., age 20.	May 6, 12, '64.	Two, lower, right ulna; by A. Surg. H. Allen, U. S. A.; crysip. Disch'd Jan. 27, '65; pens'd; deformity; limb much weaken'd.	119	Wood, D. T., Serg't, K, 64th N. Y., age 32.	July 3, 29, '63.	Two, lower, right ulna (lg. ulnar). Disch'd Dec. 21, '63; pens'd; no motion of wrist; immobility of fingers.
113	Whalen, T., Pl., D, 88th N. Y., age 63.	June 5, 12, '64.	Three, left ulna; fever, amp. arm. Recovered. Died May 29, '65, cancer of liver.	120	Wool, S., Pl., G, 121st Ohio, age 18.	June 27, July 11, 1864.	Two, upper, right ulna; by A. A. Surg. J. G. Harvey; part. paral. Disch'd May 17, '65; pens'd; false ankylosis of elbow.
114	Wheeler, C. C., Pl., D, 6th Vt., age 21.	May 6, 15, '64.	Two and a half, left radius and ulna, middle thirds; by A. A. Surg. R. E. Price.				

§ *Fatal Intermediary Excisions in the Forearm.*—Twenty-nine of the hundred and forty-nine intermediary operations resulted fatally, mainly from pyæmic complications.<sup>1</sup>

CASE 1915.—Private G. W. Wilcox, Co. I, 57th Massachusetts, aged 25 years, was wounded at Spottsylvania, May 19, 1864, and sent to Emory Hospital, Washington, where Surgeon N. R. Moseley, U. S. V., reported: "Admitted May 22, 1864, from the field. Gunshot wound of left forearm. A minie ball passed from without inward through middle third, lacerating the flesh and fracturing the radius at middle third. On May 23d, Acting Assistant Surgeon W. H. Ensign excised the radius at middle third, chloroform and ether being used as anæsthetics. At the time of the operation the limb was swollen, but the constitutional state of the patient was favorable. Splints and bandages were applied to the limb and cold-water dressings to the wound. On May 31st, erysipelatos inflammation set in with a tendency to gangrene. After the occurrence of erysipelas, carrou oil and a solution of sulphate of copper were used externally, and stimulants and anodynes were administered internally. The patient died June 11, 1864, of pyæmia." The specimen, represented in the adjoining wood-cut (FIG. 700), was contributed to the Museum by Dr.



FIG. 700.—Fragments of left ulna excised.—Spec. 2350.

Moseley. It is described as "fragments, representing about one inch of the shaft of the radius, removed by operation."

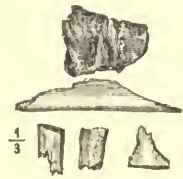


FIG. 701.—Pieces of left ulna excised for shot injury.—Spec. 2296.

CASE 1916.—Sergeant P. Welsh, Co. K, 28th Massachusetts, aged 32 years, was wounded at Spottsylvania, May 12, 1864, and sent from a Second Corps field hospital to Washington, where Surgeon O. A. Judson, U. S. V., reported: "Admitted to Carver Hospital, May 14, 1864. Gunshot wound of left forearm, by a conoidal ball, producing compound comminuted fracture of inferior third of left ulna. On May 17th, Acting Assistant Surgeon J. S. Wentz excised three inches of the shaft of the ulna through a straight incision; no ligatures were applied; the ball was also extracted. The constitutional state of the patient at time of operation was good. On May 20th, secondary hemorrhage occurred, apparently from the interosseous

artery, but ceased spontaneously. On the 24th, rigors and other pyæmic symptoms appeared, and the patient died May 28th, 1864, from pyæmia." The specimen, represented in the adjoining wood-cut (FIG. 701), was contributed to the Museum by Dr. Judson. It consists of "four pieces of bone, representing three inches of the left ulna, excised; a conoidal ball, exceedingly battered, distorted, and grooved, is mounted with the specimen."

CASE 1917.—Private John Shupe, Co. D, 155th Pennsylvania, age 18 years, was wounded at the South Side Railroad, October 27, 1864, and sent from a Fifth Corps field hospital to Washington. Surgeon N. R. Moseley, U. S. V., reported: "Admitted to Emory Hospital October 30, 1864. Gunshot wound of left forearm, with compound comminuted fracture of radius. November 2d, excision of about three inches of radius from lower third upward, through an incision about five inches in length; ball also extracted; anæsthetic—chloroform. At time of operation the tissues were very much inflamed and lacerated, the radius comminuted, and the parts infiltrated with unhealthy pus; the constitutional state of the patient was good. After the operation the parts were left open and dry lint applied; stimulants were given internally, and nourishing diet ordered." The patient died November 6, 1864, from hectic fever. The specimen, represented in the accompanying wood-cut (FIG. 702), was contributed to the Museum by the operator, Dr. Moseley. It is described by Acting Assistant Surgeon J. E. Janvier, who had charge of the case, as consisting of "the fractured portions of the radius removed during the operation. The larger piece is some two inches in length, and on making the incision was found detached from the shaft of the bone. The small spiculae were removed from the ends of the fractured bone."



FIG. 702.—Three inches of left radius excised for shot injury. Spec. 3412.

<sup>1</sup> Of the 29 patients, 12 died from pyæmia, 2 from pneumonia (?), 3 from hectic or exhaustive suppuration, 1 from diphtheritic infection, 2 from tetanus, 1 from gangrene, 2 from abdominal complications, not reported, 6.



None of the twenty-nine fatal intermediary excisions interested both bones; eighteen were in the shaft of the ulna, eleven in the shaft of the radius.<sup>1</sup>

CASE 1918.—Captain J. S. McCready, Co. H, 126th Ohio, aged 35 years, was wounded at Spottsylvania, May 10, 1864, and admitted to Emory Hospital, Washington, on the 17th. Surgeon N. R. Moseley, U. S. V., reported: "Gunshot wound of left forearm at middle third; a minié ball passed from without inward, fracturing the ulna and lacerating the radial artery. May 19th, secondary hemorrhage occurred from radial artery, which rendered ligation necessary; ten ounces of blood lost. 20th, hemorrhage recurred; temporarily arrested by compression; eight ounces of blood lost. Surgeon Moseley ligated radial artery at cardiac and at distal extremities, and also resected four inches of ulna at middle third. Constitutional state of patient at time of operation favorable; arm kept *in situ* by splint and roller. June 1st, patient doing well; hemorrhage has not recurred. 15th, pyæmia set in; hemorrhage recurred, eight ounces of blood lost. 22d, four ounces of blood lost; tonic and stimulant treatment. 27th, eight ounces of blood lost; patient still suffering from pyæmia. Hemorrhage again recurred on the 6th of July; radius and remaining portion of ulna necrosed; soft parts much swollen; sinuses extending to elbow with discharge of dark ichorous pus. Flap amputation of arm at middle third by Surgeon N. R. Moseley, U. S. V.; anæsthetic—sulphuric ether. At time of operation patient much reduced from loss of blood and excessive discharge from wound; pulse 110, weak. Nausea and hiccough, with extreme nervous prostration; treatment, tonics and stimulants with nutritious diet; adhesive straps and cold-water dressings; wound granulating healthily, with copious discharge of laudable pus until July 24th, when the discharge ceased; applied flaxseed poultices. July 31st, discharge reappearing and patient gradually improving." This officer was transferred to the care of Surgeon Thomas Antisell, U. S. V., August 4th, and on the 19th was granted a leave of absence for thirty days to visit his home in Ohio. Surgeon Antisell noted: "Died September 7, 1864, of wounds received in battle." The specimen, represented in the adjoining wood-cut (FIG. 703), was contributed to the Museum by the operator, Dr. Moseley. It consists of "the bones of the left forearm. Three and a half inches from the lowest third of the ulna appears to have been excised. The extremity of the lower fragment is carious, and the upper portion of the shaft is necrosed nearly to the olecranon. A small portion of the inner border of the radius has been absorbed as if after contusion."

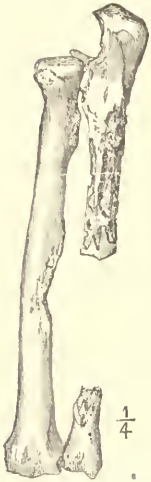

FIG. 703.—Excision of 3½ inches of ulna. Spec. 2810.

CASE 1919.—Private R. Johnson, Co. C, 6th New York Heavy Artillery, aged 18 years, was wounded at the battle of the Wilderness, May 18, 1864, and admitted to Emory Hospital, Washington, on the 22d. Surgeon N. R. Moseley, U. S. V., reported: "Gunshot wound of right forearm. A minié ball passed through from posterior to anterior surface of middle third, producing compound comminuted fracture of the radius. Excision of middle third of radius June 2, 1864, by Surgeon N. R. Moseley, U. S. V.; chloroform and ether used as an anæsthetic. At time of operation the soft parts were lacerated and sloughing; constitutional state of patient favorable. After treatment: cold-water dressings, stimulants, and nutritious diet. June 8th, dysentery set in; patient not doing well; result: died June 19, 1864." The excised portion of the radius, represented in the adjoining wood-cut (FIG. 704), was contributed to the Museum by Dr. Moseley. The specimen shows a loss of substance corresponding to the calibre of the bullet.



FIG. 704.—Excised portion radius. Spec. 2508.

CASE 1920.—Private J. Sullivan, Co. G, 49th New York, was wounded at the battle of Bull Run, August 30, 1862, and admitted to Harewood Hospital, Washington, September 5th. Surgeon T. E. Mitchell, 1st Maryland, noted: "Excision of three and a half inches of right ulna, upper third, September 14, 1862, for gunshot compound fracture of forearm." The patient died September 18, 1862. The excised portion of the ulna was contributed to the Museum by the operator, Dr. Mitchell, and is represented in the adjoining wood-cut (FIG. 705). It is described by Assistant Surgeon B. Stone, U. S. V., as "a section of shaft of the right ulna extensively comminuted by the impact of a conoidal musket ball."



FIG. 705.—Excised portion of ulna. Spec. 69.

Consecutive amputation of the upper arm was unsuccessfully resorted to in five of the twenty-nine fatal intermediary excisions:



FIG. 706.—Excision ulna. Spec. 2955.

CASE 1921.—Private W. Van Nevil, Co. E, 8th Michigan, aged 14 years, was wounded at Petersburg, June 18, 1864, and admitted to the Ninth Corps field hospital at City Point, June 21st, from a third division field hospital. On June 22d, Assistant Surgeon M. J. Asch, U. S. A., amputated the right arm on account of gangrene following an excision of one inch of the shaft of the right ulna for a shot fracture of the upper third of that bone by a minié ball. On July 1st, the patient was transferred to Washington, and admitted to the 2d to Mount Pleasant Hospital, where Assistant Surgeon C. H. McCall, U. S. A., noted: "Died July 7, 1864, of diphtheria and wounds." The specimen, represented in the adjoining wood-cut (FIG. 705), was contributed to the Museum by Dr. Asch. It consists of "the upper portion of the right ulna from which an excision has been made."

In one instance the fatal result was probably mainly due to a concomitant fracture of the spinous process of a dorsal vertebra. Two patients succumbed from tetanus. In one case the brachial artery, in one the radial, in two the interosseous, were tied, either in the course of the operation or later, for consecutive bleeding. The twenty-nine cases are tabulated on the next page.

<sup>1</sup> Excisions were of the right radius in 5 cases, of the right and left ulna in 9 cases, respectively. The extent removed from the radius varied from 1 to 3½ inches; in the ulna from 1 to 6 inches—in 8 cases from 3 to 4 inches being removed.

TABLE CXXIX.

Summary of Twenty-nine Fatal Cases after Intermediary Excisions in the Bones of the Forearm for Shot Injury.

No.	NAME, AGE, AND MILITARY DESCRIPTION.	DATES.	OPERATIONS, OPERATOR, RESULT.	No.	NAME, AGE, AND MILITARY DESCRIPTION.	DATES.	OPERATIONS, OPERATOR, RESULT.
1	Burns, J. D., Pt., II, 155th Pa., age 19.	Oct. 27, Nov. 10, 1864.	Two, right ulna, lower; by Surg. O. A. Judson, U. S. V. Died Nov. 30, 1864, pyæmia.	15	McCready, J. S., Capt., II, 126th Ohio, age 35.	May 10, 20, '64.	See CASE 1918, p. 960. <i>Spec.</i> 2810.
2	Bush, J. M., Pt., F, 57th Pennsylvania, age 49.	May 6, 19, '64.	One and a half, lower, right ulna; by A. Surg. J. Y. Cantwell, U. S. V. Died May 20, 1864.	16	McGurk, O., Pt., C, 88th New York, age 30.	May 8, 16, '64.	Four, middle, left ulna; by A. A. Surg. H. E. Price; May 25, hæm. from interosseous; ligated. Died June 4, 1864, pyæmia.
3	Carr, J. S., Pt., G, 14th New York Heavy Artillery, age 24.	June 18, July 18, 1864.	Upper and lower ends of ulna; by A. A. Surg. W. C. Mulford. Died July 30, 1864, acute diarrhœa.	17	Price, G. G., Serg't, C, 2d New York Mounted Rifles, age 20.	June 7, 18, '64.	Two and a half, right radius (other wounds). Died June 30, 1864, asthenia.
4	Cornelius, A., Pt., A, 5th New Jersey, age 19.	May 4, 12, '63.	Lower, right ulna; hæmorrhage. Died June 3, 1863, pyæmia.	18	Quigley, E., Pt., C, 95th Pennsylvania, age 20.	May 12, 21, '64.	Lower, right radius; by Surg. N. H. Moseley, U. S. V. Died June 25, 1864.
5	Daniels, W. A., Pt., E, 2d Massachusetts.	Aug. 9, 21, '62.	Upper, left ulna; hæmorrhage; August 25, amputation of arm. Died Sept. 5, 1862, pyæmia.	19	Rees, G. W., Pt., G, 20th Pennsylvania Cavalry, age 22.	April 1, 12, '65.	Two, middle, left radius, and ligated brachial; by A. A. Surg. J. Morris. Died April 26, 1865, pneumonia.
6	Davidson, J. W., Corp'l, F, 8th Maryland, age 21.	May 5, 13, '64.	Three, lower, right ulna; by Surg. O. A. Judson, U. S. V. Died May 28, 1864, pyæmia.	20	Scott, R., Pt., II, 11th Wisconsin.	May 26, June 5, 1863.	Fractured end of right radius, upper third. Died June 15, 1863, tetanus.
7	Forbes, B. F., Pt., II, 20th Maine, age 20.	May 5, 15, '64.	Three, middle, right ulna; by A. A. Surg. W. E. Clark. Died May 26, 1864, tetanus.	21	Sharin, J., Pt., F, 7th Pennsylvania Cavalry, age 35.	June 1, 8, '64.	Two and a half, lower, left ulna; by A. A. Surg. H. S. Kilbourne (gangrene). Died June 13, '64, pyæmia.
8	Gochemaur, J., Pt., D, 20th Pennsylvania, age 21.	May 12, 18, '64.	Portion upper, right radius; by A. A. Surg. W. H. Ensign (fracture vertebra). Died May 30, '64.	22	Shupe, J., Pt., D, 155th Pennsylvania, age 17.	Oct. 27, Nov. 2, '64.	See CASE 1917, p. 959. <i>Spec.</i> 3412.
9	Hughes, P., Capt., E, 37th Indiana, age 37.	June 22, July 9, 1861.	Two, upper, right ulna; by A. A. Surg. J. H. Greene; gang.; irritative fever; July 13, amp. arm. Died July 28, 1861, pyæmia.	23	Sing, P., Pt., I, 74th Pennsylvania.	May 2, 10, '63.	Six, middle, left ulna; hæm. from interosseous. Died May 22, 1863, pyæmia.
10	Ingersol, C., Pt., G, 2d Connecticut Heavy Artillery, age 21.	Sept. 19, 24, '64.	Three, left ulna; by Asst. Surg. F. C. Smith, 116th Ohio. Died September 25, 1864.	24	Stone, H., Pt., F, 11th Pennsylvania, age 19.	May 8, 13, '64.	One and a half, left radius; by Asst. Surg. H. Allen, U. S. A.; diarrhœa. Died June 24, 1864, pneumonia.
11	Johnson, R., Pt., C, 6th New York Heavy Artillery, age 18.	May 18, June 2, 1864.	See CASE 1919, p. 964. Died June 17, 1864. <i>Spec.</i> 2508.	25	Sullivan, J., Pt., E, 49th New York.	Aug. 30, Se. 14, '62.	See CASE 1920, p. 960. <i>Spec.</i> 69.
12	Lewis, J. B., Pt., A, 32d Maine, age 32.	May 17, 24, '64.	Three, middle, right ulna; by A. A. Surg. R. E. Price; May 30, ligation of interosseous artery. Died June 21, 1864, pyæmia.	26	Tinker, A. J., Pt., K, 10th Vermont, age 24.	April 2, 22, '65.	Three-fourths, middle, left radius; by Surg. G. L. Pancoast, U. S. V.; May 7, gangrene. Died June 31, 1865, colitis.
13	Loomis, B., Pt., E, 14th Infantry, age 24.	May 5, 17, '64.	Four inches left ulna; by Surg. A. F. Sheldon, U. S. V. Died May 24, 1864, exhaustion.	27	Van Nevil, W., Corp'l, E, 8th Mich., age 14.	June 18, 1864.	See CASE 1921, p. 960. <i>Spec.</i> 2985.
14	Lutes, C., Pt., D, 23d Michigan, age 22.	Dec. 3, 7, '64.	One and a half, upper, left radius; by A. A. Surg. M. L. Herr. Dec. 16, amputation of arm. Died Dec. 23, 1864, gangrene.	28	Welch, P., Serg't, K, 28th Mass., age 32.	May 12, 17, '64.	See CASE 1916, p. 959. <i>Spec.</i> 2296.
				29	Wilcox, G. W., Pt., I, 57th Massachusetts.	May 19, 23, '64.	See CASE 1915, p. 959. <i>Specs.</i> 2510 and 2350.

**Secondary Excisions in the Bones of the Forearm.**—Forty formal excisions in the shafts of the ulna or radius were practised later than the thirtieth day after shot injury.

§ *Recoveries after Secondary Excisions.*—Two cases that are illustrated by very interesting pathological specimens will be detailed:

CASE 1922.—Private J. Campbell, Co. I, 6th Wisconsin, age 20 years, was wounded at Spottsylvania, May 10, 1864. A shot fracture of the left forearm was noted at the hospital of the 4th division, Fifth Corps, by Surgeon C. N. Chamberlain, U. S. V., and at Mount Pleasant and Chester Hospitals the progress of the case is briefly noticed until the patient's transfer to Harvey Hospital, Madison, Wisconsin, whence Surgeon H. Culbertson, U. S. V., detailed the facts of the case: "Gunshot fracture of right ulna, the ball entering at middle of lower third of forearm and emerging at the junction of the upper and middle thirds. When admitted, the lower and part of the upper fragment of the ulna was carious, and there was imperfect union and overlapping of the fragments, with a large external opening over the seat of the fracture, the result of an abscess. The constitutional state of the patient was good. On August 4th, several small pieces of bone were removed by Acting Assistant Surgeon J. J. Brown. August 9th, three inches of the ulna was removed by Surgeon H. Culbertson, U. S. V., a single incision being made over the outer border of the bone, the periosteum carefully detached, and the bone sawed off obliquely, with the chain saw, both above and below. The wound was closed with sutures. On the second day gangrene appeared, which was arrested with nitric acid locally, and tincture of muriate of iron with quinine internally. 23d, wound healing kindly by granulations."



FIG. 707.—Excised part of shaft of ulna, including a partially united shot fracture.—*Spec.* 3690.

The excised portion of the ulna (FIG. 707) was contributed to the Museum by the operator, and is interesting both as a specimen of imperfect union and as an example of a sub-periosteal excision. On January 11th, the patient was transferred to Swift Hospital, Prairie Du Chien, where he was assigned to the Veteran Reserve Corps, April 13, 1865. Two months later he was mustered out and pensioned. Examiner W. A. Anderson, of La Crosse, November 20, 1867, certified: "About four inches of the ulna is entirely gone. The ring and little fingers are permanently contracted." Examiner W. A. Golt reported, April 15, 1873: "The forearm presents a shrunken and attenuated appearance, owing in part to the loss of structure in the extensor muscles and their contraction. The power of extension is very limited and must always remain so." This pensioner was paid December 4, 1875.



The forty secondary excisions in the forearm were of the shafts of both bones in seven cases, of part of the ulna in twenty-one, of the radius in eleven, unspecified in one.<sup>1</sup>

CASE 1923.—Private C. W. Harch, Co. A, 105th New York, age 29 years, was wounded in the left forearm at Antietam, September 17, 1862, and admitted to Cranch Hospital, Washington, about one week afterward. Surgeon A. Wyncoop, U. S. V., noted the injury. Entering Mount Pleasant Hospital December 5th, several days afterward the wounded man was transferred to Philadelphia. Acting Assistant Surgeon L. K. Baldwin reported: "The missile was a minié ball, which entered the left arm about two inches below the olecranon process of the ulna, and was extracted about the same distance above the wrist joint, causing a compound fracture of the bone. The patient was admitted to Satterlee Hospital on December 13th. The wound at the time of his admission presented rather an unhealthy appearance, the discharge being of a thin sanious nature, giving evidence of the existence of a considerable amount of dead bone. The patient complained of a pricking sensation in and around the seat of the injury, as though there were some pieces of loose bone in the wound. After carefully examining the injury with the probe, a number of loose pieces were discovered in the region of the wound of exit, all of which were within reach and were removed by means of a pair of forceps. By this means it was hoped to get rid of the cause of the irritation and to promote the healing; but all was to no effect, the amount of injury being so extensive, and portions of dead bone so numerous, that the irritation was still kept up, rendering an operation necessary to a cure. The patient suffered so much inconvenience from the pricking sensation already alluded to that he was quite anxious to have an operation performed for the removal of the cause of the irritation. He being of a stout and robust constitution, an operation was soon decided on. He was accordingly, in order to better fit him for an operation, placed upon quinine and iron, together with a good nutritious diet, which treatment was continued until January 10th, when he was considered in a fit condition to be operated on. The mode of procedure decided upon was the excision of as much of the ulna as was found to be in any way diseased. The patient having been put under the influence of an anæsthetic (pure chloroform has been used on this occasion), an incision was made from a short distance below the olecranon process to within about an inch of the wrist joint. The bone was found to be so much shattered by the passage of the ball as to require excision of nearly two-thirds of its whole extent, which was accordingly done. A number of pieces of bone were found lying loose in the course traversed by the ball; others were firmly united to the main shaft of the bone by granulations which had been thrown out by nature in her effort at reproduction. After the bone was removed the wound was kept open by the introduction of a piece of lint into the bottom of it, which was kept wet with cold water until the third day, when active suppuration had taken place. The wound was subsequently dressed with flaxseed poultices, and the patient's strength sustained by the administration of tonics and good nutritious diet. Active suppuration was kept up, and the wound soon began to heal kindly from the bottom. The granulations were at no time exuberant, and at the present time, January 30th, the wound is almost healed. The patient's health has not suffered any from the effects of the operation. He is beginning to have considerable motion in the arm and hand, and there is every reason to suppose that the normal use of the arm and hand will be almost wholly regained." The specimen (FIG. 708) consists of four and a half inches of the excised portion of the ulna, and shows that the bone was not broken in its entire thickness, a splinter one-fourth of an inch remaining intact. A fragment of about the same diameter and a little more than an inch in length has been fixed by new bone parallel with it. Other small fragments have been consolidated above and below it. The specimen was contributed by Acting Assistant Surgeon J. Leidy. The patient, on July 29, 1864, was discharged and pensioned. Examiner J. H. Helmer, of Lockport, January 8, 1868, certified: "The ulna was removed nearly the whole length. The thumb is flexed upon the palm, and all the fingers are flexed upon the thumb. He has no voluntary motion of the thumb or fingers." The Lockport Examining Board reported, August 4, 1875: "He is totally unable to perform manual labor. The arm is as helpless as if amputated at the shoulder joint." This pensioner was paid September 4, 1875.



FIG. 708.—Excised part of ulna showing a consolidated partial shot fracture. *Spec.* 1865.

wholly regained." The specimen (FIG. 708) consists of four and a half inches of the excised portion of the ulna, and shows that the bone was not broken in its entire thickness, a splinter one-fourth of an inch remaining intact. A fragment of about the same diameter and a little more than an inch in length has been fixed by new bone parallel with it. Other small fragments have been consolidated above and below it. The specimen was contributed by Acting Assistant Surgeon J. Leidy. The patient, on July 29, 1864, was discharged and pensioned. Examiner J. H. Helmer, of Lockport, January 8, 1868, certified: "The ulna was removed nearly the whole length. The thumb is flexed upon the palm, and all the fingers are flexed upon the thumb. He has no voluntary motion of the thumb or fingers." The Lockport Examining Board reported, August 4, 1875: "He is totally unable to perform manual labor. The arm is as helpless as if amputated at the shoulder joint." This pensioner was paid September 4, 1875.

§ *Fatal Secondary Excisions.*—The four fatal cases of the forty secondary excisions in the forearm are included in the table with the recoveries.



FIG. 709.—Excised radius. *Spec.* 3497.

CASE 1924.—Private D. M. Harrison, Co. B, 94th Ohio, aged 33 years, was wounded at Resaca, May 14, 1864, and on May 27th was admitted to Hospital No. 1, Nashville, from a Fourteenth Corps field hospital. Surgeon R. L. Stanford, U. S. A., reported: "Gunshot wound of right forearm; a minié ball entered its inner aspect three inches below the bend of the elbow, fracturing the radius at that point, and passed into the arm without emerging." Surgeon B. B. Breed, U. S. V., reported that "large abscesses formed in the bend of the elbow and were opened. On June 17th, secondary hæmorrhage occurred from the radial artery, the patient losing about six ounces of blood." Acting Assistant Surgeon H. C. May ligated the radial artery, and excised fragments of the radius to the extent of one and a half inches, the upper extremity of that bone not being disturbed. The ball ulcerated out in the flexure of the joint soon after the 17th of June. On June 24th, another hæmorrhage occurred. Surgeon Stanford reported additionally, as follows: "June 24th, antero-posterior flap amputation at junction of lower and middle thirds of arm, by Acting Assistant Surgeon H. C. May; chloroform and ether, equal parts, were used as an anæsthetic. At time of operation the patient was very feeble, the hand and forearm inflamed, and the radial artery severed by erosion. After the operation the reparative process was feeble; treatment: stimulating dressings, tonics, and stimulants. Died of exhaustion, July 2, 1864." The specimen, represented in the adjacent wood-cut (FIG. 709), was contributed to the Museum by the operator, Dr. May. It is described by Dr. Woodhull as "the bones of the right forearm, from whose radius two inches have been removed. The upper extremity is carious."—*Cat. Surg. Sect.*, 1866, p. 184.

<sup>1</sup> Of the excisions of parts of both bones, 1 was fatal; 3 were on the right, 3 on the left side, and 1 unspecified. Of the 21 excisions in the ulna, 8 were on the right, 13 on the left side. Of the 11 excisions in the radius, 4 were on the right, 6 on the left, and 1 unspecified.

TABLE CXXX.

Condensed Summary of Forty Secondary Excisions of the Bones of the Forearm.

NO.	NAME, AGE, AND MILITARY DESCRIPTION.	DATES.	OPERATIONS, OPERATOR, RESULT.	NO.	NAME, AGE, AND MILITARY DESCRIPTION.	DATES.	OPERATIONS, OPERATOR, RESULT.
1	Bierbower, J., Pt., E, 45th Pa., age 23.	Sept. 14, Nov. 5, 1862.	Portions lower, right radius and ulna; by A. A. Surg. A. V. Cherbonnier. Disch'd April 10, 1863; pens'd; anchl. wrist; fingers cont.	22	Roland, W., Pt., A, 54th Pennsylvania, age 23.	July 1, 1862, Mar. 27, 1863.	Two, middle, right ulna, and small portion of radius; by A. A. Surg. C. H. Ohr. Disch'd Aug. 19, '64; pensioned; false joint; forearm and hand nearly useless.
2	Boda, L., Corp'l, G, 5th Mich. Cav., age 27.	May 6, Se. 19, '64.	Four, left ulna, lower; by A. A. Surg. Merritt. Dis. Apr. 4, '65. See CASE 1922.	23	Roseoe, W. H., Corp'l, B, 38th Ohio, age 23.	Sept. 20, 1861, Mar. 4, 1864.	Two, middle, right ulna (gang.). To V. R. C. Aug. 29, '64; pens'd; false ankylosis of fingers; atrophy of forearm.
3	Campbell, J., Pt., I, 6th Wisconsin, age 22.	May 10, Aug. 1, '64.	Middle, right radius; by A. A. Surg. C. B. King. Disch'd June 15, 1865; pensioned; rotation.	24	Sandrett, W., Pt., A, 9th Pa. Reserves, age 25.	Aug. 30, Oct. 19, 1862.	Two, middle, right radius and ulna. Dis'd Nov. 20, '62; pens'd; partial ankylosis wrist and fingers; no rotation; 1867, bone exfoliating.
4	Chase, G. W., Corp'l, C, 122d N. Y., age 17.	May 6, Nov. 28, 1864.	Five, middle, right ulna. Disch'd Aug. 23, 1862.	25	Shroeder, C., Pt., E, 22d Michigan, age 25.	Sept. 20, 1863, May 12, 1864.	Two and a half, middle, right ulna (radius fract.); by A. A. Surg. D. O. Farrand. To V. R. C. June 30, 1864. Not a pensioner.
5	Dwyer, J., Corp'l, A, 9th Mass., age 29.	June 27, Aug. 23, 1862.	Two, upper, radius. Furloughed; recovered.	26	Silver, W. C., Pt., F, 5th New Jersey, age 30.	May 3, July 29, 1863.	Two, lower, left radius (wound of thigh). Dis'd Jan. 4, '64; pens'd; no rotation; general atrophy.
6	Frazier, S. H., Pt., F, 2d Mississippi, age 28.	July 3, Aug. 3, '65.	Four, middle, right ulna; by A. Staff Surg. N. F. Graham. Discharged July 30, '65; pensioned; elbow anchl.; bone discharging. See CASE 1923.	27	Steffers, M., Pt., A, 1st Minnesota, age 25.	Sept. 1, Oct. 3, 1862.	Two, left ulna; by Surg. A. B. Hasson, U.S.A. Disch'd Feb. 17, '63; arm impaired. Not a pens'r.
7	Garrison, W. E., Pt., G, 3d N. Y. Cav., age 20.	Oct. 19, Nov. 25, 1864.	Portion left ulna. To V. R. C. Apr. 25, 1865; pens'd; unfit for labor.	28	Sturgeon, J. K., Pt., F, 46th Ohio, age 21.	Aug. 31, 1864, Feb. 3, 1865.	Six, middle, left ulna; by A. A. Surg. W. H. Drury. Disch'd May 18, '65; pens'd; anchl. elb.; atrophy; little use of hand or arm.
8	Hareh, C., Pt., A, 105th New York, age 28.	Se. 17, '62, Ja. 10, '63.	Three, upper, left ulna; by A. A. Surg. S. F. Few. Disch'd Jan. 22, 1864; no rotation; arm atrophied, weak, and deformed.	29	Tower, J., Corp'l, A, 19th Indiana, age 37.	July 3, Aug. 4, 1863.	Portion left ulna (gang., necrosis). Disch'd July 29, '64; pensioned. limb impaired.
9	Herron, J., Corp'l, A, 43d N. Y., age 23.	Mar. 10, M'y 15, '64.	Middle, right ulna; by A. A. Surg. J. H. Janur. Disch'd Nov. 3, 1864; pensioned; part. anchl. elbow; adhesions and contract's.	30	Traveler, H., Pt., G, 13th Pa. Cav., age 25.	Dec. 8, 1864, Jan. 13, 1865.	Six, lower, left radius; by Surg. G. L. Hancock, U.S.V. Disch'd July 10, 1865; pensioned; hand disloc. inward; fingers contract'd.
10	Houts, S. D., Serg't, A, 8th Kansas, age 21.	Sept. 19, Dec. 18, 1863.	Two and a half, upper, right ulna. Disch'd April 1, '65; pensioned; arm partially paralyzed; partial flexion and extension of fingers.	31	Wagoner, J., Pt., B, 11th Pa. Reserves, age 19.	June 30, Aug. 20, 1862.	Portion middle, left ulna, and fragments; radius necrosed; pyæm. threatened—amp. arm. Disch'd November 29, 1862. Spec. 427.
11	Hunt, N. T., Pt., D, 64th New York, age 23.	June 17, July 24, 1864.	Four, middle, left ulna; by A. A. Surg. E. G. Waters. To V. R. C. Oct. 3, '63; pens'd; no flexion or extension forearm; motion of fingers fair but power alm.gone.	32	Wenglein, J., Pt., I, 105th N. Y., age 23.	M'y 10, '64 Second'y.	Two, middle, right radius. Dissected May 26, 1865. Not a pensioner.
12	Hutchins, L., Pt., C, 19th Wisconsin, age 25.	Aug. 2, Oct. 2, 1864.	Four, middle, left ulna; by A. A. Surg. S. F. Few. Disch'd June 3, '64; anchl. elb.; general atrophy.	33	Wettstein, P., Pt., B, 8th Kansas, age 33.	Sept. 19, 1863, Mar. 5, 1864.	Two, upper, ulna (fract. radius). To V. R. C. July 14, '64; pens'd; deformity; immobility of all fingers except index.
13	Kelleher, F., Pt., A, 12th Massachusetts, age 20.	Sept. 14, Nov. 6, 1862.	Rem. of spic. and excis. inch and a half left radius and ulna, middle; by A. A. Surg. G. W. Fay; false joint; hand hangs limp; useless.	34	Whipple, W. H., Pt., A, 54th Massachusetts.	July 18, Dec. 28, 1863.	Half an inch from fract'd ends of left radius, middle. Disch'd Mar. 4, '64; pens'd; fingers extended backward; wrist dislocated.
14	Langley, J. J., Pt., K, 15th Kan. Cav., age 34.	Nov. 19, Dec. 20, 1863.	Middle, left ulna (radius fract.). Dis'd Apr. 13, '63; pens'd. Apr. '72, wound open; anchl. elb.; arm straight. Died Dec. 8, 1873.	35	Wilson, R. G., Pt., A, 79th N. Y., age 32.	Sept. 1, Dec. 1, 1862.	Three, left radius and ulna; by A. A. Surg. S. S. Jessop. Disch'd February 20, 1863; pensioned; no flexion or extension.
15	Lewis, W., Pt., A, 3d Maine, age 19.	May 19, July 11, 1864.	One and a half, upper, left ulna and portion radius; by A. A. Surg. O. P. Sweet. Disch'd Mar. 2, '63; pens'd; hand and fingers extend'd.	36	Yount, G., Lieut., I, 3d Missouri, age 24.	May 22, July 4, 1863.	Portion right radius (wound lung and liver). Disch'd November 16, 1864; pensioned; good motion and strength in wrist.
16	Marr, E., Pt., B, 38th New York, age 28.	Dec. 13, 1862, Mar. 10, 1863.	Two, left ulna, by Surg. J. H. Currey, U. S. V. Toprison January 2, 1864.	37	Camp, S., Pt., A, 21st Ohio, age 21.	June 9, July 14, 1864.	Three and a half, upper, left rad.; by A. A. Surg. G. E. Stubbs (erysipelas). Died Aug. 12, 1864, gangrene.
17	Mason, D., Pt., A, 56th Massachusetts, age 37.	May 30, June 30, 1864.	Two, right radius, and several fragments (wound of groin). Exchanged October 12, 1862.	38	Cobb, S., Pt., H, 19th Indiana.	Aug. 28, Se. 28, '62.	Excision. Died Oct. 8, 1862.
18	Medary, S., Pt., A, Gilmore's Battalion.	July 3, Nov. 8, 1863.	One and a half, low, left rad. Dis. Dec. 15, '64; pens'd; part. paraly. and atrophy of hand; ulna disloc.	39	Hamlin, F. N., Lieut., K, 147th N. Y., age 32.	May 5, June 5, 1864.	Portion upper, left ulna; by Surg. H. W. Ducaet, U. S. V. (flesh wound arm; lig. of brach.; hæmorrhage). Died June 25, 1864. See CASE 1924.
19	Moore, S., Pt., A, 5th North Carolina, age 21.	May 5, July 3, 1862.	Three, upper, left radius; by Surg. D. W. Bliss, U. S. Y. Disch'd Jan. 10, 1863; pensioned; hand pronated; can feebly flex fingers.	40	Harrison, D., Pt., B, 94th Ohio, age 34.	May 14, J'e 17, '64.	

It may be observed that the secondary excisions<sup>1</sup> of this class, though less disastrous than those in the intermediary stage, had nearly as high a mortality as the primary excisions.

**Excisions in the Forearm of Uncertain Date.**—There were a hundred and thirty-two reported examples of excisions in the shafts of the bones of the forearm in which the intervals between the injury and operation were not ascertained. Unlike most series of imperfectly recorded cases, they present a small ratio of mortality—only five, or 4.3 per cent. of a hundred and sixteen determined cases having resulted in death.

<sup>1</sup> In the 7 excisions in both bones of the forearm, with 1 death, the extent of bone removed was from an inch and a half to 3 inches in the shafts of each bone. The 21 excisions in the ulna, with 1 death, for the most part interested the middle third, though sometimes extending to the upper and lower thirds,—the amount of the diaphysis removed varying from 2 to 6 inches. In the 11 excisions in the radius, the extent of bone excised was from 1 to 2½ inches in 7 cases; from 3 to 6 inches in 4 cases.



TABLE CXXXI.

Summary of One Hundred and Thirty-two Cases of Excisions in the Forearm, the Time between the Injury and Operation being unknown.

No.	NAME, AGE, AND MILITARY DESCRIPTION.	DATES.	OPERATIONS, OPERATOR, RESULT.	No.	NAME, AGE, AND MILITARY DESCRIPTION.	DATES.	OPERATIONS, OPERATOR, RESULT.
1	Allen, A. J., Pt., I, 116th Pennsylvania, age 18.	June 3, 1864.	Three, lower, right ulna. Disch'd Dec. 26, '64; pens'd; no extension and imperfect flexion of fingers.	34	Ferrill, T., Pt., C, 14th Connecticut, age 21.	Dec. 13, 1862.	Four and a half, middle, left ulna. To V. R. C. Aug. 13, '64; hand useless.
2	Allen, J. G., Corp'l, H, 24th N. C., age 23.	April 2, 1865.	Portion right radius. To prison June 11, 1865.	35	Foy, M., Pt., C, 88th New York, age 28.	Sept. 17, 1862.	Portion ulna. To V. R. C. Dec. 12, 1863; motion of hand impaired; rotation nearly perfect. Insane.
3	Atkins, A., Corp'l, C, 5th New York.	June 27, 1862.	Two, lower, radius. Disch'd Oct. 19, '62; pens'd; wrist and hand greatly distorted and impaired.	36	Gainey, J. A., Lieut., F, 24th North Carolina.	Sept. 7, 1854.	Portion lower, left ulna. Furloughed Oct. 10, 1864.
4	Barker, J. T., Lieut., 21st Georgia, age 25.	Oct. 19, 1864.	Portion middle, left radius (w'd of thigh). To prison Feb. 16, '65.	37	Garvey, J., Pt., D, 97th Pennsylvania, age 45.	Oct. 27, 1864.	Two, left ulna; no bony union; rotation lost. Disch'd June 8, 1865. Not a pensioner.
5	Bates, T. K., Capt., B, 18th Connecticut, age 28.	June 15, 1863.	Two and a half, upper, left ulna (fract. radius). Disch'd Nov. 17, 1863; pens'd; no rotation; partial extension; much deformity.	38	Gibson, J. H., Pt., II, 23d South Carolina.	Oct. 31, 1864.	Portion lower, left ulna. Furl'd December 2, 1861.
6	Berry, B., Pt., B, 5th Louisiana, age 34.	Mar. 26, 1863.	Excision of portion of radius. April 30, 1863, doing well.	39	Goggin, E. J., Capt., M, 7th South Carolina.	May 6, 1864.	Right forearm. Furloughed.
7	Birdsall, D. E., Lieut., E, 5th Michigan, age 22.	Oct. 27, 1864.	Two and a half, middle, right radius. Disch'd Jan. 12, '65; pens'd; hand bent and weak.	40	Graham, J. M., Pt., A, 95th Illinois, age 25.	May 22, 1863.	Two and a half, middle, left ulna. To V. R. C. Nov. 25, '63; pens'd; limb impaired and painful.
8	Blanchard, J. H., Pt., F, 16th Georgia.	—	Two inches of ulna. October 17, —, discharged nearly cured.	41	Graham, T. M., Pt., I, 11th Pa. Res., age 23.	May 5, 1864.	Three, right radius. Duty July 26, '64. Not a pensioner. Spec. 2300.
9	Boedecker, H. A., Pt., A, 31st Missouri, age 28.	Sept. 20, 1863.	Three and a half, right radius, lower. To V. R. C. May 9, 1864; pen'd; wrist j't dist'd; ulna dist.	42	Greely, J. S., Corp'l, D, 11th Miss., age 25.	Oct. 27, 1864.	Three, upper, left ulna. Retired Feb. 9, 1865.
10	Bowers, J. F., Lieut., B, 23d Ohio, age 22.	Sept. 22, 1864.	Three, upper, right ulna. Duty Nov. 4, 1864; pensioned; use of arm impaired.	43	Haney, T., Pt., K, 123d N. Y., age 24.	July 20, 1864.	Four, middle, left ulna. To V. R. C. Dec. 15, '64; arm deformed; hand weak and almost useless.
11	Brimley, G. W., Pt., E, 81st Indiana, age 23.	Dec. 16, 1864.	Portion lower, right ulna. Duty May 4, 1865. Not a pensioner; no disability.	44	Hart, M., Pt., D, 3d Maryland, age 30.	July 3, 1863.	Three, lower, left ulna; ham. To V. R. C. Dec. 31, 1863; false joint.
12	Brooks, J. F., Pt., C, 9th Alabama, age 30.	July 30, 1864.	Portion middle, right radius. Furloughed September 10, 1864; muscles contracted.	45	Hawkins, C., Pt., D, 4th Ky. M. Inf., age 27.	Nov. 12, 1864.	Four, lower, ulna. Disch'd Aug. 13, 1865; pensioned; wrist and fingers flexed and partially ankylosed; useless.
13	Brown, W., Pt., F, 103th Illinois, age 24.	May 15, 1864.	Lower, left ulna. Disch'd Sept. 13, '64; pens'd; joint distorted; unable to work hard.	46	Heyler, J. M., Pt., I, 48th North Carolina.	June 15, 1864.	Portion middle, left radius and ulna. Retired Mar. 14, 1865.
14	Burgess, G., Pt., A, 10th Wisconsin, age 23.	Sept. 20, 1863.	Two, upper, ulna. Disch'd Nov. 3, 1864; pensioned; use of limb much impaired.	47	Hillman, T. A., Pt., F, 1st N. Y., age 18.	June 1, 1862.	One and a half, lower, left radius. Disch'd Oct. 26, '62; pens'd; part ankyl. wrist; atrophy forearm and hand.
15	Burke, W. J., Corp'l, I, 21st Georgia, age 25.	July 12, 1864.	Portion of middle third, right radius. To prison Aug. 15, 1864.	48	Hook, S. E., Pt., A, 1st Mass. Bat., age 23.	June 2, 1864.	Portion upper, right radius. Duty Sept. 3, 1864; pens'd; Nov., '64, limb much impaired.
16	Burt, J. A., Serg't, K, 12th North Carolina, age 25.	May 12, 1864.	Two-thirds right ulna. Retired Mar. 3, 1865; arm semiflexed; atrophy; ankyl. and weakness.	49	Hughes, J. M., Pt., II, 17th Ohio.	—	Entire middle third, left radius. To V. R. C. Nov. 17, '63; pens'd; weak.
17	Byers, R. H., Pt., H, 107th Pa., age 22.	Sept. 17, 1862.	Portion middle, left ulna. Disch'd Feb. 18, '63; pens'd; limb weak.	50	Irwin, S. J., Pt., Virginia Artillery.	—	One and a half, upper, left ulna. Retired March 18, 1865.
18	Carrigan, R., Pt., C, 50th Illinois, age 20.	May 26, 1864.	Three inches, lower third, right ulna. Disch'd Jan. 5, 1865.	51	Jones, G. W., Pt., F, 3d Del., age 25.	June 18, 1864.	Portion right ulna. Disch'd June 15, '65; pens'd; rotation lost; greatly impaired.
19	Carson, C. W., Pt., A, 26th Ohio, age 27.	Sept. 19, 1863.	Three and a half, lower, right radius. Disch'd June 19, '65; pen'd; hand and arm almost useless.	52	Kareh, P., Pt., I, 150th Penn., age 20.	July 1, 1863.	Portion upper, right ulna. Disch'd Nov. 24, 1864.
20	Connelly, J., Pt., B, 14th Louisiana, age 29.	—	Three, lower, right radius. Ret'd Mar. 6, '65; ankylosis of wrist.	53	Kauffman, J., Pt., C, 155th Penn., age 37.	Mar. 31, 1865.	Two, upper, left ulna; gang. and erysip. Disch'd July 27, '65; pens'd; forearm entirely useless.
21	Cook, J. Y., Pt., F, 19th Mississippi, age 34.	Aug. 21, 1864.	Two inches, upper third, left ulna. Retired March 9, 1865.	54	Keck, J. M., Pt., F, 6th N. C., age 20.	Jan. 7, 1864.	Portions right ulna. Retired December 30, 1864.
22	Court, J., Pt., F, 101st Pennsylvania, age 26.	May 31, 1862.	Four, lower, left radius. Disch'd Aug. 29, 1862; pensioned; limb greatly impaired.	55	Keever, J. G., Pt., E, 4th N. Y. II. A., age 25.	Aug. 25, 1864.	Three, middle, left ulna. To V. R. C. Mar. 29, '65; use of limb impaired; pens'd; extension only to 135°.
23	Craig, W., Pt., D, 5th Artillery, age 35.	Sept. 17, 1863.	Three, lower, right ulna. Disch'd Oct. 25, '65; pens'd; ankylosis of wrist; hand entirely useless; health poor.	56	Kehoe, O. P., Pt., I, 7th Penn. Cav., age 31.	Aug. 21, 1864.	Four, middle, right rad. Disch'd May 24, '65; use of arm impaired.
24	Cruger, H. C., Pt., K, 34th Indiana, age 21.	July 21, 1863.	Portion lower, left radius. Disch'd Nov. 7, 1864; pensioned; use of limb impaired.	57	Kelly, W. S., Pt., C, 88th Indiana, age 28.	May 18, 1864.	Portion lower, right rad. (wound of thigh). Disch'd Feb. 8, 1865; partial paralysis of hand.
25	Davis, D. T., Pt., II, 64th Illinois, age 29.	July 22, 1864.	Two, upper, left ulna. Disch'd Aug. 1, 1865; pensioned; fingers flexed on palm.	58	Kendall, M. R., Pt., II, 43d N. C., age 37.	May 16, 1864.	Portion left ulna. Retired Feb. 18, '65; contraction of extensors.
26	Delahyde, M., Pt., I, 60th New York.	—	Large portion left ulna. Disch'd Jan. 23, 1863. Not a pensioner.	59	Ketchum, B., Pt., I, 5th New York.	June 10, 1861.	Four, left radius. Disch'd Dec. 31, 1861.
27	Dennis, M., Pt., C, 2d Cavalry, age 26.	Aug. 4, 1861.	Portion upper, left radius. Discharged April 3, 1862; pensioned; useless for manual labor.	60	Kidwell, O. D., Pt., II, 4th Alabama.	Je 22, '61.	One, upper, right ulna. Furloughed August 19, 1864.
28	Dingman, J. M., Pt., A, 64th Illinois, age 21.	Aug. 4, 1864.	Two, left ulna. Disch'd Jan. 18, '65; pens'd; atrophy; anky. and dis. of elbow; arm and hand useless.	61	Lahe, P., Pt., D, 3d V. R. C.	June 30, 1864.	Middle, left ulna. Disch'd July 12, 1865; arm nearly useless.
29	Doran, J. E., Capt., K, 149th N. Y., age 33.	July —, 1863.	Portion right radius. Discharged Feb. 5, 1864. Not a pensioner.	62	Leech, W. S., Lieut., A, 139th Pa., age 27.	Oct. 19, 1864.	Four and a half, middle, left ulna. Disch'd Jan. 16, 1865; pensioned; grasp nearly destroyed.
30	Downs, D. L., Pt., II, 22d Kentucky.	Dec. 29, 1862.	Two, middle, right ulna. Disch'd April 8, 1863; arm atrophied, weak; stiffness of elbow.	63	Lehmao, J., Pt., G, 8th Missouri.	Jan. 11, 1863.	Three, right radius. Discharged August 8, 1863; pensioned; great deformity; limb useless.
31	Dyer, I. J., Corp'l, E, 99th Illinois, age 24.	May 20, 1863.	Three, middle, left radius (fract. ulna); July 25, gang. erysipelas. Disch'd Oct. 8, '63; pensioned; artificial joint; useless append'c.	64	Lehr, C. S., Pt., F, 27th Illinois, age 22.	May 9, 1864.	Two and a half, middle, left radius and ulna. Disch'd Sept. 20, '64; pensioned; no union; arm useless.
32	Eady, W., Pt., F, 5th North Carolina.	July —, 1863.	Three, left radius. Transferred Sept. 5, 1863, for exchange.	65	Lightfoot, J. M., Col., 6th Alabama.	May 7, 1861.	Portion left ulna. Furloughed May 23, 1864.
33	Ferrell, G. A., Pt., Pamunky Art., age 19.	June 17, 1864.	Three, middle, left radius. Retired; use of limb impaired.	66	Luchsenger, H., Pt., K, 72d Pennsylvania.	June 29, 1862.	Portion upper, right radius. Discharged Nov. 5, '62; pensioned; useless for manual labor.
				67	Lyon, J. E. ....	April 18, 1864.	Four, right ulna. Retired January 27, 1865.

No.	NAME, AGE, AND MILITARY DESCRIPTION.	DATES.	OPERATIONS, OPERATOR, RESULT.	No.	NAME, AGE, AND MILITARY DESCRIPTION.	DATES.	OPERATIONS, OPERATOR, RESULT.
68	Marley, H. P., Pt., K, 191st Pennsylvania Reserves.	May 10, 1864.	Portion right radius (fract. ulna). Discharged March 25, 1865; pensioned; hand useless.	97	Smith, W. D., Corp'l, F, 12th Miss., age 22.	May 12, 1864.	Three inches, right radius. Retired Feb. 20, 1865.
69	Martin, G. W., Serg't, C, 75th Ohio.	—	Portion left ulna. To V. R. C. January 4, '64. Not a pensioner.	98	Stephens, E. J., Pt., E, 4th Wisconsin, age 22.	Oct. 21, 1861.	Portion lower, ulna. Discharged April 3, 1862; pensioned; rotation lost; hand useless.
70	Macwell, R. H., Lieut., C, 1st N. C.	Sept. 13, 1863.	Three, right radius. Furloughed October 25, 1863.	99	Strobel, D., Pt., D, 10th New York Heavy Artillery, age 29.	Mar. 31, 1865.	Two, middle, right ulna. Disch'd June 9, 1865; pens'd; atrophy forearm and hand; wrist anechnyl.
71	McCormick, T., Pt., A, 5th Kentucky.	June 24, 1863.	Three, lower, left radius. Mustered out Sept. 14, 1864; pensioned; no union; motions of hand and wrist impaired.	100	Swain, H. G., Pt., G, 1st Massachusetts.	July 2, 1863.	Two, lower, right radius. Disch'd Jan. 7, '64; limb useless; pens'd. Died Dec. 10, '71, consumption.
72	McEntyre, J. C., Pt., H, 15th Alabama, age 28.	Aug. 17, 1864.	Portion middle, ulna; gangrene. August 31, doing well. Furloughed September 30, 1864.	101	Telle, S. H., Pt., I, 143d Pennsylvania, age 43.	July 1, 1863.	Two and a half, left ulna. Disch'd Jan. 6, '64; pensioned; ankylosis of elbow. Died Mar. 8, 1869.
73	McGaw, S. P., Pt., K, 8th Illinois, age 35.	Sept. 20, 1863.	Three, middle, left radius. Disch'd Feb. 25, 1864; partial anechnyl. elbow; rotation lost; cannot flex hand; pensioned.	102	Thomas, H. O., Corp'l, D, 18th Massachusetts, age 21.	Dec. 13, 1862.	Five, right radius. Disch'd Mar. 28, '63; pens'd; rotation lost; wrist disloc.; ulna rides over carpals.
74	McKenzie, L., Pt., D, 126th Ohio, age 32.	May 5, 1864.	Two and a half, lower, left ulna. To V. R. C. January 26, 1865. Not a pensioner.	103	Till, E. R., Ensign, 9th Alabama, age 28.	Oct. 28, 1864.	Two and a half, upper, left ulna. Duty January 24, 1865.
75	McKissack, A. H., Pt., A, 15th Ala., age 22.	Aug. 16, '64	Two, left radius. Aug. 31, wound doing well. Furl'd Sept. 8, '64.	104	True, H. W., Pt., I, 25th Ohio, age 22.	July 1, 1863.	Portion lower, right ulna. Disch'd July 2, 1864; pensioned; anechnyl. wrist and fingers; atrophy. Portion of radius. Furloughed May 11, 1863; killed May 5, '64, at the Wilderness.
76	McMurry, F. L., Pt., F, 12th Miss., age 27.	Jan. 19, '64.	Portion middle, ulna. June 30, doing well. Furl'd July 15, '64.	105	Turner, J. B., Capt., & A. A. G. Gen. Meagher's Staff.	Sept. 30, 1864.	Four, left radius. Retired March 14, 1865.
77	Moore, T. J., Lieut., A, 101st Ill., age 27.	June 27, 1864.	Two, lower, left ulna. Duty Aug. 15, '64; pensioned; use impaired.	106	Tuttle, R. M., Capt., F, 26th North Carolina.	Sept. 30, 1864.	Three, lower, left radius (wound of chest). Disch'd Apr. 14, '65; pens'd; great deformity of wrist joint; hand curved forward.
78	Morgan, W., Pt., H, 29th Pennsylvania, age 34.	June 15, 1864.	Three, middle, right ulna. Disch'd Sept. 7, '65; pensioned; sensation and motion impaired in fingers.	107	Vancee, J., Pt., C, 83d Penn., age 24.	Sept. 30, 1864.	Entire shaft of right ulna. Retired Jan. 10, 1865.
79	Munger, H. W., Pt., I, 85th N. Y., age 24.	April 20, 1864.	Portion lower, left ulna. Duty Mar. 6, '65; pens'd; atrophy; fingers flexed and nearly anechnyl'd.	108	Vidal, A. J., Pt., Mari-on Artillery.	July 7, 1864.	Portion, right radius. Retired March 4, 1865.
80	Naugle, I. O., Pt., A, 17th Miss., age 19.	Nov. 29, 1863.	Portion middle, radius. January 1, 1844, doing well.	109	Ward, D., Pt., G, 25th Va. Bat., age 25.	Sept. 23, 1864.	Three, lower, right radius. Retired June 27, 1865.
81	Oberfell, J., Pt., B, 9th Illinois, age 36.	Feb. 15, 1862.	Two, middle, right radius. Discharged Sept. 5, 1864; adhesions of muscles; ulna partly disloc.	110	White, C. A., Pt., H, 59th Virginia, age 52.	June 28, 1864.	Portion left ulna. Released July 17, 1865.
82	Oliver, N. C., Pt., H, 18th Mississippi, age 20.	Jan. 4, '64.	Middle, right radius. Furloughed September 12, 1864.	111	Wilkinson, E. W., Pt., I, 15th Ga., age 31.	—	Left. Died June 8, 1864, of pyaemia.
83	Parker, W., Pt., B, 16th Virginia.	—	Portion right ulna, middle. Retired December 29, 1864.	112	Barker, A. J., Pt., D, 100th N. Y., age 27.	—	Middle, radius; erysipelas. Died Jan. 23, '65, thrombus of pulmonary artery.
84	Pennybaker, S. W., Pt., F, 2d Miss., age 21.	—	Three inches, middle third, left radius. Recovered.	113	Bowers, T., Pt., A, 47th Pennsylvania.	Oct. 19, 1864.	Portion of right ulna. Died Oct. 20, 1864.
85	Perkins, H., Corp'l, I, 10th Illinois, age 40.	May 21, 1865.	Middle, left radius; atrophy of forearm and hand; stiffness of wrist and finger joints. Disch'd July 3, 1865; pensioned.	114	Jolly, W. N., Pt., H, Palmetto Sharpshrs.	—	Right forearm. Died June 20, '64.
86	Pfiferman, D., Pt., G, 1st Louisiana, age 32.	June 26, 1863.	Portion of right radius. Disch'd Aug. 18, '64; pensioned; use of limb impaired, and deformed. Died in 1868, yellow fever.	115	Nichols, R., Pt., D, 14th Conn., age 41.	—	Portion of left ulna. Died July 11, 1864, typhoid fever.
87	Rectamus, H., Corp'l, B, 149th Pa., age 22.	May 8, 1864.	Three and a half, upper, left ulna. Disch'd Mar. 20, '65; pensioned; power of wrist much impaired.	116	Spiddle, W., Corp'l, D, 5th Penn., age 24.	June 18, 1864.	Portion of radius.
88	Ryan, J., Pt., M, 10th N. Y. Cav., age 19.	July 3, 1863.	Portion of left ulna. Disch'd Aug. 26, 1864. Not a pensioner. Spec. 4379.	117	Adlison, W., Pt., R, Palmetto Sharpshooters.	Oct. 7, 1864.	Portion of ulna.
89	Sailsbury, W. N., Serg't, F, 42d Illinois, age 20.	June 27, 1864.	Two and a half, lower, left radius. Disch'd Feb. 15, '65; pensioned; incomplete paralysis of hand; ulna dislocated.	118	Gallman, R. N., Pt., H, 5th South Carolina.	Sept. 30, 1864.	Two inches, upper third, left ulna (radius fractured). Left ulna.
90	Samoa, J., Pt., I, 96th Pennsylvania, age 21.	May 13, 1864.	Two, lower, left ulna. Duty Sept. 15, '64; pens'd; grasp weakened; fair use of hand; styloid process prominent.	119	Haxley, G. W., Pt., A, 26th Virginia.	July 24, 1864.	Ulna.
91	Schlötzer, L., Serg't, A, 187th New York, age 26.	Oct. 27, 1864.	Two, upper, right radius. Disch'd April 1, 1865; pensioned; loss of rotation.	120	Hayslip, B. G., Serg't, B, 11th Georgia.	July 30, 1864.	Right radius.
92	Seibold, F., Corp'l, B, 26th Wisconsin, age 21.	May 15, 1864.	Three, middle, left ulna. To V. R. C. Dec. 20, 1864; pens'd; no union; arm and hand useless.	121	Johnson, W. H., Pt., H, 6th Georgia.	Aug. 18, 1864.	Portion of left radius.
93	Sheridan, W. C., Capt., C, 6th Ohio, age 27.	May 14, 1864.	One, middle, right radius and ulna. Disch'd June 23, '64; pen'd; hand protruded; wrist and fing. strong.	122	Justice, T. M., Pt., C, 6th South Carolina.	Oct. 7, 1864.	Portion of left ulna.
94	Smith, D. S., Pt., I, 47th Alabama, age 48.	May, 1864.	Two, lower, left ulna. Ret'd Mar. 22, '65; hand almost useless.	123	Knight, M., 14th South Carolina.	Aug. 16, 1864.	Four inches, lower third, ulna.
95	Smith, T., Lieut., 22d Virginia Battery.	Aug. 19, 1864.	Four, left ulna. Retired Feb. 15, 1865; ankylosis of elbow.	124	Moore, J. E., Pt., C, 2d South Carolina.	Sept. 30, 1864.	Portion of right ulna.
96	Smith, W. M., Corp'l, G, 63d Pennsylvania, age 29.	June 1, 1862.	Portion lower, right ulna. Disch'd Sept. 17, '62; pensioned; necrosis; cartilaginous union.	125	Nelson, G. J., Pt., E, 59th Virginia, age 22.	Sept. 30, 1864.	Portion of right ulna.
				126	O'Briant, J. C., Lieut., B, 2d South Carolina.	Oct. 7, 1864.	Portion of right ulna.
				127	Owen, J., Pt., L, Palmetto Sharpshooters.	Oct. 7, 1864.	Radius.
				128	Parker, J. J. G., Pt., L, 7th S. C. Battery.	—	Portion of left ulna.
				129	Perry, S. W., Pt., I, Palmetto Sharpshooters.	Oct. 7, 1864.	Left forearm.
				130	Simmons, J. A., Corp'l, B, Palmetto S. S.	Oct. 7, 1864.	Lower third, radius.
				131	Spencer, W. B., Serg't, B, 38th Virginia.	—	Portion of right radius.
				132	Weesner, B. F., Pt., C, Phillip's Ga. Legion.	—	

The extent of excisions in the shafts in the hundred and thirty-two operations above enumerated is specified in the foot-note.<sup>1</sup> In three cases, both bones were interested; in seventy-two, the ulna; in fifty-three, the radius; in four, the part excised was unspecified.

<sup>1</sup> In the 3 excisions of both bones, the amounts of the shafts removed varied from an inch to 2½ inches. In the 72 excisions of the ulna, the extent of bone excised was unspecified in 28 cases; in 15 cases from 1 to 2 inches were removed; in 20 cases from 2½ to 3½ inches; in 9 cases 4 inches or more were excised, the bone being extirpated in one of these instances. In the 53 excisions in the radius of uncertain date, the extent of bone removed was not recorded in 22 cases; in 6 cases from 1½ to 2 inches were excised; in 19 from 2½ to 3 inches; in 6 from 3½ to 5 inches.



The operations were on the right extremity in fifty-two cases, on the left in sixty-seven, not reported in thirteen. Of the five fatal cases, two were excisions on the right and two on the left side, and one unspecified. Seventy-six of the patients were Union, and fifty-six Confederate soldiers.

CONCLUDING OBSERVATIONS ON EXCISIONS IN THE SHAFTS OF THE BONES OF THE FOREARM.—Of this large number of excisions in the continuity of the forearm there is little to remark, save that, in the aggregate, the mortality of shot fractures of the bones of the forearm appears to have been sensibly augmented by operative interference,<sup>1</sup> and that I have sought in vain for a single instance in which a formal excision of a portion of the shaft of either radius or ulna had a really satisfactory result, as regards the functional utility of the limb. The representations of Baudens of his Algerian experience, led the German surgeons to practise these excisions in the shafts of the long bones to some extent, in the Danish and Austrian campaigns, with very unsatisfactory results. Similar operations were resorted to with comparative frequency during the American War, and the results plainly indicate, I think, that formal primary operations of this nature should be banished from the practice of military surgery. It is bad enough to remove adherent primary sequestra, for our Museum abounds in examples where such fragments have retained their vitality and maintained the continuity of long bones. It is worse to deliberately remove unoffending healthy portions of the bone. The mortality, greatly exceeding that of the expectant conservative treatment, the numerous consecutive amputations, and the large proportion of hopelessly deformed limbs, sufficiently condemn such operations. I have found nothing in the reports of the surgery of the late Franco-German War that was not conformable to these conclusions.<sup>2</sup>

The influence of age on the results of these excisions was not marked.<sup>3</sup> There was but slight difference in the mortality in the operations practised in the Eastern and Western armies.<sup>4</sup>

Those who carefully scrutinize the foregoing tables will observe a seeming discrepancy between them and the numerical statement on page 922. But the figures are correct in both instances.<sup>5</sup> In the table of *fractures* there are given, among the twelve hundred and ninety-one fractures of both radius and ulna, eighty-seven treated by excision; but in this group *both* bones were excised in fifty-nine instances only, and the remaining twenty-eight

<sup>1</sup> The mortality in 2,943 determined cases of shot fractures in the forearm treated by expectation was 6.4;—of 965 determined cases treated by excision, the death-rate was 11.2;—of 1,256 cases of shot fracture of the forearm in which amputation in the forearm, elbow, or arm were primarily or consecutively performed, 205 or 16.3 per cent. died.

<sup>2</sup> BECK (B.) (*Chir. der Schussverletz.*, 1872, S. 665), treating of shot wounds of the forearm in the Franco-German War, observes: "Regarding resection in the continuity, I cannot approve of the operation for reasons already adduced. Aside from the fact that by such interference osteomyelitis and pyæmia may readily be caused, serious disorders, such as injuries of the blood-vessels and subsequent hæmorrhages, may be induced. In a case at Strasbourg, for instance, the artery was injured during the resection of the ulna, although the case ended well, the bleeding having been definitively controlled by ligation. The two resections performed by us in the radius and in the ulna were more properly extraction and pinching off of splinters and partial sawing off of prominent points of sharp bone, a proceeding which under some circumstances may be approved, as thereby, without injury to the wound, serious complications may be averted."

<sup>3</sup> Of 985 patients (two of the 986 operations were practised on 1 patient) 104, of whom 10 died; were under twenty years: between 20 and 24 years inclusive, there were 300 cases, with 31 deaths and 2 undetermined results; between 25 and 29 years, 212 cases, with 10 deaths and 2 undetermined results; between 30 and 34, there were 110 cases with 11 deaths; between 35 and 39 years, 45 cases with 6 deaths; 40 and over, 53 cases with 4 deaths; of age not ascertained, 161 cases with 37 deaths.

<sup>4</sup> Of 953 determined cases, 678 were of excisions on soldiers serving on the hither side of the Alleghanies, with 79 deaths, or 11.8 per cent.; 275 cases, with 30 deaths or 12.2 per cent., were on soldiers serving in the West.

<sup>5</sup> Of the 986 operations, the result was known in 965. These included 109 deaths, or 11.2 per cent. Of excisions of both bones there were 59 with 7 deaths, or 11.8 per cent., with 28 recoveries and 1 death in the operations on the right side, 28 recoveries and 5 deaths on the left side. 3 unspecified cases with 1 death. Of 496 excisions in the ulna, 483 with 48 deaths, or 9.9 per cent., were determined, of which 216 with 21 deaths were on the right side, 256 with 27 deaths on the left; 11 unspecified cases ended in recovery. Of 413 excisions in the radius, 406 were determined, with 48 deaths, or 11.8 per cent.; 183 with 25 deaths were on the right, 207 with 21 deaths on the left side; to which must be added 16 unspecified cases with 2 deaths. In 18 instances in which the bone implicated was unknown, the results of 17 with 6 deaths, or 35.2 per cent., were determined; 5 with 1 death were on the right side, and 4 with 2 deaths were unspecified.

cases go to augment the number of excisions in the ulna alone or in the radius, and so of the other categories, the numbers really conforming to those in the tables of *operations*.

### AMPUTATIONS IN THE CONTINUITY OF FOREARM FOR SHOT INJURY.—

Obviously those surgical canons—that amputation is seldom necessary after wounds in the forearm by musket balls, and that this operation can only be legitimately performed as a primary one when both bones are fractured and the radial and ulnar arteries are wounded (Tripler,<sup>1</sup> Guthrie<sup>2</sup>)—were not very generally regarded by our surgeons, since there were no less than seventeen hundred and forty-seven amputations in the forearm, of which over a thousand were primary operations. The cases were distributed as set forth in the following table, the figures representing the number of operations and not the number of patients; for in eight instances, at least, both forearms were removed in the same individual. Six hundred and eleven of the operations were done because of shot wounds of the wrist.

TABLE CXXXII.

*Numerical Statement of Seventeen Hundred and Forty-seven Cases of Amputations in the Forearm for Shot Injury.*

OPERATIONS.	CASES.				RATIO OF MORTALITY.	UPPER THIRD.			MIDDLE THIRD.			LOWER THIRD.			POINT OF ABLATION NOT SPECIFIED.		
	Recovered.	Died.	Undeterm'd.	Total.		Recovered.	Died.	Undeterm'd.	Recovered.	Died.	Undeterm'd.	Recovered.	Died.	Undeterm'd.	Recovered.	Died.	Undeterm'd.
Primary .....	910	97	.....	1,007	9.6	270	26	.....	356	25	.....	266	28	.....	18	18	.....
Intermediary .....	344	106	.....	450	23.5	97	31	.....	164	41	.....	79	21	.....	4	13	.....
Secondary .....	155	29	.....	184	15.7	46	9	.....	72	8	.....	34	6	.....	3	6	.....
Time of operation unknown	83	10	13	106	10.7	10	.....	2	8	1	1	16	1	1	49	8	9
Total .....	1,492	242	13	1,747	13.9	423	66	2	600	75	1	395	56	1	74	45	9
Aggregate percentages (1734 det'd cases, 13.9% fatal).					491 (13.4% fatal).			676 (11.1% fatal).			452 (12.4% fatal).			128 (37.8% fatal).			

The operations will be analysed in seven tabular statements, the successful and fatal primary, intermediary, and secondary cases, each occupying two tables, and those of uncertain date one. The operations in the different regions of the forearm are distinguished in each table by the alphabetical arrangement.

**Primary Amputations in the Forearm for Shot Injury.**—A thousand and seven such operations, with a mortality of 9.6 per cent., are to be enumerated. A hundred and forty-three were practised on account of disorganization of the extremity by cannon balls or shell or torpedo fragments,—fifty-six in artillery men serving the rammer and injured by premature explosion of the gun.

§ *Recoveries after Primary Amputations in the Forearm.*—There were nine hundred and ten of these operations on nine hundred and three patients, there having been seven

<sup>1</sup> TRIPLER (C. S.), *Hand-book for the Military Surgeon: Being a Compendium of War Surgery*, Cincinnati, 1861, p. 60. "Amputation of the forearm is rarely required; as the fragments may be easily removed and the arteries tied."

<sup>2</sup> GUTHRIE (G. J.) (*A Treatise on Gunshot Wounds*, 3d ed., 1827, p. 535) says: "Wounds of this part are frequently more serious in their results than their appearance at first gives reason to suspect; and the operation of amputation becomes in general a secondary, rather than a primary one, from the subsequent evils demanding it; and the principal one arises from the constitution becoming affected, so as in time to endanger life. For, although the forearm is liable to more complicated injuries than the upper arm, still it is quite under our management. The two bones can be more easily got at, and pieces extracted with ease: the arteries, particularly the radial and ulnar, can be cut down upon, and, except at the upper part, secured without any difficulty. The interosseal, ulnar, and radial arteries can and ought to be fairly tied whenever they bleed, at any sacrifice of muscular parts; and the fascia may be divided freely in every direction, as it may be found to impede the discharge of matter or cause other inconvenience to the patient. An advantage arises also from the number of the arteries supplying the lower part of the limb, for if one be wounded, another, and perhaps two, remain to support and nourish the parts below, which, from the free communication of the palmar arches, is readily effected; mortification of the fingers, therefore, seldom or never takes place from wounds of the forearm."



instances of double amputations in the forearm. In three of these the two limbs were divided in different thirds of the forearm. In four the ablations were made at corresponding points. The following case is an interesting illustration of one of the latter sub-group:

CASE 1925.—Private S. H. Decker, Co. I, 4th Artillery, aged 24 years, was wounded in both forearms, at Perryville, October 8, 1862. Surgeon J. P. Walker, 85th Illinois, recorded his admission to Hospital No. 9, October 15th, with "Amputation of both forearms." On November 3, 1862, the man was discharged from service and pensioned. He visited the Army Medical Museum in November, 1867, when the following facts in relation to his wounds were obtained from his own statement: "While ramming his piece during the battle, he had half of his right forearm, and somewhat less of the left, blown off by the premature explosion of the gun. At the same time his face and chest were badly burned. Five hours after the accident both forearms were amputated by the circular method, about the middle, by an assistant surgeon of the regular army, whose name he could not recall. He laid in the field hospital at Perryville until the wounds were partially cicatrized, when, on November 1st, he went to Louisville, where he was discharged the service. About the middle of January, 1863, the stumps were completely healed." In the autumn of 1864, Mr. Decker began to make experiments for providing himself with artificial limbs, and during the following March he produced an apparatus hitherto unrivaled for its ingenuity and utility. The photograph represented in the annexed cut (FIG. 710), was obtained on the occasion of the pensioner's visit to the Museum, and shows the appliance (FIG. 711) when in use. With the aid of this ingenious apparatus, he is enabled to write legibly, to pick up any small object, a pin for example, to carry packages of ordinary weight, and to feed and clothe himself. This pensioner has been for some years employed as a doorkeeper at the House of Representatives, and was still on duty there in March, 1876.




FIG. 710.—Amputation of both forearms. [From a photograph.]

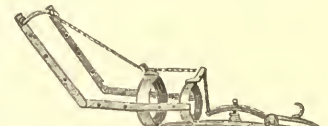


FIG. 711.—Prothetic apparatus for forearm stumps. Spec. 4783, A. M. M.

TABLE CXXXIII.

Summary of Nine Hundred and Ten Cases of Recovery after Primary Amputations in the Forearm for Shot Injury.

NO.	NAME, AGE, AND MILITARY DESCRIPTION.	DATES.	OPERATIONS, OPERATOR, RESULT.	NO.	NAME, AGE, AND MILITARY DESCRIPTION.	DATES.	OPERATIONS, OPERATOR, RESULT.
1	Ackerman, T. J., Corp'l, E. 6th N. Y., age 26.	Oct. 19, '64.	Right; circular. Disch'd May 31, 1865; pensioned; good stump.	21	Bowen, T. S., Pt., F, 36th Ill., age 21.	Nov. 25, '63.	Right; circ.: by Dr. J. G. Buchanan. Pens'd June 16, 1864.
2	Adams, R., Pt., 1, 8th Pennsylvania Res.	Dec. 13, '62.	Right; flap; by Surg. T. Jones, 8th Pa. Res. Dis. June 2, '63; pens'd.	22	Bradford, W. C., Pt., K, 60th Indiana, age 46.	Aug. 12, '64.	Left; by Surg. J. Pegue, 60th Ill. Disch'd Jan. 30, '65; pens'd.
3	Alecke, R. S., Lieut., K, 57th New York.	Dec. 13, '62.	Left; by Surg. C. S. Wood, 60th N.Y. Dis'd; pens'd; good stump.	23	Brady, E., Corp'l, D, 1st Bat'n, 17th U.S. Inf.	Sept. 17, '62.	Right; circ.: by A. Surg. W. R. Ramsey. Pens'd Dec. 13, 1862.
4	Applebee, G. B., Pt., B, 6th Maine Battery.	June 5, '64.	Right. Discharged Nov. 4, 1864; pensioned.	24	Brittain, J. H., Pt., A, 91st Penn., age 16.	June 18, '64.	Left; flap; by Surg. J. Kerr, 62d Penn. Disch'd Apr. 8, '65; pen'd.
5	Atwood, W. N., Pt., K, 12th Mass., age 42.	Dec. 13, '62.	Left; flap; by A. Surg. S. C. Whitaker, 11th Mass. Dis. Feb. 11, '63.	25	Brown, A. C., Pt., A, 33d Indiana, age 23.	May 25, '64.	Right; circ. Discharged; pensioned.
6	Ayy, W. H., Pt., H, 54th Pa., age 29.	Apr. 2, '65.	Left; flap. Discharged June 26, 1865; pensioned.	26	Brown, B. M., Pt., J, 4th N. Y. H. A., age 29.	April 6, '65.	Left; flap; by Surg. Geo. R. Sullivan. Disch'd Oct. 17, 1865.
7	Bain, R. A., Serg't, K, 24th Michigan.	Dec. 13, '62.	Right; flap; by Surg. J. H. Beach, 24th Mich. Dis. Feb. 14, '63; pen'd.	27	Bryant, J. E., Pt., I, 24th Michigan.	Dec. 13, '62.	Left; circ.: by Surg. J. H. Beach. Disch'd Mar. 5, '63; pensioned.
8	Barker, B. F., Pt., K, 93d N. Y., age 19.	June 18, '64.	Left; flap (wound right forearm). Disch'd Nov. 11, '64; pensioned.	28	Brush, D. S., Corp'l, B, 50th Penn., age 42.	June 18, '64.	Right; flap; by Surg. J. C. Lyons, 50th Penn. Disch'd Feb. 2, 1865.
9	Bartlett, N. E., Pt., F, 7th Iowa, age 19.	Oct. 4, '62.	Right. Discharged July 15, '63; pensioned; painful stump.	29	Buckman, G. C., Pt., C, 3d Mass. Bat., age 29.	May 8, '64.	Right; flap (also three fingers left). Pens'd Sept. 16, 1864.
10	Batchelder, J. E., Pt., D, 9th Maine, age 20.	July 14, '64.	Left; by Surg. A. Palmer, 9th Me. Disch'd; pens'd; sound stump.	30	Burger, F. H., Capt., E, 4th Penn. Res.	Sept. 17, '62.	Right; flap; by Dr. O. Smith. Must. out June 17, '64; pens'd.
11	Baugh, A., Pt., C, 19th Kentucky.	Jan. 11, '63.	Left; by Surg. J. B. Sparks, 19th Ky. Disch'd Mar. 18, '63; pens'd.	31	Burton, J., Pt., A, 33d Missouri, age 24.	Mar. 30, '65.	Right; by A. Surg. R. Conover. Disch'd Oct. 21, '65; pens'd.
12	Beck, G., Pt., B, 35th Illinois, age 20.	May 27, '64.	Right; circ.: by Surg. S. B. Hawley, 35th Ill.; gang.; amp. arm. Aug. 17th. Pens'd Sept. 17, '64.	32	Callahan, P., Pt., D, 4th N. Y. Bat., age 26.	Aug. 16, '64.	Right; circ. (Sept. 6, lig. brachial). Disch'd Oct. 21, '65; pensioned.
13	Beebe, H. H., Pt., C, 23d Michigan, age 23.	May 14, '64.	Right; circ.: by Surg. D. L. Heath, 23d Mich.; gangrene. Disch'd Nov. 15, 1864; pensioned.	33	Carpeniter, L., Pt., H, 14th Ohio.	Sept. 19, '63.	Left; flap; by Surg. G. E. Sloat. Disch'd Feb. 15, 1864; pens'd.
14	Benson, J. L., Pt., F, 60th New York.	Dec. 13, '62.	Left; circ.: by Surg. C. S. Wood, 60th N.Y. Dis. Mar. 5, '63; pen'd.	34	Carson, E. B., Lieut., B, 16th Ala., age 35.	Nov. 30, 1864.	Left; ant. post. flap; by Surg. McMahon, 16th Ala. To Prov. Marshal January 3, 1865.
15	Bertram, H., Pt., H, 21st Missouri, age 27.	April 6, '62.	Left. Discharged Nov. 4, 1862; pensioned.	35	Cassidy, J. E., Pt., K, 4th Artillery, age 33.	Mar. 31, '65.	Left; oval flap (right); middle; oval flap; by Surg. W. S. Thompson, U. S. V. Disch'd June 21, 1865; pensioned.
16	Bettis, G. W., Pt., E, 14th Indiana.	Aug. 7, '61.	Right; flap; by Surg. J. G. MePheters, 14th Ind. Dis.: pens'd.	36	Cavanaugh, P., Pt., D, 9th New York.	Sept. 17, '62.	Right; flap; by Surg. G. H. Humphrey. Pens'd May 7, 1863.
17	Birdwell, B. F., Serg't, D, 28th Tenn., age 23.	Nov. 30, '64.	Right; circ.: by Surg. J. R. Wilson, 28th Tenn. Pro. Mar. Jan 5, '65.	37	Cavener, E., Pt., F, 33d Missouri, age 31.	Nov. 15, '64.	Left; circular; by Asst. Surg. W. F. Draee, 33d Mo. Disch'd Jan. 15, 1865; pensioned.
18	Bissert, J., Pt., G, 13th N. H., age 26.	Oct. 23, '64.	Right; flap. Discharged April 8, 1865; pensioned; sound stump.	38	Chance, E., Pt., F, 9th New Jersey.	Mar. 14, '64.	Left; circ.: by A. Surg. L. Brann, 9th N. J. Disch'd; pensioned.
19	Boodger, T., Serg't, I, 2d N. Y. M. R., age 24.	Sept. 4, '64.	Right; flap; by Surg. R. T. Payne. Disch'd Dec. 2, 1864.	39	Chapel, C. E., Corp'l, C, 5th Minnesota.	Apr. 2, '65.	Left; by Surg. V. B. Kennedy, 5th Minn. Disch'd June 14, '65; pen'd.
20	Boozer, C., Pt., H, 1st Penn. Rifles, age 24.	May 12, '64.	Left; flap; by J. J. Comfort, 1st Penn. Disch'd Dec. 24, '64; pen'd.				

No.	NAME, AGE, AND MILITARY DESCRIPTION.	DATES.	OPERATIONS, OPERATOR, RESULT.	No.	NAME, AGE, AND MILITARY DESCRIPTION.	DATES.	OPERATIONS, OPERATOR, RESULT.
40	Chatfield, A. B., Pt., B, 33d Illinois.	May 17, 17, '63.	Right; circ.; by Surg. G. P. Rex. 33d Ill. Dis'd Sept. 25, '63; pen'd.	86	Gallagher, M., Pt., H, 50th Illinois.	Oct. 8, '62.	Left. Discharged June 23, 1863; pensioned; stump sound.
41	Christopher, L., Pt., A, 2d Pa. H. A.	Aug. 18, 19, '64.	Right; flap; by Surg. W. V. White, 54th Mass. Dis'd Apr. 21, '65; pen.	87	Geisler, F., Pt., D, 20th Mass., age 20.	Dec. 13, '62.	Left; circular. Stump healed. Discharged March 11, 1864.
42	Clark, C. W., Serg't, C, 27th Illinois.	Dec. 31, '62.	Left; circ.; by Surg. M. G. Sherman. Pens'd April 11, 1863.	88	Glancey, F., Pt., G, 12th N. H., age 21.	June 29, 29, '64.	Left; bone protruding. Aug. 18th, amp. arm. Pens'd Dec. 25, 1864.
43	Clark, J. F., Pt., D, 3d Alabama, age 23.	May 3, '63.	Right; circular. Transferred June 13, 1863.	89	Griffin, A. E., Pt., 14th Ohio Bat., age 34.	June 27, 27, '64.	Right; flap. Stump healed. Discharged Nov. 21, 1864.
44	Clauser, S., Pt., F, 148th Pennsylvania, age 25.	June 19, '64.	Right; flap. Discharged March 27, 1865; pensioned.	90	Griffin, J. B., Pt., 1st Arkansas, age 22.	Nov. 30, Dec. 1, '64.	Right; circular. Transferred to Provost Marshal Jan. 3, 1865.
45	Clay, C., Capt., K, 58th Pennsylvania, age 22.	Sept. 29, '64.	Right (w'd left forearm); by Surg. H. C. Christy, 58th Pa. Mustered out January 21, 1866.	91	Haines, B., Pt., G, 8th Cold Troops, age 34.	Feb. 20, 22, '64.	Right; circular; by A. A. Surg. 11, H. Neff. Discharged June 21, 1864; pensioned. <i>Spec.</i> 2708.
46	Cleveland, H. G., Lieut., K, 16th Wis., age 35.	July 20, 20, '64.	Left; flap; by Surg. J. S. Reeves, 78th O. Dis'd Nov. 17, '64; pen'd.	92	Hamilton, S., Pt., F, 10th Pa. Reserves.	Dec. 13, '62.	Right; circular. Disch'd April 27, 1863; pensioned; stump healed.
47	Cleveland, L., Pt., E, 38th Ohio, age 20.	Nov. 25, 26, '63.	Left; flap; by Surg. S. L. Burdett. Disch'd April 12, 1864.	93	Hamlin, J. O., Pt., E, 12th Ohio, age 31.	Sept. 19, 19, '64.	Right; circular. Disch'd March 25, 1865; pensioned.
48	Cockin, F., Pt., H, 60th New York, age 19.	July 2, 3, '63.	Left; flap. Disch'd Mar. 22, 1864; pen'd. sound stump. <i>Spec.</i> 3152.	94	Harriman, J., Corp'l, A, 23d New York.	Aug. 29, 29, '62.	Left; flap. Disch'd April 11, '63; pensioned; sound stump.
49	Cook, G. W., Lieut., H, 4th Florida, age 21.	Nov. 30, Dec. 1, '64.	Left; circ.; by Surg. C. Crosby, 4th Fla. To Pro. Mar. Jan. 7, 1865.	95	Harris, M. B., Pt., L, 63d Pa., age 24.	May 12, 12, '64.	Right; flap; by Surg. J. Kerr, 62d Pa. Disch'd Oct. 4, '64; pen'd.
50	Cooper, D. W., Corp'l, E, 27th Mich., age 28.	Dec. 12, '64.	Right; circ.; by Surg. A. F. Whelan. Pens'd October 22, 1864.	96	Hendee, O. P., Lieut., F, 8th Mich., age 23.	Aug. 19, 19, '64.	Right; by Surg. W. C. Shurlock, 51st Pa. Furloughed Oct. 6, '64.
51	Cottle, S. H., Corp'l, E, 5th Ohio.	June 9, '62.	Left. Discharged; pensioned; stump healthy.	97	Henry, P., Pt., G, 3d Delaware, age 32.	May 18, 18, '62.	Left. Discharged July 26, 1862.
52	CroTTY, P., Pt., I, 23d Massachusetts.	Dec. 16, 16, '62.	Left. Discharged March 7, 1863; pensioned; stump tender.	98	Hicks, S., Pt., A, 11th Pennsylvania, age 30.	May 6, 7, '64.	Right; circular. Pensioned; good stump.
53	Crawlers, R., Pt., A, 33d Pennsylvania.	Dec. 13, '62.	Right; circ. Sound stump. Discharged April 25, '63; pen'd.	99	Hickam, G. W., Corp'l, G, 101st Indiana.	Nov. 25, 25, '63.	Right; flap. Discharged April 22, 1864; pensioned.
54	Cunningham, P., Pt., C, 83d Ohio.	Jan. 11, '63.	Left. Discharged March 3, 1863; pensioned; stump tender.	100	Hill, J. A., Lieut.-Col., 11th Maine, age 33.	Aug. 16, 16, '64.	Right; flap.
55	Curran, J. F., Adj., 60th Ohio, age 24.	June 18, 18, '64.	Right; circ.; by Surg. W. B. Fox, 8th Mich. To V. R. C. November 27, 1864; pensioned.	101	Hill, W., Serg'l, A, 76th V. T., age 29.	April 4, 4, '65.	Left; circ.; by A. Surg. B. F. Lyford, 68th C. T.; amp. right arm. Pens'd July 22, '65; died in 1871.
56	Curtin, J. C., Pt., D, 9th New York.	April 19, 19, '63.	Left; by Surg. G. H. Humphreys, 9th N. Y. Disch'd; pensioned.	102	Hindman, W., Pt., A, 18th Infantry, age 28.	May 31, 31, '64.	Right; circ.; by Surg. B. I. Miller, 3d O. Duty Aug. 28, '64; pen'd.
57	Custer, T., Pt., H, 13th Indiana, age 32.	May 20, 20, '64.	Left; flap. Disch'd Dec. 6, 1864; pensioned; bone protruding.	103	Hinkle, E., Serg't, A, 4th New York.	July 1, 1, '62.	Left; circular. Duty April 23, '63; pensioned; stump healed.
58	Dale, G. W., Pt., A, 16th V. R. C.	Feb. 25, 25, '64.	Right; flap; by A. A. Surg. W. C. Wey. Duty Sept. 26, '64; pen'd.	104	Hite, A. H., Pt., A, 1st Pa. Artillery.	Dec. 13, 13, '62.	Left. Discharged March 24, 1863.
59	Dawson, W. F., Pt., E, 7th Iowa, age 18.	Aug. 4, 4, '64.	Left; circ.; by Surg. J. Pogue, 6th Ill. Disch'd Jan. 29, '65; pen'd.	105	Hixon, H. W., Corp'l, 21st Indiana Battery.	Mar. 25, 25, '63.	Right; by Dr. Sautler. Dis'd June 4, '64; pen'd; stump healthy.
60	Dayton, A., Pt., H, 36th Wisconsin.	June 16, 16, '64.	Right; by Surg. C. Miller, 35th Wis. Dis'd Aug. 26, '64; pen'd.	106	Hern, G., Corp'l, A, 63d Pa., age 26.	May 3, 3, '63.	Left; flap. Disch'd Jan. 20, '64; pensioned; good stump.
61	Deacon, A. G., Lieut., E, 6th Wisconsin.	Sept. 17, 17, '62.	Right; circular; by Surg. W. F. Hutchinson. Pens'd Dec. 3, '62.	107	Hoffman, A. G., Pt., K, 11th Massachusetts.	May 5, 5, '62.	Right; flap. Disch'd July 23, '62; pensioned; stump healed.
62	Dearborn, C. P., Pt., H, 15th Maine, age 24.	July 4, 4, '65.	Left; circular. Disch'd October 31, '65; pen'd; stump tender.	108	Hoover, D., Pt., G, 129th Indiana, age 17.	Nov. 30, Dec. 1, '64.	Right; antero-posterior flap. Discharged August 29, 1865.
63	Dearborn, J., Pt., H, 1st Massachusetts Heavy Artillery.	Mar. 25, 25, '63.	Right; circular; by Surg. J. B. Elkins, 1st Maine H. A. Disch'd June 26, 1865; pensioned.	109	Hoover, W. H., Pt., F, 11th New Jersey.	May 3, 3, '63.	Left; flap. Stump healed. To V. R. C. May 25, 1864.
64	Dease, S. M., Corp'l, H, 8th Florida, age 31.	May 3, 3, '63.	Flap. Discharged July 10, 1863.	110	Hopper, J. G., Pt., F, 6th N. Y. H. A., age 37.	May 31, 31, '64.	Left; flap; by Surg. C. H. Porter. Disch'd Aug. 31, 1864; pen'd.
65	Decker, B. M., Pt., C, 93d Illinois, age 30.	May 16, 17, '63.	Right. Discharged September 6, 1864; pen'd; sound stump.	111	Houng, S. W., Corp'l, A, 115th N. Y., age 20.	Aug. 18, 18, '64.	Right; circular. Stump healed. Disch'd Dec. 8, '64; pensioned.
66	Dixon, S. A., Pt., Hancock's Vet. Co., age 24.	April 11, 11, '65.	Right; circ.; by Surg. G. Derby, U. S. V. Pens'd Sept. 1, 1865.	112	Horton, J., Corp'l, L, 4th Artillery.	June 3, 3, '64.	Right; circular; by Surg. J. W. Wishart. Pens'd Jan. 19, 1865.
67	Dodge, C. W., Lieut., B, 22d C. T., age 20.	June 15, 15, '64.	Right; flap; by Surg. L. Barnes, 6th C. T. Disch'd; pen'd.	113	Houch, M., Pt., F, 2d Pa. Reserves, age 20.	May 10, 10, '64.	Left; flap; by Surg. B. Rohrer, 30th Pa. Duty Feb. 25, '65; pen'd.
68	Dooly, W., Pt., A, 1st K'y Bat. Lt. Art.	July 13, 13, '62.	Right; by Surg. C. H. Butler, 4th Ky. Cav. Disch'd; pensioned.	114	Hughes, A., Pt., G, 95th Pennsylvania, age 30.	Oct. 19, 19, '64.	Right; flap. Disch'd Jan. 8, '65; pensioned; unhealthy stump.
69	Doty, L. E., Corp'l, E, 30th Missouri.	June 9, 9, '63.	Left; flap; by Surg. C. G. Strader, 31st Mo. Dis'd Sept. 21, '63; pen'd.	115	Hughes, J. P., Pt., A, 2d N. C. Mt'd Inf.	Mar. 6, 7, '65.	Right; flap; by Dr. Ewing. Discharged July 21, 1865; pen'd.
70	Douglass, J. E., Corp'l, H, 19th Mass.	Dec. 13, 13, '62.	Right; flap; by Surg. J. F. Dyer, Pens'd December 31, 1862.	116	Hunsinger, J., Pt., E, 6th N. C., age 18.	Mar. 25, 25, '65.	Left. Released June 14, 1865.
71	Duell, G. H., Serg't, F, 12th N. J., age 21.	May 18, 18, '64.	Right; flap; by Surg. M. Rizer. Pens'd September 21, 1864.	117	Hultgren, N. J., Pt., H, 1st Illinois Artillery.	May 28, 28, '62.	Right; by Surg. E. Andrews, 1st Ill. Art. Dis'd May 9, '63; pen'd.
72	Ducey, M., Pt., K, 97th Pennsylvania, age 21.	June 15, 16, '65.	Left; flap; amp. right; good stump. Disch'd Oct. 21, 1865; pensioned.	118	Jackson, J., Pt., I, 61st Pennsylvania, age 45.	Sept. 19, 19, '64.	Right; flap; by Surg. G. T. Stevens. Pens'd March 28, 1865.
73	Dunham, D., Pt., C, 18th Massachusetts, age 19.	July 15, 15, '64.	Left; circular; by Surg. W. Holbrook. Pens'd Sept. 2, 1864.	119	James, S. P., Pt., B, 25th Indiana, age 17.	Dec. 12, 14, '64.	Left; flap; by A. A. Surg. Smith. Disch'd Apr. 17, 1865.
74	Eichel, J., Serg't, E, 2d U. S. Artillery.	Aug. 29, 29, '62.	Right; flap; by Surg. T. G. Myers. Pens'd Nov. 27, 1864.	120	Janelus, A., Pt., K, 41st New York, age 29.	Oct. 19, 19, '64.	Right; circ. Stump healed. Discharged Sept. 11, '65; pen'd.
75	Ensign, H., Pt., B, 15th Arkansas, age 29.	Nov. 30, Dec. 2, '64.	Right; antero-posterior flap. To Provost Marshal Jan. 23, 1865.	121	Jeffries, M. M., Pt., E, 15th W. Va., age 19.	June 18, 18, '64.	Right; circ. Stump healed. Discharged Sept. 11, '65; pen'd.
76	Favory, F., Pt., M, 10th N. Y. A., age 26.	June 15, 15, '64.	Right; circular. Stump healed. Discharged May 31, 1865.	122	Johnson, E. M., Corp'l, K, 1st Me. H. A., age 20.	Oct. 1, 1, '64.	Left; flap. Disch'd Feb. 13, '65; pen'd; good stump.
77	Ferguson, E. L., Pt., C, 31st Indiana.	Feb. 15, 15, '62.	Left; flap; by A. Surg. S. J. Young, 48th Ill. Dis. July 8, '62; pen'd.	123	Jelly, J., Pt., E, 83d Penn., age 27.	Aug. 1, 1, '64.	Left; circular; gang. Dec. 19, '64, amp. of arm. Disch'd June 1, '65; pen'd. Died Jan. 18, 1868.
78	Ferguson, J. S., Serg't, F, 28th Iowa, age 33.	April 8, 10, '64.	Right; flap. Discharged July 28, 1865; pensioned; stump rough.	124	Irwin, J. D., Pt., E, 123th New York, age 29.	May 3, 3, '63.	Right; circular; by Surg. C. S. Wood. Disch'd Oct. 17, 1863.
79	Fetter, H., Pt., G, 2d New Jersey.	Aug. 27, 27, '62.	Right; circular; Good stump. To V. R. C. Aug. 14, '63; pensioned.	125	Kelley, J. T., Corp'l, K, 72d Penn., age 39.	May 6, 6, '64.	Left; flap; by Surg. M. Rizer, 72d Penn. Disch'd Sept. 20, 1864; pensioned.
80	Finley, J., Pt., C, 3d Mass. Bat., age 22.	Aug. 18, 18, '64.	Right; flap; aneurism of radial; Sept. 1st, amp. arm. Mustered out Sept. 16, 1864; pensioned.	126	Kennedy, J. B., Capt., A, 15th Ark., age 31.	Dec. 16, 17, '64.	Right; circ.; by Surg. Wade, C. S. A. To Pro. Mar. Mar. 7, '65.
81	Freeley, M., Corp'l, K, 69th N. Y., age 23.	May 12, 12, '64.	Left; flap. Discharged June 27, 1865; pensioned; good stump.	127	Kennedy, O., Pt., H, 21st Wisconsin, age 35.	Mar. 19, 19, '65.	Right. Disch'd May 22, 1865; pensioned.
82	Friedel, J., Pt., H, 35th Wisconsin, age 20.	Mar. 27, '65.	Left; flap; by Surg. R. Mitchell, 37th Wis. Dis. July 17, '65; pen'd.	128	Kieplinger, A., Pt., I, 19th Indiana, age 49.	May 5, 6, '64.	Right; circ. Discharged November 11, 1864.
83	Frost, R., Corp'l, B, 7th N. Y. H. A., age 32.	Sept. 29, 29, '64.	Left; circ.; by Surg. J. E. Pomeroy. Pens'd Jan. 24, 1865.	129	Kineaid, J. R., Pt., H, 58th Mass., age 22.	Sept. 30, 30, '64.	Left; circ. Stump healed. Disch'd Feb. 25, 1865; pensioned.
84	Furby, C., Corp'l, C, 38th C. T., age 20.	Sept. 29, 29, '64.	Left; circ.; by Surg. H. Davis, 38th C. T. Disch'd Sept. 7, '65; pen'd.	130	King, J. R., Pt., F, 31st Iowa, age 24.	June 27, 27, '64.	Right; flap; by Surg. T. J. Watson. Pens'd Dec. 6, 1864.
85	Gall, G. F., Pt., 23d Bat. Ohio L. A., age 24.	April 10, '65.	Right; flap; by A. A. Surg. T. W. Brough. Dis. June 10, '65; pen'd.	131	King, N., Pt., C, 44th New York.	Aug. 31, 31, '62.	Right; flap; by Surg. Hough. Stump healed. Pens'd Oct. 8, '62.



No.	NAME, AGE, AND MILITARY DESCRIPTION.	DATES.	OPERATIONS, OPERATOR, RESULT.	No.	NAME, AGE, AND MILITARY DESCRIPTION.	DATES.	OPERATIONS, OPERATOR, RESULT.
132	Kinlock, W. Pt., Lee's Bat., age 24.	July 2, '63.	Right; circular. To Provost Marshal April 1, 1865.	178	Morse, E. L., Pt., K, 4th Mass. Volunteers.	June 14, '63.	Right; circ. Disch'd Sept. 23, '63; pensioned; sound stump.
133	Knowles, J., Pt., E, 5th New York, age 19.	June 10, '61.	Right. Disch'd Oct. 15, 1861; pens'd. Died Sept. 27, 1867.	179	Mortimer, W. H., Serg't, K, 4th Minnesota.	June 17, '63.	Right. Discharged Oct. 8, 1863; pensioned; stump sound.
134	Koeh, J., Pt., II, 21st New York.	Sept. 17, '62.	Left; by Surg. C. H. Wilcox, 21st N. Y. Pens'd Nov. 31, 1862.	180	Mott, O., Pt., C, 38th Ohio, age 25.	Aug. 5, '64.	Right; flap; by Surg. I. A. Coons; gang. Pens'd Jan. 21, 1865.
135	Kurtz, G., Serg't, K, 18th Missouri, age 21.	Aug. 11, '64.	Right; flap. Stump healed. Discharged May 24, '65; pensioned.	181	Murray, J., Pt., I, 97th New York.	Aug. 30, '62.	Left. Stump healed. Discharged February 23, 1863.
136	Lambert, J., Pt., E, 5th Pa. Cav., age 24.	May 8, '64.	Right; flap. Disch'd Dec. 24, '64; pensioned; stump healed.	182	Murphy, J., Pt., II, 2d Massachusetts.	May 15, '64.	Left; by Surg. W. H. Heath, 2d Mass. Pens'd Aug. 22, 1864.
137	Langsford, D., Pt., I, 203d Pa., age 28.	Jan. 15, '65.	Left; circ.; by Surg. G. C. Jarvis, 7th Ct. Dis. July 21, '65; pens'd.	183	Nason, W. H., Pt., 5th Maine Battery, age 23.	May 3, '63.	Right; circ. Disch'd May 3, 1864; stump sound but painful; pen'd.
138	Latham, E. P., Pt., 9th Bat. Ohio Light Art.	June 19, '62.	Right; by Surg. J. C. McFleetters, 33d Ind. Left; by Surg. C. W. McMillen, 1st Tenn. Disch'd November 20, 1862; pensioned.	184	Neibbing, J. M., Col., 21st Kentucky.	May 27, '64.	Right. Disch'd Dec. 6, '64; pen'd. Died Feb. 21, '69, consumption.
140	Lawrence, A. G., Capt., 1, 2d Colored Cavalry, age 26.	Jan. 15, '65.	Left; circ.; by A. Surg. F. B. Kimball, 3d N. H. Resigned Jan. 10, 1866. Oct. 20, 1867, excision of nerve for neuralgia of stump.	185	Nelson, C. W., Pt., B, 22d Kentucky.	Sept. 19, '63.	Left; circ.; by Surg. A. M. Morrison. Pens'd Jan. 23, 1864.
141	Laycock, W., Pt., F, 20th Indiana.	Sept. 17, '64.	Right; flap; by Surg. H. F. Lyster, 5th Mich. Dis. Dec. 19, '64; pen'd.	186	Nixon, M., Pt., A, 29th Iowa.	July 4, '63.	Right; flap; by Asst. Surg. D. F. Eakins. Pens'd Aug. 26, 1863.
142	Lema, L., Pt., II, 6th New Hampshire.	July 30, '64.	Left; flap. Sound stump. Disch'd Dec. 4, 1864; pensioned.	187	Northrup, V., Pt., L, 2d N. Y. Art., age 28.	June 4, '64.	Right; circular. Stump healed. Discharged November 2, 1864.
143	Lewis, C. A., Pt., K, 57th Mass., age 17.	July 30, '64.	Left; flap; by Surg. T. P. Oakes, 56th Mass. Disch'd Feb. 25, '65.	188	Norton, F. M., Pt., C, 70th N. Y., age 21.	May 5, '64.	Right; flap. Disch'd Sept. 16, '64; pensioned; sound stump.
144	Lewis, W. H., Pt., C, 5th Art., age 22.	June 7, '64.	Right; flap; upper. Left; flap; lower. Dis. Apr. 29, '65; pens'd.	189	O'Reilly, G., Pt., C, 3d New Jersey, age 25.	May 6, '64.	Right; circ.; by Surg. J. D. Osborne, 4th New Jersey. Duty October 26, 1864; pensioned.
145	Lockbrane, C., Pt., C, 20th Mass., age 21.	May 6, '64.	Right; flap. Disch'd Feb. 6, '65; pensioned; good stump.	190	Oberton, J. B., Corp'l, G, 2d New York Mounted Rifles, age 22.	June 17, '64.	Right; flap. Disch'd Feb. 14, '65; pensioned; healthy stump.
146	Loughorn, J., Capt., I, 19th Illinois, age 24.	Sept. 20, '63.	Right; flap; by A. Surg. C. C. Byrne, U. S. A. Duty May 16, '64; pen'd.	191	Patterson, F. N., Lieut., G, 10th Ohio.	Oct. 8, '62.	Right. Discharged; pensioned; healthy stump.
147	Loomis, C. D., Pt., E, 1st Ct. H. A., age 37.	July 9, '64.	Left; circ.; by Surg. S. W. Skinner, 1st Ct. H. A. Dis. Dec. 19, '64; pen. Left; flap; by Dr. J. McCook. Discharged; pensioned.	192	Perriman, J. K., Pt., B, 1st Mississippi Marine Brigade, age 20.	May 31, '64.	Right; flap; by Surg. J. Roberts, 1st Mississippi Marine Brigade. Discharged November 28, 1861.
148	Lough, W. H., Corp'l, C, 2d Indiana Cav.	May 30, '63.	Right; flap; by Dr. J. McCook. Discharged; pensioned.	193	Peterson, C., Pt., C, 9th N. H., age 25.	July 10, '64.	Left; circ. Disch'd Nov. 19, 1864; pensioned; good stump.
149	Lower, W. H., Pt., II, 90th Pa., age 22.	July 3, '63.	Right; circ. Discharged Oct. 10, 1863; pensioned; stump healed.	194	Pettis, J. M., Pt., I, 7th S. C., age 27.	July 3, '63.	Left. Transferred to Provost Marshal September 14, 1863.
150	Lynch, P., Pt., E, 1st Missouri Light Art.	Nov. 10, '63.	Left; flap. Stump healed. Discharged December 16, 1863.	195	Phlegar, J. H., A, Star Horse Artillery, age 32.	Dec. 13, '62.	Right; circular. Did well.
151	Lynch, T. W., Pt., A, 1st Illinois Lt. Art.	July 22, '64.	Right; by Surg. J. N. Barnes, 116th Ill. Dis. Mar. 18, '65; pen'd.	196	Pickett, J., Pt., I, 14th Connecticut, age 51.	May 6, '64.	Left. Discharged November 28, 1864; pensioned.
152	Mackin, T., Pt., K, 70th New York, age 29.	Aug. 23, '62.	Right; flap; by Surg. J. T. Cahoun. Pens'd May 13, 1863.	197	Pike, G. B., Pt., D, 1st New York Light Artillery, age 28.	Mar. 31, '65.	Right; circular; by Surg. W. S. Thompson, U. S. V. Discharged July 18, 1865; pensioned.
153	Mahony, T. J., Pt., E, 44th New York.	May 4, '63.	Left; flap; by Surg. M. W. Townsend. Pens'd Sept. 29, 1863.	198	Plunkett, C., 1st Lieut., 133th Mass., age 32.	May 23, '64.	Right; flap; by A. Surg. J. F. Sullivan. Pens'd June 21, 1864.
154	Majors, H. M., Pt., D, 23d Tenn., age 25.	July 1, '64.	Left; circ. July 31, nearly healed. Furloughed August 30, 1864.	199	Pratt, W. H., Pt., D, 2d N. Y. H. A., age 37.	June 3, '64.	Left; flap. Disch'd Oct. 17, 1864; pensioned; sound stump.
155	Maahan, W., Pt., K, 148th New York.	May 14, '64.	Right; flap. Discharged July 26, 1864; pensioned.	200	Price, I., Corp'l, F, 15th W. Va., age 34.	Oct. 13, '64.	Left; by Surg. W. S. Walsh, 15th W. Va.; amp. right arm. Discharged June 9, 1865; pens'd.
156	Marcy, D., Serg't, D, 23d Kentucky, age 38.	May 9, '64.	Left; by Surg. A. H. Stephens, 6th Ohio. Pens'd June 2, 1865.	201	Ragan, T. L., Pt., E, 11th Missouri Cav.	Feb. 7, '64.	Left; flap; by A. Surg. J. E. Tefft, 1st Ark. Cav. Disch'd May 7, '64.
157	Mark, F. Pt., A, 2d Mo. Light Artillery.	May 26, '61.	Right; nmp. left arm at should. jt.; by Dr. Schmidt. Disch'd; pen'd.	202	Ramsey, B., Corp'l, B, 105th Pa., age 41.	Oct. 27, '64.	Left. Disch'd August 3, 1865; pensioned; sound stump.
158	Markham, P. A., Corp'l, B, 154th New York.	May 8, '64.	Right; circular; by Surg. H. Van Aernam, 154th N. Y. To V. R. C. October 20, 1864; pensioned.	203	Rank, G., Pt., 11th Bat. Ind. Lt. Art., age 29.	July 25, '64.	Left; flap. Stump healed. Mustered out Dec. 30, '64; pensioned.
159	Martin, J. M., Pt., 4th N. J. Battery, age 26.	Aug. 16, '64.	Right; circular. Stump healed. Discharged July 18, 1865.	204	Rapp, A. G., Serg't II, 136th Pennsylvania.	Nov. 8, '63.	Left; by Surg. C. P. Herrington, 138th Pa.; gangrene; amp. arm. Disch'd April 12, '64; pensioned.
160	Maxwell, J., Pt., I, 2d Pa. H. A., age 35.	Sept. 29, '64.	Left; flap. Disch'd March 18, 1865; pens'd; tender stump.	205	Rasembush, P., Pt., II, 17th Missouri.	May 19, '62.	Right; circular. Stump healed; pensioned.
161	McCormick, J., Pt., D, 65th New York, age 37.	May 14, '64.	Left; circular. Transferred to Camp Parole.	206	Reynolds, W. C., Pt., G, 181st Ohio, age 47.	Dec. 8, '64.	Right; flap. Stump healed. Discharged April 17, 1865.
162	McDaniel, I., Pt., C, 18th Texas, age 25.	Nov. 30, '64.	Left; antero-posterior flap. To Provost Marshal Mar. 7, 1865.	207	Richardson, G. H., Pt., A, 11th Maine, age 26.	June 16, '64.	Left; circular. Disch'd December 5, 1864.
163	McGinley, J., Pt., B, 1st W. Virginia Artillery, age 23.	Aug. 26, '63.	Left; flap; by Surgeon W. B. Wynne, 14th Pa. Cav., Discharged Mar. 9, 1864; pensioned.	208	Riggers, L. E., Corp'l, D, 80th Indiana, age 36.	May 14, '64.	Left; flap; by A. Surg. A. W. Spain, 80th Indiana; gangrene. Disch'd Dec. 31, '64; pensioned.
164	McIlhenny, J., Pt., II, 133d Pennsylvania.	Dec. 13, '62.	Left; circular. Stump healed. Disch'd Mar. 12, '63; pensioned.	209	Rilea, G., Pt., C, 39th Illinois, age 20.	April 2, '65.	Right; flap; by Surg. C. M. Clark. Pensioned July 17, 1865.
165	McKaine, W., Pt., II, 105th Pennsylvania.	June 30, '62.	Right. Discharged January 21, 1863; pensioned; sound stump.	210	Ripley, O., Pt., K, 17th Maine.	Sept. 12, '64.	Left; flap. Disch'd January 2, 1865; pens'd; healthy stump.
166	McKean, J., Corp'l, B, 12th Michigan.	April 6, '62.	Right; flap; Surg. G. L. Benschweiler. Pens'd Sept. 29, '63.	211	Ronan, C., Pt., F, 28th C. T., age 18.	July 30, '64.	Left; circ.; by Surg. G. J. Potts, 2d C. T. Pens'd June 6, 1865.
167	McKusick, C. F., Pt., H, 6th Maine, age 21.	May 10, '64.	Right; flap; by Surg. W. Buck, 6th Maine. Pens'd Dec 15, 1864.	212	Rogers, A. W., Pt., E, 39th Illinois, age 26.	May 17, '64.	Right; flap. Disch'd October 29, '64; pens'd; sound stump.
168	McPhillips, J., Pt., C, 4th N. Y. Cav., age 25.	Sept. 16, '63.	Right; flap. Stump healed. Discharged Sept. 12, '64; pensioned.	213	Rogers, J. M., Corp'l, II, 10th Connecticut.	Dec. 14, '62.	Right; circular; by Surg. I. F. Galloupe. Pens'd Sept. 30, 1864.
169	Meiser, G., Capt., D, 23th New York.	June 9, '62.	Left. Disch'd; pens'd; stump very tender. 1866. Dr. Mussey oper'd.	214	Rosa, F., Pt., G, 24th Iowa.	May 16, '63.	Right; gangrene. August 15, '63, amp. arm. Pens'd Sept. 16, '63.
170	Merrill, N. H., Lieut., K, 25th Mich., age 23.	Aug. 6, '64.	Left; by Surg. A. M. Wilder, U. S. V. Disch'd Nov. 7, '64; pens'd.	215	Ross, J. F., Pt., A, 48th N. C., age 30.	Aug. 25, '64.	Left; circ.; by Surg. Langley, C. S. A. Furl'd Sept. 23, 1864.
171	Merrill, S., Pt., I, 1st Ohio Art., age 31.	June 18, '64.	Right; circular. Disch'd March 18, '64; pensioned; good stump.	216	Ryan, P., Pt., F, 101st New York.	Aug. —, 1862.	Left; flap; by Surg. J. W. Black. Disch'd September 29, 1862.
172	Miller, C., Pt., H, 128th Illinois.	Dec. 29, '62.	Left; by Surg. S. H. Bundy, 128th Ill. Must. out Sept. 9, '64; pens'd.	217	Ryan, T., Pt., A, 5th Vermont, age 22.	May 12, '64.	Right; circular; by Surg. A. H. Chessmore, 5th Vermont. Discharged Oct. 15, '64; pensioned.
173	Milliron, S., Pt., I, 11th Pennsylvania, age 30.	May 8, '64.	Left; flap. Disch'd December 1, 1864; pensioned.	218	Saur, M., Pt., A, 32d Indiana, age 32.	May 27, '64.	Right; circular. Must'd out Sept. 17, 1864; pens'd; stump healed.
174	Mitchell, W., Pt., A, 84th Illinois.	Dec. 31, '62.	Left. Discharged March 26, 1863.	219	Schneider, J., Pt., II, 97th New York.	Aug. 22, '62.	Left; by Surg. F. B. Hough, 97th N. Y. Pens'd Oct. 22, 1862.
175	Moore, G. P., Serg't, A, 11th Vermont, age 23.	April 3, '65.	Right; circular; by Dr. S. W. Bowles. Pens'd Aug. 17, 1865.	220	Scott, W. H., Pt., A, 1st Maine H. A., age 22.	April 6, '65.	Left; lateral flap. Discharged June 10, 1865.
176	Moore, W. E., Pt., C, 11th Pa. Reserves.	June 27, '62.	Right. Stump healed. Disch'd September 1, 1862.	221	Seaman, E. W., Pt., II, 8th Illinois Cavalry.	Mar. 5, '65.	Left; flap; by Surg. A. Hard, 8th Ill. Cav. Pens'd Mar. 30, 1865.
177	Morgan, A. A., Pt., B, 11th N. C., age 24.	July 2, '63.	Right. Transferred for exchange November 12, 1863.				

NO.	NAME, AGE, AND MILITARY DESCRIPTION.	DATES.	OPERATIONS, OPERATOR, RESULT.	NO.	NAME, AGE, AND MILITARY DESCRIPTION.	DATES.	OPERATIONS, OPERATOR, RESULT.
222	Sexton, D., Pt. E, 11th Illinois.	Feb. 15, '62.	Left. Discharged December 18, 1862; pensioned.	267	Wilbur, S. D., Pt., E, 10th N. Y., age 23.	April 2, '65.	Right; circ.; by Surg. W. S. Johnson. Disc'd June 22, '65; pens'd.
223	Shaffer, H. D., Pt., H, 54th Pa., age 22.	June 18, '61.	Left; circular; by Surg. D. Bagley. Pensioned Feb. 25, 1865.	268	Wood, H. B., Lieut., K, 48th Tenn., age 23.	Dec. 16, '64.	Left; circ. Stump healed. Transferred to Pro. Mar. Jan. 31, '65.
224	Sharp, A., Pt., K, 120th New York, age 18.	Mar. 31, '65.	Right; antero post. flap. Disch'd August 28, 1865.	269	Young, A. H., Pt., A, 6th Wisconsin.	Sept. 17, '62.	Right; flap (amp. left arm); by Surg. J. McNulty, U. S. V. Discharged Nov. 16, 1863; pens'd.
225	Showers, J., Pt. B, 82d Pennsylvania, age 22.	April 1, '65.	Right; flap. Discharged June 22, 1865.	270	Zindle, D., Pt., E, 74th New York.	May 5, '62.	Left; by Surg. J. T. Calhoun, 74th N. Y. Disc'd Oct. 1, '62; pen'd.
226	Simons, F., Pt., F, 117th New York, age 27.	May 16, '64.	Left; flap. Stump healed. Discharged Sept. 3, '64; pensioned.	271	Adams, T. M., Pt., F, 1st Ind. Cav.	July 4, '63.	Right; flap. Disc'd Aug. 26, 1863; pensioned.
227	Smith, A., Pt., F, 26th Georgia.	July 9, '64.	Left; circular. Exchanged September 19, 1864.	272	Albert, W. B., Pt., A, 5th Art.	July 1, '62.	Right; Disc'd Aug. 12, 1862; pensioned; good stump.
228	Smith, C., Pt., D, 45th Pennsylvania, age 20.	June 3, '61.	Left; circ.; by Surg. T. Crist, 45th Pa. Disc'd Nov. 14, '64; pens'd.	273	Alexander, J., Pt., D, 2d Mo. Lt. Art.	Apr. 13, '65.	Right; flap. Stump healed. Discharged; pensioned.
229	Smith, J., Pt., B, 2th N. Y. Cav., age 37.	Mar. 25, '65.	Right; circular. Stump healed. Mustered out Aug. 17, 1865.	274	Alexander, J., Pt., D, 27th Ind.	May 3, '63.	Left. Discharged Oct. 29, 1863; pensioned.
230	Smith, J. C. D., Pt., D, 40th Indiana, age 23.	Nov. 30, '64.	Right; circular; by A. Surg. C. C. Byrne, U. S. A. Dis. May 21, '65.	275	Allen, J., Pt., D, 48th Ill., age 30.	Dec. 13, '64.	Left; flap; by Surg. I. N. Barnes, 116th Ill. Pens'd Apr. 11, '65.
231	Smith, T., Pt., B, 1st Illinois Artillery.	Aug. 25, '65.	Right. Discharged Jan. 1, 1862; pensioned; good stump.	276	Allen, L., Pt., A, 3d U. S. C. H. Art.	Jan. 14, '64.	Right; by Surg. H. H. Hood, 3d C. H. Art. Pens'd June 13, '65.
232	Smith, W. C., Serg't, C, 3d Mus. Cav., age 31.	Sept. 19, '61.	Left; circular. Disc'd Jan. 19, 1865; stump healed; pensioned.	277	Allender, J., Serg't, I, 12th Mass.	July 2, '63.	Right; flap. Stump healed. Discharged May 24, '64; pensioned.
233	Sommers, D. R., Corp'l, I, 12th Wis., age 31.	July 21, '64.	Left; flap; by Surg. E. M. Rogers, 12th Wis. Dis. Dec. 19, '64; pen'd.	278	Arnacost, G. W., Pt., A, 6th Md., age 23.	Oct. 19, '61.	Left; flap. Stump healed. Disc'd June 12, 1865; pensioned.
234	Spade, H., Pt., H, 8th Pa. Cav., age 23.	Apr. 5, '65.	Right; circular. Disc'd July 11, 1865; pensioned.	279	Ayers, J. W., Pt., K, 8th Ill.	June 7, '63.	Left; circular. Disc'd Sept. 25, 1863; pensioned; stump healed.
235	Spaulding, A., Pt., C, 8th N. J., age 20.	May 16, '64.	Right; circular. Disc'd August 7, 1865; pensioned.	280	Ayers, P. B., Lieut., E, 9th Penn., age 25.	Apr. 6, '65.	Left; circ.; by Surg. D. S. Hays, 110th Pa. Pens'd May 15, 1865.
236	Spear, M. L., Corp'l, K, 23d Pa., age 20.	June 1, '64.	Left; circular; by Surg. L. M. Emanuel, 82d Pa. To V. R. C. Oct. 28, 1864; pensioned.	281	Baker, J., Pt., K, 47th Ohio, age 31.	Dec. 14, '64.	Left; circ.; by Surg. J. H. Hutcheson Disc'd June 5, 1865.
237	Sperry, R., Wagoner, E, 26th Maine, age 44.	Jan. 13, '63.	Right; circ.; by Surg. C. Abbott, 26th Me. Dis. Feb. 28, '63; pen'd.	282	Baker, R., Corp'l, H, 51st Penn., age 20.	May 6, '64.	Right; circ.; by Surg. W. B. Fox, 8th Mich. Pens'd Dec. 1, '64.
238	Spitsma, H. C., Pt., A, 3d West Virginia.	Aug. 27, '62.	Left; flap; by A. Surg. C. W. Meyers, 82d O. Pens'd Nov. 8, '62.	283	Bamberger, W., Pt., 2d Iowa Battery.	July 4, '62.	Left; by Surg. S. P. Thornhill, 8th Wis. Pens'd; stump healed.
239	Stafford, O., Pt., A, 31st Wisconsin, age 33.	Mar. 19, '65.	Right. Mustered out June 2, '65; pensioned; healthy stump.	284	Bannister, J., Lieut., H, 24th N. V. Cav., age 24.	July 8, '64.	Right; flap; by Surg. S. S. French. Duty Sept. 26, 1864.
240	Stahl, J. H., Serg't, A, 21st Kentucky Mt. Inf.	Jan. 2, '63.	Right; by Surg. C. J. Walton, 21st Ky. Dis. Apr. 4, '63; pens'd.	285	Barger, F. C., Lieut., G, 3rd New York.	Dec. 13, '62.	Right; by Surg. J. Hansen, 30th N. Y. Disc'd May 11, '64; pen'd.
241	Stein, J., Pt., B, 3d California Infantry.	Apr. 19, '65.	Right; flap; by Surg. R. K. Reid, 3d Cal. Dis. Nov. 22, '65; pens'd.	286	Barnes, B., Serg't, K, 21st Mass., age 29.	July 30, '64.	Left; flap; by Surg. G. W. Snow, 36th Mass. Pens'd Dec. 16, '64.
242	Stubbins, J., Pt., A, 5th Maryland.	Sept. 17, '62.	Left. Discharged August 31, '63; pensioned; sound stump.	287	Barnett, N. W., Serg't, I, 25th Ind., age 30.	Feb. 3, '65.	Left; flap; by Surg. A. B. Monohan. Pens'd May 30, 1865.
243	Sullivan, W., Pt., B, 9th Massachusetts.	July 1, '62.	Left. Stump healed. Discharged Sept. 20, 1862; pensioned.	288	Bateman, S., Pt., I, 30th C. T., age 17.	July 23, '64.	Left; circ.; by Surg. D. Mackey, 29th C. T. Pens'd Jan. 16, '65.
244	Swartwood, J., Pt., A, 4th U. S. Art., age 24.	Sept. 21, '64.	Right; flap; by Dr. Lee, U. S. Navy. Disc'd Apr. 6, 1865.	289	Bean, J. R., Pt., K, 80th Ohio.	Jan. 22, '63.	Left; by Surg. E. P. Buell, 80th Ohio. Disc'd Mar. 10, '63; pen'd.
245	Taylor, C. R., Pt., D, 5th Maine.	Sept. 17, '61.	Left; circular; by A. Surg. G. E. Brickett. Pens'd Nov. 19, 1861.	290	Beary, J. H., Pt., K, 5th Artillery, age 26.	July 3, '63.	Right; flap. Amp. of left arm. Disc'd May 26, '64; pensioned.
246	Taylor, D. H., Pt., A, 11th Pa. Cavalry.	Jan. 30, '63.	Left; by Surg. G. C. Hardan, 11th Pa. C. Dis'd June 23, '63; pen'd.	291	Beek, J. P., Pt., A, 124th Illinois.	Oct. 10, '63.	Right; circular. Stump healed. Disc'd Dec. 5, '63; pensioned.
247	Taylor, M. P., Pt., D, 138th Pennsylvania.	Nov. 27, '63.	Left; circular; by A. Surg. T. C. Thornton. Pens'd April 19, '64.	292	Beek, J. V., Pt., K, 87th Pennsylvania, age 24.	Nov. 30, '63.	Right; flap; by Surg. J. S. Jumierson. Pensioned July 4, 1864.
248	Thompson, H., Pt., G, 72d New York.	July 1, '62.	Right. Discharged Oct. 23, 1862; pensioned; stump sound.	293	Boeler, A. J., Corp'l, L, 1st Artillery.	Nov. 22, '61.	Right; flap; by Surg. J. Campbell, U. S. A. Disc'd; pensioned.
249	Thompson, T. M., Pt., 1st Maine Battery.	Jan. 14, '63.	Left. Amp. right wrist; by Surg. M. D. Benedict, 75th New York. Disc'd May 10, 1863; pens'd.	294	Bell, W., Pt., D, 30th C. T., age 21.	July 30, '64.	Left; circ.; by Surg. F. M. Weld, 27th C. T. Pens'd April 3, '65.
250	Thurmonst, T., Pt., E, 63d Pa., age 24.	May 6, '64.	Left; flap; by Surg. H. P. Lyster, 5th Mich. Disc'd Sept. 8, '64; pensioned.	295	Bemis, M. Y., Pt., F, 11th Vermont, age 21.	June 23, '64.	Left; by Surg. C. B. Park, 1st Vt. H. A. Disc'd Dec. 15, 1864.
251	Turner, A., Corp'l, E, 105th Pa., age 33.	June 16, '64.	Right; circular. August 13, gangrene. Disc'd Sept. 8, 1865.	296	Berger, H., Pt., B, 19th Kentucky, age 34.	April 9, '64.	Left. Discharged June 9, 1864.
252	Travis, G. H., Pt., 2d Ky. Battery, age 30.	Apr. 21, '64.	Left; flap; by A. Surg. L. W. Kennedy. Duty July 12, '64; pens'd.	297	Black, F., Pt., H, 27th Michigan, age 18.	July 23, '64.	Left; flap; by Surg. A. F. Whelan. Disc'd March 15, 1865.
253	Tucker, J. B., Serg't, B, Green River Battalion, Ky. State Troops.	July 4, '65.	Right; circ.; upper; left; lower; by A. Surg. C. F. Ulrich, of regiment; July 11, 1865, re-amp. left forearm. Disc'd Aug. 23, 1865.	298	Blanchard, J., B, 1st Ohio Artillery.	Dec. 26, '62.	Right; by A. Surg. D. Richards, 26th Ohio. Disc'd Jan. 29, 1863; pensioned.
254	Vasteen, H., Pt., A, 1st U. S. S. S., age 44.	May 6, '64.	Left; lateral flap. June 24, 1864, to insane asylum.	299	Blanchard, T. W., Corp'l, G, 15th N. H., age 20.	Sept. 29, '64.	Right; circular. Disc'd June 1, 1865; pensioned; stump healthy.
255	Wall, P., Pt., K, 4th Pa. Reserves.	Sept. 17, '62.	Right. Healed. Disc'd Feb. 11, 1863; pensioned.	300	Blank, S. C., Pt., D, 32d Iowa.	April 9, '64.	Right; circular. Mustered out Sept. 6, 1864; stump healed.
256	Walls, P., Pt., G, 47th Illinois, age 30.	Dec. 15, '64.	Right. Duty February 4, 1866; pensioned.	301	Boekvay, L., Pt., B, 1st Wisconsin H. A.	April 5, '65.	Right; circ.; by A. A. Surg. J. M. Bruce. Duty May 30, '65; pens'd.
257	Walters, C. F., Pt., C, 118th Pa., age 30.	May 6, '64.	Left; flap. Discharged September 20, 1864.	302	Boeshore, W., Pt., C, 93d Pa., age 19.	May 18, '64.	Left; flap; by Surg. E. B. Umberger. Pens'd Oct. 25, 1864.
258	Webel, O., Pt., E, 25th New York.	Aug. 24, '61.	Left; flap; by Asst. Surg. H. L. Sheldon. Pens'd Nov. 24, 1861.	303	Bohun, A., Pt., D, 19th Maine, age 21.	May 10, '64.	Right; circular; by Surg. W. J. Burr. Pensioned Feb. 6, 1865.
259	Weisenfat, J., Pt., A, 93d Pa., age 44.	June 18, '64.	Left; flap; by Surg. E. R. Umberger. Disc'd Sept. 23, '64; pens'd.	304	Bond, H., Pt., K, 29th Maine.	Oct. 19, '64.	Left; circular. Disc'd February 12, 1865; pens'd; stump sound.
260	Wellman, J. T., Pt., H, 57th Massachusetts.	Sept. 20, '64.	Left; flap. Disc'd May 4, 1865; pensioned; stump tender.	305	Boulter, J. B., Serg't, E, 5th N. H., age 27.	Aug. 25, '64.	Left; flap. Stump healed. Mustered out Oct. 27, '64; pensioned.
261	Whalen, W., Pt., E, 126th New York, age 32.	June 16, '64.	Left. Stump healed. Discharged October 11, 1864; pensioned.	306	Boutwell, J. D., A, 59th Georgia, age 26.	July 2, '64.	Right; circular. To prisoners' camp January 15, 1864.
262	Whew, J., Serg't, B, 13th N. Y. Battery, age 33.	July 20, '64.	Right; flap. Disc'd Feb. 14, '65; pens'd; sound stump. Spec. 241.	307	Bragg, M., Pt., C, 10th Missouri.	May 14, '63.	Left. Disc'd August 4, 1863; pensioned; fair stump.
263	Whiskel, W. H., Pt., F, 8th Pa. Reserves.	Dec. 13, '62.	Left; circ.; by Surg. B. Rohrer. Disc'd Jan. 25, 1863; pens'd.	308	Bratton, W. H., Pt., G, 2d Pa. H. A., age 27.	Sept. 30, '64.	Left; circ.; by Dr. Jackson, C. S. A. Disc'd June 8, '65; pensioned.
264	Whistler, J., Pt., H, 49th Ohio, age 29.	June 20, '64.	Right; flap; by Surg. C. Schussler, 6th Ind. Disc'd Jan. 4, '65; pen'd.	309	Branson, J. C., Capt., C, 57th N. Y., age 25.	Aug. 14, '64.	Right; by Surg. W. W. Potter, 57th N. Y. Pens'd Dec. 17, '64.
265	White, P., Pt., A, 2d N. Y. Cavalry, age 19.	April 2, '65.	Right; circular. Disc'd Oct. 21, 1865; pensioned; stump healed.	310	Brown, A. J., Pt., F, 27th Iowa.	April 10, '63.	Left; flap; by Surg. J. E. Sanborn. Pensioned May 13, 1863.
266	Winn, J. A., Serg't, D, 34th Mass., age 36.	Oct. 13, '64.	Left; by Surg. R. B. Clark, 31th Mass. Disc'd Feb. 13, 1865; pensioned. Spec. 1570.	311	Brown, J., Corp'l, M, 3d Cavalry.	May 29, '63.	Right. Disc'd February 12, 1863; pensioned; sound stump.
				312	Brown, N., Pt., B, 1st Maine H. A., age 55.	June 18, '64.	Left; flap; by Surg. H. F. Lyster. Pensioned Sept. 20, 1864.
				313	Burchard, E., Pt., F, 7th New York.	June 13, '62.	Left; flap. Discharged October 29, 1862; stump healed.



No.	NAME, AGE, AND MILITARY DESCRIPTION.	DATES.	OPERATIONS, OPERATOR, RESULT.	No.	NAME, AGE, AND MILITARY DESCRIPTION.	DATES.	OPERATIONS, OPERATOR, RESULT.
314	Busha, A., Pt., A, 102d Pennsylvania	June 1, '62.	Left; by Surg. W. J. Fleming, 102d Pa. Pens'd July 24, 1862.	361	Doyle, J., Pt., C, 83d New York, age 22.	May 8, '64.	Right; circ. Discharged Nov. 3, 1864. <i>Spec.</i> 4635.
315	Campbell, J., Pt., I, 10th Minnesota, age 25.	Dec., 1863.	Left; antero-post. flap. Wound healed. Disch'd Sept. 22, 1861.	362	Doxtader, P., Pt., E, 115th N. Y., age 29.	Aug. 10, '64.	Right; circular. Discharged May 20, 1865; pensioned.
316	Caan, J. B., Pt., II, 17th Maine, age 23.	June 16, '64.	Left; circular; by Surg. French. Disch'd Feb. 17, '65; pensioned.	363	Duckworth, M. G., Pt., I, 16th Ill. Cav., age 30.	July 31, Aug. 1, '64.	Left; by A. A. Surg. A. A. Shutt, 10th Ill. Cav. Pens'd Oct. 14, '64.
317	Carey, T., Pt., I, 25th New York.	June 27, '62.	Left. Discharged Oct. 29, 1862; pensioned; sound stump.	364	Dulacey, B., Pt., G, 15th New Jersey, age 25.	Oct. 19, '64.	Right; flap. Discharged July 26, 1865; pensioned; sound stump.
318	Carpenter, J. Y., Pt., C, 141st N. Y., age 22.	May 15, '64.	Left; flap; by Asst. Surg. O. G. Greenman, 141st N. Y. Pens'd Oct. 7, 1864.	365	Dunmond, E. B., Pt., A, 120th N. Y., age 21.	July 30, '64.	Left; circular; by Surg. W. Van Steinborgh. Pens'd Dec. 29, '64.
319	Cassidy, J. E., Pt., K, 4th Artillery, age 33.	Mar. 31, '65.	Right; oval flap; middle. Left; oval flap; upper; by Surg. W. S. Thompson. Pens'd June 21, '65.	366	Dunkleburg, J., Pt., B, 105th Pa., age 16.	Aug. 14, '64.	Left; flap. Discharged Dec. 6, 1864; pensioned; sound stump.
320	Casterlin, J. A., Pt., D, 148th N. Y., age 21.	June 3, '64.	Left; circular. Disch'd Oct. 4, 1864; pensioned; good stump.	367	Dunn, J., Pt., C, 7th New Jersey, age 23.	Sept. 11, '64.	Left; circular; by Surg. W. B. Reynolds. Pensioned Jan. 30, '65.
321	Chaney, T., Pt., F, 43d Indiana.	Mar. 17, '63.	Left; by Surg. M. Cousins, 3th Iowa. Dis. Apr. 23, '63; pens'd.	368	Dwyer, D., Pt., E, 9th Vermont, age 43.	Sept. 29, '64.	Right; flap (w'd of right thigh). Stump healed. Dis'd July 19, '65.
322	Chatt, T. J., Pt., I, 13th Illinois.	July 12, '62.	Right; flap. Discharged Dec. 23, 1862; stump healed.	369	Eastham, E., Pt., I, 3d N. Y. Art., age 23.	Feb. 2, '64.	Left; flap; Surg. C. A. Cowgill. Pens'd June 16, '64. <i>Spec.</i> 4013.
323	Clarke, G. W., Pt., E, 12th N. H., age 25.	May 9, '64.	Right; flap (amp. thigh); by Surg. A. C. Benedict, U. S. V. Discharged June 2, '65; pensioned.	370	Echols, J. D., Pt., D, 4th Illinois.	April 6, '62.	Left. Disch'd Aug. 21, '62; pens'd; stump healed, but is tender.
324	Claywell, J., Pt., II, 120th Illinois, age 25.	July 20, '64.	Right; circular; by Surg. A. W. Teagan. Pensioned July 3, '65.	371	Edwards, E. J., Pt., C, 3d N. C., age 19.	May 3, '63.	Right; circular. Transferred June 5, 1863.
325	Cleavland, E., Pt., K, 8th Illinois.	July 14, '63.	Left; by Surg. J. L. Diekens, 47th Indiana. Disch'd Sept. 11, 1863.	372	Eisenhardt, H., Pt., K, 33th N. Y., age 35.	April 2, '65.	Left; circ.; by Surg. C. H. Hoyt, 30th N. Y. Pens'd June 14, '65.
326	Coates, J. M., Corp'l, I, 13th Iowa.	April 6, '62.	Left; flap. Discharged May 26, 1862; pensioned.	373	English, J., Pt., D, 115th New York.	Sept. 7, '62.	Right; flap. Disch'd Nov. 14, '62; pensioned; stump healed.
327	Coates, W. H., Pt., I, 27th Kentucky, age 18.	July 21, '64.	Right; circ.; by Surg. J. W. Lawton, U. S. V.; stump tender. Dis. Left; circ.; by Surg. C. H. Porter. Disch'd Feb. 25, '65. <i>Spec.</i> 4012.	374	Erway, J., Pt., G, 109th New York.	May 6, '64.	Left; circ. Disch'd Sept. 6, 1864; pensioned; stump sound.
328	Coe, S. A., Pt., G, 6th N. Y. H. A., age 21.	July 22, '64.	Right; flap. Stump healed. To V. R. C. Feb. 4, 1864.	375	Essex, G. F. L., Pt., F, 16th Indiana.	Jan. 19, '62.	Left; flap; by A. Surg. C. S. Perkins, 16th Ind. Pens'd Apr. 5, '62.
329	Coger, J., Serg't, F, 58th Massachusetts.	July 2, '63.	Double flap; by A. Surg. W. F. Richardson, C. S. A. Transferred. Left; circular. Disch'd April 17, 1865; pensioned; good stump.	376	Evans, F. H., Corp'l, A, 2d New Hampshire.	July 10, '63.	Right; flap; by A. Surg. F. B. Kimball. Pens'd Nov. 10, '63.
330	Coleman, C., Pt., C, 25th Virginia.	Jan. 3, '65.	Left; circular. Discharged June 7, 1865.	377	Evans, J., Corp'l, K, 70th Pennsylvania.	July 18, '63.	Left; flap. Disch'd Oct. 7, 1863; pensioned; stump healed.
331	Collins, A., Pt., F, 38th Wisconsin, age 21.	June 3, '64.	Right; circular. Disch'd March 18, 1865.	378	Fay, J. S., Pt., F, 13th Massachusetts.	April 30, '63.	Right; circ. (amp. thigh); Surg. A. W. Whitney. Pens'd Sept. 9, '63.
332	Connell, W., Pt., B, 2d Conn. Art., age 22.	Aug. 9, '64.	Right; circular. Disch'd March 18, 1865.	379	Ferran, M., Pt., A, 20th Connecticut, age 23.	July 20, '64.	Left; circ. V. R. C. Oct. 29, '64. Insane Asylum July 19, 1865.
333	Connor, E., Pt., E, 38th Wisconsin, age 19.	Feb. 2, '63.	Right; amp. 26, '63, amp. left arm; by Surgs. D. E. Wolfe and J. M. Houston. Pens'd Nov. 12, 1863.	380	Finney, J. H., Pt., E, 9th Ohio, age 16.	June 27, '64.	Left; circ.; Surg. W. A. McCracken, 9th Ohio. Pens'd Oct. 28, '64.
334	Conor, J., Pt., F, 3d Delaware, age 15.	Sept. 29, '64.	Right; circular. Disch'd June 10, 1865; pensioned.	381	Fisher, J. B., Pt., B, 118th Pennsylvania.	Dec. 18, '62.	Left; by Surg. J. Thomas, 118th Pa. Disch'd Jan. 7, '63; pens'd.
335	Copestick, G., Pt., A, 130th N. Y., age 35.	Sept. 29, '64.	Left; flap. Stump healed. Discharged Oct. 8, '62; pensioned.	382	Fitch, G. M., Pt., A, 1st N. Y. Light Artillery.	April 5, '65.	Right; flap; by A. A. Surg. W. H. Miehler. Pens'd June 17, '65.
336	Copp, A., Pt., II, 4th Infantry.	Sept. 30, '64.	Right; flap; by Surg. J. Kerr, 63d Pa. Pensioned June 8, '65.	383	Fitch, N., Pt., C, 1st U. S. Sharpshooters.	Aug. 30, '62.	Left. Discharged Oct. 18, 1862; pensioned; stump sound.
337	Courtney, W. R., Serg't, Major, 118th Pa., age 21.	June 3, '64.	Left; flap. Discharged January 29, 1865; pensioned.	384	Fizell, L., Pt., A, 106th Pennsylvania, age 34.	June 16, '64.	Right; circ.; Surg. N. Hayward, 20th Mass. Pens'd July 11, '65.
338	Crazenberg, A. F., S'gt, M, 14th N. Y. H. A.	Jan. 14, '64.	Right; flap; by A. Surg. H. G. Keefer. Pensioned Oct. 22, '64.	385	Fleming, A. L., Pt., E, 6th Pa. Cavalry.	June 27, '62.	Left. Discharged August 22, '62; pensioned; good stump.
339	Crawford, D., Pt., B, 2d Ohio H. Art., age 34.	April 7, '64.	Left; circular. Disch'd June 10, 1864; pens'd; stump healed.	386	Flick, J. P., Pt., II, 148th Pennsylvania, age 26.	Aug. 25, '64.	Left; circ.; by Surg. J. Houston, 81st Pa. Disch'd Mar. 7, '65; pens'd.
340	Creaner, J. W., Pt., D, 5th Illinois.	Oct. 3, '62.	Left; flap. Discharged November 24, 1862; stump healed.	387	Folger, J., Pt., K, 12d Ohio, age 35.	July 31, '61.	Right; circular. Discharged January 18, 1865.
341	Cronan, E., Pt., I, 8th Wisconsin.	June 16, '64.	Left; flap. Stump healed. Discharged Oct. 31, '64; pensioned.	388	Follet, W., Pt., F, 2d E. Tennessee, age 21.	July 22, '64.	Right; circular; by Dr. Russell. Duty September 19, 1864.
342	Curran, D., Pt., C, 1st Massachusetts H. A.	June 18, '64.	Right; flap; by Surg. J. H. Beach, 24th Mich. Disch'd April 6, '65.	389	Follman, P., Pt., II, 43d New York, age 23.	May 5, '64.	Left; flap; Surg. G. T. Stevens, 77th N. Y. Pens'd April 7, '65.
343	Curran, T., Pt., B, 157th Pennsylvania, age 36.	July 13, '63.	Left; by Surg. L. P. Wagner, 114th N. Y. Pens'd Nov. 4, '63.	390	Fore, S. A., Pt., A, 22d Virginia, age 19.	Sept. 30, '64.	Right. Retired February 11, 1865.
344	Daley, J., Pt., E, 90th New York.	May 12, '64.	Left; flap. Stump healed. Discharged January 27, 1865.	391	Gallow, C. W., Pt., A, 124th N. Y., age 37.	May 12, '64.	Left; circ.; Surg. J. S. Jamison, 80th N. Y. Pens'd May 17, 1865.
345	Dathie, C., Pt., D, 6th Wisconsin.	July 22, '64.	Right; circular. Disch'd Sept. 29, '64; pens'd; stump healed.	392	Garman, R. R., Pt., G, 2d Iowa, age 38.	Aug. 9, '64.	Left; flap; by Surg. J. Pogue, 60th Ill. Pens'd Mar. 23, 1865.
346	Dawson, G. R., Pt., A, 39th Ohio, age 26.	May 12, '64.	Right; circular. Disch'd Nov. 3, '62; pensioned; good stumps.	393	Gaylord, T., Serg't, A, 6th Illinois, age 25.	July 19, '64.	Right; flap; by Surg. A. B. Monahan. Disch'd May 17, 1865.
347	Decker, A., Pt., M, 15th N. Y. H. A.	Oct. 8, '62.	Left; flap. Discharged November 24, 1862; stump healed.	394	Gaynor, P., Pt., E, 2d New York.	May 2, '63.	Right; flap; Surg. LeJoy McLean, 2d N. Y. Pens'd June 11, 1863.
348	Decker, S. H., Pt., I, 4th Artillery.	Oct. 11, '61.	Left; by Surg. E. Jackson. Pens'd Dec. 12, 1864; good stump.	395	Geaney, R., Pt., C, 27th Indiana.	Sept. 17, '62.	Right; by Surg. J. H. Alexander. Pensioned Dec. 27, 1862.
349	Deitrich, L. W., Lieut., E, 30th C. T.	Dec. 16, '64.	Right; circular. Disch'd Sept. 29, '64; pens'd; stump healed.	396	Gereard, P., Pt., C, 8th Connecticut, age 37.	April 1, '65.	Right; circ. Deserted October 8, 1865.
350	Dellardwa, P., Serg't, E, 11th Mo., age 36.	May 6, '64.	Left; flap. Discharged March 10, 1865; pensioned; sound stump.	397	Gibbons, F., Pt., E, 10th Connecticut, age 21.	April 2, '65.	Left; flap; by Surg. W. S. Welch. Duty June 25, '65; pensioned.
351	Delong, A., Pt., D, 83d New York, age 35.	Sept. 16, '62.	Right; circular. Good stump. Discharged Sept. 28, 1863.	398	Gilchrist, J. Q., Corp'l, G, 11th New York.	July 30, '64.	Left; circ. Disch'd May 29, 1865; pensioned.
352	Demarest, F., Drummer, G, 12th Infantry.	May 15, '64.	Right; circular; by Surg. H. E. Goodman. Pens'd Jan. 17, '65.	399	Gillan, H., Pt., D, 51st Penn., age 21.	Sept. 17, '62.	Right; circ. To V. R. C. Sept. 9, 1863. Stump healed; pens'd.
353	Denny, W., Pt., D, 29th Pa., age 20.	June 18, '64.	Left; circ.; by Surg. G. T. Stevens. Dis. Dec. 22, '64; pens'd.	400	Goldsmith, W., Pt., E, 183d Penn., age 32.	June 11, '64.	Left; circ. Pens'd July 26, 1865.
354	Devon, S., Pt., A, 1st Me. H. A., age 23.	July 15, '64.	Right; flap. Discharged April 4, 1865; pensioned.	401	Gorsell, V. W., Lieut., G, 29th Miss., age 28.	Nov. 30, '64.	Left; flap. Stump healed. To De. I, '64. Provost Marshal Feb. 10, 1865.
355	Dimmond, W., Pt., I, 77th New York, age 24.	July 29, '64.	Right; circular; by Surg. H. E. Goodman. Pens'd Jan. 17, '65.	402	Greaves, T., Pt., A, 106th Illinois.	Oct. 27, '62.	Left; by Drs. Hall, Gibson, and Walker. Pens'd April 7, '63.
356	Dickey, C. B., Pt., C, 104th Ohio, age 23.	July 29, '64.	Right; flap. Mustered out July 25, '65; pensioned; pension susp'd.	403	Griffee, J., Pt., E, 41st Illinois.	April 6, '62.	Left. Discharged; pensioned; home protruding.
357	Distler, F., Pt., II, 3d Pa. Artillery.	July 22, '64.	Right; circ.; by Surg. E. M. Rogers, 12th Wis. Dis. Sept. 12, '65.	404	Gwin, D., Pt., A, 183d Penn., age 38.	Aug. 16, '64.	Right; by Surg. A. Van Devere. Disch'd March 31, 1865; pens'd.
358	Donovan, D., Pt., C, 68th Ohio, age 26.	Nov. 4, '62.	Left. Discharged Dec. 15, 1862; pensioned; stump tender.	405	Haas, N., Pt., K, 14th Maine.	May 27, '63.	Right; flap. Disch'd Feb., 1864; stump healed.
359	Downs, T. S., Pt., D, 16th Maine.	July 2, '64.	Right; flap. Discharged July 25, '65; pensioned; pension susp'd.	406	Haut, F., Pt., A, 15th N. Y. H. A., age 47.	June 26, '64.	Left; circ. Stump healed. Discharged November 14, 1864.
360				407	Halecomb, J. M., Pt., C, 20th Mich., age 26.	Nov. 29, '63.	Right; circular; by Surg. G. B. Cogswell. Disch'd May 6, '64.
				408	Haley, G. D., Pt., E, 116th N. Y., age 19.	June 14, '63.	Left; circular. Disch'd Dec. 21, 1863; pensioned; good stump.





NO.	NAME, AGE, AND MILITARY DESCRIPTION.	DATES.	OPERATIONS, OPERATOR, RESULT.	NO.	NAME, AGE, AND MILITARY DESCRIPTION.	DATES.	OPERATIONS, OPERATOR, RESULT.
502	McNally, J., Pt., D, 5th New York H. A.	June 5, '64.	Left; flap. Disch'd Feb. 1, '65; pensioned; tender stump.	549	Ray, B., Pt., K, 8th Colored Troops, age 24.	Apr. 8, '64.	Right; flap; by Surg. S. W. Cross, U. S. V. Pens'd July 12, '64.
503	McSaulhe, J., Pt., A, 101st New York.	July 1, '62.	Right; flap; by Surg. D. Prince, U. S. V. Disch'd; pensioned.	550	Regan, M. O., Pt., E, 3d Artillery.	July 18, '63.	Right; flap. Disch'd October 16, 1863; pensioned; sound stump.
504	Meredith, I., Pt., F, 4th Ohio.	Oct. 26, '61.	Right; by Surg. H. M. McAbee, 4th Ohio. Pens'd Feb. 6, 1862.	551	Rice, H., Corp'l, B, 185th N. Y., age 35.	Mar. 29, '63.	Left; flap. Discharged June 14, 1865; pensioned; sound stump.
505	Merritt, G. W., Pt., D, 5th Vermont, age 24.	June 3, '64.	Left; flap; by Surg. A. H. Chessmore. Pens'd Sept. 27, 1864.	552	Richards, G. W., Pt., A, 2d V. R. C., age 26.	Sept. 3, '64.	Left; amp. fingers right hand; by A. A. Surg. D. O. Farrand. Disch'd July 2, 1865; pensioned.
506	Myneill, H., Bugler, D, 82d Illinois.	July 1, '63.	Left. Discharged; pensioned; stump healed but tender.	553	Richmond, C., Serg't, D, 29th C. T., age 32.	Oct. 27, '64.	Right. Discharged Mar. 6, 1865; pen'd; stump healthy, but tender.
507	Miller, A. J., Pt., K, 90th Pennsylvania, age 24.	May 12, '64.	Left; circular. Discharged December 18, 1864.	554	Robbenautt, H., Pt., K, 53d Pa., age 30.	June 1, '64.	Right; flap. Discharged December 1, 1864.
508	Miller, C. C., Serg't, I, 148th N. Y., age 41.	June 4, '64.	Left; circ.; by Surg. H. B. Fowler, 12th N. H. Pens'd Dec. 7, '64.	555	Roberts, A. W., Pt., H, 130th Indiana.	Sept. 3, '64.	Left; by A. Surg. E. S. Cooper. Disch'd Dec. 10, 1864; pens'd.
509	Miller, F., Pt., A, 49th N. Y., age 19.	Oct. 19, '64.	Right; flap; by Surg. G. T. Stevens. Disch'd Mar. 16, 1865.	556	Robinson, E. B., Pt., D, 37th Wis., age 24.	July 30, '64.	Right; circ.; by Surg. W. B. Fox. Discharged Sept. 21, 1864; pen'd.
510	Miller, G., Pt., I, 82d Pennsylvania, age 18.	April 2, '65.	Right; circular. Disch'd May 22, 1865; pensioned; stump healed.	557	Rodgers, J. M., Serg't, 10th Indiana Bat.	Oct. 3, '62.	Left; by Dr. A. Garrett Discharged 1862; pens'd.
511	Mock, E. A., Pt., K, 53th Pennsylvania, age 22.	May 20, '64.	Right; circular. Disch'd Aug. 20, 1864; pensioned; stump healed.	558	Rowen, S. W., A, 2d S. C. Cav., age 18.	Sept. 17, '62.	Right. Sent South Nov. 19, 1862; not a good stump.
512	Montgomery, T. H., Pt., G, 52d Ohio, age 22.	Aug. 5, '64.	Left; flap; by Surg. H. M. Duff, 52d Ohio. Pens'd May 31, '65.	559	Ryan, G., Capt., D, 47th Illinois.	Mar. 27, '65.	Left; by Surg. J. E. Murta. Discharged Jan. 21, 1866; pens'd.
513	Moore, E., Pt., I, 83th Illinois.	Sept. 1, '64.	Left; circular. Discharged Jan. 8, '65; pensioned; sound stump.	560	Sands, C., Pt., G, 7th Pennsylvania Res.	June 30, '62.	Left. Discharged October 15, '62; pensioned; stump healed.
514	Morton, J., Pt., A, 152d New York, age 24.	Aug. 14, '64.	Right; flap; by Dr. Walker, C. S. A. Dis'd June 21, '65; pens'd.	561	Saundersberry, W., Pt., A, 21st Indiana.	July 1, '62.	Right; flap. Discharged May 26, 1865; pensioned; stump tender.
515	Murphy J., Pt., K, 37th Massachusetts, age 20.	April 6, '65.	Right; circular. Discharged July 6, '65.	562	Schretzler, H., Pt., 13th N. Y. Ind. Bat., age 22.	May 27, '64.	Right; circ. Discharged June 2, 1865; pensioned; good stump.
516	Myers, C., Pt., A, 2d Maryland, age 37.	July 17, '64.	Right; circ.; by Surg. J. E. Beatty, 2d Md. Pens'd Mar. 18, '65.	563	Scott, A. J., Pt., K, 86th Illinois.	Jan. 1, '63.	Left; flap; by Surg. M. M. Hooton, 86th Ill. Pens'd Jan. 17, '63.
517	Myers, F., Pt., B, 10th Minnesota, age 43.	Dec. 16, '64.	Left; flap. Stump healed. Discharged June 11, 1865; pens'd.	564	Scruton, H. F., Pt., H, 11th Massachusetts.	Aug. 27, '62.	Right; circular. Disch'd Oct. 21, 1862; pensioned; stump healed.
518	Myers, J., Pt., G, 31st Iowa.	March, 1863.	Left; by Surg. G. L. Carhart, 31st Iowa. Disch'd May 5, '63; pen'd.	565	Seagrist, S., Pt., D, 99th Pennsylvania.	Dec. 13, '62.	Left; circular.
519	Myrick, R. H., Pt., B, 72d Indiana.	June 9, '62.	Left; flap; by Surg. G. W. New, 7th Ind. Pens'd Jan. 31, 1863.	566	Shelby, T., Pt., E, 1st Ohio Heavy Artillery, age 20.	April 10, '65.	Left; circ. Right; flap; by A. A. Surgs. C. F. Thomas and W. Tibbetts. Pens'd June 22, 1865.
520	Neal, T., Pt., E, 14th Illinois.	Aug. 12, '61.	Left; by A. Surg. B. F. Stephenson, 14th Ill. Pens'd Nov. 1, '61.	567	Sherry, D., Pt., I, 65th New York.	July 1, '62.	Left; flap. Discharged Oct. 4, 1862; pensioned; stump healed.
521	Newman, G., Pt., E, 12th N. H., age 39.	June 3, '64.	Right; circular (recurrent hemorrhage). Disch'd April 3, 1865.	568	Shippee, S. C., Pt., D, 3d R. I. Artillery.	July 10, '63.	Left (amp. r't arm); A Surg. H. S. Lamson. Pens'd Oct. 19, 1863.
522	Newton, T. E., Pt., H, 6th Missouri.	May 19, '63.	Left. Discharged Sept. 13, 1864; pensioned; bad stump; painful.	569	Shoults, G. N., Pt., E, 1st Mo. Lt. Artillery.	June 24, '63.	Right; by A. Surg. M. A. Mosher, 20th Wis. Pens'd Oct. 31, 1863.
523	Nichols, A., Pt., D, 29th Pennsylvania, age 20.	May 25, '64.	Left; circular. Disch'd Oct. 12, 1864; pensioned; stump tender.	570	Simons, A., Pt., K, 80th New York, age 22.	July 2, '63.	Left; flap; by Surg. J. S. Jamison, 80th N. Y. Pens'd Oct. 7, 1863.
524	Nickerson, A. M., Corp'l, F, 5th Mass., age 22.	May 25, '65.	Left; flap. Discharged June 28, 1865.	571	Simpson, P., Pt., G, 11th Connecticut, age 24.	June 3, '64.	Right; flap. Discharged October 21, 1865; pensioned.
525	Noonan, J., Pt., I, 24th Massachusetts, age 22.	Aug. 26, '63.	Right; flap; by Surg. S. A. Green, 24th Mass. Disch'd May 3, '64.	572	Skillings, G. E., Pt., 2d Maine Battery, age 22.	Nov. 27, '63.	Right; double flap; by A. A. Surg. W. H. Ensign. Disch'd March 16, 1864. Spec. 1878.
526	North, E., Corp'l, G, 35th N. Y., age 21.	Aug. 30, '62.	Left. Discharged Aug. 6, 1862; pensioned; good stump.	573	Smith, B. F., Pt., H, 1st Mich. S. S., age 13.	June 17, '64.	Right; flap; by Surg. A. F. Whelan. Disch'd Dec. 6, '64; pens'd.
527	Norton, G. A., Pt., K, 7th N. Y., age 22.	Jan. 15, '65.	Right; circ.; by Surg. F. B. Kimball, 3d N. H. Pen'd Apr. 28, '65.	574	Smith, R., Pt., 18th N. Y. Battery.	May 3, '64.	Left. Discharged; pensioned; stump healed.
528	O'Connor, D., Pt., G, 19th Massachusetts.	June 30, '61.	Right; circ.; by Surg. F. Ridgway. Disch'd July 19, 1864.	575	Smith, R. A., Capt., F, 13th Illinois.	Dec. 29, '62.	Right; by Surg. S. C. Plummer, 13th Ill. Discharged; pens'd.
529	O'Garvey, J., Pt., H, 74th N. Y., age 25.	Feb. 11, '64.	Right; circ.; by Surg. M. H. Raymond. Pens'd April 24, 1865.	576	Snyder, J., Pt., G, 87th Pennsylvania.	Sept. 19, '64.	Right; flap. Discharged; pens'd; stump healed.
530	Oleson, C., Pt., A, 26th Michigan, age 39.	Aug. 16, '64.	Left; flap. Stump healed. Discharged March 8, 1865; pens'd.	577	Stamp, J., Pt., A, 109th New York, age 22.	July 7, '64.	Left; flap; by Surg. S. S. French, 20th Mich. Pens'd Dec. 10, '64.
531	O'Neal, A., Pt., G, 32d Maine, age 21.	June 20, '64.	Left; antero-posterior flap. Discharged March 27, 1865.	578	Starr, J., Pt., G, 72d Pennsylvania.	Sept. 17, '62.	Right; circ.; by Surg. M. Rizer, 72d Pa. Pens'd Jan. 4, 1864.
532	O'Reilly, A., Pt., A, 155th N. Y., age 48.	June 3, '64.	Right; circ.; Surg. B. M. Faylor, 19th Ohio. Pens'd Oct. 28, 1861.	579	Starr, R., Pt., C, 6th New Jersey, age 24.	May 6, '64.	Left; circular. Disch'd March 8, 1865.
533	Oyer, J., Pt., B, 13th Ohio.	May 27, '64.	Left; circular. Discharged May 30, 1865; pensioned.	580	St. Clair, L., Pt., M, 2d Ohio H. A., age 22.	April 10, '65.	Right (ex. left humerus). Pens'd Sept. 15, '65. Died Dec. 12, '65.
534	Parkhurst, G. W., Corp'l, H, 3d N. H., age 20.	Aug. 16, '64.	Right; circular. Discharged May 3, 1865.	581	Stevens, J., Pt., B, 152d New York, age 29.	May 12, '64.	Right; flap. Discharged Jan. 8, 1865; stump healed.
535	Parr, J. G., Capt., C, 130th Pa., age 41.	June 3, '64.	Right. Mustered out June 21, 1865.	582	Stewart, J., Serg't, C, 3d New Jersey.	Jan. 27, '62.	Right. Discharged October 29, 1862; pensioned; stump healed.
536	Perkins, C., Pt., H, 1st Mo. Artillery, age 19.	Dec. 10, '64.	Right; circ.; To V. R. C. May 11, 1865; pensioned; stump healed.	583	Stoll, C., Pt., C, 5th New York, age 40.	June 2, '64.	Left; circ.; by Surg. A. F. Whelan, 1st Mich. S. S. Pen'd Jan. 19, '65.
537	Perry, G., Pt., D, 77th New York, age 21.	May 10, '64.	Right; circular. Disch'd March 9, 1865.	584	Strong, H., Pt., E, 10th Michigan, age 17.	Sept. 1, '64.	Left; circ.; Discharged April 11, 1865.
538	Perry, J. R., Pt., C, 38th Wisconsin, age 35.	June 17, '64.	Left; circ.; by Surgs. W. C. Shurlock, 51st Pa., and A. F. Whelan, 1st Mich. S. S. Pens'd Dec. 19, '64.	585	Tackett, G., Pt., K, 39th Kentucky.	July 4, '65.	Right; by Surg. W. E. Phillips, 30th Ky. Discharged; pens'd.
539	Petral, W., Pt., E, 27th Pa., age 28.	May 10, '63.	Left; flap; by Surg. R. Thomaine. To V. R. C. May 3, '64; pens'd.	586	Taft, A. A., Pt., D, 14th Connecticut.	Sept. 17, '62.	Right; flap; by Surg. G. W. Lovejoy, 4th N. Y. Disch'd Nov. 10, 1862; pensioned.
540	Phillips, E., Corp'l, G, 10th Pennsylvania.	Sept. 17, '62.	Left. Discharged Feb. 9, 1863; pensioned; healthy stump.	587	Taylor, E. B., Pt., A, 71st Pennsylvania.	Oct. 21, '62.	Left; by Surg. T. R. Crosby, U. S. V. Dis'd Apr. 10, '62; pens'd.
541	Phinney, G. D., Pt., A, 7th Wisconsin, age 16.	July 12, '64.	Left; circ.; by Surg. P. Harvey, U. S. V. Dis'd Oct. 8, '64; pens'd.	588	Thompson, M. M., Pt., C, 21st V. R. C.	July 4, '65.	Right; circ.; by A. A. Surg. W. W. L. Phillips. Disch'd; pens'd.
542	Plant, P., Pt., I, 37th Massachusetts, age 29.	June 10, '64.	Left; flap (amp. right arm). Discharged March 9, '64; pens'd.	590	Thwing, W., Pt., F, 10th N. H., age 19.	July 6, '64.	Left; flap; by Surg. H. N. Small. Disch'd May 31, 1865; pens'd.
543	Plunket, T., Serg't, G, 21st Massachusetts.	Dec. 13, '62.	Right; flap. Disch'd August 20, 1862; pensioned; stump healed.	591	Tiffany, E., Pt., E, 24th N. Y. Cav., age 22.	June 15, '64.	Left; circ.; by Surg. W. B. Fox, 8th Mich. Pens'd Oct. 4, 1864.
544	Post, A., Pt., B, 8th Michigan.	Mar. 10, '62.	Right; flap; by Dr. J. D. Galt, C. S. A. To prison Jan. 5, 1865.	592	Tinker, E., Pt., G, 79th Illinois, age 22.	Nov. 30, '64.	Left; flap; by Surg. B. B. Breed, U. S. V. Pens'd June 22, 1865.
545	Prieger, J. M., Pt., C, 21st Georgia, age 20.	Oct. 19, '64.	Left; circ.; by Surg. J. S. Ross. Disch'd Feb. 4, '65; pensioned.	593	Todd, J. M., Pt., H, 27th Indiana.	Dec. 1, '64.	Left; flap. To V. R. C. Sept. 15, 1863; pensioned.
546	Purrrington, C., Pt., A, 11th N. H., age 24.	June 28, '64.	Left; flap; July 22, gangrene. Discharged December 20, 1864.	594	Townsend, D., Pt., F, 135th C. T., age 20.	May 25, '65.	Left; flap; by Surg. E. Bentley, U. S. V. Disch'd Sept. 11, 1865.
547	Raines, W. R., Pt., D, 10th Ill., age 26.	June 27, '64.	Right; flap; by Surg. A. W. Reagan. Discharged Mar. 4, 1865; pensioned.	595	Trainer, W., Serg't, E, 48th Pennsylvania.	Sept. 17, '62.	Right; flap; by Surg. C. F. Rober, 48th Pa. Pens'd May 7, 1863.

NO.	NAME, AGE, AND MILITARY DESCRIPTION.	DATES.	OPERATIONS, OPERATOR, RESULT.	NO.	NAME, AGE, AND MILITARY DESCRIPTION.	DATES.	OPERATIONS, OPERATOR, RESULT.
596	Tynan, J. Pt., 14th Massachusetts Battery.	May 18, '61.	Left; flap. Disch'd Sept 26, 1864; pens'd; stump sore and tender.	643	Brewer, I. T., Pt., F., 15th Kentucky.	Dec. 15, '61.	Right; by Surg. L.P. Weatherby, 15th Ky. Pens'd June 29, 1862.
597	Underwood, J. H., Pt., B. 8th Indiana.	May 22, '63.	Left; flap; by A. Surg. J. K. Bigelow; crabs; gang. Pensioned.	644	Brolent, J., Pt., D, 42d New York.	Sept. 17, '62.	Left; by Surg. J. D. Osborne, 42d N. Y. Pens'd Nov. 14, 1862.
598	Vallereux, F. G., Pt., C, 1st Ill. Art., age 23.	July 4, '64.	Right; circular. Duty Sept. 12, 1864; pensioned; stump well.	645	Brown, G. W., Pt., D, 2th Pa., age 21.	May 15, '64.	Right; circular; by Surg. H. B. Whiton. Pensioned Feb. 7, '65.
599	Van Idestine, W. H., Pt., D, 13th N. J., age 30.	July 30, '64.	Left; flap. Stump healed. Discharged Jan. 30, 1865; pens'd.	646	Brown, S., Corp'l, K, 6th New York, age 22.	May 18, '64.	Left; flap; by Surg. J. W. Whihart. Pensioned Dec. 31, 1864.
600	Vincent, G. W., Pt., G, 26th N. C., age 22.	July 1, '64.	Flap. Doing well. Furloughed August 23, 1863.	647	Brown, W. H., Pt., H, 38th Wisconsin, age 38.	Oct. 28, '64.	Left; circular. Discharged Dec. 22, 1864; pensioned. Spec. 3479.
601	Waite, J., Pt., I, 44th Illinois.	May 14, '64.	Right; by Surgs. B. G. Pierce and H. E. Hesse. Pens'd Sept. 7, '64.	648	Brownson, H. C., Pt., C, 83d Pa., age 22.	Feb. 6, '65.	Right; circular; by Surg. J. P. Threlfield. Pens'd June 25, '65.
602	Walker, L. L., Pt., 1st Maine Battery.	July 13, '63.	Right; circular; by Dr. Darling. Disch'd Aug. 31, '63; pensioned.	649	Bruat, A. J., Pt., B, 4th Artillery.	Aug. 24, '64.	Right; flap. Discharged July 4, 1864; pensioned; stump sound.
603	Ward, T. Pt., B, 89th Illinois, age 25.	Aug. 14, '64.	Left; flap. Stump healed. Discharged; pensioned.	650	Buckley, J., Pt., H, 126th Illinois.	Dec. 26, '62.	Right; flap; by A. Surg. E. W. Mills, 126th Ill. Disch'd Jan. 31, 1863.
604	Ward, T. W., Serg't, 43d Mo. Mil., age 22.	July 7, '63.	Left; by A. A. Surg. R. A. Wells. Disch'd; pensioned.	651	Buel, H., Serg't, A, 21st Iowa.	June 13, '63.	Left; flap; by Surg. W. L. Orr, 21st Iowa. Pens'd Sept. 18, 1863.
605	Wardman, J. H., Pt., F, 11th Wisconsin.	Mar. 27, '65.	Left; by Surg. J. E. Murta, 8th Wis. Pensioned June 21, 1865.	652	Burke, W., Pt., A, 29th C. T., age 20.	Oct. 1, '64.	Left; flap; by Surg. M. Tucker. Disch'd June 24, '65. Died Apr. 22, 1866, meningitis. Spec. 2536 and 2537, A. M. M.
606	Wells, J., Pt., C, 23d Colored Troops.	July 30, '61.	Right; circ.; by Surg. G. J. Potts, 23d C. T. Pens'd June 6, 1865.	653	Burt, P. M., Pt., H, 13th Iowa, age 24.	July 22, '64.	Left; flap; by Surg. A. H. Brundage, 32d O. Pens'd Nov. 25, '64.
607	Welsh, T., Pt., A, 63d New York, age 37.	June 1, '64.	Left; circ.; by Surg. J. W. Whihart. Disch'd August 18, 1865.	654	Bush, G. W., Serg't, G, 9th New York.	June 14, '63.	Right; flap; by Surg. E. S. Haffmann. Pensioned Aug. 29, 1863.
608	Wheeler, B. O., Pt., B, 20th Pa., age 16.	April 2, '65.	Right; flap. Disch'd July 26, 1865; pensioned.	655	Cain, R., Pt., C, 9th V. R. C., age 36.	Feb. 20, '64.	Left; circ.; A. A. Surg. T. Carroll. Duty Nov. 26, 1864; pens'd.
609	White, J. T., Corp'l, 1, 34th Mass., age 23.	Sept. 19, '64.	Left; circ.; by A. Surg. J. Homans, U. S. A. Pens'd Nov. 30, 1864.	656	Canfield, F., Pt., F, 125th New York.	May 12, '64.	Right; flap; by Surg. J. W. Wishart. Pens'd Feb. 7, '65.
610	White, J. W., Capt., G, 38th Ohio.	Sept. 1, '64.	Right; by Surg. C. N. Fowler, 106th Ohio. Disch'd; pens'd.	657	Casey, J. S., Serg't, I, 176th New York, age 28.	Aug. 21, '64.	Left; circular; by Surg. J. S. Dilts. Disch'd January 18, 1865.
611	Whitford, J. W., Pt., A, 1st R. I. Battery.	June 3, '61.	Right; circular. Stump healed. Disch'd Sept. 26, '61; pensioned.	658	Cassick, D., Pt., Marcus' Light Artillery, age 45.	June 16, '64.	Right; circular. To prison Sept. 24, 1864.
612	Wierman, S. B., Pt., I, 76th Ohio, age 17.	June 16, '64.	Left; circ.; by Surg. A. Sabine, 76th Ohio. Pens'd Feb. 14, '65.	659	Carl, B., Pt., C, 12th Ohio Cavalry, age 17.	July 5, '64.	Left; flap; by Surg. S. S. French, 20th Mich. Pens'd May 30, '65.
613	Wiggin, H., Pt., H, 9th Pennsylvania, age 33.	Dec. 13, '62.	Left. Disch'd March 29, 1863; pens'd. Died Jan. 14, 1865.	660	Carr, A. C., Serg't, F, 7th Ohio, age 27.	July 20, '64.	Right; circ.; by A. Surg. G. W. Trowbridge. Pens'd Dec. 2, '64.
614	Willoughby, J., Ord'y Seaman, U. S. N.	April 23, '62.	Left; by Surg. Jackson, U. S. S. Brooklyn. Disch'd; pensioned.	661	Carr, D. W., Serg't, I, 5th New Jersey, age 34.	June 18, '64.	Left; flap. Discharged May 17, 1865; pensioned; good stump.
615	Wilton, G., Pt., 1, 1st Vt. Cav., age 17.	Oct. 19, '64.	Left; circ.; by Surg. J. W. Smith. Disch'd May 27, 1865; pens'd.	662	Caulfield, D., Pt., B, 3d Cavalry.	Aug. 10, '61.	Left; flap; A. Surg. H. M. Sprague, U. S. A. Pens'd Sept. 19, 1861.
616	Winters, H., Pt., B, 31st Massachusetts.	Jan. 16, '63.	Right; by Surg. E. C. Bidwell, 31st Mass. Pens'd May 12, 1863.	663	Chambers, D., Pt., G, 31st Indiana.	May 27, '64.	Left; by Surg. C. J. Walton, 21st Ky. Disch'd Oct. 26, '64; pens'd.
617	Wolson, C., Pt., A, 26th Michigan, age 30.	Aug. 16, '64.	Right; circular. Disch'd April 12, 1865.	664	Chieker, S., Pt., D, 94th New York, age 29.	Aug. 18, '64.	Left; flap. Discharged April 13, 1865; pensioned; stump healed.
618	Wooding, B. C., Corp'l, F, 7th Ct., age 35.	Aug. 16, '64.	Left; by Surg. G. C. Jarvis, 7th Ct. Disch'd Nov. 21, '64; pens'd.	665	Christy, H., Corp'l, K, 112th N. Y., age 21.	June 2, '64.	Left; flap. Discharged November 19, 1864.
619	Woodward, G., Pt., I, 10th Minn., age 19.	Dec. 15, '64.	Right. Discharged July, 1865.	666	Clark, T., Pt., A, 40th Ohio, age 19.	July 11, '64.	Left; circ.; by Surg. J. N. Beach; gang. To V. R. C. Dec. 5, 1864.
620	Wormuth, E., Pt., F, 3d N. Y. Artillery.	Dec. 16, '62.	Left; flap; by Surg. I. F. Galloupe, 17th Mass. Pens'd April 17, '63.	667	Cleveland, G., Pt., G, 25th Michigan.	July 11, '64.	Right; circ.; Surg. C. B. Fox (w/d of thigh). Disch'd May 30, 1865.
621	Worthy, J., Pt., H, 13th Alabama, age 34.	May 6, '64.	Left; flap. Furloughed June, 1864; favorable.	668	Clegrston, C. H., Corp'l, E, 17th Vt., age 24.	May 12, '64.	Left; circ.; by A. Surg. P. O'M'Edson. Pens'd May 27, 1865.
622	Wren, J., Pt., M, 9th N. Y. Cav., age 36.	Aug. 1, '64.	Left; circ.; by Asst. Surg. C. L. George. Pens'd Jan. 19, 1865.	669	Coimer, D., Corp'l, B, 25th Ohio.	July 3, '63.	Left; by Surg. C. G. Strother, 31st Mo. Disch'd Aug. 2, '63; pens'd.
623	Wright, P., Pt. C, 24th New York.	Aug. 30, '62.	Left; flap. Disch'd Oct. 16, '62; pensioned; good stump.	670	Colcock, C. J., Corp'l, I, 2d S. C., age 19.	July 2, '64.	Left; circ. (also wound left arm). To Provost Marshal Sept. 1, '63.
624	Young, J. P., Pt. C, 39th Pennsylvania, age 28.	Aug. 31, '64.	Right; circ.; by Surg. J. S. Jamison. Pensioned Jan. 20, 1865.	671	Collar, E. S., Pt., D, 14th New York.	June 2, '64.	Right; flap; by a Confed surgeon. Disch'd Mar. 28, 1865; pens'd.
625	Young, L. C., Pt., A, 14th N. Y. H. A., age 23.	July 2, '64.	Left; flap; by Surg. T. F. Oakes, 56th Mass. Pens'd Mar. 18, '65.	672	Colvin, R. J., Pt., 3d New York Independent Battery, age 22.	Oct. 1, '64.	Right; flap (fract. r. t. hum.; amp. finger left hand); by A. A. Surg. E. Ohlenschlager. Discharged February 20, 1865; pensioned.
626	Young, W. S., Pt., C, 183d Pa., age 28.	May 8, '64.	Left; flap; by Surg. P. E. Hubon, 28th Mass. Disch'd; pensioned.	673	Conley, D., Pt., D, 12th Iowa, age 25.	July 13, '64.	Left; flap; by Surg. S. W. Huff. To V. R. C.; pens'd, sound stump.
627	Alexander, S. B., Pt., A, 139th Pa., age 24.	May 12, '64.	Left; flap; by Surg. S. F. Chapin, 139th Pa. Disch'd; pensioned.	674	Conner, L. W., Pt., D, 89th Indiana, age 26.	Dec. 16, '64.	Left; flap; by A. A. Surg. P. B. Nofsinger. Pens'd May 17, '65.
628	Allison, S. C., Pt., G, 5th Iowa Cav., age 24.	Dec. 25, '64.	Left; flap; by Surg. McKee, C. S. A. Disch'd June 4, 1865; pens'd.	675	Connor, J., Pt., A, 98th Pennsylvania, age 29.	June 3, '64.	Right; flap; by Surg. G. T. Stevens. Dis'd Dec. 10, '64; pens'd.
629	Anderson, J., Corp'l, H, 115th N. Y., age 51.	Sept. 29, '64.	Right; circ.; by Surg. C. Macfarlane, 115th N. Y. (w/d leg). Dis. April 29, '65; pens'd. Spec. 3112.	676	Cook, H. M., Corp'l, A, 145th Pa., age 22.	Aug. 14, '64.	Left; flap. Disch'd Jan. 16, 1865; pensioned; stump very tender.
630	Anderson, J. L., Pt., E, 155th Pa., age 29.	May 12, '64.	Right; circular; by Surg. J. Kerr. Pens'd Jan. 18, '65. Spec. 686.	677	Copeland, E. C., Pt., D, 8th Maine.	Jan. 1, '61.	Left; flap. Discharged Mar. 22, 1864.
631	Apple, W. M., Pt., A, Lot's Battery, age 19.	Oct. 1, '63.	Left; flap; by Surg. G. W. Brock, C. S. A. Re-amp. Oct. 22. Recov'd.	678	Cornell, R. H., Serg't, E, 146th N. Y., age 26.	Aug. 21, '64.	Left; flap; by Surg. T. M. Flannagan. Disch'd Dec. 9, 1864.
632	Baker, R., Pt., H, 7th Ohio.	June 27, '64.	Left; flap; by Surg. H. E. Goodman. Pensioned July 17, 1865.	679	Costello, T., Corp'l, E, 93d Indiana.	June 10, '64.	Right; amp. right thigh). Pens'd August 10, 1865; good stump.
633	Banning, C. H., Pt., K, 3d New York Art.	July 28, '63.	Left; by A. Surg. J. F. Smith. Pens'd Jan. 3, 1864. Spec. 1477.	680	Cox, E. B., Pt., K, 69th Indiana.	May 1, '63.	Right; double flap. Discharged July 24, 1863.
634	Barth, E., Pt., A, 7th Wisconsin, age 17.	May 6, '64.	Left; circular. Discharged June 28, 1865; pensioned.	681	Crane, J. R., Pt., H, 7th Maine, age 19.	June 3, '64.	Right; flap; by Surg. G. T. Stevens. Disch'd Jan. 5, '65; pens'd.
635	Beamont, W., Pt., E, 36th Wisconsin, age 20.	May 18, '64.	Left; circular; by Surg. J. R. Wishart. Disch'd Dec. 8, 1864.	682	Creech, E., Pt., E, 122d Illinois, age 24.	Mar. 30, '65.	Left. Discharged July 14, 1865.
636	Bell, A., Pt., H, 3d Vermont.	Sept. 8, '63.	Left; flap; by A. A. Surg. A. M. Mills. Pens'd; healthy stump.	683	Crook, A. G., Pt., F, 4th Infantry, age 53.	May 24, '64.	Left; circ.; erysipelas. Disch'd April 3, 1865; pensioned.
637	Bennett, J., Pt., F, 95th Pennsylvania, age 31.	May 12, '64.	Left; flap; by A. Surg. C. C. McLaughlin. Pens'd Dec. 8, '64.	684	Crouse, A., Corp'l, I, 153d N. Y., age 28.	May 31, '64.	Left; lateral flap; by Surg. M. Rizzoli, 72d Pa. Pens'd Jan. 29, '65.
638	Bentley, B. F., Corp'l, H, 169th N. Y., age 38.	Sept. 29, '64.	Right; circ.; by Surg. J. Knowlson, 169th N. Y. Pen'd Oct. 21, '65.	685	Cummings, C. C., Serg't, Maj., 17th Miss., age 22.	July 7, '63.	Right; circular. Re-amp. stump; wound healed.
639	Berry, P., Pt., A, 31st Maine, age 21.	May 12, '64.	Left; ant. post. flap; cry; necrosis. July 12th, amp. arm. Disch'd September 28, 1864; pensioned.	686	Cunningham, A., Pt., C, 17th Maine, age 22.	Nov. 27, '64.	Left; flap; by Surg. D. W. Manll, 1st Del. Pens'd June 27, 1865.
640	Besat, A., Pt., D, 3d Wisconsin, age 26.	Aug. 22, '64.	Left; flap; by A. Surg. G. W. Burke, 46th Pa. Pen'd Apr. 8, '65.	687	Cunningham, H., Pt., B, 97th New York, age 27.	Feb. 6, '65.	Right; circular. Disch'd June 8, 1865; pensioned; healthy stump.
641	Blood, A., Pt., E, 32d Wisconsin, age 30.	Feb. 3, '65.	Right; flap; by Surg. A. B. Monahan. Pensioned July 17, 1865.	688	Davis, W. W., Lieut., B, 59th Mass.	July 30, '64.	Left; circ.; by Surg. T. F. Oakes, 56th Mass. Pens'd Nov. 29, '64.
642	Bragg, G., Pt., F, 40th Indiana, age 20.	Nov. 25, '63.	Right; flap; gangrene. Discharged December 6, 1864.				



No.	NAME, AGE, AND MILITARY DESCRIPTION.	DATES.	OPERATIONS, OPERATOR, RESULT.	No.	NAME, AGE, AND MILITARY DESCRIPTION.	DATES.	OPERATIONS, OPERATOR, RESULT.
689	Delany, M., Pt., A, 6th New York Heavy Artillery, age 50.	May 30, 1864.	Right; flap; by Surg. C. H. Porter. Disch'd Apr. 24, '65. Nov. 17, '65, re-amp.; recovery Dec. 3, 1866.	736	Howland, P. F., Corp'l, D, 12th N. H.	Oct. 10, 1862.	Right; by A. Surg. C. W. Hunt, 12th N. H. Pens'd Oct. 30, '62.
690	Denton, C., Pt., F, 83d New York, age 24.	May 12, '64.	Right; flap. Discharged Oct. 3, 1864; pensioned; sound stump.	737	Huebner, C., Pt., A, 9th N. J., age 26.	Dec. 16, '62.	Left; circ.; by Surg. G. A. Otis. To V. R. C. Aug. 14, '63; pens'd.
691	Dildine, N. C., Pt., A, 112th Pa., age 18.	July 14, '64.	56th Mass. Pens'd April 3, '65.	738	Huff, T. J., Pt., C, 106th Illinois.	Mar. 2, '63.	Left; by Surg. P. H. Ellsworth, 106th Ill. Pens'd April 7, 1863.
692	Dormick, C., Pt., Macon Light Artillery, age 45.	June 18, '64.	Left; flap. To prison Sept. 24, 1864. Spec. 44.	739	Huntley, S. S., Pt., D, 6th Vermont, age 35.	May 5, '64.	Left; flap. Disch'd August 25, 1864; pens'd; healthy stump.
693	Drinklow, H., Corp'l, A, 26th Mich., age 30.	Aug. 16, '64.	Left; flap; by Surg. M. H. Raymond. Pens'd June 13, 1865.	740	Jackson, J., Pt., E, 54th Ohio, age 17.	Aug. 31, '64.	Left; circ.; by Surg. A. C. Messenger. Pens'd May 18, 1865.
694	Dunham, I. H., Pt., A, 144th N. Y., age 21.	Dec. 20, '64.	Right; flap. Discharged May 15, 1865; pensioned.	741	Jackson, J. M., Pt., H, 18th S. C., age 35.	July 30, '64.	Right; circular; by Surg. T. F. Oakes. Transferred Oct. 19, '64.
695	Dyken, J., Pt., B, 61st New York, age 34.	Mar. 31, '65.	Left; circ.; by Surg. M. C. Rowland. Disch'd May 30, 1865.	742	Jecko, P., Serg't, D, 15th Missouri, age 29.	Nov. 29, '64.	Right; circular; by Surg. W. L. Graves, 6th Arkansas amp. leg. Discharged July 31, 1865.
696	Edwards, M., Pt., M, 3d N. Y. Art., age 20.	July 13, '64.	Left (amp. two fing's right hand). Disch'd April 13, '65; pensioned.	743	Jennison, G. A., Pt., L, 14th N. Y. H. A., age 19.	Mar. 25, '65.	Left; circular. Disch'd July 18, 1865; stump healed.
697	Ellis, A., Pt., G, 19th Mass., age 28.	May 6, '64.	Left; flap; by Surg. A. J. Clark. Disch'd Dec. 2, '64; pensioned.	744	Johnson, W. A., Corp'l, D, 142d Pa., age 21.	June 18, '64.	Left; flap. Disch'd Nov. 8, 1864; pensioned; sound stump.
698	Ennes, J., Pt., F, 28th New York.	Jan. 4, '63.	Left. Disch'd April 17, '63; pens'd. Died March 17, 1864.	745	Jones, R., Pt., K, 30th C. T., age 23.	July 30, '64.	Left; flap; by Surg. E. Jackson, 30th C. T. Pens'd Jan. 8, '65.
699	Farrell, J., Pt., K, 2d Artillery, age 29.	Mar. 15, '64.	Left; circular. Disch'd December 31, 1865.	746	Jones, T., Pt., E, 27th Mass., age 22.	June 18, '64.	Right; flap. Disch'd June 1, '65; pensioned; healthy stump.
700	Feig, H., Pt., H, 95th New York, age 39.	May 6, '64.	Left; flap. Discharged November 28, 1864.	747	Jordan, T. H., Serg't, H, 17th Me., age 33.	May 6, '64.	Left; circ. (wound thigh) Disch'd July 27, '65; pens'd; sound stump.
701	Ferrington, H. W., Pt., I, 4th Yt., age 25.	May 6, '64.	Right; flap; by Surg. D. M. Goodwin. Pens'd Feb. 6, 1865.	748	Keeler, M. W., Pt., K, 20th Mich., age 20.	June 3, '64.	Right; circ.; by Surg. S. S. French, 20th Mich. Pens'd Aug. 18, '65.
702	Fernan, P., Pt., H, 66th New York.	Sept. 17, '62.	Left; flap; by Surg. C. S. Wood (w. ad leg.) Pens'd Apr. 24, '63.	749	Keith, D. D., Corp'l, H, 2d Mass. H. A., age 32.	April 18, '64.	Right; circular; by Surg. Morton, C. S. A. Pens'd April 10, 1865.
703	Finucgan, C., Pt., D, 51st New York, age 20.	Oct. 1, '64.	Left; flap. Discharged July 13, 1865.	750	Keith, L. G., Pt., E, 18th Kentucky.	Aug. 9, '62.	Left; flap. Disch'd and pens'd; good stump.
704	Fisher, A., Pt., F, 48th Pennsylvania, age 25.	April 2, '65.	Left; flap. Discharged June 20, 1865; pensioned.	751	Kelley, J., Pt., K, 3d New Jersey.	Aug. 21, '61.	Left; flap; by Surg. L. H. Cox, 3d N. J. Disch'd Oct. 17, 1861; pens'd. Re-amp. Feb., 1862.
705	Fletcher, J. W., Pt., I, 8th Vermont, age 22.	Aug. 15, '64.	Left; circ.; by Surg. H. H. Gillett, 8th Vt. Pens'd May 27, 1865.	752	Kelly, J. C., Pt., G, 15th Massachusetts.	Oct. 21, '61.	Right. Disch'd March 27, 1862; pensioned; healthy stump.
706	Fox, H., Pt., E, 126th New York, age 21.	April 2, '65.	Left; circular; by A. Surg. C. S. Hoyt. Pens'd June 12, 1865.	753	King, R., Pt., G, 124th Ohio, age 23.	May 27, '64.	Right; flap; by Surg. D. C. Patterson. Disch'd Oct. 28, '64; pens'd.
707	Fries, W. H., Corp'l, I, 148th N. Y., age 22.	Sept. 29, '64.	Left. Discharged January 26, 1865.	754	Kinsey, C. W., Corp'l, B, 51st Pennsylvania.	Dec. 13, '62.	Right. Disch'd Oct. 28, '64; pens'd; stump painful, though healed.
708	Fuller, A., Pt., G, 6th Maine, age 23.	May 10, '64.	Left; circ.; by Surg. W. Buck, 6th Me. Pens'd Jan. 20, 1865.	755	Knudson, F., Pt., C, 5th Minnesota.	Jan. 29, '63.	Left; flap. Disch'd April 8, 1863; pensioned; stump healed.
709	Fulton, R., Pt., H, 148th Pennsylvania, age 18.	Aug. 15, '64.	Left; circular; gangrene. Discharged July 20, 1865.	756	Kretzler, A., Corp'l, D, 162d New York.	June 14, '63.	Right; flap; by Surg. W. B. Eager, 162d N. Y. (amp. leg.) Discharged Aug. 29, 1863; pens'd.
710	Geist, C., Pt., A, 2d Michigan.	Nov. 16, '63.	Right; circular. Disch'd May 31, 1864; pens'd; stump healed.	757	Lano, J., Pt., D, 39th Ohio, age 30.	July 22, '64.	Right; flap; by Surg. A. B. Monahan. To V. R. C. Nov. 19, '64.
711	Gerard, L. W., Pt., B, 38th Wis., age 33.	June 17, '64.	Left. Discharged December 22, 1864; pensioned.	758	Lathrop, H., Pt., 2d Kansas Battery.	July 9, '63.	Right (cont. chest; burn face and neck; eye destroyed). Disch'd July 4, 1864.
712	Good, W., Serg't, C, 129th Illinois, age 30.	May 25, '64.	Right; flap; by Surg. A. W. Reagan, 70th Ind. Dis'd Nov. 5, '64.	759	Lewis, W. H., Pt., 5th Artillery, age 22.	June 7, '64.	Left; flap (amp. right forearm). Disch'd April 29, '65; pens'd.
713	Goodman, O., Pt., I, 111th Ohio, age 14.	June 27, '64.	Left; flap; by Surg. C. D. Moore; gang. Disch'd May 26, 1865.	760	Leaveritt, J. O., Pt., B, 12th Ga. Batt'y, age 24.	Mar. 25, '65.	Also wound thigh. Released June 23, 1865.
714	Gould, B. P., Pt., I, 111th N. Y., age 21.	May 6, '64.	Left; circ.; by Surg. J. W. Wisbart. Disch'd April 1, 1865.	761	Libby, G. H., Pt., A, 12th Maine.	May 27, '63.	Left; flap; by Surg. G. Benedict, 23d Conn. Pens'd Sept. 3, 1863.
715	Graham, A., Capt., I, 12th Georgia, age 35.	July 12, '64.	Right; circular. To Old Capitol Prison March 28, 1865.	762	Loeke, S. A., Pt., H, 24th Mass., age 33.	Aug. 16, '64.	Left. Discharged February 14, 1865.
716	Green, C., Pt., G, 2d Colored Artillery.	April 1, '65.	Left; circular. Disch'd June 5, 1865; pens'd; healthy stump.	763	Loe, A., Pt., I, 7th Missouri Cavalry.	Aug. 15, '62.	Left. Discharged December 18, 1862; pensioned.
717	Griffin, W. H., Pt., A, 11th Vermont, age 22.	Oct. 19, '64.	Left; circ.; by Surg. E. Phillips, 6th Vt. Disch'd May 27, 1865.	764	Lovejoy, C. M., Pt., A, 1st Me. H. A., age 21.	May 19, '64.	Right; flap. To V. R. C. Feb. 18, 1865; pens'd; healthy stump.
718	Hammel, J., Serg't, H, 98th Pa., age 37.	May 4, '64.	Right; flap. Disch'd and pens'd; stump healed.	765	Lutz, G. V., Serg't, G, 33d Missouri, age 21.	Dec. 22, '64.	Left; flap; by Surg. A. T. Bartlett, 33d Mo. Pens'd Mar. 30, '65.
719	Hammersmith, W., Pt., D, 147th N. Y., age 26.	May 6, '64.	Left; circ.; by Surg. A. S. Coe, 147th N. Y. Pens'd Oct. 9, '64.	766	Lydie, J. R., Corp'l, K, 84th Pa., age 21.	May 3, '63.	Right; circular. To V. R. C. Dec. 3, 1863; pens'd; stump healed.
720	Harrison, W., Pt., A, 117th C. T., age 23.	Nov. 15, '64.	Right; flap; by Surg. M. D. Hendicet. Pens'd August 5, 1863.	767	Maey, G. N., Lieut., Col., 20th Massachusetts.	July 3, '63.	Left; by Surg. N. Hayward, 20th Mass. Pens'd; good stump.
721	Hart, J., Pt., A., 1st Artillery.	May 27, '63.	Left; circular; by A. Surg. A. N. Willford. Furl'd Sept. 23, '64.	768	Marsh, S., Pt., E, 3d Iowa.	Oct. 5, '62.	Left; flap; by Surg. B. F. Keables, 3d Iowa. Pens'd Nov. 14, 1862.
722	Hartley, T. H., Pt., I, 26th North Carolina.	Aug. 25, '64.	Left; flap. To V. R. C. Dec. 5, 1864; stump perfectly healed.	769	Mathes, W. A., Pt., B, 18th Indiana.	May 1, '63.	Right; circular. Disch'd Sept. 22, '63; pens'd; stump healed.
723	Hedges, S., Pt., H, 126th Ohio, age 24.	May 12, '64.	Left; circ.; by A. A. Surg. W. F. Richardson. Healed by first aid.	770	Mayo, D., Pt., C, 5th Vermont, age 24.	Sept. 19, '64.	Left; by Surg. G. T. Stevens; re-amp. Pensioned May 26, '65.
724	Henderson, O. P., Pt., F, Hampton's Legion.	Mar. 19, '65.	Right; flap; by Surg. E. Batwell. Pensioned June 21, 1865.	771	McBride, J. K., Lieut., Col., 9th Ala., age 38.	July 2, '63.	Left. Transferred to Provost Marshal September 17, 1863.
725	Hendrick, H., Serg't, F, 14th Mich., age 27.	May 19, '65.	Circular; by A. Surg. W. F. Richardson, C. S. A. Recov'd.	772	McClure, J. A., Pt., K, 30th North Carolina.	May 30, '64.	Right; by Surg. C. B. Gibson, C. S. A. Recovered.
726	Hersey, —, Pt., A, 44th Alabama.	June 1, '64.	Left; circular; by A. Surg. T. A. Helwig, 87th Pa.; gangrene. Re-amp. Nov. 19, 1864; pens'd.	773	McDonald, A., Pt., H, 16th Mich., age 20.	Aug. 19, '64.	Left; circular; by Surg. T. F. Oakes. Disch'd Jan. 27, 1865.
727	Hesselgrave, W., Corp'l, E, 106th N. Y., age 22.	June 22, '64.	Right (amp. left thumb). Disch'd January 10, 1864; pensioned.	774	McDonald, J., Pt., G, 5th Connecticut.	Nov. 16, '63.	Flap; by A. Surg. E. L. Bissell, 5th Conn. Disch'd July 25, '65.
728	Hill, W. H., Lieut., E, 110th Pennsylvania.	July 2, '63.	Right; flap. To Invalid Corps December 15, 1863.	775	McElhamon, J., Pt., D, 32d Miss., age 30.	Nov. 30, Dec. 1, '64.	Right; circular. To Provost Marshal January 3, 1865.
729	Hogan, J., Pt., D, 28th Mass., age 27.	Oct. 14, '63.	Right; flap; by Surg. E. G. Chase, 104th N. Y. Pens'd Nov. 25, '63.	776	McGovern, E., Pt., D, 116th Pa., age 45.	June 16, '64.	Left; circ. (flesh w'd hip); by Surg. J. W. Wishart, Pens'd Apr. 6, '65.
730	Hogg, B. F., Corp'l, B, 104th New York.	July 1, '63.	Right; by Surg. S. P. Smith, 2d P. H. B. Pens'd March 7, '63.	777	Melmes, H., Serg't, A, 4th R. L. age 32.	July 30, '64.	Right; flap. Disch'd July 31, '65; pensioned; stump healed.
731	Holler, J. Q., Pt., B, 2d Potomac Home Brig. e.	Aug. 30, '62.	Left; by Surg. W. Watson, 105th Pa. Disch'd Aug. 10, '64; pens'd.	778	McIntyre, F. F., Pt., C, 2d Cavalry, age 26.	May 8, '64.	Right; circular. Duty Oct. 4, '64; pensioned; good stump.
732	Holt, J., Pt., I, 138th Pennsylvania.	Nov. 27, '63.	Left; flap; by Surg. E. S. Swain, 5th Ky. Disch'd and pensioned.	779	McKnight, T., Lieut., B, 116th Pennsylvania.	June 16, '64.	Left; flap. Discharged August 2, 1864.
733	Homan, S. E., Lieut., A, 1st Ohio, age 31.	May 27, '64.	Right; flap; by Surg. J. H. Beach. Pen'd April 25, '65; stump heal'd.	780	McPherson, J., Pt., E, 118th Ohio.	May 31, '64.	Right; by Surg. S. K. Crawford, 50th Ohio. Pens'd Jan. 9, '65.
734	Horem, J. P., Corp'l, A, 24th Mich., age 24.	May 5, '64.	Left; flap; by Surg. C. M. Clark, 39th Ill. Pens'd March 30, 1865.	781	Merrill, F. L., Serg't, I, 31st Me., age 21.	April 2, '65.	Left; flap; by Surg. J. E. L. Kimball, 31st Me. Pens'd June 16, '65.
735	Howell, G., Pt., E, 39th Illinois, age 27.	Oct. 13, '64.					

No.	NAME, AGE, AND MILITARY DESCRIPTION.	DATES.	OPERATIONS, OPERATOR, RESULT.	No.	NAME, AGE, AND MILITARY DESCRIPTION.	DATES.	OPERATIONS, OPERATOR, RESULT.
782	Miller, T., Pt., A, 9th Infantry.	July 11, '63.	Right; flap; by Surg. R. A. Christian, P. S. V. Disch'd; pens'd.	829	Robinson, R. L., Pt., D, 121st N. Y., age 37.	April 2, '65.	Right; flap; by Surg. J. O. Slocum, 121st N. Y. Pens'd May 27, '65.
783	Mills, G. W., Pt., G, 12th Maine.	Sept. 15, '62.	Left; flap; by A. A. Surg. B. N. Cummings. Pens'd Nov. 20, '62.	830	Rodie, H., Pt., K, 2d Delaware, age 25.	June 16, '64.	Right; circular. To V. R. C. Jan. 6, '65; pensioned; good stump.
784	Minich, J., Pt., M, 22d Pa. Cav., age 36.	Aug. 17, '61.	Left; flap. Disch'd Jan. 19, '65; pensioned; sound stump.	831	Romig, W., Corp'l, I, 81st Pa., age 23.	July 2, '64.	Left. Discharged Feb. 12, 1864; pensioned; stump healed.
785	Mumick, J., Pt., K, 69th New York.	May 18, '64.	Left; circ.; by Surg. J. W. Wishart, 140th Pa. Pens'd Oct. 7, '64.	832	Rosswick, H., Pt., K, 5th New Jersey.	Aug. 29, '62.	Right; flap. To V. R. C. Feb. 25, 1864; pensioned; good stump.
786	Minor, E., Pt., F, Ind. Batt'n Minn. Cavalry.	Sept. 28, '64.	Both; ant. post. flaps; by Drs. Stewart and Murphy. Pens'd.	833	Runyan, J., Pt., K, 3d Kentucky.	Aug. 30, '62.	Right; by Surg. W. Berry, 7th Ky. Disch'd Dec. 2, '62; pens'd.
788	Moore, J., Pt., E, 43d New York, age 28.	Oct. 19, '64.	Left; flap; by Surg. G. T. Stevens, 77th N. Y. Pens'd May 2, 1865.	834	Sager, J., Corp'l, A, 7th Michigan, age 39.	April 1, '65.	Right; flap; by Surg. A. A. White. Pens'd June 27, 1865.
789	Morgan, J., Pt., D, 31st Ohio.	Aug. 4, '64.	Left; circ.; by Surg. J. R. Arter, 31st Ohio. Pens'd Feb. 17, '65.	835	Savage, F., Serg't, E, 4th Mich. Cav., age 24.	May 15, '64.	Left; circular; by A. Surg. J. H. Bacon. Pens'd May 17, 1865.
790	Morey, J., Pt., D, 105th Illinois, age 24.	July 3, '64.	Left; circular. Disch'd April 18, 1865; pensioned; good stump.	836	Sealin, D., Pt., D 147th New York, age 35.	Mar. 28, '64.	Right; circ.; by Surg. A. S. Coe, 147th N. Y. Pens'd Sept. 14, '64.
791	Morris, O., Pt., I, 97th Indiana, age 24.	Feb. 9, '65.	Right; circular (loss of both eyes). Discharged August 22, 1865.	837	Schneider, A., Pt., B, 12th Kentucky, age 22.	Nov. 29, '64.	Left; flap. Disch'd June 12, '65; pensioned; sound stump.
792	Morslander, D., Pt., K, 4th New Jersey, age 28.	May 10, '61.	Right; flap. Disch'd June 16, '65; pensioned; healthy stump.	838	Scott, B. J., Pt., E, 100th N. Y., age 19.	June 23, '64.	Left; flap; by Surg. M. S. Kittenberger, 100th N. Y. Disch'd Dec. 24, '64.
793	Mudge, P., Pt., H, 16th Maine.	Sept. 28, '62.	Left; flap. Disch'd April 29, '63; pensioned; good stump.	839	Scott, E. S., Lieut., G, 89th Ohio.	July 20, '64.	Left. Discharged; pensioned; good stump.
794	Mulhall, W., Pt., K, 4th Artillery, age 22.	May 3, '63.	Right; flap. Discharged; pensioned; stump healed.	840	Scott, L., Pt., C, 23d C. T., age 22.	July 30, '64.	Left; flap; by Surg. D. Mackay, 29th C. T. Pens'd Dec. 26, '64.
795	Mull, D., Serg't, H, 113th Ohio, age 29.	June 27, '64.	Right; circ.; by Surg. C. J. Walton. To V. R. C. Nov. 24, '64; pens'd.	841	Severson, K., Pt., B, 1st Mich. S. S., age 23.	June 17, '64.	Left; circ.; by Surg. W. C. Shurlock, 51st Pa. Pens'd Apr. 15, '65.
796	Mullen, P., Pt., H, 82d Pennsylvania, age 20.	June 3, '64.	Left. Discharged September 16, 1864.	842	Shannhan, P., Pt., K, 8th New Jersey, age 29.	April 2, '65.	Right; circular. Disch'd May 26, 1865; pensioned; stump healed.
797	Murphy, H., Pt., C, 27th Connecticut, age 42.	Dec. 13, '62.	Left; flap; by A. Surg. T. N. Hills, 27th Conn. (wounds right hand and thigh). Pens'd April 8, 1863.	843	Shull, W., Pt., H, 1st Illinois Art., age 19.	Dec. 19, '64.	Left; flap; by Surg. J. N. Barnes, 116th Ill. Disch'd July 1, 1865.
798	Neff, J. L., Pt., D, 111th Indiana, age 19.	July 28, '64.	Right; flap; by Surg. I. N. Barnes, 116th Ill. Pens'd Mar. 21, 1865.	844	Siemes, F., Pt., C, 32d Indiana, age 21.	Nov. 25, '63.	Left; circ. Disch'd Sept. 7, 1864; pensioned; stump healed.
799	Nelms, E., Pt., E, 9th Virginia.	May 10, '64.	Circular; by A. Surg. W. F. Richardson, C. S. A. Recovered.	845	Simon, P., Pt., K, 48th Pennsylvania.	Dec. 13, '62.	Right; flap. Disch'd March 10, 1863; pensioned.
800	Nichols, M. C., Pt., F, 30th Wis., age 28.	Aug. 14, '64.	Left; flap; by Surg. N. Hayward, 20th Mass. Pens'd Jan. 24, 1865.	846	Smeathers, J., Pt., G, 1st Mass H. A., age 18.	Aug. 15, '64.	Left; flap. Discharged Sept. 25, 1864; pens'd; sound stump.
801	North, E. A., Pt., G, 35th New York.	Aug. 17, '61.	Left; circular. Disch'd Sept. 23, 1861; pensioned; stump healed.	847	Smith, E. A., Pt., H, 27th C. T., age 20.	July 30, '64.	Right; circular; by Surg. F. M. Weld, 27th C. T.; necrosis. Disch'd Oct. 21, 1865; pensioned.
802	Palmer, M., Pt., C, 1st Ohio Artillery, age 21.	May 27, '64.	Left; flap. Discharged September 24, 1864; stump healed.	848	Smith, J., Pt., C, 8th New Hampshire.	June 14, '65.	Left; circular. Discharged July 29, 1863.
803	Parmalee, H. S., Serg't, B, 1st Conn. Cavalry.	April 6, '65.	Right. Discharged June 20, '65; pensioned; good stump.	849	Smith, J. F., Serg't, F, 4th Iowa.	Dec. 29, '62.	Left; circ.; by A. Surg. A. Shaw. Pens'd Feb. 18, 1863.
804	Parsons, I., Pt., B, 23d Kentucky.	Sept. 19, '63.	Left; flap. Discharged; stump healed.	850	Smoot, J. P., Pt., F, 46th Tenn., age 39.	Nov. 30, '64.	Right; by Surg. A. M. Wilder, H. S. V. Pens'd March 5, 1865.
805	Pa-zah-whashol, J., Pt., K, 37th Wis., age 30.	Aug. 21, '61.	Left; flap (also flesh w'd knee). Discharged; stump healed.	851	Sneed, G. W., Pt., A, 12th Ky., age 24.	Aug. 6, '64.	Right; by Surg. A. M. Wilder, H. S. V. Pens'd March 5, 1865.
806	Perry, H., Pt., H, 126th Ohio, age 18.	May 12, '64.	Left; flap; by Surg. J. S. Ely, 126th Ohio. Pens'd Jan. 27, '65.	852	Snowden, S., Pt., A, 33d C. T., age 25.	July 13, '64.	Right; circular; by Surg. J. P. Prince. Disch'd May 17, 1865.
807	Perkins, G. W., Pt., G, 8th Michigan, age 25.	Aug. 19, '64.	Left; circ.; by Surg. W. B. Fox, 8th Mich.; hæmorrh.; lig. radial. Disch'd Jan. 17, 1865; pens'd.	853	Snyder, A., Corp'l, D, 12th Indiana.	Dec. 15, '64.	Left; flap; by A. Surg. J. H. Thorne, U.S.V. Disch'd; pens'd.
808	Phelps, L. A., Pt., H, 7th N. Y. Art., age 20.	June 6, '64.	Right; circ.; by Surg. J. W. Wishart, 14th Pa. Pens'd Oct. 10, '64.	854	Stanford, R., Serg't, K, 63d Pa., age 28.	May 5, '64.	Left; flap; by Surg. Z. R. Jones, 63d Pa. Pens'd Dec. 24, 1864.
809	Phillips, E., Waggoner, K, 38th Mass.	May 27, '63.	Right; flap. Discharged; stump healed.	855	Stone, E., Pt., K, 25th Massachusetts.	May 16, '64.	Left; double flaps; by Surg. O. F. Marsden, C. S. A. Disch'd; pens'd.
810	Phitt, W., Pt., G, 89th Illinois, age 21.	June 22, '64.	Right; circ.; by Surg. H. B. Tuttle, 89th Ill. Pens'd Apr. 10, '65.	856	Stoughton, A. F., Corp'l, C, 5th Vermont, age 18.	May 12, '64.	Right; double flap; by Surg. A. H. Chasmore. Pens'd Jan. 13, '65.
811	Poe, P., Pt., B, 5th Alabama, age 19.	Sept. 27, '64.	Left; flap. To Provost Marshal December 18, 1864.	857	Stratton, W., Pt., D, 182d Pa., age 18.	May 10, '64.	Right; flap. Disch'd Dec. 25, '64; pensioned; healthy stump.
812	Powell, M., Pt., F, 1st Arkansas.	April 13, '64.	Left; by Surg. G. H. Hubbard. Pens'd Jan. 18, 1865; good stump.	858	Sullivan, D., Pt., I, 35th Massachusetts.	Dec. 13, '64.	Right; flap. Disch'd March 5, 1865; pensioned; good stump.
813	Pramo, J., Pt., A, 121st New York, age 34.	Oct. 8, '62.	Left; by A. A. Surg. S. B. Valentine, 121st N. Y. Disch'd Nov. 8, 1862; pens'd. Died Jan. 20, '71.	859	Sutton, N. G., Pt., I, 1st Georgia, age 26.	Aug. 6, '64.	Right; flap. To Provost Marshal April 1, 1865.
814	Preslin, R., Pt., E, 38th C. T., age 35.	Sept. 29, '62.	Left (also right hand). Pens'd Sept. 7, 1865; sound stump.	860	Sweat, F. R., Corp'l, E, 26th Georgia.	July 9, '64.	Left; circ.; by Surg. G. E. Felks, 26th Ga. Exchanged Sept. 19, 1864.
815	Qualls, J., Pt., H, 27th Colored Troops.	Oct. 27, '64.	Right; circ.; by Surg. F. M. Weld, 27th C. T. Disch'd May 16, '65.	861	Tappart, M. W., Serg't, H, 11th Ala., age 19.	July 2, '63.	Left. Exchanged March 3, 1864.
816	Rappole, H., Pt., 7th Co. N. Y. S. S.	May 5, '64.	Left; circular. Disch'd November 14, 1864.	862	Taylor, M., Pt., I, 198th Pennsylvania, age 18.	Oct. 2, '61.	Left; flap. Discharged Jan. 30, 1865; pensioned. Spec. 247.
817	Rasco, R., Pt., D, 140th Indiana, age 23.	Dec. 2, '64.	Right; flap. Disch'd July 11, 1865; pensioned; sound stump.	863	Thomas, F., Pt., E, 128th Pennsylvania.	Sept. 17, '62.	Left; flap. Disch'd Dec. 31, '62; pensioned; stump sore.
818	Reams, A. L., Pt., A, 7th Mich. Cav., age 19.	July 3, '64.	Left. Disch'd October 19, 1863; pensioned; stump healed.	864	Thompson, D., Pt., F, 1st C. T., age 39.	June 15, '64.	Left; flap. Disch'd Feb. 10, '65; pensioned; healthy stump.
819	Redman, H. N., Serg't, G, 8th Pennsylvania.	April 8, '65.	Left; circ.; by Surg. L. Dyer, 81st Illinois. Disch'd; pensioned.	865	Thompson, H., Pt., H, 69th N. Y., age 36.	May 18, '64.	Right; circ.; by Surg. J. W. Wishart, 140th Pa. Disch'd May 27, '65.
820	Reed, W. D., Pt., G, 7th Connecticut.	May 18, '64.	Right; circular. Disch'd September 19, 1864.	866	Thompson, R. S., Pt., E, 18th V. R. C., age 26.	July 19, '64.	Right; flap. Disch'd Oct. 5, 1864; stump entirely healed.
821	Reese, H., Pt., I, 53d Pennsylvania, age 23.	June 16, '64.	Right; circular. Disch'd Nov. 12, 1864; pens'd; sound stump.	867	Thompson, W. H., Pt., I, 39th C. T., age 32.	July 30, '64.	Right; by Surg. E. Jackson, 39th C. T. Pens'd Jan. 9, 1865.
822	Rein, F. J., Pt., G, 8th Pa. Cav., age 23.	Aug. 16, '64.	Right; circ.; gang. To V. R. C. Jan. 15, '65; pens'd; good stump.	868	Tindell, D., Pt., E, 74th New York, age 26.	May 4, '62.	Left; flap (also wound of thigh). Discharged October 1, 1862.
823	Reichender, P., Pt., H, 28th Pa., age 24.	July 20, '64.	Left; flap; gangrene; hæm.; lig. radial. Disch'd Sept. 9, 1865.	869	Trask, N., Pt., F, 26th New York.	Dec. 13, '63.	Right; flap. Disch'd Feb. 6, '63; pensioned; stump healed.
824	Rheinicker, P., Pt., D, 16th Kentucky, age 24.	Aug. 6, '64.	Left; circular; by Surg. H. W. Mullens, 12th Ky. Discharged.	870	Trickey, F. B., Pt., H, 15th Maine, age 23.	Feb. 7, '63.	Right; circular; by A. Surg. J. H. Kimball and S. G. Holt, 15th Me. Disch'd June 9, 1863; pens'd.
825	Rhodes, C. M., Pt., G, 43d Ohio.	Oct. 4, '62.	Right; flap. Discharged October 4, 1864.	871	Tucker, J. B., Serg't, B, Green River Battalion, Ky. State Troops.	July 4, '65.	Left; circ. (amp. right forearm); by A. Surg. C. F. Ulrich, of regiment. July 11, re-amp. middle third forearm. Disch'd Aug. 23, '65.
826	Richards, J. H., Pt., B, 4th N. J., age 28.	May 5, '64.	Left; flap; by Surg. J. D. Osborne, 4th N. J. Disch'd Sept. 20, 1864; pensioned.	872	Turner, P., Pt., C, 19th C. T., age 29.	Aug. 16, '64.	Left; circ.; by Surg. E. Jackson, 39th C. T. Pens'd Feb. 10, '65.
827	Roberts, W. G., Lieut., C, 28th C. T.	July 30, '64.	Left; circ.; by Surg. F. M. Weld, 27th C. T. Disch'd Jan. 16, '65.	873	Turpin, R., Pt., C, 3d Mass. Cav., age 22.	Oct. 19, '64.	Left; flap; by A. Surg. C. H. Allen, 14th V. C. Pens'd Aug. 7, '65.
828	Robinson, H., Pt., K, 8th Colored H. A.	July 15, '64.	Left; by Surg. F. De Wint, 8th Colored H. A. Disch'd; pens'd.	874	Tyler, J., Capt., G, 17th Michigan, age 38.	Nov. 16, '63.	Left; by Surg. G. B. Cogswell, 29th Mass. Disch'd; pens'd.



No.	NAME, AGE, AND MILITARY DESCRIPTION.	DATES.	OPERATIONS, OPERATOR, RESULT.	No.	NAME, AGE, AND MILITARY DESCRIPTION.	DATES.	OPERATIONS, OPERATOR, RESULT.
875	Vail, I. S., Pt., K, 31st Maine.	June 24, '64.	Left; by Surg. J. B. Mitchell, 31st Me. Disch'd Mar. 1, '65; pens'd.	893	Anderson, O. A., Pt., K, 8th Wisconsin.	Oct. 3, '62.	Left. Discharged May 5, 1863.
876	Vance, I., Lt., C, 140th Pennsylvania.	July 3, '63.	Left; circular. Discharged January 12, 1864.	894	Bradford, J., Corp'l, I, 3rd New York.	Dec. 13, '62.	Right. Duty March 3, 1863.
877	Vandercok, G., Pt., H, 115th N. Y., age 23.	Aug. 19, '64.	Right; flap. Disch'd Dec. 5, '64; pensioned; stump healed.	895	Durmany, H. S., Pt., I, 2d Florida, age 22.	July 2, '63.	Right (wound of right foot). Paroled August 22, 1863.
878	Van Gordon, A. M., Pt., H, 9th N. J., age 22.	June 3, '64.	Left; circular. Disch'd September 23, 1865.	896	Ellis, G. W., Lieut., 2d New York Cavalry.	April 1, '65.	Left. Mustered out June 5, 1865.
879	Wakefield, J., Pt., D, 41st Ohio.	May 27, '64.	Right; circular. Disch'd; pensioned; sound stump.	897	Gardner, A., Pt., B, 71st Pennsylvania.	May 31, '62.	Left. Discharged January 23, 1863.
880	Warner, G. S., Pt., F, 13th Ohio Cav., age 19.	April 7, '65.	Right; circular. Disch'd July 28, 1865; pensioned; stump healed.	898	Gooding, W. B., Capt., K, 2d N. C.	July 1, '63.	Left; by Surg. P. G. Robinson, 2d North Carolina.
881	Warren, G., Pt., F, 26th Massachusetts, age 21.	May 6, '64.	Right; flap; by Surg. N. Hayward, 26th Mass. Disch'd Dec. 30, 1864; pensioned.	899	Hamer, C., Pt., A, 29th C. T., age 32.	Oct. 1, '64.	Left. Discharged May 16, 1865.
882	Wheeler, H. C., Capt., 2d N. C., age 22.	July 1, '63.	Right (wound of left thigh). To prison April 11, 1864.	900	Lascomb, J. L., Pt., C, 18th Va., age 29.	July 1, '63.	Right. Paroled August 22, 1863.
883	Whipple, J. F., Pt., I, 1st Mass. H. A., age 23.	April 10, '65.	Right; flap; by Surg. C. N. Chamberlain. Pens'd July 5, 1865.	901	Mensch, W., Corp'l, B, 100th N. Y., age 21.	Oct. 27, '64.	Right; by Surg. G. C. Jarvis, 7th Ct. Pens'd Jan. 26, 1865.
884	White, G. Q., Pt., B, 1st Illinois Artillery.	Nov. 7, '61.	Right; flap. Disch'd Jan. 18, '62; pensioned; stump healed.	902	Miller, R. J., Pt., A, 1st Tennessee, age 31.	July 3, '63.	Right; erysipelas. Paroled Sept. 25, 1863.
885	White, T. H., Pt., B, 2d Pa. H. A., age 18.	June 22, '64.	Left; flap. Disch'd July 27, '65; pensioned; unsound stump.	903	Norton, W., Pt., C, 6th Tennessee.	May 16, '64.	By Surg. C. B. Gibson, C. S. A. Transferred; doing well.
886	Whitley, W. W., Pt., F, 85th Indiana, age 29.	July 3, '64.	Left. Discharged September 28, 1864; pensioned.	904	Parson, R. E., Pt., E, 5th Mississippi, age 20.	May 15, '64.	Furloughed May 29, 1864; convalescent.
887	Williams, A. J., Pt., H, 2d Illinois.	Dec. 31, '62.	Right. Discharged April 27, '63; pensioned; stump healed.	905	Shea, T., Major, 2d Indiana.	July 19, '64.	Left. Duty October 13, 1864.
888	Winn, R., Pt., G, 82d C. T., age 28.	April 3, '65.	Left; flap. Disch'd August 7, 1865.	906	Shepherd, J. Q., Pt., B, 3th Iowa.	June 28, '63.	Left; by Surg. P. N. Woods, 3th Iowa. Pens'd March 27, 1864.
889	Wood, B., Corp'l, M, 6th N. Y. Artillery, age 47.	May 30, '64.	Right; circular. Disch'd Jan. 30, 1865; pens'd; stump good.	907	Sutton, J. H., Serg't, G, 2d Florida, age 27.	July 2, '63.	Right (flesh wound of shoulder). To Prov. Marshal Sept. 1, 1863.
890	Woodworth, C. R., Pt., K, 52d N. Y., age 32.	May 10, '64.	Left; flap. Disch'd July 30, '64; pensioned; good stump.	908	Welby, J. H., Pt., K, 1st Missouri Light Artillery, age 24.	Aug. 10, '63.	Left; by Surg. B. C. Franklin, 5th Mo. Aug. '61, amput. arm. Pens'd April 26, '64. Died July 16, '68.
891	Wright, L., Pt., A, 31st Colored Troops.	July 30, '64.	Left; circ.; by Surg. D. MacKey, 29th C. T. Disch'd Jan. 12, '65.	909	Wilson, W. H., Serg't, C, 39th Ala., age 30.	May 16, '64.	Circular; stump healed. Furloughed June 3, 1864.
892	Yeoman, S. B., Capt., A, 54th Ohio.	Jan. 11, '63.	Right; by Surg. J. S. McGrew. Resigned June 8, '63; pensioned.	910	Wright, J., Pt., F, 8th Alabama, age 34.	May 8, '64.	Furloughed June 7, 1864.

§ *Fatal Primary Amputations in the Forearm.*—Of a thousand and seven cases, ninety-seven, or 9.6 per cent., were fatal—several after re-amputation.

CASE 1926.—Private I. Neill, Co. D, 16th Mississippi, aged 38 years, was wounded at the Weldon Railroad, August 21, 1864. From a field hospital he was admitted to the Depot Hospital, Fifth Corps, City Point, where Surgeon W. L. Faxon, 32d Massachusetts, recorded: "Gunshot wound of arm; amputation." Assistant Surgeon J. C. McKee, U. S. A., reported the

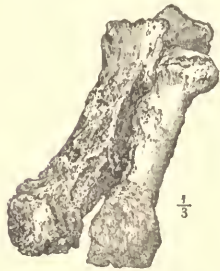

FIG. 712.—Re-amputated stump of the left forearm. *Spec. 61.*

man's admission to Lincoln Hospital, Washington, August 24th, and the following history: "Gunshot fracture of left forearm, lower third, followed by amputation at the middle third. The operation was performed by Assistant Surgeon J. T. Duffield, 7th Indiana, on the day after the injury, by the circular method. The stump continued in a very unhealthy condition until April 12, 1865, when it was re-amputated by Acting Assistant Surgeon N. A. Robbins, by a circular operation at the lower third of the humerus. (Compare CASE 26, TABLE LXXXVII, p. 788.) On the evening of the following day the patient received a severe shock on the stump by one of the attendants in the ward falling with his whole weight upon the injured member. On the next morning he commenced to fail rapidly, and the same day he was taken with a severe chill with diagnostic signs of pyæmia. Quinine exhibited in large doses failed to produce the desired effect, and the chills continued. A large abscess formed over the external aspect of the knee joint, containing dark and fetid pus. The general treatment consisted of water dressings and tonics, with a solution of bisulphate of soda, half an ounce to six ounces of water, given in doses of two teaspoonfuls every three hours, after the development of pyæmia. The patient died April 17, 1865." The specimen, represented in the annexed cut (FIG. 712), consists of the upper thirds of the bones of the forearm, and was contributed by Acting Assistant Surgeon J. P. Arthur. "Each bone is enlarged, but carious, and superficial diseased action occupies nearly the whole of the shaft of the ulna."

TABLE CXXXIV.

*Condensed Summary of Ninety-seven Fatal Cases of Primary Amputations in the Forearm.*

No.	NAME, AGE, AND MILITARY DESCRIPTION.	DATES.	OPERATIONS, OPERATOR, RESULT.	No.	NAME, AGE, AND MILITARY DESCRIPTION.	DATES.	OPERATIONS, OPERATOR, RESULT.
1	Acox, C., Pt., B, 124th Illinois.	Feb. 6, '64.	Left; circ. (both knees); by Surg. A. H. Brundage. Died Mar. 7, '64.	5	Crane, S., Pt., I, 55th Pennsylvania, age 17.	June 18, '64.	Left; flap; by Surg. G. T. Stevens. Died Feb. 4, '65, hypertrophy of heart; acute phthisis; pleurisy.
2	Balbridge, J. C., Pt., B, 6th Mississippi, age 26.	Dec. 1, '63.	Right; ant.-post. flap. Died Jan. 27, 1865, typhoid fever.	6	Catwell, A. N., Pt., E, 1st B. I. Artillery.	Nov. 7, '63.	Right, and op. arm; by A. Surg. H. G. Taylor. Died Nov. 7, '65.
3	Boyer, J., Pt., G, 2d Colored Troops.	Sept. 29, '64.	Left; flap. Died November 15, 1864.	7	Cone, J., Pt., B, 55th Pennsylvania, age 45.	June 3, '64.	Right; flap (wound of neck). Died June 12, 1864, exhaustion.
4	Butler, T., Pt., C, 9th Minnesota, age 23.	July 4, '63.	Right (other injuries); by Dr. A. Miller; gang.; delirium. Died July 14, 1863.	8	Dilley, J., Pt., B, 1st N. Y. Lt. Art., age 34.	April 2, '65.	Right; circular; necrosis. Died April 29, 1865, pyæmia.

No.	NAME, AGE, AND MILITARY DESCRIPTION.	DATES.	OPERATIONS, OPERATOR, RESULT.	No.	NAME, AGE, AND MILITARY DESCRIPTION.	DATES.	OPERATIONS, OPERATOR, RESULT.
9	Dudley, J. P., Pt., E, 9th Colored Troops, age 38.	Oct. 13, '64.	Left. Died October 18, 1864, exhaustion and pneumonia.	53	Armstrong, T., Pt., A, 13th Pa., age 40.	June 18, '64.	Right; flap; July 6, unhealthy action. Died July 12, 1864.
10	Hall, E. A., Pt., D, 1st Mass. H. A., age 31.	May 19, '64.	Right; ant.-post. flap; sloughed. Died June 9, 1864, pyæmia.	54	Dechass, H., Pt., B, 11th Pennsylvania, age 49.	June 24, '64.	Left; circular flap. Died Aug. 19, 1864, gangrene.
11	Howard, J., Pt., H, 12th Illinois, age 31.	July 31, '64.	Left; flap; by Surg. J. Pogue, 66th Illinois. Died Sept. 19, 1864.	55	Dijohn, G., Pt., B, 73d C. T., age 29.	April 10, '65.	Left; circular. Died May 2, '65, hectic fever.
12	Huntress, C. T., Pt., C, 1st Mass. H. A., age 44.	May 23, '64.	Right; flap (other w'ds); by Surg. M. Rizer. Died June 18, 1864, pyæmia.	56	Fisk, R., Pt., K, 20th Iowa.	Dec. 7, '62.	Tetanus Dec. 17, which increased in severity. Died Dec. 27, 1862.
13	Jackson, A., Pt., G, 55th Massachusetts.	Feb. 10, '65.	Right. Died March 5, 1865, inflammation of lungs.	57	Gallagher, L. G., Pt., A, 126th Ohio, age 19.	May 9, '64.	Right; flap. Died May 27, 1864.
14	Kelly, E., Pt., B, 47th Colored Troops, age 30.	Mar. 5, '64.	Right; circ.; by Surg. N. N. Horton, 47th C. T. Died June 20, '64.	58	Gweeny, H. C., Pt., C, 1st Ohio Artillery.	May 27, '64.	Right; by Surg. J. Bennett, 19th Michigan. Died May, 1864.
15	Moore, J. C., Corp'l, D, 2d N. Y. Art., age 19.	June 16, '64.	Right. Died July 20, 1864.	59	Hall, S., Pt., H, 30th Colored Troops.	July 30, '64.	Right; circ.; by Surg. J. S. Ross, 11th N. H. Died Aug. 4, 1864.
16	Price, R. S., Pt., B, 1st N. J. Art., age 25.	July 3, '62.	Right; amputat'n leg; diarrhoea. Died Aug. 22, 1863, exhaustion.	60	Hollingsworth, J., Pt., H, 3d New Jersey.	Sept. 14, '62.	Right; circular; flesh wounds left arm and thigh. Died November 1, 1862, typhoid fever.
17	Scott, E. J., Pt., F, 111th New York, age 20.	May 5, '64.	Left. Died June 3, 1864, pyæmia.	61	Hoyt, P. H., A, 1st Ark., age 34.	May 5, '64.	Left; wound arm; by Surg. J. B. Lamb; diarrhoea. Died July 11, 1864.
18	Smith, L., Corp'l, C, 111th Illinois, age 25.	July 22, '64.	Left; circ.; by Act. Staff Surg. C. B. Richards. Died Aug. 20, '64.	62	Huskey, W. H., Corp'l, 1, 3d S. C.	Nov. 18, '63.	Left; fract. right clavicle; Dec. 27, exc. clavicle. Died Jan. 24, '64.
19	Smith, L., Pt., G, 81st Pennsylvania, age 39.	July 3, '64.	Left; circular. Died September 13, 1864, consumption.	63	Kirchenberger, J., Sgt., E, 54th Ohio.	Aug. 3, '64.	Left; by Surg. I. N. Barnes, 116th Illinois. Died Sept. 7, 1864.
20	Staup, C., Pt., H, 94th Ohio.	May 7, '64.	Right; also wound of left thigh. Died June 27, 1864.	64	Lenoir, L. Y., Pt., K, 8th Louisiana.	Sept. 19, '64.	Circular; also wounds of both thighs. Died Sept. 29, 1864.
21	Stockwell, L., Pt., D, 1st N. Y. Lt. Art., age 45.	Mar. 31, '65.	Right; lateral flap. Died May 14, 1865, exhaustion.	65	Moek, T., Pt., K, 55th Pennsylvania, age 24.	June 18, '64.	Right; flap; by Surg. G. T. Stevens, 77th N. Y.; gang.; July 25, re-amp. Died Aug. 7, '64, pyæm.
22	Taylor, A., Serg't, I, 97th Ohio.	June 22, '64.	Left; by Surg. E. B. Glick, 40th Indiana. Died June 27, 1864.	66	Moody, S., Major, 27th Michigan, age 44.	June 3, '64.	Right; by Surg. H. C. Smith; tetanic symp. Died June 20, '64.
23	Trumbull, S. H., Pt., G, 24th N. Y. Cav., age 30.	June 26, '64.	Left; circ.; by Surg. W. C. Shurlock, 51st Pa. Died July 19, '64.	67	Murray, B., Pt., I, 1st Colored Troops.	June 15, '64.	Right. Died February 2, 1865.
24	Vosburgh, A. P., Pt., 16th N. Y. Battery.	April 8, '65.	Right; by Surg. V. B. Kennedy, 5th Minn. Died May 11, 1865.	68	Niles, J. W., Pt., A, 2d Vermont, age 27.	May 11, '64.	Right; circ.; w'd right shoulder; profuse suppuration. Died May 28, 1864, exhaustion.
25	Walker, P., Pt., I, 104th New York, age 40.	June 18, '64.	Left; circular; amp. right arm. Died July 9, 1864, exhaustion.	69	Penny, C., Pt., D, 124th Ohio, age 19.	Dec. 16, '64.	Right; circular. Died January 23, 1865.
26	Webster, W. H., Pt., B, 66th Illinois.	May 27, '64.	Right. Died July 6, 1864, exhaustion from suppuration.	70	Phillips, O., Corp'l, A, 7th Rhode Island.	June 3, '64.	Left. Died July 20, 1864.
27	Adams, P., Pt., E, 10th New Jersey, age 18.	June 1, '64.	Right; flap. Died of typhoid fever while on furlough.	71	Philo, H., Pt., I, 30th New Jersey, age 33.	April 2, '65.	Right; circular; by A. Surg. E. M. Smyser. Died May 1, 1865, pyæmia.
28	Benner, O. P., Pt., I, 19th Maine.	Oct. 25, '62.	Left. Died Jan. 20, 1863, small-pox.	72	Roe, J. L., Pt., L, 6th Kentucky Cavalry.	June 21, '64.	Left; wound of abdomen. Died June 24, 1864.
29	Boothe, W., Pt., K, 29th Alabama, age 38.	Dec. 15, '64.	Right; antero-posterior flap. Died Dec. 23, 1864, exhaustion.	73	Spilkey, E. B., Pt., H, 11th Missouri.	Mar. 30, '65.	Left; w'd of thorax; by Surg. M. W. Fish. Died May 26, 1865.
30	Brady, J. A., Pt., K, 26th Pa., age 18.	July 4, '64.	Left; circ.; stump healing finely. Died August 10, 1864, pyæmia.	74	Steel, J., Pt., L, 10th Mich. Cavalry, age 18.	May 19, '64.	Left; flap; by Surg. C. S. Frink, U. S. A.; gang. Died May 23, '64.
31	Burke, R., Pt., G, 131st New York.	Sept. 19, '64.	Right. Died October 27, 1864, pyæmia.	75	Tompkins, M., Pt., D, 41st Ohio.	May 27, '64.	Left. Died June 21, 1864.
32	Crawford, E., Pt., E, 92d Ill. Mt'd Infantry.	Aug. 28, '64.	Left; flap; abscess. Died July 10, 1864, pyæmic symptoms.	76	Wagner, A. B., Pt., D, 48th Pennsylvania.	April 2, '65.	Left; by Surg. J. H. Kimball, 32d Maine. Died April 15, 1865.
33	Crotty, D., Ft., G, 73d New York, age 28.	June 3, '64.	Left; flap; by Surg. N. Y. Leit, 76th Pa. Died Dec 7, '64, irri. fever.	77	Wallace, R., Pt., P, 33d Missouri.	May 18, '64.	Left, lower; right, mid.; A. Surg. C. H. Andrus. Died May, 1864.
34	Dorsey, G., Pt., G, 5th Colored Troops, age 43.	Oct. 27, '64.	Left; circ.; by Surgs. W. B. Fox, and W. C. Shurlock. Died August 8, 1864. Spec. 3971.	78	Weaver, R. A., Serg't, C, 141st N. Y., age 23.	July 23, '64.	Right; circ.; gang; bones protruded. Died Sept. 1, '64, pyæmia.
35	Fauble, J., Pt., K, 60th New York, age 18.	May 31, '64.	Left; by Surg. C. E. Swasey, U. S. V.; traumatic fever; delirium; slough. Died July 16, 1864, nervous shock.	79	Western, T., Pt., B, 18th Ohio, age 38.	Dec. 15, '64.	Right; ant.-post. flap; by Surg. B. B. Breed, U. S. V. Dec. 29th, gangrene. Died Feb. 10, 1865.
36	Ford, S., Pt., H, 13th Kansas.	July 4, '64.	Left; circular. Died Aug. 13, '64, congestive intermittent fever.	80	Boyd, J., Pt., I, 2d Delaware.	July 3, '63.	Died Sept. 19, 1862, hemorrhage.
37	Hannon, J. H., Pt., E, 57th Alabama, age 37.	July 30, '64.	Right; by Surg. S. K. Crawford, 50th Ohio. Died July 16, 1864.	81	Campbell, J., Pt., F, 13th New Jersey.	Sept. 17, '62.	Right. Died August 8, 1863.
38	Hays, D., Corp'l, G, 23d Michigan, age 30.	June 27, 1864.	Right; by Surg. D. McFalls, 142d N. Y.; Sept. 25, amp. arm. Died October 9, 1864, exhaustion.	82	Dwillely, S. L., Pt., D, 17th Maine.	July 3, '63.	Left; diarrhoea. Died August 29, 1863.
39	Henry, A., Pt., I, 142d New York, age 31.	Aug. 25, '64.	Left; flap; by Surg. J. D. Osborne. Died July 12, '64, typ. pneum.	83	Graham, J. C., Pt., F, 4th Texas, age 30.	July 3, '63.	Right. Died December 27, 1863.
40	Hoffman, W. H., Pt., C, 110th Ohio, age 26.	May 6, '64.	Right; circular. Died May 26, 1864.	84	Hall, A. J., Pt., I, 27th Illinois.	Nov. 25, '63.	Died May 27, 1864.
41	Hopbill, G., Pt., B, 3d Maryland, age 27.	May 12, '64.	Left; circ.; had pericarditis. Died May 24, '63, nervous prostration.	85	Hatcher, T., Pt., G, 19th Ohio.	May 27, '64.	Right. Died August 7, 1863.
42	Jowers, C. P., Pt., H, 8th Florida, age 22.	May 3, '63.	Right; also contusion of thorax and foot. Died June 21, 1864.	86	Hutchinson, A., Pt., I, 110th Pennsylvania.	June 3, '63.	Right. Died May 18, 1864.
43	Katz, H., Pt., C, 2d Pennsylvania.	June 17, '64.	Right. Died July 6, '64, tetanus.	87	Jacobs, E., Pt., 4th Ohio Battery.	May 14, '64.	Left; gangrene. Died August 19, 1863.
44	Marlone, J. B., Pt., C, 13th Indiana, age 43.	June 24, '64.	Left; circular; by A. Surg. J. T. Dunfield, 7th Indiana; April 12, amp. arm. Died April 18, 1865, pyæmia. Spec. 64.	88	Johnson, C. A., Corp'l, E, 19th Mass., age 18.	July 2, 1863.	Left. Died July 26, 1863.
45	Neill, J., Pt., D, 16th Miss., age 38. See CASE 1926.	Aug. 21, '64.	Left; by Surg. M. Tucker. Died Oct. 31, 1864, see hemorrhage.	89	Lansdon, R., Pt., F, 72d Illinois.	May 22, '64.	Left. Died July 8, 1864, dysentery.
46	Nott, R., Pt., G, 42d C. T., age 20.	Oct. 27, '64.	Left; by Surg. S. H. Kersey, 36th Ind. Died Aug. 22, '64, pyæmia. Died June 3, 1864.	90	Lense, J. W., Pt., D, 4th Vermont, age 28.	June 24, '64.	Left (pen. w'd abd.); by St. J. W. Muntzer. Died April 18, 1862.
47	Podige, S. W., Pt., G, 38th Illinois, age 27.	July 23, '64.	Right; by Surg. J. W. Lawton, U. S. V. Died Sept. 23, 1864.	91	Luther, J., Pt., G, 2d Rhode Island.	April 17, '62.	Right. Died September, 1864.
48	Scott, E., Pt., F, 111th New York, age 18.	May 10, '64.	Right, middle; left, lower; by A. Surg. C. H. Andrus, 128th New York. Died May, 1864.	92	Lynne, J., Pt., F, 2d Cavalry.	Sept. 1, '61.	Left. Died October 19, 1862, pyæmia.
49	Walker, R. J., Pt., 22d Ind. Bat., age 34.	July 20, '64.	Left. Died April 13, 1865.	93	Redlow, G. M., Pt., B, 4th Maine, age 18.	Sept. 1, '62.	Left. Died December 27, 1863.
50	Wallace, R., Pt., F, 33d Missouri.	May 18, '64.	Left. Died June 3, 1864, pyæmia. Spec. 3511.	94	Sumner, E., Corp'l, E, 27th Illinois.	Nov. 25, '63.	Right. Died September 19, 1864, typhoid fever.
51	Wyekoff, J. J., Pt., G, 15th New Jersey.	April 2, '65.		95	Trayer, D. K., Pt., D, 4th Artillery.	Aug. 25, '64.	Left (wounds of head and leg). Died June 9, 1864.
52	Allen, G. W., Pt., C, 32d Mass., age 25.	May 12, '64.		96	Troll, S. H., Pt., B, 6th Indiana.	May 11, '64.	Left (wounds of leg and neck). Died May 23, 1864.
				97	Woodcock, G., Pt., C, 53d Pa., age 19.	May 12, '64.	



Some series of facts supplied in the two foregoing tables on primary amputations in the forearm for shot injury are consolidated in the foot-note.<sup>1</sup> The injuries in less than a fourth of the cases were from large projectiles or explosions, causing great disorganization.<sup>2</sup>

**Intermediary Amputations in the Forearm for Shot Injury.**—Of four hundred and fifty operations practised in the interval from the third to the thirtieth day after injury, the results having been ascertained in all instances, a hundred and six, or 23.5 per cent., proved fatal,—an excessive increase over the mortality of the primary amputations.

§ *Recoveries after Intermediary Amputations in the Forearm.*—A single detailed observation may precede the tabular statement:

CASE 1927.—Private J. Sapp, Co. I, 17th Kentucky, aged 22 years, was wounded in the left forearm, while on picket near Brentwood, April 22, 1863. Assistant Surgeon C. C. Gray, U. S. A., contributed the specimen (FIG. 713), and reported the following history: "The ball entered the radial border one and three-fourths inches from the carpus, passed obliquely downward, bisecting the axis of both bones, and escaped a half inch above the carpus. The integuments in the vicinity of the wound were severely burned. (It was supposed that the wound was caused by the accidental discharge of the patient's own weapon, no other explanation appearing for the burn. The man, however, denied this.) He was admitted to Hospital No. 8, Nashville, April 23d, thirty hours after the injury, the arm being in splints, greatly swollen, hot and painful; the fracture badly comminuted, wound gaping, and soft parts everted. Removed the splints and applied cold-water dressings; patient kept in bed with the arm on a pillow. Prescribed one ounce of sulphate of magnesia at once. April 24th, slept well; no pain. Removed two fragments of radius and dressed wound with mixture of Labarraque's solution half an ounce, and camphor-water one pint, applied warm; ordered low diet. 25th, wound sloughy and gangrenous; discharge watery, sanious, and very fetid; pulse 120 and feeble. Isolated the case, and ordered a prescription of sulphate of quinine one drachm, aromatic sulphuric acid sufficient quantity, and simple syrup and water three ounces each, to be given in doses of half an ounce three times a day. Dressed the wound every two hours with compound solution of bromine and injected it; application caused no pain. Gave full diet. 23th, sloughs removed; treatment continued. Takes egg-nog one-half ounce every two hours. 27th, diluted the bromine solution one-half. Tongue moist; appetite good. 28th, separated sloughs; surface granulating. Discontinued bromine, which now causes great pain, and prescribed a mixture of Labarraque's solution one ounce, and camphor-water one pint. 29th, discharge healthy. General condition good. May 12th, granulations profuse; discharge of pus copious. Examination revealing no union and much detached bone, amputated the forearm at middle by double flap. Stump left open for the present and constantly injected. Low diet given, and forty drops of laudanum at night. 13th, reaction decided; pulse 130. Prescribed liquor ammonii acetatis three ounces, and tincture aconite eighteen minims, in doses of



FIG. 713.—Shot comminution of left wrist. Spec. 1913.

half an ounce every three hours. 14th, improving; water dressings applied. From this day recovery was rapid. \* \* The amputation was made higher than it otherwise would have been, had it not been for the injury suffered by the soft parts in the immediate vicinity of the wound by the burn." The specimen, represented in the wood-cut (FIG. 713), consists of the lower halves of the bones of the forearm, being comminuted two inches above the wrist, with a longitudinal fracture extending down the radius into the joint. The patient was subsequently discharged from Hospital No. 13, August 24, 1863, and pensioned. He died July 22, 1872. The immediate cause of death is not known.

<sup>1</sup>The cases of recovery after primary amputation in the forearm are arranged alphabetically in the three subdivisions, commencing with the amputations in the upper third of the forearm, which numbered 270 cases. The operations in the middle third begin in the second column on page 971, and include 356 cases. The amputations in the lower third commence with No. 627, on page 975, and include 266 operations; 18 cases, in which the point of ablation is not specified, are enumerated on page 978, and complete the series of 910 operations. These amputations were practised on 903 patients,—844 Union and 59 Confederate soldiers. 417 operations were on the right forearm, 475 on the left; in 18 this point was unspecified. There were 385 flap operations, 317 circular, and 208 undescribed amputations. 81 patients had wounds of more or less gravity in other regions of the body.—The 97 fatal primary amputations were practised on 98 patients, Pt. Wallace losing both forearms; 26 of the operations were in the upper, 25 in the middle, 28 in the lower third, and in 18 the point of ablation was unspecified; 43 amputations were on the right, 47 on the left side, and 7 unspecified. In 38 cases in which the method of operating was mentioned, circular incisions were employed in 21. 88 of the patients, including the one who underwent double amputation, were Union, and 8 Confederate soldiers. The approximate causes of death were imperfectly recorded. In 51 cases in which some indication was given, the fatal result is ascribed to tetanus in 3 instances, to shock in 2, to secondary hæmorrhage in 2, to gangrene in 4, to pyæmia in 15, to pneumonia or pulmonary complications in 5, to exhaustion, irritative fever, typhoidal condition in 12, to phthisis in 2, variola in 1, cardiac diseases in 1, to dysentery in 4. Very few autopsies were narrated, and but few specimens were forwarded to the Museum. Besides Spec. 61, figured on page 978, Spec. 3071 (*Cat. Surg. Sect.*, 1866, p. 192) was furnished by CASE 35 of the TABLE; and Spec. 3541 (*ibid.*) by CASE 52; all three specimens are good examples of curious stumps of amputated bones of the forearm. Three succumbed after re-amputation,—two secondary, in the upper arm (CASES 39 and 45 of TABLE CXXXIV, which appear also as CASES 16 and 26 of TABLE LXXXVII, p. 788), and one, CASE 65, re-amputated higher up in the forearm. 18 of the patients suffered from serious though not mortal wounds in other regions of the body; one of these, CASE 6, underwent amputation of the opposite arm (compare TABLE LXXXIII, No. 15, p. 747); another, CASE 25, simultaneous amputation in the upper third of the right arm. In CASE 16 the right leg was synchronously amputated. In another instance the thumb and first metacarpal of the opposite limb were removed at the same time with the forearm amputation.

<sup>2</sup>Besides the 199 cases mentioned at page 967, of injuries from large projectiles or from premature explosions of cannon, were 22 cases of dreadful laceration from explosions of ammunition caissons, bursting of cannon, wounds from large splinters, etc. The 221 cases are distributed as follows: From shells or shell fragments, 120 recoveries and 11 fatal cases; in artillery soldiers, from premature explosion of the gun, 51 recoveries and 5 fatal cases; from solid shot or large projectiles, 26 recoveries and 1 fatal case; from torpedoes, caisson explosions, etc., 7 recoveries.

TABLE CXXXV.

Condensed Summary of Three Hundred and Forty-four Successful Intermediary Amputations in the Forearm for Shot Injury.

No.	NAME, AGE, AND MILITARY DESCRIPTION.	DATES.	OPERATIONS, OPERATOR, RESULT.	No.	NAME, AGE, AND MILITARY DESCRIPTION.	DATES.	OPERATIONS, OPERATOR, RESULT.
1	Bergin, W. S., Pt., A, 121st Ohio, age 16.	June 2, 19, '64.	Right; flap: by A. Surg. C. C. Byrne, U. S. A.; hamor; ligat. artery. Pens'd Oct. 25, 1864.	37	Harrison, J. C., Pt., B, 52d Ohio, age 29.	May 11, 26, '64.	Right; circular; by A. Surg. J. A. Freeman, U. S. V. (hamor.) gang. Disch'd Aug. 31, 1865; pens'd.
2	Bertram, C., Corp'l, F, 6th Wisconsin.	Sept. 17, Oct. 8, 1862.	Left; by Surgs. B. A. Vanderkief, U. S. V., and W. B. Chambers, 60th N. Y. Pen. d. Jan. 12, '63.	38	Harvey, F. A., Serg't, B, 150th Pa., age 31.	June 18, Jul. 4, '64.	Right; circ: by A. A. Surg. G. Badger. Pens'd Sept. 25, 1864.
3	Bevine, H. F., Pt., C, 45th Tennessee, age 24.	Aug. 31, Se. 14, '61.	Right; circular. Stump entirely healed. To Prov. Mar. Dec. 8, '61.	39	Henry, W., Pt., A, 88th New York, age 31.	May 31, June 17, 1864.	Left; skin flap, circ. sec. muscles; by A. Surg. W. Webster, U. S. A. (May 31, '64, exc. rad. and ulnar gangrion). Pens'd July 27, '65.
4	Bramlette, L., Pt., H, Ia. 15, '63.	Dec. 31, '62.	Left; circ. (erysipelas); bad sores: ulceration. Disch'd May 21, '63.	40	Hinekman, W., Corp'l, B, 5th N. Y., age 25.	Aug. 19, Sept. 14, 1864.	Left; ant. post. flap: by A. Surg. J. C. McKee (sec. ham., lig. brachial). Pens'd Mar. 11, 1865.
5	Briggs, J. S., Pt., D, 27th Illinois.	Jan. 14, Feb. 8, '63.	Left; flap: by Surg. A. C. Rankin, 88th Ill. Pens'd March 15, 1864.	41	James, H., Pt., A, 77th New York.	May 2, 29, '63.	Left; flap. Disch'd May 3, 1864; pensioned; stump very tender.
6	Butz, G. W., Pt., K, 2d Pennsylvania Cavalry, age 26.	Nov. 29, Dec. 11, 1863.	Left; circular (Nov. 29, amp. part of hand); by A. A. Surg. J. Cass. Pens'd April 25, '64. Spec. 1905.	42	Jeffries, J., Pt., K, 10th New York Volunteers.	Aug. 29, Sep. 1, '62.	Left; flap: by Dr. O'Hara. Discharged June 22, 1863; pens'd.
7	Caupbell, A., Pt., D, 95th Pa., age 20.	May 3, 20, '63.	Right; by A. A. Surg. W. H. Ensign. Discharged August 10, 1864; pensioned. Spec. 1138.	43	Jones, T., Pt., K, 17th Indiana, age 33.	April 2, 7, '65.	Left; flap: by Surg. J. B. Larkin, 17th Ind. Pens'd May 31, 1865.
8	Carll, H., Pt., C, 5th Michigan, age 19.	May 25, Fe 1, '64.	Left; ant. post. flap: by A. Surg. A. Delamy. Pens'd Nov. 10, '64.	44	Justin, F., Pt., H, 31st Maine.	June 3, 1864.	Left; flap (primary excision). Discharged January 5, 1865.
9	Carver, R. E., Pt., C, 179th Ohio, age 18.	Oct. 19, No. 10, '64.	Right; circ. (pyemic); by Surg. J. R. Ludlow, U. S. V. Pens'd.	45	Knapp, M. E., Pt., K, 20th Iowa.	Dec. 7, 15, '62.	Left. Disch'd Feb. 28, '63; pensioned; stump not very good.
10	Champion, R. D., Pt., C, 157th New York.	Dec. 9, 27, '64.	Right; circ. (edematous); by A. A. Surg. E. L. Mohr. Pen. May 9, '65.	46	Low, T., Pt., H, 20th Massachusetts.	Oct. 21, 25, '61.	Right; by Surg. N. Hayward, 20th Mass. Disch'd March 5, 1862.
11	Collins, J., Pt., F, 7th N. Y. H. A., age 29.	May 24, June 4, 1864.	Left (amp. fingers); gangrene; by Surg. D. P. Smith, U. S. V. Disch'd Oct. 11, '64. Spec. 3301.	47	Linnart, J. M., Pt., H, 7th West Virginia.	Sept. 17, 27, '62.	Left. Disch'd Dec. 13, '62; pensioned; stump entirely healed.
12	Conklin, J. M., Pt., K, 11th Iowa, age 39.	July 22, Aug. 11, '64.	Right; by Surg. G. L. Lucas, 47th Ill. Pens'd Jan. 23, 1865.	48	Maxey, L., Pt., F, 2d Kentucky.	Sept. 29, 28, '63.	Left; flap: by Surg. F. Seymour, U. S. V. Pens'd April 6, 1864.
13	Cranshaw, S., Pt., C, 86th N. Y., age 45.	May 31, June 18, 1864.	Left; circ. (prim'y excis.); gang.; hamor.; by A. Surg. W. Webster, U. S. A. Disch'd Sept. 13, '65.	49	McCauley, J., Serg't, A, 1st W. Va., age 22.	June 9, 12, '62.	Left; flap: by A. Surg. S. B. Ward, U. S. V. Pens'd June 8, 1865.
14	Crosby, J., Pt., I, 2d Vermont, age 21.	May 19, June 15, 1864.	Left; ant. post. flap (gang. bone diseas'd); by A. Surg. W. Webster, U. S. A. Disch'd Dec. 29, 1864; pensioned. Spec. 4434.	50	McClure, G., Pt., A, 43d C. T., age 17.	June 9, 22, '64.	Left; flap: by A. Surg. J. M. Ward, U. S. V. Disch'd Oct. 1, 1862; stump healed.
15	Denzer, J., Pt., C, 61st Pennsylvania, age 21.	Sept. 19, Oct. 6, '64.	Left; circ: by A. A. Surg. W. P. Moon. Pens'd March 21, 1865.	51	McCue, M., Pt., F, 18th Infantry.	April 6, 12, '62.	Left; double flap. Disch'd July 10, 1864; pensioned.
16	Dougher, J., Pt., I, 7th Pa. Cav., age 26.	April 2, 8, '65.	Right; circ. May 25, stump nearly healed. Disch'd July 9, 1865.	52	McDonald, H., Pt., C, 119th N. V., age 18.	May 2, 9, '63.	Left; flap. Discharged April 14, 1865; stump healed.
17	Dow, A., Pt., A, 1st New Hampshire Cavalry, age 19.	June 29, July 21, 1864.	Right; circ. (soft parts unhealthy); by A. A. Surg. W. C. Fryor. Discharged March 18, 1865.	53	McKeegan, A. M., Pt., D, 6th Maine, age 27.	May 3, 7, '63.	Right; circ; by A. A. Surg. J. M. McGrath, Oct. 18, lig. rad.; Dec. 6, exc. l. rem. Pen'd Aug. 21, '66.
18	Dukes, G., Pt., B, 97th Pennsylvania.	Aug. 4, 29, '64.	Left; circ: by A. Surg. C. Wagner. Sept. 20, 1864, amp. arm. Pens'd Jan. 20, '65; stump healed. Died Mar. 14, '67, ham. of lungs.	54	McMullin, S., Serg't, A, 14th Pa. Cavalry, age 43.	Sept. 18, Oct. 5, 1864.	Left; by Dr. S. B. Gleaviss. Discharged; pens'd; bad stump.
19	Elliott, J., Serg't, B, 100th Pennsylvania.	Aug. 30, Se. 20, '62.	Left; flap. Discharged Dec. 11, 1862; pens'd; perfectly healed.	55	Merriam, W. F., Pt., E, 7th Ohio.	Aug. 29, Sep. 5, '61.	Left; circ: by Surg. S. B. Boyd, 84th Ind. Pens'd April 3, 1865.
20	Faulkner, T. C., Pt., H, 70th New York.	Aug. 30, Sept. 25, 1862.	Left; flap; flesh w'd abd.; bone carious; by A. A. Surg. J. Ashurst. Disch'd Jan. 21, 1863; pensioned. Spec. 264.	56	Metzger, A., Pt., G, 55th Ohio, age 19.	July 29, Aug. 18, '64.	Right; circ; by A. Surg. A. Delamy, U. S. V. Discharged April 9, 1865; pens'd. Spec. 2806.
21	Felner, J., Pt., I, 57th Illinois, age 30.	April 6, 9, '62.	Left. Discharged July 5, 1862; pensioned.	57	Miller, H. H., Pt., E, 11th Pennsylvania Reserves, age 21.	May 26, June 6, 1864.	Right; circ: by A. Surg. A. Delamy, U. S. V. Discharged April 9, 1865; pens'd.
22	Finley, J. P., Serg't, D, 4th Iowa, age 34.	Mar. 7, 28, '62.	Right; flap. Stump healed. Discharged Aug. 20, 1864; pens'd.	58	Moore, W. M., Serg't, H, 105th Illinois.	Feb. 2, 16, '65.	Right; flap (excision; sec. ham.). Disch'd May 5, 1865; pensioned.
23	Fitch, B., Pt., I, 20th New York S. M.	July 1, 8, '63.	Left; flap: by Surg. R. Longbram, 26th N. Y. S. M. Pens'd Nov. 30, '64; elbow joint ankylosed.	59	Muller, F., Pt., C, 48th New York, age 33.	June 1, 17, '64.	Right; circular. Disch'd; pens'd; healthy stump.
24	Flanders, R. W., Pt., I, 186th N. Y., age 22.	Dec. 5, 14, '64.	Left; flap: by Surg. T. R. Crosby, U. S. V. Disch'd July 19, 1865.	60	Nash, J., Pt., C, 8th Maine.	Sept. 29, Oct. 29, '64.	Left; by Surg. H. B. Fowler, 12th N. H. Dis'd Mar. 30, '65; pens'd.
25	Foley, T., Pt., G, 31st New York, age 25.	June 26, Jul. 11, '63.	Right; doub. flap: by A. A. Surg. J. R. Uldor. Pens'd Aug. 22, '62.	61	Nevins, H. M., Serg't, E, 25th New York Cavalry, age 23.	July 12, Aug. 2, 1861.	Left; circ: by A. A. Surg. P. C. Porter. Disch'd May 18, 1865; pensioned. Spec. 2921.
26	Frazier, E. C., Pt., K, 55th N. C., age 33.	July 1, 28, '63.	Left; circ: by A. Surg. B. Stone, U. S. V.; ham. Exch'd Mar. 3, '64.	62	Nieely, Z., Serg't, D, 9th Virginia, age 43.	May 9, 16, '64.	Left; lateral flap; by Surg. N. F. Graham. Pens'd Dec. 26, 1864.
27	Fuller, D., Pt., G, 53d Pennsylvania.	Sept. 17, Oct. 5, '62.	Left. Sept. 17, amputation right should. joint. Pens'd Dec. 17, '62.	63	Nickels, G. W., Pt., B, 64th Ohio, age 20.	Sept. 20, Oct. 11, '63.	Right; circ. (Sept. 20, amp. finger; erysip.; gan.). Pen'd Nov. 21, '64.
28	Funke, C., Pt., B, 49th New York, age 24.	Sept. 22, Oct. 13, 1864.	Right; ant. post. flap: by A. A. Surg. W. P. Moon (prim'y exc.). Disch'd July 4, 1865; pens'd.	64	O'Neill, T., Pt., D, 2d Artillery.	July 21, 27, '61.	Right; circ: by Dr. St. G. Peachy, Cont'd. Discharged; pensioned. Died Nov. 26, 1870, phthisis.
29	Gaffney, T. A., Pt., I, 2d New York.	Aug. 28, 31, '62.	Right. Healthy stump. Disch'd December 10, 1862; pensioned.	65	Park, C. F., Pt., E, 14th Virginia, age 26.	July 2, 22, '61.	Right; slight w'd hip and should. To Provost Mar. Sept. 1, 1863.
30	Givins, W. B., Pt., F, 60th Indiana, age 22.	April 8, 11, '64.	Right. Discharged June 16, 1864.	66	Pitts, H., Pt., F, 138th Indiana.	Aug. 20, Sept., '64.	Right; by A. A. Surg. A. Rolls. Discharged; pensioned.
31	Goodnow, C. B., Pt., I, 2d Missouri, age 18.	Jan. 11, 21, '63.	Left; wound of right elbow joint. Disch'd April 14, 1863; pens'd.	67	Priece, W., Pt., E, 16th Wisconsin, age 17.	Aug. 17, Se. 15, '64.	Left. Disch'd March 17, 1865; pensioned; good stump.
32	Gorman, J., Serg't, E, 2d Pennsylvania Heavy Artillery, age 37.	June 24, July 12, 1864.	Left; antero-posterior skin flap; by A. A. Surg. J. M. Boisont. Discharged December 13, 1864.	68	Randall, J. M., Pt., G, 20th Kentucky, age 24.	June 16, 30, '64.	Right; ant. post. flap: by A. A. Surg. A. D. White (prim'y exc. ulnar). Dis'd July 22, '65; pens'd.
33	Handly, J. E., Pt., D, 7th Alabama, age 23.	July 2, 16, '63.	Right; circular. To Provost Marshal September 17, 1863.	69	Repp, J., Pt., B, 2d Pa. H. A., age 31.	Sept. 29, Oct. 4, 1864.	Left; flap: by Surg. Gibbs, C. S. A. (wound right forearm). Duty February 5, 1866; pensioned.
34	Hanover, U. A., Corp'l, B, 10th Ct., age 39.	April 2, 17, '65.	Left; circ: by A. A. Surg. J. Monypenny. Disch'd July 15, '65.	70	Riley, J. W., Pt., 8th Co. 1st N. Y. Sharpshooters, age 29.	May 5, 25, '64.	Left; lateral skin flap; by A. A. Surg. C. B. McQueston. Disch'd October 17, 1864; pensioned.
35	Harris, D., Pt., A, 2d Maryland, age 31.	June 17, Jul. 1, '64.	Left; circ: by A. A. Surg. F. Livermore. Pens'd Sept. 30, 1864.	71	Rohrbough, W. J., Pt., E, 3d West Virginia.	Aug. 29, Sep. 7, '62.	Right; flap: by A. Surg. C. A. McCall. Pens'd March 27, '63.
36	Harris, M., Pt., G, 12th New York Cavalry, age 19.	April 17, May 3, 1864.	Left; circ: by Surg. C. A. Cowgill (April 25, amputation of finger of right hand). Discharged.	72	Ruscher, J., Corp'l, H, 46th Pa., age 20.	May 2, 10, '63.	Left (severe wind back and foot; hamor.). Disch'd Aug. 28, '63.



No.	NAME, AGE, AND MILITARY DESCRIPTION.	DATES.	OPERATIONS, OPERATOR, RESULT.	No.	NAME, AGE, AND MILITARY DESCRIPTION.	DATES.	OPERATIONS, OPERATOR, RESULT.
76	Smith, G., Pt., I, 43d New York, age 41.	May 6, 15, '64.	Left; circ.; by A. Surg. H. Allen. U. S. A. Pens'd Sept. 29, 1864.	118	Cole, L., Pt., A, 126th New York, age 21.	May 6, 24, '64.	Left; circ.; by A. A. Surg. R. Ottman. Disch'd Feb. 17, '65; pens'd.
77	Smith, G. W., Pt., II, 13th Massachusetts.	July 1, 4, '63.	Left; flap; by A. A. Surg. W. C. Wey. Disch'd Oct. 16, '63; pens'd.	119	Cooper, C. P., Pt., B, 13th Ohio Cavalry, age 21.	Mar. 31, April 19, 1865.	Right; circular (crystip.); by A. A. Surg. H. Craft. Disch'd July 20, 1865; pens'd. Spec. 188.
78	Smith, W. S., Corp'l, B, 12th Connecticut.	May 27, Sept. 19, '63.	Left; flap; by A. A. Surg. J. G. Riedly (fragments removed). Disch'd Sept. 4, '63; pens'd; unhealthy stump.	120	Corey, D. R., Pt., F, 13th Michigan.	Dec. 31, '62, Jan. 28, '63.	Right; flap; by Surg. S. R. Pratt, 8th Ind. Pens'd Mar. 7, 1863.
79	Sheehan, D., Pt., G, 139th N. Y., age 32.	Sept. 19, Oct. 14, '64.	Left; ant.-post. flap; by A. A. Surg. W. P. Moon. Disch'd Jan. 17, '65.	121	Crubb, T. W., Serg't, A, 61st Ohio, age 23.	July 20, 23, '64.	Left; flap (flesh wound of thigh); by Surg. E. Hutchinson; gang. Disch'd Feb. 10, 1865; pens'd.
80	Spade, J. C., Pt., II, 147th Pa., age 18.	June 22, July 5, 1864.	Left; flap; by A. A. Surg. J. G. Riedly (fragments removed). Disch'd Nov. 23, 1864; pens'd.	122	Crooken, J., Pt., A, 28th Massachusetts.	Sept. 1, 22, '62.	Left; circ.; by Surg. A. B. Mott, U. S. V. Pens'd Feb. 12, 1863.
81	Stewart, T., Pt., I, 80th Ohio.	May 14, July 5, '63.	Left; flap. Disch'd Jan. 22, '64; pens'd; stump perfectly healed.	123	Croissant, D. J., Pt., I, 61st New York, age 18.	Mar. 25, April 7, 1865.	Left; flap (Apr. 1, exco. metacarp.); by Surg. N. R. Mosley, U. S. V. Disch'd June 8, 1865; pens'd.
82	Stinemeyer, G., Pt., II, 118th Pa., age 44.	Sept. 20, 23, '62.	Right; flap. Discharged Mar. 4, 1864; pens'd; sound stump.	124	Davis, J., Pt., A, 57th Massachusetts, age 21.	May 6, 12, '64.	Right; flap; by Surg. W. V. White, 55th Mass. Pens'd May 16, '65.
83	Sullivan, J., Pt., K, 23d Illinois, age 31.	Sept. 19, Oct. 14, 1864.	Left; lateral oval and skin flaps; circ. sec. of muscle; by A. A. Surg. E. G. Waters. Pens'd Jan. 31, '65.	125	Dirreault, J. E., Pt., B, 18th Georgia, age 20.	April 6, 24, '65.	Right; flap; by A. A. Surg. J. P. Anthur. Released Sept. 13, '65.
84	Surby, B. F., Pt., A, 2d Wisconsin.	Dec. 13, 29, '63.	Left; by Surg. P. Pincus, U. S. V. Pens'd Mar. 21, '63. Spec. 711.	126	Dobbs, I. L., Serg't, I, 48th Illinois, age 18.	May 29, June 27, '64.	Left; circ.; A. Surg. W. B. Trull, U. S. V. Pens'd Sept. 19, 1864.
85	Twitchell, C. H., Pt., F, 17th Me., age 29.	July 2, 18, '63.	Right; flap; gangrene. Disch'd Mar. 7, 1864; pens'd. Spec. 1297.	127	Edwards, E., Pt., E, 54th Pennsylvania, age 31.	June 17, Jul. 6, '64.	Left; flap; by Surg. L. R. Stone, U. S. V. Disch'd Sept. 23, '64.
86	Van Deursen, J., Pt., C, 9th New York.	Sept. 17, 25, '62.	Right; by Surg. W. Clendenin, U. S. V.; necro. Pen'd Nov. 28, '62.	128	Egan, T., Pt., E, 88th New York, age 30.	Sept. 19, Oct. 6, 1862.	Right; lat. flap; by A. A. Surg. J. H. Bartholf. Disch'd Dec. 10, 1862; pensioned. Spec. 805.
87	Whitson, J. D., Corp'l, II, 27th Illinois, age 26.	Sept. 19, 29, '63.	Left; flap (gang.); by Surg. F. Seymour, U. S. V. Discharged July 14, 1864; pensioned.	129	Elliott, G. H., Pt., C, 9th Mass., age 23.	May 8, 15, '64.	Right; ant.-post. flap (May 8, exco. metacarp. 14th. sec. hem.); by Surg. A. F. Sheldon, U. S. V. Disch'd July 25, 1864; pens'd.
88	Williams, D., Pt., F, 17th Vermont, age 21.	July 1, 15, '64.	Left; circ. (amp. metacarp.); by A. A. Surg. H. B. Mabin. Rec'd. Died Jan. 27, 1865, small-pox.	130	Fadden, T., Pt., E, 18th Illinois.	April 6, 13, '62.	Left; flap. Discharged August 13, 1862; pensioned.
89	Williamson, W., Pt., F, 71st New York, age 24.	June 25, Jul. 24, '62.	Left; circular; by A. A. Surg. W. W. Keen, jr. Disch'd. Spec. 28.	131	Flansburgh, P., Pt., E, 43d New York, age 20.	May 5, 20, '64.	Left; circ.; by A. A. Surg. C. A. Lindsay. Disch'd June 1, 1865.
90	Wixon, A., Pt., G, 4th N. Y. H. A., age 46.	June 18, 22, '64.	Right; circ.; by Surg. W. Watson, U. S. V. Pens'd Oct. 7, '64.	132	Fogel, J. D., Pt., D, 46th Illinois, age 18.	July 7, 27, '64.	Left; circular; by A. Surg. B. H. Bradshaw. Disch'd Oct. 4, 1864.
91	Woodcock, H. B., Pt., C, 140th N. Y., age 24.	May 5, 17, '64.	Right; flap (May 7th. exco. 17th. hem.). by Surg. E. Donnelly. 2d Pa. Res. Disch'd Oct. 12, '65.	133	Fraker, J. W., Pt., F, 77th Pa., age 20.	July 4, Aug. 2, '64.	Right; flap; by Surg. H. P. Stearns, U. S. V. Dis'd Feb. 14, '65; pens'd.
92	Worrall, S., Pt., F, 39th New York, age 23.	May 31, June 10, '64.	Left; flap (hem.); by A. A. Surg. O. C. Turner. Disch'd June 5, '65.	134	Galen, W., Pt., A, 75th New York, age 22.	July 30, Aug. 4, '64.	Left; circ.; by A. A. Surg. F. W. Kelly. Dis'd Sept. 23, '64; pens'd.
93	Wright, L., Pt., II, 10th Maine.	Aug. 9, 13, '62.	Right; Disch'd Jan. 16, 1863; pensioned; stump good.	135	Gates, D. C., Pt., G, 1st Ohio.	June 17, Jul. 3, '61.	Right; circular. Disch'd July 30, 1861; pensioned.
94	Young, J., Corp'l, II, 30th Colored Troops.	July 30, Aug. 12, 1864.	Right; flap; by Surg. E. Bentley, U. S. V. Disch'd Jan. 12, 1865.	136	Geiger, T. H., Pt., B, 53d Pennsylvania.	Jan. 13, '63.	Right; flap; by A. A. Surg. C. H. Bowen. Dis'd Mar. 11, '63; pen'd.
95	Young, J. J. H., Corp'l, K, 116th Illinois.	Dec. 28, '62, Jan. 5, '63.	Left; by Surg. C. T. Alexander, U. S. A. Pens'd April 12, 1863.	137	Gessner, H., Pt., E, 63d New York, age 37.	June 1, Jul. 1, '64.	Left; flap; by A. A. Surg. H. D. Vesburg. Pens'd July 28, 1865.
96	Zehring, A., Corp'l, A, 73d Ohio.	Aug. 29, Sept. 12, '62.	Left; by A. A. Surg. B. Hodges. Disch'd Oct. 27, 1862; pens'd.	138	Gilbert, O. J., Pt., E, 19th Indiana.	Dec. 13, '62, Jan. 3, '63.	Left; circular. Discharged February 23, 1863.
97	Zimmerman, L., Pt., A, 50th Pa., age 21.	May 9, 29, '64.	Left; circ.; by A. A. Surg. B. Miles. Disch'd Jan. 13, 1865; pensioned.	139	Gilroy, S., Pt., I, 105th New York, age 25.	Mar. 31, April 24, 1865.	Right; circular (amp. finger); by A. A. Surg. W. E. Roberts. Disch'd Aug. 21, '65; pensioned.
98	Aley, J., Serg't, K, 91st New York.	June 28, Jul. 12, '63.	Left. Discharged Sept. 12, 1863; pensioned; stump healed.	140	Goodman, L. W., Pt., E, 2d Ohio Cav., age 22.	May 31, June 16, '64.	Right; flap (gangrene). Disch'd Dec. 22, '64; pen'd; sound stump.
99	Arnold, S., Pt., K, 205th Pennsylvania, age 26.	April 2, 10, '65.	Right; flap; by A. Surg. W. P. Moon. Pensioned July 20, 1865.	141	Goodrich, W. C., Pt., C, 14th Connecticut.	Sept. 17, 30, '62.	Left; by A. A. Surg. P. Middleton. Pens'd Nov. 21, 1862. Spec. 98.
100	Averill, C. W., Pt., F, 6th Maine.	June 11, 28, '62.	Left; flap; by Dr. R. M. Hodges, Boston. Pens'd Aug. 20, 1862.	142	Gorman, J., Pt., B, 35th Indiana, age 40.	June 20, 26, '64.	Left; circular; by A. Surg. J. M. Brown, U. S. A.; gangrene. Discharged April 12, 1865.
101	Bailey, T. S., Corp'l, A, 3d Iowa.	July 12, 24, '63.	Right; circ.; by Surg. B. F. Keables, 3d Iowa. Pens'd Oct. 6, '63.	143	Goychea, N., Pt., I, 8th Michigan, age 27.	June 16, Jul. 5, '64.	Left; ant.-post. flap; by Surg. R. B. Bontecou. Pens'd Aug. 20, '64.
102	Bennett, A., Pt., I, 2d Connecticut Heavy Artillery, age 22.	June 3, 10, '64.	Left; ant.-post. flap; by Surg. E. Bentley, U. S. V.; gang. Disch'd Nov. 19, '64; pens'd. Spec. 2549.	144	Graff, H., Pt., L, 5th Iowa Cavalry.	July 18, 23, '64.	Left; by a Confederate surgeon. Good stump. Disch'd; pens'd.
103	Bradshaw, A., Serg't, B, 4th Tenn., age 23.	Dec. 16, 26, '64.	Left; ant.-post. flap; A. A. Surg. E. Woodruff. Pro. Mar. Feb. 8, '65.	145	Green, W. G., Pt., 8th N. Y. H. A., age 19.	July 22, Aug. 2, 1864.	Left; circular; by A. A. Surg. E. A. Kemp. To V. R. C. February 3, 1865; pensioned.
104	Brayton, S., Pt., II, 45th Illinois.	June 26, Jul. 1, '63.	Right; circular. Disch'd Nov. 21, 1863; stump perfectly healed.	146	Griffin, W. H., Pt., E, 27th Illinois, age 26.	June 27, Jul. 27, '64.	Left; circ. (gang.); by A. A. Surg. S. Ayres. Disch'd Feb. 24, '65.
105	Breman, F. H., Serg't, B, 185th N. Y., age 30.	Mar. 29, Apr. 1, '65.	Right; circ. (May 29, amp. wrist jt.; gang.). Pens'd June 27, '65.	147	Guehning, J., Pt., K, 61st Pennsylvania.	June 1, 23, '62.	Left; flap. Discharged Dec. 8, 1862; stump healed.
106	Brooks, J. W., Pt., A, 1st New Hampshire Cavalry, age 26.	June 20, July 14, 1864.	Left; flap (gangrene; necrosis; diarrhoea); by A. A. Surg. S. Howe. Pens'd March 30, 1865.	148	Guirand, P., Pt., C, 8th Connecticut.	April 16, 29, '65.	Right. Discharged; pensioned.
107	Brown, J., Pt., C, 8th Ohio, age 28.	June 18, Jul. 1, '64.	Left; flap; by A. A. Surg. A. Ansell. Pens'd Aug. 22, '65. Spec. 3202.	149	Hall, W., Pt., D, 3d New York.	June 20, '61.	Right; circular. Disch'd August 16, 1861; pens'd; stump healed.
108	Brunley, W., Pt., K, 6th Missouri Cavalry.	May 20, June 4, '63.	Right; circular. Discharged September 21, 1863; healed.	150	Halley, J. A., Corp'l, B, 22d Kentucky.	May 22, June 10, 1863.	Left; flap (amp. part hand; crystip.); by Surg. J. G. Keenan, U. S. V. Pens'd March 23, '64. Spec. 1709.
109	Bryson, J., Pt., A, 30th New York.	Aug. 28, Sep. 1, '62.	Right. Discharged Nov. 6, 1862; pensioned; healthy stump.	151	Harris, J. A., Pt., B, 17th N. Y., age 24.	July 17, Jul. 3, '64.	Left; circ.; by A. Surg. R. J. S. Nugent. Pens'd Jun. 17, '65.
110	Burns, E., Pt., D, 175th New York, age 19.	July 4, 16, '63.	Left; circ.; by Surg. E. F. Sanger, U. S. V. Pens'd June 3, 1864.	152	Hart, G. W., Corp'l, F, 5th New York.	Sept. 1, 24, '62.	Left; flap; by A. A. Surg. H. T. Hanks. Disch'd; pensioned.
111	Butterfield, C. M., Pt., G, 121st N. Y., age 22.	July 7, 6, '63.	Left; circular. Disch'd June 29, 1864; pensioned; stump healed.	153	Hatch, J. S., Lieut., F, 1st Michigan.	Aug. 30, Sep. 5, '62.	Left; by Surg. J. E. Summers, U. S. A. Pens'd Sept. 28, 1863.
112	Cadwallder, A., Pt., II, 138th Pennsylvania.	Dec. 31, '62, Jan. 21, '63.	Left. Discharged March 18, '63; pensioned; healthy stump.	154	Hatfield, J., Pt., II, 31st Indiana.	June 14, Jul. 14, '64.	Left. Discharged Nov. 16, 1864; pensioned; good stump.
113	Callahan, W., Pt., F, 16th N. Y. H. A., age 22.	July 16, 29, '64.	Left; flap. Discharged Dec. 23, 1864; perfectly healed.	155	Havens, H. H., Pt., F, 60th New York, age 21.	July 3, 22, '63.	Left; circ.; by A. Surg. R. Bartholow, U. S. A. Pen'd Oct. 19, '63.
114	Carroll, M., Pt., F, 43d New York.	May 3, 10, '63.	Left. Disch'd Aug. 19, '63; pens'd; stump healthy and sound.	156	Heald, W., Pt., K, 3d Maine, age 44.	July 2, 7, '63.	Right; flap; perfora. w. ind. abd.; w. ind. thigh. Pens'd June 27, '64.
115	Chenveort, T., Pt., E, 3d Virginia Cavalry, age 18.	July 21, Aug. 32, 1864.	Left; ant.-post. flap (gangrene); by A. A. Surg. M. M. Townsend. Disch'd June 8, 1865; pens'd.	157	Holems, C. A., Pt., E, 127th N. Y., age 23.	Nov. 30, Dec. 14, '64.	Right; ant.-post. flap; by A. A. Surg. W. Halser. Disch'd May 27, 1865.
116	Clark, J., Pt., I, 140th New York, age 18.	June 2, 14, '64.	Right; double flap; by A. Surg. S. B. Ward, U. S. A.; gangrene. Discharged March 17, 1865.	158	Hoist, P., Pt., K, 139th Pennsylvania, age 24.	June 3, July 1, 1864.	Left; circ. (June 3, amp. finger); by A. A. Surg. A. McLetchie. Disch'd Nov. 25, '64; pensioned.
117	Collin, W., Pt., B, 43d New York, age 20.	May 5, 17, '64.	Right; ant.-post. skin flap; by A. A. Surg. W. H. Truee. Disch'd December 30, 1864.	159	Hess, B., Pt., H, 1st Missouri.	June 1, 17, '61.	Right; circular; by Dr. Barker, of St. Louis. Dis'd; pens'd; healed.

No.	NAME, AGE, AND MILITARY DESCRIPTION.	DATES.	OPERATIONS, OPERATOR, RESULT.	No.	NAME, AGE, AND MILITARY DESCRIPTION.	DATES.	OPERATIONS, OPERATOR, RESULT.
160	Hewitt, F., Pt., E, 32d Mass., age 28.	May 5, 11, '61.	Right; double flap. Discharged Dec. 15, 1863; pensioned.	202	Miller, H. C., Pt., C, 44th Illinois, age 27.	June 27, July 21, 1864.	Left; flap (June 27, amp. finger; gang.); by A. A. Surg. R. Worth. Discharged February 27, 1865.
161	Holmes, W., Pt., E, 1st Massachusetts.	October, 1861.	Left; by A. Surg. J. W. S. Gonley, U. S. A. Dis'd Nov. 15, '61; pens'd.	203	Myers, J. A., Pt., A, 35th New York, age 29.	Sept 1, '62.	Right; circular. Disch'd Nov. 6, 1862.
162	Hunter, J., Pt., F, 50th Indiana.	July 27, Aug. 5, 1862.	Left; by A. A. Surg. J. Shon. Disch'd Aug. 30, '62; pensioned. Pension suspended Aug. 15, '71.	204	Nary, R., Pt., D, 140th New York, age 44.	May 8, 23, '64.	Left; circ. (flesh w'd both arms); by A. A. Surg. H. Gibbons, Jr. Disch'd March 17, '65; pensioned.
163	Hutchinson, T., Pt., F, 71st New York, age 29.	Nov. 2, 15, '62.	Left; flap (Nov. 5, exc. radius; 11th, 13th, hamorrhages); by A. Surg. W. A. Conover, U. S. V. Disch'd Jan. 20, '63; pensioned.	205	Northouse, F. E., Pt., K, 7th Md., age 18.	May 6, 12, '64.	Left; flap (gang.); by Surg. A. F. Sheldon. Pens'd Aug. 23, '64.
164	Huff, J. F., Serg't, A, 62d Ohio.	July 18, 23, '63.	Right; circular. Disch'd October 23, 1863; pensioned; good stump.	206	O'Neill, J., Pt., G, 51st New York, age 32.	May 6, 16, '64.	Left; ant.-post. flap; by A. A. Surg. F. W. Kelly. Pens'd Jan. 16, '65.
165	Irvine, A. F., Pt., B, 153rd New York.	May 28, June 18, '63.	Left; gang.; Oct. 25, '63, amp. arm. Disch'd Jan. 17, '64; pen'd.	207	Pemberton, W., Pt., K, 84th Illinois, age 29.	July 27, Aug. 10, '64.	Left; flap (gang.); by A. A. Surg. J. C. Thorpe. Pen'd Jan. 23, '65.
166	Jefferson, G. (Pt.), A, 41st C. T., age 23.	Dec. 4, 18, '64.	Right; circular. Discharged October 12, 1865; pensioned.	208	Peterborough, R., Pt., B, 9th Me., age 33.	May 23, June 6, 1864.	Left; circ. (gangrene; ham.); by A. A. Surg. J. B. Cutler. Discharged Aug. 7, 1865.
167	Johnson, T. J., Pt., F, 3d New York Art.	Dec. 16, 28, '62.	Right; flap. Discharged June 12, 1863.	209	Phelan, S. S., Pt., G, 21st Connecticut Heavy Artillery, age 44.	July 29, Aug. 2, 1864.	Left; circ. (July 24, exc. bullur); by A. A. Surg. C. F. Bullur. Disch'd April 7, '65; pensioned.
168	Jolly, J., Pt., I, 9th New Hampshire.	Sept. 17, 25, '62.	Left; circular; by A. A. Surg. P. Middleton. Discharged April 15, 1863; pens'd. <i>Spec.</i> 89.	210	Phillips, C. S., Pt., K, 14th Pa., age 18.	July 1, 4, '63.	Right; circ.; by A. Surg. W. H. King. 14th Pa. Pen'd Oct. 1, '63.
169	Jones, E. T., Pt., J, 146th New York, age 21.	May 5, 10, '61.	Left; circular. Discharged March 17, 1865; pensioned.	211	Pickle, J., Pt., G, 63d Pennsylvania, age 19.	July 23, Aug. 23, 1864.	Right; flap; by Surg. O. A. Judson, U. S. A. Disch'd Sept. 1, '64.
170	Jones, W. M., Pt., G, 104th Illinois, age 21.	Nov. 25, Dec. 20, '63.	Left; ant.-post. flap; by A. A. Surg. C. S. Frink. Pens'd July 9, '64.	212	Pinkham, J. C., Pt., E, 11th Maine, age 43.	July 14, 1864.	Left; ant.-post. flap (abscesses; slough; ham.); by A. A. Surg. C. Styer. Disch'd May 26, '65; pensioned. <i>Spec.</i> 3660.
171	Kanar, C. G., Pt., I, 73d Indiana.	Sept. 17, 20, '62.	Left; by Dr. Dudley Bush, Lexington, Ky. Disch'd Dec. 28, '62.	213	Potts, J. G., Pt., A, 29th Illinois.	Nov. 20, Dec. 20, '61.	Left; by Surg. C. C. Guard, 29th Illinois. Disch'd; pensioned.
172	Kautz, L., Pt., F, 190th Pennsylvania, age 32.	May 6, 20, '64.	Left; circ.; by A. Surg. H. Allen, U. S. A. (May 6, exc. right ulna). Disch'd June 1, 1865; pensioned.	214	Powers, J. S., Pt., G, 50th Pa., age 20.	May 6, 14, '64.	Left; circular. Disch'd Feb. 11, 1865; pens'd; stump healed.
173	Kennedy, D., Pt., F, 179th N. Y., age 30.	June 16, 28, '61.	Left; circ. (ham.); by A. A. Surg. J. H. Butler. Disch'd Jan. 10, '65.	215	Rafferty, M., Pt., C, 37th New York.	May 3, 10, '63.	Left; circular. Disch'd Feb. 11, 1865; pens'd; stump healed. Left. Discharged; pensioned.
174	Kennison, I., Pt., I, 1st D. C. Cavalry, age 23.	Aug. 28, Sep. 11, '64.	Left; circ. (ham.); by A. A. Surg. E. C. Franklin, U. S. V. Dis'd Oct. 26, '61; pens'd.	216	Reed, S. S., Pt., I, 75th New York.	Nov. 10, 30, '62.	Left; by A. Surg. G. W. Avery, 9th Ct. Pens'd Jan. 16, 1863.
175	Knepper, G., Pt., I, 1st Kansas.	Aug. 10, Sep. 7, '61.	Right; circular. Disch'd Jan. 1, 1841; pens'd; stump healed.	217	Richey, D., Pt., B, 4th Pennsylvania Cavalry, age 25.	June 21, 1861.	Left; ant.-post. flap; by Surg. C. Page, U. S. A. Disch'd Nov. 28, 1860; pensioned. <i>Spec.</i> 3325.
176	Krueger, C. G., Pt., I, 4th Michigan.	July 2, 30, '63.	Right; circ.; by Surg. E. Bentley, U. S. V. Disch'd Oct. 20, 1862; pensioned. <i>Spec.</i> 359.	218	Rosenheim, M., Pt., H, 2d Wis. Cav., age 21.	Nov. 8, 26, '64.	Left; flap; by A. A. Surg. E. K. Deemy. Disch'd Aug. 26, '65.
177	Kuntz, J., Corp'l, G, 1st Pennsylvania H. A.	Aug. 30, Sept. 3, 1862.	Right; circ. (nervo.); by Surg. J. M. Evans. Disch'd Apr. 1, '65; pen'd.	219	Rosenheim, M., Pt., H, 2d Wis. Cav., age 21.	July 12, 15, '64.	Right; circ.; by Surg. J. Roberts, M. M. B. Pens'd Nov. 25, 1864.
178	Lamb, D., Pt., B, 18th Michigan, age 24.	June 24, Jul. 16, '64.	Right; circ. (nervo.); by Surg. J. M. Evans. Disch'd Apr. 1, '65; pen'd.	220	Sapp, J., Pt., I, 17th Kentucky, age 22.	April 22, May 12, 1863.	Left; double flap. Disch'd Aug. 21, 1863; pens'd. Died July 22, 1872. <i>Spec.</i> 1913.
179	Lander, P. H., Pt., C, 7th C. T., age 23.	Sept. 29, Oct. 15, '61.	Left; flap; by A. A. Surg. C. S. Verdi. Disch'd May 4, '65; pen'd.	221	Sauer, C., Corp'l, H, 74th New York, age 31.	May 6, 13, '64.	Left. Recovered. Not a pensioner.
180	Lee, J. K., Pt., F, 99th Indiana, age 18.	July 28, Aug. 7, '64.	Left; ant. flap; by A. A. Surg. C. F. Bullen. Pens'd May 15, 1865.	222	Schamberg, A., Lieut., C, 6th New York.	Aug. 21, Se. 17, '62.	Right; by Dr. Valentine Mott, N. Y. Pens'd Mar. 27, '63. <i>Spec.</i> 932.
181	Lewis, J., Pt., G, 19th Wisconsin, age 20.	July 19, 26, '64.	Left; by Surg. S. S. Boyd, 84th Ind. Disch'd Feb. 6, '63; pens'd.	223	Schmitzel, A., Pt., K, 3d Missouri.	Jan. 11, 21, '63.	Right. Discharged April 17, '63; pensioned; good stump.
182	Life, A., Pt., A, 84th Indiana.	Nov. 15, 24, '62.	Right; ant.-post. flap; by Surg. W. M. Wright. Pen'd Feb. 16, '65.	224	Seitz, W. S., Pt., A, 21st Pennsylvania.	June 21, July 7, 1864.	Left; circ.; by A. A. Surg. J. G. Miller (June 21, amp. fingers). Disch'd March 17, 1865; pens'd.
183	Livesay, J. W., Pt., C, 60th Illinois, age 38.	July 4, 10, '64.	Right; by A. Surg. J. S. Hillings, U. S. A. Pens'd Aug. 21, 1862.	225	Shannon, H., Serg't, A, 14th New York Heavy Artillery, age 28.	June 17, July 5, 1864.	Left; circular (June 17, excision); by A. A. Surg. S. F. Ford. Discharged Dec. 8, 1864; pens'd.
184	Long, A. D., Pt., I, 12th Pa. Reserves.	June 30, Jul. 17, '62.	Right; circ.; by A. A. Surg. J. G. Canley. Disch'd Mar. 21, '65.	226	Shaw, P., Pt., F, 8th Maine, age 29.	May 20, June 9, '64.	Left; circular; by A. Surg. W. H. Gardner. Pens'd Feb. 8, 1865.
185	Louden, S. F., Pt., A, 10th W. Va., age 35.	Sept. 19, Oct. 15, '64.	Right; circular (ham.); by A. A. Surg. M. Lampen. Disch'd Feb. 18, 1865; pensioned. <i>Spec.</i> 2745.	227	Shuegog, J., Pt., K, 1st Mich. S. V., age 22.	June 23, Jul. 3, '64.	Right; circ. (gang.); by A. A. Surg. R. H. King. Disch'd June 5, '65.
186	Lovejoy, J. W., Pt., C, 60th Illinois.	July 4, 10, '64.	Left; flap; by A. A. Surg. J. P. Arthur. Disch'd May 4, 1865; pensioned. <i>Spec.</i> 4173.	228	Shepard, C. V., Serg't, C, 101st New York.	Aug. 23, Sep. 3, '62.	Left; flap; by A. A. Surg. J. O. Trench. Pens'd Oct. 8, 1862.
187	Lowery, J., Corp'l, G, 51st New York.	Dec. 13, 17, '62.	Left (w'd chest); by Surg. J. H. Baxter and F. W. Kelly, U. S. V. Disch'd Jan. 20, '64; pensioned.	229	Six, J., Pt., I, 1st Maryland, age 26.	May 25, 29, '64.	Left; ant. flap; by Surg. A. F. Sheldon. Pens'd Sept. 16, 1864.
188	Manning, J., Corp'l, A, 19th Michigan.	Mar. 5, 21, '63.	Left (w'd chest); by Surg. J. H. Baxter and F. W. Kelly, U. S. V. Disch'd Jan. 20, '64; pensioned.	230	Sladden, G., Pt., I, 21st New York Cavalry, age 30.	July 9, 22, '64.	Left; circ.; by A. A. Surg. J. H. Bartholf. Disch'd Nov. 10, '64; pensioned. <i>Spec.</i> 3827, 1585.
189	Mauwring, A. W., Pt., K, 6th N. Y. Heavy Artillery, age 23.	June 21, July 12, 1864.	Right; double flap; by A. A. Surg. H. W. Fisher. Disch'd Mar. 17, '63.	231	Smith, A. H., Pt., B, 44th New York, age 21.	May 30, June 28, '64.	Left; ant.-post. flap; by A. Surg. H. M. Sprague. Disch'd Sept. 14, '64.
190	Martin, T., Pt., K, 96th Pennsylvania, age 20.	May 3, 13, '63.	Right; circular (ham.); by A. A. Surg. M. Lampen. Disch'd Feb. 18, 1865; pensioned. <i>Spec.</i> 2745.	232	Smith, D. C., Pt., B, 17th Ind. Mt'd Inf., age 24.	April 2, 6, '65.	Left; circ.; by Surg. J. B. Larkins. Mustered out July 27, '65; pen'd.
191	McAllister, O. J., Pt., K, 83d Pa., age 26.	May 8, 14, '64.	Right; circ.; by A. A. Surg. W. Keen, jr. Pens'd Aug. 28, '62.	233	Smith, H. S., Serg't, C, 138th Pa., age 21.	May 6, 13, '64.	Right; flap; by Surg. D. P. McKinney. Pens'd Jan. 18, 1865.
192	McCarthy, N., Pt., H, 20th Mass., age 21.	June 29, Jul. 6, '62.	Left; ant.-post. flap; by A. A. Surg. J. P. Arthur. Disch'd May 4, 1865; pensioned. <i>Spec.</i> 4173.	234	Smith, R. I., Pt., K, 59th Indiana, age 21.	May 23, June 20, 1863.	Left; flap (May 23, amp. fingers; gang.); by Surg. T. F. Azpell, U. S. V. Pens'd Jan. 22, 1864.
193	McClure, P., Pt., K, 53d Pennsylvania, age 18.	May 12, June 7, '64.	Right; circular (ham.); by A. A. Surg. M. Lampen. Disch'd Feb. 18, 1865; pensioned. <i>Spec.</i> 2745.	235	Sorrells, L., Pt., B, 10th Illinois, age 25.	July 27, Aug. 9, '64.	Left; circ.; by A. A. Surg. J. W. Digby. Pens'd Feb. 24, 1865.
194	McCormick, J., Pt., E, 24th S. C., age 23.	Nov. 20, Dec. 6, '64.	Left; ant.-post. flap; by A. A. Surg. J. M. McGrath. Dis. May 13, '65.	236	Stiles, G. W., Pt., I, 27th Michigan, age 27.	May 12, 21, '64.	Left; circ. (gang.); by Surg. A. No. 2, '63.
195	McDonough, J. H., Pt., F, 20th Mass., age 25.	Nov. 12, 27, '64.	Left; circular (ham.); by A. A. Surg. M. Lampen. Disch'd Feb. 18, 1865; pensioned. <i>Spec.</i> 2745.	237	Stinson, B., Corp'l, B, 168th Ohio, age 19.	Oct. 17, No. 2, '63.	Right; flap; by Surg. W. O. MeDonald, U. S. V. Released August 7, 1865. <i>Spec.</i> 4137.
196	McElroy, G. W., Corp'l, B, 13th Kentucky.	July 17, Jul. 7, '64.	Left; circ.; by A. A. Surg. T. F. Azpell, U. S. V. Pens'd Jan. 22, 1864.	238	Stoddard, H. B., Pt., H, 26th Georgia, age 38.	Mar. 25, April 16, 1865.	Right; ant.-post. skin flap (May 21, frag rem w'd); by Surg. O. A. Judson. Disch'd Oct. 30, 1864.
197	McGinnis, P., Pt., H, 59th New York, age 20.	Sept. 17, Oct. 7, '62.	Right; circular; by A. Surg. T. F. Azpell, U. S. V. Disch'd Feb. 3, 1864.	239	Sullivan, D., Pt., A, 3d Vermont, age 21.	May 6, 29, '64.	Left; flap; To V. R. C. Feb. 23, 1864; pensioned.
198	McGinnigle, J., Pt., G, 1st New Jersey Cav., age 21.	July 13, 1864.	Right; flap. Discharged February 1, 1862; pensioned.	240	Sullivan, J., Pt., C, 14th Ohio, age 27.	Sept. 19, Oct. 7, '63.	Left; flap; by A. Surg. D. H. Warren. Pens'd April 5, 1865.
199	McKee, L., Pt., I, 14th New York, age 20.	Mar. 29, April 17, 1865.	Left; circ.; by A. A. Surg. L. J. Draper. Disch'd Sept. 6, 1865; pensioned. <i>Spec.</i> 173.	241	Thomas, R., Pt., A, 4th Kentucky Mt'd Int.	Aug. 8, '61.	Right; by A. Surg. P. Clapp, 7th Mo. S. M. Pens'd Aug. 22, '62.
200	Meyers, H. W., Pt., H, 30th Illinois.	Nov. 7, 14, '61.	Left; flap; by A. Surg. R. Bartholow, U. S. A. Pens'd Sept. 28, '62.	242	Thrash, J. M., Serg't, G, 26th Illinois.	May 9, June 3, '62.	



No.	NAME, AGE, AND MILITARY DESCRIPTION.	DATES.	OPERATIONS, OPERATOR, RESULT.	No.	NAME, AGE, AND MILITARY DESCRIPTION.	DATES.	OPERATIONS, OPERATOR, RESULT.
243	Tierney, T., Pt., K, 57th New York, age 53.	June 16, 1864.	Right; flap; by A. A. Surg. H. Fenree, Nov. 11, ezema, Pen'd.	283	Dunton, A. A., Corp'l, I, 27th Pennsylvania.	July 4, Au. 1, '63.	Right; flap (necro.); by A. A. Surg. J. P. Agnew. Dis'd Sept. 18, '63.
244	Tillman, W., Pt., D, 10th New York.	June 29, Jul. 11, '61	Left; Discharged; pensioned; sound stump.	284	Eagan, J., Pt., B, 1st N. J. Cavalry, age 25.	April 2, 23, '65.	Left; flap; by Surg. E. Bentley; erysipelas. Pens'd July 18, '65.
245	Tipton, J., Pt., C, 78th Illinois, age 21.	Oct. 4, 17, '62.	Left; circ. (haem.; lig. brach.); by A. A. Surg. J. Sloan. Disch'd Nov. 17, 1862. Spec. 352.	285	Elger, J. H., Pt., C, 28th Massachusetts, age 20.	May 18, 28, '64.	Left; flap (haem.; lig. ulna); May 22, exc. metacarp. gang.; by Surg. G. L. Hancock. Pens'd April 13, '65; w'd open 3 years. Spec. 2477.
246	Toson, J., Pt., E, 2d New York Cavalry, age 23.	April 9, 24, '64.	Left; flap (gang.); by A. A. Surg. D. C. Bell. Disch'd Feb. 18, 1863; pensioned; healed.	286	Fahlbush, F., Pt., G, 35th Mass., age 24.	Sept. 30, Oct. 29, 1864.	Left; flap (sloughing); by A. A. Surg. J. N. Smiley. To V. R. C. March 2, 1865; pensioned.
247	Tucker, S., Pt., E, 125th Ohio, age 23.	Sept. 19, 22, '63.	Left; flap; by Surg. Thompson, C. S. A.; bone protruded. May, '64, amputation. Disch'd Apr. 3, '65.	287	Fielding, R., Pt., B, 6th Wisconsin, age 17.	May 5, 6, '64.	Left; circular. Discharged June 10, 1865; pensioned.
248	Tyler, A. R., Pt., A, 14th Vermont.	Nov. 24, Dec. 9, '62.	Right; flap. Discharged Mar. 31, 1863; pensioned; stump healed.	288	Frisby, P. W., Pt., D, 31st Iowa.	Jan. 11, 29, '63.	Left; flap; by A. A. Surg. T. T. Smiley. Pens'd Mar. 15, 1863.
249	Underwood, H. F., Pt., I, 43d Ohio.	Oct. 4, No. 1, '62.	Left; flap. Disch'd Dec. 13, '62; pens'd; stump perfectly healed.	289	Fugate, W., Pt., G, 2d West Virginia Cavalry, age 22.	July 20, 28, '64.	Left; ant.-post. flap (recr. haem.); by Surg. J. B. Lewis; haem's. Duty Jan. 4, 1865; pensioned.
250	Valentine, A., Pt., I, 7th Connecticut.	June 16, 23, '62.	Right; circ.; by A. Surg. J. E. Semple, U. S. A.; sub. operat'n. Disch'd May 12, 1863; pens'd.	290	Gannt, B., Pt., A, 12th New Jersey, age 26.	June 3, 6, '64.	Right; flap; by A. A. Surg. T. F. Gibson, E. E., 11, D, 2d Michigan, age 31.
251	Vance, W., Corp'l, K, 91st Pennsylvania, age 22.	Oct. 27, Nov. 8, 1864.	Left; flap; by A. A. Surg. I. H. Thompson. Disch'd July 20, '65; pensioned. Spec. 1733.	291	Gibson, E. E., 11, D, 2d Michigan, age 31.	June 17, July 13, 1864.	Left; circ. (gaugrene); by A. A. Surg. J. Morris. Disch'd Sept. 24, 1864; pens'd. Spec. 2841.
252	Vineent, E., Pt., D, 58th Pennsylvania, age 33.	June 1, 24, '64.	Left; circ. (gang.); by A. A. Surg. O. W. Beck; erysipelas. Dis'd Feb. 15, 1865; pensioned.	292	Gunther, T., Pt., F, 41st New York.	Aug. 30, Sep. 6, '62.	Right; flap. Discharged January 17, 1863.
253	Walden, C. G., Pt., D, 49th Illinois.	Feb. 14, Mar. 11, 1862.	Left; flap; by Dr. J. W. Coatsworth. Discharged Sept., 1862; pensioned; stump healed.	293	Hall, H. M., Pt., K, 12th W. Va., age 29.	May 15, 24, '64.	Left; circ.; by Surg. J. B. Lewis. Pens'd Jan. 17, '65. Spec. 4274.
254	Waterhouse, A. P., S'g't, F, 44th Indiana.	April 6, 18, '62.	Right (haem.); by A. A. Surg. D. Morgan. Disch'd.	294	Hawthorne, A. F., Pt., D, 1st Pa. Reserves.	June 30, Jul. 4, '62.	Right; by A. A. Surg. K. G. dard. Dis'd July 12, '62; pens'd.
255	White, J., Pt., E, 11th Massachusetts.	May 4, 25, '64.	Left; by A. A. Surg. H. B. Knowles. Disch'd May 25, 1865; pens'd.	295	Henderson, H., Corp'l, 11, 21st Ohio, age 21.	July 9, 30, '64.	Right; flap (July 9, amp. fingers; gang.); by A. A. Surg. H. Bishop; four inches necrosed ulna removed. Dis'd Apr. 27, '65; pens'd.
256	Whitney, H. P., Pt., A, 39th Illinois, age 25.	June 2, 22, '64.	Right; circ. (June 2, amp. finger; gang.); by A. A. Surg. O. W. Peck. Pens'd June 12, 1865.	296	Hoff, D., Corp'l, G, 65th Ohio.	June 27, Jul. 27, '64.	Right; by A. A. Surg. S. C. Ayres. Disch'd Dec. 10, 1864; pens'd.
257	Wilkin, J., Pt., I, 98th Ohio.	Oct. 8, 12, '62.	Left; flap. Disch'd Nov. 18, '62; pensioned; stump healed.	297	Howell, T., Pt., C, 19th Ohio, age 22.	June 22, July 14, 1864.	Left (gang.); by A. A. Surg. C. S. Merritt; erysipelas. Discharged September 22, 1864.
258	Williams, C., Pt., L, 8th Illinois Cavalry.	July 11, 25, '64.	Right; circ.; by Surg. A. Hard, 8th Ill. Cav. Pens'd Feb. 4, 1865.	298	Johnson, S., Pt., D, 6th N. Y. Artillery, age 30.	July 1, 24, '64.	Left; circ. (gang.). Disch'd Dec. 26, '64; pens'd; healthy stump.
259	Winnans, S. H., Serg't, G, 81st N. Y., age 21.	June 2, 16, '64.	Right; skin flap; by A. A. Surg. H. Craft. Pens'd Mar. 18, 1865.	299	Keis, J., Pt., E, 1st Michigan Cavalry, age 30.	Nov. 14, 1864.	Right; ant.-post. flap; by A. A. Surg. M. M. Townsend. Died May 12, 1865, of malarial fever.
260	Wise, J. E., Pt., A, 36th C. T., age 33.	Sept. 29, Oct. 3, '64.	Left. Discharged November 22, 1865; pensioned.	300	Lambert, W. D., Pt., H, 27th Michigan, age 19.	June 3, 8, '64.	Left; double flap. Discharged October 5, 1864.
261	Woodward, J. N., Pt., B, 1st Vermont Artillery, age 20.	Oct. 1, 1864.	Left; skin flap; circ. sec. muscles; by A. A. Surg. W. P. Moon. Pens'd Mar. 17, '65. Spec. 554.	301	Layton, T., Pt., D, 3d Wisconsin.	Aug. 9, 16, '62.	Right; double flap; by A. A. Surg. G. B. Mackenzie. Disch'd Oct. 14, 1862; pens'd. Spec. 49.
262	Allen, D. B., Serg't, K, 17th Indiana, age 26.	May 10, 16, '64.	Left; circ.; by Surg. A. F. Sheldon, U. S. V. Dis'd July 11, '64; pen'd.	302	Martinek, F., Pt., E, 94th Mo. S. M. Cavalry.	Aug. 15, 29, '62.	Left; by Surg. T. J. Bluthardt, 25d Mo. Pens'd Feb. 19, 1863.
263	Allen, H., Pt., G, 49th Pa., age 23.	May 10, 25, '64.	Left; ant.-post. flap; by Surg. A. F. Sheldon, U. S. V. Pen'd Feb. 9, '65.	303	Martz, I., Corp'l, B, 18th Pa., age 39.	July 9, 30, '64.	Right; flap (June 5, amp. finger; gang.); by A. A. Surg. J. G. F. Strowbridge; haem.; necro. Apr. 9, '65, amp. arm. Pens'd June 26, 1865. Specs. 551, 2672, 4170.
264	Bachellor, W. H., Pt., C, 14th Massachusetts.	June 30, Jul. 10, '63.	Left; flap; by Surg. J. H. Baxter, U. S. V. Dis'd Aug. 24, '63; pen'd.	304	Mathews, R., Corp'l, E, 18th Georgia.	April 7, 26, '65.	Right; circ. (amp. hand); by A. A. Surg. N. A. Robbins. Released May 18, 1865.
265	Barton, P., Pt., A, 19th Mass., age 17.	May 11, 21, '64.	Right; ant.-post. flap (May 11th, excision); by A. A. Surg. J. O. French. Pens'd Oct. 26, 1864.	305	McFalls, A., Pt., C, 157th Pa., age 21.	June 3, 15, '64.	Left; flap; by Surg. E. Bentley, U. S. V. Feb. 27, '65, amp. arm. Disch'd Aug. 2, 1865; pens'd.
266	Belcher, A. N., Pt., B, 47th Ohio.	Sept. 15, 18, '62.	Left; by A. Surg. J. Schenck, 37th Ohio. Pens'd Oct. 27, '62.	306	McGarry, N. S., Pt., B, 6th Maine, age 23.	Nov. 7, Dec. 4, 1863.	Right; flap (fac. seap.; haem.); by A. A. Surg. C. F. Trautman. Pens'd Feb. 15, '64. Spec. 2326.
267	Bell, J., Pt., K, 16th Maine, age 17.	May 10, 13, '64.	Left; circular. Discharged June 15, 1864.	307	McGary, T., Pt., A, 12th West Virginia.	May 19, Jc 2, '64.	Right; by A. A. Surg. J. L. Brown, 11th Ohio. Pens'd Dec. 19, '64.
268	Bergersd rf, F., Pt., A, 13th Missouri.	Apr. 6, 14, '62.	Right; circ.; by A. Surg. C. A. Me Keo. Disch'd Nov. 20, '64; pen'd.	308	McMinn, J., Pt., A, 129th Indiana, age 27.	Mar. 19, April 8, 1865.	Right; circ.; by A. A. Surg. H. Sanders. Discharged June 30, 1865; pensioned; healed.
269	Boos, L. J., Serg't, B, 6th Pa. Cav., age 24.	May 7, 13, '64.	Left; circular; by A. Surg. C. A. McCall, U. S. A. Discharged Sept. 26, '63; pens'd. Spec. 1873.	309	McPhee, D., Pt., H, 20th Massachusetts.	Dec. 11, 24, '62.	Left; flap; by A. Surg. G. M. McGill, U. S. A.; August 11, 1863, bone removed. Disch'd Sept. 21, 1863; pensioned. Spec. 559.
270	Broadwell, W. E., Serg't, B, 15th N. J., age 28.	May 3, 13, '63.	Right; flap. Discharged June 24, 1865; pensioned.	310	Meyer, H., Corp'l, A, 14th Pa., age 23.	May 10, 17, '64.	Left; ant.-post. flap; by Surg. A. F. Sheldon. Pens'd Sept. 12, '64.
271	Brooks, N., Pt., D, 4th C. T., age 19.	Sept. 30, Oct. 3, '64.	Right; flap; by A. A. Surg. G. W. Dickie. Pens'd May 8, 1863.	311	Mills, G. W., Serg't, E, 5th Michigan, age 22.	Aug. 15, 27, '64.	Left; by Surg. N. R. Mosley. Disch'd Dec. 6, '64. Spec. 2522.
272	Buckley, M., Pt., D, 69th New York.	Sept. 17, Oct. 15, '62.	Right; double flap (gang.); by A. Surg. H. M. Sprague, U. S. A.; gang.; July, '64, amp. elb. joint. Disch'd Aug. 26, 1864; pens'd.	312	Murphy, J., Pt., K, 10th N. H., age 48.	June 3, 30, '64.	Left; circ. (amp. finger); by Dr. Ferguson. Pens'd Nov. 9, '64.
273	Burroughs, M., Pt., A, 148th N. Y., age 18.	May 31, June 27, 1864.	Right; by A. Surg. O. A. Judson, U. S. V.; flaps sloughed, bones exposed. Disch'd Jan. 11, 1865; pensioned. Spec. 2277.	313	Murray, F., Pt., C, 93d New York, age 50.	Oct. 27, No. 4, '64.	Right; circ.; by A. Surg. H. Allen, U. S. A. Pens'd Feb. 27, 1865.
274	Collin, E. D., Serg't, F, 13th New York.	Sept. 17, 21, '62.	Left; flap. Discharged.	314	Newcomb, W. J., Corp'l, K, 1st Michigan.	Aug. 30, Sept. 3, 1862.	Left; necrosis; ankyel.; April 3, '63, amp. arm. Disch'd June 9, 1863; pens'd. Spec. 1175, 1176.
275	Cornelson, A. J., Pt., G, 5th Illinois.	May 9, 12, '62.	Right; flap; by A. Surg. C. A. Me Keo. Disch'd May 16, 1865.	315	Nichols, V. R., Pt., B, 87th Pa., age 23.	Aug. 12, Sep. 2, '64.	Right (gangrene); by A. A. Surg. A. V. Cheroonnier. Dis'd; pen'd.
276	Cotton, J. H., Pt., K, 17th Maine, age 33.	May 6, 11, '64.	Left; by Surg. D. MacKay, 29th C. T. Discharged May 16, 1865.	316	Owens, R., Pt., C, 100th Pennsylvania, age 24.	May 6, 29, '64.	Left; ant.-post. flap; by Surg. H. Palmer. Disch'd Jan. 20, 1865.
277	Curtis, O. B., Corp'l, D, 24th Mich., age 22.	Dec. 13, 17, '62.	Right (May 12, exc. metacarpal; caries); by A. A. Surg. W. H. Randolph. Pens'd Mar. 15, '65.	317	Phelps, F., Pt., E, 6th Maryland, age 22.	May 5, 10, '64.	Right; flap; by Surg. D. W. Bliss, U. S. V. Disch'd May 20, 1865; pensioned.
278	Davis, M., Pt., M, 14th N. Y. H. A., age 21.	June 17, 30, '64.	Right; circ.; by A. Surg. M. L. Herr. Dis'd Mar. 28, '64; pens'd.	318	Phillips, J., Pt., F, 95th New York, age 19.	May 6, 12, '64.	Left; ant.-post. muscular flap; by Surg. A. F. Sheldon, U. S. V. Disch'd Nov. 19, '64; pensioned.
279	Dillingham, R., Pt., F, 116th Colored Troops.	Mar. 13, 16, '65.	Left; flap (gang.); by Surg. J. E. Herbst. Pensioned Jan. 23, '65.	319	Pogue, W. H., Pt., G, 40th Indiana, age 29.	Nov. 30, Dec. 4, '64.	Left; flap (wound of head). Dis'd June 24, 1865; pens'd; healed.
280	Dirvans, N., Pt., I, 139th Pennsylvania, age 23.	May 12, June 11, 1864.					
281	Dowdy, G. S., Pt., C, 6th Kentucky, age 26.	Nov. 25, Dec. 13, '63.					
282	Dresie, N., Pt., C, 8th Kansas, age 28.	July 21, Au. 5, '64.					

No.	NAME, AGE, AND MILITARY DESCRIPTION.	DATES.	OPERATIONS, OPERATOR, RESULT.	No.	NAME, AGE, AND MILITARY DESCRIPTION.	DATES.	OPERATIONS, OPERATOR, RESULT.
320	Rader, H., Pt., K, 65th Ohio.	Dec. 31, '62, Jan. 5, '63.	Left, circ.; by Surg. P. Seymour, U. S. V. Pens'd May 16, 1863.	332	Stevens, J. T., Pt., I, 150th Pa., age 21.	July 2, '63.	Left; circular; by A. Surg. D. C. Peters, U. S. A. Discharged September 31, 1863. <i>Spec.</i> 1685.
321	Reed, R. T., Serg't, 48th Georgia, age 19.	July 2, '63.	Right. Paroled September 25, 1863.	333	Stoddard, A., Pt., F, 107th N. Y., age 19.	May 25, '64.	Left; circular; by A. Surg. C. C. Byrne, 108'd Aug. 18, '64; pens'd June 18, '64.
322	Reynolds, C. H., Pt., A, 16th N. Y. Cav., age 19.	July 3, '65.	Right; circular; by A. A. Surg. J. Morris. Disch'd Sept. 18, 1865.	334	Story, J. B., Serg't, II, 103d Pa., age 22.	June 18, '61.	Left; flap (other wound); by Surg. S. F. Chapin, 133th Pa., and E. R. Linberger, Pen'd Dec. 20, '64.
323	Roun, D., Pt., II, 148th New York, age 52.	June 2, 10, '64.	Light; ant.-post. flap; by A. Surg. H. Allen, U. S. A. Disch'd Oct. 19, 1864; pens'd. <i>Spec.</i> 2343.	335	Sullivan, T. C., Corp'l, K. 2d Rhode Island.	July 21, '61.	Right; circ. Disch'd Dec. 19, '61; pens'd; stump perfectly healed.
324	Robinson, A., Pt., G, 11th N. H., age 24.	Sept. 30, Oct. 21, 1864.	Right; circular; by A. A. Surg. C. W. Carrier. Disch'd July 6, 1865; pensioned. <i>Spec.</i> 3322.	336	Taylor, W., Pt., C, 23d C. T., age 18.	July 30, Aug. 4, '61.	Left; circ.; by Surg. D. Mackay. Disch'd March 8, 1865; pens'd.
325	Rose, J., Pt., B, 6th Tennessee Mounted Infantry, age 28.	Mar. 21, '65.	Right; circular (gang.); by A. A. Surg. J. W. Taylor; April 25, amp. arm. Pens'd June 21, '65.	337	Tucker, W., Pt., C, 27th Michigan, age 22.	May 12, '64.	Right; ant.-post. muscle; flap; by A. F. Sheldon, U. S. V. Discharged Oct. 25, '64. <i>Spec.</i> 2346.
326	Sanders, T., Serg't, F, 53d Indiana.	Aug. 14, '64.	Left. Discharged April 1, 1865; pensioned; stump healed.	338	Wenger, H. F., Pt., F, 128th New York.	May 27, '63.	Left; flap; by A. A. Surg. J. W. Thomas. Pens'd July 28, 1863.
327	Seibel, D., Pt., K, 27th Indiana, age 27.	May 25, June 21, 1864.	Left; circular; by A. A. Surg. C. H. Fisher. Duty December 4, 1864. <i>Spec.</i> 3366.	339	Wright, J. R., Pt., G, 34th Ohio.	Sept. 10, '62.	Left; flap; by Surg. J. E. Finch, 7th Minn. Pens'd April 24, '63.
328	Smith, E., Pt., I, 136th Pennsylvania.	Dec. 13, 20, '62.	Right; circular. Disch'd March 13, 1863; pens'd; stump healed.	340	Wyer, B. P., Corp'l, II, 58th Mass., age 37.	May 13, '64.	Left; flap; by A. A. Surg. C. A. Lindsay. Disch'd Oct. 18, 1864.
329	Smith, W., Pt., A, 1st Me. H. A., age 18.	June 3, 10, '64.	Right; flap; by Surg. O. A. Judson, U. S. V. Disch'd Feb. 20, 1865; pens'd. <i>Spec.</i> 2338.	341	Birge, W. C., Pt., G, 36th Massachusetts.	June 6, '64.	Left; by Surg. R. S. C. rebore; gang.; amp. arm. Pens'd Feb. 28, 1865.
330	Snow, R. E., Pt., A, 27th Mich., age 25.	May 24, '64.	Left; circ.; by A. A. Surg. T. Carroll. Disch'd July 17, '65; pens'd.	342	Brown, R. N., Pt., G, 23d Massachusetts.	May 16, '64.	Right; amp. arm Sept. 19, Disch'd Feb. 7, '65; pens'd; good stump.
331	Steckman, L., Pt., D, 55th Pa., age 19.	Feb. 12, '64, May 16, '64.	Left; circ.; sloughing; necrosis. Disch'd June 12, '65; pensioned.	343	Robertson, M., Pt., F, 47th C. T., age 45.	Mar. 5, '64.	Left; by Surg. N. N. Horton, 47th C. T. Disch'd January 12, 1865.
				344	Sills, E., Pt., A, 46th Illinois, age 18.	July 7, '64.	Circular; by Surg. E. Powell. Duty Aug. 28, '64; stump healed.

§ *Fatal Intermediary Amputations in the Forearm.*—Pyæmia was reported in forty-five of the one hundred and six fatal intermediary operations; secondary hæmorrhage in twenty-eight, gangrene in twenty-five, tetanus in five. There were six amputations.

CASE 1928.—Private H. C. Fowler, Co. H, 7th Michigan, aged 22 years, was wounded at Deep Bottom, July 23, 1834, and sent to Lincoln Hospital, Washington. Acting Assistant Surgeon A. F. A. King reported: "The ball entered on the dorsal aspect of the wrist joint, fracturing it and the ulna. Some splinters were extracted on the field. Abscesses extended up the forearm, and, August 15th, amputation was performed at the middle third, eight ligatures being applied. August 17th, stump considerably swollen up to the elbow; discharge scanty. Applied flaxseed poultice. 18th, swelling less; pus discharging abundantly. 20th, complains of night-sweats. Prescribed solution of quinine with elixir vitriol and McMurri's elixir of opium three times a day. 21st and 22d, still doing very well in every respect; no night-sweats; appetite not very good. Treatment the same, with aromatic fluid extract of cinchona three times a day, also a dose of castor oil to open the bowels. 23d, had a severe chill at three o'clock P. M.; arm somewhat swollen; pulse frequent; skin hot. Ordered quinine two grains every two hours. 24th, erysipelas; limb red and œdematous up to the shoulder. Gave muriated tincture of iron ten drops every two hours, and quinine every three hours. 25th, swelling increased. Patient in good spirits though rather weak and feverish. A puffy fluctuating tumor was opened to-day just above the elbow, and contained serum but no pus. Solution of sulphate of iron applied over the arm. 25th, had another chill; arm no better. Patient slightly delirious toward evening. Continued quinine, iron, and stimulants, and ordered tincture of iron and iodine for the arm. 27th, arm less swollen; pus discharged mixed with serum. 28th, arm much better. Patient complains of pain in right breast and has cough. Treatment the same, with cod-liver oil. 30th, had repeated pyæmic chills yesterday and to-day; skin looks yellow, cheeks flushed; great dullness over lower right lung; pain and tenderness over liver; pulse very frequent and weak; delirium at night. Ordered sulphate of quinine five grains, and chlorate of potassæ ten grains every three hours, also brandy egg-nog. 31st, the arm is not much swollen. It has much improved, although the patient is dying of pyæmia. He has great shortness of breath and is partly unconscious all the time. Treatment continued. September 1st, died at one o'clock P. M." A preparation of the bones of the amputated forearm, represented in the adjacent cut (FIG. 714), was contributed by Acting Assistant Surgeon H. M. Dean, who made the following report of a *post-mortem* examination: "The patient was considerably emaciated and of a sallow color. On examining the stump, the tissues were found to be infiltrated with pus. Pus was also found in the elbow joint. The periosteum was readily separated from the bones of the stump. On opening the thoracic cavity the right side was found to contain about twenty-four ounces of opaque fluid, and the lung was covered by a layer of recently deposited lymph. The lower lobe of each lung was carnified, and contained several isolated abscesses about the size of peas. The right lung weighed twenty ounces, the left thirty ounces. The spleen weighed twelve and a half ounces and contained several small isolated abscesses. Pericardium very much thickened and firmly attached to the walls of the heart. Each side of the heart contained a firm yellowish clot; the organ appeared normal. Liver normal, and weighing seventy-six ounces. Both kidneys were very large, but appeared normal, each weighing eight ounces."

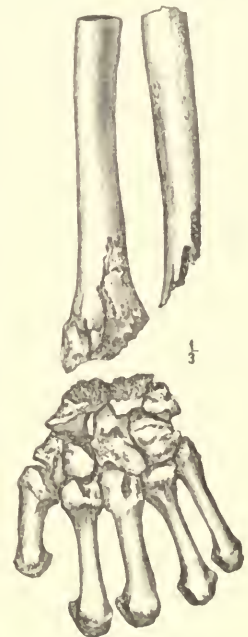

FIG. 714.—Caries after shot injury above left wrist. *Spec.* 3087.



TABLE CXXXVI.

Condensed Summary of One Hundred and Six Fatal Intermediary Amputations in the Forearm for Shot Injury.

NO.	NAME, AGE, AND MILITARY DESCRIPTION.	DATES.	OPERATIONS, OPERATOR, RESULT.	NO.	NAME, AGE, AND MILITARY DESCRIPTION.	DATES.	OPERATIONS, OPERATOR, RESULT.
1	Archibald, J., Pt., F, 33d New York, age 50.	Dec. 13, 1862, Jan. 8, '63.	Right; flap; by A. A. Surg. J. W. Digby; hæm.; diarr. Died Jan. 29, '63, pyæmia. <i>Spec.</i> 993.	33	Bissell, A. A., Serg't, F, 6th Ohio Cavalry, age 24.	June 24, July 4, 1864.	Right; by Surg. C. Page, U. S. A., Died July 15, 1864, pyæmia. <i>Spec.</i> 3326.
2	Babcock, A., Pt., F, 1st Sharpshooters, age 38.	June 3, 28, '64.	Left; flap; by Surg. H. Palmer, U. S. A., Died July 1, 1864.	34	Blood, H. P., Corp'l, E, 11th New Hampshire, age 19.	Sept. 30, Oct. 28, 1864.	Left; flap; by A. A. Surg. J. C. Morton; gangrene. Died Nov. 8, 1864, exhaustion. <i>Spec.</i> 3720.
3	Brown, L., Pt., F, 5th New York Cav., age 30.	Oct. 17, No. 1, '63.	Right; circ. (ery.); by A. Surg. R. Bartholow; hæm. Nov. 9, '63, amp. arm. Died Nov. 27, '63, pyæm.	35	Bunker, W., Pt., I, 60th New York, age 21.	July 22, Aug. 1, 1864.	Right; circ. (gangrene); by Surg. R. B. Bonteou, U. S. V., Died August 8, 1864, exhaustion.
4	Brown, W., Corp'l, I, 1st Mass. Art., age 34.	Mar. 31, Ap. 15, '65.	Left; circ. (gang.) R. B. Bonteou; diarr. Died Ap. 29, '65, ex'h'n.	36	Collins, J., Pt., C, 18th Illinois.	Dec. 17, 31, '62.	Right; circ. (amp. finger Dec. 17; hæmor.); by Surg. H. W. Davis, 18th Ill. Died Jan. 26, 1863.
5	Burlay, H. S., Pt., B, 10th Vermont, age 40.	May 25, June 12, 1864.	Right; circ.; by A. Surg. J. D. Johnson; gang.; July 21, amp. arm. Died Aug. 16, 64, chr. diarr.	37	Echtenman, W., Pt., K, 19th Mich., age 22.	May 25, June 1, 1864.	Left; circular (hæmor.); by A. A. Surg. W. H. Kilbourne. Died June 28, 1864, pyæmia.
6	Button, D., Pt., H, 149th New York, age 35.	June 25, June 12, 1864.	Left; circ.; by A. Surg. D. C. Peters. Died June 15, '64, pyæmia.	38	Evans, T., Pt., D, 24th Iowa, age 40.	Oct. 19, 28, '64.	Right; ant.-post. flap; by A. A. Surg. J. Neff. Died November 5, 1864, pyæmia.
7	Carley, H. M., Pt., K, 17th Vermont, age 34.	May 5, 21, '64.	Left (gangrene). Died May 9, 1863, pyæmia. <i>Spec.</i> 1294.	39	Fields, J., Pt., K, 4th New York Heavy Artillery, age 27.	June 12, 30, '64.	Left; double flap; by Surg. E. Bentley; gang. Died July 6, '64, from w'nd in breast. <i>Spec.</i> 2534.
8	Carlton, A. H., Pt., D, 26th Maine, age 21.	Apr. 11, May 3, '63.	Left (prim. exc. gang.); by Surg. D. P. Smith. Died May 27, 1864, pyæmia. <i>Spec.</i> 3297.	40	Follet, G., Pt., K, 8th New York Artillery, age 36.	June 3, 11, '64.	Left; ant.-post. flap; by A. A. Surg. A. F. A. King. Died Sept. 1, '64, pyæmia. <i>Specs.</i> 3067, 3100.
9	Contramam, J., Pt., G, 142d Pa., age 20.	May 11, '64.	Left; circ. (hæm., lig.; tetanus); by A. A. Surg. F. E. Marsh. Died June 18, 1864, tetanus.	41	Fowler, H. C., Pt., H, 7th Michigan, age 22.	July 26, Aug. 15, 1864.	Left; by Surg. E. Bentley; irritative fever. Died Oct. 29, '62.
10	Crant, J., Pt., M, 8th N. Y. H. Art., age 17.	June 3, 17, '64.	Left; circ. (hæm., lig.; tetanus); by Surg. A. F. Sheldon. Died May 26, 1864, toxæmia.	42	Francisco, W., Pt., F, 101st N. Y., age 18.	Aug. 29, Se. 23, '62.	Right; circ. (gang.); A. A. Surg. J. Harvey. Died July 14, '61.
11	Cummings, N. L., Pt., E, 20th Mass., age 28.	May 6, 19, '64.	Right; flap; by Surg. A. M. Speer. Died Dec. 31, 1864, pyæmia.	43	Gorman, J., Pt., I, 28th Pennsylvania, age 54.	May 25, Je 5, '64.	Left; flap (pyæm.; anæm.; hæm.); by Surg. C. E. Swasey, U. S. V., Died Aug. 21, 1864, pyæmia.
12	Easton, G. O., Pt., C, 175th Ohio, age 18.	Nov. 30, De. 18, '64.	Left; ant.-post. flap (amp. finger); by A. Surg. B. E. Fryer, U. S. A., Died Aug. 9, 1864, pneumonia.	44	Hnie, J. M., Pt., B, 12th Kansas.	Aug. 5, 17, '64.	Right; circular; by A. A. Surg. R. J. S. Nugent. Died July 23, 1864, of hædrys pericardii.
13	Eble, F., Pt., A, 5th Ohio, age 42.	July 27, 1864.	Right; circ. (May 27, amp. fingers right hand and left arm; hæm.); by A. A. Surg. W. B. Dick. Died June 17, '64, pyæmia.	45	Hare, E. J., Pt., I, 32d Maine, age 19.	June 24, July 2, 1864.	Right; ant.-post. skin flap; by A. A. Surg. R. J. S. Nugent. Died July 23, 1864, of hædrys pericardii.
14	Ferris, G. W., Corp'l, A, 36th Wis., age 34.	May 27, June 12, 1864.	Left; circular (hæmor.); by Surg. R. R. Taylor, U. S. V., Died June 30, 1864, pyæmia.	46	Haynes, W., Pt., G, 38th Wisconsin, age 38.	April 2, 9, '65.	Right; ant.-post. skin flap; circ. sec. muscles; by A. A. Surg. J. O. French. Died May 1, 1865, pleurisy. <i>Spec.</i> 4234.
15	Graham, J., Pt., I, 89th Illinois, age 28.	May 27, June 17, 1864.	Left; circular; by A. A. Surg. E. K. Hill. Died July 12, 1864, exhaustion. <i>Spec.</i> 3623.	47	Hickman, G., Pt., H, 33d Mississippi, age 20.	July 20, 25, '64.	Left; circular (diarrhœa). Died Dec. 5, 1861, chronic diarrhœa.
16	Hawkins, W. O., Pt., G, 2d New York Heavy Artillery, age 41.	June 16, July 7, 1864.	Left; circular. Died August 17, 1863, pyæmia.	48	Hightower, C. B., Pt., B, 99th Illinois.	May—, 26, '63.	Right (amp't'n fingers; necrosis). Died May 29, 1863, exhaustion.
17	Hollingsworth, S., Pt., F, 73d New York.	July 2, 31, '63.	Left; flap of skin; circ. of muscle (amp. finger; gangrene). Died August 19, 1863, pyæmia. <i>Specs.</i> 2615, 2616, 2774.	49	Horton, R., Pt., F, 77th Pennsylvania.	July 14, Aug. 10, 1864.	Right (amp. finger; gang.). Aug. 5, amp. fingers. Died August 14, 1864, pyæmia. <i>Spec.</i> 3491.
18	Kuin, J. G., Pt., G, 75th Pennsylvania, age 42.	July 1, 29, '63.	Right; flap; by Surg. A. A. White, 8th Md.; necrosis; hæm.; Sept. 17, amp. arm. Died Oct. 10, '64.	50	Hunt, C., Pt., H, 57th Indiana, age 22.	June 22, July 15, 1864.	Right (June 22, exc. ulna; gang.); by A. A. Surg. S. H. Olden. Died July 19, amp. arm. Died July 21, '64, exhaustion.
19	Liston, J. D., Pt., F, 114th Ohio.	De. 29, '62, Ja. 15, '63.	Right; ant.-post. flap; by Surg. H. Palmer, U. S. V., Died July 17, 1864, pyæmia.	51	Jackson, H., Pt., E, 1st Colored Troops, age 20.	June 17, 24, '64.	Right; ant.-post. flap (hæm.); by A. Surg. J. H. Prantz, U. S. A., Died June 25, 1864, exhaustion.
20	McGahay, A., Pt., B, 9th Indiana Cavalry, age 18.	Sept. 26, Oct. 14, 1864.	Left; flap; by A. A. Surg. C. S. Merrill; erysipelas. Died Oct. 26, 1864, surgical pneumonia.	52	Jennings, H., Serg't, K, 137th N. Y., age 23.	Oct. 28, No. 8, '63.	Left; circ. (gang.). Died Nov. 22, 1863, pyæmia. <i>Spec.</i> 2173.
21	Paugburn, H. C., Pt., I, 24th Iowa.	June 22, Jul. 9, '63.	Right; July 26, hæmor. Died Aug. 3, '63, intercurrent typhoid fever.	53	Jewell, C. H., Serg't, F, 4th New York, age 34.	Oct. 19, Nov. 7, 1864.	Left; ant.-post. flap (hæm.; gang.); by A. A. Surg. T. H. Studdiford. Died Nov. 27, 1864, exhaustion.
22	Pride, H., Pt., D, 207th Pennsylvania, age 32.	April 2, 11, '65.	Left; circular; by A. A. Surg. A. B. Haven. Died April 12, 1865, pyæmia. <i>Spec.</i> 174.	54	Johnson, N., Corp'l, H, 40th Indiana.	June 27, July 9, 1864.	Left; circular (gangrene); by A. A. Surg. W. N. S. Benjamin. Died August 8, 1864, pyæmia.
23	Reynolds, H., Pt., H, 5th N. Y., age 32.	Aug. 18, 21, '64.	Right; flap; by Surg. A. A. White, 8th Md.; necrosis; hæm.; Sept. 17, amp. arm. Died Oct. 10, '64.	55	Kemps, O., Pt., E, 3d New Hampshire, age 33.	Sept. 4, 14, '64.	Left; circ.; by A. A. Surg. W. P. Moon. Died September 24, 1864, pneumonia. <i>Spec.</i> 2305.
24	Reynolds, J. K., Pt., C, 148th N. Y., age 44.	June 3, 29, '64.	Right; ant.-post. flap; by Surg. H. Palmer, U. S. V., Died July 17, 1864, pyæmia.	56	Keyes, S., Corp'l, B, 2d North Carolina, age 27.	July 12, Aug. 11, 1864.	Right; circ. (pen. w'nd of chest; gangrene); by A. A. Surg. N. A. Robbins. Died Sept. 27, 1864.
25	Rice, C. H., Pt., E, 5th N. H., age 30.	June 18, Jul. 2, '64.	Left; ant.-post. flap; A. A. Surg. H. M. Dean. Died July 9, '64.	57	Lape, C., Pt., D, 111th New York, age 18.	May 7, Je 3, '64.	Left; circ.; by A. A. Surg. G. W. Carrier. Died July 6, '64, pyæm.
26	Slater, J., Corp'l, K, 7th New York Heavy Artillery, age 20.	June 16, 24, '64.	Right; flap; by A. A. Surg. W. H. Ensign; hæm.; lig. brachial. Died July 8, 1864. <i>Spec.</i> 2700.	58	Lindman, A., Pt., A, 63d Pennsylvania.	Nov. 27, De. 13, '63.	Right; by Surg. D. P. Smith, U. S. V., Died Dec. 15, '63. <i>Spec.</i> 2005.
27	Stevens, L. W., Pt., F, 61st Pa., age 38.	July 13, 31, '64.	Left; circ. (gang.); by A. A. Surg. F. W. Kelly. Died Aug. 23, '64.	59	McNeal, D., Pt., G, 63d Pennsylvania, age 29.	May 8, 23, '64.	Left; lat. skin flap (gangrene); by Surg. A. F. Sheldon, U. S. V., Died June 11, 1864, exhaustion.
28	Strickland, M. G., Pt., G, 50th Ga., age 22.	Sept. 4, 1862.	Left; flap; hæm.; lig. radial and ulnar; diarrhœa. Died Dec. 3, 1862, pyæmia. <i>Spec.</i> 217.	60	Nesbitt, W. M., Pt., G, 27th Michigan, age 29.	May 8, May 25, June 1, 1864.	Right; circ. (ery.); by A. A. Surg. T. F. Betton; diarr. Died Oct. 24, '64; exhaustion. <i>Spec.</i> 3253.
29	Upcroft, J., Pt., K, 62d Pennsylvania, age 21.	May 11, June 6, 1864.	Right; circular (erysip.); hæm.; diarr.); by A. A. Surg. A. A. Smith. Died June 8, 1864; exhaustion. <i>Spec.</i> 2755.	61	Patterson, J., Pt., K, 4th U. S. Infantry, age 32.	June 20, 25, '64.	Right; flap. Died August 27, 1864.
30	Trunston, J., Pt., K, 86th Indiana.	Sept. 19, Oct. 6, 1863.	Right; circ.; by Surg. A. M. McMahon, 64th Ohio; hæm.; lig. brach.; pyæm. Died Oct. 21, '63.	62	Peck, W. G., Corp'l, E, 22d New York Cavalry, age 23.	Nov. 12, 30, '64.	Left; antero-posterior flap; by A. A. Surg. J. M. Houston. Died Dec. 9, 1864, exhaustion.
31	Walker, R., Pt., F, 71st Pennsylvania, age 26.	July 30, Aug. 20, 1862.	Left; flap (July 17, exc. carpus; aneurism; hæmor.); by Surg. R. H. Coolidge. Died Aug. 10, '62.	63	Porter, L. B., Capt., K, 81st N. Y., age 38.	Sept. 29, Oct. 28, '64.	Left; circular. Died November 15, 1861, pyæmia.
32	Baker, W., Pt., G, 117th New York, age 27.	June 3, 10, '64.	Left; circ. (gang.; incip. tetanus); by A. A. Surg. T. L. Van Norden. Died June 19, 1864, pyæmia.	64	Prawdolecki, F., Corp'l, B, 7th N. Y., age 31.	Aug. 25, Sept. 19, 1864.	Right; circ. (ery.); by A. A. Surg. T. F. Betton; diarr. Died Oct. 24, '64; exhaustion. <i>Spec.</i> 3253.

No.	NAME, AGE, AND MILITARY DESCRIPTION.	DATES.	OPERATIONS, OPERATOR, RESULT.	No.	NAME, AGE, AND MILITARY DESCRIPTION.	DATES.	OPERATIONS, OPERATOR, RESULT.
65	Bunsdell, J. J., Pt., B, 20th Mass., age 22.	Sept. 19, Oct. 6, '64	Left; circular: A. A. Surg. L. K. Baldwin. Died Oct. 17, '64, pyæmia.	84	Jones, W. E., Pt., G, 10th New York.	Aug. 9, 16, '62.	Right; flap; by A. A. Surg. W. K. Cleveland. Died Sept. 29, 1862, pyæmia.
66	Rowell, E. W., Pt., B, 19th Maine.	Jan. 22, Feb. 18, 1863.	Diarrhœa. Jan. 22, disart. metacarpal; bone carious; amp. by Surg. N. Hayward, 20th Massachusetts. Died March 4, 1863.	85	Kelly, D., Corp'l, H, 6th Wisconsin, age 32.	May 12, 23, '64.	Right; circ. (hæm.); by Surg. R. H. Bontecou. Died June 23, '64.
67	Seifer, S., Pt., C, 20th Mass., age 19.	Aug. 25, Sept. 1, 1864.	Left; double flap; by A. A. Surg. W. H. Ensign. Died Sept. 18, 1864, exhaustion. <i>Spec.</i> 484.	86	McBride, E., Pt., H, 106th New York, age 31.	Aug. 10, Sept. 3, 1864.	Left; ant. post. flap (gang.; diarrhœa); by Surg. R. H. Bontecou, U. S. V. Died Sept. 3, '64, ex. h.
68	Shanahan, J., Pt., E, 10th N. Y., age 30.	Oct. 2, 21, '64.	Left; flap; by A. A. Surg. J. C. Morton. Died Oct. 30, 1864, pyæmia. <i>Spec.</i> 4719.	87	Miller, J., Pt., B, 11th U. S. Infantry, age 38.	June 18, July 9, 1864.	Left; antero-posterior flap; by A. A. Surg. A. Ansell. Died July 26, 1864, pyæmia.
69	Skilling, J. C., Pt., I, 3d N. J., age 20.	May 8, 23, '64.	Right; circ. (hæm.); by A. A. Surg. C. H. Osborne. Died May 31, 1864, pyæmia.	88	Motherspau, G. W., Major 73d Illinois, age 33.	Nov. 30, Dec. 12, 1864.	Left; flap; by A. A. Surg. J. A. Hall; cruris; hæm.; Dec. 18, re-amp. Died Dec. 18, 1864.
70	Smith, G., Pt., G, 21st Pa. Cav., age 20.	July 22, Sept. 9, 1864.	Left; ant. post. flap (June 22, amp. finger); by A. A. Surg. W. W. Vaidk. Sept. 17, amputation arm. Died October 7, 1864.	89	Norwood, E., Pt., B, 6th Pennsylvania, age 22.	Aug. 29, Se. 25, '62.	Right; flap; by Surg. O. A. Judson. Died June 23, 1864, ex. h.
71	Vanbone, P., Pt., B, 2d New York H. A.	June 2, 13, '64.	Left; ant. post. flap; by Surg. E. Bentley. Died Feb. 25, '64, pyæmia.	90	Richardson, B. F., Pt., C, 93d N. Y., age 22.	May 5, 27, '61.	Right; by Surg. D. G. Rush, U. S. V. Died Nov. 14, '61, pyæmia.
72	Walter, J., Pt., C, 2d Pa. H. A., age 22.	June 17, July 14, 1864.	Left; circ. (June 19, amp. fing.; gang.); by A. A. Surg. H. Craft. Died Aug. 10, '64, pyæmia. <i>Spec.</i> 2872.	91	Rompano, E., Lieut., G, 6th Ohio, age 28.	Oct. 13, 26, '64.	Right; circular; by A. Surg. H. M. Sprague. Died July 12, '64, pyæmia.
73	Adams, O. M., Lieut., K, 138th N. Y., age 32.	June 4, 18, '64.	Right; circular; by Surg. D. W. Bliss. Died June 19, 1864, tetanus. <i>Spec.</i> 2554.	92	Spencer, A., Pt., C, 21st Connecticut, age 34.	May 30, Feb. 15, '64.	Left; circ.; by Surg. J. R. Ludlow, U. S. V. Died Jan. 4, '65.
74	Chatfield, J., Pt., E, 6th Ohio Cav., age 32.	June 21, July 14, 1863.	Right (wind left rad.); July 14, hæm.; amp. left arm; by A. A. Surg. C. H. Osborne. Died July 14, 1863.	93	Whitmore, T., Pt., E, 51st Indiana, age 18.	Dec. 16, 26, '64.	Left; circ.; by Surg. J. A. Broekway. Furloughed. Died Oct. 12, 1864.
75	Cook, J. A., Pt., C, 104th Illinois, age 20.	June 18, 28, '64.	Left; circ.; by A. Surg. C. C. Byrne; gang. Died July 19, '64.	94	Danielson, J., Serg't, F, 11th Connecticut, age 30.	June 3, July 3, 1864.	Left; circular (gang.); by A. A. Surg. A. N. Brockway. Furloughed. Died Oct. 12, 1864.
76	Davis, A., Pt., E, 32d New York.	May 7, 31, '62.	Right; amp. left arm; by A. A. Surg. C. H. Osborne. Died July 14, 1863.	95	Dilley, A. M., Pt., C, 133d Pennsylvania.	Oct. 19, Nov. 1, 1863.	Left; by A. Surg. R. Bartholow, U. S. A. (amp. finger Oct. 19). Died December 2, 1863.
77	Dingman, D., Pt., E, 27th Michigan, age 23.	June 18, 24, '64.	Left (amp. fingers). Died June 27, 1864, tetanus.	96	Fry, H., Pt., E, 68th New York, age 24.	May 2, 15, '63.	—; gangrene. Died October 28, 1863, pyæmia.
78	Harper, S., Pt., H, 121st N. Y., age 32.	May 6, 18, '64.	Right; circ. (amp. finger); gang.; by A. A. Surg. H. C. May. Died July 18, 1864, exhaustion.	97	Jacobs, C. W., Corp'l, B, 106th New York.	Dec. 13, 22, '62.	By Surg. E. Bentley, U. S. V. Died Dec. 28, 1862, pyæmia.
79	Hartzell, J., Pt., C, 99th Ohio, age 19.	June 16, July 13, 1864.	Right; circ. (amp. finger); gang.; by A. A. Surg. H. C. May. Died July 18, 1864, exhaustion.	98	Jordan, J., Pt., F, 155th New York, age 30.	June 3, 15, '64.	Right; circular (erysipelas); by A. A. Surg. G. O. Hoody. Died July 2, 1864, pyæmia.
80	Hitchman, A., Pt., D, 6th Pa., age 19.	May 6, 25, '64.	Left; circ.; A. A. Surg. R. Ottman. Died June 21, 1864. <i>Spec.</i> 2476.	99	McCraeken, J., Serg't, B, 1st Pa. Res., age 22.	July 11, '62	By A. A. Surg. J. R. Uhler. Died July 14, 1862, ichoræmia.
81	Hood, F. A., Corp'l, F, 40th Mass., age 39.	June 3, 16, '64.	Left (hæm.); by A. A. Surg. A. V. Cherbonnier; cruris; June 26, amp. arm. Died June 27, '64.	100	Mullins, J. B., Pt., I, 5th Tennessee Cavalry.	May 18, Feb. 2, '63.	Hæmorrhage. Died June 14, '63.
82	Hunt, A., Pt., D, 8th Maryland, age 19.	May 9, 14, '64.	Left; ant. post. flap; by Surg. A. F. Sheldon, U. S. V. Died May 22, 1864, pneumonia.	101	Schmitt, F., Pt., K, 5th Michigan, age 44.	Oct. 27, No. 18, '64	Left; circular; by Dr. Tinsley, C. S. A. Died.
83	Jackson, T., Pt., B, 95th New York, age 19.	Feb. 6, 21, '65.	Left; antero-posterior flap; by A. A. Surg. J. Dickson. Died April 8, 1865, pyæmia.	102	Taylor, G. S., Pt., G, 8th Tennessee.	Sept. 13, 28, '64.	Left. Died November 3, 1864.
				103	Weidle, B., Pt., C, 143th Pennsylvania.	May 5, 14, '64.	Died May 15, 1864, tetanus.
				104	Wheeler, C. B., Pt., B, 19th Michigan, age 26.	June 21, Jul. 18, '64	Right (June 27, amput'n finger). Died August 3, 1864, pyæmia.
				105	Williams, B. F., Pt., C, 125th Pa., age 23.	Sept. 17, Oct. 8, '64.	Right. Died November 13, 1862, pyæmia.
				106	Worlen, J., Pt., E, 6th Virginia.	June 21, Jul. 6, '62.	Died July 14, 1862, pyæmia.

**Secondary Amputations in the Forearm for Shot Injury.**—A hundred and eighty-four such operations were reported.

§ *Recoveries after Secondary Amputations in the Forearm.*—One of the hundred and fifty-five cases will be detailed:

CASE 1929.—Private W. Green, Co. C, 35th Massachusetts, aged 23 years, was wounded in the right forearm, at Antietam, September 17, 1862, and admitted to Capitol Hospital, Washington, six days afterward. Assistant Surgeon E. DeW. Breneman, U. S. A., contributed the specimen (FIG. 715), and reported the following history: "The ball entered the arm anteriorly one inch above the radio-carpal articulation, on radial aspect, fracturing that bone, and escaped posteriorly at the ulnar aspect, fracturing that bone also. The patient was admitted to Satterlee Hospital, October 12th, his arm in pasteboard splints. It was greatly tumefied and he was in intense pain. Placed the limb upon a straight splint, well padded, and had cold water constantly applied. On the evening of October 19th, secondary hæmorrhage supervened, presumed to be from the radial artery; the forearm was amputated by Acting Assistant Surgeon N. P. Hickman, by the circular method, at the middle third, by the advice of Assistant Surgeon J. S. Billings, U. S. A. I made an examination of the amputated portion and found a comminuted oblique fracture of the radius, commencing an inch from the articulation of the carpus; also a transverse fracture of the ulna, with the formation of a capsular ligament, thus producing a false joint; and a detached portion of the radius driven into the interosseous space and injuring the posterior interosseous artery, from which the hæmorrhage proceeded. Considerable callus was thrown out between the injured portions of each bone posteriorly, and at this part of the radius nature also made an attempt to form a capsular ligament. The radio-carpal articulation was uninjured." This patient was transferred to the care of Assistant Surgeon A. H. Smith, U. S. A., who reports, October 23d, that "he had removed pieces of bone occasionally, and that the wound was nearly healed." The patient was discharged January 17, 1863, pensioned, and was paid September 4, 1875. The specimen (FIG. 715) shows the lower halves of the bones of the forearm, with necrosis of the fractured parts and slight osseous deposits above the lines of necrosis.



FIG. 715.—Necrosed bones of forearm after secondary amputation. *Spec.* 880.



TABLE CXXXVII.

Condensed Summary of One Hundred and Fifty-five Successful Secondary Amputations in the Forearm for Shot Injury.

No.	NAME, AGE, AND MILITARY DESCRIPTION.	DATES.	OPERATIONS, OPERATOR, RESULT.	No.	NAME, AGE, AND MILITARY DESCRIPTION.	DATES.	OPERATIONS, OPERATOR, RESULT.
1	Akin, S., Color Serg't, C, 13th Pa., age 31.	May 6, '64	Left; doub. skin flaps; by A. Surg. W. F. Norris. Pens'd May 30, '65.	41	Taft, D. W., Pt. I, 95th New York, age 20.	Mar. 3, June 5, 1865.	Right; circ.; by A. A. Surg. J. P. Agnew (excis. radius April 12). Pens'd July 22, '65. <i>Spec.</i> 4281.
2	Appleby, C. H., Pt. K, 52d Ohio, age 52.	Ap. 27, '61	Right; flap; by A. A. Surg. O. D. Norton (gangrene). Disch'd.	42	Thayer, N. D., Serg't, A, 3d Michigan.	Jan. 23, My 14, '63	Left; circular; by A. Surg. W. A. Bradley. Pens'd Aug. 5, '63.
3	Bartlett, A. A., Pt., A, 49th New York.	Se. 17, '62	Left; by Surg. O. A. Judson, U. S. V. Pens'd April 6, '63. <i>Spec.</i> 635.	43	Thompson, H. A., Pt., A, 36th Mass., age 29.	May 6, Jul. 2, '64	Left; ant.-post. flap; by Dr. H. M. Dean. Pens'd Jan. 16, 1865.
4	Branham, J. H., Pt., C, 2d Wisconsin.	Jan. 4, '63	Left; flap. Disch'd June 19, '63; pensioned; healthy stump.	44	Tibbits, W. W., Pt., B, 87th Indiana.	Sept. 19, Oct. 29, '63	Left; flap; by A. Surg. C. F. Haynes. Pens'd May 30, 1864.
5	Bruso, O., Pt., A, 121st New York, age 21.	Aug. 28, Oct. 1, '62	Left; by Dr. J. P. Foot (gang.; lig. ulnar). Disc'd Aug. 1, 1865.	45	Wall, C., Pt., H, 81st Pennsylvania.	Aug. 6, '62	Left; flap; by Surg. D. W. Bliss. Disch'd October 6, 1862; pens'd.
6	Butts, P. A., Serg't, A, 23d Kentucky, age 22.	May 27, Au. 18, '64	Left; circ.; by Surg. B. B. Breed, U. S. V. Pens'd Jan. 7, 1865.	46	Wallace, J., Pt., B, 28th Massachusetts.	De. 13, '62, June, 1863.	Left; by Dr. G. W. Gay, Boston; erysipelas. To V. R. C. Disch'd Mar. 24, 1869. Not a pensioner.
7	Cambe, S., Pt., A, 40th Indiana, age 33.	De. 31, '62	Left; by A. A. Surg. H. M. Lilly (excision). Pens'd Nov. 16, '64.	47	Becker, W., Serg't, B, 98th Pa., age 26.	July 2, Aug. 30, 1862.	Left; flap; by A. A. Surg. R. Livezey; ham.; ligation. Discharged Aug. 17, 1864; pens'd.
8	Campbell, F., Pt., A, 23d Massachusetts.	June 18, Jul. 29, '64	Left; flap; by A. A. Surg. J. W. Wolverton. Disch'd Jan. 18, '65.	48	Biegelow, W., Corp'l, D, 5th Maine, age 22.	Sept. 29, No. 7, '64	Right; circ.; by A. A. Surg. G. D. Trumpp. Pens'd Feb. 11, '65.
9	Cape, T., Pt., C, 12th Kentucky.	May 29, Oct. 30, '62	Right; by A. Surg. J. M. Study, U. S. V. Pens'd Feb. 13, 1863.	49	Bohn, A., Pt., I, 30th Wisconsin, age 21.	June 3, Jul. 12, '64	Right; flap; by A. A. Surg. W. P. Moon. Pens'd Feb. 11, 1865.
10	Casey, T., Pt., A, 69th New York, age 32.	June 3, July 11, 1864.	Left; skin flap; by A. A. Surg. S. D. Marshall (ham.). Disch'd July 24, '65; pens'd. <i>Spec.</i> 3613.	50	Brady, J., Pt., D, 17th Infantry, age 29.	July 2, Au. 4, '63	Right; flap; by A. A. Surg. W. L. Hays. Discharged; pens'd.
11	Cheney, D. J., Pt., A, 2d Massachusetts.	May 2, '63	Left; flap; by Dr. G. Kimball. <i>Spec.</i> 1152.	51	Camp, H., Corp'l, A, 113th Illinois, age 20.	May 19, Je. 28, '63	Left. Discharged September 1, 1863.
12	Conant, J. H., Pt., A, 83th Illinois, age 36.	July 4, Oct. 1, '64	Right; circ.; by A. A. Surg. S. W. Thompson. Disch'd July 2, '65.	52	Cobb, S., Pt., H, 17th Maine.	July 3, Sep. 1, '63	Right; circ.; by A. A. Surg. C. Phelps. Pens'd Oct. 10, 1863.
13	Courtenay, J. A., Pt., B, 1st Me. H. A., age 29.	May 19, Au. 18, '64	Left; flap. Disch'd July 22, '65; pensioned; stump healed.	53	Conlon, J., Corp'l, I, 136th N. Y., age 21.	Aug. 15, 1863.	Left; flap; by A. Surg. C. R. Greenleaf, U. S. A. Disch'd June 24, 1865; pens'd. <i>Spec.</i> 2531.
14	Craze, H., Pt., I, 155th New York, age 25.	June 13, Jul. 30, '64	Right; flap; by A. A. Surg. H. Craft (ham.). Pens'd Jan. 21, '65.	54	Courter, H., Corp'l, A, 5th N. J., age 39.	June 23, Aug. 29, 1864.	Right; circ.; by A. A. Surg. W. S. Hendrie (July 22, amp. fing.). Pens'd Mar. 23, '65. <i>Spec.</i> 3194.
15	Crosby, E., Serg't, I, 6th Maine, age 27.	July 3, Aug. 25, 1863.	Left; flap; by Surg. A. B. Mott, U. S. V.; July 8, amp. finger; gangrene. Disch'd Jan. 18, '64.	55	Clark, W. H., Pt., F, 18th Conn., age 25.	Je. 8, '63, Feb. 3, '64	Left; flap. Discharged May 10, 1864.
16	Drake, A. S., Pt., B, 16th Mass., age 25.	May 31, Jul. 1, '62	Left; circular; by Dr. J. E. Steele (ham.). Pens'd Oct. 14, 1862.	56	Crapsey, J., Pt., A, 110th Ohio, age 23.	May 6, June 6, 1861.	Left; circ.; by A. A. Surg. D. P. Wolhaupter. Disch'd April 17, 1865. <i>Spec.</i> 2580.
17	Egan, J., Pt., F, 6th Vermont, age 19.	May 5, June 29, 1864.	Left; flap; by Surg. E. E. Phelps (gangrene; hamer.). Disch'd Oct. 21, '65; pens'd; healed.	57	Crowley, D., Pt., D, 35th Massachusetts.	Se. 17, '62, Aug. —, 1863.	Left; flap; by A. A. Surg. J. W. Cushing (excision metacarpal). Duty Dec. 28, 1863; pensioned.
18	Green, G. W., Pt., F, 10th New York.	Sept. 17, Oct. 29, '62	Left; by A. A. Surg. L. Heard. Disch'd Nov. 14, '62; pensioned.	58	Crowley, L., Pt., F, 2d N. Y. M. R., age 39.	July 2, Aug. 5, 1864.	Left; circ.; by A. A. Surg. J. F. Wilson (amp. fingers June 18). Disch'd January 11, 1865.
19	Green, N. H., Pt., D, 6th Michigan Cavalry.	Sept. 14, Nov. 3, 1863.	Left; circular; by Dr. Bartholow (Sept 13, exc. gang); Nov. 17, amp. arm. Pens'd March 24, '64.	59	David, A., Pt., E, 111th Pennsylvania, age 18.	May 15, Jul. 1, '64	Right; circ.; by A. Surg. C. W. Lawrence. Pens'd Dec. 26, 1864.
20	Green, W., Pt., C, 27th Indiana.	May 2, Je. 6, '63	Left; circular. Disch'd March 12, 1864; pensioned; sound stump.	60	Davis, F. M., Pt., A, 51st Indiana, age 22.	April 7, Je. 24, '64	Right; ant.-post. flap; by A. A. Surg. W. H. Matlock (gang.). Pens'd Oct. 27, '64. <i>Spec.</i> 3371.
21	Guy, J. L., Pt., E, 18th Ohio.	De. 31, '62	Left; flap; by Surg. W. P. Johnson, 18th O. Pens'd Mar. 31, '63.	61	Dehn, J., Corp'l, C, 1st Minnesota.	July 3, Au. 12, '63	Right; by Surg. S. D. Freeman, U. S. V. Disch'd Nov. 19, '63; pen'd.
22	Hartigan, E., Pt., C, 3d Delaware, age 25.	Aug. 20, Se. 30, '64	Left. Discharged June 11, 1865. Not a pensioner.	62	Dickinson, R. J., Pt., B, 127th Illinois.	May 22, Jul. 29, '63	Right; flap; by Surg. A. Hammer, U. S. V. Pens'd Sept. 24, 1863.
23	Hersinger, F., Pt., I, 15th N. Y. H. A., age 42.	Feb. 6, '65	Right; circ.; ham. Disch'd June 22, '65; pens'd; stump healed.	63	Eagin, T., Pt., B, 92d New York, age 28.	Aug. 16, Sept. 19, 1864.	Left; circular; by A. A. Surg. T. L. Van Norden (amp. finger August 25). Disch'd Dec. 23, '64.
24	Herring, B. D., Pt., Madison's Art., age 22.	May 4, Je. 5, '63	Left; circ. (recurrent hamer ge). Furloughed June 30, 1864.	64	Edgell, W., Corp'l, D, 97th Ohio.	De. 31, '62, Fe. 15, '63	Left; flap. Disch'd April 9, 1863; pensioned; perfectly healed.
25	Hinds, J. D., Pt., G, 1st D. C. Cav., age 22.	Aug 28, '64	Right; flap; by A. A. Surg. G. E. Brickett. Pens'd May 19, 1865.	65	Edwards, S. M., Serg't, K, 17th Pennsylvania Cavalry, age 44.	June 11, Sept. 17, 1864.	Left; circular; by A. A. Surg. J. Winslow. Disch'd April 4, '65; pensioned. <i>Spec.</i> 3255.
26	Hughes, I. M., Pt., F, 21st Iowa.	Au 28, '64	Right; by Surg. A. Hammer, U. S. V. Disch'd Sept. 24, '63; pens'd.	66	Eggleston, A. J., Pt., M, 2d Pa. Heavy Art.	Sept. 29, No. 7, '64	Right; flap. Discharged January 2, 1865.
27	Igo, J., Pt., C, 2d New York Heavy Art.	July 11, Jul. 28, '64	Left; flap. Discharged Nov. 14, 1864; pensioned; good stump.	67	Everts, G., Pt., D, 1st Vermont.	July 12, Au. 16, '64	Right; flap; A. A. Surg. H. Craft; erysipelas. Pens'd July 24, '65.
28	Johnson, J. D., Pt., A, 115th Illinois, age 27.	Sept. 20, No. 25, '63	Left; circular; by A. Surg. B. E. Fryer. Pens'd Dec. 10, 1864.	68	Ferris, L. H., Corp'l, C, 3d Michigan.	Aug. 30, Oct. 5, '62	Left; by A. A. Surg. P. H. Brown. Discharged December 6, 1862.
29	Jones, J. T., Serg't, B, 117th New York, age 30.	Jan 15, Feb. 15, 1865.	Right; circular; by A. Surg. J. M. Palmer. Pens'd June 12, '65.	69	Flannigan, E. P., Pt., D, 9th N. H., age 32.	Sept. 30, Nov. 4, 1864.	Left; lateral flap; by A. A. Surg. H. Craft. Disch'd June 1, 1865; pensioned. <i>Spec.</i> 3284.
30	King, W. W., Corp'l, F, 8th Indiana, age 21.	Oct. 19, No. 23, '61	Left; circ.; by A. A. Surg. J. M. McGrath. Disch'd Mar. 2, 1865.	70	Garrett, I. L., Corp'l, F, 8th Kentucky.	Jan. 2, Mar., '63	Right; by A. Surg. A. B. Chapin. Disch'd April 1, 1863; pens'd.
31	Lewis, E. H., Pt., E, 145th Pa., age 18.	De. 13, '62	Left; circular (excis.); ham.; lig. Disch'd June 13, '63; pensioned.	71	Gibson, S. O., Corp'l, D, 11th New Hampshire, age 23.	June 17, Dec. 19, 1864.	Right; ant.-post. flap; by A. A. Surg. J. M. Whitaker (exc. rad. June 18). Pens'd June 2, 1865.
32	McLain, S., Pt., D, 2d Sharpshooters, age 28.	Sept. 21, Oct. 18, 1864.	Left; circ.; by A. A. Surg. R. F. Mend (excis. metacar. Sept. 21, gangrene). Disch'd Feb. 11, '65.	72	Gingry, D., Pt., E, 184th Pennsylvania, age 37.	June 10, July 28, 1864.	Left; circular; by A. A. Surg. W. B. Corbit (amp. fingers). Disch'd April 8, '65; pens'd. <i>Spec.</i> 3656.
33	McKennelly, D., Pt., G, 15th Kentucky.	Sept. 19, Oct. 30, 1863.	Right; flap; by A. Surg. C. Frink, U. S. V. (amp. finger Sept. 28; erysip.); ham.; lig. interes. To V. R. C. Aug. 26, '63; pens'd.	73	Green, W., Pt., C, 35th Massachusetts, age 20.	Sept. 17, Oct. 19, 1862.	Right; circular; by A. A. Surg. N. Hickman. Disch'd Jan. 17, 1863; pens'd. <i>Spec.</i> 880.
34	Messerve, M., Pt., C, 30th Maine, age 19.	April 23, Au. 27, '64	Left; circular; by Surg. C. Winne (cystip). Pens'd June 3, 1865.	74	Gump, A. J., Pt., C, 61st Pennsylvania, age 27.	May 6, Dec. 20, 1864.	Right; ant.-post. flap; by Surg. N. R. Mesoley, U. S. V. Disch'd Mar. 7, '65; pens'd. <i>Spec.</i> 3517.
35	Nixon, A. H., Capt., K, 84th Pa., age 31.	June 1, Jul. 9, '64	Left; flap; by Dr. S. Cullen, Camden, N. J. Disch'd; pens'd.	75	Haas, S., Lient., B, 7th New York.	De. 13, '62, Jan. 13, '63	Right; by Dr. E. Kraekowizer, N. Y. Disch'd Apr. 2, '63; pens'd.
36	Potter, H. H., Corp'l, A, 53d Ohio, age 21.	July 22, No. 10, '64	Right; circular; by A. Surg. D. J. Swarts. Pens'd April 7, 1865.	76	Hall, G. W., Pt., E, 10th Illinois, age 37.	Aug. 22, Oct. 5, 1861.	Right; circ.; by A. A. Surg. L. B. Voorhies (amp. hand Aug. 27). Disch'd July 1, 1865; pens'd.
37	Reiley, P., Serg't, F, 96th Pennsylvania.	May 10, Je. 10, '64	Right; circ.; by Dr. T. R. Crosby. Pens'd April 12, '65; arm. imp.				
38	Shafer, J., Pt., I, 127th Pennsylvania, age 26.	Dec. 13, Ja. 16, '63	Left; circ.; by Dr. J. Stearns, Jr. Pens'd April 3, '63. <i>Spec.</i> 995.				
39	Stiteler, D., Pt., G, 77th Pennsylvania.	Dec. 31, 1862.	Left; circular; by Surg. T. A. MeParlin, U. S. A. (gang.; ham.). Disch'd April 13, '63; pensioned.				
40	Street, D., Pt., B, 69th Pennsylvania, age 30.	June 2, Jul. 25, '64	Right; circ.; by Dr. A. S. Usher. Pens'd Mar. 16, '65. <i>Spec.</i> 3673.				

No.	NAME, AGE, AND MILITARY DESCRIPTION.	DATES.	OPERATIONS, OPERATOR, RESULT.	No.	NAME, AGE, AND MILITARY DESCRIPTION.	DATES.	OPERATIONS, OPERATOR, RESULT.
77	Harlow, F. M., Pt., 1, 14th Missouri, age 25.	Aug. 7, '61.	Left; circular; by Surg. J. H. Grove. Discharged.	119	Baker, J. H., Pt., G, 25th Missouri, age 18.	Oct., '61, May 2, '62.	Left. Discharged June 20, 1862; pensioned.
78	Hazen, W., Pt., B, 57th Pennsylvania.	May 6, Oct. 12, 1864.	Left flap; by A. A. Surg. D. Kennedy. To V. R. C. Jan. 14, '65; pensioned; stump healed.	120	Banghart, P., Pt., M, 18th Pennsylvania.	Feb. 6, M'h 12, '65.	Right; flap. Discharged June 22, 1865; pensioned.
79	Henderson, W., Pt., G, 1st N. J., age 21.	May 3, J'e 14, '63.	Left (hemorrhage). Disch'd Oct. 22, '63; pens'd; stump bad.	121	Barton, J. L., Pt., K, 7th Ohio Cavalry, age 23.	Dec. 15, '63, An. 15, '64.	Left; flap; by Surg. L. R. Stone, U. S. V. Pens'd Dec. 16, 1864.
80	Henant, G. S., Pt., F, 12th S. C., age 19.	May 12, Oct. 3, '64.	Right; circular; by A. A. Surg. J. Harris. To prison March 1, '65.	122	Beach, J. S., Corp'l, C, 3d Infantry.	June 27, Aug. 6, '62.	Left; flap; by Drs. Gillham, Vason, and Dudley, Brooklyn, Pens'd.
81	Hodges, B., Corp'l, G, 5th Conn., age 21.	July 20, Oct. 26, 1864.	Right; flap (exc. ulna July 24); crysipelas; gangrene. Disch'd Feb., 1865; pensioned. sound.	123	Burns, W. W., Pt., E, 91st Pennsylvania, age 28.	June 18, Aug. 1, 1864.	Right; circ.; by A. A. Surg. W. B. Corbit (June 18, amp. finger); Sept. 30, amp. arm. Discharged July 31, 1865; pensioned.
82	Jones, T., Pt., F, 10th Minnesota, age 17.	May 6, June 10, 1864.	Left; by Surg. S. B. Sheard and A. Surg. W. W. Clark, 10th Minn. Disch'd July 23, 1864.	124	Butterworth, J., Pt., F, 1st Rhode-Island Artillery, age 21.	Dec. 16, '62, Mar. 13, 1863.	Left; flap; by Surg. C. A. Cowgill, amp. wrist joint Dec. 16, 1862. Pens'd Sept. 1863. Spec. 1323.
83	Jones, W. Pt., I, 1st N. Y. Dragons, age 25.	May 7, J'e 22, '64.	Left; circular. Discharged July 21, 1865.	125	Campbell, O. C., Pt., F, 184th Pennsylvania.	Dec. 13, '63, Mar., '63.	Left; circ. Disch'd April 2, '63; pens'd; stump perfectly healed.
84	Kearnes, J. V., Pt., H, 13th Infantry.	May 19, 1863.	Right; by Dr. W. S. Boyd, Vinton, Iowa. Disch'd Sept. 17, '63; pensioned; good stump.	126	Clay, D., Pt., D, 2d Kansas C. T., age 31.	April 5, July 29, 1864.	Right; ant. post. flap; by A. A. Surg. E. A. Clark. Discharged June 26, '65; elbow ankylosed.
85	Krepps, D., Pt., C, 148th Pennsylvania.	April 1, Jul. 30, '64.	Left; flap. Discharged February 5, 1864.	127	Colwell, J., Corp'l, B, 1st W. Va., age 24.	July 25, Oct. 19, '64.	Left; flap; by A. A. Surg. T. G. Morton. Pens'd June 7, 1865.
86	Langdon, S., Pt., I, 3d New York.	April 10, 1865.	Right; flap; by A. A. Surg. T. Bartram (amp. finger July 30). Discharged; pensioned.	128	Crawford, J. B., Serg't, 75th Illinois, age 21.	June 19, July 22, 1864.	Right; by A. A. Surg. H. H. Bishop (wound of thigh); Aug. 7, re-amp. forearm. Pens'd Feb. 12, '65.
87	Lahr, J., Pt., F, 6th Infantry.	June 27, Jul. 28, '62.	Left; by A. A. Surg. W. W. Hays. Pens'd Nov. 25, 1862. Spec. 35.	129	Essey, E., Pt., B, 97th Pennsylvania, age 22.	May 20, June 27, 1864.	Left; circ.; by A. Surg. W. Webster, U. S. A. (amp. finger; gangrene). Dis'd Apr. 2, '63; pens'd.
88	Lewis, T., Serg't, E, 5th Michigan, age 26.	July 2, Aug. 26, 1863.	Right (Fend's method); by A. A. Surg. A. Hewson. Disch'd April 20, 1864; pens'd. Spec. 2794.	130	Farrington, G. E., Pt., C, 121st New York, age 22.	May 10, Aug. 20, 1864.	Right; oval skin flap; circular muscles; by A. A. Surg. W. P. Moon. Disch'd Dec. 10, 1864.
89	Mudert, J., Pt., G, 2d Infantry.	Sept. 17, Oct. 21, '62.	Right; by Asst. Surg. B. Knickerbocker. Pens'd March 9, '63.	131	Foster, J. W., Serg't, C, 20th Kentucky.	July 5, Au. 30, '63.	Left; flap. Discharged; pens'd; well healed.
90	Masters, S., Pt., H, 54th Pennsylvania.	June 17, Jul. 19, '64.	Left; circ.; by Surg. L. R. Stone, U. S. A. Dis'd Dec. 16, '64; pens'd.	132	Gallagher, B., Pt., F, 17th Infantry.	Sept. 17, Dec. 14, 1862.	Left; circular; by Dr. Pollock of Pittsburgh. Discharged Jan. 27, 1863; pensioned; good stump.
91	Mathews, B. W., Serg't, E, 47th North Carolina, age 28.	July 3, Aug. 30, 1863.	Left; ant. post. flap; by A. A. Surg. J. E. Steele (crisp.); amp. arm Oct. 25, 1863.	133	Gordon, D., Pt., E, 25th Kentucky.	April 6, Oct. 14, 1862.	Right; circular; by Surg. E. C. Franklin, U. S. V. (crisp.); Disch'd Nov. 15, '62. Spec. 1771.
92	McKiernan, J. H., Pt., K, 6th Iowa.	May 28, Jul. 5, '64.	Left; flap. Discharged November 25, 1864; pensioned.	134	Grove, J. D., Serg't, G, 184th Pa., age 25.	June 22, July 24, 1864.	Left; ant. post. flap; by Surg. N. R. Mosley (exc. meta.); gang. Pens'd June 17, '65. Spec. 2896.
93	McMillan, A., Pt., A, 7th Michigan.	Sept. 8, Oct. 23, 1862.	Left; circular; by A. Surg. A. M. Clark, U. S. V. Disch'd Dec. 3, 1862. Spec. 213.	135	Kelly, P., Pt., H, 6th Louisiana, age 31.	No. 7, '63, Jan. 2, '64.	Right; flap; by A. Surg. J. C. McKee. To prison April 11, 1864.
94	McWaugh, J., Pt., H, 119th Pennsylvania.	May 3, '63.	Left; circ. To V. R. C. Feb. 25, 1864; pens'd; healthy stump.	136	Marshall, T., Serg't, F, 3d Mass. Cav., age 37.	Sept. 19, Oct. 28, '64.	Left; double flap; by A. A. Surg. B. B. Miles. Pens'd Apr. 10, '65.
95	Moss, P. W., Pt., D, 124th Ohio, age 20.	May 27, Au. 17, '64.	Left; circ.; by Surg. R. R. Taylor, U. S. V. Pens'd Nov. 18, '64.	137	McCormick, T., Pt., H, 30th Mass., age 46.	Oct. 19, '64, Jan. 27, 1865.	Right; circ.; by A. A. Surg. F. C. Ropes (amp. carp. and meta. art.; ham.). Dis'd May 11, '65; pens'd.
96	Moses, G. F., Pt., B, 39th Mass., age 19.	May 10, 1864.	Left; circular; by A. A. Surg. J. Tyson (amp. wrist joint May 19). Pens'd Mar. 19, '65. Spec. 4197.	138	McNamara, P., Pt., A, 2d New York Heavy Artillery, age 36.	June 16, Aug. 11, 1864.	Left; ant. post. flap; by A. A. Surg. W. C. Merrill (amp. n. finger; ham.; lig.). Disch'd March 27, 1865; pensioned. Spec. 2430.
97	Mute, G., Pt., C, 47th New York, age 20.	May 15, Nov. 25, 1864.	Right; flap; by A. A. Surg. J. F. Thompson. Disch'd March 30, 1865; pens'd. Spec. 3437.	139	Milledge, J., Pt., A, 33d Wisconsin.	Dec. 22, '62, June 21, 1864.	Left; by Surg. H. Culbertson, U. S. V. (exc. Jan. and April, 1864). Pens'd Aug. 14, '63. Spec. 3623.
98	Odell, L., Pt., H, 45th Pennsylvania, age 20.	June 4, Sep. 3, '64.	Left; circ.; by Dr. J. T. Lanning (June 3, exc.). Pen'd Jan. 22, '65.	140	Montgomery, G., Pt., H, 105th Pa., age 22.	Aug. 15, Sept. 22, 1864.	Left; circular; by A. A. Surg. G. P. Sargent (gang.; ham.). Discharged June 7, 1865; pens'd.
99	Parvis, J. W., Serg't, I, 103th Indiana.	Oct. 9, '64.	Left; by Dr. J. M. Lanning, Paris, Iowa. Pens'd Jan. 27, '65.	141	Painter, S., Pt., G, 23d New Jersey, age 18.	May 3, Au. 5, '63.	Right; flap; by A. A. Surg. E. G. Waters. Pens'd Oct. 17, 1863.
100	Richmond, R. H., Pt., K, 4th Iowa.	Mar. 6, Au. 12, '62.	Left; circ.; by Dr. J. M. Lanning, Paris, Iowa. Pens'd Jan. 27, '65.	142	Parker, S. E., Pt., C, 1st Maine Cavalry.	May 11, 1864.	Left; by Dr. Seavey, of Bangor, Me. (May 20 hamor.). Disch'd February 9, 1865; pensioned.
101	Rodgers, J. M., Serg't, D, 122d Ohio, age 27.	May 7, Au. 31, '64.	Left; circ.; by A. A. Surg. J. M. McGrath. Pens'd; sound stump.	143	Potter, C., Pt., D, 10th Massachusetts.	July 1, Au. 16, '62, M'y 6, '64, Jan., '70.	Left; flap; by A. A. Surg. J. W. Diekie. Disch'd Jan. 17, 1863.
102	Rose, A. J., Pt., C, 142d Pennsylvania, age 25.	Jul. 1, '63, Au. 16, '63.	Right; circ.; by A. A. Surg. T. J. Yarrow. Pens'd Dec. 23, 1863.	144	Riekerson, C., Pt., H, 2th Massachusetts.	May 17, Aug. 12, 1864.	Right; by Dr. J. H. Mackie, pension exam'r. Disch'd; pens'd.
103	Shank, L., Pt., H, 54th Pennsylvania, age 41.	July 18, Se. 15, '63.	Right; circ.; by A. A. Surg. E. G. Waters. Pens'd Jan. 17, 1865.	145	Ryle, B., Corp'l, D, 59th Massachusetts, age 35.	June 17, Aug. 12, 1864.	Left; circular; by A. A. Surg. W. P. Moon. Pens'd Dec. 14, '64; stump decaying. Spec. 3620.
104	Smith, D., Pt., H, 124th Illinois.	J'e 26, '63, Ap. 3, '64.	Right; flap; by Dr. P. A. Allaire, Aurora, Ill. Pens'd April 25, '64.	146	Sadler, J., Pt., A, 7th New York, age 34.	Aug. 14, Sept. 15, 1864.	Left; lat flap; by A. A. Surg. W. H. Ensign; amp. finger (hem.; necrosis). Disch'd Mar. 22, '65. Spec. 3279.
105	Sprague, T. J., Pt., D, 2d Pa. H. A., age 18.	June 15, Au. 3, '64.	Left; circ.; by A. A. Surg. W. Post (gangrene). Pens'd April 8, '65.	147	Smith, J., Pt., I, 8th N. Y. H. A., age 22.	June 12, Jul. 20, '64.	Right; circ.; by A. A. Surg. J. C. DuBois. Disch'd March 31, '65.
106	Sprout, F. M., Pt., B, 23d Missouri.	April 6, M'y 9, '62.	Right. Discharged Dec. 1, 1862; pensioned; stump sound.	148	Stebbins, P., Pt., H, 122d N. Y., age 43.	July 12, Aug. 19, 1864.	Right; circ.; by A. A. Surg. A. P. Fitch (amp. fingers; gang.). Discharged; pensioned.
107	Thalheimer, J., Pt., B, 63d Pennsylvania.	Jul. 1, '62, Ap. 5, '63.	Left; flap; Drs. Pollock and Shaw. Dis. Sep. 22, '62. Died Jan. 13, '72.	149	Stotzell, A., Pt., M, 15th Pa. Cav., age 24.	July 20, Se. 29, '64.	Left; circ.; by A. Surg. T. A. McGraw, U. S. V. Dis'd Mar. 27, '65.
108	Thompson, D. A. L., Pt., B, 50th Ill., age 24.	Mar. 20, M'y 18, '65.	Left; circular; by A. Surg. S. H. Orton. Pensioned Oct. 3, '65.	150	Vanghn, W., Pt., E, 111th Illinois, age 20.	May 14, Jul. 18, '64.	Left; flap; gangrene; crysipelas. Disch'd Feb. 25, '65; pens'd.
109	Thompson, W., Pt., D, 2d Kans. C. T., age 18.	April 30, Jul. 29, '64.	Right; circ.; by A. Surg. E. A. Clark. Pens'd May 23, 1865.	151	Walker, D. H., Pt., I, 2d Pennsylvania Cavalry.	July 9, Aug. 14, 1864.	Left; circ.; by A. A. Surg. W. H. Triplett; bone removed. To V. R. C. Dec. 20, '64; pensioned.
110	Thorn, B., Pt., C, 35th Illinois, age 23.	Sept. 19, Oct. 24, '63.	Right; double flaps (crispelas). Dis'd July 7, '64; stump healed.	152	Webster, C. F., Serg't Major, 5th Me. age 25.	May 12, J'e 24, '64.	Right; circular; by A. Surg. J. C. McKee. Disch'd Nov. 25, 1864.
111	Vanakin, E., Pt., G, 120th New York.	July 2, Au. 6, '63.	Right; flap; by A. A. Surg. S. R. Skillern. Pens'd March 26, '64.	153	Byers, L. F., Serg't Maj., 6th Md., age 27.	Oct. 19, '61, Se. 26, '73.	Left; by Dr. C. B. Boyle (Oct. 20, excision of radius). Disch'd June 23, 1865; pensioned.
112	Waddle, J., Pt., D, 7th Illinois Cav., age 20.	Dec. 4, '63, Jul. 3, '64.	Left; circular; by A. A. Surg. S. Leslie. Pens'd August 9, 1864.	154	Dietz, C., Pt., H, 21st Missouri.	Feb., '62, Second y.	Left (amp. little finger and thumb). Discharged July 30, 1862.
113	White, C. L., Pt., G, 29th Massachusetts.	July 1, Aug. 10, 1862.	Left; doub. flaps. A. Surg. C. A. McCall, U. S. A. (excis. radius). Disch'd Aug. 29, '62; pensioned; stump sound. Spec. 157.	155	Williams, T., Pt., A, 11th Pa. Reserves.	June 27, Au. 27, '62.	Right; by Dr. J. K. Kane. Discharged Nov. 27, '62; pensioned.
114	White, J., Pt., B, 16th Massachusetts, age 34.	May 12, J'e 13, '64.	Left; ant. post. flap; by Dr. H. B. Knowles. Disch'd May 25, 1865.				
115	Whitney, W. A., Pt., C, 9th Michigan.	Mar. 17, Ap. 28, '62.	Left; flap; by Surg. E. Church, 9th Mich. Pens'd June 28, '62.				
116	Wilcox, D., Pt., H, 67th Ohio, age 46.	May 7, J'e 27, '64.	Left; circ.; A. Surg. W. Webster (amp. fing.). Disch'd Nov. 21, '64.				
117	Wilson, J., Pt., H, 2d Missouri, age 22.	No. 30, '64, Ja. 24, '65.	Left; ant. post. flap; by Dr. R. McNulty. Paroled March 27, '65.				
118	Wilson, W., Pt., E, 8th Ohio.	June 8, Nov., '62.	Left; by A. Surg. C. A. McCall, U. S. A. Pens'd Nov. 8, 1862.				



§ *Fatal Secondary Amputations in the Forearm.*—The secondary amputations had a mortality of 15.7 per cent.; proportionally greater by 6 per cent. than the primary.

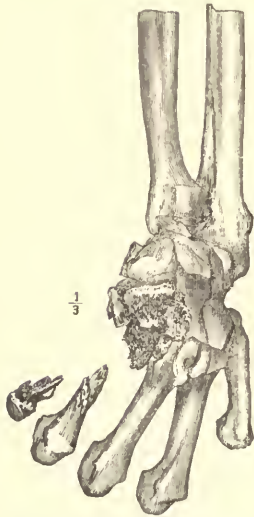

FIG. 716.—Caries after shot fracture of right carpus and metacarpus. Spec. 1953.

CASE 1930.—Private D. Johnson, Co. K, 6th Pennsylvania Cavalry, aged 32 years, was wounded in a skirmish at Bristow Station, October 17, 1863. Surgeon J. B. Coover, of the regiment, reported: "Wound of right hand, partially destroying metacarpal bones." Two days after the injury the man was admitted to Lincoln Hospital, Washington. Assistant Surgeon J. C. McKee, U. S. A., reported the following history: "The ball entered at the metacarpo-phalangeal articulation of the little finger, passing through and fracturing the fourth and fifth metacarpal bones, making its exit at the dorsum. On November 1st gangrene first appeared. This was cured, and the parts remained perfectly healthy until November 15th, when gangrene reappeared in the wound. On November 28th tetanus made its appearance: patient very weak, having no appetite and being low in spirits; tetanic spasms easily excited. On December 2d the forearm was amputated, by circular operation, at the junction of the middle and lower thirds, by Assistant Surgeon H. Allen, U. S. A. Sulphuric ether was used. During the operation the patient lost over twenty ounces of blood, producing syncope. Seven ligatures were applied. No tetanic spasms occurred after the operation. The treatment consisted of tonics, stimulants, and nutritious diet, with warm applications to the stump. The patient gradually sank, and died December 13, 1863. Some nerves must have been injured by the ball, but whether that was the cause operating to produce the fatal disease is a question. My opinion is that the primary injury done by the missile was not the cause, but the influence of the gangrene attacking the parts was the excitant of the disease." The specimen, represented in the adjacent cut (FIG. 716), was contributed by the operator. It consists of a ligamentous preparation of the carpus, metacarpus, and lowest thirds of the bones of the forearm. The dorsal surface of the os magnum and unciform are fractured, and the greater portions of the last two metacarpal bones are shattered.

TABLE CXXXVIII.

*Summary of Twenty-nine Fatal Secondary Amputations in the Forearm for Shot Injury.*

NO.	NAME, AGE, AND MILITARY DESCRIPTION.	DATES.	OPERATIONS, OPERATOR, RESULT.	NO.	NAME, AGE, AND MILITARY DESCRIPTION.	DATES.	OPERATIONS, OPERATOR, RESULT.
1	Burnham, L. M., Corp'l, D, 132d Pa., age 23.	Sept. 17, Oct. 28, 1862.	Left; double flap: by A. A. Surg. J. Ashhurst, Jr.; ham.; lig. brach. Died Nov. 15, '62, hæm. Spec. 272.	16	Roe, J. M., Pt., E, 12th New Jersey, age 33.	June 4, Jul. 23, '64	Rt; circ.; Dr. M. C. B. Richardson (June 30, exc. wrist). Died Aug. 7, 1864, pyæmia. Spec. 3641.
2	Dickson, W. J., Pt., K, 9th Pa. Reserves.	Sept. 17, No. 29, '62	Left (gangrene). Died Dec. 5, 1862, hæmorrhage. Spec. 752.	17	Wiggins, M. W., Serg't, F, 30th N. C., age 21.	May 3, J'e 3, '63.	Right; circular. Died June 8, 1863, pyæmia.
3	Dougherty, J. W., Pt., H, 89th N. Y., age 22.	June 16, Jul. 23, '64	Left; circ.: A. A. Surg. T. C. Bullard. Died Sept. 2, '64, empyæa	18	Burke, J., Pt., G, 69th Pa., age 44.	June 22, Au. 9, '64.	Right; flap; Surg. N. R. Moseley (gangrene; hæmorrhage). Died Sept. 22, 1864, pneumonia.
4	Eaton, G., Pt., I, 40th Pennsylvania, age 16.	May 12, J'e 13, '64.	Left; circ.: A. Surg. A. Delany (w'd scalp). Died June 15, '64, shock.	19	Childers, J., Pt., I, 34th Illinois.	April 7, M'y 10, '62	Left. Died May 23, 1862.
5	Eneley, T., Pt., G, 15th N. Y. Cav., age 22.	April 16, M'y 25, '64	Left; double flap; Dr. C. H. Ohr. Died July 12, 1864. Spec. 4266.	20	Dixon, R., Pt., H, 82d New York.	Sept. 14, Oct. 21, '62.	Left; flap; A. A. Surg. S. Teats. Died Oct. 27, 1862, bronchitis.
6	Guston, A. R., Pt., H, 69th Indiana, age 21.	May 1, Fe 20, '63.	Left. Died June 25, 1863, pyæmia. Spec. 1350.	21	McQuade, W., Pt., K, 24th Mass., age 26.	Au. 14, '64 March 15, 1865.	Left; by A. A. Surg. W. R. Staveley (amputation fingers Aug. 14). Died May 25, '65, typhoid fever.
7	Hitchcock, A., Pt., E, 20th Connecticut.	May 3, Au. 9, '63.	Left. Died February 29, 1864.	22	Packard, A., Pt., 9th Mass. Battery.	July 2, Au. 30, '63	Left; flap; by A. Surg. C. R. Greenleaf (erysipelatos inflammation). Died Sept. 20, 1863, pyæmia. Spec. 2598.
8	Peterson, F., Pt., C, 5th New York, age 20.	June 3, Jul. 28, '64	Circ.: by A. A. Surg. W. P. Moon. Died Aug. 4, 1864, exhaustion.	23	Steinaur, S., Pt., M, 112th Pa., age 18.	April 5, May 24, 1864.	Right; lat. flap; Dr. W. P. Moon; re-amp. forearm July 23. Died Aug. 9, '64, exhaust. Spec. 3625.
9	Sanger, G. H., Corp'l, C, 136th N. Y., age 34.	May 15, June 25, 1864.	Right; skin flap, circ. sec. muse.: A. A. Surg. J. W. Bligh (hæm.). Died July 1, 1864, cong. fever.	24	Bowman, J., Pt., K, 20th Indiana, age 25.	July 3, Au. 8, '63.	By A. A. Surg. T. G. Morton (gangrene). Died Aug. 9, 1863.
10	Armstrong, B., Pt., D, 751st Pa., age 19.	July 2, Au. 24, '63	Left. Died Sept. 6, 1863, pyæmia. Specs. 1796 and 1798.	25	Crawford, C., Pt., D, 1st Ohio, age 20.	May 27, J'e 30, '64	Right. Died July 18, 1864, chronic diarrhœa.
11	Arrance, W., Pt., D, 16th Michigan, age 23.	June 1, Jul. 4, '64.	Left; ant. post. flap; by Surg. C. Page. Died July 10, 1864, gastro-enteritis. Spec. 3327.	26	Hilkrigal, J., Pt., F, 39th Illinois, age 45.	May 16, J'e 17, '64.	Right; circ.: A. A. Surg. M. Baldwin. Died July 16, 1864, gang.
12	Atkins, J., Pt., I, 30th Illinois, age 35.	May 22, J'e 24, '63.	Right; by A. A. Surg. D. O. Farrand. Died July 1, 1863.	27	Thomas, J., Pt., K, 28th Pa., age 24.	Mar. 6, M'y 17, '65	Left; circ.: by A. A. Surg. G. Badger. Died May 27, '65, pyæmia.
13	Grover, J., Pt., D, 79th Illinois.	June 22, July 24, 1864.	Left; circ.: by A. A. Surg. D. A. Griffith (excision radius June 22). Died July 30, 1864.	28	Vandermark, N., Pt., G, 5th N. Y. Cav., age 25.	J'e 11, '64. Mar. 25, 1866.	Right (exc. ulna June 11). Dis'd Nov. 19, 1864; pens'd. Died Nov. 23, 1866, gangrene.
14	Johnson, D., Pt., K, 6th Pa. Cav., age 32.	Oct. 17, Dec. 2, '63.	Right; circ. Died Dec. 13, 1863. Spec. 1953. See CASE 1930.	29	Washburn, J., Pt., H, 38th Indiana.	Sept. 20, Oct. 26, '63	Hæmorrhage; lig. ulnar and rad. Died October 29, 1863, pyæmia.
15	Lewis, C. H., Corp'l, K, 8th Conn., age 30.	Aug. 10, Sept. 15, 1864.	Left; circ.: by A. A. Surg. L. K. Baldwin (ham'ge). Died Sept. 15, 1864, exhaustion. Spec. 3655.				

A summary of the facts regarding the hundred and fifty-five successful and twenty-nine fatal cases of secondary amputation of the forearm is embodied in the foot-note.<sup>1</sup>

<sup>1</sup>The operations were practised on 178 Union and 6 Confederate soldiers: 55 operations with 9 deaths were in the upper third, 80 with 8 deaths in the middle, and 40 with 6 deaths in the lower third. In 9 cases, 6 of which proved fatal, the point of ablation was not recorded. Seventy operations with 10 deaths were on the right side, 111 with 16 deaths on the left, and in 3 fatal cases this point was unspecified. Eighteen, including 1 fatal case, were practised subsequent to excisions in the forearm, wrist, or hand; 3 after disarticulation at the wrist; 14 after partial amputations in the hand. The numerous specimens illustrating this series are specified in the TABLES, and their histories can be consulted in the Descriptive Catalogue of the Surgical Section, 1866, Chaps. VIII and IX.

**Amputations in the Forearm of Uncertain Date.**—Of the hundred and sixty cases in this category, the results were ascertained in ninety-three; there were ten deaths.

TABLE CXXXIX.

*Tabular Statement of One Hundred and Six Cases of Amputation in the Forearm of Uncertain Date.*

SEAT OF OPERATION.	TOTAL CASES.	RECOVERIES.	FATAL CASES.	RESULT UNKNOWN.	PERCENTAGE OF FATALITY.
UPPER THIRD.....	12	10	.....	2	00.0
MIDDLE THIRD.....	10	8	1	1	11.1
LOWER THIRD.....	18	16	1	1	5.8
POINT OF ABLATION UNKNOWN.	66	49	8	9	14.0
Aggregates.....	106	83	10	13	10.7

The names of the patients and a summary of the few recorded facts regarding them appear in the foot-note.<sup>1</sup> This is the last category of the seventeen hundred and forty-seven amputations in the forearm. Seven hundred and thirty-four amputations were on the right side, nine hundred and sixty-seven on the left; in forty-six this point was undetermined. The operations were performed on seventeen hundred and thirty-nine patients. Fifteen hundred and sixty-nine cases, of which two hundred and twenty-two were fatal, were of Union soldiers, and one hundred and seventy, of which twenty were fatal, Confederates, the percentage of mortality being slightly less in the latter series.

**CONCLUDING OBSERVATIONS ON SHOT WOUNDS OF THE FOREARM.**—In reviewing the numerous cases of shot injury of the forearm considered in this Section, it is almost impossible to repress a feeling of amazement at the large amount of operative interference that was deemed requisite in these cases.<sup>2</sup> It is true that about six hundred of the seventeen hundred amputations in the forearm were practised on account of shot fractures at the wrist, yet there remain over a thousand amputations and nearly a thousand excisions performed on account of compound fractures of the bones of the forearm, of which a very small proportion were attended by absolute destruction of the parts by large projectiles or explosions, or by injuries of all the principal blood-vessels or nerves.<sup>3</sup> It has been conclusively shown that many, probably a very large proportion, of the excisions in the continuity, especially of those practised primarily, were inadvisable, augmenting the mortality, and

<sup>1</sup>Cook, J., Davis, A. N., Faulk, W. H., Fredrick, G., Gentle, D. L., Haywood, W. B., Hill, O. H. P., Major, L. O. B., Pfland, E. W., Wool, J. T., Alphin, J. J., Davis, C. M., Dunnoraunt, J. W., Fickling, C. C., Goodman, W., Holliday, C., Mattox, J., McGuirk, P. J., Austin, A. J., Banks, A. O., Byrom, J. W., Fleming, A. H., Hall, F. C., Harrison, —, Hutchinsonson, T. D. A., Jones, J. R., Kelley, L., Marshall, —, Nash, I. N., Nostrand, L., Perry, W. C., Reynolds, —, Thomas, J. H., Wait, A. K., Alexander, E. S., Ayers, J. W., Braganza, A., Brooks, A., Caghans, W., Carter, S. S., Clifton, A. S., Clifton, C. H., Collins, J., Cottrell, A. B., Dobl, J. M., Dycl, A. D., Flannery, D., Fuller, W., Gardner, R. M., Hale, J. W., Harges, C., Hase, moner, G., Hasty, D. E., Hatchet, J. P., Hoover, A. A., Howell, M. B., Hunnicutt, B. L., Hutchins, S., Jackson, W. F., Jenkins, C. J., Jones, O. M., Kelly, M., Kersey, C. L., King, E., Leister, S., Matthews, J., McPhail, D., Muse, F., Niblack, J., Osbern, M., Phillips, W. R., Prime, W. H., Ramsey, W. S., Reisonier, G., Richardson, J., Rodgers, J. M., Scott, J. R., Somers, G. A., Summers, W. C., Ward, J. J., Watson, J. K., West, W. B., Young, L. S., Jones, J. M., Garrison, J. L., Bendall, B. F., Longstreet, G., Pudgett, E., Parker, D. F., Parker, E., Smith, J. S., Stobaugh, A., Yancy, S. P., Morris, J., Weddinger, E., Brown, B. D., Ware, J. H., Brown, J., Cox, L. S., Gilham, T. D., Lassiter, J., Nash, M. W., Rape, G. W., Russell, J. H., Silsby, A., Thompson, W. W. These names will enable the student to refer to the cases in the manuscript files of the Surgeon General's Office. The details reported were so meagre that the tabulation of the cases would have been of little service. Eighty-one of the patients were Confederate, and 25 Union soldiers. Thirty-four operations with 5 deaths were on the right side, 61 with 3 deaths on the left; 11 with 2 deaths unrecorded. The fatal results were ascribed either to pyæmia or secondary hæmorrhage. In one of the fatal cases (Bendall, 53d Va.) there was a simultaneous amputation of the right leg.

<sup>2</sup>LIEFFLER states (*General-Bericht*, u. s. w., 1867, S. 196) that: "With us, shot fractures of the forearm were long since relegated to the domain of the limb-conserving art, and, in our campaigns, amputation was never performed primarily for injury of the bones alone, although there were many instances of extensive comminution. . . . Even injury of the arteries is not an adequate cause for desisting from attempts at conservation."

<sup>3</sup>Dr. H. SCHWARTZ (*Beiträge zur Lehre von den Schusswunden* 1854) remarks that: "In treating shot fractures of the forearm it may be accepted as a rule: that no fractures of the forearm, whether simple or compound, or involving one or both bones, unconditionally demand amputation. The exceptions are: 1, Cases in which cannon balls have already, so to speak, caused partial ablation of the limb; 2, where both bones are comminuted, with laceration of the blood-vessels and nerves; 3, in extensive comminution in the vicinity of joints, with fissures extending into the articulations, so that resection cannot be practised, and nothing can reasonably be expected of conservative treatment."



rarely improving the usefulness of the limbs in those patients who survived. It must also be admitted that a large number of the primary amputations were unnecessary, and, although the resulting mortality was not large when compared with any other returns than those of the British surgeons in the Crimea and the Germans in Schleswig-Holstein, yet it cannot be doubted that in a majority of cases the lives of the patients were placed in greater jeopardy by amputation than if subjected to an expectant conservative treatment. It is noticeable that cases of amputation in the forearm are prominent among the earliest recorded instances of amputation in military surgery, as, for example, those related by Paré, Vallerioli, and Bartholinus. Not possessing the tourniquet, and consequently in constant terror of immediate fatal hæmorrhage,<sup>1</sup> the old surgeons preferred to make their ablations at a convenient distance from the trunk. Now, while we have seen (p. 661) that in the War of the Rebellion *excisions* in the upper extremity became comparatively more frequent as the war progressed, the records appear to show that primary *amputations* in the forearm were relatively more numerous in the earlier periods. There were 153 instances, for example, in the year 1862, and only 146 in the year 1863, when the aggregate of shot injuries was thrice greater. It is not uncharitable, therefore, to suppose that inexperienced medical officers, hastily summoned to the field in emergencies, may have then practised such operations as their matured judgments would have condemned.

As to the frequency of amputations in the forearm for shot injury in the Confederate armies, I have been unable to obtain any reliable data. It is probable that the practice was much the same as in the Union armies.<sup>2</sup> The very limited returns that have been published give slightly more favorable results for this operation in the former than in the latter service. An analysis of fourteen hundred and eleven amputations of the forearm for shot injury, returned from European campaigns, gives an average mortality of 49 per cent. This excessive death-rate is principally due to the lamentable fatality that attended

<sup>1</sup> Though the ancients used a constricting band to benumb the limb, a circular ligature to arrest the flow of blood was not used until the latter part of the seventeenth century. DIONIS (*Cours d'opérations de chirurgie*, Paris, 1630, 4ième éd. 1750, avec notes par LAFAYE, p. 717) states that this instrument, of which he gives a drawing (See FIG. 717), was invented by an army surgeon during the siege of Besançon, in Burgundy, in 1674. LAFAYE adds that the name of this surgeon was MOREL. The first printed reference to the tourniquet is in the rare *Carrus triumphalis à Terebintho*, by JAMES YOUNG (or YONGE), of Plymouth, printed at London in 1679. In describing the mode of amputation practised by himself and his friend, LOWDHAM, of Exeter, he dwells upon the "manner of compressing the thigh by ligature, or the arm near the shoulder," whereby "you may detain the descent of the blood, etc." Although the priority of publication is due to YOUNG, and although, as SHARPE (*Critical Enquiry*, etc., 3d ed., 1754, p. 216) remarks, the utility of the tourniquet, like that of many other useful discoveries, seems so obvious, when we once know it, that one would be amazed that it was not thought of by every surgeon accustomed to amputations; and although it may have been discovered independently by YOUNG, yet it seems certain that no one ever used it before MOREL in 1674. In 1718, the illustrious J. L. PETIT (*Mém. de l'Acad. des Sciences*, 1731) devised the serew tourniquet (FIG. 718), which, variously modified, is still universally used. Any one who will search for actual specified examples of amputations for shot injury prior to the commencement of the XVIII century will be astonished at their extreme rarity. One of the earliest detailed cases of amputation in the forearm for this cause that I have met with is related by BARTHOLINUS (Th) (*Acta medica et philosophica Hafniensia*, Hafn., 1677, Vol. IV, p. 92, Cap. XXX, Spæcelus a bombardæ globulo): In 1676 an officer was shot in the left forearm just above the wrist by a leaden ball from a hostile bombard, which fractured both bones of the forearm. Intolerable pain ensued, augmented by cold during a four hours' transport to a neighboring city; pain extended to arm and shoulder blade; the usual means failed to

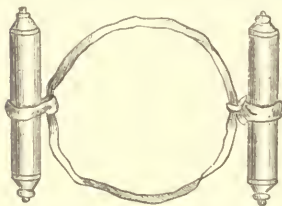


FIG. 717.—MOREL'S tourniquet. [After DIONIS.]

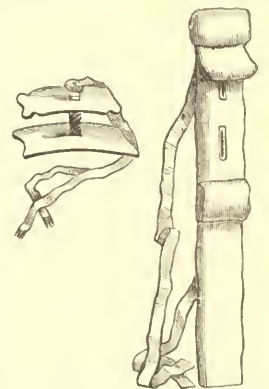


FIG. 718.—Original form of Petit's tourniquet. [From DIONIS, Pl. IV.]

check gangrene; tumor supervened, "sed striis quibusdam livido sanguineis secundum brachii longitudinem ascendentibus." The wound was enlarged, but the hand became sphacelated; on the seventh day amputation was performed, resulting in death on the same evening. The learned Bartholinus seems inclined to ascribe the fatal result to the poisoned metal.

<sup>2</sup> WARREN (E.) (*Epitome of Pract. Surg.*, 1863, p. 396) gives a consolidated report of capital operations performed in and around Richmond, from June 1 to August 1, 1862, in U. S. A. hospitals, which includes: Of amputations in the forearm, 23 primary operations with 2 deaths; 13 intermediary operations with 2 deaths; 9 secondary cases with 2 deaths—or an aggregate of 45 cases of amputation in the forearm with 6 deaths, or 13.3 per cent. CHISOLM (J. J.) (*Man. Mil. Surg.*, Columbia, 1864, p. 351), in a table collated from reports in the Confederate Surgeon General's Office, from June 1, 1862, to February 1, 1864, reports 69 primary amputations in the forearm with 2 deaths, and 45 secondary cases with 10 deaths, a total of 114 cases with 18 deaths, or 15.8 per cent. This statement is identical with one printed in the official statement of Surgeon F. SORRELL, Inspector of Hospitals, in *Confed. States Med. and Surg. Jour.*, 1864, Vol. I, p. 153.

surgical operations of almost every description among the Russian troops in the Crimean war, and in the French armies in all of their later campaigns. In the following numerical statement of four thousand and twenty-nine shot fractures in the forearm reported by European surgeons, the results of fourteen hundred and eleven amputations, of one hundred and thirty-three excisions, and of twenty-four hundred and eighty-five cases treated by expectation, are exhibited in striking contrast.

TABLE CXL.

Showing the Mode of Treatment and Results of Shot Fractures involving the Bones of the Forearm on the Occasions named and from the Authorities quoted.

ACTION, ETC.	EXPECTANT CONSERVATIVE TREATMENT.			EXCISION.			AMPUTATION IN FOREARM.		
	Recov.	Death.	Percentage of Mortality.	Recov.	Death.	Percentage of Mortality.	Recov.	Death.	Percentage of Mortality.
Siege of Constantine, 1837 (BAUDENS <sup>1</sup> )				2					
Spanish Peninsular War, 1837, (ALCOCK <sup>2</sup> )	46	1	2.1				3	2	40.0
War in Sleswick-Holstein, 1848-50 (STROMEYER <sup>3</sup> )	47	1	2.0	7			12	2	14.2
Revolution in Baden, 1849 (BECK <sup>4</sup> )							3		
French in Algiers, 1854-56 (BERTHERAND <sup>5</sup> )				5			3	4	57.1
Crimean War, 1854-56, Russian (HUBBENET <sup>6</sup> )							109	282	72.1
Crimean War, 1854-56, French (CHENU <sup>7</sup> )	677	135	16.6	5	1	16.6	177	146	45.2
Crimean War, 1854-56, British (MATTHEW <sup>8</sup> )	141	7	4.7				60	3	4.7
Italian War, 1859-60, Austrians (DEMME <sup>9</sup> )	303	53	14.8				75	37	33.0
Italian War, 1859-60, French (CHENU <sup>10</sup> )	360	42	10.4	12	3	20.0	52	39	42.8
New Zealand War, 1863-65 (MOUAT <sup>11</sup> )	11								
Danish War, 1864 (LOEFFLER <sup>12</sup> )	114	8	6.5	4	2	33.3	5	1	16.6
Prussians, 1866 (BECK, <sup>13</sup> BIEFEL, <sup>14</sup> K. FISCHER, <sup>15</sup> MAAS <sup>16</sup> )	19	2	9.5	2			10	2	16.6
Franco-German War, 1870-71 (BARTHELMESS and MERKEL, <sup>17</sup> BECK, <sup>18</sup> CHRISTIAN, <sup>19</sup> H. FISCHER, <sup>20</sup> GOLTDAMMER, <sup>21</sup> GRAF, <sup>22</sup> HERRGOTT, <sup>23</sup> HOPMANN, <sup>24</sup> JOESSELL, <sup>25</sup> KIRCHNER, <sup>26</sup> LOSSEN, <sup>27</sup> MUNDY, <sup>28</sup> OTT, <sup>29</sup> RUPPRECHT, <sup>30</sup> STEINBERG, <sup>31</sup> SCHÜLLER, <sup>32</sup> SOCIN, <sup>33</sup> STOLL, <sup>34</sup> SCHINZINGER, <sup>35</sup> STUMPF, <sup>36</sup> )	485	33	6.3	4	1	20.0	22	15	40.5
Franco-German War, 1870-71, French (CHENU <sup>37</sup> )				27	58	68.2	188	159	45.8
Aggregates	2,903	282	11.3	68	65	48.7	719	692	49.0

The evidence from our own and from foreign experience appears overwhelming that, except in the rare instances in which the tissues are almost disorganized, shot wounds and fractures of the forearm should be, in Loeffler's phrase, "relegated to the domain of the limb-conserving art."

The flap methods of amputating in the forearm were employed by the Union surgeons somewhat more frequently than circular incisions.<sup>38</sup> Some further observations on shot

<sup>1</sup> BAUDENS (L.), *Lettre sur les amputés après le siège de Constantine*, in *Gaz. méd.*, 1838, T. VI, p. 415. <sup>2</sup> ALCOCK (R.), *Notes on the Med. Hist. and Stat. of the British Legion in Spain*, London, 1838, pp. 55, 95. <sup>3</sup> STROMEYER (L.), *Maximen*, 1855, p. 757. <sup>4</sup> BECK (B.), *Die Schusswunden*, Heidelberg, 1850, Tabelle. <sup>5</sup> BERTHERAND (A.), *Campagnes de Kabylie*, Paris, 1862, p. 317. <sup>6</sup> HUBBENET (C. v.), *Die Sanitäts-Verhältnisse der Russ. Verwundeten*, 1854-1856, Berlin, 1871, p. 182. <sup>7</sup> CHENU (J. C.), *Campagne d'Orient*, Paris, 1865, pp. 294, 315, 504. <sup>8</sup> MATTHEW, *loc. cit.*, Vol. II, pp. 355, 368. <sup>9</sup> DEMME (H.), *loc. cit.*, p. 238. <sup>10</sup> CHENU (J. C.), *Camp. d'Italie*, 1869, pp. 614, 631. <sup>11</sup> MOUAT, *loc. cit.*, p. 476. <sup>12</sup> LOEFFLER (F.), *General-Bericht*, u. s. w., Berlin, 1867, pp. 196, 301. <sup>13</sup> BECK (B.), *Kriegschir. Erf.*, 1867, S. 286, 330. <sup>14</sup> BIEFEL, in *LANGENBECK'S Archiv*, B. XI, S. 474. <sup>15</sup> FISCHER (K.), *Militärärztl. Skizzen*, 1867, S. 69. <sup>16</sup> MAAS (H.), *loc. cit.*, S. 34, 73. <sup>17</sup> BARTHELMESS and MERKEL, in *Bayer. Aerztl. Intelligenzblatt*, 1871, No. 22. <sup>18</sup> BECK (B.), *Chir. der Schussverl.*, 1872, S. 663, 785. <sup>19</sup> CHRISTIAN, *loc. cit.* <sup>20</sup> FISCHER (H.), *Kriegschir. Erf.*, 1872, S. 145. <sup>21</sup> GOLTDAMMER, *Bericht*, in *Berl. Klin. Wochenschr.*, 1871. <sup>22</sup> GRAF (E.), *Reservelazarethe zu Düsseldorf*, 1872. <sup>23</sup> HERRGOTT, in *Jahresbericht*, 1870, B. II, S. 346. <sup>24</sup> HOPMANN, in *Jahresbericht*, 1873, B. II, S. 383. <sup>25</sup> JOESSELL, in *Jahresbericht*, 1871, B. II, S. 367. <sup>26</sup> KIRCHNER (C.), *Aerztl. Bericht*, u. s. w., Erlangen, 1872. <sup>27</sup> LOSSEN (H.), *loc. cit.*, S. 391. <sup>28</sup> MUNDY, *Jahresbericht*, 1871, B. II, S. 365. <sup>29</sup> OTT, *Kriegschir. Mittheilungen*, Stuttgart, 1871. <sup>30</sup> RUPPRECHT, *loc. cit.*, S. 72. <sup>31</sup> STEINBERG, *loc. cit.*, p. 48. <sup>32</sup> SCHÜLLER, *Kriegschir. Skizzen*, 1871. <sup>33</sup> SOCIN, *loc. cit.*, p. 125. <sup>34</sup> STOLL, *loc. cit.*, p. 196. <sup>35</sup> SCHINZINGER, *loc. cit.*, S. 65. <sup>36</sup> STUMPF, in *Jahresbericht*, 1872, B. II, S. 395. <sup>37</sup> CHENU (J. C.), *Aperçu Hist. Stat.*, etc., Paris, 1874, p. 492.

<sup>38</sup> Of 1231 cases in which the mode of operation was specified, 667 amputations of the forearm were practised by double or single flaps, by TEALE'S method, or by skin flaps with circular division of the muscles, the plan by double palmar-dorsal flaps made by transfexion preponderating. Five hundred and sixty-four operations were done by circular incisions. The mortality of the flap operations was 10.8, of the circular 11.3 per cent.



wounds,<sup>1</sup> fractures,<sup>2</sup> and amputations<sup>3</sup> in the forearm, and a brief bibliography of the subject<sup>4</sup> are embodied in the foot-notes.

<sup>1</sup> NEALE (H. ST. JOHN) (*Chirurgical Institutes*, London, 2d ed., 1805, p. 235) states: "Gunshot wounds of the forearm are more susceptible of bad symptoms than those of the arm. The difference arises from this, that all the muscles situated upon the forearm are conjointly wrapt up in a tendinous membrane, that is, an aponeurosis or expansion, detached from all the flexor and extensor muscles, which membrane, dipping into the interstices of all the muscles of the part, covers each of them likewise in particular. The inflammation of this membrane is therefore greatly to be feared, since in that state it strangles at once all these, and besides it may spread and communicate itself to the arm likewise. When this ensues, we observe the whole forearm swell up in a greater or less degree, and sometimes becomes so hard that a gangrene must speedily succeed if not prevented. Hence the great advantages arising from an early dilatation, so often mentioned in this work. On this account the incisions that are made should penetrate to the bottom and unbridle all the parts, but chiefly the common tendinous membrane, in every direction, especially when the radius or ulna is fractured. These incisions should be backed with all kinds of topical emollients fit for relaxing the skin and common membrane, which is now extremely tense. Should all these endeavors fail, and the swelling continue, accompanied with hardness, and increase so as to threaten a sudden gangrene over the whole part, recourse must be had without delay to the scarifications, of which we have formerly spoken. When the swelling that ensued has not been violent enough to require these scarifications, yet its existence may be sufficient to expose the forearm to some accident or another. And we sometimes meet with abscesses formed in different places; abscesses distinct one from another, and that have no communication with the cavity of the wound, because of the various partitions made by the common membrane in the interstices of the muscles. While the pus is forming here, the wound assumes a bad hue, which continues until the matter is evacuated. These abscesses must be opened as soon as the pus can be perceived to fluctuate under the fingers. The inflammation and swelling sometimes cannot be appeased till it terminates in the dissolution and rotting of the common membrane, which occasions thin spreading suppurations both under the skin and among the interstices of the muscles."

<sup>2</sup> Dr. G. H. B. MACLEOD (*Notes on the Surgery of the War in the Crimea*, 1858, p. 305), in referring to the official reports of the British army in the Crimea in regard to shot fractures of the forearm, makes the sensible criticism, which is of wide application, that the returns "do not tell the whole truth, as there is no provision made in them for showing double injuries; and many cases are made to appear as having ended fatally from these . . . injuries, which were in truth the result of a complication of accidents of which this one was chosen for registration." This is one of the great inconveniences of the statistical method, which it is difficult to avoid. It is only possible to supply the reader with the materials for eliminating the element of error. In the tabulations in this work it has been sought, as far as practicable, to specify the complications that affected the general result as to fatality. In this connection it is to be observed that in 74 of the 1485 determined cases of shot fractures at the wrist, there were serious shot wounds in other parts of the body; and that in 23 of the 193 fatal cases, the injuries in other regions contributed as much and often more to the fatal result as the injury at the wrist. Thus, 6 fatal cases were complicated by chest wounds, of which 3 were undoubtedly penetrations of the thoracic cavity. In 3 cases there were wounds of the abdomen, supposed to be limited to the parietes. In 1 fatal case a shot fracture of the clavicle resulted in inflammation of the lung. In 4 cases there were shot fractures of the opposite upper extremity; in 9 cases, wounds of the lower extremities, involving, in 2 instances, fractures of the femur.

<sup>3</sup> The views of some of the German surgeons on the treatment and results of shot fractures of the forearm in the late Franco-German campaigns will be read with interest: BECK (B.) (*Chir. der Schussverletzungen*, 1872, S. 664) remarks of shot fractures of the bones of the forearm [in the Bavarian Army Corps]: "Of the cases treated on the expectant plan, 53 in number, 5 or 9.4 per cent. died. Consecutive bleeding sometimes required ligation of the vessels, or digital compression, and even the amputation of the limb; lesions of the nerves often caused great impairment of the functions, and atrophy of the muscular tissues. The loss of substance was in some cases considerable, causing deformity, and great displacement of the osseous fragments was often noticeable." FISCHER (H.) (*Kriegschir. Erf. Erlangen*, 1872, S. 145) records 24 shot fractures of the bones of the forearm [treated before Metz]: "Both bones were fractured in 17 cases, the radius alone in 5 cases, the ulna alone in 2 instances. Three of the wounded men died, or 12.5 per cent." Dr. H. FISCHER observes (p. 146): "The treatment of these injuries was simple. When no considerable deformity existed, we used simple splints and bandages. If there was great tendency to displacement of fragments, we preferred gypsum bandages and a position of the limb midway between pronation and supination, with a slightly bent elbow. We never used the local baths that have been recommended." Dr. G. FISCHER, of the Hannoverian quota of the Prussian army, observes (*Dorf Floing und Schloss Versailles*, in *Deutsche Zeitschr. für Chir.*, 1872, B. I, S. 218): "In comminuted fractures of the bones of the forearm erysipelas and phlegmon are not rare; so that splinters should always be early removed, and the arm laid high. Drainage was employed with great advantage, especially when the wounds of entrance and exit were on the palmar side. Persistent suppuration in a wound sinus nine inches long ceased in two days after drainage was employed." Dr. A. SOCIJ, a Swiss professor, in charge of a hospital at Carlsruhe, remarks (*Kriegschir. Erf.*, Leipzig, 1872, p. 125): "In the conservative treatment of shot fractures of both bones of forearm, gypsum bandages applied with exactness are necessary on account of the strong tendency to displacement. In cases of fractures of one bone only, the most simple supporting apparatus, a wire splint or Bell's trough, will answer." Professor THEODOR BILLROTH (*Chir. Briefe aus den Kriegs-Lazarethen*, u. s. w., Berlin, 1872, S. 226) dismisses these accidents with brevity. Regarding the injuries of the forearm and hand, he remarks: "So little difference of opinion exists as to their prognosis and treatment, that I will gladly dispense with their further consideration." GORDON (C. A.) (*Lessons on Hygiene and Surgery from the Franco-Prussian War*, London, 1873, p. 147), remarking that "the available statistics are decidedly meagre," relates what he learned in his surgical mission regarding the treatment of shot injuries of the forearm by the French military surgeons. He notes 31 cases from the hospitals at Flöing, Bazailles, and some of the ambulance stations at Paris, in which conservative treatment was adopted. There were 3 deaths among 26 determined cases. For the most part the limbs were supported by wire-trough splints, and irrigation employed for some days, after which a plaster apparatus was applied. Loose fragments were extracted in all cases. Horrible lacerations from grapeshot in some instances did not interdict attempts at conservation.

<sup>4</sup> Apart from the short references in systematic works on Surgery, comparatively little has been written on amputations in the forearm. Indeed, the lamented VON PITHA (*Krankheiten der Extremitäten*, Erlangen, 1868, S. 106), who most sedulously reported the special bibliography of the subjects of which he treated, mentions, under *Amputation des Vorderarmes*, only LINHART and GÜNTHER. The literature of the subject has been to some extent adverted to in preceding notes. The following references may be added: MANGETT'S (J. J.) (*Bibliotheca Chirurgica*, Geneva, 1721, lib. VI, p. 190) gives, from BARTHOLINUS, a case of amputation in the forearm for gangrene following shot injury, which must have been soon after 1674, the year that MOIHEL'S tourniquet came into use. CHEZE, surgeon major of the Berwick-regiment, while on duty on the *Lorette*, a French corvette, furnished an "Observation sur l'amputation de l'avant-bras à la suite d'une plaie d'arme à feu, in *Jour. de Méd. Mil.*, Paris, 1783, T. II, p. 102. FREDERIC RUCSCII, (*Responsio ad M. REYERHORST, Super nova artuum decurtationum methodo* [in MANGETUS, l. c., T. II, p. 204]) defends the propriety of an amputation near the wrist for the removal of a hand invaded by large enchondromata, instead of amputating at the upper third of the forearm, as commended by PETER VERDUIN, WILHELM VLEUTEN, and others. LARREY (*Clin. Chir.*, 1829, T. III, de l'amputation de l'avant-bras, p. 603) advises that the surgeon should always regard the centre of the fleshy part of the forearm as the place of election, however near the wrist the injury may be. CONRAD (J. M. LANGENBECK'S *Nosol. und Therap. der Chirurg. Krankheiten*, Göttingen, 1830, B. IV, S. 323) treats fully of *Amputationen des Vorderarmes*, VEIPEAU (A. L. M.), *Amputation des deux avant-bras*, in *Arch. gen. de Méd.*, Paris, 1827, T. XIII, p. 203. CLOQUET (J.), *Art. Avant-Bras Oper. Chirurg.*, in *Dict. de Méd.* en XXX, 1833, T. IV, p. 447. BAUDENS (M. L.), *Amputation de l'avant-bras*, in *Clin. des plaies d'Armes à feu*, 1836, p. 564. DOHRHOFF, *Amputatio antebrachii*, in *Deutsche Klinik*, 1852, B. II, p. 36. MACLEOD (G. H. B.), *Notes on the Surgery of the War in the Crimea*, 1850, p. 305. DEHOUS, *Amputation de l'avant-bras droit pratiquée par M. le Dr. SONRIER, au moyen d'un rasoir et d'une petite scie de menuisier*, in *Rec. de mém. de méd. de chir.*, etc., Paris, 1862, T. VIII, 3<sup>e</sup> sér., p. 456. HEWETT (P.), *Excellent stumps of the forearm in amputation by means of muscular flaps and circular incisions through the skin*, in *The Lancet*, 1862, N. S., Vol. I, p. 277. LEGOUËT (L.) (*Chirurgie d'Armée*, 1863, p. 689 et p. 722) approves attempts at conservation even when the bones are comminuted with laceration of the arteries, and disagrees with LARREY as to amputating high up, when the injury is near the wrist, to avoid inflammation of the tendinous sheaths. See also WILLIAMSON (C.), *Mil. Surg.*, 1863, p. 131. DEMARQUAY (J. M.), *Art. Avant-Bras*, in *Nouv. Dict. de Méd. de Chir. Prat.*, 1866, T. IV, pp. 295-301. GIRARD (M.), *Art. de l'avant-bras*, in *Le Bordeaux Méd.*, 1872, T. I, p. 294.

## SECTION VII.

## WOUNDS AND OPERATIONS AT THE WRIST.

We shall consider in this Section only shot injuries of the wrist,<sup>1</sup> and the excisions and amputations practised at this joint for direct lesions from shot, or for the effects of wounds of the metacarpus or phalanges. Examples of punctured or incised wounds by war-weapons are not found on the returns. Frightful laceration of the wrist joint by shell fragments or by large projectiles, or by explosions, are sometimes observed. More frequently musket balls or other small missiles shatter the lower extremities of the radius or ulna and open the wrist joint, or the first or second range of carpal bones are injured by the direct or oblique passage of balls. In the first class of cases, immediate amputation is required. In the second, the indications are less simple. The joint is so surrounded by dense ligaments with layers of superimposed tendons, the whole bound down by the annular ligament, that the resistance to the inflammatory swelling is intense, and the reaction is attended by excessive pain, and, unless tension is promptly relieved, the extension of suppuration is great, involving not only the complicated articular surfaces, but the cancellous structure of the bones. Great risk of pyæmic infection then arises, and operative interference becomes necessary, at least to the extent of free incisions into the joint, and extraction of all detached splinters. How far it may be advisable to attempt to avert these dangers by primary resection is a question yet undetermined, on which the surgical record of the war throws some light. Experience as well as consideration of the anatomical relations of the part (FIG. 719) indicates that the penetration of missiles in the dorso-palmar diameter is less harmful than transverse or oblique shot perforations.<sup>3</sup> Of the various forms of this injury the most numerous were probably those in which balls shattered the lower ends of the radius and ulna and opened the wrist joint; but lodgements of balls in the carpus, perforations of the joint in all directions, and wounds from missiles entering the dorsal or palmar surfaces of the hand, fracturing the metacarpus or passing obliquely upward into or through the carpal bones, were not infrequent. Attention will be confined to shot fractures involving the wrist.<sup>4</sup> The layers of soft parts covering the joint are so thin that few shot wounds in this region amounting to more than skin-scratches fail to implicate the bones. It is not improbable that there may have been examples of periarticular flesh wounds followed by secondary involvement of the joint, but no definite description of such lesions have been observed on the returns.

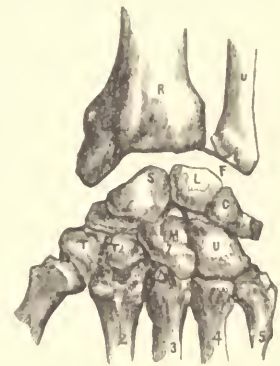

FIG. 719.—Dorsal view of bones of the left carpus. [After SAPPÉY.]  
*R*—radius. *U*—ulna. *F*—fibro-cartilage. *S*—scaphoid. *L*—semi-lunar. *C*—cuneiform. *P*—pisiform. *T*—trapezium. *Td*—trapezoid. *M*—magnum. *U*—uneiform. 1, 2, 3, 4, 5, metacarpals.

<sup>1</sup> The *wrist*, from Saxon, *wræstan*, to twist, to wrest; *Gr.*, *καρπός*; *Lat.*, *carpus*, *pugnus*; *Fr.*, *carpe*, *poignet*; *Ger.* *Hand-gelenk*; *Ital.*, *carpo*, *pólo*.

<sup>2</sup> SAPPÉY (PH. C.), *Traité d'Anatomie Descriptive*, deuxième éd., 1867, T. I, p. 384.

<sup>3</sup> LEGOUÉST (L.) (*Chir. d'Armée*, 2ème éd., 1872, p. 530) teaches that "Shot fractures of the wrist, when the region traversed in its long diameter is the seat of much shattering (*délabrements*), require amputation in the forearm. When the joint is perforated from before backward, without great disorders, by extracting splinters the limb may be preserved."

<sup>4</sup> RAYATON (*Chirurgie d'Armée*, 1758, p. 311) has some instructive observations on shot wounds of the wrist: "The numerous small bones forming the carpus," he says, "are united by such a multitude of articulations, and bound together by such an infinitude of ligaments, tendons, and strong membranes, that fractures of this part induce symptoms that must oppose the most obstinate resistance to the best-conceived methods of dressing; besides which there is other constant fear of ulterior caries, etc. These shot fractures are more or less grave in proportion to the extent of the lesions of the tendinous parts, the vehement febrile reaction which often presents itself, the good or bad constitutional condition of the subject, and his youth or age. Whether the ball enters on the dorsal or palmar surface, its exit wound will always be found larger than the entrance orifice, and near the former point splinters will always be found collected. At the exit wound, then, is the place to extract them—gently, not tearing or dragging away the fragments, but delicately dividing with the scissors the bits of tissue that retain them. . . ."



Of the large number of cases reported, more than a third were treated by amputation, and these have been enumerated in the preceding tabular statements. The comparatively novel expedient of excision was sometimes resorted to, while the large majority of cases were treated by expectant conservative measures, with a comparatively low rate of mortality. The cases are classified in the following table:

TABLE CXXI.

*Descriptive Numerical Statement of the Treatment of Fourteen Hundred and Ninety-six Shot Fractures of the Bones of the Wrist.*

MODE OF TREATMENT.	CASES.	DUTY.	DISCHARGED.	DIED.	RESULT UNDETERMINED.	MORTALITY OF DETERMINED CASES.
Treated by Expectation.....	716	254	399	54	9	7.6
Followed by—						
Excision at the Wrist.....	83	20	52	11		13.2
Excision at the Wrist and Amputation of Forearm.....	8		6	2		25.0
Excision at the Wrist and Amputation of Arm.....	5		3	2		40.0
Amputation at the Wrist.....	19	1	15	2	1	11.1
Amputation at the Wrist and Amputation of Forearm.....	2		2			0.0
Amputation at the Wrist and Amputation of Arm.....	2		1	1		50.0
Amputation of the Forearm.....	590	52	447	90	1	15.2
Amputation of Forearm and Amputation of Arm.....	11	1	7	3		27.2
Amputation at the Elbow Joint.....	3		3			0.0
Amputation at Elbow Joint and Amputation at Shoulder Joint.....	1		1			0.0
Amputation of the Arm.....	54	2	26	26		48.1
Amputation at the Shoulder Joint.....	2			2		100.0
	1,496	330	962	193	11	12.9

We shall examine briefly some of the cases treated by expectation, and those treated by excision more in detail, since the information published on the subject is comparatively limited. The operations of disarticulation at the wrist will be enumerated; the amputations in the forearm for wrist injuries have already been adduced.

**SHOT FRACTURES OF THE WRIST TREATED BY EXPECTATION.**—Shot wounds of the wrist are generally attended with fracture;<sup>1</sup> but unless the destruction of parts is great, a conservative treatment of these injuries has been recommended by the majority of military surgeons from Paré down.<sup>2</sup> Mr. Cole is one of the few who dissent from this rule of practice.<sup>3</sup> In seven hundred and seven determined cases treated throughout on the expectant plan, there were fifty-four deaths, or 7.6 per cent., a mortality greater than that of shot fractures in the continuity of the forearm; but considerably less than the death-rate in amputation in the forearm or at the wrist. It should not be forgotten,

<sup>1</sup> Surgeon H. ST. JOHN NEALE, esq. (*Chirurgical Institute, drawn from Practice on the Knowledge and Treatment of Gunshot Wounds*, 2d ed., 1805, p. 243), observes: "Gunshot wounds of the wrist are generally accompanied with a fracture; I mean, that some one, or even a number of its small bones are curtailed, ground down, or shot away; and this can never happen but when the connecting ligaments and aponeuroses of these bones must be greatly injured, and the tendons that pass over this part broken or much lacerated. With regard to the wound of the tendons, this injury may occasion such accidents as we shall treat of when we come to our remarks on wounds of the metacarpus or hand. The inflammation may be kept from spreading over the ligaments and capsule of the joint betwixt the wrist and forearm, the dissolution and rotting of the injured tendinous parts may be prevented, by the incisions and counter-openings, the regimen, the bleedings, and topical applications, and the Peruvian bark, which we have before recommended. When these things are judiciously observed, we have often seen the wounds of this part heal up with great ease."

<sup>2</sup> PARÉ (*Œuvres complètes*, éd. MALGAIGNE, Liv. VIII, Cap. XLII): "Lors qu'il y a playe au carpe . . . les doigts se doivent tenir demiflexis, etc." BOUCHER, in his celebrated paper on amputations (*Mém. de l'Acad. de Chir.*, 1753, 4to, T. II, p. 298), gives, as his seventh example of preservation of limbs after shot fracture, the case of a captain of the Orleans grenadiers, whose right wrist was wounded by a musket ball at the siege of Ypres, the missile striking the lower end of the radius and entering the wrist, tearing up the ligaments and tendons. With poultices and fomentations of warm wine and brandy, and many blood-lettings, grave accidents were hindered, yet intense pain persisted, and suppuration brought away many necrosed splinters. In eleven months, the wound was cicatrized, and the motions of the wrist became more free, as BOUCHER was able to infer, "par quelques lettres écrites de cette main."

<sup>3</sup> COLE (J. J.) (*Military Surgery or Experience of Field Practice in India*, 1852, p. 153) observes: "I have never seen a reparable gunshot wound of the wrist joint,—I mean where the bullet has passed into or through the articulation."

however, that numerous cases treated at the outset by expectation, in which excision or amputation were eventually resorted to, with an excessive ratio of mortality, were excluded from this series, and consequently the results of the conservative expectant plan are represented in a too favorable light.

More or less complete ankylosis ensued in the vast majority of cases treated by expectation, and in very many instances the mobility of the fingers was much impaired.<sup>1</sup>

CASE 1931.—Private D. Smith, Co. I, 11th Pennsylvania, aged 26 years, was wounded at Bull Run, August 30, 1862, and admitted to Ryland Chapel Hospital, Washington, two days afterward. Surgeon J. A. Lidell, U. S. V., reported as follows: "Gunshot wound of left wrist, treated without amputation or excision. The ball passed completely through the middle of the wrist, at the juncture of the carpus with the metacarpus. A great deal of inflammation followed, involving the forearm and even the arm. No large pieces of bone have been discharged, but a considerable quantity of grit and small pieces of bone with a great deal of matter flowed away. It was necessary to make incisions in the hand several times. The patient was admitted to Stanton Hospital, from Ryland Chapel, December 5th. The wounds are now healed, and there is a prospect of recovery with a useful hand. This soldier was discharged January 7, 1863," and pensioned. Examiner J. I. McCormick, of Irwin Station, Pennsylvania, May 19, 1865, certified: "A ball entered the middle of the carpus on the dorsum of the hand, and, inclining toward the thumb, emerged through the adductor pollicis muscle. The carpal and metacarpal bones are much injured. The wrist is completely ankylosed, and the fingers and thumb are permanently extended, except that the index finger at the metacarpophalangeal joint is movable, and can be brought in contact with the thumb, though without power. The little finger is abducted and slightly flexed, but firmly fixed like the rest. No power of prehension remains to him. For purposes of manual labor his injury is almost equal to the loss of his arm or hand." The pensioner was paid September 4, 1875.

Injury of one of the larger arteries complicating these fractures was not always regarded as an absolute counterindication of expectant conservative treatment:

CASE 1932.—Private P. Fallon, Co. I, 146th New York, aged 22 years, was wounded at Fredericksburg, December 13, 1862, and admitted to Point Lookout Hospital three days afterward. Assistant Surgeon C. Wagner, U. S. A., reported: "Gunshot wound of left wrist joint. Hemorrhage from the ulnar artery, to the amount of sixteen ounces, occurred on December 24th. The ulnar artery was ligated in the continuity. No recurrence of hemorrhage followed." The man was discharged from service April 23, 1863, and pensioned. Examiner S. O. Scudder, of Rome, New York, June 3, 1863, certified: "A minie ball struck obliquely the dorsal portion of the fourth metacarpal bone of the left hand and came out three inches above the wrist joint. There is slight motion of thumb and forefinger; other fingers useless. Joint stiffened." Drs. A. Churchill and C. B. Coventry, of the Utica Board, certified, December 6, 1871: "The ball lacerated the ulnar artery, which was ligated. From injury to the tendons and muscles the fingers are drawn into the palm of the hand, rendering the hand almost useless," &c. This pensioner was paid December 4, 1875.

Confined abscesses occupying the numerous sheaths, bursæ, and synovial sacs, and leading to extensive adhesions and contractions, were the most frequent complications:<sup>2</sup>

CASE 1933.—Captain T. W. Pate, Co. C, 37th Indiana, aged 49 years, was wounded at Stone River, December 31, 1862. He was admitted to the field hospital of the 2d Division, Fourteenth Corps, where Surgeon F. H. Gross noted: "Gunshot wound." Acting Assistant Surgeon J. A. Murphy, in charge of Third Street Hospital, Cincinnati, reported as follows: "A conical ball entered the left wrist joint on the dorsal side, just below the lower end of the ulna, and, passing through the joint, lodged on the palmar face just external to the insertion of the flexor carpi ulnaris, from which point it was extracted, on the field. Captain Pate obtained a leave of absence and came home. On January 29, 1863, he applied to me at this hospital for advice, when an abscess in the palm of the hand was opened, from which a large quantity of pus escaped. The entire hand and wrist joint was in a high state of inflammatory action. His general health was good; no diarrhœa, or loss of appetite, or fever. Poultices and cold-water dressings were applied until the inflammation ceased and the wound healed. April 1st, wound entirely healed. The power of flexing and extending the wrist or the forearm is somewhat limited. The ability to flex the fingers and extend them has, in a considerable degree, returned. The sensation of the hand is perfect. He returns to duty this day." Captain Pate resigned his commission April 13, 1863. He is not a pensioner.

To moderate inflammation by cold applications—by ice dressings when available,—to support the parts without constricting bandaging upon a padded splint,—to relieve inflammatory tension by free incisions as soon as suppuration took place,—to remove all

<sup>1</sup> HAMILTON (F. H.) (*A Treatise on Military Surgery and Hygiene*, 1865, p. 395) remarks: "Ankylosis is even more certain to ensue upon gunshot injuries of the wrist than of the elbow joint, a result which is due, in the case of the wrist, quite as much to the inflammation which invades the numerous tendons, obliterating their synovial surfaces and binding them together in one common mass, as to the direct injury done to the joint. The limb must not, therefore, be confined by splints or bandages, but, being made to repose upon a soft and well-fitted support, all proper means should be employed to prevent inflammation, and, at the earliest practicable period, the joint should be subjected to gentle passive motion. During the whole of the treatment the fingers should be left at liberty, and they should be occasionally flexed and extended, or they will become ankylosed also."

<sup>2</sup> BAUDENS (L.) (*Plaies d'Armes à Feu*, 1836) gives two examples of conservation of the hand after shot perforation of the wrist: "In the case of Corporal F——, 59th Infantry, the right radio-carpal articulation was traversed by a ball October 11, 1833, the end of the radius being demolished. Fragments were extracted, and recovery with complete ankylosis ensued. A sergeant of Sappers had his wrist perforated by a ball which crushed through the trapezium, trapezoid, and magnum. Numerous small abscesses retarded recovery, but, eventually, the patient had tolerable use of his hand." A multitude of analogous facts, BAUDENS adds, decided me to have recourse very rarely to amputation.



splinters and detached fragments,—and, finally, to institute passive movements of the fingers and hand at the earliest practicable moment,—were the practical indications that were chiefly insisted on in the expectant conservative treatment of shot fractures at the wrist. Ahl's felt forearm splints were sometimes used, but it was more common to lay the limb upon an improvised modification of Bond's splint for simple fracture of the distal end of the radius, bandaging lightly, avoiding all compression. It was seldom that recovery was unattended with considerable deformity.<sup>1</sup>

CASE 1934.—Private W. H. Allen, Co. K, 95th New York, aged 20 years, was accidentally wounded at Slaughter Mountain, May 1, 1864, and admitted to Carver Hospital three days afterward. Act. Ass't Surg. P. C. Gilbert reports: "I found the patient suffering great pain from a wound by a minié ball, which entered upon the palmar side of the left wrist, at the articulation of the radius and ulna with the carpus; exit at the metacarpal-phalangeal articulation, carrying away the first two fingers. All the bones of the carpus were badly fractured except the trapezium, pisiform, and cuneiform: the unciform was slightly injured. Amputation was recommended." At 2 o'clock P. M., the patient having been etherized, it was deemed expedient to attempt to save the hand. A large number of pieces of bone were removed and the wound was left to heal by granulation." On May 17th, Act. Ass't Surgeon D. C. Marsh "found the patient suffering. Ordered anodyne and an aperient, and ice-water dressings. May 18th, there was an accumulation of pus under the integument and superficial fascia." On June 16th, the man was transferred to De Camp Hospital, and subsequently to St. Mary's, Detroit. Act. Ass't Surg. A. Backus reported his discharge February 25, 1865, because of "ankylosis of left wrist, and loss of first and second fingers with their metacarpal bones." Examiner C. C. Bates, of Potsdam, March 26, 1863, certified: "The thumb at its last and the remaining fingers at their first phalangeal joints are semi-flexed. All the joints of the hand are nearly immovable. The wrist is perfectly immovable. The flexor muscles were nearly all cut off, and are contracted. The cicatrix on front of carpus is very tender. The hand is useless, except that the two fingers are a very poor hook. The limb would be more useful if the hand was amputated. The fingers catch, and are hurt by pushing them under a substance to be lifted. The hand is little else than a weak, tender, clumsy, unsightly end or stump, always suffering in cold weather." The pensioner was paid December 4, 1875.

Pyæmia was frequent in the fifty-four fatal cases treated by expectation.<sup>2</sup>

CASE 1935.—Private B. Larrick, Co. H, 116th Ohio, aged 21 years, was wounded at Berryville, September 3, 1864, and admitted to hospital at Sandy Hook on the following day. Acting Assistant Surgeon N. F. Graham reported: "Gunshot wound of right hand. Patient transferred to Frederick." Acting Assistant Surgeon E. R. Ould contributed the specimen (*Cat. Surg. Sect.*, 1866, p. 198, *Spec.* 3846) with the following history: "The patient was wounded by a minié ball entering a little above the centre of the first phalanx of the middle finger, right hand, passing to the inner side of the bone and joint, wounding neither of these structures, but fracturing the metacarpal bone of the middle finger at its centre, also the os magnum and scaphoid. The missile lodged at the head of the metacarpal bones of the middle and index fingers. His previous condition was good. He was admitted to the General Hospital at Frederick on September 6th. The day he entered the hospital, the hand and arm were enormously swollen. The fracture was not detected until the swelling subsided and pyæmia supervened. The wound was probed, but no entrance could be effected. Solution of lead and opium was applied, and anodynes given at night. September 8th, the wound was again probed, with the same result as before. No diminution in the amount of swelling. Free incisions were made which eliminated pus freely. Applied poultices and ordered tonics and stimulants. 11th, arm and hand comparatively less swollen. Inflammation extending up the thecæ of the tendons. No crepitation felt. Treatment continued. 15th, parts still greatly swollen and very painful; suppurating freely. 20th, the patient has apparently improved up to this date, but the swelling has subsided but little. 28th, has a chill, sweat, and a cadaverous countenance. Pulse 103 and weak. Pyæmia evident. October 1st, swelling greatly subsided; crepitation felt, and the fracture detected. 2d, has had chills frequently, and is in a dying condition. At the *post-mortem* examination the cartilages of the wrist joint were found ulcerated, and there were pyæmic abscesses in both lungs." The specimen shows caries of the carpals, ends of metacarpals, radius, and ulna.

The ulterior usefulness of the hand and fingers was greatly dependant upon the after-treatment; and, as the patients with this form of injury were not classed among the very

<sup>1</sup>The later European campaigns afford many instances of the conservative treatment of shot fractures of the wrist. Thus: DR. L. STROMMEYER (*Marimen*, S. 756) tabulates 2, 1 fatal; M. CHENU (*Camp. d'Orient*, p. 328) 64 cases, 5 fatal, and *Camp. d'Italie*, T. II, p. 637, 74 cases, 9 fatal; DEMME (*Studien*, B. II, S. 241) tabulates 79 Austrian cases, 11 fatal; LÖFFLER (*General-Bericht*, S. 218) records 9 cases from the Danish war, 3 fatal; BERENGER-FÉRAUD (*Études sur les blessures du poignet*, etc., in *Bull. gén. de therap.*, T. LXXXII, p. 302) details 6 cases, 2 treated by immediate amputation with 1 death, 4 conservatively at the outset with 1 recovery, and 3 fatal secondary amputations; COUSIN (*L'Union méd.*, 1872, T. XIII, p. 147) reports 3 recoveries in shot fractures at the wrist treated conservatively; BECK (*Schussverletz.*, 1872, S. 592) reports 25 recoveries with ankylosis after shot fractures of the wrist conservatively treated; SÉDILLOT (*Arch. gén. de méd.*, 1871, T. XVII, p. 418) reports 7 shot fractures of the wrist, 4 conservatively treated with 3 deaths, 3 successfully by primary amputation in the forearm; PONCET (*Montpellier Méd.*, 1872) records 3 recoveries under conservative treatment of shot fractures of the wrist; LÜCKE (*Kriegschir. Fragen.*, 1871, S. 33) records 4 shot fractures of the wrist, 3 recoveries with conservation, 1 death with deferred amputation; SCHINZINGER (*Lazareth Schwetzingen*, 1873, S. 65) records 2 recoveries after shot fracture at the wrist, 1 treated by amputation, 1 by conservation; H. FISCHER (*Kriegschir. Erf.*, 1872, S. 156) records 8 recoveries from shot fractures of the carpus, 7 treated conservatively, and 1 by conservation; KIRCHNER (C.) (*Ärztl. Bericht.*, 1872, S. 50) details 12 cases of shot fractures of the wrist conservatively treated, with 2 deaths.

<sup>2</sup>In seventeen cases, beside the one detailed, the fatal event was ascribed to pyæmia. One of these cases, that of Pt. J. McLaughlin, Co. B, 5th Wisconsin, is illustrated by *Spec.* 1337, A. M. M., showing caries following a transverse shot perforation of the left carpus, with fracture of nearly every bone. Four patients succumbed from tetanus. In 1 (*Spec.* 543, *Surg. Sect.*, A. M. M.) a round ball was found embedded in the left radio-carpal articulation. Secondary hemorrhage was fatal in one case, gangrene in 3, and phlogogenous erysipelas in 6 cases. *Specs.* 543, 1337, 1617, 2916, 2815, 3838, 3846, *Surg. Sect.*, A. M. M., illustrate shot fractures at the wrist in cases treated by expectation.

grave cases, they were frequently removed from one base hospital to another, and rarely received that minute and persevering attention to position, passive motion, and other precautions essential in order to obtain the best possible results.

**EXCISIONS AT THE WRIST FOR SHOT INJURY.**—Ninety-six such operations were returned, and are distributed into subdivisions, according to the part excised. Six cases are described as total excisions, or extirpations of both rows of carpals with resection of the distal ends of the radius and ulna.<sup>1</sup> Ninety partial excisions consisted in the removal in whole or part of one or more of the bones entering into the carpal articulation. Fifteen cases, or 15.6 per cent., resulted in death, a higher mortality-rate than was observed in amputations in the forearm for shot injury in general, but not much greater than the death-rate in amputations in the forearm *on account of shot fractures at the wrist.*<sup>2</sup> Recourse to consecutive amputation in the forearm was had in eight cases, and in the upper arm in five. Sixty excisions with ten deaths were at the left wrist, thirty-four with three deaths at the right; two remaining cases, in which the side interested was not recorded, were fatal. Nine of the operations were practised on Confederate, and eighty-seven on Union soldiers. The nature and extent of the operations, and the period after injury at which they were performed, are set forth in the succeeding tabular statement:

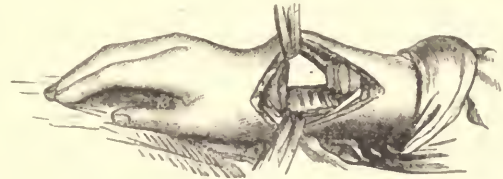


FIG. 720.—Complete excision of right wrist through lateral radial and ulnar incisions. [After BOUIGERY.]

TABLE CXLII.

*Descriptive Numerical Statement of the Nature and Results of Ninety-six Cases of Excisions at the Wrist for Shot Injury.*

PARTS EXCISED.	CASES.			PRIMARY.		INTERMEDIARY.		SECONDARY.		UNCERTAIN DATE.		FATALITY OF DETERMINED CASES.
	Total.	Recovery.	Fatal.	Recovery.	Fatal.	Recovery.	Fatal.	Recovery.	Fatal.	Recovery.	Fatal.	
Eads of Radius and Ulna with Carpus.....	6	5	1	1	.....	2	1	2	.....	.....	.....	16.6
Ends of Radius and Ulna and two Carpals....	1	.....	1	.....	.....	.....	1	.....	.....	.....	.....	100.00
Distal Ends of Radius and Ulna.....	4	4	.....	2	.....	2	.....	.....	.....	.....	.....	0
Distal Ends of Radius.....	26	24	2	14	1	6	1	2	.....	2	.....	7.7
Distal Ends of Ulna.....	19	16	3	9	2	4	.....	3	1	.....	.....	15.8
End of Radius with one or more Carpals.....	6	6	0	4	.....	.....	.....	2	.....	.....	.....	0
End of Ulna with one or more Carpals.....	10	8	2	4	1	3	1	1	.....	.....	.....	20.
One or more Carpals.....	13	9	4	6	2	.....	1	1	1	2	.....	30.7
Portions of Carpus and of Metacarpus.....	11	9	2	4	1	1	1	3	.....	1	.....	18.2
Totals.....	96	81	15	44	7	18	6	14	2	5	.....	15.6
Aggregates.....	.....	.....	.....	51		24		16		10		.....

Partly because of the diversity in extent of the operations classified under this head, and partly on account of the rarity of reports of excisions at the wrist for injury, instead

<sup>1</sup> Dr. RICHARD M. HODGES, in his excellent monograph, *The Excision of Joints*, 1861, p. 77, has well defined what is commonly understood by excisions at the wrist: "Under the term 'excision of the wrist, or radio-carpal joint,' must be included not only the removal of what strictly constitutes that articulation (radius and first row of carpal bones), but all operations which excise a part or the whole of the ends of the radius and ulna, a part of the whole carpus, the proximal ends of the metacarpal bones, or all of these at once."

<sup>2</sup> The mean fatality of 1734 determined cases of amputations in the forearm for the effects of shot injury was found (TABLE CXXXII, p. 967) to be 13.9 per cent. In 610 cases, in which amputations were performed in the forearm on account of the effect of shot fractures involving the wrist joint, there were 95 deaths, or 15.5 per cent.



of tabulating the cases of this category, brief abstracts of each will be presented. It is to be regretted that scarcely any special or circumstantial reports were made; but from the returns of different hospitals and of the pension examiners, some details have been gleaned regarding most of the cases. The abstracts are arranged in the order indicated in the descriptive numerical statement on the preceding page:

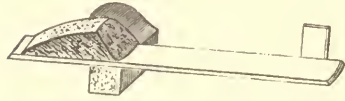

FIG. 721.—LISTER'S cork splint for excision at the wrist.

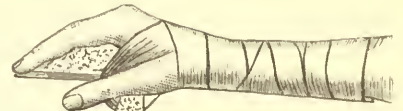

FIG. 722.—The cork splint applied. [After LISTER.]

CASES 1936-1941.—The six cases reported as complete excisions at the wrist included one primary operation, three intermediary, of which one resulted fatally, and two secondary operations. All were performed for immediate or remote lesions resulting from fractures or perforations of the carpus by musket balls: 1. Pt. *Specer*, Co. C, 53d Georgia, received, at the Wilderness, May 6, 1864, a shot fracture of the carpus and end of radius. An "excision of the entire wrist joint, including about half an inch of the radius and ulna," was performed the same day<sup>1</sup> by Surgeon J. J. Knott, P. A. C. S., through lateral incisions parallel with the radial and ulnar borders. On November 21, 1868, this man was "able to perform as much manual labor at his occupation of farming as before the reception of the wound, although there was some abduction of the hand."—2. Pt. J. Dies, 167th Pennsylvania, aged 18 years, received a shot perforation of the right wrist; the ball lodged, having been extracted from the abdominal parietes, at South Mountain, September 14, 1862. Some days subsequently, at Frederick Hospital No. 5, Assistant Surgeon C. M. Colton performed "excision of the wrist." This patient was discharged November 18, 1862, and pensioned. Examiner D. L. Beaver reported, February 14, 1863, that the ball entered at the radial side of the right wrist and passed through transversely; that the wound in the wrist was the only disabling one, having left complete ankylosis with adhesions and wasting of the arm. In March, 1867, Dr. Beaver reported: "This pensioner has some use of hand, much more than any artificial one would be, and promising to be more useful hereafter." In November, 1871, he reported that there was partial ankylosis of the wrist, and more use of fingers than formerly, and recommended a decrease of pension. Examiner E. M. Corson reported, September 16, 1873, that "the flexor tendons were contracted to such a degree that the hand was flexed, and ring and little fingers quite rigid, and movement of wrist joint greatly impaired." Pensioner paid September 4, 1875.—3. Pt. E. T. Harris, Co. F, 3d New Jersey, aged 19 years, was wounded at Gaines's Mills, June 27, 1862, receiving a shot fracture of left wrist and also a wound of right knee. He was captured and taken to Richmond. The hand became tumefied, the fingers cold and blue, and an abscess formed. He was exchanged and sent to Hygeia Hospital July 20, 1862.<sup>2</sup> An incision had been made on the palmar aspect, and the wound was dressed with a poultice, the fingers packed in cotton batting. On July 23d, Surgeon R. B. Bontecou made an H incision on the dorsum of the carpus and removed the end of the radius, the carpal bones, and the end of the first metacarpal. The patient went home in August, 1862, doing finely. He was discharged May 8, 1863, and pensioned. Examiner J. Cumminsky certified that: "One ball entered above the right patella and lodged, and led to slight lameness after long walking. Another ball penetrated the base of the first metacarpal of the left hand and came out at the ulnar dorsal surface. The fingers are stiff from agglutination of the extensor tendons." Examiner P. H. Clark certified, July, 1867, that: "Seven of the eight bones of the carpus were removed." This pensioner died January 8, 1868. The cause of death was not reported.—The third intermediary excision proved fatal: 4. Pt. J. M. Roe, Co. E, 12th New Jersey, aged 23 years, received at Cold Harbor, June 4, 1864, a shot perforation of the ends of the right radius and ulna, involving the radio-carpal joint. He was sent to Washington. Surgeon R. B. Bontecou,<sup>3</sup> at Harewood Hospital, performed complete excision of the joint. The parts became gangrenous, mortification extending to the middle of the forearm. On July 23d there was recurrent hemorrhage from the radial artery, and Acting Assistant Surgeon M. C. B. Richardson amputated in the forearm. Pyæmia set in, and the patient died August 7, 1864.—There were two secondary excisions: 5. Pt. P. Gavin, Co. F, 66th New York, aged 17 years, received a shot perforation, from palmar to dorsal aspect, of the left wrist, at Fredericksburg, December 12, 1862. He was sent to Washington, and entered Harewood Hospital. On December 31, 1862, and again five days after, there was hemorrhage, controlled by compression. On March 28, 1863, excision of the left carpus, or, according to another report, the remaining parts of the carpal bones, was performed by Surgeon T. Antisell, U. S. V. The case progressed favorably, and the man was placed, December 17, 1863, in Co. G, 10th V. R. C. He was discharged November 28, 1865, Assistant Surgeon W. Webster certifying that "there had been an excision of left carpus." He was pensioned. Examiner C. McDermont, of Hampton, reported, August 15, 1872: "The ball entered on the dorsal surface at the extremity of the left ulna and passed out at the palmar aspect. There is partial ankylosis of the joint, the hand is diminished in size, and he cannot flex the fingers or shut the hand, etc. He has free use of the thumb, and can use his hand for many purposes." This patient died July 8, 1873.—6. Pt. A. Smith, Co. H, 183d Ohio, aged 36 years, was wounded at Franklin, November 30, 1864, the ball entering the left wrist at the base of the fifth metacarpal, and emerging at the base of the first metacarpal, fracturing the extremity of the ulna. He was sent from Nashville to the Marine Hospital, Cincinnati, in May, 1865. Professor G. C. Blackman, May 17, excised the carpus, and reported the case as a recovery. The man was mustered out July 17, 1865, and pensioned. The Examining Board of Cincinnati reported, September 13, 1875: "Shot fracture of left carpus, with much deformity. Ankylosis of wrist; inability to use fingers; atrophy of forearm; hand useless; disability permanent." This pensioner was paid December 4, 1875.

<sup>1</sup> KNOTT (J. J.), *Successful Resection of the Entire Wrist Joint*, in *Med. and Surgical Reporter*, 1868, Vol. XIX, p. 454; and THOMPSON (J. W.), *Report on Resections of the Long Bones*, in *The Medical Record*, 1868, Vol. IV, p. 172. Dr. THOMPSON examined this man at Paducah 4½ years after the excision, and states "this continues to be a very useful limb, and is of great service to its owner."

<sup>2</sup> In Dr. R. B. BONTECOU'S printed but unpublished collection of cases and operations at Hygeia and Harewood, this case is printed at page 76.

<sup>3</sup> BONTECOU (R. B.), in the unpublished extract of cases before mentioned records this case (*op. cit.*, p. 81), but not the fatal termination; a fair prospect of recovery being present at the date of his report.

The first of the series of partial excisions is a fatal intermediary excision of the distal ends of the radius and ulna, together with two carpals of the first row:

CASE 1942.—Private W. I. Bartlett, Co. E, 28th Massachusetts, aged 38 years, at the Wilderness, May 5, 1864, received a shot comminution of the lower ends of the bones of the left forearm. He was sent to Mt. Pleasant Hospital, Washington, and on May 23, 1864, Acting Assistant Surgeon H. B. Knowles, through two incisions along the borders of the radius and ulna, excised the injured portions of the bones of the forearm and the cuneiform and pisiform. The wrist was but little swollen at the time of operation. The limb was placed at first upon a pillow, and then upon a padded lateral angular splint. Inflammatory reaction was comparatively slight, and the patient was sent to his home at Marblehead, July, 1864. Dr. H. H. F. Whittemore certified that at the expiration of his furlough his health was failing rapidly and he was unable to travel. "The only hope of saving his life was by amputating his arm above the elbow, which was done, July 17, 1864. At the end of three weeks the stump sloughed and there were frequent hæmorrhages, causing the patient to sink rapidly, till he was relieved by death, August 11, 1864."

There were four recoveries after two primary and two intermediary excisions of the distal ends of the radius and ulna.

CASES 1943-1946.—The primary cases were those of: 1. Pt. J. C. Hibson, Co. C, 48th New York, aged 19 years; was struck by a musket shot at the lower end of the radius, at Fort Wagner, July 18, 1863. He was taken to Hilton Head, and, July 20th, Assistant Surgeon J. E. Semple excised three and a half inches of the carpal end of the radius and an inch and a half at the lower end of ulna through a medium dorsal incision four inches long. The progress was favorable. The forearm was put on a padded splint. The limb shortened considerably, with atrophy. The lower end of the ulna united with the carpus, and there seemed to be osseous deposit filling up the interspace between the excised ends of the radius and the wrist, which was ankylosed. Movement of the fingers when the man was transferred to the V. R. C., January 5, 1864. He was discharged July 10, 1864, and pensioned. Examiner T. F. Smith certified, July 10, 1863: "Resection of three inches of radius and two of ulna; the latter has united with the carpus, the former has not been reproduced." In September, 1873, Dr. Smith reported: "The hand is twisted inward and is cold and clammy, and for the purposes of manual labor is useless."—2. Pt. J. W. Vanderburgh, Co. H, 9th New York Artillery, aged 21 years, received at Monocacy, July 9, 1864, a comminution of the right radius and ulna, opening the joint. The bones protruded through the flesh. He was sent to Patterson Park, Baltimore, and, July 10th, Acting Assistant Surgeon A. V. Cherbonnier excised, through a dorsal incision four inches long, the inferior extremities of the radius and ulna and numerous fragments, as shown in the wood-cut (FIG. 723). Treated at first by refrigerant applications and afterward by oakum dressings. This soldier was discharged and pensioned February 13, 1865. Examiner O. E. French, of Kansas, certified, March, 1874, that: "\* \* \* The parts have kindly healed; but, for want of care, the hand has curved or drawn over laterally to the ulnar side, leaving it perfectly useless."—The two intermediary cases are those of: 3. Pt. T. Donahoe, Co. B, 26th Ohio, aged 32 years; was wounded December 31, 1862, at Stone River, and sent to Nashville. Surgeon H. J. Herrick reported that the patient entered Hospital No. 13 January 5, 1863, and that on January 16th two inches of the distal extremities of the radius and ulna were resected. Inflammatory reaction was not great, and on February 18th the wound had healed. The patient was discharged May 19, 1863, and pensioned. Examiner W. Waddell, of Chillicothe, reported, March 28, 1863: "Resection of two inches of ends of bones of left forearm; limb two inches shortened; left hand useless." Examiner J. Baker, of Jefferson City, reported, August, 1872: "He suffers much from neuralgic pain; there is ankylosis of the wrist joint."—4. Pt. J. W. Hale, Co. B, 72d New York, aged 23 years, was wounded at Williamsburg, May 5, 1862. He was sent to Patterson Park, Baltimore,

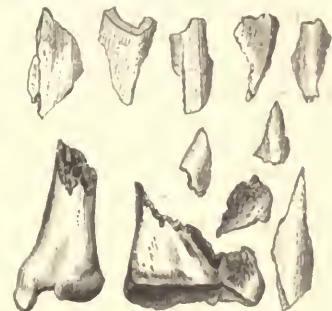

FIG. 723.—Excised distal fragments of right radius and ulna. *Spec. 2881.*

and on May 20, 1862, excision of a half inch of the distal end of the ulna with fragments of the radius was practised. He recovered with partial ankylosis of the wrist, and was discharged September 3, 1862, and pensioned. Examiner J. D. Ford, of Winona, reported, March 13, 1863: "A musket ball entered the ball of the left thumb and passed out at the carpal extremity of the ulna, fracturing both bones of the forearm." Examiner O. A. Simmons, of Jamestown, N. Y., reported, September 9, 1873: "Ulna is sub-luxated; adhesion of tendons has resulted, so that the fingers cannot be flexed; the hand consequently greatly impaired for purposes of manual labor." This pensioner was paid December 4, 1875.

Twenty-six excisions of the distal end of the radius only included fifteen primary, seven intermediary, two secondary operations, and two of uncertain date. There were two fatal cases, one each in the categories of primary and intermediary excisions.

CASES 1947-1972.—The recoveries after primary excisions are arranged alphabetically: 1. Pt. H. Blaisdell, Co. I, 9th New Hampshire, aged 18 years, received at Petersburg, July 30, 1864, a comminution of the carpal end of the right radius by a musket ball, which inflicted also a flesh wound of the hip. The lower end of the radius was excised the same day, on the field. The patient was sent to City Point, and afterward to David's Island, and discharged December 8, 1864, and pensioned. Examiner I. S. Chase, of Bristol, N. H., reported, October 27, 1866: "The right wrist is ankylosed, the bones and tendons destroyed; the hand at right angles with the forearm, and is totally lost for labor, and is much in the way." Examiner J. A. Davis, of Lebanon, September 4, 1873, found "the hand at right angle, almost useless; atrophy of the muscles of the forearm."—2. Pt. T. Coffey, Co. K, 112th New York, aged 21 years, received at Cold Harbor, June 1, 1864, a comminution of the lower part of the right radius by a small shell fragment. On the following day an excision of the lower half of the radius was performed. The patient was sent to Finley Hospital, Washington, and discharged June 29, 1865, and pensioned. Examiner J. Phillips, of



Washington, reported, April 17, 1867: "Exsection of five inches of lower end of radius for gunshot wound of right wrist joint. Cannot flex hand upon wrist." In May, 1837, this man re-enlisted in one of the veteran reserve regiments.—3. Pt. S. G. Couk, Co. I, 11th New Jersey, aged 23 years, received at Petersburg, November 10, 1864, a shot comminution of the right radius near the wrist, and simultaneously a wound of the left index finger, necessitating its amputation. Surgeon H. F. Lyster, 5th Michigan, excised two and a half inches of the distal extremity of the right radius, and removed the ball, which had entered the latissimus dorsi at the lower border of the axillary space and lodged subcutaneously over the scapula. Acting Assistant Surgeon G. K. Smith reported that the patient entered Armory Square Hospital "December 6, 1834, with phlegmonous erysipelas involving the dorsal surfaces of the hand and forearm. The case progressed favorably and there seemed promise of a fair use of the wrist joint and fingers, but muscular contraction gave a strong tendency to shortening of the callus and deflection of the hand to the radial border. This was counteracted, however, by appropriate splints and bandaging." The patient was discharged April 8, 1865, and pensioned. Examiner R. E. Van Gilson certified, March 23, 1836: "The hand is strongly drawn inward." Examiner

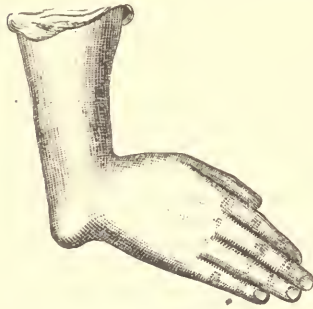


FIG. 724.—Sketch of forearm and hand laid with its palmar aspect on a flat surface.

C. McDermont certified, June 20, 1872: "The ball fractured the lower extremity of the right radius, which was removed to the extent of about three inches. The hand is contracted firmly to the radial side and pronated. The lower end of the ulna projects beyond the carpus, the scaphoid and semilunar lying against the radial side of the ulna, placing the hand almost at right angles with the arm. There is no joint at the wrist; the hand is connected by tendons agglutinated by fibrinous deposits so firm as to admit of little motion. The skin is tender and red over the projecting end of the ulna. The hand and fingers are stiff and partially paralyzed. He can only flex them far enough to touch the end of the thumb when bent to meet them. He has good use of the thumb, and can use the hand for a great variety of purposes, in eating, dressing, and seizing light objects; but for the purpose of manual labor the injury is equivalent to loss of a hand and is permanent." Dr. McDermont transmits with his report an outline tracing of the mutilated limb, which is reduced and copied in the wood-cut (FIG. 724). This pensioner was at Hampton, September 4, 1875.—4. Sergt. P. Dammel, Co. I, 79th Pennsylvania, aged 23 years, received at Hoover's Gap, June 26, 1863, a comminution of the lower end of the right radius by a

conoidal ball. The following day one and a half inches of the radius was excised. The patient was sent to York, Pennsylvania, and discharged March 23, 1834, with complete ankylosis of the wrist. Examiner P. S. Klinger, of Conestoga, reported the muscles of the forearm agglutinated and inability to close the hand. The Lancaster Board, January 6, 1875, reported the hand thrown out of position; inability to close it; the hand utterly useless, etc.—The next six cases were all comminutions of the carpal end of the radius by musket balls, followed by immediate excisions of the articular end of the bone with more or less of its shaft. All six patients recovered with stiff and greatly deformed limbs, and were pensioned. The dates of injury and pension reports will be briefly noted: 5. Corp. J. Haley, Co. C, 4th Vermont, aged 21 years, Cedar Creek, October 19, 1834. Excision of two and a half inches of right radius at 2d division, Sixth Corps, field hospital. Sent to Baxter Hospital, Burlington, and discharged May 29, 1835. Special Pension Examiner A. L. Lowell gave a minute account of the appearance of the wrist April 23, 1870. The hand was dislocated to the radial side, the integument over the projecting lower end of the ulna was red and sensitive, the temperature of the right hand slightly reduced, its prehensile power seriously impaired, pronation and supination fairly efficient, and muscles of arm and forearm well developed. Examiner C. S. Allen, of Rutland, February 12, 1872, refers to enlargement of the distal end of the ulna, and pronounces the member an encumbrance. This pensioner was paid December 4, 1875.—6. Sergt. O. Johnson, 139th New York, aged 36 years, Petersburg, August 21, 1864. Excision, an hour after the injury, of three and a half inches of the carpal end of the left radius through a linear lateral incision six inches long on the outer border. Sent to De Camp Hospital, and discharged February 6, 1865. Examiner J. T. Burdick reported, October 31, 1865, that the hand was drawn to an angle of 90° with the ulna, which report was corroborated by the Brooklyn Examining Board in 1873-75. Dr. E. D. Hudson supplied the pensioner, who was paid December 4, 1875, with an apparatus, but the deformity admitted of but little assistance from any appliance.—7. Pt. J. Little, Co. G, 5th Michigan, aged 40 years, Spottsylvania, May 12, 1864. Regimental Surgeon H. F. Lyster excised the carpal end of the right radius on the field. He was sent to Mt. Pleasant Hospital, and discharged September 26, 1864. Examiner J. Nichols reported that the ball had entered on the palmar surface, passed diagonally downward through the radius and carpus, and emerged on the dorsum of the hand; the latter was "left completely useless, and had better been amputated." Examiner D. Alsdorf, of Corunna, reported, October, 1875, hand drawn to radial side; lower end of ulna projects, and is tender and in the way. Has no use of any of the fingers or of the hand for any purpose; it is only an encumbrance.—8. Pt. T. Lockard, Co. D, 44th Illinois, aged 30 years, Kenesaw, June 22, 1864. Surgeon H. E. Hasse, 24th Wisconsin, the same day excised two inches of the lower end of the left radius. He was sent to No. 1 Hospital, Nashville, and thence to Jeffersonville, and discharged March 26, 1865. Examiner S. S. Cutter, of Coldwater, certified, October 20, 1835: "There is perfect ankylosis and partial luxation of the wrist; the hand was flexed inward laterally at an angle of about 45°." In 1873 the same examiner reports: "There is no restoration of bone or cartilage. There is cardiac affection, believed to have resulted from the injury." This pensioner was paid September 4, 1875.—9. Pt. M. McGill, Co. E, 22d Wisconsin, aged 30 years, Dallas, May 26, 1864. Excision on the field of three and a half inches of lower end of left radius. Sent to Harvey Hospital, Madison. Discharged July 1, 1865. Examiners L. J. Barrows and G. W. Burrall certified, in 1865 and 1873, that the wrist was ankylosed with great deformity, the hand displaced inward at right angles to the forearm, the fingers paralyzed. The ball had removed the little finger and injured the ring finger of the right side.—10. Pt. P. McKeena, Co. H, 158th New York, aged 38 years, Chapin's Farm, September 29, 1864. Immediate excision on the field, by Surgeon G. De Landre, 158th New York. He was sent to David's Island Hospital, and discharged August 12, 1865. Examiner C. Rowland, of Brooklyn, reported ankylosis following total loss of three inches of radius, and rendering the limb useless. The Brooklyn Examining Board, September, 1873, reported that: "Retraction of tendons has drawn the hand up to the side of the ulna, which greatly projects." This pensioner, residing

at 194 Church Street, Brooklyn, was supplied with an apparatus by Dr. E. D. Hudson, and was paid September 4, 1875.—11. Pt. E. Small, Co. C, 33d Massachusetts, aged 25 years, Lookout Mountain, October 28, 1863. Excision of lower sixth of left radius. Sent to Cony Hospital, Maine. Discharged January 19, 1865, and pensioned. Examiner J. W. Toward, of Augusta, stated, December 22, 1866, that the ball struck the dorsal surface of the bone, passed obliquely upward and inward, and emerged on the palmar surface. Three inches of the carpal end resected. Head of ulna projects; the hand bent nearly at right angle toward the radial side; can bend the fingers but little; cicatrix tender and painful; an artificial limb would be far preferable. The Augusta Examining Board in 1873 and 1875 concurred in this estimate. The pensioner was paid September 4, 1875.—In the next three cases primary excisions were followed by successful amputations in the forearm: 12. Sergt. H. Shannon, Battery A, 14th New York Artillery, Petersburg, June 17, 1864. Excision of carpal end and two inches of shaft of left radius. Sent to Mt. Pleasant Hospital. Acting Assistant Surgeon S. F. Ford, July 5, 1864, removed the forearm at middle third by circular incision (TABLE CXXXV, No. 225, p. 983). The patient was discharged December 8, 1864. The pension record reports a healthy stump when the pensioner was paid, December 4, 1875.—13. Pt. D. A. L. Thompson, Co. B, 50th Illinois, aged 24 years, Bentonville, March 20, 1865. Surgeon J. Pogue, 66th Illinois, excised the lower end of left radius at the 15th Corps field hospital. Was sent to McDougall Hospital. Assistant Surgeon S. H. Orton, U. S. A., amputated the forearm May 18, 1865 (TABLE CXXXVII, No. 108, p. 989). The pensioner was reported at Wellington, Kansas, September 4, 1875, with a sound stump.—14. Pt. C. L. White, Co. G, 29th Massachusetts, aged 32 years, Malvern Hill, July 1, 1862. A partial excision of the lower end of the left radius was practised on the field by the regimental surgeon, O. Brown. Patient was sent to Mt. Pleasant Hospital, Washington, where Assistant Surgeon C. A. McCall amputated the forearm, August 10, 1862 (TABLE CXXXVII, No. 113, p. 989). This soldier was discharged August 29, 1862, with a sound stump, and pensioned, and furnished with an artificial limb by M. Lincoln, of Boston. In his application for commutation, in 1870, he reported the artificial limb to be of no advantage, and was worn with discomfort. The specimen (*Cat. Surg. Sect.*, 1836, p. 205), represented in the adjacent wood-cut (FIG. 725), shows the disorganization of the carpals and metacarpals from shot perforation, and the partial excision of the radius. It was contributed to the Museum by Dr. McCall. Both rows of carpals are carious, and the preparation exemplifies the inutility of such incomplete primary operations.—One of the fifteen primary excisions of the distal end of the radius proved fatal: 15. Pt. W. H. Morgan, Co. D, 83d Ohio, Arkansas Post, January 11, 1863. Surgeon J. W. F. Gerrish, 67th Indiana, excised the lower third of the radius the same day, and the patient died February 7, 1863.—Of the seven intermediary excisions of the carpal extremity of the radius, six ended in recovery, and one proved fatal after secondary amputation of the arm: 16. Pt. J. Cohor, Co. B, 18th Infantry, aged 17 years, Dallas, May 25, 1864. He was sent to Chattanooga, where Assistant Surgeon C. C. Byrne, U. S. A., excised the carpal extremity of the left radius June 3, 1864. The patient was transferred to Nashville August 24th, and discharged September 7, 1864. His name is not found on the pension roll.—17. Pt. M. Culligan, Co. D, 40th Indiana, aged 40 years, Resaca, May 15, 1864. Sent to Nashville, where Acting Assistant Surgeon T. H. Hammond excised, May 27th, three and a half inches of the lower end of left radius. Copious purulent infiltration ensued. The patient was transferred to Louisville, to Indianapolis, and to Soldiers' Home, and was discharged May 19, 1865, and pensioned. Examiner T. Chestnut, of Lafayette, reported, July 24, 1866: "Complete ankylosis between the ulnar and carpal bones; the hand contracted on the wrist and completely useless." This pensioner died July 30, 1869.—18. Pt. G. Garment, Co. C, 20th Massachusetts, aged 26 years, Wilderness, May 6, 1864. Sent to Emory Hospital. A ragged lacerated shot wound of the right wrist was filled with healthy granulations. May 23, 1864, Acting Assistant Surgeon W. H. Ensign excised an inch and three-quarters of the carpal extremity of the radius (FIG. 723). The patient was discharged May 25, 1865, and pensioned. Examiner W. H. Page, of Boston, reported, November 5, 1866, that the ball penetrated the carpal end of the right radius from the dorsal to the palmar aspect, and that resection of the bone had resulted in complete ankylosis of the wrist. The hand is turned inward; no power over the fingers except to slightly move the ends. The hand is cold and livid and wasted, as is the whole forearm. There is a large cicatrix, where another ball perforated the soft parts above the right elbow. The Boston Examining Board, in 1870, 1873, and 1875, states: "Hand stands at an angle of 150° with forearm." The pensioner was paid September 4, 1875.—19. Pt. W. McGarrah, Co. D, 124th New York, aged 24 years, Chancellorsville, May 3, 1863. Sent to Columbian Hospital, Washington, where excision of the lower fourth of the left radius was performed some time in May, 1863, and discharged February 11, 1864, with great contraction and deformity of the wrist. Examiner W. P. Townsend, of Goshen, reported, September 4, 1873: "The hand is almost at right angles to the forearm, with complete ankylosis of the wrist, etc." This pensioner was paid June 4, 1875.—20. Pt. J. Nipple, Co. A, 110th Pennsylvania, aged 33 years, Winchester, March 23, 1862. Sent to St. Joseph's Hospital, Philadelphia. On March 30, 1862, an inch and a half of the distal extremity of the left radius was excised. April 26th, a tubular sequestrum was extracted. June 10th, patient transferred to Camp Curtin, Harrisburgh, and discharged September 5, 1862, and pensioned. Examiner J. McCulloch reported, February 13, 1871, that: "In consequence of resection the hand is drawn inward nearly at right angles, and the end of ulna sticks out below the hand." Pensioner paid September, 1875.—21. Corp. J. C. Speed, Co. G, 3d New Hampshire, aged 26 years, Deep Bottom, August 16, 1864. Sent to Balfour Hospital, Portsmouth, where Assistant Surgeon J. H. Frantz, U. S. A., August 26, 1864, excised the lower third of right radius. The patient was sent to Webster Hospital, Manchester, and discharged June 15, 1865. Examiner P. Spaulding, of Haverhill, reported, September 4, 1873: "The wrist is entirely ankylosed, the hand and fingers stiff and much deformed, and almost useless. The forearm does not rotate, and the elbow is nearly stiff. The whole arm is wasted, and useless for most purposes

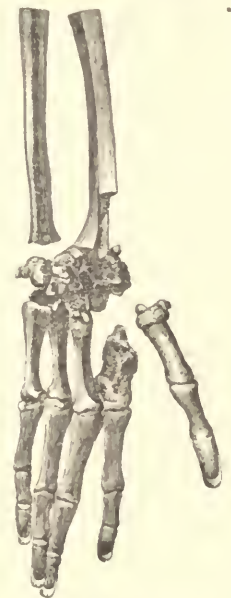

FIG. 725.—Partial excision of left radius after shot perforation of wrist. Spec. 157.



FIG. 726.—Excised extremity of right radius. Spec. 2351.



of manual labor." Pensioner paid September 4, 1875.—The fatal intermediary excision of this group was followed by an amputation in the upper arm: 22. Corp. M. E. J—, Co. F, 94th New York, Antietam, September 17, 1862. Sent to the Patent Office Hospital. Acting Assistant Surgeon C. H. Boardman, October 15, 1862, found the right radius carious and excised its lower half. Successive abscesses formed; the carpus and upper extremity of the radius became carious, and on December 19, 1862, amputation was performed in the upper arm, the point of ablation being unspecified (TABLE XC, No. 11, p. 792). He sank exhausted, and died December 30, 1862.—The two secondary excisions of this group were examples of recovery with great deformity: 23. Pt. J. Boden, Co. B, 45th Pennsylvania, aged 47 years, South Mountain, September 14, 1862, received a fracture of the lower end of the left radius, a musket ball passing from the palmar to the dorsal surface. Sent to Satterlee Hospital. Abscesses formed, and, on October 17th, Assistant Surgeon E. DeW. Breneman, U. S. A., excised through an H incision the shattered extremity of the bone. There was copious hemorrhage, and it was necessary to tie the anterior interosseous artery. The hand and forearm were laid on a well-padded Esmarch splint. The case progressed favorably, and the man was discharged April 18, 1863, and pensioned. Examiner P. S. Clinger, of Conestoga, reported, July 17, 1838: "Permanent agglutination of the muscles of the forearm and hand; no motion whatever of the wrist or fingers." Examiner S. J. Beck, of New Columbia, reported, May 19, 1875: "Joint ankylosed; hand forms a small angle deflected to the radial side." The pensioner was paid September 4, 1875.—24. Corp. P. H. Post, Co. E, 74th New York, aged 29 years, Gettysburg, July 2, 1863. Sent to Mower Hospital. Musket ball fractured the lower end of the left radius, opening the joint, and leading to diffuse suppuration; excision of the lower end of the bone was practised; eleven large fragments, constituting about two and a half inches of the end of the bone, were excised, August 6, 1863, by Acting Assistant Surgeon C. R. McLean. Patient was discharged August 22, 1864, and pensioned. Examiner O. Warner, of Paterson, New Jersey, reported, February 5, 1872: "Hand luxated to the radial side, and motion to a great extent lost; disability equalling the loss of a hand." Pensioner paid September 4, 1875. The fragments of bone are preserved as specimen 2601 in the Museum (*Cat. Surg. Sect.*, 1866, p. 183).—Two of the excisions of this group, resulting in recovery, were practised at a date after injury that has not been ascertained: 25. Pt. T. C. Mahoney, Co. A, 30th Ohio, aged 39 years, Antietam, September 17, 1862. Sent to Carver Hospital. The lower end of the left radius, comminuted by a musket ball, was excised. The patient was sent to Satterlee December 11, 1862, and discharged April 18, 1863. Examiner P. G. Clinger, of Conestoga, certified, July 19, 1864: "The hand is drawn laterally and held by the agglutination of the muscles. The fingers are stiff and hand useless; he is unable to obtain subsistence by manual labor." This pensioner re-enlisted in July, 1864.—26. Pt. R. Berry, 5th Louisiana, aged 37 years, Sharpsburg, September 17, 1862, received a shot perforation of the lower end of the right radius. Four and a half inches of the distal end of the bone was excised. The soldier was retired, on surgeon's certificate of disability, February 10, 1865.



FIG. 727.—Excision in radius. *Spec.* 487.

There were nineteen excisions of the distal end of the ulna—eleven primary, with two deaths; four intermediary recoveries; four secondary cases, with one death.

CASES 1973-1991.—Of the eleven primary excisions of the distal end of the ulna, nine resulted in recovery, after amputation in the upper arm in one instance: 1. Pt. N. Bolton, Co. K, 28th Louisiana, aged 33 years, Simonsport, May 18, 1864. Excision of the lower extremity of the right ulna was done on the field. The patient was sent to Helena, Arkansas, recovered, and was transferred to the Provost Marshal November 9, 1864.—2. Pt. R. Carrigan, Co. C, 50th Illinois, aged 22 years, Rome, May 26, 1864. Surgeon J. R. Zearing, 57th Illinois, excised an inch of the lower extremity of the left ulna, shattered by a musket ball, through a lateral incision of three inches. The patient was sent to Quincy, Illinois, and discharged January 7, 1865. His name is not on the pension list.—3. Lieut. D. F. Cheney, Co. I, 9th New Hampshire, aged 23 years, Petersburg, July 30, 1864. Excision of three inches of the lower extremity of left ulna the same day, at field hospital. Sent to Armory Square, and mustered out November 30, 1864, and pensioned. Examiner B. S. Warren, of Concord, reported, June 20, 1866: "Arm atrophied, and ring and little fingers cannot be fully flexed in consequence of adhesions and partial paralysis." Examiner H. M. Chase, of Lawrence, certified, October 1, 1873: "Excision of carpal half of ulna, deformity from loss of tissue. Can flex the fingers partially." Painful sensitiveness of the forearm, etc., is also noted. This pensioner was paid March 4, 1875.—4. Pt. D. B. Derby, Co. A, 2d New Jersey Cavalry, aged 38 years, was wounded at Memphis, January 16, 1865, by the explosion of an ammunition chest, receiving comminution of the lower part of the left ulna. Assistant Surgeon J. M. Study, U. S. V., on January 18th, excised the lower extremity of the ulna, at the Adams Hospital. The patient was discharged May 24, 1865. Examiner W. W. Dale, September 28, 1875, reports: "Removal of two inches of carpal end of left ulna. There is a deep adherent cicatrix three inches in length. Although

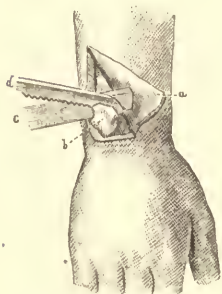


FIG. 728.—MOREAU'S method of excising the carpal end of the ulna. [After BERNARD and HUETTE.] a—triangular flap. b—ulna. c—thin slab of ivory to guard the saw, d.

there is *very good motion of the wrist joint*, the arm is considerably weakened."—5. Pt. V. LeLargue, Co. I, 28th Massachusetts, aged 31 years, Wilderness, May 6, 1864. Excision of two and a half inches of the lower end of the left ulna was practised at the field hospital the following day. The hand was placed on a straight padded splint. The patient was sent to Chestnut Hill, Philadelphia, thence to Ladies' Home, New York, and Dale Hospital, Worcester, and discharged July 21, 1865. The Hartford Examining Board certified, September, 1873: "Two and a half inches of the lower end of the left ulna has been removed. Complete ankylosis of the wrist." This pensioner was paid September 4, 1875.—6. Pt. M. McAllister, Co. C, 5th Pennsylvania Reserves, aged 26 years, Wilderness, May 6, 1864. Excision on the field, of three and a half inches

of shattered ulna. Sent to Armory Square and Philadelphia hospitals, and mustered out June 14, 1865, and pensioned. Examiner C. M. Turner, of Towanda, reported, September 14, 1869: "Carpus ankylosed; fingers powerless." Pensioner paid June 4, 1875.—7. Corp. L. H. Pierce, Co. G, 85th New York, aged 28 years, Bull Run, August 30, 1862. Excision of lower end of left ulna was practised on the field. Sent to Carver Hospital, and discharged December 29, 1862. Examiner W. S. Welsh, of Franklin, Pennsylvania, reported, September 4, 1873, that there was displacement of the hand at right angles and inability to flex the fingers, the disability being equivalent to the loss of the hand. This pensioner was paid December 4, 1875.—8. Pt. G. Williams, Co. A, 154th New York, aged 21 years, Rocky Face Ridge, May 8, 1864. Two inches of the articular end of the left ulna was excised on the field the same day by Surgeon James Reily, 33d New Jersey. The patient was sent to Buffalo, New York, and discharged February 28, 1855. Examiner G. W. Hazeltine, of Jamestown, reported motions of carpus lost; no sensation in middle and ring fingers. Examiner A. Jewett, of Dayton, Ohio, reported, February 13, 1873: "Hand in pronation and cannot be supinated." Examiner H. K. Steele reported the use of the thumb and index finger as retained. Examiner R. L. Sweeney reported, December 6, 1875: "Partial luxation of wrist; want of power to rotate forearm."—One of the primary excisions was followed, after three weeks, by amputation in the upper arm: 9. Corp. F. A. Sherman, Co. H, 11th Maine, aged 22 years, Wilderness, May 5, 1864. Surgeon H. F. Lyster, 5th Michigan, excised an inch of the distal extremity of the ulna the same day. Periostitis with caries extended up the ulna, and the limb was removed in the upper arm, May 29, 1864 (TABLE LXXVIII, No. 223, p. 766). The specimen, 2503, *Surg. Sect.*, A. M. M., is interesting. The pensioner was paid December 4, 1875, and had a sound stump.—The two fatal cases of primary excision of the distal end of the ulna are: 10. Pt. F. M. Hardy, 30th North Carolina, fully detailed on page 950 as CASE 1807. He also underwent an excision of the radius in the opposite forearm (See FIGS. 688, 689).—11. Pt. S. Young, Co. F, 63d New York, aged 25 years, Petersburg, June 16, 1864. Excision of a portion of the lower extremity of the left ulna, the same day, by Surgeon P. E. Hulon, 28th Massachusetts. He was sent to Carver Hospital, Washington, and, July 9th, Acting Assistant Surgeon R. E. Price resected a further portion of the shaft of the ulna. July 15th, pyæmia supervened, and resulted fatally July 27, 1864.—Four intermediary excisions of the lower end of the ulna resulted in recovery, one after submitting to amputation in the forearm: 12. Pt. J. L. Jones, Co. C, 120th Illinois, aged 21 years, Guntown, June 10, 1864. Sent to Adams Hospital, Memphis, where, June 25th, Acting Assistant Surgeon S. S. Jessop excised the lower sixth of the right ulna. The patient sent North, August 23, 1864, on the transport January. Pensioned October 22, 1864. Examiner G. Bratton, of Vienna, certified, July, 1859: "A musket ball struck the right carpus near its dorsal articulation with the ulna, and ranged upward, fracturing the ulna. The wrist joint is ankylosed and the fingers greatly shrivelled and flexed. Pensioner paid September 4, 1875.—13. Lieut. J. R. McGowan, Co. D, 13th Alabama, aged 23 years, Wilderness, May 8, 1864. Sent to Richmond, where, May 12, 1864, excision of four inches of the lower end of the ulna was practised. This officer was furloughed June 13, 1864.—14. Pt. W. Tyson, Co. G, 110th Pennsylvania, aged 50 years, Fredericksburg, December 13, 1862. Sent to Harewood Hospital, Washington. December 27th, excision of two inches of lower end of left ulna, and free incisions to evacuate pus which had burrowed in the metacarpus. Pensioned March 28, 1863. The Lancaster Examining Board reported, September 4, 1873: "Complete ankylosis of wrist joint; loss of control of movements of all the fingers."—The fourth intermediary case was followed by amputation: 15. Pt. E. H. Lewis, Co. E, 145th Pennsylvania, aged 18 years, was wounded at Fredericksburg, December 13, 1862. Sent to Hammond Hospital. Late in December the lower extremity of the left ulna was excised. The case progressed unfavorably, and amputation high in the forearm was practised, February 16, 1863 (See TABLE CXXXVII). March 7, 1863, there was profuse bleeding, on account of which the radial was tied in its continuity above the stump. Pensioned June 13, 1863, and paid September 4, 1875.—Three of the four secondary excisions of this group terminated in recovery, and one in death: 16. Pt. J. J. Davis, Co. F, 140th Pennsylvania, aged 27 years, Gettysburg, July 3, 1863. Sent to Satterlee, where Acting Assistant Surgeon T. G. Morton excised the lower third of the left ulna, September 3, 1863. A musket ball had perforated the bone from the dorsal to the palmar surface. To V. R. C. January 26, 1864; discharged and pensioned November 24, 1865. Examiner D. N. Rankin, of Allegheny, reports: "The ulnar nerve and artery were severed, and the hand is cold and clammy, and the sense of feeling is almost entirely destroyed. It pains him extremely in cold weather. Its motions and power are very slight." The Pittsburg Examining Board reported, September 9, 1875: "Pronation and supination are lost and the hand is weak and powerless. Equivalent to loss of hand for manual labor."—17. Sergt. J. R. Imboden, Co. C, 1st Ohio, Chickamauga, September 19, 1863. Shell fracture of lower extremity of right ulna. Sent to general hospital at Nashville, and afterward to Camp Dennison. Two months after the injury excision of the lower end of the bone was performed, and the patient was returned to duty in V. R. C. August 20, 1864. March 1, 1867, Brevet Major Harvey E. Brown, Assistant Surgeon, U. S. A., in his report on soldiers of the 1st Infantry wounded during the war, mentions this man as a private of Co. H, enlisted June 6, 1865: "There was considerable deformity about the wrist, and he is troubled with numbness of the index and middle fingers, and has rather imperfect use of hand, but is able to perform his duties as a soldier."—18. Pt. J. Quinland, Co. C, 6th Louisiana, aged 34 years, Chancellorsville, May 3, 1863. Sent to Charlottesville. Professor J. L. Cabell noted that, in consequence of a shot perforation of the left carpal articulation, the lower end of the ulna, projecting, was resected to the extent of one inch, November 1, 1863. In December the wound was nearly healed; there was some motion about the joint, though the fingers were stiff, the whole limb somewhat atrophied, and the movement of the elbow joint and forearm imperfect, supination being almost lost. The Richmond Retiring Board retired this soldier on certificate of permanent disability February 13, 1865. The certificate is filed in the War Department, and states that there was "paralysis of all the extensor muscles of the forearm, with total inability to use the hand." This case is also noted in the manuscript register of Dr. H. L. Thomas, to be cited hereafter.—19. Sergt. J. N. Chestnut, Co. C, 6th Wisconsin, Antietam, September 17, 1862. Extensive sloughing followed a musket-ball fracture of the lower end of the right ulna. Sent to Frederick Hospital No. 6. Surgeon J. B. Lewis, U. S. V., December 2, 1862, excised three and a fourth inches of the lower end of the ulna (FIG. 729). Some of the fragments agglutinated by callus are seen attached to the lower end of the bone, and osteophytic deposits extend up the shaft. The patient wasted away gradually, and died January 22, 1863.



FIG. 729.—Excised distal extremity of right ulna. *Spec.* 3584.



Next in order are six recoveries after four primary and two secondary excisions of the lower end of the radius, with one or more of the carpals. It is proper to discriminate this group, because, as Malgaigne observes,<sup>1</sup> the radio-carpal synovial membrane lines only the articular end of the radius and upper surfaces of the scaphoid, semilunar, and cuneiform bones; but as soon as the ligaments of the latter are cut into, another great synovial sac is opened, overlapping all the bones of the carpus except the pisiform.<sup>2</sup>

CASES 1992-1997.—Four primary excisions include: 1. Pt. J. Harper, Co. I, 38th Illinois, aged 23 years, Kenesaw Mountain, June 27, 1864. Surgeon J. D. Brimley, U. S. V., at the 1st division, Fourth Corps hospital, the same day excised the lower portion of the right radius and adjacent carpal bones. The ball had also inflicted a flesh wound just above the crest of the right ilium. Sent to Cumberland Hospital, Nashville: recovered, and re-enlisted in his regiment (*Ad. Gen. Report of Illinois*, Vol. IV, p. 455). Pensioned November 14, 1865. Examiner L. W. Low reported, March 19, 1867: "Atrophy of the entire arm and displacement of hand, which is at a right angle with the forearm looking inward, the lower end of ulna projecting, the wrist ankylosed, but not the finger joints." Examiner F. Ronalds reported, September 9, 1873: "Lower extremity of radius gone, hand useless." Pensioner paid September 4, 1875.—2. Pt. J. L. Miller, Co. C, 16th Kentucky, aged 17 years, Altoona, June 14, 1864. Surgeon J. H. Rodgers, 104th Ohio, excised on the same day four inches of the lower end of the left radius and the first row of carpals except the pisiform. Sent to Nashville, and pensioned March 12, 1865. Examiner T. W. Gordon, of Georgetown, reported, November 16, 1865: "Several of the carpal bones and four inches of the radius have been removed." The Cincinnati Examining Board reported, September 6, 1873: "Large depressed firmly adherent cicatrix on dorsum of left wrist; four inches of lower end of radius excised; ligamentous union with great deformity; grasp of hand feeble; impaired circulation." Examiner S. V. Piror, of Catlettsburgh, Kentucky, certified, September, 1875: "The hand is drawn inward at an angle of 95° and is entirely powerless."—3. Pt. G. W. Taylor, Co. H, 70th Ohio, accidentally, at Dallas, May 29, 1864. Surgeon J. H. Hutchinson, 15th Michigan, the same day excised the lower end of the left radius, the scaphoid and semilunar, and fragments of other carpals, at a field hospital of the 15th Corps. Examiner T. W. Gordon certified, May 14, 1870: "A musket ball entered the palmar radial side of the left wrist and passed out at dorsal side of the head of the first metacarpal, fracturing the second also. The thumb is useless though not entirely ankylosed; the fingers are permanently flexed; the second metacarpal is thickened and arched up on the back of the hand. The injury is permanent, yet, as he has the use of the hand as a hook, I cannot say that the injury is equivalent to the loss of a hand." Examiner J. Shackelford, Maysville, Kentucky, testifies to "tenderness of cicatrix from retention of buck-shot in track of wound." Pensioner resides at Bradyville, Ohio, and was paid June 4, 1874.—4. C. Murphy, 16th New York or Massachusetts (?), July, 1862. Sent to Naval Academy Hospital, Annapolis. Excision of lower end of left radius and fractured portions of carpals. Recovered.—The two secondary excisions of this group resulted in ankylosis with deformity: 5. Pt. L. S. Bard, Co. I, 1st Pennsylvania Rifles, South Mountain, September 14, 1862. Shot fracture of right carpus and lower end of radius. Sent to Frederick, where Assistant Surgeon C. Bacon, jr., October 27, 1862, excised the lower part of the radius, the scaphoid, trapezoid, and os magnum. Pensioned December 23, 1862. Examiner B. S. Gould, of Port Allegany, reported, March 30, 1863: "No use of hand or wrist. Had a flesh wound in right shoulder, of little account." Examiner S. D. Freeman, October 17, 1873, stated that the ball destroyed the carpus and lower end of the right radius. Pensioner paid September, 1875.—6. Pt. J. A. Byrd, Co. A, 99th Illinois, aged 28 years, Vicksburg, May 22, 1863. Shot wound of right wrist, injuring carpus and radius. He was sent to Jefferson Barracks. Acting Assistant Surgeon F. F. Rumbold, March 7, 1864, found the bones carious, and removed the lower end of radius and first row of carpals. Pensioned April 20, 1864. Examiner H. Jones reported ankylosis of wrist, immobility of entire hand. This pensioner died of phthisis July 21, 1869.

There were ten excisions of the lower extremity of the ulna together with one or more of the contiguous carpal bones. Fatal results followed two of these operations:

CASES 1998-2007.—There were five primary operations, of which one was fatal: 1. Pt. B. A. Bonewell, Co. F, 140th Pennsylvania, Gettysburg, July 2, 1863. Surgeon C. S. Wood excised the lower end of the left ulna, splintered by a musket ball, together with the cuneiform and pisiform, the day of injury, at the Second Corps hospital. Sent to Pittsburg Hospital, and pensioned December 26, 1863. The Pittsburg Examining Board reported, October 11, 1873: "Ankylosis of wrist; fingers contracted in palm." Pensioner paid September 4, 1875.—2. Pt. P. Euler, Co. H, 50th Illinois, aged 28, Resaca, May 16, 1864. Excision of two inches of end of left ulna and adjacent carpal bones on May 17th, through a straight lateral incision. Sent to Chattanooga, and pensioned May 18, 1865. Examiner H. C. McPherson certified, March, 1867, that the disability was equivalent to the loss of a hand. This pensioner died November 27, 1869, of pulmonary disease, remotely due, in the opinion of the attending physician, to prostration following the injury.—3. Major C. W. Hobbs, 7th New York Artillery, aged 22 years,

<sup>1</sup> MALGAIGNE (J. F.), *Manuel de Médecine Opératoire*, 7ème éd., 1861, p. 227.

<sup>2</sup> Of the experience of the French surgeons of shot injuries of the wrist joint in the Franco-German War of 1870-71, M. SÉDILLOT (*Fract. des membres par armes de guerre*, in *Arch. gén. de méd.*, 1871, p. 417) writes: "Fractures of the radio-carpal joint were not very common, and attempts at conservation found few partisans." The number and size of the bones entering into the articulation, the close vicinity of large vessels, the multiplicity of tendons and bursae, the liability of supuration, adhesions, and ankylosis, and of immobility of the fingers, are serious counter-indications to conservative essays; although the hand, however deformed and powerless, remains an appendage of some service. These reasons led us to reject not only conservation but resection, which I never practised, and, indeed, never saw practised. Nevertheless it is evident that, where disorganization is not very great, where only, for example, the lower ends of the radius or ulna or the first row of carpals may be injured, without extensive lesions of the bones or tendons, conservation or partial resection ought to be attempted; but where the radius is splintered, the joint largely opened, the ligament and tendons torn, amputation is necessary, and that this operation even cannot be depended on to save life if it be deferred, as we shall illustrate further on. Surgery requires new researches on this subject, and a detailed analysis of more facts."

Cold Harbor, June 3, 1834. The regimental surgeon, J. E. Poufret, afterward Surgeon General of New York, directly after the injury excised the shattered distal extremity of the ulna, the cuneiform, pisiform, and unciform bones, the fourth and fifth metacarpals, and the greater portion of the third metacarpal, removing the middle, ring, and little fingers. The patient was sent to Armory Square. The case progressed very favorably, and recovery took place without ankylosis of the remaining portion of the radio-carpal articulation or impairment of the movements of the thumb and forefinger. The major was mustered out and pensioned July 3, 1835. The functional activity in the remaining portions of the carpus, metacarpus, and phalanges was remarkable.<sup>1</sup> September 21, 1837, this officer was appointed second lieutenant, 3d Artillery, with which regiment he still serves. The appearance and extent of motion of the hand is indicated in the wood-cut (FIG. 730).—

4. Corp. A. J. Pulliam, Co. F, 17th Mississippi, aged 29 years, Gettysburg, July 2, 1863. Assistant Surg. W. H. Gardner, U. S. A., reports that a shell injury of the right hand, attended by great laceration of the soft parts and comminution of the lower end of the ulna and contiguous carpal and metacarpal bones, required immediate excision of the splintered bones by the saw and cutting pliers. It was difficult to get flaps of integument to cover in the sawn extremities of the bones. The patient was sent to Hammond Hospital. Refrigerant applications were perseveringly employed until September 20th, when pus burrowed among the tendons, pointing at the base of the first metacarpal. Inflammation subsided after incisions and applications of dilute tincture of iodine. Healthy granulation went on, and by October 10th the wound had entirely healed. The man's health was good, and "he had partially recovered the use of the hand." On December 5, 1863, he was transferred to the prisoners' camp, at Johnson's Island.—

The fatal primary case of this subdivision was that of: 5. Sergeant B. Stebbins, Co. I, 86th Illinois. In the report of Surgeon E. Swift, U. S. A., "of the medico-military history of the Department of the Ohio," it is stated that this man, a convalescent in Hospital 24, Nashville, while taking a walk, received a shot perforation of the right wrist, shattering the carpus and end of ulna, by a musket ball accidentally discharged, February 24, 1863. He was immediately taken to Hospital 21, where Acting Assistant Surgeon Lyman reported that: "For two days he suffered severely from tetanic spasms, when it was decided to excise two inches of the inferior extremity of the ulna and carpal bones as far as necessary." After the operation the tetanic symptoms did not return, but the patient sank, and died March 7, 1863.—There were four intermediary operations in this sub-group, with one death: 6. Lieut. W. D. Davenport, Co. H, 5th Vermont, aged 21 years, Wilderness, May 5, 1864. Musket-ball fracture of end of left ulna, involving wrist. Sent to Seminary Hospital, Georgetown, May 15, 1864. Act. Ass't Surgeon J. M. McCalla excised the lower third of ulna and adjacent carpal bones. Pensioned September 15, 1864. Examiner C. L. Allen, of Rutland, certified, September 4, 1873: "The ball entered the back of the forearm near the left wrist, injuring the ulna and several of the carpal bones, making its exit in front. The wrist is perfectly stiff and the hand useless, except that the thumb and index finger are somewhat useful though not strong. The third, fourth, and fifth fingers are stiff and contracted." Pensioner paid September 4, 1875.—7. Pt. J. Hoover, Co. A, 62d Pennsylvania, aged 26 years, Spottsylvania, May 12, 1864. A musket ball passed through both wrists.<sup>2</sup> The right forearm was amputated on the field (TABLE CXXXIII, No. 427, p. 973). Sent to Judiciary Square. May 30th, Assistant Surgeon A. Ingram, U. S. A., excised the greater part of the left carpus and carpal ends of the ulna and first metacarpal. Pensioned May 18, 1865. Examiner G. C. Ewing, of Uniontown, Pennsylvania, reports, August 10, 1865: "Wrist and thumb wholly immovable; a little motion with the fingers; cannot grasp anything; the left hand is almost if not altogether useless for purposes of manual labor." Commutation paid February 28, 1876.—8. Pt. J. C. Hopkins, Co. I, 44th Illinois, aged 18 years, Kenesaw, June 27, 1864. Shot comminution of left ulna, carpals, and metacarpals of thumb, index, and middle fingers. Sent to Mound City Hospital. Acting Assistant Surgeon J. G. Harvey, July 14, 1864, excised the lower end of ulna and fragments of carpals and metacarpals. Gangrene ensued. Pensioned March 4, 1865. Examiner E. A. Clark, of St. Louis, reported: "Complete ankylosis of wrist joint; paralysis from laceration of nerves, etc." Examiner J. B. Bell, of Potosi, reported, September 4, 1873: "Contraction and atrophy of all the fingers of the left hand." Pensioner paid September 4, 1875.—The fatal intermediary excision of this description was that of: 9. Pt. G. W. Bowers, Co. B, 35th Ohio, aged 23 years, Dallas, June 3, 1864. Musket ball perforation of left wrist, fracturing ulna. Sent to Nashville. Acting Assistant Surgeon R. L. McClure, June 21, 1864, excised an inch and a half of the left ulna and removed several fractured carpal bones. Pyæmia ushered in by rigors and vomiting supervened, and the patient died July 11, 1864.—A successful secondary case, illustrated by a preparation, is that of: 10. Private W. Birdsall, Co. B, 49th Colored Troops, aged 25 years, Vicksburg, September 1, 1865, accidentally, by a musket ball, implicating the right wrist. Acting Assistant Surgeon G. F. Rockwell found, November 1, 1865, at the post hospital, a small fungous ulcer on the external surface of the ulna, "indicating necrosis," and excised two and a half inches of the lower extremity of the ulna and the semilunar bone. The hand was placed on a padded splint and the patient was allowed generous diet. Dr. Rockwell reports that the patient was discharged March 22, 1866, "with full use of hand and tolerable use of wrist." The specimen (FIG. 731) indicates a slight superficial caries of the distal end of the ulna; the styloid process has been sawn off. There is no record of this soldier at the Pension Office.—See *Cat. Surg. Sect.*, 1866, p. 199.

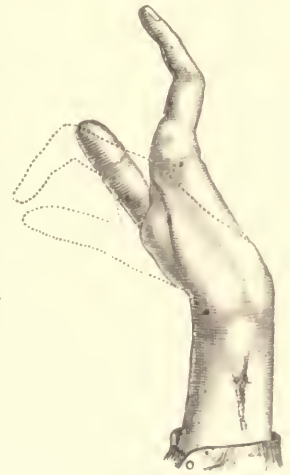


FIG. 730.—Left hand after ablation of portions of ulna, carpus, metacarpus, and three fingers. *Spec.* 2786.

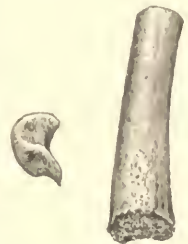

FIG. 731.—Distal end of ulna and semilunar excised secondarily. *Spec.* 2987.

Thirteen excisions, more or less complete, of the carpal bones resulted in nine recoveries and four deaths—one of the patients recovering after consecutive amputation in the forearm:

<sup>1</sup> Two plaster casts (*Specs.* 1133 and 2786) in the Museum represent the results in this remarkable case. One of them is copied in the wood-cut. A number of photographs (as *Surg. Phot.*, A. M. M., No. 59, and six photographs contributed by Professor J. H. ARMSBY, of Albany. *Contrib. Phot.*, A. M. M., Vol. V) illustrate this case.—See *Circular* No. 6, S. G. O., 1865, p. 54. <sup>2</sup> See *Surgical Report*, in *Circular* 6, S. G. O., 1865, p. 54.



CASES 2008-2020.—There were eight primary operations, of which two proved fatal: 1. Pt. G. H. Alley, Co. B, 99th Indiana, aged 23 years, Dallas, May 28, 1864. Surgeon D. Halderman, 43th Ohio, excised the scaphoid and fragments of adjacent carpal bones immediately after the injury, on account of a musket-ball fracture of the left wrist, at the Fifteenth Corps field hospital. Patient sent to Mumfreesboro', and was returned to duty July 9, 1864, and mustered out May 22, 1865. His name is not on the pension list.—2. Corp. S. Brockman, Co. C, 13th Kentucky, Resaca, May 15, 1864. A shell fragment fractured the left wrist. On May 17th, "a partial excision of the carpal bones was practised." He was sent to the hospital at New Albany, Indiana, where it was reported that there were portions of dead bone yet to be removed. Discharged January 12, 1865. Examiner A. W. Reese, of Warrensburg, certified, December 16, 1874: "Great deformity of hand and wrist. \* \* Ankylosis of wrist, with displacement and twisting inward of hand, which is immovable and entirely useless for all practical purposes. He would be better off to-day if his hand had suffered amputation above the wrist." Pensioner paid September 4, 1875.—3. Col. A. W. Dwight, 122d New York, Cedar Creek, September 19, 1864. Surgeon G. T. Stevens 77th New York, excised the semilunar, cuneiform, and pisiform bones, shattered by musket ball (another report says "outer half of carpus"), at the 2d division, Sixth Corps, field hospital. This officer resumed command of his regiment in less than two months, having a serviceable hand.<sup>1</sup> He was subsequently killed in action, at Petersburg, March 25, 1865, while leading a charge.—4. Corp. J. Estes, Co. H, 27th Massachusetts, aged 25 years, accidentally, at New Berne, December 28, 1862. A conical ball from a small-sized Smith and Wesson pistol was impacted in the left os magnum. Surgeon G. A. Otis, 27th Massachusetts Vols., reported: "Various attempts at extraction having been vainly essayed by the forceps and *tire-fond*, with the concurrence of Surgeon B. B. Breed, U. S. V., and Surgeon G. Derby, 23d Massachusetts, an incision was made between the flexor tendons, and the ball was finally brought away by means of the gouge, the greater portion of the os magnum being removed in the operation. The joint was covered with ice and the inflammatory reaction was less intense than was anticipated." The regiment moving a few days subsequently, the patient was sent to Foster Hospital. Surgeon E. P. Morong, U. S. V., reported that the inflammation of the tendons impaired the functions of the hand. The patient was transferred to Beaufort, June 18, 1863. Surgeon F. G. Ainsworth, U. S. V., reported this man's transfer to the Veteran Reserve Corps August 14, 1863. He was mustered out in 1865, and his name is not on the pension roll.—5. Corp. W. C. Turner, Co. E, 33d Massachusetts, aged 35 years, Dallas, May 25, 1864. Medical Director H. S. Hewit reports an excision of left wrist joint, for fracture by conoidal musket ball, the day of injury. Patient was sent to Readville, and transferred to V. R. C. February 3, 1865; pensioned June 1, 1865. Examiner Q. A. McCollister, of Groton, reports: "The hand is turned laterally toward the radial side. The thumb is stiff and not of much use in picking up articles or holding anything." Pensioner paid September 4, 1875.—In the next case amputation in the forearm was resorted to: 6. Pt. C. Fmuke, Co. B, 49th New York, aged 24 years, Fisher's Hill, September 22, 1864. Surgeon G. T. Stevens, 77th New York, excised a portion of the bones of the right carpus on account of fracture by musket ball. Sent to Satterlee Hospital. Intense inflammation supervened, and October 13, 1864, Acting Assistant Surgeon W. P. Moon amputated in the upper third of the forearm (TABLE CXXXV, No. 28, p. 941). Pensioned July 4, 1865, and paid September 4, 1875.—The two fatal cases were as follows: 7. Pt. J. Gordon, Co. B, 7th Indiana, Marietta, June 27, 1864. Assistant Surgeon R. McGowan, U. S. V., reported an excision of the wrist joint, practised the day of injury, on account of a shot perforation of the left carpus. The patient was sent to Chattanooga. He had also a shot flesh wound of the leg. He died July 28, 1864.—8. Pt. W. McLoughlin, Co. D, 63d New York, aged 27 years, Wilderness, May 7, 1864. Surgeon Nathan Hayward, 20th Massachusetts, excised, on account of a shell fracture, all the bones of the left carpus except the trapezium and trapezoid. The patient was sent to Emory Hospital, and died March 28, 1865.—There was one fatal intermediary excision in the carpus: 9. Capt. A. Clark, Co. C, 8th Illinois Cavalry, aged 41 years, received at Beverly Ford, June 9, 1863, a wound of the left wrist, which shattered the os magnum and cuneiform. Surgeon H. W. Ducahet, U. S. V., reported that on the patient's admission to Georgetown Seminary Hospital the wrist was intensely painful and swollen, and that on June 22d free incisions were made into the joint and the shattered cuneiform and magnum were excised. July 3d, there was severe rigors and other signs of pyemia, and the patient died July 5, 1863. *Post-mortem*: A large abscess was discovered dissecting its way up the interosseous ligament.—There was a successful and a fatal secondary excision in the carpus: 10. Pt. G. W. Neal, Co. D, 3d Wisconsin, Dallas, May 25, 1864. Musket-ball fracture of ulnar side of left carpus; ball entering the dorsal and emerging on the palmar surface. Sent to Madison, Wisconsin. June 27th, Surgeon H. Culbertson, U. S. V., made an incision on the ulnar border, extending from the pisiform bone two inches upward, and excised the cuneiform and os magnum and some spiculae of bone. Patient transferred to V. R. C. April 1, 1865, and subsequently pensioned. Examiner A. L. Huffman, of Peabody, Kansas, reported: "Partial stiffness of wrist and stiffness of the two smaller fingers." Pensioner paid to December 4, 1875.—11. Pt. T. E. Hamilton, Co. A, 1st Maryland, aged 31 years, North Anna, May 21, 1864. Shot fracture of left carpus. Sent to Paterson Park, Baltimore. Caries ensued, and, August 24, Acting Assistant Surgeon G. W. Fay excised the scaphoid, cuneiform, and trapezoid bones, and, August 10th, extracted another necrosed carpal bone that had become loose. August 5th, another operation was about to be practised, when the patient succumbed, as was supposed, from the effects of chloroform. The pathological specimen (FIG. 732) shows extended caries of the radius, carpals, and metacarpals. The excised carpals have been replaced in the preparation.—Two operations of this series, resulting in recovery with ankylosis, are of undetermined date: 12. Pt. W. H. Ekliff, Co. D, 2d Michigan, Williamsburg, May 5, 1862. Shot fracture of left wrist. Sent to Camden Street Hospital, Baltimore. Surgeon A. B. Hasson, U. S. A., reported: "Excision of some of carpal bones." Pensioned September 23, 1862. Re-enlisted in 1st Michigan Cavalry, and afterward in the 42d Infantry (V. R. C.). Surgeon J. Campbell, U. S. A., reported, September 21, 1867: "Ankylosis of the joint, destroying in a great degree the use of the hand." The pension record states that the joint is completely ankylosed; the fingers in a state of rigid atrophy; they cannot be closed on the palm of the hand. Pensioner paid September 4, 1875.—

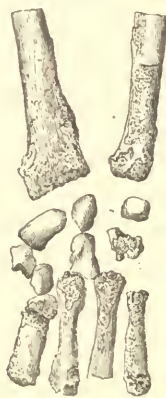

FIG. 732.—Caries of the radio-carpal and carpal-metacarpal articulations after shot injury. *Spec. 324.*

<sup>1</sup> STEVENS (G. T.). On Excisions in Cases of Gunshot Wounds, in *Transactions of the New York State Medical Society*, 1866, p. 140.

13. Pt. C. Kupferschmidt, Co. K, 2d Kentucky, aged 22 years, Stone River, December 31, 1862. Sent to Nashville. Discharged July 23, 1863, and pensioned. Examiner W. Owens, of Cincinnati, reported, September 19, 1866, that, "on account of a shot perforation of the right wrist excision of nearly the entire joint was performed." Name of the operator not remembered. The Cincinnati Examining Board reported, September 4, 1875: "Large firmly adherent cicatrices over lower fifth of forearm and carpus. Hand fixed in straight line with forearm laterally, inclined at angle of 45° with ulna. Nutrition of hand greatly impaired. Inability to flex fingers, other than very slightly, at second phalangeal articulations. \* \* \* Great atrophy of hand." Pensioner paid September 4, 1875.

The eleven operations included in this category comprise removals of parts of the carpus and metacarpus, and, in some instances, one or more fingers:

CASES 2021-2031.—Five were primary cases, one resulting in consecutive amputation, and one, complicated by shot fracture of the femur, having a fatal termination: 1. Pt. J. W. Kneeder, Co. I, 81st Ohio, aged 20 years, accidentally, June 22, 1863. A tompon and musket ball passed through the palm of the right hand, at Pocahtonas, Tennessee. Surgeon W. C. Jacobs, 81st Ohio, reported that the cuneiform, pisiform, and unciform bones were excised, and that the fourth and fifth metacarpals and little and ring fingers were removed. Surgeon J. H. Gove, U. S. V., reports this man's discharge from Benton Barracks, January 1, 1864, retaining only the thumb and index finger of the right hand, and having ankylosis of the wrist. Examiner W. H. Willson, of Greenfield, Ohio, reported, in 1873, that "the carpus is completely ankylosed. The functions of the thumb and index finger impaired."—2. Sgt. A. M. Massey, Battery F, 1st Rhode Island Artillery, aged 32 years, Goldsboro' Bridge, December 17, 1852. Shell comminution of right carpus and metacarpus. Surgeon G. A. Otis, 27th Massachusetts, reported that this man was holding a field glass when a shell fragment struck the glass, driving its fragments into the tissues and detaching the three outer fingers, and fracturing the terminal phalanx of the index finger. The shattered portions of bone were removed, viz: the pisiform, unciform, fourth and fifth metacarpals, distal extremity of third metacarpal, and the terminal phalanx of the index finger. The lacerated integument was trimmed with scissors to afford a good covering for the wound. Patient sent to New Berne. On the long march cold-water dressings were applied, but there was intense inflammatory reaction. Surgeon F. Galloupe, 17th Massachusetts, reported abscesses formed in the wrist and elbow. Surgeon E. P. Morong, 2d Maryland, reported the patient's furlough from Foster Hospital February 28, 1863. He was commissioned second lieutenant V. R. C., and discharged June 23, 1867, and pensioned. Examiner J. W. Foye, of Boston, reported, June 21, 1868: "Ankylosis of the elbow and shoulder joints. The entire member is useless." Pensioner paid September 4, 1875.—3. Pt. H. Wiggins, Co. I, 20th Massachusetts, aged 31 years, near Fairfax Court House, February 24, 1863. Rifle musket ball perforated the left wrist. He was sent to Harwood Hospital, where Surgeon G. Antisell, U. S. V., reported: "The ball fractured the carpal bones and two middle metacarpal bones. The fractured bones were removed before he was admitted to this hospital, March 9, 1863. The day following his admission there was slight hemorrhage. On March 11th, there was a second hemorrhage, a pint of blood being lost before it was suppressed by the tourniquet. On March 12th, bleeding recurred to the extent of four ounces, when the wound was enlarged and the radial artery tied. March 21, 1863, the patient was doing well under a tonic treatment. The ligature had come away early, and bleeding had not recurred." Patient was transferred to Portsmouth Grove Hospital July 8th, and discharged December 29, 1863, Assistant Surgeon W. F. Cornick certifying that he was unfit for the Invalid Corps on account of gunshot wound of left wrist. He applied for pension, and Examiner G. S. Jones certified that the disability, arising from a gunshot wound in the left hand, received in the line of duty, was probably permanent; that the ball entered the dorsal surface between the third and fourth metacarpals, and emerged at the ulnar side of the carpus. There was a fistulous opening; the hand was badly swollen, and, with the forearm, was powerless and useless. Examiner J. W. Foye, of Boston, certified, March 6, 1859: "A gunshot entered the dorsum of the left hand at a point corresponding with the juncture of the scaphoid with the semilunar, and emerged at the inner side of the ulnar-cuneiform articulation. Subsequent inflammation has removed the first row of carpal bones, and the hand has become ankylosed."<sup>1</sup>—In the next case secondary amputation in the middle third of the upper arm was practised (TABLE LXXXVI, No. 21, p. 784): 4. Pt. J. W. Cary, Co. A, 87th Illinois, Pleasant Hills, April 8, 1864. Surgeon E. F. Sanger, U. S. V., reported: Musket-ball fracture of the right wrist, on account of which excision of the trapezium and trapezoid was practised on the field, with ablation of the second metacarpal and index finger. Sent to St. James Hospital, New Orleans. Intense inflammatory action involved the tissues of the forearm, and, May 15, 1864, Surgeon W. S. Webster, 95th Colored Troops, amputated at the middle of the upper arm. Pensioned June 15, 1864, and paid September 4, 1875.—5. Pt. P. F. Bryant, Co. G, 28th Tennessee, aged 25 years, near Marietta, June 18, 1864.<sup>2</sup> Surgeon C. B. Wilson, 28th Tennessee, on account of a shot injury of the wrist excised the trapezium and second metacarpal of the right hand. There was also a ball lodged in the right femur, and the health of the patient was bad when wounded. Surgeon E. A. Fleellen reported examining this patient at Marietta, and removing a portion of the ball from the medullary canal of the right femur, comminuted near the trochanters. A Nélaton probe indicated the presence of another portion of the ball. On admission at Atlanta the patient was very feeble, and sank and died June 20, 1864.—There were two intermediary operations in this subdivision—one followed by consecutive amputation, the other by death: 6. Pt. J. W. Hobbs, Co. K, 27th Georgia, Antictam, September 17, 1862. Musket-ball perforation of right carpus. Sent to Hospital No. 5, Frederick.

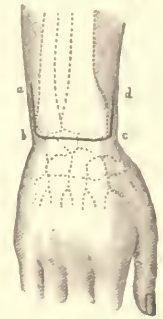


FIG. 731.—Veilpean's method for excision of the wrist joint by a quadrangular flap—a, b, c, d. [After BEHNARD and HUETIE.]

<sup>1</sup> In this case Captain A. B. Holmes, 20th Massachusetts, of Nantucket, certifies that this soldier was wounded by a minie ball in the left hand and wrist while on fatigue duty on the Orange and Alexandria Railroad, February, 1863. Said ball was fired by a party of rebels, supposed to be Mosby's guerillas, and was received while Wiggins was engaged in said service and line of his duty. . . . He was a first rate soldier, and faithful in the performance of his duty.

<sup>2</sup> O'KEEFE (D. C.) (*Surgical Cases of interest treated at Institute Hospital, Atlanta, in May and June, 1864, in Confederate States Med. and Surg. Jour.*, 1865, Vol. II, p. 33) reports this case as No. 52 of the series in his report.



Assistant Surgeon P. Adolphus, U. S. A., October 17, 1862, performed a partial excision of the carpus, removing also a part of the fourth metacarpal. The specimen (FIG. 734), sent to the Museum, shows the greater portion of the bones and fragments removed.

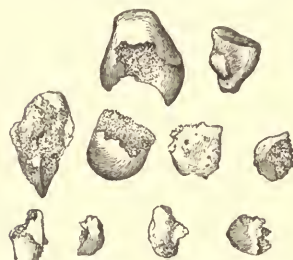

FIG. 734.—The semilunar, cuneiform, part of magnum, and other bones of left carpus. *Spec.* 437.

Surgeon H. S. Hewit, U. S. V., reported the patient improving December 29th, and transferred to Hospital No. 1. Sent to Provost Marshal February 9, 1863.—7. Pt. R. Walker, Co. F, 71st Pennsylvania, aged 26 years, White Oak Swamp, June 30, 1862. Sent to Union Chapel. Surgeon R. H. Coolidge, U. S. A., July 17, 1862, on account of a shot perforation of the left wrist, excised the unciform, os magnum, and trapezoid, together with the heads of the second and third metacarpals. It was found that a false aneurism of the radial artery had formed, and when the clots were turned out hæmorrhage occurred, which was suppressed with difficulty. Bleeding recurring, amputation of the forearm was performed, July 20, 1862 (TABLE CXXXVI, No. 31, p. 986). Patient died August 10, 1862.—There were three recoveries after secondary operations, in this subdivision: 8. Lieut. M. F. Ellsworth, Co. F, 95th Illinois, aged 26 years, Guntown, June 10, 1864. Shot comminution of fifth metacarpal of the right hand and of the ulnar side of carpus. Sent to Officers' Hospital, Memphis. Assistant Surgeon S. S. Jessop, U. S. V., December 12, 1864, excised the necrosed proximal end of the fifth metacarpal and the cuneiform, pisiform, and unciform bones through a V-shaped incision on the dorsum of the wrist. Sinuses that had burrowed in the hand and forearm were laid open. The wound was dressed with a dilute solution of permanganate of potassa. Did well, and went to modified duty January 20, 1865. Mustered out, and pensioned September 11, 1865. Examiner J. G. Davis, of Beatrice, Nebraska, reported, October 18, 1873: "Anchylousis of wrist joint: ring and little fingers permanently contracted. Pronation and supination of the forearm gone."—After the other two secondary excisions amputation in the forearm was eventually practised: 9. Pt. J. Milledge, Co. K, 33d Wisconsin, aged 26 years, near Orkney Station, December 22, 1862. Shot perforation of left carpus, with lesion of nerves. Sent to Harvey Hospital, Madison. April 2d, the parts being carious, Surgeon M. K. Taylor, U. S. V., excised the proximal ends of the first and second metacarpals, trapezium, trapezoid, and parts of scaphoid and magnum. Pensioned August 14, 1863. Wrist ankylosed; wound fistulous. Amputation of forearm (see TABLE CXXXVII, No. 139, p. 989) was performed June 21, 1864, by Surgeon H. Culbertson, U. S. V. (FIG. 735). Pensioner paid September 4, 1875.—10. Pt. C. W. Hastings, Co. E, 2d Sharpshooters, aged 21 years, Chancellorsville, May 2, 1863. Shot fracture of right wrist at junction of second metacarpal with carpus. Sent to Fairfax Seminary. June 23, 1863, Surgeon D. P. Smith, U. S. V., excised the os magnum, half of the trapezoid, and the second and third metacarpals. June 29th, there was bleeding to the extent of sixteen ounces from the deep palmar arch, and the brachial was ligated. Mortification set in, and the arm was amputated July 4, 1863. Pensioned October 9, 1863, and paid September 4, 1875.—There was one case in this category in which the interval between the injury and operation could not be ascertained: 11. Pt. P. Burns, Co. F, 69th New York, aged 29 years, Antietam, September 17, 1862. Sent to Hospital No. 5, Frederick. Surgeon H. S. Hewit, U. S. V., reported that a musket ball fractured the left wrist and inflicted a flesh wound in the left hypochondriac region. Caries of the carpus and metacarpus followed, and the fourth and fifth metacarpals and magnum, unciform, cuneiform, and pisiform bones were excised. Pensioned December 6, 1862. The New York Examining Board, July 3, 1862, reported: "The left ring finger is destroyed, and its metacarpo-phalangeal articulation. The little finger is crooked under the medius; the hand is not of much use." Pensioner paid September 11, 1865.

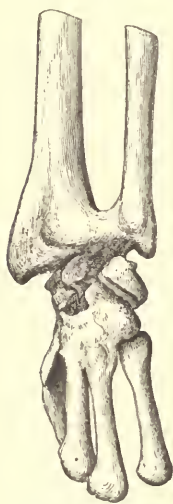

FIG. 735.—Bones of left forearm after partial excision and subsequent amputation. *Spec.* 3693.

Of the six complete excisions at the wrist, one proved fatal after recourse had been had to amputation in the forearm. The five others recovered with the functions of the hand much impaired, but, all things taken into consideration, in a better condition than if they had been subjected to amputation. Of the ninety partial excisions, one, in which the ends of the radius and ulna and two carpals were removed, terminated fatally after consecutive amputation in the upper arm.<sup>1</sup> Four patients who underwent excisions of the distal extremities of the radius and ulna recovered with considerable lateral distortion of the hand and stiffness of the fingers. Of twenty-six patients in whom the lower end of the radius was resected, two died, one after amputation in the upper arm; three submitted to amputation in the forearm. Of the twenty-one in whom the hand was preserved, nearly all recovered with anchylousis and extreme deformity. Generally the hand was strongly deflected to the radial side, often at right angles, the fingers rigidly fixed in flexion or extension, the end of the ulna projecting, and the integument over it irritable and exposed to accidental injuries; yet two of the men re-enlisted, and in several the deformed hand appears to have been preferable to any prosthetic appendage. Of nineteen

<sup>1</sup>This case, No. 1942, p. 909, does not appear on the tables of amputations in the upper arm in this volume; because the operation was not performed in a hospital or reported to the Surgeon General, and was ascertained only when the result of the excision was traced at the Pension Office.

patients who underwent excision of the lower end of the ulna, three died, one was amputated above the elbow, and one in the forearm. Fourteen recovered, nearly all with ankylosis and deformity. The hand was generally less displaced than in the cases of the preceding category; but there was an equal proportion of cases of rigidity of the fingers, and more examples, comparatively, of paralysis and of neuralgic suffering. The six patients who submitted to excision of the end of the radius, with one or more carpals, recovered with ankylosis and deformity. Of ten excisions of the distal end of the ulna, with adjacent carpals or carpals and metacarpals, two were fatal. Of the eight patients who preserved at least a portion of the hand, one is an officer now in service, whose left wrist, thumb, and index finger are very useful; another recovered with a very useful hand, and the six others suffer from ankylosis, contracted fingers, and other deformities. Of the thirteen excisions confined to the carpus, four resulted in death, and one in amputation in the forearm. Of the eight patients whose hands were saved, three, one of whom was subsequently killed in action, retained valuable mobility of the hand, while in five there was ankylosis with much deformity. Two of the eleven excisions in the carpus with removal of one or more metacarpals were fatal, one after consecutive amputation in forearm; three others resulted in amputation, two in the upper arm and one in the forearm. The six patients in whom some portion of the hand was saved suffered from ankylosis. In one or two instances the elbow, and even the shoulder joints, were stiff; there was much deformity of the hand in almost every instance. In short, in sixty-eight of the ninety-six patients whose hands were preserved, at least in part, fifty-one had ankylosis at the wrist—five mobility with deformity, and three dangling-joints. Nine, of whom two are still in service, are reported to have had comparatively useful limbs. There were no such triumphs as were achieved in excisions at the shoulder, and, in less proportion, at the elbow; yet the mortality attending the excisions was not excessive, and the results in a few of the cases not altogether unsatisfactory. Those critical in classification might regard several of the operations as partial amputations of the hand, or as merely extractions of bone fragments, rather than formal excisions.<sup>1</sup> There was such a diversity in the operations that it is hardly practicable to deduce from them any general rules of surgical interference.<sup>2</sup>

<sup>1</sup> LÖEFFLER (P.) (*General-Bericht*, . . . 1867, S. 226) remarks: "The official report of the American civil war gives 34 'excisions of the wrist.' But the explanations prove that this expression is used very vaguely, as cases have been included in which the operation was confined to the removal of bone fragments." In *Circular* 6, S. G. O., 1865, describing the extent and nature of the materials accumulated in the Surgeon General's Office for a Medical and Surgical History of the War, I described, at page 54, the data in the register entitled "Excisions of the Wrist" as follows: "The 35 cases included in this category were all examples of partial excision. In 27, the ends of the radius or ulna, or of both, were removed, and in some instances shattered fragments of the upper row of carpal bones; in 8, the greater part of the carpal bones were excised." This was a true account of the returns examined at that date, and I cannot now perceive how I could have concisely described them with more careful discrimination. Now that I have come to discuss the materials, instead of merely indicating their nature and extent, it is proper that I should be held to strict definitions and exact classification, and I have accordingly termed these operations *Excisions at the Wrist*, instead of *excision of the wrist*, and have grouped them in subdivisions according to the portions of bone implicated. I think that I have just grounds for reiterated complaint that the professed preliminary review on the materials available for a surgical history should be incessantly referred to as in fact the official report of the surgery of the war. I am sure that the lamented and scrupulously accurate writer referred to would not have fallen into this mistake had he quoted from the original report of *Circular* 6, instead of the synopsis published in some of the Continental journals. Referring to this same paragraph in *Circular* No. 6, M. LEGUEST (*Chirurgie d'Armée*, 2ème éd., 1872, p. 572) remarks: "Peu pratiquée en Europe jusqu'à présent, la résection du poignet [pour les plaies?] par coups de feu a été faite 35 fois par les chirurgiens des Etats-Unis d'Amérique pendant la guerre de la sécession, et a donné 26 guérisons radicales. Si l'on entend par *guérison radicale* l'utilité du membre conservé, les résultats obtenus par les chirurgiens américains sont remarquablement satisfaisants." I used no such expression as *radical cure*, as italicized by M. LEGUEST. I stated that: "Death took place once from pyæmia and twice from protracted suppuration and irritative fever. Twenty-six cases are reported as recovered. In 2 cases amputation of the forearm became necessary." It is added: "The reports are unsatisfactory in relation to the amount of mobility left in the hand." It would appear sufficiently plain that recovery was not meant to signify *radical cure*, or great utility in the retained limb.

<sup>2</sup> In his admirable article *POIGNET* (*Opérations*), in the *Dictionnaire de Médecine*, 1842, Vol. XXV, p. 342, VELPEAU says: "I know of but one example of resection of the wrist required by a fracture of the bones of the carpus or forearm from shot injury. It is that of BAGIEU (*Examen de plusieurs parties de la Chirurgie*, 1756, T. II, p. 440, *on* 7): The patient had the lower ends of both bones of the forearm shattered by a ball; numerous splinters were immediately extracted: an inch and a half shortening, at least, occurred, and ankylosis resulted. As the flexibility of the fingers was partly preserved, the patient could finally use the hand to write and draw almost as perfectly as before the injury. It is evident that analogous cases must have often been seen in any service and even in civil practice, and if they have not been detailed it is because surgeons have not thought them worthy of record as individual cases. Moreover, it would be impossible to trace from such observations any rule of therapeutics or of surgical interference."



EXCISIONS AT THE WRIST IN THE CONFEDERATE SERVICE.—On the register compiled by Dr. Howell L. Thomas, which furnished the valuable data on excisions at the shoulder and elbow in the Confederate service presented in the third and fifth sections of this Chapter, minutes are found of thirteen cases of excisions at the

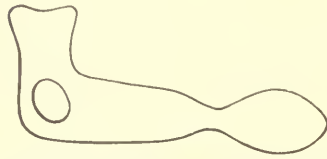

FIG. 736.—Professor Esmarch's splint for excision at the wrist. [After MACCORMAC.]

wrist for shot injury.<sup>1</sup> Unhappily the details of the cases are very meagre, and the precise results are almost uniformly left to conjecture. All of the patients are believed to have recovered from the excision without recourse to consecutive

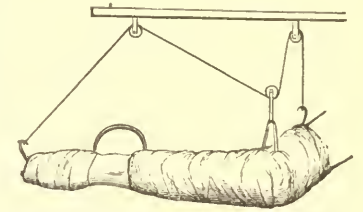


FIG. 737.—The splint applied. [After MACCORMAC.]

amputation; but a fair prospect of a useful hand is indicated in only one of the reports. There were five cases in which the operation consisted of removal of the articular extremity of the radius without interference with the first row of carpals:

CASES 2032–2036.—Private *W. Boon*, Co. E, 3d Missouri, received, June 20, 1864, a comminuted shot fracture of the lower third of the left radius. Surgeon *S. E. Chaille*, P. A. C. S., of the Ocmulgee Hospital, Macon, reports that on June 22d the radius was exarticulated at the wrist and about six inches of the bone excised. The wound became gangrenous, and little hope was entertained of a useful hand.—Private *J. Faircloth*, Co. C, 45th Georgia, aged 22 years, was wounded June 22, 1864, at Petersburg. Surgeon *J. J. Dement*, of Thomas's Brigade, reported that a minié ball passed through the lower end of the radius, opening the joint, and that an inch and a half was excised on the field by Surgeon *J. J. Wynne*, 45th Georgia, on the same day. The patient was transferred to a general hospital.—Private *A. J. Hawes*, Co. E, 59th Alabama, aged 28 years, was wounded December 14, 1863. Surgeon *R. B. Manry*, of Greenville, Alabama, reported that a ball entered the left hand at the outer edge of the second metacarpal, passed upward, and traversed the trapezium, trapezoid, and scaphoid, and was arrested against the lower end of the radius, in the space between the tendons of the extensor secundus internodii pollicis and extensor ossis metacarpi pollicis, whence it was removed by a simple incision. Necrosis extending to the radius resulted, and a straight incision was made along the dorsum of the forearm and the lower two-thirds of the radius was excised. The health of the patient was bad; he had been subject to diarrhœa for a year. A full dose of brandy was administered before inducing anæsthesia by a mixture of equal parts of ether and chloroform. The anæsthetic was not well tolerated, the patient being much depressed. He improved greatly after the operation: his diarrhœa was checked, his appetite returned, the suppuration was moderate and laudable, the wound rapidly filled with healthy granulations, and, May 31, 1864, there was a good prospect of speedy recovery.—Private *T. Mull*, Co. G, 17th Mississippi, aged 19 years, received, at Gettysburg, July 2, 1863, a shot fracture of the carpal end of the left radius. Surgeon *William A. Davis* reported that the articular extremity of the bone was excised on the field.—Private *B. F. Stewart*, Co. F, 40th Mississippi, aged 27 years, was wounded July 20, 1864, a musket ball shattering the lower end of the right radius. Dr. *H. R. Christmas*, regimental surgeon, reported that the end of the radius was removed at the wrist joint, on the field, the same day, and that on August 27, 1864, the patient was doing well and was allowed to go home on furlough.

In the cases in which the after-treatment is adverted to, it is stated that the limb was placed semi-prone on a padded splint, and ice-water or ice dressings applied, followed by cataplasms when suppuration was established. The form of splint employed is not mentioned. Those of Professor Esmarch<sup>2</sup> (Figs. 736, 737) and of Professor Lister (Figs. 721, 722) are now most approved.

<sup>1</sup> Surgeon *J. B. READ*, P. A. C. S., (*Report on Wounds of Large Joints, made to the Confederate States Association of Navy and Army Surgeons, printed in Southern Med. and Surg. Jour.*, 1866, Vol. XXI, p. 206), treating of excisions at the wrist for shot injury, says: "We have ourselves no experience thus far, and find nothing in the surgical reports bearing on this subject." His further remark, that "cases of gunshot injury of the wrist joint requiring resection are of rare occurrence," is justly inferred from the absence of cases in the records consulted. He proceeds to say that "in the majority of cases the enlargement of the wound for the removal of shattered bone suffices, as for this purpose lateral incisions on the outer side of the bones may be made. Through these incisions the ends of either the radius or ulna may be turned out and cut off with the saw or bone pliers." This statement can only be accepted as hypothetical. On the dead subject it is not feasible to turn out readily the lower extremity of the radius through any reasonably large lateral incision; nor is it an easy task to divide the lower extremity of the radius, in an adult subject, with bone pliers. Surgeon *J. J. CHISOLM*, P. A. C. S., (*Manual of Mil. Surg.*, Columbia, 3d ed., 1864, p. 387), quotes from Dr. *H. BAER* three successful excisions at the wrist derived from the records of the Confederate Surgeon General's Office, and remarks: "Instances of successful resections are recorded for injuries at the wrist joint, where the spiculated ends of both radius and ulna have been satisfactorily removed; also, instances in which either of these bones have been removed entire, for chronic osteitis and necrosis brought on from gunshot injuries." Although Dr. *J. B. READ* found nothing in the Confederate surgical reports bearing on this subject, Surgeon *P. SORRELL*, C. S. A., had published (*Confed. States Med. and Surg. Jour.*, 1864, Vol. I, p. 155) "the results of two successful primary and one successful secondary cases of excisions at the wrist," collected from the reports of the Confederate armies at the close of 1863.

<sup>2</sup> MACCORMAC (W.), *Notes and Recollections of an Ambulance Surgeon*, 1871, p. 104. Dr. MACCORMAC remarks that Professor ESMARCH has treated resections of the wrist with great success, and that his excellent apparatus is a valuable adjunct in the after-treatment, being similar in principle and application to the American anterior suspensory fracture splints.





stances. Little else could be expected with the methods of operation then practised. With the large longitudinal radial and ulnar incisions and J-shaped flaps of Moreau (Figs.

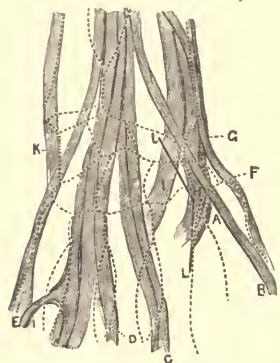


FIG. 738.—Topographical anatomy of the dorsum of the right wrist. [After J. LISTER.] The parts are: *K*—ext. carpi ulnaris. *E*—ext. minimi digiti. *D*—extensor communis. *C*—indicator tendon of extensor communis. *I*—ext. carpi radialis brevis. *H*—ext. rad. longior. *B*—ext. secundi internodii pollicis. *G*—ext. ossis metacarpi pollicis. *F*—ext. primi internodii pollicis. *A*—radial artery. The deep line *LL*, indicates the incision.

720, 728), the dorsal quadrilateral flap of Velpeau, the H-shaped incisions of other operators, such injury was almost necessarily on the tendons, and frequently on the blood-vessels and nerves, as to preclude the possibility of conservation of much functional integrity in the hand. . It cannot be claimed that the excisions at the wrist, done during the War by these rough methods, which have been figured here for warning rather than imitation, were to any extent encouraging. It remained for Professor Joseph Lister to devise, in 1864, an operative plan, which is as revolutionary in this branch of conservatism as his celebrated antiseptic method is likely to prove in the entire domain of operative surgery. It is altogether probable that, by strictly following Professor Lister's rules,<sup>1</sup> excisions of the wrist joint may be profitably practised in some cases of shot fractures and perforations of the carpus. The rules are detailed minutely, but without undue minuteness, in the foot-note. The form of splint employed in the after-treatment, and its application, are represented on page 1000 (Figs. 721, 722). The after-dressing is, of course, a

matter of the utmost importance. A simple and excellent plan is presented by Professor Es-march's suspensory splint (Figs. 736, 737). Dr. Hodgen's wire suspension splint (FIG.

<sup>1</sup> The directions of Professor JOSEPH LISTER (*The Lancet*, 1865, Vol. I, p. 335) for complete excision of the wrist for *caries* are so excellent, and (as I have assured myself by following them on the cadaver) so applicable to extirpation of the carpus for injury, with or without removal of the ends of the radius, ulna, and proximal ends of the metacarpals, that I take the liberty of transcribing them here: "Chloroform having been administered, a tourniquet is placed upon the limb to prevent the oozing of blood, which would interfere with the careful scrutiny to which the bones must be subjected.

The radial incision is then made in the situation indicated by the thick line in the accompanying diagram of the anatomy of the back of the hand (FIG. 738). This incision is planned so as to avoid the radial artery, and also the tendons of the extensor secundi internodii pollicis and indicator. It commences above at the middle of the dorsal aspect of the radius, on a level with the styloid process, this being as close to the angle where the tendons meet as it is safe to go. Thence it is at first directed toward the inner side of the metacarpo-phalangeal articulation of the thumb, running parallel in this course to the extensor secundi internodii; but on reaching the line of the radial border of the second metacarpal bone it is carried downward longitudinally for half the length of the bone, the radial artery being thus avoided, as it lies somewhat farther to the outer side of the limb. . . The soft parts of the radial side of the incision are next detached from the bones with the knife, guided by the thumb-nail, so as to divide the tendon of the extensor carpi radialis longior at its insertion into the base of the second metacarpal bone, and raise it along with that of the extensor carpi radialis brevis previously cut across, and the extensor internodii, while the radial artery is thrust somewhat outward. This prepares the way for the next step, which is the separation of the trapezium from the rest of the carpus by means of cutting forceps applied in a line with the longitudinal part of the incision—a procedure which, as experience shows, does not endanger the radial artery. The removal of the trapezium is reserved till the rest of the carpus has been taken away, when it can be dissected out without any considerable difficulty; whereas its intimate relations with the radial artery and its secure connections with neighboring parts would cause a great deal of trouble at an earlier stage of the operation. The soft parts on the ulnar side of the incision are now dissected up from the carpus as far as is convenient, the hand being bent back to relax the extensor tendons of the fingers. The separation of these is, however, best effected from the ulnar incision, which must be made very free. The knife is entered at least two inches above the end of the ulna, immediately anterior to the bone, and is carried downward between it and the flexor carpi ulnaris, and on in a straight line as far as to the middle of the fifth metacarpal bone at its palmar aspect. The dorsal lip of this incision is then raised and the tendon of the extensor carpi ulnaris is cut at its insertion into the fifth metacarpal bone, and is dissected up from its groove in the ulna, care being taken to avoid isolating it from the integuments, which would endanger its vitality. The extensors of the fingers are then readily separated from the carpus, and the dorsal and internal lateral ligaments of the wrist joint are divided; but the connections of the tendons with the radius are purposely left undisturbed. Attention is now directed to the palmar side of the incision. The anterior surface of the ulna is cleared by cutting toward the bone so as to avoid the artery and nerve; the articulation of the pisiform bone is opened, if that has not been already done in making the incision, and the flexor tendons are separated from the carpus, the hand being depressed to relax them. While this is being done the knife is arrested by the process of the ulna, which is clipped through at its base with pliers. Care is taken to avoid carrying the knife farther down the hand than the bases of the metacarpal bones; for this, besides inflicting unnecessary injury, would involve risk of cutting the deep palmar arch. . . The anterior ligament of the wrist joint is also divided, after which the junction between the carpus and metacarpus is severed with cutting pliers, and the carpus is extracted by seizing it from the ulnar incision with a serviceable pair of sequestrum forceps, and touching with the knife any ligamentous connections that may remain undivided. The hand being now forcibly everted, the articular ends of the radius and ulna will protrude at the ulnar incision. . . The ulna is divided obliquely with a small saw, . . . and the end of the radius is then cleared sufficiently to permit [what is necessary] to be sawn off. . . My earlier cases, as well as some more recent ones to which I have not yet alluded, prove that a useful hand will result in spite of very extensive excision. The metacarpal bones of the fingers are next dealt with on the same principle, each being in its turn closely investigated; the second and third being most readily reached from the radial incision, the fourth and fifth from the ulnar side. If they seem sound the articular surfaces only are clipped off; the little facets by which they articulate with one another being removed by the longitudinal application of the pliers. . . The trapezium is next seized with a strong efficient pair of forceps and dissected out, so as to avoid cutting the tendon of the flexor carpi radialis, which is firmly bound into the groove on its palmar aspect, the knife being also kept close to the bone elsewhere to preserve the radial artery. The thumb being then pushed up longitudinally by an assistant, the articular end of its metacarpal bone is cleared and removed. This may seem a superfluity, as this bone articulates with the trapezium by a separate joint. But besides the possibility of its being affected through its immediate vicinity to the other articulations, the symmetry of the hand is promoted by reducing it to the same level as the other metacarpal bones. Lastly, the articular surface of the pisiform bone is clipped off; the rest of the bone being left, if sound, as it gives insertion to the flexor carpi

652, p. 904) would be equally satisfactory,<sup>1</sup> each of the latter apparatus admitting of the convenient employment of irrigation. With our present experience of excisions at the wrist for injury, it seems probable that recovery unattended by ankylosis is seldom to be anticipated, yet that this result is not disastrous, provided the hand is in good position, and the functions of the fingers are in some degree preserved. In a very few instances, loose, flail-like, pseudo-joints have been noticed, and Dr. Heyfelder has devised an apparatus (FIG. 739) designed to remedy, to some extent, this rare disability.<sup>2</sup> The most frequent deformity is ankylosis at the wrist with the hand in extreme adduction, or slightly deflected to the radial side. This appears to be irremediable by any apparatus, and suggests the propriety of always removing the carpal extremity of the ulna at the same level with the section of the radius whenever it is necessary to excise the distal extremity of the latter.<sup>3</sup> Rigid extension or flexion or else paralysis of the fingers are other frequent deformities resulting from the operation, for which Dr. E. D. Hudson has designed several ingenious forms of apparatus.

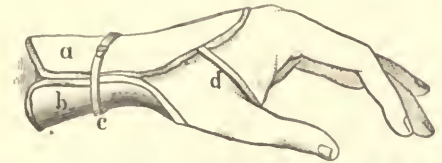

FIG. 739.—Padded tin wristlet with elastic bands, for dangle-wrist. [After HEYFELDER.]

Prior to the War there was little experience in civil practice of excisions at the wrist.<sup>4</sup>

ularis and affords attachment to the anterior annular ligament, and may serve other useful purposes in the palm. But if there is any suspicion of its unsoundness it must be dissected out completely. The same applies to the process of the ulniform. It may be observed that the extensors of the carpus are the only tendons divided; for the flexor carpi radialis is connected with the second metacarpal bone below its base and so escapes. But if it should be cut, there is no doubt that, like the extensors, it would acquire new and secure attachments. The tourniquet being now removed, it will probably be found that either no vessel at all requires ligation, or merely one or two superficial branches. The radial incision is stitched closely throughout, and also the ends of the ulnar incision, as it is desirable that union should take place there, and more especially over the end of the ulna; but the middle of this incision must be kept open by pieces of lint introduced lightly into the wound, to give support to the extensor tendons and to insure a wide opening into the cavity, which may serve for the free exit of the pus which must necessarily be found there. The limb is placed upon a splint (FIG. 721) and dressed with some porous material, arranged so as to avoid pressure upon the lines of incision, in order that it may absorb without obstructing the discharge. To the general reader the above description will, I fear, have proved wearisome; but to anyone about to perform the operation all the details will, I believe, be found well worthy of attention. The procedure consists, in fact, of a series of operations, each one of which must be executed with scrupulous care."

<sup>1</sup> Professor ESMARCI, in his *Verbandplatz und Feldlazareth, Vorlesungen für Angehende Militärärzte*, Berlin, 1868, S. 68, figures a modification of his wrist splint, in which the limb, instead of being suspended, is supported on an adjustable inclined plane, covered by a wire cradle, to which the rubber tubes from irrigators can be conveniently attached.

<sup>2</sup> HEYFELDER (O.), *Lehrbuch der Resektionen*, Wien, 1863, FIG. I, S. 267.

<sup>3</sup> LÖEFFLER (F.) (*General-Bericht*, n. s. w., 1867, p. 218) records nine cases of shot fractures of the wrist joint, and has a good word to say in behalf of excisions at the wrist: "Without exception conservative expectant treatment was attempted. The results (3 fatal—1 after secondary amputation) bring up the question whether too much concession was not made to conservative ideas, and whether and how far conservative treatment in such cases is susceptible of improvement. Resection, which was such an important resource in shot injuries, was not employed among us in wrist-joint wounds." LANGENBECK (B. V.) (*Chir. Beobachtungen*, 1873, S. 199) observes: "From my limited experience I fully agree with LÖEFFLER regarding the severe shot wounds of the wrist. Shot fractures of the epiphyses of the bones of the forearm and of the carpus, or of extensive comminutions of the latter only, especially when the missile is lodged and cannot be removed in any otherwise, certainly indicate primary resection. In simple perforations of the wrist joint or the carpus I would at first proceed on the expectant plan, but would, without hesitation, have recourse to resection as soon as infiltration could not be controlled by incision and threatened to spread to the forearm. Resection during the period of infiltration offers here better chances for success, as the wrist joint is not covered with thick layers of muscles, and as the ichorous effusions can be completely evacuated through the incisions of the operation. Resection should have preference under these circumstances." At the meeting of the society of military surgeons at Orleans, February 8, 1871, Dr. LANGENBECK gave the particulars of his cases of excisions at the wrist in the late war. He approved longitudinal incisions on the ulnar and radial sides, saving the arterio princeps pollicis, and regretted the impracticability of saving the extensor pollicis longus. Surgeon GÄHNE advocated the incision inside the extensor intermedii ("through the *tabatière*") to save the long extensors. LANGENBECK argued that this incision was liable to involve the nutritive artery of the thumb.

<sup>4</sup> In this country, apart from the operations of the War, excisions at the wrist have been little practised; although, latterly, examples are less infrequent. The following have been noted: SAYRE (L. A.) (BLACKMÁN'S MOIT'S VELPEAU, 1856, Vol. II, p. 449), in December, 1853, is said to have performed a partial excision of the carpus. Dr. SAYRE "proposed to remove both rows of bones, but was dissuaded by the other surgeons of the institution, and to this circumstance he attributes his failure, amputation having been at length required." TOLAND (H. H.) (*On the Reproduction of the Bones*, in *Pacific Med. and Surg. Jour.*, 1858, Vol. —, p. 8) relates the case of J. Allen, shot through the wrist, in February, 1857; excision December 3, 1857, of the second metacarpal, half of the third, fourth, and fifth metacarpals, the trapezoid, magnum, ulniform, and pisiform. At the date of the report "no doubt was entertained of saving the hand and restoring it to usefulness." TEWKSBURY (S. H.), *Case of Excision of the Wrist Joint*, in *Trans. of the Am. Med. Assoc.*, 1865, Vol. XVI, p. 405. COOPER (E. S.) (*Case of Successful Removal of all the Carpal and parts of all the Metacarpal Bones*, in *Boston Med. and Surg. Jour.*, 1861, Vol. LXIV, p. 446); Excision for disease, in the case of a Scotchman, aged 39 years; good recovery. "Limb restored to a degree of usefulness almost equal to its condition prior to the disease." WALTER (A. G.) (*Excision of the Wrist Joint*, in *Med. and Surg. Reporter*, 1867, Vol. XVI, p. 41); Case of J. Phillis, a boat-builder, aged 50 years; wrist excised for caries; recovery with some motion in hand and fingers. LIVINGSTON (A. T.), *Ten Cases of Excision of Joints, involving the Elbow, Wrist, Carpal, Phalangeal of Thumb, Hip, Knee, and Tarsal Articulations*, in *Buffalo Med. and Surg. Jour.*, 1873, Vol. XII, p. 285. Case of Claus von S—, aged 13 years, bones of wrist crushed; Dr. MINER excised the bones—recovery with useful hand. HODGE (H. L.), *Excision of Carpus and articular extremities of the Radius, Ulna, and the second and third Metacarpal Bones*, in *Phila. Med. Times*, 1874, p. 622 [For arthritis in the case of a man of 35]. RICHARDSON (T. G.) (*Resection of the Wrist Joint*, in *New Orleans Med. and Surg. Jour.*, 1874-75, Vol. II, p. 819); Case of J. H., aged 35 years, chronic disease of left wrist—recovery, but result of operation as to usefulness of hand not stated. LOGAN (S.) (*Case of Resection of Wrist Joint*, in *New Orleans Med. and Surg. Jour.*, 1875, Vol. III, p. 175); Case of C. E. A., aged 26 years, resection for chronic arthritis—fatal.



In a case of caries following shot perforation of the carpus, Dr. Toland, of San Francisco, in 1857 unsuccessfully attempted a partial excision, being compelled to have recourse to subsequent amputation.<sup>1</sup> There was knowledge of Moreau's and the Crimean cases, and of a few resections of the protruding extremities of the radius and ulna in cases of compound luxation. In their report of Excision of Joints for traumatic cause, these data were

<sup>1</sup> The literature of excisions at the wrist, though for the most part recent, is already quite extensive. Apart from the allusions to the subject in systematic works, the following references may be noted. They are arranged in chronological order: As of historic interest the operation of COOPER, of Bungay, in 1758, mentioned in the *Cases and Practical Remarks in Surgery* of BENJAMIN GOOCH, must be recalled. In a case of compound luxation at the wrist, "in a young subject," COOPER saved off the lower end of the radius, which had perforated and dismally lacerated the tendons at the wrist. In the edition of 1792 of GOOCH's *Chirurgical Works*, this operation is referred to in Vol. II, at p. 319, and it is stated that the patient recovered "with little or no defect in the strength or motion of the joint." British surgeons commonly refer to this as the earliest approach to excision at the wrist joint; but BAGIEU's case of the removal of the lower ends of the radius and ulna comminuted by shot, in a soldier aged 25, was published in his *Essai* (T. II, Obs. VII, p. 440) in 1756, and probably antedates the operation of COOPER. The case of removal of three inches of the diseased lower part of the ulna by DANIEL ORRED, of Chester, "in a young man of the name of Moores, about sixteen years of age," near the year 1772, is printed in the *Philosophical Transactions of the Royal Society*, 1779, Vol. LXIX, p. 10. PERCIVAL, who communicates the case, remarks that "a callus at a proper time formed in the intermediate space," whence it may be inferred that the excision was in the continuity of the bone. J. N. BILGETER (*Chirurg. Wahrnehmungen*, 1763, S. 445) reports that: "In the case of Kilian, wounded October 28, 1762, the ends of the radius and ulna, of the wrist and metacarpus, were shattered by a howitzzer shot. Stabsarzt BEYER extracted numerous large fragments, some at the time of the injury, some later. The patient recovered in four months." Dr. O. HEYFELDER reckons this a case of formal excision; but Dr. F. A. HÖRING, who has written a careful inaugural dissertation on this subject (*Die Resektionen im Handgelenk*, Tübingen, 1861, S. 22), very properly excludes it from such a category. BILGETER adduces, however, another case, which seems to have been little noticed, though more to the point. He states (*op. cit.*, p. 540) that Staff Surgeon BIRNBAUM, in the case of Voigt, a hussar of the regiment Kleist, shot through the wrist joint at Passberg, in 1759, made several incisions and excised (schälte ab) several larger and smaller pieces of bone; and that the patient recovered in eight months. Dr. HODGES states (*The Excision of Joints*, 1861, p. 74) that in July, 1794, the elder MOREAU excised the wrist for acute necrosis, in a man of 71; the case terminated fatally. I have been unable to verify this citation. The library of the Surgeon General's Office does not possess a copy of P. F. MOREAU's *Observations pratiques relatives à la résection des articulations affectée de carie*, Paris, 1803; but in KRAUSE'S German translation of the work it is stated, at page 116: "Resection may be performed also at the wrist joint; I have performed it a long time ago, for caries of the lower end of the radius. The subject was Agnes Bouclon, a seamstress of Trevaux; the result was favorable . . . I am in possession of positive information that she recovered the mobility of the fingers and even the hand, enabling her to resume her former occupation." PERCY and LAURENT, in the article *Resection*, in the *Dict. des Sci. Méd.*, T. LXVII, 1820, p. 550, refer to this case of the younger MOREAU as the "seul exemple de résection sur cette articulation" known to them. CHAMPION (*De la résect.*, etc., *op. cit.*, 1815, p. 56) mentions that he witnessed this operation. See also JEFFRAY'S PARK and MOREAU, 1806, p. 157. Two excisions of the lower ends of the radius and ulna, in cases of compound luxation, by SAINT-HILAIRE and HUBLIER, have been quoted as excisions at the wrist. I have cited them in a note on page 934, as probably operations in the continuity. Later references may be briefly noted: VERBEECK (*Bull. de l'acad. roy. de méd. de Belg.*, 1844, T. III, No. 1, p. 29) resected, about 1823, the lower end of the radius, in a boy of 14, who recovered, and entered military service. JÄGGER (M. F. RIED, *Die Resektionen der Knochen*, Nürnberg, 1860, S. 353), in 1834, resected 2 inches of the ulna for shot injury, in a man aged 48; amputation 10 days later—fatal. ROUX (P. J.) (*Lancette Française*, 1830, No. 58), in the case of widow Bonnal, aged 42, with caries, resected, May 29, 1830, the lower ends of the radius and ulna. In a second case (GERDY, *De la résect. des ext. art. des os*, 1839, p. 43), ROUX resected the lower end of the radius, but the patient died. RICORD (*Gaz. Méd. de Paris*, 1842, p. 603), [The lower end of the radius resected in a laborer, aged 23 years. Recovery with slight inclination to radial side.] ADELMANN (*Decapitation der Ulna und des Radius am Handgelenke*, in *Arch. für physiol. Heilkunde*, Stuttgart, 1846, p. 416) cites 18 cases of excision at the wrist. ROEDER, *Ueber die Resektionen am Knochengestütze der Hand*, Würzburg, 1847. HESS (W.), *Ueber die Resektion der Handgelenke*, Würzburg, 1849. MUELLER (E. T.), *De resectione ossium carpi et metacarpi*, Misnia, 1852. MAISONNEUVE, *Resection du poignet*, in *Gaz. des Hôp.*, Paris, 1853, p. 280. BOISTEDT (A.), *De resectione articuli manus*, Dorpat, 1854. ERICHSEN (J. E.) (*Excision of the Wrist Joint*, in *Lancet*, 1854, Vol. I, p. 63), case of Ann M., aged 28 years; caries of right wrist; first row of carpals removed; and (*Med. Times and Gaz.*, 1860, Vol. I, p. 366) case of —, aged 34 years; removal of lower ends of radius and ulna, carpal bones, and carpal ends of metacarpals. FERGUSSON (W.) (*Excision of the Wrist*, in *Lancet*, 1842-43, Vol. II, p. 856), in 1842, successfully excised the lower end of the ulna in a patient aged 23 years, for caries; (he repeated the operation in 1851 and 1853 (*Lancet*, 1854, I, p. 99), cases of G. G., aged 22 years, complete excision; and George M., aged 28 years, removal of greater number of carpals; also in 1857 (*Med. Times and Gaz.*, 1857, I, p. 140), woman, aged 31 years, caries; several carpal bones removed; not promising. SIMON (J.) (*Excision of the Wrist Joint*, in *Lancet*, 1854, I, p. 100), case of John L.—, aged 19 years; all bones of carpus except pisiform and trapezium; result not encouraging. STANLEY (E.) (*Lancet*, March 17, 1855, p. 288), boy, aged 13 years; removal of carpals save the trapezium. BUTCHER (R. G. H.) (*On Excision of Joints*, in the *Dublin Quart. Jour.*, November 1, 1855, Vol. XX, p. 268), case of E. R., aged 58 years; excision of carpals save the trapezium. FEARN (*Excision of Joints*, in *Med. Times and Gaz.*, 1857, I, p. 288), woman, aged 28 years; excision of extremity of the ulna and four carpals for caries. HÖRING (C. P. A.) (*Die Resektion im Handgelenk*, Tübingen, 1861), on page 38 of his very careful bibliographical summary, cites a case of excision of the entire wrist joint, by Prof. v. BRUNS, performed in 1860, for disease—patient recovered. CHASSAIGNAC (E.) (*Traité clin. et prat. des op. chirurg.*, 1861, p. 631), [blundering as usual, declares: "En fait de résection réelle de la totalité du pignet, il n'existe qu'un exemple de cette opération, etc."]. SIEHOLD (F.), *De resectione articuli manus*, Berlin, 1862. DANZEL, *Zur Resektion des Handgelenkes*, in *Archiv für Klin. Chir.*, Berlin, 1862, II, S. 512 [details the various modes of operating, etc.]. ROTH (F. R.), *Ueber die totale Resektion des Handgelenkes*, Jena, 1863. FLEUROT (E.), *De la résection de l'extrémité inférieure du cubitus*, Strasbourg, 1864. LISTER (Joseph), *On Excision of the Wrist for Caries*, in *The Lancet*, 1865, Vol. I, pp. 308, 355 [with illustrations]. COE (R. W.), *On Excision of the Wrist Joint*, in *The British Medical Journal*, 1865, Vol. I, p. 141. BUTCHER (R. G.), *Essays and Reports on Operative and Conservative Surgery*, Dublin, 1865, p. 207. HUFCHINSON (J.), *Bones of the Carpus nine years after an Excision of the Wrist Joint*, in *Transact. of the Patholog. Soc.*, London, 1866, Vol. XVII, p. 219. WOODBURY (A.) (*De resectione articulationis cubiti post vulnera sclopetaria*, Vratislavie, 1866) cites two cases of resection of the wrist joint—treated at Landslut in 1866. MACCORMAC (Wm.), *On Injuries of the Wrist and Ankle Joints*, in *Dublin Quart. Jour. of Med. Sci.*, 1867, Vol. 43, p. 281 [Removal of whole of left carpus and most of the metacarpus for injury from machinery, in the case of M. T. W., a girl of ten years. Recovery with a useful limb]. BOECKEL (Eng.), *Contributions à l'histoire de la résection totale du poignet*, in *Gaz. méd. de Strasbourg*, 1867, Vol. XXVII, p. 181. FOLET (Henry), *De la résection du poignet*, Thèse, Paris, 1867. FAYRER (J.), *Excision of the carpal ends of the Radius and Ulna*, in *Med. Times and Gaz.*, March, 1867. HANCKEN (J.), *Ueber Total-Resektion des Handgelenkes*, Berlin, 1868. HULKE (J. W.), *A Case of Excision of the Wrist*, by LISTER'S Method, in *The Lancet*, 1868, Vol. II, p. 475 [A successful complete excision, at Middlesex Hospital, in the case of a coachman, aged 23 years]. VERNEUIL, *Résections de l'articulation radio-carpienne faites à la clinique chirurg. de Padua*, in *Bull. Soc. Imp. de Chir.*, Paris, 1869, 2d Sér., T. IX, p. 11. LECKIE (D.), *Cases of Excision of the Wrist and Knee Joints*, in *Glasgow Med. Jour.*, 1869, p. 408. LANGENBECK, *Zwei Fälle von Resektion des Handgelenkes*, in *Berlin Klin. Wochenschrift*, 1870, S. 151 [Excisions for disease]. WEST (J. P.), *On Excision of the Wrist Joint*, in *Dublin Quart. Jour. of Med. Sci.*, 1870, p. 87—2 cases. GILLESPIE (J. D.), *On Resection of the Wrist Joint*, in *Edinb. Med. Jour.*, 1870, p. 499. LISTER (J.), *On some cases illustrating the results of excision of the wrist for caries*, in *Ed. Med. Jour.*, 1871, Vol. XVII, p. 144. *Ibid.* Separately reprinted. HANCOCK, *Excision of the Wrist*, in *The Lancet*, 1872, Vol. I, p. 79. VIENNON (O.), *Résection radio-carpienne pour un coup de feu*, in *Lyon Médical*, No. 12, 1872, p. 184. KÜSTER (E.), *Ueber die Resektion des Handgelenkes nach Traumen in Berlin Klin. Wochenschrift*, 1874, p. 87.

considered by the surgical advisory committee of the Sanitary Commission to afford "precedents sufficient, perhaps, to authorize renewed trials in cases not accompanied by too great laceration of the soft parts" by shot projectiles. The trials have been made; but the question whether the wrist joint, from its complexity, is altogether unfitted for the favorable performance of excision for injury, is still not fully elucidated.

**AMPUTATIONS AT THE WRIST FOR SHOT INJURY.**—Sixty-eight of these operations were reported as practised on sixty-seven patients. One patient had both hands disarticulated at the wrist. Of the sixty-six patients whose anterior histories were traced, seven died, or 10.6 per cent.

TABLE CXLIII.

Summary of Sixty-eight Amputations at the Wrist Joint for Shot Injury.

No.	NAME, AGE, AND MILITARY DESCRIPTION.	DATES.	OPERATIONS, OPERATOR, RESULT.	No.	NAME, AGE, AND MILITARY DESCRIPTION.	DATES.	OPERATIONS, OPERATOR, RESULT.
1	Allison, J. P., Serg't, 11, 15th Ill., age 23.	Oct. 5, '62.	Left; flap: by A.A. Surg. J. Van Valsey. To V. R. C.; pensioned.	34	Moran, E., Pt., D, 67th New York, age 21.	Sept. 27, '61.	Left; flap: by A. Surg. J. R. Smith. Pens'd March 6, 1862.
2	Ansonia, J. D., Pt., 1, 6th N. Y. Battery.	Oct. 19, '64.	Right. To V. R. C.; pensioned March 31, 1865.	35	Moses, G. F., Pt., B, 39th Mass., age 19.	May 10, '64.	Left: double flap: by Surg. W. Thordike; amp. forearm Jan. 7, '65; pen'd Mar. 19, '65. <i>Spec. 4197.</i>
3	Brennan, F. H., Serg't, B, 185th N. Y., age 30.	Mar. 29, '65.	Right; April amp. forearm. Pensioned June 27, '65. Died April 14, 1871, typhoid pneumonia.	36	Mesher, V. B., Pt., F, 57th N. Y., age 21.	May 10, '64.	Left; circular: by Surg. W. B. Chambers. Pens'd Jun. 10, 1865.
4	Buck, J., Pt., E, 70th N. Y., age 20.	May 5, '62.	Right. Disch'd July 3, 1862; pensioned; good stump.	37	Pock, C. S., Pt., D, 64th N. Y., age 19.	April 7, '65.	Right; circ.; Surg. M. C. Rowland. Pens'd June 8, 1865.
5	Burke, R., Pt., G, 8th C. T., age 30.	Sept. 29, '64.	Right; flap: by Surg. C. P. Heibhold. Pens'd June 4, '65.	38	Randall, H., Pt., C, 8th Connecticut, age 20.	May 16, '64.	Right; flap. Discharged March 30, 1865; pensioned.
6	Busher, J., Pt., D, 1st Ohio, age 23.	Nov. 25, '63.	Right; flap: by A. Surg. R. G. Stevenson. Pens'd Sept. 20, '64.	39	Reedy, S., Pt., F, 93d Indiana, age 25.	Dec. 16, '64.	Right; flap. Discharged April 17, 1865; pensioned.
7	Butterworth, J., Pt., F, 1st R. I. Art., age 21.	Dec. 16, '62.	Left; circular: amp. forearm. Pens'd Sept. 17, '64. <i>Spec. 1323.</i>	40	Revels, T., Pt., F, 23d South Carolina, age 19.	July 15, '64.	Left; circular. Discharged February 20, 1865.
8	Campbell, J., Pt., 1, 21st Indiana, age 19.	Aug. 17, '61.	Left; flap: by A. Surg. W. B. Ramsey. Pens'd Nov. 1, 1861.	41	Schook, J., Pt., K, 15th Indiana, age 22.	Dec. 31, '62.	Left; flap. Discharged April 7, 1865; pensioned.
9	Crawford, J. L., Serg't, 1st R. I. Art., age 19.	Oct. 18, '62.	Left; by Surg. J. S. Elliott, 8th Ind. Pens'd January 29, 1873.	42	Seivers, H., Pt., A, 14th Iowa, age 26.	May 11, '62.	Left; circ.; by Surg. G. M. Staples. Pensioned July 13, 1861.
10	Daily, H. A., Pt., B, 8th Wisconsin, age 31.	June 6, '64.	Right; by Surg. E. Muria, 8th Wis. Disch'd June 9, '65; pens'd Aug. 10, 1864.	43	Skelly, E., Pt., F, 2d N. Y. JI. A., age 28.	June 22, '64.	Left; circular: by Surg. G. L. Potter. Pensioned Jun. 24, '65.
11	Donaldson, S., Corp'l, G, 10th Ill., age 31.	Jan. 28, '64.	Left; flap: by Surg. H. R. Payne, 10th Ill. Pens'd Oct. 21, 1864.	44	Stroup, D., Pt., H, 18th Georgia, age 19.	Aug. 30, '62.	Right. Furloughed October 4, 1862.
12	Dunn, J. C., Pt., A, 1st Me. H. Art., age 23.	June 28, '64.	Left; flap: by Surg. J. W. Brackett. Pensioned Feb. 21, 1863.	45	Thompson, T. M., Pt., 1st Me. Bat., age 43.	Jan. 14, '63.	Right; amp. left forearm: Surg. M. D. Beaudier. Pen. May 12, '63.
13	Foster, E. R., Pt., L, 9th Ill. Cavalry, age 24.	Jan. 2, '63.	Right; flap: by Surg. N. Hayward. Dis'd June 17, '65; pens'd N. C. Pens'd Nov. 23, 1864.	46	Thorne, E. M., Pt., C, 2d Conn. H. A., age 20.	Oct. 19, '64.	Right; circular. Discharged June 5, 1865; pensioned.
14	Gans, G., Serg't, D, 36th Wisconsin, age 23.	June 18, '64.	Left; by Surg. V. B. Kennedy (removal of part of scapula). Pensioned June 29, 1865.	47	Tucker, S., Mus'n, K, 87th Illinois, age 19.	May 21, '63.	Left; by Surg. E. L. Stewart. Disch'd June 19, 1864; pens'd Both. Discharged Jan. 26, 1865.
15	George, J., Pt., C, 6th Maine, age 33.	May 10, '64.	Right; by Surg. W. Morrison, 14th N. C. Pens'd Nov. 23, 1864.	48	Warren, M. C., Mus., A, 20th Me., age 17.	May 5, '64.	Left; circular. Died Feb. 3, 1875.
16	Gross, J., Pt., D, 11th Missouri, age 22.	Mar. 27, '65.	Left; by Surg. V. B. Kennedy (removal of part of scapula). Pensioned June 29, 1865.	49	Wood, M. T., Pt., K, 130th Ind., age 18.	June 17, '64.	Left; circ.; by Surg. C. D. Moore. Pens'd Jan. 3, 1865; amp. arm.
17	Hanberry, J., Pt., 1, 5th South Carolina.	May 24, '64.	Left; circular: by Surg. C. B. Gibson, C. S. A. Recovery.	50	Blasland, G. B., Pt., D, 1st Mass., age 30.	Aug. 29, '62.	Left; flap: by A. A. Surg. J. W. Higby. Pens'd Feb. 25, 1863.
18	Hatch, J. O., Pt., G, 6th Wisconsin, age 26.	Aug. 4, '61.	Right; anti-post flap: by Surg. H. McKenna. Pensioned. Died June 28, 1859.	51	Day, H. H., Pt., D, 96th N. Y., age 24.	Oct. 29, '64.	Right; Nov. 14th, legum.; amp. arm. Pens'd July 25, 1865.
19	Hudson, J., Pt., 1, 130th Indiana, age 21.	June 15, '64.	Left. Discharged Jan. 10, 1865. Dropped from Pension Rolls.	52	Dye, S., Pt., C, 58th Indiana, age 23.	Dec. 31, '62.	Left; by Surg. T. Seymour, U. S. V. Disch'd April 8, '63; pensioned.
20	Hutchins, M. P., Serg't, J, 12th N. H., age 25.	Nov. 7, '62.	Left; flap: by Surg. H. B. Fowler, 12th N. H. Pen'd Dec. 10, '62.	53	Hammel, H., Pt., C, 10th Indiana, age 26.	Jan. 19, '64.	Left; Surg. S. L. Burdett (amp. fingers). Pens'd Feb. 21, 1862.
21	Keefer, D., Pt., C, 7th Pa. Res., age 31.	Sept. 17, '62.	Right; circular. Discharged Oct. 30, 1862; pensioned.	54	Harrington, T., Pt., B, 34th Wis., age 31.	Feb. 18, '63.	Left; flap: by Surg. J. B. Weinen. Pensioned May 20, 1863.
22	King, E. F., Pt., C, 10th Connecticut, age 18.	Dec. 14, '62.	Right; circ.; by Surg. I. F. Galloppe. Pens'd Dec. 31, 1864.	55	Ketchum, D. F., Pt., A, 23d Michigan, age 43.	Sept. 29, '63.	Right; flap. Disch'd Dec. 16, 1863; pens'd. Died Apr. 17, '71.
23	Kipping, W., Pt., E, 3d Artillery.	July 18, '63.	Right; by Surg. J. L. Mulford. Pens'd August 27, 1863. Died Aug. 18, 1869.	56	Teusher, J., Pt., A, 72d N. Y., age 34.	July 1, '64.	Right; A. A. Surg. W. F. Atlee (amp. thumb). Pen. Dec. 15, '62.
24	McDonald, J., Pt., G, 85th Pa., age 29.	July 20, '63.	Left; circ.; amp. right arm; Surg. S. A. Green. Pen'd Mar. 7, '64.	57	Thoma, C., Pt., G, 3d Infantry, age 29.	Jul. 21, '61.	Left; flap. Pensioned October 20, 1861.
25	McGrane, H. J., Pt., D, 164th N. Y., age 23.	May 19, '64.	Left; flap: by Surg. M. Rizer. Pensioned Nov. 28, 1864.	58	Tyler, H. R., Pt., C, 60th Illinois, age 27.	Sept. '64.	Right; by Surg. M. Goldsmith. Disch'd Feb. 10, 1865; pens'd.
26	McKinney, G., Corp'l, B, 128th Pa., age 23.	Sept. 17, '62.	Right; circ.; poor stump. Pens'd Nov. 29, '62. Died Sept. 30, '68.	59	Verrill, J., Pt., C, 3d N. H., age 45.	May 13, '64.	Right; flap: by A. A. Surg. W. P. Moon (crystallins). Pens'd Sept. 27, 1864. <i>Spec. 3622.</i>
27	Magnoonaugh, B., Pt., Ord. Corps, age 23.	May 4, '65.	Left; amp. right forearm: by A. A. Surg. E. S. Snow. Pensioned March 17, 1868.	60	Heyman, H., Pt., D, 53d Pa., age 23.	June 16, '64.	Right; by Surg. P. E. Hubon, 28th Mass. Died June 25, 1864.
28	Mann, W. H., Pt., C, 118th Ohio, age 31.	July 22, '62.	Left; by Surg. A. M. Wilder; ligation. Pens'd April 8, 1865.	61	Maathin, J., Pt., 1, 12th C. T., age 20.	Dec. 16, '64.	Left; by A. A. Surg. J. S. Giltner. Died Dec. 19, '64, tetanus.
29	Matthewson, C. B., Pt., K, 21st N. Y.	Oct. 10, '61.	Left; flap. Disch'd Nov. 11, '61; pens'd. Died March 28, 1868.	62	Oshorne, W., Corp'l, H, 54th Ohio.	July 22, '64.	Right; by Surg. I. N. Barnes. 116th Ill. Died Aug. 28, 1864.
30	Maxfield, J. T., Pt., B, 65th Indiana, age 24.	Dec. 28, '62.	Right; circular. Disch'd Sept. 9, 1863; pensioned.	63	Pippin, R. R., Pt., K, 47th Ala., age 25.	Aug. 16, '64.	Right. Died August 19, 1864.
31	Mayans, J., Pt., I, 37th Mass., age 30.	May 9, '64.	Left; flap: by Surg. J. A. Phillips, 9th Pa. Res. Pens'd Sept. 6, 1862.	64	Stanford, V. B., Pt., A, 1st Ohio Lt Art.	May 15, '64.	Left (amp. right arm): Surg. J. B. Glick, 40th Ind. Died June 4, '64.
32	Miller, C. W., Pt., F, 5th Pa. Res., age 23.	June 27, '62.	Left; by Surg. J. A. Phillips, 9th Pa. Res. Pens'd Sept. 6, 1862.	65	Henderson, J. H., Pt., D, 14th Connecticut.	Sept. 17, '62.	Left; circular. Died September 30, 1862, tetanus. <i>Spec. 115.</i>
33	Moody, W., Pt., 1, 121st Pa., age 25.	Dec. 13, '62.	Right; circ.; by Surg. C. Bower, 6th Pa. Res. Pens'd May 19, '63.	66	Thompson, J. C., Pt., B, 17th Pa. Cav., age 43.	June 12, '64.	Left; by A. A. Surg. M. K. Knorr; Sept. 29, re-amp. arm. Died Oct. 17, 1864, pyæmia. <i>Spec. 3074.</i>
				67	Thompson, T., Pt., 1, 6th Georgia.	Sept. 17, '62.	Right.



Fifty-five of the foregoing operations were primary disarticulations at the wrist, performed on fifty-four patients, with five deaths, or 9.2 per cent. Seven cases with one death, or 14.3 per cent., were intermediary disarticulations. The fatal result was due to tetanus. Five operations, of which one proved fatal, were secondary. One case was undetermined as to the period of the operation, or the result. Thirty-two of the amputations were on the right, and thirty-six on the left side. Of the seven fatal cases, four were on the left and three on the right side. Consecutive amputation in the continuity was resorted to in five instances, twice successfully in the forearm, thrice, with one fatal result, in the upper arm. A few further remarks on shot fractures,<sup>1,2</sup> excisions,<sup>3,4</sup> and amputations<sup>5,6</sup> at the wrist are adduced in the notes.<sup>7</sup>

<sup>1</sup> H. L. LEDRAN, ever inclined to conservatism, taught (*Traité on Réflexions tirées de la Pratique sur les Plages d'Armes à feu*, 1787, p. 213) that: "Shot wounds at the wrist are ordinarily attended by fracture—that is, one of the bones forming the articulation, or many of them, may be splintered, crushed, or even carried away, and that cannot take place without the ligaments and aponeuroses that bind them together being much injured, and the tendons passing over them divided and torn. . . . By incisions and counter-openings, by régime, blood-letting, and topical applications, we may prevent the ligaments and capsules that unite the wrist with the forearm participating in the inflammation, breaking down, and disorganization of the lacerated tendinous parts. With these precautions we commonly see such wounds heal quite readily."

<sup>2</sup> Dr. T. P. MATTHEW (*Hist. of Wounds and Injuries*, Part II of *Med. and Surg. History of the British Army which served . . . in the Crimea*, 1858, p. 351) states that: "Wounds of the wrist joint have been returned under the head of injury to the carpus," a statement copied, of course, by Dr. G. H. B. McLEOD (*Notes, etc.*, 1858, p. 430); but both editors seem to have overlooked the fact that the only return of injuries to the wrist joint made confounds the penetrating and perforating wounds of the carpus and metacarpus, so that it is impossible to distinguish what proportion involved the wrist. As there was but one death in 113 cases, it is probable that most of the injuries were confined to the metacarpus without involving the proximal articular ends. On pp. 372-3, Dr. MATTHEW mentions one wrist joint amputation in the Crimea, and three at the hospitals on the Bosphorus, all four operations resulting successfully. Dr. GEORGE WILLIAMSON (*Mil. Surg.*, 1863, p. 131) remarks that the number of men invalidated for wounds of the carpus and metacarpus in the British Army "is usually great, which shows their severity."

<sup>3</sup> HAMILTON (F. H.) (*The Principles and Practice of Surgery*, 1872, p. 888) remarks: "Excisions of the lower end of the radius alone, when not accompanied with a fracture and shortening of the ulna, invariably result in more or less deflection of the hand to the radial side. I have seen it turned in this direction to nearly a right angle. If, therefore, excision of the lower end of the radius is practised, and the ulna is not broken and overlapped, it will be advisable to remove at the same time an equal portion of the lower end of the ulna. In the single case in which I have adopted this practice, the subsequent inflammation and suppuration were moderate, the hand was restored, occupying its normal position, with good motion at the wrist joint and a useful amount of motion in the fingers. The great value of a thorough excision of both bones in this class of cases, as a means of insuring complete relaxation of the muscles and of preventing subsequent inflammation, will be found fully explained and illustrated by cases in my treatise on *Fractures and Dislocations*, in the chapter entitled 'Compound Dislocations of the Long Bones.'"

<sup>4</sup> ESMARICH (F.) (*Ueber Resectionen*, 1851, S. 37): "If the attendant circumstances are favorable, injuries of the wrist and ankle joints heal under proper treatment, though after long suffering, and with ankylosis. Amputation of the limb appears to be indicated only by extensive comminution of bone. We did not, however, perform resection at the wrist, because, on the one hand, on account of the numerous tendons, vessels, and nerves around the parts, and, on the other hand, because they scarcely promise a better result than is attainable by free well-directed openings of the joint capsules."

<sup>5</sup> Sir CHARLES BELL (*A System of Operative Surgery*, 1814, Vol. II, p. 492) remarks: "I have seen the arm amputated for a ball through the wrist joint; but so I have for a ball through the small head of the ulna, and in both instances the operation was altogether improper. The excess of fungus which is thrown out from such wounds, with shattered bones, betrayed the surgeon into a belief that the hand should be amputated."

<sup>6</sup> In European surgical annals for the last half century, the following references to amputations at the wrist for shot injury may be found: LARREY (H.) (*Hist. chir. siège de la citadelle d'Anvers*, 1831, p. 314) reports two cases of amputations at the wrist; one proved fatal. STROMMEYER (L.) (*Marinern*, u. s. v., S. 756) reports two cases of exarticulation of the wrist; one was fatal. MATTHEW (T. P.) (*Hist. of Wounds and Inj.*, Part II, *Med. and Surg. History of the British Army*, . . . in the Crimea, 1858, p. 372-3) tabulates three successful amputations at the wrist joint. CHEUX (J. C.) (*Rapport, etc., pendant la campagne d'Orient*, 1865, p. 655) tabulates sixty-eight amputations at the wrist, with twenty-seven deaths. CHEUX (J. C.) (*Statistique, etc., de la campagne d'Italie*, 1869, T. II, p. 611) gives thirteen amputations at the wrist, with six deaths. DEMME (H.) (*Mil. Chir. Studien*, 1861, B. II, S. 241) tabulates twelve cases of enucleation of the hand; five proved fatal. LOEFFLER (F.) (*General-Bericht*, 1867, S. 301) tabulates one successful case of exarticulation at the wrist. BIEFEL (R.) (*Im Reserve-Lazareth Kriegschir. Aphorismen von 1866*, in LANGENBECK'S *Archiv.*, 1869, B. XI, S. 475) tabulates three successful exarticulations at the wrist. BÉRENGER FÉRAUD (*Étude sur les blessures du poignet traitées dans la deuxième division des blessés du Val-de-Grâce*, in *Bulletin gén. de Thérap. méd. et chir.*, 1872, T. 82, p. 302) cites one successful case of exarticulation at the wrist joint. ARNAUD (GRELLOIS E.) (*Hist. méd. du blocus de Metz*, 1872, S. 353) tabulates three successful cases of amputations at the wrist joint. CHEUX (J. C.) (*Aperçu, etc., pendant la guerre de 1870-1871*, T. I, p. 492) tabulates one hundred and one exarticulations at the wrist, of which sixty-nine, or 68.32 per cent., were fatal. BECK (B.) (*Chirurgie der Schussverletzungen*, 1872, S. 842) gives two cases of exarticulation at the wrist joint; one patient recovered, one died. MACCORMAC (WM.) (*Notes and Recollections of an Ambulance Surgeon*, London, 1871, p. 130) tabulates two successful exarticulations at the wrist. Apart from references in systematic surgical treatises, the following writings may be consulted on amputations at the wrist: BRASIOR (*Ess. sur les amputations dans les artic.*, in *Mém. de l'Acad. de Chir.*, 1774, Vol. V, p. 789) observes: "Les fonctions de la main exigeant des mouvements variés, l'articulation du poignet à une structure relative. Les surfaces articulaires sont presque planes, leur connexion est lâche; aussi l'amputation dans cet article est elle facile à exécuter," and describes the manner of operating. BONA (C. A.), *Extirpation der Hand im Gelenk*, in *Jour. für Chir. und Augenheilkunde*, Berlin, 1825, B. VIII, p. 88. URE, *Amputation at the wrist with the cartilaginous surfaces left intact*, in *The Lancet*, 1855, Vol. I, p. 155. WARD (N.), *Amputation at the wrist joint*, in *The Lancet*, 1859, Vol. I, p. 504. *Amputation at the Wrist Joint. State of the stump sixteen years afterward*, in *Med. Times and Gaz.*, London, 1860, p. 211. BARELA (L.), *Désarticulation radio-carpienne par la méthode oblique*, de M. SOUTART, in *Arch. Bel. de Méd. Mil.*, 1852, T. XXX, p. 439. KLEIN (N. G.), *Erkrankung carpi-cubitalis*, in *Ursachen Leibeserkränken*, Fürhandl., 1874-75, p. 141. POTPARI (J. D.), *Nouveaux modes et procédés pour l'amputation des membres*, Bruxelles, 1847. PRETT (I. L.), *Remarques sur les amputations que l'on fait aux articulations*, in *Œuvres complètes posthumes*, 1844, p. 846.

<sup>7</sup> MOSSAKOWSKY (P.) (*Statistischer Bericht über 1415 Französische Invaliden des Deutsch-Französischen Krieges*, in *Deutsche Zeitschrift für Chir.*, 1872, B. I, S. 337) records 22 cases of shot fracture of the wrist joint among the French invalids that passed through the International Agency at Basel. In 19 cases, amputation had been performed—1 in the arm, 18 in the forearm. In the 3 conservatively treated cases ankylosis supervened—in 1 instance with extreme palmar contraction. BERTHOLD (*Statistik der . . . invalide gewordenen Mannschaften des 10. Armeecorps*, in *Deutsche Mil. ärztl. Zeitschrift*, 1872, B. I, S. 517) gives an account of 21 invalids of the 10th Army Corps that had received shot fractures of the wrist joint. 17 had been conservatively treated; twice amputation in the forearm had been performed, and twice resection; all were unable to support themselves by manual labor.

SECTION VIII.

WOUNDS AND OPERATIONS IN THE HAND.

The wounds of the hand<sup>1</sup> that will be considered in this Section, for the most part in the shape of numerical statements, are shot fractures of the metacarpal bones and the phalanges, the various disarticulations, amputations, and excisions necessitated by these injuries, and the complications to which they gave rise.<sup>2</sup>

TABLE CXLIV.

Numerical Statement of Eleven Thousand Three Hundred and Sixty-nine Fractures of the Bones of the Hand for Shot Injury.

MODE OF TREATMENT.	BONES OF THE HAND INJURED.													MORTALITY OF DETERMINED CASES.					
	CASES.	METACARPALS.				METACARPO-PHALANGEAL ARTICULATION.				PHALANGES.					BONES NOT SPECIFIED.				
		Discharged.	Died.	Result un-known.	Discharged.	Died.	Result un-known.	Discharged.	Died.	Result un-known.	Discharged.	Died.	Result un-known.		Discharged.	Died.	Result un-known.		
Treated by Expectation . . . . .	3092	785	1060	45	77	43	68	2	6	58	292	7	105	145	330	5	64	2.0	
Followed by—																			
Excision of Metacarpal Bones . . . . .	107	50	42	6	2	3	2	2											7.6
Excision of Metacarpal Bones and Amp. of Forearm . . . . .	9	6		3			1												22.2
Amputation of Fingers with or without Metacarpals . . . . .	7842	303	213	38	40	208	176	12	10	2286	3324	129	1103						2.6
Amp. Fing. with or without Metacarp. and Amp. at Wrist . . . . .	2	1								1									0.0
Amp. Fing. with or without Metacarp. and Amp. in Forearm . . . . .	39	12	3	4		2	1	1		8	1	7							30.7
Amp. Fing., etc.—Amp. in Forearm—Amp. in Upper Arm . . . . .	3					1				1		1							33.3
Amputation of Fingers, etc.—Amputation at Elbow . . . . .	1	1																	0.0
Amputation of Fingers, etc.—Amputation in Upper Arm . . . . .	15	2		2		2				5		4							40.0
Amputations at the Wrist . . . . .	41	22	2	3		1	1	1		1			8	2					9.7
Amputation at the Wrist and Amputation in Forearm . . . . .	1	1																	0.0
Amputations in Forearm . . . . .	175	74	12	23		4		1		4		1		46	6	3	1		16.0
Amputation in Forearm and Amputation at Elbow . . . . .	1	1																	0.0
Amputation in Forearm—Amputation in Upper Arm . . . . .	4	1				1				1			1						0.0
Amputation in Upper Arm . . . . .	35	4	2	10	1					1		2		2	1	5			50.0
Amputations in Upper Arm—Amputations at Shoulder . . . . .	2	2																	0.0
<b>Total</b> . . . . .	<b>11369</b>	<b>1265</b>	<b>1334</b>	<b>133</b>	<b>120</b>	<b>265</b>	<b>249</b>	<b>19</b>	<b>16</b>	<b>2366</b>	<b>3617</b>	<b>151</b>	<b>1208</b>	<b>209</b>	<b>339</b>	<b>13</b>	<b>65</b>		<b>3.1</b>
<b>Aggregates</b> . . . . .		<b>2852</b>				<b>549</b>				<b>7342</b>				<b>626</b>					

Though generally regarded as trivial accidents, shot wounds of the hand are extremely painful and troublesome of management.<sup>3</sup> The traditional impression that they are particularly liable to induce tetanus is not confirmed but rather disproved by the reports, since this complication supervened in only twenty-four instances in the large series of over

<sup>1</sup> The Hand, from Gothic, handus; Gr., ΧΕΪΡ, the hand, or rather arm and hand, hence ἄκρα χεῖρ, for the hand; Dutch, Ger., Sw., hand; Dan., haand; Ital., hond; Lat., manus; Fr., main; Hol., mano.

<sup>2</sup> RAVATON (*Chirurgie d'Armée*, 1768) devotes the twenty-sixth chapter of his excellent work to shot wounds of the hand, and adduces several remarkable cases. He thinks, notwithstanding the infinite variety of their injuries, they may be subdivided into those in which the missile perforates the hand by the shortest route and those in which it traverses obliquely the longest passage. He strongly advocates conservative measures, but admits that there are injuries hopelessly incurable, and observes that the closest attention and best anatomical knowledge are requisite in order to discriminate the several varieties of injury, and that the conditions should be most carefully ascertained before any decided step is taken.

<sup>3</sup> COLE (J. J.) (*Military Surgery, or Experience of Field Practice in India*, 1852, p. 157) remarks of shot injuries of the hand: "These wounds are extremely painful and slow to heal; they are, moreover, somewhat dangerous, and difficult to manage." GUTHRIE (G. J.) (*A Treatise on Gunshot Wounds*, 3d ed., 1827, p. 541) observes: "Gunshot wounds of the hand are particularly disagreeable, in consequence of the tendency they have to bring on trismus or locked jaw, and to avoid this, in many instances the hand has been removed when it might otherwise have been in part saved."



eleven thousand wounds of this description,<sup>1</sup> a very small proportion, as will appear in the comparative statement in the article on Tetanus, in the *Third Surgical Volume*.

**Shot Wounds of the Hand treated by Expectation.**—While the strictest conservatism has always been enjoined in the treatment of shot injuries of the hand, yet, as over two-thirds of the cases in this series were wounds of the fingers with irreparable disorganization of structure, for the most part demanding amputation, operative interference was avoided in but about a fourth of the cases. A large proportion of these were perforations of the hand with fracture of the metacarpals.<sup>2</sup> An illustration will be given :

CASE 2045.—Private C. J. Chappel, Co. I, 86th New York, aged 26 years, was wounded at Beverly Ford, Virginia, June 9, 1863, and was taken to the Cavalry Corps Hospital. "A musket ball had entered the palm of the right hand and emerged on the dorsum, shattering the third and fourth metacarpals. Cold-water dressings were applied, and the patient was sent to Washington. Surgeon G. S. Palmer, N. Y. Vols., records his admission to Lincoln Hospital June 10th, and transfer to Satterlee Hospital, Philadelphia, June 22d. Soon after his arrival at Lincoln, Surgeon John H. Brinton, U. S. V., recognizing the case as a typical example of palmar-dorsal shot perforations of the hand, had prepared by Mr. Stauch, of the Army Medical Museum, a water-color drawing, which is copied in the upper part of the chrono-lithograph (PLATE LII) opposite. At Satterlee Hospital Acting Assistant Surgeon J. Hampden Porter reported that: "The hand was much tumefied and very painful, and the discharge sanious. The hand was placed on a cushioned splint and treated with ice dressings. A saline cathartic was exhibited, and the patient was allowed full diet. In twenty-four hours the appearance of the wound changed for the better. The character of the discharge altered, and the tumefaction decreased. The patient had no relapse or untoward complication of any kind, either locally or in his general health. The necrosed splinters that detached themselves were removed without trouble or pain, and the wound rapidly healed, and, on September 9th, the man was transferred to Second Battalion of the Invalid Corps. When I examined him, on October 18, 1863, he had some deformity of the hand, with a tumor on the palmar surface, and loss of movement in the medius, and partial loss of power in the ring finger. The rest of the member was serviceable." The man's name does not appear on the Pension List.

I would here call attention, by a remarkable example, to the paralysis and deformities of the hand incident to shot lesions of nerves in proximal portions of the upper extremity:

CASE 2046.—The case of Private George I. Grothers, Co. H, 22d N. Y. Cavalry, aged 21 years, has been briefly adverted to at page 465 of this Chapter as CASE 1369, under the head of shot flesh wounds of the upper arm, implicating large nervous trunks. It may be reverted to as an interesting example of the effect of such shot injuries upon the nutrition and functions of the hand. The patient was sent to Washington, and entered Stanton Hospital, where Acting Assistant Surgeon D. W. Prentiss prepared the following notes of the case: "This interesting example of reflex nervous action occurred in the person of Private G. I. Grothers, 22d N. Y. Cavalry, wounded October 1, 1864, in action south of Petersburg, while holding up his left arm in reining in his restive horse. A musket ball entered the inner anterior aspect of the upper arm, and passing under the tendon of the biceps emerged two inches posteriorly, above the external condyle. The brachial artery was probably severed, the median nerve undoubtedly wounded. The patient lost much blood, and fainted on the field from the combined effect of hæmorrhage and shock. After reviving, much pain was persistently felt in the hand alone, except on the fourth and fifth days, when there was slight pain at the seat of injury. The pain in the hand was of a very sharp, burning, stinging character, and was very severe for the first few weeks; it did not appear immediately after consciousness was restored, but some hours after. Cold-water applications gave some relief to the pain. The immediate effect of the wound was a strong contraction of the flexors of the hand, causing it to clutch so strongly that the fingers could only be extended by the aid of the other hand. Stiffness and swelling of the digital joints followed, very like rheumatism. The elbow was flexed at an angle of 90°, but gradually became extended, until January 8, 1865, the limb was extended at about 135°. Perhaps the most interesting circumstance connected with the case was the reflex nervous action from the opposite hand. Whenever anything of a dry, rustling character, such as a newspaper, was taken into the right hand, pain was caused, and motion in the left index especially, and the whole of the hand, the pain being most acute in the second metacarpo-phalangeal joint. This effect was most marked when the index finger of the right hand was touched, but was shown in less degree when other fingers were tried. Pain was produced at the same points, but not motion, by pressing on the median nerve. This condition has been gradually improving under treatment by electricity and topical anodyne applications to the *hand*,—for they are not borne at the seat of wound. Acetate of lead and opium with volatile liniment were found to be the most effective local applications. Mr. Keeler, the head nurse of Ward 3, at Stanton Hospital, made a drawing of the hand, which faithfully represents its altered appearance." [The drawing is reproduced in the lower of the two figures in PLATE LII.]

In the expectant treatment of shot wounds directly involving the hand, the necessity of removing all detached splinters of bone as well as all foreign bodies, as part of the primary dressing, was generally recognized and obeyed. The utility of free incisions

<sup>1</sup> Among the 11,339 cases of shot injuries of the hand, but 24 cases of tetanus were reported, viz: 9 fatal cases after shot fractures of the metacarpus treated by expectation; 14 cases with 4 recoveries, after amputation of the fingers for shot injury; 1 fatal case after disarticulation at the wrist.

<sup>2</sup> Of 3,092 shot injuries of the hand treated by expectation, 1,967 were fractures of the metacarpals, 119 perforations of the metacarpo-phalangeal articulations, 102 injuries of the phalanges, 544 shot wounds of the hand of unspecified position. The mortality of the entire series was a little over 2 per cent.



Ed Stauch, et Keeler, pmx

T. Sinclair & Son, Chromolith

PLATE LII. EFFECTS OF DIVISION OF ULNAR NERVE AND OF SHOT PERFORATION OF HAND.





through the aponeurotic layers, and of thus preventing accumulations of matter under fasciæ and tendons, or relieving tension caused by such collections, was also appreciated, although an unreasonable dread of wounding the arteries of the palm was sometimes indulged. Hæmorrhage uncontrollable by pressure was very rare. The usual treatment was to lay the hand upon a padded palmar splint, and to employ cold-water dressings until suppuration was established and warm fomentations became more agreeable to the patient. In the comparatively infrequent attempts to preserve mangled fingers, careful coaptation of the parts on a digital splint became necessary. While some of the surgeons shared Guthrie's exaggerated aversion to poultices, others pronounced them very useful in lacerations of the hand, and thought, with Stromeyer, that they were earlier indicated and might be longer employed than in most other regions. The excellent resource of local tepid baths, of ready applicability in these injuries, was seldom used.

**Shot Wounds of the Hand treated by Excision.**—A hundred and sixteen excisions of the metacarpal bones without removal of the corresponding fingers were serious operations, ten cases proving fatal.<sup>1</sup> In nine, including two fatal cases, resort was had to amputation in the forearm.<sup>2</sup> In short, the histories of this series confirm the precept of Dr. Stromeyer, that operative interference should be unthought of in such cases. Excisions of parts or extirpation of one or more metacarpals conjointly with their corresponding fingers were not infrequent; but such ablations, which are often imperative, are usually classified as amputations or disarticulations rather than resections.<sup>3</sup> Six or seven instances were reported of alleged excisions of the articulation between the proximal and middle phalanges, and several examples of extraction of splinters or exfoliations, or extraction of carious terminal phalanges, were returned under the imposing title of excisions.

**Shot Wounds of the Hand treated by Amputation.**—Seventy-nine hundred and two

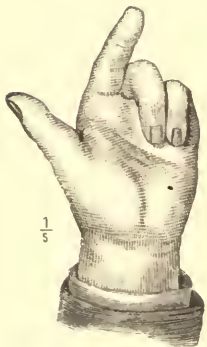


FIG. 740.—Hand six months after amputation of middle finger for shot injury. *Spec.* 2954.

cases of shot wounds of the hand were treated by partial or complete ablation of one or more fingers, with or without the ends or entire shafts of the corresponding metacarpals,<sup>4</sup> and two hundred and fifty-nine cases by amputation at the wrist or higher up in the extremity. All of the latter group have been detailed in previous Sections; they furnished a mortality of 19 per cent. In the former group, were sixty instances of re-amputation, either at the wrist or above, with a fatality of 31.6; while the fatal cases in the remainder of the series amounted to only 2.6 per cent. Imperfectness in the reports precludes the possibility of a complete classification

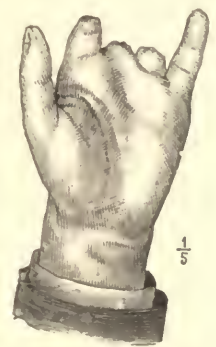

FIG. 741.—Hand three months after amputation of the index, middle, and ring fingers. *Spec.* 4027.

of the operations according to the date at which they were performed; but a scrutiny of several large series of cases of amputations of fingers determined with precision,

<sup>1</sup> Of the 116 excisions, 104 resulted favorably, 10 fatally; the results in two instances are unknown. There were 64 primary excisions, with 6 deaths, one fatal case being associated with an amputation of the thigh for shot fracture—the case of Pt. C. H. Maddock, 1st Maine Art., to be noticed hereafter, and 2 with intermediary amputation in the forearm—the cases of Pt. Cummings, 20th Mass., and Pt. Rowell, 19th Maine, recorded in TABLE CXXXVI, pp. 986-7, as Nos. 11 and 66. The 2 intermediary, 2 of uncertain date, and 6 primary fatal cases succumbed from pyæmia.

<sup>2</sup> The two cases that resulted fatally after consecutive amputation in the forearm have just been noted. Of the 7 cases of recovery, 4 were intermediary amputations in the forearm, and are recorded in TABLE CXXXV, p. 981, as Nos. 123, 129, 280, and 285; 3 were secondary operations, and appear in TABLE CXXXVII, p. 988, as Nos. 52, 57, and 131.

<sup>3</sup> Several instances of removal of fingers and metacarpals together with parts of the carpus and even of the distal ends of the bones of the forearm, have been cited in the preceding Section—*v. g.*: CASE 2000, p. 1006 (Hobbs); CASE 2022, p. 1009 (Massey); CASE 2031, p. 1010 (Burns).

<sup>4</sup> TROCCON (*Mém. sur l'amput. du poignet*, Paris, 1827) is reported to have first proposed in 1816, resection in the continuity of the metacarpals, and ROUX to have earliest practised the operation, in 1821.



shows that nearly three-fourths were primary, with a mortality of 1.4 per cent.; somewhat over one-fourth, with a mortality of 3.7 per cent., intermediary; and less than 2 per cent. secondary, no fatal cases being returned in the last category.

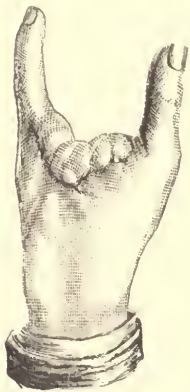

FIG. 742.—Cast of right hand after amputation of the index, middle, and ring fingers for shot injury. *Spec. 438<sup>1</sup>*.

Sixty-eight hundred and seventy cases of ablation of the digits only, gave a mortality of 2 per cent.; four hundred and thirteen cases in which the metacarpo-phalangeal articulations were interested, and ends of metacarpal bones removed, a mortality of 3.2 per cent.; six hundred and nineteen cases in which corresponding metacarpals were removed with fingers, a mortality of 7.6 per cent. An analysis of the determined cases shows that the index was the digit most frequently amputated, next the medius, next the ring finger, next the thumb, and lastly the little finger. Then followed in analogous order the amputation of two or more digits.<sup>1</sup> There was a slight preponderance of operations on the left side, and the amputations on this side show slightly less favorable results than on the right.<sup>2</sup> The results

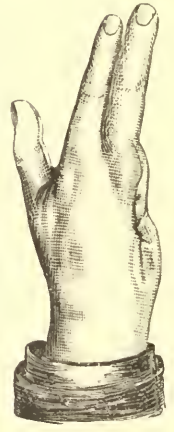

FIG. 743.—Cast of right hand after ablation of the ring and little fingers with their metacarpals. *Spec. 501*.

of many of these varieties of amputation are illustrated by drawings or casts in the Museum. A stump of the medius, after removal of the two distal phalanges, is represented by FIGURE 559, on page 788.

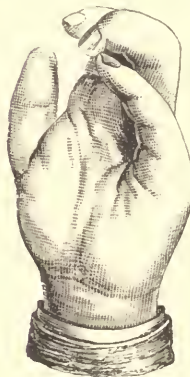

FIG. 744.—Cast after removal of fourth left metacarpal and ring finger. *Spec. 436<sup>2</sup>*.

The appearance of a hand after amputation of the middle finger<sup>3</sup> with the end of the third metacarpal is shown in FIGURE 740. Ablation through the proximal phalanges of the index, medius, and ring fingers<sup>4</sup> is illustrated by FIGURE 741. A palmar view of the results of an amputation of the same digits with the ends of the corresponding metacarpals<sup>5</sup> is presented in FIGURE 742. FIGURE 743 shows ablation of the ring and little fingers;<sup>6</sup> and the results of primary amputation of the ring finger, with removal of half of the fourth metacarpal,<sup>7</sup> is shown in FIGURES 744 and 745. On page 1007 may be found an illustration (FIG. 730) of a hand in which the three

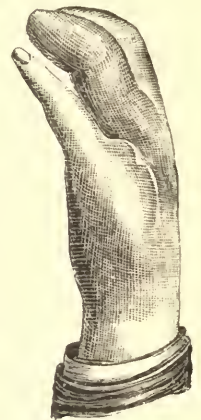


FIG. 745.—Another view of the same specimen. The cast taken six months after operation.

outer fingers with their metacarpals were removed, the thumb, index, and wrist remaining perfectly flexible and useful. Such examples offer great encouragement to the conservative practitioner. Besides these examples of grave mutilations of the hand, the Museum

<sup>1</sup> The distribution of amputations of the fingers per thousand was as follows: Index, 294; medius, 258; ring finger, 122; thumb, 110; little finger, 82. The multiple amputations run: Index and medius, 42; medius and ring fingers, 26; ring and little fingers, 16; thumb and index, 12; index, medius, and ring fingers, 14; medius, ring, and little fingers, 8; thumb, index, and medius, 4; four outer digits, 2; all five digits, 4.

<sup>2</sup> The proportions as ascertained from cases in which the side operated on was determined were: Amputations on the right side, 46.7 per cent., with a mortality rate of 2.3 per cent.; amputations on the left side, 53.3 per cent., with a fatality of 3.7 per cent., which closely agrees with the mean fatality of 2.9 per cent., given in TABLE CXLIV, as deduced from all the cases, whether the side operated on was specified or not.

<sup>3</sup> Case of Private H. Sanford, 44th New York, Wilderness, May 5, 1864. The regimental surgeon, Dr. M. W. TOWNSEND, amputated the middle finger and head of the metacarpal on the field. Assistant Surgeon J. H. ARMSBY, U. S. V., contributed a cast (FIG. 740) of the hand, six months after operation. This soldier was pensioned, and was paid December 4, 1875. It is stated that the ring and little fingers were rigidly contracted.

<sup>4</sup> Case of Private E. Southard, 119th New York, Lost Mountain, June 16, 1864. Primary amputation of three fingers on the field. Assistant Surgeon J. W. S. GOULEY, U. S. A., contributed the cast of the hand (FIG. 741).

<sup>5</sup> Case of Private P. Canavan, 88th New York, Spottsylvania, May 12, 1864. Shell laceration, followed by primary amputation. Acting Assistant Surgeon G. F. SHRADY contributed the cast (FIG. 742). This soldier was pensioned, and died of phthisis August 24, 1874.

<sup>6</sup> Case of Private W. H. Reynolds, 115th New York, near Richmond, October 27, 1864: shot fracture and removal on field of ring and little fingers, with half of the fourth and the whole of the fifth metacarpals. Professor ARMSBY contributed the specimen (FIG. 743).

<sup>7</sup> Case of Private Crans, 187th New York, Chancellorsville, May 3, 1863; amputation on field. Acting Assistant Surgeon G. F. SHRADY presented the cast (FIGS. 744, 745). Pensioner paid December 1, 1875.

possesses many illustrations of very perfect results after amputations of the fingers. In some instances of removal of the medius or ring finger, with the head of the corresponding metacarpal, the deformity is but slightly apparent.

Thirty-one instances were reported of alleged self-inflicted shot mutilations of the fingers. Conscripts seeking to evade service by self-mutilation, commonly attempt to destroy the terminal phalanx of the right index alone, and to inflict as little additional injury as practicable. In analyzing these thirty-one cases, I find more wounds on the left than on the right side, and the thumb and three outer digits together were interested more frequently than the index.<sup>1</sup>

The very important subject of wounds of the palmar arches<sup>2</sup> has been quite fully

<sup>1</sup>This accusation is frequently brought against conscripts or drafted men. This was especially the case after Bantzen and Leipzig, where the frequency of such accidents among the young French recruits excited suspicion. Baron LARREY on these occasions, after careful enquiries, completely vindicated the soldiers. The same accusation has been renewed in the War of 1870-71, by M. SABATIER (See CHENEY, *Aperçu Hist.*, 1874, T. I, p. 419); *Les mutilations volontaires des doigts ont été nombreuses dans les rangs de la garde mobile mais c'est surtout à l'armée de l'Est qu'on en a constaté le plus grand nombre.* Such allegations commonly come from inexperienced surgeons or sensational correspondents, but, after Sedan, so cool and discreet an observer as Dr. W. MACCORMAC was "astonished at the number of soldiers who had got the end of the forefinger shot off. I suppose there were nearly two dozen. Mostly it was the forefinger of the left hand." (*Notes, etc., op. cit.*, p. 19.)

<sup>2</sup>Compare the Articles *Palmaire* and *Panum de la Main*, by PARSNER, in the *Diet. des Sci. Méd.*, en LX, 1819, T. XXXIX, pp. 121, 555. BERNARD'S Article *Plaies de la Main*, in *Diet. de Méd.*, en XXX, 1838, T. XVIII, p. 527. VAN DER HEGGE ZYNEN (L.), *Verwonding der linken Handpalm; aneurysma spurium consecutivum* *gevezen door Krasot*, in *Boerhaave, T. jdschr.*, Gravenhage, 1839, B. I, p. 220. NORRIS (G. W.) *Lacerated Wound of*

*the Palm of the Hand; hemorrhages three weeks after the accident—ligature of the*

*radial artery: return of the hemorrhage on the eighth day after its application.*

*Cure by pressure*, in *Am. Jour. Med. Sci.*, 1839, Vol. XXV, p. 278. LISTON (R.),

*Wound of the Palm—Secondary Hemorrhage—Ligature of the Brachial*, in *The*

*Lancet*, 1840-41, Vol. II, p. 689. GARBE, *Befreiende Verletzung der Hand. Ent-*

*bindung der arteria radialis und ulnaris*, in *Wochenschrift für die gesammte*

*Heilkunde*, Berlin, 1842, p. 139. BUCK (G.), *Lacerated Wound of the Hand—Con-*

*secutive Hemorrhage, Erysipelas: Ligature of the Radial Artery*, in *Annuaire*,

1846, Vol. I, No. IV, p. 78. LAURENT, *Observations suivies de réflexions sur quel-*

*ques hémorragies traumatiques provenant des artères palmaires superficielle et*

*profonde*, *Rapport de M. SEUTIN*, in *Bull. de l'Acad. Roy. de Med. de Belg.*,

Bruxelles, 1852, T. XII, p. 902. DROUET (A. A. A.), *Des plaies et des hémor-*

*ragies traumatiques de la main*, Thèse de Paris, 1855, No. 277. PARKER (L.),

*Case of diffused traumatic aneurism following a wound of the palmar arch, suc-*

*cessfully treated by compression of the Brachial Artery*, in *The Lancet*, 1856, Vol.

II, N. S., p. 679. WEST (J. F.), *Report of a case of wound of the palmar arch*

*followed by traumatic aneurism, in which compression of the brachial artery was*

*successfully employed*, in *The Lancet*, 1857, Vol. I, p. 406. NAIL (A. P. M.),

*Coussures sur le traitement des plaies et des hémorragies traumatiques à la*

*main*, Thèse de Strasbourg, 1860, 2ème série, No. 538. WILLIS (J. P.), *Wound of*

*the Palm of the Hand*, in *Boston Med. and Surg. Jour.*, 1860, Vol. LXIII, p. 416.

NÉLIXON, *Plaie par arme à feu de la paume de la main gauche et des doigts.*

*Hémorragies consécutives au nombre de quatorze. Ligature de l'artère dans la*

*paume, guérison*, in *Gaz. des Hôp.*, Paris, 1862, p. 582. JARJAVAY, *Plaie de l'arcade*

*palmaire profonde; ligature de l'humérale*, in *Gaz. des Hôp.*, Paris, 1863, p. 510.

PHEVEY (G. M. A. E.), *Hémorragies artérielles traumatiques de l'avant bras et*

*de la main*, Thèse de Paris, 1861, No. 89. LE GUERN (J. M.), *Plaies des artères*

*de l'avant bras et de la paume de la main*, Thèse à Paris, 1864, No. 420. He

relates 12 cases, 4 of the ulnar, 4 of the radial at or near the wrist, and 4 of the

palmar arches. In 5 of the wounds of the radial and ulnar, both ends of the bleed-

ing vessel were secured. In 3, one of which proved fatal in spite of consecutive

ligature of the brachial, only the proximal end was secured. Three of the wounds

of the palmar arches were successfully treated by compression, and one by ligation

of the brachial. MAZADE, *Observation d'anévrysme traumatique de la main guéri*

*par la compression digitale intermittente prolongée pendant quatorze jours*, in

*Bull. gén. de théor. méd. et chir.*, Paris, 1834, T. LXVI, p. 411. BUTCHER (R. G.),

*On Wounds of the Palmar Arches and of the Arteries in the Vicinity of the Wrist*

*Joint*, in his *Essays and Reports on Operative and Conservative Surgery*, 1865,

p. 389. BRETZCKE (H.), *Wound of the Palmar Arch: Secondary hemorrhage—*

*ligature of brachial artery: Recovery*, in *The Lancet*, 1867, p. 272. JONES (S.),

*Traumatic Aneurism of the Palm cured by compression*, in *The Lancet*, 1867, Vol.

I, p. 116. FOWLER (J.), *On a case of wounded palm in which two brachial*

*arteries were tied*, in *Med. Times and Gaz.*, 1867, Vol. II, p. 486. RAUFEL-

DESLONGCHAMP (Y.), *Plaie contuse à la paume de la main droite produite par*

*l'explosion d'une cartouche au moment de son introduction dans le fusil chassepot*,

in *Rev. de Méd. de Médr. de Chir., etc.*, Paris, 1869, T. XXII, 3ème ser., p. 309.

MEFFAUER (J. P.), *Wound of the arcus sublimis of the left Hand*, in *Boston Med.*

*and Surg. Jour.*, 1871, Vol. VII, p. 191. HYLKE (J. W.), *Clinical Lecture on a*

*Wound of the Palm*, in *Med. Times and Gaz.*, London, 1875, Vol. I, p. 403. DOL-

BEU, *Leçons sur les plaies de la main et de l'avant-bras*, in *Le Courrier médical*, Paris, 1875, T. XXV, p. 67. See also references on page 437 ante.

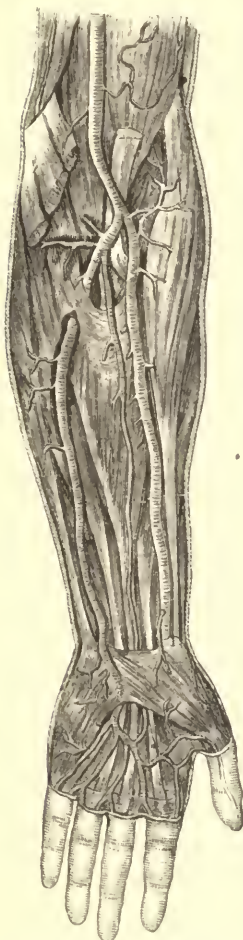

FIG. 746.—Surgical anatomy of the palmar aspect of forearm and hand. [After BOUGERY.]

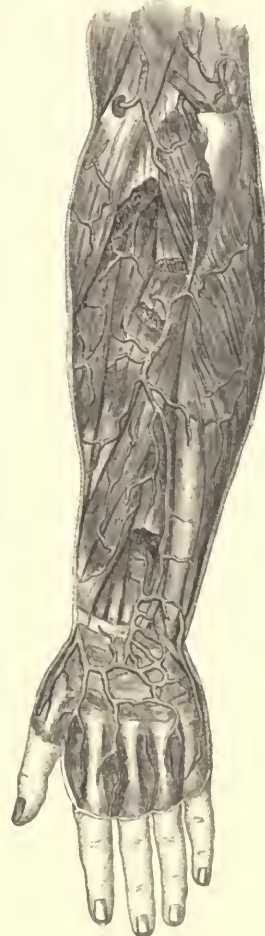

FIG. 747.—Surgical anatomy of the dorsal aspect of the forearm and hand. [After BOUGERY.]



discussed at page 437, in the first Section of this Chapter. I cite here other observations and monographs on the subject, and the excellent drawings (FIGS. 746, 747) of the surgical topography of the hand and forearm of M. Bougery. Bleeding from the palmar arches is very uncommon after shot laceration, the vessels behaving as if treated by torsion. If direct compression, unaided by styptics, does not suffice, the bleeding point should be exposed and double ligatures applied. Experience is adverse to treatment by compression or by ligation of the radial, ulnar, or brachial arteries.

Of the frequency of shot wounds of the hand in battle, it may be observed that in the series of casualty lists that have been selected as most exact, including 105,786 cases of shot wounds reported during the last year of the war, 775 of the number, or 0.7 per cent., were of the wrist; 5,708, or 5.3 per cent., of the metacarpus; 5,287, or 4.9 per cent., of the phalanges or fingers.

The advantage of one or two fingers, or the thumb and a single finger, or even of the index alone, is so great, that much should be hazarded to save them. This doctrine, confirmed by the experience of the War, has been taught by experienced military surgeons from early times. The precept of Ravaton, quoted at the beginning of this Chapter, only re-echoes the teachings of Bellose<sup>1</sup> and LeDran,<sup>2</sup> his predecessors. The pension reports, and the examinations of invalids abroad,<sup>3</sup> with rare exceptions,<sup>4</sup> attest the soundness of these views. Sometimes a middle or a ring finger, powerless or rigidly contracted in the palm, may interfere with prehension and be decidedly an encumbrance; but usually the most deformed digit is found preferable to none.

It is a grateful reflection that while this volume has treated largely of the various modes of operative interference often indispensable in the surgery of war, the general teaching deduced from the multitude of facts tends, not only in regard to the hand, but in relation to every region, to justify and encourage an enlightened conservatism.

<sup>1</sup> BELLOSTE, a military surgeon, who saw much service after Blenheim, Ramilies, Malplaquet, and the other great battles of his time, states (*Le Chirurgien d'Hôpital*, Paris, 3ème éd., 1716, p. 202) that: "From the commencement of the war I have dressed a vast number of hands, perforated, lacerated, or half torn away by missiles that struck them. These accidents are not uncommon in armies. I have also dressed many others simply penetrated by balls or injured by cutting weapons, of which I need not treat particularly. I will only say, that of all the hands I have dressed in these later times, I have always preserved what remained of the part, without the necessity of removing many splinters or losing phalanges, although there might be great laceration and injury of these organs. It is true that in wounds of this sort, as in others, I have avoided frequent dressings, and the use of maturatives, and I avow that spirits of wine has always been my favorite remedy in wounds of the extremities, and those especially of aponeurotic or nervous parts. I know that many of the ancients hold that wounds of the nerves and tendons should be kept open, to allow, as they say, to the issue of matters that might alter the substance of those tissues, but my experience is that it is more salutary for the wounded men to prevent suppuration rather than to promote it, etc."

<sup>2</sup> LEDRAN (HENRI FRANÇOISE) teaches, in his *Traité ou Reflexions tirées de la Pratique sur les Plages d'Armes à feu*, 1787, p. 214, that: "Shot wounds of the metacarpus are susceptible of many complications, both because of the number of bones that may be fractured and on account of the numerous tendons that pass to govern the movements of the fingers. These tendons when lacerated inflame, and their inflammation is usually propagated to the muscles of the forearm, when more or less considerable swelling occurs, and often interstitial abscesses. This seldom supervenes without the annular ligament, similar in structure to the tendon at the wrist, swelling also more or less." He adds that early free incisions are indispensable—and free drainage; but that it is desirable not to divide the annular ligament save under very urgent circumstances. Of shot wounds of the fingers he remarks (*op. cit.*, p. 216): "It is rarely that a shot injury of one of the fingers fails to carry away the finger wholly or in part. These wounds are often accompanied by inflammation and abscesses extending to the hand and also to the forearm. The fingers are so necessary to man that every effort for their conservation should be made; and supposing a fracture with wound, we should act as if it were an arm or thigh, the bones of which are seldom clearly fractured. Nevertheless, it is sometimes necessary to amputate the fingers, either at the articulation with the phalanges, or in the middle of a proximal phalanx above the wound."

<sup>3</sup> PIROGOFF (N.) (*Grundzüge der Allgemeinen Kriegschirurgie*, Leipzig, 1864, S. 808): "Clean perforations of the metacarpus we rarely observed; generally the wounded arrived at the field hospitals with hands mutilated in a variety of ways by shell. And yet these injuries, although frequently accompanied by large loss of substance and frightful in appearance, do not offer a worse prognosis than the injuries from small shot, as, for instance, a clean perforance of the hand by a bullet. Numerous examples of conservation of one-third of the hand with only two or even one finger only prove this. . . . Even though the preserved fingers are ever so stiff and inflexible, and resembling little sticks more than fingers, they nevertheless prove themselves afterward very serviceable little sticks."

<sup>4</sup> BERTHOLD (*Stat. der durch den Feldzug 1870-71, Invalide gewordenen Mannschaften des 10 Armee-Corps*, in *Deutsche Mil.-ärztl. Zeitschrift*, 1872, B. I. S. 518) gives an account of 158 invalids for shot injuries of the hand: in 9 instances amputation, and in 13 exarticulation of the fingers and phalanges had been performed. Dr. BERTHOLD observes: "From the certificates it is apparent that a large number of invalids were pensioned on account of a single stiff and flexed finger being bent upon the palm of the hand. Such abnormal positions of single fingers, generally the results of unimportant injuries, hinder necessarily the use of the hand, and prejudice the handling of weapons and the performance of manual labor seriously, while a disarticulation performed at the proper time would have left the hand undoubtedly useful. It is to the interest of the wounded, as well as of the Government, that the exarticulation of single phalanges or fingers be made more frequently."

# LIST OF REPORTERS AND OPERATORS.

	Page.		Page.	
ABADIE, E. H. ....	708, 724, 973	ARMSBY, J. H. ....	181, 288, 331, 549,	
ABBOTT, C. ....	974	552, 561, 689, 691, 692, 735, 761, 911, 937	BALTZELL, W. H. ....	870
ABBOTT, R. O. ....	566	ARMSTRONG, D. H. ....	771	
ABBOTT, W. W. ....	557	ARMSTRONG, H. A. ....	876	
ABERNATHY, R. T. ....	765	ARMSTRONG, J. A. ....	765	
ACHESON, J. C. ....	670	ARMSTRONG, L. G. ....	410, 547	
ADAIR, J. T. ....	701	ARNDT, P. S. ....	857	
ADAMS, J. R. ....	750	ARNER, T. ....	709	
ADAMS, S. ....	228, 281, 398	ARNOLD, W. ....	143	
ADAMS, W. S. ....	109, 219,	ARRINGTON, W. J. ....	681	
242, 420, 512, 539, 561, 576, 757, 930		ARTAUD, T. ....	760, 958, 983	
ADAMS, Z. B. ....	744	ARTER, J. R. ....	316, 977	
ADLER, J. M. ....	666, 367, 371	ARTHUR, C. S. ....	914	
ADOLPH'S, P. ....	688, 1010	ARTHUR, J. P. ....	193, 223, 781, 786, 978, 982, 983	
AGARD, A. H. ....	79, 350, 580	ASH, J. ....	726	
AGNEW, A. B. ....	919	ASHHURST, J., Jr. ....	441, 761, 779, 981, 990	
AGNEW, J. P. ....	755, 760, 984, 988	ASHMUN, G. C. ....	523	
AHL, D. ....	822, 830	ASHTON, B. B. ....	314	
AIKEN, J. ....	77, 410, 414, 416, 511, 575	ATKINSON, A. ....	704, 743	
AINSWORTH, F. S. ....	628, 632, 945, 1008	ATKINSON, L. E. ....	705	
AKIN, W. ....	733, 894	ATLEE, W. F. ....	353, 409, 451, 875	
ALBRIGHT, F. G. ....	711	ATWATER, E. W. ....	354	
ALDEN, C. H. ....	261, 686, 755	ATWATER, H. H. ....	817	
ALEXANDER, C. ....	621	ATWOOD, J. P. ....	828	
ALEXANDER, C. T. ....	548, 648, 778, 182	ATWOOD, R. N. ....	768	
ALEXANDER, J. H. ....	972	AUSTIN, H. C. ....	507	
ALEXANDER, S. J. ....	453	AUSTIN, W. S. ....	530	
ALLAIRE, P. A. ....	989	AVERDICK, H. G. ....	730	
ALLEN, C. G. ....	161, 708, 721	AVERY, G. W. ....	83, 688, 929, 933	
ALLEN, C. H. ....	977	AVERY, J. ....	703	
ALLEN, C. L. ....	154, 408, 887, 926, 956, 1002, 1007	AVRE, O. ....	633, 706, 870	
ALLEN, G. T. ....	188	AYRES, D. C. ....	532, 547, 556	
ALLEN, H. ....	53, 71, 133, 145,	AYRES, S. C. ....	198, 135, 693, 771, 182, 984	
147, 240, 230, 325, 449, 451, 461, 494, 512,		AZPELL, T. F. ....	983	
578, 579, 587, 637, 689, 717, 755, 756, 798,		BABB, T. ....	794	
773, 782, 790, 817, 870, 877, 880, 920, 954,		BABCOCK, M. T. ....	557, 678	
957, 958, 959, 961, 982, 983, 984, 985, 990		BABCOCK, W. A. ....	726, 743	
ALLEN, N. ....	934	BACHE, D. ....	45, 289, 353	
ALLEN, S. J. ....	408, 410, 412, 637, 817, 936	BACHE, T. H. ....	102, 197, 286, 312, 365, 457	
ALLEN, W. E. ....	764	BACKUS, A. ....	307, 598	
ALLEY, W. B. ....	574, 617	BACKUS, T. W. ....	379	
ALLISON, T. H. ....	888, 889	BACON, C., Jr. ....	957, 1006	
ALLISTER, E. ....	66	BACON, F. ....	267, 413, 576, 640, 726, 789, 958	
ALSDORF, D. F. ....	445, 451, 1002	BACON, J. G. ....	266, 671	
ALSTON, — ....	153	BACON, J. H. ....	977	
AMES, C. E. ....	944	BADGER, G. ....	381, 990	
AMES, F. J. ....	245	BADGER, W. ....	760	
AMSDEN, E. ....	307, 408, 707, 742	BAGLEY, D. ....	194, 296, 442, 706, 971	
ANAWALT, J. W. ....	712	BAILLY, J. R. ....	76, 534	
ANDERSON, E. A. ....	275	BAILLY, T. P. ....	605	
ANDERSON, H. P. ....	412	BAILLY, W. H. ....	937	
ANDERSON, J. V. ....	312	BAILEY, W. W. ....	836	
ANDERSON, W. ....	757	BAKER, J. ....	409, 1001	
ANDERSON, W. A. ....	373, 961	BAKER, J. S. ....	583	
ANDERSON, W. W. ....	778	BAKER, P. B. ....	603	
ANDREWS, A. W. K. ....	760	BAKER, W. ....	958	
ANDREWS, E. ....	534, 564, 592, 594, 778, 852, 969	BALDWIN, — ....	570	
ANDREWS, E. E. ....	815	BALDWIN, G. R. ....	363, 942	
ANDREWS, J. ....	628	BALDWIN, L. K. ....	307, 443, 592, 765, 957, 962, 987, 990	
ANDRUS, C. H. ....	676, 722,	BALDWIN, M. ....	470, 760, 990	
733, 766, 855, 857, 941, 979		BALL, A. ....	687, 702, 722, 727, 743, 756, 942	
ANGELL, J. W. ....	676	BALL, E. A. ....	18	
ANSELL, A. ....	510, 578, 595, 688, 768, 769, 982, 987	BALLOU, N. E. ....	551, 553	
ANTISELL, T. ....	21, 244, 311,	BALLOU, N. H. ....	741	
460, 466, 511, 553, 586, 592, 699,		BALSER, W. ....	67, 749,	
734, 764, 848, 876, 959, 1000, 1009		761, 765, 769, 874, 882, 946, 982		
		BALWELL, E. ....	84, 145, 355, 557, 620, 701, 702,	
		721, 723, 724, 729, 730, 731, 732, 742, 946, 976		
		BAUDRY, J. K. ....	786	
		BAUER, L. ....	835	
		BAUGH, T. W. ....	692	
		BAUMGRAS, P. ....	886	
		BAXTER, D. P. ....	605	
		BAXTER, J. B. G. ....	140, 723, 773	
		BAXTER, J. H. ....	417, 983, 984	
		BAXTER, S. ....	789	
		BAYARD ....	852	
		BAYLOR, W. L. ....	35, 217,	
		413, 437, 454, 460, 680, 706, 874		
		BEACH, J. N. ....	704, 763	
		BEALE, J. W. ....	604	
		BEASLEY, G. F. ....	144	
		BEATTY, J. E. ....	703, 730, 948, 974	
		BEAVER, D. L. ....	214, 412, 1000	
		BECK, E. W. H. ....	550, 551, 556	
		BECK, J. S. ....	186, 310, 930	
		BECK, S. L. ....	1004	
		BEEBE, D. C. ....	308, 576, 580, 791	
		BEEBE, G. D. ....	688	
		BEECH, W. H. ....	533, 539	



	Page.		Page.		Page.
BEECH, J. H.	700, 709, 711, 714, 729, 732, 968, 972, 976	BLAKER, G. H.	744	BRANNOCK, J. M.	601
BELDEN, A. P.	468	BLAKESLEE, T.	438	BRATTON, G.	1005
BELLA, D. C.	984	BLANCHARD, E.	710	BRAUN, L.	968
BELL, D. H.	779	BLAND, D. W.	615, 628, 939	BREAKEY, W. F.	85
BELL, J.	341, 756	BLIGH, J. W.	772, 990	BRECK, S. T.	944
BELL, J. B.	45, 95, 484, 507, 739, 927, 1007	BLISS, D. W.	16, 77, 96, 136, 140, 186, 187, 214, 254, 279, 280, 283, 294, 397, 318, 336, 366, 369, 416, 440, 442, 448, 466, 468, 469, 470, 487, 490, 494, 508, 537, 538, 539, 552, 553, 559, 564, 576, 577, 579, 584, 586, 587, 592, 644, 647, 701, 703, 731, 744, 746, 755, 756, 761, 763, 765, 769, 771, 773, 774, 779, 781, 786, 830, 847, 856, 862, 963, 984, 987, 988	BRECKENRIDGE, R. J.	720
BELL, J. J.	765	BLISS, E. L.	159, 169, 551	BREED, B. B.	104, 243, 245, 324, 329, 421, 448, 453, 478, 480, 485, 496, 538, 553, 572, 682, 711, 784, 817, 910, 962, 974, 979, 988, 1008
BELL, W.	521	BLISS, L. W.	170, 525, 680, 710, 864, 943, 945	BREED, W. M.	440, 475, 692
BELLANGEÉ, J. B.	72, 762	BLISS, Z. E.	214, 289, 327, 353, 407, 541, 567, 579, 585, 627, 667, 763, 768, 773, 818, 853, 860	BREKES, D.	765
BELLES, J. T.	100	BLOCK, M.	742	BRENEMAN, E. DeW.	141, 731, 760, 878, 987, 1004
BELLINGER, M.	602, 730	BLUNT, N. F.	721, 724	BRENNAN, G. M.	733, 739, 741
BELLOWS, C. J.	531, 707, 857	BLUTHARDT, T. J.	796, 984	BRENTON, J. L.	623, 848
BELLOWS, H. M.	489, 781, 928	BOARDMAN, C. H.	1004	BRETT, B. C.	479, 585
BELLOWS, J. W.	88, 447	BOARDMAN, J.	644	BREYARD, E. L.	624
BELTON, T. F.	773, 786, 986	BOCKEE, J.	357, 757, 878	BREWER, F.	498
BENCE, R. F.	620	BOGUE, R. G.	592, 597, 703, 733, 777	BREWER, J. W.	469
BENDOLL, H.	679, 944	BOISE, E.	289, 667	BREWER, L. A.	948
BENEDICT, A. C.	972	BOISSNOT, J. M.	757, 981	BREY, J.	642, 643, 650
BENEDICT, G.	976	BOND, B. N.	679, 719, 725, 744, 941, 942, 944, 945, 948	BRICKELL, W. E.	601, 602
BENEDICT, M. D.	313, 399, 463, 555, 560, 760, 885, 935, 971, 976	BOND, T. P.	720	BRICKETT, G. E.	446, 484, 633, 678, 757, 785, 789, 971, 988
BENJAMIN, M. N.	480, 644, 765, 986	BONINE, E. J.	701, 705, 713, 726, 731	BRIDGE, W. W.	150, 934
BENNET, G. C.	170	BONNER, S. P.	342, 685, 700, 701, 702, 704, 707, 713, 723, 730, 737, 940, 941, 944, 948, 952	BRIGGS, G. W.	781, 950
BENNETT, J.	495, 707, 731, 952, 979	BONNEY, M. H.	407	BRINT, J. S.	602
BENNETT, M. L.	327	BONTECOU, R. B.	393, 147, 223, 288, 309, 341, 351, 413, 417, 444, 445, 457, 458, 468, 482, 483, 488, 506, 509, 521, 524, 536, 527, 528, 536, 542, 543, 545, 549, 594, 566, 569, 571, 575, 577, 578, 586, 587, 589, 592, 597, 642, 643, 649, 650, 667, 672, 677, 682, 690, 757, 760, 761, 768, 773, 781, 838, 874, 875, 876, 878, 879, 882, 883, 887, 890, 924, 925, 927, 929, 930, 937, 982, 986, 987, 1000	BRINTON, D. G.	352, 436, 466, 594, 733, 937
BENNETT, W. C.	523, 920	BONTECOU, R. B.	393, 147, 223, 288, 309, 341, 351, 413, 417, 444, 445, 457, 458, 468, 482, 483, 488, 506, 509, 521, 524, 536, 527, 528, 536, 542, 543, 545, 549, 594, 566, 569, 571, 575, 577, 578, 586, 587, 589, 592, 597, 642, 643, 649, 650, 667, 672, 677, 682, 690, 757, 760, 761, 768, 773, 781, 838, 874, 875, 876, 878, 879, 882, 883, 887, 890, 924, 925, 927, 929, 930, 937, 982, 986, 987, 1000	BRINTON, J. B.	755
BENNSCHWEILER, G. L.	970	BONNE, M. H.	407	BRINTON, J. H.	77, 87, 91, 96, 146, 232, 258, 293, 294, 329, 363, 364, 366, 391, 410, 429, 430, 431, 538, 575, 576, 578, 580, 643, 736, 786
BENSON, H.	42	BONTECOU, R. B.	393, 147, 223, 288, 309, 341, 351, 413, 417, 444, 445, 457, 458, 468, 482, 483, 488, 506, 509, 521, 524, 536, 527, 528, 536, 542, 543, 545, 549, 594, 566, 569, 571, 575, 577, 578, 586, 587, 589, 592, 597, 642, 643, 649, 650, 667, 672, 677, 682, 690, 757, 760, 761, 768, 773, 781, 838, 874, 875, 876, 878, 879, 882, 883, 887, 890, 924, 925, 927, 929, 930, 937, 982, 986, 987, 1000	BRINTON, W. B.	743
BENSON, J.	785	BONNE, M. H.	407	BRISBANE, N. B.	628
BENSON, W. R.	734	BONTECOU, R. B.	393, 147, 223, 288, 309, 341, 351, 413, 417, 444, 445, 457, 458, 468, 482, 483, 488, 506, 509, 521, 524, 536, 527, 528, 536, 542, 543, 545, 549, 594, 566, 569, 571, 575, 577, 578, 586, 587, 589, 592, 597, 642, 643, 649, 650, 667, 672, 677, 682, 690, 757, 760, 761, 768, 773, 781, 838, 874, 875, 876, 878, 879, 882, 883, 887, 890, 924, 925, 927, 929, 930, 937, 982, 986, 987, 1000	BROCK, J. W.	529, 747
BENTLEY, E.	92, 135, 140, 142, 168, 183, 216, 219, 229, 260, 265, 266, 287, 288, 289, 306, 317, 330, 411, 447, 452, 457, 470, 487, 529, 541, 554, 559, 562, 576, 577, 579, 586, 587, 591, 592, 617, 638, 642, 644, 678, 684, 685, 716, 721, 736, 739, 755, 756, 760, 773, 774, 849, 874, 882, 914, 936, 974, 982, 983, 984, 986, 987	BONNE, M. H.	407	BROCKWAY, A. N.	288, 306, 546, 756, 760, 768, 773, 787, 987
BENTON, W. H.	605	BONTECOU, R. B.	393, 147, 223, 288, 309, 341, 351, 413, 417, 444, 445, 457, 458, 468, 482, 483, 488, 506, 509, 521, 524, 536, 527, 528, 536, 542, 543, 545, 549, 594, 566, 569, 571, 575, 577, 578, 586, 587, 589, 592, 597, 642, 643, 649, 650, 667, 672, 677, 682, 690, 757, 760, 761, 768, 773, 781, 838, 874, 875, 876, 878, 879, 882, 883, 887, 890, 924, 925, 927, 929, 930, 937, 982, 986, 987, 1000	BROOKES, J.	890
BERGEN, S. H.	356, 364	BONNE, M. H.	407	BROSIOUS, G. A.	727
BERNAYS, T. G.	829	BONTECOU, R. B.	393, 147, 223, 288, 309, 341, 351, 413, 417, 444, 445, 457, 458, 468, 482, 483, 488, 506, 509, 521, 524, 536, 527, 528, 536, 542, 543, 545, 549, 594, 566, 569, 571, 575, 577, 578, 586, 587, 589, 592, 597, 642, 643, 649, 650, 667, 672, 677, 682, 690, 757, 760, 761, 768, 773, 781, 838, 874, 875, 876, 878, 879, 882, 883, 887, 890, 924, 925, 927, 929, 930, 937, 982, 986, 987, 1000	BROUGH, T. W.	969
BERRY, W.	939, 977	BONNE, M. H.	407	BROUGH, D. R.	468, 688, 763, 772, 787
BERRY, W. B.	941, 944	BONTECOU, R. B.	393, 147, 223, 288, 309, 341, 351, 413, 417, 444, 445, 457, 458, 468, 482, 483, 488, 506, 509, 521, 524, 536, 527, 528, 536, 542, 543, 545, 549, 594, 566, 569, 571, 575, 577, 578, 586, 587, 589, 592, 597, 642, 643, 649, 650, 667, 672, 677, 682, 690, 757, 760, 761, 768, 773, 781, 838, 874, 875, 876, 878, 879, 882, 883, 887, 890, 924, 925, 927, 929, 930, 937, 982, 986, 987, 1000	BROWN, —	728, 733, 765
BERRYMAN, J.	838	BONNE, M. H.	407	BROWN, B. P.	616
BEVIER, J. D.	702	BONTECOU, R. B.	393, 147, 223, 288, 309, 341, 351, 413, 417, 444, 445, 457, 458, 468, 482, 483, 488, 506, 509, 521, 524, 536, 527, 528, 536, 542, 543, 545, 549, 594, 566, 569, 571, 575, 577, 578, 586, 587, 589, 592, 597, 642, 643, 649, 650, 667, 672, 677, 682, 690, 757, 760, 761, 768, 773, 781, 838, 874, 875, 876, 878, 879, 882, 883, 887, 890, 924, 925, 927, 929, 930, 937, 982, 986, 987, 1000	BROWN, D. J.	764
BEWLEY, C. H.	445	BONNE, M. H.	407	BROWN, F.	785
BICKETT, W. W.	757	BONTECOU, R. B.	393, 147, 223, 288, 309, 341, 351, 413, 417, 444, 445, 457, 458, 468, 482, 483, 488, 506, 509, 521, 524, 536, 527, 528, 536, 542, 543, 545, 549, 594, 566, 569, 571, 575, 577, 578, 586, 587, 589, 592, 597, 642, 643, 649, 650, 667, 672, 677, 682, 690, 757, 760, 761, 768, 773, 781, 838, 874, 875, 876, 878, 879, 882, 883, 887, 890, 924, 925, 927, 929, 930, 937, 982, 986, 987, 1000	BROWN, F. H.	103, 784, 831, 988
BICKFORD, A. W.	146	BONNE, M. H.	407	BROWN, G. M. A.	267
BIDLACK, W. W.	525, 731, 771, 783, 875	BONTECOU, R. B.	393, 147, 223, 288, 309, 341, 351, 413, 417, 444, 445, 457, 458, 468, 482, 483, 488, 506, 509, 521, 524, 536, 527, 528, 536, 542, 543, 545, 549, 594, 566, 569, 571, 575, 577, 578, 586, 587, 589, 592, 597, 642, 643, 649, 650, 667, 672, 677, 682, 690, 757, 760, 761, 768, 773, 781, 838, 874, 875, 876, 878, 879, 882, 883, 887, 890, 924, 925, 927, 929, 930, 937, 982, 986, 987, 1000	BROWN, H. E.	452, 692, 1005
BIGELOW, C. P.	397, 470, 494, 757, 760, 764	BONNE, M. H.	407	BROWN, H. W.	604, 605
BIGELOW, H. J.	490, 667, 690	BONTECOU, R. B.	393, 147, 223, 288, 309, 341, 351, 413, 417, 444, 445, 457, 458, 468, 482, 483, 488, 506, 509, 521, 524, 536, 527, 528, 536, 542, 543, 545, 549, 594, 566, 569, 571, 575, 577, 578, 586, 587, 589, 592, 597, 642, 643, 649, 650, 667, 672, 677, 682, 690, 757, 760, 761, 768, 773, 781, 838, 874, 875, 876, 878, 879, 882, 883, 887, 890, 924, 925, 927, 929, 930, 937, 982, 986, 987, 1000	BROWN, J. A.	231, 346, 566
BIGELOW, J. A.	719, 769	BONNE, M. H.	407	BROWN, J. B.	538, 605
BIGELOW, J. K.	407, 714, 725, 726, 755, 926, 949	BONTECOU, R. B.	393, 147, 223, 288, 309, 341, 351, 413, 417, 444, 445, 457, 458, 468, 482, 483, 488, 506, 509, 521, 524, 536, 527, 528, 536, 542, 543, 545, 549, 594, 566, 569, 571, 575, 577, 578, 586, 587, 589, 592, 597, 642, 643, 649, 650, 667, 672, 677, 682, 690, 757, 760, 761, 768, 773, 781, 838, 874, 875, 876, 878, 879, 882, 883, 887, 890, 924, 925, 927, 929, 930, 937, 982, 986, 987, 1000	BROWN, J. J.	961
BILL, C. H.	857	BONNE, M. H.	407	BROWN, J. L.	984
BILL, J. H.	587, 592, 877, 885, 889, 890	BONTECOU, R. B.	393, 147, 223, 288, 309, 341, 351, 413, 417, 444, 445, 457, 458, 468, 482, 483, 488, 506, 509, 521, 524, 536, 527, 528, 536, 542, 543, 545, 549, 594, 566, 569, 571, 575, 577, 578, 586, 587, 589, 592, 597, 642, 643, 649, 650, 667, 672, 677, 682, 690, 757, 760, 761, 768, 773, 781, 838, 874, 875, 876, 878, 879, 882, 883, 887, 890, 924, 925, 927, 929, 930, 937, 982, 986, 987, 1000	BROWN, J. M.	317, 585, 672, 729, 781, 982
BILLINGS, A. J.	712, 973	BONNE, M. H.	407	BROWN, M. M.	527
BILLINGS, J. S.	183, 223, 234, 326, 367, 540, 542, 557, 585, 587, 623, 638, 639, 708, 814, 833, 852, 879, 987	BONTECOU, R. B.	393, 147, 223, 288, 309, 341, 351, 413, 417, 444, 445, 457, 458, 468, 482, 483, 488, 506, 509, 521, 524, 536, 527, 528, 536, 542, 543, 545, 549, 594, 566, 569, 571, 575, 577, 578, 586, 587, 589, 592, 597, 642, 643, 649, 650, 667, 672, 677, 682, 690, 757, 760, 761, 768, 773, 781, 838, 874, 875, 876, 878, 879, 882, 883, 887, 890, 924, 925, 927, 929, 930, 937, 982, 986, 987, 1000	BROWN, O.	1003
BINGHAM, J. G.	703	BONNE, M. H.	407	BROWN, R. B.	355
BIRDSALL, S.	462	BONTECOU, R. B.	393, 147, 223, 288, 309, 341, 351, 413, 417, 444, 445, 457, 458, 468, 482, 483, 488, 506, 509, 521, 524, 536, 527, 528, 536, 542, 543, 545, 549, 594, 566, 569, 571, 575, 577, 578, 586, 587, 589, 592, 597, 642, 643, 649, 650, 667, 672, 677, 682, 690, 757, 760, 761, 768, 773, 781, 838, 874, 875, 876, 878, 879, 882, 883, 887, 890, 924, 925, 927, 929, 930, 937, 982, 986, 987, 1000	BROWN, R. E.	442

LIST OF REPORTERS AND OPERATORS.

III

	Page.		Page.		Page.
BUCHANAN, J. A.	781	CANTRELL, J. H.	88	CHRISTY, H. C.	969
BUCHANAN, J. G.	968	CANTWELL, J. Y.	537, 707, 769, 726, 730	CHUBBUCK, H. S.	850
BUCHANAN, W. F.	416	CAPERS, L. G.	602	CHURCH, E.	989
BUCHER, C. A.	751	CARHART, G. L.	182, 676, 679, 712, 864, 941, 974	CHURCH, W.	729
BUCK, E. J.	558, 598, 678, 684, 717, 942, 949	CARLE, C.	683, 710, 745	CHURCH, W. H.	602, 819
BUCK, G. A.	638, 766	CARLTON, C. A.	407	CHURCHILL, A.	549, 558, 747, 997
BUCK, H. A.	106, 726	CARNOCHAN, J. M.	860	CHURCHMAN, H. J.	252
BUCK, S. S.	943	CAROTHERS, A. E.	69, 76, 189, 678, 679, 946	CLAIBORNE, J. H.	530
BUCK, T.	724	CARPENTER, C. H.	155, 169	CLAPP, F.	983
BU'CK, W.	704, 713, 714, 970, 976	CARPENTER, H. W.	680	CLAPP, W. A.	272, 550
BUCKINGHAM, A.	692	CARR, G. W.	544, 707, 955	CLARK, A.	711
BUCKMAN, E. D.	765	CARRIER, C. W.	764, 768, 985, 986	CLARK, A. J.	976
BUCKMAN, J. H.	672	CARRIER, J.	355	CLARK, A. M.	71, 989
BUCKMAN, J. W.	940	CARRINGTON, W. A.	601	CLARK, A. P.	289, 525
BUCELL, E. P.	675, 742, 757, 971	CARROLL, R. W. W.	765, 788	CLARK, C. C. P.	145, 530
BUFEL, W. P.	530	CARROLL, T.	985	CLARK, C. J.	506, 603, 604
BUGBEE, A. G.	778	CARROLL, W.	644, 757, 773	CLARK, C. M.	532, 536,
BUIST, J. R.	605, 714, 786	CARTER, C.	922	556, 558, 572, 582, 594, 617, 675, 677, 678, 680,	
BULLARD, E. C.	911, 990	CARTER, J. S.	478	714, 726, 737, 738, 737, 743, 785, 942, 970, 976	
BULLEN, C. P.	579, 983	CARTER, N. M.	731	CLARK, E. A.	687, 923, 989, 1007
BUNDY, S. H.	970	CARYALLO, C.	217, 242, 248, 698, 777	CLARK, E. P.	622
BURCHFIELD, J. P.	728, 742	CASE, M.	722, 744	CLARK, H.	847
BURDETT, S. L.	969	CASE, S. H.	88	CLARK, H. C.	300
BURDICK, J. P.	142, 535	CASEY, F. P.	677	CLARK, H. G.	667
BURG, W.	703	CASEY, W. B.	771	CLARK, H. K.	555, 568
BURKE, G. W.	496, 689, 711	CASS, J.	397, 768, 981, 983	CLARK, J. H.	91, 273, 300, 315
BURKE, T. N.	757, 921	CASSELBERRY, J.	639, 726	CLARK, P. H.	1000
BURKE, W. R.	166, 266, 714, 729	CASTLE, T. B.	756, 765, 773, 789	CLARK, R.	366
BURMEISTER, F. F.	165, 307, 447, 567, 590	CATLIN, B. S.	711	CLARK, R. R.	726, 971
BURNELL, B.	779	CAVENAUGH, W. E.	693	CLARK, R. W.	677
BURNHAM, W.	373	CHADDOCK, G.	495, 531,	CLARK, S. T.	953
BURNHAM, W. S.	146	598, 623, 676, 678, 680, 684, 705,	741, 717, 854, 864, 940, 942, 946	CLARK, W. C.	955
BURNS, J. B.	713, 738	CHAFFEE, C. C.	735	CLARK, W. D.	358, 961
BURNS, J. T.	287	CHAILLÉ, S. E.	601, 602, 897, 1012	CLARK, W. W.	989
BURR, D. S.	818	CHALMERS, H. C.	277, 601, 603	CLARKE, D.	182, 253, 406
BURR, W. J.	410, 414,	CHAMBERLAIN, C. N.	251, 253,	CLARY, G.	710, 724
416, 578, 583, 624, 625, 689, 737, 738, 759, 971		413, 489, 699, 714, 863, 961, 978		CLAUDE, A.	759, 774
BURRALL, G. W.	1002	CHAMBERLAIN, D. A.	412, 726	CLEARY, P. J. A.	406, 757
BURRITT, H. L. W.	71, 79, 249,	CHAMBERLAIN, D. S.	705	CLEARY, W.	765
290, 374, 551, 557, 580, 591, 571, 781		CHAMBERLAIN, O.	943	CLEEMAN, R. A.	491, 784, 791
BURT, A.	711	CHAMBERLAIN, W. M.	270, 356,	CLEMENT, T. R.	104
BURTON, J. R.	560	367, 438, 495, 568, 670, 682		CLEMENTS, B. A.	318, 563,
BUSH, D.	983	CHAMBERS, W. B.	328, 647, 712, 745, 981	567, 586, 713, 745, 871, 875, 889, 935	
BUSSEY, E.	347	CHAMBERS, W. M.	436, 455	CLENDENIN, W.	331, 413, 786, 982
BUTCHER, B. F.	140, 687, 787	CHAMBLISS, J.	603, 606	CLENDENIN, W. H.	508
BUTLER, C. H.	969	CHAMP, G. W.	763	CLEVELAND, W. K.	640, 764, 769, 871, 875, 986
BUTLER, J. H.	973, 983	CHANDLER, C. M.	309, 727, 729, 743	CLIFF, C. B.	777
BUTLER, W. H.	291, 494, 641, 925	CHAPEL, A.	51, 315, 319, 359, 360, 500, 773, 788	CLIFTON, J. B.	602
BUTTERBAUGH, J.	638	CHAPEL, E. S.	857	CLINGER, P. S.	509, 1002, 1004
BUTTERFIELD, H. L.	743	CHAPEL, J. L.	553	CLOAK, B.	99, 408, 442, 812
BUTTON, J.	601	CHAPIN, A. B.	988	CLYMER, M.	223, 329, 538, 830
BUTTON, G. B.	733	CHAPIN, S. P.	23, 93, 251,	COALE, R. W.	436, 471, 679, 684, 756, 784, 958
BUXTON, B. F.	704	534, 618, 710, 713, 735, 741, 885, 891, 985		COATSWORTH, G.	765
BUZZELL, A. J. H.	710, 742, 745	CHAPMAN, J.	530, 531, 558, 680, 709, 711, 729	COATSWORTH, J. W.	984
BYERS, F. W.	220	CHASE, B. S.	142, 706	COBB, A. C.	790
BYERS, G.	452	CHASE, D. D.	355	COCHRAN, W. E.	692
BYINGTON, W. C.	707	CHASE, E. G.	722, 976	CODMAN, W. S.	921
BYRNE, C. C.	293, 328, 687, 688, 708, 714,	CHASE, H.	86, 341, 361, 412, 415, 566, 838	COE, A. S.	865, 529,
760, 876, 883, 970, 971, 981, 985, 987, 1003		CHASE, H. M.	1004	556, 699, 701, 705, 731, 732, 735, 743, 976, 977	
CABELL, J. L.	443, 601, 602, 603, 605, 896, 1005	CHASE, I. S.	1001	COFFEE, A. H.	834
CABOT, S.	101, 273	CHAZELL, J. P.	605	COFFMAN, V. H.	741, 745, 764
CADDEN, C. W.	45	CHEEVER, D. W.	158, 468, 535, 760, 872	COGGSWELL, G. B.	680, 683,
CADY, C. E.	707, 742	CHENEY, B. H.	692	702, 745, 749, 856, 947, 972, 977	
CADY, F. A.	214	CHERBONNIER, A. V.	65, 84, 241,	COGGSWELL, M. F.	22, 280, 289
CADY, W. F.	732	291, 760, 954, 958, 963, 984, 987, 1001		COLBURN, A. W.	232, 648
CAHOON, C. C.	309	CHESLEY, G. A.	469, 755, 760	COLBY, G. W.	532, 630
GAIN, J. S.	604	CHESSMORE, A. H.	706, 734, 744, 970, 974, 977	COLBY, J.	265, 361
CALDWELL, D. G.	958	CHESTNUT, T.	1003	COLE, H. B.	453, 759
CALDWELL, T. J.	352	CHILD, W. A.	223, 330, 419, 705, 713, 730	COLEGROVE, J. B.	438, 591
CALHOUN, J. T.	150, 315,	CHILDS, W.	723	COLEMAN, —	973
336, 568, 638, 860, 970, 971		CHISOLM, J. J.	251, 274, 279	COLEMAN, A.	146
CAMAC, W.	148, 369, 919	CHITTENDEN, G. F.	741	COLEMAN, H.	710, 727
CAMBURN, J.	702, 1008	CHOATE, D.	407, 412	COLEMAN, J. B.	346, 360, 888
CAMPBELL, A. B.	266, 311	CHRIST, T.	271, 488, 731, 742, 851, 952, 971	COLESCOTT, T. W.	166, 167, 365
CAMPBELL, C. N.	453, 530	CHRISTIAN, R. A.	225, 466, 977	COLLAMORE, G. A.	571, 684, 700, 940, 947
CAMPBELL, J.	971	CHRISTMAS, H. R.	1012	COLLINS, J.	227, 367, 369, 371,
CANADAY, J. T.	253	CHRISTY, G. B.	757, 765	387, 407, 412, 447, 538, 691, 871, 884, 885, 924	



	Page.		Page.		Page.
COLLINS, W. A.	837, 868	CROSBY, T. R.	52, 324,	DENHAM, S. N.	332
COLOSDIAN, S.	958		326, 328, 449, 476, 488, 541, 547,	DENIG, C. E.	82, 692, 731, 764, 778
COLTON, C. M.	1000		569, 687, 786, 817, 974, 984, 988	DENISE, J. C.	778
COMFORT, J. J.	570, 941, 947, 968	CROSIER, E. S.	356, 550	DERBY, G.	14, 45, 46, 52,
COMINGS, B. H.	731	CROSSLEY, G. W.	679, 766		79, 522, 524, 635, 719, 728, 744, 909, 1008
COMSTOCK, L. D.	709, 920	CULBERTSON, H.	48, 71,	DERBY, N. R.	10
CONANT, J.	410		137, 221, 261, 267, 543, 578, 648,	DEVENDORF, C.	745
CONNER, P. S.	249, 523, 715, 786, 787, 791		816, 889, 955, 961, 989, 1068, 1010	DEVENDORF, D. B.	703, 739
CONNETT, M. C.	734	CULLEN, S.	988	DEWINT, F.	977
CONOVER, R.	968	CULVER, J. E.	310	DEWITT, E.	448, 648, 781, 788, 855
CONOVER, W. A.	524, 983	CUMMINGS, B. N.	477	DEWITT, W. R., JR.	53, 64,
COOK, C.	45	CUMMINGS, J. M.	870		334, 363, 429, 531, 565, 569, 649, 776, 818, 955
COOK, G. W.	86, 362, 672	CUMMINS, S. A.	789	DEXTER, J. E.	541
COOK, T. M.	143, 722	CUMMINSKEY, J.	259, 468, 417, 445, 832, 1000	DIBBLE, F. L.	489, 458
COOL, D. M.	749	CUNNINGHAM, T.	714	DICK, W. B.	886
COOLIDGE, R. H.	494, 578,	CURRAN, R.	683, 768, 851, 860, 944, 945	DICKEN, J. L.	679, 732, 751, 972
	580, 754, 755, 773, 986, 1010	CURREY, J. H.	670, 867, 963	DICKER, I.	889
COONS, I. A.	970	CURTIS, E.	225, 336,	DICKERSON, D. E.	931
COOPER, E. S.	460, 574		453, 454, 545, 576, 585, 586, 635, 642	DICKIE, J. W.	100, 546, 547, 847, 884, 989
COOPER, G. E.	308, 555, 559, 785	CURTIS, E. M.	626	DICKIE, W. W.	318
COOPER, L. H.	744	CURTIS, J.	460, 474	DICKINSON, B. F.	605
COOPER, W. H.	602, 781	CUSHING, J. W.	591, 593, 692, 781, 988	DICKINSON, W.	817
COOPER, W. S.	549, 561,	CUTTER, C.	702, 724	DICKSON, —	525, 531, 618
	569, 709, 742, 757, 856, 929	CUTTER, G. R.	265	DICKSON, J.	528, 771, 987
COOVER, J. B.	990	CUTTER, J. B.	336, 555, 568, 592, 983	DICKSON, J. B.	558
COOVER, J. H.	692, 846	CUTTER, S. S.	1002	DICKSON, J. M.	714
CORBIT, W. B.	450, 876, 988, 989	CUTTING, H. A.	408	DIEFENDORF, J.	574
CORBIT, L. L.	45	CUTTS, J. B.	677, 730	DIGBY, J. W.	687, 760, 941, 983, 986
CORNELL, W. M.	482	DA COSTA, J. M.	5, 187, 595	DILTS, G. S.	622
CORNELL, W. S.	141	DAHLY, E. D.	652	DIXON, W. C.	605
CORNICK, W. F.	479, 783, 1009	DALE, W. J.	581	DOCKEY, W. E.	828
CORNISH, T. O.	240, 420	DALE, W. W.	1004	DOCKSPADER, J. A.	355, 410, 838
CORSON, J. K.	619	DALRYMPLE, A. P.	86	DODDS, J. F.	340
CORSON, W.	82, 226, 691, 832, 1000	DALTON, E. B.	363	DODGE, A. W.	408, 568, 671
CORWIN, W. H.	415	DANA, C. H.	306	DODGE, E. F.	700
COSINE, G.	288	DANIELS, W. C.	144, 146, 243, 818	DODGE, L. C.	573, 579
COSTAR, C. A.	62	DARBY, C. E. C.	782, 786	DODSON, R. E.	711
COTES, J. R.	532, 947	DARDEN, D. L.	603	DODSON, R. A.	129, 142, 163
COTTON, J. C.	145	DARE, G. H.	471, 671, 692, 761, 778, 874	DOHERTY, H.	341, 361, 415
COUES, E.	580, 762, 785	DARKEN, E. J.	733	DOLSON, J. S.	773
COUSINS, M.	972	DARLING, H. M.	602, 605	DOUCE, E. F.	792
COVENTRY, C. B.	439, 476, 549, 929, 997	DARLING, L.	759	DONNELLY, E.	687, 949, 982
COWAN, —	728, 732	DARROW, W. H.	944	DORE, J. C.	754, 892, 958
COWAN, W. V.	763	DAVENPORT, L.	485	DORRAN, W. M.	183, 764
COWDREY, A. H.	620	DAVID, W. G.	71	DORSCH, E.	408
COWGILL, C. A.	179, 319,	DAVIDSON, W. R.	710	DORSEY, —	723, 741
	355, 644, 680, 689, 707, 972, 981, 989	DAVIES, R.	242, 295	DORSEY, G. V.	153
COWLES, E.	400, 725	DAVIS, A.	485	DORSEY, L.	214
COX, A. L.	677, 703	DAVIS, C. H.	686	DOUGHERTY, A. N.	272, 273,
COX, C. G.	628, 730	DAVIS, H.	969		559, 570, 620, 622, 628, 710, 848, 852, 869
COX, L. L.	976	DAVIS, H. W.	708, 986	DOUGLAS, F.	496, 712, 861, 863, 945
CRAFT, H.	470, 765,	DAVIS, J. A.	1001	DOUGLAS, J. A.	709
	768, 769, 784, 785, 982, 984, 987, 988	DAVIS, J. G.	1010	DOUGLAS, W. H.	601, 602
CRAFTS, A. P.	135, 168	DAVIS, J. W.	741	DOWELL, G.	188
CRAIG, B. F.	244	DAVIS, P. C.	776, 890	DOWNER, J. A.	561
CRAIG, W. D.	310	DAVIS, S. B.	707	DOWNER, M. S.	445
CRAIG, W. H.	588, 351, 410, 549, 937	DAVIS, S. H.	706	DOWNS, D. L.	146
CRAIN, W. B.	51, 61, 539, 639, 771, 773	DAVIS, W. A.	1012	DOWNS, R. N.	768
CRANDALL, C. M.	869	DAY, B. I.	835	DRACE, W. F.	968
CRANE, C. E.	730	DAY, H. B.	141, 407, 439, 929	DRAKE, J. L.	415
CRANE, C. H.	515	DAY, J. F.	82	DRAPER, J. A.	647, 650, 760, 765, 779, 781, 912
CRANE, H. O.	143	DAYTON, F. V.	308	DRAPER, L. J.	187, 735, 983
CRANE, I. L.	779	DEAN, G.	850	DRINKARD, W. B.	188
CRANE, J. R.	556, 676	DEAN, H. C.	703	DRURY, W. H.	340, 495, 963
CRAVEN, J. J.	274, 325, 446, 588	DEAN, H. M.	133, 161, 169, 185, 334,	DRYE, J.	176
CRAWFORD, G. G.	601, 602, 604, 694		471, 510, 535, 586, 591, 595, 637, 642, 685, 755,	DUBOIS, H. A.	45, 87, 701, 704, 738, 973
CRAWFORD, H. M.	559, 629, 721, 729		757, 761, 765, 772, 781, 950, 954, 985, 986, 988	DUBOIS, J. C.	989
CRAWFORD, J. B.	487	DEBENNEVILLE, J. S.	497, 728, 768	DUCACHET, H. W.	11, 99, 246,
CRAWFORD, J. S.	397, 399, 408, 686	DECKER, D. H.	563		293, 319, 412, 539, 541, 545,
CRAWFORD, S. K.	680, 684,	DECKER, E. H.	415		691, 692, 749, 773, 963, 1068
	737, 747, 853, 942, 943, 949, 976, 979	DELANDRE, G.	743, 1002	DUDLEY, F. A.	304, 713,
CRIHORE, C. F.	732, 738, 985	DELANY, A.	586, 756,		715, 750, 827, 857, 861, 863
CRITFENDEN, A. H.	816		760, 763, 772, 773, 874, 882, 981, 990	DUDLEY, W. H.	989
CROCKET, G. R.	267	DELAVAN, J. S.	530, 575, 671	DUER, E. L.	187, 448
CROOKS, J. W.	419	DELWORTH, —	300	DUFF, H. M.	556, 721, 730, 974
CROSBY, —	969	DEMENT, J. J.	1012	DUFFELL, C. L.	729, 742
CROSBY, A. B.	831	DEMING, W. F.	142, 226, 288, 408	DUFFIELD, E.	723

LIST OF REPORTERS AND OPERATORS.

V

	Page.		Page.		Page.
DUFFIELD, J. T.	701, 705, 719, 721, 728, 737, 958, 970	EVERETS, O.	247, 288, 315, 324, 413, 453, 549, 565, 567, 616, 617, 714, 728, 836, 931	FOOT, J. P.	988
DUHAMEL, W. J. C.	345	EVINS, A.	274	FORBES, H. G.	288
DUNGLISON, R. J.	921	EWEN, C.	755	FORBES, W. T.	779
DUNHAM, C.	973	EWING, —	969	FORD, J. B.	370
DUNLAP, A. S.	310, 930	EWING, A.	648, 875	FORD, J. D.	1001
DUNN, J. L.	700, 708, 713, 726, 728, 744, 851, 855, 863, 947, 948, 949, 952	EWING, G. E.	724, 725, 1007	FORD, O. D.	765
DUNOTT, T. J.	448, 679, 680, 712, 728, 805	FAILOR, B. M.	974	FORD, S. P.	983, 1003
DUNSTER, E. S.	755	FAIRLEIGH, R. M.	706, 746	FORDYCE, B.	616, 626, 643, 700, 702, 725
DUNTON, A. M.	267	FAIRMAN, E. P.	620	FORMENTO, P.	853
DUNTON, W. R.	368, 452	FALLEY, J. W.	371, 451	FORWOOD, J. L.	271, 289, 300
DUPRÉ, D.	601	FARLEY, J.	778	FORWOOD, W. H.	141, 276, 429, 712
DURKEE, A.	223	FARLEY, J. M.	764	FOSTER, F. J.	192
DUSENBURY, H.	*164	FARNSWORTH, A.	212	FOSTER, T. C.	606
D'VAL, —	326, 722	FARNSWORTH, R.	95	FOULKES, F.	601
DWINELLE, J.	289, 556, 861	FARRAND, D. O.	406, 408, 417, 420, 471, 485, 616, 736, 963, 973, 974, 990	FOULS, L. C.	680
DYE, A. A.	314	FARRELL, S. D.	787	FOWLER, B. F.	150
DYER, J. F.	20, 78, 100, 307, 415, 496, 534, 632, 709, 713, 722, 751, 767, 848, 935, 969	FARRINGTON, J. M.	331	FOWLER, C. N.	371, 534, 556, 621, 623, 677, 734, 741, 742, 767, 707, 730, 742, 771, 974, 981
DYER, L.	743, 977	FASQUETTE, L. W.	147	FOWLER, H. B.	734
DYER, R. F.	700	FASSETT, L.	912	FOWLER, J. E.	345
DYER, W. S.	778	FATLKNER, W.	757	FOX, —	702
DYSORT, B. G.	605	FAXON, W. L.	133, 238, 271, 293, 429, 718, 978	FOX, W. H.	572, 626, 627, 632, 676, 702, 707, 710, 720, 721, 723, 728, 731, 732, 733, 742, 748, 765, 941, 958, 969, 971, 974, 977, 979, 983
EAGER, W. B.	976	FAY, G. W.	245, 408, 501, 891, 963, 1008	FOXEY, C.	603
EAKIN, A. L.	927	FEARN, H.	712, 855	FOYE, J. W.	62, 86, 261, 338, 340, 412, 458, 566, 645, 648, 764, 838, 1009
EAKINS, D. P.	970	FEEHAN, E. L.	713	FRANCE, G. W.	146, 460
EAMES, W. M.	313, 406, 921	FELAND, W.	730	FRANKLIN, B.	605
EARL, C.	368	FELDBAUSCH, P.	878	FRANKLIN, E. C.	85, 452, 480, 496, 731, 756, 763, 836, 978, 983, 989
EASTMAN, L. H.	151	FELTON, R. A.	271	FRANKLIN, M. J.	755, 773
EASTMAN, S.	188	FERGUSON, —	687, 702, 704, 984	FRANTZ, J. H.	16, 155, 436, 439, 458, 587, 639, 687, 688, 757, 875, 885, 886, 986, 1003
EATON, W. W.	722	FERGUSON, J. F.	226, 353, 596, 617, 911	FRASSE, H.	311
EBERSOLE, J.	410, 536, 624, 700, 727, 745, 941, 973	FERGUSON, W. D.	558, 703, 712, 952	FREEMAN, J. A.	555, 684, 756, 984
EDDY, W.	765, 766	FERRIS, E. H.	351	FREEMAN, O. R.	561, 721, 744, 945
EDELIN, A.	477	FERRIS, O.	709	FREEMAN, S. D.	226, 609, 704, 726, 889, 988, 1006
EDGAR, W. S.	175, 683, 684, 722, 732, 745	FEW, S. F.	963	FREEMAN, W.	872
EDMANSON, J. A.	700, 765	FEW, S. V.	466	FRENCH, G. F.	293, 491
EDMISTON, A. A.	701	FIELD, N.	727	FRENCH, J. O.	688, 761, 763, 778, 876, 957, 958, 983, 984, 986
EDSON, P. O'M.	618, 701, 744, 715, 939	FIELDS, —	713	FRENCH, L.	148
EDWARDS, E. W.	373	FIFIELD, A. K.	524, 534, 534, 558, 598, 633, 644, 677, 705, 723, 726, 731, 734, 853, 942, 944	FRENCH, L. C.	700
EDWARDS, L. A.	373, 698	FILL, E. K.	986	FRENCH, O. E.	1001
ELA, C. C.	497, 577, 755, 876, 882, 886, 889, 958	FINCH, J. E.	985	FRENCH, S.	711
ELLIOTT, W. G.	736	FINDLAY, F. D.	923	FRENCH, S. S.	559, 572, 679, 680, 681, 730, 727, 740, 952, 971, 972, 974, 976
ELLIOTT, W. S. G.	451, 778	FINDLEY, W. M.	483	FRICK, A. P.	976
ELLIS, E. R.	871	FINLEY, J. Y.	316, 379, 756	FRINK, C. S.	555, 572, 738, 857, 979, 983, 988
ELLISON, C. R.	888	FINLEY, W. H.	680	FROBLICH, M.	725, 913
ELKINE, J. B.	969	FINN, W. H.	54, 1006	FROST, C. P.	94
ELLSWORTH, —	764	FIRMIN, F. W.	416	FROTHINGHAM, W.	731
ELLSWORTH, P. H.	976	FIROR, S. V.	265	FRY, C. B.	777
ELROD, M. N.	146, 688, 874, 955	FISHER, L.	772	FRYER, B. E.	188, 214, 329, 408, 530, 647, 760, 764, 768, 773, 785, 791, 891, 986, 988
ELTON, D. F.	789	FISH, E. P.	772	FULLER, A.	288
ELY, J. S.	93, 223, 419, 700, 885, 977	FISH, M. W.	570, 623, 629, 632, 749, 853	FULLER, H. S.	925
ELY, W. S.	958	FISHER, C. H.	771, 781, 785, 877, 934, 985	FULLER, S. E.	469, 719, 760, 765, 768, 777, 788
EMANUEL, L. M.	971	FISHER, H. W.	981	FULLER, W.	732
EMANTIEL, M.	271	FISHER, J. C.	313, 451	FULLERTON, E. B.	83, 342
EMMERTSON, J. A.	52	FISHER, L.	642, 785	FURBECK, P. R.	414
EMMONS, F. A.	595, 847	FISHER, T. H.	603	GABRIEL, J. F.	331
ENNIS, J. E.	454	FITCH, A. P.	989	GALE, G. F.	674
ENSGEN, W. H.	449, 470, 472, 584, 760, 959, 961, 974, 781, 986, 987, 989, 1003	FITCH, A. T.	298, 532, 722	GALE, G. S.	367, 506
ERSTINE, A. R.	602	FITCH, E. P.	768, 791	GALE, J. S.	703
ERSTINE, J. H.	647	FITCH, L. P.	186	GALL, A. D.	260, 261, 379, 622, 648, 877
ESTES, H.	605	FITCH, P.	764	GALLAGHER, C. A.	411
ETTFER, P.	757	FITCH, T. D.	628	GALLAGHER, J. H.	141, 369
ETTING, V. V.	709	FITZ, T. M.	228, 532, 678, 724, 726, 731, 734, 737, 741, 914, 941, 947, 948, 952	GALLOUPE, I. F.	469, 651, 777, 781, 919, 970, 1009
EVANS, C. H.	358	FLEMING, W. J.	972	GALT, J. D.	971
EVANS, J.	453, 605, 627, 634, 701, 741	FLETCHER, J. R.	621	GARGELON, A.	411, 746, 748
EVANS, J. M.	487, 983	FLETCHER, S. W.	852	GARDNER, P.	707, 743
EVANS, O. J.	943	FLEWELLEN, E. A.	1009	GARDNER, W. H.	541, 591, 870, 875, 877, 983, 1007
EVANS, W. M.	227	FLOOD, J. M.	643		
EVE, P. F.	276, 462, 602, 766, 774	FLOOD, P. H.	113		
EVERARD, C.	613	FLORA, D. W.	351, 837		
EVERETT, O.	148	FLORER, T. W.	701		
EVERETT, R. A.	722, 741	FLOWERS, W. C.	325, 596, 781		
EVERHART, J. R.	453, 729, 734, 743, 914	FOLMSBEE, W. H.	727		
EVERLETH, F. M.	648, 715, 952, 973	FOLIETTE, J. A.	411		



	Page.		Page.		Page.
GARRETSON, D. E.	766, 768, 769	GRANT, G.	140, 165,	HALL, J. B.	625
GARRETSON, S. H. D.	304		308, 687, 692, 737, 753, 791, 837, 858	HALL, J. C.	143, 529, 534
GARRETT, A.	974	GRANT, J.	781	HALL, J. F.	475
GARRISON, A. D.	743	GRANT, J. F.	603, 605	HALL, J. Z.	420, 757
GARVIN, J. W.	106	GRAVES, —	499	HALL, M. S.	357
GATCH, J. D.	728	GRAVES, J. B.	850	HALL, W. D.	186, 454, 524, 676
GAUNTT, C. S.	66, 92	GRAVES, W. L.	846, 853, 970	HALLER, J.	536, 748
GAUS, G. C.	82	GRAY, A. R.	84, 156	HALSEY, C. C.	315
GAY, G. H.	78	GRAY, A. W.	700	HALSEY, W. S.	462, 596
GAY, G. W.	988	GRAY, C.	703, 711, 714, 760, 984	HALSTEAD, M. A.	248
GAY, N.	686, 709	GRAY, C. C.	543, 980	HAM, L. J.	630, 741
GAZLAY, H. C.	358, 361	GRAY, J. W.	560, 570, 684	HAMIL, J. J.	756
GEISDORF, D. E.	768	GRAY, S. S.	183, 563	HAMILTON, C. A.	644
GEISDORF, F. P.	883	GRAY, W. M.	720, 727	HAMILTON, D.	786
GELKS, —	977	GREELEY, G. P.	683, 714, 733	HAMILTON, F. H.	32, 37, 78,
GENTRY, W. A.	285	GREEN, —	704		253, 264, 401, 494, 500, 786, 811, 815, 913
GERMAINE, C. N.	91, 955	GREEN, A. S.	687	HAMILTON, J. W.	274, 342
GERRISH, J. W. F.	751, 752, 1003	GREEN, E. L.	446, 448	HAMILTON, S.	166
GETCHELL, F. H.	759, 764	GREEN, J. H.	556, 773	HAMILTON, T. B.	778
GETTY, T. M.	547	GREEN, J. M.	65	HAMILTON, W.	712, 940
GIBBON, Q.	360	GREEN, J. S.	777	HAMLIN, D. D. T.	48
GIBBON, W. H.	214, 944	GREEN, S. A.	577, 628, 708, 730, 743, 974	HAMMER, A.	111, 192, 233, 420, 496, 786, 988
GIBBONS, H., JR.	64, 818, 983	GREENE, F.	31, 99	HAMMOND, F. M.	575
GIBBS, —	625, 729, 775, 981	GREENE, J.	356	HAMMOND, T. H.	790, 1003
GIBSON, C. B.	554, 572,	GREENE, J. H.	768, 961	HAMMOND, W. A.	705
	597, 630, 760, 881, 976, 978	GREENE, M. L.	368, 446	HAMMOND, W. L.	67, 102, 181, 314
GIBSON, W. A.	712	GREENE, W. A.	557	HANAWALT, H.	387
GIBSON, W. B.	708	GREENE, W. B.	420	HAND, D. W.	509
GIDDINGS, A. W.	310	GREENLEAF, C. R.	543, 592, 777, 878, 988, 990	HANKS, H. T.	982
GIDEON, —	591	GREENMAN, O. G.	972	HANLEY, J. A. C.	983
GIDONS, —	496	GREGG, J. S.	702, 722	HANLEY, M. A.	734
GILBERT, P. C.	882, 998	GREY, —	712	HANNEN, H. S.	931
GILBERT, P. F.	317	GRIER, M. J.	766	HANSEN, J.	710, 721, 971, 973
GILL, H. Z.	32, 113, 261, 586, 591, 702, 749, 854, 857	GRIFFITH, D. A.	990	HANSON, Z. P.	703, 725
GILLET, H. H.	976	GRIFFITH, D. J.	945, 952	HAPPERSETT, J. C. G.	129, 415, 745, 755, 766
GILFILLAN, W.	687, 876, 989	GRIFFITH, D. S.	709	HARD, A.	46, 56, 551, 556, 714, 756, 832, 970, 984
GILMAN, C. O. S.	573	GRIMES, F. S.	703, 742	HARD, C.	329, 529
GILMORE, —	733	GRIMES, J. F.	778	HARD, H.	774
GILMORE, W. J.	351, 574, 954	GRINSTED, W.	926	HARDEE, W. P.	603, 604, 605
GILSON, A. J.	854	GRISWOLD, C. D.	371	HARDING, P. H.	785
GILTNER, J. S.	700, 704, 712, 719, 737, 779	GRISWOLD, E.	529, 592	HARLAN, G. C.	371, 387, 412,
GLATFELTER, N. M.	672	GRISWOLD, L. D.	446, 625, 635, 706		485, 509, 517, 554, 562, 634, 812, 831, 971
GLEASON, A. R.	687, 777	GROENINGS, J.	335	HARLOW, L. D.	457
GLENNAN, P.	32	GROSS, P. H.	538, 967	HARPER, T. S.	927, 371, 387, 409, 412
GLEAVIS, S. B.	981	GROSS, S. D.	420, 545,	HARMON, J.	553
GLICK, E. B.	554, 626, 676,		502, 692, 774, 815, 871, 878	HARRIS, E.	288
	679, 683, 706, 714, 719, 726, 737, 738, 741,	GROSS, S. W.	76, 344, 401, 449, 733, 974	HARRIS, E. B.	68, 176, 449, 760, 767, 787, 789
	743, 745, 757, 851, 863, 939, 952, 958, 979	GROVE, F. A.	91	HARRIS, J.	67, 144, 289, 411, 574, 618, 632,
GOBRECHT, W. H.	261	GROVE, J. H.	29, 688, 778, 989, 1009		683, 685, 693, 698, 849, 927, 938, 942, 945, 989
GODDARD, C. E.	33, 229, 457, 919	GROVE, W. R.	360, 509	HARRIS, J. V.	466
GODDARD, K.	984	GROVES, J. A.	603, 604	HARRISON, O. W.	701
GOLDSBOROUGH, C. E.	865	GRUBE, F.	782	HARRISON, R. G.	737, 742
GOLDSBOROUGH, C. H.	701	GRUMBEIN, W.	95, 197, 295, 765	HARRISON, W. V.	628, 750, 766
GOLDSBOROUGH, J.	625, 958	GUARD, C. C.	983	HART, C. R.	710
GOLDSMITH, M.	311, 347, 407, 436, 525, 871	GUILD, P. K.	626	HARTIGAN, J. F.	19, 23, 205
GOOD, D. R.	86	GUILFORD, W. M.	95	HARTMAN, A.	250
GOODMAN, H. E.	77, 331, 355,	GUNKLE, W.	710	HARTMAN, W. B.	569, 571
	362, 357, 369, 371, 387, 407, 447, 458, 533,	GUNN, M.	627	HARTSHORN, D. W.	85, 456, 531
	536, 538, 638, 672, 684, 691, 705, 750, 760,	GUNN, N. R.	705	HARTSHORNE, E.	442
	775, 833, 858, 871, 884, 885, 924, 946, 972	GUSTINE, J. W.	407	HARTSUFF, A.	9, 346, 386, 460, 592, 678, 781, 890
GOODWIN, D. M.	624, 700, 705, 709, 714,	HABERSHAM, S. E.	603, 623, 636	HARTWELL, S. C.	700, 712
	728, 730, 742, 743, 744, 745, 951, 973, 976	HACHENBERG, G. P.	192, 545, 761, 780	HARVEY, G.	705
GOODWIN, J. R.	741	HADDOCK, C.	778	HARVEY, J.	980
GORDON, J.	326	HAGEN, C. W.	703	HARVEY, J. G.	959, 1007
GORDON, T. W.	409, 1006	HAIGH, T. D.	280	HARVEY, P.	974
GORE, J. R.	756	HAINES, A. B.	755	HARVEY, T. B.	756
GOSLIN, A.	352, 550,	HAIR, J. H.	682	HARVEY, W. A.	220, 244, 511, 877
	559, 576, 680, 747, 763, 854, 941, 952	HALBERSTADT, A. H.	171	HASBROUCK, J. L.	563
GOTT, W. A.	558, 940, 942, 961	HALDERMAN, D.	557, 624,	HASBROUCK, J. W.	373
GOULD, B. S.	1006		629, 677, 684, 702, 714, 853, 858, 949, 1008	HASSE, H. E.	459, 533, 541, 561, 634,
GOULEY, J. W. S.	391, 436,	HALL, A. D.	187, 528, 690		677, 680, 704, 733, 741, 746, 852, 859, 1002
	641, 643, 783, 786, 935, 983	HALL, C. E.	713	HASSENBERG, F.	560, 650, 756, 791, 973
GRAHAM, J. W.	603, 604, 620, 729, 869	HALL, E.	671	HASSON, A. B.	233, 539, 643, 648, 692, 963, 1008
GRAHAM, N. F.	457, 539,	HALL, E. J.	416, 418	HASTINGS, B. F.	581
	733, 740, 742, 766, 936, 963, 981, 998	HALL, F.	937	HASTINGS, J. W.	709, 721, 738, 747
GRAHAM, S.	957	HALL, J. A.	642, 643, 678,	HATCHARD, T.	704, 722, 733
GRAHAM, W.	678, 709, 937, 943		681, 727, 760, 763, 764, 765, 768, 781, 942, 987	HATCHITT, J. G.	150, 151, 265, 289, 460, 704, 764

LIST OF REPORTERS AND OPERATORS.

VII

	Page.		Page.		Page.
HAUSSLER, F.	757	HICKMAN, T. G.	780	HORTON, N. N.	186, 726, 979, 985
HAVEN, A. H.	768, 986	HICKS, R. J.	601, 602, 606, 702, 742	HORTON, S. M.	463, 832
HAVEN, S. F.	231	HICKS, W. C.	993	HOSACK, J. P.	565, 705
HAVENS, P. B.	355	HIDDEN, J. S.	338	HOUGH, F. B.	969, 970
HAWKINS, S. C.	749	HIGGINS, R. T.	777	HOUSE, J. H.	548
HAWLEY, S. B.	687, 928	HILBURN, J. C.	168	HOUSTON, D. H.	548, 631
HAWN, E. R.	353	HILDRETH, C. C.	928	HOUSTON, J.	701, 972
HAWTHORNE, F.	601, 604, 605	HILDRETH, G. O.	232, 368, 420	HOUSTON, J. M.	777, 972, 966
HAYDEN, F. V.	451, 817	HILDRETH, J. S.	918	HOUSTON, M. W.	605
HAYES, C.	928	HILDRETH, T.	731, 853	HOUSTON, W. M.	554, 563, 626
HAYES, I. L. 21, 48, 82, 259, 310, 327, 406, 407, 438, 439, 457, 462, 466, 507, 529, 590, 616, 889, 927		HILL, E. L.	498, 741, 893	HOVEY, B. L.	96, 863
HAYES, J. A.	531, 535, 680, 744	HILL, H. C.	748	HOWARD, B.	392, 523, 525, 528, 530, 642, 677, 679, 683, 709, 712, 720, 760, 804, 819, 848, 856, 878, 882, 884
HAYES, J. H.	718	HILL, J. H.	470	HOWARD, E. W.	691
HAYES, J. M.	628, 719	HILL, J. S.	727, 773	HOW, J. C.	701
HAYNES, C. F.	524, 705, 723, 744, 759, 778, 779, 781, 914, 928	HILL, L.	756	HOWE, J.	704, 941
HAYS, D. S.	615, 623, 638, 722, 929, 971	HILL, N. S.	785	HOWE, S.	982
HAYS, W. H.	86, 477, 989	HILL, R. J.	522	HOWELL, B. P.	300
HAYS, W. L.	988	HILL, S. V. D.	603	HOWELL, O. D.	928
HAYWARD, J. M.	368	HILL, W.	406	HOWER, J. B.	341
HAYWARD, N.	412, 525, 533, 555, 598, 625, 627, 632, 677, 702, 714, 737, 741, 742, 744, 745, 765, 769, 783, 854, 855, 864, 910, 914, 945, 947, 949, 951, 957, 972, 973, 976, 977, 978, 981, 986, 1008	HILLARY, M.	253	HOY, A. H.	448
HAYWOOD, E. B.	778	HILLS, T. M.	723, 977	HOYT, C. S.	727, 972, 976
HAZARD, W. H.	544	HIMES, I. N.	622, 684, 705, 707, 728, 941	HUBBARD, G. H.	373, 549, 647, 703, 977
HAZELTINE, G. W.	1005	HINDS, W. H. W.	734	HUBBARD, H. B.	86
HAZELTON, D. W.	411, 415	HINES, A. A.	778	HUBBARD, V. B.	296
HEANEY, P.	805	HINKLE, A. G. B.	358	HUBBELL, C. L.	47, 260
HEARD, L.	784, 988	HINKLE, F.	890	HUBER, J. F.	269
HEATH, D. L.	942, 947, 968	HINKLEY, H.	468	HUBON, P. E.	533, 569, 570, 621, 678, 700, 702, 706, 711, 714, 851, 863, 864, 943, 945, 947, 952, 1005
HEATH, W. H.	554, 577, 689, 701, 705, 732, 934, 944, 970	HITCHCOCK, H. O.	307, 548, 582, 753	HUDSON, A. T.	560, 598, 622, 711, 763, 944
HEGER, A.	289, 446, 448, 459, 508, 692, 754	HIXON, D. W.	361	HUDSON, E. D.	496, 523, 548, 549, 553, 566, 567, 568, 573, 580, 590, 673, 675, 847, 849, 850, 860, 907, 936, 938, 1002, 1003
HEIGHWAY, A. E.	261	HOGG, W. H.	945	HUDSON, W. M.	642, 756
HEILAND, C.	725, 848, 859	HOBBS, W. P.	747	HUFF, S. W.	722
HEINSLING, J. H.	648	HODGE, C., Jr.	313, 356, 360, 888	HUFFMAN, A. L.	1008
HEISE, A. W.	749	HODGE, H. L.	261, 340, 361, 562, 868	HUGHES, J. C.	272, 570, 706, 786
HELMER, A. M.	757	HODGE, J. L.	353, 397	HUGHES, S.	583
HELMER, J. H.	258, 933, 962	HODGEN, J. T.	243, 323, 327, 329, 359, 431, 470, 539, 622, 761	HUMPHREY, C. E.	702
HELMSBY, T. H.	144, 147, 756, 803, 920	HODGES, B.	982	HUMPHREY, O. M.	634
HELWIG, T. A.	624, 702, 704, 707, 712, 722, 940, 976	HODGES, J. H.	777	HUMPHREY, P. H.	226
HENDEE, C. K.	785, 756	HODGES, R. M.	692, 982	HUMPHREY, W. F.	555, 629, 712, 724, 973
HENDERSON, D. W.	711	HOFF, A. H.	674	HUMPHREYS, G. H.	509, 532, 537, 578, 702, 732, 968, 969
HENDERSON, F. B.	602, 605, 724	HOFFMAN, E. S.	358, 973	HUMPHREYS, L.	165
HENDRICK, E. F.	95	HOGAN, M. K.	48, 142, 145, 213, 228, 267, 288, 328, 353, 409, 413, 444, 617, 682, 715, 787, 859, 911	HUNT, —	704
HENDRICK, H. C.	731	HOGEBOM, G. W.	308, 640, 759	HUNT, A. H.	765
HENDRICK, J. G.	808	HOLBECK, W. C.	605	HUNT, C. W.	976
HENDRIE, W. S.	441, 765, 928	HOLBROOK, L.	723, 772	HUNT, J. G.	418, 457
HENRY, D. H.	521	HOLBROOK, W.	858, 969, 973	HUNT, O. G.	683, 710, 922
HERBERT, C. L.	602	HOLDEN, A. W.	420	HUNTER, W. G.	679, 728, 730, 755
HERBST, J. E.	10, 214, 243, 328, 340, 451, 492, 523, 678, 682, 723, 747, 768, 772, 778, 817, 818, 958, 984	HOLDEN, J. T.	606	HUPP, J. C.	478, 482
HERNDON, D.	602, 604	HOLDEN, L. H.	335, 815	HURLBURT, H. N.	331
HERR, M. L.	245, 421, 496, 632, 692, 762, 766, 768, 961, 984	HOLLEY, S. J.	756	HURLBURT, S. R.	527
HERRICK, H.	746, 943, 1001	HOLLOWAY, J.	77	HURLBUT, C. S.	84, 466
HERRICK, O. Q.	743	HOLLOWAY, J. M.	602	HURSAM, N. A.	726
HERRINGTON, C. P.	970	HOLMES, W. J. R.	324, 772	HUTCHINS, E. R.	315
HERRON, W. M.	351	HOLMES, W. J.	959	HUTCHINSON, E.	816, 982
HERSCHE, C.	415	HOLSTON, J. G. F.	167, 207	HUTCHINSON, J. F.	705, 731, 733
HESS, J. F.	745	HOLT, D. M.	639	HUTCHINSON, J. H.	79, 677, 678, 683, 700, 709, 719, 731, 853, 855, 924, 946, 971, 1006
HESS, W. H.	648	HOLT, S. G.	977	HUTTON, R. C.	96
HETTS, W.	757	HOMANS, J., Jr.	50, 79, 294, 571, 578, 616, 689, 724, 728, 731, 765	HYDE, J. H.	261
HEWETSON, A. H.	80, 214	HOOD, G. H.	784	HYDE, J. N., JR.	637
HEWITT, H. S.	65, 291, 400, 528, 587, 640, 647, 738, 777, 873, 874, 875, 880, 883, 932, 957, 958, 1008, 1010	HOOD, H. H.	971	INGALLS, W.	620, 628, 708, 732, 742
HEWITT, C. N.	23	HOOD, T. B.	652, 657	INGRAM, A.	307, 328, 411, 416, 460, 585, 643, 778, 847, 890, 1007
HEWITT, G. W.	729	HOOKER, A. P.	579	IRELAND, A. B.	362
HEWSON, A.	789, 929	HOOPER, T.	521	IRISH, F.	229, 340
HEZLESS, W. B.	698, 700, 714, 723	HOOPER, W.	448	IRWIN, G. E.	623
HICKMAN, N.	145, 359, 987, 988	HOOPER, M. M.	703, 712, 718, 727, 742, 974	IRWIN, J.	485
		HOOPER, G. W.	708	IRWINE, C. K.	313, 413, 892, 847, 854
		HOPKINS, B. F.	681	ISHAM, R. N.	106, 334, 335, 692, 847, 852
		HOPKINS, D. S.	733, 914	JACKSON, —	971
		HOPKINS, T.	878, 882	JACKSON, E.	972, 976, 977
		HOPKINSON, J.	143, 145, 233, 361, 408, 418, 440, 441, 442, 443, 445, 447, 451, 494, 540, 698, 833, 850, 884		
		HORNOR, C. W.	155, 311, 446, 458, 488, 590, 676, 762, 776, 789, 817		



	Page.		Page.		Page.
JACKSON, J. A.	338	KEEN, W. W., Jr.	175, 295	KOERPER, E. A.	92, 368, 692
JACKSON, J. B. S.	273, 322		339, 461, 505, 507, 513, 609, 754, 764	KRACKOWIZER, E.	988
JACKSON, J. D.	265, 285		767, 768, 769, 784, 872, 954, 982, 983	KRAMER, E.	355, 538, 764
JACKSON, R. D.	918	KEENON, J. G.	145, 363, 436, 454	KRATZ, E. A.	412, 954
JACKSON, R. M. S.	919		545, 546, 596, 638, 648, 650, 707, 770, 785, 982	KUNKLER, J. E.	706
JACKSON, W. A.	529	KEFFER, F. A.	592, 777	KURTZ, S.	727
JACOBS, W. C.	557, 730, 941, 1009	KEIR, W. G.	713, 731	LACKEY, R. M.	931
JAMAR, J. H.	261, 443, 449, 577, 781, 963	KELLEY, B. B.	414	LADD, C. H.	556, 572, 686
JAMES, W. M.	785	KELLEY, L. E.	676	LAFORCE, J. W.	272
JAMES, J. A.	603	KELLEY, W. J.	973	LAIR, J. A.	747
JAMES, L. A.	248, 474	KELLY, E. B. P.	284, 411	LAKE, C. B.	711, 745
JAMISON, J. S.	627, 706, 721, 729, 737, 739, 742, 743, 948, 971, 972, 974	KELLY, F. W.	290, 410, 525, 585, 689, 877, 982, 983, 986	LAMB, J. B.	979
JANES, H.	280, 286, 361, 410, 456, 466, 467, 475, 486, 546, 590, 591, 616, 618, 637, 673, 749, 757, 789, 790	KELSEY, D. E.	623, 720, 740, 741	LAMB, W. W.	731, 732
JANSEN, J. A.	835	KEMP, C. P.	735	LAMBERT, A.	314
JANVRIJ, J.	961	KEMP, E. A.	982	LAMBERT, J.	836
JARVIS, G. C.	676, 681, 705, 708, 729, 724, 741, 747, 834, 850, 914, 925, 942, 952, 970, 978	KEMPSTER, M.	306	LAMBERT, T. S.	825
JENKINS, J. M.	517	KENDALL, H. W.	687	LAMPEN, M.	451, 983
JENKINS, T. F.	783	KENDALL, J. V.	676, 684, 702, 712, 723, 728, 944, 946, 952	LAMSON, H. S.	731, 974
JENNINGS, R. G.	507	KENNEDY, D.	449, 689, 989	LAND, W. J.	278
JESSOP, S. S.	454, 643, 677, 788, 856, 863, 882, 963, 1005, 1010	KENNEDY, J. T.	448, 687, 755	LANDIS, A. H.	763
JESSUP, R. B.	714, 733	KENNEDY, L. W.	706, 747, 940, 971	LANE, A. G.	692, 693, 695, 897
JEWELL, D. L.	973	KENNEDY, T.	82, 313	LANE, W. B.	981
JEWELL, W.	371, 552	KENNEDY, V. B.	532, 730, 968, 979	LANE, W. W.	275
JEWETT, A.	308, 340, 1005	KENNEY, S. B.	439	LANGLEY, —	970
JEWETT, C. C.	617, 624, 633, 640, 708, 716	KENNIER, B.	502	LANGDON, H. H.	523, 524, 728, 730, 733
JEWETT, D. L.	365	KENNON, J. C. W.	89	LANNING, J. M.	989
JEWETT, G.	722, 837	KERR, J.	677, 678, 679, 711, 968, 969, 972, 973	LANNING, J. T.	791, 989
JEWETT, P. A.	79, 445, 487	KERSKY, S. H.	531, 577, 704, 718, 727, 731, 737, 738, 744, 891, 979	LANSING, E. S.	289
JEWETT, T. H.	430	KESSLER, A.	51, 784	LAPHAM, W. B.	484
JOHNS, H. C.	561	KEYES, A. E.	689, 756, 786	LAPSLKY, J. B.	880
JOHNSON, C. M.	412	KIBBEE, A. D.	707, 755	LARKINS, J. B.	755, 981, 983
JOHNSON, G. K.	544, 567, 667	KILBOURNE, H. S.	771, 958, 961	LATHROP, H.	88
JOHNSON, H.	638	KILBOURNE, W. H.	986	LATHROP, M. C.	558
JOHNSON, H. A.	764	KIMBALL, P. B.	681, 701, 727, 737, 738, 970, 972, 974	LATHROP, W. H.	773
JOHNSON, J.	649	KIMBALL, G.	988	LATIMER, C. C.	311
JOHNSON, J. D.	241, 756, 986	KIMBALL, J. H.	704, 748, 805, 944, 976, 977, 979	LATIMER, T. S.	605
JOHNSON, J. M.	838	KIMBLY, J. T.	561, 851, 952	LAUB, C. H.	515
JOHNSON, R.	290	KING, A. F. A.	985, 986	LAUDERDALE, J. V.	584
JOHNSON, T. W.	731	KING, C. B.	475, 671, 785, 963	LAURENCE, C. W.	588
JOHNSON, W. E.	703, 713, 745, 942, 943, 971	KING, E.	543	LAWRENCE, A. A.	603
JOHNSON, W. H.	530	KING, G.	623, 712	LAWRENCE, G. C.	347
JOHNSON, W. P.	287, 354, 555, 778, 988	KING, H. B.	702, 728	LAWRENCE, J. W.	358
JONES, C. H.	508, 671, 772	KING, J. F.	274, 275	LAWSON, J. M.	731
JONES, C. T.	167	KING, R. H.	983	LAWTON, J. W.	626, 679, 723, 863, 942, 943, 944, 946, 948, 949, 972, 979
JONES, C. W.	78, 271, 456, 471, 487, 670, 765, 786, 929	KING, W. H.	983	LEACH, G.	730
JONES, D. C.	945	KING, W. N.	729	LEAK, T. W.	601
JONES, E. L.	732	KING, W. S.	724, 865	LEALE, C. A.	77, 215, 227, 254, 238
JONES, G. S.	223, 267, 361, 368, 373, 398, 415, 466, 484, 580, 589, 674, 690, 770, 838, 868, 934, 1009	KINGSBURY, E. J.	94	LEAMAN, H.	82, 449, 479, 687, 761, 792
JONES, H.	1006	KINGSTON, S. F.	676, 759	LEAVICK, —	692
JONES, R. K.	615, 837	KINLOCH, R. A.	113, 629	LEAVITT, D. F.	701, 786
JONES, S. J.	564	KINNEY, S. B.	886	LEAVITT, T. L.	49, 160, 950
JONES, S. W.	408	KIPP, C. J.	590, 591, 592	LEBBY, B. M.	603, 604
JONES, T.	940, 968	KIRKER, J.	449	LEBER, F. C.	760
JONES, W.	363	KITCHEN, J. M.	757	LECOMPTE, G. B.	496, 633, 710
JONES, W. B.	137, 239, 507	KITTINGER, M. S.	274, 489, 728, 731, 737, 743, 952, 977	LECONTE, J. L.	243
JONES, Z. R.	977	KITTRIDGE, W. A.	765	LEDLIE, J. H.	283, 742
JUDSON, O. A.	35, 73, 214, 229, 244, 311, 354, 408, 440, 446, 447, 455, 482, 483, 521, 525, 574, 575, 579, 585, 587, 617, 639, 643, 687, 735, 738, 761, 772, 874, 875, 880, 881, 882, 883, 892, 928, 953, 955, 957, 959, 961, 983, 984, 985, 987, 988	KNAPP, E. A.	701, 714	LEE, J. C.	687, 688, 763
JUSTICE, J. M.	146	KNEELAND, B. F.	737, 973	LEE, W.	187
KANE, J. K.	989	KNEELAND, S.	335, 509	LEEDOM, J. M.	444
KARBER, T. J.	911	KNICKERBOCKER, B.	989	LEGLER, H. T.	408, 524, 545, 926
KAY, J. S.	498	KNIGHT, I. D.	374, 478, 487	LEGRAND, —	726
KEABLES, B. F.	216, 733, 976, 982	KNIGHT, J. H.	353	LEHLBACH, C.	617
KEABLES, J. T.	417	KNIGHT, J. W.	784	LEICESTER, —	626
KEATING, W. V.	457, 489, 688, 789	KNIGHT, L. M.	703	LEIDY, J.	439, 506, 927, 962
KEEFER, H. G.	864, 972	KNOX, W. A.	564	LEIDY, P.	227, 371, 622, 625, 704, 705, 730, 741, 745
KEELEY, L. E.	755	KNORR, M. K.	84, 791	LEIGHTON, N. W.	487, 828
		KNOTT, J. J.	480, 529, 530, 631, 653, 793, 795, 851, 854, 856, 892, 893, 1000	LEIT, N. Y.	542, 559, 677, 708, 979
		KNOWLES, H. B.	596, 672, 773, 984, 989, 1001	LEMON, W. H.	532
		KOECHLING, C. W.	471, 869	LEMOYNE, F.	678
		KOEHLER, J. G.	311, 357	LEONARD, B. B.	478
				LEONARD, C. S.	955
				LEONARD, G. H.	270
				LEONARD, W. H.	679, 852

LIST OF REPORTERS AND OPERATORS.

	Page.		Page.		Page.
LESLIE, —	778	LYMAN, S. J.	1067	MAYER, N.	683, 946
LESLIE, S.	989	LYMAN, W. C.	595, 847	MAYNARD, —	876
LETCHER, F. M.	554	LYNCH, J. E.	628, 633, 702, 757	MAXWELL, T. J.	725, 945
LEVENSALER, H. C.	273, 738, 942	LYNDE, R. D.	422	MCABEE, H. M.	974
LEVIS, J. C.	727	LYNN, E. E.	570	MCCALLISTER, W. T.	603
LEVIS, R. J.	716, 736, 770	LYNN, J. P.	675	MCCARTHUR, J. A.	788, 945
LEWES, E. B.	604	LYON, E. B.	251, 890	MCCALL, C. A.	33, 142,
LEWIS, G. R.	144	LYONS, —	705	231, 247, 289, 314, 328, 357, 441, 445, 457, 458,	
LEWIS, J. B.	249, 406,	LYONS, J. C.	621, 703, 711, 712, 968	460, 578, 579, 580, 596, 673, 674, 685, 715, 755,	
	448, 466, 469, 506, 539, 576, 643, 687,	LYONS, W.	436, 702,	756, 762, 764, 765, 769, 782, 786, 787, 788, 828,	
	688, 756, 764, 768, 789, 883, 984, 1005		727, 733, 738, 751, 936, 945, 946	882, 883, 886, 889, 913, 938, 981, 984, 989, 1003	
LEWIS, R. A.	601, 605, 606	LYSTER, H. F.	497, 555,	MCCALLA, J. M.	524, 957, 1007
LEWIS, R. S.	148		557, 565, 567, 616, 621, 638, 676, 680, 683, 700,	MCCANDLESS, A. G.	307, 351, 451, 574, 954
LEWIS, —	778		704, 706, 708, 710, 713, 719, 722, 724, 731, 733,	MCCANDLESS, J. N.	710
LIDDALL, J. P.	314		734, 737, 742, 745, 747, 748, 757, 853, 859, 863,	MCCANDLISS, R. R.	701, 707, 943
LIDELL, J. A.	142, 171, 179,		941, 943, 946, 947, 948, 970, 971, 1002, 1005	MCCAUSLAND, M. B.	616, 786
	222, 231, 264, 293, 297, 307, 338, 354, 470, 484,	LYTLE, F. W.	337, 525, 560, 676	MCCLEARY, B. N.	773
	490, 569, 667, 675, 778, 818, 831, 833, 881, 997	MABIN, H. B.	982	MCCLELLAN, E.	53,
LIEBOLD, T.	453, 536,	MACDONALD, J. E.	310, 354, 401, 729	141, 177, 234, 251, 267, 273, 325, 327,	
	539, 543, 754, 789, 876, 879, 889	MACFARLAND, C.	741, 742, 911	333, 373, 454, 460, 487, 488, 716, 763	
LILLY, H. M.	756, 988	MACKAY, D.	267, 534, 571, 681, 685,	MCCLELLAN, J. H.	540, 541, 543, 592, 781, 877, 890
LINCOLN, F. M.	703, 785, 791		706, 708, 724, 738, 951, 971, 977, 978, 984, 985	MCCLELLAN, S.	681
LINCOLN, M.	910, 1003	MACKENZIE, G. B.	984	MCCLEINTOCK, E.	689, 742, 761
LINCOLN, N. S.	402	MACKENZIE, T. G.	46, 789, 936	MCCLOURE, R. L.	635, 705, 743, 773, 1007
LINCOLN, W. H.	728	MACKIE, J. H.	479, 989	MCCOLLISTER, J. Q. A.	1068
LINDSAY, C. A.	982, 985	MACLEAN, D.	890	MCCOLLUM, W.	487, 828
LINDSLY, W.	573, 950	MADDEN, —	683	MCCONNELL, A. P.	765
LINNEWEAVER, J. K.	757	MADILL, W. A.	700, 728	MCCOOK, G.	47, 233,
LINK, J. E.	623, 635, 700, 771, 777, 878	MADISON, R. L.	279	253, 307, 351, 408, 565, 648, 872, 954	
LINN, D. H. O.	312	MAGEE, T. L.	622, 940	MCCOOK, J.	970
LITCH, W. F.	711, 756, 773, 883	MAIRTY, W. K.	777	MCCORMICK, J. J.	507, 997
LITTLE, W. B.	706	MALLOCH, E. C.	923	MCCOY, J. A. C.	352
LIVEZEY, E.	789, 790, 988	MANLY, M. M.	26	MCCOY, G.	472, 643, 773
LIVINGSTON, W. C.	277	MANN, C. S.	949	MCCRACKEN, W. A.	972
LODGE, C.	386	MANN, J.	909	MCCULLOCH, J.	1003
LOGAN, J. C.	896	MANSFIELD, R. W.	240, 764	MCCULLOUGH, W. P.	157
LOGAN, R.	745	MANSON, O. F.	572, 581, 602	MCCUNE, G. W.	851, 947
LOGAN, S.	638	MANXTER, G. W.	778	MCCURTIDY, J.	312
LOMAX, W.	627, 680, 720, 732, 941, 945	MAR'CH, H.	213	MCDADE, G. W.	605
LOMBARD, I. S.	770	MARKOE, T. M.	277, 281, 577	MCDERMONT, C.	10, 287, 366, 779, 1000, 1002
LOMBARD, W. S.	721	MARKS, S.	26, 365, 557, 817	MCDERMOTT, W. J.	709
LONG, A. S.	363	MARR, C.	562	MCDILL, D.	760
LONG, B. H.	550	MARSDEN, O. F.	977	MCDONALD, W. O.	26, 254, 571, 574, 772, 983
LONGENECKER, J. H.	414, 508, 543, 849	MARSH, A. F.	679	MCDONNELL, E.	250, 784
LONGSHORE, W. R.	625, 634	MARSH, D. C.	998	MCELDERRY, H.	420
LOOMIS, H. N.	253	MARSH, E. J.	79, 143, 354, 561, 828	MCEWEN, R. C.	266
LOOMIS, S. L.	638	MARSH, F. E.	786, 986	MCADDEN, —	559, 723
LORD, C. H.	688, 701, 852, 957	MARSH, W. B.	771	MC FALLS, D.	677, 683, 707, 719, 726, 979
LORD, R. McC.	415	MARSH, W. R.	564, 679, 680, 732, 874	MC FARLAND, P. M.	729
LOTHROP, C. H.	352, 454	MARSHALL, —	778	MC FARLAND, T. J.	603
LOUGHRAN, R.	48, 638, 756, 981	MARSHALL, S. D.	988	MCGARRITY, —	728
LOUGHBRIDGE, W.	87, 452	MARTIN, E.	788, 951	MCGAVRAN, W. B.	647, 683, 732, 757, 859, 949
LOVE, J. C.	765	MARTIN, G.	783	MCGILL, G. M.	87, 155, 270,
LOVE, W. J.	275	MARTIN, G. H.	91, 707	324, 559, 639, 766, 772, 785, 861, 864, 876, 984	
LOVE, W. S.	52, 315, 326, 533	MARTIN, G. W.	733, 766	MCGOORISK, E. J.	480, 720, 721, 947
LOVEJOY, G. W.	974	MARTIN, H. A.	352, 768, 822	MCGOVAN, J. J.	732
LOVELL, S.	340	MARTIN, J. S.	705, 729, 730, 856	MCGOWAN, R.	340, 785, 1008
LOVERETT, F. P.	605	MARTIN, J. W.	357	MCGRATH, J. M.	447, 471,
LOW, L. W.	1006	MARTIN, O.	224, 228, 246, 353, 487	494, 543, 981, 983, 988, 989	
LOWELL, A. L.	81, 83, 96,	MARTINDALE, F. E.	524, 889	MCGRAW, T. A.	469, 533,
	100, 308, 408, 466, 486, 818, 936, 1002	MASON, J. W.	722	648, 755, 757, 765, 768, 778, 989	
LOWENTHAL, H.	923	MASON, T. L.	989	MCGREGOR, J. H.	709
LOWMAN, J.	888, 921	MASON, V. W.	408	MCGREGOR, W. D.	289
LOWMAN, W. B.	885, 888	MASTIN, C. H.	788	MCGREW, A.	692
LUCAS, G. L.	733, 981	MATCHETT, W. H.	639, 722, 731, 744, 940	MCGREW, J. S.	978
LUCKEY, F. N.	570	MATHEWS, —	744	MCGUIRE, H.	274, 275, 278, 556, 900
LUDINGTON, H.	410, 722, 952	MATLOCK, W. H.	585, 778, 781, 892, 988	MCGUIRE, J. M. G.	727, 732, 765, 863
LUDLOW, J. R.	227, 449, 525,	MATTHEWS, —	747	MCINTYRE, J. H.	644, 687, 765, 781
	557, 574, 578, 741, 778, 789, 981, 987	MATTHEWS, D.	857	MCKAY, A. S.	605
LUNG, H. B.	16, 21	MATTOW, —	766	MCKEE, —	721
LYCAN, L.	788	MAULL, D. W.	445,	MCKEE, J. C.	45, 87, 159,
LYFORD, B. F.	969		496, 511, 623, 680, 708, 719, 720, 721,	168, 169, 173, 179, 223, 271, 289, 315, 317, 328,	
LYMAN, G. H.	260		729, 730, 747, 863, 864, 942, 943, 952	334, 341, 365, 408, 416, 468, 470, 565, 577, 578,	
LYMAN, H. M.	338	MAURY, F. F.	449, 471, 773	579, 583, 586, 595, 596, 618, 637, 640, 685, 763,	
LYMAN, J. H.	785	MAURY, R. B.	1012	768, 769, 773, 875, 881, 978, 981, 984, 989, 990	
LYMAN, J. W.	529, 571, 924	MAY, H. C.	49, 95, 293, 308,	MCKENNAN, H.	413, 678,
LYMAN, M. H.	874		313, 446, 596, 768, 781, 787, 850, 962, 987	704, 733, 751, 940, 942, 945, 948, 952	



LIST OF REPORTERS AND OPERATORS.

	Page.		Page.		Page.
McKENZIE, W. G.	602	MILLER, B. F.	620, 625, 724, 969	MOSELEY, N. R.	144, 177, 232, 327,
McKINNEY, D.	618, 674	MILLER, C.	622, 729, 737, 969		330, 347, 413, 449, 453, 584, 619, 631, 641,
McKINNEY, D. F.	707, 725, 983	MILLER, D. McL.	575		678, 683, 687, 764, 767, 777, 778, 784, 788,
McKNIGHT, C. G.	544, 886	MILLER, G. L.	723, 737, 769, 859		791, 957, 959, 961, 982, 983, 984, 988, 990
McLANE, H.	711, 722	MILLER, G. McC.	508	MOSES, I.	144, 556, 639, 669,
McLANE, J. A.	920	MILLER, J. G.	347, 983		683, 687, 688, 847, 852, 855, 881, 883, 890
McLAREN, A. N.	367, 373, 467, 474	MILLER, J. N.	713	MOSHER, M. A.	974
McLAREN, P. M.	266	MILLER, L. D.	413, 726	MOSS, W.	329, 956
McLAUGHLIN, C. C.	731	MILLER, S. T.	87	MOTT, A. B.	81, 332, 457, 638, 644,
McLEAN, C. R.	440, 543, 777, 884, 889, 1004	MILLER, T. C.	523		672, 690, 777, 784, 785, 825, 982, 987, 988
McLEAN, H.	579	MILLER, T. W.	100	MOTT, V.	983
McLEAN, L.	629, 972	MILLER, W. H.	351, 410	MUDD, —	981
McLETCHIE, A.	50, 468, 469, 756, 784, 982	MILLET, A.	581	MUDGE, C.	702
McMAHON, —	968	MILLIGAN, F. H.	622, 683, 701, 719, 947	MUECKE, C. M. F.	620
McMAHON, A.	267, 448,	MILLS, A. M.	336	MULFORD, J. L.	626, 728
	449, 545, 556, 559, 567, 620, 638, 640, 643,	MILLS, C. H.	412, 723, 724, 727	MULFORD, W. C.	231, 687, 957, 961
	727, 756, 765, 777, 876, 890, 939, 948, 986	MILLS, M.	548	MULLEN, A. J.	763
McMAHON, D. S.	532	MINOR, H. A.	532, 625, 763, 947	MULLEN, I. V.	707
McMARTIN, T.	419	MINOR, W. C.	766	MÜLLER, A.	94, 978
McMILLAN, C. W.	157, 169,	MINTZER, St. J. W.	73, 171,	MULLINS, W. H.	679, 683, 942, 977
	244, 296, 557, 558, 634, 681, 701, 853, 970		265, 452, 462, 817, 979	MUMFORD, S. E.	835
McMILLEN, C.	345	MITCHELL, A.	363	MUNROE, F. LEB.	838
McMILLIN, G. W.	784	MITCHELL, C. E.	897	MURDOCK, J. B.	701, 702, 712, 973
McNABB, L. B.	784	MITCHELL, E. D.	134	MURPHY, —	977
McNEILLY, R.	737, 773	MITCHELL, G. H.	686, 795	MURPHY, J.	143
McNETT, J. B.	234	MITCHELL, J. D.	634, 724, 978	MURPHY, J. A.	778, 997
McNULTY, J.	621, 626, 714, 971	MITCHELL, J. W.	327, 725,	MURPHY, J. G.	182, 357, 387, 420
McNULTY, R.	786, 989		726, 732, 733, 741, 886	MURRAY, J. H.	602
McPARLIN, T. A.	226, 452, 457, 988	MITCHELL, R.	969	MURRAY, W. D.	577, 711
McPHEETERS, J. G.	727, 968, 970	MITCHELL, S. B. W.	79, 551	MURSICK, G. A.	102, 167,
McPHEETERS, J. S.	926	MITCHELL, S. W.	339, 461		197, 222, 448, 462, 525, 644, 883
McPIERSON, H. C.	1006	MITCHELL, T. E.	220, 306	MURTA, J. E.	940, 947, 974
McPIERSON, J. B.	781		499, 643, 717, 719, 720, 757, 846	MUSCROFT, C. S.	379, 639, 730
McQUESTON, C. B.	771, 981	MOHR, R. J.	531, 598, 676	MUSGRAVE, J. F.	729
McRAE, J. A.	280	MOLA, E. L.	981	MUSSEY, W. H.	692, 970
McREYNOLDS, L. D.	605	MONEYPENNY, J.	788, 981	MYERS, C. W.	677, 771, 971
McREYNOLDS, W. H.	411	MONMONIER, J. X. K.	526, 602, 851	MYERS, J. T.	732
McWILLIAMS, A.	698	MONOHAN, A. B.	411, 531,	MYERS, S. F.	616, 742
MEACHAM, F.	16, 289		556, 727, 943, 949, 971, 972, 976	MYERS, T. G.	969
MEAD, E.	312	MONROE, N. P.	91	MYGATT, E.	312, 955
MEAD, R. F.	988	MONT, —	634	NASH, A.	778
MEANS, T. A.	81, 763	MONTGOMERY, H. F.	87, 96, 408	NASH, R. B.	729
MEARS, G. W.	89, 144, 165, 438, 673, 926	MOODY, G. O.	987	NASH, W. M.	602, 604, 640
MEEKER, D.	186	MOON, W. P.	233, 441,	NAUMAN, A.	365
MEEH, A. R.	602, 623		442, 443, 449, 462, 468, 585, 586, 591, 596,	NEAL, E.	54, 217
MELCHER, S. H.	522, 524, 772		755, 760, 769, 771, 778, 785, 880, 883, 957,	NEAL, C. W.	836
MENZIES, S. G.	713		958, 981, 982, 984, 986, 988, 989, 990, 1008	NEFF, H. R.	969
MERCER, A.	315	MOORE, C. D.	683, 710, 747, 853, 976	NEFF, J.	773, 784, 785, 875, 986
MEREDITH, H. H.	732	MOORE, J.	141, 182, 467	NEIL, J.	410, 505, 583
MEREDITH, S.	604	MORD, —	766	NEILL, H.	548
MERRILLAT, W. C.	989	MOREHOUSE, G. R.	339	NEILL, J.	45, 66, 84, 88, 89, 250, 310, 356, 371,
MERRILL, C. S.	760, 773, 785, 984, 986	MOREL, J. S.	603		474, 538, 643, 757, 765, 769, 786, 837, 848
MERRILL, G. G.	234	MORGAN, D.	984	NELSON, A. W.	928
MERRILL, S. L.	765, 768	MORGAN, J. A.	523	NELSON, D. B.	258
MERRITT, D.	415, 420, 496, 537, 756, 948, 958	MORGAN, J. C.	449, 836	NELSON, J. C.	781
MERRITT, J. K.	936, 963	MORGAN, J. G.	644	NEW, G. W.	621, 623,
MERRON, J. M.	620, 701, 706, 709, 724, 725	MORONG, E. P.	451, 458, 577, 1008, 1009		628, 630, 698, 702, 705, 707, 728, 940, 974
MERRYWEATHER, H. C.	572, 679, 718, 745	MORRIS, F. D.	723, 732	NEWCOMBE, J. A.	80, 99,
MESSENGER, A. C.	557, 620,	MORRIS, G.	700		886, 307, 324, 671, 778, 790, 986
	683, 706, 747, 858, 951, 976	MORRIS, J.	446, 755, 781, 961, 984, 985	NEWCOMER, F. S.	926
METCALF, —	560	MORRIS, J. L.	712	NEWELL, S.	309
METCALF, G. W.	625, 629,	MORRIS, R.	560, 623, 679, 683,	NEUHAUS, C.	705
	699, 710, 711, 728, 729, 732		684, 701, 720, 731, 741, 744, 747, 858, 942	NEWLAND, B. J.	726
METCALF, J. G.	341	MORRISON, A. M.	734, 970	NEWMAN, A.	68, 454
MEYER, F.	309	MORRISON, F. W.	722	NEWTON, M. T.	542, 707
MICHEL, C.	603, 605	MORRISON, J. B.	443	NEWTON, W. S.	679
MICHLER, W. H. H.	972	MORRISON, J. M.	722	NEYMAN, A. M.	487
MIDDLETON, P.	688, 757, 982, 983	MORRISON, M. P.	733	NICHOLS, R.	151, 283, 340, 359, 418, 511, 918
MILES, B. B.	42, 49, 50, 187,	MORSE, G. M.	353	NICHOLS, H. W.	729, 730
	297, 647, 678, 756, 760, 768, 769, 774,	MORTON, —	976	NICHOLS, J.	447, 529,
	779, 781, 785, 786, 790, 876, 982, 989	MORTON, C. J.	300		567, 573, 667, 849, 888, 953, 955, 1002
MILES, F. T.	274	MORTON, C. S.	601, 605	NICHOLS, T. B.	313
MILHAU, J. J.	641, 716, 740, 938	MORTON, J. C.	440, 545, 642, 650, 986, 987	NICHOLSON, W. L.	312, 357, 414, 751, 756
MILIGAN, J. A.	602, 605, 606	MORTON, T.	704, 743, 745	NICOLASSEN, G. A.	65
MILLAR, R.	214, 544, 709, 722, 723, 724, 726	MORTON, T. G.	284,	NIGLAS, J. M.	706
MILLER, —	560, 703, 711, 743		400, 439, 441, 469, 590, 592, 646, 647,	NIMS, E. B.	558, 765
MILLER, A.	837		774, 785, 791, 867, 880, 989, 990, 1005	NOBLE, H. B.	93, 753, 755

LIST OF REPORTERS AND OPERATORS.

XI

	Page.		Page.		Page.
NOBLE, H. S.	674	PAGE, W. H.	89, 415, 1003	PHIELPS, A. J.	92, 333, 537
NOFSINGER, F. B.	586, 709, 731, 781	PAINE, —	259	PHIELPS, C.	142, 226, 288, 353, 408, 447, 672, 988
NORDMAN, L. E.	401	PAINE, A. M.	781	PHIELPS, E. E.	35, 309, 408, 673, 837, 968
NORDQUIST, C. J.	21, 310, 631, 730, 736, 887	PAINE, H. E.	768	PHIELPS, F. P.	134
NORRIS, B.	323, 376, 673, 830, 848	PAINE, O. S.	745	PHILLIPS, E.	724, 733, 743, 973, 976
NORRIS, W. F.	61, 245, 248, 313, 419, 468, 505, 538, 596, 634, 682, 765, 931, 988	PAINE, R. T.	626, 706, 711, 714, 715, 731, 742, 945, 968	PHILLIPS, G. W.	914
NORRIS, W. H.	756	PALM, P. R.	674, 833	PHILLIPS, H. A.	88
NORTH, A.	370, 421	PALMER, A. B.	264	PHILLIPS, J.	229, 498, 506, 590, 673, 885, 1001
NORTON, E. W.	725	PALMER, A. D.	677, 681, 729, 732, 968	PHILLIPS, J. H.	32, 214, 573, 590, 708, 720
NORTON, J. C.	247, 776	PALMER, G. S.	71, 133, 324, 506, 587, 616, 622, 639, 693, 703, 726, 759, 760, 783, 954	PHILLIPS, W. E.	974
NORTON, O. D.	988	PALMER, H.	85, 346, 495, 687, 755, 773, 818, 874, 882, 934, 957, 984, 986	PHILLIPS, W. H.	480
NORWOOD, E. M.	729	PALMER, H. H.	778	PHILLIPS, W. W. L.	360, 629, 888, 973
NOTSON, W. M.	65, 225, 234, 448, 469	PALMER, J. M.	223, 702, 708, 988	PIEK, A. T.	699
NOTT, J. C.	462	PALMER, T. M.	604, 605	PIERCE, B. G.	561, 634, 678
NOTT, T. E.	677	PALMER, W. H.	731	PIERCE, S. N.	266, 355
NOYES, G. H.	728	PANCOAST, G. L.	399, 400, 415, 444, 522, 525, 539, 541, 551, 565, 568, 585, 587, 688, 729, 780, 786, 809, 874, 877, 879, 880, 883, 885, 888, 890, 891, 937, 955, 958, 961, 963	PIERPONT, H.	411, 671, 866, 925
NOYES, J. F.	346, 566	PANCOAST, J.	579	PILLSBURY, J. M.	784
NUGENT, R. J. S.	982, 986	PARCHER, G.	785	PINDELL, J. T.	101
NUGENT, W.	732	PARK, C. B., JR.	627, 702, 727, 731, 738, 741, 745, 942, 952, 971, 973	PINEO, P.	464, 626, 710, 763, 764, 982
OAKES, T. F.	536, 555, 627, 677, 679, 680, 683, 703, 710, 711, 723, 726, 742, 743, 760, 941, 942, 943, 944, 945, 970, 976	PARK, W. H.	744	PINKNEY, H.	727, 856, 865
OAKLEY, L. W.	87, 627, 704, 705, 740, 741, 744, 745, 755	PARKER, F. G.	507	PIQUETTE, F. E.	32, 757, 761, 771
O'CONNELL, P. A.	368, 589	PARKER, F. L.	765	PLUMB, H.	702, 704, 714, 718, 730, 749
OCTERLONG, J. A.	37	PARKER, G. B.	953	PLUMB, S. H.	533, 541, 570, 572, 678, 680, 683, 684, 688, 704, 732, 733, 742, 855, 940, 943, 946, 947, 948
O'DONNELL, J. S.	912	PARKER, N.	406	PLUMMER, S. C.	624, 685, 700, 974
O'FARRELL, D.	774	PARKER, W.	533, 639, 650	POGUE, J.	339, 412, 536, 714, 765, 786, 856, 940, 947, 969, 972, 979, 1003
O'HARA, —	981	PARKS, —	798	POLIE, J. W.	789
OHR, C. H.	103, 194, 484, 763, 963, 990	PARMELEE, S. L.	281	POLLOCK, —	430, 989
O'KEEFE, D. C.	316, 456	PARR, A.	521	POLLOCK, A. M.	989
OLDEN, S. M.	772, 773, 952, 986	PARRIMORE, H. J.	602	POMERENE, J.	534, 713, 721, 727, 858
O'LEARY, C.	214, 693, 714	PATCH, L. N.	778	POMFRET, J. E.	288, 319, 725, 850, 862, 969, 1007
O'LEARY, R.	601, 604	PATFEN, J. R.	711	PONDRUM, Z. B.	710
OLIVER, G. P.	676, 709, 723, 733, 735, 942	PATTERSON, D. C.	678, 702, 709, 714, 724, 726, 976	POOLEY, J. H.	629
OLIVER, J.	678, 952	PATTERSON, J. W.	676	POPE, —	723
OLIVER, J. H.	223, 447, 936	PATZKI, J. H.	101	PORTER, C.	408
O'MEAGHER, W.	75, 139, 631, 940, 941	PAULLIN, G. M.	144, 293, 764	PORTER, C. H.	351, 410, 549, 741, 914, 937, 969, 972, 973, 976
O'NEV, E. H.	760, 764	PAYNE, H. R.	700, 709, 711, 722, 727, 733	PORTER, E. O.	743
O'REILLY, R. M.	105	PEABODY, A. G.	553	PORTER, F. G.	364, 522
O'REILLY, J. J.	768	PEABODY, J. H.	577, 582	PORTER, H. P.	91, 911
ORMSBY, O. B.	681, 726	PEACHV, S. E. G.	981	PORTER, M. O.	93
ORR, W. L.	214, 487	PEARCE, H.	650, 689, 984	PORTER, P. C.	768, 957, 981
ORTII, W. M.	144	PEARCE, T. J.	261	POST, A.	78
ORTON, J. G.	818	PEARSON, —	757	POST, L.	84, 165, 169
ORTON, S. H.	92, 313, 328, 354, 355, 539, 649, 692, 760, 763, 764, 773, 778, 784, 785, 790, 816, 860, 989, 1003	PEASE, R. W.	294, 850	POST, W.	989
OSBORNE, C. H.	490, 551, 642, 773, 987	PECK, E. D.	446	POTTER, A.	626
OSBORNE, H.	684	PECK, O. W.	451, 773, 984	POTTER, G. L.	531, 626, 632, 683, 700, 702, 706, 708, 710, 712, 714, 719, 721, 723, 725, 726, 728, 730, 742, 743, 747, 914, 944, 948, 973
OSBORNE, H. B.	564	PECK, W. F.	785	POTTER, J. B.	51
OSBORNE, J. D.	93, 315, 705, 938, 970, 977, 979	PEEBLES, R. S. J.	601	POTTER, W. W.	464, 466, 506, 538, 700, 716, 727, 733, 830, 939, 971
OSBORNE, W. F.	719	PEETS, G. H.	603	POTTINGER, J. H.	601, 604
OSMUN, L. M.	238	PEGG, C. H.	713, 914, 945	POTTS, G. J.	570, 681, 713, 726, 730, 738, 741, 745, 970
OTBEY, P. H.	606	PEIRCE, W. P.	355, 449, 452, 533, 541, 677, 730, 852	POTTS, T. R.	973
OTIS, G. A.	489, 624, 701, 703, 713, 725, 742, 760, 973, 976, 1008, 1009	PENN, J. N.	357	POWELL, —	605, 731
OTTERSON, W. C.	314, 359, 763, 779, 911	PERIN, G.	340, 776, 817, 818	POWELL, E.	524, 724, 747, 773, 790, 985
OTTHIE, C.	764	PERKINS, C. S.	972	POWELL, R.	400
OTTMAN, R.	525, 982, 987	PERKINS, J.	139, 146, 311, 469, 777	POWELL, W. B.	153
OULD, E. R.	420, 763, 998	PERLEY, T. F.	50	POWERS, E. M.	141, 260, 304, 474, 644, 766, 920
OWEN, D. C.	409, 937	PERRIN, G. W.	355, 365	POWERS, H.	416
OWENS, —	836	PERRY, I.	104	PRATT, F.	729, 744
OWENS, W.	1009	PERRY, J. G.	677	PRATT, J. F.	728
OWINGS, H. W.	408, 508, 671	PERRY, J. W.	707	PRATT, S. R.	982
OWINGS, T.	407, 920	PERRY, M. S.	439	PRAY, O. M.	460
PACE, W. C.	730	PERRY, R. J.	164	PRENTICE, F.	706, 722, 745
PACKARD, A. S.	347	PERRY, W. G.	938	PRICE, M. F.	710, 764, 768
PACKARD, J. H.	505, 596, 889	PETER, P.	145, 476, 488, 776, 778	PRICE, P. C.	958
PACKARD, N. J.	701	PETERS, D. C.	46, 49, 106, 144, 229, 248, 252, 267, 289, 326, 362, 366, 370, 511, 642, 715, 766, 831, 857, 985, 986	PRICE, R. E.	878, 959, 961, 1005
PAGE, C.	68, 217, 243, 251, 401, 420, 449, 470, 494, 541, 578, 617, 736, 739, 757, 760, 762, 765, 781, 784, 869, 876, 877, 935, 943, 983, 986, 990	PETTJOHN, N. J.	796	PRICE, R. N.	605
PAGE, C. G.	247, 443, 535, 778	PETTINOS, J. W.	785	PRIBETO, J.	760
PAGE, E. A.	595, 755, 759			PRINCE, D.	532, 974
PAGE, J. R.	602, 604				



	Page.		Page.		Page.
PRINCE, J. P.	182, 496, 560, 701, 708, 726, 727, 737, 742, 951, 977	RICE, J. M.	627, 713	ROHRER, B.	420, 444, 732, 744, 942, 969, 971
PROUT, J. L.	311	RICE, O. P.	712	ROLAND, —	300
PROVOST, W. G.	598, 700, 712	RICE, P. L.	768	ROLER, E. O. F.	595, 847
PRYER, W. C.	451, 778, 786, 981	RICE, W. H.	91, 709, 728	ROLLER, W. C.	713
PULLING, E.	786	RICH, W. B.	482	ROLLE, A.	681, 705, 757, 957, 981
PUTNAM, D. W.	144	RICHARDS, C. B.	571, 628, 702, 705, 708, 720, 724, 947, 948, 952, 979	ROLES, J. F.	768
PUTNEY, J.	505	RICHARDS, D.	971	ROMAYNE, J. A.	757, 772
QUICK, L.	163, 233, 250, 458	RICHARDS, F. P.	288	RONALDS, F.	1006
QUIDOR, J. E.	288	RICHARDS, J. C.	789	ROOT, J.	529
QUIMBY, S. J.	747	RICHARDSON, D. T.	601	ROOT, W. W.	536
RADCLIFFE, S. J.	918	RICHARDSON, J. R.	712	ROPER, F. C.	648, 989
RAINEY, J. R.	670	RICHARDSON, M. C. B.	692, 990, 1000	ROSE, F. M.	629, 944
RAMSAY, G. M.	324	RICHARDSON, N. S.	726	ROSS, J.	494
RAMSAY, W.	408	RICHARDSON, S. A.	373, 452, 689	ROSS, J. S.	496, 497, 618, 676, 677, 698, 701, 702, 724, 726, 938, 944, 949, 974, 979
RAMSEY, W. R.	577, 593, 712, 883, 968	RICHARDSON, W. F.	85, 470, 708, 724, 729, 738, 742, 972, 976, 977	ROSS, L. D.	408
RANDALL, B.	786	RICHINGS, C. H.	784	ROSSITER, J. P.	267
RANDALL, C. L.	781	RICHINGS, H.	506	ROUNDY, B. C.	680, 682
RANDALL, J. W.	407	RICHMOND, L.	778	ROWLAND, J. R.	214
RANDOLPH, J. F.	137, 272, 327, 773	RICHMOND, C.	143, 983	ROWLAND, C.	147, 227, 468, 494, 568, 1002
RANDOLPH, W. C. N.	896, 899	RICHMOND, C. H.	708	ROWLAND, M. C.	976
RANDOLPH, W. H.	984	RICHMOND, L. A.	366	ROY, G. G.	603, 604, 707
RANEY, —	757	RIDGWAY, F.	722, 974	ROYAL, W. W.	723
RANKIN, A. C.	329, 365, 981	RIDLEY, S. G.	834	RUGG, G. H.	889
RANKIN, D.	265	RIELLY, J. J.	982	RULISON, W. H.	99, 106, 441, 862
RANKIN, D. N.	215, 578, 580, 592, 763, 764, 1005	RILEY, C.	78	RUMBOLD, F. F.	1006
RANKIN, W. H.	603	RINGGOLD, —	571	RUSH, D. G.	52, 530, 532, 536, 539, 571, 576, 578, 581, 632, 642, 878, 987
RANNEY, G. E.	707, 785	RINGLER, E. H.	706	RUSSEL, —	332, 972
RANNEY, J. A.	626	RISLEY, —	889	RUSSELL, C. P.	639, 757, 772
RANSOM, J.	768, 771	RISTINE, H.	412	RUSSELL, E.	788
RAUCH, J. H.	231, 289, 340	RITCHEY, A. L.	745	RUSSELL, J.	146, 266
RAVOLD, J.	85	RIVERS, H. W.	370, 543, 544, 710, 722	RUSSELL, L.	785
RAWLINGS, J. W.	621, 631, 633, 731, 757	RIVES, —	620	RUSSELL, W. P.	638, 708, 710
RAWSON, C. H.	866	RIZER, M.	531, 536, 633, 634, 636, 640, 646, 649, 703, 706, 709, 711, 732, 747, 755, 763, 785, 854, 863, 864, 914, 935, 941, 942, 943, 946, 948, 969, 974, 979	RUTHERFORD, J. C.	486, 719
RAY, —	765	ROAN, —	679	SAAL, G.	308, 478, 495
RAYMOND, M. H.	625, 701, 706, 728, 974, 976	ROBARTS, J.	250, 323, 624, 679, 732, 748, 970, 983	SABINE, A.	684, 724, 729, 733, 738, 942, 946, 947, 948, 952
READ, J. B.	900	ROBBINS, H. L.	816	SAFFORD, E. D.	357
READ, L. W.	153, 238, 293, 364, 417, 707, 713, 718, 936, 941	ROBBINS, J.	409, 466, 827, 937	SAILER, R. H.	328
READ, W. H.	259	ROBBINS, J., Jr.	484	SALTER, F.	422, 633, 762, 817
REAGAN, A. W.	703, 708, 741, 751, 972, 974, 976	ROBBINS, L. H.	233	SALTER, H. F.	969
REAGAN, J. A.	757	ROBBINS, M. W.	533, 623, 701, 710, 712, 743, 944	SANBORN, J. E.	713, 732, 971
REAGLES, J.	724	ROBBINS, N. A.	168, 193, 788, 978, 984, 986	SANDERS, H.	361, 448, 470, 480, 778, 984
REAMER, F. C.	633, 679, 703, 742	ROBBINS, H.	408, 485	SANDERS, J. J.	626
REBER, C. T.	186, 722, 769, 773, 973	ROBERTS, H. C.	755	SANDS, —	785
REDFIELD, J. S.	146, 704, 733	ROBERTS, H.	408, 485	SANGER, E. F.	615, 723, 791, 837, 875, 982, 1009
REECE, M.	554, 647, 973	ROBERTS, H. C.	755	SARGENT, G. P.	789, 989
REED, —	550	ROBERTS, N. S.	624, 711, 766	SATTERLEE, D.	532
REED, M.	100	ROBERTS, W. E.	76, 982	SATTERLEE, R. S.	493
REED, T. B.	93, 163, 167, 225, 227, 267, 417, 885, 924, 936	ROBERTSON, —	644	SATTERTHWAITE, A.	300, 531, 706, 726, 732, 741
REESE, A. W.	1008	ROBERTSON, C.	629, 684, 741, 744, 752	SAUNDERS, J.	340
REESE, J. J.	346, 467	ROBERTSON, E. M.	784	SAUNDERS, W.	946
REEVE, J. T.	744, 750, 765	ROBERTSON, J.	137	SAWIN, W. J.	700, 702, 703, 706, 757
REEVES, E. M.	751	ROBILLARD, A.	777, 889	SAWTELLE, H. W.	354, 364, 594
REEVES, J. S.	676, 687, 710, 722, 732, 738, 751, 969	ROBINS, O. M.	738	SAWYERS, S. H.	357
REGAN, M. F.	683, 700, 722, 745, 747, 914, 941, 952, 973	ROBINSON, A. H.	672, 706	SAYRE, L. D.	213
REID, R. K.	971	ROBINSON, B. W.	279, 289, 515	SCARFF, W. D.	550, 886
REID, S.	550	ROBINSON, F. C.	451	SCHAPHIRT, E. F.	832
REILY, J.	558, 561, 677, 712, 725, 729, 854, 946, 948, 952, 973, 1005	ROBINSON, G. R. B.	701	SCHAPHIRT, F.	291
REITER, W. C.	618	ROBINSON, J. M.	828	SHELL, H. S.	368, 400, 444, 447, 452, 470, 471, 579, 772, 973
REX, G.	85, 135, 300, 406, 832	ROBINSON, P. G.	978	SHELTON, O. F.	712
REX, G. P.	713, 724, 969	ROBINSON, R. H.	623	SCHENCK, C.	331
REYNOLDS, F.	623, 752	ROBINSON, W.	757	SCHENCK, J.	984
REYNOLDS, L.	705, 709	ROBINSON, W. S.	415	SCHILEY, —	743
REYNOLDS, P. L. F.	575	ROBINSON, J. D.	753, 756	SCHMIDT, —	625, 692
REYNOLDS, W. B.	532, 732, 872	ROCHE, E. R.	733	SCHONBEIN, A.	706
REYNOLDS, W. D.	638	ROCKWELL, G. F.	1007	SCHONEY, L.	159
REZNER, W. B.	310, 680, 711, 719, 727, 857	ROCKWELL, P. G.	707	SCHREINER, —	785
RIBBLE, G.	956	RODDY, T. H.	912	SCHULER, M. H.	12
RICE, C. A.	606	RODGERS, J. H.	554, 556, 570, 678, 707, 710, 721, 948, 1006	SCHULTZ, L.	700, 727
RICE, J. A.	575	ROEHRIG, F. S. O.	439	SCHUPPERT, M.	554
RICE, J. B.	854	ROGERS, E. M.	744, 751, 971, 972	SCHUSSLER, C.	37, 557, 971
RICE, J. H.	312	ROGERS, J. K.	31, 778, 781	SCOBAY, W. E.	701
		ROGERS, R. J.	551	SCOFIELD, D.	142, 744
		ROGERS, S.	383, 629		

## LIST OF REPORTERS AND OPERATORS.

XIII

	Page.		Page.		Page.
SCOTT, H. S.	141, 146	SKINNER, S. W.	970	SPENCER, W. M.	616
SCOTT, I.	250, 559, 670, 714, 726, 827, 940, 941, 945, 949	SKINNER, W. M.	148	SPIEGELHALTER, J.	727, 729, 733
SCOTT, J. W.	756	SLAUGHTER, R. C.	732	SPINNEY, A. B.	232
SCOTT, W.	973	SLOAN, J.	453, 528, 541, 576, 771, 778, 779, 874, 877, 983, 984	SPINZIG, C.	721, 763
SCOTT, W. D.	722	SLOAT, G. E.	968	SPOHN, H.	618
SCOVEL, J. B.	565	SLOCUM, J. O.	701, 977	SPOONER, H. K.	557, 563, 676, 710
SCUDDER, S. O.	401, 997	SLUSSER, L.	557, 705, 725, 727, 741	SPRAGUE, A. G.	748, 952
SEABROOK, A. M.	601	SMALL, H. N.	704, 730, 940, 974	SPRAGUE, F. L.	467
SEARLE, I. H.	174	SMILEY, T. T.	234, 642, 688, 699, 713, 773, 984	SPRAGUE, G.	729
SEARLE, W. S.	530	SMITH, —	259, 534, 969	SPRAGUE, H. M.	345, 469, 759, 760, 773, 785, 913, 983, 984, 987
SEAVENNS, J.	627	SMITH, A. A.	453, 542, 728, 773, 961, 986	SPRAGUE, S. L.	89, 183
SEAVEY, H. H.	989	SMITH, A. H.	723, 987	SQUIRE, T. H.	95, 140, 155, 227, 271, 370, 379, 391, 506, 570, 705, 707, 716, 720, 726, 733, 734
SEHLBACH, C.	67	SMITH, A. J.	768, 876	SQUIRES, R. A.	485
SEMPLE, J. E.	467, 681, 699, 730, 877, 984, 1001	SMITH, A. K.	586	STAEHL, B. F.	488
SEVERGOOD, J.	77, 341	SMITH, C. H.	922	STAIL, D.	42, 155, 647, 755, 912, 914
SEVERY, J. B.	439	SMITH, D. P.	3, 48, 259, 416, 466, 541, 543, 544, 577, 586, 587, 642, 643, 735, 756, 760, 764, 767, 785, 876, 877, 878, 882, 951, 981, 986, 1010	STANCHFIELD, J. K.	447
SEYFFARTH, E.	479, 647, 693, 768, 785, 791	SMITH, E. A.	147, 227, 358, 371, 387, 412, 549, 790	STANFORD, R. L.	42, 371, 453, 469, 625, 680, 762, 773, 791, 934, 962
SEYMOUR, F.	590, 592, 756, 763, 981, 982, 985	SMITH, E. H.	602, 604, 828	STANTON, D.	574, 624, 667
SEYMOUR, F. A.	764	SMITH, E. N. B.	831	STANTON, J. O.	272, 354, 364, 464, 500, 673, 832, 836, 882, 883, 958
SEYMOUR, H. M.	231	SMITH, G. C.	91	STANWAY, J. H.	679
SEYS, H. H.	422	SMITH, G. K.	466, 518, 1002	STAPLE, P.	265
SEXTON, S.	78	SMITH, G. M.	784	STAVELY, W. R.	771, 789, 876, 900
SHACKLEFORD, J.	1006	SMITH, G. W.	483, 929	ST. CLAIR, A. K.	700, 725, 744, 853
SHANNON, T. J.	721, 725	SMITH, H. C.	979	STEARN, H. P.	453, 773, 982
SHAPLEY, W. W.	769, 951	SMITH, H. E.	683, 722	STEARN, I. H.	355, 484, 538, 569, 570, 941
SHARP, J. A.	470, 539, 768	SMITH, H. H.	300	STEARN, I. Q.	362
SHARPE, R.	49, 289, 549, 711, 755, 780, 891, 941	SMITH, I. P.	760	STEARN, J. J.	591, 617, 761, 786, 877, 988
SHAW, A.	977, 989	SMITH, J. E.	248, 446, 755	STEBBINS, B. A.	707
SHAW, B. T.	910	SMITH, J. P.	413	STEBBINS, G. S.	169, 648
SHEARDOWN, S. B.	989	SMITH, J. P. A.	79	STEELE, A.	140
SHEARER, M. M.	352	SMITH, J. R.	367, 389, 422, 547, 931	STEELE, H. K.	1005
SHELDON, A. F.	147, 315, 495, 524, 549, 567, 577, 578, 579, 585, 644, 650, 757, 759, 763, 769, 771, 773, 778, 779, 877, 878, 928, 961, 982, 983, 984, 985, 986, 987	SMITH, J. S.	238, 267, 280, 643, 830	STEELE, J. E.	648, 790, 889, 988, 989
SHELDON, H. L.	406, 493, 524, 586, 639, 724, 971, 973	SMITH, J. T.	558, 734, 973	STEGMAN, G.	308
SHERMAN, A. N.	685	SMITH, L.	45, 146	STEIN, C.	620
SHERMAN, B. F.	362, 419, 507, 672	SMITH, M. A. M.	785	STEIN, G. S.	782, 789
SHERMAN, M. G.	413, 706, 708, 711, 969	SMITH, O.	968	STEINER, G.	746
SHERMAN, N.	406	SMITH, O. I.	78	STEPHENS, A. H.	727, 755, 970
SHERMAN, S. N.	467, 725, 791	SMITH, R. A.	406	STEPHENSON, B. F.	455, 676, 678, 707, 743, 974
SHERWOOD, T. H.	367, 369, 371, 387, 407, 412, 447, 538, 691, 871, 884, 885, 924	SMITH, S.	83, 289, 495, 650, 672, 789, 951	STERLING, A.	448, 525, 785
SHIMER, J. C.	218, 867, 875	SMITH, S. D.	601	STERNBERG, G. M.	175, 214
SHINDLE, D. W.	783	SMITH, S. M.	342	STEVENS, G. T.	94, 215, 496, 526, 528, 531, 555, 559, 635, 636, 680, 681, 701, 703, 704, 705, 710, 711, 724, 725, 728, 730, 735, 737, 745, 747, 760, 765, 853, 855, 941, 942, 947, 948, 949, 969, 972, 974, 976, 977, 978, 979, 1008
SHINE, W. F.	601	SMITH, S. P.	976	STEVENS, H.	712
SHIPPEN, E.	289, 315, 319, 556, 633, 705, 708, 745, 785, 817, 863	SMITH, T. B.	165, 281, 358, 455, 486, 580, 669, 674	STEVENS, N. C.	511
SHITTLER, O.	282	SMITH, T. C.	536, 706, 715, 725, 873, 961	STEVENSON, R. R.	633
SHIVERS, J. K.	361	SMITH, T. F.	101, 142, 226, 288, 289, 354, 371, 408, 410, 505, 506, 568, 567, 617, 672, 848, 868, 869, 911, 936, 1001	STEWART, —	977
SHORT, W.	146, 266	SMITH, T. H.	340	STEWART, J. L.	356, 462, 764
SHOYER, C. C.	756	SMITH, W. A.	744	STEWART, J. T.	713
SHRADY, G. F.	318, 567, 698, 740, 836, 935, 936, 938	SMITH, W. R.	742	STEWART, P.	568
SHRADY, J.	288, 374, 786	SMITH, W. T.	625	STEWART, W. D.	47, 313
SHUFFORD, T. B.	602	SMULL, W. G.	11, 139, 769	STICKNEY, J. E.	408
SHULTZ, S. S.	214, 316, 374	SMYSER, E. M.	718, 979	STILLE, A.	596
SHURLOCK, W. C.	496, 536, 683, 700, 702, 707, 708, 713, 719, 722, 729, 741, 742, 745, 747, 771, 858, 946, 949, 969, 973, 974, 977, 979	SNEAD, A. H.	602, 899	STILLWELL, J. H.	216
SHUTT, A. A.	972	SNIVELY, J. N.	984	STILLWELL, T. H.	768
SIDNEY, R. O.	642	SNOW, C. W.	46, 96, 363, 484, 836	STILWELL, J. A.	532
SILLIMAN, H. R.	170	SNOW, E. S.	973	STIMMEL, M. A.	331
SIM, T.	954	SNOW, G. W.	535, 677, 712, 725, 744, 940, 952, 971	STINSON, C. W.	765, 771, 789
SIMONS, J.	306, 546	SNOW, T. H.	787, 882	STOCKDELL, G. L.	469, 771
SIMONS, O. H.	314, 1001	SOELLHEIM, C.	560, 676, 708, 755	STOCKER, A. A.	700, 946
SINCLAIR, L.	545, 688, 771, 786, 787, 788	SOMERS, W.	412	STOCKWELL, C. M.	936
SINGLETON, W.	76	SORRELL, F.	915	STONE, —	769
SKER, J. D.	760	SPAIN, A. W.	970	STONE, B.	420, 513, 981
SKIFF, G. V.	725	SPARKS, J. B.	635, 751, 968	STONE, H.	753
SKILLERN, S. R.	989	SPARROW, W. E.	958	STONE, L. R.	243, 763, 772, 982, 989
SKILLING, J. D.	921	SPAULDING, P.	1003	STONE, R. K.	372, 387, 494
SKILTON, J. A.	572, 623, 712	SPAYD, C. W.	440	STONE, S. E.	748
SKINNER, J. F.	467, 837	SPEER, A. M.	187, 186	STONE, V. R.	702, 910
SKINNER, J. O.	704	SPENCER, J.	408, 564	STONELAKE, A. B.	80
		SPENCER, J. A.	183, 680, 744, 747, 766, 946	STORROW, S. A.	289, 315, 460, 691, 957
		SPENCER, T. R.	87, 267, 309, 310, 358, 361, 368, 408, 484, 637, 689, 788, 847, 861	STORRS, M.	370, 385, 560, 711, 732, 849, 853, 864
		SPENCER, W.	763		



	Page.		Page.		Page.
STOVELL, M.	775	THACKER, W. H.	756	TRAU, A.	471, 511
STRACHAN, J. B.	604	THAYER, A. H.	82	TRAUTMAN, C. F.	358, 545, 772, 984
STRADER, J. C.	704	THAYER, S. W.	309, 832	TREADWELL, J. B.	86, 224, 311, 361, 412, 415, 566, 838
STRATCH, —	626	THAYER, W. H.	725	TREADWELL, P.	506, 936
STRATTON, R. F.	33	THOM, W. H.	762, 763, 772, 784	TREGANOWAN, A.	710
STREETER, B. G.	639, 681, 710, 712	THOMAIN, R.	70, 639, 764	TREMAINE, W. S.	757
STREETER, H. S.	648, 692	THOMAS, C. F.	974	TRENOR, J., JR.	52, 168, 265, 328, 387, 411, 925
STREETER, J. H.	95	THOMAS, D. W.	605	TRESKATIS, G.	259
STRICKLAND, H.	356	THOMAS, E. C.	729	TRIPLER, C. S.	231, 905
STRODE, E. C.	693, 720	THOMAS, H. L.	600, 896, 900, 1005, 1012	TRIPLET, C. E.	621, 722, 728
STRONG, H.	727, 765, 771	THOMAS, J.	560, 626, 732, 972	TRIPLET, W. H.	989
STRONG, J., JR.	245	THOMAS, J. W.	985	TROWBRIDGE, G. M.	725
STROTHER, C. G.	729, 804, 969	THOMAS, M. W.	10	TROWBRIDGE, W. H.	77, 78, 527
STROWBRIDGE, J. G. F.	788, 984	THOMAS, R.	949	TRUE, W. H.	676, 777, 958, 973, 982, 986
STUART, F. H.	170, 182	THOMAS, W. B.	406	TRULL, W. B.	219, 635, 745, 748, 763, 768, 781, 784, 946
STUB, N.	50	THOMPSON, —	984	TRUMPORE, G. D.	988
STUBBS, G. E.	958, 963, 989	THOMPSON, A.	676	TRYON, A. W.	252, 418, 735, 834
STUCKSLAGER, C. R.	725	THOMPSON, E. B.	765	TRYON, J. R.	316
STUDDIFORD, T. H.	986	THOMPSON, E. W.	75	TUCKER, M.	739, 744, 944, 979
STUDY, J. M.	232, 266, 436, 454, 469, 571, 578, 689, 763, 868, 878, 988, 1004	THOMPSON, G. K.	309, 708	TUFT, R. H.	192
STULL, T. W.	551, 712	THOMPSON, J.	546, 770	TURNER, C. M.	1005
STURDEVANT, S. B.	105, 296	THOMPSON, J. F.	138, 414, 692, 747, 778, 989	TURNER, J. H.	755
STURGIS, J. G.	288	THOMPSON, J. G.	158, 414, 572, 714	TURNER, O. C.	982
STURGIS, W.	763	THOMPSON, J. H.	577, 579, 680, 700, 708, 711, 729, 756, 776, 777, 790, 984	TURNER, S. F.	601, 604
STYER, C.	983	THOMPSON, J. W.	332, 418	TURNER, W. D.	510, 708, 731
SUCKLEY, G.	411, 587	THOMPSON, S. W.	988	TURNER, W. E.	701
SUESSEROTT, J. L.	254, 284, 594	THOMPSON, T.	756	TURNEY, S. D.	283, 533, 536, 765, 856, 857, 874
SULLIVAN, D. F.	680	THOMPSON, T. H.	787	TUTTLE, H. B.	533, 624, 678, 707, 733, 948, 977
SULLIVAN, G. R.	722, 731, 737, 755, 968	THOMPSON, W. S.	62, 497, 856, 947, 968, 970, 972	TWIFORD, W. H.	683, 700, 713, 723, 777, 945, 947, 951
SULLIVAN, J. H.	711	THOMSON, W.	11, 190, 219, 222, 234, 242, 243, 244, 247, 249, 338, 339, 402, 446, 447, 449, 470, 482, 488, 490, 493, 528, 529, 538, 539, 634, 643, 698, 757, 768, 770, 862, 924, 931	TWISS, E.	308
SULLIVAN, J. T.	970	THORN, J.	789	TYSON, J.	770, 989
SUMMERS, J. E.	672, 755, 764, 772, 982	THORNDIKE, W.	621, 700, 706, 712, 725, 947	UHLER, A. S.	988
SUTTON, G. L.	324, 464, 509	THORNE, J.	142, 889	UHLER, J. R.	639, 642, 684, 711, 740, 744, 747, 755, 981, 987
SUTTON, H. H.	312, 341, 529, 781	THORNE, S. S.	356, 364	ULRICH, C. F.	971, 977
SWAIN, E. S.	976	THORNE, W. H.	407, 469, 727, 816	UMBERGER, E. R.	704, 726, 728, 971, 985
SWALLOW, —	706	THORNHILL, S. P.	622, 701, 971	UPHAM, T. B.	687
SWART, J. I.	355, 410	THORNTON, T. C.	971	UPJOHN, W.	756
SWARTZ, D. J.	775, 988	THORPE, J. C.	442, 557, 734, 777, 778, 957, 983	UPPERMAN, E. F.	416
SWARTZWELDER, A. C.	469, 818	THRECKELD, W.	45	UTTER, A.	723
SWASEY, C. E.	359, 639, 743, 745, 979, 986	THRIFT, R. W.	772	VALENTINE, S. B.	977
SWATES, —	785	THURM, E. W.	714	VALK, W. W.	755, 760, 987
SWEENEY, R. L.	1005	THURSTON, A. H.	347, 373, 737, 885	VAN AERNAM, H.	676, 970, 973
SWEET, J.	449, 686, 687	TIBBITTS, W.	974	VAN ALSTYNE, J. L.	957
SWEET, N.	248	TILTON, H. R.	354, 777	VAN BUREN, W. H.	264
SWEET, O. P.	760, 879, 957, 963	TINDLE, R. M.	533	VAN BRUNT, J. W.	914
SWEETING, M. F.	147	TINSLEY, —	987	VANCE, T. J.	142, 591
SWIFT, E.	82, 328, 417, 456, 674, 713, 957, 1007	TIPTON, R. H.	724	VAN DELL, —	620
SWIFT, F.	626, 812	TIPTON, T. C.	368	VANDEKIEFT, B. A.	91, 226, 277, 289, 296, 315, 363, 368, 410, 411, 454, 508, 510, 593, 638, 640, 644, 650, 678, 691, 699, 739, 830, 875, 878, 921, 928, 981
SWINBURNE, J.	529, 531, 533, 561, 676, 678, 679, 837	TODD, —	859, 940, 957	VANDER VAART, S.	768
SWINDELL, —	756	TODD, C. H.	525, 560, 706, 728, 772	VAN DERVEER, A.	425, 706, 708, 939, 946, 972
TAGGART, J. F.	706	TODD, C. W.	451	VANDERVEER, H. F.	702, 745
TAYLOR, —	707	TODD, G. R. C.	914	VAN DUSER, A. E.	293
TAYLOR, A.	605	TODD, J. M.	34	VAN DUYN, A. C.	136, 448, 680, 764
TAYLOR, B. R.	723	TOLERTON, J.	737, 756	VAN GILSON, R. E.	1002
TAYLOR, D. W.	725	TOLLES, L. C.	146	VAN INGAN, J. L.	973
TAYLOR, E. F.	440, 447, 453, 521	TOMPKINS, H. C.	881	VAN METER, J. N.	972
TAYLOR, G.	336, 848	TOMPKINS, O. A.	354	VAN NORDEN, T. L.	374, 678, 764, 986, 988
TAYLOR, G. K.	312, 411	TORREY, I. A.	707	VAN NOSTRAND, A. H.	763, 935
TAYLOR, H. C.	215, 529	TOWARD, J. W.	484, 1003	VAN RENSSELLER, J. J.	723, 744
TAYLOR, H. G.	747, 978	TOWER, C. C.	776	VAN RENSALEAR, H. A.	452
TAYLOR, J. H.	16, 382, 408, 413, 460, 622, 873, 951	TOWLE, S. K.	731	VANSANT, J.	578, 877
TAYLOR, J. S.	683, 720, 723	TOWNSEND, T. B.	372	VAN SLUYCK, D. W. C.	440, 508
TAYLOR, J. T.	89, 285	TOWNSEND, E. P.	763, 982, 984	VAN STEENBERG, W.	567, 972
TAYLOR, J. W.	786, 985	TOWNSEND, M. M.	763, 982, 984	VAN TAGEN, C. H.	761
TAYLOR, J. Y.	734	TOWNSEND, M. W.	363, 725, 751, 970	VANVALZAH, J. W.	106
TAYLOR, L.	397, 442, 458, 929	TOWNSEND, T. B.	650, 778, 784	VAN VOAST, G. W.	524
TAYLOR, M. K.	234, 355, 421, 487, 678, 777	TOWNSEND, W. E.	273, 309, 671	VARIAN, W.	166, 415, 847, 874, 955, 958
TAYLOR, R. R.	32, 261, 418, 422, 449, 773, 986, 989	TOWNSEND, W. P.	326, 1003	VAUGHAN, E. J.	939
TAYLOR, V. O.	452	TOZIER, I. L.	165	VAUGHN, A. C.	742
TEATS, S.	587, 735, 787, 788, 874, 935, 990	TRACY, L. E.	760	VEDDER, J. H.	812
TEED, J. L.	37, 628, 755	TRACY, S.	317		
TEFFT, J. E.	679, 970	TRADER, J. W.	340, 564, 827		
TERRELL, J. J.	605	TRAFTON, C. L.	973		
TERRY, —	335	TRANSUE, A.	445		
TERRY, C.	278				

LIST OF REPORTERS AND OPERATORS.

XV

	Page.		Page.		Page.
VERDI, C. S.	983	WEBBER, N. W.	346, 566	WILBUR, G. A.	466, 484, 836
VEST, J. W. H.	730, 733, 742	WEBSTER, W.	24, 136, 304, 344, 354, 419, 436, 451, 456, 458, 471, 541, 576, 583, 646, 759, 760, 763, 773, 785, 790, 809, 882, 935, 981, 989, 1000, 1009	WILBUR, W. H.	756
VINCENT, O. J.	911	WEBSTER, W. A.	618, 620, 730	WILBURN, W. L.	961
VOGLE, E.	765	WEBSTER, W. S.	764, 777, 784	WILCOX, C. H.	708, 970
VOIGHT, C. B.	923	WEEKS, G. R.	142, 272, 458	WILCOX, L. K.	741
VOLLUM, E. P.	367, 506	WEEKS, J. F.	784	WILCOX, W. F.	92
VON HARLINGER, R. L.	712, 729, 731	WEIR, R. F.	65, 79, 82, 154, 227, 241, 253, 292, 358, 370, 420, 421, 481, 499, 506, 507, 555, 642, 644, 717, 740, 757, 846, 851, 865, 867, 870, 874, 875, 876, 878	WILDER, A. M.	48, 289, 339, 436, 448, 556, 569, 570, 572, 629, 679, 683, 719, 948, 949, 970, 973, 977
VOORHIES, —	778	WEISEL, D.	134	WILDER, B. G.	535
VOORHIES, L. B.	988	WEISSE, P. D.	760	WILEY, M.	724, 738
YOSBURG, H. D.	448, 469, 760, 765, 982	WEIST, J. R.	531, 537, 703	WILEY, W.	346
YOSBURG, W.	637, 703, 727, 851, 853	WELBORN, W. P.	741	WILKINS, D.	973
VOYLES, D. W.	701	WELCH, A.	362	WILKINSON, T. B.	732
WADDLE, W.	523, 1001	WELCH, W. M.	261	WILLARD, S. D.	226
WADE, —	969	WELCH, W. W.	347	WILLET, J.	914
WADE, C. H.	688	WELCOME, J. W. B.	261	WILLETTTS, A. J.	743
WADE, D. C.	87	WELD, F. M.	413, 636, 707, 726, 728, 743, 946, 952, 971, 977	WILLEY, S.	870
WAGGONER, J. S.	420, 615	WELDON, S. J.	340	WILFORD, A. N.	976
WAGNER, C.	92, 319, 368, 440, 543, 574, 578, 650, 756, 764, 770, 772, 785, 870, 877, 882, 886, 888, 820, 957, 981, 997	WELLES, W. L.	102, 442, 591, 644, 876, 929	WILLIAMS, —	719, 741
WAGNER, L. P.	79, 84, 358, 817, 920, 972	WELLING, E. L.	307, 430, 708	WILLIAMS, J. W.	150, 526, 621, 675, 677, 708
WAGONSELLER, S.	354	WELLS, J. B.	764	WILLIAMS, P. O.	144
WAKEFIELD, J. L.	417	WELLS, L.	769	WILLIAMS, S. T.	760, 768
WAKEFIELD, W.	774	WELLS, R. A.	834	WILLIAMS, T. B.	943
WALKER, A. C.	742	WELSH, W. S.	419, 714, 744, 777, 970, 972, 1005	WILLIAMSON, J.	886
WALKER, E. S.	145	WELTER, —	889	WILLIS, W. P.	367
WALKER, G. S.	548, 555, 701	WENTWORTH, C. E.	743	WILLIS, W. S.	719
WALKER, J. B.	92, 779	WENTZ, J. S.	482, 760, 958, 959	WILLOUGHBY, H. W.	743
WALKER, J. P.	968	WEST, G. S.	561, 635, 651	WILSEY, J.	701
WALKER, S. A.	357	WEST, S. B.	182	WILSON, A.	556, 946
WALKER, W. T.	974	WEST, W. F.	706	WILSON, B. B.	192, 239, 337, 469, 668, 682, 760
WALL, J. C.	733	WESTERLING, R.	879, 882, 883	WILSON, C. B.	1009
WALLACE, W. M.	356	WESTFALL, J.	617, 703, 710, 742, 914	WILSON, C. I.	624, 753, 816, 936
WALLEN, J.	757	WESTMORELAND, W. F.	604, 897	WILSON, C. L.	342, 731
WALLS, A. M.	603	WESTON, J. C.	408, 447, 615, 837	WILSON, C. R.	603
WALSII, J.	35	WETHERLEY, —	742	WILSON, E. M.	757
WALSII, R. S. L.	307	WEY, W. C.	969, 982	WILSON, G. M.	409
WALTER, A. G.	648	WHEELER, C.	626	WILSON, J.	255, 576, 579
WALTER, W.	308	WHEELER, G. A.	146	WILSON, J. C.	362, 723
WALTON, C. J.	571, 634, 683, 700, 723, 725, 737, 745, 747, 855, 857, 917, 971, 977	WHEELER, J. H.	287, 672	WILSON, J. F.	988
WALTON, G. E.	471	WHELAN, A. F.	54, 254, 413, 496, 622, 700, 708, 731, 732, 737, 859, 969, 971, 974	WILSON, J. H.	732
WALTON, W.	723	WHINSTON, E. A.	703	WILSON, J. P.	456, 487
WARD, A. J.	306, 372, 418, 445, 460, 507, 671, 703, 706, 710, 727, 764	WHITAKER, J. M.	988	WILSON, J. R.	310, 968
WARD, G. M.	646	WHITE, A. A.	531, 537, 585, 623, 626, 629, 701, 702, 703, 718, 720, 724, 725, 737, 749, 751, 855, 973, 977, 986	WILSON, J. S.	757, 799
WARD, J.	967	WHITE, A. D.	785, 957, 981	WILSON, N.	709
WARD, S. B.	447, 688, 981, 982	WHITE, C. M.	702, 733	WILSON, P.	878, 958
WARD, S. C.	757	WHITE, E.	777	WILSON, W. H.	1009
WARD, W. L.	707	WHITE, E. G.	579, 777	WILSON, W. J.	145
WARD, W. S.	471	WHITE, E. M.	727	WINDELL, J.	166
WARDNER, H.	83, 136, 142, 197, 252, 266, 315, 358, 526, 817, 827	WHITE, H. B.	453, 470, 638, 769, 786	WING, —	731
WARNER, O.	596, 883, 885, 890, 959, 1004	WHITE, J. F.	312	WINNE, C.	652, 744, 749, 988
WARREN, B. S.	95, 925, 1004	WHITE, J. S.	730	WINNE, C. K.	701
WARREN, D. H.	764, 983	WHITE, W. B.	761	WINSLOW, G. F.	747
WARREN, F. G.	702, 707, 724, 730, 745	WHITE, W. H.	732	WINSLOW, J.	988
WARREN, J. M.	345, 398	WHITE, W. J. H.	641	WIQUHART, G.	562
WARWICK, J. B.	676, 703	WHITE, W. V.	556, 727, 728, 853, 952, 969, 982	WIRTH, R.	983
WASHBURN, C. E.	704	WHITEHEAD, P. F.	621	WIRTZ, H.	701
WATERMAN, L. D.	790	WHITEHILL, J. C.	364, 463, 532	WISE, J. C.	205
WATERS, E. G.	65, 66, 226, 228, 232, 233, 327, 372, 420, 453, 508, 671, 771, 786, 834, 837, 963, 982, 989	WHITEHOUSE, J. H.	419	WISHART, J. W.	307, 351, 408, 451, 532, 552, 556, 559, 564, 570, 574, 618, 620, 624, 625, 626, 627, 628, 629, 630, 631, 633, 634, 635, 653, 700, 702, 703, 704, 705, 706, 707, 708, 710, 711, 713, 714, 719, 720, 721, 723, 726, 731, 733, 737, 741, 744, 748, 940, 942, 946, 954, 969, 972, 973, 976, 977
WATERS, E. M.	623	WHITFORD, J. H.	943	WITHERS, M. A.	929
WATKINS, E. V.	287	WHITNELL, D. T.	707, 724	WITSELL, C.	604
WATSON, A. T.	148, 214	WHITNEY, A. W.	703, 710, 744, 972, 973	WITT, W. B.	713
WATSON, B. A.	336, 549, 561, 847, 941	WHITNEY, J. J.	557	WOLCOTT, S. C.	785
WATSON, T. J.	969	WHITNEY, L. M.	670	WOLF, F.	626, 679
WATSON, W.	304, 510, 641, 644, 706, 747, 765, 771, 976, 982	WHITON, H. B.	531, 733	WOLFE, D. E.	624, 712, 777, 972
WATTS, —	914	WHITTIER, S. C.	968	WOLFE, J. A.	533, 726, 957
WAY, W. R.	265, 730	WHITTIMORE, H. H. F.	1001	WOLFLEY, W. J.	312
WAYSON, G. W.	870	WIGHT, T. M.	387	WOLHAUPTER, D. P.	756, 777, 780, 781, 786, 881, 988
WEAVER, C. H.	773	WILBER, G. D.	679, 702	WOLVERTON, J. W.	988
WEAVER, J. M.	722, 732, 947			WOLVERTON, W. D.	70, 883
WEBB, J. T.	712			WOOD, A.	857



	Page.		Page.		Page.
WOOD, C. S.....	86, 183,	WOODWARD, B.....	151, 778, 920	WYNKOOP, A.....	368, 957, 962
620, 622, 625, 627, 629, 634, 642, 704, 706,		WOODWARD, J. B.....	288	WYNNE, J. J.....	1012
708, 709, 710, 713, 714, 720, 726, 738, 751,		WOODWARD, J. J.....	791	WYNNE, W. B.....	714, 741, 970
757, 760, 764, 851, 968, 969, 976, 984, 1006		WOODWORTH, B. S.....	351	WYTHES, W. W.....	692
WOOD, E. H.....	602	WOODWORTH, J. M.....	122, 342, 348, 564, 724, 937	YANDELL, —.....	757
WOOD, G. P.....	487	WOODWORTH, M. C.....	243, 786	YARROW, T. J.....	989
WOOD, J. R.....	78	WOOLSTON, E. B.....	755, 757	YATES, L. R.....	791
WOOD, W. L.....	84	WOOSTER, S. R.....	289, 667, 737, 945	YEATES, H. H. P.....	468, 757
WOODBRIDGE, T.....	79	WORTMAN, J. D.....	792	YEATON, G. C.....	430
WOODBURY, H. E.....	99, 465	WRIGHT, C. B.....	133	YELK, —.....	709
WOODEN, J. L.....	764	WRIGHT, D. F.....	570, 707	YORK, I. H.....	53, 577
WOODHULL, A. A.....	176, 221, 479,	WRIGHT, E.....	315	YOUNG, —.....	679, 700, 721, 743
488, 511, 513, 527, 549, 619, 641, 762, 766, 962		WRIGHT, G. W.....	340, 466	YOUNG, D. S.....	704, 720, 741, 743
WOODHULL, A. W.....	315, 415, 713	WRIGHT, J. J. B.....	204	YOUNG, J. A.....	567
WOODMAN, L. O.....	492	WRIGHT, J. P.....	266, 779	YOUNG, O. H.....	689
WOODRUFF, E.....	745, 771, 982	WRIGHT, R. N.....	310	YOUNG, P. W.....	558
WOODRUFF, H. T.....	837	WRIGHT, T. J.....	33, 62	YOUNG, S. J.....	452, 536, 943, 952, 969
WOODS, H. S.....	419	WRIGHT, W. M.....	366, 778, 930, 983	YOUNGLOVE, J.....	632, 747, 773
WOODS, J. T.....	146, 263, 536, 542, 710, 712, 864	WYER, J. P.....	455, 761	YUNDT, W. S.....	945
WOODS, L. P.....	676	WYLIE, F.....	703, 723, 747	ZEARING, J. R.....	730, 853, 1004
WOODS, P. N.....	45, 731, 978	WYLIE, J. D.....	330	ZERMAN, F.....	552
WOODS, W. S.....	69, 239, 742	WYNER, W. D.....	578, 709, 781	ZIPPERLEN, A.....	766, 983

# LIST OF PLATES.

---

1. PLATE I, facing p. 23. RUPTURE OF THE JEJUNUM BY THE KICK OF A HORSE. Case of Frank R—, page 23, Spec. 6188. (Woodburytype or Photo Relief Print.)
2. PLATE II, facing p. 72. ENTEROGRAPHY FOR A SHOT WOUND OF THE ILEUM. Specimen 4390, case of W. W—, p. 72. (Woodburytype.)
3. PLATE IV, facing p. 77. FÆCAL FISTULA AFTER SHOT PERFORATION OF THE ASCENDING COLON. Case of Harsh, p. 77. (Chromolithograph.)
4. PLATE V, facing p. 81. CICATRICES AFTER SHOT PERFORATIONS OF THE ABDOMEN. *Two figures.* FIG. 1, case of Morell, p. 80. FIG. 2, case of Corson, p. 213. (Lithograph.)
5. PLATE III, facing p. 113. SHOT WOUND OF THE ILEUM CLOSED BY THE CONTINUED SUTURE. Specimen 4389, case of W. W—, p. 72. (Woodburytype.)
6. PLATE VI, facing p. 133. METASTATIC FOCI IN THE LIVER. Case of Fole; to be related in the *Third Surgical Volume.* (Chromolithograph.)
7. PLATE X, facing p. 181. HERNIA OF THE JEJUNUM THROUGH A SHOT PERFORATION. Spec. 1604, case of F—, p. 184. (Woodburytype.)
8. PLATE XI, facing p. 205. RUPTURE OF THE ILEUM BY THE KICK OF A MULE. Spec. 6269, case of S—, p. 205. (Woodburytype.)
9. PLATE XXXVI, facing p. 212. SHOT PERFORATION OF THE RIGHT ILEUM. Specimen 2869. (Woodburytype.)
10. PLATE XXXIV, facing p. 221. CARIOUS SHOT FRACTURE OF THE RIGHT ILIUM. Specimen 3900, case of I—, p. 220. (Woodburytype.)
11. PLATE XXXV, facing p. 223. FRACTURE OF THE LEFT OS INNOMINATUM BY A SHELL FRAGMENT. Specimen 4130, case of E—, p. 223. (Woodburytype.)
12. PLATE XXXVII, facing p. 225. CARIES AND NECROSIS AFTER A SHOT PERFORATION OF THE LEFT ILIUM, WITH A BALL-FRAGMENT SUSPENDED IN THE SHOT CANAL, AND A FISSURE EXTENDING INTO THE COTYLOID CAVITY. (Woodburytype.)
13. PLATE XLI, facing p. 256. INSTRUMENTS FOR RESECTION. (Chromolithograph.)
14. PLATE VII, facing p. 272. VESICAL CALCULI FORMED UPON PROJECTILES. *Seven figures.* FIG. 1, Spec. 5520, case of Cockroft, p. 273. FIG. 2, Spec. 88, case of Lotes, p. 272. FIG. 3, Spec. 4394, case of Palmer, p. 270. FIG. 4, Spec. 5019, case of *Shrimp*, p. 274. FIG. 5, case of McIntosh, p. 273. FIG. 6, Spec. 6203, case of Ely, p. 275. FIG. 7, Spec. 5931, case of Satamore, p. 276. (Lithograph.)
15. PLATE VIII, facing p. 280. VESICAL CALCULI REMOVED AFTER SHOT WOUNDS. *Five figures.* FIG. 1, Spec. 2567, case of M—, p. 294. FIG. 2, Spec. 5041, case of H—, p. 278. FIG. 3, Spec. 4712, case of *Moore*, p. 279. FIG. 4, Spec. 1687, case of Perry, p. 280. FIG. 5, Spec. 6211, case of P—, p. 291. (Lithograph.)
16. PLATE XII, facing p. 395. URETHRAL INSTRUMENTS. *Nine figures.* (Lithograph.)
17. PLATE IX, facing p. 430. LACERATION OF THE BUTTOCKS BY A SHELL FRAGMENT. Case of Tucker, p. 430. (Chromolithograph.)
18. PLATE XLV, facing p. 488. COMMUNUTED SHOT FRACTURE OF LEFT SCAPULA. Specimen 3585, case of S—, p. 488. (Woodburytype.)
19. PLATE XIII, facing p. 520. RESULTS OF EXCISIONS OF THE HEAD OF THE HUMERUS. *Four figures.* FIG. 1, case of Kelly, p. 590. FIG. 2, case of Jones, p. 521. FIG. 3, case of Yakey, p. 548. FIG. 4, case of Clarke, p. 575. (Lithograph.)
20. PLATE XIV, facing p. 529. RESULTS OF EXCISIONS OF THE HEAD OF THE HUMERUS. *Four figures.* FIG. 1, case of Jacobs, p. 553. FIG. 2, case of Henderson, p. 529. FIG. 3, case of Reardon, p. 552. FIG. 4, case of Rand, p. 529. (Lithograph.)
21. PLATE XVII, facing p. 536. RESULTS OF EXCISIONS OF THE HEAD OF THE HUMERUS. *Four figures.* FIG. 1, case of Quindlen, p. 552. FIG. 2, case of Nicholson, p. 574. FIG. 3, case of Pratt, p. 552. FIG. 4, case of Ewing, p. 550. (Lithograph.)



22. PLATE XVIII, facing p. 544. RESULTS OF EXCISIONS OF THE HEAD OF THE HUMERUS. *Four figures.* FIG. 1, case of Morrison, p. 550. FIG. 2, case of Winsor, p. 529. FIG. 3, case of Singleton, p. 574. FIG. 4, case of Ross, p. 538. (Lithograph.)
23. PLATE XLVI, facing p. 640. SHOT COMMUNIONS OF THE HUMERUS. Specimens 2822 and 1234. *Two figures.* Left-hand figure, case of Sewell, p. 640. Right-hand figure, case of *Doggett*, p. 616. (Woodburytype.)
24. PLATE L, facing p. 668. SHOT CONTUSIONS OF THE SHAFT OF THE HUMERUS. *Two figures.* FIG. 1, Spec. 6309, referred to at pp. 667-8. FIG. 2, Spec. 6312, case of Eaton, pp. 468 and 688. (Woodburytype.)
25. PLATE XXII, facing p. 736. *Two figures.* 1. OSTEOMYELITIS OF HUMERUS, case of L—, p. 736. 2. LIGATION OF POPLITEAL, case of Aseltyn; to be described in the *Third Surgical Volume.* (Chromolithograph.)
26. PLATE XV, facing p. 739. HOSPITAL GANGRENE OF AN ARM STUMP. Case of Wallen, p. 739. (Chromolithograph.)
27. PLATE XLVII, facing p. 762. TUBULAR SEQUESTRA FROM AMPUTATIONS OF THE HUMERUS. *Four figures.* Upper left-hand figure, Spec. 142, case of Millett, pp. 470, 785. Upper right-hand figure, Spec. 1266, case of Harvey, p. 770. Lower left-hand figure, Spec. 4333, case of McKnight, p. 740. Lower right-hand figure, Spec. 2309, case of *Anderson*, p. 761. (Woodburytype.)
28. PLATE XLVIII, facing p. 782. INVOLUCRA OF BONES OF THE FOREARM AND SEQUESTRUM FROM HUMERUS. Specimens 3686 and 3727, case of Strain, p. 782. (Woodburytype.)
29. PLATE XLIV, facing p. 788. NECROSIS OF THE RIGHT RADIUS AND ULNA. Specimen 4170, case of Martz, p. 788. (Woodburytype.)
30. PLATE XIX, facing p. 842. NECROSIS OF THE HUMERUS AFTER SHOT INJURY. Specimen 2749, case of W—, p. 842. (Woodburytype.)
31. PLATE LIII, facing p. 850. RESULTS OF EXCISIONS OF THE ELBOW JOINT FOR SHOT INJURY. *Two figures.* FIG. 1, case of Tracy, p. 850. FIG. 2, case of Riley, p. 869. (Lithograph.)
32. PLATE LI, facing p. 872. BONES OF ELBOW EXCISED FOR SHOT INJURY. *Six figures.* FIG. 1, Spec. 15, case of Campbell, p. 872. FIG. 2, Spec. 1365, case of Dempsey, p. 886. FIG. 3, Spec. 3466, case of Perkins, p. 891. FIG. 4, Spec. 998, case of Lewis, p. 888. FIG. 5, Spec. 925, case of Douglas, p. 870. FIG. 6, Spec. 1309, case of Sche, pp. 791, 873. (Heliotype.)
33. PLATE LIV, facing p. 908. RESULTS OF RESECTIONS AT THE ELBOW FOR SHOT INJURY. *Two figures.* FIG. 1, case of Hertzog, p. 876. FIG. 2, case of Keller, p. 889. (Lithograph.)
34. PLATE XVI, facing p. 928. HOSPITAL GANGRENE. Case of Keables, p. 928. (Chromolithograph.)
35. PLATE LII, facing p. 1020. EFFECTS OF DIVISION OF ULNAR NERVE AND OF SHOT PERFORATION OF THE HAND. *Two figures.* Upper figure, case of Chappel, p. 1020. Lower figure, case of Grothers, pp. 465 and 1020. (Chromolithograph.)

# CORRIGENDA.

- Page 9, thirty-first line, for New Orleans, read *Greenville*.
- Page 12, forty-second line, for 1864, read "1861."
- Page 13, twenty-third line, for section, read *volume*; and forty-first line, for Keene, read *Keen*.
- Page 16, third line, for J. S. Meleher, read S. S. Melcher; and fifteenth line, for F. Mecham, read F. *Meacham*; and eighteenth line, for Army read *Armory*; and nineteenth line, for V. H. B. Lung, read V. H. B. *Lang*.
- Page 25, Note 1, third line, for mesentery, read *mesenteric*.
- Page 33, twenty-eighth line, for C. K. Irvin, read C. K. *Irwine*; and fourth line of Note 1, for J. P. Cleary, read P. J. A. Cleary.
- Page 37, twentieth and twenty-sixth lines, for Thomaine, read *Thomain*; and Note 1, second line, for 1868, read "1863."
- Page 43, seventy-first line of note, for Literature, read *Litterature*.
- Page 46, forty-third line, for C. Hard, read A. *Hard*.
- Page 49, thirty-first line, for Redfern Sharpe, read *Redford Sharp*.
- Page 51, seventeenth and thirty-fifth lines, for A. Chappell, read A. *Chapel*.
- Page 54, twenty-third line, for stomacal, read *stomachal*.
- Page 59, Note 1, tenth line, for Kluykskem, read *Kluyksens*; and for 389 read "289."
- Page 63, Note, for 1852, read "1832."
- Page 68, Note 1, first line, dele the word *on*.
- Page 69, thirty-sixth line, for A. E. Caruthers, read A. E. *Carothers*.
- Page 74, Note 1, ninth line, for Raucoux, read *Raucouz*.
- Page 75, twentieth line, for naval, read *navel*.
- Page 75, Note 1, ninth line, for Tulpilus, read *Tulpius*.
- Page 76, sixth line, for 1862, read "1861."
- Page 76, thirty-first line, for July 26, read July "6."
- Page 77, ninth line, for symptoms of treatment, read *symptoms or treatment*.
- Page 81, sixty-third line, for Seaman, read *Leaman*.
- Page 83, fiftieth line, for A. L. Lovell, read A. L. *Lovell*.
- Page 84, fifth line, for Know, read *Knorr*.
- Page 84, nineteenth line, for 1363, read "1863."
- Page 87, fifty-third line, dele "Assistant."
- Page 88, sixteenth line, dele "Acting Assistant," and read *Surgeon John Neill, U. S. V.*
- Page 92, fifth line, read *Assistant Surgeon*.
- Page 93, twenty-second line, for Orton, read *Osborne*.
- Page 102, sixteenth line, for D. Bache, read T. H. *Bache*.
- Page 105, case 308, ninth line, for Acting Assistant Surgeon J. B. Sturdevant, read *Assistant Surgeon S. B. Sturdevant, 139th Pennsylvania*.
- Page 106, tenth line, for U. S. V., read *9th New York Cavalry*.
- Page 112, note 2, second line, for annoyance, read *occurrence*.
- Page 117, thirty-eighth line, for Schmidt, read *Schmid*.
- Page 119, twenty-first line, insert after the word "it" the word *is*.
- Page 126, Note 3, eighth line, for microcosms, read *micrococcus*.
- Page 131, Note 2, first line, for 1857, read "1867."
- Page 132, Cases 408-481, fifteenth line, for 2d U. S., read "3d" U. S.
- Page 132, Note 2, first line, for Vol. I, read Vol. *L*.
- Page 133, Case 440, sixth line, for anemic, read *anemic*.
- Page 136, Case 424, seventh line, should read *Assistant Surgeon*.
- Page 137, third line, and first line Note 2, for PAROISSE, read "PAROISSE."
- Page 139, Case 470, twenty-first line, before Surgeon, insert *Assistant*.
- Page 139, Case 436, third line, for Small, read *Smull*.
- Page 140, Case 316, first line, for Squires, read *Squire*.
- Page 141, Case 319, second line, for Brennerman, read *Breneman*.
- Page 143, Case 471, first line, for 29th, read "39th."
- Page 144, Case 376, sixth line, dele *Assistant*.
- Page 145, Cases 386-390, second line, for Byles, read *Nyers*.
- Page 145, Cases 391-395, fourth line, for Oweigo, read *Oswego*.
- Page 146, Cases 391-395, twenty-sixth line, for Justin, read *Justice*.
- Page 147, Case 402, sixth line, for Helsly, read *Helsby*.
- Page 148, Case 403, second line, for Cammack, read *Cumac*.
- Page 156, Case 500, fifth line, for 1865, read "1865."
- Page 156, Case 501, third line, should read William P. *McCullough*.
- Page 165, Case 514, fifteenth line, for sanious, read *sanious*.
- Page 174, Case 563, third line, for 25th, read "26th."
- Page 175, thirty-third line, for seems, read *seeris*.
- Page 182, Case 573, second line, for penetrated, read *penetrated*.
- Page 186, Case 595, third line, read C. T. *Reber*.
- Page 188, Case 603, third line, for B. E. Frayer, read B. E. *Fryer*.
- Page 192, Case 611, second line, for 1865, read "1864."
- Page 192, thirty-first line, should read G. P. *Hachenburg*.
- Page 200, Note 4, second line, for peritonis, read *peritonitis*.
- Page 204, eighth line, for catagory, read *category*.
- Page 211, thirteenth line, for relegated, read *relegated*.
- Page 213, Case 618, ninth line, for impossible, read *possible*.
- Page 214, Case 623, third line, for Herbert, read *Herbst*.
- Page 215, Case 626, first line, read *Assistant Surgeon George M. Sternberg, U. S. A.*
- Page 220, Case 641, twenty-second line, for p. 28, read p. "228."
- Page 220, Case 644, third line, insert after the word *Assistant* the word *Surgeon*.
- Page 222, Case 648, third line, for and, read *was*.
- Page 221, Case 650, fifth line, for James, read *Janes*.
- Page 228, Case 664, first line, for 57th, read "57th."
- Page 229, Case 672, first line, for May, read *February*.
- Page 232, Case 678, tenth line, read J. H. *Brinton*.
- Page 232, Case 679, seventh and ninth lines, for Assistant Surgeon J. T. Calhoun, U. S. A., read *Acting Assistant Surgeon A. W. Colburn*.
- Page 240, thirty-eighth line, for E. W. McDonnell, read E. *McDonnell*.
- Page 241, Note 1, ninth line, for Beitäge, read *Beiträge*.
- Page 241, Note 1, fourteenth line, for Tract, read *Pract*.
- Page 243, Case 705, eighth line, for John F. Hodgen, read *John T. Hodgen*.
- Page 249, Case 723, fifth line, for N. Y. V., read U. S. V.
- Page 251, Case 735, first line, for 1863, read "1862."
- Page 258, Case 759, fourth line, for November, read *April*.
- Page 260, Case 767, fourth line, dele the word "Cavalry."
- Page 264, twenty-ninth line, should read Robert B. *Potter*.
- Page 265, Case 784, third line, for Ray, read *Way*.
- Page 266, Case 785, second line, for J. Studley, read J. M. *Study*.
- Page 267, Case 794, ninth line, for 1863, read "1873;" and dele last line, after the word "urine."
- Page 269, Note 4, fourteenth line, for p. 46, read p. "246."
- Page 271, Fig. 221, first line, for Cylindroneical, read *Cylindro-conical*.
- Page 271, Case 797, third line, for Assistant Surgeon, read *Surgeon*.
- Page 271, Case 797, thirteenth line, for Thomas S. Christ, read *Theodore S. Christ*.
- Page 271, thirteenth, twenty-first, and twenty-sixth lines, for S. W., read J. W. *Hamilton*.
- Page 276, Case 804, first line, for Sitamore, read *Satomore*.
- Page 280, Note 4, eighth line, for Lect., read *Secl.*
- Page 282, TABLE VIII, Case 9, for S. W., read J. W. *Hamilton*.
- Page 288, Case 825, second line, for Surgeon O. Everts, U. S. V., read *Surgeon O. Everts, 20th Indiana*.
- Page 288, Case 828, fourth line, dele the word "General."
- Page 290, Case 846, fourteenth line, for Michigan, read *Maine*.
- Page 291, Case 850, first line, for 1863, read "1862."
- Page 293, Case 852, third line, for July, read *June 19th*.
- Page 294, Case 857, fourth line, for R. N. Pease, read R. W. *Pease*.
- Page 296, Case 862, second line, for U. S. V., read U. S. *A.*
- Page 296, Case 863, first line, for D. Bagley, read D. *Baguley*.
- Page 301, fifth line, for pathognomic, read *pathognomonic*.
- Page 302, thirtieth line, for therapeutic, read *therapeutic*.
- Page 304, Case 868, fifteenth line, for Assistant Surgeon E. M. Powers, U. S. V., read *Surgeon E. M. Powers, 7th Missouri*.
- Page 306, Case 870, second line, for A. J. Wood, read A. J. *Wurd*.
- Page 307, Case 877, first line, for June, read *July*.
- Page 311, Case 902, third line, for Lowry, read *Leery*.
- Page 324, Case 932, eleventh line, for 1863, read "1864."
- Page 324, Case 933, first line, for Tennessee, read *Pennsylvania*; also second line, for 1875, read "1865."
- Page 328, Case 957, third line, for U. S. V., read U. S. *A.*
- Page 328, Case 960, seventh line, for 1862, read "1863."
- Page 330, Case 964, first and fourteenth lines, for 1864, read "1865."
- Page 332, Case 972, fifteenth line, for anatomical, read *anatomical*.
- Page 336, Case 978, sixth line, for U. S. V., read U. S. *A.*; also twenty-second line, for October 31, read *September 30*; also twenty-sixth line, for Surgeon G. Taylor read *Assistant Surgeon J. T. Calhoun*, and omit the word "still."



- Page 352, Note 1, third line, for ill, read *il*.  
 Page 353, Case 1015, second line, for B. Bache, read *D. Bache*.  
 Page 360, seventeenth line, for rectal-urinary, read *recto-urinary*.  
 Page 361, second case, sixth line, for Hinson, read *Hizon*.  
 Page 362, third case, fifth line, for C. H. Bates, read *C. C. Bates*.  
 Page 362, third case, ninth line, for S. F. Sherman, read *B. F. Sherman*.  
 Page 362, fifth case, fourth line, for J. O. Stearns, read *J. Q. Stearns*.  
 Page 363, second case, third line, for M. N. Townsend, read *M. W. Town- send*.  
 Page 363, second case, sixteenth line, for O. Mitchell, read *A. Mitchell*.  
 Page 363, third case, second line, for Clay, read *Cony*.  
 Page 364, second case, third line, for Reed, read *Reed*.  
 Page 364, third case, fourth line, for Whitehall, read *Wh. tehill*.  
 Page 365, third case, second line, omit the word "Assistant."  
 Page 366, Case 1065, fourth line, for C. Peters, read *D. C. Peters*; and twelfth line, for McDermott, read *McDermont*.  
 Page 369, Note 1, for 228, read "288."  
 Page 371, Case 1074, second line, for C. V. Fowler, read *C. N. Fowler*.  
 Page 371, Case 1074, ninth and tenth lines, for J. W. Fally, read *J. W. Fatley*.  
 Page 371, Case 1076, thirty-sixth line, for T. Sherwood, read *T. H. Sher- wood*.  
 Page 373, Case 1083, second line, for J. K. Hasbrouck, read *J. W. Has- brouck*.  
 Page 374, Case 1084, fifth line, for J. D. Knight, read *I. D. Knight*.  
 Page 376, thirty-first line, for anti, read *ante*.  
 Page 379, fifth and forty-second lines, for U. S. V., read *10th Ohio*.  
 Page 379, forty-fifth line, for J. T. Finley, read *J. Y. Finley*.  
 Page 401, first line, for observations, read *observation*.  
 Page 402, Note 4, for Grippat, read *Gripat*; for vésica, read *vesicæ*; for 1874, read "1873."  
 Page 403, fourteenth line, for outer, read *inner*.  
 Page 406, Case 1105, second line, for P. A. Cleary, read *P. J. A. Cleary*.  
 Page 407, Case 1108, third line, for Thorn, read *Thorne*.  
 Page 407, Case 1110, sixth line, for testicles, read *testicle*.  
 Page 408, twenty-fourth line, for J. McCook, read *G. McCook*.  
 Page 408, forty-third line, for 1863, read "1864."  
 Page 409, fourteenth line, for T. S. Harper, read *T. J. Harper*.  
 Page 409, Case 1133, second line, for Acting Assistant Surgeon, read *As- sistant Surgeon, U. S. A.*  
 Page 420, forty-fifth line, for 1854, read "1864."  
 Page 421, Case 1225, for Surgeon R. F. Weir, U. S. A., read *Assistant Surgeon R. F. Weir, U. S. A.*  
 Page 422, Case 1227, third line, for F. Sadler, read *F. Saller*.  
 Page 424, Case A<sup>11</sup>, second line, strike out the words "endeavoring to rally," and insert *leading*; also strike out the words "after the mine explosion, June 30, 1864," and insert "April 2, 1865."  
 Page 437, Note 1, sixth line, for CHEEVERS, read *Cheever*.  
 Page 448, Case 9 of TABLE XIII, for Randolph, read *Bradford*.  
 Page 448, Case 19 of TABLE XIII, for W. Notson, read *W. M. Notson*.  
 Page 471, third line of third pica paragraph, after the words "the injuries of the," insert the words "soft parts of the."  
 Page 475, Case 1417, omit the words "Acting Assistant."  
 Page 487, Case 1442, second line, for May, read *March*.  
 Page 489, third line, for patients, read *patient*.  
 Page 497, the dates of injury and operation, in Case 3 of TABLE XX, should read "June 24, 1864," and the date of death "July 26, 1864."  
 Page 508, Case 1480, fourteenth line, for H. Heger, read *A. Heger*.  
 Page 509, Case 1482, tenth line, for Marshall, read *Marshal*.  
 Page 529, first and second lines, for two hundred and seventy-three, read *one hundred and twenty-five*.  
 Page 542, seventh line of pica, for interior, read *anterior*.  
 Page 607, eighth pica line, insert after "are" the word "partially."  
 PLATE XLVIII, facing page 782, second line of title, for Numerous, read *Humerus*.  
 Page 783, ninth line from bottom, for Gourley read *Gouley*.  
 Page 902, second line of pica, for methods, read *method*.  
 Page 918, Case 1843, second line, for U. S. A., read *U. S. V.*  
 Page 919, Case 1845, second line, for Surgeon D. F. Galloupe, 18th Massa- chusetts, read *J. F. Galloupe, "17th" Massachusetts*.  
 Page 920, Case 1849, second line, for U. S. A., read *U. S. V.*  
 Page 921, Case 1859, tenth line, for June, read *January*.  
 Page 927, Case 1872, eighth line, for J. G. Bell, read *J. B. Bell*.  
 Page 928, Case 1875, second line, for A. O. Judson, read *O. A. Judson*.  
 Page 929, Case 1876, eighth line, for 6th Connecticut, read *76th Pennsyl- rania*.  
 Page 940, TABLE CXXXVI, Case 61, for 31st Illinois, read *51st Illinois*.  
 Page 942, TABLE CXXXVI, Case 165, for Surgeon G. R. Baldwin, read *Assistant Surgeon G. R. Baldwin*.  
 Page 943, TABLE CXXXVI, Case 223, for J. W. Whitford, read *J. H. Whit- ford*.  
 Page 944, TABLE CXXXVI, Case 289, for Assistant Surgeon, read *Surgeon M. Tucker*.  
 Page 906, first line of Note 1, for BICE, read *Bion*.  
 Page 909, tenth and eleventh lines of Note 3, for PURMANN, read *Pur- mann*.  
 Page 944, TABLE CXXXVI, Case 292, for J. N. Kendall, read *J. V. Kendall*.  
 Page 944, TABLE CXXXVI, Case 306, for N. W. Robbins, read *M. W. Rob- bins*.  
 Page 962, Case 1924, third line, for U. S. A., read *U. S. V.*  
 Page 976, TABLE CXXXIII, Case 781, for J. E. L. Kimball, read *J. H. Kimball*.  
 Page 977, TABLE CXXXIII, Case 853, for J. H. Thorpe, read *J. C. Thorpe*.  
 Page 983, TABLE CXXXV, Case 209, for C. F. Bullur, read *C. F. Bullen*.  
 Page 986, TABLE CXXXVL, Case 54, for W. N. S. Benjamin, read *M. N. Benjamin*.














U.C. BERKELEY LIBRARIES



C035973316



