



This is a digital copy of a book that was preserved for generations on library shelves before it was carefully scanned by Google as part of a project to make the world's books discoverable online.

It has survived long enough for the copyright to expire and the book to enter the public domain. A public domain book is one that was never subject to copyright or whose legal copyright term has expired. Whether a book is in the public domain may vary country to country. Public domain books are our gateways to the past, representing a wealth of history, culture and knowledge that's often difficult to discover.

Marks, notations and other marginalia present in the original volume will appear in this file - a reminder of this book's long journey from the publisher to a library and finally to you.

### **Usage guidelines**

Google is proud to partner with libraries to digitize public domain materials and make them widely accessible. Public domain books belong to the public and we are merely their custodians. Nevertheless, this work is expensive, so in order to keep providing this resource, we have taken steps to prevent abuse by commercial parties, including placing technical restrictions on automated querying.

We also ask that you:

- + *Make non-commercial use of the files* We designed Google Book Search for use by individuals, and we request that you use these files for personal, non-commercial purposes.
- + *Refrain from automated querying* Do not send automated queries of any sort to Google's system: If you are conducting research on machine translation, optical character recognition or other areas where access to a large amount of text is helpful, please contact us. We encourage the use of public domain materials for these purposes and may be able to help.
- + *Maintain attribution* The Google "watermark" you see on each file is essential for informing people about this project and helping them find additional materials through Google Book Search. Please do not remove it.
- + *Keep it legal* Whatever your use, remember that you are responsible for ensuring that what you are doing is legal. Do not assume that just because we believe a book is in the public domain for users in the United States, that the work is also in the public domain for users in other countries. Whether a book is still in copyright varies from country to country, and we can't offer guidance on whether any specific use of any specific book is allowed. Please do not assume that a book's appearance in Google Book Search means it can be used in any manner anywhere in the world. Copyright infringement liability can be quite severe.

### **About Google Book Search**

Google's mission is to organize the world's information and to make it universally accessible and useful. Google Book Search helps readers discover the world's books while helping authors and publishers reach new audiences. You can search through the full text of this book on the web at <http://books.google.com/>



C

1543 d. 90













Taf. I.

1.



2.



3.



4.



5.



6.



7.



8.



9.



10.



11.



12.



1. The first part of the document discusses the importance of maintaining accurate records of all transactions and activities related to the business.

2. It then outlines the various methods and tools available for tracking and analyzing financial data, including spreadsheets, accounting software, and manual ledgers.

3. The document also covers the importance of regular audits and reconciliations to ensure the accuracy and integrity of the financial records.

4. Finally, it provides a detailed overview of the reporting requirements and best practices for presenting financial information to stakeholders and regulatory bodies.

5. The document concludes with a summary of the key points and a call to action for businesses to implement these practices to ensure long-term financial success and compliance.

6. The document is intended to serve as a comprehensive guide for businesses of all sizes, providing practical advice and insights into the world of financial management.

7. It is hoped that this document will be a valuable resource for anyone looking to improve their financial record-keeping and reporting practices.

8. The document is written in a clear and concise style, making it easy to read and understand for a wide range of audiences.

9. It is a testament to the importance of financial transparency and accountability in the modern business environment.

10. The document is a valuable addition to any business owner's library and is highly recommended for anyone interested in financial management.

11. The document is a comprehensive and practical guide to financial record-keeping and reporting, providing a wealth of information and insights for businesses of all sizes.

12. It is a must-read for anyone looking to improve their financial management practices and ensure the long-term success of their business.

Taf. I.

1.



THE  
MEMBRANA TYMPANI

IN  
HEALTH AND DISEASE.

ILLUSTRATED BY TWENTY-FOUR CHROMO-LITHOGRAPHS.

CLINICAL CONTRIBUTIONS TO THE DIAGNOSIS AND TREATMENT OF DISEASES OF  
THE EAR, WITH


SUPPLEMENT.

BY  
DR. ADAM POLITZER,  
OF THE UNIVERSITY OF VIENNA.

TRANSLATED BY

A. MATHEWSON, M.D., AND H. G. NEWTON, M.D.  
ASST. SURGEONS OF THE BROOKLYN EYE AND EAR HOSPITAL.  
MEMBERS OF THE AMER. OPHTHALMOL. AND OTOL. SOCIETIES.

NEW YORK:  
WM. WOOD & CO., 61 WALKER STREET.  
1869.



Entered according to Act of Congress, in the year 1860, by  
WILLIAM WOOD & CO.,  
In the Clerk's Office of the District Court of the United States for the Southern District of  
New York.

THE NEW YORK PRINTING COMPANY,  
81, 83, and 85 Centre Street,  
New York.

## CONTENTS.

---

	PAGE
INTRODUCTION .....	1
ANATOMY OF THE MEMBRANA TYMPANI.....	7
Microscopic Anatomy.....	10
INSPECTION OF THE MEMBRANA TYMPANI.....	15
Color .....	21
Lustre—Cone of Light.....	25
Inclination .....	29
Curvature .....	30
ANOMALIES IN TRANSPARENCY AND COLOR.....	33
General Opacities .....	35
Opacities of Epidermic Layer .....	36
Opacities of Dermoid Layer .....	40
Opacities of Substantia Propria.....	50
Opacities of Mucous Layer .....	54
Circumscribed Opacities.....	56
Calcareous Deposits.....	58
Tendinous Opacities.....	66
Peripheral Opacities .....	68
ANOMALIES IN COHERENCE.....	71
Perforations—	
Causes.....	71
Situation .....	74
Size .....	75
Form .....	76
Appearances in .....	77
Appearance of Ossicles and Promontory in .....	82
Ruptures .....	91
Functional Disturbance in Perforations .....	92

	PAGE
Healing of Perforations.....	93
Reproduction of Membrane.....	95
[Note.]—Treatment of Chronic Catarrh of Middle Ear.....	101
Formation of Cicatricial Membrane.....	102
Adhesion of Cicatrix to Promontory.....	110
Perforation of Cicatrix.....	120
Microscopic Character of Cicatrix.....	123
Persistent Perforations.....	127
[Note.]—Treatment of Purulent Catarrh of Middle Ear.....	128
Detachment of Manubrium from the Membrane.....	130
Fracture of Manubrium.....	133
Adhesion of Membrane to Stapes.....	134
Rare Conditions.....	136
ANOMALIES IN CURVATURE.....	139
Abnormal Convexity of Membrane—	
General Protrusion.....	139
Abscesses.....	140
Granulations.....	142
Hernial Protrusion.....	144
Abnormal Concavity of Membrane—	
General Depression.....	146
Circumscribed Depression.....	150
MOBILITY OF THE MEMBRANE—	
In Valsalvian Experiment.....	152
In the Act of Swallowing.....	154
During Respiratory Movements.....	156
Pulsatory Movements.....	156
SUPPLEMENT.	
A. Accumulation of Serum in Tympanic Cavity—	
Diagnosis and Treatment.....	161
Note.....	169
B. A Method for Preventing the Closure of Artificial Perforations.....	170
Note.....	179
C. Double Perforation of the Membrana Tympani.....	180
D. Anatomy of the Membrana Tympani.....	181

## TRANSLATORS' PREFACE.

---

It is with pleasure that the translators present to the American profession the following monograph upon the appearances of the membrana tympani in health and disease. We need not speak the praises of its author, for the name of Politzer is not only well known among aural surgeons, but is becoming familiar to the general practice, especially as connected with his method of inflating the middle ear. He has, however, placed us under still further obligation by this exhaustive treatise upon the membrane, which, to diseases of the ear, may stand in much the same relation as do works upon auscultation and percussion to diseases of the thorax.

No practitioner can undertake to diagnosticate the nature and extent of an aural affection without a knowledge of the various appearances of the membrana tympani; but with such knowledge the diagnosis is comparatively easy. Such a work as this of Politzer is therefore valuable. It throws light upon a field which is confessedly dark to many of our profession, and by means of it, in conjunction with a thorough general treatise (like the last edition of Tröltsch), a practitioner may easily prepare himself to treat successfully in their early stages many of



the cases which now are allowed to go on to incurable deafness. The early stage of aural disease is the period when treatment is most likely to meet with success, and yet this is the very period in which it is too often neglected.

We would call especial attention to the beautiful chromolithographs which accompany the work, and add greatly to its interest and value.

We have delayed publication for some months in order to add the Supplement, which presents some of the results of more recent investigation. A portion of it, indeed, was written by Dr. Mathewson in Vienna, at the dictation of the Author, who also furnished original sketches to illustrate it. We would acknowledge the kindness of Dr. Politzer in permitting us to undertake the translation, and in rendering us assistance in the completion of our task.

ARTHUR MATHEWSON, M.D.

HOMER G. NEWTON, M.D.

BROOKLYN, N. Y., *August*, 1869.

# MEMBRANA TYMPANI.

---

## INTRODUCTION.

THE chief object in publishing this series of illustrations of the *membrana tympani* is to assist the practitioner in the perception of those material changes which can be recognized in the membrane.

A comparison of the appearances observed in the parts with the illustrations presented will furnish sure means for the recognition of any existing anomaly, and the explanation accompanying the figures will lead to a proper understanding of it.

The value of these illustrations is at once apparent, if we consider the character of the diagnostic points generally furnished by *inspection* of the membrane, as compared with the less reliable data obtained by other means

The extensive employment of inspection for the purpose of diagnosis is of very recent date. But we must already recognize its importance in the advancement of modern aural surgery, for it has considerably narrowed the former extraordinarily wide domain of nervous deafness. Supported by the investigations of pathological anatomy, which have authenticated important changes in the membrane in a considerable class of cases, inspection

has materially advanced our knowledge of the morbid process.

Such a critical examination of changes perceptible in the membrana tympani was first made by Joseph Toynbee. After him, Wilde, supported by numerous observations upon aural patients, directed attention to the more minute pathological changes, previously too little regarded. The most important results in this field, however, were furnished by the profound researches of von Tröltzsch. He compared his observations, made upon patients by means of an essentially improved method of examination, with the corresponding post-mortem appearances; and, from the harmony between conjectured and authenticated causes of disease, he showed with what brilliant success inspection of the membrana tympani may be employed for the diagnosis of pathological processes in the ear.

Fully impressed with the importance of the subject, after the admirable researches mentioned, I applied myself to its study with especial interest; the more so, because the rich material of the clinics and of the several wards of the general hospital, as well as of the large asylums, was at my disposal. And since, in my opinion, the diagnostic significance of any condition of the membrana tympani can only be correctly estimated and established by a comparison with the post-mortem condition, I recorded with especial care those cases in which there was near prospect of a post-mortem examination. The considerable number of such examinations has revealed to me a class of phenomena hitherto little regarded, which, as diagnostic points, are entitled to fuller notice.

An accurate examination of the membrana tympani is indispensable for a complete and exhaustive diagnosis. In consequence of its anatomical structure, the membrane stands in very intimate relation to the diseases of the external and middle ear. The lining of the external meatus, which is continuous over the external surface of the membrana tympani, and that of the tympanic cavity, covering the inner surface, transmit to the membrane the morbid changes originating in themselves. The surfaces thus become the seat of appearances, which, revealed to us by inspection, permit a conclusion concerning the state of the external and middle ear. The lesions of the external and middle ear, on the whole, furnish the most frequent sources of functional disturbance in the auditory apparatus; and, again, such disturbances are often associated with changes in the membrane. Therefore we find anomalies upon the membrana tympani in the majority of aural patients.

Nevertheless, any one who has examined a large number of persons with normal hearing will become convinced, by repeated and accurate observation, that, in many cases, changes in the membrane can be proved to which no impairment of function whatever corresponds. These changes may be the results of a morbid process which has run its course at an earlier date with complete recovery; and sometimes, also, they may be traced to congenital malformations. On the other hand, experience teaches that, in some cases, with a pretty high degree of deafness, the membrana tympani does not present the least departure from the normal condition.

Such a negative state cannot, of course, possess that diagnostic value which we attribute to the direct perception of characteristic signs; still it permits the inference, not to be undervalued, that the cause of the functional disturbance is not in the vicinity of the membrana tympani, but in the deeper parts of the ear,—on the inner, labyrinthine wall of the tympanic cavity, or in the nervous apparatus.

In the majority of cases, however, the changes met with in the membrane are indications of a morbid process present or past, and, in connection with the other signs, will contribute to the completion of the diagnosis; for which indeed they are often alone sufficient.

If, in spite of the perfection of the present method of illumination, dissection, in certain cases, does not verify the diagnosis, this depends upon the varying position of the membrana tympani hereafter to be described, which sometimes gives rise to illusions, whereby our estimate of the anomalies of curvature, and of the variations in color, lustre, and transparency, naturally becomes less reliable. But, as such difficulties are for the most part overcome by experience, they cannot materially diminish the practical value of inspection.

Considering all these results, we are satisfied that ocular inspection essentially facilitates the establishment of a diagnosis, not only in the cases where the condition of the membrane explains the existing functional disturbance, but in those also where an irregular, even inverse ratio exists between the two. Accordingly, we very often understand the nature of the lesion from the condi-

tion when illuminated, but are never able to infer from it the degree of functional disturbance.

It is impossible to set up any fixed standard as the physiological condition of the *membrana tympani*. Color, lustre, transparency, and curvature, can, as a rule, be stated only approximatively. It is, therefore, only natural that the pathological conditions should also vary greatly, and that certain processes—perforations, calcareous deposits, and others—should occur in the most varied form and extent. We have, therefore, in the plates, selected the most exact types at our disposal, both of normal *membranæ tympani* and also of the several kinds of pathological conditions. With a knowledge of this fact, we believe that any condition met with by the practitioner may very easily be referred to the illustration, and, thus, any resulting deviation, though unessential, be at once discovered. The accompanying explanation of the figures is a faithful description of cases observed by us, and of results obtained by examination, and, consequently, best serves its purpose.

Having, in these general remarks, as we think, stated the ground we take in the treatment of the subject before us, there remains only the pleasant duty of expressing our heartfelt thanks; first, to Prof. Oppolzer, who, with his usual liberality, has allowed us, for the purpose of investigation, the use of clinical material as well as that furnished by ambulant patients; next, to Professors Rokitansky, Skoda, Arlt, von Dumreicher, Hebra and Schuh; to the visiting physicians, Chrastina, Dittl, Endlicher, Kolisko, von Peller, L. Politzer, Scholz,

Standhardtner, and Ulrich, for the readiness with which they placed at our disposal the rich material of their wards, and afforded us a fruitful field for observation.

## ANATOMY.

---

THE anatomy of the membrana tympani, which is here presented before its pathology, has especial reference to the wants of practice. We therefore arrange together in a condensed statement its form, size, position, curvature, color, lustre, and transparency, as well as the microscopic texture; because these constitute the basis of investigation, and combine, when they have undergone change, to form the pathological condition.

As regards *relative position*, the membrana tympani is, as it were, a little membrane stretched obliquely downward and inward at the end of a narrow tube, so that its plane forms with the upper wall of the tube an obtuse, but with its lower wall an acute angle. It is inserted into an osseous groove, which is interrupted for a short space above; and its *form* is thus determined by that of the surrounding ring. It is elliptical, irregularly oval, or, in case of more marked projection of the lateral portions of the ring, even heart-shaped.

We must here also notice a bulging out of the membrane at its anterior upper quadrant, over the tubercle of the malleus (short process), projecting about a line above the interrupted portion of the groove. It begins at the



periphery of the membrane, with an ill-defined base from a line and a half to two lines in breadth, has a rounded apex, and serves for the reception of the neck of the malleus.

The *size* of the membrane, in like manner, depends upon that of the osseous ring, varying more or less markedly in different individuals. On account of this variety in form and size, it is extremely difficult to harmonize the average measurements of different observers. The greatest conformity is shown in the measurements of Hyrtl and von Trötsch. The former fixes the ratio of the length to the breadth at four and three-tenths lines to four lines, while the latter states the greatest diameter, from above and anteriorly downward and backward, as from nine to ten millimetres; the shortest diameter, from below and anteriorly upward and backward, as from eight to nine.

The *inclination* of the membrana tympani depends upon its relation to the walls of the external meatus, and in adults is the result of the inclination of the *annulus tympanicus* to the axis of the meatus. The inclination of the tympanic groove, like that of an oblique section of the external meatus, naturally varies according to the differences in its linear measurement from the anterior and lower to the posterior and upper wall of the meatus. The measurements instituted in this direction vary, apparently, according as the several observers have different angles in view. Hyrtl states that the angle of inclination of the membrana tympani to the lower wall of the auditory canal is  $50^{\circ}$ ; while Huschke says that the two membranæ tympani, if produced inward and downward, would

cut each other at an angle of  $130^{\circ}$ . Von Tröltsch, in measuring a large number of cases, reckons the average angle which the plane of the membrane forms with the upper wall of the auditory canal at  $140^{\circ}$ .

In this position the *membrana tympani* is not stretched as a perfect plane upon the end of the external meatus, but is *arched* in such a manner that its concavity is presented outward, while its convexity is turned toward the inner wall of the tympanum. The deepest point of the arch, the so-called *umbo*, corresponds to the end of the handle of the malleus, inserted between the layers of the membrane. The whole membrane, indeed, is thus curved, but upon closer examination the curvature is seen to be irregular, since the anterior and lower portion, passing from the umbo toward the periphery, exhibits a slight external convexity. There is also a marked conical protrusion of the membrane at the point where the tubercle of the malleus presses it outward. It extends to either side in a longer posterior and a shorter anterior fold.

The *malleus* is a structure intimately connected with the *membrana tympani*. Its short process or tubercle lies between the layers, soon to be described, in that part of the membrane pushed forward by it; while its flat, haft-like process, the handle of the malleus, extends toward the centre of the membrane to end at the umbo in a spatula-shaped expansion. The neck of the malleus is attached at the bulging out mentioned above, whilst the head projects free into the cavity of the tympanum.

The long *malleus handle* imperfectly divides the mem-

brane, as it were, into two parts, an anterior smaller and a posterior larger.

The relation of the manubrium to the membrana tympani, leads directly to the examination of the *microscopic anatomy* of the membrane, for an accurate knowledge of which we are chiefly indebted to the thorough researches of Von Tröltsch, Toynbee, and Gerlach.

According to these, the membrane, as already known to older observers (Linke), consists essentially of three layers; a middle fibrous—the so-called *lamina propria membranæ tympani*, an external dermoid and an internal mucous layer—the two coats which the proper fibrous layer receives from the lining of the external meatus, and from that of the cavity of the tympanum. The *dermoid* layer is an extremely delicate continuation of the lining of the external meatus, which, also, in its transition to the membrane, consists of an epidermic layer, a Malpighian mucous layer, and the cutis, but contain no glandular elements or papillæ, and only a very little connective tissue. The latter, in its arrangement, differs essentially from the connective tissue of the *lamina propria*, and appears to serve as a firm covering to the vessels and nerves distributed to the external coat.

The *middle* fibrous layer consists of two separable laminae—an external radiate, and an internal circular. The pale, riband-like, sharply but delicately defined fibres of both these lamellæ, form a tissue, which, according to Gerlach, holds, as it were, an intermediate place between the ordinary fibrillated, and the homogeneous connective tissue of Reichert. The external *radiating*

fibres take their origin from the tendinous ring (*annulus cartilagineus*), and in the lower segment are inserted into the spatula-shaped end of the flattened malleus handle, but in the upper portion are attached to its anterior edge. They thus increase the thickness toward the centre, though but slightly; partly, because they are multiplied by division of fibres, and, partly, through accumulation at the umbo (v. Trölsch). Above, toward the neck of the malleus, the layer always becomes more delicate, so that upon the short process it is no longer possible to recognize distinct radiating fibres. The inner *circular* fibrous layer is formed of concentrically arranged fibres, which are wanting at the extreme periphery, but are very abundant near to it. They gradually become more scanty toward the centre, where the membrane appears almost homogeneous, with only scattered traces of circular fibres. Imbedded between the fibres of both these layers are the so-called corpuscles of the *membrana tympani*, named, after their discoverer, "the corpuscles of Trölsch." They appear fusiform in a longitudinal section, stellate in transverse, and are analogous to the corpuscles of the cornea. They vary in form and relative position in both layers, and by their long, delicate processes both anastomose with each other, and also, in part, extend to the contiguous layer.

The handle of the malleus is inserted between the radiate and circular fibrous layers, and, according to v. Trölsch, through a slit in the circular fibres, so that the uppermost portion of them lies external to the neck of the malleus, while the lower and larger part is behind,

thus surrounding the neck, as it were, with a ruffle. According to Gerlach, however, no circular fibres pass external to the handle.

The *inner* or *mucous* layer of the membrana tympani, a continuation of the mucous membrane of the cavity of the tympanum, through marked thinning of the connective tissue, consists almost entirely of a single layer of pavement epithelium. Upon this mucous layer Gerlach has found prominences in considerable numbers, sometimes globular, like the papillæ of the tongue, and sometimes finger-shaped, analogous to the villosities of the intestines. The former attain such a marked size that with transmitted light they can be seen by the naked eye. They consist throughout their central portions of ordinary connective tissue, but at the periphery are more homogeneous in structure. They contain one or more loops of capillaries, but no recognizable nerves, and are covered with a multifold layer of flattened epithelium. Since they are each connected with the mucous membrane only by a pedicle, Gerlach describes them as its villi.

Von Tröltzsch further describes a duplicature of the membrana tympani, extending from its posterior upper border forward to the manubrium, and forming a pocket with the external part of the membrane. It consists of fibrous elements connected with the circular fibres, is covered with thinned mucous membrane, and frequently contains mucus. Von Tröltzsch names the space enclosed by it "the posterior pocket of the membrana tympani," to distinguish it from "the anterior pocket," which

latter is bounded by an osseous projection arching over the neck of the malleus, by the *processus gracilis*, the *ligamentum mallei anterius*, the *chorda tympani*, the *arteria tympani inferior*, and the mucous membrane.

The *membrana tympani* has *two plexuses of vessels* completely separated by the non-vascular *substantia propria*, except at the periphery, where they anastomose with each other. Of these, the external belongs to the connective tissue lying between the epidermis and the radiate fibres, whilst the inner belongs to the mucous membrane (mucous layer). The external plexus is derived from the *arteria auricularis profunda*, which sends a branch to the centre of the membrane. This, by numerous radiating twigs, forms a wreath of capillary vessels upon the periphery, whose recurrent veins unite at the centre into two larger trunks, to run outward on either side of the artery, parallel to the manubrium. The plexus of the mucous membrane arises from the vessels of the tympanic cavity. It is a pure capillary system, with tolerably close meshes, and is developed from an artery of the cavity of the tympanum, which runs parallel to the manubrium upon the inner side of the membrane.

The *nerves* of the *membrana tympani*—which Arnold thought had their origin in the *nervus temporalis superficialis*, from the *trigeminus*, but which were first carefully examined by Tröltsch—run in the outer layer parallel to the vessels, in three or four very delicate, dimly outlined branches, whose terminations are as yet unknown. Gerlach, moreover, once observed fine marrowless fibres in the mucous coat also.

The anatomical relations here detailed correspond to the middle period of life. Many noteworthy deviations are presented in early childhood, in consequence of incomplete development of the bones of the skull.

The *position* of the membrane in the new-born and in children is referable chiefly to the inclination resulting from a greater approximation of the whole temporal bone to the base of the skull. At this period the osseous meatus is wanting, the inclination of the *annulus tympanicus*, and consequently that of the plane of the membrane, approaches the plane of the base of the cranium. With further development, the lateral portions of the skull push outward and upward, and, upon the addition of the osseous canal, the *annulus tympanicus* acquires the position described above.

With respect to *size*, the differences of age exert but little influence, because the ring, and consequently, also, the membrane, have almost reached their full development at a very early period.

Von Tröltsch: Zeitschrift für wissenschaftliche Zoologie. Bd. IX.  
und angewandte Anatomie des Ohres. 1861.

Toynbee: Diseases of the Ear. 1862.

Gerlach: Mikroskopische Studien aus der menschlichen Morphologie.

## INSPECTION.

---

AN accurate knowledge of the normal and pathological relations of the membrana tympani in the living depends chiefly upon rational methods of examination. If, in later times, we can show any real progress in the critical examination of the conditions of the membrane, and in the estimation of their diagnostic value, it is to be attributed, not alone to pathologico-anatomical investigations, but also to marked improvements in the methods of examination.

Formerly we could not, in general, obtain a sufficiently clear idea of the conditions of the membrane, because, undertaken with such imperfect means, the examination was necessarily unsatisfactory. The valvular ear specula of Kramer, which then came into use and are still employed by many observers, were intended to give a view of the membrana tympani without the aid of a reflector, simply by dilatation of the external meatus. They do not, however, fully meet the requirements of the practitioner. The inadequacy of this instrument is chiefly due to the impossibility of dilating the cartilaginous canal by its pressure. But this distention of the resistant canal is of minor importance for obtaining a distinct view. The main point is to illuminate sufficiently a membrane stretched at the



end of a dark tube. But if this illumination by the direct entrance of the sun's rays, or of artificial light, were fully sufficient in itself, still, the observer, in order to avoid obstructing the light with his head, must be at too great a distance to perceive clearly the more delicate shades of the membrane, and have a sufficiently large portion of it in view at once.

These inconveniences could of course be overcome by combination with a reflector, if the hairs, growing in the cartilaginous canal, by insinuating themselves between the opened branches of the instrument, did not interfere too much with the field of vision. The disagreeable, at times painful sensation experienced by the patient in the attempted dilatation is also to be considered a disadvantage in this valvular speculum.

Far more advantageous for the purpose of examination are the more recently constructed uncles specula, which, first employed by Dr. Ignaz Gruber, have received many modifications in size and form from Arlt, Toynebee, and Wilde. They are made of metal, are funnel-shaped or like a truncated cone, and have a polished or blackened inner surface, and a round or oval aperture, the latter difference, however, having little influence in the examination. There are three sizes, designed for corresponding differences in the calibre of the meatus.

Quite lately, an essential improvement has been introduced at our suggestion by Leiter of Vienna, who employs hard rubber for this purpose. These rubber specula have the advantage of being much lighter, and are therefore borne in the meatus by the patient, without

support far more easily than the heavy metallic cones, and, moreover, do not occasion the unpleasant cold sensation caused by a polished metal surface. The dark ground of the inner surface favors a clear definition of the illuminated parts far more than does the slight reflection of light from the polished metal, which increases the brightness of the view at the centre. Moreover, the blunt edges of the rubber entirely prevent the wounding of the lining of the meatus, a thing which is always possible in the use of the metal specula.

These specula, together with a centrally perforated concave reflector, of from four to five inches diameter and having a focal distance of from four to six inches, furnish, with moderate light, a perfectly defined illuminated view, while the distance from the observer's eye to the object is comparatively short.

This method of examination, which owes its wide introduction especially to Von Tröltzsch, is much more accessible, convenient, and safe for the practitioner than that by means of the valvular speculum already mentioned. We do not for a moment doubt that the inventor,—who has been of great service to aural surgery,—has, by his long experience and skilful practice, obtained the same clear and perfect results in the use of his speculum as those given by the newer method. Still, that instrument, which from the outset makes too great demands upon the general practitioner, is to be estimated far below the later, more reliable means of examination.

This new method, by the use of a concave mirror, secures the illumination of the membrana tympani,

either with ordinary daylight or artificial light. The latter is employed at the bedside, especially in badly lighted rooms and very cloudy weather. An ordinary moderator lamp, without the diffusing porcelain shade, answers the purpose very well; or better still, a white light—for instance, that from camphene. Although the condition will be made sufficiently clear to experts by this illumination, still the artificial light has the disadvantage of altering more or less the shades of color in the membrane, thereby disturbing in some degree its general appearance.

For this reason ordinary daylight, as it gives the most natural appearance to the membrane, is far preferable to all other kinds of light. Only a diffuse light is of value, falling upon the mirror as clear as possible from a fair sky, from isolated white clouds, or by reflection from a bright wall. The direct rays of the sun, by dazzling the eye of the observer, impair the distinctness of the object.

The *position* of the patient during the examination is of considerable importance for obtaining a distinct view. The ear should neither be turned directly toward, nor away from, the source of light; but must rather be fixed in a somewhat lateral position, turned more from the light than toward it, so that the rays, falling upon the mirror and reflected from it, completely illuminate the external meatus without the head of the patient intercepting any portion of them.

In order to introduce the speculum into the meatus thus illuminated, it is necessary, with the index and mid-

dle fingers of the left hand, to draw the concha backward and upward, as well as somewhat toward the observer. By this means the axes of the osseous and cartilaginous canals, which in the natural position form an angle with each other, fall into a more direct line and permit a free inspection of the membrane.

After these preliminaries, the rubber or the metallic speculum, slightly warmed by the breath, is pushed forward with a slow rotary movement into the cartilaginous meatus, until the hairs interfering with vision are completely pressed aside by the walls of the instrument. The mirror being held in the surgeon's right hand, the reflection is now thrown through the speculum into the meatus, and the mirror is carried to such a distance from the ear that the greatest intensity of light falls upon the membrana tympani (focal distance). Nevertheless, in very few cases can we see the whole membrane at a glance; and therefore, to inspect the various parts of it successively, movements in all directions, both of the speculum by means of the free thumb of the left hand, and of the reflector, are necessary; the observer's eye likewise following them through the central aperture.

In this manner, as a rule, we obtain the clearest views of the membrane. If, however, in certain cases, in spite of strict adherence to the method mentioned, the practitioner is able to obtain only an imperfect view, or none at all, it is due to various *obstructions*, sometimes occurring in the osseous, sometimes in the cartilaginous canal, and sometimes in both. These may have the

character of normal, or of pathological formations. In the first place, there is an abundant *growth of hair* in the cartilaginous meatus, extending even into the osseous canal, which interferes with the examination whenever the more deeply seated hairs cannot easily be reached and pushed aside by the speculum. If it should be impossible to remove this impediment by means of the scissors, it may be overcome very easily by smearing the projecting hairs with a little wax and fixing them to the external meatus. Abundant accumulations of *cerumen* are also a hindrance, sometimes as stoppers filling up the opening of the meatus, sometimes spread out upon its walls so thick as to greatly diminish the calibre of the canal. The removal of the abnormal accumulation may be accomplished by soaking or syringing, or, in some cases, simply by the use of the ear-scoop. *Detached epidermic scales*, and whitish *epidermal laminae* of pearly lustre, hanging in membraniform or stringy shreds, for the most part in the osseous portion of the meatus, should be very carefully removed by means of the bent forceps.

More important, because beyond the possibility of removal, are the obstacles to examination which arise from *congenital narrowing of the meatus* or too great *curvature of its anterior wall*. This constriction is accompanied by an insufficient illumination of the field, whilst the more or less pronounced curvature interferes with the inspection of the entire membrane to such a degree, that the portions lying before the malleus handle are entirely withdrawn from observation, and sometimes the handle itself can hardly be recognized.

Among the morbid changes which render the membrana tympani temporarily or permanently inaccessible to examination, especially prominent are the inflammatory affections of the lining of the meatus, accompanied by constriction, the accumulation of pus and mucus, granulations, polypi and exostoses.

When the membrane is brought clearly and fully to view by a proper illumination, then its color, transparency, lustre, inclination and curvature, as well as the position of the handle and short process of the malleus, are to be individually noticed; since their relations to each other, as a whole, determine the characteristic appearance of the normal, as well as of the pathological membrane.

Concerning the *color* of the normal membrana tympani we find very different statements in the text-books of anatomy and aural surgery. Whilst some authors characterize it as clear and transparent, it is described by others as pearl-gray or quite white. This difference of opinion is explained, if we remember that the anatomist finds in the cadaver a different condition of the membrane from that which the practitioner meets during life. A further source of disagreement arises partly in the different methods of investigation employed by the various authors, and in a disregard of those elements that go to make up the color of the membrane; and partly in the fact that they have not taken into account differences of age, which, however, in a great number of cases, exercise an influence upon the color. First of all, it must be borne in mind that the membrana tympani is a dull,

translucent medium, which reflects a portion of the light thrown upon it, but permits a portion to pass through, illuminating the tympanic cavity. A part of this light reaches the eye by being reflected back through the membrane, especially from the promontory opposite. The color of the membrana tympani is therefore a combination of colors, dependent upon those peculiar to the membrane and the kind of light employed, and upon the number and shade of the rays reflected from the promontory. The *peculiar shade* of the membrane cannot be accurately determined during life, since the kind of light and the surroundings exercise so great an influence upon it; and in the dead subject, where the natural color suffers through maceration of the epidermic layer, or through evaporation, it is impossible to draw an approximatively correct conclusion concerning it. In all cases, the *kind of light employed* in the examination has considerable influence upon the color of the membrane. Of this fact one is easily convinced, if, in the manner above mentioned, he examines the same membrane with light from a clear blue sky, and then with that from an oil lamp. In the former case, a delicate blue tint will be recognized upon the membrane (Pl. 1, Fig. 1), whilst in the latter it will acquire an orange hue (Pl. 1, Fig. 3). The *quantity and color of the light reflected from the promontory* depend, first, upon the degree of transparency of the membrane; next, upon its distance from the promontory; and finally, upon its inclination to the axis of the auditory canal. The more oblique the position of the membrane, the thicker is the

stratum of its substance through which the rays of light reflected from the promontory must pass in order to reach the eye; and hence, also, the intensity of the light is diminished.

For these reasons, therefore, a description of the normal condition of the *membrana tympani* will be difficult; aside from the fact that opacities, to be described hereafter, exist in a considerable number of persons having normal hearing. We cannot properly speak of the color of the membrane as a whole, since the different parts of it, with the same light, are differently tinted. In cases where we characterize the membrane as normal in appearance, its color, viewed by ordinary daylight, most nearly approaches a neutral gray, mingled with a weaker tint of violet and light yellowish-brown. The gray of the anterior portion, which lies in the angle between the manubrium and the cone of light, is very dark; whilst that of the posterior is clearer. The shade of this posterior portion of the membrane is often modified at its upper boundary by the pocket of Tröltzsch, situated on the inner surface, which with the *chorda tympani* running along its lower border gives to tolerably transparent membranes a whitish-gray opacity, concave below, and extending backward from the manubrium. When the membrane is transparent, the lower part of the illuminated long shank of the incus is often seen behind the manubrium, though not extending as far down. Indeed, in some cases, where the membranes were almost transparent, I have distinctly seen, not only the long shank of the incus, but even the posterior shank of the stapes (Pl. 1,



Fig. 4). The membrane has also a somewhat yellowish-gray color near its centre, at the lower end of the manubrium and a little behind it, on account of the pale yellow rays reflected from the promontory (Pl. 1, Figs. 1, 2, 3, 4, at the centre). A glimmering lustre is not unfrequently mingled with this color behind and near the handle of the malleus, proceeding from a faintly lustrous spot upon the moist and smooth mucous membrane of the promontory.

Besides these general diversities in the normal appearance of the membrana tympani, others are also found which depend upon age. In childhood the membrane often has a somewhat grayish opacity and dullness, though not unfrequently it is transparent and lustrous, as in adults. In children, however, the much darker gray of the membranes and the infrequency of the transmission of light through them from the promontory are often remarkable. In old age, also, we frequently find changes, such as a uniformly gray, often lustreless appearance.

The opacity caused by the *short process of the malleus*, and the *yellow, spatula-shaped end of the handle*, is furthermore to be considered as normal. The short process is visible (Pl. 1, Figs. 1, 2, 3, 4) upon the anterior upper border of the membrane as a white, pointed tubercle, passing abruptly into the manubrium, which, lying in the membrane, extends as a yellowish-white stripe backward, downward, and toward its centre. Upon the manubrium the radiate fibres of the *substantia propria* for the most part accumulate, and, from being crowded together in a

limited space, occasion the opacity mentioned. Another opacity, sometimes occurring in the normal condition, is peripheral, and appears in the form of a tendinous gray zone, not unlike the *arcus senilis*, and is located at the *annulus cartilagineus* (peripheral thickening of the circular fibres), especially upon the anterior border of the membrane.

The *lustre* of the membrane is of importance in diagnosing its condition, inasmuch as, in many cases, from the absence or the change in form and size of the so-called *cone of light* during movements of the membrane, we are able to judge, not only of the condition of the membrane itself, but also of that of the Eustachian tube. In addition to a soft lustre spread over the whole membrane (Tröltsch), there is this sharply marked cone of light upon its anterior portion in the anterior lower quadrant. It is triangular, and, with its apex at the end of the malleus handle, it spreads out downward and forward in such a manner that it makes with the manubrium an obtuse angle anteriorly (Pl. 1, Fig. 1). This angle will vary inversely as the inclination of the *membrana tympani* to the auditory canal. There are varieties in the extent and form of the light spot in different individuals. These arise, as we shall see hereafter, partly from differences of inclination, and partly from those of curvature. In its regular form, the cone of light is ordinarily from one and a half to two millimetres in breadth at its base. In many cases it is interrupted in its continuity, so that between the apex and base there is a portion without reflection (Pl. 1, Fig. 3).

Sometimes it is divided longitudinally into two parts, or finely striped. In certain cases it extends to the circumference of the membrana tympani; in others, the peripheral portion fades out (Pl. 1, Fig. 2), and only the apex remains as a little, irregular light spot. The knowledge of all these varieties of normal condition is of importance, because, if disregarded, they might, in cases of disease, easily lead to erroneous conclusions.

Different views prevail among authors respecting the *cause of this light spot*. Wilde seeks an explanation in an external convexity of the membrane at this point. Although the curvature here undoubtedly has an influence upon the size and form of the light spot, yet it is of minor importance in its production. The chief cause is the inclination of the membrane to the axis of the auditory canal, together with the concavity of the membrane produced by the manubrium.

If we carefully dry a preparation of the normal ear, and then throw light upon the membrana tympani through the meatus, we shall see the triangular light spot in the same place as in the living. Just as in the living, too, it is displaced very little by moving the eye in different directions; because the axis of vision, corresponding so nearly to the axis of the meatus, can change little with respect to its inclination to the membrane. If we remove the canal from the membrana tympani so that the membrane remains exposed in its osseous groove, and turn it so that its other portions successively acquire the position of the original cone of light, now at all these points we perceive a reflection of light which in the

neighborhood of the former cone of light has nearly the same form. Upon those portions behind the handle, however, it generally appears large, irregular, and faint, on account of the great difference between their curvature and that of the anterior portions.

Is it now asked upon what does the cone of light depend? No light would be reflected to the eye from the membrane if it were a plane surface; for, with its inclination to the auditory meatus, all rays thrown upon it would, according to the laws of optics, be reflected against the anterior lower wall of the canal. In consequence, however, of the inward curvature of the membrane from the traction of the malleus handle, its parts undergo such a change of inclination that the anterior portion stands directly at right angles to our axis of vision, and the light thrown upon it is reflected back to the eye. You can convince yourself of the correctness of this opinion by stretching a shining animal membrane over a large ring, and giving it the inclination of the *membrana tympani*. You will perceive no reflection if you examine it, holding the mirror relatively in the same direction as that in which you view the *membrana tympani*. But such a reflection will at once be seen at the spot where the cone of light is found on the *membrana tympani*, if the central portion be arched by pressure or traction inward.

Consequently, we cannot agree with Wilde respecting the cause of the cone of light; and Von Tröltzsch justly remarks that it is found not only upon the surface of the externally convex portion of the membrane mentioned

by Wilde, but also upon concave portions, its apex indeed being visible at the umbo—the most concave part of the membrane.

Although it is evident from the foregoing statements, that no conclusion respecting changes in the membrana tympani, or in the cavity of the tympanum, can be drawn from the form, size, or absence of this reflection of light,—since changes in the cone of light, like those often met with in disease, are sometimes found in persons of normal hearing,—still, in many cases, we can make use of the light spot in determining the perviousness of the Eustachian tube. If, for instance, air is forced into the cavity of the tympanum by the Valsalvian experiment; or, during the act of swallowing, it is drawn out, on examining the light spot we shall see a change in its form, since the curvature of the membrane must necessarily be altered by these sudden variations in the pressure of the air in the tympanic cavity. If, then, during the aforesaid manipulations, we perceive an alteration in the cone of light, we can say with certainty that the tube is open, though we can by no means infer the contrary from the absence of change in form and size. Frequently, during very quick and strong changes in the pressure of the air—for example, in catheterization—even in the normal condition, not the slightest movement of the membrane is visible; though a small aural manometer introduced into the meatus proves, beyond a doubt, by the movement of a little drop of fluid in it, the existence of a change of curvature.

Besides this light spot, which in disease undergoes the

most varied alterations, reflections are also sometimes found in normal ears, upon other portions of the membrane. Sometimes, for instance, there is a faint lustre upon the posterior upper portion (V. Tröltzsch), and, now and then, a small light spot in the depression already described, in front of and above the short process.

The *inclination* of the membrane to the auditory passage has a great influence on our estimate of its condition, and we must speak of it somewhat more in detail. On account of this inclination, the pathological changes in the membrane do not appear in their actual form. First of all, it must be remembered that in inspection we do not look upon the membrane vertically; and further, that its various portions, on account of their different degrees of curvature, have not the same inclination to the auditory canal. Our judgment of the degree of this inclination, derived from inspection, is very uncertain, for we estimate it much less than it proves to be in the anatomical preparation.

The marked inclination of the *membrana tympani*, in the first place, affects our judgment of its superficial area. On account of the obliquity of its plane to our axis of vision, it appears smaller on inspection than it is in reality, being seen in perspective. The less the inclination,—and, according to the foregoing statements, there are differences here very frequently,—the larger the *membrana tympani* appears to us, in case a large part of its anterior portion is not hidden by a too great curving backward of the anterior osseous wall of the meatus. In cases where the meatus is wider and short, the membrane

appears larger. Such is the difficulty of determining by inspection the proper form of the membrane, in consequence of its inclination; and to this difficulty the aforesaid relation of the anterior wall of the osseous canal also contributes. Hence it follows that *pathological alterations* of the membrane must, on account of its inclination, also undergo an apparent change in form and size. This, in many cases, as will be seen hereafter, is clearly proved on dissection.

In like manner the *curvature* of the membrane, as well as the inclination, to which it stands in intimate relation, has an influence in the diagnosis of the pathological condition. It is well known that the membrana tympani, through traction of the manubrium, is externally concave; but this is only true of the membrane as a whole. From the deepest point of its concavity, the so-called umbo, going toward the periphery, it has an external convexity as already stated. The reason of this is a purely physical one, since we see the same phenomenon upon any elastic membrane which is strongly bellied out by traction or pressure on any point whatsoever of either side. The curvature of the membrana tympani, like its inclination, differs in different individuals; and our judgment concerning its degree is in like manner defective. Just as the membrane appears to us to stand more vertically than is real, so it appears to have a less degree of inward curvature. We generally judge of the more or less pronounced curvature of the membrana tympani by the position of the handle of the malleus; yet this as will be seen in the sequel, is not a criterion in every

case. The external convexity, as we pass from the umbo toward the circumference, is not the same upon all parts of the membrane, but is somewhat greater in the anterior lower quadrant and its vicinity than upon the posterior portions. That no regular curvature can occur here, follows from the fact that the membrana tympani is not circular, and that the end of the manubrium, as stated, is not found at the centre of the membrane. These differences and irregularities of curvature in different individuals can best be estimated from the variations already mentioned in the form of the cone of light as they present themselves in persons with normal hearing.

It remains, still, to mention an appearance referable to the inclination and curvature of the membrane, which deserves full attention in the examination of patients. It is the somewhat more marked projection of the manubrium into the cavity of the tympanum, combined with a greater bulging forward of the parts lying behind it, which in many cases, on account of the oblique position of the membrane, so cover the handle that none of it, or only its ends, can be seen.

If we sum up the foregoing statements, the following is a brief synopsis of the normal condition (Pl. 1, Figs. 1, 2, 3, 4.). At the anterior upper edge of the membrane, we see a whitish prominent point, the short process of the malleus; extending from this downward and backward nearly to the centre of the membrane, a whitish or pale yellow stripe, the malleus handle, widening out at its lower end into the form of a spatula. In front of and below the end of the manubrium we see a triangular reflection, the



cone of light, its point at the umbo, its base turned forward and downward toward the periphery; the anterior portions of the membrane, lying between the manubrium and the cone of light, generally of a darker gray and seldom visible as far as the periphery; the portion behind the manubrium more or less distinctly separated from the posterior upper wall of the meatus by a lighter line, and appearing much larger and lighter, and its color modified in the manner stated, by the promontory and sometimes by the long shank of the incus shining through the membrane, and by the pocket of Tröltzsch with the *chorda tympani*.

## ANOMALIES

### IN THE TRANSPARENCY AND COLOR OF THE MEMBRANA TYMPANI.

---

THE pathological changes in the *transparency* and *color* of the membrana tympani are manifold and very frequent, and often furnish valuable data for a diagnosis. The anatomical arrangement of the several layers has already been adduced as the cause of their frequent occurrence. For affections, both of the external meatus and of the lining of the cavity of the tympanum, are transmitted to the corresponding superficial layers of the membrane, making it the seat of appearances which come under observation the more frequently, because the diseases of the external and middle ear generally furnish the most frequent cause for disturbance of function.

The disturbance of nutrition in the membrane appearing in the form of an opacity can, therefore, generally be considered only as one sign of a process still going on, or the result of one that has already run its course. But the peculiar characteristics of opacities

cannot always be traced to a definite cause. For if we examine a large number of persons of normal hearing, we shall meet with a great variety of membranes, from the very rare glassy transparent to the normally translucent or entirely opaque. Of persons having normal hearing, a certain proportion, perhaps twenty-five per cent., have normal membranæ tympani. This fact must be borne in mind, if we form a just estimate of the diagnostic value of the opacities occurring in diseases of the ear.

The causes of opacities in persons of normal hearing are various. These changes, which we will soon take account of in the special description of opacities of the membrane, must sometimes, in the absence of any positive evidence, be referred to anomalies of conformation, or to an arrest of development. The latter is the case when the membrane, which is normally dull in the new-born and in childhood, does not clear up, as is usual at a later period. Likewise, these alterations may be the result of a morbid process that has run its course with complete recovery. It is probable that the lack of transparency arising from opacity of the inner surface of the membrana tympani not unfrequently depends upon a catarrh of the cavity of the tympanum, which has passed away, leaving opacity of the mucous layer of the membrane, but no impairment of function.

Although, in the following description, we adhere by preference to the anatomical arrangement, according to the situation of the opacity in the several layers of the

membrane, still, it will easily be seen, from what has preceded, that such an arrangement cannot be strictly adhered to, because the lamellæ, so intimately bound together by the manifold nutritive relations, can scarcely be thought of as separate, and consequently, also, each individual layer must necessarily share in the derangement of the nutrition of its neighbor. Hence, in order to determine the diagnostic value of opacities, we must pay strict attention not only to their anatomical relations, but to their causes. From the *kind* and *degree* of opacity alone, a conclusion can scarcely be drawn concerning the nature of the lesion. Therefore the union of the anatomical with the etiological view is indispensable for a systematic exposition of opacities of the membrane. A conclusion from them concerning the degree of functional disturbance is hardly ever possible.

We now pass to the special description of opacities of the membrana tympani, retaining the division into two large groups; namely, *general* and *circumscribed opacities*.

#### A. GENERAL OPACITIES.

The variety of colors exhibited by general opacities are of little importance in diagnosis, since, even in affections of the same layer, they frequently present very different shades. We have already stated that, in the illumination of the membrana tympani, its color is a combination of the peculiar colors of the membrane, of the rays reflected from the promontory,

and of the kind of light employed. Now, in fully developed opacity, the transit of light through the membrane is reduced to a minimum, and consequently also the amount reflected from the promontory is extremely small, so that it can scarcely be regarded as a factor in the color. The proper color of the membrane is lost by the deposit in or upon it of an opaque substance, and hence the membrane will present the color peculiar to the opacity. In their causes, general opacities differ from each other essentially, and, according to the anatomical arrangement, are dependent, sometimes primarily, sometimes through transplanted, upon—

1. *Softening or thickening of the epidermic layer of the membrane.*
2. *Diseases of its dermoid layer.*
3. *Lack of transparency in the substantia propria.*
4. *Opacities and thickening of the mucous layer.*

1.—*Opacities of the Epidermic Layer of the Membrana Tympani.*

*Softening* of the epidermic layer of the membrana tympani is very frequent, as well in its own primary affections as in those of the external and middle ear. In the normal condition, as we have already stated, the epidermis of the membrane, like that at the points of transition from skin to mucous membrane, is composed of a thin stratum of delicate, transparent epithelial cells, which in the deeper layers have the character of the soft

mucous cells of the *rete malpighii*. As in the cadaver this stratum becomes clouded and opaque through maceration, in like manner during life it becomes softened by disease. The individual cells thereby lose their transparency, and, in consequence, the surface of the membrane becomes lustreless and dull. This softening is not uncommon in persons of normal hearing; and while we admit that, in many such cases, external circumstances are not without an influence in the too great hardening and softening of the epidermic tissue, still we must, on the other hand, bear in mind the fact, that shining transparent membranes are met with in persons having wide, straight, and short auditory passages, which make the inspection of the membrana tympani possible without any kind of illumination, and appear especially exposed to wind and dust. In pathological conditions, a softening of this kind is generally the result of a serous exudation from the membrana tympani, as it occurs in the beginning of acute catarrh of the cavity of the tympanum, in the rare forms of idiopathic myringitis, and at the outset of otitis externa.

Abnormal *thickening* of the epidermic layer is to be distinguished from simple softening. It very rarely occurs independently, but is usually a sign in part of pathological processes in the external meatus, which have been transmitted to the external layer of the membrane, and are due to frequently recurring hyperæmiæ, and to past or existing catarrhs of the external meatus. A marked hypertrophy of the epidermis is often seen during the recession of purulent catarrh of

the middle ear which has resulted in perforation of the membrane.

Thickening of the epidermis in consequence of *congestions* of the external auditory canal is not unfrequently observed in frost-bites of the external ear, in cases of frequently recurring furuncles of the meatus, in eczema and erysipelas. Here, as in hyperæmiæ of the skin, an increased formation of epidermis takes place, the meatus either appears partially filled with epidermic scales and cerumen, or is covered by a continuous, often stratified layer of thickened epidermis, which may be removed in large membraniform plates, or as a coherent cul-de-sac.

After a catarrh of the external meatus has passed off, the excessive formation of epidermis usually continues for a time. Its growth is so rapid, that, even in a single day after its removal, a new layer has formed in the meatus and upon the membrana tympani.

The opacities of the membrane from thickening of the epidermic layer differ according to its density, and the admixture of fatty particles, or of dried pus and mucus. For distinguishing them from opacities arising from thickening of the mucous membrane, we possess a sign, usually of value, in the clearness with which the manubrium and short process are seen. The most marked opacity of the mucous membrane very rarely excludes a view of these portions of the malleus; whilst, indeed, with a very slight degree of epidermal thickening, the manubrium is very indistinct, and, in case of congested vessels, is of a dirty orange color, as seen through the

layer. In more marked thickening it cannot be seen at all. The short process, however, is sometimes still recognizable, even with a somewhat greater deposit. The color of the deposit is usually grayish-white or dirty yellow, or here and there light or dark brown from the admixture of particles of cerumen. The membrane has lost its normal lustre, though at several points it may glisten with fat, or indeed throughout in case the epidermic cells are filled with it. As might be supposed, deviations in the curvature of the visible surface of the membrane are also associated with these deposits; and we find it either flattened or uneven and rough, and the boundary between the meatus and the membrane can no longer be distinguished.

The epidermic deposits seldom affect the hearing when the stratum is thin, but there are marked exceptions to this rule. Thicker strata however, especially when closely adherent to the dermis, by reducing the susceptibility of motion in the membrana tympani, will now and then occasion a high degree of deafness, and sometimes *tinnitus aurium*, which is speedily relieved by removal of the epidermis. However little influence such deposits may seem to have in the disturbance of function, still the importance of a knowledge of these facts appears in practice; for cases often come under observation in which the deafness and tinnitus aurium thus occasioned have been treated by the most varied and often strange methods, though they are speedily relieved by first dropping in some glycerine, and then syringing with lukewarm water.



2.—*Opacities from Diseases of the Dermoid Layer of the Membrana Tympani.*

To what we have already said, in the description of the microscopic anatomy of the membrane, concerning the texture of the dermoid layer, we must further add that the vascular twigs of the *membrana tympani* are invisible in the normal condition, notwithstanding their manifold ramifications and anastomoses. When somewhat *congested* however, the wide-spread vascularity is at once apparent, and hyperæmiæ of a higher degree may cause an opacity of the membrane, even without the occurrence of any change of structure. Congestion of the cutis of the *membrana tympani* not unfrequently occurs simultaneously with hyperæmic conditions of the external meatus, and of the cavity of the tympanum. In the normal condition, also, congestion limited to the membrane may be excited by mechanical influences, such as too frequent touching of the membrane, long-continued examination with the speculum and mirror (Tröltsch), and frequent irritation of the external meatus by hard substances. This, however, disappears after a time.

Congestion of the vessels of the handle of the malleus is very conspicuous in the examination of hyperæmic *membranæ tympani*, a clear red, or livid vascular bundle (Pl. 1, Fig. 3) extending along the posterior edge of the handle as far as its lower end. At the upper end, it either terminates or is continuous with

the congested vessels of the upper wall of the external meatus, at its point of union with the membrane. We often see, especially in acute catarrh of the cavity of the tympanum, a more or less defined hyperæmia at the upper edge of the membrana tympani, with a diameter of from two to three lines, affecting partly the membrane, and partly the meatus, and having in its midst the yellowish projecting short process, not unlike an acne pustule surrounded by a red areola. In one case, a small, sharply defined stripe of vessels stretched along the upper wall of the meatus beginning at its middle, and extended to the end of the manubrium, as its vascular bundle. In examining aural patients, we find a great variety in the appearance of the vessels of the manubrium, especially in chronic catarrh, without purulent secretion. In several such cases I have seen a permanent congestion of these vessels, sometimes so considerable that it entirely covered the handle of the malleus (Pl. 2, Fig. 4), so that its direction even could only be recognized by means of the injected vessels. In other cases, on the contrary, the injection was less. I have frequently seen the handle entirely surrounded by a little pink vessel, or crossed obliquely by a larger one; the latter I have also sometimes seen after the subsidence of otorrhœas with formation of cicatrices or of calcareous deposits in the membrane.

The intermittent congestions of the manubrium are worthy of notice, both in chronic affections of the tympanic cavity and in those persons whose hearing is

otherwise normal, but who, at times, through congestions of the brain and of the organs of hearing, are troubled with tinnitus aurium, mental confusion, and attacks of vertigo, with the cessation of which the injection at the manubrium also disappears.

We are indebted to the pioneer labors of Von Tröltzsch for a knowledge of the more intimate relations of the vessels of the external meatus to those of the dermoid layer of the membrana tympani. Indeed, the examination of aural patients, in whom the vascular ramifications are often plainly visible, is best calculated to convince us of the correctness of this author's views.

Besides the congestion of the vessels of the manubrium, which at once catches the eye, we may, in extensive congestions of the membrane, discover a circular wreath of vessels near its periphery, from which little converging branches run toward the centre of the membrane to anastomose with the vessels of the manubrium (Pl. 1, Fig. 5). Especially in acute catarrh of the tympanic cavity, or in relapses of chronic catarrh, these relations are prominent; and though they are not alone sufficient to determine the locality of a morbid process, yet the diagnostic value of such a condition, taken with the other symptoms, is not to be underrated.

*CASE: Acute Catarrh of the Middle Ear—Regular Course—Recovery.*

Mr. A., Student of Medicine, in the month of June of the present year, shortly after a cold bath, experienced a severe pain in the right ear, with which a loud ringing was soon associated. An examination, made the following day, revealed a uniform pink injec-

tion of the external meatus, especially in its osseous portion, the redness being more intense at its junction with the membrana tympani. This was marked at the anterior upper quadrant, near the short process, which, as a yellowish-white tubercle, was in strong contrast to its dark red surrounding. Along the manubrium extended a dark red bundle of vessels, so strongly developed as to make the handle itself invisible. Near the periphery of the membrane a circular wreath of vessels could be seen, from which small, slightly serpentine branches extended to the centre to anastomose with the vessels of the manubrium. The remaining portions of the membrane, lying between the injected parts, were dirty gray or lead colored (Von Tröltzsch), and dotted with serous exudation. The light spot was dimmed, and scarcely visible. The hearing distance was not much affected. On account of the continued severe pain, five leeches were applied close in front of the tragus, and a gargle ordered, of *Tr. Opii* ʒ ss., *Aq. Font.* ʒ iv., with a little sugar. On the following day the pain had entirely left the right side, but had attacked the hitherto unaffected left ear, with the same severity and just the same appearances of the membrane as were upon the other side. Five leeches were now also applied upon the left side, and upon their falling off the pain immediately abated. On the third day of the attack, the pain on both sides had disappeared, but the ringing in both ears continued, and the hearing distance for the watch had fallen to about three or four inches on either side (the mean normal distance being twelve feet); for conversation it had fallen to somewhat more than six feet, and the condition of the membrane was nearly the same as on the previous day. After making both Eustachian tubes pervious, simultaneously, by means of the air-douche, according to the method devised by me, the hearing distance for conversation immediately rose on the right side to twenty-one feet, and to forty-two on the left; the ringing was less, and the patient felt in all respects much relieved. On the fourth day of the attack the condition of the membranes was the same, except that they did not appear so moist. The hearing distance had sunk again to twelve feet, probably on account of the reaccumulation of mucus

in the cavity of the tympanum, but rose to the height of yesterday, after the employment of the air-douche. Upon the fifth day a considerable abatement of the injection of the external meatus and of the peripheral wreath of vessels was already apparent. Only the vessels of the malleus were still injected, and several small branches extended from the centre toward the circumference, which were sharply defined upon the dull, greenish-yellow membranes. The lustre of the membranes was entirely wanting. The hearing distance had decreased but little since the day before, and rose to fifty-four feet, for conversation, on the right side; on the left to forty-eight, and to three feet for the watch. During the three days following, the condition of the membrane, as well as the hearing distance, remained the same. Upon the ninth day of the disease there was no trace of injection in the meatus, and upon the membrane only a pale red bundle of vessels could be seen along the manubrium. The cone of light was present, although dull and somewhat faded, and the membrane was of a dull gray. The hearing distance was nearly normal, and the ringing had entirely ceased. The air-douche was continued daily. Upon the thirteenth day, all the morbid appearances of the membrane had gone. The lustre and curvature, as well as the hearing distance, were perfectly normal. I had an opportunity of verifying this again by an examination some months later.

This is nearly a typical case of acute catarrh of the middle ear, with predominantly mucous secretion from the mucous membrane of the cavity, running a favorable course and resulting in recovery. The examination of numerous cases, however, abundantly proves that sometimes there is a different condition of the membrana tympani: such as abnormal external convexity, general or circumscribed; vesicles formed by separation of certain portions of the epidermis through serous effusion; and before or behind the manubrium a circumscribed

greenish-yellow discoloration of the elsewhere injected membrane. Entirely similar conditions of the membrane may also exist in purulent catarrh of the middle ear for days, indeed for weeks, before the membrane is perforated by the accumulation of pus in the cavity. Therefore, in the first stages of the disease we can never accurately decide whether a simple or a purulent catarrh will be developed.

Next to the congestions of the membrana tympani we place its *ecchymoses*. They likewise occur in acute catarrh of the middle ear, in inflammations of the membrane, or in acute relapses of chronic catarrh. Although occurring in otherwise perfectly healthy individuals, yet they are more frequently observed in broken-down, decrepit subjects. In a case of marasmus after typhus, where, in the last stages, an acute catarrh came on with tinnitus aurium, besides small scattered ecchymoses in the membrana tympani, exactly similar ones were found in the mucous membrane of the cavity, especially upon the promontory. The recognition of ecchymoses of the membrane by inspection is very easy. We see, usually upon a more or less congested membrane (Pl. 1, Fig. 6), irregular hemorrhagic spots, in varying numbers, sometimes sharply defined, sometimes faint, and especially frequent behind the manubrium or lying partially upon it. Not unfrequently, similar ecchymoses are found in the osseous meatus; sometimes, a large patch upon its upper wall, which, as we once observed in case of an old woman, at the beginning of an inflammation of the membrana tympani, passed over upon the membrane

without interruption and covered its upper half. We seldom find such little ecchymoses in a chronically inflamed and secreting membrane, either with or without perforation.

*CASE: Acute Catarrh of the Middle Ear—Symmetrical Ecchymoses before and behind the Manubrium of each Ear—Recovery.*

Mr. S., a provincial judge, æt. 46, upon the day following a vapor bath, in which some water entered his ears during the douche, experienced a severe stinging pain in the right ear, which yielded immediately after dropping in some lukewarm oil, but gave place on this side to considerable difficulty of hearing. Upon the following day, the same symptoms presented themselves in the left ear. Examination showed the right external meatus here and there reddened, the manubrium partially covered by injected vessels, the short process clearly visible, and half a line behind the manubrium, and the same distance from the posterior periphery of the membrane, a pretty sharply defined, dark red ecchymosis, two and a half to three lines in diameter; in front of the manubrium, an exactly similar ecchymosis, only somewhat smaller. Inspection revealed a like condition of the left ear. The watch could be heard on the right side only upon contact; on the left, at the distance of three inches. Conversation could be understood on the right side, at the distance of four feet, but at more than six upon the left. Sound was transmitted by the bones upon both sides. After treatment by my method for opening the Eustachian tubes, the hearing distance rose on both sides to eighteen feet. Upon the next day the hearing distance had indeed fallen somewhat, but upon repetition of the treatment, in like manner rose again to twenty-one or twenty-four feet. This treatment was continued for three weeks. During this time, with constant increase of the hearing distance, both for the watch and for conversation, the ecchymoses in the membrane visibly decreased from day to day; then a rusty discoloration came on, and finally they disappeared entirely. The lustre of the membrane again

appeared, as also did the manubrium and short process ; but upon both sides, *after complete restoration to normal hearing*, there still remained, both in front of and behind the manubrium, grayish white patches of interstitial exudation, not sharply defined—the relics of an affection of the membrane associated with catarrh of the cavity.

In still higher grades of acute catarrh, especially when accompanied by purulent secretion, the membrana tympani, before perforation, sometimes appears so reddened, that individual ramifications of vessels can no longer be distinguished. Much oftener we find a uniformly injected surface, with no portion of the malleus recognizable, and we see this redness at the same time extending over a large part of the osseous canal.

Upon the injected membrana tympani, in acute catarrh of the middle ear with purulent secretion, in many cases, previous to the perforation we see at one or more points, especially often at the posterior lower part, greenish-yellow spots, some lines in diameter, usually faded at the circumference. These are caused by interstitial exudation in the membrane, which by pressure upon the vascular branches probably causes the disappearance of the congestion at these points. In one case, after perforation, I saw the aperture exactly at the point where the aforesaid yellow discoloration was previously seen.

The opacities arising from inflammation differ according to the degree of congestion, and its products in the dermoid and other layers. The dermoid layer has, for instance, in common with the lining of the osseous canal,



the peculiarity of assuming, in its inflammations, the characteristics of mucous membranes similarly affected. As we have stated, it is very thin normally ; but in inflammation it may become much swollen and thickened. We often find, in the cadavers of those who have been affected with otorrhœa, an intact or a perforated membrana tympani, from a half to three-quarters or a line in thickness, in which the greater part of the thickening is to be referred to swelling of the dermis ; a smaller portion to the simultaneous interstitial exudation in the substantia propria. In the microscopic examination of a cutis thus changed, exudation in the form of detritus and pus-corpuscles is sometimes visible in the midst of the meshes of loose connective tissue and the numerous varicose vessels. As might be supposed, even the slightest thickening of the cuticular layer will materially affect the transparency of the membrane, yet the changes thus caused in the original aspect of the diseased object present some differences worthy of notice.

In acute inflammations of the external layer of the membrane, and indeed in its chronic secondary inflammations, the line of demarcation between the meatus and the membrane is ill defined, on account of considerable swelling of the lining of the meatus. The superficial area of the membrane appears considerably diminished, more or less reddened by strongly injected vessels, and spotted with pus (Pl. 1, Fig. 8), or a flocculent exudation (Pl. 1, Fig. 9). The membrana tympani is thus abnormally flattened, or rendered uneven as if granulated, and the light thrown in is reflected, at one or

more places, from small circumscribed points, which, even in imperforate membranes, show a pulsation. In slighter degrees of congestion, however, the membrane will, according to the amount of exudation in its dermoid layer, appear orange-colored, in part also dirty grayish-yellow, often party-colored, and a distinction between the individual portions of the membrane will be rendered impossible. But all the opacities of this layer which are caused by swelling have the common characteristic of completely hiding the malleus handle in most cases, inasmuch as it lies behind the dermis. The short process is likewise invisible in great swelling; but in less degrees is often distinctly prominent as a reddish or yellow tubercle. Only in two cases was the malleus handle with its short process clearly distinguishable in the presence of inflammatory softening of the dermoid layer of the membrane.

The swellings of the dermoid layer, if not accompanied by perforation of the membrane, run a comparatively favorable course; for, though they often cause an opacity of the substantia propria which cannot be removed, still as often it returns to an entirely normal condition, no change of structure remaining. At first, in such cases, the congestion gradually disappears, the secretion upon the surface becomes less, and the membrana tympani appears not unlike a layer of false membrane, of a grayish-yellow or pale yellow color. While the swelling is subsiding we see, first, the short process gradually coming into view; but the malleus handle usually first appears after complete sub-

sidence of the swelling and the termination of abnormal desquamation, visible through the clear or somewhat dull gray dermis. The appearance of the manubrium is therefore usually to be regarded as a favorable sign. If, after the termination of inflammatory processes, circumscribed opacities remain here and there in the dermoid layer, they are connected, as we shall see, with changes in the substantia propria.

### 3.—*Opacities from Changes in the Substantia Propria.*

The general opacities of the membrana tympani dependent on lack of transparency in the *substantia propria* arise either by immediate transmission from the other layers of the membrane, or are secondary to affections of the deeper lying structures of the ear; and they also occur independently in old age. Only the last two kinds of these processes are limited to the substantia propria. The first are generally associated with affections of the dermoid and mucous layers, and are complicated by their opacities. Concerning the nature of the pathological changes in the substantia propria, there are at present only very incomplete investigations, although the most recent reports of post-mortem examinations have thrown some light upon the nature of the primary, as well as of the secondary opacities of this layer.

The opacities of the substantia propria do not always arise from an exudation poured into it from the vessels of the neighboring layers, for careful examination of the

pathological anatomy reveals essential differences in their character, though they are commonly recognizable only as a lack of transparency, and during life, for want of definite diagnostic points, cannot always be distinguished from opacities of the inner layer of the membrane. Though the changes which appear in the substantia propria are especially marked in the circumscribed opacities, yet also in the general opacities we usually find products, recognizable by the microscope, explaining the lack of transparency. It must, however, be admitted, that in many cases of marked general opacity which had been observed during life, where both dermoid and mucous layers were found unaltered, in the substantia propria also, no change accounting for the opacity could be discovered by means of the microscope. In the yellowish, clouded membranæ tympani of an old man, somewhat hard of hearing, the dermis and mucous membrane, on isolation of the individual layers, appeared of normal character, whilst the substantia propria was considerably hypertrophied in its fibrous structure, analogous to the condition of the membrane described by Toynebee as "fibrous lamina thickened;" and on microscopic examination we were unable to discover anything abnormal besides the fibres of the membrane.

When Toynebee, in his descriptions of diseases of the membrana tympani, speaks of an *inflammation of the substantia propria*, we can, on account of the above-mentioned anatomical conditions, agree with him only when a secondary process in the substantia propria is meant. For simultaneously with this process, in which

he describes the membrana tympani as yellow and thickened, Toynbee found adhesions between the membrane and other portions of the cavity of the tympanum. Here, therefore, the admission of a secondary exudation into the fibrous tissue, as the result of inflammation of the mucous layer, appears justifiable. It is, moreover, probable that a parenchymatous process, primary in the sense of Virchow, may exist in the substantia propria. This opinion, however, still needs proof.

On examination, the exudations into the substantia propria, secondary to inflammations of the dermoid and mucous layers, present some differences, according to the stage of the process. If we have an opportunity in acute cases—for instance, upon the cadavers of typhus patients in whom a purulent catarrh came on in the course of the disease—to examine the membrane, in such cases usually perforated and inflamed, we find it so swollen and macerated that an isolation of its several layers is impossible. The dermis exhibits the changes described in the opacities of that layer. Between the fibres of the substantia propria we find molecular detritus in great quantity and pus-corpuscles, concerning which, however, it is impossible to say whether they originated here, or came in the preparation of the section.

In cases where, after the termination of inflammatory processes in the meatus or tympanic cavity, the membrana tympani remains opaque and thickened, it is very stiff from interstitial deposit, and not unlike a little thin plate of cartilage; and upon section, besides thickening of the connective tissue of the dermoid and mucous layers, we find

a thick granular exudation in the substantia propria, in the form of a finely molecular mass. At points where the deposit is much firmer and thicker, the fibres are interrupted and partially disappear; whilst at other, less thickened points, the fibrillation remains intact. In addition to the molecular deposit among the fibres, we also find it in the stelliform corpuscles of Tröltzsch. (Compare the very interesting reports of sections by V. Tröltzsch in Virchow's Archiv. Bd. XVIII.) A similar condition is often presented by membranes which, after the subsidence of otorrhœa, are wholly or partially adherent to the promontory.

Upon examination in the living subject, a membrane thus changed appears flattened, and uneven in consequence of several unequally clouded portions. The color is a dirty bluish-white, like lustreless porcelain; or yellow predominates, and the membrane may be compared to a lamina of leather. The malleus handle is usually invisible, or is only to be recognized by means of a bundle of dirty red vessels, whilst the short process often projects as a yellowish-white nodule, or sometimes, indeed, is entirely invisible.

The opacities having their origin in and limited to the substantia propria, without affection of the dermis and mucous layers, may, in the majority of cases, as our examinations have shown, be considered a chronic fatty degeneration of this tissue. They sometimes appear, both in old and in young persons, without impairment of hearing; yet they are very marked in cases of deafness continuing for a long time, in consequence of ankylosis

of the stapes with the fenestra ovalis. In one case of this sort (Allgem. Wiener mediz. Zeitung, 1861), the membrana tympani appeared dull and bluish-white throughout. In another case, the lustre of the membrane was indeed present in a high degree, but its color was pale yellow, like parchment (Toynbee), and the anterior part in the Valsalvian experiment arranged itself in radiating folds (Pl. 1. Fig. 11).

In both cases, the examination showed little fat-globules, scattered or in groups, accumulating in larger quantity near the periphery, at the site of the *annulus tympanicus*.

#### 4.—*Opacities from Changes in the Mucous Layer of the Membrana Tympani.*

The general opacities which are caused by changes in the mucous layer of the membrana tympani are the most frequent, because they often occur as indications of a catarrh of the cavity of the tympanum; and this, as is well known, furnishes by far the greater number of cases of deafness that come under observation. Though the mucous layer is normally the thinnest stratum of the membrana tympani, yet, even in slight degrees of swelling and softening, it may occasion considerable opacity of the whole membrane. It may, however, in hypertrophy, become more than four times as thick as the normal membrane (Toynbee, V. Tröltsch). On the other hand, dissections show that sometimes, even when marked opacities have been observed during life, the mucous

layer is not thickened throughout, opacity of the epithelium alone being present.

In *acute catarrh* of the cavity without perforation, the membrana tympani has a bluish-red color, on account of congestion of its mucous layer. From opacity of the more or less sympathetically affected substantia propria, and simultaneous congestion of the dermis, this color undergoes many modifications, from the dirty ash-gray to a dark gray with a tinge of violet. The membrane sometimes presents a peculiar appearance in the first stages of an acute catarrh of the cavity, or of acute myringitis. It is, namely, very glistening, and this lustre of the external layer gives to the uniformly reddened membrane the appearance of a polished plate of copper. This condition does not long continue, for the lustre disappears after a day or two, the membrane becoming dull from softening of its epidermic layer, and sometimes divided by fissuring into irregular areas, as if covered with a white frost. After some days it becomes clear again, its lustre returns, and the invisible handle of the malleus and short process again come to view.

In *chronic* cases—and these are the most frequent—we seldom find congestion of the membrane, though the vessels of the manubrium are sometimes injected. The membrane is either bluish-white, with a tendinous opacity, or dirty gray, and usually dull. The cone of light is dimmed, as if striped; or the membrane has not lost its lustre, and through opacity of the mucous layer has the appearance of glass, ground dull or covered with vapor upon one side. The manubrium is generally visi-



ble, inasmuch as it lies in front of the opaque layer. In some cases, however, it is either invisible, in consequence of simultaneous effusion into the *substantia propria* enveloping it, or is so strongly drawn inward by thickening and subsequent retraction of the mucous membrane overlying the tendon of the *tensor tympani*, that it either appears greatly shortened by perspective (Von Tröltzsch), or, covered by the posterior portion of the membrane, cannot be seen at all. At the same time, the short process and the fold running back from it are very prominent (Pl. 1, Fig. 10). As already stated, the *substantia propria* and the dermis usually suffer in acute affections of the mucous layer of the membrane. This is also true of the chronic forms, and frequently, in uniform opacity of the mucous membrane, circumscribed or diffuse secondary opacities modifying it are also found in the *substantia propria*.

#### B. CIRCUMSCRIBED OPACITIES.

The circumscribed opacities of the *membrana tympani* are very frequently located in the *substantia propria*, and, in many respects, are of great interest. Passing by the usually unimportant and easily recognized opacities, which have their origin in circumscribed softening of the epidermic layer, we regard the consideration of the contemporary affections of the dermoid and mucous layers the more important, in a description of the circumscribed opacities of the *substantia propria*, because, on account of its non-vascular character, these opaci-

ties, in the majority of cases, are due to pathological processes in the adjacent layers. With few exceptions, they extend into the tissue of the external and inner coats.

The *origin* of the circumscribed opacities of the *substantia propria* may be traced with great accuracy in a class of cases, and this is especially true in those forms of inflammation of the external and middle ear that are accompanied by purulent secretion. Without doubt, they are to be regarded as the results of *interstitial effusion* into the *substantia propria* from the neighboring vascular layers. This may be proved by examination upon the cadaver. During life these circumscribed effusions cannot be perceived, so long as great vascularity and swelling of the dermoid layer continue. When these are not present, yellowish-white spots of varying extent appear at one or more points upon the intact or perforated membrane. They are usually faint at their edges, and only later, when the process is ended, appear as dirty white or chalky spots, and for the most part sharply defined. Less frequently, such circumscribed effusions, without simultaneous otorrhœa, appear in clearly marked, oft-recurring catarrhs of the cavity of the tympanum without perforation of the membrane. They are usually visible as irregular, ill-defined opacities, of a yellowish color, differing in form from the calcareous and osseous deposits to be described hereafter. The opacities mentioned are also not to be confounded with those occurring in the course of chronic thickening of the mucous membrane of the cavity. The latter appear

behind the manubrium in crescentic form, with the convex side turned toward the periphery. They are of a bluish-white or tendinous-gray color and ill defined. With edges gradually becoming clearer, they lose themselves in the transparent portions of the membrana tympani. Upon examination of several such cases, they proved to be deposits of fat-globules and finely granular matter between the fibres of the membrane.

*Calcareous deposits* in the membrana tympani are by no means infrequent, and are easily recognized during life. The knowledge of their occurrence appears to be of earlier date than is generally supposed. In an old work by Cassebohm (*Tractatus quatuor anatomici de aure humani. Halae, 1734*), we find the description of a preparation of the membrana tympani of an old woman, upon which there were calcareous deposits before and behind the manubrium. Besides our obligations to Toynbee, and to Wilde, who has reported more fully concerning their occurrence and form without being able to affirm anything of their structure, we are indebted to Von Tröltzsch for more accurate accounts of these interesting phenomena (*Anatomische Beiträge zur Ohrenheilkunde, Virchows Archiv. Bd. 17, und Krankh. des Ohrs, 1862*). He says: "Such calcareous deposits are, for the most part, distinctly separated from the surrounding tissue, and with their yellowish-gray or clear, whitish appearance are not to be mistaken. They occur even in childhood, and are not at all infrequent. With the exception of a few cases in which the hearing was pretty good, I have hith-

erto found them only with high degrees of deafness : so that similar earthy processes on the membrane of the fenestra rotunda, or about the foot of the stapes, may be inferred from them. How far such calcareous deposits impair the hearing power, must first be established by the observation of cases which are not complicated with other changes in the ear, if such calcifications ever occur entirely alone."

Our observations in this direction, made upon the living and upon the cadaver, are as follows :—

1. The calcareous deposits in the membrana tympani are, in the majority of cases, to be regarded as the products of otorrhœas that have passed away, where the exudation into the substantia propria from the neighboring layers has undergone a chalky metamorphosis. Even in those cases where a former discharge from the ear cannot be remembered, there is, doubtless, a number to be classed in this group, because many people are ignorant of an otitis that has run its course in childhood. That such deposits occur in the course of chronic catarrh of the middle ear is well known. But it can only be determined with certainty that such is the origin, when the formation of the deposit has been observed during life. So far as I know, Moos, of Heidelberg, was the first to observe the formation of calcareous deposits in the membrana tympani. This occurred in an old woman seventy years of age, in the course of a chronic catarrh of the middle ear, without secretion and perforation of the membrane. Since that communication I have also had an opportunity, in two similar cases, of following up the develop-

ment of these deposits. Schwartz also observed their increase in several cases.

2. During the examination of a very large number of persons of *normal hearing*, in several cases I met with calcareous deposits in the membranes, such as are found after old otorrhœas.

Fig. 1 of the accompanying sketches (Pl. II., Fig. 9) is an illustration of the right membrana tympani of Mr.

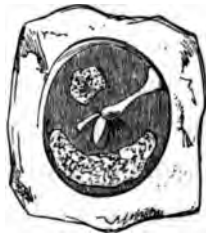

Fig. 1.

E—ch, a student, on which a large crescentic, chalky white deposit is to be seen in front of the manubrium, behind it a smaller, irregular, polygonal one, which strongly contrast with the bluish gray color of the other parts of the membrane. Several oblong reflec-

tions of light are seen at the lower end of the manubrium. According to his own and his mother's statement, no affection of his ear had ever been noticed. The hearing distance upon this side is, indeed, somewhat less for the watch than upon the left, but for speech it is just as good. Even more interesting is the condition of the membrana tympani in Mr. M—r, a student. We saw there, upon both sides of the manubrium, both before and behind, equally large, crescentic, glistening white calcareous deposits, with an otherwise normal appearance of the membrane. Nothing was known by himself or his parents of the occurrence of any former disease in the ear, and he possesses, together with a pretty good hearing distance for the watch, not only a sharp, but also finely cultivated musical ear.

Fig. 2 is taken from the cadaver of a person whom I examined during life, at the clinic of Prof. Oppolzer, and who, I was obliged to say, had normal hearing. In the microscopic examination of this preparation, I found just such changes as I shall speak of as resulting from a pathological process. In the cases just mentioned, nothing can be said with certainty concerning the manner in which these deposits originated.

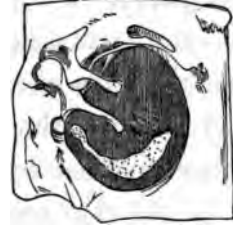


Fig. 2.

The sketches immediately following represent pathological preparations, taken from persons whom I examined during life.

Fig. 3 represents the inner side of the left membrana tympani of a girl, twenty-four years of age, who died of phthisis in the clinical department of Dr. Kolisko. In her twelfth year she had suffered for a short time from otorrhœa. Upon this side she heard my watch at the distance of one foot; my somewhat sonorous voice at from eight to ten feet sounded very hollow, as if it came out of a cellar. Besides this condition of the membrane, no anomaly could be discovered in the hearing apparatus. The calcareous deposit (Fig. 3) in front of the handle of the malleus had not only invaded all the layers of the membrane, but even projected inward markedly beyond the surface of the mucous layer. Upon the uncalcified portions of the

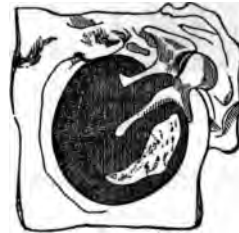

Fig. 3.

membrane, the radiate and circular fibrous layers were seen abruptly terminating at the distance of a line from the periphery. From here to the manubrium the membrane was remarkably thin and transparent, more sunken than the peripheral portion, so that the boundary between the thick peripheral and thin central portions was marked by a pretty sharp line. Only at one point of the thin part a bundle of irregularly arranged radiating fibres extended, in the form of a triangle, from the end of the manubrium toward the periphery. (See Von Tröltzsch, l. c.)

Fig. 4 is a sketch of the external surface of the right membrana tympani of a man, seventy years of age, who died in the section of Dr. Chrastina. In youth he had suffered from otorrhœa for a long time, and had become entirely deaf. Besides anchylosis of all the ossicles with the walls of the tympanic cavity, there was a small thick calcareous mass deposited in front of the handle

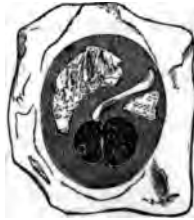

Fig. 4.

of the malleus, and behind it was a larger one. All the layers of the membrane were involved. Below the manubrium was a perforation with cicatrized edges. A bridge of the tissue of the membrane still remained, dividing it into two parts.

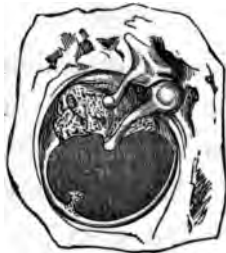

Fig. 5.

Fig. 5 represents the inner surface of a preparation taken from the left ear of a man, thirty-five years of age, who died in the

clinical department of Prof. Oppolzer, of cancerous degeneration of the retro-peritoneal glands. He had suffered from otorrhœa in earliest childhood, and became gradually deaf upon this side. In the tympanic cavity I found the malleus handle and incus slightly movable, the stapes completely ankylosed, and the membranous semicircular canals remarkably atrophied. The upper half of the *membrana tympani* (Pl. II., Fig. 11) was partially ossified, and the thickness of the membrane thus degenerated amounted to two lines. From the larger calcareous mass a thin, narrow, whitish stripe extended along the rest of the periphery of the membrane, from whose lower portion an opacity of the size of a pin-head, mounted on a pedicle, projected into the uncalcified part of the membrane. This part, corresponding to the lower half, is clear and transparent, and not a single fibre of the *substantia propria* can be recognized upon it by the glass. Although it is probable that this is the cicatrix of an old perforation, yet I will not venture to state it positively.

Besides these cases I had an opportunity to examine a large number of calcareous deposits in membranes, which were for the most part obtained incidentally in post-mortems. These, as well as the large number of observations made during life, show how much the deposits vary in form, extent, location, and structure. Most frequently they appear in the crescentic form described, in front of, or behind the *manubrium*, or in both places at once (Pl. II., Figs. 9, 10). Less frequently they are shaped like a horse-shoe, and occupy the lower two-thirds of the cir-



cumference, surrounding the handle of the malleus. Occasionally there are cases in which the calcareous deposits, especially after otorrhœa, extend from the extreme periphery to the handle of the malleus, and sometimes so completely envelop the latter that only the short process is visible (Pl. II., Fig. 11). In other cases we find, either upon membranes otherwise nearly normal, or associated with circumscribed tendinous opacities or perforations, little isolated or grouped (Pl. II., Fig. 4) calcareous deposits, not always well defined, which have been formed during or after catarrhs of the middle ear, or primary affections of the membrane.

3. The *microscopic* examination of the calcified portions disclosed varieties in the different cases, which are worthy of notice. In a series of preparations, where the deposit was not very thick, the dermoid layer was pretty easily separated from the calcified parts. The mucous layer was a little more adherent. In other cases the separation could not be accomplished, and the external and middle layers proved to be involved in the calcific process, especially when the deposit was of considerable thickness. The deposit consisted of an amorphous, finely granular mass, lying partly between the fibres of the membrane, and partly in the corpuscles—a condition similar to that already recorded in one case by Von Tröltzsch (l. c. sect. 4).

Besides the amorphous carbonate of lime, usually occurring in the form stated, which accumulates at some points in trifling amount, at others to such a degree of thickness that none of the original elements can

be discovered, I found in one of the above-described cases (Fig. 5) (Pl. II. Fig. 11), together with the calcareous deposit, a true osseous formation. A thin section presented the appearance of new bone (as, for instance, that from the skull of a new-born child), with pretty large, thickly-spread corpuscles, furnished with short processes. I think that Prof. Hyrtl first discovered this anomaly in the membrana tympani of an opossum. In the midst of the calcified portions I once found black or dark brown pigment (See Toynebee, Diseases of the Ear, German translation by Moos of Heidelberg), lying in circular groups or in stripes, and it appeared also to be accumulated in fusiform or stellate cells. In addition, there were fat-globules everywhere, in varying amount. The fibres of the membrane had undergone a variety of changes, in certain cases, both in the calcified portions and their vicinity. In one case, the riband-like fibres of the substantia propria could be isolated, at points where the calcareous mass had not entirely supplanted the elements of the membrane, and the individual fibres were frequently so changed as to appear occupied throughout with small fat-globules and punctiform granules. In sections where the calcareous salt had been removed by the addition of acetic acid, the stellate corpuscles could be seen well preserved; in others they were either irregularly arranged and stunted, or upon the apparently homogeneous surface little scattered, roundish, or somewhat irregular strongly refracting corpuscles were brought to light by the addition of the acid. These had the appearance of

shrivelled nuclei. The change in the *substantia propria* in one case was peculiar: its fibres, namely, were blended into broad homogeneous lamellæ, which were laid one upon another—a condition such as Professor Wedl not unfrequently found in pathological changes of connective tissue. Moreover, the pathological changes are not so definitely limited as might be supposed from the marked border of the calcareous deposit, being also found in the apparently normal portions, especially in the parts adjoining the deposit.

Besides the circumscribed opacities already mentioned, more or less circumscribed opacities are found affecting one or more spots upon the *membrana tympani*, both in its pathological and also, not unfrequently, in its normal condition. These vary in form as well as in extent and color. Very frequently we find upon imperforate membranes, generally behind the manubrium, tendinous gray, oblong, and uniformly faint or striped areas, which are separated by either normal or slightly clouded portions—a condition such as is often met with in chronic catarrhs, and after otorrhœas, but also frequently enough in persons of normal hearing, especially in old age. The seat of these circumscribed opacities is chiefly the *substantia propria*, and, next to this, the mucous layer, where I once found, as the cause, little circumscribed deposits (amorphous exudation).

Those tendinous opacities which affect the whole membrane, with the exception of one or more small portions, are worthy of notice. The transparent parts, since they permit more light to pass through, appear

darker, and therefore also far more in the background, on inspection, than the grayish-white opacities. An unpractised observer, disregarding this circumstance, might easily mistake such a transparent dark spot, sharply defined from the light gray surrounding, for a partial retraction. Not unfrequently they have an elliptical or fusiform shape (Pl. II. Fig. 5), upon the lower or posterior portions of the membrane, and at first glance might readily be taken for slit-like perforations. In one case of chronic thickening of the mucous membrane of the tympanic cavity, which caused a moderate degree of deafness, inspection showed, behind the manubrium, a sharply defined, long, oval, dark spot, over three lines in length, which, in the midst of the elsewhere grayish-white, pearly, lustrous membrane, had the appearance of a distinctly marked retraction. The examination of the ear of a person who died of tuberculosis proved the opinion formed during his life to be incorrect, since the transparent spot mentioned was a partially circumscribed, atrophied, but not sunken portion of the membrane. Sometimes several such thin spots group themselves in a semi-circle around the lower end of the manubrium, and I have found this state of things in chronic catarrhs, with slight, but often also with high degrees of functional disturbance. In case of a man twenty-three years of age, who, according to his own account, became hard of hearing in his thirteenth year, the membrane of the right ear presented on examination a condition such as we have just described. The patient was entirely deaf on this side, and the condition was not changed after the

opening of the Eustachian tube. He died of phthisis pulmonalis in Dr. Kolisko's division, and post-mortem examination showed opacity of the membrane—especially in its mucous layer. In the vicinity of the umbo were five very transparent atrophied spots in form of a half circle, of which the two middle and larger were a line and a half in diameter. The manubrium projected strongly inward toward the promontory. The tendon of the tensor tympani appeared much shortened. The head of the malleus and the body of the incus, firmly ankylosed, were adherent to the upper and outer wall of the tympanic cavity. The stapes was movable, though not so much so as in the normal state. In other respects the lining of the tympanum presented no anomaly worthy of notice.

Circumscribed opacities in many cases are *peripheral*, and are circular in form. As already mentioned, the circular fibres accumulate near the periphery of the membrana tympani to such a degree that it is not only somewhat more rigid at this point in the normal condition, but also, in the majority of cases, less transparent than at other portions. This peripheral dulness sometimes exists in normal states, and in pathological conditions is often so plainly marked, that it is at once recognizable as a distinct grayish-white opacity varying in breadth. (Pl. I. Fig. 12.)

This may best be likened to the arcus senilis of the cornea, and sections at this point show that sometimes the opacity is caused simply by the deposits of fat-globules between the thickly crowded peripheral circular fibres;

while in other cases the membrane appears remarkably thicker and more rigid at this point, through simultaneous thickening of the corresponding mucous layer. That in such cases the central portion of the membrana tympani often undergoes a change of curvature, especially inward, we will explain more in detail hereafter; only be it remarked that, even where this is not the case, the central portion, on inspection, because more transparent and darker, appears to lie deeper than the dull periphery.

If we submit the *functional disturbances* accompanying opacities to careful clinical observation, we find, as a general rule, that they bear no proportion to the changes visible on the membrane, since, in one series of observations, the changes are only insignificant, or may be entirely wanting, where there is a marked functional disturbance; while, on the other hand, as is clear from what has been said before, extensive opacities, which at once strike the eye, will be observed not unfrequently in cases where the impairment of function is very slight, or in persons of perfectly normal hearing.

As regards diagnostic value, the results of these clinical investigations may be summed up in the following points:

1. Diseases of the membrana tympani are, for the most part, combinations of the signs of diseases of the external and middle, less frequently of the inner ear.
2. Opacities occur frequently in aural disease, according to the unanimous testimony of authors, and in many cases afford important data for a diagnosis.
3. The fact, however, that analogous opacities occur

also in persons with normal hearing, diminishes their diagnostic value not a little. Nevertheless they deserve, in given cases, full consideration; since, taken in connection with the other signs, with the nature and course of the case, and the degree of functional impairment, they often essentially facilitate the diagnosis.

**Itard** : *Traité des Maladies de l'oreille et de l'audition*, 1821.

**Saissy** : *Maladies de l'oreille*, 1829. Deutsch von Fitzler.

**Lincke** : *Handbuch der theoretischen u. praktischen Ohrenheilkunde*, 1837.

**Rau** : *Lehrbuch der Ohrenheilkunde*, 1856.

**Wilde** : *Practical Observations on Aural Surgery*, 1855. Deutsch von Haselberg.

**Toynbee** : *Diseases of the Ear*, 1860. Deutsche Bearbeitung von Moos in Heidelberg.

**Kramer** : *Die Ohrenheilkunde der Gegenwart*, 1860.

**V. Tröltsch** : *Anatomie des Ohrs*, 1861.

**V. Tröltsch** : *Krankheiten des Ohrs*, 1863.

**Schwartz** : *Praktische Beiträge zur Ohrenheilkunde*, 1864.

## ANOMALIES

### IN COHERENCE AND CURVATURE OF THE MEMBRANA TYMPANI.

---

THE solutions of continuity of the membrana tympani, usually termed *perforations*, very frequently come under observation in Aural Surgery. It is generally easy to recognize them, but to accurately determine their size is very important, since, under similar conditions, the prognosis respecting recovery and the cicatrization of the gap in the membrane depends upon the extent of its loss of substance.

The most frequent *cause* of perforation is purulent catarrh of the middle ear. Generally, several causes work together in the production of ruptures in the membrane. It seems certain that every severe inflammation of the mucous membrane of the tympanic cavity, affecting also the mucous layer of the membrana tympani, produces a softening, such as occurs in inflammation of other tissues. The secretion of pus and mucus in the cavity of the tympanum now becomes so abundant, that, as it accumulates, it exercises a strong pressure on the walls of the cavity, and the membrane,



softened by inflammatory action, is the more easily ruptured. This commonly happens in cases of acute purulent catarrh of the middle ear, as it occurs in the exanthemata, in severe naso-pharyngeal catarrh, or, primarily also, during other maladies. In other cases, a sudden excessive pressure of air in the cavity of the tympanum leads to rupture of the membrane, yet only where the mucous lining of the tympanum is already diseased, and the tissue of the membrane has suffered the change just indicated. We observe this not unfrequently in purulent catarrh of the middle ear, as it often presents itself in cachectic, tuberculous, and scrofulous persons. The process, in these cases, usually commences with scarcely perceptible inflammatory symptoms, sometimes with only slight tinnitus aurium, or occasional pricking sensations in the ear, or without any subjective symptom, the first intimation that the patient has of any lesion of the ear being the whistling of the air through it in blowing the nose or sneezing, followed at once by a more or less copious discharge from the ear.

If a post-mortem examination of such cases is made shortly after their inception (and this affection not unfrequently occurs in the last stages of phthisis), we generally find the mucous membrane of the middle ear pale, seldom hyperæmic, and covered with a thin layer of creamy muco-purulent secretion, and in the membrana tympani, usually in its lower segment, an irregular perforation from a line to a line and a half in diameter, the border of the opening being softened and collapsed in folds.

Far less frequently the destruction of the membrane

takes place in the opposite direction, and this results either from traumatic injuries, or from consecutive inflammation of its dermoid layer. For instance, in diffuse inflammation of the external meatus, the dermoid layer being sympathetically affected, an inflammatory softening of the part occurs, just as in inflammation of the mucous layer, and perforation may take place without the intervention of any further mechanical force, simply by the breaking down of the membrane at some point, or by the simultaneous formation of an abscess in it; or it may occur, as in the case above mentioned, in the act of sneezing or blowing the nose.

Perforation may result here also from ulceration. Although this method of origin is alleged by Toynbee to be pretty frequent, yet its recognition during life is very difficult, I might say impossible, since it would not be easy to recognize on inspection, even after careful cleansing, a little ulcer upon a membrane swollen and covered with secretion, and soaked with exudation; and since isolated elevations and depressions appear upon every inflamed *membrana tympani*, post-mortem examination furnishes the only ground of belief that ulceration can lead to perforation. We find, for instance, though but rarely, in cases of long-continued otorrhœa with perforation of the membrane, after careful removal of the secretion, one or more irregular erosions near the opening, which extend into the middle layer of the membrane. Whether such erosions, occurring where an opening is already found, can lead to complete perforation of the rest of the membrane, I cannot determine, since, so

far as I know, there has been no case observed where there were two openings in the membrane.

We can usually be certain concerning the manner in which the perforation occurs only when we have observed the process previously to the rupture, and can accurately determine its locality. After rupture has taken place, we cannot easily determine with certainty whether the perforation has originated in the cavity of the tympanum, in the external meatus, or in primary inflammation with abscess of the membrane. We can, in given cases, arrive at a probable conclusion only by comparing the early history of the disease, as remembered, with its course. Thus, it is to be inferred that the lesion had its origin in the cavity of the tympanum when a severe catarrh, or an idiopathic or exanthematous angina has preceded the discharge. When the history of the case is not clear, we can only determine what is most probable by the fact that the majority of otorrhoeas have their origin in the cavity of the tympanum.

Although we may be convinced by a long series of observations that rupture may take place at any point of the membrana tympani, and loss of substance extend out from this, yet it appears that the perforation much more frequently occurs in the parts intermediate between the malleus handle and the *annulus cartilagineus* (peripheral ring of the membrana tympani) than at the periphery, or near the manubrium. The reason of this is to be found in the fact that the elastic elements of the substantia propria are accumulated to a much greater extent at the last-mentioned places, and consequently a greater

resistance to pressure and erosion is offered here than at other portions of the membrane. According to Wilde, perforations are much more frequent in the parts lying in front of the manubrium, because they are most exposed to the pressure of air coming in through the Eustachian tube. The cases, however, are frequent enough in which perforations occur below or behind the manubrium.

The *size* of perforations varies from that of a small pin-hole to a complete absence of the membrane. Both extremes, however, are rare. Most frequently the diameter is from three to five lines. In regard to its pathological anatomy, we must generally discriminate whether the perforation is a rupture or a loss of substance. After a rupture the loss of substance is at first very slight, and it is only as the process advances that a breach, more or less extended, is formed by a gradual ulceration of the edges of the wound. The extent of the loss of substance, however, is not in proportion to the duration of the otorrhœa, or to its intensity and character. I have observed cases in which the discharge from the ear has existed continuously for years without any loss of the substance of the membrane resulting, the edges of the fissure being in contact, and separating only on forcing air through the cavity of the tympanum. The most extensive perforations occur in otorrhœas which come on after scarlatina; though I have been surprised, in many cases of primary affection of the ear, where discharge or even temporary moisture in the meatus was denied, to see pretty extensive breaches in the membrane, involving more than one-third of it.

Although the membrana tympani may be entirely destroyed in the manner stated, yet, in extensive erosions, we very frequently observe a power of resistance in certain parts. These are the peripheral portion of the membrane (V. Tröltsch), which remains as a falciform remnant, and the part lying above the pocket of Tröltsch, which, usually swollen and thickened, adheres to the upper end of the manubrium.

Perforations of the membrana tympani present many variations of form and size on inspection. We can say in general that, in one class of cases, the post-mortem condition exactly corresponds with the appearance presented during life, but differs more or less in others. In my opinion, this latter fact depends upon the swelling of the edges of the perforation, upon the amount of secretion lying in and about it, and, finally, also upon a change in the appearance of the opening from inclination of the membrane.

It is easier to determine during life the actual form of the perforation in all those cases in which the secretion has become scanty. When secretion is present the form and size vary much, partly on account of the deposit on the edges of the rupture, and partly because of their varied amount of swelling; so that, even at short intervals, we have a variety of appearances.

If we examine a perforated membrana tympani, where the secretion is very abundant, we shall frequently enough, especially in children, be unable to distinguish either the individual parts of the membrane or the opening in it, the secretion being accumulated in large amount

before it, while a pulsating reflection often, though not always, appears on the surface of the muco-purulent mass. Even after removal of the secretion, the appearance in many cases changes but little; the membrane has a mottled, greenish hue, and the boundary-line between its periphery and the wall of the meatus is indistinct; the manubrium and short process are not to be seen, and, at one or more points, there are reflections with or without pulsating movement. The point of perforation either cannot be distinguished at all from its surroundings, or is only visible when, by the Valsalvian experiment or the air douche, the lips of the perforation are separated, and air and pus pass through the opening out of the tympanum into the meatus in the form of bubbles. This often happens also in blowing the nose, with a sensation as of air whistling through the ear, and, in such cases, we frequently find on examination one or more bubbles near the membrana tympani, from which we may always infer the existence of a perforation.

Besides these cases, in which, after removal of the secretion, the locality of the perforation cannot at once be made out on inspection, we find others, in which the situation of the aperture, most frequently in front of and below the manubrium, is indicated by a more or less marked depression, ill defined, filled with secretion, and often presenting a small reflection. This depression is puffed out on making the Valsalvian experiment, if the Eustachian tube is pervious; and the lips of the opening being separated by the pressure of the air, the same appearance is presented as we have seen in the previous cases.

If the perforation is upon the anterior lower portion of the membrane, which is concealed by the anterior lower wall of the osseous canal, we shall not be able to discover it by inspection, and can only infer its presence from the signs afforded by auscultation (see V. Tröltsch, *Anat. d. Ohres*).

The appearances are different where there is no contact of the lips of the lesion, but a gap from actual loss of substance. The appearances which here present themselves vary greatly. If the gap is so small as not to measure more than a line in diameter, and the secretion with it is inconsiderable, we see, most frequently below or behind the manubrium, a dark opening, usually round (Pl. I. Fig. 9), which sometimes does not exceed the size of a pin-hole, and which might be easily mistaken at first sight for a small black particle lying upon the membrane. But if by the Valsalvian experiment we force air into the cavity of the tympanum, we usually perceive some secretion coming out of it, at first filling up the perforation and making it invisible. By continuing the pressure, air-bubbles pass through the opening, and remain for a short time accumulated before the membrane. After their disappearance we again see the aperture, or it may be closed by secretion, or one of the air-bubbles may remain just in the perforation, and the light spot formed upon it may show a pulsating movement (Wilde, V. Tröltsch), though this is not always present. The perforations, which attain the size of a millet- or hempseed, present a similar condition, only that here, on inspection on different days, a variation in the size of

the opening will be observed,—an appearance which might be easily mistaken for actual enlargement or diminution of the gap, did we not remember that this frequently occurs from greater or less deposit of secretion upon its edges. We may mark, indeed, that by this occurrence the opening may completely disappear under our eyes.

The perforations which have attained a diameter of three or four lines are more easily recognized. They are either circular or oval, or, less often, angular, and more frequently before and beneath the malleus handle than behind it, often changing their form rapidly, even with slight secretion, partly from increase and diminution of the swelling of their edges, and partly from deposit of secretion. The edges of the gap are either bright red, or pale, or dirty gray, and covered with creamy fluid. The appearance within the area of the opening varies according to the relation of the diseased *membrana tympani* to the promontory. If the mucous membrane of the inner wall of the cavity of the tympanum is not much softened, and, at the same time, the *membrana tympani* not strongly drawn inward, the edges of the perforation standing free, we see behind the opening, either secretion in the cavity, or the dark grayish-red mucous surface of the promontory. If, on the contrary, the *membrana tympani* approaches the inner wall of the tympanic cavity so near that it comes in contact with its very much softened mucous covering, we see, less often, only a portion, but, generally, the entire circumference of the perforation attached to the promontory. In these



cases, also, the edges generally appear sharply defined, and the gray or brownish-red mucous membrane of the cavity, visible in the opening, may project even somewhat beyond their level. In other cases, however, the boundary between the edges of the perforation and the mucous membrane of the promontory cannot be recognized, or can only be partially seen, since the remains of the membrana tympani and the promontory appear to blend with each other, without any line of demarcation. But in this, as in the before-mentioned cases, changes may occur very rapidly in consequence of increase and diminution in the swelling of the parts, and different appearances be presented on different days.

The membrana tympani presents in these, as well as in smaller erosions, a very variable appearance. In some cases it is covered with a layer of purulent secretion, and we see, in the midst of the greenish-yellow field, the dark or reddish gap. In others, the greenish-yellow coloring of the membrana tympani is dependent only partly on the secretion deposited upon it, and partly upon interstitial exudation. Not unfrequently, however, the membrane, through vascularization of the dermoid layer, exhibits a more or less intense redness, which either extends over its entire surface, or is only seen at certain spots, while the other portions, from secretion (Pl. I., Fig. 8), or interstitial exudation (Pl. II., Fig. 1), appear yellowish-green or dirty brown. In all these cases, where the middle ear and the membrane are secreting, we can but very seldom distinguish

the manubrium, while the short process of the malleus is more frequently seen, like a small dirty yellow protuberance, at the anterior upper quadrant of the membrane.

In perforations of the size specified, appearances change as soon as the secretion from the diseased parts ceases. We then see the aperture with dry, sharply defined edges, dark when small, but when it is three or four lines in diameter we distinguish the pale, grayish-yellow surface of the promontory. Not unfrequently the gap is entirely or partly filled with a greenish, dirty brown crust of still remaining secretion, which, sometimes shaped like a sausage, extends into the external meatus, and, on the other side, projects into the cavity of the tympanum. The short process is generally to be seen at the place designated, while the manubrium sometimes appears well marked or even prominent; but at other times, in consequence of thickening of the layers of the membrane, is surrounded by interstitial exudation, and invisible, or is only indicated by a dark red (Pl. II., Fig. 4) or dirty brown bundle of vessels. The membrane, according to the density of the interstitial effusion, appears at some points, or more rarely throughout, of a pale yellow color or pearly gray, with glistening spots; frequently with a sharply-defined, crescent-shaped calcareous deposit before the manubrium, and more rarely an irregular calcification upon the posterior portion of the membrane, or in the vicinity of the perforation (Pl. II., Fig. 4). The greater the loss of substance in the membrane, the more clearly does the inner wall of the tympanum come to view. If the anterior lower half of the membrane is de-

stroyed, the gap is bounded by the edge of the posterior remnant and the handle of the malleus, which sometimes lies against the promontory. The visible portion of the promontory is more or less reddened, or pale; and we sometimes see the recess extending forward toward the osseous portion of the Eustachian tube. In children I have very often seen the anterior half of the membrane destroyed, the posterior portion appearing as a crescentic fold, with its sharply cut concave edge distinct from the dark red promontory, partly through difference of color, and partly by its shadow. When the lower two-thirds of the membrane is destroyed, the perforation is generally kidney-shaped, from projection of the malleus handle into the gap. In other cases the aperture is bounded by irregular edges. (See V. Tröltsch, *Krankheiten des Ohres.*)

The appearances are particularly interesting when the posterior half or the greater part of the membrane is destroyed; for then, besides the manubrium, we frequently obtain a view of portions of the incus and stapes, as well as of both fenestræ of the labyrinth. The appearances in this case also frequently vary according to the degree of swelling in the mucous membrane of the promontory, and the change of position which the auditory ossicles undergo through inflammatory softening, through retraction of the diseased mucous membrane, and of the tendons of the intrinsic muscles of the ear.

If the posterior portion of the membrane is perforated, and the parts are still swollen and softened, we frequently see behind the anterior portion, which is thick-

ened and covered with secretion, only the uniformly reddened mucous membrane of the promontory, without any trace whatever of the auditory ossicles. On the other hand, if the swelling is slight, or has entirely disappeared, the anterior portion of the membrane appears either pearl gray, glistening, or even somewhat transparent, and sometimes has a calcareous deposit in it. The border of the perforation is formed by the posterior edge of the clearly defined manubrium, and, below, by the sharply cut edge of the membrane, which, when it does not lie against the inner wall of the cavity, throws a noticeable shadow on the promontory.

At other times this anterior portion may be seen as an irregular, much thickened, dirty yellow remnant (Pl. II., Fig. 3). The promontory appears as a pale yellow elevated surface, often with one large and several smaller reddish-blue arborescent veinlets. At the most prominent parts, and indeed at those near the fenestra rotunda, a reflection from the moistened mucous membrane is generally visible. We see in the posterior upper quadrant of the field—yet only where the membrane is destroyed to the extreme periphery—the articulation of the stapes and incus, and also the lower third of the long process of the incus, which is like a long yellow wand, one to two lines in length, standing out in relief. From its lower end the posterior shank of the stapes may be seen running backward and somewhat upward. The process of the incus and the posterior shank of the stapes, consequently, form an acute angle looking backward and upward—like that in the illustration of a transparent membrane (Pl. I., Fig.

4)—and if the long process of the incus is only moderately slender, it may be mistaken by the inexperienced for the anterior shank of the stapes.

In the majority of these cases, if the posterior portion of the membrane is wanting as far as the periphery, we may discover the niche of the fenestra rotunda below the visible portions of the incus and stapes, in the posterior lower quadrant of the field. It is to be seen as a roundish dark recess, from one to two lines in diameter, bounded by the posterior lower rim of the annulus tympanicus. Indeed, in most cases, on account of the oblique inclination of the fenestra rotunda to the axis of the meatus, we see only the shaded niche leading to the foramen. The membrane itself can only be seen in those rare exceptional cases in which, as Voltolini first observed, the fenestra is anomalously placed directly opposite to the external meatus. Where the secretion still continues, the niche is entirely or partially filled with it, and a small punctiform reflection then frequently appears upon its surface. If the secretion has entirely ceased, the recess appears more or less dark (Pl. II., Fig. 3). I have seen only one case in which there was a distinct reflection at the bottom of the niche of the fenestra rotunda, of which, however, I cannot determine whether it was formed on the membrane of the fenestra, or on a false membrane in the niche.

The appearance is different in those cases in which almost the whole membrana tympani is destroyed. Usually, as already stated, the portion lying near the short process of the malleus remains, as well as a part or

the whole of the firm tendinous peripheral ring. The former is seen either as a shapeless, thickened, grayish-red, or dirty white roll, at the anterior upper quadrant of the membrana tympani, or there are two crescentic or sickle-shaped folds (Pl. II., Fig. 2), which extend down to either side of the short process of the malleus, and shade the upper portion of the red or pale yellow promontory. If the extreme periphery of the membrane remains, it is most distinct anteriorly, and also appears as a sharply-defined, sickle-shaped, prominent band\* — especially in those cases in which little secretion adheres to the deep parts.

The appearances further change according to the condition of the mucous membrane of the promontory, its degree of swelling and hyperæmia, and the position of the auditory ossicles. The promontory appears (after the secretion is thoroughly removed from the ear) either uniformly deep red, with glistening spots here and there; or the ramifications of the vessels are clearly distinguishable, and the promontory more yellowish-red, as seen in Pl. II., Fig. 2 and 3.

Sometimes, however, and particularly in cases where the suppurative process in the middle ear has long since ceased, we find the promontory of normal aspect, without swelling or hyperæmia, and not at all differing in appearance from a preparation of the normal ear taken from the dead subject.

In the course of otorrhœa of long standing, vegetations

\* See the excellent descriptions of these conditions of the membrana tympani by V. Tröltzsch, in his *Krankheiten des Ohres*. 1863.

not unfrequently occur on the softened mucous membrane of the promontory. It then appears uneven, glandulous, uniformly dark red, or covered here and there with grayish exudation, and, even when the membrane is completely destroyed, there is nothing to be seen of the fenestra rotunda or ovalis. Only in one case could I see the head of the stapes with its slight depression in the midst of the swollen membrane. The manubrium, with the short process, sometimes projects out free into the field of view, as a yellowish-gray, usually short rod; and its outline, sharply defined from the deeper-lying background, upon which it sometimes casts a visible shadow, enables us, at the first glance, to recognize the promontory as such, and renders it impossible to mistake it for an inflamed membrana tympani. If, however, the hypertrophy of the mucous membrane is so considerable that it extends out beyond the level of the annulus tympanicus, the malleus is either enveloped in it, or destroyed by caries, or extruded; and we certainly cannot then easily determine, even when the reddened surface presents a change of curvature on forcing air into the cavity of the tympanum, whether it is the membrana tympani or the promontory that lies before us. It is sometimes impossible to make a diagnosis in these cases, even with the most careful examination, and our first information of the true state of things is derived from the course of the disease. There was a case illustrating this, which I watched for a long time at the clinic of Prof. Oppolzer. It was that of a girl who for several years had had a discharge from both ears. After carefully cleansing the right ear of

secretion, inspection showed a uniformly reddened, uneven surface at the bottom of the meatus. On forcible pressure, the air whistled out through the middle ear into the meatus without any change whatever being perceptible in the appearance. The hearing distance was considerably diminished. On careful touching with a sound bent at right angles, we found softened spongy tissue upon a moderately resistant base, and from all the appearances concluded that the membrana tympani was completely destroyed, and that we were looking at the mucous membrane of the promontory, considerably softened, and rising above the annulus tympanicus. By the daily employment of the air douche, and by cauterization every third day with a little drop of caustic melted upon a wire bent at right angles, we expected a decrease in the swelling of the mucous membrane, and a freer movement of the imbedded stapes. After about fourteen days, however, the short process of the malleus became quite distinctly visible anteriorly and above, and, after a few days more, we could recognize, in the no longer secreting surface, the very opaque membrana tympani, with a perforation at its anterior lower part some lines in diameter, and the manubrium marked by a brownish-red injection. The hearing distance for speech amounted to more than twelve feet.

Just as we have seen that an inflamed and softened membrana tympani may sometimes be mistaken for the promontory, so it is possible, on the other hand, also to mistake the swollen mucous membrane of the promontory for the membrana tympani. This occurs especially in



cases where there is a pulsating reflection on the uneven surface of the field of view, which changes place and form when air is forced into the middle ear. We are convinced that these appearances are presented, not only when an inflamed *membrana tympani* swells out upon the entrance of air into the cavity of the tympanum, but may also occur on the swollen mucous membrane of the promontory. For instance, if air is forced into the tympanum by the Valsalvian experiment, a venous congestion of the cerebral parts always takes place during the manipulation. Now, since this congestion also affects the mucous membrane of the promontory, it becomes more swollen, even when no air enters the cavity, and the reflection upon it consequently shows a change of place analogous to that which occurs in the arching out of an inflamed *membrana tympani*.

That the position of the auditory ossicles must be a varying one where there is great loss of substance in the *membrana tympani*, is evident from the fact that their points of support and attachment become variously altered by the morbid process. The handle of the malleus seldom remains in the normal position when loosed from its attachment to the *membrana tympani*. Since the tendon of the *tensor tympani* would draw the manubrium inward, acting in antagonism to the elastic elements of the membrane, when the membrane is destroyed it will naturally, in consequence of the withdrawal of the antagonizing force, obtain the mastery, and pull the manubrium inward more or less strongly. In consequence, its lower end is usually strongly inclined to-

ward the inner wall of the tympanum with perspective foreshortening, so that it often appears like a little button below and behind the short process (Pl. II., Fig. 2). Hence it not unfrequently happens that the lower end of the manubrium is brought into contact with the inner wall of the cavity of the tympanum, and, with continued contact, adheres to the mucous membrane of the promontory. It appears then usually somewhat thickened at the point of contact, and, not unfrequently, one or more little vessels extend from this point downward on the promontory (Pl. II., Fig. 2). The breaking up of this anomalous adhesion is, in many cases, not without difficulty. When the lower end of the manubrium is within half a line of the promontory, we can scarcely say—even where the meatus is uncontracted—whether it is in contact or not. This will be at once explained when we consider that the direction of our axis of vision, in inspecting the deep parts of the meatus, can scarcely be changed to any considerable extent, and that, consequently, our judgment concerning the degree of separation of parts lying behind one another, especially where the distance is small, is entirely unreliable.

In some cases, however, the diagnosis is by no means difficult, when, as we once observed it, the end of the manubrium is connected with the promontory by a little band more or less strongly developed, appearing like a projecting fold. On the other hand, the recognition of the condition is impossible where the central part of the membrana tympani is destroyed, and the loosely attached manubrium is so drawn inward and backward that its

lower half is concealed by the posterior portion of the membrane still remaining (Pl. II., Fig. 1).

In contradistinction to this apparent shortening, we meet, in many cases, with a real shortening of the manubrium through atrophy, the result of long-continued suppuration in the ear. In such cases we find it not only shorter, but, especially at its lower end, reduced in size, uneven, and pointed like a rusty tack.

Yet, even in complete destruction of the membrane, we shall sometimes be unable to discover anything of the manubrium. It may be wanting, in consequence of the extrusion of the entire malleus, or be destroyed by caries as far as the neck, or drawn by retraction of the tensor tympani, or by anomalous bands of connective tissue, so far backward and into the upper recess of the cavity of the tympanum, that it is concealed by the upper and posterior wall of the osseous meatus.

Similar changes are also observed in the long process of the incus, which, in like manner, atrophies, or, after separation from the head of the stapes, is drawn inward and upward by anomalous adhesions, and consequently disappears from view. The condition of the membrane is especially noteworthy in luxation of the articulation of the stapes and incus. I have observed this lesion in two cases. In one, a part of the anterior portion of the membrane was still adherent to the distinctly recognizable manubrium. In the other, the membrane was reduced to a small remnant on either side the short process, the manubrium being quite free; and close behind this we distinctly saw the long process of the in-

Taf. II.

1.



2.



3.



4.



5.



6.



7.



8.



9.



10.



11.



12.



the

we

the

of the

the ex-

the

the

the

the

the

the

in the

the

the

the

the

the

the

the

the

the

the

the

the

the

Taf. II.

1.



2.



3.



4.



5.



6.



7.



8.



9.



10.




11.



12.





cus, completely loosened however from its connection with the stapes, which, also free, was visible with the articular depression on its head and its two crura. The hearing distance for speech in one case still amounted to six feet or more.

A view of the stapes, as has been said, is only possible when the posterior portion of the membrane has been destroyed to the periphery, and we can hardly ever see the entire chain of auditory ossicles. In its natural connection with the incus, only the posterior shank of the stapes is to be seen; while, in detachment or destruction of the long process of the incus, the head and both crura are visible, though the base is only partially so, because the posterior half of the fenestra ovalis is concealed by the posterior portion of the annulus tympanicus. For this reason, also, when the crura of the stapes are both destroyed by caries, we only obtain a view of the anterior part of the fenestra ovalis closed by the base of the stapes.

With perforations of the membrane we class the *ruptures* arising from direct mechanical violence, or from concussion. The form of the aperture varies with the shape of the instrument inflicting the wound, and the nature of the force. Accordingly we find it roundish (as, for instance, when a hair-pin has been thrust in), or quite irregular, with ragged edges suffused with blood, if the wound has been made by a blunt instrument (for instance, by pressing in a foreign body that has entered the meatus). The ruptures occurring among artillerists, from sharp concussions of air, are described



as rectilinear slits lying behind the manubrium and parallel with it, which, after healing, leave a linear grayish-white scar.

The *impairment of function* occurring in consequence of perforation of the membrane, as older observations have already shown, is not proportioned to the extent of the loss of substance. With small perforations we find not unfrequently a high degree of deafness; while sometimes, on the other hand, in case of perforations involving more than two-thirds of the membrane, the hearing distance, if not normal, may still be pretty good. In the impairment of function, there are generally several factors to be taken into account. Apart from the fact that, in consequence of the loss of substance, the vibrating surface is diminished, and irregular vibrations of the membrane occur, there also come in, as essential factors in the impairment of function, the thickening of the *membrana tympani*, the diminished mobility of the auditory ossicles by the accumulation of secretion, and by being enveloped in the swollen and hypertrophied mucous membrane, and by the formation of adhesions, and, finally, the altered relations of pressure upon the labyrinth arising from the pathological changes at the *fenestra ovalis* and *rotunda*. It is the changes at the *fenestræ*, especially, that regulate the degree of impairment of function. If the mobility of the stapes in the *fenestra ovalis* is not materially interfered with, and the covering of the *fenestra rotunda* not much thickened, the waves of sound, passing by the *membrana tympani*, the malleus, and incus, will strike directly upon the

base of the stapes through the perforation, and so still reach the labyrinth in considerable number. In this way only can the slight degree of impairment of function in case of extensive loss of substance be explained.

*Healing of Perforations.*

The fact that gaps in the membrana tympani arising from loss of substance can close again, has been remarked by several authors in the older literature of aural surgery. Yet these cases are regarded as so infrequent that, even to the present day, physicians as well as the laity connect with the diagnosis of perforation of the membrane a decidedly unfavorable prognosis as regards its curability. The more recent pathologico-anatomical researches of Toynbee, Von Trötsch, and others have, nevertheless, shown that cicatrization pretty frequently occurs, even with extensive loss of substance. And Von Trötsch especially, after many observations, has demonstrated (*loc. cit.*) a considerable degree of recuperative power of the membrane, which he connects with its great vascularity.

The *conditions* for the healing of perforations depend principally upon the state of the mucous membrane of the tympanic cavity. So long as the purulent secretion in the middle ear continues, if only in a moderate degree, permanent cicatrization of the perforation is impossible. I have repeatedly, in the course of purulent catarrh of the middle ear, seen distinctly

recognizable perforations—through which, on forcing air into the tympanum, bubbles came out into the meatus—rapidly close, so that, on the following day, the greenish-yellow, swollen, and secreting membrane was bulged out by the pressure of air, without any passing through at the points before observed. Such unions last but a short time, often only a few hours, and are then overcome by the pressure of the pus meanwhile accumulated in the cavity—a strong sensation of tickling in the depths of the ear often preceding. I have, however, seen these temporary closures in the course of otorrhœa only in cases where the edges of the perforation were in contact, having never been able to observe them during the continuance of the discharge; the perforations were somewhat larger, amounting to more than two or three lines in diameter. Yet I am of opinion that sometimes simply a closer superposition of the edges of the rupture without actual union, may suffice to present such resistance, when air is pressed into the tympanum, that the membrane arches outward without any separation of the edges occurring.

Manifold are the variations presented in the process of healing in case of perforations—not only with respect to the alteration of the form and position of the membrane, but also to the consequent impairment of function. These varieties should be successively examined in detail, and, keeping the practical aim of this work in view, we will illustrate the descriptions of the various forms by the records of cases.

In one series of cases the perforations heal with *com-*

*plete recovery of the hearing power, and without leaving behind any pathological changes in the membrane.* I have more frequently observed this result after the subsidence of acute purulent catarrh of the middle ear, but, in some cases also, after the cessation of chronic otorrhœa. The process of healing sometimes goes on very rapidly. In short, we are completely surprised to find an unbroken glistening surface, where a few days before a swollen, mottled, or reddish-yellow membrane, could be seen, on which no traces of the malleus were discoverable. In some cases, however, we have an opportunity of watching the progress of the healing process, where we observe, first, a noticeable decrease of the secretion, soon after a diminution and, finally, a closure of the perforation; the membrane, as well as the adjoining parts of the osseous meatus, becomes covered with a moist, dirty brown, often tenaciously adherent layer of secretion and epidermis, which soon dries, and when this is worn off or removed by artificial means, the normal membrana tympani comes to view.

*CASE: Acute Catarrh of the Middle Ear on both sides with high degree of Deafness.—On the right side: Croupous Hemorrhagic Exudation into the Tympanic Cavity, with Perforation of the posterior part of the Membrana Tympani.—On the left: Accumulation of Pus in the cavity, with Bulging of the Membrane.—Paracentesis of the Membrane.—Complete Recovery.*

Miss D., aet. 15, native of Bavaria, blonde, well-developed, and of vigorous appearance, was, while in Vienna, on the 13th of January, 1862, attacked by so violent a fever that, during the first few days, the outbreak of an exanthema, or the appearance of an exudative process, was expected. On the evening of the third day, the patient

first complained of sharp pain and stinging in the ears, soon followed by a slight degree of deafness, which, on the following day, after the fever had suddenly abated, became very great. On the fifth day some blood was noticed in the right meatus, and the hearing power was almost entirely lost.

Upon the sixth day of the illness I saw the patient for the first time. She was out of bed, but looked pale and exhausted, and was compelled by fatigue to sit down after a few steps. She complained of tinnitus aurium and stinging in the left ear, but her head was free from pain and vertigo.

Examination revealed the following condition: On the right side, some coagulated blood in the meatus, after the removal of which with the syringe, a perforation is seen upon the posterior upper portion of the membrane, occupying nearly a third of its whole extent. A croupous, fibrinous exudation projects from the cavity of the tympanum through the opening into the meatus, in the form of a brownish-red irregular mass. The anterior lower half of the membrane is still strongly arched outward, with apparently little change of structure and the cone of light well marked. The manubrium is invisible. Upon the left side, there is intense injection of the osseous portion of the meatus, the redness extending to the membrana tympani, which, with the exception of the anterior upper quadrant, appears livid, lustreless, and soaked with serum. At the anterior upper portion mentioned the membrane is seen projecting in the midst of the red field, in the form of a sac of the size of a lentil, hanging down and having a purulent green color.

The hearing distance on both sides is greatly diminished; my watch (the average normal distance being twelve feet) is not heard on either side, even when firmly pressed against the external ear. The perception of the sound of the watch through the cranial bones is likewise completely lost, and the power of understanding speech is entirely wanting on the right side, while on the left only very loudly spoken words can be heard at the distance of two feet.

We proceeded to the examination of the Eustachian tube. As the patient was weak and exhausted by the preceding fever, the

introduction of the Eustachian catheter did not seem advisable; wherefore I employed the new method devised by me for opening the Eustachian tube, a short description of which we will here repeat for the benefit of those readers to whom it may not yet be known. The patient, being seated, takes some water into his mouth, to be swallowed at a given signal. The surgeon, placing himself most conveniently at the right of the patient, grasps with his right hand an india-rubber bag about as large as the two fists, and introduces the nozzle of a somewhat curved hard-rubber tube, movably connected with it, about half an inch into the nostril, so that its concavity is in contact with the floor of the naris. The signal to swallow is now given, both alæ are at the same time closed air-tight over the instrument with the thumb and forefinger of the left hand, and, by a forcible pressure of the right hand, the air is driven out of the bag into the now shut nasal cavity.

After we had in this manner compressed the air in the cavity, the patient stated that she had felt nothing in the right ear, while on the left she had distinctly perceived the entrance of the air into the tympanic cavity. The trial of the hearing distance, now repeated, showed no change on the right side; but on the left the distance amounted to two inches for the watch, and to three feet for the voice, and, what was remarkable, she now heard the watch through the cranial bones quite distinctly.

From the result of the examination, we inferred the following changes in the ear: Acute inflammation of the mucous membrane of the middle ear, and, as a consequence, on the right side a croupous hemorrhagic exudation, which was formed in such quantity that it had forced through the posterior portion of the membrana tympani, strongly arched the remainder, and, by completely enveloping the auditory ossicles, wholly stopped their vibrations, and hence the entire deafness. On the left, we might infer from the greenish circumscribed protrusion of the membrane, a copious formation of pus. The loss of the perception of sound through the cranial bones might either have been the result of excessive pressure from the cavity of the tympanum upon the fenestræ rotunda and ovalis, and

consequently, also, upon the contents of the labyrinth; or, simultaneously with the acute inflammation in the middle ear, a serous soaking of the membranous labyrinth might have occurred, and the susceptibility of the auditory nerve been in this way impaired.

We could corroborate the first inference respecting the left ear after the employment of the air-douche, since, as soon as a part of the pus was forced out of the cavity by the current of air, and the pressure in the tympanum thereby diminished, the perception of sound through the cranial bones returned again. On the other hand, the air-douche, as has been stated, was without effect upon the right ear, because the resistance opposed by the stiff exudation in the cavity was too great to be overcome by it.

The treatment employed had for its object the softening and speedy removal of the stiff exudation in the right ear. For this purpose, warm water was directed to be dropped into the right meatus every two hours; and since, in the left ear, rupture of the membrana tympani by the accumulated secretion was imminent, and the pent up purulent matter might, in the mean time, exercise an injurious influence on the neighboring parts of the organ, we decided on performing paracentesis of the membrane at once after the first examination of the patient. For this purpose, having the auricle drawn backward and upward, so as to straighten the meatus, I illuminated the membrane by a reflector held in the left hand, then carried a sharp cataract needle toward the prominence designated, and, entering it at the most prominent point, enlarged the wound somewhat downward in withdrawing the instrument. Several drops of pus immediately came out of the opening into the meatus.

On the following (7th) day we found already on the left side a copious discharge through the artificial opening, while in the right ear the condition was unchanged. After the employment of the air-douche, the hearing distance on the left side again improved—to four inches for the watch, to five feet for the voice; hearing distance on the right side was unchanged, the air not entering the tympanum. The instillation of warm water was continued.

The right ear showed an essential change on the day after. The

stiff mass of exudation was broken up, and the meatus was filled with a brownish-colored pus, after the removal of which we observed a pulsating movement of the secretion in the perforation. After the air-douche, an essential improvement in the hearing on this side was at once apparent, the watch being heard at two inches and the voice at four feet; and on examining the meatus again, we saw at the bottom of it a large number of air-bubbles. The resistance which the exudation had opposed to the air-douche on the previous days was consequently overcome by its softening into pus, and the air could now easily enter the cavity of the tympanum. The perception of sound through the cranial bones was still entirely wanting.

On the ninth day the discharge was equally abundant on both sides. After syringing out the right ear, we discovered a perforation, four or five lines in diameter, and with intensely injected edges, through which, on trial of the "new method," the air passed in bubbles. In the left ear, the edges of the perforation, which were in front of the manubrium, were in contact, and separated from each other as soon as the air was forced through the middle ear. The hearing distance, compared with yesterday's, was somewhat less, but, after the air-douche, rose to two feet for the watch and twelve feet for the voice, on both sides. There was also perception of sound through the cranial bones on both sides. General condition very good. *Ordered:* To syringe out the ears with lukewarm water several times a day, and, since the signs of irritation had entirely disappeared, to fill the meatus after each syringing with a solution of sulphate of zinc, two grains to the ounce, and allow it to remain ten minutes in the ear.

During the next three days the air-douche by the new method was daily employed, and we observed a constant improvement. The secretion rapidly grew less. The perforation on the right side diminished, and the hearing distance rose to four feet for the watch and to thirty-six for the voice.

From that time the improvement was rapid, so that on the fourteenth day the secretion had ceased, and both perforations had cicatrized simultaneously. After removal of the dried secretion remain-



ing in the meatus, we saw, for some days still, a slight hyperæmia on the manubrium, and after this had passed away the membrana tympani appeared *entirely normal*, as well in respect to lustre as in curvature and color, and the hearing distance, both for watch and voice, was likewise fully normal. The young lady, whom I have since seen repeatedly, has not, from the time of that attack till now,—that is, for two years and a half,—experienced the slightest trouble in the ears.

When, as sometimes happens after an obstinate discharge from the middle ear has been checked, the perforation cicatrizes without leaving behind any change in the membrana tympani, yet a certain degree of deafness remains, this depends either upon a deposit of pathological products around the auditory ossicles, whose vibration is thereby interfered with, or there is still present some degree of swelling of the mucous membrane of the tympanic cavity, and of the lining of the Eustachian tube,—this latter usually occurring at the same time. The difficulty of hearing is then consequent upon the temporary closure of the tube, the air in the cavity of the tympanum becoming absorbed, and the membrana tympani, together with the auditory ossicles, being so strongly forced inward by the pressure of the external air as to lose a part of the vibratory power.

Recovery from all these conditions is possible. So long as the morbid products are not organized they can be broken up and removed by frequent air-douches by means of the catheter or of the new method, and, further, by saline injections into the cavity of the tympanum through the Eustachian tube. Swellings of the

lining membrane of the tube and of the tympanum are also curable by means of the air-douche and injections of astringent solutions. Where, on the contrary, organized exudations affect the mobility of the auditory ossicles, or the elasticity of the fenestræ of the labyrinth, we cannot expect a restoration of the normal hearing distance.\*

\* I take the liberty of giving, in the following note, a brief abstract of the *treatment of chronic catarrh of the middle ear and Eustachian tube* without perforation of the membrana tympani. After first inspecting the meatus and membrane, we determine the hearing distance, both for the watch and the voice, and then proceed to the examination of the Eustachian tube—forcing air through it into the cavity of the tympanum in the way before specified (“new method”), or by the catheter, by means of an otoscope determining whether a current of air enters the cavity. When the hearing distance is hereupon noticeably increased,—an inch or a foot for the watch, and several feet or fathoms for the voice,—and we may infer therefrom the existence of swelling of and secretion from the mucous membrane of the tympanum and Eustachian tube, besides the employment of the “new method,” injection of a solution of zinc into the middle ear is indicated. We use for this purpose a solution of from four to eight grains to the ounce of water. The catheter (the best for this purpose are those made of hard rubber, after our design, by Leiter of Vienna) is introduced into the Eustachian tube, and fixed with the left hand. Some of the astringent solution is dropped into it by means of a little glass tube, and blown into the cavity of the tympanum by compressing with the right hand a rubber bag attached to the catheter. These injections should generally be repeated every three days, and continued for from three to five weeks. If, as in many chronic cases, no complete recovery, but only a more or less marked improvement, takes place, the injections, after some months, should be renewed for two or three weeks, in order, if possible, to prevent the further increase of deafness.

If, on the contrary, after repeated trial of the air-douche, there is little or no increase in the hearing distance, so that we may infer that the deafness is caused by the sequelæ of the catarrhal affection—viz., thickening of the mucous membrane, and of the covering of the auditory ossicles, with rigidity and diminished mobility—we can expect improvement only from the use of moderately stimulating injections, together with the air-douche. The follow-

The cases in which, after closure of the perforation, distinctly visible *cicatrices* remain in the membrana tympani are more frequent than those just described. For even perforations of long standing are closed by the outgrowth of connective tissue from their edges, often in a surprisingly short time. The cicatrix thus formed consists of a thin stratum of connective tissue, covered on either side by a delicate epithelial layer. Elastic fibres, such as constitute the substantia propria, are entirely wanting in it.

The *size* of these cicatrices varies from that of a pin-head to two-thirds of the area of the membrane, but those which most frequently come under observation lie

ing solutions seem best fitted for injection: ℞ *Ammoniac muriat.* gr. xx., *Aq. dest.* ℥j.; or, ℞ *Potass. iodid.* gr. x., *Aq. dest.* ℥j.; or, ℞ *Sodii chloridi* gr. v., *Aq. dest.* ℥j. After the employment of these injections from two to four times a week, in the same manner and with the same intervals as those before mentioned, we shall in some cases obtain essential improvement in the hearing, in others only slight, and in others still, shall overcome the faint ringing and vertigo—symptoms which accompany the chronic thickening of the mucous membrane of the middle ear.

The improvement obtained by the use of these saline injections, in the cases supposed, seldom continues, since the thickened tissue of the mucous membrane, which was somewhat softened by the air-douche and the stimulating injections, has, like cicatricial tissue, a tendency to retract, whereby the rigidity of the auditory ossicles returns. We must, therefore, repeat the injections and air-douche from time to time—for instance, every three, four, or six months—every other day during from two to four weeks. The introduction of elastic bougies into the Eustachian tube, when it is contracted, is sometimes attended with essential improvement.

We must mark the fact, as of especial importance, that a constant or too long employment of the injections, or of the air-douche, is injurious, while a treatment interrupted by intervals of weeks or months proves most effectual.

between these extremes, having a diameter of from three to five lines.

Their *shape* is, as a rule, roundish or elliptical, sometimes triangular; but large cicatrices, occupying the inferior and lateral parts, from the projection of the manubrium down into them, appear kidney-shaped. Like the perforations, they present themselves at the parts lying intermediate between the annulus cartilagineus (peripheral portion of the membrana tympani) and the manubrium. The thin cicatrix very rarely extends to the extreme periphery, more frequently, however, to the edges of the manubrium.

On inspection of the membrana tympani the cicatrices appear as sharply defined, usually depressed, transparent spots, which, because the surrounding parts are commonly of a dull grayish white, also present a darker appearance. Their depression below the other parts of the membrane is in consequence of the lack of elastic elements, whereby their power of resistance to the pressure of the external air becomes considerably diminished. This external pressure preponderates even in the normal condition, if tubal obstruction has existed only for a little time. Very frequently, at the bottom of such depressions, one or more punctiform, or larger irregular reflections, are to be seen.

The border of the cicatrix is, in perhaps the majority of cases, sharply defined all around (Plate II., Fig. 6, before and under the manubrium), so that the edges often appear with a double contour and glistening. Sometimes, however, the border is distinct only on one

side, while on the other sides it sinks imperceptibly into the surrounding parts (Plate II., Fig. 10, behind the manubrium). Indeed, there are cases where the cicatrix appears like a shallow depression without any distinct border, which, in the Valsalvian experiment, is very easily swelled out, thus forming folds and glistening spots. The color of these depressions differs according to the degree of their transparency. Rarely they are of a dull pearl gray, and their color is then little modified by the parts lying behind. On the other hand, the cases are more frequent,—the more so the nearer the cicatrix approaches the inner wall of the tympanum,—in which the color of the deeper parts can be seen through them, and an inference respecting the condition of those parts consequently be drawn. We shall, therefore, see the promontory of a dark violet red, where there is still existing hyperæmia of the mucous membrane of the tympanum, and of a pale yellow when in the normal condition. Sometimes I have seen one or more well-developed vessels of new formation extending even upon the cicatrix.

Just as, in case of perforations behind the manubrium, under the conditions before stated, we distinctly saw parts of the incus and stapes, as well as both fenestræ of the labyrinth, so we find also that these parts are to be seen through extensive cicatricial formations at these points. Most frequently the lower end of the long process of the incus, and its articulation with the head of the stapes are visible. In one case we could quite distinctly make out the head of the stapes turned

Outward and downward with the tendon of the stapedius muscle. Less frequently have I been able to see, through the cicatrix, the niche of the fenestra rotunda.

These structures are naturally the more distinct the nearer the cicatrix approaches the inner wall of the tympanum, so that sometimes indeed, in cases where they are in contact, the process of the incus and the head of the stapes, at first sight, seem to be adherent to the cicatrix, since they form projecting prominences on its surface. These, however, disappear when, by forcing air into the tympanum, the cicatrix is pressed outward, and thus its contact with the deeper parts of the middle ear for a short time prevented.

Where there is close contact between the cicatrix and the promontory, the latter also stands out as a marked prominence, reddish or yellowish in color, and usually glistening, and upon it we sometimes discover, through the cicatricial tissue, one or more well-developed vessels. In one case, I could distinguish through the cicatrix irregular, friable, white or yellowish-white masses,—standing out from the lower or posterior wall of the tympanum into its cavity,—which were interpreted as the calcareous residua of old morbid processes.

If in a given case we have to distinguish a depression from an actual adhesion of the cicatrix to the inner wall of the tympanum, we must accurately observe the changes which the membrane undergoes whenever air is in any way forced into the middle ear. Depressed cicatrices always undergo, thereupon, a marked change

of curvature, swelling out to the level of the rest of the membrane or beyond it. The reflections disappear or become faint. The cicatrix itself often forms irregular folds and loses its transparency, especially when the air is pretty strongly forced in, becoming suddenly of a dull gray. If the cicatrix were larger, and approached the inner wall of the tympanum even to contact, and we could previously see the promontory with isolated vessels, and portions of the long process of the incus and the stapes, the appearance completely changes upon forcing air into the cavity, for the cicatrix is then arched out, and there is nothing to be seen of the structures within. After a time, however, the air which was forced in is absorbed, and the former appearance is again presented.

The parts of the membrana tympani surrounding the cicatrices are seldom of normal transparency, but commonly are more or less uniformly dull gray, and thickened. I have pretty frequently found, with a large kidney-shaped cicatrix extending from the manubrium downward and laterally, little calcareous deposits, from one and a half to two lines in diameter, before and behind the upper end of the handle. The manubrium itself undergoes noteworthy change of position only in those cases where it, in great part, projects into the cicatricial area, and its lower end is drawn toward the promontory.

We must remark, as especially worthy of notice, that changes in the membrane, similar to those we have described as cicatricial, are observed also in cases where

no perforation has previously occurred, particularly in the course of chronic catarrh of the middle ear without rupture of the membrane; for, in this disease, circumscribed affections of the mucous layer of the membrana tympani not unfrequently occur, in consequence of which the layers of the substantia propria corresponding to the affected spots become atrophied. From the immediate contact of the mucous and dermoid layers a thinned area is now presented in the membrane, not differing at all in appearance from cicatricial formations. We have observed the development of such circumscribed atrophies in several cases. We can speak with certainty of cicatrices only when they have been formed under our own eyes after perforation. We can only conjecturally regard them as such, when the patient states that there has been a previous discharge from the ear; while in cases in which there is no recollection of an otorrhœa, the diagnosis between cicatrices and circumscribed atrophies is impossible.

What we have said of perforations, relatively to impairment of function, holds good also of the cicatricial formations just described, which are not adherent to the inner wall of the tympanum. Accordingly we find, not unfrequently, with extensive cicatrices formed after the subsidence of otorrhœas, and often involving two-thirds of the membrane, pretty good hearing if the morbid process in the middle ear has terminated without impairing the movements of the articulations of the auditory ossicles, or at the fenestræ. Inversely, a high degree of deafness occurs with small cicatrices, if the



mobility of the ossicles or at the fenestræ is impaired.

*CASE: Discharge from the right Ear, with Perforation of the Membrane before the Manubrium.—Recovery, with formation of depressed Cicatrix.—Death in consequence of Phthisis Pulmonalis.—Post-mortem Examination of the Ear.*

Mr. N. N., æt. 41, civil officer, was admitted into the clinical department of Dr. Kolisko, affected with hæmoptysis. According to his account, he noticed, five years before, for the first time, a discharge from the right ear accompanied by very slight pain. This ceased after some months, but frequently returned after intervals of weeks and months. Several months previously the discharge had entirely ceased, and since that time also he had no longer noticed the whistling of air through the ear upon vigorously blowing the nose. The hearing distance in this ear was small during the otorrhœa; in the intervals it was always better. Tinnitus aurium occurred only occasionally.

On examination, we saw in front of and below the manubrium (Pl. II., Fig. 6) an oval, transparent and therefore dark, depressed spot, bounded by light glistening edges. The remaining portions of the membrane were tendinous gray, here and there completely opaque, and at the place of the cone of light beneath the end of the manubrium there was a curved glistening line. The manubrium lay horizontally, and appeared bent like a scimitar; from its posterior end several vessels ran toward the posterior portion of the membrane. The hearing distance for my watch was one foot; for the voice, from twenty-seven to thirty feet. An examination of the Eustachian tube could not be made on account of the apprehension of the patient.

Post-mortem examination of the right ear revealed the following condition: The membrana tympani, with the exception of the parts which appeared transparent during life, was dull and opaque, and the layers, taken together, thicker by a half than in the normal state,

yet here and there less thickened and opaque. Nothing could be seen of the hyperæmia observed during life at the posterior parts of the membrane. Before the somewhat curved manubrium was the sharply defined elliptical spot mentioned, very thin and of almost glassy clearness. Its transverse diameter was two and a half lines; its longitudinal, parallel to the manubrium, amounted to three and a half. Compared with the appearance on inspection during life, the thin spot was larger than could have been supposed. This is explained by the inclination of the membrane to the axis of the meatus, as already stated. The lining membrane of the cavity of the tympanum and of the Eustachian tube, as well as the covering of the auditory ossicles, was smooth. There was no anomalous adhesion in the cavity, except that the lower end of the long process of the incus was closely adherent to the membrana tympani near the upper end of the manubrium, whereby the mobility of the malleus, as well as of the articulation of the malleus and incus, was entirely lost.

*CASE: Chronic Inflammation and Perforation of the right Membrana Tympani.—Recovery, with a formation of a thin, ill-defined Cicatrix.*

Mr. S. Gr., æt. 35, merchant, from Hungary, states that about twelve years ago he experienced severe pain in the right ear, after a cold bath in which he plunged from a height. Soon a moderate discharge from the ear followed, which, after its origin, had very rare and short intermissions. Occasionally, severe pain and a disagreeable pressure in the ear was experienced; after violent emotion, subjective sounds occurred, ringing and whistling in the ear.

On examination the membrana tympani (Pl. I., Fig. 9) appeared uniformly bright red and flattened; at the upper part of the membrane two yellowish-white flakes of exudation were adherent; at the lower half we saw a round black spot as large as a pin-head, of which we could not, at first sight, say whether it was a perforation or a little foreign body upon the membrane.

To determine this point the Valsalvian experiment was employed,

whereupon a small quantity of secretion came out at the black spot, soon followed by air-bubbles mixed with secretion. Thus the proof of perforation was supplied.

The hearing distance for the watch amounted to one foot and a half; for the voice, nine feet. The Eustachian tube was easily pervious.

The treatment consisted in syringing the ear once a day with lukewarm water, and subsequent instillation of half a teaspoonful of a lotion composed of: *Collyr. adstr. luteum* ʒ ij.; *Aq. dest.* ʒ j.

After from eight to ten days' employment of this means the discharge had entirely ceased; the membrane appeared dry, but dull and lustreless; the handle of the malleus and the short process were plainly distinguishable; the vessels of the manubrium injected, the gap in the membrane cicatrized, and the spot was not to be seen. The hearing distance amounted to four feet for the watch, and to eighteen for the voice. For a disagreeable sensation of dryness and itching affecting the external meatus after the discharge had ceased, the following application was ordered: *℞ Hydrarg. ox. rub., gr. iij.; Ungt. emollient., ʒ ij.; Tinct. opii, gtts., iij. M. S. To be applied to the meatus with a brush twice a week.*

I saw the patient again three years later. The discharge had not reappeared. The membrana tympani was transparent and glistening; the short process and manubrium clearly marked. At the spot corresponding to the former perforation was an ill-defined depression with a diffuse lustre, and perhaps from two to three lines in diameter. On the Valsalvian experiment this rapidly swelled out, and appeared very shining and folded, and, after the pressure of air had ceased, sank back again just as quickly.

The hearing distance amounted to six feet for the watch, and to forty or fifty for the voice.

The cases where the *perforated membrane adheres to the inner wall of the tympanic cavity* to a greater or less extent, by means of cicatricial tissue, are as frequent as those which terminate favorably with healing of the per-

foration, as already described. The changes of the form of the membrana tympani occurring in the process of adhesion are so manifold, and the correct interpretation of the appearances so important in diagnosis, that a more thorough discussion of the condition certainly seems appropriate.

We have already remarked that in many cases the edges of the perforation are so pushed inward that they appear, either in part or throughout their whole extent, to be in contact with the inner wall of the tympanum. This contact can now give rise, in certain cases, to adhesion of the membrane to the promontory, and this adhesion will also involve the entire periphery of the perforation, or only take place at certain points. Most frequently, in such cases, we find the posterior portions of the membrane and those lying close above the manubrium adherent, while the anterior and lower part stands out free, and distinctly separated from the inner wall of the tympanum. In the Valsalvian experiment the air whistles through the gap, but the adherent parts thereby undergo no change of position.

On the other hand, the appearance is entirely different where the edges of the perforation are adherent all around to the promontory, and the diagnosis is often very difficult. In some cases it is easy to recognize the well-defined limit between the adherent edges of the perforation and the promontory; in others, however, and indeed frequently, where the adhesion is of long standing, the former edges are no longer distinguishable, since, by the outgrowth of connective tissue

from the adherent edges, a cicatrix is formed, which covers the free promontory, and unites with it, and no line of demarcation between the cicatrix and the remaining parts of the membrane is visible.

It is evident that the condition of the membrane varies essentially, according to the form and size of the previous perforation. The most frequent appearance, with some variations, is the following: The short process of the malleus is very prominent; extending back from it, as a thick gray roll, is the projecting fold of the membrane, which normally is but slightly raised. The upper portions of the manubrium are sharply defined, and it distinctly stands out as a yellow band, the membrane being greatly retracted on both sides. The lower end of the manubrium is strongly drawn in, and is imperceptibly lost in the gray cicatricial tissue lying on the pro-



FIG. 6.

montory. The entire malleus handle is, consequently, seen in perspective foreshortening. (See Fig. 6.) The membrane adherent to the inner wall presents a peculiar, and, with respect to the diagnosis of adhesions, a very noteworthy relation to the annulus tympanicus. Thus, for the experienced, it will be very easy, in cases of this kind, to distinguish the annulus tympanicus, either by its strong relief from the background, or by the fact that at one portion of its periphery, most frequently in front and below, a sharp border (peripheral portion of the membrana tympani) rises up, and from it the thickened remnant of the membrane, blended with the cicatrix, is bent

back at an abrupt angle (Fig. 6, *a*), and extends to the promontory at the inferior and lateral walls of the tympanum. The following case presented such an appearance :—

*CASE: Adhesion of Membrana Tympani to the Promontory after Purulent Catarrh of Middle Ear.—Post-mortem Examination.*

Mrs. H. K., æt. 42, servant, was received into Dr. Chrastina's division, affected with phthisis pulmonalis. In childhood she suffered from otorrhœa, which in later years ceased, to return again from time to time; but for twelve years no discharge from the ear had been noticed, and during this period the deafness had gradually attained a high degree. The condition of the membrane in the right ear was that just described; in the left, the membrane was mottled by irregular deposit of calcareous matter, extending to the periphery. The watch was neither heard in contact with the auricle nor through the cranial bones. She could not understand conversation at all upon the left side; but on the right, if one shouted loudly in her ear, she understood everything. The examination of the Eustachian tube could not be made, owing to the reduced condition of the patient. To convince myself of the correctness of the diagnosis, I touched the different points of the background in the right ear very cautiously with a blunt-pointed metallic sound, bent at a right angle, illuminating the meatus with the reflector held in the left hand. The contact of the sound enabled me to recognize quite distinctly a firm osseous substratum for several lines about the lower end of the manubrium; while, toward the periphery, the parts touched seemed yielding and elastic.

Post-mortem examination of the right ear confirmed, essentially, the diagnosis of adhesion of the membrana tympani with the promontory by means of a thick cicatrix. Fig. 6 shows us, in vertical section through the external meatus and tympanum, the relation of the cicatrized membrane to the inner wall. The sharp projection at *a* corresponds to the sickle-shaped band seen, during life, at the

anterior lower periphery of the annulus tympanicus, which proved to be a stiff, thickened remnant of the peripheral portion of the membrana tympani. From this edge the thickened remnant of the membrane, blended with the cicatrix, extends to the lower and lateral parts of the tympanic cavity, to become there firmly united to the inner wall. The manubrium, abruptly bent, rests its lower end against the inner wall of the tympanum, as the figure shows, and the infolding of its end in dense cicatricial tissue explains why the malleus handle seemed, on inspection, to pass imperceptibly into the gray cicatrix.

Upon opening the tympanum from above, we found its cavity filled with a pale yellow, spongy mass of connective tissue, in which the auditory ossicles were completely imbedded. After removal of this mass from the upper recess of the tympanic cavity, we could not go farther down on account of the adhesion of the upper parts of the membrane and the manubrium to the inner wall of the tympanum. Likewise, a sound introduced through the Eustachian tube could not be advanced into the tympanic cavity, because the cicatrix, extending from the annulus tympanicus in front of the tympanic mouth of the Eustachian tube to the promontory, obstructed the passage. The membrana tympani and the cicatricial formation were adherent to the promontory to the extent of perhaps three and a half lines, and the spongy connective tissue mentioned was accumulated between the peripheral parts of the membrane and the inner wall of the tympanum. On examination during life, these parts were yielding and elastic to the touch of the sound. The mobility of the auditory ossicles became much greater after removal of the mass of connective tissue.

From the difficulty of making a diagnosis of adhesions of the membrane with the promontory in a considerable number of cases, the cautious employment of the sound, as we have used it in the cases just described, seems at all events justifiable. We can by no means infer the pres-

ence of adhesions from the strong retraction of the membrane and of the end of the manubrium, or because the depressed spots fail to swell out, even if we observe a sharply-defined angle between the peripheral and central parts of the membrane. For such angles by no means infrequently occur in long-continued occlusion of the Eustachian tube, as well as in chronic catarrh of the middle ear, without previous perforation. If the membrane is thereby much thickened, we shall perceive scarcely any, or only a partial swelling out of the membrane, on forcing air into the cavity of the tympanum. In one case of this kind, where, during life, we made the diagnosis of adhesion of the membrane to the promontory, we found after death no adhesion whatever.

On the other hand, observations made during life, compared with post-mortem conditions, have taught us that sometimes even extensive adhesions cannot be diagnosed, especially in those cases where the bridge of connective tissue joining the membrane to the inner wall of the tympanum is longer than usual, the membrane consequently not being much retracted. Touching such a spot with the sound would, of course, furnish no sure data, since such points, adhering by broad bands, are yielding and elastic.

*CASE: Former Otorrhœa.—Adhesion of the Membrana Tympani to the Inner Wall of the Tympanum by a long cicatricial band, without Change in the Curvature of the Membrane.—Autopsy.*

Fig. 8, Pl. II., is the illustration of the left membrana tympani of a woman twenty-five years of age, who died of phthisis pulmonalis in the section of Dr. Scholtz, and who had suffered in her childhood,



for several years, from otorrhœa. After its cessation considerable deafness remained, which, in the course of time, still increased, so that upon this side, in the examination, she heard the watch neither when laid upon the ear nor through the cranial bones, and in loud speaking near the ear distinguished only the sound of the voice. On inspection of the membrane, the short process of the malleus was distinctly seen anteriorly and above, but the manubrium was covered by a brown pigmentary deposit which extended over the greater part of the membrane, while grayish-white irregular opacities mottled the peripheral parts. An examination of the Eustachian tube could not be obtained. The post-mortem examination showed the external layer of the membrana tympani colored to an extent corresponding to the appearances shown in the illustration. The pigmented spots proved to be, chiefly, cicatricial tissue, while at the peripheral parts we could still distinguish the layers of the membrane, though opaque and thickened. No line of demarcation between cicatricial and normal tissue could be discovered. On blowing air through the Eustachian tube, we observed no motion of the membrane. After removal of the upper wall of the tympanum, its mucous lining appeared five or six times the normal thickness; and, removing this, we found the upper recess of the cavity of the tympanum partially filled with a transparent, brown fluid, changeable from the presence of crystals of cholesterine. When this was removed, the auditory ossicles appeared imbedded in the mucous membrane, likewise much thickened and deeply pigmented, and from it the head of the malleus and the body of the incus could with difficulty be separated. The membrana tympani, from the highest point of its upper edge to the bottom of the tympanic cavity, was bound to the inner wall by a colored cicatrix, from two to two and a half lines in length, measuring from within outward. The *ostium tympanicum tubæ* was likewise blocked up in the same way, and we could not penetrate into the cavity of the tympanum with the sound introduced through the tube.

Among the rare conditions we must number those ad-

hesions of the membrane to the promontory in which the upper remnant, together with the manubrium, is connected to the inner wall of the tympanum by a thick cicatrix formed at its lower edge, while the lower peripheral portion is not adherent, and appears as a prominent falciform border.

CASE: *Otorrhœa many years before.—Adhesion of the upper remnant of the Membrana Tympani with the Promontory.—Autopsy.*

A. L., æt. 68, workwoman, was received into the section of Dr. Scholtz, affected with cancer of the stomach. She stated that many years before she had suffered from otorrhœa, after the cessation of which she became deaf, so that at the present she could only hear a very loud noise near the ear. There was some cerumen in both ears, after the removal of which, we found on the left side an uneven, opaque, lustreless membrane, while on the right the condition was very similar to that adhesion of the membrane with the promontory described on page 112 (See Fig. 6). While syringing out the cerumen the patient became nauseated, and said that a quantity of water had passed into her throat. The diagnosis of perforation of the membrane and partial adhesion with the promontory was made, and the high degree of deafness was thought to have arisen from ankylosis of the ossicles, dependent upon a former morbid process. The autopsy showed that, besides a considerable thickening of the membrana tympani, the malleus and incus were scarcely movable, and the stapes was firmly fixed to the fenestra ovalis. The condition of the right ear is represented in Fig. 7, a vertical section through the meatus and tympanum. The short process was very prominent, while the manubrium, with the thickened fibrous upper portion of the membrane, was drawn inward, and adhered to the promontory by a dense cicatrix, which extended downward and forward toward the Eustachian tube. The



FIG. 7.

upper part of the cavity of the tympanum, above the adherent portions of the membrane, was filled with a caseous mass, consisting of epidermic cells, detritus and cholesterine crystals, after the removal of which the ossicles, rigid and scarcely movable, came to view. At the anterior lower part of the annulus tympanicus there still remained a stiff falciform remnant of the membrane, half a line in breadth. The sound, introduced into the Eustachian tube, passed with facility out into the external meatus.

The varieties of adhesion already mentioned differ from those in which a thin cicatrix closing the perforation lies upon the inner wall of the tympanum, and adheres to it, not, as in the previous cases, by dense, but by loose connective tissue. This anomaly is very interesting in a clinical point of view. For instance, just as we have seen in the process of closure of the perforations of the membrana tympani by thin transparent cicatrices, here, also, an outgrowth of connective tissue from the edges of the erosion takes place, both in the small and larger gaps of the membrane, which, from want of elastic resistance, is gradually pushed inward, and after long-continued contact unites with the promontory. The appearance of the membrane in such cases, during life, does not differ at all from that of a perforation with sharply defined edges, through which we see the pale yellow or somewhat reddish promontory (Pl. II., Fig. 2). On the other hand, if we force air into the tympanum by the Valsalvian experiment, or the air-douche, we at once see a strongly injected membrane rising up from the promontory, and swelling out toward the perforation, and after the

pressure ceases, immediately sinking back again, and becoming pale yellow.

*CASE: Adhesion of a large Cicatrix of the Membrana Tympani to the Promontory.—Autopsy.*

J. S., æt. 26, tailor, was received into the section of Dr. Kolisko, affected with tuberculosis of the lungs. He had suffered, when a child, from otorrhœa in the left ear, which subsided after several years, leaving a considerable degree of deafness. In the right, a high degree of deafness, without discharge, had developed itself since his thirteenth year. Tinnitus aurium was always present on the right side, on the left occasionally. The hearing distance on the left was one inch for the watch, and two and a half feet for the voice; on the right, there was only perception of sound. Perception of sound through the cranial bones was wanting on both sides. On examination of the left ear, the membrane appeared perforated around and beneath the manubrium to the extent of about six lines. At the lower and lateral parts of the periphery of the membrane its sharply defined remnant was to be seen, from one to one and a half lines in breadth, while above a broader portion of the membrane adhered to the upper third of the manubrium. The short process was prominent, while the lower end of the manubrium approached the promontory very closely. Through the gap the pale yellow promontory could be seen, glistening with moisture, and at the anterior lower part of the field of view a bridge, directly perceptible on account of several reflections of light, extended from the sharply cut edge of the membrane to the promontory. During the Valsalvian experiment a uniformly injected membrane suddenly rose up from the promontory toward the perforation. After the experiment it fell back and became pale again. The patient died of phthisis pulmonalis.

Fig. 8 illustrates in vertical section, after removal of the posterior wall of meatus and tympanum, the pathologico-anatomical condition of the left ear. We find a very delicate, folded membrane

of connective tissue, extending to the promontory from the sharp edges of the perforation below, as well as above and at the sides, and spreading out over it. If we examine this membrane, which is easily movable on the promontory, we find it fastened by delicate threads of connective tissue.



FIG. 8.

Introducing a sound into the Eustachian tube, in order to reach the cavity of the tympanum, we push before it the membrane stretched across the tympanic mouth of the tube. A sort of cul-de-sac is thereby formed, and the tympanic cavity separated into three divisions: the middle, communicating with the external meatus; the posterior, with the mastoid cells, and enclosing the auditory ossicles; and the anterior, leading to the Eustachian tube. This condition readily explains the appearance during life. Thus the air driven in through the tube, forcing its way between the meshes of the cicatrix adherent to the promontory, swelled it out, and the circulation in the vessels of the cicatrix and promontory becoming impeded, sudden congestion and injection of the cicatrix took place. The ossicles were stiff and scarcely movable. Concerning the condition of the right ear, see page 67.

The pathologico-anatomical condition just described is to be regarded as, in reality, a variety of the adhesions between cicatrices of the membrane and the promontory already mentioned. It is worthy of note, however, that even the cul-de-sac-like cicatrix, extending from the edges of the perforation to the promontory, is sometimes perforated. Thus, I found in a preparation taken from a young man, who became deaf after long-continued otorrhœa and died of tuberculosis, a condition similar to that described above, with the exception that in the delicate sac, which could easily be moved upon the promontory, there was an opening from

two and a half to three lines in breadth at that part lying anteriorly and opposite the mouth of the Eustachian tube. This perforation probably arose from the frequent impulse of air upon this point in blowing the nose. In another case I found a gap two lines in breadth, leading into the upper recess of the tympanic cavity, at the upper wall of the sac, which was here adherent to the tendon of the tensor tympani. If, now, in a case like the one just mentioned, there is an opening three lines in breadth opposite the mouth of the Eustachian tube, in the Valsalvian experiment the air will pass through the middle ear into the external meatus without much impediment, and the cicatrix will not be lifted from the promontory. Only when the opening in the sac is so small that the air cannot be forced through except against strong resistance, shall we observe, together with a loud hissing noise, a swelling out of the cicatrix, loosely connected with the promontory.

These new formations are traversed by several large capillaries, and the vessels of the mucous membrane of the promontory, usually of a dark bluish red, can also be partially seen through them. In one case, I saw very distinctly those portions of the long process of the incus which were covered by cicatrix and adherent to it, as well as a portion of the stapes.

We have hitherto especially dwelt upon the extensive adhesions of the membrane, or its cicatrices, to the inner wall of the tympanum. It still remains to say something of smaller adhesions, and of the union of the membrana tympani to the auditory ossicles. In describ-

ing the healing process in case of smaller perforations, we have made the fact prominent, that adhesions to the inner wall of the tympanum much less frequently occur in them than in the healing of larger perforations. But if an adhesion results, it is in consequence of continued contact between the edges of the perforation and the promontory, and after the cessation of the discharge we see a sharply defined gap in the opaque, or here and there calcified, membrane. From its edges a funnel-shaped cicatrix, dotted with reflections of light, extends toward the promontory, as is illustrated in Fig. 9, by a vertical section through the meatus and tympanum. In other

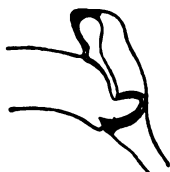


FIG. 9.

cases, the transition from membrane to cicatrix is not so sharply defined, and the partial adhesion is only marked by a shallow depression. In the former case, adhesion between the membrana tympani and promontory can be diagnosticated with certainty, but it is impossible in the latter.

With adhesions are to be classed those riband-like connecting bridges, which are not unfrequently found in normal as well as pathological conditions of the ear. In the normal ear these bands, single or multiple, and more or less strongly developed, extending from the manubrium or membrana tympani inward to the inner wall of the middle ear or to the ossicles, must be regarded as relics of the gelatinous connective tissue substance which, in the new-born, fills the cavity of the tympanum, and often degenerates into pus (V. Tröltsch). We may infer, since they not unfrequently occur in per-

sons of normal hearing, that as a rule they exercise no influence on the mobility of the auditory ossicles. I could, also, perceive no sensible change in the curvature of the external surface of the membrana tympani where bands of this kind existed in the middle ear. This generally holds true also of the bands found in diseased ears, concerning which it can never be determined that they did not exist before the disease. Only in a few preparations could I discover a shallow depression on the external surface of the membrane, corresponding to the attachment of the band. Such depressions, however, are of no diagnostic value when seen upon the living, for slight inequalities are not infrequent on diseased membranæ tympani.

Circumscribed pitted depressions are found, not only in limited adhesion of the membrane to the promontory, but, in cases where it is adherent to a larger extent, we also see sharply defined recesses (Pl. II., Fig. 12), which result partly from stronger retraction of the cicatricial tissue at some points, partly from limited atrophy of the slightly yielding substantia propria. Furthermore, the unequal separation of the membrane from the inner wall has an influence upon the irregular depression of certain parts, since, as is well known, the central portion of the membrane is nearer the promontory than the peripheral.

The relation of the elements of the membrane to the cicatricial tissue differs in individual cases. Where the perforation is closed by a sharply defined, thin, and depressed cicatrix, we find, under the microscope, as a rule,



the elements of the *substantia propria* abruptly terminating at the border of the cicatrix, but here and there extending like prongs into the cicatricial tissue. The cicatrix itself arises from the connective tissue of the dermoid and mucous layers, but is much more delicate, and not separable into laminae. The layer of epithelium on either side is far more delicate than on the rest of the membrane. Only in one case have I seen the dermoid layer of the membrane terminate like the *substantia propria* at the edge of the cicatrix, the cicatricial membrane seeming to be formed of the connective tissue of the mucous layer. (See Dissections of Von Tröltzsch in Virchow's Archiv, Sect. 16.)

Where, on the contrary, the remnants of the membrane are joined to the promontory by dense and thick cicatricial tissue, it is sometimes not easy to discover the limit between the elements of the membrane and those of the cicatrix, since the elements of the *substantia propria* extend into the cicatricial tissue in scattered and irregular filaments, terminating at different distances. Sometimes the fibres of the membrane are so changed by the morbid process that they cannot be distinguished from those of the cicatrix. (Concerning the structural changes of the membrane adherent to the promontory, see pages 52 and 53.)

The uppermost epithelial laminae of the cicatrices which close the perforations without adhering to the inner wall of the cavity are always horny, and the cicatrices are consequently dry; but in those cases in which the cicatrices are adherent, the external surface is most frequently

moist, occasionally secreting, though sometimes dry after a long lapse of time.

After the subsidence of otorrhœa, we have sometimes found upon the promontory cicatricial formations analogous to those occurring in adhesions, though no union of the membrane and the inner wall of the cavity is present. Thus, in the course of long-continued otorrhœa, hypertrophy and the formation of new connective tissue in the mucous membrane of the promontory not unfrequently occur. After the secretion has ceased, the hyperæmia and swelling of the softened mucous membrane disappear, but the newly formed connective tissue still remains, as thickened cicatricial structure, to such an extent, indeed, as not only to fill the depressions of the inner wall in the neighborhood of the tube, but also the niches of the fenestra ovalis and fenestra rotunda. The inner wall then has the appearance of an uneven surface, in part of a pale yellow color, and in part tendinous gray, with glistening spots here and there, and, when the membrane is destroyed to its periphery, may be easily mistaken at first glance for a thickened and opaque membrana tympani, unless we pay attention to the distinctly prominent, riband-like remnant of the membrane perhaps still left, or to the isolated stump of the manubrium projecting into the gap, or to the well defined border of the annulus tympanicus. In the cases of this kind which I have observed, where the membrane was wanting to its periphery, the field of view in the background was very much larger than it is when the membrane is intact.

What we have before said respecting the cautious use

of metallic sounds bent at right angles, is applicable here also for determining whether we have before us membrana tympani or promontory; yet we can very seldom decide that these cicatricial tissues on the promontory are not connected, at one or more points, with cicatrices extending from the remnants of the membrane along the lateral walls in such a way as to be concealed by the osseous portions of the external wall of the tympanum, consequently not falling within the compass of vision.

The functional disturbances which occur in consequence of adhesions between the membrane and the inner wall of the tympanum vary greatly, and the degree of deafness, as the observations of Toynebee, Von Tröltzsch, Schwartze, and others show, bears no proportion to the extent of the adhesion. Here, as follows from the above-described dissections, those changes must also be taken into account which impair the mobility of the auditory ossicles, such as outgrowths of connective tissue, calcareous deposits, and hypertrophied mucous membrane, which envelop the ossicles; the adhesion also of the ossicles to each other and to the walls of the cavity, and, finally, the changes at the fenestræ of the labyrinth.

From what has been already said, it is evident how difficult the diagnosis of adhesions in the middle ear frequently is. Yet in a certain class of cases, as the above descriptions show, we shall, by inspection of the membrane, be enabled with certainty to pronounce that diagnosis. We can by no means agree with those pathologists who affirm that no further significance can be attached

to it. On the contrary, we are convinced that in special cases it is essential to the prognosis, which plays an important part in aural surgery. For even when the impairment of function is inconsiderable in spite of the adhesions, experience teaches that no permanent results are obtained by treatment, and that relapses are probable in the course of time, even after essential improvement of the hearing by the air-douche and by the injection of moderately stimulating solutions into the middle ear.

The process of cicatrization is at an end *when the edges of the perforation become cicatrized, the gap remaining.* Although we especially observe this result where there is great loss of substance, extending as far as the annulus tympanicus, yet sometimes we also find smaller gaps persistent. Nevertheless, in some cases I have observed, after the subsidence of otorrhœa, perforations from two to five lines in diameter, continuing for months, indeed, for two years, and subsequently becoming closed by thin cicatricial tissue.

Fig. 10 is taken from a preparation of the right ear of a boy fifteen years old, who died of phthisis pulmonalis in the section of Prof. Kolisko. He had formerly suffered from a copious discharge from the ear, which had, however, ceased two years before. On examination the membrana tympani presented an oval perforation beneath the manubrium, with sharply cut edges, into which the end of the manubrium projected from above, thus making it kidney-shaped. The membrane was pearl-gray and faintly lustrous. The manu-



FIG. 10.

brium and short process were plainly visible. The portion of the mucous membrane of the promontory seen through the gap was pale yellow and glistening with moisture. On the Valsalvian experiment, with little effort the air passed out through the perforation. The hearing distance was one foot and a half for my watch, more than twenty-four feet for the voice. The post-mortem examination showed the membrana tympani moderately thickened, the gap kidney-shaped, as mentioned, five lines in transverse, and from three to three and a half in vertical diameter, its edges rounded, at some points covered by connective tissue, at others only with epithelium, after the removal of which we could easily separate the individual layers of the membrane.\* The lining of the cavity of the tympanum was smooth, and the auditory ossicles, so far as could be determined by the usual rough method of examination, appeared somewhat less movable than is normal.†

\* NOTE.—Schwartz states in his "Praktische Beiträge" that large perforations which have existed for a long time, and have thick, sharply cut, or especially calcified edges, can by no means be closed. This is a great detriment to the patient, because the way lies open to new troubles of the mucous membrane of the middle ear.

† NOTE.—We give here a short abstract of the *treatment of purulent catarrh of the middle ear* with perforation of the membrane.

If the affection is acute, and comes on with severe pain and febrile movement, the membrane and meatus at the same time appear much injected and swollen, we apply just in front of the tragus from two or three to five leeches, according to the intensity of the symptoms and the general condition of the patient. Internally we prescribe, especially at night, from one to three one-twelfth grain doses of acetate of morphia. Externally, about the ear we apply twenty drops of an embrocation composed of two drachms of oil of almonds

With solutions of continuity in the membrana tympani and their results, were also described the changes which the auditory ossicles thereby undergo. It is necessary still to mention some rare conditions, which are re-

and a drachm of chloroform. Warm poultices and cold are equally injurious; but, on the contrary, where the pain is very severe before or after the rupture of the membrane, dropping lukewarm water into the meatus (Von Trölsch) sometimes proves very beneficial. If alarming symptoms appear, such as convulsions or great mental confusion, leading us to infer an accumulation of pus in the middle ear, and we find the membrane at one point greenish-yellow and swelled out, we perform paracentesis with a rather large cataract-needle, in order to provide an exit for the pus.

If otorrhœa has come on, we syringe the ear with lukewarm water from two to four times a day, according to the amount of discharge. If the secretion has a penetrating odor, we add to the tepid water a little *aqua chlorata*, about a teaspoonful to half a tumblerful of water, or a weak solution of chloride of lime, one scruple to six ounces of water, two tablespoonfuls of which is to be added to half a tumblerful of water.

Of the astringents employed in otorrhœa, the following have proved most efficacious: ℞ *Zinci Sulphat.* grs. ij–v. *Aq. Dest.* ℥j. M. S. Morning and evening, pour in a teaspoonful and allow it to remain ten minutes. ℞ *Tinct. Ferri Muriat.* ℥j–ij. *Aq. Dest.* ℥j. M. S. Use as above. ℞ *Plumbi Acetat.* grs. ij–v. *Aq. Dest.* ℥j. M. S. Use as above. ℞ *Acidi Tannici*, grs. ij. *Aq. Dest.* ℥j. M. S. Use as above. Alum and nitrate of silver do not act as favorably. The astringent decoctions of bark are to be wholly rejected.

If these agents have been employed in special cases without essential benefit, the following preparations of zinc may still be prescribed: ℞ *Zinci Acetat.* grs. j–ij. *Aq. Dest.* ℥j. M. S. To be dropped in. ℞ *Collyrii Adslut.* ℥xv.–℥j. *Aq. Dest.* ℥j. M. S. To be dropped in.

The pus is best removed from the meatus by syringing; but as that in the recesses of the cavity of the tympanum is not reached by the stream of water, and consequently by its stagnation the suppuration is kept up, and, moreover, through calcification may give rise to ankylosis and fixation of the ossicles, it is therefore necessary, in order to cleanse the cavity of secretion, that we should from time to time force a strong current of air into it through the Eustachian tube. This is best accomplished in the manner already described;

cognizable on inspection, and full of interest as regards diagnosis.

Here, first of all, belongs *the separation of the manubrium from the membrana tympani*, an anomaly repeat-

and this method, moreover, may be employed at the same time to bring the astringent solution fully into contact with the mucous membrane of the cavity of the tympanum.

For this purpose, while the patient sits with the head inclined, we fill the meatus with a lukewarm solution of sulphate of zinc, from two to four grains in half an ounce of distilled water, and, if both ears are affected, the meatus which is filled being closed by the patient's finger, the other is filled with the same solution, and the air forced into both cavities during the act of swallowing, in the manner before described. The air which now passes through the tympanic cavities appears in the passages, filled with the solution, in the form of bubbles, and, simultaneously with its escape, the fluid enters the cavity of the tympanum through the perforation. This often takes place so quickly that the fluid runs through the Eustachian tube into the throat during the experiment. It must be explicitly stated that for this purpose we employ only the sulphate or acetate of zinc, because they form no adherent precipitate, as do acetate of lead or muriate of iron. This method of treatment is practised three times a week for several weeks, and after an intermission of several weeks or months is renewed again.

Vegetations in the external meatus, on the membrana tympani, or the promontory, which so long as they remain keep up the otorrhœa, must be removed when they can be easily reached, or destroyed by touching with a concentrated solution of muriate of iron, or, if hard, by nitrate of silver in substance. We employ for the latter a simple metallic wire of the length of a sound, bent at right angles at the middle, immersing the point several times in nitrate of silver, melted in a little porcelain cup, till the caustic has hardened upon it in the form of a little ball.

If, in given cases, it is a question as to the indication for an artificial drum, everything which temporarily reduces the hearing power must first be removed. Thus, in the first place, in order to free the tympanic cavity of purulent secretion, we must force air through it either by introducing a catheter into the Eustachian tube, or, better and more simply, by the method devised by me, driving the pus partly back into the mastoid cells, and partly

edly mentioned by Toynbee in his "Descriptive Catalogue" of his pathologico-anatomical collection, as well as in his *Diseases of the Ear* (German translation by Moos of Heidelberg). I have observed it in three cases, and in one instance the diagnosis made during life corresponded with the post-mortem condition. In the examination of such a membrane, we see the pale yellow

through the perforation into the external meatus, whence it will then be removed by syringing. Then we proceed to determine the hearing distance both for the watch and for the voice. After this the auricle is drawn somewhat backward and upward with the left hand, in order to make the meatus as straight as possible, and the moistened artificial membrane introduced with the right hand. We shall generally meet with some slight resistance disagreeable to the patient at the middle of the meatus, on account of its narrowness. But in spite of this, the membrane can easily be carried to the end of the meatus. If the patient immediately experiences marked improvement in hearing, or complains of pain on pressing it further in, we must at once abstain from any further effort to carry it deeper, and with the speculum ascertain the condition of things at the bottom of the meatus. If the trial made after this shows no (or only insignificant) improvement of hearing, *we must not abstain from further attempt*, but by slight turning or new introduction of the instrument give another position to the little plate of rubber, by which change we shall not unfrequently obtain astonishing improvement.

I have in my charity practice introduced a modification of the artificial membrane, which in effect fully supplies the place of Toynbee's. The preparation of this little apparatus is so easy that any practitioner may readily undertake it, and the price of the materials for a hundred is so very trifling that it is hardly worth taking into account in the single pieces. Thus, I cut out of the sides of a thick india rubber tube little pieces from four to five lines long, and from one and a half to two in thickness, the lower end somewhat broader than the upper. These are perforated and fastened to a moderately stout wire. The method of introduction and application is just the same as with Toynbee's artificial membrane. It is also necessary, in special cases, to bend the end of the wire in such a manner that the instrument shall remain in the position in which it was placed and not fall out.



line, which indicates the course of the manubrium, interrupted at a point near the middle or above it, so that only the upper portion of the manubrium is visible. This visible portion either abruptly terminates at its lower part or is gradually lost upon the membrane, as Fig. 5, Pl. II., illustrates. The umbo is usually flattened, and we find the membrane either only moderately opaque, or calcified in spots, or having circumscribed attenuated areas. The occurrence of separation of the lower part of the manubrium is especially favored by the traction of the tensor tympani. In inflammatory conditions of the membrana tympani, which result in loosening and softening of its tissue, separation of the manubrium by the traction of the membrane is conceivable, and this takes place all the more readily when the portions of the membrane surrounding the malleus handle are partly destroyed. The manubrium is then, as was mentioned in case of perforations, drawn inward; and while the breach in the membrane cicatrizes, the lower portion of the manubrium remains in its position



inclined inward, without being enveloped in the cicatrix. On opening the tympanum, we consequently find the handle, like a blunt rounded cone, projecting free into the cavity, or a bridge extends from it to the membrane, whereby it presents in profile the appearance of a nose, as the vertical section through the meatus and tympanum in Fig. 11 illustrates. Whether this separation of the manubrium occurs also in affections which run their course without perforation of the mem-

brane, is left entirely to conjecture, for the proof is yet to be supplied.

As another anomaly properly belonging here *fracture of the manubrium* is worthy of mention.

The few observations already made were, together with one of his own, mentioned by Von Tröltzsch in his "Diseases of the Ear," page 73. He says, "Menière (Gaz. Médicale, 1856) reports such an observation, in the case of a gardener who, accidentally falling, thrust a twig of a pear tree into his ear. There was very extensive laceration of the membrane, and the several parts of the malleus, with the remnants of the membrane to which they were attached, could be plainly seen to move. The healing of this remarkable lesion occurred without any special aid from art." I have myself seen one case of fracture of the manubrium. A wine-merchant, in crossing his court, was scratching his right ear with a pen-holder, when his elbow unexpectedly struck a door, which stood open, driving the pen-holder deep into the ear. With a sharp cry of pain he fell down fainting, and did not revive for some minutes. As cold water was immediately poured into his ear, he cannot tell whether there was any hemorrhage. Since then he has heard badly, and suffers from constant ringing, especially when he lies upon the right side. When I saw the case a year later, I was struck with the peculiar distorted position of the manubrium, which at one point, close beneath the short process, appeared unusually thick and prominent, and from this point out, as it were, twisted upon its axis. In short, I was convinced that

the condition could only be the result of a united fracture of the handle of the malleus. Hyrtl also has very recently described such a united fracture (Wiener med. Wochenschrift, 1862, 11). He found it in the ear of a prairie dog (*Arctomys ludovicianus*), also close beneath the neck of the malleus, and having a precisely similar appearance. He adds, that such a lesion is not to be wondered at, since this animal, a congener of our marmot, lives principally in holes underground, and on account of the shortness of the meatus its membrana tympani is very superficial.

Among the less frequent conditions of the membrana tympani are further to be classed the *adhesions of the membrane, or of a cicatrix in the membrane, to the stapes*. Tröltsch (*loc. cit.*) gives an accurate description of this condition, and Toynebee's collection of pathologico-anatomical preparations of the ear contains several specimens in which this anomaly is present. With regard to these conditions, the adhesion appears to occur especially after the subsidence of otorrhœa, since a yielding of the articulation of the incus and stapes results from the inflammatory process, and the membrana tympani, usually thinned or patched at points with thin cicatricial tissue, is pressed inward and lies against the inner wall of the tympanum, and after continued contact unites with the head and crura of the stapes. Whether adhesions of this kind, between the membrane and stapes, also occur without preceding otorrhœa, further observations must determine.

If one only has some anatomical knowledge of the

ear it will not be difficult, even if he is inexperienced, to interpret the condition of the membrane in this anomaly. We discover, for instance, at the posterior portion of the membrane (Pl. II., Fig. 7) an outline which, from its peculiar form, is at once recognized as corresponding to the parts of the stapes. The head of the stapes is usually turned downward, while its two crura are directed upward and somewhat backward. It is worthy of note, that on inspection the outline of the stapes cannot always be seen at the periphery of the the posterior upper quadrant, as it would be in order to correspond with its anatomical position, but frequently (as in Pl. II., Fig. 7) further down. Indeed, the outline of the stapes may be seen in front of the malleus handle, if, after the dislocation of the ossicles, the anterior portion of the membrane unites with the stapes, as I saw it in one preparation to be found in Toynbee's collection.

Fig. 7, Pl. II., is a representation of the left membrana tympani of a girl eighteen years old, who had an otorrhea with perforation of the membrane upon the right side, but had noticed no purulent discharge upon the left. In looking at the membrane, we found the short process of the malleus, as well as the upper part of the manubrium, very prominent, while the lower end was drawn inward. Behind the manubrium an outline was visible upon the membrane, corresponding to the head and upturned crura of the stapes. The membrane was very thin, transparent, and uneven, with here and there large irregular reflections of light upon it. Upon forcing air into the tympanic cavity, certain portions of the

membrane stood out more prominently; the reflections altered their form and size, while the visible portions of the stapes did not change their shape, thus proving that the membrane was adherent to them. The hearing distance on this side varied, yet sometimes amounted to seventy-five or eighty feet for the voice. The transmission of sound from the membrane to the labyrinth was effected by the stapes alone, without the intervention of the malleus and incus; and hence this anomaly is analogous to the sound-conducting apparatus of birds, where, as is well known, the transmission from the membrane to the labyrinth is accomplished by a single auditory ossicle, the *collumella* (stapes).

With the preceding cases we class as *rare* those conditions in which a portion of the *upper wall of the external meatus has been absorbed* in the course of an otorrhoea, and after cessation of the secretion the head of the malleus and body of the incus, lying in the upper recess of the cavity of the tympanum, have become visible; or, if these are destroyed, those portions of the inner wall are seen which normally are hidden by the osseous meatus. The very large extent of illuminated background is characteristic of these anomalies.

Fig. 12, Pl. II., is taken from the membrane of a preparation which, from its rarity, is worthy of description, although the person affected was not under observation during life. On illuminating the background, we notice at once the large extent of the field of view. Toward the upper part of the field we see a large yellowish body with processes. It is the head of the

malleus connected with the body of the incus, together with the processes of the incus and the handle of the malleus. Beneath this appear several pitted depressions of varying size, one of which, at the lower part of the field, is remarkable for its extent. The upper wall of the meatus is so thinned by atrophy that only its upper lamella remains. The meatus consequently appears wide, and the auditory ossicles, which normally are masked by the thick wall of the meatus, now lie open to view. On removing the upper wall of the tympanum, we found the head of the malleus forming a bony union with it, but the incus free and somewhat movable at the articulation with the malleus. The malleus and incus, as well as the membrane, are united to the inner wall of the tympanum by bands of connective tissue, which are tense at some points and loose at others, thus giving rise to the irregular pitted depressions.

I found an essentially different condition of the membrane in the left ear of a Polish merchant, thirty-six years of age. From childhood he had suffered from otorrhœa, which, however, had ceased four years before. Being consulted on account of difficulty of hearing in the left ear, I found the meatus filled with cerumen, after the removal of which, the hearing distance rose from one to four inches for the watch, from six to twenty-four feet for the voice. On inspection of the membrane, it appeared somewhat flattened and slightly opaque. The short process of the malleus and the manubrium were distinctly marked and in normal position. Above the upper border of the membrana tympani, which

was separated from its osseous insertion to the extent of six or seven lines, I observed a loss of substance in the osseous meatus, through which the glistening gray lining of the cavity of the tympanum could be seen. Singularly, however, through the gap, whose lower edge was formed by that portion of the periphery of the membrane lying above and to the side of the short process of the malleus, nothing could be seen of the head of the malleus or of the body of the incus—a fact which could only be accounted for by a partial destruction and extrusion of these ossicles.

## ANOMALIES

### IN THE CURVATURE OF THE MEMBRANA TYMPANI.

BESIDES the changes described, affecting the color and transparency as well as coherence of the membrana tympani in diseases of the ear, its *curvature* also undergoes many variations, which are of essential importance with reference to diagnosis. We have already become acquainted with a large class of such changes among the anomalies discussed in the previous sections; and we turn now to the consideration of another series of observations, describing abnormal convexity, the conditions, first, of outward, and then of abnormal concavity.

The *external convexity* of the membrane seldom affects it throughout its entire extent. I have observed this only in cases of *very severe acute catarrh of the middle ear, with simultaneous inflammation and swelling of the whole membrane*, which appeared arched out like a globe, had a bluish-red suffusion, and glistened with moisture. Such globular convexities differ little in outward appearance from certain forms of polypi which grow out of the cavity of the tympanum. These vegetations, however, are excluded by the short duration of the affection in the cases before us. As a rule, these protrusions continue only for a short time, since, with the disappearance of



the inflammatory symptoms, the swelling also rapidly subsides, the membrane becomes flattened, and, though still much injected and covered with softened epidermis, the redness gradually passes away, the short process and manubrium come to view, and the membrane may either return to the normal state, or opacities of varying degree still remain, or ruptures of the membrane may take place before the swelling subsides, upon which it sinks down and becomes flattened.

More frequently the protrusions of the membrane are limited. Both *in acute inflammation of the membrane*, and also *in acute catarrh of the middle ear*, we not unfrequently find the upper half of the membrane strongly arching out, of a dark bluish-red color, and covered with a thin layer of gray, cracked epithelium. The manubrium and short process are invisible. The lower part of the membrane, however, has undergone no change of curvature, and in contrast with the bulging upper portion, appears very much in the background. The convexity often disappears after only a day's duration, and, then, the changes which afterwards occur are analogous to the appearances we have already mentioned (page 42) in the description of acute catarrh.

*Abscesses* in the membrane also appear as circumscribed convexities. They are among the rare conditions of the membrane, and are developed in the course of acute myringitis, or acute catarrh of the middle ear. Wilde saw circumscribed collections of pus in two cases. Upon opening one with a cataract needle, pus was discharged into the meatus. Von Tröltzsch observed, at the upper

edge of the membrane in a case of acute myringitis, a tumor as large as a hemp-seed, yellowish, and doughy to the touch, which gradually diminished as the inflammation subsided. Schwartze saw abscesses occur after touching the membrane with a solution of nitrate of silver. In one case of acute catarrh of the middle ear, I observed three greenish pustules of the size of a poppy-seed along the manubrium, surrounded by a red areola. They disappeared after two days without leaving a trace behind. In one other case, I saw, in the course of the same disease, on the third day, an ill-defined, greenish-yellow swelling behind the manubrium, about the size of a small pea. The vessels of the manubrium were injected; otherwise, the membrane was little changed, except that the lustre was somewhat faded. The following day, on examining the membrane, nothing could be seen of the circumscribed swelling, and not until the examination had continued for some time did the spot designated swell out again, and appear of the same extent and color as on the preceding day. This puzzling phenomenon appeared again on the next day, but not afterwards. It was observed, at the same time with myself, by several of those attending my lectures.

I have, moreover, observed the formation of abscesses in the membrana tympani during acute purulent catarrh of the middle ear. Yet, although interstitial abscesses doubtless occur simultaneously with acute suppuration of the mucous lining of the tympanum, still it is very difficult to determine, in such cases, whether a greenish circumscribed protrusion on the membrane proceeds

from an abscess in its substance, or from an accumulation of pus in the cavity of the tympanum. In one case of simple acute catarrh of the middle ear, I observed on the injected and swollen membrane several vesicles of the size of a millet-seed, filled with a fluid of a watery transparency. They had already disappeared upon the following day.

The external surface of the membrane, in many cases, undergoes a change of curvature from the formation of *granulations* upon it. They arise in the course of chronic otorrhœa with perforation of the membrane, and but very seldom in chronic otitis externa without lesions of the membrane. They are papillary vegetations of the connective tissue of the dermoid layer of the membrana tympani, and appear either singly or in groups, or scattered in larger numbers over the entire surface. We see, therefore, upon the dirty gray or greenish-yellow membrane, which is injected and swollen, one or more fleshy excrescences from the size of a millet seed to that of a hemp seed. If its surface is covered with vegetations, the membrane appears like a raspberry—bluish-red, and dotted with numerous light spots. Occasionally similar vegetations are simultaneously visible upon the osseous portion of the external meatus.

The diagnosis of granulations of the membrana tympani can be made with certainty in one class of cases, where, together with the vegetations, we discover a perforation from which pus, or, upon forcing air into the tympanic cavity, bubbles come out; or where the opening on the granulated surface becomes visible by the separa-

tion of its lips through the pressure of air. Yet, not unfrequently it is so concealed by one or more vegetations, that, even on forcing in air, nothing can be seen of an opening though we distinctly hear the air hissing through it. In such cases it is very difficult to distinguish between vegetations on the membrane and those upon the inner wall of the tympanum, extending out to the level of the membrane (see page 86). Even the change of the position of the light spot, or of the curvature of the granulating surface, on forcing air into the middle ear, is not decisive proof that we have a granulating membrana tympani before us, since, as has been stated, these phenomena are observed also on the softened and hypertrophied mucous membrane of the cavity of the tympanum. In like manner, a polypus at the bottom of the meatus, growing out of the cavity, and having a warty surface, may easily be mistaken for a softened and glandulous membrana tympani. Since the diagnosis in such cases is of great importance with reference to the treatment to be employed, we should, when inspection is not decisive, make an examination with a sound bent at right angles. If we succeed in carrying the sound around the growth by cautiously pushing along the edges, and showing it to be easily movable, the diagnosis of polypus is thereby confirmed; though even then we cannot always say with certainty whether it arises from the external or the middle ear, or, as very rarely happens, from the membrana tympani itself. In one class of cases, however, the diagnosis cannot be made at all, or is first established in the course of changes which are decisive with respect to it.

The vegetations on the membrana tympani sometimes disappear spontaneously, or after frequent cleansing of the meatus and the use of astringent washes, especially the solutions of sulphate of zinc and tincture of the muriate of iron. In several cases, painting the hypertrophied surface with concentrated tincture of the muriate of iron was followed by decided improvement; but in others it was ineffectual, and the granulations could only be removed by frequent applications of nitrate of silver in substance.

In case of a young man who had suffered from otorrhoea for eight years, the membrana tympani was studded with numerous little warts, dark red, and very shining (Pl. I., Fig. 7). During the Valsalvian experiment we heard the air whistle through, and saw several air-bubbles appear on the background without being able to discover any opening. The hearing distance for my watch was four inches, and more than four feet for the voice. The air-douche made no change in it. By six applications of the caustic employed every third day, the vegetations were removed, and a perforation of the size of a pin-head appeared below the manubrium, the secretion ceased, the short process and the manubrium became visible, and the membrane had an irregular grayish opacity. After some days the opening cicatrized, and the hearing distance, steadily improving during treatment, was quite normal in ten days.

With the circumscribed protrusions of the membrana tympani are also to be classed those *bleb-like prominences* which, in many cases of chronic disease of the

middle ear, come to view upon the employment of the air-douche, arising either in consequence of a partial loss of substance in the mucous and fibrous layers, the air accumulating beneath the dermoid layer (Von Tröltsch), or from hernial protrusion of the mucous membrane between the separated or absorbed fibres of the substantia propria. The former was first observed by Von Tröltsch (*Krankheiten des Ohrs*, p. 92) at the posterior upper portion of the membrane, where a pretty large uneven protrusion swelled out into the meatus, projecting down over the end of the manubrium, and as it were covering it. After a short time these protrusions disappear again. From my own observations I can confirm the statements of Von Tröltsch, and will further mention a condition which argues that these bubble-like swellings may arise also from hernial protrusions of the mucous layer. In a man who was consumptive and hard of hearing, and upon whom the air-douche could not be employed, there were diffuse opacities on the right membrana tympani, but no anomalies of curvature. In the post-mortem examination I observed a thin-walled bubble, of the size of a small pea, appearing upon the external surface of the membrana tympani, behind the manubrium, on forcing air through the Eustachian tube. This again became smaller and disappeared when I rarefied the air in the middle ear. Upon opening the tympanum, the mucous membrane, at the point of the inner surface corresponding to the protrusion, projected into the cavity of the tympanum in the form of a wrinkled cone, and closer

examination showed the fibres of the substantia propria separated from each other, and the mucous membrane, with the adherent dermoid tissue, attenuated and folded together in the manner described.

Besides the pathological changes in the membrana tympani already mentioned, there are protrusions at points upon it, the result of interstitial exudation, of accumulations of pus and mucus in the cavity (see page 95), and of polypoid growths in it. In one case I saw the membrane forced outward by the accumulation in the cavity of an inspissated, cheesy mass of epidermis. So manifold are the diversities of condition which an examination in all these changes furnishes, that a detailed description must evidently be regarded as impracticable. Only a knowledge of the normal and morbid anatomy of the ear, and an accurate comprehension of the course of the disease, will here, in many cases, lead to a correct diagnosis. When, therefore, Dr. W. Kramer, privy sanitary counsellor in Berlin, characterizes the results obtained by the study of the physiology and pathological anatomy of the ear as wholly useless in aural surgery, we must pity the man who, grown gray under constant opposition and strife, has, by his unremitting outbursts of rage against the recent progress of aural surgery, gained a truly unenviable name in the annals of science.

We meet with abnormal *inward curvature* of the membrane still more frequently than with external curvature. It affects either the entire membrane, or in-

dividual parts of it. Most frequently we find the whole membrane pressed inward in long continued occlusion of the Eustachian tube, in consequence of which the air in the cavity of the tympanum is absorbed, and the membrane forced in by atmospheric pressure. Yet I believe that we should call attention to another factor, in this case having an essential influence upon the inward curvature of the membrane. It is the *secondary retraction of the tendon of the tensor tympani*. If, for instance, the membrane is strongly pressed inward, the point of insertion of the tendon upon the manubrium must also approach the inner wall of the tympanum. The tendon, previously stretched, now becomes slack, and since its antagonizing force, the tension of the elastic membrane, is partially overcome by the atmospheric pressure, it will contract in the same way—to use a comparison—as the tendons of the flexors of the leg, when it has been bent at the knee-joint for a long time. Evidently, such a shortening of the tendon may still further increase the inward curvature of the membrane, and on longer continuance, even when the permeability of the Eustachian tube and the balance between the pressure of the external and internal air are restored, may still always act as an abnormal inward traction; and, consequently, it is obvious that disturbances of function of varying degree may also occur, from the strong pressure exercised upon the chain of ossicles, and through them upon the labyrinth.

If the inward curvature of the membrane has continued for a long time, it loses a part of its elasticity; since



by the constant stretching an atrophied condition (Von Tröltsch) is developed, especially in the substantia propria. The membrane becomes thin and lax, and the disproportion between its tension and that of the auditory ossicles must lead to disturbance in the transmission of sound.

In chronic catarrh of the middle ear, without occlusion of the Eustachian tube, we have also not unfrequently observed marked concavity of the membrana tympani. It results, according to Von Tröltsch, either from adhesion of the membrane to the inner wall of the tympanum, or from peripheral thickening of its mucous layer. Yet it cannot be doubted, and repeated dissections have taught me, that in chronic thickening of the mucous membrane of the cavity, a shortening of the tendon of the tensor tympani, by retraction of its thickened mucous covering, may, not unfrequently, cause a concavity of the membrane.

In discussing the normal relations of curvature and inclination of the membrane, we have already said that our judgment in respect to them is not reliable. This holds good also, in part, of the relations of curvature in morbid conditions of the membrane; nevertheless, there are certain data by which we are able, generally, to determine an abnormal change of curvature, even if we cannot accurately measure its degree. In the first place, the inclination of the lower end of the manubrium inward is marked, and therefore also the apparent shortening of the whole handle (Pl. I., Fig 10). In consequence of this inclination of the manubrium, the short process of the malleus (which is upon the upper

arm of the lever formed by the malleus) stands out more prominently, and causes a more marked projection of the parts of the membrane lying next to it, in the form of two folds (Von Tröltzsch).

The anterior fold is usually not very prominent. The posterior extends, like a roll, from the projecting short process along the upper border of the membrane backward, and may be easily mistaken by the inexperienced for the manubrium, especially if the malleus handle is so hidden by the posterior part of the membrane that either it cannot be seen at all, or only at its lower end.

Since the membrane approaches the inner wall of the tympanum, it not unfrequently comes in contact with the long process of the incus, which we see as a short, frequently prominent band, behind the manubrium. The chorda tympani and the pocket of Tröltzsch not unfrequently, in these cases, lie very close to the membrane, and show through it.

The *color* of the membrana tympani, in inward curvature resulting from tubal obstruction, is quite unchanged, or it is dark violet where there is simultaneous injection of the mucous coat of the membrane or promontory. In one class of cases, however, it presents a peculiar dark-gray and dusky aspect. In catarrh of the middle ear of long standing, we usually find the tendinous gray, striated opacities already described.

The *lustre* of the membrana tympani undergoes important changes. The soft diffuse gleam often appears remarkably heightened; the cone of light, from the change of curvature, loses its previous form, and is seen

in the vicinity of the umbo as an irregular, faint, light spot. We must notice as of importance a bright linear stripe in the neighborhood of the cone of light, frequently observed in tubal catarrhs. This stripe is sometimes connected at one point with the light spot in front of the umbo, but is longer than the normal breadth of the cone of light. It is traced upon an edge which is formed near the periphery of the membrane by a sharp depression of the central portion of the membrane. The peripheral portion of the membrane, through aggregation of the circular fibres of the substantia propria, possesses, for the width of perhaps a line, a far greater power of resistance than the central portion where the elastic elements are less abundant. The central part will therefore yield more to the pressure of the external air, and consequently move further inward than the peripheral,



usually at the anterior lower part of the membrane, as is shown in Fig. 12 (see pages 68 and 69).

FIG. 12.

These angles of the central portion of membrane occur, though very rarely, in persons of normal hearing. Sometimes I have found them upon normal membranes in post-mortem examinations of children; twice in adhesions of the membrane with the promontory. We have already described in detail the anomalies of curvature in adhesions of the membrane, when speaking of the healing process of perforations, but will remark further, that, according to our experience, adhesions of the membrane with the promontory are rare in catarrhs that run

their course without suppuration and perforation—much more so than has hitherto been supposed.

If we observe the changes taking place in these inward curvatures of the membrane during the air-douche, we shall find that in one class of cases the membrane at once makes a considerable movement outward, while in others we shall either perceive no motion at all, or only very slight. Even where a complete restoration of the hearing power results after removal of the affection of the middle ear or Eustachian tube, I have frequently noticed that the membrane never regained its former position.

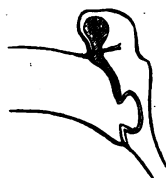

FIG. 13.

The circumscribed depressions were likewise fully discussed in previous sections. We have already remarked as worthy of note (see page 107), that formations analogous to the attenuated sunken cicatrices are also observed in cases of catarrh without perforation of the membrane, and that only the development of the depression while the case is under observation can decide whether cicatrix or partial atrophy is present, since the appearances are precisely the same. The circumscribed depressions which arise from atrophy are found at one or more points on the membrane. In one case, in consequence of many sharply defined depressions, it presented the appearance of a surface with shining facets. Since experience shows that several perforations can seldom occur in the membrane, we may therefore infer, where there are several limited depressions, even if there has previously been perforation, that the thinned spots

may still be the result of atrophy, caused by inflammation of the membrana tympani attending purulent catarrh of the middle ear.

*Appearances produced by Movements of the Membrana Tympani.*

The variations in the pressure of air in the cavity of the tympanum, when not too inconsiderable, always produce a recognizable movement in the elastic membrane. There is a difference, however, in the mobility of the various portions of the membrane,—the peripheral parts and those next to the manubrium are moved only to a slight extent, while there is considerable motion in those lying midway between the periphery and manubrium.

These rapidly occurring changes in the position of the membrane in the normal condition are, in the majority of cases, recognized either by a perceptible alteration in the form of the cone of light, or by a visible movement of that portion of the membrane lying behind the manubrium. We have, however, observed cases where no change in the membrane could be perceived on forcing air into the middle ear (see page 28).

If we examine a *normal* membrana tympani while air is being forced into the middle ear by the Valsalvian experiment, by the new method or by the catheter, we see no change in the position of the manubrium, although it moves from a quarter to half a line. The posterior portion sometimes moves very noticeably, and a fainter reflection of light appears upon it. The cone

of light pushes outward, often becomes indistinct and faint, and alters its shape and size, but in very different degrees in different individuals. When the pressure of the air ceases the membrane at once regains its former aspect.

The case is different *in diseases of the middle ear, and in morbid changes of the membrane itself.* When the Eustachian tube is impervious, and the pressure of air employed cannot overcome the obstruction, and when there are extensive adhesions of the membrane to the inner wall of the tympanum, or when there is considerable thickening of the membrane, no movement will be perceived. An irregular movement of certain points occurs in limited adhesions, in irregular thickening, in cicatricial formations, and in partial atrophy of the membrane.

In other cases, on the contrary, we observe very free movements of the membrane if the Eustachian tube is abnormally wide (Von Trölsch, Autopsies in cases of Deafness), and the stream of air presses with full force into the cavity of the tympanum.

The movements will be so much the greater if the membrane, from atrophy of its substantia propria or of all its tissues, has lost a part of its elasticity. Not unfrequently I have seen, in case of persons who had suffered from chronic catarrh, and had frequently employed the Valsalvian experiment for the improvement of their hearing power, a great change in the position of the usually dull and lustreless membrane, and a perceptible protrusion of the malleus handle. I have observed

still greater movement in membranes which, in the course of chronic catarrh of the middle ear and Eustachian tube, have been reduced by atrophy to a transparent pellicle, not unlike a thin layer of collodion. The membrane in these cases appears relaxed when in a state of repose, and lies in numerous folds, on the summits of which striated reflections are seen running out like radii. In the Valsalvian experiment the lateral portions of the membrane, especially, swell out very strongly, the folds disappear, and the reflections become more faint. When the pressure ceases, the membrane sinks back and becomes folded again. For this condition of the membrane the term "*Collapsus Membranæ Tympani*," which Wilde employed for inward curvatures, would be more suitable,—by no means, however, in the sense of a primary affection.

Perceptible movements of the membrane, furthermore, occur on rarefying the air in the tympanum. Thus, *in the act of swallowing* with the mouth and nostrils closed, we likewise see the light spot change its form, but in a different manner in different individuals. Sometimes it seems as if the cone of light made a movement outward, by which the erroneous impression might be given, that the air was forced into the tympanum by the act of swallowing with closed nostrils. A rarefaction of the air can, however, be easily proved by the movement of a drop of colored fluid in a manometer fixed air-tight in the meatus.

We must further add on this point, however, that at the first instant of the act of swallowing, a slight

condensation of the air in the cavity of the tympanum really does occur, but afterwards a considerable degree of rarefaction. This can be most clearly seen in membranes having thin, depressed cicatrices, or circumscribed atrophied spots. At the first instant of the act of swallowing with the nostrils closed, the depression swells out quickly, but immediately sinks back again toward the promontory still deeper than before.

If the nostrils are not closed during the act, we observe, as a rule, no movement in the normal membrane. On the contrary, in membranes with thin, depressed cicatrices, or atrophied, I have seen marked movements, and changes in the form of the light spot. The fact that, in these cases, movements of the membrane result from the simple act of swallowing, while they do not occur in the normal condition, is explained as follows: When we swallow without closing the nostrils, a slight momentary rarefaction of the air in the throat occurs, which, since the Eustachian tube is simultaneously opened, also affects the air in the tympanic cavity. The pressure of the external air would now force the membrane inward, but that it offers resistance in consequence of its elastic elements; and, since this power of resistance is greater than the force which is exerted by the slight difference between the pressure of the air within and that without the tympanum, no movement ensues. On the contrary, where there are circumscribed thin spaces, or atrophy of the entire membrane, its elastic resistance is so considerably diminished that, even in slight variations in the pres-



sure of the air in the cavity of the tympanum, movements of certain portions must result.

As a rule, no changes are perceptible on the normal membrane *during the movements of respiration* ; only in rare cases have I seen, in tranquil respiration, a synchronous to and fro movement of the membrane, from which it was inferred that the Eustachian tube was wide open. If, however, by quickly repeated respirations we make the air pass rapidly through the nasal cavity, the Eustachian tube will frequently, but not always, become pervious, from the increased pressure in the pharynx, and a movement of the membrane result from the transmitted fluctuation of the pressure of air. We maintain this opinion (see Report of the Session of the Academy of Sciences in Vienna, March, 1861), and must call it an error when it is affirmed that the tube is opened with every respiratory movement.

*Pulsations* are to be classed among the frequent phenomena on the membrane. Wilde was the first to call attention to their presence in perforation, and they have hitherto been regarded as pathognomonic. I have already, in a former work (*Zeitschrift für pract. Heilkunde*, 1862), spoken of the perception of pulsating movements upon imperforate membranæ tympani, and these observations have been very recently confirmed by private communications from Von Tröltzsch and Schwartze. The normal membrane, on account of the slight capacity of its blood-vessels, shows no pulsation. We can, however, produce it, if we irritate the membrane by frequently touching it, inducing a greater fulness of its

vessels. We may perhaps even then perceive no pulsation on inspection, but it becomes very apparent if, as I have seen in some cases, a thin bit of straw, extending out of the meatus as an indicator, be carefully attached to the membrane by a little drop of gum, the external end of the indicator moving synchronously with the pulse.

I first noticed pulsations of the imperforate membrane in some cases of acute catarrh of the middle ear. Below and behind the manubrium, on the intensely injected and serum-soaked membrane, I saw one or more punctiform reflections, which moved to and fro with the movements of the pulse, or disappeared during the diastole and came to view with the systole.

On the perforated membrane we find one or more reflections with pulsatory movement. The pulsation is seen in the perforation on a reflection either from an air-bubble, or frequently from a drop of pus. It sometimes ceases, but usually becomes very active when we irritate the meatus by touching or syringing it. Now and then we notice numerous striated reflections from the secretion lying on the membrana tympani, which in the movements of pulsation cross each other in various directions, and present an appearance very similar to the motions of a fluid in which a number of maggots are stirring. Pulsation on perforate membranes is caused by expansion of the vessels of the swollen and softened mucous lining of the middle ear, and of the membrana tympani itself. Since the advancing blood-wave expands the vessels, the area of the tympanic cavity is diminished, the accumu-

lated secretion and the air compressed and pushed toward the opening.

In certain cases I have seen a reflection, formed upon the secretion in the perforation, move to and fro very perceptibly in the act of swallowing without closure of the nostrils. Inasmuch as I convinced myself in these cases that no air could enter the cavity of the tympanum through the Eustachian tube, I was forced to the conclusion that the secretion accumulated in the tube and middle ear was set in motion by the movements of the tube itself.

We herewith conclude our observations upon changes of the membrana tympani occurring in diseases of the ear. After having, as we think, sufficiently proved the importance of a knowledge of them in the diagnosis of aural disease, we must still make especially prominent the value of inspection of the membrane in judicial and military affairs. How often are persons who are not subject to military duty sent from the rendezvous for a longer time to the inspection-room, under suspicion of simulating deafness, when subsequent examination showed clearly perceptible changes in the membrane, such as perforations, depressions, or calcareous deposits.

The proof of demonstrable changes in the membrane is still more important in medical jurisprudence. Lesions from blows upon the head will be easily recognized when recent. If the medical jurist rests his decision on a later examination, and the lesion has, in the mean time, completely healed, though a certain degree of

deafness still remains in consequence of deeper-seated changes, then that decision will not be so favorable for the injured party as it would have been had the examination been made directly after the injury.

Still another case:—A person hard of hearing gets into a scuffle, and then prosecutes his antagonist for injuring his ear. If, now, the medical jurist discovers soon after the occurrence a calcareous deposit, or a depression in the membrane,—changes which occur only in affections of longer duration,—his decision will be essentially different from what it would have been had the examination been deferred to a later period, in order to first obtain the opinion of an expert.

Besides the previously mentioned works on aural surgery, the following papers are worthy of notice :

Moos: Ueber plötzlich entstandene Taubheit. *Wiener med. Wochenschrift.* 1863.

Lucæ: Anatomisch-physiologische Beiträge. *Virchow's Archiv.* B. xxix.

Pagenstecher: *Deutsche Klinik.* 1863. Nos. 41–43.

Voltolini: *Virchow's Archiv.*

At the beginning of this work we remarked that in a considerable number of cases of deafness no abnormal changes are perceptible upon the *membrana tympani*. If, now, we find the Eustachian tube quite pervious, and little or no improvement in the hearing after the employment of the air-douche, it is difficult, often impossible, to determine whether the affection is of the tympanic cavity or of the labyrinth.

These cases have hitherto all been classed together as nervous deafness (Kramer); but since pathological anat-

omy has been recognized and cultivated as the groundwork of all accurate knowledge in otology as well as in other branches of medicine, we have been led to the conclusion that, in a great number of these cases, the seat of the trouble is in the cavity of the tympanum. The dissections of Toynbee and Von Trötsch sufficiently prove this; and I am of the opinion, from my own dissections, that circumscribed affections quite certainly do occur in the middle ear which lead at one time to adhesion between the malleus, incus, and upper wall of the tympanum, at another, to union of the stapes with the edge of the fenestra ovalis, without the membrana tympani or the Eustachian tube being in any way sympathetically affected.

We must frankly confess that the diagnosis in these cases still rests on uncertain grounds; and it will be the task of physiological and pathological investigation to establish a method of discriminating the cases of impairment of function which are caused by obstacles to the transmission of sound in the cavity of the tympanum, from those caused by primary affections of the terminal branches of the auditory nerve in the labyrinth.

## SUPPLEMENT.

---

### A.

#### *Accumulation of Serum in the Tympanic Cavity— Diagnosis and Treatment.*

THE mucous layer of the membrana tympani is usually affected in those diseases of the lining membrane of the middle ear which are accompanied by mucous secretion.

The changes in the membrana tympani occurring in consequence—namely, softening of the vascular and epithelial layers of the mucous coat, simultaneous softening of the substantia propria, and frequently, also, congestion of the dermoid layer—cause such opacities that, as a rule, we can no longer see the structures or the morbid products lying behind the membrane.

But occasionally cases present themselves in which the membrana tympani is not involved in the diseases affecting the lining of the cavity. The membrane then possesses such a degree of transparency that it admits light enough into the cavity to enable us to discover, without much difficulty, changes behind the membrane, such as congestion of the mucous membrane of the prom-

ontory and the accumulation of secretion, provided these lie within the field of vision.

The literature of aural surgery has hitherto furnished only a few observations upon this point. Von Tröltsch, by whose meritorious labors the method of examining the membrane was so essentially improved, first recognized by inspection the presence of mucus-bubbles in the tympanic cavity (*Krankheit des Ohrs*, 2 Auflag. 1862). Another observation was made by Lucae, who, after injecting the middle ear through the Eustachian tube, could see the injected fluid through the membrane. But in that case the membrane was abnormally thin at one point, and consequently very transparent.

After numerous personal observations, I can testify to the presence of visible mucus-bubbles, such as Tröltsch describes, in the tympanic cavity. Very frequently I have seen them in large children who, in consequence of tonsillitis, or of a severe cold in the head, suffered from catarrh of the middle ear by transplantation. Within the field of vision were, generally, a number of sharply defined circles, of varying size, which, upon continued observation, sometimes changed their place. The opening of the Eustachian tubes by my method caused an entire or partial disappearance of the accumulated bubbles, or a brisk movement and change of place.

Of not less interest are the accumulations of *serum* in the cavity, which have not hitherto been described, but which can be diagnosticated by inspection.

I have thought the following observations worthy of communication, inasmuch as the appearances in several

of the cases observed by me were so distinctly marked, and the patients also presented another set of symptoms of diagnostic interest.

Upon the 24th of May, 1866, Franciska L., a washer-woman, presented herself at our clinic for aural disease, in the General Hospital, with the statement that four weeks previously, while washing at the well, she had suddenly experienced a ringing in both ears, which was soon followed by considerable deafness. She ascribed this to the sudden change of temperature to which she was exposed in transferring her washing from the warm to the cold water. From that time the ringing continued uninterruptedly in both ears. The deafness occasionally varied, the patient hearing better upon some days, though the improvement was of very short duration. At the same time she felt a great pressure and heaviness throughout the whole head. Sounds and voices appeared deadened and as if they came from a distance, and her own voice had an increased resonance. The deafness was so marked, that she could understand speech only at the distance of one foot from the right ear, and two or three inches from the left.

The objective examination gave the following result: The membrana tympani, at first sight, seemed very much sunken; the manubrium somewhat foreshortened by too great projection of its lower end into the tympanic cavity, and the short process was very prominent, as well as the folds running forward and backward from it. The whole manubrium is sharply defined, and behind it, in the posterior upper quadrant, the long shank



of the incus can be seen shining through the membrane. The membrane is not opaque, but rather is very transparent, and of a yellowish color mingled with a light tint of violet. Upon closer examination, however, about one-half of the membrane, in its upper portion,



FIG. 1.

appears of a lighter shade than the lower part, which is dark gray. The boundary between the two differently colored portions is very distinct, and is marked by a fine black line, which, beginning at the anterior periphery of the annulus tympanicus, at about the height of the middle of the manubrium, extends to the posterior periphery, being concave above. This line has the appearance of a black hair lying upon the membrane.

From these different shades of color in the membrana tympani, so sharply defined, we inferred the accumulation of a fluid in the sloping portions of the tympanic cavity; and, therefore, causing the patient to lie down, we examined the membrane while she was in the horizontal position. After a few minutes we could see that the black line had changed its place, still having a horizontal position with a concavity above, and situated parallel to and just behind the manubrium. Accordingly, the difference in color mentioned was not presented now, as before, by the upper and lower, but by the anterior and posterior portions of the mem-



FIG. 2.

brane. When the patient stood upright the original appearance returned (Fig. 1), so that the left membrana tympani showed no essential changes besides a

distinct concavity, a dark-gray color, and marked hyperæmia of the vessels of the manubrium.

As there could be no doubt now that in the case before us we had an accumulation of fluid in the tympanic cavity, air was forced through the Eustachian tube by my method, and the membrana tympani inspected at the same time. At the moment the air entered the cavity the following changes occurred. The lateral portions of the membrane bulged out, and instead of the distinct limitation in the colors of the membrane before described, we saw almost the whole field covered with rings of various sizes, having dark contours. The explanation of this was not difficult. The air streaming into the cavity caused the formation of bubbles in the serous fluid, visible through the membrane as sharply outlined rings (Fig. 3).



FIG. 3.

This change in the appearance of the membrana tympani was also accompanied by a striking improvement in the hearing distance, which upon the right side increased from one foot to more than forty; upon the left, however, the increase was not more than six feet. With this sudden improvement in hearing there was, according to the statement of the patient, a marked relief in the head symptoms, for the heaviness and pressure ceased, and the loud ringing immediately disappeared. A great crackling which she perceived soon after air was forced into the cavity proceeded from the movement of the air-bubbles. (Schwartz.)

Upon inspection the following day a distinct change

in the serous fluid could be proved; for we saw the dark line which formed the boundary between the air and serum much lower, so that the latter occupied scarcely a fourth part of the visible field. The hearing distance was indeed less by several feet than upon the previous day, but increased again to six or eight feet upon the employment of my method. After the air-douche, bubbles could be seen, though in much smaller number than on the previous day.

The further treatment of the case consisted in the employment of the air-douche every second day. The mucous membrane of the nares and pharynx being at the same time softened, and secreting abundantly, a little pulverized alum was blown in through a rubber tube, of the size of a large catheter, which was introduced into the pharyngeal space, in the neighborhood of the Eustachian tube, through the lower nasal passage.

The result was so favorable that in the course of three weeks the hearing distance could be considered normal, and nothing of an abnormal character could be discovered in the membranes.

If we seek the cause of serous accumulation in this case, two facts must be considered, namely: The imperviousness of the Eustachian tubes and the hyperæmic condition of the tympanic cavities. In the normal state, the lining membrane secretes a small quantity of serous fluid, which is carried by the ciliary movement in the cavity toward the tube, and flows through it into the pharynx. An obstruction of the

tube preventing the escape of the serum may cause an accumulation. Clinical experience, however, teaches that the tube may be impervious for a long time without any such accumulation resulting. Especially can this be demonstrated in those patients whose membranæ tympani do not lose their transparency even when greatly sunken. In addition, then, to the swelling and accompanying closure of the tube, there must also be in these cases a more than ordinary degree of congestion of the mucous membrane of the cavity, causing the secretion of a greater quantity of serum.

In certain cases we can scarcely doubt the serous character of the secretion. The fluid would not have changed its place so rapidly and readily if the secretion were tenacious mucus, such as occurs in catarrhal affections of the mucous membrane of the tympanic cavity. That viscid masses in the cavity cannot be easily moved I could plainly see in several autopsies which I made upon persons who died of puerperal fever, and during the disease had been attacked by catarrh of the middle ear. The muco-purulent secretion, mingled with streaks of blood, was here so tenacious that it could only be removed in coherent masses.

The recovery of hearing in the case related was effected by rendering the Eustachian tube pervious.

The pressure of air employed, in accordance with my method, not only completely accomplished this, but removed the accumulated fluid from the cavity. Catheterization of the tube was therefore entirely unnecessary. Indeed, according to my experience, it is proba-

ble that recovery would not have been brought about by its employment in so short a time. This opinion is substantiated by similar therapeutic trials, which were made in a large number of cases of acute catarrh of the tube and cavity.

In the great majority, the cure or improvement of the affection in the middle ear was quicker and more permanent when my method was employed than when it was effected by catheterization. This was most striking in those cases in which the catheter had already been used for some time with little and temporary improvement, my method, in the same cases, working quicker and more permanent results. The reason of this appears to be found not only in the difference in the amount of pressure exercised in the two methods, but in the fact that the catheter comes into immediate contact with the mucous membrane of the tube and thus causes a new irritation and swelling, whilst with my method no irritation of the tube by the instrument can take place. In certain cases of chronic catarrh of the middle ear we are able to prove clearly that the swelling of the lining of the tube is increased by the use of the catheter. For if before its employment we have recognized the entrance of air into the tympanic cavity, either by hearing through the otoscope the sound of its impulse upon the membrana tympani, or by perceiving upon inspection the bulging out of the membrane, then, indeed not unfrequently, after the use of the catheter we may convince ourselves that it is either more difficult or utterly impossible to force air into the cavity by the Valsalvian experiment—a fact

which can only be accounted for by increased swelling of the lining of the tube, consequent upon the mechanical irritation of the catheter.

NOTE.—To the above we would add the following observations, as the result of later experience in the treatment of serous accumulation in the tympanic cavity :—

In the majority of Dr. Politzer's cases the treatment has consisted in the employment of his method for inflating the middle ear, with the following modification. After the patient has taken a little water into his mouth, his head is bent over to the opposite side and somewhat forward, and in this position the air-douche is employed.

With the head thus inclined, the Eustachian tube takes such a direction that its pharyngeal end is turned downward, while the tympanic end is directly upward, and, therefore, when the air enters the cavity the serous fluid will be driven downward into the pharynx. That the fluid in the cavity was really diminished was proved by inspection, for its level was much lower than before the experiment. In several other cases the fluid accumulation was lessened when Dr. Politzer's method was employed, the patient lying upon a sofa with the head bent backward. In this position the fluid is driven through the openings in the posterior wall of the tympanum into the mastoid cells, where it is absorbed.

The secretion is not always so fluid, however, that it can be thus easily removed from the tympanic cavity, for when it has been retained for a long time a gelatinous, viscid matter is formed. This will either be absorbed in course of time, or removed by the employment of Politzer's air-douche, or by the catheter.

In such cases, when the membrane was much sunken, and presented a dark, greenish-yellow color, Dr. Politzer, after using the air-douche with only temporary success, performed paracentesis, and immediately afterward forced air through the ear by his method, thus driving the mucous matter out into the external meatus. The opening in the membrane usually closed by the following day, and the hearing power was restored to its normal standard, or returned after several applications of the air-douche. (A. M.)

## B.

*A Method for Preventing the Closure of Artificial Perforations of the Membrana Tympani.*

THE excision of a piece of the membrana tympani in aural patients, in order to improve the diminished hearing power, was, as you know, recommended by Riolan, even in the middle of the 17th century. It was scarcely noticed by the distinguished surgeons of the 17th and 18th centuries, probably because the results were so uncertain. The first communications of scientific value date from the commencement of the present century. For Astley Cooper and Himly simultaneously and independently of each other had performed the operation, and, encouraged by the immediate favorable results, had urgently recommended it. But, although the immediate results were so favorable, Cooper and Himly soon became convinced that the wonderful success was only transient, for the artificial opening was almost always closed again by neoplastic cicatricial tissue, and the former degree of deafness returned.

In the mean time accounts of Cooper's brilliant success were published upon the continent; and while Cooper himself, convinced of the inutility of the operation, had entirely abandoned it, still for a long time it was performed in France and Germany with unparalleled zeal, upon many hundred patients. To Himly belongs the credit of setting a limit to the pernicious employment of an operation, practised with damage to so many aural

patients. By bringing together the results obtained by the reliable surgeons of that day, he has furnished proof that in very few cases did even a slight benefit result from the operation, whilst no improvement was obtained in the majority of patients upon whom it was performed without regard to pathologico-anatomical changes, present in the middle ear and up to that time little known.

Attempts, indeed, to keep the perforation open were not wanting. Bits of catgut, little rods of fish-bone, and lead wires were introduced, in the anticipation that after long continuance in the opening the edges of the wound would heal over. But a closure of the perforation always followed their removal.

There is an interesting report by Bonnafont\* of a case upon which he operated. Excision of a piece of the membrane was practised in case of a very deaf person, and it was followed by considerable improvement in hearing. In spite of frequent cauterization of the edges of the wound with a pencil of lunar caustic, and the introduction of catgut into the artificial opening, it was closed after six months by cicatricial tissue, with loss of the improvement in hearing which had been obtained. In the course of the next two years the operation was repeated upon the same person nine or ten times, always followed, however, by closure of the perforation. After performing the operation once more upon this patient, Bonnafont, in order to prevent cicatrization, introduced into the opening a silver canula, whose length was equal to that of the whole external meatus, and permitted

\* *Traité théorique et pratique des maladies de l'oreille.* Paris, 1860.



it to remain there forty-five days. Six days after its removal, however, the perforation had considerably diminished in size and it was necessary to remove a smaller metal canula which had been introduced, inasmuch as it became troublesome to the patient, and thus again the closure occurred as before.

The disagreeable results of the operation, and the impossibility of keeping the artificial perforation open, have led to the almost entire abandonment of the procedure, especially during the last twenty years or more. Only very lately was it resumed, and one would think that he who should undertake to introduce an operation generally declared useless, would present a new method for keeping the perforation open. This was not the case, however, for it was rather by means of a useless complicated apparatus that excision was performed in case of an old man, and a portion of the membrane torn away. I had an opportunity to convince myself that the hearing distance was essentially increased, and the subjective sounds, as the patient stated, had diminished. Although the frequent employment of the Valsalvian experiment was enjoined upon the patient by the operating surgeon, the perforation, nevertheless, closed. When he presented himself during my course, at the general hospital, I could demonstrate to the students the cicatrix occupying the site of the artificial opening. Not only had the improvement which followed the operation disappeared, but the deafness was even more marked, and the subjective sounds were intolerable, as before. Another operation, performed by the same surgeon, had no better result

suppuration and a renewed closure of the perforation following. Several years have passed since that time, and how honestly one means to deal with science is seen, when, shortly after an operation, with great pomp he carelessly proclaims to the world a favorable result, but at a later period neglects to confess the failure.

We must therefore agree with Schwartz, who from his own experience declares that artificial perforations of the membrana tympani are, almost without exception, closed by cicatricial tissue, and the operation is therefore entirely useless, so long as no means are found for keeping them open.

Very recently the opinion was expressed by Wreden, that a permanent opening could be established by cutting out a piece of the handle of the malleus (sphinctomie). He thought that, as a portion of the blood-conveying vessels would be removed with the handle, regeneration of the membrane at the gap would thereby be prevented. Apart from the fact that clinical experience is wanting concerning the result of the operation, some objections arise even to the theory. For the vessels which proceed from the external meatus to the membrana tympani anastomose abundantly, by means of radiating twigs, with a vascular wreath upon the periphery of the membrane and with the arteries in the cavity of the tympanum. This can be seen in a successful injection of the human membrana tympani.\* Hence, if a piece of the malleus with the blood-vessels be excised,

\* Compare Prussak: *Zur Physiologie und Anatomie des Blutstromes in der Trommelhöhle.* Verhandlungen des kgl. sächsisch. Academie.

a collateral circulation is necessarily established, by which regeneration of the membrane will be effected.

Whether or not a permanent opening in the membrane can be obtained by means of the galvano-caustic, as lately proposed by Voltolini, is yet undetermined, for both the data of Voltolini and reports adverse to the practice are wanting.

The means which I have employed for keeping the artificial perforation open consist in the *introduction of a hard-rubber eyelet, having a groove upon its periphery, in which the edges of the perforation lie, thus holding the eyelet fast.* Its permanent connection with the membrane is secured by the growth of the edges into the groove.

The method of procedure is as follows: The membrana tympani being well illuminated, a linear incision is made in the posterior lower quadrant of the membrane, through a hard-rubber speculum, by means of a double-edged cataract-needle, which is bent at an angle, and is about five and a half centimetres in length. Then we introduce into the slit a bit of moistened laminaria, two inches long and one-quarter of a line in thickness, allowing it to remain in the ear several hours. The laminaria gradually swells, causing more or less pain. After its removal a roundish opening appears in the membrane, into which the eyelet is introduced by means of a forceps.

The eyelets which I use (manufactured by Joseph Leiter of Vienna) are from a line to a line and a half in length, and the longest diameter of their oval aperture is half a line. Upon the outer end of each eyelet there is also a little aperture at the side, for the introduction

of a silk thread, by which the eyelet can be withdrawn if it accidentally slips from the forceps. The thread, however, is carefully removed when the instrument is in its proper position.

We are also influenced, as will be seen hereafter, in the choice of a place for the establishment of a perforation by the presence of a cicatrix in the membrane. If a cicatrix be perforated it will be unnecessary to accomplish dilatation by means of the laminaria, for, elastic elements being absent, there will be no resistance to the introduction of the eyelet into the aperture. The hard-rubber eyelets are light, are bad conductors of heat, and cause no inflammatory irritation in the membrane, the patient being scarcely aware of the presence of a foreign body in the ear. We now proceed to a description of the first case operated on by us.

Upon the 22d of October, 1868, Anna P., æt. 48, wife of a joiner at Vienna, presented herself at our clinic for aural patients in the General Hospital. According to her statement, she had two years before suddenly experienced a severe pain in her left ear, which ceased after eight days upon the appearance of a copious otorrhœa. She said that the discharge from the ear continued for some days, but deafness and whistling of air through the meatus were of several weeks' longer duration. The secretion was entirely stopped by an ear-wash which a surgeon had ordered, and the hearing was considerably improved, and continued so for two months. After this time, however, deafness rapidly came on in this ear, and was accompanied by very severe and troublesome subjective

symptoms, a ringing and roaring which continued uninterruptedly. The deafness has been as great for a year past as it is at the present time.

The disease in the right ear is of three months' duration. Here also the affection began with severe pain, which continued for three weeks, although a purulent discharge occurred very early in the disease. The discharge, as well as a constant hissing in the ear, has lasted up to the present time.

Upon examination, the left membrana tympani was found to have a tendinous gray opacity, the short process of the malleus was very prominent, the anterior and posterior folds were sharply defined, and the less clearly



FIG. 4.  
Left membrana tympani,  
with cicatrix beneath the  
manubrium.

marked manubrium was strongly drawn inward. Beneath the manubrium was a dark, oval, depressed spot, obliquely situated, and about a line in transverse and half a line in vertical diameter. This was the cicatrix of the previous perforation.

In testing the hearing power, a cylinder watch could be heard only when laid upon the auricle, or when pressed upon the temple. Speech could be understood only at a distance of three feet. Upon opening the Eustachian tubes by my method, the thin depressed cicatrix bulged out; the hearing distance for the watch, however, had not increased, whilst for speech the improvement amounted to one foot.

In the right membrana tympani, in front of, and below, the manubrium, we found a perforation as large as a pin-

head, out of which, upon the Valsalvian experiment, came a drop of thick pus, soon followed by several air-bubbles. When the pus had been removed from the meatus, the watch was heard at a distance of two inches, speech at five feet, and the ticking of the watch could be perceived when laid upon the temple. The tuning-fork placed upon the vertex was more distinctly heard in the left ear, because, the impediment to the conduction of sound out of this ear being greater, the vibrations transmitted through the cranial bones were retained and more clearly perceived. We had, therefore, in this case to deal with a purulent catarrh of the middle ear, upon the right side, associated with perforation of the membrana tympani.

The same process was also present, at an earlier period, in the left ear, though there had been no suppuration from the mucous membrane of the cavity for more than a year, and the perforation had been closed by cicatricial tissue. The fact that a perceptible improvement in hearing did not follow upon forcing air into the middle ear, led to the conclusion that the deafness was neither the result of closure of the Eustachian tube, nor of the accumulation of mucus in the cavity of the tympanum, but was caused by adhesions between the ossicles and the walls of the cavity. Since, according to the history of the case, the deafness on the left side was inconsiderable during the time when the patient could force air through the ear, that is, during the existence of the perforation, but, on the contrary, attained a high degree when this was no longer possible, the conclusion seemed justifiable

that, in this case, dense bands of connective tissue had fixed the malleus or incus to the walls of the cavity; that so long as the perforation existed the waves of sound could pass through it, and, falling upon the base of the stapes, reach the labyrinth; but after the closure of the opening the vibrations could not be transmitted from the membrane to the stapes, in consequence of the impediments presented by the malleus and incus, and hence the great deafness.

The removal of the thin cicatrix was thus indicated, so as to admit again the waves of sound into the cavity through the re-established perforation. Therefore I undertook the operation, upon the 26th of October. Having introduced a large hard-rubber speculum into the external meatus, I illuminated the membrane by means of a mirror fastened to spectacle-frames, and divided the cicatrix in the direction of its longest diameter, using the double-edged cataract-needle. The pain caused by the incision was very little. Then a hard-rubber eyelet, having several grooves, was grasped with the forceps, and pushed through the incision into the cavity of the tympanum to the depth of half a line (Fig. 5). The thin and inelastic cicatrix presented very slight resistance, and the patient had not the least unpleasant sensation in the ear, either during the introduction or afterward. Through



FIG. 5.

the aperture of the eyelet we could now see the pale orange-colored mucous membrane of the promontory, and the patient stated, without previous

questioning, that she suddenly heard better, and that the subjective sounds had considerably abated.

After I had convinced myself, by inclining the head of the patient to the left, and severely shaking it, that the eyelet was firmly held in the perforation, that, consequently, the edges of the opening were lying in the grooves, I proceeded to test accurately the hearing distance. The watch, which before could only be perceived upon contact with the auricle, was now heard at the distance of nine inches. The hearing distance for speech was only three feet before, but now it had risen to more than forty (measured at Oppolzer's clinic). I was able, repeatedly, to verify this striking improvement during the weeks following, and to-day, thirty-six days later, the condition of the membrane is just the same as immediately after the operation, the eyelet retaining its original position, and not the slightest change affecting the rest of the membrane. The improvement in hearing also remains the same, and the formerly intense subjective sounds have almost entirely disappeared. The patient does not notice at all the presence of the eyelet in the ear. She remains under observation, and I will not fail to report further concerning her, after several months.

*NOTE.*—Since this case was published six months have passed. During that time the little eyelet has remained fixed in the membrane without causing any inflammation. A change in its position of a line and a half from the original has taken place. The hearing power increased from nine inches after the operation to twenty-two at the present time, and a whisper is heard very distinctly with this ear across a large room.

[Dr. P. has since that operation performed it on other patients with good success. In two cases only he observed irritation and tympanic catarrh, with secretion of mucus, so that the eyelet was forced out. (A. M.)]



## C.

*Double Perforation of the Membrana Tympani.*

IN the foregoing work the author stated that he had seen no case in which the membrana tympani was perforated at two points. Since that time, however, he has observed several such cases. The diagnosis was in two instances confirmed by post-mortem examination. Of four cases observed by Dr. Politzer, the appearance presented in three is shown in the accompanying sketch,



FIG. 6.

Fig. 6; namely, two large oval perforations, one before and one behind the malleus handle, separated from each other by a grayish-yellow bridge, formed by the handle and a remnant of the membrane extending from its end down to the inferior periphery.

In Dr. Politzer's pathological collection I saw a preparation of such a membrane taken from a young man



FIG. 7.

who had suffered for a long time from otorrhœa and died of phthisis pulmonalis. In another preparation, taken from a child who died of pemphigus tabescentium, the appearance differs from that above described. We find, namely, behind the manubrium a perforation two lines in diameter, and another as large as a pin-head in the lower part of the membrane, Fig. 7.

A. M.

## D.

*Anatomy of the Membrana Tympani.*

To the anatomical description of the membrana tympani given in the foregoing work, we must here add some of the results of more recent investigation.

It is well known that there is an anterior and a posterior fold extending forward and backward from the short process of the malleus, and that they are of great importance in diagnosing anomalies of curvature, being very prominent in case of abnormal concavity of the membrane. Near these folds, at the anterior upper border of the membrane, we find two short, straight, grayish stripes, which, starting from the spinous processes upon the anterior upper portion of the tympanic ring, converge toward the short process of the malleus. These striæ were first described by Prussak. In the examination of the living they are very frequently visible at the place designated, as white lines. In the dried preparation they appear somewhat sunken. That portion of the membrane which is bounded by them, and by the receding ungrooved tympanic edge of the temporal bone, is commonly called the *membrana flaccida shrapnelli*.

It is much thinner and more relaxed than the other portions of the membrane, and usually presents a little pitted depression, and forms the external wall of a small pocket communicating with the tympanic cavity, which

Prussak has named "the upper pocket of the membrana tympani."

In the dermoid layer of the membrane along the malleus handle, there are, according to Kesel, little glandular acini, delicate hairs, and papillæ. The vessels along the handle form plexuses, which are chiefly venous. The arteries pass, in part, directly into the veins, but some run in a straight course to the periphery of the membrane.

The nerves going from the external meatus to the membrana tympani also form plexuses, which accompany the vessels of the external surface of the membrane.

The circular fibrous layer is more intimately connected with the radiating fibres at their peripheral origin, but from this point to the malleus handle the two layers are easily separable from each other. At the handle they become interlaced and are attached to it, completely surrounding its lower third. Higher up, the circular fibres pass more to the external surface of the handle, and thus the latter appears prominent upon the inner side of the membrane. At the short process there is a layer of true cartilage in considerable amount, which, according to Grüber, articulates with a corresponding layer of cartilage on the membrana tympani. Prussak has demonstrated that all of the cartilage belongs to the malleus, being the residuum of the cartilaginous malleus of the fœtus, and that no joint-like connection exists between the manubrium and membrane. This assertion of Prussak was confirmed by Kesel and Moos.

The statement that the mucous layer of the membrana tympani is covered with pavement epithelium must be modified, inasmuch as Köppen has in some cases found ciliated epithelium upon it.

Above the short process, according to Bochdolek, is a short canal, the foramen of Rivini, which was formerly considered an artificial opening in the membrane. This foramen, however, does not appear to be constant.

NOTE.—See Prussak, *Zur Physiologie und Anatomie des Blutstromes in der Trommelhöhle*. Verhandlungen d. kgl. sächsisch. Academie.

## ERRATA.

---

- PAGE 7, 6th line from bottom, for "projection" read "separation."  
" 7, 4th " " " for "bulging out" read "extension."  
" 9, 8d " " " " " " " "  
" 71, 2d " " top, erase "AND CURVATURE."  
" 94, 14th " " " erase the semicolon and insert "if".  
" 99, 16th " " " for "were" read "was."  
" 189, 18th " " bottom, erase "outward" and transpose "abnormal convexity"  
and "the conditions, first, of"









