

MBL/WHOI



0 0301 0018807 4



THE AMERICAN ANATOMICAL MEMOIRS

THE MORPHOLOGY AND EVOLUTIONAL
SIGNIFICANCE OF THE PINEAL BODY

BEING

PART I

OF

A CONTRIBUTION TO THE STUDY OF THE EPIPHYSIS
CEREBRI WITH AN INTERPRETATION OF THE
MORPHOLOGICAL, PHYSIOLOGICAL AND
CLINICAL EVIDENCE

4624
FREDERICK TILNEY, M.D., PH.D.

PROFESSOR OF NEUROLOGY, COLUMBIA UNIVERSITY

AND

LUTHER F. WARREN, A.B., M.D.

PROFESSOR OF MEDICINE, LONG ISLAND COLLEGE HOSPITAL

1919

PUBLISHED BY
THE WISTAR INSTITUTE OF ANATOMY AND BIOLOGY
PHILADELPHIA

4210

CONTENTS OF PART I

1. Introduction.....	5
2. Nomenclature.....	7
3. General review of the literature.....	9
4. The comparative morphology of the pineal region.....	17
1. In cyclostomes.....	21
2. In selachians.....	23
3. In ganoids.....	25
4. In teleosts.....	27
5. In dipnoi.....	29
6. In amphibia.....	30
7. In reptilia.....	31
8. In aves.....	36
9. In mammals.....	37
5. The comparative embryology of the epiphyseal complex.....	39
1. In cyclostomes.....	39
2. In selachians.....	41
3. In ganoids.....	48
4. In teleosts.....	50
5. In amphibia.....	53
6. In reptilia.....	56
7. In aves.....	67
8. In mammals.....	72
6. The comparative anatomy and histology of the epiphyseal complex.....	80
1. In cyclostomes.....	80
2. In selachians.....	92
3. In ganoids.....	98
4. In teleosts.....	103
5. In amphibia.....	114
6. In reptilia.....	119
7. In aves.....	148
8. In mammals.....	155
7. Discussion.....	196
1. Significance of the pineal region.....	196
2. Evidence based on the gross morphology of the epiphyseal complex....	203
<i>a.</i> Phyletic constancy.....	203
<i>b.</i> Phyletic variation and morphologic specialization.....	205
<i>c.</i> Relative constancy of the epiphyseal complex with reference to other structures of the pineal region.....	211
<i>d.</i> Relative constancy of the epiphyseal complex with predomi- nance of the proximal portion.....	211

<i>e.</i> The increase of the epiphysocerebral index during life in man..	213
<i>f.</i> The resistance to the encroachment of the corpus callosum in mammals.....	216
3. Evidence based on the histology of the epiphyseal complex.....	217
4. The relation of the parietal eye to the pineal body.....	226
5. The phylogenetic significance of the parietal eye with reference to vertebrate and invertebrate.....	233
8. Summary and conclusions.....	238
9. Bibliography.....	240

1. INTRODUCTION

“Son siège au milieu de parties très-importantes de l'encéphale, sa constance chez l'homme et le vertèbrés, font pourtant présumer que ses usages, s'ils ne sont pas d'un ordre aussi important qu'on le supposait á l'époque des Esprits Vitaux, n'en sont pas moins réels et très-intéressant à connaître.”

Legros. Thésé de Paris, 1873, page 24.

“Vix ulla unquam corporis nostri particula tantam famam inter eruditos non modo, sed etiam inter illiteratos naeta est, ac cerebri sic dicta glandula pinealis.” These words written by Soemmering³⁵⁹ in 1785 still hold true. Not only did this organ attract much early medical attention, but its reputation was extended by the metaphysicians and even further increased by the satirical literature of an uncommonly virile period. Descartes (1649)⁸⁹ in his discourse on the sources of the human passions, expressed the belief that the pineal body was the seat of the soul. This interpretation passed current during the epoch of Vital Spirits. It did not, however, go altogether unassailed. Voltaire⁴¹¹ so successfully made it the subject of parody that his whimsical conception of the pineal body became more influential than the original hypothesis of Descartes. According to Voltaire, the epiphysis should be regarded as the driver which, by means of two nerve bands, guides the action of the cerebral hemispheres. These nerve bands were long referred to by the anatomists as “the reins of the soul.”

During the past hundred years an increasing volume of research has revealed the difficulties in the epiphyseal problem and shown how far we are from a solution of it. In fact, the views advanced by the students of this subject are so numerous and often so divergent that any decision at the present time

would seem ill-advised. The separation between those who consider the pineal body a useless vestige and those who assign to it extensive responsibilities in the sphere of internal secretion is too great to be reconciled on any but the most careful investigation of the grounds for their differences. The phylogenesis of the organ among the vertebrates, especially in its relation to the third or parietal eye, as well as the significance of the structure as a possible mark of identification in the line of evolution from the invertebrate to the vertebrate phylum, has raised many perplexing questions. Although the researches of morphologists, physiologists, and clinicians have established many significant facts, it still remains to assemble this evidence as much in its entirety as possible in order to furnish a satisfactory basis for the discussion of the problem.

It is the purpose of this work to gather the recorded facts concerning the pineal body and present them in several parts under the following headings:

Part I. The morphology and evolutionary significance of the pineal body.

Part II. The physiology and pathology of the pineal body.

Part III. The clinical aspects of the pineal body.

THE MORPHOLOGY AND EVOLUTIONAL SIGNIFICANCE OF THE PINEAL BODY

The morphological problem of the epiphysis may be formulated in the following questions:

1. What is the significance of the pineal region in its relation to the epiphysis?
2. Is the pineal body a vestige or is it an organ in some way necessary to metabolism?
3. Does its structure furnish evidence of its function?
4. What relation does it bear to the third or parietal eye?
5. What is the phylogenetic significance of the parietal eye with reference to the vertebrates and invertebrates?

Before submitting these questions to discussion, it seems advisable to offer the evidence as much in extenso as is practicable, having particular regard for historical sequence.

2. NOMENCLATURE

The pineal body was known to the Greeks and called by them the *σωμα κωνοειδες* and *κωναριον* because of its conical shape. It was also termed the *epiphysis* because of its relation to the rest of the brain. Latin authors refer to it as the *turbo*, *corpus turbinatum*, *glandula turbinata*, *glandula piniformis*, *glandula conoides*, *conarium*, *penis cerebri*, and *virga cerebri*.

Because of its resemblance to a pine cone, it was called by Chaussier⁶³ and Willis⁴²⁹ the *corpus pineale*. It has been called by the Germans the *Zirbel* and *Zirbeldrüse*, a designation which doubtless has led to the more or less general use at present of the term pineal gland. Several of the early writers called it the *glandula superior* in contradistinction to the pituitary gland which was referred to as the *glandula inferior*.

Since all of these terms were, in the main, devised to meet the conditions in man and the higher mammals, it might be expected

that they would not prove wholly satisfactory for some of the lower vertebrates. Earlier works on the pineal body, even such as dealt with ichthyopsid and sauropsid forms, employed the terms epiphysis and corpus pineale with so little discrimination that these definitions became rather vague. The complexity of the structure in the lower reptiles, in amphibia, and in fish is such that it may only in a very general way be denominated the epiphysis. In the first place, many of the forms just mentioned present, instead of a single epiphyseal process, two well-marked structures projecting dorsad from the roof of the interbrain. Ontogenetically, both of these processes are connected with the epiphyseal anlage, and yet if one of them were called the epiphysis which should it be and by what term should the other be designated?

In a certain respect the suggestion of Hill ('91)¹⁷⁹ to call one process the *anterior epiphysis* and the other the *posterior epiphysis* has much to recommend it on morphological grounds. Unfortunately, connotation has so rigidly associated the term epiphysis with the much altered and modified conditions as they occur in man and mammals, as almost certainly to lead to confusion in the broader application proposed by Hill. More available, although not without their defects, are the proposals of Studnicka ('96)³⁵⁶ according to which the posterior epiphyseal process becomes the *pineal organ* and the anterior process the *parapineal organ*. The use of the term *pineal* at once reverts to the mammalian forms, for description of which it was first employed. To apply this term, as, for example, in the fish where it has no descriptive value, cannot be in accord with the best morphological tendencies. Yet to Studnicka should be accredited the most thorough and extensive consideration of this subject; his definitions may, for this reason, be regarded as standards, especially if the desire to avoid new terms is kept in mind. Accepting Studnicka's terminology of an anterior process, the parapineal organ, and the posterior one, the pineal organ, it is necessary to recognize certain subdivisions in each of these organs. The pineal organ has an *end-sac*, a *stalk*, and a *proximal portion*, the latter in some cases is connected with the rest of the interbrain

by means of a short, slightly constricted piece, the *peduncle*. The parapineal organ, likewise, has an *end-sac*, a *stalk*, and a less well defined *proximal portion*. Much variation exists in the forms presenting these several parts—in many instances, one or more of the parts described may be absent, yet, to make the terminology as comprehensive as possible, all of these portions should be included. Upon this basis the following constituents may be recognized in the *epiphyseal complex*:

I. The pineal organ, consisting of:

- | | |
|--------------------|------------------------|
| 1. An end-vesicle. | 3. A proximal portion. |
| 2. A stalk. | 4. A peduncle. |

II. The parapineal organ, consisting of:

- | | |
|--------------------|------------------------|
| 1. An end-vesicle. | 3. A proximal portion. |
| 2. A stalk. | |

The proximal portion and peduncle of the pineal organ correspond to the epiphysis or corpus pineale of mammalian anatomy. The proximal portion is probably analogous to the cellular part of the pineal body while the peduncle is comprised largely of nerve fibers.

3. GENERAL REVIEW OF THE LITERATURE

Galen (1576)¹³³ gave a description of the conarium in its relation to the third ventricle as well as to the chorioid plexus and blood vessels about it. According to his interpretation, the organ serves as the support for the great vessels converging upon that portion of the brain. Oribasius (1554)²⁸⁵ mentioned but did not describe the epiphysis. Uvarthonus⁴⁰¹ believed that delicate nerve fibers enter the pineal body; these fibers seem to take origin in the lower portion of the spinal cord. Bauhinus (1616)¹⁶ considered the conarium to be a glandular structure related to the chorioid plexus. Diemberbroeck (1633)⁹¹ showed certain differences between the pineal body in man and in other mammals. Dionis (1706)⁹³ described the pineal body as attached upon either side to the chorioid plexus by a small band. This band may be a nerve derived from the sympathetic system.

Duverney (1761),¹⁰⁰ in support of the theory of Descartes (1649),⁸⁹ claimed that the pineal body did not exist in the dog. Vieq-d'Azyr (1781)⁴⁰⁸ observed the epiphysis in man, but could not find it in fish. Stannius³⁷³ found it in all species which he examined and made a particular study of it in the salmon. In this form he spoke of it as a highly vascular structure. Perrault³⁰⁶ found the epiphysis in the ostrich. Borrieh and Harder³⁸ observed the pineal body in the eagle. Malacarne²⁵⁸ found the epiphysis in birds as did Cuvier ('45).⁷⁷ Bichat (1802)²⁸ considered the pineal body a gland, and in it he found granules of some calcareous substance. The general character of the pineal body is something like the cortical substance of the brain. Soemmering (1785)³⁵⁹ gave an accurate account of the form of the conarium and also its dimensions in man. In his description he confines himself largely to the fact that there occur in the organ accumulations of a substance which he calls brain sand or *acervulus cerebri*. Soemmering noted many different conditions under which this brain sand was apt to collect in the different parts of the pineal body. Haller (1768)¹⁶⁵ believed the concretions were pathological and related to mental disorders. Many observers made mention of calcareous concretions in the pineal body, among them being Saltzmann, Ruysch, Meibomius, Vieussens, Vieq-d'Azyr, Malacarne, Brunner, Kruger, Bartholin, Winslow, Petermann, and Santorini. Parisini³⁰⁰ described the pineal body in the camel, elephant, and lion, and Harder¹⁷⁰ gave a description of it in the dog. Carus (1814)⁵⁹ described the epiphysis as having the form of a small peaked sac with almost no nerve fibers in it. He was unable to find the organ in the salmon. Chaussier⁶³ described the form of the pineal body in some mammals, suggesting that its shape compared to the *pomme de pin*, which comparison led eventually to the adoption by the French of the term *corpus pineale*. The Wenzels (1812),⁴²⁰ in their description of the pineal body, call attention to the fact that the organ varies greatly in size according to the period of life. Its size from the seventh year is augmented regularly until middle life and then a successive diminution occurs until old age. *Acervulus cerebri* is not found in the embryo nor in

the fetus, but after the seventh year of life this element makes its appearance and tends to increase until old age. Cruveilhier,⁷² in his description of the conarium, drew attention to a cavity situated near the base of the structure which frequently contained a fluid. Gratiolet,¹⁵⁷ referring to this cavity, described it as the *ventricle of the pineal gland*.

Majendie, (1795)²⁵⁷ commenting at considerable length upon the hypothesis of Descartes concerning the seat of the soul, ingenuously remarks that he himself has a better conception of the nature and function of the pineal body which he desires to substitute for the theory of Descartes. His own suggestion, says Majendie, is not only very simple, but actual and true, for it must be obvious from the situation as well as from the structure and form of the pineal body that it serves as a tampon designed to expand and in this way to close off the aqueduct of Sylvius or, at other times, shrinking, to permit this aqueduct to open again so that the fluid in the ventricles may have free access from the third chamber to the fourth. Majendie, however, does not state upon what grounds the internal structure of the pineal body justifies such a belief, but he is none the less emphatic in calling attention to the valve-like nature of the conarium with reference to the cerebrospinal fluid.

Gunz (1753)¹⁶¹ attributed dementia to impeding of the flow of spirits caused by the pineal body. Burdach ('19-'26)⁴⁸ considered the pineal body as supplementary to both the cerebellum and cerebral hemispheres. Tiedemann ('23)³⁹⁵ found the epiphysis in reptiles, birds, and mammals. Serres ('24-'28)³⁵³ and Willis⁴²⁹ both make the statement that the epiphysis occurs in fish, birds, and reptiles—in fact, in all classes of vertebrates. Andral ('29)⁴ also described the organ as occurring in all the classes of vertebrates. Brandt ('29)⁴⁰ recognized a glandular structure under a small scale in the head of *Lacerta agilis* which corresponded to a circular depression in the parietal region of the skull. This he regarded as a special gland. Milne-Edwards ('29),¹⁰⁷ in his researches on lizards, figures but does not describe certain plaques in the head of these animals. He indicates these as the occipital plaque, the parietal plaque, and the interparietal

plaque. The latter is a black spot corresponding exactly to the position of the pineal gland. Duges ('29)⁹⁷ also figures the same appearance in certain lizards. As early as 1835 Hollard¹⁸⁸ had made the observation that the epiphysis was entirely nervous in structure. He is also authority for the statement that this body does not occur in fish. Göttsche ('35),¹⁵⁴ however, states that the pineal body does exist in all fish. Valentin ('43)⁴⁰³ concurred in Hollard's idea, although he was of the opinion that the elements in the pineal body differed considerably from the gray matter of the brain. Guillot ('84)¹⁶⁰ makes the statement that, although the pineal body exists in all vertebrates, it is not until the reptiles are reached that the pineal apparatus makes its appearance in most complete form. Reguléas ('45)³²⁵ recognized that in man the pineal body, both in its volume and form, was variable.

Observations concerning the structural character of the pineal body were made at a remarkably early period. It was not, however, until the methods of histological technique were fairly well advanced that much attention was devoted to the minute structure of the conarium. Kölliker ('87)²¹² observed two types of cells in the pineal body; that is, small round cells and multipolar nerve cells with compact bundles of nerve fibers. These latter were few in number. From his observation Kölliker was led to believe that the pineal body is entirely nervous in type. Clarke ('60)⁶⁹ found nerve fibers, nuclei, and brain sand but no nerve cells in the pineal body. He also observed a reticular structure which resembled the olfactory mucous membrane. The arrangement of the cells, he believed, was similar to that of the fourth layer of the olfactory bulb in sheep and cats.

Faivre ('55)¹¹⁴ was among the first to make an extensive comparative histological study of the pineal body. He examined the minute structure in man, horse, guinea-pig, dog, ox, rabbit, pig, hen, turkey, dove, and tortoise. As a result of his observations, he recognized three elements in the human pineal body: first, a fibrovascular envelope; second, a globular parenchyma, and, third, *acervulus cerebri*. Faivre is in general accord with Valentin, in that the pineal body differs essentially from the

rest of the nervous system and has an appearance strikingly like the pituitary gland. He, apparently, was first to recognize that the cells of the epiphysis contained granules in their cytoplasm. These he called parenchymal cells. He also observed that these cells were smaller in childhood than in adult life and concluded that the parenchyma of the pineal body is composed of a large number of globules. The globules are generally elliptical and irregular in shape. Faivre believed the globules to be the nuclei of the cells, and to him must be accredited the first observation of these cellular characteristics of the pineal body.

Marshall ('61)²⁶¹ made some observations concerning size, weight, and sand-content in a chimpanzee. Schmidt ('62)^{347B} showed the continuity of the epiphysis with the brain in the human fetus and its relation as an evagination of the encephalic roof. Stieda ('69)³⁷⁶ studied the pineal body of birds and mammals and described anastomoses of the cytoplasm of the cells in the form of a reticulum. Luys ('65)²⁵³ advances an ingenious conception concerning the nature and connections of the pineal body. In his opinion, this organ is a mass of gray substance pertaining to the central gray matter surrounding the third ventricle and having the same histological characters. He claims that originally in the human embryo the structure is bilobed like the mammillary bodies and that, therefore, it should be considered as a transitory bilobed structure, a true posterior mammillary body which has fused across the median line. Luys concludes that the gray substance of the conarium, the hippocampal convolution, and the mammillary tubercles form with the anterior pillars of the fornix a complete system. The mammillary bodies and the conarium are centers of reception for fibers convergent from the hippocampal convolution. Efferently these centers are connected with the optic thalami. Luschka ('67)²⁵² noted the presence of fibers in the pineal body of man. Frey ('67)¹³¹ believed that the pineal body was made up exclusively of nerve tissue. He found in the adult the following elements: 1) multipolar ganglionic cells; 2) round cells with prolongations, and 3) isolated nerve tubes. Leydig ('68)²³² states that the

pineal body in the mouse resembles the pituitary body in reptiles with certain small differences. Meynert ('77)²⁷¹ expresses the opinion that the parallelism between the pineal body and the pituitary body is a mistaken idea. He believes that the epiphysis should be considered a ganglionic derivative of the tegmentum. It contains two types of cells, namely, those with a diameter of 15 micra and those with a diameter of 6 micra. The pineal body, in Meynert's opinion, differs from other ganglia only in the fact that the cells are very close together. Krause ('76)²¹³ observed in the pineal body nerve fibers having a double contour. Henle ('71)¹⁷¹ described the parenchyma of the pineal body as subdivided by fibrous processes called septa such as occur in lymph glands. These divisions gave rise to more or less independent follicles or acini varying in size from 6 micra to 30 micra in diameter. It was Henle's opinion that the pineal body resembles more exactly lymph glands than any other tissue in the body. Stieda ('65)³⁷⁵ in several species of amphibia observed an epithelial structure between the eyes in the frontal region of the head which he called the *frontal cutaneous gland*. Subsequent investigation revealed that this so-called cutaneous gland was in fact a portion of the epiphyseal complex. Pawlowsky ('74)³⁰⁵ described fibers in the epiphysis which seemed to be derived from the posterior commissure. Huxley ('76)¹⁹¹ described the pineal body in *Ceratodus forsteri*. In this form it occurs as a slender, cylindrical body. Baudelot ('70)¹⁴ gave a detailed description of the pineal body in *Gadus merlangus*. He also found it in the salmon and in the *Cyprinoids*. Camper,⁵⁵ although he observed it in many fish, was not able to find it in haddock or cod. Arsaky⁸ was unable to detect the pouch of the pineal body in fish. Haller (1768)¹⁶⁵ did not observe the pineal body in birds nor did he observe it in the pike or trout. He did find it, however, in the carp and tench.

Owen's ('81)²⁹³ view of the conariohypophyseal organs is such that it at least deserves comment, if only as a historical curiosity. According to Owen, the central nervous system in annelids forms a ring through which passes the œsophagus (œsophageal ring). In higher vertebrates, especially in embryonic life, the nervous

system manifests this same disposition, for here the brain curves itself backward in such a way as to constitute a ring above the region destined to become the mouth, thus producing a deep fossa directed toward the brain. Owen regards this as part of a canal which traverses the brain, now disposed as the œsophageal ring of articulates. Early, however, the process is arrested and the tube-like invagination comes to form the pituitary gland. The original tube from the mouth region is completed by an invagination from the dorsal region of the head which is connected with the skin. This element becomes atrophic and its remains constitute the pineal gland. Baraldi ('84)¹³ modified the theory of Owen by stating that the hypophysis was a derivative of the wall of the mouth of the gastrula or, in other words, the last vestige of the extreme anterior portion of the alimentary canal of worms. Robin's³³⁴ idea seemed to offer some confirmation to this opinion in the fact that he found in the epiphysis, upon microscopic examination, a follicular, gray substance containing a granular liquid very similar to that in the intestines.

Schwalbe ('81)³⁴³ found medullated nerve fibers which accompany the blood vessels and come into relation with bipolar and multipolar cells in the pineal body. He believes there existed some similarity between the pineal body and lymph corpuscles, but regards the cells of the former to be modified epithelial elements. Ganser ('82)¹⁴² thought the pineal body to be an unpaired process of the ganglion habenulæ. Flehsig ('83)¹²⁴ maintained that the epiphysis sends fibers to the fasciculus retroflexus. Sappey ('87)³⁴⁴ considered the pineal body analogous to the substance of the cerebral cortex. Mingazzini ('89)²⁷⁶ regarded the elements of the pineal body as similar to those of the lymphatic corpuscles. Möller ('90),²⁷⁸ investigating the epiphysis in the chimpanzee, distinguishes an unpaired peduncle which constitutes the largest part of the pineal body. The organ itself is 3 mm. x 2 mm. long. The peduncle is 4 mm. long and consists of nervous tissue. The pineal recess is extensive. Möller regards the structure as a rudimentary organ in a retrograde state. Charpy ('94)⁶² considers the epiphysis as a degenerating organ made up exclusively of epithelial elements

and some nerve fibers. Debierre ('94)³⁴ believes the pineal body to be a blood vascular gland with many degenerated elements. Lotheissen ('94)²⁵⁰ studying a large number of mammals, recognized in marsupials (*Macropus giganteus*) some fibers of the fasciculus retroflexus which penetrate the pineal body, also some fibers which leave the summit of the epiphysis which he believes represent the remains or rudiment of the parietal nerve in reptiles. Cajal ('95)⁵³ thinks that the nerve fibers in the pineal body are sympathetic and the body itself is a blood vascular gland. Condorelli-Francaviglia ('95)⁷⁰ in studying the brain of a marsupial (*Halmaturus dorsalis*), noted in consequence of poor development of the corpus callosum that the pineal body was only 2 mm. long and 1.5 mm. wide. Heitzmann ('96)^{169B} described the epiphysis as composed of gray substance. Staderini ('97)³⁷² investigated the development in many mammals. Soury ('99)³⁶⁵ described connective tissue septa dividing the pineal body into compartments which are occupied by a second tissue resembling adenoid tissue in which are round cells and cells with long prolongations. Bechterew ('00)²⁰ found evidence of nerve fibers passing from the posterior commissure to the peduncle of the pineal body. Zanela ('06)⁴³² studied the histology of the epiphysis in man. He observed cells in the parenchyma which consist of a scant protoplasm and large nuclei. These cells have a stellate form and prolongations which often bifurcate at acute angles and then ramify still further. The cells lie in a mesh of fibrils apparently nervous in character. By the methods of Cajal, Weigert, and Biondi, he was unable to interpret these cells either as nerve elements or as glandular cells. He believed they are of a neuroglial character and advances the hypothesis that they have an internal secretory function. Around the calcareous concretions he found necrobiotic areas. Romiti ('82)³³⁶ studied the development of the epiphysis in the rabbit. Anglade and Ducos ('08)⁵ found the organ made up mostly of neuroglia in man.

4. THE COMPARATIVE MORPHOLOGY OF THE PINEAL REGION

To make the proper evaluation of the pineal body this organ should be considered in relation to its immediate encephalic environment. Indeed, any study of the pineal organ which omitted this environment would give but an inadequate view of the epiphysis. A number of structures make their appearance in connection with the roof-plate of the forebrain. Some of these have a marked constancy; some are transitory, making their appearance in one or two classes of vertebrates only, yet all of them have a definite, phylogenetic significance in connection with the epiphyseal complex. Embryologically, the roof-plate of the primitive forebrain vesicle, that is, the prosencephalon, gives rise to a number of evaginations. Certain of these eventually become prominent, adult organs. The most conspicuous, both because of its constancy throughout the phylum and its numerous adaptations, is the pineal or epiphyseal complex. It has been suggested that the structures which form the roof of the interbrain be known collectively as the *pineal region*. This suggestion made by Minot ('01)²⁷⁷ offers a convenient term for the identification of a complex area of the brain. According to Minot, the pineal region begins at the lamina terminalis or lamina neuroporica which is its cephalic limit and comprises the following elements:

1. The paraphyseal arch.
2. The velum transversum.
3. The postvelar arch, also known as the dorsal sac.
4. The epiphysis, also known as the corpus pineale.
5. The posterior commissure.

Minot's specification of the pineal region needs some extension in order to meet the requirements of all classes of vertebrates. The following description of the pineal region makes provision for all of the elements which may and in some instances do appear in this area of the brain.

Paraphysis. The paraphysis is an evagination situated at the extreme cephalic end of the forebrain roof-plate. Ventrally it is continued into the lamina neuroporica. Dorsally it is continuous with the velum transversum. Minot assumed that the

pineal region develops a series of structures which seem to be directly concerned with the formation of the fluid in the cavities of the brain. He holds that the chorioid plexus supplies the main bulk of this fluid, but the gland-like organization of the paraphysis indicates that it may supply a secretion of special chemical substances to the encephalic fluid. The organ reaches its highest degree of development in amphibia, where it becomes a large, complicated, glandular structure with a central canal from which a complicated set of anastomosing tubules are given off. It has a well-marked sinusoidal type of circulation. These conditions have been observed by Warren⁴¹⁶ in *Siredon*, *Necturus*, *Proteus*, *Siren*, *Ichthyophis*, *Triton*, *Rana*, *Amblystoma*, and *Diemyctylus*. The paraphysis has a well-developed, glandular character in amphibians and lizards; in birds it is reduced to a single, thick-walled outgrowth of small dimensions. Selenka³⁵² in 1890 observed the organ in opossum; it has also been observed by Warren ('17)⁴¹⁷ in the sheep, and also by Francotte¹²⁷ in 1887 in the human embryo. The paraphysis is much reduced in the upper and lower ends of the vertebrate series, while in the middle, especially in amphibia, it is much developed. In amphibia its character is glandular, as it is also, to a less degree, in reptiles.

The paraphysis was erroneously regarded as the conarium by Selenka ('90).³⁵² It has also been called the anterior epiphysis by Burekhardt ('90)⁴² and the pre-paraphysis by His ('68).¹⁸² Sorensen ('94),³⁶³ called it the posterior chorioid plexus.

The velum transversum. This is a transverse furrow, immediately caudad to the paraphysis, which projects into the ventricle and separates the paraphysis from the dorsal sac. In some instances this furrow is simple and flat, but in others it is thrown into many subsidiary folds and becomes highly vascular in the form of a plexus. In some forms, as in *Petromyzon*, it is altogether wanting, and under such circumstances the paraphysis passes over without sharp line of demarcation directly into the dorsal sac. In *Chimaera* there is a lack of the velum and also a small paraphysis so that the dorsal sac seems to pass over into the lamina supraneuroporica without demarcation. In

Dipnoians the velum presents a pair of folds or it may develop, as in certain amphibia, as an unpaired chorioid plexus.

The dorsal sac. This element of the pineal region was called the Zirbelpolster by Burekhardt⁴² in 1890, the parencephalon by Kupffer²²² in 1887, and the post-paraphysis by Sorensen³⁶² in 1893. Goronowitsch ('88)¹⁵³ appears to be the first to apply to it the term dorsal sac. This sac is a dilated vesicle usually extending far above the roof-plate. In mammalia, however, in those forms in which the corpus callosum has made its appearance, the sac becomes much flattened and is difficult to recognize because of the altered condition consequent upon the development of the corpus callosum. The walls of the dorsal sac are lined internally by ependymal cells. In many instances these walls may be thin and definite or quite thick, containing many folds which may or may not be vascular; in certain instances these folds attain such a vascularity that they resemble a chorioid plexus.

The pars intercalaris anterior. The more caudal portion of the dorsal sac as it approaches the level of the roof-plate may become much thickened and contain a dense mass of neuroglia tissue. Usually this intercalated portion is not of any great extent. It appears only in a few forms.

The commissura habenularis. This element was called by Osborn²⁸⁸ in 1884 the superior commissure and by Göttsche in 1835¹⁵⁴ the commissura tenuissima. It affords a connection between the two ganglia habenulae. In some cases, as in *Petro-myzon*, the connection established by this commissure is such as to include the mass of the two ganglia in the general commissural region. In the immediate neighborhood of this commissure and coming into direct connection with it is often seen the ending of the nerve from the parapineal organ. This is particularly the case in Saurians, and it is by this means that the so-called *parietal nerve* makes its connection with the brain. Its fibers may be traced in some instances as far as the ganglia habenulae.

The epiphyseal complex. This complex comprises two distinct elements, a pineal and a parapineal organ. The pineal organ may consist of an end-sac or terminal vesicle, a stalk, a proximal

portion, and a peduncle. In all probability the proximal portion of the epiphyseal complex gives rise to the epiphysis cerebri or what has been called the pineal gland. In some forms nerve fibers have been found making their course through the stalk of this pineal organ and have thus given rise to the term *nervus pinealis*. The parapineal organ is the second, though less constant, portion of the epiphyseal complex. When present, it also consists of an end-vesicle, a stalk, and a somewhat dilated proximal portion. Most of these evaginations contain cavities which are in communication with the third ventricle. The recess which connects the pineal organ with this ventricle is known as the recessus pinealis.

The pars intercalaris posterior. The caudal wall of the proximal portion of the pineal organ often shows a marked increase in thickness as it approaches the level of the diencephalic roof. This thickening interposes an area between the proximal portion of the pineal organ and the posterior commissure. Often this intercalated part shows considerable dimensions. In the forms in which it is most developed, the fibers of the pineal nerve may be seen to enter this intercalated portion in the roof of the interbrain. It has been called the *pars intercalaris* by Burekhardt in 1890,⁴² but the necessity of designating it the *posterior intercalated portion* becomes obvious in view of the fact that an anterior structure of like character has already been described.

The posterior commissure. The last and caudalmost structure in the roof of the interbrain is the posterior commissure. This has already been assigned by Minot in 1901²⁷⁷ to the mid-brain, but the fact that certain fibers from the tractus pinealis and the nervus pinealis may be traced into direct relation with this commissure seems to ally it more with the derivatives of the roof-plate in the interbrain region rather than that of the mesencephalon.

The homology of all of these parts in the roof-plate of the prosencephalon has been given for the different classes of vertebrates by Burekhardt in 1890⁴² in his work on *Protopterus* and again in his work (45) on the structural plan of the brain. With this view of the generalized plan of the pineal region in verte-

brates, it will now be possible to consider in detail some of the variations which the region presents in the different classes.

1. *The pineal region in cyclostomes*

In cyclostomes the absence of the velum transversum causes the paraphysis to pass over into the dorsal sac without sharp line of demarcation. In fact, it is difficult to make out with any degree of certainty a true paraphyseal process. What there is of a paraphysis is a small evagination from the most cephalic portion of the dorsal sac, and the morphological lines of differentiation are such as to leave it still open to doubt whether there is an actual paraphysis in these forms. Studnicka ('99)³³³ is authority for the statement that such an organ does exist in *Petromyzon*. In *Ammocetes* the epiphysis is more clearly defined. The lamina supraneuroporica in cyclostomes is more specialized than in other vertebrates. In the most dorsal portion of this membrane there occurs a thickening which lodges fibers passing in a transverse direction and constitutes a commissure known as the *commissura pallii*. The dorsal sac is unusually high and deflected in a cephalic direction as a result of the pressure put upon it by the pineal and parapineal organs. Its dorsocaudal wall shows a marked invagination as a result of the pressure not only of the epiphyseal complex, but also of the ganglion habenulae. No chorioid plexus or other vascular formation appears in direct connection with either the paraphysis or the dorsal sac. The pars intercalaris anterior is absent, but a very massive commissura habenularis is observed in all forms, making its appearance early in the course of development.

The epiphyseal complex presents a pineal organ and a parapineal organ. Both of these lie in close apposition to each other extending cephalodorsad in such a direction that their terminal portions come to overlies the dorsal sac. The dorsal wall of the pineal organ lies immediately beneath the frontal region of the skull. The posterior intercalated portion is also absent, but a large posterior commissure occurs in all forms. The pineal, as well as the parapineal organ, possesses a nerve, that connected

with the pineal organ, the so-called pineal nerve, ends in the posterior commissure, while the parapineal nerve has its termination in the commissura habenularis.

Probably the first observation upon this region in the cyclostomes was made by Serres³⁵³ in 1825. Other contributions followed by Schlemm and d'Alton^{347c} in 1838. Johannes Müller²⁸⁰ in 1838 and Siebold and Stannius³⁵⁵ in 1854 added their studies of this region. Mayer²⁶⁵ in 1864 mentioned the occurrence of

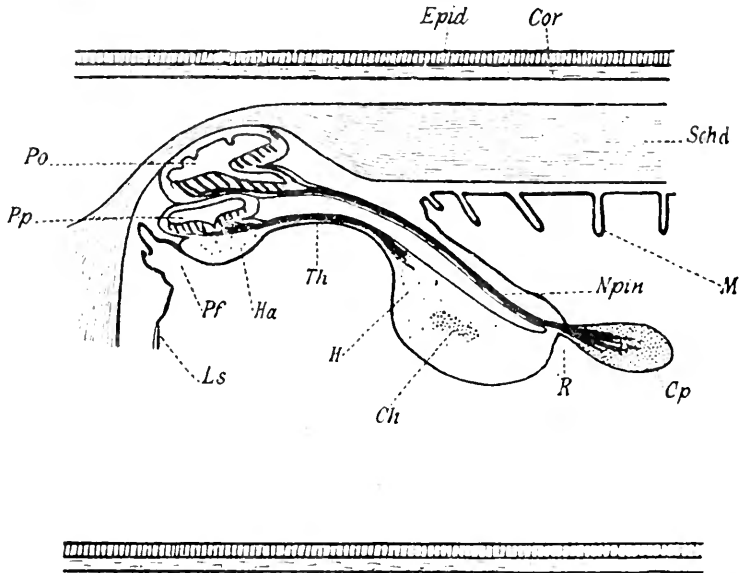


Fig. 1 Schematization of pineal region in Cyclostomes, according to Studnicka, 1905.

Ls., lamina terminalis; *Pf.*, paraphysis; *Pp.*, parapineal organ; *Po.*, pineal organ; *Ha.*, habenular ganglion; *Th.*, parapineal nerve; *Ch.*, commissura habenularis; *R.*, recessus pinealis; *Cp.*, commissura posterior; *n.*, *Npin.*, nervus pinealis.

many calcium corpuseles in and about the pineal organ. Wiedersheim⁴²² in 1880 spoke of the epiphysis as a small, saccular body, but it was not until 1883 that Ahlborn² first described the microscopic appearances of the epiphyseal complex in which he was able to observe two superposed vesicles. Ahlborn, however, did not interpret these two vesicles as independent evaginations from the roof of the interbrain, but considered them as subdivisions of the epiphysis.

Later, Beard ('87)¹⁷ and Owsiannikow ('88)²⁹⁵ following Ahlborn's lead, both spoke of two epiphyseal vesicles. Studnicka ('99)³⁸⁸ and Kupffer ('94)²²⁴ showed that these two vesicles were, in fact, independent parts of the epiphyseal complex. Studnicka called the anterior vesicle the parapineal organ and considered it homologous to the parietal eye of reptiles. This he later confirmed in a subsequent work. Kupffer, however, saw in the parapineal organ or parietal eye of reptiles the homologue of the paraphysis in *Petromyzon*. Retzius ('95)^{331B} was the first to employ the Golgi method in *Petromyzon* and *Ammocetes*. By this means he was able to demonstrate the nerve elements of the stalk of these two epiphyseal organs. The finer structure of the pineal and parapineal organs in *Petromyzon marinus* was given by Leydig in 1853²³¹ and Studnicka in 1899,³⁸⁸ while Johnston in 1902¹⁹⁵ described these organs in *Lampetra wilderi*.

2. The pineal region in selachians

The pineal region in selachians is very similar to that of *Petromyzon* with the exception that in the epiphyseal complex the parapineal organ does not appear. The selachians are remarkable for another fact, namely, that one member of this class, *Torpedo*, develops no part whatsoever of the epiphyseal complex; that is to say, both the pineal and parapineal organs are wanting.

In *Notidanus*, Burekhardt in 1890⁴² distinguishes the following parts: At the dorsal extremity of a thickened and invaginated lamina neuroporica there appears a slightly developed paraphysis. Immediately following this in the roof-plate there is a marked invagination defining the velum transversum, which appears in these forms as a simple infolding of the roof-plate without any vascular development. The dorsal sac presents itself as a more conspicuous element in the roof of this species than in the cyclostomes. There is no anterior intercalated portion and the epiphyseal complex shows only the presence of the pineal organ. A short pars intercalaris posterior has been described followed by the posterior commissure. This description given by Burekhardt in *Notidanus* holds true for most of the forms of selachians with the exception of *Torpedo*.

d'Erchia ('96)¹⁰⁹ differentiated in *Pristiurus* the same elements as in *Notidanus*, but in *Torpedo* he found that the epiphyseal complex was entirely wanting. He further observed that the development of the velum transversum occurred much earlier than the pineal organ. Minot ('01)²⁷⁷ maintained that an actual paraphysis does not develop in selachians. In comparing the pineal regions of cyclostomes with selachians, the most striking

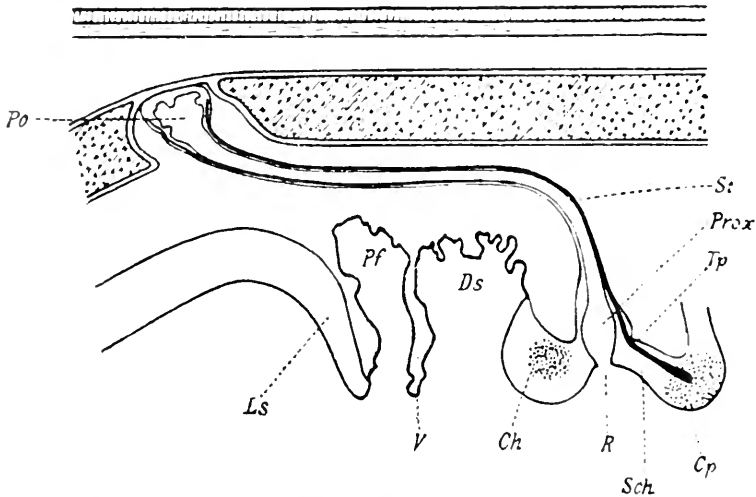


Fig. 2 Schematization of pineal region in Selachians, according to Studnička 1905.

Ls., lamina terminalis; *Pf.*, paraphysis; *V.*, velum transversum; *Ds.*, dorsal sac; *Po.*, pineal organ; *St.*, stalk of pineal organ; *Ch.*, commissura habenularis; *R.*, recessus pinealis; *Cp.*, commissura posterior; *Sch.*, pars intercalaris posterior; *Prox.*, proximal portion; *Tp.*, tractus pinealis.

differences appear to be in the extreme development of the parapineal and pineal organs in *Petromyzon* and allied forms, while the parapineal organ is absent in selachians. Furthermore, the absence of any distinct velum transversum in cyclostomes makes the presence of a definite paraphysis extremely doubtful, while the velum transversum in selachians differentiates very clearly a fairly well formed paraphysis. The pineal region in *Elasmobranchs* is much shorter than in *Petromyzon*.

Of the early workers upon the selachian pineal region, Jackson and Clarke ('75)¹⁹³ appear to be the first to make mention of the actual pineal organs as they occur in these forms. They described this region in the brain of *Echinorhynchus spinosus*. According to their description, the structure was a small projection extending from the roof of the interbrain to the surface of the skull. Ehlers¹⁰⁸ in 1878 gave the first detailed description of the relation of these parts in *Acanthias* and *Raia*. Balfour ('78)¹⁰ in the same year described the embryological development of the pineal region in selachians. Cattie ('82)⁶⁰ gave the description of the pineal organ in a large number of *Elasmobranchs*. Carrington ('90)⁵⁸ described the organ in *Lamna cornubica* and Galeotti ('96)¹⁴⁰ employing certain cytological methods in his investigations of the pineal region, gave an important description of these parts from a histological point of view. d'Erechia's work on *Pristiurus* and *Torpedo* has already been referred to. His was the notable observation that the epiphyseal complex was entirely absent in *Torpedo*.

3. The pineal region in ganoids

This region in ganoids is characterized by the presence of the usual elements with the exception that the parapineal organ does not develop. In *Amia* alone is there any rudiment of an anterior portion of the epiphyseal complex, and even here it is so slight as hardly to justify the attempt to homologize it with the parapineal organ in *Petromyzon*. Goronowitsch ('88)¹⁵³ and Kupffer ('93)²²³ described the pineal region in *Acipenser* and recognized in it all of the parts usually observed in this area of the brain. Following a broad lamina supraneuroporica there is a well-marked paraphysis which at first is truly membranous but subsequently becomes highly vascular and takes on the form of a tubular gland eventually concealing the great part of the lamina terminalis. In certain forms, as in *Polyodon*, the paraphysis, although well developed, is relatively much smaller than in *Acipenser*. The next element in the forebrain roof, namely, the velum transversum, is broad and much convoluted although not very highly vascular. The dorsal sac presents the form of a

large evagination, generally membranous, and in several forms having marked prolongations. Thus in *Amia* there are two such prolongations, the more dorsal of which extends as far back as the midbrain, while in *Polypterus* a prolongation of the dorsal sac arches over the midbrain and extends as far caudad as the cerebellum. No anterior intercalated part is present in the ganoid, but a well-marked habenular commissure is present immediately cephalad of the epiphyseal complex. This latter consists of a single evagination from the roof-plate. The anterior epiphyseal element is absent in the ganoid so that the pineal organ alone is encountered in this region. Immediately following the latter structure is a short pars intercalaris posterior and then a large posterior commissure.

The pineal region in ganoids differs from that in selachians mainly in the presence of a large and glandular paraphysis; also in the existence of an unusually large and extensive dorsal sac, prolongations of which are apt to extend far beyond the usual limits of this structure, even arching over the midbrain and reaching the cerebellum.

Of the early works upon ganoids, Salensky³⁴¹ in 1881 first gave a description of the development of the pineal region in *Acipenser*. Accounts of the ontogenesis in this same form were later given by Owsiannikow ('90)²⁹⁷ and Kupffer ('93).²²³ Balfour and Parker ('82)¹² gave a description of the development of this region in *Lepidosteus*. Hill ('94)¹⁵⁰ contends that there are two epiphyseal outgrowths from the roof of the interbrain in *Amia calva*. The more anterior of these two outgrowths or vesicles, Hill thinks, is homologous with the parietal eye of *Lacertilia*, and he further maintains that it is extremely probable that the two vesicles in their primitive position were side by side, thus indicating the existence of two organs which in the primitive form, like the lateral eyes, were arranged as a pair for some definite function. Eycleshymer and Davis ('97)¹¹³ confirmed the findings of Hill and added the further important observations that in the late embryonic state nerve fibers could be seen connecting the commissure habenularis with the parapineal as well as the pineal organ.

4. *The pineal region in teleosts*

In teleosts the parapineal organ does not appear and the pineal organ itself is present only in a seemingly retrogressive condition. During the early stages of development, however, in a few forms there is an anlage of the parapineal organ. The lamina supraneuroporica is, if anything, more broad and more pronounced than in the ganoids, but it differs from this structure in the latter forms in the fact that it is not vascular nor does it come into relation with any vascular network. A paraphysis does not develop, as a rule, or if it does occur, it only appears as a small evagination from the roof-plate, as in *Belone acus*. Not infrequently in the earlier stages of development in *Lophius*, the paraphysis appears as a small bud in the roof region. In the larval forms of some species, as, for example, *Anguilla* and *Cepola*, the paraphysis has the form of a very small evagination from the roof consisting of a thin wall, but is not vascular and in no way connected with a vascular net. The velum transversum is a simple, flat, transverse fold which is not in connection with the chorioid plexus in any portion. In certain instances this element is very little developed and may, in a few cases, be entirely absent. The dorsal sac is, as a rule, very large and presents itself in several different forms. Frequently it is thrown into many folds, particularly the portion representing the superior wall and in these folds are found numerous blood-vessels in a plexiform arrangement. Sometimes the sac along its caudal wall is grooved in the midsagittal plane and in this groove rests the stalk of the pineal organ. An anterior intercalated portion is absent, but a well-marked habenular commissure is always observed. Following this commissure is the pineal organ and caudal to it a short pars intercalaris posterior followed by the posterior commissure (fig. 3).

Among the early workers in this region in teleosts are listed some of the great pioneer names in morphology. Albrecht Haller in 1768¹⁶⁵ described the epiphysis in the carp, but did not find it in the trout. Cuvier in 1845⁷⁷ also observed it in teleosts, and Carus in 1814⁵⁹ found it to be a saccular formation extending from the dorsal region of the brain. Tiedemann³⁹⁴

in 1816 could not find it in the bony fish, while Göttsche¹⁵⁴ in 1835 found it in these animals, but thought that it was connected by blood vessels or a membrane with the ganglion habenulae and the commissura habenularis. Mayer in 1864²⁶⁵ gave a description of the epiphysis as being merely a vascular convolution in the roof of the interbrain, while Owen²⁹⁴ in 1866 was not at all sure of its existence even as a vascular convolution of the roof-plate. In 1870 Baudelot¹⁴ described the epiphysis as a

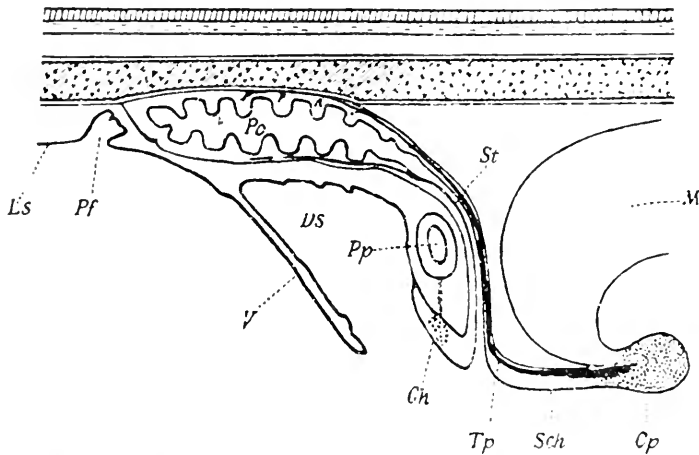


Fig. 3 Schematization of pineal region in Teleosts, according to Studnicka, 1905.

Ls., lamina terminalis; *Pf.*, paraphysis; *Ds.*, dorsalsac; *V.*, velum transversum; *Ch.*, commissura habenularis; *Po.*, pineal organ; *St.*, stalk of pineal organ; *Tp.*, tractus pinealis; *Sch.*, pars intercalaris anterior; *Cp.*, commissura posterior; *M.*, midbrain.

round or pear-shaped body between the lobi optici. The first exact description of the organ was given by Rabl-Rückhard³¹⁹ in 1883 on the basis of microscopic sections. Cattie⁶⁰ in 1882 described the gross appearances of the organ in a large number of teleosts, and Hill¹⁵⁰ in 1894 gave one of the most detailed and reliable accounts of this region in teleosts, basing his description on his findings in salmon. Other excellent descriptions of the organ in teleosts have been given by Ussow ('82),⁴⁰² Leydig ('96),²³⁹ and Handrick ('01).¹⁶⁸

The work of Galeotti¹⁴⁰ in 1896 on these forms is of particular interest. This observer, applying certain means of cellular differentiation in the technique, showed that some cells of the pineal organ give definite evidence of secretory activity. In *Leuciscus* he found that the nuclei of the cells contained fuchsinophile granules and also that the nucleoli in these nuclei were often extruded and later appeared in the protoplasm of the cells. The product of such secretion in Galeotti's opinion was delivered to the cavity of the organ.

The chief difference between the pineal region in ganoids and teleosts lies in the fact that in the latter forms the paraphysis is entirely absent while in ganoids it constitutes a conspicuous element.

5. *The pineal region in dipnoi*

In dipnoi the only portion of the epiphyseal complex which develops is the pineal organ and this is much less well defined than in the lower forms. No anlage of the parapineal organ makes its appearance. The paraphysis develops later than the pineal organ. The lamina supraneuroporica, according to Burekhardt ('90),⁴² as it appears in *Protopterus*, is very thick and well developed. The absence of any well-defined velum transversum makes it appear as if the paraphysis were an anterior division of the dorsal sac, and yet a paraphysis may be said to exist in these forms, although no sharp line of demarcation may be drawn between it and the dorsal sac. The paraphysis itself presents a number of transverse folds beginning in the attenuated membrane immediately dorsal to the lamina supraneuroporica. In *Ceratodus* the entire paraphysis has the appearance of a glandular structure, the lumen of which is in connection with the ventricle of the brain by means of a small canal. Although an actual velum transversum does not, in the strict sense, exist, Kerr ('03),²⁰² in *Lepidosiren*, and Studnicka ('95, '96),³⁸⁶ in *Ceratodus*, have both described several folds in a position dorsal to the paraphysis. The dorsal sac is but little developed, although it does appear as a membranous structure extending from the roof of the interbrain. No pars intercalaris

anterior is observed, but there is a well-marked commissura habenularis as well as the pineal organ, a posterior intercalated portion, and the posterior commissure.

The earliest work upon this region of the dipnoi was by Huxley¹⁹¹ in 1876. In this he described the pineal organ as a cylindrical structure which had a cordiform enlargement at its distal extremity. This latter lay deeply seated in a small excavation of the cartilaginous skull roof. Wilder⁴²⁷ in 1887 showed an unusually large paraphysis in *Ceratodus*, but did not observe the pineal organ. Sanders³⁴³ in 1889 saw the end-vesicle of the pineal organ in the form of a small body situated above the choroid plexus of the interbrain. Studnicka ('95, '96),³⁵⁶ distinguished in *Ceratodus* a dorsal sac and a paraphysis, the former lying closely compressed against the latter. He also observed a pineal organ with a long stalk which lies in a fold along the superior wall of the dorsal sac, while the end-vesicle is situated above the paraphysis. In *Protopterus annectens*, Wiedersheim ('80)⁴²³ and Beauregard ('81)¹⁹ mistook the dorsal sac for the pineal organ, and Fülliquette ('86)¹³² was unable to distinguish between the ganglion habenulae and the pineal organ. The erroneous identifications made by these authors go to show the great difficulties which the pineal region in dipnoians presents. It was not until 1890 and 1892 that Burekhardt⁴²⁷⁻⁴⁴ first gave the proper description of the pineal organ in these forms.

6. *The pineal region in amphibia*

In Urodela and Apoda only the pineal organ develops and this in but an extremely rudimentary form. The portions of the pineal organ which are present in these forms represent the proximal part of that structure. In no other group of vertebrates is the pineal organ so little developed; it presents itself as a sac lying close to the interbrain, the lumen of which is subdivided into numerous branches. deGraaf¹⁵⁵ in 1886 was first to recognize this condition and describe it in amphibia.

In Anura, as in Urodela and Apoda, the pineal organ only develops. It usually consists of the proximal saccular part of

this structure and the end-vesicle. The latter constitutes the cutaneous gland. These two parts, connected by a stalk of fine fibers which lead to the brain roof as the tractus pinealis, are the distinguishing features of this region in Anura. The proximal part alone in Anura is the homologue of the very rudimentary organs observed in Urodela. The pineal organ of the frog's brain has often been mistaken for the highly developed chorioid plexus, for the paraphysis, or for the dorsal sac. Such errors have been made by Wymann⁴³¹ in 1853, Reissner³²³ in 1864, and Stieda³⁷⁹ in 1875. Goette¹⁵¹ in 1873 first recognized the proximal portion of the pineal organ and called it the epiphysis. This he observed in the early stages of development in *Bombinator*. Gravenhearst¹⁵³ many years before this found the distal part of the pineal organ in the head of *Rana subsaltans*, situated in relation to a light colored spot on the skin over the head. Reissner³²³ also noted a similar spot. Stieda called this spot the *Scheitelfleck* (parietal spot). To this spot he gave an interpretation of much interest, for he believed that it marked the situation of a peculiar, subcutaneous frontal gland directly under the skin and this gland, therefore, became known as the *frontal subcutaneous gland* of Stieda. A fine, thread-like structure led from the skull to this gland and thus connected them. Ciaccio⁶⁵ in 1867, following Stieda's lead, placed this structure among the so-called nerve glands of Luschka. Leydig²³³ in 1856 considered the organ merely as a skin gland, but Goette¹⁵¹ in 1873-75 studied the epiphysis developmentally and stated that the subcutaneous frontal gland was nothing more than the detached distal end of the epiphysis.

The pineal region in amphibia, generally speaking, comprises the following structures: The lamina supraneuroporica, which is a short and thick end wall of the forebrain. The next and, perhaps, most conspicuous element of the pineal region in amphibia is the massive and vascular paraphysis which, according to certain authorities, reaches its highest development in these forms. It has all the characteristics of a tubular gland with a definite sinusoidal circulation and a canal which connects it with the ventricles of the brain. The velum transversum is short

and plexiform, in many forms attaining a marked vascularity. The next structure in the pineal region is the commissura habenularis, following which is a long pars intercalaris anterior. Then follows the epiphysis or the proximal portion of the pineal organ with a marked pineal recess. There can be little doubt that this particular form in which the pineal organ presents itself is the actual proximal part of other species. Following the epiphysis is a thick pars intercalaris posterior, and finally the posterior commissure.

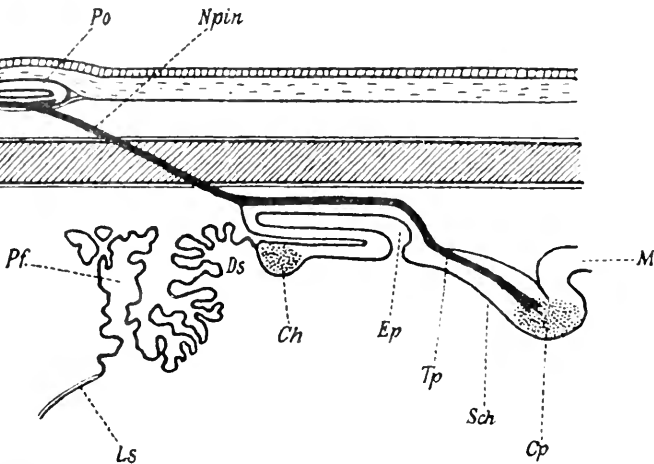


Fig. 4 Schematization of the pineal region in Amphibia, according to Studnicka, 1905.

Ls., lamina terminalis; *Pf.*, paraphysis; *Ds.*, dorsal sac; *Ch.*, commissura habenularis; *Po.*, pineal organ; *Npin*, nervus pinealis; *Ep.*, proximal portion pineal organ; *Tp.*, tractus pinealis; *Sch.*, pars intercalaris posterior; *Cp.*, commissura posterior; *M.*, midbrain.

7. The pineal region in reptilia

In Prosaurians and Saurians, as in *Petromyzon* and some teleosts, both the pineal and parapineal organs make their appearance, but the order which they hold in the lower forms is somewhat reversed here since the parapineal organ gives rise to an eye-like structure called the *parietal eye*. This parietal eye, however, is present only in the lower reptiles. The pineal organ,

on the other hand, in most forms presents a less well-developed appearance, and in many instances (in *Lensu stricto*) an epiphysis cerebri alone may be observed. The parietal eye, earlier but incorrectly called the pineal eye, is absent in many forms even among the lower reptiles. It is undoubtedly the homologue of the anterior epiphyseal organ or parapineal organ of teleosts and perhaps the parapineal organ of *Petromyzon*.

No chapter in the morphology of the pineal organ is more replete with interest or full of incentive to further research than that dealing with the remarkable conditions observed in this region of the brain in reptilia. From the observations on the Saurians and Prosaurians have come far-reaching theories into the phylogensis of the vertebrates as well as many illuminating efforts to trace the evolution of this phylum by means of the unpaired parietal eye back to the invertebrates. Brandt⁴⁰ in 1829 was first to mention the presence of the epiphysis in the Saurian brain. Milne-Edwards¹⁰⁷ and Duges⁹⁷ both in 1829 referred to certain scales in the head of *Lacerta*. Neither of these authors described the structures, but their illustrations plainly indicate that they had perceived the area in the skull in which the parietal eye comes to the surface. Cuvier⁷⁷ and Tiedemann³⁹⁵ had both observed the organ in reptiles. Leydig²³⁴ in 1872 studied the embryo of *Lacerta* and *Anguis*, giving particular attention to the parietal region of the skull. He described a peculiar body made up of long, epithelioid, and cylindrical cells. These cells were so arranged as to form a rim, the border of which comprises cells of a deep black pigment. This organ was not, as one might think, the epiphysis, for this latter structure lies distinctly above the organ described by Leydig. Leydig, furthermore, mentioned a parietal foramen and a spot on the skull indicating the position of the organ which lies beneath it. This structure Leydig called the *frontal organ*, and while he strongly suspected that it was possessed of sensory function, he did not commit himself to such a theory at the time in which he wrote. Strahl³⁸² in 1884 thought that this frontal organ of Leydig had certain relations to the epiphysis and seemed able to demonstrate that Leydig's organ was nothing more than a

detached distal portion of the epiphysis, the homologue of the frontal gland in amphibians. The idea advanced by Strahl was subsequently confirmed by Hoffmann¹⁵⁶ in 1886 and again by Béraneck²¹ in 1887. But it is to deGraaf¹⁵⁵ that we are indebted for the first demonstration that the *organ of Leydig* was provided with a lens and a retina and was, hence, a real visual organ. This work of deGraaf in 1886 was almost simultaneously con-

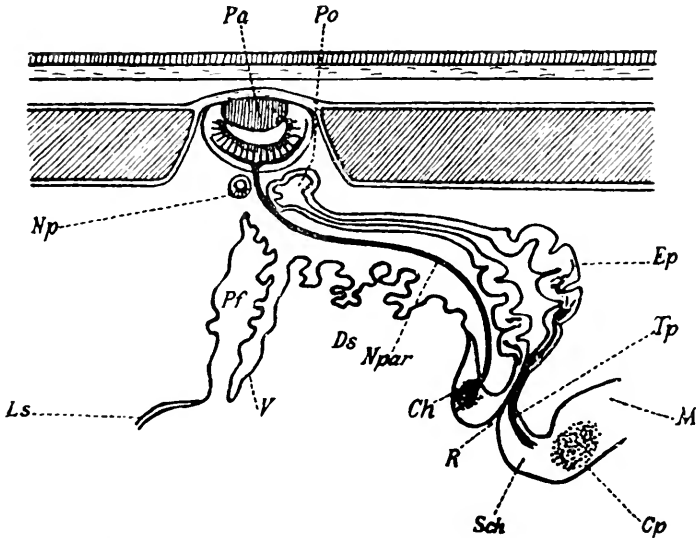


Fig. 5 Schematization of the pineal region in Sphenodon, according to Studnicka, 1905.

Ls., lamina terminalis; *V.*, velum transversum; *Pf.*, paraphysis; *Ds.*, dorsal sac; *Ch.*, commissura habenularis; *Pa.*, parapineal organ; *Npar.*, nervus parapinealis; *Po.*, pineal organ; *Ep.*, proximal portion pineal organ; *Tp.*, tractus pinealis; *Sch.*, pars intercalaris posterior; *Cp.*, commissura posterior; *M.*, midbrain, *Np.*, accessory parapineal organ; *R.*, Recessus pinealis.

firmed in the same year by Spencer³⁶⁶ who carried on a large number of observations upon many different Saurian forms, confirming in detail the proposition advanced by deGraaf that the structure described by Leydig as the frontal organ contained not only a lens, but a definite retina. These works led up to the later investigations on the parietal eye and also on what has been called the third eye of vertebrates.

The parietal eye which occurs in many forms of Lacertilia is, on the other hand, entirely absent in Ophidians, Chelonians, and Crocodilians. In all reptiles, with the exception of Lacertilia, the epiphyseal complex is so rudimentary that only the proximal portion of the pineal organ remains. Indeed, in Crocodilia even this is said to be absent.

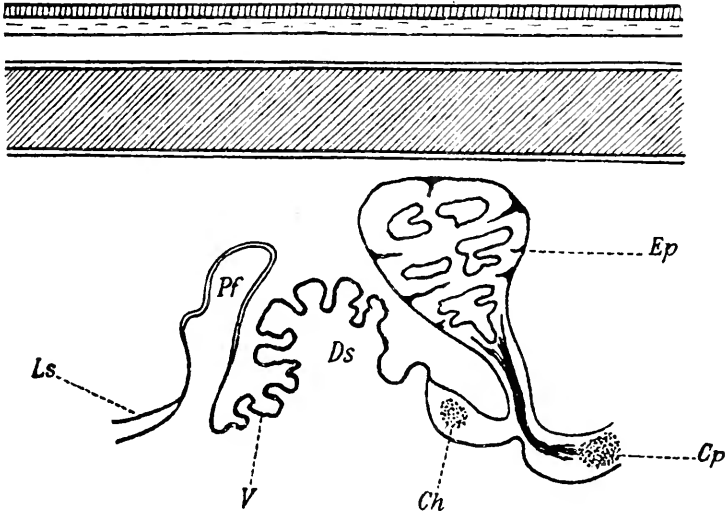


Fig. 6 Schematization of the pineal region in Ophidia, according to Studnicka, 1905.

Ls., lamina terminalis; *Pf.*, paraphysis; *V.*, velum transversum; *Ds.*, dorsal sac; *Ch.*, commissura habenularis; *Ep.*, proximal portion of pineal organ (epiphysis); *Cp.*, posterior commissure.

Burekhardt⁴⁵ in 1893 gave the first description of the pineal region in the brain of *Lacerta*. He described a thin and flat lamina supraneuroporica above which arose, to a considerable height, a simple tubular paraphysis. In adult animals, as a rule, this structure has the form of a thin-walled sac lined by cuboidal ependymal cells. The paraphysis at first is without vascularization, but later, by the ingrowth of blood vessels, it becomes highly plexiform in character; yet in no instance is it comparable to the vascularity observed in Amphibians. The distal extremity of the paraphysis is flexed dorsally and often

comes in contact with the ventrally flexed distal extremity of the parietal eye. The velum transversum is well developed and is plexiform in character, being highly vascular in structure. Following the velum transversum is a dorsal sac usually, however, less conspicuous than the paraphysis and oftentimes smaller than that organ. The commissura habenularis follows and is in connection with two symmetrical ganglia habenulae. A pars intercalaris anterior is not observed.

The epiphyseal complex has a different arrangement in the several different classes of reptilia. In most Lacertilia the part which seems to be the homologue of the parapineal organ has become converted into a definite parietal eye with lens, retina, and nerve of its own. The pineal organ, on the other hand, is much reduced and appears but a remnant of the homologue of this structure in some of the lower forms. In the orders of reptilia, other than Lacertilia, the parapineal organ does not develop and the pineal organ itself is reduced to a mere rudiment, being represented wholly by the development of its proximal portion. A short pars intercalaris posterior follows the epiphyseal complex while a relatively large posterior commissure forms the caudalmost structure in the roof of the interbrain.

8. *The pineal region in aves*

In birds, only the proximal portion of the pineal organ, the part usually called the epiphysis or corpus pineale, develops. It usually appears as a small circumscribed sac connected with the roof of the interbrain or else it has a definitely glandular structure with acini of varying size. Mihalkoviez²⁷⁴ in 1874-77 studied the epiphysis in *Meleagris gallopavo* and in this bird called attention to the definite follicular and glandular character of the tissue. Mihalkoviez' description is the most complete concerning the epiphysis in birds. Galeotti¹⁴⁰ in 1892 added some details to Mihalkoviez' description of this structure and confirmed the opinion that it was glandular in its nature. The pineal region in birds is compressed cephalodorsad because of the marked development of the hemispheres and the cere-

bellum. This region contains in more or less rudimentary form the following structures: A paraphysis, a very simple velum transversum, a small and compressed dorsal sac, a commissura habenularis, an epiphysis, undoubtedly the homologue of the proximal portion of the pineal organ with a definite pineal recess and a pineal peduncle, a pars intercalaris posterior of varying size depending upon the species, and a fairly well-marked posterior commissure. The relation of the epiphysis to the brain roof in birds is different from that encountered in any of the

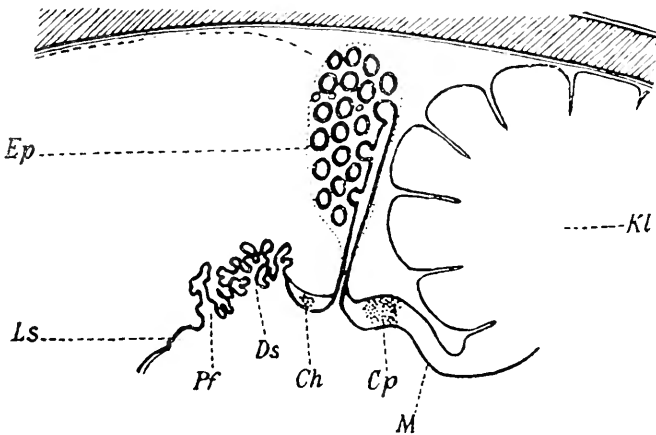


Fig. 7 Schematization of the pineal region in Aves, according to Studnicka, 1905.

Ls., lamina terminalis; *Pf.*, paraphysis; *Ds.*, dorsal sac; *Ch.*, commissura habenularis; *Ep.*, proximal portion of pineal organ (epiphysis); *Cp.*, posterior commissure; *M.*, midbrain.

lower forms in that here the axis of the organ is at right angles to the roof, whereas, lower in the scale the tendency has been for the body to show a definite anterior or ventral flexion.

9. The pineal region in mammals

This region is made up as follows in the mammal: Following a thin lamina supraneuroporica there occurs, according to Francotte¹²⁹ in 1894 in the early stages of development in the human embryo, a short tubular process which he terms the paraphysis.

d'Erchia ('96)¹⁰⁹ found this structure only as a simple fold in the embryo, while recently Warren ('17)⁴¹⁷ has identified a small but solid protuberance at the anterior extremity of the inter-brain roof-plate in the human embryo which he believes is the anlage of the paraphysis. This, however, soon disappears, leaving no trace of its presence, although there develops in the neighborhood of its origin certain prolongations which Warren has described as the *diencephalic prolongations*. In the adult brain of other mammalian forms no paraphysis has been observed. The velum transversum, if present at all, has been observed in the early embryonic period only and then as a simple fold. This statement is based on the observations of d'Erchia. The dorsal sac, because of the much-altered condition in the mammalian brain due to the development of the corpus callosum, has become much flattened and reduced to the level of the general plain of the roof-plate. It has undergone further change in the fact that it has acquired a rich vascularization and become definitely plexiform, giving rise to the tela chorioidea superior of human anatomy. The caudalmost portion of the dorsal sac immediately in front of the epiphysis is elevated and pushed back over the dorsal surface of the pineal body in such a way as to form a thin, roofed sac whose ventral wall lies upon the dorsal surface of the epiphysis. This is the *recessus suprapinealis* described by Reicher³²⁶ in 1859. A commissura habenularis is the next element in the roof-plate, and this is situated in relation with the peduncle of the epiphysis. The epiphysis in mammals undoubtedly represents the proximal portion of the pineal organ. The epiphysis itself is a solid, more or less conical shaped body connected with the roof of the brain by one or more sets of so-called peduncles. As a result of the development of the corpus callosum, the epiphysis has gradually been brought to assume a position which brings it into relation with the superior colliculi of the midbrain. Situated between the epiphyseal peduncles there is a small pineal recessus. The entire epiphysis is located in a position much removed from the inner surface of the skull.

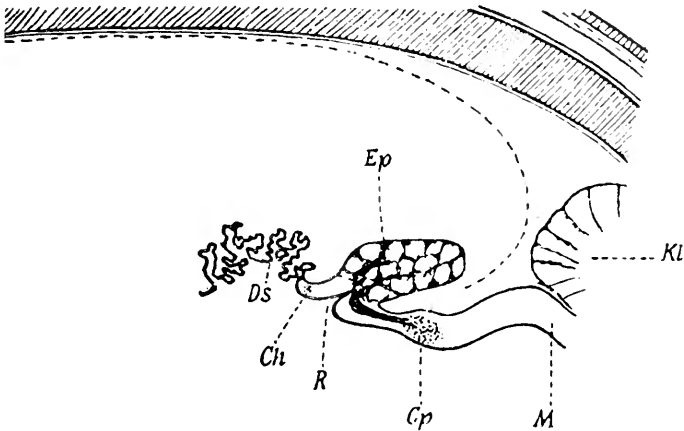


Fig. 8 Schematization of the pineal region in Mammals, according to Studnicka, 1905.

Ds., dorsal sac; *Ch.*, commissura habenularis; *R.*, recessus pinealis; *Ep.*, proximal portion of the pineal organ (epiphysis); *Cp.*, commissura posterior; *M.*, midbrain.

In the light of the phyletic review just given concerning the structures constituting the pineal region, it becomes clear that any satisfactory consideration of the epiphyseal complex must take into account the characters of the parapineal organ as well as those of the pineal organ. It seems advantageous to discuss the comparative embryology of these two parts and then to consider the phyletic characteristics of each of them separately. In this way the modifications of each organ may be followed consecutively from one order to the next.

5. THE COMPARATIVE EMBRYOLOGY OF THE EPIPHYSEAL COMPLEX

1. *The development of the epiphyseal complex in cyclostomes*

According to Studnicka ('93)³⁸⁴ and other observers, a small evagination in the caudal portion of the roof-plate of the inter-brain makes its appearance as a simple and single protrusion from the roof. This is the pineal organ. There can be no question but that it develops first of the two elements in the epiphyseal complex in these forms. The anlage of the pineal organ increases greatly in size so as to present an end-sac or

end-vesicle, a stalk and a proximal portion connecting it with a ventricle of the brain. At first, the end-vesicle contains a cavity which gradually decreases in size so that the lumen becomes little more than a cleft or entirely disappears. The stalk also contains a large canal which is gradually reduced in size. The ventral wall of the end-sac becomes converted into a structure resembling the retina, in which many nerve fibers are to be observed. In the dorsal wall of the sac nerve fibers running from the end-vesicle soon make their appearance. These fibers come into relation with the posterior commissure and constitute what is known as the *nervus pinealis*. The proximal portion is represented by a very short, dilated structure which contains the *recessus pinealis*.

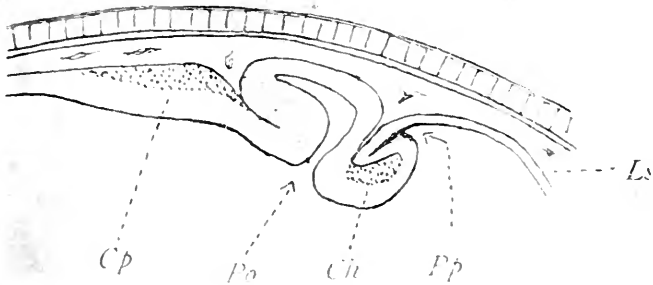


Fig. 9 Anlage of the epiphyseal complex in an embryo of *Petromyzon*, according to Kupffer, 1904.

Ls., lamina terminalis; *Pp.*, paraphysis; *Ch.*, commissura habenularis; *Po.*, pineal organ; *Cp.*, commissura posterior.

At a considerably later embryonic period the anlage of Studnicka's parapineal organ first makes its appearance. It develops entirely independent of the anlage of the pineal organ. The evagination which first makes its appearance as the parapineal anlage shortly becomes greatly elongated to form a tubular prolongation from the roof of the brain. The terminal portion of this tubular evagination becomes dilated to form, as in the case of the pineal organ, an end-vesicle, while a slender stalk connects the latter with the brain roof. The ventral wall of the end-sac of the parapineal organ, as in the case of the pineal organ, develops

a pigmented structure and in it appears a number of nerve fibers. In the later embryonic stages the stalk connecting the end-vesicle of the parapineal organ with the brain attenuates, loses its lumen, and shows the presence in it of numerous nerve fibers which may be traced to the commissura habenularis. The rapid elongation of the stalk in the parapineal and pineal organs as development advances causes these structures to be moved further away from the roof-plate and near the under surface of the skull. The general direction of this growth is cephalodorsad. Gaskell¹⁴⁵ showed in *Ammocetes* a right and left pineal eye. It is his opinion that the pineal and parapineal organs represent a paired set of eyes. Their relation to each other, in which the parapineal organ occupies the more cephalic position, was determined, according to Gaskell, by the exigencies of development. In reality, however, he believes that the ancestors of vertebrates must have possessed a pair of median eyes.

Dendy⁸⁶ also observed in cyclostomes a double evagination from the roof-plate giving rise to the epiphyseal complex. It is his opinion that the right evagination produces the parietal eye while the left becomes the parapineal organ, and Dendy, like Gaskell, maintains that the ancestors of the vertebrates must have been possessed of a pair of parietal eyes which may have been serially homologous with the ordinary vertebrate eyes. Scott ('81)³⁴⁹ and Dohrn ('75)⁹⁵ both showed that the epiphyseal complex developed as evaginations from the roof of the interbrain. These observations were essentially confirmed by Shipley ('87),³⁵⁴ Owsianikow ('88),²⁹⁵ Studnicka ('93),³⁸⁴ and Kupffer ('94).²²⁴

2. *The development of the epiphyseal complex in selachians*

Balfour¹⁰ in 1878, in *Acanthias*, d'Erchia¹⁰⁹ in 1896, in *Pristiurus*, and Minot²⁷⁷ in 1902, also in *Pristiurus*, investigated the development of the epiphyseal complex. According to all of these authors, a single evagination arises in the roof-plate immediately in front of what is later to be the posterior commissure. This evagination gives rise to the pineal organ inasmuch as the parapineal organ does not appear in selachians. From its

inception this evagination is a small, cordiform enlargement which rests at first directly upon the ectoderm of the upper surface of the head. The gradual lengthening of the tubular pineal organ, which is similar to what occurs in *Petromyzon*, is in the main due to the fact that a very large amount of mesenchyme makes its appearance between the roof of the brain and the under surface of the skull. In this way the end-vesicle of the pineal organ maintains its relative position to the ectoderm and thus always remains near the surface of the skin. In many instances the end-vesicle comes to lie in a large foramen of the skull, that is, the parietal foramen which makes its appearance at a later stage of development.

Considering the embryological development of the pineal region in selachians, Loey²⁴⁴ holds that two pairs of accessory optic vesicles are preserved in the cephalic plate of *Elasmo-branchs*, his particular reference being to *Squalus acanthias*. These accessory optic vesicles together with the primary optic vesicles give rise to two pairs of rudimentary eyes. The epiphysis is, therefore, of double origin, forming a united pair of accessory optic vesicles, and since the latter are homologous with the lateral eyes, the epiphysis itself must be homologous with these eyes also. His contention that the pineal outgrowths arise from two pairs of vesicles that are homologous with those giving origin to the lateral eyes has not been altogether sustained by other observers. Loey is also of the opinion that it is highly probable that the enlarged distal end of the epiphysis in *Squalus* is homologous with the pineal eye in those forms in which it is differentiated. Goette¹⁵² in 1875 expressed the opinion that the epiphysis in selachians was a product of differentiation at the point of union between the brain and the epidermis. He compares the pineal organ to the pore which persists for a long time in the embryo of *Amphioxus* and leads into the encephalic cavities. Ehlers¹⁰⁵ in 1878 confirmed the findings of Balfour in *Raia clavata* and *Acanthias vulgaris*. An interesting observation in this connection is the finding by Cattie⁶⁰ of the pineal organ in *Torpedo marmorata*. Cattie observed the organ in the embryonic state in this form. The importance of this observa-

tion lies in the fact that Studnicka³⁹¹ says that the organ is absent in *Torpedo marmorata* and d'Erechia¹⁰⁹ says that in *Torpedo ocellata* there is no pineal organ.

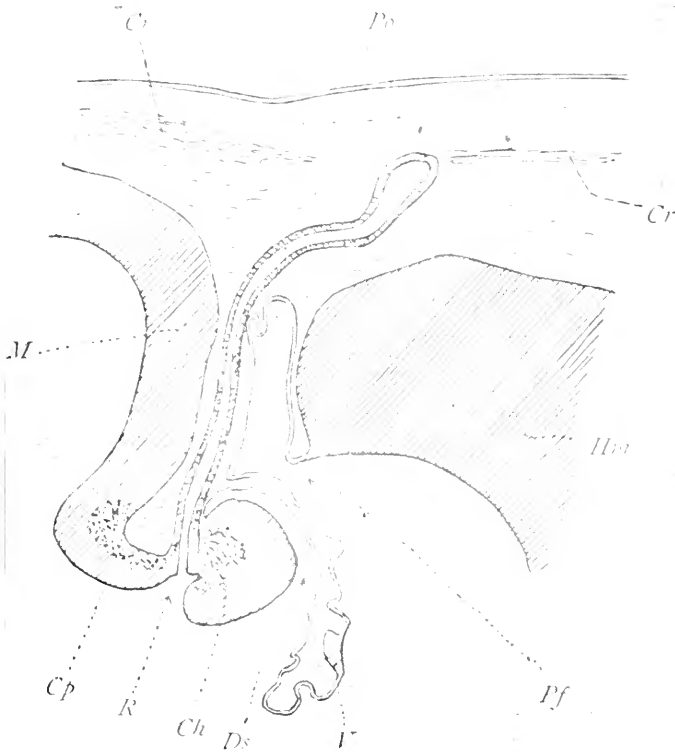


Fig. 10 The epiphyseal complex in an 86 mm. embryo of *Acanthias vulgaris*, according to Minot, 1901.

Hm., hemisphere; *Pf.*, paraphysis, *V.*, velum transversum; *Ds.*, dorsal sac; *Ch.*, commissura habenularis; *R.*, recessus pinealis; *Po.*, pineal organ; *Cp.*, commissura posterior; *M.*, midbrain.

One of the authors, Tilney ('15),³⁹⁶ studying the interbrain in *Mustelus laevis*, illustrated the development of the pineal organ in reconstruction models through a number of stages. The anlage of the epiphyseal complex in *Mustelus* makes its first appearance in the 9 mm. embryo as a single evagination from the roof-plate. It is a prominent element in this region for some

time before the appearance of the paraphysis. In the embryo of an 11 mm. *Mustelus* the evagination appears rising well above the general plane of the roof.

It is bounded by a thin cephalic and a thicker caudal wall. A recess of considerable depth extends into it; it retains com-

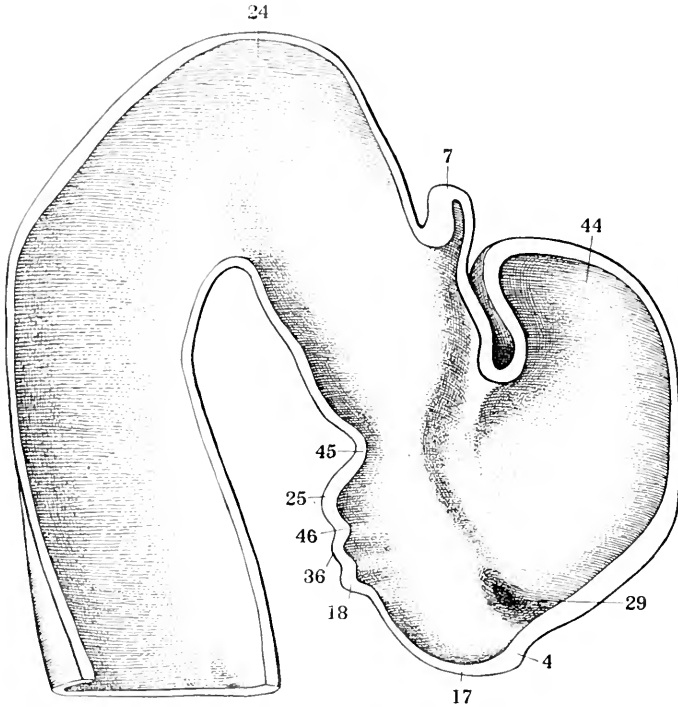


Fig. 11 Mesial view of forebrain reconstruction of 11 mm. *Mustelus* embryo. $\times 100$. The unshaded area shows the cut surfaces of the reconstruction. According to Tilney, 1915.

4, chiasm; 7, epiphysis; 18, infundibular evagination; 24, midbrain; 25, mamillary region; 29, optic evagination; 36, post-infundibular evagination; 44, telencephalon; 45, tuberculum postero-superius; 46, tubercle of the floor of Schulte.

munication with the third ventricle. The inception of the velum transversum may be discerned, but no paraphysis is present. The changes observed in passing from the 11 mm. to the 20 mm. embryo consist in the now definite appearance of the velum transversum and the elongation of the pineal organ.

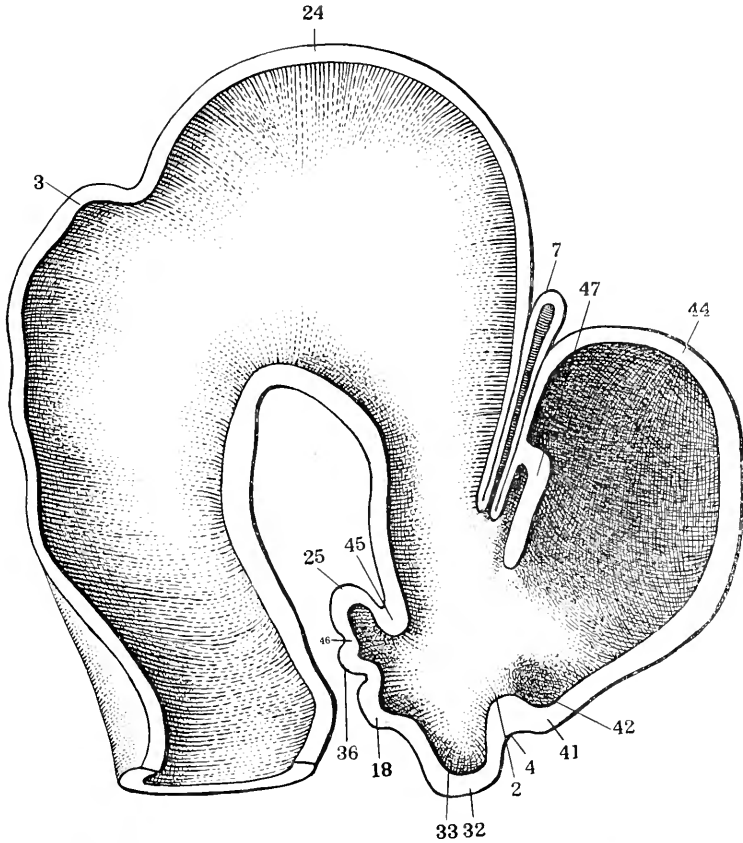


Fig. 12 Mesial view of forebrain reconstruction of 20 mm. *Mustelus*. $\times 75$. The unshaded area shows the cut surfaces of the reconstruction. According to Tilney, 1915.

2, chiasmatic process; 3, cerebellum; 4, chiasm; 7, epiphysis; 18, infundibular evagination; 24, midbrain; 25, mammillary region; 32, post-chiasmatic eminence; 33, post-chiasmatic recess; 36, post-infundibular eminence; 41, supra-optic crest; 42, supra-optic recess; 44, telencephalon; 45, tuberculum postero-superius; 46, tubercle of the floor of Schulte; 47, velum transversum.

In the latter there is a slight tendency for the evagination to become expanded as if to form an end-vesicle. It is, therefore, possible at this time to recognize a stalk and an end-sac. Neither in this stage nor in any subsequent period of development is there evidence of a parapineal organ. The paraphysis

has not yet made its appearance. In the 50 mm. embryo, however, the paraphyseal anlage is present and the pineal organ has become still further elongated.

The tendency toward expansion of the distal extremity is not as marked as in the 20 mm. embryo. The pineal organ still contains a lumen throughout its entire extent. The expansion of the pineal organ to form an end-sac is again pronounced at the stage of 70 mm.

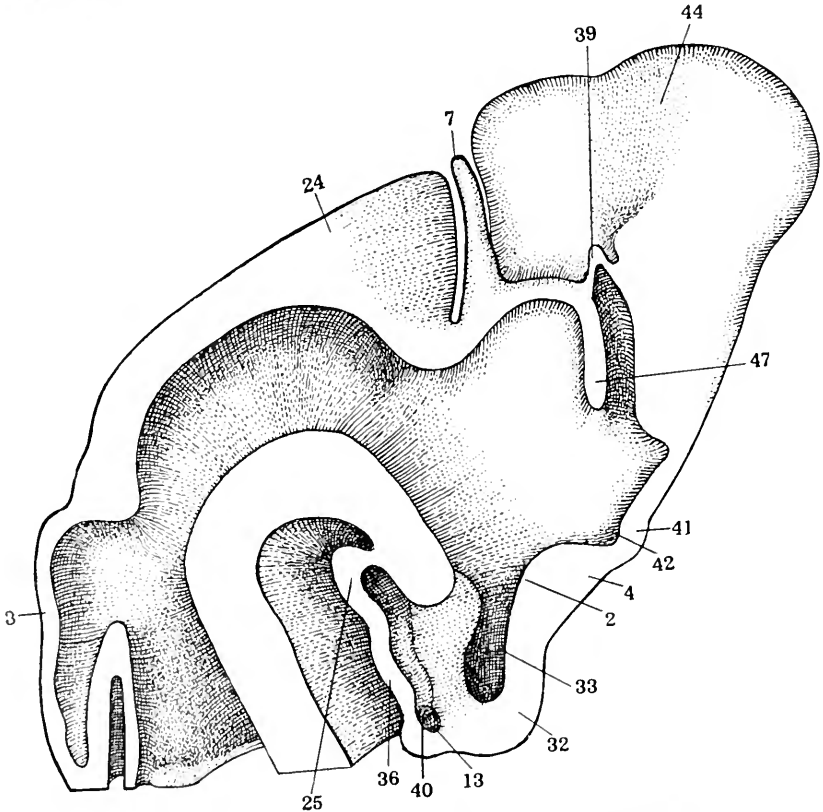


Fig. 13 Mesial view of forebrain reconstruction of 50 mm. *Mustelus*. $\times 50$. The unshaded area shows the cut surfaces of the reconstruction. According to Tilney, 1915.

2, chiasmatic process; 3, cerebellum; 4, chiasm; 7, epiphysis; 13, infundibular process; 24, midbrain; 25, mammillary region; 32, post-chiasmatic eminence (lobus-inferior); 33, post-chiasmatic recess (recess of inferior lobe); 36, post-infundibular evagination; 39, paraphysis; 40, recess of infundibular process; 41, supra-optic crest; 42, supra-optic recess; 44, telencephalon; 47, velum transversum.

The sac is hollow and in communication with the ventricle by means of a slender, hollow stalk. A proximal portion may now be distinguished so that all three elements of the pineal organ are present. The habenular ganglion is recognizable at this stage as a marked thickening in the roof-plate cephalad of the pineal organ. The paraphysis and velum have increased in promi-

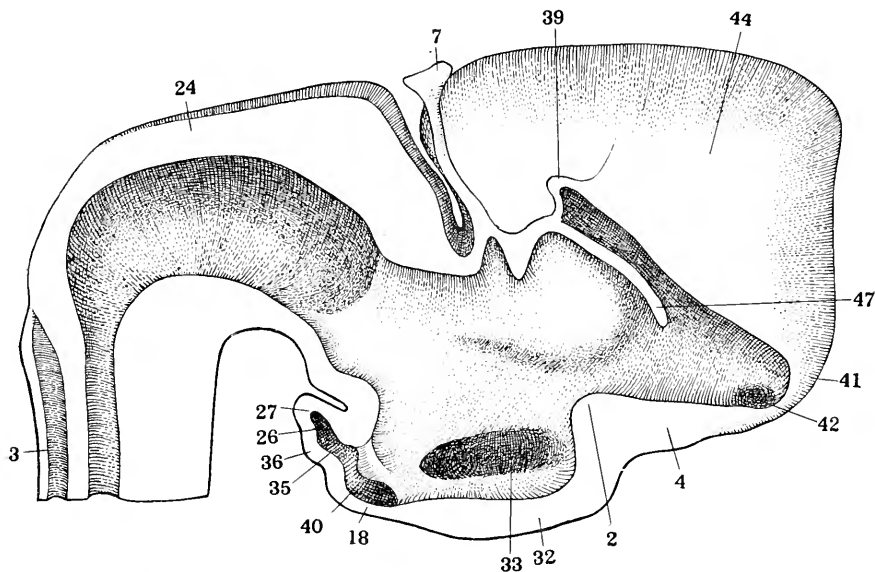


Fig. 14 Mesial view of forebrain reconstruction of 70 mm. *Mustelus*. $\times 50$. The unshaded area shows the cut surfaces of the reconstruction. According to Tilney, 1915

2, chiasmatic process; 3, cerebellum; 4, chiasm; 7, epiphysis; 18, infundibular evagination; 24, midbrain; 26, mammillary recess; 27, mammillary body (posterior lobe); 32, post-chiasmatic eminence (inferior lobe); 33, post-chiasmatic recess (recess of inferior lobe); 35, post-infundibular recess; 36, post-infundibular eminence; 39, paraphysis; 40, recess of infundibular process; 41, supra-optic crest; 42, supra-optic recess; 44, telencephalon; 47, velum transversum.

nence. The brains of the 100 mm. and 300 mm. *Mustelus* approximate the adult conditions shown in figures 15, 16 and 17.

Here, with one exception, i.e., the parapineal organ, all of the elements in the pineal region may be identified, including the two parts of the paraphyseal arch, the velum transversum, a short dorsal sac, a massive habenular commissure and habenular

ganglion, a pineal organ consisting of an end-vesicle, stalk and proximal portion, and finally the posterior commissure.

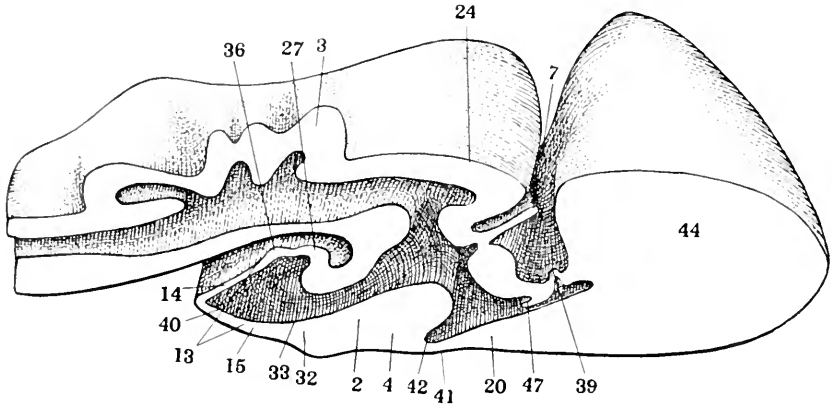


Fig. 15 Mesial view of brain reconstruction of 100 mm. *Mustelus*. $\times 25$. The unshaded area shows the cut surfaces of the reconstruction. According to Tilney, 1915.

2, chiasmatic process; 3, cerebellum; 4, chiasm; 7, epiphysis; 13, infundibular process; 14, infundibular process, saccular surface; 15, infundibular process, pituitary surface; 20, lamina terminalis; 24, midbrain; 27, mammillary body (posterior lobe); 32, post-chiasmatic eminence (lobus inferior); 33, post-chiasmatic recess (recess of inferior lobe); 36, post-infundibular evagination; 39, paraphysis; 40, recess of infundibular process; 41, supra-optic crest; 42, supra-optic recess; 44, telencephalon; 47, velum transversum.

3. The development of the epiphyseal complex in ganoids

Kupffer²²³ 1893 gave the first detailed description of the development of the epiphyseal complex in *Acipenser*. The anlage of the organ he describes as a small single evagination which later becomes a stalk with an end-vesicle. Kupffer could find nothing of the anterior or parapineal organ. Owsianikow ('88)²⁹⁵ gave a description according to which in the three- or four-weeks old embryo of *Acipenser* just in front of the pineal organ there appears a small, round or cordiform structure. Hill⁵⁰ in 1894 described a small rudiment of the anterior or parapineal organ in *Amia calva*. In the 10 mm. embryo this body was ovoid in form and situated immediately in front and

to the left of the pineal organ. It was connected with the roof-plate by means of a thin stalk. In the 13 mm. embryo this organ has come to lie above the commissura habenularis and still later it is consolidated into a mass of cells lying to the left beneath the now markedly developed and ventrally flexed pineal organ. Eycleshymer and Davis¹¹³ in 1897 confirmed the observation of Hill and noted that the anterior or parapineal

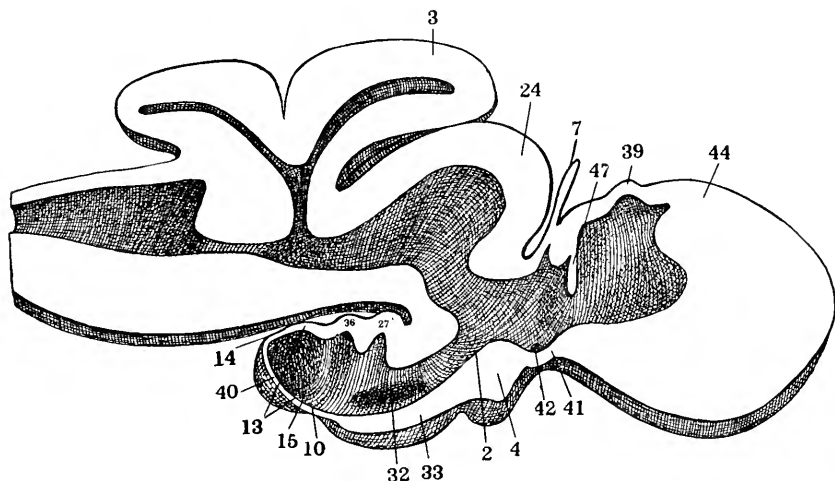


Fig. 16 Mesial view of brain reconstruction of 300 mm. *Mustelus*. $\times 25$. The unshaded area shows the cut surfaces of the reconstruction. According to Tilney, 1915.

2, chiasmatic process; 3, cerebellum; 4, chiasm; 7, epiphysis; 10, hypophyseal recess; 13, infundibular process; 14, infundibular process, saccular surface; 15, infundibular process, pituitary surface; 24, midbrain; 27, mammillary body (posterior lobe); 32, post-chiasmatic eminence (inferior lobe); 33, post-chiasmatic recess (recess of inferior lobe); 36, post-infundibular evagination; 39, paraphysis; 40, recess of the infundibular process; 41, supra-optic crest; 42, supra-optic recess; 44, telencephalon; 47, velum transversum.

organ possessed a lumen late in the course of development. Both the anterior and posterior pineal organs in the embryonic stages have nerve fibers which connect them with the habenular commissure. The earlier works upon this region in ganoids were done by Salensky³⁴¹ in 1881 and Balfour and Parker¹² in 1882 (fig. 18).

4. *The development of the epiphyseal complex in teleosts*

Rabl-Rückhard³¹⁸ in 1882 gave the first explanation of the development of the epiphyseal complex in teleosts. Hoffmann¹⁸⁵ in 1884 also described the ontogenesis of the pineal organ in

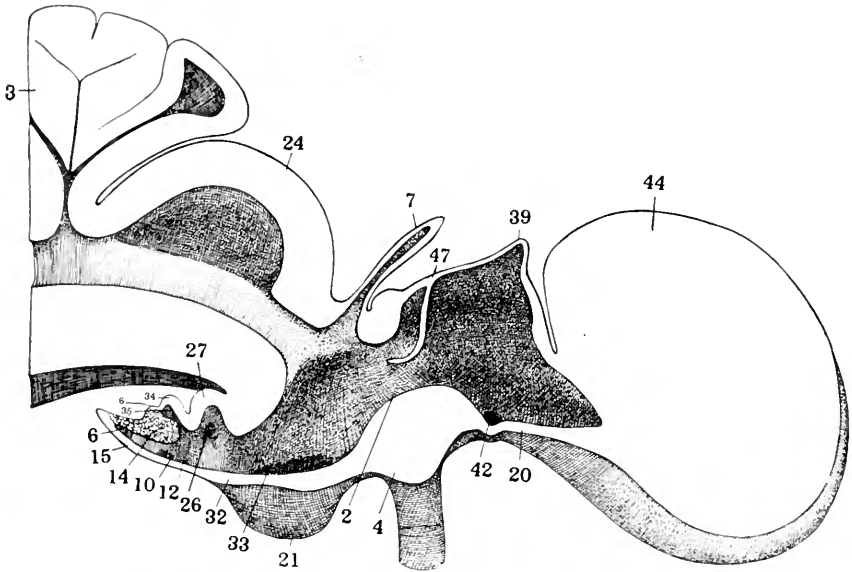


Fig. 17 Mesial view of brain reconstruction in adult *Mustelus laevis*. $\times 25$. The unshaded area shows the cut surfaces of the reconstruction. According to Tilney, 1915.

2, chiasmatic process; 3, cerebellum; 4, chiasm; 6, diverticular sacci vasculosi; 7, epiphysis; 10, hypophyseal recess; 12, infundibular canal; 14, infundibular process, saccular surface; 15, infundibular process, pituitary surface; 20, lamina terminalis; 21, median chiasmatic groove; 24, midbrain; 26, mammillary recess (recess of posterior lobe); 27, mammillary body (posterior lobe); 32, post-chiasmatic eminence (inferior lobe); 33, post-chiasmatic recess (recess of inferior lobe); 34, post-infundibular eminence; 35, post-infundibular recess; 39, paraphysis; 42, supra-optic recess; 44, telencephalon; 47, velum transversum.

teleosts. Both authors employed the same forms, namely, *Salmo fario* and *Salmo salar*. According to their descriptions, the anlage begins as a small evagination which gradually elongates and grows more and more narrow. It has produced a proximal portion, a stalk and an end-vesicle which lie just beneath the inner surface of the skull in the frontal region.

Still later many small diverticula develop in the walls of the end-vesicle which become unusually large. A feature of the description of the development given by these authors is the absence of any anterior or parapineal element in the epiphyseal complex, for this organ, according to their observations, does

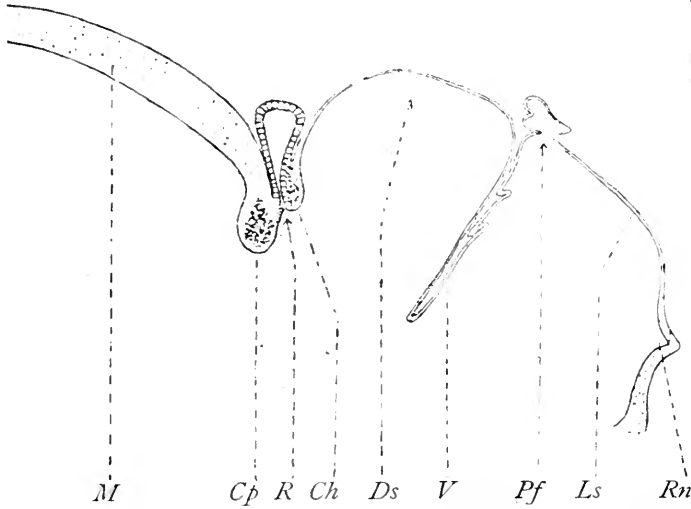


Fig. 18 The epiphyseal complex in a four months old embryo of *Acipenser sturio*, according to Kupffer, 1893.

Ls., lamina terminalis; *Pf.*, paraphysis; *V.*, velum transversum; *Ds.*, dorsal sac; *Ch.*, commissura habenularis; *R.*, recessus pinealis and pineal organ; *Cp.*, commissura posterior; *M.*, midbrain.

not even make its appearance in anlage. Holt ('91)¹⁸⁹ described the development of the epiphyseal complex in *Clupea harengus*. In this form the organ began as a solid sprout and later developed a lumen. The walls of the end-vesicle were eventually thrown into a number of diverticula. McIntosh and Prince²⁵⁴ in 1891 confirmed the findings of Hoffmann and Rabl-Rückhard. Hill's¹⁷⁹ observation in 1891 is of unusual importance, for this observer, working upon *Coregonus albus* and later¹⁸⁰ in 1894 on *Salmo catostomus teres*, *Stizosthetium vitreum*, and *Liponus callidus*, found what he took to be the anlage of the anterior or parapineal element just as he had found this element in *Amia*

calva. In the embryo of *Salmo fontinalis*, Hill¹⁵⁰ found the anlage of the epiphyseal complex to be a double evagination which communicated with the third ventricle by means of a common canal. Of the two sacs thus formed the posterior was much the larger. This, the anlage of the pineal organ, was situated immediately in front of the posterior commissure and in the mid-line, while the anterior evagination was close to the left as if both sacs were related to the roof-plate by a common stalk and later the anterior one was detached from the connection. Hill concluded that there are two epiphyseal outgrowths from the roof in teleosts of which the more anterior vesicle, both in teleosts and in *Amia*, is homologous with the parietal eye of

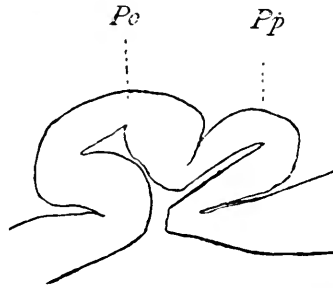


Fig. 19 Anlage of the epiphyseal complex in a 37-days old embryo of *Salmo fontinalis*, according to Hill, 1894.

Pp., parapineal organ; *Po.*, pineal organ.

Lacertilia. He thinks it probable that the two vesicles in their primitive position were side by side and believes it likely that the anterior vesicle is the homologue of the parapineal organ in *Petromyzon*. Hill also found this condition in embryos as well as in a two-year-old salmon.

Dendy⁸⁶ maintained that the double evagination in the epiphyseal anlage occurs in *Amia* as well as *teleosts*. Of these two vesicles the right gives rise to the epiphysis while the left separates from the brain and degenerates. Cattie,⁶⁰ examining the adult condition in plagiostomes, ganoids, and teleosts, came to a conclusion similar to the hypotheses of Goette¹⁵² and Van Wijhe¹⁰⁷ that the pineal body was derived as the final product of closure at the anterior neuropore where the ectoderm of the epidermis

and of the nerve tube remained longest in continuity. Van Wijhe⁴⁰⁷ in 1884 expressed the belief that the epiphysis in teleosts was a remnant of the anterior neuropore, but later he gave up this idea. Rabl-Rückhard³¹⁸ in 1882, studying the epiphysis in embryos of bony fish, summarized the process of development from the comparative standpoint in the following words:

Allein während diese unter Mitwirkung des sich zur Linse einstülpenden Ectoderms und des Mesoderms complicirte Veränderungen einge-
 gehen, die schliesslich zur Entwicklung des höchst entwickelten Sinnesorgans, des Auges, führen, sehen wir an der Zirbeldrüse trotz der günstigen Lage ihres distalen Endes dicht unter dem Ectoderm nichts dergleichen. Man denke sich eine ähnliche Wucherung und ihre Folgen, wie an dem die Augenblasen bedeckenden Ectoderm, das Auftreten von Pigment im sich betheiligenden Mesoderm, und nichts steht der Vorstellung im Wege, *dass sich aus der Zirbel ein dem Auge ähnliches, unpaares Sinnesorgan entwickelt*. Interessant ist, dass diese Gegend in einem bestimmten Embryonal-stadium bei Reptilien (*Lacerta Anguis*) eine ähnliche Entwicklung wenigstens andeutungsweise zeigt, und dass hier am Scheitelbeine des fertigen Thieres sich ein Kreisrundes Loch befindet. Bekanntlich hat schon *Leydig* diesen Befund eingehend erörtert und die Vermuthung ausgesprochen, dass es sich vielleicht um ein "Organ des 6. Sinnes" handelt.

And again in 1886:

Das Schädeldach der riesigen fossilen Enaliosaurier des Lias des Ichthyosaurus und Plesiosaurus besitzt ein unpaares Loch, welches seiner Lage nach mit dem Loch in Scheitelbein der Saurier übereinzustimmen scheint. Vielleicht lag auch hier das viel entwickeltere Zirbelorgan mit seinem distalen Endtheil zu Tage, und man könnte sich vorstellen das seine Leistung nicht sowohl die eines Sehorgan als die eines Organs des Wärmesinnes war, dazu bestimmt, seine Träger vor der zu intensiven Einwirkung der trophischen Sonnenstrahlen zu warnen, wenn sie in träger Ruh, nach Art ihrer noch lebenden Vetter der Crocodile, sich am Strande und auf den Sandbänken der Laisse sonnten.

5. *The development of the epiphyseal complex in amphibia*

In *Urodela*, deGraaf ('86)¹⁵⁵ found that the embryo of *Triton* had the anlage of its epiphyseal complex in a simple and single saccular evagination from the roof of the interbrain. These observations were confirmed upon *Amblysioma* embryos by Orr²⁵⁶ in 1899, by His¹⁵³ in 1892 and by Eyeleshymer¹¹² in 1892. Beraneek²⁴ in 1893, working upon *Salamandra* embryos, observed

the anlage of the epiphyseal complex to be a hollow sac which later became saccular and cylindrical, containing throughout its entire extent a lumen which still opened into the third ventricle. In this form it was possible to identify an end-vesicle, a stalk, and a proximal portion. These conditions were obtained at a period of 12 mm. embryo, but at the stage of the 18-mm. embryo the lumen in the stalk was obliterated. In this manner the stalk of the pineal organ became gradually reduced in size until finally it presented itself as a mere strand connecting an almost completely isolated end-vesicle lying beneath the skull with a well-marked proximal portion in communication with the third ventricle. In *Salamandra* the paraphysis develops very early and assumes extensive proportions resembling the chorioid plexus. The embryological conditions in *Anura* are, according to most descriptions, quite similar to those in *Urodela*. Goette¹⁵² in 1873-75 observed in the anlage of the pineal organ the remains of the anterior neuropore. This error, as has already been stated, was pointed out by Hoffmann¹⁸⁶ in 1886 and Heckscher^{169c} in 1890. In *Rana*, Béraneck²⁴ described the first appearance of the anlage of the epiphyseal complex as a small, ellipsoid evagination which later becomes cylindrical. This evagination contains a small lumen. Elongation gradually occurs so that an end-vesicle, a stalk, and a proximal portion are formed. In the later stages of development the stalk undergoes attenuation until it is reduced to a mere strand containing, it is thought, some nerve fibers. This leaves the end-vesicle situated at a point remote from the brain beneath the skull, while the proximal portion is a large and somewhat spacious evagination still maintaining a wide connection with the third ventricle. The nearly isolated end-vesicle Béraneck calls the *corpus epitheliale*. This body lies beneath the skin over the head and has the appearance of a gland-like structure. In embryos of *Bufo*, Béraneck²⁴ observed close to the commissura habenularis a small prominence which early disappears; this he identified as the anlage of a transitory parapineal organ. For the most part, however, observers have found that a single evagination in the roof-plate marks the anlage of the epiphyseal complex (fig. 20).

Eycleshymer,¹¹² in attempting to explain the unpaired origin of the epiphysis in *Amblystoma*, maintained that in the phylogenetic period when the lateral eyes became implicated by the closing of the neural fold, a median eye would arise and thus become most highly functional during the time when the lateral eyes were little, if at all, functional. Cameron,⁵⁰ working with the embryos of *Rana*, *Bufo*, and *Triton*, concluded that the

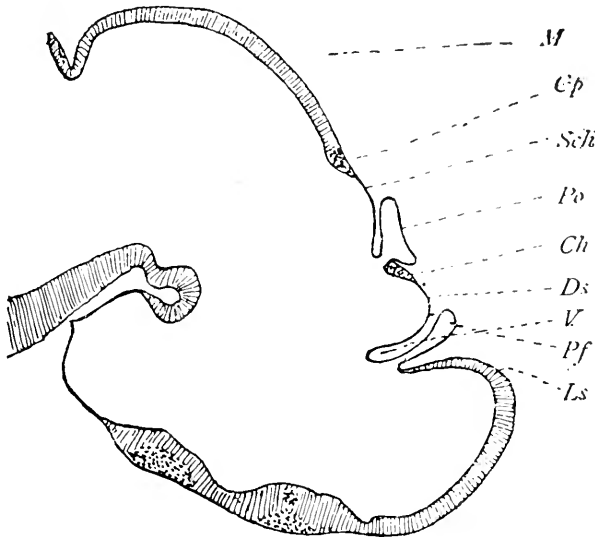


Fig. 20 Anlage of the epiphyseal complex in a 13 mm. embryo of *Salamandra maculata*, according to Kupffer, 1893.

Ls., lamina terminalis; *Pf.*, paraphysis; *V.*, velum transversum; *Ds.*, dorsal sac; *Ch.*, commissura habenularis; *Po.*, pineal organ; *Schi.*, pars intercalaris posterior; *Cp.*, commissura posterior; *M.*, midbrain.

epiphysis in amphibia arises as two primary outgrowths from the roof of the forebrain (fig. 21).

These are placed one on either side of the mesial plane. The outgrowth situated to the right of the middle line disappears at an early age by blending with the left outgrowth. The latter shows most active growth so that the epiphyseal opening becomes situated to the left of the mesial plane. The left outgrowth,

however, is the more important of the two in amphibia. Cameron believes that there is evidence of a bilateral origin to be found in the later stages of amphibian development. The portion of the anlage in connection with the superior commissure corresponds to the parietal eye of *Sphenodon* while the remainder corresponds to the epiphyseal stalk. From this evidence in amphibia he is inclined to agree with Dendy⁸⁶ that the ancestors of vertebrates must have possessed a pair of parietal eyes (figs. 22 and 23).

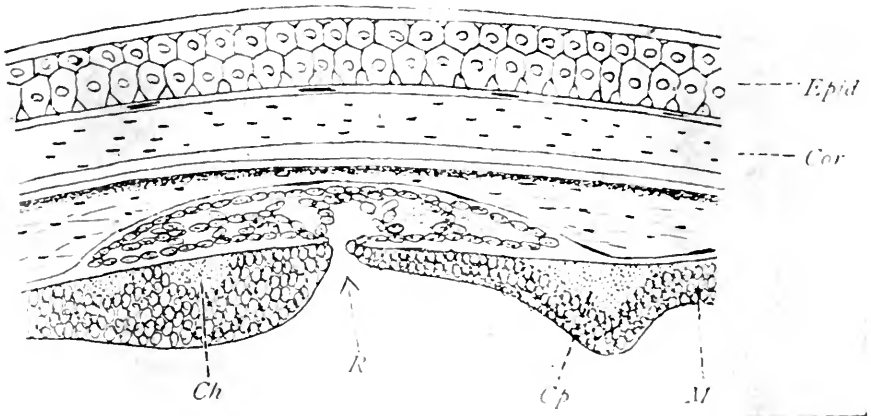


Fig. 21 Anlage of the epiphyseal complex in an embryo of *Triton cristatus*, according to deGraaf, 1886.

Ch, commissura habentularis; *R*., recessus and pineal organ; *Cp*., commissura posterior; *M*., midbrain; *Epid.*, epidermis; *Cor.*, corium.

6. The development of the epiphyseal complex in reptilia

The fact that in *Prosaurians* and *Saurians* a well developed eye is found in many forms has been the cause of much discussion as to the embryological process by means of which this structure is differentiated from the epiphyseal complex. According to the older view, the parietal eye arose, as in the case of the isolated end-vesicle of amphibia, by a process of constriction from the terminal portion of the pineal organ. Subsequently the view was advanced that instead of a process of constriction

it was rather a subdivision of a single evagination from the roof-plate which gave rise to the parietal eye; more recently, however, the opinion has been expressed by several observers, that the parietal eye owes its existence to an anlage quite independent from that of the pineal organ and situated anterior to the latter in its point of development from the roof-plate of the inter-brain. The fact that the parietal eye was not the constricted end of the epiphysis, but was independently connected by

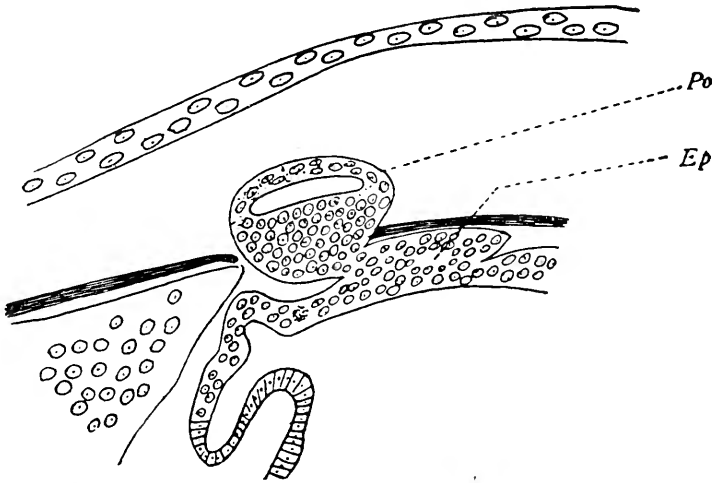


Fig. 22 Anlage of the epiphyseal complex in an 11 mm larva of *Bufo vulgaris* according to Béraneck, 1893.

Po., pineal organ (end-vesicle); *Ep.*, proximal portion.

means of a nerve of its own to the roof of the brain, was shown conclusively by Strahl and Martin³⁸³ as well as Béraneck,²³ who was first to call attention to the nerve fibers connecting the parietal eye with the brain, namely, the *parietal nerve*. Having thus dispensed with the idea that the parietal eye was merely a constricted portion of the end of the epiphysis proper, it remained for subsequent investigation to demonstrate the actual process by means of which the parietal eye arose. Advocating the view that the anlage of the epiphyseal complex in Reptilia, and particularly in the Saurian and Prosaurian forms, is an evagination subdivided into an anterior and a posterior compart-

ment, there has been assembled a formidable array of evidence. Hoffmann,¹⁵⁶ from his observations on *Lacerta agilis*, Strahl and Martin,³⁸³ in *Anguis* and *Lacerta vivipara*, Francotte,¹²⁷ on *Lacerta vivipara*, Klinekowitz,²⁰⁷ in *Iguana*, McKay,²⁵⁵ in *Grammatophora muricata*, and Schauinsland,³⁴⁶ in *Sphenodon* all advocate this view (fig. 24).

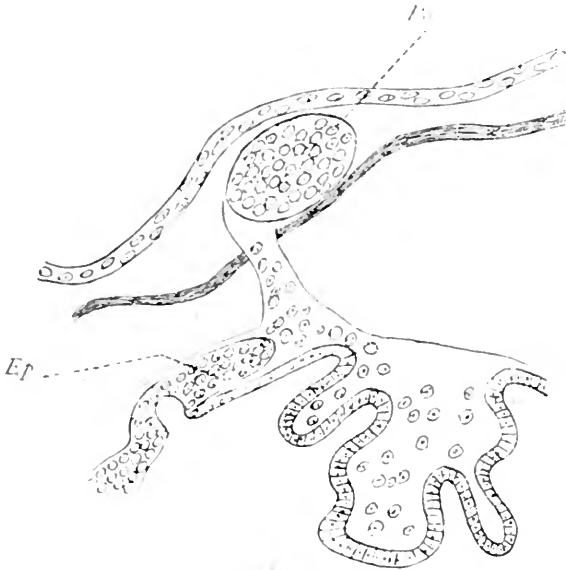


Fig. 23 Aulage of the epiphyseal complex in a 12 mm. larva of *Bufo vulgaris* according to Béraneck, 1893.

Po., pineal organ; *Ep.*, proximal portion.

Béraneck,²³ on the other hand, in his well-known work upon the parietal eye and the morphology of the third eye of vertebrates, concludes that the parietal eye should not be considered as a simple diverticulum of the pineal gland. In *Lacerta* and *Anguis* it constitutes an independent organ which develops from the thalamencephalon as the epiphysis, but develops parallel to the latter not dependent upon it. The parietal eye is attached by a neural fasciculus which is transitory and not in any sense derived from the epiphysis (fig. 25).

It is part of the small mass of cells situated between the base of the pineal gland and the first fold of the chorioid plexus. The unpaired eye is an evagination of the dorsal wall of the interbrain and constitutes an optic vesicle. The separation which sometimes occurs between the crystalline and retina of this vesicle is ordinarily unilateral, rarely bilateral. It appears relatively late in embryonic development and should not be considered a proof of the duality of origin of the parietal organ as Beard¹⁵ has considered it. The unpaired eye does not occur in chordates nor does it have its homologue in the other branches of the metazoa. Sometimes it has its physiological analogue in the median eye of Crustaceans. It is an ancestral organ which was atrophied in the majority of extant forms of the different

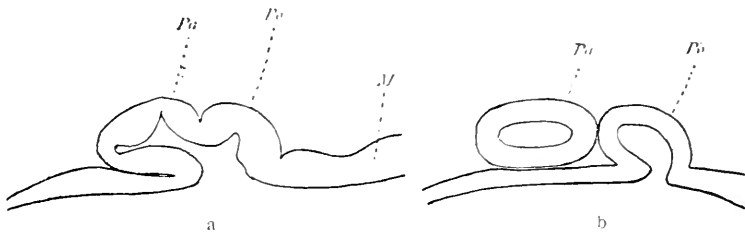


Fig. 24 Two successive stages in the development of the epiphyseal complex in *Lacerta vivipara*, according to Francotte, 1896.

Pa., parapineal organ; *Po.*, pineal organ; *M.*, midbrain.

branches of the chordate phylum. The primitive optic vesicle is still recognizable in cyclostomes and Saurians; it is rudimentary in teleosts and amphibians, but appears to be absent in selachians. On the other hand, the epiphysis in these latter forms is very long and broadened at its distal extremity without forming an optic vesicle. The epiphysis is also derived from an evagination of the interbrain roof. It does not represent the optic pedicle of the parietal eye. It is an organ *sui generis* whose function is still unknown. It reveals no marked sensory characteristics even in selachians where it is markedly developed. It appears in the entire series of vertebrates and is an ancestral organ. The paired eye and epiphysis appertain to the interbrain while the paraphysis is part of the endbrain. This

paraphysis shows no features of sensory function. Of these three encephalic diverticula from the roof-plate in Saurians, the parietal eye alone seems to have had ancestral sensory function (fig. 26).

In a later communication, combating the contention of Klinek-owstroem²⁰⁷ to the effect that the evolutionary process observed in *Anguis* is normal and more primitive while that in *Lacerta* is a simple modification of this primitive form, Béraneck²⁵ pro-

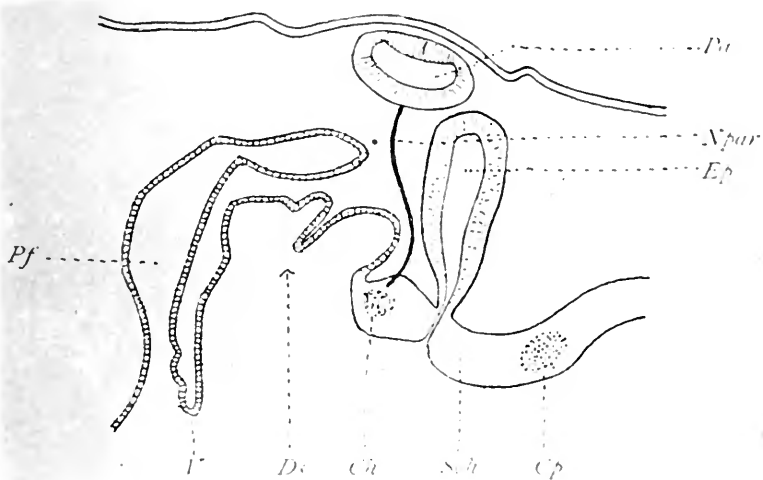


Fig. 25 The epiphyseal complex in a 27 mm. embryo of *Anguis fragilis*, according to Béraneck, 1892.

Pf., paraphysis; *V.*, velum transversum; *Ds.*, dorsal sac; *Ch.*, commissura habenularis; *Npar.*, nervus parapinealis; *Pa.*, parapineal organ; *Ep.*, pineal organ; *Sch.*, pars intercalaris posterior; *Cp.*, commissura posterior.

posed this question, "If in *Anguis* the parietal eye is only a differentiation of the distal extremity of the epiphysis, how in *Lacerta* does this visual organ develop parallel to the epiphysis and not dependent upon it?" Béraneck maintains that Klinek-owstroem escapes the difficulty proposed by this question in claiming that the pineal eye of *Iguana* and *Lacerta* upon the one hand and *Anguis* upon the other take origin from different parts of the epiphyseal evagination. Béraneck formulates the hypothesis that the parietal eye and epiphysis represent in

Lacerta two distinct evaginations of the thalamencephalic roof. If they appear to be different in *Iguana* and *Anguis* that is due to secondary modifications of this region. The evolution of the parietal eye in *Iguana* is intermediate between the conditions observed in *Lacerta* and *Anguis*. In his conclusion, Béraneck emphasizes his belief that the embryonic facts contradict the

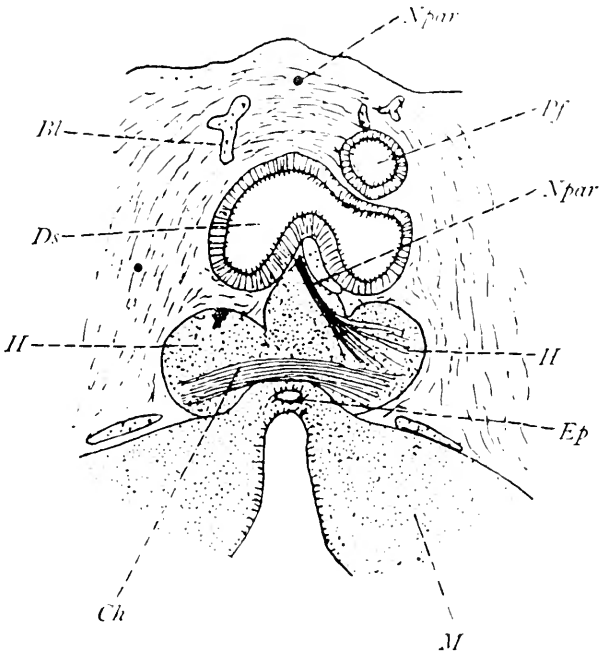
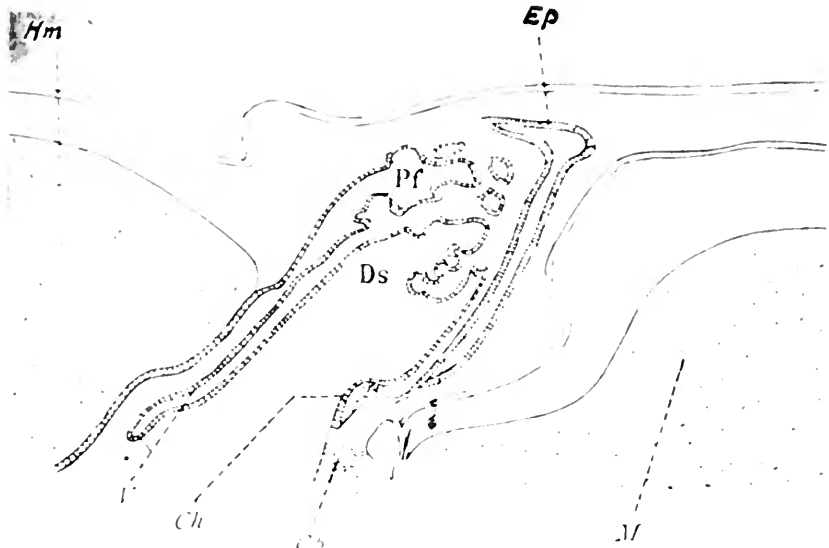


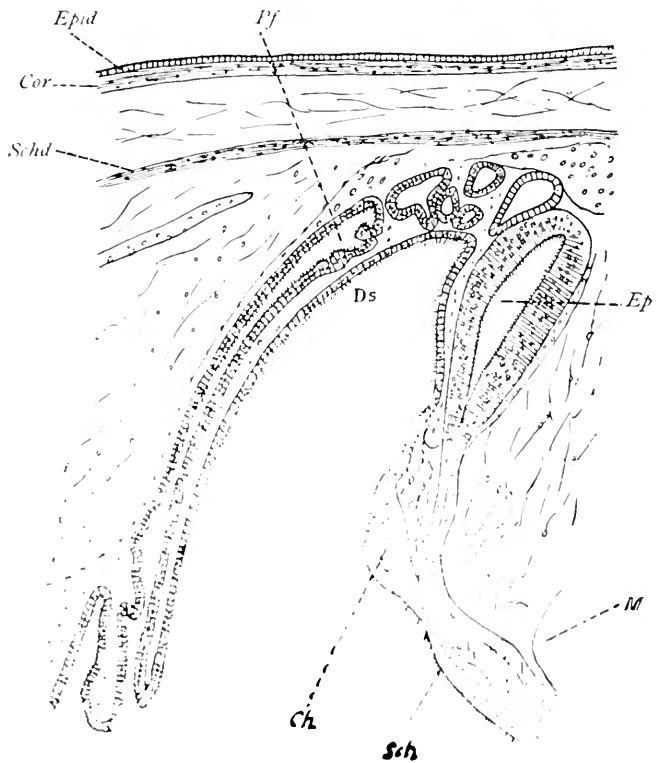
Fig. 26 Frontal section showing epiphyseal complex in a 26-day old *Iguana tuberculata*, according to Klinckowstroem, 1894

Pf., paraphysis; *Ds.*, dorsal sac; *Npar.*, nervus parapinealis; *Ep.*, proximal portion of pineal organ; *Ch*, commissura habenularis; *M.*, midbrain

epiphyseal origin of the parietal eye in Saurians and confirm the hypothesis of its embryonic individuality. Leydig²³⁸ in 1891 confirmed the view of Béraneck in *Lacerta agilis*. Dendy⁸⁶ also states that the parietal eye and what he calls the parietal stalk arise from two distinct evaginations in the roof-plate of the interbrain. By parietal stalk, Dendy refers to the portion of the epiphyseal complex here referred to as the pineal organ.



27



28
62

The development of the epiphyseal complex in *Ophidia*, *Chelonia*, and *Crocodylia*. The embryonic description which holds good for the more primitive forms of reptiles must be much modified in dealing with the more highly organized and modern forms of this class. Hoffmann¹⁸⁶ showed that in these reptiles the anlage of the epiphyseal complex is laid down as a single evagination

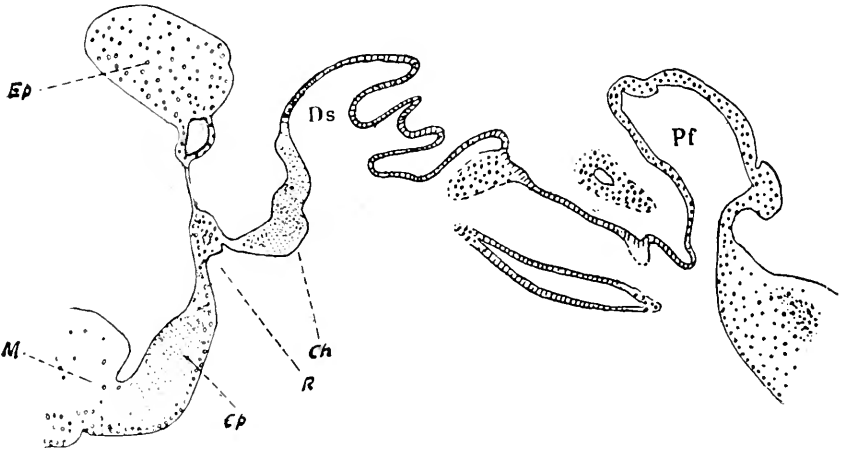


Fig. 29 The epiphyseal complex in *Tropidonotus natrix*, according to Studnicka, 1893.

Pf., paraphysis; *Ds.*, dorsal sac; *Ch.*, commissura habenularis; *Ep.*, proximal portion of pineal organ; *R.*, recessus pinealis. *Cp.*, commissura posterior; *M.*, midbrain.

from the roof-plate immediately anterior to the posterior commissure. This hollow evagination is ultimately transformed into a solid body. Such a transformation has been shown by Leydig²⁴⁰ and Studnicka³⁸⁹ in *Tropidonotus* (figs. 29 and 30).

Fig. 27 The epiphyseal complex in a 31 mm. embryo of *Gehyra oceanica*, according to Stemmler, 1900.

Pf., paraphysis; *V.*, velum transversum; *Ds.*, dorsal sac; *Ch.*, commissura habenularis; *Ep.*, pineal organ; *Cp.*, posterior commissure; *M.*, midbrain.

Fig. 28 The epiphyseal complex in a 33 mm. embryo of *Platydictylus muralis*, according to Melchers, 1899.

Pf., paraphysis; *Ds.*, dorsal sac; *Ch.*, commissura habenularis; *Ep.*, pineal organ; *Sch.*, pars intercalaris posterior; *M.*, midbrain.

The cells constituting this solid organ arrange themselves more or less in alveolar or aciniform cell groups and the whole body ultimately becomes attached to the roof-plate by means of a thin stalk or peduncle. No evidence of an anterior evagination representing the parapineal element has been observed nor is there any evidence to show that any effort toward the development of the parietal eye in Ophidia, Chelonia, or Crocodilia

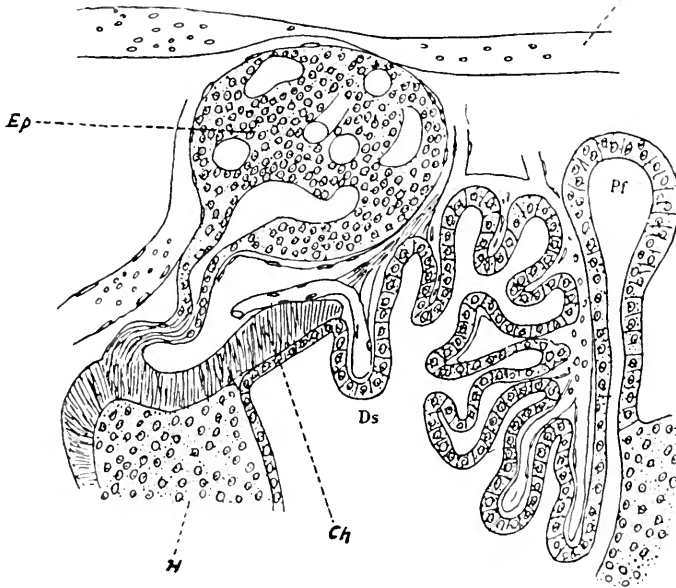
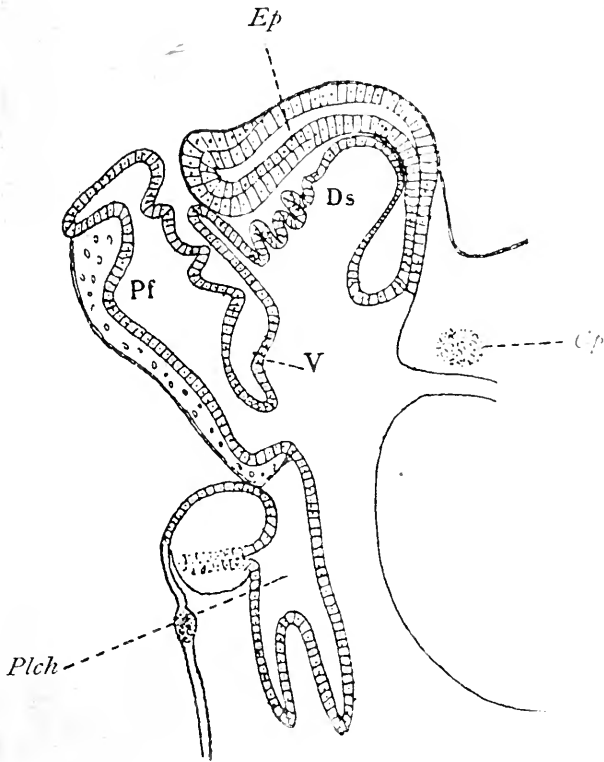


Fig. 30 The epiphyseal complex in an older *Tropidonotus* embryo, according to Leydig, 1897.

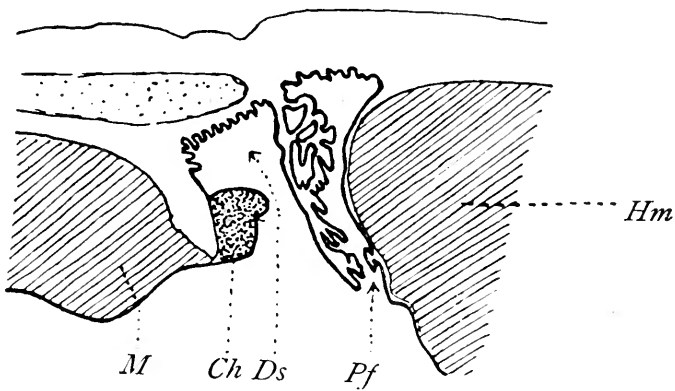
Pf., Paraphysis; *Ds.*, dorsal sac; *Ch.*, commissura habenularis; *Ep.*, proximal portion of pineal gland.

is present. In fact, in the latter forms, namely, Crocodilia, the entire epiphyseal complex is said to be wanting and no evidence of its development occurs at any time during ontogenesis (figs. 31 and 32).

One of the authors, studying the development of the epiphysis in turtles, reconstructed the forebrain of *Thalassochelys caretta* in several stages. The conditions in the 30 mm. embryo are shown in figure 33. Here the pineal region consists of a well-



31



32

Fig. 31 The epiphyseal complex in an old embryo of *Chelydra serpentina*, according to Humphrey, 1894.

Pf., paraphysis; *V.*, velum transversum; *Ds.*, dorsal sac; *Ep.*, pineal organ; *Cp.*, posterior commissure.

Fig. 32 The pineal region in an old embryo of *Caiman niger*, according to Voeltzkow, 1903.

Hm., hemisphere; *Pf.*, paraphysis; *Ds.*, dorsal sac; *Ch.*, commissura habenu-laris; *M*, midbrain.

marked paraphyseal evagination, a velum transversum, a dorsal sac, a commissura habenularis, and a single thick-walled anlage of the pineal body whose apex is directed cephalad. The most caudal structure in the pineal region is the posterior commissure.

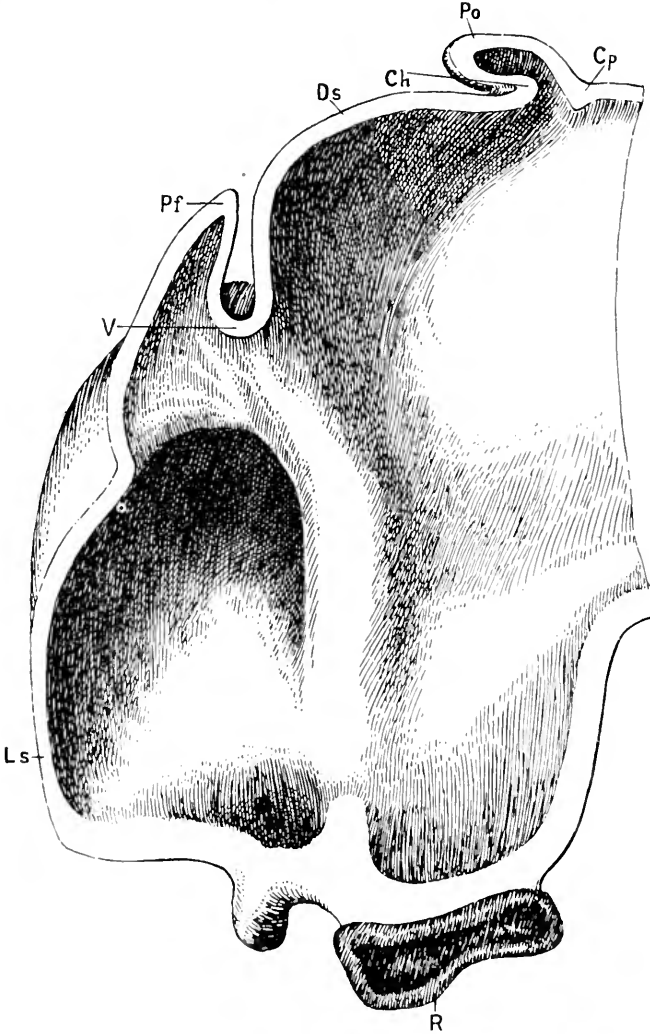


Fig. 33 Reconstruction of a 30 mm. embryo of *Thalassochelys caretta*.

Ls., lamina terminalis; *Pf.*, paraphysis; *V.*, velum transversum; *Ds.*, dorsal sac; *Ch.*, commissura habenularis; *Po.*, epiphysis; *Cp.*, posterior commissure; *R.*, Rathke pocket.

7. *The development of the epiphyseal complex in aves*

In birds, the anlage of the epiphyseal complex makes its first appearance as a simple and single evagination. This was first observed and described by Reissner³²⁹ in 1851 and called by Reichert³²⁶ in 1859 the *recessus pinealis*. Lieberkühn²⁴² in 1871 identified this evagination in birds as the anlage of the epiphysis.

In many instances the presence of a double evagination of the roof-plate has been reported in the anlage of the epiphysis in birds. Saint Remy³⁴⁰ in 1897 found on either side of the still unclosed neural tube a small evagination in the region of the

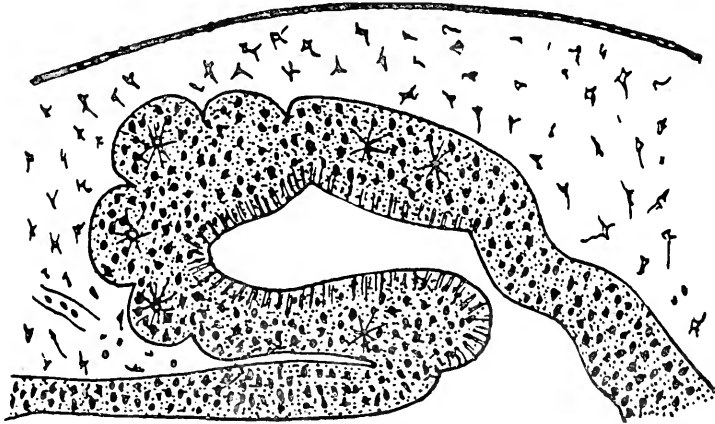


Fig. 34 The epiphyseal complex in an 8-day embryo of *Anas domestica*, according to Hechscher, 1890.

epiphyseal anlage. This observation was made upon *Gallus*, but Parker³⁰¹ in 1892, in *Apieryx*, and Klinckowstroem²⁰⁶ in 1892, in *Larus*, mentioned an evagination in front of the epiphyseal anlage. Hill¹⁸¹ in 1900 observed in a closed neural tube two such evaginations. Whether it is justified to consider the anlage of the epiphysis in birds as bilateral or double or whether one of these evaginations represent the remnant of the para-pineal organ, is a difficult question to decide. By many these reduplications in the anlage are considered as pathological since they occur only in isolated instances of the several species described. The most common form in which the anlage in birds

presents itself is a single evagination in front of the posterior commissure. The further differentiation of the epiphysis is given by Lieberkühn²⁴² in *Gallus* and also in much more detail by Mihalkovicz²⁷⁴ in 1874 and 1877. According to the description of the latter, the principal change from the original saccular evagination in the roof-plate consists in the conversion of the original sac into a folliculated structure which presents many alveoliform cell groups as a result of the rapid proliferation in the walls of the original saccular anlage. Henriehs ('96)¹⁷³ found that the follicles first developed as hollow buds in communication with the main cavity of the original epiphysal anlage. Later these buds become branched and in this way a rich follicular system is developed.

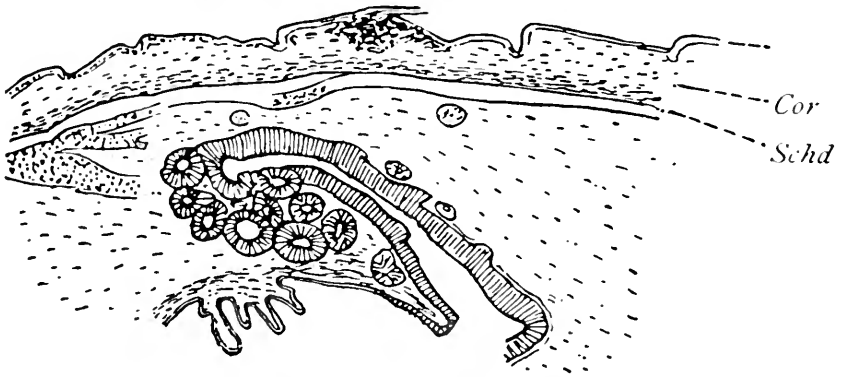


Fig. 35 The epiphysal complex in an embryo of *Sterna hirundo*, according to Klinckowstroem, 1891.

According to Henriehs, the paraphysis first appears as a solid sprout and later acquires a lumen. Cameron³¹ showed in the chick that the epiphysal anlage is a double outgrowth, the left being the larger. These two evaginations ultimately coalesce. Practically the same condition is observed in amphibia. Garjano¹⁴⁴ makes the observation which in the main covers the conditions observed in birds, namely, that as compared with the lower vertebrates the pineal body is a profoundly altered organ in birds and mammals.

One of the authors in a recent work on the diencephalon reproduces illustrations of reconstruction models which show the development in the pineal region of *Gallus gallus*. The first

evidence of the epiphyseal complex in the chick makes its appearance at five days and twenty hours as a sprout from the caudal extremity of the interbrain roof-plate. This sprout contains a narrow canal and at this very early period shows an apparent differentiation into an expanded distal portion, a stalk, and an expanded proximal portion.

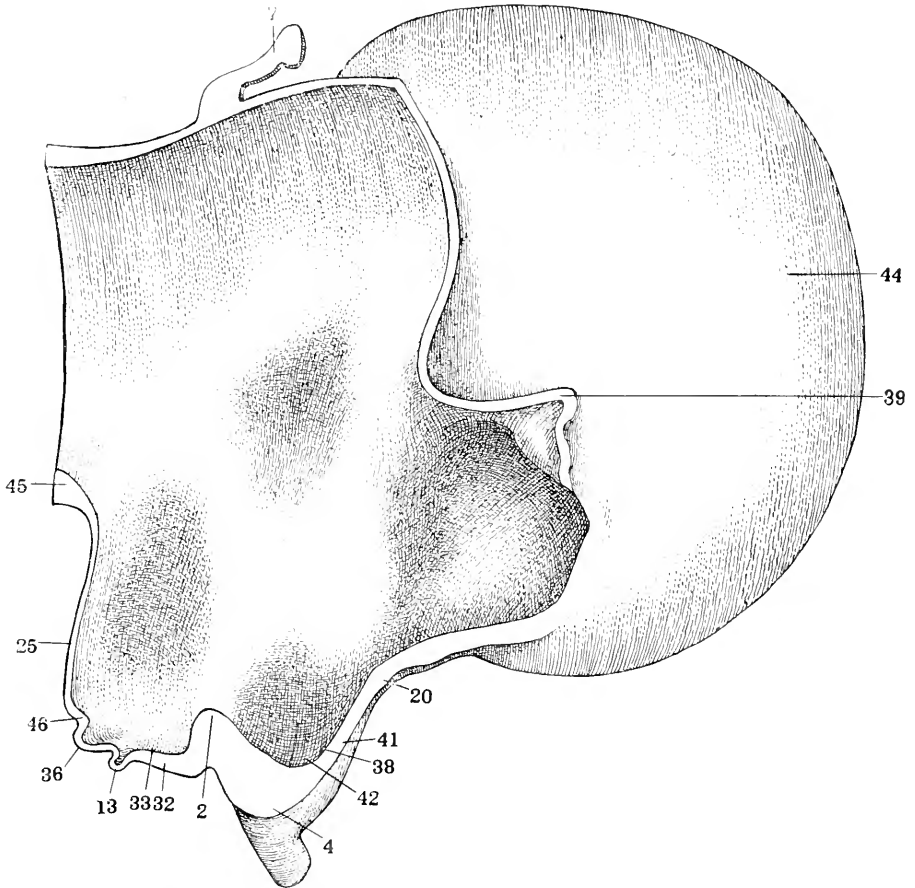


Fig. 36 Mesial view of forebrain reconstruction of chick of 5 days and 20 hours. $\times 100$. The unshaded area shows the cut surfaces of the reconstruction according to Tilney, 1915.

2, chiasmatic process; 4, chiasm; 7, epiphysis; 13, infundibular process; 20, lamina terminalis; 25, mammillary region; 32, post-chiasmatic eminence; 33, post-chiasmatic recess; 36, post-infundibular eminence; 38, pre-optic recess; 39, paraphysis; 41, supra-optic crest; 42, supra-optic recess; 44, telencephalon; 45, tuberculum postero-superius; 46, tubercle of the floor of Schulte.

At this time the pineal region presents a well-marked paraphysis, a velum transversum, and a dorsal sac. At the stage of eight days in the chick a marked change is noticed, for at this period of development the pineal anlage has the appearance of a wide and expansive evagination in free communication with the third ventricle.

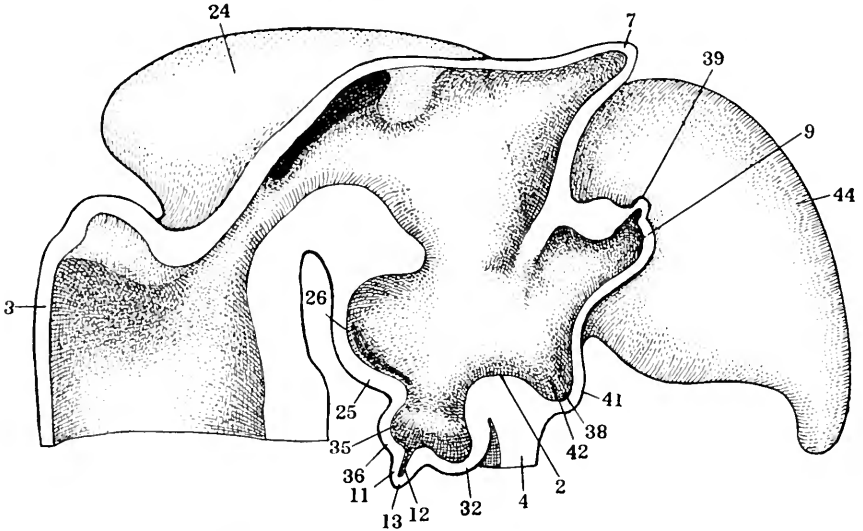


Fig. 37 Mesial view of forebrain reconstruction of chick of 8 days. $\times 50$. The unshaded area shows the cut surfaces of the reconstruction, according to Tilney, 1915.

2, chiasmatic process; 3, cerebellum; 4, chiasm; 7, epiphysis; 9, foramen of Monro; 11, infundibular stem; 12, infundibular canal; 13, infundibular process; 24, midbrain; 25, mammillary region; 26, mammillary recess; 32, post-chiasmatic eminence; 35, post-infundibular recess; 36, post-infundibular eminence; 38, pre-chiasmatic recess; 39, paraphysis; 41, supra-optic crest; 42, supra-optic recess; 44, telencephalon.

The brain of the chick at fourteen days and eighteen hours shows a marked alteration in the pineal region, as a result of which the development of the epiphysis seems to overshadow all other structures in this region. The walls of the evagination which characterize the pineal organ in the eight-day chick have become greatly thickened near the distal extremity of the epiphysis so that now this portion of the organ is practically solid

with the exception of a very small lumen which extends almost throughout its entire extent. A very large pineal recess is present. The dorsal sac and paraphysis are both much reduced in size. There is no evidence of any distal portion of the pineal organ at this period. No sign of an evagination or anlage which might be interpreted as the parapineal organ was found in this study.

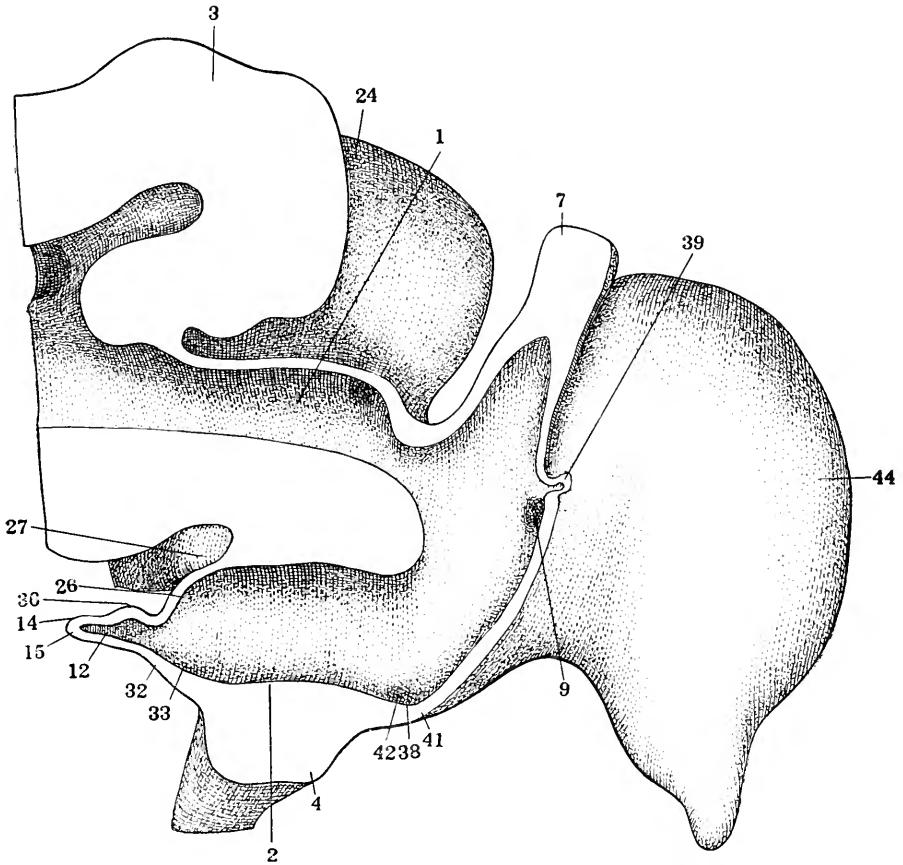


Fig. 38 Mesial view of forebrain reconstruction of 14 days and 18 hours chick. $\times 25$, according to Tilney, 1915.

1, aqueduct of Sylvius; 2, chiasmatic process; 3, cerebellum; 4, optic chiasm; 7, epiphysis; 9, foramen of Monro; 12, infundibular canal; 14, infundibular process, saccular surface; 15, infundibular process, pituitary surface; 24, midbrain; 26, mammillary body; 27, mammillary recess; 32, post-chiasmatic eminence; 33, post-chiasmatic recess; 36, post-infundibular eminence; 38, pre-chiasmatic recess; 39, paraphysis; 41, supra-optic crest; 42, supra-optic recess; 44, telencephalon.

8. *The development of the epiphyseal complex in mammals*

The only portion of the epiphyseal complex which appears in the anlage in mammals is, in all probability, the proximal part of the pineal organ, for there is no evidence of the anterior or parapineal element. Mihalkoviez²⁷⁵ in 1877 gave a description of the development of the organ in mammals and called attention to the fact that it resembled very closely that of birds. At first the anlage is a simple evagination, then several lateral diverticula about the same size make their appearance and later give rise to many follicles. The lumen of each follicle from the beginning is smaller than that in birds and ultimately is obliterated so that there are finally solid follicles surrounded by connective tissue and blood vessels. The epiphysis always retains its connection with the interbrain by means of a set of peduncles. These peduncles vary in their arrangement and number according to the form of the animal. In man they are described by Testut³⁹³ as being three pairs, known respectively as the superior, middle, and inferior peduncles of the pineal body. Mihalkoviez gave his description of the relations of the anlage to the roof-plate as he observed them particularly in the rabbit.

Kraushaar²²¹ in 1885 confirmed these findings in the mouse and Kölliker²¹¹ in 1879 in the rabbit and sheep. d'Erchia¹⁰⁹ in 1896 found that the epiphysis in the guinea-pig is laid down as a solid bud or sprout, while in man it has in its anlage a small lumen from the beginning (fig. 39).

Neumeyer²⁵² in 1899 found in the rabbit that the epiphyseal anlage was a long, tubular structure with a narrow lumen and considerably convoluted. The original lumen of the anlage is ultimately reduced until it occupies the proximal portion only where it is known as the recessus pinealis, according to Reichert,³²⁶ or the recessus infrapinealis, according to Mihalkoviez.²⁷⁵ This distinction takes account of the description already given by Reichert of the suprapineal recess.

In studying the development of the diencephalon in the domestic cat one of the authors illustrates by reconstruction models of the following embryos: In *Felis domestica*, the pineal

organ shows the first appearance of the epiphyseal complex at the stage of 30 mm. embryo where it takes the form of a wide, single evagination immediately cephalad to the posterior commissure. This evagination contains a recess in free communication with the third ventricle (fig. 40).

In a cat embryo of 51 mm. a notable change has taken place in the epiphyseal anlage shown in the fact that the original single evagination has now become subdivided into two smaller sacs separated by a marked thickening in the original diverticulum. This is shown in figure 41.

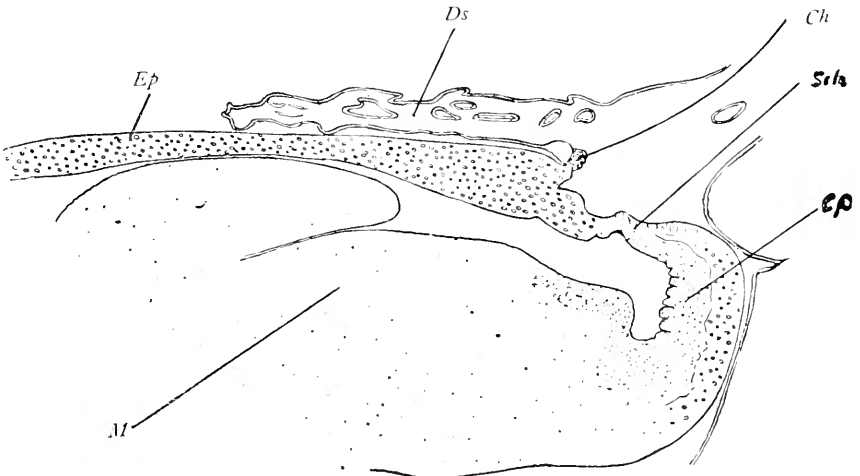


Fig. 39 The pineal body in *Cavia cobaya*, according to d'Erchia, 1896

Ds, dorsal sac; *Ch.*, commissura habenularis; *Sch.*, pars intercalaris; *Ep.*, epiphysis cerebri; *M*, midbrain.

In so far as is known no similar occurrence has been noted in mammals with the exception of a single report by Cutore⁷⁴ in the new-born *Bos taurus* in which two distinct evaginations in the epiphyseal complex were observed. This appearance was interpreted by Cutore as indicative of an anlage both for the pineal and parapineal organs, and if such an interpretation seems acceptable, it might be applied to the appearances just mentioned in the embryos of the domestic cat. The tendency for this double diverticulum to persist through the development

of the later stages in the cat is shown in figure 42, illustrating the conditions in a 70 mm. embryo. Models by one of the authors show the existence of this twofold structure in the cat as late as 120 mm. embryo.

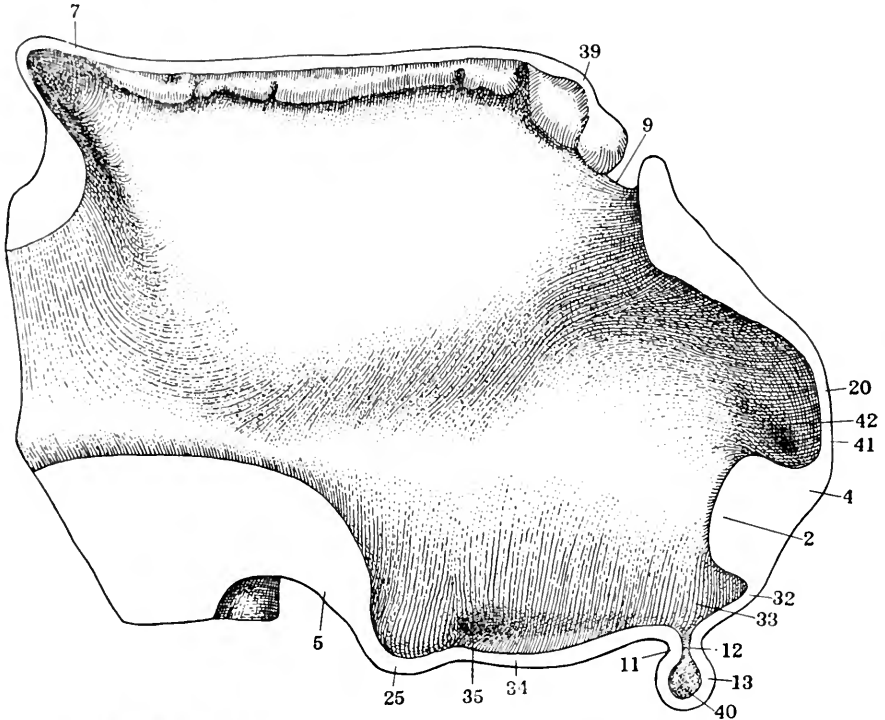


Fig. 40 Mesial view of forebrain reconstruction of 30 mm. cat embryo. $\times 50$. The unshaded area shows the cut surfaces of the reconstruction, according to Tilney, 1915

2, chiasmatic process; 4, chiasm; 5, corpus interpedunculare; 7, epiphysis; 9, foramen of Monro; 11, infundibular stem; 12, infundibular canal; 13, infundibular process; 20, lamina terminalis; 25, mammillary region; 32, post-chiasmatic eminence; 33, post-chiasmatic recess; 34, post-infundibular eminence; 35, post-infundibular recess; 39, dorsal sac; 40, recess of the infundibular process; 41 supra-optic crest; 42, supra-optic recess.

The most recent study of the pineal region in mammals is that of John Warren,⁴¹⁷ in which he brings to a conclusion his excellent series of papers upon the interpretation of this region of the brain in vertebrates. Of the human embryo he gives the following description (fig. 43):

The primary arches can be demonstrated in early human embryos from 10 to 15 mm. in length.

Of the embryos of 15 mm. and over examined there were about thirty in which the brain was in suitable condition to warrant making observations, and in addition to these a number of others were studied but excluded on account of injury or distortion of the forebrain. In the thirty specimens only eight showed any possible signs of a paraphysis and most of these were mostly rudimentary in character. By counting every possible case we get a result of 27 per cent. The fact remains,

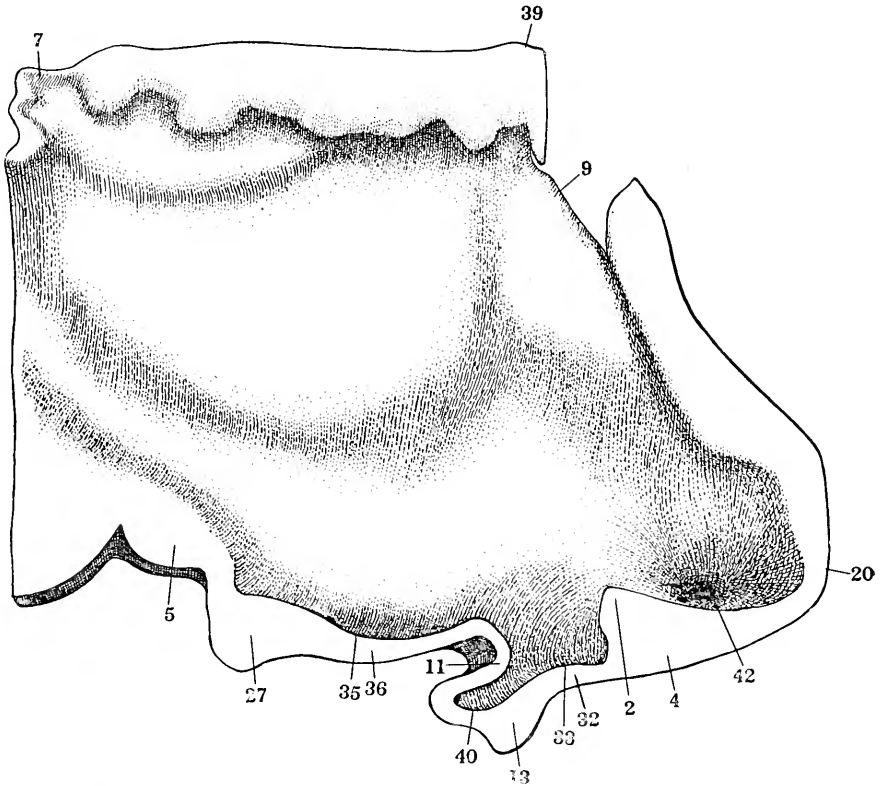


Fig. 41 Mesial view of forebrain reconstruction of 51 mm. cat embryo $\times 50$. The unshaded area shows the cut surfaces of the reconstruction, according to Tilney, 1915.

2, chiasmatic process; 4, chiasm; 5, corpus interpedunculare; 7, epiphysis; 9, foramen of Monro; 11, infundibular stem; 13, infundibular process; 20, lamina terminalis; 27, mammillary body; 32, post-chiasmatic eminence; 33, post-chiasmatic recess; 35, post-infundibular recess; 36, post-infundibular evagination; 39, dorsal sac; 40, recess of the infundibular process; 42, supra-optic recess.

however, that the structure can be found in human embryos, though in a rudimentary and inconstant condition.

The so-called postveolar tubules or diverticula can be clearly followed in every degree of complexity in embryos of 19 mm. up to 44 mm. and appear in every specimen studied in those stages. They

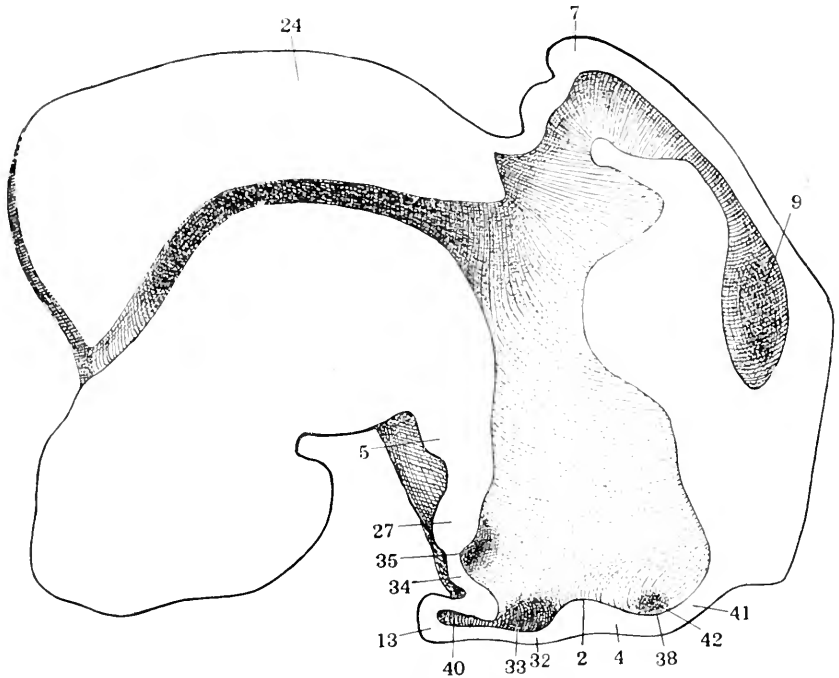


Fig. 42 Mesial view of forebrain reconstruction of 70 mm. cat embryo. $\times 25$. The unshaded area shows the cut surface of the reconstruction. According to Tilney, 1915.

2, chiasmatic process; 4, chiasm; 5, corpus interpedunculare; 7, epiphysis; 9, foramen of Monro; 13, infundibular process; 24, midbrain; 27, mammillary body; 32, post-chiasmatic eminence; 33, post-chiasmatic recess; 34, post-infundibular eminence; 35, post-infundibular recess; 38, pre-chiasmatic recess; 40, recess of infundibular process; 41, supra-optic crest; 42, supra-optic recess.

begin at the diencephalic lip of the velum, have definite limits and involve a relatively short extent of the oral end of the diencephalic roof-plate. They always appear as outgrowths from the brain roof and are to be distinguished from ingrowths due to plexus formation.

Warren's¹⁷ description of the conditions in the sheep is as follows:

The primary arches consist of the paraphyseal arch, the postvelar arch, the epiphyseal arch and the pars intercalaris (synencephalic arch) and together with the velum are formed in the roof of the forebrain of early sheep embryos.

The paraphysis can be followed in practically all sheep embryos from 20 mm. up to 48 mm. It is characterized by its short, broad, and irregular outline and its solid structure, the cavity being in most cases reduced to a minimum.

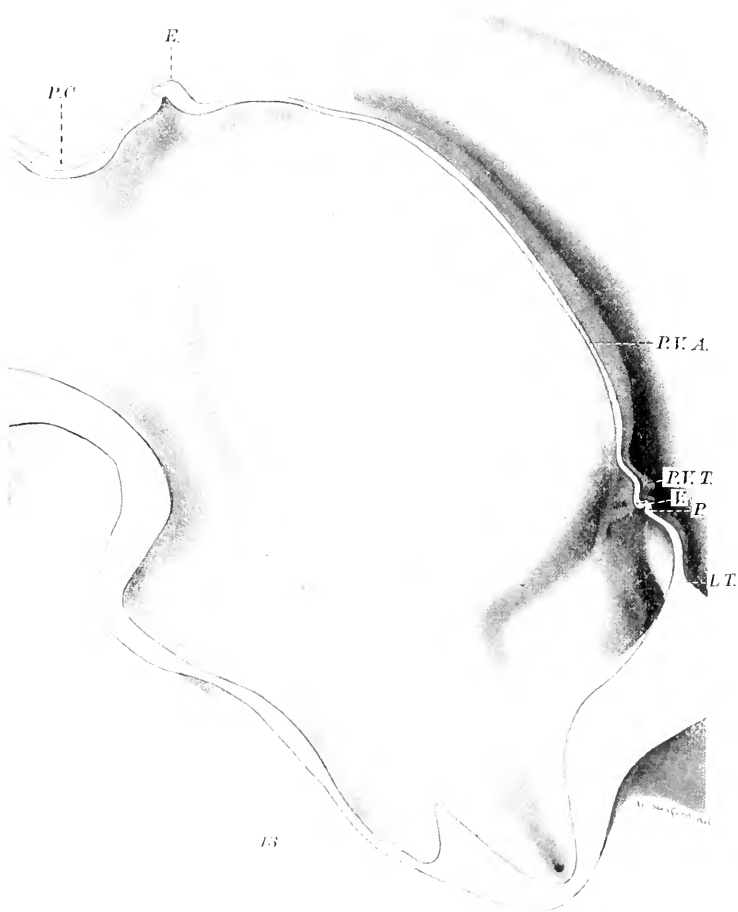


Fig. 43 Reconstruction showing development of the pineal region in man, 23 mm. embryo, according to John Warren, 1917.

L.T., lamina terminalis; *P.*, paraphysis; *V.*, velum; *P.V.A.*, Post-velar arch; *E.*, epiphysis; *P.C.*, posterior commissure.

The diencephalic choroid plexus and lateral telencephalic plexuses are well marked and develop essentially as described in other vertebrates. There is no trace of the median telencephalic plexus so noticeable in Amphibia.

The epiphysis forms a short hollow stalk with thick walls and inclined slightly backward over the posterior commissure.

The superior and posterior commissures are formed as in other vertebrates. The posterior commissure is characterized by its precocious development and by the extent that it invades the pars intercalaris of the forebrain in early embryos (fig. 44).

It will be observed that in the ontogenesis of each element in the epiphyseal complex, three distinct parts may be discerned in each of the two organs entering into it. Thus, the pineal organ may have an end-sac, a stalk, and a proximal portion, and the same is true of the parapineal organ. Considered in the light of comparative embryology, it will be seen that the most constant part throughout the phylum is the proximal portion of the pineal organ. This, beginning with a moderate prominence, as in the cyclostomes, rises to a very prominent element in selachians and maintains this prominence with somewhat of an increase in its importance throughout the entire series, with the single exception of crocodilia, in which the pineal body is said by Sorensen³⁶³ to be entirely wanting. On the other hand, the proximal portion of the parapineal organ shows a strikingly low percentage of occurrence throughout the phylum. It may perhaps be accredited to the cyclostomes, if one takes into account the thickened portion of the unusually large commissura habenularis, but thereafter in the series it seems to disappear entirely.

The next most constant structure in the epiphyseal complex is the end-vesicle of the pineal organ. This maintains a high degree of prominence in cyclostomes, selachians, ganoids, teleosts, urodeles and anura. It shows a conspicuous tendency to attenuate in the prosaurians and saurians and finally in the ophidians, and in all the orders thereafter it is notable for its absence. The analogue of the pineal end-vesicle, namely, the parapineal end-vesicle, is much more irregular in its occurrence throughout the phylum, but on the other hand, in certain forms it presents such

striking characteristics as to make it one of the most prominent and important elements in the epiphyseal complex. Its appearance in cyclostomes is almost as striking as the pineal end-vesicle, but its tendency to irregularity is noted by a complete absence

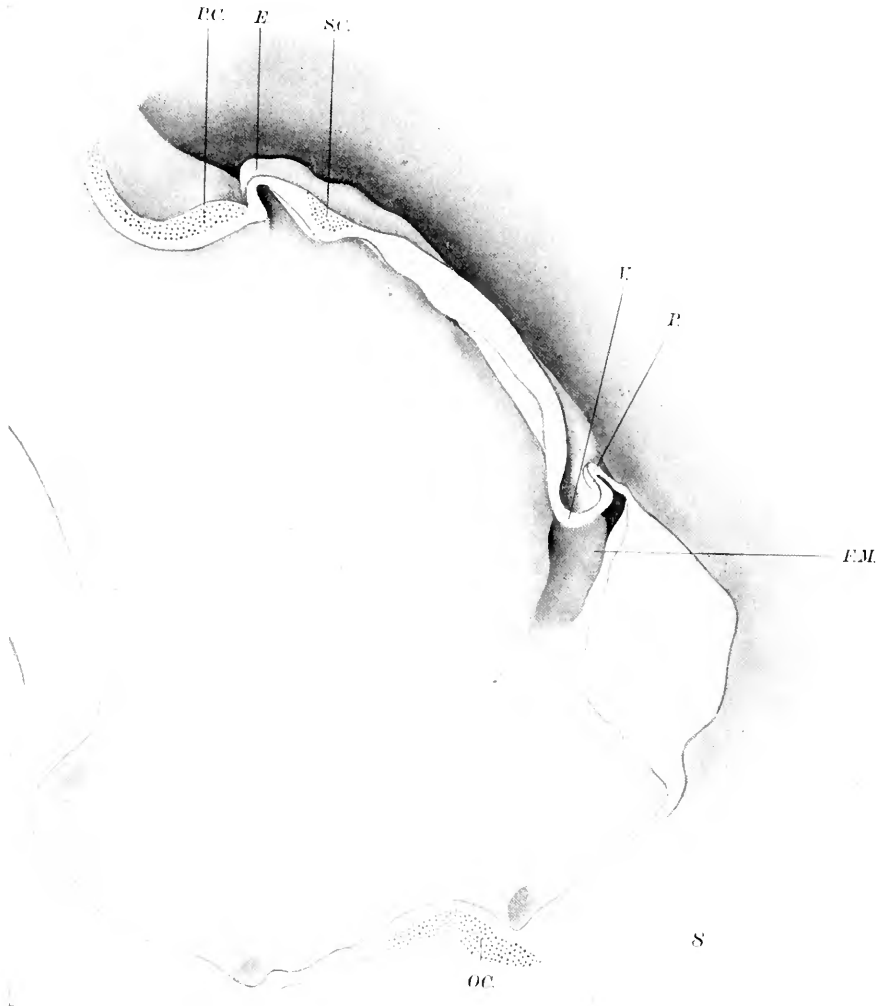

Fig. 44 Reconstruction showing the development of the pineal region of a sheep embryo of 48.4 mm., according to John Warren, 1917.

F.M., foramen of Monro; *P.*, paraphysis; *V.*, velum; *S.C.*, commissura habenularis; *E.*, epiphysis; *P.C.*, posterior commissure.

in the selachians. It makes a somewhat abortive appearance in the ganoids and teleosts. In urodeles and anura it disappears altogether but when again it does occur as a feature of the epiphyseal complex, it has assumed such proportions as to make it by far the most prominent structure in this area of the brain. In the prosaurians and the saurians, it is a most conspicuous element. As may easily be presumed, the pineal stalk and its analogue, the parapineal stalk, follow very closely the frequency of occurrence of the two end-vesicles. Thus the pineal stalk is present in cyclostomes, selachians, ganoids, teleosts, urodeles, anura, prosaurians and saurians, but disappears in the higher forms. The parapineal stalk is present in the cyclostomes, but does not appear in selachians. It has an abortive form in ganoids and teleosts, is absent in urodeles and anura, occurs in its most marked representation in prosaurians and saurians, and thereafter disappears altogether.

6. THE COMPARATIVE ANATOMY AND HISTOLOGY OF THE EPIPHYSEAL COMPLEX

In the light of the embryological development of the epiphyseal complex, the difficulties in the adult morphology of these organs are much diminished. The following description will deal with the comparative anatomy and histology of the two epiphyseal elements in the different classes of vertebrates and will be based upon the observations of the different species already investigated.

1. The comparative anatomy and histology of the epiphyseal complex in cyclostomes

The pineal organ in cyclostomes presents the three characteristic parts, namely, a proximal portion, a stalk, and an end-vesicle. Each of these is more or less highly specialized. The *end-vesicle* has the form of a small elliptical vesicle. In its longest diameter cephalocaudad, it is 0.35 mm. in length. This measurement was made in *Petromyzon* by Studnicka.³⁸⁴ It presents

certain parts, as for example, a dorsal wall and a ventral wall, which are to be distinguished from each other by certain histological features. These two walls bound a cavity or lumen concerning which there has been much discussion and to which the name of *atrium* is usually applied. Ahlborn² in 1883 states that this atrium presents a peculiar lacunar appearance.

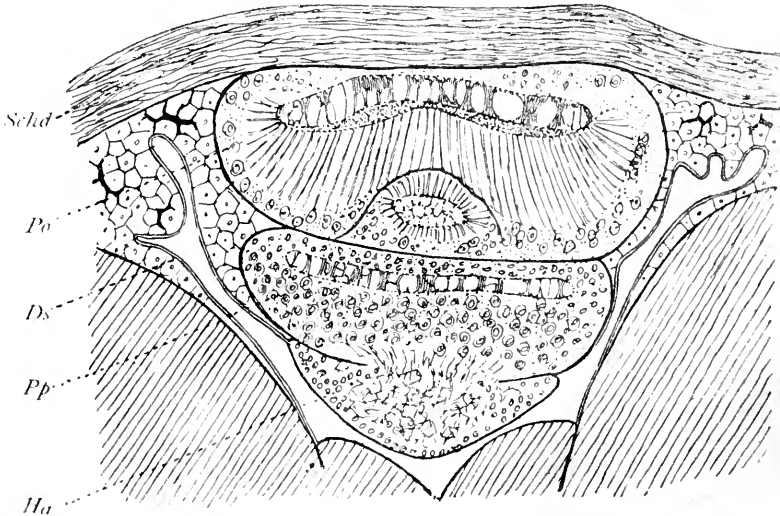


Fig. 45 Cross section of the epiphyseal complex in *Petromyzon*, according to Ahlborn, 1883.

Po., pineal organ; *Ds.*, dorsal sac; *Pp.*, parapineal organ; *Ha.*, habenular ganglion.

Beard¹⁸ in 1889 thought the atrium contained a coagulated fluid, and Owsianikow²⁹⁵ in 1888 was of the same opinion. Gaskell,¹⁴⁵ however, in 1890 found that the atrium of the pineal organ in *Ammocetes* was in reality filled with cellular tissue and, according to this observer, the pineal organ in these forms had a general structure which was similar to the composite eye of *Arthropods*. Leydig²³⁹ in 1896 found the atrium filled with what he calls secretory fibers extending inward from the retinal cells of the organ. Studnicka³⁵⁴ in the later stages of *Ammocetes* found in the lumen of the end-vesicle a peculiar,

fibroid, hyaline substance attached to the free end of the cells in the retina. This took on the form of a coagulum in the semifluid contents of the atrium. Later Studnicka³⁸⁸ in 1899 described in *Petromyzon marinus* similar hyaline bodies and showed that they were the thickened extremities of the retinal cells projecting into the lumen of the end-vesicle.

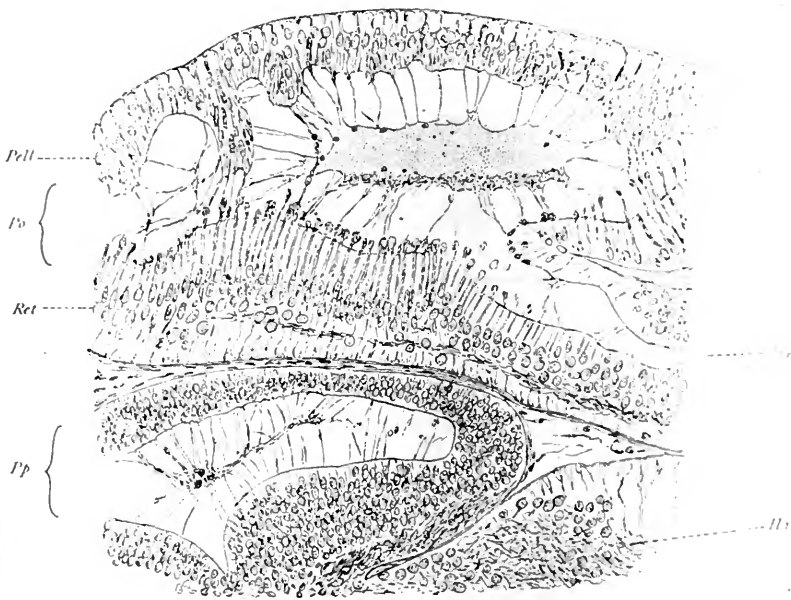


Fig. 46—Sagittal section of the epiphyseal complex of *Petromyzon flaviatilis* showing synectal masses in the Atrium, according to Studnicka, 1899.

Pell., pellucida; *Po.*, pineal organ; *Ret.*, retina; *Pp.*, parapineal organ.

In this way these processes from the retinal cells formed a virtual synectium which almost completely fills the atrium. Of the two walls forming the end-vesicle, the ventral wall presents certain characteristics which seem to justify the recognition in it of a retinal structure. For this reason the ventral wall is known as the *retina* of the pineal organ in cyclostomes. The dorsal wall has an entirely different structural character, and because it is quite without pigmentation is known as the *pellucida*.

The *retina* of the pineal organ in cyclostomes shows its most marked development in embryonic and larval stages. Beard¹⁷ in 1887 found in *Ammocetes* rod cells, and Owsiannikow²⁹⁵ in 1888 showed in *Petromyzon fluviatilis* that there were five distinct layers of cells and fibers in the retina. The first of these layers consisted of nerve fibers; the second, of large nerve cells; the third was fibrous; the fourth consisted of small cells interspersed among the large rod-shaped cells, and the fifth was an ependymal layer. Gaskell¹⁴⁵ in 1890 was able to find rod cells only in the retina of *Ammocetes*, and he was of the opinion that the so-called pineal eye in this form was a compound structure in which the light-receiving bodies were formations comparable to the rhabdites of the Arthropod eye. Studnicka ('93)³⁸⁴ recognized four layers of cells and fibers in the retina of cyclostomes. The first of these was a layer of nerve fibers, the second were basal cells, the third small cells, and the fourth, large cylindrical cells. Leydig²³⁹ in 1896 found two types of cells, an inner cylindrical and an outer layer of round cells. Retzius,^{331B} however, in 1895, could find no evidence of the sensory organ in the so-called pineal eye of cyclostomes and he did not consider it to be an eye. Mayer²⁶⁴ in 1897 found ganglionic cells in the retina, and Studnicka³⁸⁸ in 1899 found still more evidence of the retinal nature of the ventral wall of the end-vesicle.

The pellucida becomes best developed in *Petromyzon marinus*, for the dorsal wall of the pineal organ appears in the more or less constant form of a plane or convexed lens, the flattened surface of which is ectally directed. In *Petromyzon planeri* and *fluviatilis*, the pellucida is extremely irregular in its thickness as well as in its form. It must not, therefore, be maintained that even in those forms where the pellucida has a lenticular shape and arrangement that it is actually a lens structure. One feature about it, however, suggests that it is an organ designed for the transmission of light rays, namely, its almost complete lack of pigment except perhaps at the peripheral edges where it passes over into the ventral wall or so-called retina of the pineal eye. This lack of pigment led Carrière³⁷ in 1890 to call the dorsal wall

of the pineal organ the *pellucida*. Histologically the pellucida is, according to Ahlborn² made up of cells of considerable size together with connective tissue. Owsianikow²⁹⁶ found both fibers and small cells. Whitwell⁴²¹ and Beard¹⁸ in 1888 found

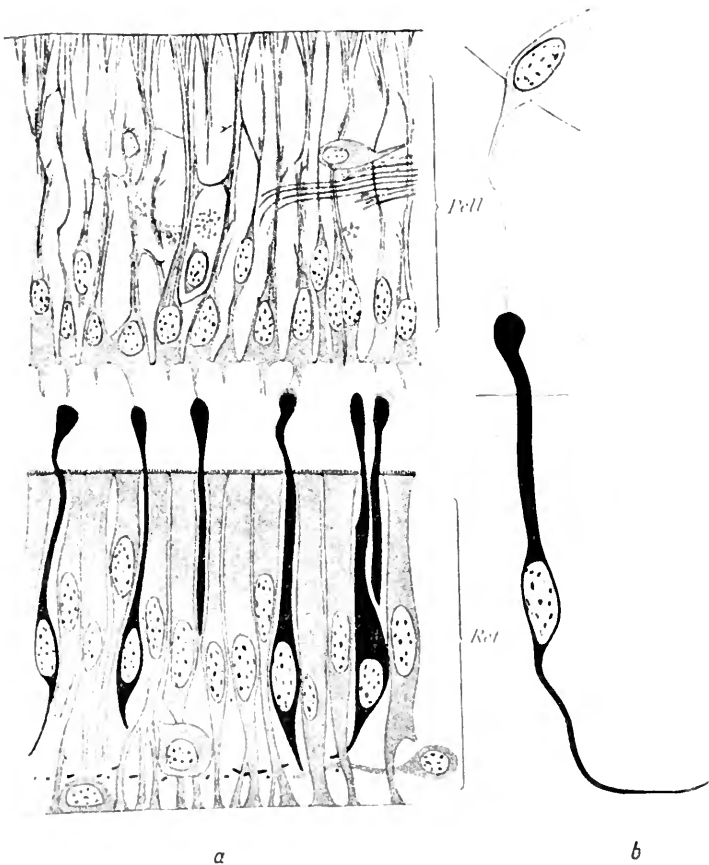


Fig. 47 Retina and pellucida of the pineal organ in a full-grown *Petromyzon marinus*, according to Studnicka, 1899.

Pell., pellucida; *Ret.*, retina.

that the pellucida consisted of cylindrical cells. Gaskell¹⁴⁵ in 1890 observed cylindrical and small cells, and Studnicka³⁸⁸ as well as Retzius^{331b} found that the structure was made up almost exclusively of large cylindrical cells.

The white pigment of the retina. Mayer²⁶⁵ in 1864 observed that the epiphyseal complex in *Petromyzon* contained many calcium bodies. Subsequently Ahlborn² made the observation that there were a large number of small bodies of a peculiar white substance which he called the *white pigment* and regarded it as similar to the brain sand of the higher vertebrates. This white substance filled in the cells of the retina in such a way as to prevent the passage of transmitted light and to give the appearance of a glistening white when illuminated. According to Studnicka,³⁸⁸ this pigment does not appear in *Ammocætes* younger than those of 50 mm. in length, but thereafter gradually increases in amount until the adult form is attained. Leydig²³⁹ in 1896 differentiated two kinds of pigment bodies—those which are small in amount, of a dark brown black color and those of the second type which by transmitted light appear to be a brownish yellow. By direct light these pigments appear to be white.

The stalk of the pineal organ in cyclostomes. In cyclostomes the pineal stalk becomes much reduced in size and it completely loses its lumen in the adult. It becomes conspicuous, however, by the development in it of certain nerve fibers whose collected bundle was first called by Leydig²³⁹ in 1896 the 'Zirbelnerv.' This structure, later in 1898, was called by Gaupp¹⁴⁷ the *tractus pinealis* and finally the *nervus pinealis* by Studnicka.³⁸⁸ This pineal nerve established a fiber connection between the peculiar organ situated beneath the roof-plate and known as the pineal eye in cyclostomes, and the roof of the brain. The fibrous nature of its structure was first observed by Whitwell¹²¹ in 1888. Owsianikow²⁹⁵ noted that in addition to the nerve fibers there were to be observed in the pineal stalk a bundle of fine nerve fibers. The diameter of these fibers, according to his measurement, was 50 micra. Running with the nerves were numerous blood vessels. Gaskell¹⁴⁵ could not distinguish whether nerve fibers or processes of cells made their course within the nerve sheaths. It was only at the entrance of the nerve into the eye that he found a lumen. Studnicka,³⁸⁸ however, maintained that the stalk was an actual nerve and therefore applied to it the term

nervus pinealis. He was able to trace the nerve fibers from the so-called retina of the pineal eye into the stalk. Retzius^{331b} in 1895, using Golgi preparations in *Ammocetes*, was able to demonstrate the actual presence of nerve fibers of the pineal nerve which he followed from the pineal organ to the brain. This observation in similar preparations was confirmed by Mayer²⁶⁴ in 1897. Leydig²³⁹ in 1896 found in *Petromyzon fluviatilis* that nerve fibers were present only in the proximal third of the stalk, while Johnston¹⁹⁵ in 1902 in *Lampetra wilderi* found that the nerve fibers in the proximal portion of the stalk seemed to be obliterated in some preparations. The pineal nerve has a definite sheath of its own consisting of elements similar to those covering the brain. There is a *membrana limitans externa* composed of neuroglia. Surrounding this is a layer of pia mater and still more externally a process from the dura mater.

The central endings of the *nervus pinealis* have been traced by Ahlborn² and Gaskell¹⁴⁵ to the posterior commissure. Gaskell showed that the nerve was connected with the right habenular ganglion and that this nerve structure was, therefore, the optic ganglion of the pineal eye. Studnicka³⁸⁸ followed some of the fibers to the inner portion of the posterior commissure. He thought that the *pineal nerve* ended in the left habenular ganglion while the nerve of the parapineal organ ended in the right structure of this name. Mayer²⁶⁴ traced the fibers by means of silver impregnation to the posterior commissure. The proximal portion of the pineal organ in cyclostomes is much reduced in size because of the close approximation between the posterior commissure and the commissura habenularis. A small recess, however, marks the position of the proximal portion in these forms and is situated between the two commissures just mentioned. This is the *recessus pinealis*. The pineal organ in cyclostomes has been called the epiphysis, the epiphysis cerebri, and the superior vesicle of the epiphysis, according to Ahlborn in 1883.²

The parapineal organ in cyclostomes. The more cephalic of the two epiphyseal elements in cyclostomes has been called by

Studnicka³⁸⁸ the parapineal organ. According to Ahlborn,² it was the inferior vesicle of the epiphysis. Owsianikow²⁹⁵ termed it the visceral vesicle, while it was called by Kupffer²²² the paraphysis. It presents an end-vesicle, a stalk, and a proximal portion. In its general form it resembles the pineal organ and is situated as a more or less distinct vesicle between the pineal organ and the roof of the brain in the region immediately cephalad to the habenular ganglion and the commissura habenularis. The vesicular portion is in relation with the habenular ganglion, being situated dorsal to it, while the stalk and proximal portion are in relation with the commissura habenularis. In size the parapineal organ is considerably smaller than the pineal organ, and though it varies considerably in this respect, the following tabulation made by Studnicka³⁸⁸ shows the general dimensions of the organ in *Ammocoetes* and *Petromyzon planeri*. These figures apply to the end-vesicles.

	PINEAL ORGAN	PARAPINEAL ORGAN
	<i>mm.</i>	<i>mm.</i>
23 mm. <i>Ammocoetes</i>	0.23	0.105
26 mm. <i>Ammocoetes</i>	0.15	0.12
30 mm. <i>Ammocoetes</i>	0.15	0.09
49 mm. <i>Ammocoetes</i>	0.22	0.15
94 mm. <i>Ammocoetes</i>	0.24	0.14
117 mm. <i>Ammocoetes</i>	0.31	0.20
<i>Petromyzon planeri</i>	0.35	0.25

Ahlborn² in 1883 found that the parapineal organ in general has the same form, although it is smaller than the pineal organ while the cellular elements in the two structures correspond very closely. The lumen of the parapineal organ contains a fibrous tissue having many histological features in common with that in the pineal organ. Beard¹⁸ in 1889 found the parapineal organ in *Ammocoetes* only a little less developed than the pineal organ, in which opinion Gaskell¹⁴⁵ concurs. In *Petromyzon fluviatilis*, Owsianikow²⁹⁵ in 1888 found that the parapineal organ was smaller than the pineal organ, but in no other way different from the latter. The end-vesicle contained a retina

in which there were several layers of cells, including rod- and cylindrical-shaped cells measuring from 7.4 to 8.3 micra in diameter. There were also some larger cells scattered among the rod cells with a mean diameter of 14 micra. He found in the retina many nerve fibers which made their way into a definite fasciculus constituting a parapineal nerve. Studnicka³⁸⁸ did not agree wholly with Owsiannikow in the idea that the parapineal end-vesicle was as well developed as the corresponding structure of the pineal organ. He states that the difference between these two structures is the fact that the parapineal

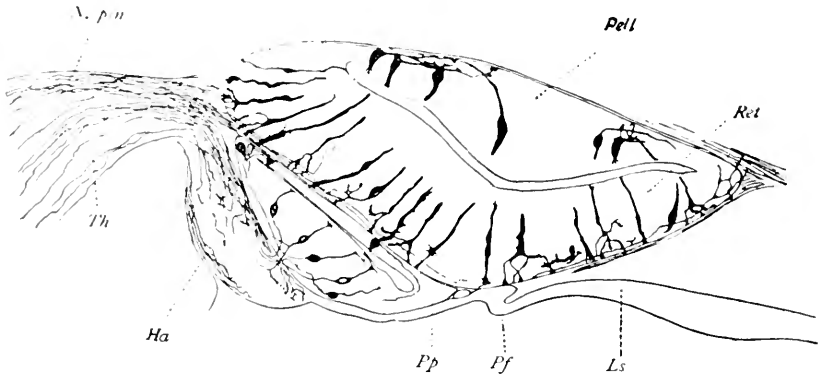


Fig. 48. Sagittal section of the pineal and parapineal organs in *Ammocetes* with silver impregnation, according to Retzius, 1895.

Ls., lamina terminalis; *Pf.*, paraphysis; *Pp.*, parapineal organ; *Ha.*, habenular ganglion; *Ret.*, retina; *Pell.*, pellucida; *N. pin.*, pineal nerve.

end-vesicle is not as highly developed a retinal structure as is the case with the pineal end-vesicle. Studnicka, however, finds that there is in the dorsal wall of the parapineal vesicle a definite pellucida made up of several layers of cells. Those cells identified in the retinal layer by Owsiannikow²⁹⁵ and Studnicka³⁸⁸ as the rod cells were recognized by Retzius^{331b} in 1895 by means of the Golgi method as bipolar cells.

By this method Retzius^{331b} was able to trace nerve fibers which took origin in the left habenular ganglion and passed to the parapineal end-vesicle. Leydig²³⁹ in *Petromyzon fluviatilis* found that the parapineal end-vesicle was less developed, but at

its base he was able to discern fibers which seemed to cross to the opposite side. These nerve fibers extended backward from the cells in the parapineal organ. Leydig was unable to identify any structure which he considered a retina or a lens. The stalk in the adult form becomes reduced to a mere strand containing fibers which by many authors are considered to be nerve fibers. The primitive lumen present in the stalk of the parapineal organ very early disappears and the proximal portion rapidly becomes inconspicuous and finally is lost by the marked development of the commissura habenularis.

The majority of investigators who have studied this part of the brain in cyclostomes are in accord along several general lines. They believe that the cells found in the parapineal end-vesicle are ependymal cells, spindle or rod cells, and some sensory cells. It is also their opinion that there are nerve fibers connecting these cells situated among which are larger ganglionic elements from which the fibers may take their origin. In a general way the same constituents occur in the retina of the parapineal organ as are present in the pineal organ. The main differences between these two structures consist in the size and disposition of their respective elements. In the adult the parapineal organ is situated upon the most anterior portion of the membranous forebrain roof while directly in front of it is the paraphysis and above it the pineal vesicle. Situated in this position the two end-vesicles of the epiphyseal complex have the appearance of a pair of eyes which are rudimentary and which, in attempting to assume visual function, have morphologically fallen short in the attainment of that object. It should be noted that their position places them in the midsagittal plane, one behind the other, and that according to the most reliable evidence concerning cyclostomes available at the present time, there is no definite tendency toward lateralization in one or the other of these elements in the epiphyseal complex. The two end-vesicles, practically in contact with each other, occupy a deep fossa formed by a depression on the inner surface of the skull. This fossa is especially well marked in adults and more particularly in *Petromyzon marinus*.

What has been termed a parietal cornea of the pineal eye consists of a layer of almost fiberless tissue of considerable thickness between the dorsal surface of the pial capsule and the inner surface of the bony depression in the skull. The epidermis immediately above this so-called cornea is quite without pigment, forming a small, circular area in the frontal region of the head situated almost immediately in the midsagittal line. This area was recognized long before its significance was understood and was described by Whitwell⁴²¹ in 1888, by Ahlborn² in 1883, and by Gage¹³⁵ in 1893. Gaskell¹⁴⁵ in 1890 erroneously likened a cranial thickening above the pineal organ in *Ammocetes* to the cuticular lens of Arthropods. Studnicka³⁸⁴ in 1893 found that the cornea is discernible in the 25 mm. *Ammocetes*. Gaskell,¹⁴⁵ in his discussion of the origin of vertebrates from a crustacean-like ancestor, makes the statement that in *Ammocetes* there are two pineal eyes, one, dorsally placed, much larger and intensely white in color, lies in front of the right habenular ganglion. The other, ventrally placed, is an insignificant structure. The first is similar to the crustacean parietal eye in its pigmentary character. The second is similar to this eye in crustacea because of the termination of the nerve endings with the attached rhabdites. According to Gaskell, the type of eye is clearly arthropodic. The arrangement of the nerve endings, the shape of the internal cavity, and the position and simplicity of the attached rhabdites all point to larval characteristics and, therefore, to an ancient type. The anterior wall is not a lens. Gaskell believes the lens is cuticular in character and, if so, this is all the more reason for believing that the pineal eye is definitely arthropod in type.

Much emphasis has been laid upon the occurrence in cyclostomes of these two structures which have so many characteristics suggestive of visual function. The statement has been made that this is competent evidence upon which to establish the claim that in vertebrates the parietal or third eye was primitively paired. It is to be noted, however, that in no other class of vertebrates does the duality of the parietal visual apparatus, if such indeed it may be considered, attain such a high degree of

development. One or the other element of the epiphyseal complex may show the tendency toward the development of visual characteristics, but in no other form do both of these elements take on these features so suggestive of visual function.

Differences observed in the epiphyseal complex of the various species of cyclostomes already investigated. Although all of the three European forms of *Petromyzon* have been carefully studied by several investigators, the differences between them are not striking. This statement also applies to the North American form, *Lampetra wilderi*, described by Johnston¹⁹⁵ in 1902.

1. *Petromyzon planeri*. Ahlborn ('83),² Beard ('89),¹⁸ Whitwell, ('88)⁴²¹ and Studnicka ('93).³⁸⁴ The epiphyseal complex as a whole is not separated as far from the brain as in other forms, due to the fact that the paraphysis and dorsal sac are but little developed. The parietal fossa is very shallow and is absent in *Ammocætes* as is also the white pigment.

2. *Petromyzon fluviatilis*. Ostroumoff ('87),²⁹¹ Owsianikow, ('88),²⁹⁵ Leydig, ('96)²³⁹ and Studnicka ('99).³⁸⁸ In this form the evagination of the roof is very high and the fossa in the skull of considerable depth. The atrium contains a definite syncytium made up of processes not only from the retinal cells, but also from those situated in the pellucida as well.

3. *Petromyzon marinus*. Studnicka ('99).³⁸⁸ Although the dorsal sac is extremely high, the depression in the skull is no deeper than in the case of *Petromyzon fluviatilis*.

4. *Petromyzon wilderi*. Johnston ('02).¹⁹⁵ In this form the stalk of the pineal organ has not the significance as in other forms, for the pineal nerve is absent and the stalk contains no nerve fibers.

5. *Mordacia mordax*. Spencer ('90).³⁶⁹ In this form the pineal organ presents a thin, pigmented upper wall corresponding to the pellucida of *Petromyzon* and a thicker ventral wall in the form of a retina. No definite statement is made as to the presence of an atrium, although the lumen of the organ is said to be filled by a coagulum. There is no evidence of any parapineal organ, but on the surface of the head, midway between the paired eyes, there is a parietal spot.

6. *Myxine glutinosa* (*Bdellostoma*). Kupffer ('04).²²⁶ In this form there is no anlage of the epiphysel complex whatsoever. The roof is entirely flat, but in spite of the absence of the epiphysel complex, both habenular ganglia are present. Such descriptions of the epiphysis in *Myxine* as appear in the literature seem to be an error. Andrae Retzius^{331A} in 1822 described the pineal body in connection with the habenular ganglion, interpreting the latter to be the epiphysis. Leydig²³⁹ in 1896 believed that he had found in *Myxine* the pineal body, but in reality mistook a large lymph space near the surface of the head for this organ. Studnicka,³⁸⁸ however, in his studies was unable to find any evidence of the pineal body in *Myxine*.

2. *The comparative histology and anatomy of the epiphysel complex in selachians*

Since the pineal organ is the only part of the epiphysel complex to make its appearance in selachians, the structure is much more simple than in cyclostomes. Furthermore, such parts of the pineal organ as do develop in selachians are relatively rudimentary. All of the three usual elements of the pineal organ, however, may be identified; that is to say, a hollow end-vesicle, a stalk, and a proximal portion. The end-vesicle in no instance presents the two distinct walls, namely, the ventral and dorsal walls distinguishable in cyclostomes, and the end-sac itself is much smaller than in the forms already considered. Slight differences in the thickness of the wall of the end-vesicle may be observed in different places, but with no great uniformity. In consequence of this lack of differentiation, there is no evidence of the formation of a retina, of a pellucida, or of a white substance, nor do any nerve fibers make their appearance in connection with the end-vesicle. In fact, it is a question whether the pineal organ of selachians is a primitive structure or one that is distinctly retrograde. In form there may be a considerable difference in the terminal vesicle; it may be wedge-shaped, cylindrical, conical, or flattened, but in all instances it is hollow, containing a lumen, in spite of the statement of Cattie⁶⁰ to the contrary in his descriptions of *Mustelus*, *Raia*, and *Acanthias*.

Frequently the wall of the vesicle presents reduplication, as in the case of *Spinax niger* where there is a distinct tendency to lobulation, or as in *Acanthias* where the folding of the wall results in the production of two adjacent vesicles. In a single instance only is there a marked differentiation between the ventral and dorsal walls. This occurs in *Lamna cornubica*, particularly in the embryonic state, described by Carrington⁵⁸ in 1890. In this form the under wall was thicker than the dorsal wall. Studnicka³⁸⁹ found some tendency to such a differentiation in *Spinax*.

Histologically, the walls of the end-vesicle are made of ependymal cells, but there are no cylindrical or spindle cells to be observed in this structure. The cells described in cyclostomes as having prolongations of such a character as to warrant the description of ciliated cells are absent in selachians so that no such processes make their way into the lumen of the end-vesicle, as is the case in *Petromyzon*. The nuclei of these cells are situated at varying distances from the surface of the wall so that the ependyma gives the impression of stratified epithelium, whereas in reality it is a single layered epithelial structure. Some cells have a rather long process which approach, but do not enter, the lumen of the end-vesicle. This manifestation is taken as a probable sign of an excretory function of the cells in question. Galeotti¹⁴⁰ in 1896 described in *Scyllium* peculiar appearances which seemed to indicate a secretory or excretory activity on the part of the cells in this portion of the pineal organ. Among the more usual cells, according to Studnicka,³⁸⁹ there are many smaller cells scattered here and there of a similar type to the sense cells in the retina of *Petromyzon*. The significance of these cells is not at all clear, and Studnicka himself is not willing to accredit them with a definitely receptor function.

The stalk of the pineal organ. Macroscopically, this appears to be a long, narrow strand connecting the end-vesicle with the roof-plate of the interbrain. Upon microscopic examination it is found, however, to contain a central but narrow lumen, the entire structure, therefore, being tubular. In most instances this stalk maintains an equal diameter throughout its entire

extent, although in certain cases it becomes much attenuated as it approaches the end-vesicle. A few nerve fibers course in the dorsal wall of this hollow stalk, but these cannot properly be considered the homologue of the pineal nerve in selachians.

The proximal portion in selachians may be readily made out. As the stalk approaches the roof of the interbrain, it gradually becomes dilated and increased in its transverse diameter. Its lumen becomes larger and the walls bounding it are thrown into numerous folds. Although the transition from stalk to proximal portion is gradual, it is nevertheless distinct. In a few cases

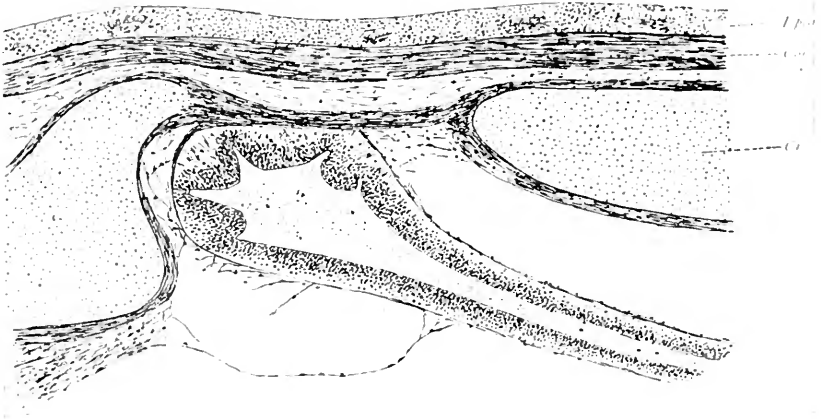


Fig. 49 End-vesicle in the pineal organ of *Acanthias vulgaris*, according to Studnicka, 1893.

only, such, for example, as *Centrophorus*, described by Cattie⁶⁰ in 1882, is there an absence of this reduplication of the walls of the proximal portion. As the dorsal wall of this portion approaches the posterior commissure there appear in it a few strands of nerve fibers constituting what may be called the *tractus pinealis*. It is doubtful, however, whether the commissura habenularis receives any of the fibers which enter into the formation of this tract.

The sheaths of the pineal organ are the same as those in *Petro-myzon*, namely, a membrana limitans externa, a process from

the pia mater and another from the dura mater. Some authors, among them Cattie,⁶⁰ have described a parietal foramen. In *Acanthias vulgaris* this opening in the cartilaginous skull appears to be doubled, the two openings being separated by a small, cartilaginous bridge. Neither Studnicka³⁸⁹ nor Ehlers¹⁰⁸ was able to discover any such openings in the forms which they investigated. The parietal cornea is absent and the parietal spot is very infrequently observed.

Differences observed in the epiphyseal complex of the various species of selachians already investigated.

ELASMO BRANCHI

1. *Scyllium canicula* and *catulus*. Balfour ('78)¹⁰ studying the embryonic development; Owsianikow ('88),²⁹⁵ studying the conditions in a 65 mm. embryo; Cattie ('82),⁶⁰ in the adult, and Galeotti ('96),¹⁴⁰ studying the histology. The proximal portion in these forms is not well developed and the end-vesicle is conical. The middle piece or stalk is cylindrical in shape. The structure, according to Galeotti, shows stellate cells and ependymal cells, in addition to which, there are certain cells which are definitely fuchsinophile, which, according to this observer, indicate secretory function because he considers these granules secretory in their nature.

2. *Acanthias vulgaris*. Ehlers¹⁰⁸ in 1878 and Cattie⁶⁰ in 1882. In this form the proximal portion is thicker than the stalk and both are of unusual thickness for selachians. The end-vesicle, according to Cattie, is solid. Its walls show much reduplication and the lumen is solidly filled with a syncytium. There is a definite parietal foramen.

3. *Echinorhynchus spinosus*. Jackson and Clarke ('75)¹⁹³. The pineal organ in this form is a long, strand-like body extending far over the telencephalon in the midsagittal plane.

4. *Galeus canis*. Cattie ('82).⁶⁰ A conical end-vesicle and a conical proximal portion with a strand-like stalk characterize the pineal organ in this form. The end-vesicle and the stalk are solid while the proximal portion retains its lumen and has, in addition, many small accessory canaliculae.

5. *Mustelus lavis*. Cattie ('82).⁶⁰ In this form the pineal organ is extremely simple, consisting of an end-vesicle, a stalk, and a proximal portion. The end-vesicle is flat and shows no tendency toward reduplication.

6. *Centrophorus granulosus*. Cattie ('82).⁶⁰ The end-vesicle in this form has a hammer-shaped appearance. The stalk is strand-like and the proximal portion conical. The pineal organ is hollow throughout its entire course. A marked parietal depression lodges the structure and this is surrounded by connective tissue.

7. *Lamna cornubica*. Carrington ('90).⁵⁸ This form presents an end-vesicle which is conical and a stalk which is cylindrical. Both contain an irregular lumen. The ventral wall of the end-vesicle is thicker than the dorsal wall. The cells in this vesicle are for the most part ependymal, although there are many others scattered among the cells of this character. The pineal organ is lodged in a depression surrounded by connective tissue and there is a corresponding slight depression in the epithelium above the organ.

8. *Spiuax niger*. Studnicka ('93).³⁸⁴ In embryos, larval and adult forms, this species presents all three portions of the pineal organ. It is slender and directed at right angles to the roof-plate in the embryo, is slightly bent in larval forms, and is flexed at right angles in adults. The end-vesicle is pressed into a cartilaginous skull, although there is no actual parietal foramen. The parietal portion consists of ependymal cells and neuroglia cells. A parietal spot is present in the form of an oval white area. There is, however, no parietal cornea.

9. *Notidanus griseus*. Studnicka ('93).³⁸⁴ The entire pineal organ in this form is sharply flexed forward above the forebrain. The proximal part is not particularly developed, but in other respects has the same general form as other species.

10. *Pristiurus melanostomus*. d'Erchia ('96)¹⁰⁹ and Minot ('01).²⁷⁷ Here the pineal organ extends directly forward in the horizontal plane above the forebrain in the midsagittal plane. The end-vesicle is much attenuated and the stalk is merely a strand-like connection between the former and the roof-plate

of the interbrain. There is a small conical, proximal portion. Cattie⁶⁰ states that the parietal foramen is closed only by the dura mater.

RAIIDAE

1. *Raia clavata*. Ehlers ('78);¹⁰⁸ Cattie ('82).⁶⁰ In this species a thin, long stalk extends far forward and terminates in a definite end-vesicle which is enclosed in a deep prefrontal fossa.

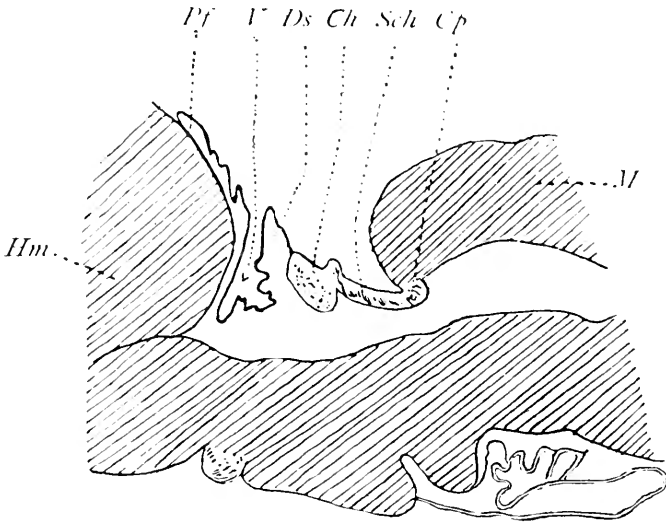


Fig. 50 The pineal region of *Torpedo ocellata*, according to d'Erchia, 1896.

Hm., hemisphere; *Pf*, paraphysis; *V.*, velum transversum; *Ds.*, dorsal sac; *Ch.*, commissura habenularis; *Sch*, pars intercalaris posterior; *Cp*, posterior commissure; *M.*, midbrain

2. *Raia foliatica*. Studnicka ('95).³⁸⁵ The pineal organ here is found as a thick stalk with a lumen. There is no special proximal portion. In the lumen there is a syncytium.

3. *Myliobatis aquila*. Studnicka ('95).³⁸⁵ In this form, as in *Raia clavata*, the stalk is tubular and reaches from the interbrain to the roof of the skull. The end-vesicle is dorsoventrally flattened and rests in the region of the prefrontal fossa, which latter shows but a slight deepening in the skull.

4. *Torpedo marmorata*. Studnicka ('95).³⁸⁵ In this form the pineal organ fails to appear, although there are present two well-developed ganglia habenulae.

5. *Torpedo ocellata*. d'Erechia ('96).¹⁰⁹ No evidence of developmental differentiation into a pineal organ was found in the early stages of this form. A well-developed paraphysis, however, is present.

HOLOCEPHALI

1. *Callorhynchus*. Parker and Haswell ('97).³⁰²

2. *Chimaera monstrosa*. Studnicka ('96).³⁸⁶ In both of these forms there is a well-defined epiphysis and a large dorsal sac. The pineal organ has a form similar to other selachians; that is to say, a fairly well-marked proximal portion, a long, slender stalk extending forward and expanding slightly to form an end-vesicle at its extremity.

In all, seventeen species of selachians have been examined; that is, ten *Elasmobranchs*, five *Rays*, and two *Holocephali*. In two species a complete absence of the pineal organ is reported, namely, *Torpedo ocellata* and *Torpedo marmorata*. All of the other species present a pineal organ more or less well developed. In one form, that is, *Galeus canis*, histological evidence has been presented showing that there is some reason to believe that a secretory function obtains in the pineal organ of this form. Wherever mention is made of the paraphysis it seems to be an organ of considerable size.

3. Comparative anatomy and histology of the epiphyseal complex in ganoids

In all the species of Ganoids there develops a fairly well-marked pineal organ. In one form only, namely, *Amia*, is there any indication of the presence of a parapineal organ. Stannius,³⁷³ giving the first description of the structure of the parapineal organ in *Acipenser sturio* in 1854, states that the structure is a wide evagination extending from the roof of the interbrain and connected with the commissura habenularis. It reaches forward to a fossa in the roof of the skull. Cattie⁶⁰ in 1882, also in *Acipenser sturio*, and Coronowitsch¹⁵³ in 1888, on *Acipenser ruthenus*, gave similar descriptions of the pineal organ. Garman¹¹³ in 1896 and Johnston¹⁹¹ in 1901 by means of the Golgi

method described the structure in *Acipeaser rubicundus*. Both observers were able to differentiate a saecular proximal portion resembling the recessus pinealis, a thin, dorsoventrally extending stalk, the latter producing a groove in the dorsal surface of the dorsal sac, and finally an end-vesicle greatly dilated. The end-vesicle was of considerable size and contained a well-marked cavity.

Its walls showed no tendency to differentiation into a dorsal pellucid layer or a ventral retinal layer. According to Studnicka,³⁵⁶ the entire end-vesicle consists of rather long cylindrical

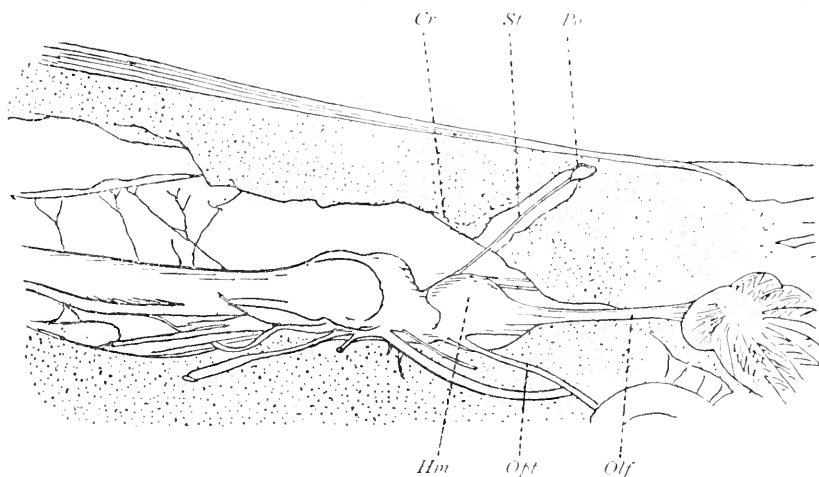


Fig. 51 The pineal region in *Polyodon folium*, according to Garman, 1896.

Olf., olfactory lobe; *Opt.*, optic nerve; *Hm.*, hemisphere; *Po.*, pineal organ; *St.*, stalk.

cells with a generally oval nucleus and two processes, one a slender extension reaching in toward the lumen of the pineal organ and the other a more diffuse ending, extending toward the ectal surface of the wall. Scattered here and there among these cells, which are in the majority, are a number of large elements more distinctly oval in character with a rounded nucleus situated near the center. Some smaller elements are also found scattered more numerous among both types of cells. Studnicka describes them, first, as ependymal cells; second, as sense cells, a larger-sized cell which he thinks may

be ganglionic cells, and, third, neuroglia cells which are smaller and generally more deeply situated elements in the walls of the end-vesicle. The stalk is strand-like in appearance and may

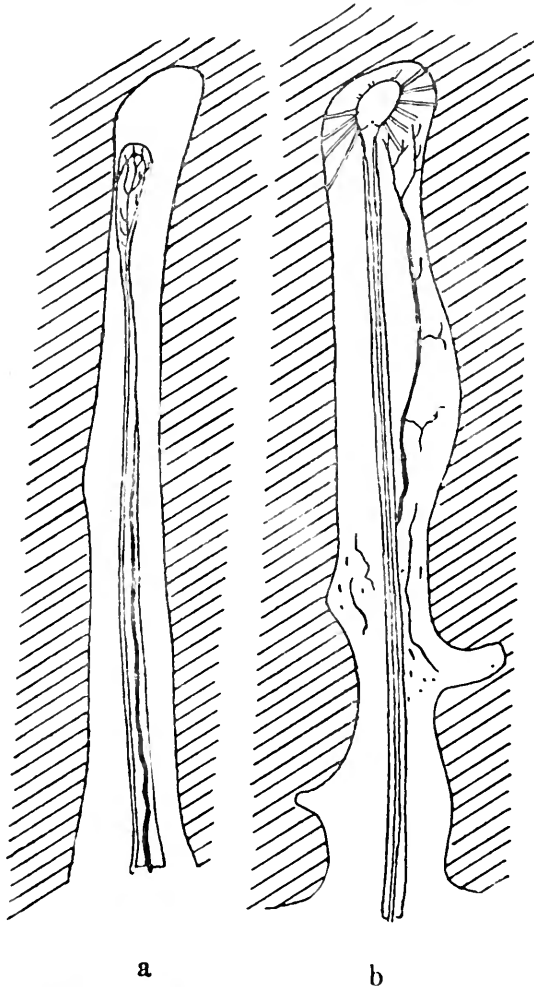


Fig. 52 a, Pineal organ in *Acipenser rubicundus*. b, Pineal organ in *Polyodon folium*.

contain a lumen in part of its extent or else running the entire length from the roof-plate end-vesicle. Its walls are made up of small neuroglia cells, while in the more dorsal of the two walls

Johnston¹⁹⁴ found a number of nerve fibers constituting a layer which extends from the proximal portion to the commissura habenularis, where it apparently undergoes decussation forming the so-called *decussatio epiphysis*. These observations were made by means of the Golgi method. Other fibers end freely between the cells of the stalk. These cells, Johnston thinks, are rudimentary or degenerated nuclei, perhaps related to the pineal

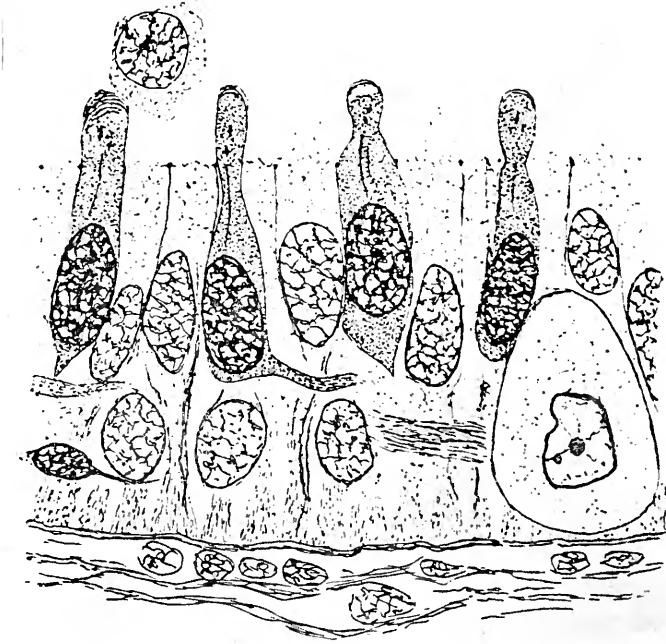


Fig. 53 Histological structure of the wall of the pineal organ in *Acipenser sturio*, according to Studnicka, 1893.

eye. He found a third type of fibers in a decussation which comes into relation with the ganglia habenulae. Herrick¹⁷⁷ in 1891 also mentioned such fibers in *Acipenser*. The proximal portion consists, in the main, of small neuroglia elements with some nerve fibers running in it, as already described. Studnicka³⁸⁶ does not think that there is any indication of a glandular activity in this part of the pineal organ which is in any way comparable to that of the proximal portion in the pineal organ of selachians.

Differences observed in the epiphyseal complex in the various species of ganoids already investigated

1. *Acipenser sturio*, *ruthenus*, and *rubicundus*. Cattie ('82),⁶⁰ Goronowitsch ('88),¹⁵³ Garman ('96),¹⁴³ and Johnston ('01),¹⁹⁴ The conditions in these forms have been described above.

2. *Lepidosteus ossesus*. Balfour and Parker ('82).¹² The pineal organ in this form was first mentioned by these authors and later by Sorensen³⁶³ in 1894, who described the structure as having a distinctly saecular form.

3. *Amia calva*. Goronowitsch ('88)¹⁵³ and Gage ('93).¹³⁵ Both of these authors showed that the pineal organ was a simple sac in this species. Hill¹⁵⁰ in 1894 found in the embryonic stages evidences of both parietal organs, namely, what he calls the anterior epiphysis and the posterior epiphysis which probably corresponded to the parapineal and pineal organs in *Petromyzon*, while the anterior epiphysis is considered the homologue of the parietal eye in *Saurians*. In the later embryonic stages the connection with the brain of the anterior sac is lost. Finally the pineal organ is pushed to the left side. Eycleshymer¹¹² found that the anterior organ has a lumen as late as the 15 to 16 mm. embryo. Nerve fibers were observed as late as the 12 to 13 mm. embryo going from the commissura habenularis to the interior of the anterior organ. Kingsbury²⁰⁵ in 1897 observed both the pineal and parapineal organs in the adult *Amia*. The anterior organ was lying to the left of the pineal stalk and was connected with the left habenular ganglion by means of a thick, neural fasciculus.

4. *Polyodon folium*. Garman ('96).¹⁴³ This species possessed processes which look like nerve fibers. These processes go from the interbrain roof and extend out to an end-sac deeply situated in a parietal fossa of the skull. In one case only was there a complete parietal foramen.

5. *Polypterus bichir*. Waldschmidt ('87)⁴¹²

6. *Polypterus senegalus*. Waldschmidt.⁴¹² Both of these species of *Crossopterygii* present a pineal organ which has a tubular stalk and rises above the dorsal sac, first upward, then turns sharply forward to end in a slightly dilated end-vesicle.

The walls of the organ have, in addition to the usual ependymal cells, some special sensory cells. In the lumen are free cells with no particular syncytial formation.

In the ganoids no mention is made of any evidence indicative of glandular activity. Six ganoids in all have been carefully studied and in only one, as already stated, are there signs of the parapineal organ, namely, in *Amia*, otherwise all species present a pineal organ which is not as well developed as in the selachians.

4. Comparative anatomy and histology of the epiphyseal complex in teleosts

The epiphyseal complex in teleosts differs from that in selachians and ganoids in its greater size. In some forms, however, it is only rudimentary, being but a solid bud, while in others, it is a complicated end-sac. It is never in any case like an eye and seldom does it come into relation with the surface of the head as in the cyclostomes. The number of species already examined is perhaps too limited to make certain of all of these observations. The only part of the epiphyseal complex which develops and appears in the adult is the pineal organ. In a few instances, during the very early stages of development, there is present what may be considered the anlage of the parapineal organ. The parts which the pineal organ presents in teleosts are an end-vesicle, a stalk, and an ill-defined proximal portion. In many instances the stalk is short and the end-sac large. In most species the end-vesicle is pear-shaped and connected with the roof by a hollow stalk. The walls of the end-vesicle are either flat or formed into many folds, thus producing lateral diverticula and giving the sac the appearance of a tubular gland. In some cases the end-vesicle does not develop as such, the pineal organ being a broad sac connected with the brain by a slightly constricted area. The entire pineal organ may be a rudiment as in *Syngnathus*, where it is almost solid throughout its entire extent. The vast majority of the cells in the end-vesicle are small and set closely together. Some cells have an epithelial arrangement: these are doubtless neuroglia. The presence of

actual ganglionic cells is doubtful. Some cells observed by Hill⁸⁰ in 1894 have very long processes. Studnicka³⁸⁶ observed that whatever the character of the cells of the end-vesicle may be, whether special sensory or not, the entire organ is not a gland. By this he does not deny the possibility that the structure may be in part glandular. Galeotti¹⁴⁰ in 1896 found some

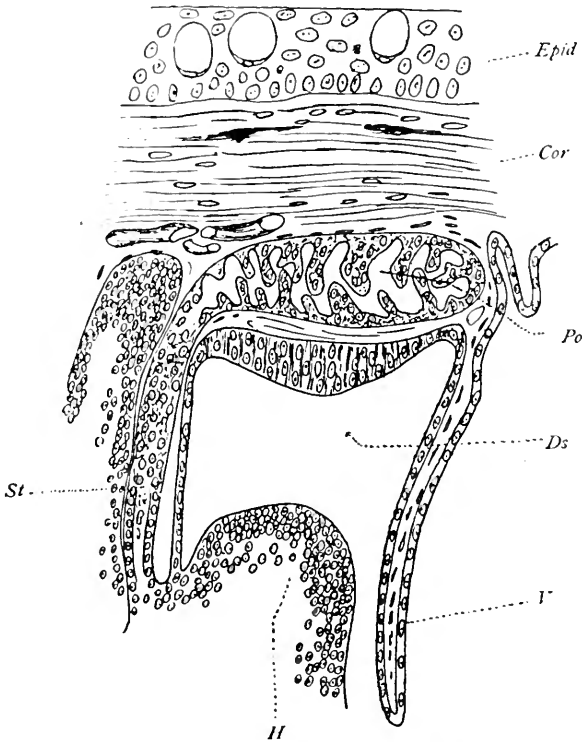


Fig. 54 The epiphyseal complex in *Anguilla fluviatilis*, according to Leydig, 1896.

V., velum transversum; Ds., dorsal sac; Po., pineal organ; St., stalk.

evidence of secretory activity in the cells of the pineal organ in these forms. In *Leuciscus*, he observed nuclei which had fuchsinophile granules and also nucleoli which later appeared in the protoplasm. The product of this secretion was, in his opinion, delivered to the lumen of the end-vesicle which is completely surrounded by blood vessels. The stalk, when definitely pres-

ent, has a form similar in character to the end-sac and is made up, in the main, of small neuroglia cells. Nerve fibers constituting what has been called the pineal nerve of the stalk have been observed making their way to the posterior commissure. Hill¹⁸⁰ observed in *Salmo purpuratus*, and Studnicka³⁸⁶ in *Cyprinus carpio*, *Carassius auratus*, *Esca lucius*, and *Cobitis fossilis* what may be termed a tractus pinealis running from the posterior commissure through the pars intercalaris posterior to the

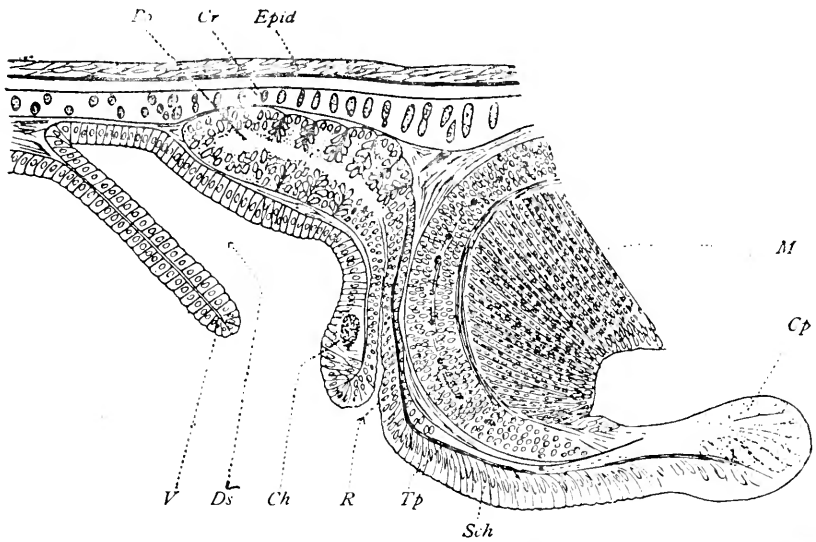


Fig. 55 The epiphyseal complex in *Salmo purpuratus*, according to Hill, 1894.

V., velum transversum; Ds., dorsal sac; Ch., commissura habenularis; R., proximal portion; Po., pineal organ; Tp., tractus pinealis; Sch., pars intercalaris posterior; Cp., posterior commissure.

stalk and then in the dorsal wall of the stalk to the end-vesicle. Hill says these fibers are connected with elements in the latter vesicle.

With reference to the site and relation of the pineal organ to the skull, it has infrequently been observed that this organ occupies a prefrontal fossa. What has been designated a cornea, namely, a large mass of fiberless connective tissue above the end-vesicle, has been described in teleosts, but there is no parietal spot in any other form thus far investigated.

Differences observed in the epiphyseal complex in the various species of teleosts already investigated

PHYSOSTOMI

1. *Esox lucius*. Göttsche ('35)¹⁵⁴ mentioned for the first time the pineal organ in this form. Stieda³⁷⁸ in 1873 called it a red body of very insignificant size. Cattie⁶⁰ in 1882 distinguished an end-vesicle and a stalk, the former richly supplied with blood and deeply sunken into a fossa in the roof of the skull. He described oval ependymal cells, and pear-shaped cells in the end-vesicle. The stalk was hollow and its dorsal wall contained a tractus pinealis. There were many folds in the end-vesicle.

2. *Tinca vulgaris*. Cattie ('82).⁶⁰ In this form there is a well-defined proximal portion, which, however, is a fine strand-like structure. The end-vesicle is flattened and much expanded.

3. *Salmo salar*. Cattie ('82).⁶⁰ This species has an end-vesicle which is pear-shaped and a very short, highly vascular stalk. The end-vesicle is in contact with the roof of the skull.

4. *Salmo fario*, *purpuratus* and *fontinalis*. Rabl-Rückhard ('83);³¹⁹ Hill ('94).¹⁸⁰ These forms present a pineal organ having an end-vesicle in a depression of the skull and a stalk connecting it with the posterior commissure. The stalk has a central canal, the lumen of which is bounded by cylindrical cells. Hill found in embryos not only the pineal organ, but the parapineal organ as well; the latter remains rudimentary. Hill called the pineal organ the posterior epiphysis. It presents a proximal, narrow portion and a distal, flattened end-vesicle which is thick and lodged in a deep fossa of the skull. It has many diverticula and is rich in blood vessels. A long canal runs through the stalk; nerve fibers connecting with some of these cells in the end-vesicle make their way through a portion of the stalk, and a definite tractus pinealis in the dorsal wall of the stalk ends in the posterior commissure. In the adult of two years old, Hill described a distal end-sac which retains the embryonic form. The rest disappears. In the distal part of the sac are many cell groups containing granular or colloid masses

in irregular acini. The tractus pinealis persists. The anterior epiphysis in the adult is reduced to a small mass of cells.

5. *Anguilla fluviatilis*. Cattie ('82).⁶⁰ In this species there is a proximal portion and a cylindrical end-sac. Leydig²³⁹ in 1896 described the end-vesicle as very much reduplicated and highly vascular. Galeotti¹⁴⁰ in 1896 saw a clear earyoplasm and no granules or nucleoli in the end-vesicle. He, therefore, concludes that there is no evidence of secretory activity in this form.

6. *Clupea alosa*. Cattie ('82).⁶⁰ A strand-like stalk and an expanded end-vesicle are observed in this form both of which are solid.

7. *Clupea harengus*. Holt ('91).¹⁸⁹ In the late larval stages, the epiphysis in this species is a solid body. In younger embryos a nerve bundle extends from the pars intercalaris up the stalk. In the later stages there is a saccular epiphysis with a wide lumen three or four cells deep. The lumen is filled with a coagulum. The tractus pinealis is present in the dorsal wall of the stalk.

8. *Leuciscus rutilus*. Rabl-Rückhard ('83).³¹⁹ The distal end of the organ in this form is flattened out against the inner surface of the skull. There is a very thin but long stalk (fig. 56).

9. *Leuciscus cephalus*. Galeotti ('96)¹⁴⁰ found in the cells of the pineal organ those above-mentioned structural peculiarities, which he considered indications of secretory activity.

10. *Amiurus catus*. Ramsay Wright ('84).⁴³⁰ The pineal organ in this species is tubular and has the same thickness throughout its entire extent. It ends in a fatty tissue. Its end-vesicle does not reach the cranial roof. Its walls are thin and form no folds.

11. *Callichthys asper* and *litoralis*. Dean ('88).⁸¹ In both of these forms there is a parietal foramen with a retinoid tissue lying beneath it. Klinekowstroem²⁰⁸ in 1893 found a parietal foramen closed by connective tissue in these forms. An end-vesicle was located here, but showed no particular specialization.

12. *Doras*, *Clarias*, *Loricaria*. Dean ('88).⁸¹ In these species there is a parietal foramen.

13. *Coregonus albus*. Hill ('91).¹⁷⁹ In the embryonic state of this species the anlagen of the pineal and parapineal organs both occur.

14. *Catostomus teres*. Hill ('94)¹⁸⁰ found the anlagen of the anterior and posterior epiphysis in embryos of this form. These were almost transversely placed in relation to each other.

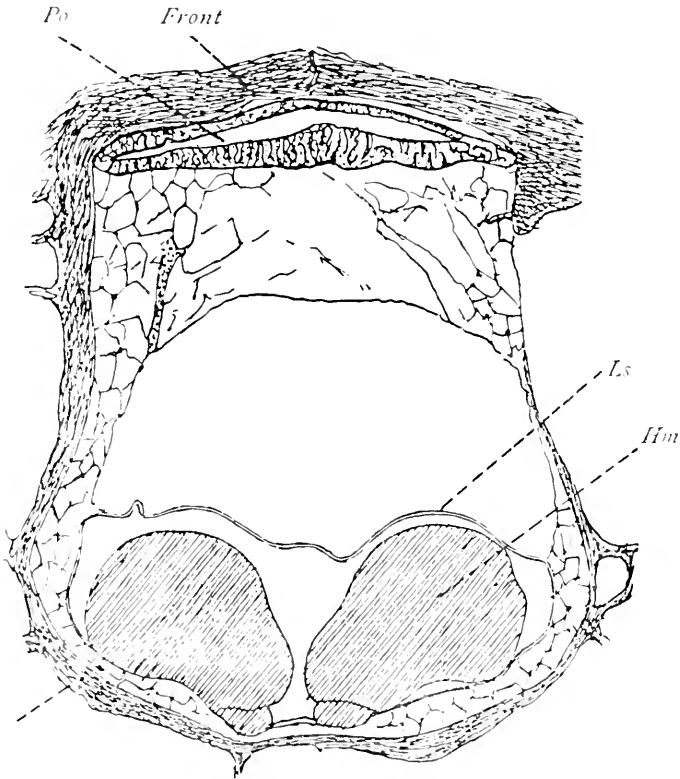


Fig. 56 Transverse section through the end-vesicle of the pineal organ in *Leuciscus rutilus*, according to Rabl-Rückhard, 1883.

Po., pineal organ; *Hm.*, hemispheres.

15. *Cobitis fossilis* and *barbatula*. Studnieka ('96).³⁸⁶ The pineal organ in these species is tubular. The distal end forms a large sac which lies beneath the skull. The tractus pinealis is present.

16. *Belone acus*. Studnicka ('96).³⁸⁵ In this species there is a long, tubular stalk. Ependymal cells form the walls of this stalk and have an arrangement reminiscent of the retinal sensory cells of the retina of *Petromyzon* especially of the region of the large end-vesicle (fig. 57).

17. *Cyprinus carpio*. Studnicka ('96).³⁸³ The end-vesicle in this form is a circumscribed dilatation and has a thin, hollow

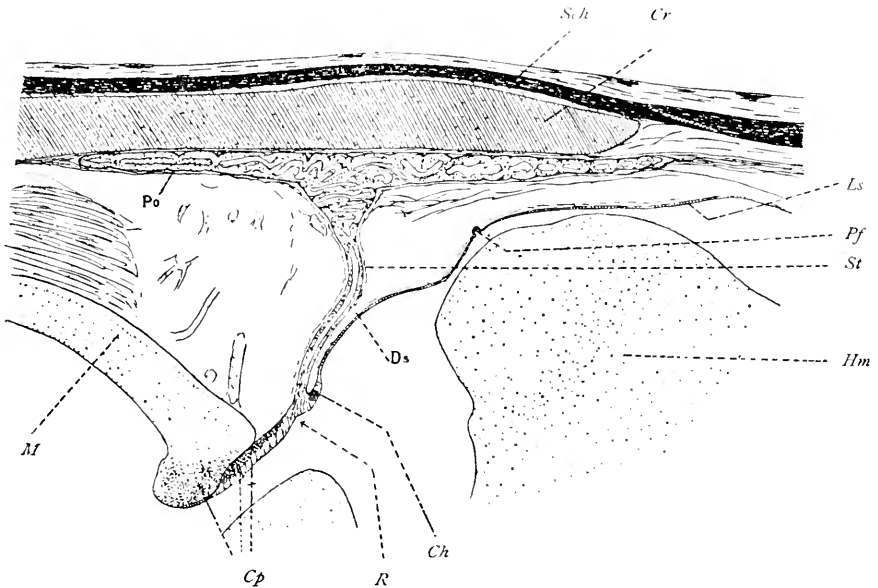


Fig. 57 The epiphyseal complex in *Belone acus*, according to Studnicka, 1896.

Ls., lamina terminalis; *Pf.*, paraphysis; *D.*, dorsal sac; *Ch.*, commissura habenularis; *R.*, proximal portion; *Po.*, pineal organ; *Cp.*, posterior commissure; *M.*, midbrain.

stalk, in the dorsal wall of which there courses the tractus pinealis.

18. *Carassius auratus*. Studnicka ('96).³⁸⁶ The pineal organ in this form is tubular throughout its entire extent. There is a tractus pinealis as usual in the stalk, but no fossa in the skull.

19. *Argyropelecus hemigymnus*. Handrick ('01).¹⁶⁸ In the adult of this form both the pineal and parapineal organs appear to be present. The pineal organ has a thin stalk and a large

end-vesicle which is much folded and highly vascular, being mushroom in shape. This sac has much to suggest glandular activity. No tractus pinealis could be discovered in the stalk. The end-vesicle lies beneath the roof in the frontal region and there is in this particular area an actual frontal or parietal foramen. The parapineal organ is tubular in form and lies in front

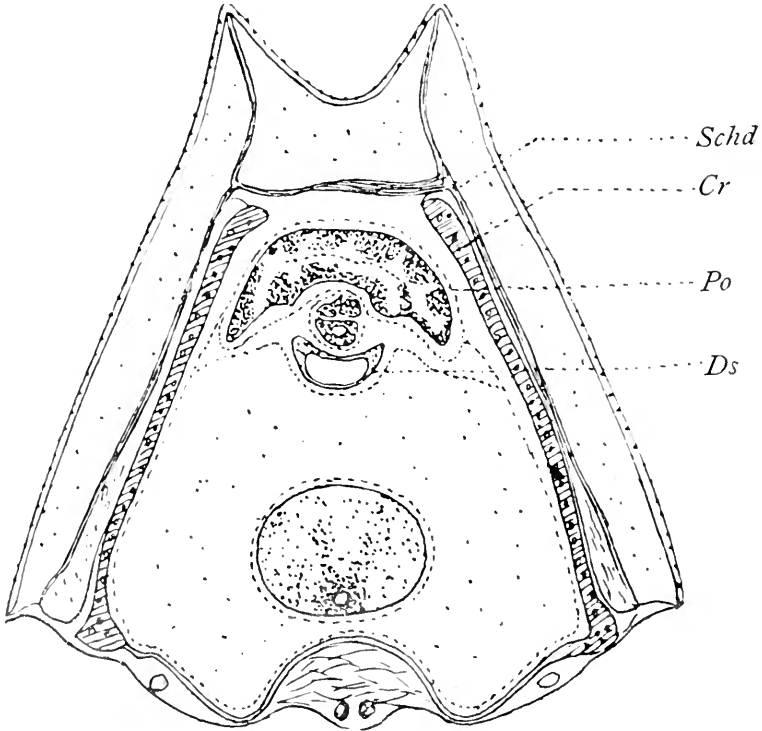


Fig. 58—Cross section of pineal organ and dorsal sac in *Argyropelecus hemigymnus*, according to Handrick, 1901.

Ds., dorsal sac; *Po.*, pineal organ.

of the pineal organ. It is shorter than the pineal organ and does not reach the parietal foramen. It has a long stalk. Studnicka³⁸⁶ thinks Handrick's parapineal organ is nothing more than a peculiar formation of the dorsal sac.

20. *Opsanus*. Terry ('11).³⁹² The pineal organ in this species presents an oval end-vesicle with a long slender stalk, both of

which contain a lumen, but neither have connection with the third ventricle. The cavity of the pineal organ is traversed by protoplasmic processes forming a dense meshwork from wall to wall. Although the pineal organ is highly vascular in *Opsanus*, it does not conform in structure to any of the known ductless glands, and is, therefore, probably not glandular. There is no pineal nerve, no parietal foramen or fossa, no dorsal sac or paraphysis.

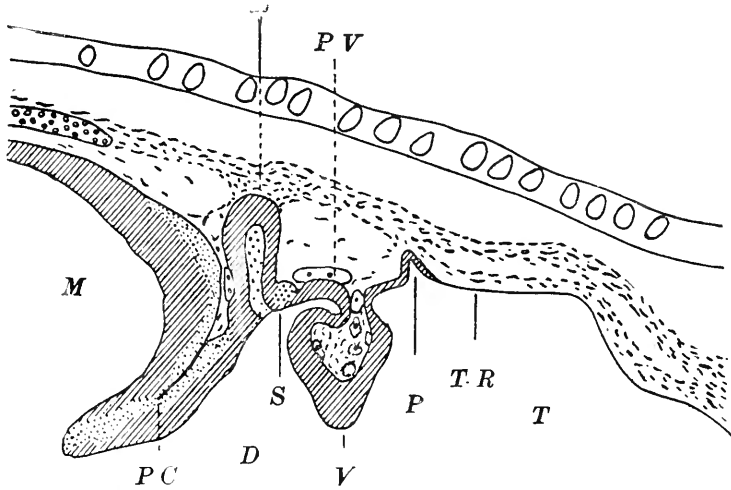


Fig. 59 Pineal region in an embryo of *Opsanus*, according to Terry, 1911.

T.R., lamina terminalis; *P.*, paraphysis; *V.*, velum transversum; *P.V.*, post-velar arch (dorsal sac); *S.*, commissura habenularis; *E.*, epiphysis; *P.C.*, posterior commissure.

PHYSOCLYSTI

21. *Gadus morrhua*. Baudelot ('70).¹⁴ The pineal organ in this species is a long, pear-shaped structure. Cattie⁶⁰ in 1882 distinguishes a strand-like proximal portion and an end-vesicle rich in blood vessels. In the latter are round and oval nuclei and round and pear-shaped cells with one or two processes.

22. *Trigla hirundo*. Ussow ('82).⁴⁰ A short pineal organ with a hollow end-stalk is the characteristic in this species. The end-vesicle is convoluted and reminiscent of the conditions in the hypophysis. The cells bordering upon the lumen are ciliated while the parenchymal cells are probably neuroglia.

23. *Cyclopterus lumpus*. Cattie ('82).⁶⁰ In this form the pineal organ is only rudimentary, being made up of a short, conical body representing the stalk, while the distal part is entirely absent.

24. *Lota vulgaris*. Cattie ('82).⁶⁰ As in *Gadus*, the end-vesicle in this species lies against the roof of the skull. The cells in this vesicle are similar to those in *Gadus*.

25. *Pleuronectes platessa*. Cattie ('82).⁶⁰ In this species the stalk is solid and so also is the end-vesicle. The latter is highly vascular and the stalk is very long.

26. *Lucioperca vitrea*. Hill ('94).¹⁸⁰ In this species the anlagen of both the parapineal organ and the pineal organ appear.

27. *Lophius piscatorius*. Studnicka ('96).³⁸⁶ An end-vesicle and a stalk are present in this form. The end-vesicle is in a deep fossa. There are two types of cells in it besides the ependymal layer, namely, neuroglia cells and sensory cells. Nerve fibers were observed in the stalk.

28. *Cepola rubescens*. Studnicka ('96).³⁸⁶ A thin stalk with an expanded end-vesicle sharply flexed forward is the characteristic in this species. The lumen in both is conspicuous. The end-vesicle is much convoluted and rests against the roof of the skull.

29. *Anarrhichas lupus*. Studnicka ('96).³⁸⁶ In this form there is a very long stalk, but no recognizable end-vesicle. There is a tractus pinealis in the dorsal wall of the stalk and a plasmatic lens in its lumen.

30. *Ophidium barbatum*. Studnicka ('96).³⁸⁶ In this species there is a thin, long, hollow stalk and a very small but elongated end-vesicle. There is no fossa in the skull and no tractus pinealis, but many blood vessels accompany the stalk as far as the end-vesicle.

31. *Arnoglossus lanterna*. Studnicka ('96).³⁸⁶ In this species there is a hollow and long stalk with a well-marked end-vesicle. This vesicle is vascular, but is situated in a position far removed from the skull roof.

LOPHOBRANCHII

32. *Syngnathus acus*. Studnicka ('96).³⁸⁶ The pineal organ in this species is rudimentary, only the proximal portion of it being present. In this there is a small lumen.

33. *Hippocampus spinosus*. Studnicka ('96).³⁸⁶ The pineal organ in this form is a small, short sprout, the distal end of which does not reach the roof.

In all, thirty-three species of teleosts have been investigated. Of these, thirty species present a more or less well-developed pineal organ. In one form it is almost entirely absent presenting itself only as an inconspicuous rudiment. This is the case in *Syngnathus acus*. In a second instance, *Hippocampus spinosus*, the pineal organ is little more than a short sprout. In five instances among the teleosts both pineal and parapineal organs appear, the latter occurring either in the adult, which is rare, or during the earlier stages of development. Both organs appear in the anlagen in *Coregonus albus*, *Lucioperca vitrea*, and *Catostomus teves*, but later disappear in these forms. Both organs are well marked in anlagen and remain as discernible rudiments in *Salmo purpuratus* and *fario* and also in *Argyrops leuciscus hemigymnus*. In one instance, *Leuciscus cephalus*, there was definite evidence of secretory activity in the pineal organ. In three species there was evidence of a retina in the pineal organ, either because of the presence of specialized sensory cells or of nerve fibers coming into connection with these cells. In three instances there was a distinct parietal foramen. It is significant in this connection to note that in no instance in which there was a retinal-like structure or cellular formation and arrangement suggestive of a retina, did there occur a parietal foramen. In seven cases the end-vesicle of the pineal organ was lodged in a fossa on the under surface of the skull. In seven species, namely, *Cobitis fossilis* and *barbatula*, *Lophius piscatorius*, *Cyprinus carpio*, *Carassius auratus*, *Anarrhichas lupus*, *Pleuronectes platessa*, and *Clupea harengus*, there is evidence of a nervus pinealis or a tractus pinealis. All of these descriptions except one are given by Studnicka.³⁸⁶ This observer makes the statement that there is no nervus pinealis in *Ophidium barbatum*.

5. Comparative anatomy and histology of the epiphyseal complex
in amphibia

In amphibia the pineal organ alone makes its appearance. In no other form is this organ so little developed. It presents a small end-vesicle which Stieda³⁷⁹ first recognized and described as the *frontal subcutaneous gland*. This end-vesicle is attached by means of a thread-like strand to a considerably expanded proximal portion, to which latter the name of epiphysis or corpus pineale has been ascribed. The pineal organ consists, there-

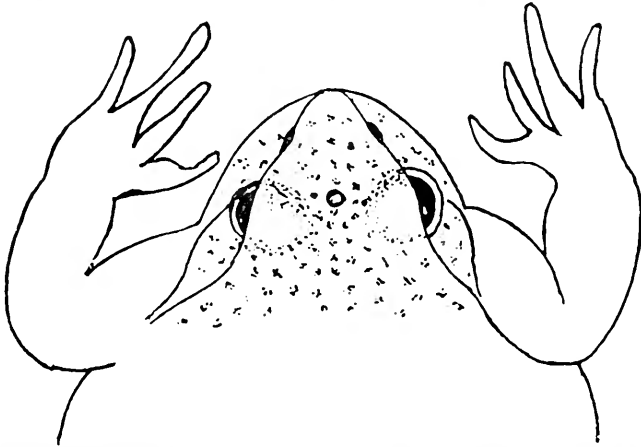


Fig. 60 Head of *Rana temporaria* showing the unpaired pineal eye, situated between the paired eyes, according to Stieda, 1865.

fore, of the usual parts, namely, an end-vesicle, a stalk, and a proximal portion which is particularly conspicuous in amphibia.

The end-vesicle in so far as is known, is present in all forms except *Hyla arborea*, the absence in this form being noted both by deGraaf,¹⁵⁵ and Leydig.²³⁸ In shape, the end-vesicle is round, oval, or kidney-shaped. Stieda³⁷⁹ and deGraaf¹⁵⁵ found it solid, containing a lumen only in *Bombinator*. According to Stieda, its diameters are from .12 to .15 mm. deGraaf found these diameters in *Rana esculenta* from .126 to .145 mm., while Lessona²⁴¹ in the forms studied by him found that the diameter was less than 1 mm. A number of observers, including Ostroumoff²⁹¹ ('87); Leydig²³⁸ ('91); Galeotti¹⁴⁰ ('96), and Braem³⁹ ('98),

maintain that the frontal organ contains a cavity. According to Leydig, this organ contains pigment in *Bombinator*, but otherwise, in frogs, the cells are pigment-free. Histologically, the cellular elements of the frontal organ show no definite arrangement. These cells are usually long and their mass is traversed by a few isolated fibers. deGraaf and Leydig both found evidence of fatty degeneration in the organ. The so-called frontal subcutaneous gland of Stieda is situated, as described by that author, directly under the corium of the skin

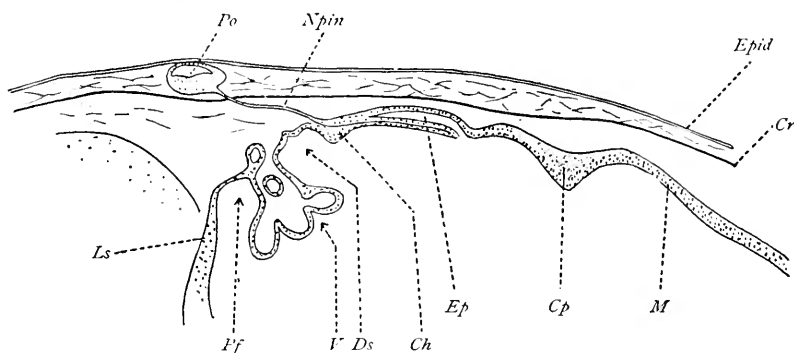


Fig. 61 The epiphysal complex in the pineal region of *Rana temporaria*, according to Braem, 1898.

Ls., lamina terminalis; *Pf.*, paraphysis; *V.*, velum transversum; *Ds.*, dorsal sac; *Po.*, pineal organ; *N.pin.*, pineal nerve; *Ch.*, commissura habenularis; *Ep.*, proximal portion; *Cp.*, posterior commissure; *M.*, midbrain.

in the midline of the head and upon a transverse line from pupil to pupil. According to Lessona,²⁴¹ its position is marked by a clear, white spot on the top of the head, not well developed in all forms, but first described by Stieda³⁷⁵ as the *Scheitelfleck* or parietal spot. According to Leydig,²³⁸ this spot is best made out in *Rana arvalis* and *agilis*. It also occurs in *Rana esculenta*.

The stalk of the pineal organ in amphibia exists as a thin, strand-like structure. Stieda³⁷⁵ in 1865 first referred to it as a thread connecting the frontal gland with the skull. Ciaccio⁶⁵ in 1867 recognized the nerve fibers in this strand. Lessona²⁴¹ in 1880, deGraaf¹⁵⁵ in 1886, and Leydig²³⁸ in 1891, all observed the nerve fasciculus in older animals, but did not appreciate its significance. They thought it to be the remnant of the connect-

ing strand between the attached and detached parts of the pineal organ, thus representing a degenerative process. Braem³⁹ in 1898 also found this fasciculus and made the further observation that it contained heavily myelinated nerve fibers. He likewise was of the opinion that there was evidence of degeneration in this nerve fasciculus, in this way confirming the view of deGraaf and Leydig. Haller¹⁶⁶ in 1898 stated that the fibers of the tractus pinealis spring from two branches of roots connected with the thalamus ventromedial to the commissura posterior. Gaupp¹⁴⁷ in 1898, who first applied the term of tractus pinealis to these fibers, observed fine nerve bundles passing in the ventral portion of the epiphyseal stalk. Most observers believe that these fibers come into relation with the posterior commissure.

The proximal portion of the pineal organ. This, as already stated, was known as the epiphysis or corpus pineale. It was also called by Gaupp¹⁴⁷ in 1898 the *pediculus corporis pinealis*. Osborn²⁸⁸ in 1884 described it as a cylindrical, hollow, anteriorly flexed sac whose lumen was in communication with the third ventricle. Rabl-Rückhard³¹⁷ in 1880 states that the proximal portion is solid. Osborn, on cross section, described it as round. Gaupp¹⁴⁷ and Braem³⁹ state that the organ has an elliptical form with many short diverticula which give it a glandular appearance. In this feature it is like some teleosts, reptiles, and birds. Galeotti¹⁴⁰ in 1896 found evidence of secretory activity in *Rufo* and *Rana*, for example, granules in the cytoplasm staining with acid fuchsine. Studnicka³⁸⁶ in 1896 saw the same appearances in adult animals which he thought were sensory cells and which he likened to the sense cells in the pineal organ in *Petromyzon*. Ostroumoff²⁹¹ in 1887 found fine fibers between these cells.

Differences observed in the epiphyseal complex of the various species of amphibia

URODELA

1. *Amblystoma mexicanum*. Stieda ('75).³⁷⁹ In this form the chorioid plexus was first mistaken for the epiphysis. Orr²⁸⁶ in

1889 first discovered the pineal organ in embryos. Eycleshymer¹¹² in 1892 made a more extensive study of this organ and found the epiphysis to be a long, glove-finger shaped structure. The cells in the under wall were somewhat larger than those in the upper wall and some of them contained pigment.

2. *Amphiuma means*. Osborn ('83).²⁸⁷ In this species there is a marked plexiform paraphysis, while the pineal organ extends forward as a small sac over the commissura habenularis.

3. *Menopoma alleghaniense*. Osborn ('84).²⁸⁸ The pineal organ in this species is a saccular evagination with a lumen opening into the third ventricle.

4. *Menobanchus*. Osborn ('84).²⁸⁸ In this form the pineal organ is a long, flattened sac completely detached from the brain. Kingsbury²⁰⁴ in 1895 showed that there is a well-marked paraphysis and also that there are nerve fibers in connection with the pineal organ.

5. *Salamandra maculosa*. Burekhardt ('91).⁴³ The pineal organ in this species is a short, hollow, and rudimentary stalk. There is a flattened end-vesicle in which there appears evidences of degeneration.

6. *Diemyctylus viridescens*. Gage ('93).¹³⁵ The pineal organ in this form is very small in the adult and there is no lumen in any portion of it. There is, however, a well-developed paraphysis.

7. *Desmognathus fuca*. Fish ('95).¹¹⁹ The pineal organ in this species is a small compressed structure. It contains no lumen in the adult, but in the larva the organ is hollow.

8. *Triton taeniatus*, *cristatus* and *alpestris*. deGraaf ('86).¹⁵⁵ The pineal organ in these species is rudimentary. There is a short, hollow stalk and a flattened end-sac in which there is evidence of a process of degeneration. This same form was studied by Blanc³⁴ in 1900 with practically the same results.

9. *Spelerpes fuscus*. Galeotti ('96).¹⁴⁰ In this species the pineal organ is oval and hollow. The end-sac is directly in connection with the commissura habenularis and there is no stalk. The cells have an epithelial arrangement and are formed in alveoli, giving the structure a glandular appearance.

10. *Proteus anguinus*. Galeotti ('96).¹⁴⁰ The pineal organ in this form is small and pyriform and has no evidence of secretory function.

11. *Salamandrina perspicillata*. Galeotti ('96).¹⁴⁰ In this species the pineal organ is a small, flattened structure.

APODA.

1. *Ichthyophis glutinosa*. Burekhardt ('90).⁴² The pineal organ in this form is small and pyriform and has a short stalk, but does not reach the skull roof. A well-developed paraphysis is present. Fibers from the end-vesicle seem to make their way to the commissura habenularis.

ANURA

1. *Rana esculenta*. Leydig ('68).²³³ In this species the end-vesicle has a figure-of-eight shape and is solid. Leydig²³³ later in 1891, could find no evidence of a parietal spot in *Rana fusca*. deGraaf¹⁵⁵ in 1886 found a well marked end-vesicle which was solid and round and a well-developed parietal spot.

2. *Ceratophrys*. Lessona ('80).²⁴¹ There is a fairly well-marked end-vesicle in this species.

3. *Bufo cinereus*. Lessona ('80)²⁴¹ did not observe a pineal organ in this form, but it was found subsequently by deGraaf¹⁵⁵ in 1886. Studnicka³⁵⁶ also found it in young larva.

4. *Pelobates fuscus*. Lessona ('80)²⁴¹ found the end-vesicle in this species.

5. *Discoglossus*. Lessona ('80).²⁴¹ A fairly well-marked end-vesicle exists in this species.

6. *Alytes obstetricans*. Lessona ('80).²⁴¹ In this form there is a well-marked end-vesicle which was first accurately described by deGraaf.¹⁵⁵

7. *Rana occipitalis* and *tigrina*. Lessona ('80).²⁴¹ In these forms the pineal organ presents a well-marked end-vesicle.

8. *Pipa americana*. Lessona ('80).²⁴¹ In this species there is no end-vesicle.

9. *Hyla arborea*. deGraaf ('86).¹⁵⁵ and Leydig ('91)²³⁸ both found that the end-vesicle was absent and that the skin in the usual position of the parietal spot showed nothing of the existence of such a structure.

10. *Bombinator igneus*. Leydig ('68);²³³ deGraaf ('86).¹⁵⁵ In this species the end-vesicle is saccular.

In the twenty-two species of amphibia investigated, the great majority present a well-developed paraphysis. In but a single well-defined instance is there evidence of a tendency toward the formation of a retina. This occurs in *Amblystoma mexicanum* in which there is evidence of pigment formation in some of the cells of the end-vesicle. In several forms the stalk contained fibers suggestive of the pineal nerve. With reference to the possible glandular character of the organ it must be borne in mind that Stieda's³⁷⁹ original description referred to the structure as the frontal subcutaneous gland. The general arrangement of the cells, both in the end-vesicle and in the proximal portion, has epithelial masses which tend to lend weight to the view that the organ may have secretory function. In only one instance, however, that is in *Spelerpes fuscus*, has there been observed any definite evidence of glandular activity in the pineal organ.

6. Comparative anatomy and histology of the epiphyseal complex in Reptilia

In considering the conditions present in the epiphyseal complex of reptilia, two groups of these animals must be distinguished. The first group is that comprising the more ancient reptiles, e.g., the saurians and also the prosaurians as represented by *Sphenodon*. In the second group are the reptiles of more recent history, including ophidians, chelonians and crocodilians. It is in the first group, however, that the most striking appearances are observed in the epiphyseal complex. In these forms there develops a structure so remarkable for the many features which identify it as a visual organ that the term parietal or third eye by which it has been designated seems altogether justified. Quite as striking in a negative way, on the other hand, are the conditions in the ophidians and in the chelonians where this eye not only altogether fails, but there is no evidence whatever of a parapineal organ either in adult forms or in the anlage, while the pineal organ also shows marked regressive

alterations in the loss of several of its parts as compared with the lower forms already considered. Finally the reported absence of any epiphyseal structures whatsoever in crocodilia offers much room for speculation or, perhaps, serves as an incentive to reinvestigation.

The pineal organ in saurians and prosaurians (form *Sphenodon*) seldom presents all three of the several parts usually observed in the pineal organ, and it is not possible to identify an end-

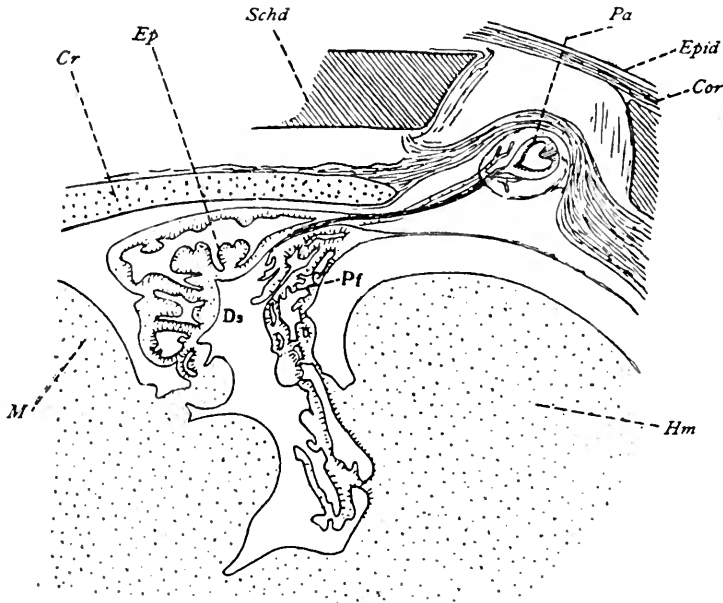


Fig. 62 The epiphyseal complex in *Sphenodon* according to Spencer, 1886.

Pa., parapineal organ (end-vesicle); *Pf.*, paraphysis; *Ds.*, dorsal sac; *Ep.*, proximal portion of pineal organ; *M.*, midbrain.

vesicle, a stalk, or a proximal portion. Often the end-vesicle is absent, and in no instance does it assume the proportions or the characteristics of a visual organ. The stalk is usually hollow, but contains no nerve fibers, and in the instances in which the end-vesicle is absent, the stalk is drawn out into a tapering process or end-tube. Melchers²⁶⁹ in 1899 showed that not only may the end-sac be absent, but the rest of the parapineal organ may present itself in a degenerative condition. This is true in

Platydactylus. In some cases, as in *Gehyra oceanica* and *Hemidactylus mabouia*, described by Stemmler³⁷⁴ in 1900, the entire epiphyseal complex may be only recognized in the slightest rudiment possible. In one instance reported by Studnicka,³⁸⁶ namely, *Pseudopus pallasi*, there is an end-vesicle, a stalk, and a proximal portion. The stalk is, in fact, a double one, or, in other words, there is a main stalk and a secondary accessory connection between the end-vesicle and the roof-plate of the brain.

The proximal portion of the pineal organ, known as the epiphysis or corpus pineale, is present in all forms. In some cases the proximal portion is a simple pyriform structure attached by a thin stalk to the roof of the interbrain. In other instances it is spindle-shaped or oval. The walls of the proximal portion are thick and usually flat inside as well as outside. In some cases there are inner reduplications, as in the fish. Leydig²³⁸ in 1891 found thick accessory spaces in the organ of *Lactera ocellaia* and *Anguis fragilis* due to septal formation. The wall may be much folded, giving the appearance of a complicated glandular structure. Edinger¹⁰⁵ in 1890 showed this in one of his cuts (fig. 63).

The histological structure of the pineal organ. The chief cellular constituent of the pineal organ, both in its end-vesicle when present and in the proximal portion, is the ependymal cell. Neuroglia cells also occur interspersed among the ependymal elements, but there are no ganglionic cells. Nerve fibers lie parallel with the outer dorsal surface quite similar to the nerve fibers in other pineal organs. These are probably the nerve fibers which constitute the tractus pinealis. Klinckowstroem²⁰⁷ in 1893 found cilia on the cells of the pineal organ in embryos of *Iguana* and *Tejus*, but not in the adults of these species. Pigmentation is either entirely absent in all parts of the pineal organ or when present it is in the interior of the cylindrical cells placed in the lumen. A tractus pinealis was described by Leydig²³⁹ in 1896 in *Platydactylus*. Melchers, however,²⁶⁹ in 1899, showed these fibers were probably connective tissue. Saurians, as a rule, although they do not in every case present a well-

marked tractus pinealis, nevertheless in a certain number of instances a nerve tract may be observed connecting the pineal organ with the roof of the interbrain.

In *Ophidia* the pineal organ is rudimentary. Only the proximal portion persists in the snakes. This, however, has undergone considerable modification from the proximal portion already encountered in the lower vertebrates. In the true snakes it is a compact, highly vascular structure to which the term epiphysis or corpus pineale may, in the strict sense, be applied. Hoff-

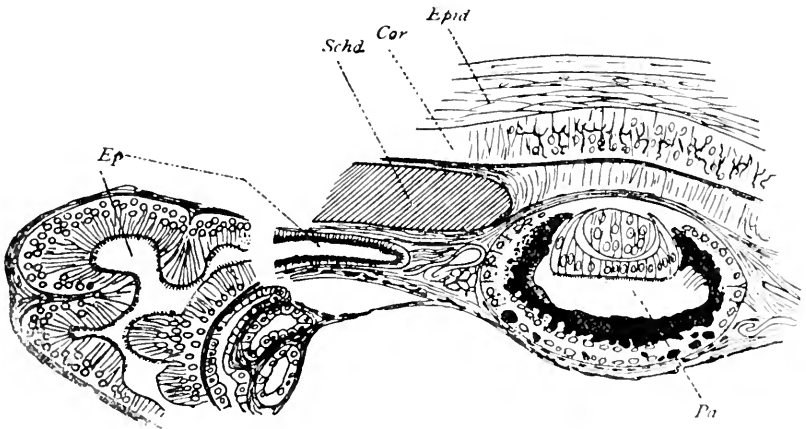


Fig. 63 The epiphysal complex in *Anguis fragilis*, according to Leydig, 1891.

P.a., parapineal organ; *Ep.*, proximal portion of pineal organ.

mann¹⁸⁶ in 1886 showed that the corpus pineale in ophidia begins in its development as a simple evagination from the interbrain roof. How it attains its later complicated, compact form is not yet exactly known. No doubt the solid epiphysis due to the proliferation of the wall of the anlage causes the obliteration of the lumen of the original evagination. A paraphysis develops early in ophidians and has in its inception the same general form as the epiphysis. The pineal region in the adult consists, therefore, of a paraphysis which is a thick-walled structure associated with the choroid plexus, a velum transversum and a dorsal sac

also complicated in the chorioid plexus, a commissura habenularis, an epiphysis with a fairly well marked recessus pinealis and a posterior commissure. Herrick¹⁷⁷ in 1891 described the epiphysis in ophidia as a compact, somewhat rounded or oval body whose interior consists of a connective tissue network with many blood vessels, thus giving it the appearance of a branched, tubular gland. Studnicka³⁸⁶ maintains that nothing definite is known of the significance of the epiphysis in snakes. Its unusually rich capillary blood supply speaks in favor of the supposition that the organ is a gland which contributes its product to the blood stream.

In *Chelonia* the pineal organ is only in a rudimentary condition and develops in these forms an epiphysis or corpus pineale. Just as in ophidians, the end-vesicle and the stalk of the pineal organ appear not to be laid down in anlage, or if it does occur in the early stages of the development, it soon disappears, leaving only the proximal portion to represent the pineal organ in these forms. Neither in chelonia nor in ophidia is there any evidence of an anterior epiphysis, that is to say, a parietal eye. The first description of turtles was given by Bojanus³⁶ in 1819. Tiedemann³⁹⁵ also mentioned the epiphysis in turtles, but probably mistook the chorioid plexus for that structure. Voeltzkow⁴¹⁰ in 1903, describing the embryology of *Chelone imbricata*, mentions the first appearance of the epiphysis as a simple evagination. Secondly, a stalk develops between the pineal organ and the roof of the interbrain, so that, according to Voeltzkow, the epiphysis in *Chelone imbricata* separates itself entirely from the roof-plate. The pineal region in chelonia presents the usual features, namely, a large paraphysis which forms an unusually extensive sac. The end of this sac lies directly over the epiphysis. The velum transversum and dorsal sac are incorporated in the chorioid plexus. There is a fairly well marked commissura habenularis, the epiphysis in its usual chelonial form, and also the posterior commissure. The form of the epiphysis in the turtle is oval or ovoid; it lies close to the roof-plate. The surface, as Herrick¹⁷⁷ has shown in 1891, is uneven and may indicate a process of lobulation. Many

trabeculae of connective tissue extend inward toward the center of the organ from the capsule. The cellular elements are for the most part ependymal cells and neuroglia. No ganglionic cells and no nerve fibers were observed. There is no clear evidence of secretory function in the epiphysis of *Chelonia*. The organ contains a small cavity.

In *Crocodylia*, the pineal organ, according to Sorensen ('94),³⁶³ as well as the other elements of the epiphyseal complex, is entirely absent. In the roof of the interbrain there is a well marked commissura habenularis and a posterior commissure with possibly a dorsal sac and a paraphysis. Voeltzkow⁴¹⁰ in 1903 found no epiphysis in *Crocodylus madagascariensis*. Rabl-Rückhard³¹⁶ in 1878 showed in *Alligator mississippiensis* a long, rounded conarium. This observation, according to later observers, is probably an error, the paraphysis and chorioid plexus having been mistaken for the pineal body.

The parietal eye in Reptilia. The parapineal element in saurians and *sphenodon* gives rise to what is known as the third or parietal eye of reptiles. Among the saurians it is not universally present. Its absence has been noted in certain of the Geckonidae, as for example, *Hemidactylus*, *Gehyra*, *Gecko*, and *Platydactylus*. It is also absent in certain Agamidae, such as *Draco*, *Ceratophora*, *Lyriocephalus*, and *Moloch*. It has not been observed in *Tejus* and *Cyclodus*. The general form of the parietal eye is saccular with the upper wall corresponding to a lens which is pigment free while the under or ventral wall which corresponds to the retina is deeply pigmented. The third eye presents several different forms in the different species:

1. It may be pyriform, as is the case in *Sphenodon*, Spencer³⁶⁶ and Leydig,²³⁶ and *Iguana*, Spencer.³⁶⁷ It is also of this shape in *Varanus nebulosus* and *Anguis*, Hanitsch,¹⁶⁹ also in *Pseudopus pallasi*, Studnicka.³⁵⁶

2. Dorsoventrally elongated and ovoid as in *Anolis* and *Lyriocephalus*, Spencer.³⁶⁷

3. Spherical or hemispherical, in which latter case the lens is flattened, as in *Lacerta ocellata*, *Chameleon*, *Grammatophora barbata*, *Moloch horridus*, and *Agama hispida*, Leydig²³⁸ and Spencer.³⁶⁸

4. Lenticular and flattened, as in *Anguis fragilis*, *Lacerta vivipara*, *Lacerta agilis*, *Lacerta viridis*, *Seps tridactylus*, *Varanus giganteus*, *Plica*, *Iguana*, and *Calotes*.

5. Flattened so that the under wall is pressed inward, as in *Varanus bengalensis*, *Leiolaemus nitidus*, and *Calotes ophiomachus*.

6. Flattened and decidedly elongated, as in *Seps chalcidica* and *Calotes versicolor*.

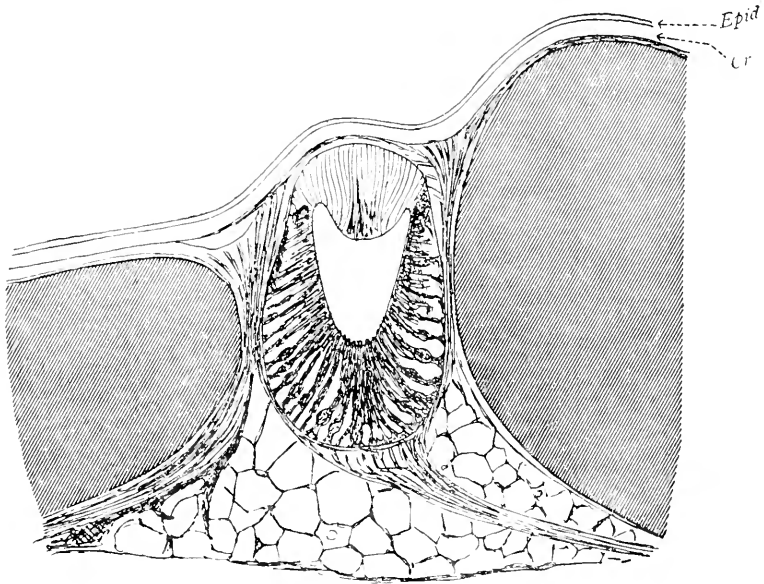


Fig. 64 The pineal eye of *Anolis*, according to Spencer, 1886

While the dorsal wall of the parapineal vesicle forms the true lens of the parietal eye, the ventral wall is pigmented and gives rise to the retina. The latter consists of layers of different types of cells. In the embryonic stages it is attached to the brain by a tubular prolongation from the roof-plate. The first detailed description of the parietal or third eye in reptiles was given by deGraaf¹⁵⁵ in 1886. Spencer's³⁶⁶ work appeared in the same year, and a number of investigations have been reported since then confirming in a general way the conclusions of these

early workers. These researches include those of Beraneck ('87)²¹ in *Anguis* and *Lacerta*; Francotte ('87)¹²⁷ in *Anguis*; McKay ('88)²⁵⁵ in *Grammatophora* and *Hinulia*; Strahl and Martin ('88)³⁵³ in *Lacerta*, and Ritter ('91)³³² in *Phrynosoma*. There is a general agreement regarding the histological structure of the retina among saurians, and the following layers have been identified by most of the investigators mentioned:

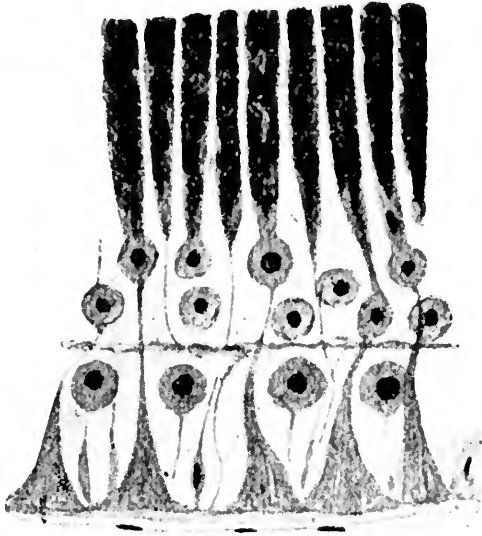


Fig. 65 The structure of the retina in the pineal eye in *Sphenodon punctatum*, according to Spencer, 1886.

1. An inner layer of long, cylindrical cells, called the rods or rod-like bodies of Spencer³⁶⁶ or the *cellules batonnets* of Francotte.¹²⁷ In these cells pigment occurs.

2. An inner layer of cells, called the '*couche cellulaire interne*' by Francotte.¹²⁷ This consists of round cells with a large round nuclei. Ritter³³² distinguishes two types of nuclei in this layer, namely, those which are round and small and those which are oval and long.

3. A molecular layer described by Spencer³⁶⁶ and Francotte¹²⁷ or a layer of nerve fibers described by Strahl and Martin.³³³ The latter observers and Klinckowstroem²⁰⁶ maintain that these fibers are in connection with the parietal nerve. Leydig²³⁸ and Dendy⁵⁶ believed that a cleft occurred in this layer which, according to Leydig, gives rise to a lymph space.

4. An outer cellular layer of round cells somewhat deeper than the second layer.

5. A membrana limitans externa.

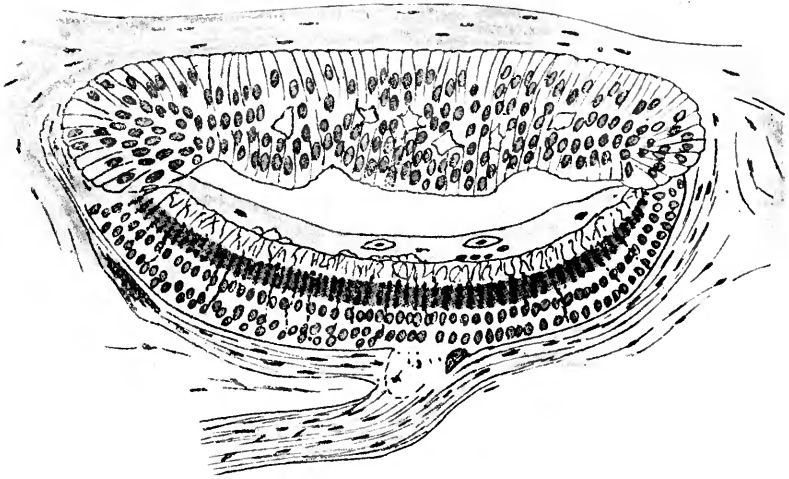


Fig. 66 The pineal eye in *Iguana tuberculata*, according to Klinckowstroem, 1894.

The most important elements in the retina are the rod cells which appear to correspond to the ependymal cells of the retina in the pineal organ of *Petromyzon*. They are long, cylindrical elements in which may be differentiated an outer thread-like part and a more cylindrical portion. The nucleus occupies an enlargement in the area of transition between these two portions. The inner cylindrical parts lie close together; the outer thread-like parts have broad spaces between them in which are lodged neuroglia and some ganglionic cells. The peripheral processes come to the surface of the retina and spread out against

the membrana limitans externa. The pigment in the cells is in some cases arranged in transverse bands or stripes, according to Spencer³⁶⁶ in *Sphenodon* and Leydig ('91),²³⁸ in *Anguis*. All of the rod cells are similar. The connection of the retinal elements with fibers of the parietal nerve is not yet altogether understood. In adults the organ is rudimentary. It is not known whether the nerve fibers come from the large retinal elements, from the ganglionic cells of the deep retinal layer, or from the large cylindrical cells of the inner layer. The latter seems most probable in view of the conditions in *Petromyzon*.

The parietal nerve. This nerve was first described by Spencer³⁶⁶ in 1886 and has been observed by many others since then. Spencer believes that the parietal nerve is connected with the end of the epiphysis, that is to say, a direct continuation of the pineal organ. The entire course of the parietal nerve from the parietal eye to the brain roof was first traced by Strahl and Martin³⁵³ in 1888 in older embryos of *Lacerta vivipara* and *Anguis fragilis*. These observers showed that the nerve was completely independent of the epiphysis. Beraneck²³ in 1892 made more exact studies and confirmed the view of Strahl and Martin. Other authors are also emphatic in stating the complete independence between the epiphysis and the parietal eye. Among them are Studnicka ('93),³⁸⁴ in *Lacerta*; Klinckowstroem ('94)²⁰⁹ in *Iguana*; Leydig ('96)²³⁹ and Dendy ('99)⁸⁷ in *Sphenodon*, and Schauinsland ('03)^{347A} also in *Sphenodon*. The parietal nerve begins to develop shortly after the separation from the roof of the parietal eye. Of the direction of its fibers, whether from the brain to the eye or, as is the case in the pineal organ and the paired eyes, from the eye to the brain, there is no proof. The latter course, however, is most probable. In *Anguis*, the parietal nerve first appears at 50 mm. embryo size and reaches its maximum of development between the 27 and 30 mm. size. In *Iguana*, the nerve is well developed at fourteen days and is at its maximum at twenty-four to twenty-six days. Between the thirtieth and fortieth days it shows signs of reduction. Strahl and Martin³⁵³ showed that the nerve comes into relation with the ganglionic cells forming a prominence with the brain

roof. This Beraneck²³ designated in 1892 as the *noyau parietal*. The prominence thus described can be nothing else than the closely set ganglia habenulae of the interbrain as shown by Studnicka³⁵⁴ in 1893 in *Lacerta*, by Klinckowstroem²⁰⁹ in 1894 in *Iguana*, and by Leydig²³⁹ in 1896 in *Lacera*. The parietal nerve is made up of fine fibrils; it has a perineurium, a connec-

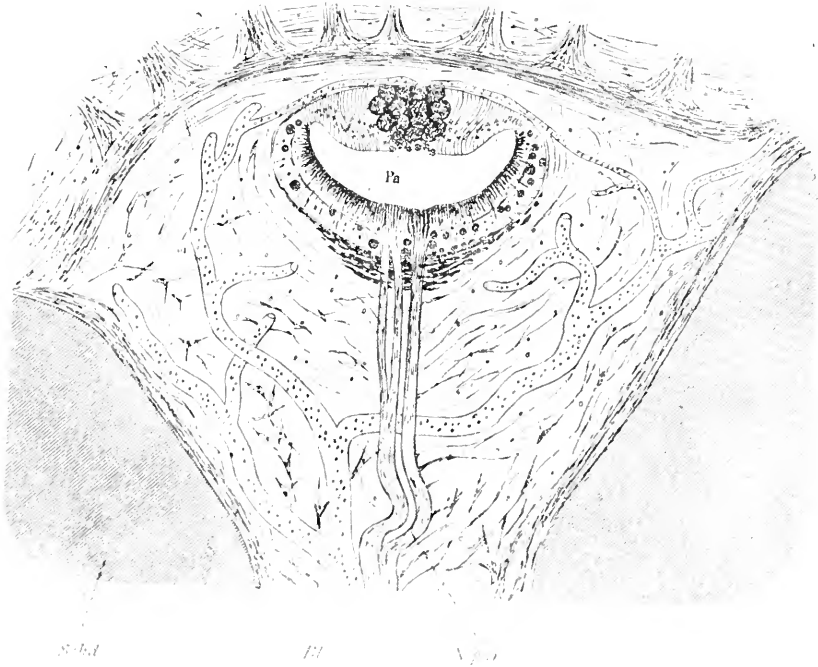


Fig. 67 The pineal eye of *Varanus giganteus*, according to Spencer, 1886.
Pa., parapineal organ; *N par.*, parapineal nerve; *Bl.*, blood vessel.

tive tissue, and glial sheaths. In *Iguana* it degenerates and disappears in the adults, according to Klinckowstroem ('94).²⁰⁹ In some cases Spencer³⁶⁶ found the parietal nerve divided into two or three strands, for example, in *Lacerta ocellata* and *Varanus giganteus*. A similar splitting was found by Studnicka³⁵⁴ in 1893 in *Petromyzon*. Klinckowstroem²⁰⁹ in *Iguana* recognized a second parietal nerve which arose from the left habenular

ganglion and passed close behind the first nerve to the parietal eye. The lens of the parietal eye is not uniform in its shape; it occurs in the following different forms:

1. Regular bi-concave lens, both surfaces curved, which is most common in *Lacerta vivipara*, *Lacerta agilis* and *Lacerta ocellata*, *Leiolacmus nitidus*, *Seps chalcidica*, *Phrynosoma douglassi*, and *Sphenodon*.

2. Bi-convex, with the under surface more convexed than the upper, as in *Anolis* and *Sphenodon*.

3. Plano-convex, as in *Anguis* and *Iguana*.

4. Concavo-convex, as in *Calotes*, *Varanus bengalensis*, and *Varanus giganteus*.

The structure of the lens is made up of peculiar, long, cylindrical cells apparently derived from modified ependymal cells. These are the so-called lens cells. There are some intercellular spaces, probably lymph spaces, according to Leydig ('91).²³⁸ The lens cells are nearly free of pigment. The substance of these cells is very hard. Their nuclei are oval or round and are seldom scattered over the entire lens surface or its entire thickness. They are most numerous at the border of the lens where the latter passes over into the retina.

The parietal foramen. Leydig²³⁴ in 1872 found a round or oval opening in the skull of *Sphenodon* situated in the osparietal, which seemed either directly to serve as the outlet for the parietal organ or else for the entrance of light rays. It was reminiscent of a similar opening in the cartilaginous roof of the cranium in selachians. In most cases the parietal eye is in, or directly under, this foramen. Species which do not possess a parietal eye have a parietal foramen which is filled by the pineal organ, in which case, the end-vesicle takes the place of a third eye as far as location is concerned. The foramen is absent in a large number of saurians, particularly in the Geckonidae, and it is also absent in *Ceratophora aspera*. There are also instances in which the foramen does actually appear in some individuals of a species and yet in other individuals of the same species it is closed by bone. The eye usually lies in the middle of this foramen or near its upper edge. The relation between eye and foramen is

different in different periods of life. The foramen is not the result of direct pressure of the eye, but occurs for the purpose of permitting the passage of light rays. As a rule, the parietal eye lies in the foramen or under it, so that its optic axis corresponds to that of the foramen. In *Sphenodon* a single exception to this rule is noted by Spencer.³⁴⁶ Here the organ is tipped forward so that the light rays cannot reach the entire retina. The size of the foramen differs and bears no direct relation to the size of the parietal eye. The third eye is connected to the foramen by means of connective tissue and is surrounded by lymph spaces while blood vessels make up a net about the edges of the foramen. No mention of muscular tissue or discrete muscles has been made in connection with the parietal eye.

Leydig²³⁸ in 1891 found in *Lacerta muralis*, near the tip of the epiphysis, four round, free, calcium bodies. Similarly in *Varanus nebulosus* many small pieces of calcium carbonate have been observed. These, however, have nothing to do with the more common deposits of brain sand in the pineal organ of mammals, as Leydig²³⁸ originally thought.

The interior of the parietal eye contains a coagulum, the vitreous or the corpus vitreum. This consists of a syncytial layer of cells entirely free of pigment. A sclera has been described as developing in connection with the membrana limitans externa which passes over into the connective-tissue sheath of the eye. There is a space between these two layers which was originally supposed by Leydig²³⁸ to be a large lymph space. In most cases the connective tissue forms a sheath for the eye which may be considered as a sclera. In other instances it is absent. The connective-tissue capsule of the parietal eye is considered analogous to the sheath of the eye in *Petromyzon*. The connective tissue above the eye becomes differentiated as a cornea and contains no pigment. It is almost fiberless connective tissue. A parietal spot is absent in those saurians in which no parietal eye or no parietal foramen develops. It is recognized as a less pigmented area in the skin and presents many different appearances, as well as differences in size, in the several species of saurians (fig. 68).

Accessory pineal and parapineal organs in Reptilia. A number of observers have reported the appearance of accessory structures in connection with both the pineal and parapineal organs. Such observations have been made by Spencer ('86)³⁶⁶ in *Plica umbra*; by Duval and Kalt ('89)⁹⁹ in *Anguis fragilis*; by Carrière⁵⁷ in 1890; by Prenant³¹¹ in 1893-94-96; by Leydig²³⁷ in 1890-91, and by Francotte¹³⁰ in 1896. Accessory organs were also found

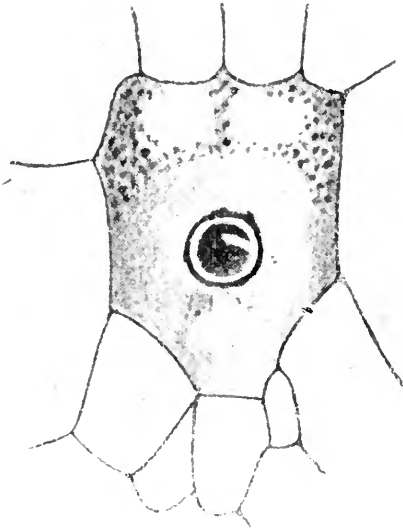


Fig. 68. The corneal scale in *Calotes*, according to Spencer, 1886

in *Lacerta vivipara* by Burckhardt⁴⁶ in 1894; by Francotte¹³⁰ in 1896; by Klinekowsroem ('94)²⁰⁹ in *Iguana*, and by Studnicka ('93)³⁸⁴ in *Pseudopus pallasii*. Accessory epiphyseal organs may arise either from the lateral wall of the end-vesicle of the pineal organ or the under wall of the parietal eye. There are two types of accessory organs: 1) accessory pineal organs, and 2) accessory parietal eye organs. The following are the possibilities for accessory pineal organs:

1. Evaginations of the distal end of the epiphysis as in *Anguis* and *Iguana*.

2. Independent buds off the epiphysis or extrusions from it held in relation by pigment strands of cells, as in *Lacerta vivipara*.

3. Isolated extrusions from the end of the epiphysis.

Accessory parietal eye organs are less common. Carrière⁵⁷ in 1890 showed a diverticulum from the under wall of the parietal eye. Prenant³¹² in 1895 made the same observation. Francotte¹²⁷ found that these accessories consist of a lens and retina which are still in connection with the chief organ. Accessory organs usually have pigment in them, but this is not so in *Phrynosoma* and *Sphenodon*. Only the under wall is pigmented as a rule, so that the under wall corresponds to the retina while the upper wall corresponds to the lens. Such accessory organs attached to the parietal eye indicate an attempt to produce another optic organ. Only exceptionally does the upper or dorsal wall show a lens formation. In *Pseudopus*, Studnicka³⁸⁴ in 1893 found that the interior of the accessory parietal eye contained a syncytium as does the actual parietal eye. Prenant³¹² in 1895 differentiated the following types of accessory organs in *Anguis*:

1. Epiphyseal eye. This lies close to the epiphysis, yet separated from it and is entirely derived from that organ.

2. Interparietal-epiphyseal eye. This is situated in the mid-line between the epiphysis and the parietal eye. It is the most frequent of the accessory parietal eye organs.

3. Intraparietal eye. This is connected with the retina and under wall of the parietal eye or else is included in it.

4. Accessory chorioidal eye. This is found very infrequently. It is widely separated from both parietal organs and presents itself as a pigmented hollow vesicle lying on the upper surface of the chorioid plexus.

Accessory parietal organ structures are most frequent in embryos and tend to disappear in the adult. This observation is agreed to by most authors.

Differences observed in the epiphyseal complex in the various species of reptiles already investigated.

PROSAURIANS

1. *Sphenodon punctatum* (*Hatteria*). Spencer ('86);³⁶⁷ Leydig ('91);²³⁸ Hoffmann ('90);¹⁵⁷ Dendy ('99)⁸⁷ described a development, as did also Schauinsland³⁴⁶ in 1899 and 1903.

The pineal organ in the embryo is a simple evagination with a thin stalk which is solid. The walls of the end-vesicle have many folds. Only the cells in the interior retain a brown pigment. The parietal nerve, according to Spencer, is a prolongation from the end of the epiphysis. Such a connection does exist in some adults, but is of a connective tissue character. Dendy and Schauinsland identified the actual parietal nerve. It arises in front of the epiphysis and is independent of it. The parietal eye is conical or pyriform in shape and the retina and lens are both well developed. In older embryos the nerve does not enter the middle, but rather comes into relation with the posterior third of the eye. The structure of the retina was most minutely described by Spencer, Leydig, and Dendy. It has rod cells and several other layers of cells. It contains pigment as well as a molecular layer and a layer of large ganglionic cells. The lens is bi-convex. The entire organ is surrounded by a connective tissue capsule. Dendy mentions a thin-walled sac in the embryo between the epiphysis and paraphysis. This undoubtedly is an accessory organ. *Sphenodon* has a parietal foramen and a superficial apparatus usually connected with the parietal eye.

SAURIANS—LACERTILIA VERA.

GECKONIDAE. 1. *Gecko verus*. Spencer ('86).³⁶⁷ In this species only the epiphysis is present. There is no parietal foramen and no parietal spot.

2. *Platydictylus muralis*. Spencer ('86);³⁶⁷ Leydig ('91);²³⁸ Melchers ('99).²⁶⁹ In this form there is no parietal eye, the epiphysis being the only element to appear. This latter consists of an end-vesicle which is large and thick-walled having no folds; its stalk is short and solid. The entire pineal organ is

flask-shaped. There are many intercellular spaces in the end-vesicle. These same observations hold good for *Mauritanicus*.

3. *Hemidactylus verruculatus*. Leydig ('91).²³⁵ This species possesses no parietal eye. There is an end-vesicle which contains a brown pigment. The vesicle is drawn out into a small point.

4. *Hemidactylus mabouia*. Stemmler ('00).³⁷⁴ In this form the pineal organ only is present and the end-vesicle is an attenuated bud. The proximal portion of the stalk is solid. There is no pigment and no fibers in connection with the organ.

5. *Gehyra oceanica*. Stemmler ('00).³⁷⁴ The parietal eye is not well developed. The pineal organ alone makes its appearance and has a definite end-vesicle. The stalk has a lumen in its proximal portion. The cells in the end-vesicle are ependymal in type. There are no folds in the wall.

AGAMIDAE. 1. *Draco volans*. Spencer ('86).³⁶⁷ Studnicka ('93).³⁸⁴ There is no parietal eye in this species. The pineal organ is a broad, dorsoventrally compressed end-vesicle containing no pigment.

2. *Ceratophora aspera*. Spencer ('86).³⁶⁷ In this form there is no parietal eye. An end-vesicle develops, but there is no parietal foramen.

3. *Lyriocephalus scutatus*. Spencer ('86).³⁶⁷ There is no parietal eye in this species. An end-vesicle exists with an attenuated stalk. There is no pigment, but the animal has a definite parietal spot.

4. *Calotes ophiomachus* and *versicolor*. Spencer ('86).³⁶⁷ The epiphysis ends at the edge of the parietal foramen. The parietal eye is present. Spencer saw only rods in the retina. The lens is concavo-convex. Some of the lens cells and retinal cells are pigmented. A well-marked parietal foramen is present and there is a small modified cornea with parietal spots.

5. *Agama hispida*. Spencer ('86).³⁶⁷ This species has a parietal eye, a retina, lens, and a parietal foramen, together with a cornea and parietal spot.

6. *Grammatophora barbata*. Spencer ('86).³⁶⁷ In this form there was found some evidence of a parietal eye, the under

wall of which was definitely pigmented. McKay ('88)²⁵⁵ found a bi-convex lens, a good retina with rod cells and round cells, a molecular layer, and also a spindle-celled layer and peculiar, triangular elements. The lumen was traversed by a fine strand.

7. *Moloch horridus*. Spencer ('86).³⁶⁷ In this species the organ is strongly pigmented, more likely an end-vesicle with a stalk than a parietal eye. The parietal foramen in which the organ rests is present. Both cornea and parietal spot are present.

8. *Agama caucasica*. Owsiannikow ('88).²⁹⁵ In this species there is a relatively large parietal eye with rods in the retina, which latter is otherwise well developed. There is also a lens, a parietal foramen, a vitreous, cornea, and a parietal spot. In one case, Ritter ('94)³³³ found an accessory organ which he called the parapineal organ. It was situated in the parietal foramen somewhat to the left of the parietal eye. No corium was above it. A common, connective tissue capsule contained both organs. The accessory organ was larger than the parietal eye. There was no lens or retina in the accessory organ.

9. *Phrynocephalus Vlangalii*. Owsiannikow ('88).²⁹⁵ In the 20 mm. embryo this species has a parietal eye. The organ is deeply pigmented.

IGUANIDAE. 1. *Phrynosoma orbiculare*. Studnicka ('93).³³⁴ In this species the epiphysis is broad and globular and connected by a stalk to the roof of the brain. It presents an end-bud on its distal extremity. Ependymal cells in the body contain a brown pigment. In the lumen there is a coagulum which consists of a syncytium of pigment-containing cells. The parietal nerve was not observed. The parietal eye is small, dorso-ventrally flattened with a well-developed lens and retina. The lens is bi-convex. The cells of the lens have their nuclei situated near the under surface. The retina is filled with pigment, hiding its main structure. The position of the parietal eye is in a wide foramen, four times as large as the parietal eye itself. The parietal cornea and spot are present.

2. *Anolis*. Spencer ('86).³⁶⁷ This species presents a well-developed parietal eye which is ovoid in form and has a well-developed,

thick retina. The latter is pigmented and contains rod cells. The lens is bi-convex. What Spencer considered a nerve was in all probability connective-tissue remains of a former nerve. A narrow parietal foramen occurs while the cornea and parietal spot are absent.

3. *Leiolaemus niividus*. Spencer ('86).³⁶⁷ In this form the epiphysis exists as a hollow, proximal part and a horizontal solid end portion. The latter is stretched forward to reach the parietal foramen. The parietal eye is dorsoventrally flattened and has a narrow lumen. The upper surface of the retina is flat and horizontal. The lens is present. There are rod cells which are the chief elements in the retina. The lens is bi-convex and the nuclei of the lens cells lie in a layer deeply situated. There is a parietal foramen in which the eye is lodged. The corium is clear. There is a light colored parietal spot.

4. *Leiolaemus tenuis*. Spencer ('86).³⁶⁷ The epiphysis extends forward to a well-marked parietal eye. There is no connection between the two. The parietal eye has a pigmented retina and a lens. The parietal cornea and parietal spot are present.

5. *Plica umbra*. Spencer ('86).³⁶⁷ The epiphysis has a proximal part and a horizontal portion which is solid and reaches the parietal eye. The latter is connected with the epiphyseal end-sac. The parietal eye is much flattened and the retina is pigmented. It is situated in a deep parietal foramen. The cornea is present as well as the parietal spot.

6. *Iguana tuberculata*. Spencer ('86);³⁶⁷ Leydig ('96);²³⁹ Klinekowsstroem ('93).²⁰⁷ In this form the epiphysis is well developed with a large end-bud in connection with the proximal portion. The latter has a more or less follicular appearance. In embryos the cells have cilia, but these later disappear. Klinekowsstroem in the 18 mm. embryo describes a tractus pinealis in the distal end of the epiphysis. A parietal nerve is described by the same author in 1894. In embryonic stages it connects the retina with the roof of the brain. The parietal eye is globular and in some forms a highly differentiated retina is present. An actual nerve layer appears only in the embryo and later disap-

pears. The pigment increases in the older animals. The lens is plano-concave. The eye rests in a parietal foramen. The cornea is present as well as a marked parietal spot.

7. *Phrynosoma douglassi*. Ritter ('91).³³² There is an epiphyseal vesicle in this form and a posteriorly flattened vesicle which contains no lumen. It is connected by a very thin stalk to the epiphysis. The parietal eye is connected with the brain roof and is a laterally compressed vesicle. The lens and retina are both well developed. The retina has an outer cell layer, a molecular layer, and an inner layer with two elements, one round and the other elongated, and finally an inner layer of rod cells. There is a coagulum in the cavity of the eye vesicle. The lens is slightly bi-convex. The nuclei of the lens cells lie near the inner periphery of the lens. The position of the eye is in a broad foramen. The parietal cornea and pit, as well as a parietal spot, are all present.

8. *Uta stansburiana*. Ritter ('91);³³² Studnieka ('95).³⁵⁶ The parietal eye in this form is also ventrally flattened. The lens is separated from the retina. There is deep pigment in the retina and the eye rests in a parietal foramen.

9. *Sceloporus undulatus*. Herrick ('91)¹⁷⁸ in describing the epiphysis in this form, states that the under wall has some similarity to the retina.

10. *Phrynosoma coronatum*. Ritter ('91);³³² Sorensen ('93).³⁶¹ The epiphysis is similar to that in *Phrynosoma douglassi*. It is a thick-walled vesicle. The cells in the interior are deeply pigmented. There is a connective-tissue strand running to the parietal eye. The parietal nerve extends from the commissura posterior to the parietal eye. The eye is not as well differentiated as in *Phrynosoma douglassi*, although it is present.

11. *Sceloporus striatus*. Sorensen ('94).³⁶³ In this form the epiphysis is attached to the roof by a thin, peculiarly white stalk. The parietal nerve presents no peculiarities, but arises from the anterior portion of the commissura habenularis. It is solid to the extreme end of the epiphysis where it proceeds to the parietal eye, the latter apparently being independent of the end of the epiphysis. No parietal foramen is present. The

parietal eye has the form of a dorsoventrally compressed sac which has a lens and well-marked retina, the latter has a double layer of well-pigmented cells. Rod cells also are present. The entire parietal organ is enclosed in a connective-tissue capsule.

ANGUIDAE. 1. *Anguis fragilis*. Leydig ('96);²³⁹ deGraaf ('86);¹³⁵ Spencer ('86);³⁶⁸ Béranek ('92);²³ Hanitsch ('88);^{169A} Strahl and Martin ('88);³⁸³ Francotte ('96);¹³⁰ Owsianikow ('88);²⁹⁵ Duval and Kalt ('89);⁹⁹ Carrière ('90);⁵⁷ Prenant, ('95),³¹² and Studnicka ('93).³⁸⁴

The epiphysis in this species consists of a proximal and a distal portion. The end portion of the epiphysis is deeply pigmented. The parietal eye is connected by a connective-tissue strand to the epiphysis. The parietal nerve is present only in embryos and arises from the ganglion habenulae. The parietal eye is lenticular in form, dorsoventrally flattened, and has a deeply pigmented retina. The lens is bi-convex and plano-convex. The lumen contains a coagulated substance with a syncytium. There is a well-developed capsule. Accessory organs are common. The position of the eye is in a parietal foramen. The parietal cornea, pit, and spot are present.

2. *Varanus bengalensis*. Spencer ('86).³⁶⁸ The pineal organ has a distal and proximal portion and there is no parietal nerve. The parietal eye is present and contains a lumen. The retina contains rod cells and several layers of smaller cells. The lens is convexo-concave. The parietal foramen is of large size. There is a capsule, a parietal pit, and a parietal spot.

3. *Varanus nebulosus*. Leydig ('91).²³⁸ In this species the pineal organ is as in other forms, but there is no end-sac. The parietal eye is pyriform but there is no distinct retina.

4. *Pseudopus pallasi*. Owsianikow ('88);²⁹⁵ Hoffmann ('90),¹⁸⁷ in Bronns "Klassen und Ordnungen."

In this form there is a well-developed lens, retina, and vitreous. Studnicka³⁸⁶ in 1895 described the conditions as follows: There is a complete pineal organ with an end-vesicle, a stalk, and proximal portion, the latter being the epiphysis. This is connected with the brain-roof by a secondary stalk. The parietal eye is semiglobular in shape. There is a lens and retina, the

latter having rod cells, a layer of small cells and a layer of large, probably ganglionic, cells. There is a parietal nerve and a connective-tissue strand connecting the organ to the epiphysis. The lens is bi-convex. An accessory organ is also present. There is a capsule of connective-tissue and a broad parietal foramen. A parietal cornea, pit, and spot also exist.

5. *Varanus giganteus*. Spencer ('86).³⁶⁵ In this form there is no mention of an epiphysis. The parietal nerve has a special feature. From the end of the epiphysis to the parietal eye such a nerve is seen to extend. Two or three strands of the nerve are found which become confluent. The parietal eye is dorso-ventrally flattened. There is a lens and retina present, the latter contains rod cells and several other layers. In the cavity there is a vitreous. The lens is thin and bi-convex. In the center is a mass of round cells deeply pigmented indicative of a rudimentary character of the organ. The parietal capsule consists of connective tissue. There is a parietal foramen, pit, and spot.

6. *Varanus griseus*. Edinger (00).¹⁰⁶ This species shows, in a sagittal section through the brain, an unusually large epiphysis thrown into many folds. It resembles the epiphysis of *Pseudopus*.

TEJIDAE. 1. *Ameiva corvina*. Spencer ('86).³⁶⁶ In this form neither a parietal foramen nor a corneal pit is present.

2. *Tejus teguixin*. Klinekowitz (94).²⁰⁹ An embryo of this form seemed to show only a pineal organ well developed, while above it was a rudimentary parietal eye. Studnicka³⁵⁴ does not believe the parietal eye develops in this form.

LACERTIDAE. 1. *Lacerta vivipara*. Spencer ('86).³⁶⁶ Owsianikow ('88).²⁹⁵ Strahl and Martin ('88).³⁵³ Leydig ('91).²³⁸ Studnicka ('93).³⁵⁴ In this species the pineal organ is globular and pyriform; its extremity alone contains pigment. This is connected with the parietal eye by a vascular connective-tissue strand. The parietal nerve is independent of this strand. The parietal eye is a flattened vesicle and there is a much-reduced lumen. The retina is deeply pigmented; its structure is obscured by this vesicle. The lens is bi-convex. The capsule

is not well developed. The eye eventually makes its way into the parietal foramen. The corneal pit is present.

2. *Lacerta viridis*. Spencer ('86);³⁶⁶ Leydig ('91).²³⁸ In this form, extending from the parietal organ into the epiphysis is a fibrous strand. The end of the epiphysis is deeply pigmented. The parietal eye is flattened dorsoventrally. The retinolenticular transition is gradual. There is much pigment in the retina. The lens is bi-convex. The parietal foramen is present. There is a corneal pit, cornea, and a parietal spot.

3. *Lacerta ocellata*. Spencer ('86);³⁶⁶ Leydig ('91).²³⁸ The pineal organ is expended at its distal end with an end-sac process. The wall is folded to form twelve accessory spaces in the epiphysis. The end of the epiphysis is pigmented. There is a parietal nerve and a well-developed parietal eye which is globular and slightly flattened. The retinolenticular transition is gradual. The retina is pigmented and contains cylindrical and ganglionic cells. The lens is bi-convex. The capsule is well developed. The parietal foramen contains the eye. The parietal cornea is present. There is also the parietal spot.

4. *Lacerta agilis*. Owsianikow ('88);²⁹⁵ Leydig ('91);²³⁸ Studnicka ('93).³⁸⁴ The pineal organ is present in the form of an epiphysis, which is saccular and has a hollow stalk. The parietal nerve, according to Leydig ('96),²³⁹ is present. It takes origin in the ganglion habenulae and extends to the parietal eye. This eye is a flattened, saccular vesicle. The retina and lens are sharply demarcated. The retina is less pigmented than in other forms. It is connected with the brain by a parietal nerve. The lens is bi-convex. There is a special parietal sheath made up of connective tissue. The parietal foramen, corneal pit, and parietal spot are present. Exceptionally, the foramen is closed by bone.

5. *Lacerta muralis*. Leydig ('91);²³⁸ Studnicka ('93).³⁸⁴ The epiphysis is present as is also the parietal eye. The retina is deeply pigmented. The corneal pit and parietal spot are also present.

SCINCIDAE. 1. *Cyclodus gigas*. Spencer '86).³⁶⁶ The pineal organ arches forward over the hemispheres to enter the region

of the parietal foramen. The epiphysis is hollow. The stalk opens into the ventricle. The proximal tubular portion is present. The distal portion is within the foramen. The end-vesicle of the pineal organ comes into this relation. Spencer thought it was a rudimentary eye. The corneal pit, parietal foramen, and parietal spot are present.

2. *Chalcides tridactylus*. Spencer ('86);³⁶⁶ Leydig ('91).²³⁵ The epiphysis is a globular vesicle. The end is prolonged into a tapering process. The epithelium is much thickened. The parietal eye is separate from the epiphysis. The retinolenticular transition is gradual. The lens is bi-convex. There is a parietal foramen, cornea, spot, and pit.

3. *Himulia*. McKay ('88);²⁵⁵ Sorensen ('94).³⁶³ In this form there is a well-developed parietal eye which is unattached to the epiphysis. The lens is bi-convex. The retina contains rod cells, round cells, a molecular layer, spindle cells, and pigment cells.

4. *Scincus officianalis*. Prenant ('96).³¹³ There is a parietal eye and a parietal foramen well developed in this form.

5. *Gongylus ocellatus*. Legge ('96).²²³ In an embryonic study of this form the epiphysis with a proximal portion and a distal part was present. Only in the embryonic stages was the parietal eye observed. It contains a brown pigment. There is a lens which is bi-convex. The parietal nerve is not present. The parietal cornea, foramen, and spot were not observed.

CHAMAELEONTIDAE. 1. *Chamaeleon vulgaris*. Spencer ('86);³⁶⁶ Owsiannikow ('88);²⁹⁵ Studnicka ('93).³⁵⁴ The pineal organ in the form of the epiphysis is a folliculated, hollow sac, which is flexed forward, the walls being much flattened. It runs out into a long, strand-like point. The parietal nerve is probably not present in the adult. The connection between the pineal organ and the eye is connective tissue and not nerve. As to the parietal eye, authors differ; some say there is a good lens and retina, others regard this as rudimentary in all respects. There is a good capsule and a good parietal foramen. The parietal cornea, pit, and spot are absent.

ORUIDA. 1. *Python uigris*. Rabl-Rückhard ('94).³²³ In this species there is an oval-shaped glandular structure, having

many reduplications in its walls. It is rich in blood vessels and has a small cell content. Over it lies the chorioid plexus.

2. *Eutaenia sirtalis*. Sorensen ('94).³⁶³ The epiphysis in this species is globular in form and glandular in structure. It is embedded in connective tissue. Herriek ('91)¹⁷⁶ agrees in these observations.

3. *Tropidonotus natrix*. Studnicka ('93);³⁸⁴ Leydig ('97).²⁴⁰ In this form there is a paraphysis and epiphysis in older embryos and in the adult. The epiphysis is definitely glandular in character. There is a thin stalk, the latter probably secondary and not analogous to the stalk in lower forms. Ssobolew³⁶⁴ in 1907, working on embryos of *Tropidonotus natrix* and *Vipera berus*, found that the epiphysis develops earlier than the paraphysis. The parietal eye does not appear in either of the forms studied, nor is there a parietal foramen. The cells of the epiphysis are arranged in colonies as in the glands of internal secretion. The organ seems to have nothing to do with light perception and the same applies to heat perception. There is no parietal nerve and the primitive canal in the organ is lost (fig. 69).

4. *Tropidonotus rhombifer*. Sorensen ('94).³⁶³ The epiphysis is glandular in character.

5. *Bascanium constrictor*. Sorensen ('94).³⁶³ In the embryo of this species the epiphysis has a glandular form and is connected with a stalk to the roof of the interbrain (fig. 70).

6. *Coluber aesculapii*. Studnicka ('93).³⁸⁴ In this species the epiphysis is globular in form and covered with connective tissue. It contains a dark pigment and lies close to the brain.

7. *Coronella austriaca*. Leydig ('97).²⁴⁰ There is no parietal organ in this species in relation with the skull. In the embryo the epiphysis is well developed.

8. *Pelias berus*. Hanitsch ('88);^{169A} Studnicka ('93).³⁸⁴ In this species Hanitsch believed that he discerned a parietal organ with much pigment and a lens. Studnicka disagrees with this and describes the epiphysis as a typically glandular structure.

9. *Vipera ursinii*. Leydig ('97).²⁴⁰ In this species the structure is definitely glandular.

CHELONIA. 1. *Chelone mydas*. Rabl-Rueckhard ('86).³²² In this species the epiphysis is a massive, bilobed structure.

2. *Cistudo europaea*. Bojanus ('19).³⁶ This author first described the epiphysis in this form as a short, pediculated structure with a dilated extremity which was flexed forward. Faivre¹¹⁵ in 1857 describes it as a conical body containing small particles of calcium phosphate. Herrick¹⁷⁶ in 1891 defined it as a lobulated sac attached to the roof of the brain. The distal portion is non-vascular. Sorensen ('93),³⁶¹ reconstructed the pineal organ in this form (fig. 71).

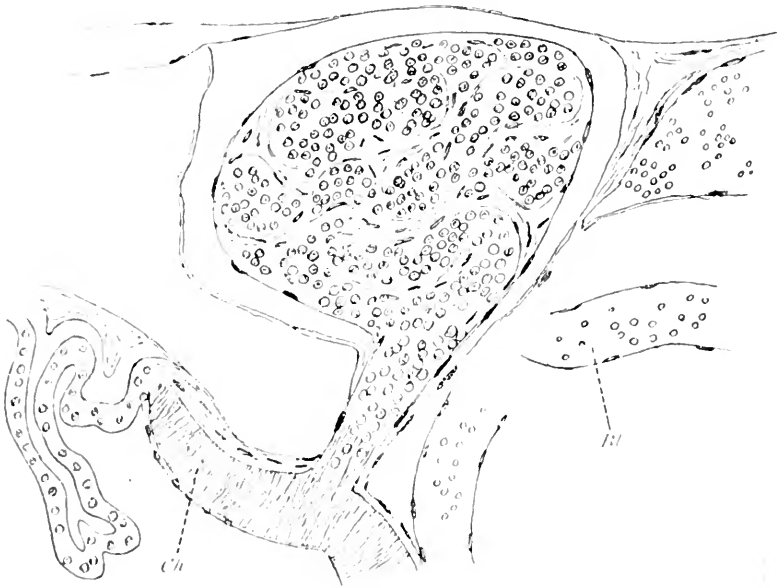


Fig. 69 The epiphysal complex in a young *Tropidonotus natrix*, according to Leydig, 1897.

3. *Aspidonectes spinifer*. Herrick ('91).¹⁷⁶ In this species the epiphysis has the form of a tubular structure arching forward. Its lumen opens into the ventricle through a short stalk.

4. *Chelydra serpentina*. Humphrey ('94).¹⁹⁰ The embryo of this species has the same form as the saurians. In the early stages it is a dilated sac connected with the third ventricle by a short stalk. Later this stalk becomes hollow and in adults it shows lobulation.

5. *Amida mutica*. Gage ('95).¹³⁵ The epiphysis in this species is similar to other chelonians.

6. *Chelone imbricata*. Voeltzkow ('03).⁴¹⁰ The epiphysis in this species is entirely separated from the brain.

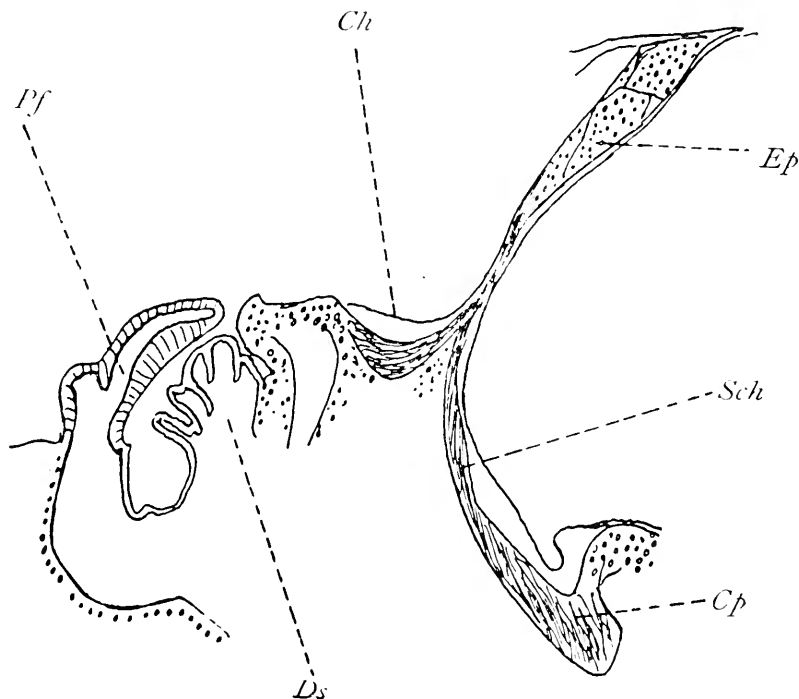


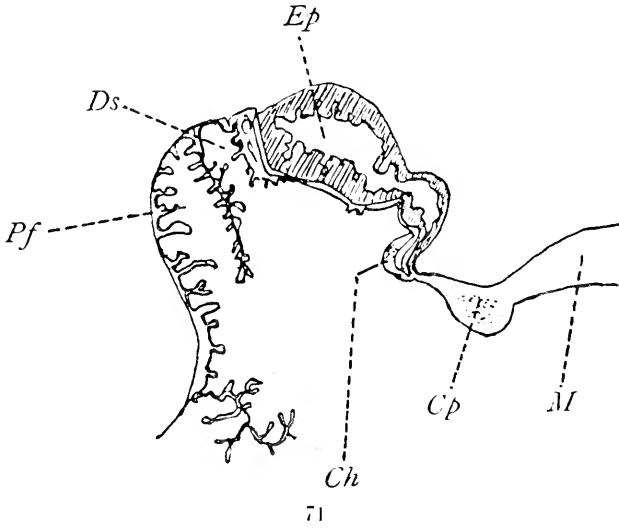
Fig. 70 The pineal region of *Boscanium constrictor*, according to Sorensen, 1894.

Pf., paraphysis; *Ds.*, dorsal sac; *Ch.*, commissura habenularis; *Ep.*, proximal portion of pineal organ; *Sch.*, pars intercalaris posterior; *cp.*, posterior commissure.

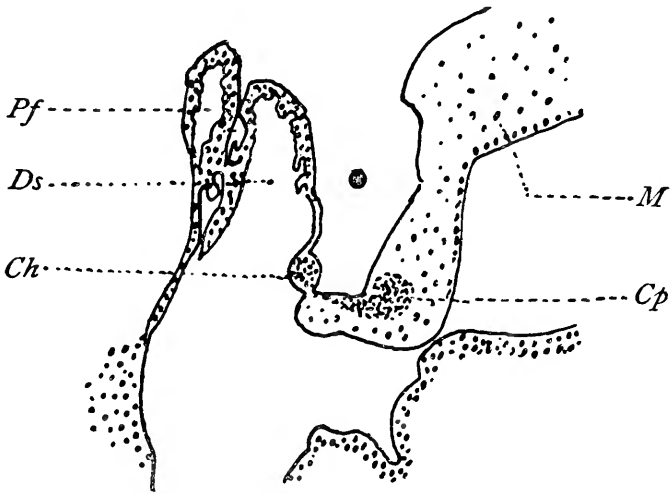
Crocodylia. Sorensen ('94).³⁶³ As already stated, this author did not find the epiphysis or any portion of the parietal organ in the alligator. Voeltzkow⁴¹⁰ in 1903 in *Crocodylus madagascariensis* found no epiphysis (fig. 72).

The conditions and relations of the epiphyseal complex in Reptilia are so important as to necessitate the following tabulation:

SPECIES, CLASS OR FAMILY	NUMBER INVESTIGATED	PARIETAL EYE	RETINA	LENS	PARIETAL NERVE	CORNEA	PARIETAL FORAMEN	PINEAL ORGAN COMPLETE	PINEAL NERVE	GLANDULAR EPITHYLSIS PROXIMAL	ACCESSORY ORGANS
Sphenodon.....	1	Present	Present	Present	Present	Present	Present	Rudiment	None	Proximal portion convoluted	Present
Geckoniidae.....	5	Absent in 5	Absent in 5	Absent in 5	Absent in 5	Absent in 5	Absent in 5	Present in 5	Absent in 5	Present in 3 Absent in 5	None
Araniidae.....	9	Present in 5 absent in 2	Present in 5 absent in 2	Present in 5 absent in 2	Present in 5 absent in 2	Present in 5 absent in 2	Present in 5 absent in 2	Present in 2	None	Proximal portion	None
Iguanidae.....	11	Present in 11	Present in 11	Present in 11	Present in 11	Present in 11	Present in 11	Present in 8	Present in 1	Present in 1	Present in 1
Anolis.....	6	Present in 5	Present in 4 absent in 2	Present in 5 absent in 1	Present in 4 absent in 2	Present in 5	Present in 5	Present in 4	None	Present in 1 None	None
Trojidae.....	2	Absent in 2	Absent in 2	Absent in 2	Absent in 2	Absent in 2	Absent in 2	Present in 2	None	None	Present in 1
Lacertidae.....	5	Present in 5	Present in 5	Present in 5	Present in 5	Present in 5	Present in 5	Present in 5	None	None	None
Scincidae.....	4	Present in 3	Present in 3	Present in 3	Present in 2 absent in 1	Present in 3	Present in 3	Present in 4	None	None	None
Chamaeleontidae.....	1	?	?	?	?	Absent in 1	Absent in 1	Present in 1	None	None	None
Ophidia.....	9	Absent in 9	Absent in 9	Absent in 9	Absent in 9	Absent in 9	Absent in 9	Absent in 9	Absent in 9	Present in 9	None
Chelonia.....	6	Absent in 6	Absent in 6	Absent in 6	Absent in 6	Absent in 6	Absent in 6	Absent in 6	Absent in 6	Present in 5	None
Crocodylia.....	2	Absent in 2	Absent in 2	Absent in 2	Absent in 2	Absent in 2	Absent in 2	Absent in 2	Absent in 2	Absent in 2	None



71



72

Fig. 71 The pineal body of *Cistudo europaea*, according to Sorensen, 1896.

Fig. 72 The pineal region in the Alligator, according to Sorensen, 1896.

Pf., paraphysis; *Ds.*, dorsal sac; *Ch.*, commissura habenularis; *Cp.*, posterior commissure; *M.*, midbrain.

The parietal or third eye does not make its appearance in reptiles except in *Sphenodon* and *Lacertilia vera*. In these latter forms it is by no means constant. Of forty-four species examined, the parietal eye has been observed in 29 instances, the retina in 28, the lens in 24, the parietal nerve in 25, the cornea in 24, and the parietal foramen in 28. It was impossible to detect these structures in the same number of species as follows: Parietal eye absent in 9, retina absent in 11, lens absent in 10, nerve absent in 12, cornea absent in 10, and parietal foramen absent in 10. The pineal organ, either complete in all its three portions or as the proximal portion (epiphysis proper), was present in all of the forty-four species. A complete pineal organ was observed in thirty-one species while a highly developed proximal portion, possibly suggestive of glandular formation, was present in eight species.

In *Ophidia* and *Chelonia* there was a total absence of the parietal eye and structures pertaining thereto in all of the fifteen species examined. In nine species of ophidians the pineal organ was represented in nine instances by a definitely glandular proximal portion, the epiphysis proper or corpus pineale. This gland seems to contribute its secretion to the ventricles, but may also be of the blood-vascular type as well. In *Chelonia* there is evidence that the pineal organ which appears as the proximal portion of that structure may also be glandular in nature. The absence of the parietal eye elements as well as the pineal organ has already been mentioned in *Crocodylia*.

It is evident from this summary that only the proximal portion of the pineal organ persists in the more modern reptiles, while the parapineal element as well as the end-vesicle and stalk of the pineal organ, have entirely disappeared.

7. *Comparative Anatomy and Histology of the Epiphyseal Complex in Birds*

As in ophidians, the only element of the epiphyseal complex which persists in birds is the proximal portion of the pineal organ. This presents itself as the epiphysis or corpus pineale.

In form the avian epiphysis is conical or cylindrical, sometimes being flattened by the approximation of the cerebellum and cerebral hemispheres. Its size varies considerably in different

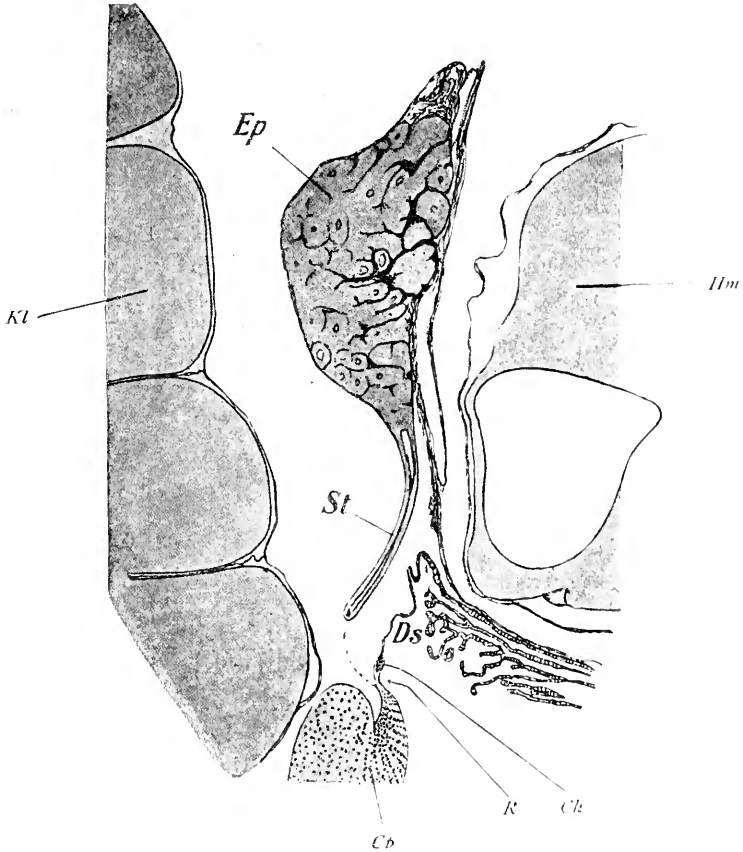


Fig. 73 The pineal region in *Gallus domesticus*, according to Studnicka, 1896. *Ds.*, dorsal sac; *Ch.*, commissura habenularis; *R.*, recessus pinealis; *St.*, pineal stalk; *Ep.*, pineal body; *Cp.*, commissura posterior.

species, but the following figures give a general idea of the dimensions.

In <i>Meleagris gallopavo</i>	5 mm. long by 2.5 mm. thick
In <i>Gallus domesticus</i>	2.5 mm. long by 1.5 mm. thick
In <i>Strix</i>	6 mm. long

It is situated close to the roof of the interbrain, its long axis being as a rule, perpendicular to the latter. In no instance does it approach or come in contact with the inner surface of the skull.

The histology of the structure discloses several different forms which the organ may assume. Studnicka ('05),³⁹¹ distinguishes three distinct types: 1) A long sac with thick walls containing many follicles. Such an organ is found in *Passer*—Gage ('95).¹³⁶ 2) A solid body with communicating or independent acini which connect with the lumen of the pineal body by means of a still potent canal. Between the follicles are many blood vessels and much connective tissue. The stalk is solid as in *Meleagris gallopavo*—Mihalkovicz ('77).²⁷⁵ 3) A solid organ in which there are solid, blind acini instead of hollow follicles. These acini make up solid lobules.

In brief, these three types may be termed, 1) saccular; 2) follicular or acinal, and, 3) solid. There are a number of transitional forms in addition to those already mentioned.

Funkquist¹³³ in 1912 describes two morphogenetic types in birds.

1. The organ has a simple tubular character which, during growth, shows a thickening of its walls and a general enlargement. In some cases the organ is solid except at its base where it retains a cavity, the *recessus pinealis*.

2. In this type the organ has a tubular character, in many instances retaining its connection with the original pineal evagination and in others being cut off from it. These bud-like tubular processes resemble tubuli of the dorsal sac. The pineal organ has its original anlage in an epithelial structure. Later, development causes a transition into neuroglia tissue in much the same way as the transition occurs in the central nervous system. In some cases (canary and turkey) the acinus-formation, giving rise to simple pineal tubules, persists, while in other instances these acini are more or less obliterated.

Two types of cells may be identified, according to Funkquist, namely, large epithelial cells with clear protoplasm and small darkly staining cells.

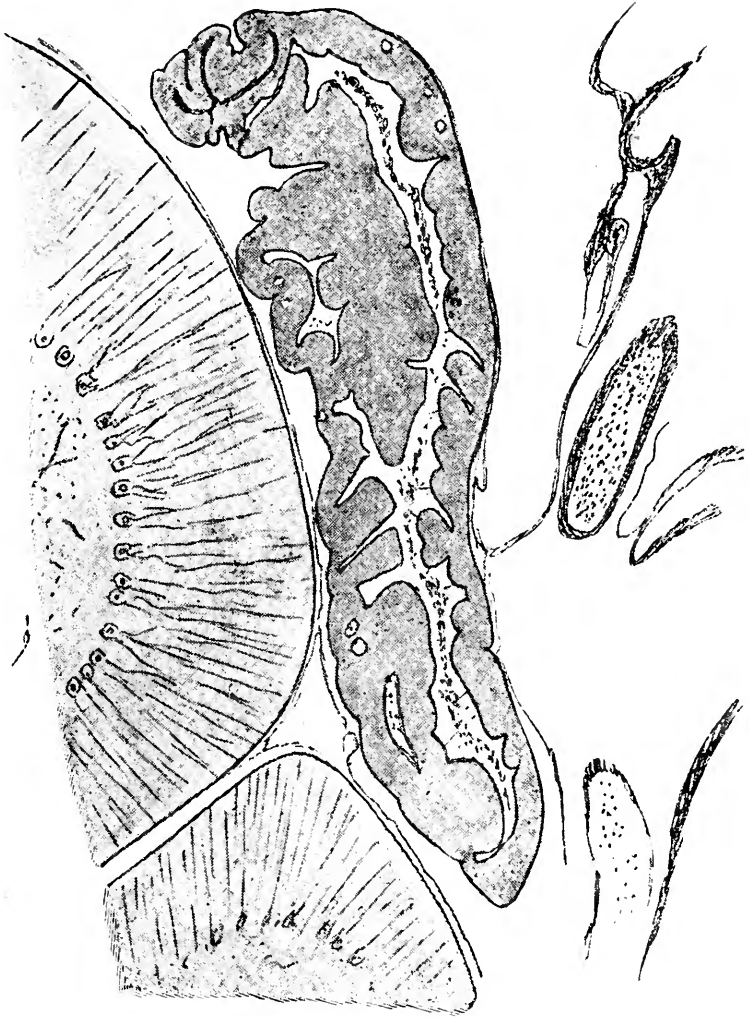


Fig. 74. The pineal body in *Coccothraustes vulgaris*, according to Studnicka, 1896.

Galeotti¹⁴⁰ in 1896 also recognized two types of cells, i.e., radially arranged, cylindrical cells which bound the lumen of

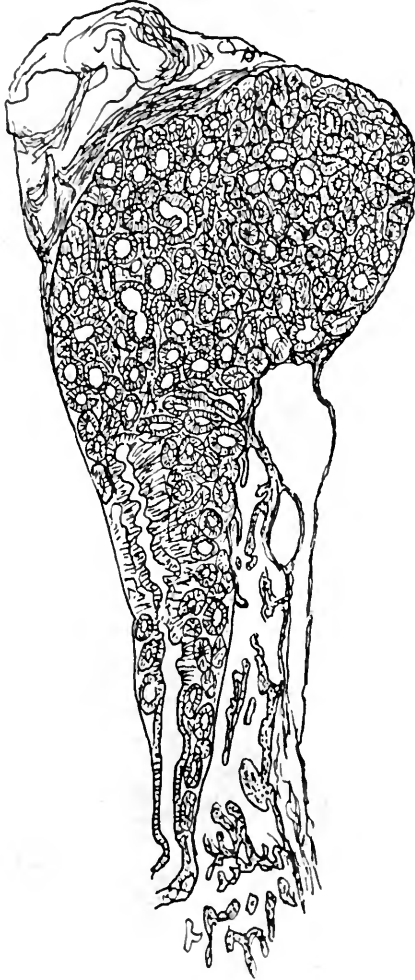


Fig. 75 The pineal body in *Meleagris gallopavo*, according to Studnicka, 1896, the organ and small cells between the larger ones. In the large, cylindrical cells, Galeotti found hyaline masses which he considered a secretory product ultimately delivered to the lumen of

the acini. Studnicka³⁹¹ regarded these cells as ependymal in type just as in the lower vertebrates, but found no sensory cells. In addition to the ependymal elements there were neuroglia cells, and Studnicka in *Meleagris* also observed some very large cells with clear cytoplasm scattered among the other groups. There may be ganglionic cells, as in *Acipenser*. No nerve fibers were observed. The epiphysis contains many isolated cells and a secretion derived apparently from the ependymal cells. No pigment was observed.

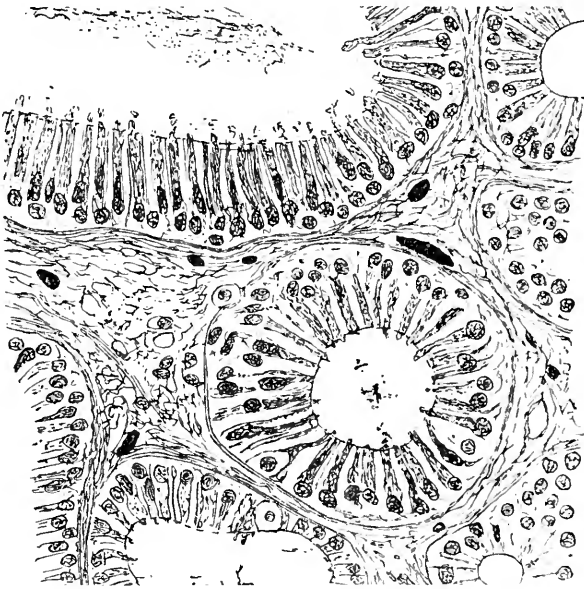


Fig. 76 Section of the pineal body of *Meleagris gallopavo*, showing follicles, according to Studnicka, 1896.

The stalk of the epiphysis, which is of course in no sense homologous with the stalk of the pineal organ, being a secondary character of the epiphysis, is usually short and contains the recessus pinealis. In some instances, however, it is solid. No nerve fibers have been observed in it, so that the organ has no neural connection with the brain. The epiphysis, including its stalk or peduncle, is enclosed within a sheath of pia mater and arachnoid.

Klinckowstroem²⁰⁶ in 1892 has shown in certain aquatic birds during embryonic stages, a very early appearing, peculiarly pigmented spot on the head. This he found in twelve out of two hundred embryos of *Sterna hirundo*, *Larus canus*, *Larus marinus*, *Larus glaucus*, and *Anser brachyrhynchus*. In adults of these forms no such spot exists. There is little evidence to indicate the tendency to the formation of a parietal foramen.

Dexter ('02)⁹⁰ observed in *Gallus domesticus* that the paraphysis is an appendix of the paraphyseal arch, developed from the brain wall. He believes it to be glandular in character. In the adult of this form it is composed of a modified ectodermic tissue. In the younger stages its walls are thin and its cavity is large, but in the adult chicken or hen the reverse is true. It is oval in shape and lies nearly parallel with the longitudinal axis of the cavity of the forebrain. It is a constant structure, and Dexter has identified it time and again in the embryo, in the chicken, and finally in the full-grown fowl. Its position is very characteristic. The paraphysis is situated immediately dorsad to the foramen of Munro and anterior to the prominent fold of the chorioid plexus which must morphologically correspond to the velum transversum.

Differences observed in the epiphyseal complex in the various species of birds already investigated.

1. *Gallus domesticus*. Stieda ('69);³⁷⁶ Dexter ('02);⁹⁰ Galeotti ('96).¹⁴⁰ It was observed in this form that the epiphysis is follicular in structure and glandular in character.

2. *Meleagris gallopavo*. Mihalkovicz ('77)²⁷⁵ observed that the epiphysis is follicular in this form.

3. *Sterna hirundo*. Klinckowstroem ('92)²⁰⁶ found remains of the parietal spot in the embryo.

4. *Anas domesticata*. Klinckowstroem ('92).²⁰⁶ In this form the author observed that the epiphysis is follicular.

5. *Apteryz*. Parker ('92).³⁰¹ The epiphysis in this form is usually anteflexed, although in some instances it is dorsiflexed.

6. *Perdix cinerea*. Studnicka (96).³⁸⁶ The epiphysis in this species is follicular.

7. *Strix flammea*. Studnicka ('96).³⁸⁶ In this form the epiphysis is partly solid and partly follicular.

8. *Lanius excubitor*. Studnicka ('96).³⁸⁶ In this species the epiphysis is saccular.

9. *Turdus pilaris*. Studnicka ('96).³⁸⁶ The epiphysis is follicular in this form.

10. *Coccothraustes vulgaris*. Studnicka ('96).³⁸⁶ In this species the epiphysis is hollow and saccular in its entire extent.

11. *Passer domesticus*. Gage ('95).¹³⁶ The epiphysis is hollow and saccular in this form.

In birds, as in ophidians, the evidence of the glandular nature of the epiphysis is pronounced. Every form examined yields many suggestive indications that the pineal body in birds is a glandular organ. The element pertaining to the parietal eye has not been observed in the avian forms examined and the epiphysis is evidently the highly specialized proximal portion of the pineal organ. The stalk and end-vesicle have disappeared. The element referred to in birds as the stalk is something entirely different from that portion of the lower forms which connects the proximal portion and the end-vesicle. The avian stalk is a secondary development consequent upon the marked enlargement and solidification of the proximal portion. During this process the pineal body tends to move slightly away from the roof, and in so doing produces an elongation in the originally constricted area which connects the epiphysis with the roof of the interbrain. This, in contradistinction to the stalk of the end-vesicle, is the stalk or peduncle of the epiphysis. The pineal recess contained within this peduncle is not entirely homologous with the pineal recess of the lower forms, for in the latter instances the recess extends into the proximal portion its entire length, while in birds it is restricted to the peduncle.

8. *Comparative anatomy and histology of the epiphyseal complex in mammals*

In mammals the only element of the epiphyseal complex which persists is the proximal portion of the pineal organ. In but a single instance thus far recorded is there evidence of the parapineal element, i.e., Cutore's⁷⁴ observation of a small anterior

protuberance in front of the epiphysis in the new-born *Bos taurus*. As a rule, the proximal portion is solid in the greater part of its extent and attached by a more or less constricted portion to the roof of the interbrain. This part of the epiphysis, sometimes referred to as the stalk, is not to be confused with the stalk of the lower vertebrates which, together with the end-vesicle, fails to develop in mammals. The mammalian stalk is more properly designated the pineal peduncle. The solid portion of the epiphysis is regarded by many as a glandular structure, and hence the term pineal gland. In mammals the following parts may be defined: The epiphysis or pineal body which consists of 1) the pineal gland and 2) the pineal peduncle. In the latter there is a recess of greater or less extent, the pineal recess. The peduncle consists in a large part of nerve fibers, while the pineal gland comprises several different constituents. In man the peduncle becomes so specialized in the nerve fibers which enter it as to constitute, according to some authorities, distinct peduncular bundles or epiphysal peduncles.

The form of the pineal body in mammals varies considerably. It is for the most part cone-shaped; it may be long or relatively short. In marsupials it is round or pyriform. In rodents it is, according to Flesch,¹²¹ more or less cylindrical, or, as Cutore⁷⁶ states, cylindricconical. In the pig, d'Erchia¹⁰⁹ describes it as spindle-shaped. In carnivores and primates the organ is generally conical or oval. According to Schwalbe ('81),³⁴³ it is a dorsoventrally flattened globule. In the primates the peduncle is paired, with the exception of *Troglodytes niger*, in which, according to Möller ('90),²⁷⁹ the epiphysis is kidney-shaped and connected with the brain by means of a single unpaired stalk 4 mm. in length. The epiphysis in most mammals is dorsiflexed so that its free extremity is directed toward the cerebellum. It thus presents a ventral surface in relation with the midbrain, a dorsal surface usually in relation with the corpus callosum (although there are certain exceptions to this statement), a base related to the roof of the interbrain, and an apex. The dorsal surface is in contact with a reduplication of the dorsal sac known as the lamina superior pediculorum and also with

the remnant of the pars intercalaris anterior forming the lamina inferior. These two laminae form the walls of a cul-de-sac, the suprapineal recess. The small space bounded by the pineal peduncle is the pineal recess.

In regard to its relation to the corpus callosum, Cutore ('10)⁷⁶ states that there are three varieties of the pineal body in mammals, i.e., 1) subcallosal, as in marsupials, some artiodactyla, insectivora, carnivora, and primates; 2) retrocallosal, as in most artiodactyla and perissodactyla; 3) supracallosal, as in rodents. Cutore ('10)⁷⁶ gives the following figures indicating the relative weight of the pineal body to the brain and also the pineal index:

ANIMAL	WEIGHT OF BRAIN	WEIGHT OF EPIPHYSIS	PINEAL INDEX
	<i>grams</i>	<i>grams</i>	
Sheep.....	480.00	0.350	0.070
Pig.....	140.00	0.040	0.020
Goat.....	119.80	0.075	0.060
Horse.....	512.00	0.440	0.080
Ass.....	420.00	0.520	0.100
Mule.....	430.00	0.860	0.200
Rabbit.....	8.46	0.010	0.100
Rat.....	1.86	0.002	0.100
Dog.....	85.20	0.080	0.005
Man.....	1300.00	0.220	0.010

The following tables give the diameters of the pineal body in man, according to several different observers, and also the differences at different periods of development as reported by Cutore:⁷⁶

Diameter of the pineal body in man in millimeters

	HENLE	SCHWALBE	LORD	TESTUT	ROMITI	CHARPY	CUTORE
Longitudinal.....	8	12	5-9	7-8	12	10-12	9-10
Transverse.....	6	8	3-8	4-6	8	5-8	5-7
Anteroposterior....		4	2-4		4	5	4-5

AGE	SEX	WEIGHT OF BODY	LENGTH OF BODY	ANTEROPOSTERIOR DIAMETER OF BRAIN	TRANSVERSE DIAMETER OF BRAIN	WEIGHT OF BRAIN	WEIGHT OF HYPHYPHYSIS	WEIGHT OF PINEAL BODY
		<i>grams</i>	<i>cm.</i>	<i>cm.</i>	<i>cm.</i>	<i>grams</i>	<i>grams</i>	<i>grams</i>
Newborn.....	Female	2,322	49.5	10.0	8.6	340	0.032	0.007
8 days.....	Female	3,030	50.0	11.5	8.8	395	0.100	0.010
1 month.....	Female	2,207	52.0	11.5	9.4	470	0.100	0.040
3 months.....	Male	3,700	63.0	13.8	11.4	762	0.110	0.035
6 months.....	Male	5,700	67.0	14.9	10.8	793	0.115	0.053
10 months.....	Female	5,972	73.0	15.0	12.0	836	0.160	0.045
13 months.....	Female	6,390	68.0	15.0	12.0	795	0.140	0.060
15 months.....	Male	6,550	73.0	17.0	12.5	872	0.170	0.025
15 months.....	Male	4,248	73.0	14.4	11.0	507	0.120	0.080
18 months.....	Female	6,200	73.5	15.8	12.5	905	0.160	0.050
20 months.....	Female	6,722	74.0	15.3	11.3	710	0.180	0.060
3 years, 3 months....	Male	5,625	80.0	16.1	12.0	990	0.192	0.093
3 years, 6 months....	Male	8,208	84.0	15.9	12.9	1,000	0.200	0.050
4 years.....	Female		91.0	16.5	11.8	1,075	0.190	0.070
9 years.....	Male		115.0	17.7	14.3	1,100	0.250	0.100
11 years.....	Male		120.0	17.2	13.5	1,257	0.400	0.120
13 years.....	Female		130.0	16.7	13.1	1,219	0.340	0.170
18 years.....	Male		142.0	16.7	13.2	1,200	0.310	0.125
19 years.....	Female		150.0	17.5	13.1	1,193	0.320	0.060
22 years.....	Female		165.0	18.0	13.3	1,237	0.690	0.070
23 years.....	Male		162.0	16.9	12.5	1,162	0.780	0.120
24 years.....	Male		163.0	17.9	13.6	1,300	0.440	0.220
60 years.....	Female		152.0	17.2	14.0	1,273	0.440	0.100
70 years.....	Female		147.0	16.9	13.0	1,000	0.650	0.140
70 years.....	Female		149.0	17.2	13.0	1,102	0.420	0.150

In the development of the pineal organ in all vertebrates, only two of the germ layers play a part, i.e., the ectoderm and the mesoderm. It is advantageous, therefore, in considering the histological character of the pineal body, concerning which there is much difference of opinion, to discuss the ectodermogenic and mesodermogenic elements entering into that body. Of the elements derived from the ectoderm the following have been observed: 1) parenchymal cells, 2) ependymal cells, 3) neuroglial cells, 4) ganglionic cells, and 5) nerve fibers. The following elements derived from the mesoderm have been described: 1) connective tissue cells, 2) connective tissue trabeculae, 3) blood

vessels, 4) certain cells called muscle or myoid cells, 5) lymphocytes, and 6) lymphoid reticulum.

Hollard¹⁸⁸ in 1837 regarded the epiphysis as a glandular structure with nerve fibers in its peduncle only. Valentin⁴⁰³ in 1843 believed that the pineal body possessed a parenchyma which was something entirely different from the gray matter of the brain. He observed certain 'nuclear formations' which had a striking resemblance to the tissue of the pituitary gland. Kölliker²¹⁰ in 1850 described the epiphysis in mammals as consisting of small, round cells, multipolar nerve cells and compact bundles of nerve fibers. But it is to Faivre¹¹⁴ in 1855 that we are indebted for the first extensive study in the comparative histology of the epiphysis. Faivre investigated microscopically the pineal body of man, horse, guinea-pig, dog, ox, rabbit, and pig. He recognized three elements in the human pineal body, i.e., 1) a fibrovascular envelope, 2) a globular parenchyma, and 3) *acervulus cerebri*. Faivre's observation was in accord with Valentin's,⁴⁰³ that the pineal body differs essentially from the brain. He concludes that the parenchyma is made up largely of those globules which were nuclei of large elliptical cells in the organ. He seems to have been the first to recognize that these cells contained granules and also that the parenchymal cells were smaller in the child than in the adult. Clarke⁶⁹ in 1860 found nerve fibers, nuclei and brain sand, but no nerve cells. These elements were arranged in a reticular structure which resembled the olfactory mucous membrane. Luys²⁵³ in 1865 considered the organ as a structure composed of nerve cells and fibers, in general, analogous to the mammillary bodies. Leydig²³² in 1868 states that the pineal body in the mouse resembles the pituitary gland in reptiles with certain small differences. Frey ('67)¹³¹ observed in adults multipolar ganglionic cells, rounded cells without prolongations and isolated nerve tubes. Meynert ('77)²⁷¹ asserts that the parallelism between the pituitary body and the epiphysis is a mistaken idea. The pineal body should be considered a ganglionic derivative of the tegmentum. It contains two types of cells, one having a diameter of 15 micromillimeters, the others 6 micro-

millimeters in diameter. It differs from other ganglia only in the fact that the cells are much closer together. Krause ('68)²¹⁹ described nerve fibers in the epiphysis having a double contour. Stieda ('69)³⁷⁶ observed anastomosing processes of cytoplasm with nuclei in a reticulum. Bizzozero ('71)³² found two distinct elements in the organ, namely, stroma consisting of prolongations of the capsule and a definite parenchyma. In this latter were two types of cells. In the larger of these the cytoplasm contained granules. He noted that the pineal gland in the newborn and in the infant contains the same elements as in the adult. The only difference is in the fact that the smaller elements have a few branches while the larger cells have none. The cells are arranged in alveoli. Meynert ('77)²⁷¹ concluded that the epiphysis was a nerve ganglion. Hagemann ('72)¹⁶⁴ found two types of epithelial cells, namely, round cells and fusiform cells which are bipolar and multipolar nerve cells. The pineal body, in his opinion, is a combination of epithelial cells and nerve cells. Cruveilhier ('77)⁷³ found in the epiphysis pale, round cells, small nerve cells, large multipolar cells, and calcareous concretions. Mihalkoviez ('77)²⁷⁵ concluded that the pineal cells were not lymphatic corpuscles, but resembled the cells in the lining of the cerebral ventricles. Schwalbe ('81)³⁴⁸ considered the pineal cells to be modified epithelium with a striking resemblance to lymphatic corpuscles. Cionini ('85-'86)^{66, 67} first demonstrated the presence of neuroglial elements, the nerve fibers observed belonging to the blood vessels. Darkschewitsch ('86)⁷⁹ refutes the idea that the pineal body is nothing more than a 'simple gland.' By the Weigert method he found the nerve fibers from the following sources: 1) internal capsule, 2) striae medullares, 3) Meynert's bundle, 4) optic tract, and 5) posterior commissure. Meynert²⁷¹ and Pawlowsky³⁰⁵ have already noted the connection between the posterior commissure and the pineal body. Henle^{172b} in 1887 considered the pineal body as a lymphatic ganglion. Its parenchyma consisted of two types of cells, i.e., round cells resembling lymph corpuscles and angular cells with many points.

Ellenberger ('87)¹¹⁰ maintains that the pineal body in the horse is very similar to a lymphatic gland. It is highly vascular; in it are but a few nerve fibers and these are difficult to trace to their origin. Flesch ('88)¹²³ studied the pineal body in the horse, pig, dog, bat, and man. He was able to find brain sand in man only. He does not believe that the organ is rudimentary, but regards it as an epithelial structure. There are some nerve

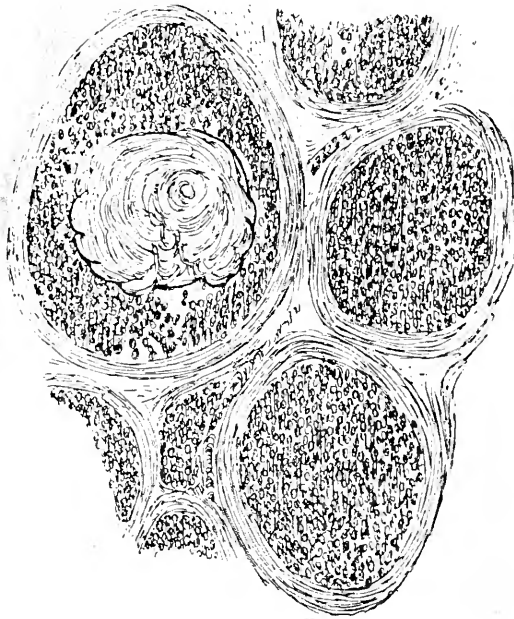


Fig. 77 Follicles and parenchyma of pineal body in man, showing concretion of brain sand, according to Henle, 1879.

fibers in it. Its relation to the size of the brain is not definite. It has, in Flesch's opinion, a physiological action in mammals, is very vascular, while its specific cells contain pigment granules. It seems to be a secretory organ and may contain a heat-regulating centre.

Edinger ('97)¹⁰⁴ found the pineal body in the higher mammals to be formed of neuroglia cells. True nerve elements are absent. Chauveau ('85)⁶⁴ observed groups of polyhedral cells

separated by connective-tissue trabeculae. He also mentions calcareous deposits in domestic animals. Mingazzini ('89)²⁷⁶ believes the pineal elements resemble lymphatic corpuscles. Soury ('99)³⁶⁵ found a substance like adenoid tissue filling the spaces of a fine network. Weigert ('95)⁴¹⁹ describes the pineal body, especially its ventral portion, as composed of a thick layer of neuroglia fibers of such a specific nature that the like of it is not found elsewhere in the central nervous system. The cells are very numerous and traversed by many fibers. Cajal ('95)⁵³ found sympathetic fibers entering the pineal body with the vessels. These fibers form a rich interstitial plexus. The fibers surround but do not penetrate the cytoplasm of the glandular cells. Galeotti ('96-'97)¹⁴⁰ makes the claim that the pineal body is a secretory organ and believes there is evidence of this in many vertebrates besides mammals. The pineal cells elaborate a pigment in addition to their secretory product. He recognized nerve cells which are in relation with the superior and posterior commissures, ependymal cells constituting the middle portion of the body, in relation with the pineal recess, and epithelial cells which constitute the epiphyseal tube in some animals and the epiphysis in mammals. Lord ('99)²⁴⁹ described the parenchyma of the human pineal body as formed of small stellate cells resembling those of adenoid tissue together with other paler cells of variable size. Nicolas ('00)^{233B} found striated muscle cells in the distal portion of the pineal body in the ox and calf. Dimitrova ('01),⁹² a pupil of Nicolas', studied the pineal body in mammals, young and old, including man, ox, calf, sheep, horse, dog, and cat. She maintains that Nicolas' observations were confirmed by her studies and that striped muscle cells do occur in the pineal body of the ox and calf. In her opinion, the essential constituent of the epiphysis in mammals is neuroglia and she concludes that in addition to the essential neuroglial nature of the pineal body there exists in the ox, calf, sheep, and dog certain cavities which resemble thyroid vesicles or the anterior pituitary lobe. In young cats some cells which are independent of the neuroglia seem to resemble the elements described by Cajal⁵⁴ and Retzius^{331A} as sympathetic' and may be

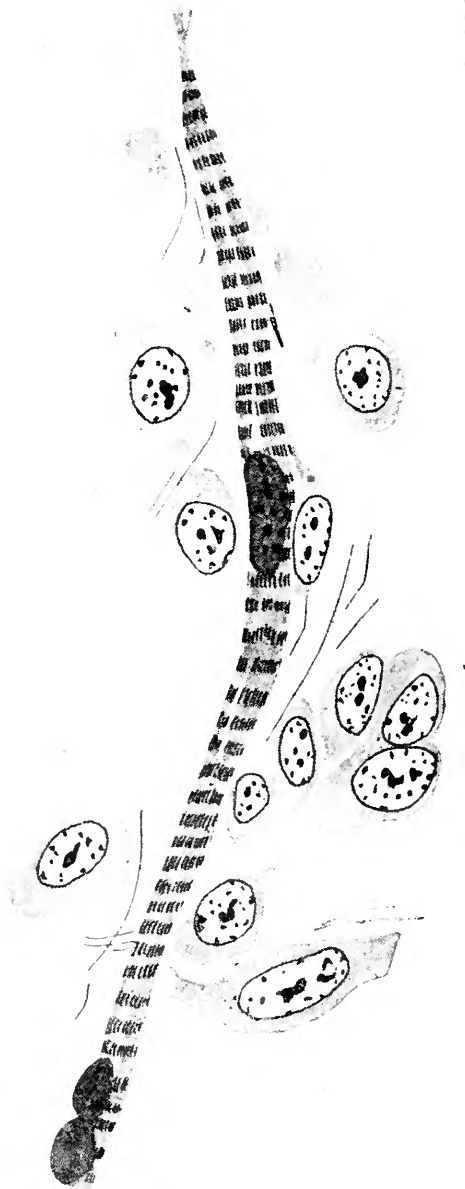


Fig. 78 A striated muscle fiber from the pineal body of *Bos taurus*, according to Dimitrova, 1901.

neuroglia cells in process of development. Favaro ('04)¹¹⁸ gives the following conclusions of his studies by means of the Weigert method upon many mammals, including artiodactyla, perissodactyla, rodentia, insectivora, carnivora, and primates. Fibers found in relation to the pineal body are:

1. Prepineal fibers:
 - a) Transverse commissural
 - b) Oblique commissural




Fig. 79 Cells and fibers in the pineal body of *Bos taurus* (Weigert's method), according to Dimitrova, 1901.

2. Fibrae seu fasciculus prepinealis.
3. Pineal fibers:
 - a) Superior transverse commissural fibers
 - b) Superior oblique commissural fibers
 - c) Posterior transverse commissural fibers
 - d) Diagonal commissural fibers
 - e) Superior and posterior fibrae propriae

Anglade and Ducos ('08-09)⁵ found neuroglia constantly present in the human pineal body but also alveoli-formed cells

of a different character. Sarteschi ('10)³⁴⁵ found that, as compared with the adult animals, the epiphysis in the young rabbit and guinea-pig was distinctly more glandular and in this regard similar to the organ in birds. In the course of growth certain regressive changes occur. Neuroglia and glandular cells were present in all of the forms which Sarteschi studied. Constantini ('10)⁷¹ studied the pineal body of the ox, horse, and man. He describes two types of epithelial cells, i.e., 1) acidophiles and 2) basophiles. He concludes that the pineal body in mammals is an organ of internal secretion. Cutore ('10),⁷⁶ on the basis of a study of many different mammals, concludes that there are the following histological elements in the pineal body: 1) Epithelial cells containing granules and delimiting the cavities of tubules or acini. 2) Lymphatic elements very numerous in larger mammals and massed about the epithelial cells. 3) Connective tissue forming trabeculae producing an apparent trabeculation of the parenchyma. This connective tissue contains elastic fibers, blood vessels, lymph spaces, and pigment cells probably belonging to the category of mast cells. Some of the latter cells give evidence of a process of fragmentation. 4) Calcareous concretions of calcium carbonate and phosphate. These latter are sometimes found as inclusions in the cytoplasm or in the meshes of the connective tissue. Cutore believes it to be an organ of such complex structure, constituted of neuroglia, epithelium, lymphatic and connective tissues, so arranged as to form acini and so highly vascular, that it cannot be considered to be in a state of regression as is claimed by Möller,²⁷⁸ Charpy,⁶² Dejerine,⁸⁵ and others. Indeed, the highly specialized and characteristic structure of the pineal body is sufficient justification to attribute to it an internal secretory function. Galasescu and Urechia ('10)¹³⁷ found in the vicinity of some of the blood vessels round and oval cells with deeply staining nuclei situated centrally in a cytoplasm which stains with acid stains, e.g., eosin and fuchsin. The cytoplasm is granular and well demarcated. These acidophiles resemble those seen in the parathyroids. The authors propose to term these cells the 'paravascular acidophiles.' They believe these elements play a definite part in the internal secretion of the pineal body.

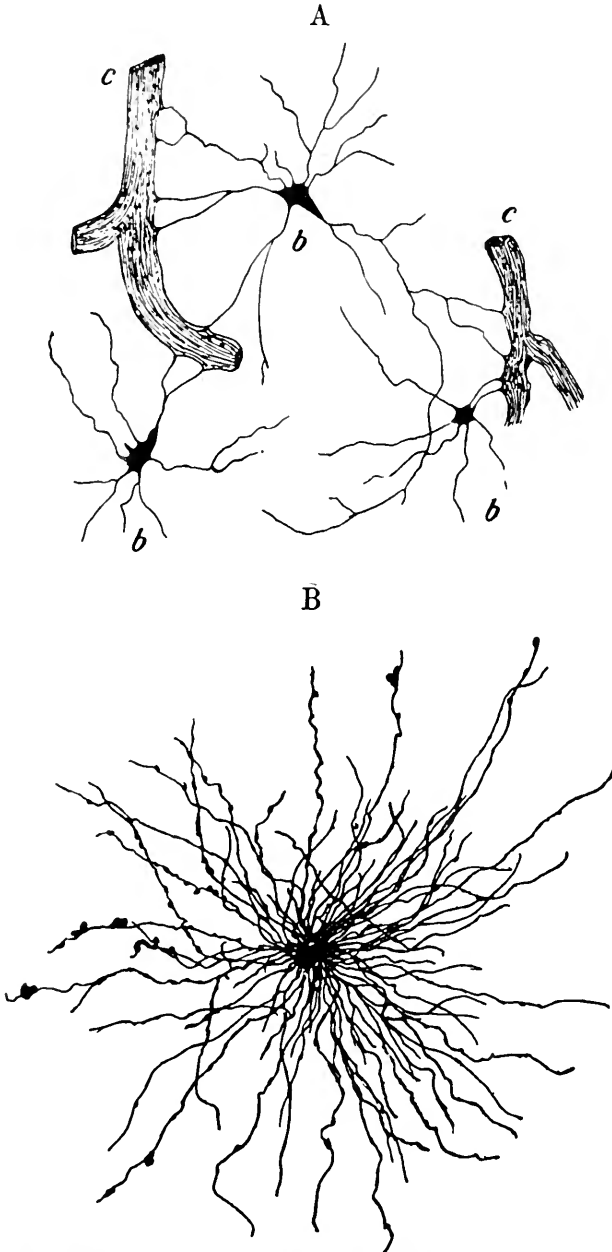


Fig. 80 Neuroglia cells in the human pineal body (Golgi's method). A, according to Cionini, 1889; B, according to Dimitrova, 1901.

Krabbe ('11)²¹⁷ studied one hundred human pineal bodies, both male and female, from birth to seven years of age and from fourteen years to ninety-two years. There was a gap in his subjects between the ages of seven and fourteen years. He found two types of cells in the epiphysis: 1) special pineal cells and 2) neuroglia cells. He thinks the granules in the cells leave the protoplasm, traverse the intercellular space to enter the blood, lymph, or cerebrospinal fluid. Krabbe does not agree with Dimitrova⁹² that the fundamental element of the pineal

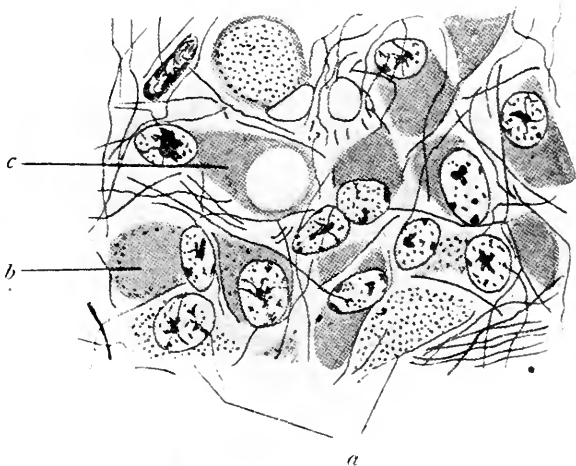


Fig. 81 Cells with granular protoplasm in the pineal body of *Bos taurus* (Weigert's method), according to Dimitrova, 1901.

body is neuroglia, for he considers her criteria in distinguishing neuroglia insufficient. He himself never observed muscle fibers in any of the forms which he has studied. Krabbe concludes that the epiphysis in man shows certain signs of involution, as, for example, concretions, hyperplasia of connective tissue, neuroglial plaques with cysts, and the presence of cells in a state of disintegration. The involution begins at seven years of age, but even in the adult the pineal body shows signs of active function. The secretory process is manifest in the following

manner: 1) basophilic granules in the nuclei; 2) the latter evacuated into cytoplasm. This process goes on during the entire life of the individual even into old age.

Biondi ('12)¹⁴⁹ calls attention to the finding of Constantini⁷¹ and Galeotti¹⁴⁰ of acidophiles in the pineal body. Biondi made a special study for mitochondria by the method of Regand. He was able to demonstrate small granules which he thinks must be regarded as mitochondria. This he cites as evidence of the secretory nature of the epiphysis. He calls attention to the fact, however, that Nageotte²⁸¹ and Mawas²⁶³ have both stated that neuroglia cells also contain mitochondria.

Jordan, ('11)¹⁹⁷ following the histogenesis of the pineal body of the sheep, studied six stages from 5 em. to 21 em., also of the eight months' lamb, yearling, and old sheep. He found no muscle fibers. Between birth and the first year the pineal body increases fivefold in size. In the fetus there are blind alveoli and the organ is definitely lobulated by ingrowths from the pia. Parenchymal cells form these alveoli. Vascular follicles are abundant. The parenchyma consists of a more or less differentiated ependyma. After the first year there are signs of local degeneration manifesting themselves as an increase in connective tissue, neuroglia, brain sand, clumps of pigment granules, and a decrease of parenchymal cells. The entire pineal body decreases in size after the first year. He concludes that there is no cytologic evidence in favor of the secretory function of the sheep's pineal body. He points out, however, that the general structure of the epiphysis, including its lobulation, its connective tissue framework, its parenchymal follicles, blind alveoli, perivascular lymph spaces, great vascularity, and presence of cytoplasmic granules, is indicative of a glandular function of internal secretion. He interprets the cysts which appear in the pineal body and the melanic cytoplasmic granules as probably having an ancestral significance. In Jordan's opinion, if the pineal body subserves any important function at all, this is true only of the first eight months of postnatal life.

Jordan¹⁹⁸ in the same year, studying the pineal body in the opossum, states that the organ in this species has two forms:

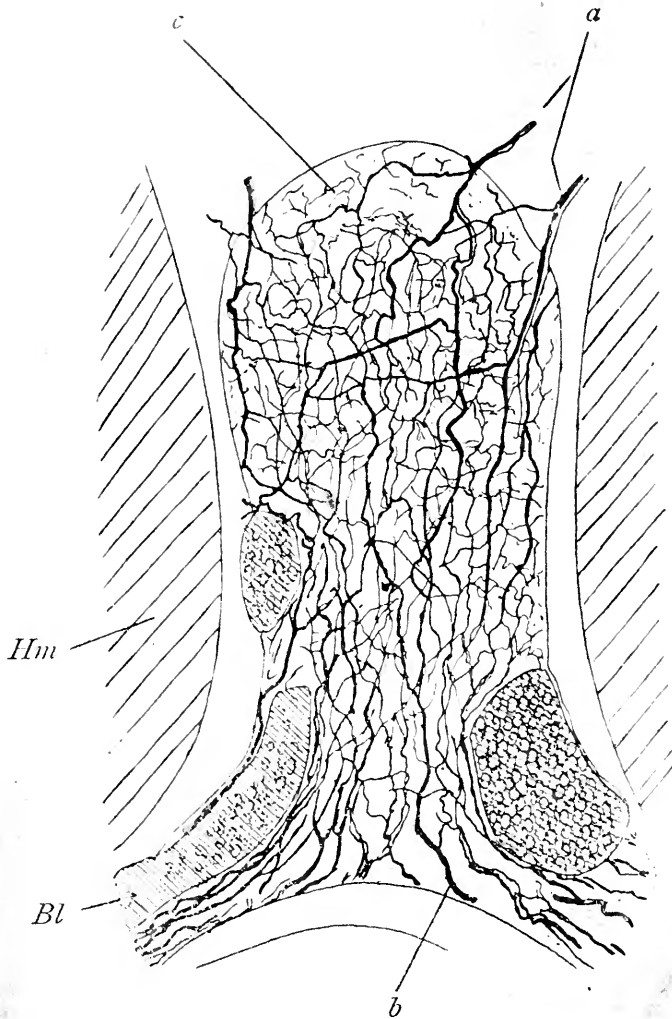


Fig. S2 Transverse section of the pineal body in the rat, according to Ramon y Cajal, 1904

a-b, sympathetic nerve fibers; *c.*, interstitial nerve plexus; *Bl.*, blood vessel; *Hm*, hemisphere

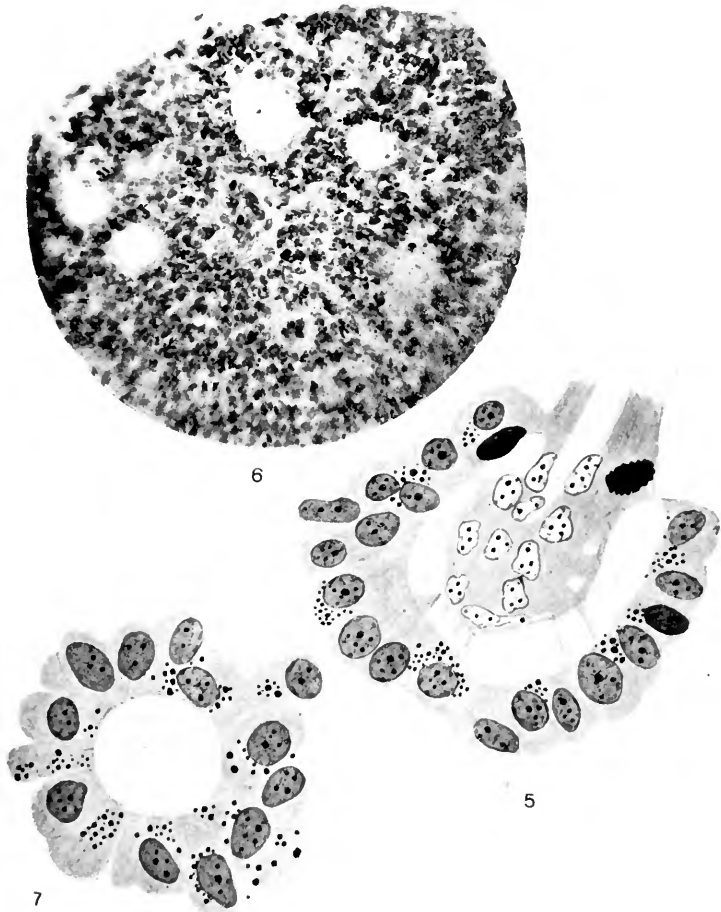


Fig 83 Histological characters of the pineal body in the sheep, according to Jordan, 1911.

1) long and tubular, as in birds and reptiles; 2) short and cup-shaped, resembling particularly that of carnivora. The epiphysis is composed of a syncytial network, in the meshes of which are scattered more or less highly differentiated or modified ependymal cells and delicate bundles of nerve fibers. In the opossum it appears to be in a state of instability. Its long, tubular form connects it phylogenetically with the birds and reptiles, while its short, cup-shaped form affiliates it with the carnivora. Regarding the function of the pineal body in the opossum, Jordan believes that his observations show it to be unimportant in the body metabolism of mammals. This does not necessarily mean that there is no specific secretion from the organ, but rather that it has no direct or indirect influence upon vegetative functions.

Nerve fibers in the mammalian epiphysis have been observed by Kölliker²¹⁰ in 1850, who appears to be the first to demonstrate these elements. Krause²¹⁹ in 1868 recognized the fact that the fibers have a double contour, and Darkschewitsch⁷⁹ in 1886 showed that they were myelinated nerve fibers. Connections have been demonstrated to exist between the pineal body by means of these fibers with the following parts: 1) internal capsule; 2) striae medullares; 3) Meynert's bundle; 4) optic tract by Darkschewitsch, ('86)⁷⁹ and 5) posterior commissure by Meynert ('77),²⁷¹ Pawlowsky ('74),³⁰⁵ Cionini ('88),⁶³ Favaro, ('04)¹¹⁸ and Cutore ('10);⁷⁶ 6) commissura habenularis by Kölliker ('50)²¹⁰ Hagemann ('72),¹⁶⁴ Favaro ('04)¹¹⁸ and Cutore ('10),⁷⁶ 7) sympathetic system, Henle ('79),¹⁷² Cionini ('86),⁶⁷ and Cajal ('04).⁵⁴ Ganglion or nerve cells in the epiphysis have been described by Kölliker²¹⁰ in 1850 and Hagemann¹⁶⁴ in 1872. Cajal⁵³ in 1895 also found ganglion cells in the pineal body and described two types. Dimitrova⁹² in 1901 was able to find ganglionic cells in young cats only.

Pigment has been found in the epiphysis of mammals by Fleisch¹²³ ('88). Galeotti ('96)¹⁴⁰ observed pigment particles in the cytoplasm and nuclei. Dimitrova ('01)⁹² found a golden-brown pigment in the parenchymal cells. Cutore ('10)⁷⁶ observed pigment in the pineal cells. Brain sand has been described

by many authors in a number of mammals. Haller (1768)¹⁶⁵ considered it pathological, but Soemmering's³⁶⁰ classical study upon the acervulus clearly demonstrated that these concretions are normal in man. Malacarne (1795)²⁵⁸ found brain sand in the epiphysis of the goat. Wenzel (1812)⁴²⁰ described it in man as being of two varieties according to its color, i.e., yellow or white. Hagemann ('72)¹⁶⁴ considered it a normal constituent of the adult pineal body in man. He also observed it in the ox. Krause ('76)²¹⁸ found it in many adult mammals. Fleisch¹²³ describes brain sand in the epiphysis of the horse, sheep, pig, and dog.

A parietal foramen has never been observed in mammals, but the white spot which frequently appears in the frontal region of the horse's head has been suggested as a vestigial indication of this aperture in the skull seen in many of the lower vertebrates.

Differences observed in the epiphyseal complex in the various species of mammals already investigated.

MARSUPIALS. 1. *Macropus giganteus*. Lotheissen ('94).²⁵⁰ In this species some nerve fibers penetrate into the substance of the pineal gland. These come from the fasciculus retroflexus of Meynert.²⁷¹ They were not observed in other mammals.

2. *Halmaturus dorsalis*. Condorelli-Francaviglia ('95).⁷⁰ In this form, because of the rudimentary corpus callosum, the pineal body extends dorsad between the hemispheres. Its length is 2 mm. and its thickness 1.5 mm.

3. *Didelphys virginiana*. Jordan ('11).¹⁹⁸ In the opossum the pineal body occurs in two forms, i.e., either as a long tubular organ or as a short, cup-shaped structure. It is composed of ependymal cells in a syncytial network.

ARTIODACTYLA. 1. *Bos taurus*. Faivre ('55);¹¹⁴ Hagemann ('72);¹⁶⁴ Chauveau ('85)⁶⁴ Nicolas ('00);^{283B} Dimitrova ('01);⁹² Favaro ('04);¹¹⁷ Constantini ('10);^{71A} Cutore ('09).⁷⁴ In this species the pineal body is cylindric conical. Its diameters are:

	<i>cm.</i>
Longitudinal.....	1.5
Transverse.....	0.7
Anteroposterior.....	0.7

It consists of large parenchymal cells, neuroglia, and lymphatic elements. It is very vascular. Cutore could find no muscle cells. Some observers have found brain sand in the organ.

2. *Sus scrofa domesticus*. Faivre ('55),¹¹⁴ Hagemann ('72);¹⁶⁴ Flesch ('87);¹²¹ Favaro ('04);¹¹⁸ Cutore ('10).⁷⁶ In this form the pineal body is long and pointed toward its distal extremity. Its diameters are:

Longitudinal.....	cm. 1.0
Transverse.....	0.5
Anteroposterior.....	0.4

Fibers connect it with the ganglion habenulae and the posterior commissure. It contains no concretions and no pigment. Histologically it resembles the pineal body of *Bos taurus*.

3. *Capra hircus*. Malacarne ('95);²⁵⁸ Hagemann ('72);¹⁶⁴ Staderini ('97);³⁷² Cutore ('10).⁷⁶ In this species the pineal body is relatively short and conical. Its diameters are:

Longitudinal.....	cm. 0.70
Transverse.....	0.55
Anteroposterior.....	0.45

Malacarne described brain sand in the organ. Cutore could find neither concretions nor pigment. Fibers connect the base of the epiphysis to the posterior commissure and habenular region.

4. *Camelus dromedarius*. Parisini.³⁰⁰ In this form the author described concretions.

5. *Ovis aries*. Flesch ('87);¹²⁷ Dimitrova ('01);⁹² Favaro ('04);¹¹⁸ Jordan ('11).¹⁹⁹ In the adult of this species Jordan describes signs of degeneration, including hyperplasia, brain sand, clumps of pigment granules, and a decrease of parenchymal cells.

PERISSODACTYLA. 1. *Equus caballus*. Faivre ('55);¹¹⁴ Hagemann ('72);¹⁶⁴ Ellenberger ('87);¹¹⁰ Flesch ('88);¹²³ Favaro ('04);¹¹⁸ Cutore ('10).⁷⁶ In this species the pineal body is conical. Its diameters are:

	<i>cm.</i>
Longitudinal.....	0.8
Transverse.....	0.6
Anteroposterior.....	0.5

Nerve fibers are found in the base of the epiphysis. Histologically, the pineal body consists principally of a delicate connective-tissue framework, in the meshes of which are found lymphatic elements. Many pigment cells are also found having a brownish color and occupying usually a perivascular position. Neuroglia and ependymal cells are also present.

2. *Equus asinus*. Cutore ('10).⁷⁶ In this species the pineal body is larger than in the horse and its form is oval. Its diameters are:

	<i>cm.</i>
Longitudinal.....	1.5
Transverse.....	0.6
Anteroposterior.....	0.6

Its histology is much the same as that of the horse. Perivascular pigmented cells are present in large numbers.

3. *Equus mulus*. Cutore ('10).⁷⁶ The pineal body in this species is relatively large. Its diameters are:

	<i>cm.</i>
Longitudinal.....	1.5
Transverse.....	0.6
Anteroposterior.....	0.6

It is conical in form. Histologically, it consists of parenchymal cells containing pigment granules. In addition, there are ependymal cells, neuroglia, and lymphatic elements.

4. *Elephas indicus*. Parisini.³⁰⁰ In this animal Parisini reports the presence of concretions.

INSECTIVORA. 1. *Erinaceus europaeus*. Cutore ('10).⁷⁶ In this species the epiphysis is triangular and is situated in the intercollicular sulcus. It presents a well developed pineal recess. Histologically, its elements resemble those of other mammals, the cells being arranged in acini, not unlike the cellular formations in the hypophysis.

RODENTIA. 1. *Talpa*. Ganser ('82).¹⁴² In this form the pineal body was considered an unpaired ganglion habenulae. It receives fibers from the thalami and the posterior commissure.

2. *Lepus cuniculus*. Tiedemann ('23);³⁹⁵ Marshall ('61);²⁶¹ Krause ('68);²¹⁹ Bizzozero ('68);³⁰ Hagemann ('72);¹⁶⁴ Mihalkovicz ('77);²⁷⁵ Edinger ('97);¹⁰⁴ Staderini ('97);³⁷² Neumayer ('99);²⁸² Favaro ('04);¹¹⁸ Cutore ('10);⁷⁶ Sarteschi ('10).³⁴⁵

The pineal body in this species is long and cylindrical and of such a shape as to justify the ancient term, *penis cerebri*. Its diameters are:

Longitudinal.....	cm. 1.0
Transverse.....	0.3
Anteroposterior.....	0.2

Its histological appearance resembles that of adenoid tissue. There are no pigment cells and no concretions.

3. *Cavia cobaya*. Faivre ('55);¹¹⁴ Hagemann ('72);¹⁶⁴ d'Erchia ('96);¹⁰⁹ Staderini ('97);³⁷² Favaro ('04);¹¹⁸ Cutore ('10);⁷⁶ Sarteschi ('10).³⁴⁵ In this species the pineal body is similar in form to that of the rabbit. Its diameters are:

Longitudinal.....	cm. 0.8
Transverse.....	0.4
Anteroposterior.....	0.3

Histologically, the organ resembles that of the rabbit.

4 *Mus decumanus*. Staderini '97;³⁷² Cutore ('10).⁷⁶ The pineal body in this species is elongated. Its diameters are:

Longitudinal.....	cm. 0.5
Transverse.....	0.3

Histologically, it presents a rich vascularization and parenchymal cells similar to those of other rodents. Pigment and calcareous concretions are absent. Neuroglia, nerve fibers, elastic fibers, and lymphatic elements are also observed.

5. *Dasyprocta agouti*. Sperino and Balli ('09).³⁷⁰ In this species the form of the pineal body is cylindricoconical. Its appearance is brownish, its apex is retroflexed so that the structure rests in the intercollicular sulcus. Its diameters are:

Longitudinal.....	cm. 0.5
Transverse.....	0.3

CARNIVORA. 1. *Phoca vitulina* and *Rosmarus obesus*. Turner ('88).⁴⁰⁰ In the walrus and seal the pineal body has a greater relative magnitude than in other mammals.

2. *Canis familiaris*. Tiedemann ('23);³⁹⁵ Faivre ('55);¹¹⁴ Flesch ('88);¹²³ Dimitrova ('01);⁹² Favaro ('04);¹¹⁸ Cutore; ('10).⁷⁶ In this species the pineal body is conical in form. It is relatively small. Its diameters are:

	cm.
Longitudinal.....	0.4
Transverse.....	0.3
Anteroposterior.....	0.1

Histologically, it consists of neuroglia, nerve fibers, and parenchymal cells which are polyhedral in form and arranged in acini. Some cells contain pigment granules. In addition to these elements there are large cylindrical ependymal cells. There are no concretions present.

3. *Felis domestica*. Tilney ('15).³⁹⁶ The pineal body in the cat is even smaller than in the dog and it is ovoid in form. Its diameters are:

	cm.
Longitudinal.....	0.20
Transverse.....	0.15
Anteroposterior.....	0.10

Histologically, it resembles the epiphysis of the dog.

4. *Felis leo*. Parisini.³⁰⁰ This author described concretions in the pineal body of the lion.

PRIMATES. 1. *Troglodytes niger*. Möller ('90);²⁷⁸ Marshall ('61);²⁶¹ Dendy and Nicolls ('11).⁸³ In this species the pineal gland lies in a groove between the superior colliculi and has an unpaired peduncle. There is a deep pineal recess and a well developed suprapineal recess. No concretions were described in this species.

2. *Macacus sinicus*. Cutore ('12).⁷⁶ In this species the dimensions of the pineal body are:

	cm.
Longitudinal.....	0.5
Transverse.....	0.2
Anteroposterior.....	0.2

The pineal body is cylindricoeconical in form in *Macacus sivicus* and presents a great number of nerve fibers.

3. *Cercopithecus griseus viridis*. Cutore ('10).⁷⁶ In this species the dimensions of the pineal body are:

Longitudinal.....	0.3
Transverse.....	0.2
Anteroposterior.....	0.2

The pineal body in this form is conical in shape. The structure of the organ is evidently glandular.

4. *Homo sapiens*. A large number of observers have given their attention to the pineal body in man and many diverse opinions have been expressed concerning it. Cutore's⁷⁶ summary giving the histology and dimensions of the pineal body in man is the most recent and complete review. The figures have already been cited (p. 157). Cutore concludes that the human pineal body develops slowly, retaining even up to the time of birth its primitive diverticular form. In the adult, however, this organ has become relatively voluminous and the original recess is much reduced to form the ventriculus or recessus pinealis. The superior or habenular commissure is small. The pineal fibers are limited in number and distributed to the inferior third of the organ. In the disposition of the parenchyma there is seen a distinct tendency for the cells to arrange themselves in circular areas clearly delimiting small cavities in which there appears an amorphous or crystalline substance. Elastic tissue is scanty, but pigment cells are numerous and concretions of varying sizes appear in large numbers. The vascularization is rich especially around the aciniform groups of cells. Neuroglia and cylindrical ependymal cells are also present. Connective-tissue processes from the pia mater form an irregular partition of the tissue into lobules. Siegneur³⁵¹ considers the pineal body in man a gland, the cells of which are of two types, those which are polyhedral with granules in the cytoplasm. These granules are most numerous about the nucleus. Some of the cells have vacuoles. The second type of cells are even larger and contain large nuclei which stain deeply and occupy an excentric position in

the protoplasm. In the new-born, lobation of the gland is much more easily discerned than in the later periods of life.

The histology of the pineal body of the following mammals has not heretofore been given, and as it seems to furnish some details in the finer structure of the organ, the authors have considered it advantageous to include these original observations in this work. All of the material was obtained from the study collections of the Department of Anatomy, Columbia University. It includes specimens of *Marcopus grayi*, *Camelus dromedarius*, *Capra hylocrius*, *Zalophus californianus*, *Lepus cuniculus*, and *Simia satyrus*. In addition to these species, the later stages of development in the human fetus and in *Felis domestica* were studied. The staining methods used were the Van Giesen, hæmatoxylin-eosin, and Weigert's iron hæmatoxylin. On account of the limited amount of tissue it was impossible to do any silver impregnation so that no evidence was obtained concerning the nature of the nerve fibers in the pineal body.

1. *Macropus grayi*. In this species the cellular constituents of the pineal body present the most striking features of any of the mammals studied. Four types of cells are noted:

First. Large cells with extensive cytoplasm and a large vesicular nucleus. The nuclei of these cells stain very deeply.

Second. Cells of a similar size with vesicular nuclei which stain feebly.

Third. Smaller cells with a large nucleus and a very small amount of cytoplasm. The nuclei are intensely basophilic.

Fourth. Small cells with feebly staining nuclei showing many granules.

The cells of these four varieties arrange themselves in a more or less distinctive manner. The large epithelial elements of both types are disposed in such a way as to form well-defined acini. Interspersed between these acinous groups are more or less irregularly convoluted chains or cords of cells made up of both varieties of the large type. The smaller cellular elements are scattered among the cords and acini in an irregular manner. Trabeculae of connective tissue serve to give the impression of lobulation to the structure, although these lines of separation

are irregular. The pineal body of *Macropus* is highly vascular. The larger vessels follow the lines of the connective-tissue septum. No concretions were observed in any part of the pineal body. The impression given by the arrangement and character of the cells in the pineal body of this species is that of a glandular structure resembling in a general way this organ in reptiles and birds (fig. 84).

2. *Capra hyllocrius*. In this animal four types of cells may be distinguished, as in the kangaroo. Here, however, the large elements with a deeply staining nuclei are more abundant and a smaller number of the small cells with pycnotic nuclei are observed. The arrangement of the cells is typically aciniform, although there are areas in which no such disposition of the cells can be made out. These portions of the pineal body, therefore, in which the acini do appear stand out conspicuously in contrast to the areas of the tissue in which the cellular arrangement is more diffuse. The size of the acini varies greatly from about 10 micra to 60 or 70 micra in diameter. The connective tissue observed in the pineal body of the ibex is prominent both because of the extensive network which it forms and also on account of the unusual thickness of its trabecular strands. The body is highly vascular and supplied by a rich capillary network (fig. 85).

3. *Camelus dromedarius*. In the camel, as in *Capra hyllocrius*, four types of cells may be differentiated, namely, the large cells with deeply staining nuclei, large cells with faintly staining nuclei in which nucleolus and accessory nucleoli are distinguishable, small cells with deeply staining, and small cells of faintly staining nuclei. The cellular arrangement has the same general appearance as in the ibex, although the tendency toward the formation of acini is not as pronounced. In the main, the arrangement is that of wide strands of cells bounded by irregularly disposed trabeculae of connective tissue. The connective tissue forms a prominent element in the pineal body of the camel and in general resembles the connective tissue of the *Persian ibex*. The pineal body in the camel is highly vascular. There were no concretions observed in it (fig. 86).

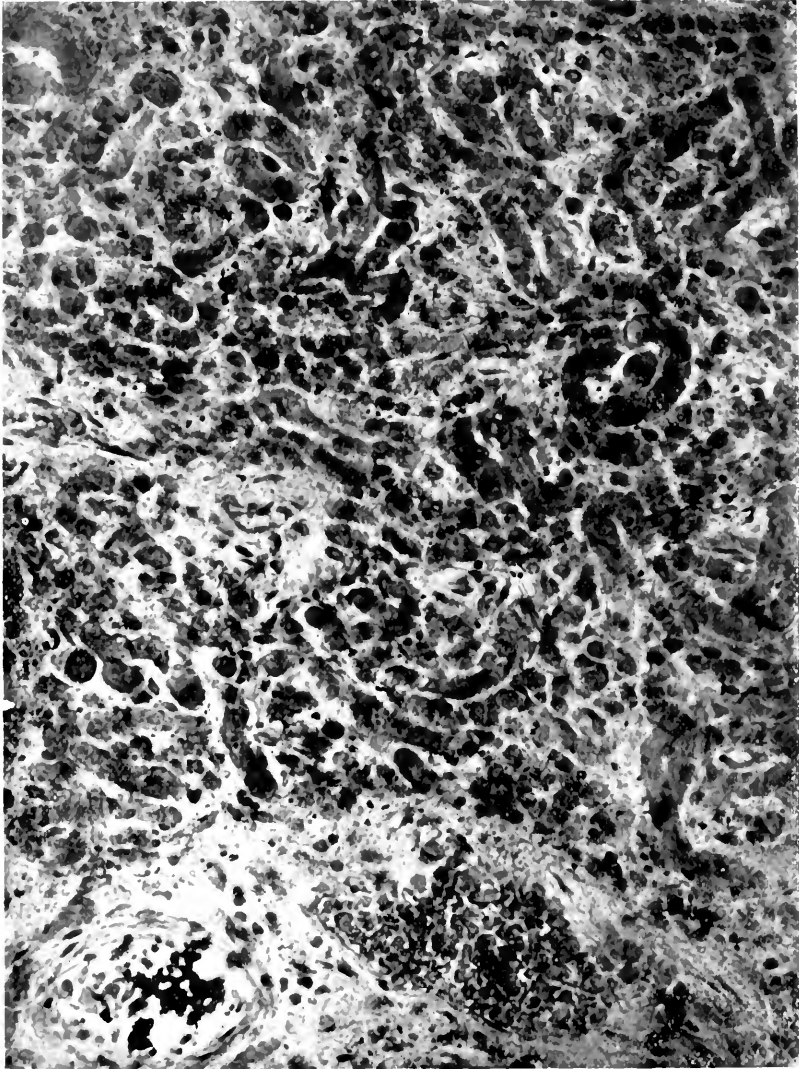


Fig. 81 Section of the pineal body in *Macropus grayi*, according to Tilney and Warren, 1947

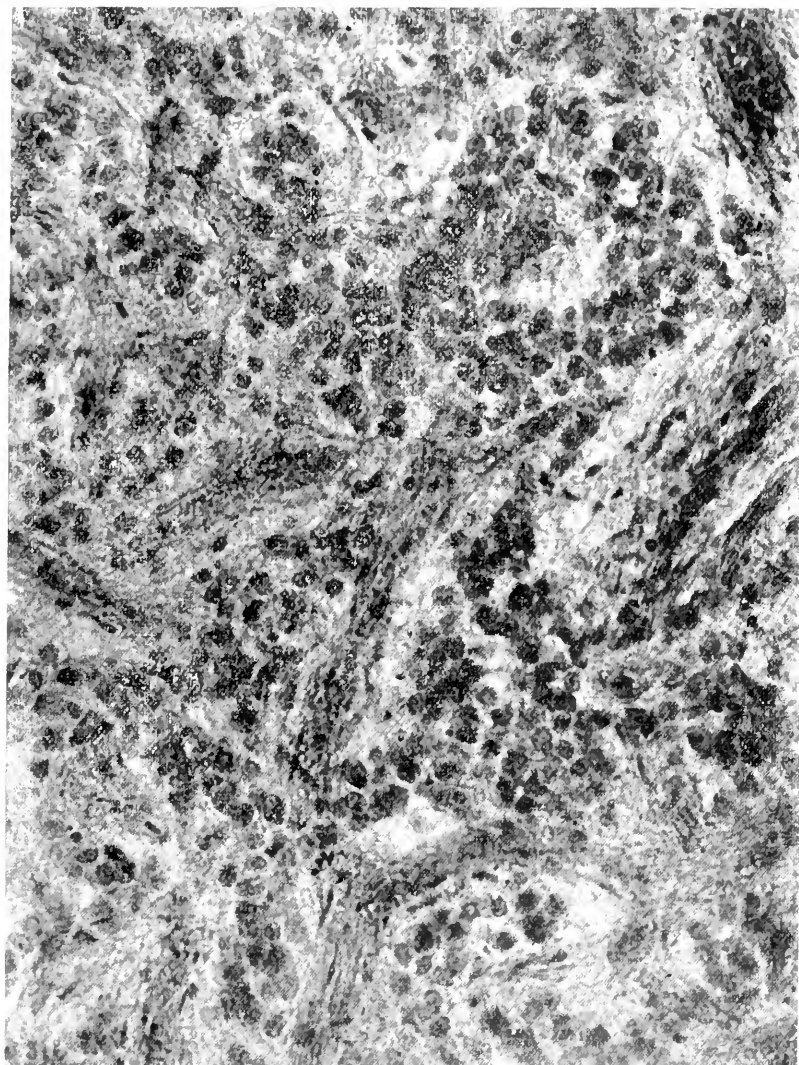


Fig. 85 Section of the pineal body in *Capra hircorius*, according to Tilney and Warren, 1917.

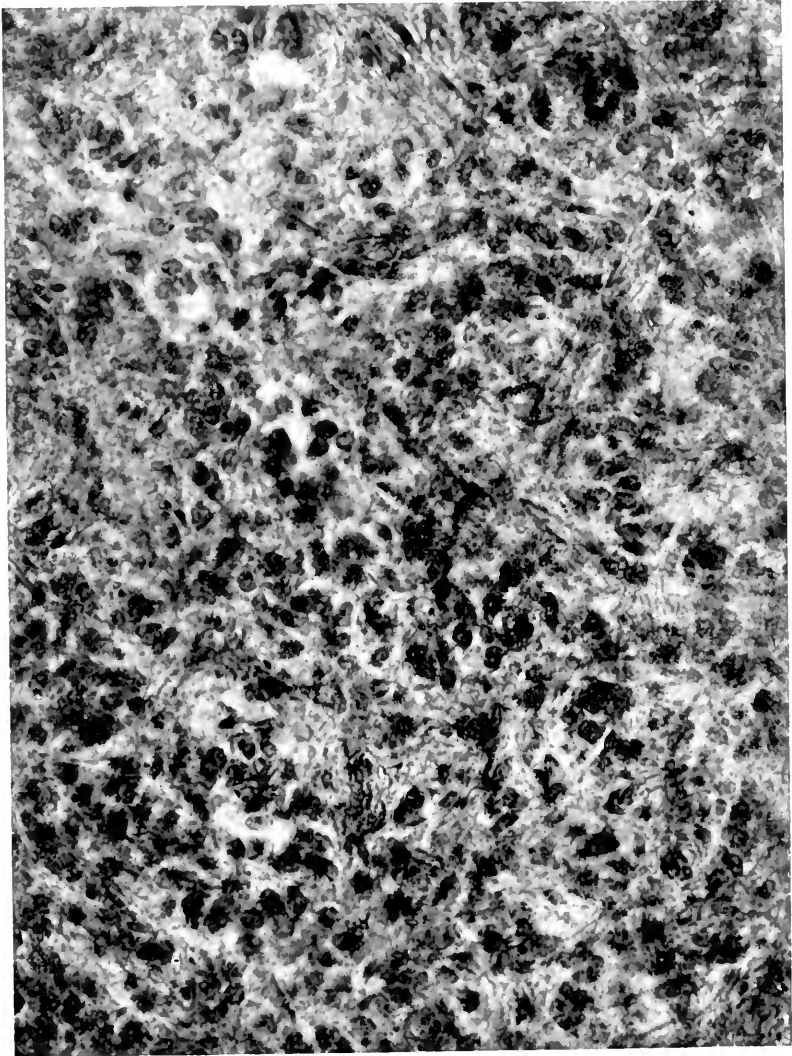


Fig. 86 Section of the pineal body in *Camelus dromedarius*, according to Tilney and Warren 1917

4. *Zalophus californianus*. In the sea-lion, although it is difficult to discern the four types of cells already described with clearness, as in the forms already noted, nevertheless, in certain areas there appear many large cells with extensive nuclei which stain deeply. Here and there scattered throughout the body appear large cells of relatively the same size as those just mentioned, the nuclei of which, however, stain but faintly. Small cells with deeply staining pycnotic nuclei are present in numbers about equal to that of the first type while a small variety of cell whose nucleus stains feebly is the least common variety observed. The cells arrange themselves in cords or columns which, upon transverse section, seem to be circular. These cords apparently are much convoluted and not infrequently a section of what appears to be the same cords is seen in transverse as well as longitudinal outline. There is a rich connective tissue network which appears to surround the cell cords. The pineal body in *Zalophus* is highly vascular. No concretions were observed (fig. 87).

5. *Lepus cuniculus*. In the rabbit the pineal body is long and cylindrical in form. In it may be recognized the four types of cells already described, the predominant type being the large cell with abundant granular cytoplasm and a large deeply staining nucleus. Dispersed among these cells are small cells of both types and the large cells with faintly staining nuclei. The general arrangement of the cells in this body is that of columns or cords whose long axes are transverse to the axis of the pineal gland itself. The columns of cells are separated by delicate trabeculae of connective tissue in the meshes of which capillary vessels make their way. Each of the cell cords varies in thickness in different parts. They are seldom more than six to eight cells deep, but in some places their transverse diameter seems to be the thickness of two cells. The gland is very vascular and no concretions are seen (fig. 88).

6. *Simia satyrus*. In the orang, it is not difficult to recognize the four types of cells already described in the other forms. Perhaps the chief difference in the histology of the gland in this animal is the great prominence which the large cells attain

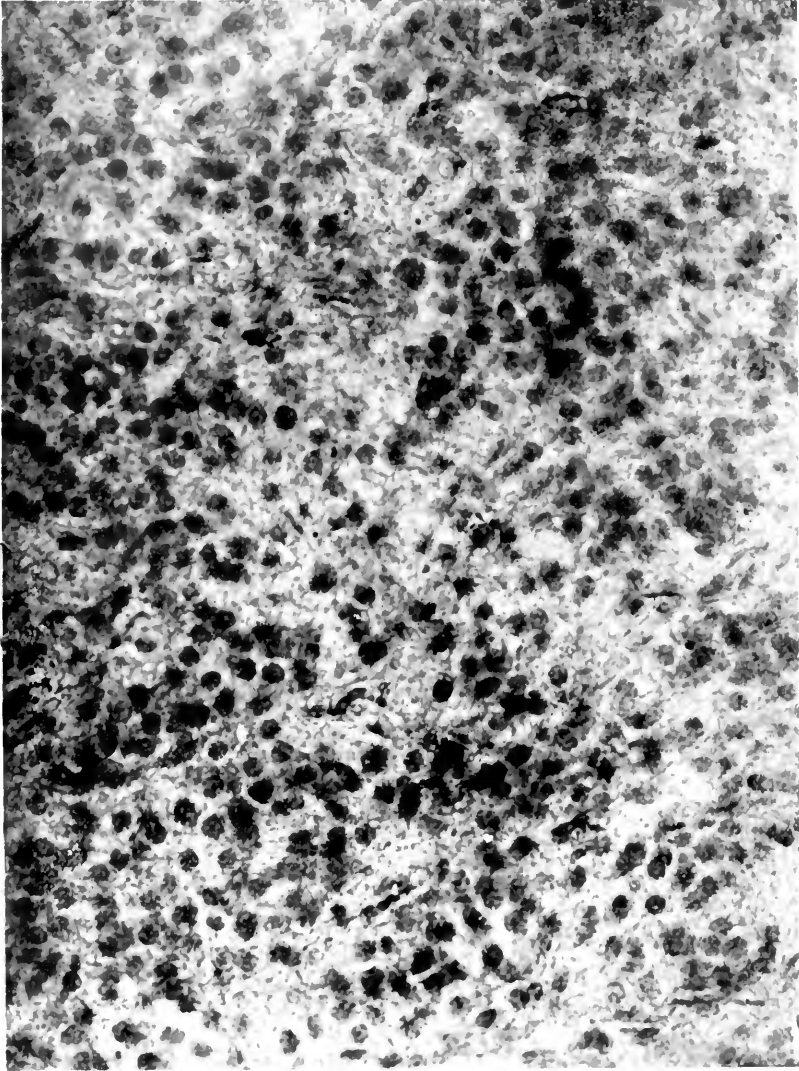


Fig. 57. Section of the pineal body in *Zalophus californianus*, according to Tilney and Warren, 1917.

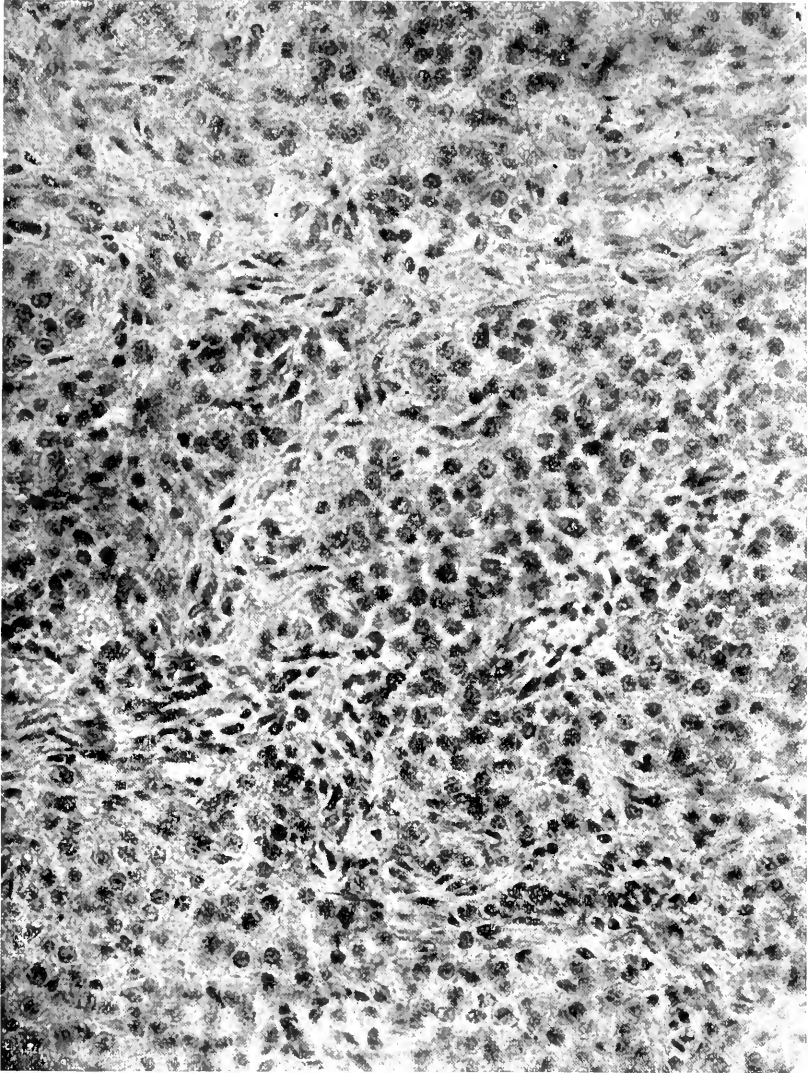


Fig 88 Section of the pineal body in *Lepus cuniculus*, according to Tilney and Warren, 1917.

both because of their tendency to be collected into well-defined groups, as well as the unusual dimensions of their cytoplasm. Here, as in none of the other forms already described, does the character of the pineal cell stand out. Not only is it much larger, but it has the granular appearance so notable in the human pineal cell. The large cells with the faintly staining nuclei are found scattered among the cells just mentioned and also scattered diffusely throughout the organ. The small cells are less prominent, although both types may be recognized. The cells are arranged according to an apparent design, although the large pineal cells group themselves in irregular masses. No tendency to cord formation is, however, observed. There is a rich and delicate network of connective tissue, and many capillaries surround the cell masses. No concretions were observed (fig. 89).

7. *Homo sapiens*. In the adult human pineal body the types of cells already described as present in the epiphysis of other mammals may be observed here also. The large cells with granular cytoplasm and large deeply staining nuclei are the most prominent elements. They are arranged in regular masses very similar to those observed in *Simia satyrus*, although the intervening areas are less extensive, so that in man the cell masses seem to run into each other without sharp line of demarcation. A very dense network of connective-tissue trabeculae forms the frame work of the organ, while the vascularity of the structure is richer than that of any other form observed. Concretions of varying sizes are present throughout the entire gland (fig. 90).

The histogenesis of the pineal gland was studied in the cat and human. The inception of differentiation in the cat presents itself as a marked thickening in the walls of the more caudal of the two evaginations. In the 70 mm. cat this thickening is so pronounced that the recess in the anlage is reduced to a narrow lumen. The cells multiply at the caudal extremity of the now almost solid epiphysis. From the stage of 120 mm. to term a process of diverticular formation occurs. This starts at the base of the gland at its attachment to the roof-plate and grad-

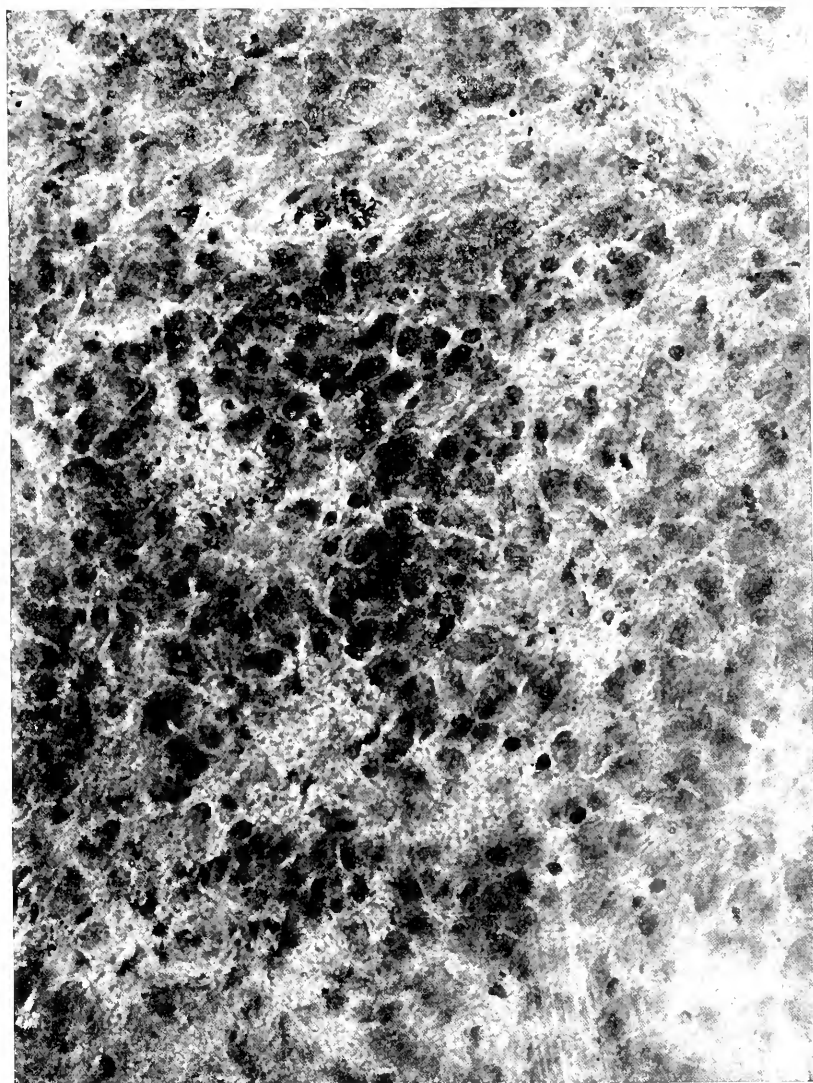


Fig. 89 Section of the pineal body of *Simia satyrus* according to Tilney and Warren, 1917

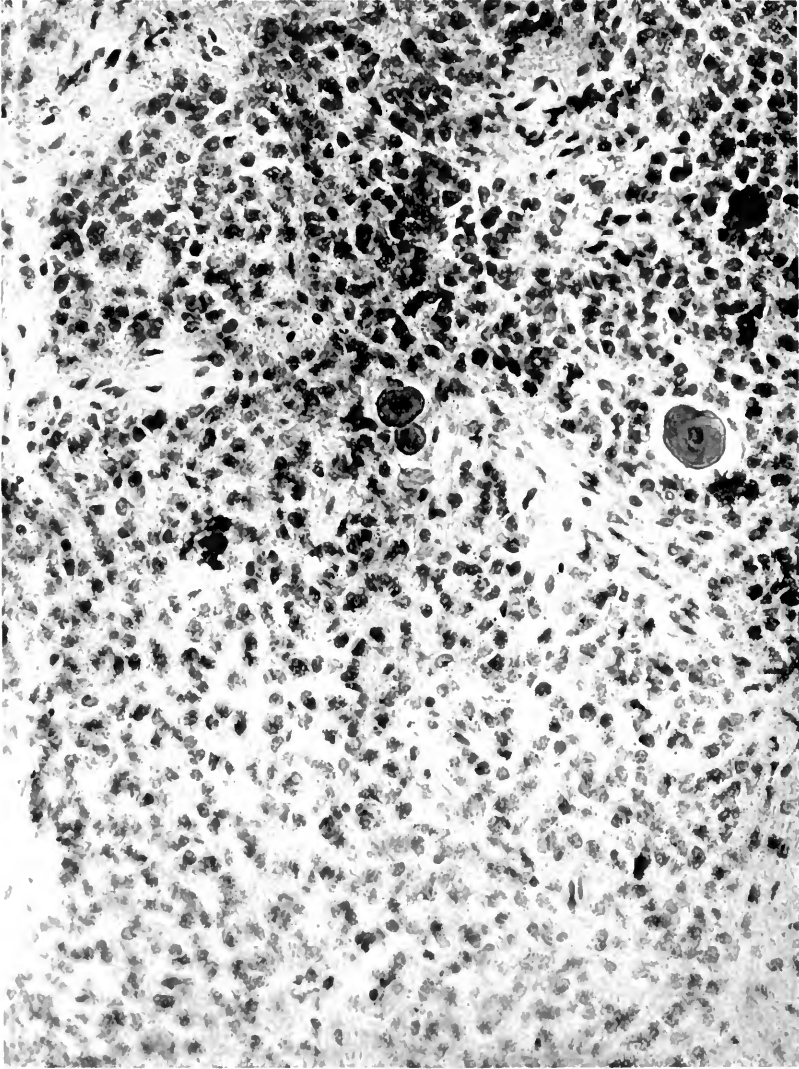


Fig. 40 Section of the pineal body of human adult, according to Tilney and Warren, 1917.

ually extends to its distal extremity. Many of these diverticula remain in connection with the third ventricle, but as they elongate toward the tip of the pineal body many of the diverticula lose this connection and finally appear as blind acini or cell cords. In this way the original more or less indifferent cell area of the primitive anlage is invaded by cells from the diverticula above described. Simultaneous with the invasion of these diverticula, blood vessels are seen to make their way into the tissue between the acini and cell cords. This vascular invasion seems to take place from the periphery going to the center, but it is possible that independent blood spaces are formed which, by conresence, subsequently form a vascular network, the latter coming into relation with the blood vessels surrounding the pineal body. These characters of the ontogenesis of the pineal body in the cat are shown in figure 91.

The process just described in the histogenesis of the cat is much better illustrated in the development of the human fetus. In man, the process of diverticular invasion into the original cellular mass of the primitive anlage is well shown in figure 92, representing the condition in a human fetus of six months. Here it will be noted that the invasion begins at the base of the epiphysis and manifests itself in the thick strand of darkly staining cells extending out and into a mass of undifferentiated tissue. At term the invasion has extended completely through the epiphysis and the deeply staining strands of cells are now arranged in convoluted cords or take the form of apparent acini. In the meshes between these cords capillaries appear to have made their way in from the surface of the epiphysis and form a rich network about the cell cords and apparent acini. This ontogenetic differentiation in the two forms just described would certainly seem to indicate a process which had as its object the rich vascularization of discretely outlined epithelial areas. Such a differentiation would seem to adapt itself best to the purposes of internal secretion.

Marburg²⁵⁹ shows in the development of the pineal gland in man histological appearances very closely resembling those illustrated in figures 91, 92, 93, and 94 of the authors (fig. 95).

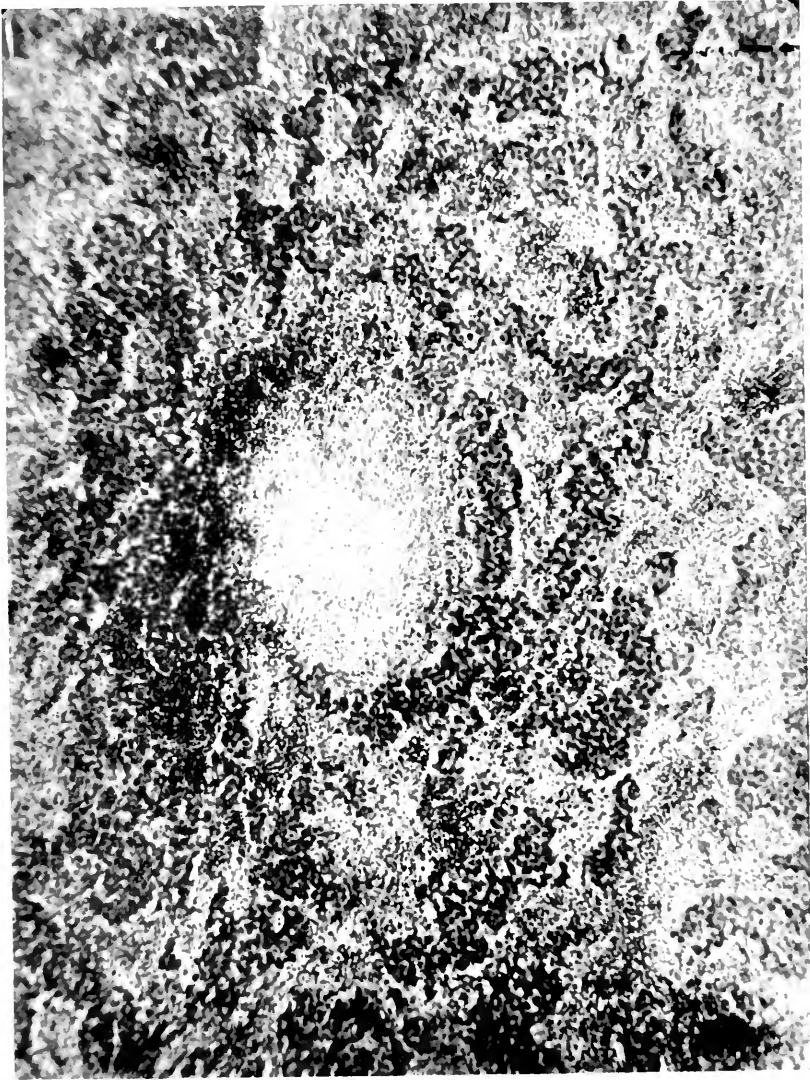


Fig. 91. Section of the pineal body of a two months old kitten, according to Tilney and Warren, 1917.

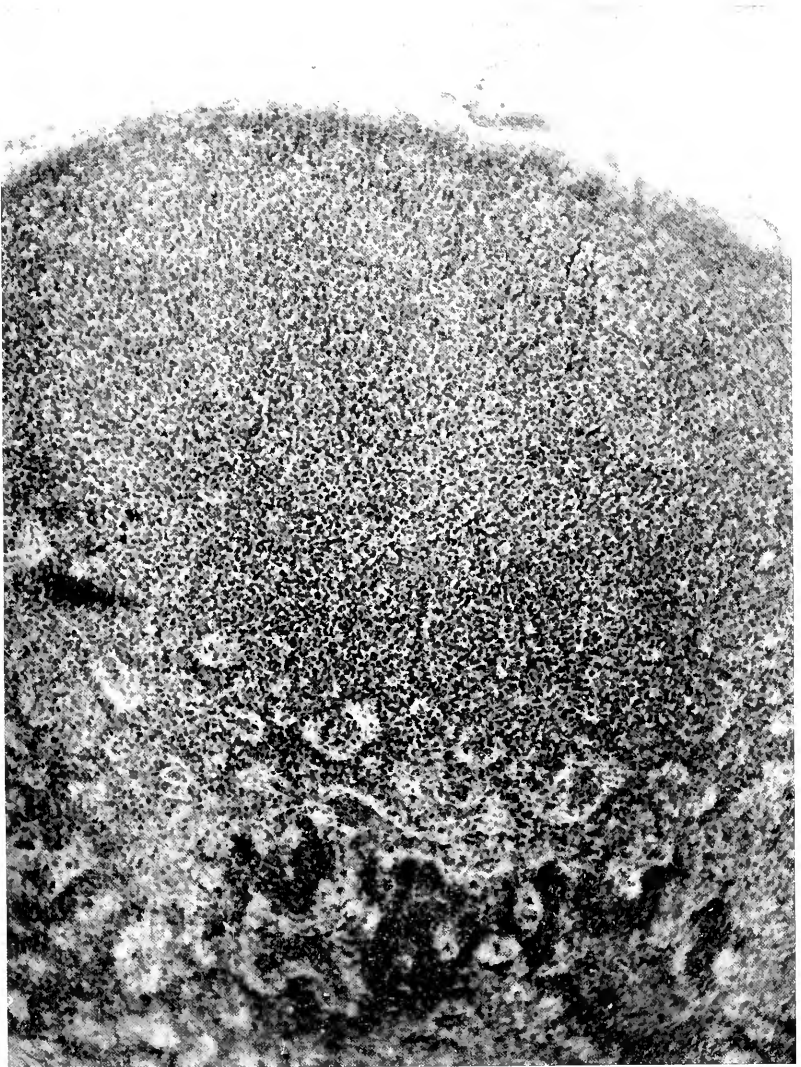


Fig. 92 Section of the pineal body in a six months human fetus showing the diverticular invasion, according to Tilney and Warren, 1917.

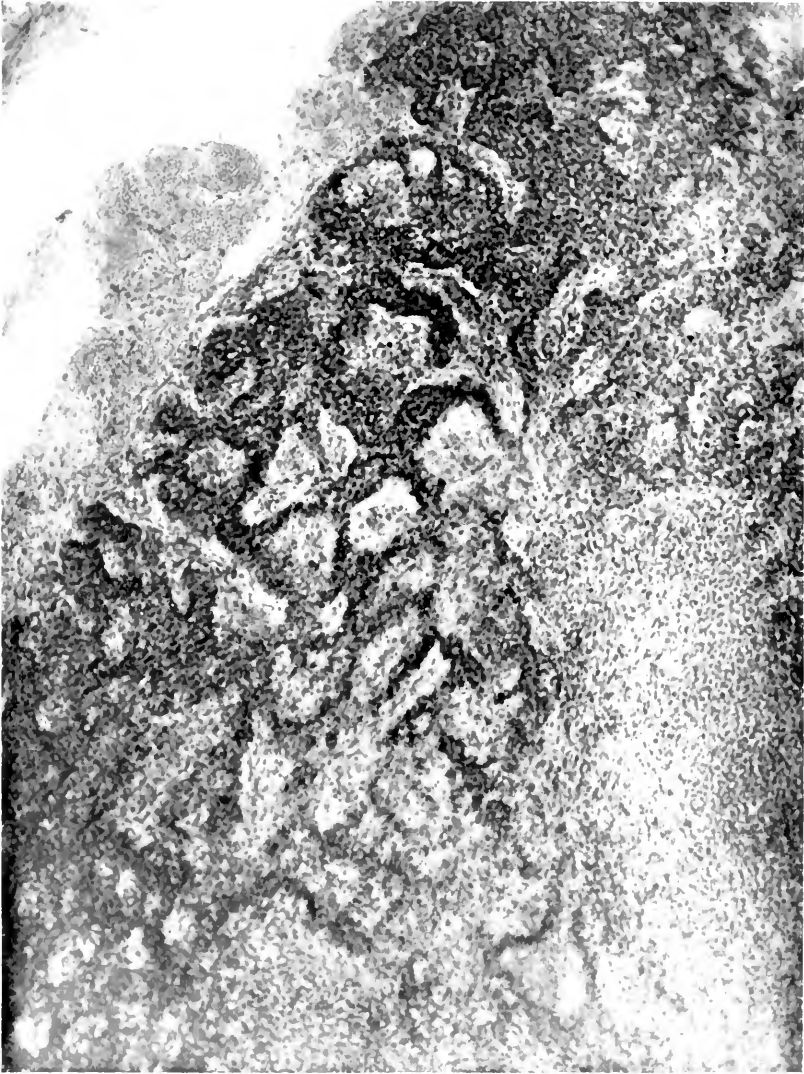

Fig. 93 Section of the pineal body in a six months human fetus showing the diverticular invasion beginning at the base and extending toward the apex, according to Tilney and Warren, 1917.

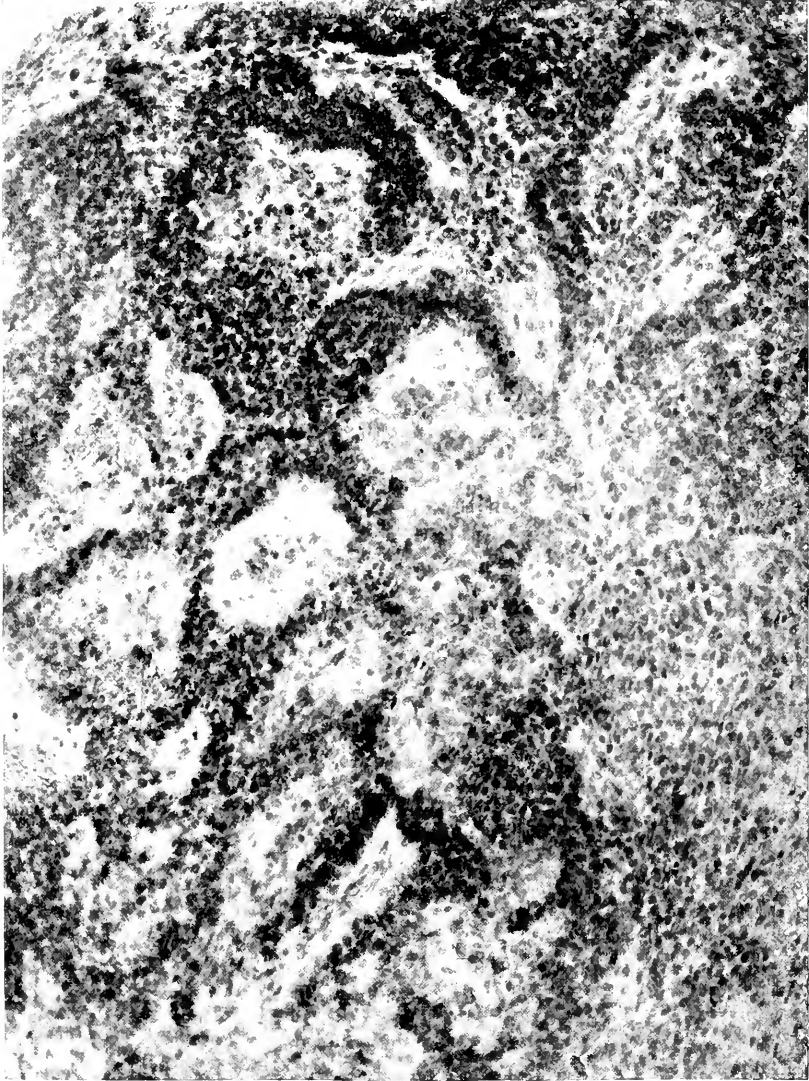

Fig. 94 Section of the pineal body in a new-born infant showing the completion of the diverticular invasion from base to apex, according to Tilney and Warren, 1917 (300 diameters).

Marburg also gives an interesting description of the development of the suprapineal recess in man which is illustrated in figure 96. According to his description, the suprapineal recess is formed by the dorsal reflection of the taenia which originally was directed cephalad. The dorsal surface of the taenia secondarily becomes fused with the dorsal surface of the pineal gland while the ventral surface is turned dorsad. In this way the suprapineal recess results from a deep evagination of the roof-

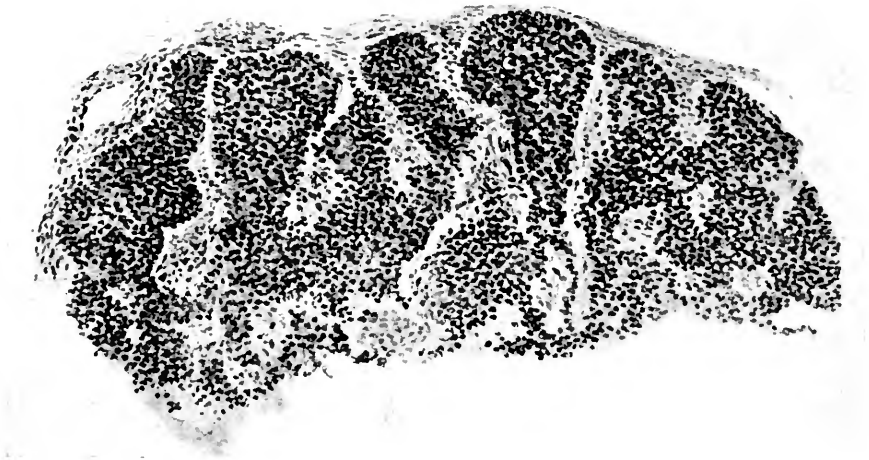


Fig. 95 Cross section of the pineal gland in a 26 mm. human embryo, according to Marburg, 1909.

plate which comes to lie above the pineal body and extends in most cases the entire length of that organ. The suprapineal recess in its relation to the pineal gland in adult man is shown in figure 97.

With reference to the pineal body Marburg maintains that in spite of all the involution processes in the gland, it cannot be denied that even up to the late periods of life in man there are wholly intact glandular cells present in the organ which must certainly be taken to indicate a still existing function.

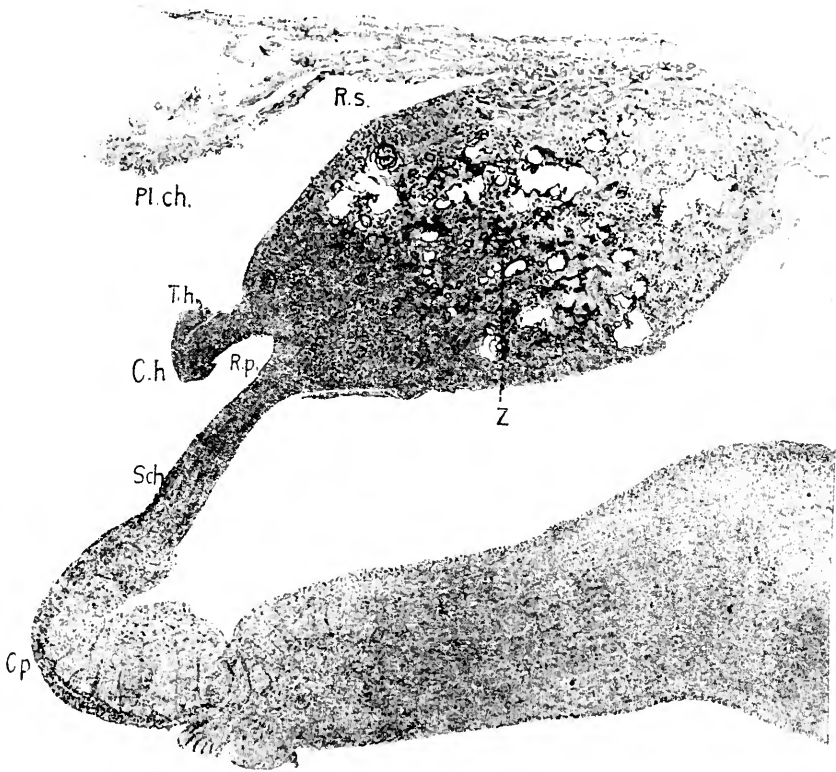
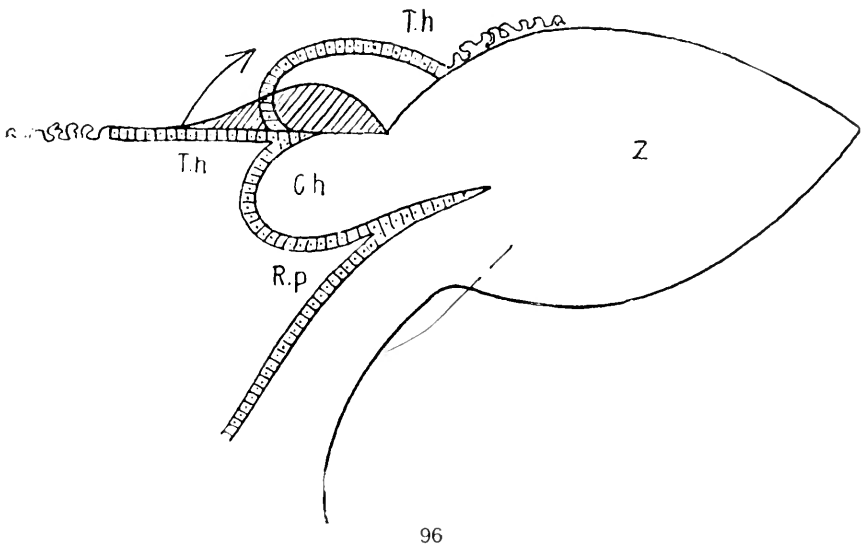


Fig. 96 Scheme showing the development of the supra-pineal recess, according to Marburg, 1909.

Fig. 97 The pineal gland in man, according to Marburg, 1909.

Ch., commissura habenularis; *Cp.*, commissura posterior; *Pl.ch.*, chorioid plexus; *Rp.*, recessus pinealis; *Rs.*, recessus suprapinealis; *Sch.*, pars intercalaris; *Th.*, taenia habenularis; *Z.*, pineal gland.

7. DISCUSSION

1. *Significance of the pineal region*

It is now possible, with the facts presented as evidence, to discuss the problem of the pineal body and, perhaps, to formulate some conclusions concerning it.

The question uppermost about the epiphysis to-day is whether the structure is a mere vestige or whether it has, in mammals and more especially in man, some definite function. Besides this highly important consideration there is still another which, in its way, has an even more far-reaching significance, namely, the value of the pineal structures as one of the indices which may point out the lines of evolution running through the vertebrate phylum and those leading back to the invertebrate, ancestral stock.

If the pineal body is a vestige, it is essential to ascertain to what previously active structures it is related and for what reasons it has become vestigial. In this sense the survey of its phylogenetic relations cannot be too broad and should include the entire environment of the organ. If, as is held by many, the pineal organs have significance as a connecting link between the vertebrates and invertebrates, then, on the basis of embryology and comparative morphology, the effort must be made to homologize not one, but all of the parts associated with or adjacent to the pineal body. In such a light every derivative of the roof-plate of the primitive forebrain becomes fundamentally important, and no discussion of the pineal body could be complete which did not recognize the character of the *pineal region* as a whole.

The portion of the brain known as the pineal region was first so designated by Minot²⁷⁷ in 1901. It has also been termed the *parietal region*. It extends from the dorsal extremity of the lamina terminalis to the caudal limit of the posterior commissure and comprises all of the structures which develop from the roof-plate of the primitive forebrain. It presents, according to Minot,²⁷⁷ a series of three arches or vaults, arranged one in front of the other. The most cephalic of the three arches is

the *paraphyseal arch*, which extends from the dorsal extremity of the lamina terminalis to the most cephalic depression in the roof, namely, the *velum transversum*. The portion of the roof immediately caudad of the velum forms the *middle* or *postvelar arch*, which in turn is separated from the third or caudalmost arch by a slight depression containing the superior or habenular commissure. This is the *epiphyseal arch*. In some species a small intercalated portion of modified gray matter inserts itself between the caudal limit of the postvelar arch and the superior commissure. This is the *pars intercalaris anterior*. Caudally, the epiphyseal arch extends toward the cephalic extremity of the posterior commissure, but between the latter and the caudal extremity of the arch there is interposed a small area of modified gray matter, the *pars intercalaris posterior*. The caudalmost element in the pineal region is the posterior commissure, and to this, perhaps, should be added the *subcommissural organ*, recently described by Dendy and Nicolls⁸⁸ and others.

These structures of the pineal region or their homologues exist in all vertebrates either in the embryonic or adult condition. The paraphyseal or prevelar arch is common to all vertebrates. From its caudal portion, i.e., the region of the arch nearest the velum transversum, there develops a specialized structure, the *paraphysis*. This structure, either in anlage or as an adult organ, appears in all vertebrates.

In cyclostomes (Kupffer²²⁴ in *Ammocetes*, Burekhardt⁴⁷ in *Petromyzon*) the paraphysis is a small sac-like diverticulum, if not itself highly vascular yet in close relation with the vascular mesenchyme immediately above it. In selachians (Minot²⁷⁷ and Locy²⁴³ in *Acanthias*) the structure is a small outgrowth from the paraphyseal arch. In ganoids (Kupffer²²³ in *Acipenser*, Hill,¹⁸⁰ Eycleshymer and Davis¹¹³ in *Amia*) the paraphysis is a large diverticulated and vascular organ. In many teleosts (Burekhardt,⁴⁷ Studnicka,³⁹¹ and Terry)³⁹² the paraphysis appears to be rudimentary. In dipnoians (Burekhardt⁴⁴ in *Protopterus*) the organ is a wide outgrowth with many small diverticula and rich in blood vessels. The paraphysis in amphibians attains its greatest conspicuity as an organ. It is highly differentiated in

the adult (Warren⁴¹⁶ in *Necturus*, Osborn²⁸⁹ in *Siredon*, *Siren* and *Proteus*.) It is an elaborately folded, glandular structure (Burekhardt⁴³ in *Triton* and *Ichthyophis*), a solid vascular mass (Sorensen³⁶¹ in *Menopoma*), or a tubular and digitated structure (Eyeleshymer¹¹² in *Amblystoma*). In *Rana*, according to Minot,²⁷⁷ the paraphysis is characterized by a glandular epithelium, a tubular arrangement of its cells, and an apparently sinusoidal circulation. In *Lacertilia* (Warren⁴¹⁵ in *Lacerta muralis*, *L. agilis* and *L. viridis*) it is large and glandular in character, forming a conspicuous element of the pineal region. In many instances it is so extensive as to reach caudad as far as the midbrain, or even the cerebellum. In ophidians, chelonians and crocodilians, the paraphysis is small and rudimentary. In birds it was first demonstrated in the chick by Selenka³⁵² and later described by Minot²⁷⁷ in the chick and Burekhardt⁴⁶ in the embryo crow. Dexter⁹⁰ found it constant in the chick and common fowl. He believes it to be a gland in which there are no sensory elements.

In mammals Selenka³⁵² gave the first description of the paraphysis in the opossum. Francotte¹²⁸ observed it in a 12 mm. human embryo. Usually, however, although it has been recognized in anlage, in mammals it disappears early and the paraphyseal arch bears no trace of it in the fetal period.

Thus it will be seen that the glandular nature of the paraphysis in the middle portion of the phyletic series, including amphibia and lacertilia, is quite beyond dispute. Some of this character it retains in the more modern reptiles and birds. On the other hand, it is relatively inconspicuous as an organ among the lowest vertebrates and disappears altogether in most mammals. Manifestly, therefore, whatever tendency toward specialization the paraphysis presents is in the interest of glandular formation. As a gland, it appears either to contribute its secretion directly to the cerebrospinal fluid in the ventricles or indirectly to the blood. In no instance is there evidence of a tendency toward the development of sensory structure nor do the histological elements entering into the paraphysis suggest its direct participation in any neural mechanism.

From the remainder of the paraphyseal arch there develop in many classes of vertebrates several chorioidal processes. In cyclostomes, selachians, teleosts, and ganoids, two such plexuses, more or less well developed, may be recognized, namely, the lateral and inferior telencephalic chorioid plexuses. The inferior chorioid plexus attains its most marked proportions in amphibia, while in all of the higher vertebrates its prominence declines. This is likewise true of the lateral chorioid plexus. Histologically and topographically, the significance of these plexuses is not difficult to discern; their rich vascularization, their tendency toward glomerular arrangement together with the relations and modifications of the ependymal cells which enter into them leave little room to doubt that they are glandular in nature. Indeed, the present tendency is to refer to these structures as *chorioidal glands*, thus deputing to them a definite, secretory function in relation to the cerebrospinal fluid. Even the older conceptions of the chorioid plexuses recognized this physiological possibility in connection with the plexuses.

The morphological fact concerning the first and most cephalic of the three arches in the pineal region discloses a predominant tendency for its derivatives to give rise to glandular structures, while, on the other hand, there is no evidence that it has ever been engaged in definite neural mechanisms.

The structure which forms the boundary between the prevelar or paraphyseal arch and the postvelar arch is the velum transversum. Like the paraphyseal arch, it attains its greatest conspicuity in the lower vertebrates and in the higher forms becomes less prominent. In mammals its appearance is most pronounced in the embryonic period from which time it becomes progressively reduced, being present in the adults of most orders as a more or less well-marked rudiment. In most classes of vertebrates it becomes associated with a dense mesenchymatous invasion which results in a fairly rich vascularization. This combination of ependymal cells and blood vessels often takes the form of a plexus, and when such is the case the velum transversum aligns itself with the structures derived from the paraphyseal arch in the absence of any definitely neural elements and the tendency toward glandular formation.

The middle or postvelar arch (so called by Minot²⁷⁷) in the pineal region has also been designated the *Zirbelpolster* by Burekhardt,⁴⁷ the postparaphysis by Sorensen,³⁶¹ the dorsal sac by Goronowitsch,¹⁵³ and the roof of the parencephalon by Kupffer.²²⁶ This structure, with few exceptions, forms a prominent element of the pineal region throughout the vertebrate series. In cyclostomes it is present as a simple membranous sac with scant vascularity of its own, although in close approximation with the highly vascular mesenchyme dorsal to it. In selachians it is usually somewhat more extensive yet similar in its structural details. In ganoids it becomes immensely expanded as shown by Balfour,¹¹ Huxley,¹⁹¹ Wiedersheim,⁴²⁵ Goronowitsch,¹⁵³ Wilder,⁴²⁸ and Kingsbury.²⁰⁴ Herrick¹⁷⁸ describes the dorsal sac as a pouch lined with a single row of ependymal cells with long cilia which appear to be of the epithelial, secretory type. It is highly vascular in these fish. In teleosts, on the other hand, it is not always prominent. In *Opsanus*, Terry³⁹² found that the dorsal sac was small and perhaps disappeared altogether. In some teleosts, as in ganoids, the postvelar arch is not only highly vascular, but presents ridges, secondary folds, and diverticula. In amphibia, reptiles, and birds, the postvelar arch becomes definitely associated with the formation of the chorioid plexuses, and it does, in fact, contribute the epithelial elements to the chorioid plexus of the dienecephalon. With the advent of the corpus callosum in mammals the dorsal sac or postvelar arch becomes somewhat overshadowed, due to the introduction of the transverse commissure which lies above and tends to flatten it. It, however, loses none of its tendency to participate in the plexus formation, which latter in mammals attains a greater development than in many of the lower forms.

This element of the pineal region, therefore, is to be associated with the paraphyseal arch in its tendency toward specialization. From the lowest vertebrates upward through the phylum it manifests no attempt toward the development of sensory or other definitely neural elements, while the entire trend of its evolution reveals a glandiferous potentiality.

The postvelar arch is separated from the caudalmost or epiphyseal arch of the pineal region by a shallow invagination of the diencephalic roof, which usually contains commissural nerve fibers. This is known as the superior commissure or commissura habenularis. In some forms, as in amphibia, it is associated with a small, somewhat thickened area of the roof in which the histological elements are largely neuroglia. This is the pars intercalaris anterior. Although the structure, or its homologue, occurs in such a limited number of animals, its recognition as a distinct part seems advisable in the description of this area of the brain. In cyclostomes, prosaurians, and saurians, the superior or habenular commissure seems to be connected with the parapineal or parietal nerve and, perhaps, through this relation is brought into connection with the end-vesicle of the parapineal organ. If such is the case, it may well be that this commissure in cyclostomes, in prosaurians, and in saurians is related to an organ of special sense. In this light the superior commissure must be accounted as engaged in the organization of a specialized neural mechanism, and thus becomes the first of the structures encountered in the pineal region to show this tendency in differentiation. The significance of the pars intercalaris anterior is not altogether clear, although it is possible that it may represent a residue of an unutilized sustentacular area developed in the interest of the commissural formation. The presence in it of a few nerve fibers would seem to substantiate this view.

The caudalmost or epiphyseal arch is by far the most complex of the three arches in the pineal region. In order that its description may be comprehensive enough to include all vertebrates, a number of different elements are to be recognized, either as appearing in the embryo or giving rise to definite adult structures whose composit may, for convenience, be termed the *epiphyseal complex*. This complex, then, consists of two principal organs, namely, the pineal organ and the parapineal organ. Each of these organs is in turn susceptible of subdivision into certain portions as follows:

1. Pineal organ.

- a) Proximal portion.
- b) Stalk.
- c) End-vesicle.

2. Parapineal organ.

- a) Proximal portion.
- b) Stalk.
- c) End-vesicle.

Of all of these parts the proximal portion of the pineal organ is phyletically the most constant, occurring in all classes of vertebrates. The stalk and end-vesicle of the pineal organ are much less constant, for they cease to appear in ophidians and are absent in all the forms higher than the snakes. The parapineal organ as a whole is limited to but a few classes of vertebrates. It is prominent only in cyclostomes, in prosaurians and saurians. It is rudimentary in ganoids and teleosts. It is developmentally transitory or entirely absent in selachians, amphibia, ophidians, chelonia, crocodilians, birds, and mammals.

Considered, for a moment, quite apart from the inferences which may be drawn from the intrinsic structural characters of the epiphyseal complex itself, there is one outstanding feature of unquestionable importance, namely, the genetic association of this complex with a series of organs which under no conditions have manifested a tendency to become specialized in the interest of definitive neural mechanisms, but which, wherever differentiated, have given rise to glandular tissue.

The caudalmost element in the pineal region is the posterior commissure. It is, perhaps, not definitely settled that this assignment of the commissure to the interbrain is in all respects justifiable. If, however, it is to be accounted as a structure of the pineal region, the function of the commissure appears to be related to a specialized portion of the pineal organ, namely, the end-vesicle, with which latter the posterior commissure is said to be in connection by means of nerve fibers. Admitting, for the moment, the correctness of the morphological and physiological interpretation given the subcommissural body by Dendy and Nicolls,⁸⁸ the structure may tentatively be considered as a part of the pineal region. Its function, apparently, is in some way connected with the fiber of Reissner and the entire organ thus associated with equilibration. Both of these elements,

constituting the caudalmost constituents of the pineal region, are obviously specialized as neural mechanisms in the interest of special sense receptors. The pars intercalaris posterior has, no doubt, the same functional significance as the anterior intercalated area associated with the superior commissure.

From a review of the several structures associated with the epiphyseal complex in the pineal region, it is clear that the majority of them when differentiated at all give rise to glandular organs, while those which participate in neural mechanisms are not only in the minority, but constitute a relatively small portion of this area in the brain. Thus the paraphysis and paraphyseal arch as a whole, the velum transversum, and the postvelar arch are genetically glandiferous, while the superior commissure and posterior commissure alone bear any apparent relation to neural activity.

In view of these facts, it would seem that whatever the functions of the epiphyseal complex may be, the morphogenetic impulse imparted to it from a region of the brain so preponderatingly glandiferous in its constituents could not fail to have a profound influence upon the evolutionary adaptation of the epiphysis. Yet, in spite of the illumination which this genetic association of the epiphyseal complex with definitely glandular structures seems to shed upon its inherent tendencies in differentiation, it must be in the intrinsic characters of the complex itself that the solution of its problem is ultimately to be sought.

2. Evidence based on the gross morphology of the epiphyseal complex

a. Phyletic constancy. If such evidence as may be obtained from the gross morphology of the epiphyseal complex is taken into account, a number of reasons may be advanced to show that it is quite impossible to conceive of the pineal body as a vestigial structure. These reasons seem so cogent as to place upon the arguments which would refute them an unusually heavy burden.

The most significant feature with reference to the functional activity of the pineal body appears to be the fact of its marked phyletic constancy. Certainly, a structure which is marked for regression or in which it is claimed that the evidences of regression may easily be found, would scarcely show such remarkable tenacity throughout the phylum. Its occurrence in cyclostomes, in all the fish, in amphibians and reptiles, in birds and mammals reveals it as a structure which must have been called into being in response to some definite demand, for why, otherwise, should all of these classes of vertebrates so constantly present this morphologic condition?

It is, perhaps, laying overmuch stress upon the phyletic constancy of the epiphyseal complex to draw from these facts alone the inference that it must be a physiologically active organ. Its reported absence in the *Myxinoïds*, in *Torpedo ocellata*, and *Torpedo marmorata* as well as in *Crocodylia* would seem to call into question the full value attached to the argument of its otherwise general constancy. On the other hand, it must not be overlooked that in the history of the observations devoted to the pineal body, a relatively large number of investigators have reported the absence of the epiphysis in one form or another, only to have their error corrected by subsequent research and the presence of the organ clearly demonstrated. By far the greater majority of observers in the morphology of this portion of the brain are to-day of the opinion that the epiphyseal complex as a whole or in some of its parts exists in all vertebrates. It is certainly pertinent to the reported absence of the organ in the forms mentioned to recall Kidd's²⁰³ observation that the conditions in *Torpedo* need further review before final acceptance of the statement that the epiphysis is absent in these forms. The same also applies to *Crocodylia*, and until this order has been more extensively examined, much reservation should be made in concluding that the pineal body is absent in these reptiles. Again, Kidd's²⁰³ contention with reference to the *Myxinoïds* adds another view which would render less serious the reported absence of the epiphysis in the forms mentioned. According to Kidd, it is not surprising that in *Myxinoïds* the

epiphysis is wanting, since these are considered, by most authorities, as degenerated forms.

With these exceptions, then, so much in the minority, this negative evidence should be accepted with much hesitancy. In fact, the phyletic constancy of the epiphyseal complex is so pronounced as to render the total absence of the organ in *Myxinioids*, *Torpedo*, and *Crocodylia* open to doubt.

b. Phyletic variations and morphologic specialization. If the constancy already considered lends itself to the weight of evidence in favor of the supposition that the pineal body is a functional organ, then even more will the phyletic variations and morphologic specializations which present themselves in this organ support the view that the epiphysis is not a vestige, but plays some physiologically definite rôle.

Certainly, when the marked specialization in the epiphyseal complex in the various orders of vertebrates is taken into account, it is difficult to escape the conclusion that such modifications must have been in the interest of definite adaptations. If these specializations referred to were indefinite or diffuse, it might still be a question whether the processes were actually in the interest of adaptation; but when, as is the case, form after form shows such a high state of differentiation, such a definite and discrete specialization, there seems to be little room for doubt that a process of adaptation has been carried forward in order to satisfy the demands for the development of specialized organs.

On the other hand, it cannot be denied that even such discrete differentiation as the epiphyseal complex presents in many forms, may represent but the rudiments of an adaptive process which in some extinct forms, or perhaps even in some of the proto-vertebrates, may have attained their functional consummation only to impart an impulse in this direction to those vertebrates which show the most definite specialization in the pineal organs.

In this sense, all of the differentiation of the epiphyseal complex throughout the vertebral phylum expresses an inherent attempt to consummate the formation of organs which have been essential in extinct forms or in the ancestors of the verte-

brates. This contention, while it must have its place in the discussion, seems to lose force in view of the special development of the pineal organ in certain vertebrates. Thus, in cyclostomes there is present, to a degree seen in no other vertebrates, a development of the major constituents of the epiphyseal complex. That is to say, both the pineal organ and parapineal organ attain a degree of differentiation which at least justifies the supposition that one, if not both of them have functional activities of a visual nature. The presence in these forms of a well-marked retinal structure, seen in the pineal organ as well as in the parapineal organ, an end-vesicle containing a syncytial structure comparable in many respects to the vitreous, a pigment-free, ectal wall enclosing the end-vesicle and resembling a lens, together with a bundle of nerve fibers connected with the posterior commissure in the case of the pineal organ, and the superior commissure in the case of the parapineal organ, constitute irrefutable evidence of morphological specialization adapting the organ to photo-receptive, if not visual purposes. This supposition is further borne out by the fact that the organs in their development grow rapidly away from the roof of the brain and ultimately take up a position which, from its relation to the surface of the body, affords certain epiphyseal structures the best opportunity of becoming distance receptors. From the striking position which the pineal and parapineal organs hold in the vault of the skull, lodged as they are in a deep fossa, it would seem evident that they have become so situated that they might the more readily receive sensory impulses impinging upon the surface of the head.

That this visual or photo-receptive tendency in the selachians, ganoids, and teleosts should almost altogether disappear, although the pineal organ itself remains as a conspicuous structure, would speak in favor of a pluripotentiality in the differentiation of the epiphyseal complex. It is certain that in the higher fish there is no evidence pointing to the development of anything resembling the visual structures observed in cyclostomes. In selachians the parapineal organ is entirely absent; the pineal organ, on the other hand, is a large and prominent

structure presenting a proximal portion, a prolonged stalk, and a fairly well marked end-vesicle. No tendency, however, is observed toward the development of a photo-receptive apparatus. The thickened proximal portion communicates directly with the ventricle on the one hand, and through the stalk with the end-vesicle on the other. The fact that this latter portion of the pineal organ is lodged in a deep fossa of the skull and thus brought into close relation with the epidermis, would favor the belief that in this structure may be observed the arrested or abortive effort toward the formation of a physiological organ. That this organ, however, deprived of the opportunity to reach such a goal in its differentiation, should remain so prominent a structure connected with the brain, would seem to refute the conception that it is a mere vestige or rudiment; indeed, it seems to compel the belief that it exists in the interest of some other function as yet not entirely clear.

When, however, the finer histological structure of the pineal organ in selachians is discussed, it may be possible to disclose evidence which will at least suggest, that the structure in these forms is functionally active. The point which the gross morphological conditions in selachians does lay emphasis upon is the presence of so prominent a structure, showing no evidence in itself of retrogression and yet quite devoid of such specialization as would connect it definitely with visual function.

In the teleosts, the observation made with reference to the selachians assumes even more importance, for here the pineal organ shows a marked specialization which is entirely contrary to the lines of differentiation followed in the development of a visual organ. In most of the teleosts the pineal organ presents a small proximal portion, a relatively short stalk, and a voluminous thick-walled end-vesicle. The general follicular appearance of the end-vesicle, together with its relatively large size and the fact that it has neither migrated to such a great distance from the roof-plate of the interbrain nor come to occupy a definite fossa in the vault of the skull, all go to disprove any inherent tendency in the structure to differentiate as a visual organ. In many teleosts a small parapineal organ develops, but never

reaches dimensions comparable with the pineal organ. As in the case of the selachians, the histology of the pineal organ of the teleost will prove helpful in the interpretation of its function.

Thus, in the four great classes of fish, cyclostomes, selachians, ganoids, and teleosts, the epiphyseal complex shows a remarkable variation in its specialization, and while the tendency to develop visual or photo-receptive structures is marked in the cyclostomes, it is suspended, if not entirely absent, in selachians, ganoids, and teleosts.

In the latter forms, however, the epiphyseal complex is so conspicuous an element of the brain as to make the conclusion that it is without function a difficult one to maintain. For these reasons, it would seem justifiable to conclude that the epiphyseal complex is pluripotential in its specialization and that while it may be vested with the possibility of giving rise to a visual or photo-receptive apparatus, it may and does become differentiated as organs having some significance other than sensory.

Still greater modifications present themselves in the amphibia, for in these forms the pineal organ shows an even more marked differentiation than any of the other lower classes. The parapineal organ does not develop in urodela or anura. When, however, the structure of the pineal organ is considered, the fact that it develops a proximal portion of such conspicuous dimensions as to be secondary to the paraphysis in the roof of the interbrain, from the free extremity of which there extends a thin nerve filament connecting with an end-vesicle, it becomes clear that the entire process of adaptation in this instance cannot be in the interest of sensory function, for if that were the case, why, then, should the proximal portion of the pineal organ assume such conspicuity?

Stieda's³⁷⁹ interpretation of the end-vesicle in amphibia as a *frontal subcutaneous gland* is, of course, quite untenable, since the end-vesicle manifests by its position and connections some obvious adaptation to sensory activity. Yet to its proximal portion might well be attributed a glandular function, not only because of its unusually large dimensions, but also because of the position which it holds with reference to the third ventricle.

If the argument bearing upon the pluripotentiality of specialization of the epiphyseal complex needed support or confirmation, this is found in the conditions of amphibians.

The evidence afforded by the reptiles goes, perhaps, as far as may be deemed necessary to confirm the pluripotentiality of the pineal organ and its derivatives. In the ancient and primitive reptiles, including the prosaurians and saurians, there is a tendency for both pineal and parapineal organs to attain remarkable development. But in these forms, it is the parapineal organ which assumes predominance in the development of a sensory apparatus. In *sphenodon* and many of the lizards the parietal or third eye reaches such a high state of differentiation as to leave little doubt concerning its visual function. The well marked optic vesicle, lodged in a parietal fossa and brought into relation with the external epidermis by means of specialized cells, affords incontrovertible evidence that this organ is adapted as a distance receptor. The pineal organ, while it presents some tendency towards the development of a visual organ, does, as a matter of fact, fall far short of such attainment. Its end-vesicle is smaller than in any of the other forms already considered. Its stalk is shorter; on the other hand, its proximal portion has assumed characters not as yet observed in the lower members of the vertebrate series. So pronounced is the specialization of this proximal portion that it needs no microscopic investigation to disclose the marked differentiation of the structure. Its walls are not only thick and convoluted, giving it a lobulated appearance, but its diameters are greater than those of the lower forms.

Upon passing to the more modern reptiles, including the ophidians and chelonians, the tendency to specialization which has previously been emphasized in this discussion, receives still further accentuation. In these forms, the parapineal organ disappears altogether and nothing remains to indicate that it ever had existence in reptilia. There is no parietal fossa and no specialization of the cutaneous surface in the head which might even vaguely suggest the remnants of the parietal eye so conspicuous in the ancient reptiles. Yet, on the other hand, the

pineal organ manifests such marked alterations as to leave no doubt that a process of specialization is going on in this structure. It is a much more voluminous organ having a greater solidity and presenting only one of the three fundamental portions observed in the pineal organ of the lower forms. The end-vesicle and the stalk of the end-vesicle have disappeared. The proximal portion alone remains to represent the epiphyseal complex. It also manifests certain modifications in its relation to the brain, since now it no longer communicates with the ventricle through a canal. Furthermore, it has developed a shallow intermediate stem or stalk connecting it with the roof-plate.

The inception of the process resulting in the formation of the pineal peduncle is first witnessed in the *sphenodon* and lacertilia. The conditions in birds and mammals show a still further tendency along the lines of specialization first manifested in ophidians, for, as in these latter forms, neither the parapiueal organ nor the end-vesicle or stalk of the pineal organ makes its appearance. The epiphysis in many of the birds becomes a solid organ with no canal connecting it with the third ventricle, although in certain birds this canal is present. In mammals the canal has never been observed and the pineal body presents itself as a dense, solid structure in close proximity to the roof of the interbrain or resting upon the roof-plate of the midbrain.

Another observation made by Kidd²⁰³ is pertinent in this connection, to the effect that if nature is endeavoring to be rid of the pineal body it has taken a remarkably long time imperfectly, if at all, to accomplish this end. The evidence that the reptiles in the Palaeozoic era possessed a parietal eye is substantiated by the parietal foramen in these extinct forms, as demonstrated by Bashford Dean.⁸²

All of this evidence concerning the phyletic variations and morphologic specialization seems to justify the conclusion that the epiphyseal complex is possessed of a pluripotentiality which in a few forms has been realized as a more or less diffuse visual structure, but which fundamentally appears to be in the interest of a differentiation whose functional significance is not sensory.

c. Relative constancy of the epiphyseal complex with reference to other structures of the pineal region. The phyletic constancy of the epiphyseal complex, when considered in conjunction with the other derivatives of the diencephalic roof-plate, brings to light a fact of no little significance. It has already been shown how constant the epiphyseal complex, either in its entirety or in some of its parts, is in the vertebrate phylum, and this becomes further emphasized by the fact that this structure alone of all the elements derived from the roof-plate presents such undeniable constancy. If compared with one of the most conspicuous roof-plate derivatives, the paraphysis, the epiphyseal complex stands out in marked contrast. The paraphysis is present in its highest state of evolution in the middle of the vertebrate series; that is to say, in amphibians and in older reptiles. It is a conspicuous organ, showing but little differentiation in cyclostomes and in fishes generally. In ophidians, birds, and mammals it is absent. The inference which may be drawn from these facts seems to be that the roof-plate of the interbrain is capable of developing a structure which, when it no longer subserves any purpose, ceases to exist. When the phyletic constancy of the epiphyseal complex is compared with that of the paraphysis, it would seem evident that this very constancy argues a demand on the part of the organ for the presence in the animal of this complex or some of its parts.

To a less degree, the comparison in favor of the pineal organs may be drawn with reference to the velum transversum, telencephalic chorioid plexus, and dorsal arch. None of these show such a marked tenacity as the epiphyseal complex, a fact which but serves to emphasize the significance of the relative constancy among the structures derived from the diencephalic roof-plate.

d. Relative constancy of the several parts of the epiphyseal complex, with the predominance of the proximal portion. Since each organ of the epiphyseal complex presents three more or less well-defined portions, namely, the proximal portion, the stalk, and the end-vesicle, it would be interesting to note the relative constancy of the several parts in the phyletic series in order to ascertain, if possible, which of these is the most fundamental

element in the complex. Both organs are well developed in cyclostomes. The proximal portion of the pineal organ, although present, is not conspicuous, but it is doubtful whether any structure which may be designated a proximal portion can be discerned in the parapineal organ. The stalks and end-vesicles are present and highly specialized. The stalks have lost their original lumina and consist of two sets of nerve fibers. Both end-vesicles are well differentiated.

In selachians the parapineal organ is entirely absent. The proximal portion of the pineal organ is well marked, its stalk is long and hollow, and its end-vesicle a dilated sac.

In ganoids and teleosts the parapineal organ is rudimentary; in the embryo it presents a small proximal portion which subsequently becomes much reduced in size, rendering it difficult of recognition in the adult. The stalk is short and slender and contains no lumen. The end-vesicle is very small. The proximal portion of the pineal organ shows a considerable dilatation and is connected, by means of a hollow stalk, with an extensive end-vesicle.

In amphibia the parapineal organ is absent. The proximal portion of the pineal organ is a large, dilated sac whose lumen communicates with the third ventricle. The stalk is reduced to a slender nerve strand extending from the free extremity of the proximal portion to the end-vesicle which lies immediately beneath the skin in the region of the head.

In the primitive reptiles, including *sphenodon* and lacertilia, the parapineal organ is present and shows a marked development. In the embryo there is a prominent proximal portion, which, however, becomes gradually reduced in size, and in the adult is difficult to distinguish. The stalk of the parapineal organ presents itself in the form of a long slender fasciculus of nerve fibers which connects the superior commissure with an end-vesicle. The pineal organ shows a highly specialized proximal portion which is large and convoluted. Its cavity communicates with the third ventricle through a narrow canal. The stalk is short and contains a cavity which communicates with the end-vesicle at its distal extremity and also with the proximal por-

tion. In ophidians and chelonians the parapineal organ is entirely absent, and the only element of the pineal organ which persists is the proximal portion which has become converted into a more or less solid structure extending from the roof of the brain dorsad toward the vault of the skull. Similarly, in birds and mammals, the only element of the epiphyseal complex which may be recognized is the proximal portion of the pineal organ. This, as in reptiles, is an organ of considerable density close to the roof of the brain.

From these facts it will be seen that the proximal portion of the pineal organ is the most constant element of the epiphyseal complex, the next in point of frequency being the end-vesicle and stalk of the pineal organ. It would seem, therefore, that the proximal portion of the pineal organ should be considered the fundamental element of the epiphyseal complex, and its structure would, therefore, demand particular attention. That this element in the epiphyseal complex does show a marked tendency toward specialization from the selachians to reptiles, birds and mammals is convincing evidence that this structure is not to be considered a vestige, for were such the case it would scarcely manifest such a definite tendency toward specialization in the processes of evolution.

e. The epiphyso-cerebral index. Not alone is the evidence obtained from the comparative studies of the pineal body in favor of its progressive specialization, but quite as much the facts obtained from ontogenesis of the organ in man. We are fortunate to possess a careful series of observations made by Cutore⁷⁶ in which the weight of the brain as well as the weight of the epiphysis and the hypophysis have been recorded. These statistics are based upon the observations ranging from the newborn to the seventieth year of life. In all, twenty-five brains were studied, and it would seem that from such material, limited though it may be, some light might be shed upon the ontogenetic evolution, upon the epiphysis in its relation to the rest of the brain and also to a recognized endocrinal organ, the hypophysis,

If, as has been frequently maintained, the pineal body is a vestige and of no functional significance, then the tendency for

this organ should be to manifest the signs of regression through the periods of growth in man. Or if, on the other hand, as is thought to be the case by many, the organ is functional only in the fetal and in the early postnatal stages, then the relative weight of the organ to the rest of the brain should show an alteration in its ratio, indicating a progressive retrograde process taking place in its structural elements.

In preparing the figures of Cutore, in order most effectively to assemble the facts necessary to this argument, his cases were grouped in such a way as to constitute five more or less well-defined epochs of life.

1. Six examples of infants in the first year.
2. Five examples of infants in the second year.
3. Six examples of children from 3 to 14 years.
4. Five examples of adults from 15 to 25 years.
5. Three examples of adults from 60 to 70 years.

Epoch	AVERAGE WEIGHT IN GRAMS			INDEX TO BRAIN	
	Brain	Hypophysis	Epiphysis	Hypophysis	Epiphysis
1st	600	0.103	0.031	0.00017	0.00005
2nd	734	0.154	0.055	0.407	0.00007
3rd	1,105	0.262	0.100	0.00024	0.00009
4th	1,218	0.508	0.119	0.00040	0.00009
5th	1,125	0.500	0.130	0.00040	0.00010

It will be seen from these figures that of the three structures considered, the average weight of the epiphysis alone tends to increase constantly through the five epochs differentiated in this study. The brain itself shows a constant increment in weight from the first year to and through the twenty-fifth year, but in the fifth epoch, from sixty to seventy years, there is an apparent decrease of nearly 100 grams in brain weight. The increase in the hypophysis runs parallel to that of the brain, for up to the fourth epoch and including it the increment in weight in the hypophysis is constant, but in the fifth epoch, from sixty to seventy years, the figures seem to indicate a definite decrease in weight. The indices expressing the epiphyso-

cerebral and hypophyso-cerebral ratio bear out this observation and definitely indicate an increase in the proportion between the brain and the epiphysis from the first year of life to the fifth epoch, between sixty and seventy years. If compared with the conditions observed in a definitely known endocrinic organ, the hypophysis, it will be observed that in the first period the weight of the pineal body is 30 per cent of the hypophysis; in the second epoch it is also 30 per cent; in the third epoch it is 35 per cent, an increase which is of much importance and interest in this connection, since it is the general supposition that the gland has its greatest functional activity during this time of life. In the fourth epoch the epiphysis is 22 per cent of the hypophyseal weight, while in the fifth epoch it is 25 per cent.

It should be borne in mind, while considering these figures, that the hypophysis is a compound organ, being made up of a neural portion in addition to an element derived from the oral ectoderm. Its greater weight, therefore, is in part, at least, explained by its non-glandular neural portion, and its total glandular weight would be represented by a fraction only of this total. In this light, the proportion between the epiphysis and the hypophysis would be materially changed, and while it is impossible to say exactly what ratio the neural portion of the hypophysis bears to the glandular portion, it would be safe to assume that the proportion is as 1:2.

From this standpoint, the figures concerning the epiphysis assume more definite significance and would seem to point strongly to the supposition that an organ destined to become regressive would scarcely keep pace so constantly in its weight increment with an organ like the hypophysis of known endocrinic function. The figures cited are suggestive in another sense, namely, they would seem to show that the activity of the pineal organ, should such be accredited to it, does not cease at any particular period of life, and that while there may be reason to believe that the greatest functional activity is present in the third epoch, between the third and fifteenth years, there are good reasons to believe that the organ does not cease to perform its functions even up to the time of old age.

f. Resistance to the encroachment of the corpus callosum. Another characteristic in the ontogenesis of the epiphysis, especially in mammals, speaks against the possibility of its being a vestige and indicates in it a tenacity as a morphologic structure so marked as to suggest the probability of some inherent functional activity. With the advent of the commissural fibers whose massive collection goes to make up the corpus callosum, the mammalian brain takes on a character not observed in the lower forms. The gradual extent of this great interhemispherical commissure in a caudal direction subjects the entire roof of the diencephalon to new conditions. The influence of these new conditions is readily seen in the flattening of the dorsal sac and the reduction of the paraphyseal arch. Yet, even in the instances in which the corpus callosum extends far enough caudad to reach the midbrain, the epiphysis withstands its encroachment and gives evidence of a resistive adaptation against the pressure of the new structure. It seems fair to presume that if there were vested in the pineal body an inherent tendency to retrograde, under the pressure of this newly developed mammalian structure which has so uniformly altered the configuration of other elements in the diencephalic roof-plate, the epiphysis itself must have given evidence of much less resistance or perhaps have succumbed altogether. Its evident effort at adaptation has already been referred to in the classification of the epiphysis in mammals which, according to Cutore,⁷⁶ shows a disposition on the part of the organ to accommodate itself to the presence of the corpus callosum, in some forms being retrocallosal in position, in others supracallosal, and still again maintaining itself in all its morphologic intactness in a distinctly subcallosal position.

If the epiphysis is to be considered a vestige, in view of the morphologic evidence above summarized, it seems apparent that the burden of proof rests with those making the claim that it is a rudimentary structure. To maintain this position they must meet with some well-sustained objections the following established facts:

1. The phyletic constancy of the epiphysis.
2. Its phyletic variations and morphologic specializations.
3. Its relatively greater phyletic constancy with reference to other structures in the pineal region.
4. The phyletic predominance of the proximal portion of the pineal organ.
5. The evidence of its progressive specialization in ophidians, birds, and mammals.
6. The increase of the epiphyso-cerebral index from the earliest stages to the latest periods of life in man.
7. The resistance to the encroachment of a prominent neomorph in the mammalian brain such as is the corpus callosum, whose presence has produced such a marked alteration in the other constituents of the diencephalic roof-plate.

3. Evidence based on the histology of the epiphyseal complex

From the comparative histology of the epiphyseal complex, it becomes evident that specialization in these organs has followed two main lines: First, the structures have either differentiated in the interest of forming visual organs or, second, they have given rise to glandular tissue. In some instances, both of these tendencies may be observed, that is to say, in certain species the differentiation has been in the interest of visual apparatus in one part of the epiphyseal complex, while in another part, distinct glandular tendencies are apparent. It seems advisable for the purpose of obtaining as comprehensive a view as possible of the histology of this portion of the brain to consider the leading features of the finer structure in the pineal body of each of the classes of vertebrates.

Histological evidence in cyclostomes. The striking histological features in cyclostomes are the specializations in both pineal and parapineal organs in the interest of forming visual structures. The end-vesicle of the parapineal as well as the pineal organ presents a retina. This structure in the pineal organ contains cells of a distinct rod-like shape which have, therefore, been designated the *rod cells*. Other cellular elements are also ob-

served in the ventral wall of the end-vesicle which appear to be of a sensory nature. Certain large elements have been recognized in the deeper layers of the tissue and by some authorities are considered to be ganglionic cells. In addition, there are cells of an ependymal nature or modifications of the latter which give the impression of neuroglia tissue. There can be little question that the retina of this organ is well enough defined to deserve that designation. Whether it is actually functional as a visual organ is not altogether clear, for the relation of the pineal eye in cyclostomes to the surface of the head does not afford the most advantageous conditions for a distance receptor.

The end-vesicle of the parapineal organ closely resembles the finer structure in the corresponding part of the pineal organ. There are, however, certain differences which are more those of degree than of kind. The rod cells, such conspicuous elements in the pineal organ, are less well defined in the parapineal organ and so also are the ganglionic cells.

The differentiation of the dorsal wall of the end-vesicle in the pineal as well as in the parapineal organ manifests a tendency toward lens formation, for in both cases the cells in this region are entirely pigment-free and give rise to a translucent structure known as the *pellucida*. Further evidence of the visual adaptation observed in the end-vesicle of the two structures of the epiphyseal complex is the fact that the cavity of the vesicle is filled with a coagulum in the meshes of a delicate synectium, a structure which so closely resembles a primitive vitreous that it may be regarded as analogous, if not homologous to that structure. The presence in the retina of a widely distributed white pigment lends the necessary opacity to the visual membrane. Both end-vesicles contain this pigment; its presence serves further to convey the impression of differentiation along visual lines.

The stalks of both the pineal and parapineal organs bear a certain amount of confirmatory evidence in favor of the belief that the epiphyseal complex in cyclostomes has made the attempt at visual adaptation. Nerve fibers are uniformly ob-

served in the stalks; those coming from the pineal end-vesicle terminate in the posterior commissure, while those seemingly in connection with the parapineal end-vesicle end in the habenular commissure. Some collateral evidence is afforded by the appearance of a parietal cornea, a fiberless tissue which surrounds the pineal and parapineal end-vesicles.

All of these histological facts, based upon the observation of cyclostomes, indicate what may be considered an abortive yet a well-advanced attempt to the formation of two eyes. There is no evidence of glandular formation in any part of the epiphyseal complex in cyclostomes.

Histological evidence in selachians. The characteristics of finer structures, so conspicuous in *petromyzon* and its congeners, is strikingly absent in the next higher order, the selachians. In consequence of the apparent lack of differentiation, the entire parapineal organ is absent, while the pineal organ, although conspicuous for its size, shows no tendency toward the formation of a retina, pellucida, white pigment, or nerve fibers. It is a question whether the pineal organ in selachians should be considered as a primitive organ or as one in a stage of retrogression. The walls of the end-vesicle are made up exclusively of ependymal cells and contain neither spindle nor rod cells. In one form, *Scyllium*, Galeotti¹⁴⁰ described a peculiar appearance of the cells of the end-vesicle which seemed to indicate a secretory function. This conclusion of Galeotti's depends on the appearance of fuchsinophile granules not only in the nuclei of the cells, but scattered diffusely throughout the cytoplasm. Studnicka³⁹¹ also recognized these cells and, while he was unwilling to attribute any definite function to them, he was of the opinion that they could not be secretory in their nature.

It is apparent, therefore; in passing from the cyclostomes to the selachians that there is a striking absence of any visual differentiation or any tendency in this direction, while the presence of certain histological characters in the cells furnishes evidence pointing to a possible glandular formation in the end-vesicle of the pineal organ.

Histological evidence in ganoids. The pineal organ alone develops in ganoids, although in a single form, namely, *Amia*, an abortive parapineal organ makes its appearance. The end-vesicle of the pineal organ in ganoids generally shows some tendency toward the development of a retinal or pellucidal layer, although neither of these is well marked. Studnicka,³⁹¹ as the result of his studies upon ganoids, does not believe that there is any evidence of glandular activity in the end-vesicle or proximal portion which is at all comparable to that of the corresponding parts in selachians. On the other hand, he does not deny that there may possibly be secretory function in the pineal organ of ganoids.

Histological evidence in teleosts. The epiphyseal complex in teleosts differs from that in selachians and ganoids in being a much larger structure. The end-vesicle, furthermore, manifests, in nearly every species, a pronounced tendency toward the convolution of its walls. Not only is this process apparent upon the surface, but section of the vesicle shows it to consist of many folds and diverticula, all of which give to it the appearance of a tubular gland in communication with the third ventricle by means of a long hollow stalk. Galeotti¹⁴⁰ in *Leuciscus* found evidence of secretory activity in the presence of fuchsinophile granules similar to those described by him in selachians. The product of this secretion, he thinks, is delivered to the lumen of the end-vesicle and thus to the ventricle of the diencephalon. Studnicka³⁹¹ observed cells having a similar appearance, and although he did not commit himself definitely as to their nature, he nevertheless expressed the belief that the organ is not entirely a gland. Some nerve fibers of the stalk seem to represent a rudimentary pineal nerve.

Histological evidence in amphibia. The first recognition and description given by Stieda³⁷⁹ in which he called the end-vesicle a frontal subcutaneous gland was evidently a misinterpretation of the conditions in amphibia. The end-vesicle in these animals is fairly well developed, presenting a retina and lens which, although clearly recognizable as such, have attained scarcely more than an abortive state in their development. A long

slender stalk made up almost exclusively of nerve fibers connects this organ with the tip of the proximal portion and constitutes a *nervus pinealis*, in the strict sense, which terminates in the posterior commissure. Galeotti¹⁴⁰ in *Spelerpes fuscus* observed evidence of secretory activity, and this he also found in *Bufo* and *Rana*. The evidence of secretory activity depended upon the appearance of fuchsinophile granules in the cytoplasm. Studnicka,³⁹¹ following Galeotti, found, as he had previously observed in selachians and teleosts, many cells in adult amphibia containing cytoplasmic granules. These he interpreted as cells having a sensory nature. Galeotti based his belief of secretory activity in the pineal organ not merely upon the presence of fuchsinophile granules, but quite as much upon epithelial characters of the cells which were arranged in alveoli, thus giving the end-vesicle and the proximal portion a glandular appearance.

It is apparent from this evidence that amphibia in general present a very abortive attempt toward the formation of retinal and lenticular structures, while the end-vesicle and the proximal portion of the pineal organ both show some evidence of glandular formation.

Histological evidence in reptilia. The finer structure of the epiphyseal complex in the primitive reptiles, including *Sphenodon* and lacertilia, shows that in these forms the parapineal organ attains its highest differentiation as a visual structure. The pineal organ, however, shows no tendency whatsoever in this direction, while, on the other hand, its proximal portion affords many indications that its differentiation has been along glandular lines. In ophidia and chelonia the proximal portion of the pineal organ alone persists and has the appearance of a highly vascular, richly branched, tubular gland. The structure generally known as the parietal eye is a prominent morphological feature in primitive forms of reptiles. It is absent in certain geckonidae and in a number of agamidæ. It attains its greatest differentiation in *Sphenodon* and here presents a well marked retina, lens, vitreous, cornea, and nerve, the latter relating to the ganglion habenulæ. The accessory structures related to the parietal eye, including the cornea, parietal

fossa, and parietal spot, all give evidence of the most complete adaptation for visual function.

Studnicka³⁹¹ believes that the rich capillary blood supply in ophidia speaks in favor of the glandular nature of the organ, its secretion being contributed to the blood stream. In chelonia the cellular elements are mostly ependymal and neuroglial and no nerve cells or nerve elements are found. There is, however, no clear evidence of the secretory nature of the epiphyseal complex in these forms.

The conclusions which may be drawn with reference to reptiles seem to indicate that in the primitive forms the parapineal organ assumes the highest differentiation which it attains as a visual structure. There is some evidence that the pineal organ, even in the animals, manifests a tendency toward glandular formation. In ophidians, however, there can scarcely be a doubt that the proximal portion of the pineal organ is the only element which persists and that it has a definitely glandular structure. This is probably true also in chelonians. The pineal gland in the snake and turtle probably contributes its secretion to the blood stream, but may also impart a portion of it to the cerebrospinal fluid. The more recent reptiles manifest no disposition on the part of the epiphyseal complex to develop any sensory or other type of neural mechanism.

Histological evidence in birds. The conspicuous change in the epiphyseal complex noted in the transition from the primitive reptiles to those of more recent history is strikingly emphasized when the conditions in this region of the brain in birds are reviewed. Here, as in the snakes and turtles, there is complete suppression of the parapineal organ, and that tendency toward the differentiation of a visual apparatus which seems to have reached its height in *Sphenodon*, has so far receded as to leave no indication in birds of its earlier existence. This histological feature of itself is highly significant, but when taken in conjunction with the appearance offered by the finer structure of the pineal body in birds, it seems to set all doubt aside as to the inherent tendency of the epiphyseal complex along its major lines of differentiation. In every species of birds which has so

far come under observation, the differentiation in the pineal body has been in the interest of glandular formation. This evidence is not alone to be found in the character of the cells which compose the body, but even more in the arrangement of these cells whose alveolar patterns constitute irrefutable reasons for regarding the epiphysis as a true gland in birds.

Three types of this gland are found in the avian forms, namely, 1) the tubular type, in which the secretion is delivered to the ventricular system; 2) the endocrinic type, in which the secretion reaches the blood stream, and 3), a mixed type, partaking of the character of each of the former varieties. This evidence afforded by birds is so conclusively in favor of the glandular nature of the epiphysis as to leave no grounds for dispute.

Histological evidence in mammals. It is perhaps in mammals that the most extensive observations have been made with reference to the histology of the pineal body. Indeed, it is in these animals that the greatest variety of opinion has been expressed. It would seem advisable to take into account these different views concerning the histological character of the organ. A large group of investigators adheres to the belief that the pineal body is a blood vascular gland. This group includes, among others, Valentin,⁴⁰³ Faivre,¹¹⁴ Leydig,²³¹ Bizzozero,³¹ Galeotti,¹⁴⁰ Constantini,⁷¹ Cutore,⁷⁶ Galasescu-Urechia,¹³⁷ Krabbe,²¹⁷ Biondi,⁴⁹ and Kidd.²⁰³ Jordan,¹⁹⁹ although he does not advocate the improbability of glandular formation, believes that the organ is essentially neural in its structure.

Several investigators maintain that the epiphysis in mammals consists exclusively of neuroglia. Among these are Cionini,⁶⁶ Edinger,¹⁰³ and Weigert.⁴¹⁸ Mihalkowicz²⁷⁴ believed that the cellular consistency of the pineal body in mammals was exclusively of the ependymal type. Those of another group assert that the epiphysis resembles a lymph gland. Of this opinion are Schwalbe,³⁴⁸ Henle,¹⁷¹ Ellenberger¹¹⁰ Mingazzini,²⁷⁶ and Lord.²⁴⁹

Although it has been frequently claimed by many writers among both the early and recent workers in this field that the epiphysis is a vestige, it is interesting to note that no suggestion of such a possibility is made by any of the authorities just

cited. This is of particular significance because this list includes the names of those who have given the most extensive attention to the histological character of the epiphysis in mammals. Milhalkoviez'²⁷⁴ conception of the histology of the pineal body seems hardly tenable, for it requires little study covering a number of different mammalian forms to become convinced that the cellular elements entering into the epiphysis have nothing in common with the ependymal cells. Even though it may be admitted that a certain number of the cellular constituents of the epiphysis are ependymal in type, it cannot, in the light of our present knowledge, be held that the organ is made up exclusively of this type of cells.

On the other hand, it is not possible to accede to the contention of those who uphold the idea that the epiphysis is similar to lymphatic glands. Not only does the character of the chief cellular elements in the pineal body of mammals make this position seem untenable, but even more does the arrangement of these cells point away from the supposition that this is in any sense lymphoid in character. Few cells in the body are more conspicuous for their histological character than the chief or parenchymatous elements of the mammalian epiphysis. The large and centrally placed nucleus, the extensive and glandular cytoplasm mark these cells so definitely that they may be recognized without any difficulty even in those instances when they become ectopic because of such migration as not infrequently results from tumor formation in the pineal body.

Our own work in this regard is illustrated in the figures which show the character of the pineal gland cells in *Macropus grayi*, *Zalophus*, *Camelus dromedarius*, *Capra hircorius*, *Lepus*, *Simia satyrus*, and in man. Furthermore, our observations in the ontogenesis of the epiphysis in *Felis domestica* and in man, illustrations of which are given in figures 91 and 92, show that in the early stages of differentiation the nuclei of the ependymal cells are so large and the cytoplasm so scanty that they give the impression of lymphoid tissue, but in the later stages the cytoplasm increases so considerably in amount that it is no longer possible to conceive of these cells as lymphoid in char-

acter. In fact, they have in the later periods of fetal and early postnatal life all the appearances usually associated with glandular cells. As compared to the cells in the glandular portion of the hypophysis, the size of the pineal cells is two or three times as great. This difference in size affords a striking point of differentiation in those pathological conditions in which the pineal cells in the course of tumor formation have migrated into and through the posterior lobe of the hypophysis and invaded the pituitary gland. The contrast is so marked as to present no difficulty in the identification of the two varieties of cells.

That the epiphysis is made up of neuroglia cells in large part, if not entirely, has been the contention of several observers. The presence of short, branching fibers in close proximity to the pineal cells has seemed to be the basis for this. On the other hand, if the pineal cells in mammals are to be regarded as neuroglia, it must be granted that they are certainly unlike the neuroglia cells observed in other parts of the central nervous system. Dimitrova,⁹² who makes out such a strong case from her histological study in favor of the neuroglial character of the epiphysis, seems to base her conclusions upon criteria which are not wholly convincing, for the mere presence of demonstrable fibers in the neighborhood of the cells does not of itself indicate that these cells are neuroglial in character. Furthermore, this view neglects to take into account the highly specialized character of the pineal cells. If, on the other hand, it be granted that the cell constituency of the epiphysis is, in major part, neuroglial, this admission would not wholly invalidate the idea that the structure is glandular in nature, for, according to the most recent researches of Nageotte²⁸¹ and Mawas,²⁶³ neuroglia cells contain mitochondria and hence, according to these investigators, should be considered as glandular elements. In this light, the neuroglia throughout the entire nervous system is endowed with secretory function. In general, however, it does not seem necessary to invoke this interpretation of the neuroglia in order to place the pineal body in the class of glandular structures, for the character of the pineal cells is in itself sufficient argument in favor of a function different from that

attributed to neuroglia in the ordinary sense and most in favor of a glandular activity.

The observations of Nicolas,^{283A} later confirmed by Dimitrova,⁹² in which muscle cells were reported as histological elements of the epiphysis in several *Ungulates*, have not been confirmed by any other observers, and some authorities have been categorical in their affirmation concerning the absence of such elements. That the epiphysis may contain nerve cells and nerve fibers is probable, but there is no evidence in mammals of the existence of any neural mechanism in the pineal body.

To consider the epiphysis in mammalia as a vestige in the light of the histological evidence here summarized seems to be an attitude which is wholly untenable, all the more so when this histological evidence points to the fact that the structure is a gland. For in this respect not only is the character of the cells significant, but their arrangement in definite acini, the rich vascular network about these acini, and the trabeculation by means of connective tissue which gives this structure the appearance common to all glands, are also suggestive of this fact.

The final conclusion to be drawn from the histological evidence in the epiphyseal complex of vertebrates would seem clearly to indicate that this structure of the pineal region possesses a pluripotentiality whose fundamental, inherent tendency is in the interest of glandular differentiation and that in a few instances, as in cyclostomes, amphibia, and in primitive reptiles, the parapineal or pineal organ may become further differentiated in the interest of a highly specialized sensory mechanism which has, or has had, visual function.

4. *The relation of the parietal eye to the pineal body*

Much of the difficulty in interpreting the relation between the parietal eye and pineal body arises from a confusion in the use of terms. If by pineal body is meant the epiphysis as it appears in mammals, it becomes relatively simple to discuss the relation between this structure and the third eye of vertebrates. It may perhaps be arbitrary thus to limit a term which

has not always been restricted to the sense here advocated, and yet, as has been previously pointed out, it was from precisely the conditions in mammals that the descriptive conception, pineal body, took origin.

The theory that the pineal body is the vestige of the parietal eye is accepted by many. According to this view, the third eye of vertebrates should be regarded as primordial and the pineal body an arrested development in the attempt to reach such differentiation. The evidence, however, is by no means conclusive, for, as has previously been shown, the entire epiphyseal complex springs from a region which is fundamentally glandiferous, while only in a very few instances is a tendency toward sensory differentiation recognizable in it. By far the great majority of vertebrates manifest in the epiphyseal complex no tendency whatsoever toward the development of any neural mechanism. This would seem to indicate that the tendency for the epiphyseal complex to develop visual structures is a secondary and not a primordial character. Furthermore, if the pineal body was in any true sense the vestige of the parietal eye, it would seem almost inevitable that the organ should contain remnants indicative of visual specialization. The absence of such evidence at least raises a reasonable doubt that the pineal body had at any time possessed visual function. The almost universal absence of true ganglionic cells as well as the lack of nerve fibers, which may be regarded as belonging to some category other than those of the sympathetic system, would seem to call into question the possibility of the pineal body ever having participated in the formation of a neural mechanism. This may be considered negative evidence. There remains to be mentioned, however, the significant fact that the pineal body in all of the higher vertebrates manifests a tendency to differentiate along lines which cannot be interpreted as in the interests of visual function. As has been previously shown, the differentiation which does occur in the higher reptiles, birds, and mammals gives rise to glandular tissue. From these facts it seems possible to conclude that the pineal body is not a vestige of the parietal eye.

The supposition advanced by Hertwig¹⁷⁵ and others that the pineal process in birds and mammals undergoes metamorphoses which give rise to an organ of a glandular or follicular structure has little to support it. Peytoureau^{305B} maintained that in the evolution through the vertebrate phylum the pineal body has become partly atrophic and partly metamorphosed in such a way as to cause a modification in the connection with the nerve centers. Ultimately, it has taken on the characters of an epithelial organ, in fact, a highly vascular gland represented in the higher mammals by the pineal gland and its peduncle. To assume that an actual process of metamorphosis, in a literal sense, from a visual organ to a glandular structure, is responsible for the differences between the parietal eye and the pineal gland seems wholly unsatisfactory. If, however, this view has reference to a deflection in the ontogenetic process, as a result of which the pineal anlage in certain forms, instead of giving rise to a visual structure, produces a gland, there may be some justification of ascribing these changes to metamorphosis. Yet, even in this sense, to attribute the differences between the parietal eye of *Sphenodon* and the pineal gland of the bird to such an indefinite process of alteration does little more than apply a term to the process without offering an explanation for it.

Certain investigators, among them Rabl-Rückhard,³²² Ahlborn,² and Spencer,³⁶⁸ regard the pineal body as an unpaired parietal eye which, in many classes, for example, reptiles, appears to be tolerably well preserved, but in most vertebrates is in a process of degeneration. This theory goes a step further than that which regards the pineal body as a vestige. According to the former view, the pineal differences between such forms as possess a parietal eye and those in which no such structure develops are attributed to a process of degeneration, while the latter theory ascribes them to an arrested development. Evidence of degeneration in the higher vertebrates is difficult to discern. The figures already cited in reference to the human pineal gland (p. 158) makes it hard to believe that a retrograde process is present, even in the late periods of life. The appearance of brain sand in itself is not sufficient to justify such a con-

clusion. Furthermore, in no instance is there the slightest indication that the pineal body in the higher vertebrates contains histological elements which may, in any sense, be regarded as degenerated products of the visual structures in the parietal eye. That the pineal body in birds and mammals may be interpreted as the result of a degenerative process affecting the parietal eye seems wholly untenable in the absence of any convincing signs of such degeneration and also because the weight of evidence furnished by many facts indicates the glandular nature of the organ.

It is interesting in this connection to give the opinion of Bashford Dean,⁸³ in which that author expresses doubt concerning the connection between the epiphysis and the median eye of vertebrates.

The evidence as to the presence primitively of a median eye in fishes is certainly far from satisfactory. It is possible that fishes and amphibia may in their extant forms have lost all definite traces of this ancestral (visual) organ on account of some peculiar conditions of their aquatic living. On this supposition evidence of its presence might be sought in the pineal structures of the earliest palaeozoic fishes, whose terrestrial kindred and probable descendants may alone have retained the living conditions which fostered its functional survival. It is of interest, accordingly, to find that in a number of fossil fishes the pineal region retains an outward median opening whose shape and position suggest that it may have contained an optic capsule. If the median eye existed in these forms it may well have been passed along in the line of descent through the early amphibia (where substantial traces of a parietal foramen occur, e.g. *Cricotus*) to the ancestral reptiles.

The evidence that the median opening in the head-shields of ancient fishes actually enclosed a pineal eye is now felt by the present writer to be more than questionable. The remarkable pineal funnel of the Devonian *Dinichthys* is evidently to be compared with the median foramen of *Ctenodus* and *Palaeodophus*, but this can no longer be looked upon as having possessed an optic function, and thus practically renders worthless all the evidence of a median eye presented by fossil fishes.

It must, for the present, be concluded accordingly that the pineal structures of true fishes do not tend to confirm the theory that the epiphysis of the ancestral vertebrates was connected with a median unpaired eye. More probably it was connected with the innervation of the sensory canals of the head.

The theory that the epiphysis in the true fishes is connected with the innervation of the sensory canals of the head adds a

new interpretation concerning the function of the pineal organ. It is not our purpose to discuss this hypothesis, but we do desire to emphasize the improbability of the pineal body in higher vertebrates being the vestige of any neural mechanism. This opinion is based on the general absence of definitely neural elements in the pineal gland other than those connected with the sympathetic system.

Terry^{3,92} in *Opsanus* could find no evidence to support Dean's supposition that the epiphysis of true fishes is connected with the innervation of the sensory canals of the head. He was, moreover, unable to discover the evidence in the teleost to support the theory that the pineal body is an ocular organ either degenerate or rudimentary.

The portion of the epiphyseal complex which becomes specialized as the eye-like structure of the lower vertebrates constitutes the end-vesicle. This end-sac may be part of the pineal or of the parapineal organ, depending upon the form in which it occurs. In every instance the appearance of visual elements is limited to the end-vesicle. Not only is the structure notable for the eye-like character of its histological elements, but it occupies a position with reference to the brain and also to the skull which further serves to distinguish it. Its connection with the roof of the interbrain is by means of an attenuated stalk, which gives the entire structure the appearance of a long appendage of the brain. The junction of the stalk with the roof is usually not a direct one since the connection in most forms is accomplished through the proximal portion. These several parts, which may be recognized in the pineal and parapineal organs of certain classes, should be regarded as separate morphologic entities. The proximal portion has little in common with the end-vesicle. Its position and histological characters mark it as strikingly different. Its only actual relation with the vesicle is one of continuity through the stalk. This continuity may, in some cases, be almost lost or maintained only by a small filament of nerve fibers. Such, for example, is the condition in amphibia, a class which, perhaps, affords the most conspicuous instance of the morphologic distinction between the

end-vesicle and the proximal portion of the pineal organ. Were it not for a slender fasciculus of nerve fibers these two portions of the epiphyseal complex would appear as independent entities. As it is, both parts are well differentiated and well developed, one as an eye-like organ, the other with some of the characters of a gland. This distinction between the end-vesicle and proximal portion should not be underestimated. It not only shows how remote the relationship between the two parts may be, but also gives an added prominence to the proximal portion. This latter part has already been shown to be the most constant element in the epiphyseal complex, while the end-vesicle is much more limited in its occurrence.

The process by means of which the end-vesicle and proximal portion of the pineal organ are rendered so distinctive in amphibia takes on a new phase in *Sphenodon* and lacertilia. In these forms the necessity for the end-vesicle to assume visual characters has apparently ceased, and this structure together with the stalk is evidently in a state of involution. The contrary, however, is true of the proximal portion which has taken on not only more conspicuous dimensions, but also more pronounced glandular characters. In the ophidians, in birds, and in mammals the process of involution in the end-vesicle and stalk has been carried to its final stage. No trace of the end-vesicle or the stalk is to be found in any of the orders above lacertilia. The proximal portion, on the other hand, in ophidians, birds, and mammals gains prominence because of its glandular structure.

The process here described from amphibia to mammals clearly demonstrates the progressive involution of the eye-like end-vesicle and the gradual ascendancy of the glandular proximal portion. At one end, namely in amphibia, the end-vesicle and proximal portion must be regarded as coördinate in prominence. At the other end, i.e., in ophidia, the proximal portion is pre-eminent because of the disappearance of the end-vesicle. This phenomenon can best be interpreted on the basis of a pluri-potentiality in the anlage of the epiphyseal complex, of such a nature that the adaptive possibility for the development of a

parietal eye or of a gland, or the simultaneous development of both of these, is given in their origin.

According to this conception, it is not possible to consider the parietal eye as primordial; it seems far more likely that it is an adaptive modification developing in response to special requirements in a limited number of forms. The proximal portion, on the other hand, maintains its entity with such marked persistency throughout the series that it seems possessed of the more primitive characters. This is emphasized when the proximal portion is considered in connection with the other glandular derivatives of the dienecephalic roof. Embryologically, in those instances in which both an eye-like end-vesicle and a glandular proximal portion develop the anlage of these parts must have been pluripotential. This is equally true in the instances in which one portion of the epiphyseal complex, as, for example, the parapineal organ, develops an eye-like structure while the pineal organ develops a marked tendency to glandular formation. Such an interpretation of the pluripotentiality in the epiphyseal anlage when applied to the various orders reveals the following conditions:

In cyclostomes the epiphyseal anlage seems to contain elements which are exclusively engaged in the differentiation of eye-like structures which form the pineal and parapineal eyes.

In selachians, ganoids, teleosts, and dipnoians the epiphyseal anlage has completely lost its potentiality to differentiate as a visual organ, and while there may be some debate as to the character of the adult structures, there is some evidence which points to their glandular nature.

In amphibia both potentialities are present in the pineal organ. In *Sphenodon* and lacertilia both potentialities are also present, but in these instances the parapineal portion of the epiphyseal complex gives rise to the eye-like structure while the pineal portion develops glandular characters. In ophidians and all the higher vertebrates the potentiality for the development of visual structures is lost.

Even accepting the probability of this dual potentiality, it should be borne in mind that the median eye-like structure may

in no instance signify a functionally active visual organ. In all cases the attempt to develop a median eye may represent but the abortive and partially attained differentiation of far remote primitive ancestors in which such an eye was functionally active. Its persistence into extant forms even as an abortive structure may thus be taken to indicate the transmitted potentiality of the epiphyseal complex to develop a visual organ.

The theory that the two elements in the epiphyseal complex, namely, the pineal and parapineal organs, represent a pair of parietal eyes similar to those of invertebrates, has little to recommend it. The hypothesis of Dendy⁵⁶ that the ancestral vertebrates were possessed of such a pair of visual organs, while interesting, is based upon too few facts in living vertebrates to justify its acceptance. After considering the several theories concerning the relation of the parietal eye to the pineal body, we have come to the conclusion that none of them is adequate to explain all of the facts. But with a full appreciation of the investigation already devoted to this subject we desire to offer a new interpretation which to us seems more tenable. According to our views, there is no direct relation between the parietal eye and the pineal body, but each is of itself an adaptive modification answering the demands for, or representing an inherent impulse toward, the development of a parietal eye, on the one hand, or of a glandular organ, on the other. In other words, the epiphyseal anlage is pluripotential in its derivatives.

5. The phylogenetic significance of the parietal eye with reference to vertebrates and invertebrates

Much has been written concerning the significance of the parietal eye as one of the possible indices in the evolution from invertebrates to vertebrates. Although little evidence bearing upon this point has been presented in the general consideration of this work, the subject seems of enough interest to warrant the inclusion of the views of certain investigators who have devoted some attention to this matter.

Mathias Duval⁹⁸ in 1888 brought to a conclusion a notable series of lectures with the statement that the history of the pineal gland has played an important rôle in the study of homologies in the structure of the vertebrates and invertebrates. He further states that the situation of the pineal body in relation to the nervous system of vertebrates and in comparison with the oesophageal ring in invertebrates gives the structure a new significance. From this it might be possible to determine one of the clues which should reveal how the vertebrates resulted from the successive transformation of the invertebrates.

Several years prior to this observation, Ahlborn² suggested that the parietal organ was comparable to the unpaired eye of amphioxus and tunicata, while Rabl-Rückhard³²² was of the opinion that an homology existed between the pinal organ and the parietal eye of arthropoda. Baudouin¹⁵ expressed the view that of the proto-vertebrates, larval ascidians possess an unpaired eye which, however, disappears in the adult. This organ is situated immediately beneath the epidermis and consists of a retina, a lens, and a pigment layer. It is derived from the cerebral vesicle and supposed to be the vestige of a transitory eye which previously existed in adult ascidians. Indeed, in pyrosomes this unpaired eye is well developed in the adult, possessing a retina, lens, and optic nerve. There are no lateral eyes in these invertebrates, and hence the unpaired eye must functionate as a visual organ. In tunicates there exists both the paired and unpaired eyes. In amphioxus there is a pigmentary patch placed above a dilation of the brain, but one is not justified in considering this the homologue of the unpaired eye in tunicates.

Peytoureau^{308B} held the opinion that the pineal eye exists in vertebrates in a degenerated state only. In extant forms of the tunicates it still exists as a functional organ, occupying in these animals almost exactly the same position and having the same disposition as in lizards and amphibia. In tunicates there is an unpaired eye and two paired eyes which he believes functionate simultaneously, the unpaired eye being comparable to the parietal eye of the lizard and amphibia not only because of

its position, but also because of its anatomy and connections. He is of the opinion that the unpaired eye is more ancient than the lateral eyes. This is the more probable since the ancestors of the vertebrates were mon-ophthalmic, examples of which are to be found in the pyrosomes which have but a single median eye. Subsequently, the lateral eyes make their appearance in tunicates and these functionate simultaneously with an unpaired eye. Peytoureau^{305B} gives six diagrams showing the degenerative process from the median eye of pyrosomes to the epiphysis in the higher mammals, as follows: 1, In pyrosomes, a simple vesicle with a lens; 2, in larval urodela there is a vesicle with nerve connections and nerve centers but no lens; 3, in chamaeleon there is only an epithelial vesicle which has no connections or neural characteristics; 4, in batrachians the organ is a detached epithelial cluster having no connection with the central nervous system; 5, in cyclodus the organ is a gland attached to the third ventricle by means of a peduncle; 6, in mammals and birds it is connected with the brain by a solid pedicle but presents no vesicle.

Gaskell,¹⁴⁶ in his summary concerning the evidence of the organs of vision and their bearing upon the origin of vertebrates, writes as follows:

The most important discovery of recent years which gives a direct clue to the ancestry of the vertebrates is undoubtedly the discovery that the pineal gland is all that remains of a pair of median eyes which must have been functional in the immediate ancestor of the vertebrate, seeing how perfect one of them still is in *Ammocœtes*. The vertebrate ancestor, then, possessed two pairs of eyes, one pair situated laterally, the other median. In striking confirmation of the origin of the vertebrate from Palæostracans it is universally admitted that all the Eurypterids and such-like forms resembled *Limulus* in the possession of a pair of median eyes, as well as a pair of lateral eyes. Moreover, the ancient mailed fishes, the Ostracodermata, which are the earliest fishes known, are all said to show the presence of a pair of median eyes as well as of a pair of lateral eyes. This evidence directly suggests that the structure of both the median and lateral vertebrate eyes ought to be very similar to that of the median and lateral arthropod eyes. Such is, indeed, found to be the case.

The retina of the simplest form of eye is formed from a group of the superficial epidermal cells, and the rods or rhabdites are formed from the cuticular covering of these cells; the optic nerve passes from these cells to the deeper-lying brain. This kind of retina may be called

a simple retina, and characterizes the eyes, both median and lateral, of the scorpion group.

In other cases a portion of the optic ganglion remains at the surface, when the brain sinks inwards, in close contiguity to the epidermal sense-cells which form the retina; a tract of fibres connects this optic ganglion with the under-lying brain, and is known as the optic nerve. Such a retina may be called a compound retina and characterizes the lateral eyes of both crustaceans and vertebrates. Also, owing to the method of formation of the retina by invagination, the cuticular surface of the retinal sense-cells, from which the rods are formed, may be directed towards the source of light or away from it. In the first case the retina may be called upright, in the second inverted.

The evidence of the optic apparatus of the vertebrate points most remarkably to the derivation of the Vertebrata from the Palæostraca.

Gaskell, in this argument, seems to have lost sight of his well-known contention that the roof of the brain in vertebrates is to be considered the dorsal wall of the invertebrate stomach. The stress which he laid upon this relation, to which he gave further emphasis by calling attention to the glandular appearance of the roof-plate in *Ammocetes*, does not coincide well with his idea that the pineal body is primordially a portion of a neural mechanism. He, of course, admits that the pineal eye in vertebrates must be considered as resulting from a neural invasion of the roof-plate, yet from his contention this roof-plate is primitively the dorsal wall of the stomach, and neural derivatives appearing in it must be due to a secondary neural invasion and, therefore, cannot be considered primordial.

In a word, by holding the pineal eye to be fundamentally neural in structure he did injury to his own theory concerning the evolution of the vertebrates.

Patten,³⁰³ in considering the significance of the parietal eye, gives the following conclusions:

The parietal eye of vertebrates is homologous with the parietal eye of such arthropods as *Limulus*, scorpion, spiders, phyllopods, copepods, trilobites, and merostomes, but not with the frontal stemmata or other ocelli of insects.

In the arthropods, various stages in the evolution of a cerebral eye are shown in detail, from functional eyes on the outer margin of the cephalic lobes, to a median group of ocelli enclosed within a tubular outgrowth of the brain roof.

The most primitive type of a parietal eye is seen in the nauplii of phyllopo^ds and entomostraca, where the eye is a pear-shaped sac, opening by a median pore or tube on the outer surface of the head. In the higher arachnids, the process of forming an embryonic eye vesicle merged with the process of forming a cerebral vesicle, the external opening of the forebrain vesicle and that of the parietal eye tube, forming a common opening or anterior neuropore.

The parietal eye of arthropods is an important visual organ until the lateral eyes, which represent a later product, are fully developed. It may then diminish in size and activity, but it rarely, if ever, wholly disappears.

During the revolution of vertebrates from arachnids, there was a considerable period during which the lateral eyes were adjusting themselves to their new position inside the brain chamber, and when they were in functional abeyance. At this period, ancestral vertebrates were mon-oculate, that is they were dependent solely on the parietal eye, which had come to them from their arachnid ancestors as an efficient and completely formed organ.

When the lateral eyes again became functional, the parietal eye began to decrease in size and effectiveness.

The parietal eye is the only one now present in tunicates. In the oldest ostracoderms, like *Pteraspis*, *Cyathaspis*, *Palæaspis*, the lateral eyes are absent, or at least do not reach the surface of the head, the only functional one being the parietal eye, which is of unusual size.

In the lampreys we see the same conditions, the parietal eye being very well developed in the larvæ, while the lateral eyes are deeply buried in the tissues of the head, and useless. During the transformation, the lateral eyes again become functional, and the parietal begins to atrophy, finally losing many of its structural details and its function, although still retaining very nearly its original form.

All the theories advanced concerning the significance of the parietal eye as an index to the process of evolution from the invertebrates to the vertebrates have their great value in the suggestions which they offer. To accept any of them without further evidence seems unwise at the present time. It is possible to conceive of the median eye of invertebrates as analogous to the parietal eye of vertebrates. It is, however, a long step for the most part without the intervening support of evidence to maintain that these structures are homologous. In fact it seems out of the question to establish any such basis of comparison until this subject of homology in the invertebrate and vertebrate brain is on much firmer ground than it is to-day. It is evident that nothing short of the definite establishment of an

invertebrate pineal region of the brain can satisfy the requirements in this field of homology. Not only must such an area in its general outlines be recognized, but the demonstration must be given that every element entering into it has its homologue in the vertebrate brain. For this reason it seems impossible at present to accept any other view than that the median eye in invertebrates and the parietal eye of vertebrates are analogous. The supposition that they are homologues, however suggestive and stimulating, can hardly be regarded, at present, as other than speculative morphology.

S. SUMMARY AND CONCLUSION

I. The pineal region is preponderatingly glandiferous in its derivatives. The morphogenetic impulse imparted by such a gland-forming area could not fail to have a profound influence upon one of its constituents, the epiphysis.

II. *a.* The pineal body cannot be a vestige from the evidence based upon its gross morphology, for the following reasons:

1. The phyletic constancy of the epiphysis in the vertebrate phylum.

2. Its variations and morphologic specializations.

3. Its relatively greater phyletic constancy with reference to other structures in the pineal region.

4. The gross evidence of its progressive specialization in ophidians, birds, and mammals.

5. The increase in the epiphysio-cerebral index, from the earliest stages to the latest periods of life in man.

6. The resistance to the encroachment of a prominent neomorph in the mammalian brain, that is, the corpus callosum, which has produced such marked alterations in the other constituents of the diencephalic roof-plate.

b. The pineal gland cannot be considered a vestige in the light of the histological evidence, since the tendency toward specialization is definitely in the interest of glandular formation in ophidians, chelonians, birds, and mammals. Ontogenetically, in two forms at least, in *Felis domestica* and man, the develop-

ment of the pineal body follows the general lines of glandular differentiation. The pineal body is, therefore, a glandular structure and as such, is necessary in some way to metabolism.

III. The histology of the organ gives clear evidence that the epiphyseal complex of vertebrates possesses a pluripotentiality whose fundamental inherent tendency is in the interest of glandular differentiation, but in a few instances, as in cyclostomes, amphibia, and in primitive reptiles, the pineal organ may become further differentiated in the interest of a highly specialized sensory mechanism which has, or has had, visual function. As a gland, it may in some cases, contribute its secretion to the cerebrospinal fluid, but in the higher vertebrates, as in ophidians, chelonians, birds, and mammals, it is an endocrinic organ, contributing the products of its secretion to the blood stream.

IV. *a.* There is no direct relation between the parietal eye and the pineal body, but each is of itself an adaptive modification answering the demands for, or representing, an inherent impulse toward the development of a parietal eye, on the one hand, or a glandular organ, on the other.

b. The pineal body as it appears in mammals cannot be regarded as the vestigial or metamorphosed degenerated or atrophic residuum of the parietal eye in vertebrates.

V. The phylogenetic significance of the parietal eye in vertebrates as the homologue of the median eye in invertebrates should be accepted with much reservation. Until such time as the homology between the vertebrate pineal region and some corresponding area of the invertebrate brain is much more firmly established than at present, the parietal eye as an index in the evolution of the vertebrates from the invertebrates has but little value.

The authors desire to acknowledge their great indebtedness and to express their appreciation to Professor George S. Huntington for his assistance in the preparative of this monograph. They also wish to express their thanks to Professor M. Allen Starr for his liberality in supplying the means which have made publication possible.

BIBLIOGRAPHY

- 1 *ACHUECARRO, N., AND SACRUTAN, J. M. 1912 Sobre la histologia de la glandula pineal humana. *Rev. Clinica de Madrid*, 8, p. 336, 2 plates.
- 2 AHLBORN, F. 1883 Untersuchungen über das Gehirn der Cyclostomen. *Zeitschrift f. wiss. Zool.*, Bd. 39, S. 331.
- 3 1881 Über die Bedeutung der Zirbeldrüse (Glandula pinealis; Conarium. Epiphysis cerebri). *Ibidem*, Bd. 60.
- 4 ANDRAL 1829 *Precis d'Anat. Pathologique*. Paris.
- 5 ANGLADE AND DUCOS 1908 Note preliminaire sur l'anatomie et la physiologie de la glande pineale. *Soc. d'Anat. et de Physiol. de Bordeaux*. Process verbal officiel de la séance du 14 Décembre.
- 6 1912 Sur les pédoncules de la glande pineale. *Jour. de Méd. de Bordeaux*, 42, p. 772.
- 7 1912 Les plaques et les formations lacunaires dans la glande pineale. *Jour. de Méd. de Bordeaux*, 42, p. 772.
- 8 ARSAKY Cited by Legros, Thésé de Paris, 1873.
- 9 BAER Über Entwicklungsgeschichte der Thiere. Beobachtung und Reflexion I, S. 130, Königsberg.
- 10 BALFOUR, F. M. 1878 A monograph on the development of the Elasmobranch fishes. London, p. 177.
- 11 1881 *Handbuch der vergleichenden Embryologie*. Deutsch v. B. Vetter, Jena.
- 12 BALFOUR, F. M., AND PARKER 1882 On the structure and development of *Lepidosteus osseus*. *Phil. Trans. Royal Soc.*, vol. 1, Pt. 11, London (1878).
- 13 BARALDI 1884 Due parole sulla filogenia del corpo pituitario e del pineale. Pisa.
- 14 BAUDELOT, E. 1870 Étude sur l'anatomie comparée de l'encéphale des Poissons. *Mem. de la Soc. des Sciences Natur. de Strassbourg*, T. 6, 2 Livr., p. 98.
- 15 BAUDOIN, J. 1887 La glande pineale et le troisième oeil des Vertébrés. *Progres. Medical*, No. 50-51.
- 16 BAUHNUS 1616 *Institutiones anatomicae*. Francoforté.
- 17 BEARD, J. 1887 The parietal eye in fishes. *Nature*, vol. 36, p. 246.
- 18 1889 Morphological studies, No. I. The parietal eye of cyclostome fishes. *Quart. Jour. of Micr. Science*, vol. 29.
- 19 BEAUREGARD, F. 1881 Encephale et nerfs craniens du *Ceratodus Forsteri*. *Jour. de l'Anat. et de la Physiologie*.
- 20 BECHTEREW, WM. 1900 Les voies de conduction du cerveau et de la moelle. Paris.
- 21 BÉRANECK, E. 1887 Über das Parietalauge der Reptilien. *Jena. Zeitschrift*, Bd. 21.
- 22 1891 Sur le nerf de l'oeil pariétal. *Archives des Sciences Physiques et Naturelles*, Ser. 3, T. 26.
- 23 1892 Sur le nerf parietal et la morphologie du troisième oeil des vertébrés. *Anat. Anz.*, p. 674. Oct., 1892. *Centralb. f. die Gesamte Wissensch. Anatomie*.

* This reference not obtainable, added for completeness.

- 24 BÉRANECK, E. 1893 Contribution a l'embrogénie de la glande pinéale des Amphibiens. *Revue suisse de Zoologie*.
- 25 1893 L'individualité, de l'oeil parietal. Reponse á M. de *Klinchowsstroem*. *Anat. Anz.*, Bd. 6.
- 26 1893 *Anat.*, *Anz.*, Bd. 8, p. 669.
- 27 BERNARD, H. M. 1897 An attempt to deduce the vertebrate eyes from the skin. *Quart. Jour. of Micr. Science*, vol. 39.
- 28 BICHAT 1802 *Traité d'Anat. descriptive*. T. 3, Paris.
- 29 BIEHL Citato da Poppi-L'ipofisi cerebrale, faringea e la ghiandola pineale in patologia.
- 30 BIZZOZERO, G. 1868 Sul parench'ima della ghiandola pineale. *R. Ist. Lomb. di Sc. et Lett. Milano*.
- 31 1871 Beitrag zur Kenntnis des Baues der Zirbeldrüse. Vorläufige Mitteilung. *Zentralb. f. Med. Wissensch.*, No. 46, Jahrg. 9.
- 32 1871 Sulla struttura del parenchima della ghiandola pineale umana. *R. Ist. Lomb. di Sc. et Lett. Milano*.
- 33 1862-1879 *Opera Scient. Milano*, 1905, 1, p. 175.
- 34 BLANC, H. 1900 Epiphysis and paraphysis in *Salamandra atra*. *Arch. Sciences Phys. Nat.*, vol. 10, p. 571.
- 35 1900 Sur le development de l'épiphysse et de la paraphysse chez la *Salamandra atra*. *Compt. Rend.*, 83. Sess. *Helv. Soc.*
- 36 BOJANUS, L. H. 1819-1821 *Anatome testudinis europeae*. Vilnae.
- 37 BORN, G. 1889 Über das Scheitelauge. *Jahrg. d. Schles. Gessell. f. Vaterländische Kultur*, Bd. 67.
- 38 BORRICH AND HARDER Cited by Legros. *Thésé de Paris*, 1873.
- 39 BRAEM, P. 1898 Epiphysis und Hypophysis von *Rana*. *Zeitschr. f. Wiss. Zool.*, Bd. 63.
- 40 BRANDT, E. K. 1829 (*Lacerta agilis*) *Medizinische Zoologie*, Bd. 1, p. 260.
- 41 BUGNION, E. 1897 Recherches sur le développement de l'épiphysse et de l'organ pariétal chez les Reptiles (*Iguana*, *Lacerta*, *Coluber*). *Compt. Rend. Trav. 80. Sess. Soc. Helv. Sc. Nat.*, p. 56.
- 42 BURCKHARDT, R. 1890 Die Zirbel von *Ichthyophis glutinosus* und *Protopterus annectens*. *Anat. Anz.*, Jahrg. 6.
- 43 1891 Untersuchungen am Hirn und Geruchsorgan von Triton und *Ichthyophis*. *Zeitschr. f. Wiss. Zool.*, Bd. 52.
- 44 1892 Das Zentralnervensystem von *Protopterus annectens*. Berlin.
- 45 1893 Die Homologien des Zwischenhirndaches und ihre Bedeutung für die Morphologie des Hirns bei niederen Vertebraten. *Anat. Anz.*, Jahrg. 9.
- 46 1894 Die Homologien des Zwischenhirndaches bei Reptilien und Vögeln. *Anat. Anz.*, Jahrg. 9, no. 10
- 47 1894 Der Bauplan des Wirbeltiergehirns. *Morpholog. Arbeiten* von G. Schwalbe, Bd. 4.
- 48 BURDACH 1819-1826 *Vom Baue und Leben des Gehirns*. Leipzig.
- 49 BIONDI, C. 1912 Histologische Beobachtungen an der Zirbeldrüse. *Zeit. f. d. Ges. Neurol. in Psychiat.*, Bd. 9, S. 43.

- 50 CAMERON, JOHN 1903 On the origin of the pineal body as an amesial structure. *Anat. Anz.*, Bd. 23, S. 394.
- 51 1903 Same in extenso. *Proc. of the Roy. Soc. of Edinburgh*, vol. 3, p. 340.
- 52 1904 On the presence and significance of the superior commissure throughout the Vertebrata. *Jour. of Anat. and Physiol.*, vol. 38.
- 53 CAJAL, RAMON Y. 1895 Apuntes para el estudio del bulbo raquideo cerebelo y origen de los nervios encefalicos. *Anales de la sociedad Espanola de historia natural*.
- 54 1901 *Texture del sistema nervioso del hombre y de los vertebrados*. T. 2, Madrid.
- 55 CAMPER *Demonstrat. Anat. patholog.*, S. 12.
- 56 CARRIÈRE, J. 1885 *Die Schorgane der Tiere, vergleichend anatomisch dargestellt*. München, S. 205
- 57 Neuere Untersuchungen über das Parietalorgan. *Biol. Zentralbl.*, Bd. 9.
- 58 CARRINGTON, P. G. 1890 On the pineal eye of *Lamna cornubica* or Porbeagle shark. *Proceed. of Roy. Phy. Soc.*, Sess. 90-91.
- 59 CARUS, C. G. 1814 *Versucheiner Darstellung des Nervensystems*. Leipzig, S. 149.
- 60 CATTIE, J. T. 1882 *Recherches sur la glande pineale des Plagiostomes, des Ganoides et des Teleostiens*. *Arch. de Biol.*, T. 3.
- 61 1883 Über das Gewebe der Epiphyse von Plagiostomen, Ganoiden und Teleostiern. *Zur Verteidigung*. *Zeitschr. f. wissen. Zool.*, Bd. 39.
- 62 CHARPY 1894 *Eucéphale* in Poirier. *Traité d'Anat. Humaine*. T. 3 Paris.
- 63 CHAUSSIER Cited by Legros. *Thésé de Paris*, 1873.
- 64 CHAUVEAU, A. 1885 *Comparative anatomy of the domesticated animals*. Translated. New York, p. 681.
- 65 CIACCIO 1867 *Intorno allo minuta fabbrica della pelle della Rana esculenta*. Palermo. Cited by Leydig, 1891, vol. 3, p. 443.
- 66 CIONINI, A. 1885 Sulla struttura della ghiandola pineale. *Riv. sperim. di freniatria a di Med. Legale*, T. 11. Reggio Emilia, Fasc. 1.
- 67 1886 Sulla struttura della ghiandola pineale. *Ibidem* T. 12, Fasc. 4.
- 68 1888 La ghiandola pineale e il terzo occhio dei vertebrati. *Riv. sperim. di freniatria*, vol. 14. *Neurol. Zentralbl.*, 1887, No. 20.
- 69 CLARKE 1860 *Structure of the pineal gland*. *Proceed. of the Royal Soc.*, vol. 11.
- 70 CONDORELLI-FRANCAVIGLIA 1895 *L'encefalo dell' Helmaturus dorsalis Gray*. *Boll. d. Soc. Romana per gli studi Zoologici*. T. 4.
- 71 CONSTANTINI 1910 *Intorno ad alcune particolarita di struttura della ghiandola pineale*. *Pathologica*.
- 72 CRUVEILHIER *Anatomic pathologique*.
- 73 CRUVEILHIER AND SEE 1877 *Traité d'Anat. Descriptive*. T. 3.
- 74 CUTURE, G. 1909 *Di una particolare formazione prepineale nel Bos taurus L.* *Arch. di Anat. e di Embriologia*. T. 3.

- 75 CUTORE, G. 1912 Alcune notizie sul corpo pineale del *Macacus sinicus* L. e del *Cercopithecus griseus viridis* L. *Fol. neuro-biol.*, T. 6, No. 4, p. 267.
- 76 1910 Il corpo pineale di alcuni mammiferi. *Arch. Ital. d. Anat. e di Embriol.*, T. 9, p. 402.
- 77 CUVIER 1845 *Lecons d'Anatomie Comparée*, T. 3, p. 135.
- 78 DA FANO 1907 Osservazioni sulla fine struttura della nevroglia. Ricerche fatte nel Laboratorio di Anatomia normale della R. Università di Roma, etc., T. 12, Fasc. 2-3, Roma.
- 79 DARKSCHEWITSCH, L. v. 1886 *Anatomie der Glandula pinealis*. *Neurol. Zentralb.*, Bd. 5.
- 80 1886 Einige Bemerkungen über den Faserverlauf in der hinteren Commissur des Gehirns. *Neurol. Zentralb.*, Bd. 5.
- 81 DEAN, BASHFORD 1888 The pineal fontanelle of Placodermata and catfish. 19. New York.
- 82 1895 The early development of Amid. *Quart. Jour. Micr. Science*, vol. 38.
- 83 1895 Fishes, living and fossil. New York, p. 53.
- 84 DEBIERRE 1894 *La Moelle épinière et l'encéphale*. Paris.
- 85 DEJERINE 1895 *Anatomie des centres nerveux*. Paris.
- 86 DENDY, A. On the structure, development and morphological interpretation of the pineal organs and adjacent parts of the brain in the Tuatara (*Sphenodon punctatum*). *Philos. Trans. Soc. London.*, Series B, vol. 201.
- 87 1899 On the development of the parietal eye and adjacent organs in *Sphenodon* (Hatteria). *Quart. Jour. of Micr. Science*, vol. 42, pt. 2, p. 111.
- 88 DENDY AND NICOLLS 1910 On the occurrence of a mesocoelic recess in the human brain, and its relation to the subcommissural organ of the lower vertebrates. *Anat. Anz.*, Bd. 37.
- 89 DESCARTES 1649 *Les Passions de l'Ame*. Art. 31 et 32. Amsterdam.
- 90 DEXTER, F. 1902 The development of the paraphysis in the common fowl. *Amer. Jour. Anat.*, vol. 2.
- 91 DIEMERBROECK 1633 *Anatome corporis humani*. Lugduni.
- 92 DIMITROVA, Z. 1901 Recherches sur la structure de la glande pineale chez quelques mammifères la Nevraxe, T. 2, Fasc. 3.
- 93 DIONIS 1706 *Anatomie de l'Homme*, 5 edit.
- 94 DISDIER 1778 *Esposit exact. ou Tabl. anat. des diff. part du corps humain*. Paris.
- 95 DOHRN, A. 1875 *Der Ursprung der Wirbeltiere und das Prinzip des Funktionswechsels*. Leipzig, s. 87.
- 96 1882 Studien zur Urgeschichte des Wirbeltierkörpers. *Mitteilungen aus der Zool. Station zu Neapel*. Bd. 4.
- 97 DUGES, A. 1829 *Mémoire sur les espèces indigènes du genre Lacerta*. *Annal. des Sciences Naturelles*. T. 16, p. 337.
- 98 DUVAL, M. 1888 Le troisième oeil de Vertébrés. *Jour. de Micrographie*, Paris, T. 12, pp. 250, 273, 308, 336, 368, 401, 429, 459, 500, 523; T. 13, pp. 16, 42, 76.

- 99 DUVAL AND KALT 1889 Des yeux pinéaux multiples chez l'orvet. *Compt. Rend. de la Soc. de Biol. a Paris.* T. 1, No. 6.
- 100 DUVERNEY 1761 *Oeuvres Anatomiques.*
- 101 ECKER, A. 1857-1859 *Icones Physiologicae.* Pl. 21, fig. 7.
- 102 1872 Gehirn eines Cebus apella. *Arch. f. Anthropol.,* Bd. 5.
- 103 EDINGER, L. 1892 Untersuchungen in der vergleichenden Anatomie des Gehirns. II. Das Zwischenhirn der Selachier und der Amphibien. *Abhandlungen der Senckenberg. Naturf. Ges. in Frankfurt a/M.*
- 104 1897 *Lexioni sulla struttura degli organi nervosi centrali dell'uomo e degli animali.* Trad. Ital. Milano.
- 105 1900 *Vorlesungen über den Bau der Nervösen Zentralorgane.* Leipzig.
- 106 1909 *Bau und Verrichtungen des Nervensystems.* Leipzig.
- 107 EDWARDS (MILNE-EDWARDS) 1829 *Recherches zoologiques pour servir a l'histoire des Lézards.* *Annales des Sciences Natur.,* T. 16, p. 50.
- 108 EILERS, E. 1878 Die Epiphyse am Gehirn der Plagiostomen. *Zeit. f. Wiss. Zool.,* Bd. 30, Supplement.
- 109 d'ERCHIA, F. 1896 Contributo allo studio della volta del cervello intermedio e della regione parafisaria in embrioni di pesci e mammiferi. *Monit. Zool. Ital., Ann.* 7.
- 110 ELLENBERGER 1887 *Vergleichende Histologie der Haussäugethiere.*
- 111 ESTEVES AND BEATTI 1909 Klinische und Anatomische Studien eines Epithel. der Zirbeldrüse. *Arch. de Pedagogia de la Plata.*
- 112 EYCLESHYMER, A. C. 1892 Paraphysis and Epiphysis in *Amblystoma.* *Anat. Anz., Jahrb.* 7.
- 113 EYCLESHYMER AND DAVIS 1897 The early development of the epiphysis and paraphysis in *Amia.* *Jour. of Compt. Neurol.,* vol. 2.
- 114 FAIVRE, E. 1855 *Observations sur le Conarium.* *Comp. Rend. Soc. di Biol., Paris.*
- 115 1857 *Étude sur le conarium et les plexus choroides chez l'homme et les animaux.* *Annales des Sciences Natur., Ser 4., T.* 7.
- 116 FAVARO 1903 Intorno al sacco dorsale del pulvinar pineale nell'encefalo dei Mammiferi. *Monitore Zoologico Ital.,* T. 14.
- 117 1904 Di un organs speciale della volta diencefalica in *Bos taurus.* *Ibidem,* T. 15.
- 118 1904 Le fibre nervose prepineale e pineali nell'encefalo dei mammiferi. *Arch. di Anat. e di Embriologia,* T. 3.
- 119 FISH, P. A. 1895 The central nervous system of *Desmognathus fusca.* *Jour. Morph.,* vol. 10, no. 1.
- 120 FLATEAU-JACOBSON 1899 *Handb. u. vergl. Anat. d. Centralnervensystems der Säugetiere.* Berlin.
- 121 FLESCU, MAX 1887 Über das Scheitelauge der Wirbeltiere. *Mitteilungen der Naturf. Ges. in Bern.*
- 122 1887 Struktur des zentralen Nervensystems des Sympathikus usw. In *Ellenberger: Vergleichende Histologie der Haussäugetiere.* Berlin S. 749.
- 123 1888 Über die Deutung der Zirbel bei den Säugetieren. *Anat. Anz.,* Bd. 3.

- 124 FLECHSIG 1883 Plan des menschlichen Gehirns. Leipzig.
- 125 FORSTER 1858 Virchow's Arch. f. path. Anat., 13, p. 271.
- 126 FOSTER AND BALFOUR 1876 Grundzüge der Entwicklungsgeschichte der Tiere.
- 127 FRANCOITTE, P. 1887 Contribution à l'étude du développement de l'épiphysse et du troisième oeil des reptiles. Bull. de l'Acad. Royal de Belgique, No. 12.
- 128 1888 Recherches sur le développement de l'épiphysse. Arch. de Biol., T. 8, p. 757.
- 129 1894 Note sur l'oeil pariétal l'épiphysse, la paraphysse et les plexus choroïdes du troisième ventricule. Bull. de l'Acad. Roy. de Belgique, No. 1.
- 130 1896 Contribution à l'étude de l'oeil pariétal de l'épiphysse et de la paraphysse chez les Lacertilia. Mem. cour. de l'Acad. Roy. de Belgique, T. 55.
- 131 FREY 1867 Handbuch der Histologie und Histochemie des Menschen. Leipzig, S. 650.
- 132 FÜLLIQUETTE, G. 1886 Recherches sur le cerveau du Protopterus annectens. Recueil Zool. Suisse.
- 133 FUNKQUIST, H. 1912 Zur Morphogenie und Histogenese des Pinealorgans bei den Vögeln und Säugetieren. Anat. Anz., Jena, Bd. 17, s. 3.
- 134 FÜRBRINGER, MAX 1902 Morphologische Streitfragen. Morpholog. Jahrbücher, Bd. 30, S. 130.
- 135 GAGE, S. P. 1893 The brain of *Diemyctylus viridescens*. The Wilder Quart. Century Book, Ithaca, N. Y.
- 136 1895 Comparative morphology of the brain of the soft-shelled turtle (*Amida mutica*) and the English sparrow (*Passer domesticus*). Proceed. of the American Microscop. Soc., vol. 17.
- 137 GALASESCU AND URECHIA 1910 Les cellules acidophiles de la glande pineale. Compt. Rend. Hebdom. des Seances de la Societe de Biol., T. 68.
- 138 GALEN 1576 De usu partium—L. VIII c. 3. Galeni omnia quae exstant opera. T. 1, 5 ed., Venetiis.
- 139 1679 De Anat. administ. L. IX c. 3 Hippoc. et Galeni opera. T. 4. Lutetiae, Parisorum.
- 140 GALEOTTI, G. 1896 Studie morfologiche e citologiche della volta del diencefola in alcuni vertebrati. Rivista di Patol. nervosa e mentale. T. 2.
- 141 GALL Cited by Legros. Thésis de Paris. 1873.
- 142 GANSER 1882 Vergleichend-anatomische Studien über das Gehirn des Maulwurfs. Morph. Jahrb., Bd. 5.
- 143 GARMAN, H. 1896 Some notes on the brain and pineal structures of *Polyodon folium*. Bull. Illinois State Laborat. of Nat. Hist., vol. 4.
- 144 GARJANO, C. 1909 Lo sviluppo dell'occhio pineale. Giornale Internazionale delle Science Med., T. 31, p. 505.
- 145 GASKELL, W. H. 1890 On the origin of vertebrates from a crustacean-like ancestor. Quart. Jour. of Micro. Science, vol. 31.
- 146 1908 The origin of vertebrates. London, p. 117.

- 147 GAUPP, E. 1898 Zirbel, Parietalorgan und Paraphysis. *Ergebnisse der Anat. und Entwicklungsgeschichte von Merkel und Bonnet*, Bd. 7.
- 148 1904 Lehre vom Integument und von den Sinnesorganen. *Das Stirnorgan. Eckers und Wiedersheims Anat. des Frosches*. Braunschweig, S. 758.
- 149 GERLACH, F. 1917 Untersuchungen an der Epiphysis von Pferd und Rind. *Anat. Anz.*, Bd. 50, No. 3-4.
- 150 GIANNELLI 1905 Contributo allo studio comparativo delle formazioni del tetto del cervello intermedio in base a ricerche praticate sul loro sviluppo in embrioni di Rettile (*Seps chalcides*) e Mammiferi (*Sus scropha domestica* e *Lepus cuniculus*). *Arch. Ital. di Anat. e di Embriol.*, T. 4, Firenze.
- 151 GOETTE, A. 1873 Kurze Mitteilungen aus der Entwicklungsgeschichte der Unke. *Archiv. f. Mikr. Anat.*, Bd. 9.
- 152 1875 Die Entwicklungsgeschichte der Unke. Leipzig.
- 153 GORONOWITSCH, N. 1888 Das Gehirn und die Cranialnerven von *Acipenser ruthenus*. *Morph. Jahrbuch.*, Bd. 13.
- 154 GÖTTSCHE, M. C. 1835 Vergleichende Anatomie des Gehirns der Grätenfische. *Muller's Archiv. f. Anat. u. Phys. Jahrb.*, p. 456.
- 155 GRAAF, H. W. de 1886 Zur Anatomie und Entwicklung der Epiphyse bei Amphibien und Reptilien. *Zoolog. Anz.*, Jahrb. 9.
- 156 GRANEL 1887 Le glande pinéale, Anatomie comparée et fonctions. *Gaz. Hebd. des Sciences Nat. de Montpellier*, p. 361.
- 157 GRATIOLLET Anatomie Comparée du Système nerveux. T. 2, p. 73, (Leuret et Gratiolet).
- 158 GRAVENHEARST 1829 Reptilia musei Zoologici Vratislaviensis. Fasc. 1, Leipzig (Tab. 7).
- 159 GRIEB, A. 1901 Contributione allo studio dell'organo parietale del *Podiceps muralis*. *Monitore Zoolog. Italiano*, Ann., 12, No. 8.
- 160 GUILLOT, N. 1884 Exposition anatomique de l'organisation du centre nerveux dans les quatre classes d'animaux vertébrés. Paris.
- 161 GUNZ 1753 De lapillis glandulae pinealis in quinque mente alien Lipsia.
- 162 GUTZEIT 1896 Ein Teratom der Zirbeldrüse. *Inag. Dissert.*, Königsberg.
- 163 HACKEL *Archiv. f. Anat. und Physiol.*, Bd. 16, S. 259.
- 164 HAGEMANN 1872 Über den Bau des Conarium. (Dissert. Göttingen.) *Arch. f. Anat. und Phys.*, S. 429.
- 165 HALLER, ALBRECHT 1768 De Cerebro avium et piscium. *Operum anatomici argumenti minorum*. T. 3. Lausannae.
- 166 HALLER, BELA 1898 Vom Bau des Wirbeltiergehirns. I. *Salmo* und *Seyllium*. *Morph. Jahrb.*, Bd. 26.
- 167 1900 II. *Emys*. Bd. 28.
- 168 HANDRICK 1901 Zur Kenntnis des Nervensystems und der Leuchtorgane von *Argyrolepeus hemigymnus*. *Bibliotheca Zool.*, Heft 32.
- 169 A HANITSCH, P. 1888 On the pineal eye of the young and adult of *Anguis fragilis*. *Proc. Liverpool Biol. Soc.*, vol. 3, p. 78, 1 plate.
- 169 B HEITZMANN 1896 *Anat. umana, descrip. e Top. Trad. Ital.*
- 169 C HECKSCHER, W. 1890 Bidrag til kundskaben om Epiphysis cerebri udviklings historie. Kjöbenhavn.

- 170 HARDER Cited by Legros, Thésé de Paris, 1873.
- 171 HENLE, J. 1871 *Nervenlehre*. In *Handbuch der Anatomie*, Braunschweig. Bd. 3, Abt. 2, S. 288.
- 172 A 1879 *Handbuch der Nervenlehre*.
- 172 B 1887 *Handbuch der Systematischen Anat. des Menschen*. *Nervenlehre*.
- 173 HENRICH, G. 1896 *Untersuchungen über die Anlage des Grosshirns beim Hühnchen*. *Sitzungsber. d. Ges. f. Morphologie und Physiologie in München*, Bd. 12.
- 174 HERDMAN, W. A. 1886 *Recent discoveries in connection with the pineal and pituitary body*. *Proc. Liverpool Biolog. Soc.*, vol. 1.
- 175 HERTWIG, O. 1908 *Text-book of the embryology of man and mammals*. London, p. 435.
- 176 HERRICK, C. L. 1891 *Topography and histology of the brain of certain reptiles*. *Jour. Comp. Neur.*, vol. 1, 3.
- 177 1891 *Contributions to the morphology of the brain of bony fishes*. *Jour. Comp. Neur.*, vol. 1.
- 178 HERRICK, C. J. 1891 *Topography and histology of the brain of certain ganoid fishes*. *Jour. Comp. Neur.*, vol. 1.
- 179 HILL, C. 1891 *Development of the epiphysis in Coregonus albus*. *Jour. Morph.*, vol. 3.
- 180 1894 *The epiphysis of Teleosts and Amia*. *Jour. Morph.*, vol. 9.
- 181 1900 *Two epiphyses in a four-day chick*. *Bull. of the Northwestern University Med. School*. Nov., 1900.
- 182 HIS, W. 1868 *Untersuchungen über die ersten Anlage des Wirbelthierleibes*. Leipzig.
- 183 1892 *Zur allgemeinen Morphologie des Gehirns*. *Archiv. f. Anat. und Physiol., Anat. Abteilung*.
- 184 1893 *Vorschläge zur Einteilung des Gehirns*. *Archiv. f. Anat. und Phys., Anat. Abteilung*.
- 185 HOFFMANN, C. K. 1884 *Zur Ontogenie der Knochenfische*. *Archiv. f. Mikr. Anat.*, Bd. 23.
- 186 1886 *Weitere Untersuchungen zur Entwicklung der Reptilien*. *Morph. Jahrbuch.*, Bd. 11, S. 192.
- 187 1890 *Epiphyse und Parietalauge*. *Bronns Klassen und Ordnungen des Tierreiches*. Bd. 6, Abt. 3, S. 1981. Leipzig.
- 188 HOLLARD, H. 1837 *Precis d'Anat. Comparée en tableau de l'organisation consistées dans l'ensemble de la série animale*. Paris, p. 586.
- 189 HOLT, E. W. L. 1891 *Observations upon the development of the Teleostean brain, with especial reference to that of Clupea harengus*. *Zoolog. Jahrbücher, Abt. f. Anat. und Ontog. d. Tiere*, Bd. 4.
- 190 HUMPHREY, O. D. 1894 *On the brain of the snapping turtle (Chelydra serpentina)*. *Jour. Comp. Neur.*, vol. 4.
- 191 HUXLEY, T. H. 1876 *On Ceratodus forsteri*. *Proc. Sc. Meeting Zool. Soc. London*.
- 192 HYRTL 1889 *Lehrb. d. Anat.*, 9 Aufl., p. 777.
- 193 JACKSON, H., AND CLARKE, E. 1875 *The brain and cranial nerves of Echinorhynchus spinosus with notes on the other viscera*. *Jour. of Anat. and Phys.*, vol. 10.

- 194 JOHNSTON, J. B. 1901 The brain of *Aeipenser*. Zool. Jahrb., Anat. Abt., Bd. 15.
- 195 1902 The brain of *Petromyzon*. Jour. Comp. Neur., vol. 12.
- 196 1909 The morphology of the forebrain vesicle in Vertebrates. Jour. Comp. Neur., no. 19.
- 197 JORDAN, H. E. 1911-1912 Histogenesis of pineal body of sheep. Amer. Jour. Anat., vol. 12, p. 249.
- 198 1911 The microscopic anatomy of the epiphysis of the opossum. Anat. Rec., Phil., vol. 5, p. 325.
- 199 1912 Results of recent studies of the mammalian epiphysis cerebri. Trans. Am. Micr. Soc., 31, p. 231.
- 200 JULIN, C. 1887 De la signification morphologique de l'épiphyse des Vertébrés. Bull. Scient. du Nord de la France, T. 10, 2 series.
- 201 KARCHER, J. B. 1733 De glanduli pineali lapides ents. Ref. Index-Catalogue of the Library of the Surgeon-General's Office. U. S. A., vol. 13, p. 378.
- 202 KERR, GRAHAM 1903 The development of *Lepidosiren paradoxa*. Pt. III. Quart. Jour. Micr. Sc., vol. 46.
- 203 KIDD, L. J. 1913 The pineal body; a review. Review of Neurology and Psychiatry, vol 2, p. 1.
- 204 KINGSBURY, B. F. 1895 On the brain of *Neoturus maculatus*. Jour. Comp. Neur., vol. 5.
- 205 1897 The encephalic evaginations in Ganoids. Jour. Comp. Neur., vol. 7.
- 206 KLINCKOWSTROEM, A. de 1892 Untersuchungen über den Scheitelfleck bei Embryonen einiger Schwimmvögel. Zool. Jahrb., Abt. f. Anat. u. Ontog., Bd. 5.
- 207 1893 Le premier développement de l'oeil pariétal l'épiphyse et de nerf pariétal chez *Iguana tuberculata*. Anat. Anz., Jahrb. 8.
- 208 1893 Die Zirbel und das Foramen parietale bei *Callichthys (asper und littoralis)*. Anat. Anz., Jahrb. 8.
- 209 1894 Beiträge zur Kenntnis des Parietalauges. Zool. Jahrb., Abt. f. Anat. u. Ontog. d. Tiere.
- 210 KÖLLIKER, A. VON. 1850 Mikroskopische Anatomie des Menschen. Bd. 2, Leipzig.
- 211 1879 Entwicklungsgeschichte des Menschen und der höheren Tiere. Zweite Auflage, Leipzig.
- 212 1887 Über das Zirbel oder Scheitelaug. Sitzungsber der Würzburger phys.-med. Gesellsch., Münchener mediz. Wochenschr., Bd. 34, S 210.
- 213 1896 Handbuch der Gewebelehre des Menschen. Leipzig.
- 214 KOLLMAN 1907 Handatlas der Entwicklungsgeschichte der Menschen. Zweiter Teil.
- 215 KORSCHULT, E. 1886 Über die Entdeckung eines dritten Auges bei Wirbeltieren. Kosmos, Heft 3.
- 216 KRABBE, K. H. 1915 Histologie studies of the pineal gland. Histologehi Andersogelsis over corpus pineale. Biblio f. Laeges, Kibin 107, p. 175.
- 217 1911 Sur la Glande Pineale chez l'Homme. Nouvell Iconograph. de la Salpêtrière. T. 24, p. 257.

- 218 KRAUSE, W. 1876 Allgemeine und mikroskopische Anatomie. Hanover.
 219 1868 Die Anatomie des Kaninchens. Leipzig.
 220 1884 Die Anatomie des Kaninchens. Leipzig.
 221 KRAUSHAAR, R. 1885 Entwicklung der Hypophysis und Epiphysis bei
 Nagetiären. Zeitschrift. f. Wiss. Zool., Bd. 41.
 222 KUPFFER, D. VON 1887 Über die Zirbeldrüse des Gehirns. Münch. med.
 Wochenschrift, Bd. 34, S. 205.
 223 1893 Die Entwicklung des Kopfes von *Acipenser sturio*. Studien
 zur vergleichenden Entwicklungsgeschichte des Kopfes der Kranio-
 ten. Heft 1, München.
 224 1894 Die Entwicklung des Kopfes von *Ammocoetes planeri*. Idem.,
 Heft 2.
 225 1 00 Zur Kopfentwicklung von *Bdellostoma*. Idem., Heft 4.
 226 1904 Die Morphogenie des Zentralnervensystems. In Handbuch
 der vergleichenden u. experimentellen Entwicklungslehre der Wirbel-
 tiere. Edited by O Hertwig. Lief. 13-16.
 227 LEBERT Anat. pathol., 2, p. 40.
 228 LEGGE, F. 1896 Sullo sviluppo del occhio pineale del *Gongylus ocellatus*
 Forsk. Boll. R. Acad. med. Roma. Anno 22.
 229 LEGROS 1873 Étude sur la glande pinéale et ses divers états pathologiques.
 Thésé de Paris.
 230 LENDENFELD, R. 1888 Die Leuchtorgane der Fische. Biolog. Zentralb.,
 Bd. 7.
 231 LEYDIG, F. 1853 Anatomisch-histologische Untersuchungen über Fische
 und Reptilien. Berlin.
 232 1868 Traité d'Histologie Comp. de l'Homme et des Animaux, p. 199.
 233 1868 Über Organe eines sechsten Sinnes, zugleich ein Beitrag zur
 Kenntnis des Feineren Baues der Haut bei Amphibien und Reptilien.
 Nova Acta Acad. Leopold. Carol., Bd. 34.
 234 1872 Die in Deutschland lebenden Arten der Saurier.
 235 1887 Das Parietalorgan der Wirbeltiere. Zool. Anz., Jahrg. 10.
 236 1889 Das Parietalorgan der Reptilien und Amphibien kein Sinnes-
 werkzeug. Biolog. Zentralb., Bd. 8, S. 706.
 237 1890 Das Pari talorgan. Zweite vorläufige Mitteilung, Biolog.
 Zentralb., Bd. 10, S. 278.
 238 1891 Das Parietalorgan der Amphibien und Reptilien. Abhand-
 lungen der Senckenbg. Gesellsch., Frankfurt a/M., Bd. 16.
 239 1896 Zur Kenntnis der Zirbel und Parietalorgane. Abhandlungen
 der Senckenbg. Naturf. Ges. Frankfurt a/M., Bd. 16.
 240 1897 Zirbe und Jacobsonsche Organe einiger Reptilien. Archiv. f.
 Mikr. Anat., Bd. 50.
 241 LESSONA, M. 1880 Sulla ghiandola frontale degli anfibi anuri. Atti
 della Reale Acad. d. Science di Torino. T. 15.
 242 LIEBERKÜHN, N. 1871 Über die Zirbeldrüse. Sitzungsber. d. Gesellsch.
 zur Beförderung d. Naturwiss. zu Marburg. No. 4, June 29.
 243 LOCY, W. A. 1893 The derivation of the pineal eye. Anat. Anz., Bd. 9,
 S. 169.

- 244 LOCY, W. A. 1894 The optic vesicles of Elasmobranchs and their serial relation to other structures on the cephalic plate. *Jour Morph.*, vol. 9.
- 245 1894 The midbrain and the accessory optic vesicles. *Anat. Anz.*, Jahrb. 9.
- 246 1894 Metamerie segmentation in the medullary folds and embryonic rim. *Anat. Anz.*, Jahr. 9.
- 247 1895 Contribution to the structure and development of the vertebrate head. *Jour. Morph.*, vol. 11.
- 248 LONGET, F. A. 1847 *Anatomie und Physiologie des Nervensystems d. Menschen und der Wirbeltiere*. Bd. 1, Leipzig.
- 249 LORD, J. R. 1899 The pineal gland; its normal structure, some general remarks on its pathology; a case of syphilitic enlargement. *Transact. of the Pathological Society of London*, vol 50, p. 18.
- 250 LOTHUISSEN 1894 Über die Stria medullaris Thalami optici und ihre Verbindungen. *Vergleichend=Anat. Studie, Anatomische Hefte*.
- 251 LUDWIG *Script. Neurol. Memories*, T. 4.
- 252 LUSCHKA 1867 *Die Anatomie des Menschen*. Tübingen.
- 253 LUYS 1865 *Recherches sur le systeme nerveux cerebrospinale*. Paris.
- 254 McINTOSH AND PRINCE 1891 Development and life histories of food and other fishes. *Transact. R. Soc. Edinburgh*, vol. 35.
- 255 McKAY, E. J. 1888 Development and structure of the pineal eye in *Hinulia* and *Grammatophora*. *Proceed. of the Linnean Society of New South Wales*, 2 ser., vol. 3, p. 332.
- 256 MAJENDIE 1828 *Memoir physiologique experimentale et pathologique*. T. 7, p. 211.
- 257 1795 *Encefalotomia di Aleuni Quadrupli*. T. 4, p. 31.
- 258 MALACARNE Cited by Legros, *Thésé de Paris*, 1873.
- 259 MARBURG, O. 1908-1909 Zur Kenntniss der normalen und pathologischen Histologie der Zirbeldrüse die Adipositas cerebialis. *Arbeiten a.d. Neurol. Institut. a. d. Wien. Univ. Leipzig und Vienna*, Bd., 17, S. 217.
- 260 1912 Die Klinik der Zirbeldrüsen Krankheiten. *Ergeb. Med. u. Kinderh.*, Bd. 10, S. 146.
- 1908 Adipositas cerebialis. *Wien. Med. Wehnschr.*, 58, 2617.
- 261 MARSHALL 1861 On the brain of a young chimpanzee. *Nat. Hist. Review*.
- 262 1893 *Vertebrate embryology*. London.
- 263 MAWAS, J. 1910 Note sur la structure et la signification glandulaire probable des cellules neuroglie du Systeme nerveux central des Vertébrés *Science et Memoir de la Soc. de Biol.* vol. 69, p. 45.
- 264 MAYER, F. 1897 Das Zentralnervensystem von *Ammocoetes*. I. Vorder Zwischen und Mittelhirn. *Anat. Anz.*, Jahrb. 13.
- 265 1864 Über den Bau des Gehirns der Fische. *Nova Acta Akad. Leopold.*, Bd. 30.
- 266 MECKEL, J. F. 1815 Versuch einer Entwicklungsgeschichte der Zentralthelle des Nervensystems in den Säugetieren. *Deutsch. Arch. f. Phys.*, Bd. 1, S. 644.
- 267 1765 1795 *Observationes anatomicae de glandula pineali, septo lucido, et origine paris septimi nervorum cerebri*. *Scrip. Neurol. Memor. Select. Lipsiae*. 9-10.

- 268 MEHNERT, E. 1898 Biomechanik. Erschlossen aus dem Prinzip der Organogenese. Fischer.
- 269 MELCHERS, F. 1899 Über rudimentäre Hirnanhangsgebilde bei Gecko (Epipara und Hypophyse). Zeitschr. f. Wiss. Zoll., Bd. 67.
- 270 MESTREZAT, W. 1912 Le liquide cephalo-rachidien, normal et pathologique. Paris.
- 271 MEYNERT, T. 1877 Vom Gehirn der Säugetiere. Strickers Handb. der Lehre von Geweben, Bd. 2, S. 743.
- 272 MICLUCHO MACLAY, N. VON 1870 Beiträge zur vergleichenden Neurologie der Wirbeltiere. Leipzig.
- 273 MIDDLEMAAS 1895 A heavy brain. The Lancet, p. 1432.
- 274 MIHALKOVICZ, V. 1874 Entwicklung der Zirbeldrüse. Zentralb. f. med. Wiss., No. 17.
- 275 1877 Entwicklungsgeschichte des Gehirns. Leipzig, S. 94.
- 276 MINGAZZINI 1889 Organi nervosi. Roma.
- 277 MINOT, C. S. 1901 On the morphology of the pineal region, based upon its development in Acanthias. Amer. Jour. Anat., vol. 1.
- 278 MÖLLER, J. VON 1890 Einiges über die Zirbeldrüse des Chimpanse. Verhandl. d. naturf. Gesellsch. in Basel, S. 755.
- 279 1890 On the anatomy of the chimpanzee brain. Archiv f. Anthropologie, Bd. 17.
- 280 MÜLLER, JOHANNAS 1838 Vergleichende Neurologie der Myxinoiden. Verhandl. der Akad. d. Wissenschaften in Berlin.
- 281 NAGOTTE, J. 1910 Phénomènes de Sécrétion dans le protoplasma des cellules neuroglique de la substance grise. Seances et Memoir de la Soc. Biol., T. 68, p. 1068.
- 282 NEUMEYER, L. 1899 Studie zur Entwicklungsgeschichte des Gehirns der Säugetiere. Festschrift zum 70. Geburtstag von Carl von Kupffer.
- 283A NICOLAS, M. 1891 Sur le troisième oeil der Vertébrés.
- 283B 1900 Note sur la présence des fibres musculaires striées dans la glande pinéale de quelques mammifères. Comp. Rend. de la Soc. de Biol., Paris, T. 2, p. 876.
- 284 OBERSTEINER 1893 Anatomie des centres nerveux. Trad. franc.
- 285 ORIBASIVS 1554 Synopsis ad Eustathium filium. Libri IX, quibus tota Medicina in compendium redacta continetur. I. B. Rosario interprete. Venetiis.
- 286 ORR 1899 Note on the development of Amphibians, chiefly concerning the central nervous system. Quart. Jour. of Micr. Science, vol. 29.
- 287 OSBORN, H. F. 1883 Preliminary observation upon the brain of Amphiuma. Proceed. Philadelphia Acad. Nat. Sc.
- 288 1884 Preliminary observations upon the brain of Menopoma and Rana. Idem.
- 289 1889 Contributions to the internal structure of the Amphibian brain. Jour. Morph., vol. 2, no. 1.
- 290 1887 A pineal eye in the Mesozoic Mammalia. Science, N. Y., p. 92.
- 291 OSTROUMOFF, F. VON 1887 Zur Frage über das dritte auge der Wirbeltiere 96. Beilage zu den Protokollen der naturf. Ges. an der kais. Universität zu Kasan, 1-13.

- 292 OWEN 1837 Structure du cerveau des Marsupiaux. *Annales des Sciences Naturelles*, 2 series, T. 8, Zoologie, Paris.
- 293 1881 On the homology of the conario-hypophyseal tract or the so-called pineal and pituitary glands. *Linnean Soc. Jour. Zool.*, p. 131.
- 294 1866 *Anatomy of the Vertebrates*, vol. 1, p. 280, London.
- 295 OWSIANNIKOW, P. 1888 Über das dritte auge bei *Petromyzon fluviatilis*, nebst einigen Bemerkungen über dasselbe Organ bei anderen Tieren. *Memoires de l'Acad. Imper. de St. Petersburg*, Ser. 7, T. 36.
- 296 1890 Über das Parietalauge von *Petromyzon*. *Travaux de la Soc. des Naturalistes de St. Petersburg*, Sect. Zool., T. 15, Pt. 1.
- 297 1890 Übersicht der Untersuchungen über das Parietalauge bei Amphibien, Reptilian und Fischen. *Revue des sc. naturelles de la soc. des naturalistes de St. Petersburg*, Annee 2, No. 2.
- 298 PAPPENHEIMER 1910 Über Geschwülste des Corpus pineale. *Virchow's Archiv f. path. Anat.*, p. 122.
- 299 PARDI 1909 Per la storia e la migliore conoscenza dei clasmatociti di Ranvier—*Atti d. societa Toscana di Scienze Naturali Memorie*, T. 25.
- 300 PARISINI Cited by Cutore in il Corpo pineale di alcuni Mammiferi. *Arch. Ital. di Anat. e. di Embriol.*, T. 9, p. 402, 1910.
- 301 PARKER, JEFFERY 1892 Observations on the anatomy and development of *Apteryx*. *Phil. Transact. of the Roy. Soc. of London for the year 1891*, vol. 182.
- 302 PARKER, J., AND HASWELL, W. A. 1897 *A text-book of zoology*, vol. 2, London.
- 303 PATEN, WILLIAM 1890 On the origin of vertebrates from Arachnids. *Quart. Jour. of Mier. Science*, vol. 31, p. 340.
- 304 1894 On the morphology and physiology of the brain and sense organs of *Limulus*. *Quart. Jour. of Mier. Science*, vol. 35, p. 76.
- 305 PAWLOWSKY 1874 Über dan Faserverlauf in der hinteren Gehirneommissur. *Zeitschr. f. wiss. Zool.*, Bd. 24.
- 306 PERRAULT Cited by Legros, *Thésé de Paris*, 1873.
- 307 PETTITT AND GERARD 1902-03 Sur la fonction secretoire et la morphologie des plexus Choroides. *Arch. d'Anat. Micos.*, 5.
- 308A PEYTOUREAU, S. A. 1886 La glande pinéale et le troisième oeil des Vertébrés. Bordeaux, 1887. *Thésé de Bordeaux*, No. 95, p. 68, 142 fig.
- 308B 1889 La glande pinéale et la troisième oeil des Vertébrés. *Thésé de Paris*.
- 309 POLEJAEFF, N. 1891 Über das Scheitelauge der Wirbeltiere in seinem Verhältnis zu den Seitenaugen. *Revue Scientifique de la Societe des Naturalistes de St. Petersburg*, No. 5, p. 178.
- 310 POLVANI, F. 1913 Studio anatomico della glandula pineale umana *Rassun di studio psich'at.* Siena, T. 3, p. 3.
- 311 PRENANT, A. 1893 Sur l'oeil pariétal accessoire. *Anat. Anz.*, Jahrb. 9, No. 4.
- 312 1895 Les yeux pariétaux accessoires d'*Anguis fragilis* sous le rapport de leur situation, de leur nombre et de leur fréquence. *Bibliographie anatomique* T. 1.

- 313 PRENANT, A. 1896 *Eléments d'embryologie de l'homme et des vertébrés.* Livre deuxième, Paris, p. 566.
- 314 1896 *L'appareil pineal de Scincus officianalis et de Agama bibroni.* Bull. de la soc. des sciences de Nancy.
- 315 PRENANT AND BOUIN 1911 *Traite d'Histologie.* T. 2, Paris.
- 316 RABL-RÜCKHARD, H. 1878 *Das Zentralnervensystem des Alligator.* Zeitschrift f. wiss. Zool., Bd. 30.
- 317 1880 *Das gegenseitige Verhältnis der Chorda. Hypophysis und des mittleren Schädelbalkens bei Haifischembryonen.* Morpholog. Jahrb., Bd. 6.
- 318 1882 *Zur Deutung und Entwicklung des Gehirns der Knochenfische.* Archiv. f. Anat. und Physiol., Anat. Abteilung.
- 319 1883 *Das Grosshirn der Knochenfische und seine Anhangsgebilde.* Archiv. f. Anat. und Physiol., Anat. Abteilung.
- 320 1884 *Das Gehirn der Knochenfische.* Biolog. Zentralblatt, Bd. 4, Deutsch med. Wochenschr., No. 33.
- 321 1884 *Weiteres zur Deutung des Gehirns der Knochenfische.* Biolog. Zentralblatt. Bd. 3.
- 322 1886 *Zur Deutung der Zirbeldrüse (Epiphyse).* Zoologischer Anzeiger, Jahrb. 9.
- 323 1894 *Einiges über das Gehirn der Riesenschlange.* Zeitschrift f. wiss. Zool., Bd. 54.
- 324 REAL COLUMBI 1559 *De re Anatomica.* Venetiis.
- 325 REGULÉAS 1845 *Lezioni di Anatomica Umana.* T. 3, pt. 2, Catania.
- 326 REICHERT, K. B. 1859-1861 *Der Bau des menschlichen Gehirns.* 2 Abt. Leipzig.
- 327 REINHOLD, H. 1886 *Inaug. Dissert.* Leipzig.
- 328 REISSNER 1864 *Der Bau des Zentralnervensystems der ungeschwänzten Batrachier.* Dorpat.
- 329 1851 *De Auris internae formatione.* Dorpat.
- 330 REMAK *Observat. Anat. de System Nervor. Structur.* S. 26.
- 331A RETZIUS, A. 1822 *Bidrag til Ader og Nerfssystemets anatomie hos Myxine glutinosa.* Kong. Vetén, akad. Handlingar, Stockholm.
- 331B RETZIUS, G. 1895 *Über den Bau des sogen. Parietaltauges von Ammonoetes.* Biolog. Untersuchungen, N. F., Bd. 7.
- 332 RITTER, W. E. 1891 *The parietal eye in some lizards from the western United States.* Bull. of the Museum of Comp. Zool., vol. 20.
- 333 1894 *On the presence of a parapineal organ in Phrynosoma coronata.* Anat. Anzeiger, Jahrb. 9.
- 334 ROBIN Cited by Legros, *Thésé de Paris*, 1873.
- 335 ROLANDO *Jour. Majendie*, vol. 3.
- 336 ROMITI 1882 *Lo sviluppo del conario.* Atti d. Soc. Toscana di Sc. Naturali Prox. verbali, T. 3.
- 337 ROMITI AND PARDI 1906 *Clasmatoocytes et Mastzellen.* XV Congress in International de Medicine. Section 1 (Anatomic), Lisbonne.
- 338 *Anatomia dell'umana.* Milano.
- 339 RUYSCH *Thesaurus anatomicus quintus.* Tab. 3, sec. 18.

- 340 SAINT REMY, G. 1897 Notes teratologiques. I. Ébauches épiphysaires et paraphysaires paires chez un embryon de poulet monstrueux. *Bibliographie anatomique*, T. 5.
- 341 SALENSKY, W. 1881 Recherches sur le développement du sterlet (*Acipenser ruthenus*). *Archives de Biologie*, Bd. 2 und 3. (Arbeiten der naturforschenden Gesellschaft an der kaiserlichen Universität zu Kasan, 1879.)
- 342 1894 Morphologische Studien an Tunicaten. I. Über das Nervensystem der Larve und Embryonen von *Distaplia magnilarva*. *Morphol. Jahrb.*, Bd. 20, S. 69.
- 343 SANDERS, A. 1889 Contribution to the anatomy of the central nervous system in *Ceretodus forsteri*. *The Annals and Mag. of Natur. History*, London.
- 344 SAPPEY 1887 *Traité d'Anatomie descriptive*, T. 3.
- 345 SARTESCHI, U. 1910 Ricerche istologica sulla glandula pineale. *Folia neuro-biologica*, p. 675.
- 346 SCHAUINSLAND, H. 1899 Beiträge zur Biologie und Entwicklung der Hatteria, nebst Bemerkungen über die Entwicklung der Sauropsiden. *Anat. Anzeiger*, Jahrb. 15.
- 347A 1903 Beiträge zur Entwicklungsgeschichte und Anatomie der Wirbeltiere. I-III. *Bibliotheca zoologica*, Stuttgart.
- 347B SCHMIDT 1862 Beiträge zur Entwicklung des Gehirns. *Zeitsch. wiss. Zool.*, Bd. 11.
- 347C SCHLEMM UND D'ALTON 1838 Über das Nervensystem der Petromyzonten. *Müller's Archiv*.
- 348 SCHWALBE, G. 1881 *Lehrbuch der Neurologie*. (Hoffmann's Handbuch der anatomie des Menschen. 2 Aufl., Bd. 2, Abt. 2.)
- 349 SCOTT, E. B. 1881 Beiträge zur Entwicklungsgeschichte von Petromyzon. *Morphol. Jahrbuch*, Bd. 7.
- 350 1888 The embryology of Petromyzon. *Jour. Morph.*, vol. 1.
- 351 SEIGNEUR, P. 1912 Étude critique sur la glande pineale normale et pathologique. *Thèse de Paris*, No. 375.
- 352 SELENKA, E. 1890 Das Stimmorgan der Wirbeltiere. *Biolog. Zentralbl.*, Bd. 10.
- 353 SERRES 1824-1828 *Anatomie comparée du cerveau dans les quatre classes des animaux vertébrés*. Paris.
- 354 SHIPLEY, A. E. 1887 On some points in the development of Petromyzon fluviatilis. *Quart. Jour. of Mier. Science*, vol. 27.
- 355 SIEBOLD AND STANNIUS 1854 *Handbuch der Zootomie*. Bd. 2. Die Wirbeltiere. 2 Aufl., Berlin.
- 356 1846 *Lehrbuch der Vergleichende Anat.*, 2, p. 59.
- 357 SMITH, G. ELLIOT 1897 On the morphology of the cerebral commissures, etc. *Trans. Linnæan Soc. London*, S. 2 series. *Zool.*, p. 455.
- 358 SOEMMERING 1785 De Capillis vel prope, vel untra glandulam pinealem sitis Magouza.
- 359 1785 *Scriptores neurolog. minores selectit*, T. 3.
- 360 1798 *De corpor. humani fabrica*, T. 4.

- 361 SORENSEN, A. D. 1893 The pineal and parietal organ in *Phrynosoma coronata*. Jour. Comp. Neur., vol. 3.
- 362 1893 The roof of the Diencephalon. Jour. Comp. Neur., vol. 3.
- 363 1894 Comparative study of the epiphysis and roof of the Diencephalon. Jour. Comp. Neur., vol. 4.
- 364 SSOBOLEW, L. W. 1907 Zur Lehre von Paraphysis und Epiphysis bei Schlangen. Arch. f. Micro. Anat., Bd. 70, S. 318.
- 365 SOURY 1899 System nerveux central. Paris.
- 366 SPENCER, E. BALDWIN 1886 The parietal eye of *Hatteria*. Nature, vol. 34.
- 367 1886 Preliminary communication on the structure and presence in *Sphenodon* and other lizards of the median eye, described by Von Graaf in *Anguis fragilis* (communicated by Prof. H. N. Moseley). Proceedings of the Roy. Soc. of London, June 10.
- 368 1886 On the presence and structure of the pineal eye in *Lacertilia*. Quart. Jour. of Micr. Science, vol. 27, pp. 165-238.
- 369 1890 The pineal eye of *Mordacia mordax*. Roy. Soc. of Victoria.
- 370 SPERINO AND BALLI 1909 L'encefalo del *Dasyprocta aguti*. Memorie della r. Acad. di Scienze. Lettere ed Arti in Modena. Serie 3, T. 10, Sezione Scienze, Modena.
- 371 SPRONCK 1887 De epiphysis cerebri als rudiment van een derde of parietal organ. Neederl. Weekbl., No. 7.
- 372 STADERINI 1897 Intorno alla ghiandola pineale dei mammiferi. Monitore Zoologico Ital., T. 8, No. 1.
- 373 STANNIUS 1854 Lehrbuch d. vergleichende Anat. der Wirbeltiere, S. 59.
- 374 STEMMLER, J. 1900 Die Entwicklung der Anhänge am Zwischenhirndach beim Gecko (*Gehyra oceanica* und *Hemidaectylus mabouia*). Ein Beitrag zur Kenntnis der Epiphysis, des Parietalorganes und der Paraphyse. Leipziger Dissertation. Limburg.
- 375 STIEDA, L. 1865 Über den Bau der Haut des Frosches (*Rana temporaria*). Archiv. f. Anat. Phys. u. wiss. Med., S. 52.
- 376 1869 Studien über das zentrale Nervensystem der Vögel und Säugetiere. Zeitschr. f. wiss. Zool., Bd. 19.
- 377 1870 Studien über das zentrale Nervensystem der Wirbeltiere (Frosch, Kaninchen, Hund). Zeitschr. f. wiss. Zool., Bd. 20.
- 378 1873 Über die Deutung der einzelnen Teile des Fischgehirns. Zeitschr. f. wiss. Zool., Bd. 23.
- 379 1875 Über den Bau des zentralen Nervensystems der Amphibien und Reptilien.
- 380 1875 Über den Bau des zentralen Nervensystems des Axolotl.
- 381 1875 Über den Bau des zentralen Nervensystems der Schildkröte. Zeitschr. f. wiss. Zool., Bd. 25.
- 382 STRAHL, H. 1884 Das Leydig'sche organ bei Eidechsen. Sitzungsber. d. Gesellschaft zur Beforderung d. ges. Naturwissenschaften zu Marburg, Mai.
- 383 STRAHL, H. AND MARTIN, E. 1888 Die Entwicklungsgeschichte des Parietalauges bei *Anguis fragilis* and *Lacerta vivipara*. Arch. f. Anat. und Phys., Anat. Abt., S. 146-161.

- 384 STUDNICKA, F. K. 1893 Sur les organes parietaux de *Petromyzon planeri*. Sitzungsber. der. Kg. Ges. d. Wissensch. in Prag.
- 385 1895 Zur Anatomie der sogenannten Paraphyse des Wirbeltiergehirns. Sitzungsber. der Kg. Ges. d. Wissensch. in Prag.
- 386 1895-6 Beiträge zur Anatomie und Entwicklungsgeschichte des Vorderhirns der Kranioten. Idem., Abt. 1, 1895, 2, 1896.
- 387 1898 Zur Kritik einiger Angaben über die Existenz eines Parietalanges bei *Myxine glutinosa*. Idem.
- 388 1899 Über den feineren Bau der Parietalorgane von *Petromyzon marinus*. Idem.
- 389 1900 Zur Kenntnis der Parietalorgane und der sog. Paraphyse der niederen Wirbeltiere. Verhandl. der Anat. Ges. auf der XVII Versammlung in Pavia.
- 390 1900 Untersuchungen über das Ependym der nervösen Zentralorgane. Anatom. Hefte, Bd. 15.
- 391 1905 Die Parietalorgane. In Oppel-Lehrb. d. vergl. mikrosk. Anat. d. Wirbelt., Bd. 5 (Monograph).
- 392 TERRY, R. J. 1911 The morphology of the pineal region in Teleosts. Jour. Morph., vol. 21, p. 321.
- 393 TESTUT 1900 *Traité d'Anat. Humaine*. 4 ed., T. 2.
- 394 TIEDEMANN, F. 1816 Anatomie und Bildungsgeschichte des Gehirns im Fötus des Menschen. Nürnberg, S. 172.
- 395 1823 Anatomie du Cerveau. Trad. par a Jourdan. Paris.
- 396 TILNEY, F. 1915 The morphology of the diencephalic floor. Jour. Comp. Neur., vol. 25, p. 213.
- 397 TOLDT 1888 Lehrbuch der Gewebelehre.
- 398 TOURNEUX 1909 Embryologie humaine. Paris.
- 399 TURNER, C. H. 1891 Morphology of the avian brain. Jour. Comp. Neur., vol. 1.
- 400 TURNER, W. 1888 The pineal body (*Epiphysis cerebri*) in the brain of the walrus and seals. Jour. of Anat. and Physiol., vol. 22. (Referat in Hermann Schwalbes Jahresb., Bd. 17, p. 261.)
- 401 UVARHONUS Cited by Cutore in: Il Corpo Pineale di Alcuni Mammiferi. Arch. Ital. di Anat. e. di Embriol. 1910-11, T. 9, p. 403.
- 402 USSOW 1882 De la structure des lobes accessoires de la moelle épinière de quelques poissons osseux. Archiv. de Biol., T. 3.
- 403 VALENTIN 1843 *Traité de Neurologie*. Trans. by A. J. L. Jourdan, Paris, p. 164.
- 404 VAN GEUGHTEN 1906 Anatomie du système nerveux de l'Homme. Louvain.
- 405 VARIANI, H. 1886 Le troisième oeil des Vertébrés. Revue scientifique.
- 406 VAN WILHE, J. W. 1883 Über die Mesodermsegmente und die Entwicklungsgeschichte der Nerven des Schlähierkopfes. Verhandl. d. k. Akad. d. Wetensch., Bd. 22. Amsterdam.
- 407 1881 Über den vorderen Neuroporus und die phylogenetische Funktion des Canalis neurentericus der Wirbeltiere. Zoolog. Anzeiger, 7.
- 408 VICQ-D'AZYR 1781 *Memoires de l'Acad. roy des Sciences*.
- 409 VIRCHOW Cited by Legros, Thésé de Paris, 1873.

- 410 VOELTZKOW, A. 1903 Epiphyse und Paraphyse bei Krokodilen und Schildkröten. *Abhandl. d. Senckenberg. Naturf. Ges.*, Bd. 27.
- 411 VOLTAIRE Cited by Majendie in: *Memoir physiologique experimentale et pathologique*. T. 7, p. 211, 1828.
- 412 WALDSCHMIDT, J. 1887 Beitrag zur Anatomie des Zentralnervensystems und des Geruchsorganes von *Polypterus bichir*. *Anat. Anz.*, 2.
- 413 1887 Zur Anatomie des Nervensystems der Gymnophionen. *Zeit. f. Med. u. Naturwiss.*, Bd. 20.
- 414 WALTER, F. K. 1913 Beiträge zur histologie der menschlichen Zirbeldrüse. *Zeit. f. d. ges. Neurol. in Psychiat.* Bd. 27, S. 65.
- 415 WARREN, J. 1911 The development of the paraphysis and pineal region in Reptilia. *Amer. Jour. Anat.*, vol. 2, p. 313.
- 416 1906 The development of the paraphysis and pineal region in *Necturus maculata*. *Amer. Jour. Anat.*, p. 1.
- 417 1917 The development of the paraphysis and pineal region in Mammalia. *Jour. Comp. Neur.*, vol. 28.
- 418 WEIGERT, C. 1875 *Virchow's Arch. f. path. Anat.*, 65, p. 212.
- 419 1895 Beitrag zur Kenntnis normalen menschlichen Neuroglia. *Abhandl. d. Senckenbg. Naturf. ges. Frankfurt a/M.*, Bd. 19.
- 420 WENZEL, J. A. 1812 *De penitiori structura cerebri hominis atque brutorum*. Tübingae.
- 421 WHITWELL, J. R. 1888 The epiphysis cerebri in *Petromyzon fluviatilis*. *Jour. of Anat. and Physiol.*
- 422 WIEDERSHEIM, R. 1880 Das Gehirn von *Ammocoetes* und *Petromyzon planeri* mit besonderer Berücksichtigung der spinalartigen Hirnnerven. *Jena. Zeit.*, Bd. 14, S. 7.
- 423 1880 Skelet und Nervensystem von *Lepidosiren annectens*. *Jena. Zeit.*, Bd. 14.
- 424 1886 Über das Parietalauge der Saurier. *Anat. Anz.*, 1.
- 425 1898 Grundriss der vergleichenden Anatomie der Wirbeltiere. *Jena.*
- 426 WILDER, B. G. 1896 The names epiphysis, conarium and corpus pineale. Correction of an error. *Science, N. S.*, vol. 4, no. 85.
- 427 1887 The Dipnoian brain. *Amer. Naturalist*, June.
- 428 1896 The dorsal sac, the aulix and the diencephalic flexure. *Jour. Comp. Neur.*, vol. 6.
- 429 WILLIS, T. *Cerebri anatome*. Cap. 14, p. 46.
- 430 WRIGHT, RAMSAY 1884 On the nervous system and sense organs of *Amiurus*. *Proceed. Canad. Inst. Toronto*, vol. 2, Fasc. 3.
- 431 WYMAN 1853 *Anatomy of the nervous system of Rana pipiens*. *Smithsonian Contributions to Knowledge*, vol. 4.
- 432 ZANCLA 1906 *Sulla fine struttura del Conarium umano*. *Arch. di Anat. patol. e Scienze affini*, 2, Palermo.

